Diseases of Poultry

13th EDITION

Editor in Chief: David E. Swayne

Associate Editors: John R. Glisson, Larry R. McDougald, Lisa K. Nolan, David L. Suarez, and Venugopal Nair

WILEY-BLACKWELL

aaap AMERICAN ASSOCIATION OF AVIAN PATHOLOGISTS

13th Edition

Diseases of Poultry

13th Edition

Diseases of Poultry

Editor-in-Chief

David E. Swayne
Laboratory Director
Southeast Poultry Research Laboratory
Agricultural Research Service
U.S. Department of Agriculture
Athens, Georgia
United States

Associate Editors

John R. Glisson
Professor Emeritus
Poultry Diagnostic and Research Center
Department of Population Health
College of Veterinary Medicine
University of Georgia
Athens, Georgia
United States

Larry R. McDougald
Professor
Department of Poultry Science
College of Agricultural and Environmental Sciences
University of Georgia
Athens, Georgia
United States

Lisa K. Nolan
Professor and Dr. Stephen G. Juelsgaard Dean
College of Veterinary Medicine
Iowa State University
Ames, Iowa
United States

David L. Suarez
Research Leader
Exotic and Emerging Avian Viral Diseases Research Unit
Southeast Poultry Research Laboratory
Agricultural Research Service
U.S. Department of Agriculture
Athens, Georgia
United States

Venugopal Nair
Head
Avian Viral Diseases Programme
The Pirbright Institute
Compton Laboratory
Compton, Berkshire
United Kingdom

WILEY-BLACKWELL
A John Wiley & Sons, Inc., Publication

aaap
AMERICAN ASSOCIATION OF AVIAN PATHOLOGISTS

This edition first published 2013 © 2013 by John Wiley & Sons, Inc.
First edition, © 1943 Iowa State University Press
Second edition, © 1948 Iowa State University Press
Third edition, © 1952 Iowa State University Press
Fourth edition, © 1959 Iowa State University Press
Fifth edition, © 1965 Iowa State University Press
Sixth edition, © 1972 Iowa State University Press
Seventh edition, © 1978 Iowa State University Press
Eighth edition, © 1984 Iowa State University Press
Ninth edition, © 1991 Iowa State University Press
Tenth edition, © 1997 Iowa State University Press
Eleventh edition, © 2003 Iowa State Press
Twelfth edition, © 2008 Blackwell Publishing Ltd.

Editorial Offices
1606 Golden Aspen Drive, Suites 103 and 104, Ames,
Iowa 50010, USA
The Atrium, Southern Gate, Chichester, West Sussex, PO19 8SQ, UK
9600 Garsington Road, Oxford, OX4 2DQ, UK

For details of our global editorial offices, for customer services and for information about how to apply for permission to reuse the copyright material in this book please see our website at www.wiley.com/wiley-blackwell.

Authorization to photocopy items for internal or personal use, or the internal or personal use of specific clients, is granted by Blackwell Publishing, provided that the base fee is paid directly to the Copyright Clearance Center, 222 Rosewood Drive, Danvers, MA 01923. For those organizations that have been granted a photocopy license by CCC, a separate system of payments has been arranged. The fee codes for users of the Transactional Reporting Service are ISBN-13: 978-0-4709-5899-5/2013.

Designations used by companies to distinguish their products are often claimed as trademarks. All brand names and product names used in this book are trade names, service marks, trademarks or registered trademarks of their respective owners. The publisher is not associated with any product or vendor mentioned in this book.

The contents of this work are intended to further general scientific research, understanding, and discussion only and are not intended and should not be relied upon as recommending or promoting a specific method, diagnosis, or treatment by health science practitioners for any particular patient. The publisher and the author make no representations or warranties with respect to the accuracy or completeness of the contents of this work and specifically disclaim all warranties, including without limitation any implied warranties of fitness for a particular purpose. In view of ongoing research, equipment modifications, changes in governmental regulations, and the constant flow of information relating to the use of medicines, equipment, and devices, the reader is urged to review and evaluate the information provided in the package insert or instructions for each medicine, equipment, or device for, among other things, any changes in the instructions or indication of usage and for added warnings and precautions. Readers should consult with a specialist where appropriate. The fact that an organization or Website is referred to in this work as a citation and/or a potential source of further information does not mean that the author or the publisher endorses the information the organization or Website may provide or recommendations it may make. Further, readers should be aware that Internet Websites listed in this work may have changed or disappeared between when this work was written and when it is read. No warranty may be created or extended by any promotional statements for this work. Neither the publisher nor the author shall be liable for any damages arising herefrom.

Library of Congress Cataloging-in-Publication Data

Diseases of poultry. – 13th ed. / editor-in-chief, David E. Swayne ; associate editors, John R. Glisson … [et al.].
p. ; cm.
Includes bibliographical references and index.
ISBN 978-0-470-95899-5 (hardback : alk. paper)
I. Swayne, David E.
[DNLM: 1. Poultry Diseases. SF 995]
SF995
636.5′0896–dc23

2013007104

A catalogue record for this book is available from the British Library.

Wiley also publishes its books in a variety of electronic formats. Some content that appears in print may not be available in electronic books.

Cover design by Modern Alchemy LLC

Set in 9.5/12pt Times New Roman by SPi Publisher Services, Pondicherry, India

1 2013

Dedicated to

Dr. Y.M. Saif, Associate Editor,
Diseases of Poultry, 10th edition
Editor-in-Chief, 11th and 12th editions

Dr. A.M. Fadly, Associate Editor,
Diseases of Poultry, 11th and 12th editions

Contents

Contributors xi

Preface xix

Introduction xxv

SECTION I: GENERAL CONCEPTS OF POULTRY DISEASES **1**

1 Principles of Disease Prevention, Diagnosis, and Control 3
Introduction, *S.R. Collett*
Principles of Disease Prevention, Diagnosis, and Control Introduction, *S.R. Collett*
Antimicrobial Therapy (Including Resistance), *C.L. Hofacre, R.S. Singer and T.J. Johnson*
Public Health Significance of Poultry Diseases, *R.D. Berghaus and B. Stewart-Brown*

2 Host Factors for Disease Resistance 61
Introduction, *J.M. Sharma*
The Avian Immune System, *J.M. Sharma and S. Rautenschlein*
Genetics of Disease Resistance, *H.H. Cheng and S.J. Lamont*

SECTION II: VIRAL DISEASES **87**

3 Newcastle Disease, Other Avian Paramyxoviruses, and Avian Metapneumovirus Infections 89
Introduction, *D.L. Suarez*
Newcastle Disease, *P.J. Miller and G. Koch*
Avian Paramyxoviruses 2–11, *E. Mundt*
Avian Metapneumovirus, *R.C. Jones and S. Rautenschlein*

4 Infectious Bronchitis, *M.W. Jackwood and S. de Wit* 139

5 Infectious Laryngotracheitis, *M. García, S. Spatz, and J.S. Guy* 161

6 Influenza, *D.E. Swayne, D.L. Suarez, and L.D. Sims* 181

7 Infectious Bursal Disease, *N. Eterradossi and Y.M. Saif* 219

8 Chicken Infectious Anemia Virus and Other Circovirus Infections 247
Introduction, *K.A. Schat and L.W. Woods*
Chicken Infectious Anemia, *K.A. Schat and V.L. van Santen*
Circovirus Infections of Avian Species, *L.W. Woods and K.S. Latimer*

9 Adenovirus Infections 289
Introduction, *S.D. Fitzgerald*
Aviadenovirus Infections, *M. Hess*
Atadenovirus (Egg Drop Syndrome and Related Infections), *J.A. Smyth*
Hemorrhagic Enteritis and Related Infections, *F.W. Pierson and S.D. Fitzgerald*
Quail Bronchitis, *W.M. Reed and S.W. Jack*

10 Pox, *D.N. Tripathy and W.M. Reed* 333

11 Reovirus Infections, *R.C. Jones* 351

12 Viral Enteric Infections 375
Introduction, *Y.M. Saif*
Turkey Coronavirus Enteritis, *J.S. Guy*
Rotavirus Infections, *J.M. Day*
Astrovirus Infections, *S.L. Schultz-Cherry*
Avian Enterovirus-Like Virus Infections, *C.S. Hayhow*
Enteric Parvovirus Infections of Chickens and Turkeys, *L. Zsak*

13 Viral Infections of Waterfowl 417
Introduction, *P.R. Woolcock*
Duck Hepatitis, *P.R. Woolcock and H.-J. Tsai*
Duck Virus Enteritis (Duck Plague), *S.A. Metwally*
Hemorrhagic Nephritis Enteritis of Geese, *J.-L. Guérin*
Parvovirus Infections of Waterfowl, *V.J. Palya*

14 Other Viral Infections 465
Introduction, *Y.M. Saif*
Miscellaneous Herpesvirus Infections, *J.P. Duchatel and H. Vindevogel*
Avian Nephritis, *D. Todd and T. Imada*
Arbovirus Infections, *J.S. Guy*
Turkey Viral Hepatitis, *J.S. Guy*
Avian Encephalomyelitis, *D.L. Suarez*
Avian Hepatitis E Virus Infections, *X.J. Meng and H.L. Shivaprasad*

15 Neoplastic Diseases 513
Introduction, *V. Nair*
Marek's Disease, *K.A. Schat and V. Nair*
Leukosis/Sarcoma Group, *V. Nair and A.M. Fadly*
Reticuloendotheliosis, *V. Nair, G. Zavala, and A.M. Fadly*
Other Tumors, *S. Hafner, R.L. Reece, and S.M. Williams*

SECTION III: BACTERIAL DISEASES 675

16 Salmonella Infections 677
Introduction, *R.K. Gast*
Pullorum Disease and Fowl Typhoid, *H.L. Shivaprasad and P.A. Barrow*
Paratyphoid Infections, *R.K. Gast*
Arizonosis, *H.L. Shivaprasad*

17 Campylobacteriosis, *Q. Zhang and O. Sahin* 737

18 Colibacillosis, *L.K. Nolan, H.J. Barnes, J.-P. Vaillancourt, T. Abdul-Aziz, and C.M. Logue* 751

19 Pasteurellosis and Other Respiratory Bacterial Infections 807
Introduction, *J.R. Glisson*
Fowl Cholera, *J.R. Glisson, C.L. Hofacre, and J.P. Christensen*
Riemerella anatipestifer Infection, *J.A. Ruiz and T.S. Sandhu*
Ornithobacterium rhinotracheale Infection, *R.P. Chin, P.C.M. van Empel, and H.M. Hafez*
Bordetellosis (Turkey Coryza), *M.W. Jackwood and Y.M. Saif*

20 Infectious Coryza and Related Bacterial Infections, *P.J. Blackall and E. Soriano-Vargas* 859

21 Mycoplasmosis 875
Introduction, *N. Ferguson-Noel*
Mycoplasma gallisepticum Infection, *Z. Raviv and D.H. Ley*
Mycoplasma meleagridis Infection, *R.P. Chin*
Mycoplasma synoviae Infection, *N. Ferguson-Noel and A.H. Noormohammadi*
Mycoplasma iowae Infection, *J.M. Bradbury and Z. Raviv*
Other Mycoplasmal Infections, *N. Ferguson-Noel*

22 Clostridial Diseases 943
Introduction, *C.M. Logue*
Ulcerative Enteritis, *J.G. Songer and F. Uzal*
Necrotic Enteritis, *K. Opengart and J.G. Songer*
Botulism, *H. Skarin, G. Blomqvist and V. Båverud*
Gangrenous Dermatitis, *K. Opengart*

23 Other Bacterial Diseases 971
Introduction, *C.M. Logue*
Staphylococcosis, *C.B. Andreasen*
Streptococcus and Enterococcus, *S.G. Thayer and W.D. Waltman*
Erysipelas, *J.M. Bricker and Y.M. Saif*
Avian Intestinal Spirochetosis, *D.J. Hampson*
Tuberculosis, *R.M. Fulton and S. Sanchez*
Miscellaneous and Sporadic Bacterial Infections, *T. Abdul-Aziz and H.J. Barnes*

24 Avian Chlamydiosis, *D. Vanrompay* 1055

SECTION IV: FUNGAL DISEASES 1075

25 Fungal Infections, *M.J. Dykstra, B.R. Charlton, R.P. Chin, and H.J. Barnes* 1077

SECTION V: PARASITIC DISEASES 1097

26 External Parasites and Poultry Pests, *N.C. Hinkle and R.M. Corrigan* 1099

27 Internal Parasites, *L.R. McDougald* 1117

28 Protozoal Infections 1147
Introduction, *L.R. McDougald*
Coccidiosis, *L.R. McDougald and S.H. Fitz-Coy*
Cryptosporidiosis, *L.R. McDougald*
Histomoniasis (Blackhead) and Other Protozoan Diseases of the Intestinal Tract, *M. Hess and L.R. McDougald*
Miscellaneous and Sporadic Protozoal Infections, *A.J. Bermudez*

SECTION VI: NONINFECTIOUS DISEASES 1203

29 Nutritional Diseases, *K.C. Klasing* 1205

30 Developmental, Metabolic, and Other Noninfectious Disorders, *R. Crespo and H.L. Shivaprasad* 1233

31 Mycotoxicoses, *F.J. Hoerr* 1271

32 Toxins and Poisons, *R.M. Fulton* 1287

SECTION VII: OTHER DISEASES **1317**

33 Emerging Diseases and Diseases of Complex or Unknown Etiology
Introduction, *Y.M. Saif*
Multicausal Respiratory Diseases, *J.R. Glisson*
Multicausal Enteric Diseases, *M.J. Pantin-Jackwood*
Hypoglycemia-Spiking Mortality Syndrome of Broiler Chickens, *J.F. Davis* 1319
Proventriculitis and Proventricular Dilatation of Broiler Chickens, *S. Hafner and J.S. Guy*

Index 1341

Contributors

Tahseen Abdul-Aziz
Veterinary Pathologist
Rollins Animal Disease Diagnostic Laboratory
North Carolina Department of Agriculture
and Consumer Services
Raleigh, North Carolina, USA

Claire B. Andreasen
Associate Dean for Academic and Student Affairs
Professor
College of Veterinary Medicine
Iowa State University
Ames, Iowa, USA

H. John Barnes
Professor
Department of Population Health and Pathobiology
College of Veterinary Medicine
North Carolina State University
Raleigh, North Carolina, USA

Paul A. Barrow
Professor
Veterinary Infectious Diseases
School of Veterinary Medicine and Science
Nottingham University
Sutton Bonington, Leicestershire, United Kingdom

Viveca Båverud
Associate Professor, Head
Department of Bacteriology
National Veterinary Institute
Uppsala, Sweden

Roy D. Berghaus
Associate Professor
Department of Population Health
College of Veterinary Medicine
University of Georgia
Athens, Georgia, USA

Alex J. Bermudez*
Director
Veterinary Medical Diagnostic Laboratory
College of Veterinary Medicine
University of Missouri
Columbia, Missouri, USA

Pat J. Blackall
Senior Principal Research Fellow
Queensland Alliance for Agriculture and Food
Innovation
The University of Queensland
Queensland, Australia

Gunilla Blomqvist
Department of Virology, Immunology and Parasitology
National Veterinary Institute
Uppsala, Sweden

Janet M. Bradbury
Emeritus Professor
School of Veterinary Science—Leahurst Campus
University of Liverpool
Neston, Wirral, United Kingdom

Joseph M. Bricker
Global Bios Research
Zoetis
Kalamazoo, Michigan, USA

Bruce R. Charlton
Professor
California Animal Health and Food Safety
Laboratory System
University of California—Davis
Turlock, California, USA

Hans H. Cheng
Supervisory Research Geneticist
Avian Disease and Oncology Laboratory
Agricultural Research Service
U.S. Department of Agriculture
East Lansing, Michigan, USA

* Deceased

Richard P. Chin
Professor
California Animal Health and Food Safety Laboratory System
University of California—Davis
Tulare, California, USA

Jens P. Christensen
Associate Professor
Department of Veterinary Disease Biology
Faculty of Life Sciences
University of Copenhagen
Frederiksberg, Copenhagen, Denmark

Stephen R. Collett
Clinical Associate Professor
Poultry Diagnostic and Research Center
Department of Population Health
College of Veterinary Medicine
University of Georgia
Athens, Georgia, USA

Robert M. Corrigan
Private Consultant
Urban Rodentologist
RMC Pest Management Consulting
Richmond, Indiana, USA

Rocio Crespo
Associate Professor
Avian Health and Food Safety Laboratory (WADDL)
Department of Veterinary Microbiology and Pathology
Washington State University
Pullman, Washington, USA

James F. Davis
Veterinary Director of Diagnostics—North Georgia
Georgia Poultry Laboratory Network
Oakwood, Georgia, USA

J. Michael Day
Microbiologist
Endemic Poultry Viral Diseases Research Unit
Southeast Poultry Research Laboratory
Agricultural Research Service
U.S. Department of Agriculture
Athens, Georgia, USA

Sjaak de Wit
Poultry Veterinarian
Animal Health Service
Deventer, The Netherlands

Jean Pierre Duchatel
Department of Infectious and Parasitic Diseases
Faculty of Veterinary Medicine
University of Liege
Liege, Belgium

Michael J. Dykstra
Director and Research Professor
Laboratory for Advanced Electron and Light Microscopy Methods
Department of Population Health and Pathobiology
College of Veterinary Medicine
North Carolina State University
Raleigh, North Carolina, USA

Nicolas Eterradossi
Agence Nationale de Securite Sanitaire de l'Alimentation, de l'Environnement et du Travail (Anses)
Laboratoire de Ploufragan/Plouzane
Unite de Virologie Immunologie et Parasitologie Aviaires et Cunicoles
Laboratoire de reference de l'Organisation Mondiale de la Sante Animale pour la bursite infectieuse aviaire
Ploufragan, France

Aly M. Fadly
Research Leader and Laboratory Director
Avian Disease and Oncology Laboratory
Agricultural Research Service
U.S. Department of Agriculture
East Lansing, Michigan, USA

Naola Ferguson-Noel
Assistant Professor
Poultry Diagnostic and Research Center
Department of Population Health
College of Veterinary Medicine
University of Georgia
Athens, Georgia, USA

Scott D. Fitzgerald
Professor
Department of Pathobiology and Diagnostic Investigation
College of Veterinary Medicine
Michigan State University
East Lansing, Michigan, USA

Steve H. Fitz-Coy
Poultry Parasitologist
Merck Animal Health
Salisbury, Maryland, USA

Richard M. Fulton
Associate Professor
Diagnostic Center for Population and Animal Health
College of Veterinary Medicine
Michigan State University
East Lansing, Michigan, USA

Maricarmen García
Professor
Poultry Diagnostic and Research Center
Department of Population Health
College of Veterinary Medicine
University of Georgia
Athens, Georgia, USA

Richard K. Gast
Supervisory Microbiologist
Egg Safety and Quality Research Unit
Agricultural Research Service
U.S. Department of Agriculture
Athens, Georgia, USA

John R. Glisson
Professor Emeritus
Poultry Diagnostic and Research Center
Department of Population Health
College of Veterinary Medicine
University of Georgia
Athens, Georgia, USA

Jean-Luc Guérin
Associate Professor
Poultry Health and Virology
National Veterinary College of Toulouse
Toulouse, France

James S. Guy
Professor
Department of Population Health and Pathobiology
College of Veterinary Medicine
North Carolina State University
Raleigh, North Carolina, USA

Hafez M. Hafez
Head
Institute of Poultry Diseases
Faculty of Veterinary Medicine
Free University of Berlin
Berlin, Germany

Scott Hafner
Veterinary Medical Officer
Eastern Laboratory
Food Safety Inspection Service
U.S. Department of Agriculture
Athens, Georgia, USA

David J. Hampson
Professor and Dean
School of Veterinary and Life Sciences
Murdoch University
Murdoch, Western Australia, Australia

Christopher S. Hayhow
Director of Regulatory Affairs
Biologics, North America
Merial, Inc.
Athens, Georgia, USA

Michael Hess
Head
Clinic for Avian, Reptile and Fish Medicine
Department for Farm Animals and Veterinary Public Health
University of Veterinary Medicine
Vienna, Austria

Nancy C. Hinkle
Professor
Department of Entomology
College of Agricultural and Environmental Sciences
University of Georgia
Athens, Georgia, USA

Fredric J. Hoerr
Pathologist
Veterinary Diagnostic Pathology, LLC
Auburn, Alabama, USA

Charles L. Hofacre
Professor
Poultry Diagnostic and Research Center
Department of Population Health
College of Veterinary Medicine
University of Georgia
Athens, Georgia, USA

Tadao Imada
One-time Research Manager (Emeritus)
National Institute of Animal Health
Kammondai, Tsukuba, Japan

Sherman W. Jack
Professor
Department of Pathobiology and Population Medicine
College of Veterinary Medicine
Mississippi State University
Mississippi State, Mississippi, USA

Mark W. Jackwood
Head and J. R. Glisson Professor of Veterinary Medicine
Poultry Diagnostic and Research Center
Department of Population Health
College of Veterinary Medicine
University of Georgia
Athens, Georgia, USA

Timothy J. Johnson
Associate Professor
Department of Veterinary and Biomedical Sciences
College of Veterinary Medicine
University of Minnesota
St. Paul, Minnesota, USA

Richard C. Jones
Emeritus Professor
School of Veterinary Science—Leahurst Campus
University of Liverpool
Neston, Wirral, United Kingdom

Kirk C. Klasing
Professor
Department of Animal Science
College of Agricultural and Environmental Sciences
University of California—Davis
Davis, California, USA

Guus Koch
Senior Scientist
Department of Virology
Central Veterinary Institute Wageningen UR
Lelystad, The Netherlands

Susan J. Lamont
C.F. Curtiss Distinguished Professor of Agriculture and Life Sciences
Department of Animal Science
Iowa State University
Ames, Iowa, USA

Kenneth S. Latimer
Research Clinical Pathologist
Covance Laboratories, Inc.
Madison, Wisconsin, USA

David H. Ley
Professor
Department of Population Health and Pathobiology
College of Veterinary Medicine
North Carolina State University
Raleigh, North Carolina, USA

Catherine M. Logue
Professor
Department of Veterinary Microbiology and Preventive Medicine
College of Veterinary Medicine
Iowa State University
Ames, Iowa, USA

Larry R. McDougald
Professor
Department of Poultry Science
College of Agricultural and Environmental Sciences
University of Georgia
Athens, Georgia, USA

X.J. Meng
Professor
Department of Biomedical Sciences and Pathobiology
College of Veterinary Medicine
Virginia Polytechnic Institute and State University (Virginia Tech)
Blacksburg, Virginia, USA

Samia A. Metwally
Animal Health Officer (Virologist)
Food and Agriculture Organization of the United Nations
Animal Health and Production Division
Rome, Italy

Patti J. Miller
Veterinary Medical Officer
Exotic and Emerging Avian Viral Diseases Research Unit
Southeast Poultry Research Laboratory
Agricultural Research Service
U.S. Department of Agriculture
Athens, Georgia, USA

Egbert Mundt
Animal Health
IDT Biologika GmbH
Am Pharmapark
Dessau-Rossiau, Germany

Venugopal Nair
Head
Avian Viral Diseases Programme
The Pirbright Institute
Compton Laboratory
Compton, Berkshire, United Kingdom

Lisa K. Nolan
Professor and Dr. Stephen G. Juelsgaard Dean
College of Veterinary Medicine
Iowa State University
Ames, Iowa, USA

Amir H. Noormohammadi
Associate Professor
School of Veterinary Science
University of Melbourne
Werribee, Victoria, Australia

Kenneth Opengart
Vice President
Live Operations and Processing
Keystone Foods
Huntsville, Alabama, USA

Vilmos J. Palya
Director
Scientific Support and Investigation Laboratory
Ceva Phylaxia Veterinary Biological Co.
Budapest, Hungary

Mary J. Pantin-Jackwood
Veterinary Medical Officer
Exotic and Emerging Avian Viral Diseases Research Unit
Southeast Poultry Research Laboratory
Agricultural Research Service
U.S. Department of Agriculture
Athens, Georgia, USA

F. William Pierson
Professor and Director
Veterinary Teaching Hospital
Virginia and Maryland Regional College
of Veterinary Medicine
Virginia Polytechnic Institute and State University
(Virginia Tech)
Blacksburg, Virginia, USA

Silke Rautenschlein
Professor and Director
Clinic for Poultry
University of Veterinary Medicine
Hannover, Germany

Ziv Raviv
Assistant Professor and Head of Poultry Medicine Studies
Koret School of Veterinary Medicine
The Hebrew University of Jerusalem
Rehovot, Israel

Rodney L. Reece
Senior Veterinary Research Officer
NSW Department of Primary Industries
State Veterinary Diagnostic Laboratory
Elizabeth MacArthur Agricultural Institute
New South Wales, Australia

Willie M. Reed
Dean and Professor
College of Veterinary Medicine
Purdue University
West Lafayette, Indiana, USA

Jaime A. Ruiz
Director
Cornell University Duck Research Laboratory
New York State Animal Health Diagnostic Center
College of Veterinary Medicine
Cornell University
Eastport, New York, USA

Orhan Sahin
Research Assistant Professor
Department of Veterinary Microbiology
and Preventive Medicine
College of Veterinary Medicine
Iowa State University
Ames, Iowa, USA

Y.M. Saif
Professor and Head Emeritus
Food Animal Health Research Program
Ohio Agricultural Research and
Development Center
The Ohio State University
Wooster, Ohio, USA

Susan Sanchez
Professor
Athens Veterinary Diagnostic Laboratory
College of Veterinary Medicine
University of Georgia
Athens, Georgia, USA

Tirath S. Sandhu
Director (retired)
Cornell University Duck Research Laboratory
College of Veterinary Medicine
Cornell University
Eastport, New York, USA

Karel A. Schat
Professor Emeritus
Department of Microbiology
and Immunology
College of Veterinary Medicine
Cornell University
Ithaca, New York, USA

Stacey L. Schultz-Cherry
Associate Member
Department of Infectious Diseases
St. Jude Children's Research Hospital
Memphis, Tennessee, USA

Jagdev M. Sharma
Research Professor, Biodesign Institute
Visiting Professor of Life Sciences,
School of Life Sciences
Arizona State University
Tempe, Arizona, USA

H.L. Shivaprasad
Professor
California Animal Health and Food Safety Laboratory
System—Tulare Branch
University of California—Davis
Tulare, California, USA

Leslie D. Sims
Director
Asia Pacific Veterinary Information
Services Pty. Ltd.
Montmorency, Victoria
Australia

Randall S. Singer
Associate Professor
Department of Veterinary and Biomedical Sciences
College of Veterinary Medicine
University of Minnesota
St. Paul, Minnesota, USA

Hanna Skarin
Department of Bacteriology
National Veterinary Institute
Uppsala, Sweden

Joan A. Smyth
Professor
Department of Pathobiology and Veterinary Science
University of Connecticut
Storrs, Connecticut, USA

J. Glenn Songer
Professor
Department of Veterinary Microbiology
and Preventive Medicine
College of Veterinary Medicine
Iowa State University
Ames, Iowa, USA

Edgardo Soriano-Vargas
Professor
Centro de Investigacion y Estudios Avanzados en
Salud Animal
Facultad de Medicina Veterinaria y Zootecnia
Universidad Autonoma del Estado de Mexico
Toluca, Mexico

Stephan Spatz
Microbiologist
Endemic Poultry Viral Diseases Research Unit
Southeast Poultry Research Laboratory
Agricultural Research Service
U.S. Department of Agriculture
Athens, Georgia, USA

Bruce Stewart-Brown
Senior Vice President
Food Safety and Quality
Perdue Farms
Salisbury, Maryland, USA

David L. Suarez
Research Leader
Exotic and Emerging Avian Viral Diseases Research Unit
Southeast Poultry Research Laboratory
Agricultural Research Service
U.S. Department of Agriculture
Athens, Georgia, USA

David E. Swayne
Laboratory Director
Southeast Poultry Research Laboratory
Agricultural Research Service
U.S. Department of Agriculture
Athens, Georgia, USA

Stephan G. Thayer
Retired
Poultry Diagnostic and Research Center
Department of Population Health
College of Veterinary Medicine
University of Georgia
Athens, Georgia, USA

Daniel Todd
Virology Branch
Agri-Food and Biosciences Institute
Stormont, Belfast, United Kingdom

Deoki N. Tripathy
Professor Emeritus
Department of Pathobiology
College of Veterinary Medicine
University of Illinois
Urbana, Illinois, USA

Hsiang-Jung Tsai
Professor
School of Veterinary Medicine
National Taiwan University
Taipei, Taiwan

Francisco A. Uzal
Professor
California Animal Health and Food Safety
Laboratory System
San Bernadino Branch
School of Veterinary Medicine
University of California—Davis
San Bernadino, California, USA

Jean-Pierre Vaillancourt
Professor
Department of Clinical Sciences
Faculty of Veterinary Medicine
University of Montreal
St-Hyacinthe, Quebec, Canada

Paul C.M. van Empel
Global Technical Manager Bacteriology
MSD-Animal Health
Boxmeer, The Netherlands

Daisy Vanrompay
Professor
Faculty of Bioscience Engineering
Department of Molecular Biotechnology
Ghent University
Ghent, Belgium

Vicky L. van Santen
Professor
Department of Pathobiology
College of Veterinary Medicine
Auburn University
Auburn, Alabama, USA

H. Vindevogel
Professor
Clinic of Avian Diseases
Faculty of Veterinary Medicine
University of Liege
Liege, Belgium

W. Douglas Waltman
Technical Director for Bacteriology
Georgia Poultry Laboratory Network
Oakwood, Georgia, USA

Susan M. Williams
Associate Professor
Poultry Diagnostic and Research Center
Department of Population Health
College of Veterinary Medicine
University of Georgia
Athens, Georgia, USA

Leslie W. Woods
Professor
California Animal Health and Food Safety
Laboratory System
School of Veterinary Medicine
University of California—Davis
Davis, California, USA

Peter R. Woolcock
Professor
California Animal Health and Food Safety
Laboratory System
School of Veterinary Medicine
University of California—Davis
Davis, California, USA

Guillermo Zavala
Associate Professor
Poultry Diagnostic and Research Center
Department of Population Health
College of Veterinary Medicine
University of Georgia
Athens, Georgia, USA

Qijing Zhang
Professor
Department of Veterinary Microbiology
and Preventive Medicine
College of Veterinary Medicine
Iowa State University
Ames, Iowa, USA

Laszlo Zsak
Research Leader
Endemic Poultry Viral Diseases Research Unit
USDA ARS SAA Southeast Poultry Research Laboratory
Agricultural Research Service
U.S. Department of Agriculture
Athens, Georgia

Preface: Historical Review of *Diseases of Poultry*

Forewords for *Diseases of Poultry*, beginning with the first one written by John R. Mohler in 1943, have briefly described the nature and contents of the edition, along with substantive reasons for its publication and distribution to potential users. Mohler pointed out that for a profitable poultry industry, "Knowledge of the characteristics of each disease is necessary....as the first step in building up an effective barrier against it." He further noted that "This unusually comprehensive book is intended for students, veterinarians, pathologists, and workers in specialized fields." These words are as applicable today as they were 70 years ago and the importance of the text is supported by publication of 13 editions.

For the 6th edition in 1972, Dr. P.P. Levine offered an accounting of some of the changes in the poultry industry that moved it from a small-scale farm activity to "a highly sophisticated industry marketing products worth over $6 billion per year in the United States alone." He correctly attributed some of the many advances in disease control through eradication, genetic selection, immunization practices, management improvements, etc. to major advances founded in research. Such new knowledge strongly dictates a need for revised texts. Levine further predicted that "infectious diseases will decline in importance; toxicologic, nutritional, genetic, and husbandry problems will demand increasing attention. Change is the order of life, and avian diseases are no exception." In the 7th edition (1978), he pointed out many of the important new advances in identifying the etiology of several conditions, and the need for *Diseases of Poultry* to "keep up with the rapid developments in avian diseases."

Ben Pomeroy, in the 8th (1984) and 9th (1991) editions, reiterated the need for new editions to keep up with the "explosion of knowledge on the prevention and control of avian diseases." The inclusion of contributions from experts from many countries of the world, and the importance of such in the face of global issues of disease control, was emphasized by Charles Beard in the Foreword of the 10th (1997) edition. He pointed out that understanding the molecular genetics of causative agents is also important and the use of molecular methods is necessary for poultry disease researchers to understand and control infectious diseases; yet another reason for timely updates.

The message is clear: a changing and global poultry industry and its many allied industries need the most recent information available to keep pace with the challenges of providing adequate health care and disease prevention. It is important not only to poultry flocks, but also to the consumers who expect safe, as well as nutritious, poultry products. This, the 13th edition, upholds the long-standing reputation of this book for keeping scientists, breeders, poultry producers, and poultry health professionals supplied with the latest and most comprehensive information available.

Seventy years have passed since the first edition was printed. Before all details are lost forever, it is fitting to look back at how this "Bible" in the field of poultry diseases came to be and how it has evolved into what it is today. It all began in the 1930s. In a memorandum addressed to the American Association of Avian Pathologists (AAAP) dated December 22, 1965, H.E. Biester related the events that preceded the decision by the Iowa State College (now University) Press (ISU Press) to undertake the publication of *Diseases of Poultry*. During the 1930s, Louis DeVries, a member of the Department of Modern Languages at the college, translated a 1929 German book entitled *Handbuch der Geflügelkrankheiten und der Geflügerzucht*, published by Ferdinand Enke, Stuttgart. The translation laid dormant for several years until Dr. D.M. Campbell, the Chicago publisher of *Veterinary Medicine*, saw the translation and expressed some interest in it. Dr. Biester, who described himself as an "innocent bystander, having no special interest in the project," told Dr. Campbell that the manuscript was unacceptable for a variety of reasons and he suggested that if he were serious about publication, then selected specialists should edit or rewrite the material. Dr. Biester later was pulled into the project and he ultimately concluded that the German book was obsolete. Apparently, a number of men had accepted invitations to cooperate in developing an American book, and according to Biester, they agreed that "it would be better to prepare a totally new book based on American conditions."

Thus, the die was cast. Dr. Campbell gave up his plans, and the ISU Press decided to publish an original text. Drs. Biester and DeVries served as editors, and 34 American investigators were engaged in the project. There were chapters on general subjects such as anatomy, digestion, genetics, hematology, hygiene and sanitation, nutrition, and surgery, as well as those dealing with specific infectious and noninfectious diseases and conditions. A separate chapter dealt with diseases of turkeys. In 1943, the 1st edition was ready. The publication costs

Edition	Year	Editors	Pages	Chapters	No. USA Authors	No. Non-USA Authors (No. Countries)
1st	1943	H.E. Biester Louis Devries	1,005	40	34	0
2nd	1948	H.E. Biester L.H. Schwarte	1,154	40	33	0
3rd	1952	H.E. Biester L.H. Schwarte	1,245	41	35	0
4th	1959	H.E. Biester L.H. Schwarte	1,103	41	33	0
5th	1965	H.E. Biester L.H. Schwarte	1,382	41	37	0
6th	1972	M.S. Hofstad (EC) B.W. Calnek C.F. Helmboldt W.M. Reid H.W. Yoder, Jr.	1,176	33	40	0
7th	1978	M.S. Hofstad (EC) B.W. Calnek C.F. Helmboldt W.M. Reid H.W. Yoder, Jr.	949	33	45	1 (Czechoslovakia)
8th	1984	M.S. Hofstad (EC) H. John Barnes B.W. Calnek W.M. Reid H.W. Yoder, Jr.	831	34	51	4 (United Kingdom)
9th	1991	B.W. Calnek (EC) H. John Barnes C.W. Beard W.M. Reid H.W. Yoder, Jr.	929	35	61	17 (Australia, Belgium, Canada, Germany, Hungary, Israel, Japan, United Kingdom)
10th	1997	B.W. Calnek (EC) H. John Barnes C.W. Beard L. R. McDougald Y.M. Saif	1,081	37	78	18 (Australia, Belgium, Canada, Germany, Japan, Pakistan, United Kingdom)
11th	2003	Y.M. Saif (EC) H. John Barnes A.M. Fadly J.R. Glisson L.R. McDougald D.E. Swayne	1,231	34	63	25 (Australia, Belgium, Canada, Denmark, France, Germany, Japan, Israel, Netherlands, Saudi Arabia, United Kingdom)
12th	2008	Y.M. Saif (EC) A.M. Fadly J.R. Glisson L.R. McDougald L.K. Nolan D.E. Swayne	1,324	33	71	25 (Australia, Belgium, Canada, Denmark, France, Germany, Japan, Israel, Mexico, Netherlands, United Kingdom)
13th	2013	D.E. Swayne (EC) J.R. Glisson L.R. McDougald V. Nair* L.K. Nolan D.L. Suarez	1420	33	72	30 (Australia, Austria, Belgium, Canada, Chinese Taipei, Denmark, France, Germany, Hungary, Italy, Japan, Mexico, The Netherlands, Sweden, United Kingdom)

EC = Editor-in-Chief

* First non-USA Associate Editor (United Kingdom)

were considerable for a book that was thought to have limited distribution, so it was decided to omit royalties and accept a subsidy for illustrations from the Dean of the College. Fifteen hundred copies were printed and placed on sale for $7.50; to everyone's surprise, a second printing of 2,500 copies was needed after less than 9 months and there was yet another printing of 2,500 copies 2 years later. Royalties were then instituted! The ISU Press was concerned that without some remuneration, the authors might be reluctant to remain "dedicated."

The inclusion of Dr. DeVries as an editor is a bit puzzling since he had no medical background; perhaps it was in recognition of his effort with the translation of the German text. In any case, he was replaced in subsequent editions by Dr. L.H. Schwarte, a member of the Veterinary Research Institute in Ames who had written 4 chapters in the 1st edition. The book was thereafter referred to by many as "Biester and Schwarte," even for a period after they were no longer associated with it. They continued at the helm through the 5th edition, published in 1965. Although Dr. Schwarte contributed several chapters in each of the first 5 editions, Dr. Biester apparently confined his efforts to editorial tasks. Their memo to the AAAP stated that they both were responsible for making the index, and they personally checked practically all of the references because they felt that they "owed to the reader accuracy." A total of 61 persons served as authors under their editorial supervision; 12 of them contributed to all five editions.

Ultimately, the passage of time dictated that Drs. Biester and Schwarte should relinquish their roles as editors and they decided that the 5th edition (1965) would be their last. As noted in the Preface to the 6th edition, it was their wish "that future editions of the book become the responsibility of the AAAP…" which had become a strong and representative organization to which many of the users of *Diseases of Poultry* belonged. Also the AAAP was already in the business of publishing the journal *Avian Diseases* and so it was considered a logical move. The AAAP appointed a committee, chaired by Dr. M. S. Hofstad who had been one of the book's authors and who was on the faculty in Ames. Drs. Biester, J.E. Williams, B.S. Pomeroy, and C.F. Helmboldt filled out the committee and, in June 1966, they recommended that the AAAP sponsor future editions of *Diseases of Poultry* which would continue to be published by ISU Press in Ames. They asked the Board of Directors to appoint an editorial committee consisting of an editorial chairman and 4 associate editors by January 1, 1967. A letter from Dr. G.H. Snoeyenbos (AAAP secretary-treasurer) to Dr. C.A. Bottorff (AAAP president) dated November 23, 1966, suggested that Dr. P.P. Levine had declined a proposal that he assume the editorship for the book. Dr. Hofstad was subsequently named editor, and he personally requested that Drs. Helmboldt, B.W. Calnek, W.M Reid, and H.W. Yoder, Jr., be invited to be the associate editors. Each was given responsibility for a group of chapters that largely represented their individual interests and strengths. An agreement between the AAAP and the ISU Press was executed on May 8, 1967, and it was agreed that manuscripts would be delivered to the publisher by September 1, 1969. So the transfer was complete and official.

The 6th edition, under totally new editorial support, underwent some significant changes. The length of the book was beginning to be of concern and there was some discussion about perhaps needing to split it into 2 volumes. To avoid this, several chapters (anatomy, nutrition, genetics, and hematology) were eliminated based on good coverage in other publications. Also, there was a consolidation of other material; for instance, all neoplastic diseases were placed in a single chapter and turkey diseases were incorporated in other chapters based on etiology. There were sweeping changes in authorship. Only 14 of the 40 contributors to the 6th edition had participated in the 5th. Clearly, a new era had arrived!

Also, following concern for the book's length, Dr. Hofstad asked that the number of listed references be reduced by *selective* citation. He agreed that the reader should find, *or be directed to*, all pertinent literature on each of the covered topics, the latter through citation of review papers, etc. Space allocated to references became an issue in subsequent editions as well. In the 7th and 8th editions, titles of all references were removed. This was controversial and not all editors agreed, including B.W. Calnek—senior author of this review—and reference titles appeared again beginning with his tenure as editor of the 9th edition. Interestingly, based on the number of pages, the 3rd edition (1,245 pages) was actually longer than the 11th (1,231 pages), but by increasing page size, decreasing type size, and splitting into 2 columns/page, it was possible to include more than twice the amount of written material in the latter.

Unlike the situation with Drs. Biester and Schwarte, citations and their accuracy became the responsibility of the individual authors. When it was observed that many errors existed, authors of the 9th edition were asked by Dr. Calnek to check every single reference against the original work to assure accuracy. This met with an enormous number of groans and considerable resistance until each author (with perhaps an exception or 2) followed this strict instruction. The subsequent turn-around in their attitude was truly amazing when nearly all of them found errors, including the citation of references that did not even exist. It was not uncommon to detect mistakes in as many as 10% of citations in some chapters, probably due in large part to a common practice of copying reference citations from other lists.

Beginning with the 9th edition, the book entered the electronic age. All material was submitted or copied into a word processing program that allowed spell-checking and reformatting. Initially, it was a tedious job, particularly because personal computers at that time were slow and the skill of the individual authors in mastering a new approach varied considerably. However, improvements in software and

computers and the possibility of rapid transfer of texts between authors, editors, and the publisher made the preparation of a new edition pleasurable compared to the old "hard-copy" approach.

There has been a continuum of changes that have improved *Diseases of Poultry* and kept it relevant over the years. For the 10th edition, the editors carefully reviewed and upgraded illustrations and for the first time included a number of color plates. Another major improvement that was gradually incorporated was the inclusion of molecular biology in many of the chapters. This was particularly important with regard to new applications of molecular techniques in diagnostic procedures, descriptions of etiological agents and significant elements of their molecular makeup, understanding the significance of selected genes in the pathogenesis of the diseases, and the development of genetically engineered vaccines. Our understanding of the fundamental nature of many diseases is now founded on the use of molecular approaches in the research laboratory.

Another of the more significant evolutionary changes was the addition of foreign authors to make the book truly international in flavor. One of the original AAAP-appointed editors argued strongly that *Diseases of Poultry* should be an "American" book, and the authorship was so aligned. The 6th edition had the first "foreign" contributor, although she (Bela Tumova, from Prague, Czechoslovakia) was actually a visiting professor at the University of Wisconsin working with B.C. Easterday on avian influenza at the time. It wasn't until the 8th edition that invitations to contribute to the book were extended to workers outside of the United States. Drs. P.M. Biggs and L.N. Payne from England and Drs. J.B. McFerran and M.S. McNulty from Northern Ireland thus paved the way by providing parts of the chapters on neoplastic diseases, adenoviruses and miscellaneous viral infections. The next edition (9th) was truly international with 17 contributors from 8 countries outside of the U.S., and by the 11th edition, there had been a total of 25 different contributors from 11 countries. The worldwide reputation the book was certainly enhanced by the selection of authors based on their knowledge and contributions to our understanding of individual diseases and conditions without regard to their geographic location.

The importance of *Diseases of Poultry* as a text for the world is also reflected in its translation into foreign languages or publication in a "copied" form in other countries. There have been several authorized translations into Spanish, Chinese, and Russian, and an agreement between the publisher and India has allowed what is essentially a photocopied version of the original to be made.

An ongoing review of the relative importance of individual diseases or conditions has led to a good deal of reshuffling over the years. Chapters have been added, combined, split, or eliminated to meet the changing picture of what is important to the field of avian diseases and disorders. Periodically, and especially with a change in authorship, major rewriting of some sections takes place. New chapters such as one dealing with new and emerging diseases appear when needed.

Beginning with the 12th edition emphasis was placed on the significance of each disease to public health considering the ever increasing interest in food safety. Emphasis was also placed on standardizing the format for all the subchapters by using the same headings thus making the book more reader friendly. In addition several non-USA residents became contributing authors.

Despite our increased understanding of disease processes there remains much to learn. Only in very few cases do we know the molecular markers of virulence, pathogenicity, or immunogenicity of pathogens and, needless to say, the molecular basis for disease resistance is a wide open field. In many cases, our understanding of disease-triggering mechanisms is poor and diseases of multiple etiologies remain problematic.

As indicated, the introduction of molecular techniques has greatly enhanced our understanding of disease but it has also created some confusion as we strive to understand the underlying genetics of important biologic characteristics of pathogens. The early euphoria from thinking that 1 gene is responsible for a given biologic characteristic is being replaced by the realization that more than 1 gene is usually involved. This makes it difficult to decipher our observations. Another point of confusion resulted from the definition of the term genotype and early attempts to relate it to serotype or protective type. Again, it became clear that such a relationship is lacking in most cases and genotyping is useful mainly for epidemiologic studies. Considering all these gaps in our knowledge, and the unprecedented speed of knowledge generation, it is understandable that we need a new edition every 5–6 years to keep our text continually updated.

Finally, the euphoria of the last century, suggesting that we will conquer infectious diseases as stated to the U.S. Congress in 1969, by then Surgeon General of the United States William H. Stewart ("We can close the books on infectious diseases…"), and our own P.P. Levine's prediction in 1973 stated earlier in this section ("Infectious diseases will decline in importance…") proved terribly wrong. Microbes are a tough and nimble foe capable of changing and adjusting to new environments mostly created by man. Thus, we think that infectious diseases will continue to be a top health priority for poultry, another reason why we continue to need new editions of this book.

Changes in editors occurred over the years so that by the 11th edition, none of the 1968 group appointed by the AAAP remained. After riding herd on 3 editions (6th–8th), Dr. Hofstad retired and was replaced by Dr. Calnek (9th and 10th) and he, in turn, passed the baton to Dr. Y.M. Saif (11th–12th), and most recently to Dr. D.E. Swayne (13th). Likewise, associate editors that have replaced or been added to the original group appointed by the AAAP in 1968 include Drs. H.J. Barnes (8th–11th), C.W. Beard (9th and 10th), L.R. McDougald (10th–13th), Y.M. Saif (10th), J.R. Glisson (11th–13th), A.M. Fadly (11th and 12th), D.E. Swayne

(11th and 12th), L.K. Nolan (12th and 13th), and D.L. Suarez and V. Nair (13th). Dr Nair is the first non-USA resident to serve on the editorial board of the book, another indication of the universal reach of the book.

In summary, it is obvious that the "Bible" in the field of avian diseases is an evolving, vibrant, and ever-current source of information relevant to all practitioners in the field of poultry medicine. It continues to be a reference source of significance to a vast number of persons with many different relationships to the poultry industry.

Bruce W. Calnek
Y.M. Saif
David E. Swayne

Introduction

This edition is appropriately dedicated to 2 colleagues who have devoted their careers to creating new knowledge and passing on existing wisdom on poultry health through successive editions of *Diseases of Poultry*: Dr. Y.M. Saif, who served as Associate Editor for the 10th edition and Editor-in-Chief for the 11th and 12th editions, and Dr. Aly Fadly, who served as an Associate Editor for the 11th and 12th editions. Both have been instrumental in maintaining the high quality of this book, and, indeed, we are highly grateful for their efforts. In addition, I am personally grateful to Dr. Saif, who has mentored me over the past quarter century as a scientist, writer, and editor, especially in the past 5 years in transitioning to Editor-in-Chief for the 13th edition of *Diseases of Poultry*. With this edition, Drs. Venugopal Nair and David L. Suarez joined the existing Associate Editors, Drs. John R. Glisson, Larry R. McDougald, and Lisa K. Nolan. We are very appreciative of their services.

This edition has a major emphasis on electronic versions with expansion of color figures and availability of 3 specific electronic formats to accommodate a variety of media from traditional computers to stand-alone electronic books to smartphones. The new generation of poultry veterinarians and scientist are living and working in the electronic age and rely upon instantaneous access to crucial information to do their jobs, and *Diseases of Poultry* will be at their fingertips or in their pockets for daily and mobile use. In addition, the widely used high quality, hard copy is also preserved as a reference text, but with fewer color plates than in the electronic formats.

This 13th edition represents a continuation of the tradition established earlier of providing the latest information on poultry diseases. Earlier trends of expansion of authorship to include authors from around the globe were continued in this edition, as was the appointment of our first non-USA Associate Editor. The Preface was updated and expanded to a more comprehensive review of the history of Diseases of Poultry, including valuable new metric data.

All of the book chapters were updated with the most current and accurate knowledge and many with new figures, especially color figures of gross lesions. Much of the historical information was removed and readers are referred to prior editions. A new subchapter on public health significance of poultry diseases was added to Principles of Disease Prevention, Diagnosis, and Control, (Chapter 1) and public health information was reduced in the individual chapters. A new subchapter on enteric parvoviruses was added to Chapter 12, Viral Enteric Infections. Major revisions were accomplished for Principles of Poultry Production, Health and Disease Control in Commercial Systems; Newcastle Disease; Avian Paramyxoviruses 2-11, and Internal Parasites. With no new cases in 2 decades, the torovirus chapter was removed and readers are referred to prior editions of *Diseases of Poultry* for such information.

Subchapters on Dermal Squamous Cell Carcinoma and Multicentric Histiocytosis were merged into the subchapter on Other Tumors. *Cochlosoma anatis* Infections was merged in with the subchapter on Miscellaneous and Sporadic Protozoal Infections. These changes were dictated by the increasing or decreasing significance of some diseases or the increasing knowledge on a given disease. Some subchapters have been moved to different chapters because of recent findings indicating that they fit within different areas.

A sincere thank you goes to the authors who contributed to the current and earlier editions of the book. It has been a wonderful experience working with all of you.

The personnel at Wiley-Blackwell that worked on this edition have been most helpful and accommodating, and we sincerely appreciate their support.

This is the first time that I served as Editor-in-Chief of *Diseases of Poultry*, and I (DES) am indebted to my colleagues, the associate editors, for their tireless efforts in the review process and their support and advice.

Finally, I would like to acknowledge special assistance provided by two students, Jessica Self and Jamie Conner, in reviewing and formatting reference lists and retyping figure legends.

Editor-in-Chief
David E. Swayne

Associate Editors
John R. Glisson
Larry R. McDougald
Venugopal Nair
Lisa K. Nolan
David L. Suarez

General Concepts of Poultry Diseases

Chapter 1	Principles of Disease Prevention, Diagnosis, and Control	3
Chapter 2	Host Factors for Disease Resistance	61

Chapter 1

Principles of Disease Prevention, Diagnosis, and Control

Introduction

Stephen R. Collett

Poultry product prices have not kept pace with rapidly escalating input costs, causing profit margins to diminish throughout the poultry industries. Producers are faced with the challenge of consistently achieving expected performance while satisfying stringent food safety and animal welfare requirements; they can no longer tolerate even the slightest deviation from expected performance.

In an effort to cost-effectively meet demand, producers have had to increase the size and throughput of their production systems. These large close confinement rearing systems, designed to improve economies of scale and maximize productivity by optimizing bird comfort, unfortunately also increase the risk of disease challenge. The physiological stress of keeping pace with genetic potential for production makes birds more vulnerable to disease challenge, and the close proximity of susceptible hosts increases the chance and rate of infectious disease spread. Diseases previously recognized as unimportant, because they have been adequately controlled, have now reemerged as significant concerns. Most of today's disease challenges are not new problems; rather, they have merely expanded their geographic distribution or reemerged primarily because of management techniques and production system design constraints.

Methods of disease control have evolved with intensification of the industry. While initially focused on diseases of catastrophic nature, attention has rapidly shifted from defined, clinical disease at the individual house or farm level to less well-defined subclinical disease and bird welfare. Similarly, cost justification in decisions on whether or not to implement prevention or control measures has become more complex, requiring the aid of formal economic appraisal.

To maximize flock efficiency, disease challenge management requires a carefully designed, multi-tiered approach, which includes consideration of elements ranging from flock health and productivity to chick or poult viability. In addition, the term "efficiency" implies the all-important economic component. Because the production system is profit driven, decisions regarding disease challenge can rarely be made based solely on biological grounds. Disease management intervention also requires sound economic justification, which begins with clearly defining the financial risk associated with disease.

Unless a disease poses a specific risk to human health or animal welfare, its mere presence in a flock may not be significant from a business perspective. It is often difficult for the veterinarian, trained in disease prevention, diagnosis, and control, to appreciate that the presence of a disease in a flock could be considered superfluous. Unless it is economically advantageous to take action against a disease challenge, its presence in a flock is tolerated. Intervention strategies are consequently chosen based on both their economic and biological efficiency. This process requires a dynamic, integrated combination of an epidemiologic and economic analysis to determine and quantify the production effect of the disease challenge as well as a proposed intervention strategy. Such integrated analysis has become far more significant in today's intensive production systems because the outcome of disease challenge is so markedly influenced by the environmental conditions.

The economic impact of disease is difficult to assess. This is particularly so in a production system in which the economic return is governed not only by flock productivity but also by product quality and viability. In addition, the consequential loss from disease challenge will be, at best, only partially recoverable. Using the cost of disease to justify intervention over-emphasizes the consequence of inaction and it is only useful in justifying intervention strategies directed at disease prevention. As the process of economic analysis has evolved, the focus has shifted from the cost of disease to the benefit derived from disease control strategies.

Diseases of Poultry, Thirteenth Edition. David E. Swayne.
© 2013 John Wiley & Sons, Inc. Published 2013 by John Wiley & Sons, Inc.

Bird performance continues to increase linearly because of efficient breeding and selection programs, but each increment in improvement is 1 step closer to the point of physiological limit and diminishing returns. Production systems need to be modified to better satisfy bird requirements, and disease prevention, diagnosis, and control strategies changed to preclude physiological, nutritional, and agent-induced pathologies from affecting performance.

Acknowledgement

The author is greatly indebted to Alex J. Bermudez for his contribution to earlier editions of this subchapter.

Principles of Disease Prevention, Diagnosis, and Control Introduction

Stephen R. Collett

Flock Health

Disease is the antithesis of health but neither state is easy to define in production animals. Health is defined in the human individual as a state of physical, mental, and spiritual well-being. It is impossible to apply this definition to an animal, and production animals have in the past been classified as healthy if they were free from clinical disease and performing to standard. Although individual animals are frequently described as healthy or diseased, these terms are not mutually exclusive. The impact of disease challenge on productivity is apparent long before clinical signs of disease appear. Production animals are expected to perform at their genetic potential, and to achieve this they need to be physically and mentally well or stress free.

Stress has been defined as a nonspecific response of the body to any demand made upon it. From a physiological point of view this can be restated as the metabolic response of the body to external factors that impact well-being (34). Stress is cumulative and only measurably impacts performance once the aggregate of each individual stress exceeds the host's coping mechanisms. An interesting study by Klasing et al. (52) has shown that the degree to which an adverse stimulus or stress will negatively impact bird performance is directly proportional to the existing stress load. Any stress will impact productivity once the stress threshold is surpassed. In a production system in which animals are expected to produce at genetic potential, the definition of health needs to be expanded to freedom from disease or stress. In this context, health is proportional to the difference between stress level and stress threshold.

Disease prevention and control strategies tend to be too focused on addressing the precipitating cause, and too little attention is given to the predisposing causes of disease. The traditional paradigm of disease has been shaped by the study of specific diseases in individual animals and tends to overemphasize the importance of the infectious agent. In intensive animal agriculture it is the influence of environmental disease determinants that decides the economic outcome of infectious agent challenge. The focus of flock health management has consequently shifted. Initially aimed at avoiding mortality because of an inadequate immune response, health management is now directed at avoiding an exaggerated or inappropriate immune response because it may depress productivity. The task of the veterinarian has shifted from the prevention, diagnosis, and control of specific disease conditions in the individual bird to preventing and limiting the consequence of more complex multifactorial disease outcomes to maximize the productivity of the flock.

Resistance and Resilience

An animal's resistance to disease can be defined as its capacity to prevent an overwhelming infection by a disease-causing organism. Disease resistance is determined by immune competence and health status at the time of challenge. Because stress negatively impacts health it also negatively impacts resistance. Ironically, the process of mounting an effective immune response is itself a source of stress because of the demands made on the immune system and the consequence of the resulting fever response. An immune response that is adequate to contain disease can be considered as the cost of health. There is a delicate balance between too little and too much because an inappropriate immune response, whether inadequate or excessive, will depress performance.

The resilience of an animal is a measure of its capacity to continue to perform while preventing a disease challenge from causing an overwhelming infection. As with resistance, resilience is negatively impacted by poor health but in this case the negative impact of the resulting stress is more significant. The chemical messengers (cytokines) released in response to a disease challenge depress production directly by influencing metabolism and indirectly by suppressing appetite and feed intake (52). While immune response is crucial to maintaining health, its consequence is depressed productivity.

The skin and respiratory, urogenital, and gastrointestinal tracts form the interface between foreign (antigenic) material and animal cells (self). To protect the bird from disease the immune system has to develop exquisite sensitivity as to whether foreign antigens are friend (nutrients or normal flora)

or foe (pathogenic). An inappropriate immune response to gastrointestinal antigens will, for example, have a negative impact on feed efficiency. The fever response induced by foreign antigens will depress feed intake, while the inflammatory response damages the gut lining, thus reducing the nutrients available for production. The capacity of an animal to fight off a disease challenge while avoiding the negative impact of the induced immune response on productivity (resilience) depends on how close the prevailing level of stress is to the bird's stress threshold. The success of any health program thus hinges on balancing immunity and health to maximize resilience. There is a dynamic interface between nutrition, immunity, and productivity. The aim of any production veterinarian should be to optimize feed utilization by modulating the immune response: enhancing the protective response to prevent clinical disease while simultaneously suppressing the acute phase or fever response.

Population Dynamics

Like human medicine, traditional veterinary medicine is focused on the study of the disease process in individuals. In modern flock medicine, where the emphasis is on prevention, diagnosis, and control of disease in finite and confined populations, the focus shifts to the epidemiology of the disease. Flock health is a rather nebulous term. Because health and disease are not mutually exclusive, individual birds within the flock will at any point in time be in various stages of health/disease (Poisson distribution). At what point is a flock diseased or healthy? Productivity gives a good estimate of an individual's state of well-being and welfare. Similarly, a flock that is performing to standard is assumed to be healthy, based on the fact that the birds act and produce as an equivalent nonstressed sibling would in a laboratory situation. This approach unfortunately takes little cognizance of the flock variance, because flock performance indicators are based on flock averages. Population variance or range is a much better indicator of flock health.

Modern population-based health management requires the complex integration of animal husbandry (housing environment), medical management (host and agent factors), and epidemiological practice (analysis of causal relationships). Modern risk management approaches facilitate the transformation of epidemiologically derived statistical data into a population health management tool. The probability of exposure to health risk factors and their expected outcomes are used first, to guide the response to a disease challenge, and second to improve the health program design/management to better respond to future potential population health challenges.

Each component of the production process can be evaluated on the basis of cost and contribution. In the past, intensive agriculture has been production driven, and contribution measured in terms of performance. In today's market-driven enterprise, value is regarded as a function of quality, yield, and cost of production with the emphasis shifting from performance to profit through the chain of realization. In this scenario the simplest strategy for improving productivity is to reduce within- and between-flock variance. By reducing variability and thus eliminating the extremes, it is possible to improve the quality, speed, and cost of production. Improved uniformity translates to improved productivity and hence profitability. Health (the difference between stress level and stress threshold) is probably the single most important determinant of flock uniformity. Within a group of animals the threshold and level of stress experienced by each individual will vary. The relative efficiency of a production manager to minimize in-house environmental variation, and therefore host-, agent-, and environment-dependent stress, is reflected in flock uniformity.

Challenges of Disease Prevention, Diagnosis, and Control in Modern Poultry Production

Because the goal of a poultry operation is to convert feed into food as economically as possible, it is critical to manage both the risk and consequence of disease challenge. While the biological efficiency of feed conversion is governed primarily by intrinsic or genetic determinants, in an intensive production system it is the extrinsic disease determinants that ultimately decide the efficiency of the operation in both biological and financial terms. Capital investment in the housing's environmental control capability, and the effective operation of these controls, is fundamental to economic success. Even subtle disease challenge such as vaccination with live respiratory disease vaccines can compromise efficiency if exacerbated by environmental disease determinants.

Viral diseases are challenging to control because there are no effective treatment options, while bacterial, protozoal, and parasitic diseases present a challenge because the treatment options are either no longer available or no longer effective. The approach to controlling diseases within these 2 categories is very different.

The molecular structure of a virus particle is relatively simple, making immunological recognition very acute and the control of known viral diseases possible through immunization. Provided the immune system has been primed by vaccination, immunological protection against viral disease challenge is usually highly successful. Emerging and reemerging viral diseases arise when novel or immunologically distinct viruses are introduced into naïve populations (48). In the absence of prior exposure, immune recognition and activation is delayed and the extent of the primary immune response is frequently inadequate to prevent clinical disease (45). Under such conditions virus replication and spread occurs rapidly with potentially devastating consequences (22). While the majority of emerging viral diseases in humans are the result of exposure to novel viruses, it is the emergence of variant strains that pose the biggest threat to the poultry industry (88). Although controlled environment housing and good biosecurity practices have been highly effective in preventing

the introduction of novel viruses, increased population density and vaccination have likely enhanced the emergence of variant strain viruses. The high population densities provide the opportunity for antigenic shift through gene recombination, while vaccination creates positive selection pressure for the variant strain viruses (79).

In contrast to viruses, bacteria and protozoa are structurally and immunologically complex, making protection through vaccination much less successful. Although a great deal of research effort is and has been focused on developing effective immunization strategies for these diseases, antibiotics have remained the primary means of control (24)—a point well illustrated by the escalating difficulties experienced in the European Union with the current systematic withdrawal of in-feed antibiotics (33). It is no coincidence that the downward trend in prophylactic (in-feed) antibiotic usage has been matched by an increase in therapeutic use (58). Many expert committees blame the use of in-feed antibiotics in food animal agriculture for the proliferation of antibiotic-resistant strains of bacteria and for the increase in prevalence of antibiotic-resistant infections in humans (47). This is undoubtedly providing the impetus to ban in-feed antibiotic use, even though a link to increased antibiotic-resistant bacterial disease in humans has not been conclusively established (29). Consumer pressure to remove antibiotics from the food animal nutritionist's arsenal is, however, winning the battle and the trend toward reemergence of previously controlled bacterial and protozoal diseases will likely continue. The industry must adapt to remain competitive.

The Principles

Disease prevention and control involves the 3 interrelated processes of bioexclusion, surveillance, and biocontainment. Disease prevention is difficult, expensive, and requires total commitment because it invariably involves eradication. Eradication programs are appropriate when the economic consequence of the disease is so devastating that it is economically advantageous to implement such drastic control measures. It is only feasible if there is an effective means of detecting infection, containing the infection through cleanout and disinfection, and preventing dissemination of the disease causing agent (75). There are 3 categories of disease for which eradication is an appropriate means of control: those that significantly threaten public health, those that have a devastating effect on bird performance, and those that severely compromise product quality. With diseases of this nature, the control effort is focused on the complete elimination of the agent from the environment (75). This places the emphasis on preventing contact between the agent and the host (bioexclusion). Early diagnosis and containment is in this case the contingency plan for failure in bioexclusion.

In contrast to eradication, control programs are aimed at limiting disease challenge to a tolerable level. There is a subtle shift in emphasis from prevention, through bioexclusion, early detection, and elimination, to reducing the consequence or economic impact of the disease, i.e. damage control. Although monitoring and surveillance are still used to gather prevalence data, the primary focus is to measure the level of protection and challenge, not the mere presence of the disease. The principles of prevention through biosecurity still apply, but in a disease control program the focus shifts to limiting the extent and consequence of exposure. In reality, many of the biosecurity measures taken to eradicate the more devastating diseases provide a solid foundation for the control of the erosive diseases, and immunization is usually used to bolster host resistance.

Methods of disease management have evolved with intensification of the industry. While initially focused on diseases of catastrophic nature, focus has rapidly shifted from defined, clinical disease at the individual house or farm level to less well-defined sub-clinical disease and bird well-being or welfare. Similarly, cost justification in decisions on whether or not to implement control measures has become more complex, requiring the aid of formal economic appraisal.

The presence of disease in a flock only becomes significant when the functional derangement of normal metabolic and homeostatic processes causes a decline in productivity that is sufficiently large to affect economic efficiency. This occurs either as a result of disease-induced anorexia or through specific effects on the physiological processes of nutrient metabolism, respiration, and excretion. Only in severe cases does disease cause mortality, and yet mortality rate is used universally as a measure of flock health status. Health and disease are not mutually exclusive, yet a flock is assumed to be healthy when it is performing to standard and is free of clinical disease. Productivity provides a much more sensitive measure of flock health, but because it is the composite output of a population it gives no indication of the variance in health status between individuals within the flock. Within-flock variance provides the most sensitive measure of flock health status but flock uniformity is still a fairly coarse measure of health status.

Disease challenge management must be considered to be an integral part of any poultry business risk management program. It involves the development and implementation of a stringent biosecurity plan which comprises a hierarchy of components directed at preventing or limiting the risk and consequence of disease. Economic analysis is a critical step in biosecurity plan design because resource allocation must match risk (10). Although it is difficult to accurately determine the precise risk and consequence of a disease challenge, it is possible to rank disease challenge according to relative risk (39). From a risk analysis point of view, emerging diseases can be considered in 2 broad categories, those that are unlikely to occur but are catastrophic in nature and those that are highly likely to occur but have less of a financial impact.

Disease prevention, tantamount to eradication, is an appropriate means of risk management for diseases that have a devastating effect on profitability through their impact on productivity or sales (75). In contrast, disease control is aimed at keeping the prevalence and economic impact of disease at a tolerable level. There is a subtle shift in emphasis from prevention through early detection and elimination to limiting the

consequence or economic impact of the disease, i.e. damage control.

No disease control or prevention/eradication program would be successful without diligent diagnostic surveillance. The objective of the data collection system is to provide incisive and epidemiologically informative indicators which will permit objective judgment and decision making. To support an eradication program, surveillance must be sufficiently intense to detect the source case of an outbreak so that biocontainment through quarantine and slaughter can be carried out before disease spread occurs. The difficulty lies in confident early detection because this requires frequently testing a large sample of the population. The heavy economic burden of such intense surveillance is difficult to carry and frequently biases risk management decisions, especially when the probability of a disease outbreak is low. Potentially devastating diseases such as high pathogenicity avian influenza (HPAI) can be effectively eradicated provided adequately robust bioexclusion, surveillance, and biocontainment programs are in place. The fact that this disease has public health connotations has helped to justify sufficient commitment to surveillance, the linchpin between bioexclusion and biocontainment.

For disease control purposes, a surveillance program is aimed at identifying when disease prevalence changes are sufficient to initiate corrective action. The difficulty is in distinguishing common cause (background variation) from special cause (a disease effect). Surveillance for the purpose of disease control, or more appropriately flock health management, remains an art. There are no specific tests that can be carried out to determine the health status of a flock, thus placing the emphasis/burden on skilful clinical assessment. Flock health monitoring systems involve a combination of clinical observation and necropsy findings. The sample size and frequency constraints of these procedures severely limit sensitivity, thus emphasizing the need for careful sample selection and attention to detail. The focus should be on identifying and eliminating subtle disease challenge because even a mildly exaggerated or inappropriate immune response will compromise performance.

In contrast to respiratory disease, where early signs of disease are outwardly apparent and relatively easy to detect, low-grade gastrointestinal disease is much more insidious. Breeding and selection for performance has down-regulated the clinical signs of intestinal disease: birds continue to eat and drink at normal levels even when gastrointestinal disease is quite advanced. Early changes in intestinal absorptive capacity, normally indicated by litter moisture changes because of compromised water balance, are often masked by litter buffering capacity and good ventilation. Similarly, accelerated cellular sloughing usually indicated by the presence of orange mucus in the feces is to a degree masked by high feed through-flow rates.

Biosecurity

In poultry production, biosecurity includes all procedures implemented to reduce the risks and consequence of introducing an infectious disease into a flock. These preventive measures, which are based on applied microbiology and epidemiology, must be practical, enforceable, and cost effective and thereby form an integral part of the production system. Because the implementation of biosecurity carries a cost, it is necessary to relate this cost to the risk and consequence of infectious disease. Unfortunately there is no way of accurately defining the relative risk and financial consequence of disease exposure or, for that matter, the effectiveness of preventive measures. Clearly, the development of a cost-effective biosecurity system must entail a calculated estimate of these parameters.

A comprehensive biosecurity program comprises a hierarchy of conceptual, structural, and operational components directed at preventing infectious disease transmission from bird to bird, house to house, site to site, complex to complex, operation to operation, region to region, company to company, or country to country.

Every event in the production process that involves movement across the house/site/farm/complex boundary creates risk of contact between an infectious organism and the host. Avoidance is the best form of prevention. Where the event is unavoidable, biosecurity measures need to be implemented to alleviate risk. This can be achieved by reducing the frequency of the transgression or the probability of the event resulting in colonization or infection.

Conceptual Biosecurity

Conceptual biosecurity is the primary level of biosecurity and involves the location of a poultry operation and its various components. Physical isolation is the most effective means of limiting disease risk and should therefore be the primary consideration in establishing a new complex or farm. This physical separation will limit the use of common vehicles and facilities, preclude visitation of personnel not directly involved with the operation, and reduce the possibility of indirect spread of disease by vermin, wild birds, or wind. Farms should not be located adjacent to a public road, especially in an area that has a high density of poultry.

Structural Biosecurity

The second level of biosecurity includes farm layout, perimeter fencing, drainage, change rooms, and housing design. Long-range planning and programming of the operation, whether large or small, is very important and should consider movement patterns of various vehicles and equipment, work traffic of regular and holiday caretakers and special work crews, feed delivery and storage, and the system for moving eggs and flocks from the farm. An avian pathologist can be helpful in avoiding some common pitfalls, but to avoid high-risk disease situations, consultation should be done when the farm is being designed and the production programmed, rather than after it is developed and serious trouble is evident.

Procedural Biosecurity

The third level of biosecurity comprises implementation and control of routine procedures intended to prevent the introduction (bioexclusion) and spread (biocontainment) of infection

within a complex or enterprise. These activities can be adjusted on short notice to respond to disease emergencies, and constant review of these procedures is necessary.

Risk

The success of a disease control program hinges on the ability to identify and then address the risk of infection. Disease risk in a flock situation is characterized by the probability of point infection and subsequent spread occurring. Aggregate risk is the sum of each individual risk of adverse health effects in an exposed population. The spread and consequence of point infection is influenced by several factors referred to as disease determinants.

Disease Determinants

An infectious disease is the result of a complex interaction between several factors. Any factor that influences the risk and consequence of disease challenge is thus a disease determinant. Disease determinants have traditionally been classified as primary or secondary; intrinsic or extrinsic; and host, agent, or environment associated. The latter best describes infectious disease in intensive poultry production units. In an intensive poultry production system the house environment, agent, and host determinants are largely under the control of the manager. The management thus becomes the most important disease determinant influencer.

Risk Assessment

Risk assessment involves determining the probability of exposure to an infectious agent, the probability of that exposure resulting in infection and spread of the disease, and the consequence of the disease outbreak.

While the chi-squared test can be used to test statistically whether a specific factor or process is a disease risk (correlated with disease), it gives no indication of the extent of the risk. The strength of association or degree of risk is determined by the ratio of association (51).

$$\text{Risk Ratio} = \frac{P_r(D \mid E)}{P_r(D \mid \overline{E})} = \frac{\text{the probability of disease given exposure}}{\text{the probability of disease given no exposure}}$$

For disease control purposes it is appropriate to evaluate each part of the production process in terms of the probability or chance of the process or event causing infection, and the frequency with which that event occurs.

Risk of infection = probability of the event causing infection × frequency of the event.

Limiting the frequency of an event that carries any form of health risk is the obvious first step in any flock health program.

Establishing the degree of risk requires further analysis. The probability of infection occurring after exposure is influenced by the resistance of the host and the challenge dose and virulence of the organism.

$$\text{Risk of infection} = \frac{\text{challenge dose} \times \text{agent virulence} \times \text{challenge frequency}}{\text{host resistance}}$$

The probability of infection occurring can thus be reduced by improving host resistance through immunization, reducing the challenge dose through cleaning and disinfection, or reducing organism virulence by medication or competitive exclusion.

Host Resistance

Bird resistance to disease challenge is primarily governed by the efficiency of its immune response. An appropriate immune response, adequate to contain infectious disease and minimize its impact on productivity, is the cost of health. An inappropriate (excessive or inadequate) immune response will depress performance unnecessarily. Inherent resistance to disease challenge varies among individuals, and baseline variance is due primarily to genetic differences and thus invariably demonstrates normal (Poisson) distribution within a flock.

Immune suppression as a result of stress, nonspecific disease challenge, or disease of the immune system will reduce both individual immunity and flock immunity. Because the impact of individual stressors is cumulative, the "poor doers" in the flock will be more adversely affected by stress or disease challenge when compared with the best birds in the flock. The distribution of resistance within stressed flocks thus becomes skewed to the right and flock immunity drops dramatically because of the presence of highly susceptible individuals within the population.

Disease Challenge (Dose × Virulence × Frequency)

The outcome of an event that causes a disease challenge is influenced by host resistance, challenge dose, and agent virulence. In this case challenge dose is the number of organisms that an individual bird is exposed to and agent virulence is the inherent capability of the agent to infect the host (infectivity) and cause disease (pathogenicity). Because the challenge dose required to cause disease in an individual varies, the infective dose 50 (ID_{50}) is traditionally used as an estimate of agent virulence. ID_{50} is the challenge dose required to infect 50% of the birds in a specific population. Although the ID_{50} helps in estimating the risk of exposure for the average bird in a flock, it is in fact the challenge dose required to infect the least resistant bird in the flock that is important when designing a flock health program. A chain is only as strong as its weakest link. Once 1 bird in a flock becomes infected or diseased, the process of agent replication increases the challenge of exposure (dose and possibly agent virulence) for other birds in the flock. The level of challenge escalates with each infection until even the most resistant birds in the flock are at risk.

Epidemiology

Epidemiology is the unbiased study of the interrelationships between the various factors (disease determinants) that affect the frequency and distribution of disease in a population. Because the prevalence and consequence of any infectious disease involves a complex interaction between several disease determinants it is critical to have a thorough understanding of

epidemiology (causal relationships between exposures and outcomes) to design an effective flock health or biosecurity program.

For flock health management purposes, each disease must be analyzed in terms of its relative risk first to determine whether it is necessary to implement control procedures and second in terms of its epidemiological characteristics to ensure optimum resource allocation. The important epidemiological characteristics for disease control purposes include:

- Source of infection. Although an infected bird is the obvious source of infection, the shedding pattern, host range, mode of transmission and farming practices will vary and ultimately determine the relative importance of a particular source.
- Transmission. While within-flock spread might be the result of direct bird-to-bird contact, indirect contact through contaminated objects (fomites) can accelerate the rate of transmission within a flock and increase the extent of transmission to other noncontact birds/flocks. This type of transmission is commonly referred to as horizontal or lateral transmission. This is in contrast to vertical transmission in which the disease agent is transmitted from parent to offspring. While vertical transmission may occur as a result of eggshell contamination, some disease-causing agents are able to reside inside the egg or embryo and spread by transovarial transmission.
- Spread. The incubation period, replication rate, resilience, and virulence of the disease agent will determine the course of the disease within an individual (acute, subacute, or chronic) and the spread of the disease within a flock (defined population). An acute disease caused by a resilient organism with a short incubation period and high replication/shed rate will, for example, spread very rapidly in a susceptible flock.
- Susceptible host. The host range of a disease agent (species, breed, type) is important in control program design. The proximity of species that are not susceptible is irrelevant to control.
- Predisposition. Several host, agent, and environmental disease determinants can enhance the detrimental outcome of exposure to a disease-causing agent. It is necessary to know the causal relationships between exposures and outcomes to design an effective flock health program. For example, any environmental stress could compromise the immune system and predispose to infection. Similarly, host factors such as breed, sex, size, and age, and agent factors such as concomitant infection with different organisms or immune suppressive disease can predispose birds to infection.
- Prevalence. The prevalence of a disease is directly proportional to the risk of challenge. Endemic diseases (those that are always present in the area under consideration) are difficult to prevent, whereas those that are exotic (do not occur in the area under consideration) or occur sporadically as an epidemic are easier to contain and eradicate through surveillance and biocontainment.
- Morbidity. Morbidity describes the number of birds in a flock that show clinical signs of disease at a point in time (specific) or at the peak of the epidemiological curve (general) and is usually expressed as a percentage. The morbidity rate will be high in rapidly spreading diseases and low in diseases that spread slowly.
- Mortality. The percentage of birds, in a finite population, that are expected to die during a particular disease outbreak.
- Recovery. The course of a disease is influenced by a multitude of factors (disease determinants). Epidemiological statistics on the expected outcome of a disease outbreak aid in determining the best course of action for limiting the current and future financial risk of that particular disease.

Disease Prevention: Bioexclusion

Preventing or reducing disease challenge requires a systematic approach to eliminating or decreasing the number of disease-causing organisms within the bird's environment. This is achieved through the implementation of cost-effective procedures to prevent pathogen movement across physical or imaginary barriers demarcating protection zones around the bird. The establishment of zone boundaries should be based on sound epidemiological principles while making use of existing physical and geographical barriers.

Global Perspective: Top Down

The poultry industry has become a global industry. Poultry and poultry products are shipped internationally on a daily basis. Whereas the World Trade Organization (WTO) is focused on ensuring free trade, the World Organization for Animal Health is the guardian of flock health. It is important to understand the workings of this organization because it pertains to disease prevention, diagnosis, and control. In order to trade internationally in poultry and poultry products, control measures implemented at the farm level must ultimately comply with the organization's stipulated requirements.

The World Organization for Animal Health is an intergovernmental organization responsible for improving animal health worldwide. This organization was initially called the Office International des Epizooties (OIE). Despite the name change in 2003 the OIE acronym remains in use. It is recognized as a reference organization by the WTO and currently represents 178 member countries, including the United States. It is led by the World Assembly of Delegates, consisting of representatives from each member country.

The reader is referred to the official OIE Website for details of the rules and regulations as laid out in the OIE Terrestrial Animal Health Code (Terrestrial Code). In summary the objectives of the OIE are to: (1) ensure transparency in the global animal disease situation by reporting detected disease, (2) collect, analyze, and disseminate veterinary scientific information on animal disease control, (3) encourage international solidarity in the control of animal diseases by providing technical support to member countries requesting assistance with animal disease control and eradication operations, including diseases transmissible to humans, (4) safeguard

world trade by publishing health standards for international trade in animals and animal products that member countries can use to protect themselves from the introduction of diseases and pathogens, without setting up unjustified sanitary barriers, (5) improve the legal framework and resources of national veterinary services, and (6) provide a better guarantee of food of animal origin and promote animal welfare through a science-based approach. The OIE works in conjunction with the Codex Alimentarius Commission to improve the safety of food of animal origin and is viewed as the leading international organization for animal welfare.

Country Perspective: Responsible Trade Through Risk Reduction and Disease Containment

The movement of animals or animal products across country borders carries a risk of disease spread. The OIE plays an important role in establishing the Agreement on the Application of Sanitary and Phytosanitary Measures (SPS Agreement) worldwide. This agreement of the WTO provides definitions and describes the OIE in-house procedure for settlement of disputes. It also provides guidelines and principles for conducting transparent, objective, and defensible risk analyses for international trade. The principal aim of import risk analysis is to provide importing countries with an objective and defensible method of assessing the disease risks associated with the importation of animals, animal products, animal genetic material, feedstuffs, biological products, and pathological material.

Risk analysis involves identification and estimation of the risk and may be qualitative or quantitative. Qualitative assessment is usually adequate in the case of OIE-listed diseases because the risk is well recognized and there are well developed internationally agreed-upon standards.

OIE-Listed Diseases

Diseases are included on the OIE list based on international prevalence and capacity for spread, resultant morbidity and mortality, zoonotic potential, and emergent properties. The details of the criteria and decision process are outlined in Chapter 2.1.1 in the Terrestrial Animal Health Code (5). The following avian diseases are included in the OIE list (7): avian chlamydiosis, avian infectious bronchitis, avian infectious laryngotracheitis, avian mycoplasmosis (*Mycoplasma gallisepticum*), avian mycoplasmosis (*M. synoviae*), duck virus hepatitis, 7Eastern equine encephalomyelitis, Fowl cholera, Fowl typhoid, highly pathogenic avian influenza and low pathogenic avian influenza in poultry as per Chapter 10.4. of the Terrestrial Animal Health Code, infectious bursal disease (Gumboro disease), Marek's disease, Newcastle disease (ND), pullorum disease, Q fever, tularemia, turkey rhinotracheitis, and West Nile fever.

Region or State Perspective: Zoning and Compartmentalization

The Terrestrial Code makes allowances for zoning and compartmentalization to address the difficulties in controlling the disease status and management practices of poultry flocks across the vast expanse of large countries like the United States (8). By defining subpopulations based on flock health status, member countries are able to limit the damaging effect of a listed disease outbreak on international trade without exposing the importing country to the risk of disease spread. Compartmentalization applies to a subpopulation separated by biosecurity procedures, while zoning applies to a subpopulation separated on a geographical basis. The details of the requirements to establish these subpopulations vary according to the disease in question and the requirements of the trading partners. These details are ideally decided on prior to the disease outbreak. Of particular interest are the epidemiology of the disease, environmental factors, applicable biosecurity measures (including movement controls, use of natural and artificial boundaries, commercial management, and husbandry practices), and surveillance and monitoring. To establish a zone or compartment within its territory for international trade purposes, the veterinary services of an exporting country should clearly define the subpopulation as stipulated in the Terrestrial Code. These claims must be communicated to the veterinary services of an importing country and supported by detailed documentation published through official channels.

Because the borders of a zone are based on natural, artificial, or legal boundaries, they can be established relatively easily and made public by the veterinary services through official channels. Compartments are a little more difficult to define in that they must be established based on biosecurity procedures. This involves developing a partnership between the company and the veterinary authority to develop clearly stipulated responsibilities. To meet the requirements for a compartment, the biosecurity plan, operating procedures, and management practices must be adequate and documented and evidence of compliance documented.

The plan must adequately demonstrate robust disease surveillance, animal identification, and traceability. This requires that detailed records are kept on bird movement, flock production, feed source, disease surveillance results, chick source, visitor's log, flock morbidity and mortality, vaccination and medication, and personnel training. Risk mitigation also requires that the biosecurity plan is regularly audited, reviewed, and adjusted when necessary.

Company Perspective: Bottom Up

From a biosecurity perspective a company operates as a compartment within the country, state, or region. In order to trade internationally, companies must at the very least comply with international standards and in so doing meet the OIE requirements for biosecurity. Compartment, as defined by the Terrestrial Code, means an animal subpopulation contained in 1 or more establishment under a common biosecurity management system with a distinct health status with respect to a specific disease or specific diseases for which required surveillance, control, and biosecurity measures have been applied for the purpose of international trade (8). The implication of this is that in order to trade internationally each company, region, state, or country should classify OIE-listed diseases according

to expected prevalence to design, document, and implement a biosecurity plan to prevent or control these diseases through bioexclusion, surveillance, and biocontainment and provide proof of compliance with this plan. For this purpose the biosecurity plan should identify potential pathways for the introduction and spread of disease within the company, and describe the measures which are being or will be applied to mitigate the disease risk in accordance with the recommendations in the OIE Terrestrial Code. This biosecurity plan should form the foundation for the prevention, diagnosis, and control strategy for all diseases.

Disease Status: Classification of Diseases for Biosecurity Purposes

The allocation of resources to the prevention of diseases that have a major biological and financial impact is relatively easy. First, the control measures are the cost of doing business; freedom from the disease in question is a prerequisite to doing business. Second, through eradication the cost of the disease is usually totally recoverable. In contrast, designing a disease control strategy for diseases that are likely to occur with a high degree of certainty but have less of a financial impact is much more difficult (39). The process begins by clearly defining the estimated cost that the disease presence may incur and the potential benefits that the options for control may provide. Unfortunately there are several unknowns in health-related matters, and it is consequently impossible to perform a detailed and accurate cost/benefit analysis to ensure optimum resource allocation. Instead, partial farm budgeting is commonly used to compare the economic efficiencies of the various control options, including nonaction. In such instances immunization and its related biological and financial impact is the cost of health. One of the more difficult but important factors to quantify is the degree of productivity recovery that the control option provides because disease losses are in this case seldom if ever totally recoverable.

For biosecurity purposes, diseases should initially be grouped into those that are exotic and those that are enzootic to the region because this helps to optimize resource allocation to biosecurity. In the case of foreign diseases, the emphasis is on reducing the risk of disease through prevention and eradication. In the case of endemic diseases, the emphasis is on limiting the consequence of the disease.

The success of an eradication program hinges on good biosecurity and early detection of disease through the collection, analysis, and interpretation of data from the population under consideration. The design of these biosecurity and disease surveillance programs must be guided by the epidemiological characteristics of the disease causing-agent and its interaction with the host and environmental disease determinants. In the United States the following diseases are usually prevented by eradication:

- Bacterial diseases: pullorum disease (*Salmonella enterica* serovar Pullorum), fowl typhoid (*Salmonella enterica* serovar Gallinarum), *salmonellosis* (*Salmonella enterica* serovar Enteritidis and *Salmonella enterica* serovar Typhimurium), avian mycoplasmosis (*Mycoplasma gallisepticum*, *Mycoplasma* synoviae, *Mycoplasma* meleagridis, and *Mycoplasma* iowa), avian chlamydiosis (*Chlamydia psittisae*), and avian tuberculosis (*Mycobacterium avium*).
- Viral diseases: high pathogenicity avian influenza (HPAI), low pathogenicity avian influenza (LPAI) of H5 and H7 types, velogenic viscerotropic Newcastle disease (vvND), west Nile fever, duck virus hepatitis, duck virus enteritis, eastern equine encephalomyelitis, tularemia. and Q fever.

Disease challenge reduction requires a systematic approach to decreasing the number of disease-causing organisms within the bird's environment through the implementation of cost-effective procedures to prevent pathogen movement across physical or imaginary barriers demarcating protection zones around the bird. The establishment of zone boundaries should be based on sound epidemiological principles while making use of existing physical and geographical barriers. Biosecurity program design thus begins with the identification of critical control points or epidemiological unit boundaries at which bioexclusion practices can be implemented. For the purposes of disease control an epidemiological unit is a group of birds with a defined epidemiological relationship that shares approximately the same likelihood of exposure to a pathogen.

Primary Control Zone: Poultry House and Hatchery

Bioexclusion begins at the boundary of the smallest epidemiological unit within the company, in this instance the poultry house. The birds in the house form an epidemiological unit because they share a common environment and common management practices and have approximately the same likelihood of exposure to a pathogen. In addition the roof and walls of the house provide a well-defined barrier to entry and an ideal site for the implementation of critical control procedures. From a biosecurity standpoint every crossing of the house perimeter (event) should be considered as a potential means of pathogen transfer or disease risk.

$$\textit{Risk} \text{ of infection} = \textit{probability} \text{ of the event causing infection} \times \textit{frequency} \text{ of the event}$$

The process of risk reduction begins with an all-in-all-out placement strategy, so that decontamination of the house environment by thorough physical cleaning followed by chemical disinfection and/or "down time" is possible between successive placements. After placement the emphasis shifts first to limiting the frequency of any house perimeter crossing (event) and second to reducing the probability of pathogen transmission and infection if the event is unavoidable or essential.

The Poultry House

Management of the House Environment in Disease Prevention. While it is important to keep disease out, it is equally important to prevent the house environmental conditions from

causing discomfort or stress. Traditional thinking, stimulated by widespread acceptance of Koch's Postulates in the 1900s, over emphasizes the importance of infectious agents in the disease process. As production systems have evolved, environmental and host disease determinants have played a more obvious role in the disease process, emphasizing the multifactorial nature of disease. The prevalence of specific infectious disease entities has declined as knowledge and control measures have improved. In contrast, the predisposition to and prevalence of noninfectious disease has increased with intensification and genetic change. The distinction between infectious and noninfectious disease has become somewhat blurred in intensive agriculture, and a more fully encompassing epidemiological approach to disease diagnosis and control has become necessary.

The poultry house environment, with all its intricacies, is a crucial disease determinant because stress of any kind stimulates a cascade of physiological and biochemical changes which erodes host resistance and productivity (74). The negative impact that a particular stressor has on performance is directly proportional to the existing stress load, because stress is cumulative and measurably impacts animal performance once the aggregate of individual stresses exceeds coping mechanism capacity (52). Stress level, and hence competence to cope with additional stress, varies with each individual within a flock, thus emphasizing the need to consider the epidemiology of disease within a confined, finite population. Stress lowers the minimum dose of infective agent required for development of infection and increases the risk of infectious or noninfectious challenge developing into clinically detectable disease. The risk and consequence of infectious disease spread within the population is increased by the presence of stress, because susceptible individuals act as amplifiers for the infectious organisms, and thus increase the challenge dose to which the pen mates are exposed. While the introduction of a noninfectious disease to a flock may also lower individual resistance, there is no risk of spread (75). The influence of the house environment on viral disease of poultry has been reviewed by Anderson and Hanson (2).

Turnaround Time and Down Time. Turn-around time is the time lapse from the start of depletion/transfer to the start of subsequent placement. Down time, which is of greater significance, is the time between the removal of all poultry, poultry by-products, and litter to the start of the next placement. The process of bioexclusion is pointless if the production system does not start off disease or specific pathogen free (SPF). The risk of pathogen carry-over from one production cycle to the next is directly linked to the time interval between the removal of 1 flock and the subsequent placement of the next. Pathogen attrition occurs with time and the chance of pathogen carry-over from one grow-out cycle to the next is reduced by extending down time. The longer the bird-free period, the greater the reduction in disease challenge. In a low-challenge situation or if prevailing conditions preclude the removal of litter from the house, an extended turn-around time can be used to substitute for cleanout and disinfection.

In the United States, true cleanout and decontamination is seldom practiced at broiler level and extended turn-around times (minimum of 14 days) are commonplace. Decontamination of the house through cleanout and disinfection hastens the attrition rate of pathogens within the house environment and therefore serves to reduce the need for long down time. While the process of cleanout and disinfection carries a cost, it reduces turn-around time and hence improves return on investment. The decision as to whether to implement a cleanout and disinfection program or to reuse litter is complex and should involve a detailed analysis of the fixed vs. variable cost benefit, the level of disease challenge, the nature of the prevailing diseases, the type of housing, stocking densities, etc.

Decontamination: Cleanout and Disinfection. Cleanout is designed to reduce the risk of disease through the physical removal of all poultry, poultry by-product and litter, and the sequential washing, disinfection and possibly fumigation of all the houses. The relative importance of this process increases as the length of turn-around time diminishes. Decontamination is a sequential process which requires careful planning, execution, and control. As outlined in Chapter 5 of the American Association of Avian Pathologists (AAAP) publication *A Practical Guide for Managing Risk in Poultry Production*, decontamination involves 5 steps: removal of debris, detergent application, washing with water, drying, and disinfecting (60).

After depopulation, the litter or droppings should be removed. Once the bulk of the litter has been removed as much of the remaining solid material as possible should be brushed out of the house before the washing process begins. With development of huge specialized poultry farms, proper and economical disposal of litter and poultry manure has become a serious problem. There is no clear-cut answer. A general recommendation is to remove it far enough from the buildings so that insects will not crawl or fly back into the houses, and to dry it, compost it, or spread it onto fields and work it into the soil. If cleaning is done while chickens are still present (cages), remember that contracted personnel, trucks, and equipment may recently have been on another farm where a disease outbreak occurred.

In some cases, the nature of a pathogen may dictate that some extra precautions (wetting down or soaking with disinfectant, delaying removal, burying, burning) be taken with litter, even though they may be expensive. Any treatment of manure or litter must consider residual effects of the applied compounds on plant life when treated manure is spread on the land. For most disease agents, composting of litter or droppings is sufficient. Whatever method is used, it is important to remember that wherever litter is spilled or piled, it remains as a pathogen reservoir for varying lengths of time.

In the case of outside runs such as turkey and game bird ranges, the topsoil should be scraped off and hauled some distance from the site. Sunlight and soil activity combine over a long period to destroy most pathogens. Anything that can be

done to aid the destruction process is helpful. Removal of organic residues, such as leaf beds and manure accumulations, helps to reduce the danger for future broods. It is best to rotate the ranges or dirt yards so that they stand idle for 1 complete flock cycle.

Washing begins with blow-down, a process by which water (preferably hot) and detergent sprayed through high-pressure nozzles is used to wet the surfaces and remove most of the dirt and dust from the house. This is followed by cleaning with water (preferably hot) sprayed at high pressure to remove residual dust and dirt. The detergent helps to dissolve the organic biofilm and aids the cleaning process. If washing is not possible, dry cleaning must be thorough and include scraping and sweeping or vacuuming surfaces, corners, ledges, nests, and feeders.

Once the house is physically clean and free of organic matter the process of disinfection can begin. Disinfection involves the application of correctly diluted disinfectant to all internal surface of the house by low-pressure spray (preferably as foam to increase contact time). The concentration and volume of chemical applications must be correct to ensure adequate success. Dry cleaning will significantly compromise the disinfection process. The amount of disinfectant used on dry-cleaned surfaces must be increased over that required for washed surfaces.

Disinfectants. Many effective disinfectants are sold under variety of trade names; follow the manufacturers' recommendations. A disinfectant is a physical agent or chemical agent that destroys vegetative forms of harmful microorganisms, usually on inanimate objects but sometimes on the animals (4).

In the United States, disinfectants are regulated by the Environmental Protection Agency (EPA) under the Federal Insecticide, Fungicide, and Rodenticide Act (FIFRA); Title 40 of the Code of Federal Regulations (CFR). Individual states also have regulations which may be stricter than the federal regulation. The Worker Protection Standards (WPS) are a specific portion of FIFRA (Title 40 CFR Part 170) which requires the protection of employees from agricultural pesticides (including disinfectants). Supervisors of individuals who will apply disinfectants must read the label on the disinfectant closely and look specifically for references to the Worker Protection Standards. If the labeling refers to WPS, compliance is mandatory. Copies of *WPS How to Comply* may be obtained from local cooperative Extension offices.

Complete discussions of various disinfectants and sterilization methods should be consulted (4, 16, 49, 60). Additional references on disinfectants and their use (28, 50) and textbooks on pharmacology and therapeutics should be consulted. The virucidal activities of several commercial disinfectants against vvND have been determined. A list of commercial disinfectants approved for use against avian influenza virus is available from the Environmental Protection Agency (USA) (49). The list provides product names, basic formulations, and dilutions along with the names, addresses, and telephone numbers of appropriate distributors or formulators. For a detailed review of disinfection or to order the Scientific Technical Review, volumes 14(1) and 14(2), 1995, see the OIE website (http://www.oie.int/en/publications-and-documentation/scientific-and-technical-review-free-access/list-of-issues/).

After disinfecting the house, all subsequent processes and movement should be controlled to prevent recontamination. This requires that clean and dirty areas are clearly demarcated. Stringent sanitary practices are frequently ineffective because the pathogen in tracked in after the buildings and equipment are cleaned and disinfected, or because some step in the total program was omitted.

Feed bins should he emptied and cleaned between grow-out/production cycles and special care must be taken to ensure that the inside is totally dry before new feed is delivered.

Water lines should be drained, cleaned, and disinfected. It is important to strip the lines of biofilm before disinfecting the system. The water line biofilm is composed of both a minera1 and organic component so the cleaning process entails dissolution of the mineral component (acid or alkali) and destruction of the organic fraction (oxidation and disinfection) (57, 84).

Built-Up Litter and Uncleaned Buildings. Commercial producers require that chicks and poults are delivered disease free. To maintain this status, it is preferable to place these healthy, new flocks in cleaned and disinfected buildings with fresh, clean litter. This is an expensive and time-consuming task. Litter material is becoming scarce and litter disposal requires detailed nutrient management program compliance. Rearing of several successive flocks on the same (built-up) litter has become an economically acceptable practice with broilers, where the life span is very short and single ages of birds/farm permit complete depopulation at the end of each brood. Cleaning and disinfecting of houses is in such instances reserved for disease outbreak control.

Whereas young poults are usually placed in cleaned and disinfected buildings with fresh, clean litter, the litter in turkey grow-out buildings is frequently used for several successive flocks. Rearing of meat birds on reused litter has become commonplace with the development and use of litter-processing machinery. This equipment is used after flock depletion to break up or remove caked litter to ensure that a deep friable and absorbent layer of bedding material remains for the next brood. This practice of reusing litter will unfortunately result in the accumulation of microbial pathogens and parasites within the litter and is strongly discouraged in egg-producing operations.

Culling. Culls are birds that are removed from the flock for humane reasons because they are injured, diseased, or poor performers. The practice of using hospital pens to separate sick birds from the main flock should be discouraged because they act as a source of infection for the rest of the flock. Instead, birds that are injured, diseased, or dying should be

humanely destroyed and removed from the chicken house as soon as possible to avoid unnecessary suffering and disease spread. Such culling must be done judiciously, performed in a humane manner, and started from placement.

Mortality. Any dead bird which is left in the poultry house poses a serious threat to the flock health. The carcass undergoes decomposition with the production of millions of decomposition bacteria and potentially pathogenic organism within the carcass. These are released when the carcass breaks. Occasionally toxins may be formed in the carcass and cause problems for the flock. Dead birds should be removed daily and categorized/house according to the likely cause of death. If daily mortality is abnormally high (greater than 1/1,000 in broilers and greater than 0.3/1,000 in breeders), further investigation is indicated.

Nest and Egg Hygiene. The most important consideration in hatching egg sanitation is to manage the flock so that eggs are clean when gathered. It is crucial to keep the litter dry to prevent soiling of nests, nest material, and eggs. Table-egg breeding stock is traditionally raised on slatted or sloping wire-floor houses which greatly reduces the number of dirty eggs. Broiler and turkeys breeders do not perform as well on these floors, so combinations of part slat and part litter are used to aid in litter management.

Automatic nest boxes are, generally speaking, more biosecure than manual collection nest boxes. The plastic mats lining the automatic nest boxes are less likely to cause egg contamination and the eggs spend much less time in the nest box. It is essential to keep the nest box environment as clean as practically possible. Dirty or contaminated nest boxes can result in egg contamination, vertical transmission of disease agents, and infection of the hen's oviduct. The shell of an egg laid by a healthy breeder hen is warm, moist, and clean when it first makes contact with the nest box shavings. Debris will adhere to the moist surface and as the egg cools, particles that are small enough, such as microorganisms, may be drawn in through the pores before the cuticle has had time to dry. During oviposition there is a tendency for the distal section of the reproductive tract to prolapse. In many instances this delicate moist tissue actually makes contact with the nesting material and is therefore very easily contaminated. Microorganism contamination of the nest box can thus be the cause of infectious reproductive disorders and peritonitis.

It is essential that the nest boxes are thoroughly cleaned of all organic material, and disinfected during terminal disinfection of the laying houses. If wood shavings are used as nesting material, there should be a very low proportion of sawdust and the shavings must be dry and free of contaminants including fungus and preferably even fungal spores. Ideally the shavings should be fumigated with formalin prior to use to ensure there are no live microorganisms present. The nesting material should be "topped up" with clean material every 2 weeks to keep it filled to a depth of 5–10 cm and ideally replaced (and the nest box disinfected) monthly. Any extraneous material (i.e., broken eggs, fecal material, etc.) should be removed from the nest box as soon as possible.

From a biosecurity point of view, the house environment is classified as a dirty area and the eggs need to be removed from this environment as soon as possible. If manual collection is practiced, eggs need to be collected as frequently as possible—at least 4 times a day. Each egg collection must be a complete process so that each nest box is emptied. The operator's hands need to be washed before commencing with egg collection and every effort must be made to keep hands clean during collection to prevent contamination of the eggs. Every effort must be made to ensure that the hatching eggs do not get wet. Eggs and egg trays must be dry cleaned (compressed air) prior to fumigation to remove all the dust and debris that has accumulated during collection.

Very dirty eggs and floor eggs must not be used as hatching eggs. They should be collected separately and must not be placed on the egg trays that are used for collection of clean nest eggs. It is important that the floor eggs are stored away from the nest eggs to avoid cross contamination.

The eggs need to be sanitized or fumigated within 2 hours of being laid (i.e., immediately after collection) to derive maximum benefit from any disinfection procedure. Effective formalin fumigation of hatching eggs is a proven method of reducing eggshell contamination with the vegetative and spore forms of bacteria and fungi. While formalin fumigation has been the backbone of most egg hygiene programs in the past, the classification of formalin in 2004 as a known human carcinogen by the International Agency for Research on Cancer has made its use much more arduous. Stringent health and safety regulations apply even in the United States, where the EPA has classified formalin as a probable human carcinogen (6, 28).

After fumigation the eggs should be transferred to the egg store room. Control of temperature and relative humidity during storage is critical to the survival of the embryo. Temperature and relative humidity fluctuation during storage reduce embryo viability and cause condensation and wetting of the shell surface (sweating). This increases the chance of egg contamination and vertical transmission of bacteria and fungi. The egg storage room should be maintained at a constant 13°C–16°C with a relative humidity 75%. Movement of eggs in and out of the store room should be done as quickly as possible to avoid excessive fluctuation in temperature and humidity. Dirty/floor eggs should be stored separate from clean nest eggs. Care during delivery and collection of eggs is essential to avoid cross contamination.

Egg washing is routine practice in the commercial egg industry. These table eggs are washed with warm (43°C–51.8°C) detergent solution and then sanitized with a chlorine compound, quaternary ammonia product, or other sanitizing agent. It is critical that the washing water is at least 16.6°C higher than the egg itself but not higher than 54°C. While this procedure is often employed successfully with turkey hatching eggs, it is seldom used in the broiler

industry. If hatching egg washing is attempted, a brush conveyer machine that uses continuous-flow water is preferable, and very careful supervision and meticulous management is essential to avoid contaminating rather than sanitizing the eggs. It is also important to consider water quality. If, for example, the iron content of the wash water exceeds 5 ppm, a serious egg spoilage problem is likely. A complete review of egg sanitizing agents is presented by McKenzie(60) and Scott (72).

Feed and Drinking Water. The potential for feed- or waterborne challenge occurs every time the birds eat or drink, so the frequency of challenge is very high. This means that even a low level of contamination poses a high risk for introduction or spread of disease. Contamination of feed with fecal pellets from rats, mice, and other rodents is particularly worrying. First, they are likely carriers of dangerous pathogens such as *Salmonella* species. Second, the fecal pellet provides a concentrated source of pathogens in a package that birds are highly likely to selectively pick out and consume.

Litter scratched into feed and water troughs and feed spilled into litter increases intake of litter and litter-borne disease agents (e.g., more coccidial oocysts and less coccidiostat are ingested, and a clinical infection may result). If poultry are permitted to consume litter, considerable mortality and depression can occur from impaction of the ventriculus (gizzard), and litter fragments may cause enteritis by mechanical irritation.

Feed troughs should have some type of guard to keep poultry out and should not be overfilled so that feed is spilled into the litter. Feeders without guards permit defecation into feed, which encourages spread of diseases shed in feces. Wet feed in litter provides a good medium for growth of molds, which can cause liver, kidney, immune system, and other damage to the well-being of poultry. Growing and laying cages for egg production flocks in light- and temperature-controlled houses eliminate most of the problems associated with litter. Many good automated feeding and watering systems are available commercially, but sometimes these are not installed or oriented as the manufacturer intended, and consequently health problems develop.

Roost areas over screened dropping pits are common in floor-laying and breeder hen houses to keep chickens away from their feces. Screened roost areas are also desirable in rearing houses for layers and breeders to prevent piling by the birds and excessive fouling of litter with feces, which in turn leads to packing and caking. Feeders and drinkers over the pits keep the birds on the roost area much of the daytime as well as at night, so most droppings collect out of reach. Spilled water also falls under the roosts, so the litter area stays drier.

Drinkers are frequently set or hung over the litter area. In this case, drinkers should be managed so that spillage onto the litter is minimized.

Drinkers can be put into 2 basic categories: those that provide a constant reservoir of water, which is maintained automatically (troughs, cups, and hanging plastic bells), and nipple drinkers (Figure 1.1), which supply water on demand when activated by a bird. Drinkers that provide an open reservoir of water must be cleaned and disinfected regularly to prevent the buildup of potentially pathogenic organisms in the water supply. These drinkers are also more prone to spillage and the associated problems of wet litter. Starting day-old birds is somewhat easier with drinkers that have an open and visible water reservoir. The advantages of nipple drinkers are found in the significant improvement they offer in providing water free of organisms commonly found in the poultry house environment and in decreased water spillage.



Figure 1.1. Nipple drinkers are effective in preventing microbiological contamination of clean water and help maintain dry litter conditions.

Feed and Water Medication. Facilities for quick treatment by medication in water or feed should be provided in case birds become sick. When thousands of birds are grouped in 1 pen, segregation and treatment of individuals is impractical so mass medication is essential.

Feed medication is not the best method of treatment because sick birds have little or no appetite and are unable to compete for feed. Water medication is better because the sick will still frequently drink. Mass medication, while not completely successful in curing the sick, may hold the disease in check until the host can respond with a successful immune response. Provision should also be made for mass vaccination through drinking water, because this is an accepted and successful labor-saving practice. If drinking water is chlorinated or otherwise treated, the sanitizing agent may destroy the vaccine, so provision must be made to permit the use of untreated or distilled water for mixing and administering water vaccines.

Several methods can be used to reduce, remove, or neutralize chlorine in chlorinated water supplies. The only practical method for dealing with this problem on poultry farms is to

add protein to the water when mixing water vaccines. A common practice is to add 1 cup of nonfat dried milk to 50 gallons of water in tanks or canned liquid nonfat milk mixed with vaccine in a proportioner.

If a building is constructed with a bulk water tank for gravity-flow watering devices, the tank should be plastic or lined with a nonreactive protective substance and be readily accessible for cleaning and for mixing medicaments. If the watering devices are operated on high pressure, the pipe leading into the pen should have a bypass system with proper valve arrangement so that a medicament proportioner can be installed quickly when needed. A metering device to measure feed and water consumption is useful to keep track of the health of the flock.

Bulk feed delivery, metal bulk storage tanks, and automatic feeders are common in modern poultry operations. They eliminate the possibility of rodent contamination because feed is always in closed tanks rather than in bags or open bins, but the system leads to difficulties when short-term emergency medication in feed is desirable and the bulk tank is full. Two alternative systems are useful: an additional smaller bulk tank may be installed just for emergency medicated feed, or a small dispensing tank may be interposed between the bulk tank and feed troughs so that emergency medicated feed can be put in the smaller tank by hand.

House Access: People. People, especially visitors, pose the greatest biosecurity risk to any poultry operation. Their mobility, duties, curiosity, ignorance, indifference, carelessness, or total concentration on current profit margin make them one of the most likely causes of disease spread. Rarely is this because they become infected and shed the pathogen, but rather because they track in infectious agents, use contaminated equipment, or manage their flocks in such a way that spread of disease is inevitable. At least 1 avian pathogen (i.e., Newcastle disease virus; NDV) has been found to survive for several days on the mucous membrane of the human respiratory tract and has been isolated from sputum (83). It is a sound principle of disease prevention that no employee of a commercial unit should have any contact with non-company poultry, pet, or hobby birds, at home or elsewhere. The backyard flock maintained without regard for disease control can perpetuate a disease that constitutes a threat to a large, productive industry. The greatest hazard to commercial producers that is created by fancy breeds and backyard flocks is the possible perpetuation of diseases that have been eradicated from the industry.

Disease outbreaks in a community have been known to follow the path of a careless visitor. If visitors do not enter premises or buildings, they cannot track in pathogens. The easiest and most effective means of reducing this risk is to reduce the frequency of visits to those that are essential. When it is necessary to enter the house steps must be taken to reduce the probability of inadvertently transporting infectious agents into the house. As an absolute minimum any person entering the house should don coveralls, a hair net, gloves, and boot covers to reduce the risk of pathogen transfer. While it is not practical to change protective clothing between houses on the same farm, special attention must be given to hands and feet because they are the most likely means of infectious agent transfer.

When moving from one house to another it is best to change boot covers or use house-dedicated footwear. Foot baths might work well when the boots or boot covers are clean and the disinfectant is clean and at the correct concentration. However, foot baths are notoriously difficult to manage and frequently end up enhancing disease transmission rather than preventing it. When using house-dedicated footwear it is best to set up a step-over partition barrier just inside the entrance to the house. It is thus possible to maintain a clear barrier between clean and dirty by stepping over the partition barrier into a new pair of shoe covers or into a house-dedicated pair of boots on entering the house and stepping out of them on exiting the house.

Bird contact is invariably made with the hands so it is essential to pay close attention to hand hygiene. Using disposable latex or nitile gloves is the best option, but hand washing and disinfection between houses is acceptable. It is preferable to have hand wash basins with running water and soap/liquid soap next to each entrance/exit. Where this is not possible there should at the very least be a hand sanitizer dispenser appropriately placed for use on entrance and exit.

Personnel that frequently visit many different types of poultry enterprises, farms, and farm units such as veterinarians, managers, supervisors, and company owners are high risk for disease transfer. Apart from needing to set an example they must to be meticulous in following procedural biosecurity practices to prevent spreading disease-causing agents. Procedural biosecurity is as much a culture as it is a discipline.

The source of a new or dreaded disease is often puzzling. World trade and travel are becoming more commonplace. It is not uncommon for a person to leave one farm in the morning and be visiting another farm or place of business in another part of the country or another continent on the same day. Some disease agents can survive that time frame easily. All who travel should be cognizant of this and guard against introduction of pathogens into their own flocks or onto the premises of clients, competitors, friends, or fellow producers when returning from a trip. Protective footwear and clothing are not readily available in all countries and poultry areas. A good preventive measure when returning from a trip is to sanitize shoes and launder all clothing worn on farms.

Many poultry farm procedures require sporadic use of specialized crews (e.g., blood testing, beak trimming, vaccinating, inseminating, sexing, weighing, and moving birds from one location to another). These crews travel about the poultry community handling many flocks and must be regarded as a potential source of infection. Thus, they should take stringent precautions to safeguard the health of every flock with which they work.

House Access: Animals. No animals should be allowed into the poultry house. All openings in the outer structure of the house must be sealed to exclude animal entry into the house.

Dogs and cats, like rodents, are capable of harboring enteric organisms that are infectious to poultry. When these pets are not confined to the household area, but roam continually among the poultry in the pens and yards, they constitute a serious health hazard. Such pets are just as capable of tracking contaminated material on their feet and in their hair as people.

Wild birds are capable of carrying a variety of microbial pathogens and parasites. Some cause infection or illness in the wild birds themselves, while with others, the birds act as mechanical carriers. Every effort should be made to prevent their nesting in the poultry area. The first rule in poultry house construction is to exclude free-flying wild birds. Poultry raised on range or with access to the outdoors are especially vulnerable to pathogens carried by wild birds. For this reason and for improved sanitary practices, the trend has been to house poultry in closed or partially closed bird-proof houses. However, the advent and growth of the free range and organic industries threaten to compromise carefully designed national programs to eradicate devastating diseases such as high-pathogenicity avian influenza.

Imported zoological specimens destined for zoos are not a direct contact threat because the zoos are located in cities, but they should be considered as a potential source of introduction of an exotic microbial pathogen or parasite. Exotic ornamental pet birds constitute a real hazard because they become widely dispersed and may be purchased by poultry workers. On numerous occasions, exotic birds in or those destined for pet stores have been found infected with a vvND virus, which in at least 1 instance was the source of a serious and costly outbreak in poultry. Stringent entry quarantine requirements to apprehend and destroy infected birds provide a good barrier against the introduction and dissemination by carrier birds, but failures can occur (illegal smuggling), and producers should be wary of such personal pets. Domestic pigeons also can be a source of dangerous strains of NDV.

Rodents contaminate feed and litter with their excrement. They are particularly hazardous to Salmonella control, because they are frequently infected with these organisms and can perpetuate the disease on a farm by serving as a continual source of Salmonella. The house should be monitored for signs of rodent presence. Regular baiting of rodent stations and breeding areas must be enforced. Housekeeping must be of such a standard as to deter the vermin from settling. This can be achieved by the removal of rubble and waste materials from the house, the avoidance of feed spillage, and the regular rotation of chemical control products and traps used. For more detail on rodent control the reader is referred to Chapter 9 of the AAAP publication *A Practical Guide for Managing Risk in Poultry Production* (86) and Chapter 26 of this book.

House Access: Insect, Mite, and Tick Control. Many insects act as transmitters of pathogens. Some are intermediate hosts for blood or intestinal parasites, others are mechanical carriers of pathogens through their biting parts. They also act as reservoirs of infectious agents in that they can transfer an infectious agent from one flock to the next. The litter beetle is not only a major pest in the poultry house environment but can play a vital role in the spread or carryover of some disease-causing agents. The control of litter beetle is based primarily on spraying insecticide during the clean-out process. Flies and mosquitoes are less of a problem but can still play a role in disease transmission. Mites and tick can also pose a threat to flock health. Control measures need to be directed primarily at the breeding areas of these insects.

The EPA defines a pesticide as any substance intended for preventing, destroying, repelling, or mitigating any pest. A pest can be any insect, animal, plant, or microorganism. Insecticides destroy animal parasites such as lice, mites, ticks, and fleas. They also destroy other undesirable insects (flies, beetles, ants, and sow bugs) in the environment. The limited number of available commercial parasiticides and their active chemical properties, limitations, tolerances, and various applications are discussed in detail in Chapter 26. Also see Chapter 32 for toxic effects of some insecticides. For more detail on insect control the reader is referred to Chapter 8 of the AAAP publication (69).

Building Construction. An apron of concrete at the entrance to a poultry house helps prevent tracking of pathogens into the unit. Rain and sunshine help keep the apron clean and sterilized. A water faucet, boot brush, and covered pan of disinfectant available on the apron for disinfecting footwear are further aids in keeping litter and soil-borne pathogens out of the house. Boots must be thoroughly cleaned before the wearer steps into the pan of disinfectant. The disinfectant is useless, however, unless renewed frequently enough to ensure a potent solution at all times.

All surfaces inside the building should preferably be of impervious material (such as concrete) to permit thorough washing and disinfection. It is impossible to sterilize a dirt floor.

Raised slatted floors have been used successfully for years for laying chickens, both for adults and for rearing birds. Such floors have alternating wooden pieces and spaces, each about 3/4-inch wide (Figure 1.2), to permit droppings to fall through, out of reach of birds and to prevent recycling infection of intestinal parasites and diseases. Commercial meat birds are inclined to develop leg problems and breast blisters if raised on slatted or wire floors. A modification of this system, with part of the floor or yard raised slightly and covered with slats, has been used for broiler breeders.

Keeping laying hens in some type of cage has become an accepted practice in closed houses (Figure 1.3) and open-type houses found in hot climates. Cages and wire floors also are widely used to rear pullets destined for cages as adults.

The Hatchery

The building and equipment in which the fertile egg is converted to a day-old chick, poult, or other fowl and the equipment used to process and deliver it to the farm must be clean and sanitary. An individual hatched from a pathogen-free egg

Figure 1.2. Slat floors aid in the control of intestinal diseases and parasites. Droppings fall through open spaces and out of reach of the flock.

Figure 1.3. Poultry are kept in cages in well-built, ventilated, light- and temperature-controlled houses in many countries. Good housing reduces stresses associated with variations in weather, and cages reduce intestinal diseases and parasitism.

will remain pathogen-free only if it hatches in a clean hatcher, is put in a clean box and held in a clean room where it can breathe clean air, and is then hauled to the farm in a clean delivery van.

Design and Location. A hatchery should be located away from sources of poultry pathogens such as poultry farms, processing plants, necropsy laboratories, rendering plants, and feed mills. It is not good practice to retail poultry equipment and supplies from a hatchery building because this draws producers and service workers who may introduce contaminating material.

A good hatchery design has a one-way traffic flow from the egg-entry room through egg-traying, incubation, hatching, and holding rooms to the chick-loading area. The clean-up area and hatch-waste discharge should be off the hatching room, with a separate load-out area. Each hatchery room should be designed for thorough washing and disinfecting. The ventilation system is equally important and must be designed to prevent recirculation of contaminated and dust-laden air. Gentry et al. (38) found that hatcheries with poor floor designs and faulty traffic patterns were highly contaminated compared with those with one-way flow.

Importance of Good Sanitation. Factors that aid in obtaining pathogen-free chicks and poults are hatchery cleanliness and sanitation, well-arranged traffic flow, and well-controlled ventilation. Techniques have been devised for evaluating the sanitary status of commercial hatcheries by culturing fluff samples (91), detecting microbial populations in hatchery air samples (27, 38, 54), and culturing various surfaces in the hatchery (56). By relating results of these techniques to hatchery management, it has been observed by Magwood (55) that bacterial counts of egg shells dropped quickly in clean air, and low counts persisted on all surfaces to completion of hatching. Chute and Barden (26) found fungal flora of hatcheries to be related to management and sanitation programs.

To minimize bacterial contamination of eggs and hatching chicks, hatchery premises must be kept free of reservoirs of contamination, which readily become airborne (55). Trays used for hatching should be thoroughly cleaned with water and then disinfected before eggs are placed in them. This can be done by dipping in a tank of suitable disinfectant (see "Disinfectants"), washing with hot water or steam followed with disinfectant spray, or fumigating with formaldehyde in the hatcher. Trays and eggs are frequently fumigated together immediately after eggs are transferred to the hatcher. Fumigation is sometimes done during the hatch (at about 10% hatch), but concentrations low enough to avoid harming the hatching chick probably serve only to give the down a pleasing yellow color. Formaldehyde fumigation in one case increased the severity of mold infection rather than overcoming it (89). Wright (90) emphasized the practical meaning of hatchery sanitation and how to attain it. He concluded that no fumigation program should be used to replace cleanliness, but rather to supplement it.

As chicks hatch, the exposed embryo fluids collect bacteria from contaminated shells, trays, and ventilating air. The combination of the nutritious fluids and warm temperature forms an excellent environment for bacteria and they multiply very

rapidly (38). The cleaner the air and environment the less likely the navel is to become infected (omphalitis).

Breeder Codes. The breeder code is a designation used to denote the source of hatching eggs. It usually denotes breeders of the same age on the same or different farms, all breeders on a particular farm, or any other grouping. There is a tendency to keep breeders in larger flocks and to avoid as much as practicable the mixing of hatching eggs from flocks of many different microbial, nutritional, and genetic backgrounds. If breeders are kept free of disease and fed a good ration, hatching eggs are produced clean and properly disinfected, and chicks are hatched and handled in clean surroundings. Keeping chicks of different breeder codes separate has little practical meaning other than providing that all have more nearly the same level of maternal antibodies against the same diseases. This may permit a more uniform response to vaccines applied to chicks the first 2–3 weeks of life when maternal antibodies have a protective effect.

Occasionally, a disease is believed to be egg transmitted from a breeder flock to the offspring. When this occurs, the disease nearly always appears in several offspring flocks derived from the same breeder flock(s) and delivered to different farms. A hatch of chicks is frequently divided into deliveries to several farms, and if a disease occurs in only those delivered to 1 farm it indicates that the disease is farm associated and not hatchery or breeder-flock associated.

Chick Sexers. Unless the output of one hatchery is so great as to demand them full time, chick sexers may go from one hatchery to another, which introduces the possibility of carrying disease-causing pathogens. Most sexers are aware of this hazard and are eager to follow proper biosecurity procedures. If sexers must also service other hatcheries, facilities should be provided so that their equipment can remain at the hatchery. They should have a clean area in which to change clothes and wash themselves and their equipment and should have clean protective garments to wear. Their habits should be at least as clean as those of the hatchery crew.

Surgical Procedures. Beak trimming is commonly practiced in breeder flocks, meat turkeys, and cage layers. Proper beak trimming promotes maximum performance. Done improperly, it provides a portal of entry for normally nonpathogenic organisms such as *Staphylococcus aureus* or primary pathogens such as *Erysipilothrix rhuseopathiae*. Similarly, other surgical procedures, such as removing wattles, combs, or toenails of certain toes must be done as aseptically as possible.

Storage Facilities. After fumigation or other shell sterilization, hatching eggs are frequently stored in a cool room (about 10°C) at the hatchery until set. Cool rooms should be clean and free of mold and bacteria and periodically disinfected to prevent recontamination of shells. Holding hatching eggs too long or under improper storage temperature, humidity, and environment can result in poor quality chicks. Clinical histories indicate that infection in young chicks may sometimes be traceable to fungus-contaminated hatching eggs; infections have been produced experimentally by contaminating shells with fungus spores (89). Whenever cold eggs are moved into a warm, humid atmosphere, moisture condenses on the cold shells (called "sweating"). This moisture provides a medium for the growth of bacteria and fungi already present on the shell or from contaminated warm air around the eggs. Therefore, cold eggs should be warmed (preheating) to room temperature in clean, low-humidity air before placing them in an incubator.

Secondary Control Zone: Farm or Site

The company farms or sites constitute the next logical zone or compartment for disease control. For this purpose, the farm and not the house is defined as the epidemiological unit. First, the farm has a defined boundary, and second, because the houses are in close proximity, the birds on the farm share a defined epidemiological relationship (common environment, with common management practices) and thus have approximately the same likelihood of exposure to a pathogen.

The boundary of the farm/site serves as a physical (fenced) or imaginary (nonfenced) line of access control to the secondary contro1 zone—the most crucial zone for disease control. The farmer should enforce full biosecurity with no uncontrolled access from the start of the disinfection process—the site is "closed." The farmer should enforce general biosecurity from the start of transfer/depletion with access only granted to necessary vehicular traffic—the site is "open." The farmer should enforce routine control from the point of last bird removal—the site is "fully open." In the event of a disease outbreak, the site should remain closed until the responsible veterinarian declares the site clean.

Isolation

Not all producers follow the same disease control practices. A close neighbor may disregard sound principles and be burdened with diseases until forced out of business by economic pressures. Disease agents present on his or her premises may be blown or carried by various vectors and fomites to adjacent premises. Until a disease has been eradicated from a flock like this, it serves as a reservoir and potential source of infection for future flocks on the same premises and those on adjacent premises. The closer houses or premises are to one another, the more likely it is for disease to spread.

Highly concentrated poultry production areas frequently deteriorate into problem zones of disease of one type or another. Farms are so close together that the area forms an epidemiological unit from a disease perspective. Within these areas there are several different age groups of birds and many managers, each vaccinating, treating, or exposing birds without regard to the programs of others. In such situations a system of a single age of fowl, permitting complete depopulation at the end of each rearing or laying cycle, goes a long way

toward solving the problem. This is even more successful if coordinated area depopulation and restocking is practiced.

One Age of Fowl/Farm

Removing carriers from a flock and premises is an effective way of preventing a recurrence of some diseases, but it is impossible or impractical for others. The best way to prevent infection from carrier birds is to remove the entire flock from the farm before any new replacements are added and to rear young stock in complete isolation from older recovered birds on a separated farm segment or preferably on another farm and in an isolated area. This practice is often called all-in-all-out production.

Where birds of different ages exist on a large farm, depopulation seems drastic, but considering mortality, poor performance, and endless drug expense, it could be the most economical solution. Where only 1 age of bird is maintained, depopulation occurs each time pullets or poults are moved to the layer or breeder premises, each time the broilers or turkeys are moved to slaughter, and each time the old layers or breeders are sent to market. Should a disease occur, the flock can be quarantined, treated, and handled in the best way possible until it is disposed. Depopulated premises are then cleaned out, washed, and disinfected, and left idle for at least 2 weeks before new healthy stock is introduced.

Functional Units

For certain economic reasons (breeding farm or small specialized market trade) it is not always possible to limit the entire farm to a single age of poultry. In such instances, it should be divided into separate quarantinable units or areas for different groups of birds (rearing area, pedigree unit, production groups, and experimental birds) (Figure 1.4). Each area can periodically be depopulated, cleaned, and sanitized. Much stricter security procedures for personnel, bird, and equipment movements are necessary for this type of operation. A very rigid monitoring system is also essential to detect any disease early enough to bring it under control while it is still confined to 1 quarantinable segment.

Figure 1.4. This isolated breeding farm benefits from several fundamental disease prevention and control principles. It is isolated from other poultry farms, is surrounded by forest land, and is divided into quarantinable sections separated by woods as well as distance.

Farm Environment

The farm or site must be maintained to minimize the breeding areas and any overt protection given to vermin, predators, or other organisms. The grass must be kept short and the aprons free of grass and weeds. Vermin are vulnerable to predation when crossing these exposed areas.

Water must not be allowed to accumulate on site in open pools. Drainage must be sufficient to remove excess water, especially during storms and cleanout. Stagnant water is an ideal breeding ground for insects and other organisms. No rubble or waste debris should be stored on site and equipment must be stored to avoid offering shelter or protection to unwanted creatures.

Farm Access Control

The site should ideally be completely fenced with sufficient deterrents to access from predators, vermin, and unauthorized people. There should preferably be only 1 access point into the site. This entrance should be protected by gates which should be locked at all times and access control must be exercised by site personnel to limit vehicle, equipment, and people movement.

Only poultry considered to be part of the site flock must be allowed on site and they must be confined to the house or free-range enclosure. No domestic or wild animals must be allowed within the perimeter fence and wild birds must be actively discouraged from the site through the control of any activity that may attract (feed spillage) or harbor (nesting) these birds.

People. Farm/site personnel should ideally be the only people permitted on site and even they must not have had contact with other avian species for at least 2 days prior to entering the farm. Only essential visits by authorized personnel such as mechanics, managers, working crews, etc. should be allowed on site. They must not have had contact with other noncompany poultry or domestic birds for at least 2 days and must observe the prevailing biosecurity procedures for house access if entering a poultry house.

All nonessential visits by company employees and all noncompany personnel visits must be authorized by the relevant authority (live production manager or veterinarian). No such visitor must have had contact with other poultry or domestic birds for at least 2 days.

The visitation sequence to sites should always be from youngest flock age to oldest flock age. In the event of a disease outbreak, the disease control should always supersede the age sequence (i.e., affected flocks must always be visited last, even after visiting an older healthy flock).

A visitor and vehicle register must be maintained to record all visitors (defined as a person not working on site on a daily basis)

and all vehicle movements onto and off the site. Such records should include the reason for and the duration of the visit.

In situations where a "shower-in-shower-out" policy is in place, the shower unit is the crucial point separating the site from the outside environment. The shower complex must therefore be unidirectional with the shower unit in-line. All transit or personal clothing and personal items must be stored on the external side of the shower. Any item not suited to washing must not be taken onto the site unless it can be fumigated or suitably decontaminated. Anyone or anything entering the shower unit must be thoroughly cleansed prior to exiting onto the site side of the unit.

After showering, or if there is no shower in place, any person entering the farm/site must don site-dedicated protective wear: coveralls, hairnets, and protective footwear or plastic shoe covers. Hands should be cleaned with running water and soap/liquid soap prior to entering and on leaving the site.

The purpose of protective clothing is to provide site personnel with a standard uniform that has not had outside contact or contamination and therefore poses no disease risk to the poultry. The protective clothing colors also can be used to distinguish between departments and the various biosecurity zones.

The office should be a separate room and must only be accessible from the site side. Nothing should enter this room until it has passed through the designated cleaning and disinfection procedures.

Specialist crews and people performing specialist tasks are frequently called upon to visit more than 1 site/day and sometimes not in the prescribed visitation sequence. Such crews and their equipment pose a serious disease risk to the site so they need to be particularly vigilant about following biosecurity protocols.

Vehicle Access. To reduce the risk of disease agent transmission it is best to prohibit vehicle access to the site. It is seldom necessary for vehicles to drive onto the site. However, all vehicles entering the site should be suitably disinfected prior to entry. This means that the vehicle must pass through a full spray bay, which has the capacity to deliver a coarse to fine spray of disinfectant over the entire vehicle to ensure total wetting of the exterior. The disinfectant used must be applied at the recommended dosage rate and should not be unduly corrosive or damage the painted surfaces of vehicles. A vehicle wheel dip should be built into the spray bay to ensure that all vehicles entering and leaving the site at any stage of production cycle pass through this dip. Any vehicle that carries live birds or nonwettable exposed cargo (shavings) or with no roof or side protection for the driver (tractor) must have a full undercarriage spray. The spray bay must be designed to spray the entire vehicle including the undercarriage. Vehicle drivers must not leave their vehicles while on site unless the cab has been suitably disinfected on entering the site and the driver has gone through the correct access control procedures applicable to personnel. Site-dedicated vehicles must not leave their area of dedication except for repairs, servicing, and fueling. On return, site-dedicated vehicles must be completely disinfected at the point of re-entry.

Equipment. All equipment entering a site should be suitably decontaminated by a soap wash disinfectant spray and/or fumigation. Some equipment does not lend itself to fumigation or wetting and such items (cell phones, beepers, vaccine syringes, pens, etc.) must be suitably cleaned at the point of dispatch to remove gross contamination or stored in a sealed plastic bag, or the exposed surfaces may be wiped with a moist disinfectant cloth.

All site equipment must be sanitized during the clean-out process. Site equipment must be dedicated to a site or have at least a 14-day outside storage period to reduce the risk of disease spread. House equipment such as chick fonts, feeder or scratch pans, crates, plastic sheeting, partitions, nest boxes, etc. should not leave a site to be used on another site.

Placement Transfers and Depletion

All placements, transfers, and depletions must be synchronized to ensure that sites are placed in a suitable sequence within complexes and operations. All placements and transfers require that the live birds be kept for some time within the company's transport equipment and therefore, all vehicles and equipment must be cleaned and disinfected between loads. This should be done at the point of origin for placements and transfers and at the point of delivery and again at the complex/site entrance for depletions.

Egg Room

The egg room is a holding room for eggs prior to dispatch to the hatchery. The eggs originate from the houses on site (dirty area) and eggs should preferably be fumigated prior to entering the egg room (clean area). Although the egg room is part of the site, no eggs or buggies placed into an egg room should be taken back on site. The external door is the physical demarcation of the site side of the egg room and must only be opened for the purpose of removing filled egg bogeys. It is preferable to wheel the egg bogeys leaving the egg room through a wheel-dip containing a suitable disinfectant to reduce the chance of spreading a disease agent off site.

The egg truck, egg bogeys, and egg trays form an important epidemiological link between all the company farms (broilers and breeders) via the hatchery. It is thus essential to implement and enforce strict controls at this interface. All bogeys and egg trays coming from the hatchery must enter the site through the fumigation room to ensure decontamination. The egg room must be cleaned and disinfected at least once a day, preferably immediately after eggs are dispatched to the hatchery (i.e., when the room is empty).

Fumigation Room

Fumigation is the process of decontamination of an object through the use of a gas compound. Because gases can penetrate tiny holes, this form of disinfection is ideal for most

objects that are otherwise difficult to clean. The fumigation room must have 2 access points: one on the site side and the other to the outside. The external access must be used for loading all objects that need to be taken onto the site. The site access must be used for receiving fumigated goods onto the site and for dispatching potentially contaminated goods from the site. Only 1 access point must be open at any given time. Nothing should be allowed to be taken onto the site unless it has been showered (soap wash), disinfected, or fumigated. Certain exceptions exist and include live birds and nonwettable cargo such as shavings and feed.

Dead Bird Disposal

All dead birds should be taken to a designated collection point on the farm/ site and: (1) stored in suitable containers in a cool environment (shade or refrigerator) to delay the rate of decomposition, avoid ground contamination through leakage and spillage, and prevent predation; (2) mortalities must be disposed of on a daily basis, either on site through incineration, pickling, pit or tank (Figure 1.5A), composting (Figure 1.5B) or burial, or off site through burial, composting, central depots, or rendering plants (63); and (3) mortality collection vehicles must not enter any site and must always follow strict visitation sequences (young to old, and healthy to diseased) and disinfection procedures.

Tertiary Control Zone: Complex

An epidemiological unit also may refer to groups of birds that share a communal animal handling facility. For example, the sites/farms within a complex will invariably share a hatchery, feed mill, and processing plant, and thus form an epidemiological unit. Similarly, production processes within the complex such as pullet rearing farms, breeder or laying farms, and broiler farms also form separate epidemiological units. Depending on the level of biosecurity these areas can be demarcated and classified as tertiary control zones.

Tertiary control zones are frequently set up around high-value sectors of the operation because resource allocation to biosecurity is easier to justify. For example, grandparent stock are substantially more valuable than broiler breeders, which are in turn more valuable than broilers, so the implementation of tertiary control zones becomes easier to justify as one moves up the production pyramid. Tertiary critical control points (transit facilities) may be established beyond the outer confines of the site perimeter to reduce the risk of disease agent transmission. Control procedures such as showering or merely changing into protective clothing at this point and using site-/zone-dedicated transport to move to the site significantly reduce the chance of pathogen transmission. The tertiary control zone is seldom fenced so the access control boundary is usually imaginary.

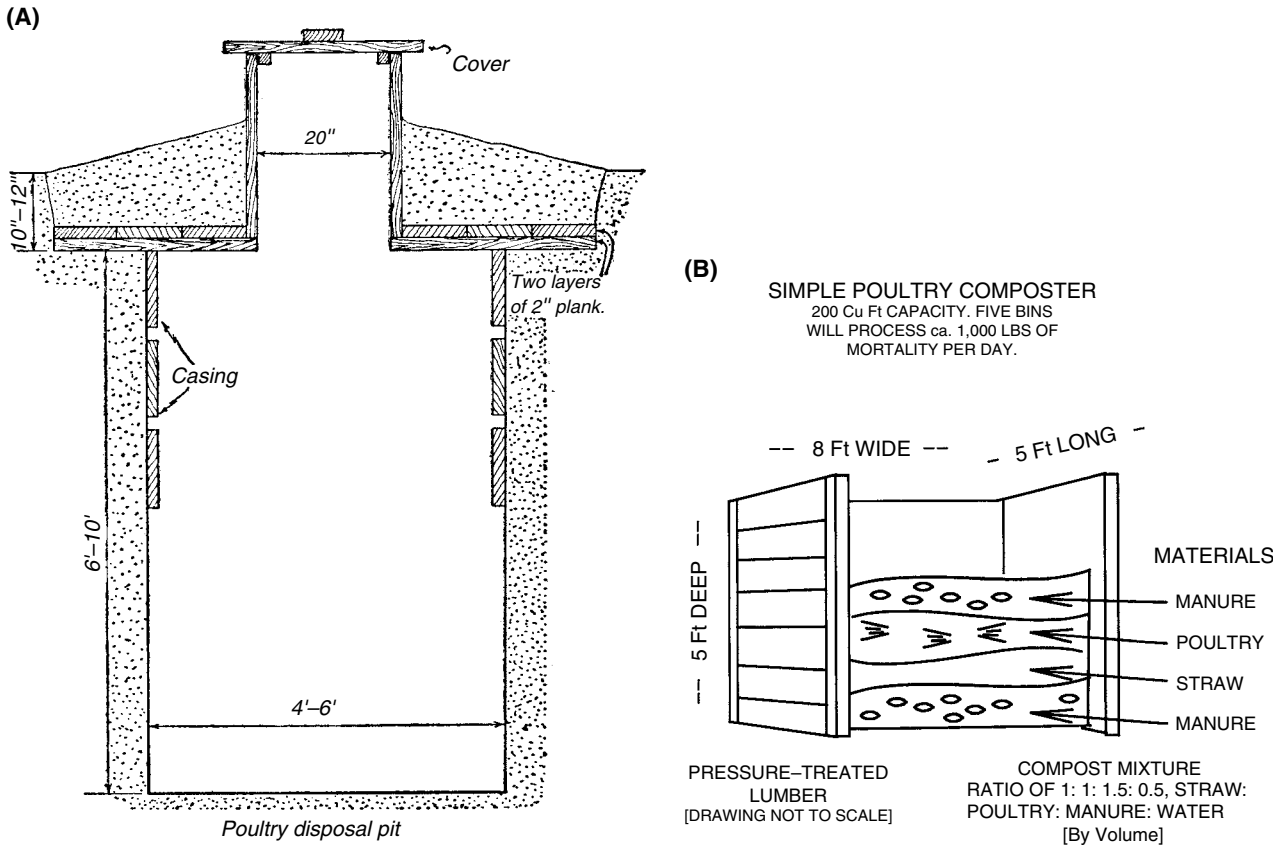

Figure 1.5. (A) Poultry disposal pit. Such a pit can be made any size that is convenient. (B) A simple above-ground poultry carcass composter of 200 ft^3 (5.7 m^3) capacity. Five such bins will process 1,000 lbs. (455 kg) of carcasses/day. (Courtesy of the University of Marlyand Poultry Science Department)

Complex Environment

In rare situations a group of sites within a geographical location can be protected as a single unit by the erection of an enclosure (perimeter fence) with access control (transit facility). In other situations the boundary may he operational in nature. Such a complex does not merely exist because 2 or more sites are on the same location, but rather as a means of implementing bioexclusion procedures. The entrance to such a complex is referred to as a transit facility, and the complex a disease-free area or control zone. A complex must always be considered to be closed in terms of the enforcement of biosecurity control measures and dedicated vehicle transport used within this control zone.

Although a complex can be a large expanse of land, the same principles to housekeeping on the site are applicable. The land around each site must be maintained to minimize breeding sites and overt protection given to vermin, predators and other organisms. The grass outside the site perimeter fence must be kept short and free of any rubble and debris.

Complex Access: Transit Facility

The transit facility is the entrance to the complex and serves as a biosecurity critical control point to reduce the risk of disease. Site and complex personnel should ideally be the only people within the complex. Only essential visits by authorized personnel such as mechanics, direct managers, working crews, etc. should be allowed onto a complex. All nonessential visits by company employees must be authorized by the veterinarian. All noncompany visits must be authorized by the relevant authority. In the event of a disease outbreak, the veterinarian is responsible for the imposition of additional control measures appropriate to the disease.

Access to the Complex

Procedures for people, vehicle, and equipment access to a complex are the same as those for a farm. Anybody intending to visit any part of the tertiary control zone (complex) must comply with transit facility controls. This should involve a clear separation between clean and dirty areas/items. Anybody or anything entering the complex should ideally be "decontaminated" by washing with soap and water. People entering the complex should at the very least leave all personal clothing and personal items in the transit facility and change into complex clothing. Complex-dedicated vehicles should be used to move between the transit facility and the farms/sites and a visitor and vehicle register similar to those at farm level must be maintained.

Diagnosis: Monitoring, Surveillance, and Confirmation

The poultry business is exactly that, a business, the aim of which is to make a profit. Judicious use of cost items such as antibiotics and nonantibiotic feed additives makes both scientific and economic sense and begins with accurate and early diagnosis. No disease control or eradication program would be successful without diligent surveillance, because early detection followed by rapid and effective biocontainment is critical to the success of disease control or eradication.

Monitoring and Surveillance

Monitoring and surveillance are both terms used to describe the ongoing collection of data to describe the prevalence and severity of disease in a population. A monitoring program is usually designed to accumulate statistically reliable disease prevalence data over time to indicate a change in the incidence or severity of a disease. In contrast, a surveillance program is usually designed to collect prevalence data from a readily available sector of the population (potential sample bias) with the primary purpose of implementing timely corrective action when there is a perceived increase in incidence of a disease. As flock size and production intensity increases, management control becomes more remote, so monitoring and surveillance programs become more important.

With eradication programs implemented to control diseases of catastrophic nature, the objective of the surveillance program should be to detect the source case of an outbreak so that biocontainment through quarantine and slaughter can be initiated before the diseases spreads. If the goal is less than eradication, the degree of deviation from normal prevalence necessary to stimulate corrective action needs to be set at such a level to differentiate common cause (background variation) from special cause (a disease effect).

Several parameters such as the sample size, necessary to detect specific levels of prevalence, can be calculated by equation and it is important to realize that the significance of this in program design. The objective of the data collection system is to provide incisive and epidemiologically informative indicators which will permit objective judgment and decision making.

For disease eradication and trade purposes it is often necessary to demonstrate freedom from infection (absence of the pathogenic agent) in the country, zone, or compartment (company). It is not possible to prove with 100% confidence that a population is free from infection (unless every member of the population is examined simultaneously with a perfect test with 100% sensitivity and specificity). Therefore, a surveillance system to demonstrate freedom from infection should be designed to predict with an acceptable level of confidence that infection is below a specified level of prevalence in the target population. Any evidence of infection at any level in the target population automatically invalidates any freedom from infection claim.

For disease control purposes surveillance is used to determine the distribution and occurrence of infection or immunity within a zone or compartment to aid in the decision-making process. In this instance surveillance is designed to collect data on several variables relevant to flock health, including prevalence or incidence of infection, morbidity and mortality rates, flock immunity as indicated by frequency distribution of antibody titres, farm production records, etc.

Poultry flock health tracking requires that the poultry are monitored for disease at regular intervals. A change in prevalence over time indicates a change in incidence which signals the need for corrective action to prevent disease spread. Unless monitoring includes true random sampling, results cannot be taken to be absolute measures of disease incidence and prevalence, but may serve as adequate indicators for intervention.

The following formula provides a simplified method of estimating the number of animals that need to be tested for the probability of selecting at least 1 diseased animal in a finite population of birds to be greater than a preset confidence level (commonly 95%).

$$n = \left[1 - (1 - p)^{1/d}\right] \times \left[N - d/2\right] + 1$$

where n = sample size, N = flock size, p = probability of selecting at least 1 diseased animal, and d = the number of animals affected for the desired level of prevalence.

Although this method of sample size determination is widely used, its accuracy is based on several assumptions. Violation of the assumptions (that the disease is present at a certain minimum prevalence, the diagnostic tests used are 100% sensitive and 100% specific, sampling is performed with replacement and the data is collected by simple random sampling) renders the estimate inaccurate (19, 21). A more accurate determination of sample size is given with a computer program such as FreeCalc. This program uses trial and error to calculate the exact sample size required for a specified probability, can be used on finite populations, and takes account of test imperfections (19).

Sample frequency must be calculated based on the epidemiology of the disease under consideration. With *Mycoplasma gallisepticum* (MG), for example, the index case could produce infected eggs within 17 days but peak shedding occurs when colonization peaks at 3–6 weeks after flock exposure (41, 42, 71). After flock exposure to MG, there is a latent phase of 12–21 days in which less than 5% of the flock has a detectable antibody response (61). To prevent vertical transmission the monitoring system must be capable of detecting infection at the 5% level with 99% confidence. The sample size (n) that must be tested to have 99% confidence in determining whether MG is present at a prevalence of 5% in a flock of 7,000 birds can be estimated by calculation as 90 birds (21). To prevent infected eggs from entering the hatchery it would be necessary to sample flocks every 2 weeks (assuming 100% sensitivity for the test system). The testing interval can be extended by 2 weeks where hatchery tracking systems allow infected egg removal from the setters.

Performance Parameters

Metrics generally used to judge overall health, which encompasses vaccine program efficacy, are culls at the hatchery, 7-day mortality, 14-day mortality, final flock livability, feed-conversion efficiency, rate of gain, condemnation, egg production, and egg quality. Many of these metrics have standards or comparative histories established through each company's own historical data or, in the United States at least, national reporting services such a AgriStats (AgriStats, Fort Wayne, IN), or Agrimetrics (Agrimetrics Associates, Inc., Midlothian, VA), and government reporting services such as the poultry slaughter reports published monthly by the National Agricultural Statistics Service (NASS), Agricultural Statistics Board, U.S. Department of Agriculture. An additional metric that can be used over time is antimicrobial and antiparasitic drug usage. Although this is influenced by many things, including management changes and climatic shifts, monitoring usage is an essential tool for evaluating overall health and vaccination program efficacy.

Examination of Field Birds

Health surveys (9, 50) that include extensive gross and microscopic evaluation of necropsy specimens, and controlled challenge studies (64) to measure a relative protection level, are both useful in assessing vaccine program effectiveness. Perhaps the most frequent controlled challenge work done is to measure passive protection of broiler chicks from hens hyperimmunized to infectious bursal disease (64). Trends in program efficiency may be identified over time if sufficient groups of chicks are sampled.

Serologic Monitoring

Serologic monitoring (76) is only useful in production medicine if adequate samples have been analyzed over time to establish a normal baseline for a specific program, in a specific location, in a specific bird, using specific and consistent application techniques, with samples run consistently by a specific laboratory. After a baseline is established, flocks can be identified that have serologic profiles above or below the established baseline.

In broiler and turkey production flocks, an effective monitoring program can be the regular sampling and testing of blood as the birds are slaughtered at the processing plant. This serologic monitoring will establish a baseline of antibody titers that are the result of both vaccination and field challenge. Changes in the usually observed antibody titers may indicate a decrease in the efficacy of vaccine administration or an increased field challenge by a particular pathogen. A regular serologic monitoring program is also helpful to determine whether a flock has been exposed to a new pathogen not previously present in the region.

Serologic monitoring of layer flocks should be performed before the flock is placed in the layer building, with periodic serologic monitoring throughout the production cycle. This type of program will assess both the efficacy of vaccine administration and the disease challenge the flock experiences in the field. Breeder flocks should be monitored in the same way as layer flocks and, in certain instances, breeders can be revaccinated during production to boost the maternal antibody titers of their progeny if they are found to be low.

Interpretation of Serologic Data

It is usually impossible to differentiate between antibodies that are produced by vaccination vs. those induced by field exposure to a given infectious agent. The only difference that

may be observed is that the antibody titer following a field challenge may be higher than that observed following vaccination. A valid interpretation of serologic results requires a complete knowledge of the flock's vaccination history.

It usually takes poultry 1–3 weeks to produce detectable levels of antibodies in their serum. It is possible, therefore, to collect blood during the middle of a disease outbreak and not be able to detect any antibodies to the causative disease agent. If this same flock is tested 2 weeks later, however, serum-antibody levels will be high. A useful practice in establishing a disease diagnosis is to take acute and convalescent serum samples from the flock as it is undergoing an unknown disease challenge. Typically, the acute serum sample collected during the initial phase of the disease outbreak will be negative for antibodies to the suspected disease agent. The convalescent serum sample, taken shortly after the flock has recovered, if positive, will provide a definitive diagnosis when interpreted in conjunction with the clinical signs and lesions of the case. An important concept in the interpretation of serologic results is that a single positive serologic test only indicates that the flock was exposed to that disease agent during its life.

Different laboratories often conduct serologic tests using different reagents or techniques. Because of this, comparing antibody titers (a titer is a measure of the level or concentration of antibody in the serum) reported from different laboratories may be confusing. It is best to use 1 laboratory for a given test so that a familiar range for negative, low, or high titers is established. With experience and training, production managers can become skilled at the interpretation of serologic results.

Flock Profiling

Today's disease problems often represent the sum of various subclinical disorders occurring at different times throughout the life of a flock. Acquisition of the fullest understanding of this sequential collection of serologic and other data concerning multiple pathogens requires disciplined and careful organization. The systematic, graphic presentation of this data is commonly called a flock profile. The establishment of such profiles is facilitated by enzyme-linked immunosorbent assay (ELISA) technology because a single basic test system is used to monitor for a broad array of diseases (61).

Snyder et al. (77) demonstrated the value of correlating ELISA profiling data with flock performance. The further evolution and diagnostic advantages of the graphic presentation of ELISA-based flock profiling data in combination with gross and microscopic pathology data was described by Mallinson et al. (57). The method has broad applicability to epizootiologic investigations, field research, and quality control. Baseline profiles can be established both as targets for vaccination goals and as a base from which deviations from the norm may be demonstrated when a field problem is subsequently encountered. Several flock-profiling kits and systems are now commercially available. Their value is enhanced when good data retrieval and graphic presentation of data (Figure 1.6) are combined with the diagnostician's veterinary skills and experience in assimilating medical information and establishing a plausible diagnosis.

Diagnostic Procedures

Many satisfactory diagnostic and necropsy methods exist. The techniques and instruments used by one pathologist may vary considerably from those used by another. Some suggestions are offered here to guide the student and beginner. The goal of the necropsy is to determine the cause of impaired performance, signs, or mortality by examining tissues and organs and to obtain the best specimens possible to carry out microbiologic, serologic, histopathologic, or animal inoculation tests. It is important that in the process, infectious materials do not endanger the health of humans, livestock, or other poultry. By proceeding in an orderly fashion, possible clues are less apt to be overlooked, and tissues will not be grossly contaminated prior to examination. Remember that a blood sample or tissue specimen determined later to be superfluous can always be discarded. It's better to save tissues and then discard them if they are later determined to be unnecessary or unimportant to the diagnosis.

A key to good poultry diagnosis is the art of "seeing the forest as well as the trees." Try to identify the most significant flock problem(s) rather than becoming engrossed in individual bird disorders. Watch for telltale patterns of pathology as presented by the total diagnostic consignment.

The techniques and procedures necessary to make an accurate diagnosis and identify specific disease agents are found in the technical information contained in succeeding chapters of this book and in the following excellent reference manuals: *A Laboratory Manual for Isolation, Identification and Characterization of Avian Pathogens* (32), *Avian Disease Manual* (25), *Avian Histopathology* (35), and *Color Atlas of Diseases and Disorders of the Domestic Fowl and Turkey* (67). *Avian Hematology and Cytology* (20) should be consulted for detailed information on avian blood elements and methods for preparation and study. New information is continually being presented in the journals *Avian Diseases, Avian Pathology, and Poultry Science*; in the proceedings of several regional poultry disease conferences; and in other avian pathology and science journals.

Case History

The pathologist who has not seen the farm or the flock before attempting to diagnose the problem and recommend corrective measures is at a disadvantage. This can be partially overcome by getting a complete history of the disease and all pertinent events leading to the outbreak. The more information pathologists have about the history and environment, the more directly they can proceed to determining solutions for the problems. Unfortunately, the history includes only the situations, events, and signs that the caretaker, owner, service worker, or neighbor

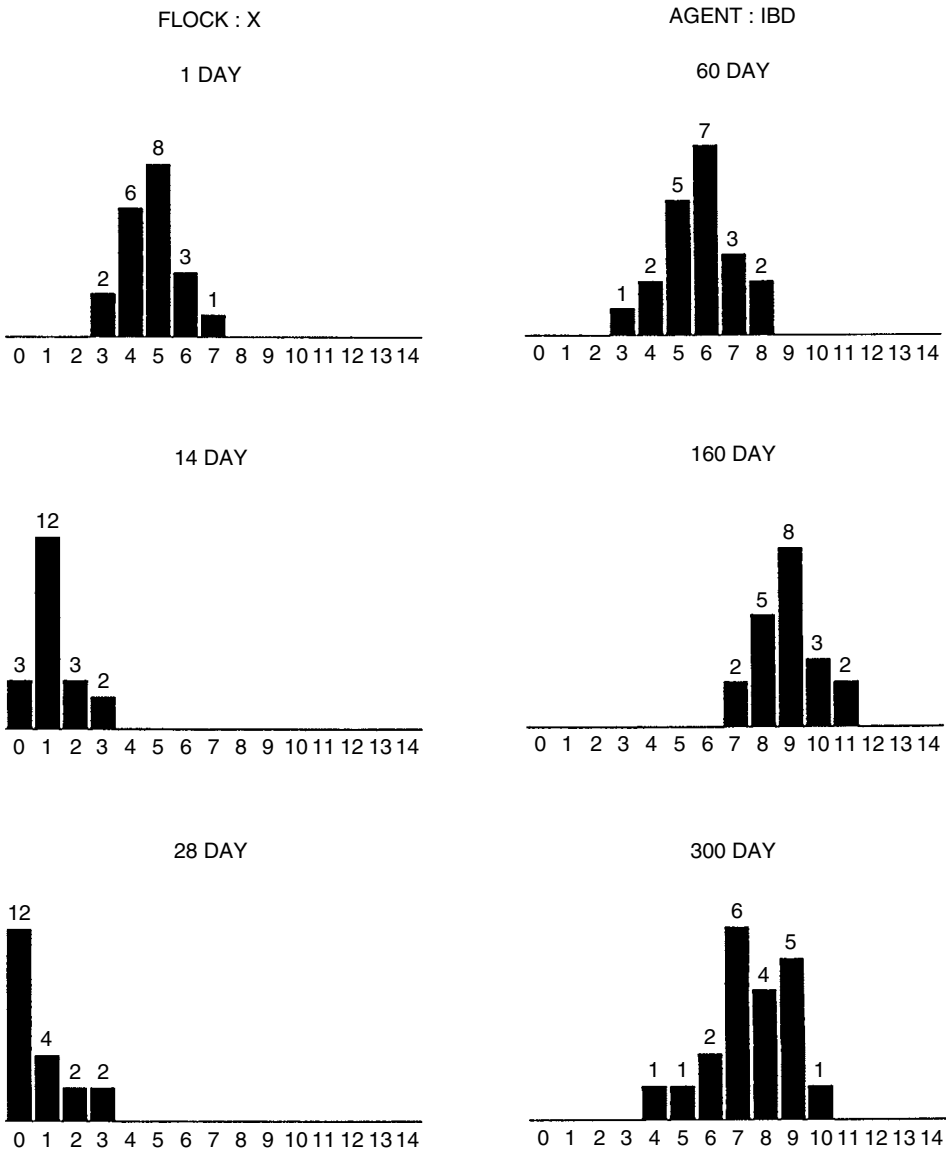

Figure 1.6. Temporal graphic distribution of infectious bursal disease (IBD) enzyme-linked immunosorbent assay (ELISA) group titer levels at 1, 14, 28, 60, 160, and 300 days of age for an IBD-vaccinated broiler breeder flock. Numbers on the X-axis represent group titer levels obtained by ELISA. Titers of 0 are group 0, 1–350 are group 1, 351–1,500 are group 2, 1,501–2,500 are group 3, 2,501–3,550 are group 4, etc., with titers of 12,500 comprising group 14. Numbers above each bar represent the number of samples reacting at each level on the indicated day of age.

has observed and remembered. Knowledge of management factors such as ventilation; feeding and watering systems; accurate records of egg production, feed consumption, feed formulation, and body weight; lighting program; beak trimming practices; brooding and rearing procedures; routine medication and vaccination used; age; previous history of disease; farm location; and unusual weather or farm events may make the difference between diagnosis of the flock problem and the finding of a few miscellaneous conditions in a sample that may or may not be representative. Duration of the signs, the number of sick and dead, and when and where they were found dead can be important clues.

Poultry producers have developed a high degree of knowledge about poultry diseases and usually recognize those resulting in dramatic or clear-cut signs and lesions. The veterinarian, therefore, is often confronted with obscure, undramatic, and complicated disease cases requiring extensive investigation. Even if all indications are that reduced performance is most likely due to a management factor, the veterinarian must check all reasonable disease possibilities. This requires a systematic approach to be sure that nothing is overlooked.

External Examination

Look for external parasites. Lice and northern fowl mites (*Ornithonyssus silviarum*) can be found on the affected chicken. If red mites (*Dermanyssus gallinae*) or blue bugs/fowl ticks (*Argas persicus*) are suspected, examination of roosting areas and cracks and crevices in the houses and around the yards must be made, because these species do not stay on birds. See Chapter 26 for diagnosis and identification of external parasites.

The general attitude of live birds and all abnormal conditions should be noted carefully. It is very important to observe evidence of incoordination, tremors, paralytic conditions, abnormal gait and leg weakness, depression, blindness, and respiratory signs before the specimens are killed. It is very helpful to place birds in a cage where they can be observed after they have become accustomed to the surroundings and perform at their best. It is sometimes advisable to save some of the affected birds to observe possible recovery from a transitory condition (transient paralysis), respiratory infection, chemical toxicity, feed or water deprivation on the farm, or overheating during transport to the laboratory.

Examination should be made for tumors, abscesses, skin changes, beak condition, evidence of cannibalism, injuries, diarrhea, nasal and respiratory discharges, conjunctival exudates, feather and comb conditions, dehydration, and body condition. These are all useful clues.

Blood Samples

Blood specimens may be taken at this time (or immediately after the bird is euthanized). Frequently, it is desirable to have 2 (paired) blood samples several days apart to determine a rising or falling titer of antibodies to some disease (Newcastle disease) in the serum. In this case, a blood specimen may be taken from the main (brachial) wing vein or jugular vein or by heart puncture, and the bird then is saved for a second sample.

Venipuncture of the brachial vein is usually the simplest and best method for obtaining blood from turkeys, chickens, and most poultry under field conditions, especially when the bird is to be returned to the flock. Ducks are bled from the saphenous vein near the hock. Expose the vein to view by plucking a few feathers from the ventral surface of the humeral region of the wing. The vein will be seen lying in the depression between the biceps brachialis and triceps humeralis muscles. It is more easily seen if the skin is first dampened with 70% alcohol or other colorless disinfectant. To facilitate venipuncture, extend both wings dorsally by gripping them firmly together in the area of the wing web with the left hand. Insert the needle into the vein of the right wing holding the syringe in the right hand (Figure 1.7). The needle should be inserted opposite to the direction of blood flow.

Heart puncture can be made anteromedially between the sternum and metasternum (44), laterally through the rib cage, or anteroposteriorly through the thoracic inlet. Only through experience can one learn exactly where and at what angle to insert the needle. It is best to practice these techniques on freshly killed specimens before attempting to bleed live birds. A general rule for the lateral puncture is to form an imaginary vertical line at the anterior end of—and at a right angle with—the keel, and then palpate along that line. The heartbeat can be felt, and the needle inserted to the proper depth.

For heart puncture through the thoracic inlet, the bird should be held on its back with the keel up. The crop and contents are then pressed out of the way with a finger while the needle is guided along the ventral angle of the inlet. After penetrating the inlet, the needle is directed horizontally and posteriorly along the midline until reaching the heart.

Figure 1.7. Obtaining a blood sample from the wing vein.

The site for heart puncture between the sternum and metasternum is (in a mature chicken) about an inch above and posterior to the anterior point of the keel. The needle is directed at approximately a 45-degree angle in the anteromedial direction toward the opposite shoulder joint. The needle should pass through the angle formed by the sternum and metasternum and directly into the heart. For further details and illustrations, see Hofstad (44).

The size and length of the needle required for heart and venipuncture depends on the size of the bird: for young chicks and poults, use a 1/2-inch, 20-gauge needle; for mature chickens, a 2-inch, 20-gauge needle is needed. Mature turkeys may require larger needles. For quick and accurate bleeding, it is essential that the needle be sharp. A very slight vacuum should be developed intermittently to determine when vein or heart puncture has occurred. After vein puncture, a steady, slight vacuum should be continuous to withdraw blood. If the vacuum is too great, the vessel wall may be drawn into the needle and plug the beveled opening. It is sometimes necessary to rotate the needle and syringe to be sure the beveled opening is free in the lumen of the vessel.

For most serologic studies, the serum from 2 ml blood is adequate. The blood should be removed aseptically and placed in a clean vial, which then is laid horizontally, or nearly so, until the blood clots. An occasional sample may require a long time to clot. This is especially true of turkey blood. Clotting can be hastened by adding a drop of tissue extract, made by killing and pooling a number of 10- to 12-day-old chicken embryos, grinding in a blender, and freezing for future use. After the clot is firm, the vial may be returned to the vertical position to permit serum to collect in a pool at the bottom. Plastic vials are available for blood collection. The clot does not adhere to the vial, and special positioning during clotting is unnecessary. Frequently, the serum from fat hens will appear milky due to lipids. Placing vials in an incubator will hasten the separation of the blood clot and serum. A fresh blood sample should never be refrigerated immediately after collection because this will hinder the clotting process. Sera should not be frozen if agglutination tests are to be performed because this frequently causes false-positive reactions.

If an unclotted blood sample is required, it should be drawn into sodium citrate solution at the rate of 1.5 ml 2% solution/10 ml fresh blood, or deposited in a vial containing sodium citrate powder at the rate of 3 mg/1 ml whole blood, and the mixture should be shaken gently . One way to prepare tubes for collecting sterile citrated blood is to add the proper amount of 2% sodium citrate solution to the collecting tubes ahead of time and then sterilize the solution and evaporate the moisture in an oven.

Blood-collecting vials containing the anticoagulants heparin or ethylenediaminetetraacetic acid (EDTA) also can be obtained commercially from laboratory supply companies. For certain types of serologic tests, fresh blood can be absorbed on the tips of filter paper strips, dried, and sent to the diagnostic laboratory, where antibodies can be recovered for testing by placing pieces of the treated paper into saline solution.

If a blood parasite or blood dyscrasia is suspected, smears of whole blood should be made on clean glass slides previously warmed to promote rapid drying. For staining techniques, see Campbell (20).

A drop of blood for a wet mount or smear may be obtained from very small chicks by pricking the vein on the posteromedial side of the leg or by pricking or cutting the immature comb.

Killing Birds for Necropsy

Cervical Dislocation

Several methods can be used to kill poultry, and each has certain advantages. The objective is to kill the bird instantaneously so it will not suffer in the process. Cervical dislocation, as described, is considered a humane method of poultry euthanasia by the American Veterinary Medical Association (AVMA)(3).

Bovine Burdizzo castration forceps can be used for killing large chickens and turkeys. It is difficult for one person to perform this operation and hold the bird at the same time, but it is quite easily done with the aid of an assistant. This technique also prevents agonal regurgitation and aspiration of crop contents into the respiratory passages if the forceps are left clamped until reflex muscle spasms cease. The neck of a young chick also can be broken easily by pressing it firmly against a sharp table edge, or by pinching between thumb and index finger, or by using the inside, noncutting angles of a surgical scissor such as a small Burdizzo.

Others

Specimens selected for diagnosis also may be killed by intravenous injection of euthanasia solutions. Another satisfactory method is euthanasia by placing the bird in a chamber filled with carbon dioxide (CO_2). Local availability of a CO_2 source may limit use of this technique. Other methods of euthanasia can be found in a report of the AVMA (3). The method selected depends upon the existing situation: species, size, and number of birds to be necropsied or sacrificed; tissues, fluids, and cultures to be taken; etc.

Necropsy Precautions

If there is reason to suspect that birds to be necropsied are infected with disease that may be contagious for humans (chlamydiosis, erysipelas, or equine encephalitis), stringent health precautions are essential. The carcass and the necropsy table surface should be wet thoroughly with a disinfectant. Good rubber gloves should be worn and care should be taken that neither the pathologist nor assistants puncture the skin of their hands or inhale dust or aerosols from tissues or feces. It is advisable to wear a fine-particle respiratory mask to prevent inhalation of contaminated dust. All laboratory personnel who may come in contact with carcasses, tissues, or cultures should be informed of their possible infectious nature and precautions to be taken.

With some notable exceptions (see sections on the specific diseases), most commonly encountered poultry disease agents are not considered pathogenic for humans. Nevertheless, it is wise to wear rubber gloves at all times while performing necropsies. For a review of poultry diseases in public health, see Galton and Arnstein (37) or the Public Health Significance of Poultry Diseases suchapter below.

Adequate instruments for routine work are necropsy shears to cut bones, enterotome scissors to incise the gut, a necropsy knife to cut skin and muscle, and a scalpel for fine examination of tissues. These should be supplemented with forceps, sterile syringes, needles, vials, and petri dishes for collecting blood samples and tissue specimens as the situation dictates.

Necropsy Technique

Internal Organs

The specimen is laid on its back and each leg in turn drawn outward away from the body while the skin is incised between the leg and abdomen. Each leg is then grasped firmly in the area of the femur and bent forward, downward, and outward until the head of the femur is broken free of the acetabular attachment so that the leg will lie flat on the table (Figure 1.8A).

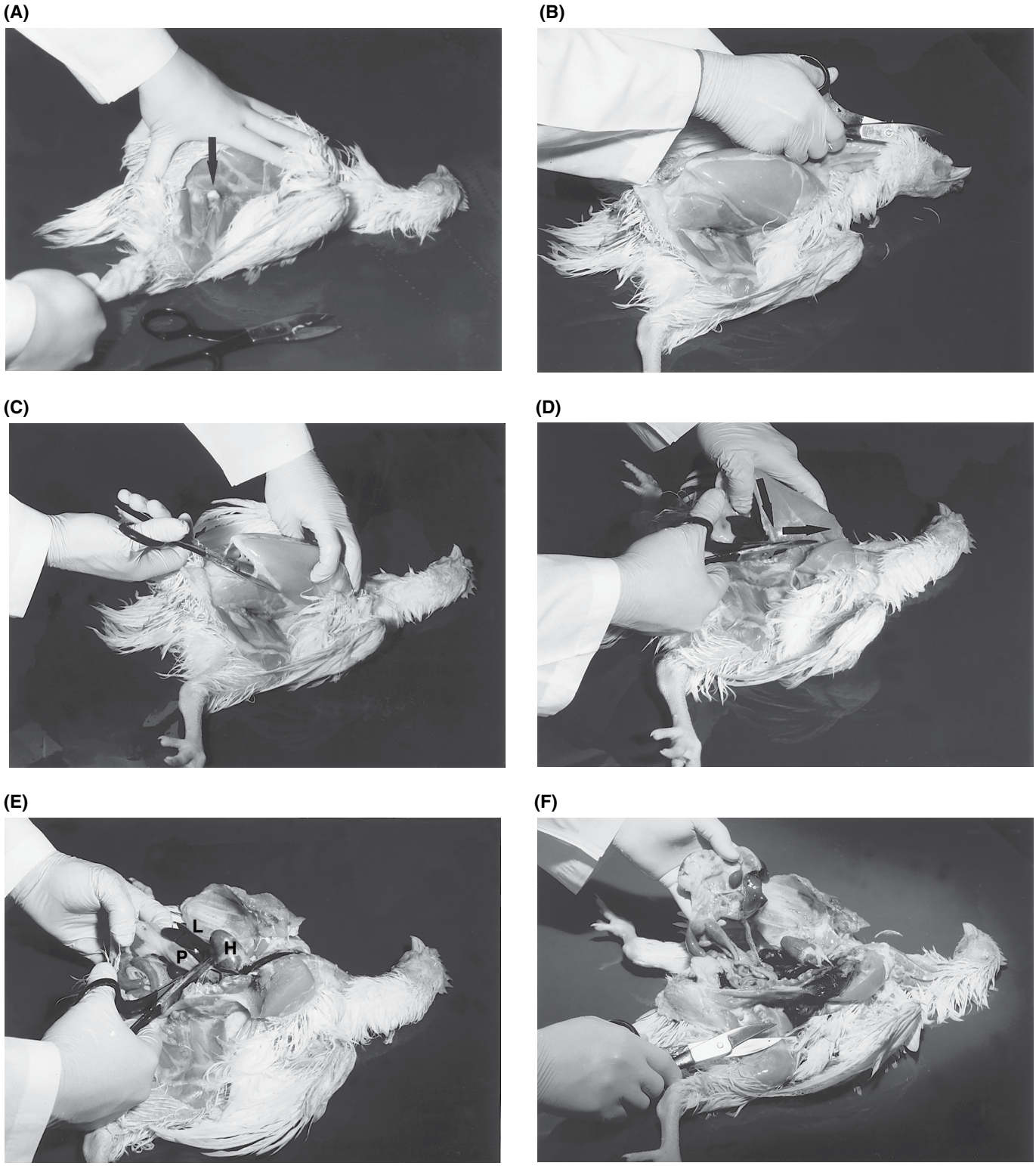

Figure 1.8. Each pathologist will develop his or her own systematic technique for conducting a necropsy. The illustrated technique will aid the beginner. (A) The skin and fascia between the leg and abdomen are cut, and the legs are pulled and twisted to disarticulate the head of the femur (arrow) from the hip. (B) The skin from the vent to the beak is incised and reflected. (C) The body cavity is entered at the ventral tip of the sternum. The incision is made at the margin of the pectoral muscle and continues through 2–3 ribs. A similar incision is made on the opposite side of the breast. (D) The shears are reoriented (arrows), and the incision is continued through bone and muscle to the thoracic inlet. The breast is broken over to the opposite side (or removed), exposing the viscera. At this point of the necropsy, microbiological samples are collected. (E) The intestinal viscera are freed by cutting through the esophagus and vessels of the liver just anterior to the proventriculus and liver. Heart (H), liver (L), and proventriculus (P) are indicated. (F) The intestines can be removed by gentle traction, which tears mesenteric and air sac attachments. The lungs, heart, and kidneys remain in the body cavity for later examination.

The skin is cut between the 2 previous incisions at a point midway between keel and vent. The cut edge is then forcibly reflected forward, cutting as necessary, until the entire ventral aspect of the body, including the neck, is exposed (Figure 1.8B). Hemorrhages of the musculature, if present, can be detected at this stage.

Either of 2 procedures is now used to expose the viscera. The poultry shears are used to cut through the abdominal wall transversely midway between keel and vent and then through breast muscles on each side (Figure 1.8C). Bone shears are used to cut the rib cage and then the coracoid and clavicle on both sides (Figure 1.8D). With some care, this can be done without severing the large blood vessels. The process also may be completed equally well in reverse order, cutting through the clavicle and coracoid and then through the rib cage and abdominal wall on each side. The sternum and attached structures can now be removed from the body and laid aside. The organs are now in full view and may be removed as they are examined (Figure 1.8E and F).

If a blood sample has not previously been taken and the bird was killed just prior to necropsy, a sample can be promptly taken by heart puncture before clotting occurs. Large veins leading into the leg may be incised, allowing blood to pool in the inguinal region for subsequent collection.

Laboratory Procedures

Bacterial Cultures

If gross lesions indicate bacterial cultures are needed, they can be made from unexposed surfaces of the viscera without searing the surface. If contamination has occurred, the surface of the organs should be seared with a hot spatula or other iron designed for that purpose before inserting a sterile culture loop. Care must be taken not to sear and heat the tissue excessively. It is often desirable to transfer large tissue samples aseptically to a sterile petri dish and take them to the microbiology laboratory for initial culture in cleaner surroundings.

Respiratory Virus Isolation

If a respiratory disease is suspected and virus culture or bird passage is desirable, an intact section of lower trachea, the bronchi, and upper portions of the lungs is removed aseptically with sterile scissors and forceps and transferred to a sterile container. Other tissues (air sac tissue) can be added aseptically to the sample or transferred to other sterile containers for separate study. The trachea can now be incised. If exudate is present, it can be added to the preceding collection or saved in separate vials. Similar procedures can be followed for initial virus isolation from various parenchymatous organs.

Salmonella Cultures

All other visceral organs should be examined for abnormalities (microabscesses, discoloration, swelling, and friability). If abnormalities are observed, inoculum from the affected tissues should be transferred to suitable solid or liquid media for culture before the intestinal tract is opened. Once opened, gross contamination of other organs with gut contents is almost certain to occur. If Salmonella infection is suspected, selected sections of the gut are removed with sterile forceps and scissors and placed directly into a sterile petri dish for later culture. For routine examination, a single section comprising the lower ileum, proximal portions of the ceca and cecal "tonsils," and proximal portion of the large intestine may be used. All are minced or ground aseptically to produce an inoculum. Additional areas of the intestinal tract or tissues of other visceral organs may be added to the gut collection or cultured separately. Alternatively, sterile swabs may be used to obtain samples from the exposed gut lining for Salmonella cultures. See Chapter 2 of *A Laboratory Manual for Isolation and Identification of Avian Pathogens* (32) for detailed culture technique.

Gross Necropsy

After necessary cultures have been collected, a thorough gross examination of all tissues should be performed. Enlargement of the liver, spleen, and kidney should be evaluated. A clear indication of hepatomegaly is rounded liver margins. The intestine may be examined for inflammation, exudates, parasites, foreign bodies, malfunctions, tumors, and abscesses. The various nerves, bone structure, marrow condition, and joints can now be examined. The sciatic nerve can be examined by dissecting away the musculature on the medial side of the thigh. Inside the body cavity, the sciatic plexus is obscured by kidney tissue. These nerves can best be exposed by scraping away the tissue with the blunt end of a scalpel. Nerves of the brachial plexuses are easily found on either side near the thoracic inlet and should be examined for enlargement. Examination of vagus nerves in their entirety should be made, or otherwise short enlargements may be missed.

The ease or difficulty with which bones can be cut with the bone shears is indicative of their condition. The costochondral junctions should be palpated and examined for enlargement ("beading") and the long bones cut longitudinally through the epiphysis to examine for abnormal calcification. Rigidity of the tibiotarsus or metatarsus should be tested by bending and breaking to check for nutritional deficiency. A healthy bone will make an audible snap when it breaks. Bones from a chicken deficient in vitamin D or minerals may be so lacking in mineral elements that they can be bent at any angle without breaking.

Joint exudate, if present, can be removed after first plucking the feathers and searing the overlying skin with a hot iron. After searing, the skin may be incised with a sterile scalpel and exudate removed with a sterile inoculating loop or swab. Paranasal sinus exudates can be removed and examined in a similar manner.

Exposure and Removal of Brain

Removing the intact brain is not easy, because meningeal layers are attached firmly to bony structures in some places. The following technique can be performed quickly and is satisfactory for examination and removal of the brain in most instances.

Remove the head at the atlanto-occipital junction and remove the lower mandible. Sear the cut surface and trim away excess loose tissue. Reflect the skin forward over the skull and upper mandible and hold it firmly in that position with 1 hand. Sterile instruments should be used for the succeeding steps if a portion of the brain is desired for animal inoculation, virus isolation, or fungal or bacterial culture.

With the sterilized tips of heavy-jawed bone shears or strong surgical scissors, nip just through the bone to the cranial cavity on both sides of the head, beginning at the occipital foramen and proceeding forward laterally to the midpoint at the anterior edge of the cranial cavity (Figure 1.9A). Lift off the cut portion of bone and expose the entire brain (Figure 1.9B).

If a portion is needed for culture or animal inoculation (e.g., avian encephalomyelitis virus suspect) and also 1 for histopathologic examination (e.g., vitamin E deficiency), cut the brain medially from anterior to posterior along the midline with a sharp, sterile scalpel blade. With sterile, sharp curved scissors, cut the nerves and attachments carefully from 1 of the brain halves while the head is tipped upside down, so that the loosened portion falls into a jar of formalin as it is freed (Figure 1.9C). The second half can now be removed aseptically (but without concern for preservation of tissue structure) to a sterile petri dish or sterile mortar and pestle. Be careful not to contaminate brain tissue intended for virus isolation with instruments that have been in contact with formalin. The separate halves also may be removed in reverse order (Figure 1.9D). If all of the brain is required for either purpose, proceed with proper precautions for the purpose intended. If the brain is destined only for sectioning, it may be fixed *in situ* and then removed. Large brain portions should be incised longitudinally to permit good penetration of fixative.

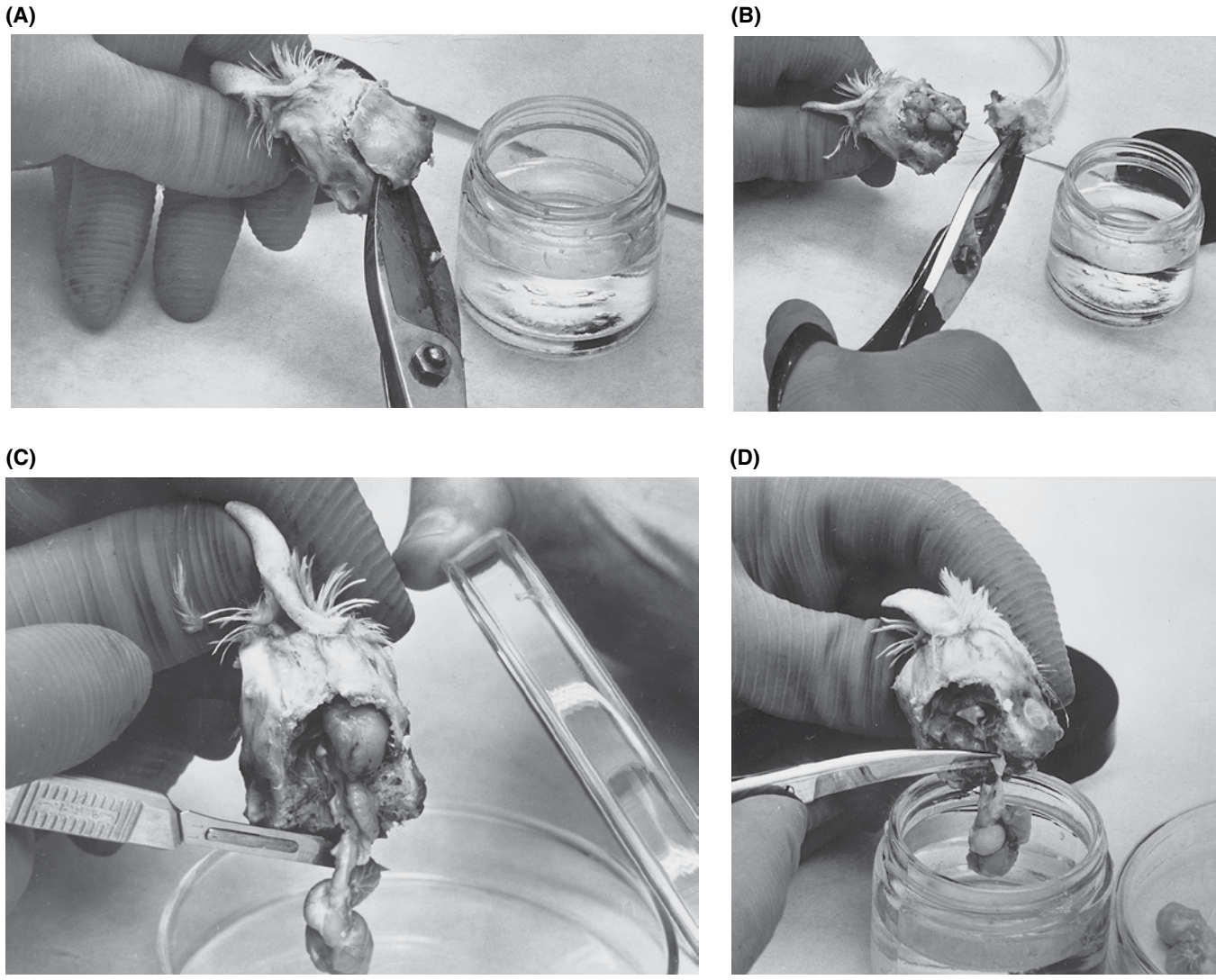

Figure 1.9. With a little practice, the brain can be removed with a minimum of trauma. (A) Incise bone all the way around the periphery of the cranial cavity with heavy bone shears. (B) Remove loosened portion of the bony skull. (C) Incise brain longitudinally with sterile, sharp scalpel and remove one-half for sterile culture technique. (D) Remove second half by dropping it into 10% formalin for histologic techniques.

Tissues for Histopathologic Examination

Frequently, stained tissue sections are needed. The quality of the slide is no better than the quality of the specimen and the care taken to preserve it. For good preservation, the tissue pieces from killed birds should be saved immediately after death, especially gastrointestinal, brain, and kidney tissues, which deteriorate rapidly. Specimens should be small to allow quick penetration of fixative, gently incised with a sharp scalpel or razor blade to preserve tissue structure, and preserved in 10 times their own volume of 10% formalin or other fixative. Bone pieces should be sawed with a sharp bone saw unless thin or soft enough to cut with scissors or scalpel. After proper labeling and dating, they should be sent immediately to the processing laboratory.

Lung tissue usually floats on the surface of the fixing solution because of trapped air. Satisfactory fixation can be accomplished by placing absorbent cotton over the tissue, which serves to keep it immersed. Methods to exhaust air from air spaces in lung tissue by creating a vacuum over the fixative can be used but are less satisfactory and may result in artifacts.

After fixing, bone tissue must be decalcified by immersion in a decalcification solution made by mixing equal parts of aqueous 8% hydrochloric acid and aqueous 8% formic acid (66). Decalcification typically takes 1–3 days, depending on the size and density of the bone sample.

If eye tissue is to be saved for sectioning, the whole eye should be removed and all ocular muscles trimmed off the globe to allow for rapid penetration by the fixative.

Any tissue held too long in formalin fixative becomes excessively hard. If processing is to be delayed, tissues should be transferred to 70% alcohol after 48 hours in fixative. Textbooks on histologic techniques (65, 66, 80) should be consulted for detailed procedures.

Progressive Examination Hints

The following procedures during the course of necropsy may be helpful to the beginner in checking for some commonly encountered diseases. They are not intended as definitive diagnostic methods. To arrive at a diagnosis, the student and beginning diagnostician must refer to the characteristic signs and lesions, diagnostic procedures, and characteristics of the infectious agent discussed under the specific diseases in succeeding chapters, and also to the manual *Isolation and Identification and Characterization of Avian Pathogens* (7).

Coccidia. Observe and note the subserosa before incising the intestine. Make wet mount smears of mucosal scrapings from various segments of the intestine and cecal contents and examine directly under the microscope for suspended oocysts and merozoites and stages undergoing development in epithelial cells (tissue stages).

Other Protozoa. Make wet mounts of affected areas, adding a little warm physiologic saline solution if necessary to provide fluid, and examine under a microscope for hexamita, histomonads, and trichomonads.

Capillarids and Ascarid Larvae. Collect mucous exudate and deep mucosal scrapings and press into a thin layer between 2 thick pieces of plate glass. Examine before a strong light or under low-power magnification for the presence of parasites. Under magnification, look for bipolar, lemon-shaped eggs in the female capillarids.

Fungi. Make wet mount smears of scrapings of affected areas and add 20% sodium or potassium hydroxide. Digest with frequent warming for 15 minutes or more and examine under high-power magnification for mold hyphae.

Campylobacter. Examine fresh bile wet mounts under dark-field or phase illumination. Only positive findings may have significance.

Bacteremia and Blood Parasites. Make fresh mounts, preferably with citrated blood, and examine under light- and dark-field illumination for viable organisms. Make fresh blood smears and air dry for staining by Giemsa's, Gram's, Wright's, or other method.

Exudates. If infectious coryza is suspected, make thin smears of clear nasal or sinus exudate for staining by Giemsa's, Gram's, methylene blue, or other method. Inoculate appropriate media or susceptible chickens for isolation of the organism.

Abscesses. Select appropriate culture media suitable for the growth of a variety of infectious organisms that may be suspected of causing the abscess. Sear and incise the surface of the abscess and inoculate culture media with the extracted material, using a sterile inoculating loop or swab. Make smears from the abscess on clean glass slides, diluting with a drop of water if the material is too thick. Air dry and flame slides and make Gram's, acid-fast, or any other stain as desired.

Embryo Inoculation for Virus Isolation. For routine virus isolation, centrifuged and/or filtered fine-ground suspensions of suspect tissues (trachea, bronchi, lung, liver, spleen, kidney, brain, bone marrow) or body fluids and exudates may be inoculated into the chorioallantoic cavity and yolk sac and onto the chorioallantoic membrane (CAM) of embryos at various stages of incubation. See discussions of the specific diseases for virus culture techniques. Also see *A Laboratory Manual for the Isolation and Identification of Avian Pathogens* (32) for selection of the proper age of embryo and route of inoculation for various disease agents as well as detailed inoculation procedures. Embryos from specific pathogen free hens should be used for culture to be sure that any agent recovered originated in the inoculum and not in the hens that produced the eggs. Equally important is assurance that negative cultures are due to absence of infectious agents in inoculum, rather than to interference of passive antibodies in eggs. Because the purpose of virus isolation is to determine which may be present, it is advisable to inoculate

various ages of embryo by the various routes. Several blind passages may be necessary before the culture attempt can reasonably be considered negative. A simple technique that does not require dropping the CAM has been described (43).

The CAM may be drawn away from the shell (dropped) to facilitate inoculation. First, drill or punch a small hole in the shell over the air cell and then slowly drill or punch a second hole through the shell at a point on the side over the embryo. Applying mild suction through a rubber tube over the hole into the air cell causes the CAM to drop away from the inner shell membrane under the second drilled hole. A bright candling light should be used while suction is applied to determine when the CAM has dropped.

For yolk sac inoculation, the needle can be directed through the air cell and directly to the center of the egg. Some yolk may be withdrawn into the syringe to verify the location of the needle.

For chorioallantoic cavity inoculation, a hole is drilled over the edge of the air cell at a spot previously marked with the aid of a candling light. The cavity lies adjacent to the shell and can be easily penetrated from that point. All holes should be sealed with suitable sterile material before reincubating.

Cell culture procedures are becoming more common in diagnostic laboratories. Technicians with this capability may inoculate the cell cultures directly with tissue extracts or body fluids, or they may use embryos for primary screening and transfer embryo fluids or extracts to cell culture for further study and identification.

Disposing of the Specimen

If a disease infectious for humans is suspected, the carcass should be autoclaved, incinerated, or otherwise rendered incapable of transmitting the pathogen to laboratory or other personnel. Similar precautions should be followed during disposal of carcasses infected with a virulent poultry pathogen that presents a health hazard to the industry. The necropsy area, instruments, and gloves should then be cleaned, washed, and disinfected.

Communication

Flock owners are not always interested in technical data. They want to know what the problem is and what should be done to correct it and/or how to prevent reoccurrences. Sometimes technical data are necessary to clarify the diagnosis, but the report should be in language and terms that owners will understand. A minimum of complicated scientific and medical technology words should be used. When medical terms are apt to be confusing, they should always be explained in lay terms.

The report should include the necropsy findings, results of laboratory studies, (histopathologic, serologic, and cultural), diagnosis (temporary or final), and conclusions and recommendations. The owner is seeking professional advice. The veterinarian should give his or her best conclusions and recommendations based on the facts available. A verbal report or telephone call to the flock owner, manager, or service worker soon after completion of the necropsy and initial tests is highly advisable. A tentative diagnosis can be offered pending further confirmation.

Disease Control: Biocontainment

Disease control strategies are designed to reduce the consequence of disease challenge by limiting challenge (bioexclusion), enhancing bird resistance (immunization), and preventing spread (quarantine). In the case of eradicable diseases, quarantine is usually followed by emergency slaughter. Control measures are implemented routinely for diseases that are endemic to the epidemiological unit and sporadically when there is an unexpected epidemic disease outbreak.

The word quarantine has several different meanings: (1) enforced isolation of animals that may have been exposed to a contagious or infectious disease (e.g., when entering a country), (2) a place in which animals spend a period of isolation to prevent the spread of disease, and (3) the period of time during which animals are kept in isolation to prevent the spread of disease. For live bird and product importation, quarantine is routine. To prevent the introduction of a pathogen into a country, region, zone, or compartment it is essential that potentially infectious material is kept in isolation until it have been shown to be clear of the pathogen(s) in question.

In a production setting quarantine is the first step of biocontainment and it involves the immediate enforced isolation of birds that have been exposed to a contagious disease. The movement of anything into, onto, from, or through the area of control must be restricted and monitored. The extent of the control zone depends on the risk associated with the disease but usually involves the house, farm, site, or complex within a particular company. If the disease is of national or regional importance, the control zone is usually a circle with a 2-mile radius around the affected farm. It is important to establish the extent of the disease outbreak through disease monitoring, first within the quarantine zone and then in a demarcated surrounding contact zone. In the case of foreign/notifiable diseases the relevant veterinary authority assumes control. In the United States, each state has a predetermined emergency response plan carefully designed to handle all of the relevant details of containment and eradication.

Chemoprophylaxis

Prophylactic medication in the form of in-feed medication, and in specific cases, water medication, may be used to reduce the risk of disease by reducing agent virulence.

$$\text{Risk of infection} = \frac{\text{challenge dose} \times \text{agent virulence} \times \text{challenge frequency}}{\text{resistance}}$$

Chemoprophylaxis is used routinely in the control of coccidiosis worldwide. Chemicals and ionophores are added to broiler diets to reduce virulence of the *Eimeria* species challenge.

Immunization

Immunization through vaccination is a commonly used method of reducing the risk (increased ID_{50}) and consequence (reduced pathogenicity) of bird or flock exposure to a disease-causing agent. Vaccination is the practice of administering live and/or killed vaccines which have been modified to minimize disease manifestation yet maximize immunity. The primary purpose of immunization is to raise the ID_{50} of the flock to prevent clinical disease following subsequent challenge. While some vaccines are given to protect that individual bird against disease, others are given to pass the protection on to the next generation, and others are given to prevent disease in the hen and subsequent transmission of the disease to the chick.

Vaccines and vaccine programs vary widely in their effectiveness, and this is frequently by design. Some vaccines are designed to incite high levels of immunity to protect birds in the face of aggressive endemic disease challenges, such as vvND. These vaccines may cause a mild form of the disease themselves but are deemed appropriate and useful because of the risk associated with eventual infection of the deadly field pathogen. Vaccine selection and how they are programmed frequently becomes an exercise in risk management and cost efficiency. Local conditions must always be considered when evaluating and critiquing a vaccination program.

A second reason for the vaccination of poultry flocks is to hyperimmunize hens to maximize maternally derived antibody passed through the egg to the hatching progeny. Chicks frequently receive up to 3 weeks of protection from maternal antibodies, allowing their immune system to mature to a level capable of eliciting an efficient active immune response if exposed to a potentially harmful virus or bacteria. Antibodies are not always completely protective but for viruses such as infectious bursal disease (IBD), many areas of the world have found maternal antibodies a very useful tool in IBD prevention and control.

The success of vaccination does not rest solely with the manufacturing or research of vaccines. More important is the maintenance of the cold chain, protection of the vaccine from the elements, and the correct application of the vaccine to the bird. Vaccination programs should be documented for each operation by the responsible veterinarian and operations manager. All vaccines must be stored at the correct temperature. Most vaccines require refrigeration at 2°C to 8°C. Some vaccines, mostly killed oil vaccines, can be safely stored at room temperature. Some vaccines need to be stored at temperatures below 0°C. Vaccines are adversely affected by exposure to sunlight and heat. Vaccines must be administered using suitably cleaned equipment and be given to every bird in the defined epidemiological unit.

Types of Vaccines

Poultry vaccines are typically characterized as live or inactivated. General characteristics of vaccines are summarized in Table 1.1 (18). Live vaccines are available for numerous viral, bacterial, and coccidial organisms.

Techniques used in the development of live vaccines have varied widely. Table 1.2 shows some of the most common methods used to generate an acceptable live vaccine candidate and examples of each method.

Live vaccines are widely used throughout the world because they are commonly effective when mass applied, and they are relatively economical. Immunity from live vaccines is generally short-lived, particularly following initial exposure. Some exceptions to this exist for vaccines such as for infectious laryngotracheitis, fowlpox, and Marek's disease, which give long-lived immunity.

For live vaccines to work as they were designed, they must be stored, mixed, dosed, and applied appropriately. Storage of live vaccines is generally in a dark, refrigerated area. Liquid nitrogen freezing of live vaccines preserves and prolongs cell culture viability that is essential for cell-associated vaccines such as Marek's disease vaccines. Licensed live vaccines have an expiration date printed on the vial that, if stored according to label directions, ensures that the appropriate minimum dose is maintained through the dating period. Shelf life varies widely with live vaccines, but most generally are licensed with 18 months to 2 years before expiration. Mixing directions also vary widely, but many recommend the use of a water stabilizer such as powdered skim milk. Water stabilizers minimize some of the negative effects of residual chlorine, metals, and high temperature on the reconstituted virus. Cell-associated Marek's vaccines generally have very specific diluents aimed at maintaining cell culture viability through the time period between reconstitution and inoculation. The dose needed to get an appropriate immune response from a live vaccine is frequently dependent on the virus, genetic background of the bird, age of the bird, existing circulating antibody within the bird, and the method to be used when applying a vaccine. Vaccines generally are licensed based on protection studies performed in an SPF-type leghorn bird, without any circulating antibody to that particular agent, at the youngest age on the label, and at the minimum titer expected at the end of the dating period allowed for each given vaccine. With all of these variables, it is not difficult to imagine why clinical veterinarians and other health professionals may adjust dosages of live vaccines according to local field conditions.

Severe vaccine reactions or insufficient protection can result from misjudging any of these variables. As a final note, poultry house conditions and local disease risks need to be taken into account when optimizing the use of live vaccines.

A second type of live vaccine is emerging with the development of genetically engineered, live virus- and bacteria-vectored vaccines and gene deletion mutants of a pathogenic parent organism. The recombinant vaccines are made using live virus or bacteria as a vector to transport the gene coding for the protective antigen of a second infectious agent, for which immunity is desired. Examples of live virus-vectored vaccines include recombinant fowlpox virus vaccine expressing genes to protect against H5 avian influenza (13), fowlpox virus expressing Newcastle disease virus antigen (17), fowlpox virus expressing infectious bursal disease virus antigens (11), and baculovirus expressing infectious bursal disease virus antigens(84). Bacteria-vectored vaccines described in poultry include bacteria such as *E. coli* (46) and *Salmonella* spp. (68) expressing antigens from

Table 1.1. General characteristics of live and inactivated vaccines for poultry.

Live vaccines	Inactivated vaccines
Smaller quantity of antigen. Vaccination response relies on multiplication within the bird.	Large amount of antigen. No multiplication after administration.
Can be mass administered—drinking water, spray.	Almost always injected.
Adjuvanting live vaccines is not common.	Adjuvanting killed vaccines is frequently necessary.
Susceptible to existing antibody present in bird.	More capable of eliciting an immune response in the face of existing antibody.
In immune bird, booster vaccination is ineffective.	In immune bird, additional immune response frequently seen.
Local immunity stimulated (i.e., trachea or gut).	Local immunity may be re-stimulated if used as a booster but poor if not a secondary response.
Danger of vaccine contamination (e.g., egg drop syndrome, reticuloendotheliosis virus).	Little danger of vaccine contamination.
Tissue reaction commonly referred to as a "vaccine reaction" is possible and frequently visible in a variety of tissues.	No microbe replication; therefore, no tissue reaction outside that which is adjuvant dependent.
Relatively limited combinations—due to interference of multiple microbes given at the same time (e.g., infectious bronchitis, Newcastle disease virus, and laryngotracheitis).	Combinations are less likely to interfere.
Rapid onset of immunity.	Generally slower onset of immunity.

Table 1.2. Methods of generating live vaccine candidate.

Method	Example
Virulent organism inoculated to a less susceptible target tissue or at a controlled dose	Laryngotracheitis-cloacal route
Naturally occurring mild pathotype	*Mycoplasma gallisepticum* F strain
Egg passage of virulent parent	Infectious bronchitis—Arkansas strain
Temperature-sensitive mutant of virulent parent	Turkey coryza vaccine—*Bordetella avium*
Chemically derived mutants of virulent parent	M-9 Fowl cholera vaccine
Tissue culture / passage of virulent parent	Laryngotracheitis
Combination of egg passage and tissue culture passage of virulent parent	Infectious bursal disease—Lukert virus
Plaque selected "clones" of parent virus	Newcastle disease virus—cloned Lasota vaccines
Selection of subpopulations or organisms based on replication characteristics *in vivo*	Precocious strains of *Eimeria* spp.
Relatively virulent organisms given at an age that minimizes disease	Avian Encephalomyelitis

coccidia and *E. coli*, respectively. A vaccine to reduce salmonella infection, made from a gene deletion mutant of *Salmonella typhimurium* (30), is commercially available.

These recombinant and gene deletion mutant vaccines have been shown to be relatively protective, when compared to controls, against pathogenic challenge under experimental conditions. The efficacy and cost effectiveness of the recombinant vaccines under field conditions are yet to be determined. This type of vaccine may offer advantages where the spread of traditional vaccines to susceptible populations cannot be properly managed. Additionally, these technologies allow for diagnostic differentiation of vaccine from virulent field challenge. This property may be useful when used in eradication programs such as infectious laryngotracheitis. Regulatory considerations when acquiring a federal license for vectored vaccines include demonstrating the genetic and phenotypic stability of recombinant viruses or bacteria and documenting any alterations in the host range or tissue tropism of the recombinant organism, as compared to the parent organism (62).

Inactivated vaccines or killed vaccines used in poultry are generally whole bacteria or virus preparations combined with an adjuvant that are designed for subcutaneous or intramuscular injection. They are frequently, but not always, used in commercial egg layer and breeding birds to stimulate long-lasting immunity and/or antibody levels to specific antigens. Inactivated vaccines generally consist of 2 distinct components, often referred to as aqueous and adjuvant phases, emulsified into a homologous liquid. The aqueous phase contains the antigen and the adjuvant generally enhances the bird's response to this antigen. The ratio of antigen to adjuvant differs greatly depending on the vaccine. This ratio generally is determined by factoring in the properties of the adjuvant(s), the antigen(s), viscosity, immune response, and tissue reactivity. Mineral oil is the most commonly used adjuvant, although aluminum hydroxide is a common alternative in notoriously reactive inactivated vaccines such as fowl cholera and infectious coryza. Adjuvant technology continues to grow, and vegetable, fish, and animal oils used as adjuvants offer some opportunities for lower viscosity, immunogenic vaccines (65).

Accidental injection of humans that are administering these inactivated vaccines should be prevented. Serious injuries have been reported from accidentally injecting vaccine into a finger or hand. The site of injection can become swollen, red, and painful, and the function of the area may be affected. Victims should seek medical treatment at once and inform attending physicians of the organism(s) and adjuvant contained in the inactivated vaccine.

DNA vaccines are an entirely new type of vaccine that evolved in the late 1990s. These vaccines can achieve both humoral and cell-mediated immunity, are similar to live vaccines, and have the relative safety associated with inactivated or vectored vaccines. Experimental DNA vaccines have been tested with success in poultry for avian influenza and Newcastle disease in chickens (36, 70) and duck hepatitis B in ducks (82). Although promising, DNA vaccines have both technological and economical challenges to overcome before they are commercially viable.

Vaccine Delivery Systems

Improper vaccine application is the most common reason vaccines and vaccine programs fail. With the success and growth of the poultry industry throughout the world came tremendous challenges in efficient and economic application of poultry vaccines. The most commonly used application techniques in commercial poultry include *in ovo* at 17–19 days of embryonation, subcutaneous or intramuscular injection at day of hatch, spray in the hatchery, intraocular or nasal drop in the hatchery or on the farm, spray on the farm, through the drinking water on the farm, wing web stab, and subcutaneous or intramuscular injection on the farm.

In Ovo Vaccination. *In ovo* vaccination is performed during the process of transferring incubating eggs in the hatchery from the setter to the hatcher. After poking a hole in the shell, vaccine, most frequently Marek's disease vaccine, is injected just under the membranes at the floor of the air cell. Depending on the embryo age at transfer, generally between 17 and 19 days of incubation for chickens, approximately 25%–75% of the vaccine (0.05 ml in most cases) is injected into the area of the neck and shoulder. In the remaining 25%–75%, vaccine is administered into the extra embryonic compartment (40). The original experiments on *in ovo* vaccination with Marek's disease vaccine showed that chicks were protected earlier than those vaccinated after hatch (73). However, in the United States, where more than 80% of broiler chickens are vaccinated against Marek's disease *in ovo*, the primary reason for its acceptance has been the labor savings when compared to day-old injection (81). Using an egg injection system (Embrex Inovoject Egg Injection System, Research Triangle Park, NC), 1 machine with 3 people generally inoculates 20,000–30,000 eggs/hour (Figure 1.10). This method of vaccination leaves a hole in the egg for the final few days prior to hatch and in poorly sanitized hatcheries has resulted in poor early livability due to bacterial or fungal contamination while in the hatcher. Hatcheries must be acutely aware of their aspergillosis levels to run an egg injection system successfully (87).

Figure 1.10. A modern hatchery with an egg injection system for *in ovo* vaccination.

Subcutaneous or Intramuscular Injection at Day of Hatch. Day-old vaccination, most commonly using Marek's disease vaccine, is generally accomplished by giving 0.2 ml of vaccine subcutaneously under the skin at the back of the neck or 0.5 ml intramuscularly in the leg. The automatic vaccination machines used in many parts of the world generally are designed for neck injection. A skilled operator can vaccinate about 1,600–2,000 chicks/hour. A 20-gauge needle generally is used, because smaller gauge needles restrict the flow in cell-associated vaccines. Needles should be changed several times during the course of the day to prevent damage from burred or bent needles. Improper positioning of the chick or a bent needle can result in damage to the neck muscles or vertebrae. A dye is frequently mixed with the vaccine to allow visualization of the vaccine under the skin after injection. A quality check of technique generally means examining each bird in several boxes, 100 to a box, after vaccination, looking for colored dye under the skin. The most frequent cause of missed birds is the operator trying to go too fast, resulting in chicks being pulled off the needle before proper deposition of vaccine.

Spray in the Hatchery. Spray vaccination of birds in the hatchery generally is done using a spray box that is triggered each time a box of chicks is placed inside or an in-line spray cabinet that sprays boxes as they move down a controlled-speed conveyor line in an automated hatchery. Both methods, frequently used to deliver NDV, infectious bronchitis virus, or coccidiosis vaccine, attempt to mimic eye-drop vaccination. Spray vaccination in the hatchery generally works well if the droplets generated have a particle diameter of approximately 100–150 microns. Particle size is very important. Low relative humidity may decrease the particle size by the time it reaches the bird, resulting in too fine a spray. Fine spray, generally something less than 20 microns in diameter, can travel deep into the respiratory tract, resulting in excessive vaccine

reaction if using a respiratory disease vaccine. Although there is some variability, NDV and infectious bronchitis virus vaccines are often delivered in 7 ml of distilled water/100 chicks. Coccidiosis vaccines generally use more distilled water, approximately 20–25 ml/100 chicks. Birds preening themselves and each other immediately following spray vaccination is thought to be important to the resulting vaccination response, although little data exists to support this concept.

Spray Vaccination on the Farm. With the increased acceptance and use of closed watering systems and the increased cost of labor required to effectively vaccinate through the drinking water, spray vaccination of respiratory vaccines, such as NDV and infectious bronchitis virus, has become increasingly popular. This method of vaccination frequently uses spray equipment adapted from insecticide and pesticide application technologies. As with the hatchery spray vaccination, the method is designed to mimic eye-drop vaccination but allows the vaccinator to avoid handling each bird in the poultry house.

Distilled water generally is used to reconstitute the vaccine(s). Although the volume of water used varies depending on the spray machine selected, 5 gallons of water/20,000 birds vaccinated is a good general recommendation. It generally is preferred to vaccinate a flock first thing in the morning. Fans should be turned off, if possible, and the lights should be as dim as the vaccinator can allow and still walk through the house. In floor houses, if another person is available, 1 person can split the flock while the vaccinator slowly sprays 1 side at a time. If possible, running fans should be minimized for the 15 minutes following vaccination.

An effective spray vaccination technique allows exposure of birds to aerosolized vaccine for approximately 5–10 seconds. This is best accomplished by spraying a relatively coarse spray, in the range of 100–150 microns, and walking slowly through the poultry house.

A visual evaluation of a spray pattern can be done with each vaccination. Look for an even distribution and consistent projection. A crude estimation of droplet size may be made using the analogies listed in Table 1.3 (78).

Intraocular or Nasal Drop in the Hatchery or on the Farm. Intraocular or nasal drop is a highly effective but labor-intensive method used to deliver respiratory disease vaccines for diseases such as infectious laryngotracheitis. This method generally involves depositing approximately 0.03 ml of reconstituted vaccine in the eye or nares. Both techniques generally require the vaccinator to pause briefly as the vaccine disappears in the appropriate opening. A dye-colored diluent helps to visualize the vaccine and allows a quality check on technique by looking around the nares or eye for dye. Frequently some dye can be seen by looking in the bird's mouth around the choanal cleft or edges of the tongue.

Table 1.3. Visual analogy to droplet size diameter.

Analogy	Diameter (microns)
Wet fog	25–40
Visible droplets	50
Misty rain	50–100
Light rain	200–400

Drinking Water Vaccination on the Farm. A very common and useful technique in commercial poultry has been to apply vaccine through the drinking water. Proper preparation of the watering system to be used through removal of all disinfectants, such as chlorine, should be done 2 days prior to vaccination. It is best to buffer the system by flushing it with a weak solution of powdered skim milk, generally 1 cup powdered skim milk to 50 gallons of water (23). This type of buffer generally is also used while administering the vaccine.

Best results are achieved through a process that creates a mild degree of thirst by eliminating access to drinking water for approximately 2 hours prior to the vaccination procedure. This time varies widely. Climatic conditions may necessitate longer or shorter time periods. Thirst is optimal when the time between the first and last access to vaccine is approximately 2 hours. Two hours generally allows all birds, even those lower in the social order, adequate time to get a drink of water containing vaccine. This technique requires constant adjustment as the climate changes.

Wing Web Stab. Wing web vaccination requires individual bird handling but can be done relatively rapidly. There are 2 commonly used wing web application tools. The first is the traditional small plastic handle, approximately 3 cm long, that has 2 solid stainless steel prongs, approximately 2 cm long, with a bevel on each prong toward the needle end. The second, newer application tool is referred to as a Grant inoculator. This tool has a self-contained reservoir for vaccine, most often used for fowlpox or fowl cholera vaccination, in which a needle passes through, loading a new dose of vaccine for each bird inoculated. Both tools are designed to deliver approximately 0.01 ml on the needles to the bird's wing web. The wing web is an area that has relatively few feathers, bone, or muscle. The vaccinator loads the applicator and sticks the needle(s) completely through the skin on both sides of the web, originating from the underside of the wing. There is little or no bleeding, and vaccine has been inoculated through the needle holes. Wing web vaccination technique can be checked by returning to the vaccinated flock 7–10 days after vaccination and palpating the wing web area for nodular scabs or granulomas. These areas created by the vaccine are commonly referred to as "takes." Proper vaccination technique frequently results in 95%–100% take.

Subcutaneous or Intramuscular Injection on the Farm. Subcutaneous and intramuscular injections are frequently used in breeder pullets and commercial egg-laying pullets prior to egg production. These vaccines are generally recommended for use at least 4 weeks prior to the onset of egg production to minimize

any adverse effect the handling or the vaccine may have on egg production performance. Subcutaneous vaccination is most frequently performed using a 1/2-inch, 18-gauge needle in the neck. The area halfway between the head and the shoulder is optimal and allows the vaccinator to lift the skin away from the neck muscle and insert the needle, pointed toward the body of the bird, into the subcutaneous area and deposit the vaccine. Intramuscular injection generally is performed using a 1/2-inch, 18-gauge needle to inject vaccine into the breast or leg muscle. Breast muscle injections are safest when the vaccine is deposited in the superficial pectoral muscle 2–3 cm lateral to the keel bone. If the needle is kept at a 45-degree angle to the bird, any accidental injections into the body cavity or liver can be avoided (53). Leg vaccination generally is done in the lateral gastrocnemius muscle. Both intramuscular injection sites may result in residual emulsion being present for an extended period of time (31). A residual deposit in muscle depends on many factors including the antigen and the adjuvant found in the vaccine. Care should be taken to determine the intended use of meat before injecting intramuscularly.

Vaccine Failure

Numerous factors can cause a vaccine failure. One of the most common causes of vaccine failure is the inappropriate administration of the vaccine. Certain live vaccines, such as Marek's disease vaccine, are easily killed, and failure to follow the manufacturer's recommended handling practices will result in the inactivation of the virus prior to administration. Likewise, viable vaccines administered in the drinking water can be destroyed before they reach the bird if they are mishandled or if water sanitizers have not been removed from the water prior to the addition of the vaccine. Vaccines that are administered by intramuscular or subcutaneous injection can also fail if vaccinators do not deliver the vaccine to the appropriate vaccination site.

Although the most common cause of vaccine failure is an inadequacy or error in vaccine delivery, numerous instances of vaccines simply not providing adequate protection have occurred. In some cases, the field strain of an organism is of very high virulence, and the vaccine strain is highly attenuated. In this situation, the flock may be effectively vaccinated, but the immunity is insufficient to protect against disease completely. Many infectious agents have several different serotypes, and vaccine failure may be the result of the antigens in the vaccine serotype being different and not providing protection against the particular serotype of the agent causing the field challenge. It is not uncommon for a vaccine break to occur with infectious bronchitis virus when the field challenge is of a serotype different from that of the vaccine used (12).

Management conditions play an important role in the prevention of vaccine failures. If infectious disease agents are allowed to build up on a farm over successive flocks without clean-out and disinfection, it is possible that the challenge dose of a particular infectious agent will be so great, or so soon, that a normally effective vaccination program will be overwhelmed. The immune status of the breeder flock also can be involved in a vaccine failure. If the breeder flock provides progeny with high levels of maternal antibodies, vaccination during the first 2 weeks of life may result in the vaccine being neutralized. The timing of the vaccination of young poultry with viable vaccines must always take the presence or absence of maternal antibodies into consideration.

Certain infectious disease agents and mycotoxins are immunosuppressive and may result in vaccine failure. Infectious bursal disease virus (Chapter 7), infectious anemia (Chapter 8), and Marek's disease virus (Chapter 15) are examples of agents that may cause severe immunosuppression in chickens. One mycotoxin, aflatoxin, has been shown experimentally to be immunosuppressive and has been implicated in decreased resistance to disease (see Chapter 32).

Handling Disease Outbreaks

Good poultry producers watch feed and water consumption and egg production at all times, but more important, they observe normal sounds and actions of the flock. They sense immediately when any of these conditions are abnormal and interpret them as signs of abnormal health. When this happens, it should be assumed that an infectious disease has gained entry and may be tracked elsewhere during the investigation period. In a modern poultry production system, any disease creates serious disruption in the economical operation of the farm and the plant's processing products from it. Serious infectious diseases can create havoc. The following steps should be followed when disease is suspected.

Take precautions against tracking an infectious agent that may be present, but investigate management errors immediately. A high percentage of so-called disease problems referred to laboratories for diagnosis are noninfectious conditions related to management: beak trimming errors; consumption of litter and trash; feed and water deprivation; chilling of chicks; injury from rough handling, automatic equipment, or drug injection; electrical failures; cannibalism; smothering; overcrowding; poor arrangement of feeders, waterers, and ventilators; inexpensive low-quality feed ingredients; ingredients causing feed refusal; improper particle size of feed ingredients; and rodent and predator attacks (1, 15). Zander observed a severe drop in egg production in an SPF flock after a 48-hour failure of a mechanical feeder (92). Bell (14) observed marked reduction in lay from water deprivation related to a beak trimming system that resulted in long lower beaks, making it difficult to obtain water when the level was low. These are conditions that do not require the services of a diagnostic laboratory. External parasites (mites, lice, and ticks) can be determined by producers if they examine affected birds.

Quarantine the Flock

In the event that no management factors can be found, the next step is to set up a quarantine of the pen, building, farm unit area, or entire farm, depending upon its design and programming. If this emergency was anticipated when the farm

was laid out and programmed originally, the quarantine will be a minor problem. If the basic principle of "a single age in quarantinable units" was disregarded in original farm planning, a disease outbreak can be an economic disaster. Separate caretakers should be established for affected birds or at least sick ones should be visited last.

Submit Specimens or Call a Veterinarian

The owner or caretaker should submit typical specimens to a diagnostic laboratory or call a veterinarian to visit the farm and establish the diagnosis. Owners should seek professional diagnosis rather than trying to hide some disease because of possible public recrimination. Veterinarians and caretakers can and should help dispel this apprehension by maintaining high ethical standards and refraining from discussing one producer's problems with others. Yet, there comes a time when all producers must be apprised of a problem. Service workers frequently are requested to examine the flock, select specimens for the laboratory, and initiate first aid procedures until the veterinarian can be called or visited. If so, they should wear protective footwear and clothing when they enter the house. No other farm should be visited en route to the laboratory.

Diagnosis

It is important to get a diagnosis as soon as possible. The course of action will be determined by the nature of the disease. A producer should not procrastinate for any reason when a disease threatens, or it may get completely out of hand before a diagnosis is made. It is not always possible to treat a disease or check its deleterious effects, but to plan effectively for the future, it is important to identify any and all diseases that occur. A veterinarian should also be aware of the owner's economic plight at such times and render advice and assistance as quickly as information is available or a judgment can be made.

Special Precautions

In addition to causing serious losses in poultry, some diseases (chlamydiosis, erysipelas, and salmonellosis) are especially hazardous for humans. When these conditions are suspected or diagnosed, extra precautions must be taken to ensure against human infection. The proper government health authorities should be notified of chlamydiosis outbreaks, and all handling and processing personnel should be apprised of the disease, hazards, and necessary precautions.

In some states, certain diseases (mycoplasma infections, avian chlamydiosis, and infectious laryngotracheitis) must be reported immediately to the state/provincial animal disease control authorities so that proper investigation and action can be taken to protect the human population and the poultry industry. Common sense dictates that when a condition suggestive of an exotic disease, such as vvND, fowl typhoid, or avian influenza, is encountered, the proper state and federal regulatory authorities should be informed.

Nursing Care

Nursing care plays an important role in the outcome of a disease outbreak. Additional heat should be supplied to young chicks that begin huddling because of sickness. Clean and fresh (or medicated) water should be available at close range. Temporary, more accessibly located waterers are sometimes necessary during sickness. If water founts normally are located where chickens must jump onto some raised device or turkeys must cross through hot sunlight to reach them, the sick will not have the energy or initiative to seek water. They will soon become dehydrated, an early step on the road to death.

The same principles are true for feed. Sick birds can be encouraged to eat if the caretaker will proceed through the house, stirring feed and rattling feed hoppers or adding small quantities of fresh feed. Some antibiotics appear to stimulate feed consumption when included in the diet; however, any additive that proves distasteful to the bird should be removed immediately.

Sometimes birds become so depressed and moribund that the caretaker must walk among them frequently to rouse them so that they will eat or drink.

Hopelessly sick and crippled birds should be killed in a manner to preclude or control the discharge of blood or exudates (see Diagnostic Procedures). Dead and destroyed birds should be disposed of immediately (see Dead Bird Disposal).

Drugs

Therapeutic medication in response to primary and secondary disease should be prescribed by the veterinarian after the problem has been diagnosed. Therapy is not a sustainable method of disease control and should not be considered as an ongoing part of any biosecurity program. The flock response to medication merely provides the time necessary to investigate, design, and implement further control measures to avert further need for therapeutic medication.

No drugs should be given until a diagnosis is obtained or a veterinarian consulted. If the wrong drug is given it can be a waste of money or it may be harmful or even disastrous. If an infectious disease is found and corrective drugs are indicated, they should be used very carefully according to directions.

Strict regulations govern the use of drugs in mixed feeds for food-producing animals. For information, write to the U.S. Food and Drug Administration (FDA), 5600 Fishers Lane, Rockville, MD, 20857. A handy reference is the annually updated Feed Additive Compendium published by Miller Publishing Co., Minnetonka, MN. Feed manufacturers must have FDA clearance to include drugs in mixed feeds. When treated flocks are to be marketed, a specified period (depending on the drug used) must follow cessation of treatment to allow dissipation of drug residues from tissues before slaughter. If the flock is producing table eggs when treated, the drug must be permitted for use in laying flocks, or eggs must be discarded during, and for varying lengths of time after, treatment, which is a costly alternative.

If the flock is producing hatching eggs when it becomes infected and there is danger that egg transmission of the infectious agent from dams to offspring may occur (salmonellosis, mycoplasmosis, and avian encephalomyelitis), eggs should not be used for hatching until the danger has passed. It also should be kept in mind that in fertile eggs, residues of drugs used to treat breeders occasionally may cause abnormalities in some embryos.

Disposition of the Flock

The flock should not be moved or handled until it has recovered, unless the move is to a more favorable environment as part of the therapy. After treatment, if any, has been completed and the flock appears to be completely healthy, it may be marketed or moved to permanent quarters if such a move is part of the management program. Some healthy carriers may remain. If the flock is moved to another depopulated farm, this will present no problem except that occasionally a disease may flare up from stress of handling and moving. If the recovered flock is moved to a multiple-age farm, carriers can introduce the disease into susceptible flocks already there. If the recovered flock is already in permanent quarters having multiple ages, newly introduced flocks may be exposed and contract the disease, a common occurrence, especially with respiratory and litter-borne diseases.

Acknowledgement

The author is greatly indebted to Alex J. Bermudez and Bruce Stewart-Brown for their contributions to earlier editions of this subchapter.

Antimicrobial Therapy (Including Resistance)

Charles L. Hofacre, Randall S. Singer and Timothy J. Johnson

Introduction

Successfully treating a bacterial infection without any adverse effects involves many important factors when deciding to treat and the choice of antimicrobials. One side effect from antimicrobial therapy of any food animal is the potential for increasing the level of resistance in the bacterial population of those food animals. This topic will be reviewed later in this section.

This chapter will not discuss the antimicrobials or the dosages to treat particular bacteria – that discussion will be left to the authors of the chapters on each bacterial infection. This chapter will focus on the many factors that must be taken into consideration to improve the chances of a successful treatment. Treatment of commercial poultry can be divided into 3 broad categories: prevention of infection, treatment of subclinical bacteria disease, and treatment of clinically affected birds. The prevention category includes the group of antibiotics commonly referred to as the "growth promotant" antibiotics. These are a group of drugs that at the approved doses prevent clinical enteric disease, commonly referred to as necrotic enteritis, resulting from a *Clostridium perfringens* infection (1). In every flock of birds exhibiting clinical signs of a bacterial infection, there are birds that are healthy but susceptible, or birds incubating the disease but showing no clinical signs and the overtly ill. The choice to treat or not treat is a decision by the veterinarian based upon the proportion of birds in each category, the age of the birds (how close to slaughter), the value of the birds (breeders vs. broilers), and many other factors that will be discussed in detail.

Routes of Medication

Commercial poultry are raised to provide a safe, wholesome protein source that is very economical to the world's human population. To that end, we must take into account the welfare of the bird and the cost of the meat. In disease prevention, it is generally accepted that feed-grade antimicrobials are less expensive than the same drug in a water-soluble formulation. It must be emphasized that sick birds will have a decline in both feed and water consumption. However, the decline in water consumption is usually less than the decline in feed consumption. Therefore, in choosing a route to administer an antimicrobial to a clinically affected flock, especially early in the infection, water medication may be more effective than by the feed. In the event that the course of the disease lasts longer than 5–7 days, as is often the case with some diseases such as *Pasteurella multocida* in breeders, the veterinarian may choose to switch the route of administration after initially reducing the signs by water medication to the same drug in the feed.

Another consideration in selecting a water route of administration is the ambient temperature. Because poultry have very limited means to eliminate heat from their bodies, they utilize the cooling effect of increasing water consumption. Therefore, water consumption increases significantly as the ambient temperature increases. This must be taken into account when selecting an antimicrobial and its dosage. This is especially important when considering the use of a sulfonamide, because the therapeutic dose is close to the level that can result in toxicity (2).

Flock treatment is almost always the preferred route, and thus mass methods of administering antimicrobials are

generally used. Therefore, parenteral administration of antimicrobials to individual birds in an entire flock is cost prohibitive except when the flock is in the hatchery, i.e., *in ovo* at 18–19 days of incubation or 1 day of age. If an antimicrobial is to be administered in the hatchery, be aware of the effects some antimicrobials may have on any live vaccine that may be concurrently administered. For example, the aminoglycoside gentamicin has a highly basic pH and can damage the cells for the cell-associated Marek's disease vaccine if used at too high a dose (greater than 0.2 mg/chick) or if the antibiotic is improperly mixed with the vaccine in the diluent (3).

Feeding, watering, and lighting schedules also must be taken into consideration. Laying hens will begin to eat, and then consume water, when the lights are turned on. In replacement birds that are under feed restriction to control body weight, both feed and water are limited to only a few hours each day. Broiler chickens and turkeys, which have continuous feed and water availability, tend to eat and then drink on intermittent intervals of 3–4 hours.

Administration of Antimicrobials to Commercial Poultry

Antimicrobials administered in the feed must be uniformly mixed and remain stable until consumed. The prescribing veterinarian must take into consideration the length of time to have the feed manufactured and transported to the farm and then the length of time to deliver it through the farm's feeding system (i.e., amount of nonmedicated feed currently in the feed tank).

Administering the antimicrobial in the drinking water allows for a more rapid delivery of the antimicrobial but requires several calculations to be considered:

- Freshly medicated solutions should be prepared every day.
- The volume of water consumed in 24 hours in the house to be treated must be determined.
- Bulk tank medication administration method is achieved by adding the volume of medication for that day into the total volume of water to be consumed by the flock for that day.
- The proportioner administration method is used for farms that do not have a bulk tank. A water proportioner is a device that meters the antimicrobial from a highly concentrated "stock" solution into the drinking water to achieve the appropriate concentration.
- Dosing based on body weight (i.e., mg/kg of body weight) of a representative sample of birds is much preferred to dosing based on water consumption. If the dose is calculated on water consumption, the ambient temperature must be taken into consideration or a toxic overdose may occur if the temperature rises or an under dose may occur below the therapeutic level if the temperature declines. A rule of thumb is for every 1°F increase in environmental temperature above 70°F results in a corresponding increase of water consumption by approximately 4%. In addition, younger birds consume more water daily/unit of body weight than older birds. Hens in egg production drink more water/unit of weight than nonlaying hens or roosters.
- Pulse dosing can be considered when the birds' water consumption is limited (i.e., broiler breeder pullets) (4). This is a short intensive treatment in which all of the medication to be administered in a 24-hour period is consumed by the flock in a 4- to 6-hour period. Note: This method should only be used with bactericidal antimicrobials that have a wide margin of safety for toxicity.

Pharmacologic Consideration

The primary goal of antimicrobial treatment is to cure the flock from the current illness. Success requires taking many interacting factors into consideration. The activity of an antimicrobial against a bacterial strain is referred to as being either resistant or sensitive. The methods used to determine this sensitivity of a particular isolate are all performed on artificial media in a diagnostic laboratory. They do not consider whether the drug can be absorbed from the birds' intestines (i.e., aminoglycosides) or whether the drug is bound by ingredients in the feed or water (i.e., tetracyclines/calcium level) or whether the drug can reach the site of the infection (i.e., synovial fluid of a joint). It should also be remembered that the *in vitro* susceptibility is usually determined on only 1 bacterial isolate from the flock and in many infections of poultry the bacterial infection is often secondary to a viral or environmental insult. This results in a flock infection of several different bacteria which may have a wide range of antimicrobial susceptibilities. This is especially true with *E. coli* airsacculitis (5).

The immune status of the flock also must be considered when selecting an antimicrobial agent. A bacteriostatic drug, such as oxytetracycline, may be highly effective for treating *E. coli* secondary to an infectious bronchitis virus challenge. For an *E. coli* airsacculitis infection following the immune suppressive virus, infectious bursal disease, the same oxytetracycline therapy may be ineffective in curing the flock. In cases in which the immune system is compromised, it is recommended to use bacteriocidal antimicrobials because bacteriostatic drugs inhibit or slow the bacterial growth and require the birds' immune system to kill the bacteria.

Judicious Use Principles in Poultry

Judicious use of antimicrobials in poultry that are being raised for production of meat or eggs for human consumption begins with disease prevention. However, when a flock begins to exhibit the clinical signs of a bacterial disease, the veterinarian must base the decision to treat upon good professional judgment (i.e., experience), laboratory results, medical knowledge, and information about the flock to be treated. The birds

should be physically examined, if possible, by the veterinarian or by a skilled paraprofessional (service person) which should include antemortem and postmortem examination. When possible, a bacterial culture can be done to confirm the diagnosis and determine the susceptibility of the isolates. The rapid spread of disease on poultry farms often necessitates beginning treatment prior to the results of the bacterial culture and sensitivity. When laboratory results are completed, the veterinarian must use clinical judgment to decide between continuation or change in therapy. Because a flock will have birds in the 3 categories of illness (clinically ill, incubating with no outward signs of illness, unaffected susceptible), all of the birds in a house and not just the clinically affected will be treated. This strategic use of antimicrobials in anticipation of a major disease spread is justifiable under good husbandry practices. Finally, responsible antimicrobial therapy allows sufficient withdrawal time for the antimicrobial from the feed or water to ensure no drug residue in the meat or eggs for human consumption. In some instances, the veterinarian may require a longer withdrawal than is written on the drug label because of clinical judgment. For example, some sulfonamides are excreted in the birds' droppings in an altered but active metabolite and because birds are caprophagic, they may have sulfaonamide exposure even after the drug is removed from the feed or water.

Antimicrobial Resistance

Antibiotic resistance is a growing concern for human health because many of the genes encoding antibiotic resistance are transferable between bacteria, there is a concern regarding the impact of antibiotic use in food animals. Currently, there is no conclusive information regarding how much of an impact the use of antibiotics in poultry has on antibiotic resistant human bacterial pathogens.

The use of antimicrobials selects for bacteria that can survive in the presence of that antimicrobial. Therefore, development of a large number of bacteria that are resistant to an antimicrobial is greatly dependent on the level of that antimicrobial agent that is achieved at the site of infection in the bird's body. If the dose of the antimicrobial does not reach a concentration high enough to kill or inhibit the target bacteria growth, then selection pressure exists to move the bacteria population to have greater numbers that survive in the presence of that antimicrobial. This process is simple selection and use of antimicrobials does not create resistance.

There are specific genes that give the bacterium the ability to survive in the presence of an antimicrobial. Some are genes normally present on the bacterial genome that mutate to a form that renders the antibiotic ineffective. Other genes are acquired from other bacteria, a process known commonly as horizontal gene transfer. An example of gene mutation to allow the bacteria to grow in the presence of the antimicrobial occurs when there is a mutation in the DNA gyrase gene that results in fluoroquinolone resistance. These resistant bacteria survive to reproduce and the resistance then spreads by multiplication of the resistant bacterial strain.

The rapid dissemination of most antimicrobial resistance in Gram-negative bacteria is primarily achieved through horizontal gene transfer, or the movement of genetic material between 2 unrelated bacterial cells (6). Genes encoding antimicrobial resistance are most commonly moved between bacteria via their presence on conjugative bacterial plasmids (7). Plasmids are extrachromosomal elements that are self-replicating, not essential to the bacterial host cell, and often capable of self-movement (conjugation) from one bacterium to another. They are also highly stable once established in a bacterium. Plasmids are associated with resistance to antimicrobial agents because of their propensity to acquire additional genetic material within their genome, and they come in a variety of different types, each with unique replicons and a distinct set of genetic traits (7). Plasmid type determines many phenotypic traits, such as the frequency of conjugative transfer, the range of bacterial hosts in which it can successfully replicate, and the propensity to acquire resistance genes. Among *Escherichia coli* and *Salmonella enterica* alone, there are more than 30 plasmid types identified and this number continues to grow (6). Plasmids associated with multidrug resistance are primarily a concern among *E. coli*, *S. enterica*, and *Klebsiella pneumoniae*, although numerous other Gram-negative bacteria have been shown to possess multidrug resistance-encoding plasmids (8, 9, 10).

Each plasmid type has 1 or more distinct genetic load regions where they are able to acquire accessory genes, such as antimicrobial resistance genes. Some plasmids have more of these regions than others, and some plasmids are able to acquire more genetic load within a region than others. Resistance genes are usually inserted into these genetic load regions via conjugative transposons or mobile units called integrons (11). With integrons, resistance genes are not fixed once acquired; that is, they can be discarded and/or additional genes can be acquired at any time. These flexible elements play a major role in plasmid evolution and the evolution of resistance phenotypes. The primary multidrug resistance-associated plasmid types that are a concern in poultry are known as IncF, IncI1, and IncA/C (12). Each type mentioned has signature sets of resistance genes that they commonly possess. For example, IncA/C plasmids often contain the genes $bla_{\text{CMY-2}}$ and *floR*, encoding resistance to third-generation cephalosporins and phenicols, respectively (9). IncI1 plasmids commonly carry extended spectrum beta lactamase genes belonging to the bla_{TEM} and bla_{CTX} classes. In poultry, *E. coli* and *Salmonella* spp. often harbor these genes and plasmids.

In poultry production, plasmid-associated antimicrobial resistance is of concern for several reasons. First, many plasmids are considered to be highly plastic and capable of acquiring arrays of resistance genes encoding resistance to multiple antimicrobial agents. For example, IncA/C plasmids have recently been identified among *E. coli* and *S. enterica* of poultry and encode resistance to up to 12 different classes of antimicrobial agents (12). In addition to the carriage of multiple resistance genes by a single plasmid, bacteria of poultry commonly carry multiple plasmids (12).

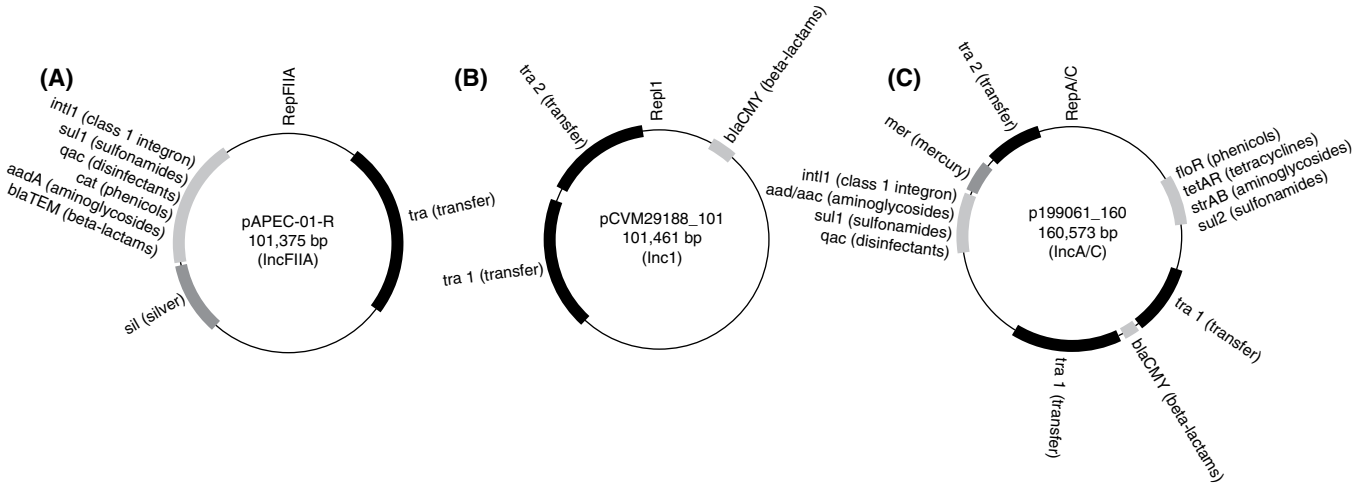

Figure 1.11. Circular maps of transmissible resistance-encoding plasmids isolated from poultry bacteria. Transfer regions are shaded in black, antibiotic resistance genes are shaded in light gray, and heavy metal resistance genes are shaded in dark gray. (A) Map of pAPEC-O1-R, an IncFIIA plasmid isolated from avian pathogenic *E. coli*. (B) Map of pCVM29188_101, an IncI1 plasmid isolated from *S. Kentucky*. (C) Map of p199061_160, an IncA/C plasmid isolated from avian pathogenic *E. coli*.

Finally, co-carriage of antimicrobial resistance genes with genes conferring other phenotypes routinely occurs. For example, avian pathogenic *E. coli* often carry virulence factors that co-reside with antimicrobial resistance-encoding genes (13). Furthermore, these plasmids also may possess genes encoding resistance to heavy metals and disinfectants (14). Therefore, a scenario emerges in which resistance genes may be selected for in the absence of antimicrobial pressures. This complicates the ability to control the dissemination of multidrug-resistant bacteria once they are established in an environment. Examples of these complex plasmid structures containing antimicrobial resistance and disinfectant and heavy metal resistance as well as virulence factors can be seen in Figure 1.11A, B, and C.

The dissemination of multidrug resistance in poultry has become a major concern in *Salmonella* spp. because of the potential risk that these bacteria pose to human health via food-borne transmission. It seems that certain *Salmonella* serovars have a greater propensity to acquire multidrug resistance than others, and 1 serovar of particular concern in poultry is *Salmonella* Heidelberg. *S*. Heidelberg isolates harboring multiple resistance genes have been identified in live chickens, live turkeys, humans, and retail meats, and some are identical using pulsed-field gel electrophoresis (15, 16, 17). Of particular concern are the IncA/C plasmids, which have been identified among serovars Heidelberg, Kentucky, and Typhimurium in poultry and humans (18, 19, 20, 21). Isolates harboring this plasmid are typically resistant to ampicillin, amoxicillin/clavulanic acid, cefoxitin, ceftiofur, chloramphenicol, sulfisoxazole, tetracycline, trimethoprim/sulfamethoxazole, and gentamicin. Other plasmid types, such as IncF and IncI1, are also common among *Salmonella* spp. of poultry but do not confer such a wide array of phenotypic resistances. Also, unlike IncI1 and IncF plasmids, IncA/C plasmids have a broad host range and are likely also moved between *Salmonella* spp. and other Proteobacteria within the environment (22).

Once multidrug-resistant bacterial populations are established within an environment, they are difficult to eliminate. Certainly, plasmid dissemination from 1 bacterium to another can occur within the avian gastrointestinal tract, within poultry litter, and among beetles (23, 24, 25). There is documented evidence that antimicrobial therapy in response to disease will enhance the dissemination of plasmid-encoded multidrug resistance (26). Cessation or reduction of antibiotic usage has been suggested as a method to reduce the numbers of multidrug resistant organisms. However, the evidence for this effect is contradictory in the scientific literature. The best current practices to limit the spread of multidrug-resistant organisms are likely the same as those used to reduce disease transmission, such as thorough clean-out procedures and good biosecurity practices. In those instances in which a bacterial infection occurs and treatment becomes necessary, follow judicious use guidelines with isolation of the bacteria, determination of antimicrobial sensitivity, and use the appropriate dose and duration of therapy.

Summary

Judicious antimicrobial therapy includes proper diagnosis, knowledge of antibiotic properties, dosage, spectrum, interactions, and early initiation of treatment. It is not as simple as offering the drug to a poultry flock. The limited arsenal of drugs available for poultry makes it imperative that we combine an accurate diagnosis with antimicrobial knowledge to result in the most efficacious and cost-effective approach to disease treatment with minimal potential risk of antimicrobial resistance development and selection.

Acknowledgement

The authors wish to acknowledge Dennis P. Wages for his substantial contributions to this current chapter.

Public Health Significance of Poultry Diseases

Roy D. Berghaus and Bruce Stewart-Brown

Introduction

Poultry and humans have dramatically different physiologies, and consequently, many pathogens are incapable of crossing the species barrier between birds and man. Nevertheless, there are a number of diseases that humans and poultry share. These can be zoonoses (poultry to humans) or reverse zoonoses (humans to poultry). Most zoonotic diseases can be prevented through an understanding of basic disease transmission principles and the adoption of preventive practices.

Infectious organisms are transmitted by direct or indirect mechanisms. Direct routes include body-surface-to-body-surface contact, contact with soil or vegetation harboring infectious organisms, and large droplet transmission over short distances. Indirect routes include airborne transmission by small particles suspended in air, vehicle-borne transmission by objects that passively carry the organism or provide an environment for growth, and vector-borne transmission by an insect or other living carrier via mechanical carriage or biological propagation.

Common biosecurity practices including the use of gloves, eye and respiratory protection, and protective outerwear are all important elements of zoonotic disease prevention (121). Good hand hygiene and routine injury prevention are also essential. Thoroughly washing hands with soap and water after working with poultry is always recommended. When soap and water are not available, the use of antiseptic hand sanitizers may be an effective alternative. Protection of eyes, nose, and mouth helps reduce the risk of mucous membrane exposure and inhalation. Protective outerwear should include disposable or reusable coveralls that can be sanitized between uses, head covers to help keep the hair and scalp free of gross contamination, and disposable or washable footwear. Skin lacerations should be kept covered, and injuries resulting from contact with animals or equipment should be promptly cleaned and protected. Eating and drinking should be done away from the poultry house.

All personnel that work around poultry should be trained and educated on zoonotic disease prevention, including who to contact if questions should arise. Persons with weakened immune systems are at increased risk for contracting many zoonotic diseases. Populations with increased susceptibility may include young children, pregnant women, the elderly, and persons who are immunocompromised due to medications or disease. Individuals with immune dysfunction are encouraged to discuss their health status with a health care professional before working around poultry or other animals.

This chapter provides a brief overview of public health issues for several infectious diseases that are common to poultry and man. It does not include all such diseases and it is not meant to serve as a human medical reference. Rather, it provides a short synopsis of the disease manifestations in humans and may serve as a starting point for further inquiry. Diseases are presented alphabetically within categories defined by the type of infectious agent (i.e., viral, bacterial, fungal, and parasitic). For each organism or disease, there is a brief description of the nature of the disease in humans, its occurrence, and reservoirs and sources of infection. Specific preventive measures are provided for some diseases.

Viral Diseases

Arboviral Encephalitis

Arbovirus is a generic term referring to viruses transmitted to vertebrates by the bite of arthropod vectors including mosquitoes, ticks, and flies. More than a dozen arboviruses are capable of causing neurological disease in humans (41, 91). However, the discussion here will be limited to 3 that cause disease in both humans and poultry: Eastern equine encephalitis virus (EEEV), Western equine encephalitis virus (WEEV), and West Nile virus (WNV).

Nature of the Disease in Humans

The clinical presentation varies with virus and host characteristics, but most infections are asymptomatic (41). Of those patients that do become ill, most experience a flu-like illness with sudden-onset fever, headache, and fatigue. A variable number of patients progress to develop neuroinvasive disease with typical signs of meningitis or encephalitis. Recovery from neuroinvasive disease can take several weeks to months, and sequelae such as weakness and paralysis are common. Case-fatality risks for patients with severe illness caused by EEEV, WEEV, and WNV infections have been estimated at 50%–70%, 3%–7%, and 3%–17%, respectively (86, 146).

Occurrence

The distribution of arboviruses depends on their specific reservoir hosts and vectors. EEEV and WEEV are found in both North and South America. In North America, EEEV is found primarily along the Atlantic and Gulf coasts, and WEEV is found primarily in the western United States. WNV has been identified in Europe, Africa, Asia, and North and South America. WNV was not detected in the Western hemisphere until 1999, but has since become the most commonly reported arboviral infection in the U.S. Between 1999 and 2007, the number of human WNV neuroinvasive cases reported in the U.S. was 11,125, compared to 80 cases for EEEV and 1 case for WEEV (114). In North America, approximately 90% of human cases are identified between July and September.

Neuroinvasive disease is more likely in organ transplant recipients and the elderly (86).

Reservoirs and Sources of Infection

The principal mode of transmission to humans is from the bite of an infected arthropod vector. For all 3 of the viruses discussed here, the primary enzootic transmission cycles occur between birds and mosquitoes. Transmission is not limited to ornithophilic mosquito species, however, as several other genera of mosquitoes have the potential to act as bridging vectors between birds and humans (17, 146). The incubation period is typically 5–15 days (91). Humans do not produce a sufficient viremia to serve as an amplifying host; however, nonvector-borne transmission has been documented via blood transfusion, organ transplantation, breast feeding, and needle-stick injury (17). An increased incidence of seroconversion was reported in goose farmers and veterinarians during an outbreak of WNV in Israel during 1999–2000, although it is not clear whether this may have been attributable to contact with infected birds or concurrent transmission from infected mosquitoes (13).

Avian Influenza

Avian influenza (AI) is caused by type A influenza viruses which are classified by their hemagglutinin (H1-H16) and neuraminidase (N1-N9) subtypes (110). Human disease caused by direct infection with poultry-adapted viruses is rare, but has been reported with specific virus lineages in some subtypes: H5N1, H7N2, H7N3, H7N7, H9N2, and H10N7 (77, 93). Pathogenicity in poultry is not indicative of the pathogenicity in humans.

Nature of the Disease in Humans

Clinical manifestations of human infections with AI viruses vary from mild to severe and depend on the subtype. H7 subtypes have mainly been associated with conjunctivitis and mild influenza-like illness, whereas H5N1 viruses have been associated with more severe respiratory disease (1, 55). Common presenting signs include fever, cough, dyspnea, pneumonia, and myalgia. In some cases gastrointestinal signs have been reported. Acute respiratory distress syndrome is a common complication of H5N1 virus infections, which have a case-fatality risk of approximately 60%.

Occurrence

AI viruses are found worldwide, although the distribution of specific subtypes varies. Most cases of human infection reported to date, and all deaths, have been caused by either the H5N1 or H7N7 subtypes (77, 93, 110). Between 2003 and 2011, 574 human illnesses and 337 deaths due to H5N1 AI viruses (Guangdong lineage) were reported to the World Health Organization (WHO) from 15 countries across Asia, Africa, and the Middle East (145). The H7N7 subtype was associated with 89 human cases and 1 fatality in a single large HPAI outbreak in the Netherlands during 2003 (55). All other AI virus subtypes combined accounted for approximately 20 documented human infections between 1959 and 2009 (77).

Reservoirs and Sources of Infection

Wild aquatic birds belonging to the orders *Anseriformes* and *Charadriiformes* are the natural reservoirs for AI viruses (77). Influenza viruses are shed in the feces and respiratory secretions of infected birds, and direct contact is believed to be the most important route of transmission to humans (1, 110). Mucous membrane exposures and the inhalation of potentially infectious aerosols should be avoided. Ingestion is of theoretical concern, although AI viruses are readily destroyed by cooking and to date there have been no documented cases of human infection due to the consumption of infected poultry. The incubation period is typically 2–5 days, but may be as long as 9 days (1). Person-to-person transmission of AI viruses is uncommon, but has been reported among relatives having close contact with persons infected with the H5N1 subtype (137). Viral RNA of H5N1 viruses has been identified in the respiratory secretions of infected persons for as long as 3–4 weeks after onset (1).

Preventive Measures

The U.S. Centers for Disease Control and Prevention (CDC) recommends that persons involved with AI outbreak control and eradication procedures wear appropriate personal protective equipment including disposable gloves, protective outer garments, shoe covers, and a fitted respirator of class N-95 or higher (27). CDC also recommends that workers receive a seasonal influenza vaccination and prophylactic antiviral drugs while handling potentially infectious materials.

Newcastle Disease

Newcastle disease, also known as Ranikhet disease, avian pneumoencephalitis, and pseudo-fowl pest, is caused by avian paramyxovirus serotype 1 (APMV-1) (31, 131). The virulence of strains varies widely, with the severity of disease in poultry ranging from inapparent to near 100% mortality. However, virulence in birds is not a predictor of the potential for human infection.

Nature of the Disease in Humans

In humans, NDV typically causes a transient, unilateral, acute follicular conjunctivitis with no involvement of the cornea. Swelling of the preauricular lymph nodes is common. Conjunctivitis typically lasts for 3–4 days but may persist for as long as 3 weeks (101). Mild generalized signs of illness such as low-grade fever, chills, headache, and pharyngitis are uncommon but may be more likely following an aerogenous exposure (64). Patients typically make a complete spontaneous recovery.

Occurrence

NDV has been reported in every poultry-producing region of the world. Vaccination is widely practiced, although periodic outbreaks still occur in countries where virulent strains of the virus are no longer endemic. Human infection following contact with infected live birds is uncommon (131). Most reported

cases have been in diagnostic and vaccine laboratory workers, veterinarians, and processing plant workers (31).

Reservoirs and Sources of Infection
Birds are the natural reservoir for NDV; more than 240 species have been reported to be susceptible to infection (75). Transmission between birds occurs by inhalation of respiratory droplets or the fecal-oral route (3). Transmission to humans occurs by splashing contaminated liquids in the eye, or by touching the eyes after contact with contaminated tissues or feces. The incubation period in humans ranges from 1–4 days, but 1–2 days is typical (64). Secondary transmission from 2 infected mothers to their children was suspected in 1 study of broiler plant workers, but was not confirmed (135). Most references flatly state that secondary transmission has never been documented (3, 31, 64). Transmission from infected humans to susceptible poultry, however, is a potential concern (131).

Preventive Measures
Eye protection should be worn when working with NDV in the laboratory or when handling live vaccines or infected tissues. Wearing disposable gloves and washing hands with soap and water after handling infectious materials is also advisable. Wearing a respirator or mask reduces the risk of aerosol inhalation, although human infection by this route is believed to be uncommon.

Bacterial Diseases

Botulism

Botulism is a paralytic intoxication caused by botulinum toxin, which prevents acetylcholine release from motor neuron synaptic terminals. Botulinum toxin is produced by *Clostridium botulinum* as well as related species *C. baratii* and *C. butyricum* (124, 127). Although *C. botulinum* is considered a single species, different strains can be distinguished by the type of toxin they produce. There are 7 recognized toxin types (A–G), but only types A, B, E, and rarely F cause human illness. Toxin types C and D are the most common causes of botulism in wild birds and poultry but are not associated with human disease (26). Cattle and sheep are susceptible to type C and D toxins, however, and several outbreaks in these species have been linked to exposure to poultry litter (107).

Nature of the Disease in Humans
Four naturally occurring forms of botulism are recognized in humans: food-borne intoxication, wound botulism, infant botulism, and adult intestinal toxemia (toxicoinfection). Regardless of the form, the clinical presentation is characterized by flaccid symmetric descending paralysis that begins with cranial nerve palsies and may progress to respiratory arrest. The availability of antitoxin along with improvements in supportive care and mechanical ventilation has decreased the case-fatality risk in the U.S. to 3%–5% (127).

Occurrence
Clostridium botulinum has a worldwide distribution. The median annual number of cases in the U.S. between 1973 and 1996 was 24 for food-borne botulism, 3 for wound botulism, and 71 for infant botulism (124). Most food-borne intoxications result from the consumption of improperly preserved home-canned foods. Wound botulism is typically associated with deep tissue injuries such as open fractures, or in recent years with the nonintravenous injection of black tar heroin (127). Infant botulism is believed to result from a toxicoinfection rather than the ingestion of preformed toxin, and has been associated with the consumption of honey in up to 15% of cases (124). Adult intestinal toxemia is rare, and occurs in patients with a history of abdominal surgery, gastrointestinal abnormalities, or recent disruption of the normal flora as a consequence of antibiotic administration.

Reservoirs and Sources of Infection
Clostridium botulinum is found in soils throughout the world. Heat-resistant *C. botulinum* spores are capable of surviving many food preparation methods, and germination occurs when they are exposed to a warm anaerobic environment with nonacidic pH (greater than 4.6) and low salt and sugar concentrations. The incubation period for food-borne intoxications is typically 12–36 hours, but may range from 6 hours–10 days (26). Contact transmission from animal to person or person to person does not occur.

Clostridium perfringens Infection

Clostridium perfringens causes 2 different types of food-borne disease as well as gas gangrene in humans (22). Food-borne disease is usually caused by enterotoxin-producing strains of *C. perfringens* type A, and rarely by *C. perfringens* type C.

Nature of the Disease in Humans
C. perfringens type A food poisoning results when enterotoxin is produced during sporulation of vegetative cells in the intestine. Typical symptoms include acute abdominal pain and cramping, nausea, and diarrhea. Most cases are self-limiting and resolve without treatment in 24 hours (128). *C. perfringens* type C food poisoning is primarily mediated by beta-toxin and is associated with necrotic enteritis in humans. Symptoms include acute abdominal pain and distension, bloody diarrhea, and sometimes vomiting (22). The case fatality risk for type A food poisoning is less than 0.1%, while that for type C food poisoning is 15%–25% (22, 120).

Occurrence
C. perfringens type A is one of the most common causes of food-borne disease worldwide. In the U.S., it causes an estimated 1 million illnesses annually (120). *C. perfringens* type C food poisoning is rare, and is usually limited to patients with abnormally low intestinal protease production who are unable to inactivate beta-toxin (60). Young children and the elderly

are at increased risk for severe illness due to type A food poisoning, whereas malnourished individuals and diabetics are at increased risk for developing necrotic enteritis due to type C food poisoning (22, 128).

Reservoirs and Sources of Infection

C. perfringens is a common inhabitant of soil and intestinal tracts of animals and humans, and is commonly isolated from retail meat products including poultry. Food-borne illness caused by *C. perfringens* results from improper food handling techniques, especially the inadequate cooling and reheating of dishes containing meat (7). Spores survive the initial cooking, and after germination can propagate rapidly under inadequate refrigeration. The incubation period for type A food poisoning ranges from 6–24 hours, but is most commonly 10–12 hours (122). Direct exposure to infected persons or animals does not constitute a disease risk, but colonized individuals may serve as a source of contamination during food preparation and handling (65).

Campylobacteriosis

Campylobacteriosis is an enteric infection caused by members of the genus *Campylobacter* (5, 69). Most human infections are caused by the thermophilic species *C. jejuni* or *C. coli*.

Nature of the Disease in Humans

Campylobacter causes an acute gastroenteritis characterized by fever, abdominal pain, and profuse diarrhea that is frequently bloody (5, 15). Most patients recover within 1 week without antimicrobial treatment. Bacteremia and other extraintestinal infections are uncommon complications (16). Reactive arthritis may occur as a sequela of enteric *Campylobacter* infections in 1%–5% of patients, and Guillain-Barré syndrome occurs in approximately 0.1% of patients (111, 132).

Occurrence

Campylobacter is one of the most commonly reported causes of bacterial gastroenteritis worldwide (5, 69). In the U.S., *Campylobacter* causes an estimated 845,000 cases of food-borne illness and 76 deaths each year (120). Most cases are sporadic; outbreaks are uncommon, but have been linked to unpasteurized milk, contaminated water, and the ingestion of undercooked poultry (15). In developed countries there is a male predisposition, a seasonal peak in cases during the late spring and summer, and a bimodal age distribution with infection being most common in children less than 1 year of age and in young adults from 15–44 years old (5). In developing countries there is less evidence of a seasonal pattern, and infection is common in children younger than 2 years of age but uncommon in adults (38).

Reservoirs and Sources of Infection

Campylobacter species are normal intestinal inhabitants of wild and domesticated animals and birds. Colonization of broiler chickens is common, and contaminated poultry meat is considered to be the most important source of human infections (69). Transmission occurs by ingestion of the organism, and approximately 80% of domestically acquired infections in the U.S. are considered to be food-borne (120). Transmission to poultry processing plant workers has been well documented (56). Contact with colonized animals or drinking untreated water are additional potential sources of exposure. The incubation period ranges from 1–10 days, but is most commonly 2–5 days (106). Person-to-person transmission can occur but is uncommon. The duration of fecal shedding can range from 2–7 weeks, although the median duration of shedding is less than 3 weeks (15, 106).

Preventive Measures

Cook poultry to a minimum internal temperature of 74°C (165°F) and avoid cross contamination between raw poultry and other foods (106). Avoid drinking unpasteurized milk and wash hands after contact with poultry or other animals.

Chlamydiosis (Psittacosis)

Psittacosis, also known as ornithosis or parrot fever, is a respiratory disease of humans caused by *Chlamydophila psittaci* (126). The corresponding disease in birds is referred to as avian chlamydiosis (6). *C. psittaci* is an obligate intracellular pathogen.

Nature of the Disease in Humans

Psittacosis is primarily a respiratory disease in humans that ranges from a mild flu-like illness to severe pneumonia with respiratory failure and death (10, 126). Typical symptoms include fever, chills, headache, and myalgia. A nonproductive cough is common and may be accompanied by respiratory difficulty. Occasional signs include a nonspecific rash and enlarged spleen. Complications include endocarditis, myocarditis, hepatitis, arthritis, keratoconjunctivitis, and encephalitis. Most cases respond well to antibiotic therapy.

Occurrence

Psittacosis and avian chlamydiosis have a worldwide distribution. Psittacosis is a reportable disease in most countries, but the number of reported cases is likely an underestimate of the true incidence because many cases are mild, the symptoms are nonspecific, and diagnosis can be difficult. Sixty-six cases were reported to the U.S. Centers for Disease Control and Prevention between 2005 and 2009. Beeckman and Vanrompay summarized reported cases of psittacosis from 24 countries between 1996 and 2007, with Australia, Germany, Japan, The Netherlands, and Great Britain having comparatively high numbers of reported cases (10). Most cases are sporadic, but outbreaks have occurred in groups of people exposed to infected pet birds and poultry (49). There is no evidence to suggest that immunocompromised individuals are at increased risk for infection (8).

Reservoirs and Sources of Infection

Birds are the natural reservoir for *C. psittaci*, and *Chlamydophila spp*. have been identified by culture or serology in 467 bird species from 30 different orders, including all of the major domestic poultry species (76). Human infections are most frequently associated with exposure to psittacines, pigeons, turkeys, and ducks, although psittacosis is rare in modern poultry production systems. Different serotypes have been identified more frequently in certain bird species, although all serotypes are considered to be potentially infectious to humans (6). Humans become infected by inhalation of aerosolized organisms shed in the feces or respiratory secretions of infected birds, or by direct contact with infected carcasses or tissues. Intermittent shedding by subclinically infected birds is common. The incubation period in humans ranges from 1–30 days, although 5–14 days is typical. Possible secondary transmission of *C. psittaci* has been reported in a hospital setting but has not been confirmed (68).

Preventive Measures

Wearing gloves, protective eyewear, and a properly fitted respirator with an N95 rating or higher are recommended when working with potentially infected birds (126). Loose-fitting surgical masks may not provide adequate respiratory protection. Necropsies on potentially infected birds should be performed in a biological safety cabinet and carcasses should be moistened with a disinfectant solution to minimize the generation of aerosols during the procedure.

Erysipelothrix rhusiopathiae Infection

The most common clinical manifestation of infection with *Erysipelothrix rhusiopathiae* in humans is called erysipeloid, which is distinct from human erysipelas, a condition that is usually caused by *Streptococcus pyogenes* (113).

Nature of the Disease in Humans

Three forms of *E. rhusiopathiae* infection are typically recognized in humans (141). Erysipeloid is the most common and is characterized by a localized cutaneous lesion, usually on the hand. Pain and swelling may be severe, although there is no suppuration or pitting edema. Systemic illness is uncommon and the condition usually resolves without treatment in 3–4 weeks, or within 48 hours after beginning antibiotic therapy (61). Diffuse cutaneous and systemic forms of the infection are much less common, although endocarditis has been reported in approximately 90% of systemically infected patients with a corresponding case fatality risk of 38% (58). Other clinical manifestations of infection, including arthritis and peritonitis, also have been recognized (46).

Occurrence

E. rhusiopathiae has a worldwide distribution although the incidence is unknown. Persons with exposure to animals or animal products, including processing plant workers, butchers, fish handlers, food handlers, farmers, and veterinarians are at increased risk of infection (58). Transmission from infected quail and laying chickens to processing plant employees and animal caretakers has previously been reported (99, 100).

Reservoirs and Sources of Infection

E. rhusiopathiae is a pathogen or commensal organism in a wide variety of animal species. Swine are the most commonly affected domestic animal and are considered to be the most important reservoir, although several poultry species including turkeys, chickens, ducks, and emus are also susceptible (141). *E. rhusiopathiae* can survive weeks to months in farm and marine environments, and is commonly found in the mucoid slime coating of fish (21). Transmission occurs by inoculation of the organism into an abrasion, cut, or puncture wound when working with infected animals or in contaminated environments. The incubation period for erysipeloid is 2–7 days (61). Person-to-person transmission of *E. rhusiopathiae* infection has not been documented.

Escherichia coli Infection

Most strains of *Escherichia coli* are commensal inhabitants of the lower intestinal tracts of warm-blooded animals; however, some strains possess virulence traits that allow them to cause disease. Strains that cause intestinal pathology are categorized as belonging to 1 of 6 pathotypes: enterohemorrhagic (EHEC), enterotoxigenic (ETEC), enteroinvasive (EIEC), enteropathogenic (EPEC), enteroaggregative (EAEC), or diffuse-adherence *E. coli* (DAEC) (54). Strains with recognized extraintestinal virulence factors or that exhibit enhanced virulence in an animal model of extraintestinal infection have been designated as extraintestinal pathogenic *E. coli* (ExPEC) (118). Of the 6 intestinal pathotypes, only the EHEC strains (e.g., O157:H7) are considered to be zoonotic pathogens (142). Avian pathogenic *E. coli* (APEC) have not been associated with human intestinal infections, but some APEC strains are indistinguishable from human ExPEC strains (72, 138). The discussion here will be limited to the potentially zoonotic EHEC and ExPEC strains.

Nature of the Disease in Humans

Intestinal infection with EHEC serotypes of Shiga toxin producing *E. coli* (STEC) such as O157:H7 typically causes abdominal cramps with an initially watery diarrhea progressing to bloody diarrhea in 1–4 days (109, 115). Approximately 10%–15% of patients develop hemolytic uremic syndrome (HUS) with thrombocytopenia, microangiopathic hemolytic anemia, and acute renal failure within 5–13 days after the onset of diarrhea. Extraintestinal *E. coli* infections are associated with a variety of illnesses including urinary tract infection, newborn meningitis, and septicemia (118).

Occurrence

Enterohemorrhagic *E. coli* strains are recognized as an important problem in North and South America, Europe, Japan, and southern Africa (54). Extraintestinal *E. coli* infections are

an important worldwide problem. Shiga toxin producing *E. coli* cause an estimated 176,000 illnesses and 20 deaths in the United States each year (120). Extraintestinal *E. coli* infections are estimated to account for 85%–95% of approximately 130–175 million cases of uncomplicated cystitis globally each year (117).

Reservoirs and Sources of Infection

EHEC strains of Shiga toxin producing *E. coli* have previously been identified in retail chicken samples and in fecal samples collected from turkeys and pigeons (42, 63, 67). Chickens are also readily colonized with *E. coli* O157:H7 in experimental trials (123). Cattle and other ruminants are the most important source of human EHEC infections, however, and avian species are not considered to be an important reservoir (53, 142). Transmission of EHEC strains occurs via contaminated foods, person-to-person contact, or contact with colonized animals. Human infections with ExPEC strains typically originate from the person's own intestinal tract, although poultry may potentially serve as a reservoir for human colonization (72, 138). The incubation period for EHEC strains ranges from 2–10 days, with a median of 3–4 days (54). Secondary transmission of EHEC strains is common, especially among children in daycare centers (112). The duration of shedding is typically 1 week or less in adults, but may be 3 or more weeks in children (54).

Listeriosis

Listeriosis is caused by *Listeria monocytogenes*. Thirteen serotypes have been described (51), although 3 are most frequently associated with human disease: 1/2a, 1/2b, and 4b (4, 83).

Nature of the Disease in Humans

L. monocytogenes can result in a variety of clinical syndromes, ranging from febrile gastroenteritis to severe invasive disease (4). Septicemia and meningoencephalitis are most frequently reported in pregnant women, neonates, and immunocompromised adults. Focal infections may include brain and hepatic abscesses, cholecystitis, conjunctivitis, endocarditis, joint infections, skin infections, and osteomyelitis (4, 51). Infection of pregnant women may result in fetal infection or death (71, 83).

Occurrence

L. monocytogenes has a worldwide distribution, and has been estimated to cause approximately 1,500 hospitalizations and 250 deaths in the United States each year (120). Populations at increased risk of systemic infection include pregnant women and neonates, immunocompromised adults, and the elderly (130). Veterinarians and farm workers are at increased risk for developing cutaneous infections, particularly following large-animal obstetric procedures (94). Listeria conjunctivitis has previously been reported in 2 poultry processing workers (52). Most cases of listeriosis are sporadic, but common source outbreaks are frequently identified (4, 130). The prevalence of asymptomatic intestinal carriage has been estimated at 1%–5% in animals and 5%–10% in humans (51).

Reservoirs and Sources of Infection

L. monocytogenes is widely distributed in nature and can be identified in soil, water, silage, and animal feces. *Listeria* is commonly found on poultry farms and in processing plants (34, 37). It is an important source of environmental contamination in processing plants because of its ability to grow at low temperatures and form biofilms that are resistant to routine sanitation procedures (134). Most cases of human listeriosis result from food-borne transmission (4, 71). Several outbreaks have been associated with ready-to-eat delicatessen meats and soft cheeses made from unpasteurized milk (130). The incubation period ranges from 3–70 days, with a median of 3 weeks (4). Transplacental transmission from pregnant mothers to the fetus is common, but transmission from infected patients to household contacts has not been reported.

Mycobacteriosis

Mycobacterial species other than *M. tuberculosis* and *M. leprae* that are associated with human disease are commonly called nontuberculous mycobacteria (NTM). More than 125 NTM species have been recognized, but only around 20 have been associated with human illness (62). The discussion here will be limited to members of the *Mycobacterium avium* complex (MAC), which along with *M. genavense* are responsible for most cases of avian mycobacteriosis (133).

Nature of the Disease in Humans

The most common clinical syndromes associated with MAC infections are pulmonary disease, lymphadenitis, and disseminated infection. Common signs of pulmonary disease include chronic cough, fever, chills, night sweats, dyspnea, and weight loss (139). Lymphadenitis frequently manifests as a painless unilateral swelling of the cervical, submandibular, submaxillary, or preauricular lymph nodes. Disseminated infection is characterized by intermittent fever, sweats, weakness, anorexia, and weight loss (70).

Occurrence

Members of the *M. avium* complex cause disease in humans worldwide. Exposure is common but disease is rare in immunocompetent persons. Pulmonary MAC infections are typically identified in men with pre-existing lung disease, in elderly women with no history of underlying lung disease, and in adolescents with cystic fibrosis (70, 139). Lymphadenitis is most common in children from 1–5 years of age, and disseminated infections are usually recognized in severely immunocompromised persons, especially those with advanced AIDS.

Reservoirs and Sources of Infection

Nontuberculous mycobacteria, including MAC, are ubiquitous in the environment and are commonly isolated from soil and water (70). Humans become infected by ingestion or inhalation of MAC organisms from the environment.

Infected animals and birds commonly shed mycobacteria in their feces, but are not considered to be an important source of human infections (133). While birds may serve as an important reservoir of some *M. avium* strains, molecular studies have suggested that bird-type *M. avium* isolates are genetically distinct from those that are typically isolated from humans and swine (95, 136). Person-to-person transmission of MAC has not been documented and is not believed to occur (57, 70).

Salmonellosis

Nontyphoidal *Salmonella* infections may be caused by any of the nonhost-specific *Salmonella* serotypes that commonly affect both animals and humans. Based on World Health Organization estimates, *S*. Enteritidis and *S*. Typhimurium were the 2 most common nontyphoidal serovars isolated from humans between 2001 and 2007 (66). *Salmonella* Gallinarum and *Salmonella* Pullorum are rarely isolated from humans.

Nature of the Disease in Humans

Nontyphoidal salmonellosis typically manifests as an acute enterocolitis or gastroenteritis with sudden-onset headache, abdominal pain, diarrhea, nausea, and sometimes vomiting. Fever is usually present (11). Most cases are self-limiting, with diarrhea resolving without treatment after 3–7 days. Bacteremia is a potentially serious complication that occurs in approximately 5% of cases (125). Possible sequelae of bacteremia include endarteritis and disseminated focal infections.

Occurrence

Salmonella has a worldwide distribution. It has been estimated that there are 93.8 million human cases of nontyphoidal salmonellosis and 155,000 deaths globally each year, with 80.3 million of these cases resulting from food-borne transmission (92). Children, the elderly, and people with compromised immune systems are more likely to develop severe disease (59, 125). Poultry and eggs are frequently identified as sources of infection in food-borne salmonellosis outbreaks. Of the 40 salmonellosis outbreaks identified in the U.S. during 2008 that could be attributed to a single food commodity, 11 were attributed to poultry (28).

Reservoirs and Sources of Infection

Nontyphoidal *Salmonella* are capable of colonizing the gastrointestinal tracts of a broad range of wild and domesticated animal hosts including poultry. Transmission occurs by the fecal-oral route and can be achieved by direct contact with infected animal feces or indirectly by the consumption of contaminated food products. The incubation period is typically 12–36 hours, but can range from 6–72 hours. Secondary transmission can occur but is uncommon with appropriate hygiene. The median duration of fecal shedding is approximately 5 weeks after infection, although *Salmonella* can still be identified 1 year post infection in 5% of children younger than 5 years of age and in 1% of adults (23).

Staphylococcus aureus Infection and Foodborne Intoxication

Staphylococcus aureus frequently colonizes the skin and mucous membranes of humans and animals, including poultry. It is both a commensal organism and a frequent cause of clinically important infections. Antibiotic-resistant strains, especially methicillin-resistant *S. aureus* (MRSA), have become increasingly common in recent years (82).

Nature of the Disease in Humans

S. aureus causes a wide variety of clinical manifestations ranging from minor skin pustules to septicemia and death (18, 88, 143). Common cutaneous infections include impetigo, cellulitis, folliculitis, carbuncles, furuncles, and abscesses. Most superficial infections respond well to cleaning and topical antibiotics. Hematogenous spread of localized infections can lead to serious complications including arthritis, endocarditis, osteomyelitis, pneumonia, meningitis, and sepsis. Staphylococcal food-borne intoxication is mediated by the production of heat-stable enterotoxins in uncooked or inadequately refrigerated foods (18). Signs include acute onset of nausea, abdominal cramps, vomiting, and often diarrhea. Most cases of food-borne intoxication resolve without treatment in 1–2 days. *S. aureus* is also the causative agent of toxic shock syndrome in humans (88).

Occurrence

S. aureus has a worldwide distribution and is 1 of the most common pathogens associated with skin and soft-tissue infections. *S. aureus* is the second most common cause of hospital-acquired bloodstream infections (143), and causes approximately 240,000 foodborne intoxications in the U.S. each year (120). Newborn infants and the chronically ill are at increased risk for developing *S. aureus* skin infections (18).

Reservoirs and Sources of Infection

The anterior nares are the most common site of human colonization. Approximately 20% of persons are persistent carriers, 30% are intermittent carriers, and 50% are noncarriers (143). Transmission is by direct or indirect contact. Hands are the most important vehicle for transmission, and at least one-third of skin infections are believed to result from autoinfection (18). Airborne transmission is uncommon but may occur as a consequence of sneezing by nasal carriers. Retail chicken meat is frequently contaminated with enterotoxigenic *S. aureus* strains, although colonized food handlers are believed to be responsible for most cases of food-borne intoxication (81, 122). Signs typically appear within 2–4 hours after ingesting staphylococcal enterotoxins (122). Person-to-person transmission of *S. aureus* from asymptomatic carriers or persons with draining skin lesions is common.

Fungal Diseases

Cryptococcosis

Cryptococcosis is a fungal infection caused by members of the genus *Cryptococcus*. There are at least 37 species belonging to this genus, although only *C. neoformans* and *C. gattii*

are considered to be major human and animal pathogens (85). Cryptococcosis is not considered to be a zoonosis; rather, humans and animals both acquire infection from environmental sources (14).

Nature of the Disease in Humans

The central nervous system (CNS) and lungs are the most frequently recognized sites of *Cryptococcus* infection. Meningitis is the most common presentation in immunocompromised patients, while pulmonary disease may be more common in immunocompetent patients (35). Even with appropriate anti-fungal treatment, the 3-month case fatality risk for cryptococcal meningitis in HIV-infected patients remains approximately 20% (87).

Occurrence

Cryptococcus neoformans has a worldwide distribution and occurs most frequently in immunocompromised persons. *Cryptococcus gattii* has historically been limited to tropical and subtropical regions, although it has recently been recognized in British Columbia, Canada, and in the Pacific Northwest region of the United States (39). In contrast to *C. neoformans*, *C. gattii* causes disease in both immunocompromised and immunocompetent individuals. It has been estimated that there are approximately 720,000 cases of cryptococcal meningitis in HIV-infected persons in Sub-Saharan Africa each year, with approximately 500,000 fatalities (105).

Reservoirs and Sources of Infection

Humans are infected with *Cryptococcus* by inhalation of desiccated encapsulated yeast cells or basidiospores from the environment (84). Pigeon guano from old pigeon lofts or roosts is an important environmental source of *C. neoformans*, while *C. gattii* is frequently found in the hollows of *Eucalyptus* and other tree species (39, 102). The incubation period is unknown but CNS disease may be preceded by a pulmonary infection acquired months or years previously. Person-to-person transmission has been reported but is believed to be rare (140).

Dermatophytosis (Favus)

Microsporum gallinae is a contagious zoophilic fungus that is responsible for causing dermatophytosis in poultry and also in humans (19, 43). This condition is alternatively referred to as favus, dermatomycosis, or ringworm.

Nature of the Disease in Humans

Like other dermatophytes, *M. gallinae* affects keratinized areas of the body including the hair, nails, and skin (20). Lesions begin as small circumscribed areas of erythema, crusting, and scaling, and subsequently spread peripherally. Skin lesions are not associated with systemic illness, although treatment with topical and/or systemic antifungal medications for 4–8 weeks may be required to eliminate the infection (33).

Occurrence

M. gallinae possibly has a worldwide distribution, although it is rarely reported as a cause of disease in either poultry or man. Miyasoto et al. identified a total of 44 human cases that had been reported in the literature as of 2010 (96). Thirty-four of these cases were reported from 2 studies conducted in Nigeria and Iran (79, 103). Young children, the elderly, immunosuppressed persons, and those with diabetes may be at increased risk of infection.

Reservoirs and Sources of Infection

Gallinaceous birds are considered to be the most important reservoir for *M. gallinae*. Transmission occurs by direct contact with infected animals or humans, or indirect contact via contaminated fomites (36). The incubation period is unknown, but for other dermatophytes has been reported as 4–14 days (20). Dermatophyte infections are easily transmitted from person to person while lesions are present. Infectious materials may remain viable in the environment or on contaminated objects for months to years (36).

Histoplasmosis

Histoplasmosis is caused by the fungus *Histoplasma capsulatum* (78). Two varieties cause disease in humans: *H. capsulatum* var. *capsulatum* and *H. capsulatum* var. *duboisii*. The discussion here will focus on the more widely distributed and well known *H. capsulatum* var. *capsulatum*. *Histoplasma* is not considered to be either a contagious or zoonotic pathogen.

Nature of the Disease in Humans

Histoplasmosis is associated with a wide spectrum of clinical illness, with as many as 95% of sporadic infections in endemic areas being asymptomatic (25, 78). Acute pulmonary histoplasmosis is characterized by fever, myalgia, nonproductive cough, dyspnea, and chest pain. The infection is usually self limiting, but immunocompromised patients or those exposed to a large inoculum may progress to acute respiratory distress syndrome. Chronic pulmonary histoplasmosis is a progressive infection characterized by the formation of cavitary lesions in patients with pre-existing emphysema. Progressive disseminated histoplasmosis is a systemic manifestation that typically only occurs in individuals with inadequate T-cell immunity. Complications of histoplasmosis include mediastinal granuloma, fibrosing mediastinitis, pericarditis, and broncholithiasis.

Occurrence

H. capsulatum var. *capsulatum* causes histoplasmosis across the Americas, parts of Africa, eastern Asia, Australia, and rarely in Europe (25). In the United States, *H. capsulatum* is endemic in the Ohio and Mississippi River valleys. In a study of U.S. naval recruits conducted from 1958–1965, the overall prevalence of histoplasmin sensitivity was 20%, and recruits from endemic areas in the east-central part of the country had sensitivity prevalences greater than 80% (48). Young children, the elderly, and immunosuppressed persons are at increased risk for developing histoplasmosis. While most cases are sporadic, large outbreaks have been reported, often in association with construction projects or other activities that involve disturbing soil in the vicinity of bird roosts (25).

Reservoirs and Sources of Infection
Histoplasma grows in the soil, particularly in areas contaminated with undisturbed bird and bat droppings such as wild bird roosts, old chicken coops, and bat caves (2). Humans become infected by inhalation of airborne microconidia. The typical incubation period is between 4 and 14 days (25). Transplacental transmission has been reported, but contact transmission from animal-to-person or from person-to-person does not occur (25, 144).

Parasitic Diseases

Avian Mite Dermatitis

Avian mite dermatitis is most frequently caused by *Dermanyssus gallinae* (the poultry red mite or chicken mite) or *Ornithonyssus sylviarum* (the northern fowl mite) (89, 104). Synonyms include gamasoidosis, acariasis, and fowl mite dermatitis.

Nature of the Disease in Humans
Typical clinical signs in humans include pruritic erythematous papules, vesicles, and dermatitis on exposed skin (12, 89). Excoriation of lesions is common. Avian mites also have been associated with occupational asthma and otitis externa in poultry workers (90, 116). Symptoms are alleviated when the source of mites is removed. Mites are not typically observed on human skin because they leave quickly after biting. Not all exposed persons develop bite reactions (89).

Occurrence
Avian mites have a worldwide distribution. Avian mite dermatitis is not a reportable disease and the incidence is unknown. Most published case reports result from proximate exposures to abandoned bird nests in an urban setting (9, 24, 104). Mite infestation of layer and breeder flocks is common, however, and is recognized as a frequent cause of discomfort in poultry workers (98, 129).

Reservoirs and Sources of Infection
A broad variety of avian species serve as the natural hosts for *Dermanyssus* and *Ornithonyssus*, although mites from these genera can survive at least 5 months and 3 weeks, respectively, without a host (104). When no birds are available, the mites will seek out alternative food sources, including humans and other mammals. Humans are an accidental host and do not serve as a reservoir of avian mites (104).

Cryptosporidiosis

Cryptosporidiosis is caused by intracellular protozoan parasites belonging to the genus *Cryptosporidium*. Three avian *Cryptosporidium* species are currently recognized: *C. baileyi*, *C. galli*, and *C. meleagridis*. Of these three, only *C. meleagridis* is considered to be a zoonotic pathogen (119).

Nature of the Disease in Humans
Cryptosporidiosis is primarily associated with enteric disease in humans. Watery diarrhea, abdominal cramping, and increased gas production are the most common clinical signs, and may be accompanied by vomiting, fever, and loss of appetite (29, 32, 40). The median duration of illness in immunocompetent persons is 10–14 days, and signs may persist for up to 1 month. Immunocompromised persons may experience severe chronic diarrhea, and are at increased risk for complications including pancreatitis, cholangitis, bronchial involvement, and death.

Occurrence
Cryptosporidium species have a worldwide distribution and are 1 of the most common causes of protozoal diarrhea in humans. More than 95% of human infections are caused by *C. hominis* or *C. parvum*. *Cryptosporidium meleagridis* is the third most commonly identified species in humans, accounting for approximately 1% of infections in the U.K. (50, 108). Young children, immunocompromised persons, and people with occupational exposure to infected animals are at increased risk of infection.

Reservoirs and Sources of Infection
C. meleagridis has been identified in a wide range of avian and mammalian hosts including turkeys, quail, chickens, partridges, parakeets, deer, mice, dogs, and humans (30). Birds are not considered to be a major reservoir for *C. parvum*, which is the most common zoonotic species. Infectious oocysts are shed in the feces of infected animals and humans, and can survive for several months in the environment. Transmission to susceptible hosts occurs by the fecal-oral route. The incubation period is 3–12 days (40). Large numbers of oocysts are shed in the feces of infected individuals, and person-to-person transmission is common. In some cases, oocyst shedding may continue for several weeks after the resolution of clinical symptoms (29).

Toxoplasmosis

Toxoplasmosis is caused by infection with the obligate intracellular protozoan *Toxoplasma gondii*. Cats are the definitive host for *T. gondii*. Mammals and birds serve as intermediate hosts.

Nature of the Disease in Humans
Postnatal infection with *T. gondii* is asymptomatic in approximately 90% of immunocompetent children and adults (97). In the remaining 10%, mild transient cervical or occipital lymphadenopathy is the most common clinical presentation. Immunocompromised persons frequently experience severe disease including encephalitis, chorioretinitis, and pneumonitis. Infection of pregnant mothers is usually asymptomatic, but may lead to abortion or infection of the fetus. Congenital infections can result in chorioretinitis, hydrocephalus, intracranial calcifications, and mental retardation (73).

Occurrence
Toxoplasma gondii has a worldwide distribution, and exposure to the organism is common. The overall seroprevalence in the adolescent and adult U.S. population has been estimated at 23%, and the prevalence among women from 15–44 years

of age was estimated at 15% (74). There are an estimated 400–4,000 cases of congenital toxoplasmosis in the U.S. each year (73). Immunocompromised persons and infants with congenital infections are at increased risk for severe disease.

Reservoirs and Sources of Infection

Cats become infected after ingesting an infected intermediate host, and will shed oocysts in their feces for 1–3 weeks following their first infection. Oocysts do not become infective until 1–5 days after excretion, although they can remain viable in the environment for several months. Humans become infected by ingesting oocysts shed by cats or by consuming infected intermediate hosts. Historically, undercooked lamb and pork have been common sources of human infection (80). Commercial poultry raised in confinement is rarely infected with *T. gondii*; however, infection of free-range chickens is common (44, 45). The incubation period is 5–23 days (47). Toxoplasma can be transmitted from mother to fetus, although this typically occurs only when the mother's first exposure to the parasite occurs during gestation (73). Person-to-person transmission does not occur by direct contact, but transmission by organ transplantation or blood transfusion has been documented.

References

Principles of Disease Prevention, Diagnosis, and Control Introduction

1. Adams, A.W. 1973. Consequences of depriving laying hens of water a short time. *Poult Sci.* 52:1221–1223.
2. Anderson, D.P., and R.P. Hanson. 1965. Influence of environment of virus diseases of poultry. *Avian Dis.* 14:171–182.
3. Andrews, E., B. Bennett, J. Clark, K. Houpt, P. Pascoe, G. Robinson, and J. Boyce. 1993. Report of the American Veterinary Medical Association Panel on Euthanasia. *J Am Vet Med Assoc.* 202:229–249.
4. Anonymous. 2003. *Operational Guidelines Cleaning and Disinfection*, National Animal Health Emergency Management System Guidelines. U.S. Department of Agriculture. http://www.aphis.usda.gov/animal_health/emergency_management/downloads/nahems_guidelines/cleaning_disfection.pdf. Accessed February 13, 2013.
5. Anonymous. Chapter 2.1. Important Risk Analysis. In: *Terrestrial Animal Health Code. World Organization for Animal Health*, Paris. http://www.oie.int/fileadmin/Home/eng/Health_standards/tahc/2010/en_chapitre_1.2.1.htm. Accessed February 13, 2013.
6. Anonymous. 2006: Formaldehyde, 2-butoxyethanol and 1-tert-butoxypropan-2-ol. *IARC Monogr Eval Carcinog Risks Hum* 88:1–478.
7. Anonymous. 2012. OIE Listed Diseases. World Orgaization of Animal Health. http://www.oie.int/animal-health-in-the-world/oie-listed-diseases-2011/. Accessed February 13, 2013.
8. Anonymous. 2010. Zoning and compartmentalization. In: *Terestrial Animal Health Code*. World Organization for Animal Health, Paris. http://web.oie.int/eng/normes/mcode/en_chapitre_1.4.3.pdf. Accessed February 13, 2013.
9. Bagley, R.A. 1972. Monitoring for disease control and prevention. 21st Western Poultry Disease Conference. 48–52.
10. Bale, M.J., M. Bennett, J.E. Berringer, and M. Hinton. 1993. The survival of bacteria exposed to desiccation on surfaces associated with farm buildings. *J Appl Bacteriol.* 75:519–528.
11. Bayliss, C.D., R.W. Peters, J.K. Cook, R.L. Reece, K. Howes, M.M. Binns, and M.E. Boursnell. 1991. A recombinant fowlpox virus that expresses the VP2 antigen of infectious bursal disease virus induces protection against mortality caused by the virus. *Arch Virol.* 120:193–205.
12. Beard, C. 1979. *Avian immunoprophylaxis. Avian Dis.* 23: 327–334.
13. Beard, C.W., W.M. Schnitzlein, and D.N. Tripathy. 1991. Protection of chickens against highly pathogenic avian influenza virus (H5N2) by recombinant fowlpox viruses. *Avian Dis.* 35:356–359.
14. Bell, D. 1966. Water shortages can cut egg production. *Poultry Trib.* 72:30.
15. Bierer, B.W., T.H. Eleazer, and D.E. Roebuck. 1965. Effect of feed and water deprivation on chickens, turkeys, and laboratory mammals. *Poult Sci.* 44:768–773.
16. Block, S.S. 1991. Definition of terms. In: *Disinfection, Sterilization, and Preservation*, 4th ed. S.S. Block, ed. Lea and Febiger, Philadelphia. 18–25.
17. Boursnell, M.E., P.F. Green, A.C. Samson, J.I. Campbell, A. Deuter, R.W. Peters, N.S. Millar, P.T. Emmerson, and M.M. Binns. 1990. A recombinant fowlpox virus expressing the hemagglutinin-neuraminidase gene of Newcastle disease virus (NDV) protects chickens against challenge by NDV. *Virology*. 178: 297–300.
18. Box, P. 1984. Poultry vaccines—Live or killed? *Poult Internat.* 23:58–66.
19. Cameron, A.R., and F.C. Baldock. 1998. A new probability formula for surveys to substantiate freedom from disease. *Prev Vet Med.* 34:1–17.
20. Campbell, T.W. 1995. *Avian Hematology and Cytology*, 2nd ed. Iowa State University Press, Ames, Iowa.
21. Cannon, R.M., and R.T. Roe. 1982. *Livestock Disease Surveys: A Field Manual for Veterinarians*. Australia Government Publishing Service, Canberra. 35p.
22. Capua, I., S. Marangon, M. dalla Pozza, C. Terregino, and G. Cattoli. 2003. Avian influenza in Italy 1997–2001. *Avian Dis.* 47:839–843.
23. Cervantes, H. 1995. Farm vaccination—Water method. *ACPV Workshop on Poultry Vaccination Techniques and Evaluation, 46th North Central Avian Disease Conference*. University of Minnesota, St. Paul, Minnesota.
24. Chapman, H.D., T.E. Cherry, H.D. Danforth, G. Richards, M.W. Shirley, and R.B. Williams. 2002. Sustainable coccidiosis control in poultry production: the role of live vaccines. *Int J Parasitol.* 32:617–629.
25. Charlton, B.R., A.J. Bermudez, M. Boulianne, D.A. Halvorson, J.S. Jeffrey, L.J. Newman, J.E. Sander, and P.S. Wakenell. 2000. *Avian Disease Manual*. American Association of Avian Pathologists, Kennett Square, Pennsylvania.
26. Chute, H., and E. Barden. 1964. The fungous flora of chick hatcheries. *Avian Dis.* 8:13–19.
27. Chute, H., and M. Gershman. 1961. A new approach to hatchery sanitation. *Poult Sci.* 40:568–571.
28. Cogliano, V., Y. Grosse, R. Baan, K. Straif, B. Secretan, and F. El Ghissassi. 2004. Advice on formaldehyde and glycol ethers. *Lancet Oncol.* 5:528.

29. Cox, L.A., Jr., and P.F. Ricci. 2008. Causal regulations vs. political will: Why human zoonotic infections increase despite precautionary bans on animal antibiotics. *Environ Internat*. 34(4):459–75.
30. Curtiss, R., 3rd, and S.M. Kelly. 1987. Salmonella typhimurium deletion mutants lacking adenylate cyclase and cyclic AMP receptor protein are avirulent and immunogenic. *Infect Immun.* 55:3035–3043.
31. Droual, R., A.A. Bickford, B.R. Charlton, and D.R. Kuney. 1990. Investigation of problems associated with intramuscular breast injection of oil-adjuvanted killed vaccines in chickens. *Avian Dis.* 34:473–478.
32. Dufour-Zavala, L., Swayne, D.E., J.R. Glisson, M.W. Jackwood, J.E. Pearson, and W.M. Reed. 2008. *A Laboratory Manual for the Isolation, Identification and Characterization of Avian Pathogens*, 5th ed. American Association of Avian Pathologists, Jacksonville, Florida.
33. Fabri, T.H.F. 1992. Necrotic enteritis, clostridial enteritis or dysbacteriosis? In: *XIX World Poultry Congress*, Amsterdam, The Netherlands. 580–584.
34. Ferket, P.R., and M.A. Qureshi. 2001. *The Immune System in Poultry*. Department of Poultry Science, College of Agriculture and Life Sciences, North Carolina State University.
35. Fletcher, O.J., T. Abdul-Aziz, H.J. Barnes, and H.L. Shivaprasad. 2008. *Avian Histopathology*, 3rd ed. American Association of Avian Pathologists, Jacksonville, Florida.
36. Fynan, E.F., H.L. Robinson, and R.G. Webster. 1993. Use of DNA encoding influenza hemagglutinin as an avian influenza vaccine. *DNA Cell Biol.* 12:785–789.
37. Galton, M.M., and P. Arnstein. 1960. Poultry diseases in public health. Review for epidemiologists. *Public Health Service*. 767.
38. Gentry, R.F., M. Mitrovic, and G.R. Bubash. 1962. Application of Andersen Sampler in hatchery sanitation. *Poult Sci.* 41: 794–804.
39. Gifford, D.H., S.M. Shane, M. Hugh-Jones, and B.J. Weigler. 1987. Evaluation of biosecurity in broiler breeders. *Avian Dis.* 31:339–344.
40. Gildersleeve, R.P., and D.R. Klein Fluke. 1995. *In ovo* technology for vaccine delivery. *Proc North Central Avian Dis Conf.* 46: 35–41.
41. Glisson, J.R., and S.H. Kleven. 1984. Mycoplasma gallisepticum vaccination: effects on egg transmission and egg production. *Avian Dis.* 28:406–415.
42. Glisson, J.R., and S.H. Kleven. 1985. Mycoplasma gallisepticum vaccination: Further studies on egg transmission and egg production. *Avian Dis.* 29:408–415.
43. Gorham, J.R. 1957. A simple technique for the inoculation of the chorioallantoic membrane of chicken embryos. *Am J Vet Res.* 18:691–692.
44. Hofstad, M.S. 1950. A method of bleeding chickens from the heart. *J Am Vet Med Assoc.* 116:353–354.
45. Janeway, C.A., and P. Travers. 1997. *Immuno Biology: The Immune System in Health and Disease*, 3rd ed. Garland Publishing, New York.
46. Jenkins, M.C., M.D. Castle, and H.D. Danforth. 1991. Protective immunization against the intestinal parasite *Eimeria acervulina* with recombinant coccidial antigen. *Poult Sci.* 70:539–547.
47. Joint Expert Technical Advisory Committee on Antibiotic Resistance. 1999. The use of antibiotics in food-producing animals: antibiotic-resistant bacteria in animals and humans. In: *Report of the Joint Expert Technical Advisory Committee on Antibiotic Resistance (JETACAR)*. Office of National Health and Medical Research, Canberra. http://www.health.gov.au/internet/main/publishing.nsf/content/2A8435C711929352CA256F180057901E/$File/jetacar.pdf. Accessed February 13, 2013.
48. Jones, K.E., N.G. Patel, M.A. Levy, A. Storeygard, D. Balk, J.L. Gittleman, and P. Daszak. 2008. Global trends in emerging infectious diseases. *Nature.* 451:990–993.
49. Kahrs, R.F. 1995. General disinfection guidelines. *Rev Sci Tech.* 14(1):105–122.
50. Keirs, R.W. 1973. Health monitoring improves management efficiency. *Proc West Poult Dis Conf.* 22:99–101.
51. Kelsey, J.L., W.D. Thompson, and A.S. Evans. 1986. *Methods in Observational Epidemiology*. Oxford University Press, New York.
52. Klasing, K.C., D.E. Laurin, R.K. Peng, and D.M. Fry. 1987. Immunologically mediated growth depression in chicks: influence of feed intake, corticosterone and interleukin-1. *J Nutr.* 117:1629–1637.
53. Lovell, E.J. 1995. Farm vaccination—Injection method oil emulsion vaccines. ACPV Workshop on Poultry Vaccination Techniques and Evaluation, 46th North Central Avian Disease Conference. University of Minnesota, St. Paul, Minnesota.
54. Magwood, S. 1964. Studies in hatchery sanitation: 1. Fluctuations in microbial counts of air in poultry hatcheries. *Poult Sci.* 43:441–449.
55. Magwood, S. 1964. Studies in hatchery sanitation: 3. The effect of air-borne bacterial populations on contamination of egg and embryo surfaces. *Poult Sci*. 43:1567–1572.
56. Magwood, S., and H. Marr. 1964. Studies in hatchery sanitation: 2. A simplified method for assessing bacterial populations on surfaces within hatcheries. *Poult Sci*. 43:1558–1566.
57. Mallinson, E.T., D.B. Snyder, W.W. Marquardt, and S.L. Gorham. 1988. Immunoassays for veterinary and food analysis-1. In: *Immunoassays for Veterinary and Food Analysis-1*. B.A. Morris, M.N. Clifford, and R. Jackman, eds. Elsevier, London and New York. 109–117.
58. MARAN. 2005. *Monitoring of Antimicrobial Resistance and Antibiotic Usage in Animals in The Netherlands in 2005*. CVI-Lelystad, Lelystad, The Netherlands.
59. McCoy, J. 2011. Water treatment for disease control in the poultry industry. In: *A Practical Guide for Mananging Risk in Poultry Production*. R.L. Owen, ed. American Association of Avian Pathologists. 55–69.
60. McKenzie, K.S. 2011. Poultry sanitation in live production: Chemical selection vs cleaning process. In: *A Practical Guide for Managing Risk In Poultry Production*. R.L. Owen, ed. American Association of Avian Pathologists. 35–54.
61. McMartin, D.A., M.I. Khan, T.B. Farver, and G. Christie. 1987. Delineation of the lateral spread of Mycoplasma-Gallisepticum infection in chickens. *Avian Dis.* 31:814–819.
62. McMillen, J. 1995. Use of vector vaccines in poultry. *Proc North Central Avian Dis Conf.* 46:4–6.
63. Murphy, D. 1988. Composting as a dead bird disposal method. *Poult Sci*. 67 (Supp. 1):124.
64. Odor, E.M., J.K. Rosenberger, S.S. Cloud, and M. Salem. 1995. Infectious bursal disease laboratory monitoring. ACPV Workshop on Poultry Vaccination Techniques and Evaluation, 46th North Central Avian Disease Conference. University of Minnesota, St. Paul, Minnesota.
65. Preece, A. 1965. *A Manual for Histological Technicians*. 2nd ed. Little, Brown & Co., Boston.

66. Prophet, E.B., B. Mills, J.B. Arrington, and L.H. Sobin. 1992. *Laboratory Methods in Histotechnology*. American Registry of Pathology, Washington, DC.
67. Randall, C.J. 1991. *A Color Atlas of Diseases and Disorders of the Domestic Fowl and Turkey*, 2nd ed. Iowa State University Press, Ames, Iowa.
68. Roland, K., R. Curtiss, 3rd, and D. Sizemore. 1999. Construction and evaluation of a delta cya delta crp *Salmonella typhimurium* strain expressing avian pathogenic *Escherichia coli* O78 LPS as a vaccine to prevent airsacculitis in chickens. *Avian Dis.* 43:429–441.
69. Rowland, R. 2011. Insect problems in poultry production facilities. In: *A Practical Guide for Managing Risk in Poultry Production*. B.L. Owen, ed. American Association of Avian Pathologists. 117–129.
70. Sakaguchi, M., H. Nakamura, K. Sonoda, F. Hamada, and K. Hirai. 1996. Protection of chickens from Newcastle disease by vaccination with a linear plasmid DNA expressing the F protein of Newcastle disease virus. *Vaccine.* 14:747–752.
71. Sasipreeyajan, J., D.A. Halvorson, and J.A. Newman. 1987. Effect of mycoplasma gallisepticum bacterin on egg-transmission and egg production. *Avian Dis.* 31:776–781.
72. Scott, T.A.S., and C. Swetnam. 1993. Screening sanitizing agents and methods of application for hatching eggs II. Effectiveness against microorganisms on the egg shell. *J Appl Poult Res*. 2:7–11.
73. Sharma, J.M., and B.R. Burmester. 1982. Resistance to Marek's disease at hatching in chickens vaccinated as embryos with the turkey herpesvirus. *Avian Dis.* 26:134–149.
74. Siegel, H. 1994. Stress and immunity. Proceedings of the 9th European Poultry Conference. Glasgow, UK. 22–125.
75. Smith, R.D. 1995. Cost of disease. In: *Veterinary Clinical Epidemiology: A Problem Oriented Approach*. R. Smith, ed. CRC Press, Inc., Boca Raton, Florida. 227–246.
76. Snyder, D.B., W.W. Marquardt, E.T. Mallinson, E. Russek-Cohen, S. Gorham, E. Odor, J.G. Stein, and S. Bakos. 1985. Cooperative serologic survey of Delmarva broiler flocks by enzyme linked immunosorbent assay. 20th National Meeting on Poultry Health and Condemnations. 110–120.
77. Snyder, D.B., W.W. Marquardt, E.T. Mallinson, E. Russek-Cohen, P.K. Savage, and D.C. Allen. 1986. Rapid serological profiling by enzyme-linked immunosorbent assay. IV. Association of infectious bursal disease serology with broiler flock performance. *Avian Dis*. 30:139–148.
78. Stewart-Brown, B. 1995. Applying poultry vaccines via the aerosol route on the farm: Technique and critique. ACPV Workshop on Poultry Vaccination Techniques and Evaluation, 46th North Central Avian Disease Conference. University of Minnesota, St. Paul, Minnesota.
79. Swayne, D.E., and D.A. Halvorson. 2008. Influenza. In: *Diseases of Poultry*, 12th ed. Y.M. Saif, A.M. Fadly, J.R. Glisson, L.R. McDougald, L.K. Nolan, and D.E. Swayne, eds. Blackwell Publishing, Ames, Iowa. 153–184.
80. Thompson, S.W. 1966. *Selected histochemical and histopathological methods*, Vol. 1. Charles C. Thomas, Springfield, Illinois.
81. Thornton, G. 1993. *In ovo* vaccination trials at golden poultry. *Broiler Industry*. October:28–30.
82. Triyatni, M., A.R. Jilbert, M. Qiao, D.S. Miller, and C.J. Burrell. 1998. Protective efficacy of DNA vaccines against duck hepatitis B virus infection. *J Virol.* 72:84–94.
83. Utterback, W.W., and J.H. Schwartz. 1973. Epizootiology of velogenic viscerotropic Newcastle disease in southern California, 1971–1973. *J Am Vet Med Assoc.* 163:1080–1088.
84. Vakharia, V.N., D.B. Snyder, J. He, G.H. Edwards, P.K. Savage, and S.A. Mengel-Whereat. 1993. Infectious bursal disease virus structural proteins expressed in a baculovirus recombinant confer protection in chickens. *J Gen Virol.* 74:1201–1206.
85. Watkins, S.E. 2007. In search of the ideal water line cleaner. *Avian Advice*. 9(1): 1–2. http://www.avianadvice.uark.edu/AA%20PDFs/avianadvice_sp07.pdf. Accessed February 13, 2013.
86. White Jr., R.A., and M.P. Noalan III. 2011. Rodent control in poultry operations. In: *A Practical Guide for Managing Risk in Poultry Production*. L.O. Owen, ed. American Association of Avian Pathologists. 131–153.
87. Williams, C.J., C.L. Griffin, D.R. Klein, W.R. Sorrell, M.N. Secrest, A.M. Miles, and R.P. Gildersleeve. 1994. A microbiological survey of broiler hatcheries in North America—The prevalence of aspergillus and other deuteromycetes. *Poult Sci.* 73:166.
88. Woolhouse, M.E. 2008. Epidemiology: emerging diseases go global. *Nature.* 451:898–899.
89. Wright, M., G. Anderson, and J. McConachie. 1961. Transmission of aspergillosis during incubation. *Poult Sci.* 40:727–731.
90. Wright, M.L. 1958. Hatchery sanitation. *Can J Comp Med Vet Sci.* 22:62–66.
91. Wright, M.L., G.W. Anderson, and N.A. Epps. 1959. Hatchery sanitation. *Can J Comp Med Vet Sci.* 23:288–290.
92. Zander, D.V. 1977. Unpublished observations.

Antimicrobial Therapy (Including Resistance)

1. Hofacre C.L., R. Froyman, B. George, M.A. Goodwin, and J. Brown. 1998. Use of Aviguard, virginiamycin, or bacitracin MD against Clostridium perfringens-associated necrotizing enteritis. *J Appl Poultry Res.* 7(4):412–8.
2. Goren E., W.A. de Jong, and P. Doornenbal. 1984. Some pharmacokinetic aspects of four sulphonamides and trimethoprim, and their therapeutic efficacy in experimental Escherichia coli infection in poultry. *Vet Quart.* 6:134.
3. Kinney N., and A. Robles. 1994. The effect of mixing antibiotics with Marek's disease vaccine. *Proc West Poult Dis Conf.* 43:96–7.
4. Charleston B., J.J. Gate, I.A. Aitken, B. Stephan, and R. Froyman. 1998. Comparison of the efficacies of three fluoroquinolone antimicrobial agents, given as continuous or pulsed-water medication, against *Escherichia coli* infection in chickens. *Antimicrob Agents Ch.* 42(1):83–7.
5. Glisson J.R., C.L. Hofacre, and G.F. Mathis. 2004. Comparative efficacy of enrofloxacin, oxytetracycline, and sulfadimethoxine for the control of morbidity and mortality caused by *Escherichia coli* in broiler chickens. *Avian Dis.* 48(3):658–62.
6. Frost L.S., R. Leplae, A.O. Summers, and A. Toussaint. 2005. Mobile genetic elements: the agents of open source evolution. *Nat Rev Microbiol.* 9:722–32.
7. Johnson T.J., and L.K. Nolan. 2009. Pathogenomics of the virulence plasmids of *Escherichia coli*. *Microbiol Mol Biol Rev.* 73(4):750–74.
8. Welch T.J., W.F. Fricke, P.F. McDermott, D.G. White, M.L. Rosso, D.A. Rasko, M.K. Mammel, M. Eppinger, M.J. Rosovitz, D. Wagner, L. Rahalison, J.E. LeClerc, J.M. Hinshaw, L.E. Lindler, T.A. Cebula, E. Carniel, and J. Ravel. 2007. Multiple

antimicrobial resistance in plague: an emerging public health risk. *PLoS ONE.* 2(3):e309.
9. Fernandez-Alarcon C., R.S. Singer, and T.J. Johnson. 2011. Comparative genomics of multidrug resistance-encoding IncA/C plasmids from commensal and pathogenic *Escherichia coli* from multiple animal sources. *PLoS ONE.* 6(8):e23415.
10. Fricke W.F., T.J. Welch, P.F. McDermott, M.K. Mammel, J.E. LeClerc, D.G. White, T.A. Cebula, and J. Ravel. 2009. Comparative genomics of the IncA/C multidrug resistance plasmid family. *J Bacteriol.* 191(15):4750–7.
11. Liebert C.A., R.M. Hall, and A.O. Summers. 1999. Transposon Tn*21*, flagship of the floating genome. *Microbiol Mol Biol Rev.* 63(3):507–22.
12. Johnson T.J., C.M. Logue, J.R. Johnson, M.A. Kuskowski, J.S. Sherwood, H.J. Barnes, C. DebRoy, Y.M. Wannemuehler, M. Obata-Yasuoka, and L.K. Nolan. 2011. Associations between multidrug resistance, plasmid content, and virulence potential among extraintestinal pathogenic and commensal *Escherichia coli* from humans and poultry. *Foodborne Pathog Dis.* 9(1):37–46.
13. Johnson T.J., D. Jordan, S. Kariyawasam, A.L. Stell, N.P. Bell, Y.M. Wannemuehler, C.F. Alarcon, G. Li, K.A. Tivendale, C.M. Loque, and L.K. Nolan. 2010. Sequence analysis and characterization of a transferable hybrid plasmid encoding multidrug resistance and enabling zoonotic potential for extraintestinal *Escherichia coli*. *Infect Immun.* 78(5):1931–42.
14. Johnson T.J., K.E. Siek, S.J. Johnson, and L.K. Nolan. 2005. DNA sequence and comparative genomics of pAPEC-O2-R, an avian pathogenic *Escherichia coli* transmissible R plasmid. *Antimicrob Agents Chemother.* 49(11):4681–8.
15. Han J., D.E. David, J. Deck, A.M. Lynne, P. Kaldhone, R. Nayak, R. Stefanova, and S.L. Foley. 2011. Comparison of *Salmonella enterica* serovar Heidelberg isolates from human patients with those from animal and food sources. *J Clin Microbiol.* 49(3):1130–3.
16. Kaldhone P., R. Nayak, A.M. Lynne, D.E. David, P.F. McDermott, C.M. Logue, and S.L. Foley. 2008. Characterization of *Salmonella enterica* serovar Heidelberg from turkey-associated sources. *Appl Environ Microbiol.* 74(16):5038–46.
17. Patchanee P., B.M. Zewde, D.A. Tadesse, A. Hoet, and W.A. Gebreyes. 2008. Characterization of multidrug-resistant *Salmonella enterica* serovar Heidelberg isolated from humans and animals. *Foodborne Pathog Dis.* 5(6):839–51.
18. Martin L.C., E.K. Weir, C. Poppe, R.J. Reid-Smith, and P. Boerlin. 2012. Characterization of *bla*CMY-2 plasmids in *Salmonella* and *Escherichia coli* isolates from food animals in Canada. *Appl Environ Microbiol.* 78(4):1285–7.
19. Folster J.P., G. Pecic, A. Singh, B. Duval, R. Rickert, S. S. Ayers, J. Abbott, B. McGlinchey, J. Bauer-Turpin, J. Haro, K. Hise, S. Zhao, P.J. Fedorka-Cray, J. Whichard, and P.F. McDermott. 2012. Characterization of extended-spectrum cephalosporin-resistant *Salmonella enterica* serovar Heidelberg isolated from food animals, retail meat, and humans in the United States 2009. *Foodborne Pathog Dis.* 9(7):638–45.
20. Folster J.P., G. Pecic, A. McCullough, R. Rickert, and J.M. Whichard. 2011. Characterization of *bla*(CMY)-encoding plasmids among *Salmonella* isolated in the United States in 2007. *Foodborne Pathog Dis.* 8(12):1289–94.
21. Lindsey R.L., J.G. Frye, P.J. Fedorka-Cray, and R.J. Meinersmann. 2011. Microarray-based analysis of IncA/C plasmid-associated genes from multidrug-resistant *Salmonella enterica*. *Appl Environ Microbiol.* 77(19):6991–9.
22. Johnson T.J., and K.S. Lang. 2012. IncA/C plasmids: An emerging threat to human and animal health? *Mob Genet Elements.* 2(1):55–8.
23. Dhanarani T.S., C. Shankar, J. Park, M. Dexilin, R.R. Kumar, and K. Thamaraiselvi. 2009. Study on acquisition of bacterial antibiotic resistance determinants in poultry litter. *Poult Sci.* 88(7):1381–7.
24. Poole T., and T. Crippen. 2009. Conjugative plasmid transfer between *Salmonella enterica* Newport and *Escherichia coli* within the gastrointestinal tract of the lesser mealworm beetle, Alphitobius diaperinus (Coleoptera: Tenebrionidae). *Poult Sci.* 88(8):1553–8.
25. Levy S.B., G.B. FitzGerald, and A.B. Macone. 1976. Spread of antibiotic-resistant plasmids from chicken to chicken and from chicken to man. *Nature.* 260(5546):40–2.
26. Dheilly A., L. Le Devendec, G. Mourand, A. Bouder, E. Jouy, and I. Kempf. 2012. Resistance gene transfer during treatments for experimental avian colibacillosis. *Antimicrob Agents Chemother.* 56(1):189–96.

Public Health Significance of Poultry Diseases

1. Abdel-Ghafar, A.N., T. Chotpitayasunondh, Z. Gao, F.G. Hayden, D.H. Nguyen, M.D. de Jong, A. Naghdaliyev, J.S. Peiris, N. Shindo, S. Soeroso, and T.M. Uyeki. 2008. Update on avian influenza A (H5N1) virus infection in humans. *N Engl J Med.* 358:261–273.
2. Ajello, L. 1964. Relationship of Histoplasma Capsulatum to avian habitats. *Public Health Rep.* 79:266–270.
3. Alexander, D.J. 2000. Newcastle disease and other avian paramyxoviruses. *Rev Sci Tech.* 19:443–462.
4. Allerberger, F., and M. Wagner. 2010. Listeriosis: a resurgent foodborne infection. *Clin Microbiol Infect.* 16:16–23.
5. Allos, B.M. 2001. Campylobacter jejuni infections: update on emerging issues and trends. *Clin Infect Dis.* 32:1201–1206.
6. Andersen, A.A., and D. Vanrompay. 2000. Avian chlamydiosis. *Rev Sci Tech.* 19:396–404.
7. Andersson, A., U. Ronner, and P.E. Granum. 1995. What problems does the food industry have with the spore-forming pathogens *Bacillus cereus* and *Clostridium perfringens*? *Int J Food Microbiol.* 28:145–155.
8. Angulo, F.J., C.A. Glaser, D.D. Juranek, M.R. Lappin, and R.L. Regnery. 1994. Caring for pets of immunocompromised persons. *J Am Vet Med Assoc.* 205:1711–1718.
9. Auger, P., J. Nantel, N. Meunier, R.J. Harrison, R. Loiselle, and T.W. Gyorkos. 1979. Skin acariasis caused by Dermanyssus gallinae (de Geer): an in-hospital outbreak. *Can Med Assoc J.* 120:700–703.
10. Beeckman, D.S., and D.C. Vanrompay. 2009. Zoonotic Chlamydophila psittaci infections from a clinical perspective. *Clin Microbiol Infect.* 15:11–17.
11. Behravesh, C.B., M. Lynch, and J. Schlundt. 2008. Salmonellosis. In: *Control of Communicable Diseases Manual*, 19th ed. D.L. Heymann, ed. APHA, Washington, D.C. 534–540.
12. Bellanger, A.P., C. Bories, F. Foulet, S. Bretagne, and F. Botterel. 2008. Nosocomial dermatitis caused by Dermanyssus gallinae. *Infect Control Hosp Epidemiol.* 29:282–283.

13. Bin, H., Z. Grossman, S. Pokamunski, M. Malkinson, L. Weiss, P. Duvdevani, C. Banet, Y. Weisman, E. Annis, D. Gandaku, V. Yahalom, M. Hindyieh, L. Shulman, and E. Mendelson. 2001. West Nile fever in Israel 1999–2000: from geese to humans. *Ann N Y Acad Sci.* 951:127–142.
14. Blaschke-Hellmessen, R. 2000. Cryptococcus species—etiological agents of zoonoses or sapronosis? *Mycoses.* 43 Suppl 1:48–60.
15. Blaser, M.J. 1997. Epidemiologic and clinical features of *Campylobacter jejuni* infections. *J Infect Dis.* 176(Suppl 2): S103–105.
16. Blaser, M.J., G.P. Perez, P.F. Smith, C. Patton, F.C. Tenover, A.J. Lastovica, and W.I. Wang. 1986. Extraintestinal Campylobacter jejuni and Campylobacter coli infections: host factors and strain characteristics. *J Infect Dis.* 153:552–559.
17. Blitvich, B.J. 2008. Transmission dynamics and changing epidemiology of West Nile virus. *Anim Health Res Rev.* 9:71–86.
18. Board, E. 2008. Staphylococcal diseases. In: *Control of Communicable Diseases Manual*, 19th ed. D.L. Heymann, ed. APHA, Washington, D.C. 567–576.
19. Bradley, F.A., A.A. Bickford, and R.L. Walker. 1993. Diagnosis of favus (avian dermatophytosis) in Oriental breed chickens. *Avian Dis.* 37:1147–1150.
20. Brandt, M. 2008. Dermatophytosis. In: *Control of Communicable Diseases Manual*, 19th ed. D.L. Heymann, ed. APHA, Washington, D.C. 172–179.
21. Brooke, C.J., and T.V. Riley. 1999. Erysipelothrix rhusiopathiae: bacteriology, epidemiology and clinical manifestations of an occupational pathogen. *J Med Microbiol.* 48:789–799.
22. Brynestad, S., and P.E. Granum. 2002. Clostridium perfringens and foodborne infections. *Int J Food Microbiol.* 74:195–202.
23. Buchwald, D.S., and M.J. Blaser. 1984. A review of human salmonellosis: II. Duration of excretion following infection with nontyphi Salmonella. *Rev Infect Dis*. 6:345–356.
24. Cafiero, M.A., A. Camarda, E. Circella, G. Santagada, G. Schino, and M. Lomuto. 2008. Pseudoscabies caused by Dermanyssus gallinae in Italian city dwellers: a new setting for an old dermatitis. *J Eur Acad Dermatol Venereol.* 22:1382–1383.
25. Cano, M.V., and R.A. Hajjeh. 2001. The epidemiology of histoplasmosis: a review. *Semin Respir Infect.* 16:109–118.
26. Centers for Disease Control. 1998. Botulism in the United States, 1899–1996: *Handbook for Epidemiologists, Clinicians, and Laboratory Workers*. Atlanta, Georgia.
27. Centers for Disease Control. 2006. Interim guidance for protection of persons involved in U.S. avian influenza outbreak disease control and eradication activities. http://www.cdc.gov/flu/avian/professional/protect-guid.htm. Accessed February 13, 2013.
28. Centers for Disease Control. 2011. Surveillance for foodborne disease outbreaks—United States, 2008. *MMWR Morb Mortal Wkly Rep.* 60:1197–1202.
29. Chalmers, R.M., and A.P. Davies. 2010. Minireview: clinical cryptosporidiosis. *Exp Parasitol.* 124:138–146.
30. Chalmers, R.M., and M. Giles. 2010. Zoonotic cryptosporidiosis in the UK—challenges for control. *J Appl Microbiol.* 109:1487–1497.
31. Chang, P.W. 1981. Newcastle disease. In: *CRC Handbook*. Series in zoonoses. Section B: Viral zoonoses. Volume II. G.W. Beran, ed. CRC Press, Boca Raton, Florida. 261–274.
32. Chappell, C.L., P.C. Okhuysen, R.C. Langer-Curry, D.E. Akiyoshi, G. Widmer, and S. Tzipori. 2011. Cryptosporidium meleagridis: infectivity in healthy adult volunteers. *Am J Trop Med Hyg.* 85:238–242.
33. Charles, A.J. 2009. Superficial cutaneous fungal infections in tropical countries. *Dermatol Ther.* 22:550–559.
34. Chemaly, M., M.T. Toquin, Y. Le Notre, and P. Fravalo. 2008. Prevalence of Listeria monocytogenes in poultry production in France. *J Food Prot.* 71:1996–2000.
35. Chen, S., T. Sorrell, G. Nimmo, B. Speed, B. Currie, D. Ellis, D. Marriott, T. Pfeiffer, D. Parr, and K. Byth. 2000. Epidemiology and host- and variety-dependent characteristics of infection due to Cryptococcus neoformans in Australia and New Zealand. Australasian Cryptococcal Study Group. *Clin Infect Dis*. 31: 499–508.
36. Chermette, R., L. Ferreiro, and J. Guillot. 2008. Dermatophytoses in animals. *Mycopathologia.* 166:385–405.
37. Chiarini, E., K. Tyler, J.M. Farber, F. Pagotto, and M.T. Destro. 2009. Listeria monocytogenes in two different poultry facilities: Manual and automatic evisceration. *Poult Sci.* 88:791–797.
38. Coker, A.O., R.D. Isokpehi, B.N. Thomas, K.O. Amisu, and C.L. Obi. 2002. Human campylobacteriosis in developing countries. *Emerg Infect Dis.* 8:237–244.
39. Datta, K., K.H. Bartlett, R. Baer, E. Byrnes, E. Galanis, J. Heitman, L. Hoang, M.J. Leslie, L. MacDougall, S.S. Magill, M.G. Morshed, and K.A. Marr. 2009. Spread of Cryptococcus gattii into Pacific Northwest region of the United States. *Emerg Infect Dis.* 15:1185–1191.
40. Davies, A.P., and R.M. Chalmers. 2009. Cryptosporidiosis. *Brit Med J.* 339:b4168.
41. Davis, L.E., J.D. Beckham, and K.L. Tyler. 2008. North American encephalitic arboviruses. *Neurol Clin.* 26:727–757.
42. Doyle, M.P., and J.L. Schoeni. 1987. Isolation of *Escherichia coli* O157:H7 from retail fresh meats and poultry. *Appl Environ Microbiol.* 53:2394–2396.
43. Droual, R., A.A. Bickford, R.L. Walker, S.E. Channing, and C. McFadden. 1991. Favus in a backyard flock of game chickens. *Avian Dis.* 35:625–630.
44. Dubey, J.P. 2010. Toxoplasma gondii infections in chickens (*Gallus domesticus*): prevalence, clinical disease, diagnosis and public health significance. *Zoonoses Public Health.* 57: 60–73.
45. Dubey, J.P., H. Salant, C. Sreekumar, E. Dahl, M.C. Vianna, S.K. Shen, O.C. Kwok, D. Spira, J. Hamburger, and T.V. Lehmann. 2004. High prevalence of *Toxoplasma gondii* in a commercial flock of chickens in Israel, and public health implications of free-range farming. *Vet Parasitol.* 121:317–322.
46. Dunbar, S.A., and J.E. Clarridge, 3rd. 2000. Potential errors in recognition of Erysipelothrix rhusiopathiae. *J Clin Microbiol.* 38:1302–1304.
47. Eberhard, M., J. Jones, F. Meslin, and H.V. Nielsen. 2008. Toxoplasmosis. In: *Control of Communicable Diseases Manual*, 19th ed. D.L. Heymann, ed. APHA. 613–617.
48. Edwards, L.B., F.A. Acquaviva, V.T. Livesay, F.W. Cross, and C.E. Palmer. 1969. An atlas of sensitivity to tuberculin, PPD-B, and histoplasmin in the United States. *Am Rev Respir Dis.* 99(Suppl):1–132.
49. Eidson, M. 2002. Psittacosis/avian chlamydiosis. *J Am Vet Med Assoc.* 221:1710–1712.
50. Elwin, K., S.J. Hadfield, G. Robinson, and R.M. Chalmers. 2012. The epidemiology of sporadic human infections with unusual cryptosporidia detected during routine typing in England and Wales, 2000-2008. *Epidemiol Infect.* 140(4):673–83.
51. Farber, J.M., and P.I. Peterkin. 1991. Listeria monocytogenes, a food-borne pathogen. *Microbiol Rev.* 55:476–511.

52. Felsenfeld, O. 1951. Diseases of poultry transmissible to man. *Iowa State Coll Vet.* 13:89–92.
53. Ferens, W.A., and C.J. Hovde. 2011. *Escherichia coli* O157:H7: animal reservoir and sources of human infection. *Foodborne Pathog Dis.* 8:465–487.
54. Fontaine, P., P. Griffin, O. Henao, D. Lo Fo Wong, E. Mintz, R. Mody, C. O'Reilly, and J. Schlundt. 2008. Diarrhea, acute. In: *Control of Communicable Diseases Manual*, 19th ed. D.L. Heymann, ed. APHA, Washington, D.C. 179–195.
55. Fouchier, R.A., P.M. Schneeberger, F.W. Rozendaal, J.M. Broekman, S.A. Kemink, V. Munster, T. Kuiken, G.F. Rimmelzwaan, M. Schutten, G.J. Van Doornum, G. Koch, A. Bosman, M. Koopmans, and A.D. Osterhaus. 2004. Avian influenza A virus (H7N7) associated with human conjunctivitis and a fatal case of acute respiratory distress syndrome. *Proc Natl Acad Sci USA*. 101:1356–1361.
56. Friis, C., T.M. Wassenaar, M.A. Javed, L. Snipen, K. Lagesen, P.F. Hallin, D.G. Newell, M. Toszeghy, A. Ridley, G. Manning, and D.W. Ussery. 2010. Genomic characterization of Campylobacter jejuni strain M1. *PLoS One.* 5:e12253.
57. Glassroth, J. 2008. Pulmonary disease due to nontuberculous mycobacteria. *Chest.* 133:243–251.
58. Gorby, G.L., and J.E. Peacock, Jr. 1988. Erysipelothrix rhusiopathiae endocarditis: microbiologic, epidemiologic, and clinical features of an occupational disease. *Rev Infect Dis.* 10:317–325.
59. Gordon, M.A. 2008. Salmonella infections in immunocompromised adults. *J Infect.* 56:413–422.
60. Granum, P.E. 1990. Clostridium perfringens toxins involved in food poisoning. *Int J Food Microbiol.* 10:101–111.
61. Grieco, M.H., and C. Sheldon. 1970. Erysipelothrix rhusiopathiae. *Ann NY Acad Sci.* 174:523–532.
62. Griffith, D.E., T. Aksamit, B.A. Brown-Elliott, A. Catanzaro, C. Daley, F. Gordin, S.M. Holland, R. Horsburgh, G. Huitt, M.F. Iademarco, M. Iseman, K. Olivier, S. Ruoss, C.F. von Reyn, R.J. Wallace, Jr., and K. Winthrop. 2007. An official ATS/IDSA statement: diagnosis, treatment, and prevention of nontuberculous mycobacterial diseases. *Am J Respir Crit Care Med.* 175:367–416.
63. Grossmann, K., B. Weniger, G. Baljer, B. Brenig, and L.H. Wieler. 2005. Racing, ornamental and city pigeons carry shiga toxin producing *Escherichia coli* (STEC) with different shiga toxin subtypes, urging further analysis of their epidemiological role in the spread of STEC. *Berl Munch Tierarztl Wochenschr.* 118:456–463.
64. Hanson, R.P., and C.A. Brandly. 1958. Newcastle disease. *Ann NY Acad Sci.* 70:585–597.
65. Heikinheimo, A., M. Lindstrom, P.E. Granum, and H. Korkeala. 2006. Humans as reservoir for enterotoxin gene-carrying Clostridium perfringens type A. *Emerg Infect Dis.* 12:1724–1729.
66. Hendriksen, R.S., A.R. Vieira, S. Karlsmose, D.M. Lo Fo Wong, A.B. Jensen, H.C. Wegener, and F.M. Aarestrup. 2011. Global monitoring of salmonella serovar distribution from the World Health Organization global foodborne infections network country data bank: results of quality assured laboratories from 2001 to 2007. *Foodborne Pathog Dis.* 8:887–900.
67. Heuvelink, A.E., J.T. Zwartkruis-Nahuis, F.L. van den Biggelaar, W.J. van Leeuwen, and E. de Boer. 1999. Isolation and characterization of verocytotoxin-producing *Escherichia coli* O157 from slaughter pigs and poultry. *Int J Food Microbiol.* 52:67–75.
68. Hughes, C., P. Maharg, P. Rosario, M. Herrell, D. Bratt, J. Salgado, and D. Howard. 1997. Possible nosocomial transmission of psittacosis. *Infect Control Hosp Epidemiol.* 18:165–168.
69. Humphrey, T., S. O'Brien, and M. Madsen. 2007. Campylobacters as zoonotic pathogens: a food production perspective. *Int J Food Microbiol.* 117:237–257.
70. Inderlied, C.B., C.A. Kemper, and L.E. Bermudez. 1993. The Mycobacterium avium complex. *Clin Microbiol Rev.* 6:266–310.
71. Jackson, K.A., M. Iwamoto, and D. Swerdlow. 2010. Pregnancy-associated listeriosis. *Epidemiol Infect.* 138:1503–1509.
72. Johnson, T.J., Y. Wannemuehler, S.J. Johnson, A.L. Stell, C. Doetkott, J.R. Johnson, K.S. Kim, L. Spanjaard, and L.K. Nolan. 2008. Comparison of extraintestinal pathogenic *Escherichia coli* strains from human and avian sources reveals a mixed subset representing potential zoonotic pathogens. *Appl Environ Microbiol.* 74:7043–7050.
73. Jones, J., A. Lopez, and M. Wilson. 2003. Congenital toxoplasmosis. *Am Fam Physician.* 67:2131–2138.
74. Jones, J.L., D. Kruszon-Moran, M. Wilson, G. McQuillan, T. Navin, and J.B. McAuley. 2001. Toxoplasma gondii infection in the United States: seroprevalence and risk factors. *Am J Epidemiol.* 154:357–365.
75. Kaleta, E.F., and C. Baldauf. 1988. Newcastle disease in free-living and pet birds. In: *Newcastle Disease*. D.J. Alexander, ed. Kluwer Academic Publishers, Boston. 197–246.
76. Kaleta, E.F., and E.M. Taday. 2003. Avian host range of Chlamydophila spp. based on isolation, antigen detection and serology. *Avian Pathol.* 32:435–461.
77. Kalthoff, D., A. Globig, and M. Beer. 2010. (Highly pathogenic) avian influenza as a zoonotic agent. *Vet Microbiol.* 140:237–245.
78. Kauffman, C.A. 2007. Histoplasmosis: a clinical and laboratory update. *Clin Microbiol Rev.* 20:115–132.
79. Khosravi, A.R., M.R. Aghamirian, and M. Mahmoudi. 1994. Dermatophytoses in Iran. *Mycoses.* 37:43–48.
80. Kijlstra, A., and E. Jongert. 2008. Control of the risk of human toxoplasmosis transmitted by meat. *Int J Parasitol.* 38:1359–1370.
81. Kitai, S., A. Shimizu, J. Kawano, E. Sato, C. Nakano, H. Kitagawa, K. Fujio, K. Matsumura, R. Yasuda, and T. Inamoto. 2005. Prevalence and characterization of Staphylococcus aureus and enterotoxigenic Staphylococcus aureus in retail raw chicken meat throughout Japan. *J Vet Med Sci.* 67:269–274.
82. Klevens, R.M., M.A. Morrison, J. Nadle, S. Petit, K. Gershman, S. Ray, L.H. Harrison, R. Lynfield, G. Dumyati, J.M. Townes, A.S. Craig, E.R. Zell, G.E. Fosheim, L.K. McDougal, R.B. Carey, and S.K. Fridkin. 2007. Invasive methicillin-resistant Staphylococcus aureus infections in the United States. *JAMA.* 298:1763–1771.
83. Lamont, R.F., J. Sobel, S. Mazaki-Tovi, J.P. Kusanovic, E. Vaisbuch, S.K. Kim, N. Uldbjerg, and R. Romero. 2011. Listeriosis in human pregnancy: a systematic review. *J Perinat Med.* 39:227–236.
84. Lester, S.J., R. Malik, K.H. Bartlett, and C.G. Duncan. 2011. Cryptococcosis: update and emergence of Cryptococcus gattii. *Vet Clin Pathol.* 40:4–17.
85. Li, S.S., and C.H. Mody. 2010. Cryptococcus. *Proc Am Thorac Soc.* 7:186–196.
86. Lindsey, N.P., J.E. Staples, J.A. Lehman, and M. Fischer. 2010. Surveillance for human West Nile virus disease—United States, 1999-2008. *MMWR Surveill Summ.* 59:1–17.
87. Lortholary, O., G. Poizat, V. Zeller, S. Neuville, A. Boibieux, M. Alvarez, P. Dellamonica, F. Botterel, F. Dromer, and G. Chene. 2006. Long-term outcome of AIDS-associated cryptococcosis in the era of combination antiretroviral therapy. *AIDS.* 20:2183–2191.

88. Lowy, F.D. 1998. Staphylococcus aureus infections. *N Engl J Med.* 339:520–532.
89. Lucky, A.W., C. Sayers, J.D. Argus, and A. Lucky. 2001. Avian mite bites acquired from a new source—pet gerbils: report of 2 cases and review of the literature. *Arch Dermatol.* 137:167–170.
90. Lutsky, I., H. Teichtahl, and S. Bar-Sela. 1984. Occupational asthma due to poultry mites. *J Allergy Clin Immunol.* 73:56–60.
91. Mackenzie, J., and R. Shope. 2008. Arthropod-borne viral encephalitides. In: *Control of Communicable Diseases Manual*, 19th ed. D.L. Heymann, ed. APHA, Washington, D.C. 42–49.
92. Majowicz, S.E., J. Musto, E. Scallan, F.J. Angulo, M. Kirk, S.J. O'Brien, T.F. Jones, A. Fazil, and R.M. Hoekstra. 2010. The global burden of nontyphoidal Salmonella gastroenteritis. *Clin Infect Dis.* 50:882–889.
93. Malik Peiris, J.S. 2009. Avian influenza viruses in humans. *Rev Sci Tech.* 28:161–173.
94. McLauchlin, J., and J.C. Low. 1994. Primary cutaneous listeriosis in adults: an occupational disease of veterinarians and farmers. *Vet Rec.* 135:615–617.
95. Mijs, W., P. de Haas, R. Rossau, T. Van der Laan, L. Rigouts, F. Portaels, and D. van Soolingen. 2002. Molecular evidence to support a proposal to reserve the designation Mycobacterium avium subsp. avium for bird-type isolates and 'M. avium subsp. hominissuis' for the human/porcine type of M. avium. *Int J Syst Evol Microbiol*. 52:1505–1518.
96. Miyasato, H., S. Yamaguchi, K. Taira, A. Hosokawa, S. Kayo, A. Sano, H. Uezato, and K. Takahashi. 2011. Tinea corporis caused by Microsporum gallinae: first clinical case in Japan. *J Dermatol.* 38:473–478.
97. Montoya, J.G., and O. Liesenfeld. 2004. Toxoplasmosis. *Lancet.* 363:1965–1976.
98. Mullens, B.A., R.K. Velten, N.C. Hinkle, D.R. Kuney, and C.E. Szijj. 2004. Acaricide resistance in northern fowl mite (*Ornithonyssus sylviarum*) populations on caged layer operations in Southern California. *Poult Sci.* 83:365–374.
99. Mutalib, A., R. Keirs, and F. Austin. 1995. Erysipelas in quail and suspected erysipeloid in processing plant employees. *Avian Dis.* 39:191–193.
100. Mutalib, A.A., J.M. King, and P.L. McDonough. 1993. Erysipelas in caged laying chickens and suspected erysipeloid in animal caretakers. *J Vet Diagn Invest.* 5:198–201.
101. Nelson, C.B., B.S. Pomeroy, K. Schrall, W.E. Park, and R.J. Lindeman. 1952. An outbreak of conjunctivitis due to Newcastle disease virus (NDV) occurring in poultry workers. *Am J Public Health Nations Health.* 42:672–678.
102. Nielsen, K., A.L. De Obaldia, and J. Heitman. 2007. Cryptococcus neoformans mates on pigeon guano: implications for the realized ecological niche and globalization. *Eukaryot Cell.* 6:949–959.
103. Nweze, E.I. 2001. Etiology of dermatophytoses amongst children in northeastern Nigeria. *Med Mycol.* 39:181–184.
104. Orton, D.I., L.J. Warren, and J.D. Wilkinson. 2000. Avian mite dermatitis. *Clin Exp Dermatol.* 25:129–131.
105. Park, B.J., K.A. Wannemuehler, B.J. Marston, N. Govender, P.G. Pappas, and T.M. Chiller. 2009. Estimation of the current global burden of cryptococcal meningitis among persons living with HIV/AIDS. *AIDS* 23:525–530.
106. Patrick, M., and J. Schlundt. 2008. Campylobacter enteritis. In: *Control of Communicable Diseases Manual*, 19th ed. D.L. Heymann, ed. APHA, Washington, D.C. 94–98.
107. Payne, J.H., R.A. Hogg, A. Otter, H.I. Roest, and C.T. Livesey. 2011. Emergence of suspected type D botulism in ruminants in England and Wales (2001 to 2009), associated with exposure to broiler litter. *Vet Rec.* 168:640.
108. Pedraza-Diaz, S., C.F. Amar, J. McLauchlin, G.L. Nichols, K.M. Cotton, P. Godwin, A.M. Iversen, L. Milne, J.R. Mulla, K. Nye, H. Panigrahl, S.R. Venn, R. Wiggins, M. Williams, and E.R. Youngs. 2001. Cryptosporidium meleagridis from humans: molecular analysis and description of affected patients. *J Infect.* 42:243–250.
109. Pennington, H. 2010. Escherichia coli O157. *Lancet.* 376: 1428–1435.
110. Perdue, M.L., and D.E. Swayne. 2005. Public health risk from avian influenza viruses. *Avian Dis.* 49:317–327.
111. Pope, J.E., A. Krizova, A.X. Garg, H. Thiessen-Philbrook, and J.M. Ouimet. 2007. Campylobacter reactive arthritis: a systematic review. *Semin Arthritis Rheum.* 37:48–55.
112. Rangel, J.M., P.H. Sparling, C. Crowe, P.M. Griffin, and D.L. Swerdlow. 2005. Epidemiology of *Escherichia coli* O157:H7 outbreaks, United States, 1982-2002. *Emerg Infect Dis.* 11:603–609.
113. Reboli, A.C., and W.E. Farrar. 1989. Erysipelothrix rhusiopathiae: an occupational pathogen. *Clin Microbiol Rev.* 2:354–359.
114. Reimann, C.A., E.B. Hayes, C. DiGuiseppi, R. Hoffman, J.A. Lehman, N.P. Lindsey, G.L. Campbell, and M. Fischer. 2008. Epidemiology of neuroinvasive arboviral disease in the United States, 1999-2007. *Am J Trop Med Hyg.* 79:974–979.
115. Robins-Browne, R.M., and E.L. Hartland. 2002. *Escherichia coli* as a cause of diarrhea. *J Gastroenterol Hepatol.* 17:467–475.
116. Rossiter, A. 1997. Occupational otitis externa in chicken catchers. *J Laryngol Otol.* 111:366–367.
117. Russo, T.A., and J.R. Johnson. 2003. Medical and economic impact of extraintestinal infections due to *Escherichia coli*: focus on an increasingly important endemic problem. *Microbes Infect.* 5:449–456.
118. Russo, T.A., and J.R. Johnson. 2000. Proposal for a new inclusive designation for extraintestinal pathogenic isolates of *Escherichia coli*: ExPEC. *J Infect Dis.* 181:1753–1754.
119. Sampers, I., L. Jacxsens, P.A. Luning, W.J. Marcelis, A. Dumoulin, and M. Uyttendaele. 2010. Performance of food safety management systems in poultry meat preparation processing plants in relation to Campylobacter spp. contamination. *J Food Prot*. 73:1447–1457.
120. Scallan, E., R.M. Hoekstra, F.J. Angulo, R.V. Tauxe, M.A. Widdowson, S.L. Roy, J.L. Jones, and P.M. Griffin. 2011. Foodborne illness acquired in the United States—major pathogens. *Emerg Infect Dis.* 17:7–15.
121. Scheftel, J.M., B.L. Elchos, B. Cherry, E.E. DeBess, S.G. Hopkins, J.F. Levine, C.J. Williams, M.R. Bell, G.D. Dvorak, R.H. Funk, S.D. Just, O.M. Samples, E.C. Schaefer, and C.A. Silvia. 2010. Compendium of veterinary standard precautions for zoonotic disease prevention in veterinary personnel: NASPHV Veterinary Infection Control Committee 2010. *J Am Vet Med Assoc.* 237:1403–1422.
122. Schlundt, J. 2008. Food-borne intoxications. In: *Control of Communicable Diseases Manual*, 19th ed. D.L. Heymann, ed. APHA, Washington, D.C. 239–250.
123. Schoeni, J.L., and M.P. Doyle. 1994. Variable colonization of chickens perorally inoculated with *Escherichia coli* O157:H7 and subsequent contamination of eggs. *Appl Environ Microbiol.* 60:2958–2962.
124. Shapiro, R.L., C. Hatheway, and D.L. Swerdlow. 1998. Botulism in the United States: a clinical and epidemiologic review. *Ann Intern Med.* 129:221–228.

125. Shimoni, Z., S. Pitlik, L. Leibovici, Z. Samra, H. Konigsberger, M. Drucker, V. Agmon, S. Ashkenazi, and M. Weinberger. 1999. Nontyphoid Salmonella bacteremia: age-related differences in clinical presentation, bacteriology, and outcome. *Clin Infect Dis.* 28:822–827.
126. Smith, K.A., C.T. Campbell, J. Murphy, M.G. Stobierski, and L.A. Tengelsen. 2010. Compendium of measures to control Chlamydophila psittaci infection among humans (psittacosis) and Pet Birds (avian chlamydiosis). http://www.nasphv.org/Documents/Psittacosis.pdf. March 25, 2013.
127. Sobel, J. 2005. Botulism. *Clin Infect Dis*. 41:1167–1173.
128. Songer, J.G. 2010. Clostridia as agents of zoonotic disease. *Vet Microbiol.* 140:399–404.
129. Sparagano, O., A. Pavlicevic, T. Murano, A. Camarda, H. Sahibi, O. Kilpinen, M. Mul, R. van Emous, S. le Bouquin, K. Hoel, and M.A. Cafiero. 2009. Prevalence and key figures for the poultry red mite Dermanyssus gallinae infections in poultry farm systems. *Exp Appl Acarol.* 48:3–10.
130. Swaminathan, B., and P. Gerner-Smidt. 2007. The epidemiology of human listeriosis. *Microbes Infect.* 9:1236–1243.
131. Swayne, D.E., and D.J. King. 2003. Avian influenza and Newcastle disease. *J Am Vet Med Assoc.* 222:1534–1540.
132. Tam, C.C., L.C. Rodrigues, I. Petersen, A. Islam, A. Hayward, and S.J. O'Brien. 2006. Incidence of Guillain-Barre syndrome among patients with Campylobacter infection: a general practice research database study. *J Infect Dis.* 194:95–97.
133. Tell, L.A., L. Woods, and R.L. Cromie. 2001. Mycobacteriosis in birds. *Rev Sci Tech.* 20:180–203.
134. Tompkin, R.B. 2002. Control of Listeria monocytogenes in the food-processing environment. *J Food Prot.* 65:709–725.
135. Trott, D.G., and R. Pilsworth. 1965. Outbreaks of conjunctivitis due to the Newcastle disease virus among workers in chicken-broiler factories. *Br Med J.* 2:1514–1517.
136. Turenne, C.Y., R. Wallace, Jr., and M.A. Behr. 2007. Mycobacterium avium in the postgenomic era. *Clin Microbiol Rev.* 20:205–229.
137. Ungchusak, K., P. Auewarakul, S.F. Dowell, R. Kitphati, W. Auwanit, P. Puthavathana, M. Uiprasertkul, K. Boonnak, C. Pittayawonganon, N.J. Cox, S.R. Zaki, P. Thawatsupha, M. Chittaganpitch, R. Khontong, J.M. Simmerman, and S. Chunsutthiwat. 2005. Probable person-to-person transmission of avian influenza A (H5N1). *N Engl J Med.* 352: 333–340.
138. Vincent, C., P. Boerlin, D. Daignault, C.M. Dozois, L. Dutil, C. Galanakis, R.J. Reid-Smith, P.P. Tellier, P.A. Tellis, K. Ziebell, and A.R. Manges. 2010. Food reservoir for *Escherichia coli* causing urinary tract infections. *Emerg Infect Dis.* 16:88–95.
139. Wagner, D., and L.S. Young. 2004. Nontuberculous mycobacterial infections: a clinical review. *Infection.* 32:257–270.
140. Wang, C.Y., H.D. Wu, and P.R. Hsueh. 2005. Nosocomial transmission of cryptococcosis. *N Engl J Med.* 352:1271–1272.
141. Wang, Q., B.J. Chang, and T.V. Riley. 2010. Erysipelothrix rhusiopathiae. *Vet Microbiol.* 140:405–417.
142. Wasteson, Y. 2001. Zoonotic *Escherichia coli*. *Acta Vet Scand Suppl.* 95:79–84.
143. Wertheim, H.F., D.C. Melles, M.C. Vos, W. van Leeuwen, A. van Belkum, H.A. Verbrugh, and J.L. Nouwen. 2005. The role of nasal carriage in Staphylococcus aureus infections. *Lancet Infect Dis.* 5:751–762.
144. Whitt, S.P., G.A. Koch, B. Fender, N. Ratnasamy, and E.D. Everett. 2004. Histoplasmosis in pregnancy: case series and report of transplacental transmission. *Arch Intern Med.* 164:454–458.
145. World Health Organization. 2011. Cumulative number of confirmed human cases of avian influenza A(H5N1) reported to WHO. http://www.who.int/influenza/human_animal_interface/H5N1_cumulative_table_archives/en/index.html. Accessed February 13, 2013.
146. Zacks, M.A., and S. Paessler. 2010. Encephalitic alphaviruses. *Vet Microbiol.* 140:281–286.

Chapter 2

Host Factors for Disease Resistance

Introduction

Jagdev M. Sharma

Domesticated and wild birds are vulnerable to many microorganisms that share the environment in which they live. The microorganisms comprise viruses, bacteria, fungi, and parasites. In confined houses, such as the ones used for intensive rearing of commercial poultry, the concentrations of microorganisms can reach very high levels. Some of these microorganisms are pathogenic and invasive and can cause severe clinical disease or death. The birds manage to survive the microbial challenge primarily because the immune system provides protection against infection and unrestricted replication of microorganisms. Because of the importance of immunity in health and disease, the study of the mechanisms of immunity has received much attention within the last few decades, leading to effective disease control strategies. One of the most important contributions of immunity to human and animal health has been the development of vaccines that have dramatically reduced the incidence of infectious diseases. The development in the 19th century of the first avian vaccine against fowl cholera by Louis Pasteur initiated an era of sustained quest for newer and better vaccines. Today, highly effective vaccines, including genetically engineered recombinant vaccines, are commercially available to protect poultry populations against a multitude of infectious agents.

Although the avian immune system has not been studied as extensively as that of mammals, important advances have been made. In the first subchapter, a broad outline of the basic elements of the avian immune system will be presented. Although there are great similarities between immune mechanisms of birds and mammals, there are also important differences.

The second subchapter will address the role of genetics in regulating immune-mediated resistance to disease. The genetic background of a host determines how the immune response to a given microorganism will evolve, and, ultimately, if protective immunity will be generated. This is well demonstrated by the great variation that is often observed between individuals within a population in their response to a common disease agent. Some individuals may succumb to infection and die, whereas others may show no phenotypic signs of infection. This wide variation in response to the same agent is attributed to an intrinsic polymorphism of genes that regulate the expression and interaction of various components of the immune system. Although genetic resistance to a disease is a multigenic trait, resistance or susceptibility to disease is often attributed to the genes that regulate the major histocompatibility complex (MHC). The MHC encodes a set of cell surface proteins that are necessary for antigen recognition by T cells and, consequently, the ability of T cells to generate specific immunity. The MHC proteins are genetically diverse and polymorphic. Association of specific MHC haplotypes with disease resistance has been exploited by designing breeding programs that select for resistance. The entire chicken genome has been sequenced, which has provided new opportunities to identify and manipulate genes that control immunity and resistance to disease. The second subchapter will provide information on how recent advances in molecular technology have facilitated the study of genetic linkages to disease resistance. This new information is likely to have a major impact on commercial poultry production.

The Avian Immune System

Jagdev M. Sharma and Silke Rautenschlein

Introduction

The immune system plays a critical role in defending birds against environmental pathogens. The overall organization and mechanisms of immunity in birds are quite similar to those in mammals. Early studies on the cloacal bursa (bursa of Fabricius) and the thymus of chickens provided some of the basic information that led to the identification of the dichotomy of the immune system into B and T cell compartments. The recognition of this dichotomy initiated an era of

Diseases of Poultry, Thirteenth Edition. David E. Swayne.
© 2013 John Wiley & Sons, Inc. Published 2013 by John Wiley & Sons, Inc.

extensive research on the mechanisms of immunity in mammalian, avian, and amphibian species. This influx of research activity that began more than five decades ago continues unabated, and is responsible for making immunology one of the fastest growing branches of biology. Emerging concepts of immune mechanisms are constantly being revised by new information.

The immune system of birds, as of mammals, is complex and comprises a number of cells and soluble factors that must work in concert to produce a protective immune response. A properly functioning immune system is of special importance to birds because commercial poultry flocks are raised under intensive rearing conditions. Under such conditions, the flocks are vulnerable to rapid spread of infectious agents and disease outbreaks. A variety of vaccines must be used, often repeatedly, to protect flock health. The protective efficacy of a vaccine depends upon a vigorous immune response against the antigens present in the vaccine. If animals are immunosuppressed and respond poorly to a vaccine, the flock health is placed in jeopardy. The understanding of how the immune response is generated is of interest, as is the knowledge of how to protect flocks from stresses that may induce immunosuppression.

This review is intended to provide a broad overview of selected aspects of the avian immune system. For more detailed information, the reader should consult several books and reviews (15, 16, 25, 28, 60, 66, 68, 74).

Anatomy of the Immune System

The immune cells reside in primary lymphoid organs (PLO) or secondary lymphoid organs (SLO). The thymus and the bursa of Fabricius (also called bursa cloacalis or cloacal bursa), respectively, are the PLO where T and B cell precursors differentiate and undergo maturation. The thymus is an elongated, multilobular structure located along the length of both sides of the trachea with some lobes extending into the anterior thoracic cavity (Figure 2.1A). Thymic lobes are divided into lobules, and each lobule has a peripheral cortical area where lymphocytes are densely packed and a central medullary area

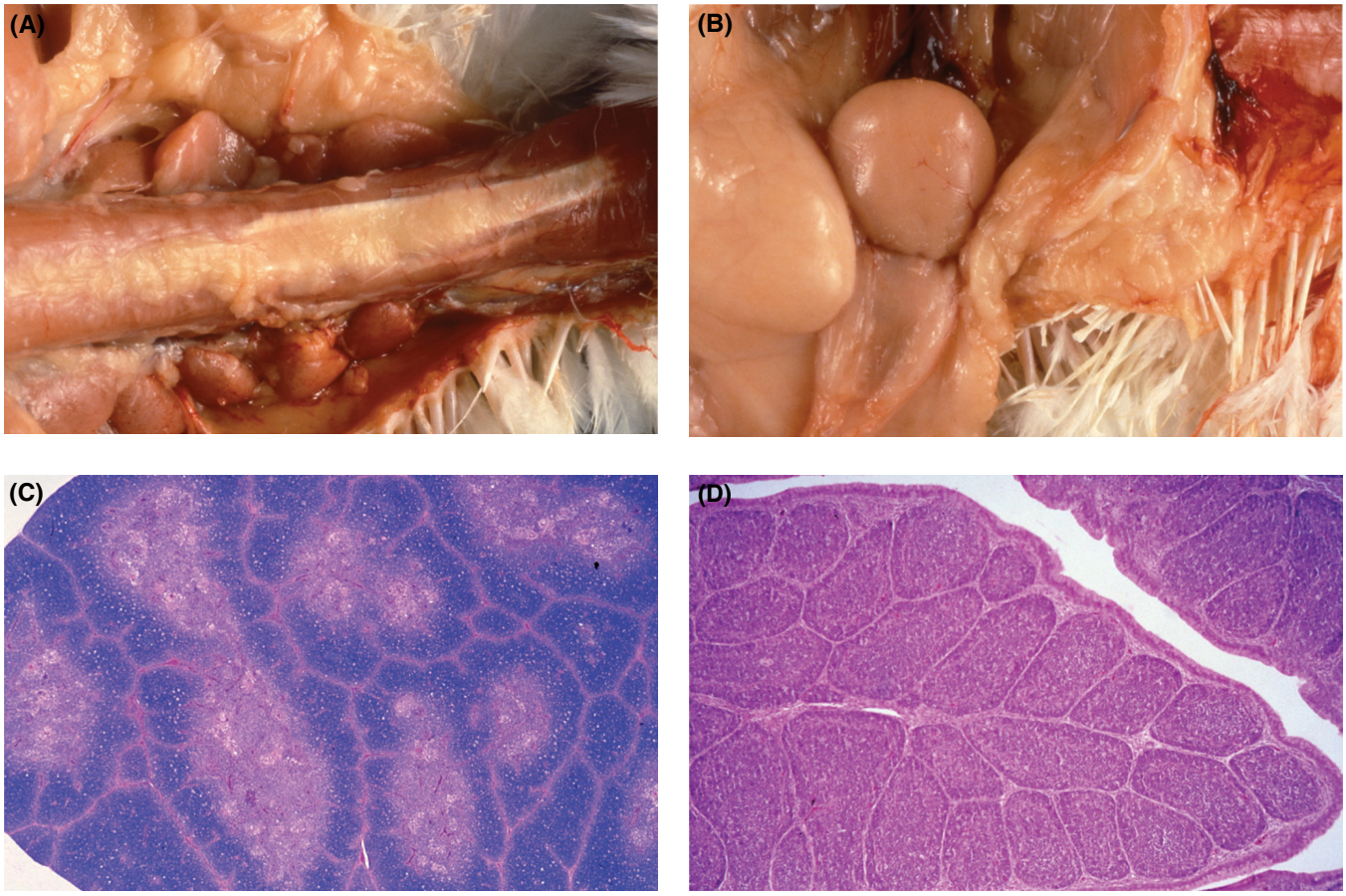

Figure 2.1. (A) Multiple lobes of the thymus lie on each side of the trachea. (B) The cloacal bursa (bursa of Fabricius) is the sac-like structure extending from the end of the intestine. (C) The multilobular histologic structure of the thymus is evident; each lobule is comprised of the dark-staining cortex and the pale medulla. (D) Bursal lymphoid follicles are separated by thin connective tissue septae. (From Fletcher, O.J., and H.J. Barnes. 1998. Lymphoid organs and their anatomical distribution. In: J.M. Sharma, section ed., Avian Immunology. In: Partoret P.P., P. Griebel, H. Bazin, and A. Govaerts, eds., *Handbook of Veterinary Immunology*, Academic Press, San Diego. 73–80. With permission).

where the lymphocytes are less densely packed (Figure 2.1B). The bursa of Fabricius is a sac-like extension of the hindgut and is located above the cloaca (Figure 2.1C). The bursa of Fabricius is organized into follicles; each follicle is filled with lymphocytes. As in the thymus, the lymphocytes are arranged into a peripheral cortex and a central medulla (Figure 2.1D).

Functional immune cells leave the PLO and populate the SLO, the principal sites of antigen-induced immune response. The SLO, characterized by aggregates of lymphocytes and antigen-presenting cells, are scattered through the body (Figure 2.2A–H). Examples of SLO include the spleen, bone marrow, gland of Harder (located ventral and posteriomedial to the eyeball), conjunctival-associated (CALT), bronchial-associated (BALT), and gut-associated lymphoid tissue (GALT). Bursa also may serve as an SLO. Chickens lack the mammalian equivalent of lymph nodes but have lymphoid nodules along the course of lymphatics.

General Features of the Avian Immune System

An outline of the mechanisms birds use to defend against pathogens is presented in Figure 2.3. Birds have well-developed innate defense mechanisms. Physical barriers such as feathers, skin, ciliary movement in the respiratory tract or normal mucosal microflora prevent pathogens from entering the body. For the pathogens that enter the body, the first line of defense is provided by innate immune mechanisms such as phagocytic cells that include granulocytes (mainly heterophils), macrophages (55), complement (39), thrombocytes (63), and natural killer (NK) cells (20, 70).

Innate Immunity

Macrophages that are scattered extensively in the tissues of the host are the first line of defense against pathogens that cross the physical barriers. These cells, identifiable by cell surface-specific antibodies (48), phagocytose and destroy the invading pathogens and prevent active infection. Macrophages and dendritic cells, another phagocytic cell present in the tissues, respond to the encounter with the pathogen by secreting cytokines and chemokines that initiate a local inflammatory process. Heterophils and serum proteins accumulate at the site of inflammation in an attempt to localize and destroy the pathogen. The recognition of pathogens by the cells of the innate defense such as macrophages, neutrophils, and dendritic cells is facilitated by the presence of toll-like receptors (TLRs) that are present on the cell surface or intracellulary (3). TLRs are proteins that recognize common antigenic patterns expressed by many pathogens. The interaction of TLRs on macrophages and dendritic cells induces these cells to produce cytokines and chemokines.

Complement is a heat-labile component present in normal plasma of birds. The complement system is an important and essential part of the defense against bacterial pathogens. The activation of the complement system results in the production of a series of proteins. Some of these proteins bind covalently to bacteria. This binding results in bacterial death or enhanced bacterial phagocytosis and destruction. The complement system can be activated by a number of different pathways (4). Three pathways are homologous to the mammalian species: the classical complement pathway (CCP), the alternate complement pathway (ACP), and the recently described lectin pathway (LP). In the CCP, the complement system is activated by antibodies bound to the surface of the pathogen. In the ACP, a spontaneously activated complement protein destroys bacteria by attaching to bacterial surface. The LP is activated by the binding of lectin proteins in serum and tissue fluids to pathogen-associated molecular patterns (PAMP) (29).

NK cells are non-T, non-B lymphoid cells that are cytotoxic for virus-infected and tumor cells. These cells are present in normal animals and do not need to be induced by immunization. Avian NK cells express surface CD8$\alpha\alpha$ homodimer and are large granular lymphocytes, morphologically similar to their mammalian counterparts. The NK cytotoxic activity is not restricted by the MHC. In chickens, intestinal epithelial cells are particularly rich in NK cells although these cells are also present in spleen and peripheral circulation (20). A monoclonal antibody that reacts specifically with intestinal NK cells has been described (20) and the combination of a panel of antibodies and functional assays should facilitate studies on NK cell activity in healthy and diseased chickens (35). Distribution of NK cells in normal chickens suggests that precursors of these cells originate in the bone marrow and migrate to spleen and intestinal epithelium where they acquire functional maturation. The *in vivo* NK cell numbers and activity in chickens vary with age, genetic background, exposure to infectious agents, and presence of tumors (70).

NK cells and certain other effector cells also may induce target cell lysis if the target cells are coated with antibody. The antibody molecules present on the surface of target cells interact with Fc receptors present on NK cells and this interaction triggers the cytotoxic attack against the target. The destruction of antibody-coated target cell is called antibody-dependent cellular cytotoxicity (ADCC). The ADCC activity contributes to host defense and has been detected in several avian species (70).

Pathogens that cannot be denied entry by physical barriers or controlled by innate immune defense mechanisms initiate a specific immune response (adaptive immunity). Adaptive immunity is highly specific to the agent that stimulates its development, whereas non-adaptive or innate immunity is not antigen-specific. Cells mediating specific immunity retain "memory" of their encounter with the pathogen even after the pathogen has been cleared from the body and detectable immune response has subsided. Memory cells respond to the subsequent exposure to the same pathogen by initiating a rapid and highly effective immune response. Booster vaccinations, used routinely in poultry, take advantage of this memory response.

Adaptive immunity is mediated by a variety of cells, the most important of which are T cells, B cells, macrophages,

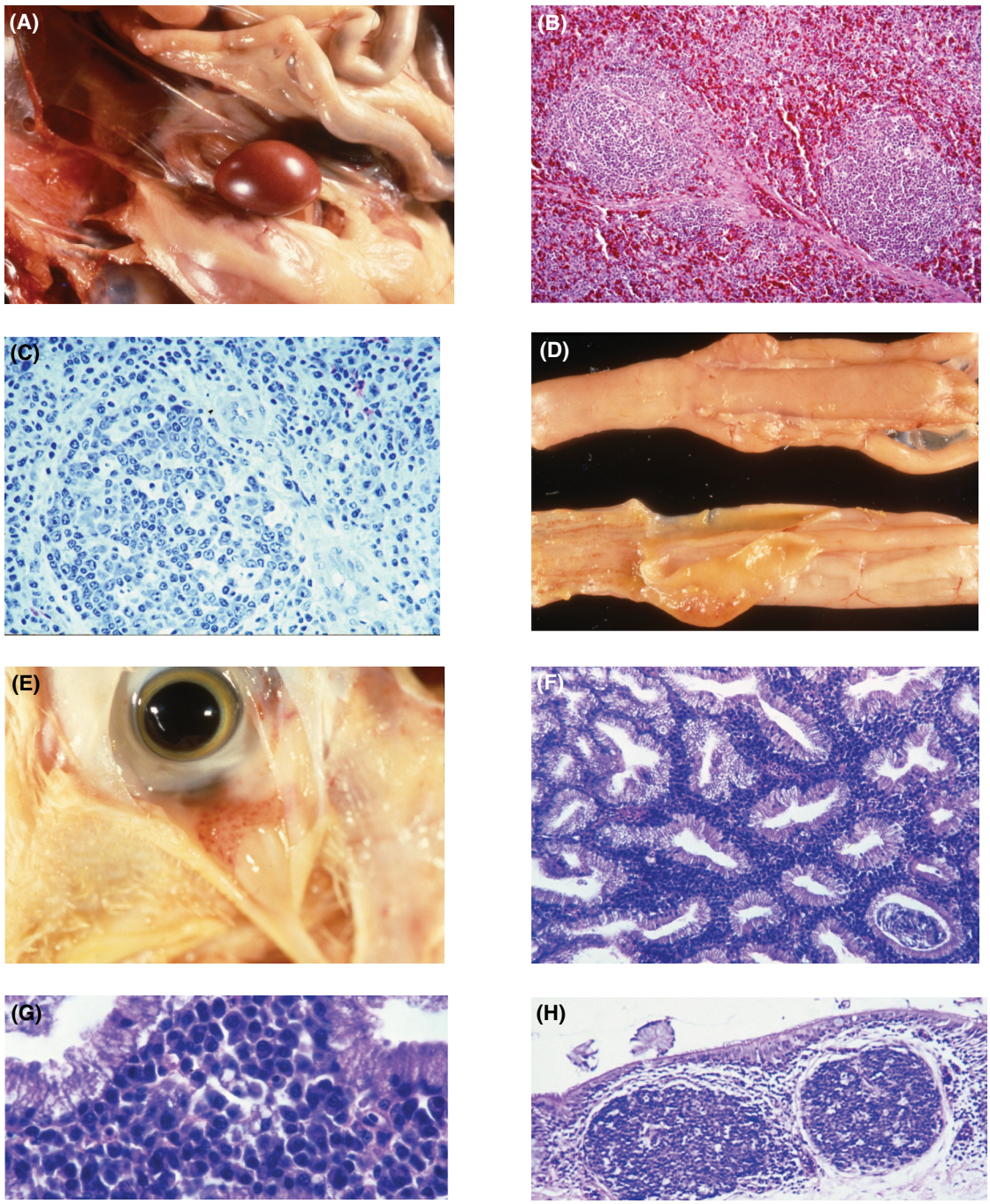

Figure 2.2. (A) The spleen is the oval organ in the central area of the photograph. (B) Periarterial lymphoid sheaths are located in the white pulp of the spleen. (C) A bursa-dependent lymphoid follicle is located adjacent to a small artery and surrounded by thymus-dependent lymphoid cells. (D) Cecal tonsils, unopened (top) and opened (bottom). (E) Small nodules in the conjunctiva and the conjunctival-associated lymphoid tissue (CALT). (F) The Harderian gland contains lymphoid cells in the connective tissue between the glands. (G) Plasma cells are the predominant cell population in the Harderian gland. (H) Nodular deposits of lymphoid tissue are located in the mucosa of the trachea. (From Fletcher, O.J., and H.J. Barnes. 1998. Lymphoid organs and their anatomical distribution. In: J.M. Sharma, section ed., Avian Immunology. In: Partoret P.P., P. Griebel, H. Bazin, and A. Govaerts, eds., *Handbook of Veterinary Immunology*, Academic Press, San Diego. 73–80. With permission).

and dendritic cells. T cells, the principal cells of cell-mediated immunity (CMI), recognize foreign antigens after the antigens (such as microorganisms) have been processed by antigen-presenting cells (APC). Macrophages, dendritic cells, and B cells are among the most important APC. Thrombocytes also may serve as APC (81). The APC generally break down complex antigens and present to T cells small fragments of the antigen in conjunction with the MHC

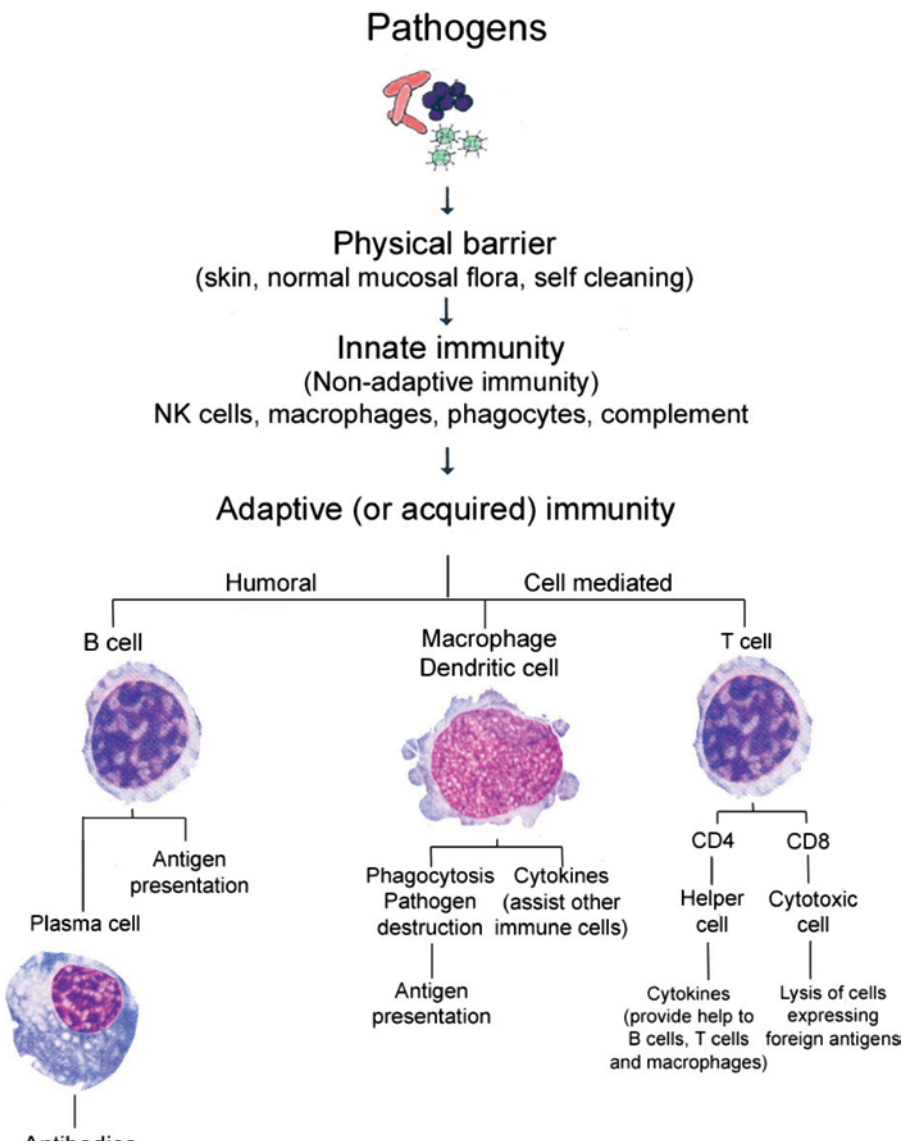

Figure 2.3. Physical and immunological mechanisms of defense against pathogens in birds.

molecules. T cells and the APC must share the same MHC for T cells to recognize and react to the antigen being presented.

The MHC molecules are glycoprotein receptors coded by the genes within the MHC. The chicken MHC, also referred to as the B locus, is much smaller than the mammalian MHC and contains only 19 genes in comparison with the human MHC that contains more than 200. The organization of the chicken MHC is also quite different from that of the mammalian MHC (33). The B locus consists of at least three loci: BF that encodes class I antigens, BL that encodes class II antigens, and BG that encodes class IV antigens. Class I and class II molecules are highly polymorphic and are critical for antigen presentation by the APC. The BF molecules (class I antigens) are present on a wide variety of nucleated cells including erythrocytes. The expression of the BL molecules (class II antigens) is much more restricted. These molecules are expressed on macrophages, dendritic cells, monocytes, B cells, and activated T cells.

Whereas T cells require that the antigen be processed before it can be recognized, the recognition of an antigen by B cells is not dependent on prior processing. B cells can recognize the antigen as it interacts with immunoglubulins that project from the cell surface. B cells are responsible for humoral immunity and produce antibodies against the antigen.

Most microorganisms stimulate both CMI and humoral immunity, although the type of immunity most critical for defense may vary with the microorganism. Some of the important features of the CMI and humoral immunity are discussed below.

Table 2.1. Common monoclonal antibodies for chicken T lymphocyte antigens.

Antigen	Monoclonal antibodies	Molecular mass (kDa)	(%) Homology with human gene	Distribution	References
ChT1	CT1, CT1a, $T_{10}A_6$, RR5–89, Mul83	63 and 45 and dimers	0	Thymocytes, some T lymphocytes	(2, 7, 26)
CD3	CT3	20, 19, 17, 16	36–40	All T lymphocytes	(1, 10)
CD4	CT4, 2–6, 2-35	64	23	Subpopulation of αβ T lymphocytes and thymocytes	(12, 45)
CD5	2–191, 3–58	64	38	T and B lymphocytes	R. Koskinen and O. Vainio, unpublished data
CD25	anti-CD25	…	....	3%–7% naïve thymocytes, 10% spleen, 15% other lymphoid organs, none in bursa stimulated thymocytes, CD4+ and CD4- T cells in most lymphoid organs	(65)
CDw6	S3	110	…	Splenic γδ and most αβ T lymphocytes, some thymocytes	…
ChT6	INN-CH-16	50	…	Activated T lymphocytes	(59)
ChT7	…	110	…	Activated T lymphocytes	(42)
CD8α	CT8, EP72, 11–39, 3–298, AV12, AV13, AV14, CVI-ChT-74.1	34	37	Subpopulations of α, β, γδ and NK-like T lymphocytes and thymocytes	(5, 45, 50, 75)
CD8β	EP42	34	34	Subpopulation of α, β T lymphocytes	…
ChT11	A19	120, 90, 28	…	Intestinal and activated splenic T lymphocytes	(23)
CD28	2–4, 2–102, AV7	40	50	αβ T lymphocytes	(76, 82)
γδ TCR	TCR1	50, 40	30–33	γδ T lymphocytes	(71)
$\alpha\beta_1$ TCR	TCR2	50, 40	26–35	Subpopulation of αβ T lymphocytes	(5, 11)
$\alpha\beta_2$ TCR	TCR3	48, 40	26–35	Subpopulation of αβ T lymphocytes	(6, 9)

(Modified from Jeurissen, S.H.M., O. Vainio, and M.J.H. Ratcliffe. 1998. Leukocyte markers in the chicken. In: J.M. Sharma, section ed., Avain Immunology. In: Partoret P.P., P. Griebel, H. Bazin, and A. Govaerts, eds., *Handbook of Veterinary Immunology*, Academic Press, San Diego. 81–86. With permission.) Additional antibodies and their cross-reactivity within avian species are presented in (15).

Adaptive Immunity

Cell-Mediated Immunity

T cells are the most important cells of cell-mediated immunity (CMI). Many subpopulations of T cells with diverse functions have been identified in chickens. These subpopulations express unique surface antigens that can be detected with monoclonal antibodies. Table 2.1 shows a list of commonly used monoclonal antibodies that recognize some of the surface markers of chicken T cells. This table will undoubtedly undergo periodic revisions as new antibodies are developed.

As in mammals, avian T cells have two surface receptors that bind antigens: T cell receptor (TCR)αβ or TCRγδ. Chickens have a higher proportion of γδ T cells than mice or humans and may reach 30%–50% of circulating lymphocytes (71). Both types of TCRs (αβ and γδ) are closely associated with another molecule called CD3, which is present on all T cells. Only the TCR portion of the TCR-CD3 complex interacts with the antigen. The CD3 molecule, which is comprised of a complex set of proteins, transmits to the cell the signal of antigen/TCR interaction. The TCR molecules are diversified by rearrangement of single V, D, and J segments derived from multiple polymorphic copies of genes. The chicken TCRβ locus is different from that of mammals and contains two V_β families: $V_{\beta1}$ and $V_{\beta2}$ (8).

Surface molecules CD4 and CD8 differentiate two important functional subsets of T cells. CD4 is mainly expressed on the surface of helper T (T_H) lymphocytes, whereas CD8 is expressed on the surface of cytotoxic T lymphocytes (CTL). There is great interspecies and MHC-haplotype dependent variation in the relative proportions of circulating CD4 and CD8 cells. Double positive cells (CD4 + CD8+) are detectable mainly in the thymus and are an indication for premature T cells but may also appear in the periphery (83). CD4 cells coexpressing CD25 marker ($CD4^+CD25^+$) are defined as regulatory T cells (Tregs) (65). These cells downregulate immunity and disruption in their function may result in autoimmune and other inflammatory diseases.

Helper T Cells

T_H cells (CD4+ cells) recognize processed exogenous antigens in conjunction with MHC II and other co-stimulatory molecules. When the TCR on the surface of T cells comes in contact with the specific antigenic fragment on the surface of the APC, T cells become activated, proliferate, and initiate an immune response directed against the antigen.

As demonstrated in mammals, recent studies in chickens provide evidence that antigen-induced activation stimulates T_H cells to differentiate into two types of effector populations: T_H1 and T_H2 (24, 61). Differentiation of T_H cells into T_H1 or T_H2 populations is determined by the nature of the stimulating antigen and is mediated by soluble proteins called cytokines (see below). Intracellular pathogens that accumulate within macrophages and dendritic and other cells stimulate the differentiation of T_H1 cells, whereas extracellular antigens stimulate the differentiation of T_H2 cells. T_H1 effector cells promote proliferation of CD8+ CTL, activate macrophages, and enhance their microbicidal activity. The principal function of T_H2 effector cells is to help B cells produce antigen-specific immunoglubulins of various isotypes.

Cytotoxic T Cells

Most cytotoxic T cells (CTL) express CD8 surface molecules. A small proportion of mammalian CD4 T cells also may have cytotoxic activity, although the presence of avian CD4 T cells with cytotoxic ability has not been documented. CD8+ CTL recognize endogenous antigens in conjunction with MHC I (46). Internalized antigens such as viruses are degraded into small peptides by a large proteolytic complex called a proteasome. Small antigen peptides, usually 7–13 amino acids long, are then transported to the endoplasmic reticulum, where the peptides become attached to MHC I. The peptide-MHC I complex is then transported to the cell surface for possible recognition by antigen-specific CTL.

One of the most important functions of CTL is the elimination of virus-infected cells. Because most nucleated cells express surface MHC I, virus infection of almost any cell can lead to potential recognition and lysis by CTL. *In vitro* assays to quantitate CTL in chickens have been difficult to establish because of MHC restriction of effector and target cells. Despite this difficulty, CTL activity has been shown to regulate pathogenesis of avian viral and neoplastic diseases (13, 28, 31, 60).

Avian Cytokines

Cytokines are small, biologically active proteins secreted by a number of cells, most notably immune cells. Cytokines bind to specific receptors on the surface of target cells and regulate immune response by signaling between cells. They may act systemically or locally in an autocrine or paracrine fashion. Receptor-bound cytokines and other membrane-associated molecules often act together to stimulate the effector function in a target cell. T cells, B cells, macrophages, and dendritic cells all secrete cytokines. Cytokines produced by T_H cells in particular play a key role in modulating an immune response. T_H1 cells, which promote a CMI response, produce predominantly IFN-γ, which activates macrophages and enhances destruction of cell-associated pathogens. Other major cytokines produced by T_H1 cells include IL-2 and tumor necrosis factor-α (TNF-α). IL-2 is critical for proliferation of a number of immune cells including T_H, T_H1, and T_H2 cells; CTL; NK cells; and B cells. The T_H1 cell activity and cytokine secretion is stimulated by IL-12 and IL-18, both produced by macrophages, dendritic cells, and B cells.

Cytokines produced by T_H2 cells, which promote B cell activation and antibody production, include IL-4, IL-5, and IL-10. IL-1β, a product of a number of cell types, most notably macrophages, stimulates the T_H2 cell activity.

Genes encoding most major avian cytokines and their receptors have been cloned and sequenced and a number of recombinant cytokines are available (30). The biological activity of avian cytokines is generally quite similar to their mammalian counterparts, although avian cytokines show little cross-species biological reactivity.

Humoral Immunity

Immunoglobulins (Ig) or antibodies secreted by B cells constitute the principal component of humoral immunity. Antibodies may be present in many body fluids but are most readily detected in the serum or the plasma fractions of blood. Exposure of birds to microorganisms stimulates the production of specific antibodies, which, in turn, react with microorganisms and hasten their destruction. Important mechanisms by which antibodies contribute to defense against pathogens include: (a) neutralization: antibodies bind to and neutralize specific pathogens, particularly viruses. Neutralized viruses are unable to attach to surface receptors of target cells and are thus prevented from replication; (b) opsonization: bacterial pathogens, which can replicate extracellularly, are more readily internalized and destroyed by phagocytes if the pathogens are coated with antibodies; and (c) complement activation: antibodies bound to the surface of pathogens can activate complement and produce new complement proteins. The complement proteins attach to receptors on phagocytes, which facilitate the phagocytosis and destruction of pathogens.

Chickens have three main classes of immunoglobulins: IgM, IgG, and IgA (Table 2.2). Figure 2.4 shows the typical structure of an Ig molecule. All Ig molecules have two distinct types of polypeptide chains. The smaller polypeptide chain called the "light chain" is common to all classes of Ig, whereas the larger chain called the "heavy chain" is structurally distinct for each class or subclass of Ig. Covalent and non-covalent forces connect the two chains. The structure of the heavy chain determines the biological function of each class of Ig. Genes encoding all three classes of avian Ig have been cloned and sequenced, which has facilitated the generation of recombinant avian and chimeric antibodies *in vitro* and expression of recombinant avian Ig in plants (14, 21, 47, 53, 58, 79).

Table 2.2. Properties of chicken immunoglobulin isotypes.

Isotype	Heavy chain (kDa)	#H chain Ig domains	Homology to mammalian	Serum concentration	Sources	Structure and comments
IgM	70 kDa	5	About 30%	1–2 mg/ml	Serum	900 kDa consistent with heavily glycosylated $(\mu_2 L_2)_5$ plus a J chain
			78% for TM*		Cell surface	$\mu_2 L_2$ monomer of membrane IgM, no J chain
IgG	67 kDA	4	30%–35%	5–10 mg/ml	Serum egg yolk	175 kDa, $\gamma_2 L_2$ monomeric form $\gamma_2 L_2$, high concentrations (10 mg/ml) of IgG are found in egg yolk (low concentrations in egg white)
IgA	65 kDa	4	32%–41%	~3 mg/ml	Serum	170 kDa, $\alpha_2 L_2$-monomeric form without J-chain
					Bile	350 kDa, consistent with $(\alpha_2 L_2)_2$ plus a J-chain
					Mucosa (tears, saliva)	600–700 kDa, consistent with $(\alpha_2 L_2)_4$ plus a J-chain

TM refers to the transmembrane and cytoplasmic domains of chicken sIgM. (From Demaries, S.L., and M.J.H. Ratcliffe. 1998. Cell surface and secreted immunoglubulins in B cell development. In: J.M. Sharma, ed., Avian Immunology. In: Partoret P.P., P. Griebel, H. Bazin, and A. Govaerts, eds., *Handbook of Veterinary Immunology*, Academic Press, San Diego. 89–91. With permission.)

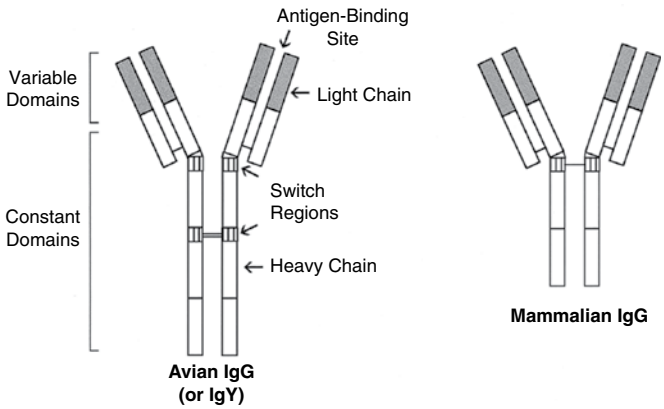

Figure 2.4. Typical structure of an Ig molecule and comparison between avian and mammalian IgG molecules.

IgM is found on the surface of most B cells and is the first antibody produced following primary immunization. As the immune response progresses, the IgM-producing cells switch to the production of IgG or IgA. This phenomenon is called "class switch." The antigen-binding ability of the antibodies does not alter during or after the switch. The class switch occurs because the antibody-producing B cell begins to splice the variable (V) region genes (V genes) to the constant (C) region genes (C genes) of the heavy chain of a different class of Ig. Cytokines including IL-4, TGF-β and IFN-γ stimulate the B cell to undergo class switch (18).

A typical immune response of a chicken begins with IgM production. After some time, IgM production switches over to IgG production. IgG is also the principal antibody produced after secondary immunization and is the predominant Ig class in chicken blood. Because avian (and also amphibian, reptile, and piscine) IgG is larger than its mammalian counterpart, the chicken IgG is often called IgY (77). Figure 2.4 compares the relative structure of mammalian and avian IgG. Molecular cloning data suggest that IgY may be the ancestral precursor of mammalian IgG and IgE (77).

IgA is the most important Ig involved in mucosal immunity. Chicken secretory IgA (sIgA) exists as a dimer in mucosal secretions, whereas circulating IgA is polymeric or monomeric. IgA complexes with a secretory component present on the surface of mucosal epithelial cells to form sIgA (80). The acquisition of the secretory component protects IgA from proteolytic digestion in the gut. IgA is most concentrated on mucosal surfaces, although small quantities may be found in the circulation. Bile is also a rich reservoir of IgA in birds. IgA protects mucosal surfaces against pathogens, particularly viruses, by neutralizing and preventing their attachment to receptors on target cells.

As noted earlier, B cells use surface Ig to bind to antigens. Each B cell produces only one type of heavy and light chain and is committed to one kind of antigenic determinant. Thus, for an antigen to initiate antibody production and clonal expansion, the antigen must interact with a B cell that expresses the homologous Ig receptor. There are potentially thousands

of antigens and millions of antigenic shapes in the environment. How does the immune system maintain an inventory of B cells with such a wide variety of antigenic specificities? This is accomplished by a number of genetic mechanisms during the development and maturation of B cells. In mammals, Ig gene rearrangement leads to extensive Ig diversity. In the chicken, because of a relatively small number of Ig genes, the rearranged genes must undergo a process called gene conversion to attain needed diversity (18). In gene conversion, the rearranged light and heavy chain gene complexes acquire clusters of chromosomal pseudogenes. Large segments of highly homologous pseudogenes are present in the vicinity of light and heavy chain genes in the chicken chromosome (56, 57).

Maternal Transfer of Immunity

Transmission of immunity from the hen to the newly hatched chick is critical for protecting the chick against infections during early life. In chickens, Ig are the principal mode of transfer of immunity. There is little evidence that the mother's immune cells are passed on to the embryo. Ig from hen's circulation is deposited in the superficial epithelial and glandular cells of the oviduct (38). From the oviduct, IgG is transferred into the maturing oocyst in the ovarian follicle and accumulates in the yolk sac. The concentration of IgG in yolk is often greater than in the hen. Ig produced locally in the oviduct likely constitutes an insignificant proportion of the transferred Ig. The developing chick acquires maternal IgG from the yolk sac, which then appears in embryonal circulation. Absorption begins at embryonation day seven and accelerates sharply during three days before hatch (40). Absorption continues at least until 24 hours after hatch. Total serum IgG levels in the newly hatched chick increase to their maximum value about two days after hatch. As the egg passes down the oviduct, locally secreted IgM and IgA are deposited in the albumin. During embryonal development, albumin diffuses into the amniotic fluid. The embryo acquires IgM and IgA by swallowing the amniotic fluid. Thus, the newly hatched chick has IgG in the circulation and IgM and IgA in the intestine.

Assays to Measure Immunity

Natural Killer Cells

NK cell assays are based on *in vitro* cytotoxicity against susceptible target cells (19, 41, 70). The most commonly used targets are the cells of the line LSCC-RP9 (69). These cells were derived from a retrovirus-induced tumor in a B^2B^{15} male chicken (51). The target cells are incubated with effector cells, often spleen cell suspensions, and the target cell lysis is measured by radioactivity or flow cytometry (27, 70). In the radioactive assay, the target cells are labeled with ^{51}Cr and incubated *in vitro* with varying concentrations of cell suspension being tested for NK cell activity (effector cells). Two controls are important: (a) adding "neutral" cells such as thymocytes to target cells at the same effector: target ratios as used for the effector cells and (b) the use of NK-resistant target cells. After four hours of incubation at 37 °C, the radioactivity released into the medium is quantitated. Specific cytotoxicity, a measure of NK cell lysis, is calculated by the following formula:

% cytotoxicity = counts per minute (cpm) in target cells mixed with effector cells – cpm in target cells mixed with normal thymus cells/total cpm incorporated in target cells - cpm in target cells mixed with normal thymus cells × 100.

Macrophages

Macrophages, a phenotypically diverse population of cells, are present in almost all tissues. Because most macrophages adhere to substrates, they can be readily isolated from short-term *in vitro* cultures of peripheral blood cells (PBL) or single cell suspensions of spleen (35). Peritoneal macrophages also may be induced in birds by intraperitoneal injections of inflammatory stimulants such as Sephadex beads. Some of the assays used to assess macrophage functions include: (a) phagocytosis, (b) cytokine production upon stimulation with mitogens (lipopolysaccharide), (c) ability to lyse tumor cells, and (d) production of nitric oxide (NO) upon activation by T cell-produced cytokines, most notably IFN-γ. Some of the functional characteristics of avian macrophages have been described (34, 35, 49, 52, 55, 67).

T Cells and Cytokines

Most T_H cell assays are based on *in vitro* stimulation of cells with mitogens or specific antigens (36, 37, 73). Stimulated cells proliferate and secrete cytokines. Mitogen-induced proliferation is a common assay of T-cell competence. Concanavalin A (Con A) and phytohemagglutinin (PHA) are the mitogens of choice. These mitogens bind to cell surface glycoproteins on T cells and stimulate the cells to proliferate. In the typical assays, spleen cells, PBL, or diluted whole blood are cultured *in vitro* in medium containing Con A or PHA. After 40 hours of incubation at 37 °C–41 °C, the cells are pulse labeled with radioactive thymidine. The incorporation of the label in cellular DNA is quantitated. Actively proliferating cultures incorporate higher levels of radioactivity than non-proliferating cultures. If the proliferative response of the test group of chickens is lower than the response in age-matched healthy controls, the test group is viewed as being deficient in functional T cells. This general conclusion should be viewed with caution because the mitogen-induced proliferation is not antigen-specific, and response to mitogen is an *in vitro* function of T cells. The *in vivo* relevance of this function to other *in vitro* or *in vivo* functions of T cells is not known, and functional T cells may be prevented from proliferating by non-T suppressor cells or suppressor products present in the culture (36, 54).

T cells recovered from immunized animals may proliferate *in vitro* when cocultured with the antigen used for immunization (37, 73). This antigen-specific proliferation has been shown with several avian viruses, although the ideal assay conditions are not well established and the test is not widely used.

Mitogen- or antigen-induced stimulation of T cells *in vitro* also results in secretion of cytokines. Quantitation of cytokines in the culture medium by enzyme linked immunosorbent assay (ELISA) or biological activity tests (22, 62, 64) gives an indication of the functional capability of T cells. A nitric oxide inducing factor (NOIF) test has been described in which macrophage-stimulating cytokines such as IFN-γ can be quantitated. Macrophage line cells are exposed to the test supernatants and NO concentration in the supernatants is calculated (32). Molecular tests such as quantitative real-time polymerase chain reaction (RT-PCR) also may be used to measure up-regulation of induced cytokines; however, this assay may or may not correlate with actual release of bioactive polypeptides.

CTL activity can be measured *in vitro* by flow cytometric-based tests or by the chromium-release assay after co-culturing effector cells with radio-labeled target cells (44, 46). The protocols for the chromium-release assay are quite similar to those described above for NK cell cytotoxicity assays. Because the cytotoxic activity of CTL is MHC I-restricted, the CTL assays are difficult to perform in outbred populations of birds. For a successful assay, both effector and target cells must come from the same bird or syngeneic birds. Because of these limitations, the use of CTL assays continues to be restricted to research laboratories.

Certain *in vivo* assays also may be used to assess T cell functions. The delayed type hypersensitivity assay measures antigen-specific response. In this test, an animal immunized against an antigen is intradermally injected with the same antigen. Swelling at the site of the injection comprises a positive response. Local swelling at the site of an intradermal injection of mitogens such as PHA also has been attributed to a non-specific T cell response.

Antibody Levels

Birds exposed to pathogens develop circulating antibodies that generally persist for several weeks after the antigen has been cleared. Detection of these antibodies is much more convenient than detecting cellular immunity and a number of serologic assays are available to quantitate antibodies. Some of the commonly used serologic tests include agar gel precipitation test, virus neutralization test, immunofluorescence test, hemagglutination inhibition test, and ELISA. Protocols for conducting these tests have been described (72). Antibodies against diverse antigens present in a single serum sample may be quantitated using multiplexed immunoassays (78)

ELISA is by far the most common serologic assay used under commercial settings. Automated technology allows rapid processing of large numbers of serum samples. Computerized data transmission facilitates flock profiling and provides useful information on environmental exposure to pathogens and response to vaccination. ELISA kits that can be used to detect antibodies against most of the common viral and bacterial pathogens of poultry are available commercially. Commercially available ELISA kits may vary in specificity and sensitivity and give conflicting antibody titers (17).

As noted above, the transfer of IgG from the yolk sac to the embryo or the hatchling occurs by absorption into the recipient's circulation. Yolk sac is highly vascularized and IgG is transferred by receptor-mediated endocytosis across the yolk sac epithelium (43). Maternally derived antibodies decline linearly in the recipient and become undetectable after two to five weeks.

Although maternal antibodies are important for the well being of the newly hatched chick, the antibodies may interfere with active immunization with live vaccines. Neonatal or *in ovo* vaccination is often necessary to protect newly hatched birds against diseases to which they may be exposed shortly after hatch. Besides neutralizing the antigen present in the vaccine, preexisting antibodies also may interfere with the development of active immunity by providing negative feedback to the immune system. In contrast, data in wild birds indicate that presence of maternal antibodies against an antigen may enhance active immunity following immunization with the same antigen.

Genetics of Disease Resistance

Hans H. Cheng and Susan J. Lamont

Introduction

Genetic resistance to infectious diseases is alluring from both the industrial and academic viewpoints (53). With respect to poultry companies, losses due to diseases induced by infectious pathogens continue to be a significant issue and can be the key factor in determining economic viability. This is because pathogens lead to loss or condemnation of birds, inhibit the immune response making birds susceptible to other pathogens and diseases, divert critical resources from growth and production, add expenses for vaccination programs, and force changes in husbandry practices, all of which increase the cost of production. Furthermore, certain pathogens may cause disruption in trade between countries or produce a loss of public confidence in food product safety. Consequently, genetic resistance can be a powerful approach in combination with other management practices to eliminate or manage infectious diseases of agronomic interest, especially

as a long-term solution in light of the emergence of new and more virulent pathogens and increasing restrictions on the use of antibiotics.

From the academic side, modern molecular genetics has provided an arsenal of new tools for identifying disease resistance genes. As a component of genomics, there is great excitement that some of the complexity of biology, and in particular the immune response, may finally become fully elucidated. It is reasonable to expect that genetics will continue to identify genes, or at least genomic regions containing these genes (known as QTL or quantitative trait loci), that control complex traits such as disease resistance. It is also expected that information will be forthcoming on how these genes function and interact as well as respond to changing environments to control disease. Ultimately, this information will be transferred to poultry companies to generate elite lines with superior disease resistance. On the other hand, it is clear that the field is still in its formative years, and our ability to predict and model complex traits is limited. While advancements in biotechnology will continue, technology cannot speed up the maturation rate, generation intervals, the number of progeny produced per day or per bird, and other biologically-limited traits. Consequently, it is anticipated with the rapidly changing landscape of biological knowledge that long-held assumptions will be shattered requiring revised models and paradigms. Fortunately, the momentum for continued progress in genomics remains high along with the seemingly unending string of technological advancements (34, 42, 43).

Besides these interests, studies on genetic resistance and genetics in general are the forerunners of change that will undoubtedly occur in all areas of biology including veterinary medicine and diagnostics. With the advent of molecular genetic maps and genome sequences, genomics and "discovery-driven research" emerged as the preeminent method for dissecting and understanding complex traits. Consequently, while genetics has always been a field that used a holistic approach to examine the entire organism, with the ability to measure and record millions of data points at the DNA, RNA, protein, and metabolite levels quickly and economically, the power of the existing and upcoming technologies has and will continue to shift the field toward large-scale unbiased screens using molecular and computational biology and their integration. This does not mean that scientists and clinicians need to become facile in genomic technologies; rather, it indicates that knowledge and information can be more readily transferred to other fields.

In this section, we focus on recent advancements in genetic resistance to disease, namely molecular and quantitative genetics. The targeted audience is animal health professionals and others that may not be familiar with molecular or quantitative genetics. We hope to convey the high level of excitement (as well as limitations) in these areas, which has been brought about with the release of the chicken genome sequence and other related technologies. To achieve these goals, sections are presented on (1) a review of basic genetic concepts, (2) molecular genetic approaches to identify disease resistance genes, (3) complementary functional genomic approaches that provide insights on pathways of disease resistance, (4) brief summaries of genetic resistance and experimental studies for specific diseases, and (5) thoughts on how this information may be applied in poultry breeding to improve host resistance to infectious disease. The emphasis throughout these sections is on basic concepts, because given the short history and dynamics of the field, knowledge and state-of-the art methods will change rapidly.

Review of Quantitative and Molecular Genetics

Classical or Mendelian genetics trains us to think about biology in mathematical (quantifiable) terms by using defined phenotypes (measurable traits) that are explained by one or a few genetic loci. Certainly, there are "simple" or qualitative traits as evidenced by the large number of loci and alleles, often with interesting and descriptive names that account for plumage color and patterns, e.g., dominant white, slow feathering. However, for the majority of traits, there is natural variation with continuous (or quantitative) rather than discrete (or qualitative) phenotypic classes within a population. This phenotypic variation can arise from the segregation of a single gene with multiple alleles (forms of genetic variants), or numerous genes, combined with modulating effects due to interactions with the environment. The critical difference is that for a quantitative trait, the phenotypic variation *among* individuals of a specific genotype is larger than the average phenotypic difference *between* genotypes.

Genetics strives to understand how the phenotypes of organisms are influenced by their genotypes (genetic makeup). More specifically with modern molecular genetics, we wish to know the relationship between genetic variation and phenotypic variation. In other words, the goal is to determine how variation within a population can be accounted for at the genetic level, which should for example facilitate selection of the trait in a breeding program. This does not mean to say that a gene with no discernible allelic variation does not contribute to the trait but rather that there is no variation within this population for selection and genetic improvement. At the simplest level, we wish to know whether different alleles for a given gene or locus give statistical significant differences in a particular trait. With the advent of molecular genetic maps, we can extend this same question to the entire genome. In short, the goal of genetics is to predict the phenotype of offspring produced by specific parents. More specifically, the major goal of molecular and quantitative genetics is to identify the genes and alleles that account for phenotypic variation within a population. This result is achieved by mapping the traits genetically and by understanding the mechanistic basis of the genetic contributions to phenotype.

The basic genetics concepts, which are described below, have been established for many years and used well as evidenced by the great progress made by poultry breeding

companies. What has changed is the emergence of genomics and related technologies, which have had a dramatic and positive impact. It is now possible to identify the underlying genetic basis for complex traits such as disease resistance. It is anticipated that many genes and gene products discussed in the prior subchapter will contribute to genetic resistance to disease.

Phenotypic Distributions

Even within individuals with identical genotypes, there is a range of phenotypes, i.e., while an individual's genotype certainly influences its phenotypes, it does not mean that genotype equals phenotype. This range is due to the fact that traits are not the outcome of the contributing genes only, but normal biological variation, response to the environment, and other factors. For simple and qualitative traits, the phenotypic distributions of unique genotypes may be very tight and not overlap with others to give discrete classes. This is often not the situation when dealing with complex and quantitative traits where a continuum is found. This also implies that individuals with different genotypes may have the same phenotype.

Disease presents unique issues with analysis of quantitative traits, as the definition often varies according to the pathogen. Disease is the unfavorable outcome of the interactions between the host, pathogen, and environments whereby conditions exist to favor pathogen growth and spread. Disease resistance could mean absolute resistance to infection or tolerance to debilitating symptoms. Regardless of the situation, it is necessary to define what disease means for that pathogen.

Disease is usually considered as a simple two-state trait, resistant or susceptible. It would be advantageous for disease to be broken down into continuously variable, quantifiable, and/or measurable components. Using Marek's disease (MD) as an example, besides asking whether a bird gets tumors or enlarged nerves (i.e., diseased), one could monitor the amount of virus after infection, the days until death, and many other measurable MD-associated traits. Besides providing additional statistical power, it has the potential advantage that disease resistance can be ascribed to one or more components. *It is in the ability to define and quantify disease traits that veterinarian pathologists and immunologists may significantly help studies on genetic resistance*.

Heritability

A prerequisite of genetics and breeding (genetic improvement) is that the trait of interest is heritable. This can be determined somewhat by observing if related birds are more similar to each other than unrelated ones assuming the same environmental conditions for all birds. A more direct test would be to take individuals at the two extreme ends of the phenotypic distributions, mate them to birds of similar phenotype, and then determine if the measurable differences between the two groups of offspring are maintained, thus, inherited.

This extent of similarity from parent to offspring, or heritability, can be quantified. Variation in a trait within a population results from variation in the genotypes (genetic effect) and variation due to mainly the environment. The genetic variation can be further broken down into what are called the additive and dominance variance components. Suffice it to say that the additive genetic variance accounts for the average effect of each allele of a gene, whereas the dominance variance component measures deviation from the predicted average of the two alleles. What is normally reported for the heritability of a trait is the amount of phenotypic variation that can be accounted for by the additive genetic variation and is represented as h^2. Values range from 0 (no heritability) to 1, where the trait measures of the parents would exactly predict the value of the offspring. By knowing the heritability estimate of a trait, breeders can predict the response to selection.

For disease resistance, in general, heritability estimates for specific diseases are reported to be low to moderate (37). However, it is important to note that heritability estimates are for a particular population (set of birds and genetic composition) under a single environment. This may be one of the main reasons why there is a range of reported h^2 for the same traits as the populations and environments are not constant between experiments and estimates. This also shows that heritability is not fixed for any one population and may change following selection (genotypes are altered) or in a different environment.

Linkage

Linkage, or the non-random association (co-inheritance) of alleles, is the main weapon in the molecular geneticist's toolbox. It is this ability that can determine if a disease resistance gene is nearby or linked to a specific genetic marker. To illustrate this point, let's start with the simplest example of a single gene trait. We'll assume that there is a gene that encodes the cellular receptor to "nasty virus," and virus binding to this receptor is required for cellular infection. The "R" allele of the gene makes a defective receptor, thus, confers resistance to infection and disease while the other allele, "r," makes the normal protein, which confers virus entry and susceptibility. Because the bird only needs one r allele for disease susceptibility, disease resistance is a recessive trait, because a bird would need two R alleles to prevent viral-induced disease. If one mated a susceptible bird with the R/r genotype (chickens are diploid, thus, have two alleles for each locus) with a resistant bird (R/R), about half of the progeny should be susceptible with the R/r genotype while the other half should be resistant with the R/R genotype.

To locate the disease resistance gene, one can test for co-segregation using molecular markers. In Figure 2.5, for 100 backcross (BC) progeny, if we find that all 50 resistant and 50 susceptible birds always are M/M and M/m, respectively, for a marker, then the marker is completely linked with and cannot be separated from the disease resistance gene. This is not to say that marker M is the disease resistance gene, but only that the two loci were not separated genetically when the gametes were formed during meiosis.

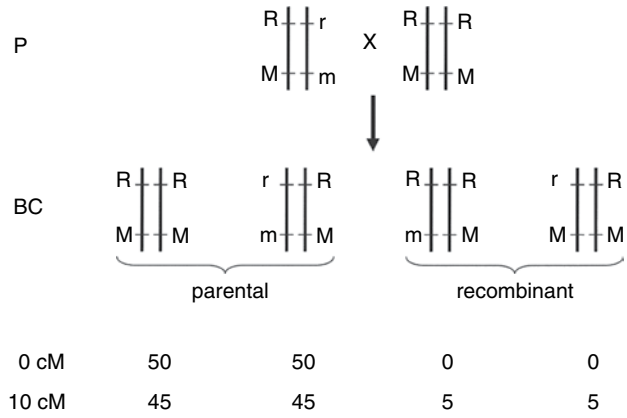

Figure 2.5. Linkage between a hypothetical virus receptor with defective (R) and functional receptor (r) alleles and a molecular marker with alleles M and m. In this example, parental (P) chickens that are susceptible (R/r) and resistant (R/R) to the virus are intermated to produce backcross (BC) progeny. If the loci encoding the viral receptor and the molecular marker are completely linked at the genetic level, then the molecular marker will absolutely predict the virus resistance status of the bird because all resistant birds will have the M/M genotype while all susceptible birds will be M/m. However, if loci are linked but can be separated at the genetic level during meiosis, if the distance between the loci is 10 cM, then the molecular marker will again be predicted but only 90% of the time.

This also demonstrates that alleles M and R and alleles m and r are in linkage disequilibrium (LD). If the marker locus and disease resistance gene were unlinked, then the alleles should randomly segregate. But this is not the case because M occurs more frequently than is expected by chance in resistance birds, and thus, the marker allele M is predictive of the disease resistance gene allele.

But what if the two loci are not absolutely linked? Imagine that of the 50 disease-resistant birds, 45 had the M/M genotype and five were the M/m genotype. Likewise, of the 50 susceptible birds, 45 had the M/m genotype whereas five had the M/M genotype. Having the M allele is still a very good indicator of disease resistance (or vice versa with the m allele) but it is not 100% accurate. In this case, we can determine the linkage of the two loci by quantifying the percentage of recombinant alleles (non-parental ones, e.g., R and m, or r and M). In this example, there are ten recombinant progeny out of 100, which means that the disease resistance gene and the marker are 10 centiMorgan (cM) away. The genetic term cM reflects the number of recombination events between two loci detected in 100 progeny. In other words, the extent of linkage between these two loci is determined by the amount of genetic recombination that occurs during meiosis, which can be determined by measuring how often particular alleles within each locus are inherited together.

To make the situation even more difficult and to put into perspective the challenge of finding genes for complex disease resistance, imagine now that each disease resistance gene accounts for only a small percentage (e.g., 2%) of the total observed variation in the population, as is typical for most diseases. Furthermore, not all R/r birds are susceptible because the r allele may not always be expressed at sufficient levels to allow virus entry. Or not all the birds get challenged with nasty virus because natural exposure is being used. While daunting, these challenges can be overcome with properly controlled experiments, the use of molecular markers that encompass the entire chicken genome, many progeny to give more statistical power, accurate phenotypes, and biometrical analyses.

Experimental Approaches for Molecular Genetics

The development of genetic maps based on molecular markers defined the birth of genomics. No longer were scientists limited to assaying for genetic effects using markers at undefined locations. Now it was possible to systematically query the entire genome. This ability also changed the way experiments were primarily conducted. Rather than using the reductionist approach of formulating a hypothesis about a specific gene and then testing it, genomics is a "discovery driven" field in which the end results allow definition of the next series of experiments. It is fair to say that genomics approaches dominate modern genetic studies, and are being reinforced and strengthened with whole genome sequences and high-throughput technologies that deliver quick, accurate, and low-cost data points.

Candidate Genes

In the preceding subchapter, a number of genes and gene products have been identified that modulate the immune response. Many of these immune function genes have or may be good candidates for conferring disease resistance. Consequently, prior knowledge to identify candidate genes for specific disease resistance is a valid method and often the best first choice for testing for a genetic effect and if present, determining its influence. This approach requires a population that is segregating for disease or disease-associated traits, and an informative DNA polymorphism.

Although a gene and its gene product may be a critical component of the immune response and disease resistance, it is possible that there is no variation and genetic effect attributable to the gene in a specific population. Consequently, the first requirement is to identify polymorphisms (structural variations in the DNA) and alleles of the gene that are segregating within the population. Furthermore, evidence for a genetic effect does not prove causation by that gene, but may be a result of linkage between the causal gene and the analyzed gene. Finally, only that specific gene and genomic region is being screened for genetic effects, and no information is generated about other genomic regions that also may influence resistance to the disease.

The MHC represents a unique situation and opportunity. Due to its importance in many diseases, chicken lines have

been developed that theoretically vary only in the MHC or B locus (4, 9, 58). These lines have near identical genetic background and carry unique and defined MHC haplotypes. So rather than using a genetic marker to the MHC and asking if it is associated with disease resistance, these "B congenic" strains can be used to quickly screen for MHC influences on disease resistance by challenging each line with the pathogen of interest and monitoring disease and disease traits. Furthermore, due to the inbred nature of each line, there is less genetic variation that has to be accounted for, which translates into fewer chickens needing to be measured to detect genetic associations with traits.

Whole Genome Scans

With availability of the chicken molecular genetic map, it is possible to screen the entire chicken genome for disease resistance genes. In brief, what is called a resource population is identified or produced in which birds segregate for disease resistance. Some or all of the animals are measured for disease or disease-associated traits. Likewise, the same animals are genotyped for molecular markers spaced evenly throughout the entire chicken genome. Statistical analyses are performed to see if certain genomic regions or QTL (genotypes) are associated with disease resistance (phenotypes) and, if yes, then how much each region accounts for.

Two approaches can be used in genome-wide QTL scans. The difference between the two lies in how the resource populations are produced, which also influences the density and, consequently, number of genetic markers required.

Linkage Analysis

In this approach, for each marker, one tests whether the inheritance of alleles influences disease resistance in a defined population. This type of linkage is known as identity by descent (IBD). Parents that differ markedly in disease resistance are selected and mated to produce progeny, which favors the use of inbred or divergently selected experimental lines due to their genetic simplicity and defined disease status. In initial QTL scans, the mating structures are often backcross (BC) or F_2 populations. Due to the limited number of generations and recombination events that can erode the amount of LD, marker spacing can be relatively high at 20–40 cM apart, which reduces the number and cost of markers that need to be genotyped.

To validate and fine-map a QTL, additional generations are required to reduce LD and break apart distant marker-disease gene linkages through recombination, leaving only markers that are tightly linked to the disease resistance gene. A popular approach, known as advanced intercross lines (AILs), is to intermate progeny to get F_3, F_4, F_5, etc. (40). With each passing generation, the extent of LD grows smaller, which increases QTL resolving power.

Although simple in concept, the actual execution of the experiment entails a number of factors. Probably the biggest factor that one can control is the number of progeny. The ability to detect QTL with smaller effects increases with more progeny. From a practical standpoint, this means at least 200 birds, if not 1,000 or more. Normally, the generation and measurement of resource populations is the rate-limiting step in disease-related studies.

Association

A pedigreed population is not required in association or LD mapping, which makes it attractive for use in the commercial environment because existing populations can be tested. The power of this approach is that it relies on historical recombination events to greatly minimize the extent of LD. Rather than following the inheritance of specific alleles (identify by descent), association mapping analyzes genetic marker allele frequency or identity by state (IBS). Thus, resistance birds should be highly enriched for a specific marker allele while the other allele(s) is found in the susceptible birds. This method has both advantages and disadvantages. On the positive side, given the tight linkage required to detect a disease resistance gene, any genetic marker with a significant association will be relatively close, which means that it is almost immediately amenable to further verification and implementation in a breeding program. On the other hand, because LD is small, larger numbers of genetic markers are required so that each region is screened.

Association mapping has only been pursued for a few years in poultry, which reflects the recent availability of affordable platforms for genotyping many thousands of genetic markers. Specifically, chips capable of scoring 3,000 and 60,000 single nucleotide polymorphisms (SNPs) have been developed and employed (57, 110). However, most uses of these SNP chips have been employed in genomic selection where the primary goal is to evaluate breeding values, which is the sum of all the genetic marker effects. In addition, individual SNP effects can be calculated that influence a trait such as disease resistance. Consequently, it is likely that we'll see genome-wide association studies (GWAS) in the very near future.

Functional Genomics

As described above, genetics relies on statistical association of genotypic variation with phenotypic variation to identify genomic regions and determine how much variation each region contributes. Consequently, the ability to identify a disease resistance gene relies on statistical power and probabilities. For IBD, the best QTL mapping resolution is 5–20 cM intervals, which contains more than 1 million bases of DNA and is insufficient for identifying individual genes. For GWAS, the resolution will be much better, but based on human studies, it is still difficult to identify the causative gene for a genetic marker that is highly associated with a phenotype.

To complement this genetic approach, there are a number of tools that query at the RNA, protein, or metabolite level. These functional genomic tools strive to identify components that vary between two or more states, for example, gene transcripts that are differentially expressed between disease-resistant and -susceptible chickens. The hope is that by

identifying these molecules, gene function and biological pathways can be ascribed to every gene.

Functional genomic assays identify gene transcripts, proteins, or other molecules which, combined with genome-wide scans, can reveal positional candidate genes. Below are a few enabling technologies, which can be applied in a number of ways beyond genetics, such as veterinary diagnostics.

Transcriptome Profiling

In one of the key technological developments, Brown and colleagues developed DNA microarrays (123). For many years, scientists had used hybridization, which detects complementary sequences, for DNA and RNA analysis of specific sequences using labeled probes. In an elegant extension of this concept, all of the probe sequences, instead of being individually labeled, were arrayed onto a microscope slide and the total mRNA population of the tested individual was labeled. As a consequence, the relative expression of thousands of genes in a single sample could be simultaneously measured in one step.

DNA microarray experiments generate a list of genes that are expressed more or less between two or more samples. For example, genes A, B, and C may be expressed more in the thymus of five-day-old resistant birds compared to age-matched susceptible birds. It is important to note that because gene expression (RNA) is being measured, unlike DNA, it can vary depending on the bird, tissue, time point, and other influences. Because of this natural biological variation, even for a given set of conditions, it is critical that several replicates are conducted. Unfortunately, this technique is still a relatively expensive procedure, which when combined with more variables (e.g., several tissues, more time points) inflates the total experiment cost quickly.

With the advances in sequencing technologies, it is now feasible, more powerful, and even cheaper to sequence the entire RNA. Unlike microarrays, sequencing typically results in millions of short reads (30 to 400 bases), which provides an actual count of each RNA transcript. However, the challenge is to computationally handle and analyze these very large datasets. Furthermore, for chicken, errors and gaps in the genome sequence can negatively impact the results. Still, depending on the experimental objective, RNA sequencing is likely to replace microarrays.

The list of genes can be further analyzed to provide a higher order understanding. For example, if all the genes belonging to a specific biological or functional class are elevated in the resistant bird compared to the susceptible bird, then most likely this pathway is involved in disease resistance. Tools to better analyze and extend the biological meaning of array results are an area of intense study.

Proteomics

Moderate to large scale global screening at the protein level is also available today. For identification of proteins in a complex mixture, mass spectrometry is the technique of choice (44). Typically, protein samples are fractioned to reduce the complexity, then peptides are analyzed by the mass spectrometer, and finally the data sets are analyzed to deduce the identity of proteins. Although simple in concept, analysis of proteins is much more challenging than that of either DNA or RNA simply because for each gene there are many proteins with varying post-translational modifications, and the concentration of proteins encompasses many orders of magnitude. Consequently, it is fairly simple to identify the abundant proteins but difficult for the ones in low quantity. Like DNA microarrays, cost can be a serious issue, which partially explains the minimal usage of this technique thus far in poultry research, though the situation is gradually changing (25).

Besides identifying individual proteins, it is possible to screen for protein-protein interactions, which can capitalize on direct protein interactions between hosts and pathogens. The classic method, known as the two-hybrid screen (49, 50), takes advantage of the ability to reconstitute the activity of a transcription factor that is in two parts. By fusing a cDNA (prey) library to the activation domain (AD) of a transcriptional activator, it is possible to identify proteins that interact with bait (protein of interest) that is fused with the DNA-binding domain (BD). Because the AD and BD do not need to be physically connected to promote transcription, if two proteins interact, a reporter gene is expressed if AD and BD are brought into close proximity of each other.

Genetic Resistance to Specific Diseases

As discussed above, one generally needs to first demonstrate heritability of resistance to disease to demonstrate a genetic component. Although differences for disease resistance between chicken genetic lines may suggest a genetic basis, they are insufficient to prove it. Combined with the need in molecular genetics for controlled disease challenges and marker associations, the number of studies conducted to date is limited, especially for genome-wide scans. There is, however, evidence for genetic control of poultry diseases caused by a wide range of pathogens, including viruses, bacteria, and parasites.

Avian Leukosis

As described in Chapter 15, avian leukosis viruses (ALV) are a group of retroviruses that can induce tumors. ALVs are classified into various subgroups based on virus-specific cellular receptors and virus envelope glycoproteins. The subgroups that infect chicken are A–E and J with all but subgroup J being exogenous ALVs.

Genetic resistance to ALV subgroups A–E is well defined and based on specific cellular receptors. Because a single functioning receptor allele is all that is required for virus entry, susceptibility is dominant and the genetics is simple with only one locus involved. Molecular studies taking advantage of this fact have revealed not only the encoding gene but the basis for differences between resistant and susceptible lines.

Interestingly, although the ALV subgroups are related and thought to have arisen from a common ancestor, no cellular receptors show obvious sequence or structural similarity.

Resistance to ALV subgroup A is determined by the *tva* locus found on chromosome 28, and encodes a protein member of the low-density lipoprotein receptor (LDLR) family of unknown function (14, 45). There have been two alleles identified that confer resistance. The tva^{r} allele contains a single nucleotide mutation that results in a protein with very low binding affinity to the ALV subgroup A envelope while the other resistance allele, tva^{r2}, has a 4-nucleotide insertion near the beginning of the coding sequencing, which results in an altered protein.

The *tvc* locus, which confers resistance to ALV C, is approximately 1 cM from *tva* (46). This receptor shows homology to butyrophilins, a member of the immunoglobulin superfamily. The resistant allele contains a premature stop codon and, thus, would not produce a complete and functioning receptor (47).

Resistance to ALV subgroups B, D, and E (endogenous) are all controlled by the *tvb* locus (5), which is located on chromosome 22 (126). There are several reported alleles for this receptor, which is related to the tumor necrosis factor receptor (TNFR) family. A single nucleotide change that generates a premature stop codon results in a non-functioning receptor and resistance to all three subgroups. The tvb^{s1} or wild-type allele is susceptible to all three subgroups, whereas the tvb^{s3} allele confers resistance to subgroup E as the result of a different single nucleotide mutation (81). The *tvb* genotype can be determined by molecular tests (142).

Although the receptor for ALV subgroup J has been identified and shown to be Na+/H+exchanger 1 (NHE1) (33), no cellular resistance is known, which suggests that variants that do not allow for virus binding are lethal. Field reports showing differences between lines suggest a genetic basis for differences in resistance to the myeloid leucosis.

Marek's Disease

Chickens resistant to Marek's disease (MD) are those that fail to develop characteristic symptoms upon exposure to Marek's disease virus (MDV) (Chapter 15). Genetic differences in resistance to fowl paralysis, assumed to be MD, have been reported for more than 70 years (7). Resistance to MD is complex and controlled by multiple genes or QTLs (10).

The best understood mechanism for the involvement of genetic resistance to MD involves the major histocompatibility complex (MHC) or, as it is known in the chicken, the *B* complex. The MHC contains three tightly linked regions known as *B-F* (class I), *B-G* (class II), and *B-L* (class IV), which control cell surface antigens. The *B-G* locus is expressed in erythrocytes, which enables convenient typing of blood groups. By measuring the allelic frequency of specific blood groups, it has been observed that certain *B* alleles are associated with resistance or susceptibility. Chickens with the B^{21} allele are more resistant than those with other *B* haplotypes (8, 12). Other studies have allowed for the relative ranking of the other *B* alleles: moderate resistance, B^{2}, B^{6}, B^{14}; susceptibility, B^{1}, B^{3}, B^{5}, B^{13}, B^{15}, B^{19}, B^{27} (100). The MHC also influences vaccinal immunity because some haplotypes develop better protection with vaccines of one serotype than of a different serotype (11, 13).

In addition to the MHC, chromosome 16 contains another set of class I and class II MHC genes that is called the *Rfp Y* locus (109). Work by Wakenell (136) using data obtained from commercial chickens challenged with MDV suggests an association with MD resistance. However, results from matings with experimental lines indicate that the *Rfp-Y* genes do not influence any MD-associated trait in these genetic backgrounds (134). These conflicting results further demonstrate the complexity of genetic resistance to MD and the probable influence of genetic background.

Besides the MHC, other genetic factors have a major influence on resistance to MD. For example, lines 6 and 7 chickens share the same *B* haplotype, B^{2} (68), yet are MD-resistant and -susceptible, respectively. Due to the availability of these characterized lines and their genetic simplicity, genome-wide QTL scans have been conducted (22, 62, 108, 133, 138) where up to up to 21 QTL were discovered that explain MD incidence or MD-associated traits. It is important to note that all of the QTL were of small to moderate effect; however, there was relatively good agreement among the various studies with respect to consistency of the QTL positions.

As described previously, going from a QTL to identification of the underlying causative genes is a tremendous challenge, even in model organisms. Consequently, additional functional genomic approaches have been incorporated to give further screens. Approaches used in combination with genetic mapping include DNA microarrays (94, 127) and two-hybrid assays that have identified nine MDV-chicken protein-protein interactions confirmed by an *in vitro* binding assay (112). As a result, growth hormone (*GH1*) (95), *LY6E* [lymphocyte complex 6, locus E, aka, stem cell antigen 2 (*SCA2*) and thymic shared antigen 1 (*TSA1*)] (96), and *BLB*, the gene for MHC class II β chain (113), are viewed as genes that confer MD genetic resistance based on the genetic linkage to MD incidence, differential gene expression between MD resistance and susceptible chicks following MDV challenge, and direction protein interaction with an MDV protein.

Recent studies in other organisms have pointed to an increasing role of transcriptional regulation to explain phenotypic variation (e.g., 77, 120, 124). Taking advantage of this knowledge, genome-wide surveys have identified up to 3,700+ genes with alleles that respond differentially to MDV challenge (102). The major unresolved question is whether all of these genes contribute to genetic resistance to MD. However, if this is the case, then it would highlight the multigenic nature of disease resistance to MDV.

Salmonellosis

Control of salmonellosis presents special challenges to the poultry industries. Some species of *Salmonella* bacteria are highly pathogenic in chickens, whereas other species cause little response in the host birds, which can then become

asymptomatic carriers, transmitting bacteria to flockmates or into the human food chain (Chapter 16). Chicks infected with *Salmonella* immediately after hatch can be persistently colonized to maturity, shedding bacteria vertically to infect table or hatching eggs or horizontally to infect other hens (52).

Heritability estimates of various parameters of *Salmonella* response, including mortality (16), cecal carrier state (18), number of colonizing bacteria (39), and antibody response (16, 76), indicate that genetic selection to improve resistance to salmonellosis and carrier state is feasible. Many genes are associated with genetic control of response to *Salmonella*, with the individual effect of most genes on the disease phenotypic variation being relatively small (see reviews 28, 85). With astute choices, genetic selection can proceed based on variation in genomic structure or expression (15, 27, 88, 129). Measuring antibodies is less expensive and laborious than measuring bacterial colonization and because vaccine antibody has a negative genetic correlation with cecal colonization, vaccine antibody is a useful biomarker to improve resistance to colonization (74).

The comparative genomics approach very effectively identified major genes controlling salmonellosis resistance in chickens because *Salmonella* response was previously studied in the mouse, a model organism. Chicken homologs of major loci controlling natural resistance of mice to *S. typhimurium* infection were examined as candidate genes. Both *NRAMP1* (natural resistance-associated macrophage protein 1, now called *SLC11A1*, solute carrier family 11 member 1) and *TNC* (a locus closely linked to *TLR4*, which binds lipopolysaccharide, a major component of Gram-negative bacteria membranes) were associated with differential resistance in *Salmonella*-induced mortality in a backcross of inbred lines (66). The *NRAMP1* association was confirmed for several additional parameters of host response to *Salmonella* in other chicken populations (17, 83, 97), as was the *TLR4* association (17, 89, 103). For resistance candidate genes based upon their genomic location near *NRAMP1* (55), the *CD28* gene was associated with enteric *Salmonella* infection (103), and *VIL1* with visceral infection (56).

Biological candidate genes are selected based upon involvement in functions or pathways that are hypothesized to be important in host response to *Salmonella*. The *MD2* gene product interacts with the TLR4 receptor, and *MD2* SNPs are associated with persistence of *Salmonella* cecal colonization (103). The MHC is associated with resistance to *Salmonella* colonization, morbidity, and mortality (39, 99). Several cytokines have SNPs associated with response to *Salmonella* (54, 83, 104). Genes in apoptotic pathways, specifically *CASP1* and *IAP1*, are associated with various *Salmonella* resistance traits (83, 98). Several *avian beta-defensins* (*AvBD*, also known as gallinacins), members of a family of antimicrobial peptides, have SNPs associated with *Salmonella* response (41, 59).

The design of most candidate gene experiments does not preclude that the causal gene could be a nearby gene rather than the specific one studied. Having additional supporting lines of evidence, therefore, such as confirmation in independent populations—by genome-wide QTL scans, by gene expression studies, or from comparative genomics—helps to add confidence in the detected gene-resistance associations.

Genome scans have identified many QTL regions associated with resistance to *Salmonella* colonization or salmonellosis (1, 26, 29, 51, 60, 75, 105, 131). One of the major *Salmonella* resistance QTL with greatest effect, *SAL1*, is on chromosome 5. Fine-mapping the *SAL1* QTL region identified functional candidate genes, CD27-binding protein (*SIVA*) and *AKT1* (protein kinase B, PKB)(51), and fine-mapping of heterophil functional response to *Salmonella* in a more advanced intercross strongly supported *SIVA* (116).

Recent studies on host gene expression in response to *Salmonella* reveal differential expression in genes that may be active in pathways controlling resistance. Targeted expression studies in specific genes for which SNPs are associated with *Salmonella* response are generally supporting these genes' role in *Salmonella* response, including *TLR* genes (2, 3, 64, 111), cytokines (35, 73, 117, 130, 137), and beta-defensins (41, 121). Use of microarrays, either immune-system targeted or global, are providing a more comprehensive picture of host genes and pathways involved in resistance to *Salmonella* (36, 92, 135, 143). Although there is variation among studies in factors such as type of bird and age tested, *Salmonella* challenge strain and route, and tissue or cell type analyzed, some observations of highly represented gene families and pathways are supported across multiple studies, suggesting that they have a robust role in response to Salmonella. Among these are *TLR*s, cytokines and cytokine receptors, apoptotic pathways, antimicrobial peptides, T cell receptors and signaling pathways, and CD antigens.

Escherichia coli

E. coli is both a source of colibacillosis in production flocks and a potential food safety pathogen (Chapter 18). Genetic control of resistance to *E. coli* has primarily been studied through analysis of chicken lines that were divergently selected for circulating antibody level to *E. coli* vaccine in young birds (86). The underlying principle is that vaccine-induced antibody is related to resistance and that resistance is under genetic control; therefore, genetic selection for antibody response generates lines that differ in resistance genetics, which can be used to identify the specific genetic differences controlling resistance.

Divergent selection for *E. coli* vaccine antibody response successfully modulated mortality rate and the immune response to pathogenic *E. coli* and several other antigens (63). When divergently selected lines were crossed, molecular probes for three genes in the MHC region (*B-F, B-G*, and *TAP2*) were associated with antibody traits (140). Cavero et al. (32) also reported an association of the MHC (B blood group) with mortality after *E. coli* challenge of laying hens. Genome scans of additional resource populations produced from the antibody-selected lines revealed QTL for antibody response and mortality. An initial

low-density scan identified three markers associated with antibody response to *E. coli*, Newcastle disease virus, and/or sheep red blood cell (SRBC), and one with mortality (139). Additional crosses generated 1,700 progeny that were immunized with *E. coli* and *Salmonella enteritidis* vaccine (141). Genotyping the individuals with extreme phenotypes (highest and lowest antibody levels) revealed 12 markers associated with *E. coli* antibody, and six of these were also associated with *S. enteritidis* antibody, indicating that some genetic control was likely shared across humoral response to multiple bacteria.

Use of microarray technologies to assess gene expression levels generates a more comprehensive picture of the genes and genetic networks that are potentially involved in host response to *E. coli*. Hundreds of genes were differentially expressed between broilers that were infected or non-infected with avian pathogenic *E. coli* (122). These genes were highly represented in several immune pathways, including *TLR*, *Jak-STAT*, and cytokine signaling, which suggests an important role of these immune pathways in host response to *E. coli* infection. Using smaller, immune-focused microarrays and isolated macrophage cells, the cytokines and cytokine receptor genes again were identified as strongly associated with response to *E. coli* (87).

Coccidiosis

Coccidiosis is caused by several species of parasites of the genus *Eimeria*, each of which has tropism for a different area of the gastrointestinal tract (Chapter 28). Population differences, and the ability to genetically select lines for divergent resistance/susceptibility, illustrate the feasibility of improvement in genetic resistance to coccidiosis (21, 70, 115).

Studies comparing *B*-congenic lines (30, 38, 90, 119) or populations in which MHC haplotypes segregate within line or differ among lines (20, 37, 107, 132) provide strong support for the MHC being a coccidiosis resistance locus. However, effects of specific MHC haplotypes greatly vary, dependent upon factors such as *Eimeria* challenge strain and the specific trait used to characterize resistance (for example, antibody, oocyst shedding, weight gain, severity of intestinal lesions). Both MHC and non-MHC genes control resistance to coccidiosis (91, 93). Erythrocyte loci in addition to the *B* locus have been associated with resistance to coccidiosis, including *Ea-AE*, *Ea-C* (70), and *Ea-I* (106).

Multiple genome scan studies have identified genomic regions or genes associated with response to *Eimeria*. A strong QTL for *E. maxima* oocyst shedding in broilers was located on chromosome 1 (144), and subsequent fine-mapping confirmed this QTL (78). Association analysis of candidate gene SNPs in this QTL region supported the *xyzin* gene as a coccidiosis-resistance gene (65). Using a diverse cross of Fayoumi (resistant) and white leghorn (susceptible) lines, a genome scan identified 21 QTL regions, and suggested candidate genes in the cytokine and tumor-necrosis families and pathways related to innate immune and inflammatory responses (114).

Functional genomics reveals a more comprehensive picture of the genetic control of coccidiosis resistance (92). Genes involved in metabolism of lipids and carbohydrates, as well as innate immunity genes, change in expression in *Eimeria*-infected birds (79), suggesting a mechanism for the growth depression that typically accompanies coccidiosis. Both local and systemic expression of the cytokines is modulated during infection (80). Expression changes in liver-expressed antimicrobial peptide (*LEAP-2*) are associated with *E. maxima*-induced lesion scores (31).

Infectious Bursal Disease

Infectious bursal disease virus (IBDV) causes acute infection and depletion of B cells in the bursa and other organs, often resulting in severe and permanent immunosuppression of the host (Chapter 7). Differences between chicken lines have been reported, indicating a genetic basis (6, 61). Mating of resistant and susceptible lines to form F_1, F_2, and BC populations demonstrated IBDV-induced mortality to be under the control of a fully or partially dominant autosomal resistance gene (23, 24). Multiple studies have examined the MHC for association with IBDV resistance, with none showing effect (23, 24, 67); however, an MHC effect was detected on resistance parameters of specific antibody to IBDV and cloacal bursa histopathology (71, 72). The differences among studies are likely to be a result of examination of different MHC haplotypes in varied genetic backgrounds. Collectively, studies on genetics of IBDV resistance suggest involvement of the MHC and at least one other, currently unidentified, autosomal gene. Global transcriptional profiling has revealed numerous genes that are differentially regulated between IBDV-resistant and -susceptible lines, and suggests that resistance may be mediated by more rapid inflammatory response and more extensive p53-related apoptosis of target B cells, thus limiting viral replication in resistant birds (118). Addition of IFNα inhibits IBDV replication *in vitro*, but this effect was not influenced by the *Mx* genotype (113).

Avian Influenza

Influenza A viruses are of significant interest to the poultry industries and human health. Infection of gallinaceous poultry species such as chicken and turkey is relatively frequent (128), with highly pathogenic H5 and H7 strains causing extremely high mortality rates (Chapter 6). Viral infection triggers the synthesis of type I and III IFN, which in turn activate the expression of numerous IFN-induced genes including *Mx*. Mx proteins, dynamin-like large GTPases, block an early step in the influenza virus replication cycle (84). The chicken *Mx* gene has multiple polymorphisms, though antiviral activity depends only on the protein having Asn at amino acid position 613 (82). There are limited but conflicting reports on the association of *Mx* to confer genetic resistance in chickens (48, 125), which could be explained in part by the use of viruses that differ in nucleoprotein (NP), the viral protein that determines Mx sensitivity (145). Use of B congenic

strains has indicated a small role of the MHC region on resistance (69). Thus, it appears likely that genetic resistance to avian influenza is complex and controlled by many genes, as is the case for mice (19).

Given the human health concerns, engineering genetic resistance to avian influenza might be one of the few examples that would make genetically modified chickens acceptable to consumers. Consequently, several groups have explored the use of transgenic technology. The most notable success has been the clever use of expressing a small RNA piece that acts as a decoy to the viral polymerase (101). As a result, transgenic chickens expressing this RNA do not horizontally transmit influenza virus to healthy cage mates. While the transgene does not prevent infection, indicating that further progress still needs to be made, this is an important "proof of concept" that could be applied to combat other avian pathogens.

Future Perspectives

Genetic resistance to disease for any one individual or line of chickens is the overall outcome of a very complex set of signals and responses with which the chicken and pathogen interact. The ability for molecular genetics to unravel this biological complexity has been very impressive. Despite the rapid pace of advancements, there is a long way to go before scientists develop a detailed understanding of the molecular pathways and poultry breeders are able to transfer this information to improve their commercial products.

Poultry breeding companies have achieved enhanced disease resistance in their flocks to many pathogens using traditional methods. However, this is a laborious process that requires the intentional exposure of individuals from elite lines to pathogens, or progresses rather slowly due to indirect selection on overall livability. With the emergence of molecular genetics and the field of genomics, there is optimism that studies will be able to identify genes and alleles that confer superior disease resistance. When applied to breeding, the information will provide for the rapid and accurate improvement of commercial lines. In application, the poultry breeders do not necessarily rely on the identification of the disease resistance gene itself, but may use markers in linkage disequilibrium to increase the frequency of favorable alleles. However, as science has shown many times, increasing knowledge gives increasing power that can often be applied in novel ways. So the ultimate goal should be to identify disease resistance genes and their pathways to reveal biological function and pathways.

So what will hasten the advancement of knowledge? With high-throughput platforms to determine genotypes, the rate limit step is in producing and measuring resource populations. With respect to animal production, one solution would be to increase the partnerships between poultry breeding companies and molecular geneticists, which allows for the leveraging of expertise and resources. This partnership also allows for scientists to work at the population level with all of the diverse sets of genes and allele combinations. Beyond this, trait measurements will be critical. As DNA microarrays and proteomics have already shown, breaking down a trait into specific components provides critical information on biological processes that cannot be or are difficult to obtain by traditional phenotypic measurements. Thus, veterinary medicine can make key contributions by refining trait measurements associated with disease and disease progression.

References

The Avian Immune System

1. Bernot, A. and C. Auffray. 1991. Primary structure and ontogeny of an avian CD3 transcript. *Proc Natl Acad Sci USA*. 88:2550–2554.
2. Boyd, R.L., T.J. Wilson, A.G. Bean, H.A. Ward, and M.E. Gershwin. 1992. Phonotypic characterization of chicken thymic stromal elements. *Dev Immunol.* 2:51–66.
3. Brownlie, R., and B. Allan. 2011. Avian toll-like receptors. *Cell Tissue Res.* 343:121–130.
4. Carroll, M.C. 2004. The complement system in regulation of adaptive immunity. *Nat Immunol.* 5:981–986.
5. Chan, M.M., C.L. Chen, L.L. Ager, and M.D. Cooper. 1988. Identification of the avian homologues of mammalian CD4 and CD8 antigens. *J Immunol.* 140:2133–2138.
6. Char, D., P. Sanchez, C.L. Chen, R.P. Bucy, and M.D. Cooper. 1990. A third sublineage of avian T cells can be identified with a T cell receptor-3-specific antibody. *J Immunol.* 145:3547–3555.
7. Chen, C.H., T.C. Chanh, and M.D. Cooper. 1984. Chicken thymocyte-specific antigen identified by monoclonal antibodies: ontogeny, tissue distribution and biochemical characterization. *Eur J Immunol.* 14:385–391.
8. Chen, C.H., T.W. Gobel, T.Kubota, and M.D. Cooper. 1994. T cell development in the chicken. *Poult Sci.* 73:1012–1018.
9. Chen, C.H., J.T. Sowder, J.M. Lahti, J. Cihak, U. Losch, and M.D. Cooper. 1989. TCR3: a third T-cell receptor in the chicken. *Proc Natl Acad Sci USA*. 86:2351–2355.
10. Chen, C.L., L.L. Ager, G.L. Gartland, and M.D. Cooper. 1986. Identification of a T3/T cell receptor complex in chickens. *J Exp Med.* 164:375–380.
11. Chen, C.L., J. Cihak, U. Losch, and M.D. Cooper. 1988. Differential expression of two T cell receptors, TcR1 and TcR2, on chicken lymphocytes. *Eur J Immunol.* 18:539–543.
12. Cihak, J., HW. Ziegler-Heitbrock, H. Trainer, I. Schranner, M. Merkenschlager, and U. Losch. 1988. Characterization and functional properties of a novel monoclonal antibody which identifies a T cell receptor in chickens. *Eur J Immunol.* 18:533–537.
13. Collisson, E.W., J. Pei, J. Dzielawa, and SH. Seo. 2000. Cytotoxic T lymphocytes are critical in the control of infectious bronchitis virus in poultry. *Dev Comp Immunol.* 24:187–200.
14. Dahan, A., C.A. Reynaud, and W.J.C. 1983. Nucleotide sequence of a chicken u heavy chain mRNA. *Nucl Acid Res.* 11:5381–5389
15. Davison, T.F., B. Kaspers, and K.A. Schat 2008. *Avian Immunology*. Elsevier Limited, Amsterdam. 1–481.
16. Davison, T.F., T.R. Morris, and L.N. Payne. 1996. Poultry Immunology. Poultry Science Symposium Series. Carfax Publishing Company, Abingdon, UK.

17. de Wit, J.J., J.F. Heijmans, D.R. Mekkes, and A.A.W.M. van Loon. 2001. Validation of five commercially available ELISAs for the detection of antibodies against infectious bursal disease virus (serotype 1). *Avian Pathol.* 30:543–549.
18. Demaries, S.L., and M.J. Ratcliffe 1998. Cell surface and secreted immunoglobulins in B cell development. In: *Avian Immunology*, J. M. Sharma. ed. In: Handbook of Vertebrate Immunology, Pastoret, P.P., P. Griebel, H. Bazin, and A. Govaerts).
19. Gobel, T.W. 2000. Isolation and analysis of natural killer cells in chickens. *Method Mol Biol.* 121:337–345.
20. Gobel, T.W., B. Kaspers, and M. Stangassinger. 2001. NK and T cells constitute two major, functionally distinct intestinal epithelial lymphocyte subsets in the chicken. *Int Immunol.* 13:757–762.
21. Greunke, K., E. Spillner, I. Braren, H. Seismann, S. Kainz, U. Hahn, T. Grunwald, and R. Bredehorst. 2006. Bivalent monoclonal IgY antibody formats by conversion of recombinant antibody fragments. *J Biotechnol.* 124:446–456.
22. Gyorfy, Z., A. Ohnemus, B. Kaspers, E. Duda, and P. Staeheli. 2003. Truncated chicken interleukin-1 beta with increased biological activity. *J. Interferon Cytokine Res.* 5:223–228.
23. Haury, M., Y. Kasahara, S. Schaal, R.P. Bucy, and M. D. Cooper. 1993. Intestinal T lymphocytes in the chicken express an integrin-like antigen. *Eur J Immunol.* 23:313–319.
24. He, H., K.J. Genovese, and M.H. Kogut. 2011. Modulation of chicken macrophage effector function by T(H)1/T(H)2 cytokines. *Cytokine.* 53:363–369.
25. Higgins, D.A., and G. W. Warr. 2000. The avian immune responseto infectious diseases. Special Issue. *Dev. Comp. Immunol.* 24:85–101.
26. Houssaint, E., E. Diez, and F.V. Jotereau. 1985. Tissue distribution and ontogenic appearance of a chicken T lymphocyte differentiation marker. *Eur J Immunol.* 15:305–308.
27. Jansen, C.A., P.M. van de Haar, D. van Haarlem, P. van Kooten, S. de Wit, W. van Eden, B.C. Viertlbock, T.W. Gobel, and L. Vervelde. 2010. Identification of new populations of chicken natural killer (NK) cells. *Dev Comp Immunol.* 34:759–767.
28. Jeurissen, S.H., A.G. Boonstra-Blom, S.O. Al-Garib, L. Hartog, and G. Koch. 2000. Defense mechanisms against viral infection in poultry: A Review. *Vet Quart.* 22:204–208.
29. Juul-Madsen, H.R., L.R. Norup, K.J. Handberg, and P.H. Jorgensen. 2007. Mannan-binding lectin (MBL) serum concentration in relation to propagation of infectious bronchitis virus (IBV) in chickens. *Viral Immunol.* 20:562–570.
30. Kaiser, P., and T.F. Davison. 2008. Resources available for studying avian immunology. In: *Avian Immunology*. T.F. Davison, B. Kaspers, and K. A. Schat, eds. Elsevier, Amsterdam. 459–465.
31. Kapczynski, D.R., K. liljebjelke, G. Kulkarni, H.D. Hunt, H.J. Jiang, and D. Petkov. 2011. Cross reactive cellular immune responses in chickens previously exposed to low pathogenic avian influenza. *BMC Proc*. 5 Suppl. 4:S13.
32. Karaca, K., I.J. Kim, S.K. Reddy, and J.M. Sharma. 1996. Nitric oxide inducing factor as a measure of antigen and mitogen-specific T cell responses in chickens. *J Immunol Methods.* 192:97–103.
33. Kaufman, J., J. Jacob, I. Shaw, B. Walker, S. Milne, S. Beck, and J. Salomonsen. 1999. Gene organisation determines evolution of function in the chicken MHC. *Immunol Rev.* 167:101–117.
34. Khatri, M., J.M. Palmquist, R.M. Cha, and J.M. Sharma. 2005. Infection and activation of bursal macrophages by virulent infectious bursal disease virus. *Virus Res.* 113:44–50.
35. Khatri, M., and J.M. Sharma. 2006. Infectious bursal disease virus infection induces macrophage activation via p38 MAPK and NF-kappaB pathways. *Virus Res.* 118:70–77.
36. Kim, I.J., and J.M. Sharma. 2000. IBDV-induced bursal T lymphocytes inhibit mitogenic response of normal splenocytes. *Vet Immunol Immunopathol.* 74:47–57.
37. Kim, I.J., S.K. You, H. Kim, H.Y. Yeh, and J.M. Sharma. 2000. Characteristics of bursal T lymphocytes induced by infectious bursal disease virus. *J Virol.* 74:8884–8892.
38. Kimijama, T., H.Y. H. Kitagawa, Y. Kon, and M. Sugimura. 1990. Localization of immunoglogulins in the chicken oviduct. *Japanese J. Vet. Sci.* 52:299–305
39. Koppenheffer, TL. 1998. Complement. In: *Handbook of Vertebrate Immunology*, Pastoret, P.P., P. Griebel., H. Bazin, and A. Govaerts, eds. Section IV. *Avian Immunology,* J. Sharma, ed. Academic Press, San Diego. 99–100.
40. Kowalczyk, K., J. Daiss, J. Halpern, and T.F. Roth. 1985. Quantitation of maternal-fetal IgG transport in the chicken. *Immunology.* 54:755–762.
41. Kushima, K., M. Fujita, A. Shigeta, H. Horiuchi, H. Matsuda, and S. Furusawa. 2003. Flow cytometric analysis of chicken NK activity and its use on the effect of restraint stress. *J Vet Med Sci.* 65:995–1000.
42. Lee, T.H., and C.H. Tempelis. 1992. A possible 110-kDa receptor for interleukin-2 in the chicken. *Dev Comp Immunol.* 16:463–472.
43. Linden, C.D., and T.F. Roth. 1978. IgG receptors on fetal chicken yolk sac. *J Cell Sci.* 33:317–328.
44. Liu, G., Q. Wang, T. Tong, Y. Xiao, Y. Bai, S. Liu, and D. Wu. 2008. Construction of functional test of a chicken MHC-1 (BF2*15)/peptide tetramer. *Vet Immunol Immunopathol.* 15:1–7.
45. Luhtala, M., J. Salomonsen, Y. Hirota, T. Onodera, P. Toivanen, and O. Vainio. 1993. Analysis of chicken CD4 by monoclonal antibodies indicates evolutionary conservation between avian and mammalian species. *Hybridoma.* 12:633–646.
46. Maccubin, D.L., and L.W. Schierman. 1986. MHC restricted cytotoxic response of chicken T cells: expression, augmentation and clonal characterisation *J Immunol*. 136:12–16.
47. Mansikka, A. 1992. Chicken IgA H chains. Implications concerning the evolution of H chain genes. *J Immunol*. 149:855–861.
48. Mast, J., B.M. Goddeeris, K. Peeters, F. Vandesande, and L.R. Berghman. 1998. Characterisation of chicken monocytes, macrophages and interdigitating cells by the monoclonal antibody KUL01. *Vet Immunol Immunopathol.* 61:343–357.
49. Mellata, M., M. Dho-Moulin, C.M. Dozois, R. Curtiss, 3rd, B. Lehoux, and J.M. Fairbrother. 2003. Role of avian pathogenic Escherichia coli virulence factors in bacterial interaction with chicken heterophils and macrophages. *Infect Immun.* 71:494–503.
50. Noteborn, M.H., et al. 1991. Characterization of cloned chicken anemia virus DNA that contains all elements for the infectious replication cycle. *J Virol.* 65:3131–3139.
51. Okazaki, W., R.L. Witter, C. Romero, K. Nazerian, J.M. Sharma, A. Fadly, and D. Ewert. 1980. Indication of lymphoid leukosis transplantable tumours and the establishment of lymphoblastoid cell lines. *Avian Pathol.* 9:311–329
52. Palmquist, J.M., M. Khatri, R.M. Cha, B.M. Goddeeris, B. Walcheck, and J.M. Sharma. 2006. In vivo activation of chicken macrophages by infectious bursal disease virus. *Viral Immunol.* 19:305–315.

53. Parvari, R., A. Avivi, F. Lentner, E. Ziv, S. Tel-Or, Y. Burstein, and I. Schechter. 1988. Chicken immunoglobulin gamma-heavy chains: limited VH gene repertoire, combinatorial diversification by D gene segments and evolution of the heavy chain locus. *Embo J.* 7:739–744.
54. Pertile, T.L., K. Karaca, M.M. Walser, and J.M. Sharma. 1996. Suppressor macrophages mediate depressed lymphoproliferation in chickens infected with avian reovirus. *Vet Immunol Immunopathol.* 53:129–145.
55. Qureshi, M.A., C.L. Heggen, and I. Hussain. 2000. Avian macrophage: effector functions in health and disease. *Dev Comp Immunol.* 24:103–119.
56. Reynaud, C.A., V. Anquez, H. Grimal, and J.C. Weill. 1987. A hyperconversion mechanism generates the chicken light chain preimmune repertoire. *Cell.* 48:379–388.
57. Reynaud, C.A., A. Dahan, V. Anquez, and J.C. Weill. 1989. Somatic hyperconversion diversifies the single Vh gene of the chicken with a high incidence in the D region. *Cell.* 59:171–183.
58. Sapats, S.I., H.G. Heine, L. Trinidad, G.J. Gould, A.J. Foord, S.G. Doolan, S. Prowse, and J. Ignjatovic. 2003. Generation of chicken single chain antibody variable fragments (scFv) that differentiate and neutralize infectious bursal disease virus (IBDV). *Arch Virol.* 148:497–515.
59. Scauenstein, K., G. Kronerm, K. Hala, G. Bock, and G. Wick. 1988. Chicken-activated-T-lymphocyte antigen (CATLA) recognized by monoclonal antibody INN-CH-16 represents the IL-2 receptor. *Dev Comp Immunol.* 12:823–831.
60. Schat, K.A., and Z. Xing. 2000. Specific and nonspecific immune responses to Marek's disease virus. *Dev Comp Immunol.* 24:201–221.
61. Schwarz, A., M. Gauly, H. Abel, G. Daş, J. Humburg, A. T. Weiss, G. Breves, and S. Rautenschlein. 2011. Pathobiology of Heterakis gallinarum mono-infection and co-infection with Histomonas meleagridis in layer chickens. *Avian Pathol.* 40:277–287.
62. Schwarz, H., O. Harlin, A. Ohnemus, B. Kaspers, and P. Staeheli. 2004. Synthesis of IFN-beta by virus-infected chicken embryo cells demonstrated with specific antisera and a new bioassay. *J Interferon Cytokine Res.* 179–184.
63. Scott, T., and M.D. Owens. 2008. Thrombocytes respond to lipopolysaccharide through Toll-like receptor-4, and MAP kinase and NF-kappaB pathways leading to expression of interleukin-6 and cyclooxygenase-2 with production of prostaglandin E2. *Mol Immunol*. 45:1001–1008.
64. Scott, T.R., and H.S. Lillehoj. 2006. Monoclonal antibodies against chicken interleukin-6. *Vet Immunol Immunopathol.* 114:173–177.
65. Shanmugasundaram, R., and R.K. Selvaraj. 2011. Regulatory T cell properties of chicken CD4+CD25+ cells. *J Immunol.* 186:1997–2002.
66. Sharma, J.M. 1991. *Avian Cellular Immunology*. CRC Press, Boca Raton, FL. 1–207.
67. Sharma, J.M. 1983. Presence of adherent cytotoxic cells and non-adherent natural killer cells in progressive and regressive Marek's disease tumors. *Vet Immunol Immunopathol.* 5:125–140.
68. Sharma, J.M. 1997. The structure and function of the avian immune system. *Acta Vet Hung.* 45:229–238.
69. Sharma, J.M., and W. Okazaki. 1981. Natural killer cell activity in chickens: target cell analysis and effect of antithymocyte serum on effector cells. *Infect Immun.* 31:1078–1085.
70. Sharma, J.M., and K.A. Schat. 1991. Natural Immune Functions. In: *Avian Cellular Immunology*, J.M. Sharma, ed. CRC Press, Boca Raton, FL. 51–70.
71. Sowder, J.T., C.L. Chen, L.L. Ager, M.M. Chan, and M.D. Cooper. 1988. A large subpopulation of avian T cells express a homologue of the mammalian T gamma/delta receptor. *J Exp Med.* 167:315–322.
72. Thayer, S.G., and C.W. Beard. 1998. Serologic Procedures. In: A Laboratory Manual for Isolation and Identification of Avian Pathogens, D.E. Swayne, J.R. Glisson, M.W. Jackwood, J.E. Pearson, and W.M. Reed, eds. Am Assoc Avian Pathologist.
73. Timms, L.M., C.D. Bracewell, and D.J. Alexander. 1980. Cell mediated and humoral immune response in chickens infected with avian infectious bronchitis. *Br Vet J.* 136:349–346.
74. Toivanen, A., and P. Toivanen 1987. *Avian Immunology*. CRC Press, Boca Raton, FL. 1–236.
75. Tregaskes, C.A., F.K. Kong, E. Paramithiotis, C.L. Chen, M.J. Ratcliffe, T.F. Davison, and J.R. Young. 1995. Identification and analysis of the expression of CD8 alpha beta and CD8 alpha alpha isoforms in chickens reveals a major TCR-gamma delta CD8 alpha beta subset of intestinal intraepithelial lymphocytes. *J Immunol.* 154:4485–4494.
76. Vainio, O., B. Riwar, M.H. Brown, and O. Lassila. 1991. Characterization of the putative avian CD2 homologue. *J Immunol.* 147:1593–1599.
77. Warr, G.W., K.E. Magor, and D.A. Higgins. 1995. IgY: clues to the origins of modern antibodies. *Immunol Today.* 16:392–398.
78. Watson, D.S., S.M. Reddy, V. Brahmakshatriya, and B. Lupiani. 2009. A multiplexed immunoassay for detection of antibodies against avian influenza virus. *J Immunol Methods.* 340:123–131.
79. Wieland, W.H., A. Lammers, A. Schots, and D.V. Orzaez. 2006. Plant expression of chicken secretory antibodies derived from combinatorial libraries. *J Biotechnol.* 122:382–391.
80. Wieland, W.H., D. Orzaez, A. Lammers, H.K. Parmentier, M.W. Verstegen, and A. Schots. 2004. A functional polymeric immunoglobulin receptor in chicken (Gallus gallus) indicates ancient role of secretory IgA in mucosal immunity. *Biochem J.* 380: 669–676.
81. Wu, Z., and P. Kaiser. 2011. Antigen presenting cells in a non-mammalian model system, the chicken. *Immunobiol*.
82. Young, J.R., T.F. Davison, C.A. Tregaskes, M.C. Rennie, and O. Vainio. 1994. Monomeric homologue of mammalian CD28 is expressed on chicken T cells. *J Immunol.* 152:3848–3851.
83. Zuckermann, F. 1999. Extrathymic CD4/CD8 double positive T cells. *Vet Immunol Immunopathol.* 72:55–66.

Genetics of Disease Resistance

1. Abasht, B., J.C.M. Dekkers, and S.J. Lamont. 2006. Review of quantitative trait loci identified in the chicken. *Poult Sci.* 85:2079–2096.
2. Abasht, B., M.G. Kaiser, and S.J. Lamont. 2008. Toll-like receptor gene expression in cecum and spleen of advanced intercross line chicks infected with *Salmonella enterica* Serovar Enteritidis. *Vet Immunol Immunopath.* 123:314–323.
3. Abasht, B., M.G. Kaiser, J. van der Poel, and S.J. Lamont. 2009. Genetic lines differ in Toll-like receptor gene expression in spleen of chicks inoculated with *Salmonella enterica* Serovar Enteritidis. *Poult Sci.* 88:744–749.
4. Abplanalp, H. 1992. Inbred lines as genetic resources of chickens. *Poult Sci Rev.* 4:29–39.
5. Adkins, H.B., J. Brojatsch, and J.A. Young. 2000. Identification and characterization of a shared TNFR-related receptor for subgroup B, D, and E avian leukosis viruses reveal cysteine

residues required specifically for subgroup E viral entry. *J Virol.* 74:3572–3578.
6. Aricibasi, M., A. Jung, E.D. Heller, and S. Rautenschlein. 2010. Differences in genetic background influence the induction of innate and acquired immune responses in chickens depending on the virulence of the infecting infectious bursal disease virus (IBDV) strain. *Vet Immunol Immunopath.* 135:79–92.
7. Asmundson, V.S., and J. Biely. 1932. Inheritance and resistance to fowl paralysis (neuro-lymphomatosis gallinarum). I. Differences in susceptibility. *Canadian J Res.* 6:171–276.
8. Bacon, L.D. 1987. Influence of the major histocompatibility complex on disease resistance and productivity. *Poult Sci.* 66:802–811.
9. Bacon, L.D., H.D. Hunt, and H.H. Cheng. 2000. A review of the development of chicken lines to resolve genes determining resistance to diseases. *Poult Sci.* 79:1082–93.
10. Bacon, L.D., H.D. Hunt, and H.H. Cheng. 2001. Genetic resistance to Marek's disease. *Curr Top Microbiol Immunol.* 255:121–141.
11. Bacon, L.D., and R.L. Witter. 1992. Influence of turkey herpesvirus vaccination on the B-haplotype effect on Marek's disease resistance in 15.B-congenic chickens. *Avian Dis*. 36:378–385.
12. Bacon, L.D., and R.L. Witter. 1994. B haplotype influence on the relative efficacy of Marek's disease vaccines in commercial chickens. *Poult Sci.* 73:481–487.
13. Bacon, L.D., and R.L. Witter. 1994. Serotype specificity of B-haplotype influence on the relative efficacy of Marek's disease vaccines. *Avian Dis.* 38:65–71.
14. Bates, P., L. Rong, H.E. Varmus, J.A. Young, and L.B. Crittenden. 1998. Genetic mapping of the cloned subgroup A avian sarcoma and leukosis virus receptor gene to the TVA locus. *J Virol.* 72:2505–2508.
15. Beaumont, C., H. Chapuis, J. Protais, N. Sellier, P. Menanteau, P. Fravalo, and P. Velge. 2009. Resistance to Salmonella carrier state: selection may be efficient but response depends on animal's age. *Genet Res. (Camb.)* 91:161–169.
16. Beaumont, C., J. Protais, J.F. Guillot, P. Colin, K. Proux, N. Millet, and P. Pardon. 1999. Genetic resistance to mortality of day-old chicks and carrier-state of hens after inoculation with *Salmonella enteritidis*. *Avian Pathol.* 28:131–135.
17. Beaumont, C., J. Protais, F. Pitel, G. Leveque, D. Malo, F. Lantier, F. Plisson-Petit, P. Colin, M. Protais, P. Le Roy, J.M. Elsen, D. Milan, I. Lantier, A. Neau, G. Salvat, and A. Vignal. 2003. Effect of two candidate genes on the Salmonella carrier state in fowl. *Poult Sci.* 82:721–726.
18. Berthelot, F., C. Beaumont, F. Mompart, O. Girard-Santosuosso, P. Pardon, and M. Duchet-Suchaux. 1998. Estimated heritability of the resistance to cecal carrier state of *Salmonella enteritidis* in chickens. *Poult Sci.* 77:797–801.
19. Boon, A.C., J. deBeauchamp, A. Hollmann, J. Luke, M. Kotb, S. Rowe, D. Finkelstein, G. Neale, L. Lu, R.W. Williams, and R.J. Webby. 2009. Host genetic variation affects resistance to infection with a highly pathogenic H5N1 influenza A virus in mice. *J Virol.* 83:10417–10426.
20. Brake, D.A., C.H. Fedor, B.W. Werner, T.J. Miller, R.L. Taylor, Jr., and R.A. Clare. 1997. Characterization of immune response to *Eimeria tenella* antigens in a natural immunity model with hosts which differ serologically at the B locus of the major histocompatibility complex. *Infect Immun.* 65:1204–1210.
21. Bumstead, J.M., N. Bumstead, L. Rothwell, and F.M. Tomley. 1995. Comparison of immune responses in inbred lines of chickens to *Eimeria maxima* and *Eimeria tenella*. *Parasitology* 111 (Pt. 2):143–151.
22. Bumstead, N. 1998. Genomic mapping of resistance to Marek's disease. *Avian Pathol.* 27:S78–S81.
23. Bumstead, N., M.B. Huggins, and J.K. Cook. 1989. Genetic differences in susceptibility to a mixture of avian infectious bronchitis virus and *Escherichia coli*. *Br Poult Sci.* 30:39–48.
24. Bumstead, N., R.L. Reece, and J.K. Cook. 1993. Genetic differences in susceptibility of chicken lines to infection with infectious bursal disease virus. *Poult Sci.* 72:403–410.
25. Burgess, S.C. 2004. Proteomics in the chicken: tools for understanding immune responses to avian diseases. *Poult Sci.* 83:552–573.
26. Calenge, F., F. Lecerf, J. Demar, K. Feve, F. Vignoles, F. Pitel, A. Vignal, P. Velge, N. Sellier, and C. Beaumont. 2009. QTL for resistance to Salmonella carrier state confirmed in both experimental and commercial chicken lines. *Anim Genet.* 40:590–597.
27. Calenge, F., A. Legarra, and C. Beaumont. 2011. Genomic selection for carrier-state resistance in chicken commercial lines. *BMC Proc.* 5(Suppl 4):S24.
28. Calenge, F., P. Kaiser, A. Vignal, and C. Beaumont. 2010. Genetic control of resistance to salmonellosis and to Salmonella carrier-state in fowl: a review. *Genet Sel Evol.* 42:11–21.
29. Calenge, F., A. Vignal, J. Demars, K. Fève, P. Menanteau, P. Velge, and C. Beaumont. 2011. New QTL for resistance to Salmonella carrier-state identified on fowl microchromosomes. *Mol Genet Genomics* 285:237–243.
30. Caron, L.A., H. Abplanalp, and R.L. Taylor, Jr. 1997. Resistance, susceptibility, and immunity to *Eimeria tenella* in major histocompatibility (B) complex congenic lines. *Poult Sci.* 76:677–682.
31. Casterlow, S., H. Li, E.R. Gilbert, R.A. Dalloul, A.P. McElroy, D.A. Emmerson, and E.A. Wong. 2011. An antimicrobial peptide is downregulated in the small intestine of *Eimeria maxima*-infected chickens. *Poult Sci.* 90:1212–1219.
32. Cavero, D., M. Schmutz, H.C. Philipp, and R. Preisinger. 2009. Breeding to reduce susceptibility to *Escherichia coli* in layers. *Poult Sci.* 88:2063–2068.
33. Chai, N., and P. Bates. 2006. Na+/H+exchanger type 1 is a receptor for pathogenic subgroup J avian leukosis virus. *Proc Natl Acad Sci USA*. 103:5531–5536.
34. Cheng, H.H. 2010. Viral diseases in chicken. In: *Breeding for Disease Resistance in Farm Animals*, 3rd ed., S.C. Bishop, R.F.E. Axford, F.W. Nicholas, and J.B. Owen, eds. CABI, Cambridge, MA, 70–87.
35. Cheeseman, J.H., M.G. Kaiser, C. Ciraci, P. Kaiser, and S.J. Lamont. 2007. Breed effect on early cytokine mRNA expression in spleen and cecum of chickens with and without *Salmonella enteritidis* infection. *Dev Comp Immunol.* 31:52–60.
36. Chiang, H.-I., C.L. Swaggerty, M.H. Kogut, S.E. Dowd, X. Li, I.Y. Pevzner, and H. Zhou. 2008. Gene expression profiling in chicken heterophils with *Salmonella enteritidis* stimulation using a chicken 44K Agilent microarray. *BMC Genomics* 9:526–536.
37. Clare, R.A., R.G. Strout, R.L. Taylor, Jr., W.M. Collins, and W.E. Briles. 1985. Major histocompatibility (B) complex effects on acquired immunity to cecal coccidiosis. *Immunogenetics* 22:593–599.
38. Clare, R.A., R.L. Taylor, Jr., W.E. Briles, and R.G. Strout. 1989. Characterization of resistance and immunity to *Eimeria tenella* among major histocompatibility complex B–F/B–G recombinant hosts. *Poult Sci.* 68:639–645.

39. Cotter, P.F., R.L. Taylor, Jr. and H. Abplanalp. 1998. B-complex associated immunity to *Salmonella enteritidis* challenge in congenic chickens. *Poult Sci.* 77:1846–1851.
40. Darvasi, A., and M. Soller. 1995. Advanced intercross lines, an experimental population for fine genetic mapping. *Genetics* 141:1199–1207.
41. Derache, C., E. Esnault, C. Bonsergent, Y. Le Vern, P. Quéré, and A.-C. Lalmanach. 2009. Differential modulation of β-defensin gene expression by *Salmonella Enteritidis* in intestinal epithelial cells from resistant and susceptible chicken inbred lines. *Devel Comp Immunol.* 33:959–966.
42. Dodgson, J.B. 2007. The chicken genome: some good news and some bad news. *Poult Sci.* 86, 1453–9.
43. Dodgson, J.B., M.E. Delany, and H.H. Cheng. 2011. Poultry genome sequences: progress and outstanding challenges. *Cytogenet Genome Res.* 134:19–26.
44. Domon, B., and R. Aebersold. 2006. Mass spectrometry and protein analysis. *Science* 312:212–217.
45. Elleder, D., D.C. Melder, K. Trejbalova, J. Svoboda, and M.J. Federspiel. 2004. Two different molecular defects in the Tva receptor gene explain the resistance of two tvar lines of chickens to infection by subgroup A avian sarcoma and leukosis viruses. *J Virol.* 78:13489–13500.
46. Elleder, D., J. Plachy, J. Hejnar, J. Geryk, and J. Svoboda. 2004. Close linkage of genes encoding receptors for subgroups A and C of avian sarcoma/leucosis virus on chicken chromosome 28. *Anim Genet.* 35:176–181.
47. Elleder, D., V. Stepanets, D.C. Melder, F. Senigl, J. Geryk, P. Pajer, J. Plachy, J. Hejnar, J. Svoboda, and M.J. Federspiel. 2005. The receptor for the subgroup C avian sarcoma and leukosis viruses, Tvc, is related to mammalian butyrophilins, members of the immunoglobulin superfamily. *J Virol.* 79:10408–10419.
48. Ewald, S.J., D.R. Kapczynski, E.J. Livant, D.L. Suarez, J. Ralph, S. McLeod, and C. Miller. 2011. Association of Mx1 Asn631 variant alleles with reductions in morbidity, early mortality, viral shedding, and cytokine responses in chickens infected with a highly pathogenic avian influenza virus. *Immunogen.* 63:363–75.
49. Fields, S. 2005. High-throughput two-hybrid analysis. The promise and the peril. *FEBS J*. 272:5391–5399.
50. Fields, S., and O. Song. 1989. A novel genetic system to detect protein-protein interactions. *Nature* 340:245–246.
51. Fife, M., J. Howell, N. Salmon, P. Hocking, P. Vandiemen, M. Jones, M. Stevens, and P. Kaiser. 2011. Genome-wide SNP analysis identifies major QTL for Salmonella colonization in the chicken. *Anim Genet.* 42:134–140.
52. Gast, R.K., and P.S. Holt. 1998. Persistence of *Salmonella enteritidis* from one day of age until maturity in experimentally infected layer chickens. *Poult Sci.* 77:1759–1762.
53. Gavora, J.S. 1990. Disease Genetics. In: *Poultry Breeding and Genetics*, R.D. Crawford, ed., Elsevier Science Publishers, B.V., New York, 805–846.
54. Ghebremichael, S.B., J.R. Hasenstein, and S.J. Lamont. 2008. Association of interleukin-10 cluster genes and Salmonella response in the chicken. *Poult Sci.* 87:22–26.
55. Girard-Santosuosso, O., N. Bumstead, I. Lantier, J. Protais, P. Colin, J.F. Guillot, C. Beaumont, D. Malo, and F. Lantier. 1997. Partial conservation of the mammalian NRAMP1 syntenic group on chicken chromosome 7. *Mamm Genome* 8:614–616.
56. Girard-Santosuosso, O., F. Lantier, I. Lantier, N. Bumstead, J.M. Elsen, and C. Beaumont. 2002. Heritability of susceptibility to *Salmonella enteritidis* infection in fowls and test of the role of the chromosome carrying the NRAMP1 gene. *Genet Sel Evol.* 34:211–219.
57. Groenen, M.A.M., H.-J. Megens, Y. Zare, W.C. Warren, L.W. Hillier, R.P.M.A. Crooijmans, A. Vereijken, R. Okimoto, W.M. Muir, and H.H. Cheng. 2011. The development and characterization of a 60K SNP chip for chicken. *BMC Genomics* 12:274.
58. Hala, K. 1987. Inbred lines of avian species. In: *Avian Immunology: Basis and Practice*, Vol. II, A. Toivanen and P. Toivanen, eds. CRC Press, Bacon Raton, 85–99.
59. Hasenstein, J.R., and Lamont, S.J. 2007. Chicken *Gallinacin* gene cluster associated with *Salmonella* response in advanced intercross line. *Avian Dis.* 51:561–567.
60. Hasenstein, J.R., A.T. Hassen, J.C.M. Dekkers, and S.J. Lamont. 2008. High resolution, advanced intercross mapping of host resistance to Salmonella colonization. *Dev Biol.* 132:213–218.
61. Hassan, M.K., M. Afify, and M.M. Aly. 2002. Susceptibility of vaccinated and unvaccinated Egyptian chickens to very virulent infectious bursal disease virus. *Avian Pathol.* 31:149–156.
62. Heifetz, E.M., J.E. Fulton, N.P. O'Sullivan, J.A. Arthur, H. Cheng, J. Wang, M. Soller, and J.C.M. Dekkers. 2009. Mapping QTL affecting resistance to Marek's disease in an F6 advanced intercross population of commercial layer chickens. *BMC Genomics* 10:20.
63. Heller, E.D., G. Leitner, A. Friedman, Z. Uni, M. Gutman, and A. Cahaner. 1992. Immunological parameters in meat-type chicken lines divergently selected by antibody response to *Escherichia coli* vaccination. *Vet Immunol Immunopathol.* 34:159–172.
64. Higgs, R., P. Cormican, S. Cahalane, B. Allan, A.T. Lloyd, K. Meade, T. James, D.J. Lynn, L.A. Babiuk, and C. O'Farrelly. 2006. Induction of a novel chicken toll-like receptor following *Salmonella enterica* Serovar Typhimurium infection. *Infect Immun.* 74:1692–1698.
65. Hong, Y.H., E.-S. Kim, H.S. Lillehoj, E.P. Lillehoj, and K.-D. Song. 2009. Association of resistance to avian coccidiosis with single nucleotide polymorphisms in the zyxin gene. *Poult Sci.* 88:511–518.
66. Hu, J., N. Bumstead, P. Barrow, G. Sebastiani, L. Olien, K. Morgan, and D. Malo. 1997. Resistance to salmonellosis in the chicken is linked to NRAMP1 and TNC. *Genome Res.* 7:693–704.
67. Hudson, J.C., E.J. Hoerr, S.H. Parker, and S.J. Ewald. 2002. Quantitative measures of disease in broiler breeder chicks of different major histocompatibility complex genotypes after challenge with infectious bursal disease virus. *Avian Dis.* 46:581–592.
68. Hunt, H.D., and J.E. Fulton. 1998. Analysis of polymorphisms in the major expressed class I locus (B-FIV) of the chicken. *Immunogen.* 47:456–476.
69. Hunt, H.D., S. Jadhao, and D.E. Swayne. 2010. Major histocompatibility complex and background genes in chickens influence susceptibility to high pathogenicity avian influenza virus. *Avian Dis.* 54:572–575.
70. Johnson, L.W., and S.A. Edgar. 1986. *Ea-B* and *Ea-C* cellular antigen genes in Leghorn lines resistant and susceptible to acute cecal coccidiosis. *Poult Sci.* 65:241–252.
71. Juul-Madsen, H.R., O.L. Nielsen, T. Krogh-Maibom, C.M. Rontved, T.S. Dalgaard, N. Bumstead, and P.H. Jorgensen. 2002. Major histocompatibility complex-linked immune response of young chickens vaccinated with an attenuated live infectious bursal disease virus vaccine followed by an infection. *Poult Sci.* 81:649–656.

72. Juul-Madsen, H.R., T.S. Dalgaard, C.M. Rontved, K.H. Jensen, and N. Bumstead. 2006. Immune response to a killed infectious bursal disease virus vaccine in inbred chicken lines with different major histocompatibility complex haplotypes. *Poult Sci.* 85:986–998.
73. Kaiser, M.G., J.H. Cheeseman, P. Kaiser, and S.J. Lamont. 2006. Cytokine expression in chicken peripheral blood mononuclear cells after in vitro exposure to *Salmonella enterica* serovar Enteritidis. *Poult Sci.* 85:1907–1911.
74. Kaiser, M.G., N. Lakshmanan, T. Wing, and S.J. Lamont. 2002. Salmonella enterica serovar enteritidis burden in broiler breeder chicks genetically associated with vaccine antibody response. *Avian Dis.* 46:25–31.
75. Kaiser, M.G., and S.J. Lamont. 2002. Microsatellites linked to *Salmonella enterica* Serovar Enteritidis burden in spleen and cecal content of young F1 broiler-cross chicks. *Poult Sci.* 81:657–663.
76. Kaiser, M.G., T. Wing, A. Cahaner, and S.J. Lamont. 1997. Aviagen, 12th International Symposium on Current Problems in Avian Genetics, Prague, Czech Republic.
77. Keane, T.M., L. Goodstadt, P. Danecek, M.A. White, K. Wong, B. Yalcin, A. Heger, A. Agam, G. Slater, M. Goodson, N.A. Furlotte, E. Eskin, C. Nellåker, H. Whitley, J. Cleak, D. Janowitz, P. Hernandez-Pliego, A. Edwards, T.G. Belgard, P.L. Oliver, R.E. McIntyre, A. Bhomra, J. Nicod, X. Gan, W. Yuan, L. van der Weyden, C.A. Steward, S. Bala, J. Stalker, R. Mott, R. Durbin, I.J. Jackson, A. Czechanski, J.A. Guerra-Assunção, L.R. Donahue, L.G. Reinholdt, B.A. Payseur, C.P. Ponting, E. Birney, J. Flint, and D.J. Adams, 2011. Mouse genomic variation and its effect on phenotypes and gene regulation. *Nature* 477:289–294.
78. Kim, E.S., Y.H. Hong, W. Min, H.S. Lillehoj. 2006. Fine-mapping of coccidia-resistant quantitative trait loci in chickens. *Poult Sci.* 85:2028–2030.
79. Kim, C.-H., H.S. Lillehoj, Y.-H. Hong, C.L. Keeler Jr., and E.P. Lillehoj. 2011. Analysis of global transcriptional responses of chicken following primary and secondary *Eimeria acervulina* infections. *BMC Proc.* 5(Suppl 4):S12–15.
80. Kim, D.K., H.S. Lillehoj, Y.H. Hong, D.W. Park, S.J. Lamont, J.Y. Han, and E.P. Lillehoj. 2008. Immune-related gene expression in two B-Complex disparate genetically inbred Fayoumi chicken lines following *Eimeria maxima* infection. *Poult Sci.* 87:433–443.
81. Klucking, S., H.B. Adkins, and J.A. Young. 2002. Resistance to infection by subgroups B, D, and E avian sarcoma and leukosis viruses is explained by a premature stop codon within a resistance allele of the tvb receptor gene. *J Virol.* 76:7918–7921.
82. Ko, J.H., A. Takada, T. Mitsuhashi, T. Agui, and T. Watanabe. 2004. Native antiviral specificity of chicken Mx proteins depends on amino acid variation at position 631. *Anim Genet.* 35: 119–122.
83. Kramer, J., M. Malek, and S.J. Lamont. 2003. Association of twelve candidate gene polymorphisms and response to challenge with *Salmonella enteritidis* in poultry. *Anim Genet.* 34:339–348.
84. Krug, R. M., M. Shaw, B. Broni, G. Shapiro, and O. Haller. 1985. Inhibition of influenza viral mRNA synthesis in cells expressing the interferon-induced Mx gene product. *J Virol.* 56:201–206.
85. Lamont, S.J. 2010. Salmonella in chickens. In: *Breeding for Disease Resistance in Farm Animals*, 3rd ed., S.C. Bishop, R.F.E. Axford, F.W. Nicholas, and J.B. Owen, eds. CABI, Cambridge, MA, 70–87.
86. Lamont, S.J., M.-H. Pinard-van der Laan, A. Cahaner, J.J. van der Poel, and H.K. Parmentier. 2003. Selection for disease resistance: direct selection on the immune response. In: *Poultry Genetics, Breeding and Biotechnology*, W.M. Muir and S.E. Aggrey, eds. CAB International, Oxfordshire, UK, pp. 399–418.
87. Lavric, M., M.N. Maughan, T.W. Bliss, J.E. Dohms, D. Bencina, C.L. Keeler Jr., and M. Narat. 2008. Gene expression modulation in chicken macrophages exposed to *Mycoplasma synoviae* or *Escherichia coli*. *Vet Micro.* 126:111–121.
88. Legarra, A., F. Calenge, P. Mariani, P. Velge, and C. Beaumont. 2011. Use of a reduced set of single nucleotide polymorphisms for genetic evaluation of resistance to Salmonella carrier state in laying hens. *Poult Sci.* 90:731–736.
89. Leveque, G., V. Forgetta, S. Morroll, A.L. Smith, N. Bumstead, P. Barrow, J.C. Loredo-Osti, K. Morgan, and D. Malo. 2003. Allelic variation in TLR4 is linked to susceptibility to *Salmonella enterica* serovar Typhimurium infection in chickens. *Infect Immun.* 71:1116–1124.
90. Lillehoj, H.S., M.C. Jenkins, and L.D. Bacon. 1990. Effects of major histocompatibility genes and antigen delivery on induction of protective mucosal immunity to *E. acervulina* following immunization with a recombinant merozoite antigen. *Immunology.* 71:127–132.
91. Lillehoj, H.S., M.C. Jenkins, L.D. Bacon, R.H. Fetterer, and W.E. Briles. 1988. *Eimeria acervulina*: evaluation of the cellular and antibody responses to the recombinant coccidial antigens in B-congenic chickens. *Exp Parasitol.* 67:148–158.
92. Lillehoj, H.S., C.H. Kim, C.L. Keeler Jr., and S. Zhang. 2007. Immunogenomic approaches to study host immunity to enteric pathogens. *Poult Sci.* 86:1491–1500.
93. Lillehoj, H.S., M.D. Ruff, L.D. Bacon, S.J. Lamont, and T.K. Jeffers. 1989. Genetic control of immunity to *Eimeria tenella*. Interaction of MHC genes and non-MHC linked genes influences levels of disease susceptibility in chickens. *Vet Immunol Immunopathol*. 20:135–148.
94. Liu, H.C., H.H. Cheng, V. Tirunagaru, L. Sofer, and J. Burnside. 2001. A strategy to identify positional candidate genes conferring Marek's disease resistance by integrating DNA microarrays and genetic mapping. *Anim Genet.* 32:351–359.
95. Liu, H.C., H.J. Kung, J.E. Fulton, R.W. Morgan, and H.H. Cheng. 2001. Growth hormone interacts with the Marek's disease virus SORF2 protein and is associated with disease resistance in chicken. *Proc Natl Acad Sci USA*. 98:9203–9208.
96. Liu, H.C., M. Niikura, J.E. Fulton, and H.H. Cheng. 2003. Identification of chicken lymphocyte antigen 6 complex, locus E (LY6E, alias SCA2) as a putative Marek's disease resistance gene via a virus-host protein interaction screen. *Cytogenet Genome Res.* 102:304–308.
97. Liu, W., M.G. Kaiser, and S.J. Lamont. 2003. Natural resistance-associated macrophage protein 1 gene polymorphisms and response to vaccine against or challenge with *Salmonella enteritidis* in young chicks. *Poult Sci.* 82:259–266
98. Liu, W., and S.J. Lamont. 2003. Candidate gene approach: potentional association of caspase-1, inhibitor of apoptosis protein-1, and prosaposin gene polymorphisms with response to *Salmonella enteritidis* challenge or vaccination in young chicks. *Anim Biotechnol.* 14:61–76.
99. Liu, W., M.M. Miller, and S.J. Lamont. 2002. Association of MHC class I and class II gene polymorphisms with vaccine or challenge response to *Salmonella enteritidis* in young chicks. *Immunogenetics* 54:582–590.
100. Longenecker, B.M., and T.R. Mosmann. 1981. Structure and properties of the major histocompatibility complex of the

chicken. Speculations on the advantages and evolution of polymorphism. *Immunogenetics* 13:1–23.
101. Lyall, J., R.M. Irvine, A. Sherman, T.J. McKinley, A. Núñez, A. Purdie, L. Outtrim, I.H. Brown, G. Rolleston-Smith, H. Sang, and L. Tiley. 2011. Suppression of avian influenza transmission in genetically modified chickens. *Science* 331:223–226.
102. MacEachern, S., W.M. Muir, and H.H. Cheng. 2011. Genome-wide identification of allele-specific expression (ASE) in response to Marek's disease virus infection using next generation sequencing. *BMC Proc.* 5 (Suppl. 4):S14.
103. Malek, M., J.R. Hasenstein, and S.J. Lamont. 2004. Analysis of chicken TLR4, CD28, MIF, MD-2, and LITAF genes in a *Salmonella enteritidis* resource population. *Poult Sci.* 83:544–549.
104. Malek, M., and S.J. Lamont. 2003. Association of INOS, TRAIL, TGF-beta2, TGF-beta3, and IgL genes with response to *Salmonella enteritidis* in poultry. *Genet Sel Evol.* 35 Suppl 1:S99–111.
105. Mariani, P., P.A. Barrow, H.H. Cheng, M.M. Groenen, R. Negrini, and N. Bumstead. 2001. Localization to chicken chromosome 5 of a novel locus determining salmonellosis resistance. *Immunogenetics* 53:786–791.
106. Martin, A., W.B. Gross, E.A. Dunnington, R.W. Briles, W.E. Briles, P.B. Siegel. 1986. Resistance to natural and controlled exposures to *Eimeria tenella*: genetic variation and alloantigen systems. *Poult Sci.* 65:1847–1852.
107. Medarova, Z., W.E. Briles, and R.L. Taylor, Jr. 2003. Resistance, susceptibility, and immunity to cecal coccidiosis: effects of B complex and alloantigen system L. *Poult Sci.* 82:1113–1117.
108. McElroy, J.P., J.C.M. Dekkers, J.E. Fulton, N.P. O'Sullivan, M. Soller, E. Lipkin, W. Zhang, K.J. Koehler, S.J. Lamont, and H.H. Cheng. 2005. Microsatellite markers associated with resistance to Marek's disease in commercial layer chickens. *Poult Sci.* 84:1678–1688.
109. Miller, M.M., R.M. Goto, R.L. Taylor, Jr., R. Zoorob, C. Auffray, R.W. Briles, W.E. Briles, and S.E. Bloom. 1996. Assignment of Rfp-Y to the chicken major histocompatibility complex/NOR microchromosome and evidence for high-frequency recombination associated with the nucleolar organizer region. *Proc Natl Acad Sci USA*. 93:3958–3962.
110. Muir, W.M., G.K.-S. Wong, Y. Zhang, J. Wang, M.A.M. Groenen, R.P.M.A. Crooijmans, H.-J. Megens, H.M. Zhang, J.C. McKay, S. McLeod, R. Okimoto, J.E. Fulton, P. Settar, N.P. O'Sullivan, A. Vereijken, A. Rattink, G.A.A. Albers, C. Taylor Lawley, M.E. Delany, and H.H. Cheng. 2008. Review of the initial validation and characterization of a 3K chicken SNP array. *WPSJ.* 64:219–25.
111. Nerren, J.R., C.L. Swaggerty, K.M. MacKinnon, K.J. Genovese, H. He, I. Pevzner, and M.H. Kogut. 2009. Differential mRNA expression of the avian-specific toll-like receptor 15 between heterophils from Salmonella-susceptible and -resistant chickens. *Immunogen.* 61:71–77.
112. Niikura, M., H.C. Liu, J.B. Dodgson, and H.H. Cheng. 2004. A comprehensive screen for chicken proteins that interact with proteins unique to virulent strains of Marek's disease virus. *Poult Sci.* 83:1117–1123.
113. O'Neill, A.M., E.J. Livant, and S.J. Ewald. 2010. Interferon a-induced inhibition of infectious bursal disease virus in chicken embryo fibroblast cultures differentiating Mx genotype. *Avian Dis.* 54:802–806.
114. Pinard-van der Laan, M.-H., B. Bed'hom, J.-L. Coville, F. Pitel, K. Feve, S. Leroux, H. Legros, A. Thomas, D. Gourichon, J.-M. Repérant, and P. Rault. 2009. Microsatellite mapping of QTLs affecting resistance to coccidiosis (*Eimeria tenella*) in a Fayoumi × White Leghorn cross. *BMC Genomics* 10:31–43.
115. Pinard-van der Laan, M.H., J.L. Monvoisin, P. Pery, N. Hamet, and M. Thomas. 1998. Comparison of outbred lines of chickens for resistance to experimental infection with coccidiosis (*Eimeria tenella*). *Poult Sci.* 77:185–191.
116. Redmond, S.B., P. Chuammitri, C.B. Andreasen, D. Palic, S.J. Lamont. 2011. Genetic control of chicken heterophil function in advanced intercross lines: associations with novel and with known Salmonella resistance loci and a likely mechanism for cell death in extracellular trap production. *Immunogen.* 63:449–458.
117. Redmond, S.B., P. Chuammitri, D. Palic, C.B. Andreasen, and S.J. Lamont. 2009. Chicken heterophils from commercially selected and non-selected genetic lines express cytokines differently after in vitro exposure to *Salmonella enteritidis*. *Vet Immunol Immunopath.* 132:129–134.
118. Ruby, T., C. Whittaker, D.R. Withers, M.K. Chelbi-Alix, V. Morin, A. Oudin, J.R. Young, and R. Zoorob. 2006. Transcriptional profiling reveals a possible role for the timing of the inflammatory response in determining susceptibility to a viral infection. *J Virol.* 80:9207–9216.
119. Ruff, M.D., and L.D. Bacon. 1989. Eimeria acervulina and Eimeria tenella in 15.B-congenic White Leghorns. *Poult Sci*. 68:380–385.
120. Sackton, T.B., B.P. Lazzaro, and A.G. Clark. 2010. Genotype and gene expression association with immune function in *Drosophila*. *PLoS Genetics* 6:e1000797.
121. Sadeyen, J-R., J. Trotereau, J. Protais, C. Beaumont, N. Sellier, G. Salvat, P. Velge, and A.-C. Lalmanach. 2006. Salmonella carrier-state in hens: study of host resistance by a gene expression approach. *Microbes Infect.* 8:1308–1314.
122. Sandford, E.E., M. Orr, E. Balfanz, N. Bowerman, X. Li, H. Zhou, T.J. Johnson, S. Kariyawasam, P. Liu, L.K. Nolan, and S.J. Lamont. 2011. Spleen transcriptome response to infection with avian pathogenic *Escherichia coli* in broiler chickens. *BMC Genomics* 12:469–481.
123. Schena, M., D. Shalon, R.W. Davis, and P.O. Brown. 1995. Quantitative monitoring of gene expression patterns with a complementary DNA microarray. *Science.* 270:467–470.
124. Siepel, A., G. Bejerano, J.S. Pedersen, A.S. Hinrichs, M. Hou, K. Rosenbloom, H. Clawson, J. Spieth, L.W. Hillier, S. Richards, G.M. Weinstock, R.K. Wilson, R.A. Gibbs, W.J. Kent, W. Miller, and D. Haussler. 2005. Evolutionarily conserved elements in vertebrate, insect, worm, and yeast genomes. *Genome Res.* 15:1034–1050.
125. Sironi, L., J.L. Williams, A. Stella, G. Minozzi, A. Moreno, P. Ramelli, J. Han, S. Weigend, J. Wan, G. Lombardi, P. Cordioli, and P. Mariani. 2011. Genomic study of the response of chicken to highly pathogenic avian influenza virus. *BMC Proc*. 5 (Supp. 4):S25.
126. Smith, E.J., and H.H. Cheng. 1998. Mapping chicken genes using preferential amplification of specific alleles. *Microb Comp Genomics* 3:13–20.
127. Smith, J., J.R. Sadeyen, I.R. Paton, P.M. Hocking, N. Salmon, M. Fife, V. Nair, D.W. Burt, and P. Kaiser. 2011. Systems analysis of immune responses in Marek's disease virus-infected chickens identifies a gene involved in susceptibility and highlights a possible novel pathogenicity mechanism. *J Virol.* 85:11146–11158.

128. Suarez, D.L. 2000. Evolution of avian influenza viruses. *Vet Micro.* 74:15–27.
129. Swaggerty, C.L., I.Y. Pevzner, H. He, K.J. Genovese, D.J. Nisbet, P. Kaiser, and M.H. Kogut. 2009. Selection of broilers with improved innate immune responsiveness to reduce on-farm infection by foodborne pathogens. *Food Path Dis.* 6:777–793.
130. Swaggerty, C.L., I.Y. Pevzner, P. Kaiser, and M.H. Kogut. 2008. Profiling pro-inflammatory cytokine and chemokine mRNA expression levels as a novel method for selection of increased innate immune responsiveness. *Vet Immunol Immunopath.* 126:35–42.
131. Tilquin, P., P.A. Barrow, J. Marly, F. Pitel, F. Plisson-Petit, P. Velge, A. Vignal, P.V. Baret, N. Bumstead, and C. Beaumont. 2005. A genome scan for quantitative trait loci affecting the Salmonella carrier-state in the chicken. *Genet Sel Evol.* 37:539–561.
132. Uni, Z., D. Sklan, N. Haklay, N. Yonash, and D. Heller. 1995. Response of three class-IV major histocompatibility complex haplotypes to *Eimeria acervulina* in meat-type chickens. *Br Poult Sci.* 36:555–561.
133. Vallejo, R.L., L.D. Bacon, H.C. Liu, R.L. Witter, M.A. Groenen, J. Hillel, and H.H. Cheng. 1998. Genetic mapping of quantitative trait loci affecting susceptibility to Marek's disease virus induced tumors in F2 intercross chickens. *Genetics* 148:349–360.
134. Vallejo, R.L., G.T. Pharr, H.C. Liu, H.H. Cheng, R.L. Witter, and L.D. Bacon. 1997. Non-association between Rfp-Y major histocompatibility complex-like genes and susceptibility to Marek's disease virus-induced tumours in 6(3) 3 7(2) F2 intercross chickens. *Anim Genet.* 28:331–337.
135. van Hemert, S., A.J.W. Hoekman, M.A. Smits, and J.M.J. Rebel. 2007. Immunological and gene expression responses to a Salmonella infection in the chicken intestine. *Vet Res.* 38:51–63.
136. Wakenell, P.S., M.M. Miller, R.M. Goto, W.J. Gauderman, and W.E. Briles. 1996. Association between the Rfp-Y haplotype and the incidence of Marek's disease in chickens. *Immunogenetics* 44:242–245.
137. Wigley, P., S.D. Hulme, L. Rothwell, N. Bumstead, P. Kaiser, and P.A. Barrow. 2006. Macrophages isolated from chickens genetically resistant or susceptible to system salmonellosis show magnitudinal and temporal differential expression of cytokines and chemokines following *Salmonella enterica* challenge. *Infect Immun.* 74:11425–1430.
138. Yonash, N., L.D. Bacon, R.L. Witter, and H.H. Cheng. 1999. High resolution mapping and identification of new quantitative trait loci (QTL) affecting susceptibility to Marek's disease. *Anim Genet.* 30:126–135.
139. Yonash, N., H.H. Cheng, J. Hillel, D.E. Heller, and A. Cahaner. 2001. DNA microsatellites linked to quantitative trait loci affecting antibody response and survival rate in meat-type chickens. *Poult Sci.* 80:22–28.
140. Yonash, N., M.G. Kaiser, E.D. Heller, A. Cahaner, and S.J. Lamont. 1999. Major histocompatibility complex (MHC) related cDNA probes associated with antibody response in meat-type chickens. *Anim Genet.* 30:92–101.
141. Yunis, R., E.D. Heller, J. Hillel, and A. Cahaner. 2002. Microsatellite markers associated with quantitative trait loci controlling antibody response to Escherichia coli and *Salmonella enteritidis* in young broilers. *Anim Genet.* 33:407–414.
142. Zhang, H.M., L.D. Bacon, H.H. Cheng, and H.D. Hunt. 2005. Development and validation of a PCR-RFLP assay to evaluate TVB haplotypes coding receptors for subgroup B and subgroup E avian leukosis viruses in White Leghorns. *Avian Pathol.* 34:324–331.
143. Zhou, H., and S.J. Lamont. 2007. Global gene expression profile after *Salmonella enterica* serovar Enteritidis challenge in two F8 advanced intercross chicken lines. *Cytogenet Genome Res.* 117:131–138.
144. Zhu, J.J., H.S. Lillehoj, P.C. Allen, C.P. Van Tassell, T.S. Sonstegard, H.H. Cheng, D. Pollock, M. Sadjadi, W. Min, and M.G. Emara. 2003. Mapping quantitative trait loci associated with resistance to coccidiosis and growth. *Poult Sci.* 82:9–16.
145. Zimmermann, P., B. Mänz, O. Haller, M. Schwemmle, and G. Kochs. 2011. The viral nucleoprotein determines Mx sensitivity of influenza A viruses. *J Virol.* 85:8133–8140.

II Viral Diseases

Chapter 3	Newcastle Disease, Other Avian Paramyxoviruses, and Avian Metapneumovirus Infections	89
Chapter 4	Infectious Bronchitis	139
Chapter 5	Infectious Laryngotracheitis	161
Chapter 6	Influenza	181
Chapter 7	Infectious Bursal Disease	219
Chapter 8	Chicken Infectious Anemia Virus and Other Circovirus Infections	247
Chapter 9	Adenovirus Infections	289
Chapter 10	Pox	333
Chapter 11	Reovirus Infections	351
Chapter 12	Viral Enteric Infections	375
Chapter 13	Viral Infections of Waterfowl	417
Chapter 14	Other Viral Infections	465
Chapter 15	Neoplastic Diseases	513

Chapter 3

Newcastle Disease, Other Avian Paramyxoviruses, and Avian Metapneumovirus Infections

Introduction

David L. Suarez

The virus families Paramyxoviridae, Filoviridae, Bornaviridae, and Rhabdoviridae form the virus order Mononegavirales that includes negative sense, single-stranded RNA viruses with helical capsid symmetry. The family Paramyxoviridae includes many important veterinary and human pathogens and is divided into 2 subfamilies, Paramyxovirinae and Pneumovirinae (5).

The subfamily Paramyxovirinae currently has 8 genera that include important human and veterinary pathogens such as Rubulavirus, which includes human mumps virus; Respiroviruses, containing mammalian parainfluenza 1 and 3; Morbillivirus, which includes canine distemper, rinderpest, and measles; Henipavirus, containing Nipah and Hendra virus; and the Avulavirus genus that contains Newcastle disease virus (NDV) and other avian paramyxoviruses (APMV) (5).

Eleven serotypes of avian paramyxoviruses have been recognized: APMV-1 to APMV-11, with APMV-10 and APMV-11 only being recently described (Table 3.1) (2, 4, 6). Of these, APMV-1 remains the most important pathogen for poultry with the virulent forms of the serotype defined as Newcastle disease virus (NDV). NDV remains a serious impediment for poultry production in Asia and Africa, and remains a control problem throughout the world. Several of the other APMV serotypes including APMV-2, APMV-3, APMV-6, and APMV-7 may also cause disease in poultry. All of the APMV serotypes are known or likely to have wild bird reservoirs that can spill over to poultry, but the wild bird ecology of these serotypes is largely unknown. The virulent Newcastle disease viruses seem to be the major exception of a wild bird reservoir, with the virulent viruses being endemic in poultry and domestic and feral pigeons. The single well defined example of virulent NDV in wild birds is in cormorants in North America, which is associated with periodic die-offs in this species (3).

The subfamily Pneumovirinae has 2 genera: Pneumovirus, consisting of mammalian pneumoviruses, and Metapneumovirus, consisting of both human and avian metapneumoviruses (ICTV). The avian metapneumovirus infections continue to emerge as a disease threat with 4 defined serotypes, A–D, being recognized and producing clinical disease in both turkeys and chickens. The serotype C viruses are genetically closely related to the recently recognized human metapneumovirus (8). The avian metapneumoviruses also have a wild bird reservoir, but it is unclear how or if wild birds play a role in outbreaks in poultry (7).

Newcastle Disease

Patti J. Miller and Guus Koch

Introduction

The order Mononegavirales is divided into 4 families: Bornaviridae (1 genus), Filoviridae (2 genera), Rhabdoviridae (6 genera), and Paramyxoviridae (2 subfamilies). The 2 subfamilies of Paramyxoviridae, Paramyxovirinae, and Pneumovirinae are further divided into 5 genera and 2 genera, respectively. All viruses within the order Mononegavirales are single-stranded, nonsegmented, negative-sense, enveloped RNA viruses (141). The Paramyxoviridae subfamilies include viruses that are the etiological agents of important human diseases (measles, mumps, human respiratory syncytial virus), animal diseases (distemper, rinderpest, Newcastle disease), and zoonotics deadly for both humans and animals (Hendra and Nipah viruses) (141).

Diseases of Poultry, Thirteenth Edition. David E. Swayne.
© 2013 John Wiley & Sons, Inc. Published 2013 by John Wiley & Sons, Inc.

Table 3.1. Prototype avian paramyxoviruses and their host range (1, 2, 4, 6).

Prototype virus strain	Usual natural hosts	Other hosts	Disease produced in poultry
APMV-1 Newcastle disease virus	Numerous	See text	Varies from extremely pathogenic to inapparent, depending on strain and host infected
APMV-2/chicken/California/Yucaipa/56	Turkeys, passerines	Chickens, psittacines, rails	Mild respiratory disease or egg production problems, severe if exacerbation occurs
APMV-3*/turkey/Wisconsin/68	Turkeys	None	Mild respiratory disease but severe egg production problems worsened by exacerbating organisms or environment
APMV3*/parakeet/Netherlands/449/75	Psittacines, passerines	None known	None known
APMV-4/duck/Hong Kong/D3/75	Ducks	Geese	None known
APMV-5/budgerigar/Japan/Kunitachi/74	Budgerigars	None known	No infections of poultry reported
APMV-6/duck/Hong Kong/199/77	Ducks	Geese, rails, turkeys	Mild respiratory disease and slightly elevated mortality in turkeys; none in ducks or geese
APMV-7/dove/Tennessee/4/75	Pigeons, doves	Turkeys, ostriches	Mild respiratory disease in turkeys
APMV-8/goose/Delaware/1053/76	Ducks and geese	None known	No infection of poultry reported
AMPV-9/domestic duck/New York/22/78	Ducks	None known	Inapparent infection of commercial ducks
APMV-10/Rock Hopper/Falkland Islands/324/2007	Rock Hopper Penguin (*Eudyptes chrysocome*)	Magellanic penguins (*Spheniscus magellanicus*)	No infection of poultry reported
APMV-11/Common Snipe/France/100212/2010	Common snipe (*Gallinago gallinago*)	None known	No infection of poultry reported

* Serological tests may distinguish between turkey and psittacine isolates.

Infections with viruses from these subfamilies also cause disease in avian species. The focus of this chapter is viruses of avian paramyxovirus serotype-1 (APMV-1). All isolates of APMV-1 are of one serotype and are referred to as Newcastle disease viruses (NDV). Newcastle disease (ND) is caused only by infections with virulent isolates of APMV-1 (virulent NDV or vNDV). Virulent NDV are characterized by an intracerebral pathogenicity index (ICPI) in day-old chickens of 0.7 or greater or demonstration of multiple basic amino acids in the virus (either directly or by deduction) at the C-terminus of the F2 protein and a phenylalanine at residue 117 (222). While infections with NDV of low virulence (loNDV) do not cause ND, they can still lead to clinical respiratory disease when other infections or suboptimal environmental conditions are present. Sometimes APMV-1 is used when discussing loNDV, and NDV is used when referring to the virulent forms of NDV (10). However, to avoid confusion in this chapter vNDV will be used to denote strains that cause ND.

Of the 11 defined APMV serotypes, serotype APMV-1 is the most important for poultry (14, 46, 205). When comparing the number of countries reporting outbreaks of 71 important animal diseases from 2006–2009, ND was the second most prevalent disease reported in 56 of the 167 member countries of the World Organization for Animal Health (OIE), and this number is likely an under-reporting of the countries with the disease (38). Because clinical signs of infected birds vary depending on the host species, the virulence and dose of the infecting virus, and the immune status and age of the host, it can be especially difficult to recognize the disease. Clinical signs may range from 100% mortality among nonvaccinated chickens to a drop in egg production among seemingly healthy, well-vaccinated layers (63).

Pathotypes of disease, defined by clinical signs in chickens after experimental inoculation, were created to describe the virulence of the NDV strains and are listed in decreasing order of virulence: (1) velogenic, (2) mesogenic, (3) lentogenic, and (4) asymptomatic enteric (122). Velogens are able to produce high mortality rates in any age naíve chicken and are further divided into viscerotropic velogenic Newcastle disease (VVND), consisting of hemorrhagic lesions in the

gastrointestinal tract and often neurologic signs and neurotropic velogenic ND (NVND), which produces neurological signs with some respiratory involvement. Birds infected with NVND strains may have hypermetric stepping and appear clumsy before torticollis, body tremors, and paralysis become obvious. Mesogens are less pathogenic, producing neurological disease with deaths in only young birds. Lentogens cause primarily respiratory infections that in specific pathogen free (SPF) chickens cause asymptomatic infections and are commonly used as live vaccines. Viruses of the asymptomatic enteric pathotype have a tropism for the gastrointestinal tract, and are not thought to cause or contribute to clinical disease and are also used as live vaccines.

Definitions and Synonyms

Newcastle disease is defined as an infection of birds caused by a virus of avian paramyxovirus serotype 1 (APMV-1) that meets one of the following criteria for virulence:

1. The virus has an intracerebral pathogenicity index (ICPI) in day-old chicks (*Gallus gallus*) of 0.7 or greater; or
2. Multiple basic amino acids have been demonstrated in the virus (either directly or by deduction) at the C-terminus of the F2 protein and phenylalanine at residue 117, which is the N-terminus of the F1 protein. The term multiple basic amino acids refers to at least 3 arginine or lysine residues between residues 113 and 116. Failure to demonstrate the characteristic pattern of amino acid residues as described above would require characterization of the isolated virus by an ICPI test.

In this definition, amino acid residues are numbered from the N-terminus of the amino acid sequence deduced from the nucleotide sequence of the F0 gene, and 113–116 corresponds to residues –4 to –1 from the cleavage site (222).

Newcastle disease also has been referred to as exotic Newcastle disease (END), pseudo-fowl pest, pseudovogel-pest, atypische Geflugelpest, pseudo-poultry plague, avian pest, avian distemper, Ranikhet disease, Tetelo disease, Korean fowl plague, and avian pneumoencephalitis. In addition, variant APMV-1 isolates from pigeons are referred to as pigeon paramyxovirus type 1 (PPMV-1). Based on the OIE definition, by containing multiple amino acids in the fusion cleavage site, the PPMV-1 isolates are vNDV and upon infection of poultry are defined as ND and are reportable to the OIE. However, only some PPMV-1 cause signs of clinical disease in chickens, giving IPCI values of less than 0.7, but increasing in virulence after multiple passages in chickens (204). In this chapter, mesogens and velogens that fit the OIE definition will be referred to as vNDV and asymptomatic or NDV of low virulence will be referred as loNDV.

Economic Significance

Poultry diseases have a significant impact on human welfare, especially in rural areas where village or backyard chickens are a source of income and a crucial food source (165). Countries with industrialized poultry production also expend large amounts of money to prevent ND or prevent losses from ND, to maintain a ND-free status, or eradicate ND after an outbreak (186).

Public Health Significance

The isolation of NDV from humans is rare; however, when it does occur it is most often isolated from those who work closely with poultry species, have laboratory-acquired infections, or have infection from live NDV vaccines (148). A self-limiting conjunctivitis without involvement of the cornea is the most common presentation after direction inoculation of the eye with infective fluids or aerosol transmission (58). The rare reports of flu-like symptoms in humans after ocular inoculation (49, 58) increase to 88% upon intravenous inoculation (IV) of virus used for cancer therapy (184). Other side effects of IV inoculation in humans are neutropenia, leucopenia, and thrombocytopenia (238). Casual contact with vaccinated or infected poultry represents a low risk of human infection. However, immunosuppression may increase the possibility of infection and severe pneumonia (108). There are no reports of human-to-human spread.

History

The first documented outbreaks of ND occurred in 1926 in Java, Indonesia, and Newcastle-upon-Tyne, England (85). However, there were reports of disease outbreaks in chickens and pigeons in Central Europe prior to 1926 similar to what we now recognize as ND (192). Even though Doyle initially suggested "Newcastle disease" as a temporary moniker for outbreaks caused by these viruses, over time it has become the *de facto* designation (86). The synonym, avian paramyxovirus type 1 (APMV-1), was suggested by Tumova years later to distinguish NDV from other serotypes of avian paramyxoviruses (308).

While all NDV can be considered APMV-1, according to definitions used by the OIE, only infections with virulent APMV-1 cause ND. The term APMV-1 is often used to refer to NDV of avirulence or low virulence to avoid confusion. Previous editions of this chapter have more information about the origins of ND and the initial characterization of the virus (12, 26).

Etiology

Classification

See the introduction at the beginning of this chapter for more information regarding classification.

Morphology

Members of the Paramyxoviridae family have a lipid bilayer envelope that originates from budding of the plasma membrane of the host cells in which the virus replicates (178). Newcastle disease virions are pleomorphic, but may appear round with a diameter between 100 and 500 nm or filamentous in shape with a diameter of about 100 nm and variation in length (26). The fusion (F) and hemagglutinin-neuraminidase (HN) glycoproteins, 17 nm in length, are densely packed onto the surface of the virion (196). The nucleocapsid protein appears to be in a herringbone type of pattern and is associated with the phosphoprotein (P) and large polymerase protein (L) (196) (Figure 3.1).

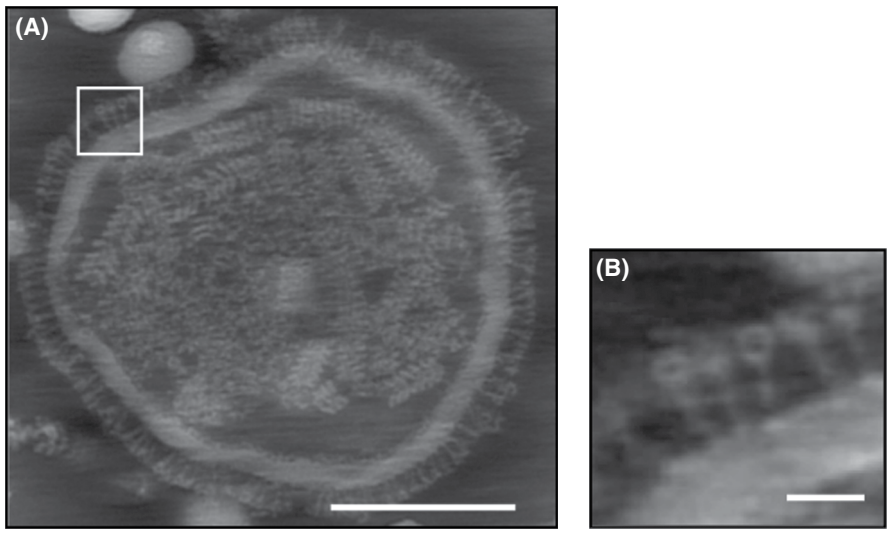

Figure 3.1. Negative staining and electron tomographic analysis of Newcastle disease virus. (A) 44-nm thick digital section taken at the level of the envelope. Bar = 100 nm. (B) Glycoprotein protruding from the envelope. Bar = 10 nm. Reproduced with permission (196).

Chemical Composition

The molecular mass (Mr) of a single Paramyxovirus genome is approximately 500×10^6, the buoyant density in sucrose is 1.18–1.20 g/cm^3, and the sedimentation coefficient $S_{20,W}$ is about 1000S (141). APMV-1 isolates have at least 3 genome sizes; 15,186; 15,192; and 15,198 (71) in keeping with the rule of six (242). Virus particles are approximately 20%–25% weight for weight (w/w) lipid derived from the host cell and about 6% w/w carbohydrate. The NDV genome is composed of 6 structural proteins, listed from 3′ to 5′: nucleocapsid protein (N), phosphoprotein (P), matrix (M), fusion (F), hemagglutinin-neuraminidase (HN), and the RNA-dependent RNA polymerase (RNAP), designated the large polymerase (L) (178).

The N, P, and L are nucleocapsid associated, and there are 3 membrane-associated proteins: the unglycosylated inner membrane M protein, the glycosylated F protein, and the glycosylated attachment protein HN (141). RNA editing of the P protein produces an additional protein, the V protein, when 1 guanine residue is added to the conserved editing site of the mRNA by the RNAP (57). The V protein is rich in cysteine and binds zinc (287), and the carboxy-terminus portion has an anti-interferon activity, allowing the virus to reduce the innate immune response of the host (140, 234). The host protein actin also is incorporated into virus particles and is used for virus entry, replication, and transport across the cell (213).

Biologic Properties

Hemagglutination Activity

The ability of NDV and other avian paramyxoviruses to agglutinate red blood cells (RBCs) is due to the binding of the HN protein to the sialic acid receptors on the surface of the RBCs (37). The agglutination property of the virus and its inhibition by antisera (49) have proven to be powerful tools in the diagnosis of the disease. Chicken RBCs usually are used in hemagglutination (HA) tests, but NDV causes agglutination of RBCs from other species (143). Ito et al. (143) showed that the ability to agglutinate RBCs not only varied with the strain of NDV, on the species it was isolated from, and the species the RBCs were collected from. This suggests that the receptor differences between species may affect the transmissibility and replication between species.

Neuraminidase Activity

The HN protein also has neuraminidase enzyme activity (mucopolysaccharide N-acetyl neuraminyl hydrolase) that degrades the sialic acid receptor, preventing self-attachment of viral particles and the resultant clumping of progeny virus. The enzyme activity also allows RBCs to eventually elute from the virus (179).

Cell Fusion and Hemolysis

Paramyxovirus fusion proteins are able to induce the hemolysis or cell fusion of other cells and this fusion is pH independent and occurs at a neutral pH (138, 180). The fusing activity and infectivity of the virus depends on the proteolytic cleavage by a host protease of the precursor F0 protein into the heterodimer (F1 and F2) linked by a disulfide bond (138). Cleavage also may be performed by bacterial proteases (215). Attachment of the virus to the host receptor site during replication is followed by fusion of the virus membrane with the cell membrane, which may result in the fusion of neighboring cells, and the formation of multi-nucleated cells or syncytia. The rigid membrane of the RBCs usually ruptures when the virus membrane fuses, causing hemolysis. The F0 is cleaved, as discussed previously, and relates to the pathogenicity of the NDV strain, which is discussed later in this chapter.

Virus Replication

The HN attaches the virus to the host cell receptor and triggers the F protein to fuse the virus to the host cell membranes, allowing the viral nucleocapsid complex to enter the host cell. Entry of the virus is possibly dependent on the presence of cholesterol and may occur through the process of endocytosis (52, 195). Paramyxoviruses replicate entirely in the cytoplasm

of the host cell. Replication starts when the RNA-dependent RNA polymerase (L) carried in the virus particle is released in the cytoplasm, beginning the transcribing of the negative sense RNA genome into positive sense, 5′ capped and 3′ polyadenylated messenger RNAs (mRNA). The genes are transcribed in a sequential and polar manner, 5′ to 3′ of the coding sequence, leading to a decreased level of transcription of downstream genes (178). Therefore, the 5′ structural proteins are produced in much higher amounts than the 3′ polymerase protein. After the mRNA is translated into viral proteins, the negative sense genome is replicated, producing a full-length antigenomic RNA that serves as a template for the synthesis of full-length genomic RNA (242).

The HN protein of some strains of NDV is also produced as a precursor, HN0. Posttranslational cleavage is needed to remove a 45 amino acid region of the carboxy terminus (113). The HN0 can be cleaved by trypsin and other proteases (chymotrypsin, thermolysin, elastase) that do not cleave the fusion protein of these low virulence viruses (214). The viral HN proteins synthesized in an infected cell are transported to and are incorporated into the cell membrane. Following the alignment of the nucleocapsid and viral RNA close to the regions of the cell membrane containing the viral glycoproteins, virus particles bud from the cell surface.

Susceptibility to Physical and Chemical Agents

Many physical and chemical agents are able to destroy the infectivity of NDV. However, the amount of time or concentration of the chemical needed to destroy infectivity will likely vary slightly for each strain of NDV and the type of media or material containing the virus (294).

It is critical that organic matter is removed; if possible, before the disinfection protocol is enacted (32). A 1% disinfectant composed of either a phenol/quaternary ammonium mixture or a cresol/surfactant/organic acid blend will inactivate NDV (65, 153). Information on the stability of NDV to heat, UV irradiation, hydrogen ion concentrations, chemicals, and solar and gamma radiation can be found elsewhere (39, 120).

Virulent NDV has been found in eggs and other poultry products produced from infected poultry (11, 21, 53). The Terrestrial Animal Health Code of the OIE (http://www.oie.int/international-standard-setting/terrestrial-manual/access-online/) allows international trade in processed poultry products from countries with enzootic ND if these products have been processed to ensure the destruction of the ND virus (224). Core temperatures and times are given as a guideline for the inactivation with a 7-log reduction of NDV in whole egg, liquid egg white, 10% salted yolk, dried egg white, and poultry meat (224). The times and temperatures needed vary greatly with the inactivation methods used, the type of egg or egg products containing the virus, and the stability of each strain (114, 162, 294). A recent evaluation of the California/2002 strain (55°C for 12.4 minutes, 56°C for 9.3 minutes, 56.7°C for 6.2 minutes, 57°C for 5 minutes, 58°C for 3.7 minutes, and 59°C 1.7 minutes for Dt values) suggests the current pasteurization protocol of the Food Safety Inspection Services of 56.7 °C for 4.6 minutes for inactivation of salmonella in fat-free liquid egg white products may need to be increased to 57.7°C for 6.3 minutes if the vNDV amount is substantial (34, 61).

Specific times and temperatures are suggested by the OIE to achieve a 7-log reduction of vNDV-infected chicken meat: 65°C for 840 seconds, 70°C for 574 seconds, 74°C for 280 seconds, and 80°C for 203 seconds (224). More recent studies designed to generate thermal inactivation curves and Dt values, both vNDV (United States (US) California/2002) and loNDV (Northern Ireland/Ulster/1967) were inactivated at the same rates in naturally infected and artificially infected meat and were effectively inactivated in chicken meat cooked following the United States Department of Agriculture (USDA) guidelines to reduce salmonella (70°C or 73.9°C for less than 1 second) (302).

Strain Classification

The term strain is used to indicate a well-characterized isolate of a virus or bacteria. The suggested nomenclature for APMV-1 isolates is similar to avian influenza isolates. The isolate should be listed in full the first time mentioned in a document: APMV-1/Species/Country (state, city or more specific location)/isolate number, name, or other unique identifier/year of isolation (example: APMV-1/Chicken/USA (CA)/S0212676/2002) and then subsequently may be abbreviated as appropriate (CA/2002). Certain isolates have been so well characterized that they often are listed by one name (LaSota, B1, Ulster, Herts33, etc.), even though viruses with the same name may differ (72). The important objective in characterizing viruses is to group similar viruses, usually based on virulence. Unrelated biologic properties of NDV vary with different strains and isolates, and these properties have been used to classify isolates.

All APMV-1 isolates are of one serotype because antibodies to 1 strain can neutralize all NDV isolates. However, antigenic variation does occur and it has been suggested that the specificity of antibodies induced by a vaccine to the challenge or outbreak virus is important in reducing the amount of virus shed from vaccinated animals and in prevention of a decrease in egg production among layers (62, 206, 208). That being said, antigenicity may not be related to the amount of virus shed from an infected bird (82).

Antigenicity

While all isolates of APMV-1 are of one serotype, minor antigenic variations between different isolates of NDV have been demonstrated by virus neutralization (VN), agar gel diffusion assays, monoclonal antibodies (mAb), and cross hemagglutination inhibition assays (1, 25, 182, 208, 243, 273). Monoclonal antibodies have been used to place strains of NDV into groups on the basis of their ability to react with the different mAb (266). Monoclonal antibody typing also was used to establish the uniqueness of the variant NDV responsible for the pigeon panzootic and to confirm its presence in many countries (20, 25, 237). There is

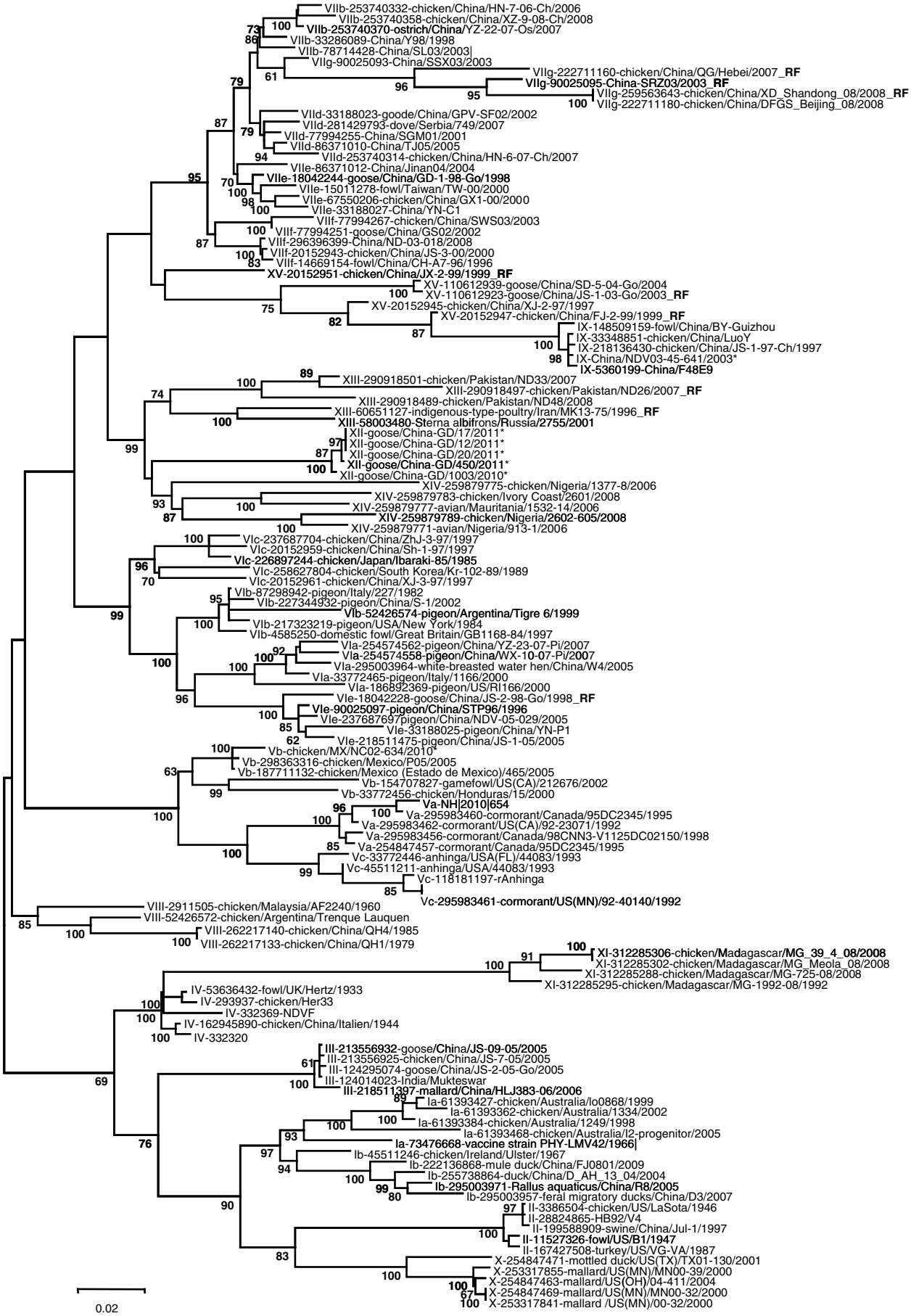
VIIb-253740332-chicken/China/HN-7-06-Ch/2006
VIIb-253740358-chicken/China/XZ-9-08-Ch/2008
VIIb-253740370-ostrich/China/YZ-22-07-Os/2007
VIIb-33286089-China/Y98/1998
VIIb-78714428-China/SL03/2003
VIIg-90025093-China/SSX03/2003
VIIg-222711160-chicken/China/QG/Hebei/2007_RF
VIIg-90025095-China-SRZ03/2003_RF
VIIg-259563643-chicken/China/XD_Shandong_08/2008_RF
VIIg-222711180-chicken/China/DFGS_Beijing_08/2008
VIId-33188023-goode/China/GPV-SF02/2002
VIId-281429793-dove/Serbia/749/2007
VIId-77994255-China/SGM01/2001
VIId-86371010-China/TJ05/2005
VIId-253740314-chicken/China/HN-6-07-Ch/2007
VIIe-86371012-China/Jinan04/2004
VIIe-18042244-goose/China/GD-1-98-Go/1998
VIIe-15011278-fowl/Taiwan/TW-00/2000
VIIe-67550206-chicken/China/GX1-00/2000
VIIe-33188027-China/YN-C1
VIIf-77994267-chicken/China/SWS03/2003
VIIf-77994251-goose/China/GS02/2002
VIIf-296396399-China/ND-03-018/2008
VIIf-20152943-chicken/China/JS-3-00/2000
VIIf-14669154-fowl/China/CH-A7-96/1996
XV-20152951-chicken/China/JX-2-99/1999_RF
XV-110612939-goose/China/SD-5-04-Go/2004
XV-110612923-goose/China/JS-1-03-Go/2003_RF
XV-20152945-chicken/China/XJ-2-97/1997
XV-20152947-chicken/China/FJ-2-99/1999_RF
IX-148509159-fowl/China/BY-Guizhou
IX-33348851-chicken/China/LuoY
IX-218136430-chicken/China/JS-1-97-Ch/1997
IX-China/NDV03-45-641/2003*
IX-5360199-China/F48E9
XIII-290918501-chicken/Pakistan/ND33/2007
XIII-290918497-chicken/Pakistan/ND26/2007_RF
XIII-290918489-chicken/Pakistan/ND48/2008
XIII-60651127-indigenous-type-poultry/Iran/MK13-75/1996_RF
XIII-58003480-Sterna albifrons/Russia/2755/2001
XII-goose/China-GD/17/2011*
XII-goose/China-GD/12/2011*
XII-goose/China-GD/20/2011*
XII-goose/China-GD/450/2011*
XII-goose/China-GD/1003/2010*
XIV-259879775-chicken/Nigeria/1377-8/2006
XIV-259879783-chicken/Ivory Coast/2601/2008
XIV-259879777-avian/Mauritania/1532-14/2006
XIV-259879789-chicken/Nigeria/2602-605/2008
XIV-259879771-avian/Nigeria/913-1/2006
VIc-237687704-chicken/China/ZhJ-3-97/1997
VIc-20152959-chicken/China/Sh-1-97/1997
VIc-226897244-chicken/Japan/Ibaraki-85/1985
VIc-258627804-chicken/South Korea/Kr-102-89/1989
VIc-20152961-chicken/China/XJ-3-97/1997
VIb-87298942-pigeon/Italy/227/1982
VIb-227344932-pigeon/China/S-1/2002
VIb-52426574-pigeon/Argentina/Tigre 6/1999
VIb-217323219-pigeon/USA/New York/1984
VIb-4585250-domestic fowl/Great Britain/GB1168-84/1997
VIa-254574562-pigeon/China/YZ-23-07-Pi/2007
VIa-254574558-pigeon/China/WX-10-07-Pi/2007
VIa-295003964-white-breasted water hen/China/W4/2005
VIa-33772465-pigeon/Italy/1166/2000
VIa-186892369-pigeon/US/RI166/2000
VIe-18042228-goose/China/JS-2-98-Go/1998_RF
VIe-90025097-pigeon/China/STP96/1996
VIe-237687697pigeon/China/NDV-05-029/2005
VIe-33188025-pigeon/China/YN-P1
VIe-218511475-pigeon/China/JS-1-05/2005
Vb-chicken/MX/NC02-634/2010*
Vb-298363316-chicken/Mexico/P05/2005
Vb-187711132-chicken/Mexico (Estado de Mexico)/465/2005
Vb-154707827-gamefowl/US(CA)/212676/2002
Vb-33772456-chicken/Honduras/15/2000
Va-NH|2010|654
Va-295983460-cormorant/Canada/95DC2345/1995
Va-295983462-cormorant/US(CA)/92-23071/1992
Va-295983456-cormorant/Canada/98CNN3-V1125DC02150/1998
Va-254847457-cormorant/Canada/95DC2345/1995
Vc-33772446-anhinga/USA(FL)/44083/1993
Vc-45511211-anhinga/USA/44083/1993
Vc-118181197-rAnhinga
Vc-295983461-cormorant/US(MN)/92-40140/1992
VIII-2911505-chicken/Malaysia/AF2240/1960
VIII-52426572-chicken/Argentina/Trenque Lauquen
VIII-262217140-chicken/China/QH4/1985
VIII-262217133-chicken/China/QH1/1979
XI-312285306-chicken/Madagascar/MG_39_4_08/2008
XI-312285302-chicken/Madagascar/MG_Meola_08/2008
XI-312285288-chicken/Madagascar/MG-725-08/2008
XI-312285295-chicken/Madagascar/MG-1992-08/1992
IV-53636432-fowl/UK/Hertz/1933
IV-293937-chicken/Her33
IV-332369-NDVF
IV-162945890-chicken/China/Italien/1944
IV-332320
III-213556932-goose/China/JS-09-05/2005
III-213556925-chicken/China/JS-7-05/2005
III-124295074-goose/China/JS-2-05-Go/2005
III-124014023-India/Mukteswar
III-218511397-mallard/China/HLJ383-06/2006
Ia-61393427-chicken/Australia/Io0868/1999
Ia-61393362-chicken/Australia/1334/2002
Ia-61393384-chicken/Australia/1249/1998
Ia-61393468-chicken/Australia/I2-progenitor/2005
Ia-73476668-vaccine strain PHY-LMV42/1966
Ib-45511246-chicken/Ireland/Ulster/1967
Ib-222136868-mule duck/China/FJ0801/2009
Ib-255738864-duck/China/D_AH_13_04/2004
Ib-295003971-Rallus aquaticus/China/R8/2005
Ib-295003957-feral migratory ducks/China/D3/2007
II-3386504-chicken/US/LaSota/1946
II-28824865-HB92/V4
II-199588909-swine/China/Jul-1/1997
II-11527326-fowl/US/B1/1947
II-167427508-turkey/US/VG-VA/1987
X-254847471-mottled duck/US(TX)/TX01-130/2001
X-253317855-mallard/US(MN)/MN00-39/2000
X-254847463-mallard/US(OH)/04-411/2004
X-254847469-mallard/US(MN)/MN00-32/2000
X-253317841-mallard /US(MN)/00-32/2000
0.02

Figure 3.2.

continued evaluation of antigenic differences, especially in areas of the world where ND is endemic and severely affects the economy (131, 231, 306). Genetic analysis, however, has replaced the use of mAbs for typing NDV isolates (76).

Immunogenicity

In the broadest sense, all vaccine studies test immunogenicity or the ability of one vaccine to provide significantly better protection over other vaccines for that specific situation. This evaluation may involve the amount of antibodies produced, the reduction in number of sick or dead birds after challenge, and as mentioned above, the decreased amount of virulent challenge virus shed. Vaccines formulated with the same NDV strain and even NDV clones may not have the same immunogenicity. Clones of LaSota have been found to be less protective than vaccines formulated with the wild type LaSota strain (329). The immunogenicity of a virus also depends on the route of administration of the vaccine (197, 327).

Genetic or Molecular

Phylogenetic analysis of genome sequences is now the standard procedure adopted by most laboratories to characterize NDV strains. While the first analyses focused on partial sequences of the F gene (8, 67, 164, 192, 276), due to its importance in virulence determination, more recent efforts compare the full F or full genome sequences (78, 202, 212, 304). For molecular determination of virulence the partial fusion protein of 274 base pairs (bp) in length, surrounding the site where F0 precursor is cleaved to F1 and F2 fragments, is sufficient (221).

With low rates of recombination, but considerable antigenic drift over time, the genetic diversity is represented by groups of viruses denoted by lineages or genotypes (8, 76, 192, 205, 207). Strains of APMV-1 can be grouped into 2 main classes, class I and class II (71). Class I viruses are mostly loNDV found in wild birds and class II viruses originally were broken into multiple genotypes representing loNDV and vNDV (205). With the addition of more complete genomes available for analysis, a new system to define genotypes based on a mean evolutionary distance between genetic groups of 10% has been suggested to define the current genotypes and to identify new genotypes as they arise (76) (Figure 3.2). While most of the sequence data available is for the class II viruses that contain both vaccine viruses and virulent outbreak viruses, more full genome sequence data on loNDV isolated from wild birds is becoming available (146, 157). There are 3 lengths of the HN protein (571, 577, and 616 amino acid residues) (117), but only some loNDV are known to produce an HN0 precursor that is cleaved at the carboxy terminus to an active form with 616 amino acids residues (215). There is only one documented instance of a vNDV from class I (18).

Pathogenicity Tests

Before molecular assays and sequencing were readily available, pathotypes were created based on results from pathogenicity assays. The terms "velogenic," "mesogenic," and "lentogenic" were defined as the mean death times (MDT) in chicken embryos, after allantoic sac inoculation, of less than 60 hours, 60–90 hours, and greater than 90 hours, respectively (39, 124). These terms are now also applied to mean high-virulence, moderate-virulence, and low-virulence viruses regardless of the pathogenicity test employed.

The intracerebral pathogenicity index (ICPI) in day-old chicks differentiates lentogenic viruses with ICPI values of less than 0.7 from virulent mesogenic strains with ICPI values equal to or greater than 0.7 and less than 1.5, and velogenic viruses with ICPI values greater than 1.5 (122). For the ICPI, ten 24- to 40-hour-old SPF chicks are inoculated with 0.05 ml of a 1:10 dilution of bacteria-free, isotonic NDV containing allantoic fluid with a HA titer greater than 16 and watched daily for 8 days. Birds are rated 0 = normal, 1 = sick, and 2 = dead. The ICPI is the mean score per bird observations.

The ICPI also is used as one determinant of NDV that requires reporting to OIE. The intravenous pathogenicity index (IVPI) in 6-week-old chickens also has been used to distinguish velogenic NDV from mesogenic and lentogenic NDV, but now is not often used because mesogenic viruses, like the velogens, are defined as vNDV by the OIE. With PPMV-1 strains it is common to have virulent fusion cleavage sites, but mesogenic ICPI values with lentogenic MDT values (237). However, pathogenicity indices may increase in virulence with multiple passages in chickens (22).

Since the OIE has defined NDV as an infection with any virus that has an ICPI equal to or greater than 0.7, the IVPI is not as commonly performed as the ICPI. While sequencing of the fusion cleavage site is acceptable to demonstrate virulence, if the cleavage site data reveal an NDV of low virulence, the ICPI test is required by the OIE for the *in vivo* determination of virus virulence (see below) (221).

Laboratory Host Systems

Animals

The virus is known to infect more than 236 avian species (150). ND infections of birds from 20 of the 26 Orders in the Clements classification system for modern birds have been

Figure 3.2. Phylogenetic analysis based on the complete nucleotide sequence of the F gene of viruses representing Newcastle disease virus class II. At least 4 sequences representing each NDV genotype were used in the analysis. The evolutionary history was inferred by using the Maximum Likelihood method. The tree with the highest log likelihood (-23299.0541) is shown. The percentage of trees in which the associated taxa clustered together is shown next to the branches. Initial tree(s) for the heuristic search were obtained automatically as follows. A discrete Gamma distribution was used to model evolutionary rate differences among sites (4 categories (+G, parameter = 1.2175)). The rate variation model allowed for some sites to be evolutionarily invariable ([+I], 30.6963% sites). The tree is drawn to scale, with branch lengths measured in the number of substitutions per site. The analysis involved 123 nucleotide sequences. Codon positions included were first, second, third, and noncoding. All positions containing gaps and missing data were eliminated. There were a total of 1,647 positions in the final dataset. Evolutionary analyses were conducted in MEGA5. RF = recombinant form identified with the program RDP3. Reproduced with permission (76).

documented. In addition to poultry species, pigeons, cormorants, and psittacines are commonly infected with vNDV (77, 125, 128, 149, 171). The virus can cause a localized infection in animals other than birds, which allows for the use of NDV as a vector vaccine for many diseases, such as rabies, avian influenza, respiratory syncytial virus, and severe acute respiratory syndrome (SARS) in mammals (47, 103, 167, 194).

Chicken Embryos

Most avian paramyxoviruses replicate to high titers with allantoic sac inoculation into SPF embryonating chicken eggs. However, there are rare reports that a strain, likely well-adapted to a host other than the chicken, may need to be propagated first in chicken embryo kidney cells before being propagated in eggs (169, 199).

Cell Cultures

Newcastle disease virus strains can replicate in primary cells and cell lines of multiple species (35, 95, 144, 163, 168, 183, 185). Not all NDV isolates will replicate to a high titer in cell culture unless they are passed multiple times to adapt them to the system, and some NDV strains may not adapt to some cell types as is seen with the Madin-Darby Canine Kidney (MDCK) system (209). Cell systems, like chicken embryo fibroblasts, require an exogenous protease to be added for loNDV to undergo more than 1 round of viral replication (260). The most commonly used cells are primary chicken embryo fibroblasts (CEF) and kidney cells (CEK), chicken fibroblast cell line (DF1), African green monkey kidney epithelial cell line (VERO), baby hamster kidney fibroblast cell line (BHK), and human epithelial type-2 cell line (Hep-2). Cytopathic effects (CPE) consist of cytoplasmic inclusions, giant cells (syncytia), or plaques if an overlay media is used. In general, there can be a 1–2 log decrease in the amount of virus produced in a cell culture system compared to NDV grown in embryonating chicken eggs.

Pathogenicity

Virulence Determinants

F Gene. Entry of NDV into host cells requires the activation of viral envelope fusion glycoprotein through cleavage of the precursor glycoprotein F0 into F1 and F2. Only virus with a cleaved F0 can mediate the fusion of the viral and cellular membrane, which is required for infection of a cell (102, 214). The posttranslational cleavage is mediated by nonviral proteases and the types of proteases capable of cleaving F0 depends on the amino acid sequence motif around the cleavage site. The amino acid sequence of the F0 precursor (Table 3.2) of loNDV are characterized by a monobasic amino acid sequence motif at the C-terminus of the F2 protein and a leucine at the N-terminus of the F1 protein, ^{112}G-R/K-Q-G-R↓L^{117} (11, 66, 68, 116, 154, 218, 278, 305, 326). F0 of loNDV are cleaved only extracellularly by trypsin-like proteases present in the respiratory and intestinal tract. Virulent strains have a multibasic amino acid sequence motif at the C-terminus of the F2 protein, 112R/G/K-R-Q/K-K/R-R↓F^{117} and a phenylalanine at the N-terminus of the F1 protein and that are cleaved intracellularly by ubiquitous furin-like proteases found in most host tissues (107, 214, 215, 219). This difference in protease activation is the major determinant of systemic replication associated with severe disease of vNDV.

The importance of the cleavage site motif is confirmed by using reverse genetics to convert the sequence motif of loNDV

Table 3.2. Amino acid sequence at the F0 cleavage site.

Virus strain	Virulence[a]	ICPI	Cleavage site AA 111-118[b]	Reference
Herts33	High	1.88	G-**R-R**-Q-**R-R**↓F-I	(305)
Essex '70	High	1.86	G-**R-R**-Q-**K-R**↓F-V	(66)
135/93	High	1.30	V-**R-R-K-K-R**↓F-I	(218)
617/83	High	1.46	G-G-**R**-Q-**K-R**↓F-I	(68)
34/90	High	1.81	G-**K-R**-Q-**K-R**↓F-I	(66)
Beaudette	High	1.46	G-**R-R**-Q-**K-R**↓F-I	(66)
LaSota	Low	0.40	G-G-**R**-Q-G-**R**↓L-I	(66)
D26	Low	0.00	G-G-**K**-Q-G-**R**↓L-I	(305)
MC110	Low	0.00	G-E-**R**-Q-E-**R**↓L-V	(66)
1154/98	Low	0.60	G-**R-R**-Q-G-**R**↓L-I	(11)
Australian isolates				
Peats Ridge	Low	0.41	G-**R-R**-Q-G-**R**↓L-I	(326)
QV4	Low	0.39	G-**K-R**-Q-G-**R**↓L-I	(276, 326)
Somersby 98	Low	0.51	G-**R-R**-Q-**R-R**↓L-I	(154, 326)
Dean Park	High	1.60–1.70	G-**R-R**-Q-**R-R**↓F-I	(326)
PR-32	Low	0.64	G-**K-R**-Q-G-**R**↓F-I	(154, 326)
African isolates				
Chicken/MG/'92	High	-[c]	G-**R-R-R-R-R**↓F-V	(278)
Chicken/Mali/'07	High	-[c]	G-**R-R-R-K-R**↓F-V	(278)

[a] Virulence for chickens.

[b] ↓ = cleavage point. Basic amino acids in bold. Note that all virulent viruses have phenylalanine (F) at position 117 (the F1 N terminus).

[c] Unknown ICPI.

isolates into those of a vNDV, which increases the ICPI values from 0 or 0.01 to 1.12–1.28 [see table 1 in (80)] (229, 241, 259). The opposite is also true that when the virulent strain ZJ1 cleavage is modified to a loNDV strain the ICPI is decreased from 1.89 to 0.13 (139). The ICPI does not always correlate with virulence observed after infection of adult chickens via a more natural route of infection. Thus, LaSota virus that was manipulated via reverse genetics to comprise a virulent cleavage site with a virulent ICPI value only slightly increased its pathogenicity, defined by the clinical disease and the viral tissue distribution observed compared to its parent virus (319). Changing the amino acid at position 114 from a glutamine to an arginine and/or an isoleucine at position 118 into a valine also reduced virulence as measured by ICPI and retarded death after infection via the respiratory route (269). These mutations were recently detected in viruses isolated from vaccinated birds with neurological and other signs in Africa and Madagascar (278, 284). Unfortunately, the virulence of these isolates was not confirmed *in vivo* in the laboratory.

Altogether, these studies show that the cleavage site motif of F0 is a reliable indicator of the *potential* virulence of NDV viruses, but other factors are clearly involved for the virus to have a virulent phenotype. For example, many PPMV-1 have a multiple basic amino acid sequence motif yet have a low virulence phenotype on the ICPI. These viruses can acquire virulence after multiple passages in chickens (22, 166). A PPMV-1 strain, AV324, rescued from an infectious clone, confirmed that the low virulence is an intrinsic property of the particular strain and not due to mixtures of low- and high-virulent isolates (81). Furthermore, the exchange of the F gene of the low-virulent PPMV-1 and of a virulent strain in both directions had no effect on the virulence measured by ICPI (81). All observations on the role of the cleavage site suggest that there must be other factors that contribute to the virulence, such as HN amino acid substitutions.

HN Gene. The basic function of HN has been described in the Biologic Properties section. Studies of the contribution of HN to virulence are complicated by the close association of HN and F, which may require changes to be made to both HN and F to maintain the interaction. The 3 HN genotypes (see the Genetic or Molecular) that comprise different HN lengths appear to have no effect on virulence (259). Other reverse genetics studies were not conclusive on the contribution of HN to virulence [reviewed by Dortmans (80)].

V Gene. The V protein allows for NDV to evade the host response by interrupting the type I and II interferon response and apoptosis induction by NDV infection. Prior expression of the V protein rescues NDV replication in primary CEF treated with IFNα/β, and this activity resides in the C-terminal portion of the protein (234). Moreover, V protein-deficient NDV produced by reverse genetics is highly attenuated in CEF and ECE compared to wild-type virus (233). The attenuated phenotype could be restored by the insertion of an influenza A NS1 protein also known to interfere with the IFN response. Growth kinetics of these V protein-deficient NDV mutants in humans cells suggest that the IFN-disrupting activity is species-specific because the titer of the NS1-expressing, V-deficient NDV virus is higher than that of the recombinant parent virus (234).

V protein-deficient NDV also are less virulent in chickens as revealed by a decrease of ICPI and IVPI. The outcome of the assay, however, may depend on the inoculation dose (80, 140, 320). Viruses, which are deficient in expressing the V protein, are unable to target the STAT1 protein for degradation (140), which is an important element of the interferon-signaling pathway. Moreover, cells infected with these NDV mutants have increased levels of apoptosis (234) and *in vivo* the viruses infected fewer tissues and induced milder clinical signs than infections observed with the reverse genetic parent virus (126). Altogether, all studies indicate that the V protein is essential for replication and virus survival in the host. More experimental studies, particularly those using natural routes of infection, are needed to determine whether the V protein also contributes to virulence of different NDV strains and how NDV behaves in different hosts.

Replication Complex (NP/P/L Genes). A correlation between virulence and level of viral replication has been observed in many viruses. The NP, P, and L proteins form the replication complex and their involvement in NDV virulence also has been studied by reverse genetics (84, 261). Whereas in one study the exchange of L protein alone had a small effect on virulence (261), a different study, in which genes of a vNDV and PPMV-1 strain of low virulence were exchanged, indicated that all 3 proteins (NP, P, and L) had a significant effect on the virulence of NDV (84). Moreover, passing the PPMV-1 isolate in chicken brain revealed 3 mutations—2 in the L and 1 in the P protein—that correlated with increased replication going along with an increased virulence for chickens (83).

In summary, studies indicate that NDV virulence is a complex trait due to the effect of multiple genes, with the multiple basic amino acid cleavage motif of F_0 being the minimum requisite of virulence.

Emergence of Virulent Viruses

Outbreaks of vNDV could arise from transmission of virulent viruses that are enzootic in other bird species. The best-characterized endemic virulent wild bird genotype is in cormorants in North America (264). These strains cause periodic outbreaks with mortality in cormorant populations, and the ICPI in chickens is above 0.7 (77). However, cormorant viruses from sub-genotype Va are rarely reported in poultry (76). Apart from cormorants, vNDV strains have been rarely isolated from wild birds and most are detected in association with infected poultry. However, loNDV strains have been isolated frequently from wild birds and appear to be endemic in some duck species (42). Whether loNDV strains circulating in waterfowl may form a reservoir of emerging vNDV is under discussion.

Three observations indicate that loNDV may be a true threat. First, reverse genetics have demonstrated that only 3 mutations are required for a LaSota strain to acquire virulence

(240). Second, vNDV may evolve from loNDV isolates from waterfowl by passage in chickens (281). Third, the Australian epizootic of 1998–2000 demonstrated that it is possible that some loNDV strains could evolve into a virulent phenotype by similar mutations (326) because virulent strains were closely related to a loNDV circulating in the same region. These viruses had only 2 nucleotide differences at the site coding for the F0 cleavage site (118). Earlier a similar observation was made in Ireland during 1990 (67).

The movement of caged birds, especially psittacine species, started the 1970s panzootic (64). Although there are many reports of caged birds being infected (242, 292), it is not certain if the virus is endemic in these captive birds or if infection results from the transmission from infected poultry (159).

The emergence of PPMV-1 is another example of how a panzootic begins. It was concluded from phylogenetic studies that pigeon-type APMV-1 strains emerged as a result of chicken-to-pigeon transmission of NDV strains (12, 325). Over time, PPMV-1 isolates appear to have increased its adaptation and virulence in pigeons with a corresponding decrease in adaptation and virulence for chickens (31, 339).

Pathobiology and Epidemiology

Incidence and Distribution

There are few areas of the world that have not been affected by ND. From July 2009 through December 2011, 86 countries reported vNDV infections to the OIE (221). Newcastle disease is particularly problematic for poultry producers in countries in the Middle East, Africa, and Asia. Confusing the situation, some countries with endemic vNDV still use mesogenic NDV strains as live vaccines that are defined as virulent due to their cleavage sites and high ICPI values (331). Because differentiating vaccinated from infected (DIVA) strategies do not exist for ND it is difficult to discern infected from vaccinated animals.

The spread of vNDV between countries of Asia, the Middle East, Europe, and Africa has been documented (2, 127). Potential transmission from wild pigeons and cormorants continues to be a concern for poultry producers (77, 87). Sporadic outbreaks also occur in countries that do not have vNDV endemic in poultry and where vaccination for ND is routine (151). Underreporting in certain areas confounds the issue on what NDV genotypes are currently circulating among different bird species around the world. (76, 205, 304).

The 4 panzootics of ND proposed by Alexander since the disease was recognized in 1926 have been previously reviewed (11, 26). Briefly, the first panzootic, or the first recognized outbreak of the disease that spread worldwide, appears to have started in Southeast Asia in 1926 and moved to England during that same year. The genotypes associated with this panzootic are genotypes II, III, and IV (335).

In the late 1960s, when the poultry industry was becoming highly commercialized with significant amounts of international trade, the second panzootic began in the Middle East and spread to many other countries by 1973. These viruses, from genotype V, were associated with imported caged psittacine species and led to quarantine stations and vaccine programs to control the disease (217, 321, 335).

The third panzootic that started in the late 1970s involved "variant strains" of vNDV found in pigeons designated PPMV-1. These isolates are of the same serotype as other APMV-1 isolates, but have unique epitopes and can be differentiated with monoclonal antibodies (24). These PPMV-1 isolates, believed to have originated in Northern Africa and/or the Middle East, began to be isolated from pigeons and doves in the early 1970s and quickly spread to the rest of the world (236). During the early 1980s the neurotropic presentation of ND in pigeons, from infections with PPMV-1, began to be more prevalent (7, 298, 309). Multiple outbreaks of PPMV-1 in chickens have occurred, but interestingly PPMV-1 produces variable and often-unpredictable disease in chickens (23, 99). The threat of PPMV-1 infection in poultry continues today, as these viruses continue to circulate worldwide (158, 235, 317).

The fourth panzootic began in the 1980s in Southeast Asia with the isolation of genotype VII vNDV that quickly spread to Africa and Western Europe and finally to South America in 2008 (245).

Natural and Experimental Hosts

While some species may require a higher infectious dose of NDV than other species to become infected, as with turkeys compared to chickens (9), infection with NDV has been documented in at least 241 species (150). Likely all avian species are susceptible to NDV infection; however, infectious dose and clinical signs depend not only on the species of the host, but also vary with individual NDV isolates.

Transmission, Carriers, Vectors, Spread

Horizontal transmission of NDV has been documented many times. Infected birds shed NDV in oropharyngeal secretions and fecal matter (161). Susceptible birds may become infected by inhaling contaminated dust or aerosolized virus (188), or by ingesting such material. Infection by inhaling aerosolized virus is illustrated by the success of applying live NDV vaccines using nebulizers (197). The ingestion of contaminated feces or contaminated carcasses can cause infection in chickens (28) and raptors (271). Applying vaccine to chickens via the drinking water is another demonstration of oral infection (301). While immunized chickens may shed vNDV for 6–9 days after challenge or until they succumb (151), parrots, cormorants, and pigeons may have prolonged shedding of vNDV, usually in feces, without clinical signs (93, 170, 318).

Cases of vertical transmission of NDV from parent to offspring are difficult to prove definitively due to the possibility of hatchlings being infected by contaminated feces through eggshell cracks or by exposure to a contaminated environment. At least 2 reports of virulent NDV isolated from

embryonating chicken eggs (53), day-old hatchlings, and dead-in-shell birds (262) have been documented. Some NDV may have a tropism for the oviduct, which can be observed indirectly through microscopic lesions and directly using immunohistochemistry (51). Reports of embryos infected with virulent NDV from naturally infected layer hens have been reported, but as expected, the embryos usually die before hatching (183). Vaccine virus has been found in reproductive organs after vaccination (251). A small number of embryonating chicken eggs experimentally inoculated with 1 mean egg lethal dose of virulent NDV survived and shed virus in feces (60). Until eggs from naturally infected birds are cleaned and hatched under experimental conditions in a negative pressure isolator and shown to be shedding virulent NDV identical to the outbreak virus, doubt will exist as to the importance of vertical transmission. While this topic is especially critical for endemic countries, it is also important for countries free of ND.

Any bird can be infected with NDV of low virulence, mount an immune response, be subsequently infected with vNDV, and without demonstrating clinical signs shed the vNDV to susceptible birds, acting as a carrier of the ND. However, as mentioned above, apparently healthy adult cormorants (129), pigeons (14), and parrots (230) are often found to be infected and possibly chronically shedding NDV. That being said, molecular epidemiology studies examining outbreak viral sequences in poultry do not implicate the viruses from these species. That is, strains isolated from pigeons are usually pigeon variants of PPMV-1, and viruses isolated from cormorants are different from chicken strains (158, 205). Wild birds probably are not important in the secondary spread of vNDV. While some NDV strains have a tropism for a specific species, this tropism can change if the virus is passed multiple times in a new avian species (83), which may occur if biosecurity measures are not fully implemented (275).

Evidence that humans, mammals, or insects are biological vectors of spread of ND is lacking, although humans can be infected and develop conjunctivitis. It is possible that with the use of NDV strains—for instance, some virulent strains such as those used as treatments for human cancer therapy—this potential risk could increase as virus is shed in saliva and urine (287). However, spread by humans is more likely mediated by transport of contaminated fomites (94). NDV-contaminated equipment, clothing, shoes, feed, water, vaccines, and poultry products, and NDV-infected birds (wild or domestic) moved or placed into contact with susceptible birds where virus can be inhaled or ingested can lead to the spread of ND (50, 147, 314). Migratory birds and illegally imported birds have been implicated in the introduction of the disease in certain regions (17, 230). Two different fly species from ND outbreak locations were confirmed to be carrying vNDV, albeit in amounts too small for the flies to be considered competent vectors (56).

Biosecurity with strict importation and quarantine procedures preventing the movement of infected birds, bird products, and equipment from outbreak areas is critical to contain ND and to keep the disease from entering a poultry facility or country free of disease (15, 183).

Incubation Period

The time between exposure to NDV and the development of clinical signs varies depending on the host species, the immune status of the host to NDV, the age of the host, the health of the host, the virulence of the virus, the dose or amount of virus received, and even the route of exposure. The incubation period for natural exposures to NDV varies between 2 and 15 days, averaging around 5–6 days, but may be take 3–4 weeks in some circumstances. Experimental infection with virulent viscerotropic NDV in chickens usually results in a 1- to 4-day incubation period depending on the challenge dose. Aerosol transmission may have a shorter incubation time than an infection started through ingestion of the virus.

Clinical Signs

The factors that influence the incubation period, as noted above, also account for the variation in the clinical signs observed after infection. Neither the clinical signs nor the gross lesions are pathognomonic for ND. Nonvaccinated chickens infected with virulent viscerotropic isolates become listless and depressed 2 days after infection (Figure 3.3A), ending with 100% mortality by the third or fourth day (293). With an oculonasal route of infection, bilateral conjunctivitis with some facial swelling may be present. Often clear mucus will pour from the mouths of infected birds if their heads droop toward the ground, leaving the bird gasping for air as it tries to clear the oral cavity of fluid. This fluid may appear to be nasal secretions but is more likely crop fluid related to stasis of the gastrointestinal tract, and it pours from the mouth when the crop is compressed as the bird is handled (Figure 3.3B). The feces of infected birds may be green and watery. The comb may become blue as the bird becomes cyanotic, but hemorrhages are only seen with some isolates.

The clinical presentations of chickens infected with virulent neurotropic NDV strains that were commonly isolated in the United States during the 1940s and 1950s were like a completely different disease compared to present day outbreaks with velogenic strains. Birds may seem excitable and hypermetric 3 or 4 days after infection. Approximately 5 days after infection, head or muscular tremors, torticollis, and paralysis of 1 wing or 1 leg may occur. Typically these birds are bright and alert and die from the inability to reach food and water 9 or more days after infection. Mortality is usually around 50%, with greater mortality in younger birds. Mesogenic strains usually result in low or no mortality in 4-week-old chickens, and will present with neurological signs such as head tremors, torticollis, and paralysis (293). Pigeon isolates in chickens may lead to no clinical signs (166).

Well-vaccinated layers infected with vNDV may only present with a decrease in egg production 1 week after infection, with the fewest eggs produced 2 to 3 weeks post infection, after which the number of eggs produced will start to increase (63). The percentage decrease in egg production depends on

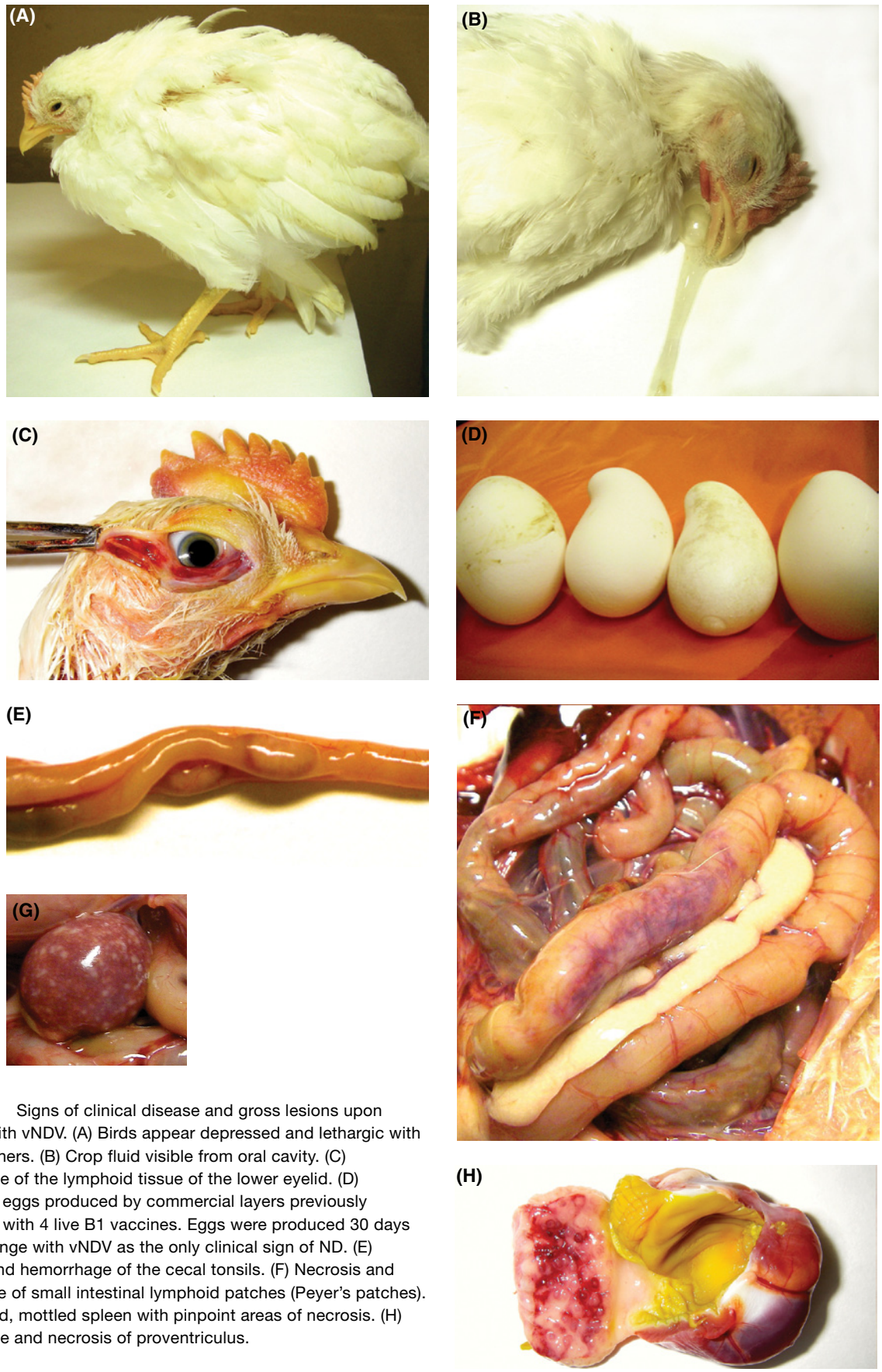

Figure 3.3. Signs of clinical disease and gross lesions upon infection with vNDV. (A) Birds appear depressed and lethargic with ruffled feathers. (B) Crop fluid visible from oral cavity. (C) Hemorrhage of the lymphoid tissue of the lower eyelid. (D) Misshapen eggs produced by commercial layers previously vaccinated with 4 live B1 vaccines. Eggs were produced 30 days after challenge with vNDV as the only clinical sign of ND. (E) Necrosis and hemorrhage of the cecal tonsils. (F) Necrosis and hemorrhage of small intestinal lymphoid patches (Peyer's patches). (G) Enlarged, mottled spleen with pinpoint areas of necrosis. (H) Hemorrhage and necrosis of proventriculus.

the strain of NDV. At 1 month after infection, misshapen and/or bleached eggs may appear for the life of the chicken (Figure 3.3D).

Strains of low virulence usually do not cause disease in adult birds. However, young naïve birds may present with serious respiratory distress following the application of the LaSota vaccine strain. Respiratory disease also may be observed if there are secondary infections or high ammonia levels, or if aerosolized droplets of vaccine are so small that they are delivered deep into lung tissue during vaccination (29, 316).

Clinical signs in other poultry species can be different and depend not only on the species, but also on the specific breed of bird. For example, clinical disease in nonvaccinated commercial turkeys may be less severe than what is observed in SPF turkeys (318). Generally, the order of most susceptible, showing the most clinical signs, to the least susceptible, showing the fewest clinical signs, are chickens, turkeys, pigeons, and ducks (9, 318). Geese are usually grouped with ducks in terms of susceptibility, but there are reports of clinical disease in geese from Asia with genotype VII isolates or with particular strains of NDV (190, 324). Nonvaccinated pheasants are highly susceptible with clinical signs similar to those observed in chickens (6). Ostriches usually present with nervous signs and mortality present only in young birds (13). Chicken isolates in pigeons may cause body tremors (318).

Pathology

Gross Lesions

As with clinical signs, gross lesions and the organs affected depend on many factors and are not pathognomonic for ND. Lesions will likely be absent in vaccinated birds and possibly in nonvaccinated birds. Necrosis and hemorrhagic lesions in the lymphoid-dependent areas of the intestines (lymphoid tissue of lower eyelid, cecal tonsils, Peyer's patches) of infected chickens and turkeys are common with virulent viscerotropic isolates (Figure 3.3C, E, F) (247, 293, 318). Enlarged spleens, with hemorrhagic thymic and proventricular tissues, are also common (Figure 3.3G, H). Chickens will occasionally present with moderate splenic congestion and mild thymic atrophy after infection with a virulent neurotropic NDV, such as a cormorant virus (293). Gross lesions are not seen in the central nervous system of birds infected with any vNDV. Lesions in the respiratory tract are rare (55), except for thickening of the air sacs due to secondary infection (39). In chickens, necrosis and hemorrhage of the laryngeal tonsils in the cranial portion of the trachea is consistently observed with the virulent viscerotropic NDV that caused the last outbreak in the United States during 2002 (55, 318). Egg yolk peritonitis with atrophied follicles and degenerated oviduct may appear during birds in lay (51). Cormorants infected with NDV often present with neurological signs, along with intestinal hemorrhages (36).

Microscopic Lesions

The same variables previously mentioned affect the microscopic lesions found with NDV infection. More detailed information on histological lesions has been published (55). Some of the more common lesions in chickens and turkeys for virulent NDV included (1) necrosis with lymphoid depletion of cecal tonsils, spleen, thymus, eyelid, and bursa; (2) histiocytic airsacculitis; (3) lymphohistiocytic airsacculitis; (4) gliosis with perivascular cuffing; medulla, cerebellum, and brainstem; (5) yolk peritonitis with foamy macrophages of subserosal space of oviduct; (6) necrotic myocarditis; (7) bone marrow necrosis; (8) pancreatic, thymic, hepatic necrosis; (9) necrosis and ulceration of epithelium of intestine; and (10) hemorrhagic, ulcerative tracheitis. For loNDV, infections in chickens and turkeys commonly cause lymphoplasmacytic tracheitis with deciliation (175).

Ultrastructural Lesions

Embryos infected with the LaSota vaccine strain show epithelial erosions with loss of cilia (175). Virulent NDV causes apoptosis and necrosis in lymphocytes (177) and possibly erythrocytes (175) as well as macrophages (174). Electron microscopy of NDV-infected cardiac tissue demonstrated perivascular edema with shortening of sarcomeres (176).

Immunity

Active Immunity

As soon as 6 hours after exposure, splenic cells produce alpha and beta interferon, and interleukin 6 (IL-6) when exposed to vNDV, but not to loNDV (264). Interferon gamma (IFN-γ) secreted from NK cells activates macrophages and promotes cell-mediated immunity (CMI) 1 day after infection (75, 193). Whole chicken genome arrays of the host immune response to NDV at 1–2 days after infection demonstrate the induction of type I and II interferons, cytokines, chemokines, and inducible nitric oxide synthase (4, 264, 282, 283). Upon infection, chicken embryo fibroblasts produce interferon alpha but little to no interferon beta (274). The innate immune response alone is not enough to ensure survival of the host after an exposure to a vNDV. However, the activity of NK cells, which are able to destroy virus-infected cells, improves as chickens age and this improvement could provide some explanation for decreased susceptibility with older birds (187). Once the virus overcomes the innate immune response, cellular (257, 181) and humoral responses are initiated by the host.

T-lymphocyte differentiation occurs in the thymus gland, producing cells able to rapidly expand after being exposed to the antigen a second time, providing CMI that is measured by lymphocyte proliferation or cytokine secretion (181). Cytotoxic T lymphocytes (CD8) are found in splenic cells of chickens twice infected with NDV (145). Cell-mediated immunity of a T helper cell type 1 (Th1) response, characterized by the production of IFN-γ by macrophages, can be detected 3 days after infection with a live NDV vaccine strains (303), thus providing signals for a humoral response to develop by the host.

Macrophages also induce nitric oxide (NO) production (337) and the amount of NO produced is elevated in birds with higher antibody levels, demonstrating how CMI and humoral immunity affect each other (119). Similar to innate immunity,

CMI alone is not enough to ensure survival of the host after an exposure to a vNDV (257). However, IFN-γ produced in large quantities at the same time as the vNDV is replicating in the host significantly reduces mortality and moderately reduced morbidity, providing evidence of the role of CMI in NDV infection (292). This also underscores the need for humoral immunity.

After exposure to NDV, B-lymphocytes differentiate into plasma cells that secrete 3 types of neutralizing antibodies specific to the antigen (181). These antibodies are necessary to protect birds from morbidity and mortality after infection with vNDV (256, 270). First, IgM is produced and can be detected as early as 4 days after vaccination (5). After 7 days, IgG (referred to as IgY in birds due to a structural difference) and IgA, which is important to the local immunity of the Harderian gland and cecal tonsils, can be detected (5). At 7 days post-infection the splenic tissue is comprised of 56% IgM, 37% IgY and 7% IgA (145). Again, evidence for the intertwining of CMI and humoral immunity is demonstrated with IL-4 secretion, improving the humoral immune response (270). Local immunity is evaluated by the amount of antigen-specific IgA antibodies that can be detected in tears, tracheal washings, and bile after intranasal or intraocular exposure to live NDV vaccines. Local immunity (IgA) is important in neutralizing free virions in the respiratory and gastrointestinal tracts (101, 246, 267).

Hemagglutination inhibition (HI) assays are commonly performed to evaluate antibody response post vaccination because they correlate well with the more laborious virus neutralization (VN) assays (300). Commercial ELISA kits are also available and are sometimes used to evaluate the uniformity of vaccination for a poultry flock; however, because they do not specifically measure neutralizing antibodies they may not correlate well with protection (300). Neutralizing antibodies against the HN and/or the F glycoproteins bind to the virions and prevent their attachment to the host cells, which reduces virus replication (43, 191, 297). Commercial or experimental viral vectored vaccines for NDV generally include only the F gene product, which produces neutralizing antibodies that do not inhibit NDV hemagglutination, providing the possibility to use the concept of differentiation between infected and vaccinated animals (DIVA) (228, 296). While 1 glycoprotein alone can be protective, others have demonstrated improved protection when both the F and HN are present (172, 206, 310).

Passive Immunity

Maternal antibodies passed to embryos through the egg yolk may be protective depending on the amount of antibody transferred, and the dose and virulence of the challenge virus. If present at the time of vaccination with a live NDV vaccine, maternal antibodies can neutralize the live vaccine and lead to vaccine failures (310). Levels of antibody in day-old chicks are directly related to titers in the parent. On average, the amount of HI antibodies decreases by half every 4–5 days depending on the breed. In broilers, maternal antibodies are detectable until 7–10 days of age.

Environment, nutrition, stress, bacterial infections, and immunosuppressive viruses can lead to the suppression of the immune system (105, 134). If the bursa of Fabricius (cloacal bursa) has atrophied from infectious bursal disease virus (IBDV), a decreased immune response will be induced for any vaccine. Ironically, infections with NDV also have the ability to immunosuppress the host and prevent a proper immune response to other vaccines, such as to IBDV (252). While the effect on chickens is unknown, for humans treated with NDV as an oncolytic treatment, initial anemia, leucopenia, and neutropenia are often induced shortly after treatment is started (173, 272). Some NDV isolates produce a V protein that limits the infected hosts cells from producing interferon, effectively decreasing the initial innate and CMI response after infection (201, 288).

Diagnosis

For effective disease management, it is important to be able to identify birds that are infected with NDV and distinguish vaccine viruses from virulent viruses. As discussed earlier, the clinical signs and lesions observed with vNDV infections are not pathognomonic, and therefore are not specific enough for a diagnosis. In many countries infections with loNDV strains may be due to lentogenic and/or vaccine virus and thus are not reportable. In addition, loNDV are commonly found in apparently healthy wild birds (159). Further characterization of these NDVs is necessary to verify their virulence. Of importance are 2 instances in which loNDV that were circulating in wild birds passed into poultry and mutated to vNDV (18, 118).

Isolation and Identification of the Causative Agent

Tracheal, oropharyngeal, and/or cloacal swabs from live birds, or organ tissue samples (brain, liver, spleen, kidney, or organs with lesions) from dead birds suspended in an antibiotic/antifungal media should be kept at 4°C for 1–2 hours or frozen on dry ice or liquid nitrogen until they are able to be thawed and processed. Swabs should be fully submerged in media and for tissue samples a 20% w/v suspension is required for transport. Once centrifuged at 1,000 g for 10 minutes, 100–200 μL of a sample is inoculated into the chorioallantoic sac of a 9- to 11-day-old SPF embryonating chicken egg (ECE). If SPF eggs cannot be obtained, eggs from a flock free of NDV antibodies should be used for the assay. The eggs are incubated at 37°C and examined daily for 4–7 days (27).

Allantoic fluid from any eggs containing embryos that died after 24 hours and all eggs at the end of the 7-day incubation period should be collected after the eggs are chilled at 4°C to be tested for hemagglutinating activity (HA). This fluid also may undergo RNA extraction for use in molecular techniques. All HA-positive samples should be tested for specific inhibition with an antiserum to NDV (APMV-1), referred to as a hemagglutination-inhibition (HI) assay. All HA-negative samples should be passaged again in ECE and tested for HA

activity. APMV-1 isolates may cross react with APMV-3 and with APMV-7, and on rare occasions with APMV-2 and APMV-4. However, the cross-reacting titers to these other APMVs are usually much lower that they are to APMV-1. Additionally, monoclonal antibodies specific for APMV-1 are therefore useful additional reagents for discrimination of APMV serotypes in the HI test. Molecular diagnostic tests, such as real-time RT-PCR (RRT-PCR) are also routinely used for confirmation. Any diagnostic sample causing embryo death 24–72 hours after inoculation should be further investigated even if there is no HA activity.

If the HA is positive but the HI is negative, in addition to any of the APMV-2-11 serotypes or H1-16 AIV subtypes, bacteria may be the cause of the HA activity in birds. The allantoic fluid can be passed through a 45-nm filter before being repeated. Strains from cormorants isolated in the United States after 2002 rarely demonstrate HA activity with chicken RBCs, but will cause embryo mortality (77, 264). As an alternative to using ECE, cell culture may be used for detecting NDV. However, loNDV will not replicate more than 1 round without the addition of trypsin to the media, except in some kidney cells, such as CEKs.

Direct detection of viral RNA isolated from swab samples or tissues may be tested using RT-PCR (109) or RRT-PCR. RRT-PCR assays are not only able to distinguish APMV-1, but also distinguish vNDV from loNDV (79, 97, 98, 112, 144, 156, 160, 216, 263, 295, 332). While there are many assays for NDV, only some have been validated for routine use (132). Reference laboratories can inform researchers which specific assays should be used for different areas of the world. In addition, cDNA from RT-PCR fusion gene product can be used to sequence the F cleavage site to assess the number of basic amino acids and the presence or absence of the phenylalanine at the 117 position which is an important predictor of virulence (66). Immunohistochemistry, immunocytochemistry, and immunoflourescent techniques allow the detection of the specific locations of the viral antigens in tissues or cells (51, 55, 88, 293).

Serology

Serology usually is not a useful tool for the diagnosis of ND, because current serologic methods cannot differentiate antibodies induced from an infection with vNDV, loNDV from wild birds, or those induced by vaccination with live or inactivated vaccines. Diagnostically, serology is most often used to measure the effectiveness of a vaccination program (299). In countries that do not vaccinate, serology can confirm exposure to NDV, but few countries are in a position to do so. In well-managed flocks that take periodic serum samples, rising HI titers with clinical signs suggest that an exposure occurred.

While there are many methods to detect and quantify antibodies to NDV (59, 64, 104, 121), HI assays and enzyme-linked immunosorbent assays (ELISAs) are used most commonly (204, 258, 285). Although HI assays detect antibodies to only the HN gene, and the ELISA platform typically detects antibodies against all NDV proteins, there is some correlation between the assays. ELISAs are usually specific for the host species because they depend on the use of 1 monoclonal antibody (mAb) to NDV and another species-specific secondary mAb. Caution should be taken when using sera from species other than chickens in the HI test because they may cause false positives (less than or equal to 1:8) from nonspecific agglutination of chicken RBCs (73). Such agglutination may be removed by adsorption with chicken RBCs before testing (223). Variations in results from different laboratories have occurred (41) and attention to using the OIE approved protocol is suggested (223). When using 4 HA units of antigen, titers greater than 1:16 are considered positive. The cutoff is greater than 1:8 when using 8 HA units (27).

Differential Diagnosis

The clinical presentation of other diseases, such as aspergillosis, mycoplasmosis, infectious laryngotracheitis, fowl cholera, infectious bronchitis, and highly pathogenic avian influenza, can be confused with ND. A limited number of avian viruses have the ability to hemagglutinate chicken RBCs: virus from the avian paramyxovirus serotypes, the avian influenza virus, and the etiological agent of egg drop syndrome, an adenovirus. Confirmation of APMV-1 can be quickly performed with NDV polyclonal antisera. Appropriate positive and negative controls should be used in the HI assays to prevent a misdiagnosis from cross reactions with other APMV serotypes.

Molecular Techniques in the Diagnosis of ND

A quick and prompt diagnosis of the disease in the laboratory is essential to the control of ND. The application of new molecular techniques means that results can be obtained within a few hours after receiving the samples in the laboratory. Conventional diagnostic techniques can take 2–14 days to isolate the virus, and initially characterize the virus to a level that an outbreak can be confirmed. Quick confirmation is also essential to reduce the economic effects caused by the standstill that likely is imposed on a farm pending the outcome of an investigation. Preparedness to report suspicions and submit samples to the laboratory is directly related to measures imposed by regulatory agencies (91). While molecular techniques can produce more rapid results if the lack of clinical signs does not allow for the proper selection of diseased birds, which might be, for instance, the case in vaccinated flocks or the case of infections with loNDV, virus isolation is necessary. Keep in mind that sampling clinically ill or dead birds from vaccinated flocks is more advantageous than random testing of healthy birds.

Molecular technologies to detect NDV have been reviewed by Aldous and Alexander (7) and more recently by Hoffmann et al. (135) and Miller et al. (205). Molecular assays should not only detect NDV, but also differentiate vaccine or loNDV strains from vNDV isolates, according to the OIE definition of ND. Problems with any molecular assays are related to the genetic variation of the fusion gene of different genotypes of NDV and particularly the cleavage site in F0. Currently there

is no single test that has been fully validated to detect and simultaneously pathotype all class I and II viruses worldwide. Most molecular techniques involve reverse transcription (RT) followed by a polymerase chain reaction (PCR) to produce a DNA copy of the RNA genome as an essential initial step.

Conventional RT-PCR assays have mostly been replaced by RRT-PCR protocols that use fluorogenic probes to detect amplification in real time. RRT-PCRs can be automated and thus are better suited for high throughput. Most RRT-PCR protocols use primers targeting conserved sites attempting to enable detection of all genotypes. Whereas primers and probes targeting the M gene were shown to detect most class II genotype viruses, later it was determined that they often failed to detect class I viruses (159). To accommodate the detection of class I viruses, primers and probes were targeted at the L gene such that primer/probe sequences and assay conditions were compatible with the M gene RT-PCR, allowing for a multiplex RRT-PCR (160). Although this multiplex assay was not validated in the field, a recent ring trial of member states of the European Union (within the EPIZONE network of excellence) demonstrated that this assay performed equally well for the detection of class II viruses with the added benefit of detecting class I viruses, albeit at a lower sensitivity (Steven Van Borm, personal communication).

Another laboratory determined that the same M gene RRT-PCR protocol failed to detect some of their isolates and subsequently used a shortened, degenerate probe using locked nucleic acids to maintain probe stability and improve efficiency (54). The multiplex RRT-PCR allows the detection of most NDVs, but not their virulence, and therefore only can be used to exclude ND as a possible cause of an outbreak, but it is not suited to confirm a vNDV infection. RRT-PCR that targets the fusion gene at the cleavage site could be used to detect and pathotype the NDV isolate in a single assay (31, 98). The assay designed by Wise et al. was validated with clinical samples and successfully applied during an ND outbreak in California during 2002, and this assay is authorized for use in laboratories of the National Animal Health Network as a surveillance tool in the United States (330). The primers and probes were targeted to the California outbreak strain, and sequences mismatches have to be considered when detecting vNDV worldwide.

Fuller et al. (98) used a similar strategy but modified the forward primer and the probe by using the universal base inosine to correct for mismatches and locked nucleic acids to increase binding activity. Furthermore, the investigators designed different probes to detect loNDV or vNDV. Unfortunately, the detection limits of all tests varied between 10^1 and 10^3 EID_{50}. Moreover, detection limits may vary with viruses belonging to other genotypes depending on how probe and primer sequences match the target sequences. In addition, the probe specific for loNDV used in this assay does not detect all class I viruses.

In summary, virus isolation should still be required in parallel to molecular techniques when making an initial diagnosis of an NDV outbreak because the presence of embryo mortality ensures further investigation, either if a mismatch in primer or probes is present. As more information on the sequence of an outbreak virus is determined, greater reliance on molecular diagnostic tests can be employed.

Intervention Strategies

Regardless of whether ND control is applied at the international, national, or farm level, the objective is either to prevent susceptible birds from becoming infected or to reduce the number of susceptible birds by vaccination. For the former strategy, each method of disease spread must be considered in prevention policies.

Management Procedures

International Control Policies

A good definition is indispensable for defining the disease status for ND. The OIE is responsible to the World Trade Organization for the standardization of matters relating to animal health that affect trade and has formulated a definition of ND (225). "Newcastle disease (ND) is defined as an infection of birds caused by a virus (NDV) of avian paramyxovirus serotype 1 (APMV-1 that meets one of the following criteria for virulence:

(1) the virus has an intracerebral pathogenicity index (ICPI) in day-old chicks (*Gallus gallus*) of 0.7 or greater; or

(2) multiple basic amino acids have been demonstrated in the virus (either directly or by deduction) at the C-terminus of the F2 protein and phenylalanine at residue 117, which is the N-terminus of the F1 protein. The term 'multiple basic amino acids' refers to at least three arginine or lysine residues between residues 113 and 116. Failure to demonstrate the characteristic pattern of amino acid residues as described above would require characterisation of the isolated virus by an ICPI test."

In this definition, amino acid residues are numbered from the N-terminus of the F protein amino acid sequence deduced from the nucleotide sequence of the F0 gene, 113–116 corresponds to residues –4 to –1 from the cleavage site.

The definition is also required because of the enormous variation in clinical manifestation of the disease and possible masking of infection by vaccination practices to control the disease. Moreover, a DIVA principal is not yet widely practiced because DIVA vaccines currently are only available as vector vaccines that are not yet widely used during poultry production. Therefore, suspected cases in a naïve or vaccinated host, or a host of different susceptibility, have to be confirmed in the laboratory using techniques that reproducibly differentiate between loNDV and vNDV.

National Control Policies

After the international movement of infected psittacine birds was found to be the cause of the panzootic during the 1970s, many countries increased regulations on the importation of live birds, eggs, and poultry products (123). The importance of biosecurity and preventing domestic poultry from contacting other birds was reinforced. Quarantine stations were designed to be

able to hold imported psittacine birds for long lengths of time to ensure they were not infected and shedding vNDV (92, 93).

Recommendations for ND control can be found on the OIE website (http://www.oie.int/international-standard-setting/terrestrial-manual/access-online/)(225). Since 1933 Newcastle disease has been known to infect pigeons (86) and it has continued to infect them worldwide. It is known to be the cause of the third ND pandemic that continues today (14, 149, 158, 235). The role of pigeons in the spread of ND has led to strict regulations concerning racing pigeons and mandatory vaccination, even in some countries where poultry are not regularly vaccinated.

In many countries ND is often controlled by identifying and culling infected animals while simultaneously restricting the movement of birds and bird products within a defined area surrounding the infected birds. Disposing of infected carcasses and litter without further disseminating the virus is problematic. Vaccination within a defined area around an outbreak area also may be employed. While each outbreak situation has the same goal of containing and preventing the spread of NDV to other areas, there are variations for each country concerning control policies. However, it is clear that all countries will need to address not only the control of ND in poultry species, but also in wild bird species that continue to harbor vNDV worldwide (14, 87). In addition, the concept of evaluating vaccines for their ability to decrease, if not prevent, the shedding of vNDV from vaccinated birds, as seen with avian influenza vaccine development (249, 286), should be required, especially for countries where vNDV is endemic in the environment. Currently, NDV vaccines are evaluated only for their ability to prevent morbidity and mortality (311, 313).

Vaccination policies vary with each country. Preventative or prophylactic vaccination is allowed in most countries of the world. Estonia, Finland, and Sweden currently do not allow preventative vaccination of chickens (69). Finland also prohibits the rearing of poultry outside for portions of the year when they are more likely to mingle with wild birds and requires the administration of inactivated ND vaccines for racing pigeons.

Biosecurity at the farm level is critical to preventing the introduction of diseases to domestic poultry and must be designed taking into account requirements for each location (279). Water and feed quality and pest and litter management are areas that need to be tightly controlled. Routine disinfection and cleaning procedures (45) and post-outbreak protocols should be in place prior to an ND outbreak (32, 198). Biosecurity measures also should be employed in backyard bird situations (210).

Table 3.3. Commonly used live lentogenic (loNDV) vaccine strains, rarely used mesogenic vaccine strains, and virulent challenge virus strains and their genotype and pathogenicity indices for chickens (15, 156, 190, 227, 239, 276).

Virus strain	Pathotype	Genotype	ICPI[a]
Ulster 2C	Asymptomatic	I	0.0
QV4	Asymptomatic	I	0.0
VG/GA	Asymptomatic/ lentogenic	II	0.0
Hitchner B1	Lentogenic	II	0.2
LaSota	Lentogenic	II	0.4
Mukteswar	Mesogenic	IV	1.4
Roakin	Mesogenic	II	1.5
Beaudette C	Mesogenic	II	1.6
TXGB	Velogenic	II	1.8
Herts 33/1956	Velogenic	III	1.9
CA/2002	Velogenic	Vb	1.8
ZJ1	Velogenic	VIId	1.9

[a] ICPI, intracerebral pathogencity index in day-old chickens.

Vaccination

The role of vaccination in the control of ND has been to prevent losses from morbidity and mortality because vaccines are not able to completely prevent vaccinated birds from being infected with vNDV, but vaccines will decrease the number of birds infected and the quantity of vNDV shed into the environment (19, 151, 206, 208, 314). Comprehensive reviews and historical aspects of ND vaccination have been reviewed in other publications, including previous editions of this chapter (26, 30, 136, 203, 277, 280). Vaccination is to be used along with good management and biosecurity practices. In some areas of the world where vNDV is endemic, vaccination is necessary for the survival of backyard or village poultry.

The chapter Principles of Veterinary Vaccine Production in *The Manual of Diagnostic Tests and Vaccines for Terrestrial Animals* reviews guidelines and procedures for vaccine production (226). Regulations from the European Union directive 93/152/EEC states that viruses used as live NDV vaccines should have an ICPI of less than 0.4 or 0.5, depending on the dose (33). The OIE Biological Standards Commission states that the virus should have an ICPI less than 0.7, but that to increase the safety margin the master seed ICPI should not be greater than 0.4 (220). Commonly used live vaccines and their pathogenicity indices for chickens are listed in Table 3.3 (16, 156, 190, 227, 239, 276). The US Code of Federal Regulations, Title 9 (9CFR), sections 113.329 and 113.205, reviews parameters for the production of the master seed virus and the experimental testing of vaccines for live and killed NDV vaccines, respectively (311, 313).

Types of Vaccines

Inactivated and live NDV vaccines formulated with NDV strains of low virulence, such as B1 and LaSota, are the most commonly administered vaccines. Some countries, usually those with endemic vNDV, continue to use live mesogenic NDV vaccines that are considered by the OIE to be reportable for the purposes of trade if isolated from poultry (156, 254, 255). Live B1 and LaSota, developed in the 1940s, continue to be used worldwide (110, 133). More recent strains, Ulster (115, 268), QV4 (44, 96), and VG/GA (40, 246) are also commonly used. QV4 (also called V4) and the I-2 strains have

some ability to withstand heat and are often used in areas where a "cold-chain" is not reliable (322).

Mass application of live NDV vaccines in drinking water, sprays, or aerosols is inexpensive and less labor intensive than administering inactivated vaccines to individual birds. Unfortunately, with mass application of live vaccines it is difficult to produce protective antibodies in high percentages of birds in a flock. Ocular delivery provides the best response (93%), while vaccine delivery in water or spray may produce protective antibodies in only 53% to 60% of the birds (74). The inability to control the amount of water consumed per bird, inactivation of vaccine by heat, or impurities make water delivery problematic. The addition of dried skim milk may increase the stability of the vaccine virus for water application (106).

If applying the ND vaccine in a spray or aerosol, the correct particle size is critical to ensure a proper immune response. If the particles are too small vaccine reactions may develop in the form of respiratory disease because the virus is deposited deep in the lungs, and if the particles are too big, the immune response may not be optimal because the virus drops out of the air before the birds can become infected (333, 334). For day-old chickens with maternal antibodies, aerosol delivery produced a better immune response than water delivery (90). Some live vaccine viruses with ICPI equal to or greater than 0.7 are injected intradermally into the wing-web to decrease the severity of respiratory disease from the vaccine (222).

While live vaccines are relatively inexpensive, easy to administer and provide mucosal immunity, there are some disadvantages to their use. While the value may change slightly depending on each situation, herd immunity may only be reached if greater than 85% of the flock is immunized (315). The live vaccine virus will be shed from immunized birds to their nonvaccinated flock mates, extending the amount of time that live virus circulates on the farm. This may lead to vaccine reactions demonstrated by respiratory disease, especially if secondary infections or high ammonia levels are present. Most importantly, live vaccines are inactivated by high temperatures and require refrigeration. Live vaccine viruses are neutralized by maternal antibodies and this is problematic for countries with stringent vaccine protocols for breeders, which subsequently produce chicks with high maternal antibody levels. Because birds in countries with endemic vNDV have to be well-vaccinated to be able to survive the vNDV they are exposed to in the environment, these birds may not appear sick even though they are infected and shedding vNDV (211).

Inactivated vaccines were first adjuvanted with aluminum hydroxide, but oil emulsions have proved to be more effective (100, 291). Formalin, beta-Propiolactone (BPL), and binary ethylenimine (BEI) are used to inactivate NDV. Whereas BEI is not known to affect the HA potential of the virus after inactivation, formalin and BPL both decrease the HA titers after inactivation (48, 162). The same strains used as live vaccine are also used in inactivated vaccines.

Inactivated vaccines are more expensive to produce and more laborious to administer because they are given intramuscularly or subcutaneously. Immune responses induced by inactivated vaccines are less affected by maternal antibodies than by live vaccines. Inactivated vaccines produce high neutralizing antibody levels (206, 208). They are often formulated with other avian pathogen vaccines and delivered as a multivalent product to decrease the cost of administration. There is a 42-day minimum holding period between the time of injection and slaughter for consumption using oil emulsion vaccines in the US, which restricts their use in broilers (289). Special attention to avoid to accidental human injections is required when working with oil emulsion vaccines because they can cause severe inflammatory responses in humans (325).

Recombinant technology has allowed for the commercial production of recombinant fowl pox or Marek's disease virus serotype-3, also designated as herpes virus of turkeys (HVT), as live-vector vaccines to express the glycoprotein(s) of NDV (130, 228, 253, 296). These vaccines may be delivered *in ovo*, produce no respiratory vaccination reactions, and can be administered to chicks with maternal antibody. They must be reconstituted as directed by the manufacturers, and require more time, typically 3–4 weeks, before immunity is reached in chickens. Other experimental vaccines (e.g., virosomes, virus-like particles, immune stimulating complexes [ISCOMS], NDV antigen expression in transgenic plants) also have been shown to provide effective immunity (111, 137, 152, 200, 232, 336). Cytokine genes inserted into recombinant NDV strains to act as adjuvants to modulate the immune response also are being characterized for use to enhance protection against ND (189, 270, 286).

Although all APMV-1 are of one serotype, there has been more discussion since 2007 concerning the use of recombinant NDV strains engineered to either contain attenuated glycoproteins of circulating virulent viruses or the attenuated glycoproteins inserted into the backbone of commonly used vaccines such as the LaSota strain (208). While these vaccines have not improved protection by reducing morbidity or mortality, there is evidence that the amount of virulent virus shed from the vaccinated birds can be decreased and that there is some abatement of losses in egg production (3, 63, 205). Others have stated that suboptimal mass application methods rather than antigenic differences are the cause of reported vaccine failures (82).

Field Vaccination Protocols and Regimens

Vaccination programs may be controlled by government policies depending on the ND status of a country. These programs should take into account the amount of NDV exposure a flock will likely be faced with, the quality of biosecurity available, the vaccines available, maternal immunity in hatchlings, the use of other vaccines that could interfere with vaccination (248, 328), available labor, ambient temperature, previous vaccination history, time until slaughter, type of chicken (broiler, breeder, layer), and cost. Many countries have regulations for the restricted use of any genetically modified organisms (GMO), plants, or vaccines. The vaccination protocol used depends on the type of production, the amount of maternal antibodies present, and the frequency and severity of the expected challenge virus (277). In the US, broiler breeders

receive at least 3 live vaccines over their lifespan and broilers get 1 live vaccine at day of age with 1 or 2 live booster vaccines later in the field. Layers will likely receive 1 inactivated and 3 live vaccines with additional live vaccine boosts over their lifespan. Turkeys require at least 3 vaccines to maintain sufficient antibody levels (100).

The protective immune response is usually evaluated by examination of HI antibody titers. Single vaccination of a 3-week-old SPF white leghorn with a live lentogenic strain will produce an HI response of around 2^3 to 2^4, whereas a single inactivated vaccine will produce between 2^6 to 2^8. An HI titer greater than 2^4 is considered positive when using 4 HAU (8 when using 8 HAU) (225).

Vaccines developed for chickens are given to other avian species, but the immune responses differ depending on the species. The genetic lineage of turkeys is an important factor in quantity of HI antibodies produced and the amount of antibody may not correlate directly with the prevention of mortality (307). These genetic differences could account for the discrepancies in results from similar vaccine experiments in turkeys (155). Pheasants are highly susceptible to vNDV and vaccination decreases mortality, but does not prevent shedding of vNDV (6, 244). Guinea fowl and partridges are highly susceptible to vNDV (89, 142), but both are able to mount an effective immune response to NDV following vaccination (250, 323). The quality and size of eggs produced from partridges may be negatively affected by vaccination (70). Ostriches mount good immune responses to NDV vaccines but need to receive booster vaccines to maintain the immune response up to the time of slaughter at 1 to 1.5 years of age (42, 265). Pigeons are commonly vaccinated with inactivated vaccines produced with PPMV-1 strains that greatly reduce the amount of vNDV shed from infected animals (290).

Treatments

There are no treatments for vNDV and in most instances all infected birds are culled to contain an outbreak. In special instances exotic or endangered species in an outbreak area may, for a fee, be allowed to move to a USDA quarantine facility for 30 days to be tested for vNDV (312).

Avian Paramyxoviruses 2–11

Egbert Mundt

Introduction

Definition and Synonyms

Avian paramyxoviruses (APMV) belonging to the genus *Avulavirus* were named based on their historical order of isolation, identification, and characterization as an avian paramyxovirus with 11 serotypes currently identified (APMV 1–11) (Table 3.1).

Economic Significance

The main economic significance among the members of the genus *Avulavirus* has resulted from the APMV-1 serotype viruses. Usually APMV other than APMV-1 were isolated from wild birds but occasionally they were also isolated from poultry. For example, APMV-2 infections have been associated with severe respiratory disease and a drop in egg production in turkeys (14, 47). APMV-3 played an important role for disease in turkeys (8, 12, 34, 49), but isolates from chickens (69) and recently from farmed ostriches in South Africa have been described (38). APMV-6 has been described to possibly induce mild respiratory disease and problems in egg production in turkeys (4). An APMV-7 isolate obtained from turkeys was able to induce clinical disease which was characterized by rhinitis and airsacculitis (63), whereas another APMV-7 was isolated from ostriches (81). In conclusion, there is no primary economic significance for APMV other than APMV-1, but the viruses should be considered as a possible isolated cause or individual cases of respiratory diseases and problems in egg production.

Public Health Significance

Viruses of the APMV serotypes 2–10 are likely not important as a threat for the public health. The only description of an APMV which might have the potential to infect humans were 4 virus isolates obtained from cynomolgus monkeys showing respiratory signs of disease (58), which were classified as APMV-2 serotype viruses (45). Furthermore, serological evidence of an APMV-2 infection of the Yukapaia group was found in Senegal (25). It needs to be considered that these classifications are solely based on serological cross reactivities with characterized APMV-2 viruses.

History

The first isolation of APMV from chickens other than APMV-1 was described in 1956 (15). It was named after its location of isolation (Yucaipa, California, USA) and was later shown to be different from APMV-1 and was eventually classified as APMV-2 (23). APMV-3 viruses were first isolated from turkeys in Ontario, Canada, in 1967 and in Wisconsin in 1968, and were later detected serologically in turkeys in other states of the United States (77). This was followed by the description of a new APMV serotype isolated from a duck in Hong Kong (70) which was later characterized as APMV-4 (5). The first isolate for APMV-5 was described from an epizootic outbreak involving budgerigars (*Melopsittacus undulatus*) in Japan in 1974 (57). The isolation of the first APMV-6 strain was from a domestic

duck in Hong Kong in 1977, which served as the prototype strain for this APMV serotype (71). An APMV isolate from a hunter-killed dove was later designated as the first APMV-7 based on HI and NI assays (9). The first APMV-8 strain was obtained from a wild Canada goose in 1976 (21), while the first APMV-9 virus was isolated from a domestic duck in 1978 (10). Thirty-two years later the tenth serotype of APMV was isolated from a rockhopper penguin in the Falkland Islands (52). The more detailed description about the history of APMV isolates can be obtained from the 12th edition of *Diseases of Poultry*.

Etiology

Classification

All avian paramyxoviruses belong to the family *Paramyxoviridae*, subfamily *Paramyxovirinae*, genus *Avulavirus* (78), which are enveloped viruses containing a single-stranded negative-sense RNA genome. Avian paramyxoviruses (APMV) are grouped in serotypes 1–11 primarily based on their reactivity in the hemagglutination inhibition (HI) assay using APMV serotype-specific sera. Due to the an increasing availability of sequences to APMV 1–11, future classification will likely be defined based on phylogenetic similarities.

Morphology

Avian paramyxoviruses 2–11 where observed as pleomorphic virus particles. The diameter of the viral particles can vary between 100 and 500 nm. Besides being pleomorphic, filamentous forms of variable length also were observed. The viral glycoproteins cover the viral surface and were observed as projections of about 8 nm in length.

Chemical Composition

The viral particle of APMV 2–11 consists of single-stranded RNA surrounded by a viral envelope containing glycosylated proteins. Nonglycosylated proteins mainly build the inner ribonucleoprotein complex along with the viral RNA. In recent years the full-length genome sequences of at least 1 strain of each APMV 2–10 has been determined (20, 36, 43, 44, 52, 56, 60, 64, 65, 74, 75, 82, 83). It has been shown that the virus genomes from each APMV serotype varied in length (see below).

Virus Replication

The virus replication of APMV 1–11 occurs in the cytoplasm of infected cells and is assumed to be similar among all the different serotypes.

Susceptibility to Chemical and Physical Agents

Due to their very similar chemical composition, viruses of APMV 2–11 are likely susceptible to chemical agents as has been described for APMV-1.

Strain Classification

Antigenicity

Discrimination between the APMV serotypes occurs routinely by the hemagglutination inhibition (HI) assay using either serotype-specific defined APMV antigens for the detection of antibodies or well-characterized APMV serotype-specific antisera usually obtained after repeated vaccination of specific pathogen free chickens. The tests can be performed as recommended by the OIE in chapter 2.3.14 of the *Manual of Diagnostic Tests and Vaccines for Terrestrial Animals 2011* for the determination of APMV-1 antigen or antibodies (59). Reference sera usually are produced in well-defined SPF chickens, and analysis of sera from species other than chicken or chickens with antibodies against a variety of pathogens might pose a problem for a clear diagnosis (79). It was also found that high-antibody titers against 1 APMV serotype might result in cross reactivity with other serotypes (79). Based on HI and neuraminidase inhibition (NI), Lipkind and Shimanter (48) divided APMV 1–9 isolates into 2 subgroups. The first subgroup contained APMV-2 and 6 and the second subgroup contained APMV 1, 3, 4, 7, 8, and 9. Alternative serological tests including the NI assay (35, 39, 57, 77), serum neutralization (55, 77), and agar gel diffusion tests (1, 10, 35, 41) have shown similar antigenic groups to the HI test. Miller et al. (52) suggested that with the availability of sequences for all APMV serotypes, new classification guidelines should be established that incorporate genome sequence comparisons. Xiao et al. (82) also proposed that with the determination of full-length sequences the APMV serotypes should be grouped based on their phylogenic relationship.

Immunogenicity or Protective Characteristics

APMV of different serotypes show limited cross reactivity, and little information is available for APMV 2–11 of how APMV isolates of the same serotype might differ (55). In the few published reports, marked immunogenicity was observed in chickens with APMV-2 inducing rather high HI titers, but APMV-4 and 6 infections induced delayed and comparatively low antibody responses (80). In a different study chickens were infected with virus isolates belonging to APMV 1–9. The highest antibody titers were observed for APMV-1 and 3; moderate antibody titers were observed for APMV-2, 8, and 6; and low antibody titers were observed for APMV-4, 7, and 9; a very low antibody response for APMV-5. The chickens in this study were challenged with a virulent APMV-1 strain with complete protection in birds previously infected with APMV-1 and 3, partial protection after infection with APMV-2, 7, 8, and 9, and no protection after infection with APMV-4, 5, and 6 (55).

Genetic or Molecular

The determination of full-length sequences for 9 of the APMV serotype viruses closes an important gap for understanding the biology of the genus *Avulavirus* and has been summarized by Samuel et al. (65). In addition, the almost complete sequence for a recently described APMV-10 isolate from rockhopper penguins (52) added new knowledge. The complete genomes vary in length with 14904 nt (APMV-2), 15064 nt (APMV-4), 15186 nt (APMV-1), 15342 nt (APMV-8), 15438 nt (APMV-9), 15480 nt (APMV-7), 16272 nt

(APMV-3), 16236 (APMV-6), and 17262 nt (APMV-5), and fulfill the rule of 6 for the family *Paramyxoviridae* (18). The general genomic organization follows the order of proteins NP-M-P-F-HN-L (65, 52). The 3′ leader region was conserved with 55 nt in length. The very first 8 nucleotides of the leader region were highly conserved and were a complement to the trailer sequence located at the 5′ end of the virus genome. Each mRNA encoding for the single protein contains 5′ and 3′ noncoding regions that vary in length between the proteins and between the viruses. In addition, the intergenic regions vary in length and likely function as regulatory regions for the transcription cascade. The presence of RNA editing sites within the region encoding for the P protein has been identified, which might result in mRNA's encoding for the V and W proteins in APMV 1–9 (65). One additional coding sequence for a small hydrophobic protein (SH protein) was identified for APMV-6 (83).

Laboratory Host Systems

The isolation of APMV has most commonly been with 9- to 11-day-old embryonating SPF chicken eggs. However, Muscovy duck eggs also have been used for virus isolation (3). Inoculation via the allantoic cavity (63) is the most commonly used method but the intra-amniotic route was also used, as shown for APMV-5 (57). The yolk sack route of inoculation also was used for APMV-5 isolation (32).

Pathogenicity

Isolates of APMV 2–10 can be grouped as lentogenic in chickens when using the NDV scale for classification. Infection of SPF chickens with isolates from all APMV serotypes (2–9) did not show any clinical signs (55). The intracerebral pathogencity index of 1-day-old chickens was that of a lentogenic NDV after inoculation with APMV-2 (76), APMV-3 (42), APMV-8 (53), or APMV-10 (52). APMV-2 infection of 1-day-old chickens and 4-week-old chickens and turkeys did not induce clinical signs (76). A similar phenotype in 1-day-old chickens also was observed for APMV-2, 4, and 6 (80). Infection of 1-day-old or in 2-week-old turkeys with 2 different APMV-3 isolates did not induce disease (42), but a separate study showed impaired growth of chickens after intramuscular infection with an APMV-3 isolate (7). This indicates likely differences between virus isolates from the same APMV serotype. Experimental infection of chickens and pigeons with APMV-5 did not cause disease, but caused fatal enteritis in young budgerigars (54, 32). Virus isolates pertaining to the APMV-6 serotype caused mild respiratory disease and a drop in egg production in turkeys (4), whereas infection in chickens did not induce clinical signs (20, 80). Interestingly, an APMV-7 was isolated from dead collared doves but whether the virus isolate was the cause was not proven (30). For APMV-7, an isolate was described which induced clinical signs and affected the production of eggs in turkeys (63). After infection of chickens and ducks with an APMV-8 isolate from wild birds no signs of disease were observed (53).

Pathobiology and Epizootiology

Incidence and distribution

APMV-2

Four Yucaipa-like viruses (APMV-2) were isolated in China from the imported Gouldian Finch (*Chloebia gouldiae*) (84) while isolates from the same APMV serotype were isolated from domestic and wild birds in Costa Rica (28). In general, APMV-2 was isolated from a variety of species including robin, eagle, pheasant, parrot, canary, domestic poultry, and waterfowl (50, 22).

APMV-3

APMV-3 has been isolated from turkeys in Canada, the United States, and England (49, 77); chickens in Israel (69); and nondomesticated species such as *Psittaciformes* and *Passeriformes* (2, 67). The prototype APMV-3 strain parakeet/Netherlands/449/75 was isolated from parakeets in the Netherlands (6). Recently the isolation of APMV-3 from ostriches from Namibia has been reported (38).

APMV-4

APMV-4 was obtained from mallard ducks (27, 36, 68) and a ringed teal (31). So far no APMV-4 isolate has been described from domestic poultry, although serologic evidence has been described (79).

APMV-5

Viruses of the APMV-5 serotype have been described exclusively from budgerigars in Australia (54) and England (32).

APMV-6

Viruses of the AMPV-6 antigenic serotype have been described from a variety of species and regions around the globe: domestic ducks in Hong Kong (71), wild mallard ducks in USA (80), domestic ducks in Taiwan (20), and mallard ducks in New Zealand (73). In addition, serologic evidence of an APMV-6 infection in chickens has been reported (79).

APMV-7

The first APMV-7 isolate was obtained from a hunter-killed dove in 1977 in Tennessee in the USA (9). The presence of APMV-7 was diagnosed in diseased turkeys (63), ostriches (81), and collared doves (30).

APMV-8

APMV-8 (Goose/Delaware/1053/76) was first isolated in the USA from a hunter-killed Canada goose (*Branta canadensis*) (62). A serological survey (from 1990 to 1992) of wild fowl in southern Spain showed a notable prevalence of APMV-8 antibodies in up to 43% of the tested sera (51), and 56% of sera obtained from healthy mallard ducks in New Zealand APMV-8 antibodies were observed (73). With the exception of a few waterfowl isolates, APMV-8 was isolated while the populations were being surveyed for avian influenza viruses (72).

APMV-9

Only 2 reports of detection for APMV-9 have been reported. The first described isolate was from waterfowl obtained during routine surveillance (10). Capua et al. (19) described the isolation of a second APMV-9 isolate from migratory waterfowl in Italy.

APMV-10

The discovery of the first new APMV in more than 30 years, APMV-10, was described by Miller et al. (52), in which viruses were obtained from Rockhopper penguins (*Eudyptes chrysocome)* from the Falkland Islands. The presence of APMV-10 in another penguin species, Magellanic penguins (*Spheniscus magellanicus*), was recently described (26).

APMV-11

The sequence of a purported new subtype, APMV-11, isolated from a common snipe (*Gallinago gallinago*), has been described (see the Introduction to this chapter).

Natural and Experimental Hosts

The presence of APMV 2–11 in their natural hosts has been described above. It needs to be mentioned that these descriptions are certainly just a snapshot of the natural presence of APMV given the low number of birds that have been tested. The presence of APMV 2–11 in wild birds suggests that this is their natural reservoir. Infection of chickens and turkeys as experimental hosts does not usually induce disease with clinical signs (55). This might also be dependent on the virus isolate used for the experiments. The infection of mammals such as mice (40) and hamsters (66) did not induce clinical signs except for an APMV-9 isolate, which induced moderate clinical signs in the hamster model.

Transmission, Carriers, and Vectors

The route of transmission for APMV 2–11 appears similar to that of other paramyxoviruses where the oro-fecal as well as the respiratory route are the primary routes of transmission. It also should be mentioned that most experiments were performed using direct inoculation into the experimental hosts via the oral route. The role of carriers and vectors is unknown, but the worldwide trade of animals, regardless whether it is domestic birds or wild birds, certainly will help to transmit such viruses to naïve territories.

Incubation Period

Because almost no clinical disease is observed, the determination of an incubation period is difficult. After infection of young budgerigars with APMV-5, all diseased birds died within 14 days post infection (PI) (57). A similar observation was described for another APMV-5 isolate after infection of young budgerigars (54).

Clinical Signs

Morbidity and Mortality

In general, data for experimental infection of naïve birds are very rare. Experimental infection with APMV 2–11 in naïve chickens did not result in any clinical signs (55, 80, 52), but other controlled studies reported clinical signs. The infection of African cutthroat finches with an APMV-2 isolate resulted in a decrease in activity (29). Clinical signs which may be associated with APMV-3 isolates have been summarized recently (38). Mild respiratory signs were observed after infection with APMV-3 in 1-day-old chickens and turkeys, while no clinical signs were observed in older birds (42). APMV-3 has been associated with encephalitis and high mortality in caged birds and with respiratory disease in turkeys (77). A severe drop in egg production has been observed in turkeys in which APMV-3 was isolated (13). It also has been reported that APMV-3 causes acute pancreatitis and central nervous system symptoms in Psittacine and Passeriformes birds (16). No clinical signs of a disease have been reported for APMV-4. The discovery of APMV-5 was associated with disease in budgerigars that was associated with depression, dyspnea, diarrhea, and torticollis before death (57). APMV-6 might cause a mild respiratory disease and problems in egg production in turkeys (4). The infection of turkeys with virus isolates which have been grouped with APMV-7 caused respiratory signs that were expressed as rhinitis and airsacculitis (63). For viruses that belong to APMV-8, 9, and 10, no clinical disease has been described after infection.

Pathology

Gross Pathology

When turkeys become infected with APMV-2, sinusitis and respiratory signs have been observed (46). Enlarged liver and spleen were observed in red-crowned parakeets where APMV-3 was isolated (37). Interestingly, postmortem examination of 2-week-old chickens and turkeys revealed enlargement of the pancreas with focal necrosis at 5 days after infection with APMV-3 (42). Budgerigars infected with APMV-5 showed hemorrhages in the proventriculus, duodenum, jejunum, and rectum, and sometimes discoloration of the liver and splenomegaly (54). Enlarged pancreas and airsacculitis was observed in turkeys after infection with an APMV-7 isolate (63). In doves in which an APMV-7 was isolated, enlarged and congested livers and spleens were observed (30).

Microscopic Pathology

Catarrhal tracheitis, mild enteritis, and gastrointestinal associated lymphoid tissue (GALT) hyperplasia were observed in chickens infected with APMV-2, 4, and 6 (80). In addition, mild interstitial pneumonia and lymphocytic infiltrates in the pancreas where observed in the same study in chickens infected with APMV-4 and 6. In parakeets infected with APMV-3, lymphocyte infiltration in the kidneys and moderate lymphoid cell infiltration in hepatic and pulmonary tissue was documented while other organs showed no microscopic

changes (brain, inner ear, pancreas, spleen, and intestine), indicating a specific tissue tropism (37). The infection of budgerigars with APMV-5 resulted in extensive loss of mucosal epithelium, edema of the intestinal wall, and vascular engorgement (54). APMV-7 infection in turkeys caused a mild multifocal or nodular lymphocytic airsacculitis, which may be discernable from observation of gross lesions (63).

Pathogenesis of the Infectious Process

The pathogenesis of infection with APMV other than APMV-1 is not well investigated. Usually the infection is restricted to the respiratory tract and sometimes also to the digestive tract. With the exception for APMV-5 in budgerigars, where death upon infection was observed, no serious disease was detected. It is assumed that there is transient self-limited replication immediately after infection. The cleavage of the F protein (F0–F1 and F2) is a prerequisite for a subsequent infection of the deeper layer of tissues. Virulent APMV-1 contain a polybasic amino acid sequence between F1 and F2, and this allows the cleavage by endogenous proteases present in most tissues which results in a systemic infection as well as a very efficient replication in cell culture. In contrast, some APMV serotypes (APMV-2, 4, 6, and 7) do not have such a polybasic amino acid sequence but they can still replicate efficiently in cell culture without the addition of exogenic proteases (82). On the other hand they do not induce a systemic infection. The underlying molecular mechanism is unknown.

Immunity

Infection of domestic birds (chickens and turkeys) with APMV 2–10 resulted in a seroconversion of the birds (52, 55, 80). The level of antibody response might vary between single isolates of the same APMV serotype and among different serotypes (55). Infection of chickens with APMV 2–9 induced protection from death after an NDV challenge infection only in APMV-3-infected chickens and limited protection in chickens infected with APMV-2, 7, 8, and 9 (55).

Diagnosis

Isolation and Identification of Causative Agent

Identifications of APMV 2–11 were performed mainly after inoculation of sample material in the allantoic fluid of embryonating SPF chicken eggs. The allantoic fluid was harvested and employed in a hemagglutination assay using chicken red blood cells. APMV-5 was not isolated from the allantoic cavity but from the amniotic cavity of embryonating SPF eggs. Propagation of APMV-5 was best in cells obtained from embryonating chicken eggs (57). A passage via the yolk sack might help to isolate APMV-5 (32). The virus isolates can be distinguished by electron microscopy as paramyxoviruses. Furthermore, with the recent availability of full-length sequences from all 10 APMV serotypes, diagnostic tests such as reverse transcriptase polymerase chain reaction (RT-PCR) to perform serotype specific assays might become available.

Serology

Infection of birds in addition to mammals with APMV serotypes results in seroconversion (40, 52, 55). It needs to be mentioned that in the presence of high APMV-1 antibody titers cross reactivity with APMV-2 serotype-specific antigen was observed (79). The serologic method of choice is the HI test, either with known APMV serotype-specific antigen or well-characterized antiserum. Seroconversion was observed between 7 and 14 days after infection regardless of species infected.

Differential Diagnosis

For differential diagnosis all viruses causing respiratory signs or macroscopic changes in the intestine in birds could be suspicious. Viruses such as low pathogenicity avian influenza virus, infectious bronchitis virus, infectious laryngotracheitis virus (ILTV), and avian metapneumovirus need to be excluded by either molecular assays or virus propagation and detection of the antigen by appropriate tests. The detection of inclusion bodies in the trachea would be suspicious for ILTV. The combination of molecular assays, classical methods such as virus isolation in the embryonating SPF chicken eggs combined with electron microscopy for distinguishing morphology, has the highest probability of success for excluding other viruses such as APMV.

Intervention Strategies

Management Procedures

High biosecurity levels on the farm certainly minimize the risk of introduction of APMV and other important diseases in the poultry house. For APMV the possibility that wild birds gain access to poultry houses is probably still the main source for virus introduction. Wild birds on poultry farms have been considered potentially important in the transmission of APMVs in part because they have been found to transfer NDV from farm to farm (33).

Vaccination

Types of Vaccine

Vaccines to prevent APMV-1 infections are well known and broadly used. In contrast, the development of vaccines other than APMV-1-based vaccines is restricted to specific situations. Beck et al. (16) described several APMV-3 vaccine candidates that could be used to vaccinate parakeets against the disease. More important is APMV-3 in turkeys, where it can cause a serious disease. Licensed oil-emulsion vaccines against APMV-3 infection and disease have been available for several years in Europe and the United States (17, 24). They have been used to prevent egg production losses associated with APMV-3 infections in laying turkeys and have demonstrated efficacy and safety. Recently the determination of the full-length sequence of at least 1 virus of each APMV serotype (except APMV-10 and APMV-11) was performed (see above). The

long-term goal is to elucidate these viruses as potential live vaccine vectors for use in mammals, including humans (40).

Treatment

There are no reports of treatment of animals affected with APMV 2–11. The main tool to prevent infection, especially those that cause clinical disease of birds, is high biosecurity with a quarantine management program to prevent the introduction of any new infectious agents. In the case of APMV 2–9 the quarantine should be a minimum of 2 weeks, which will reduce the chance of virus shedding in birds just infected at the time of purchase.

Avian Metapneumovirus

Richard C. Jones and Silke Rautenschlein

Introduction

Definition and Synonyms

The clinical diseases that may result from avian metapneumovirus (aMPV) infections of turkeys or chickens have been termed turkey rhinotracheitis (TRT), avian pneumovirus infection of turkeys (APV), swollen head syndrome (SHS), and avian rhinotracheitis (ART), based on clinical signs and lesions. However, these clinical signs and lesions are not specific for aMPV infections and can be confused with disease resulting from mono- or co-infections with other respiratory pathogens. Nevertheless, it is now universally accepted that the conditions referred to as TRT, SHS, or ART can occur as a result of infection with aMPV. The more severe form of associated disease probably results from dual or secondary infection with other organisms, and for SHS, the characteristic swollen head appears as a result of co-infection with secondary adventitious bacteria, usually *Escherichia coli*.

Economic Significance

aMPV infections of poultry are associated with economic and animal welfare problems, particularly in commercial turkey flocks. Even in countries where vaccination against avian pneumovirus has become routine, the disease is still considered one of the most significant respiratory diseases of turkeys (94). Since the initial outbreaks of aMPV infection in turkeys in the USA during 1996 losses in production have caused serious economic problems for many years (15). It has been estimated that from 1997 to 2002 the losses to the Minnesota turkey industry were $15 million/year (99). In many countries aMPV infection is also associated with SHS in broilers and broiler breeders as well as aMPV-induced losses in egg production, which may have a significant economic impact.

Public Health Significance

A genetically similar metapneumovirus is associated with upper respiratory disease in humans (hMPV) (148). After experimental infection of turkeys, all 4 hMPV genotypes caused transient respiratory disease as evidenced by clinical, histologic, and virological examination (152). While there are no reports of human disease from aMPV, an American serological analysis of human adults showed that occupational exposure to turkeys can be a risk factor for infection with aMPV (85). Further investigation of cross-species pathogenicity of hMPV and aMPV and its importance for human and animal health is needed.

History and Epidemiology

Avian metapneumovirus was first described in turkeys in South Africa in the late 1970s (18). Later the disease was reported from Europe and the etiological agent was isolated at about the same time in the United Kingdom and France (110). The infectious agent was characterized as a virus belonging to the family Paramyxoviridae and initially placed in the genus Pneumovirus (38). Additionally, in chickens a disease associated with the same infectious agent was observed which consisted of upper respiratory tract signs followed by a small number of flocks exhibiting swollen heads, later known as swollen head syndrome (SHS) (2).

During the early 1990s vaccines were developed for use in turkeys and chickens originating from the primary turkey isolates. In 1994 it was shown by Juhasz and Easton that 2 subtypes of aMPV existed, termed A and B (83), and it was subsequently found that vaccines developed from a subtype A strain could confer protection against subtype B viruses (45).

Today many European, Asian, South and Central American, and African countries have reported outbreaks associated with aMPV (8, 10, 30, 116), among others. Apart from Australasia, all major poultry rearing regions of the world have reported the presence of aMPV infections. In 1996 aMPV was first described in turkeys in the United States (131). The Colorado outbreak was eradiated by vigorous biosecurity measures, but later the virus was detected and became endemic in turkey-dense Minnesota and neighboring states (15) and was shown experimentally to cause mild clinical diseases in chickens (132). The virus was later shown to be antigenically distinct from subtypes A and B (129). All subsequent isolates from turkeys in North America have been shown to be antigenically similar and are referred to as subtype C aMPVs. Interestingly the disease has not yet been observed in chickens in North America.

Viruses similar to subtype C, but of a different genetic lineage, also have been reported to occur in Muscovy ducks in France (142) and pheasants in Korea associated with respiratory signs and egg production problems (89). A recent study also detected this subtype C lineage in mallards, graylag geese, and common gulls in the Netherlands (147).

A retrospective molecular analysis of viruses isolated from turkeys in France in the 1980s indicated the presence of a fourth subtype of aMPV, designated subtype D (13, 143), which was not reported again after 1985.

Etiology

Classification

Avian metapneumoviruses are members of the subfamily Pneumovirinae, belonging to the family Paramyxoviridae. Two genera belong to the subfamily Pneumovirus consisting of mammalian respiratory syncytial viruses and mouse pneumovirus, and Metapneumovirus in which avian (a) and human (h) pneumoviruses are placed (100, 122, 149). Interestingly, aMPV subtype C is more closely related to hMPV than to the other aMPV subtypes (113, 148, 149). One experimental study demonstrated that avian species may be susceptible to infections with hMPV and develop respiratory disease (152), whereas other studies indicated resistance of turkeys and chickens against hMPV infection (148). A study of evolutionary dynamics contended that the most recent common ancestor of human and avian metapneumoviruses existed around 200 years ago (52). Avian metapneumoviruses have been classified into 4 subtypes (A, B, C, and D) based on nucleotide and deduced amino acid sequence data (49).

Morphology

Negative contrast electron microscopy of aMPV reveals pleomorphic fringed particles, usually roughly spherical, 80–200 nm in diameter, although occasionally round particles with diameters of 500 nm or more can be seen (Figure 3.4). Fringed filamentous forms 80–100 nm in diameter and up to 1,000 nm long also may be present, particularly in preparations from organ culture propagation. Collins and Gough (36) reported the surface projections to be 13–14 nm in length and the helical nucleocapsid to be 14 nm in diameter.

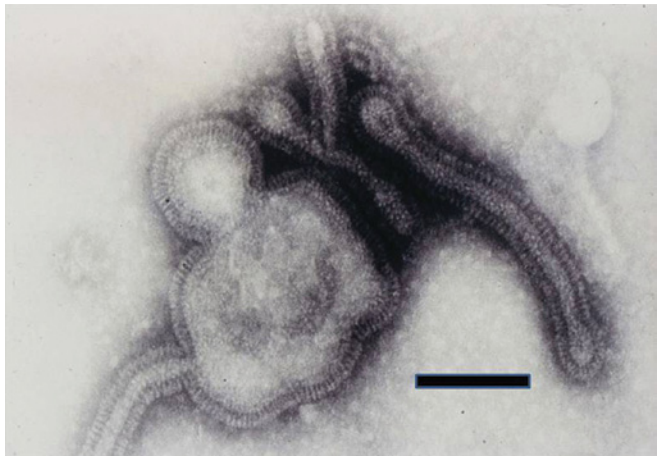

Figure 3.4. Avian metapneumovirus particles. Bar = 100 nm. Reprinted with permission (79).

Chemical Composition

The virus genome is nonsegmented and composed of single-stranded negative sense RNA of approximately 14 kilobases. In sucrose gradients the buoyant density of an isolate from turkeys was 1.21g/ml with an approximate molecular weight of 500×10^6. The same virus was shown to have about 8 structural polypeptides of which 2 were glycosylated and 3 were nonstructural virus-specified proteins (36). These have been identified as nucleoprotein (N), phosphoprotein (P), matrix protein (M), fusion protein (F), second matrix protein (M2), small hydrophobic protein (SH), surface glycoprotein (G), and a large, viral RNA-dependent RNA polymerase (L), flanked by a leader and trailer at the 3′ and 5′ ends, respectively (92). The fusion protein was shown to be highly conserved, while the G-protein showed higher heterogeneity even within subtypes, suggesting its role in virus evolution (26). The composition of aMPVs has been described in detail by Easton et al. (54).

Virus Replication

Few detailed studies on aMPV have been published but virus mechanisms are thought to be similar to related negative strand viruses such as respiratory syncytial virus (RSV). A study of RSV has shown that virus replication and transcription both start at the 3′ leader sequence (56). Because of polymerase dissociation, genes are transcribed and expressed at reduced levels ongoing from the leader to trailer of the genome. The development of a reverse-genetics system for aMPV subtype A (112) has confirmed that as for RSV, the minimum replicative unit is the ribonuclear complex which comprises the nucleocapsid, phosphoprotein, and M2 protein together with the viral polymerase. This study showed that the SH and attachment proteins can be deleted to leave viable but slower growing viruses, at least in tissue culture. This suggests that the fusion protein also can play a role in virus attachment in addition to glycoprotein G. The replication of aMPVs has been described in detail by Easton et al. (54).

Most of the discoveries on aspects of the replication of aMPVs have depended on the use of reverse genetics. Deletion of the SH gene of a type A aMPV impaired replication in cell culture and in turkeys (93). However, replication of G- and M2-deleted viruses was impaired more seve ely in turkeys than in cell culture despite antibody production, suggesting that replication sites other than the trachea may be important. A single polymerase (L) mutation in a subtype B aMPV increased the virulence and increased virus viability at an elevated temperature, suggesting that increased viral virulence may be related to increased ability to replicate in tissues away from the cool respiratory tract of the bird (17).

For a subtype C virus, deletion of the G gene resulted in attenuation, showing it to be important for pathogenicity and immunogenicity (67). Serial passages of aMPV-C in cell culture and in turkeys led to truncation of the G gene which may be a mechanism of virus evolution for survival in a new host or environment (153). Genetic variation in the length of the G gene among type C aMPVs showed that a large portion of the extracellular domain (333aa) of the viral attachment protein is not essential for virus viability *in vitro* or *in vivo* but may play a role in enhancing virus attachment specificity in the natural host (160). Further gene-deletion work by the same group (161) showed that for subtype C, the M2-2 protein is not essential for *in vitro* replication but is required for sufficient replication to maintain pathogenicity and immunogenicity in the turkey.

Susceptibility to Chemical and Physical Agents

Early studies with a European turkey isolate of aMPV reported that the virus was sensitive to lipid solvents, stable at pH 3.0 to 9.0, and inactivated at 56°C after 30 minutes (38). A subtype C strain from turkeys in Minnesota showed a similar resistance to pH. The study reported that the isolate had lost viability by 12 weeks at 4°C, 4 weeks at 20°C, 2 days at 37°C, and 6 hours at 50°C. Several disinfectants were effective in reducing the viability of the virus including quaternary ammonia, ethanol, iodophor, a phenol derivative, and sodium hypochlorite (bleach).

Surprisingly, the aMPV isolate remained viable after 7 days of drying at room temperature (144). The survival of an aMPV subtype C isolate in built-up turkey litter indicated that virus could survive for up to 60 days at a temperature between -12°C and 8°C, and viral RNA was still detectable in the litter kept at 8°C after 90 days (151). A report from Italy in 2011 described disease due to vaccine-derived virus in turkeys in a region where vaccine had not been used for at least 6 months (98), suggesting that virus may survive in the environment for longer than previously thought.

Strain Classification

Early studies using cross neutralization, ELISA techniques, and polypeptide profiling suggested that there were few strain differences between European isolates of aMPV (12, 63). However, more detailed studies using monoclonal antibodies (mAbs) produced to a variety of isolates demonstrated considerable antigenic differences between strains (37, 44). Further confirmation of subtype differences was obtained following nucleotide sequence analysis of the G (attachment) glycoprotein which showed that 2 subgroups, designated A and B, existed within the 1 serogroup (83). Subtype A and B viruses have been isolated from, and can infect, both chickens and turkeys (39).

Subtype C US isolates were shown to have no significant serological relationship with subtype A and B strains from Europe using neutralization tests with monospecific polyclonal and monoclonal antibodies (46). Sequence analyses among American subtype C viruses had 89%–94% nucleotide sequence identity within the N, P, M, F, and M2 protein genes. Comparison of American subtype C viruses with European subtype A and B showed between 41% and 77% nucleotide sequence identity with subtype A and B viruses (129, 135). Retrospective analysis of 2 viruses isolated in France in 1985, subsequently referred to as subtype D, showed differences in the G gene sequence from subtypes A, B, and C isolates (13). Phylogenetic comparison of the 4 subtypes has shown that A, B, and D viruses are more closely related to each other than to subtype C (6, 13, 143), which is in turn more closely related to the hMPV than the other 3.

Laboratory Host Systems

Inoculation of infective mucus into the yolk sac of turkey or chicken embryos resulted in embryo mortality after 4 or 5 passages, but virus remained at a low titer (3). Similarly, inoculation of turkey or chicken tracheal organ cultures (TOCs) resulted in ciliostasis, but again, virus only replicated to low titers (62, 106). Isolates adapted to embryos or TOCs, however, were capable of replication in cultures of primary chicken and turkey embryo cells, mammalian cells such as VERO, BS-C-1, and MA104 cells with a characteristic cytopathic effect of syncytium formation and relatively high virus titers. A continuous quail tumor cell line (QT-35) also has been used to propagate the virus (68). In a recent comparison of several primary cells and perpetual cell lines, Coswig (50) concluded that chick embryo-related cells were suitable for primary isolation of aMPVs and most appropriate for high titer propagation.

Whereas subtypes A and B can be isolated in TOC, subtype C viruses have only been isolated in cell culture or fertile eggs.

Pathogenicity

Despite the high morbidity and occasionally higher mortality rate associated with aMPV in the field, the pathogenicity of aMPV isolates has been difficult to assess in the laboratory. Experimentally, infected birds often show recognizable signs of rhinotracheitis, but these are milder than those seen in the field (162). Chickens show, at most, only mild respiratory disease in laboratory infections (Figure 3.5) and nasal mucus may often only be discernible after light squeezing behind the nostrils. Transmission and infection studies in 2- or 3-week-old broiler chicks with aMPV-turkey isolates of subtype A, B, and C induced clinical signs of coughing and sneezing for up to 8 days post inoculation (PI). Respiratory tissue and intestinal samples from the broilers were positive by PCR for up to 11 days PI (9, 132). An isolate of aMPV from chickens with SHS was able to produce rhinotracheitis in infected turkey poults (121).

Presumably, the difference in pathogenicity between laboratory and field infections is related to the conditions under which the birds are kept and the presence or absence of exacerbative organisms. In laboratory studies concurrent infection of turkey poults with aMPV and respiratory bacteria, such as *E coli, Bordetella avium, Mycoplasma gallisepticum, Riemerella anatipestifer*, and *Ornithobacterium rhinotracheale* (1, 43, 60, 77, 104, 110, 125) and low virulent (lentogenic) Newcastle

Figure 3.5. Avian metapneumovirus infection in a chick. Experimental infection showing foaming eyes and nasal discharge. (S. Rautenschlein)

disease virus (145), significantly exacerbate and prolong clinical signs and morbidity. In experimentally infected turkey poults pre-infection with *Chlamydia psittaci* also was shown to significantly increase the severity of aMPV infection (150).

Pathobiology

Natural and Experimental Hosts

Turkeys and chickens, apparently of any age, are known natural hosts of aMPV.

aMPV has been detected in pheasants with respiratory signs in the United Kingdom and Japan (66, 114, 156), and serological studies suggest that the virus is widespread in game birds (156). A natural infection in pheasants with type C was reported in a market in Korea but clinical signs were not specified (89). Swollen head syndrome has been reported in guinea fowl (96). Picault et al. (120) found aMPV antibodies in flocks of guinea fowl *(Numida meleagris)* and were able to produce a rhinotracheitis-like disease in this species with virus isolated from aMPV-affected turkeys. Avian metapneumovirus has been detected by reverse transcriptase polymerase chain reaction (RT-PCR) and occasionally virus isolation in nasal turbinates of sparrows, ducks, geese, swallows, gulls, and starlings sampled in the north central region of the United States and was shown to be closely related to subtype C viruses isolated from commercial turkeys (14, 15, 133, 134). A survey by Turpin et al. (146) showed the presence of aMPV subtype C in American coots, American crows, Canada geese, cattle egrets, and rock pigeons in Georgia, South Carolina, Arkansas, and Ohio. From oral swabs, coots and geese were positive for virus by RT-PCR. This study demonstrated that wild birds can be a reservoir for the American aMPV in other regions of the USA where diseases in poultry have not been reported.

Subtype C-like viruses also have been reported to occur in commercial Muscovy ducks associated with respiratory signs and egg production problems (142). In Brazil, subtypes A and B related to chicken isolates have been detected in wild birds and pigeons (57), though another study contended that pigeons and sparrows probably act as mechanical vectors because infection is short lived (61).

In experimental infections with a subtype A aMPV, Gough et al. (64) demonstrated susceptibility with clinical signs in turkeys, chickens, and pheasants and an immune response to the virus in guinea fowl, although pigeons, geese, and ducks appeared to be refractory to infection with the virus. Antibodies to aMPV have been reported in farmed ostriches in Zimbabwe (20) and in seagulls in the Baltic (72). In transmission studies in mice, rats, and waterfowl using a turkey aMPV isolate from Minnesota, virus was detected for up to 14 days in mice and 6 days in rats where there was seroconversion but no clinical disease (108). No clinical signs were observed in the waterfowl, but viral RNA was detected by PCR for up to 21 days post infection.

Transmission

In most countries where aMPV has appeared as a new disease, it has spread rapidly. Subtype A viruses detected in China and Nigeria were genetically closely related to UK and Brazilian strains (116) but how aMPVs travel between continents is unknown. The methods by which such spread takes place are unclear and, even on a single site, spread is unpredictable. Contaminated water and movement of affected or recovered poults, of personnel and equipment, feed trucks, etc. have all been implicated in outbreaks, while airborne spread also has been put forward as a possibility. At present, only contact spread has been confirmed. Cook et al. (43) demonstrated that the virus was transmissible from infected to susceptible turkey poults placed in direct contact for a 9-day period after infection. Those authors stressed the apparent importance of direct contact because in their experiments virus failed to spread to susceptible birds housed in the same room but in a different pen. Similar results have been reported by Alkhalaf et al. (4) using a subtype C aMPV. There is no published evidence that aMPV can be vertically transmitted even though high levels of virus can be detected in the reproductive tract of laying birds (81). Inoculation with filtered or unfiltered mucus, nasal washings, or other materials from the respiratory tract of affected birds also established aMPV infection (3, 105).

After experimental infection of chicks and poults (88) subsequent T-cell immunosuppression did not cause reactivation of virus and to date no experimental evidence of long-term aMPV persistence in chickens or turkeys has been demonstrated. It seems highly likely that the density of the poultry population, particularly turkeys, has a significant influence on the degree of spread of the virus (78). Migratory birds, particularly wild fowl, have been suggested as transmitters of aMPVs, although evidence of infection in wild species does not necessarily confirm this. Minnesota, the epicenter of subtype C aMPV infection in the USA, lies in major wild fowl flyways which reach from Canada to Central and South America. However, there has been no apparent spread of subtype A and B viruses from South and Central America to the USA and no evidence of subtype C viruses spreading south.

Pathogenesis, Clinical Signs, Morbidity, and Mortality

aMPV targets the epithelial cells of the respiratory tract as well as the reproductive tract (21, 73, 76, 81). Virus replication induces ciliostasis and possibly loss of cilia, allowing secondary pathogens to invade the host. Some aMPV strains also may have transient immunosuppressive abilities, supporting further secondary infections and reducing vaccine responses (31, 32, 149).

The clinical disease in turkeys has been described in detail elsewhere (39, 95, 109, 136). Typically, clinical signs in young poults include snicking, rales, sneezing, nasal discharge, foamy conjunctivitis, swollen infraorbital sinus, and submandibular edema. Coughing and head shaking are frequently observed, particularly in older poults. In laying birds there may be a drop in egg production of up to 70% with an increased incidence of poor shell quality and peritonitis (81). Coughing associated with lower respiratory tract involvement may lead to prolapses of the uterus in breeding turkeys. When disease is seen, morbidity in birds of all ages is usually described as up to 100%. Flock mortality ranges from as low as 0.4% to as high as 50%, particularly in fully susceptible young poults. In uncomplicated infections recovery usually occurs between 10 and 14 days.

Avian metapneumovirus infection in chickens is less clearly defined and may not always be associated with clinical signs (39, 79). The virus has been associated with swollen head syndrome in chickens, which is characterized by the following clinical signs: swelling of the periorbital and infraorbital sinuses, torticollis, disorientation, and opisthotonous, probably due to virus effects on the ear. Usually less than 4% of the flock is affected, although widespread respiratory signs are usually present. Mortality rarely exceeds 2% and in broiler breeders egg production is frequently affected. In commercial layers aMPV infection also may affect the quality of eggs (39, 79). In laboratory studies the intravenous route of infection had a significant effect on the severity of clinical signs and egg production compared to the oculonasal route, in which egg production remained normal (47, 73). Earlier reports suggest that infectious bronchitis virus together with *E. coli* may also be associated with SHS (53, 107).

aMPV was detected with infectious bronchitis virus in the testes of cockerels in a flock with reduced fertility in Brazil (155) but the role of aMPV in this condition needs further investigation.

Pathology

Gross Lesions

Experimental infection of susceptible 5-week-old turkeys with a European isolate of aMPV resulted in complete deciliation of the trachea by 96 hours after infection (80). Following infection of laying turkeys a watery to mucoid exudate was found in the turbinates 1–9 days PI, with excess mucus in the trachea (81). Various reproductive tract abnormalities also were reported by the same authors, including egg peritonitis, folded shell membranes in the oviduct, misshapen eggs, ovary and oviduct regression, and inspissated albumin and solid yolk. Hens in lay may show prolapsed oviducts due to violent coughing. During natural field outbreaks, exacerbated by secondary pathogens, a variety of gross lesions have been described including airsacculitis, pericarditis, pneumonia, and perihepatitis (39, 65, 79, 130, 136).

In aMPV-infected chickens the only significant lesions noted are those associated with SHS in broilers or broiler breeders. The major gross lesions include extensive yellow gelatinous to purulent edema in the subcutaneous tissues of the head, neck, and wattles. Varying degrees of swelling of the infraorbital sinuses also may be seen (79, 105, 137).

Similar gross lesions have been reported to occur in commercially raised pheasant poults in Japan (114)

Microscopic Lesions

Detailed histological studies have been performed in experimentally inoculated turkey poults and broiler chickens (9, 21, 80, 91, 102, 103, 109, 124). Postmortem examination of the turbinates reveals increased glandular activity, focal loss of cilia, hyperemia, and mild mononuclear infiltration of the submucosa at 1 to 2 days PI. Between 3 and 6 days PI the peak of damage to the epithelial layer and a copious mononuclear inflammatory infiltration in the submucosa is observed. Some transient lesions also may be seen in the trachea, nasal turbinates, or primary bronchi. The lesions in chickens may be milder and of shorter duration than those observed in turkeys.

Immunity

Antibody production and local accumulation of cells of the cell-mediated branch of the immune system begins to rise at the peak of virus replication, which then quickly brings the infection under control and clinical symptoms recede (90, 91).

Active Immunity

Cell-Mediated Immunity. The results of laboratory studies suggest that the cell-mediated immune response provides the main resistance to infection of the respiratory tract with aMPV (86). Jones et al. (82) showed that chemically bursectomized poults given a live attenuated aMPV vaccine when they were 1 day old were unable to seroconvert but were still resistant to challenge with a virulent strain of the virus. Chemically T cell compromised turkeys showed a slower recovery from clinical signs and histological lesions, as well as an extended virus shedding compared to T cell intact birds, supporting the speculation of the important role of T cells in the control of aMPV-infection (127). T cells may locally infiltrate the Harderian gland, may be activated as suggested by the expression of IFN-γ, and possibly control aMPV replication at the site of virus entry (91, 124). Preliminary data provide circumstantial evidence that variations in the T cell response may contribute to the differences in aMPV-pathogenesis between chicken and turkey (124).

Humoral Immunity. Many authors have described the humoral immune response of turkeys to aMPV infection, and

these have been reviewed (109). Following infection of turkeys aMPV antibodies were detected as early as 7 days PI by ELISA and virus neutralization (VN) tests and were maintained for up to 89 days, when the trial was terminated (81). The peak of neutralizing antibody levels in tracheal washes and tears was detected around 10–14 days PI, which coincided with the clearance of detectable aMPV, and then VN-titers declined (91, 124). Cha et al. (27) also demonstrated the accumulation of different B cell populations locally in the nasal turbinates, and the release of IgA into nasal secretions indicating the stimulation of a local humoral immune response. Increased levels of aMPV-specific IgA also were detected in bile, lacrimal fluid, and tracheal washes (58). Humoral antibodies protect the oviduct in the mature hen (73).

Passive Immunity

Hens with circulating aMPV antibodies pass these to their progeny via the egg yolk. Titers are directly related to the levels of circulating antibody in the parent bird. There is evidence that the presence of high levels of maternally derived antibody in 1-day-old turkey poults will not prevent clinical disease following challenge with aMPV (111). Also, high levels of experimentally passively transferred aMPV-antibodies, which were found not only in the circulation but also locally in tracheal fluid, did not protect against homologous challenge (126).

Diagnosis

Isolation and Identification of Avian Metapneumovirus

Successful virus isolation was achieved in chicken or turkey embryos or chicken tracheal organ cultures and these have been used on a routine basis. Molecular techniques, particularly RT-PCR tests, have been developed to detect the virus.

Choice and Timing of Samples for Isolation

Although virus has been isolated from trachea, lung, and viscera of affected turkey poults, ocular and nasal secretions, choanal swabs, or tissue scraped from the sinuses or turbinates were shown to be better sources for virus detection (9). It is extremely important to obtain samples as early as possible after infection because virus may only be present in the sinuses and turbinates for 6–7 days (9, 49, 64). Isolation of virus is rarely successful from birds showing severe signs; presumably the extreme signs are a result of secondary, adventitious bacterial infections in birds predisposed by earlier virus infection. This probably accounts for the lack of success in isolating virus from chickens with SHS, because the characteristic signs appear to be due to secondary *E. coli* infection. Furthermore, for reasons that are unclear, virus isolation from chickens appears to be more difficult than that from turkeys.

Due to the labile nature of the virus it is essential that samples for attempted virus isolation are sent immediately to the laboratory on ice (49, 65). Where delays are unavoidable samples should be frozen at –50°C to -70°C or on dry ice.

Virus Isolation

The various methods used for the primary isolation of aMPV have been published elsewhere (49, 65, 68). What is apparent from the European and more recently, the American experience, is that multiple approaches to diagnosis should be used to maximize the chances of successfully isolating the virus.

Tracheal Organ Cultures. Tracheal organ cultures are prepared from turkey or chicken embryos shortly before hatching or from 1- to 2-day-old chicks originating from aMPV antibody-free flocks. The cultures can be maintained for several weeks and following inoculation with samples they are observed for ciliostasis, which may take several passages before a consistent effect is observed (49). However, TOCs were found to be unsuitable for the isolation of subtype C viruses because the isolates did not cause ciliostasis (46).

Culture in Embryonating Eggs. Six- to 8-day-old embryonating turkey and chicken eggs from aMPV-negative flocks have been used to isolate the virus following inoculation by the yolk-sac route. Usually, serial passage is required before the agent causes consistent embryo mortality. This technique was used to isolate the original aMPV strain in South Africa in 1980 and the original subtype C aMPV strains from the United States (19, 117).

Cell Cultures. Cell cultures generally are not successful for the primary isolation of aMPV strains. Occasionally, chicken embryo cells and VERO cells have been used successfully (68). Where positive results were obtained multiple blind passages were required before the virus produced a consistent cytopathic effect (CPE). QT-35 cells also have proved suitable for the primary isolation of APV strains (68). Once adapted to growth in embryonating eggs and TOC the virus can be cultivated to high titers in a range of avian and mammalian cells. The virus produces a characteristic CPE with the formation of syncytia within 7 days.

Virus Identification

The isolated virus shows a paramyxovirus-like morphology when examined by negative contrast electron microscopy. Details are described in Virus Morphology, above.

The physiochemical properties of the isolated virus can be investigated to aid identification and these have been described in detail elsewhere (49, 65).

Strains have previously been distinguished using monoclonal antibodies but now universally by molecular methods which demonstrate differences in the nucleotide sequences of the attachment protein (G) and other protein genes (49).

Direct Detection of Viral Antigens

A number of assays have been developed to detect and demonstrate the presence of aMPV antigen in both fixed and unfixed tissues and smears. The most widely used are immunoperoxidase (IP) and immunofluorescence (IF) staining (21, 81, 102).

Molecular Identification

In recent years significant advances have been made in the diagnosis of aMPV based on the development of RT-PCR techniques. There is no doubt that molecular techniques are significantly more sensitive and rapid than conventional virus isolation methods (24, 49, 65, 115). An important consideration when using PCR methods is whether to use subtype-specific or generic-type PCRs, designed to detect several if not all aMPV subtypes (147). In Europe, where all 4 subtypes of aMPV have been reported, this is clearly an important consideration and commercial quantitative RT-PCRs (qRT-PCRs) are available today to detect all 4 subtypes. RT-PCR methods using primers targeted to the F, M, and G genes have been developed but are limited in specificity and may not detect all subtypes (49, 65). RT-PCR methods using primers directed to the conserved region of the N gene have been described with the ability to detect representative aMPV isolates of subtypes A, B, C, and D (13). Using this method, positive products can be further analyzed to determine the subtype using subtype-specific RT-PCRs or by sequencing and restricting fragment length analysis. A variety of RT-PCR techniques have been developed and evaluated and these have been extensively reviewed elsewhere (25, 49, 99, 113). It should be remembered that molecular methods do not provide the live virus, so isolation also must be attempted if pathogenesis or vaccine studies are proposed.

Serology

The ELISA is the most commonly employed serological method but other techniques include virus neutralization and indirect immunofluorescence (11, 49, 55, 65, 141). A variety of commercial and in-house kits have been developed for detecting aMPV antibodies (39, 65, 115). It has been shown that vaccinal antibodies may not be detected if heterologous strains of aMPV are used to prepare the coating antigen for the ELISA plates (55). Studies using ELISA kits incorporating subtype A or B antigens were found to be relatively insensitive for detecting antibodies to the Colorado strain of aMPV (46). Some competitive ELISA kits incorporate a specific aMPV monoclonal antibody that facilitates the testing of sera from different avian species. However, the kits were found to be unsuitable for the detection of antibodies against aMPV isolates from the US (46). More recently ELISAs have been developed and evaluated which incorporate whole virus antigens prepared from Colorado and Minnesota isolates of aMPV (45, 33, 101). More sensitive and specific ELISAs using M and N protein-expressed antigens in sandwich-capture ELISAs for detecting subtype C antibodies also have been described (69). The use of antibodies from egg yolk in laying hens has been described (34) with good correlation with serum antibody levels.

Antibodies to aMPV can be detected by standard virus neutralization (VN) techniques using sensitive cell cultures or TOC. The test in chicken embryo cells has been detailed elsewhere (65). Cross reactivity occurs with subtype A and B viruses and good correlation with ELISA and indirect immunofluorescence test has been reported (11, 49). However, the VN test is time consuming, expensive, and unsuitable for mass serological screening of poultry flocks. The serological response in chickens following infection or vaccination is often weak compared to the response in turkeys.

In common with all serological tests, both acute and convalescent sera should be submitted for analysis. The sera should be heat treated at 56°C for 30 minutes to remove nonspecific inhibitors and if delays in testing are unavoidable stored at –20°C.

Differential Diagnosis

Strain Variability

The morphological appearance of aMPV gives no indication of the strain or subtype. Subtype A and B viruses were originally differentiated on the basis of nucleotide sequence analysis of the attachment (G) protein gene (83) and mAB analysis (37, 44), although they belong to the same serotype. With the emergence of subtype C in the USA, and evidence of subtypes C and D in France, it remains to be seen whether further subtypes of aMPV will be detected. It is possible that current RT-PCR methods may fail to detect the presence of "new" subtypes of aMPV. Clearly a multidiagnostic approach is required to detect further subtypes of aMPV, including virus isolation, electron microscopy, and the development of more sensitive PCR methods (49).

Other Viruses

Paramyxoviruses, particularly Newcastle disease virus and APMV-3, infectious bronchitis, and influenza viruses may cause respiratory disease and egg production problems in chickens and turkeys that closely resemble aMPV infection. Paramyxoviruses and some avian influenza virions are similar in morphology but can be easily distinguished from aMPV because they possess hemagglutinin and neuraminidase activity. Infectious bronchitis virus can be differentiated from aMPV by morphological and molecular characteristics.

Bacteria Including Mycoplasmas

A wide range of bacteria including mycoplasma species can cause disease signs very similar to those of an aMPV infection (94). These organisms often act as secondary opportunistic pathogens following aMPV infection and may cause considerable diagnostic problems. Only by isolating or identifying aMPV in the affected birds can a clear distinction be made.

Intervention Strategies

Management Procedures

It is now accepted that management factors significantly influence the severity of aMPV infection in commercial poultry, particularly turkeys. Poor management practices

such as inadequate ventilation and temperature control, high stocking densities, poor litter quality and general hygiene, multi-age stock, and the presence of secondary pathogens can all exacerbate aMPV infection (65, 79, 94, 136). Debeaking or vaccinating flocks at a critical time also can influence the severity of clinical signs and eventual mortality due to aMPV infection (7). As a general principle, good biosecurity is essential in preventing the introduction and spread of aMPV onto poultry farms because evidence suggests that wild birds also may act as carriers of the virus. Disinfection of equipment and feed trucks should be routine as well as changing clothes and boots and good hygiene for delivery and catching crews.

Success in reducing the severity of the disease may be achieved by controlling secondary adventitious bacteria with antibiotics (71).

Vaccination Strategies

Both live attenuated and inactivated aMPV vaccines are available commercially for use in turkeys and chickens. Early work on the attenuation of the virus was difficult due to poor attenuation of the virus and problems in reproducing a suitable challenge model in the laboratory (140). However, several reports describe the successful attenuation of aMPV strains in a variety of cell cultures and their effective use as vaccines (19, 40, 41, 42, 118, 157). The live vaccines are normally given by spray or in the drinking water and a recent study showed that with accurate application, both give similar immunity equivalent to that induced by eye drop (59). Live attenuated vaccines have been shown to stimulate both systemic immunity and local immunity in the respiratory tract (86, 91). In turkeys and particularly chickens, the humoral antibody response is poor following primary live vaccination but birds may still be protected against challenge via cell-mediated immunity in the respiratory tract (157). The immunity may be significantly compromised in T cell-suppressed birds, which leads to insufficient protection against challenge.

Similarly, high levels of maternally derived antibody does not prevent young turkey poults from developing clinical disease following exposure to virulent aMPV (111). Studies have shown that good cross protection occurs following vaccination with subtype A and B vaccines (45) and that vaccines produced from both subtype A and B strains of aMPV will confer protection against the Colorado subtype C strain of the virus (39). To produce complete protection in adult birds oil-adjuvanted inactivated aMPV vaccines are administered to birds previously primed with live vaccines. Live vaccination may have to be repeated at least 2 to 3 times, especially in male turkeys, depending on the field pressure situation. The strategy is to produce cell-mediated immunity in the respiratory tract. Vaccination reactions may occur due to the presence of secondary pathogens. Breeding stock receive an additional inactivated vaccine at 16–20 weeks.

Cook et al. (48) produced evidence that the use of a live infectious bronchitis (IB) vaccine interferes with the replication of live aMPV vaccine, resulting in a reduction in the antibody response but with no adverse effect on the induction of protective immunity.

Future Developments

Further developments in aMPV vaccination strategies will become necessary because reversion of aMPV vaccine strains to virulence have been reported in a variety of recent studies (22, 98). Field strains also show evolution mechanisms to circumvent protective immunity in vaccinated birds (23, 26). Furthermore, evidence of increased virulence has been reported in recent isolates from the United States (154). Reports from Brazil(30) and Israel (10) on the co-circulation of field and vaccine subtypes A and B in commercial chicken and turkey flocks are disturbing and further illustrate that there is a continuing need to devise improved vaccines and protocols.

These findings furthermore suggest that regular appraisal of the efficacy of available commercial vaccines against the new isolates is necessary.

Recombinant vaccines that incorporate specific immunogens, such as the fusion (F) glycoprotein, in fowlpox or Newcastle disease virus (75, 159) and different DNA plasmids (90, 138) also have been evaluated. From the results obtained with the poxvirus recombinant vaccine it was concluded that experimental vaccination induced aMPV antibodies in experimental turkeys and produced some protection to challenge (159). Studies in turkeys on the immunity to an aMPV vaccine following *in ovo* vaccination also have been reported (28, 74, 158). The results indicated that this route of vaccination has several advantages compared to conventional methods of vaccination (158). A cold adapted strain of aMPV was evaluated as a vaccine and was shown to produce protection to challenge for up to 14 weeks post vaccination (119). Recent studies indicated that the application of inactivated vaccines in combination with poly I:C as an adjuvant through the respiratory route also may induce a protective immunity against aMPV-challenge and reduction of virus shedding (29). A further study (123) showed that a potent cytokine inducer can maintain the immunogenicity of a partially attenuated aMPV vaccine.

Subunit and deletion mutant vaccines as well as virosome-based vaccine candidates also are being developed and evaluated (84, 90). The reverse genetics system for aMPV allowed the development of mutated viruses, which may lead to improved vaccines (35). Brown et al. have identified 2 regions within the fusion protein of the subtype A virus which are recognized by neutralizing antibodies (16) . Such findings are likely to be useful in guiding future vaccine design.

References

Introduction

1. Alexander, D.J., and D.A. Senne. 2008. Newcastle disease. In: *Diseases of Poultry*, 12th ed. Y.M. Saif, A.M. Fadly, J.R. Glisson, L.R. McDougald, L.K. Nolan, and D.E. Swayne, eds. Blackwell Publishing, Ames, Iowa. 75–100.
2. Briand, F.X., A. Henry, P. Massinand, and V. Jestin. 2012. Complete genome sequence of a novel avian paramyxovirus. *J Virol.* 86(14):7710.
3. Diel, D.G., P.J. Miller, P.C. Wolf, R.M. Mickley, A.R. Musante, D.C. Emanueli, K.J. Shively, K. Pedersen, and C.L. Afonso. 2012. Characterization of Newcastle disease viruses isolated from cormorant and gull species in the United States in 2010. *Avian Dis.* 56:128–33.
4. Fornells, L.A., T.F. Silva, I. Bianchi, C.E. Travassos, M.H. Liberal, C.M. Andrade, M.P. Petrucci, V.F. Veiga, M.F. Vaslin, and J.N. Couceiro. 2012. Detection of paramyxoviruses in Magellanic penguins (*Spheniscus magellanicus*) on the Brazilian tropical coast. *Vet Microbiol.* 156:429–433.
5. International Committee on Taxonomy on Viruses. 2012. *Virus Taxonomy: Ninth Report of the International Committee on Taxonomy of Viruses*. Academic Press, Waltham, MA.
6. Miller, P.J., C.L. Afonso, E. Spackman, M.A. Scott, J.C. Pedersen, D.A. Senne, J.D. Brown, C.M. Fuller, M.M. Uhart, W.B. Karesh, I.H. Brown, D.J. Alexander, and D.E. Swayne. 2010. Evidence for a new avian paramyxovirus serotype 10 detected in Rockhopper penguins from the Falkland Islands. *J Virol.* 84:11496–11504.
7. Turpin, E.A., D.E. Stallknecht, R.D. Slemons, L. Zsak, and D.E. Swayne. 2008. Evidence of avian metapneumovirus subtype C infection of wild birds in Georgia, South Carolina, Arkansas and Ohio, USA. *Avian Pathol*. 37:343–51.
8. van den Hoogen, B.G., J.C. de Jong, J. Groen, T. Kuiken, R. de Groot, R.A.M. Fouchier, and A.D.M.E. Osterhaus. 2001. A newly discovered human pneumovirus isolated from young children with respiratory tract disease. *Nature Med.* 7:719–724.

Newcastle Disease

1. Abenes, G.B., H. Kida, and R. Yanagawa. 1986. Biological activities of monoclonal antibodies to the hemagglutinin-neuraminidase (HN) protein of Newcastle disease virus. *Jpn J Vet Sci.* 48:353–362.
2. Abolnik, C., R.F. Horner, S.P.R. Bisschop, M.E. Parker, M. Romito, and G.J. Viljoen. 2004. A phylogenetic study of South African Newcastle disease virus strains isolated between 1990 and 2002 suggests epidemiological origins in the Far East. *Arch Virol.* 149:603–619.
3. Absalon, A.E., A. Mariano-Matias, A. Vasquez-Marquez, A. Morales-Garzon, D.V. Cortes-Espinosa, R. Ortega-Garcia, and E. Lucio-Decanini. 2012. Complete genome sequence of a velogenic Newcastle disease virus isolated in Mexico. *Virus Genes.* 45:304–310.
4. Ahmed, K.A., V.K. Saxena, A. Ara, K.B. Singh, N.R. Sundaresan, M. Saxena, and T.J. Rasool. 2007. Immune response to Newcastle disease virus in chicken lines divergently selected for cutaneous hypersensitivity. *Int J Immunogenet.* 34:445–455.
5. Al-Garib, S.O., A.L.J. Gielkens, E. Gruys, L. Hartog, and G. Koch. 2003. Immunoglobulin class distribution of systemic and mucosal antibody responses to Newcastle disease in chickens. *Avian Dis.* 47:32–40.
6. Aldous, E.W., and D.J. Alexander. 2008. Newcastle disease in pheasants (*Phasianus colchicus*): A review. *Vet J.* 175:181–185.
7. Aldous, E.W., C.M. Fuller, J.K. Mynn, and D.J. Alexander. 2004. A molecular epidemiological investigation of isolates of the variant avian paramyxovirus type 1 virus (PPMV-1) responsible for the 1978 to present panzootic in pigeons. *Avian Pathol.* 33:258–269.
8. Aldous, E.W., J.K. Mynn, J. Banks, and D.J. Alexander. 2003. A molecular epidemiological study of avian paramyxovirus type 1 (Newcastle disease virus) isolates by phylogenetic analysis of a partial nucleotide sequence of the fusion protein gene. *Avian Pathol.* 32:239–257.
9. Aldous, E.W., J.M. Seekings, A. McNally, H. Nili, C.M. Fuller, R.M. Irvine, D.J. Alexander, and I.H. Brown. 2010. Infection dynamics of highly pathogenic avian influenza and virulent avian paramyxovirus type 1 viruses in chickens, turkeys and ducks. *Avian Pathol.* 39:265–273.
10. Alexander, D.J. 2009. Ecology and Epidemiology of Newcastle Disease. In: *Avian Influenza and Newcastle Disease: A Field and Laboratory Manual*. I. Capua and D.J. Alexander, eds. Springer, New York. 19–26.
11. Alexander, D.J. 2001. Newcastle Disease. *Brit Poult Sci*. 42:5–22.
12. Alexander, D.J. 1997. Newcastle Disease and other Avian Paramyxoviridae Infections. In: *Diseases of Poultry*, 10th ed. Iowa State University Press, Ames, Iowa. 541–569.
13. Alexander, D.J. 2000. Newcastle disease in ostriches (*Struthio camelus*)—a review. *Avian Pathol.* 29:95–100.
14. Alexander, D.J. 2011. Newcastle disease in the European Union 2000 to 2009. *Avian Pathol.* 40:547–558.
15. Alexander, D.J. 1988. Newcastle disease: Methods of spread. In: *Newcastle Disease*. D.J. Alexander, ed. Kluwer Academic Publishers, Dordrecht, Netherlands; Boston, Massachusetts, USA. 256–272.
16. Alexander, D.J., and W.H. Allan. 1974. Newcastle disease virus pathotypes. *Avian Pathol.* 3:269–278.
17. Alexander, D.J., J. Banks, M.S. Collins, R.J. Manvell, K.M. Frost, E.C. Speidel, and E.W. Aldous. 1999. Antigenic and genetic characterisation of Newcastle disease viruses isolated from outbreaks in domestic fowl and turkeys in Great Britain during 1997. *Vet Rec.* 145:417–421.
18. Alexander, D.J., G. Campbell, R.J. Manvell, M.S. Collins, G. Parsons, and M.S. McNulty. 1992. Characterisation of an antigenically unusual virus responsible for two outbreaks of Newcastle disease in the Republic of Ireland in 1990. *Vet Rec.* 130:65–68.
19. Alexander, D.J., R.J. Manvell, J. Banks, M.S. Collins, G. Parsons, B. Cox, K.M. Frost, E.C. Speidel, S. Ashman, and E.W. Aldous. 1999. Experimental assessment of the pathogenicity of the Newcastle disease viruses from outbreaks in Great Britain in 1997 for chickens and turkeys, and the protection afforded by vaccination. *Avian Pathol.* 28:501–511.
20. Alexander, D.J., R.J. Manvell, P.A. Kemp, G. Parsons, M.S. Collins, S. Brodkman, P.H. Russell, and S.A. Lister. 1987. Use of monoclonal antibodies in the characterization of avian paramyxovirus type 1 (Newcastle disease virus) isolates submitted to an international reference laboratory. *Avian Pathol*. 16:533–565.
21. Alexander, D.J., R.J. Manvell, and G. Parsons. 2006. Newcastle disease virus (strain Herts 33/56) in tissues and organs of chickens infected experimentally. *Avian Pathol.* 35:99–101.
22. Alexander, D.J., and G. Parsons. 1984. Avian paramyxovirus type 1 infections of racing pigeons: 2. Pathogenicity experiments in pigeons and chickens. *Vet Rec*. 114:466–469.
23. Alexander, D.J., G. Parsons, and R. Marshall. 1984. Infections of fowls with Newcastle disease virus by food contaminated with pigeon faeces. *Vet Rec.* 115:601–602.

24. Alexander, D.J., P.H. Russell, and M.S. Collins. 1984. Paramyxovirus type 1 infections of racing pigeons: 1. Characterization of isolated viruses *Vet Rec*. 114:444–446.
25. Alexander, D.J., P.H. Russell, G. Parsons, E.M. Elzein, A. Ballouh, K. Cernik, B. Engstrom, M. Fevereiro, H.J.A. Fleury, M. Guittet, E.F. Kaleta, U. Kihm, J. Kosters, B. Lomniczi, J. Meister, G. Meulemans, K. Nerome, M. Petek, S. Pokomunski, B. Polten, M. Prip, R. Richter, E. Saghy, Y. Samberg, L. Spanoghe, and B. Tumova. 1985. Antigenic and biological characterisation of avian paramxovirus type 1 isolates from pigeons—an international collaborative study. *Avian Pathol.* 14:365– 376.
26. Alexander, D.J., and D.A. Senne. 2008. Newcastle disease, other avian paramyxoviruses, and pneumovirus infections. In: *Diseases of Poultry*, 12th ed. Y.M. Saif, A.M. Fadly, J.R. Glisson, L.R. McDougald, L.K. Nolan, and D.E. Swayne, eds. Iowa State University Press, Ames, Iowa. 75–116.
27. Alexander, D.J., and D.E. Swayne. 1998. Newcastle disease virus and other avian paramyxoviruses. In: *A Laboratory Manual for the Isolation and Identification of Avian Pathogens*, 4th ed. D.E. Swayne, J.R. Glisson, M.W. Jackwood, J.E. Pearson, and W.M. Reed, eds. The American Association of Avian Pathologists, Kennett Square, PA. 156–163.
28. Alexander, D.J., G.W.C. Wilson, P.H. Russell, S.A. Lister, and G. Parsons. 1985. Newcastle disease outbreaks in fowl in Great Britain during 1984. *Vet Rec.* 117:429–434.
29. Allan, W.H., and L.J. Borland. 1979. The stress index: a method for indicating the pathogenicity H. *Avian Pathol.* 8:401–409.
30. Allan, W.H., J.E. Lancaster, and B. Toth. 1978. Newcastle disease vaccines their production and use. *FAO Animal Production and Health Series No. 10*. Food and Agriculture Organization of the United Nations, Rome.
31. Almkvist, J., C. Dahlgren, H. Leffler, and A. Karlsson. 2004. Newcastle disease virus neuraminidase primes neutrophils for stimulation by galectin-3 and formyl-Met-Leu-Phe. *Exp Cell Res.* 298:74–82.
32. Alphin, R.L., C.D. Ciaverelli, D.P. Hougentogler, K.J. Johnson, M.K. Rankin, and E.R. Benson. 2010. Postoutbreak disinfection of mobile equipment. *Avian Dis.* 54:772–776.
33. Anonymous. 1993. *Commission of the European Communities: Commission decision of 8 February 1993 laying down the criteria for vaccines to be used against Newcastle disease in the context of routine vaccination programmes*. European Commission, Brussels. http://eur-lex.europa.eu/LexUriServ/LexUriServ.do?uri=CONSLEG:1993D0152:20101201:EN:PDF. Accessed January 21, 2013.
34. Anonymous. 2008. Pasteurization of liquid eggs. Title 9, Code of Federal Regulations, 590.570. http://www.access.gpo.gov/nara/cfr/waisidx_08/9cfr590_08.html. Accessed January 21, 2013.
35. Arifin, M.A., M. Mel, M.I. Abdul Karim, and A. Ideris. 2010. Production of Newcastle disease virus by Vero cells grown on cytodex 1 microcarriers in a 2-litre stirred tank bioreactor. *J Biomed Biotechnol.* 2010:7.
36. Banerjee, M., W.M. Reed, S.D. Fitzgerald, and B. Panigrahy. 1994. Neurotropic velogenic Newcastle disease in cormorants in Michigan: Pathology and virus characterization. *Avian Dis.* 38:873–878.
37. Bang, F.B., and R. Libert. 1952. The effect of Newcastle disease virus on chicken red blood cells: II. A study of the adsorption, sensitization, and elution process. *Am J Epidemiol*. 55:373–385.
38. Bank, W. 2011. World Livestock Disease Atlas. A Quantitative Analysis of Global Animal Health Data. (2006–2009). Washington, DC. http://www.oie.int/doc/ged/D11291.PDF. Accessed January 21, 2013.
39. Beard, C.W., and R.P. Hanson. 1984. Newcastle disease. In: *Diseases of Poultry*, 8th ed. M.S. Hofstad, H.J. Barnes, B.W. Calnek, W.M. Reid, and H.W. Yoder, eds. Iowa State University Press, Ames, Iowa. 452–470.
40. Beard, C.W., P. Villegas, and J.R. Glisson. 1993. Comparative efficacy of the B-1 and VG/GA vaccine strains against velogenic viscerotropic Newcastle disease virus in chickens. *Avian Dis.* 37:222–225.
41. Beard, C.W., and W.J. Wilkes. 1985. A comparison of Newcastle disease virus hamagglutination-inhibition test results from diagnostic laboratories in the southeastern U.S. *Avian Dis*. 29:1048–1056.
42. Blignaut, A., W.P. Burger, A.J. Morley, and D.U. Bellstedt. 2000. Antibody responses to LaSota strain vaccines of Newcastle disease virus in Ostriches (*Struthio camelus*) as detected by enzyme-linked immunosorbent assay. *Avian Dis.* 44:390–398.
43. Boursnell, M.E.G., P.F. Green, A.C.R. Samson, J.I.A. Campbell, A. Deuter, R.W. Peters, N.S. Millar, P.T. Emmerson, and M.M. Binns. 1990. A recombinant fowlpox virus expressing the hemagglutinin-neuraminidase gene of Newcastle disease virus (NDV) protects chickens against challenge by NDV. *Virology.* 178:297–300.
44. Bouzari, M., and P. Spradbrow. 2006. Early events following oral administration of Newcastle disease virus strain V4. *J Poult Sci.* 43:408–414.
45. Bragg, R.R., and P. Plumstead. 2003. Continuous disinfection as a means to control infectious diseases in poultry. Evaluation of a continuous disinfection programme for broilers. *Onderstepoort J of Vet*. 70:219–229.
46. Briand, F.X., A. Henry, P. Massin, and V. Jestin. 2012. Complete genome sequence of a novel avian paramyxovirus. *J Virol.* 86:7710.
47. Bukreyev, A., and P.L. Collins. 2008. Newcastle disease virus as a vaccine vector for humans. *Curr Opin Mol Ther.* 10:46–55.
48. Buonavoglia, C., A. Fioretti, M. Tollis, F. Menna, and V. Papparella. 1988. A preliminary vaccine potency trial of a Newcastle disease virus inactivated with binary ethylenimine. *Vet Res Commun.* 12:195–197.
49. Burnet, F.M. 1943. Human infection with the virus of Newcastle disease of fowls. *Med J Australia.* 2:313–314.
50. Burridge, M.J., H.P. Riemann, and W.W. Utterback. 1975. Methods of spread of velogenic viscerotropic Newcastle disease virus in the southern Californian epidemic of 1971–1973. *Avian Dis.* 19:666–678.
51. Bwala, D.G., S. Clift, N.M. Duncan, S.P. Bisschop, and F.F. Oludayo. 2011. Determination of the distribution of lentogenic vaccine and virulent Newcastle disease virus antigen in the oviduct of SPF and commercial hen using immunohistochemistry. *Res Vet Sci.* 93:520–528.
52. Cantin, C., J. Holguera, L. Ferreira, E. Villar, and I. Munoz-Barroso. 2007. Newcastle disease virus may enter cells by caveolae-mediated endocytosis. *J Gen Virol.* 88:559–569.
53. Capua, I., M. Scacchia, T. Toscani, and V. Caporale. 1993. Unexpected isolation of virulent Newcastle disease virus from commercial embryonated fowls' eggs. *J Vet Med B.* 40:609–612.
54. Cattoli, G., C. De Battisti, S. Marciano, S. Ormelli, I. Monne, C. Terregino, and I. Capua. 2009. False negative results of a validated real time protocol for Newcastle disease due to genetic variability of the matrix gene. *J Clin Microbiol.* 47:3791–3792.
55. Cattoli, G., L. Susta, C. Terregino, and C. Brown. 2011. Newcastle disease: a review of field recognition and current methods of laboratory detection. *J Vet Diagn Invest.* 23:637–656.
56. Chakrabarti, S., D.J. King, C. Afonso, D. Swayne, C.J. Cardona, D.R. Kuney, and A.C. Gerry. 2007. Detection and isolation of

exotic Newcastle disease virus from field-collected flies. *J Med Entomol.* 44:840–844.
57. Chambers, P., and A.C.R. Samson. 1982. Non-structural proteins in Newcaslte disease virus-infected cells. *J Gen Virol.* 58:1–12.
58. Chang, P.W. 1981. Newcastle disease. In: *CRC Handbook Series in Zoonoses, Section B: Viral Zoonoses*, Volume II, J.H. Steele, ed. CRC Press, Inc., Boca Raton, Florida. 261–274.
59. Charan, S., A. Rai, V.M. Mahajan, and L.P. Agarwal. 1981. Modified single radial heamolysis technique: measurement of the antibodies to Newcaslte disease virus. *J Immunol Methods.* 40:239–242.
60. Chen, J.P., and C.H. Wang. 2002. Clinical epidemiologic and experimental evidence for the transmission of Newcastle disease virus through eggs. *Avian Dis.* 46:461–465.
61. Chmielewski, R.A., J.R. Beck, and D.E. Swayne. 2011. Thermal inactivation of avian influenza virus and Newcastle disease virus in a fat-free egg product. *J Food Prot.* 74:1161–1168.
62. Cho, S.H., H.J. Kwon, T.E. Kim, J.H. Kim, H.S. Yoo, and S.J. Kim. 2008. Variation of a Newcastle disease virus hemagglutinin-neuraminidase linear epitope. *J Clin Microbiol.* 46:1541–1544.
63. Cho, S.H., H.J. Kwon, T.E. Kim, J.H. Kim, H.S. Yoo, M.H. Park, Y.H. Park, and S.J. Kim. 2008. Characterization of a recombinant Newcastle disease vaccine strain. *Clin Vaccine Immunol.* 15:1572–1579.
64. Chu, H.P., G. Snell, D.J. Alexander, and G.C. Schild. 1982. A single radial immuno diffusion test for antibodies to Newcastle disease virus. *Avian Pathol.* 11:227–234.
65. Cobb, S.P. 2011. The spread of pathogens through trade in poultry meat: overview and recent developments. *Rev Sci Tech.* 30:149–164.
66. Collins, M.S., J.B. Bashiruddin, and D.J. Alexander. 1993. Deduced amino acid sequences at the fusion protein cleavage site of Newcastle disease viruses showing variation in antigenicity and pathogenicity. *Arch Virol.* 128:363–370.
67. Collins, M.S., S. Franklin, I. Strong, G. Meulemans, and D.J. Alexander. 1998. Antigenic and phylogenetic studies on a variant Newcastle disease virus using anti-fusion protein monoclonal antibodies and partial sequencing of the fusion protein gene. *Avian Pathol.* 27:90–96.
68. Collins, M.S., I. Strong, and D.J. Alexander. 1994. Evaluation of the molecular basis of pathogenicity of the variant Newcastle disease viruses termed "pigeon PMV-1 viruses." *Arch Virol.* 134:403–411.
69. Commission, European. 1992. Directorate General, Health and Consumers, Overview, Animal Health and Welfare, Newcastle Disease Control Measures. European Commission, Brussels. http://eur-lex.europa.eu/LexUriServ/LexUriServ.do?uri=CELEX:31992L0066:EN:NOT. Accessed January 25, 2013.
70. Cucco, M., I. Pellegrino, and G. Malacarne. 2010. Immune challenge affects female condition and egg size in the grey partridge. *J Exp Zool A Ecol Genet Physiol.* 313:597–604.
71. Czegledi, A., D. Ujvari, E. Somogyi, E. Wehmann, O. Werner, and B. Lomniczi. 2006. Third genome size category of avian paramyxovirus serotype 1 (Newcastle disease virus) and evolutionary implications. *Virus Res.* 120:36–48.
72. Czegledi, A., E. Wehmann, and B. Lomniczi. 2003. On the origins and relationships of Newcastle disease virus vaccine strains Hertfordshire and Mukteswar, and virulent strain Herts'33. *Avian Pathol.* 32:271–276.
73. de Sousa, R.L.M., H.J. Montassier, and A.A. Pinto. 2000. Detection and quantification of antibodies to Newcastle disease virus in ostrich and rhea sera using a liquid phase blocking enzyme-linked immunosorbent assay. *Clin Diagn Lab Immun.* 7:940–944.
74. Degefa, T., L. Dadi, A. Yami, K.G. Mariam, and M. Nassir. 2004. Technical and economic evaluation of different methods of Newcastle disease vaccine administration. *J Vet Med A.* 51:365–369.
75. Degen, W.G., N. Daal, L. Rothwell, P. Kaiser, and V.E. Schijns. 2005. Th1/Th2 polarization by viral and helminth infection in birds. *Vet Microbiol.* 105:163–167.
76. Diel, D.G., L.H. da Silva, H. Liu, Z. Wang, P.J. Miller, and C.L. Afonso. 2012. Genetic diversity of avian paramyxovirus type 1: Proposal for a unified nomenclature and classification system of Newcastle disease virus genotypes. *Infect Genet Evol.* 12:1770–1779.
77. Diel, D.G., P.J. Miller, P.C. Wolf, R.M. Mickley, A.R. Musante, D.C. Emanueli, K.J. Shively, K. Pedersen, and C.L. Afonso. 2012. Characterization of Newcastle disease viruses isolated from cormorant and gull species in the United States in 2010. *Avian Dis.* 56:128–133.
78. Diel, D.G., L. Susta, S. Cardenas Garcia, M.L. Killian, C. C. Brown, P.J. Miller, and C.L. Afonso. 2011. Complete genome and clinicopathological characterization of a virulent Newcastle disease virus isolated from poultry in South America. *J Clin Microbiol.* 50:378–387.
79. Dortmans, J.C., G. Koch, P.J. Rottier, and B.P. Peeters. 2011. A comparative infection study of pigeon and avian paramyxovirus type 1 viruses in pigeons: evaluation of clinical signs, virus shedding and seroconversion. *Avian Pathol.* 40:125–130.
80. Dortmans, J.C., G. Koch, P.J. Rottier, and B.P. Peeters. 2011. Virulence of newcastle disease virus: what is known so far? *Vet Res.* 42:122.
81. Dortmans, J.C., G. Koch, P.J. Rottier, and B.P. Peeters. 2009. Virulence of pigeon paramyxovirus type 1 does not always correlate with the cleavability of its fusion protein. *J Gen Virol.* 90(Pt 11):2746–2750.
82. Dortmans, J.C., B.P. Peeters, and G. Koch. 2012. Newcastle disease virus outbreaks: Vaccine mismatch or inadequate application? *Vet Microbiol.* 160:17–22.
83. Dortmans, J.C., P.J. Rottier, G. Koch, and B.P. Peeters. 2011. Passaging of a Newcastle disease virus pigeon variant in chickens results in selection of viruses with mutations in the polymerase complex enhancing virus replication and virulence. *J Gen Virol.* 92:336–345.
84. Dortmans, J.C., P.J. Rottier, G. Koch, and B.P. Peeters. 2010. The viral replication complex is associated with virulence of Newcastle disease virus (NDV). *J Virol.* 84:10113–10120.
85. Doyle, T.M. 1927. A hitherto unrecorded disease of fowls due to a filter-passing virus. *J Comp Pathol Therap.* 40:144–169.
86. Doyle, T.M. 1933. The virus diseases of animals with special reference to those of poultry. *J Comp Pathol.* 46:90–107.
87. Dundon, W.G., A. Heidari, A. Fusaro, I. Monne, M.S. Beato, G. Cattoli, G. Koch, E. Starick, I.H. Brown, E.W. Aldous, F.X. Briand, G. Le Gall-Recule, V. Jestin, P.H. Jorgensen, M. Berg, S. Zohari, G. Metreveli, M. Munir, K. Stahl, E. Albina, S. Hammoumi, P. Gil, R.S. de Almeida, K. Smietanka, K. Domanska-Blicharz, Z. Minta, S. Van Borm, T. van den Berg, A.M. Martin, I. Barbieri, and I. Capua. 2012. Genetic data from avian influenza and avian paramyxoviruses generated by the European network of excellence (EPIZONE) between 2006 and 2011—review and recommendations for surveillance. *Vet Microbiol.* 154:209–221.

88. Ecco, R., L. Susta, C.L. Afonso, P.J. Miller, and C. Brown. 2011. Neurological lesions in chickens experimentally infected with virulent Newcastle disease virus isolates. *Avian Pathol.* 40:145–152.
89. Echeonwu, G.O.N., C.U. Iroegbu, and A.C. Emeruwa. 1993. Recovery of velogenic Newcastle disease virus from dead and healthy free-roaming birds in Nigeria. *Avian Pathol.* 22:383–387.
90. Eidson, C.S., S.G. Thayer, P. Villegas, and S.H. Kleven. 1982. Vaccination of broiler chicks from breeder flocks immunized with a live or inactivated oil emulsion Newcastle disease vaccine. *Poult Sci.* 61:1621–1629.
91. Elbers, A.R., M.J. Gorgievski-Duijvesteijn, K. Zarafshani, and G. Koch. 2010. To report or not to report: a psychosocial investigation aimed at improving early detection of avian influenza outbreaks. *Rev Sci Tech OIE.* 29:435–449.
92. Erickson, G.A., C.J. Mare, G.A. Gustafson, L.D. Miller, and E.A. Carbrey. 1977. Interactions between viscerotropic velogenic Newcastle disease virus and pet birds of six species II. Viral evolution through bird passage. *Avian Dis.* 21:655–669.
93. Erickson, G.A., C.J. Mare, G.A. Gustafson, S.J. Proctor, L.D. Miller, and E.A. Carbrey. 1977. Interactions between viscerotropic velogenic Newcastle disease virus and pet birds of six species I. Clinical responses and viral excretion. *Avian Dis.* 21:642–654.
94. Evans, A.S. 1955. Pathogenicity and immunobiology of Newcastle disease virus (NDV) in man. *Am J Public Health.* 45:742–745.
95. Fontaine, M.P., M. Fontaine, D. Chabas, and A.J. Brion. 1965. Presence of Newcastle disease-like agent in chicken embryo cells. *Avian Dis.* 9:1–7.
96. Foster, H.A., H.R. Chitukuro, E. Tuppa, T. Mwanjala, and C. Kusila. 1999. Thermostable Newcastle disease vaccines in Tanzania. *Vet Microbiol.* 68:127–130.
97. Fuller, C.M., L. Brodd, R.M. Irvine, D.J. Alexander, and E.W. Aldous. 2010. Development of an L gene real-time reverse-transcription PCR assay for the detection of avian paramyxovirus type 1 RNA in clinical samples. *Arch Virol.* 155:817–823.
98. Fuller, C.M., M.S. Collins, and D.J. Alexander. 2009. Development of a real-time reverse-transcription PCR for the detection and simultaneous pathotyping of Newcastle disease virus isolates using a novel probe. *Arch Virol.* 154:929–937.
99. Fuller, C.M., M.S. Collins, A.J. Easton, and D.J. Alexander. 2007. Partial characterisation of five cloned viruses differing in pathogenicity, obtained from a single isolate of pigeon paramyxovirus type 1 (PPMV-1) following passage in fowls' eggs. *Arch Virol.* 152:1575–1582.
100. Gallili, G.E., and D. Ben-Nathan. 1998. Newcastle disease vaccines. *Biotechnol Adv.* 16:343–366.
101. Ganapathy, K., P. Cargill, E. Montiel, and R.C. Jones. 2005. Interaction between live avian pneumovirus and Newcastle disease virus vaccines in specific pathogen free chickens. *Avian Pathol.* 34:297–302.
102. Garten, W., W. Berk, Y. Nagai, R. Rott, and H.D. Klenk. 1980. Mutational changes of the proease susceptibility of glycoproteins of Newcastle disease virus: effects of pathogenicity. *J Gen Virol.* 50:135–147.
103. Ge, J., X. Wang, L. Tao, Z. Wen, N. Feng, S. Yang, X. Xia, C. Yang, H. Chen, and Z. Bu. 2011. Newcastle disease virus-vectored rabies vaccine is safe, highly immunogenic, and provides long-lasting protection in dogs and cats. *J Virol.* 85:8241–8252.
104. Gelb, J., Jr., and C.G. Cianci. 1987. Detergent-treated Newcastle disease virus as an agar gel precipitin test antigen. *Poult Sci.* 66:845–853.
105. Gelb, J., B.S. Ladman, M.J. Licata, M.H. Shapiro, and L.R. Campion. 2007. Evaluating viral interference between infectious bronchitis virus and newcastle disease virus vaccine strains using quantitative reverse transcription-polymerase chain reaction. *Avian Dis.* 51:924–934.
106. Gentry, R.F., and M.O. Braune. 1972. Prevention of virus inactivation during drinking water vaccination of poultry. *Poult Sci.* 51:1450–1456.
107. Glickman, R.L., R.J. Syddall, R.M. Iorio, J.P. Sheehan, and M.A. Bratt. 1988. Quantitative basic residue requirments in the cleavage-activation site of the fusion glycoprotein as a determinant of virulence for Newcastle disease virus. *J Virol.* 62:354–356.
108. Goebel, S.J., J. Taylor, B.C. Barr, T.E. Kiehn, H.R. Castro-Malaspina, C.V. Hedvat, K.A. Rush-Wilson, C.D. Kelly, S.W. Davis, W.A. Samsonoff, K.R. Hurst, M.J. Behr, and P.S. Masters. 2007. Isolation of avian paramyxovirus 1 from a patient with a lethal case of pneumonia. *J Virol.* 81:12709–12714.
109. Gohm, D.S., B. Thur, and M.A. Hofmann. 2000. Detection of Newcastle disease virus in organs and faeces of experimentally infected chickens using RT-PCR. *Avian Pathol.* 29:143–152.
110. Goldhaft, T.M. 1980. Historical note on the origin of the La Sota strain if Newcastle disease virus. *Avian Dis.* 24:297–301.
111. Gomez, E., S.C. Zoth, S. Asurmendi, C.V. Rovere, and A. Berinstein. 2009. Expression of hemagglutinin-neuraminidase glycoprotein of Newcastle disease virus in agroinfiltrated Nicotiana benthamiana plants. *J Biotechnol.* 144:337–340.
112. Gopinath, V.P., G.D. Raj, A. Raja, K. Kumanan, and S. Elankumaran. 2011. Rapid detection of Newcastle disease virus replication in embryonated chicken eggs using quantitative real time polymerase chain reaction. *J Virol. Methods* 171:98–101.
113. Gotoh, B., T. Sakaguchi, K. Nishikawa, N.M. Inocencio, M. Hamaguchi, T. Toyoda, and Y. Nagai. 1988. Structural features unique to each of the three antigenic sites on the hemagglutinin-neuraminidase protein of Newcastle disease virus. *Virology.* 163:174–182.
114. Gough, R.E. 1973. Thermostability of Newcastle disease virus in liquid whole egg. *Vet Rec.* 93:632–633.
115. Gough, R.E., and W.H. Allan. 1974. The potential as an aerosol vaccine of Ulster 2Cstrain, Newcastle disease virus. *Vet Rec.* 95:263–265.
116. Gould, A.R. 2004. Molecular epidemiology of Newcastle disease virus in Australia. An analysis of the genome of Australian Newcastle disease viruses to better understand the epidemiology of virulent disease outbreaks and their control. Rural Industries Research and Development Corporation (Australia), Sydney. 26p.
117. Gould, A.R., E. Hansson, K. Selleck, J.A. Kattenbelt, M. Mackenzie, and A.J. Della-Porta. 2003. Newcastle disease virus fusion and haemagglutinin-neuraminidase gene motifs as markers for viral lineage. *Avian Pathol.* 32:361–373.
118. Gould, A.R., J.A. Kattenbelt, P. Selleck, E. Hansson, A. Della-Porta, and H.A. Westbury. 2001. Virulent Newcastle disease in Australia: Molecular epidemiological analysis of viruses isolated prior to and during the outbreaks of 1998–2000. *Virus Res.* 77:51–60.
119. Guimaraes, M.C., L.V. Guillermo, M.F. Matta, S.G. Soares, and R.A. DaMatta. 2011. Macrophages from chickens selected for high antibody response produced more nitric oxide and have

greater phagocytic capacity. *Vet Immunol. Immunopathol* 140:317–322.
120. Hamar, G., F. Misak, V. Palya, and J. de Foucauld. 2010. A preliminary study on viral decontamination of chicken serum using gamma-irradiation. *Biologicals.* 38:358–361.
121. Hanson, R.P. 1975. Newcastle disease. In: *Isolation and Identification of Avian Pathogens*. S.B. Hitchner, ed. American Association of Avian Pathologists, Ithaca, N.Y. 160–173.
122. Hanson, R.P. 1980. Newcastle disease. In: *Isolation and Identification of Avian Pathogens*. S.B. Hitchner, C.H. Domermuth, H.G. Purchase, and J.E. Williams, eds. American Association Avian Pathologists, College Station, TX. 63–66.
123. Hanson, R.P. 1972. World wide spread of viscerotropic Newcastle disease. *Proc USAHA.* 76:276–279.
124. Hanson, R.P., and C.A. Brandly. 1955. Identification of vaccine strains of Newcastle disease virus. *Science.* 122:156–157.
125. Hanson, R.P., and S.K. Sinha. 1952. Epizootic of Newcastle disease in pigeons and studies on transmission of the virus. *Poultry Sci.* 31:404–408.
126. Harrison, L., C. Brown, C. Afonso, J. Zhang, and L. Susta. 2011. Early occurrence of apoptosis in lymphoid tissues from chickens infected with strains of newcastle disease virus of varying virulence. *J Comp Pathol.* 145:327–335.
127. Hassan, W., S.A. Khair, B. Mochotlhoane, and C. Abolnik. 2010. Newcastle disease outbreaks in the Sudan from 2003 to 2006 were caused by viruses of genotype 5d. *Virus Genes.* 40:106–110.
128. Heckert, R.A. 1993. Newcastle disease in cormorants. *Can Vet J.* 34:184.
129. Heckert, R.A., M.S. Collins, R.J. Manvell, I. Strong, J.E. Pearson, and D.J. Alexander. 1996. Comparison of Newcastle disease viruses isolated from cormorants in Canada and the USA in 1975, 1990 and 1992. *Can J Vet Res.* 60:50–54.
130. Heckert, R.A., J. Riva, S. Cook, J. McMillen, and R.D. Schwartz. 1996. Onset of protective immunity in chicks after vaccination with a recombinant herpesvirus of turkeys vaccine expressing Newcastle disease virus fusion and hemagglutinin-neuraminidase antigens. *Avian Dis.* 40:770–777.
131. Hemmatzadeh, F., B. Nayeri, and E.R. Tofighi. 2006. Antigenic differences in Newcastle disease viruses isolated in Iran. *Int J Poult Sci.* 5:408–410.
132. Hines, N.L., and C.L. Miller. 2012. Avian paramyxovirus serotype-1: a review of disease distribution, clinical symptoms, and laboratory diagnostics. Vet Med Int DOI: 10.1155/2012/708216.
133. Hitchner, S.B., and E.P. Johnson. 1948. A virus of low virulence for immunizing fowls against Newcastle disease (avian pneumoencephalitis). *Vet Med.* 43:525–530.
134. Hoerr, F.J. 2010. Clinical aspects of immunosuppression in poultry. *Avian Dis.* 54:2–15.
135. Hoffmann, B., M. Beer, S.M. Reid, P. Mertens, C.A. Oura, P.A. van Rijn, M.J. Slomka, J. Banks, I.H. Brown, D.J. Alexander, and D.P. King. 2009. A review of RT-PCR technologies used in veterinary virology and disease control: Sensitive and specific diagnosis of five livestock diseases notifiable to the World Organisation for Animal Health. *Vet Microbiol.* 139:1–23.
136. Hofstad, M.S. 1968. Comparative immunogenicity of three strains of Newcastle disase virus used in inactivated vaccines. *Avian Dis.* 12:665–669.
137. Homhuan, A., S. Prakongpan, P. Poomvises, R.A. Maas, D.J. A. Crommelin, G.F.A. Kersten, and W. Jiskoot. 2004. Virosome and ISCOM vaccines against Newcastle disease: Preparation, characterization and immunogenicity. *Eur J Pharm Sci.* 22:459–468.
138. Homma, M., and M. Ohuchi. 1973. Trypsin action on the growth of Sendai virus in tissue culture cells. III. Structural difference of Sendai viruses grown in eggs and tissue culture. *J Virol*. 12:1457–1465.
139. Hu, S., H. Ma, Y. Wu, W. Liu, X. Wang, Y. Liu, and X. Liu. 2009. A vaccine candidate of attenuated genotype VII Newcastle disease virus generated by reverse genetics. *Vaccine.* 27:904–910.
140. Huang, Z.H., S. Krishnamurthy, A. Panda, and S.K. Samal. 2003. Newcastle disease virus V protein is associated with viral pathogenesis and functions as an alpha interferon antagonist. *J Virol.* 77:8676–8685.
141. ICTV. 2012. *Virus Taxonomy: Ninth Report of the International Committee on Taxonomy of Viruses*. Academic Press, Waltham, MA.
142. Irvine, R.M., E.W. Aldous, R.J. Manvell, W.J. Cox, V. Ceeraz, C.M. Fuller, A.M. Wood, J.C. Milne, M. Wilson, R.G. Hepple, A. Hurst, C.E. Sharpe, D.J. Alexander, and I.H. Brown. 2009. Outbreak of Newcastle disease due to pigeon paramyxovirus type 1 in grey partridges (*Perdix perdix*) in Scotland in October 2006. *Vet Rec.* 165:531–535.
143. Ito, T., Y. Kawaoka, C. Kameda, J. Yasuda, H. Kida, and K. Otsuki. 1999. Differences in receptor specificity between Newcastle disease viruses originating from chickens and waterfowl. *J Vet Med Sci.* 61:951–953.
144. Jang, J., S.H. Hong, and I.H. Kim. 2011. Validation of a real-time RT-PCR method to quantify Newcastle disease virus (NDV) titer and comparison with other quantifiable methods. *J Microbiol Biotechnol.* 21:100–108.
145. Jeurissen, S.H.M., A.G. Boonstra-Blom, S.O. Al-Garib, L. Hartog, and G. Koch. 2000. Defence mechanisms gainst viral infection in poultry: A review. *Vet Quart.* 22:204–208.
146. Jindal, N., Y. Chander, A.K. Chockalingam, M.D. Abin, P. T. Redig, and S.M. Goyal. 2009. Phylogenetic analysis of Newcastle disease viruses isolated from waterfowl in the upper midwest region of the United States. *Virol J.* 6:191.
147. Jorgensen, P.H., K.J. Handberg, P. Ahrens, R.J. Manvell, K.M. Frost, and D.J. Alexander. 2000. Similarity of avian paramyxovirus serotype 1 isolates of low virulence for chickens obtained from contaminated poultry vaccines and from poultry flocks. *Vet Rec.* 146:665–668.
148. Kahn, M.I. 1994. Newcastle disease. In: *Handbook of Zoonoses, Section B: Viral*. G.W. Beran and J.H. Steele, eds. CRC Press, Inc., Boca Raton, Florida. 473–481.
149. Kaleta, E.F., D.J. Alexander, and P.H. Russell. 1985. The first isolation of the avian pmv-1 virus responsbile for the current panzootic in pigeons? *Avian Pathol.* 14:553–557.
150. Kaleta, E.F., and C. Baldauf. 1988. Newcastle disease in free-living and pet birds. In: *Newcastle Disease*. D.J. Alexander, ed. Kluwer Academic Publishers, Dordrecht, Netherlands; Boston, Massachusetts, USA. 197–246.
151. Kapczynski, D.R., and D.J. King. 2005. Protection of chickens against overt clinical disease and determination of viral shedding following vaccination with commercially available Newcastle disease virus vaccines upon challenge with highly virulent virus from the california 2002 exotic Newcastle disease outbreak. *Vaccine.* 23:3424–3433.
152. Kapczynski, D.R., and T.M. Tumpey. 2003. Development of a virosome vaccine for Newcastle disease virus. *Avian Dis.* 47:578–587.

153. Kassaify, Z.G., R.G. El Hakim, E.G. Rayya, H.A. Shaib, and E.K. Barbour. 2007. Preliminary study on the efficacy and safety of eight individual and blended disinfectants against poultry and dairy indicator organisms. *Veter Ital.* 43:821–830.
154. Kattenbelt, J.A., M.P. Stevens, and A.R. Gould. 2006. Sequence variation in the Newcastle disease virus genome. *Virus Res.* 116:168–184.
155. Kelleher, C.J., D.A. Halvorson, and J.A. Newman. 1988. Efficacy of viable and inactivated Newcastle disease virus vaccines in turkeys. *Avian Dis.* 32:342–46.
156. Khan, T.A., C.A. Rue, S.F. Rehmani, A. Ahmed, J.L. Wasilenko, P.J. Miller, and C.L. Afonso. 2010. Phylogenetic and biological characterization of Newcastle disease virus isolates from Pakistan. *J Clin Microbiol.* 48:1892–1894.
157. Kim, L.M., D.J. King, P.E. Curry, D.L. Suarez, D. Swayne, D.E. Stallknecht, R.D. Slemons, J.C. Pedersen, D. Senne, K. Winker, and C.L. Afonso. 2007. Phylogenetic diversity among low-virulence Newcastle disease viruses from waterfowl and shorebirds and comparison of genotype distributions to those of poultry-origin isolates. *J Virol.* 81:12641–12653.
158. Kim, L.M., D.J. King, H. Guzman, R.B. Tesh, A.P. Travassos da Rosa, R. Bueno, Jr., J.A. Dennett, and C.L. Afonso. 2008. Biological and phylogenetic characterization of pigeon paramyxovirus serotype-1 circulating in wild North American pigeons and doves. *J Clin Microbiol.* 46:3303–3310.
159. Kim, L.M., D.J. King, D.L. Suarez, C.W. Wong, and C.L. Afonso. 2007. Characterization of class I Newcastle disease virus isolates from Hong Kong live bird markets and detection using real-time reverse transcription-PCR. *J Clin Microbiol.* 45:1310–1314.
160. Kim, L.M., D.L. Suarez, and C.L. Afonso. 2008. Detection of a broad range of class I and II Newcastle disease viruses using a multiplex real-time reverse transcription polymerase chain reaction assay. *J Vet Diagn Invest.* 20:414–425.
161. Kinde, H., P.J. Hullinger, B. Charlton, M. McFarland, S.K. Hietala, V. Velez, J.T. Case, L. Garber, S.H. Wainwright, A.B. Mikolon, R.E. Breitmeyer, and A.A. Ardans. 2005. The isolation of exotic Newcastle disease (END) virus from nonpoultry avian species associated with the epidemic of END in chickens in southern California: 2002–2003. *Avian Dis.* 49:195–198.
162. King, D.J. 1991. Evaluation of different methods of inactivation of Newcastle disease virus and avian influenza virus in egg fluids and serum. *Avian Dis.* 35:505–514.
163. King, D.J. 1993. Newcastle disease virus passage in MDBK cells as an aid in detection of a virulent subpopulation. *Avian Dis.* 37:961–969.
164. King, D.J., and B.S. Seal. 1998. Biological and molecular characterization of Newcastle disease virus (NDV) field isolates with comparisons to reference NDV strains. *Avian Dis.* 42:507–516.
165. Knueppel, D., C. Cardona, P. Msoffe, M. Demment, and L. Kaiser. 2010. Impact of vaccination against chicken Newcastle disease on food intake and food security in rural households in Tanzania. *Food Nutr Bull.* 31:436–445.
166. Kommers, G.D., D.J. King, B.S. Seal, and C.C. Brown. 2001. Virulence of pigeon-O\origin Newcastle disease virus isolates for domestic chickens. *Avian Dis.* 45:906–921.
167. Kortekaas, J., S.M. de Boer, J. Kant, R.P. Vloet, A.F. Antonis, and R.J. Moormann. 2010. Rift Valley fever virus immunity provided by a paramyxovirus vaccine vector. *Vaccine.* 28:4394–4401.
168. Kournikakis, B., and J. Fildes. 1988. Titration of avirulent Newcastle disease virus by the plaque assay method. *J Virol Methods.* 20:285–293.
169. Kouwenhoven, B. 1993. Virus infections of vertebrates. In: *Newcastle Disease*, Vol. 4. J.B. McFerran and M.S. McNultry, eds. Elsevier Science, Amsterdam. 341–361.
170. Kuiken, T., R.A. Heckert, J. Riva, F.A. Leighton, and G. Wobeser. 1998. Excretion of pathogenic Newcastle disease virus by double-crested cormorants (*Phalacrocorax auritus*) in absence of mortality or clinical signs of disease. *Avian Pathol.* 27:541–546.
171. Kuiken, T., F.A. Leighton, G. Wobeser, K.L. Danesik, J. Riva, and R.A. Heckert. 1998. An epidemic of Newcastle disease in double-crested cormorants from Saskatchewan. *J Wildl Dis.* 34:457–471.
172. Kumar, S., B. Nayak, P.L. Collins, and S.K. Samal. 2011. Evaluation of the Newcastle disease virus F and HN proteins in protective immunity by using a recombinant avian paramyxovirus type 3 vector in chickens. *J Virology.* 85:6521–6534.
173. Lam, H.Y., S.K. Yeap, M. Rasoli, A.R. Omar, K. Yusoff, A.A. Suraini, and N. Banu Alitheen. 2011. Safety and clinical usage of newcastle disease virus in cancer therapy. *J Biomed Biotechnol.* 2011:718710.
174. Lam, K.M. 1996. Growth of Newcastle disease virus in chicken macrophages. *J Comp Pathol.* 115:253–263.
175. Lam, K.M. 2003. Newcastle disease virus-induced damage to embryonic tracheae and red blood cells. *Avian Dis.* 47: 197–202.
176. Lam, K.M. 1996. Ultrastructural changes in the cardiac muscle of chickens infected with the GB strain of Newcastle disease virus. *J Comp Pathol.* 114:73–79.
177. Lam, K.M., and A.C. Vasconcelos. 1994. Newcastle disease virus-induced apoptosis in chicken peripheral blood lymphocytes. *Vet Immunol Immunopathol.* 44:45–56.
178. Lamb, R., and Parks, G.D. 2007. Paramyxoviridae: The viruses and their replication. In: *Fields Virology*, Vol. 1. B. Fields, D.M. Knipe, and P.M. Howley, eds. Lippincott Williams and Wilkins, Philadelphia. 1449–1496.
179. Lamb, R.A., and D. Kolakovsky. 1996. Paramyxoviridae: The viruses and their replication. In: *Fields Virology*, 2nd ed. Lippincott-Raven Publishers, Philadelphia. 1177–1204.
180. Lamb, R.A., R.G. Paterson, and T.S. Jardetzky. 2006. Paramyxovirus membrane fusion: lessons from the F and HN atomic structures. *Virology.* 344:30–37.
181. Lambrecht, B., M. Gonze, G. Meulemans, and T.P. Van Den Berg. 2004. Assessment of the cell-mediated immune response in chickens by detection of chicken interferon-gamma in response to mitogen and recall Newcastle disease viral antigen stimulation. *Avian Pathol.* 33:343–350.
182. Lana, D.P., D.B. Snyder, D.J. King, and W.W. Marquardt. 1988. Characterization of a battery of monoclonal antibodies for differentiation of Newcastle disease virus and pigeon paramyxovirus-1 strains. *Avian Dis.* 32:273–281.
183. Lancaster, J.E., and D.J. Alexander. 1975. Newcastle disease—virus and spread, a review of some of the literature. *Canada Department of Agriculture, Monograph No. 11.*
184. Laurie, S.A., J.C. Bell, H.L. Atkins, J. Roach, M. Bamat, J.D. O'Neil, M.S. Roberts, W.S. Groene, and R.M. Lorence. 2006. A phase 1 clinical study of intravenous administration of pv701, an oncolytic virus, using two-step desensitization. *Clin Cancer Res.* 12:2555–2562.

185. Lawton, P., Z. Karimi, L. Mancinelli, and J.T. Seto. 1986. Persistent infections with Sendai virus and Newcastle disease viruses. *Arch Virol.* 89:225–233.
186. Leslie, J. 2000. Newcastle disease: Outbreak losses and control policy costs. *Vet Rec.* 146:603–606.
187. Lessard, M., D. Hutchings, and N.A. Cave. 1997. Cell-mediated and humoral immune responses in broiler chickens maintained on diets containing different levels of vitamin A. *Poult Sci.* 76:1368–1378.
188. Li, X., T. Chai, Z. Wang, C. Song, H. Cao, J. Liu, X. Zhang, W. Wang, M. Yao, and Z. Miao. 2009. Occurrence and transmission of Newcastle disease virus aerosol originating from infected chickens under experimental conditions. *Vet Microbiol.* 136:226–232.
189. Liu, W.Q., M.X. Tian, Y.P. Wang, Y. Zhao, N.L. Zou, F.F. Zhao, S.J. Cao, X. T. Wen, P. Liu, and Y. Huang. 2011. The different expression of immune-related cytokine genes in response to velogenic and lentogenic Newcastle disease viruses infection in chicken peripheral blood. *Mol Biol Rep.* 39(4):3611–8361.
190. Liu, X.F., H.Q. Wan, X.X. Ni, Y.T. Wu, and W.B. Liu. 2003. Pathotypical and genotypical characterization of strains of Newcastle disease virus isolated from outbreaks in chicken and goose flocks in some regions of China during 1985–2001. *Arch Virol.* 148:1387–1403.
191. Loke, C.F., A.R. Omar, A.R. Raha, and K. Yusoff. 2005. Improved protection from velogenic Newcastle disease virus challenge following multiple immunizations with plasmid DNA encoding for F and HN genes. *Vet Immunol Immunopathol.* 106:259–267.
192. Lomniczi, B., E. Wehmann, J. Herczeg, A. Ballagi-Pordany, E. F. Kaleta, O. Werner, G. Meulemans, P.H. Jorgensen, A. P. Mantè, A.L. J. Gielkens, I. Capua, and J. Damoser. 1998. Newcastle disease outbreaks in recent years in Western Europe were caused by an old (VI) and a novel genotype (VII). *Arch Virol.* 143:49–64.
193. Lowenthal, J.W., M.R. Digby, and J.J. York. 1995. Production of interferon-gamma by chicken T cells. *J Interferon Cytokine Res.* 15:933–938.
194. Maamary, J., F. Array, Q. Gao, A. Garcia-Sastre, R.M. Steinman, P. Palese, and G. Nchinda. 2011. Newcastle disease virus expressing a dendritic cell-targeted HIV gag protein induces a potent gag-specific immune response in mice. *J Virol.* 85:2235–2246.
195. Martin, J.J., J. Holguera, L. Sanchez-Felipe, E. Villar, and I. Munoz-Barroso. 2012. Cholesterol dependence of Newcastle disease virus entry. *Biochim Biophys Acta.* 1818:753–761.
196. Mast, J., and L. Demeestere. 2009. Electron tomography of negatively stained complex viruses: application in their diagnosis. *Diagn Pathol.* 4:1–7.
197. Mazija, H., S. Cajavec, N. Ergotic, I. Ciglar-Grozdanic, Z. Gottstein, and W.L. Ragland. 2010. Immunogenicity and safety of Queensland V4 and Ulster 2C strains of Newcastle disease virus given to maternally immune, newly hatched chickens by nebulization. *Avian Dis.* 54:99–103.
198. McCluskey, B.J., B. Burgess, J. Glover, H. Kinde, and S. Hietala. 2006. Use of sentinel chickens to evaluate the effectiveness of cleaning and disinfection procedures in noncommercial poultry operations infected with exotic Newcastle disease virus. *J Vet Diagn Invest.* 18:296–299.
199. McFerran, J.B., and R. Nelson. 1971. Some properties of an avirulent Newcastle disease virus. *Arch Ges Virusforsch.* 34:64–74.
200. McGinnes, L.W., P. Homer, J.P. Laliberte, K.A. Gravel, S. Jain, and T.G. Morrison. 2010. Assembly and biological and immunological properties of Newcastle disease virus-like particles. *J Virol.* 84:4513–4523.
201. Mebatsion, T., S. Verstegen, L.T.C. De Vaan, A. Romer-Oberdorfer, and C.C. Schrier. 2001. A recombinant Newcastle disease virus with low-level V protein expression is immunogenic and lacks pathogenicity for chicken embryos. *J Virol.* 75:420–428.
202. Meng, C., X. Qiu, S. Jin, S. Yu, H. Chen, and C. Ding. 2012. Whole genome sequencing and biological characterization of Duck/JS/10, a new lentogenic class I Newcastle disease virus. *Arch Virol.* 157:869–880.
203. Meulemans, G. 1988. Control by vaccination. In: *Newcastle Disease*. D.J. Alexander, ed. Kluwer Academic Publishers, Dordrecht, Netherlands; Boston, Massachusetts, USA. 318–332.
204. Meulemans, G., T.P. Van Den Berg, M. Decaesstecker, and M. Boschmans. 2002. Evolution of pigeon Newcastle disease virus strains. *Avian Pathol.* 31:515–519.
205. Miller, P.J., E.L. Decanini, and C.L. Afonso. 2010. Newcastle disease: Evolution of genotypes and the related diagnostic challenges. *Infect Genet Evol.* 10:26–35.
206. Miller, P.J., C. Estevez, Q. Yu, D.L. Suarez, and D.J. King. 2009. Comparison of viral shedding following vaccination with inactivated and live Newcastle disease vaccines formulated with wild-type and recombinant viruses. *Avian Dis.* 53:39–49.
207. Miller, P.J., L.M. Kim, H.S. Ip, and C.L. Afonso. 2009. Evolutionary dynamics of Newcastle disease virus. *Virology.* 391:64–72.
208. Miller, P.J., D.J. King, C.L. Afonso, and D.L. Suarez. 2007. Antigenic differences among Newcastle disease virus strains of different genotypes used in vaccine formulation affect viral shedding after a virulent challenge. *Vaccine.* 25:7238–7246.
209. Moresco, K.A., D.E. Stallknecht, and D.E. Swayne. 2012. Evaluation of different embryonating bird eggs and cell cultures for isolation efficiency of avian influenza A virus and avian paramyxovirus serotype 1 from real-time reverse transcription polymerase chain reaction-positive wild bird surveillance samples. *J Vet Diagn Invest.* 24:563–567.
210. Msoffe, P.L., D. Bunn, A.P. Muhairwa, M.M. Mtambo, H. Mwamhehe, A. Msago, M.R. Mlozi, and C.J. Cardona. 2010. Implementing poultry vaccination and biosecurity at the village level in Tanzania: a social strategy to promote health in free-range poultry populations. *Trop Anim Health Prod.* 42:253–263.
211. Munir, M., M. Abbas, M.T. Khan, S. Zohari, and M. Berg. 2012. Genomic and biological characterization of a velogenic Newcastle disease virus isolated from a healthy backyard poultry flock in 2010. *Virol J.* 9:1–11.
212. Munir, M., S. Zohari, M. Abbas, and M. Berg. 2012. Sequencing and analysis of the complete genome of Newcastle disease virus isolated from a commercial poultry farm in 2010. *Arch Virol.* 157:765–768.
213. Munir, S., J.M. Sharma, and V. Kapur. 2005. Transcriptional response of avian cells to infection with Newcastle disease virus. *Virus Res.* 107:103–108.
214. Nagai, Y., and H.D. Klenk. 1977. Activation of precursors to both glycoproteins of Newcasltle disease virus by proteolytic cleavage. *Virology.* 77:125–134.
215. Nagai, Y., H.D. Klenk, and R. Rott. 1976. Proteolytic cleavage of the viral glycoproteins and its significance for the virulence of Newcastle disease virus. *Virology.* 72:494–508.

216. Nidzworski, D., L. Rabalski, and B. Gromadzka. 2011. Detection and differentiation of virulent and avirulent strains of Newcastle disease virus by real-time PCR. *J Virol Methods.* 173:144–149.
217. O'Donoghue, K., B. Lomniczi, B. McFerran, T.J. Connor, B. Seal, D. King, J. Banks, R. Manvell, P.S. White, K. Richmond, P. Jackson, and M. Hugh-Jones. 2004. Retrospective characterization of Newcastle disease virus Antrim '73 in relation to other epidemics, past and present. *Epidemiol Infect.* 132:357–368.
218. Oberdorfer, A., and O. Werner. 1998. Newcastle disease virus: Detection and characterization by PCR of recent German isolates differing in pathogenicity. *Avian Pathol.* 27:237–243.
219. Ogasawara, T., B. Gotoh, H. Suzuki, J.I. Asaka, K. Shimokata, R. Rott, and Y. Nagai. 1992. Expression of factor xand its significance for the determination of paramyxovirus tropism in the chick embryo. *EMBO J.* 11:467–472.
220. OIE. 2000. Biological Standards Commission. *Report of the meeting of the OIE Standards Commission*. OIE, Paris.
221. OIE. 2009. Manual of diagnostic tests and vaccines for terrestrial animals: mammals, birds and bees. *Biological Standards Commission*, Vol. 1, Part 2, Chapter 2.3.14. OIE, Paris. 576–589
222. OIE. 2012. Manual of diagnostic tests and vaccines for terrestrial animals: mammals, birds and bees. *Biological Standards Commission*, Vol. 1, Part 2, Chapter 2.03.14. OIE, Paris. 1–19.
223. OIE. 2004. Manual of diagnostic tests and vaccines for terrestrial animals: mammals, birds and bees. *Biological Standards Commission*, Vol. 1, Part 2, Chapter 2.1.15. OIE, Paris.
224. OIE. 2011. Newcastle disease. *Terrestrial Animal Health Code*. 10.13. OIE, Paris.
225. OIE. 2011. Newcastle disease. *Terrestrial Animal Health Code*. Chapter 10.9. OIE, Paris.
226. OIE. 2008. Principles of veterinary vaccine production. *Manual of Diagnostic Tests and Vaccinesfor Terrestrial Animals*. 1.1.8. OIE, Paris.
227. Orsi, M.A., J.L. Doretto, D. Reischak, L.H.A. da Silva, F.R. Spilki, M.G. Buzinaro, and C.W. Arns. 2009. Newcastle disease virus vaccine strains: Immunogenicity is not influnced by ICPI. *Braz J Poult Sci.* 11:129–133.
228. Palya, V., I. Kiss, T. Tatar-Kis, T. Mato, B. Felfoldi, and Y. Gardin. 2012. Advancement in vacination against Newcastle disease: recombinat HVT NDV provides high clinical protection and reduction challenge virus shedding, with the absence of vaccine reaction. *Avian Dis.* 56:282–287.
229. Panda, A., Z.H. Huang, S. Elankumaran, D.D. Rockernann, and S.K. Samal. 2004. Role of fusion protein cleavage site in the virulence of Newcastle disease virus. *Microb Pathogenesis.* 36:1–10.
230. Panigrahy, B., D.A. Senne, J.E. Pearson, M.A. Mixson, and D.R. Cassidy. 1993. Occurrence of velogenic viscerotropic Newcastle disease in pet and exotic birds in 1991. *Avian Dis.* 37:254–258.
231. Panshin, A., E. Shihmanter, Y. Weisman, C. Orvell, and M. Lipkind. 2002. Antigenic heterogeneity among the field isolates of Newcastle disease virus (NDV) in relation to the vaccine strain 1. Studies on viruses Isolated from wild birds in Israel. *Comp Immunol Microb.* 25:95–108.
232. Pantua, H.D., L.W. McGinnes, M.E. Peeples, and T.G. Morrison. 2006. Requirements for the assembly and release of Newcastle disease virus-like particles. *J Virol.* 80:11062–11073.
233. Park, M.S., A. Garcia-Sastre, J.F. Cros, C.F. Basler, and P. Palese. 2003. Newcastle disease virus V protein is a determinant of host range restriction. *J Virol.* 77:9522–9532.
234. Park, M.S., M.L. Shaw, J. Munoz-Jordan, J.F. Cros, T. Nakaya, N. Bouvier, P. Palese, A. Garcia-Sastre, and C.F. Basler. 2003. Newcastle disease virus (NDV)-based assay demonstrates interferon-antagonist activity for the NDV V protein and the Nipah virus V, W, and C proteins. *J Virol.* 77:1501–1511.
235. Pchelkina, I.P., T.B. Manin, S.N. Kolosov, S.K. Starov, A.V. Andriyasov, I.A. Chvala, V.V. Drygin, Q. Yu, P.J. Miller, and D.L. Suarez. 2012. Characteristics of pigeon paramyxovirus serotype-1 isolates (PPMV-1) from the Russian Federation from 2001 to 2009. *Avian Dis*. In press.
236. Pearson, G.L., and M.K. McCann. 1975. The role of indigenous wild, semidomestic, and exotic birds in the epizootiology of velogenic viscerotropic Newcastle disease in southern California, 1972–1973. *J Am Vet Med Assoc.* 167:610–614.
237. Pearson, J.E., D.A. Senne, D.J. Alexander, W.D. Taylor, L.A. Peterson, and P.H. Russell. 1987. Characterization of Newcastle disease virus (Avian paramyxovirus-1) isolated from pigeons. *Avian Dis.* 31:105–111.
238. Pecora, A.L., N. Rizvi, G.I. Cohen, N.J. Meropol, D. Sterman, J.L. Marshall, S. Goldberg, P. Gross, J.D. O'Neil, W.S. Groene, M.S. Roberts, H. Rabin, M.K. Bamat, and R.M. Lorence. 2002. Phase I trial of intravenous administration of Pv701, an oncolytic virus, in patients with advanced solid cancers. *J Clin Oncol.* 20:2251–2266.
239. Pedersen, J.C., D.A. Senne, P.R. Woolcock, H. Kinde, D.J. King, M.G. Wise, B. Panigrahy, and B.S. Seal. 2004. Phylogenetic relationships among virulent Newcastle disease virus isolates from the 2002–2003 outbreak in California and other recent outbreaks in North America. *J Clin Microbiol.* 42:2329–2334.
240. Peeters, B.P.H., O.S. De Leeuw, G. Koch, and A.L.J. Gielkens. 1999. Rescue of Newcastle disease virus from cloned cDNA: Evidence that cleavability of the fusion protein is a major determinant for virulence. *J Virol.* 73:5001–5009.
241. Peeters, B.P.H., O.S. De Leeuw, I. Verstegen, G. Koch, and A.L.J. Gielkens. 2001. Generation of a recombinant chimeric Newcastle disease virus vaccine that allows serological differentiation between vaccinated and infected animals. *Vaccine.* 19:1616–1627.
242. Peeters, B.P.H., Y.K. Gruijthuijsen, O.S. De Leeuw, and A.L.J. Gielkens. 2000. Genome replication of Newcastle disease virus: Involvement of the rule-of-six. *Arch Virol.* 145:1829–1845.
243. Pennington, T.H. 1978. Antigenic differences between strains of Newcastle disease virus. *Arch Virol.* 56:345–351.
244. Pennycott, T.W. 1998. Vaccination of pheasants against Newcastle disease. *Vet Rec.* 142:119–120.
245. Perozo, F., R. Marcano, and C.L. Afonso. 2012. Biological and phylogenetic characterization of a genotype VII Newcastle disease virus from Venezuela: efficacy of field vaccination. *J Clin Microbiol.* 50:1204–1208.
246. Perozo, F., P. Villegas, R. Dolz, C.L. Afonso, and L.B. Purvis. 2008. The VG/GA strain of Newcastle disease virus: mucosal immunity, protection against lethal challenge and molecular analysis. *Avian Pathol.* 37:237–245.
247. Piacenti, A.M., D.J. King, B.S. Seal, J. Zhang, and C.C. Brown. 2006. Pathogenesis of Newcastle disease in commercial and specific pathogen-free turkeys experimentally infected with isolates of different virulence. *Vet Pathol.* 43:168–178.

248. Raggi, L.G., and G.G. Lee. 1964. Infectious bronchitis virus interference with growth of Newcastle disease virus. II. Interference in chickens. *Avian Dis*. 8:471–480.
249. Ramp, K., J. Veits, D. Deckers, M. Rudolf, C. Grund, T.C. Mettenleiter, and A. Romer-Oberdorfer. 2011. Coexpression of avian influenza virus H5 and N1 by recombinant Newcastle disease virus and the impact on immune response in chickens. *Avian Dis.* 55:413–421.
250. Randi, E., M. Chiricolo, M. Spagnesi, G. Savigni, A. Giovannini, and C. Francheschi. 1985. Antibody response in partridge (*Perdix perdix*) 1. Effect of sex and age on the immune response to sheep red blood cells (SRBC), Newcastle disease virus (NDV) and Brucella abortus (Buck 19). *Dev Comp Immunol*. 9:679–690.
251. Raszewska, H. 1964. Occurence of the LaSota strain (NDV) in the reproductive tract of laying hens. *Bull Vet Inst Pulawy.* 8:130–136.
252. Rautenschlein, S., C. Kraemer, E. Montiel, J. Vanmarcke, and C. Haase. 2007. Bilateral effects of vaccination against infectious bursal disease and Newcastle disease in specific-pathogen-free layers and commercial broiler chickens. *Avian Dis.* 51:14–20.
253. Rauw, F., Y. Gardin, V. Palya, S. Anbari, S. Lemaire, M. Boschmans, T. van den Berg, and B. Lambrecht. 2010. Improved vaccination against Newcastle disease by an *in ovo* recombinant HVT-ND combined with an adjuvanted live vaccine at day-old. *Vaccine.* 28:823–833.
254. Rehmani, S.F. 1996. Newcastle disease vaccination: A comparison of vaccines and routes of administration in Pakistan. *Prev Vet Med.* 25:241–248.
255. Rehmani, S.F., and S. Firdous. 1995. Passive immunity in chicks from a laying flock vaccinated with the Mukteswar strain of Newcastle disease virus. *Prev Vet Med.* 23:111–118.
256. Reynolds, D.L., and A.D. Maraqa. 2000. Protective immunity against Newcastle disease: the role of antibodies specific to Newcastle disease virus polypeptides. *Avian Dis.* 44:138–144.
257. Reynolds, D.L., and A.D. Maraqa. 2000. Protective immunity against Newcastle disease: the role of cell-mediated immunity. *Avian Dis.* 44:145–154.
258. Rivetz, B., Y. Weisman, M. Ritterband, F. Fish, and M. Herzberg. 1985. Evaluation of a novel rapid test kit for the visual detection. *Avian Dis.* 29:929–942.
259. Romer-Oberdorfer, A., O. Werner, J. Veits, T. Mebatsion, and T.C. Mettenleiter. 2003. Contribution of the length of the HN protein and the sequence of the F protein cleavage site to Newcastle disease virus pathogenicity. *J Gen Virol.* 84:3121–3129.
260. Rott, R. 1985. Differentiating pathogenic and non-pathogenic avian influenzavirus in cell culture. *Berl Munch Tierarztl.* 98:37–39.
261. Rout, S.N., and S.K. Samal. 2008. The large polymerase (L) protein is associated with virulence of Newcastle disease virus. *J Virol.* 82:7828–7836.
262. Roy, P., and A.T. Venugopalan. 2005. Unexpected Newcastle disease virus in day old commercial chicks and breeder hen. *Comp Immunol Microb.* 28:277–285.
263. Rue, C.A., L. Susta, C.C. Brown, J.M. Pasick, S.R. Swafford, P.C. Wolf, M.L. Killian, J.C. Pedersen, P.J. Miller, and C.L. Afonso. 2010. Evolutionary changes affecting rapid diagnostic of 2008 Newcastle disease viruses isolated from double-crested cormorants. *J Clin Microbiol.* 48:2440–2448.
264. Rue, C.A., L. Susta, I. Cornax, C.C. Brown, D.R. Kapczynski, D.L. Suarez, D.J. King, P.J. Miller, and C.L. Afonso. 2011. Virulent Newcastle disease virus elicits a strong innate immune response in chickens. *J Gen Virol.* 92:931–939.
265. Ruenphet, S., A. Jahangir, D. Shoham, and K. Takehara. 2012. Situation of serum antibodies against Newcastle disease virus in slaughter-age ostriches after vaccination campaign in Japan. *J Vet Med Sci.* 74:477–480.
266. Russell, P.H., and D.J. Alexander. 1983. Antigenic variation of Newcastle disease virus strains detected by monoclonal antibodies. *Arch Virol.* 75:243–253.
267. Russell, P.H., and G.O. Ezeifeka. 1995. The Hitchner B1 strain of Newcastle disease virus induces high levels of IgA, IgG and IgM in newly hatched chicks. *Vaccine.* 13:61–66.
268. Russell, P.H., and G. Koch. 1993. Local antibody forming cell responses to the Hitchner B1 and Ulster strains of Newcastle disease virus. *Vet Immunol Immunopathol.* 37:165–180.
269. Samal, S., S. Kumar, S.K. Khattar, and S.K. Samal. 2011. A single amino acid change, Q114R, in the cleavage-site sequence of Newcastle disease virus fusion protein attenuates viral replication and pathogenicity. *J Gen Virol.* 92:2333–2338.
270. Sawant, P.M., P.C. Verma, P.K. Subudhi, U. Chaturvedi, M. Singh, R. Kumar, and A.K. Tiwari. 2011. Immunomodulation of bivalent Newcastle disease DNA vaccine induced immune response by co-delivery of chicken IFN-gamma and IL-4 genes. *Vet Immunol Immunopathol.* 144:36–44.
271. Schettler, E., J. Fickel, H. Hotzel, K. Sachse, W.J. Streich, U. Wittstatt, and K. Frolich. 2003. Newcastle disease virus and Chlamydia psittaci in free-living raptors from Eastern Germany. *J Wildlife Dis.* 39:57–63.
272. Schirrmacher, V., and P. Fournier. 2009. Newcastle disease virus: a promising vector for viral therapy, immune therapy, and gene therapy of cancer. *Methods Mol Biol.* 542:565–605.
273. Schloer, G., J. Spalatin, and R.P. Hanson. 1975. Newcastle disease virus antigens and strain variations *Am J Vet Res*. 36:505–508.
274. Schwarz, H., O. Harlin, A. Ohnemus, B. Kaspers, and P. Staeheli. 2004. Synthesis of IFN-beta by virus-infected chicken embryo cells demonstrated with specific antisera and a new bioassay. *J Interferon Cytokine Res.* 24:179–184.
275. Seal, B.S., D.J. King, and J.D. Bennett. 1995. Characterization of Newcastle disease virus isolates by reverse transcription PCR coupled to direct nucleotide sequencing and development of sequence database for pathotype prediction and molecular epidemiological analysis. *J Clin Microbiol.* 33:2624–2630.
276. Seal, B.S., D.J. King, D.P. Locke, D.A. Senne, and M.W. Jackwood. 1998. Phylogenetic relationships among highly virulent Newcastle disease virus isolates obtained from exotic birds and poultry from 1989 to 1996. *J Clin Microbiol.* 36:1141–1145.
277. Senne, D.A., D.J. King, and D.R. Kapczynski. 2004. Control of Newcastle disease by vaccination. *Dev Biol.* 119:165–170.
278. Servan de Almeida, R., O.F. Maminiaina, P. Gil, S. Hammoumi, S. Molia, V. Chevalier, M. Koko, H.R. Andriamanivo, A. Traore, K. Samake, A. Diarra, C. Grillet, D. Martinez, and E. Albina. 2009. Africa, a reservoir of new virulent strains of Newcastle disease virus. *Vaccine.* 27:3127–3129.
279. Shapiro, D., B. Steward-Brown, D. Hermes, and R. Sharpton. 2011. *Designing an on farm biosecurity program*. In: *A Practical Guide for Managing Risk in Poultry Production*. American Association Avian Pathologists, Jacksonville, Florida. 13–22.

280. Sharma, J.M. 1999. Introduction to poultry vaccines and immunity. In: *Advances in Veterinary Medicine*, Vol. 41. R.D. Schultz, ed. Elsevier Academic Press, San Diego. 481–494.
281. Shengqing, Y., N. Kishida, H. Ito, H. Kida, K. Otsuki, Y. Kawaoka, and T. Ito. 2002. Generation of velogenic Newcastle disease viruses from a nonpathogenic waterfowl isolate by passaging in chickens. *Virology.* 301:206–211.
282. Sick, C., K. Schneider, P. Staeheli, and K.C. Weining. 2000. Novel chicken CXC and CC chemokines. *Cytokine.* 12:181–186.
283. Sick, C., U. Schultz, U. Munster, J. Meier, B. Kaspers, and P. Staeheli. 1998. Promoter structures and differential responses to viral and nonviral inducers of chicken type I interferon genes. *J Biol Chem.* 273:9749–9754.
284. Snoeck, C.J., M.F. Ducatez, A.A. Owoade, O.O. Faleke, B.R. Alkali, M.C. Tahita, Z. Tarnagda, J.B. Ouedraogo, I. Maikano, P.O. Mbah, J.R. Kremer, and C.P. Muller. 2009. Newcastle disease virus in West Africa: new virulent strains identified in noncommercial farms. *Arch Virol.* 154:47–54.
285. Snyder, D.B., W.W. Marquardt, E.T. Mallinson, P.K. Savage, and D.C. Allen. 1984. Rapid serological profiling by enzyme-linked immunosorbent assay. III. Simultaneous measurements of antibody titers to infectious bronchitis, IBD, and Newcastle disease viruses in a single serum dilution. *Avian Dis*. 28:12–24.
286. St. Paul, M., A.I. Mallick, L.R. Read, A.I. Villanueva, P. Parvizi, M.F. Abdul-Careem, E. Nagy, and S. Sharif. 2012. Prophylactic treatment with Toll-like receptor ligands enhances host immunity to avian influenza virus in chickens. *Vaccine*. 30:4524–4531.
287. Steward, M., A.C.R. Samson, W. Errington, and P.T. Emmerson. 1995. The Newcastle disease virus V protein binds zinc. *Arch Virol.* 140:1321–1328.
288. Steward, M., I.B. Vipond, N.S. Millar, and P.T. Emmerson. 1993. RNA editing in Newcastle disease virus. *J Gen Virol.* 74:2539–2547.
289. Stone, H.D. 1993. Efficacy of experimental animal and vegetable oil-emulsion vaccines for Newcastle disease and avian influenza. *Avian Dis.* 37:399–405.
290. Stone, H.D. 1989. Efficacy of oil-emulsion vaccines prepared with pigeon paramyxovirus 1, Ulster, and LaSota Newcastle disease viruses. *Avian Dis.* 33:157–162.
291. Stone, H.D. 1997. Newcastle disease oil emulsion vaccines prepared with animal, vegetable, and synthetic oils. *Avian Dis.* 41:591–597.
292. Susta, L., I. Cornax, D.G. Diel, S. Cardenas Garcia, P.J. Miller, C. Brown, and C. Afonso. 2012. Expression of interferon gamma by a highly virulent Newcastle disease virus decreases its pathogenicity in chickens. *PLoS One*. In press.
293. Susta, L., P.J. Miller, C.L. Afonso, and C.C. Brown. 2011. Clinicopathological characterization in poultry of three strains of Newcastle disease virus isolated from recent outbreaks. *Vet Pathol.* 48:349–360.
294. Swayne, D.E., and R. Beck Joan. 2004. Heat inactivation of avian influenza and Newcastle disease viruses in egg products. *Avian Pathol.* 33:512–518.
295. Tan, S.W., A. Ideris, A.R. Omar, K. Yusoff, and M. Hair-Bejo. 2009. Detection and differentiation of velogenic and lentogenic Newcastle disease viruses using SYBR green I real-time PCR with nucleocapsid gene-specific primers. *J Virol Methods.* 160:149–156.
296. Taylor, J., L. Christensen, R. Gettig, J. Goebel, J.F. Bouquet, T.R. Mickle, and E. Paoletti. 1996. Efficacy of a recombinant fowl pox-based Newcastle disease virus vaccine candidate against velogenic and respiratory challenge. *Avian Dis.* 40:173–180.
297. Taylor, J., C. Edbauer, A. Reysenelonge, J.F. Bouquet, E. Norton, S. Goebel, P. Desmettre, and E. Paoletti. 1990. Newcatle disease virus fusion protein expressed in a fowlpox virus recombinant confers protection in chickens. *J Virol.* 64:1441–1450.
298. Terregino, C., G. Cattoli, B. Grossele, E. Bertoli, E. Tisato, and I. Capua. 2003. Characterization of Newcastle disease virus isolates obtained from Eurasian collared doves (*Streptopelia decaocto*) in Italy. *Avian Pathol.* 32:63–68.
299. Thayer, S.G., and C.W. Beard. 2008. Serologic procedures. In: *A Laboratory Manual for the Identificaiton and Characterization of Avian Pathogens, 5*. L. Dufour-Zavala, ed. American Association of Avian Pathologists, Jacksonville, Florida. 222–229.
300. Thayer, S.G., P. Villegas, and O.J. Fletcher. 1987. Comparison of two commercial enzyme-linked immunosorbent assays and conventional methods for avian serology *Avian Dis*. 31:120–124.
301. Thekisoe, M.M.O., P.A. Mbati, and S.P.R. Bisschop. 2004. Different approaches to the vaccination of free ranging village chickens against Newcastle disease in Qwa-Qwa, South Africa. *Vet Microbiol*. 101:23–30.
302. Thomas, C., D.J. King, and D.E. Swayne. 2008. Thermal inactivation of avian influenza and Newcastle disease viruses in chicken meat. *J Food Prot*. 71:1214–1222.
303. Timms, L., and D.J. Alexander. 1977. Cell-mediated immune response of chickens to Newcastle disease vaccines. *Avian Pathol.* 6:51–59.
304. Tirumurugaan, K.G., S. Kapgate, M.K. Vinupriya, K. Vijayarani, K. Kumanan, and S. Elankumaran. 2011. Genotypic and pathotypic characterization of newcastle disease viruses from India. *PLoS One.* 6:e28414.
305. Toyoda, T., T. Sakaguchi, H. Hirota, B. Gotoh, K. Kuma, T. Miyata, and Y. Nagai. 1989. Newcastle disease virus evolution II. Lack of gene recombination in generating virulent and avirulent strains. *Virology*. 169:273–282.
306. Tsai, H.J., K.H. Chang, C.H. Tseng, K.M. Frost, R.J. Manvell, and D.J. Alexander. 2004. Antigenic and genotypical characterization of Newcastle disease viruses isolated in Taiwan between 1969 and 1996. *Vet Microbiol.* 104:19–30.
307. Tsai, H.J., Y.M. Saif, K.E. Nestor, D.A. Emmerson, and R.A. Patterson. 1992. Genetic variation in resistance of turkeys to experimental infection with Newcastle disease virus. *Avian Dis.* 36:561–565.
308. Tumova, B., A. Stumpa, V. Janout, M. Uvizl, and J. Chmela. 1979. A Further member of the Yucaipa group isolated from the common wren (*Troglodytes troglodytes*). *Acta Virol.* 23:504–507.
309. Ujvari, D., E. Wehmann, E.F. Kaleta, O. Werner, V. Savic, E. Nagy, G. Czifra, and B. Lomniczi. 2003. Phylogenetic analysis reveals extensive evolution of avian paramyxovirus type 1 strains of pigeons (*Columba livia*) and suggests multiple species transmission. *Virus Res.* 96:63–73.
310. Umino, Y., T. Kohama, M. Kohase, A. Sugiura, H.D. Klenk, and R. Rott. 1987. Protective effect of antibodies to two viral envelope gylcoproteins on lethal infection with Newcastle disease virus. *Arch Virol.* 94:97–107.
311. USDA. 2012. 9 CFR 113.205—Animal and Animal Products. Chapter I. Animal and Plant Health Inspection Service,

Department of Agriculture, Part 113 Standard Requirments, Newcastle Disease Vaccine, Killed Virus. Code of Federal Regulations. 740.
312. USDA. 2008. 9CFR 82.5. Live Pet Birds: Exotic Newcastcastle Disease: Quarantine Restrictions. Code of Federal Regulations. 302991–330299.
313. USDA. 2012. Animal and Animal Products. Chapter I. Animal and Plant Health Inspection Service, Department of Agriculture Part 113 Standard Requirments, Section 113.329 Newcastle Disease Vaccine. Code of Federal Regulations 779–781.
314. Utterback, W.W., and J.H. Schwartz. 1973. Epizootiology of velogenic viscerotropic Newcastle disease in Southern California, 1971–1973. *J Am Vet Med Assoc.* 163:1080–1088.
315. van Boven, M., A. Bouma, T.H.F. Fabri, E. Katsma, L. Hartog, and G. Koch. 2008. Herd immunity to Newcastle disease virus in poultry by vaccination. *Avian Pathol.* 37:1–5.
316. Van Eck, J.H.H., and E.V. Goren. 1991. An Ulster 2C strain-derived Newcastle disease vaccine: Vaccinal reaction in comparison with other lentogenic Newcastle disease vaccines. *Avian Pathol.* 20:497–507.
317. Vidanovic, D., M. Sekler, R. Asanin, N. Millic, J. Nisavic, T. Petrovic, and V. Savic. 2011. Characterization of velogenic Newcastle disease viruses isolated from dead wild birds in Serbia during 2007. *J Wildl Dis.* 47:433–441.
318. Wakamatsu, N., D.J. King, D.R. Kapczynski, B.S. Seal, and C.C. Brown. 2006. Experimental pathogenesis for chickens, turkeys, and pigeons of exotic Newcastle disease virus from an outbreak in California during 2002–2003. *Vet Pathol.* 43: 925–933.
319. Wakamatsu, N., D.J. King, B.S. Seal, B.P. Peeters, and C.C. Brown. 2006. The effect on pathogenesis of Newcastle disease virus LaSota strain from a mutation of the fusion cleavage site to a virulent sequence. *Avian Dis.* 50:483–488.
320. Wakamatsu, N., D.J. King, B.S. Seal, S.K. Samal, and C. Brown. 2006. The pathogenesis of Newcastle disease: a comparison of selected Newcastle disease virus wild-type strains and their infectious clones. *Virology.* 353:333–343.
321. Walker, J.W., B.R. Heron, and M.A. Mixson. 1973. Exotic Newcastle disease eradication program in the United States. *Avian Dis.* 17:486–503.
322. Wambura, P.N. 2006. Comparative propagation of Newcastle disease virus (strains I-2 and V4) on chicken embryo tracheal explants. *Vet Res Comm.* 30:673–677.
323. Wambura, P.N., and S. Kataga. 2011. Putative protective antibody response following oral vaccination of multi-age free ranging helmeted guinea fowls (*Numida meleagris*) with Newcastle disease virus strain I-2 coated on oiled rice. *Trop Anim Health Prod.* 43:99–102.
324. Wan, H.Q., L.G. Chen, L.L. Wu, and X.F. Liu. 2004. Newcastle disease in geese: Natural occurrence and experimental infection. *Avian Pathol.* 33:216–221.
325. Weese, J.S., and D.C. Jack. 2008. Needlestick injuries in veterinary medicine. *Can Vet J.* 49:780–784.
326. Westbury, H. 2001. Newcastle disease virus: an evolving pathogen? *Avian Pathol.* 30:5–11.
327. Westbury, H.A. 1984. Comparison of the immunogenicity of Newcastle disease virus strains V4, B1 and La Sota in chickens. 1. Tests in susceptible chickens. *Aust Vet J.* 61:5–9.
328. Winterfield, R.W. 1984. Vaccination of chickens with Newcastle disease and infectious bronchitis vaccines administered singly and in combination. *Poult Sci.* 63:182–184.
329. Winterfield, R.W., and A.S. Dhillon. 1981. Comparative immune response from vaccinating chickens with lentogenic Newcastle disease virus strains. *Poult Sci.* 60:1195–1203.
330. Wise, M.G., D.L. Suarez, B.S. Seal, J.C. Pedersen, D.A. Senne, D.J. King, D.R. Kapczynski, and E. Spackman. 2004. Development of a real-time reverse-transcription PCR for detection of Newcastle disease virus RNA in clinical samples. *J Clin Microbiol.* 42:329–338.
331. Wu, S., W. Wang, C. Yao, X. Wang, S. Hu, J. Cao, Y. Wu, W. Liu, and X. Liu. 2010. Genetic diversity of Newcastle disease viruses isolated from domestic poultry species in Eastern China during 2005–2008. *Arch Virol.* 2:253–261.
332. Yacoub, A., M. Leijon, M.J. McMenamy, K. Ullman, J. McKillen, G. Allan, and S. Belak. 2012. Development of a novel real-time PCR-based strategy for simple and rapid molecular pathotyping of Newcastle disease virus. *Arch Virol.* 157:833–844.
333. Yadin, H. 1981. Aerosol vaccination against Newcastle disease: Factors affecting the serological response in chickens. *Avian Pathol.* 10:329–341.
334. Yadin, H., and F.W. Orthel. 1978. A study of Newcastle disease vaccine virus in sprays and aerosols. *Avian Pathol.* 7:357–371.
335. Yang, C.Y., H.K. Shieh, Y.L. Lin, and P.C. Chang. 1999. Newcastle disease virus isolated from recent outbreaks in Taiwan phylogenetically related, to viruses (genotype VII) from recent outbreaks in Western Europe. *Avian Dis.* 43:125–130.
336. Yang, Z.Q., Q.Q. Liu, Z.M. Pan, H.X. Yu, and X.A. R. Jiao. 2007. Expression of the fusion glycoprotein of Newcastle disease virus in transgenic rice and its immunogenicity in mice. *Vaccine.* 25:591–598.
337. Yeh, H.Y., B.J. Winslow, D.E. Junker, and J.M. Sharma. 1999. *In vitro* effects of recombinant chicken interferon-gamma on immune cells. *J Interf Cytok Res.* 19:687–691.

Avian Paramyxoviruses 2–11

1. Abenes, G.B., H. Kida, and R. Yanagawa. 1983. Avian paramyxoviruses possessing antigenically related HN but distinct M proteins. *Arch Virol.* 77:71–76.
2. Alexander, D.J. 1980. Avian paramyxoviruses. *Vet Bull.* 50:737–752.
3. Alexander, D.J. 1989. Newcastle disease. In: *A Laboratory Manual for the Isolation and Identification of Avian Pathogens*. H.G. Purchase, L.H. Arp, S.B. Hitchner, C.H. Domermuth, and J.E. Pearson, eds. American Association of Avian Pathologists, Jacksonville, Florida. 110–112.
4. Alexander, D.J. 1997. Newcastle disease and other avian paramyxoviridae infections. In: *Diseases of Poultry*, 10th ed. B.W. Calnek, ed. Iowa State University Press, Ames, Iowa. 541–569.
5. Alexander, D.J., M. Aymard, N. Kessler, and M.S. Collins. 1979. Antigenic and structural relationships between avian paramyxoviruses isolated from ducks in Hong Kong and Mississippi, USA. *J Gen Virol.* 44:839–842.
6. Alexander, D.J., and N.J. Chettle. 1978. Relationship of parakeet/Netherland/449/75 virus to other avian paramyxovirus. *Res Vet Sci.* 25:105–106.
7. Alexander D.J., and M.S. Collins. 1982. Pathogenicity of PMV-3/parakeet/Netherlands/449/75 for chickens. *Avian Pathol.* 11:179–185.

8. Alexander, D.J., and M.S. Collins. 1984. Characterization of avian paramyxoviruses of serotype PMV-3 isolated from commercial turkey in Great Britain. *Avian Pathol.* 13:215–221.
9. Alexander, D.J., V.S. Hinshaw, and M.S. Collins. 1981. Characterization of viruses from doves representing a new serotype of avian paramyxoviruses. *Arch Virol.* 68:265–269.
10. Alexander, D.J., V.S. Hinshaw, M.S. Collins, and N. Yamane. 1983. Characterization of viruses which represent further distinct serotypes (PMV-8 and PMV-9) of avian paramyxoviruses. *Arch Virol.* 78:29–36.
11. Alexander, D.J., and D.A. Senne. 2008. Avian paramyxoviruses 2–9. In: *Diseases of Poultry*, 12th ed. Y.M. Saif, A.M. Fadly, J.R. Glisson, L.R. McDougald, L.K. Nolan, and D.E. Swayne, eds. Blackwell, Ames, Iowa. 110–115.
12. Awang, I.P.R., and P.H. Russell. 1990. Turkey avian paramyxovirus type 3 infections in poultry. *World's Poult Sci J.* 46: 211–218.
13. Bahl, A.K., and M.L. Vickers. 1982. Egg drop syndrome in breeder turkeys associated with turkey parainfluenza virus-3 (TPIV-3). *Proc West Poult Dis Conf.* 31:113.
14. Bankowski, R.A., J. Almquist, and J. Dombruski. 1995. Effect of paramyxovirus Yucaipa on fertility, hatchability, and poultry yield of turkeys. *Avian Dis.* 25:517–520.
15. Bankowski, R.A., R.E. Corstvet, and G.T. Clark. 1960. Isolation of an unidentified agent from the respiratory tract of chickens. *Science.* 132:292–293.
16. Beck, I., H. Gerlach, E. Burkhardt, and E.F. Kaleta. 2003. Investigation of several selected adjuvants regarding their efficacy and side effects for the production of a vaccine for parakeets to prevent a disease caused by a paramyxovirus type 3. *Vaccine.* 21:1006–1022.
17. Box, P. 1987. PMV3 disease of turkeys. *Int Hatch Prac.* 2:4–7.
18. Calain, P., and L. Roux. 1993. The rule of six, a basic feature for efficient replication of Sendai virus defective interfering RNA. *J Virol.* 67:4822–4830.
19. Capua, I., R. De Nardi, M.S. Beato, C. Terregino, M. Scremin, and V. Guberti. 2004. Isolation of an avian paramyxovirus type 9 from migratory waterfowl in Italy. *Vet Rec.* 155:156.
20. Chang, P.C., M.L. Hsieh, J.H. Shien, D.A. Graham, M.S. Lee, and H.K. Shieh. 2001. Complete nucleotide sequence of avian paramyxovirus type 6 isolated from ducks. *J Gen Virol.* 82:2157–2168.
21. Cloud, S.S., and J.K. Rosenberger. 1980. Characterization of nine avian paramyxoviruses. *Avian Dis.* 24:139–152.
22. Coffee, L.L., B.A. Hanson, M.P. Luttrell, D.E. Swayne, D.A. Senne, V.H. Goekjian, L.J. Niles, and D.E. Stallknecht. 2010. Avian paramyxoviruses in shorebirds and gulls. *J Wildl Dis.* 46:481–487.
23. Dinter, Z., S. Hermodsson, and L. Hermodsson. 1964. Studies on myxovirus Yucaipa: Its classification as a member of the paramyxovirus group. *Virology.* 22:297–304.
24. Eskelund, K.H. 1988. Vaccination of turkey breeder hens against paramyxovirus type 3 infection. *Proc West Poult Dis Conf.* 37:43–45.
25. Fleury, H.J., J.F. Bonnici, M. Babin, P. du Pasquier, and A. Samb. 1984. Serological evidence of human infection with the paramyxovirus Yucaipa in Senegal, West Africa. *Am J Trop Med Hyg*. 33:190–191.
26. Fornells, L.A., Silva, T.F., I. Bianchi, C.E. Travassos, M.H. Liberal, C.M. Andrade, M.P. Petrucci, V.F. Veiga, M.F. Vaslin, and J.N. Couceiro. 2012. Detection of paramyxoviruses in Magellanic penguins (*Spheniscus magellanicus*) on the Brazilian tropical coast. *Vet Microbiol.* 156(3–4):429–33.
27. Goekjian, V.H., J.T. Smith, D.L. Howell, D.A. Senne, D.E. Swayne, and D.E. Stallknecht. 2011. Avian influenza viruses and avian paramyxoviruses in wintering and breeding waterfowl populations in North Carolina, USA. *J Wildl Dis*. 47: 240–245.
28. Goodman, B.B., and R.P. Hanson. 1988. Isolation of avian paramyxovirus-2 from domestic and wild birds in Costa Rica. *Avian Dis.* 32:713–717.
29. Goodman, B.B., R.P. Hanson, T.C. Moermond, and B.M. Christensen. 1990. Experimental avian PMV-2 infection in a domesticated wild host: daily behavior and effect on activity levels. *J Wildl Dis.* 26:22–27.
30. Gough, R.E., and D.J. Alexander. 1983. Isolation and preliminary characterisation of a paramyxovirus from collared doves (*Streptopelia decaocto*). *Avian Pathol.* 12:125–134.
31. Gough, R.E., and D.J. Alexander.1984. Avian paramyxovirus type 4 isolated from a ringed teal (*Calonetta leucophrys*). *Vet Rec.* 115:653.
32. Gough, R.E., R.J. Manvell, S.E. Drury, P.F. Naylor, D. Spackman, and S.W. Cooke. 1993. Deaths in budgerigars associated with a paramyxovirus-like agent. *Vet Rec.* 133:123.
33. Hanson, R.P. 1975. Avian reservoirs of Newcastle diseases. In: *Wildlife Diseases*. L.A. Page, ed. Plenum Press, New York. 185–195.
34. Ianconescu, M., R.A. Bankowski, R.H. McCapes, G.Y. Ghazikhanian, and B.J. Kelly. 1985. Paramyxovirus type 3 (PMV-3) in California turkeys: serologic study of PMV-3 antibody with an enzyme-linked immunosorbent assay. *Avian Dis.* 29:364–372.
35. Ishida, M., K. Nerome, M. Matsumoto, T. Mikami, and A. Oye. 1985. Characterization of reference strains of Newcastle disease virus (NDV) and NDV-like isolates by monoclonal antibodies to HN subunits. *Arch Virol.* 85:109–121.
36. Jeon, W.J., E.K. Lee, J.H. Kwon, and K.S. Choi. 2008. Full-length genome sequence of avian paramyxovirus type 4 isolated from a mallard duck. *Virus Genes.* 37:342–350.
37. Jung, A., C. Grund, I. Müller, and S. Rautenschlein. 2009. Avian paramyxovirus serotype 3 infection in Neopsephotus, Cyanoramphus, and Neophema species. *J Avian Med Surg.* 23:205–208.
38. Kaleta, E.F., O. Werner, and Y. Hemberger. 2010. Isolation and characterization of avian paramyxovirus type 3b from farmed Namibian ostriches (*Struthio camelus f. dom.*). *Berl Munch Tierarztl Wochenschr*. 123:103–110.
39. Kessler, N., M. Aymard, and A. Calvet. 1979. Study of a new strain of paramyxoviruses isolated from wild ducks: Antigenic and biological properties. *J Gen Virol.* 43:273–282.
40. Khattar, S.K., S. Kumar, S. Xiao, P.L. Collins, and S.K. Samal. 2011. Experimental infection of mice with avian paramyxovirus serotypes 1 to 9. *PLoS One* 6(2):e16776.
41. Kida, H., and R. Yanagawa. 1981. Classification of avian paramyxoviruses by immunodiffusion on the basis of the antigenic specificity of their M protein antigens. *J Gen Virol.* 52:103–111
42. Kumar, S., F. Militino-Dias, B. Nayak, P.L. Collins, and S.K. Samal. (2010a). Experimental avian paramyxovirus serotype-3 infection in chickens and turkeys. *Vet Res.* 41:72.
43. Kumar, S., B. Nayak, P.L. Collins, and S.K. Samal. 2008. Complete genome sequence of avian paramyxovirus type 3 reveals an unusually long trailer region. *Virus Res.* 137:189–197.

44. Kumar, S. B., A. Nayak, A.S. Samuel, S. Xiao, P.L. Collins, and S.K. Samal. 2010b. Complete genome sequence of avian paramyxovirus-3 strain Wisconsin: evidence for the existence of subgroups within the serotype. *Virus Res.* 149:78–85.
45. Kusagawa, S., H. Komada, X. Mao, M. Kawano, F. Nishikawa, M. Tsurudome, H. Matsumura, H. Ohta, T. Yuasa, M. Nishio, and Y. Ito. 1993. Antigenic and molecular properties of Murayama virus isolated from cynomolgus monkeys: the virus is closely related to avian paramyxovirus type 2. *Virology.* 194:828–832.
46. Lang, G., A. Gagnon, and J. Howell. 1975. Occurrence of paramyxovirus Yucaipa in Canadian poultry. *Can Vet J.* 16:233–237.
47. Lipkind, M., D.J. Alexander, E. Shihmanter, Y. Weisman, and M. Collins.1995. Antigenic heterogeneity of avian paramyxoviruses of serotype 2 ('Yucaipa-like') isolated from domestic and wild birds in Israel. *Comp Immunol Microbiol Infect Dis.* 18:189–207.
48. Lipkind, M., and E. Shihmanter. 1986. Antigenic relationships between avian paramyxoviruses. I. Quantitative characteristics based on hemagglutination and neuraminidase inhibition tests. *Arch Virol*. 89:89–111.
49. MacPherson, I., R.G. Watt, and D.J. Alexander. 1983. Isolation of avian paramyxovirus other than Newcastle disease virus from commercial poultry in Great Britain. *Vet Rec.* 112:479–480.
50. Mahmood, S., D.J. Alexander, M.J. Slomka, R.J. Manvell, A. Hanna, C.M. Fuller, and I.H. Brown. 2010. Phylogenetic analysis of the nucleotide sequences for the HN gene of 22 avian paramyxovirus type 2 viruses reveals marked heterogeneity. *Avian Pathol.* 39:453–458.
51. Maldonado, A., A. Arenas, M.C. Tarradas, I. Luque, R. Astorga, J.A. Perea, and A. Miranda. 1995. Serological survey for avian paramyxoviruses from wildfowl in aquatic habitats in Andalusia. *J Wildl Dis.* 31:66–69.
52. Miller, P.J., C.L. Afonso, E. Spackman, M.A. Scott, J.C. Pedersen, D.A. Senne, J.D. Brown, C.M. Fuller, M.M. Uhart, W.B. Karesh, I.H. Brown, D.J. Alexander, and D.E. Swayne. 2010. Evidence for a new avian paramyxovirus serotype 10 detected in rockhopper penguins from the Falkland Islands. *J Virol.* 84:11496–11504.
53. Mundt, E., M. Bublot, T. Mebatsion, and N.J. Pritchard. 2010. Recombinant avian paramyxovirus vaccine and method for making and using thereof. US patent 20110081374.
54. Mustaffa-Babjee, A., P.B. Spradbrow, and J.L. Samuel. 1974. A pathogenic paramyxovirus from a budgerigar (*Melopsittacus undulatus*). *Avian Dis.* 18:226–230.
55. Nayak, B., F.M. Dias, S. Kumar, A. Paldurai, P.L. Collins, and S.K. Samal. 2012. Avian paramyxovirus serotypes 2-9 (APMV-2-9) vary in the ability to induce protective immunity in chickens against challenge with virulent Newcastle disease virus (APMV-1). *Vaccine.* 30(12):2220–2227.
56. Nayak, B., S. Kumar, P.L. Collins, and S.K. Samal. 2008. Molecular characterization and complete genome sequence of avian paramyxovirus type 4 prototype strain duck/Hong Kong/D3/75. *Virol J.* 5:124.
57. Nerome, K., M. Nakayama, M. Ishida, and H. Fukumi. 1978. Isolation of a new avian paramyxovirus from budgerigar (*Melopsittacus undulatus*). *J Gen Virol.* 38:293–301.
58. Nishikawa, F., T. Sugiyama, and K. Suzuki, 1977. A new paramyxovirus isolated from cynomolgus monkeys. *Jap J Med Sci Biol.* 30:191–204.
59. OIE. 2011. http://www.oie.int/en/international-standard-setting/terrestrial-manual/access-online/. Accessed January 21, 2013.
60. Paldurai, A., M. Subbiah, S. Kumar, P.L. Collins, and S.K. Samal. 2009. Complete genome sequences of avian paramyxovirus type 8 strains goose/Delaware/1053/76 and pintail/Wakuya/20/78. *Virus Res.* 142:144–153.
61. Redmann, T., M.M. Zeydanli, W. Herbst, and E.F. Kaleta. 1991. Isolation of a paramyxovirus-3 from turkeys with respiratory tract disease in Germany. *Dtsch Tierarztl Wochenschr.* 98:138–141.
62. Rosenberger, J.K., W.C. Krauss, and R.D. Slemons. 1974. Isolation of Newcastle disease and type-A influenza viruses from migratory waterfowl in the Atlantic flyway. *Avian Dis.* 18:610–613.
63. Saif, Y.M., R. Mohan, L. Ward, D.A. Senne, B. Panigrahy, and R.N. Dearth. 1997. Natural and experimental infection of turkeys with avian paramyxovirus-7. *Avian Dis.* 41:326–329.
64. Samuel, A.S., S. Kumar, S. Madhuri, P.L. Collins, and S.K. Samal. 2009. Complete sequence of the genome of avian paramyxovirus type 9 and comparison with other paramyxoviruses. *Virus Res.* 142:10–18.
65. Samuel, A.S., A. Paldurai, S. Kumar, P.L. Collins, and S.K. Samal. 2010. Complete genome sequence of avian paramyxovirus (APMV) serotype 5 completes the analysis of nine APMV serotypes and reveals the longest APMV genome. *PLoS One.* 5:e9269.
66. Samuel, A.S., M. Subbiah, H. Shive, P.L. Collins, and S.K. Samal. 2011. Experimental infection of hamsters with avian paramyxovirus serotypes 1 to 9. *Vet Res.* 42:38.
67. Shihmanter, E., Y. Weisman, A. Lublin, S. Mahani, A. Panshin, and M. Lipkind. 1998. Isolation of avian serotype 3 paramyxoviruses from imported caged birds in Israel. *Avian Dis.* 42:829–831.
68. Shihmanter, E., Y. Weisman, R. Manwell, D. Alexander, and M. Lipkind. 1997. Mixed paramyxovirus infection of wild and domestic birds in Israel. *Vet Microbiol.* 58:73–78.
69. Shihmanter, E., Y. Weisman, A. Panshin, R. Manvell, D. Alexander, and M. Lipkind. 2000. Isolation of avian paramyxovirus serotype 3 from domestic fowl in Israel: close antigenic relationship with the psittacine strain of avian paramyxovirus serotype 3. *J Vet Diagn Invest.* 12:67–69.
70. Shortridge, K.F., and D.J. Alexander. 1978. Incidence and preliminary characterization of a hitherto unreported, serologically distinct, avian paramyxovirus isolated in Hong Kong. *Res Vet Sci.* 25:128–130.
71. Shortridge, K.F., D.J. Alexander, and M.S. Collins. 1980. Isolation and properties of viruses from poultry in Hong Kong which represent a new (sixth) distinct group of avian paramyxoviruses. *J Gen Virol.* 49:255–262.
72. Stallknecht, D.E., D.A. Senne, P.J. Zwank, S.M. Shane, and M.T. Kearney. 1991. Avian paramyxoviruses from migrating and resident ducks in coastal Louisiana. *J Wildl Dis.* 27:123–128.
73. Stanislawek, W.L., C.R. Wilks, J. Meers, G.W. Horner, D.J. Alexander, R.J. Manvell, J.A. Kattenbelt, and A.R. Gould. 2002. Avian paramyxoviruses and influenza viruses isolated from mallard ducks (*Anas platyrhynchos*) in New Zealand. *Arch Virol.* 147:1287–1302.
74. Subbiah, M., S. Nayak, P.L. Collins, and S.K. Samal. 2010. Complete genome sequences of avian paramyxovirus serotype 2 (APMV-2) strains Bangor, England and Kenya: evidence for the existence of subgroups within serotype 2. *Virus Res.* 152:85–95.
75. Subbiah, M., S. Xiao, P.L. Collins, and S.K. Samal. 2008. Complete sequence of the genome of avian paramyxovirus type

2 (strain Yucaipa) and comparison with other paramyxoviruses. *Virus Res.* 137:40–8.
76. Subbiah, M., S. Xiao, S.K. Khattar, F.M. Dias, P.L. Collins, and S.K. Samal. 2010b. Pathogenesis of two strains of avian paramyxovirus serotype 2, Yucaipa and Bangor, in chickens and turkeys. *Avian Dis.* 54:1050–1057.
77. Tumova, B., J.H. Robinson, and B.C. Easterday. 1979. A hitherto unreported paramyxovirus of turkeys. *Res Vet Sci*. 27:135–140.
78. Wang, L.-F., P.L. Collins, R.A.M. Fouchier, G. Kurath, R.A. Lamb, R.E. Randall, and B.K. Rima 2011. Paramyxoviridae. In: *Virus Taxonomy Classification and Nomenclature of Viruses*, 9th Report. A.M.Q. King, M.J. Adams, E.B. Carstens, and E.J. Lefkowitz, eds. Elsevier, Oxford, United Kingdom. 672–685.
79. Warke, A., L. Appleby, and E. Mundt E. 2008a. Prevalence of antibodies to different avian paramyxoviruses in commercial poultry in the United States. *Avian Dis*. 52:694–697.
80. Warke, A., D. Stallknecht, S.M. Williams, N. Pritchard, and E. Mundt. 2008b. Comparative study on the pathogenicity and immunogenicity of wild bird isolates of avian paramyxovirus 2, 4, and 6 in chickens. *Avian Pathol*. 37:429–434.
81. Woolcock, P.R., J.D. Moore, M.D. McFarland, and B. Panigrahy. 1996. Isolation of paramyxovirus serotype 7 from ostriches (Struthio camelus). *Avian Dis*. 40:945–949.
82. Xiao, S., A. Paldurai, B. Nayak, M. Subbiah, P.L. Collins, and S.K. Samal. 2009. Complete genome sequence of avian paramyxovirus type 7 (strain Tennessee) and comparison with other paramyxoviruses. *Virus Res*. 145:80–91.
83. Xiao, S., M. Subbiah, S. Kumar, R. De Nardi, C. Terregino, P.L. Collins, and S.K. Samal. 2010. Complete genome sequences of avian paramyxovirus serotype 6 prototype strain Hong Kong and a recent novel strain from Italy: evidence for the existence of subgroups within the serotype. *Virus Res*. 150:61–72.
84. Zhang, G.Z., J.X. Zhao, H.W. Wang, A.M. Yang, C.Y. Bu, and M. Wang. 2006. Isolation, identification, and comparison of four isolates of avian paramyxovirus serotype 2 in China. *Avian Dis*. 50:386–390.

Avian Metapneumovirus

1. Al-Ankari, A.R., J.M. Bradbury, C.J. Naylor, K.J. Worthington, C. Payne-Johnson, and R.C. Jones. 2001. Avian pneumovirus infection in chicks inoculated with E. coli at difference time intervals. *Avian Pathol*. 30:257–267.
2. Alexander, D.J. 1993. Pneumoviruses (turkey rhinotracheitis and swollen head syndrome of chickens). In: *Virus Infections of Birds*. J.B. McFerran and M.S. McNulty, eds. Elsevier Science Publishers B.V., Amsterdam. 375–382.
3. Alexander, D.J., E.D. Borland, C.D. Bracewell, N.J. Chettle, R.E. Gough, S.A. Lister, and P.J. Wyeth. 1986. A preliminary report of investigations into turkey rhinotracheitis in Great Britain. *State Vet J.* 40:161–169.
4. Alkahalaf, A.N., L.A. Ward, R.N. Dearth, and Y.M. Saif. 2002. Pathogenicity, transmissibility and tissue distribution of avian pneumovirus in turkey poults. *Avian Diseases.* 46:650–659.
5. Alkahalaf, A.N., D.A. Halvorson, and Y.M. Saif. 2002a. Comparison of enzyme linked immunosorbent assays and virus neutralisation test for detection of antibodies to avian pneumovirus. *Avian Dis.* 46:700–703.
6. Alvarez, R., H.W. Lwamba, D.R. Kapczynski, M.K. Njenga, and B.S. Seal. 2003. Nucleotide and predicted amino acid sequence-based analysis of the avian metapneumovirus type C cell attachment glycoprotein gene: Phylogenetic analysis and molecular epidemiology of U.S. pneumoviruses. *J Clin Microbiol*. 41:1730–1735.
7. Andral, B.C., C. Louzis, D. Trap, J.A. Newman, D. Toquin, and G. Bennejean. 1985. Respiratory disease (rhinotracheitis) in turkeys in Brittany, France, 1981–1982. I. Field observation and serology. *Avian Dis*. 29:35–42.
8. Arns, C.W., and H.M. Hafez. 1995. Isolation and identification of APV from broiler breeder flocks in Brazil. Proceedings of the 44th Western Poultry Disease Conference, Sacramento, U.S.A. 124–125.
9. Aung, Y.H., M. Liman, U. Neuman,n and S. Rautenschlein. 2008. Reproducibility of swollen sinuses in broilers by experimental infection with avian metapneumovirus subtypes A and B of turkey origin and their comparative pathogenesis. *Avian Pathol.* 37:65–74.
10. Banet-Noach, C., L. Simanov, and S. Perk. 2005. Characterization of Israeli avian metapneumovirus strains in turkeys and chickens. *Avian Pathol.* 34:220–226.
11. Baxter-Jones, C., J.K.A. Cook, J.A. Fraser, M. Grant, R.C. Jones, A.P.A. Mockett, and G.P. Wilding. 1987. Close relationship between TRT virus isolates. *Vet Rec.* 120:562.
12. Baxter-Jones, C., M. Grant, R.C. Jones, and G.P. Wilding. 1989. A comparison of three methods for detecting antibodies to turkey rhinotracheitis virus. *Avian Pathol.* 18:91–98.
13. Bayon-Auboyer, M.H., C. Arnauld, D. Toquin, and N. Eterradossi. 2000. Nucleotide sequences of the F, L and G protein genes of two non-A/non-B avian pneumoviruses (APV) reveal a novel APV subgroup. *J Gen Virol.* 81:2723–2733.
14. Bennett, R.S., B. McComb, H.J. Shin, M.K. Njenga, K.V. Nagaraja, and D.A. Halvorson. 2002. Detection of avian pneumovirus in wild Canadian geese (*Branta canadensis*) and blue-winged teal (*Anas discors*). *Avian Dis.* 46:1025–1029.
15. Bennett, R.S., J. Nezworski, B.T. Velayudhan, K.V. Nagaraja, D.H. Zeman, N. Dyer, T. Graham, D.C. Lauer, M.K. Njenga, and D.A. Halvorson. 2004. Evidence of avian pneumovirus spread beyond Minnesota among wild and domestic birds in Central North America. *Avian Dis.* 48:902–908.
16. Brown, P., M. Bonci, E. Ricchizzi, R.C. Jones, and C.J. Naylor. 2009. Identification of two regions within the subtype A avian metapneumovirus fusion protein (amino acids 211-310 and 336-479) recognised by neutralizing antibodies. *Virus Res.* 146:13–18.
17. Brown, P.A., C. Lupini, E. Catelli, J. Clubbe, E. Ricchizzi, and C.J. Naylor. 2011. A single polymerase (L) mutation in avian metapneumovirus increased virulence and partially maintained virus viability at an elevated temperature. *J Gen Virol.* 92:346–54.
18. Buys, S.B., and J.H. du Preez. 1980. A preliminary report on the isolation of a virus causing sinusitis in turkeys in South Africa and attempts to attenuate the virus. *Turkeys.* 36:46.
19. Buys, S.B., J.H. du Preez, and H.J. Els. 1989. The isolation and attenuation of a virus causing rhinotracheitis in turkeys in South Africa. *Onderstepoort J Vet Res.* 57:87–98.
20. Cadman, H.F., P.J. Kelly, R. Zhou, F. Davelaar, and P.R. Manson. 1994. A serosurvey using ELISA for antibodies against poultry pathogens in ostriches (*Struthio camelus*) from Zimbabwe. *Avian Dis.* 38:621–625.
21. Catelli, E., J.K.A. Cook, J. Chesher, S.J. Orbell, M.A. Woods, W. Baxendale, and M.B. Huggins. 1998. The use of virus isolation,

histopathology and immunoperoxidase techniques to study the dissemination of a chicken isolate of avian pneumovirus in chickens. *Avian Pathol.* 27:632–640.
22. Catelli, E., M. Cecchinato, C.E. Savage, R.C. Jones, and C.J. Naylor. 2006. Demonstration of loss of attenuation and extended field persistence of a live avian metapneumovirus vaccine. *Vaccine.* 24:6476–82.
23. Catelli, E., C. Lupini, M. Cecchinato, E. Ricchizzi, P. Brown, and C.J. Naylor. 2010. Field avian metapneumovirus evolution avoiding vaccine induced immunity. *Vaccine.* 28:916–21.
24. Cavanagh, D., K. Mawditt, P. Britton, and C.J. Naylor. 1999. Longitudinal field studies of infectious bronchitis virus and avian pneumovirus in broilers using type-specific polymerase chain reactions. *Avian Pathol.* 28:593–605.
25. Cecchinato, M., E. Catelli, C.E. Savage, R.C. Jones, and C.J. Naylor. 2004. Design, validation and absolute sensitivity of a novel test for the molecular detection of avian pneumovirus. *J Vet Diag Invest.* 16:582–585.
26. Cecchinato, M., E. Catelli, C. Lupini, E. Ricchizzi, J. Clubbe, M. Battilani, and C.J. Naylor. 2010. Avian metapneumovirus (AMPV) attachment protein involvement in probable virus evolution concurrent with mass live vaccine introduction. *Vet Microbiol.* 146:24–34.
27. Cha, R.M., M. Khatri, and J.M. Sharma. 2007. B-cell infiltration in the respiratory mucosa of turkeys exposed to subtype C avian Metapneumovirus. *Avian Dis.* 51:764–770.
28. Cha, R.M., M. Khatri, M. Mutnal, and J.M. Sharma. 2011. Pathogenic and immunogenic responses in turkeys following *in ovo* exposure to avian metapneumovirus subtype C. *Vet Immunol Immunopathol.* 1401–2:30–6.
29. Cha, R.M., M. Khatri, and J.M. Sharma. 2011. Protection against avian metapneumovirus subtype C in turkeys immunized via the respiratory tract with inactivated virus. *Vaccine.* 29:459–65.
30. Chacon, J.L., M. Mizuma, M.P. Vejerano, D. Toquin, N. Eterradossi, D.P. Patnayak, S.M. Goyal, and A.J. Ferriera. 2011. Avian metapneumovirus subtypes circulating in Brazilian vaccinated and nonvaccinated chicken and turkey farms. *Avian Dis.* 55:82–9.
31. Chary, P., S. Rautenschlein, M.K. Njenga, and J.M. Sharma. 2002. Pathogenic and immunosuppressive effects of avian pneumovirus in turkeys. *Avian Dis.* 46:153–161.
32. Chary, P., S. Rautenschlein, and J.M. Sharma. 2002. Reduced efficacy of hemorrhagic enteritis virus vaccine in turkeys exposed to avian pneumovirus. *Avian Dis.* 46:353–359.
33. Chiang, S.J., A.M. Dar, S.M. Goyal, M.A. Sheik, J.C. Pedersen, B. Panigrahy, D. Senne, D.A. Halvorson, K.V. Nagaraja, and V. Kapur. 2000. A modified enzyme-linked immunosorbent assay for the detection of avian pneumovirus antibodies. *J Vet Diag Invest.* 12:381–384.
34. Choi, K.S., E.K. Lee, W.J. Jeon, Y.N. Yoo, and J.H. Kwon. 2010. Diagnostic utility of egg yolk for the detection of avian metapneumovirus antibodies in laying hens. *Avian Dis.* 54:1230–1236.
35. Clubbe, J., and C.J. Naylor. 2011. Avian metapneumovirus M2:2 protein inhibits replication in Vero cells: modification facilitates live vaccine development. *Vaccine.* 29:9493–8.
36. Collins, M.S., and R.E. Gough. 1988. Characterisation of a virus associated with turkey rhinotracheitis. *J Gen Virol.* 69:909–916.
37. Collins, M.S., R.E. Gough, and D.J. Alexander. 1993. Antigen differentiation of avian pneumovirus isolates using polyclonal antisera and mouse monoclonal antibodies. *Avian Pathol.* 22:469–479.
38. Collins, M.S., R.E. Gough, S.A. Lister, N. Chettle, and R. Eddy. 1986. Further characterisation of a virus associated with turkey rhinotracheitis. *Vet Rec.* 119:606.
39. Cook, J.K.A. 2000. Avian rhinotracheitis. *Rev Sci Tech OIE.* 19:602–613.
40. Cook, J.K.A., M.M. Ellis, C.A. Dolby, H.C. Holmes, P.M. Finney, and M.B. Huggins. 1989. A live attenuated turkey rhinotracheitis virus vaccine. I. Stability of the attenuated strain. *Avian Pathol.* 18:511–522.
41. Cook, J.K.A., M.M. Ellis, C.A. Dolby, H.C. Holmes, P.M. Finney, and M.B. Huggins. 1989. A live attenuated turkey rhinotracheitis virus vaccine. 2. The use of the attenuated strain as an experimental vaccine. *Avian Pathol.* 18:523–534.
42. Cook, J.K.A., and M.M. Ellis. 1990. Attenuation of turkey rhinotracheitis virus by alternative passage in embryonated chicken eggs and tracheal organ cultures. *Avian Pathol.* 19: 181–185.
43. Cook, J.K.A., M.M. Ellis, and M.B. Huggins. 1991. The pathogenesis of turkey rhinotracheitis virus in turkey poults inoculated with the virus alone or together with two strains of bacteria. *Avian Pathol.* 119:181–185.
44. Cook, J.K.A., B.V. Jones, M.M. Ellis, J. Li, and D. Cavanagh. 1993. Antigenic differentiation of strains of turkey rhinotracheitis virus using monoclonal antibodies. *Avian Pathol.* 22: 257–273.
45. Cook, J.K.A., M.B. Huggins, M.A. Wood, S.J. Orbell, and A.P.A. Mockett. 1995. Protection provided by a commercially available vaccine against different strains of turkey rhinotracheitis virus. *Vet Rec.* 136:392–393.
46. Cook, J.K.A., M.B. Huggins, S.J. Orbell, and D.A. Senne. 1999. Preliminary antigenic characterisation of an avian pneumovirus isolated from commercial turkeys in Colorado, USA. *Avian Pathol.* 28:607–617.
47. Cook, J.K.A., J. Chesher, F. Orthel, M.A. Woods, S.J. Orbell, W. Baxendale, and M.B. Huggins. 2000. Avian pneumovirus infection in laying hens: experimental studies. *Avian Pathol.* 29:545–556.
48. Cook, J.K.A., M.B. Huggins, S.J. Orbell, K. Mawditt, and D. Cavanagh. 2001.Infectious bronchitis virus vaccine interferes with the replication of avian pneumovirus vaccine in domestic fowl. *Avian Pathol.* 30:233–242.
49. Cook, J.K.A., and D. Cavanagh. 2002. Detection and differentiation of avian pneumoviruses (metapneumoviruses). *Avian Pathol.* 31:117–132.
50. Coswig, L.T., dos Santos, M.B., Hafez, H.M., Ferriera, H.L., and Arns, C.L. 2010. Propagation of avian metapneumovirus subtypes A and B using chick embryo related and other cell systems. *J Virol Methods.* 167:1–4.
51. D'Arce, R.C.F., L.T. Coswig, R.S. Almeida, I.M. Trevisol, M.C.B. Monteiro, L.I. Rossini, J. di Fabio, H.M. Hafez, and C.W. Arns. 2005. Subtyping of new Brazilian avian metapneumovirus isolates from chickens and turkeys by reverse transcriptase-nested polymerase chain reaction. *Avian Pathol.* 34:133–136.
52. de Graaf, M., A.D. Osterhaus, R.A. Fouchier, and E.C. Holmes. 2008. Evolutionary dynamics of human and avian metapneumoviruses. *J Gen Virol.* 89:2933–2342.
53. Droual, R., and P.R. Woolcock. 1994. Swollen head syndrome associated with E. coli and infectious bronchitis virus in the Central Valley of California. *Avian Pathol.* 23:733–742.

54. Easton A.J., J.B. Domachowske, and H.F. Rosenberg. 2004. Animal pneumoviruses: molecular genetics and pathogenesis. *Clin Microbiol Rev.* 17:390–412.
55. Eterradossi, N., D. Toqin, M. Guittet, and G. Bennejean. 1992. Discrepancies in turkey rhinotracheitis ELISA results using different antigens. *Vet Rec.* 131:563–564.
56. Fearns, R.M., M.E. Peeples, and P.L. Collins. 2002. Mapping the transcription and replication promoters of respiratory syncytial virus. *J Pathol.* 76:1663–1672.
57. Felippe, P.A., L.H. Silva, M.B. Santos, S.T. Sakata, and C.W. Arn, 2011. Detection of and phylogenetic studies with avian metapneumovirus recovered from feral pigeons and wild birds in Brazil. *Avian Pathol.* 40:445–452.
58. Ganapathy, K., P. Cargill, E. Montiel, and R.C. Jones. 2005. Interaction between live avian pneumovirus and Newcastle disease virus vaccines in specific pathogen free chickens. *Avian Pathol.* 34:297–302.
59. Ganapathy, K., A. Bufton, A., Pearson, S. Lemiere, and R.C. Jones. 2010. Vaccination of commercial broiler chicks against avian metapneumovirus infection: a comparison of drinking water, spray and oculo-oral delivery methods. *Vaccine.* 28:3944–3948.
60. Garmyn, A., A. Martel, R. Froyman, H. Nauwynck, L. Duchateau, F. Haesebrouck, and F. Pasmans. 2009. The effect of reduced treatment time and dosage of enrofloxacin on the course of respiratory disease caused by avian metapneumovirus and *Ornithobacterium rhinotracheale*. *Poult Sci.* 88: 2315–23.
61. Gharaibeh, S., and Shamoun, M. 2011. Avian pneumovirus subtype B experimental infection and tissue distribution in chickens, sparrows and pigeons. *Vet Pathol.* 40:704–709.
62. Giraud, P., G. Bennejean, M. Guittet, and D. Toquin. 1986. Turkey rhinotracheitis in France: Preliminary investigation on a ciliostatic virus. *Vet Rec.* 119:606–607.
63. Gough, R.E., and M.S. Collins. 1989. Antigenic relationships of three turkey rhinotracheitis viruses. *Avian Pathol.* 18:227–238.
64. Gough, R.E., M.S. Collins, W.J. Cox, and N.J. Chettle. 1988. Experimental infection of turkeys, chickens, ducks, guinea-fowl, pheasants and pigeons with turkey rhinotracheitis virus. *Vet Rec.* 123:58–59.
65. Gough, R.E., and J.C. Pedersen. 2008. Avian metapneumovirus. In: *Isolation and Identification of Avian Pathogens*. L. Dufour-Zavala, D.E. Swayne, M.W. Jackwood, J.E. Pearson, W.M. Reed, and P. Woolcock, eds. American Association of Avian Pathologists, Jacksonville, Florida. 142–145.
66. Gough, R.E., S.E. Drury, E. Aldous, and P.W. Laing. 2001. Isolation and identification of an avian pneumovirus from pheasants. *Vet Rec.* 149:312.
67. Govindarajan, D., S.H. Kim, and S.K. Semal. 2010. Contribution of the attachment G glycoprotein to pathogenicity and immunogenicity of avian metapneumovirus subgroup C. *Avian Dis.* 54:59–66.
68. Goyal, S.M., S.J. Chiang, A.M. Dar, K.V. Nagaraja, D.P. Shaw, D.A. Halvorson, and V. Kapur. 2000. Isolation of avian pneumovirus from an outbreak of respiratory illness in Minnesota turkeys. *J Vet Diag Invest.* 12:166–168.
69. Gulati, B.R., S. Munir, D.P. Patnayak, S.M. Goyal, and V. Kapur. 2001. Detection of antibodies to US isolates of avian pneumovirus by a recombinant nucleocapsid protein-based sandwich enzyme-linked immunosorbent assay. *J Clin Microbiol.* 39: 2967–2970.
70. Hafez, H.M. 1993. The role of pneumovirus in swollen head syndrome of chickens: review. *Archiv fur Geflugelkunde.* 57:181–185.
71. Hafez, H.M., J. Emele, and H. Woernle. 1990. Turkey rhinotracheitis: serological flock profiles and economic parameters and treatment trials using Enrofloxacin (Baytril). *Zeitschr Gebiete Veterin.* 45:111–114.
72. Heffels-Redmann, U., U. Neumann, S. Branne, J.K.A. Cook, and J. Pruter. 1998. Serological evidence for susceptibility of sea gulls to avian pneumovirus (APV) infection. Proceedings International Symposium on Infectious Bronchitis and Pneumovirus Infections in Poultry. U. Heffels-Redmann and E. Kaleta, eds. Rauischholzhausen, Germany. 23–25.
73. Hess, M., M.B. Huggins, R. Mudzamiri, and U. Heincz. 2004. Avian metapneumovirus excretion in vaccinated and non-vaccinated specified pathogen free laying chickens. *Avian Pathol.* 33:35–40.
74. Hess, M., M.B. Huggins, and U. Heincz. 2004. Hatchability, serology and virus excretion following *in ovo* vaccination of chickens with an avian metapneumovirus vaccine. *Avian Pathol.* 33:576–580.
75. Hu, H., J.P. Roth, C.N. Estevez, L. Zsak, B. Liu, and Q. Yu. 2011. Generation and evaluation of a recombinant Newcastle disease virus expressing the glycoprotein (G) of avian metapneumovirus subgroup C as a bivalent vaccine in turkeys. *Vaccine.* 29: 8624-33.
76. Jirjis, F.F., S.L. Noll, D.A. Halvorson, K.V. Nagaraja, and D.P. Shaw. 2001. Immunohistochemical detection of avian pneumovirus in formalin-fixed tissues. *J Vet Diag Invest.* 13:13-16.
77. Jirjis, F.F., S.L. Noll, D.A. Halvorson, K.V. Nagaraja, F. Martin, and D.P. Shaw. 2004. Effects of bacterial coinfection on the pathogenesis of avian pneumovirus in turkeys. *Avian Dis.* 48:34–49.
78. Jones, R.C. 1996. Avian pneumovirus infection: questions still unanswered. *Avian Pathol.* 25:639–648.
79. Jones, R.C. 2007. Pneumovirinae. In: *Poultry Diseases*, 6th ed. M. Pattison, P. McMillan, J. Bradbury, and D. Alexander, eds. Saunders-Elsevier, Philadelphia. 309-316.
80. Jones, R.C., C. Baxter-Jones, G.P. Wilding, and D.F. Kelly. 1986. Demonstration of a candidate virus for turkey rhinotracheitis in experimentally inoculated turkeys. *Vet Rec.* 119: 599–600.
81. Jones, R.C., R.A. Williams, C. Baxter-Jones, C.E. Savage, and G.P. Wilding. 1988. Experimental infection of laying turkeys with rhinotracheitis virus: distribution of virus in the tissues and serological response. *Avian Pathol.* 17:841–850.
82. Jones, R.C., C.J. Naylor, A. Al-Afelaq, K.J. Worthington, and R. Jones. 1992. Effect of cyclophosphamide immunosuppression on the immunity of turkeys to viral tracheitis. *Res Vet Sci.* 53:38–41.
83. Juhasz, K., and A.J. Easton. 1994. Extensive sequence variation in the attachment (G) protein gene of avian pneumovirus: evidence for two distinct subtypes. *J Gen Virol.* 75:2873–2880.
84. Kapczynski, D.R. 2004. Development of a virosome vaccine against avian metapneumovirus subtype C for protection in turkeys. *Avian Dis.* 48:332-343.
85. Kayali, G., E.J. Ortiz, M.L Chorazy, K.V. Nagaraja, J. DeBeauchamp, R.J. Webby, and G.C. Gray, 2011. Serologic evidence of avian metapneumovirus infection among adults occupationally exposed to turkeys. *Vector Borne Zoonotic Dis.* 11:1453–1459.

86. Kehra, R.S. 1998. Avian pneumovirus infection in chickens and turkeys: studies on some aspects of immunity and pathogenesis. PhD Thesis. University of Liverpool. 216.
87. Kehra, R.S., and R.C. Jones. 1999. *In vitro* and *in vivo* studies on the pathogenicity of avian pneumovirus for the chicken oviduct. *Avian Pathol.* 28:257–262.
88. Khehra, R.S., and R.C. Jones. 1999. Investigation into avian pneumovirus persistence in poults and chicks using cyclosporin A immunosuppression. *Res Vet Sci.* 66:161–163.
89. Lee, E.H., M.S. Song, J.Y. Shin, Y. M. Lee, C.J. Kim, Y.S. Lee, H. Kim, and Y.K. Choi. 2007. Genetic characterization of avian metapneumovirus subtype C isolated from pheasants in a live bird market. *Virus Res.* 128:18–25.
90. Liman, M., L. Peiser, G. Zimmer, M. Propsting, H.Y. Naim, and S. Rautenschlein. 2007. A genetically engineered prime-boost vaccination strategy for oculonasal delivery with poly(D,L-lactic-co-glycolic acid) microparticles against infection of turkeys with avian metapneumovirus. *Vaccine.* 25:7914–7926.
91. Liman, M., and S. Rautenschlein. 2007. Induction of local and systemic immune reactions following infection of turkeys with avian metapneumovirus (aMPV) subtypes A and B. *Vet Immunol Immunopathol.* 115:273–85.
92. Ling, R., A.J. Easton, and C.R. Pringle. 1992. Sequence analysis of the 22K, SH and G genes of turkey rhinotracheitis virus and their intergenic regions reveal a gene order different from that of other pneumoviruses. 1992. *J Gen Virol*. 73:1709–1715.
93. Ling, R., S. Sinkovic, D. Toquin, O, Guione, N. Eterradossi, and A.J. Easton. 2008. Deletion of the SH gene from avian metapneumorvirus has greater impact on virus production and immunogenicity in turkeys than deletion of the G gene or M2-2 gene open reading frame. *J Gen Virol.* 89:525–533.
94. Lister, S.A. 1998. Current experiences with respiratory diseases in meat turkeys in the U.K. In: 1st International Symposium on Turkey Diseases. H.M. Hafez, ed. German Veterinary Medicine Society, Berlin. 104–113.
95. Lister, S.A., and D.J. Alexander. 1986. Turkey rhinotracheitis: A review. *Vet Bull.* 56:637–663.
96. Litjens, J.B., F.C. Kleyn van Willigen, and M. Sinke. 1980. A case of swollen head syndrome in a flock of guinea-fowl. *Tijdschr Diergen.* 114:719–720.
97. Lu, Y.S., Y.S. Shien, H.J. Tsai, C.S. Tseng, S.H. Lee, and D.F. Lin. 1994. Swollen head syndrome in Taiwan—isolation of an avian pneumovirus and serological survey. *Avian Pathol.* 23:169–174
98. Lupini, C., M. Cecchinato, E. Ricchizzi, C.J. Naylor, and E. Catelli. 2011. A turkey rhinotracheitis outbreak caused by the environmental spread of a vaccine-derived avian metapneumovirus. *Avian Pathol.* 40:525–30.
99. Lwamba, H.C.M., R.S. Bennett, D.C. Lauer, D.A. Halvorson, and M.K. Njenga. 2002. Characterisation of avian metapneumoviruses isolated in the USA. *Anim Health Res Rev.* 3:107–117.
100. Lwamba, H.C.M., R. Alvarez, M.G. Wise, Q. Yu, D. Halvorson, M.K. Njenga, and B.S. Seal. 2005. Comparison of the full-length genome sequence of avian metapneumovirus subtype C with other paramyxoviruses. *Virus Res.* 107:83–92.
101. Maherchandani, S., D.P. Patnayak, C.A. Munoz-Zanzi, D. Lauer, and S.M. Goyal. 2005. Evaluation of five different antigens in enzyme linked immunosorbent assay for the detection of avian pneumovirus antibodies. *J Vet Diag Invest.* 17:16–22.
102. Majo, N., G.M. Allan, C.J. O'Loan, A. Pagès, and A.J. Ramis. 1995. A sequential histopathologic and immunocytochemical study of chickens, turkeys, poults and broiler breeders experimentally infected with turkey rhinotracheitis virus. *Avian Dis.* 39:887–896.
103. Majo, N., M. Marti, C.J. O'Loan, S.M. Allan, A. Pagès, and A. Ramis. 1996. Ultrastructural study of turkey rhinotracheitis virus infection in turbinates of experimentally infected chickens. *Vet Microbiol.* 52:37–48.
104. Marien, M., A. Decostere, A. Martel, K. Chiers, R. Froyman, and H. Nauwynck. 2005. Synergy between avian pneumovirus and *Ornithobacterium rhinotracheale* in turkeys. *Avian Pathol.* 34:204–211.
105. McDougall, J.S., and J.K.A. Cook. 1986. Turkey rhinotracheitis: preliminary investigations. *Vet Rec.* 118:206–207.
106. Mekkes, D.R., and J.J. de Wit. 1998. Comparison of three commercial ELISA kits for the detection of rhinotracheitis virus antibodies. *Avian Pathol.* 27:301–305.
107. Morley, A.J., and D.K. Thomson. 1984. Swollen-head syndrome in broiler chickens. *Avian Dis.* 28:238–243.
108. Nagaraja, K.V., H.J. Shin, and D.A. Halvorson. 2000. Avian pneumovirus of turkeys and its host range. Proceedings of the 3rd International Symposium on Turkey Diseases. H.M. Hafez, ed. German Veterinary Medicine Society, Berlin. 208–213.
109. Naylor, C.J., and R.C. Jones. 1993. Turkey rhinotracheitis: a review. *Vet Bull.* 63:439–449.
110. Naylor, C.J., A.R. Al-Ankari, A.I. Al-Afaleq, J.M. Bradbury, and R.C. Jones. 1992. Exacerbation of *Mycoplasma gallisepticum* infection in turkeys by rhinotracheitis virus. *Avian Pathol.* 21:295–305.
111. Naylor, C.J., K.J. Worthington, and R.C. Jones. 1997. Failure of maternal antibodies to protect young turkey poults against challenge with turkey rhinotracheitis virus. *Avian Dis.* 41: 968–971.
112. Naylor C.J., P.A. Brown, N. Edworthy, R. Ling, R.C. Jones, and A.J. Easton. 2004. Development of a reverse-genetics system for avian pneumovirus demonstrates that the small hydrophobic (SH) and attachment (G) genes are not essential for virus viability. *J Gen Virol.* 85:3219–3227.
113. Njenga, M.K., H.M. Lwamba, and B.S. Seal. 2003. Metapneumoviruses in birds and humans. *Virus Res.* 91:163–169.
114. Ogawa, A., S. Murakami, and T. Nakane. 2001. Field cases of swollen-head syndrome in pheasants. *J Jpn Vet Med Assoc.* 54:87–91.
115. Ongor, H., M. Karahan, R. Kalin, H. Bulut, and B. Cetinskaya. 2010. Detection of avian metapneumovirus subtypes in turkeys using RT-PCR. *Vet Rec.* 166:363–6.
116. Owoade, A.A., M.F. Ducatez, J.M. Hubschen, A. Sausy, H. Chen, Y. Guan, and C.P. Mullen. 2008. Avian metapneumovirus subtype A in China and subtypes A and B in Nigeria. *Avian Dis.* 52:502–506.
117. Panigrahy, B., D.A. Senne, J.C. Pedersen, T. Gidlewski, and R.K. Edson. 2000. Experimental and serologic observations on avian pneumovirus (APV/turkey/Colorado/97) infection in turkeys. *Avian Dis.* 44:17–22.
118. Patnayak, D.P., A. Tiwari, and S.M. Goyal. 2005. Growth of vaccine strains of avian pneumovirus in different cell lines. *Avian Pathol.* 34:123–126.
119. Patnayak, D.P., and S.M. Goyal. 2006. Duration of immunity engendered by a single dose of a cold-adapted strain of avian pneumovirus. *Can J Vet Res.* 70:65–67.

120. Picault, J.P., P. Drouin, J. Lamande, J. Toux, I. Marter, and P. Girault. 1986. El Síndrome Infeccioso de la Cabeza Hinchada: situación actual de las investigaciones etiológicas. *L'Aviculteur.* 467:43
121. Picault, J.P., P. Giraud, P. Drouin, M. Guittet, G. Bennejean, J. Lamande, D. Toquin, and C. Gueguen. 1987. Isolation of a TRT-like virus from chickens with swollen head syndrome. *Vet Rec.* 121:135.
122. Pringle, C.R. 1998. Virus taxonomy. *Arch Virol*. 143:1449–1459.
123. Rautenschlein, S., A.M. Sheikh, D.P. Patnayak, R.L. Miller, J.M. Sharma, and S.M. Goyal. 2002. Effect of an immunomodulator on the efficacy of an attenuated vaccine against avian pneumovirus in turkeys. *Avian Dis.* 46:555–561.
124. Rautenschlein, S., Y.H. Aung, and C. Haase. 2011. Local and systemic immune responses following infection of broiler-type chickens with avian metapneumovirus subtypes A and B. *Vet Immunol Immunopathol.* 140:10–22.
125. Rubbenstroth, D., M. Ryll, K.P. Behr, and S. Rautenschlein. 2009. Pathogenesis of *Riemerella anatipestifer* in turkeys after experimental mono-infection via respiratory routes or dual infection together with the avian metapneumovirus. *Avian Pathol.* 38:497–507.
126. Rubbenstroth, D., and S. Rautenschlein. 2009. Investigations on the protective role of passively transferred antibodies against avian metapneumovirus infection in turkeys. *Avian Pathol.* 38:427–36.
127. Rubbenstroth, D., T.S. Dalgaard, S. Kothlow, H.R. Juul Madsen, and S. Rautenschlein. 2010. Effects of cyclosporin A induced T-lymphocyte depletion on the course of avian metapneumovirus (aMPV) infection in turkeys. *Dev Comp Immunol.* 34:518–29.
128. Rubbenstroth, D., and S. Rautenschlein. 2010. Compromised T-cell immunity in turkeys may lead to an unpredictable avian metapneumovirus vaccine response and variable protection against challenge. *Avian Pathol.* 39:349–57.
129. Seal, B. 1998. Matrix protein gene nucleotide and predicted amino acid sequence demonstrate that the first US avian pneumovirus isolate is distinct from European strains. *Virus Res.* 58:45–52.
130. Seal, B. 2000. Avian pneumovirus and emergence of a new type in the United States of America. *Anim Health Res Rev.* 1:67–72.
131. Senne, D.A., J.C. Pedersen, R.K. Edson, and B. Panigrahy. 1997. Avian pneumovirus update. Proceedings of the 134th Annual American Veterinary Medical Association Congress, Reno, Nevada. 190.
132. Shin, H.J., B. McComb, A. Back, D.P. Shaw, D.A. Halvorson, and K. Nagaraja. 2000. Susceptibility of broiler chicks to infection by avian pneumovirus of turkey origin. *Avian Dis.* 44:797–802.
133. Shin, H.J., M.K. Njenga, B. McComb, D.A. Halvorson, and K.V. Nagaraja. 2000a. Avian pneumovirus RNA from wild and sentinel birds in the US has genetic homology with APV isolates from domestic turkeys. *J Clin Microbiol.* 38:4282–4284.
134. Shin, H.J., K.V. Nagaraja, B. McComb, D.A. Halvorson, F.F. Jirjis, D.P. Shaw, B.S. Seal, and M.K. Njenga. 2002. Isolation of avian pneumovirus from mallard ducks that is genetically similar to viruses isolated from neighbouring commercial turkeys. *Virus Res.* 83:207–212.
135. Shin, H.J., K.T. Cameron, J.A. Jacobs, E.A. Turpin, D.A. Halvorson, S.M. Goyal, K.V. Nagaraja, B. McComb, C.K. Mahesh, D.A. Lauer, B.S. Seal, and M.K. Njenga. 2002. Molecular epidemiology of subtype C avian pneumovirus isolated in the United States and comparison with subgroups A and B viruses. *J Clin Microbiol.* 40:1687–1693.
136. Stuart, J.C. 1989. Rhinotracheitis: turkey rhinotracheitis (TRT) in Great Britain. In: *Recent Advances in Turkey Science*. C. Nixey and T.C. Grey, eds. Poultry Science Symposium Series. No 21. Butterworth, London. 217–224.
137. Tanaka, M., H. Takuma, N. Kokumai, E. Oiski, T. Obi, K. Hiramatsu, and Y. Shimazu. 1995. Turkey rhinotracheitis virus isolated from broiler chickens with swollen head syndrome. *J Vet Med Sci.* 57:939–941.
138. Tarpey, I., M.B. Huggins, P.J. Davis, R. Shilleto, S.J. Orbell, and J.K.A. Cook. 2001. Cloning, expression and immunogenicity of the avian pneumovirus (Colorado isolate) F protein. *Avian Pathol.* 30:471–474.
139. Timms, L.M., K.L. Jahans, and R.N. Marshall. 1986. Evidence of immunosuppression in turkey poults affected by rhinotracheitis. *Vet Rec.* 119:91-92.
140. Tiwari, A., D.P. Patnayak, and S.M. Goyal. 2006. Attempts to improve on a challenge model for subtype C avian pneumovirus. *Avian Pathol.* 35:117–121.
141. Toquin, D., N. Eterradossi, and M. Guittet. 1996. Use of a related ELISA antigen for efficient TRT serological testing following live vaccination. *Vet Rec.* 139:71–72.
142. Toquin, D., M.H. Bäyon-Auboyer, N. Eterradossi, H. Morin, and V. Jestin. 1999. Isolation of a pneumovirus from a Muscovy duck. *Vet Rec.* 145:680
143. Toquin, D., M.H. Bäyon-Auboyer, D.A. Senne, and N. Eterradossi. 2000. Lack of antigenic relationship between French and recent North American non-A/non-B turkey rhinotracheitis viruses. *Avian Dis.* 44:977–982.
144. Townsend, E., D.A. Halvorson, K.E. Nagaraja, and D.P. Shaw. 2000. Susceptibility of an avian pneumovirus isolated from Minnesota turkeys to physical and chemical agents. *Avian Dis.* 44:336–342.
145. Turpin, E.A., L.E.L. Perkins, and D.E. Swayne. 2002. Experimental infection of turkeys with avian pneumovirus and either Newcastle disease virus or *Escherichia coli*. *Avian Dis.* 46:412–422.
146. Turpin, E.A., D.E. Stallnecht, R.D. Slemens, L. Zsak, and D.E. Swayne. 2008. Evidence of avian metapneumovirus subtype C infection of wild birds in Georgia, South Carolina, Arkansas and Ohio, USA. *Avian Pathol*. 37:343–351.
147. van Boheemen S., T.M. Bestebroer, J.H. Verhagen, A.D. Osterhaus, S.D. Pas, S. Herfst, and R.A. Fouchier. 2012. A family-wide rt-PCR assay for detection of paramyxoviruses and application to a large-scale surveillance study. *PLoS One.* 7:34961.
148. van den Hoogen, B.G., J.C. de Jong, J. Groen, T. Kuiken, R. de Groot, R.A.M. Fouchier, and A.D. Osterhaus. 2001. A newly discovered human pneumovirus isolated from young children with respiratory tract disease. *Nature Med.* 7:719–724.
149. van den Hoogen, B.G., T.M. Bestebroer, A.D. Osterhaus, and R.A. Fouchier. 2002. Analysis of the genomic sequence of a human metapneumovirus. *Virology.* 295:119–132.
150. van Loock, M., D. Vanrompay, S. Van den Zande, H. Nauwyck, G. Volckaert, and B.M. Goddeeris. 2002. Pathogenicity of an avian pneumovirus infection in Chlamydophila psittaci infected turkeys. In: *4th International Symposium on Turkey Diseases*. H.M. Hafez, ed. German Veterinary Medicine Society, Berlin. 149–150.
151. Velayudhan, B.T., V.C. Lopes, S.L. Noll, D.A. Halvorson, and K.V. Nagaraja. 2003. Avian pneumovirus and its survival in poultry litter. *Avian Dis.* 47:764–768.

152. Velayudhan, B.T., K.M. Nagaraja, A.J. Thachil, D.P. Shaw, G.C. Gray, and D.A. Halvorson. 2006. Human metapneumovirus in turkey poults. *Emerg Inf Dis.* 12:1853–1859.
153. Velayudhan, B.T., Q. Yu, C.N. Estevez, K.V. Nagaraja, and D.A Halvorson. 2008. Glycoprotein gene truncation in avian metapneumvirus subtype C isolates from the United States. *Virus Genes.* 37:266–272.
154. Velayudhan, B.T., S.L. Noll, A.J. Thachil, D.A. Halvorson, D.A. Shaw, S.M. Goyal, and K.V. Nagaraja. 2008. Comparative pathogenicity of early and recent isolates of avian metapneumovirus subtype C in turkeys. *Can J Vet Res.* 72:371–375.
155. Villarreal, L.Y., P.E. Brandao, J.L. Chacon, M.S. Assayag, P.C. Majork, P., Raffi, A.B. Saidenberg, and R.C. Jones. 2007. Orchitis in roosters with reduced fertility associated with avian infectious bronchitis and avian metapneumovirus infections. *Avian Dis.* 51:900–904.
156. Welchman, D.B., J.M. Bradbury, D. Cavanagh, and N.J. Aebischer. 2002. Infectious agents associated with respiratory disease in pheasants. *Vet Rec.* 150:658–664.
157. Williams, R.A., C.E. Savage, and R.C. Jones. 1991. Development of a live attenuated vaccine against turkey rhinotracheitis. *Avian Pathol.* 20:45–55.
158. Worthington, K.J., B.A. Sargent, F.G. Davelaar, and R.C. Jones. 2000. Immunity to avian pneumovirus infection in turkeys following *in ovo* vaccination with an attenuated vaccine. *Vaccine.* 21:1355–1362.
159. Yu, Q., T. Barrett, T.D.K. Brown, J.K.A. Cook, P. Green, M.A. Skinner, and D. Cavanagh. 1994. Protection against turkey rhinotracheitis pneumovirus (TRTV) induced by a fowl pox virus recombinant expressing the TRTV fusion glycoprotein (F). *Vaccine.* 12:569–573.
160. Yu, Q., C.N. Estevez, M. Song, D. Kapczynski, and L. Zsak. 2010. Generation and biological assessment of recombinant avian metapneumovirus subgroup C (aMPV-C) viruses containing different lengths of the G gene. *Virus Res.* 147: 182–188.
161. Yu, Q., C.N. Estevez, J.P. Roth, H. Hu, and L. Zsak. 2011. Deletion of the M2-2 gene from avian metapneumovirus subgroup C impairs virus replication and immunogenicity in turkeys. *Virus Genes.* 42:339–346
162. Zande, van de. S., H. Nauwynck, S. de Jonghe, and M. Pensaert. 1999. Comparative pathogenesis of a subtype A with a subtype B avian pneumovirus in turkeys. *Avian Pathol.* 28:239–244.

Chapter 4

Infectious Bronchitis

Mark W. Jackwood and Sjaak de Wit

Introduction

Avian infectious bronchitis (IB) is an economically important, highly contagious, acute, upper-respiratory tract disease of chickens and other fowl, caused by the avian coronavirus infectious bronchitis virus (IBV). The virus is found worldwide and is transmitted by inhalation or direct contact with infected birds or contaminated litter, equipment, or other fomites. Vertical transmission of the virus within the embryo has not been reported, but virus may be present on the shell surface of hatching eggs via shedding from the oviduct or gastrointestinal tract. High virus replication rates resulting in genetic mutations and genome recombination events can lead to the emergence of new serotypes of the virus, which do not cross protect, complicating control by vaccination. Infectious bronchitis has no known human health significance.

In young chickens, IBV infection causes an upper respiratory tract disease. In addition to respiratory signs, reduced weight gain and reduced feed efficiency are observed in meat-type broiler chickens. Infection also predisposes broilers to secondary opportunistic bacterial infections that can result in airsacculitis, pericarditis, and perihepatitis. Morbidity is almost always 100%, but mortality can vary between 0% and 82%, depending on the age and immune status of the birds, the strain of the virus, and if secondary bacterial or viral pathogens are involved. Some strains of IBV are nephropathogenic and can cause high mortality due to kidney failure in susceptible flocks.

In layer and breeder chickens, infection may result in reduced egg production of up to 70% and eggshell quality declines. The virus can replicate in the oviduct and cause permanent damage in immature females and pullets resulting in limited egg production over a prolonged period of time and birds that fail to come into production (false layers). Eggs from breeds with pigmented shells may be pale, and the albumen can have a watery viscosity. Egg production often recovers but may be permanently depressed in highly susceptible flocks.

Avian coronaviruses similar to IBV also have been found in pheasants (*Phasianus colchicus*) and peafowl (*Galliformes*) and IBV-like viruses have been isolated from turkeys, teal (*Anas crecca*), geese (*Anserinae*), pigeons (*Columbiformes*), guinea fowl (*Numida meleagris*), partridge (*Alectoris*), and ducks (*Anseriformes*) (36). The turkey coronaviruses (TCoV) are described in Chapter 12.

History

Infectious bronchitis was first observed in the United States in North Dakota in 1930, and the first documented description of the disease was published by Schalk and Hawn in 1931 (169). Initially, IB was recognized as primarily a disease of chicks. Early descriptions of the disease showed that it was caused by a filterable agent (a virus), which actually may have been a mild form of infectious laryngotracheitis (ILT) (24), but in 1936, Beach and Schalm using neutralization studies in chicks showed that the virus that caused IB was different from the virus that causes ILT (10). Sometime later the virus was observed in semi-mature and laying flocks.

An important discovery occurred in 1937 when Beaudette and Hudson (12) found that IBV could be propagated in the allantoic cavity of embryonating eggs. In 1941, Delaplane and Stuart (72) suggested that IBV propagated in embryonating eggs might have immunizing value, which led to the first IB vaccine report by van Roeckel et al. (186). The first IBV vaccine in the United States was developed using the van Roekel M-41 strain, which is a Mass serotype virus isolated at the University of Massachusetts, Amherst, in 1941. That virus strain was given to Vineland Laboratories, Inc. (Vineland, New Jersey) and to Salsbury Laboratories (Salsbury, Maryland) in the early 1950s and became the parent of the M41 or Mass 41 type vaccines used in the United States today (M.W. Jackwood personal communication with Dr. Hiram Lasher, Millsboro Delaware).

By the early 1960s IB had been diagnosed in Holland and this led to the development of a Mass type vaccine known as the H strain ("H" stands for the name of the farmer [Huyben], from whose chickens the isolate was made, and not, as is often thought, for the country, Holland). The resulting vaccines, known as H120 and H52, soon became widely used, with the H120 vaccine likely the most commonly used IBV vaccine worldwide today.

Diseases of Poultry, Thirteenth Edition. David E. Swayne.
© 2013 John Wiley & Sons, Inc. Published 2013 by John Wiley & Sons, Inc.

Another important discovery relating to the control of the virus was made by Jungherr in 1956 when he reported that an IBV isolated in Connecticut did not cross protect chickens against challenge with the original Mass isolate (116). This led to the awareness that different serotypes of the virus existed and that they did not cross protect.

In the 1960s, it was discovered that IBV could interfere with growth of Newcastle disease virus (NDV) in embryonating eggs and cell culture, which was significant because IBV and NDV vaccines are often given together (11, 163). Also in the 1960s, Winterfield and Hitchner reported that some strains of IBV can cause a nephritis-nephrosis syndrome, and the nephropathogenic strains Gray and Holte were isolated (190). Most of the work in the 1970s and 1980s involved identification of different serotypes and variants of the virus by serum neutralization testing in embryonating eggs.

A significant advancement in the diagnosis of IBV occurred in the 1990s when several laboratories began identifying the type of IBV using molecular techniques (103, 121, 126, 134). This allowed for the rapid identification of many isolates and the comparison of viruses around the world. Unfortunately, advances in vaccine production have not progressed beyond attenuation of the virus by passage in embryonating eggs. More about the early history of IB research can be found in the review by Fabricant (76).

Etiology

Classification

Infectious bronchitis virus is a gammacoronavirus in the subfamily Coronavirinae and family Coronaviridae (http://talk.ictvonline.org/media/p/1230.aspx). The Coronaviridae family includes 2 subfamilies, Coronavirinae and Torovirinae, and within the coronavirinae subfamily there are 3 genera, alphacoronavirus, betacoronavirus, and gammacoronavirus. Alphacoronaviruses and betacoronaviruses are mammalian viruses. The gammacoronaviruses include avian coronaviruses IBV and TCoV, as well as coronaviruses isolated from other avian species (36, 113), and the Beluga whale coronavirus SW1 (147). Additional viruses in the gammacoronavirus genera, which appear to be distantly related to IBV, include viruses isolated from an Asian leopard cat, Chinese ferret badger, bulbul, munia, parrot, and thrush (74, 194).

Morphology

Infectious bronchitis virus is an enveloped virus with a round to pleomorphic shape. The virus particles are approximately 120 nm in diameter with club-shaped surface projections (spikes) about 20 nm in length (Figure 4.1), which gives the virus a crown-like appearance and hence the name corona (Latin for crown). The appearance of toroviruses and coronaviruses visualized with an electron microscope can be very similar (56).

Infectious bronchitis virus strains differ in their density in sucrose gradients; particles with a full complement of spikes have a density of 1.18 g/ml, and lesser-spiked particles may be as low as 1.15 g/ml.

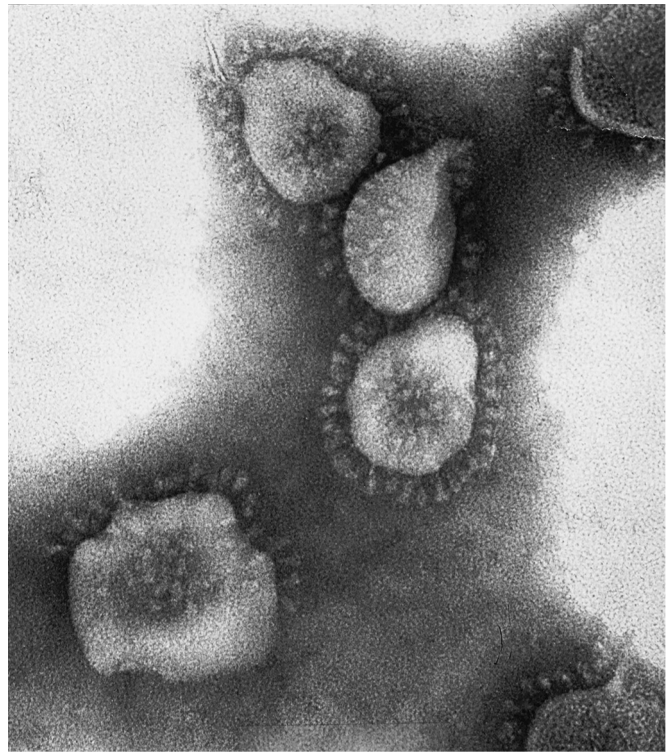

Figure 4.1. Virion of avian IBV illustrating club-shaped projections. Preparation negatively stained with phosphotungstic acid. ×3,300,000. (Berry and Almeida)

Chemical Composition and Structure

The viral genome is a single-stranded positive sense strand of RNA that is approximately 27.5 to 28 Kb in length. It is 5′ capped and has a poly-A tail at the 3′ end. The virions are made up of spike (S), envelope (E), membrane (M), and nucleocapsid (N) structural proteins (160). The S glycoprotein appears to be a trimer made up of 2 subunits, S1 and S2 (approximately 520 and 625 amino acids, respectively). The spike glycoprotein is a type I membrane protein containing a receptor binding domain, cleavage site, precoil domain, fusion peptide, heptad repeat regions, interhelical domain, transmembrane domain, and cytoplasmic tail (125, 160). It is involved in host cell attachment as well as virus and cell membrane fusion and entry into the cell (28, 189). Virus-neutralizing and hemagglutination-inhibiting (HI) antibodies are directed against the first third of the NH3 end of the spike (29, 102, 125). The E protein is a small integral membrane protein involved in assembly of the virus (168). The M glycoprotein spans the viral envelope 3 times with a portion of the NH3 end exposed on the outer surface of the virus. The N phosphoprotein encapsidates the viral RNA genome to form the helical nucleocapsid within the virion and interacts with the M and E proteins for virus assembly (110).

Virus Replication

For an overview of coronavirus replication see (75). The gene organization is 5′ untranslated region (UTR)-leader-1a/1ab-S-3a-3b-E-M-5a-5b-N-3′UTR (Figure 4.2). The UTRs are

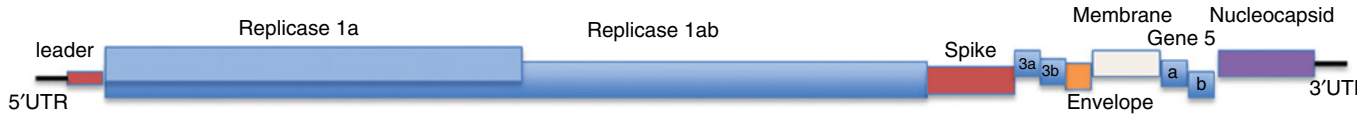

Figure 4.2. Organization of the IBV genome.

involved in viral RNA transcription and replication. The open reading frames (ORFs) 1a and 1ab encode polyproteins that are post translationally cleaved into 15 nonstructural proteins (Nsps) by a papain-like protease (PLP) and the main protease (Mpro), both of which are encoded on the polyprotein itself. The Nsps make up the viral RNA-dependent RNA polymerase (reviewed in (160)). Most coronaviruses have 16 Nsps but IBV as well as other gammacoronaviruses lack Nsp 1. The 1ab protein is translated through a -1 frame-shift at a "slippery" heptanucleotide sequence that is just upstream of an RNA pseudoknot structure. The 3a, 3b, 5a, and 5b ORFs are nonstructural proteins with largely unknown function. The virus replicates in the cytoplasm of the host cell and produces a 3′coterminal nested set of 5 subgenomic messenger RNAs. Each mRNA has a 5′ leader sequence that is joined to the mRNA during transcription. Although some of the subgenomic mRNAs are polycistronic, for the most part each mRNA encodes the protein at the extreme 5′ end. The full-length genome (mRNA1) encodes the viral polymerase polyproteins. Subgenomic mRNAs 2, 3, 4, 5, and 6 encode S, 3a/3b/E, M, 5a/5b, and N, respectively.

The S glycoprotein mediates host cell attachment, virus and cell membrane fusion, and entry into the host cell. Once in the cell, the viral genome acts as mRNA encoding nsps 2 to 16, which forms to create the viral polymerase in double membrane vesicles at the Golgi (94). Transcription of viral subgenomic RNA and subsequent translation of viral proteins occurs in the cytoplasm. The S, E, and M proteins are inserted into the golgi membrane, whereas the N protein binds to the newly synthesized viral genome to form the nucleocapsid. Interactions between nucleocapsid and E and M proteins result in budding of the virus particles at the cytoplasmic surfaces of the endoplasmic reticulum. The virus particles are transported to the plasma membrane in vesicles where fusion occurs to release the virus particles from the cell.

Susceptibility to Chemical and Physical Agents

Centrifugation forces of greater than 100,000 xg can sometimes result in the loss of spikes, or at least the S1 subunit. Incubation at 37°C also can result in the loss of the S1 subunit, which is noncovalently attached to the S2 subunit by disulphide bonds (177).

Thermostability

Coronaviruses are heat liable, being inactivated after 15 minutes at 56°C, but samples containing protein should be treated at 60°C for at least 30 minutes to inactive the virus (161). Long-term storage of IBV is recommended at –80°C. Survival up to 12 days in spring and 56 days when ambient temperatures are below freezing has been reported, but a cold chain should always be maintained for samples sent to the laboratory for diagnosis.

Lyophilization

Infectious allantoic fluid lyophilized, sealed under vacuum, and stored in a refrigerator has remained viable for at least 30 years (reviewed in (37)). Attenuated vaccines can be lyophilized in the presence of sucrose or lactose to preserve potency and extend shelf life.

Ph Stability

The reduction in titer, following extremes of pH, are variable depending on virus strain. A pH 3 treatment at room temperature for 4 hours resulted in reductions in titer of 1–2 log10 for most isolates, but up to 5 log10 for others (reviewed in (37)). Infectious bronchitis virus in cell culture was more stable in medium at pH 6.0 and 6.5 than at pH 7.0 to 8.0 (2).

Chemical Agents

Infectious bronchitis virus, being an enveloped virus, is sensitive to ether, 50% chloroform, and 0.1% sodium deoxycholate at 4°C for 18 hours. Most common disinfectants used in the poultry house inactivate IBV and no one type is recommended over another. The area to be disinfected should be free of organic material and disinfectants should be used at the manufacturer's recommended concentration. Treatment with 0.05% or 0.1% beta-propiolactone (BPL) or 0.1% formalin eliminated IBV infectivity. Only BPL treatment had no adverse effect on IBV hemagglutination (HA) activity, making it a good choice for creating HA antigen and killed vaccines.

Strain Classification

Many methods are used to differentiate and classify isolates of IBV, and they have been thoroughly compared (68). However, serotype and more recently genotype classification, based on the sequence of the S protein, are most commonly used to classify strains. Serotype classification involves treatment of the virus with neutralizing antibodies, whereas genotype classification involves examining the sequence of the S1 protein. Although not a hard and fast rule, strains of the virus that have greater than 90% amino acid similarity in the S1 gene (genotype) are serologically related (serotype).

There has been a lack of standardization of IBV strain nomenclature throughout the years, but recently scientists have begun adopting the system suggested by Cavanagh in 2001 (32), which is similar to that used for avian influenza viruses. Basically, IBV strains are to be identified by the following scheme: IBV/bird type/country of origin/genotype or serotype/strain designation/year of isolation. Often IBV and

bird type (assuming the isolate is from a chicken) are dropped, but if the isolate is not from a chicken or the type of chicken (broiler, layer, breeder) is important it is included. Examples of some viruses are US/Ark/arkdpi/81, US/Mass/Mass41/41, Italy/Italy-02/497/02, China/LX4/QX/99, and IBV/Pheasant/UK/24/B171-3/99.

Serotype Classification

Traditionally, IBV serotypes have been defined by 2-way cross-virus neutralization (VN) testing in embryonating chicken eggs (87). This typing method involves reacting the unknown virus with antisera against known strains; then serotype-specific antibody is prepared against the unknown virus and reacted with known strains. The data are used to calculate a relatedness value using the Archetti and Horsfall formula (7). Some laboratories have used monoclonal antibodies specific to a given serotype in an enzyme-linked immunosorbent assay (ELISA), indirect immunofluorescence assay, or VN assay, but these monoclonal antibodies are only available for a small number of serotypes (118, 119).

Strain classification by HI tests has also been used, but most IBV strains do not spontaneously hemagglutinate and must be treated with neuraminidase for HA activity (167). The HI antibody response following a single exposure of the virus can be highly strain specific, and the specificity and limited cross-reactivity of the early immune response are the basis for serotyping isolates by HI tests. However, multiple exposures to the virus, which is common in vaccinated birds, results in high and variable cross-reactions making it difficult to clearly differentiate strains using the HI test (52, 82).

Genetic Classification

Currently, most laboratories use nucleic acid approaches to characterize IBV isolates by genotype (103, 121, 131). Typically, the reverse transcriptase polymerase chain reaction (RT-PCR) is used to amplify the S1 gene or the hypervariable region of the S1 gene, followed by nucleic acid sequencing (133) or less frequently, restriction fragment length polymorphism (RFLP) analysis (126, 134). The sequence of the whole genome has been established for many isolates, and the sequence of the structural protein genes is available from Genbank (www.ncbi.nlm.nih.gov) for a large number of IBV strains from all over the world.

The deduced amino acid sequence of the S1 protein (or hypervariable region of the S1 protein) is used to genetically type IBV isolates. Comparison of the deduced S1 amino acid sequences by either the Basic Local Alignment Search Tool (BLAST, blast.ncbi.nlm.nih.gov) or by phylogenetic analysis has revealed that many of the serotypes defined by VN tests commonly differ by more than 10% (106, 133), but exceptions occur. For example, the US/Conn/Conn46/51 and US/FL/FL18288/71 strains are different serotypes, yet their S1 proteins differ by only 6.2%. Similarly, several isolates that had 97% amino acid identity with Dutch isolate D274 were defined in serum VN tests as belonging to different serotypes (30). These findings and the sequencing of VN-monoclonal-antibody escape mutants (118, 152) indicate that a minimum number of changes can affect the conformationally dependent neutralizing epitopes on the S1 protein. Studies have shown that the degree of cross protection between strains decreases as the differences between their S1 sequences increases (31, 84, 128). It is important to note that it is not possible at the present time to differentiate vaccine and pathogenic field strains on the basis of sequencing of the S gene.

Strains of IBV and Viral Evolution

It is well known that a number of different types, subtypes, and variants of IBV exist, which is due to a high degree of genetic diversity that occurs through a high mutation rate and recombination events. Mutations include substitutions, which are the result of a high error rate and limited proofreading capability of the viral RNA-dependent RNA polymerase (RDRP), as well as insertions and deletions, caused by recombination events or by RDRP stuttering or slippage. Although IBV (and other coronaviruses) has a 3′ to 5′ exoribonuclease (exon) domain in Nsp 14 that is involved in proofreading and repair (148), the average rate of synonymous mutation is still high at approximately 1.2×10^{-3} substitutions/site/year (95, 97). Recombination has been reported in many coronaviruses including IBV (22, 132, 179). Recombination in the nonstructural proteins associated with the RDRP can alter replication efficiency of the virus, which can in turn affect pathogenicity. Because the S glycoprotein gene is involved in host cell attachment and contains viral neutralizing epitopes, recombination in the S glycoprotein gene can result in the emergence of new strains or serotypes of the virus as well as new viruses capable of causing disease in other host species. New IBV types, subtypes, and variants, whether the result of mutations, recombination, or both, continue to emerge, making control of IBV extremely challenging (105).

Laboratory Host Systems

Chicken Embryos

IBV grows well in developing specific pathogen free (SPF) chicken embryos following the inoculation of the allantoic cavity. The maximum virus titer in allantoic fluid (AF) is reached 1–2 days post inoculation (PI), although this peak can be delayed for non-egg-adapted field strains (68). For isolation of non-egg-adapted field strains (a "field" strain could also be a re-isolation of vaccine), several sequential passages can be performed to achieve high titers of virus in the AF. The extent of changes to the infected embryos that are induced by IBV vary greatly and are dose dependent. Characteristic lesions such as stunting (dwarfing) and curling of the embryo and its feet (137) occur with increasing passage as does the incidence of embryo mortality, which for an embryo-adapted strain can be observed as early as 2–3 days PI. Upon opening the air cell end of the egg, the embryo is seen curled into a spherical form with feet deformed and compressed over the head and with the thickened amnion adhered to it (Figure 4.3). A common internal lesion of the IBV-infected embryo is the presence of urates in the mesonephros of the embryonic kidney. This lesion is not

Figure 4.3. Comparison of normal 16-day-old embryo (left) and curled, dwarfed, and infected embryo of the same age (right).

pathognomonic for IBV infection and also can be observed in embryos infected with avian adenovirus.

Inoculation of 8-day-old embryos results in more extensive lesions and mortality than the same inoculation at 10–11 days of age. Differences in the degree of lesions and mortality are also seen between strains, even within the same serotype or genotype. The characteristic embryo changes are seen several days after inoculation of the virus. Especially for field strains, the visible changes in the embryos in the first passages can be minimal. Usually, embryo mortality and dwarfing increase as the number of serial passages increases. Confirmation of the presence of IBV antigen or viral RNA in inoculated eggs by antigen detection method is therefore preferably performed 2–3 days PI and independent from occurrence of embryo lesions.

Microscopic lesions in embryos infected with the IBV-M41 strain have been studied (137). Congestion with perivascular cuffing and some necrosis of the liver by the sixth day PI was observed. Lungs were pneumonic, characterized by congestion, cellular infiltration, and serous exudate in the bronchial sacs. In the kidney, interstitial nephritis with edema and distension of the proximal convoluted tubules and the presence of casts was noted. Glomeruli were not altered. The chorioallantoic membrane (CAM) and amniotic membrane were edematous. No inclusion bodies were observed.

Cell Culture

Primary isolation of IBV field strains directly from pathological material in conventional monolayer cell cultures has proved unsuccessful (48). Adaptation of IBV strains is often necessary for sufficient replication leading to induction of cytopathic effect (CPE) (90). The number of passages that is needed for the adaptation can vary widely, even within the same serotype/genotype. Chick embryo kidney (CEK) cells and chicken kidney (CK) cells show the highest sensitivity for adapted IBV strains (139, 156). Chicken kidney cells form syncytia, which quickly round up and detach from the culture surface, appearing as large spheres with refractile contents. A few strains of IBV (e.g., the Beaudette strain) have been propagated successfully in the African green monkey Vero cell line, which has been used for many fundamental studies of IBV.

Organ Cultures

The propagation of IBV in organ cultures (OC) of trachea and other tissues has been reviewed (59). Tracheal organ cultures (TOCs) have proved very useful for the isolation, titration, and serotyping of IBV, because no adaptation of field strains is required for growth and the induction of ciliostasis. The sensitivity of TOCs for the detection of IBV strains is comparable to that of the use of embryonating SPF eggs. Following infection with IBV, ciliostasis, which is easily observed by low-power microscopy, usually occurs within 3–4 days (68). The presence of IBV in field samples has to be confirmed by an IBV-specific test because ciliostasis also can be induced by many other agents. Pheasant coronavirus replicates to only very low titer in chicken TOC.

Pathogenicity

Infectious bronchitis is primarily a disease of chickens. The pathogenicity of IBV can vary widely between strains. The clinical outcome of an infection in chickens depends on many variables such as the virus strain and type; sex and age of the chicken; immune status (vaccination, immune suppression, and maternally derived antibodies); co-infections; and environmental circumstances such as climate, dust, ammonia, and cold stress.

Infection is initiated via the respiratory tract regardless of the tissue tropism of the strain (respiratory, kidney, reproductive organs). The virus replicates and produces lesions in many types of epithelial cells, including those of the respiratory tract (nasal turbinates, Harderian gland, trachea, lungs, and air sacs), kidney, and reproductive organs (oviduct, testes). The virus also grows in many cells of the alimentary tract (esophagus, proventriculus, duodenum, jejunum, cloacal bursa [bursa of Fabricius], cecal tonsils, rectum, and cloaca) often with little pathobiological clinical effect (reviewed in (73)).

All IBV strains produce lesions of varying severity in the respiratory tract depending on their virulence, chicken age at infection, genetic susceptibility of the chicken line, climate, and maternal or active immunity of the chicken. Therefore, IBV infections often increase the susceptibility to secondary respiratory infections or increase the damage of infections

with primary respiratory pathogens. These increases have been shown for agents such as *Escherichia coli* (49, 92, 143, 144, 175), *Mycoplasma gallisepticum* (reviewed in (79), *Mycoplasma synoviae* (98, 123, 130), *Mycoplasma imitans* (79), and *Haemophilus paragallinarum* (162). The damage caused by these secondary infections can be substantial, especially in broilers, resulting in a higher mortality, growth depression, increase of feed conversion, use of antibiotics, and higher condemnation rates. Proper vaccination against IBV also can be useful to prevent the chickens developing clinical IB and subsequent *E. coli* airsacculitis (144).

Although some strains of IBV are highly nephropathogenic, causing extensive and reproducible kidney disease in experimental conditions, many strains of IBV may be associated with nephritis to some degree in the field; environmental factors are probably important as to whether kidney complications are significant. Cumming (58) enumerated some of the management factors that contribute to IB-related kidney disease in Australia. Greater mortality was seen in males, with cold stress, in certain breeds, or when animal byproducts were the major component of high-protein diets. Some of these factors known to exacerbate the clinical disease have been used in experimental models to evaluate the clinical outcome of interaction between such factors and different IBV strains.

Chickens fed increased levels of dietary calcium followed by infection with the nephropathogenic Gray IBV strain frequently developed urolithiasis and kidney lesions, while a similar infection introduced 8 weeks prior to feeding chickens a diet including increased levels of calcium did not induce urolithiasis (91). The virulence of the strains for the kidney also depends on the age of infection. Young birds (less than 2 weeks of age) typically show more severe nephritis and higher mortality than older birds (1, 25, 193). An inverse age resistance was reported (140) for the H52 strain post intravenous inoculation, which was likely due to the route of inoculation. In addition, the significant role of serum neutralizing antibodies, which might be maternally derived, in the protection of the kidney of young birds was shown by the effect of passive immunization (141).

Virulence for the reproductive tract also may differ among IBV strains. Presence of maternal antibody could prevent damage to the oviduct during an early-age IBV infection (21). In susceptible layers, different IBV strains produced a range of effects varying from shell pigment changes with no production drop to production drops of up to 70% (17, 18).

The virulence of IBV strains for other organs such as the alimentary tract seems to be low (reviewed in (164)). However, several groups have reported outbreaks of a "proventricular-type" IBV infection in chickens (188, 195) by QX and Q1 strains. The studies did not show proof of local replication of the involved IBV strains, and the mortalities were exceptionally high for a solely IBV-induced disease. It remains unclear whether the reported signs were only caused by the IB strain or that another agent might be involved.

In recent years, coronaviruses have been detected in an increasing number of bird species. With a few exceptions, the strains were not isolated but were only detected by RT-PCR and no clinical signs were observed in these birds. As a consequence, the majority of the detected strains could not be inoculated into chickens to determine infectivity and virulence. An exception are the coronaviruses isolated from pheasants with respiratory and kidney disease. These viruses differ in gene sequence from IBV to an extent similar to that exhibited by different serotypes of IBV (34). When 3 coronavirus isolates from pheasants were inoculated into chickens, no signs of disease were observed (135), which led to pheasant coronavirus (PhCoV) being officially considered as a species distinct from IBV. The turkey coronavirus is also considered to be a distinct coronavirus species. The issue of the coronavirus species determination is thoroughly discussed (33, 93).

Pathogenesis and Epizootiology

Incidence and Distribution

Infectious bronchitis is distributed worldwide and many dozens of serotypes and genotypes have been detected in all continents except Antarctica (70). The first IBV variants were detected in the 1950s in the United States (76); however, a retrospective study (111) has shown that IBV variants were already circulating in the U.S. poultry industries in the 1940s. Several serotypes can cocirculate in a given region with some strains being detected on several continents, while others seem to be regional.

Natural and Experimental Hosts

As explained previously, it is no longer accepted that the chicken is the only host for IBV, although it is possible that IBV only causes disease in the chicken.

Age of Host Commonly Affected

All ages are susceptible, but the disease is most severe in chicks, often causing some mortality. As age increases, chickens become more resistant to the nephropathogenic effects, oviduct lesions, and mortality due to infection (1, 26, 42, 56).

Transmission, Carriers, and Vectors

Infectious bronchitis virus is highly contagious and spreads rapidly among chickens in a flock (67, 145). The disease has a short incubation period: Susceptible birds placed with recently infected chickens usually develop clinical signs within 24–48 hours.

Transmission may be by either inhalation or ingestion of infectious virus particles by direct contact between infected and susceptible birds; by indirect contact through aerosol droplets or feces; and by exposure to virus-contaminated fomites, such as clothing, shoes, tools, etc. Aerosol generation from the respiratory tract is a significant mode of transmission because of high virus concentrations in the respiratory tract during the acute stage of the infection. The highest concentration of IBV can be detected in the trachea during the

first 3–5 days PI. After this period, the virus titer in the respiratory tract drops rapidly and in the second week PI can be below the level of detection. Most likely, transmission by aerosol is especially effective over short distances, such as within a flock or premises, because the enveloped virion is inactivated relatively quickly in the environment.

The virus is also excreted in the feces and urine. During the chronic stage of an IBV infection, virus can be more readily detectable in the intestinal tract (cecal tonsils or cloaca swabs) and for a longer time than in the respiratory tract (68). Several authors report a long-term recovery (2–7 months) of IBV from infected or vaccinated flocks (3, 4, 42, 154); others report a re-excretion of IBV following T cell suppression by cyclosporine (15, 73) or at onset of lay (115). Possible explanations of long-term isolations or re-excretion of an inoculated virus are continual cross-infection within infected or vaccinated flocks (46), continual excretion of the virus at levels usually below the detection levels of tests, or reactivation after true latency (15). The 2 candidate sites mentioned in these reports for persistence are cecal tonsils and kidney. The phenomena of possible long-term excretion and re-excretion may result in flock-to-flock transmission by direct or indirect contact with contaminated litter, fomites, or personnel, but further study is needed to understand if this is a common source of transmission.

Vertical transmission does not seem to be relevant for IBV, although Cook (47) could re-isolate the challenge virus after infection in laying SPF hens and cockerels for 2 weeks from semen, for 1–7 weeks from the vitelline membrane of the eggs, and even from a small number of hatched chicks. However, the implication of this last finding for the field remained unclear, because these chicks developed no clinical signs, did not seroconvert, and were not protected against challenge.

In view of the recent discovery of IBV in species other than the chicken, it should be considered that other species of birds might not only be able to transport IBV mechanically but also may actively multiply IBV or be a source of IBV outbreaks.

Incubation Period

The incubation period of IB is dose dependent and can be as short as 18 hours for intratracheal inoculation and up to 36 hours for ocular application.

Clinical Signs

The nonspecific respiratory signs of IB in susceptible chicks are gasping, coughing, sneezing, tracheal rales, and nasal discharge. Watery eyes may be observed, and an occasional chick may have swollen sinuses. The chicks appear depressed and may be seen huddled under a heat source. Feed consumption and weight gain are significantly reduced. In chickens older than 6 weeks of age, the signs are usually less clear, and the disease may even go unnoticed unless the flock is examined carefully by handling the birds or listening to them at night when the birds are normally quiet. The severity of the respiratory signs is influenced by the quality of the climate, housing, kind of bird, strain involved, IB vaccination program, and presence of co-infections including secondary infections.

Broiler chickens infected with a nephropathogenic virus may appear to recover from the respiratory phase and then show signs of depression, ruffled feathers, wet droppings, increased water intake, and mortality (58). Cold stress, breed of chicken, and high-protein diets containing animal byproducts as the protein source are predisposing factors for the development of clinical signs during an infection with a nephropathogenic strain (58, 124).

In laying flocks, declines in egg production and quality are seen in addition to respiratory signs. The respiratory signs also can be absent or very mild, even in cases of clear production drops and the production of eggs with pale, unpigmented shells. The severity of the production decline may vary from slight up to 70% (17, 18) and depends on factors such as the causative virus strain and level of immunity against that strain, the timing of infection within the period of lay (185), and by co-infections such as egg drop syndrome (EDS) adenovirus (185). A co-infection of IBV increased the percentage of eggshell apex abnormalities caused by *Mycoplasma synoviae* (77). Following IBV infection at the onset of production a more severe drop in total production of normally shelled eggs, an increase in the number of abnormally shelled eggs, and more lasting adverse effects on egg weight and internal egg quality were observed, in comparison with infection after peak production. With mild drops in production, a normal level of production can be restored in 1 or 2 weeks. With severe drops of production, 6–8 weeks may elapse before production returns to the pre-infection level, but in some cases this is never attained.

In addition to production declines, IBV infections can cause a range of effects on the egg quality varying from loss of shell pigment, shell quality (misshapen, thin, soft-shelled and rough-shelled, Figure 4.4), thin to watery albumen (Figure 4.5) in a fresh egg, and decreased hatchability. Flocks with false layers fail to reach the normal rate of lay, whereas the flock looks healthy, behaves normally, and produces good quality eggs. The peak of production can be as low as 35% of expected production values (21). The D388 strain was isolated from 19-day old breeders with respiratory signs and nephritis. This flock had a peak in egg production of 36%. An infection of day-old SPF birds resulted in 30% mortality due to nephritis, and the survivors had 81% incidence of cystic oviducts (71).

Morbidity and Mortality

All birds in the flock become infected, but mortality is variable depending on virulence and pathotype of the infecting strain; age of infection; status of immunity, either maternal or active; and stresses such as cold or secondary bacterial infections. The highest mortality is usually seen with infections of nephropathogenic strains in young birds.

Pathology

Gross Pathology

Infected chickens have serous, catarrhal, or caseous exudate in the trachea, nasal passages, and sinuses. Air sacs may be foamy during the acute infection and then may become cloudy

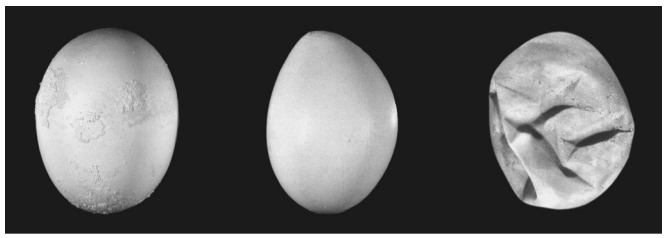

Figure 4.4. Thin-shelled, rough, and misshapen eggs laid by hens during an outbreak of IB. (Van Roekel)

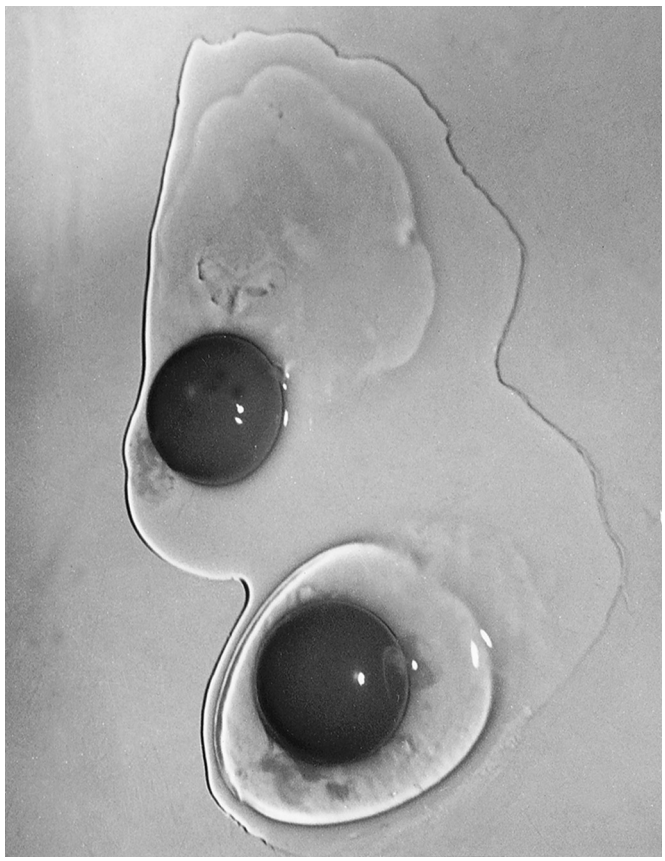

Figure 4.5. Contents of two eggs. Normal egg (bottom). Egg from chicken exposed to IBV at 1 day of age (top). Note watery albumen with yolk separated from thick albumen. (Hofstad)

and contain a yellow caseous exudate. Areas of pneumonia may be observed around the large bronchi. Nephropathogenic infections produce swollen and pale kidneys with the tubules and ureters often distended with urates (57, 197) (Figure 4.6).

Fluid yolk material may be found in the coelomic (abdominal) cavity of chickens that are in production, but this is also seen with other diseases that cause a marked drop in egg production. Cystic oviducts may be a consequence of IBV infection at a very young age (13, 21, 41, 55, 71, 114) and are a cause of a reduced peak in egg production when reaching maturity. The younger the bird is at exposure the more likely that it will be a false layer at maturity (21, 55). Effects of IBV infection on the reproductive tract of chickens in production have been detailed by Sevoian and Levine

Figure 4.6. Kidney lesions associated with IB caused by T strain of virus. Note swollen kidneys with tubules and ureters distended with urates. (Cumming)

(172). They observed reduced length and weight of the oviduct in infected birds as well as regression of the ovaries.

Microscopic

The tracheal mucosa of chickens with IB is edematous. There is loss of cilia, rounding and sloughing of epithelial cells, and minor infiltration of heterophils and lymphocytes within 18 hours of infection. Regeneration of the epithelium starts within 48 hours. Hyperplasia is followed by massive infiltration of the lamina propria by lymphoid cells and the formation of a large number of germinal centers often forming after 7 days. If air sac involvement occurs, there is edema, epithelial cell desquamation, and some fibrinous exudate within 24 hours. Increased heterophils can be observed later with lymphoid nodules, fibroblast proliferation, and regeneration by cuboidal epithelial cells (165) (Figure 4.7A, B, C, D, E, F).

The histological changes post IB vaccination and challenge in the Harderian gland includes a sharp increase in the number

of plasma cells, hyperemia, and extensive lymphoid follicle formation (63, 183).

The kidney lesions of IB are principally those of an interstitial nephritis (Figure 4.7G and H) (165, 174). The virus causes granular degeneration, vacuolation and desquamation of the tubular epithelium, and massive infiltration of heterophils in the interstitium in acute stages of the disease. The lesions in tubules are most prominent in the medulla. Focal areas of necrosis may be seen along with indications of attempted regeneration of the tubular epithelium. During recovery, the inflammatory cell population changes to lymphocytes and plasma cells. In some cases, degenerative changes may persist and result in severe atrophy of one or all of the divisions of the nephrons. In urolithiasis, the ureters associated with atrophied kidneys are distended with urates and often contain large calculi composed mainly of urates.

Ultrastructural studies of infected kidney tissue revealed epithelial cells of the lower nephron and ducts to be the primary targets for IBV replication (38, 39). Infected epithelial cells containing virus particles were more abundantly found in the collecting ducts, collecting tubules, distal convoluted tubules, and Henle's loops than in the proximal convoluted tubules. Cytoplasmic changes in the infected epithelial cells were characterized by swelling of the mitochondria, dilation of Golgi vesicles, and an increase in the amount of rough endoplasmic reticulum (RER). Virus particles were seen budding from the RER, and as the virus replication progressed, virus particles were enclosed in dilated RER, cytoplasmic vesicles, or virus-containing electron-dense bodies.

Experimental IBV infection of the oviduct of mature hens resulted in decreased height and loss of cilia from epithelial cells; dilation of the tubular glands; infiltration by lymphocytes, other mononuclear cells, plasma cells, and heterophils; and edema and fibroplasia of the mucosa of all regions of the oviduct (165, 172).

The histological lesions in the enteric tract appear to be very mild for IBV infections that are free of co-infections. No lesions were detected in any part, from proventriculus to ileum, in chickens that had been infected with the enterotropic G strain; only the rectum showed desquamation of the cells from the tips of villi, congestion, and focal infiltration with lymphocytes, macrophages, and some heterophils (6).

Immunity

Aspects of immunity to IBV have been reviewed previously (35, 73). Although differences in both breed- and strain-related genetic resistance to IBV infection have been described in chickens (9, 23, 45, 54, 157), relevant data about the genetic resistance of commercial lines of chickens are not available.

Innate Immunity

Traditionally, innate immune responses were only considered important in the earliest phases of microbial invasion, limiting the spread of the pathogen until adaptive responses by the B and T cells become mobilized to clear the infection. In reality, the innate and adaptive responses are highly integrated. The innate immune system is involved in directing the adaptive responses and can also act as expresser of the adaptive immunity (117). Much is still to be discovered on this subject but it was already shown that IBV induced a diversity of local innate effectors and Th1-based adaptive immunity during the early phase of IBV infection, and that these immune effectors are responsible for the rapid clearance of virus from the trachea (187). Mannose-binding lectin (MBL), an innate pathogen pattern-recognition molecule, is involved in the regulation of the adaptive immune response to IBV (117).

Active Immunity

Cell-Mediated Immunity. Work on cell-mediated immune responses to IBV has been reviewed (73), and specifically for the cytotoxic T lymphocytes (CTL) (44). Work with the nephropathogenic Gray strain showed that the MHC-class 1 restricted CTL response correlated much better with the initial elimination of virus from lungs and kidneys during the acute phase of infection than the humoral IgM and IgG response (170). Adoptive transfer of different kinds of immune T cells to chicks prior to infection with the Gray strain demonstrated that IBV-primed CTLs with αβ T cell receptors (TCR2) could protect chicks from acute infection in the respiratory tract (171).

Humoral Immunity. Vaccination or infection with IBV results in an antibody response that can be detected using different kinds of group-specific and serotype-specific techniques. Usually, the first antibodies can be detected in serum and lacrimal fluid between 1 and 2 weeks PI. However, the level of antibody response depends on many variables including age at inoculation, presence of maternally derived antibodies, level of immunity at time of vaccination/infection, application route, genetics, and immunosuppression (reviewed in (68)). In serum, IgA, IgG (IgY), and IgM can be detected; in lacrimal fluid and tracheal washings, IgA and IgG are the commonly detected antibody classes. An important part of the IgA in the lacrimal fluid originates from the Harderian glands (8, 65). The IgG concentration in the same fluid is largely the result of passive transport of IgG from the serum (65, 182). IgM is only present for a few weeks after infection or vaccination; therefore, its detection is indicative of a recent vaccination or infection (68).

Serotype-specific virus neutralizing antibodies are induced by the amino-terminal S1 subunit of the S glycoprotein (30). Despite many studies that have detected neutralizing IBV serum and local antibodies, the relevance of antibodies in the mechanism of protection against infection and disease is still unknown. A protective role of antibody is shown by the significantly longer period of virus persistence PI in chickens that were immunocompromised by infectious bursal disease virus (IBDV) infection at 1 day of age (166). A similar effect was reported after *in-ovo* bursectomy in line C White leghorns. These birds experienced a more severe and longer lasting

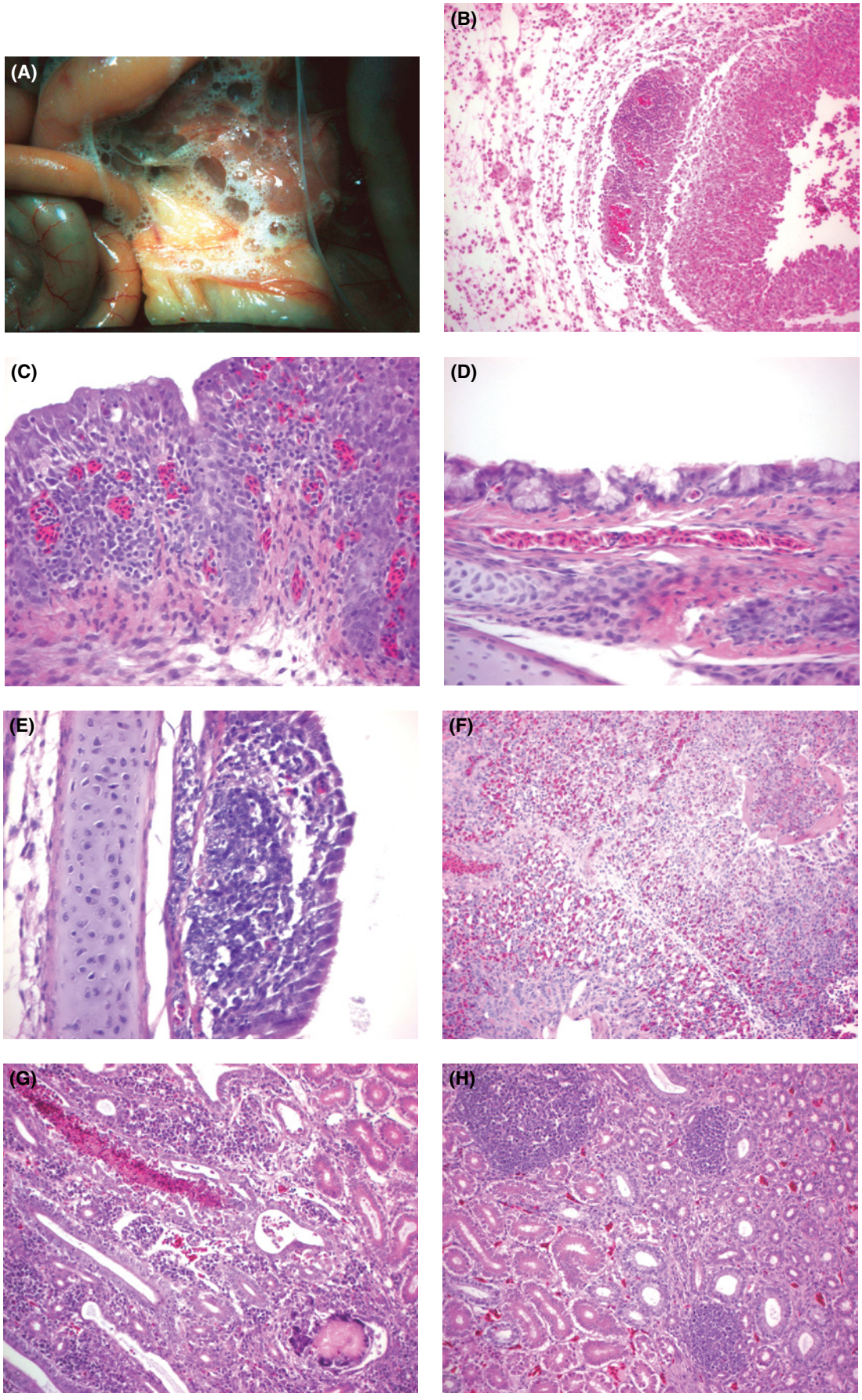

Figure 4.7

infection than the intact birds and also developed less respiratory protection against a secondary challenge (50). The antibody response and efficacy of the Mass/H52/55 vaccination at 8 days of age was decreased in broilers that had been infected with a virulent IBDV strain at day 25 (192). The antibody response and efficacy of the Mass/H120/55 vaccination was decreased in broilers that had been infected with a virulent IBDV strain, especially the birds that had been infected at day 1 or 5 (158). A US/Ark/Ark-DPI/81 challenge at 15 days of age in immunodeficient SPF birds by a combined chicken anemia virus and IBDV inoculation at 7 days of age resulted in more severe and persistent clinical signs and lesions, a delayed and reduced antibody response, and increased and persisting viral shedding (184).

The IBV ELISA and VN antibody levels in tears were not accurate indicators of IBV immunity as determined by challenge with Mass/Mass41/41. High tear IBV antibody titers were observed in some chickens determined to be susceptible to IBV challenge and low tear antibody titers were detected in some protected chickens (85). No correlation was found between the serum ELISA antibody titers and the degree of kidney protection against the nephropathogenic Belgium/B1648/96 strain (159). In another study, no antibody was detectable post vaccination in post hatch cyclophosphamide bursectomized chickens and still the birds resisted challenge (43). In laying birds, a clear correlation was found between the level of HI antibodies against the challenge virus and the level of protection against egg drop (17, 18, 19, 78).

Maternally Derived Immunity

High levels of maternally derived antibodies significantly reduced the extent of clinical signs or damage to trachea, kidneys, and oviduct due to IBV infection in chicks during the first days of life (21, 58, 61, 71, 150, 151). Several groups have reported a negative effect of high levels of maternal antibodies against the vaccine strain when it is applied on day of hatch (159), whereas others did not detect a lower efficacy of the day-old vaccination in presence of maternal antibodies (50, 61, 64).

Diagnosis

Diagnosis of IB is based on the clinical history, lesions, seroconversion (rising IBV antibody titers), IBV antigen detection by a number of antibody-based antigen capture assays, virus isolation, and detection of IBV RNA (87). Thorough diagnosis of IBV includes identification of the serotype or genotype of the virus so that appropriate vaccines can be used. The many approaches used to detect IBV or antibodies induced by it have been described and critically compared (68). At the outset, it should be stated that no one technique, whether based on antibodies, antigen capture, virus isolation, or nucleic acid technology, is totally satisfactory for confirmation of infection by a specific IBV serotype in the field.

Isolation and Identification of the Causative Agent

Although primarily a respiratory pathogen, IBV also can infect epithelial cells in the kidney, oviduct, and gastrointestinal tract. Knowledge of the pathogenesis of IBV, reviewed in (73), has been instructive for the detection of the virus. Factors to be taken into account include the time elapsed between infections and sampling and the immune status of the bird at infection. These and other factors have been discussed (68).

Virus Isolation

Tracheal swabs or fresh tracheal tissue is the preferred sample, especially within the first week of infection, and samples should constantly be kept cold (on wet ice) until tested. Titers of IBV reach a maximum in the trachea by day 3–5 PI, after which they decline rapidly. Because the virus initially grows in the upper respiratory tract and then spreads to nonrespiratory tissues, kidney and cecal tonsils collected at post mortem examination can be of value in cases in which more than 1 week has elapsed

Figure 4.7. (A) Foamy airsacculitis associated with an early field infection with the Delaware 072 strain of IBV. (University of Delaware, Ed Odor) (B) Airsacculitis from a severe IBV field vaccine reaction in a 4-day-old broiler. Inflammation-related thickening of the air sac wall with heterophils and macrophages present in the air sac lumen. Peripheral to the air sac wall is soft tissue inflammatory edema to include lymphocytic perivascular cuffing around congested blood vessels. (C) Viral tracheitis related to an experimental infection with the Arkansas strain of IBV at 3 days PI. Visible is cilia loss, partial mucous gland depletion, and mucosal epithelial degenerative changes to include rare heterophil infiltration, mucosal epithelial hyperplasia, congestion, lymphocytic perivasular cuffing, and submucosal edema. (D) Normal trachea from sham inoculated negative control at 3 days PI for comparison with (C). Cilia and mucous glands are prominent, and there is a lack of inflammation-based mucosal thickening. (E) Trachea from an experimental IBV infection at 14 days PI. There is a lack of acute inflammation. Cilia are apparent, the mucosa contains a developing germinal center, and lymphocytes are present in the submucosa. (F) Bronchopneumonia related to an experimental infection with the Arkansas strain of IBV at 6 days PI. A heterophilic bronchopneumonia involves a parabronchus resulting in the filling of the parabronchial lumen with heterophils and heterophilic infiltration of associated exchange tissue. A portion of a normal parabronchus is adjacent to the parabronchus with the bronchopneumonia. (G) Tubulointerstital nephritis of a medullary cone at 10 days PI following exposure to the nephrogenic PA/Wolgemuth/98 strain of IBV. Degenerated-necrotic misshapened, often dilated tubules containing urate, heterophilic, and degenerated epithelial casts are accompanied by an interstitium expanded by mostly plasma cells, lymphocytes, and a few heterophils. (H) Germinal centers in and at the margin of a medullary cone are an indication of an area of near complete healing at 10 days PI following exposure to the nephrogenic PA/Wolgemuth/98 strain of IBV. (University of Delaware, Conrad R. Pope, Brian S. Ladman, and Jack Gelb, Jr.).

since the start of infection. However, it should be recognized that vaccine viruses could also be found persisting in cecal tonsils (3, 115, 138). Although the virus can replicate in the gastrointestinal tract, cloacal swabs or fecal material are difficult samples from which to isolate the virus. Additionally, samples from the lung, kidney, and oviduct should be considered, depending on the clinical history of the flock.

When collecting samples from a large flock, both healthy birds and those with clinical signs should be sampled. Typically, clinical signs begin 3–5 days following infection when the virus is no longer at peak titer. In mild cases of the disease, clinical signs due to the virus may go unnoticed until secondary pathogens become involved, at which time IBV is no longer present. Alternatively, the placement of susceptible sentinel chickens has been described (83) and can be beneficial when direct sampling is unsuccessful.

Samples for virus isolation commonly are inoculated into the allantoic cavity of 9- to 10-day-old embryonating chicken eggs or tracheal organ cultures, preferably from an SPF source. Fluids should be harvested after 48–72 hours from either culture system and passed at least 3–4 times before being called negative based on failure to cause lesions or death in embryos, or ciliostasis in tracheal organ cultures (87). However, these observations are not in themselves sufficient to confirm the presence of IBV; the presence of the virus must be confirmed by VN, HI, immunofluorescence, immunohistochemistry, detection of the viral nucleic acid, or electron microscopy.

Coronaviruses in pheasants can be detected by collecting appropriate samples and inoculation of embryonating chicken eggs (34, 135). In contrast, coronaviruses detected by RT-PCR in graylag geese, mallards, and pigeons could not be propagated in chicken eggs following allantoic sac inoculation (113).

Confirmation and Typing of IBV by Antibody-Based Methods

Detection of IBV directly using postmortem material (scrapings of tracheal mucosa or other tissues) or virus grown in embryonating eggs may be attempted by immunofluorescence, immunohistochemistry, or immunoperoxidase assays, using IBV-specific polyclonal sera or monoclonal antibodies (reviewed in (68, 87)). However, the results are not always easy to interpret, especially from direct field specimens because of nonspecific reactions. Tracheal material and AF also can be used in the agar gel precipitin (AGP) test, which has a sensitivity greater than might be expected (68). Because the amount of IBV precipitin antigen in infected chicken embryos can sometimes be low, sections of the CAM or cells sedimented from the AF can be used for immunofluorescence or immunoperoxidase assays. TOC infected with IBV can be tested for the virus by immunofluorescence without fixation of the cultures using low power microscopy (14). Infectious bronchitis virus in AF, or after growth in TOC, also may be detected and identified as to serotype, using monoclonal antibodies in indirect or antigen-capture ELISA (101). It should be noted that coronaviruses isolated from pheasants have been poorly cross reactive in antibody-based methods using IBV-specific antiserum, and antigenic cross reactions between TCoV and IBV have been demonstrated (136).

Serotype of the virus can be determined by the VN or HI test (see Serotype Classification, above). Virus-neutralization testing, whether conducted in embryonating eggs or in TOC, is time consuming and labor intensive, and the HI test suffers from nonspecific cross reactivity. For the most part, molecular-based tests have replaced VN and HI testing.

Confirmation and Typing of IBV by Nucleic Acid-Based Methods

The real time RT-PCR test, also known as quantitative RT-PCR, is becoming more widely used to detect IBV directly from clinical samples (27, 62). Advantages of this test are that many samples can be examined in a short period of time, it is cost effective, and it gives an indication of the level of viral nucleic acid in the sample. Conventional RT-PCR also can be used to identify the presence of IBV nucleic acid; however, passage in embryonating eggs may be necessary before a positive result is obtained. When only small amounts of viral RNA are available (e.g., on swabs), nested RT-PCR, in which some of the DNA produced in the first RT-PCR is used in a second PCR, have been used. However, nested RT-PCR tests are arguably too sensitive for routine diagnostic use and suffer from a high probability of cross-contamination resulting in false positive tests. Finally, it should be recognized that a positive RT-PCR test only indicates the presence of viral nucleic acid and is not sufficient to determine IBV type.

Identification of the type of IBV in the sample must be determined by analysis of amplicons from the S1 gene (see Genetic Classification, above). Advantages of genotyping methods include a rapid turnaround time and the ability to detect a wide variety of IBV types. Restriction fragment length polymorphism analysis of S1 amplicons differentiates IBV types based on unique electrophoresis banding patterns (126, 134). Genotype-specific RT-PCR using strain or type-specific primers for Mass, Conn, Ark, JMK, DE/072/92, and California viruses has also been used (121).

The most widely used genetic typing method for IBV is sequence analysis of the amplified S1 or hypervariable region of the S1 gene. The data can be used diagnostically to identify any IBV type as well as previously unrecognized field isolates and variants (122, 133, 153, 155). Phylogenetic analysis of unknown field isolates and variants with reference strains for establishing potential relatedness is a significant advantage of sequencing.

Serology

Demonstration of rising antibody titers against IBV between preclinical and convalescent sera is generally used to diagnose IBV infection. All IBV serotypes appear to have common epitopes (group-specific antigens) likely due to the moderately high amino acid sequence identity within the N and M

proteins and conserved regions of the S2 protein. Following a first infection with IBV, most of the antibody response is serotype-specific. A second infection, even with the same serotype, results in a more broadly reactive serum. Because chickens in the field will almost certainly have been vaccinated (sometimes multiple times) with modified live vaccines (broilers and pullets) and killed vaccines (layers and breeders) against IB, field sera are not very useful for serotyping. Only sera induced experimentally (the procedure can be found in (87)) using SPF chickens should be used for serotyping. Because the ELISA, immunofluorescence, and AGP tests all bind antibody to group-specific antigens, they cannot be used to differentiate serotypes.

Currently the ELISA test is the most widely used serologic test for antibodies against IBV because it is inexpensive and can be used to test a large number of samples in a short time. Commercial tests are available and typically detect antibodies (IgG) after 1 week post infection (142, 149).

Routine serology also can be done with the AGP and HI tests (reviewed in (68)). Although the AGP test can detect antibodies within the first week of infection, the strongest precipitating antibodies (IgM) are short-lived, and IgG is poorly reactive. Thus, the AGP test is not recommended for detection of antibodies beyond 2 weeks PI (66). Although cross-reactive antibodies can be detected in the HI test, sensitivity may suffer, because this is largely a serotype-specific reaction. Nonetheless, the low cost, simple equipment, and speed of the HI test makes it a useful procedure as long as the test limitations are considered. Because it is labor intensive and expensive to conduct, the VN test conducted in embryonating chicken eggs is not used for routine IBV serology.

A monoclonal antibody-based blocking or competition ELISA has been described for the detection of antibodies specific to North American serotypes Mass/Mass41/41 and Ark/Ark-DPI/81 and variant viruses in Taiwan (40, 120). Briefly, that test involves adding chicken serum containing IBV antibodies to virus-coated microtiter plates followed by serotype-specific monoclonal antibody. Chicken antibody specific to an IBV serotype blocks binding of monoclonal antibody specific to the same serotype, and the blocking was proportional to the concentration of antibody in chicken serum. Specificity of the blocking ELISA compared well with that of the VN test.

Differential Diagnosis

The clinical presentation of IB may resemble mild forms of other acute respiratory diseases such as Newcastle disease (ND), ILT, low-pathogenicity avian influenza, and infectious coryza. Newcastle disease caused by velogenic viscerotropic or neurotropic strains of paramyxovirus type 1 produces much higher mortality than IBV. Lentogenic ND virus infections with pneumotropic strains and low pathogenicity strains of avian influenza produce mild to moderate respiratory disease with low mortality and, thus, may resemble IB. Infectious laryngotracheitis tends to spread more slowly in a flock, but respiratory signs may be more severe than with IB, and infectious coryza typically causes facial swelling that occurs only rarely in IB. Egg production declines and shell quality problems in flocks infected with ND virus, avian influenza virus, ILT virus, and *Haemophilus gallinarum* (infectious coryza) as well as avian mycoplasmas and EDS adenovirus are similar to those seen with IBV, except that in the case of EDS adenovirus, internal egg quality is not affected.

Intervention Strategies

Management Procedures

Ideal management includes strict isolation, high biosecurity, and repopulation with only day-old chicks, following the cleaning and disinfection of the poultry house and equipment in contact with poultry or poultry litter and composting or removal of the feces from the premises. Because IBV is highly infectious, immunization is needed in many areas in an attempt to prevent production losses due to IB.

Vaccination

Chickens just recovered from infection or recently vaccinated are protected from challenge with the same virus (homologous protection), but the extent of protection against challenge with other IBV strains (heterologous protection) varies. Challenge of vaccinated birds with homologous virus results in much lower shedding of challenge virus, and for a shorter period, than in unvaccinated birds (49, 67, 129, 159).

Types of Vaccine

Both live and inactivated virus vaccines are used in IBV immunization. Live vaccines are used in meat type (broiler) chickens and for the initial vaccination and priming of breeders and layer pullets. Infectious bronchitis virus strains used for live vaccines are attenuated by serial passage in embryonating chicken eggs (16), sometimes in combination with heat treatment (108). Extensive passage is avoided to prevent a reduction in immunogenicity. The degree and stability of such attenuation probably varies among vaccines. Evidence that some vaccines increased in virulence after back-passage in chickens (99) demonstrates the potential for enhancement of virulence of such vaccines by continued circulation of the vaccine virus, a rolling infection, in a flock that is often caused by poor vaccination procedure, resulting in vaccination of only a fraction of birds in the house. The use of fractional doses of IB-attenuated vaccines has been associated with enhancing cyclic infections in a flock and an increase in vaccine-associated virulence.

The Mass/Mass41/41 strain, Mass/H120/55, and other vaccines of the Massachusetts serotype are commonly used in most countries. The goal of a vaccination program is to cover the antigenic spectrum of isolates in a particular country or region. When vaccinations with a single serotype are not providing sufficient protection against the prevailing field strains, vaccines of other serotypes can be added to the program. The broadening of the protection can be achieved by adding vaccines to the program that are homologous to the most important prevailing field strains (80, 81, 100, 104, 108)

and/or by using combinations of vaccines that are able to induce a broad cross protection against many strains (53, 70, 88, 178).

Several studies have shown that live IBV, Newcastle, and avian metapneumovirus vaccines might interfere with each other's replication, humoral response, and induced level of protection when administered together or in relatively short intervals of each other (20, 51, 86, 163, 180, 181). The level and direction of interference is likely dependent on strains, dose, method and interval of application, maternally derived antibodies, and active immunity (60, 69, 191).

Inactivated oil-emulsion vaccines are administered to breeders and layers prior to the onset of egg production. Pullets may be vaccinated between 10 and 18 weeks of age depending on the immunization program. The seed viruses for inactivated vaccines need not be attenuated because they will be inactivated using formalin, beta propiolactone, or other suitable inactivant. Mineral oil adjuvants are commonly used to formulate the vaccine (109). The efficacy of inactivated vaccines depends heavily on proper priming with live vaccine(s). Inactivated vaccines must be administered to birds individually, by intramuscular or subcutaneous injection. Inactivated vaccines induce high levels of serum antibody and provide protection to internal tissues, kidney, and reproductive tract (17, 18, 19, 70, 127). In contrast to live vaccines, inactivated vaccines are not nearly as effective at preventing infection of the respiratory tract following challenge with the homologous virulent virus (49).

New "variant" strains may be used to prepare inactivated autogenous vaccines for controlling IB in laying birds without the risks of using a live variant that could spread to and potentially cause disease in nearby flocks. Inactivated variant vaccines may offer better protection against challenge with the virulent live variant IBV than inactivated vaccines containing standard serotypes such as Mass and Conn (127).

Application Methods

Under experimental conditions, live vaccines are usually administered individually by eye drop or intranasal application. In the field, live vaccines are usually applied by the mass application methods including coarse spray, aerosol, or drinking water. The mass application of IBV vaccines in the field is known for its many variations in (a) application technique (eye drop, coarse spray, drinking water, aerosol); (b) quantity, quality, and temperature of the water used to dilute the vaccine; (c) dosage; and (d) the combination of different vaccines (e.g., IBV with NDV vaccines). Many of these factors can have a negative effect on the efficacy of the vaccine under field conditions.

A field study in the United States with commercial broilers that had been vaccinated at day 1 in the hatchery with Ark-DPI and DE072 vaccines and had a revaccination by spray at day 17 with the same vaccines found protection against the DE072 challenge varying from 87.5%–100% and protection against the Ark-DPI challenge that varied from 37.5%–62.5%. In a European study, the protection against a homologous Mass41 challenge in commercial broilers that had been vaccinated in the field at 14 days of age by coarse spray or drinking water varied from 0%–86%, whereas the controls that had been vaccinated with the same vaccine by eye drop showed protection varying from 89%–100% (69). In a subsequent field study, the IgM response to IBV vaccination was compared to detailed information of the vaccination process of 360 spray-vaccinated flocks of about 2-week-old broilers, layer pullets, broiler breeders, and broiler grandparents (69). Significant associations were detected between the level of IgM response and factors regarding type of bird, flock size, housing type, ventilation management, light management, age/interval of vaccination, interval between vaccination and blood sampling, and temperature of the water used to reconstitute the vaccine.

Application by the drinking water system requires management measures to be taken to assure that all birds can drink a sufficient amount of freshly prepared vaccine within a few hours, and should include the complete emptying of the water system before filling it with the vaccine. The water that is used with the vaccine should be of high quality, cold, and free of chemicals that can harm the vaccine such as sanitizers (many municipal sources of water contain chlorine, which can inactivate the vaccine). The incorporation of powdered skim milk at a 1:400 concentration or another suitable product has been shown to stabilize the virus titer during vaccine administration and resulted in better IBV and NDV immune responses in a field trial with 76 flocks (89).

These results show that the complexity of mass application methods can easily be underestimated resulting in decreased efficacy and undesired circulation of the vaccine through the flock. This might lead to an increased susceptibility to secondary bacterial infections (49, 92, 143, 144, 175) and reversion of the vaccine virus to virulence (99). Possibly some live vaccine strains might be more involved in complications than others such as the Ark/Ark-DPI/81 strain in the United States, which has been shown to persist in the respiratory tract, especially when administered in combination with another attenuated IBV strain (5, 107).

Despite the potential negative effect of the maternally derived antibodies on the efficacy of the vaccination in the first days of life (see Immunity), vaccination of maternally immune 1-day-old commercial chicks is routinely performed, especially in the broiler industry. Besides the convenience, vaccination in a hatchery can be much better controlled than that in the poultry house. A second vaccine of the same or different serotype is often given to broilers at 10–18 days of age to broaden and extend protection.

Broiler breeders and commercial layers are likely to be first inoculated with live IB vaccine at about 2–3 weeks of age. In areas with an increased level of field challenge, live attenuated vaccines are also used periodically during the laying period with the intention of keeping the local protection of the respiratory tract at a high level. Inactivated vaccines are also given to breeders and layers and require injection of individual birds. These IB vaccines are usually administered at 10–18 weeks of age and are given 4–6 weeks after 1 or more priming immunization with live vaccine. The purpose of killed vaccines in breeders is to induce high serum antibody titers that

are passed on to the progeny. As yet, no IB vaccines have been applied *in ovo*; all commercially available vaccines reduce hatchability to unacceptable levels.

Future Vaccines

There are probably dozens of serotypes/genotypes of IBV currently awaiting discovery, and IBV by nature is constantly changing through mutations and recombinations, which will pose challenges to the poultry industries and to vaccine developers. Given the current technology, it will only be economically feasible to develop new vaccines against a small number of new types of IBV. Therefore, control of IB will continue to involve "juggling" a very small selection of vaccines, in combination with good management practices. Vaccines or combinations of a few vaccines that are able to induce a broad cross protection against many strains would be more useful than strains that only provide protection against a homologous challenge.

The development of reverse genetics and viral vectored recombinant vaccines for IBV offer the prospect of a new era of genetically more defined and stable vaccines, and possibly also vaccines for application *in ovo*. Several unique vaccines have been reported, including recombinant IBV expressing a heterologous spike gene (96), a fowl adenovirus vector-based vaccine expressing the S1 of IBV (112, 196), recombinant baculovirus expressing S1 glycoprotein of an IBV strain (176), recombinant fowlpox virus expressing IBV S1 gene and chicken interferon-gamma gene (173), and a mucosal vaccination with recombinant viral proteins (146). However, all of these recombinant vaccines are challenged to faithfully reproduce the conformationally dependent neutralizing epitopes encoded on spike and thus, to date only provide partial protection against homologous challenge.

Indeed, the challenges for the new generation of vaccines are tremendous, especially for use in the broiler industry. The desired broad cross protection should be induced within a week after a single application, preferably by a mass application method that can be used at any age. Maternally derived antibodies or active immunity against the vector should not interfere with the induction of protection and it would be highly desirable that the vaccine can be combined with vaccines against other agents. It is possible that these demands explain why the new generation of IB vaccines is not yet available, in contrast to vaccines for several other major diseases in poultry.

Treatment

No specific treatment exists for IB. Provision of additional heat to eliminate cold stress, good air quality, elimination of overcrowding, and attempts to maintain feed consumption to prevent weight loss are flock management factors that may help reduce losses from IB. Treatment with appropriate antibacterials may be used to aid in reducing the losses from airsacculitis resulting from infection by secondary bacterial pathogens. A decrease in protein levels in the food and a supply of electrolyte replacers in the drinking water are recommended and were used in Australia to compensate for the acute loss of sodium and potassium and thereby reduce losses from nephritis. The recommended concentration for treatment is 72 mEq of sodium and/or potassium, with at least one-third in the citrate or bicarbonate salt form (58).

References

1. Albassam, M.A., R.W. Winterfield, and H.L. Thacker. 1986. Comparison of nephropathogenicity of four strains of infectious bronchitis virus. *Avian Dis*. 30:468–476.
2. Alexander, D.J., and M.S. Collins. 1975. Effect of pH on the growth and cytopathogenicity of avian infectious bronchitis virus in chick kidney cells. *Arch Virol*. 49:339–348.
3. Alexander, D.J., and R.E. Gough. 1977. Isolation of avian infectious bronchitis virus from experimentally infected chickens. *Res Vet Sci*. 23:344–347.
4. Alexander, D.J., and R.E. Gough. 1978. A long-term study of the pathogenesis of infection of fowls with three strains of avian infectious bronchitis virus. *Res Vet Sci*. 24:228–233.
5. Alvarado, I.R., P. Villegas, J. El-Attrache, and M.W. Jackwood. 2006. Detection of Massachusetts and Arkansas serotypes of infectious bronchitis virus in broilers. *Avian Dis*. 50:292–297.
6. Ambali, A.G., and R.C. Jones. 1990. Early pathogenesis in chicks of infection with an enterotropic strain of infectious bronchitis virus. *Avian Dis*. 34:809–817.
7. Archetti, I., and F.L. Horsfall. 1950. Persistent antigentic variation of influenza A viruses after incomplete neutralization *in vivo* with heterologous immune serum. *J Exp Med*. 92:441–462.
8. Baba, T., K. Masumoto, S. Nishida, T. Kajikawa, and M. Mitsui. 1988. Harderian gland dependency of immunoglobulin A production in the lacrimal fluid of chicken. *Immunol*. 65:67–71.
9. Bacon, L.D., D.B. Hunter, H.M. Zhang, K. Brand, and R. Etches. 2004. Retrospective evidence that the MHC (B haplotype) of chickens influences genetic resistance to attenuated infectious bronchitis vaccine strains in chickens. *Avian Pathol*. 33:605–609.
10. Beach, J.R., and O.W. Schalm. 1936. A filterable virus, distinct from that of laryngotracheitis, the cause of a respiratory disease of chicks. *Poultry Sci*. 15:199–206.
11. Beard, C.W. 1967. Infectious bronchitis virus interference with Newcastle disease virus in monolayers of chicken kidney cells. *Avian Dis*. 11:399–406.
12. Beaudette, F.R., and C.B. Hudson. 1937. Cultivation of the virus of infectious bronchitis. *J Am Vet Med Assoc*. 90:51–58.
13. Benyeda, Z., T. Mato, T. Suveges, E. Szabo, V. Kardi, Z. Abonyi-Toth, M. Rusvai, and V. Palya. 2009. Comparison of the pathogenicity of QX-like, M41 and 793/B infectious bronchitis strains from different pathological conditions. *Avian Pathol*. 38:449–456.
14. Bhattacharjee, P.S., C.J. Naylor, and R.C. Jones. 1994. A simple method for immunofluorescence staining of tracheal organ cultures for the rapid identification of infectious bronchitis virus. *Avian Pathol*. 23:471–480.
15. Bhattacharjee, P.S., S.D. Carter, C.E. Savage, and R.C. Jones. 1995. Re-excretion of infectious bronchitis virus in chickens induced by cyclosporin. *Avian Pathol*. 24:435–441.
16. Bijlenga, G., J.K. Cook, J. Gelb, Jr., and J.J. de Wit. 2004. Development and use of the H strain of avian infectious bronchitis virus from the Netherlands as a vaccine: a review. *Avian Pathol*. 33:550–557.

17. Box, P.G., A.V. Beresford, and B. Roberts. 1980. Protection of laying hens against infectious bronchitis with inactivated emulsion vaccines. *Vet Rec*. 106:264–268.
18. Box, P.G., and K.R. Ellis. 1985. Infectious bronchitis in laying hens: interference with response to emulsion vaccine by attenuated live vaccine. *Avian Pathol*. 14:9–22.
19. Box, P.G., H.C. Holmes, P.M. Finney, and R. Froymann. 1988. Infectious bronchitis in laying hens: the relationship between haemagglutination inhibition antibody levels and resistance to experimental challenge. *Avian Pathol*. 17:349–361.
20. Bracewell, C.D., P.S. Dawson, and W.H. Allan. 1972. Antibody responses to a live Newcastle disease vaccine when combined with a live infectious bronchitis vaccine. *Vet Rec*. 90:248–249.
21. Broadfoot, D.I., B.S. Pomeroy, and W.M. Smith, Jr. 1954. Effect of infectious bronchitis on egg production. *J Am Vet Med Assoc*. 124:128–130.
22. Brooks, J.E., A.C. Rainer, R.L. Parr, P. Woolcock, F. Hoerr, and E.W. Collisson. 2004. Comparisons of envelope through 5B sequences of infectious bronchitis coronaviruses indicates recombination occurs in the envelope and membrane genes. *Virus Res*. 100:191–198.
23. Bumstead, N., R.L. Reece, and J.K. Cook. 1993. Genetic differences in susceptibility of chicken lines to infection with infectious bursal disease virus. *Poult Sci*. 72:403–410.
24. Bushnell, L.D., and C.A. Brandly. 1933. Laryngotracheitis in chicks. *Poultry Sci*. 12:55–60.
25. Butcher, G.D., J. Gelb, Jr., and E.W. Collisson. 1990. Comparisons of the genomic RNA of Arkansas DPI embryonic passages 10 and 100, Australian T, and Massachusetts 41 strains of infectious bronchitis virus. *Avian Dis*. 34:253–259.
26. Butcher, G.D., R.W. Winterfield, and D.P. Shapiro. 1990. Pathogenesis of H13 nephropathogenic infectious bronchitis virus. *Avian Dis.* 34:916–921.
27. Callison, S.A., D.A. Hilt, T.O. Boynton, B.F. Sample, R. Robison, D.E. Swayne, and M.W. Jackwood. 2006. Development and evaluation of a real-time Taqman RT-PCR assay for the detection of infectious bronchitis virus from infected chickens. *J Virol Methods*. 138:60–65.
28. Casais, R., B. Dove, D. Cavanagh, and P. Britton. 2003. Recombinant avian infectious bronchitis virus expressing a heterologous spike gene demonstrates that the spike protein is a determinant of cell tropism. *J Virol*. 77:9084–9089.
29. Cavanagh, D., P.J. Davis, and A.P. Mockett. 1988. Amino acids within hypervariable region 1 of avian coronavirus IBV (Massachusetts serotype) spike glycoprotein are associated with neutralization epitopes. *Virus Res*. 11:141–150.
30. Cavanagh, D., P.J. Davis, J. Cook, D. Li, A. Kant, and G. Koch. 1992. Location of the amino acid differences in the S1 spike glycoprotein subunit of closely related serotypes of infectious bronchitis virus. *Avian Pathol*. 21:33–43.
31. Cavanagh, D., M.M. Elus, and J.K. Cook. 1997. Relationship between sequence variation in the S1 spike protein of infectious bronchitis virus and the extent of cross-protection *in vivo*. *Avian Pathol*. 26:63–74.
32. Cavanagh, D. 2001. A nomenclature for avian coronavirus isolates and the question of species status. *Avian Pathol*. 30:109–115.
33. Cavanagh, D., K. Mauditt, M. Sharma, S.E. Drury, H.L. Ainsworth, P. Britton, and R.E. Gough. 2001. Detection of coronavirus from turkey poults in Europe genetically related to infectious bronchitis virus of chickens. *Avian Pathol*. 30: 355–368.
34. Cavanagh, D., K. Mawditt, B. Welchman Dde, P. Britton, and R.E. Gough. 2002. Coronaviruses from pheasants (*Phasianus colchicus*) are genetically closely related to coronaviruses of domestic fowl (infectious bronchitis virus) and turkeys. *Avian Pathol*. 31:81–93.
35. Cavanagh, D. 2003. Severe acute respiratory syndrome vaccine development: experiences of vaccination against avian infectious bronchitis coronavirus. *Avian Pathol*. 32:567–582.
36. Cavanagh, D. 2005. Coronaviruses in poultry and other birds. *Avian Pathol*. 34:439–448.
37. Cavanagh, D., and J. Gelb Jr. 2008. Infectious Bronchitis. In: *Diseases of Poultry*, 12th ed. Y.M. Saif, ed. Blackwell Publishing, Ames, Iowa. 117–135.
38. Chen, B.Y., S. Hosi, T. Nunoya, and C. Itakura. 1996. Histopathology and immunohistochemistry of renal lesions due to infectious bronchitis virus in chicks. *Avian Pathol*. 25: 269–283.
39. Chen, B.Y., and C. Itakura. 1997. Histopathology and immunohistochemistry of renal lesions due to avian infectious bronchitis virus in chicks uninoculated and previously inoculated with highly virulent infectious bursal disease virus. *Avian Pathol*. 26:607–624.
40. Chen, H.W., C.H. Wang, and I.C. Cheng. 2011. A type-specific blocking ELISA for the detection of infectious bronchitis virus antibody. *J Virol Methods*. 173:7–12.
41. Chew, P.H., P.S. Wakenell, and T.B. Farver. 1997. Pathogenicity of attenuated infectious bronchitis viruses for oviducts of chickens exposed *in ovo*. *Avian Dis*. 41:598–603.
42. Chong, K.T., and K. Apostolov. 1982. The pathogenesis of nephritis in chickens induced by infectious bronchitis virus. *J Comp Pathol*. 92:199–211.
43. Chubb, R.C. 1974. The effect of the suppression of circulating antibody on resistance to the Australian avian infectious bronchitis virus. *Res Vet Sci*. 17:169–173.
44. Collisson, E.W., J. Pei, J. Dzielawa, and S.H. Seo. 2000. Cytotoxic T lymphocytes are critical in the control of infectious bronchitis virus in poultry. *Dev Comp Immunol*. 24:187–200.
45. Cook, J., K. Otsuki, M. Huggins, and N. Bumstead. 1990. Investigations into resistance of chicken lines to infection with infectious bronchitis virus. *Adv Exp Med Biol*. 276:491–496.
46. Cook, J.K. 1968. Duration of experimental infectious bronchitis in chickens. *Res Vet Sci*. 9:506–514.
47. Cook, J.K. 1971. Recovery of infectious bronchitis virus from eggs and chicks produced by experimentally inoculated hens. *J Comp Pathol*. 81:203–211.
48. Cook, J.K., J.H. Darbyshire, and R.W. Peters. 1976. Growth kinetic studies of avian infectious bronchitis virus in tracheal organ cultures. *Res Vet Sci*. 20:348–349.
49. Cook, J.K., H.W. Smith, and M.B. Huggins. 1986. Infectious bronchitis immunity: its study in chickens experimentally infected with mixtures of infectious bronchitis virus and *Escherichia coli*. *J Gen Virol*. 67:1427–1434.
50. Cook, J.K., T.F. Davison, M.B. Huggins, and P. McLaughlan. 1991. Effect of *in ovo* bursectomy on the course of an infectious bronchitis virus infection in line C White Leghorn chickens. *Arch Virol*. 118:225–234.
51. Cook, J.K., M.B. Huggins, S.J. Orbell, K. Mawditt, and D. Cavanagh. 2001. Infectious bronchitis virus vaccine interferes with the replication of avian pneumovirus vaccine in domestic fowl. *Avian Pathol*. 30:233–242.
52. Cook, J.K.A., A.J. Brown, and C.D. Bracewell. 1987. Comparison of the hemagglutination inhibition test and the serum

neutralization test in tracheal organ cultures for typing infectious bronchitis virus strains. *Avian Pathol*. 16:505–511.
53. Cook, J.K.A., Orbell, S.J., Woods, M.A., and Huggins, M.B. 1999. Breadth of protection of the respiratory tract provided by different live-attenuated infectious bronchitis vaccines against challenge with infectious bronchitis viruses of heterologous serotypes. *Avian Pathol*. 28:477–485.
54. Cook, K.A., K. Otsuki, N.R. Martins, M.M. Ellis, and M.B. Huggins. 1992. The secretory antibody response of inbred lines of chicken to avian infectious bronchitis virus infection. *Avian Pathol*. 21:681–692.
55. Crinion, R.A. 1972. Egg quality and production following infectious bronchitis virus exposure at one day old. *Poult Sci*. 51:582–585.
56. Crinion, R.A., and M.S. Hofstad. 1972. Pathogenicity of four serotypes of avian infectious bronchitis virus for the oviduct of young chickens of various ages. *Avian Dis*. 16:351–363.
57. Cumming, R.B. 1963. Infectious avian nephrosis (uraemia) in Australia. *Austral Vet J*. 39:145–147.
58. Cumming, R.B. 1969. The control of avian infectious bronchitis/nephrosis in Australia. *Austral Vet J*. 45:200–203.
59. Darbyshire, J.H. 1978. Organ culture in avian virology: a review. *Avian Pathol*. 7:321–335.
60. Darbyshire, J.H., and R.W. Peters. 1984. Sequential development of humoral immunity and assessment of protection in chickens following vaccination and challenge with avian infectious bronchitis virus. *Res Vet Sci*. 37:77–86.
61. Darbyshire, J.H., and R.W. Peters. 1985. Humoral antibody response and assessment of protection following primary vaccination of chicks with maternally derived antibody against avian infectious bronchitis virus. *Res Vet Sci*. 38:14–21.
62. Das, A., E. Spackman, M.J. Pantin-Jackwood, and D.L. Suarez. 2009. Removal of real-time reverse transcription polymerase chain reaction (RT-PCR) inhibitors associated with cloacal swab samples and tissues for improved diagnosis of Avian influenza virus by RT-PCR. *J Vet Diagn Invest*. 21:771–778.
63. Davelaar, F.G., and B. Kouwenhoven. 1976. Changes in the Harderian gland of the chicken following conjunctival and intranasal infection with infectious bronchitis virus in one- and 20-day-old chickens. *Avian Pathol*. 5:39–50.
64. Davelaar, F.G., and B. Kouwenhoven. 1977. Influence of maternal antibodies on vaccination of chicks of different ages against infectious bronchitis. *Avian Pathol*. 6:41–50.
65. Davelaar, F.G., A. Noordzij, and J.A. Vanderdonk. 1982. A study on the synthesis and secretion of immunoglobulins by the Jarderian gland of the fowl after eyedrop vaccination against infectious bronchitis at 1-day-old. *Avian Pathol*. 11:63–79.
66. de Wit, J.J., D.R. Mekkes, B. Kouwenhoven, and J.H.M. Verheijden. 1997. Sensitivity and specificity of serological tests for detection of infectious bronchitis virus induced antibodies in broilers. *Avian Pathol*. 26:105–118.
67. de Wit, J.J., M.C.M. de Jong, A. Pijpers, and J.H.M. Verheijden. 1998. Transmission of infectious bronchitis virus within vaccinated and unvaccinated groups of chickens. *Avian Pathol*. 27:464–471.
68. de Wit, J.J. 2000. Detection of infectious bronchitis. *Avian Pathol*. 29:71–93.
69. de Wit, J.J., W.A. Swart, and T.H. Fabri. 2010. Efficacy of infectious bronchitis virus vaccinations in the field: association between the alpha-IBV IgM response, protection and vaccine application parameters. *Avian Pathol*. 39:123–131.
70. de Wit, J.J., J.K. Cook, and H.M. van der Heijden. 2011. Infectious bronchitis virus variants: a review of the history, current situation and control measures. *Avian Pathol*. 40:223–235.
71. de Wit, J.J., J. Nieuwenhuisen-van Wilgen, A. Hoogkamer, H. van de Sande, G.J. Zuidam, and T.H. Fabri. 2011. Induction of cystic oviducts and protection against early challenge with infectious bronchitis virus serotype D388 (genotype QX) by maternally derived antibodies and by early vaccination. *Avian Pathol*. 40:463–471.
72. Delaplane, J.P., and H.O. Stuart. 1941. The modification of infectioius bronchitis virus of chickens as the result of propagation in embryonated chicken eggs. Rhode Island Agricultural Experiment Station, RI Bulletin 284.
73. Dhinaker Raj, G., and R.C. Jones. 1997. Infectious bronchitis virus: Immunopathogenesis of infection in the chicken. *Avian Pathol*. 26:677–706.
74. Dong, B.Q., W. Liu, X.H. Fan, D. Vijaykrishna, X.C. Tang, F. Gao, L.F. Li, G.J. Li, J.X. Zhang, L.Q. Yang, L.L. Poon, S.Y. Zhang, J.S. Peiris, G.J. Smith, H. Chen, and Y. Guan. 2007. Detection of a novel and highly divergent coronavirus from Asian leopard cats and Chinese ferret badgers in Southern China. *J Virol*. 81:6920–6926.
75. Enjuanes, L., D. Brian, D. Cavanagh, K.K. Holmes, M.M. Lai, H. Laude, P.S. Masters, P.J. Rottier, S.G. Siddell, W.J. Spaan, F. Taguchi, and P. Talbot. 2000. Coronaviridae. In: *Virus Taxonomy*. F.A. Murphy, C.M. Fauquet, D.H.L. Biship, S.A. Ghabrial, A.W. Jarvis, G.P. Martelli, M.A. Mayo and M.D. Summers, eds. Academic Press, New York. 835–849.
76. Fabricant, J. 1998. The early history of infectious bronchitis. *Avian Dis*. 42:648–650.
77. Feberwee, A., C.J. Morrow, S.A. Ghorashi, A.H. Noormohammadi, and W.J. Landman. 2009. Effect of a live Mycoplasma synoviae vaccine on the production of eggshell apex abnormalities induced by a M. synoviae infection preceded by an infection with infectious bronchitis virus D1466. *Avian Pathol*. 38:333–340.
78. Finney, P.M., P.G. Box, and H.C. Holmes. 1990. Studies with a bivalent infectious bronchitis killed virus vaccine. *Avian Pathol*. 19:435–450.
79. Ganapathy, K., and J.M. Badbury. 1999. Pathogenicity of Mycoplasma imitans in mixed infection with infectious bronchitis virus in chickens. *Avian Pathol*. 28:229–237.
80. Geerligs, H.J., G.J. Boelm, C.A. Meinders, B.G. Stuurman, J. Symons, J. Tarres-Call, T. Bru, R. Vila, M. Mombarg, K. Karaca, W. Wijmenga, and M. Kumar. 2011. Efficacy and safety of an attenuated live QX-like infectious bronchitis virus strain as a vaccine for chickens. *Avian Pathol*. 40:93–102.
81. Gelb, J., Jr., and S.S. Cloud. 1983. Effect of serial embryo passage of an Arkansas-type avian infectious bronchitis virus isolate on clinical response, virus recovery, and immunity. *Avian Dis*. 27:679–687.
82. Gelb, J., Jr., and S.L. Killian. 1987. Serum antibody responses of chickens following sequential inoculations with different infectious bronchitis virus serotypes. *Avian Dis*. 31:513–522.
83. Gelb, J., Jr., J.K. Rosenberger, P.A. Fries, S.S. Cloud, E.M. Odor, J.E. Dohms, and J.S. Jaeger. 1989. Protection afforded infectious bronchitis virus-vaccinated sentinel chickens raised in a commercial environment. *Avian Dis*. 33:764–769.
84. Gelb, J., Jr., C.L. Keeler, Jr., W.A. Nix, J.K. Rosenberger, and S.S. Cloud. 1997. Antigenic and S-1 genomic characterization of the Delaware variant serotype of infectious bronchitis virus. *Avian Dis*. 41:661–669.

85. Gelb, J., Jr., W.A. Nix, and S.D. Gellman. 1998. Infectious bronchitis virus antibodies in tears and their relationship to immunity. *Avian Dis*. 42:364–374.
86. Gelb, J., Jr., B.S. Ladman, M.J. Licata, M.H. Shapiro, and L.R. Campion. 2007. Evaluating viral interference between infectious bronchitis virus and Newcastle disease virus vaccine strains using quantitative reverse transcription-polymerase chain reaction. *Avian Dis*. 51:924–934.
87. Gelb, J.J., and M.W. Jackwood. 2008.Infectious Bronchitis. In: *A Laboratory Manual for the Isolation, Identification, and Characterization of Avian Pathogens*, 5th ed. L. Dufour-Zavala, D.E. Swayne, J.R. Glisson, J.E. Pearson, W.M. Reed, M.W. Jackwood, and P. Woolcock, eds. American Association of Avian Pathologists, Kennett Square, PA. 146–149.
88. Gelb Jr., J., Y. Weisman, B.S. Ladman, and R. Meir. 2005. S1 gene characteristics and efficacy of vaccination against infectious bronchitis virus field isolates from the United States and Israel (1996 to 2000). *Avian Pathol*. 34:194–203.
89. Gentry, R.F., and M.O. Braune. 1972. Prevention of virus inactivation during drinking water vaccination of poultry. *Poult Sci*. 51:1450–1456.
90. Gillette, K.G. 1973. Plaque formation by infectious bronchitis virus in chicken embryo kidney cell cultures. *Avian Dis*. 17:369–378.
91. Glahn, R.P., R.F. Wideman, Jr., and B.S. Cowen. 1989. Order of exposure to high dietary calcium and Gray strain infectious bronchitis virus alters renal function and the incidence of urolithiasis. *Poult Sci*. 68:1193–1204.
92. Goren, E. 1978. Observations on experimental infection of chicks with *Escherichia coli*. *Avian Pathol*. 7:213–224.
93. Guy, J.S., J.J. Breslin, B. Breuhaus, S. Vivrette, and L.G. Smith. 2000. Characterization of a coronavirus isolated from a diarrheic foal. *J Clin Microbiol*. 38:4523–4526.
94. Hagemeijer, M.C., M.H. Verheije, M. Ulasli, I.A. Shaltiel, L.A. de Vries, F. Reggiori, P.J. Rottier, and C.A. de Haan. 2010. Dynamics of coronavirus replication-transcription complexes. *J Virol*. 84:2134–2149.
95. Hanada, K., Y. Suzuki, and T. Gojobori. 2004. A large variation in the rates of synonymous substitution for RNA viruses and its relationship to a diversity of viral infection and transmission modes. *Mol Biol Evol*. 21:1074–1080.
96. Hodgson, T., R. Casais, B. Dove, P. Britton, and D. Cavanagh. 2004. Recombinant infectious bronchitis coronavirus Beaudette with the spike protein gene of the pathogenic M41 strain remains attenuated but induces protective immunity. *J Virol*. 78:13804–13811.
97. Holmes, E.C. 2009. *The Evolution and Emergence of RNA Viruses*, 1st ed. Oxford University Press Inc., New York.
98. Hopkins, S.R., and H.W. Yoder, Jr. 1982. Influence of infectious bronchitis strains and vaccines on the incidence of Mycoplasma synoviae airsacculitis. *Avian Dis*. 26:741–752.
99. Hopkins, S.R., and H.W. Yoder, Jr. 1986. Reversion to virulence of chicken-passaged infectious bronchitis vaccine virus. *Avian Dis*. 30:221–223.
100. Huang, Y.P., and C.H. Wang. 2006. Development of attenuated vaccines from Taiwanese infectious bronchitis virus strains. *Vaccine*. 24:785–791.
101. Ignjatovic, E.J., and F. Ashton. 1996. Detection and differentiation of avian infectious bronchitis viruses using a monoclonal antibody-based ELISA. *Avian Pathol*. 25:721–736.
102. Ignjatovic, J., and L. Galli. 1994. The S1 glycoprotein but not the N or M proteins of avian infectious bronchitis virus induces protection in vaccinated chickens. *Arch Virol*. 138:117–134.
103. Jackwood, M.W., N.M. Yousef, and D.A. Hilt. 1997. Further development and use of a molecular serotype identification test for infectious bronchitis virus. *Avian Dis*. 41:105–110.
104. Jackwood, M.W., D.A. Hilt, and T.P. Brown. 2003. Attenuation, safety, and efficacy of an infectious bronchitis virus GA98 serotype vaccine. *Avian Dis*. 47:627–632.
105. Jackwood, M.W., D.A. Hilt, C.W. Lee, H.M. Kwon, S.A. Callison, K.M. Moore, H. Moscoso, H. Sellers, and S. Thayer. 2005. Data from 11 years of molecular typing infectious bronchitis virus field isolates. *Avian Dis*. 49:614–618.
106. Jackwood, M.W., D.A. Hilt, S.M. Williams, P. Woolcock, C. Cardona, and R. O'Connor. 2007. Molecular and serologic characterization, pathogenicity, and protection studies with infectious bronchitis virus field isolates from California. *Avian Dis*. 51:527–533.
107. Jackwood, M.W., D.A. Hilt, A.W. McCall, C.N. Polizzi, E.T. McKinley, and S.M. Williams. 2009. Infectious bronchitis virus field vaccination coverage and persistence of Arkansas type viruses in commercial broilers. *Avian Dis*. 53:175–183.
108. Jackwood, M.W., D.A. Hilt, H.S. Sellers, S.M. Williams, and H.N. Lasher. 2010. Rapid heat-treatment attenuation of infectious bronchitis virus. *Avian Pathol*. 39:227–233.
109. Jansen, T., M.P. Hofmans, M.J. Theelen, F. Manders, and V.E. Schijns. 2006. Structure- and oil type-based efficacy of emulsion adjuvants. *Vaccine*. 24:5400–5405.
110. Jayaram, H., H. Fan, B.R. Bowman, A. Ooi, J. Jayaram, E.W. Collisson, J. Lescar, and B.V. Prasad. 2006. X-ray structures of the N- and C-terminal domains of a coronavirus nucleocapsid protein: implications for nucleocapsid formation. *J Virol*. 80:6612–6620.
111. Jia, W., S.P. Mondal, and S.A. Naqi. 2002. Genetic and antigenic diversity in avian infectious bronchitis virus isolates of the 1940s. *Avian Dis*. 46:437–441.
112. Johnson, M.A., C. Pooley, J. Ignjatovic, and S.G. Tyack. 2003. A recombinant fowl adenovirus expressing the S1 gene of infectious bronchitis virus protects against challenge with infectious bronchitis virus. *Vaccine*. 21:2730–2736.
113. Jonassen, C.M., T. Kofstad, I.L. Larsen, A. Lovland, K. Handeland, A. Follestad, and A. Lillehaug. 2005. Molecular identification and characterization of novel coronaviruses infecting graylag geese (*Anser anser*), feral pigeons (*Columbia livia*) and mallards (*Anas platyrhynchos*). *J Gen Virol*. 86:1597–1607.
114. Jones, R.C., and F.T. Jordan. 1972. Persistence of virus in the tissues and development of the oviduct in the fowl following infection at day old with infectious bronchitis virus. *Res Vet Sci*. 13:52–60.
115. Jones, R.C., and A.G. Ambali. 1987. Re-excretion of an enterotropic infectious bronchitis virus by hens at point of lay after experimental infection at day old. *Vet Rec*. 120:617–618.
116. Jungherr, E.I., T.W. Chomiak, and R.E. Luginbuhl. 1956. Immunologic differences in strains of infectious bronchitis virus. Proc. 60th Annual Meeting U.S. Livestock Sanitary Association. 203–209.
117. Juul-Madsen, H.R., L.R. Norup, P.H. Jorgensen, K.J. Handberg, E. Wattrang, and T.S. Dalgaard. 2011. Crosstalk between innate and adaptive immune responses to infectious bronchitis virus after vaccination and challenge of chickens varying in serum mannose-binding lectin concentrations. *Vaccine*. 29:9499–9507.
118. Kant, A., G. Koch, D.J. van Roozelaar, J.G. Kusters, F.A. Poelwijk, and B.A. van der Zeijst. 1992. Location of antigenic

sites defined by neutralizing monoclonal antibodies on the S1 avian infectious bronchitis virus glycopolypeptide. *J Gen Virol*. 73:591-596.
119. Karaca, K., S. Naqi, and J. Gelb, Jr. 1992. Production and characterization of monoclonal antibodies to three infectious bronchitis virus serotypes. *Avian Dis*. 36:903–915.
120. Karaca, K., and S. Naqi. 1993. A monoclonal antibody blocking ELISA to detect serotype-specific infectious bronchitis virus antibodies. *Vet Microbiol*. 34:249–257.
121. Keeler, C.L., Jr., K.L. Reed, W.A. Nix, and J. Gelb, Jr. 1998. Serotype identification of avian infectious bronchitis virus by RT-PCR of the peplomer (S-1) gene. *Avian Dis*. 42:275–284.
122. Kingham, B.F., C.L. Keeler, Jr., W.A. Nix, B.S. Ladman, and J. Gelb, Jr. 2000. Identification of avian infectious bronchitis virus by direct automated cycle sequencing of the S-1 gene. *Avian Dis*. 44:325–335.
123. Kleven, S.H., D.D. King, and D.P. Anderson. 1972. Airsacculitis in broilers from Mycoplasma synoviae: effect on air-sac lesions of vaccinating with infectious bronchitis and Newcastle virus. *Avian Dis*. 16:915–924.
124. Klieve, A.V., and R.B. Cumming. 1988. Immunity and cross-protection to nephritis produced by Australian infectious bronchitis viruses used as vaccines. *Avian Pathol*. 17:829–839.
125. Koch, G., L. Hartog, A. Kant, and D.J. van Roozelaar. 1990. Antigenic domains on the peplomer protein of avian infectious bronchitis virus: correlation with biological functions. *J Gen Virol*. 71:1929–1935.
126. Kwon, H.M., M.W. Jackwood, and J. Gelb. 1993. Differentiation of infectious-bronchitis virus serotypes using polymerase chain-reaction and restriction-fragment-length-polymorhism analysis. *Avian Dis*. 37:194–202.
127. Ladman, B.S., C.R. Pope, A.F. Ziegler, T. Swieczkowski, C.J. Callahan, S. Davison, and J. Gelb, Jr. 2002. Protection of chickens after live and inactivated virus vaccination against challenge with nephropathogenic infectious bronchitis virus PA/Wolgemuth/98. *Avian Dis*. 46:938–944.
128. Ladman, B.S., A.B. Loupos, and J. Gelb, Jr. 2006. Infectious bronchitis virus S1 gene sequence comparison is a better predictor of challenge of immunity in chickens than serotyping by virus neutralization. *Avian Pathol*. 35:127–133.
129. Lambrechts, C., M. Pensaert, and R. Ducatelle. 1993. Challenge experiments to evaluate cross-protection induced at the trachea and kidney level by vaccine strains and Belgian nephropathogenic isolates of avian infectious bronchitis virus. *Avian Pathol*. 22:577–590.
130. Landman, W.J., and A. Feberwee. 2004. Aerosol-induced Mycoplasma synoviae arthritis: the synergistic effect of infectious bronchitis virus infection. *Avian Pathol*. 33:591–598.
131. Lee, C.W., D.A. Hilt, and M.W. Jackwood. 2000. Redesign of primer and application of the reverse transcriptase-polymerase chain reaction and restriction fragment length polymorphism test to the DE072 strain of infectious bronchitis virus. *Avian Dis*. 44:650–654.
132. Lee, C.W., and M.W. Jackwood. 2000. Evidence of genetic diversity generated by recombination among avian coronavirus IBV. *Arch Virol*. 145:2135–2148.
133. Lee, C.W., D.A. Hilt, and M.W. Jackwood. 2003. Typing of field isolates of infectious bronchitis virus based on the sequence of the hypervariable region in the S1 gene. *J Vet Diagn Invest*. 15:344–348.
134. Lin, Z., A. Kato, Y. Kudou, and S. Ueda. 1991. A new typing method for the avian infectious bronchitis virus using polymerase chain reaction and restriction enzyme fragment length polymorphism. *Arch Virol*. 116:19–31.
135. Lister, S.A., J.V. Beer, R.E. Gough, R.G. Holmes, J.M. Jones, and R.G. Orton. 1985. Outbreaks of nephritis in pheasants (*phasianus colchicus*) with a possible coronavirus aetiology. *Vet Rec*. 117:612–613.
136. Loa, C.C., T.L. Lin, C.C. Wu, T.A. Bryan, H.L. Thacker, T. Hooper, and D. Schrader. 2000. Detection of antibody to turkey coronavirus by antibody-capture enzyme-linked immunosorbent assay utilizing infectious bronchitis virus antigen. *Avian Dis*. 44:498–506.
137. Loomis, L.N., C.H. Cunningham, M.L. Gray, and F. Thorp, Jr. 1950. Pathology of the chicken embryo infected with infectious bronchitis virus. *Am J Vet Res*. 11:245–251.
138. Lucio, B., and J. Fabricant. 1990. Tissue tropism of three cloacal isolates and Massachusetts strain of infectious bronchitis virus. *Avian Dis*. 34:865–870.
139. Lukert, P.D. 1965. Comparative sensitivities of embryonating chicken's eggs and primary chicken embryo kidney and liver cell cultures to infectioius bronchitis virus. *Avian Dis*. 9:308–316.
140. Macdonald, J.W., C.J. Randall, and D.A. McMartin. 1980. An inverse age resistance of chicken kidneys to infectious bronchitis virus. *Avian Pathol*. 9:245–259.
141. Macdonald, J.W., C.J. Randall, D.A. McMartin, M.D. Dagless, and P. Gazdzinski. 1981. Active and passive immunisation against nephritis induced by an avian infectious bronchitis virus. *Avian Pathol*. 10:121–129.
142. Marquardt, W.W., D.B. Snyder, and B.A. Schlotthober. 1981. Detection and quantification of antibodies to infectious bronchitis virus by enzyme-linked immunosorbent assay. *Avian Dis*. 25:713–722.
143. Matthijs, M.G., J.H. van Eck, W.J. Landman, and J.A. Stegeman. 2003. Ability of Massachusetts-type infectious bronchitis virus to increase colibacillosis susceptibility in commercial broilers: a comparison between vaccine and virulent field virus. *Avian Pathol*. 32:473–481.
144. Matthijs, M.G., J.H. van Eck, J.J. de Wit, A. Bouma, and J.A. Stegeman. 2005. Effect of IBV-H120 vaccination in broilers on colibacillosis susceptibility after infection with a virulent Massachusetts-type IBV strain. *Avian Dis*. 49:540–545.
145. Matthijs, M.G., A. Bouma, F.C. Velkers, J.H. van Eck, and J.A. Stegeman. 2008. Transmissibility of infectious bronchitis virus H120 vaccine strain among broilers under experimental conditions. *Avian Dis*. 52:461–466.
146. Meir, R., S. Krispel, L. Simanov, D. Eliahu, O. Maharat, and J. Pitcovski. 2012. Immune responses to mucosal vaccination by the recombinant A1 and N proteins of infectious bronchitis virus. *Viral Immunol*. 25:55–62.
147. Mihindukulasuriya, K.A., G. Wu, J. St. Leger, R.W. Nordhausen, and D. Wang. 2008. Identification of a novel coronavirus from a beluga whale by using a panviral microarray. *J Virol*. 82:5084–5088.
148. Minskaia, E., T. Hertzig, A.E. Gorbalenya, V. Campanacci, C. Cambillau, B. Canard, and J. Ziebuhr. 2006. Discovery of an RNA virus 3′->5′ exoribonuclease that is critically involved in coronavirus RNA synthesis. *Proc Natl Acad Sci USA*. 103:5108–5113.
149. Mockett, A.P., and J.H. Darbyshire. 1981. Comparative studies with an enzyme-linked immunosorbent assay (ELISA) for antibodies to avian infectious bronchitis virus. *Avian Pathol*. 10:1–10.

150. Mockett, A.P., J.K. Cook, and M.B. Huggins. 1987. Maternally derived antibody to infectious bronchitis virus: Its detection in chick trachea and serum and its role in protection. *Avian Pathol*. 16:407–416.
151. Mondal, S.P., and S.A. Naqi. 2001. Maternal antibody to infectious bronchitis virus: its role in protection against infection and development of active immunity to vaccine. *Vet Immunol Immunopathol*. 79:31–40.
152. Moore, K.M., M.W. Jackwood, and D.A. Hilt. 1997. Identification of amino acids involved in a serotype and neutralization specific epitope within the s1 subunit of avian infectious bronchitis virus. *Arch Virol*. 142:2249–2256.
153. Moore, K.M., J.D. Bennett, B.S. Seal, and M.W. Jackwood. 1998. Sequence comparison of avian infectious bronchitis virus S1 glycoproteins of the Florida serotype and five variant isolates from Georgia and California. *Virus Genes*. 17:63–83.
154. Naqi, S., K. Gay, P. Patalla, S. Mondal, and R. Liu. 2003. Establishment of persistent avian infectious bronchitis virus infection in antibody-free and antibody-positive chickens. *Avian Dis*. 47:594–601.
155. Nix, W.A., D.S. Troeber, B.F. Kingham, C.L. Keeler, Jr., and J. Gelb, Jr. 2000. Emergence of subtype strains of the Arkansas serotype of infectious bronchitis virus in Delmarva broiler chickens. *Avian Dis*. 44:568–581.
156. Otsuki, K., K. Noro, H. Yamamoto, and M. Tsubokura. 1979. Studies on avian infectious bronchitis virus (IBV). II. Propagation of IBV in several cultured cells. *Arch Virol*. 60:115–122.
157. Otsuki, K., M.B. Huggins, and J.K. Cook. 1990. Comparison of the susceptibility to avian infectious bronchitis virus infection of two inbred lines of white leghorn chickens. *Avian Pathol*. 19:467–475.
158. Pejkovski, C., F.G. Davelaar, and B. Kouwenhoven. 1979. Immunosuppressive effect of infectious bursal disease virus on vaccination against infectious bronchitis. *Avian Pathol*. 8:95–106.
159. Pensaert, M., and C. Lambrechts. 1994. Vaccination of chickens against a Belgian nephropathogenic strain of infectious bronchitis virus B1648 using attenuated homologous and heterologous strains. *Avian Pathol*. 23:631–641.
160. Perlman, S., T. Gallagher, and E.J. Snijder. 2008. *Nidoviruses*. ASM Press, Washington, DC.
161. Rabenau, H.F., J. Cinatl, B. Morgenstern, G. Bauer, W. Preiser, and H.W. Doerr. 2005. Stability and inactivation of SARS coronavirus. *Med Microbiol Immunol*. 194:1–6.
162. Raggi, L.G., D.C. Young, and J.M. Sharma. 1967. Synergism between avian infectious bronchitis virus and Haemophilus gallinarum. *Avian Dis*. 11:308–321.
163. Raggi, L.G., and G.G. Lee. 1963. Infectious bronchitis virus interference with growth of Newcastle disease virus. I. study of interference in chicken embryos. *Avian Dis*. 7:106–122.
164. Raj, G.D., and R.C. Jones. 1997. Infectious bronchitis virus: Immunopathogenesis of infection in the chicken. *Avian Pathol*. 26:677–706.
165. Riddell, C. 1987. *Avian Histopathology*. American Association of Avian Pathology, Kennett Square, PA.
166. Rosenberger, J.K., and J. Gelb, Jr. 1978. Response to several avian respiratory viruses as affected by infectious bursal disease virus. *Avian Dis*. 22:95–105.
167. Ruano, M., J. El-Attrache, and P. Villegas. 2000. A rapid-plate hemagglutination assay for the detection of infectious bronchitis virus. *Avian Dis*. 44:99–104.
168. Ruch, T.R., and C.E. Machamer. 2011. The hydrophobic domain of infectious bronchitis virus E protein alters the host secretory pathway and is important for release of infectious virus. *J Virol*. 85:675–685.
169. Schalk, A.F., and M.C. Hawn. 1931. An apparent new respiratory disease of baby chicks. *J Am Vet Med Assoc*. 78:413–422.
170. Seo, S.H., and E.W. Collisson. 1997. Specific cytotoxic T lymphocytes are involved in *in vivo* clearance of infectious bronchitis virus. *J Virol*. 71:5173–5177.
171. Seo, S.H., J. Pei, W.E. Briles, J. Dzielawa, and E.W. Collisson. 2000. Adoptive transfer of infectious bronchitis virus primed alphabeta T cells bearing CD8 antigen protects chicks from acute infection. *Virology*. 269:183–189.
172. Sevoian, M., and P.P. Levine. 1957. Effects of infectious bronchitis on the reproductive tracts, egg production and egg quality of laying chickens. *Avian Dis*. 1:136–164.
173. Shi, X.M., Y. Zhao, H.B. Gao, Z. Jing, M. Wang, H.Y. Cui, G.Z. Tong, and Y.F. Wang. 2011. Evaluation of recombinant fowlpox virus expressing infectious bronchitis virus S1 gene and chicken interferon-gamma gene for immune protection against heterologous strains. *Vaccine*. 29:1576–1582.
174. Siller, W.G. 1981. Renal pathology of the fowl—a review. *Avian Pathol*. 10:187–262.
175. Smith, H.W., J.K. Cook, and Z.E. Parsell. 1985. The experimental infection of chickens with mixtures of infectious bronchitis virus and Escherichia coli. *J Gen Virol*. 66 (Pt 4):777–786.
176. Song, C.S., Y.J. Lee, C.W. Lee, H.W. Sung, J.H. Kim, I.P. Mo, Y. Izumiya, H.K. Jang, and T. Mikami. 1998. Induction of protective immunity in chickens vaccinated with infectious bronchitis virus S1 glycoprotein expressed by a recombinant baculovirus. *J Gen Virol*. 79:719–723.
177. Stern, D.F., and B.M. Sefton. 1982. Coronavirus proteins: Biogenesis of avian infectious bronchitis virus virion proteins. *J Virol*. 44:794–803.
178. Terregino, C., A. Toffan, M.S. Beato, R. De Nardi, M. Vascellari, A. Meini, G. Ortali, M. Mancin, and I. Capua. 2008. Pathogenicity of a QX strain of infectious bronchitis virus in specific pathogen free and commercial broiler chickens, and evaluation of protection induced by a vaccination programme based on the Ma5 and 4/91 serotypes. *Avian Pathol*. 37:487–493.
179. Thor, S.W., D.A. Hilt, J.C. Kissinger, A.H. Paterson, and M.W. Jackwood. 2011. Recombination in avian gamma-coronavirus infectious bronchitis virus. *Viruses*. 3:1777–1799.
180. Thornton, D.H., and J.C. Muskett. 1973. Comparison of immunity to Newcastle disease after vaccination with Newcastle disease vaccine given alone or together with infectious bronchitis vaccine. *Vet Rec*. 92:373–374.
181. Thornton, D.H., and J.C. Muskett. 1975. Effect of infectious bronchitis vaccination on the performance of live Newcastle disease vaccine. *Vet Rec*. 96:467–468.
182. Toro, H., P. Lavaud, P. Vallejos, and A. Ferreira. 1993. Transfer of IgG from serum to lachrymal fluid in chickens. *Avian Dis*. 37:60–66.
183. Toro, H., E. Reyes, T. Redmann, and E.F. Kaleta. 1996. Local and systemic specific antibody response of different chicken lines after ocular vaccination against infectious bronchitis. *Zentralbl Veterinarmed B*. 43:449–454.
184. Toro, H., V.L. van Santen, L. Li, S.B. Lockaby, E. van Santen, and F.J. Hoerr. 2006. Epidemiological and experimental evidence for immunodeficiency affecting avian infectious bronchitis. *Avian Pathol*. 35:455–464.

185. van Eck, J.H. 1983. Effects of experimental infection of fowl with EDS'76 virus, infectious bronchitis virus and/or fowl adenovirus on laying performance. *Vet Q*. 5:11–25.
186. van Roeckel, H., K.L. Bullis, O.S. Flint, and M.K. Clarke. 1942. Poultry disease control service. Massachusetts Agricultural Experiment Station, MA. Annual Report. *Bulletin*. 388:99–103.
187. Wang, X., A.J. Rosa, H.N. Oliverira, G.J. Rosa, X. Guo, M. Travnicek, and T. Girshick. 2006. Transcriptome of local innate and adaptive immunity during early phase of infectious bronchitis viral infection. *Viral Immunol*. 19:768–774.
188. Wang, Y.D., Y.L. Wang, Z. Zhang, G. Fan, Y. Jlang, X. Liu, J. Ding, and S. Wang. 1998. Isolation and identification of glandular stomach type IBV (QX IBV) in chickens. *Chin J Anim Quar*. 15:1–3.
189. Wickramasinghe, I.N., R.P. de Vries, A. Grone, C.A. de Haan, and M.H. Verheije. 2011. Binding of avian coronavirus spike proteins to host factors reflects virus tropism and pathogenicity. *J Virol*. 85:8903–8912.
190. Winterfield, R.W., and S.B. Hitchner. 1962. Etiology of an infectious nephritis-nephrosis syndrome of chickens. *Am J Vet Res*. 23:1273–1278.
191. Winterfield, R.W. 1968. Respiratory signs, immunity response, and interference from vaccination with monovalent and multivalent infectious bronchitis vaccines. *Avian Dis*. 12:577–584.
192. Winterfield, R.W., F.J. Hoerr, and A.M. Fadly. 1978. Vaccination against infectious bronchitis and the immunosuppressive effects of infectious bursal disease. *Poult Sci*. 57:386–391.
193. Winterfield, R.W., and M.A. Albassam. 1984. Nephropathogenicity of infectious bronchitis virus. *Poult Sci*. 63:2358–2363.
194. Woo, P.C., S.K. Lau, C.S. Lam, K.K. Lai, Y. Huang, P. Lee, G.S. Luk, K.C. Dyrting, K.H. Chan, and K.Y. Yuen. 2009. Comparative analysis of complete genome sequences of three avian coronaviruses reveals a novel group 3c coronavirus. *J Virol*. 83:908–917.
195. Yu, L., Y. Jiang, S. Low, Z. Wang, S.J. Nam, W. Liu, and J. Kwangac. 2001. Characterization of three infectious bronchitis virus isolates from China associated with proventriculus in vaccinated chickens. *Avian Dis*. 45:416–424.
196. Zeshan, B., M.H. Mushtaq, X. Wang, W. Li, and P. Jiang. 2011. Protective immune responses induced by *in ovo* immunization with recombinant adenoviruses expressing spike (S1) glycoprotein of infectious bronchitis virus fused/co-administered with granulocyte-macrophage colony stimulating factor. *Vet Microbiol*. 148:8–17.
197. Ziegler, A.F., B.S. Ladman, P.A. Dunn, A. Schneider, S. Davison, P.G. Miller, H. Lu, D. Weinstock, M. Salem, R.J. Eckroade, and J. Gelb, Jr. 2002. Nephropathogenic infectious bronchitis in Pennsylvania chickens 1997–2000. *Avian Dis*. 46:847–858.

Chapter 5

Infectious Laryngotracheitis

Maricarmen García, Stephen Spatz, and James S. Guy

Introduction

Infectious laryngotracheitis (ILT) is a respiratory tract infection of chickens caused by *Gallid herpesvirus type 1* (GaHV-1). This virus may cause severe production losses due to mortality and/or decreased egg production. Severe epizootic forms of infection are characterized by signs of respiratory distress including gasping and expectoration of bloody mucus, with high morbidity and moderate-to-high mortality. Milder enzootic forms of infection are encountered increasingly in developed poultry industries and manifest variously as mucoid tracheitis, sinusitis, conjunctivitis, general unthriftiness, and low mortality. *Gallid herpesvirus type 1* is a pathogen selected for exclusion from specific pathogen free (SPF) chicken flocks.

Economic Significance

The economic significance of ILT has not been precisely determined. However, the U.S. poultry industry can expect to experience multimillion dollar losses each year as a consequence of GaHV-1-induced mortality and decreased egg production. Similar losses are likely to occur in intensive poultry industries of other countries.

Public Health Significance

No evidence suggests that GaHV-1 is transmissible to human beings and other mammals.

History

The disease was first described in 1925 (102) and it has been given several different names including laryngotracheitis, infectious laryngotracheitis, and avian diphtheria. Some early investigators also referred to the disease as infectious bronchitis. The term laryngotracheitis was used as early as 1930 (7, 56). The Special Committee on Poultry Diseases of the American Veterinary Medical Association adopted the name infectious laryngotracheitis in 1931. The cause of ILT was first shown to be a filterable virus by Beaudette (8). Subsequently, in 1934, Brandly and Bushnell devised a method for immunization of chickens based on application of virulent virus to the cloaca (10). Infectious laryngotracheitis was the first avian viral disease for which an effective vaccine was developed.

Etiology

Classification

The causative agent of ILT is *Gallid herpesvirus type 1* (GaHV-1), a member of the genus *Iltovirus*, subfamily *alphaherpesviridae* of the *Herpesviridae* family (30, 146) within the order *Herpesvirales*. Based on complete genome comparisons other alphaherpesvirus, *Psittacid herpesvirus type 1 (PsHV-1)*, belongs to the genus *Iltovirus*. This member is the causative agent of Pacheco's disease, a lethal respiratory infection of psittacine birds.

Morphology

Early electron micrographs of GaHV-1-infected chicken embryo cells demonstrated the presence of nucleocapsids with icosahedral symmetry similar to those of human herpes simplex virus Type 1 (HHV-1) (157). The hexagonal nucleocapsids measure 80–100 nm in diameter and the complete virus particle consist of an irregular envelope surrounding the nucleocapsid with a diameter of 195–250 nm (29, 157). The envelope has characteristic surface projections identified as surface glycoprotein spikes localized by immunoelectron microscopy studies (Figure 5.1A and B) (47). Electron microscopy analysis of GaHV-1-infected cells has shown the morphogenesis of viral capsids egressing from the nucleus, acquiring the primary envelopment at the nuclear membrane (Figure 5.2A and B). While in the trans-Golgi region of the cytoplasm, mature capsids are formed by the incorporation of the tegument material (Figure 5.2C) and secondary envelopment (Figure 5.2D and F). Mature virions are released from cells by exocytosis (Figure 5.2 F) (47).

Diseases of Poultry, Thirteenth Edition. David E. Swayne.
© 2013 John Wiley & Sons, Inc. Published 2013 by John Wiley & Sons, Inc.

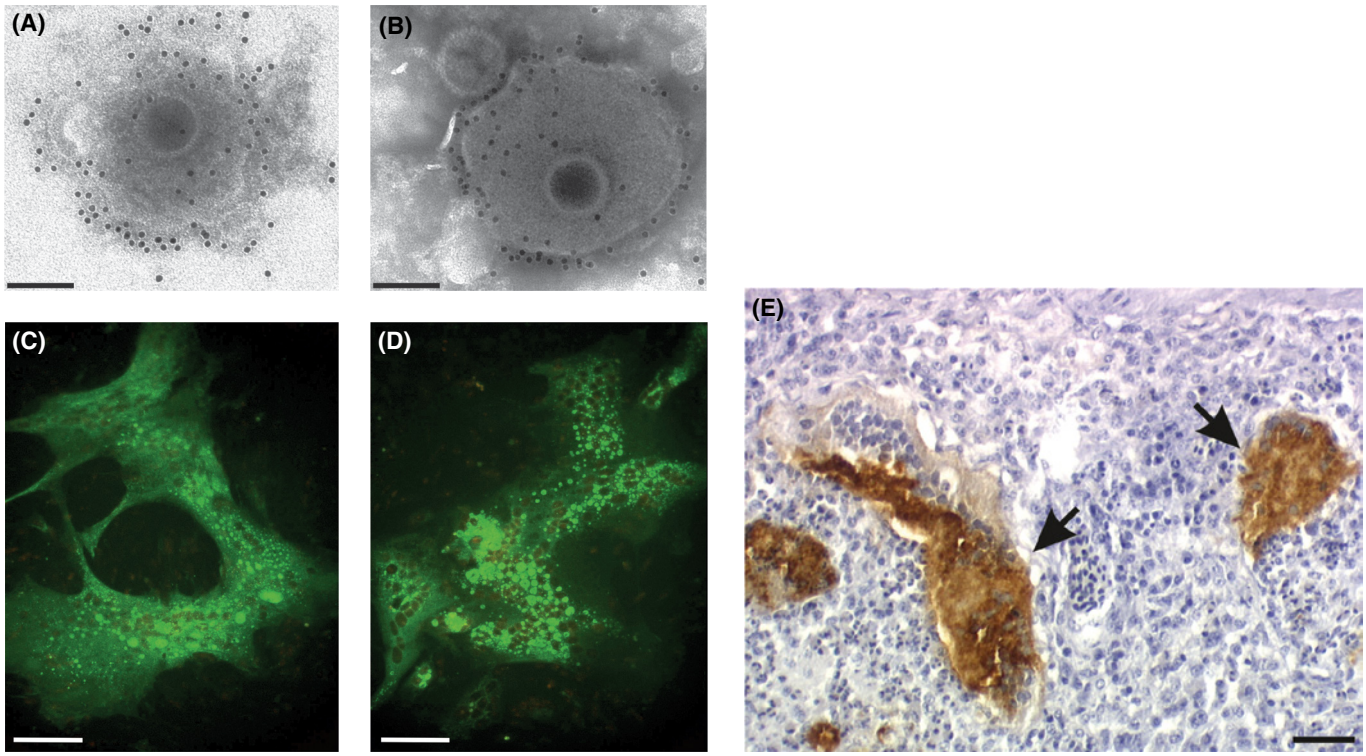

Figure 5.1. GaHV-1 reactivity to monoclonal antibodies (MAb) against viral glycoproteins gC and gJ. (A and B) Immunoelectron microscopy of purified GaHV-1. Virus particles were stained with phosphotungstic acid, and virions surface envelope glycoproteins detected by anti-gC MAb (A) and anti-gJ (B) followed by gold-tagged secondary antibodies. (C and D) Indirect immunofluorescence assay in infected chicken kidney cells fixed 24 hours after infection with methanol and acetone (1:1). MAb binding was detected with fluorescein-conjugated secondary antibodies, and chromatin was counterstained with propidium iodide. (E) Immunohistochemical staining of a lung section from a GaHV-1-infected chicken was performed by the ABC method. A gJ-specific MAb detected viral antigen in the cytoplasm of several syncytia (arrows). Bars represent 150 nm (A and B), 100 µm (C and D), and 50 µm (E). (Used with permission Fuchs 2007)

Chemical Composition

As a member of the *Herpesviridae* family, the GaHV-1 genome is a linear double-stranded DNA molecule. Initial restriction mapping revealed that the GaHV-1 genome is composed of a unique long (U_L) and unique short (U_S) region flanked by inverted repeats (80); this genome composition allows for the formation of two isomeric forms with differently oriented U_S regions (95). Comparisons of avian herpesvirus genomes revealed that GaHV-1 and PsHV-1 represent a unique clade of avian herpesviruses that are distinct from the Marek's disease-like viruses members of the genus *Mardivirus*, and belong to the *Iltovirus* genus (146).

The first published GaHV-1 complete genome was assembled from overlapping genomic fragments of different GaHV-1 strains. This composite genome sequence had a length of 148,687 base pairs (bp) with a G/C content of 48.2% 154. A total of 79 open reading frames (ORFs) were predicted: 64 located within the U_L, 8 within the U_S, 6 within the inverted repeats, and 1 spanning the U_S/TR_S junction. With the exception of 8 ORFs (Figure 5.3, ORFs A, B, C, D, E, F, U_L-0 and U_L-1) that are unique to the members of the *Iltoviruses*, the majority of the remaining ORFs are homologues to genes of other alphapherpesviruses. Like other alphaherpesviruses, GaHV-1 contains three origins of viral DNA replication: *Ori*L located within the U_L region and the diploid *Ori*S located in the inverted repeats. The order of the genes within the genomes of GaHV-1 and PsHV-1 is similar to that of other alphaherpesviruses. The unique long segment is inverted with respect to other type-D genomes and contains an additional inversion of the conserved genes U_L22 to U_L44 after a block of 5 unique ORFs (ORFs A–E) (153). This inversion is similar to the U_L27–U_L44 inversion found in the genome of the porcine herpesvirus pseudorabies (169). Another interesting difference within the GaHV-1 genome is the location of the HHV-1 UL47 homologue (Sorf1, Figure 5.3) within the unique short region.

Recently comparative sequence analysis of GaHV-1 genomes for both vaccine and virulent strains was reported. Lee and co-workers published the complete noncomposite sequence of chicken embryo origin (CEO) live attenuated vaccine known as the Serva strain. Considerable differences in the size of the predicted translation products of six genes (U_L29, U_L30, U_L36, U_L37, U_L38, and U_L54) were reported between the Serva vaccine and the composite genome (94). Additional nucleotide sequences of four virulent strains (the USDA reference strain, 63140,

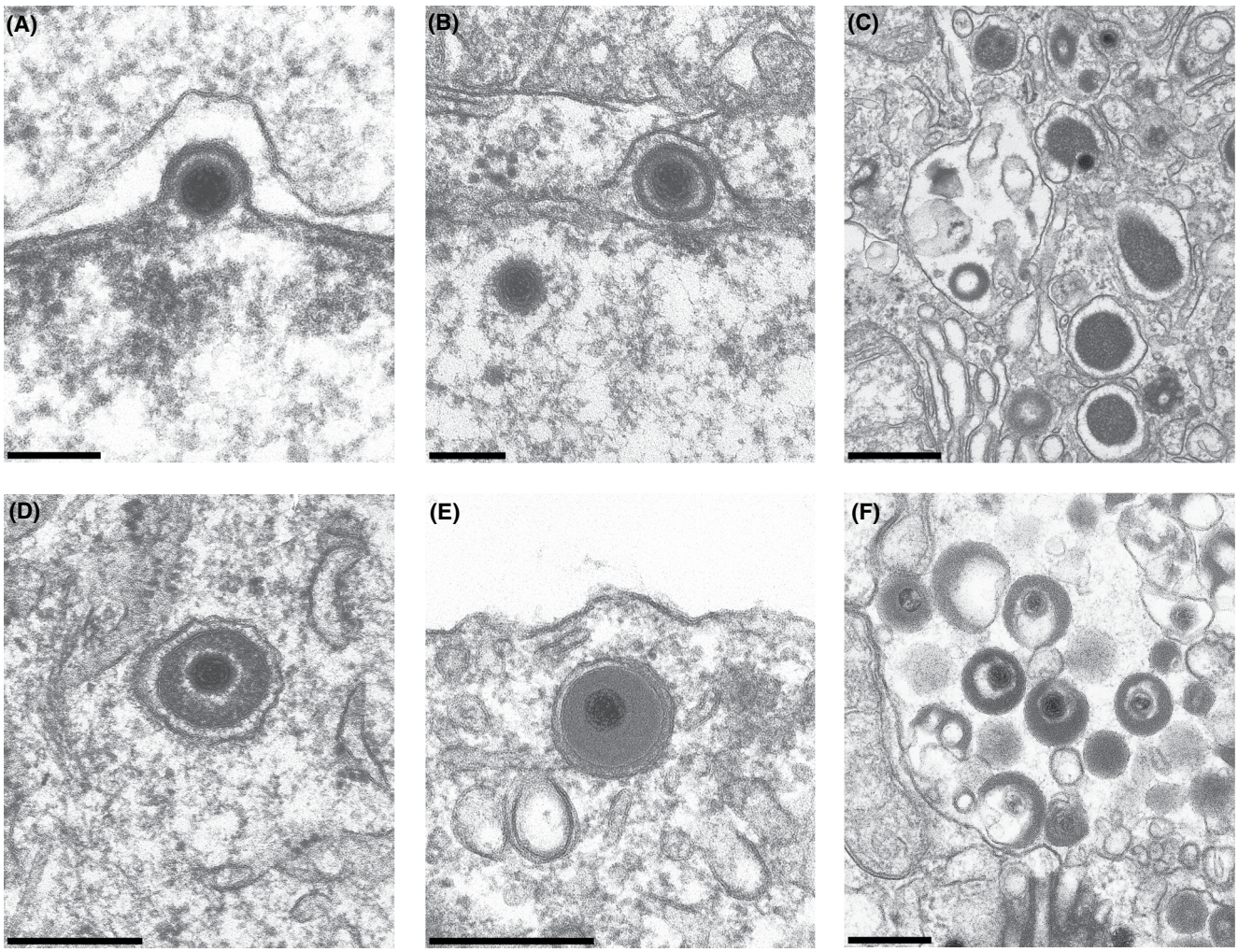

Figure 5.2. Electron microscopy of GaHV-1 morphogenesis. Chicken hepatoma (LMH) cells were fixed and embedded 18 hours after infection, and ultrathin sections were stained with uranyl acetate and lead salts. The micrographs show nuclear egress by primary envelopment of capsids at the nuclear membrane (A and B), and formation of mature and capsid-less particles by assembly of tegument and secondary envelopment in the trans-Golgi region of the cytoplasm (C and D). Virions are released from cells by exocytosis (E and F). Bars represent 150 nm (A and B), 500 nm (C), and 300 nm (D, E, and F). (Modified and used with permission of Fuchs 2007)

1874C5, and 81658) were published in 2011 (144). In addition to the gene length differences (94), 10 genes (U_L56, ORFF, U_L53, U_L25, U_L31, U_L39, U_L41, U_L42, U_L43, and ICP4) were reported to differ relative to those found in the composite genome (144). Two large deletions located at the 5 termini of the U_L region and the unique short/repeat junction were identified in some virulent strains. Only four ORFs (ORFC, U_L37, ICP4, and U_S2) differed in amino acid lengths among the four virulent sequenced genomes. The exact termini and the sequences involved in cleavage and packaging of the GaHV-1 genomes (e.g., *pac*-1 and *pac*-2) were determined and redefined the junction between the U_L and IR_S segments, as well as the total length of the GaHV-1 genome. On average, the total length of the GaHV-1 genome is 151,607 nt with unique long and unique short regions of 111,275 and 13,094 nt, respectively, and 13,619 nt comprising the inverted repeats (144). Figure 5.3 shows a schematic diagram of the complete genome for virulent isolate GaHV-1 63140, previously genotyped as closely related to the CEO vaccines (144).

Besides protein encoding genes, the genome of GaHV-1 also encodes short RNAs (approximately 22 nt) known as microRNAs. A total of ten microRNAs have been identified and map to two regions of the genome (127, 156). The genes encoding miR-l1-5p, miR-l1-3p, mIR-l2-5p, mIR-l3-3p, and mIRl4-5p cluster at the 5' termini of the genome in a region devoid of large ORFs. One microRNA, miR-l7-3p, maps to the binding site of the origin-binding protein U_L9 within the stem-loop sequence of the origin of replication (*Ori*L). Four microRNA mir-l6-3p, mIR-l6-5p, mIR-l5-3p, and mIR-l5-5p, were mapped to the gene encoding the immediate early protein ICP4. The roles of these microRNAs in the silencing of viral or host transcription/translation are generally unknown. However, Waidner and co-workers (155) provided convincing evidence that synthetic mimics of mIR-l5 and

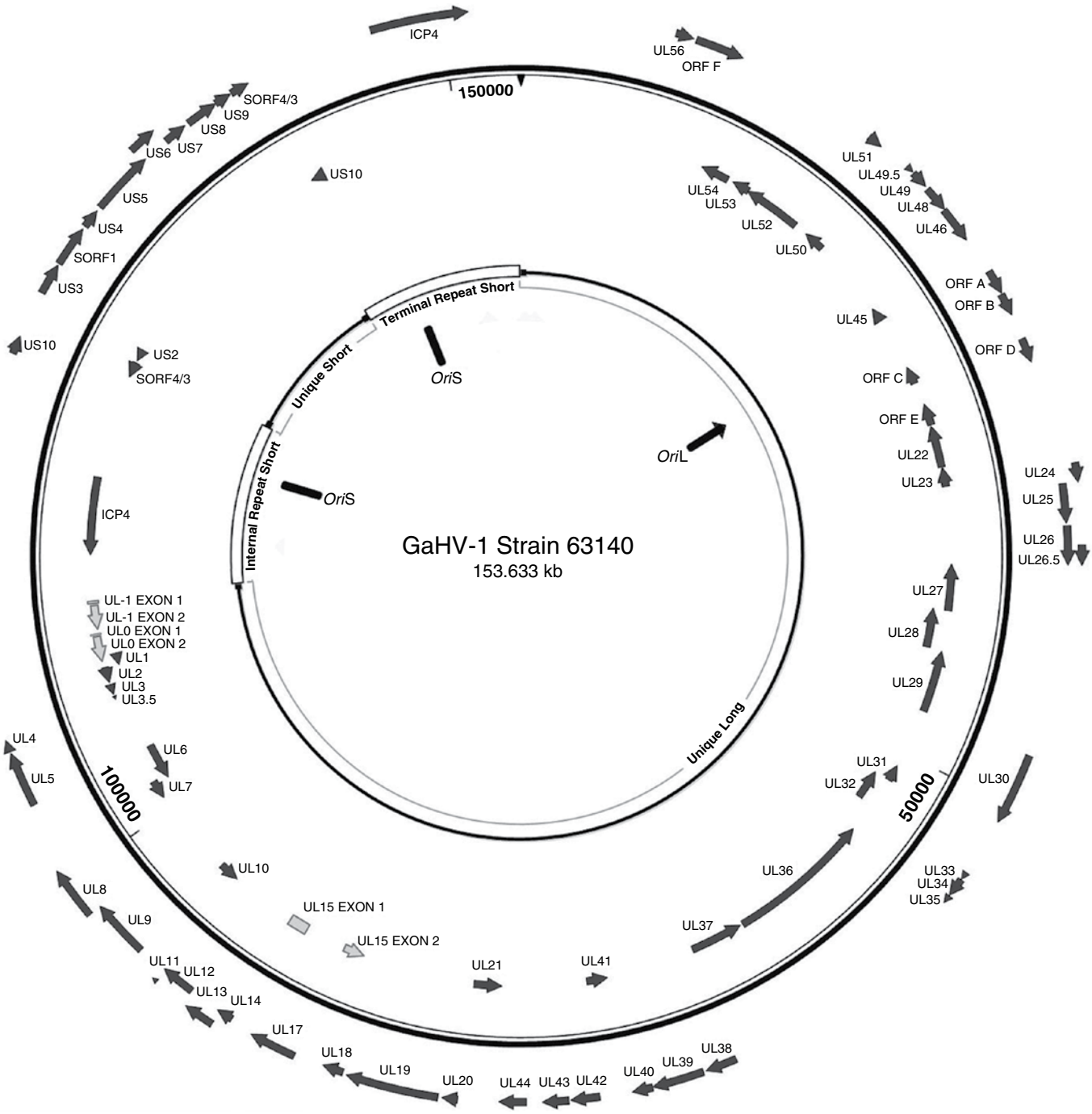

Figure 5.3. Genomic organization of the GaHV-1 strain 63140. The terminal and internal repeat short regions, the unique long region, and the unique short region are shown in the inner circle. The positions of the origins of DNA replication (OriL and OriS) are indicated by a black arrow and black bars, respectively, within the inner circle. Black arrows bracketing the outer circle represent the locations and directions of transcription of the respective open reading frames. The exons of spliced gene products are shown as open gray boxes and gray arrows (Stephen Spatz).

mIR-l6 can reduce the expression of ICP4 by direct binding and cleavage of ICP4 mRNA. For a more detailed review on the molecular biology of GaHV-1 see the review article by Fuchs et al. (47).

In addition to their roles in host range and pathogenicity, the glycoproteins of GaHV-1 are immunogenic and responsible for stimulating humoral and cell-mediated immune responses (165, 167, 168). Twelve HHV-1 homologues glycoprotein-coding genes have been identified in the GaHV-1 genome and are designated gK, gN, gH, gB, gC, gM, gL, gG, gJ, gD, gI, and gE (146). Functional HHV-1 homologues of glycoproteins gB (122, 123), gC (88, 151), gN (46), and gJ (48) have

been identified in GaHV-1-infected cells and virions. Like gG homologues of other alphaherpesviruses, the gG product of GaHV-1 is not incorporated in the virus particle but secreted from infected cells (91). Unlike other gM homologues, the gM product of GaHV-1 is not modified by glycosylation (45). Based on chicken antibody responses and the monoclonal antibodies raised in various laboratories, glycoproteins J and C have been identified as the most immunogenic surface proteins of GaHV-1 (48, 152). Major tegument proteins and nonstructural protein U_L31 also were identified using monospecific antisera (65). For further information on the identified gene products refer to Fuchs et al. (47).

Virus Replication

Replication of GaHV-1 appears to be similar to that of other alphaherpesviruses such as HHV-1 (133). GaHV-1 initiates infection by attachment followed by fusion of the envelope with the host cell plasma membrane. The nucleocapsid is released into the cytoplasm and transported to the nuclear membrane. Viral DNA is released from the nucleocapsid and migrates into the nucleus through nuclear pores. Transcription and replication of viral DNA occur within the nucleus (58).

The traditional paradigm classifies gene expression in HHV-1-infected cells into classes—immediate-early (IE), early (E), and late (L)—according to their order of expression during infection and their dependence on prior transcription or DNA replication (133). In a recent study, the transcription of all GaHV-1 genes was evaluated and, showed that transcription kinetics of GaHV-1 genes was not strictly maintained and appeared quite "leaky" as transcripts from most of the genes could be detected within 1 hour PI (100). This study concluded that GaHV-1 gene transcription is subjected to more complex patterns of regulation than those classically described for HHV-1. GaHV-1 transcripts were categorized into immediate-early (IE), early (E), early-late (E/L), and late (L) (100). The transcription of 74 GaHV-1 genes was confirmed, several are enzymes and DNA-binding proteins that regulate viral DNA replication, but most are viral structural proteins including capsid, tegument, and envelope glycoproteins (100).

Following DNA replication concatemeric virus DNA is cleaved into unit lengths and encapsulated into nucleocapsids. DNA-filled nucleocapsids acquire an envelope by migration through the inner lamellae of the nuclear membrane (58, 104). Enveloped particles then migrate through the endoplasmic reticulum and accumulate within vacuoles in the cytoplasm. Enveloped virions are released by cell lysis or by vacuolar membrane fusion and exocytosis (58, 104).

Susceptibility to Chemical and Physical Agents

Most of the initial GaHV-1 thermostability studies were done under laboratory conditions using fresh and desiccated tracheal exudates, trachea from carcasses, chorioallantoic membranes of embryos, and virus diluted in glycerol and nutrient broth (83). GaHV-1 was able to survive in tracheal exudates and chicken carcasses for periods of 10–100 days at ambient temperatures of 13°C–23°C. Later studies showed that the infectivity of GaHV-1 was rapidly inactivated by heat, from 15 minutes to one hour when exposed to 55°C or 56°C, or for 48 hours when exposed to 38°C (87, 109). In more applied field studies, Jordan et al. (82) demonstrated that the virus was vulnerable to light exposure, and survived for four days in moist litter, and for 20 days in dry-dusty litter at temperatures ranging from 11°C–24.5°C. In droppings held at temperatures ranging from 11°C–19.5°C, the virus survived for three days (84).

As expected of an enveloped virus, GaHV-1 was sensitive to the effects of lipolytic agents such as chloroform and ether (44, 105), and the virus was readily destroyed by common disinfectants (138). Under laboratory conditions a solution of 5% phenol, 3% cresol, or 1% sodium hydroxide inactivated GaHV-1 in less than one minute (138), The efficacy of commercially available disinfectants to inactivate GaHV-1 was decreased considerably by the presence of organic matter (134). Improved efficiency of disinfection was achieved when 5% hydrogen peroxide mist was applied to poultry equipment (109).

Virus levels in GaHV-1-contaminated poultry litter were significantly reduced by either heating the house to 38°C for 24 hours, by treating the litter with commercially available poultry litter treatments, or by composting the litter (54). Use of commercially available biofilm-reducing sanitizers were an effective treatment for removing residual GaHV-1 vaccine virus from the water lines and nipple drinkers after consecutive flock vaccinations via the drinking water (117).

Strain Classification

Antigenicity

Virus-neutralization and cross-protection studies done in the 1960s indicated that GaHV-1 vaccine strains in the United States are antigenically homogeneous (143). However, minor antigenic variations among 1970's Australian field isolates have been documented based on cross-reactivity studies with heterologous antisera (135). Although evidence of cross protection between a different genotype and live attenuated vaccine stains exists (132). The antigenic relationships among contemporary GaHV-1 isolates by virus neutralization have not been assessed recently.

Molecular Classification

Due to the conserved antigenicity of GaHV-1, discrimination among viruses has been done mostly at the DNA level. Diverse molecular techniques had been used to detect genome differences among viruses, particularly between live attenuated vaccines and field isolates. To review the early molecular assays used to classify GaHV-1 viruses the reader is referred to the 12th edition of this chapter (59). In the past ten years with the increased availability of GaHV-1 gene sequences, amplification of a single or multiple viral loci by polymerase chain reaction (PCR) followed by restriction fragment length polymorphisms (RFLP) and/or sequencing analysis have been the most widely used methods to genotype GaHV-1 strains from

North America, South America, Australia, Europe, and the Middle East. Through trial and error, multi loci PCR-RFLP assays have successfully identified "target" virus genes useful in strain differentiation (90, 108, 111, 113, 114). In more recent reports, PCR-RFLP analysis of the ICP18.5 and ICP4 genes partitioned GaHV-1 isolates from commercial poultry and game birds from nine regions of Australia into nine genotypes (9). PCR-RFLP and sequencing analysis of the gE, gG, TK, ICP4, UL36, and ORFB-TK genes demonstrated that outbreak-related isolates from Italy were closely related to the CEO vaccines (106).

Using PCR-RFLP of the TK, gE, gG, and ICP4 genes, GaHV-1 vaccines and strains from Brazil and Peru were differentiated into three genotypes (15). Sequencing analysis of two regions of the ICP4 gene provided better discrimination to differentiate among live attenuated vaccines and field strains from Peru and Brazil than PCR-RFLP (14).

With the increased number of full-length genomic sequences available and evolving inexpensive sequencing technologies, the future molecular classification of GaHV-1 strains will require full genome comparisons rather than single- or multi-loci PCR-based analysis.

Laboratory Host Systems

GaHV-1 can be readily propagated in embryonating chicken eggs and in a variety of avian cell cultures. In embryonating chicken eggs, the virus induces opaque plaques on the embryo choriallantoic membrane (CAM) that result from necrosis and proliferation of the affected cells. The severity of plaques may vary from a few scattered foci to large numbers. Chorioallantoic membrane plaques generally have opaque edges and a central depressed area of necrosis. Plaques can be observed as early as two days post inoculation (PI) and embryo deaths occur 2–8 days PI (148). Early Hitchner and White (69) demonstrated that inoculation of the embryo CAM consistently produced higher viral titers than other routes of embryo inoculation. Survival time of inoculated embryos increases with additional egg passages, allowing effective propagation of the virus to significant titers for the economical production of vaccines.

GaHV-1 has been propagated in a variety of avian cell cultures including chicken embryo liver (CEL), chicken embryo lung, chicken embryo kidney (CEK), and chicken kidney (CK) (Figure 5.1C and D) (1, 17, 72). Hughes and Jones (72) compared several laboratory host systems for efficiency of GaHV-1 isolation and propagation. The CEL and CK cells were found to be the preferred culture systems, while CEK cells, chicken embryo lung cells, and CAM inoculation of embryonating chicken eggs were less sensitive. Although not suitable for isolation, primary chicken embryo fibroblast (CEF) cells have been used to propagate a cell-associated strain of GaHV-1 (146), the USDA reference strains, (105) and a turkey GaHV-1 isolate (121).

Viral cytopathology can be observed in cell culture as early as 4–6 hours PI with a high multiplicity of infection. Cytopathology consists of increased refractiveness and swelling of cells, chromatin displacement, and rounding of the nucleoli. Cytoplasmic fusion results in formation of multinucleated giant cells (syncytia). Intranuclear inclusion bodies can be detected as early as 12 hours PI, with the highest concentration occurring 30–36 hours PI. Large cytoplasmic vesicles develop in the multinucleated CEK cells, which become more basophilic as cells degenerate (128).

GaHV-1 was also shown to replicate in avian leukocyte cultures derived from chicken buffy coats; a progressive clumping of the nuclei and formation of syncytial cells was observed 72 hours PI (18). A later study indicated that a pathogenic GaHV-1 strain replicated to a lesser degree in macrophage cultures obtained from bone marrow and spleen than an attenuated strain (154). Calnek et al. (12) determined that although restricted virus replication, most macrophage cultures tested were susceptible to GaHV-1 infection and both cell genotype and virus genotype influenced the extent of virus replication. Other cell types including lymphocytes, thymocytes, buffy-coat leukocytes, and activated T cells were either refractory or nearly refractory to GaHV-1 infection.

GaHV-1 replicates in a continuous avian cell line derived from a chemically induced chicken liver tumor cell line named LMH (leghorn male hepatoma) (86). LMH cells permit replication of GaHV-1 but propagation requires previous adaptation; therefore, this cell line is unsuitable for primary isolation (138). The LMH cell line has been instrumental in the construction of recombinant GaHV-1 and for the molecular biological study of this important avian pathogen (47). In contrast to LMH cells, replication of GaHV-1 in other cell lines such as quail-origin (QT35 or IQ1A) and monkey kidney (e.g., vero) cells is limited (73, 105). However, subculturing of infected quail cells onto uninfected monolayers produced viral titers of 3 $\log_{10}$. The limited replication of GaHV-1 in quail cells is due to the inability of the cell free virions to adsorb and penetrate these cells, a necessary stage to initiate virus replication (139).

Pathogenicity

From early epizootics of ILT to recent outbreaks, severe and mild forms of the disease have been described (83) and viral isolates collected (124). Severe forms of the disease are characterized by marked dyspnea with expectoration of blood-stained mucus, moderate-to-severe conjunctivitis, high morbidity, and moderate-to-high mortality (59). Sporadic appearances of milder forms of the disease still occur today and are characterized by production of mucoid tracheitis, mild conjunctivitis and mild respiratory rales, low-to-moderate morbidity, and no increased mortality (97, 142, 147). Although characterization of isolates that cause mild outbreaks of the disease has been limited, PCR-RFLP analysis suggested that some of these isolates originated from live attenuated chicken embryo origin (CEO) vaccines (149).

It has been demonstrated that embryo mortality patterns of Japanese GaHV-1 strains correlated closely with virulence in

birds (76). Differences in plaque size and morphology in cell culture and CAM of embryonating chicken eggs exists among GaHV-1 field isolates and vaccine strains (115). However, these differences did not correlate with the degree of virulence in birds. Virulence of field isolates as compared to vaccine strains was best evaluated by recording the intratracheal pathogenicity index and mortality after inoculation of SPF chickens (60). In recent studies it was found that microscopic lesions in the trachea were not reliable indicators of virulence because do not necessarily correlate with mortality rates (89). Scoring of clinical signs from 3–14 days PI was necessary to evaluate the virulence of US isolates (115).

Pathobiology and Epidemiology

Incidence and Distribution

Infectious laryngotracheitis is a serious disease of poultry that is present wherever susceptible poultry populations are located. The disease is particularly common in regions with large poultry concentrations and intensive poultry production. A trend toward growing denser poultry populations in shorter cycles, rearing different types of poultry (commercial layers and broilers) in the same area, and lax biosecurity are some of the factors that have contributed to the increase of ILT outbreaks worldwide.

Natural and Experimental Hosts

The chicken is the natural host of GaHV-1, and although the disease affects all ages, the most characteristic signs of the disease can be observed as early as three weeks of age (41). Since the early description of the disease, GaHV-1 infections have been reported in pheasants, pheasant-chicken crosses and peafowls (26, 87). Winterfield and So (162) were able to induce respiratory signs and lesions in the upper respiratory tract of young turkeys and found substantial differences in the infectivity and pathogenicity of the different isolates tested. Recently a case of natural infection in turkeys (121) and a subclinical infection in ducks with seroconversion were reported (163). Embryonating eggs of turkeys and chickens are susceptible to GaHV-1. Duck eggs are also susceptible but to a lesser degree. Eggs of guinea fowl and pigeons are not susceptible to GaHV-1 infection (84).

Transmission, Carriers, and Vectors

Natural portals of entry for GaHV-1 are through the upper respiratory and ocular routes (84). Ingestion also can be a mode of infection, although exposure of nasal epithelium following ingestion is necessary (130). Egg transmission of virus contained in the interior or exterior of the egg has not been demonstrated and the spread among 1-day-old birds is minor. Direct bird-to-bird transmission occurs more readily from acutely infected birds than through contact with clinically recovered carrier birds.

Birds that have been vaccinated with live attenuated vaccines or recovered from the disease carry the virus in a latent stage (3). The virus can be reactivated spontaneously or when the flock is exposed to stress conditions (71). Once the virus has been reactivated direct bird-to-bird transmission occurs and the disease will recrudesce in susceptible populations of birds (70). Indirect transmission of the virus occurs frequently through exposure to contaminated equipment, personnel clothing and shoes, through exposure from improperly disposed contaminated litter, manure, and infected carcasses (41). Although it has not been directly demonstrated, it is believed that the spread of GaHV-1 to susceptible flocks occurs during live hauling of infected birds to the processing plant (31). Winds may play an important role in the spread patterns of the disease. Farms affected with ILT were 10 times most likely to be located within the wind vector of an infected flock during the estimated 14-days incubation period of the infection (82).

Backyard flocks may represent a source of the virus to commercial poultry because infected survivors most likely will become carriers of the virus. A risk analysis study found that broiler flocks affected with the disease were 36 times more likely to be located within a mile of a backyard flock than unaffected poultry flocks (81). There is plenty of field evidence that lax biosecurity is a predominant factor in initiating ILT outbreaks (31). Outbreak related virus can originate from backyard flocks, vaccinated long-lived birds that serve as carriers of the virus (41), or vaccine virus that has gained virulence after circulating in the field (61).

Incubation Period

Clinical signs generally appear 6–14 days following natural exposure (83). Experimental inoculation via the intratracheal route resulted in shedding at two days PI and the peak of clinical signs appeared four days PI (33). In a more recent experimental intratracheal infection study it was shown that the peak of clinical signs induced by infection with different US strains was observed between 4–7 days PI (115).

Clinical Signs

GaHV-1 virus causes an acute respiratory disease in chickens. From early epizootics of ILT to current times, both severe and mild forms of the disease have been described. Clinical signs related to severe forms of the disease are marked dyspnea with expectoration of blood-stained mucus and moderate-to-severe conjunctivitis (83). Mild enzootic forms of ILT also have been observed in intensive poultry producing areas of Europe, Australia, New Zealand, and the United States. Clinical signs characteristic of mild forms of the disease include unthriftiness, decreased egg production, watery eyes, conjunctivitis, swelling of infraorbital sinuses, mild mucoid tracheitis, persistent nasal discharge, mild hemorrhagic conjunctivitis, and respiratory rales (25, 97, 141, 142, 147, 158). The course of the infection varies with the severity of lesions. Generally, in natural outbreaks most chickens recover in 10–14 days, but extremes of three weeks have been reported (83).

Morbidity and Mortality

Severe epizootic forms of the disease cause high morbidity (90%–100%) and variable mortality; mortality can vary from 5%–70% but usually is in the range of 10%–20% (83). On the other hand, mild enzootic forms of the disease result in morbidity as low as 5% and very low mortality (0.1%–2%) (24, 97, 141, 147, 158).

Pathology

Gross lesions may be found in the conjunctiva and throughout the respiratory tract of GaHV-1-infected chickens, but are most consistently observed in the larynx and trachea. Tissue changes in tracheal and laryngeal tissues may be mild, consisting only of excess mucus, or severe with hemorrhage and/or diphtheritic changes. In severe forms, mucoid inflammation is observed early in infection with degeneration, necrosis, and hemorrhage occurring in later stages. Diphtheritic changes are common and may be seen as mucoid casts that extend the entire length of the trachea. In other cases, severe hemorrhage into the tracheal lumen may result in blood casts (Figure 5.4C), or blood may be found in with mucus and necrotic tissue. Inflammation may extend down the bronchi into the lungs and air sacs.

In mild forms of the disease, gross lesions in the trachea may consist of moderate mucoid tracheitis with varying degrees of hemorrhage localized to the larynx and upper trachea (Figure 5.4D) (97, 142, 147). In addition, only edema and congestion of conjunctiva with watery eyes is observed (Figure 5.4B) (97, 142). In the severe forms of the disease, birds develop nasal discharge and conjunctivitis with watering eyes, frothy ocular secretion, and swelling of the infraorbital sinuses (Figure 5.4A) (83).

Microscopic changes vary with the stage of the disease. After two days PI early microscopic changes in tracheal mucosa can be observed including the loss of goblet cells and infiltration of mucosa with inflammatory cells. As the viral infection progresses, respiratory and conjunctiva epithelial cells enlarge and become edematous. Multinucleated cells (syncytia) are formed and lymphocytes, histiocytes, and plasma cells migrate into the mucosa and submucosa after three days (Figure 5.4E and F). Inclusion bodies generally are present in both trachea and conjunctiva epithelial cells only in the early stages of infection (1–5 days) (Figure 5.4G and H) (62) and disappear as infection progresses due to necrosis and desquamation of the epithelium. As an outcome of cell destruction and desquamation, the mucosal surface will be reduced to a thin layer of basal cells or will lack any epithelial covering. Blood vessels within the lamina propria may protrude into the tracheal lumen and hemorrhage may occur in cases of severe epithelial destruction and desquamation with exposure and rupture of blood capillaries.

Pathogenesis of the Infectious Process

Many factors such as host age, route of exposure, virulence of the challenge virus, and initial viral load can affect the outcome of infection, GaHV-1 replication is limited to the respiratory tissues with no evidence of viremia. Chickens of almost any age can become infected and develop disease, usually starting at four weeks of age, but outbreaks have been reported in chickens as early as three weeks of age (41).

Experimental studies using intratracheal, intranasal, intraconjunctival, and aerosol inoculations, as well as bird-to-bird transmission models, have independently confirmed that the peak of virus replication occurs in the trachea epithelium from 2–5 days PI (4, 68, 89, 115, 125, 130). After the acute phase of replication, the virus remains in the trachea at very low levels, i.e., viral DNA of live attenuated vaccines has been detected in the trachea of eye-drop vaccinated birds 18–28 days post vaccination (22, 131). In addition to the trachea, other mucous membranes such as conjunctiva, respiratory sinuses, air sacs, and lungs can become infected (4, 68, 115, 125, 130). Although increased viral replication in the trachea correlated with the degree of microscopic lesions observed in the trachea, mortality was not necessarily related to the trachea pathology. Considerable variation exists among GaHV-1 strains' tropism for trachea and conjunctiva (90). Early studies showed that chickens could be successfully vaccinated with live attenuated vaccines at one day of age (124); however, severe vaccine reactions are most likely to occur. This apparent increased susceptibility of younger birds maybe related to the pathogenic effect of extra-tracheal spread of the virus to the lungs of very young birds (1–3 days of age) (4).

Establishment of the latent state after infection is the main mechanism used by herpesviruses to evade host immunity, and GaHV-1 is no exception. Extratracheal spread of GaHV-1 to trigeminal ganglia was first reported by Bagust et al. (4). Using tracheal organ cultures the virus was isolated from trigeminal ganglia of chickens 4–7 days after tracheal exposure with a virulent Australian GaHV-1 strain (4). William et al. (161) used PCR to confirm that the trigeminal ganglion was the principal site of ILTV latency. Using the same technology, Han et al. (64) found that extra-tracheal migration of challenge and vaccine strain viruses to the trigeminal ganglia occurs as early as two days PI. Viral reactivation was documented 3–16 months PI in tracheal organ explants from recovered chickens (3). Organ culture explants of different sections of the tracheas were utilised, suggesting that in addition to the trigeminal ganglia, sites for latency are also distributed throughout the trachea (3). Repeated tracheal swabbing of chickens 2–4 months after experimental infection with either a mildly pathogenic field or vaccine strains showed an apparent spontaneous and intermittent shedding of virus in apparently healthy birds (70, 73). Another study reported the re-excretion of GaHV-1 from chickens following the stress of re-housing and the onset of reproduction (71). Unlike reactivation studies with other alphaherpesviruses, treatments with immunosuppressive drugs (e.g., cyclophosphamide, dexamethasone) have not been successful in reactivating latent GaHV-1 infections (3, 73, 74).

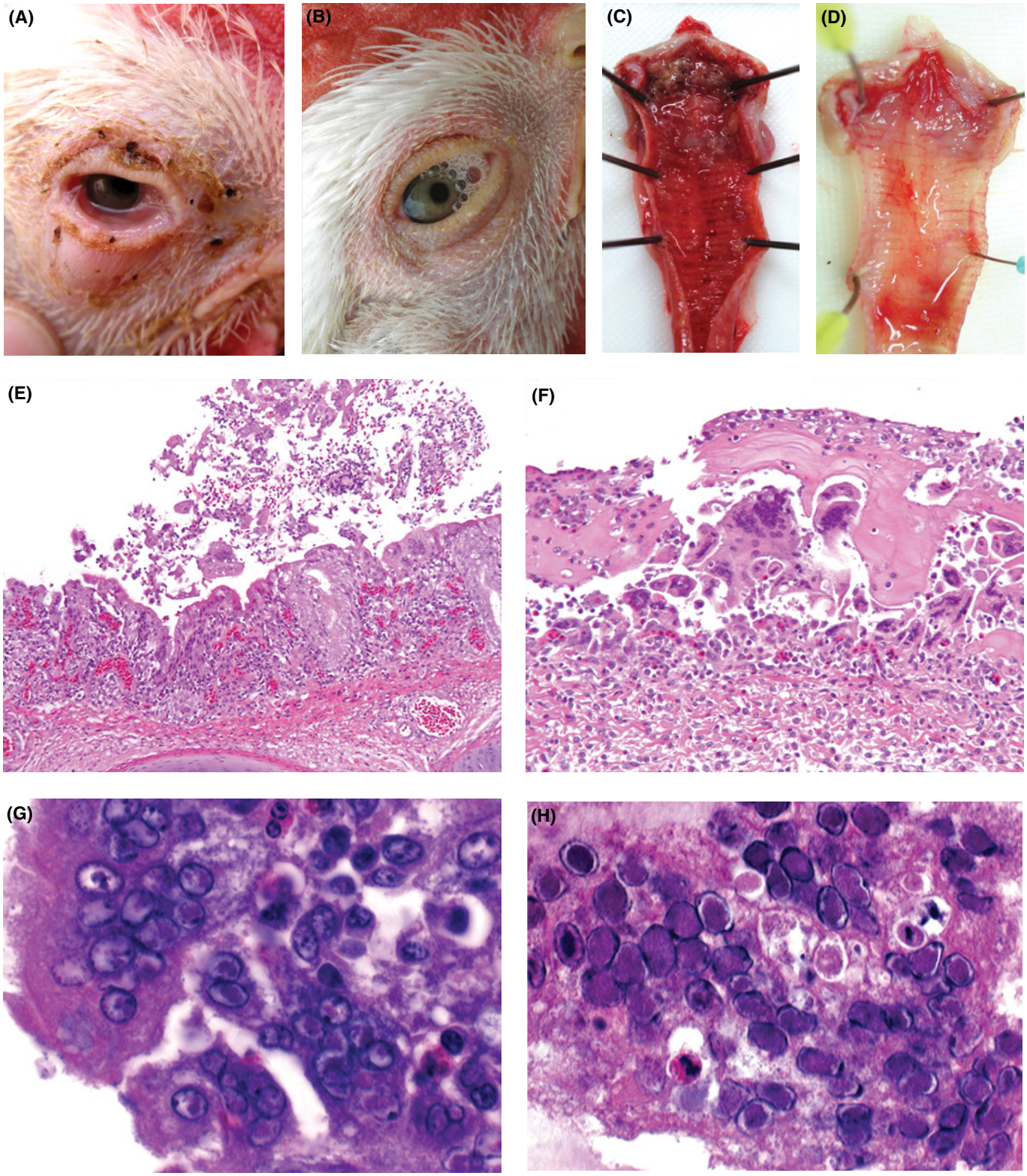

Figure 5.4. Gross pathology characteristic of GaHV-1 infection. Severe (A) and moderate (B) conjunctivitis characteristics of severe and mild forms of the disease, respectively (Guillermo Zavala) (C) Severe hemorrhagic tracheitis (Guillermo Zavala) (D) Mild hemorrhagic-mucous tracheitis (Holly Sellers) Histopathological examination of GaHV-1 infection in formalin fixed, parafilm embedded, hematoxylin and eosin-stained tissues. (E) Trachea. Moderate to severe lymphocytic infiltrates and congestion in the lamina propria. The respiratory epithelium has multiple areas of acute necrosis with syncytial formation and the lumen has cellular debris along with syncytial cell formation. ×200. (Susan Williams) (F) Eyelid. There is diffuse ulceration of the conjunctival epithelium with numerous syncytial cells with type B eosinophilic intranuclear inclusions, abundant fibrin along with inflammatory cells covering the affected area, and mild to moderate lymphocytes in the underlying stroma. ×200. (Susan Williams) (G and H) Trachea. Typical syncytia and Cowdry type A intranuclear inclusion bodies surrounded by a pale halo and marginated chromatin limited by the nuclear envelope detected in the trachea during the acute phase of infection. ×400. (Guillermo Zavala)

Immunity

Active Immunity

Although a variety of immune responses are generated following GaHV-1 infection, not all provide ILT resistance. Early studies on humoral responses to GaHV-1 infection demonstrated that virus-neutralizing antibodies can be detected within 5–7 days PI, peak around 21 days PI, then decrease over the next several months to low levels (85). Virus-neutralizing antibodies may be detectable for a year or more (3). Local antibodies may be detected in tracheal secretions from approximately seven days PI and plateau at days 10–28 PI (3, 167).

Although antibody titers in serum and mucosal surfaces are associated with the stage of GaHV-1 infection (167), independent studies agree that a poor correlation generally exists between antibody titers and the immune status of flocks (50, 96). The poor correlation between the humoral immune response and protection against ILT was explained in experiments performed with bursectomized chickens. Bursal-dependent responses were demonstrated to be non-essential in preventing replication of virus in vaccinated chickens. This suggests that local cell-mediated immune (CMI) (136) responses in the trachea are the principal mechanism behind ILT resistance (43, 129). Fahey et al. demonstrated that ILT resistance could be transferred using spleen cells and peripheral blood leukocytes from congenic immune donors, further emphasizing the importance of CMI responses (42).

Similar to other mammalian alphaherpesviruses, GaHV-1 glycoprotein G functions as a viral chemokine-binding protein (vCKBP) (39). Chickens inoculated with a gG deletion mutant had decreased level of serum-neutralizing antibodies and increased numbers of $CD8^+$ T lymphocytes in the tracheal mucosa as compared to the wild type or gG revertant virus. The authors postulated that by binding chemokines, gG directs the host immune response away from the cell-mediated arm toward an antibody-mediated immune response to create conditions that favor virus replication (39). The components of the cell-mediated immunity response elicited by GaHV-1 infection had not been elucidated. However, early work demonstrated delayed-type hypersensitivity responses to GaHV-1 infection (168). In a recent study the transcriptional profile of GaHV-1-infected chicken embryonic lung cells was evaluated, a significant difference in the expression of genes responsible for antigen presentation, cell-mediated immunity, and inflammation was observed relative to uninfected controls (92).

Passive Immunity

Initial studies have demonstrated that although maternal antibodies to GaHV-1 are transmitted to offspring via the egg (85); these do not confer protection to infection or interfere with vaccination (41). A recent study confirmed the transfer of GaHV-1 maternal antibodies from hens to their one-day-old progeny (53).

Diagnosis

The diagnosis of GaHV-1 requires laboratory assistance because a sole diagnosis based on clinical presentation can be misleading. Other respiratory pathogens of poultry can cause similar clinical signs and lesions. Diagnosis should be based on more than one laboratory procedure. Histopathological examination, virus isolation, detection of GaHV-1 antigens, and detection of GaHV-1 DNA are the most used methods for the diagnosis of GaHV-1 infections (148).

Histopathology

Lesions produced by GaHV-1 infection are characterized by pathognomonic intranuclear inclusion bodies in respiratory and conjunctival epithelial cells. Intranuclear inclusion bodies may be detected in tissues stained with Giemsa or hematoxylin and eosin. Histopathological examination for the detection of inclusion bodies is considered a rapid (results within 24 hours) diagnostic method of high specificity when the appropriate tissue processing techniques are applied (62).

Isolation and Identification of Causative Agent

Isolation of GaHV-1 is accomplished by inoculation of 9- to 12-day-old embryonating chicken eggs or susceptible cell cultures (see Laboratory Host Systems). Clinical samples suitable for isolation can be swabs, tissue homogenates, or exudates from trachea, larynx, lung, and conjunctiva. Samples must be collected early in the course of infection, as experimental studies indicate that GaHV-1 is not detected or detected inconsistently after 6 days PI (4, 62, 166).

The preferred route of inoculation of embryonating eggs for isolation of GaHV-1 is the CAM inoculation route because it is the most sensitive (69). Chorioallantoic membrane plaques can be observed as early as two days PI; these generally have opaque edges and a central depressed area of necrosis.

Chicken embryo liver cells and CK cells from adult chickens are the cell cultures of choice for GaHV-1 isolation. Viral cytopathic effect may be observed in cell culture as early as 24 hours PI and consists of increased refractiveness and swelling of cells and formation of multinucleated giant cells (syncytia) (Figure 5.1C and D). In some instances more than 1 passage in CEL and CK cell cultures will be required to ensure isolation of GaHV-1 from clinical samples (3, 72).

Chicken embryo liver cells are the most sensitive laboratory system for GaHV-1 isolation, although CK cells were a

satisfactory alternative. Both CEL and CK cells are superior to CAM inoculation of embryonating eggs for isolation of GaHV-1 (72). Confirmation of GaHV-1 isolation is achieved by fluorescent antibody (FA) or immunohistochemistry (IHC) staining, PCR, or electron microscopy (40).

Although virus isolation is the benchmark criteria in the diagnosis of GaHV-1, it can take up to 1–2 weeks to reach a diagnosis. In order to implement the appropriate measures in the field and avoid the spread of the disease to neighboring flocks the laboratory needs to provide a diagnosis in 24–48 hours. Several assays have been established to allow the rapid diagnosis of GaHV-1.

Histopathological examination remains the standard method for the rapid diagnosis of GaHV-1 (62). However, lesions characteristic of GaHV-1 infection, syncytial cell formation of the trachea epithelial cells with intranuclear inclusion bodies, are usually present only from 1–5 days PI. Early studies demonstrated that GaHV-1 viral antigen could be detected up to 8 days PI from trachea epithelium smears by direct fluorescent antibody assay (DFA) (4, 68, 159). Similarly, GaHV-1 antigen was detected in frozen sections (62) of trachea and in formalin-fixed, paraffin-embedded tracheal and laryngeal tissues (147) by IHC procedures (Figure 5.1E). In both studies GaHV-1 antigens were detected up to 9 days PI and the IHC procedure was shown to be more sensitive than indirect fluorescent antibody (IFA) assay in the detection of GaHV-1 antigens (67). In addition to *in situ* detection of GaHV-1 antigens, ELISA format methods to capture viral antigens have been developed using GaHV-1 monoclonal antibodies that were as accurate as virus isolation but significantly less time consuming (166).

In the past two decades, conventional PCR-based assays in combination with histopathology examination have been used for the rapid diagnosis of GaHV-1. Conventional PCR assays have been used to successfully detect GaHV-1 DNA from the trachea (160), and from extra-tracheal sites such as the conjunctiva (1) and trigeminal ganglia (64, 161). Overall PCR procedures are more sensitive than virus isolation and allowed for the detection of GaHV-1 DNA in samples contaminated with other microorganisms, such as adenoviruses, that will prevent GaHV-1 isolation in cultures or embryos (160).

To allow the simultaneous detection of multiple avian respiratory pathogens, including GaHV-1, in a single sample, multiplex PCR assays have been developed to detect GaHV-1, fowlpox virus (145), and other avian respiratory agents (118). Nested PCRs, with increased sensitivity, have also been developed. These assays can detect viral DNA during lytic and latent infections (13) independently of the presence of syncytial and intranuclear inclusions in trachea and conjunctiva tissues (85).

Due to its inherent speed, sensitivity, reproducibility, and ability to quantify directly from clinical samples, real-time PCR has replaced conventional PCR in many poultry diagnostic laboratories. A diverse group of chemistries has been used for the real-time detection and quantification of GaHV-1 DNA. The most widely used assays in diagnostic laboratories are the SYBR Green PCR melting curve analysis (27, 99) and Taqman PCR assays (11, 116). Callison et al. developed a Taqman assay for GaHV-1 with a detection limit of 100 genome copy numbers/reaction and validated it using samples from experimentally and naturally infected chickens (11). Notably, viral DNA could be detected up to 22 days post exposure in the trachea of contact-exposed chickens and not surprisingly, the relative amounts of viral DNA decreased as the infection progressed. This Taqman assay was evaluated with trachea samples collected during an outbreak of the disease and it was shown to be more sensitive than DFA and histology examination. Tracheas positive by histological examination had a viral DNA concentration higher or equal to 4 $\log_{10}$ genome copy numbers (28). A sensitive SYBR Green PCR assay, with an extended dynamic range of 7 orders of magnitude as compared to the 5 orders of magnitude reported for the Taqman assay, was developed and validated (99).

Serology

Several techniques have been described for the detection of GaHV-1-specific antibodies including agar-gel immunodiffusion (AGID), virus neutralization (VN), indirect fluorescent antibody (IFA) test, and ELISA. These methods are not recommended as diagnostic assays but rather as tools to evaluate seroconversion induced by vaccination. Among the techniques, AGID was found to be the least sensitive, while ELISA, IFA, and VN were equally sensitive. In addition to its high degree of sensitivity, ELISA has the advantage of speed and suitability for testing of large sample numbers without the inherent subjectivity associated with IFA (6). Therefore ELISA is the preferred system for detection and quantitation of GaHV-1 antibodies.

However, identification of GaHV-1 infected flocks by serological monitoring is not a suitable diagnostic tool because all commercial ELISAs (110, 164) and cannot differentiate antibody responses of infected carriers from vaccinated birds. With the advent of recombinant viral vector vaccines carrying GaHV-1 glycoproteins, a combination of glycoprotein-specific ELISAs (16) could be used as a tool to screen flocks and differentiate between vaccinated and infected birds. Glycoproteins B and I antibodies were detected from birds vaccinated with recombinant viral vector vaccines pre and post challenge (150).

Differential Diagnosis

ILTV must be distinguished from other respiratory pathogens of poultry that may cause similar clinical signs and lesions. These include the diphtheritic form of avian poxvirus and infections caused by Newcastle disease virus, avian influenza virus, infectious bronchitis virus, fowl adenovirus, and Aspergillus spp.

Intervention Strategies

Management Procedures

Cooperative control of ILT outbreaks by collaboration between government and industry is most desirable. Correctly implemented (41), this approach may obviate the need for widespread use of ILT vaccine. In controlling ILT outbreaks, the most effective approach is a coordinated effort to obtain a rapid diagnosis, institute a vaccination program, and prevent further virus spread (5, 41). In broiler production sites, recovered flocks should be moved for processing under quarantine as soon as possible.

The importance of site quarantine and hygiene in preventing the movement of potentially contaminated personnel, feed, equipment, and birds is central to successful prevention and control of ILT (63). GaHV-1 infections resulting from field exposure or vaccination will result in latently infected carrier birds; thus, it is extremely important to avoid mixing vaccinated or recovered birds with susceptible chickens. Special precautions should be taken to obtain a complete history when mixing breeding stock.

Rodent and dog control measures also should be in place. Additionally, the threat posed by latent GaHV-1 infections in backyard and exhibition poultry flocks (103) should be recognized and guarded against.

Therapeutic vaccination with live attenuated vaccines in an already infected flock appears to shorten the length of an outbreak and limits virus spread. Spread of GaHV-1 between sites can be prevented by taking appropriate biosecurity measures such as cleaning and disinfecting equipment, practicing on-site, in-house composting, cleaning and disinfecting vehicles off farm, discouraging visitors, and not allowing bird contact for 72 hours before entering poultry facilities (63).

GaHV-1 is readily inactivated outside the host by disinfectants and warm temperatures; thus, carryover between successive flocks in a house can be prevented by adequate cleanup and extended downtime. Buildings and equipment should be washed and then sprayed with disinfectants suchas phenolics, sodium hypochlorite, iodophors, or quaternary ammonium compounds. All disinfectants should be used only at the dilutions recommended by the manufacturer. It is recommended that all potentially contaminated carcasses, feathers, feed, water, and litter be kept within the poultry house, and the house heated to 38°C for 100 hours (41).

Vaccination

Vaccination with live attenuated vaccines has proven to be a satisfactory method for developing resistance in susceptible chicken populations (see Immunity). However, this is only recommended for use in geographic areas where the disease is enzootic because live attenuated vaccine strains can establish lifelong latent infections. The appropriate regulatory agency responsible should be contacted to determine the use of approved vaccines in the region. Although effective, poor application and lax biosecurity in live attenuated vaccinated flocks has allowed vaccine strains to circulate in the field, regain virulence, and become the source of future outbreaks of the disease (see Molecular Classification). The majority of the U.S. commercial poultry outbreaks of ILT are caused by viruses genetically closely related to the CEO vaccines; therefore, recurrent outbreaks of the disease in endemic areas are called "vaccinal laryngotracheitis" (VLT) (31). In a recent report from Australia genome sequence data provided evidence that two live attenuated vaccine strains of GaHV-1 recombined to generate virulent "hybrid" field viruses that became the dominant strains responsible for widespread disease (93).

New viral vector vaccines utilizing on fowlpox virus (FPV) and herpesvirus of turkey (HVT) expressing GaHV-1 antigens provide a safer vaccination alternative against GaHV-1. These vector vaccines are highly attenuated, lack the ability to transmit from bird to bird, and do not regain virulence. However, field evidence indicated that viral vector vaccines have not been as efficient as the live attenuated vaccines to contain outbreaks of the disease in endemic areas (150).

Commercially Available Live Attenuated GaHV-1 Vaccines

The origin of GaHV-1 live attenuated vaccines are virulent field isolates that have been attenuated by sequential passage in cell cultures (52, 77, 78) and embryonating chicken eggs (137). Vaccines produced in this manner are referred to as tissue culture origin (TCO) and chicken embryo origin (CEO) vaccines, respectively.

Administration of live attenuated GaHV-1 vaccines in drinking water or by spray are desirable methods for rapid mass applications. These methods are effective as long as the vaccination is done to ensure the best possible coverage of the flock using a high titer vaccine. Flock coverage is critical, because as the vaccine virus spreads, it increases its virulence and may cause disease in birds missed during the vaccination (50, 101). CEO vaccines can be given by eye drop, water, or spray (67, 68, 136), whereas the TCO vaccine can only be given by eye drop (51). Because the CEO vaccine can be applied by mass, it is the most practicable vaccination option for broilers in the face of an outbreak. Immunity post vaccination with CEO or TCO vaccines can last for at least 15–20 weeks (2, 51).

Several problems have been associated with mass application of GaHV-1 vaccines. Spray vaccination of CEO has been repeatedly reported to cause severe reactions in chickens due to insufficient attenuation of vaccine virus and deep penetration of respiratory tract due to small droplet size of the spray (20, 55, 126). To achieve optimal vaccination coverage via the drinking water it is recommended to limit access to water several hours prior to vaccination.

There is ample field and experimental evidence that live attenuated vaccines can spread from vaccinated to nonvaccinated birds when in close contact during the early replication of vaccine viruses (21, 22, 93, 131, 136). Vaccinated birds can become latent carriers and re-excrete the virus (70). In particular,

CEO vaccines have been characterized to maintain some residual virulence (60).

It has been documented under experimental conditions that circulation of vaccine viruses in immunologically naïve birds results in the generation of more virulent strains as documented experimentally (61). After 20 consecutive bird-to-bird passage of the CEO vaccine, severe respiratory disease and mortality were observed. The TCO vaccine caused a milder respiratory response at the same passages level, (61).

Spread of vaccine viruses may be prevented by assuring good flock vaccine coverage, establishing biosecurity measures to prevent flock-to-flock spread, and managing vaccination programs to ensure simultaneous infection of all susceptible birds on a farm located in a densely populated poultry area. Consideration also must be given to the overall vaccination program when using modified-live GaHV-1 vaccine viruses in combination with other poultry vaccines. Interference with the development of protective immunity against ILT was observed in chickens simultaneously vaccinated by eye drop with modified live TCO vaccine and modified live Newcastle disease and/or infectious bronchitis vaccine. Simultaneous application of these vaccines decreased the trachea replication of GaHV-1 vaccine viruses and decreased protective immune responses (149). Interestingly, interference with eye drop-administered modified live CEO vaccine was not observed in this study.

Commercially Available Viral Vector GaHV-1 Recombinant Vaccines

The use of recombinant-based ILT vaccines, in conjunction with quarantine and hygiene measures, was first suggested as a strategy for regional GaHV-1 eradication programs in 1995 (5). Currently viral-vectored recombinant vaccines are commercially available in the US. The HVT-ILT vaccine contains the U_S6 and U_S7 GaHV-1 genes encoding viral glycoproteins D and I, respectively (79), and the FPV-ILT vaccine contains the U_L27 and U_L34 GaHV-1 genes encoding viral glycoprotein B and membrane-associated protein (MAP), respectively.

Davison and co-workers (32) evaluated the protective efficiency of the FPV-ILT vaccine in layers when applied at 7 weeks of age via the wing web, and reported that adequate protection was achieved after the challenge performed 20 weeks post vaccination. Johnson et al. (79) evaluated the protective efficacy of HVT-ILT and FPV-ILT vaccines when delivered by the *in ovo* route to commercial broiler eggs and reported only partial protection compared with that induced by a CEO vaccine. Vagnozzi and colleagues (150) reported that when the HVT-ILT vaccine was delivered *in ovo* or subcutaneously (1 day of age), it was more effective than the FPV-ILT vaccine, mitigating the disease and reducing levels of the challenge virus in the trachea, while the FPV-ILT vaccine mitigated clinical signs more effectively when administered subcutaneously than *in ovo*. Overall, both commercially available viral vector recombinant ILT vaccines provided partial protection to broilers, mitigating the disease and moderately reducing viral loads in the trachea (150).

Experimental GaHV-1 Vaccines

Gene Deleted GaHV-1 Mutants. Potential live attenuated GaHV-1 vaccine candidates were constructed via the alteration or deletion of viral genes coding for virulence factors. Gene deleted or modified results in attenuated viral strains that may be capable of inducing protective immunity without inducing disease. Several GaHV-1 deletion mutants have been developed (46, 49, 57, 98, 112, 118, 140, 152, 153). These include a recombinant GaHV-1 expressing the β-galactosidase marker gene (57); recombinant GaHV-1 viruses lacking the thymidine kinase gene (112, 140); a U_L50 gene deletion mutant (49) and recombinant GaHV-1 deletion mutants lacking the genes encoding glycoproteins J (48, 107), G (35, 36, 37), C (119), and U_L0 genes (158). These later recombinants were generally shown to have minor growth defects in cell culture and had an attenuated phenotype in chickens while still maintaining their immunogenicity. A variety of other GaHV-1 deletion mutant viruses have been constructed, but applicability of these to ILT control has not been determined (34, 45, 46, 153).

Vaccines comprised of gene deletions in the gC gene (119), gG gene (35, 36), or gJ (48, 107) genes are considered to be the most likely vaccine candidates because of their protective indices and suitability in developing a differentiation of infected from vaccinated animals (DIVA) strategy. The lack of specific glycoproteins in these vaccine strains will allow for the identification of GaHV-1-infected birds by assaying antibodies specific to the deleted glycoprotein (36, 48, 119). The recombinant GaHV-1 gG deletion mutant derived from a virulent Australian isolate (36) has been fully evaluated for safety, efficacy, and horizontal transmission, as compared to commercially available live attenuated vaccines (22, 23, 35, 38).

Recombinant GaHV-1 deletion mutants also have been used as a vector to express antigens of other important poultry pathogens. Most notable are the GaHV-1 recombinants expressing the H7 and H5 genes of avian influenza virus. These bivalent vaccines have been demonstrated to induce protection against GaHV-1 and avian influenza infections (98, 120, 152).

Vaccination Programs

Because of the high risk of infection and unacceptable economic consequences to poultry companies, most long-lived birds in dense poultry production areas are vaccinated against GaHV-1. In certain areas, the CEO vaccine is still used in long-lived birds, whereas in others, authorities allow only TCO and/or viral vector recombinant vaccines. There could be an advantage to using only TCO and/or recombinant vaccines to decrease the chance of CEO latent carriers or the circulation of CEO isolates within a susceptible poultry population. This is not always feasible because of the limited supply of the TCO vaccine (31). In areas where only the TCO vaccination is allowed for breeders and layers, outbreaks in their broiler populations are not as common.

The disadvantage of this strategy is that in the event of an outbreak in a TCO or viral vector recombinant-vaccinated area, it may become necessary to introduce CEO vaccines.

In an attempt to provide for better and longer flock protection some regions have implemented vaccination programs in their long-lived birds in which two vaccinations are applied. There are many combinations of products and ages within vaccination programs for breeders and layers. As a rule chickens vaccinated early in life, before two weeks of age, generally are not good responders to the vaccination. This is most likely due to the immaturity of their cell-mediated immune system rather than the effects of maternal antibodies (2, 24, 51, 52). Early GaHV-1 vaccination of layers and breeders is performed at 4–6 weeks of age with a CEO vaccine, followed by eye drop vaccination with TCO or CEO vaccines at 10–12 weeks of age.

Broilers are usually not vaccinated unless there is an outbreak in that segment of the population. Many backyard operations do not vaccinate their birds for ILT. In the event of an outbreak, broilers are typically vaccinated with either viral vector recombinant vaccines given *in ovo* or subcutaneously at the hatchery, or with CEO vaccines at 14–18 days of age. Mass application of CEO vaccines for this age range often requires an off-label use of vaccines because some are not labeled for use before 21 days of age or for application by water or spray. Prior to implementation of any vaccination program it is important to review the country's regulations for the use of vaccines against GaHV-1.

Treatment

No drug has been shown to be effective in reducing the severity of lesions or relieving clinical signs. If a diagnosis of GaHV-1 is obtained early in an outbreak, vaccination of unaffected birds may induce adequate protection before they become exposed.

Eradication

An early review article (5) specified that the eradication of GaHV-1 from intensive poultry production sites was highly feasible owing to several biologic and ecologic properties of the virus. These properties included the high degree of host specificity of GaHV-1, the fragility of virus infectivity outside the chicken, and the genome stability and antigenic homogeneity of GaHV-1. The chicken is the primary host species and reservoir host; wildlife reservoirs are believed either to be nonexistent or of minor importance in GaHV-1 ecology. Backyard and fancier chicken flocks are likely reservoirs of GaHV-1; thus, any eradication effort would require identification and inclusion of these birds (41).

Recent work has shown that vaccine viruses survive outside the host for longer periods of time than earlier speculated (117). That "vaccinal laryngotracheitis" is responsible for most of the commercial poultry outbreaks of the disease in the US (31). That the use of multiple distinct live attenuated GaHV-1 vaccines can result in the emergence of virulent viruses responsible for severe outbreaks of the disease (93). Therefore, eradication of GaHV-1 will require the advancement of current ILT vaccination practices. This includes improving the protective immunity and safety of future vaccine candidates, improving mass vaccination methods, and developing diagnostic techniques capable of identifying latently infected birds in real time.

Acknowledgement

The authors wish to acknowledge T.J. Bagust, who authored Infectious Laryngotracheitis in previous editions of *Diseases of Poultry*, for his substantial contributions to this chapter.

References

1. Alexander, H.S., and E. Nagy. 1997. Polymerase chain reaction to detect infectious laryngotracheitis virus in conjunctival swabs from experimentally infected chickens. *Avian Dis.* 41:646–653.
2. Alls, A.A., J.R. Ipson, and W.D. Vaughan. 1969. Studies on an ocular infectious laryngotracheitis vaccine. *Avian Dis.* 13:36–45.
3. Bagust, T.J. 1986. Laryngotracheitis (Gallid-1) herpesvirus infection in the chicken. 4. Latency establishment by wild and vaccine strains of ILT virus. *Avian Pathol*. 15:581–595.
4. Bagust, T.J., B.W. Calnek, and K.J. Fahey. 1986. Gallid-1 herpesvirus infection in the chicken. 3. Reinvestigation of the pathogenesis of infectious laryngotracheitis in acute and early post-acute respiratory disease. *Avian Dis*. 30:179–190.
5. Bagust, T.J. and M.A. Johnson. 1995. Avian infectious laryngotracheitis: virus-host interactions in relation to prospects for eradication. *Avian Pathol.* 24:373–391.
6. Bauer, B., J.E. Lohr, and E.F. Kaleta. 1999. Comparison of commercial ELISA test kits from Australia and the USA with theserum neutralization test in cell cultures for the detection of antibodies to the infectious laryngotracheitis virus of chickens. *Avian Pathol.* 28:65–72.
7. Beach, J.R. 1930. The virus of laryngotracheitis of fowls. *Science.* 72:633–634.
8. Beaudette, F.R. 1937. Infectious laryngotracheitis virus. *Poult Sci.* 16:103–105.
9. Blacker, H.P., N.C. Kirkpatrick, A. Rubite, D. O'Rourke, and A.H. Noormohammadi. 2011. Epidemiology of recent outbreaks of infectious laryngotracheitis in poultry in Australia. *Aust Vet J.* 89:89–94.
10. Brandly, C.A., and L.D. Bushnell. 1934. A report of some investigations of infectious laryngotracheitis. *Poult Sci.* 13:212–217.
11. Callison, S.A., S.M. Riblet, I. Oldoni, S. Sun, G. Zavala, S. Williams, R.S. Resurreccion, E. Spackman, and M. Garcia. 2007. Development and validation of a real-time Taqman PCR assay for the detection and quantitation of infectious laryngotracheitis virus in poultry. *J Virol Methods.* 139:31–38.
12. Calnek, B.W., K.J. Fahey, and T.J. Bagust. 1986. *In vitro* infection studies with infectious laryngotracheitis virus. *Avian Dis.* 30:327–336.

13. Chacon, J.L., and A.J. Ferreira. 2008. Development and validation of nested-PCR for the diagnosis of clinical and subclinical infectious laryngotracheitis. *J Virol Methods.* 151:188–193.
14. Chacon, J.L., and A.J. Ferreira. 2009. Differentiation of field isolates and vaccine strains of infectious laryngotracheitis virus by DNA sequencing. *Vaccine.* 27:6731–6738.
15. Chacon, J.L., M.Y. Mizuma, and A.J. Piantino Ferreira. 2010. Characterization by restriction fragment length polymorphism and sequence analysis of field and vaccine strains of infectious laryngotracheitis virus involved in severe outbreaks. *Avian Pathol.* 39:425–433.
16. Chang, P.C., K.T. Chen, J.H. Shien, and H.K. Shieh. 2002. Expression of infectious laryngotracheitis virus glycoproteins in *Escherichia coli* and their application in enzyme-linked immunosorbent assay. *Avian Dis.* 46:570–580.
17. Chang, P.W., V. Jasty, D. Fry, and V.J. Yates. 1973. Replication of a cell-culture-modified infectious laryngotracheitis virus in experimentally infected chickens. *Avian Dis.* 17:683–689.
18. Chang, P.W., F. Sculco, and V.J. Yates. 1977. An *in vivo* and *in vitro* study of infectious laryngotracheitis virus in chicken leukocytes. *Avian Dis.* 21:492–500.
19. Chin, R.P., M. Garcia, C. Corsiglia, S. Riblet, R. Crespo, H.L. Shivaprasad, A. Rodriguez-Avila, P.R. Woolcock, and M. Franca. 2009. Intervention strategies for laryngotracheitis: impact of extended downtime and enhanced biosecurity auditing. *Avian Dis.* 53:574–577.
20. Clarke, J.K., G.M. Robertson, and D.A. Purcell. 1980. Spray vaccination of chickens using infectious laryngotracheitis virus. *Aust Vet J.* 56:424–428.
21. Coppo, M.J.C., J.M. Devlin, and A.H. Noormohammadi. 2012. Comparison of the replication and transmissibility of an infectious laryngotracheitis virus vaccine delivered via eye-drop or drinking-water. *Avian Pathol.* 41:99–106.
22. Coppo, M.J.C., J.M. Devlin, and A.H. Noormohammadi. 2012. Comparison of the replication and transmissibility of two infectious laryngotracheitis virus chicken embryo origin vaccines delivered via drinking water. *Avian Pathol.* 41:195–202.
23. Coppo, M.J.C., A.H. Noormohammadi, C.A. Hartley, J.R. Gilkerson, G.F. Browning, and J.M. Devlin. 2011. Comparative *in vivo* safety and efficacy of a glycoprotein G-deficient candidate vaccine strain of infectious laryngotracheitis virus delivered via eye drop. *Avian Pathol.* 40:411–417.
24. Cover, M.S. 1960. The Effect of parental immunity and age on the response to infectious laryngotracheitis vaccination. *Avian Dis.* 4:467–473.
25. Cover, M.S., and W.J. Benton. 1958. The biological variation of infectious laryngotracheitis virus. *Avian Dis.* 2:375–383.
26. Crawshaw, G.J., and B.R. Boycott. 1982. Infectious laryngotracheitis in peafowl and pheasants. *Avian Dis.* 26:397–401.
27. Creelan, J.L., V.M. Calvert, D.A. Graham, and S.J. McCullough. 2006. Rapid detection and characterization from field cases of infectious laryngotracheitis virus by real-time polymerase chain reaction and restriction fragment length polymorphism. *Avian Pathol.* 35:173–179.
28. Crespo, R., P.R. Woolcock, R.P. Chin, H.L. Shivaprasad, and M. Garcia. 2007. Comparison of diagnostics techniques in an outbreak of infectious laryngotracheitis from meat chickens. *Avian Dis.* 51:858–862.
29. Cruickshank, J.G., D.M. Berry, and B. Hay. 1963. The fine structure of infectious laryngotracheitis virus. *Virology.* 20:376–378.
30. Davison, A.J. 2010. Herpesvirus systematics. *Vet Microbiol.* 143:52–69.
31. Davison, S., L. Dufour-Zavala, M. García, H. Ghorin, F. Hoerr, B. Hopkins, J. Smith, and D. Waldrip. 2005. Vaccinal laryngotracheitis—Overview in the United States. Proceedings of the 109th Annual Meeting of the United States Animal Health Association. 580.
32. Davison, S., E.N. Gingerich, S. Casavant, and R.J. Eckroade. 2006. Evaluation of the efficacy of a live fowlpox-vectored infectious laryngotracheitis/avian encephalomyelitis vaccine against ILT viral challenge. *Avian Dis.* 50:50–54.
33. Davison, S., G. Smith, and R.J. Eckroade. 1989. Laryngotracheitis in chickens: the length of the preinfectious and infectious periods. *Avian Dis.* 33:18–23.
34. Devlin, J.M., G.F. Browning, and J.R. Gilkerson. 2006. A glycoprotein I- and glycoprotein E-deficient mutant of infectious laryngotracheitis virus exhibits impaired cell-to-cell spread in cultured cells. *Arch Virol.* 151:1281–1289.
35. Devlin, J.M., G.F. Browning, J.R. Gilkerson, S.P. Fenton, and C.A. Hartley. 2008. Comparison of the safety and protective efficacy of vaccination with glycoprotein-G-deficient infectious laryngotracheitis virus delivered via eye-drop, drinking water or aerosol. *Avian Pathol.* 37:83–88.
36. Devlin, J.M., G.F. Browning, C.A. Hartley, and J.R. Gilkerson. 2007. Glycoprotein G deficient infectious laryngotracheitis virus is a candidate attenuated vaccine. *Vaccine.* 25:3561–3566.
37. Devlin, J.M., G.F. Browning, C.A. Hartley, N.C. Kirkpatrick, A. Mahmoudian, A.H. Noormohammadi, and J.R. Gilkerson. 2006. Glycoprotein G is a virulence factor in infectious laryngotracheitis virus. *J Gen Virol.* 87:2839–2847.
38. Devlin, J.M., C.A. Hartley, J.R. Gilkerson, M.J.C. Coppo, P. Vaz, A.H. Noormohammadi, A. Rubite, N.K. Dhand, and G.F. Browning. 2011. Horizontal transmission dynamics of a glycoprotein G deficient candidate vaccine strain of infectious laryngotracheitis virus and the effect of vaccination on transmission of virulent virus. *Vaccine.* 29:5699–5704.
39. Devlin, J.M., A. Viejo-Borbolla, G.F. Browning, A.H. Noormohammadi, J.R. Gilkerson, A. Alcami, and C.A. Hartley. 2010. Evaluation of immunological responses to a glycoprotein G deficient candidate vaccine strain of infectious laryngotracheitis virus. *Vaccine.* 28:1325–1332.
40. Diallo, I.S., J. Taylor, J. Gibson, J. Hoad, A. De Jong, G. Hewitson, B.G. Corney, and B.J. Rodwell. 2010. Diagnosis of a naturally occurring dual infection of layer chickens with fowlpox virus and gallid herpesvirus 1 (infectious laryngotracheitis virus). *Avian Pathol.* 39:25–30.
41. Dufour-Zavala, L. 2008. Epizootiology of infectious laryngotracheitis and presentation of an industry control program. *Avian Dis.* 52:1–7.
42. Fahey, K.J., T.J. Bagust, and J.J. York. 1983. Laryngotracheitis herpesvirus infection in the chicken: The role of humoral antibody in immunity to a graded challenge infection. *Avian Pathol.* 12:505–514.
43. Fahey, K.J., and J.J. York. 1990. The role of mucosal antibody in immunity to infectious laryngotracheitis virus in chickens. *J Gen Virol.* 71:2401–2405.
44. Fitzgerald, J.E., and L.E. Hanson. 1963. Comparison of some properties of laryngotracheitis and herpes simplex viruses. *Am J Vet Res.* 24:1297–1303.

45. Fuchs, W., and T.C. Mettenleiter. 1999. DNA sequence of the UL6 to UL20 genes of infectious laryngotracheitis virus and characterization of the UL10 gene product as a nonglycosylated and nonessential virion protein. *J Gen Virol.* 80:2173–2182.
46. Fuchs, W., and T.C. Mettenleiter. 2005. The nonessential UL49.5 gene of infectious laryngotracheitis virus encodes an O-glycosylated protein which forms a complex with the non-glycosylated UL10 gene product. *Virus Res*. 112:108–114.
47. Fuchs, W., J. Veits, D. Helferich, H. Granzow, J.P. Teifke, and T.C. Mettenleiter. 2007. Molecular biology of avian infectious laryngotracheitis virus. *Vet Res.* 38:261–279.
48. Fuchs, W., D. Wiesner, J. Veits, J.P. Teifke, and T.C. Mettenleiter. 2005. *In vitro* and *in vivo* relevance of infectious laryngotracheitis virus gJ proteins that are expressed from spliced and nonspliced mRNAs. *J Virol.* 79:705–716.
49. Fuchs, W., K. Ziemann, J.P. Teifke, O. Werner, and T.C. Mettenleiter. 2000. The non-essential UL50 gene of avian infectious laryngotracheitis virus encodes a functional dUTPase which is not a virulence factor. *J Gen Virol.* 81:627–638.
50. Fulton, R.M., D.L. Schrader, and M. Will. 2000. Effect of route of vaccination on the prevention of infectious laryngotracheitis in commercial egg-laying chickens. *Avian Dis.* 44:8–16.
51. Gelenczei, E.F., and E.W. Marty. 1964. Studies on a tissue-culture-modified infectious laryngotracheitis virus. *Avian Dis.* 8:105–122.
52. Gelenczei, E.F., and E.W. Marty. 1965. Strain stability and immunologic characteristics of a tissue-culture-modified infectious laryngotracheitis virus. *Avian Dis.* 14:44–56.
53. Gharaibeh, S., K. Mahmoud, and M. Al-Natour. 2008. Field evaluation of maternal antibody transfer to a group of pathogens in meat-type chickens. *Poult Sci.* 87:1550–1555.
54. Giambrone, J.J., O. Fagbohun, and K.S. Macklin. 2008. Management practices to reduce infectious laryngotracheitis virus in poultry litter. *J Appl Poult Res.* 17:64–68.
55. Gough, A.W., J.R. Pettit, A. Gagnon, and L.J. Weber. 1977. An outbreak of infectious laryngotracheitis in commercial poultry flocks in Ontario. *Can J Comp Med.* 41:146–151.
56. Graham, R.F., F. Throp, and W.A. James. 1930. Subacute or chronic infectious avian laryngotracheitis. *J Infect Dis.* 47:87–91.
57. Guo, P., E. Scholz, B. Maloney, and E. Welniak. 1994. Construction of recombinant avian infectious laryngotracheitis virus expressing the beta-galactosidase gene and DNA sequencing of the insertion region. *Virology.* 202:771–781.
58. Guo, P., E. Scholz, J. Turek, R. Nodgreen, and B. Maloney. 1993. Assembly pathway of avian infectious laryngotracheitis virus. *Am J Vet Res.* 54:2031–2039.
59. Guy, J., and M. García. 2008. Laryngotracheitis. In: *Diseases of Poultry*, 12th ed. Y.M. Saif, ed. Blackwell Publishing, Ames, Iowa. 137–152.
60. Guy, J.S., H.J. Barnes, and L.M. Morgan. 1990. Virulence of infectious laryngotracheitis viruses: comparison of modified-live vaccine viruses and North Carolina field isolates. *Avian Dis.* 34:106–113.
61. Guy, J.S., H.J. Barnes, and L. Smith. 1991. Increased virulence of modified-live infectious laryngotracheitis vaccine virus following bird-to-bird passage. *Avian Dis.* 35:348–355.
62. Guy, J.S., H.J. Barnes, and L.G. Smith. 1992. Rapid diagnosis of infectious laryngotracheitis using a monoclonal antibody-based immunoperoxidase procedure. *Avian Pathol.* 21:77–86.
63. Halvorson, D.A. 2011. Biosecurity on multi-age egg production complex: a 15-year experience. *Avian Dis.* 55:139–142.
64. Han, M.G., and S.J. Kim. 2003. Efficacy of live virus vaccines against infectious laryngotracheitis assessed by polymerase chain reaction-restriction fragment length polymorphism. *Avian Dis.* 47:261–271.
65. Helferich, D., J. Veits, T.C. Mettenleiter, and W. Fuchs. 2007. Identification of transcripts and protein products of the UL31, UL37, UL46, UL47, UL48, UL49 and US4 gene homologues of avian infectious laryngotracheitis virus. *J Gen Virol.* 88:719–731.
66. Hilbink, F., T. Smit, and H. Yadin. 1981. Drinking water vaccination against infectious laryngotracheitis. *Can J Comp Med.* 45:120–123.
67. Hilbink, F.W., H.L. Oei, and D.J. van Roozelaar. 1987. Virulence of five live vaccines against avian infectious laryngotracheitis and their immunogenicity and spread after eye-drop or spray application. *Vet Q.* 9:215–225.
68. Hitchner, S.B., J. Fabricant, and T.J. Bagust. 1977. A fluorescent-antibody study of the pathogenesis of infectious laryngotracheitis. *Avian Dis.* 21:185–194.
69. Hitchner, S.B., and P.G. White. 1958. A comparison of embryo and bird infectivity using five strains of laryngotracheitis virus. *Poult Sci.* 37:648–690.
70. Hughes, C.S., R.M. Gaskell, J.M. Bradbury, F.T. Jordan, and R.C. Jones. 1991. Survey of field outbreaks of avian infectious laryngotracheitis in England and Wales. *Vet Rec.* 129:258–260.
71. Hughes, C.S., R.M. Gaskell, R.C. Jones, J.M. Bradbury, and F.T. Jordan. 1989. Effects of certain stress factors on the re-excretion of infectious laryngotracheitis virus from latently infected carrier birds. *Res Vet Sci.* 46:274–276.
72. Hughes, C.S., and R.C. Jones. 1988. Comparison of cultural methods for primary isolation of infectious laryngotracheitis virus from field material. *Avian Pathol.* 17:295–303.
73. Hughes, C.S., R.C. Jones, R.M. Gaskell, F.T. Jordan, and J.M. Bradbury. 1987. Demonstration in live chickens of the carrier state in infectious laryngotracheitis. *Res Vet Sci.* 42:407–410.
74. Hughes, C.S., R.A. Williams, R.M. Gaskell, F.T. Jordan, J.M. Bradbury, M. Bennett, and R.C. Jones. 1991. Latency and reactivation of infectious laryngotracheitis vaccine virus. *Arch Virol.* 121:213–218.
75. Humberd, J., M. Garcia, S.M. Riblet, R.S. Resurreccion, and T.P. Brown. 2002. Detection of infectious laryngotracheitis virus in formalin-fixed, paraffin-embedded tissues by nested polymerase chain reaction. *Avian Dis.* 46:64–74.
76. Izuchi, T., and A. Hasegawa. 1982. Pathogenicity of infectious laryngotracheitis virus as measured by chicken embryo inoculation. *Avian Dis.* 26:18–25.
77. Izuchi, T., A. Hasegawa, and T. Miyamoto. 1983. Studies on a live virus vaccine against infectious laryngotracheitis of chickens. I. Biological properties of attenuated strain C7. *Avian Dis*. 27:918–926.
78. Izuchi, T., A. Hasegawa, and T. Miyamoto. 1984. Studies on the live-virus vaccine against infectious laryngotracheitis of chickens. II. Evaluation of the tissue-culture-modified strain C7 in laboratory and field trials. *Avian Dis*. 28:323–330.
79. Johnson, D.I., A. Vagnozzi, F. Dorea, S.M. Riblet, A. Mundt, G. Zavala, and M. Garcia. 2010. Protection against infectious laryngotracheitis by *in ovo* vaccination with commercially available viral vector recombinant vaccines. *Avian Dis.* 54:1251–1259.
80. Johnson, Y.J., M.M. Colby, N.L. Tablante, F.N. Hegngi, M. Salem, N. Gedamu, and C. Poppe. 2004. Appilcation of commercial and backyard poultry geographic information system databases for the identification of risk factors for clinical

infectious laryngotracheitis in a cluster of cases on the Delmarva Peninsula. *Intl J Poult Sci.* 3:201–205.
81. Johnson, M.A., C.T. Prideaux, K. Kongsuwan, M. Sheppard, and K.J. Fahey. 1991. Gallid herpesvirus 1 (infectious laryngotracheitis virus): cloning and physical maps of the SA-2 strain. *Arch Virol.* 119:181–198.
82. Johnson, Y.J., N. Gedamu, M.M. Colby, M.S. Myint, S.E. Steele, M. Salem, and N.L. Tablante. 2005. Wind-borne transmission of infectious laryngotracheitis between commercial poultry operations. *Intl J Poult Sci.* 4:263–267.
83. Jordan, F.T. 1966. A review of the literature on infectious larynotracheitis (ILT). *Avian Dis.* 10:1–26.
84. Jordan, F.T., H.M. Evanson, and J.M. Bennett. 1967. The survival of the virus of infectious laryngotracheitis. *Zentralbl Veterinarmed B.* 14:135–150.
85. Jordan, F.T.W. 1981. Immunity to infectious laryngotracheitis. *Avian Immunol.* 245–254.
86. Kawaguchi, T., K. Nomura, Y. Hirayama, and T. Kitagawa. 1987. Establishment and characterization of a chicken hepatocellular carcinoma cell line LMH. *Cancer Res.* 47:4460–4464.
87. Kernohan, G. 1931. Infectious laryngotracheitis in pheasants. *J Am Vet Med Assoc.* 78:553–555.
88. Kingsley, D.H., J.W. Hazel, and C.L. Keeler, Jr. 1994. Identification and characterization of the infectious laryngotracheitis virus glycoprotein C gene. *Virology.* 203:336–343.
89. Kirkpatrick, N.C., A. Mahmoudian, C.A. Colson, J.M. Devlin, and A.H. Noormohammadi. 2006. Relationship between mortality, clinical signs and tracheal pathology in infectious laryngotracheitis. *Avian Pathol.* 35:449–453.
90. Kirkpatrick, N.C., A. Mahmoudian, D. O'Rourke, and A.H. Noormohammadi. 2006. Differentiation of infectious laryngotracheitis virus isolates by restriction fragment length polymorphic analysis of polymerase chain reaction products amplified from multiple genes. *Avian Dis.* 50:28–34.
91. Kongsuwan, K., M.A. Johnson, C.T. Prideaux, and M. Sheppard. 1993. Identification of an infectious laryngotracheitis virus gene encoding an immunogenic protein with a predicted M(r) of 32 kilodaltons. *Virus Res.* 29:125–140.
92. Lee, J.Y., J.J. Song, A. Wooming, X. Li, H. Zhou, W.G. Bottje, and B.W. Kong. 2010. Transcriptional profiling of host gene expression in chicken embryo lung cells infected with laryngotracheitis virus. *BMC Genomics.* 11:445.
93. Lee, S.W., P.F. Markham, M.J. Coppo, A.R. Legione, J.F. Markham, A.H. Noormohammadi, G.F. Browning, N. Ficorilli, C.A. Hartley, and J.M. Devlin. 2012. Attenuated vaccines can recombine to form virulent field viruses. *Science.* 337:188.
94. Lee, S.W., P.F. Markham, J.F. Markham, I. Petermann, A.H. Noormohammadi, G.F. Browning, N.P. Ficorilli, C.A. Hartley, and J.M. Devlin. 2011. First complete genome sequence of infectious laryngotracheitis virus. *BMC Genomics.* 12:197.
95. Leib, D.A., J.M. Bradbury, C.A. Hart, and K. McCarthy. 1987. Genome isomerism in two alphaherpesviruses: Herpesvirus saimiri-1 (Herpesvirus tamarinus) and avian infectious laryngotracheitis virus. *Brief report. Arch Virol.* 93:287–294.
96. Leong, V.Y., J.R. Glisson, R.S. Resurreccion, and I.H. Cheng. 1994. Infectious laryngotracheitis virus in commercial hens: a serological study based on enzyme-linked immunosorbent assay. *Avian Dis.* 38:304–307.
97. Linares, J.A., A.A. Bickford, G.L. Cooper, B.R. Charlton, and P.R. Woolcock. 1994. An outbreak of infectious laryngotracheitis in California broilers. *Avian Dis.* 38:188–192.
98. Luschow, D., O. Werner, T.C. Mettenleiter, and W. Fuchs. 2001. Protection of chickens from lethal avian influenza A virus infection by live-virus vaccination with infectious laryngotracheitis virus recombinants expressing the hemagglutinin (H5) gene. *Vaccine.* 19:4249–4259.
99. Mahmoudian, A., N.C. Kirkpatrick, M. Coppo, S.W. Lee, J.M. Devlin, P.F. Markham, G.F. Browning, and A.H. Noormohammadi. 2011. Development of a SYBR Green quantitative polymerase chain reaction assay for rapid detection and quantification of infectious laryngotracheitis virus. *Avian Pathol.* 40:237–242.
100. Mahmoudian, A., P.F. Markham, A.H. Noormohammadi, and G.F. Browning. 2011. Kinetics of transcription of infectious laryngotracheitis virus genes. *Comp Immunol Microbiol Infec Dis.* 35:1–13.
101. Mallinson, E.T., K.F. Miller, and C.D. Murphy. 1981. Cooperative control of infectious laryngotracheitis. *Avian Dis.* 25:723–729.
102. May, H.G., and R.P. Tittsler. 1925. Tracheolaryngotracheitis in poultry. *J Am Vet Med Assoc.* 67:229–231.
103. McNulty, M.S., G.M. Allan, and R.M. McCracken. 1985. Infectious laryngotracheitis in Ireland. *Irish Vet J.* 39:124–125.
104. Mettenleiter, T.C. 2002. Herpesvirus assembly and egress. *J Virol.* 76:1537–1547.
105. Meulemans, G., and P. Halen. 1978. Some physico-chemical and biological properties of a Belgian strain (U76/1035) of infectious laryngotracheitis virus. *Avian Pathol.* 7:311–315.
106. Moreno, A., A. Piccirillo, A. Mondin, E. Morandini, L. Gavazzi, and P. Cordioli. 2010. Epidemic of infectious laryngotracheitis in Italy: characterization of virus isolates by PCR-restriction fragment length polymorphism and sequence analysis. *Avian Dis.* 54:1172–1177.
107. Mundt, A., E. Mundt, R.J. Hogan, and M. Garcia. 2011. Glycoprotein J of infectious laryngotracheitis virus is required for efficient egress of infectious virions from cells. *J Gen Virol.* 92:2586–2589.
108. Neff, C., C. Sudler, and R.K. Hoop. 2008. Characterization of western European field isolates and vaccine strains of avian infectious laryngotracheitis virus by restriction fragment length polymorphism and sequence analysis. *Avian Dis.* 52:278–283.
109. Neighbor, N.K., L.A. Newberry, G.R. Bayyari, J.K. Skeeles, J.N. Beasley, and R.W. McNew. 1994. The effect of microaerosolized hydrogen peroxide on bacterial and viral poultry pathogens. *Poult Sci.* 73:1511–1516.
110. Ohkubo, Y., K. Shibata, T. Mimura, and I. Takashima. 1988. Labeled avidin-biotin enzyme-linked immunosorbent assay for detecting antibody to infectious laryngotracheitis virus in chickens. *Avian Dis.* 32:24–31.
111. Ojkic, D., J. Swinton, M. Vallieres, E. Martin, J. Shapiro, B. Sanei, and B. Binnington. 2006. Characterization of field isolates of infectious laryngotracheitis virus from Ontario. *Avian Pathol.* 35:286–292.
112. Okamura, H., M. Sakaguchi, T. Honda, A. Taneno, K. Matsuo, and S. Yamada. 1994. Construction of recombinant infectious laryngotracheitis virus expressing the LacZ gene of E. coli with thymidine kinase gene. *J Vet Med Sci.* 56:799–801.
113. Oldoni, I., and M. Garcia. 2007. Characterization of infectious laryngotracheitis virus isolates from the US by polymerase chain reaction and restriction fragment length polymorphism of multiple genome regions. *Avian Pathol.* 36:167–176.

114. Oldoni, I., A. Rodriguez-Avila, S. Riblet, and M. García. 2008. Characterization of infectious laryngotracheitis virus (ILTV) isolates from commercial poultry by polymerase chain reaction and restriction fragment length polymorphism (PCR-RFLP). *Avian Dis.* 52:59–63.
115. Oldoni, I., A. Rodriguez-Avila, S.M. Riblet, G. Zavala, and M. García. 2009. Pathogenicity and growth characteristics of selected infectious laryngotracheitis virus strains from the United States. *Avian Pathol.* 38:47–53.
116. Ou, S.-C., J.J. Gaimbrone, and K.S. Macklin. 2012. Comparison of a Taqman real-time polymerase chain reaction assay with a loop-mediated isothermal amplification for detection of Gallid herpesvirus 1. *J Vet Diag Invest.* 21:138–141.
117. Ou, S.C., J.J. Giambrone, and K.S. Macklin. 2011. Infectious laryngotracheitis vaccine virus detection in water lines and effectiveness of sanitizers for inactivating the virus. *J Appl Poult Res.* 20:223–230.
118. Pang, Y., H. Wang, T. Girshick, Z. Xie, and M.I. Khan. 2002. Development and application of a multiplex polymerase chain reaction for avian respiratory agents. *Avian Dis.* 46:691–699.
119. Pavlova, S.P., J. Veits, U. Blohm, C. Maresch, T.C. Mettenleiter, and W. Fuchs. 2010. *In vitro* and *in vivo* characterization of glycoprotein C-deleted infectious laryngotracheitis virus. *J Gen Virol.* 91:847–857.
120. Pavlova, S.P., J. Veits, G.M. Keil, T.C. Mettenleiter, and W. Fuchs. 2009. Protection of chickens against H5N1 highly pathogenic avian influenza virus infection by live vaccination with infectious laryngotracheitis virus recombinants expressing H5 hemagglutinin and N1 neuraminidase. *Vaccine.* 27:773–785.
121. Portz, C., N. Beltrao, T.Q. Furian, A.B. Junior, M. Macagnan, J. Griebeler, C.A. Lima Rosa, E.M. Colodel, D. Driemeier, A. Back, O.M. Barth Schatzmayr, and C.W. Canal. 2008. Natural infection of turkeys by infectious laryngotracheitis virus. *Vet Microbiol.* 131:57–64.
122. Poulsen, D.J., C.R. Burton, J.J. O'Brian, S.J. Rabin, and C.L. Keeler, Jr. 1991. Identification of the infectious laryngotracheitis virus glycoprotein gB gene by the polymerase chain reaction. *Virus Genes.* 5:335–347.
123. Poulsen, D.J., and C.L. Keeler, Jr. 1997. Characterization of the assembly and processing of infectious laryngotracheitis virus glycoprotein B. *J Gen Virol.* 78:2945–2951.
124. Pulsford, M.F. 1963. Infectious laryngotracheitis of poultry. Part 1. Virus variation, immunology and vaccination. *Vet Bull.* 33:415–420.
125. Purcell, D.A., and J.B. McFerran. 1969. Influence of method of infection on the pathogenesis of infectious laryngotracheitis. *J Comp Pathol.* 79:285–291.
126. Purcell, D.A., and P.G. Surman. 1974. Letter: Aerosol administration of the SA-2 vaccine strain of infectious laryngotracheitis virus. *Aust Vet J.* 50:419–420.
127. Rachamadugu, R., J.Y. Lee, A. Wooming, and B.W. Kong. 2009. Identification and expression analysis of infectious laryngotracheitis virus encoding microRNAs. *Virus Genes.* 39:301–308.
128. Reynolds, H.A., A.M. Watrach, and L.E. Hanson. 1968. Development of the nuclear inclusion bodies of infectious laryngotracheitis. *Avian Dis.* 12:332–347.
129. Robertson, G.M. 1977. The role of bursa-dependent responses in immunity to infectious laryngotracheitis. *Res Vet Sci.* 22:281–284.
130. Robertson, G.M., and J.R. Egerton. 1981. Replication of infectious laryngotracheitis virus in chickens following vaccination. *Aust Vet J.* 57:119–123.
131. Rodriguez-Avila, A., I. Oldoni, S. Riblet, and M. Garcia. 2007. Replication and transmission of live attenuated infectious laryngotracheitis virus (ILTV) vaccines. *Avian Dis.* 51:905–911.
132. Rodriguez-Avila, A., I. Oldoni, S.M. Riblet, and M. Garcia. 2008. Evaluation of the protection elicited by direct and indirect exposure to live attenuated infectious laryngotracheitis virus vaccines against a recent challenge strain from the United States. *Avian Pathol.* 37:287–292.
133. Roizman, B., D.M. Knipe, and R.J. Whiley. 2007. Herpes simplex virus. In: *Fields Virology*. D.M. Knipe and P.M. Howley, eds. Lippincott Williams & Wilkins, Philadelphia. 2501–2601.
134. Ruano, M., J. El-Attrache, and P. Villegas. 2001. Efficacy comparisons of disinfectants used by the commercial poultry industry. *Avian Dis.* 45:972–977.
135. Russell, R.G., and A.J. Turner. 1983. Characterization of infectious laryngotracheitis viruses, antigenic comparison by kinetics of neutralization and immunization studies. *Can J Comp Med.* 47:163–171.
136. Samberg, Y., E. Cuperstein, U. Bendheim, and I. Aronovici. 1971. The development of a vaccine against avian infectious laryngotracheitis. IV. Immunization of chickens with a modified laryngotracheitis vaccine in the drinking water. *Avian Dis.* 15:413–417.
137. Samberg, Y., and I. Aronovici. 1969. The development of a vaccine against infectious laryngotracheitis. 1. Modification of a laryngotracheitis virus. *Ref Vet*. 26:54–59.
138. Schnitzlein, W.M., J. Radzevicius, and D.N. Tripathy. 1994. Propagation of infectious laryngotracheitis virus in an avian liver cell line. *Avian Dis.* 38:211–217.
139. Schnitzlein, W.M., and D.N. Tripathy. 1995. Replication of infectious laryngotracheitis virus in a quail cell line, QT-35. *Avian Dis.* 39:528–531.
140. Schnitzlein, W.M., R. Winans, S. Ellsworth, and D.N. Tripathy. 1995. Generation of thymidine kinase-deficient mutants of infectious laryngotracheitis virus. *Virol.* 209:304–314.
141. Seddon, H.R., and L. Hart. 1935. The occurence of infectious laryngotracheitis in fowls in New South Wales. *Aust Vet J.* 11:212–222.
142. Sellers, H.S., M. García, J.R. Glisson, T.P. Brown, J.S. Sander, and J.S. Guy. 2004. Mild infectious laryngotracheitis in broilers in the southeast. *Avian Dis.* 48:430–436.
143. Shibley, G.P., R.E. Luginbuhl, and C.F. Helmbolt. 1962. A study of infectious laryngotracheitis virus. Comparison of serologic and immunogenic properties *Avian Dis.* 6:59–71.
144. Spatz, S.J., J.D. Volkening, C.L. Keeler, G.F. Kutish, S.M. Riblet, C.M. Boettger, K.F. Clark, L. Zsak, C.L. Afonso, E.S. Mundt, D.L. Rock, and M. Garcia. 2012. Comparative full genome analysis of four infectious laryngotracheitis virus (Gallid herpesvirus-1) virulent isolates from the United States. *Virus Genes.* 44:273–285.
145. Tadese, T., A.E. Potter, S. Fitzgerald, and W.M. Reed. 2007. Concurrent infection in chickens with fowlpox virus and infectious laryngotracheitis virus as detected by immunohistochemistry and a multiplex polymerase chain reaction technique. *Avian Dis.* 51:719–724.
146. Thureen, D.R., and C.L. Keeler, Jr. 2006. Psittacid herpesvirus 1 and infectious laryngotracheitis virus: Comparative genome

sequence analysis of two avian alphaherpesviruses. *J Virol.* 80:7863–7872.

147. Timurkaan, N., F. Yilmaz, H. Bulut, H. Ozer, and Y. Bolat. 2003. Pathological and immunohistochemical findings in broilers inoculated with a low virulent strain of infectious laryngotracheitis virus. *J Vet Sci.* 4(2):175–180.
148. Tripathy, D.N., and M. García. 2008. Laryngotracheitis. In: *A Laboratory Manual for the Isolation and Identification of Avian Pathogens*. American Association of Avian Pathologists, Jacksonville, Florida. 94–98.
149. Vagnozzi, A., M. García, S.M. Riblet, and G. Zavala. 2010. Protection induced by infectious laryngotracheitis virus vaccines alone and combined with Newcastle disease virus and/or infectious bronchitis virus vaccines. *Avian Dis.* 54:1210–1219.
150. Vagnozzi, A., G. Zavala, S.M. Riblet, A. Mundt, and M. Garcia. 2012. Protection induced by commercially available live attenuated and recombinant viral vector vaccines against infectious laryngotracheitis virus in broiler chickens. *Avian Pathol.* 41:21–31.
151. Veits, J., B. Kollner, J.P. Teifke, H. Granzow, T.C. Mettenleiter, and W. Fuchs. 2003. Isolation and characterization of monoclonal antibodies against structural proteins of infectious laryngotracheitis virus. *Avian Dis.* 47:330–342.
152. Veits, J., D. Luschow, K. Kindermann, O. Werner, J.P. Teifke, T.C. Mettenleiter, and W. Fuchs. 2003. Deletion of the nonessential UL0 gene of infectious laryngotracheitis (ILT) virus leads to attenuation in chickens, and UL0 mutants expressing influenza virus haemagglutinin (H7) protect against ILT and fowl plague. *J Gen Virol.* 84:3343–3352.
153. Veits, J., T.C. Mettenleiter, and W. Fuchs. 2003. Five unique open reading frames of infectious laryngotracheitis virus are expressed during infection but are dispensable for virus replication in cell culture. *J Gen Virol.* 84:1415–1425.
154. von Bulow, V., and A. Klasen. 1983. Effects of avian viruses on cultured chicken bone-marrow-derived macrophages. *Avian Pathol.* 12:179–198.
155. Waidner, L.A., J. Burnside, A.S. Anderson, E.L. Bernberg, M.A. German, B.C. Meyers, P.J. Green, and R.W. Morgan. 2011. A microRNA of infectious laryngotracheitis virus can downregulate and direct cleavage of ICP4 mRNA. *Virol.* 411:25–31.
156. Waidner, L.A., R.W. Morgan, A.S. Anderson, E.L. Bernberg, S. Kamboj, M. Garcia, S.M. Riblet, M. Ouyang, G.K. Isaacs, M. Markis, B.C. Meyers, P.J. Green, and J. Burnside. 2009. MicroRNAs of Gallid and Meleagrid herpesviruses show generally conserved genomic locations and are virus-specific. *Virol.* 388:128–136.
157. Watrach, A.M., L.E. Hanson, and M.A. Watrach. 1963. The structure of infectious laryngotracheitis virus. *Virol.* 21:601–608.
158. Webster, R.G. 1959. Studies on infectious laryngotracheitis in New Zealand. *NZ Vet J.* 7:67–71.
159. Wilks, C.R., and V.G. Kogan. 1979. An immunofluorescence diagnostic test for avian infectious laryngotracheitis. *Aust Vet J.* 55:385–388.
160. Williams, R., C.E. Savage, and R.C. Jones. 1994. A comparison of direct electron microscopy, virus isolation, and a DNA amplification method for the detection of avain infectious laryngotracheitis virus in field material. *Avian Pathol.* 23:709–720.
161. Williams, R.A., M. Bennett, J.M. Bradbury, R.M. Gaskell, R.C. Jones, and F.T. Jordan. 1992. Demonstration of sites of latency of infectious laryngotracheitis virus using the polymerase chain reaction. *J Gen Virol.* 73:2415–2420.
162. Winterfield, R.W., and I.G. So. 1968. Susceptibility of turkey to infectous laryngotracheitis. *Avian Dis.* 12:191–202.
163. Yamada, S., K. Matsuo, T. Fukuda, and Y. Uchinuno. 1980. Susceptibility of ducks to the virus of infectious laryngotracheitis. *Avian Dis.* 24:930–938.
164. York, J.J., K.J. Fahey, and T.J. Bagust. 1983. Development and evaluation of an ELISA for the detection of antibody to infectious laryngotracheitis virus in chickens. *Avian Dis.* 27:409–421.
165. York, J.J., S. Sonza, and K.J. Fahey. 1987. Immunogenic glycoproteins of infectious laryngotracheitis herpesvirus. *Virol.* 161:340–347.
166. York, J.J., and K.J. Fahey. 1988. Diagnosis of infectious laryngotracheitis using a monoclonal antibody ELISA. *Avian Pathol.* 17:173–182.
167. York, J.J., J.G. Young, and K.J. Fahey. 1989. The appearance of viral antigen and antibody in the trachea of naive and vaccinated chickens infected with infectious laryngotracheitis virus. *Avian Pathol.* 18:643–658.
168. York, J.J., and K.J. Fahey. 1990. Humoral and cell-mediated immune responses to the glycoproteins of infectious laryngotracheitis herpesvirus. *Arch Virol.* 115:289–297.
169. Ziemann, K., T.C. Mettenleiter, and W. Fuchs. 1998. Infectious laryngotracheitis herpesvirus expresses a related pair of unique nuclear proteins which are encoded by split genes located at the right end of the UL genome region. *J Virol.* 72:6867–6874.

Chapter 6

Influenza

David E. Swayne, David L. Suarez, and Leslie D. Sims

Introduction

Disease in poultry caused by Type A influenza viruses in the family *Orthomyxoviridae* has been recognized since the late 19th century, causing mainly sporadic but serious outbreaks of disease. In 1997, H5N1 influenza A viruses caused severe fatal disease in both poultry and humans in the Hong Kong Special Administrative Region (SAR) of the Republic of China. Subsequent spread of these viruses from China into other parts of Asia and on to Europe and parts of northern Africa occurred from 2003 onward and they remain enzootic in poultry in a number of countries. Avian influenza (AI) has become the most widely reported avian disease.

Free-flying aquatic birds are the natural hosts of Type A influenza viruses. A dynamic cycle of infection occurs within aquatic avian species, many of which are migratory, and between these birds, poultry, and other animals. Spillover of viruses from wild aquatic birds to poultry and other species occurs frequently. Many of these spillovers are transient, whereas occasionally some of these influenza viruses evolve to become adapted to specific hosts other than free flying aquatic birds.

Today, orthomyxoviruses are recognized as the cause of significant numbers of natural infections and disease, usually of the upper and lower respiratory tract, in humans, horses, domestic pigs, dogs, and various bird species. Sporadic disease has occurred in mink and a variety of marine mammals (75, 100, 198, 399). Infection of domestic poultry by avian influenza (AI) viruses typically produces syndromes ranging from asymptomatic infection to respiratory disease and drops in egg production to severe, systemic disease with near 100% mortality (95). The disease produced depends on the virus strain as well as the species, age, and immune status of the infected poultry. The form of disease with high mortality is usually the result of infection by highly pathogenic (HP) AI viruses. Disease is usually absent with AI virus infection in most free-flying waterfowl species unless the strain involved is a H5N1 HPAI virus (Guangdong lineage) (313).

For more detail, see recent books (55, 58, 272, 365), special issues of journals (308, 209), and special articles on avian influenza topics (313, 330, 360, 385).

Definitions and Synonyms

"Avian influenza" is a broad term used to describe any infection or disease in birds caused by Type A influenza viruses. The term "avian influenza viruses" is used to describe influenza A viruses found customarily in birds. Wild waterfowl and other aquatic birds are the primordial reservoir of all influenza A viral genes (333). The appellation "bird flu" is used as a simplified alternative to avian influenza by the media to describe infections in poultry, humans, and other mammals with Type A influenza viruses derived from birds.

The highly lethal systemic disease caused by AI viruses is referred to as "highly pathogenic avian influenza" (26). "High pathogenicity" is an equivalent grammatical variant of "highly pathogenic" and can be used interchangeably. From the late 1870s to 1981, HPAI was known by various names including fowl plague (most common), fowl pest, peste aviaire, Geflugelpest, typhus exudatious gallinarium, Brunswick bird plague, Brunswick disease, fowl disease, and fowl or bird grippe (319, 320). These terms are no longer used to describe the disease.

Milder forms of AI were first recognized in various domestic poultry species between 1949 and the mid-1960s and have been termed low pathogenic, pathogenic, non-highly pathogenic, and low pathogenicity AI (LPAI) (13, 92, 277). Their impact on poultry production and trade has been much less severe than with HPAI. The official designation since 2002 is "low pathogenicity" for AI viruses that are not HPAI viruses (109).

The World Organization for Animal Health (Office International des Epizooties [OIE]) uses the designation of notifiable AI (HP notifiable AI [HPNAI] and LP notifiable AI [LPNAI]) for international animal health regulatory purposes (16, 231). HPNAI encompasses all HPAI, whereas LPNAI encompasses only H5 and H7 LPAI, subtypes that have been shown to convert from LP to HP viruses naturally in poultry. For more information see the Pathotype subsection under Strain Classification.

Economic Significance

Economic losses from AI have varied depending on the strain of virus, species of bird infected, number of farms involved, control methods used, and speed of implementation of control or

Diseases of Poultry, Thirteenth Edition. David E. Swayne.
© 2013 John Wiley & Sons, Inc. Published 2013 by John Wiley & Sons, Inc.

eradication strategies. Many of the economic losses associated with outbreaks of HPAI are due to consumer avoidance of poultry products and the measures implemented, especially if wide-area culling around infected premises is used. In most developed countries, HP and LPAI have not been enzootic diseases in the commercial poultry industries. Most outbreaks and economic losses have occurred from epidemics of HP or LPAI in commercially raised poultry, predominately chickens and turkeys. In some developing countries LPAI is enzootic in commercially raised poultry, especially viruses of the H9N2 subtype, and in some developed countries, H9N2, H5N2, and H6N1 LPAI have been enzootic in backyard and live poultry market (LPM) systems that mainly serve ethnic populations of large metropolitan areas. Since 2003, H5N1 HPAI has become enzootic in village poultry, especially domestic ducks in a few countries in Asia and Africa (364).

Generally, the most accurate reports on losses have come from HPAI eradication programs (Table 6.1). Direct losses in HPAI outbreaks have included high morbidity and mortality losses, depopulation and disposal costs, cleaning and disinfection, quarantine and surveillance costs, and indemnities paid for the birds. However, indirect costs such as uncompensated losses to the poultry industry including temporary or permanent loss in poultry exports, income lost by farmers and communities during the production down time, increased consumer costs from reduced supply of poultry products, and losses from decreases in consumer purchases can easily escalate losses by five- to 10-fold. The economic costs for eradication of HPAI have varied greatly, but eradication costs have been very high and appear to be proportional to the number of birds that died and were culled (Table 6.1). However, in the 1983–84 USA H5N2 HPAI epidemic, the projected cost of not implementing an eradication program was $500 million for losses ($1.3 billion in 2012 funds) to poultry farmers and $5.5 billion ($12.2 billion in 2012 funds) in increased customer costs (185).

Low pathogenicity AI outbreaks have caused significant economic losses for producers of chickens, turkeys, and ducks, especially when accompanied by secondary bacterial or viral pathogens, but accurate documentation of such costs are generally not available. In general, losses have been less than with HPAI outbreaks because infected flocks have typically been eliminated through a controlled marketing program, the mortality rates have been lower, no federal eradication costs were incurred, and national and international trade usually have not been disrupted, although bans are placed on imports by some countries when LPNAI occurs (Table 6.1). Losses from LPAI epidemics include mortality losses, increased condemnations at slaughter, medication against secondary bacterial infections, cleaning and disinfection, delayed placements of new birds, and for LP H5 and H7 outbreaks, restrictions in trade of poultry and poultry products has become increasingly common. Poorly documented but more costly have been the enzootic H9N2 LPAI poultry infections in much of Asia and the Middle East, and H5N2 LPAI poultry infections in Mexico, Central America, and the Caribbean with vaccination programs adding to the cost of production (281). Because LPAI is usually not dealt with by traditional stamping-out programs, the costs of LPAI are usually unknown. However, when a stamping-out program was undertaken in the Virginia 2002 H7N2 LPAI outbreak, the eradication program had similar costs as previous HPAI outbreaks (Table 6.1). In developed countries, stamping-out programs have emerged to be the principle control method for H5 and H7 LPAI (238), although methods used to achieve this vary and include vaccination followed by controlled marketing (129).

The scale of investment into control of avian influenza following the emergence of H5N1 HPAI in Asia was largely due to concerns that the virus might become readily transmissible between humans and the very high cost of a human pandemic caused by an influenza virus that produced high-level mortality in humans (207).

Public Health Significance

In general, influenza viruses exhibit host species adaptation with transmission occurring most frequently and with ease between individuals of the same species; occasionally interspecies transmission to closely related species occurs (330, 344). Although rare, AI viruses or their genes have been transferred to humans (Table 6.2) (95). These have occurred via (1) transfer of complete AI viruses (*in toto*) with individual sporadic infections, and (2) appearance of individual AI viral gene segments in pandemic human influenza viruses (i.e., reassortment of gene segments). Although such transfers have produced severe clinical disease with hospitalization, serological evidence suggests cross species transmission resulting in sub-clinical infection or mild disease occurs more frequently (390). The H5N1 HPAI virus (Guangdong lineage) is unique among AI viruses, having caused more human infections than all the other AI viruses combined. For more details see Public Health Significance of Poultry Diseases in Chapter 1.

History

The term "influenza" originally referred to epidemics of acute, rapidly spreading catarrhal fevers of humans caused by viruses in the family *Orthomyxoviridae* (166). The history of AI can be divided into four general periods: (1) early reports of HPAI, (2) recognition of less severe AI disease (LPAI) in domestic poultry, (3) identification of AI viruses from asymptomatic wild bird reservoirs, and (4) widespread reports of HPAI from the 1990s onward, including H5N1 HPAI (Guangdong lineage), which remains enzootic to a number of developing countries (104). AI was first reported as HPAI ("fowl plague") in 1878 by Perroncito in Italy (320). Initially, the disease was confused with the acute septicemic form of fowl cholera until 1880, when Rivolto and Delprato differentiated the two based on clinical and pathological features. In 1901, Centanni and Savonuzzi determined the cause was a filterable agent, but the virus was not identified nor classified as an influenza virus until 1955 (269, 270, 320).

Table 6.1. Examples of economic losses from HP and LPAI epizootics as reported in US dollars.

Year	Outbreak	Birds dead or culled	Cost item	Original cost	Cost in 2012 $US unless specified otherwise	Cost/farm in 2012 $US	Reference
HPAI							
1924–25	USA: Fowl plague	Unknown	Direct losses	$1M	$13.2M	–	(320)
1983–84	USA: H5N2 HPAI	17M (449 farms)	USDA eradication	$63M	$142M	$316,000	(108, 185)
			Non-indemnified industry losses	$15M	$34M	$7600	
			Increased customer costs	$349M	$788M	$1.8M	
1985	Australia: H7N7 HPAI	238,518 (1 farm)	Eradication cost	$1.4M	$2.9M	$2.9M	(76)
1999–2000	Italy: H7N1 HPAI	13M (413 farms)	Compensation	$100M	$135M	$327,000	(350)
			Indirect costs	$500M	$675M	$1.63M	
1997	Hong Kong: H5N1 HPAI	1.5M	Eradication	$13M	$18.2M	–	(350)
February–May 2003	Netherlands: H7N7 HPAI	30M	a) Government, control of the disease b) Industry trade disruption	a) €270M b) €500M	a) $290 b) $539	–	(http://ec.europa.eu/food/international/organisations/wto_regional/ai_netherlands_en.pdf; A. McLeod, personal communication, 2012)
Late 2003–mid-2005	Asia: H5N1 HPAI	140M	Losses to the poultry industries	>$10B	>$10B	–	(409)
LPAI							
1978	Minnesota, USA: various LPAI	141 farms	Losses to the poultry industries	$5M	$17.3M	$123,000	(125)
1995	Minnesota, USA: H9N2 LPAI	178 farms	Losses to the poultry industries	$6M	$8.9M	$50,000	(125)
1978–1995	Minnesota, USA: various LPAI	1,058 farms	Losses to the poultry industries	$22M	–	$21,000	(125)
1995	Utah, USA: H7N3 LPAI	2M (60 farms)	Losses to the poultry industries	$2M	$3M	$50,000	(125, 250)
2002	Virginia, USA: H7N2 LPAI	4.7M (197 farms)	USDA eradication	$81M	$101M	$513,000	(5)
			Losses to the poultry industries	$130M	$163M	$827,000	
			State government	$1M	$1.25M	$6300	

Table 6.2. Listing of confirmed human cases of infection with AI viruses (modified from [402, 257]).

Year	Virus	Location	Symptoms	Exposure	Cases	Deaths	Reference
1959	H7N7 HPAI	USA	Hepatitis	Unknown	1	0	(83)
1977	H7N7 HPAI	Australia	Conjunctivitis	Laboratory accidental exposure	1	0	(371)
1978–79	H7N7 LPAI	USA	Conjunctivitis	Seals with respiratory disease	3	0	(392, 393)
1996	H7N7 LPAI	United Kingdom	Conjunctivitis	Tending domestic ducks that mixed with wild ducks on a pond	1	0	(28, 179)
1998, 2003, 2007	H9N2 LPAI	Hong Kong and mainland China	3 = respiratory symptoms; 6 = influenza-like illness	1 = contact with live poultry in LPM, 7 = not reported	9	0	(119, 252, 253, 402)
2002–03	H7N2 LPAI	USA	1 = asymptomatic, 1 = respiratory symptoms	1 = outbreak crew, 1 = unknown	2	0	(61, 62)
2003	H7N7 HPAI	Netherlands	Conjunctivitis > influenza-like illness > other symptoms	Depopulation crews, poultry workers and farmers from poultry H7N7 HPAI outbreak	89	1	(174)
2004	H7N3 HPAI	Canada	Conjunctivitis, coryza, and headache	Depopulation crews for poultry H7N3 HPAI outbreak	2	0	(381)
2006	H7N3 LPAI	United Kingdom	Conjunctivitis	Poultry	1	0	(226)
2007	H7N2 LPAI	United Kingdom	influenza-like illness (ILI) and/or conjunctivitis	Small holding poultry	4	0	(22)
1997–2012	H5N1 HPAI	Asia, Africa[1]	Respiratory symptoms > gastrointestinal	Exposure to live or dead infected poultry in LPM or villages	601	350	(218, 251, 404)
				Total	711	351	

[1]Reflect the cases as of 01/27/2012. Since completing this chapter, in 2013 a LPAI virus of the H7N8 subtype has caused severe disease in humans with transmission to humans associated with LPM.

In 1894, a severe outbreak of HPAI occurred in Northern Italy and was disseminated via chickens to eastern Austria, Germany, Belgium, and France (205, 319). HPAI was spread throughout Germany as the result of the 1901 Brunswick Fowl Exposition (319). During the first half of the 20th century, HPAI was reported in Western and Eastern Europe, the Middle East, Asia, North Africa, and North and South America (91, 176, 213, 320). In many parts of Europe, HPAI was enzootic until the mid-1930s (17). HPAI was reported in the United States in LPM of New England and the Midwest during 1924 and 1925 and in a few flocks in New Jersey during 1929 (320). Quarantine, depopulation, cleaning, and disinfection were used to eradicate HPAI from the United States.

The outbreaks of HPAI between 1901 and the mid-1950s were caused by viruses of the H7N1 and H7N7 subtypes (see Strain Classification) (95). The H5 subtype for HPAI was first diagnosed during 1959 in chickens of Scotland (H5N1) and during 1961 in common terns (*Sterna hirundo*) of South Africa (H5N3) (345). Table 6.3 lists the summaries and references of HPAI outbreaks between 1959 and 2012. Of the 32 epizootics, 30 have involved domesticated poultry, principally chickens and turkeys, one involved exclusively wild birds (i.e., common terns), and one involved both domestic poultry, including ducks and geese, and wild birds.

Milder diseases caused by AI viruses were recognized beginning in the middle of the 20th century (91); i.e., LPAI (see Strain Classification—Pathogenicity). The oldest existing LPAI virus, the Dinter strain from Germany, was isolated from chickens in 1949, but it was not identified as an AI virus until 1960 (A/chicken/Germany/49 [H10N7]). Similarly, LPAI viruses were isolated from domestic ducks with respiratory disease between 1953 and 1963 in Canada, Czechoslovakia, England, and the Ukraine (91). Low pathogenicity AI viruses emerged as a cause of respiratory disease and drops in egg production in turkeys in Canada and the United States during the 1960s and early 1970s. Since 1971, numerous H5 and H7 LPAI viruses have been isolated and characterized, thus dispelling the myth that all H5 and H7 subtypes are HP (11, 95, 136). H9N2 viruses were first identified in poultry in the 1960s and became widespread in Asian poultry in the 1990s (118).

Many AI viruses have been isolated from asymptomatic infections in wild birds, primarily healthy wild aquatic birds in the orders *Anseriformes* and *Charadriiformes*, populations of which are regarded as asymptomatic reservoirs of AI viruses (312). AI viruses from wild birds have been mostly LP for domestic poultry. Initially, surveys of migratory waterfowl during the 1960s showed serologic evidence of infection by AI viruses (90). During 1972, AI viruses were isolated from migratory ducks in California (296) and from a pelagic seabird (shearwater) in Australia (87). However, some HPAI viruses have been isolated from wild birds: (1) during an epidemic with high mortality in common terns (A/tern/South Africa/61 [H5N3]); (2) single isolations of A/finch/Germany/72 (H7N1), A/gull/Germany/79 (H7N7) and A/Peregrine Falcon/UAE/2384/98 (H7N3); and (3) during the H5N1 HPAI outbreak in Asia, Europe, and Africa with multiple isolations from wild birds (14, 66, 195, 201).

Table 6.3. Thirty-two documented epidemics of HPAI since the discovery of AI virus as cause of fowl plague in 1955, modified from (350, 345, 17).

Dates	Prototype AI virus	Subtype	Number affected with high mortality or were depopulated[a]	Specific References
1959	A/chicken/Scotland/59	H5N1	Scotland: 2 flocks of chickens (*Gallus gallus domesticus*): total number of birds affected not reported	(258) (D.J. Alexander, personal communication, 2000)
1961	A/tern/South Africa/61	H5N3	South Africa: 1,300 common terns (*Sterna hirundo*)	(38)
1963	A/turkey/England/63	H7N3	England: 3 small farms, 29,000 breeder turkeys (*Meleagridis gallopavo*)	(400)
1966	A/turkey/Ontario/7732/66	H5N9	Canada: 1 farm, 8,100 breeder turkeys	(182)
1976	A/chicken/Victoria/76	H7N7	Australia: 2 farms, 25,000 laying chickens, 17,000 broilers, and 16,000 ducks (*Anas platyrhyncos*)	(21, 380)
1979	A/chicken/Germany/79	H7N7	Germany (former East Germany): 1 chicken farm (600,000 dead or culled), 1 goose farm (80 dead or culled	(17, 18)
1979	A/turkey/England/199/79	H7N7	England: 3 commercial turkey farms, 9,000 birds	(9, 10, 15)
1983–84	A/chicken/ Pennsylvania/1370/83	H5N2	United States: 452 flocks, 17 million poultry; most were chickens or turkeys, a few chukar partridges (*Alectoris chukar*) and guinea fowl (*Numida meleagris*)	(95, 96, 382)
1983	A/turkey/Ireland/1378/83	H5N8	Ireland: 3 farms, 800 meat turkeys died on original farm; 8,640 turkeys, 28,020 chickens, and 270,000 ducks were depopulated on original farm and 2 adjacent farms	(14, 206)
1985	A/chicken/Victoria/85	H7N7	Australia: 1 farm, 24,000 broiler breeders, 27,000 laying chickens, 69,000 broilers, and 118,518 unspecified type of chickens	(29, 76)
1991	A/turkey/England/50-92/91	H5N1	England: 1 farm, 8,000 turkeys	(15)
1992	A/chicken/Victoria/92	H7N3	Australia: 2 farms, 12,700 broiler breeders, 5,700 ducks	(275, 401)
1995	A/chicken/Queensland/95	H7N3	Australia: 1 farm, 22,000 laying chickens	(401)
1994–95	A/chicken/ Puebla/8623-607/94 A/chicken/ Queretaro/14588-19/95	H5N2	Mexico: Many farms, chickens[b]	(387, 95)
1994–95, 2001, 2004	A/chicken/Pakistan/447/95 A/chicken/ Pakistan/1369-CR2/95	H7N3	Pakistan: Many farms, 3 incursions: (1) 3.2 million broilers and broiler breeder chickens (northern part of country, 1994–95), (2) 300,000 chickens (central part of country, 2001), and (3) 2.52 million layers (Karachi, 2004)[c]	(95, 221)
1996–cont.	A/goose/Guangdong/3/1996 A/chicken/Hong Kong/220/97	H5N1	Asia, Africa, and Europe (65 countries/regions): More than 4000 million birds dead or culled (http://www.fao.org/docrep/014/i2249e/i2249e00.pdf, http://www.fao.org/docrep/015/an388e/an388e.pdf), mostly chickens, but also ducks, geese, Japanese quail, and some wild birds[d]	(103, 291, 292)
1997	A/chicken/New South Wales/1651/97	H7N4	Australia: 3 farms, 128,000 broiler breeders, 33,000 broilers, 261 emu (*Dromaius novaehollandiae*)	(255)
1997	A/chicken/Italy/330/97	H5N2	Italy: 8 farms, 2,116 chickens, 1,501 turkeys, 731 guinea fowl, 2,322 ducks, 204 quail (species unknown), 45 pigeons (*Columbia livia*), 45 geese (species unknown), and 1 pheasant (species unknown)	(53)
1999–2000	A/turkey/Italy/4580/99	H7N1	Italy: 413 farms, 8.1 million laying chickens; 2.7 million meat and breeder turkeys; 2.4 million broiler breeders and broilers; 247,000 guinea fowl; 260,000 quail, ducks, and pheasants, 1,737 backyard poultry; and 387 ostriches	(56)
2002	A/chicken/ Chile/184240-1/2002	H7N3	Chile: 2 farms, multiple houses; 617,800 broiler breeders, unspecified number turkey breeders (2 houses)	(268)

(*continued*)

Table 6.3. (*continued*)

Dates	Prototype AI virus	Subtype	Number affected with high mortality or were depopulated[a]	Specific References
2003	A/chicken/Netherlands/621557/2003	H7N7	Netherlands, Belgium, and Germany: (1) Netherlands: 255 infected flocks, 1381 commercial and 16,521 backyard/smallholder flocks depopulated; 30 million died or depopulated – majority were chickens; (2) Belgium: 8 farms, 2.3 million poultry dead or culled; (3) Germany: 1 farm, 500 dead and 32,400 culled poultry on premise, pre-emptive culling 419,000 poultry	(18, 98)
2004	A/Chicken/Canada/AVFV2/04	H7N3	Canada: 42 commercial and 11 backyard flocks infected (1.2 million poultry); approximately 16 million commercial poultry depopulated, most were chickens	(142, 227)
2004	A/chicken/Texas/298313/2004	H5N2	United States: 1 non-commercial farm and 2 live poultry markets, 6,600 chickens	(191, 228)
2004, 2006	A/ostrich/South Africa/N227/2004, A/ostrich/South Africa/AI1091/2006	H5N2	South Africa: 2004: 11 ostrich farms with depopulation of 23,625 ostriches and 3,550 other poultry (chickens, turkeys, geese, ducks, and pigeons); 2006: 7,342 ostriches dead or culled	(229, 232, 233)
2005	A/chicken/North Korea/1/2005	H7N7	North Korea: 3 farms, 218,882 chickens culled; number dead not reported	(230)
2007	A/chicken/Saskatchewan/HR-00011/2007	H7N3	Canada: 1 farm, 10 barns, 49,500 broiler breeder hens and roosters; 540 dead, 48,500 culled; LPAI virus appeared first, with rapid mutation to HPAI virus	(40, 234)
2008	A/chicken/England/1158-114061/2008	H7N7	England: 1 farm, 25,000 layer chickens; 10,000 dead, 15,000 culled; HPAI viruses derived from LPAI virus on premise	(82, 235)
2009	A/chicken/Spain/6279-2/2009	H7N7	Spain: 1 farm, 5 barns; 308,640 layer chickens; 30,000 dead, 278,640 culled	(150, 237)
2011–cont.	A/ostrich/South Africa/AI2114/2011	H5N2	South Africa: 50 farms, 55,043 ostriches, 108 deaths, 4,930 culled, and 43,917 slaughtered; loss of export markets. As of 5/7/13.	(241)
2012	Not available	H5N2	Chinese Taipei: broiler breeder, 804 deaths, 4,036 culled; native chickens, 318 deaths, 9,307 culled; layers, 426 deaths, 8,221 culled	(240)
2012–cont.	A/chicken/Jalisco/12283/2012	H7N3	Mexico: layer and breeder chickens, 22.4 million; deaths (1.2 million), culled on affected farms (10.2 million), and preemptively culled on neighboring farms (11 million) as of 12/20/12; resurgence, 48 farms, 5,461,534 poultry affected as of 4/23/2013	(242)
2012	A/chicken/Australia/2012	H7N7	Australia (New South Wales): Free range egg laying chickens, 5,000 deaths and 45,000 culled as of 12/22/2012	http://www.oie.int/wahis_2/public/wahid.php/Reviewreport/Review?reportid=12612

[a] Most outbreaks were controlled by "stamping out" or depopulation policies for infected and/or exposed populations of birds. Chickens, turkeys, and birds in the order *Galliformes* had clinical signs and mortality patterns consistent with HPAI, while ducks, geese, and other birds lacked or had low mortality rates or infrequent presence of clinical signs.

[b] "Stamping-out" policy was not used for control. The AI outbreak had concurrent circulation of LP and HPAI virus strains. However, HPAI virus strains were present only from late 1994 to mid-1995. Estimates of number of birds infected with HP AI strains are unavailable but 360 commercial chicken flocks were "depopulated" for AI in 1995 through controlled marketing.

[c] "Stamping-out" policy was not used for control. Surveillance, quarantine, vaccination, and controlled marketing were used as the control strategy. The numbers affected are crude estimates from three separate time periods of clinical disease outbreaks, but the virus lineage is the same between the outbreaks.

[d] The H5 and N1 gene lineages have been maintained among the HPAI viruses from outbreaks in various Asian, African, and European countries (1996–cont.). The six internal gene segments have undergone reassortment. The initial H5N1 HPAI outbreaks were reported in China (1996) with three incursions in Hong Kong (1997, 2001, and 2002). This was followed by regional extension with outbreaks in 2003–2005 within Southeast Asia (South Korea, Vietnam, Japan, Indonesia, Thailand, Cambodia, Laos, China, and Malaysia). In mid-late 2003, outbreaks occurred in both wild birds and poultry in central Asia with extension to Eastern Europe and the Middle East by fall of 2005. In 2006, outbreaks were reported in Africa. Initially, chickens were the main species affected with disease and death, but in many of the outbreaks, domestic ducks have emerged to be a major species in maintenance and epidemiology of the viruses. Various wild birds have succumbed to infections.

The period from the 1980s onward saw a marked increase in the number and severity of outbreaks of HPAI, coinciding with but not necessarily due to a massive increase in the number of poultry reared globally. The spread of H5N1 HPAI across multiple continents from 2003 onward was unprecedented. Because AI is an international concern, global interest in AI resulted in the convening of international symposia in 1981, 1986, 1992, 1997, 2002, 2006, 2009, and 2012 to deal with AI issues (27, 93, 94, 331, 341, 349, 357). Because influenza is an international problem, solutions will require international, national, and state/provincial efforts and cooperation (95).

Etiology

Classification

AI viruses are classified in the family *Orthomyxoviridae*, genus *Influenzavirus* A (74).

Morphology

Virions are typically spherical to pleomorphic (120 nm) but can be filamentous with lengths up to several hundred nm (Figure 6.1) (74). The surface is covered by two types of glycoprotein projections (10–14 nm in length and 4–6 nm in diameter): (1) rod-shaped trimers of hemagglutinin (HA), and (2) mushroom-shaped tetramers of neuraminidase (NA). Virus buoyant density is 1.19 g/cm^3 in aqueous sucrose and single virion molecular weight (Mr) is 250×10^6 (74).

The nucleocapsid is helical. The viral genome is composed of eight segments of single-stranded, negative-sense RNA that code for 10 or 11 proteins depending on strain. Their size and function are listed in Table 6.4. Eight proteins are constituents of the virus (HA, NA, nucleoprotein [NP], M1, M2, PB1, PB2, and PA, and minor amount of NS2), and a nonstructural protein (NS1) is located in the host cell cytoplasm (180). Expression of PB1-F2 is variable, depending on the virus strain (67).

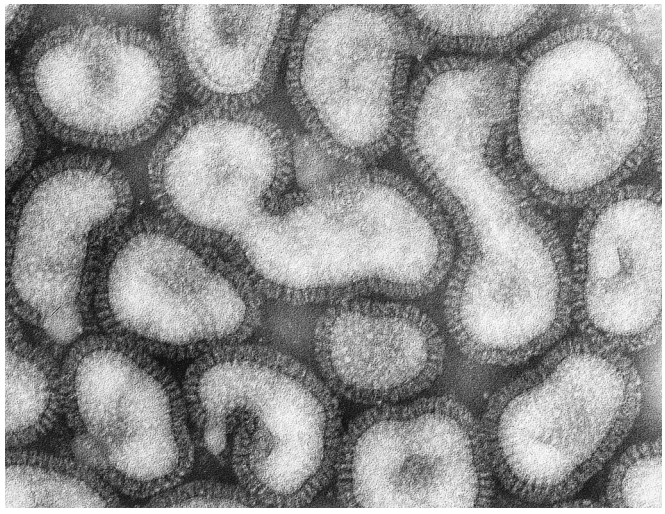

Figure 6.1. Purified A/WSN/33 AI virus. Negative stain with 2% phosphotungstic acid. ×282,100. (Gopal Murti)

Chemical Composition

Influenza virions are composed of 0.8%–1% RNA, 5%–8% carbohydrate, 20% lipid, and 70% protein (180). The carbohydrates are contained within glycolipids and glycoproteins and include galactose, mannose, fucose, and glucosamine (168). Ribose is contained in the RNA genome. Lipids are present in the viral envelope and are derived from the host cell. Most of the lipids are phospholipids, but small amounts of cholesterol and glycolipid are present. The viral genome specifies the proteins and their potential glycosylation sites.

Virus Replication

The stages of virus replication have been reported by various investigators in great detail (180, 245). In brief, AI virus HA adsorbs to host cell receptors containing sialic acid, thus initiating receptor-mediated endocytosis. In the endosomes, low-pH-dependent fusion occurs via HA-mediated fusion of the envelope with the endosome membrane. Proteolytic cleavage of HA into HA1 and HA2 is an essential prerequisite for fusion and infectivity. The viral nucleocapsids are transported to the nucleus where viral transcriptase complex synthesizes mRNA. Transcription is initiated with 10–13 nucleotide RNA fragments generated from host heterogenous nuclear RNA via viral endonuclease activity of PB2. Six monocistronic mRNAs are produced in the nucleus and transported to the cytoplasm for translation into HA, NA, NP, PB1, PB2, and PA proteins. The mRNA of NS and M gene segments undergo splicing with each producing two mRNAs, which are translated into NS1, NS2, M1, and M2 proteins. The HA and NA proteins are glycosylated in the rough endoplasmic reticulum, trimmed in the Golgi, and transported to the surface where they are embedded in the plasma membrane. The eight viral gene segments along with internal viral proteins (NP, PB1, PB2, PA, and M2) assemble and migrate to areas of the plasma membrane containing the integrated HA, NA, and M2 proteins. The M1 protein promotes close association with the plasma membrane and budding of the virions.

Susceptibility to Chemical and Physical Agents

AI viruses are relatively unstable in the environment. Physical factors such as heat, extremes of pH, hypertonic conditions, and dryness can inactivate AI viruses. Because AI viruses have lipid envelopes, they are inactivated by organic solvents and detergents such as sodium desoxycholate and sodium dodecylsulfate. In the presence of organic matter, AI virus can be destroyed by chemical inactivants such as aldehydes (formaldehyde or gluteraldehyde), beta-propiolactone, and binary ethylenimine. After removal of organic matter, chemical disinfectants such as phenolics, ammonium ions (including quaternary ammonium disinfectants), oxidizing agents (such as sodium hypochlorite), dilute acids, and hydroxylamine can destroy AI viruses (113, 189).

Table 6.4. Gene and protein information on *Influenzavirus A* (74, 181, 245).

Genome		Proteins coded				
Segment	Length (nucleotides[a])	Name	Length (aa)	App. no. molecules/virion	Type	Function
1	2341	PB1	759	30–60	Polymerase complex	Transcriptase
2	2341	PB2	757	30–60	Polymerase complex	Endonuclease
3	2233	PA	716	30–60	Polymerase complex	1. Viral RNA replication. 2. Proteolytic activity
4	1778	Hemagglutinin (HA)	566	500	Integrated type I membrane glycoprotein	1. Virus attachment to sialyloligosaccharide cell receptors including hemagglutinating activity. 2. Envelop fusion. 3. Antibody-mediated viral neutralization
5	1565	Nucleoprotein (NP)	498	1000	Major structural protein—associated with viral RNA segments	1. Cytoplasmic to nuclear (NP) protein—transport of viral RNP. 2. Necessary for full length vRNA synthesis. 3. Antigen target for cytotoxic T lymphocytes
6	1413	Neuraminidase (NA)	454	100	Integrated type II membrane glycoprotein	1. Cell receptor-destroying enzyme (sialic acid residues) that causes virus elution. 2. Antibody-mediated virus neutralization restricts virus spread
7	1027	Matrix 1 (M1)	252	3000	Non-glycosylated structural protein beneath viral envelope	Most abundant protein—role in virus budding
		Matrix 2 (M2)	97	20–60	Integrated type III glycosylated membrane protein	Ion channel
8	890	Non-structural 1 (NS1)	230	–	RNA binding protein	1. Inhibit processing of cellular mRNA. 2. Enhance cytoplasmic translation of viral mRNA. 3. Possible inhibition of interferon pathways
		Non-structural 2 (NS2)	121	130–200	Nuclear export protein	Nuclear export of viral RNP

[a]Number of nucleotides based on human influenza strain A/PR/8/34 (H1N1).

Laboratory Situation

AI viruses are relatively stable in protein-containing solutions, but long-term storage should be at –70°C or following lyophilization. Egg grown virus can be maintained for several weeks at 4°C without loss of infectivity, but hemagglutinating and NA activities can be maintained longer even when the virus is no longer infectious. Inactivation by degrading the viral RNA can retain hemagglutinating and NA activities and antigenicity using various concentrations of formalin, binary ethylenimine, and beta-propiolactone, making these methods valuable for vaccine production (167). Most commonly used detergents and disinfectants (such as phenolics, quaternary ammonium surfactant compounds, and sodium hypochlorite) inactivate AI viruses, but RNA may be preserved and detected by molecular tests long after viable virus cannot be isolated (327).

Field Situation

Influenza viruses when shed are protected by organic material such as nasal secretions or feces, which increase resistance to physical and chemical inactivation (95). Cool and moist

conditions favor increased survival of AI viruses in the environment. AI viruses have remained viable in liquid manure for 105 days in the winter and in feces for 30–35 days at 4°C, for seven days at 20°C, and for four days at 25°C–32°C in the shade (32, 108, 305, 391). In water at 28°C, the concentration of A/Whooping Swan/Mongolia/244/05 (H5N1) (Mongolia/05) and A/Duck Meat/Anyang/01 (H5N1) (Anyang/01) were reduced by 1 log in four and five days, respectively, and no virus was detected after 26 and 30 days, respectively. However, at 17°C, Mongolia/2005 and Anyang/2001 virus could persist until 158 and 94 days, respectively (43). The H5N1 HPAI virus had shorter environmental survival times compared to LPAI viruses obtained from wild waterfowl (43), but some H5N1 HPAI viruses have variation in survival times that can be longer (244).

Inactivation and elimination of AI viruses shed into the environment is essential in the control of field infection and can be accomplished through integrated approaches including heating of buildings to 90°F–100°F (32°C–38°C) for one week, thorough removal and proper disposal of manure and litter, cleaning and disinfecting of buildings and equipment, and allowing a vacancy period before restocking (122). Virus in manure and litter must be inactivated or disposed of by burial, composting, or incineration. Composting was effective at killing HPAI viruses within poultry carcasses in less than 10 days (279). Effective disinfectants against AI viruses on clean surfaces include 5.25% sodium hypochlorite, 2% sodium hydroxide (lye), phenolic compounds, acidified ionophor compounds, chlorine dioxide disinfectants, strong oxidizing agents, and 4% sodium carbonate/0.1% sodium silicate (71). However, organic material must be removed before disinfectants can work properly.

Pasteurization and cooking are effective means of inactivating AI viruses. USDA standard cooking times for poultry meat which achieves an internal temperature of 165°F, and pasteurization (55.6°C–63.3°C, 210–372 s) are adequate to kill AI viruses 352, 355, 372).

Strain Classification

Antigenicity

Influenza viruses are classified to genus ("type") based on serologic reactions of the internal proteins, principally NP and M1 proteins. This is typically done by an immunoprecipitation test (i.e., agar gel immunodiffusion test [AGID]) (363). All AI viruses are Influenzavirus A or type A. Influenzaviruses B and C (i.e., Types B and C) occur in humans and rarely in seals and pigs, but neither has been isolated from birds.

Influenzavirus A is further subtyped based on serologic reactions of the HA and NA surface glycoproteins or sequence analysis of HA and NA gene segments. Sixteen subtypes of HA (H1-16) and nine subtypes of NA (N1-9) are recognized for AI viruses. Serologic subtyping of HA is done by the hemagglutinin inhibition (HI) test and subtyping of NA by neuraminidase inhibition (NI) test (110, 363). Most combinations of the 16 HA and 9 NA AI virus subtypes have been reported in domestic or wild birds, but distribution varies by year, geographic location, and host species. Since 1980, nomenclature for subtyping of HA and NA has been standardized for all type A influenza viruses from birds, pigs, horses, and humans (405). Prior to 1980, subtypes of HA and NA were classified according to the species of origin. Recently, a purported H17 influenza virus has been isolated from Central American bats, but its definitive classification awaits further debate (374). H5N1 HPAI viruses (Guangdong lineage) have been further classified into clades to reflect molecular variation and evolution in genes encoding the HA protein that have occurred since these viruses first emerged in 1996. Ten first order clades and some second (e.g., Clade 2.2), third (e.g., Clade 2.2.1) and fourth order clades have been identified. Criteria for establishing these clades have been set based on molecular differences between and within clades (403).

Convalescent sera from chickens and ferrets and monoclonal antibodies have been used for determining antigenic relatedness of influenza viruses within the individual subtype (95). Such studies typically have used HI, enzyme-linked immunosorbent assays (ELISA), and/or virus neutralization tests. Monoclonal antibodies have been useful for the detailed study of individual antigenic epitopes such as comparing the HA of H1N1 viruses from turkeys and pigs to establish antigenic relatedness of their HAs (23, 137). Antigenic cartography has been applied to H7N3 and H5N1 HPAI viruses (1, 88).

Strain Nomenclature

Standard international nomenclature for the designation of influenza virus strains has been established (405). The naming of the influenza virus strains includes the type (A, B, or C), host of origin (except for human, where the "host of origin" is omitted), geographic site, strain number (if any), and year of isolation followed by the antigenic subtype designating HA (H) and NA (N) in parentheses for type A influenza viruses (95). For example, a type A influenza virus isolated from chickens in Pennsylvania during 1983 and classified as H5N2 is designated "A/chicken/Pennsylvania/1370/83 (H5N2)."

Antigenic Variation of Strains—Drift and Shift

As has been demonstrated historically with seasonal human influenza viruses (H1N1 and H3N2), influenza A viruses have a high frequency of antigenic variation in the surface glycoproteins (HA and NA) because of two phenomena, drift and shift (219).

Antigenic drift in influenza viruses arises from point mutations in the HA and/or NA genes that results in minor antigenic changes in the coding proteins (219). In vaccinated poultry populations, immune pressure, or more likely improper, incomplete, or inadequate population immunity, may play a role in selecting antigenic variants (59, 190) as it does *in vitro* (145). In areas where LPAI viruses are enzootic, such as H9N2 LPAI viruses in the Middle East and Asia, H5N2 LPAI viruses in the Americas, and H5N1 HPAI viruses in Asia and Africa, infection by field viruses is widespread and antigenic variants have arisen. Vaccination programs that do not produce strong population immunity that use improper and inadequate vaccination have been associated temporally with

the appearance of drift variants in the field, although causation has not been established (364).

Antigenic shift arises from genetic reassortment between the gene segments of two influenza viruses that infect the same cell and result in the acquisition of novel HA and/or NA antigen combinations in a virus that can infect a population with no preexisting immunity (219). In LPM, antigenic shift in HA and/or NA subtypes has been documented. In addition, genetic reassortment has resulted in the exchange of viral genes other than those coding for the HA and NA, as reported for HPAI viruses in Asia in chickens and geese (60, 322, 323). Commonly, wild ducks have co-infection with different influenza viruses which provides opportunities for reassortment of influenza virus genes to occur (285).

Immunogenicity or Protective Characteristics

After natural infection or vaccination, antibodies are produced to a number of viral proteins, but only antibodies produced to the surface proteins HA, NA, or M2 are protective. The HA protein is the major antigen that elicits antibodies that are protective against death and clinical signs. Antibodies to the HA protein are subtype specific (i.e., they only neutralize influenza virus of the homologous HA subtype both *in vivo* and *in vitro* assays) (46). Antibodies produced against the NA protein also can provide protection against homologous NA subtypes in birds (367), but such protection requires higher levels of antibody to provide protection similar to the HA. Antibodies to the M2 protein, which in some vaccine experiments can provide partial protection in mice, provided minimal protection of chickens against HPAI (413).

Antibodies against the internal proteins do not confer protection from death or clinical signs following challenge by HPAI viruses (398). However, immunization with NP or other influenza proteins can induce a cellular immune response that reduces virus replication during the late stages of the infectious process (172). Because the internal proteins are more conserved than the HA and NA proteins, heterotypic protection has been observed. (282). However, such heterotypic immunity has not been of sufficient length and level to provide protective vaccines in the field. Work on so-called universal vaccines against Type A influenza for humans has focused on conserved areas of the HA, the NP, and M2e protein as well as systems to boost cell mediated immunity (131, 304).

Genetic or Molecular Characteristics

With the widespread availability of sequencing technology, more than 50,000 influenza viruses have been either partially or fully sequenced. This has resulted in detailed phylogenetic comparisons of strains for purposes of molecular epidemiology, identification of reassortant gene segments, and identification of specific mutations and their correlation with biological properties. Because of the large amount of sequence data available, multiple influenza specific websites have been developed to help manage the data. Studies of gene sequences have highlighted gaps in AI surveillance based on gaps in phylogenetic trees between newly identified viruses and those identified previously.

Pathotype

Based on pathogenicity (i.e., the ability to produce disease), AI viruses from poultry are classified into two pathotypes: HP and LP (i.e., non-HP). This terminology was originally based on lethality in experimentally inoculated chickens, but in 1994, molecular criteria were added to the definition (383). To foster international control of specific AI viruses, OIE Terrestrial Code lists "notifiable" AI viruses as all HPAI (i.e., HPNAI) viruses and all H5 and H7 LPAI (i.e., LPNAI) viruses (239). H5 and H7 LPAI viruses became LPNAI in 2006 because these subtypes can mutate to the HP form when allowed to circulate in poultry populations (236). The OIE Terrestrial Code now lists "notifiable" AI (HPNAI and LPNAI) as follows (231, 239):

1. HPNAI viruses have an IVPI in six-week-old chickens greater than 1.2 or, as an alternative, cause at least 75% mortality in four- to eight-week-old chickens infected intravenously. H5 and H7 viruses which do not have an IVPI of greater than 1.2 or cause less than 75% mortality in an intravenous lethality test should be sequenced to determine whether multiple basic amino acids are present at the cleavage site of the hemagglutinin molecule (HA0); if the amino acid motif is similar to that observed for other HPNAI isolates, the isolate being tested should be considered as HPNAI viruses.
2. LPNAI viruses are all influenza A viruses of H5 and H7 subtype that are not HPNAI viruses.

In addition, the OIE code creates by default a third category of AI viruses—non-H5 and non-H7 LPAI viruses for which there is no formal requirement to report to OIE, unless they are causing a severe disease, but these viruses may be reportable to national and state/provincial authorities. However, based on pathobiological criteria (e.g., disease, lesions, and signalment), LPAI viruses are indistinguishable irrespective of the H and N subtype. Although the pathogenicity classification is specific for chickens, similar *in vivo* test results have been obtained for related birds in the order *Galliformes* (7, 259). However, most AI viruses that are HP for chickens have been LP for domestic ducks except for some strains of H5N1 HPAI virus (Guangdong lineage) which are also highly lethal for young domestic ducks, but not always highly lethal in older ducks (7, 152). Pathogenicity test results are specific for the host used in the test.

Being H5 or H7 subtypes are not predictors of HP; i.e., only a small percentage of H5 and H7 AI viruses have mutated to the HP phenotype. By contrast, all naturally occurring H1-4, H6, and H8-16 AI viruses have been of low virulence (i.e., LP) for chickens experimentally when given by the natural route of challenge.

Laboratory Host Systems

The preferred method for isolation and propagation of AI viruses has been nine- to 11-day-old embryonating chicken eggs inoculated via the chorioallantoic sac (CAS) (363), but with some isolates, inoculation by the yolk sac route or inoculation

onto the chorioallantoic membrane resulted in isolation where CAS route failed (194, 407). In embryonating chicken eggs, AI viruses generally grow to high titers and have a cleaved HA (95). Most inactivated vaccines have been produced by cultivation in embryonating eggs.

AI viruses replicate in a limited number of cell culture systems (95). Primary cultures of chicken embryo fibroblasts (CEF) or kidney cells are most commonly used for plaque assays and virus neutralization tests. Madin-Darby canine kidney cell cultures also have been used. However, in CEF and some other cells, LPAI viruses require the addition of exogenous trypsin to the medium or agar overlay to cleave the HA and produce infectious virus (95). Absence of exogenous trypsin will produce plaques less than 1 mm in size or no plaques depending on the virus strain. The HPAI viruses do not require the addition of exogenous trypsin for cleavage of HA and the subsequent production of infectious virus.

The chicken (*Gallus gallus domesticus*) has been the most frequently used animal in laboratory studies to determine pathogenicity and study pathogenesis. Other commonly used laboratory species include the turkey (*Meleagridis gallopavo*), domestic duck (*Anas platyrhynchos*), house mouse (*Mus musculus*), guinea pig (*Cavia porcellus*), and ferret (*Mustela putorius furo*). The mouse, guinea pig, and ferret have been used as models to assess the risk of interspecies transmission of AI viruses to mammals (89), and the other hosts provide assessment of infections in natural host species.

Pathogenicity

Clinical Groups in the Field

Although only two pathotypes of AI viruses can be demonstrated in the laboratory (HP and LP), natural infection by AI viruses results in a wide range of clinical outcomes which are dependent on virus strain, host species, host age, host immunity, and environmental factors. From mortality patterns, clinical signs, and lesions in the field, AI can be categorized into four clinical groups: (1) highly virulent, (2) moderately virulent, (3) mildly virulent, and (4) avirulent. First, the highly virulent clinical group results from infection by HP H5 or H7 AI viruses, usually in chickens or closely related gallinaceous birds, and is expressed as a severe, highly fatal systemic disease that affects most organ systems. Morbidity and mortality approach 100%. Experimentally, the HPAI viruses alone reproduce the lesions and high mortality rates seen in the field (345).

Second, the moderately virulent clinical group results from infection by LPAI viruses, of any HA or NA subtype, usually with co-infection by secondary pathogens or accompanied by other stress factors (51, 225, 358). The mortality rates vary but range from 5%–97% with the highest mortality occurring in young birds, reproductively active hens, or severely stressed birds (45, 51, 155). Lesions usually have been in the respiratory tract, reproductive organs, kidney, or pancreas (51, 144, 415). Some of these cases may have involved concurrent infection with bacteria that secreted proteases which cleaved HA of LPAI viruses, thus exacerbating the AI virus infection (301).

Third, the mildly virulent clinical group results from infection by LPAI virus producing low mortality and mild respiratory disease or drops in egg production. Mortality is usually less than 5%, and is typically in older birds.

Fourth, the avirulent clinical group results from infections by LPAI viruses without any increased mortality or clinical signs. This has been most frequent with infections by LPAI viruses in wild birds of orders *Anseriformes* and *Charadriiformes* (344). In poultry, this has been seen following the introduction of a poorly host-adapted LPAI virus from wild birds. Such an example would be the first cases of AI in range turkeys following exposure to wild waterfowl AI viruses that resulted in sero-conversion detected at slaughter without any previously noted clinical signs (344). Occasionally HP and LP viruses may appear together and this causes confusion in the field and the laboratory. In individual field situations, the clinical outcomes can be a mixture of the four clinical groups. For example, during the changing of an H5 or H7 LP to HPAI virus, gross lesions consistent with highly virulent AI will be seen in some dead birds, but the mortality rates will be low, similar to mildly or moderately virulent AI.

Effect of the Hemagglutinin Protein on Pathogenicity

The HA gene is the primary but not the only determinant of high pathogenicity in chickens; a proper constellation of all eight gene segments is required for the maximal expression of virulence potential (41). In brief, the cleavage of the HA protein into the HA1 and HA2 proteins is essential for the virus to be infectious and produce multiple replication cycles. With LPAI viruses, they are released from the host cell with an uncleaved HA protein and are not infectious. The protein can be cleaved by trypsin-like proteases found in restricted anatomical sites, such as respiratory and intestinal epithelial cells, which accounts for the restricted replication and lower virulence. The difference between the cleavage site of LPAI and HPAI viruses is the number of basic amino acids in the HA1 near the cleavage site or an insertion of amino acids near the cleavage site that determines whether trypsin-like proteases or furin-like proteases can cleave the protein. The LPAI viruses generally have only two non-consecutive basic amino acids at the carboxy-terminus of the HA1 that is only cleavable by trypsin-like proteases. In contrast, H5 and H7 HPAI viruses have either multiple basic amino acids or an insertion of amino acids at the carboxy-terminal of the HA1 protein that allows proteolytic cleavage by ubiquitous furin proteases that are present in many cells throughout the body (315). For HPAI virus, the HA is cleaved inside the cell before virus assembly and is infectious when it is released from the host cell. This effectively increases the cell tropism of the virus leading to virus replication in numerous visceral organs, the nervous system, and the cardiovascular system, leading to systemic disease with high mortality (Table 6.5). HPAI viruses are not believed to normally circulate in wild birds, but LPAI viruses can mutate under some circumstances to the HPAI form by changes of the HA cleavage site including (1) substitutions of non-basic with basic amino acids, (2) insertions of

multiple basic amino acids from codons duplicated at the hemagglutinin cleavage site, (3) short inserts of basic and non-basic amino acids from unknown source, or (4) non-homologous recombination with inserts which lengthen the proteolytic cleavage site but which may or may not contain additional basic amino acids (Table 6.5) (51, 115, 146, 254, 255, 256). One additional factor, the presence or absence of a glycosylation site at the amino terminal end of the HA1 protein, has been shown to influence HA cleavage. This glycosylation site, when present, because it is physically located close to the HA cleavage site, can shield the cleavage so that furin-like proteases cannot function, and the viruses may have an LPAI phenotype even with multiple basic amino acids at the cleavage site (Table 6.5) (115, 160). Experimentally, an H5N1 HPAI virus from which multiple basic amino acids at the cleavage site of the HA were deleted was still capable of causing neurological and dermal disease in four-week-old chickens (271).

In vitro tests have been used to predict pathogenicity potential and are based on structural variations in the proteolytic cleavage site of the hemagglutinin and its susceptibility to cleavage by different enzymes in various tissues. For example, the ability to produce large plaques in tissue culture, such as chicken embryo fibroblast cultures, without trypsin supplementation correlates with furin cleavage of HA and HP in chickens in *in vivo* tests, but LPAI viruses require the addition of exogenous trypsin to cleave the HA and produce large plaques (41). Detection of a cleaved HA in tissue cell cultures without trypsin by radioimmunoprecipitation correlates with HP (277). All HP and LPAI viruses produce cleaved HA in embryonating chicken eggs. Detection of multiple basic amino acids at the HA proteolytic cleavage site correlates with HP or potential to become HP (342, 397). Experiments have shown that if multiple basic amino acids are incorporated into HA cleavage sites of some non-H5 or non-H7 subtypes, viruses capable of causing systemic infection in poultry can be produced (386).

An issue separate from HA cleavability is receptor binding between the receptor-binding site of the HA and the receptor on the host cells. AI viruses have preferential binding to N-acetylneuraminic acid-α2,3-galactose linkage on sialoligosaccharide (α2,3 linkage) receptors of avian cells (151). However, the binding avidity varies greatly depending on the structure of the oligosaccharide. This is a poorly understood phenomenon but impacts host specificity (host-adaption) and

Table 6.5. Examples of genetic mechanisms for LP to HP change based on deduced amino acid sequence of HA proteolytic cleavage sites in H5 and H7 AI viruses (modified from (280)).

				Mechanism[1]					
Influenza virus	**Subtype**	**Pathotype**	**Amino acid sequence**	**1**	**2**	**3**	**4**	**5**	**References**
Typical H5 LPAI	H5	LP	PQ……..RETR*GLF						(280)
A/Turkey/England/1991	H5N1	HP	PQ….RKRKTR*GLF	X	X				(280)
A/Chicken/PA/1370/1983	H5N2	HP	PQ…….KKKR*GLF	X				X	(280)
A/Tern/South Africa/1961	H5N9	HP	PQRETRRQKR*GLF	X		X			(280)
A/chicken/ Puebla/8623-607/1994	H5N2	HP	PQ….RKRKTR*GLF	X	X				(115, 146)
A/chicken/ Queretaro/14588-19/1995	H5N2	HP	PQRKRKRKTR*GLF	X	X				(115)
A/ostrich/South Africa/ AI2114/2011	H5N2	HP	PQRRKKR*GLF	X	X				Abolnik et al.[6]
Typical H7 LPAI	H7	LP	PEIP… .....KTR*GLF						(280)
A/Chicken/Victoria/1985	H7N7	HP	PEIP..... ..KKREKR*GLF			X			(280)
A/turkey/Italy/4580/1999	H7N1	HP	PEIPKG… .SRVRR*GLF			X			(51)
A/chicken/Chile/176822/2002	H7N3	HP	PEKPKTCSPLSRCRETR*GLF[2]				X		(328)
A/Chicken/Canada/AVFV2/2004	H7N3	HP	PENPK …QAYRKRMTR*GLF[3]				X		(249)
A/chicken/Saskatchewan/ HR-00011/2007	H7N3	HP	PENPKTTKPRPRR*/GLF[4]				X		(40)
A/chicken/Jalisco/12383/2012	H7N3	HP	PENPKDRKSRHRRTR-GLF[5]				X		(D. Suarez, unpublished)

[1] Mechanisms: (1) substitutions of non-basic with basic amino acids, (2) insertions of multiple basic amino acids from codons duplicated from hemagglutinin cleavage site, (3) short inserts of basic and non-basic amino acids from unknown source, (4) non-homologous recombination with inserts which lengthen the proteolytic cleavage site, (5) loss of the shielding glycosylation site at residue 13.

[2] 30 nucleotides from nucleoprotein gene of same virus coding 10 amino acid insert.

[3] 21 nucleotides from matrix gene of same virus coding 7 amino acid insert.

[4] 18 nucleotides from unidentified chicken gene coding 6 amino acids insert.

[5] 24 nucleotides from 28S chicken ribosomal RNA coding 8 amino acids insert.

[6] Information added after submission (Abolnik et al. *Avian Dis*. 56:865–879, 2012).

cell, tissue, and organ tropism within the host. Changes in the receptor-binding site of the HA have been shown to change the host range of an influenza virus (222). Both the virus and host impact receptor binding.

Mechanisms of Cellular Pathobiology

Based on morphologic and biochemical evidence, AI viruses exert pathological effect on avian cells by two mechanisms: necrosis or apoptosis (141, 273, 322). Necrosis has been identified in many cell types including kidney tubule cells, pancreatic acinar epithelium, cardiac myocytes, adrenal cortical cells, and pulmonary epithelial cells in chickens (322). Necrosis has been associated with intense virus replication and demonstration of abundant AI viral nucleoprotein in the nucleus and cytoplasm (332). Apoptotic cell death has been demonstrated in various cell culture systems and involved several cytokines including interferon-beta and transforming growth factor-beta (141, 273, 274, 369). *In vivo*, apoptotic cell death has been identified most often in lymphocytes, especially in the absence of direct AI viral replication (322). However, apoptosis has been demonstrated in neurons, respiratory epithelium, and pulmonary alveolar cells of mice infected with mouse-adapted influenza viruses (216, 217). In chicken embryos, apoptosis and necrosis may share similar biochemical features and indicate that differentiation morphologically and biochemically between them is not always easy nor clear (107).

Pathobiology and Epizootiology

Incidence and Distribution

AI viruses have a worldwide distribution with reports of isolations from Africa, Asia, Australia, Europe, and North and South America, and serologic evidence of infection in penguins from Antarctica (95, 214, 309, 345). Proceedings of the International Symposia on AI have tabulated LP and HPAI outbreaks and incidences since 1981 (27, 93, 94, 331, 341, 349, 357).

AI viruses have been isolated from free-flying aquatic birds, especially of the orders *Anseriformes* (ducks and geese) and *Charadriiformes* (shorebirds, gulls, terns, and auks), which are considered the biological and genetic reservoirs of all AI viruses (312). In these species, AI virus infections usually have caused no disease (LPAI viruses) with the exception of high mortality in common terns of South Africa during 1961 and infections and mortality in a variety of wild birds with H5N1 HPAI virus that originated from Asia in 1996 (Table 6.3). Dabbling ducks, especially mallards (*Anas platyrhynchos*) in the Atlantic Migratory Flyway, and northern shovelers (*Anas clypeata*) in the Pacific Migratory Flyway of North America, have the highest reported isolation rates of AI viruses with more than 30% of juvenile ducks being infected prior to migration in the late summer (133, 138). This frequency decreases during migration with the lowest rate (0.4%–3.1%) being seen in ducks on the wintering grounds (311). However, the frequency of infection in native, non-migratory ducks increases when migratory ducks arrive in the wintering grounds (130, 311). The H3, H4, H6, N2, N6, and N8 subtypes have been dominant among AI viruses isolated from free-flying ducks (138, 175, 267, 298, 312). For shorebirds (Order: *Charadriiformes*), the greatest number of isolations have been in the spring with a second peak during the fall migration (159). The dominant AI virus subtypes have been H3, H9, H11, H13, N2, N4, N8, and N9 (117, 159, 175). However, most combinations of the 16 HA and 9 NA subtypes have been reported in free-flying birds. AI viruses are infrequently isolated from wild terrestrial birds because they occupy non-aquatic ecosystems that do not favor maintenance of AI viruses (312). However, H5N1 HPAI viruses have been found in some wild terrestrial birds including species used for religious release ceremonies (120).

AI viruses have been isolated sporadically from domestic poultry, most frequently chickens, turkeys, and ducks, and captive wild birds held as caged pets, or in quarantine stations, private collections/reserves, and zoological parks (11, 14). However, incidence and distribution varies greatly with geographic region, species, age of bird, time of year, and the environmental or agricultural system occupied.

Turkeys and other gallinaceous birds (including chickens) are not natural reservoirs of AI viruses (255, 324). Humans have altered the natural ecosystems of birds through captivity, domestication, industrial agriculture, national and international commerce, and nontraditional raising practices (344, 359). This has created new niches for AI viruses and variations in the incidence and distribution of AI infections. Five distinct man-made ecosystems have been identified that have impacted AI virus ecology (344, 359): (1) integrated indoor commercial poultry; (2) range-raised commercial poultry, especially domestic ducks in paddy rice field rearing systems; (3) live poultry market (LPM); (4) village, backyard, and hobby flocks; and (5) bird collection and trading systems.

The frequency of AI infections within each system has varied. For example, in most integrated commercial poultry systems in developed countries, AI has been a rare occurrence considering more than 55 billion chickens are reared each year (364). However, when AI infections do occur, they sometimes spread rapidly throughout the integrated system from farm to farm, resulting in epidemics of HPAI (Table 6.3) or LPAI. In commercial poultry, outbreaks have been most frequently reported in turkeys, slightly less frequently in laying chickens, and rarely in other domesticated poultry. A vaccination and controlled marketing strategy has reportedly eliminated H5N2 HPAI virus from Mexico, but H5N2 LPAI virus continues to circulate in commercial chickens of Central America (387). In some developing countries of Asia and the Middle East during the middle to late 1990s, H9N2 LPAI became enzootic in commercial chickens with some Asian countries having H3 and H6 enzootically in poultry. As of 2012, H5N1 HPAI was enzootic in Bangladesh, China, eastern India, Egypt, Indonesia, and Vietnam, and in addition H5N1 HPAI viruses caused epizootics in 10 other Middle Eastern and Asian countries. The H5N1 HPAI virus is being maintained in the complex poultry sector comprising a mix of millions of

small village or rural poultry flocks mixed with larger commercial farms, and includes contributing risk factors such as deficient biosecurity practices, numerous free ranging ducks, and the sale of millions of live poultry every day, often moved by unregulated traders through poorly regulated markets. This combination of factors has provided sufficient susceptible poultry to allow H5N1 viruses to remain enzootic to these areas since they were first identified (104, 238).

Historically, LPAI outbreaks occurred in the fall in range-reared turkeys in Minnesota (USA) during the 1970s and 1980s (121, 127). However, eliminating range rearing prevented exposure to migratory waterfowl infected with LPAI virus, thus eliminating seasonal LPAI outbreaks in turkeys (127). That said, migratory waterfowl exposure alone does not adequately explain year-to-year variations in seasonal LPAI outbreaks in turkeys. Individual virus strain and host species impact interspecies transmission of AI viruses from migratory waterfowl to poultry and among poultry species (361). For example, the H7N2 LPAI virus in Virginia during 2002 produced a higher proportion of affected turkey than chicken farms, and in experimental laboratory tests, this virus was more infectious for turkeys than chickens as is evident by requiring 100–250 times less virus to infect turkeys than chickens (379). Similar differences in species susceptibility, based on dose delivered, have also been identified with H5N1 viruses (6, 379).

In both developed and developing countries, village and rural poultry and LPM systems have some of the highest AI virus infection rates (288). Historically, poorly controlled movement and lack of biosecurity caused AI to become enzootic in some poultry populations, especially between 1900 and 1930 in Europe and some areas of Asia (320). This holds true today. The 1924-1925 HPAI outbreak in the United States occurred in an LPM-type system but was eliminated by depopulation before becoming enzootic (176). Recent surveys of poultry in LPM of Hong Kong, New York, and other large cities have indicated that LPAI viruses have become enzootic in these agricultural systems (278, 288, 377, 286, 396). LPMs in Hong Kong were found to have a high prevalence of H5N1 HPAI virus in 1997 and AI viruses were detected regularly in LPM between 2001 and 2003. LPMs were the site of a 1997 H5N2 AI outbreak in Italy, and the most likely source of LPAI virus that mutated to HPAI virus causing the 1983-1984 outbreak in the United States (53, 288, 322, 396).

Most influenza infections in domestic poultry have been from avian-origin influenza A viruses. However, H1N1, H1N2, and H3N2 swine influenza A viruses have infected turkeys, especially turkey breeders, causing severe and prolonged decreases in egg production with considerable economic losses (95, 212, 325, 370), and the 2009 human H1N1 pandemic influenza virus has also infected some turkey flocks (204).

Natural and Experimental Hosts

AI viruses have been shown to naturally infect a wide variety of wild and domestic birds, especially free-living birds occupying aquatic habitats. Some AI infections have involved wild terrestrial birds; these birds do not represent a major source or reservoir of AI viruses (312), but potentially play an important role in local transmission of H5N1 HPAI virus (289, 290). In brief, AI viruses have been isolated from more than 90 species of free-living birds representing 13 different orders: *Anseriformes* (ducks, geese, and swans), *Charadriiformes* (e.g., shorebirds [turnstones and sandpipers], gulls, terns, puffins, and guillemots), *Ciconiiformes* (herons and ibis), *Columbiformes* (doves), *Falconiformes* (raptors), *Galliformes* (partridge and pheasant), *Gaviiformes* (loons), *Gruiformes* (coots and moorhen), *Passeriformes* (perching birds, e.g., mynahs, finches, and weaverbirds), *Pelecaniformes* (cormorant), *Piciformes* (woodpecker), *Podicipediformes* (grebe), and *Procellariiformes* (shearwater) (11, 12, 14, 201, 310). This represents 61% of known avian families, but the actual number of naturally infected species is most likely much greater (14). Most AI infections have not produced recognizable disease in free-living birds; the exception is H5N1 HPAI viruses (Guangdong lineage).

In man-made ecosystems (agriculture, caged, hobby flocks, and exhibition systems), infections have been reported in *Psittaciformes* (parrots, cockatoos, and parakeets), *Casuariiformes* (emu), *Struthioniformes* (ostrich), *Rheiformes* (rhea), and most domesticated *Galliformes* and *Anseriformes*. The latter two groups include chickens, turkeys, Japanese quail (*Coturnix japonica*), helmeted guineafowl (*Numida meleagris*), Bobwhite quail (*Colinus virginianus*), pheasants (various species), chukar partridges (*Alectoris chukar*), geese (*Anser anser domesticus*), and ducks (mallards [*Anas platyrhynchos domesticus*] and Muscovy [*Cairina moschata domesticus*]) (95). Birds of the orders *Psittaciformes* probably are infected after capture and during mixing with infected birds at holding sites or in quarantine (95). Some infections of free-living *Passeriformes* (perching birds—starlings and sparrows) have been associated with outbreaks on poultry farms where they may have acquired infections from close contact with poultry (193, 215). Experimentally, sparrows have been shown to be capable of transmitting infection back to poultry (120).

LPAI viruses have caused epidemics of respiratory disease in mink, seals, and whales (49, 100, 116, 140, 184, 198, 393). Recently, the H5N1 HPAI virus has caused sporadic infections in tigers, leopards, domestic dogs, house cats, Owston's palm civets, a stone martin, and pigs (102, 177). Most of these cases involved close contact or consumption of infected birds. A few cases of natural infections by AI viruses in humans have been reported (see Public Health Significance) and there is serological evidence of more widespread infection.

In experimental studies, specific strains of AI viruses have been shown to infect pigs, ferrets, rats, rabbits, guinea pigs, mice, dogs, foxes, cats, mink, nonhuman primates, and humans (36, 91, 95, 135, 166, 177, 287).

Transmission and Carriers

AI virus is shed from the nares, mouth, conjunctiva, and cloaca of infected birds into the environment because of virus replication in the respiratory, intestinal, renal, and/or reproductive organs. HPAI viruses also can be detected in epidermis including feathers, feather follicles, and glands such as preen gland, resulting in environmental contamination (84, 259). In intranasally

inoculated three- to four-week-old chickens, peak levels of HPAI virus recovery have been greatest from the oropharynx (swabs—$10^{4.2–7.7}$ mean chicken embryo infective doses [EID_{50}]/mL of respiratory secretions), and peak levels from the cloaca have been lower (swabs—$10^{2.5–4.5}$ EID_{50}/gm of feces) (347, 353); LPAI viruses typically produce lower oropharynx (swabs—$10^{1.1–5.5}$ EID_{50}/mL) and cloacal (swabs—$10^{1.0–4.3}$ EID_{50}/mL) titers (353). With HPAI viruses, high virus levels in tissues of infected birds make consumption of carcasses through predation or cannibalism another source of virus transmission to susceptible birds. Titers in meat vary with virus strain, bird species, and clinical stage of infection: (1) titers from dead chickens infected with 1983 H5N2 HPAI Pennsylvania virus had $10^{2.2–3.2}$ EID_{50}/gm of meat while 2003 H5N1 HPAI S. Korean virus had $10^{5.5–8.0}$ EID_{50}/gm of meat, and (2) H5N1 HPAI viruses (Guangdong lineage) produced different titers in clinically normal ($10^{2.0–3.4}$ EID_{50}/gm) or sick ($10^{4.0–6.0}$ EID_{50}/gm) domestic ducks (353, 372).

The virus is transmitted by direct contact between infected and susceptible birds or indirect contact through aerosol droplets or exposure to virus-contaminated fomites (95). Aerosol generation from the respiratory tract is a significant mode of transmission because of high virus concentrations in the respiratory tract, but the large volume of lower concentration AI virus in infected feces makes fomites a major mode of transport. Thus, AI viruses are readily transported to other premises by people (contaminated shoes and clothing) and equipment shared in production, live-haul, or live-bird marketing (95).

Influenza viruses exhibit varying degrees of adaptation to individual host species with frequent and easy intraspecies transmission (344, 359). However, interspecies transmission does occur, especially between closely related host species in the same taxonomic family, such as chickens, turkeys, guinea fowl, and quail of the order *Galliformes*, family *Phasianidae*. Interspecies transmission can occur across different orders within the same class such as with free-flying duck-(Order: *Anseriformes*)-to-turkey (Order: *Galliformes*), but this is less frequent than occurs with closely related host species (344). Furthermore, interspecies transmission between different phylogenetic classes is even less frequent as has occurred rarely with chicken-to-human (344). One exception to the preceding rule has been the ease and frequency of transfer of swine H1N1 and H3N2 viruses to turkeys when the two species were raised in close geographic proximity (212, 326, 344, 370). Obviously, many factors such as geographic restriction of host distribution, intermixing of species, age and density of birds, weather, and temperature also impacted the ability of the AI virus to move within and between host species and affected the overall incidence of infections (344).

Sources of infection for the initial introduction of the influenza virus into commercial poultry flocks (i.e., primary infections) include (1) other domestic and confined poultry, (2) migratory waterfowl and other wild birds, (3) domestic pigs, and (4) companion or pet birds (11, 14). The relative risk associated with each of these sources varies depending on the likelihood of direct or indirect contact with poultry.

First, the LPM system poses a significant risk to the introduction of LP and HPAI viruses into the commercial integrated poultry systems. Theoretically, transmission could occur by airborne dissemination as proposed in some AI outbreaks (79). However, high volume air sampling during the 1983–1984 H5N2 HPAI outbreak in the United States failed to yield influenza virus when samples were taken more than 45 meters downwind from an infected house (47). This suggests airborne transmission may have a limited role in most interflock dissemination of AI virus as compared to mechanical movement of fomites on equipment, clothing, or shoes (47). Others have suggested that dust particles could potentially play a role (42). Especially high risk is movement of dead infected birds from farms through a shared rendering system or from the farm for burial without adequate sealing and decontamination of transport vehicles (42).

Second, introduction of AI viruses (especially LPAI viruses) from wild birds, especially waterfowl, has been documented (121). The source is suspected to be contaminated feces from the ducks either through direct contact with poultry or indirectly through contamination of feed or water (134). The transmission potential of AI viruses from wild waterfowl emphasizes the need for producers of commercial poultry to separate domestic and wild bird populations (95).

Third, turkeys can be infected by introduction of H1N1, H1N2, or H3N2 and potentially other subtypes of swine-origin influenza viruses, either by mechanical methods or via humans infected with swine-origin influenza viruses (95).

Fourth, AI viruses have been recovered from caged birds, usually during quarantine, but transmission from this source to poultry has not been documented as has occurred with Newcastle disease virus (95). To minimize the risk of introduction and dissemination of AI viruses, producers should raise only one species of bird in an individual operation, have an all-in-all-out production system, or add new birds only after testing and quarantine and practice a high degree of biosecurity, which is not the case in many places where H5N1 HPAI viruses are enzootic.

Secondary dissemination of AI viruses during an outbreak can be by mechanical transmission of virus on fomites, movement of infected poultry, or in some situations possibly airborne dissemination. Wild birds may play a major role in initial introduction of AI viruses in domestic poultry, but once established or adapted in commercial or LPM poultry, wild birds have had a very limited or no role in secondary dissemination (139, 224). However, with the recent H5N1 HPAI viruses, wild birds have been infected and likely played an important role of the spread of the virus to Europe in the winter of 2005–06. This lineage of virus has persisted at a low level in wild birds and has been associated with other outbreaks since then. However, at this time it appears that the H5N1 HPAI Guangdong lineage has this unique property of wild bird persistence and transmission to poultry that has not been previously observed with other HPAI viruses (106).

Although horizontal transmission of AI viruses commonly occurs, proof of vertical transmission is lacking (95).

However, HPAI virus infection of hens has resulted in virus recovery from the eggshell surface and the internal contents of the eggs (50, 165). In experimental studies with H5N2 HPAI virus from Pennsylvania, most eggs laid on days three and four post-inoculation contained virus (32). However, AI viruses are embryo lethal, and hatching of internally contaminated eggs has not been demonstrated (32). Temperatures maintained during incubation should be sufficient to destroy surface contaminants. Cleaning of fecal material and disinfection of egg shells may be necessary to prevent hatchery-associated dissemination of AI viruses. Most LPAI and HPAI viruses cause reduction or cessation, respectively, of egg production, further limiting the potential for vertical transmission of AI virus.

Successful experimental routes of exposure include aerogenous, intranasal, intrasinus, intratracheal, oral, conjunctival, intramuscular, intraperitoneal, intracaudal air sac, intravenous, intracloacal, and intracranial administration of the various viruses (95).

In experimental studies, AI virus has been shown to replicate and be excreted from individual ducks for up to 30 days (391), chickens for up to 36 days (333), pheasant up to 45 days (147), and turkeys for up to 72 days (92, 143), but in most studies the virus shedding peaks at 4–5 days and infections after 7 days are uncommon. However, on a population basis, AI virus can be maintained for much longer time periods in agricultural operations or can re-emerge after a significantly stressful event. For example, a LP H7N2 AI virus in Pennsylvania during 1997-1998 was recovered from dead chickens collected from a layer flock with normal mortality six months after the initial AI infection on the farm and in another flock eight weeks after the induction of a molt (415). Once a large flock is infected, it should be considered a potential source of virus until depopulated unless measures are taken to eliminate the virus from the flock (129). In wild waterfowl, AI viruses are maintained by passage in susceptible birds throughout the year, with peak prevalence in migratory waterfowl being in juvenile birds prior to fall migration likely because the juveniles are naïve to infection and congregate in larger numbers than usual (95, 133). Prevalence of AI virus in migratory waterfowl is low as they arrive in the wintering grounds, but upon arrival, they can infect susceptible resident waterfowl which go through their own cycle of infection (130, 311). Thus, resident ducks contribute to the generation of virus during the winter and this source might re-infect migrating waterfowl prior to the spring migration. No information is available on the duration of infection in a flock of infected domestic ducks.

Incubation Period

The incubation periods for the various diseases caused by these viruses range from as short as a few hours in intravenously inoculated birds to three days in naturally infected individual birds and up to 14 days in a flock (95). In timed studies, intranasally inoculated chickens with H5N1 HPAI virus from Mongolia developed clinical signs within 24 hours (77). The incubation period depends on the dose of virus, the route of exposure, the species exposed, and the ability to detect clinical signs (95). However, for international regulatory purposes, OIE recognizes 21 days as the incubation period (231), a period much longer than that normally observed in the field, where incubation period is defined as the time from exposure to the onset of clinical signs. However, this criterion may not be applicable to all AI viruses, especially LPAI viruses. Many infections by LPAI viruses do not cause clinical disease in all ages and all species of birds. "Infectious period," as defined as the time from exposure or detection of the virus to when the virus is no longer detected, may be more applicable for control and eradication purposes, especially in dealing with LPNAI viruses.

Clinical Signs

The pathotype of AI virus (LP or HP) has a major impact on the clinical manifestation of the disease. However, clinical signs of disease are extremely variable and depend on other factors including host species, age, sex, concurrent infections, acquired immunity, and environmental factors (95).

Low Pathogenicity Avian Influenza Viruses

Most infections by LPAI viruses in wild birds produce no clinical signs. However, in experimental studies in mallard ducks, LPAI virus infections suppressed T-cell function and produced a one-week depression in egg production (186, 188).

In domestic poultry (chickens and turkeys), clinical signs reflect abnormalities in the respiratory, digestive, urinary, and reproductive organs. The most frequent signs represent infection of the respiratory tract and include mild to severe respiratory signs such as coughing, sneezing, rales, rattles, and excessive lacrimation. In layers and breeders, hens may exhibit increased broodiness and decreased egg production. In addition, domestic poultry will exhibit generalized clinical signs including huddling, ruffled feathers, listlessness, decreased activity, lethargy, decreased feed and water consumption, and occasionally diarrhea. Emaciation has been reported but is infrequent because AI is an acute, not a chronic disease.

In ratites, LPAI viruses produced similar respiratory signs to those in gallinaceous poultry and in some cases green diarrhea or green "urine" (19, 55, 156, 202, 243, 246, 339).

High Pathogenicity Avian Influenza Viruses

In wild and domestic waterfowl, most HPAI viruses replicate to a limited degree and produce few clinical signs because of poor adaptation to non-gallinaceous species. The major exception to this rule are some of the recent H5N1 HPAI viruses which have a completely different phenotype where they can infect and cause clinical disease including neurological signs, depression, anorexia, and sudden death (192, 378). Occasional sporadic, isolated cases of mortality have been reported in wild birds with other HPAI viruses. One additional unusual outbreak in wild birds occurred in 1961 with an H5N3 HPAI outbreak in common terns in South Africa, which produced sudden death without any other clinical signs.

This outbreak was unusual in that it seemed to originate and stay localized to the tern population without involvement of gallinaceous birds (38).

In domestic chickens, turkeys, and related galliformes, clinical signs reflect virus replication and damage to multiple visceral organs and cardiovascular and nervous systems. However, clinical manifestations vary depending on the extent of damage to specific organs and tissues (i.e., not all clinical signs are present in every bird). In most cases in chickens and turkeys, the disease is fulminating with some birds being found dead prior to observation of any clinical signs. If the disease is less fulminating and birds survive for three to seven days, individual birds may exhibit nervous disorders such as tremors of head and neck, inability to stand, torticollis, opisthotonus, and other unusual positions of head and appendages. The poultry houses may be unusually quiet because of decreased activity and reduction in normal vocalizations of the birds. Listlessness is common as are significant declines in feed and water consumption. Precipitous drops in egg production occur in breeders and layers with typical declines including total cessation of egg production within six days. Respiratory signs are less prominent than with LPAI viruses but can include rales, sneezing, and coughing. Other poultry have similar clinical signs but may live longer and have evidence of neurologic disorders such as paresis, paralysis, vestibular degradation (torticollis and nystagmus), and general behavior aberrations (259). Corneal opacity has been observed in domestic ducks infected with H5N1 HPAI viruses (412).

In ostriches (*Struthio camelus*), reduced activity and appetite, listlessness, ruffled feathers, sneezing, hemorrhagic diarrhea, and open mouth breathing have been reported (52, 55, 69, 70, 202). In addition, some birds were uncoordinated, exhibited torticollis, and had paralysis of the wings and tremors of the head and neck. However, signs observed depend on the virulence of the virus, for example the recent H5N2 AI virus in South Africa caused subclinical infection in most ostriches (373).

Morbidity and Mortality

In chickens, turkeys, and related gallinaceous birds, morbidity and mortality rates are as variable as the signs and are dependent on virus pathogenicity and the host as well as age, environmental conditions, and concurrent infections (95). For the LPAI viruses, high morbidity and low mortality rates are typical. Mortality rates are usually less than 5% unless accompanied by secondary pathogens or if the disease is in young birds. For example, in the 1999 Italian H7N1 LPAI outbreak, mortality rates as high as 97% were observed in turkey poults less than four weeks of age when accompanied by secondary pathogens (51).

With the HPAI viruses, morbidity and mortality rates are very high (50%–89%) and can reach 100% in some flocks. Typically, the virus spreads rapidly among poultry housed on the floor with peak mortality (70%–100%) occurring in three to five days of first clinical signs, but in poultry housed in cages, the virus spreads slower through the house with peak mortality taking 10–15 days. With the H5N1 HPAI viruses, the mean death times in experimental studies (intranasal-inoculation) are much shorter for chickens and turkeys than for other gallinaceous birds (262). In domestic ducks, the mortality from H5N1 HPAI viruses is dependent on virus strain and the age of the ducks (247). The H5N1 HPAI viruses from 1997–2001 did not cause illness or death in intranasally-inoculated ducks but many viruses from 2001–2012 caused varying mortality rates in two- to three-week old ducklings (65, 192, 321, 378). Differences in mortality have been observed based on the age of the duck, where two-week-old ducklings have high mortality, but five- to six-week-old ducklings have no mortality (247). This experimental variation based on age provides one explanation of why mortality rates in domestic ducks and geese in the field have been low (293, 411). Ducks also seem to have a different tolerance to even systemic infection, where experimentally a South Korean H5N1 virus infected and caused systemic disease with high levels of virus in muscle tissue, but no clinical signs were observed (378).

In ostriches, LP and HPAI viruses usually produce moderate morbidity and low mortality rates but this depends on the strain of virus (2, 52). Typically, the morbidity and mortality have been highest in young birds (less than three months) with mortality of 30% being seen (52), but mortality rates as high as 80% have been reported for LPAI viruses in chicks less than one month of age (19).

Pathology

Numerous reviews have been published on the pathology of AI virus (11, 14, 144, 152, 177, 213, 248, 262, 319, 320, 362). Details of field outbreaks and experimental studies have been published and are summarized in this section (4, 27, 31, 51, 52, 54, 55, 72, 91, 95, 157, 169, 170, 176, 186, 187, 188, 211, 243, 246, 255, 259, 260, 261, 263, 284, 297, 299, 322, 332, 333, 334, 335, 336, 337, 338, 339, 340, 345, 378). The lesions in wild birds have been reported for some H5N1 HPAI viruses, but such information is beyond the scope of this chapter.

Gross

Gross lesions have been extremely variable with regard to their location and severity, depending greatly on the host species, pathogenicity of the infecting virus, and presence of secondary pathogens. Most frequently, descriptions of gross lesions have been provided for naturally occurring or experimental infections in chickens and turkeys.

Low Pathogenicity Avian Influenza Viruses. In gallinaceous poultry, the most frequent lesions are in the respiratory tract, especially sinuses, and are characterized as catarrhal, fibrinous, serofibrinous, mucopurulent, or fibrinopurulent inflammation. The tracheal mucosa can be edematous with congestion and occasionally hemorrhages. Tracheal exudates may vary from serous to caseous, with occasional occlusion of airways and resulting asphyxiation.

Fibrinous to fibrinopurulent air sacculitis may be present. The fibrinopurulent inflammation usually is accompanied by secondary bacterial infections. The infraorbital sinuses may be swollen with muco-to-mucopurulent nasal discharge. Fibrinopurulent bronchopneumonia can result when accompanied by secondary pathogens such as *Pasteurella multocida* or *Escherichia coli*.

Catarrhal to fibrinous inflammation may be noted in the air sacs and coelomic cavity ("peritoneal cavity"), and "egg yolk peritonitis" may be observed. Catarrhal-to-fibrinous enteritis may be observed in the ceca and/or intestine, especially in turkeys. Inflammatory exudates may be found in the oviducts of laying birds, and the last few eggs laid will have reductions in calcium deposition within the eggshells. Resulting eggs may be misshapen and fragile with loss of pigmentation. Ovaries will undergo regression, beginning with hemorrhage in the large follicles and progressing to colliquation. The oviduct may be edematous and contain catarrhal-to-fibrinous luminal exudates before undergoing involution. In a few natural cases in laying hens and in intravenously inoculated chickens, swollen kidneys occurred and were accompanied by visceral urate deposition ("visceral gout").

Sporadically, other lesions have been reported including firm pancreas with pale mottling and hemorrhage, usually in turkeys.

In domestic ducks and geese, LPAI viruses may produce lesions in the respiratory tract such as sinusitis, conjunctivitis, and other respiratory lesions. Co-infections with bacteria are common.

In rheas (*Rhea americana*) and emus (*Dromaius novaehollandiae*), LPAI virus infection produced ocular discharge; fibrinous sinusitis, tracheitis, and air sacculitis; interstitial pneumonia; congested visceral organs; hemorrhage in trachea; and occasional fibrinous perihepatitis and pericarditis.

Highly Pathogenic Avian Influenza Viruses. In gallinaceous poultry, HPAI viruses produce a variety of edematous, hemorrhagic, and necrotic lesions in visceral organs and the skin. Although, when death is peracute, no gross lesions may be observed. In chickens, swelling of the head, face, upper neck, and feet may be observed which results from subcutaneous edema and may be accompanied by petechial-to-ecchymotic hemorrhages (Figures 6.2, 6.3, and 6.4). Periorbital edema may be seen (Figure 6.3). Necrotic foci, hemorrhage, and cyanosis of the non-feathered skin have been reported, especially wattles and combs. Lesions in visceral organs vary with virus strain but most consistently are represented by hemorrhages on serosal or mucosal surfaces and foci of necrosis within parenchyma of visceral organs. Especially prominent are hemorrhages on the epicardium (Figure 6.5), in pectoral muscles, and in mucosa of the proventriculus and ventriculus (Figure 6.6). With the H5N1 HPAI viruses (Guangdong lineage), necrosis and hemorrhage in Peyer's patches of the small intestine were common as was reported with outbreaks of fowl plague in the early 1900s (Figure 6.7). In addition, these strains of HPAI viruses tend to produce more severe hemorrhage and edema in the lungs (Figure 6.8).

Figure 6.2. Multifocal necrosis and hemorrhage of comb and wattles, H5N2 HPAI virus, 7 DPI. (USDA, M. Brugh)

Figure 6.3. Severe edema of comb and wattles with accompanying periorbital edema and necrosis of epidermis at base of the comb, H5N2 HPAI virus, 7 DPI. (USDA, D. Swayne)

Figure 6.4. Severe subcutaneous hemorrhages of feet, three-week-old chicken, intranasal exposure to A/Hong Kong/156/1997 (H5N1), 5 DPI. (USDA, D. Swayne)

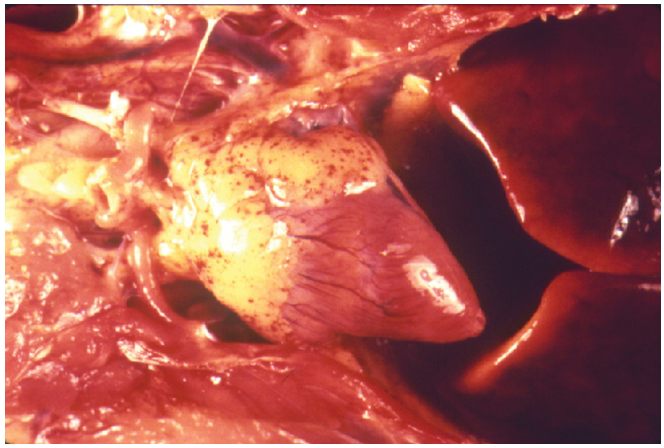

Figure 6.5. Petechial hemorrhages in epicardial fat, H5N2 HPAI virus, 4 DPI. (USDA, M. Brugh)

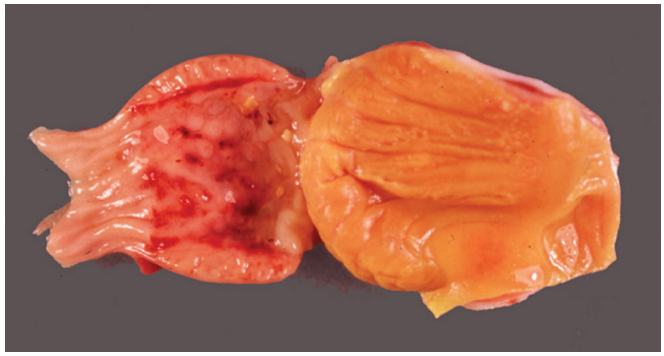

Figure 6.6. Mucosal petechial hemorrhages surrounding proventricular glands, three-week-old chicken, intravenous exposure to A/Hong Kong/156/1997 (H5N1), 2 DPI. (USDA, D. Swayne)

Figure 6.7. Hemorrhage in lymphoid tissue of Peyer's patches and Meckel's diverticulum of the jejunum, three-week-old chicken, intravenous exposure to A/chicken/Hong Kong/27402/1997 (H5N1) HPAI virus, 1 DPI. (USDA, D. Swayne)

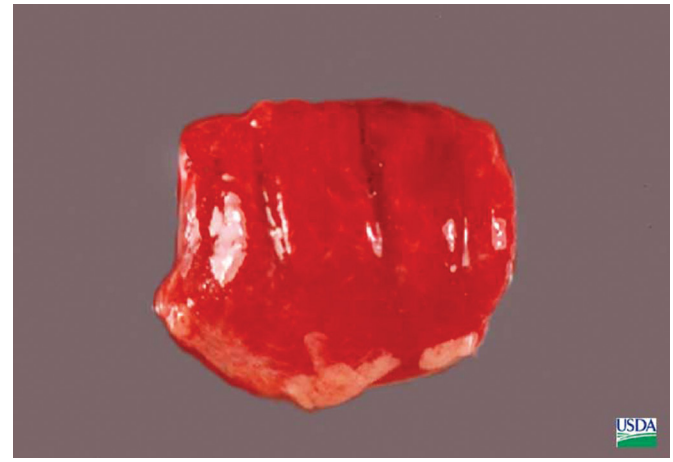

Figure 6.8. Severe pulmonary hemorrhage and edema, three-week-old chicken, intravenous exposure to A/chicken/Hong Kong/156/1997 (H5N1) HPAI virus, 2 DPI. (USDA, D. Swayne)

Figure 6.9. Hemorrhage and necrosis in pancreas, three-week-old turkey, intranasal exposure to A/chicken/Hong Kong/220/1997 (H5N1)HPAI virus, 2.5 DPI. (USDA, D. Swayne)

With most HPAI viruses, necrotic foci are common in pancreas (Figure 6.9), spleen, and heart, and occasionally in liver and kidney. The kidney lesions may be accompanied by urate deposits. Lungs have focal ventral-to-diffuse interstitial pneumonia with edema. The lungs can be congested or hemorrhagic. The cloacal bursa and thymus are usually atrophic. Splenomegaly is recorded frequently in gallinaceous birds infected with H5N1 HPAI virus.

In ostriches, HPAI viruses produced edema of head and neck, severe hemorrhagic enteritis, enlarged and firm pancreas, mild-to-severe air sacculitis, hepatitis, peritonitis, renomegaly, and splenomegaly.

Microscopic

Low Pathogenicity Avian Influenza Viruses. In poultry, LPAI viruses produce pneumonia varying in character from ventromedial, fibrinocellular-to-peribronchiolar lymphocytic. In severe cases, the pneumonia may be diffuse with air capillary edema. Heterophilic-to-lymphocytic tracheitis and bronchitis

have been common. On intravenous (IV) or intranasal inoculation and in field cases in chickens, nephrosis and nephritis have been reported. However, this renal tropism is virus-strain specific and most consistently produced with IV inoculation. In turkeys, experimental and natural cases of pancreatitis with acinar necrosis have been seen, especially with the 1999 Italian H7N1 AI virus. Pancreatitis is less common in chickens than turkeys. Birds that die from LPAI have lymphocyte depletion and necrosis or apoptosis of lymphocytes in the cloacal bursa, thymus, and spleen, and whereas other tissues such as trachea and nasal cavity have lymphocyte accumulations. Viral antigen is rarely seen in lymphocytes but is commonly demonstrated in necrotic respiratory epithelium, renal tubule epithelium, and pancreatic acinar epithelium. The former is primarily in IN-inoculated chickens.

In rheas (*Rhea americana*), the LPAI viruses produced heterophilic-to-pyogranulomatous sinusitis, bronchitis, and pneumonia with necrosis of respiratory epithelium. In ostriches, lesions of splenic and hepatic necrosis, enteritis, and sinusitis were seen.

Highly Pathogenic Avian Influenza Viruses. Lesions in natural outbreaks have been reported and have been reproduced in experimental studies with chickens. Histologic lesions are most consistent in tissues having gross lesions. Specific histopathologic descriptions for experimental studies vary with individual viruses as a result of variations in inoculum doses, strain of chicken, route of inoculation, and passage history. Basically, the histologic lesions consist of multi-organ necrosis and/or inflammation. The most consistent and most severely affected tissues are brain, heart, lung, pancreas, and primary and secondary lymphoid organs. Lymphocytic meningoencephalitis with focal gliosis, neuronal necrosis, and neuronophagia are common, but edema and hemorrhage may be seen. Focal degeneration to multifocal-diffuse coagulative necrosis of cardiac myocytes has been reported, usually with accompanying lymphohistiocytic inflammation. Lesions in the brain and heart have abundant associated influenza virus proteins in neurons and myocytes, respectively. Other common lesions associated with AI virus replication include necrosis in skeletal myofibers, kidney tubules, vascular endothelial cells, corticotrophic cells of adrenal, and pancreatic acinar cells. If the birds survive for three to five days, the quantity of necrosis is reduced and the intensity of lymphohistiocytic inflammation is increased. In lymphoid tissue, necrosis, apoptosis, and depletion are common in cloacal bursa, thymus, and spleen, but AI viral antigen is rarely seen in lymphocytes. The lesions in the respiratory tract vary widely from minimal to severe. The non-feathered skin contains numerous microthrombi within dermal and hypodermal capillaries and small blood vessels. This is accompanied by vasculitis, perivascular-to-generalized edema, subcutaneous edema, and necrosis of capillary endothelium. The epidermis has various stages of vesicle formation progressing to full-thickness necrosis. Virus can be demonstrated in feather shaft and follicle epithelium.

In gallinaceous species other than chickens and turkeys, lesions are similar to above, but in general, because the birds survive longer than chickens or turkeys, the necrosis and inflammation are more common and prominent in tissues.

In ostriches, HPAI viruses produced coagulative necrosis in spleen, kidney, and liver. Fibrinoid necrosis was common in the arterioles of the brain and spleen. The pancreas had necrosis of acinar cells with mild mononuclear cell inflammation and fibrosis. Foci of malacia and neuronophagia were present in brains, and necrotic and hemorrhagic lesions were in the intestine.

Pathogenesis of the Infectious Process

In poultry, the process begins by inhalation or ingestion of infectious LP or HPAI virions. Because trypsin-like enzymes in respiratory and intestinal epithelial cells allow cleavage of the surface hemagglutinin, multiple replication cycles occur in respiratory and/or intestinal tracts with either type of virus. In gallinaceous poultry, the nasal cavity is a major site of initial replication.

With HPAI viruses, after initial replication in respiratory epithelium, the virions invade the submucosa, entering capillaries. The virus replicates within endothelial cells and spreads via the vascular or lymphatic systems to infect and replicate in a variety of cell types in visceral organs, brain, and skin. Alternatively, the virus may become systemic before having extensive replication in vascular endothelial cells. The virus is present in the plasma and red and white blood cell fractions. Macrophages appear to play a role in systemic virus spread. The presence of a HA proteolytic cleavage site that can be cut by ubiquitous furin-like cellular enzymes is responsible for this pantropic replication. Clinical signs and death are due to multiple organ failure. Damage caused by AI viruses is the result of one of four processes: (1) direct virus replication in cells, tissues, and organs; (2) indirect effects from production of cellular mediators such as cytokines; (3) ischemia from vascular thrombosis, and (4) cardiovascular collapse from coagulopathy or disseminated intravascular coagulation.

For the LPAI viruses, replication usually is limited to the respiratory or intestinal tracts. Illness or death is most often from respiratory damage, especially if accompanied by secondary bacterial infections. Sporadically in some species, LPAI viruses spread systemically, replicating and causing damage in kidney tubules, pancreatic acinar epithelium, oviduct, and other organs with epithelial cells having trypsin-like enzymes.

Pathogenesis of the infection process is less well understood in non-gallinaceous birds.

Immunity

Active

Infection with AI viruses as well as immunization with vaccines elicits a humoral antibody response at both the systemic and mucosal levels (324). This includes a systemic IgM response by five days post-infection, followed shortly by an

IgG response. The antibody response is influenced by the age of the bird, concurrent infection with immunosuppressive viruses, the level of host adaptation of the virus, and the antigenicity of the virus itself. The mucosal immune response is poorly characterized (324). The intensity of the antibody response varies with bird species. Leghorn-type chickens appear to have the highest antibody response followed by pheasants, turkeys, quail, and ducks (132, 324).

Antibodies against both the surface proteins, HA and NA, are neutralizing and protective, but antibodies to the HA are superior to NA for protection (265, 324, 367). The level of protection against mucosal infection and subsequent shedding of challenge virus may depend on the degree of antigenic (or protein sequence) similarity between HA of vaccine and challenge virus (343, 347, 348). Duration of protection is unknown, but in layers, experimental protection against clinical signs and death has been demonstrated to at least 30 weeks following a single immunization (46). Birds that have recovered from field exposure are protected from the same HA and NA subtypes. Under field conditions, most meat producing poultry, such as waterfowl, turkeys, and chickens, require two vaccinations to maintain adequate protection, and long-lived poultry, such as breeders and layers, may require three or more vaccinations throughout their lives (97, 364). Single vaccination may only be effective for short-lived, highly immune competent broiler chickens that lack maternal antibodies to the AI virus of concern.

Passive

Partial protection by maternal antibodies to homologous HA or NA have been reported experimentally (80, 200). Such antibodies can provide protection from virulent challenge during the first 10–21 days post-hatch, depending on concentration of such antibodies in progeny. Maternal antibodies also interfere with active immunity in progeny, when using either live or inactivated AI vaccines (80, 208).

Diagnosis

A definitive diagnosis of AI is established by (1) direct detection of AI viral proteins or genes in specimens such as tissues, swabs, cell cultures, or embryonating eggs; or (2) isolation and identification of AI virus. A presumptive diagnosis can be made by detecting antibodies to AI virus. During outbreaks of HPAI, mortality rates, clinical signs, and lesions may be useful as part of the case definition in deciding which farms to quarantine and possibly for depopulation of birds for eradication purposes.

Sample Selection and Storage

AI viruses are commonly recovered from tracheal, oropharyngeal, or cloacal swabs of either live or dead birds, because most HP and LPAI viruses replicate in the respiratory and intestinal tracts. The swabs should be placed in a sterile transport medium containing high levels of antibiotics to reduce bacterial growth or immediately placed on wet ice for prompt shipment to the laboratory (363). Tissues, secretions, or excretions from these tracts are appropriate for virus isolation or detection. Tissues can be collected and placed into sterile plastic tubes or bags and also kept on wet ice until transported to the laboratory. In the examination of organs for virus, efforts should be made to collect and store internal organs separately from the respiratory and intestinal tract tissues because isolation of virus from internal organs may be an indication of systematic spread and is most often associated with the HPAI viruses. In the case of systemic infections produced by HPAI viruses, virtually every organ can yield virus because of the high titer viremia or direct replication in parenchymal cells.

If the samples for virus detection can be tested within 48 hours after collection, they may be kept at 4°C; however, if the samples must be held for additional time, storage at −70°C or colder is recommended. Every freeze-thaw cycle will reduce the amount of infectious virus in the sample, so proper planning in the laboratory is essential. Before testing for virus, tissues should be ground as a 5%–10% suspension in the transport medium and clarified by low-speed centrifugation.

Direct Detection of AI Viral Proteins or Nucleic Acids

The direct demonstration of influenza virus RNA or viral proteins in samples from animals is routinely used as a diagnostic screening test, both in the laboratory and as rapid "point-of-care" tests in the field. Several commercial antigen detection kits are available for detection of influenza A nucleoprotein and have been used to detect influenza viral antigen in avian specimens and allantoic fluid of inoculated embryonating chicken eggs (39, 68, 78, 171, 300, 408). These antigen capture immunoassays vary in sensitivity with the best tests being 3-4 log less sensitive than virus isolation or real-time reverse transcriptase polymerase chain reaction (rRT-PCR) (408), but have greatest utility when used as "rule in" tests on dead poultry provided appropriate samples are collected from multiple dead birds (302). Polyclonal and monoclonal antibodies are useful for localizing viral antigen in tissues by immunofluorescent or immunoperoxidase staining methods (294, 297, 384).

Reverse transcriptase polymerase chain reaction (RT-PCR) and rRT-PCR methods have been developed and used in some laboratories for experimental studies and field case diagnosis of AI (5, 306, 410). The rRT-PCR has a three-hour test time, and sensitivity and specificity comparable to virus isolation procedures, providing accelerated influenza diagnosis, and field monitoring (111). In the USA, screening of tracheal or oropharyngeal samples from gallinaceous birds is done using a matrix gene rRT-PCR test and if positive, the samples are tested with H5 and H7 subtype specific rRT-PCR tests (307). For waterfowl and wild birds, both tracheal and cloacal swabs are screened because some AI viruses are more enterotropic and respiratory screening alone may have lower sensitivity (73, 154). Field tests based on nucleic acid amplification using robust equipment has been developed and deployed for surveillance studies in wild birds (329, 368).

Virus Isolation

Methods for the isolation and identification of influenza viruses have been described in detail (236, 363). Chicken embryos, nine to 11 days old, are inoculated via the allantoic cavity with approximately 0.2 mL of sample. In some cases, yolk sac inoculation has yielded viruses when allantoic cavity inoculation has failed (194, 407).

The death of inoculated embryos within 24 hours after inoculation usually results from bacterial contamination or inoculation injury, and these eggs should be discarded. A few viruses may grow rapidly and kill the embryos by 48 hours; however, in most cases the embryos will not die before this time. After 72 hours, or at death, the eggs should be removed from the incubator, chilled, and allantoic fluids collected. The presence of virus is demonstrated by hemagglutinating activity using chicken erythrocytes; however, the presence of NDV must be excluded.

Generally, if virus is present in a sample, there will be sufficient growth in the first passage to result in hemagglutination, and repeated passage is unnecessary. Repeated passage of samples increases the risk of cross-contamination in the laboratory.

Long-term storage of viruses should be done at −70°C or below. Lyophilization of viruses is also appropriate for long-term storage; however, these stocks should be tested periodically to ensure infectivity.

Virus Identification

Standardized methods for testing the egg fluids for the presence of hemagglutinating activity using chicken erythrocytes by macro- or micro-techniques are employed (236, 363). Allantoic fluid positive for hemagglutination is used for virus identification.

It is important to determine whether the hemagglutinating activity detected in the allantoic fluid is due to influenza virus or other hemagglutinating viruses, such as paramyxoviruses such as Newcastle disease virus (NDV). Thus, the isolate is tested in HI assays against Newcastle disease and other antiserum. If negative, the virus then is tested for the presence of the type A specific antigen to establish that an influenza A virus is present. The type-specific NP (nucleoprotein) or matrix protein may be detected by the double immunodiffusion test (30, 86), the single-radial-hemolysis test (86), or commercial antigen capture immunoassay. Monoclonal antibodies that react with the nucleoprotein or matrix proteins have proven useful in identifying these antigens in ELISA (389).

The next step in the identification procedure is to determine the antigenic subtype of the surface antigens, HA and NA. The NA subtype is identified by a micro-NI assay with antisera prepared against the nine known NAs (236, 363). The HA is identified in the HI test (236, 363) using a panel of polyclonal antisera prepared against whole virus representing the 16 distinct HA subtypes. Subtyping is facilitated by using antisera against the HA alone (i.e., not the whole virus) or against reassortant viruses with heterologous NAs; this helps avoid steric inhibition due to antibodies against the NA (161, 163). An influenza virus with a new HA would not be detected in tests using antisera to the known HA subtypes. Therefore, it is essential to confirm that the unknown hemagglutinating agent is an influenza virus using the type-specific test described previously.

Alternatively, screening is often performed directly with RT-PCR or rRT-PCR to confirm the presence of a Type A influenza virus, and positive samples are reflexively tested for H5 or H7 because of the greater significance of isolation of these subtypes.

Final identification is most commonly accomplished by state, federal, or OIE influenza reference laboratories.

Serology

Serologic tests are used to demonstrate the presence of AI-specific antibodies, which may be detected as early as five days after infection. Several techniques are used for serologic surveillance and diagnosis. In serologic surveillance programs, a double immunodiffusion test (agar gel immunodiffusion or AGID) for the detection of anti-NP antibody is frequently used, because this detects antibodies to type A-specific antigens shared by all influenza A viruses. ELISA assays have been developed to detect antibodies to AI viruses (3, 37, 105, 210, 283, 303, 414). Several ELISAs are commercially available for detecting antibody to influenza including indirect ELISAs for chickens and turkeys or competitive ELISAs that can be used with any species. Although the competitive tests can be used with any species, these species have been validated with a limited number of species and true sensitivity and specificity are likely not known for all avian species. In general the ELISA tests are more sensitive than AGID or HI, but they also appear to be more prone to false positive results as well (203). ELISA species are now commonly used for screening purposes, and positive results are confirmed by AGID or HI tests. Once influenza is detected by immunodiffusion or ELISA, HI tests can be used to determine the HA subtype.

In serologic assays, there is considerable variation in the immune response among the various avian species. For example, antibodies to the NP are generally prominent in turkeys and pheasants but may be undetectable in ducks (295). In addition, antibodies may be induced in ducks, as well as other species, which fail to be detected in conventional HI tests performed with intact virus (164, 197).

The sera of many species contain nonspecific inhibitors that may interfere with the specificity of the HI and other tests. Because these inhibitors are especially active against certain viruses, they present a practical problem in serologic testing and the identification of viruses. Therefore, sera should be treated to reduce or destroy such activity, although it should be recognized that some treatments may lower specific antibody levels. The two most commonly used treatments for these inhibitors have been receptor destroying enzyme (RDE) and potassium periodate (63, 86). In addition to the non-specific inhibitors of hemagglutination, sera from other bird species, such as turkey and goose, may cause non-specific agglutination of the chicken erythrocytes used in the HI test. This may

mask low levels of HI activity. Such hemagglutinating activity can be removed by pretreatment of the serum with chicken erythrocytes (223). This problem may sometimes be avoided by using erythrocytes in the HI test of the same species as the serum being tested.

Differential Diagnosis

Because of the broad spectrum of signs and lesions reported with infections by AI viruses in several species, a definitive diagnosis must be made by virologic and serologic methods. For HPAI viruses, other causes of high mortality must be excluded such as velogenic Newcastle disease, septicemic fowl cholera, heat exhaustion, water deprivation, and some toxins. For LPAI viruses, other causes of respiratory disease and drops in egg production must be investigated such as lentogenic Newcastle disease virus, avian metapneumovirus and other paramyxoviruses, infectious laryngotracheitis, infectious bronchitis, chlamydia, mycoplasma, and various bacteria. Concurrent infections with other viruses or other bacteria have been commonly observed (95).

Intervention Strategies

Management Procedures

There are three different goals or outcomes in the control of AI: (1) prevention, (2) management, and (3) eradication (351). These outcomes are accomplished based on strategies using combinations of five specific, interrelated components: (1) education (including behavioral change communications), (2) biosecurity (including modifications to the way poultry are reared and sold, movement management, and cleaning and disinfection), (3) diagnostics and surveillance, (4) elimination of infected poultry, and (5) decreasing host susceptibility. The effectiveness of each strategy is dependent upon how many of the five components are used and how thoroughly they are or can be practiced in the field, which in turn depends on the quality of veterinary and animal production services and the nature of the poultry industries in the area where the outbreak occurs (104). The goals for individual LPAI and HPAI control strategies may differ depending on the country, subtype of the virus, economic situation, and risk to public health.

There is no "one single" control strategy for AI and a combination of measures must be used. In most developed countries, HPAI outbreaks have been eradicated within three months to a year by traditional stamping-out programs, coupled with movement controls and tracing, but in some developing countries, the lack of indemnities, poor veterinary infrastructure, and complex poultry production systems has made immediate eradication unachievable. In these situations, management of the disease to a low infection rate has been a realistic option. By comparison, control of LPAI has varied greatly among individual countries, and even between states and provinces within a single country (354). Notably good control programs have emerged from Minnesota (124, 264) and Pennsylvania (79), which have been successful in eradicating LPAI and LPNAI viruses on multiple occasions. Recommendations and responsibilities for containing influenza outbreaks have been described (108). The designation of H5 and H7 LPAI as LPNAI has increased the international use of stamping out programs in dealing with these two AI subtypes as a means to prevent emergence of HPAI viruses. Historically, HPAI viruses have emerged after LPAI H5 or H7 viruses circulated widely in susceptible poultry for several months but in some places LPNAI viruses have circulated for many years without converting to HP strains.

Education and Behavioral Change

One critical aspect in control is the education of all poultry and allied industry personnel regarding how the viruses are introduced, how they spread, and how such events can be prevented. An individual's control of risky behaviors greatly reduces the spread of AI virus by controlling fomite or aerosol movement of the virus, thus preventing AI virus movement on the farm and between farms. Behavioral change campaigns have been a cornerstone of efforts to contain H5N1 HPAI, although these do not eliminate all high risk practices (388).

Biosecurity

Biosecurity is the first line of defense (Chapter 1) and is practiced as inclusion biosecurity, such as quarantine, to keep the virus on infected premises, and exclusion biosecurity to keep the virus out of virus-free premises (359). Biosecurity measures also apply to countries and in areas around sites of outbreaks and cover practices such as cleaning and disinfection and restrictions on movement of poultry and items associated with poultry. Measures to prevent introduction and prevention of infection in LPM are also important lines of defense. The most likely source of virus for poultry is other infected birds, so the basic means for the prevention of infection of poultry with influenza viruses is the separation of susceptible birds from infected birds and their secretions and excretions. Transmission can occur when susceptible and infected birds are in close contact or when infectious material from infected birds is introduced into the environment of susceptible birds. Such introductions are associated with the movement of cages, equipment, footwear and clothing, vehicles, insemination equipment, etc. The presence of virus in fecal material and respiratory secretions is a likely means for movement of the virus either by ingestion, contact with mucus membranes, or inhalation. Contaminated poultry manure is a high risk source for virus transmission between flocks. Certain things have been identified that contribute to spread once AI has been introduced into commercial flocks: moving unclean equipment and crews, partial flock marketing, marketing an actively infected flock, shared rendering pick-up of daily mortality, moving the birds, and inadequate cleaning and disinfection (126). Poultry raised outdoors or which have outdoor access have been infected following exposure to wild birds, primarily to infected ducks and shorebirds. In some countries, LPM and village poultry are an important reservoir of influenza virus and pose a risk for introduction to commercial poultry if adequate biosecurity is not practiced. Swine may

serve as a source of H1 and H3 swine influenza viruses to turkeys where the virus is transmitted mechanically or by infected people or pigs (95).

All biosecurity practices limit spread of influenza by preventing contamination; controlling the movement of birds or their products, people, and equipment; or reducing the amount of the virus (e.g., cleaning and disinfection) (122, 359). Persons who have direct contact with birds or their manure have been the cause of most virus transmission events between houses or premises, but airborne transmission has served as a source to some farms in association with certain depopulation and cleaning activities during the peak of infection (42, 79, 276). Equipment that comes in direct contact with birds or their manure should not be moved from farm to farm without adequate cleaning and disinfection, and it is important to keep the traffic area near the poultry house free from contamination by manure. Visitors on farms should not be allowed or should be strictly controlled with mandatory disinfection of footwear and cleaning of clothing. Farm-to-farm spread of influenza virus must first be brought under control before the disease can be eradicated.

Special biosecurity procedures must be used when depopulating or marketing infected or dangerous contact flocks, including re-routing trucks from infected farms away from other poultry farms; and sealing, cleaning and disinfection of depopulation trucks before they leave farms. In addition, special biosecure practices are needed in repopulating within an infected zone or compartment during the recovery phase to prevent resurgence of the virus.

Experiences with H5N1 HPAI have demonstrated that some production and marketing practices need to be modified for successful control and prevention of infection. These have included measures such as compulsory vaccination of poultry destined for live poultry markets (99), segregation of species and introduction of market rest days, in which all poultry remaining unsold in a market are killed at the end of a trading day, and no new poultry are introduced until the market has been thoroughly cleaned and disinfected. Some cities have shifted from sale of live poultry in markets to sale of chilled carcasses from central slaughterhouses.

Diagnostics and Surveillance

Accurate and rapid diagnosis of AI is a prerequisite to early and successful control. The speed with which AI is controlled is largely dependent upon how quickly the first case or cases are detected, the existing biosecurity, and how quickly control strategies are implemented, especially if eradication is the goal. Passive surveillance is critical to differentiate LPAI virus as the cause of respiratory disease or drops in egg production from causes of enzootic diseases with similar signs. Similarly, HPAI virus must be differentiated from other causes of high mortality events. Active surveillance is essential for detecting infection in species such as domestic ducks that can be infected subclinically or to detect infection with LPAI viruses that do not cause clinical disease in gallinaceous birds. Determining where the virus is located within a country, zone, or compartment can best be accomplished through either serological testing of birds for antibodies and/or random testing of daily mortality for the presence of AI virus. Surveillance is also crucial for ongoing evaluation of the success of control strategies and for use in decision making as a prelude to improving control strategies. Serological testing has been used to certify a country, zone, or compartment as AI free, or during an AI outbreak to determine the extent of the infected zone for quarantine purposes.

Elimination of Infected Poultry

After identification of infected flocks, elimination of infected flocks, their eggs, and manure is essential to preventing future transmission. For HPAI, this has been typically accomplished through depopulation and disposal of carcasses, eggs, and manure by an environmentally sound method such as composting, incineration, rendering, or landfill burial. For LPAI, orderly marketing of birds after recovery from infection has been an acceptable means for elimination, and eggs can be marketed if properly cleaned. Most influenza virus shedding occurs during the first two weeks of infection, and usually by four weeks after the initiation of the infection, virus cannot be detected by sampling. Sero-positive flocks have not been associated with a high risk of transmission if maintained under biosecure practices. However, there should be no contact with recovered flocks because the length of time birds within a population shed virus is not clearly defined. Because the economic losses due to influenza may be severe, the control program should not unnecessarily penalize the growers. Indemnities by federal governments may be necessary for control and eradication of both HPNAI and LPNAI. Methods used for depopulation are rapidly evolving and include the use of foam (20).

Decreasing Host Susceptibility

If poultry are at risk to AI virus exposure, increasing the resistance of birds to infection may be necessary to break the infection cycle. Theoretically, this can be achieved by genetic selection for resistant bird strains or breeds, but to date, only minor resistance of some chicken breeds to LPAI virus have been identified and scientifically verified (337); resistance to HPAI virus in chickens is unsubstantiated (148). However, transgenic chickens with inserted short-hairpin RNA that inhibits and blocks influenza viral polymerase resulted in reduced transmission of the virus, but did not prevent infection and death when inoculated directly into the chickens (199). Another method to increase resistance is through active or passive immunity to the AI viral HA or NA. This is predominantly done through vaccination, but antibody and immune cell transfer can be protective.

Vaccination

Various vaccine technologies have been developed in the laboratory and have shown efficacy in experimental studies, mostly in chickens and turkeys, to provide protection from LPAI and HPAI viruses (351). The most frequently licensed AI vaccine

technology has been inactivated whole AI virus vaccines, typically made using LPAI field outbreak strains and more recently reverse genetic generated AI vaccine strains, followed by chemical inactivation and oil emulsification (356, 366). Live recombinant fowl poxvirus and Newcastle disease vaccines with AI H5 gene inserts (rFP-AIV-H5 and rNDV-AIV-H5, respectively) have been licensed and used in a few countries (364). Vaccines have been used in a variety of poultry and other avian species, and their effectiveness in preventing clinical signs and mortality is well documented. However, protection is virus subtype specific. Birds are susceptible to infection with influenza viruses belonging to any of the 16 HA subtypes, and there is no way to predict their exposure to any particular subtype. Thus, it is not practical to use preventive vaccination against all possible subtypes. However, if a particular HA subtype is at risk for introduction or after an outbreak occurs and the hemagglutinin subtype of the virus is identified, vaccination may be a useful tool in a control program (123). At this time there is no substantive data to indicate vaccines based on conserved AI proteins (such as nucleoprotein, matrix proteins, or polymerase proteins) will provide any practical field protection.

Numerous experimental studies (8, 25, 44, 46, 48, 158, 162, 317, 318, 395, 406) have demonstrated that AI vaccines are capable of inducing antibody and providing protection against mortality, morbidity, and declines in egg-production. In addition, properly administered vaccines increase resistance to AI virus infection, reduce the number of birds shedding virus, greatly reduce the titer of challenge virus shed, and prevent contact transmission. Carefully controlled use of vaccines in an H5 and H7 LPNAI outbreak may reduce the chance of the emergence of HPAI viruses by reducing the amount of virus replication. Most frequently, vaccines are administered by subcutaneous administration. Chickens can be immunized successfully by *in ovo* administration of inactivated oil emulsion and recombinant non-replicating or live vaccines (24, 314, 316, 375). The rFP-AI-H5 vaccine is given by subcutaneous or wing web inoculation at one day post-hatch in chickens only. The rFP-AI-H5 vaccines cannot be used in chickens that have received a prior pox virus vaccine or have been infected by a field strain of fowl poxvirus or AI protection will be inconsistent (346). The rNDV-AIV-H5 is administered by spray or eye drop. Both rFP-AIV-H5 and rNDV-AIV-H5 have been used primarily as a priming vaccine at one day of age followed by a boost 10–21 days later with inactivated AI vaccine. Maternal antibodies to NDV vector or AI virus interfere with active immunity from the recombinant vaccines. In the USA, only USDA licensed AI vaccines are allowed. The State Veterinarian can approve field use of H1-4, H6, and H8-16 vaccines, but the field use of H5 or H7 AI vaccines also requires approval by USDA.

One limitation of AI vaccination is the impeding of simple serologic surveillance, and viral infection can occur and persist in the absence of disease. However, antibodies from infection by circulating LPAI viruses in poultry could also impede detection of HPAI infected flocks. To counter the problem, surveillance must be designed and used to identify infected birds within a vaccinated population; i.e., so called DIVA (differentiate infected from vaccinated animals) strategy. One method is surveillance for active infection by detection of AI virus among the daily mortality using antigen capture immunoassay or rRT-PCR. Another method is serological surveillance for antibodies in vaccinated flocks either using routine serological tests (AGID, ELISA, or HI) in non-vaccinated sentinel birds or use of appropriate serological tests for vaccinated birds. For example, with birds vaccinated with a heterologous NA vaccine, detection of anti-NA antibodies against the NA of the field AI virus (57) is indicative of infection in vaccinated birds. If using recombinant vaccines that expresses only the AI virus hemagglutinin (such as rFP-AI-H5), detection of antibodies against AI virus NP or M proteins (AGID or ELISA) indicate infection in vaccinated chickens. Vaccinated flocks cannot be considered influenza virus-free without adequate surveillance. Vaccinated flocks must be identified and monitored for the presence of AI virus until slaughtered, although this is not feasible in developing countries where infection in poultry is enzootic and vaccination is being used as part of the control and prevention program against H5N1 HPAI.

Positive marker vaccines containing tetanus toxoid have been developed experimentally that allow detection of vaccinated poultry (153).

Additional considerations that influence decisions on vaccination for H5 or H7 LPNAI viruses have been discussed (33, 124, 128). Previously, the lack of a government indemnity program for LPNAI resulted in some industry segments (e.g., egg layers) being subject to severe economic damage from LPNAI virus. By withholding vaccine availability, regulatory agencies have provided the producer with an incentive to intentionally expose his/her flock to reduce the economic impact of LPNAI on egg production or air sac condemnations. Intentional exposure is likely to contribute to the spread of the disease. Controlled, effective vaccine use will reduce the population of susceptible poultry and reduce the quantity of virus shed if infection occurs. Recent examples where inactivated H5 or H7 vaccine has been used as an aid in controlling LPNAI include Minnesota (128, 354), Utah (112, 125), Italy (101), and Connecticut (354). A national USA program for control of H5 and H7 LPNAI has been approved under the National Poultry Improvement Plan. This plan provides for indemnities, surveillance guidelines, federal-state-industry partnership, and the ability to use vaccines under appropriate conditions (http://www.aphis.usda.gov/newsroom/hot_issues/avian_influenza/contents/printable_version/Uniform_Standards_2008.pdf).

Experimental vaccine approaches to AI vaccines including the use of other vectored vaccines (herpesvirus of turkeys, Rous sarcoma virus, vaccinia, infectious laryngotracheitis, Venezuelan Equine Encephalitis virus, salmonella, and adenoviruses) or DNA vaccines incorporating HA genes have provided protection (35, 64, 81, 114, 149, 178, 220, 266, 366, 376). HA-based vaccines have been shown to provide protection against a broad array of homologous HA subtype viruses (173, 343, 347). Recently developed vaccine technologies show

promise for application by mass immunizing methods which are not possible with current AI vaccine technology, such as recombinant duck virus enteritis vaccine (196).

It is clear that opportunities to develop a variety of effective vaccines exist, but the main issue is the logistics for proper administration in the field to induce effective population immunity. The ensuing debate (33) centers on the role they should play in controlling influenza viruses of varying pathogenicity in different domestic bird populations in different geographic regions. Based on the multitude of influenza A viruses in wild bird populations, it is reasonable to expect that these viruses will continue to cause serious disease problems when introduced into the LPM, rural or village poultry, and commercial poultry industries. Therefore, judicious use of vaccines may be appropriate to reduce influenza transmission and decrease susceptibility of poultry to the viruses, so eradication methods can be implemented before the disease spreads and becomes enzootic. Vaccination also may be applicable in high risk places where virus has become enzootic, allowing time for other control measures to be introduced such as improvements to farm biosecurity, market hygiene, and movement management. In such cases monitoring and surveillance programs need to be implemented to detect antigenic variant viruses to ensure that appropriate closely matched vaccine antigens are incorporated into vaccines. Vaccination programs should be targeted at high risk populations, and regular reviews on the need for vaccination as well as the target population conducted. This approach is used in a number of countries where elimination of H5N1 HPAI by classical methods proved impossible and remains a distant goal.

Treatment

Presently, no practical, specific treatment exists for AI virus infections in commercial poultry. Amantadine has been shown experimentally to be effective in reducing mortality (34, 85, 95, 183, 394), but the drug is not approved for food animals, and its use rapidly gives rise to amantadine-resistant viruses. Supportive care and antibiotic treatment have been employed to reduce the effects of concurrent bacterial infections. The use of human anti-influenza drugs such as M2 inhibitors (amantadine and rimantadine) and NA inhibitors (oseltamivir and zanamivir) is strongly discouraged because of the potential to generate resistance that can result in a loss of these drugs for public health use.

References

1. Abbas, M.A., E. Spackman, R. Fouchier, D. Smith, Z. Ahmed, N. Siddique, L. Sarmento, K. Naeem, E.T. McKinley, A. Hameed, S. Rehmani, and D.E. Swayne. 2011. H7 avian influenza virus vaccines protect chickens against challenge with antigenically diverse isolates. *Vaccine*. 29:7424–7429.
2. Abolnik, C., B.Z. Londt, R.J. Manvell, W. Shell, J. Banks, G.H. Gerdes, G. Akol, and I.H. Brown. 2009. Characterisation of a highly pathogenic influenza A virus of subtype H5N2 isolated from ostriches in South Africa in 2004. *Influ Other Respir Viruses*. 3:63–68.
3. Abraham, A., V. Sivanandan, D.A. Halvorson, and J.A. Newman. 1986. Standardization of enzyme-linked immunosorbent assay for avian influenza virus antibodies in turkeys. *Am J Vet Res*. 47:561–566.
4. Acland, H.M., L.A. Silverman Bachin, and R.J. Eckroade. 1984. Lesions in broiler and layer chickens in an outbreak of highly pathogenic avian influenza virus infection. *Vet Pathol*. 21:564–569.
5. Akey, B.L. 2003. Low pathogenicity H7N2 avian influenza outbreak in Virginia during 2002. *Avian Dis*. 47:1099–1103.
6. Aldous, E.W., J.M. Seekings, A. McNally, H. Nili, C.M. Fuller, R.M. Irvine, D.J. Alexander, and I.H. Brown. 2010. Infection dynamics of highly pathogenic avian influenza and virulent avian paramyxovirus type 1 viruses in chickens, turkeys and ducks. *Avian Pathol*. 39:265–273.
7. Alexander, D.J., W.H. Allan, D.G. Parsons, and G. Parsons. 1978. The pathogenicity of four avian influenza viruses for fowls, turkeys and ducks. *Res Vet Sci*. 24:242–247.
8. Alexander, D.J. and G. Parsons. 1980. Protection of chickens against challenge with virulent influenza A viruses of Hav5 subtype conferred by prior infection with influenza A viruses of Hsw1 subtype. *Arch Virol*. 66:265–269.
9. Alexander, D.J. 1981. Current situation of avian influenza in poultry in Great Britian. In: *Proceedings of the First International Symposium on Avian Influenza*, R.A. Bankowski, ed. U.S. Animal Health Association, Richmond, Virginia. 35–45.
10. Alexander, D.J., and D. Spackman. 1981. Characterisation of influenza A viruses isolated from turkeys in England during March-May 1979. *Avian Pathol*. 10:281–293.
11. Alexander, D.J. 1982. Avian influenza. Recent developments. *Vet Bull*. 52:341–359.
12. Alexander, D.J. and R.E. Gough. 1986. Isolations of avian influenza virus from birds in Great Britain. *Vet Rec*. 118:537–538.
13. Alexander, D.J. 1987. Criteria for the definition of pathogenicity of avian influenza viruses. In: *Proceedings of the Second International Symposium on Avian Influenza*, B.C. Easterday, ed. U.S. Animal Health Association, Richmond, Virginia. 228–245.
14. Alexander, D.J. 1993. Orthomyxovirus infections. In: *Virus Infections of Birds*, J.B. McFerran and M.S. McNulty, eds. Elsevier Science, London. 287–316.
15. Alexander, D.J., S.A. Lister, M.J. Johnson, C.J. Randall, and P.J. Thomas. 1993. An outbreak of highly pathogenic avian influenza in turkeys in Great Britian in 1991. *Vet Rec*. 132:535–536.
16. Alexander, D.J. 1996. Highly pathogenic avian influenza (fowl plague). In: *OIE Manual of Standards for Diagnostic Tests and Vaccines. List A and B Diseases of Mammals, Birds and Bees,* Anonymous Office International des Epizooties, Paris. 155–160.
17. Alexander, D.J. 2000. The history of avian influenza in poultry. *World Poultry*. 7–8.
18. Alexander, D.J., I. Capua, and G. Koch. 2008. Highly pathogenic avian influenza outbreaks in Europe, Africa and Asia since 1959, excluding the Asian H5N1 virus outbreaks. In: *Avian Influenza*, D.E. Swayne, ed. Blackwell Publishing, Ames, Iowa. 217–237.
19. Allwright, D.M., W.P. Burger, A. Geyer, and A.W. Terblanche. 1993. Isolation of an influenza A virus from ostriches (*Struthio camelus*). *Avian Pathol*. 22:59–65.
20. Alphin, R.L., M.K. Rankin, K.J. Johnson, and E.R. Benson. 2010. Comparison of water-based foam and inert-gas mass emergency depopulation methods. *Avian Dis*. 54:757–762.
21. Anonymous. 1976. The outbreak of fowl plague in Victoria. In: *Annual Report*, Anonymous Division of Animal Health, Department of Agriculture, Victoria. 4–6.

22. Anonymous. 2007. Avian influenza A/(H7N2) outbreak in the United Kingdom. *Euro Surveill*. 12:E070531
23. Austin, F.J., and R.G. Webster. 1986. Antigenic mapping of an avian H1 influenza virus haemagglutinin and interrelationships of H1 viruses from humans, pigs and birds. *J Gen Virol*. 67:983–992.
24. Avakian, A.P., R.M. Poston, F. Kong, K.R. Van Kampen, and C. Tang De-Chu. 2006. Automated mass immunization of poultry: the prospect for nonreplicating human adenovirus-vectored in ovo vaccines. *Expert Rev Vaccines* 6:457–465.
25. Bahl, A.K., and B.S. Pomeroy. 1977. Efficacy of avian influenza oil-emulsion vaccine in breeder turkeys. *J Am Vet Med Assoc*. 171:1105.
26. Bankowski, R.A. 1981. Introduction and objectives of the symposium. In: *Proceedings of the First International Symposium on Avian Influenza*, R.A. Bankowski, ed. U.S. Animal Health Association, Richmond, Virginia. vii–xiv.
27. Bankowski, R.A. 1981. Proceedings of the First International Symposium on Avian Influenza, U.S. Animal Health Association, Richmond, Virginia. 1–215.
28. Banks, J., E. Speidel, and D.J. Alexander. 1998. Characterisation of an avian influenza A virus isolated from a human—is an intermediate host necessary for the emergence of pandemic influenza viruses? *Arch Virol*. 143:781–787.
29. Barr, D.A., A.P. Kelly, R.T. Badman, A.R. Campey, M.D. O'Rourke, D.C. Grix, and R.L. Reece. 1986. Avian influenza on a multi-age chicken farm. *Aust Vet J*. 63:195–196.
30. Beard, C.W. 1970. Avian influenza antibody detection by immunodiffusion. *Avian Dis*. 14:337–341.
31. Beard, C.W., and D.H. Helfer. 1972. Isolation of two turkey influenza viruses in Oregon. *Avian Dis*. 16:1133–1136.
32. Beard, C.W., M. Brugh, and D.C. Johnson. 1984. Laboratory studies with the Pennsylvania avian influenza viruses (H5N2). *Proc US Anim Heal Assoc*. 88:462–473.
33. Beard, C.W. 1987. To vaccinate or not to vaccinate. In: *Proceedings of the Second International Symposium on Avian Influenza*, B.C. Easterday and C.W. Beard, eds. U.S. Animal Health Association, Richmond, Virginia. 258–263.
34. Beard, C.W., M. Brugh, and R.G. Webster. 1987. Emergence of amantadine-resistant H5N2 avian influenza virus during a simulated layer flock treatment program. *Avian Dis*. 31:533–537.
35. Beard, C.W., W.M. Schnitzlein, and D.N. Tripathy. 1991. Protection of chickens against highly pathogenic avian influenza virus (H5N2) by recombinant fowlpox viruses. *Avian Dis* 35:356–359.
36. Beare, A.S., and R.G. Webster. 1991. Replication of avian influenza viruses in humans. *Arch Virol*. 119:37–42.
37. Beck, J.R., and D.E. Swayne. 1998. Evaluation of ELISA for avian influenza serologic and diagnostic programs: Comparison with agar gel precipitin and hemagglutination inhibition tests. In: *Proceedings of the Fourth International Symposium on Avian Influenza*, D.E. Swayne and R.D. Slemons, eds. U.S. Animal Health Association, Richmond, Virginia. 297–304.
38. Becker, W.B. 1966. The isolation and classification of Tern virus: influenza A-Tern South Africa—1961. *J Hyg* 64:309–320.
39. Belak, S., I. Kiss, and G.J. Viljoen. 2009. New developments in the diagnosis of avian influenza. *Rev Sci Tech—OIE* 28:233–243.
40. Berhane, Y., T. Hisanaga, H. Kehler, J. Neufeld, L. Manning, C. Argue, K. Handel, K. Hooper-McGrevy, M. Jonas, J. Robinson, R.G. Webster, and J. Pasick. 2009. Highly pathogenic avian influenza virus a (H7N3) in domestic poultry, Saskatchewan, Canada, 2007. *Emerg Infect Dis*. 15:1492–1495.
41. Bosch, F.X., M. Orlich, H.D. Klenk, and R. Rott. 1979. The structure of the hemagglutinin, a determinant for the pathogenicity of influenza viruses. *Virology*. 95:197–207.
42. Bowes, V.A., S.J. Ritchie, S. Byrne, K. Sojonky, J.J. Bidulka, and J.H. Robinson. 2004. Virus characterization, clinical presentation, and pathology associated with H7N3 avian influenza in British Columbia broiler breeder chickens in 2004. *Avian Dis*. 48:928–934.
43. Brown, J.D., D.E. Swayne, R.J. Cooper, R.E. Burns, and D.E. Stallknecht. 2007. Persistence of H5 and H7 avian influenza viruses in water. *Avian Dis*. 51:285–289.
44. Brugh, M., C.W. Beard, and H.D. Stone. 1979. Immunization of chickens and turkeys against avian influenza with monovalent and polyvalent oil emulsion vaccines. *Am J Vet Res*. 40:165–169.
45. Brugh, M., and C.W. Beard. 1986. Influence of dietary calcium stress on lethality of avian influenza viruses for laying chickens. *Avian Dis*. 30:672–678.
46. Brugh, M., and H.D. Stone. 1987. Immunization of chickens against influenza with hemagglutinin-specific (H5) oil emulsion vaccine. In: *Proceedings of the Second International Symposium on Avian Influenza*, C.W. Beard and B.C. Easterday, eds. U.S. Animal Health Association, Richmond, Virginia. 283–292.
47. Brugh, M., and D.C. Johnson. 1987. Epidemiology of avian influenza in domestic poultry. In: *Proceedings of the Second International Symposium on Avian Influenza*, B.C. Easterday and C.W. Beard, eds. USAHA, Athens, Georgia. 177–186.
48. Butterfield, W.K., and C.H. Campbell. 1979. Vaccination of chickens with influenza A/Turkey/Oregon/71 virus and immunity challenge exposure to five strains of fowl plague virus. *Vet Microbiol*. 4:101–107.
49. Callan, R.J., G. Early, H. Kida, and V.S. Hinshaw. 1995. The appearance of H3 influenza viruses in seals. *J Gen Virol*. 76:199–203.
50. Cappucci, D.T., Jr., D.C. Johnson, M. Brugh, T.M. Smith, C.F. Jackson, J.E. Pearson, and D.A. Senne. 1985. Isolation of avian influenza virus (subtype H5N2) from chicken eggs during a natural outbreak. *Avian Dis*. 29:1195–1200.
51. Capua, I., F. Mutinelli, S. Marangon, and D.J. Alexander. 2000. H7N1 avian influenza in Italy (1999 to 2000) in intensively reared chickens and turkeys. *Avian Pathol*. 29:537–543.
52. Capua, I., F. Mutinelli, M.A. Bozza, C. Terregino, and G. Cattoli. 2000. Highly pathogenic avian influenza (H7N1) in ostriches (*Struthio camelus*). *Avian Pathol*. 29:643–646.
53. Capua, I., S. Marangon, L. Selli, D.J. Alexander, D.E. Swayne, M.D. Pozza, E. Parenti, and F.M. Cancellotti. 1999. Outbreaks of highly pathogenic avian influenza (H5N2) in Italy during October 1997–January 1998. *Avian Pathol*. 28:455–460.
54. Capua, I., and S. Marangon. 2000. The avian influenza epidemic in Italy, 1999–2000: a review. *Avian Pathol*. 29:289–294.
55. Capua, I., and F. Mutinelli. 2001. A color atlas and text on avian influenza, Papi Editore, Bologna. 1–287.
56. Capua, I., S. Marangon, and F.M. Cancellotti. 2003. The 1999-2000 avian influenza (H7N1) epidemic in Italy. *Vet Res Comm*. 27:123–127.
57. Capua, I., C. Terregino, G. Cattoli, F. Mutinelli, and J.F. Rodriguez. 2003. Development of a DIVA (Differentiating Infected from Vaccinated Animals) strategy using a vaccine containing a heterologous neuraminidase for the control of avian influenza. *Avian Pathol*. 32:47–55.
58. Capua, I., and D.J. Alexander. 2009. *Avian Influenza and Newcastle Disease: A Field and Laboratory Manual*, Springer, Milan. 1–186.

59. Cattoli, G., A. Milani, N. Temperton, B. Zecchin, A. Buratin, E. Molesti, M.M. Aly, A. Arafa, and I. Capua. 2011. Antigenic drift in H5N1 avian influenza virus in poultry is driven by mutations in major antigenic sites of the hemagglutinin molecule analogous to those for human influenza virus. *J Virol*. 85:8718–8724.
60. Cauthen, A.N., D.E. Swayne, S. Schultz-Cherry, M.L. Perdue, and D.L. Suarez. 2000. Continued circulation in China of highly pathogenic avian influenza viruses encoding the hemagglutinin gene associated with the 1997 H5N1 outbreak in poultry and humans. *J Virol*. 74:6592–6599.
61. CDC. 2008. Avian influenza infection in humans. http://www.cdc.gov/flu/avian/gen-info/avian-flu-humans.htm. Accessed: 27 October 2012.
62. CDC. 2012. Outbreaks in North America with transmission to humans. http://www.cdc.gov/flu/avianflu/past-outbreaks.htm. Accessed: 27 October 2012.
63. CDC. 1982. Concepts and procedures for laboratory based influenza surveillance, Centers for Disease Control, United States Department of Health and Human Services, Washington DC.
64. Chambers, T.M., Y. Kawaoka, and R.G. Webster. 1988. Protection of chickens from lethal influenza infection by vaccine-expressed hemagglutinin. *Virology*. 167:414–421.
65. Chen, H., G. Deng, Z. Li, G. Tian, Y. Li, P. Jiao, L. Zhang, Z. Liu, R.G. Webster, and K. Yu. 2004. The evolution of H5N1 influenza viruses in ducks in southern China. *Proc Natl Acad Sci USA*. 101:10452–10457.
66. Chen, H., G.J.D. Smith, S.Y. Zhang, K. Qin, J. Wang, K.S. Li, R.G. Webster, J.S.M. Peiris, and Y. Guan. 2005. H5N1 virus outbreak in migratory waterfowl: a worrying development could help to spread this dangerous virus beyond its stronghold in southeast Asia. *Nature (London)*. 436:191–192.
67. Chen, W., P.A. Calvo, D. Malide, J. Gibbs, U. Schubert, I. Bacik, S. Basta, R. O'Neill, J. Schickli, P. Palese, P. Henklein, J.R. Bennink, and J.W. Yewdell. 2001. A novel influenza A virus mitochondrial protein that induces cell death. *Nat Med*. 7:1306–1312.
68. Chua, T.H., T.M. Ellis, C.W. Wong, Y. Guan, S.X. Ge, G. Peng, C. Lamichhane, C. Maliadis, S.W. Tan, and P. Selleck. 2007. Performance evaluation of five detection tests for avian influenza antigen with various avian samples. *Avian Dis*. 51, 1:96–105.
69. Clavijo, A., J.E. Riva, J. Copps, Y. Robinson, and E.M. Zhou. 2001. Assessment of the pathogenicity of an emu-origin influenza A H5 virus in ostriches (*Struthio camelus*). *Avian Pathol* 30:83–89.
70. Clavijo, A., J.E. Riva, J. Copps, Y. Robinson, and E.M. Zhou. 2001. Assessment of the pathogenicity of an emu-origin influenza A H5 virus in ostriches (*Struthio camelus*). *Avian Pathol* 30:83–89.
71. Committee on Foreign Animal Diseases. 1998. Appendix 3: Cleaning and disinfection. In: *Foreign animal diseases*, Anonymous U.S. Animal Health Association, Richmond, Virginia. 445–448.
72. Cooley, A.J., H. Van Campen, M.S. Philpott, B.C. Easterday, and V.S. Hinshaw. 1989. Pathological lesions in the lungs of ducks infected with influenza A viruses. *Vet Pathol*. 26:1–5.
73. Costa, T.P., J.D. Brown, E.W. Howerth, and D.E. Stallknecht. 2011. Variation in viral shedding patterns between different wild bird species infected experimentally with low-pathogenicity avian influenza viruses that originated from wild birds. *Avian Pathol*. 40:119–124.
74. Cox, N.J., F. Fuller, N. Kaverin, H.D. Klenk, R.A. Lamb, B.W. Mahy, J.W. McCauley, K. Nakamura, P. Palese, and R.G. Webster. 2000. Orthomyxoviridae. In: *Virus taxonomy. Seventh report of the international committeeon taxonomy of viruses*, M.H. Van Regenmortel, C.M. Fauquet, D.H.L. Bishop, E.B. Carstens, M.K. Estes, S.M. Lemon, J. Maniloff, M.A. Mayo, D.J. McGeoch, C.R. Pringle, and R.B. Wickner, eds. Academic Press, San Deigo. 585–597.
75. Crawford, P.C., E.J. Dubovi, W.L. Castleman, I. Stephenson, E.P. Gibbs, L. Chen, C. Smith, R.C. Hill, P. Ferro, J. Pompey, R.A. Bright, M.J. Medina, C.M. Johnson, C.W. Olsen, N.J. Cox, A.I. Klimov, J.M. Katz, and R.O. Donis. 2005. Transmission of equine influenza virus to dogs. *Science* 310:482–485.
76. Cross, G.M. 1987. The status of avian influenza in poultry in Australia. In: *Proceedings of the Second International Symposium on Avian Influenza*, B.C. Easterday, ed. U.S. Animal Health Association, Richmond, Virginia. 96–103.
77. Das, A.M., E. Spackman, C. Thomas, D.E. Swayne, and D.L. Suarez. 2008. Detection of H5N1 high-pathogenicity avian influenza virus in meat and tracheal samples from experimentally infected chickens. *Avian Dis*. 52:40–48.
78. Davison, S., A.F. Ziegler, and R.J. Eckroade. 1998. Comparison of an antigen-capture enzyme immunoassay with virus isolation for avian influenza from field samples. *Avian Dis*. 42:791–795.
79. Davison, S., R.J. Eckroade, and A.F. Ziegler. 2003. A review of the 1996-1998 nonpathogenic H7N2 avian influenza outbreak in Pennsylvania. *Avian Dis*. 47:823–827.
80. De Vriese, J., M. Steensels, V. Palya, Y. Gardin, K.M. Dorsey, B. Lambrecht, S. Van Borm, and T. van den Berg. 2010. Passive protection afforded by maternally-derived antibodies in chickens and the antibodies' interference with the protection elicited by avian influenza inactivated vaccines in progeny. *Avian Dis*. 54:246–252.
81. De, B.K., M.W. Shaw, P.A. Rota, M.W. Harmon, J.J. Esposito, R. Rott, N.J. Cox, and A.P. Kendal. 1988. Protection against virulent H5 avian influenza virus infection in chickens by an inactivated vaccine produced with recombinant vaccinia virus. *Vaccine*. 6:257–261.
82. DEFRA. 2011. Highly pathogenic avian influenza H7N7, Oxfordshire, June 2008. http://archive.defra.gov.uk/foodfarm/farmanimal/diseases/atoz/ai/documents/epireport-080711.pdf. Accessed: 22 October 2012.
83. Delay, P.D., H. Casey, and H.S. Tubiash. 1967. Comparative study of fowl plague virus and a virus isolated from man. *Public Health Rep*. 82:615–620.
84. Delogu, M., M.A. De Marco, L. Di Trani, E. Raffini, C. Cotti, S. Puzelli, F. Ostanello, R.G. Webster, A. Cassone, and I. Donatelli. 2010. Can preening contribute to influenza A virus infection in wild waterbirds? *PLoS ONE* 5(6):e11315.
85. Dolin, R., R.C. Reichman, H.P. Madore, R. Maynard, P.N. Linton, and J. Webber Jones. 1982. A controlled trial of amantadine and rimantadine in the prophylaxis of influenza A infection. *N Engl J Med*. 307:580–584.
86. Dowdle, W.R., and G.C. Schild. 1975. Laboratory propagation of human influenza viruses, experimental host range and isolation from clinical materials. In: *The Influenza Viruses and Influenza*, E.D. Kilbourne, ed. Academic Press, New York. 257–261.
87. Downie, J.C., and W.G. Laver. 1973. Isolation of a type A influenza virus from an Australian pelagic bird. *Virology*. 51:259–269.
88. Ducatez, M.F., Z. Cai, M. Peiris, Y. Guan, Z. Ye, X.F. Wan, and R.J. Webby. 2011. Extent of antigenic cross-reactivity among highly pathogenic H5N1 influenza viruses. *J Clin Microbiol*. 49:3531–3536.
89. Dybing, J.K., S. Schultz Cherry, D.E. Swayne, D.L. Suarez, and M.L. Perdue. 2000. Distinct pathogenesis of Hong Kong-origin H5N1 viruses in mice as compared to other highly pathogenic H5 avian influenza viruses. *J Virol*. 74:1443–450.

90. Easterday, B.C., D.O. Trainer, B. Tumova, and H.G. Pereira. 1968. Evidence of infection with influenza viruses in migratory waterfowl. *Nature*. 219:523–524.
91. Easterday, B.C., and B. Tumova. 1972. Avian influenza. In: *Diseases of Poultry*, M.S. Hofstad, B.W. Calnek, C.F. Helmbolt, W.M. Reid, and H.W. Yoder, Jr., eds. Iowa State University Press, Ames. 670–700.
92. Easterday, B.C., and B. Tumova. 1978. Avian influenza. In: *Diseases of Poultry*, M.S. Hofstad, B.W. Calnek, C.F. Helmbolt, W.M. Reid, and H.W. Yoder, Jr., eds. Iowa State University Press, Ames, Iowa. 549–573.
93. Easterday, B.C. 1987. *Proceedings of the Second International Symposium on Avian Influenza*, U.S. Animal Health Association, Richmond, Virginia. 1–475.
94. Easterday, B.C., and C.W. Beard. 1992. *Proceedings of the Third International Symposium on Avian Influenza*, U.S. Animal Health Association, Richmond, Virginia. 1–458.
95. Easterday, B.C., V.S. Hinshaw, and D.A. Halvorson. 1997. Influenza. In: *Diseases of Poultry*, B.W. Calnek, H.J. Barnes, C.W. Beard, L.R. McDougald, and Y.M. Saif, eds. Iowa State University Press, Ames, Iowa. 583–605.
96. Eckroade, R.J., and L.A. Silverman-Bachin. 1986. Avian influenza in Pennsylvania. The beginning. In: *Proceedings of the Second International Symposium on Avian Influenza*, B.C. Easterday, ed. U.S. Animal Health Association, Richmond, Virginia. 22–32.
97. Eggert, D., and D.E. Swayne. 2010. Single vaccination provides limited protection to ducks and geese against H5N1 high pathogenicity avian influenza virus. *Avian Dis*. 54:1224–1229.
98. Elbers, A.R.W., T.H.F. Fabri, T.S. de Vries, J.J. de Wit, A. Pijpers, and G. Koch. 2004. The highly pathogenic avian influenza A (H7N7) virus epidemic in The Netherlands in 2003—lessons learned from the first five outbreaks. *Avian Dis*. 48:691–705.
99. Ellis, T.M., L.D. Sims, H.K.H. Wong, C.W. Wong, K.C. Dyrting, K.W. Chow, C. Leung, and J.S.M. Peiris. 2006. Use of avian influenza vaccination in Hong Kong. *Dev Biol (Basel)* 124:133–143.
100. Englund, L., B. Klingeborn, and T. Mejerland. 1986. Avian influenza A virus causing an outbreak of contagious interstitial pneumonia in mink. *Acta Vet Scand*. 27:497–504.
101. European Commission. 2000. The definition of avian influenza and the use of vaccination against avian influenza.Sanco/B3/AH/R17/2000:1–35.
102. FAO. 2006. H5N1 in cats—8 March 2006. http://www.fao.org/avianflu/es/animals_es.html. Accessed: 27 October 2012.
103. FAO. 2006. Summary of confirmed HPAI outbreaks in affected countries. *FAO AIDE News—AI Bulletin*. 41:9–10.
104. FAO. 2011. Approaches to controlling, preventing and eliminating H5N1 Highly Pathogenic Avian Influenza in endemic countries. *FAO Animal Production and Health Paper*. 171:1–50.
105. Fatunmbi, O.O., J.A. Newman, V. Sivanandan, and D.A. Halvorson. 1989. A broad-spectrum avian influenza subtype antigen for indirect enzyme-linked immunosorbent assay. *Avian Dis*. 33:264–269.
106. Feare, C.J. 2010. Role of wild birds in the spread of highly pathogenic avian influenza virus H5N1 and implications for global surveillance. *Avian Dis*. 54:201–212.
107. Fernandez, P.A., R.J. Rotello, Z. Rangini, A. Doupe, H.C.A. Drexler, and J.Y. Yuan. 1994. Expression of a specific marker of avian programmed cell death in both apoptosis and necrosis. *Proc Natl Acad Sci USA*. 91:8641–8645.
108. Fichtner, G.J. 1987. The Pennsylvania/Virginia experience in eradication of avian influenza (H5N2). In: *Proceedings of the Second International Symposium on Avian Influenza*, B.C. Easterday, ed. U.S. Animal Health Association, Richmond, Virginia. 33–38.
109. Fifth International Symposium on Avian Influenza. 2003. Recommendations of the Fifth International Symposium on Avian Influenza. *Avian Dis*. 47:1260–1261.
110. Fouchier Ron, A.M., V. Munster, A. Wallensten, T.M. Bestebroer, S. Herfst, D. Smith, G.F. Rimmelzwaan, B. Olsen, and D.M.E. Osterhaus Albert. 2005. Characterization of a novel influenza a virus hemagglutinin subtype (H16) obtained from black-headed gulls. *J Virol*. 79:2814–2822.
111. Fouchier, R.A., T.M. Bestebroer, S. Herfst, L. Van Der Kemp, G.F. Rimmelzwaan, and A.D. Osterhaus. 2000. Detection of influenza A viruses from different species by PCR amplification of conserved sequences in the matrix gene. *J Clin Microbiol*. 38:4096–4101.
112. Frame, D.D., B.J. McCluskey, R.E. Buckner, and F.D. Halls. 1996. Results of an H7N3 avian influenza vaccination program in commercial meat turkeys. *Proc West Poult Dis Conf*. 45:32
113. Franklin, R.M., and E. Wecker. 1959. Inactivation of some animal viruses by hydroxylamine and the structure of ribonucleic acid. *Nature*. 84:343–345.
114. Fynan, E.F., R.G. Webster, D.H. Fuller, J.R. Haynes, J.C. Santoro, and H.L. Robinson. 1993. DNA vaccines: protective immunizations by parenteral, mucosal, and gene-gun inoculations. *Proc Natl Acad Sci USA*. 90:11478–11482.
115. Garcia, M., J.M. Crawford, J.W. Latimer, M.V.Z.E. Rivera-Cruz, and M.L. Perdue. 1996. Heterogeneity in the hemagglutinin gene and emergence of the highly pathogenic phenotype among recent H5N2 avian influenza viruses from Mexico. *J Gen Virol*. 77:1493–1504.
116. Geraci, J.R., D.J. St. Aubin, I.K. Barker, R.G. Webster, V.S. Hinshaw, W.J. Bean, H.L. Ruhnke, J.H. Prescott, G. Early, A.S. Baker, S. Madoff, and R.T. Schooley. 1982. Mass mortality of harbor seals: pneumonia associated with influenza A virus. *Science*. 215:1129–1131.
117. Graves, I.L. 1992. Influenza viruses in birds of the Atlantic flyway. *Avian Dis.* 36:1–10.
118. Guan, Y., K.F. Shortridge, S. Krauss, and R.G. Webster. 1999. Molecular characterization of H9N2 influenza viruses: were they the donors of the "internal" genes of H5N1 viruses in Hong Kong? *Proc Natl Acad Sci USA*. 96:9363–9367.
119. Guo, Y.J., J. Li, X. Cheng, M. Wang, and Y. Zhou. 1999. Discovery of man infected by avian influenza virus. *Chin J Exp Clin Virol*. 13:105–108.
120. Gutierrez, R.A., S. Sorn, J.M. Nicholls, and P. Buchy. 2011. Eurasian Tree Sparrows, risk for H5N1 virus spread and human contamination through Buddhist ritual: an experimental approach. *PLoS One*. 6:e28609
121. Halvorson, D.A., C.J. Kelleher, and D.A. Senne. 1985. Epizootiology of avian influenza: Effect of season on incidence in sentinel ducks and domestic turkeys in Minnesota. *Appl Env Microbiol*. 49:914–919.
122. Halvorson, D.A. 1987. A Minnesota cooperative control program. In: *Proceedings of the Second International Symposium on Avian Influenza*, B.C. Easterday, ed. U.S. Animal Health Association, Richmond, Virginia. 327–336.
123. Halvorson, D.A., D. Karunakaran, A.S. Abraham, J.A. Newman, V. Sivanandan, and P.E. Poss. 1987. Efficacy of vaccine

in the control of avian influenza. In: *Proceedings of the Second International Symposium on Avian Influenza*, C.W. Beard and B.C. Easterday, eds. U.S. Animal Health Assocaition, Richmond, Virginia. 264–270.
124. Halvorson, D.A. 1998. Strengths and weaknesses of vaccines as a control tool. In: *Proceedings of the Fourth International Symposium in Avian Influenza*, D.E. Swayne and R.D. Slemons, eds. U.S. Animal Health Association, Richmond, Virginia. 223–227.
125. Halvorson, D.A., D.D. Frame, K.A.J. Friendshuh, and D.P. Shaw. 1998. Outbreaks of low pathogenicity avian influenza in U.S.A. In: *Proceedings of the Fourth International Symposium on Avian Influenza*, D.E. Swayne and R.D. Slemons, eds. U.S. Animal Health Association, Richmond, Virginia. 36–46.
126. Halvorson, D.A. 2000. The control of avian influenza. In: *Proceedings of the Third International Symposium on Turkey Diseases*, Anonymous Germany Veterinary Medical Society, Berlin. 131–138.
127. Halvorson, D.A. 2002. Twenty-five years of avian influenza in Minnesota. In: *Proceedings of the 53rd North Central Avian Disease Conference*, Anonymous North Central Avian Disease Conference, Minneapolis, Minnesota. 65–69.
128. Halvorson, D.A. 2002. The control of H5 or H7 mildly pathogenic avian influenza: a role for inactivated vaccine. *Avian Pathol*. 31:5–12.
129. Halvorson, D.A. 2009. Prevention and management of avian influenza outbreaks: experiences from the United States of America. *Rev Sci Teche—OIE*. 28:359–369.
130. Hanson, B.A., D.E. Stallknecht, D.E. Swayne, L.A. Lewis, and D.A. Senne. 2003. Avian influenza viruses in Minnesota ducks during 1998–2000. *Avian Dis*. 47:867–871.
131. Hashem, A., B. Jaentschke, C. Gravel, M. Tocchi, T. Doyle, M. Rosu-Myles, R. He, and X. Li. 2012. Subcutaneous immunization with recombinant adenovirus expressing influenza A nucleoprotein protects mice against lethal viral challenge. *Hum Vaccin Immunother*. 8(4):425–430.
132. Higgins, D.A. 1996. Comparative immunology of avian species. In: *Poultry Immunology*, T.F. Davison, T.R. Morris, and L.N. Payne, eds. Carfax Publishing Co, Abingdon. 149–205.
133. Hill, N.J., J.Y. Takekawa, C.J. Cardona, B.W. Meixell, J.T. Ackerman, J.A. Runstadler, and W.M. Boyce. 2012. Cross-seasonal patterns of avian influenza virus in breeding and wintering migratory birds: a flyway perspective. *Vector Borne Zoonotic Dis*. 12:243–253.
134. Hinshaw, V.S., R.G. Webster, and B. Turner. 1979. Water-bone transmission of influenza A viruses? *Intervirology*. 11:66–68.
135. Hinshaw, V.S., R.G. Webster, B.C. Easterday, and W.J.J. Bean. 1981. Replication of avian influenza A viruses in mammals. *Infect Immun*. 34:354–361.
136. Hinshaw, V.S., and R.G. Webster. 1982. The natural history of influenza A viruses. In: *Basic and Applied Influenza Research*, A.S. Beare, ed. CRC Press, Boca Raton, FL. 79–104.
137. Hinshaw, V.S., D.J. Alexander, M. Aymand, P.A. Bachmann, B.C. Easterday, C. Hannoun, H. Kida, M. Lipkind, J.S. MacKenzie, K. Nerome, G.C. Schild, C. Scholtissek, D.A. Senne, K.F. Shortridge, J.J. Skehel, and R.G. Webster. 1984. Antigenic comparisons of swine-influenza-like H1N1 isolates from pigs, birds and humans: an international collaborative study. *Bull WHO*. 62:871–878.
138. Hinshaw, V.S., J.M. Wood, R.G. Webster, R. Deibel, and B. Turner. 1985. Circulation of influenza viruses and paramyxoviruses in waterfowl originating from two different areas of North America. *Bull WHO*. 63:711–719.
139. Hinshaw, V.S., V.F. Nettles, L.F. Schorr, J.M. Wood, and R.G. Webster. 1986. Influenza virus surveillance in waterfowl in Pennsylvania after the H5N2 avian outbreak. *Avian Dis*. 30:207–212.
140. Hinshaw, V.S., W.J. Bean, J. Geraci, P. Fiorelli, G. Early, and R.G. Webster. 1986. Characterization of two influenza A viruses from a pilot whale. *J Virol*. 58:655–656.
141. Hinshaw, V.S., C.W. Olsen, N. Dybdahlsissoko, and D. Evans. 1994. Apoptosis: A mechanism of cell killing by influenza A and B viruses. *J Virol*. 68:3667–3673.
142. Hirst, M., C.R. Astell, M. Griffith, S.M. Coughlin, M. Moksa, T. Zeng, D.E. Smailus, R.A. Holt, S. Jones, M.A. Marra, M. Petric, M. Krajden, D. Lawrence, A. Mak, R. Chow, D.M. Skowronski, S.A. Tweed, S. Goh, R.C. Brunham, J. Robinson, V. Bowes, K. Sojonky, S.K. Byrne, Y. Li, D. Kobasa, T. Booth, and M. Paetzel. 2004. Novel avian influenza H7N3 strain outbreak, British Columbia. *Emerg Infect Dis.* 10:2192–2195.
143. Homme, P.J., B.C. Easterday, and D.P. Anderson. 1970. Avian influenza virus infections II. Experimental epizootology of influenza A/turkey/Wisconsin/1966 virus in turkeys. *Avian Dis*. 14:240–247.
144. Hooper, P., and P. Selleck. 1998. Pathology of low and high virulent influenza virus infections. In: *Proceedings of the Fourth International Symposium on Avian Influenza*, D.E. Swayne and R.D. Slemons, eds. U.S. Animal Health Association, Richmond, Virginia. 134–141.
145. Hoper, D., D. Kalthoff, B. Hoffmann, and M. Beer. 2012. Highly pathogenic avian influenza virus subtype H5N1 escaping neutralization: more than HA variation. *J Virol*. 86:1394–1404.
146. Horimoto, T., E. Rivera, J. Pearson, D. Senne, S. Krauss, Y. Kawaoka, and R.G. Webster. 1995. Origin and molecular changes associated with emergence of a highly pathogenic H5N2 influenza virus in Mexico. *Virology*. 213:223–230.
147. Humberd, J., K. Boyd, and R.G. Webster. 2007. Emergence of influenza a virus variants after prolonged shedding from pheasants. *J Virol*. 81:4044–4051.
148. Hunt, H.D., S. Jadhao, and D.E. Swayne. 2010. Major histocompatibility complex and background genes in chickens influence susceptibility to high pathogenicity avian influenza virus. *Avian Dis*. 54:572–575.
149. Hunt, L.A., D.W. Brown, H.L. Robinson, C.W. Naeve, and R.G. Webster. 1988. Retrovirus-expressed hemagglutinin protects against lethal influenza virus infections. *J Virol*. 62:3014–3019.
150. Iglesias, I., M. Martinez, M.J. Munoz, A. De la Torre, and J.M. Sanchez-Vizcaino. 2010. First case of highly pathogenic avian influenza in poultry in Spain. *Transbound Emer Dis*. 57:282–285.
151. Ito, T., J.N.S.S. Couceiro, S. Kelm, L.G. Baum, S. Krauss, M.R. Castrucci, I. Donatelli, H. Kida, J.C. Paulson, R.G. Webster, and Y. Kawaoka. 1998. Molecular basis for the generation in pigs of influenza A viruses with pandemic potential. *J Virol*. 72:7367–7373.
152. Jackwood, M.J.P., and D.E. Swayne. 2007. Pathobiology of Asian H5N1 avian influenza virus infections in ducks. *Avian Dis*. 51:250–259.
153. James-Berry, C.M., D. Middleton, J.P. Mansfield, S.G. Fenwick, and T.M. Ellis. 2010. Use of a tetanus toxoid marker to allow differentiation of infected from vaccinated poultry without affecting the efficacy of a H5N1 avian influenza virus vaccine. *Vet Rec*. 167:695–699.

154. Jindal, N., M. De Abin, A.E. Primus, S. Raju, Y. Chander, P.T. Redig, and S.M. Goyal. 2010. Comparison of cloacal and oropharyngeal samples for the detection of avian influenza virus in wild birds. *Avian Dis*. 54:115–119.
155. Johnson, D.C., and B.G. Maxfield. 1976. An occurrence of avian influenza virus infection in laying chickens. *Avian Dis*. 20:422–424.
156. Jorgensen, P.H., O.L. Nielsen, H.C. Hansen, R.J. Manvell, J. Banks, and D.J. Alexander. 1998. Isolation of influenza A virus, subtype H5N2, and avian paramyxovirus type 1 from a flock of ostriches in Europe. *Avian Pathol*. 27:15–20.
157. Jungherr, E.L., E.E. Tyzzer, C.A. Brandly, and H.E. Moses. 1946. The comparative pathology of fowl plague and newcastle disease. *Am J Vet Res*. 7:250–288.
158. Karunakaran, D., J.A. Newman, D.A. Halvorson, and A. Abraham. 1987. Evaluation of inactivated influenza vaccines in market turkeys. *Avian Dis*. 31:498–503.
159. Kawaoka, Y., T.M. Chambers, W.L. Sladen, and R.G. Webster. 1988. Is the gene pool of influenza viruses in shorebirds and gulls different from that in wild ducks? *Virology*. 163:247–250.
160. Kawaoka, Y., and R.G. Webster. 1989. Interplay between carbohydrate in the stalk and the length of the connecting peptide determines the cleavability of influenza virus hemagglutinin. *J Virol*. 63:3296–3300.
161. Kawaoka, Y., S. Yamnikova, T.M. Chambers, D.K. Lvov, and R.G. Webster. 1990. Molecular characterization of a new hemagglutinin, subtype H14, of influenza A virus. *Virology*. 179:759–767.
162. Kendal, A.P., C.R. Madeley, and W.H. Allan. 1971. Antigenic relationships in avian influenza A viruses: identification of two viruses isolated from turkeys in Great Britain during 1969-1970. *J Gen Virol*. 13:95–100.
163. Kendal, A.P. 1982. New techniques in antigenic analysis with influenza viruses. In: *Basic and Applied Influenza Research*, A.S. Beare, ed. CRC Press, Inc., Boca Raton, FL. 51–78.
164. Kida, H., R. Yanagawa, and Y. Matsuoka. 1980. Duck influenza lacking evidence of disease signs and immune response. *Infect Immun*. 30:547–553.
165. Kilany, W.H., A. Arafa, A.M. Erfan, M.S. Ahmed, A.A. Nawar, A.A. Selim, S.G. Khoulosy, M.K. Hassan, M.M. Aly, H.M. Hafez, and E.M. Abdelwhab. 2010. Isolation of highly pathogenic avian influenza H5N1 from table eggs after vaccinal break in commercial layer flock. *Avian Dis*. 54:1115–1119.
166. Kilbourne, E.D. 1987. *Influenza*, Plenum, New York. 1–359.
167. King, D.J. 1991. Evaluation of different methods of inactivation of Newcastle disease virus and avian influenza virus in egg fluids and serum. *Avian Dis*. 35:505–514.
168. Klenk, H.D., W. Keil, H. Niemann, R. Geyer, and R.T. Schwarz. 1983. The characterization of influenza A viruses by carbohydrate analysis. *Curr Top Microbiol Immunol*. 104:247–257.
169. Kobayashi, Y., T. Horimoto, Y. Kawaoka, D.J. Alexander, and C. Itakura. 1996. Pathological studies of chickens experimentally infected with two highly pathogenic avian influenza viruses. *Avian Pathol*. 25:285–304.
170. Kobayashi, Y., T. Horimoto, Y. Kawaoka, D.J. Alexander, and C. Itakura. 1996. Neuropathological studies of chickens infected with highly pathogenic avian influenza viruses. *J Comp Pathol*. 114:131–147.
171. Kodihalli, S., V. Sivanandan, K.V. Nagaraja, S.M. Goyal, and D.A. Halvorson. 1993. Antigen-Capture Enzyme-Immunoassay for detection of avian influenza-virus in turkeys. *Am J Vet Res*. 54:1385–1390.
172. Kodihalli, S., V. Sivanandan, K.V. Nagaraja, D. Shaw, and D.A. Halvorson. 1994. A type-specific avian influenza virus subunit vaccine for turkeys: Induction of protective immunity to challenge infection. *Vaccine*. 12:1467–1472.
173. Kodihalli, S., D.L. Kobasa, and R.G. Webster. 2000. Strategies for inducing protection against avian influenza A virus subtypes with DNA vaccines. *Vaccine*. 18:2592–2599.
174. Koopmans, M., B. Wilbrink, M. Conyn, G. Natrop, H. van der Nat, H. Vennema, A. Meijer, J. van Steenbergen, R. Fouchier, A. Osterhaus, and A. Bosman. 2004. Transmission of H7N7 avian influenza A virus to human beings during a large outbreak in commercial poultry farms in the Netherlands. *Lancet*. 363:587–593.
175. Krauss, S., D. Walker, S.P. Pryor, L. Niles, L. Chenghong, V.S. Hinshaw, and R.G. Webster. 2004. Influenza A viruses of migrating wild aquatic birds in North America. *Vector Borne Zoonotic Dis*. 4:177–189.
176. Krohn, L.D. 1925. A study on the recent outbreak of a fowl disease in New York City. *J Am Vet Med Assoc*. 20:146–170.
177. Kuiken, T., J. Van Den Brand, R.D. van, M. Pantin-Jackwood, and D.E. Swayne. 2010. Comparative pathology of select agent influenza a virus infections. *Vet Pathol*. 47:893–914.
178. Kuroda, K., C. Hauser, R. Rott, H.D. Klenk, and W. Doerfler. 1986. Expression of the influenza virus haemagglutinin in insect cells by a baculovirus vector. *EMBO J*. 5:1359–1365.
179. Kurtz, J., R.J. Manvell, and J. Banks. 1996. Avian influenza virus isolated from a woman with conjunctivitis [letter]. *Lancet*. 348:901–902.
180. Lamb, R.A. and R.M. Krug. 1996. Orthomyxoviridae: The viruses and their replication. In: *Fields Virology*, B.N. Field, D.M. Knipe, and P.M. Howley, eds. Lippincott-Raven, New York. 1353–1395.
181. Lamb, R.A., and R.M. Krug. 2001. Orthomyxoviridae: The viruses and their replication. In: *Fields Virology*, D.M. Knipe and P.M. Howley, eds. Lippincott-Raven, New York. 1487–1531.
182. Lang, G., O. Narayan, B.T. Rouse, A.E. Ferguson, and M.C. Connell. 1968. A new influenza A virus infection in turkeys II. A highly pathogenic variant, A/turkey/Ontario/7732/66. *Can Vet J*. 9:151–160.
183. Lang, G., O. Narayan, and B.T. Rouse. 1970. Prevention of malignant avian influenza by 1-adamantanamine hydrochloride. *Arch Gesamte Virusforsch*. 32:171–184.
184. Lang, G., A. Gagnon, and J.R. Geraci. 1981. Isolation of an influenza A virus from seals. *Arch Virol*. 68:189–195.
185. Lasley, F.A. 1986. Economics of avian influenza: control vs noncontrol. In: *Proceedings of the Second International Symposium on Avian Influenza*, C.W. Beard, ed. U.S. Animal Health Association, Richmond, Virginia. 390–399.
186. Laudert, E., V. Sivanandan, and D. Halvorson. 1993. Effect of an H5N1 avian influenza virus infection on the immune system of mallard ducks. *Avian Dis*. 37:845–853.
187. Laudert, E., D. Halvorson, V. Sivanandan, and D. Shaw. 1993. Comparative evaluation of tissue tropism characteristics in turkeys and mallard ducks after intravenous inoculation of type A influenza viruses. *Avian Dis*. 37:773–780.
188. Laudert, E.A., V. Sivanandan, and D.A. Halvorson. 1993. Effect of intravenous inoculation of avian influenza virus on reproduction and growth in mallard ducks. *J Wildl Dis*. 29:523–526.
189. Laver, G. 1963. The structure of influenza viruses. II. Disruption of the virus particles and separation of neuraminidase activity. *Virology.* 20:251–262.

190. Lee, C.W., D.A. Senne, and D.L. Suarez. 2004. Effect of vaccine use in the evolution of Mexican lineage H5N2 avian influenza virus. *J Virol*. 78:8372–8381.
191. Lee, C.W., D.E. Swayne, J.A. Linares, D.A. Senne, and D.L. Suarez. 2005. H5N2 avian influenza outbreak in Texas in 2004: the first highly pathogenic strain in the United States in 20 years? *J Virol*. 79:3692–3702.
192. Lee, C.W., D.L. Suarez, T.M. Tumpey, H.W. Sung, Y.K. Kwon, Y.J. Lee, J.G. Choi, S.J. Joh, M.C. Kim, E.K. Lee, J.M. Park, X. Lu, J.M. Katz, E. Spackman, D.E. Swayne, and J.H. Kim. 2005. Characterization of highly pathogenic H5N1 avian influenza A viruses isolated from South Korea. *J Virol*. 79:3692–3702.
193. Lipkind, M., E. Shihmanter, and D. Shoham. 1982. Further characterization of H7N7 avian influenza virus isolated from migrating starlings wintering in Israel. *Zentralbl Veterinarmed B*. 29:566–572.
194. Lira, J., K.A. Moresco, D.E. Stallknecht, D.E. Swayne, and D.S. Fisher. 2010. Single and combination diagnostic test efficiency and cost analysis for detection and isolation of avian influenza virus from wild bird cloacal swabs. *Avian Dis*. 54:606–612.
195. Liu, J., H. Xiao, F. Lei, Q. Zhu, K. Qin, X.-W. Zhang, X.-L. Zhang, D. Zhao, G. Wang, Y. Feng, J. Ma, W. Liu, J. Wang, and G.F. Gao. 2005. Highly pathogenic H5N1 influenza virus infection in migratory birds. *Science*. 309:1206.
196. Liu, J., P. Chen, Y. Jiang, L. Wu, X. Zeng, G. Tian, J. Ge, Y. Kawaoka, Z. Bu, and H. Chen. 2011. A duck enteritis virus-vectored bivalent live vaccine provides fast and complete protection against H5N1 avian influenza virus infection in ducks. *J Virol*. 85:10989–10998.
197. Lu, B.L., R.G. Webster, and V.S. Hinshaw. 1982. Failure to detect hemagglutination-inhibiting antibodies with intact avian influenza virions. *Infect Immun*. 38:530–535.
198. Lvov, D.K., V.M. Zdanov, A.A. Sazonov et al. 1978. Comparison of influenza viruses isolated from man and from whales. *Bull WHO*. 56:923–930.
199. Lyall, J., R.M. Irvine, A. Sherman, T.J. McKinley, A. Nunez, A. Purdie, L. Outtrim, I.H. Brown, G. Rolleston-Smith, H. Sang, and L. Tiley. 2011. Suppression of avian influenza transmission in genetically modified chickens. *Science*. 331:223–226.
200. Maas, R., S. Rosema, Z.D. van, and S. Venema. 2011. Maternal immunity against avian influenza H5N1 in chickens: limited protection and interference with vaccine efficacy. *Avian Pathol*. 40:87–92.
201. Manvell, R.J., P. McKinney, U. Wernery, and K.M. Frost. 2000. Isolation of a highly pathogenic influenza A virus of subtype H7N3 from a peregrine falcon (*Falco peregrinus*). *Avian Pathol*. 29:635–637.
202. Manvell, R.J., C. English, P.H. Jorgensen, and I.H. Brown. 2003. Pathogenesis of H7 influenza A viruses isolated from ostriches in the homologous host infected experimentally. *Avian Dis*. 47:1150–1153.
203. Marche, S., and T. van den Berg. 2010. Evaluation of different strategies for the use of ELISA tests as first screening tools for serologic surveillance of low pathogenic avian influenza in the Belgian poultry sector. *Avian Dis*. 54:627–631.
204. Mathieu, C., V. Moreno, P. Retamal, A. Gonzalez, A. Rivera, J. Fuller, C. Jara, C. Lecocq, M. Rojas, A. Garcia, M. Vasquez, M. Agredo, C. Gutiérrez, H. Escobar, R. Fasce, J. Mora, J. Garcia, J. Fernández, C. Ternicier, and P. Avalos. 2010. Pandemic (H1N1) 2009 in breeding turkeys, Valparaiso, Chile. *Emerg Infect Dis*. 16:709–711.
205. McFadyean, J. 1908. The ultravisible viruses. *J Comp Pathol Therap*. 21:58–242.
206. McNulty, M.S., G.M. Allan, R.M. McCracken, and P.J. McParland. 1985. Isolation of a highly pathogenic influenza virus from turkeys. *Avian Pathol*. 14:173–176.
207. Meltzer, M.I., N.J. Cox, and K. Fukuda. 1999. The economic impact of pandemic influenza in the United States: priorities for intervention. *Emerg Infect Dis*. 5:659–671.
208. Mesonero, A., D.L. Suarez, S.E. van, D.C. Tang, and H. Toro. 2011. Avian influenza in ovo vaccination with replication defective recombinant adenovirus in chickens: vaccine potency, antibody persistence, and maternal antibody transfer. *Avian Dis*. 55:285–292.
209. Mettenleiter, T. 2009. Avian influenza. *Rev Sci Tech Off Int Epiz*. 28:1–418.
210. Meulemans, G., M.C. Carlier, M. Gonze, and P. Petit. 1987. Comparison of hemagglutination-inhibition, agar gel precipitin, and enzyme-linked immunosorbent assay for measuring antibodies against influenza viruses in chickens. *Avian Dis*. 31:560–563.
211. Mo, I.P., M. Brugh, O.J. Fletcher, G.N. Rowland, and D.E. Swayne. 1997. Comparative pathology of chickens experimentally inoculated with avian influenza viruses of low and high pathogenicity. *Avian Dis*. 41:125–136.
212. Mohan, R., Y.M. Saif, G.A. Erickson, G.A. Gustafson, and B.C. Easterday. 1981. Serologic and epidemiologic evidence of infection in turkeys with an agent related to the swine influenza virus. *Avian Dis*. 25:11–16.
213. Mohler, J.R. 1926. Fowl Pest in the United States. *J Am Vet Med Assoc*. 21:549–559.
214. Morgan, I.R., and H.A. Westbury. 1981. Virological studies of Adelie Penguins (*Pygoscelis adeliae*) in Antarctica. *Avian Dis*. 25:1019–1026.
215. Morgan, I.R., and A.P. Kelly. 1990. Epidemiology of an avian influenza outbreak in Victoria in 1985. *Aust Vet J*. 67:125–128.
216. Mori, I., and Y. Kimura. 2000. Apoptotic neurodegeneration induced by influenza A virus infection in the mouse brain. *Microbes Inf*. 2:1329–1334.
217. Mori, I., T. Komatsu, K. Takeuchi, K. Nakakuki, M. Sudo, and Y. Kimura. 1995. In vivo induction of apoptosis by influenza virus. *J Gen Virol*. 76:2869–2873.
218. Mounts, A.W., H. Kwong, H.S. Izurieta, Y. Ho, T. Au, M. Lee, B.C. Buxton, S.W. Williams, K.H. Mak, J.M. Katz, W.W. Thompson, N.J. Cox, and K. Fukuda. 1999. Case-control study of risk factors for avian influenza A (H5N1) disease, Hong Kong, 1997. *J Infect Dis*. 180:505–508.
219. Murphy, B.R., and R.G. Webster. 1996. Orthomyxoviruses. In: *Fields Virology*, B.N. Fields, D.M. Knipe, and P.M. Howley, eds. Lippincott-Raven, Philadelphia. 1397–1445.
220. Murphy, T.M. 1986. The control and epidemiology of an influenza A outbreak in Ireland. In: *Acute Virus Infections of Poultry*, J.B. McFerran and M.S. McNulty, eds. Martinus Nijhoff, Dordrecht. 23–28.
221. Naeem, K. 1998. The avian influenza H7N3 outbreak in South Central Asia. In: *Proceedings of the Fourth International Symposium on Avian Influenza*, D.E. Swayne and R.D. Slemons, eds. USAHA, Richmond, Virginia. 31–35.
222. Naeve, C.W., V.S. Hinshaw, and R.G. Webster. 1984. Mutations in the hemagglutinin receptor-binding site can change the biological properties of an influenza virus. *J Virol*. 51:567–569.
223. Nakamura, R.M., and B.C. Easterday. 1967. Serological studies of influenza in animals. *Bull World Health Organ*. 37:559–567.

224. Nettles, V.F., J.M. Wood, and R.G. Webster. 1985. Wildlife surveillance associated with an outbreak of lethal H5N2 avian influenza in domestic poultry. *Avian Dis*. 29:733–741.
225. Newman, J., D. Halvorson, and D. Karunakaran. 1981. Complications associated with avian influenza infections. In: *Proceedings of the First International Symposium on Avian Influenza, Anonymous*. U.S. Animal Health Association, Richmond, Virginia. 8–12.
226. Nguyen-Van-Tam, J.S., P. Nair, P. Acheson, A. Baker, M. Barker, S. Bracebridge, J. Croft, J. Ellis, R. Gelletlie, N. Gent, S. Ibbotson, C. Joseph, H. Mahgoub, P. Monk, T.W. Reghitt, T. Sundkvist, C. Sellwood, J. Simpson, J. Smith, J.M. Watson, M. Zambon, and N. Lightfoot; Incident Response Team. 2006. Outbreak of low pathogenicity H7N3 avian influenza in UK, including associated case of human conjunctivitis. *Euro Surveill*. 11:E060504
227. OIE. 2004. Highly pathogenic avian influenza in Canada. Follow-up report no. 7 (final report). In: OIE Disease Information vol. 17, No. 30. http://www.oie.int/eng/info/hebdo/AIS_35.HTM#Sec6. Accessed: 17 May 2005.
228. OIE. 2004. Highly pathogenic avian influenza in the United States of America. In: OIE Disease Information vol. 17, No. 9.
229. OIE. 2004. Highly pathogenic avian influenza in South Africa. Follow-up report No. 3. In: OIE Disease Information vol. 17, No. 44.
230. OIE. 2005. Event summary: Highly pathogenic avian influenza, Korea (Dem. People's Rep.). http://web.oie.int/wahis/reports/en_imm_0000007128_20050408_101131.pdf. Accessed: 27 October 2012.
231. OIE. 2006. Avian influenza. In: *Manual of Diagnostic Tests and Vaccines for Terrestrial Animals*. 15th ed. OIE, Paris. 302–309.
232. OIE. 2006. Highly pathogenic avian influenza in South Africa. Follow-up report No. 2. http://web.oie.int/wahis/reports/en_fup_0000004418_20060728_170326.pdf. Accessed: 27 October 2012.
233. OIE. 2006. Highly pathogenic avian influenza in South Africa. Final Report http://web.oie.int/wahis/reports/en_fup_0000004531_20061027_120900.pdf Accessed: 27 October 2012.
234. OIE. 2007. Highly pathogenic avian influenza, Canada. Immediate Notification. http://web.oie.int/wahis/reports/en_imm_0000006260_20070928_132724.pdf. Accessed: 27 October 2012.
235. OIE. 2008. Highly pathogenic avian influenza, United Kingdom. http://web.oie.int/wahis/reports/en_fup_0000007028_20080512_112233.pdf. Accessed: 27 October 2012.
236. OIE. 2009. Avian Influenza. http://www.oie.int/fileadmin/Home/eng/Health_standards/tahm/2.03.04_AI.pdf. Accessed: 22 October 2012.
237. OIE. 2010. Highly pathogenic avian influenza, Spain. http://web.oie.int/wahis/reports/en_fup_0000008894_20100127_185906.pdf. Accessed: 27 October 2012.
238. OIE. 2011. World Animal Health Information System. http://web.oie.int/wahis/public.php?page=home. Accessed: 22 October 2012.
239. OIE. 2011. Terrestrial Animal Health Code. Avian influenza. http://www.oie.int/index.php?id=169&L=0&htmfile=chapitre_1.10.4.htm. Accessed: 22 October 2012.
240. OIE. 2011. Highly pathogenic avian influenza, Chinese Taipei.http://web.oie.int/wahis/reports/en_imm_0000011703_20120303_150915.pdf. Accessed: 27 October 2012.
241. OIE. 2012. Highly pathogenic avian influenza, South Africa. http://web.oie.int/wahis/reports/en_fup_0000012050_20120628_162150.pdf. Accessed: 27 October 2012.
242. OIE. 2012. Highly pathogenic avian influenza, Mexico. http://web.oie.int/wahis/reports/en_imm_0000012067_20120622_132313.pdf. Accessed: 27 October 2012.
243. Olivier, A.J. Ecology and epidemiology of avian influenza in ostriches. *Dev Biol (Basel)*. 124:51–57.
244. Paek, M.R., Y.J. Lee, H. Yoon, H.M. Kang, M.C. Kim, J.G. Choi, O.M. Jeong, J.S. Kwon, O.K. Moon, S.J. Lee, and J.H. Kwon. 2010. Survival rate of H5N1 highly pathogenic avian influenza viruses at different temperatures. *Poult Sci*. 89:1647–1650.
245. Palese, P., and A. Garcia-Sastre. 1999. Influenza viruses (orthomyxoviruses): molecular biology. In: *Encylopedia of Virology*: Volume 2, A. Granoff and R.G. Webster, eds. Academic Press, San Deigo. 830–836.
246. Panigrahy, B., D.A. Senne, and J.E. Pearson. 1995. Presence of avian influenza virus (AIV) subtypes H5N2 and H7N1 in emus (*Dromaius novaehollandiae*) and rheas (*Rhea americana*): Virus isolation and serologic findings. *Avian Dis*. 39:64–67.
247. Pantin-Jackwood, M.J., D.L. Suarez, E. Spackman, and D.E. Swayne. 2007. Age at infection affects the pathogenicity of Asian highly pathogenic avian influenza H5NI viruses in ducks. *Virus Res*. 130:151–161.
248. Pantin-Jackwood, M.J., and D.E. Swayne. 2009. Pathogenesis and pathobiology of avian influenza virus infection in birds. *Rev Sci Tech Off Int Epiz*. 28:113–136.
249. Pasick, J., K. Handel, J. Robinson, J. Copps, D. Ridd, K. Hills, H. Kehler, C. Cottam-Birt, J. Neufeld, Y. Berhane, and S. Czub. 2005. Intersegmental recombination between the haemagglutinin and matrix genes was responsible for the emergence of a highly pathogenic H7N3 avian influenza virus in British Columbia. *J Gen Virol*. 86:727–731.
250. Pearson, J.E., D.A. Senne, and B. Panigrahy. 1998. Avian influenza in the Western Hemisphere including the Pacific Basin 1992–1996. In: *Proceedings of the Fourth International Symposium on Avian Influenza*, D.E. Swayne and R.D. Slemons, eds. U.S. Animal Health Association, Richmond, Virginia. 14–17.
251. Peiris, J.S., W.C. Yu, C.W. Leung, C.Y. Cheung, W.F. Ng, J.M. Nicholls, T.K. Ng, K.H. Chan, S.T. Lai, W.L. Lim, K.Y. Yuen, and Y. Guan. 2004. Re-emergence of fatal human influenza A subtype H5N1 disease. *Lancet*. 363:617–619.
252. Peiris, J.S.M. 2009. Avian influenza viruses in humans. *Rev Sci Tech Off Int Epi*. 28:161–174.
253. Peiris, M., K.Y. Yuen, C.W. Leung, K.H. Chan, P.L. Ip, R.W. Lai, W.K. Orr, and K.F. Shortridge. 1999. Human infection with influenza H9N2 [letter]. *Lancet*. 354:916–917.
254. Perdue, M.L., M. Garcia, D. Senne, and M. Fraire. 1997. Virulence-associated sequence duplication at the hemagglutinin cleavage site of avian influenza viruses. *Virus Res*. 49:173–186.
255. Perdue, M.L., D.L. Suarez, and D.E. Swayne. 1999. Avian Influenza in the 1990's. *Poult Avian Biol Rev*. 11:1–20.
256. Perdue, M.L., and D.L. Suarez. 2000. Structural features of the avian influenza virus hemagglutinin that influence virulence. *Vet Microbiol*. 74:77–86.
257. Perdue, M.L., and D.E. Swayne. 2005. Public health risk from avian influenza viruses. *Avian Dis*. 49:317–327.
258. Pereira, H.G., B. Tumova, and V.G. Law. 1965. Avian influenza A viruses. *Bull WHO*. 32:855–860.

259. Perkins, L.E.L., and D.E. Swayne. 2001. Pathobiology of A/chicken/Hong Kong/220/97 (H5N1) avian influenza virus in seven gallinaceous species. *Vet Pathol*. 38:149–164.
260. Perkins, L.E.L., and D.E. Swayne. 2002. Pathogenicity of a Hong Kong-origin H5N1 highly pathogenic avian influenza virus for emus, geese, ducks, and pigeons. *Avian Dis*. 46:53–63.
261. Perkins, L.E.L., and D.E. Swayne. 2002. Susceptibility of laughing gulls (*Larus atricilla*) to H5N1 and H5N3 highly pathogenic avian influenza viruses. *Avian Dis*. 46:877–885.
262. Perkins, L.E.L., and D.E. Swayne. 2003. Comparative susceptibility of selected avian and mammalian species to a Hong Kong-origin H5N1 high-pathogenicity avian influenza virus. *Avian Dis*. 47:956–967.
263. Perkins, L.E.L., and D.E. Swayne. 2003. Varied pathogenicity of a Hong Kong-origin H5N1 avian influenza virus in four passerine species and budgerigars. *Vet Pathol*. 40:14–24.
264. Poss, P.E., K.A. Friendshuh, and L.T. Ausherman. 1987. The control of avian influenza. In: *Proceedings of the Second International Symposium on Avian Influenz*a, Anonymous U.S. Animal Health Association, Richmond, Virginia. 318–326.
265. Ramp, K., J. Veits, D. Deckers, M. Rudolf, C. Grund, T.C. Mettenleiter, and A. Romer-Oberdorfer. 2011. Coexpression of avian influenza virus H5 and N1 by recombinant Newcastle disease virus and the impact on immune response in chickens. *Avian Dis*. 55:413–421.
266. Robinson, H.L., L.A. Hunt, and R.G. Webster. 1993. Protection against a lethal influenza virus challenge by immunization with a haemagglutinin-expressing plasmid DNA. *Vaccine*. 11:957–960.
267. Rohm, C., N. Zhou, J. Suss, J. MacKenzie, and R.J. Webster. 1996. Characterization of a novel influenza hemagglutinin, H15: criteria for determination of influenza A subtypes. *Virology*. 217:508–516.
268. Rojas, H., R. Moreira, P. Avalos, I. Capua, and S. Marangon. 2002. Avian influenza in poultry in Chile. *Vet Rec*. 151:188.
269. Schafer, J.R., Y. Kawaoka, W.J. Bean, J. Suss, D. Senne, and R.G. Webster. 1993. Origin of the pandemic 1957 H2 influenza-A virus and the persistence of its possible progenitors in the avian reservoir. *Virology*. 194:781–788.
270. Schafer, W. 1955. Vergleichende sero-immunologische untersuchungen uber die viren der influenza unf klassichen geflugelpest. *Zeitschrift fur Naturforschung*. 10B:81–91.
271. Schat, K.A., J. Bingham, J.M. Butler, L.M. Chen, S. Lowther, T.M. Crowley, R.J. Moore, R.O. Donis, and J.W. Lowenthal. 2012. Role of position 627 of PB2 and the multibasic cleavage site of the hemagglutinin in the virulence of H5N1 avian influenza virus in chickens and ducks. *PLoS One.* 7:e30960
272. Schrijver, R.S., G. Koch, R.S. Schrijver, and G. Koch. 2005. *Avian Influenza: Prevention and Control*, WAGENINGEN UR FRONTIS SERIES, Wageningen.
273. Schultz-Cherry, S., and V.S. Hinshaw. 1996. Influenza virus neuraminidase activates latent transforming growth factor beta. *J Virol*. 70:8624–8629.
274. Schultz-Cherry, S., R.M. Krug, and V.S. Hinshaw. 1998. Induction of apoptosis by influenza virus. *Sem Virol*. 8:491–498.
275. Selleck, P.W., L.J. Gleeson, P.T. Hooper, H.A. Westbury, and E. Hansson. 1997. Identification and characterization of an H7N3 influenza A virus from an outbreak of virulent avian influenza in Victoria. *Aust Vet J* .75:289–292.
276. Selleck, P.W., G. Arzey, P.D. Kirkland, R.L. Reece, A.R. Gould, P.W. Daniels, and H.A. Westbury. 2003. An outbreak of highly pathogenic avian influenza in Australia in 1997 caused by an H7N4 virus. *Avian Dis*. 47:806–811.
277. Senne, D.A., J.E. Pearson, Y. Kawaoka, E.A. Carbrey, and R.G. Webster. 1986. Alternative methods for evaluation of pathogenicity of chicken Pennsylvania H5N2 viruses. In: *Proceedings of the Second International Symposium on Avian Influenza*, B.C. Easterday, ed. U.S. Animal Health Association, Richmond, Virginia. 246–257.
278. Senne, D.A., J.E. Pearson, and B. Panigrahy. 1992. Live poultry markets: A missing link in the epidemiology of avian influenza. In: *Proceedings of the Third International Symposium on Avian Influenza*, B.C. Easterday, ed. University of Wisconsin-Madison, Madison, Wisconsin. 50–58.
279. Senne, D.A., B. Panigrahy, and R.L. Morgan. 1994. Effect of composting poultry carcasses on survival of exotic avian viruses: highly pathogenic avian influenza (HPAI) virus and adenovirus of egg drop syndrome-76. *Avian Dis*. 38:733–737.
280. Senne, D.A., B. Panigrahy, Y. Kawaoka, J.E. Pearson, J. Suss, M. Lipkind, H. Kida, and R.G. Webster. 1996. Survey of the hemagglutinin (HA) cleavage site sequence of H5 and H7 avian influenza viruses: amino acid sequence at the HA cleavage site as a marker of pathogenicity potential. *Avian Dis*. 40:425–437.
281. Senne, D.A. 2010. Avian influenza in North and South America, the Caribbean, and Australia, 2006–2008. *Avian Dis*. 54:179–186.
282. Seo, S.H., and R.G. Webster. 2001. Cross-reactive, cell-mediated immunity and protection of chickens from lethal H5N1 influenza virus infection in Hong Kong poultry markets. *J Virol*. 75:2516–2525.
283. Shafer, A.L., J.B. Katz, and K.A. Eernisse. 1998. Development and validation of a competitive enzyme-linked immunosorbent assay for detection of Type A influenza antibodies in avian sera. *Avian Dis.* 42:28–34.
284. Shalaby, A.A., R.D. Slemons, and D.E. Swayne. 1994. Pathological studies of A/chicken/Alabama/7395/75 (H4N8) influenza virus in specific-pathogen-free laying hens. *Avian Dis*. 38:22–32.
285. Sharp, G.B., Y. Kawaoka, D.J. Jones, W.J. Bean, S.P. Pryor, V. Hinshaw, and R.G. Webster. 1997. Coinfection of wild ducks by influenza A viruses: distribution patterns and biological significance. *J Virol*. 71:6128–6135.
286. Shortridge, K.F. 1981. Avian influenza in Hong Kong. In: *Proceedings of the First International Symposium on Avian Influenza*, R.A. Bankowski, ed. U.S. Animal Health Association, Richmond, Virginia. 29.
287. Shortridge, K.F., N.N. Zhou, Y. Guan, P. Gao, T. Ito, Y. Kawaoka, S. Kodihalli, S. Krauss, D. Markhill, G. Murti, M. Norwood, D. Senne, L. Sims, A. Takada, and R.G. Webster. 1998. Characterization of avian H5N1 influenza viruses from poultry in Hong Kong. *Virology* 252:331–342.
288. Shortridge, K.F. 1999. Poultry and the influenza H5N1 outbreak in Hong Kong, 1997: Abridged chronology and virus isolation. *Vaccine*. 17:S26–S29.
289. Siengsanan, J., K. Chaichoune, R. Phonaknguen, L. Sariya, P. Prompiram, W. Kocharin, S. Tangsudjai, S. Suwanpukdee, W. Wiriyarat, R. Pattanarangsan, I. Robertson, S.D. Blacksell, and P. Ratanakorn. 2009. Comparison of outbreaks of H5N1 highly pathogenic avian influenza in wild birds and poultry in Thailand. *J Wildl Dis*. 45:740–747.

290. Siengsanan-Lamont, J., I. Robertson, S.D. Blacksell, T. Ellis, S. Fenwick, S. Saengchoowong, S. Suwanpukdee, P. Yongyuttawichai, L. Sariya, P. Prompiram, K. Chaichoun, W. Wiriyarat, D. Pothieng, and P. Ratanakorn. 2011. Virological and molecular epidemiological investigations into the role of wild birds in the epidemiology of influenza A/H5N1 in central Thailand. *Vet Microbiol*. 148:213–218.
291. Sims, L.D., T.M. Ellis, K.K. Liu, K. Dyrting, H. Wong, M. Peiris, Y. Guan, and K.E. Shortridge. 2003. Avian influenza in Hong Kong 1997–2002. *Avian Dis*. 47:832–838.
292. Sims, L.D., Y. Guan, T.M. Ellis, K.K. Liu, K. Dyrting, H. Wong, N.Y.H. Kung, K.F. Shortridge, and M. Peiris. 2003. An update on avian influenza in Hong Kong 2002. *Avian Dis*. 47:1083–1086.
293. Sims, L.D., J. Domenech, C. Benigno, S. Kahn, A. Kamata, J. Lubroth, V. Martin, and P. Roeder. 2005. Origin and evolution of highly pathogenic H5N1 avian influenza in Asia. *Vet Rec*. 157:159–164.
294. Skeeles, J.K., R.L. Morressey, A. Nagy, F. Helm, T.O. Bunn, M.J. Langford, R.E. Long, and R.O. Apple. 1984. The use of fluorescent antibody (FA) techniques for rapid diagnosis of avian influenza (H5N2) associated with the Pennsylvania outbreak of 1983-84. In: *Proceedings of the 35th North Central Avian Disease Conference*, Anonymous. 32.
295. Slemons, R.D., and B.C. Easterday. 1972. Host response differences among five avian species to an influenza virus A/turkey/Ontario/7732/66 (Hav5N?). *Bull WHO.* 47:521–525.
296. Slemons, R.D., D.C. Johnson, J.S. Osborn, and F. Hayes. 1974. Type-A influenza viruses isolated from wild free-flying ducks in California. *Avian Dis*. 18:119–124.
297. Slemons, R.D., and D.E. Swayne. 1990. Replication of a waterfowl-origin influenza virus in the kidney and intestine of chickens. *Avian Dis.* 34:277–284.
298. Slemons, R.D., M.C. Shieldcastle, L.D. Heyman, K.E. Bednarik, and D.A. Senne. 1991. Type A influenza viruses in waterfowl in Ohio and implications for domestic turkeys. *Avian Dis*. 35:165–173.
299. Slemons, R.D., and D.E. Swayne. 1992. Nephrotropic properties demonstrated by A/chicken/Alabama/75 (H4N8) following intravenous challenge of chickens. *Avian Dis*. 36:926–931.
300. Slemons, R.D., and M. Brugh. 1998. Rapid antigen detection as an aid in early diagnosis and control of avian influenza. *Avian Dis*. 47:313–317.
301. Slemons, R.D., B. Byrum, and D.E. Swayne. 1998. Bacterial proteases and co-infections as enhancers of virulence. In: *Proceedings of the Fourth International Symposium on Avian Influenza*, D.E. Swayne and R.D. Slemons, eds. U.S. Animal Health Association, Richmond, Virginia. 203–208.
302. Slomka, M.J., T.L. To, H.H. Tong, V.J. Coward, I.C. Mawhinney, J. Banks, and I.H. Brown. 2012. Evaluation of lateral flow devices for identification of infected poultry by testing swab and feather specimens during H5N1 highly pathogenic avian influenza outbreaks in Vietnam. *Infl Other Resp Vir*. 6(5):318–27.
303. Snyder, D.B., W.W. Marquardt, F.S. Yancey, and P.K. Savage. 1985. An enzyme-linked immunosorbent assay for the detection of antibody against avian influenza virus. *Avian Dis*. 29:136–144.
304. Sommerfelt, M.A. 2011. T-cell-mediated and humoral approaches to universal influenza vaccines. *Expert Rev Vaccines*. 10:1359–1361.
305. Songserm, T., R. Jam-on, N. Sae-Heng, and N. Meemak. 2006. Survival and stability of HPAI H5N1 in different environments and susceptibility to disinfectants. *Dev Biol (Basel)*. 124:254.
306. Spackman, E., D.A. Senne, T.J. Myers, L.L. Bulaga, L.P. Garber, M.L. Perdue, K. Lohman, L.T. Daum, and D.L. Suarez. 2002. Development of a real-time reverse transcriptase PCR assay for type A influenza virus and the avian H5 and H7 hemagglutinin subtypes. *J Clin Microbiol*. 40:3256–3260.
307. Spackman, E., D.A. Senne, T.J. Myers, L.L. Bulaga, L.P. Garber, M.L. Perdue, K. Lohman, L.T. Daum, and D.L. Suarez. 2002. Development of a real-time reverse transcriptase PCR assay for type A influenza virus and the avian H5 and H7 hemagglutinin subtypes. *J Clin Microbiol*. 40:3256–3260.
308. Spackman, E. 2008. Avian influenza virus. *Methods in Molecular Biology*. 436:1–141.
309. Spackman, E., D.E. Stallknecht, R.D. Slemons, K. Winker, D.L. Suarez, M. Scott, and D.E. Swayne. 2005. Phylogenetic analyses of type A influenza genes in natural reservoir species in North America reveals genetic variation. *Virus Res*. 114:89–100.
310. Stallknecht, D.E., and S.M. Shane. 1988. Host range of avian influenza virus in free-living birds. *Vet Res Comm*. 12:125–141.
311. Stallknecht, D.E., S.M. Shane, P.J. Zwank, D.A. Senne, and M.T. Kearney. 1990. Avian influenza viruses from migratory and resident ducks of coastal Louisiana. *Avian Dis*. 34:398–405.
312. Stallknecht, D.E. 1998. Ecology and epidemiology of avian influenza viruses in wild bird populations: waterfowl, shorebirds, pelicans, cormorants, etc. In: *Proceedings of the Fourth International Symposium on Avian Influenza*, D.E. Swayne and R.D. Slemons, eds. U.S. Animal Health Association, Richmond, Virginia. 61–69.
313. Stallknecht, D.E., E. Nagy, D.B. Hunter, and R.D. Slemons. 2007. Avian influenza. In: *Infectious Diseases of Wild Birds*, N.J. Thomas, D.B. Hunter, and C.T. Atkinson, eds. Blackwell Publishing, Ames, Iowa. 108–130.
314. Steel, J., S.V. Burmakina, C. Thomas, E. Spackman, A. Garcia-Sastre, D.E. Swayne, and P. Palese. 2007. A combination *in-ovo* vaccine for avian influenza virus and Newcastle disease virus. *Vaccine*. 26:1742–1750.
315. Stieneke Grober, A., M. Vey, H. Angliker, E. Shaw, G. Thomas, C. Roberts, H.D. Klenk, and W. Garten. 1992. Influenza virus hemagglutinin with multibasic cleavage site is activated by furin, a subtilisin-like endoprotease. *EMBO J*. 11:2407–2414.
316. Stone, H., B. Mitchell, and M. Brugh. 1997. *In ovo* vaccination of chicken embryos with experimental Newcastle disease and avian influenza oil-emulsion vaccines. *Avian Dis*. 41:856–863.
317. Stone, H.D. 1987. Efficacy of avian influenza oil-emulsion vaccines in chickens of various ages. *Avian Dis*. 31:483–490.
318. Stone, H.D. 1988. Optimization of hydrophile-lipophile balance for improved efficacy of Newcastle disease and avian influenza oil-emulsion vaccines. *Avian Dis*. 32:68–73.
319. Stubbs, E.L. 1926. Fowl pest. *J Am Vet Med Assoc*. 21:561–569.
320. Stubbs, E.L. 1948. Fowl pest. In: *Diseases of Poultry*, H.E. Biester and L.H. Schwarte, eds. Iowa State University Press, Ames, Iowa. 603–614.
321. Sturm-Ramirez, K.M., D.J. Hulse-Post, E.A. Govorkova, J. Humberd, P. Seiler, P. Puthavathana, C. Buranathai, T.D. Nguyen, A. Chaisingh, H.T. Long, T.S.P. Naipospos, H. Chen, T.M. Ellis, Y. Guan, J.S.M. Peiris, and R.G. Webster. 2005. Are ducks contributing to the endemicity of highly pathogenic H5N1 influenza virus in Asia? *J Virol*. 79:11269–11279.
322. Suarez, D.L., M.L. Perdue, N. Cox, T. Rowe, C. Bender, J. Huang, and D.E. Swayne. 1998. Comparison of highly virulent H5N1 influenza A viruses isolated from humans and chickens from Hong Kong. *J Virol*. 72:6678–6688.

323. Suarez, D.L. 2000. Evolution of avian influenza viruses. *Vet Microbiol*. 74:15–27.
324. Suarez, D.L., and C.S. Schultz. 2000. Immunology of avian influenza virus: a review. *Dev Comp Immunol*. 24:269–283.
325. Suarez, D.L., P.R. Woolcock, A.J. Bermudez, and D.A. Senne. 2002. Isolation from turkey breeder hens of a reassortant H1N2 influenza virus with swine, human, and avian lineage genes. *Avian Dis*. 46:111–121.
326. Suarez, D.L., E. Spackman, and D.A. Senne. 2003. Update on molecular epidemiology of H1, H5, and H7 influenza virus infections in poultry in North America. *Avian Dis*. 47:888–897.
327. Suarez, D.L., E. Spackman, D.A. Senne, L. Bulaga, A.C. Welsch, and K. Froberg. 2003. The effect of various disinfectants on detection of avian influenza virus by real time RT-PCR. *Avian Dis*. 47:1091–1095.
328. Suarez, D.L., D.A. Senne, J. Banks, I.H. Brown, S.C. Essen, C.W. Lee, R.J. Manvell, C. Mathieu-Benson, V. Moreno, J.C. Pedersen, B. Panigrahy, H. Rojas, E. Spackman, and D.J. Alexander. 2004. Recombination resulting in virulence shift in avian influenza outbreak, Chile. *Emerg Infect Dis.* 10:693–699.
329. Suarez, D.L., A. Das, and E. Ellis. 2007. Review of rapid molecular diagnostic tools for avian influenza virus. *Avian Dis*. 51 suppl. 1:201–208.
330. Suarez, D.L. 2010. Avian influenza: our current understanding. *Anim Health Res Rev*. 11:19–33.
331. Suarez, D.L. 2010. Proceedings of the Seventh International Symposium on Avian Influenza. *Avian Dis*. 54:173–786.
332. Swayne, D.E., and R.D. Slemons. 1990. Renal pathology in specific-pathogen-free chickens inoculated with a waterfowl-origin type A influenza virus. *Avian Dis*. 34:285–294.
333. Swayne, D.E., and R.D. Slemons. 1992. Evaluation of the kidney as a potential site of avian influenza virus persistence in chickens. *Avian Dis*. 36:937–944.
334. Swayne, D.E., M.D. Ficken, and J.S. Guy. 1992. Immunohistochemical demonstration of influenza A nucleoprotein in lungs of turkeys with natural and experimental influenza respiratory disease. *Avian Pathol*. 21:547–557.
335. Swayne, D.E., and D.J. Alexander. 1994. Confirmation of nephrotropism and nephropathogenicity of 3 low-pathogenic chicken-origin influenza viruses for chickens. *Avian Pathol*. 23:345–352.
336. Swayne, D.E., and R.D. Slemons. 1994. Comparative pathology of a chicken-origin and two duck-origin influenza virus isolates in chickens: The effect of route of inoculation. *Vet Pathol*. 31:237–245.
337. Swayne, D.E., M.J. Radin, T.M. Hoepf, and R.D. Slemons. 1994. Acute renal failure as the cause of death in chickens following intravenous inoculation with avian influenza virus A/chicken/Alabama/7395/75 (H4N8). *Avian Dis* 38:151–157.
338. Swayne, D.E., and R.D. Slemons. 1995. Comparative pathology of intravenously inoculated wild duck- and turkey-origin type A influenza virus in chickens. *Avian Dis*. 39:74–84.
339. Swayne, D.E., J.R. Beck, M.L. Perdue, M. Brugh, and R.D. Slemons. 1996. Assessment of the ability of ratite-origin influenza viruses to infect and produce disease in rheas and chickens. *Avian Dis*. 40:438–447.
340. Swayne, D.E. 1997. Pathobiology of H5N2 Mexican avian influenza virus infections of chickens. *Vet Pathol*. 34:557–567.
341. Swayne, D.E., and R.D. Slemons. 1998. *Proceedings of the Fourth International Symposium on Avian Influenza*, U.S. Animal Health Association, Richmond, Virginia. 1–401.
342. Swayne, D.E., J.R. Beck, M. Garcia, M.L. Perdue, and M. Brugh. 1998. Pathogenicity shifts in experimental avian influenza virus infections in chickens. In: *Proceedings of the Fourth International Symposium on Avian Influenza*, D.E. Swayne and R.D. Slemons, eds. U.S. Animal Health Association, Richmond, Virginia. 171–181.
343. Swayne, D.E., J.R. Beck, M. Garcia, and H.D. Stone. 1999. Influence of virus strain and antigen mass on efficacy of H5 avian influenza inactivated vaccines. *Avian Pathol*. 28:245–255.
344. Swayne, D.E. 2000. Understanding the ecology and epidemiology of avian influenza viruses: implications for zoonotic potential. In: *Emerging Diseases of Animals*, C.C. Brown and C.A. Bolin, eds. ASM Press, Washington, D.C. 101–130.
345. Swayne, D.E., and D.L. Suarez. 2000. Highly pathogenic avian influenza. *Rev Sci Tech Off Int Epiz*. 19:463–482.
346. Swayne, D.E., J.R. Beck, and N. Kinney. 2000. Failure of a recombinant fowl poxvirus vaccine containing an avian influenza hemagglutinin gene to provide consistent protection against influenza in chickens preimmunized with a fowl pox vaccine. *Avian Dis*. 44:132–137.
347. Swayne, D.E., M. Garcia, J.R. Beck, N. Kinney, and D.L. Suarez. 2000. Protection against diverse highly pathogenic H5 avian influenza viruses in chickens immunized with a recombinant fowlpox vaccine containing an H5 avian influenza hemagglutinin gene insert. *Vaccine*. 18:1088–1095.
348. Swayne, D.E., M.L. Perdue, J.R. Beck, M. Garcia, and D.L. Suarez. 2000. Vaccines protect chickens against H5 highly pathogenic avian influenza in the face of genetic changes in field viruses over multiple years. *Vet Microbiol*. 74:165–172.
349. Swayne, D.E., and D.L. Suarez. 2003. Proceedings of the Fifth International Sympsoium on Avian Influenza. *Avian Dis*. 47:783–1267.
350. Swayne, D.E., and D.A. Halvorson. 2003. Influenza. In: *Diseases of Poultry*, Y.M. Saif, H.J. Barnes, A.M. Fadly, J.R. Glisson, L.R. McDougald, and D.E. Swayne, eds. Iowa State University Press, Ames, IA. 135–160.
351. Swayne, D.E. 2004. Application of new vaccine technologies for the control of transboundary diseases. *Dev Biol (Basel)*. 119:219–228.
352. Swayne, D.E., and J.R. Beck. 2004. Heat inactivation of avian influenza and Newcastle disease viruses in egg products. *Avian Pathol*. 33:512–518.
353. Swayne, D.E., and J.R. Beck. 2005. Experimental study to determine if low pathogenicity and high pathogenicity avian influenza viruses can be present in chicken breast and thigh meat following intranasal virus inoculation. *Avian Dis*. 49:81–85.
354. Swayne, D.E., and B. Akey. 2005. Avian influenza control strategies in the United States of America. In: *Avian Influenza. Prevention and Control*, R.S. Schrijver and G. Koch, eds. Springer, Dordrecht. 113–130.
355. Swayne, D.E. 2006. Microassay for measuring thermal inactivation of H5N1 high pathogenicity avian influenza virus in naturally-infected chicken meat. *Int J. Food Microbiol.* 108:268–271.
356. Swayne, D.E. 2006. Avian influenza vaccine technologies and laboratory methods for assessing protection. In: *Proceedings for the Requirements for Production and Control of Avian Influenza Vaccines*, European Directorate for the Quality of Medicines, AnonymousStrasbourg, France. 15–25.
357. Swayne, D.E. 2007. Proceedings of the Sixth International Symposium on Avian Influenza. *Avian Dis*. 51:157–514.

358. Swayne, D.E. 2008. The global nature of avian influenza. In: *Avian Influenza*, D.E. Swayne, ed. Blackwell Publishers, Ames, Iowa. 123–143.
359. Swayne, D.E. 2008. Epidemiology of avian influenza in agricultural and other man-made systems. In: *Avian Influenza*, D.E. Swayne, ed. Wylie-Blackwell Publishing, Ames, Iowa. 59–85.
360. Swayne, D.E., and D.R. Kapczynski. 2008. Strategies and challenges for eliciting immunity against avian influenza virus in birds. *Immunol Rev.* 225:314–331.
361. Swayne, D.E., and R.D. Slemons. 2008. Using mean infectious dose of wild duck- and poultry-origin high and low pathogenicity avian influenza viruses as one measure of infectivity and adaptation to poultry. *Avian Dis.* 52:455–460.
362. Swayne, D.E., and M. Pantin-Jackwood. 2008. Pathobiology of avian influenza virus infections in birds and mammals. In: *Avian Influenza*, D.E. Swayne, ed. Blackwell Publishing, Ames, Iowa. 87–122.
363. Swayne, D.E., D.A. Senne, and D.L. Suarez. 2008. Avian influenza. In: *Isolation and Identification of Avian Pathogens*, L. Dufour-Zavala, D.E. Swayne, J.R. Glisson, J.E. Pearson, W.M. Reed, M.W. Jackwood, and P.R. Woolcock, eds. American Association of Avian Pathologist, Jacksonville, Florida. 128–134.
364. Swayne, D.E., G. Pavade, K. Hamilton, B. Vallat, and K. Miyagishima. 2011. Assessment of national strategies for control of high pathogenicity avian influenza and low pathogenicity notifiable avian influenza in poultry, with emphasis on vaccines and vaccination. *OIE Rev Sci Tech*. 30:839–870.
365. Swayne, D.E. 2008. *Avian Influenza*, Blackwell Publishing, Ames, Iowa. xvi, 605.
366. Swayne, D.E. 2009. Avian influenza vaccines and therapies for poultry. *Comp Immunol Microbiol Infect Dis*. 32:351–363.
367. Sylte, M.J., B. Hubby, and D.L. Suarez. 2007. Influenza neuraminidase antibodies provide partial protection for chickens against high pathogenic avian influenza infection. *Vaccine*. 25:3763–3772.
368. Takekawa, J.Y., N.J. Hill, A.K. Schultz, S.A. Iverson, C.J. Cardona, W.M. Boyce, and J.P. Dudley. 2011. Rapid diagnosis of avian influenza virus in wild birds: use of a portable rRT-PCR and freeze-dried reagents in the field. *J Vis Exp*. 166(1–2):92–7
369. Takizawa, T., R. Fukuda, T. Miyawaki, K. Ohashi, and Y. Nakanishi. 1995. Activation of the apoptotic fas antigen-encoding gene upon influenza virus infection involving spontaneously produced beta- interferon. *Virology*. 209:288–296.
370. Tang, Y., C.W. Lee, Y. Zhang, D.A. Senne, R. Dearth, B. Byrum, D.R. Perez, D.L. Suarez, and Y.M. Saif. 2005. Isolation and characterization of H3N2 influenza A virus from turkeys. *Avian Dis*. 49:207–213.
371. Taylor, H.R., and A.J. Turner. 1977. A case report of fowl plague keratoconjunctivitis. *Brit J Ophthal*. 61:86–88.
372. Thomas, C., and D.E. Swayne. 2007. Thermal inactivation of H5N1 high pathogenicity avian influenza virus in naturally infected chicken meat. *J Food Prot*. 70:674–680.
373. Toffan, A., A. Olivier, M. Mancin, V. Tuttoilmondo, D. Facco, I. Capua, and C. Terregino. 2010. Evaluation of different serological tests for the detection of antibodies against highly pathogenic avian influenza in experimentally infected ostriches (*Struthio camelus*). *Avian Pathol*. 39:11–15.
374. Tong, S., Y. Li, P. Rivailler et al. 2012. A distinct lineage of influenza A virus from bats. *Proc Natl Acad Sci USA*. 109:4269–4274.
375. Toro, H., D.C. Tang, D.L. Suarez, M.J. Sylte, J. Pfeiffer, and K.R. Van Kampen. 2006. Protective avian influenza in ovo vaccination with non-replicating human adenovirus vector. *Vaccine*. 25:2886–2891.
376. Tripathy, D.N., and W.M. Schnitzlein. 1991. Expression of avian influenza virus hemagglutinin by recombinant fowlpox virus. *Avian Dis*. 35:186–191.
377. Trock, S.C. 1998. Epidemiology of influenza in live bird markets and ratite farms. In: *Proceedings of the Fourth International Symposium on Avian Influenza*, D.E. Swayne and R.D. Slemons, eds. U.S. Animal Health Association, Richmond, Virginia. 76–78.
378. Tumpey, T.M., D.L. Suarez, L.E.L. Perkins, D.A. Senne, J.G. Lee, Y.J. Lee, I.P. Mo, H.W. Sung, and D.E. Swayne. 2002. Characterization of a highly pathogenic H5N1 avian influenza a virus isolated from duck meat. *J Virol*. 76:6344–6355.
379. Tumpey, T.M., D.R. Kapczynski, and D.E. Swayne. 2004. Comparative susceptibility of chickens and turkeys to avian influenza A H7N2 virus infection and protective efficacy of a commercial avian influenza H7N2 virus vaccine. *Avian Dis*. 48:167–176.
380. Turner, A.J. 1976. The isolation of fowl plague virus in Victoria. *Aust Vet J*. 52:384.
381. Tweed S.A., D.M. Skowroski, S.T. David, A. Larder, M. Petric, W. Lees, Y. Li, J. Katz, M. Krajden, R. Tellier, C. Halpert, M. Hirst, C. Astell, D. Lawrence, and A. Mak. 2004. Human illness from avian influenza H7N3, British Columbia. *Emerg Infect Dis*. 10:2196–2199.
382. USAHA. 1985. Report of the Committee on Transmissible Diseases of Poultry and Other Species. *Proc US Anim Heal Assoc*. 89:296–305.
383. USAHA. 1994. Report of the Committee on Transmissible Diseases of Poultry and Other Avian Species. Criteria for determining that an AI virus isolation causing an outbreak must be considered for eradication. *Proc US Anim Heal Assoc*. 98:522.
384. Van Campen, H., B.C. Easterday, and V.S. Hinshaw. 1989. Virulent avian influenza A viruses: Their effect on avian lymphocytes and macrophages *in vivo* and *in vitro*. *J Gen Virol*. 70:2887–2895.
385. van den Berg, T., B. Lambrecht, S. Marche, M. Steensels, B.S. Van, and M. Bublot. 2008. Influenza vaccines and vaccination strategies in birds. *Comp Immunol Microbiol Infect Dis*. 31:121–165.
386. Veits, J., S. Weber, O. Stech, A. Breithaupt, M. Graber, S. Gohrbandt, J. Bogs, J. Hundt, J.P. Teifke, T.C. Mettenleiter, and J. Stech. 2012. Avian influenza virus hemagglutinins H2, H4, H8, and H14 support a highly pathogenic phenotype. *Proc Natl Acad Sci USA*. 109:2579–2584.
387. Villareal, C.L., and A.O. Flores. 1998. The Mexican avian influenza (H5N2) outbreak. In: *Proceedings of the Fourth International Symposium on Avian Influenza*, D.E. Swayne and R.D. Slemons, eds. U.S. Animal Health Association, Richmond, Virginia. 18–22.
388. Waisbord, S.R., T. Michaelides, and M. Rasmuson. 2008. Communication and social capital in the control of avian influenza: lessons from behaviour change experiences in the Mekong Region. *Glob Public Health*. 3:197–213.
389. Walls, H.H., M.W. Harmon, J.J. Slagle, C. Stocksdale, and A.P. Kendal. 1986. Characterization and evaluation of monoclonal antibodies developed for typing influenza A and influenza B viruses. *J Clin Microbiol*. 23:240–245.

390. Wang, T.T., M.K. Parides, and P. Palese. 2012. Seroevidence for H5N1 Influenza Infections in Humans: Meta-Analysis. *Science*. 335(6075):1463
391. Webster, R.G., M. Yakhno, V.S. Hinshaw, W.J. Bean, and K.G. Murti. 1978. Intestinal influenza: replication and characterization of influenza viruses in ducks. *Virology*. 84:268–278.
392. Webster, R.G., J. Geraci, G. Petursson, and K. Skirnisson. 1981. Conjunctivitis in human beings caused by influenza A virus of seals [letter]. *N Engl J Med*. 304:911.
393. Webster, R.G., V.S. Hinshaw, W.J. Bean, K.L. van Wyke, J.R. Geraci, D.J. St. Aubin, and G. Petursson. 1981. Characterization of an influenza A virus from seals. *Virology*. 113:712–724.
394. Webster, R.G., Y. Kawaoka, W.J. Bean, C.W. Beard, and M. Brugh. 1985. Chemotherapy and vaccination: a possible strategy for the control of highly virulent influenza virus. *J Virol*. 55:173–176.
395. Webster, R.G., Y. Kawaoka, and W.J. Bean. 1986. Vaccination as a strategy to reduce the emergence of amantadine- and rimantadine-resistant strains of A chick/Pennsylvania/83 (H5N2) influenza virus. *J Antimicrob Chemo*. 18:157–164.
396. Webster, R.G., W.J. Bean, Y. Kawaoka, and D. Senne. 1986. Characterization of H5N2 influenza viruses from birds in live poultry markets in USA. *Proc US Anim Heal Assoc*. 90:278–286.
397. Webster, R.G., and R. Rott. 1987. Influenza virus A pathogenicity : the pivotal role of hemagglutinin. *Cell*. 50:665–666.
398. Webster, R.G., Y. Kawaoka, J. Taylor, R. Weinberg, and E. Paoletti. 1991. Efficacy of nucleoprotein and haemagglutinin antigens expressed in fowlpox virus as vaccine for influenza in chickens. *Vaccine*. 9:303–308.
399. Webster, R.G., W.J. Bean, O.T. Gorman, T.M. Chambers, and Y. Kawaoka. 1992. Evolution and ecology of influenza A viruses. *Microbiol. Rev.* 56:152–179.
400. Wells, R.J.H. 1963. An outbreak of fowl plague in turkeys. *Vet Rec*. 75:783–786.
401. Westbury, H.A. 1998. History of highly pathogenic avian influenza in Australia. In: *Proceedings of the Fourth International Symposium on Avian Influenza*, D.E. Swayne and R.D. Slemons, eds. U.S. Animal Health Association, Richmond, Virginia. 23–30.
402. WHO. 2005. Avian influenza: assessing the pandemic threat. http://www.who.int/influenza/resources/documents/h5n1_assessing_pandemic_threat/en/index.html. Accessed: 27 October 2012.
403. WHO. 2011. Evolution of the Asian H5 Hemagglutinin . http://www.who.int/influenza/gisrs_laboratory/201101_h5n1evoconceptualdiagram.pdf. Accessed: 22 October 2012.
404. WHO. 2012. Cumulative number of confirmed human cases for avian influenza A(H5N1) reported to WHO, 2003-2012. http://www.who.int/influenza/human_animal_interface/EN_GIP_20120116CumulativeNumberH5N1cases.pdf. Accessed: 27 October 2012.
405. WHO Expert Committee. 1980. A revision of the system of nomenclature for influenza viruses: A WHO memorandum. *Bull WHO*. 585–591.
406. Wood, J.M., Y. Kawaoka, L.A. Newberry, E. Bordwell, and R.G. Webster. 1985. Standardization of inactivated H5N2 influenza vaccine and efficacy against lethal A/chicken/Pennsylvania/1370/83 infection. *Avian Dis*. 29:867–872.
407. Woolcock, P.R., M.D. McFarland, S. Lai, and R.P. Chin. 2001. Enhanced recovery of avian influenza virus isolates by a combination of chicken embryo inoculation methods. *Avian Dis*. 45:1030–1035.
408. Woolcock, P.R., and C.J. Cardona. 2005. Commercial immunoassay kits for the detection of influenza virus type A: evaluation of their use with poultry. *Avian Dis* 49:477–481.
409. World Bank. 2006. Economic impact of avian flu. http://web.worldbank.org/WBSITE/EXTERNAL/COUNTRIES/EASTASIAPACIFICEXT/EXTEAPHALFYEARLYUPDATE/0,,contentMDK:20708543~menuPK:550232~pagePK:64168445~piPK:64168309~theSitePK:550226,00.html. Accessed: 27 October 2012.
410. Xie, Z., Y. Pang, X. Deng, X. Tang, and J. Liu. 2005. Development of multiplex RT-PCR for identification of H5 and H7 subtypes of avian influenza virus. *Chin J Vet Sci Tech*. 35:437–440.
411. Xu, X., K. Subbarao, N.J. Cox, and Y. Guo. 1999. Genetic characterization of the pathogenic influenza A/Goose/Guangdong/1/96 (H5N1) virus: similarity of its hemagglutinin gene to those of H5N1 viruses from the 1997 outbreaks in Hong Kong. *Virology*. 261:15–19.
412. Yamamoto, Y., K. Nakamura, K. Kitagawa, N. Ikenaga, M. Yamada, M. Mase, and M. Narita. 2007. Severe nonpurulent encephalitis with mortality and feather lesions in call ducks (*Anas platyrhyncha var. domestica*) inoculated intravenously with H5N1 highly pathogenic avian influenza virus. *Avian Dis*. 51:52–57.
413. Zhang, X., M. Liu, C. Liu, J. Du, W. Shi, E. Sun, H. Li, J. Li, and Y. Zhang. 2011. Vaccination with different M2e epitope densities confers partial protection against H5N1 influenza A virus challenge in chickens. *Intervirology*. 54(5):290–299.
414. Zhou, E.M., M. Chan, R.A. Heckert, J. Riva, and M.F. Cantin. 1998. Evaluation of a competitive ELISA for detection of antibodies against avian influenza virus nucleoprotein. *Avian Dis*. 42:517–522.
415. Ziegler, A.F., S. Davison, H. Acland, and R.J. Eckroade. 1999. Characteristics of H7N2 (nonpathogenic) avian influenza virus infections in commercial layers, in Pennsylvania, 1997–98. *Avian Dis*. 43:142–149.

Chapter 7

Infectious Bursal Disease

Nicolas Eterradossi and Y.M. Saif

Introduction

Infectious bursal disease (IBD) is an acute, highly contagious viral infection of young chickens that has lymphoid tissue, especially the cloacal bursa (bursa of Fabricius) as its primary target. IBD was first described by Cosgrove (44) in 1962 and was referred to as avian nephrosis because of the extreme kidney damage found in birds that succumbed to infection. Since the first outbreaks occurred in the area of Gumboro, Delaware, Gumboro disease is still a frequently used synonym for this disease. The economic importance of this disease is manifested in 2 ways. First, some virus strains may cause up to 60% mortality in chickens 3 weeks of age and older. The second, and more important, manifestation is a severe, prolonged immunosuppression of chickens infected at an early age. Sequelae that have been associated with immunosuppression induced by the virus include gangrenous dermatitis, inclusion body hepatitis-anemia syndrome, *Escherichia coli* infections, and vaccination failures. Protection of young chicks from early infection is paramount. This is usually accomplished by a combination of transfer of maternal antibodies, and active immunization of the newly hatched chick. The virus does not affect humans and has no public health significance.

History

Early studies to identify the etiologic agent of IBD (avian nephrosis) (44) were clouded by the presence of infectious bronchitis virus (IBV) with nephropathogenic tendencies in the kidneys of field cases (353). In subsequent studies with IBD, Winterfield et al. (354) succeeded in isolating an agent in embryonating eggs. The isolate was referred to as infectious bursal agent and was identified as the true cause of IBD. Hitchner (115) proposed the term infectious bursal disease as the name of the disease causing specific pathognomonic lesions of the cloacal bursa.

In 1972, IBD virus (IBDV) infections at an early age were recognized as immunosuppressive (6), a finding that greatly increased the interest in their control. The existence of a second serotype was reported in 1980 (207). Control of IBDV infections has been complicated by the recognition of "variant" strains of serotype 1 IBDV, which were found in the Delmarva poultry-producing area (269, 276). These strains were breaking through maternal immunity against "standard" strains, and they also differed from standard strains in their biological properties (273, 274). These variants, or subtypes, were either already present in nature but unrecognized or were new mutants that have arisen, possibly due to immune pressure. In the late 1980s, very virulent strains of IBDV (vvIBDV) were isolated in the Netherlands (33). vvIBDV strains quickly spread to Africa, Asia, and South America (56) and were reported occasionally in the United States in late 2008 (306, 143). vvIBDV have not been reported from Australia or New Zealand.

Etiology

Classification

Infectious bursal disease virus is a member of the *Birnaviridae* family (27, 59, 218), named for the bisegmented double-stranded RNA nature of the genome of its members (194, 218, 305). The family has 4 genera designated *Aquabirnavirus*, whose type species is infectious pancreatic necrosis virus (IPNV) of fish, molluscs, and crustaceans; *Blosnavirus*, whose type species is blotch snakehead virus or BSNV; *Avibirnavirus*, whose type species is IBDV, which infects birds; and *Entomobirnavirus*, whose type species is Drosophila X virus, which infects insects (55). Birnaviruses not yet assigned to any genus include Tellina virus 1 (235), chicken proventricular necrosis virus (98), and Espirito Santo virus isolated from mosquito cells (330).

Morphology

The virus is a single-shelled, nonenveloped virion with icosahedral symmetry and a diameter varying from 55–65 nm (Figure 7.1) (100, 112, 233, 243, 248).

Buoyant density of complete particles in cesium chloride gradients has been reported to range from 1.31–1.34 g/mL. Lower density values were reported for incomplete virus particles. For a review, see (156).

The capsid symmetry is askew, with a triangulation number of T = 13 and a typical laevo icosahedral geometry (45, 257).

Diseases of Poultry, Thirteenth Edition. David E. Swayne.
© 2013 John Wiley & Sons, Inc. Published 2013 by John Wiley & Sons, Inc.

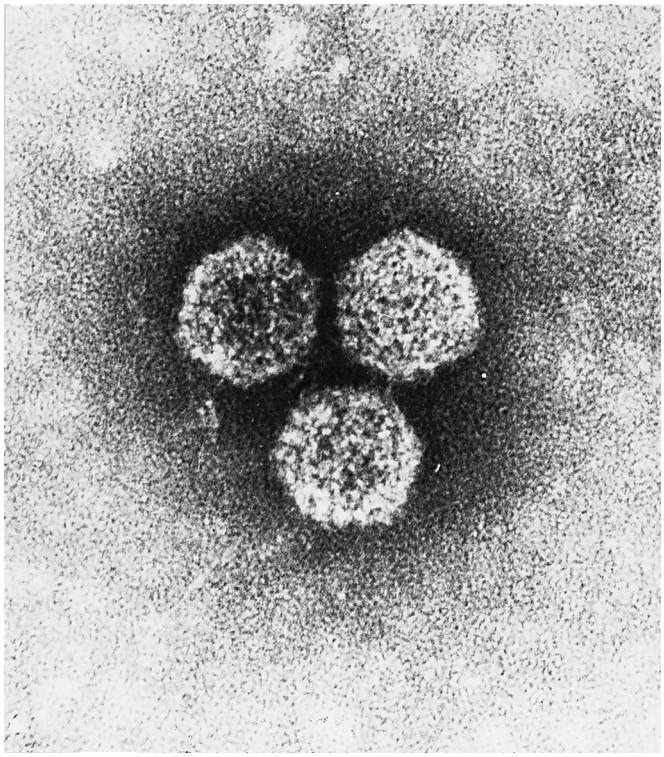

Figure 7.1. Electron micrograph of negatively stained infectious bursal disease (IBD) viral particles. ×200,000. (D.E. Reed)

Chemical Composition

The dsRNA of the IBDV genome has 2 segments designated A and B (15, 59, 136, 218). The nucleotide sequence of the whole genome of both serotype 1 and serotype 2 IBDV isolates has been determined (223). IBDV is one of the rare polyploid RNA viruses: each virus particle may incorporate up to 4 dsRNA segments. Incorporation of less than 4 genome segments creates incomplete particles with reduced buoyant densities that show up as multiple bands in cesium chloride gradients (191).

Five viral proteins designated VP1, VP2, VP3, VP4, and VP5 are recognized (15, 57, 59, 224, 233, 318, 324) with approximate molecular weights of 97 kD, 41 kD, 32 kD, 28 kD, and 21 kD, respectively. Additional proteins, such as VPX or pVP2, have been observed and have a precursor-product relationship (57). See references (156, 158) for an early review of IBDV proteins. VP2, VP3, and VP1 are the structural proteins of IBDV. In serotype 1 viruses, they constitute 51%, 40%, and 3% of the virus proteins, respectively (59). Once believed to make as much as 6% of IBDV structural proteins (59), VP4 has now been recognized as a non-structural protein that may be copurified with virus particles in cesium chloride gradients (94). In addition to the structural viral proteins, mature virus particles also harbor at their surface 4 small peptides that are formed when VP2 is progressively matured (49).

VP1 is the viral RNA-dependent RNA polymerase (RdRp) and it exhibits an original organization as compared with other viral RdRps (91, 339). It is present in virus capsids both as a genome-linked and as a free protein (217). VP2 is the capsid protein. It forms 260 trimers which are the basic units of the virus shell, the crystal structure of which has been determined (45, 86, 169). VP3, the other major structural protein, interacts with all other components of the virus particles and plays a critical role in virion morphogenesis, encapsidation, and replication (35, 87, 180, 310). VP3 is not exposed at the surface of the virion, but is tightly associated with dsRNA into filamentous structures (192). VP3 further interacts with and thus activates VP1, the virus polymerase (87, 202). Finally, interactions involving VP3 C terminal amino acids are critical for a correct assembly of VP2 into T13 capsids (35, 201). VP4 is a viral protease (122, 229) that exhibits an unusual Ser-Lys catalytic dyad (24, 171). VP4 plays a major role in the maturation of capsid protein VP2 by progressively trimming several peptides at the VP2 carboxy-terminal extremity during virus assembly (171). However, the complete processing of pVP2 into mature and correctly assembled VP2 also involves an autoproteolytic activity of pVP2 residue 431 (124). The crystal structure of a birnavirus protease has been determined in blotched snakehead virus (76). VP5 has a regulatory function in virus release and dissemination, as well as an anti-apoptotic function at the early stages of infection (178, 181, 226, 346). Two of the peptides that arise from the maturation process of pVP2 are crucial determinants that control the geometry of the virion assembly process (34, 49). One of these peptides, pep46, also has a destabilizing effect on cellular membranes (34, 49).

The small segment of the IBDV genome (B, approximately 2.9 kbp) codes for VP1, whereas the large segment (A, approximately 3.3 kbp) encodes the VP5 protein and, in another and partially overlapping reading frame, a 110 kDa polyprotein that will yield VP2, VP4, and VP3 upon co-translational cleavage by VP4 (9, 122, 214). In both genome segments, the coding regions are flanked by short 5' and 3' untranslated regions (79–111 nucleotides long) (223). The secondary structure of the 3' untranslated region appears to be critical for an efficient replication (19).

The molecular basis for IBDV antigenicity is now better understood. The VP2 and VP3 proteins were identified in western-blotting experiments with convalescent sera as important IBDV-derived antigens (71).

VP3 was first believed to represent IBDV major immunogen (72) but it was subsequently shown to mostly elicit non-neutralizing and nonprotective antibodies (16, 74). Up to 4 VP3-located antigenic domains have been identified (146, 196, 241, 365). All contain epitopes common to both serotypes (group-specific epitopes), whereas 2 of these domains also contain serotype-specific epitopes (196).

VP2 is the essential immunogen of IBDV (16, 73). Two antigenic domains were identified in the VP2/pVP2 protein (10). One domain is conformation-independent, located at the carboxy-terminal end of VP2/VPX, and elicits nonneutralizing monoclonal antibodies (10, 16, 74). Some of these are group specific (16); others are strain specific (335). The second major VP2 antigenic domain is conformation-dependent

and is encoded by the mid-third of the VP2 gene (10). Due to the higher frequency of amino acid changes in this region, it is known as VP2 variable domain (14). It groups serotype- or strain-specific epitopes that elicit neutralizing and passively protective antibodies (74, 301). This general pattern is not absolute, though, as Snyder et al. reported an anti-VP2 monoclonal antibody that neutralized both serotypes (299, 301). The largest panels of neutralizing monoclonal antibodies (67, 74, 265, 301, 332, 365) detect as many as 6 VP2-located neutralizing epitopes, which co-locate in at least 3 overlapping antigenic sites. Further analysis of IBDV strains with different Mab reactivities identified hot spots for antigenically significant amino acid changes (68, 107, 166, 279, 327, 332, 348). These are located within stretches of hydrophilic amino acids in the VP2 sequence: aa 212–224 and 314–324 are known as VP2 major hydrophilic peaks or hydrophilic peaks A and B, respectively (279), whereas aa 248–252 and 279–290 are designated as VP2 minor hydrophilic peaks 1 and 2, respectively (332). Structural studies demonstrated that these "peaks" correspond to the loops located in the most exposed part of the projection domain of VP2 and to amino acids displayed at the most external surface of the virus particle (45, 174).

Although some progress has been made, the molecular basis for pathogenicity of the virus has not been determined. The development of reverse genetics systems (227, 259) made it possible to manipulate the virus genome. Using this approach, segment A was demonstrated to form the genetic basis for bursal tropism in serotype 1 IBDV (374). Swapping the VP2 gene between vv and attenuated IBDV strains and characterizing *in vivo* the resulting recombinant viruses showed that VP2 is not the sole determinant of virulence (20). However, introduction into VP2 of a pathogenic virus of the amino acid changes required for adaptation to cell culture resulted in attenuation (25, 175, 222, 336). Epidemiological and experimental evidence suggests that both genome segments might be required for the expression of the vvIBDV or pathogenic phenotypes (22, 117, 125, 172, 173, 177). It has been suggested that reassortment phenomena might be involved in the emergence of vvIBDV (28, 117). Reassortant IBDV strains with segment A of a vvIBDV and segment B derived from another serotype 1 (172) or serotype 2 (145) virus have been described. They have a reduced pathogenicity as compared with typical vvIBDV. Some phylogenetic studies have suggested that intra-segment homologous recombination events between different IBDV strains may occur (106, 118).

Virus Replication

Kibenge et al. (156) and Nagarajan and Kibenge (228) reviewed the subject of virus replication some years ago. Several laboratory hosts for IBDV are described later in this chapter.

The virus was shown to attach to chicken embryo kidney cells maximally 75 minutes after inoculation (185). The multiplication cycle in chicken embryo cells is 10–36 hours, and the latent period is 4–6 hours (15, 136, 185, 233). In Vero and BGM-70 cells, a longer (48-hour) multiplication cycle was described (139, 157, 188).

Serotype 1 and serotype 2 IBDV may use several receptors, either common to both serotypes or serotype specific, on different cell types (234). However, IBDV strains adapted or not to Vero cells were shown to bind to the same receptor. This suggests that some barriers to the propagation of vvIBDV in cell culture may exist beyond the attachment step (368). Ogawa et al. demonstrated that the receptor for virulent IBDV is an N-glycosylated membrane protein expressed in the IgM-bearing immature B lymphocytes (237). The λ light chain of surface IgM (190), chicken heat-shock protein 90 α (176, 371), and the α4β1 integrin heterodimer (52) have been identified as parts of the IBDV receptor in the avian DT40, avian DF1, and murine 3T3 cell lines, respectively. The α4β1 integrin interacts with an integrin-binding motif conserved in the most exposed domain of VP2 in all IBDV strains (52).

The internalization of the bound IBDV particles occurs by a clathrin-independent endocytosis mechanism, dependent on several cellular factors (369). Ca^{2+} ions have a stabilizing effect on the conformation of the virus particle (86). Their low concentration in the endosomal environment triggers the loss of the compact structure of the virus particle (169) and promotes the release of peptide pep46 (34, 49, 81). Pep46 further destabilizes the endosomal membrane by creating pores into it (82), a process that has been shown to be critical for IBDV infectivity (81).

The mechanism of viral RNA synthesis has not been clearly determined. A dsRNA-dependent RNA polymerase, VP1, was described (304, 339). Genome-linked proteins have been demonstrated, indicating that the virus replicates its nucleic acid by a strand displacement mechanism (304). Von Einem et al. showed that a baculovirus expressed IBDV RdRp specifically used the 3' untranslated region of an IBDV positive strand template to initiate the synthesis of a complementary strand by a "copy-back" mechanism (339). RNA polymerase activity could be demonstrated without the pretreatment of the virus, indicating that transcription and replication occurred following cell penetration without the uncoating of the virus (304). Interaction between VP1 and a VP1-binding motif of VP3 induces a conformational change that activates VP1 (87). It has been hypothetized that nonpolyadenylated mRNAs are extruded through pores possibly located at the 5-fold symmetrical axis in IBDV capsid (45).

The synthesis of host proteins is not shut off in chicken embryo fibroblasts (CEFs) infected with IBDV (15). In chicken bursal lymphoid cells grown *in vitro*, the viral polypeptides were detected in the cells and their culture media at 90 minutes and 6 hours post innoculation (PI), respectively (216). Tacken et al. demonstrated an interaction between VP1 and eukaryotic translation initiation factor 4AII; this association suggests that VP1 also could be involved in the translation of IBDV RNA (311). The lack of accumulation of the polyprotein in infected cells suggests its co-translational cleavage (216). The model currently proposed for the assembly of IBDV particles involves most virus proteins: VP1 most probably first interacts with virus RNA, as described in

IPNV, another birnavirus (58). VP3 then interacts with itself, pVP2, VP1, and the viral genome, thus playing a critical chaperone role in virion morphogenesis and encapsidation (35, 180, 310). The final maturation of pVP2 by serial cleavage of its last carboxy-terminal peptides occurs within the virus capsid (34, 36).

Virus particles accumulate within the cytoplasm of infected cells (189, 199). This could be favored by the fact that VP5 prevents apoptosis at the early stages of infection, by interfering with the caspases and NF-KB pathways (178). However, VP5 (366) and/or VP2 (77) also have been reported to induce apoptosis in infected cells. The VP5-mediated formation of pores in the membrane of the infected cells (181) would contribute to virus release.

Susceptibility to Physical and Chemical Agents

Infectious bursal disease virus is very stable (40). IBDV resisted treatment with ether and chloroform, and was inactivated at pH 12 but unaffected by pH 2 (18). The virus was unaffected by exposure for 1 hour at 30°C to 0.5% phenol and 0.125% thimerosal. There was a marked reduction in virus infectivity when exposed to 0.5% formalin for 6 hours. The virus also was treated with various concentrations of 3 disinfectants (an iodine complex, a phenolic derivative, and a quaternary ammonium compound) for a period of 2 minutes at 23°C. Only the iodine complex had any deleterious effects. A 0.5% chloramine killed the virus after 10 minutes (167). High concentrations of a compound that releases methyl isothiocyanate as a fumigant were able to inactivate IBDV in contaminated litter after 1 hour of contact (88). Invert soaps with 0.05% sodium hydroxide either inactivated or strongly inhibited the virus (286). IBDV in bursal homogenates heated at 70°, 75°, and 80°C exhibited a rapid initial drop in virus titer followed with a gradual decline. A drop of 1 $\log_{10}$ at 70°, 75°, and 80°C took 18.8, 11.4, and 3 minutes, respectively (5). Chicken parts or chicken products inoculated with the virus and then cooked to an internal temperature of 71° and 74°C, respectively, allowed recovery of viable virus (200). IBDV was fully inactivated in infected tissues after 14 days composting, with 8.8 days above 55°C (97). Gamma-irradiation at 3 kiloGrays, the maximum level approved by the Food and Drug Administration (FDA), did not significantly reduce the titer of vaccine or pathogenic IBDV strains (142).

Certainly, the hardy nature of this virus is one reason for its persistent survival in poultry houses even when thorough cleaning and disinfection procedures are followed.

Strain Classification

A variety of phenotypic and molecular genetic procedures have been developed to classify isolates of IBDV. Classification systems based on phenotypic traits, such as serotyping, have been used successfully since the discovery of the virus. Serotyping of IBDV isolates using polyclonal antibodies in cross virus neutralization (VN) tests has correlated very well with protection studies. The newer molecular genetic procedures have proved extremely useful for diagnostics and epidemiologic studies, but at this point documented criteria are still lacking to reliably correlate sero- and molecular grouping. Following are some of the procedures used to classify IBDV isolates. See paragraph "pathogenicity" for classification according to pathotypes.

Antigenicity

Two serotypes of IBDV, designated as 1 and 2, have been recognized, first in Ireland (207) and in the United States (135, 184, 208). IBDV serotypes 1 and 2 share only 30% antigenic relatedness (207). Antigenic relatedness of only 33% between 2 strains of serotype 2 was reported (208), indicating an antigenic diversity similar to that of serotype 1 viruses.

The 2 serotypes are differentiated by VN tests, but not by fluorescent antibody tests or enzyme-linked immunosorbent assay (ELISA). Immunization against serotype 2 does not protect against serotype 1. The reverse situation cannot be tested because no virulent serotype 2 viruses are available for challenge (128, 138). The first isolates of serotype 2 (135) originated from turkeys, but later studies showed that serotype 2 viruses also could be isolated from chickens (128), and antibodies to serotype 2 IBDVs are common in both chickens and turkeys (133, 276).

Variant viruses of serotype 1 were described (129, 276). Vaccine strains available at the time they were isolated did not elicit full protection against the variants, which are antigenically different from the standard serotype 1 isolates. Six subtypes were distinguished by cross-neutralization among 13 serotype 1 vaccine or field strains. One of the subtypes included all of the variant isolates (134). Snyder et al. (300, 301), using monoclonal antibodies, suggested that a major antigenic shift in serotype 1 viruses had occurred in the field. Sequencing studies later identified several amino acid changes in VP2 hydrophilic peaks that correlated with the antigenic changes observed in the variant viruses (107, 166, 327). Australian (280) and European (63, 174) strains evocative of variant viruses (modified reactivity with monoclonal antibodies, amino acid changes in antigenically significant VP2 positions) also were identified but they differ genetically and antigenically from North American variant viruses. The impact of antigenic variation on cross protection has been less documented for these Australian and European viruses.

The vvIBDV strains that were first described in Europe (33) were shown to be mostly antigenically similar to the classic serotype 1 viruses (2, 23, 65, 321, 331, 335). However, further characterization with monoclonal antibodies demonstrated 1 modified neutralizing epitope in typical vvIBDV, as compared with classic serotype 1 viruses (67). Some atypical vvIBDV with more extensive epitope changes have been occasionally identified (68, 69). Sapats et al. recently developed a chicken recombinant antibody (laboratory-produced synthetic antibody derived from the lymphocytes of chickens immunized with vvIBDV, same use as monoclonal antibody) that positively recognizes vvIBDV (281).

In summary, there are currently 3 well-documented antigenic types. These are classic (often called standard) and variant serotype 1 (possibly including an American and an

Australian group) and serotype 2 viruses. Subtypes of the 3 antigenic types also have been described.

Immunogenicity or Protective Types

The term protective type was coined by Lohr (179) to describe a practical procedure to classify IBV based on their protective potential. Classification of IBV has been problematic. This classification is based on cross-protection studies in live birds. As indicated earlier, cross-challenge studies with IBDV have yielded results similar to those obtained by cross VN studies used for the antigenic classification (127). There are currently 2 serotype 1 protective types, classic/standard and variant groups. Serotype 2 viruses do not protect against challenge with serotype 1 viruses.

Molecular Genetic Types and Gene Sequencing

Molecular genetic techniques are increasingly used to group different isolates of IBDV (140). These techniques have become popular because of their sensitivity, the time they save, the ability to use them on crude samples or inactivated samples, and the fact that they do not require replication of the virus. The most commonly used procedure is the reverse transcriptase/polymerase chain reaction-restriction enzyme fragment length polymorphisms (RT/PCR-RFLP), mostly applied to the characterization of the genomic region encoding VP2 variable domain (see above). A RT-PCR/RFLP approach also has been implemented for the molecular grouping of IBDV strains according to their segment B restriction profile (317). Currently described molecular groups do not always correspond to antigenic or protective groups, and it is important to be careful in interpreting the significance of this classification.

A more thorough molecular characterization can be achieved by sequencing the virus genome and studying the phylogenetic relationships of the studied isolate with reference viruses. It is important that both genome segments should be characterized for an optimum assessment of genetic relatedness (172, 145). Because the genetic basis for virulence has not been defined yet, attempts to infer the phenotype from genetic data should still be considered as tentative.

Laboratory Host Systems

Chicken Embryos

Initially, most workers had difficulty in isolating virus or, if successful, in serially transferring virus using chicken embryos (167).

Continued studies (115) uncovered 3 factors that could explain these difficulties: (1) Embryonating eggs that originated from flocks recovered from the disease were highly resistant to growth of the virus; (2) In early virus passage, the allantoamnionic fluid (AAF) had very low virus content and the chorioallantoic membrane (CAM) and embryo each had a much higher and nearly equal virus content; and (3) Comparison of the allantoic sac, yolk sac, and CAM as routes of inoculation showed the allantoic sac to be the least desirable, yielding embryo-infective dose—50% (EID_{50}) virus titers of 1.5–2 $\log_{10}$—lower than those obtained after inoculation by the CAM route. The yolk sac route gave titers that were intermediate.

An embryo-adapted virus was shown to reach a peak virus concentration in the embryo 72 hours PI (115).

Injection of the virus into 10-day-old embryonating eggs results in embryo mortality from days 3–5 PI. Gross lesions observed in the embryo were edematous distention of the abdominal region; cutaneous congestion and petechial hemorrhages, particularly along feather tracts; occasional hemorrhages on toe joints and in the cerebral region; mottled appearing necrosis and ecchymotic hemorrhages in the liver (latter stages); pale "parboiled" appearance of the heart; congestion and some mottled necrosis of kidneys; extreme congestion of lungs; and pale spleen, occasionally with small necrotic foci. The CAM had no plaques, but small hemorrhagic areas were observed at times. Lesions induced in embryos by IBDV variants differ from those induced by standard isolates. Splenomegaly and liver necrosis are characteristic of the lesions induced by the variants, but there is little mortality (273). vvIBDV strains induce similar lesions in embryos as the classic strains, and the CAM was the most sensitive route for infecting chicken embryos with vvIBDV, but the yolk sac route was a good alternative (312). It is the authors' experience that serotype 2 viruses usually do not induce typical lesions when inoculated via the CAM route into embryonating chicken eggs, the only signs being feeble, pale, and yellowish embryos.

Cell Culture

Many strains of IBDV have been adapted to cell cultures of chicken embryo origin, and cytopathic effects have been observed, allowing for plaque assay or microtiter techniques. Chicken embryo fibroblasts (CEF) proved suitable to propagate egg-adapted strains of IBDV (268, 251). CEF proved more sensitive than either embryonating eggs or suckling mice. Cell cultures from the chicken embryo cloacal bursa also were used, followed by passage in embryo kidney cells and subsequent propagation in CEF, to develop an attenuated live virus vaccine from a wild-type virus (185). In addition to cells of chicken origin, the virus has been grown in turkey and duck embryo cells (209).

Several continuous cell lines of avian origin also have been used to propagate IBDV strains. These include the avian fibroblastic lines DF1 (344) and QT35 (46), a chicken macrophage cell line from North Carolina State University (153), the avian leukosis virus-induced DT40 lymphoma cell line (314, 190), and the B-lymphoblastoid cell line LSCC-BK3 (110). The 2 latter lines were reported to successfully propagate pathogenic IBDV strains that had not been previously adapted to CEF (314, 320). The DT40 cell line may become persistently infected with IBDV (53).

Mammalian cell lines also have been used to propagate IBDV. These were derived from rabbit kidneys (RK-13) (268), murine embryonic cells (BALB/c 3T3) (52), monkey kidneys (Vero, MA104) (112, 188), and baby grivet monkey kidney cells (BGM-70) (139). In 1 study, the Vero, MA104, and

BGM70 cell lines could all propagate several IBDV strains of both serotypes including serotype 1 variants but cytopathic effects were most pronounced in the BGM-70 cells (139). The growth curve of 1 strain tested in BGM-70 cells was similar to that in CEFs, and VN titers in BGM-70 cultures compared well with those in CEFs.

Host cells in the infected chicken were first characterized by Hirai and Calnek who propagated virulent IBDV in normal chicken lymphocytes (and in a lymphoblastoid B-cell line derived from an avian leukosis virus-induced tumor) and showed that IgM-bearing B lymphocytes were the probable target cells of IBDV (111, 230). Müller (215) enriched Ig-bearing cells by rosetting and cell sorting and observed that IBDV replicated preferentially in a population of proliferating cells and that susceptibility did not correlate with expression of immunoglobulins on their surface. In a recent study, chicken mesenchymal stem cells isolated from the bone marrow of normal chickens were shown to also be susceptible to IBDV infection (155).

Isolation of IBDV from field cases of the disease may be difficult. McFerran et al. (207) found it very difficult to isolate and serially propagate the virus in cell cultures of chicken embryo origin. Lee and Lukert (168) attempted isolations of IBDV from turkeys and chickens as well as from samples of challenge strains received from other laboratories. Turkey strains (5 of 5) were readily adapted to CEF cells after 3–10 blind passages. Only 2 of 9 chicken strains could be adapted to CEF cells; the other 7 strains could be grown only in chicken embryo cloacal bursa cells, even after 20 bursal cell passages.

BGM-70 cells were used successfully for isolation of IBDV from the cloacal bursas of naturally infected chickens (277). Usually, a cytopathic effect was detected after 2 or 3 blind passages. Passage of the virus 6 times in BGM-70 cells or CEF resulted in loss of pathogenicity, but similar passages in chicken embryos did not affect the pathogenicity of the virus (102). Later, it was reported that adaptation of the virus to BGM-70 cells resulted in a significant reduction in the ability of the virus to replicate in the cloacal bursa (3).

One aspect that should be considered concerning *in vitro* replication of the virus is the possibility of development of defective particles. Müller et al. (220) reported that serial passages of undiluted virus in chicken embryo cells resulted in fluctuations in infectivity and the development of a stable small-plaque-forming virus that interfered with the replication of the standard virus and favored the generation of defective particles. The defective particles had lost the large segment of dsRNA.

Compared to classic and variant strains of serotype 1, adaptation of the vvIBDV viruses to cell culture has been very difficult (2). Tsukamoto et al. reported that LSCC-BK3 cells were superior to BGM-70 cells and CEF in an infectivity assay; however, IBDV had to be detected by antigen capture in their supernatant (320).

Site-directed mutagenesis (227) has been used to identify single amino acids (VP2 amino acid positions 253, 279, and 284) that restrict propagation of IBDV in fibroblast cell cultures (175, 222).

Pathogenicity

Chickens are the only animals known to develop clinical disease and distinct lesions when exposed to IBDV. Care should be taken, when comparing experiments aimed at assessing the pathogenicity of different IBDV isolates, that these experiments include relevant control IBDV strains with well-characterized pathogenicity. Major variables to be standardized in comparative trials are the breed or genetic lineage, age and immune status of the challenged chickens, the dose and route of inoculation of the challenge virus and the possible presence of contaminating viruses in the inoculum (357). Field viruses exhibit different degrees of pathogenicity in chickens. In the authors' experience based on the experimental reproduction of acute IBD in specific pathogen free (SPF) white leghorn chickens, variant IBDV induce little if any clinical signs and mortality but marked bursal lesions, classical IBDV induces approximately 10%–50% mortality with typical signs and lesions, and vvIBDV induces approximately 50%–100% mortality with typical signs and lesions (357). Comparative studies show that it may prove difficult to define cut-off values, and that putative vvIBDV, when identified by the genetic sequence of their segment A only, may greatly vary in pathogenicity (145, 172, 334). Vaccine viruses also have varying pathogenic potential in chickens, as is discussed later in this chapter.

There has been interest in studying the potential pathogenicity of viruses belonging to serotype 2 in chickens and turkeys. In most studies, neither clinical signs nor gross nor microscopic lesions were observed in chickens inoculated with serotype 2 isolates (128, 138), irrespective of the species (chicken or turkey) from which the serotype 2 virus had been isolated. In turkey poults inoculated at 1–8 days of age, an isolate of serotype 2 from turkeys failed to cause disease or gross or microscopic lesions in the cloacal bursa, thymus, or spleen (137); however, the virus was infectious, and the poults responded serologically to the infection. Nusbaum et al. (236) studied experimental infection in 1-day-old poults with isolates representing serotypes 1 and 2 that originated from turkeys. Virus-infected cells were detected by immunofluorescence in the cloacal bursa, thymus, spleen, and the Harderian gland of infected birds, but no clinical disease resulted. Only slight gross changes were observed, and no histologic differences were seen between infected and noninfected birds. In general, the distribution of fluorescing (infected) cells from these tissues seemed to indicate that the majority were not lymphocytes. The number of plasma cells in the Harderian gland was reduced at 28 days of age. As indicated earlier, the effect of the host system on pathogenicity of the virus may be profound (102, 319). In recent studies, the OH strain of serotype 2 virus that was back passaged 5 times in chicken embryos was shown to be pathogenic to the embryos. Nonetheless, that virus was not pathogenic for 2-week-old SPF chickens or turkeys (4).

Pathobiology and Epidemiology

Incidence and Distribution

Infections with serotype 1 IBDV are worldwide in distribution, occurring in all major poultry-producing areas. The incidence of infection in these areas is high; essentially, all flocks are exposed to the virus during the early stages of life, either by natural exposure or vaccination. Because of vaccination programs carried out by most producers, all chickens eventually become sero-positive to IBDV. Clinical cases are very rare in the United States because infections are either modified by antibodies or are due to variant strains that do not cause obvious clinical disease. These variant strains seem to be the predominating viruses that exist in the United States, but isolated outbreaks due to vvIBDV occurred in late 2008 in California (143). Classical viruses and a local type of variants have been reported in Australia (280). In Europe, Africa, Asia, and South America, the vvIBDV strains seem to predominate.

In the United States, it was shown that antibodies to serotype 2 IBDV were widespread in chicken (133, 276) and turkey flocks (11, 38, 135), indicating the common prevalence of the infection.

Natural and Experimental Hosts

Chickens and turkeys are the natural hosts of the virus. A serotype 1 virus was isolated from two 8-week-old ostrich chicks that had lymphocyte depletion in the cloacal bursa, spleen, and/or thymus (356). Serotype 1 isolates were obtained from healthy (207) or dead (148) waterfowl. The latter viruses were genetically related to vvIBDV and pathogenic for chickens (148). Other vvIBDV were isolated from a dead magpie (148) in Korea and from turkeys in Nigeria (242). Viruses genetically related to vvIBDV were detected by reverse transcriptase polymerase chain reaction (RT-PCR) from apparently healthy pigeons and guinea fowl in eastern Africa (151). A serotype 2 IBDV was isolated from captive penguins that died without specific clinical signs (92). Van den Berg (333) inoculated pheasants, partridges, quail, and guinea fowl with vvIBDV. These authors did not report any clinical signs or lesions in these species; however, quail replicated the virus in their bursa, shed it for 5 days in their feces, and developed neutralizing antibodies. This contrasts with a previous study by Weisman and Hitchner, who could not infect Coturnix quail with a chicken-origin virus (347), but confirms an earlier report that IBDV-inoculated guinea fowl did not develop lesions or antibody (239).

Several species of free-living and captive birds of prey were examined for antibodies to IBDV, and positive results were obtained from accipitrid birds (326). Antibodies to IBDV were also detected in rooks, wild pheasants, and several rare avian species (31); in Antartic penguins (85); in ducks, gulls, and shearwaters (350); and crows, gulls, and falcons (238).

For many years, the chicken was considered the only species in which natural infections occurred. All breeds were affected, and many investigators observed that white leghorns exhibited the most severe lesions and clinical signs and had the highest mortality rate. Meroz (211), however, found no difference in mortality between heavy and light breeds in a survey of 700 outbreaks of the disease.

The period of greatest susceptibility to clinical disease is 3–6 weeks of age. Susceptible chickens younger than 3 weeks do not exhibit clinical signs but have subclinical infections that are economically important as a result of severe immunosuppression of the chicken. This immunosuppressive effect of IBDV is discussed later in this chapter.

The age susceptibility of chickens to IBDV has been linked in several studies with the availability of a functional cloacal bursa, the target organ of the virus. Fadly et al. (70) treated 3-day-old chicks with cyclophosphamide and found that they were refractory to clinical signs and lesions when challenged at 4 weeks of age. Kaufer and Weiss (152) found similar results with birds surgically bursectomized at 4 weeks of age. When they were challenged immediately or 1 week later, there was no clinical disease, whereas 100% of the control nonbursectomized chickens died. Bursectomized chickens challenged with virulent virus produced 1,000 times less virus than control birds, produced VN antibodies by day 5, and had only very discrete and transient necrosis of lymphatic tissues.

Several studies on the pathogenesis of IBDV infections have been conducted. Skeeles et al. (293) attempted to demonstrate that the hemorrhagic lesions were a result of formation of immune complexes, as proposed by Ivanyi and Morris (131). Histologic lesions in the cloacal bursa resemble an Arthus reaction (necrosis, hemorrhage, and large numbers of polymorphonuclear leukocytes). This reaction is a type of localized immunologic injury caused by antigen-antibody-complement complexes that induce chemotactic factors, which cause hemorrhage and leukocyte infiltration. They found that 2-week-old chickens 72 hours PI had little complement compared with 8-week-old chickens. They postulated that the reason why 2-week-old chickens did not develop Arthus-type lesions was a lack of sufficient complement.

In recent studies, a role for mast cells in the pathogenesis of acute IBDV was reported (342). Mast cell populations, tryptase expression, and histamine release were all increased in the bursa of SPF chickens challenged with vvIBDV, while prevention of mast cell degranulation with ketotifen resulted in a dramatic reduction of both signs, gross and histological bursal lesions, and mortality.

Kosters et al. (162) and Skeeles et al. (293, 296) found increased clotting times in IBDV-infected chickens and suggested that such coagulopathies could contribute to the hemorrhagic lesions observed with this disease in an age-dependent way.

The key to the pathogenesis of IBDV in birds of different ages may lie with the factors involved in the clotting of blood and/or an immunologic injury. The pathogenesis is certainly not straightforward and simple.

Naturally occurring infections of turkeys and ducks by sero types 2 and serotype 1 viruses, respectively, have been recorded (150, 207, 209, 244). McNulty et al. (209) examined turkey serum from several flocks and could not detect IBDV antibodies

prior to 1978, suggesting that IBDV infections of turkeys were a relatively new occurrence. Owoade et al. reported the isolation of an IBDV strain with genetic relatedness to vvIBDV in a turkey flock in Nigeria (242).

Giambrone et al. (90) found that experimental IBDV infections of turkeys were subclinical in 3- to 6-week-old poults, producing microscopic lesions in the cloacal bursa. Virus-infected cells in the bursa were detected by immunofluorescence. Neutralizing antibody was detected 12 days PI, and the virus could be reisolated after 5 serial passages in chicken embryos. Weisman and Hitchner (347) could not reisolate virus from their 6- to 8-week-old IBDV-infected poults, but they observed an increase in VN antibody. Infection was subclinical, and no damage to the bursa was evident.

Transmission, Carriers, and Vectors

Infectious bursal disease is highly contagious, and the virus is persistent in the environment of a poultry house. Benton et al. (17) found that houses from which infected birds were removed were still infective for other birds 54 and 122 days later. They also demonstrated that water, feed, and droppings taken from infected pens were infectious after 52 days.

No evidence suggests that IBDV is transmitted through the egg or that a true carrier state exists in recovered birds. Resistance of the virus to heat and disinfectants is sufficient to account for virus survival in the environment between outbreaks. Snedeker et al. (297) demonstrated that the lesser mealworm (*Alphitobius diaperinus*), taken from a house 8 weeks after an outbreak, was infectious for susceptible chickens when fed as a ground suspension. In another study (206), the virus was isolated from several tissues of surface-sterilized lesser mealworm adults and larvae that were fed the virus earlier.

Howie and Thorsen (119) isolated IBDV from mosquitoes (*Aedes vexans*) that were trapped in an area where chickens were being raised in southern Ontario. The isolate was nonpathogenic for chickens. Okoye and Uche (240) detected IBDV antibodies by the agar-gel precipitin (AGP) test in 6 of 23 tissue samples from rats found dead on 4 poultry farms that had histories of IBDV infection. There has been no further evidence to support a conclusion that either mosquitoes or rats act as vectors or reservoirs of the virus.

Pagès-Manté et al. reported that a dog fed chickens that had died of acute IBD shed viable vvIBDV in its feces for up to 2 days after ingestion (245).

As indicated earlier in this chapter, several avian species were shown to be susceptible to the infection or to have antibodies against the virus.

A recent study in 46 processing plants in the Eastern United States showed that 25% of the pools of cloacal bursae (collected in 42% of the studied plants) allowed molecular detection of nonvaccine IBDV strains and that infectious IBDV could be reisolated (144). Actual data on the frequency of contamination of commercial poultry products by IBDV are still lacking, but increasing concern has been expressed that serotype 1 IBDV should be considered as potentially transmitted through the trade of poultry meat (42).

Incubation Period and Clinical Signs

The incubation period is short, and clinical signs of the disease are seen within 2–3 days after exposure.

One of the earliest signs of infection in a flock is the tendency for some birds to pick at their own vents. Cosgrove (44) described soiled vent feathers, whitish or watery diarrhea, anorexia, depression, ruffled feathers, trembling, severe prostration, and finally, death. Affected birds became dehydrated, and in terminal stages of the disease, had a subnormal temperature.

Morbidity and Mortality

In fully susceptible flocks, the disease appears suddenly, and there is a high morbidity rate, usually approaching 100%. Mortality may be nil but can be as high as 20%–30%, exceptionally higher with vvIBDV, usually beginning on day 3 PI and peaking and receding in a period of 5–7 days. In the late 1980s, vvIBDV strains became a problem in Europe. Several of these isolates caused mortality rates of 90% (33) to 100% (331) in 4-week-old susceptible leghorn chickens. A 1970 isolate (52/70) (30) was compared with 2 vvIBDV isolates in a study; it caused 50% mortality compared with 90% for the vvIBDV strains (33). In another such study, the vvIBDV isolates caused lower mortality; however, percent mortality was again at least twice as much as that caused by the 52/70 isolate (65).

Initial outbreaks on a farm are usually the most acute. Recurrent outbreaks in succeeding broods are less severe and frequently go undetected. Many infections are silent, owing to age of birds (less than 3 weeks old), infection with avirulent field strains, or infection in the presence of maternal antibody.

Pathology

Gross Lesions

Birds that succumb to the infection are dehydrated, with darkened discoloration of pectoral muscles. Frequently, hemorrhages are present in the thigh and pectoral muscles (Figure 7.2). There is increased mucus in the intestine, and renal changes (44) may be prominent in birds that die or are in advanced stages of the disease. Such lesions are most probably a consequence of severe dehydration. In birds killed and examined during the course of infection, the kidneys appear normal.

The cloacal bursa appears to be the primary target organ of the virus. Cheville (37) made a detailed study of bursal weights for 12 days PI. It is important that the sequence of changes be understood when examining birds for diagnosis. On day 3 PI, the bursa begins to increase in size and weight because of edema and hyperemia (Figure 7.3). By day 4, it usually is double its normal weight, and the size then begins to recede. By day 5, the bursa returns to normal weight, but it continues to atrophy, and from day 8 forward, it is approximately one-third its original weight, or even less.

By day 2 or 3 PI, the cloacal bursa has a gelatinous yellowish transudate covering the serosal surface. Longitudinal striations on the surface become prominent, and the normal white color turns to cream color. The transudate disappears as the

bursa returns to its normal size, and the organ may become gray during and following the period of atrophy.

Isolates of variant IBDV were reported not to induce an inflammatory response (270, 284), although 1 variant strain (IN) did so (103).

The infected bursa often shows necrotic foci and at times petechial or ecchymotic hemorrhages on the mucosal surface. Occasionally, extensive hemorrhage throughout the entire bursa has been observed (Figure 7.3); in these cases, birds may void blood in their droppings.

The spleen may be slightly enlarged and often has small gray foci uniformly dispersed on the surface (267). Occasionally, hemorrhages are observed in the mucosa at the juncture of the proventriculus and ventricultus (gizzard) and may cause melena (digestive content stained black with digested blood).

Compared with a moderately pathogenic strain of the virus, the vvIBDV strains caused a greater decrease in thymic weight index and more severe lesions in the cecal tonsils, thymus, spleen, and bone marrow, but bursal lesions were similar. It was also shown that pathogenicity correlated with lesion production in nonbursal lymphoid organs, suggesting that pathogenicity may be associated with antigen distribution in nonbursal lymphoid organs (313).

Figure 7.2. Hemorrhages (arrows) in thigh and breast muscles, at 3 days post inoculation in 2-week-old SPF chickens inoculated with 10^6EID_{50} of bursa-derived classic IBDV (STC). (A. Rauf and Y.M. Saif)

Microscopic Lesions

Microscopic lesions of IBD occur primarily in the lymphoid tissues (i.e., cloacal bursa, spleen, thymus, Harderian gland, and cecal tonsil). Histopathology at the level of light microscopy has been originally studied by Helmboldt and Garner (109), Cheville (37), Mandelli et al. (199), and Peters (252). Changes were most severe in the cloacal bursa. As early as 1 day PI, there was degeneration and necrosis of lymphocytes in the medullary area of bursal follicles. Lymphocytes were soon replaced by heterophils, pyknotic debris, and hyperplastic reticuloendothelial cells. Hemorrhages often appeared but were not a consistent lesion. All lymphoid follicles were affected by 3 or 4 days PI. The increase in bursal weight seen at this time was caused by severe edema, hyperemia, and marked accumulation of heterophils. As the inflammatory reaction declined, cystic cavities developed in medullary areas of follicles; necrosis and phagocytosis of heterophils and plasma cells occurred; and there was a fibroplasia in interfollicular connective tissue. Proliferation of the bursal epithelial layer produced a glandular structure of columnar epithelial cells containing globules of mucin.

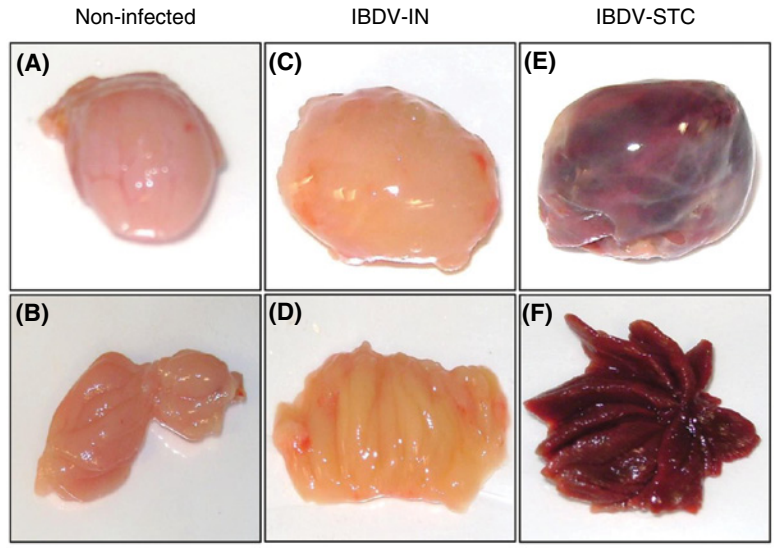

Figure 7.3. Cloacal bursa of 2-week-old SPF chickens at 3 days post inoculation. (A and B) Noninfected control chicken. (C and D) Chicken inoculated with 10^6EID_{50} of bursa-derived variant (IN) IBDV. (E and F) Chicken inoculated with 10^6EID_{50} of bursa-derived classic (STC) IBDV. Lesion in panel C is characterised by pale yellow bursal color with yellowish transudate. (A. Rauf and Y.M. Saif)

During the suppurative stage, scattered foci of lymphocytes appeared but did not form healthy follicles during the observation period of 18 days PI (109). Some of the histologic changes observed in the cloacal bursa are shown in Figure 7.4. A recent isolate (variant A) of IBDV was reported to cause extensive lesions in the cloacal bursa, but an inflammatory response was lacking (284).

A sequential study (355) of the recovery of the cloacal bursa after neonatal infection by classical IBDV demonstrated that the initial depletion of B lymphocytes was maximal during the first week, and combined with a transient massive influx of T cells and macrophages until 3 days PI. From 1–8 weeks PI, 2 distinct types of bursal follicles were then observed: large, reconstituted functional follicles, most likely reconstituted from endogenous bursal stem cells that survived IBDV infection, and small, poorly developed follicles lacking a discernible cortex and medulla. The structure of these small follicles suggested they were unable to produce functional peripheral B cells, a hypothesis that was confirmed by the lack of active antibody responses in birds lacking large reconstituted follicles. After their initial influx in the bursa, T cells declined in number along with viral clearance and persisted mostly in the small follicles during the recovery phase. Inflammatory foci persisted during the recovery phase, possibly centered on antigen-presenting cells. It is not known whether their presence was associated with persistent IBDV infection in some cells (355). Essentially similar but more severe and more persistent histological lesions have been described following challenge with a vvIBDV, which, however, also induced thymic lesions (351).

The spleen had hyperplasia of reticuloendothelial cells around the adenoid sheath arteries in early stages of infection. By day 3, there was lymphoid necrosis in the germinal follicles and the periarteriolar lymphoid sheath. The spleen recovered from the infection rather rapidly, with no sustained damage to the germinal follicles.

The thymus and cecal tonsils exhibited some cellular reaction in the lymphoid tissues in early stages of infection, but, as in the spleen, the damage was less extensive than in the bursa, and recovery was more rapid. A variant virus (A) was reported to cause milder lesions in the thymus than a standard isolate (IM) (284).

Survashe et al. (309) and Dohms et al. (61) found that the Harderian gland was severely affected following infection of 1-day-old chicks with IBDV. Normally, the gland is infiltrated and populated with plasma cells as the chicken ages. Infection

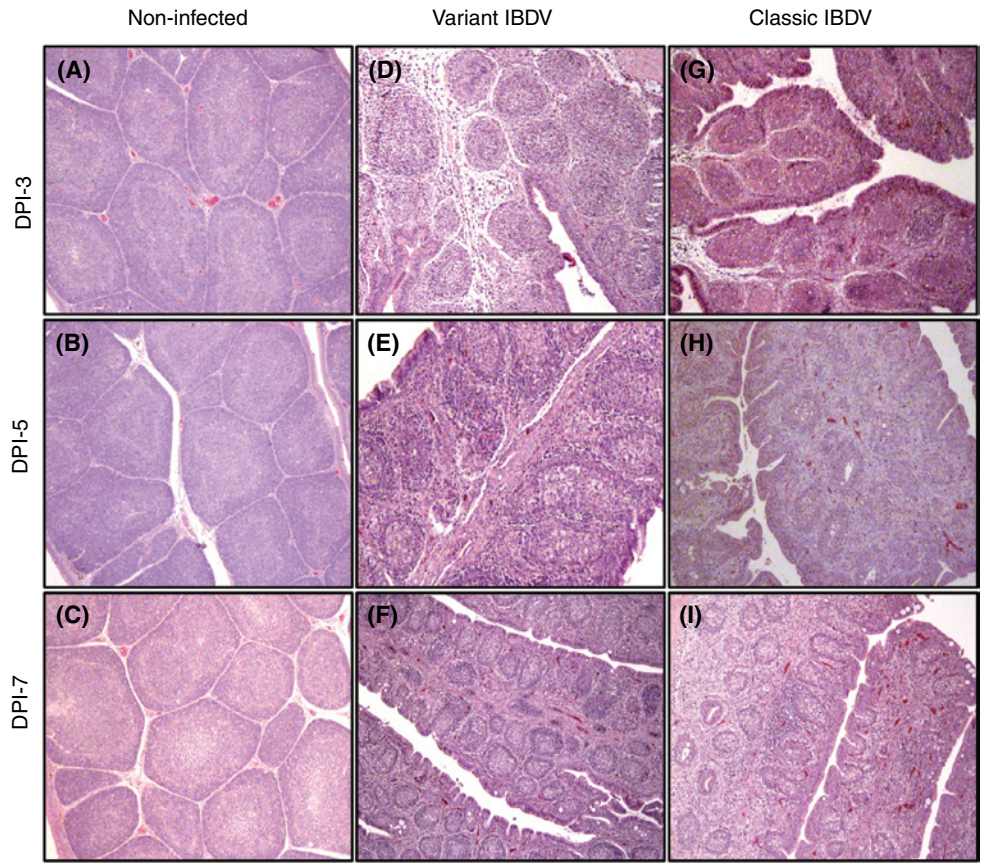

Figure 7.4. Histopathological lesions in the cloacal bursa at 3, 5, and 7 days post inoculation (DPI). (A, B, and C) Normal lymphoid follicles in noninfected control chicken. ×60. (D, E, and F) Mild to moderate follicular lymphocyte depletion in chickens inoculated with 10^4EID_{50} of bursa-derived variant (IN) IBDV. ×60. (G, H, and I) Severe follicular lymphocyte depletion in chickens inoculated with 10^4EID_{50} of bursa-derived classic (STC) IBDV. ×60). (A. Rauf and Y.M. Saif)

with IBDV prevented this infiltration. From 1 week of age, the glands of infected chickens had populations of plasma cells 5– to 10-fold fewer than those of uninfected controls (61). In contrast, broilers inoculated with IBDV at 3 weeks of age had plasma cell necrosis in the Harderian gland 5–14 days PI, and the plasma cells were reduced by 51% at 7 days PI (62). Reduction in plasma cells, however, was transient, and the numbers were normal after 14 days.

Histologic lesions of the kidney are nonspecific (252) and probably occur because of severe dehydration of affected chickens. Helmboldt and Garner (109) found kidney lesions in less than 5% of birds examined. Lesions observed were large casts of homogeneous material infiltrated with heterophils.

The liver may have slight perivascular infiltration of monocytes (252).

Ultrastructural

Naqi and Millar (231) followed the sequential changes in the surface epithelium of the cloacal bursa of IBDV-infected chicks by scanning electron microscopy. They observed a reduction in number and size of microvilli on epithelial cells at 48 hours PI. There was gradual loss of the button follicles normally seen at the surface, and by 72 hours, most had involuted. By 96 hours, there were numerous erosions of the epithelial surface. The surface was intact by day 9 PI, but follicles were involuted, leaving deep pits.

Pathogenesis of the Infectious Process

Helmboldt and Garner (109) detected histologic evidence of infection in the cloacal bursa within 24 hours. In sequential studies of tissues from orally infected chickens using immunofluorescence, viral antigen was detected in macrophages and lymphoid cells in the cecum at 4 hours PI; a hour later, virus was detected in lymphoid cells in the duodenum and jejunum (219). The virus first reaches the liver, where it is detected 5 hours PI. It then enters the bloodstream, where it is distributed to other tissues including the bursa; the bursal infection is followed by a second massive viremia; however, virus peak titer in the nonlymphoid organs is several $\log_{10}$ lower than in the bursa and limited to the viremic period.

Studies of gene expression during acute IBD demonstrated the activation of spleen macrophages (159) and of bursal T cells (160). Ruby et al. provided an extensive transcriptional study (275) of the early host responses to neonatal infection with a classical IBDV (F52/70). Changes in the expression levels of bursal genes closely mirrored the early histological changes discussed earlier in this chapter: low level of expression of B cell-specific genes in relation with B-cell depletion, and enhanced expression of numerous genes related with the activation of macrophages, T cells, and NK cells. Early upregulated genes included genes of the antiviral interferon system (IFN a/b and the IFN-induced genes), cytokines (IL-18, IL-6), and chemokines (IL-8, MIP-1b…); genes involved in the innate immune response (MD-1 and MD-2, complement components, heat shock proteins HSP70 and 47); some genes encoding cytoskeleton proteins; and genes involved in both the proinflammatory and inflammatory responses. Interestingly, the latter genes had significantly more expression at 24 hours PI in an IBD-resistant chicken line, as compared with a susceptible one. Another difference in the resistant line was a transient overexpression of p53 at 48 hours PI. On the other hand, a number of genes involved in B and T cell proliferation were down-regulated by IBDV infection. The authors propose that in resistant birds, a more rapid inflammatory response and more-rapid activation of apoptotic pathways in IBDV target cells would limit virus replication and its subsequent pathological effects (275).

In another recent study, upregulation of the perforin-granzyme pathway genes in the bursa was demonstrated, and perforin-producing CD4+ and CD8+ T cells were detected by immunochemistry mostly at days 5 and 7 PI with classical strain STC (262). The same authors studied how different IBDV pathotypes interact with the Toll-like receptor (TLR) pathways (261) in 3-week-old SPF chickens challenged with the classical STC or the IN variant IBDV strains. Three to seven days PI and as compared with variant IBDV, classical IBDV induced a higher expression of IFNα and β, of proinflammatory cytokine IL-6 and iNOS, of chemokines IL8 and MIP-α, and of TLR3 and TLR7 (cellular receptors that detect dsRNA and ssRNA, respectively) (261).

IBDV was shown to persist in bursal tissues of experimentally inoculated SPF chickens up to 3 weeks, but it persisted for shorter periods in the presence of maternal antibodies in commercial broilers (1).

Based on the fact that IBDV-induced pathology still progresses several days after the viral load starts to decline (5 days PI), Williams and Davison suggested that the disease mechanism is related to immunopathology as well as to virus-induces lysis (351).

Immunity

Viruses of both serotypes of IBDV share common group antigen(s) that can be detected by the fluorescent antibody test and ELISA (126, 135). Hence, it is not possible to distinguish serotypes or their antibodies by these tests. The common (group) antigens for both serotypes are on VP2 (40 kD) and VP3 (32 kD). VP2 also has serotype-specific group antigens that induce VN antibodies (10, 16). Becht et al. (16) reported that antibodies against VP3 do not have any protective effect. *In vivo* studies (127, 138) corroborated this observation, because chickens having antibodies to serotype 2 viruses were not protected against serotype 1 viruses. The current thought is that VP2 has the major antigens that induce protection (10, 16).

Traditionally, serotype 1 viruses have been used for studies of the immune response to IBDV (352). All known isolates of serotype 2 were reported to be nonpathogenic in chickens and turkeys (128, 137, 138) or of very low pathogenicity (41, 236, 250). The discovery of variant strains of serotype 1 has heightened interest in furthering the knowledge of the immune response to IBDV (352). It was interesting that variants were originally isolated from chickens that had VN antibodies to

serotype 1 (270, 276). Inactivated vaccines and a live vaccine made from variant strains protected chickens from disease caused by either variant or standard strains, whereas inactivated vaccines made from standard strains did not protect, or only partially protected, against challenge with variant strains (127, 274).

Five different subtypes of serotype 1 IBDV were tested as inactivated vaccines against a variant strain of a different subtype (127). Vaccines made with 10^8 but not 10^5 mean tissue-culture-infective doses ($TCID_{50}$) were protective against a challenge dose of 10^2 EID_{50}. Even the higher vaccine dose did not protect against challenge with $10^{3.5}$ EID_{50}. Based on these results, it was suggested that all of the subtypes of serotype 1 share a minor antigen(s) that elicits protective antibodies.

The contribution of humoral immunity to protection has been well documented as indicated by protection conferred by passive transfer of antibodies. Evidence is accumulating on the additive effect of cell-mediated immunity in protection from the disease (264, 285). Recent studies indicated the natural resistance of some breeds of chickens to the disease (101).

Active Immunity

Field exposure to the virus, or vaccination with either live or killed vaccines, stimulates active immunity. Antibody response may be measured by several methods—VN, AGP, or ELISA tests. Antibody levels are normally high after field exposure or vaccination, and VN titers greater than 1:1,000 are common. Adult birds are resistant to oral exposure to the virus but produce antibody after intramuscular or subcutaneous inoculation of IBDV (116). However, partial protection against IBD was achieved in chickens in the absence of detectable neutralizing antibodies, as a result of experimental immunization with a fowlpox recombinant virus that expresses the VP2 protein (13), which is an indication that cell-mediated immunity also may play an important role in protecting against IBD.

Passive Immunity

Antibody transmitted from the hen via the yolk of the egg can protect chicks against early infections with IBDV, with resultant protection against the immunosuppressive effect of the virus. The half-life of maternal antibodies to IBDV is between 3 and 5 days (295). Therefore, if the titer of neutralizing antibodies in the progeny is known, the time that chicks will become susceptible can be predicted. Lucio and Hitchner (182) demonstrated that after antibody titers fell below 1:100, chicks were 100% susceptible to infection, and titers from 1:100 to 1:600 gave approximately 40% protection against challenge. Skeeles et al. (295) reported that titers must fall below 1:64 before chickens can be vaccinated effectively with an attenuated strain of IBDV. These figures should be considered as tentative, since significant differences have been reported in the neutralizing titers determined by different laboratories (210). Use of killed vaccines in oil emulsions (including variant strains) to stimulate high levels of maternal immunity is extensively practiced in the field. Studies by Lucio and Hitchner (182) and Baxendale and Lutticken (12) indicated that oil emulsion IBD vaccines can stimulate adequate maternal immunity to protect chicks for 4–5 weeks, and progeny from breeders vaccinated with live vaccines are protected for only 1–3 weeks. As with many diseases, passively acquired immunity to IBDV can interfere with stimulation of an active immune response.

The yolk of eggs laid by hens immunized against IBDV is an abundant source of large amounts of anti-IBDV immunoglobulins that can be easily purified (66). Semi-purified anti-IBDV antibodies have been obtained by this approach and have been used experimentally in countries where virulent IBD is widespread for passive immunization, either parenterally in diseased birds (197) or via the drinking water (370). Although these authors reported lower signs and mortality in the treated birds, the potential risk of disseminating IBDV itself or a possible extraneous agent contaminating the purified IgY has to be taken into account when such strategies are considered.

Immunosuppression

Allan et al. (6) and Faragher et al. (75) first reported immunosuppressive effects of IBDV infections. Suppression of the antibody response to Newcastle disease virus was greatest in chicks infected at 1 day of age. There was moderate suppression when chicks were infected at 7 days, and negligible effects when infection was at 14 or 21 days (75). Hirai et al. (113) demonstrated decreased humoral antibody response to other vaccines as well. Not only was response to vaccines suppressed, but chicks infected early with IBDV were more susceptible to inclusion body hepatitis (70), coccidiosis (7), Marek's disease (39, 282), hemorrhagic-aplastic anemia and gangrenous dermatitis (272), infectious laryngotracheitis (271), infectious bronchitis (249), chicken anemia agent (372), salmonellosis and colibacillosis (358), and campylobacter infection and shedding (307).

A paradox associated with IBDV infections of chickens is that although there is immunosuppression against many antigens, the response against IBDV itself is normal, even in 1-day-old susceptible chickens (294). It has been suggested that the ability of the chickens to develop an active anti-IBDV antibody response correlates, after challenge at 1 day old, with the development of large bursal follicles during the recovery phase (355). This may not be the only mechanism, though, because older chickens that did not succumb to infection and exhibit an extreme bursal atrophy often develop high titers of neutralizing antibodies. Hence, it should be further investigated whether there is a selective stimulation of the proliferation of B cells committed to anti-IBDV antibody production.

The effect of IBD on cell-mediated immune (CMI) responses is transient and less obvious than that on humoral responses. Panigrahy et al. (246) reported that IBDV infections at a young age caused a delayed skin graft rejection; however, other workers (89, 121) found no effect from early IBDV infections on skin graft rejection or tuberculin-delayed hypersensitivity reaction. Sivanandan and Maheswaran (290) observed suppression of CMI responsiveness using the

lymphoblast transformation assay. They found that maximal depression of cellular immunity occurred 6 weeks PI. Nusbaum et al. (236) detected a significant suppression of T-cell response to the mitogen concanavalin A in poults from 3 days–4 weeks PI. There was no reduction, however, in tuberculin reactions in IBDV-infected poults. In a sequential study of peripheral blood lymphocytes from chickens inoculated with IBDV, a transient depression of mitogenic stimulation was reported (43). Sharma and Lee (283) reported an inconsistent effect of IBDV infection on natural killer cell toxicity and a transient early depression of the blastogenic response of spleen cells to phytohemagglutinin. Craft et al. (47) demonstrated that a variant IBDV strain (A) had a significantly more severe effect on the CMI response than a standard strain (Edgar) when given to 1-day-old chicks, and the CMI was suppressed for 5 weeks. A similar transient suppression of the CMI was observed in chickens infected at 3 weeks of age.

Another component of the immune system is the Harderian gland, which is associated with the local immune system of the upper respiratory tract. Pejkovski et al. (249) and Dohms et al. (61) reported that IBDV infection of 1– to 5-day-old chicks produced a drastic reduction in plasma cell content of the Harderian gland that persisted for up to 7 weeks. There have been similar observations with IBDV infections of poults (236). In other studies on broilers infected with IBDV at 3-weeks of age, extracts from the Harderian gland and serum had reduced antibody titers to *Brucella abortus* (a T-cell-independent antigen) and sheep red blood cells (SRBC, a T-cell-dependent antigen). Compared with SRBC antibody response, diminished antibody responses to *B. abortus* were evident at a later time period. A variant virus of serotype 1 produced a similar effect in chickens (60).

Chickens infected with IBDV at 1 day of age were completely deficient in serum immunoglobulin G and produced only a monomeric immunoglobulin M (IgM) (130, 131). The number of B cells in peripheral blood was decreased following infection with IBDV, but T cells were not appreciably affected (114, 288). The virus appears to replicate primarily in B lymphocytes of chickens (111, 130, 364). IBDV has a predilection for actively proliferating cells (215), and it was suggested that the virus affected "immature," or precursor B lymphocytes to a greater extent than mature B lymphocytes (237, 289).

Besides lymphocyte lysis, apoptosis is another mechanism of immunosuppression. Apoptosis is also a mechanism of lesion development and could occur in a variety of tissues and organs (165, 315, 337, 338).

Although evidence is accumulating on the role of T cells in protection, there is also evidence of a role in immunopathogenesis (264, 285) resulting from tissue destruction enhancement mediated by cytokines.

Diagnosis

Acute clinical outbreaks of IBD in fully susceptible flocks are easily recognized, and a presumptive diagnosis can be readily made. The rapid onset, high morbidity, spiking mortality curve, and rapid recovery (5–7 days) from clinical signs are characteristics of this disease. Confirmation of the diagnosis can be made at necropsy by examination for characteristic grossly visible changes in the cloacal bursa. Remember that there are distinctive changes in size and color of the bursa during the course of infection (i.e., enlargement due to inflammatory changes followed by atrophy) (see Gross Lesions).

Infections of young chicks, or chicks with maternal antibody, are usually subclinical and are diagnosed retrospectively at necropsy with observations of macroscopic and microscopic bursal atrophy. Infections of chickens of any age with variant strains of IBDV will be detected only by histopathology of the cloacal bursa or by virus isolation.

Isolation and Identification of the Causative Agent

The cloacal bursa and spleen are the tissues of choice for the isolation of IBDV, but the bursa is the most commonly used because it contains the highest virus titers. Other organs contain the virus, but at a lower concentration and probably only because of the viremia. Tissues should be macerated in an antibiotic-treated broth or saline and centrifuged to remove the larger tissue particles. The supernatant fluid then is used to inoculate embryonating eggs or cell cultures.

Hitchner (115) demonstrated that the CAM of 9- to 11-day-old embryos was the most sensitive route for isolation of the virus. The virus subsequently could be adapted to the allantoic sac and yolk sac routes of inoculation. Death of infected embryos usually occurs in 3–5 days. Variant strains of IBD differ from standard viruses in that they induce splenomegaly and liver necrosis of embryos and produce little mortality (273). The embryonating egg may be the most sensitive substrate for isolation of IBDV. McFerran et al. (207) reported that 3 of 7 chicken isolates of IBDV failed to grow in chicken embryo fibroblast (CEF) cells; however, they could be propagated in embryonating eggs.

Isolation and propagation of IBDV in cell culture was discussed previously in this chapter (see Laboratory Host Systems). Because the virus has been shown to replicate in B lymphocytes, either primary cells derived from the cloacal bursa or continuous cell lines of B-cell origin would be the cells of choice for the isolation of the virus. It appears that some strains of virus are very fastidious, and although they may replicate in embryonating eggs or B lymphocytes, they cannot readily be adapted to CEF cells or cells from other organs such as the kidney and liver (168, 207). The use of immunofluorescence and electron microscopy of infected embryos and cell cultures has proven to be of tremendous value for the early detection and identification of IBDV. Cell cultures containing 50% bursal lymphocytes and 50% CEF have been used to successfully isolate and serotype IBDV (183). The fibroblasts serve as a matrix for the lymphocytes, and the infected lymphocytes are detected by immunofluorescence. Identification of the virus by direct immunofluorescent staining of affected organs or direct examination by electron

microscopy has proven to be an adjunct to the isolation and identification of IBDV (207). If antigen or virus is detected by these methods from field cases of disease, every effort should be made to isolate the virus using both embryonating eggs and cell culture techniques. The isolation, antigenic analysis, and pathogenicity studies of viruses from field cases of IBD are needed continually so that changes in the wild virus population can be detected.

Nucleic acid probes (132) and antigen-capture enzyme immunoassays using monoclonal antibodies (299) to detect and differentiate IBDV directly in tissues may prove beneficial for rapid diagnosis and typing of field viruses. One study (104) compared antigen-capture enzyme immunoassay with cell cultures and determined that cell culture was more sensitive than antigen-capture and, in turn, that antigen-capture with polyconal antibody was more sensitive than with monoclonal antibody. A rapid monoclonal-antibody-based antigen-capture test under a 1-step strip format has been recently proposed (373). In a study using several procedures for detection of the virus in bursa of experimentally infected chickens, the RT-PCR was the most sensitive test (1, 4). Recent developments of the RT-PCR technique include multiplex RT-PCR (164) or real-time RT-PCR (RRT-PCR)(212, 253) protocols aimed at detecting and differentiating the different strains of IBDV (classic, variant, and vvIBDV) directly from infected tissues. Provided an adequate dose effect curve is available, RRT-PCR also may be used to quantify the virus load in the studied sample (213, 253) and to study the transcription/replication equilibrium (differential quantification of positive and negative genome strands) (64).

Reverse transcription of the IBDV genome followed by its amplification by loop-mediated isothermal amplification (RT-LAMP) has been recently described as a possible alternative to RT-PCR for the molecular detection of IBDV, because RT-LAMP is less demanding in laboratory equipment than RT-PCR (362, 363).

Smears of infected tissues on filter paper cards that can be soaked into some IBDV-inactivating chemical to limit biological hazards during handling, shipment, or storage have been reported as practical and easily shipped samples that allow subsequent molecular characterization of IBDV strains (205, 258).

Differential Diagnosis

The sudden onset, morbidity, ruffled feathers, and droopy appearance of the birds in initial disease outbreaks are suggestive of an acute outbreak of coccidiosis. In some cases, there is blood in the droppings that would lead one to suspect coccidiosis. The muscular hemorrhages and enlarged edematous or hemorrhagic cloacal bursas would, however, suggest IBD.

Birds that die from IBD may show an acute nephrosis. Because of many other conditions that may cause nephrosis and the inconsistency of kidney lesions, such lesions should not be sufficient cause for a diagnosis of IBD. Again, involvement of the cloacal bursa usually will distinguish IBD from other nephrosis-causing conditions. Water deprivation will cause kidney changes and possibly gray, atrophied bursas that closely resemble those associated with IBD infection. However, unless this occurs as a flock condition, such changes would be seen in relatively few birds. A history of the flock is essential in aiding in the differential diagnosis of these cases.

Certain nephropathogenic strains of infectious bronchitis virus cause nephrosis (353). These cases can be differentiated from IBD by the fact that there are no changes in the cloacal bursa, and deaths usually are preceded by respiratory signs. The possibility that the 2 diseases may occur simultaneously in a flock should not be overlooked.

The muscular hemorrhages and mucosal hemorrhages seen at the juncture of the proventriculus and gizzard are similar to those reported for hemorrhagic syndrome and could be differentiated on the basis of bursal changes that accompany IBDV infections. It is not unlikely that before IBD was recognized some cases were diagnosed as hemorrhagic syndrome.

Jakowski et al. (147) reported bursal atrophy in experimentally induced infection with 4 isolates of Marek's disease. The atrophy was observed 12 days PI, but the histologic response was distinctly different from that found in IBD (Chapter 15).

Grimes and King (96) reported that experimental infections of 1-day-old SPF chickens with a type 8 avian adenovirus produced small bursas and atrophy of bursal follicles at 2 weeks PI. Several other organs such as the liver, spleen, pancreas, and kidneys were grossly affected, and intranuclear inclusion bodies were observed in the liver and pancreas.

Serology

The ELISA procedure is presently the most commonly used serological test for the evaluation of IBDV antibodies in poultry flocks. Marquardt et al. (203) first described an indirect ELISA for measuring antibodies, and since that time, several workers (26, 198, 298, 303, 316) have reported on the use of ELISA and its comparison to VN test results. The ELISA procedure has the advantage of being a rapid test with the results easily entered into computer software programs. With these programs, one can establish an antibody profile on breeder flocks that will indicate the flock immunity level and provide information for developing proper immunization programs for both breeder flocks and their progeny. To perform an antibody profile on a flock for the evaluation of the efficacy of vaccination programs, no less than 30 serum samples should be tested; many producers submit as many as 50–100 samples. The antibody profiles may be performed with serum collected either from the breeders or from 1-day-old progeny. If progeny serums are used, titers normally will be 60%–80% lower than those in the breeders. It should be recognized that the indirect ELISA does not differentiate between antibodies to serotypes 1 and 2 (128) and that commercial kits may detect antibodies to both serotypes (8). It should also be kept in mind that ELISA kits may vary in sensitivity and specificity (54), and that being a very sensitive technique, ELISA may present both intra-laboratory and inter-laboratory variation (163). Thus, the introduction in the panel of tested sera of a reference sentinel serum with a known reactivity is advisable.

New generations of ELISA based on recombinant antigens (expressed IBDV proteins, alone or in combinations) have been developed and some have a good sensitivity and specificity (287). Improved ELISA reagents may prove useful to monitor the serological response to vector or subunit vaccines (e.g., expressing only VP2 of IBDV) because the antibody response of the vaccinated birds will be more specific for this protein (170) than when replicating attenuated vaccines are used. Furthermore, the use of subunit ELISA antigens specific for some IBDV proteins that are not present in the vectored or recombinant vaccines (e.g., using a VP3 ELISA antigen) would allow the implementation of a differentiate infected from vaccinated animals (DIVA) strategy, in which birds vaccinated with the vectored or recombinant-subunit vaccines (e.g., without anti-VP3 antibodies) can be differentiated from infected animals (e.g., with anti-VP3 antibodies), according to the DIVA principle (221).

Prior to the use of the ELISA, the most common procedure for antibody detection was the constant virus-diluting serum VN test performed in a microtiter system (294). The VN test is the only serological test that will detect the different serotypes of IBDV and it is still the method of choice to discern antigenic variations between isolates of this virus. The indicator virus used for VN can make a significant difference in test results due to the fact that within a given serotype there are several antigenic subtypes (134). Significant discrepancies in the determination of virus-neutralizing titers in different laboratories are also not uncommon (210). Most chicken serums from the field have high levels of neutralizing antibody to a broad spectrum of antigenically diverse viruses owing to a combination of field exposure, vaccine exposure, and cross-reactivity from high levels of antibody.

The other method used for the detection of IBDV antibodies is the AGP test. In the United Kingdom, a quantitative AGP test is routinely used (48); however, as used in the United States, the test is not quantitative. This test does not detect serotypic differences; it primarily measures antibodies to group-specific soluble antigens.

Intervention Strategies

Contact with infected birds and contaminated fomites readily causes spread of the infection. The relative stability of this virus to many physical and chemical agents increases the likelihood that it will be carried over from 1 flock to a succeeding flock. The sanitary precautions that are applied to prevent the spread of most poultry infections must be rigorously used in the case of IBD. This certainly includes a control of personal and material movements. In their study of the epidemiological factors associated with the spread of vvIBDV in Denmark, Sanchez et al. demonstrated that the highest risk for farms was when another case of IBD occurred during a short period of time or within a short range, a finding that emphasizes the role of local factors in the spread of IBDV (278). The possible involvement of other vectors (e.g., the lesser mealworm, mosquitoes, dogs, and rats) already has been discussed; they could certainly pose extra problems for the control of this infection.

Management Procedures

At one time, before the development of attenuated vaccine strains, intentional exposure of chicks to infection at an early age was used for controlling IBD. This could be advised on farms that had a history of the disease, and the chicks normally would have maternal antibodies for protection. Also, young chicks less than 2 weeks of age did not normally exhibit clinical signs of IBD. When the severe immunosuppressive effect of early IBD infections was discovered, the practice of controlled exposure with virulent strains became less appealing. On many farms, the clean-up and disinfection between broods (including buildings and all materials and equipment) is not thorough, and due to the stable nature of the virus, it easily persists and provides an early exposure by natural means.

Immunization

Immunization is the principal method used for the control of IBD in chickens and IBD vaccines have been reviewed recently (221). Especially important is the immunization of breeder flocks to confer parental immunity to their progeny. Such maternal antibodies protect the chick from early immunosuppressive infections. Maternal antibody will normally protect chicks for 1–3 weeks, but by boosting the immunity in breeder flocks with oil-adjuvanted vaccines, passive immunity may be extended to 4 or 5 weeks (12, 182).

The major problem with active immunization of young maternally immune chicks with attenuated IBDV vaccines is determining the proper time of vaccination. Of course, this varies with levels of maternal antibody, route of vaccination, and virulence of the vaccine virus. Environmental stresses and management may be factors to consider when developing a vaccination program that will be effective. Monitoring antibody levels in a breeder flock or its progeny (flock profiling) can aid in determining the proper time to vaccinate. It should be mentioned that although they produce correlated antibody titers, the ELISA and VN tests may result in predicting different dates for vaccine susceptibility in progeny chicks (51). It is therefore advisable that the formula used for calculating the dates of vaccination be extensively evaluated.

Many choices of live vaccines are available based on virulence and antigenic diversity. According to virulence, vaccines that are available in the United States are classified as mild, mild intermediate, intermediate, intermediate plus, or hot. Vaccines that contain Delaware variants, either in combination with classic strains or alone, are also available. Highly virulent (hot), intermediate, and avirulent strains break through maternal VN antibody titers of 1:500, 1:250, and less than 1:100, respectively (182, 295). Intermediate strains vary in their virulence and can induce bursal atrophy and immunosuppression in 1-day-old and 3-week-old SPF chickens (186). If maternal VN antibody titers are less than 1:1,000, chicks may be vaccinated by injection with avirulent strains of virus. Some

vaccine virus replicates in the thymus, spleen, and cloacal bursa where it persists for 2 weeks (187, 292). After the maternal antibody is catabolized, there is a primary antibody response to the persisting vaccine virus. A vaccine made by mixing an intermediate plus vaccine strain with a measured amount of IBDV antibody before injection is used with reported success to immunize day-old chicks in the presence of maternal antibody (99).

Killed-virus vaccines in oil adjuvant are used to boost and prolong immunity in breeder flocks. It has been proposed that their antigenic content may be measured by quantifying in the AC-ELISA the amount of VP2 or VP3 contained in the vaccine (193). Killed-virus vaccines are usually not practical or desirable for inducing a primary response in young chickens; however, injection of a fraction of a dose in broiler or pullet chicks between 1 and 10 days of age has sometimes been reported (359, 361). Oil-adjuvant vaccines are most effective in chickens that have been "primed" with live virus either in the form of vaccine (360) or field exposure to the virus. Oil-adjuvant vaccines presently may contain both standard and variant strains of IBDV. Antibody profiling of breeder flocks is advised to assess effectiveness of vaccination and persistence of antibody.

A more recent concept for the vaccination of chickens for IBD and other agents is *in ovo* vaccination at 18 days of incubation (80, 349). *In ovo* is a labor-saving technique and may provide a way for vaccines to circumvent the effects of maternal antibody and initiate a primary immune response. The injected material is a live IBD vaccine, either alone (80) or in combination with an anti-IBDV antibody to form immune complexes (349). The working mechanism of *in ovo* vaccination is not yet fully elucidated: *In ovo* injection of an intermediate IBD vaccine alone experimentally resulted in a faster recovery of bursal lesions, as compared with post-hatch vaccination, and in similar protection against challenge (263). Jeurissen proposed the working mechanism of the immune complex vaccine to be related to its specific cellular interactions with follicular dendritic cells in spleen and bursa (149). *In ovo* and post-hatch vaccinations have been reviewed by Negash et al. (232).

Advances in biotechnologies also allowed the development of new generations of vaccines, most of which are still experimental.

Production of IBD subunit vaccines has been attempted mainly from baculovirus- (204, 302, 328, 329, 367) or yeast- (195, 256) expressed proteins, with a report of expression using a Semliki forest virus vector (254). Several studies reported that baculovirus-expressed recombinant VP2 conferred good to very good protection against IBDV challenge (204, 255, 328). The efficacy of baculovirus-expressed recombinant vaccines was shown to critically depend on the conformation and assembly of the expressed proteins (204); this process is now better understood (35, 36). A baculovirus-expressed VP2 protein has been used commercially in broiler breeders, and immunity was transferred to their progeny (367). More recently, Pitcovski et al. (256) described an oil-adjuvanted vaccine based on a purified recombinant VP2 antigen expressed in the *Pichia pastoris* yeast. This vaccine induced a protection level similar to conventional inactivated IBD vaccine and has been used in broilers in the field in Israel (256).

DNA vaccination is another approach, still experimental, based on plasmids expressing either the polyprotein gene (78, 32) or the VP2 gene alone (161, 340). Significant levels of protection were observed, provided high amounts of plasmid DNA were repeatedly injected. Attempts have been made to increase the efficacy of IBD DNA vaccines by co-administrating interleukin genes (123, 308) or synthetic oligodeoxynucleotides containing unmethylated CpG dinucleotide motifs (340) with an adjuvant effect or by changing the route of administration of the DNA vaccine (105).

Finally, live recombinant virus vectors expressing IBDV immunogens have been reported. These include fowlpox virus (13, 29, 108), herpes virus of turkey (HVT) (50, 323), Marek's disease virus (322), chick embryo lethal orphan (CELO) virus (79), and Newcastle disease virus (120). Additional recombinant vaccine viruses include IBDV vaccines that have been modified to broaden their antigenic spectrum (225) or to allow the differentiation of vaccine-induced antibodies (21). The currently commercially available recombinant vaccines are derived from HVT and induce an active anti-IBDV antibody response facing high levels of neutralizing maternally derived antibodies (93, 170).

A universal vaccination program cannot be offered because of the variability in maternal immunity, management, and operational conditions that exists. If high levels of maternal antibody are achieved and the field challenge is reduced, then vaccination of broilers may not be needed. Vaccination timing with attenuated and intermediate vaccines varies from as early as 7 days–2 or 3 weeks. If broilers are vaccinated at 1 day of age, the IBDV vaccine can be given by injection along with Marek's disease vaccine. Priming of breeder replacement chickens may be necessary, and many producers vaccinate with a live vaccine at 10–14 weeks of age. Killed oil-adjuvant vaccines commonly are administered at 16–18 weeks. Revaccination of breeders may be required if antibody profiling indicates a major drop in flock titers.

The use of restriction fragment length polymorphisms of the VP2 gene of IBDV can be a powerful tool from an epidemiologic point of view. The original work by Jackwood and Sommer (140) described 5 molecular groups from 13 vaccine viruses and 5 IBDV isolates from the United States. When the same workers (141) examined 81 strains from around the world, they identified 16 more molecular groups. This certainly should indicate that this technique will identify strains of virus but does not indicate antigenic differences in the virus and, therefore, would not be helpful in predicting the immunogenicity of a vaccine.

To conclude, a number of experimental vaccinal approaches have been suggested from experimental work but have not yet reached the stage where they are used in the field. These include (1) the adaptation of attenuated IBDV to macrophages to modify the early steps of the immune response (154), (2) the engineering of a viral vector to directly induce in the

vaccinated bird the expression of the Fc fragment of anti-IBDV antibodies (95), or (3) the immunization of the birds not with IBDV itself, but with a combination of synthetic peptides that mimic the epitopes recognized by anti-IBDV neutralizing monoclonal antibodies. These synthetic antigens, called mimotopes, can be expressed as a synthetic protein (341) or inserted into a carrier protein that may form virus-like particles (345). Among the most promising approaches is the genetic manipulation of IBDV genome itself using reverse genetics (227, 259) to introduce into the genome of an IBDV strain some interesting characteristics such as attenuating mutations or a VP2 gene more related to the prevalent field strains (84, 225) or mutations that both attenuate and allow to propagate the studied IBDV strain in cell culture (336, 260). This genetic engineering of IBDV could certainly enable a quick and accurate tailoring of new live attenuated—but genetically-modified—vaccines in the future. The resulting vaccines will nevertheless be submitted to the same limitations as current nongenetically modified live vaccines: need for safety and stability, and competition with maternally derived antibodies (221).

Beyond the scope of this review are some attempts to use IBDV as a carrier or as a vector by using molecular techniques to insert foreign epitopes into IBDV proteins. This has been achieved either in VP2 expressed alone, with FMDV epitopes exhibited on the surface of modified virus-like particles of IBDV (nonreplicative strategy) (266), or by inserting the nucleotidic sequence encoding foreign epitopes from hepatitis C virus in the genes encoding VP2 or VP5 in a genetically modified replicative IBDV strain (325). Special care is certainly needed with the latter approach to ensure that the binding properties of the modified VP2, and the host range of the resulting IBDV recombinant, are not modified.

Treatment

No therapeutic or supportive treatment has been found to change the course of IBDV infection (44, 247). Because of the rapid recovery of the affected flock, treatments might appear highly effective if nontreated controls were not maintained for comparison.

There are no reports in the literature concerning the use of some of the newer antiviral compounds and interferon inducers for the treatment of IBD. Experimental immunotherapy has been mentioned above (197). Ketotifen was reported experimentally to prevent the development of bursal damage and reduce signs and mortality induced by vvIBDV challenge when administered 1 hour before IBDV inoculation (342). Inhibition of IBDV in cell culture by vector-expressed miRNA (343) or DNA-expressed siRNA (83) targeting mostly the VP1 gene has been described, but this strategy has not been explored yet for *in vivo* treatment.

References

1. Abdel-Alim, G.A., and Y.M. Saif. 2001. Detection and persistence of infectious bursal disease virus in specific pathogen-free and commercial broiler chickens. *Avian Dis*. 45:646–654.
2. Abdel-Alim, G.A., and Y.M. Saif. 2001. Immunogenicity and antigenicity of very virulent strains of infectious bursal disease viruses. *Avian Dis*. 45:92–101.
3. Abdel-Alim, G.A., and Y.M. Saif. 2001. Pathogenicity of cell culture-derived and bursa-derived infectious bursal disease virus in specific-pathogen-free chickens. *Avian Dis*. 45:844–852.
4. Abdel-Alim, G.A., and Y.M. Saif. 2002. Pathogenicity of embryo-adapted serotype 2 strain of infectious bursal disease virus in chickens and turkeys. Personal communication.
5. Alexander, D.J., and N.J. Chettle. 1998. Heat inactivation of serotype 1 infectious bursal disease virus. *Avian Pathol*. 27:97–99.
6. Allan, W.H., J.T. Faragher, and G.A. Cullen. 1972. Immunosuppression by the infectious bursal agent in chickens immunized against Newcastle disease. *Vet Rec*. 90:511–512.
7. Anderson, W.I., W.M. Reid, P.D. Lukert, and O.J. Fletcher. 1977. Influence of infectious bursal disease on the development of immunity to *Eimeria tenella*. *Avian Dis*. 21:637–641.
8. Ashraf, S., G. Abdel-Alim, and Y.M. Saif. 2006. Detection of antibodies against serotypes 1 and 2 infectious bursal disease virus by commercial ELISA kits. *Avian Dis*. 50:104–109.
9. Azad, A.A., S.A. Barrett, and K.J. Fahey. 1985. The characterization and molecular cloning of the double-stranded RNA genome of an Australian strain of infectious bursal disease virus. *Virol*. 143:35–44.
10. Azad, A.A., M.N. Jagadish, M.A. Brown, and P.J. Hudson. 1987. Deletion mapping and expression in *Escherichia coli* of the large genomic segment of a birnavirus. *Virol*. 161:145–152.
11. Barnes, H.J., J. Wheeler, and D. Reed. 1982. Serological evidence of infectious bursal disease virus infection in Iowa turkeys. *Avian Dis*. 26:560–565.
12. Baxendale, W., and D. Lutticken. 1981. The results of field trials with an inactivated Gumboro vaccine. *Dev Biol Stand*. 51:211–219.
13. Bayliss, C.D., R.W. Peters, J.K.A. Cook, R.L. Reece, K. Howes, M.M. Binns, and M.E.G. Boursnell. 1991. A recombinant fowlpox virus that expresses the VP2 antigen of infectious bursal disease virus induces protection against mortality caused by the virus. *Arch Virol*. 120:193–205.
14. Bayliss, C.D., U. Spies, K. Shaw, R.W. Peters, A. Papageorgiou, H. Muller, and M. Boussnell. 1990. A comparison of the sequences of segment A of four infectious bursal disease virus strains and identification of a variable region in VP2. *J Gen Virol*. 71:1303–1312.
15. Becht, H. 1980. Infectious bursal disease virus. *Curr Top Microbiol Immunol*. 90:107–121.
16. Becht, H., H. Müller, and H.K. Müller. 1988. Comparative studies on structural and antigenic properties of two serotypes of infectious bursal disease virus. *J Gen Virol*. 69:631–640.
17. Benton, W.J., M.S. Cover, and J.K. Rosenberger. 1967. Studies on the transmission of the infectious bursal agent (IBA) of chickens. *Avian Dis*. 11:430–438.
18. Benton, W.J., M. S. Cover, J.K. Rosenberger, and R.S. Lake. 1967. Physicochemical properties of the infectious bursal agent (IBA). *Avian Dis*. 11:438–445.

19. Boot, H.J., and S.B. Pritz-Verschuren. 2004. Modifications of the 3′UTR stem-loop of infectious bursal disease virus are allowed without influencing replication or virulence. *Nucl Ac Res*. 32:211–222.
20. Boot, H.J., A.A. ter Hurne, A.J. Hoekman, B.P. Peeters, and A.L. Gielkens. 2000. Rescue of very virulent and mosaic infectious bursal disease virus from cloned cDNA: VP2 is not the sole determinant of the very virulent phenotype. *J Virol*. 74:6701–6711.
21. Boot, H.J., A.A. ter Hurne, A.J. Hoekman, J.M. Pol, A.L. Gielkens, and B.P. Peeters. 2002. Exchange of the C-terminal part of VP3 from very virulent infectious bursal disease virus results in an attenuated virus with a unique antigenic structure. *J Virol*. 76:10346–55.
22. Boot, H.J., A.J. Hoekman, and A.L. Gielkens. 2005. The enhanced virulence of very virulent infectious bursal disease virus is partly determined by its B-segment. *Arch Virol*. 150:137–144.
23. Box, P. 1989. High maternal antibodies help chicks beat virulent viruses. *World Poultry*. 53:17–19.
24. Birghan, C., E. Mundt, A.E. Gorbalenya. 2000. A non-canonical Lon proteinase lacking the ATPase domain employs the Ser-Lys catalytic dyad to exercise broad control over the life cycle of a double-stranded RNA virus. *EMBO J*. 19:114–123.
25. Brandt, M., K. Yao, M. Liu, R.A. Heckert, and V.N. Vakharia. 2001. Molecular determinants of virulence, cell tropism, and pathogenic phenotype of infectious bursal disease virus. *J Virol*. 75:11974-82.
26. Briggs, D.J., C.E. Whitfill, J.K. Skeeles, J.D. Story, and K.D. Reed. 1986. Application of the positive/negative ratio method of analysis to quantitate antibody responses to infectious bursal disease virus using a commercially available ELISA. *Avian Dis*. 30:216–218.
27. Brown, F. 1986. The classification and nomenclature of viruses: Summary of results of meetings of the International Committee on Taxonomy of Viruses in Sendai. *Intervirol*. 25:141–143.
28. Brown, M.D., and M.A. Skinner. 1996. Coding sequences of both genome segments of a European "very virulent" infectious bursal disease virus. *Virus Res*. 40:1–15.
29. Butter, C.D., T.D. Sturman, B.J. Baaten, and T.F. Davison. 2003. Protection from infectious bursal disease virus (IBDV)-induced immunosuppression by immunization with a fowl-pox recombinant containing IBDV-VP2. *Avian Pathol*. 32:597–604.
30. Bygrave, A.C., and J.T. Faragher. 1970. Mortality associated and Gumboro disease. *Vet Rec*. 86:758–759.
31. Campbell, G. 2001. Investigation into evidence of exposure to infectious bursal disease virus and infectious anaemia virus in wild birds in Ireland. *Proceedings II International Symposium on Infectious Bursal Disease and Chicken Infectious Anaemia*. Rauischholzhausen, Germany. 230–235.
32. Chang, H.C., T.L. Lin, and C.C. Wu. 2001. DNA-mediated vaccination against infectious bursal disease in chickens. *Vaccine*. 20:328–35.
33. Chettle, N., J.C. Stuart, and P.J. Wyeth. 1989. Outbreak of virulent infectious bursal disease in East Anglia. *Vet Rec*. 125:271–272.
34. Chevalier, C., M. Galloux, J. Pous, C. Henry, J. Denis, B. Da Costa, J. Navaza, J. Lepault, B. Delmas. 2005. Structural peptides of a nonenveloped virus are involved in assembly and membrane translocation. *J Virol*. 79:12253–12263.
35. Chevalier, C., J. Lepault, B. Da Costa, and B. Delmas. 2004. The last terminal residue of VP3, glutamic acid 257, controls capsid assembly of infectious bursal disease virus. *J Virol*. 78:3296–3303.
36. Chevalier, C., J. Lepault, I. Erk, B. Da Costa, and B. Delmas. 2002. The maturation process of pVP2 requires assembly of infectious bursal disease virus capsids. *J Virol*. 76:2384–2392.
37. Cheville, N.F. 1967. Studies on the pathogenesis of Gumboro disease in the bursa of Fabricius, spleen and thymus of the chicken. *Am J Pathol*. 51:527–551.
38. Chin, R.P., R. Yamamoto, W. Lin, K.M. Lam, and T.B. Farver. 1984. Serological survey of infectious bursal disease virus: Serotypes 1 and 2 in California turkeys. *Avian Dis*. 28:1026–1036.
39. Cho, B.R. 1970. Experimental dual infections of chickens with infectious bursal and Marek's disease agents. I. Preliminary observation on the effect of infectious bursal agent on Marek's disease. *Avian Dis*. 14:665–675.
40. Cho, Y., and S.A. Edgar. 1969. Characterization of the infectious bursal agent. *Poult Sci*. 48:2102–2109.
41. Chui, C.H., and J.J. Thorsen. 1984. Experimental infection of turkeys with infectious bursal disease virus and the effect on the immunocompetence of infected turkeys. *Avian Dis*. 28:197–207.
42. Cobb, S.P. 2011. The spread of pathogens through trade in poultry meat: overview and recent developments. *OIE Rev Sci Tech*. 30(1):149–64.
43. Confer, A.W., W.T. Springer, S.M. Shane, and J.F. Conovan. 1981. Sequential mitogen stimulation of peripheral blood lymphocytes from chickens inoculated with infectious bursal disease virus. *Am J Vet Res*. 42:2109–2113.
44. Cosgrove, A.S. 1962. An apparently new disease of chickens—avian nephrosis. *Avian Dis*. 6:385–389.
45. Coulibaly, F., C. Chevalier, I. Gutsche, J. Pous, J. Navaza, S. Bressanelli, B. Delmas, and F. Rey. 2005. The birnavirus crystal structure reveals structural relationship among icosahedral viruses. *Cell*. 120:761–772.
46. Cowen, B.S., and M.O. Braune. 1988. The propagation of avian viruses in a continuous cell line (QT35) of Japanese quail origin. *Avian Dis*. 32:282–297.
47. Craft, D.W., J. Brown, and P.D. Lukert. 1990. Effects of standard and variant strains of infectious bursal disease virus on infections of chickens. *Am J Vet Res*. 51:1192–1197.
48. Cullen, G.A., and P.J. Wyeth. 1975. Quantitation of antibodies to infectious bursal disease. *Vet Rec*. 97:315.
49. Da Costa B., C. Chevalier, C. Henry, J.C. Huet, S. Petit, J. Lepault, H. Boot, and B. Delmas. 2002. The capsid of infectious bursal disease virus contains several peptides arising from the maturation process of pVP2. *J Virol*. 76:2393–2402.
50. Darteil, R., M. Bublot, E. Laplace, J.F. Bouquet, J.C. Audonnet, and M. Riviere. 1995. Herpesvirus of turkey recombinant viruses expressing infectious bursal disease virus (IBDV) VP2 immunogen induce protection against an IBDV virulent challenge in chickens. *Virol*. 211:481–490.
51. De Herdt, P., E. Jagt, G. Paul, S. Van Volen, R. Renard, C. Destrooper, and G. van den Bosch. 2005. Evaluation of the enzyme linked immunosorbent assay for the detection of antibodies against infectious bursal disease virus (IBDV) and the estimation of the optimal age for IBDV vaccination in broilers. *Avian Pathol*. 34:501–504.
52. Delgui, L., A. Oña, S. Gutiérrez, D. Luque, A. Navarro, J.R. Castón, and J.F. Rodríguez. 2009. The capsid protein of infectious bursal disease virus contains a functional alpha 4 beta 1 integrin ligand motif. *Virol*. 386:360–72.
53. Delgui, L., D. González, J.F. and Rodríguez. 2009. Infectious bursal disease virus persistently infects bursal B-lymphoid DT40 cells. *J Gen Virol*. 90:1148–52.

54. De Wit, J.J., J.F. Heijmans, D.R. Mekkes, and A.A.W.M. van Loon. 2001. Validation of five commercially available ELISAs for the detection of antibodies against infectious bursal disease virus (serotype 1). *Avian Pathol*. 30:543–549.
55. Delmas, B., F.S.B. Kibenge, J.C. Leong, E. Mundt, V.N. Vakharia, and J.L. Wu. 2004. Birnaviridae. In: *Virus Taxonomy: Eighth Report of the International Committee on Taxonomy of Viruses*. C.M. Fauquet, M.A. Mayo, J. Maniloff, U. Desselberger, and L.A. Ball, eds. Academic Press, London. 561–569.
56. DiFabio J., L. Rossini, N. Eterradossi, D. Toquin, and Y. Gardin. 1999. European-like pathogenic infectious bursal disease virus in Brazil. *Vet Rec*. 145:203–204.
57. Dobos, P. 1979. Peptide map comparison of the proteins of infectious bursal disease virus. *J Virol*. 32:1046–1050.
58. Dobos, P. 1995. Protein-primed synthesis *in vitro* by the virion associated RNA polymerase of infectious pancreatic necrosis virus. *Virol*. 208:19–25.
59. Dobos, P., B.J. Hill, R. Hallett, D.T. Kells, H. Becht, and D. Teninges. 1979. Biophysical and biochemical characterization of five animal viruses with bisegmented double-stranded RNA genomes. *J Virol*. 32:593–605.
60. Dohms, J.E., and J.S. Jaeger. 1988. The effect of infectious bursal disease virus infection on local and systemic antibody responses following infection of 3-week-old broiler chickens. *Avian Dis*. 32:632–640.
61. Dohms, J.E., K.P. Lee, and J.K. Rosenberger. 1981. Plasma cell changes in the gland of Harder following infectious bursal disease virus infection of the chicken. *Avian Dis*. 25:683–695.
62. Dohms, J.E., K.P. Lee, J.K. Rosenberger, and A.L. Metz. 1988. Plasma cell quantitation in the gland of Harder during infectious bursal disease virus infection of 3-week-old broiler chickens. *Avian Dis*. 32:624–631.
63. Domanska, K., T. Mato, G. Rivallan, K. Smietanka, Z. Minta, C. de Boisseson, D. Toquin, B. Lomniczi, V. Palya, and N. Eterradossi. 2004. Antigenic and genetic diversity of early European isolates of infectious bursal disease virus prior to the emergence of the very virulent viruses: early European epidemiology of infectious bursal disease virus revisited? *Arch Virol*. 149:465-80.
64. Escaffre, O., M. Queguiner, and N. Eterradossi. 2010. Development and validation of four real-time quantitative RT-PCRs specific for the positive or negative strands of a bisegmented dsRNA viral genome. *J Virol Methods*. 170:1–8.
65. Eterradossi, N., J.P. Picault, P. Drouin, M. Guittet, R. L'Hospitalier, and G. Bennejean. 1992. Pathogenicity and preliminary antigenic characterization of six infectious bursal disease virus strains isolated in France from acute outbreaks. *Zentralbl Veterinaermed Reihe B*. 39 9:683–691.
66. Eterradossi, N., D. Toquin, H. Abbassi, G. Rivallan, J.P. Cotte, and M. Guittet. 1997. Passive protection of specific pathogen free chicks against infectious bursal disease by *in-ovo* injection of semi-purified egg-yolk antiviral immunoglobulins. *Zentralbl Veterinarmed B*. 44:371–83.
67. Eterradossi, N., D. Toquin, G. Rivallan, and M. Guittet. 1997. Modified activity of a VP2-located neutralizing epitope on various vaccine pathogenic and hypervirulent strains of infectious bursal disease virus. *Arch Virol*. 142:255–270.
68. Eterradossi, N., C. Arnauld, D. Toquin, and G. Rivallan. 1998. Critical amino acid changes in VP2 variable domain are associated with typical and atypical antigenicity in very virulent infectious bursal disease viruses. *Arch Virol*. 143:1627–1636.
69. Eterradossi, N., C. Gauthier, I. Reda, S. Comte, G. Rivallan, D. Toquin, C. de Boisseson, J. Lamande, V. Jestin, Y. Morin, C. Cazaban, and P.M. Borne. 2004. Extensive antigenic changes in an atypical isolate of very virulent infectious bursal disease virus and experimental clinical control of this virus with an antigenically classical live vaccine. *Avian Pathol*. 33:423–431.
70. Fadly, A.M., R.W. Winterfield, and H.J. Olander. 1976. Role of the bursa of Fabricius in the pathogenicity of inclusion body hepatitis and infectious bursal disease virus. *Avian Dis*. 20:467–477.
71. Fahey, K.J., I.J. O'Donnell, and A.A. Azad. 1985. Characterization by western blotting of the immunogens of infectious bursal disease virus. *J Gen Virol*. 66:1479–1488.
72. Fahey, K.J., I.J. O'Donnell, and T.J. Bagust. 1985. Antibody to the 32 K structural protein of infectious bursal disease virus neutralizes viral infectivity *in vitro* and confers protection on young chickens. *J Gen Virol*. 66:2693–2702.
73. Fahey, K.J., K.M. Erny, and J. Crooks. 1989. A conformational immunogen on VP2 of infectious bursal disease virus that passively protects chickens. *J Gen Virol*. 70:1473–1481.
74. Fahey, K.J., P. McWaters, M.A. Brown, K. Erny, V.J. Murphy, and D.R. Hewish. 1991. Virus neutralizing and passively protective monoclonal antibodies to infectious bursal disease of chickens. *Avian Dis*. 35:365–373.
75. Faragher, J.T., W.H. Allan, and C.J. Wyeth. 1974. Immunosuppressive effect of infectious bursal agent on vaccination against Newcastle disease. *Vet Rec*. 95:385–388.
76. Feldman, A.R., J. Lee, B. Delmas, and M. Paetzel. 2006. Crystal structure of a novel viral protease with a serin/lysin catalytic dyad mechanism. *J Mol Biol*. 358:1378–1389.
77. Fernandez-Arias, A., S. Martinez, and J.F. Rodriguez. 1997. The major antigenic protein of infectious bursal disease virus, VP2, is an apoptotic inducer. *J Virol*. 71:8014–8018.
78. Fodor, I., E. Horvath, N. Fodor, E. Nagy, A. Rencendorsh, V.N. Vakharia, and S.K. Dube. 1999. Induction of protective immunity in chickens immunised with plasmid DNA encoding infectious bursal disease virus antigens. *Acta Vet Hung*. 47:481–92.
79. Francois, A., C. Chevalier, B. Delmas, N. Eterradossi, D. Toquin, G. Rivallan, and P. Langlois. 2004. Avian adenovirus CELO recombinants expressing VP2 of infectious bursal disease virus induce protection against bursal disease in chickens. *Vaccine*. 22:2351–2360.
80. Gagic, M., C. St. Hill, and J.M. Sharma. 1999. *In ovo* vaccination of specific-pathogen-free chickens with vaccines containing multiple antigens. *Avian Dis*. 43:293–301.
81. Galloux, M., S. Libersou, N. Morellet, S. Bouaziz, B. Da Costa, M. Ouldali, J. Lepault, and B. Delmas. 2007. Infectious bursal disease virus, a non-enveloped virus, possesses a capsid-associated peptide that deforms and perforates biological membranes. *J Biol Chem*. 282:20774–84.
82. Galloux, M., S. Libersou, I.D. Alves, R. Marquant, G.F. Salgado, H. Rezaei, J. Lepault, B. Delmas, S. Bouaziz, and N. Morellet. 2010. NMR structure of a viral peptide inserted in artificial membranes: a view on the early steps of the birnavirus entry process. *J Biol Chem*. 285:19409–21.
83. Gao, Y., W. Liu, H. Gao, X. Qi, H. Lin, X. Wang, and R. Shen. 2008. Effective inhibition of infectious bursal disease virus replication *in vitro* by DNA vector-based RNA interference. *Antiviral Res*. 79:87-94.317.
84. Gao, L., X. Qi, K. Li, H. Gao, Y. Gao, L. Qin, Y. Wang, and X. Wang. 2011. Development of a tailored vaccine against challenge with very virulent infectious bursal disease virus of chickens using reverse genetics. *Vaccine*. 29:5550–7.

85. Gardner, H., K. Kerry, M. Riddle, S. Brouwer, and L. Gleeson. 1997. Poultry virus infection in Antartic penguins. *Nature*. 387:245.
86. Garriga, D., J. Querol-Audí, F. Abaitua, I. Saugar, J. Pous, N. Verdaguer, J.R. Castón, and J.F. Rodriguez. 2006. The 2.6-Angstrom structure of infectious bursal disease virus-derived T = 1 particles reveals new stabilizing elements of the virus capsid. *J Virol*. 80:6895–905.
87. Garriga D., A. Navarro, J. Querol-Audí, F. Abaitua, J.F. Rodríguez, and N. Verdaguer. 2007. Activation mechanism of a noncanonical RNA-dependent RNA polymerase. *Proc Natl Acad Sci USA*. 104:20540–5.
88. Gay, L., and E. Mundt. 2010. Testing of a new disinfectant process for poultry viruses. *Avian Dis*. 54(1 Suppl):763–7.
89. Giambrone, J.J., J.P. Donahoe, D.L. Dawe, and C.S. Eidson. 1977. Specific suppression of the bursa-dependent immune system of chicks with infectious bursal disease virus. *Am J Vet Res*. 38:581–583.
90. Giambrone, J.J., O.J. Fletcher, P.D. Lukert, R.K. Page, and C.E. Eidson. 1978. Experimental infection of turkeys with infectious bursal disease virus. *Avian Dis*. 22:451–458.
91. Gorbalenya, A.E., F.M. Pringle, J.L. Zeddam, B.T. Luke, C.E. Cameron, J. Kalmakoff, T.N. Hanzlik, K.H.J. Gordon, and V.K. Ward. 2002. The palm subdomain-based active site is internally permuted in viral RNA-dependent RNA polymerases of an ancient lineage. *J Mol Biol*. 324:47–62.
92. Gough, R.E., S.E.N. Drury, D.D.B. Welchman, J.R. Chitty, and G.E.S. Summerhays. 2002. Isolation of birnavirus and reovirus-like agents from penguins in the United Kingdom. *Vet Rec*. 151:422–424.
93. Goutebroze, S., M. Curet, M.L. Jay, C. Roux, and F.X. Le Gros. 2003. Efficacy of a recombinant vaccine HVT-VP2 against Gumboro disease in the presence of maternal antibodies. *Br Poult Sci*. 44:824–825.
94. Granzow H., C. Birghan, T. Mettenleiter, J. Beyer, B. Kollner, and E. Mundt. 1997. A second form of infectious bursal disease virus-associated tubule contains VP4. *J Virol*. 71:8879–8885.
95. Greenall, S.A., S.G. Tyack, M.A. Johnson, and S.I. Sapats. 2010. Antibody fragments, expressed by a fowl adenovirus vector, are able to neutralize infectious bursal disease virus. *Avian Pathol*. 39:339–48.
96. Grimes, T.M., and D.J. King. 1977. Effect of maternal antibody on experimental infections of chickens with a type-8 avian adenovirus. *Avian Dis*. 21:97–112.
97. Guan, J., M. Chan, B.W. Brooks, and J.L. Spencer. 2010. Infectious bursal disease virus as a surrogate for studies on survival of various poultry viruses in compost. *Avian Dis*. 54:919–22.
98. Guy J.S., M.A. West, and F.J. Fuller. 2011. Physical and genomic characteristics identify chicken proventricular necrosis virus (R11/3 virus) as a novel birnavirus. *Avian Dis*. 55:2–7.
99. Haddad, E., C. Whitfill, A. Avakian, C. Ricks, P. Andrews, J. Thomas, and P. Wakenell. 1997. Efficacy of a novel infectious bursal disease virus immune complex vaccine in broiler chickens. *Avian Dis*. 41:882–889.
100. Harkness, J.W., D.J. Alexander, M. Pattison, and A.C. Scott. 1975. Infectious bursal disease agent: Morphology by negative stain electron microscopy. *Arch Virol*. 48:63–73.
101. Hassan, M.K., M. Afify, and M.M. Aly. 2002. Susceptibility of vaccinated and unvaccinated Egyptian chickens to very virulent infectious bursal disease virus. *Avian Pathol*. 31: 149–156.
102. Hassan, M.K., and Y.M. Saif. 1996. Influence of the host system on the pathogenicity, immunogenicity, and antigenicity of infectious bursal disease viruses. *Avian Dis*. 40:553–561.
103. Hassan, M.K., M.Q. Al-Natour, L.A. Ward, and Y.M. Saif. 1996. Pathogenicity, attenuation, and immunogenicity of infectious bursal disease virus. *Avian Dis*. 40:567–571.
104. Hassan, M.K., Y.M. Saif, and S. Shawky. 1996. Comparison between antigen-capture ELISA and conventional methods used for titration of infectious bursal disease virus. *Avian Dis*. 40:562–566.
105. Haygreen, E.A., P. Kaiser, S.C. Burgess, and T.F. Davison. 2006. *In ovo* DNA immunisation followed by a recombinant fowlpox boost is fully protective to challenge with virulent IBDV. *Vaccine*. 24:4951–4961.
106. He, C.Q., L.Y. Ma, D. Wang, G.R. Li, and N.Z. Ding. 2009. Homologous recombination is apparent in infectious bursal disease virus. *Virol*. 384:51-58.
107. Heine, H.G., M. Haritou, P. Failla, K.J. Fahey, and A.A. Azad. 1991. Sequence analysis and expression of the host-protective immunogen VP2 of a variant strain of infectious bursal disease virus which can circumvent vaccination with standard serotype 1 strains. *J Gen Virol*. 72:1835–1843.
108. Heine, H.G., and D.B. Boyle. 1993. Infectious bursal disease virus structural protein VP2 expressed by a fowlpox virus recombinant confers protection against disease in chickens. *Arch Virol*. 131:277–292.
109. Helmboldt, C.F., and E. Garner. 1964. Experimentally induced Gumboro disease (IBA). *Avian Dis*. 8:561–575.
110. Hihara, H., H. Yamamoto, K. Arqi, W. Okazaki, and T. Shimizu. 1980. Conditions for successful cultivation of tumor cells from chickens with lymphoid leucosis. *Avian Dis*. 24:971–979.
111. Hirai, K., and B.W. Calnek. 1979. *In vitro* replication of infectious bursal disease virus in established lymphoid cell lines and chicken B lymphocytes. *Infect Immun*. 25:964–970.
112. Hirai, K., and S. Shimakura. 1974. Structure of infectious bursal disease virus. *J Virol*. 14:957–964.
113. Hirai, K., S. Shimakura, E. Kawamoto, F. Taguchi, S.T. Kim, C.N. Chang, and Y. Iritani. 1974. The immunodepressive effect of infectious bursal disease virus in chickens. *Avian Dis*. 18:50–57.
114. Hirai, K., K. Kunihiro, and S. Shimakura. 1979. Characterization of immunosuppression in chickens by infectious bursal disease virus. *Avian Dis*. 23:950–965.
115. Hitchner, S.B. 1970. Infectivity of infectious bursal disease virus for embryonating eggs. *Poult Sci*. 49:511–516.
116. Hitchner, S.B. 1976. Immunization of adult hensagainstinfectious bursal disease virus. *Avian Dis*. 20:611–613.
117. Hon C.C., T.Y. Lam, A. Drummond, A. Rambaut, Y.F. Lee, C.W. Yip, F. Zeng, P.Y. Lam, P.T. Ng, and F.C. Leung. 2006. Phylogenetic analysis reveals a correlation between the expansion of very virulent infectious bursal disease virus and reassortment of its genome segment B. *J Virol*. 80:8503–8509.
118. Hon, C.C., T.T. Lam, C.W. Yip, R.T. Wong, M. Shi, J. Jiang, F. Zeng, and F.C. Leung. 2008. Phylogenetic evidence for homologous recombination within the family Birnaviridae. *J Gen Virol*. 89:3156–64.
119. Howie, R.I., and J. Thorsen. 1981. Identification of a strain of infectious bursal disease virus isolated from mosquitoes. *Can J Comp Med*. 45:315–320.
120. Huang, Z., S. Elankumaran, A.S. Yunus, and S.K. Samal. 2004. A recombinant Newcastle disease virus (NDV) expressing VP2

protein of infectious bursal disease virus (IBDV) protects against NDV and IBDV. *J Virol*. 78:10054–10063.
121. Hudson, L., H. Pattison, and N. Thantrey. 1975. Specific B lymphocyte suppression by infectious bursal agent (Gumboro disease virus) in chickens. *Eur J Immunol*. 5:675–679.
122. Hudson, P.J., N.M. McKern, B.E. Power, and A.A. Azad. 1986. Genomic structure of the large RNA segment of infectious bursal disease virus. *Nucleic Acids Res*. 14:5001–5012.
123. Hulse, D.J., and C.H. Romero. 2004. Partial protection against infectious bursal disease virus through DNA-mediated vaccination with the VP2 capsid protein and chicken IL-2 genes. *Vaccine*. 22:1249–1259.
124. Irigoyen N., D. Garriga, A. Navarro, N. Verdaguer, J.F. Rodríguez, and J.R. Castón. 2009. Autoproteolytic activity derived from the infectious bursal disease virus capsid protein. *J Biol Chem*. 284:8064–72.
125. Islam, M.R., K. Zierenberg, and H. Müller. 2001. The genome segment B encoding the rNA-dependent RNA polymerase protein VP1 of very virulent infectious bursal disease virus (IBDV) is phylogenetically distinct from that of all other IBDV strains. *Arch Virol*. 146:2481–2492.
126. Ismail, N., and Y.M. Saif. 1990. Differentiation between antibodies to serotypes 1 and 2 infectious bursal disease viruses in chicken sera. *Avian Dis*. 34:1002–1004.
127. Ismail, N., and Y.M. Saif. 1991. Immunogenicity of infectious bursal disease viruses in chickens. *Avian Dis*. 35:460–469.
128. Ismail, N., Y.M. Saif, and P.D. Moorhead. 1988. Lack of pathogenicity of five serotype 2 infectious bursal disease viruses in chickens. *Avian Dis*. 32:757–759.
129. Ismail, N., Y.M. Saif, W.L. Wigle, G.B. Havenstein, and C. Jackson. 1990. Infectious bursal disease virus variant from commercial leghorn pullets. *Avian Dis*. 34:141–145.
130. Ivanyi, J. 1975. Immunodeficiency in the chicken. II. Production of monomeric IgM following testosterone treatment of infection with Gumboro disease. *Immunol*. 28:1015–1021.
131. Ivanyi, J., and R. Morris. 1976. Immunodeficiency in the chicken. IV. An immunological study of infectious bursal disease. *Clin Exp Immunol*. 23:154–165.
132. Jackwood, D.J. 1988. Detection of infectious bursal disease virus using nucleic acid probes [abst]. *J Am Vet Med. Assoc*192:1779.
133. Jackwood, D.J., and Y.M. Saif. 1983. Prevalence of antibodies to infectious bursal disease virus serotypes I and II in 75 Ohio chicken flocks. *Avian Dis*. 27:850–854.
134. Jackwood, D.J., and Y.M. Saif. 1987. Antigenic diversity of infectious bursal disease viruses. *Avian Dis*. 31:766–770.
135. Jackwood, D.J., Y.M. Saif, and J.H. Hughes. 1982. Characteristics and serologic studies of two serotypes of infectious bursal disease virus in turkeys. *Avian Dis*. 26:871–882.
136. Jackwood, D.J., Y.M. Saif, and J.H. Hughes. 1984. Nucleic acid and structural proteins of infectious bursal disease virus isolates belonging to serotypes I and II. *Avian Dis*. 28:990–1006.
137. Jackwood, D.J., Y.M. Saif, P.D. Moorhead, and G. Bishop.1984. Failure of two serotype II infectious bursal disease viruses to affect the humoral immune response of turkeys. *Avian Dis*. 28:100–116.
138. Jackwood, D.J., Y.M. Saif, and P.D. Moorhead. 1985. Immunogenicity and antigenicity of infectious bursal disease virus serotypes I and II in chickens. *Avian Dis*. 29:1184–1194.
139. Jackwood, D.J., Y.M. Saif, and J.H. Hughes. 1987. Replication of infectious bursal disease virus in continuous cell lines. *Avian Dis*. 31:370–375.
140. Jackwood, D.J., and S.E. Sommer. 1997. Restriction length polymorphism in the VP2 gene of infectious bursal disease viruses. *Avian Dis*. 41:627–637.
141. Jackwood, D., and S. Sommer. 1999. Restriction fragment length polymorphisms in the VP2 gene of infectious bursal disease viruses from outside the United States. *Avian Dis*. 43:310–314.
142. Jackwood, D.J., S.E. Sommer-Wagner, and H.J. Pharo. 2007. The use of gamma irradiation for the inactivation of infectious bursal disease virus. *Avian Dis*. 51:606–608.
143. Jackwood D.J., S.E. Sommer-Wagner, A.S. Stoute, P.R. Woolcock, B.M. Crossley, S.K. Hietala, and B.R. Charlton. 2009. Characteristics of a very virulent infectious bursal disease virus from California. *Avian Dis*. 53:592–600.
144. Jackwood, D.J., and S.E. Sommer-Wagner. 2010. Detection and characterization of infectious bursal disease viruses in broilers at processing. *Prev Vet Med*. 97:45–50.
145. Jackwood D.J., S.E. Sommer-Wagner, B.M. Crossley, A.S. Stoute, P.R. Woolcock, and B.R. Charlton. 2011. Identification and pathogenicity of a natural reassortant between a very virulent serotype 1 infectious bursal disease virus (IBDV) and a serotype 2 IBDV. *Virol*. 420:98–105.
146. Jagadish, M.N., and A.A. Azad. 1991. Localization of a VP3 epitope of infectious bursal disease virus. *Virol*. 184:805–807.
147. Jakowski, R.M., T.N. Fredrickson, R.E. Luginbuhl, and C.F. Helmboldt. 1969. Early changes in bursa of Fabricius from Marek's disease. *Avian Dis*. 13:215–222.
148. Jeon, W.J., E.K. Lee, S.J. Joh, J.H. Kwon, C.B. Yang, Y.S. Yoon, and K.S. Choi. 2008. Very virulent infectious bursal disease virus isolated from wild birds in Korea: epidemiological implications. *Virus Res*. 137:153–6.
149. Jeurissen, S.H.M., E.M. Janse, P.R. Lerbach, E.E. Haddad, A. Avakian, and C.E. Whitfill. 1998. The working mechanism of an immune complex vaccine that protects chickens against infectious bursal disease. *Immunol*. 95:494–500.
150. Johnson, D.C., P.D. Lukert, and R.K. Page. 1980. Field studies with convalescent serum and infectious bursal disease vaccine to control turkey coryza. *Avian Dis*. 24:386–392.
151. Kasanga, C.J., T. Yamaguchi, P.N. Wambura, H.M. Munang'andu, K. Ohya, and H. Fukushi. 2008. Detection of infectious bursal disease virus (IBDV) genome in free-living pigeon and guinea fowl in Africa suggests involvement of wild birds in the epidemiology of IBDV. *Virus Genes*. 36:521–9.
152. Kaufer, I., and E. Weiss. 1980. Significance of bursa of Fabricius as target organ in infectious bursal disease of chickens. *Infect Immun*. 27:364–367.
153. Khatri, M., and J.M. Sharma. 2007. Replication of infectious bursal disease virus in macrophages and altered tropism of progeny virus. *Vet Immunol Immunopathol*. 117:106–15.
154. Khatri, M., and J.M. Sharma. 2008. IFN-gamma upregulation and protection by macrophage-adapted infectious bursal disease virus. *Vaccine*. 26:4740–6.
155. Khatri, M., and J.M. Sharma. 2009. Susceptibility of chicken mesenchymal stem cells to infectious bursal disease virus. *J Virol Methods*. 160:197–9.
156. Kibenge, F.S.B., A.S. Dhillon, and R.G. Russell. 1988. Biochemistry and immunology of infectious bursal disease virus. *J Gen Virol*. 69:1757–1775.
157. Kibenge, F.S.B., A.S. Dhillon, and R.G. Russell. 1988. Growth of serotypes I and II and variant strains of infectious bursal disease virus in vero cells. *Avian Dis*. 17:298–303.

158. Kibenge, F.S.B., A.S. Dhillon, and R.G. Russell. 1988. Identification of serotype II infectious bursal disease virus proteins. *Avian Pathol*. 17:679–687.
159. Kim, I.J., K. Karaka, T.L. Pertile, S.A. Erickson, and J.M. Sharma. 1998. Enhanced expression of cytokine genes in spleen macrophages during acute infection with infectious bursal disease virus in chickens. *Vet Immunol Immunopathol*. 61:331–341.
160. Kim, I.J., S.K. You, H. Kim, H.Y. Yeh, and J.M. Sharma. 2000. Characteristics of bursal T lymphocytes induced by infectious bursal disease virus. *J Virol*. 74:8884–8892.
161. Kim, S.J., H.W. Sung, J.H. Han, D. Jackwood, and H.M. Kwon. 2004. Protection against very virulent infectious bursal disease virus in chickens immunized with DNA vaccines. *Vet Microbiol*. 101:39–51.
162. Kosters, J., H. Becht, and R. Rudolph. 1972. Properties of the infectious bursal agent of chicken (IBA). *Med Microbiol Immunol*. 157:291–298.
163. Kreider, D.L., J.K. Skeeles, M. Parsley, L.A. Newberry, and J.D. Story. 1991. Variability in a commercially available enzyme-linked immunosorbent assay system. II Laboratory variability. *Avian Dis*. 35:288–293.
164. Kusk, M., S. Kabell, P.H. Jorgensen, and K.J. Handberg. 2005. Differentiation of five strains of infectious bursal disease virus: development of a strain-specific multiplex PCR. *Vet Microbiol*. 109:159–167.
165. Lam, K.M. 1997. Morphological evidence of apoptosis in chickens infected with infectious bursal disease viruses. *J Comp Pathol*. 116:367–377.
166. Lana, D.P., C.E. Beisel, and R.F. Silva. 1992. Genetic mechanisms of antigenic variation in infectious bursal disease virus: analysis of a naturally occurring variant virus. *Virus Genes*. 6:2474–259.
167. Landgraf, H., E. Vielitz, and R. Kirsch. 1967. Occurrence of an infectious disease affecting the bursa of Fabricius (Gumboro disease). *Dtsch Tieraerztl Wochenschr*. 74:6–10.
168. Lee, L.H., and P.D. Lukert. 1986. Adaptation and antigenic variation of infectious bursal disease virus. *J Chin Soc Vet Sci*. 12:297–304.
169. Lee, C.C., T.P. Ko, C.C. Chou, M. Yoshimura, S.R. Doong, M.Y. Wang, and A.H. Wang. 2006. Crystal structure of infectious bursal disease virus VP2 subviral particle at 2.6A resolution: implications in virion assembly and immunogenicity. *J Struct Biol*. 155:74–86.
170. Le Gros, F.X., A. Dancer, C. Giacomini, L. Pizzoni, M. Bublot, M. Graziani, and F. Prandini. 2009. Field efficacy trial of a novel HVT-IBD vector vaccine for 1-day-old broilers. *Vaccine*. 27:592–6.
171. Lejal, N., B. Da Costa, J.C. Huet, and B. Delmas. 2000. Role of Ser-652 and Lys-692 in the protease activity of infectious bursal disease VP4 and identification of its substrate cleavage sites. *J Gen Virol*. 81:983–992.
172. Le Nouen, C., G. Rivallan, D. Toquin, P. Darlu, Y. Morin, V. Beven, C. de Boisseson, C. Cazaban, S. Comte, Y. Gardin, and N. Eterradossi. 2006. Very virulent infectious bursal disease virus: reduced pathogenicity in a rare natural segment-B-reassorted isolate. *J Gen Virol*. 87:209–216.
173. Le Nouën, C., D. Toquin, H. Müller, R. Raue, K.M. Kean, P. Langlois, M. Cherbonnel, and N. Eterradossi. 2012. Different domains of the RNA polymerase of infectious bursal disease virus contribute to virulence. *PLoS One*. 7:e28064.
174. Letzel, T., F. Coulibaly, F.A. Rey, B. Delmas, E. Jagt, A.A. van Loon, and E. Mundt. 2007. Molecular and structural bases for the antigenicity of VP2 of infectious bursal disease virus. *J Virol*. 81:12827–35.
175. Lim, B., Y. Cao, T. Yu, and C. Mo. 1999. Adaptation of very virulent infectious bursal disease virus to chicken embryonic fibroblasts by site-directed mutagenesis of residues 279 and 284 of viral coat protein VP2. *J Virol*. 73:2854–2862.
176. Lin, T.W., C.W. Lo, S.Y. Lai, R.J. Fan, C.J. Lo, Y.M. Chou, R. Thiruvengadam, A.H. Wang, and M.Y. Wang. 2007. Chicken heat shock protein 90 is a component of the putative cellular receptor complex of infectious bursal disease virus. *J Virol*. 81:8730–41.
177. Liu, M., and V.N. Vakharia. 2004. VP1 protein of infectious bursal disease virus modulates the virulence in vivo. *Virol*. 330:62–73.
178. Liu, M., and V.N. Vakharia. 2006. Non structural protein of infectious bursal disease virus inhibits apoptosis at the early stage of virus infection. *J Virol*. 80:3369–3377.
179. Lohr, J.E. 1988. Differentiation of IBV strains. Proceedings of the First International Symposium on Infectious Bronchitis. E.F. Kaleta and V. Heffels-Redman, eds. Rauischolzhausen, Germany. 52–53.
180. Lombardo, E.A., A. Maraver, I. Espinosa, A. Fernadez-Arias, and J.F. Rodriguez. 1999. VP1, the putative RNA-dependent RNA polymerase of infectious bursal disease virus, forms complexes with the capsid protein VP3, leading to efficient encasidation into virus-like particles. *J Virol*. 73:6973–6983.
181. Lombardo, E.A., A. Maraver, I. Espinosa, A. Fernadez-Arias, and J.F. Rodriguez. 2000. VP5, the non structural polypeptide of infectious bursal disease virus, accumulates within the host plasma membrane and induces cell lysis. *Virol*. 277:345–357.
182. Lucio, B., and S.B. Hitchner. 1979. Infectious bursal disease emulsified vaccine: Effect upon neutralizing-antibody levels in the dam and subsequent protection of the progeny. *Avian Dis*. 23:466–478.
183. Lukert, P.D. 1986. Serotyping recent isolates of infectious bursal disease virus. Proc 21st Natl Meet Poult Health Condemn: Ocean City, MD. 71–75.
184. Lukert, P.D. 1988. Unpublished data.
185. Lukert, P.D., and R.B. Davis. 1974. Infectious bursal disease virus: Growth and characterization in cell cultures. *Avian Dis*. 18:243–250.
186. Lukert, P.D., and L.A. Mazariegos. 1985. Virulence and immunosuppressive potential of intermediate vaccine strains of infectious bursal disease virus [abst]. *J Am Vet Med Assoc*. 187:306.
187. Lukert, P.D., and D. Rifuliadi. 1982. Replication of virulent and attenuated infectious bursal disease virus in maternally immune day-old chickens [abst]. *J Am Vet Med Assoc*. 181:284.
188. Lukert, P.D., J. Leonard, and R.B. Davis. 1975. Infectious bursal disease virus: Antigen production and immunity. *Am J Vet Res*. 36:539–540.
189. Lunger, P.D., and T.C. Maddux. 1972. Fine-structure studies of the avian infectious bursal agent. I. *In vivo* viral morphogenesis. *Avian Dis*. 16:874–893.
190. Luo, J., H. Zhang, M. Teng, J.M. Fan, L.M. You, Z.J. Xiao, M.L. Yi, Y.B. Zhi, X.W. Li, and G.P. Zhang. 2010. Surface IgM on DT40 cells may be a component of the putative receptor complex responsible for the binding of infectious bursal disease virus. *Avian Pathol*. 39:359–65.

191. Luque D., G. Rivas, C. Alfonso, J.L. Carrascosa, J.F. Rodríguez, and J.R. Castón. 2009. Infectious bursal disease virus is an icosahedral polyploid dsRNA virus. *Proc Natl Acad Sci USA*. 106:2148–52.
192. Luque D., I. Saugar, M.T. Rejas, J.L. Carrascosa, J.F. Rodríguez, and J.R. Castón. 2009. Infectious bursal disease virus: ribonucleoprotein complexes of a double-stranded RNA virus. *J Mol Biol*. 386:891–901.
193. Maas, R., S. Vanema, A. Kant, H. Oei, and I. Claassen. 2004. Quantification of infectious bursal disease viral proteins 2 and 3 in inactivated vaccines as an indicator of serological response and measure of potency. *Avian Pathol*. 33:126–132.
194. MacDonald, R.D. 1980. Immunofluorescent detection of double-stranded RNA in cells infected with reovirus, infectious pancreatic necrosis virus, and infectious bursal disease virus. *Can J Microbiol*. 26:256–261.
195. Macreadie, I.G., P.R. Vaughan, A.J. Chapman, N.M. McKern, M.N. Jagadish, H.G. Heine, C.W. Ward, K.J. Fahey, and A.A. Azad. 1990. Passive protection against infectious bursal disease virus by viral VP2 expressed in yeast. *Vaccine*. 8:549–552.
196. Mahardika, G.N.K., and H. Becht. 1995. Mapping of cross-reacting and serotype-specific epitopes on the VP3 structural protein of infectious bursal disease virus. *Arch Virol*. 140:765–774.
197. Malik, M.W., N. Ayub, and I.Z. Qureshi. 2006. Passive immunization using purified IgYs against infectious bursal disease of chickens in Pakistan. *J Vet Sci*. 7:43–6.
198. Mallinson, E.T., D.B. Snyder, W.W. Marquardt, E. Russek-Cohen, P.K. Savage, D.C. Allen, and F.S. Yancey. 1985. Presumptive diagnosis of subclinical infections utilizing computer-assisted analysis of sequential enzyme-linked immunosorbent assays against multiple antigens. *Poult Sci*. 64:1661–1669.
199. Mandelli, G., A. Rinaldi, A. Cerioli, and G. Cervio. 1967. Aspetti ultrastrutturali della borsa di Fabrizio nella malattia di Gumboro de pollo. *Atti Soc Ital Sci Vet*. 21:615–619.
200. Mandeville III, W.F., F.K. Cook, and D.J. Jackwood. 2000. Heat lability of five strains of infectious bursal disease virus. *Poult Sci*. 79:838–842.
201. Maraver A., A. Oña, F. Abaitua, D. González, R. Clemente, J.A. Ruiz-Díaz, J.R. Castón, F. Pazos, and J.F. Rodriguez. 2003. The oligomerization domain of VP3, the scaffolding protein of infectious bursal disease virus, plays a critical role in capsid assembly. *J Virol*. 77:6438–49.
202. Maraver A., R. Clemente, J.F. Rodríguez, and E. Lombardo. 2003. Identification and molecular characterization of the RNA polymerase-binding motif of infectious bursal disease virus inner capsid protein VP3. *J Virol*. 77:2459–68.
203. Marquardt, W., R.B. Johnson, W.F. Odenwald, and B.A. Schlotthober. 1980. An indirect enzyme-linked immunosorbent assay (ELISA) for measuring antibodies in chickens infected with infectious bursal disease virus. *Avian Dis*. 24:375–385.
204. Martinez-Torrecuadrada, J.L., N. Saubi, A. Pagès-Manté, J.R. Caston, E. Espuna, and J.I. Casal. 2003. Structure dependent efficacy of infectious bursal disease virus (IBDV) recombinant vaccines. *Vaccine*. 21:3342–3350.
205. Maw, M.T., T. Yamaguchi, C.J. Kasanga, K. Terasaki, and H. Fukushi. 2006. A practical tissue sampling method using ordinary paper for molecular detection of infectious bursal disease virus RNA by RT-PCR. *Avian Dis*. 50:556-60.
206. McAllister, J.C., C.D. Steelman, L.A. Newberry, and J.K. Skeeles. 1995. Isolation of infectious bursal disease virus from the lesser mealworm, Alphitobius diaperinus (Panzer). *Poult Sci*. 74(1):45–49.
207. McFerran, J.B., M.S. McNulty, E.R. McKillop, T.J. Conner, R.M. McCracken, D.S. Collins, and G.M. Allan. 1980. Isolation and serological studies with infectious bursal disease viruses from fowl, turkey and duck: Demonstration of a second serotype. *Avian Pathol*. 9:395–404.
208. McNulty, M.S., and Y.M. Saif. 1988. Antigenic relationship of non-serotype 1 turkey infectious bursal disease viruses. *Avian Dis*. 32:374–375.
209. McNulty, M.S., G.M. Allan, and J.B. McFerran. 1979. Isolation of infectious bursal disease virus from turkeys. *Avian Pathol*. 8:205–212.
210. Mekkes, D.R., and de Wit, J.J. 2002. Report of the second international ring trail for infectious bursal disease virus (IBDV) antibody detection in serum. Annual report and proceedings 2002 of COST Action 839: Immunosuppressive viral diseases in poultry. European Union Directorate General for Research and Innovation, Brussels. 210–226.
211. Meroz, M. 1966. An epidemiological survey of Gumboro disease. *Refu Vet.* 23:235–237.
212. Mickael, C.S., and D.J. Jackwood. 2005. Real time RT-PCR analysis of two epitope regions encoded by the vP2 gene of infectious bursal disease viruses. *J Virol Met.* 128:37–46.
213. Moody, A., S. Sellers, and N. Bumstead. 2000. Measuring infectious bursal disease virus RNA in blood by multiplex real-time quantitative RT-PCR. *J Virol Met.* 85:55–64.
214. Morgan, M.M., I.G. Macreadie, V.R. Harley, P.J. Hudson, and A.A. Azad. 1988. Sequence of the small double-stranded RNA genomic segment of infectious bursal disease virus and its deduced 90-K Da product. *Virol.* 163:240–242.
215. Müller, H. 1986. Replication of infectious bursal disease virus in lymphoid cell. *Arch Virol.* 87:191–203.
216. Müller, H., and H. Becht. 1982. Biosynthesis of virus-specific proteins in cells infected with infectious bursal disease virus and their significance as structural elements for infectious virus and incomplete particles. *J Virol.* 44:384–392.
217. Müller, H., and N. Nitschke. 1987. The two segments of infectious bursal disease virus genome are circularized by a 90,000 Da protein. *Virol.* 159:174–177.
218. Müller, H., C. Scholtissek, and H. Becht. 1979. Genome of infectious bursal disease virus consists of two segments of double-stranded RNA. *J Virol.* 31:584–589.
219. Müller, R., I.K. Weiss, M. Reinacher, and E. Weiss. 1979. Immunofluorescent studies of early virus propagation after oral infection with infectious bursal disease virus (IBDV). *Zentralbl Veterinaermed [B]*. 26:345–352.
220. Müller, H., H. Lange, and H. Becht. 1986. Formation, characterization and interfering capacity of a small plaque mutant and of incomplete virus particles of infectious bursal disease virus. *Virus Res.* 4:297–309.
221. Müller, H., E. Mundt, N. Eterradossi, and M.R. Islam. 2012. Current status of vaccines against infectious bursal disease. *Avian Pathol.* 41:133–9.
222. Mundt, E. 1999. Tissue culture infectivity of different strains of infectious bursal disease virus is determined by distinct amino acids in VP2. *J Gen Virol.* 80:2067–2076.
223. Mundt, E. and H. Müller. 1995. Complete nucleotide sequences of 59 and 39 non-coding regions of both segments of different strains of infectious bursal disease virus. *Virol.* 209:10–18.

224. Mundt, E., J. Beyer, and H. Müller. 1995. Identification of a novel viral protein in infectious bursal disease virus-infected cells. *J Gen Virol.* 76:437–443.
225. Mundt, E., N. de Haas, and A.A. van Loon. 2003. Development of a vaccine for immunization against classical as well as variant strains of infectious bursal disease virus using reverse genetics. *Vaccine.* 21:4616–4624.
226. Mundt, E., B. Kollner, and D. Kretzschmar. 1997. VP5 of infectious bursal disease virus is not essential for virus replication in cell culture. *J Virol.* 71:5647–5651.
227. Mundt, E., and V.N. Vakharia. 1996. Synthetic transcripts of double-stranded birnavirus genome are infectious. *Proc Natl Acad Sci USA*. 93:11131–11136.
228. Nagarajan, M.M., and F.S.B. Kibenge. 1997. Infectious bursal disease virus: A review of molecular basis for variations in antigenicity and virulence. *Can J Vet Res.* 61:81–88.
229. Nagy, E., R. Duncan, P. Krell, and P. Dobos. 1987. Mapping of the large RNA genome segment of infectious pancreatic necrosis virus by hybrid arrested translation. *Virol.* 158:211–217.
230. Nakai, T., and K. Hirai. 1981. *In vitro* infection of fractionated chicken lymphocytes by infectious bursal disease virus. *Avian Dis.* 25:831–838.
231. Naqi, S.A., and D.L. Millar. 1979. Morphologic changes in the bursa of Fabricius of chickens after inoculation with infectious bursal disease virus. *Am J Vet Res.* 40:1134–1139.
232. Negash, T., S.O. Al-Garib, and E. Gruys. 2004. Comparison of *in ovo* and post-hatch vaccination with particular reference to infectious bursal disease: A review. *Vet Quarter.* 26:76–87.
233. Nick, H., D. Cursiefen, and H. Becht. 1976. Structural and growth characteristics of infectious bursal disease virus. *J Virol.* 18:227–234.
234. Nieper, H., and H. Müller. 1996. Susceptibility of chicken lymphoid cells to infectious bursal disease virus does not correlate with the presence of specific binding sites. *J Gen Virol.* 77: 1229–1237.
235. Nobiron I., M. Galloux, C. Henry, C. Torhy, P. Boudinot, N. Lejal, B. Da Costa, and B. Delmas. 2008. Genome and polypeptides characterization of Tellina viris 1 reveals a fifth genetic cluster in the *Birnaviridae* family. *Virol.* 371:350–361.
236. Nusbaum, K.E., P.D. Lukert, and O.J. Fletcher. 1988. Experimental infection of one-day-old poults with turkey isolates of infectious bursal disease virus. *Avian Pathol.* 17:51–62
237. Ogawa, M., T. Yamaguchi, A. Setiyono, T. Ho, H. Matsuda, S. Furasawa, H. Fukushi, and K. Hirai. 1998. Some characteristics of a cellular receptor for virulent infectious bursal disease virus using flow cytometry. *Arch Virol.* 143:2327–2341.
238. Ogawa, M., T. Wakuda, T. Yamaguchi, K. Murata, A. Setiyono, H. Fukushi, and K. Hirai. 1998. Seroprevalence of infectious bursal disease virus in free-living wild birds in Japan. *J Vet Med Sci.* 60, 1277–1279.
239. Okoye, J.O.A., and G.C. Okpe. 1989. The pathogenicity of an isolate of infectious bursal disease virus in guinea fowls. *Acta Vet Brno.* 58:91–96.
240. Okoye, J.O.A., and U.E. Uche. 1986. Serological evidence of infectious bursal disease virus infection in wild rats. *Acta Vet Brno.* 55:207–209.
241. Öppling, V., H. Müller, and H. Becht. 1991. The structural polypeptide VP3 of infectious bursal disease virus carries group- and serotype-specific epitopes. *J Gen Virol.* 72:2275–2278.
242. Owoade, A.A., M.N. Mulders, J. Kohnen, W. Ammerlaan, and C.P. Muller. 2004. High sequence diversity in infectious bursal disease virus serotype 1 in poultry and turkey suggests West-African origin of very virulent strains. *Arch Virol.* 149:653–672.
243. Ozel, M., and H. Gelderblom. 1985. Capsid symmetry of viruses of the proposed birnavirus group. *Arch Virol.* 84:149–161.
244. Page, R.K., O.J. Fletcher, P.D. Lukert, and R. Rimler. 1978. Rhinotracheitis in turkey poults. *Avian Dis.* 22:529–534.
245. Pagès-Manté, A., D. Torrents, J. Maldonado, and N. Saubi. 2004. Dogs as potential carriers of infectious bursal disease virus. *Avian Pathol.* 33:205–209.
246. Panigrahy, B., L.K. Misra, S.A. Naqi, and C.F. Hall. 1977. Prolongation of skin allograft survival in chickens with infectious bursal disease. *Poult Sci.* 56:1745.
247. Parkhurst, R.T. 1964. On-the-farm studies of Gumboro disease in broilers. *Avian Dis.* 8:584–596.
248. Pattison, M., D.J. Alexander, and J.W. Harkness. 1975. Purification and preliminary characterization of a pathogenic strain of infectious bursal disease virus. *Avian Pathol.* 4:175–187.
249. Pejkovski, C., F.G. Davelaar, and B. Kouwenhoven. 1979. Immunosuppressive effect of infectious bursal disease virus on vaccination against infectious bronchitis. *Avian Pathol.* 8:95–106.
250. Perelman, B., and E.D. Heller. 1983. The effect of infectious bursal disease virus on the immune system of turkeys. *Avian Dis.* 27:66–76.
251. Petek, M., P.N. D'Aprile, and F. Cancellotti. 1973. Biological and physicochemical properties of the infectious bursal disease virus (IBDV). *Avian Pathol.* 2:135–152.
252. Peters, G. 1967. Histology of Gumboro disease. *Berl Munch Tierarztl Wochenschr.* 80:394–396.
253. Peters, M.A., T.L. Lin, and C.C. Wu. 2005. Real-time RT-PCR differentiation and quantitation of infectious bursal disease virus strains using dual-labeled fluorescent probes. *J Virol Met.* 127:87–95.
254. Phenix, K.V., K. Wark, C.J. Luke, M.A. Skinner, J.A. Smyth, K.A. Mawhinney, and D. Todd. 2001. Recombinant Semliki Forest virus vector exhibits potential for avian virus vaccine development. *Vaccine.* 19:3116–23.
255. Pitcovski, J., D. Di Castro, Y. Shaaltiel, A. Azriel, B. Gutter, E. Yarkoni, A. Michael, S. Krispel, and B.Z. Levi. 1996. Insect cell-derived VP2 of infectious bursal disease virus confers protection against the disease in chickens. *Avian Dis.* 40:753–761.
256. Pitcovski, J., B. Gutter, G. Gallili, M. Goldway, B. Perelman, G. Gross, S. Krispel, M. Barbakov, and A. Michael. 2003. Development and large scale use of recombinant VP2 vaccine for the prevention of infectious bursal disease virus of chickens. *Vaccine.* 21:4736–4743.
257. Pous, J., C. Chevalier, M. Ouldali, J. Navaza, B. Delmas, and J. Lepault. 2005. Structure of birnavirus-like particles determined by combined electron cryomicroscopy and X-ray crystallography. *J Gen Virol.* 86:2339–2346.
258. Purvis, L.B., P. Villegas, and F. Perozo. 2006. Evaluation of FTA paper and phenol for storage, extraction and molecular characterization of infectious bursal disease virus. *J Virol Methods.* 138:66–9.
259. Qi, X., Y. Gao, H. Gao, X. Deng, Z. Bu, X. Wang, C. Fu, and X. Wang. 2007. An improved method for infectious bursal disease virus rescue using RNA polymerase II system. *J Virol Methods.* 142:81–8.
260. Raue, R., M.R. Islam, M.N. Islam, K.M. Islam, S.C. Badhy, P.M. Das, and H. Müller. 2004. Reversion of molecularly engineered, partially attenuated, very virulent infectious bursal

disease virus during infection of commercial chickens. *Avian Pathol.* 33:181–9.
261. Rauf, A., M. Khatri, M.V. Murgia, K. Jung, and Y.M. Saif. 2011. Differential modulation of cytokine, chemokine and Toll like receptor expression in chickens infected with classical and variant infectious bursal disease virus. *Vet Res.* 42:85.
262. Rauf, A., M. Khatri, M.V. Murgia, and Y.M. Saif. 2011. Expression of perforin-granzyme pathway genes in the bursa of infectious bursal disease virus-infected chickens. *Dev Comp Immunol.* 35:620-627.
263. Rautenschlein, S., and C. Haase. 2005. Differences in the immunopathogenesis of infectious bursal disease virus (IBDV) following *in ovo* and post-hatch vaccination of chickens. *Vet Immunol Immunopathol.* 106:139–150.
264. Rautenschlein, S., H.Y. Yeh, M.K. Njenga, and J.M. Sharma. 2002. Role of intrabursal T cells in infectious bursal disease virus infection: T cells promote viral clearance but delay follicular recovery. *Arch Virol.* 147:285–304.
265. Reddy, S.K., A. Silim, and M.J. Ratcliffe. 1992. Biological roles of the major capsid proteins and relationships between the two existing serotypes of infectious bursal disease virus. *Arch Virol.* 127:209–222.
266. Rémond, M., B. Da Costa, S. Riffault, S. Parida, E. Breard, F. Lebreton, S. Zientara, and B. Delmas. 2009. Infectious bursal disease subviral particles displaying the foot-and-mouth disease virus major antigenic site. *Vaccine.* 27:93–8.
267. Rinaldi, A., G. Cervio, and G. Mandelli. 1965. Aspetti epidemiologici, anatomo-clinici ed istologici di una nuova forma morbosa dei polli verosimilmente identificabile con la considdetta Malattia di Gumboro. *Atti Conv Patol Aviare. Societa Italiana de Patologia Aviare.* 77–83.
268. Rinaldi, A., E. Lodetti, D. Cessi, E. Lodrini, G. Cervio, and L. Nardelli. 1972. Coltura del virus de Gumboro (IBA) su fibroblast de embrioni di pollo. *Nuova Vet.* 48:195–201.
269. Rosenberger, J.K., and S.S. Cloud. 1985. Isolation and characterization of variant infectious bursal disease viruses [abst]. *J Am Vet Med Assoc.* 189:357.
270. Rosenberger, J.K., and S.S. Cloud. 1986. Isolation and characterization of variant infectious bursal disease viruses [abst]. *J Am Vet Med Assoc.* 189:357.
271. Rosenberger, J.K., and J. Gelb, Jr. 1978. Response to several avian respiratory viruses as affected by infectious bursal disease virus. *Avian Dis.* 22:95–105.
272. Rosenberger, J.K., S. Klopp, R.J. Eckroade, and W.C. Krauss. 1975. The role of the infectious bursal agent and several avian adenoviruses in the hemorrhagic-aplastic-anemia syndrome and gangrenous dermatitis. *Avian Dis.* 19:717–729.
273. Rosenberger, J.K., S.S. Cloud, J. Gelb, Jr., E. Odor, and J.E. Dohms. 1985. Sentinel bird survey of Delmarva broiler flocks. Proc 20th Natl Meet Poult Health Condemn: Ocean City, MD. 94–101.
274. Rosenberger, J.K., S.S. Cloud, and A. Metz. 1987. Use of infectious bursal disease virus variant vaccines in broilers and broiler breeders. Proc 36th West Poult Dis Conf: University of California, Davis, California. 105–109.
275. Ruby, T., C. Whittaker, D.R. Withers, M.K. Chelbi-Alix, V. Morin, A. Oudin, J.R. Young, and R. Zoorob. 2006. Transcriptional profiling reveals a possible role for the timing of the inflammatory response in determining susceptibility to a viral infection. *J Virol.* 80:9207–9216.
276. Saif, Y.M. 1984. Infectious bursal disease virus types. Proc 19th Natl Meet Poult Health Condemn: Ocean City, MD. 105–107.
277. Saif, Y.M. 1995. Unpublished data.
278. Sanchez, J., H. Stryhn, M. Flensburg, A.K. Ersbøll, and I. Dohoo. 2005. Temporal and spatial analysis of the 1999 outbreak of acute clinical infectious bursal disease in broiler flocks in Denmark. *Prev Vet Med.* 71:209–23.
279. Schnitzler, D., F. Bernstein, H. Müller, and H. Becht. 1993. The genetic basis for the antigenicity of the VP2 protein of the infectious bursal disease virus. *J Gen Virol.* 74:1563–1571.
280. Sapats, S.I., and J. Ignjatovic. 2000. Antigenic and sequence heterogeneity of infectious bursal disease virus strains isolated in Australia. *Arch Virol.* 145, 773–785.
281. Sapats, S.I., L. Trinidad, G. Gould, H.G. Heine, T.P. Van den Berg, N. Eterradossi, D. Jackwood, L. Parede, D. Toquin, and J. Ignjatovic. 2006. Chicken recombinant antibodies specific for very virulent infectious bursal disease virus. *Arch Virol.* 151:1551–1566.
282. Sharma, J.M. 1984. Effect of infectious bursal disease virus on protection against Marek's disease by turkey herpes virus vaccine. *Avian Dis.* 28:629–640.
283. Sharma, J.M., and L.F. Lee. 1983. Effect of infectious bursal disease virus on natural killer cell activity and mitogenic response of chicken lymphoid cells: Role of adherent cells in cellular immune suppression. *Infect Immun.* 42:747–754.
284. Sharma, J.M., J.E. Dohms, and A.L. Metz. 1989. Comparative pathogenesis of serotype 1 and variant serotype 1 isolates of infectious bursal disease virus and the effect of those viruses on humoral and cellular immune competence of specific pathogen free on chickens. *Avian Dis.* 33:112–124.
285. Sharma, J.M., S. Rautenschlein, and H.Y. Yeh. 2001. The role of T cells in immunopathogenesis of infectious bursal disease virus. Proceedings II International Symposium on Infectious Bursal Disease and Chicken Infectious Anaemia. Rauischholzhausen, Germany. 324–327.
286. Shirai, J., R. Seki, R. Kamimura, and S. Mitsubayashi. 1994. Effects of invert soap with 0.05% sodium hydroxide on infectious bursal disease virus. *Avian Dis*. 38:240–243.
287. Singh, N.K., S. Dey, C. Madhan Mohan, J. Mohan Kataria, and V.N. Vakharia. 2010. Evaluation of four enzyme linked immunosorbent assays for the detection of antibodies to infectious bursal disease in chickens. *J Virol Methods.* 165:277–82.
288. Sivanandan, V., and S.K. Maheswaran. 1980. Immune profile of infectious bursal disease. I. Effect of infectious bursal disease virus on peripheral blood T and B lymphocytes in chickens. *Avian Dis*. 24:715–725.
289. Sivanandan, V., and S.K. Maheswaran. 1980. Immune profile of infectious bursal disease (IBD). II. Effect of IBD virus on pokeweed-mitogen-stimulated peripheral blood lymphocytes of chickens. *Avian Dis*. 24:734–742.
290. Sivanandan, V., and S.K. Maheswaran. 1981. Immune profile of infectious bursal disease. III. Effect of infectious bursal disease virus on the lymphocyte responses to phytomitogens and on mixed lymphocyte reaction of chickens. *Avian Dis*. 25:112–120.
291. Sivanandan, V., J. Sasipreeyajan, D.A. Halvorson, and J.A. Newman. 1986. Histopathologic changes induced by serotype II infectious bursal disease virus in specific-pathogen-free chickens. *Avian Dis*. 30:709–715.
292. Skeeles, J.K., and P.D. Lukert. 1980. Studies with an attenuated cell-culture-adapted infectious bursal disease virus: Replication sites and persistence of the virus in specific-pathogen-free chickens. *Avian Dis*. 24:43–47.

293. Skeeles, J.K., P.D. Lukert, E.V. De Buysscher, O.J. Fletcher, and J. Brown. 1979. Infectious bursal disease virus infections. I. Complement and virus-neutralizing antibody response following infection of susceptible chickens. *Avian Dis*. 23:95–106.
294. Skeeles, J.K., P.D. Lukert, E.V. De Buysscher, O.J. Fletcher, and J. Brown. 1979. Infectious bursal disease virus infections. II. The relationship of age, complement levels, virus-neutralizing antibody, clotting and lesions. *Avian Dis*. 23:107–117.
295. Skeeles, J.K., P.D. Lukert, O.J. Fletcher, and J.D. Leonard. 1979. Immunization studies with a cell-culture-adapted infectious bursal disease virus. *Avian Dis.* 23:456–465.
296. Skeeles, J.K., M.F. Slavik, J.N. Beasley, A.H. Brown, C.F. Meinecke, S. Maruca, and S. Welch. 1980. An age-related coagulation disorder associated with experimental infection with infectious bursal disease virus. *Am J Vet Res.* 41:1458–1461.
297. Snedeker, C., F.K. Wills, and I.M. Moulthrop. 1967. Some studies on the infectious bursal agent. *Avian Dis.* 11:519–528.
298. Snyder, D.B., W.W. Marquardt, E.T. Mallinson, E. Russek-Cohen, P.K. Savage, and D.C. Allen. 1986. Rapid serological profiling by enzyme-linked immunosorbent assay. IV. Association of infectious bursal disease serology with broiler flock performance. *Avian Dis*. 30:139–148.
299. Snyder, D.B., D.P. Lana, B.R. Cho, and W.W. Marquardt. 1988. Group and strain-specific neutralization sites of infectious bursal disease virus defined with monoclonal antibodies. *Avian Dis.* 32:527–534.
300. Snyder, D.B., D.P. Lana, P.K. Savage, F.S. Yancey, S.A. Mengel, and W.W. Marquardt. 1988. Differentiation of infectious bursal disease viruses directly from infected tissues with neutralizing monoclonal antibodies: Evidence of a major antigenic shift in recent field isolates. *Avian Dis.* 32:535–539.
301. Snyder, D.B., V.N. Vakharia, and P.K. Savage. 1992. Naturally occurring neutralizing monoclonal antibody escape variants define the epidemiology of infectious bursal disease viruses in the United States. *Arch Virol.* 127:89–101.
302. Snyder, D.B., V.N. Vakharia, S.A. Mengel-Whereat, G.H. Edwards, P.K. Savage, D. Lutticken, and M.A. Goodwin. 1994. Active cross-protection induced by a recombinant baculovirus expressing chimeric infectious bursal disease virus structural proteins. *Avian Dis.* 38:701–707.
303. Solano, W., J.J. Giambrone, and V.S. Panangala. 1985. Comparison of a kinetic-based enzyme-linked immunosorbent assay (KELISA) and virus-neutralization test for infectious bursal disease virus. I. Quantitation of antibody in white leghorn hens. *Avian Dis*. 29:662–671.
304. Spies, U., H. Müller, and H. Becht. 1987. Properties of RNA polymerase activity associated with infectious bursal disease virus and characterization of its reaction products. *Virus Res.* 8:127–140.
305. Steger, D., H. Müller, and D. Riesner. 1980. Helix-core transitions in double-stranded viral RNA: Fine resolution melting and ionic strength dependence. *Biochem Biophys Acta.* 606:274–285.
306. Stoute S.T., D.J. Jackwood, S.E. Sommer-Wagner, G.L. Cooper, M.L. Anderson, P.R. Woolcock, A.A. Bickford, C.G. Sentíes-Cué, and B.R. Charlton. 2009. The diagnosis of very virulent infectious bursal disease in California pullets. *Avian Dis.* 53:321–6.
307. Subler, K.A., C.S. Mickael, and D.J. Jackwood. 2006. Infectious bursal disease virus-induced immunosuppression exacerbates *Campylobacter jejuni* colonization and shedding in chickens. *Avian Dis.* 50:179–84.
308. Sun, J.H., Y.X. Yan, J. Jiang, and P. Lu. 2005. DNA immunization against very virulent infectious bursal disease virus with VP2–4–3 gene and chicken IL-6 gene. *J Vet Med B.* 52:1–7.
309. Survashe, B.D., I.D. Aitken, and J.R. Powell. 1979. The response of the Harderian gland of the fowl to antigen given by the ocular route. I. Histological changes. *Avian Pathol*. 8:77–93.
310. Tacken, M.G.J., B.P.H. Peeters, A.A.M. Thomas, P.J.M. Rottier, and H.J. Boot. 2002. Infectious bursal disease virus capsid protein VP3 interacts both with VP1: The RNA dependent RNA polymerase, and with double-stranded RNA. *J Virol.* 76:11301–11311.
311. Tacken, M.G., A.A. Thomas, B.P. Peeters, P.J. Rottier, and H.J. Boot. 2004. VP1, the RNA-dependent RNA polymerase and genome-linked protein of infectious bursal disease virus, interacts with the carboxy-terminal domain of translational eukaryotic initiation factor 4AII. *Arch Virol.* 149:2245–60.
312. Takase, K., G.M. Baba, R. Ariyoshi, and H. Fujikawa. 1996. Susceptibility of chicken embryos to highly virulent infectious bursal disease virus. *J Vet Med Sci.* 58(11):1129–1131.
313. Tanimura, N., K. Tsukamoto, K. Nakamura, M. Narita, and M. Maeda. 1995. Association between pathogenicity of infectious bursal disease virus and viral antigen distribution detected by immunochemistry. *Avian Dis.* 39:9–20.
314. Terasaki, K., H. Hirayama, C.J. Kasanga, M.T. Maw, K. Ohya, T. Yamaguchi, and H. Fukushi. 2008. Chicken B lymphoma DT40 cells as a useful tool for *in vitro* analysis of pathogenic infectious bursal disease virus. *J Vet Med Sci.* 70:407–10.
315. Tham, K.M., and C.D. Moon. 1996. Apoptosis in cell culture induced by infectious bursal disease virus following in vitro infection. *Avian Dis.* 40:109–113.
316. Thayer, S.G., P. Villegas, and O.J. Fletcher. 1987. Comparison of two commercial enzyme-linked immunosorbent assays and conventional methods for avian serology. *Avian Dis.* 31:120–124.
317. Tiwari, A.K., R. Kataria, S. Indervesh, N. Prasad, and R. Gupta. 2003. Differentiation of infectious bursal disease viruses by restriction enzyme analysis of RT-PCR amplified VP1 gene sequence. *Comp Immunol Microbiol Infect Dis.* 26:47–53.
318. Todd, D., and M.S. McNulty. 1979. Biochemical studies with infectious bursal disease virus: Comparison of some of its properties with infectious pancreatic necrosis virus. *Arch Virol.* 60:265–277.
319. Tsai, H.J., and Y.M. Saif 1992. Effect of cell-culture passage on the pathogenicity and immunogenicity of infectious bursal disease virus. *Avian Dis.* 36:415–422.
320. Tsukamoto, K., T. Matsumura, M. Mase, and K. Imai. 1995. A highly sensitive, broad-spectrum infectivity assay for infectious bursal disease virus. *Avian Dis.* 39:575–586.
321. Tsukamoto, K., N. Tanimura, S. Kakita, K. Ota, M. Mase, K. Imai, and H. Hihara. 1995. Efficacy of three live vaccines against highly virulent infectious bursal disease virus in chickens with or without maternal antibodies. *Avian Dis.* 39:218–229.
322. Tsukamoto, K., C. Kojima, Y. Komori, N. Tanimura, M. Mase, and S. Yamaguchi. 1999. Protection of chickens against very virulent infectious bursal disease virus (IBDV) and Marek's disease virus (MDV) with a recombinant MDV expressing IBDV VP2. *Virol.* 257:352–362.
323. Tsukamoto, K., S. Saito, S. Saeki, T. Sato, N. Tanimura, T. Isobe, M. Mase, T. Imada, N. Yuasa, and S. Yamaguchi. 2002. Complete, long-lasting protection against lethal infectious bursal disease virus challenge by a single vaccination with an avian herpesvirus vector expressing VP2 antigens. *J Virol.* 76:5637–45.

324. Ture, O., and Y.M. Saif. 1992. Structural proteins of classic and variant strains of infectious bursal disease viruses. *Avian Dis*. 36:829–836.
325. Upadhyay, C., A. Ammayappan, D. Patel, I. Kovesdi, and V.N. Vakharia. 2011. Recombinant infectious bursal disease virus carrying hepatitis C virus epitopes. *J Virol.* 85:1408–14.
326. Ursula, Höfle, J.M. Blanco, and E.F. Kaleta. 2001. Neutralizing antibodies against infectious bursal disease virus in sera of free-living and captive birds of prey from central Spain (preliminary results). Proceedings II International Symposium on Infectious Bursal Disease and Chicken Infectious Anaemia. Rauischholzhausen, Germany. 247–251.
327. Vakharia, V.N., B. Ahamed, and D.B. Snyder. 1994. Molecular basis of antigenic variation in infectious bursal disease virus. *Virus Res.* 31:265–273.
328. Vakharia, V.N., D.B. Snyder, J. He, G.H. Edwards, P.K. Savage, and S.A. Mengel-Whereat. 1993. Infectious bursal disease virus structural proteins expressed in a baculovirus recombinant confer protection in chickens. *J Gen Virol.* 74:1201–1206.
329. Vakharia, V.N., D.B. Snyder, D. Lutticken, S.A. Mengel-Whereat, P.K. Savage, G.H. Edwards, and M.A. Goodwin. 1994. Active and passive protection against variant and classic infectious bursal disease virus strains induced by baculovirus expressed structural proteins. *Vaccine.* 12:452–456.
330. Vancini, R., A. Paredes, M. Ribeiro, K. Blackburn, D. Ferreira, J.P. Jr. Kononchik, R. Hernandez, and D. Brown. 2012. Espirito Santo virus: a new birnavirus that replicates in insect cells. *J Virol.* 86:2390–2399.
331. Van den Berg, T.P., M. Gonze, and G. Meulemans. 1991. Acute infectious bursal disease in poultry: Isolation and characterization of a highly virulent strain. *Avian Pathol.* 20:133–143.
332. Van den Berg, T.P., M. Gonze, D. Morales, and G. Meulemans. 1996. Acute infectious bursal disease in poultry: Immunological and molecular basis of antigenicity of a highly virulent strain. *Avian Pathol.* 25:751–768.
333. Van den Berg, T.B., A. Ona, D. Morales, and J.F. Rodriguez. 2001. Experimental inoculation of game/ornamental birds with a very virulent strain of IBDV. Proceedings II International Symposium on Infectious Bursal Disease and Chicken Infectious Anaemia. Rauischholzhausen, Germany. 236–246.
334. Van den Berg, T.P., D. Morales, N. Eterradossi, G. Rivallan, D. Toquin, R. Raue, K. Zierenberg, M.F. Zhang, Y.P. Zhu, C.Q. Wang, H.J. Zheng, X. Wang, G.C. Chen, B.L. Lim, and H. Müller. 2004. Assessment of genetic, antigenic and pathotypic criteria for the characterization of IBDV strains. *Avian Pathol.* 33:470–476.
335. Van der Marel, R., D.B. Snyder, and D. Luetticken. 1991. Antigenic characterization of IBDV field isolates by their reactivity with a panel of monoclonal antibodies. *Dtsch Tieraerztl Wochenschr.* 97:81–83.
336. van Loon, A.A., N. de Haas, I. Zeyda, and E. Mundt. 2002. Alteration of amino acids in VP2 of very virulent infectious bursal disease virus results in tissue culture adaptation and attenuation in chickens. *J Gen Virol.* 83:121–9.
337. Vasconcelos, A.C., and K.M. Lam. 1994. Apoptosis in chicken embryos induced by the infectious bursal disease virus. *J Comp Pathol.* 112:327–338.
338. Vasconcelos, A.C., and K.M. Lam. 1995. Apoptosis induced by infectious bursal disease virus. *J Gen Virol.* 75:1803–1806.
339. Von Einem, U.I., A.E. Gorbalenya, H. Schirrmeier, S.E. Behrens, T. Letzel, and E. Mundt. 2004. VP1 of infectious bursal disease virus is an RNA-dependent RNA polymerase. *J Gen Virol.* 85:2221–2229.
340. Wang, X., P. Jiang, S. Deen, J. Wu, X. Liu, and J. Xu. 2003. Efficacy of DNA vaccines against infectious bursal disease virus in chickens enhanced by coadministration with CpG oligodeoxynucleotide. *Avian Dis.* 47:1305–1312.
341. Wang, Y.S., H.J. Fan, Y. Li, Z.L. Zheng-Liang Shi, Y. Ying Pan, and C.P. Lu. 2007. Development of a multi-mimotope peptide as a vaccine immunogen for infectious bursal disease virus. *Vaccine.* 25:4447–55.
342. Wang, D., Y. Liu, R. She, J. Xu, L. Liu, J. Xiong, Y. Yang, Q. Sun, and K. Peng. 2009. Reduced mucosal injury of SPF chickens by mast cell stabilization after infection with very virulent infectious bursal disease virus. *Vet Immunol Immunopathol.* 131:229–37.
343. Wang, Y., H. Sun, P. Shen, X. Zhang, and X. Xia. 2009. Effective inhibition of infectious bursal disease virus replication by recombinant avian adeno-associated virus-delivered microRNAs. *J Gen Virol.* 90:1417–22.
344. Wang, Y., X. Qi, H. Gao, Y. Gao, H. Lin, X. Song, L. Pei, and X. Wang. 2009. Comparative study of the replication of infectious bursal disease virus in DF-1 cell line and chicken embryo fibroblasts evaluated by a new real-time RT-PCR. *J Virol Methods.* 157:205–10.
345. Wang, Y.S., W. Ouyang, X.J. Liu, K.W. He, S.Q. Yu, H.B. Zhang, H.J. Fan, and C.P. Lu. 2012. Virus-like particles of hepatitis B virus core protein containing five mimotopes of infectious bursal disease virus (IBDV) protect chickens against IBDV. *Vaccine.* 30:2125–30.
346. Wei, L., L. Hou, S. Zhu, J. Wang, J. Zhou, and J. Liu. 2011. Infectious bursal disease virus activates the phosphatidylinositol 3-kinase (PI3K)/Akt signaling pathway by interaction of VP5 protein with the p85α subunit of PI3K. *Virol.* 417:211–20.
347. Weisman, J., and S.B. Hitchner. 1978. Infectious bursal disease virus infection attempts in turkeys and coturnix quail. *Avian Dis.* 22:604–609.
348. Whetzel, P.L., and D.J. Jackwood. 1995. Comparison of neutralizing epitopes among infectious bursal disease viruses using radioimmunoprecipitation. *Avian Dis.* 39:499–506.
349. Whitfill, C.E., E.E. Haddad, C.A. Ricks, J.K. Skeeles, L.A. Newberry, J.N. Beasley, P.D. Andrews, J.A. Thoma, and P.S. Wakenell. 1995. Determination of optimum formulation of a novel infectious bursal disease (IBD) vaccine constructed by mixing bursal disease antibody with IBDV. *Avian Dis.* 39:687–699.
350. Wilcox, J.E., R.L. Flower, and W. Baxendale. 1983. Serological survey of wild birds in Australia for the prevalence of antibodies to egg drop syndrome 1976 and infectious bursal disease viruses. *Avian Pathol.* 12:135–139.
351. Williams, A.E., and T.F. Davison. 2005. Enhanced immunopathology induced by very virulent infectious bursal disease virus. *Avian Pathol.* 34:4–14.
352. Winterfield, R.W. 1969. Immunity response to the infectious bursal agent. *Avian Dis.* 13:548–557.
353. Winterfield, R.W., and S.B. Hitchner. 1962. Etiology of an infectious nephritis-nephrosis syndrome of chickens. *Am J Vet Res.* 23:1273–1279.
354. Winterfield, R.W., S.B. Hitchner, G.S. Appleton, and A.S. Cosgrove. 1962. Avian nephrosis, nephritis and Gumboro disease. *L & M News Views.* 3:103.
355. Withers, D.R., J.R. Young, and T.F. Davison. 2005. Infectious bursal disease virus-induced immunosuppression in the chick is

associated with the presence of undifferentiated follicles in the recovering bursa. *Viral Immunol.* 18:127–137.
356. Woolcock, P.R., R.P. Chin, and Y.M. Saif. 1995. Personal communication.
357. World Organization for Animal Health (Office International des Epizooties). 2004. Chapter 2.7.1. Infectious bursal disease. In: *OIE Manual of Diagnostic Tests and Vaccines for Terrestrial Animals*, 5th ed. OIE, Paris. 817–832.
358. Wyeth, P.J. 1975. Effect of infectious bursal disease on the response of chickens to *S. typhimurium* and *E. coli* infections. *Vet Rec*. 96:238–243.
359. Wyeth, P.J., and N.J. Chettle. 1990. Use of infectious bursal disease vaccines in chicks with maternally derived antibodies. *Vet Rec.* 126:577–578.
360. Wyeth, P.J., and G.A. Cullen. 1978. Transmission of immunity from inactivated infectious bursal disease oil-emulsion vaccinated parent chickens to their chicks. *Vet Rec.* 102:362–363.
361. Wyeth, P.J., N.J. Chettle, and A.R. Mohepat. 1992. Use of an inactivated infectious bursal disease oil emulsion vaccine in commercial layer chicks. *Vet Rec.* 130:30–32.
362. Xu, J., Z. Zhang, Y. Yin, S. Cui, S. Xu, Y. Guo, J. Li, J. Wang, X. Liu, and L. Han. 2009. Development of reverse-transcription loop-mediated isothermal amplification for the detection of infectious bursal disease virus. *J Virol Methods.* 162:267–71.
363. Xue, C., Y. Zhang, Q. Zhou, C. Xu, X. Li, and Y. Cao. 2009. Rapid detection of infectious bursal disease virus by reverse transcription loop-mediated isothermal amplification assay. *J Vet Diagn Invest.* 21:841–3.
364. Yamaguchi, S., I. Imada, and H. Kawamura. 1981. Growth and infectivity titration of virulent infectious bursal disease virus in established cell lines from lymphoid leucosis. *Avian Dis.* 25:927–935.
365. Yamaguchi, T., K. Iwata, M. Kobayashi, M. Ogawa, H. Fukushi, and K. Hirai. 1996. Epitope mapping of capsid proteins VP2 and VP3 of infectious bursal disease virus. *Arch Virol.* 141: 1493–1507.
366. Yao, K., and V.N. Vakharia. 2001. Induction of apoptosis *in vitro* by the 17 kDa non-structural protein of infectious bursal disease virus: possible role in viral pathogenesis. *Virol.* 285:50–58.
367. Yehuda, H., M. Goldway, B. Gutter, A. Michael, Y. Godfried, Y. Shaaltiel, B.Z. Levi, and J. Pitcovski. 2000. Transfer of antibodies elicited by baculovirus derived VP2 of very virulent infectious bursal disease virus strains to progeny of commercial breeder chickens. *Avian Pathol.* 29:13–19.
368. Yip, C.W., Y.S. Yeung, C.M. Ma, P.Y. Lam, C.C. Hon, F. Zeng, and F.C. Leung. 2007. Demonstration of receptor binding properties of VP2 of very virulent strain infectious bursal disease virus on Vero cells. *Virus Res.* 123:50–6.
369. Yip, C.W., C.C. Hon, F. Zeng, and F.C. Leung. 2012. Cell culture-adapted IBDV uses endocytosis for entry in DF-1 chicken embryonic fibroblasts. *Virus Res.* 165:9–16.
370. Yousif, A.A., W.A. Mohammad, M.H. Khodeir, A.Z. Zeid, A.A. el-Sanousi, M.S. Saber, and I.M. Reda. 2006. Oral administration of hyperimmune IgY: an immunoecological approach to curbing acute infectious bursal disease virus infection. *Egypt J Immunol*. 2006;13(2):85–94.
371. Yuan, W., X. Zhang, X. Xia, and H. Sun. 2012. Inhibition of infectious bursal disease virus infection by artificial microRNAs targeting chicken heat-shock protein 90. *J Gen Virol.* 93:876–9.
372. Yuasa, N., T. Taniguchi, T. Noguchi, and I. Yoshida. 1980. Effect of infectious bursal disease virus infection on incidence of anemia by chicken anemia agent. *Avian Dis.* 24:202–209.
373. Zhang, G.P., Q.M. Li, Y.Y. Yang, J.Q. Guo, X.W. Li, R.G. Deng, Z.J. Xiao, G.X. Xing, J.F. Yang, D. Zhao, S.J. Cai, and W.M. Zang. 2005. Development of a one strip test for the diagnosis of chicken infectious bursal disease. *Avian Dis.* 49:177–181.
374. Zierenberg, K., R. Raue, H. Nieper, M.R. Islam, N. Eterradossi, D. Toquin, and H. Müller. 2004. Generation of serotype1/serotype 2 reassortant viruses of the infectious bursal disease virus and their investigation *in vitro* and *in vivo*. *Virus Res.* 105:23–34.

Chapter 8

Chicken Infectious Anemia Virus and Other Circovirus Infections

Introduction

Karel A. Schat and Leslie W. Woods

During the last 20 years many new small viruses with single-stranded covalently closed circular DNA have been described in free-living birds as well as in commercial poultry including chickens, ducks, geese, and pheasants. Originally these viruses were classified as *Circoviridae* and subsequently divided into *Circovirinae* and *Gyrovirinae* (14). The *Circovirinae* include pigeon circovirus (PiCV) and psittacine beak and feather disease virus (PBFDV or BFDV), while chicken (infectious) anemia virus (CAV or CIAV) is currently listed as the only virus in the *Gyrovirinae* (14). However, the International Committee on Taxonomy of Viruses (ICTV) is considering a proposal to include the *Gyrovirinae* with one genus (*Gyrovirus*) into the proposed new family of *Anelloviridae* (3). In addition to the *Gyrovirinae*, the *Anelloviridae* contain the *Anellovirinae*, with 14 different genera with the human torque-teno virus (2) as the best known example of the *Alphatorquevirus*, and the *Tornovirinae*. The ICTV also proposes to place the avian genera of the *Circovirinae* into the genus *Betacircovirus* (PiCV, PBFDV, finch circovirus, starling circovirus, canary circovirus, and gull circovirus) or *Gammacircovirus* (duck circovirus, goose circovirus, and swan circovirus) (4). The *Alphacircovirus* genus contains porcine circovirus (PCV), which was the first discovered circovirus (13). Relevant members of the *Gyrovirinae* and the avian *Circovirinae* (*Beta-* and *Gammacircoviruses)* are described in detail below.

Both the *Gyrovirinae* and *Circovirinae* have single-stranded, circular DNA genomes consisting of approximately 1,800 to 2300 nucleotides (nt). The nt sequence and genome organization is very different between *Gyrovirinae* and *Circovirinae*. The CIAV genome has a negative sense organization, whereas the *Circovirinae* have an ambisense organization. For both groups, genome replication most likely occurs by a rolling circle which initiates at a stem-loop structure for the *Circovirinae*. The origin of replication has not been determined for CIAV, and a stem-loop structure has not been identified. A key characteristic for the *Anelloviridae* is the presence of an apoptosis-inducing protein (5, 10), which is essential for virus replication.

Porcine circovirus, PBFDV, and plant nanoviruses (15) are closely related (1, 9). The vertebrate circoviruses may have evolved as the consequence of a recombinational event in which the N-terminus of the *rep* (replication initiator protein) gene came from a nanovirus and the C-terminal region came from a picorna-like virus (6). Recently, many new viruses have been found that most likely will be accepted as members of the newly recognized subfamily *Cyclovirinae* of the *Circoviridae*, some of which have been found in chickens (7, 8). Two new viruses with characteristics of *Gyrovirus* were also recently described in chickens (11) and humans (12). The relevance of these viruses as pathogens has not been established.

Although nt sequences and replication strategies are very different for these two virus families, the common denominator is that virus replication requires dividing cells. In many instances these viruses were detected in samples from birds with putative immunosuppression with or without feather abnormalities. The primary histopathological changes associated with infections with CIAV and the different avian *Circovirinae* are lymphocytic depletion in the primary lymphoid tissues in addition to changes associated with secondary infections.

Acknowledgement

The authors are greatly indebted to V. von Bülow for his contribution to earlier editions of this chapter.

Diseases of Poultry, Thirteenth Edition. David E. Swayne.
© 2013 John Wiley & Sons, Inc. Published 2013 by John Wiley & Sons, Inc.

Chicken Infectious Anemia

Karel A. Schat and Vicky L. van Santen

Introduction

Chicken infectious anemia (CIA) was first recognized by Yuasa et al. (238). The disease is characterized by aplastic anemia and generalized lymphoid atrophy with concomitant immunosuppression and is frequently complicated by secondary viral, bacterial, or fungal infections. Since the first description of this disease and subsequent isolation of chicken infectious anemia virus (CIAV) in Japan (241), the virus has been isolated in virtually all countries with poultry industries. CIAV appears to play a major role in the etiology of a number of multifactorial diseases associated with hemorrhagic syndromes and/or aplastic anemias. In addition to anemia and associated syndromes, subclinical CIAV infections, without anemia and increased mortality, are frequently observed in commercial flocks.

Definition and Synonyms

The terminology for the causative agent has varied over the years. The agent was originally designated chicken anemia agent (CAA) (238) but after morphologic and biochemical characterization (52, 117, 194), it was renamed chicken anemia virus (CAV) (52, 138). The name CAV has been accepted by the International Committee for the Taxonomy of Viruses (203). However, because the disease is commonly referred to as chicken infectious anemia, the causative virus is more logically referred to as chicken infectious anemia virus (CIAV) (231). This terminology will be used in this chapter.

CIA and closely associated syndromes have commonly been termed hemorrhagic syndrome (247), anemia-dermatitis (219), or blue wing disease (9, 44).

Economic Significance

Infection with CIAV has been confirmed as the cause of disease in chicken flocks between two and four weeks of age with syndromes suggestive of infectious anemia (171). In these flocks growth was retarded and mortality was generally between 10% and 20%, but occasionally it reached 60%. In chickens six or more weeks of age, the etiologic significance of CIAV infection associated with aplastic anemia-hemorrhagic syndromes (61, 148, 242) has not been definitely established.

Infection with CIAV constitutes a serious economic threat, especially to the broiler industry and the producers of specific-pathogen-free (SPF) eggs. McIlroy et al. (111) reported a loss of net income of about 18.5% due to decreased weight at processing and increased mortality around three weeks of age in 15 broiler flocks. Approximately 30% of these broilers were derived from a common breeder flock, which was free of CIAV antibodies at 20 weeks of age, making the offspring susceptible to CIAV infection at a very early age. Interestingly, feed conversion ratios were not affected in the broilers with CIA. Davidson et al. (30) documented 14%–24% reductions in weight of meat sold, as well as changes in feed conversion ratios, from CIAV-infected flocks exhibiting clinical signs characteristic of CIA.

Studies addressing the impact of subclinical CIAV infection on broiler flock performance have yielded conflicting results. In one study, subclinically infected flocks in Northern Ireland yielded a 13% lower net income than CIAV antibody-negative flocks, mostly due to decreased weight at processing and suboptimal feed conversion ratios (120). A Belgian study demonstrated a higher slaughterhouse condemnation rate in CIAV positive flocks compared to CIAV negative flocks, but was unable to detect differences in other performance criteria (34). However, others were unable to confirm the negative influence of subclinical infection on production in the United States (60) and Denmark (95). In a retrospective case-control study in the United States, although presence of CIAV was found to be a risk factor for disease (gangrenous dermatitis, coccidiosis, or respiratory disease), and disease was associated with production losses, the detection of CIAV alone was not associated with statistically significant decreases in performance or production losses (67). It is likely, however, that the impact of subclinical infection with CIAV is underestimated, especially because subclinical infection significantly reduces the development of antigen-specific cytotoxic T lymphocytes (CTL) (108) and also adversely affects macrophage function (109).

The economic importance for the SPF industry is difficult to estimate, but seroconversion frequently occurs during the laying period (54, 237). As a consequence of seroconversion the flock is considered positive and the eggs are no longer SPF. The importance of this depends on legislation for vaccine production. The European Union requires the absence of CIAV from eggs used for the production of all poultry vaccines for administration in birds less than seven days of age. Eggs from CIAV-positive flocks may be used according to USDA guidelines. Vaccines for human use, such as measles and mumps, require the use of eggs free of CIAV in Australia, Europe, and the United States.

Public Health Significance

Results of serologic tests suggest that CIAV has no public health significance (231).

History

CIAV (Gifu-1 strain) was first isolated in 1979 in Japan by Yuasa et al. (238). However, the virus was present in chickens at least as early as 1970, when Jakowski et al. (87) described a condition of hematopoietic destruction in chickens with

Marek's disease (MD). The ConnB isolate of CIAV was later isolated from an ampoule of tumor cells obtained from those chickens (183, 236). The demonstration of CIAV antibodies in archived sera indicates that CIAV was present in the United States as early as 1959 (206). Aplastic anemia syndromes, including inclusion-body hepatitis, were described many years before CIAV was detected. Their possible etiologic association with CIAV infection has been reviewed and discussed in several papers dealing with CIA (119, 163, 230).

A major breakthrough was achieved in 1983 when Yuasa et al. (242) reported that virus could be propagated in certain chicken lymphoblastoid cell lines, e.g., Marek's disease chicken cell (MDCC)-MSB1 (MSB1), causing cytopathic effects (CPE). This enabled the development of *in vitro* serological assays such as indirect immunofluorescence assays (223, 245) and virus-neutralization (VN) tests (243). In addition virus could be easily purified from supernatant fluids of CIAV-infected cell cultures and characterized (52, 63, 82, 117, 194).

Virus identification was followed by studies that unraveled much of the pathogenesis and epizootiology of the infection. In the early 1990s, remarkable progress was made in research on the molecular biology of CIAV (reviewed in 172). This resulted in the development of refined diagnostic methods and the potential for development of new types of vaccines (85, 100, 142).

Etiology

Classification

The nomenclature of the *Circoviridae* is discussed in detail in the introduction of Chapter 8. CIAV is currently classified as the only member of the genus Gyrovirus of the *Circoviridae* (201). However, the genome of a second gyrovirus was recently amplified from serum from a diseased chicken in Southern Brazil. This virus, tentatively named avian gyrovirus 2 (AGV2), has a genome of 2,383 nt with a similar genome organization as CIAV and an nt identity of approximately 40% (168). Subsequently AGV2 was detected in additional chickens in Southern Brazil and in the Netherlands. Sequence analysis indicates that at least three genotypes exist with 16% divergence between the groups (39). The importance of AGV2 as a disease agent has not been established.

Morphology

CIAV virions consist of non-enveloped, icosahedral particles with an average diameter of 25 to 26.5 nm, as visualized in preparations negatively stained with 1% uranyl acetate (52, 82, 117). In such preparations, two types of virus particles differing in their orientation on the grid are commonly detected. Type I particles exhibit three-fold rotational symmetry and show a pattern of one central hollow surrounded by six neighboring hollows with a center-to-center distance of 7.5 nm, forming a regular surface network (Figure 8.1B). Type II particles exhibit five-fold rotational symmetry and are characterized by 10 evenly spaced surface protrusions giving the impression of a "cog-wheel" structure (Figure 8.1A). The appearance of these particles suggested a regular T = 3 icosahedron with 32 morphologic subunits. However, modeling of unstained cryopreserved CIAV particles indicated a T = 1 lattice with 60 copies of VP1 in a capsid consisting of 12 pentagonal trumpet-shaped capsomers. These protruding capsomers distinguish CIAV from other Circoviridae, which have a smoother capsid surface (27).

Virions have a buoyant density in cesium chloride gradients variously reported as 1.33–1.34 g/mL (6, 194) or between 1.35 and 1.37 g/mL (52, 63). The sedimentation coefficient of CIAV has an estimated value of 91S in isokinetic sucrose gradients (6).

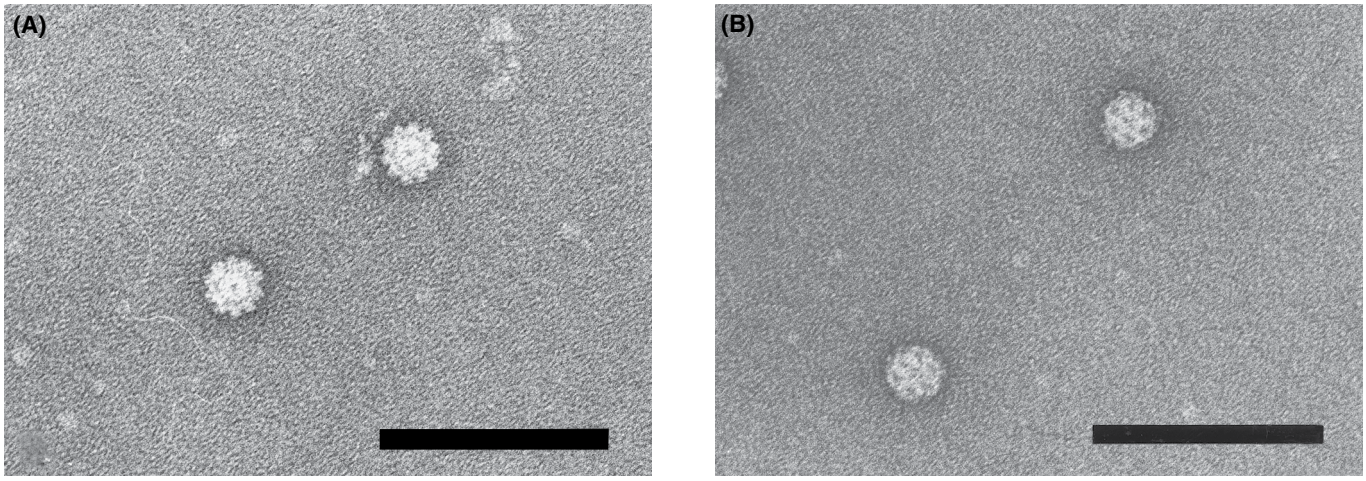

Figure 8.1. Electron micrographs of chicken CIAV. Different structural aspects of the CIAV capsids become apparent in negative-stained preparations. Two types of particle projections are obvious. (A) Particle projection type II characterized by 10 peripheral protrusions. ×250,000. Bar = 100 nm. (Gelderblom) (B) Projection type I showing CIAV capsids that exhibit six stain-filled morphologic units that surround one central hole.

Chemical Composition

Viral DNA

The genome of CIAV consists of single-stranded, circular, covalently closed DNA (52, 194) of negative sense (138). Noteborn et al. (138) and Claessens et al. (23) published the first complete sequences of CIAV. Since then many more sequences have been published. Nearly all CIAV genomes are 2,298 nucleotides in length, and contain four 21-base tandem direct repeats (DR), with a 12-base insert between the second and third DR. Todd et al. (197) reported that a fifth DR, upstream of the 12-bp insert, was obtained after about 30 passages of the Cux-1 strain in MSB1 cells, yielding a 2,319-nucleotide genome. In infected cells, both single-stranded and double-stranded DNA are present, but virions contain only the circular minus-strand DNA (161, 197).

All sequenced genomes have three partially overlapping open reading frames (ORFs) coding for proteins of 52 (VP1, ORF1), 24 (VP2, ORF2) and 13 kDa (VP3, ORF3), one promoter region, and one polyadenylation signal. ORF3 is located within ORF2, and ORF2 partly overlaps ORF1. This genomic organization distinguishes CIAV from other members of the *Circoviridae*, which transcribe mRNA from both strands of their replicative intermediates, making their genomes ambisense (135).

The promoter-enhancer region, consisting of the four or five 21-base DR and the 12-base insert, is located upstream of ORF2 (141). The repeat units and the 12 bp insert contain recognition sites for different transcription factors (122, 129, 130, 138). Optimal transcription requires both the DR and the 12 bp insert. The presence of the extra repeat enhances transcriptional activity (141), whereas deletion of the first two DR reduces transcriptional activity by 40%–50% (161). Disruption of the relative spacing of the DR region with other promoter elements and the start of transcription by insertion of a 7-bp linker decreases rate of virus replication in culture (143). Noteborn (unpublished data cited in 143) found that CIAV DNA containing three DR but lacking the 12-bp insert was not able to produce viable virus particles. Although the 12-bp insert binds the transcription factor SP1 (141), substitution of a different 12-bp sequence did not further impair replication of virus already impaired by insertion of a 7-bp linker between the DR region and the rest of the CIAV promoter (143). Some changes in the length of the 12-bp insert region resulted in decreased cytopathogenicity and rate of spread in culture, but the virus-neutralizing epitope was still produced (143). The DRs contain sequences similar to the estrogen response element consensus half sites and compete with estrogen response elements for estrogen receptor binding in nuclear extracts (129). Expression from the CIAV promoter is higher in cells expressing estrogen receptor and is further increased by addition of estrogen (129), while binding of the transcription factor COUP-TF1 inhibits transcription (130). An additional negative regulator of transcription is the E-box-like sequence at the transcription initiation site, which binds delta-EF-1 (130).

Initially, only one unspliced, polycistronic mRNA of 2.1 kb, containing all three ORFs, and a minor transcript of approximately 4 kb were identified. Use of internal AUG start codons is required for the synthesis of VP1 and VP2 (139, 161). Subsequently, minor spliced mRNAs were identified in addition to the major unspliced mRNA by both Northern blotting and RT-PCR (98). One of the spliced mRNAs potentially encodes a protein that shares amino- and carboxy-terminal sequences with VP1, but lacks 197 amino acids (positions 132–328) of VP1's 449 amino acids. Other spliced mRNAs potentially encode novel proteins with frame-shifts. However, protein products of the spliced mRNAs have not been demonstrated.

Viral Proteins

A 50-kDa viral protein (VP1) is the only protein detected on highly purified virus particles and forms the capsid (194). The N-terminal 40 amino acids show a limited similarity to histone proteins, suggesting a DNA binding role (23, 122). The non-structural 30 kDa VP2 probably acts as a scaffold protein during virion assembly, so that VP1 folds in the proper way (100, 142). The third viral protein, VP3 (16 kDa), is associated with nuclei in infected cells (20, 40, 140), but not with highly purified virus particles (13).

Studies using neutralizing monoclonal antibodies (MAb) in Western blots suggested that VP1 neutralizing epitope(s) are conformational in nature (13). Neutralizing antibodies were induced after inoculation of chickens with insect cells containing both VP1 and VP2, but not with cells containing only VP1 or only VP2 (100). Virus-neutralizing MAb reacted with baculovirus-produced VP1 only if VP2 was co-produced. However, virus-neutralizing MAb bind to the native VP1 in virus capsids, which contain no VP2, but not to denatured VP1, lending further support to the role of VP2 as a scaffolding protein (142).

VP2 and VP3 are nonstructural proteins. VP2 is a multifunctional protein. In addition to its putative role as a scaffold protein enabling VP1 to attain its proper conformation, VP2 has serine/threonine and tyrosine protein phosphatase activities (157). VP3, also named apoptin, is a strong inducer of apoptosis in chicken thymocytes and chicken lymphoblastoid cell lines (140).

Virus Replication

Virions probably enter the cell by conventional adsorption and penetration. Low levels of the 2.1-kb polycistronic viral RNA transcript can be demonstrated at eight hours post infection of MSB1 cells, with maximum levels attained at 48 hours (139, 161).

Viral DNA replication occurs via a double-stranded replicative form (RF), probably by the rolling-circle mechanism (198). The actual initiation site for DNA replication has not been identified, although Bassami et al. (8) reported the presence of a nonanucleotide motif that may be involved in the initiation of DNA replication. Transfection experiments with cloned tandemly-repeated CIAV RF suggest that homologous recombination can occur (198). This process can lead to double-stranded circular molecules that are identical to RF.

The double-stranded RF may lead to the presence of latent episomal DNA and be responsible for the presence of viral DNA in gonadal tissues as reported by Cardona et al. (19). Todd (200) suggested that VP1 may have a role in DNA replication based on the presence of three amino acid motifs associated with rolling-circle replication of DNA.

VP3 can be detected at six hours, whereas VP2 is present at 12 hours post infection. The capsid protein VP1 is not detectable until 30 hours post infection (40).

The protein phosphatase activity of VP2 is very important, but not absolutely required, for CIAV replication. CIAV with a mutation of the catalytic cysteine of VP2, which abolishes both serine/threonine and tyrosine phosphatase activities (157), exhibits impaired replication and cytopathogenicity in MSB1 cells, reaching titers 10,000-fold lower than wild-type virus (158). Surprisingly, another VP2 catalytic site mutation that increases the tyrosine phosphatase activity and reduces serine/threonine phosphatase activity by only 30% impairs viral replication to a similar degree as the mutation abolishing both phosphatase activities (158). Other VP2 mutations, expected to have only subtle or no effects on protein phosphatase activity, resulted in varying degrees of impairment of CIAV replication (159). Unfortunately, the phosphatase activity of these other VP2 mutants was not reported. In addition to impaired replication, the VP2 mutants apparently exhibit reduced cytopathogenicity, which must be assessed subjectively, in culture. Interestingly, one VP2 mutation resulted in reduced cytopathogenicity without affecting viral replication efficiency, which suggests that viral replication functions and cytopathogenicity can be separated. In contrast to wild type CIAV, in cells infected with VP2 mutants, VP3 is cytoplasmic rather than nuclear in location, suggesting a role for VP2 in VP3 trafficking and function. This is significant, because the nuclear location of VP3 correlates with its ability to cause apoptosis in transformed, but not primary cells, where VP3 remains cytoplasmic (29).

VP3 is essential for the virus replication cycle (164). Truncated apoptin lacking the last 11 amino acids is unable to induce apoptosis in transfected MSB-1 cells. Interestingly, VP3 was found to induce apoptosis in several malignant human lymphoblastoid cell lines (254) and human osteosarcoma cells (255), but not in normal human cells (28). This finding has been confirmed in more than 70 cell types tested and extended to growth-transformed cells and cells from cancer-prone individuals exposed to UV irradiation (reviewed in 147). Animal experiments using adenovirus vectors expressing VP3 suggest that VP3 may be used to treat humans with cancer (162, 211). The potential of VP3 as an anti-tumor agent has stimulated investigation into the mechanism whereby it induces apoptosis in transformed cells, which has been reviewed by Schat and van Santen (171) and de Smit and Noteborn (35).

Whether VP3 has functions in the CIAV replication cycle in addition to induction of apoptosis is not known. However, VP3 multimers form non-sequence-specific complexes with double- and single-stranded DNA and with RNA, with preference for ends in double-stranded DNA (104). Association with VP3 induces bends in DNA. These observations suggest VP3 could affect gene expression or DNA replication.

The replication of CIAV in very young chickens occurs primarily in hemocytoblasts in the bone marrow and T cell precursors in the cortex of the thymus (reviewed in 4, 128). Replication of the virus in the cortex of the thymus results in cell death by apoptosis (89) caused by VP3. Virus replication also has been demonstrated in other organs, where it is usually but not always associated with lymphocytes (180). In chickens infected at three or six weeks of age, CIAV replicates in the thymic cortex, but CIAV-positive cells are rare in the bone marrow (181).

Resistance to Chemical and Physical Agents

CIAV is extremely resistant to most treatments (119, 238, 251). Treatment of virus in liver suspensions with 50% phenol for five minutes inactivates CIAV but treatment with 5% phenol for two hours at 37°C is ineffective. The virus is resistant to treatment with 50% ethyl ether for 18 hours and chloroform for 15 minutes. Treatment of liver suspensions with 0.1 N NaOH for two hours at 37°C or 24 hours at 15°C inactivates CIAV incompletely. Treatment with 1% glutaraldehyde for 10 minutes at room temperature, 0.4% β-propiolactone 24 hours at 4°C, or 5% formaldehyde 24 hours at room temperature inactivates the virus completely. Commercial disinfectants based on invert soap, amphoteric soap, or orthodichlorobenzene are not effective against CIAV.

Treatments with iodine or hypochlorite are effective, but require two hours at 37°C with final concentrations of 10% rather than the generally recommended concentrations of 2%. Formaldehyde or ethylene oxide fumigation for 24 hours does not inactivate CIAV completely. CIAV is also resistant to acid treatment at pH 3 for three hours. Treatments with disinfectants with pH 2 are widely used by the SPF industry and are apparently effective in inactivating the virus (54, 237).

CIAV is also resistant to treatment with 90% acetone for 24 hours (191). As a consequence, acetone-fixed slides of CIAV material may remain infectious and need to be sterilized prior to final disposal. CIAV is resistant to heating at 56°C or 70°C for one hour and at 80°C for 15 minutes (45, 61, 238). However, it is only partially resistant to heating at 80°C for 30 minutes, and is completely inactivated within 15 minutes at 100°C (61). With regard to heat inactivation of CIAV, it is important to distinguish between CIAV in liquid substrates and in a dried state. Lyophilized CIAV is resistant to treatment at 120°C for 30 minutes (235). Inactivation of CIAV in infected chicken byproducts requires a core temperature of 95°C for 35 minutes or 100°C for 10 minutes, whereas fermentation is ineffective (210).

Strain Classification

Antigenicity

No antigenic differences have been recognized among various Japanese, European, and American isolates of CIAV using polyclonal chicken antibodies (45, 223, 229, 246). As a consequence, it is generally accepted that all strains belong to one serotype (119, 145). However, based on differences in reaction

patterns with MAb (118, 176, 182) and DNA sequence differences resulting in changes in the predicted protein folding patterns (167), it is expected that strains may differ in antigenicity.

A second serotype of CIAV, represented by CIAV-7, has been reported (185, 186). CIAV-7 has physical characteristics similar to CIAV (186), and produces similar clinical disease and gross and microscopic lesions (185). However, thymic and bone marrow lesions and anemia produced by CIAV-7 are much milder than those generated by CIAV. Furthermore, the lack of any antigenic cross reactivity using polyclonal chicken sera and lack of cross hybridization under low-stringency conditions suggest that CIAV-7 is a novel virus rather than a new serotype of CIAV. This virus has not been further reported since the original description.

Molecular Differences

Partial or complete genome sequences of numerous strains from different parts of the world have been determined and amino acid sequences predicted. The genetic variation among isolates is limited and generally less than 5%, with most of the variation in the VP1 coding region. As more CIAV sequences have been determined, slightly more variability has been found. For example, Nogueira et al. (135) found more than 10% nucleotide sequence differences between partial sequences of some CIAV samples obtained from Brazilian chickens after 1998 and sequences of older CIA isolates. However, these nucleotide sequence differences led to relatively few amino acid sequence differences in VP1. Molecular evolution model analyses of 46 complete VP1 sequences identified six to eight amino acid positions in VP1 that are subject to positive selection (233). Analysis of a smaller number of partial VP1 sequences found evidence for positive selection in only one of 15 sequences compared (68). Isolates are currently divided into three or four groups (reviewed in 172) and some of the genotypes have recently been subdivided (43, 99). Some isolates appear to have arisen by recombination between genomes of different molecular groups (71). In addition, apparent phylogenetic relationships may be influenced by adaptation to culture (22). Furthermore, it is not clear whether these groups differ biologically. For these reasons, the significance of groupings based on phylogenetic relationships of CIAV sequences remains unclear.

Minor differences in predicted amino acid sequences have been noted, especially for the amino acids 139–151 of VP1 (hypervariable region), and also at the carboxy terminus of VP2 and VP3 (167). The predicted protein structure of VP1 is affected by the observed differences in the hypervariable region. Chimeric constructs in which a fragment encoding the hypervariable region had been exchanged between the highly passaged Cux-1 and low-passage CIA-1 strains demonstrated that differences in the hypervariable region can influence virus replication in MSB1 cells. (167). Noqueira et al. (137) and van Santen et al. (216) reported that the inability to isolate CIAV strains in MSB1 was not solely linked to changes in the hypervariable region. The importance of the hypervariable region for *in vivo* pathogenicity is not clear. Meehan et al. (123) examined the pathogenicity of a number of chimeric viruses with multiple changes, including those in the hypervariable region, and concluded that changes in the hypervariable regions did not contribute disproportionately to pathogenicity. However, studies with changes only in this region have not been reported, and the question of the importance of the hypervariable region for the pathogenicity remains unresolved.

Pathogenicity

Although it is generally accepted that strains isolated worldwide do not differ substantially in pathogenicity, very few studies have directly compared different strains under identical experimental conditions. Yuasa and Imai (246) compared 11 isolates which were each passaged 12 times in MSB1 cells prior to inoculation. Minor differences in virulence were found when chicks were inoculated at seven days but not at one day of age; inoculation at 14 days of age failed to induce lesions. Natesan et al. (134) compared the pathogenicity of four isolates in one-day old chicks and detected no differences. Toro et al. (204) reported thymus and bone marrow lesions when ten-week-old broiler breeders were infected with strain 10343, but comparative studies with other isolates in these birds were not reported.

Attenuation

Attenuation of CIAV by cell culture passages has been problematic with conflicting results; details can be found in references 171 and 172. Attenuation of Cux-1 was reported after 49 passages in cell culture by von Bülow and Fuchs (224), while Todd et al. (197) found that Cux-1 became substantially less pathogenic only after 173 passages in MSB1 cells. Moreover, the attenuation at this level was not stable even when molecular clones were analyzed (202). Additional serial passages were analyzed at p320 and some molecular clones were indeed further attenuated (112), but the stability of the attenuation was not reported. Attenuation of isolates other than Cux-1 was also attempted but without success after 40 (63, 241) or 129 (187) passages. On the other hand, Chowdhury et al. (22) reported that two Malaysian CIAV isolates were partly attenuated at p60 and one was further attenuated at p123 in MSB1 cells. Stability of attenuation and which changes were responsible for attenuation were not examined.

In addition to cell-culture passage, site-directed mutagenesis of VP2 was used to attenuate CIAV (159, 160). Inoculation of these mutant viruses in cell culture suggested that the mutants were attenuated. The results in chickens were less clear (97) and the stability of the one mutant that was apathogenic in chicks was not established.

Recently, Schat (172) reviewed the molecular changes associated with attenuation and concluded that the molecular basis for attenuation is complex and poorly understood.

Laboratory Host Systems

CIAV can be propagated and assayed in cell cultures, one-day-old chicks, or in chicken embryos.

Cell Cultures

The use of cell cultures is the preferred method for virus isolation and propagation since Yuasa (242) reported that some chicken lymphoblastoid T cell lines (e.g., MDCC-MSB1 and MDCC-JP2) and the B cell line LSCC-1104B1 are suitable for propagation and assay of CIAV. However, many other chicken T cell and B cell lymphoblastoid cell lines, whether producers or non-producers of the respective transforming viruses, are resistant to CIAV (15, 226, 242). Two mammalian lymphoblastoid cell lines were recently tested and are resistant to CIAV (70).

MSB1 cell cultures have been preferred for *in vitro* cultivation, although sublines of MSB1 differ in their susceptibility to infection. Some strains of CIAV, e.g., CIA-1 (105), do not replicate in one subline of MSB1 (MSB1-L) and poorly in another subline of MSB1 (MSB1-S), whereas both sublines are susceptible to infection with Cux-1. Furthermore, the sensitivity of susceptible MSB1 cells to CIAV is reduced after subculturing the cells, in some cases for as little as eight weeks (15, 216, 223). The MDCC-CU147 (CU147) cell line is superior to MSB-1 for propagation of CIAV, including the CIA-1 strain (15), regeneration of CIAV from CIAV genomes molecularly cloned directly from field specimens (216), and virus titrations (15).

Virus titrations require subculturing of inoculated cells every two to four days until cells inoculated with the endpoint dilution of CIAV are destroyed (223, 242). Alternatively, endpoints can be determined by PCR (214) or immunofluorescence assay (15).

Chickens

Inoculation of one-day-old chicks free of maternal antibodies can be used to isolate and propagate CIAV in instances where the clinical syndrome suggests that CIAV may be present, but *in vitro* virus isolation and/or PCR assays are negative. Positive chicks develop anemia and gross lesions in lymphoid tissues and bone marrow after 12 to 16 days (238). Mortality may occur between 12 and 28 days post-inoculation but usually remains low, rarely exceeding 30%. Neonatal (249) or embryonal bursectomy (105) can enhance the sensitivity of isolation, especially if samples with low titers are analyzed. Chicks with maternal anti-CIAV antibody are resistant to CIAV infection and cannot be used for isolation or propagation of CIAV (239).

Chicken Embryos

Propagation of CIAV in chicken embryos following yolk sac inoculation has been reported (228). Moderate virus yields were obtained after 14 days from all parts of the embryo, but not from yolk or chorioallantoic membrane. Depending on the virus isolate, lesions including embryo mortality may be absent or present between 16 and 20 days of incubation (31, 103, 187, 228).

Pathobiology and Epizootiology

Incidence and Distribution

CIAV is ubiquitous in all major chicken-producing countries of the world (reviewed in 231).

Natural and Experimental Hosts

The chicken is the only known host for CIAV. All ages are susceptible to infection, but susceptibility to anemia rapidly decreases in immunologically intact chicks during the first one to three weeks of life (61, 170, 238, 240, 246), although some strains have been reported to cause a reduction in hematocrit values after experimental infection of ten-week-old broiler breeders (204). Chickens three weeks of age and older continue to be susceptible to effects of CIAV on immune function (108, 109, 165, 181, 204).

Antibodies to CIAV have been detected in Japanese quail but not in ducks, pigeons, and crows in Japan, but information on the specific species was not provided (49). Fancy chicken breeds in The Netherlands were frequently positive for CIAV antibodies (36). A survey in Ireland found CIAV antibodies in jackdaws, rooks, and rare avian breeds, but not in pigeons, pheasants, or ducks (16). McNulty et al. (114) failed to detect antibodies in turkey and duck sera. Turkey poults inoculated at one day of age with high doses of the virus were resistant to infection and did not develop antibodies to CIAV (119). However, a circovirus similar to CIAV, but with low pathogenicity in chickens, has been isolated from turkeys (175).

Transmission

CIAV spreads both horizontally and vertically. Horizontal transmission most likely occurs through the fecal-oral route based on the presence of high concentrations of virus in the feces of chickens for five to seven weeks after infection (74, 243). However, infection via the respiratory route, as shown in chicks after intratracheal inoculation (170), also may be possible in the field. In addition to virus shedding through the feces, virus also can be shed through feather follicle epithelium (32). CIAV spreads easily among chickens in a group only if they are immunosuppressed (240). In naturally exposed flocks, it commonly takes two to four weeks until most birds have seroconverted (114, 184, 229). Isolation may prevent early seroconversion; 70% of grandparent flocks that were imported into Sweden and kept in quarantine remained seronegative until 16 weeks of age (47).

It is important to differentiate vertical transmission in commercial flocks from that in SPF flocks experiencing sporadic breaks. In the former, vertical transmission of virus through hatching eggs is considered to be the most important means of dissemination (21, 47). Vertical transmission occurs when antibody-negative hens become infected by horizontal infection or by semen from infected cocks (75). Egg transmission only occurred from eight to 14 days after experimental infection of hens (75, 244). After the development of immune responses egg transmission of virus could not be demonstrated, even when birds were stressed by injections with betamethasone or exchanging hens in cages. Field observations indicate that vertical transmission can occur during a period of three to nine weeks after exposure with peak transmission at one to three weeks. The duration of egg transmission in a flock depends on the rate of spread of infection and development of immunity to CIAV (9, 21, 44, 219). In contrast to earlier studies showing the absence of vertical transmission after the

development of antibodies, later studies demonstrated CIAV DNA in progeny of hens with high titers of neutralizing antibody. Detection of CIAV relied on highly sensitive nested PCR, and no disease or lesions were found in the progeny (12, 68).

Seroconversion patterns in SPF flocks suggest a more complex situation than described for commercial birds. Seroconversion in SPF chickens has been reported for commercial and non-commercial SPF flocks and often occurs during the first laying cycle (17, 48, 54, 114, 115, 173, 237, 245). When CIAV was accidentally introduced in three genetically different SPF flocks maintained at Cornell University, seroconversion coincided with the development of sexual maturity even while birds were housed in a CIAV-infected environment. Not 100% of birds of all genetic strains seroconverted during a 60-week period while birds were kept in colony cages in an environment contaminated with CIAV. However, CIAV DNA could be detected in both seronegative and seropositive birds by nested PCR assays of gonadal tissues and spleens, even in chickens that had been antibody positive for more than 40 weeks (17, 19).

Horizontal spreading in SPF flocks kept in cages may be less efficient than described for field flocks. Miller et al. (126) followed seroconversion in a flock of 90 chicks hatched from eggs supplied by an SPF producer. All birds were bled monthly and one bird seroconverted at six weeks of age; this bird was euthanized. The remainder of the flock remained seronegative until 16 or 20 weeks of age when two additional birds became antibody positive. In a horizontal transmission experiment, a rooster shedding virus through semen was placed in a cage flanked by cages with seronegative chickens, which remained virus-negative over at least a two-month period (18). Significant differences in seroconversion rates were noted among genetic strains (17), but even between different generations of the same genetic strains, seroconversion ranged from close to 0% to 95% (126). Schat and Schukken (173) followed seroconversion of SPF flocks in a completely closed environment during an eight-year period and found remarkable fluctuations in the percent seroconversions from flock to flock. Examination of tissues from embryos obtained from hens positive for viral DNA in the gonads showed that the embryos can carry the viral DNA without signs of virus replication, thus continuing the transmission cycle (127). These data strongly support the hypothesis, first made by McNulty (119), that CIAV can establish a latent infection (128, 172).

Incubation Period

In experimental infections, anemia and distinct histologic lesions can first be detected at eight days after parenteral inoculation of virus. Clinical signs generally develop after 10 to 14 days, and mortality begins at 12 to 14 days after inoculation (66, 189, 238). Clinical signs are delayed and milder after oral inoculation compared to intramuscular inoculation (187, 213).

Under field conditions, congenitally infected chicks show clinical signs and increased mortality beginning at 10–12 days of age, with a peak at 17 to 24 days (21, 44, 62, 94, 219). In heavily infected flocks, there can be a second peak of mortality at 30–34 days (44, 94), probably due to horizontal infection.

Clinical Signs

The only specific sign of CIAV infection is anemia, with a peak at 14 to 16 days post inoculation (PI). Anemia is characterized by hematocrit values ranging from 6%–27%. Affected birds are depressed and become pale. Weight gain is depressed between 10 and 20 days after experimental infection. Affected birds may die between 12 and 28 days PI. If mortality occurs, it generally does not exceed 30%. Surviving chicks completely recover from depression and anemia by 20–28 days PI (61, 170, 188, 226, 238), although retarded recovery and increased mortality may be associated with secondary bacterial or viral infections. Secondary infections, causing more severe clinical signs, are frequently seen in field cases, but they also may occur inadvertently in experimental chicks (46, 62, 219, 226).

Hematology

In general, hematocrit values greater than 27% are considered normal, but values may vary between inbred lines of chickens (86). Normal values are lower in white leghorn chicks than in broilers and decrease in both types of birds with increasing age (56, 57, 59). Blood of severely affected chicks is more or less watery, the clotting time is increased, and the blood plasma is paler than normal. Hematocrit values begin to drop below 27% at eight to 10 days PI, are mostly in the range of 10%–20% at 14 to 20 days, and may drop to 6% in moribund birds. In convalescent chicks, hematocrit values increase after 16 to 21 days and return to normal (29%–35%) by 28 to 32 days PI (66, 77, 169, 189, 238).

Low hematocrit values in CIAV-infected chickens are due to a pancytopenia as a consequence of infection of hemocytoblasts as early as three to four days PI (4, 180, 189), resulting in markedly decreased numbers of erythrocytes, white blood cells, and thrombocytes. Anisocytosis has been noticed as early as eight days PI. Juvenile forms of erythrocytes, granulocytes, and thrombocytes begin to appear in peripheral blood by 16 days PI, and the incidence of immature erythrocytes may exceed 30% several days later. The blood picture in convalescent chicks returns to normal by 40 days (189). Decreased clotting is most likely the direct consequence of thrombocytopenia and may lead to the hemorrhages associated with CIA. Co-infection with infectious bursal disease virus (IBDV) may aggravate the thrombocytopenia (163).

Morbidity and Mortality

The outcome of CIAV infection is influenced by a number of viral, host, and environmental factors. Uncomplicated infectious anemia, especially if caused by horizontal infection, may result in nothing more than slightly increased mortality and transient poor performance of affected flocks, and, therefore, it could even go unobserved in commercial settings. However, subclinical infections with CIAV can aggravate other diseases (see Immunosuppression).

Morbidity and mortality are considerably enhanced if chicks are dually infected with CIAV and Marek's disease virus (MDV), reticuloendotheliosis virus (REV), or IBDV, probably due to virus-induced immunosuppression (24, 151,

170, 226, 227, 240). Because lymphocytic depletion of the bursa often precedes lymphocytic depletion of the thymus associated with CIAV infection in commercial chickens (184, 207), immunosuppression by other viral agents, such as IBDV, likely plays an important role in the outcome of CIAV infection in commercial flocks. Certain strains of reovirus also can be immunosuppressive in chickens (46, 177), which may explain the enhanced pathogenicity of CIAV in the presence of reovirus (46). Dual infections between *Cryptosporidium baileyi* and CIAV can enhance CIA as well as cryptosporidiosis under experimental conditions (76). Occasional outbreaks of disease due to concurrent infections have been reported in commercial flocks (37).

Pathology

Lesions associated with CIA may vary depending on the route of infection, age of exposure, viral dose, and immune status of the host. Moreover, CIAV infection often may be involved in diseases caused by other pathogens and can be complicated by other pathogens. The pathology will be described for uncomplicated infections mostly based on experimental infections, as part of the hemorrhagic-aplastic anemia syndrome, and as a complicating factor in other diseases.

Gross Lesions

Thymic atrophy (Figure 8.2), sometimes resulting in an almost complete absence of thymic lobes, is the most consistent lesion especially when chicks develop age resistance to anemia (61, 89, 181, 189). The thymic remnants may have a dark reddish color. Bone marrow atrophy is the most characteristic lesion seen and is best evaluated in the femur (66, 189). Affected bone marrows become fatty and yellowish or pink (Figure 8.3). In some instances, its color appears dark red, although distinct lesions can be detected by histologic examination. Bursal atrophy is less commonly associated with CIAV infection. In a small proportion of birds, the size of the cloacal bursa (bursa of Fabricius) may be reduced. In many cases, the outer bursal wall appears translucent, so plicae become visible. Hemorrhages

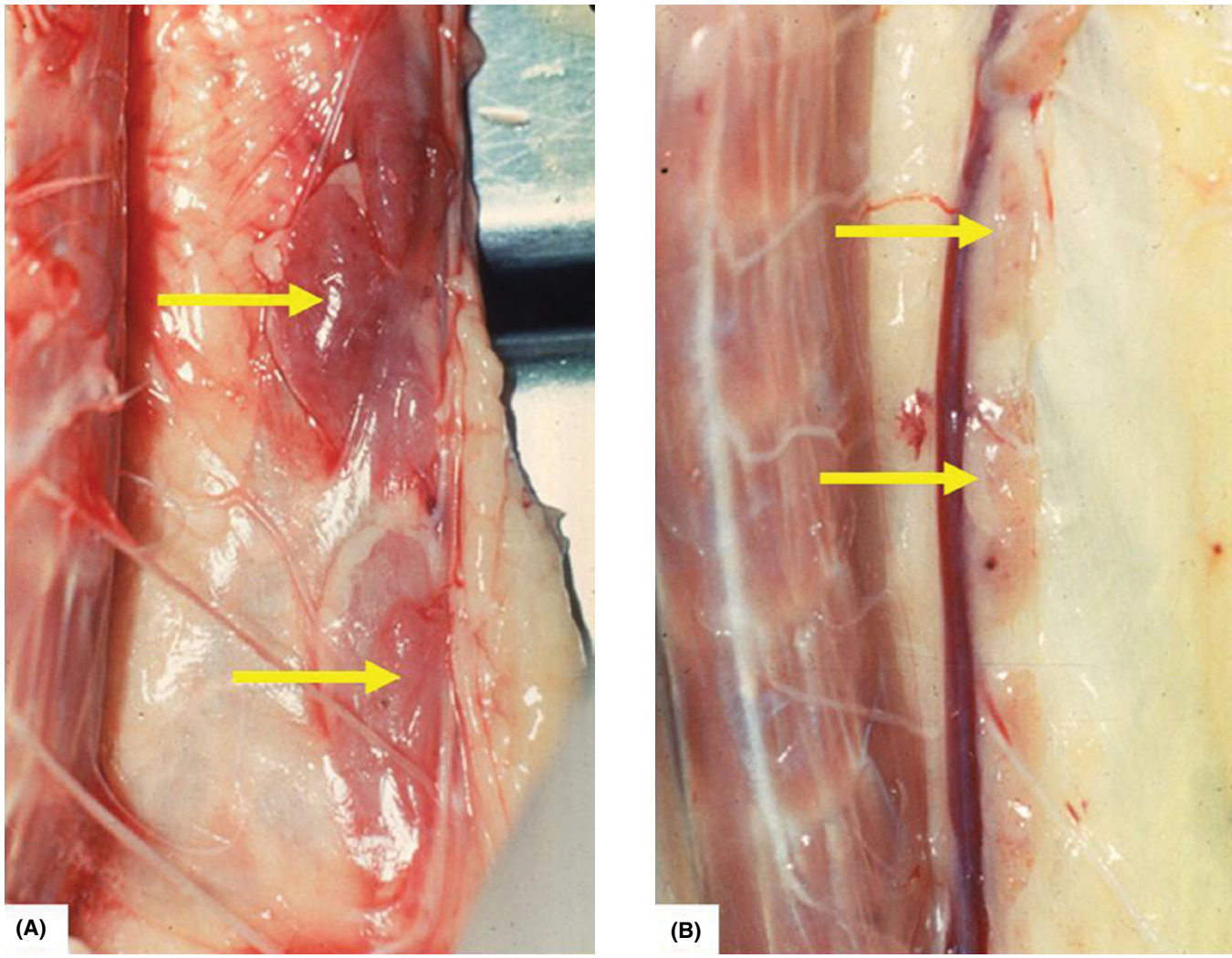

Figure 8.2. Thymus atrophy in chickens infected with CIAV. (A) Control thymus. (B) Thymus with chicken CIAV–induced atrophy, 14 days PI with the CIA-1 strain of CIAV. (Lucio and Hu)

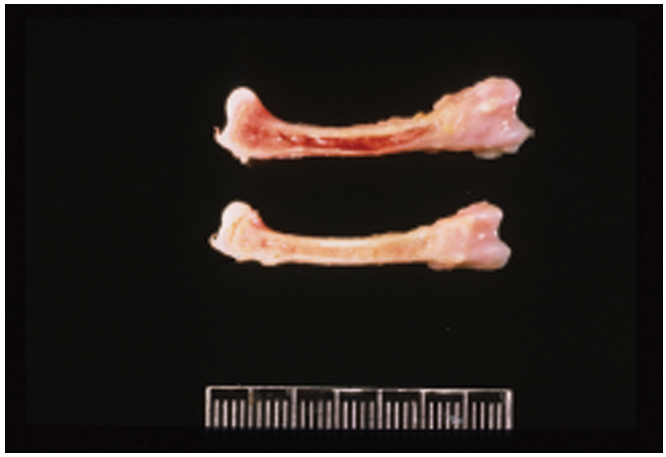

Figure 8.3. Femur with normal dark red bone marrow (top) and femur with pale aplastic bone marrow (bottom), 14 days PI with the CIA-1 strain of CIAV. (Lucio and Shivaprasad)

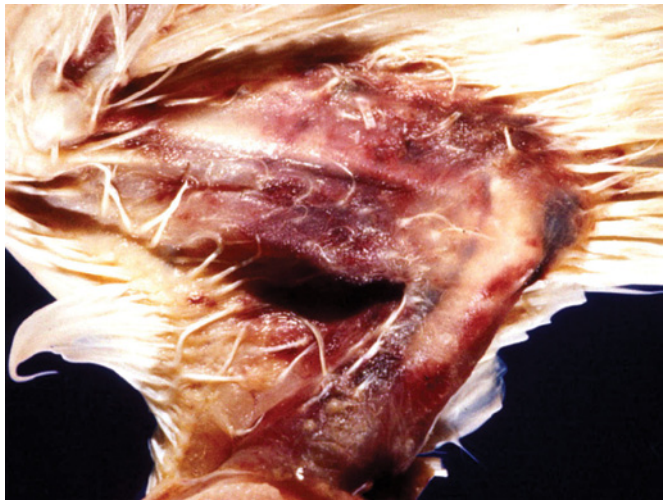

Figure 8.4. Lesions in chickens associated with chicken infectious anemia and hemorrhagic anemia disease. Gangrenous dermatitis (blue wing disease). (Cornell University collection)

in the proventricular mucosa and subcutaneous and muscular hemorrhages are sometimes associated with severe anemia (61, 66, 105, 169, 188, 189, 226). More pronounced hemorrhages or bursal atrophy, and lesions in other tissues, e.g., swollen and mottled livers (66, 169), also have been reported but may be caused by secondary infections with other agents.

Hemorrhagic-Aplastic Anemia Syndrome

Outbreaks of infectious anemia in field flocks are mostly associated with the so-called hemorrhagic syndrome, with or without concurrent (gangrenous) dermatitis (Figure 8.4) (e.g., 9, 21, 38, 44, 219, 247). CIAV also is involved in the etiology of aplastic anemia associated with inclusion body hepatitis (IBH) (227) and with the IBH/hydropericardium syndrome or infectious bursal disease (IBD) (163). Hemorrhages seen in chickens with IBD may, in most instances, be a sequel of CIAV rather than IBDV infection.

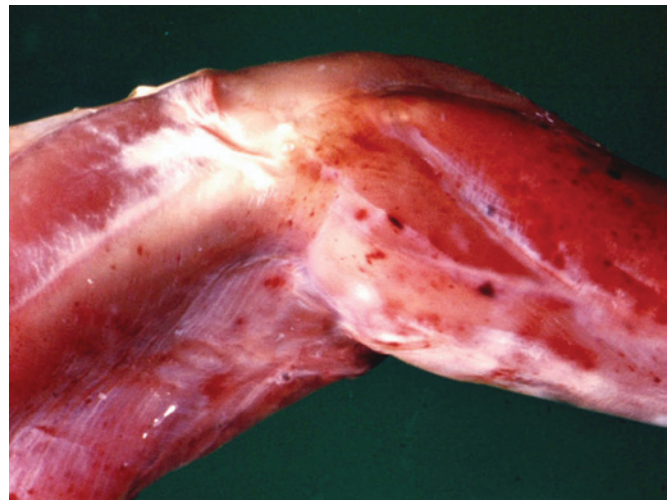

Figure 8.5. Lesions in chickens associated with chicken infectious anemia and hemorrhagic anemia disease. Hemorrhages in thigh and leg muscles. (Cornell University collection)

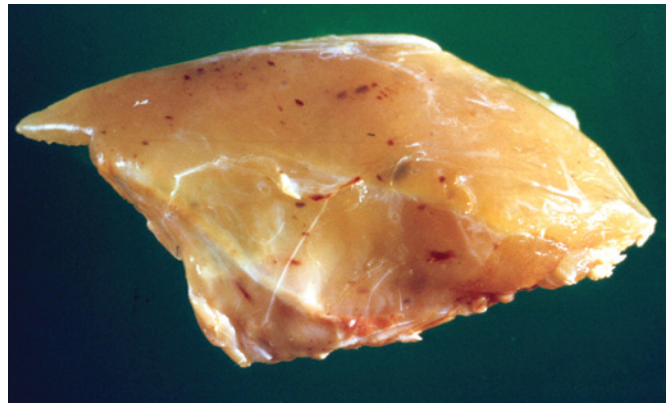

Figure 8.6. Lesions in chickens associated with chicken infectious anemia and hemorrhagic anemia disease. Hemorrhages in breast muscle. (Cornell University collection)

Characteristic lesions of so-called hemorrhagic syndrome are intracutaneous, subcutaneous, and intramuscular hemorrhages (Figures 8.5, 8.6). Punctuate hemorrhages may be present even more frequently in the mucosa of the distal part of the proventriculus (Figure 8.7). Intracutaneous or subcutaneous hemorrhages of the wings are often complicated by severe edema and subsequent dermatitis, which may become gangrenous due to bacterial infection (44). Subcutaneous hemorrhage of shanks and feet may result in formation of ulcers. Affected chicks also sometimes appear to be predisposed to develop pododermatitis.

Hemorrhages are not consistently seen in anemic chicks, although their occurrence is mostly correlated with the severity of anemia. Increased clotting time associated with thrombocytopenia, therefore, does not completely explain hemorrhages. Endothelial lesions and impaired liver functions, partly caused by viral infection and enhanced by secondary bacterial infection, are likely to be more important in the pathogenesis of hemorrhagic diathesis.

Microscopic Pathology

Histopathologic changes in anemic chicks have been characterized as panmyelophthisis and generalized lymphoid atrophy (66, 88, 105, 163, 180, 188, 189, 225, 226). In the bone marrow, atrophy and aplasia involve all compartments and hematopoietic lineages (Figure 8.8). Necrosis of residual small cell foci may occasionally be seen. Hematopoietic cells are replaced by adipose tissue or proliferating stroma cells. Regenerative areas consisting of proerythroblasts appear 16–18 days after experimental infection, and there is hyperplasia of bone marrow between 24 and 32 days PI in birds that recover.

Severe lymphoid depletion is seen in the thymus, starting with the cortical lymphocytes, but the non-lymphoid leukocytes and stroma cells are not affected. The thymus cortex and medulla become equally atrophic, with hydropic degeneration of residual cells and occasional necrotic foci (Figure 8.9). In chicks that recover, repopulation of the thymus with lymphocytes becomes distinct at 20–24 days, and the morphology returns to normal by 32–36 days PI.

Lesions in the cloacal bursa may be present. These lesions consist of mild to severe atrophy of the lymphoid follicles with occasional small necrotic foci, infolded epithelium, hydropic epithelial degeneration, and proliferation of reticular cells. Repopulation of lymphocytes until complete recovery is similar to that in the thymus.

In the spleen, depletion of T cells with hyperplasia of reticular cells is seen in the lymphoid follicles as well as in the Schweigger-Seidl sheaths. Necrotic foci in follicles or sheaths have been observed rarely.

In the liver, kidneys, lungs, proventriculus, duodenum, and cecal tonsils, lymphoid foci are depleted of cells, making them smaller and less dense than those in unaffected birds. Liver cells are sometimes swollen, and hepatic sinusoids may be dilated.

Small eosinophilic nuclear inclusions have been detected in altered, enlarged cells of affected tissues, predominantly in the thymus and bone marrow, where they are most frequent at five to seven days after experimental infection (66, 180).

Figure 8.7. Lesions in chickens associated with chicken infectious anemia and hemorrhagic anemia disease. Hemorrhages in proventriculus. (Cornell University collection)

Ultrastructural Lesions

Few ultrastructural studies have been described for CIAV-infected chicks (64, 65, 90). Changes in hematopoietic cells and thymocytes were first observed at six days PI and were most advanced at eight days PI. The affected cells had electron-dense regions in the cytoplasm and inclusion bodies consisting of homogeneous or fine granular materials. In addition, irregular plasma membranes, vacuolization, and pseudopod formation were seen. Between days 12 and 16 PI, many degenerative cells were seen, as well as actively phagocytizing cells. Apoptotic bodies were present in infected thymocytes. After 20 days, regeneration started to occur.

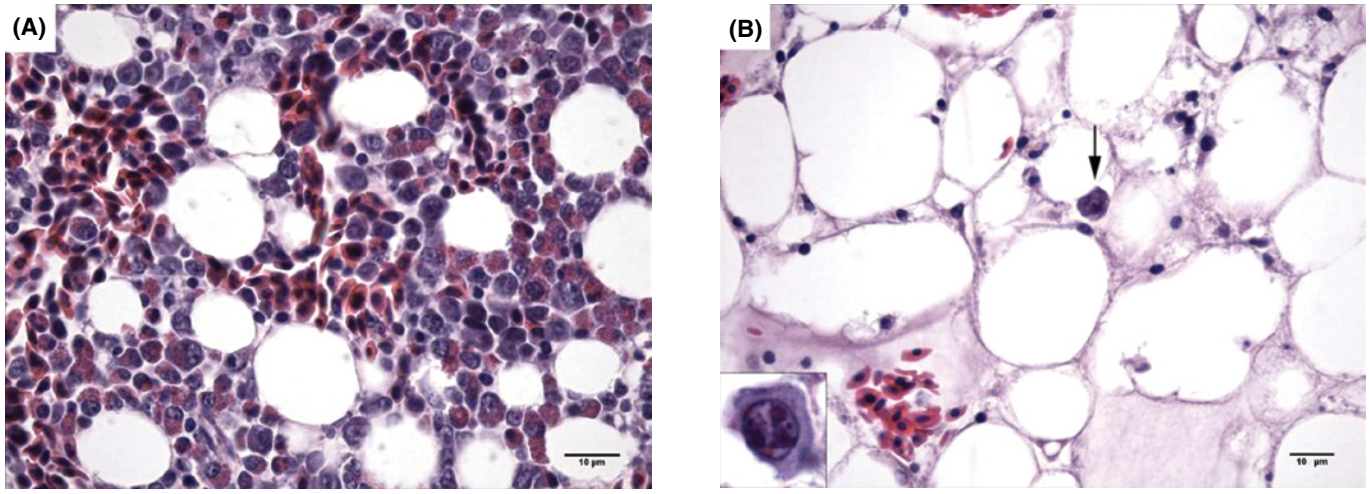

Figure 8.8. (A) Normal femoral bone marrow from a four-week-old broiler chicken. H & E, bar = 10 microns. (B) Femoral bone marrow from a four-week-old broiler chicken with CIAV lesions. Note atrophy of hematopoietic and myeloid tissue and presence of fat cells. Few cells have small intranuclear inclusion bodies (arrow) and insert (×1,400). H & E, bar = 100 microns. (Fletcher)

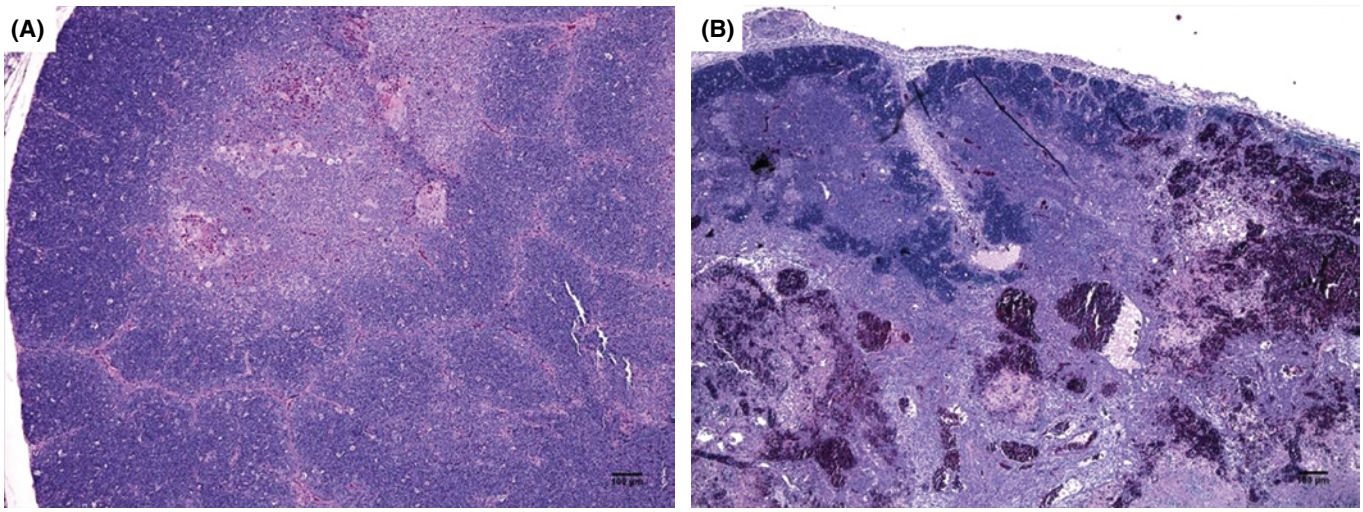

Figure 8.9. (A) Normal thymus from a five-week-old broiler chicken. H & E, bar = 100 microns. (B) Thymus from a five-week-old broiler chicken with CIAV lesions. Note the large region of hemorrhage and necrosis resulting in absence of demarcation between medulla and cortex. H & E, bar = 100 microns. (Fletcher)

Pathogenesis

The basic events during the pathogenesis of CIAV infection have been elucidated by sequential histopathologic (66, 180, 181, 189), ultrastructural (64, 65, 90) and immunocytochemical studies (73, 180, 181). Hemocytoblasts in the bone marrow and lymphoblasts in the thymus cortex are primarily involved in early cytolytic infection at six to eight days PI leading to a rapid depletion by apoptosis of these cells. Besides enlarged proerythroblasts and degenerating hematopoietic cells, macrophages with ingested degenerated hematopoietic cells have been observed in the bone marrow. In contrast to the thymus, depletion of lymphoid cells and occasional necrosis in the cloacal bursa, spleen, and lymphoid foci of other tissues have not been detected before 10 to 12 days PI (66, 180, 189, 226). Repopulation of the thymus with lymphocytes, repopulation of the bone marrow with proerythroblasts and promyelocytes, and recovery of hematopoietic activity, beginning 16 days PI, all appear to coincide with the beginning of antibody formation (see Immunity). These events result in complete recovery by 32–36 days.

Treatment of formalin-fixed thymus tissues with proteases III or XIV, needed to unmask viral antigens (113), facilitated immunocytochemical studies (2, 73, 78, 180). Large numbers of cortical thymic lymphoblasts become virus positive within four to six days PI. In addition, intrasinoidal and extrasinoidal hemocytoblasts, reticular cells in the bone marrow, and mature T cells in the spleen can be virus antigen-positive. Infected cells in the thymus and bone marrow are most abundant at six to seven days PI and can be detected until 10 to 12 days or even later. Viral antigen also has been demonstrated in lymphoid tissues in many other organs (180). Infection of proventriculus, ascending part of the duodenum, kidney, and lung could provide an explanation for virus shedding. Infected cells in these tissues usually cannot be detected for more than 22 days after infection at one day of age (180), although virus may persist in tissues until 28 days and in rectal contents until 49 days or later (243).

Although CIAV has a tropism for lymphoid tissue, particularly for the thymus cortex (88), susceptibility of thymocytes or spleen cells to infection is not dependent on the expression of particular cell markers such as CD4 or CD8 (2, 88). On the other hand, transient severe depletion of $CD4^+$ and $CD8^+$ lymphocytes, or a selective decrease in cytotoxic T lymphocytes (CTL), may play an important role in the mechanism of CIAV-induced immunosuppression (2, 24, 78, 88).

Age Resistance

Under experimental conditions, age resistance to anemia develops rapidly during the first week of life and becomes complete by three weeks or even earlier in immunologically competent chickens. The degree of resistance may vary based on the virulence of the virus, dose, and route of infection (61, 169, 204, 240, 246). Development of age resistance is closely associated with the ability of the chicken to produce antibodies against the virus (240, 246). Chickens infected at six weeks of age with high doses of CIAV rapidly develop neutralizing antibodies and do not shed virus, whereas chickens infected with a lower dose require more time to develop detectable antibody and do shed virus (42). Antibody development is considerably delayed by immunosuppression, e.g., by simultaneous infection with IBDV (84, 170, 240) or by bursectomy (77, 249). Dual infection with IBDV increases the persistence of CIAV in blood cells of chickens infected at six weeks of age and prolongs viral shedding (84).

The finding that embryonally bursectomized chickens develop severe anemia when challenged at five weeks of age (77) emphasizes the ability to produce antibodies as an important mechanism of age resistance. In contrast to age resistance to anemia, several studies have demonstrated a lack of age resistance to the subclinical disease characterized by reduced

cellular immune responses (108, 109, 165, 181, 204). Inoculation of six-week-old chickens with relatively low doses of CIAV [10^4 tissue culture infective doses ($TCID_{50}$)] via the ocular route resulted in virus replication in thymus, spleen, and liver, and subclinical disease resulting in reduced weight gain (96).

Although most CIAV experiments have been conducted in leghorn chickens, Joiner et al. (92) showed that broilers also exhibit age resistance to clinical disease and have low viral loads under experimental conditions. However, under commercial conditions, anemia in association with CIAV infection and accompanied by bacterial and parasitic diseases indicative of immunosuppression is observed in chickens up to 130 days of age (30, 209, 234). This suggests that the concept of age resistance may not always be valid in commercial operations, possibly due to environmental factors or other pathogens that affect the immune function of the flocks.

Route of Infection and Virus Dose

Virus dosage affects the severity of anemia or the proportion of affected chicks, but infection can be established by intramuscular injection of doses as low as $10^{0.75}$ $TCID_{50}$ (116, 170, 238). The route of inoculation also plays a role in experimental infection because infection by contact usually does not cause anemia in immunologically intact chicks, in contrast to immunologically compromised birds (170, 240). Oral, nasal, or ocular infection routes are much less effective than parenteral inoculation in inducing disease (170, 187, 213, 250).

Genetic Resistance

There is little information on genetic resistance to infection and disease. Hu (79) suggested that S13 (MHC: $B^{13}B^{13}$) chicks seemed to be more susceptible to disease than N2a (MHC: $B^{21}B^{21}$) and P2a (MHC: $B^{19}B^{19}$) chicks. This observation is compatible with the finding that S13 chickens have a poor seroconversion rate after natural exposure and after vaccination with a commercial vaccine using an adjuvant. S13 chickens had only a 73% seroconversion seven weeks post vaccination, whereas the N2a and P2a strains were 100% and 85% seropositive, respectively (17). In an experiment designed to detect MHC influences on CIAV susceptibility in four-week-old broiler chickens, Joiner et al. (92) found no statistically significant differences among MHC types in seroconversion rates and viral loads two weeks PI.

Immunity

Active Immunity

Antibody responses are the major arm of protective immunity to CIAV, but neutralizing antibodies cannot be detected until three weeks PI of susceptible one-day-old chicks. Titers are low (1:80) and show little increase (1:320) until four weeks. Chickens inoculated intramuscularly at two to six weeks of age have a faster response with neutralizing antibody detectable as early as four to seven days and with maximum titers (1:1280–1:5120) at 12 to 14 days PI (42, 243, 245). Humoral antibody formation is delayed if chickens are infected orally rather than intramuscularly (187, 213). Yuasa et al. (243) reported that increasing antibody production coincides with decreasing virus concentrations in chicken tissues. However, comparing the levels of antibody detectable by ELISA at 14 days PI among individual chickens inoculated at four weeks of age, Joiner et al. (92) found that higher virus levels corresponded to higher antibody levels, suggesting that higher antibody levels were a result of greater stimulation by virus.

Seroconversion in horizontally infected breeder flocks may be detected as early as eight to nine weeks of age, and most flocks have antibodies to CIAV at 18–24 weeks (83, 114). High titers of neutralizing antibody persist in all birds of a flock for at least 52 weeks. The prevalence of antibodies detected by indirect immunofluorescence assays, however, may decrease with increasing age (83) and is frequently less than 100% in a flock (55, 114). Antibodies detected by a commercial ELISA kit will remain present until 60–80 weeks of age in CIAV-infected SPF flocks (17, 173). There is no information on the importance of cell-mediated and non-specific immunity, although Hu et al. (77) noted that some embryonally bursectomized birds recovered from anemia in the absence of antibodies.

Passive Immunity

Maternal antibodies provide complete protection of young chicks against CIAV-induced anemia (239). This protection can be abrogated if chicks are immunosuppressed by other factors, including viral infections, especially infections such as IBDV, that affect humoral immune responses (170, 225). Maternally derived immunity, including protection against experimental challenge, persists for about three weeks (114, 153). Furthermore, vertical transmission of the virus is unlikely to occur from antibody-positive hens, but viral DNA can still be transmitted (12, 19, 68, 127). Outbreaks of infectious anemia in the field are often correlated with the absence of anti-CIAV antibody in the respective parent flocks (21, 47, 219, 247).

Immunosuppression

Impairment of the immune response by CIAV infection may result directly from damage to hematopoietic and lymphopoietic tissues and subsequent generalized lymphoid depletion and perhaps also from cytokine imbalances. Splenocytes from experimentally infected one- to seven-day-old chicks had depressed responses to mitogen stimulation between seven to 15 days but not at 18–21 days PI (1, 10, 149, 150). Depressed mitogen responses also were noted between 14 and 21 days after oral infection of three-week-old chickens (109). Decreases in macrophage functions such as Fc receptor expression, interleukin (IL)-1 production, phagocytosis, and bactericidal activity were noted after infection of one-day-old and three-week-old chicks (109, 110). Although transient, effects on macrophage function persisted longer than effects on T-cell mitogen responses, up to six weeks PI (109, 110). Interferon (IFN) production by mitogen-stimulated splenic lymphocytes *in vitro* was increased at eight days and decreased between 15 and 29 days PI (1, 3, 109). IFN-γ mRNA levels also were increased in the spleens of CIAV-infected chickens

seven days PI. Although IFN-γ mRNA levels in the spleen subsequently decreased, at 14 days PI they were not reduced compared to uninfected control chickens (108). T cell growth factor production (presumed to be IL-2) after *in vitro* stimulation also was decreased between 14 and 21 days PI (109), but a decrease in levels of IL-2 mRNA in spleens of infected chickens was not detected (108). CIAV infection interfered with the increase in both IFN-α and IFN-γ mRNA levels in blood cells induced within four hours in response to vaccination with trivalent inactivated IBDV/NDV/IBV vaccine (165). This marked effect on early innate responses was found one, two, and three weeks PI of four-week old chickens. Markowski-Grimsrud and Schat (108) found that CIAV infection significantly reduced the development of antigen-specific CTL for MDV and REV in chickens infected with CIAV after three weeks of age, suggesting that CIAV can impact vaccinal immunity and recovery from infections when cell-mediated immune responses are important.

CIAV as a Co-Factor in Other Diseases

Based on the impact of clinical or subclinical CIAV infection on specific and non-specific immune responses, it is not surprising that infection has been linked to increased susceptibility to other pathogens. Immunosuppression in anemic CIAV-infected birds has been linked to increased bacterial and fungal infections (62, 166, 188, 226, 232) and to enhanced pathogenicity of adenovirus (205, 227), reovirus (45), and infectious bronchitis virus (IBV) (207, 215). Experimental infection with CIAV reduced CD4+/CD8+ T cell ratios and suppressed generation of IBV-specific IgA-secreting cells in Harderian glands, delayed development of IBV-specific IgA in tears, prolonged respiratory signs, and delayed IBV clearance in IBV-infected chickens (212, 215). Genetic characterization of IBV during serial passages of IBV vaccine in CIAV-infected chickens provided experimental evidence supporting the assumption that CIAV-induced immunosuppression allows persistence of the vaccine virus in flocks, and can lead to establishment of a presumably more fit IBV vaccine subpopulation in vaccinated flocks (51).

Experimental infection with CIAV and *Salmonella enterica* serovar Enteritidis resulted in a decrease in the number of gut-associated T cells, IgA^+ cells, and the level of intestinal *Salmonella*-specific IgA compared to chickens infected with *Salmonella* alone. However, there was no significant increase of *Salmonella*-positive cells in dually infected birds (178). Hagood et al. (67) found a significant association between both presence of CIAV DNA and thymic atrophy and coccidiosis, gangrenous dermatitis, or respiratory disease in commercial broiler flocks. De Boer et al. (33) used live attenuated Newcastle disease (ND) LaSota-type vaccine in one- and ten-day-old chicks, which were infected at one day of age with CIAV. Severe respiratory distress was noted in the dually infected chicks without affecting the HI titers against ND virus. Impaired humoral immune response to inactivated ND vaccine may occur (11, 25) but is not a usual phenomenon in commercial flocks (58). Toro et al. (208) demonstrated an exacerbating effect of CIAV infection on bursal atrophy resulting from IBDV infection in commercial chickens under experimental conditions. Commercial broiler chickens with maternal antibodies to both CIAV and IBDV, and vaccinated against IBDV *in ovo*, when exposed to CIAV and IBDV in drinking water under experimental conditions, exhibited bursal atrophy at an earlier age (20 days of age) and higher IBDV levels in cloacal bursae at 20 days of age compared to chickens exposed to IBDV alone.

Dual infections with CIAV and MDV have led to increased early mortality and increased incidence of MD (50, 148, 222, 253). A high proportion of MDV isolates from 14- to 24-week-old layers exhibiting acute MDV infection also contain CIAV, and inoculation of CIAV into commercial chickens reactivates latent MDV infections (50). Two factors may influence the degree of interactions. Infection with CIAV enhanced the incidence of lymphoproliferative MD lesions when low doses of MDV were given, whereas CIAV decreased the incidence of MD lesions induced by high doses of MDV (91). The virulence of the MDV strain also may influence the outcome of dual infections. Miles et al. (125) found that co-infection with CIAV and very virulent (vv)MDV strains exacerbated the mortality and thymus atrophy, but that this was less evident with vv + MDV strains. Haridy et al. (69) examined interactions between virulent (v)MDV and CIAV and vvMDV and CIAV. SPF chickens were inoculated with MDV at one day of age and CIAV at four weeks of age. The CIAV challenge of MDV-infected chickens increased mortality compared to infection with MDV alone, although these differences did not reach significance with the small number of experimental birds. Regeneration of thymus and spleen was negatively impacted by the combination of vMDV and CIAV. This was not observed in birds challenged with vvMDV and CIAV, probably because vvMDV alone already causes severe depletion of lymphocytes in these organs. Depletion of CD4+ and CD8+ cells also was observed in the spleen and thymus after dual infection with MDV and CIAV, supporting the finding that CIAV can deplete CTL after dual infections (108). MDV vaccinal immunity is depressed by CIAV infection even if infection occurs at 14 days of age (149, 150, 248), and based on the ablation of MDV-specific CTL responses (108), probably at later times as well.

Diagnosis

Isolation and Identification of CIAV

Detailed procedures for the isolation and identification of CIAV have been published (121). Virus can be isolated from most tissues, buffy coat cells, and rectal contents from diseased chickens with maximum virus titers detected at seven days after infection (121). Virus titers will decrease after antibodies develop, but whole blood, buffy coat cells, and thymic homogenates were found to be infectious for at least 14 days PI, even from birds with neutralizing antibodies (213, 222, 252).

Lymphocytes from the spleen or buffy coat are preferred sources for virus isolation. Clarified homogenates can be

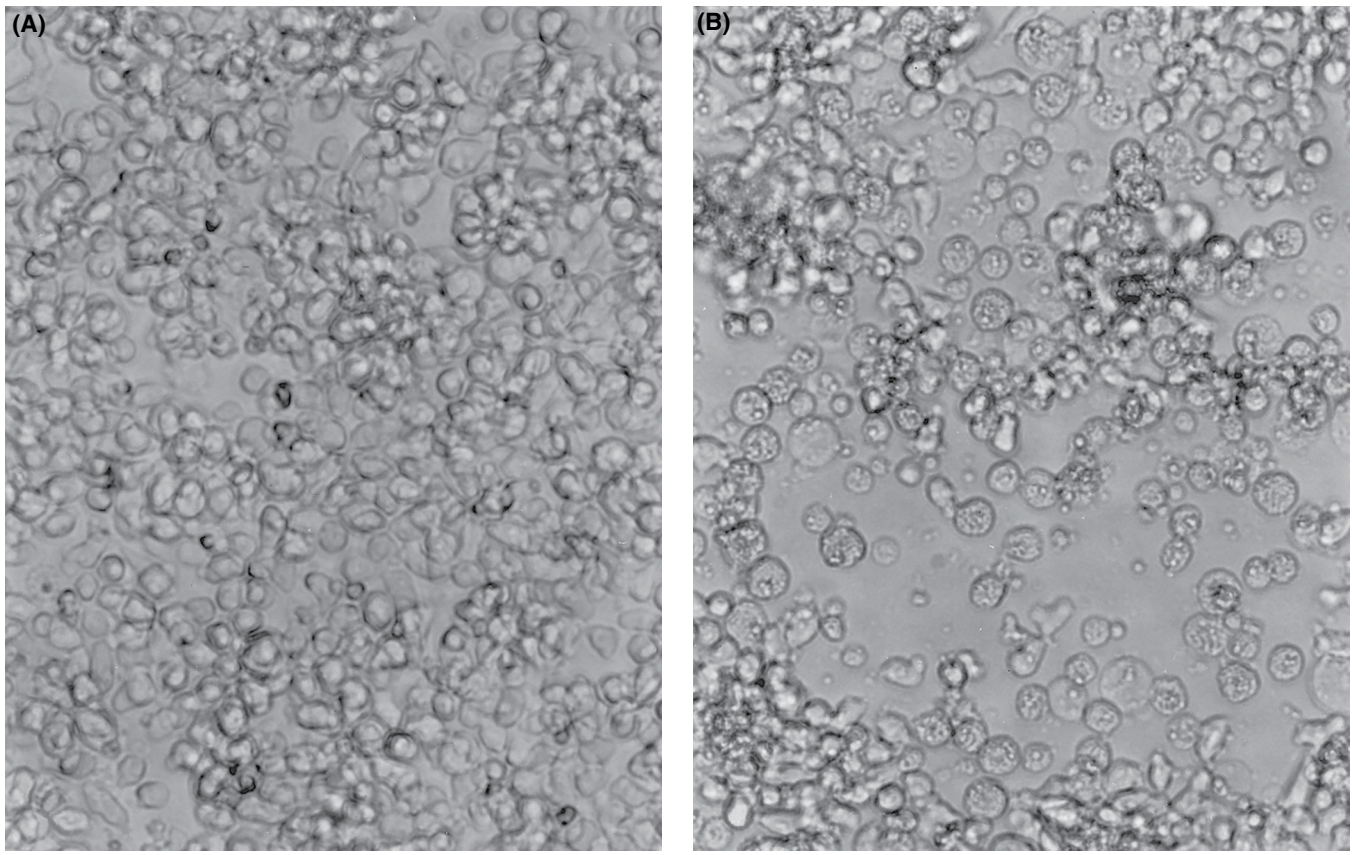

Figure 8.10. Cytopathic effects in cultured MSB1 cells two days PI with CIAV. (A) Uninfected cells. (B) Cells infected with a high dose of virus. Unstained. ×230. (von Bülow)

heated for five minutes at 70°C (61) or treated with chloroform to eliminate or inactivate possible contaminants before inoculating cell cultures.

MDCC-CU147 or MSB1 cell cultures are preferred for virus isolation and titrations (15, 241, 242). Some CIAV strains do not readily replicate in MSB1 and differences in susceptibility of MSB1 sublines have been reported (167). Freshly prepared cultures containing 2×10^5 cells/mL and seeded at 10^5 cells/cm^2 should be used. Cells are inoculated with 0.1 mL/1 mL of culture with 1:20 or greater dilutions (or serial 10-fold dilutions) of appropriately prepared tissue homogenates. Cultures are split every two to four days for 10 passages or until cell death is observed. Microscopic examination of cultures between 36 and 48 hours after passage is recommended to distinguish between virus-induced cytopathic effects (Figure 8.10) and non-specific cell degeneration. Isolation of CIAV should be verified by CIAV-specific antibody or PCR analysis and sequencing.

Bioassay by intramuscular or intraperitoneal inoculation of susceptible one-day-old chicks is the most sensitive method available for primary isolation of CIAV. This approach can be used if CIAV is suspected, but virus was not isolated in cell culture. The bioassay is as much as 100-fold more sensitive than cell culture and the sensitivity can be further increased by bursectomy (77, 249). Between 14 and 21 days PI hematocrit values are examined; values below 27% are considered indicative of the presence of CIAV (105, 169). Postmortem examination for bone marrow atrophy can be used in the case of non-anemic birds. Confirmation that CIAV is present in the lesions by PCR or immunohistochemistry is important.

DNA-Based Detection of CIAV

Polymerase Chain Reaction-Based Techniques

PCR assays have become the assay of choice for the detection of CIAV DNA in infected cell cultures, chicken tissues, archived formalin-fixed paraffin-embedded tissues, or vaccines (41, 144, 183, 192, 193, 196). PCR assays have proven to be specific and much more sensitive than cell-culture isolation of the virus and facilitate sequence analysis. The potential presence of CIAV in vaccines is an important concern for vaccine manufacturers. The European Pharmacopoeia requires avian viral vaccines to be free of adventitious agents based on testing in embryonating hen eggs, cell cultures, and two-week-old SPF chicks. The move away from *in vivo* tests has led to the developments of standardized PCR assays, which will likely replace the *in vivo* tests in the near future (7, 101, 154).

Very high sensitivity is achieved with a nested PCR, which, however, is also most sensitive to cross-contamination (19, 183). Recently, loop-mediated isothermal amplification assays have been developed for a number of pathogens including

CIAV (80). This technique is highly sensitive, does not require a thermocycler, and positive samples can be detected by observing color change during the reaction. Real-time PCR assays for the quantitation of viral DNA and RNA also have been developed (107, 214) and have replaced the conventional PCR in many laboratories. For routine assays primers are best selected from the conserved ORF regions. DNA can be extracted from the same tissues as used for virus isolation. Miller et al. (127) used nested PCR to screen embryonal tissues and egg membranes obtained after hatching to analyze the presence of viral DNA in offspring of SPF hens. *In situ* PCR assays have been used to detect CIAV infected cells in the absence of detectable levels of VP3 (19).

DNA Probes

DNA probes for the detection of CIAV DNA in formalin-fixed, paraffin-embedded tissues have been described (5, 42, 136), and although seldom used for diagnosis, can be of interest if historical samples are available. The use of DNA probes for the detection of CIAV by dot-blot hybridization has been reviewed (171), but such probes are no longer used.

Detection of CIAV by Antibodies

Detection of CIAV using indirect immunohistochemistry or immunofluorescence is a standard approach in pathogenesis studies and has been reviewed in the 12th edition of *Diseases of Poultry* (171).

Electron Microscopy

Electron microscopy for routine diagnostic examination for CIAV is not recommended due to its lack of sensitivity.

Serology

Three serological assays are routinely used: ELISA-based assays, indirect immunofluorescence assays, and virus neutralization (VN) tests. Selection of a given test depends on the purpose of the serological examination and costs associated with each assay.

Enzyme Immunoassays

Various commercially available enzyme-linked immunosorbant assay (ELISA) techniques for the detection and measurement of CIAV antibodies in chicken sera have been developed and are routinely used to screen breeder flocks in countries where vaccines are available (47), but false-positive responses have been reported (124). Antigens are generally prepared from partially purified virus preparations grown in MSB1 cells, which may include MDV antigens. Recombinant technology has been used to produce VP3 as a fusion protein in bacterial systems (156) or VP1, VP2, and VP3 in baculovirus systems (85). VP3 and VP2, but not VP1, proteins could be used as ELISA antigens. Unfortunately, these antigens will not detect VN antibodies. However, Todd et al. (199) developed a blocking ELISA using an MAb, 2A9, that reacts with field isolates from different parts of the world and recognizes a VN epitope (118, 195). A similar assay, using the same neutralizing MAb but an Australian CIAV isolate as antigen, also has been developed (190). The blocking assays have advantages in terms of costs (199) compared to the indirect assay described earlier (195) and yield fewer false positive results than commercial indirect ELISA kits that do not use a blocking format (190).

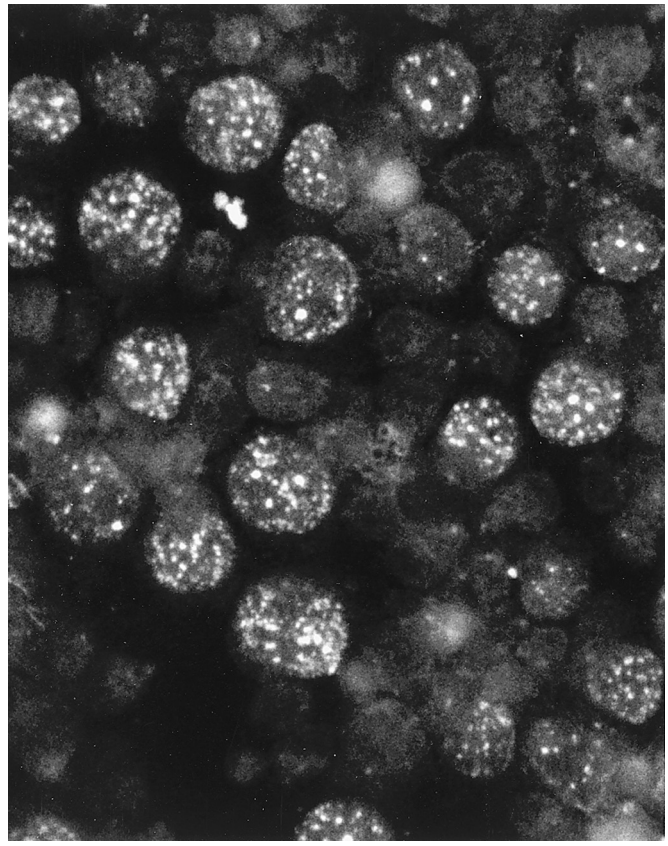

Figure 8.11. CIAV antigens detected by immunofluorescent staining in cytospin preparations of MSB1 cells harvested at 40 hours PI. Antigens are seen in enlarged cells with characteristic intranuclear granular fluorescence. ×400. (von Bülow)

Indirect Fluorescent Antibody (IFA) Tests

The indirect IFA test (114, 223, 245) for the detection of antibodies is a standard IFA test. Although it has been largely replaced by ELISA tests, it is still a useful assay, especially as a follow-up test to confirm ELISA-positive results for SPF chickens. CIAV-infected MSB1 or CU147 cells are used as the source of antigen. Cells are collected just before the beginning of cell lysis, usually 36–42 hours after inoculation, placed on glass slides, and acetone fixed. Fluorescent staining of rather small, irregularly shaped granules in the nucleus of enlarged cells (Figure 8.11) is considered evidence for antibody in the test serum. The concurrent appearance of fluorescent, somewhat irregular circular structures is also specific, but less frequent. This pattern of immunofluorescence is considered typical of tests with neutralizing CIAV antibody (13, 118, 195). Positive and negative reference sera should always be included in FA tests. Uninfected cells need to be used as a

control, because sera may have antibodies against MDV and CU147 and MSB1 cells can express MDV antigens in the nucleus and cytoplasm. Non-specific staining and background staining masking specific reactions can be largely reduced by using sufficiently diluted test sera, i.e., 1:40 to 1:100 or even more (114). Non-specific staining due to direct binding of anti-IgG conjugates (106) may be controlled by selection of pretested conjugates.

Virus-Neutralization Tests

The VN test (223, 243) is considered the gold standard for the detection of serum and yolk antibodies. Micro-well plates are recommended if large numbers of sera have to be examined (81, 93). It may take up to five weeks, requiring eight to nine subcultures, before the assay is completed; however, results can be obtained much earlier, and subcultures can be omitted, if the virus concentration in the mixture is increased to $10^{5.0}$ to $10^{5.5}$ $TCID_{50}$/0.1 mL (152, 223, 229). In this instance, inoculated cultures should be examined microscopically for CIAV-specific CPE after two and three days. One subculture may be required if complete destruction of virus-control cultures is desired to establish the endpoint. Subcultures also can be omitted if virus replication is assessed by PCR three to four days PI (214).

Qualitative VN tests for flock screening can be made with a constant serum dilution of 1:80–1:100 and a high dose of test virus as described above. Lower serum dilutions are not recommended because they can occasionally be cytotoxic or cause non-specific inhibition of the virus. This type of test can be rendered semi-quantitative by making a series of subcultures; the relative antibody level is indicated by the number of subcultures in which the inoculated cells stay alive (223, 229).

Direct comparisons between an ELISA test, IFA assay, and VN test were made by Otaki et al. (152). The VN test was more sensitive than the other two assays and the IFA assay frequently gave false positive results, especially when sera were tested at dilutions of less than 1:50. Unfortunately, no reports compare commercial ELISA kits with VN assays.

Differential Diagnosis

Infection criteria have only limited value in diagnosis of CIAV-induced disease because CIAV is virtually ubiquitous among chickens. Demonstration of the virus, viral antigens, or viral DNA may be considered etiologically significant if detected at sufficiently high levels in a high proportion of affected birds. In chickens under six weeks of age, a typical combination of signs, hematologic changes, gross and microscopic lesions, and flock history are suggestive of CIA. However, no particular lesions can be considered pathognomonic.

Aplastic anemia, but not a pancytopenia, with a concurrent atrophy of thymus and cloacal bursa, and depressed immune response also can be caused by osteopetrosis virus. Anemia induced by erythroblastosis virus can be distinguished from CIAV-induced anemia by microscopic examination of blood smears. MDV can cause severe atrophy of the thymus and cloacal bursa, especially after infection with very virulent viruses (14, 125). IBDV induces atrophy of lymphoid tissues with typical histologic lesions but normally does not affect the thymus. MDV and IBDV normally do not cause anemia, although anemia has been described with some strains of MDV (53). Aplastic anemia that may be associated with acute IBDV occurs and disappears much earlier than CIAV-induced anemia (146). Adenovirus is a major cause of an inclusion body hepatitis-aplastic anemia syndrome that occurs most frequently between five and 10 weeks of age (26). It does not, however, induce aplastic anemia after a single infection of experimental chickens.

Intoxication with high doses of sulfonamides, or mycotoxins such as aflatoxin, can result in aplastic anemia and "hemorrhagic syndrome." Aflatoxin also may impair the immune system. In the field, however, chickens are rarely exposed to doses of aflatoxin or sulfonamides that are sufficient to cause acute disease. On the other hand, subclinical intoxication of chickens might add to the pathogenicity of CIAV or vice versa.

Intervention Strategies

Management Procedures

Attention should be paid to management and hygiene procedures to prevent immunosuppression by environmental factors or other infectious diseases and to prevent early exposure to CIAV. Improved hygiene has reduced seroconversion rates, but this may cause problems when flocks are exposed later in life (47, 95, 111). Eradication of CIAV is virtually impossible under field conditions and may be difficult on infected SPF premises. In the latter case, this is not only because of the high resistance of CIAV to disinfection, but also because viral DNA can be transmitted vertically, which may be reactivated during the laying cycle (19, 127). Monitoring of breeder flocks for the presence of CIAV antibody should be done to avoid vertically transmitted disease outbreaks or to test the efficacy of vaccinations. The potential to develop transgenic chickens expressing short-hairpin (sh)RNAs targeting CIAV VP transcripts may provide a method to develop SPF flocks resistant to CIAV. *In vitro* assays have shown that these shRNAs can decrease CIAV replication in MSB1 cells (72).

Vaccination

Current vaccine strategies are based on the prevention of vertical transmission and horizontal transmission of virus to very young chicks by immunization of breeder flocks and have been successful in reducing the incidence of anemia in young chicks (47). Artificial exposure of young breeder flocks was originally achieved by transfer of litter from CIAV-infected flocks or by providing drinking water containing CIAV-positive tissue homogenate. This method is still used in countries where vaccines are not available or where vaccines are not applied for economic reasons. However, these procedures are very risky with regard to hygiene and level of exposure and should be discouraged (219). Commercial live vaccines for pullets are available in several countries (218, 220,

221). Vaccination should be performed at about nine to 15 weeks of age, but never later than 3–4 weeks before the first collection of hatching eggs to avoid the hazard of vaccine virus spread through the egg. Vaccines can be applied in the drinking water or by injection in the presence of adjuvants. Based on the negative effect of CIAV on the generation of CTL when infection occurs after maternal antibodies have disappeared (108), vaccination for broilers may be necessary. Recently a vaccine for use in broilers has been licensed in the United States.

Several strategies using various combinations of natural exposure, monitoring for seroconversion, and vaccination of breeders are actually used in the broiler industry. Smith (179) surveyed 68 complexes of eight large vertically integrated broiler production companies across the United States to determine which strategies are most commonly used for broiler breeders. He found that the majority of operations relied on natural exposure. Half of the operations did not routinely test for seroconversion, but some of those operations vaccinated breeders in new or cleaned houses where natural exposure might not occur. Approximately one-third of the operations relying on natural exposure did routinely test for seroconversion and subsequently applied commercial vaccines to flocks that did not exhibit adequate seroconversion. Smith noted the relatively high cost of commercial live CIAV vaccines as the reason for reliance on natural exposure. However, approximately one-third of the complexes surveyed did routinely vaccinate all breeder pullets between 10 and 12 weeks of age. Males are not usually vaccinated.

Although the live vaccines are considered safe and efficacious, further studies are needed to examine potential deregulation of immune responses as a consequence of vaccination. Recently, Vaziry et al. (217) showed that inoculation of one-day-old SPF chickens with a vaccine licensed for pullets results in persistence of the vaccine virus in the thymus and spleen in some birds, altering thymopoiesis and inducing a low antibody response to CIAV.

The paucity of information on the stability of current vaccines and the effects of vaccination on immune responses have led to several approaches to develop safer vaccines. An inactivated vaccine has been tested in SPF breeder hens. Vaccinated hens showed seroconversion and their offspring were protected against challenge (155). Unfortunately, viral titers in MSB1 cells and embryos are generally low (119) and therefore inactivated vaccines may not be cost-effective. Kaffashi et al. (97) evaluated CIAV with specific mutations in VP2. One of the mutants (E186G) caused minimal lesions and protected against challenge. However, the stability of this VP2 mutant needs to be established, especially in light of spontaneous mutations found in cell cultures infected with another VP2 mutant (R129G). Schat et al. (174) inoculated one-day-old SPF chickens with antigen-antibody complexes and showed that specific combinations of antigen and antibody induced a protective response against challenge with a different strain. However, additional studies need to be conducted in maternal antibody-positive chicks to determine if this approach can be used. Based on the work by Koch et al. (100) and Noteborn et al. (142) indicating that coexpression of VP1 and VP2 is required for induction of neutralizing antibodies, recombinant vaccines expressing VP1 and VP2 are possible. Moeini et al. (131, 132) inoculated 2-week-old SPF chickens with plasmids co-expressing VP1 and VP2 or VP1 alone. Inoculation with VP1 + VP2, but not VP1 alone, resulted in the induction of neutralizing antibodies and a Th1 response. Linkage of the MDV VP22 coding sequence to the CIAV VP1 gene significantly increased the titers of neutralizing antibodies. However, protection of chickens against challenge with CIAV was not evaluated. They also showed that Lactobacillus acidophilus displaying purified VP1, which was synthesized in *Escherichia coli* in the presence of VP2 as a fusion protein with a cell wall binding domain, can be potentially used as an oral vaccine although the antibody titers were rather low (133). Finally, a plant-based vaccine may be possible. *Nicotiana benthamiana* transfected with VP1 and VP2 coding sequences expressed these proteins, although experimental inoculation of chickens was not reported (102).

Treatment

No specific treatment for chickens affected by CIAV infection is available. Treatment with broad-spectrum antibiotics to control bacterial infections usually associated with CIA might be indicated.

Circovirus Infections of Avian Species

Leslie W. Woods and Kenneth S. Latimer

Introduction

Definition and Synonyms

Viruses belonging to the family *Circoviridae* are the smallest pathogenic DNA viruses that have been identified in mammalian (15, 32, 44, 56, 126, 129), avian (63, 64, 122, 129, 131), and fish species (59). Circovirus infections have been documented in more than 60 species of Old World, New World, and South Pacific psittacine birds (129) and in more than 18 species of non-psittacine birds. Thus far, infection has been documented in birds representing seven orders (Passeriformes, Psittaciformes, Galliformes, Charadiiformes, Columbiformes, Anseriformes and Struthioniformes) and 10 families (*Psittacidae* (18, 51, 138), *Cacatuidae* (43, 47, 65, 86), *Fringillidae* (31, 69, 76, 109),

Columbidae (33, 74, 82, 108, 110, 141, 142), *Sturnidae* (45), *Corvidae* (120), *Anatidae* (4, 5, 12, 30, 37, 39, 112, 115, 117, 147, 150), *Phasianidae* (125), *Laridae* (113, 137), and *Struthionidae* (24, 25), but the list will likely continue to expand as infection is documented in more avian species.

Previously proposed names for this family of circoviruses have included *Diminuviridae* and *Circodnaviridae*. These names were based on the small size of the virion and the circular configuration of the DNA genome, respectively. Ultimately, the International Committee on Taxonomy of Viruses designated the new viral family as *Circoviridae* on the basis of the circular configuration of the genome (60). Synonyms of circoviral-associated diseases in various avian genera have included psittacine beak and feather disease (psittacine birds), feather and beak disease (psittacine birds), French moult (budgerigars), black spot (canaries), young pigeon disease syndrome or young bird sickness (103) (pigeons), fading chick syndrome (ostriches), and runting syndrome (geese).

The difficulties in propagating avian circoviruses in cell culture systems have limited the knowledge concerning these viruses and their associated diseases, and prior to recombinant technology, have thwarted attempts at commercial vaccine production. Recognition of circoviral infections in production flock species such as geese, ducks, pheasants, and pigeons has increased awareness of the disease and the potential impact of circoviruses on commercial poultry operations. Current disease management requires extrapolation of biological understanding of viral disease from the well-researched companion bird circovirus, beak and feather disease virus (BFDV), and the clinical disease it produces.

Economic Significance

Psittacine beak and feather disease (BFD) is one of the most frequently diagnosed viral diseases of psittacine birds, and therefore has caused tremendous economic loss in the pet bird trade and aviculture industry. The economic significance of many of the non-psittacine circovirus-associated diseases has yet to be ascertained. Ultimately, the economic importance of circovirus diseases will be based on the future elucidation of the clinicopathologic significance of these circovirus infections in various avian species and circovirus prevalence and global distribution. Circovirus infections in pigeons and geese have been demonstrated to be highly prevalent in some regions of the world and likely have global distribution. Putative immunosuppression and developmental abnormalities have been associated with circovirus infections in pigeons (13, 127, 141, 142), geese (115), pheasants (125), and ducks (117). Therefore, circovirus infections would have a more globally significant economic impact if they have a high prevalence in countries with large production industries of these species (4, 12, 117, 147). In addition to the economic impact, BFDV could have devastating effects on avian populations because some endangered species such as the Cape parrot (*Poicephalus robustus*) and black-cheeked lovebird (*Agapornis nigrigenis*) are highly susceptible to disease (40, 48).

Public Health Significance

Thus far, experimental work with a small number of the circoviruses has not demonstrated infectivity across host orders. In addition, natural cases of disease associated with atypical host infection with avian circoviruses have not been reported to date (82). Therefore, the public health significance of avian circoviruses appears to be minimal. Phylogenetic analyses have shown no substantial homologies between *Circovirus* genera and human TT virus (TTV) and TTV-like mini virus, previously proposed members of the family *Circoviridae* (68, 123). In fact, these viruses are currently classified in the family *Anelloviridae* (10). Using degenerate PCR primers, both circovirus and cyclovirus related sequences were detected in chicken muscle from Nigeria (56). The circoviruses detected were subtypes of pigeon circovirus (57). Whether the molecular detection of circovirus was an indication of infection or contamination is unknown, and no reports of human illness were reported associated with this finding. Cycloviruses have recently been identified in chimpanzee and human feces (56). The public health significance of these findings is currently unknown.

History

Feather changes consistent with beak and feather disease (BFD) have been observed in wild Australian parrots since the early 1900s (80). Beak and feather disease was fully described and associated with a viral etiology in the 1970s and 1980s (51, 55, 73, 75, 80, 85, 86, 88). Since that time, circoviral infections have been reported in more than 60 species of psittacine birds (131). During the 1980s and 1990s, pathologists recognized intracellular inclusions in the lymphoid tissues of pigeons that resembled those of PBFDV (34, 99, 141). Pigeon circovirus (PiCV) was subsequently identified and characterized in the United States (141, 142), South Africa (28), Canada (72, 142), Australia (142), the United Kingdom (110), Germany (114), Belgium (124), France (1), and Italy (13). During the next decade, circoviruses were identified and characterized in numerous other companion, captive, production and free-ranging avian species (37, 39, 45, 76, 115, 117, 120, 125, 137).

Etiology

Classification

Circovirus genus in the family *Circoviridae* includes 11 species (http://ictvonline.org/virusTaxonomy.asp?version=2009&bhcp=1). These are the beak and feather disease virus (BFDV), canary circovirus (CaCV), duck circovirus (DuCV), finch circovirus (FiCV), goose circovirus (GoCV), gull circovirus (GuCV), pigeon circovirus (PiCV), porcine circoviruses-1 (PCV-1), porcine circoviruses-2 (PCV-2), starling circovirus (StCV), and swan circovirus (SwCV). Chicken infectious anemia virus (CIAV) is placed in a second genus, *Gyrovirus*, based on CIAV's larger virion and genome and different genomic organization (9, 132). Each species is distinct based upon phylogeny and genomic structure: BFDV (6),

GoCV (12, 128, 147), DuCV (39), PiCV (62, 128, 135), CaCV (76), FiCV (109), StCV (45), GuCV (134), SwCV (37), and raven circovirus (RaCV) (120).

Morphology

Ultrastructure

Ultrastructurally, circoviruses appear as nonenveloped virions with spherical to icosahedral (T = 1) structures containing 60 capsid protein molecules arranged in 12 pentamer clustered units (14, 97) and no obvious surface structures (flat capsomeres). Negatively stained particles have a mean diameter of 14–17 nm (14, 67, 129).

Genomic Size and Density

The entire sequence of the BFDV genome was published in 1998 by Niagro et al. (70) and Bassami et al. (6). Analyses have revealed BFDV genomic sequences ranging from 1,992 to 2,018 nucleotide bases (7). Variations of nucleotide size and identity were attributed to point mutations, deletions, and insertions in coding and noncoding regions of the genome. Analyses of genomic sequences of numerous other avian species followed. Genome sizes of 2,037, 1,996, 1,898, 1,952, 2063, and 1,820–1,821 nucleotide bases were determined for PiCV (62), DuCV (39), RaCV (120), CaCV (76), StCV (45), and GoCV (12), respectively. The buoyant density of circovirus in cesium chloride (CsCl) gradient is 1.38 g/cc (3, 86).

Chemical Composition

The DNA viral genome of members of the family *Circoviridae* is circular and single-stranded with a characteristic stem loop structure (67, 126, 129). Early work by Ritchie et al. comparing several isolates of BFDV from different species of psittacine birds identified three major viral proteins with molecular weights: 26,000, 23,000, and 15,000 Daltons (87). Minor proteins with molecular weights of 48,000 and 58,000 also were observed. Later work, however, demonstrated only two viral proteins, 26,000 and 23,000, which are believed to represent the capsid protein and putative replicase-associated protein encoded by open reading frames C1 and V1, respectively (61, 62, 127).

Virus Replication

Because of the difficulty in the propagation of avian circoviruses in long-term cell cultures or chicken embryos, little is known about their replication. At present, only two current members of the family *Circoviridae* have been propagated in cell culture (67, 129) and provide much of the available information on replication. CIAV has been grown in MDCC-MSB1 cells derived from Marek's disease lymphoma, and porcine circovirus (PCV) has been grown in PK-15 cells (porcine kidney cell line). Due to the limited size of the genome, circoviruses are highly dependent on cellular enzymes for replication. Circoviruses typically replicate in the nucleus, produce intranuclear inclusions, and probably depend on cellular proteins produced during the S phase of the cell cycle (129). Mitosis is needed for DNA to be taken up into the nucleus and replication likely occurs in targeted rapidly dividing cells such as the basal feather follicular epithelium, lymphoid tissues, and intestinal crypt epithelium. Results of immunohistochemical studies of birds with natural BFDV infection suggest viral persistence or replication may occur within the intestinal tract and its associated organs (50). Replication of the genome is believed to occur via a rolling circle that originates at the stem-loop structure. A replication-associated protein is encoded within the open reading frame V1 of the viral genome (61, 62, 126, 129). This highly conserved region exhibits marked similarity with the putative replication-associated protein of plant nanoviruses and geminiviruses (6, 29, 70, 129).

Susceptibility to Chemical and Physical Agents

Chemical and physical stabilities have primarily been determined for the circoviruses that can be propagated in cell culture systems (CAV and PCV). As a group, circoviruses are environmentally stable (67, 129, 132). These viruses are relatively resistant to inactivation by many common disinfectants, acidic environments (pH 3), ether, chloroform, and high temperatures (60° for 30 minutes; 70°C for 15 minutes) (129, 132). Ten percent iodine and hypochlorite are required to inactivate CIAV following treatment at 37°C for two hours (149). PCV tested at 20°C and 10°C under protein load (40% fetal calf serum in virus suspension) with various combinations and amounts of glutaraldehyde, formic acid, formaldehyde, and glyoxilic acid required more than 60 minutes for inactivation (145). BFDV still retains ability to agglutinate erythrocytes after incubation at 80°C for 30 minutes (81). Because innate resistance to deleterious agents makes viral inactivation difficult, a commercially produced, killed circovirus vaccine has not been a viable option (93, 94).

Strain Classification

Antigenicity

A comparative study of four different BFDV preparations from two different species of cockatoos, an Amazon parrot, and a peach-faced lovebird showed that all four isolates were antigenically related using rabbit anti-BFDV polyclonal antibody (87). Despite distinct genetic differences between BFDV isolates from lovebirds, lorikeets, and cockatoos, there is considerable cross-reactivity between these different genotypes (46, 104). Based on the paucity of reports of BFDV infection in cockatiels, Shearer et al. investigated the seroprevalence in cockatiels and found zero seroprevalence (HA) of circovirus infection in 88 cockatiels from three different commercial aviaries in Australia. They concluded the circovirus isolates that infect cockatiels (*Nymphicus hollandicus*) are antigenically and genetically distinct from other BFDV isolates and warrant consideration as a separate strain (105).

Circoviruses that infect pigeons and Senegal doves are antigenically distinct from BFDV. Immunohistochemical staining using both polyclonal (rabbit origin) and monoclonal (murine hybridoma origin) (92) anti-BFDV primary antibodies did not demonstrate visible chromagen deposition in circovirus-infected pigeon tissues (141). Tissue suspensions

from psittacine birds infected with BFDV agglutinated cockatoo erythrocytes, while tissue suspensions of feather, liver, kidney, and gastrointestinal tract from circovirus-infected doves failed to hemagglutinate erythrocytes from galahs (82). Anti-psittacine circoviral hemagglutination inhibition antibodies were not found in doves exposed to psittacine birds infected with BFDV or in doves inoculated with BFDV.

Expression of ORF C1 in insect cells using a baculovirus expression system produces recombinant protein that self-assembles into virus-like particles which exhibit antigenic properties for serological detection, demonstrating that this is the region of the genome primarily responsible for antigenic properties of the virus (11, 121). PiCV has been demonstrated to display high genetic variation in the ORF C1 region believed to be associated with antigenic differences (135). Similar capsid protein diversity demonstrated in duck isolates implies antigenic diversity and the existence of more than one genotype (140).

Immunogenicity or Protective Characteristics

Clinically normal birds exposed to BFDV were demonstrated to have higher titers than birds with active viral infections, suggesting that antibody is protective against both viral infection and the development of clinical disease (91). Preliminary work with BFDV also demonstrated that maternal antibody is protective (90). Chicks from vaccinated hens remained clinically normal when challenged with BFDV, whereas chicks from unvaccinated hens were susceptible to viral infection and development of disease. Immunogenicity of the BFDV capsid protein produced by expression of ORF C1 in insect cells using a baculovirus expression system was demonstrated to be effective in reducing virus replication in experimentally challenged birds (11). In this study, four of 97 blood samples collected from vaccinated long-billed corellas (*Cacatua tenuirostris*) after virus challenge tested positive by PCR, whereas 17 of 35 serum samples collected from non-vaccinated birds tested positive. Vaccinated birds did not develop feather lesions, had only transient PCR-detectable viremia, and had no evidence of persistent infection 270 days post challenge. Non-vaccinated birds were PCR-positive up to 41 days post challenge.

Very few inoculation studies have been performed thus far with circoviruses infecting other avian orders. Anti-psittacine circoviral hemagglutination inhibition antibodies were not found in doves exposed to psittacine birds infected with BFDV or in doves inoculated with BFDV (82), so cross protective immunity does not appear to develop in avian species exposed to non-host circoviruses. However, further detailed studies are needed to clarify this observation.

Genetic and Molecular Characteristics

Putative phylogenies, comparative sequence analysis, and geographic distribution suggest there is an evolutionary link between the animal circoviruses (PCV and BFDV) and the plant nanoviruses and geminiviruses (29, 66, 70). It is speculated that the circoviruses evolved from plant nanovirus DNA after a host-switch to a vertebrate, coupled with recombination in which the sequence encoding part of the replicase-associated protein combined with DNA from a calici-like virus.

Circoviruses have circular, covalently linked single-stranded DNA, use an ambisense genome, and contain two major ORFs in opposite orientation. One ORF codes for a putative replication protein (ORF V1) and the other ORF codes for capsid protein (ORF C1) (129). These ORFs initiate close to a small noncoding region containing the potential stem loop and nonanucleotide motif (TAGTATTAC) associated with initiation of rolling circle replication of the viral DNA (6, 129).

Early work with pigeon circovirus demonstrated that it was related to, but distinct from, BFDV using DNA *in situ* hybridization with a short (40-base), single-stranded, oligonucleotide probe and a long (1,900 bp), double-stranded, PCR-generated DNA probe (141). Complete nucleotide sequencing of the columbid circovirus (CoCV)/pigeon circovirus (PiCV) by Mankertz et al. displayed 55% homology to the genome of BFDV and 34% and 36% homology to PCV types 1 and 2, respectively (62). Nucleotide sequence analyses have been performed on most of the newly described members of the avian circoviruses. Canary circovirus (CaCV) shares greatest sequence homology to PiCV (58.3%) (76). Starling CV is closely related to CaCV (67%) (45). Goose CV is less closely related to BFDV than PiCV is to BFDV (128). Sequence analysis of DuCV demonstrated 60% sequence homology with GoCV, 44% with PiCV, and 39% with CaCV (39). Swan CV is most closely related to GoCV (73.2% genome sequence similarity) (37). Raven CV has greatest homology to CaCV and PiCV (120) and the capsid proteins of finch (FiCV) and gull (GuCV) circoviruses share highest amino acid identity values with those of CaCV (62.0%) and PiCV (40.6%), respectively (134). Sequence analysis of isolates from budgerigars (*Melopsittacus undulatus*) in South Africa demonstrated such diversity with all other full-length BFDV sequences that it was proposed that this circovirus is a new species and should not be included with BFDV (138). Recent analyses of 87 complete BFDV genomes suggests that currently, there are 14 strains of BFDV using a definition of 94% genome-wide sequence identity as a strain demarcation threshold, with isolates sharing more than 94% identity belonging to the same strain, and strain subtypes sharing more than 98% identity (139).

Early studies with BFDV isolates showed no evidence supporting a relationship between genetic variation and region, pathogenicity, antigenicity, or other physicochemical characteristics (7). In contrast, later investigations have suggested a relationship does exist between viral strain and region, species-specificity, and pathogenicity. Recent studies have demonstrated that phylogenetic variation exists between isolates that infect different species within avian orders, suggesting the existence of viral strains. The first evidence presented to suggest variation in clinical disease and species susceptibility was reported in 1993 (48). In this report, 100% mortality occurred in captive black-cheeked and Lillian's lovebirds

(*Agapornis nigrigensis* and *A. lilianae*), whereas exposed Fischer (*Agapornis fischeri)* and peach-faced (*A. roseicollis*) lovebirds had transient feather abnormalities and recovered. Sequence diversity has been demonstrated with BFDV isolates. Strains that infect lories and strains that cause the acute form of disease in African grey parrots (*P. erithacus*) are specific genotypes (83). Ritchie demonstrated three distinct BFDV lineages in New Zealand in cockatoos, budgerigars, and lorikeets, suggesting a genotypic association between virus and host (95). Another study in 2005 provided further evidence of BFDV genotypes clustering in parallel with *Loriidae*, *Cacatuidae*, and *Psittacidae* (46). Khalesi also provided evidence that isolates from lorikeets can infect other psittacine bird species. Therefore it is apparent that different psittacine circoviral strains can infect different psittacine species causing disease in some but not other individuals within a species or family.

Individual avian species are often infected by closely related strains of circovirus, but highly divergent strains also have been detected. Multiple genotypes have been demonstrated within a species. Capsid protein diversity demonstrated in duck isolates implies antigenic diversity and the existence of multiple DuCV genotypes (140). Shearer et al. concluded the circovirus isolates that infect cockatiels (*Nymphicus hollandicus*) are antigenically and genetically distinct from other BFDV isolates and warrant consideration as a separate strain (105).

Different strains were detected in one clinically ill bird, suggesting either infection with multiple strains of BFDV or genetic divergence of nonpathogenic strains that mutated into a pathogenic strain (18). Three distinct genetic groups of GoCV have been demonstrated but no differences were found between subclinical and clinically significant strains (148). Most studies thus far have focused on the C1 gene as the main determinant of pathogenicity of the virus (40, 83). It has since become clear that parts of the sequence other than the C1 and V1 gene play a significant role as well as host factors (cell surface receptors for virus attachment or MHC presentation) (105). The relationship between viral strains, the avian species they infect, and the pathogenicity of the strains is complex, and definite conclusions cannot be drawn at this time as to the nucleotide sequence of the genome of the infecting virus and its ability to cause disease (18).

The association between strains and the regions in which they are found has been investigated. Phylogenetic variation has been demonstrated between isolates from different regions. For example, variation exists between isolates of GoCV from Germany, Taiwan, and China (4, 12). There is variation between BFDV isolates from New Zealand, Australia, and South Africa (40). South African BFDV isolates were shown to have diverged from viruses in other parts of the world with 8.3%–10.8% diversity between African isolates and Australian isolates. In contrast, similarities exist between Australian and New Zealand circoviral isolates, suggesting evolution of genotypic association between viruses and hosts predates dissemination throughout the world (81). High nucleotide similarity between circovirus detected in Pekin ducks in New York and the European isolates from Germany and Hungary suggest shared ancestry (5). Sequence analysis of isolates from budgerigars (*Melopsittacus undulatus*) in South Africa demonstrated high sequence identity to budgerigar isolates from Thailand (138).

DNA sequence analysis of 10 PBFDV isolates demonstrated that the sequence encoding the replicase-associated protein is highly conserved (146). Variation of findings evaluating the association of genotypes and factors such as region, host specificity, and pathogenicity may be related to the region or length of the genome compared. Some investigations have evaluated variable lengths of the highly conserved replication-associated protein (ORF V1). Other studies have examined the ORF C1 region of the genome encoding the capsid protein which may more accurately reflect virus-host interaction.

There is a high degree of genetic diversity among the avian circoviruses and as more sequence data is available, new genotypes will continue to emerge. There is evidence that recombination might contribute more to genetic variation than genetic drift within the ORF V1 (46), and recombination has been demonstrated to occur in most BFDV strains, in the intergenic region and the C-terminal portion of the C1 ORF.

Pathogenicity

Different clinical responses of different avian species to exposure and infection with circoviruses may be associated with numerous factors such as age of the bird at the time of exposure, natural resistance of individuals and species, viral load, and the strain of virus. The relationship between viral strains, the avian species infected, the clinical response, and the pathogenicity of the strains is complex (18). The pathological significance of avian circoviruses has yet to be elucidated. There is substantial histologic and clinical evidence that immunosuppression is associated with natural circoviral infection in avian species (51, 53, 84, 85, 93, 94, 115, 127, 129, 137, 141, 142). Histopathological and clinical responses to experimental infections thus far have demonstrated that clinical disease associated with circovirus is multifactorial. In one study, experimental infection in pigeons did not elicit clinical disease or apparent immunosuppression as demonstrated by accessing humoral response to vaccination with PMV-1 (100). However, lymphoid depletion and necrosis with intralesional botryoid inclusions were reproduced by experimental infection. It was concluded in this study that the pathogenesis of young pigeon disease syndrome is multifactorial and may require a stressful trigger. In another study, 10 GoCVs from five different farms in China with no report of clinical disease were sequenced, demonstrating homology greater than 90% to previously reported GoCV associated with clinical signs, indicating variation in pathogenicity may not be reflected in genetic variation (147). Detailed evaluation of both humoral and cell-mediated immune function following experimental infection with avian circoviruses is needed in future studies to fully elucidate the clinical significance of avian circovirus infections.

Pathobiology and Epizootiology

Incidence and Distribution

PBFD has worldwide distribution (51) and is strongly linked to international trade of exotic birds (139). The disease has been described in captive and wild populations in Australia (7, 65, 74), New Zealand (80), Africa (2, 40, 48, 49), Europe (8, 41, 77), North America (16, 72) and Asia (47, 71) and is likely present in most regions of the world. The seroprevalence of BFD in different flocks of free-ranging psittacine birds in New South Wales ranged from 41%–94% (80). In a 1993 study in which 10,000 captive birds in the United States were evaluated using a DNA probe test, 5% of birds tested positive for PBFD viral antigen in blood (16). The majority of these birds did not have clinical signs of BFD, suggesting many birds may be subclinically or transiently infected with BFDV. Old World psittaciformes showed the highest incidence of positive tests. Eclectus parrots had the highest incidence of viremia (10.2%) followed by cockatoos (8.7%) and African grey parrots (8%). New World psittaciformes exhibited a much lower incidence of positive test results. Positive test results in lovebirds exceeded 30%. Prevalence of BFDV in free-ranging native birds in New Zealand was very low based on PCR assay on blood or feathers (36).

Pigeon circovirus is distributed over a wide geographic area encompassing the United States (141), South Africa (28), Canada (72, 142), Australia (82, 142), and Europe (110, 114, 116, 124). The general practice of intermixing young, susceptible pigeons coupled with fecal shedding (33) and extreme persistence of the virus in environment may suggest widespread PiCV infection of racing pigeons on all continents. Goose circovirus is highly prevalent in goose flocks in Hungary, Taiwan, and China (4, 12, 147). In Hungary, GoCV was detected in 48% of 214 diseased or dead birds tested, representing 65% of 76 flocks tested. Antibodies were detected in 88.6% of 159 samples obtained from 27 or 28 geese breeder flocks tested in Hungary (102). Infection rate of DuCV sampling 742 ducks from 70 duck farms in China was 33.3% (150). Circovirus was detected in free-ranging gulls (*Larus argentatus* and *Larus ridibundus*) from Sweden and New Zealand (113).

Natural and Experimental Hosts

BFD has been reported in more than 60 species of Old World, South Pacific, and New World psittacine birds with the highest prevalence in Old World and lowest prevalence in New World psittacine birds (129). Infection has been documented in both free-ranging and captive birds. Surveillance studies have demonstrated higher infection rates in Old World psittacine species (8, 16). Viral infection may cause acute to chronic, debilitating disease resulting in death. A few spontaneous clinical recoveries have been observed in budgerigars (*Melopsittacus undulatus*), lorikeets, and lovebirds (*Agapornis* sp.) with previous lesions of PBFD (48, 51). Pigeon circovirus infects racing pigeons (*Columba livia*) and Senegal doves (*Streptopelia senegalensis*). It is currently unknown whether the PiCVs from pigeons and doves are genetically identical. Reports of natural circoviral infection in other avian species include infection of canaries (*Serinus canaria*) (31, 76), finches (*Poephila castanotis*)(69, 109), geese (4, 12, 115, 147), ostriches (*Struthio camelus*) (24, 25), pheasants (125), an Australian raven (*Corvus coronoides*)(120), ducks (Pekin and hybrid Mulard)(5, 39, 117), a western scrub jay (*Aphelocoma californica*) (Woods, unpublished), a southern black-backed gull (*Larus dominicanus*) (137), a black-headed gull (*Larus ridibundus*) and herring gulls (*Larus argentatus*)(113), starlings(45), and mute swans (*Cygnus olor*) (37). Experimental inoculation studies with avian circoviruses have been frustrated by the inability to replicate the avian circoviruses *in vitro*. Experimental inoculation studies have successfully reproduced disease and/or lesions in psittacine birds (91, 144), pigeons (100), and geese (35) infected with circovirus purified from feather pulp or tissue homogenates. Experimental inoculation of doves with BFDV did not produce clinical disease or antibody response (82).

Age of Host Commonly Affected

Circoviral infection is typically reported in young birds (less than 3 years of age in psittacine birds and less than 1 year of age in pigeons), but has been reported to occur in birds as old as 20 years of age without previous clinical signs of disease (51, 85). This latter observation indicates that adult naive birds may become infected and develop clinical disease, although subclinical or latent infection at a younger age or an extended incubation period of disease cannot be discounted. It is generally agreed, however, that birds are susceptible to infection prior to involution of the cloacal bursa. In single case reports of clinical circoviral disease in geese (2 to 9 weeks old) (115), ducks (6 weeks old) (117), ostriches (less than 8 weeks old) (24), finches (3 to 6 months old) (69), canaries (10–20 days old) (31), pheasants (10–30 days old) (125), and in a gull (bursa present) (137), the age of the affected birds were noted as neonates or juveniles. Subclinical infections with circoviruses have been demonstrated to be highly prevalent in both young and adult birds. In one study, 101/1,516 apparently healthy parrots tested positive for BFDV by PCR; 72% of those were young birds (8). In another study of clinically healthy psittacine birds, 58/146 tested positive for BFDV (77). In two other studies, 13/20 healthy older pigeons (1 to 9 years) tested positive by PCR (21) and another study using a PCR-based test detected circovirus in 45 of 50 healthy adult pigeons (26).

Transmission, Carriers, and Vectors

Neonatal budgerigars and galahs experimentally infected through the combined oral, intracloacal, and intranasal routes developed clinical PBFD (89, 93, 94). Additionally, circovirus was demonstrated in crop secretions, feces, and feather dust of BFDV-infected psittacine birds. Results of this study suggest that aerosolized viral particles or direct ingestion of contaminated materials may account for natural routes of viral exposure. Transmission of BFDV most commonly occurs through

shedding of virus in feather dander, followed by fecal shedding, and occasionally feeding of chicks with regurgitated crop contents. Hess demonstrated that virus could be detected most frequently in the feathers which did not correlate with clinical signs, suggesting this may be where the virus persists and is shed by adult birds (41). Direct inoculation of the bursa via the cloaca has been suggested as another mode of viral transmission to psittacine birds in nests contaminated with feces and feather dander (79). Circoviruses have been demonstrated by direct electron microscopic examination of negatively-stained preparations of intestinal contents from circovirus-infected pigeons, suggesting that shedding and transmission of virus may occur through ingestion or inhalation of fecal-contaminated materials (28, 141). In another study by Duchatel et al., PiCV could be demonstrated in 13 of 20 apparently healthy pigeons that ranged from one to nine years of age (21). Viral DNA was detected most commonly in the respiratory organs (trachea, pharynx, lung) followed by spleen, kidney, and liver. Crop washings, which have been suggested as source of infection in pigeons, were tested by Duchatel. Of 64 crop specimens that were tested, none were positive for circovirus (20). The PCR test results on blood and intestinal contents from healthy pigeons were increasingly positive with the age of the pigeon (26). This observation indicates that the major direction of transmission is likely horizontal.

Similar results were obtained by Duchatel in which cloacal swabs from 15.8% of the birds were positive at 37 days of age and 100% at 51 days of age, suggesting that pigeons probably became infected in the rearing loft through horizontal transmission of the virus (21). Vertical transmission has been suggested in psittacine birds, pigeons and ostriches with circovirus infection. Chicks derived from artificially incubated eggs of a BFDV-positive Little Corella (*Cacatua sanguinea*) hen consistently developed PBFD after hatching (51). Additionally, 1-day-old pigeons had microscopic lesions compatible with circoviral infection that suggested probable vertical transmission (72). Circoviral DNA was detected in 8 of 22 pigeon embryos, supporting vertical transmission (21). Circovirus was demonstrated in livers from non-hatched ostrich chicks, supporting the theory of vertical transmission in ostriches (24). RT-PCR detected large amounts of virus in semen and cloacal swabs in pigeons, confirming PiCV may be transmitted by vertical and horizontal routes (22).

Incubation Period

The incubation period of PBFD has been determined experimentally and varies with species and age at the time of viral exposure. In two studies with BFDV, experimentally inoculated chicks developed clinical signs of disease 25–40 days post-inoculation (90, 144). Disease incubation for galah cockatoos (*Eolophus roseicapillus*) and sulphur-crested cockatoos (*Cacatua galerita*) was three to four weeks (79). There are a few reports of circoviral infection in older birds 4 to 5 years old (97) and 10–20 years old (51), suggesting that either older naïve birds can become infected or these birds were infected as young birds with a prolonged incubation period and/or latency of infection (51, 85). Clinical signs were first detected in geese with experimental infection 17–30 days post-inoculation with tissue homogenate (35). Viremia was detected at 14 days PI.

Clinical Signs

Morbidity and Mortality

Mortality and clinical signs in psittacine birds infected with BFDV are variable and dependent on the species of bird; age of the bird at the time of infection; possibly the viral strain; and presence or absence of concurrent viral, bacterial, fungal, or parasitic infections (51, 52). In some species, infected birds generally survive less than 6 months, but supportive care can considerably lengthen survival time. Secondary infections account for 69% of deaths in birds infected with BFDV. Putative immunosuppression may be associated with hypogammaglobulinemia and virus-associated infection and destruction of lymphoid tissue. Jacobson found that birds infected with BFDV had lower serum protein concentrations with lower prealbumin and gamma-globulin concentrations (42). Experimentally inoculated birds became acutely depressed and anorectic four weeks post inoculation (90, 144). Progressive symmetric feather dystrophy and loss subsequently developed. Less frequently, beak and claw deformities also occurred. Raue and coworkers found that African grey parrots had two distinct, genetically diverse strains of circovirus (83). One strain was associated with the acute form of disease characterized by severe leucopenia and non-regenerative anemia without feather disorders, as described by Doneley et al. and Schoemaker et al., respectively (19, 101). The other strain of circovirus was associated with feather disorders.

In most disease outbreaks, circoviral infection in pigeons is associated with high morbidity and low mortality. However, mortality in circovirus-infected pigeon lofts may approach 100% in the young birds. Overall mortality ultimately depends upon age of the birds and presence of concurrent infections, as is the case with PBFD (142, 143). A broad range of signs and severity of clinical disease is observed in infected pigeons. In one report, clinical signs were not observed in circovirus-infected king pigeons ranging from less than 1 week to 6 weeks of age (72). Red blood cell values and concentrations of hemoglobin and total protein were unaffected by viral infection. White blood cell values were more variable but apparently did not correlate with the degree of bursal damage.

When circoviral infection spreads through a pigeon loft, the most commonly reported clinical signs are poor performance, diarrhea, and ill thrift. Spontaneous clinical recoveries have been observed in some pigeons with clinical circoviral disease. Loss of flight and tail feathers was the only clinical sign reported in *Streptopelia senegalensis* (laughing turtle doves) with circoviral infection (74). Association between a clinical syndrome in ostrich chicks called fading chick syndrome and circoviral infection was demonstrated in 23 of 52 ostrich chicks with depression, weight loss, anorexia, and diarrhea prior to death (24).

Circovirus was detected in a canary with canary black spot disease and may be associated with this syndrome (31). Clinical signs in canaries with black spot include abdominal distension and failure to thrive. Chicks typically die within seven days. Feather anomalies are not usually seen. Clinical signs of circovirus infection in Mulard ducks include feather dystrophy along the dorsum (hemorrhagic shafts) and poor body condition with low weight gain (39). Growth retardation and rearing losses between 10% and 70% have been reported (117). Experimental infection of 21-day-old geese with PCR-positive cloacal bursa (bursa of Fabricius) homogenate elicited diarrhea at 17–30 days, marked differences of growth rate, and feather disorders in three of 30 geese (35).

A single case report of circovirus infection in a ten-week-old finch described nasal discharge, dyspnea, anorexia, and depression (109). In a separate report, circovirus virions were detected by electron microscopy in spleen from four three- to six-month old finches with feather loss over the neck, trunk, and dorsal region (69).

Pathology

Gross Lesions

Feather loss in birds infected with BFDV may vary from subtle to severe, depending upon the stage of feather development when viral infection occurs (51, 74, 144). Older birds may develop a chronic form of the disease in which the feathers stop growing shortly after emerging from the follicles. The number of dystrophic feathers increases during each successive molt. In some species, the powder down feathers over the hips are typically the first to show signs of dystrophy. The disease then progresses to involve the contour feathers in most tracts, followed by dystrophic changes in the primary, secondary tail, and crest feathers. Feather dystrophy and loss is roughly symmetrical. Changes in the feathers include retention of sheaths, hemorrhage within the pulp cavity, fracture of the proximal rachis, and failure of developing feathers to exsheathe. Short clubbed feathers, deformed curled feathers, stress lines within vanes, and circumferential constrictions may be observed. When present, beak deformities may occur including abnormal elongation, palantine necrosis, and transverse to longitudinal fractures or delaminations. Infrequently, the claws may develop deformities and the nails may slough.

Feather dystrophy is rare in racing pigeons with circoviral infection. The only gross lesion that can be attributed to circovirus infection in pigeons is cloacal bursal atrophy, but this lesion may not be present in all infected pigeons. The majority of the gross lesions observed at necropsy in pigeons that die of circovirus infection are usually attributable to secondary infections with other agents, such as concurrent viruses, bacteria, or fungi (142). However, there is a single report that describes feather dystrophy associated with an outbreak of circoviral infection in commercial pigeons in southern California (118). The gross appearance of the feathers was similar to that in psittacine birds infected with BFDV. Symmetrical feather dystrophy and loss have been reported in Senegal doves with circoviral infection (74, 82). Feathering disorders also have been observed in finches (69), a raven (120), ducks (117), and geese (115) that were infected with circovirus. Canaries with circovirus infection or "black spot" have been reported to develop abdominal enlargement and gall bladder congestion (31). Necropsy findings in ostriches with fading chick disease include gastric stasis, yolk sac infection, and enteritis (24).

Microscopic Lesions

Variable degrees of necrosis and inflammation commonly are observed in dystrophic feathers of birds infected with BFDV (41, 51, 52, 73, 144). Similar lesions have been reported in Senegal doves (74, 82), commercial squabs (118), geese (115), ducks (117), and finches (69). Multifocal to diffuse necrosis is evident in the basal feather (pterlogenic) epithelium, and inflammatory cell infiltrates comprised of variable combinations and quantities of heterophils and mononuclear inflammatory cells are seen with and without hemorrhage in the pulp cavity. Lesions also occur in the follicular epithelium but generally are less frequent and less severe. Basophilic to amphophilic nuclear inclusions are typically confined to feather and follicular epithelial cells (52), whereas multiglobular, "botryoid," or needle-like cytoplasmic inclusions are confined to macrophages in the feather epithelium, follicular epithelium, pulp cavity, and feather sheath. Associated degenerative changes occasionally are seen in the beak and claws. Cleft formation in the beak results from degeneration and necrosis of epithelial cells in the basal and intermediate cell layers of the rhamphotheca. These changes may be accompanied by hyperkeratosis and the presence of viral inclusions. In some psittacine birds such as African grey parrots, peracute infection with BFDV may be unaccompanied by feather and beak lesions; however, leukopenia, anemia (hypoperfusion of the lungs), bursal lesions, and hepatic necrosis may be observed (101).

Changes in primary and secondary lymphoid tissues in birds infected with avian circoviruses may be a direct or indirect effect of circoviral infection. A broad range of microscopic changes may be observed in lymphoid tissues of circovirus-infected birds. These changes range from lymphofollicular hyperplasia with discrete lymphocellular necrosis to severe lymphoid depletion that is often accompanied by globular cytoplasmic viral inclusions within macrophages in the cloacal bursa, spleen, and bronchial-associated and gut-associated lymphoid tissues (51, 142). Bursal follicles show discrete lymphocellular necrosis, marked lymphoid depletion, and intracytoplasmic botryoid inclusions (Figures 8.12 and 8.13).

Microscopic lesions, other than those in cutaneous and lymphoid tissues, include multiorgan lymphocytic infiltration (142, 35). Other changes are generally dependent upon concurrent infections. One study that examined the extracutaneous distribution of viral inclusions in more than 35 naturally infected psittacine birds reported intracytoplasmic inclusions in macrophages of lymphoid tissues (cloacal bursa, thymus, bone marrow, spleen), beak, hard palate, esophagus, crop, tongue, parathyroid gland, liver, intestine, thyroid gland,

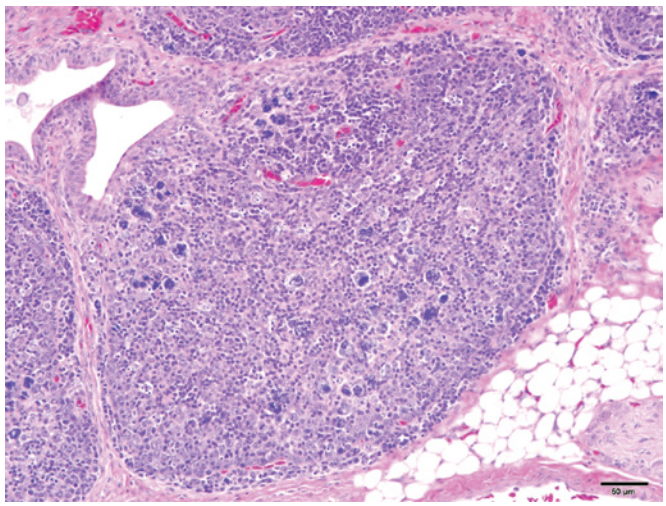

Figure 8.12. Photomicrograph of the cloacal bursa from a pigeon infected with circovirus. In the bursal follicle there is discrete lymphocellular necrosis and numerous intracytoplasmic amphophilic "botryoid" inclusions. H&E. Bar = 60 µm.

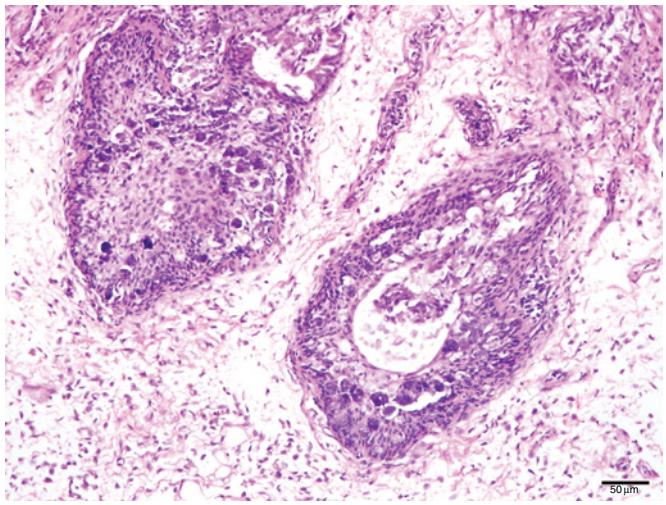

Figure 8.13. Photomicrograph of the cloacal bursa from a pigeon infected with circovirus. In the bursal follicle, there is marked lymphoid depletion with replacement histiocytosis and interfollicular interstitial edema. There are numerous bursal epithelial cells and macrophages with intracytoplasmic circoviral inclusions. H&E. Bar = 6 µm.

adrenal gland, pancreas, and nail bed (50). Intranuclear inclusions were seen in epithelial cells in the intestine, beak, palate, esophagus, crop, nail bed, and testicular germinal epithelium. Inclusions were limited to the cytoplasm of macrophages in the thymus, tongue, parathyroid gland, bone marrow, liver (Kupffer cells only), spleen, thyroid gland, adrenal gland, and pancreas. Although multisystemic distribution of circoviral inclusions occurs in psittacine birds, this has not been reported in pigeons. However, using PiCV *in situ* hybridization has demonstrated systemic distribution of circovirus including within liver, kidney, trachea, lung, brain, crop, intestine, spleen, bone

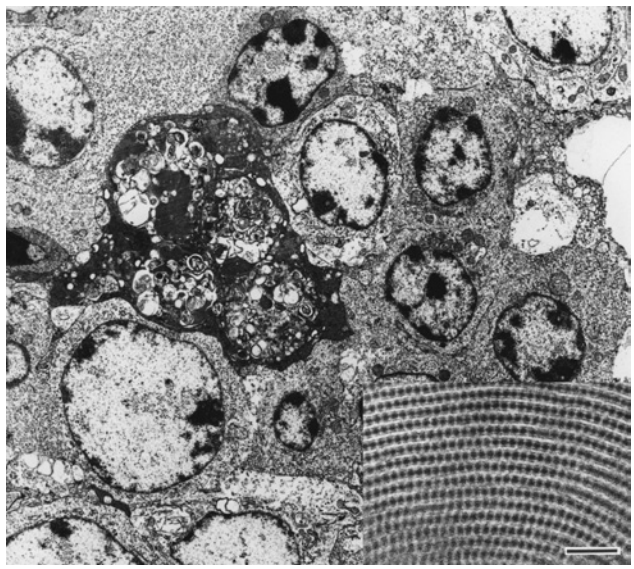

Figure 8.14. Transmission electron photomicrograph of the cloacal bursa from a pigeon infected with circovirus. The central large cytoplasmic inclusion is comprised of paracrystalline and semicircular arrays of circovirus particles. The inset demonstrates a portion of a semicircular array of virions. Uranyl acetate, lead citrate. Bar = 150 nm.

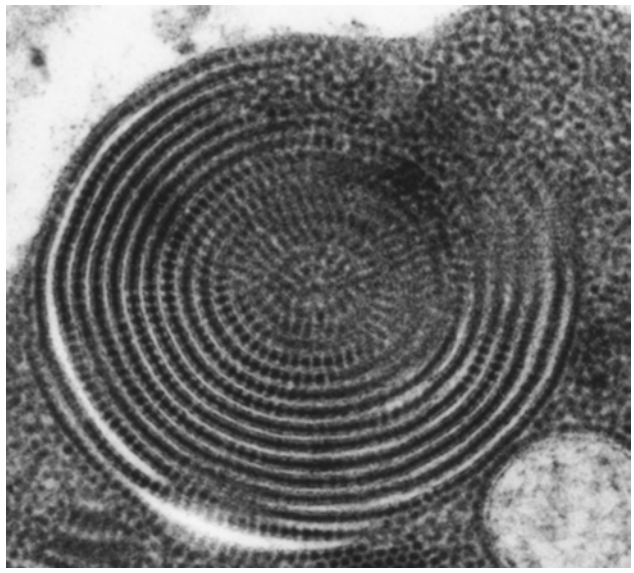

Figure 8.15. Transmission electron photomicrograph of the cloacal bursa from a pigeon infected with circovirus. Semicircular array of 14–17 nm circovirus virions. Uranyl acetate, lead citrate.

marrow, and heart (111). *In situ* hybridization also has demonstrated viral distribution in the nucleus of cells in the sinusoids of the liver in ostriches with fading chick syndrome (24).

Ultrastructural Observations

Cytoplasmic inclusions within macrophages and bursal epithelium appear as relatively organized paracrystalline arrays, circles, or semi-circles of viral particles (Figures 8.14 and 8.15). Infrequently, loosely arranged viral particles also may

be observed in epithelial or endothelial cell nuclei. Virions typically measure 14–17 nm in diameter (97, 141, 142).

Pathogenesis

Feather dystrophy and beak and claw deformities can be attributed to circoviral-induced necrosis of the basal epithelium in psittacine birds infected with BFDV. In one study, circovirus-infected pigeons had increased numbers of apoptotic cells in bursal lymphoid tissue as compared to uninfected birds undergoing physiologic apoptosis (1). The absence of demonstrated viral antigen within lymphocytes suggests that accelerated activation of apoptosis is not likely a direct effect of virus but an indirect cytokine-mediated event. Premature apoptosis of lymphocytes was demonstrated in geese with experimental infection compared to uninfected geese (35). Circoviral cytoplasmic inclusions are typically found in macrophages and bursal epithelium and may correlate with phagocytic activity of infected cells rather than endogenously replicating virus.

The small circoviral genome with limited protein-encoding capacity depends on the host cell DNA replication machinery. Therefore, circovirus exhibits tropism for rapidly dividing cells in mitosis (129) such as basal follicular epithelium, lymphoid tissue, and intestinal epithelium. Secondary infections account for approximately 70% of deaths in birds infected with BFDV, suggesting that viral infection results in acquired immunodeficiency (51). Putative immunosuppression and death from secondary infections also has been reported in pigeons (142), ducks (117), geese (115), a black-backed gull (137), and other avian species infected with circovirus (24). Lymphocellular necrosis and lymphoid depletion in the cloacal bursa and spleen easily explain hypogammaglobulinemia, lack of humoral response to vaccination, and multiple concurrent infections that occur in circovirus-infected birds. Lymphocellular necrosis and depletion may directly impair both humoral and cell-mediated immunity. However, acquired immunodeficiency also may occur in circovirus-infected birds with microscopically normal-to-hyperplastic lymphoid tissues. In such cases, circoviral infection initially may target the monocyte-macrophage system, affecting antigen presentation and cell-mediated immunity. Studies designed to investigate immune function of experimentally inoculated birds will help to clarify the pathogenesis of circoviral infections.

Immunity

Active Immunity

Birds exposed to BFDV have been shown to seroconvert (78, 79, 81, 91). Clinically normal birds that have been exposed to BFDV have higher titers than birds with active infections, suggesting that antibody is protective against both viral infection and development of clinical disease. The prevalence of PCR-positive young geese far exceeds the seroprevalence in young geese, demonstrating a later onset of seroconversion versus infection. This may either reflect lack of sensitivity of the serologic assays developed or demonstrates the immunosuppressive effect of circovirus on humoral immunity (4, 102). PCR-negative birds were 12.7 times more likely to have HI antibody than PCR-positive birds, based on diagnostic samples collected from 679 samples from a range of psittacine birds species suspected of being infected with BFDV (46).

Antibody was first detected in experimentally infected geese 27 days post-infection. Seroprevalence surveys of farmed geese with natural infection demonstrated antibody was first detected in birds 53 days of age (102).

Passive Immunity

Experimental vaccination studies have demonstrated that chicks from vaccinated hens remain clinically normal following challenge with PBFDV (90, 91). In contrast, chicks from unvaccinated hens succumbed to PBFD when challenged with the same virus. These observations indicate that hens that have been inoculated with killed BFDV can transfer protective antibodies to their offspring.

Diagnosis

Presumptive diagnosis of avian circoviral infection is based on clinical signs of disease and histopathology. The primary histologic finding is the presence of characteristic intranuclear and/or intracytoplasmic viral inclusions. Definitive diagnosis of circovirus infection requires the specific observation of characteristic virions by electron microscopy, demonstration of circoviral antigen by immunohistochemistry, or confirmation of circoviral nucleic acid using nucleic acid-based tests such as polymerase chain reaction (PCR), dot-blot hybridization (DBH), nested PCR, or *in situ* hybridization techniques (4, 8, 24, 26, 27, 38, 41, 54, 71, 83, 93, 96, 112, 130).

Hemagglutination (HA) and hemagglutination inhibition (HI) tests can be used to demonstrate BFDV antigen and antibody, respectively. Because circoviral infections can be highly prevalent and subclinical and latent infections can occur, demonstration of specific antibodies using hemagglutination inhibition indicates viral exposure but is not definitive for current viral infection. Additionally, erythrocyte suitability for HA/HI testing varies among species. Erythrocytes collected from many of the Australian and African birds will agglutinate in the presence of BFDV but there is no agglutinating activity using erythrocytes from South American species such as macaws and Amazon parrots (which correlates with resistance of South American avian species to clinical beak and feather disease) (49). Variation in erythrocyte sensitivities between avian species and individual birds have made standardization of HA and HI assays problematic. Additionally, HI is not effective for demonstrating antibodies in chronically infected birds, and birds with circovirus infections may have low antibody titers due to immunosuppression. A novel "blocking" competitive ELISA for detection of anti-BFDV antibodies in psittacine sera was demonstrated to be a sensitive and specific diagnostic test in 160 corellas (*Cacatua tenuiostris*) vaccinated with recombinant capsid protein and challenged with live virus (106).

It is well accepted that a positive PCR test result, on its own, is not a demonstration of active viral infection, and non-replicating DNA may take up to 3 months to clear from blood, so retesting is necessary for a definitive diagnosis of infection (16). Coupled with clinical signs, lesions, or serology, however, polymerase chain reaction assay (PCR) is a powerful tool for diagnosis and management of circovirus infections, as well as in the study of the pathogenesis of circovirus infections. Most studies using PCR assays use primers to amplify the relatively conserved ORF V1 segment of the genome (146, 95) and some of the ORF C1 portion of the genome (17). In two separate studies, Smyth demonstrated that nucleic acid-based tests are more sensitive than histopathology at detecting infected birds (111). Of 107 pigeons, 89% were detected by *in situ* hybridization using degenerate primers designed to specify conserved amino acid regions within ORF V1, and 66% were detected by histopathology. Liver, kidney trachea, lung, brain, crop, intestine, spleen, bone marrow, and heart were positive in circovirus-infected pigeons. Smyth suggested that when cloacal bursa is not available, liver is the next best tissue to examine for circovirus. Smyth also showed that routine histopathology was not adequate to detect GoCV infection in geese (112). Goose circovirus was demonstrated in cloacal bursa, thymus, bone marrow, liver, kidney, lung, heart, and intestines by *in situ* hybridization.

Hess showed that feathers are the tissue of choice over cloacal swabs and blood to detect circovirus-infected birds, but that blood, rather than feathers, best correlates with clinical disease (41). The virus also may persist in feathers of carriers (41). Newly erupted quills are the best samples of feathers to examine for viral infection (19). Contamination from aerosolized feather dander and feces and increased viral load in environment may be responsible for false positives of feather samples. However, Khalesi found that PCR was more sensitive in blood than feathers (46). Blood should be drawn from the vein and not the toenail due to possible environmental viral contamination. Toenail blood may be used to screen for circovirus infection, but if the test result is positive, blood should then be collected via venipuncture for confirmation testing (16). Duchatel tested pharyngeal swabs, cloacal swabs, and blood immediately before sacrificing birds and found that these samples did not correlate with PCR results on tissues collected at necropsy (21). He concluded that these specimens are not good samples to take to eliminate birds with asymptomatic viral infection. Respiratory tract tissues most commonly tested positive followed by spleen, kidney, and liver. Todd et al. demonstrated that PiCV infections were more readily detected in cloacal swabs than blood; PiCV can be detected in some birds for at least 27 weeks and that a small portion of adult pigeons may excrete virus (133).

Khalesi demonstrated PCR was more specific and sensitive than HA for detecting BFDV in feathers (46). The advantage of using HA, however, was quantification of virus in infected birds. Development of quantitative, real-time PCR assays have proved extremely sensitive, allowed for quantification of DNA, and don't require the post-reaction processing to visualize the PCR products (22, 107). Todd (130) and Ball (4) demonstrated that dot-blot hybridization (DBH) was less sensitive than PCR. Dot-blot hybridization detected between 4 and 40 pg of viral DNA, whereas PCR can detect 0.10 fg of viral DNA. Todd suggested that even though DBH is less sensitive than PCR, it is more useful for several reasons. Results of DBH are more likely to correlate with clinical disease if virus load is considered to be an indicator of disease. Higher circoviral titers likely correlate with clinical disease in avian species, as is the case in pigs with PCV. DBH is semiquantitative, cross-contamination is not probable, and DBH is not limited by minor sequence variation like PCR.

Nested PCR using DNA from dried blood collected by venipuncture was a very sensitive test and in fact was 10–100 times more sensitive than PCR (38, 47). Nested broad-spectrum PCR detected five known circovirus species in clinical samples and picked up previously unidentified circoviruses. Due to high variability within the circovirus genome sequences, detection systems developed for distinct circoviruses may sometimes fail. Use of degenerate primers in combination with sequencing will allow for detection of new avian circoviruses (37).

Isolation and Identification of Causative Agent

Long-term propagation of the avian circoviruses in cell culture systems and embryonating chicken eggs has been unsuccessful. Only CIAV has been propagated in MDCC-MSB1 cells derived from Marek's disease lymphoma.

Serology

Hemagglutination and hemagglutination inhibition have been used historically to confirm certain viral infections (hemagglutination) or to detect viral exposure by demonstrating viral-specific antibodies (hemagglutination inhibition). Ritchie et al. (91) and Raidal et al. (78, 81) have reported on BFDV-induced hemagglutination and the development of a hemagglutination inhibition test for detection of BFDV antibodies. These techniques have been used experimentally to partially elucidate the pathogenesis of BFD and to document the exposure of companion and free-ranging birds to BFDV.

The non-cultivable nature of avian circovirus in conventional virus propagation systems has hindered development of diagnostic methods. More recently, virus-like particles produced by expression of ORF C1 (capsid protein) produced by insect cells using a baculovirus expression system (11, 104, 121), or by baby hamster kidney cells using the eukaryotic Semliki forest virus expression vector (102), have demonstrated antigenic properties key to development of standardized diagnostic serological assays. Monoclonal antibody specific to the capsid protein of BFDV has application in western blot, immunohistochemistry, ELISA, and hemagglutination-inhibition. A recombinant truncated capsid protein produced by overexpression in Escherichia coli was used in development of indirect ELISAs to detect specific antibodies to PiCV and DuCV (17, 58).

Differential Diagnosis

Feather folliculitis (due to bacterial, fungal, or other viral infections such as polyomavirus), metabolic imbalance, endocrinopathy, and nutritional disease may result in feather dystrophy that mimics the clinical appearance of PBFD. Because secondary infections are common in circovirus-infected birds, circovirus should always be considered in conjunction with other infectious agents.

Intervention Strategies

Management Procedures

Prevention of circoviral infection is difficult in pigeon lofts and free-ranging bird populations where individuals of various age, origin, and species may intermix freely. Routine biosecurity and isolation procedures will be more effective in preventing viral spread in closed aviaries and commercial poultry operations. After circovirus infection is established, disinfection of lofts, houses, and aviaries is difficult to impossible. Based on results of studies with chicken infectious anemia virus, the circoviruses as a group appear environmentally stable and relatively resistant to inactivation by many common disinfectants. The widespread nature of circovirus infection as demonstrated by antigen and antibody detection assays suggests eradication will be unlikely and circovirus disease in commercial flocks will better be managed by ensuring that all birds are vaccinated and breeder birds have high levels of antibodies before lay.

Infection of macrophages and destruction of lymphoid tissues during viral infection undoubtedly affect both humoral and cell-mediated immunity. Therefore, vaccination of birds while viral infection is active should be avoided. Pigeons vaccinated with poxvirus and paramyxovirus (PMV-1) vaccines during active circoviral infection failed to elicit an antibody response to either virus (142). In contrast, antibodies directed against PMV-1 were detected by HI at 14 days post vaccination in experimentally infected pigeons that were vaccinated with PMV-1 vaccine simultaneously with PiCV inoculation (100). Contrasting findings may be due to the timing of infection and vaccination or absence of stress in the experimental study. Therefore, antibody titers of birds in an aviary or loft vaccinated near or during the time of circoviral infection should be evaluated to determine the efficacy of vaccination. If postvaccinal serum antibody titers are low, revaccination should be performed after clinical signs of disease have subsided. The stress of vaccination of pigeons during active infection has not been shown to be a risk factor in development of clinical disease in circovirus-infected birds (23). Vaccination programs in aviaries and houses should always remain current because concurrent viral infections often are responsible for increased mortality during circoviral outbreaks.

Vaccination

Currently, an effective, commercial vaccine does not exist to prevent BFD in psittacine birds or circoviral infections in pigeons or other avian species. Preliminary work with BFDV has shown that maternal antibody is protective (81, 91,). In early studies with BFDV, vaccination was shown to be effective against the development of clinical disease but not against viral infection (79). Therefore, subclinical carriers are not prevented by vaccination. BFDV is extremely difficult to inactivate completely and is highly infectious to susceptible birds. Therefore, inactivated vaccines containing whole virus that is obtained from infected bird tissues have been too dangerous for clinical use (94). In one study, 3 sibling sufphur-crested cockatoos were vaccinated with inactivated vaccine but all three died of BFDV prior to challenge with live virus (79). It is speculated that these birds may have been infected prior to vaccination, but the possibility of vaccine-induced disease was also considered. Resistance of avian circoviruses to inactivation coupled with inability to grow in cell culture made recombinant technology essential for vaccine development. Immunogenicity of the BFDV capsid protein produced by expression of ORF C1 in insect cells using a baculovirus expression system has been demonstrated to be effective in reducing virus replication in experimentally challenged birds (11). In this study, 4 of 97 blood samples collected from vaccinated long-billed corellas (*Cacatua tenuirostris*) after virus challenge tested positive by PCR, while 17 of 35 serum samples collected from non-vaccinated birds tested positive. Vaccinated birds did not develop feather lesions, had only transient PCR-detectable viremia, and had no evidence of persistent infection 270 days post-challenge. Non-vaccinated birds were PCR-positive up to 41 days post-challenge.

Treatment

At the present time, an effective treatment does not exist for circoviral infections in avian species. Because most birds infected with circovirus die from secondary infections with viral, bacterial, protozoal, or fungal agents, attempts should be made to diagnose and treat any secondary infections. Avian gamma interferon has shown some promise as part of a treatment regimen in birds with active infection. In one study (119), 7 of 10 African grey parrots (*Psittacus erithacus*) with active BFDV infection (PCR-positive and severe leukopenia) responded to treatment with avian gamma interferon (1 million IU IM SID ×R 90 d) coupled with quaternary ammonium (1:125; 15 minutes, BID) nebulization. Leukocyte counts in surviving birds returned to normal 180 days after treatment was initiated. One study demonstrated improvement of plumage in horned parakeets with chronic circovirus infection after three months of β-d-glucan administration (136) and clearance of viremia in parakeets and cockatoos after 7 to 9 months of treatment.

Commercial vaccines using recombinant technology used for commercial poultry flocks could be made available for companion birds and exotic avian collections. Wildlife conservation strategies will entail understanding the global distribution and host/isolate specificity of the avian circoviruses by continued mapping of the genomic diversity worldwide (138).

References

Introduction

1. Bassami, M.R., D. Berryman, G.E. Wilcox, and S.R. Raidal. 1998. Psittacine beak and feather disease virus nucleotide sequence analysis and its relationship to porcine circovirus, plant circoviruses, and chicken anaemia virus. *Virology*. 249:453–459.
2. Biagini, P. 2009. Classification of TTV and related viruses (anelloviruses). *Curr Top Microbiol Immunol*. 331:21–33.
3. Biagini, P. 2011. Restructuring and expansion of the family *Anelloviridae*. http://talk.ictvonline.org/files/proposals/taxonomy_proposals_general1/m/gen01/default.aspx. Oct 14, 2011.
4. Biagini, P. 2011. Restructuring and expansion of the family *Circoviridae*. http://talk.ictvonline.org/files/proposals/taxonomy_proposals_general1/m/gen01/default.aspx. Oct 14, 2011.
5. de Smit, M.H., and M.H. Noteborn. 2009. Apoptosis–inducing proteins in chicken anemia virus and TT virus. *Curr Top Microbiol Immunol*. 331:131–149.
6. Gibbs, M.J., and G.F. Weiller. 1999. Evidence that a plant virus switched hosts to infect a vertebrate and then recombined with a vertebrate-infecting virus. *Proc Natl Acad Sci USA*. 96: 8022–8027.
7. Li, L., A. Kapoor, B. Slikas, O.S. Bamidele, C. Wang, S. Shaukat, M.A. Masroor, M.L. Wilson, J.-B.N. Ndjango, M. Peeters, N.D. Gross-Camp, M.N. Muller, B.H. Hahn, N.D. Wolfe, H. Triki, J. Bartkus, S.Z. Zaidi, and E. Delwart. 2010. Multiple diverse circoviruses infect farm animals and are commonly found in human and chimpanzee feces. *J Virol*. 84:1674–1682.
8. Li, L., T. Shan, O.B. Soji, M.M. Alam, T.H. Kunz, S.Z. Zaidi, and E. Delwart. 2011. Possible cross-species transmission of circoviruses and cycloviruses among farm animals. *J Gen Virol*. 92: 768–772.
9. Niagro, F.D., A.N. Forsthoefel, R.P. Lawther, L. Kamalanathan, B.W. Ritchie, K.S. Latimer, and P.D. Lukert. 1998. Beak and feather disease virus and porcine circovirus genomes: intermediates between the geminiviruses and plant circoviruses. *Arch Virol*. 143:1723–1744.
10. Noteborn, M.H., D. Todd, C.A. Verschueren, H.W. de Gauw, W.L. Curran, S. Veldkamp, A.J. Douglas, M.S. McNulty, A.J. van der Eb, and G. Koch. 1994. A single chicken anemia virus protein induces apoptosis. *J Virol*. 68:346–351.
11. Rijsewijk, F., H. dos Santos, T. Teixeira, S. Cibulski, A. Varela, D. Dezen, A. Franco, and P. Roehe. 2011. Discovery of a genome of a distant relative of chicken anemia virus reveals a new member of the genus *Gyrovirus*. *Arch Virol*. 156:1097–1100.
12. Sauvage, V., J. Cheval, V. Foulongne, M.A. Gouilh, K. Pariente, J.C. Manuguerra, J. Richardson, O. Dereure, M. Lecuit, A. Burguiere, V. Caro, and M. Eloit. 2011. Identification of the first human gyrovirus, a virus related to chicken anemia virus. *J Virol*. 85:7948–7950.
13. Tischer, I., H. Gelderblom, W. Vettermann, and M.A. Koch. 1982. A very small porcine virus with circular single-stranded DNA. *Nature*. 295:64–66.
14. Todd, D., P. Biagini, M. Bendinelli, S. Hino, A. Mankertz, S. Mishiro, C. Niel, Okamoto H, S.R. Raidal, B.W. Ritchie and C.G. Teo. 2005. *Circoviridae*. In: Virus Taxonomy, Eighth Report of the International Committee for the Taxonomy of Viruses. C.M. Fauquet, M.A. Mayo, J. Maniloff, U. Desselberger, and L.A. Ball, eds. Elsevier/Academic Press, London. 327–334.
15. Vetten, H.J., P.W.G. Chu, J.L. Dale, R. Harding, J. Hu, L. Katul, M. Kojima, J.W. Randles, Y. Sano, and J.E. Thomas. 2005. Family Nanoviridae. In: Virus Taxonomy. Classification and Nomenclature of Viruses. Seventh Report of the International Committee of Taxonomy of Viruses. M.H.V. van Regenmortel, C.M. Fauqet, D.H.L. Bishop, E.B. Carstens, M.K. Estes, S.M. Lemon, J. Maniloff, M.A. Mayo, D.J. McGeogh, C.R. Pringle, and R.B. Wickner, eds. Academic Press, New York. 343–352.

Chicken Infectious Anemia

1. Adair, B.M., F. McNeilly, C.D. McConnell, D. Todd, R.T. Nelson, and M.S. McNulty. 1991. Effects of chicken anemia agent on lymphokine production and lymphocyte transformation in experimentally infected chickens. *Avian Dis*. 35:783–792.
2. Adair, B.M., F. McNeilly, C.D. McConnell, and M.S. McNulty. 1993. Characterization of surface markers present on cells infected by chicken anemia virus in experimentally infected chickens. *Avian Dis*. 37:943–950.
3. Adair, B.M., and M.S. McNulty. 1997. Lymphocyte transformation and lymphokine production during chicken anaemia virus infection. In: *Cytokines in Veterinary Medicine*. V.E.C.J. Schijns and H.C. Horzinek, eds. CAB International, Wallingford. 301–310.
4. Adair, B.M. 2000. Immunopathogenesis of chicken anemia virus infection. *Dev Comp Immunol*. 24:247–255.
5. Allan, G.M., J.A. Smyth, D. Todd, and M.S. McNulty. 1993. In situ hybridization for the detection of chicken anemia virus in formalin-fixed, paraffin-embedded sections. *Avian Dis*. 37: 177–182.
6. Allan, G.M., K.V. Phenix, D. Todd, and M.S. McNulty. 1994. Some biological and physico-chemical properties of porcine circovirus. *Zentralbl Veterinarmed. [B]* 41:17–26.
7. Amer, H.M., H.M. Elzahed, E.A. Elabiare, A.A. Badawy, and A.A. Yousef. 2011. An optimized polymerase chain reaction assay to identify avian virus vaccine contamination with chicken anemia virus. *J Vet Diagn Invest*. 23:34–40.
8. Bassami, M.R., D. Berryman, G.E. Wilcox, and S.R. Raidal. 1998. Psittacine beak and feather disease virus nucleotide sequence analysis and its relationship to porcine circovirus, plant circoviruses, and chicken anaemia virus. *Virology*. 249: 453–459.
9. Bisgaard, M. 1983. An age related and breeder flock associated hemorrhagic disorder in Danish broilers. *Nord Vet Med*. 35: 397–407.
10. Bounous, D.I., M.A. Goodwin, R.L.J. Brooks, C.M. Lamichlane, R.P. Campagnoli, J. Brown, and D.B. Snyder. 1995. Immunosuppression and intracellular calcium signaling in splenocytes from chicks infected with chicken anemia virus, CL-1 isolate. *Avian Dis*. 39:135–140.
11. Box, P.G., H.C. Holmes, A.C. Bushell, and P.M. Finney. 1988. Impaired response to killed Newcastle disease vaccine in chicken possessing circulating antibody to chicken anaemia agent. *Avian Pathol*. 17:713–723.
12. Brentano, L., S. Lazzarin, S.S. Bassi, T.A. Klein, and K.A. Schat. 2005. Detection of chicken anemia virus in the gonads and in the progeny of broiler breeder hens with high neutralizing antibody titers. *Vet Microbiol*. 105:65–72.

13. Buchholz, U., and V. von Bülow. 1994. Characterization of chicken anaemia virus (CAV) proteins. In: Proceedings of the International Symposium on Infectious Bursal Disease and Chicken Infectious Anaemia. Rauischholzhausen, Germany. 366–375.
14. Calnek, B.W., R.W. Harris, C. Buscaglia, K.A. Schat, and B. Lucio. 1998. Relationship between the immunosuppressive potential and the pathotype of Marek's disease virus isolates. *Avian Dis*. 42:124–132.
15. Calnek, B.W., B. Lucio-Martinez, C. Cardona, R.W. Harris, K.A. Schat, and C. Buscaglia. 2000. Comparative susceptibility of Marek's disease cell lines to chicken infectious anemia virus. *Avian Dis*. 44:114–124.
16. Campbell, G. 2001. Investigation into evidence of exposure to infectious bursal disease virus (IBDV) and chick infectious anaemia virus (CIAV) in wild birds in Ireland. In: Proceedings of the Second International Symposium on Infectious Bursal Disease and Chicken Infectious Anaemia. Rauischholzhausen, Germany. 230–233.
17. Cardona, C., B. Lucio, P. O'Connell, J. Jagne, and K.A. Schat. 2000. Humoral immune responses to chicken infectious anemia virus in three strains of chickens in a closed flock. *Avian Dis*. 44:661–667.
18. Cardona, C.J., and K.A. Schat. 1999. Unpublished data.
19. Cardona, C.J., W.B. Oswald, and K.A. Schat. 2000. Distribution of chicken anaemia virus in the reproductive tissues of specific-pathogen-free chickens. *J Gen Virol*. 81:2067–2075.
20. Chandratilleke, D., P. O'Connell, and K.A. Schat. 1991. Characterization of proteins of chicken infectious anemia virus with monoclonal antibodies. *Avian Dis*. 35:854–862.
21. Chettle, N.J., R.K. Eddy, P.J. Wyeth, and S.A. Lister. 1989. An outbreak of disease due to chicken anaemia agent in broiler chickens in England. *Vet Rec*. 124:211–215.
22. Chowdhury, S.M.Z.H., A.R. Omar, I. Aini, M. Hair-Bejo, A.A. Jamaluddin, B.M. Md-Zain, and Y. Kono. 2003. Pathogenicity, sequence and phylogenetic analysis of Malaysian chicken anaemia virus obtained after low and high passages in MSB-1 cells. *Arch Virol*. 148:2437–2448.
23. Claessens, J.A., C.C. Schrier, A.P. Mockett, E.H. Jagt, and P.J. Sondermeijer. 1991. Molecular cloning and sequence analysis of the genome of chicken anaemia agent. *J Gen Virol*. 72:2003–2006.
24. Cloud, S.S., H.S. Lillehoj, and J.K. Rosenberger. 1992. Immune dysfunction following infection with chicken anemia agent and infectious bursal disease virus. I. Kinetic alterations of avian lymphocyte subpopulations. *Vet Immunol Immunopathol*. 34:337–352.
25. Cloud, S.S., J.K. Rosenberger, and H.S. Lillehoj. 1992. Immune dysfunction following infection with chicken anemia agent and infectious bursal disease virus. II. Alterations of in vitro lymphoproliferation and in vivo immune responses. *Vet Immunol Immunopathol*. 34:353–366.
26. Cowen, B.S. 1992. Inclusion body hepatitis-anaemia and hydropericardium syndromes: Aetiology and control. *World's Poultry Sci J*. 48:247–254.
27. Crowther, R.A., J.A. Berriman, W.L. Curran, G.M. Allan, and D. Todd. 2003. Comparison of the structures of three circoviruses: chicken anemia virus, porcine circovirus type 2, and beak and feather disease virus. *J Virol Meth*. 77:13036–13041.
28. Danen-Van Oorschot, A.A., D.F. Fischer, J.M. Grimbergen, B. Klein, S. Zhuang, J.H. Falkenburg, C. Backendorf, P.H. Quax, A.J. Van der Eb, and M.H. Noteborn. 1997. Apoptin induces apoptosis in human transformed and malignant cells but not in normal cells. *Proc Natl Acad Sci USA*. 94:5843–5847.
29. Danen-Van Oorschot, A.A., Y.H. Zhang, S.R. Leliveld, J.L. Rohn, M.C. Seelen, M.W. Bolk, A. Van Zon, S.J. Erkeland, J.P. Abrahams, D. Mumberg, and M.H. Noteborn. 2003. Importance of nuclear localization of apoptin for tumor-specific induction of apoptosis. *J Biol Chem*. 278:27729–27736.
30. Davidson, I., M. Kedem, H. Borochovitz, N. Kass, G. Ayali, E. Hamzani, B. Perelman, B. Smith, and S. Perk. 2004. Chicken infectious anemia virus infection in Israeli commercial flocks: virus amplification, clinical signs, performance, and antibody status. *Avian Dis*. 48:108–118.
31. Davidson, I., E. Loeb, A. Lublin, I. Shkoda, and K.A. Schat. 2007. Assessment of various criteria to determine the chicken anemia virus pathogenicity in embryonated eggs and in day-old chicks. *Curr Top Virol*. 6:95–111.
32. Davidson, I., N. Artzi, I. Shkoda, A. Lublin, E. Loeb, and K.A. Schat. 2008. The contribution of feathers in the spread of chicken anemia virus. *Virus Res*. 132:152–159.
33. de Boer, G.F., D.J. Van Roozelaar, R.J. Moormann, S.H.M. Jeurissen, J.C. van den Wijngaard, F. Hilbink, and G. Koch. 1994. Interaction between chicken anaemia virus and live Newcastle disease vaccine. *Avian Pathol*. 23:263–275.
34. De Herdt, P., G. Van den Bosch, R. Ducatelle, E. Uyttebroek, and C. Schrier. 2001. Epidemiology and significance of chicken infectious anemia virus infections in broilers and broiler parents under nonvaccinated European circumstances. *Avian Dis*. 45: 706–708.
35. de Smit, M.H., and M.H. Noteborn. 2009. Apoptosis-inducing proteins in chicken anemia virus and TT virus. *Curr Top Microbiol Immunol*. 331:131–149.
36. de Wit, J.J., J.H. van Eck, R.P. Crooijmans, and A. Pijpers. 2004. A serological survey for pathogens in old fancy chicken breeds in central and eastern part of The Netherlands. *Tijdschr Diergeneeskd*. 129:324–327.
37. Dobos-Kovács, M., I. Varga, L. Békési, C.N. Drén, I. Németh, and T. Farkas. 1994. Concurrent cryptosporidiosis and chicken anaemia virus infection in broiler chickens. *Avian Pathol*. 23:365–368.
38. Dorn, P., J. Weikel, and E. Wessling. 1981. Anämia, Rückbildung der lymphatischen Organe und Dermatitis—Beobachtungen zu einem neuen Krankheitsbild in der Geflügelmast. *Dtsch. Tierärztl. Wochenschr*. 88:313–315.
39. dos Santos, H.F., M.B. Knak, F.L. de Castro, J. Slongo, G.A. Ritterbusch, T.A.P. Klein, P.A. Esteves, A.D. Silva, I.M. Trevisol, E.A.W. Claassen, L.A.H.M. Cornelissen, M. Lovato, A.C. Franco, P.M. Roehe, and F.A.M. Rijsewijk. 2012. Variants of the recently discovered avian gyrovirus 2 are detected in Southern Brazil and The Netherlands. *Vet Microbiol*. 155(2–4):230–6.
40. Douglas, A.J., K. Phenix, K.A. Mawhinney, D. Todd, D.P. Mackie, and W.L. Curran. 1995. Identification of a 24 kDa protein expressed by chicken anaemia virus. *J Gen Virol*. 76: 1557–1562.
41. Dren, C.N., G. Koch, A. Kant, C.A.J. Verschueren, A.J. van der Eb, and M.H.N. Noteborn. 1994. A hot start PCR for the laboratory diagnosis of CAV. In: International Symposium on Infectious Bursal Disease and Chicken Infectious Anaemia. Rauischholzhausen, Germany. 413–420.
42. Drén, C.N., A. Kant, D.J. Van Roozelaar, L. Hartog, M.H. Noteborn, and G. Koch. 2000. Studies on the pathogenesis of chicken infectious anaemia virus infection in six-week-old SPF chickens. *Acta Vet Hung*. 48:455–467.

43. Eltahir, Y., K. Qian, W. Jin, P. Wang, and A. Qin. 2011. Molecular epidemiology of chicken anemia virus in commercial farms in China. *Virol J*. 8:145.
44. Engström, B.E., and M. Luthman. 1984. Blue wing disease of chickens: signs, pathology and natural transmission. *Avian Pathol*. 13:1–12.
45. Engström, B.E. 1988. Blue wing disease of chickens. Isolation of avian reovirus and chicken anaemia agent. *Avian Pathol*. 17:23–32.
46. Engström, B.E., O. Fossum, and M. Luthman. 1988. Blue wing disease of chickens: Experimental infection with a Swedish isolate of chicken anaemia agent and an avian reovirus. *Avian Pathol*. 17:33–50.
47. Engström, B.E. 1999. Prevalence of antibody to chicken anaemia virus (CAV) in Swedish chicken breeding flocks correlated to outbreaks of blue wing disease (BWD) in their progeny. *Acta Vet Scand*. 40:97–107.
48. Fadly, A.M., J.V. Motta, R.L. Witter, and R.M. Nordgren. 1994. Epidemiology of chicken anemia virus in specific-pathogen-free chicken breeder flocks. In: Proceedings of the International Symposium on Infectious Bursal Disease and Chicken Infectious Anaemia. Rauischholzhausen, Germany. 447–455.
49. Farkas, T., M. Maeda, H. Sugiura, K. Kai, K. Hirai, K. Ostuki, and T. Hayashi. 1998. A serological survey of chickens, Japanese quail, pigeons, ducks and crows for antibodies to chicken anaemia virus (CAV) in Japan. *Avian Pathol*. 27:316–320.
50. Fehler, F., and C. Winter. 2001. CAV infection in older chickens: an apathogenic infection? In: Proceedings of the Second International Symposium on Infectious Bursal Disease and Chicken Infectious Anaemia. Rauischholzhausen, Germany. 391–394.
51. Gallardo, R.A., V.L. van Santen, and H. Toro. 2012. Effects of chicken anaemia virus and infectious bursal disease virus-induced immunodeficiency on infectious bronchitis virus replication and phenotypic drift. *Avian Pathol*. 41:451–458.
52. Gelderblom, H., S. Kling, R. Lurz, I. Tischer, and V. von Bülow. 1989. Morphological characterization of chicken anaemia agent (CAA). *Arch Virol*. 109:115–120.
53. Gilka, F., and J.L. Spencer. 1995. Extravascular hemolytic anemia in chicks infected with highly pathogenic Marek's disease viruses. *Avian Pathol.* 24:393–410.
54. Girshick, T. 2001. Personal communication.
55. Goodwin, M.A., J. Brown, M.A. Smeltzer, C.K. Crary, T. Girchik, S.L. Miller, and T.G. Dickson. 1990. A survey for parvovirus-like virus (so-called chick anemia agent) antibodies in broiler breeders. *Avian Dis*. 34:704–708.
56. Goodwin, M.A., J. Brown, K.S. Latimer, and S.L. Miller. 1991. Packed cell volume reference intervals to aid in the diagnosis of anemia and polycythemia in young leghorn chickens. *Avian Dis*. 35:820–823.
57. Goodwin, M.A., J. Brown, J.F. Davis, T. Girshick, S.L. Miller, R.M. Nordgren, and J. Rodenberg. 1992. Comparisons of packed cell volumes (PCVs) from so-called chicken anemia agent (CAA; a virus)-free broilers to PCVs from CAA-free specific-pathogen-free leghorns. *Avian Dis*. 36:1063–1066.
58. Goodwin, M.A., J. Brown, M.A. Smeltzer, T. Girshick, S.L. Miller, and T.G. Dickson. 1992. Relationship of common avian pathogen antibody titers in so-called chicken anemia agent (CAA)-antibody-positive chicks to titers in CAA-antibody-negative chicks. *Avian Dis*. 36:356–358.
59. Goodwin, M.A., J.F. Davis, and J. Brown. 1992. Packed cell volume reference intervals to aid in the diagnosis of anemia and polycythemia in young broiler chickens. *Avian Dis*. 36:440–443.
60. Goodwin, M.A., M.A. Smeltzer, J. Brown, T. Girshick, B.L. McMurray, and S. McCarter. 1993. Effect of so-called chicken anemia agent maternal antibody on chick serologic conversion to viruses in the field. *Avian Dis*. 37:542–545.
61. Goryo, M., H. Sugimura, S. Matsumoto, T. Umemura, and C. Itakura. 1985. Isolation of an agent inducing chicken anaemia. *Avian Pathol*. 14:483–496.
62. Goryo, M., Y. Shibata, T. Suwa, T. Umemura, and C. Itakura. 1987. Outbreak of anemia associated with chicken anemia agent in young chicks. *Jpn J Vet Sci*. 49:867–873.
63. Goryo, M., T. Suwa, S. Matsumoto, T. Umemura, and C. Itakura. 1987. Serial propagation and purification of chicken anaemia agent in MDCC-MSB1 cell line. *Avian Pathol*. 16:149–163.
64. Goryo, M., S. Hayashi, K. Yoshizawa, T. Umemura, C. Itakura, and S. Yamashiro. 1989. Ultrastructure of the thymus in chicks inoculated with chicken anaemia agent (MSB1-TK5803 strain). *Avian Pathol*. 18:605–617.
65. Goryo, M., T. Suwa, T. Umemura, C. Itakura, and S. Yamashiro. 1989. Ultrastructure of bone marrow in chicks inoculated with chicken anaemia agent (MSB1-TK5803 strain). *Avian Pathol*. 18:329–343.
66. Goryo, M., T. Suwa, T. Umemura, C. Itakura, and S. Yamashiro. 1989. Histopathology of chicks inoculated with chicken anaemia agent (MSB1-TK5803 strain). *Avian Pathol*. 18:73–89.
67. Hagood, L.T., T.F. Kelly, J.C. Wright, and F.J. Hoerr. 2000. Evaluation of chicken infectious anemia virus and associated risk factors with disease and production losses in broilers. *Avian Dis*. 44:803–808.
68. Hailemariam, Z., A.R. Omar, M. Hair-Bejo, and T.C. Giap. 2008. Detection and characterization of chicken anemia virus from commercial broiler breeder chickens. *Virol J*. 5:128.
69. Haridy, M., M. Goryo, J. Sasaki, and K. Okada. 2009. Pathological and immunohistochemical study of chickens with co-infection of Marek's disease virus and chicken anaemia virus. *Avian Pathol*. 38:469–483.
70. Haridy, M., M. Goryo, J. Sasaki, and K. Okada. 2010. Comparative susceptibility of some avian and mammalian lymphoblastoid cell lines to chicken anemia virus. *J Vet Med. Sci*. 72:1637–1641.
71. He, C.-Q., N.-Z. Ding, W. Fan, Y.-H. Wu, J.-P. Li, and Y.-l. Li. 2007. Identification of chicken anemia virus putative intergenotype recombinants. *Virology* 366:1–7.
72. Hinton, T.M., and T.J. Doran. 2008. Inhibition of chicken anaemia virus replication using multiple short-hairpin RNAs. *Antiviral Res*. 80:143–149.
73. Hoop, R.K., and R.L. Reece. 1991. The use of immunofluorescence and immunoperoxidase staining in studying the pathogenesis of chicken anaemia agent in experimentally infected chickens. *Avian Pathol*. 20:349–355.
74. Hoop, R.K. 1992. Persistence and vertical transmission of chicken anaemia agent in experimentally infected laying hens. *Avian Pathol*. 21:493–501.
75. Hoop, R.K. 1993. Transmission of chicken anaemia virus with semen. *Vet Rec*. 133:551–552.
76. Hornok, S., J.F. Heijmans, L. Békési, H.W. Peek, M. Dobos-Kovács, C.N. Drén, and I. Varga. 1998. Interaction of chicken anaemia virus and Cryptosporidium baileyi in experimentally infected chickens. *Vet Parasitol*. 76:43–55.
77. Hu, L.-b., B. Lucio, and K.A. Schat. 1993. Abrogation of age-related resistance to chicken infectious anemia by embryonal bursectomy. *Avian Dis*. 37:157–169.

78. Hu, L.-b., B. Lucio, and K.A. Schat. 1993. Depletion of CD4+ and CD8+ T lymphocyte subpopulations by CIA-1, a chicken infectious anemia virus. *Avian Dis*. 37:492–500.
79. Hu, L. 1992. Role of humoral immunity and T cell subpopulations in the pathogenesis of chicken infectious anemia virus. MS Thesis. Cornell University, Ithaca, NY. 1–148.
80. Huang, C.H., G.H. Lai, M.S. Lee, W.H. Lin, Y.Y. Lien, S.C. Hsueh, J.Y. Kao, W.T. Chang, T.C. Lu, W.N. Lin, and H.J. Chen. 2010. Development and evaluation of a loop-mediated isothermal amplification assay for rapid detection of chicken anaemia virus. *J Appl Microbiol*. 108:917–924.
81. Imai, K., and N. Yuasa. 1990. Development of a microtest method for serological and virological examinations of chicken anemia agent. *Nippon Juigaku Zasshi* 52:873–875.
82. Imai, K., M. Maeda, and N. Yuasa. 1991. Immunoelectron microscopy of chicken anemia agent. *J Vet Med Sci*. 53:1065–1067.
83. Imai, K., S. Mase, K. Tsukamoto, H. Hihara, T. Matsumura, and N. Yuasa. 1993. A long term observation of antibody status to chicken anaemia virus in individual chickens of breeder flocks. *Res Vet Sci*. 54:392–396.
84. Imai, K., M. Mase, K. Tsukamoto, H. Hihara, and N. Yuasa. 1999. Persistent infection with chicken anaemia virus and some effects of highly virulent infectious bursal disease virus infection on its persistency. *Res Vet Sci*. 67:233–238.
85. Iwata, N., M. Fujino, K. Tuchiya, A. Iwata, Y. Otaki, and S. Ueda. 1998. Development of an enzyme-linked immunosorbent assay using recombinant chicken anemia virus proteins expressed in a baculovirus vector system. *J Vet Med Sci*. 60:175–180.
86. Jaffe, P. 1960. Differences in numbers of erythrocytes between inbred lines of chickens. *Nature*. 186:978–979.
87. Jakowski, R.M., T.N. Fredrickson, T.W. Chomiak, and R.E. Luginbuhl. 1970. Hematopoietic destruction in Marek's disease. *Avian Dis*. 14:374–385.
88. Jeurissen, S.H., J.M. Pol, and G.F. de Boer. 1989. Transient depletion of cortical thymocytes induced by chicken anaemia agent. *Thymus*. 14:115–123.
89. Jeurissen, S.H., M.E. Janse, D.J. Van Roozelaar, G. Koch, and G.F. De Boer. 1992. Susceptibility of thymocytes for infection by chicken anemia virus is related to pre- and posthatching development. *Dev Immunol*. 2:123–129.
90. Jeurissen, S.H., F. Wagenaar, J.M. Pol, A.J. van der Eb, and M.H. Noteborn. 1992. Chicken anemia virus causes apoptosis of thymocytes after in vivo infection and of cell lines after in vitro infection. *J Virol*. 66:7383–7388.
91. Jeurissen, S.H., and G.F. de Boer. 1993. Chicken anaemia virus influences the pathogenesis of Marek's disease in experimental infections, depending on the dose of Marek's disease virus. *Vet Q*. 15:81–84.
92. Joiner, K.S., S.J. Ewald, F.J. Hoerr, V.L. van Santen, and H. Toro. 2005. Oral infection with chicken anemia virus in 4-wk broiler breeders: lack of effect of major histocompatibility B complex genotype. *Avian Dis*. 49:482–487.
93. Jørgensen, P.H. 1990. A micro-scale serum neutralisation test for the detection and titration of antibodies to chicken anaemia agent—prevalence of antibodies in Danish chickens. *Avian Pathol*. 19:583–593.
94. Jørgensen, P.H. 1991. Mortality during an outbreak of blue wing disease in broilers. *Vet Rec*. 129:490–491.
95. Jørgensen, P.H., L. Otte, O.L. Nielsen, and M. Bisgaard. 1995. Influence of subclinical infections and other factors on broiler performance. *Br Poult Sci.* 36:455–463.
96. Kaffashi, A., A.H. Noormohammadi, M.L. Allott, and G.F. Browning. 2006. Viral load in 1-day-old and 6-week-old chickens infected with chicken anaemia virus by the intraocular route. *Avian Pathol*. 35:471–474.
97. Kaffashi, A., S. Shrestha, and G.F. Browning. 2008. Evaluation of chicken anaemia virus mutants as potential vaccine strains in 1-day-old chickens. *Avian Pathol*. 37:109–114.
98. Kamada, K., A. Kuroishi, T. Kamahora, P. Kabat, S. Yamaguchi, and S. Hino. 2006. Spliced mRNAs detected during the life cycle of chicken anemia virus. *J Gen Virol*. 87:2227–2233.
99. Kim, H.R., Y.K. Kwon, Y.C. Bae, J.K. Oem, and O.S. Lee. 2010. Molecular characterization of chicken infectious anemia viruses detected from breeder and broiler chickens in South Korea. *Poult Sci*. 89:2426–2431.
100. Koch, G., D.J. van Roozelaar, C.A. Verschueren, A.J. van der Eb, and M.H. Noteborn. 1995. Immunogenic and protective properties of chicken anaemia virus proteins expressed by baculovirus. *Vaccine*. 13:763–770.
101. Kulcsar, G., A. Farsang, and T. Soos. 2010. Testing for viral contaminants of veterinary vaccines in Hungary. *Biologicals*. 38:346–349.
102. Lacorte, C., H. Lohuis, R. Goldbach, and M. Prins. 2007. Assessing the expression of chicken anemia virus proteins in plants. *Virus Res*. 129:80–86.
103. Lamichhane, C.M., D.B. Snyder, M.A. Goodwin, S.A. Mengel, J. Brown, and T.G. Dickson. 1991. Pathogenicity of CL-1 chicken anemia agent. *Avian Dis*. 35:515–522.
104. Leliveld, S.R., R.T. Dame, M.A. Mommaas, H.K. Koerten, C. Wyman, A.A. Danen-van Oorschot, J.L. Rohn, M.H. Noteborn, and J.P. Abrahams. 2003. Apoptin protein multimers form distinct higher-order nucleoprotein complexes with DNA. *Nucleic Acids Res*. 31:4805–4813.
105. Lucio, B., K.A. Schat, and H.L. Shivaprasad. 1990. Identification of the chicken anemia agent, reproduction of the disease, and serological survey in the United States. *Avian Dis*. 34:146–153.
106. Lucio, B., K.A. Schat, and S. Taylor. 1991. Direct binding of protein A, protein G, and anti-IgG conjugates to chicken infectious anemia virus. *Avian Dis*. 35:180–185.
107. Markowski-Grimsrud, C.J., M.M. Miller, and K.A. Schat. 2002. Development of strain-specific real-time PCR and RT-PCR assays for quantitation of chicken anemia virus. *J Virol Meth*. 101:135–147.
108. Markowski-Grimsrud, C.J., and K.A. Schat. 2003. Infection with chicken anemia virus impairs the generation of antigen-specific cytotoxic T lymphocytes. *Immunology*. 109:283–294.
109. McConnell, C.D., B.M. Adair, and M.S. McNulty. 1993. Effects of chicken anemia virus on cell-mediated immune function in chickens exposed to the virus by a natural route. *Avian Dis*. 37:366–374.
110. McConnell, C.D., B.M. Adair, and M.S. McNulty. 1993. Effects of chicken anemia virus on macrophage function in chickens. *Avian Dis*. 37:358–365.
111. McIlroy, S.G., M.S. McNulty, D.W. Bruce, J.A. Smyth, E.A. Goodall, and M.J. Alcorn. 1992. Economic effects of clinical chicken anemia agent infection on profitable broiler production. *Avian Dis*. 36:566–574.
112. McKenna, G.F., D. Todd, B.J. Borghmans, M.D. Welsh, and B.M. Adair. 2003. Immunopathologic investigations with an attenuated chicken anemia virus in day-old chickens. *Avian Dis*. 47:1339–1345.

113. McNeilly, F., G.M. Allan, D. Moffett, and M.S. McNulty. 1991. Detection of chicken anaemia agent in chickens by immunofluorescence and immunoperoxidase staining. *Avian Pathol*. 20:125–132.
114. McNulty, M.S., T.J. Connor, F. Mc Neilly, K.S. Kirkpatrick, and J.B. McFerran. 1988. A serological survey of domestic poultry in the United Kingdom for antibody to chicken anemia agent. *Avian Pathol*. 17:315–324.
115. McNulty, M.S., T.J. Connor, and F. Mc Neilly. 1989. A survey of specific pathogen-free chicken flocks for antibodies to chicken anemia agent, avian nephritis virus and group A rotavirus. *Avian Pathol*. 18:215–220.
116. McNulty, M.S., T.J. Connor, and F. McNeilly. 1990. Influence of virus dose on experimental anaemia due to chicken anaemia agent. *Avian Pathol*. 19:161–171.
117. McNulty, M.S., W.L. Curran, D. Todd, and D.P. Mackie. 1990. Chicken anemia agent: an electron microscopic study. *Avian Dis*. 34:736–743.
118. McNulty, M.S., D.P. Mackie, D.A. Pollock, J. McNair, D. Todd, K.A. Mawhinney, T.J. Connor, and F. McNeilly. 1990. Production and preliminary characterization of monoclonal antibodies to chicken anemia agent. *Avian Dis*. 34:352–358.
119. McNulty, M.S. 1991. Chicken anemia agent: a review. *Avian Pathol*. 20:187–203.
120. McNulty, M.S., S.G. McIlroy, D.W. Bruce, and D. Todd. 1991. Economic effects of subclinical chicken anemia agent infection in broiler chickens. *Avian Dis*. 35:263–268.
121. McNulty, M.S., and D. Todd. 2008. Chicken anemia virus. In: A Laboratory Manual for the Isolation, Identification and Characterization of Avian Pathogens 5th ed. L. Dufour-Zavala, D.E. Swayne, J.R. Glisson, J.E. Pearson, W.M. Reed, M.W. Jackwood, and P.R. Woolcock, eds. American Association of Avian Pathologists, Jacksonville, FL. 124–127.
122. Meehan, B.M., D. Todd, J.L. Creelan, J.A.P. Earle, E.M. Hoey, and M.S. McNulty. 1992. Characterization of viral DNAs from cells infected with chicken anaemia agent: sequence analysis of the cloned replicative form and transfection capabilities of cloned genome fragments. *Arch Virol*. 124:301–319.
123. Meehan, B.M., D. Todd, J.L. Creelan, T.J. Connor, and M.S. McNulty. 1997. Investigation of the attenuation exhibited by a molecularly cloned chicken anemia virus isolate by utilizing a chimeric virus approach. *J Virol*. 71:8362–8367.
124. Michalski, W.P., D. O'Rourke, and T.J. Bagust. 1996. Chicken anaemia virus antibody ELISA: problems with non-specific reactions. *Avian Pathol*. 25:245–254.
125. Miles, A.M., S.M. Reddy, and R.W. Morgan. 2001. Coinfection of specific-pathogen-free chickens with Marek's disease virus (MDV) and chicken infectious anemia virus: effect of MDV pathotype. *Avian Dis*. 45:9–18.
126. Miller, M.M., W.B. Oswald, J. Scarlet, and K.A. Schat. 2001. Patterns of chicken infectious anemia virus (CIAV) seroconversion in three Cornell SPF flocks. In: Proceedings of the Second International Symposium on Infectious Bursal Disease and Chicken Infectious Anaemia. Rauischholzhausen, Germany. 410–417.
127. Miller, M.M., K.A. Ealey, W.B. Oswald, and K.A. Schat. 2003. Detection of chicken anemia virus DNA in embryonal tissues and eggshell membranes. *Avian Dis*. 47:662–671.
128. Miller, M.M., and K.A. Schat. 2004. Chicken infectious anemia virus: an example of the ultimate host-parasite relationship. *Avian Dis*. 48:734–745.
129. Miller, M.M., K.J. Jarosinski, and K.A. Schat. 2005. Positive and negative regulation of chicken anemia virus transcription. *J Virol*. 79:2859–2868.
130. Miller, M.M., K.W. Jarosinski, and K.A. Schat. 2008. Negative modulation of the chicken infectious anemia virus promoter by COUP-TF1 and an E box-like element at the transcription start site binding δEF1. *J Gen Virol.* 89:2998–3003.
131. Moeini, H., A.R. Omar, R.A. Rahim, and K. Yusoff. 2011. Development of a DNA vaccine against chicken anemia virus by using a bicistronic vector expressing VP1 and VP2 proteins of CAV. *Comp Immunol Microbiol Infect Dis.* 34:227–236.
132. Moeini, H., A.R. Omar, R.A. Rahim, and K. Yusoff. 2011. Improving the potency of DNA vaccine against chicken anemia virus (CAV) by fusing VP1 protein of CAV to Marek's disease virus (MDV) type-1 VP22 protein. *Virol J*. 8:119.
133. Moeini, H., R.A. Rahim, A.R. Omar, N. Shafee, and K. Yusoff. 2011. Lactobacillus acidophilus as a live vehicle for oral immunization against chicken anemia virus. *Appl Microbiol Biotechnol*. 90:77–88.
134. Natesan, S., J.M. Kataria, K. Dhama, S. Rahul, and N. Baradhwaj. 2006. Biological and molecular characterization of chicken anaemia virus isolates of Indian origin. *Virus Res*. 118:78–86.
135. Niagro, F.D., A.N. Forsthoefel, R.P. Lawther, L. Kamalanathan, B.W. Ritchie, K.S. Latimer, and P.D. Lukert. 1998. Beak and feather disease virus and porcine circovirus genomes: intermediates between the geminiviruses and plant circoviruses. *Arch Virol*. 143:1723–1744.
136. Nielsen, O.L., P.H. Jørgensen, M. Bisgaard, and S. Alexandersen. 1995. In situ hybridization for the detection of chicken anaemia virus in experimentally-induced infection and field outbreaks. *Avian Pathol*. 24:149–155.
137. Nogueira, E.O., A.J. Piantino Ferreira, R. Martins Soares, E. Luiz Durigon, S. Lazzarin, and L. Brentano. 2007. Genome sequencing analysis of Brazilian chicken anemia virus isolates that lack MSB-1 cell culture tropism. *Comp Immunol Microbiol Infect Dis*. 30:81–96.
138. Noteborn, M.H., G.F. de Boer, D.J. van Roozelaar, C. Karreman, O. Kranenburg, J.G. Vos, S.H. Jeurissen, R.C. Hoeben, A. Zantema, G. Koch, H. Van Ormondt, and A.J. Van Der Eb. 1991. Characterization of cloned chicken anemia virus DNA that contains all elements for the infectious replication cycle. *J Virol*. 65:3131–3139.
139. Noteborn, M.H., O. Kranenburg, A. Zantema, G. Koch, G.F. de Boer, and A.J. van der Eb. 1992. Transcription of the chicken anemia virus (CAV) genome and synthesis of its 52-kDa protein. *Gene*. 118:267–271.
140. Noteborn, M.H., D. Todd, C.A. Verschueren, H.W. de Gauw, W.L. Curran, S. Veldkamp, A.J. Douglas, M.S. McNulty, A.J. van der Eb, and G. Koch. 1994. A single chicken anemia virus protein induces apoptosis. *J Virol*. 68:346–351.
141. Noteborn, M.H., C.A. Verschueren, A. Zantema, G. Koch, and A.J. van der Eb. 1994. Identification of the promoter region of chicken anemia virus (CAV) containing a novel enhancer-like element. *Gene*. 150:313–318.
142. Noteborn, M.H., C.A. Verschueren, G. Koch, and A.J. Van der Eb. 1998. Simultaneous expression of recombinant baculovirus-encoded chicken anaemia virus (CAV) proteins VP1 and VP2 is required for formation of the CAV-specific neutralizing epitope. *J Gen Virol*. 79:3073–3077.
143. Noteborn, M.H., C.A. Verschueren, H. van Ormondt, and A.J. van der Eb. 1998. Chicken anemia virus strains with a mutated

enhancer/promoter region share reduced virus spread and cytopathogenicity. *Gene*. 223:165–172.
144. Noteborn, M.H.M., C.A.J. Verschueren, D.J. van Roozelaar, S. Veldkamp, A.J. van der Eb, and G.F. de Boer. 1992. Detection of chicken anaemia virus by DNA hybridisation and polymerase chain reaction. *Avian Pathol*. 21:107–118.
145. Noteborn, M.H.M., and G. Koch. 1995. Chicken anaemia virus infection: molecular basis of pathogenicity. *Avian Pathol*. 24:11–31.
146. Nunoya, T., Y. Otaki, M. Tajima, M. Hiraga, and T. Saito. 1992. Occurrence of acute infectious bursal disease with high mortality in Japan and pathogenicity of field isolates in specific-pathogen-free chickens. *Avian Dis*. 36:597–609.
147. Oro, C., and D.A. Jans. 2004. The tumour specific pro-apoptotic factor apoptin (Vp3) from chicken anaemia virus. *Curr Drug Targets*. 5:179–190.
148. Otaki, Y., T. Nunoya, A. Tajima, H. Tamada, and Y. Nomura. 1987. Isolation of chicken anaemia agent and Marek's disease virus from chickens vaccinated with turkey herpesvirus and lesions induced in chicks by inoculating both agents. *Avian Pathol*. 16:291–306.
149. Otaki, Y., T. Nunoya, A. Tajima, A. Kato, and Y. Nomura. 1988. Depression of vaccinal immunity to Marek's disease by infection with chicken anaemia agent. *Avian Pathol*. 17:333–347.
150. Otaki, Y., M. Tajima, K. Saito, and Y. Nomura. 1988. Immune response of chicks inoculated with chicken anemia agent alone or in combination with Marek's disease virus or turkey herpesvirus. *Jpn J Vet Sci*. 50:1040–1047.
151. Otaki, Y., T. Nunoya, M. Tajima, K. Saito, and Y. Nomura. 1989. Enhanced pathogenicity of chicken anemia agent by infectious bursal disease virus relative to the occurrence of Marek's disease vaccination breaks. *Nippon Juigaku Zasshi*. 51:849–852.
152. Otaki, Y., K. Saito, A. Tajima, and Y. Nomura. 1991. Detection of antibody to chicken anaemia agent: a comparison of three serological tests. *Avian Pathol*. 20:315–324.
153. Otaki, Y., K. Saito, M. Tajima, and Y. Nomura. 1992. Persistence of maternal antibody to chicken anaemia agent and its effect on the susceptibility of young chickens. *Avian Pathol*. 21:147–151.
154. Ottiger, H.P. 2010. Development, standardization and assessment of PCR systems for purity testing of avian viral vaccines. *Biologicals*. 38:381–388.
155. Pagès-Manté, A., N. Saubi, C. Artigas and E. Espuña. 1997. Experimental evaluation of an inactivated vaccine against chicken anaemia virus. *Avian Pathol*. 26:721–729.
156. Pallister, J., K.J. Fahey, and M. Sheppard. 1994. Cloning and sequencing of the chicken anaemia virus (CAV) ORF-3 gene, and the development of an ELISA for the detection of serum antibody to CAV. *Vet Microbiol*. 39:167–178.
157. Peters, M.A., D.C. Jackson, B.S. Crabb, and G.F. Browning. 2002. Chicken anemia virus VP2 is a novel dual specificity protein phosphatase. *J Biol Chem*. 42:39566–39573.
158. Peters, M.A., B.S. Jackson, B.S. Crabb, and G.F. Browning. 2005. Mutation of chicken anemia virus VP2 differentially affects serine/threonine and tyrosine protein phosphatase activities. *J Gen Virol*. 86:623–630.
159. Peters, M.A., B.S. Crabb, E.A. Washington, and G.F. Browning. 2006. Site-directed mutagenesis of the VP2 gene of chicken anemia virus affects virus replication, cytopathology and host-cell MHC class I expression. *J Gen Virol*. 87:823–831.
160. Peters, M.A., B.S. Crabb, K.A. Tivendale, and G.F. Browning. 2007. Attenuation of chicken anemia virus by site-directed mutagenesis of VP2. *J Gen Virol*. 88:2168–2175.
161. Phenix, K.V., B.M. Meehan, D. Todd, and M.S. McNulty. 1994. Transcriptional analysis and genome expression of chicken anaemia virus. *J Gen Virol*. 75:905–909.
162. Pietersen, A.M., M.M. van der Eb, H.J. Rademaker, D.J. van den Wollenberg, M.J. Rabelink, P.J. Kuppen, J.H. van Dierendonck, H. van Ormondt, D. Masman, C.J. van de Velde, A.J. van der Eb, R.C. Hoeben, and M.H. Noteborn. 1999. Specific tumor-cell killing with adenovirus vectors containing the apoptin gene. *Gene Ther*. 6:882–892.
163. Pope, C.R. 1991. Chicken anemia agent. *Vet Immunol Immunopathol*. 30:51–65.
164. Prasetyo, A.A., T. Kamahora, A. Kuroishi, K. Murakami and S. Hino. 2009. Replication of chicken anemia virus (CAV) requires apoptin and is complemented by VP3 of human torque teno virus (TTV). *Virology*. 385:85–92.
165. Ragland, W.L., R. Novak, J. El-Attrache, V. Savic, and K. Ester. 2002. Chicken anemia virus and infectious bursal disease virus interfere with transcription of chicken IFN-alpha and IFN-gamma mRNA. *J Interferon Cytokine Res*. 22:437–441.
166. Randall, C.J., W.G. Siller, A.S. Wallis, and K.S. Kirkpatrick. 1984. Multiple infections in young broilers. *Vet Rec*. 114:270–271.
167. Renshaw, R.W., C. Soine, T. Weinkle, P.H. O'Connell, K. Ohashi, S. Watson, B. Lucio, S. Harrington, and K.A. Schat. 1996. A hypervariable region in VP1 of chicken infectious anemia virus mediates rate of spread and cell tropism in tissue culture. *J Virol*. 70:8872–8878.
168. Rijsewijk, F., H. dos Santos, T. Teixeira, S. Cibulski, A. Varela, D. Dezen, A. Franco, and P. Roehe. 2011. Discovery of a genome of a distant relative of chicken anemia virus reveals a new member of the genus Gyrovirus. *Arch Virol*. 156:1097–1100.
169. Rosenberger, J.K., and S.S. Cloud. 1989. The isolation and characterization of chicken anemia agent (CAA) from broilers in the United States. *Avian Dis*. 33:707–713.
170. Rosenberger, J.K., and S.S. Cloud. 1989. The effects of age, route of exposure, and coinfection with infectious bursal disease virus on the pathogenicity and transmissibility of chicken anemia agent (CAA). *Avian Dis*. 33:753–759.
171. Schat, K.A., and V. van Santen. 2008. Chicken infectious anemia. In: *Diseases of Poultry*, 12th ed. Y.M. Saif, A.M. Fadly, J.R. Glisson, L.R. McDougald, L.K. Nolan, and D.E. Swayne, eds. Wiley-Blackwell. Ames, IA. 211–235.
172. Schat, K.A. 2009. Chicken anemia virus. *Curr Top Microbiol Immunol*. 331:151–184.
173. Schat, K.A., and Y.H. Schukken. 2010. An 8-year longitudinal survey for the presence of antibodies to chicken infectious anemia virus in two specific-pathogen-free strains of chickens *Avian Dis*. 54:46–52.
174. Schat, K.A., N.R. Martins, P.H. O'Connell, and M.S. Piepenbrink. 2011. Immune complex vaccines for chicken infectious anemia virus. *Avian Dis*. 55:90–96.
175. Schrier, C.C., and H.J.M. Jagt. 2004. Chicken anemia viruses of low pathogenicity. In: US patent 6,723,324.
176. Scott, A.N., T.J. Connor, J.L. Creelan, M.S. McNulty, and D. Todd. 1999. Antigenicity and pathogenicity characteristics of molecularly cloned chicken anaemia virus isolates obtained after multiple cell culture passages. *Arch Virol*. 144:1961–1975.

177. Sharma, J.M., and J.K. Rosenberger. 1987. Infectious bursal disease and reovirus infection of chickens: immune responses and vaccine control. In: *Avian Immunology: Basis and Practice*. Vol II. A. Toivanen and P. Toivanen, eds. CRC Press, Boca Raton, FL. 144–157.
178. Sheela, R.R., U. Babu, J. Mu, S. Elankumaran, D.A. Bautista, R.B. Raybourne, R.A. Heckert, and W. Song. 2003. Immune responses against Salmonella enterica serovar enteritidis infection in virally immunosuppressed chickens. *Clin Diagn Lab Immunol*. 10:670–679.
179. Smith, J.A. 2006. Broiler industry strategies for control of chicken infectious anemia virus infection. In: *Impact of Subclinical Immunosuppression on Poultry Production*. R.F. Silva, A.M. Fadly, D.J. Jackwood, and K.A. Schat, eds. American Association of Avian Pathologists. Jacksonville, FL. 42–48.
180. Smyth, J.A., D.A. Moffett, M.S. McNulty, D. Todd, and D.P. Mackie. 1993. A sequential histopathologic and immunocytochemical study of chicken anemia virus infection at one day of age. *Avian Dis*. 37:324–338.
181. Smyth, J.A., D.A. Moffett, T.J. Connor, and M.S. McNulty. 2006. Chicken anaemia virus inoculated by the oral route causes lymphocyte depletion in the thymus in 3-week-old and 6-week-old chickens. *Avian Pathol*. 35:254–259.
182. Snyder, D.B., G. Noel, C. Schrier, and D. Lutticken. 1992. Characterization of neutralizing monoclonal antibodies to strains of chicken anemia virus isolated in the Unites States. In: XIX World Poultry Congress. Ponsen and Looijen, Wageningen, Amsterdam. 423.
183. Soiné, C., S.K. Watson, E. Rybicki, B. Lucio, R.M. Nordgren, C.R. Parrish, and K.A. Schat. 1993. Determination of the detection limit of the polymerase chain reaction for chicken infectious anemia virus. *Avian Dis*. 37:467–476.
184. Sommer, F., and C. Cardona. 2003. Chicken anemia virus in broilers: Dynamics of the infection in two commercial broiler flocks. *Avian Dis*. 47:1466–1473.
185. Spackman, E., S.S. Cloud, C.R. Pope, and J.K. Rosenberger. 2002. Comparison of a putative second serotype of chicken infectious anemia virus with a prototypical isolate. I. Pathogenesis. *Avian Dis.* 46:945–955.
186. Spackman, E., S.S. Cloud, and J.K. Rosenberger. 2002. Comparison of a putative second serotype of chicken infectious anemia virus with a prototypical isolate. II. Antigenic and physicochemical characteristics. *Avian Dis.* 46:956–963.
187. Tan, J., and G.A. Tannock. 2005. Role of viral load in the pathogenesis of chicken anemia virus. *J Gen Virol*. 86:1327–1333.
188. Taniguchi, T., N. Yuasa, M. Maeda, and T. Horiuchi. 1982. Hematopathological changes in dead and moribund chicks induced by chicken anemia agent. *Natl Inst Anim Health Q. (Tokyo)*. 22:61–69.
189. Taniguchi, T., N. Yuasa, M. Maeda, and T. Horiuchi. 1983. Chronological observations on hemato-pathological changes in chicks inoculated with chicken anemia agent. *Natl Inst Anim Health Q. (Tokyo)*. 23:1–12.
190. Tannock, G.A., J. Tan, K.A. Mawhinney, D. Todd, D. O'Rourke and T.J. Bagust. 2003. A modified blocking ELISA for the detection of antibody to chicken anaemia virus using an Australian strain. *Aust Vet J*. 81:428–430.
191. Taylor, S.P. 1992. The effect of acetone on the viability of chicken anemia agent. *Avian Dis*. 36:753–754.
192. Tham, K.-M. 1995. Polymerase chain reaction analysis of chicken anemia virus DNA in fresh and paraffin-embedded tissues. In: *PCR: Protocols for Diagnosis of Human and Animal Virus Diseases*. Y. Becker and G. Darai, eds. Springer-Verlag, Berlin. 555–563.
193. Tham, K.M., and W.L. Stanislawek. 1992. Detection of chicken anaemia agent DNA sequences by the polymerase chain reaction. *Arch Virol*. 127:245–255.
194. Todd, D., J.L. Creelan, D.P. Mackie, F. Rixon, and M.S. McNulty. 1990. Purification and biochemical characterization of chicken anaemia agent. *J Gen Virol*. 71:819–823.
195. Todd, D., D.P. Mackie, K.A. Mawhinney, T.J. Connor, F. McNeilly, and M.S. McNulty. 1990. Development of an enzyme-linked immunosorbent assay to detect serum antibody to chicken anemia agent. *Avian Dis*. 34:359–363.
196. Todd, D., K.A. Mawhinney, and M.S. McNulty. 1992. Detection and differentiation of chicken anemia virus isolates by using the polymerase chain reaction. *J Clin Microbiol*. 30:1661–1666.
197. Todd, D., T.J. Connor, V.M. Calvert, J.L. Creelan, B. Meehan, and M.S. McNulty. 1995. Molecular cloning of an attenuated chicken anaemia virus isolate following repeated cell culture passage. *Avian Pathol*. 24:171–187.
198. Todd, D., J.L. Creelan, B.M. Meehan, and M.S. McNulty. 1996. Investigation of the transfection capability of cloned tandemly-repeated chicken anaemia virus DNA fragments. *Arch Virol*. 141:1523–1534.
199. Todd, D., K.A. Mawhinney, D.A. Graham, and A.N. Scott. 1999. Development of a blocking enzyme-linked immunosorbent assay for the serological diagnosis of chicken anaemia virus. *J Virol Methods*. 82:177–184.
200. Todd, D. 2000. Circoviruses: immunosuppressive threats to avian species: a review. *Avian Pathol*. 29:373–394.
201. Todd, D., M.S. McNulty, A. Mankertz, P.D. Lukert, J.W. Randles, and J.L. Dale. 2000. Family Circoviridae. In: *Virus Taxonomy. Classification and Nomenclature of Viruses*. Seventh Report of the International Committee of Taxonomy of Viruses. M.H.V. van Regenmortel, C.M. Fauqet, D.H.L. Bishop, E.B. Carstens, M.K. Estes, S.M. Lemon, J. Maniloff, M.A. Mayo, D.J. McGeogh, C.R. Pringle, and R.B. Wickner, eds. Academic Press, New York. 299–303.
202. Todd, D., J.L. Creelan, T.J. Connor, N.W. Ball, A.N.J. Scott, B.M. Meehan, G.F. McKenna, and M.S. McNulty. 2003. Investigation of the unstable attenuation exhibited by a chicken anaemia virus isolate. *Avian Pathol*. 32: 375–382.
203. Todd, D., P. Biagini, M. Bendinelli, S. Hino, A. Mankertz, S. Mishiro, C. Niel, H. Okamoto, S.R. Raidal, B.W. Ritchie, and C.G. Teo. 2005. Circoviridae. In: *Virus Taxonomy*, 8th Report of the International Committee for the Taxonomy of Viruses. C.M. Fauqet, M.A. Mayo, J. Maniloff, U. Desselberger and L.A. Ball, eds. Elsevier/Academic Press, London. 327–334.
204. Toro, H., A.M. Ramirez, and J. Larenas. 1997. Pathogenicity of chicken anaemia virus (isolate 10343) for young and older chickens. *Avian Pathol*. 26:485–499.
205. Toro, H., C. Gonzalez, L. Cerda, M. Hess, E. Reyes, and C. Geissea. 2000. Chicken anemia virus and fowl adenoviruses: association to induce the inclusion body hepatitis/ hydropericardium syndrome. *Avian Dis*. 44:51–58.
206. Toro, H., S. Ewald, and F.J. Hoerr. 2006. Serological evidence of chicken infectious anemia virus in the United States at least since 1959. *Avian Dis*. 50:124–126.
207. Toro, H., V.L. van Santen, L. Li, S.B. Lockaby, E. van Santen, and F.J. Hoerr. 2006. Epidemiological and experimental evidence for immunodeficiency affecting avian infectious bronchitis. *Avian Pathol*. 35:455–464.

208. Toro, H., V.L. van Santen, F.J. Hoerr, and C. Breedlove. 2009. Effects of chicken anemia virus and infectious bursal disease virus in commercial chickens. *Avian Dis*. 53:94–102.
209. Tosi, G., A. Lavazza, and F. Paganelli. 2001. Chicken infectious anaemia in Italy: Virological investigations and immunodepressive effects. In: Second International Symposium on Infectious Bursal Disease and Chicken Infectious Anaemia. Rauischholzhausen, Germany. 222–224.
210. Urlings, H.A., G.F. de Boer, D.J. van Roozelaar, and G. Koch. 1993. Inactivation of chicken anaemia virus in chickens by heating and fermentation. *Vet Q.* 15:85–88.
211. van der Eb, M.M., A.M. Pietersen, F.M. Speetjens, P.J. Kuppen, C.J. van de Velde, M.H. Noteborn, and R.C. Hoeben. 2002. Gene therapy with apoptin induces regression of xenografted human hepatomas. *Cancer Gene Ther*. 9:53–61.
212. van Ginkel, F.W., V.L. van Santen, S.L. Gulley, and H. Toro. 2008. Infectious bronchitis virus in the chicken Harderian gland and lachrymal fluid: viral load, infectivity, immune cell responses, and effects of viral immunodeficiency. *Avian Dis*. 52:608–617.
213. van Santen, V.L., K.S. Joiner, C. Murray, N. Petrenko, F.J. Hoerr, and H. Toro. 2004. Pathogenesis of chicken anemia virus: Comparison of the oral and the intramuscular routes of infection. *Avian Dis*. 48:494–504.
214. van Santen, V.L., B. Kaltenboeck, K.S. Joiner, K.S. Macklin and R.A. Norton. 2004. Real-time quantitative PCR-based serum neutralization test for detection and titration of neutralizing antibodies to chicken anemia virus. *J Virol. Methods* 115:123–135.
215. van Santen, V.L., H. Toro, F.W. van Ginkel, K.S. Joiner, and F.J. Hoerr. 2006. Effects of chicken anemia virus and/or infectious bursal disease virus on infectious bronchitis virus infection and immune responses. In: Fifth International Symposium on Avian Corona- and Pneumoviruses and Complicating Pathogens. Rauischholzhausen, Germany. 296–299.
216. van Santen, V.L., H. Toro, and F.J. Hoerr. 2007. Biological characteristics of chicken anemia virus regenerated from clinical specimen by PCR. *Avian Dis*. 51:66–77.
217. Vaziry, A., A. Silim, C. Bleau, D. Frenette, and L. Lamontagne. 2011. Chicken infectious anaemia vaccinal strain persists in the spleen and thymus of young chicks and induces thymic lymphoid cell disorders. *Avian Pathol*. 40:377–385.
218. Vielitz, E., V. von Bülow, H. Landgraf, and C. Conrad. 1987. Anämie des Mastgeflügels: Entwicklung eines Impfstoffes für Elterntiere. *Zentralbl. Veterinarmed. [B]* 34:553–557.
219. Vielitz, E. and H. Landgraf. 1988. Anaemia-dermatitis of broilers: Field observations on its occurrence, transmission and prevention. *Avian Pathol*. 17:113–120.
220. Vielitz, E., C. Conrad, M. Voss, V. von Bülow, P. Dorn, J. Bachmeier, and U. Lohren. 1991. Impfungen gegen die infektiöse Anämie des Geflügels (CAA): Ergebnisse von Feldversuchen. *Dtsch. Tierarztl. Wochenschr*. 98:144–147.
221. Vielitz, E., and M. Voss. 1994. Experiences with a commercial CAV vaccine. In: International Symposium on Infectious Bursal Disease and Chicken Infectious Anaemia. Rauischholzhausen, Germany. 465–481.
222. von Bülow, V., B. Fuchs, E. Vielitz, and H. Landgraf. 1983. Frühsterblichkeitssyndrom bei Küken nach Doppelinfektion mit dem Virus der Marekschen Krankheit (MDV) und einem Anämia-Erreger (CAA). *Zentralbl. Veterinarmed. [B]* 30:742–750.
223. von Bülow, V., B. Fuchs, and M. Bertram. 1985. Untersuchungen über den Erreger der infektiösen Anämie bei Hühnerküken (CAA) in vitro: Vermehrung, Titration, Serumneutralisationstest in indirekter Immunfluoreszentest. *Zentralbl. Veterinarmed. [B]* 32:679–693.
224. von Bülow, V., and B. Fuchs. 1986. Attenuierung des Erregers der aviären infektiösen Anämie (CAA) durch Serienpassagen in Zellkulturen. *J Vet Med. B* 33:568–573.
225. von Bülow, V., B. Fuchs, and R. Rudolph. 1986. Avian infectious anaemia caused by chicken anaemia agent (CAA). In: *Acute Virus Infections of Poultry*. J.B. McFerran and M.S. McNulty, eds. Martinus Nijhoff Publishers, Dordrecht. 203–212.
226. von Bülow, V., R. Rudolph, and B. Fuchs. 1986. Erhöhte Pathogenität des Erregers der aviären infektiösen Anämia bei Hühnerküken (CAA) bei simultaner Infektion mit Virus der Marekschen Krankheit (MDV), Bursitisvirus (IBDV) oder Reticuloendotheliosevirus (REV). *J Vet Med. B* 33:93–116.
227. von Bülow, V., R. Rudolph, and B. Fuchs. 1986. Folgen der Doppelinfektion von Küken mit Adenovirus oder Reovirus und dem Erreger der aviären infektiösen Anämie (CAA). *Zentralbl. Veterinarmed. [B]* 33:717–726.
228. von Bülow, V., and M. Witt. 1986. Vermehrung des Erregers der aviären infektiosen Anämie (CAA) in embryonierten Hühnereiern. *Zentralbl. Veterinarmed. [B]* 33:664–669.
229. von Bülow, V. 1988. Unsatisfactory sensitivity and specificity of indirect immunofluorescence tests for the presence or absence of antibodies to chicken anaemia agent (CAA) in sera of SPF and broiler breeder chickens. *Zentralbl. Veterinarmed. [B]* 35:594–600.
230. von Bülow, V. 1991. Avian infectious anemia and related syndromes caused by chicken anemia virus. *Crit Rev Poultry Biol*. 3:1–17.
231. von Bülow, V., and K.A. Schat. 1997. Chicken infectious anemia. In: *Diseases of Poultry*, 10th ed. B.W. Calnek, J.H. Barnes, C.W. Beard, L.R. McDougald, and Y.M. Saif, eds. Iowa State University Press, Ames, Iowa. 739–756.
232. von Weikel, J., P. Dorn, H. Spiess, and E. Wessling. 1986. Ein Beitrag zur Diagnostik und Epidemiologie der infektiösen Anaemia (CAA) beim Broiler. *Berl. Münch. Tierärztl. Wschr*. 99:119–121.
233. Wang, D., F. Fan, G.Z. Han, and C.Q. He. 2009. The selection pressure analysis of chicken anemia virus structural protein gene VP1. *Virus Genes* 38:259–262.
234. Wang, X., X. Song, H. Gao, X. Wang, D. Wang, and G. Li. 2001. The epidemiological survey and analyses of chicken infectious anemia. In: Proceedings of the Second International Symposium on Infectious Bursal Disease and Chicken Infectious Anaemia. Rauischholzhausen, Germany. 225–229.
235. Welch, J., C. Bienek, E. Gomperts, and P. Simmonds. 2006. Resistance of porcine circovirus and chicken anemia virus to virus inactivation procedures used for blood products. *Transfusion* 46:1951–1958.
236. Wellenstein, R.C. 1989. Personal communication.
237. Yersin, A.G. 2001. Personal communication.
238. Yuasa, N., T. Taniguchi, and I. Yoshida. 1979. Isolation and some characteristics of an agent inducing anemia in chicks. *Avian Dis*. 23:366–385.
239. Yuasa, N., T. Noguchi, K. Furuta, and I. Yoshida. 1980. Maternal antibody and its effect on the susceptibility of chicks to chicken anemia agent. *Avian Dis*. 24:197–201.
240. Yuasa, N., T. Taniguchi, T. Noguchi, and I. Yoshida. 1980. Effect of infectious bursal disease virus infection on incidence of anemia by chicken anemia agent. *Avian Dis*. 24:202–209.
241. Yuasa, N. 1983. Propagation and infectivity titration of the Gifu-1 strain of chicken anemia agent in a cell line (MDCC-MSB1) derived from Marek's disease lymphoma. *Natl Inst Animal Health Q. (Jpn.)*. 23:13–20.

242. Yuasa, N., T. Taniguchi, M. Goda, M. Shibatani, T. Imada, and H. Hihara. 1983. Isolation of chicken anemia agent with MDCC-MSB1 cells from chickens in the field. *Natl Inst Animal Health Q. (Jpn.)*. 23:75–77.
243. Yuasa, N., T. Taniguchi, T. Imada, and H. Hihara. 1983. Distribution of chicken anemia agent (CAA) and detection of neutralizing antibody in chicks experimentally inoculated with CAA. *Natl Inst Animal Health Q. (Jpn.)*. 23:78–81.
244. Yuasa, N., and I. Yoshida. 1983. Experimental egg transmission of chicken anemia agent. *Natl Inst Animal Health Q. (Jpn.)*. 23:99–100.
245. Yuasa, N., K. Imai, and H. Tezuka. 1985. Survey of antibody against chicken anaemia agent (CAA) by an indirect immunofluorescent antibody technique in breeder flocks in Japan. *Avian Pathol*. 14:521–530.
246. Yuasa, N., and K. Imai. 1986. Pathogenicity and antigenicity of eleven isolates of chicken anaemia agent (CAA). *Avian Pathol*. 15:639–645.
247. Yuasa, N., K. Imai, K. Watanabe, F. Saito, M. Abe, and K. Komi. 1987. Aetiological examination of an outbreak of haemorrhagic syndrome in a broiler flock in Japan. *Avian Pathol*. 16:521–526.
248. Yuasa, N., and K. Imai. 1988. Efficacy of Marek's disease vaccine, herpesvirus of turkeys, in chickens infected with chicken anemia agent. In: *Advances in Marek's Disease Research*. S. Kato, T. Horiuchi, T. Mikami and K. Hirai, eds. Japanese Association on Marek's Disease. Osaka, Japan. 358–363.
249. Yuasa, N., K. Imai, and K. Nakamura. 1988. Pathogenicity of chicken aneamia agent in bursectomized chickens. *Avian Pathol*. 17:363–369.
250. Yuasa, N. 1989. CAA: Review and recent problems. In: Proceedings 38th Western Poultry Disease Conference. Tempe AZ. 14–20.
251. Yuasa, N. 1992. Effect of chemicals on the infectivity of chicken anaemia virus. *Avian Pathol*. 21:315–319.
252. Yuasa, N. 1994. Pathology and pathogenesis of chicken anemia virus infection. In: International Symposium on Infectious Bursal Disease and Chicken Infectious Anaemia. Rauischholzhausen, Germany. 385–389.
253. Zanella, A., and P. Dall'Ara. 2001. Interaction between Marek's disease and chicken infectious anemia virus. In: *Current Progress on Marek's Disease Research*. K.A. Schat, R.M. Morgan, M.S. Parcells, and J.L. Spencer, eds. American Association of Avian Pathologists, Kennett Square, PA. 11–19.
254. Zhuang, S.M., J.E. Landegent, C.A. Verschueren, J.H. Falkenburg, H. van Ormondt, A.J. van der Eb, and M.H. Noteborn. 1995. Apoptin, a protein encoded by chicken anemia virus, induces cell death in various human hematologic malignant cells in vitro. *Leukemia*. 9:S118–120.
255. Zhuang, S.M., A. Shvarts, H. van Ormondt, A.G. Jochemsen, A.J. van der Eb, and M.H. Noteborn. 1995. Apoptin, a protein derived from chicken anemia virus, induces p53-independent apoptosis in human osteosarcoma cells. *Cancer Res*. 55:486–489.

Circovirus Infections of Avian Species

1. Abadie, J., F. Nguyen, C. Groizeleau, C. Amenna, B. Fernandez, C. Gueraud, L. Guigand, P. Robart, B. Lefebvre, and M. Wyers. 2001. Pigeon Circovirus infection: Pathology observations and suggested pathogenesis. *Avian Pathol*. 30:149–158.
2. Albertyn, J., K.M. Tajbhai, and R.R. Bragg. 2004. Psittacine beak and feather disease virus in budgerigars and ring-neck parakeets in South Africa. *Onderstepoort J Vet Res*. 71:29–34.
3. Allan, G.M., K.V. Phenix, D. Todd, and B.M. Adair. 1994. Some biological and physico-chemical properties of porcine circovirus. *J Vet Med*. 41:17–26.
4. Ball, N.W., J.A. Smyth, J.H. Weston, B.J. Borghmans, V. Palya, R. Glavits, E. Ivanics, A. Dan, and D. Todd. 2004. Diagnosis of goose circovirus infection in Hungarian geese samples using polymerase chain reaction and dot blot hybridization tests. *Avian Pathol*. 33:51–58.
5. Banda, A., R.I. Galloway-Haskins, T.S. Sandhu, and K.A. Schat. 2007. Genetic analysis of a duck circovirus detected in commercial Pekin ducks in New York. *Avian Dis*. 51:90–95.
6. Bassami, M.R., D. Berryman, G.E. Wilcox, and S.R. Raidal. 1998. Psittacine beak and feather disease virus nucleotide sequence analysis and its relationship to porcine circovirus, plant circoviruses, and chicken anaemia virus. *Virology*. 249:453–459.
7. Bassami, M.R., I. Ypelaar, D. Berryman, G.E. Wilcox, and S. R. Raidal. 2001. Genetic diversity of beak and feather disease virus detected in psittacine species in Australia. *Virology*. 279:392–400.
8. Bert, E., L. Tomassone, C. Peccati, M.G. Navarrete, and S.C. Sola. 2005. Detection of beak and feather disease virus (BFDV) and avian polyomavirus (APV) DNA in psittacine birds in Italy. *J Vet Med*. 52:64–68.
9. Biagini, P. 2011. Restructuring and expansion of the family *Circoviridae*. In: Virus Taxonomy, Proposals from the IXth Report of the International Committee for the Taxonomy of Viruses.http://talk.ictvonline.org/files/proposals/taxonomy_proposals_general1/m/gen01/default.aspx. 14 October 2011.
10. Biagini, P., D. Todd, M. Bendinelli, S. Hino, A. Mankertz, S. Mishiro, C. Niel, H. Okamoto, S. Raidal, B.W. Ritchie, and C.G. Teo. 2005. Genus *Anellovirus*. In: *Virus Taxonomy, 8th Report of the International Committee for the Taxonomy of Viruses*, C.M. Fauqet, M.A. Mayo, J. Maniloff, U. Desselberger, and L.A. Ball, eds. Elsevier/Academic Press, London. 335–341.
11. Bonne, N., P. Shearer, M. Sharp, P. Clark, and S. Raidal. 2009. Assessment of recombinant beak and feather disease virus capsid protein as a vaccine for psittacine beak and feather disease. *J Gen Virol*. 90:640–647.
12. Chen, C.L., P.C. Chang, M.S. Lee, J.H. Shien, S.J. Ou, and H.K. Shieh. 2003. Nucleotide sequences of goose circovirus isolated in Taiwan. *Avian Pathol*. 32:165–171.
13. Coletti, M., M.P. Franciosini, G. Asdrubali, and F. Passamonti. 2000. Atrophy of the primary lymphoid organs of meat pigeons in Italy associated with circovirus-like particles in the bursa of Fabricius. *Avian Dis*. 44:454–459.
14. Crowther, R. A., J.A. Berriman, W.L. Curran, G.M. Allan, and D. Todd. 2003. Comparison of the structures of three circoviruses: Chicken anemia virus, porcine circovirus type 2, and beak and feather disease virus. *J Virol*. 77:13036–13041.
15. Daft, B.M., R.W. Nordhausen, K.S. Latimer, and F.D. Niagro. 1996. Interstitial pneumonia and lymphadenopathy associated with circoviral infection in a 6-week old pig. In: *Proceedings of the American Association of Veterinary Laboratory Diagnosticians*. Little Rock, Arkansas. 39:32.
16. Dahlhausen, B., and S. Radabaugh. 1993. Update on psittacine beak and feather disease and avian polyomavirus testing. *Proceedings of the Association of Avian Veterinarians*. Nashville, Tennessee. 14:5–7.

17. Daum, I., T. Finsterbusch, S. Hartle, T.W. Gobel, A. Mankertz, R. Korbel, and C. Grund. 2009. Cloning and expression of a truncated pigeon circovirus capsid protein suitable for antibody detection in infected pigeons. *Avian Pathol*. 38:135–141.
18. de Kloet, E., and S.R. deKloet. 2004. Analysis of the beak and feather disease viral genome indicates the existence of several genotypes which have a complex psittacine host specificity. *Arch Virol*. 149:2393–2412.
19. Doneley, R.J.T. 2003. Acute beak and feather disease in juvenile African Grey parrots—an uncommon presentation of a common disease. *Aust Vet J*. 81:206–207.
20. Duchatel, J.P., D. Todd, A. Curry, J.A. Smyth, J.C. Bustin, and H. Vindevogel. 2005. New data on the transmission of pigeon circovirus. *Vet Rec*. 157:413–415.
21. Duchatel, J.P., D. Todd, J.A. Smyth, J.C. Bustin, and H. Vindevogel. 2006. Observations on detection, excretion and transmission of pigeon circovirus in adult, young and embryonic pigeons. *Avian Pathol*. 35:30–34.
22. Duchatel J.P., D. Todd, C. Willeman, and B. Losson. 2009. Quantification of pigeon circovirus in serum, blood, semen and different tissues of naturally infected pigeons using a real-time polymerase chain reaction. *Avian Pathol*. 38:143–148.
23. Duchatel J.P., T. Jauniaux, S. Smyth, I. Habsch, M. de Bournonville, B. Losson, and D. Todd. 2010. Effect of a commercial paratyphus vaccine on the development of pigeon circovirus infection in young pigeons (*Columba livia domestica*). *J Avian Med Surg*. 24:107–114.
24. Eisenberg, S.W.F., A.J.A.M. van Asten, A.M. van Ederen, and G.M. Dorrestein. 2003. Detection of circovirus with a polymerase chain reaction in the ostrich (*Struthio camelius*) on a farm in The Netherlands. *Vet Microbiol*. 95:27–38.
25. Els, H.J., and D. Josling. 1998. Viruses and virus-like particles identified in ostrich gut contents. *J S Afr Vet Assoc*. 69:74–80.
26. Franciosini, M.P., E. Fringuelli, O. Tarhuni, G. Guelfi, D. Todd, P. Casagrande Proietti, N. Falocci, and G. Asdrubali. 2005. Development of a polymerase chain reaction-based *in vivo* method in the diagnosis of subclinical pigeon circovirus infection. *Avian Dis*. 49:340–343.
27. Fringuelli, E., A.N.J. Scott, A. Beckett, J. McKillen, J. A. Smyth, V. Palya, R. Glavits, E. Ivanics, A. Mankertz, M. P. Fanciosini, and D. Todd. 2005. Diagnosis of duck circovirus infections by conventional and real-time polymerase chain reaction tests. *Avian Pathol*. 34:495–500.
28. Gerdes, G.H. 1993. Two very small viruses—a presumptive identification. *J S Afr Vet Assoc.* 64:2.
29. Gibbs, M.J., and G.F. Weiller. 1999. Evidence that a plant virus switched hosts to infect a vertebrate and then recombined with a vertebrate-infecting virus. *Proc Nat Acad Sci USA*. 96:8022–8027.
30. Glavits, R., E. Ferenczi, E. Ivanics, T. Bakonyi, T. Mato, P. Zarka, and V. Palya. 2005. Co-occurrence of West Nile fever and circovirus infection in a goose flock in Hungary. *Avian Pathol*. 34:408–414.
31. Goldsmith, T.L. 1995. Documentation of passerine circoviral infection. *Proceedings of the Association of Avian Veterinarians*. Houston, Texas. 16:349.
32. Gopi, P.S., A.L. Hamel, L. Lin, C. Sachvie, E. Grudeski, and G. Spearman. 1999. Evidence for circovirus in cattle with respiratory disease and from aborted bovine fetuses. *Can Vet J*. 40:277–278.
33. Gough, R.E., and S.E. Drury. 1996. Circovirus-like particles in the bursae of young racing pigeons. *Vet Rec*. 138:167.
34. Graham, D.L. 1990. Feather and beak disease: Its biology, management, and an experiment in its eradication from a breeding aviary. In: *Proceedings of the Association of Avian Veterinarians*. Phoenix, Arizona. 11:8–11.
35. Guo, J., J. Tian, X. Tan, H. Yu, S. Ding, H. Sun and X. Yu. 2011. Pathological observations of an experimental infection of geese with goose circovirus. *Avian Pathol*. 40:55–61.
36. Ha, H.J., M.R. Alley, J.I. Cahill, L. Howe, and B.D. Gartrell. 2009. The prevalence of psittacine beak and feather disease virus infection in native parrots in New Zealand. *N Z Vet J*. 57:50–52.
37. Halami, M.Y., H. Nieper, H., Muller, and R. Johne. 2008. Detection of a novel circovirus in mute swans (*Cygnus olor*) by using nested broad-spectrum PCR. *Virus Res*. 132:208–212.
38. Hattermann, K., D. Soike, C. Grund, and A. Mankertz. 2002. A method to diagnose pigeon circovirus infection *in vivo*. *J Virol Methods*. 104:55–58.
39. Hattermann, K., C. Schmitt, D. Soike, and A. Mankertz. 2003. Cloning and sequencing of duck circovirus (DuCV). *Arch Virol*. 148:2471–2480.
40. Heath, L., D.P. Martin, L. Warburton, M. Perrin, W. Horsfield, C. Kingsley, E.P. Rybicki, and A.-L. Williamson. 2004. Evidence of unique genotypes of beak and feather disease virus in southern Africa. *J Virol*. 78:9277–9284.
41. Hess, M., A. Scope, and U. Heincz. 2004. Comparative sensitivity of polymerase chain reaction diagnosis of psittacine beak and feather disease on feather samples, cloacal swabs and blood from budgerigars (*Melopsittacus undulates*, Shaw 18005). *Avian Pathol*. 33:477–481.
42. Jacobson, E.R., S. Clubb, C. Simpson, M. Walsh, C.D. Lothrop, J. Gaskin, J. Bauer, S. Hines, G.V. Kollias, P. Poulos, and G. Harrison. 1986. Feather and beak dystrophy and necrosis in cockatoos: Clinicopathologic evaluations. *J Amer Vet Med Assoc*. 189:999–1005.
43. Jergens A.E., T.P. Brown, and T.L. England. 1988. Psittacine beak and feather disease syndrome in a cockatoo. *J Amer Vet Med Assoc*. 193:1292–1294.
44. Jestin A. 2004. ssDNA viruses of plants, birds, pigs and primates. *Vet Microbiol*. 98:79–80.
45. Johne, R., D. Fernandez-de-Luco, U. Hofle, and H. Muller. 2006. Genome of a novel circovirus of starlings, amplified by multiply primed rolling-circle amplification. *J Gen Virol*. 87:1189–1195.
46. Khalesi B., N. Bonne, M. Stewart, M. Sharp, and S. Raidal. 2005. A comparison of haemagglutination, haemagglutination inhibition and PCR for the detection of psittacine beak and feather disease virus infection and a comparison of isolates obtained from loriids. *J Gen Virol*. 86:3039–3046.
47. Kiatipattanasakul-Banlunara, W., R. Tantileartcharoen, K. Katayama, K. Suzuki, T. Lekdumrogsak, H. Nakayama, and K. Doi. 2002. Psittacine beak and feather disease in three captive sulphur-crested cockatoos (*Cacatua galerita*) in Thailand. *J Vet Med Sci*. 64:527–529.
48. Kock, N.D., P.U. Hangartner, and V. Lucke. 1993. Variation in clinical disease and species susceptibility to psittacine beak and feather disease in Zimbabwean lovebirds. *Onderstepoort J Vet Res*. 60:159–161.
49. Kondiah, K., J. Albertyn, and R.R. Bragg. 2005. Beak and feather disease virus haemagglutinating activity using erythrocytes from African Grey parrots and Brown-headed parrots. *Onderstepoort J Vet Res*. 72:263–265.
50. Latimer, K.S., P.M. Rakich, I.M. Kircher, B.W. Ritchie, F.D. Niagro, W.L. Steffens, and P.D. Lukert. 1990. Extracutaneous

viral inclusions in psittacine beak and feather disease. *J Vet Diagn Invest*. 2:204–207.
51. Latimer, K.S., P.M. Rakich, F.D. Niagro, B.W. Ritchie, W.L. Steffens, R.P. Campagnoli, D.A. Pesti, and P.D. Lukert. 1991. An updated review of psittacine beak and feather disease. *J Assoc Avian Vet*. 5:211–220.
52. Latimer, K.S., P.M. Rakich, W.L. Steffens, I.M. Kircher, B.W. Ritchie, F.D. Niagro, and P.D. Lukert. 1991. A novel DNA virus associated with feather inclusions in psittacine beak and feather disease. *Vet Pathol*. 28:300–304.
53. Latimer, K.S., W.L. Steffens, P.M. Rakich, B.W. Ritchie, F.D. Niagro, I.M. Kircher, and P.D. Lukert. 1992. Cryptosporidiosis in four cockatoos with psittacine beak and feather disease. *J Am Vet Med Assoc*. 200:707–710.
54. Latimer, K.S., F.D. Niagro, P.M. Rakich, R.P. Campagnoli, B.W. Ritchie, W.L. Steffens III, D.A. Pesti, and P.D. Lukert. 1992. Comparison of DNA dot-blot hybridization, immunoperoxidase staining and routine histopathology in the diagnosis of psittacine beak and feather disease in paraffin-embedded cutaneous tissues. *J Assoc Avian Vet*. 6:165–168.
55. Latimer, K.S., F.D. Niagro, W.L. Steffens III, B.W. Ritchie, and R.P. Campagnoli. 1996. Polyomavirus encephalopathy in a Ducorps' cockatoo (*Cacatua ducorpsii*) with psittacine beak and feather disease. *J Vet Diagn Invest*. 8:291–295.
56. Li, L., A. Kapoor, B. Slikas, O.S. Bamidele, C. Wang, S. Shaukat, M.A. Masroor, M.L. Wilson, and J.B. Ndjango. 2010. Multiple diverse circoviruses infect farm animals and are commonly found in human and chimpanzee feces. *J Virol*. 84:1674–1682.
57. Li, L., T. Shan, O.B. Soji, M.M. Alam, T.H. Kunz, S.Z. Zaidi, and E. Delwart. 2011. Possible cross-species transmission of circoviruses and cycloviruses among farm animals. *J Gen Virol*. 92:768–772.
58. Liu, S., X. Zhang, J. Zou, Z. Xie, Y. Zhu, Q. Zhao, E. Zhou, and S. Jiang. 2010. Development of an indirect ELISA for the detection of duck circovirus infection in duck flocks. *Vet Microbiol*. 145:41–46.
59. Lorincz, M., A. Csagola, S.L. Farkas, C. Szekely, and R. Tuboly. 2011. First detection and analysis of a fish circovirus. *J Gen Virol*. 92:1817–1821.
60. Lukert, P.D., G.F. de Boer, J.L. Dale, P. Keese, M.S. McNulty, J.W. Randles, and I. Tischer. 1995. The *Circoviridae*. In: *Virus Taxonomy. Classification and Nomenclature of Viruses. Sixth Report of the International Committee on Taxonomy of Viruses*. F.A. Murphy, C.M. Fauquet, D.H.L. Bishop, et al., eds. Springer-Verlag: New York. 166–168.
61. Mankertz, J., H.–J. Buhk, G. Blaess, and A. Mankertz. 1998. Identification of a protein essential for the replication of porcine circovirus. *J Gen Virol*. 79:381–384.
62. Mankertz, A., K. Hattermann, B. Ehlers, and D. Soike. 2000. Cloning and sequencing of columbid circovirus (CoCV), a new circovirus from pigeons. *Arch Virol*. 145:2469–2479.
63. Marlier, D., and H. Vindevogel. 2006. Viral infections in pigeons. *Vet J*. 172:40–51.
64. McNulty, M., J. Dale, P. Lukert, A. Mankertz, J. Randles, D. Todd. 2000. *Circoviridae*. In: *Virus Taxonomy. Seventh Report of the International Committee on Taxonomy of Viruses*. M.H.V. van Regenmortel, C.M. Fauquet, D.H.L. Ghabrial, E.B.C. Bishop, M.K. Estes, S.M. Lemon, J. Maniloff, M.A. Mayo, D.J. McGeoch, C.R. Pringle, R.B. Wickner, eds. Academic Press, New York. 299–303.
65. McOrist, S., D.G. Black, D.A. Pass, P.C. Scott, and J. Marshall. 1984. Beak and feather dystrophy in wild sulphur-crested cockatoos (*Cacatua galerita*). *J Wildl Dis*. 20:120–124.
66. Meehan, B.M., J.L. Creelan, M.S. McNulty, and D. Todd. 1997. Sequence of porcine circovirus DNA: affinities with plant circoviruses. *J Gen Virol*. 78:221–227.
67. Murphy, F.A., E.P.J. Gibbs, M.C. Horzinek, and M.J. Studdert. 1999. *Circoviridae*. In: *Veterinary Virology*, 3rd ed. Academic Press, San Diego. 357–362.
68. Mushahwar, I.K., J.C. Erker, A.S. Muerhoff, T.P. Leary, J.N. Simons, L.G. Birkenmeyer, M.L. Chalmers, T.J. Pilot-Matias, and S.M. Dexai. 1999. Molecular and biophysical characterization of TT virus: Evidence for a new virus family infecting humans. *Proc Nat Acad Sci USA*. 96:3177–3182.
69. Mysore, J., D. Read, B.M. Daft, H. Kinde, and J. St. Leger. 1995. Feather loss associated with circovirus-like particles in finches. In: *Proceedings of the American Association Veterinary Laboratory Diagnosticians*, Histopathology section. San Diego. 38.
70. Niagro, F.D., A.N. Forsthoefel, R.P. Lawther, L. Kamalanathan, B.W. Ritchie, K.S. Latimer, and P.D. Lukert. 1998. Beak and feather disease virus and porcine circovirus genomes: intermediates between the geminiviruses and plant circoviruses. *Arch Virol*. 143:1723–1744.
71. Ogawa, H., T. Yamaguchi, and H. Fukushi. 2005. Duplex shuttle PCR for differential diagnosis of budgerigar fledgling disease and psittacine beak and feather disease. *Microbiol Immunol*. 49:227–237.
72. Pare, J.A., M.L. Brash, D.B. Hunter, and R.J. Hampson. 1999. Observations on pigeon circovirus infection in Ontario. *Can Vet J*. 40:659–662.
73. Pass, D.A., and R. A. Perry. 1984. The pathology of psittacine beak and feather disease. *Aust Vet J*. 61:69–74.
74. Pass, D.A., S.L. Plant, and N. Sexton. 1994. Natural infection of wild doves (*Streptopelia senegalensis*) with the virus of psittacine beak and feather disease. *Aust Vet J*. 71:307–308.
75. Perry, R.A. 1981. A psittacine combined beak and feather disease syndrome. In: *Proceedings Post-Graduate Committee Veterinary Science, Cage and Aviary Birds*. 61:69–74.
76. Phenix, K.V., J.H. Weston, I. Ypelaar, A. Lavazza, J.A. Smyth, D. Todd, G.E. Wilcox, and S.R. Raidal. 2001. Nucleotide sequence analysis of a novel circovirus of canaries and its relationship to other members of the genus *Circovirus* of the family *Circoviridae*. *J Gen Virol*. 82:2805–2809.
77. Rahaus, M., and M.H. Wolff. 2003. Psittacine beak and feather disease: a first survey of the distribution of beak and feather disease virus inside the population of captive birds in Germany. *J Vet Med*. 50:368–371.
78. Raidal, S.R., M. Sabine, and G.M. Cross. 1993. Laboratory diagnosis of psittacine beak and feather disease by haemagglutination and haemagglutination inhibition. *Aust Vet J*. 70:133–137.
79. Raidal, S.R., G.A. Firth, and G.M. Cross. 1993. Vaccination and challenge studies with psittacine beak and feather disease virus. *Aust Vet J*. 70:437–441.
80. Raidal, S.R., C.L. McElnea, and G.M. Cross. 1993. Seroprevalence of psittacine beak and feather disease in wild birds in New South Wales. *Aust Vet J*. 70:137–139.
81. Raidal, S.R., and G.M. Cross. 1994. The haemagglutination spectrum of psittacine beak and feather disease virus. *Avian Pathol*. 23:621–630.
82. Raidal, S.R., and P.A. Riddoch. 1997. A feather disease in senegal doves (*Streptopelia senegalensis*) morphologically similar to psittacine beak and feather disease. *Avian Pathol*. 26:829–836.
83. Raue, R., R. Johne, L. Crosta, M. Burkle, H. Gerlach, and H. Muller. 2004. Nucleotide sequence analysis of a C1 gene

fragment of psittacine beak and feather disease virus amplified by real-time polymerase chain reaction indicates a possible existence of genotypes. *Avian Pathol*. 33:41–50.
84. Raue, R., V. Schmidt, M. Freick, B. Reinhardt, R. Johne, L. Kamphausen, E.F. Kaleta, H. Muller, and M. Krautwald-Junghanns. 2005. A disease complex associated with pigeon circovirus infection, young pigeon disease syndrome. *Avian Pathol*. 34:418–425.
85. Ritchie, B.W., F.D. Niagro, P.D. Lukert, K.S. Latimer, W.L. Steffens, and N. Pritchard. 1989. A review of psittacine beak and feather disease. Characteristics of the PBFD virus. *J Assoc Avian Vet*. 3:143–149.
86. Ritchie, B.W., F.D. Niagro, P.D. Lukert, W.L. Steffens, and K.S. Latimer. 1989. Characterization of a new virus from cockatoos with psittacine beak and feather disease. *Virology*. 171:83–88.
87. Ritchie B.W., F.D. Niagro, K.S. Latimer, P.D. Lukert, W.L. Steffens, P.M. Rakich, and N. Pritchard. 1990. Ultrastructural, protein composition, and antigenic comparison of psittacine beak and feather disease virus purified from four genera of psittacine birds. *J Wildl Dis*. 26:196–203.
88. Ritchie, B.W., F.D. Niagro, and K.S. Latimer. 1990. Advances in understanding the PBFD virus. In: *Proceedings of the Association of Avian Veterinarians*. Phoenix, Arizona. 11:12–24.
89. Ritchie, B.W., F.D. Niagro, K.S. Latimer, W.L. Steffens, D. Pesti, J. Ancona, and P.D. Lukert. 1991. Routes and prevalence of shedding of psittacine beak and feather disease virus. *Am J Vet Res*. 52:1804–1809.
90. Ritchie B.W., F.D. Niagro, K.S. Latimer, W.L. Steffens, D. Pesti, and P.D. Lukert. 1991. PBFD virus: Disease prevention through experimental vaccination. In: *Proceedings of the Association of Avian Veterinarians Chicago*, Illinois. 12:50–55.
91. Ritchie, B.W., F.D. Niagro, K.S. Latimer, W.L. Steffens, D. Pesti, R.P. Campagnoli, and P.D. Lukert. 1992. Antibody response to and maternal immunity from an experimental psittacine beak and feather disease vaccine. *Am J Vet Res*. 53:1512–1518.
92. Ritchie, B.W., F.D. Niagro, K.S. Latimer, W.L Steffens, D. Pesti, L. Aron, and P.D. Lukert. 1992. Production and characterization of monoclonal antibodies to psittacine beak and feather disease virus. *J Vet Diagn Invest*. 4:13–18.
93. Ritchie, B.W., and K.S. Latimer. 1995. Beak and feather disease virus. In: *Kirk's Current Veterinary Therapy XII: Small Animal Practice*, J.D. Bonagura, R.W. Kirk, and C.A. Osborne, eds. W.B. Saunders Co., Philadelphia. 1288–1294.
94. Ritchie, B.W. 1995. *Avian Viruses: Function and Control*. Wingers Publishing, Inc. Lake Worth. 223–252.
95. Ritchie, P.A., I.L. Anderson, and D.M. Lambert. 2003. Evidence for specificity of psittacine beak and feather disease virus among avian hosts. *Virology*. 306:109–115.
96. Roy, P., A.S. Dhillon, L. Lauerman, and H.L. Shivaprasad. 2003. Detection of pigeon circovirus by polymerase chain reaction. *Avian Dis*. 47:218–222.
97. Sanada, Y., N. Sanada, and M. Kubo. 1999. Electron microscopical observations of psittacine beak and feather disease in an umbrella cockatoo (*Cacatua alba*). *J Vet Med Sci*. 61: 1063–1065.
98. Sanada, N., and Y. Sanada. 2000. The sensitivities of various erythrocytes in a haemagglutination assay for the detection of psittacine beak and feather disease virus. *J Vet Med*. 47:441–443.
99. Schmidt, R.E. 1992. Circovirus in pigeons. *J Assoc Avian Vet*. 6:204.
100. Schmidt V., J. Schlomer, C. Luken, R. Johne, B. Biere, H. Muller, and M. Krautwald-Junghanns. 2008. Experimental infection of domestic pigeons with pigeon circovirus. *Avian Dis*. 52:380–386.
101. Schoemaker, N.J., G.M. Dorrestein, K.S. Latimer, J.T. Lumeij, M.L.J. Kik, M.H. van der Hage, and R.P. Campagnoli. 2000. Severe leukopenia and liver necrosis in young African grey parrots (*Psittacus erithacus erithacus*) infected with psittacine circovirus. *Avian Dis*. 44:470–478.
102. Scott, A.N.J., A. Beckett, J.A. Smyth, N.W. Ball, V. Palya, and D. Todd. 2006. Serological diagnosis of goose circovirus infections. *Avian Pathol*. 35:495–499.
103. Scullion, F.T., and M.G. Scullion. 2007. Pathologic findings in racing pigeons (*Columba livia domestica*) with "young bird sickness." *J Avian Med Surg*. 21:1–7.
104. Shearer P.L., N. Bonne, P. Clark, M. Sharp, and S.R. Raidal. 2008. Development and applications of a monoclonal antibody to a recombinant beak and feather disease virus (BFDV) capsid protein. *J Virol Methods*. 147:206–212.
105. Shearer P.L., N. Bonne, P. Clark, M. Sharp, and S.R. Raidal. 2008. Beak and feather disease virus infection in cockatiels (*Nymphicus hollandicus*). *Avian Pathol*. 37:75–81.
106. Shearer P.L., M. Sharp, N. Bonne, P. Clark, and S.R. Raidal. 2009. A blocking ELISA for the detection of antibodies to psittacine beak and feather disease virus (BFDV). *J Virol Methods*. 158:136–140.
107. Shearer P.L., M. Sharp, N. Bonne, P. Clark, and S.R. Raidal. 2009. A quantitative, real-time polymerase chain reaction assay for beak and feather disease virus. *J Virol Methods*. 159:98–104.
108. Shivaprasad, H.L., R.P. Chin, J.S. Jeffrey, K.S. Latimer, R.W. Nordhausen, F.D. Niagro, and R.P. Campagnoli. 1994. Particles resembling circovirus in the bursa of Fabricius of pigeons. *Avian Dis*. 38:635–641.
109. Shivaprasad H.L., D. Hill, D. Todd, and J.A. Smyth. 2004. Circovirus infection in a Gouldian finch (*Chloebia gouldiae*). *Avian Pathol*. 33:525–529.
110. Smyth, J.A., and B.P. Carroll. 1995. Circovirus infection in European racing pigeons. *Vet Rec*. 136:173–174.
111. Smyth, J.A., J. Weston, D.A. Moffett, and D. Todd. 2001. Detection of circovirus infection in pigeons by *in situ* hybridization using cloned DNA probes. *J Vet Diagn Invest*. 13:475–482.
112. Smyth, J.A., D. Soike, D. Moffett, J.H. Weston, and D. Todd. 2005. Circovirus-infected geese studied by *in situ* hybridization. *Avian Pathol*. 34:227–232.
113. Smyth, J.A., D. Todd, A. Scott, A. Beckett, C.M. Twentyman, C. Brojer, H. Uhlhorn, and D. Gavier-Widen. 2006. Identification of circovirus infection in three species of gull. *Vet Rec*. 159:212–214.
114. Soike, D. 1997. Circovirusinfektion bei Tauben (Circovirus in doves). *Tierarztliche-Praxis*. 25:52–54.
115. Soike, D., B. Kohler, and K. Albrecht. 1999. A circovirus-like infection in geese related to a runting syndrome. *Avian Pathol*. 28:199–202.
116. Soike, D., K. Hattermann, K. Albrecht, J. Segales, M. Domingo, C. Schmitt, and A. Mankertz. 2001. A diagnostic study on columbid circovirus infection. *Avian Pathol*. 30:605–611.
117. Soike, D., K. Albrecht, K. Hattermann, C. Schmitt, and A. Mankertz. 2004. Novel circovirus in mulard ducks with developmental and feathering disorders. *Vet Rec*. 154:792–793.
118. St. Leger, J., B.M. Daft, R.W. Nordhausen, and K.S. Latimer. 1997. Feather dystrophy associated with circovirus infection in

columbiformes. In: *Proceedings Western Poultry Disease Conference*. Tempe, Arizona. 18:38.
119. Stanford, M. 2004. Interferon treatment of circovirus infection in grey parrots (*Psittacus e erithacus*). *Vet Rec*. 154:435–436.
120. Stewart, M.E., R. Perry, and S.R. Raidal. 2006. Identification of a novel circovirus in Australian ravens (*Corvus coronoides*) with feather disease. *Avian Pathol*. 35:86–92.
121. Stewart, M.E., N. Bonne, P. Shearer, B. Khalesi, M. Sharp, and S. Raidal. 2007. Baculovirus expression of beak and feather disease virus (BFDV) capsid protein capable of self-assembly and haemagglutination. *J Virol Method*. 141:181–187.
122. Studdert, M.J. 1993. *Circoviridae*: new viruses of pigs, parrots and chickens. *Aust Vet J*. 70:121–122.
123. Takahashi K., Y. Iwasa, M. Hijikata, and S. Mishoro. 2000. Identification of a new human DNA virus (TTV-like mini virus, TLMV) intermediately related to TT virus and chicken anemia virus. *Arch Virol*. 145:979–993.
124. Tavernier, P., P. De Herdt, M. Bos, H. Thoonen, H. De Bosschere, G. Charlier, M. Vereecken, and R. Ducatelle. 1999. Circovirus infection in the pigeon: Review and first experiences in Flanders. *Vlaams Diergeneeskundig Tijdschrift*. 68:31–36.
125. Terregino, C., F. Montesi, F. Mutinelli, I. Capua, and Pandolfo A. 2001. Detection of a circovirus-like agent from farmed pheasants in Italy. *Vet Rec*. 149:340.
126. Todd, D.L., F.D. Niagro, B.W. Ritchie, W. Curran, G.M. Allan, P.D. Lukert, K.S. Latimer, W.L. Steffens, and M. S. McNulty. 1991. Comparison of three animal viruses with circular single-stranded DNA genomes. *Arch Virol*. 117:129–135.
127. Todd, D.L. 2000. Circoviruses: Immunosuppressive threats to avian species: A review. *Avian Pathol*. 29:373–394.
128. Todd, D., J.H. Weston, D. Soike, and J.A. Smyth. 2001. Genome sequence determinations and analyses of novel circoviruses from goose and pigeon. *Virology*. 286:354–362.
129. Todd, D., M.S. McNulty, B.M. Adair, and G.M. Allan. 2001. Animal circoviruses. *Adv Virus Res*. 57:1–70.
130. Todd, D., J.P. Duchatel, J.H. Weston, N.W. Ball, B.J. Borghmans, D.A. Moffett, and J.A. Smyth. 2002. Evaluation of polymerase chain reaction and dot blot hybridization tests in the diagnosis of pigeon circovirus infections. *Vet Microbiol*. 89:1–16.
131. Todd, D. 2004. Avian circovirus diseases: lessons for the study of PMWS. *Vet Microbiol*. 98:169–174.
132. Todd, D., M. Bendinelli, P. Biagini, S. Hino, A. Mankertz, S. Mishiro, C. Niel, H. Okamoto, S.R. Raidal, B.W. Ritchie, and C.G. Teo. 2005. *Circoviridae*. In: *Virus Taxonomy, 8th Report of the International Committee for the Taxonomy of Viruses*. C.M. Fauqet, M.A. Mayo, J. Maniloff, U. Desselberger, and L.A. Ball, eds. Elsevier/Academic Press, London. 327–334.
133. Todd, D., J.-P. Duchatel, J.C. Bustin, F.T. Scullion, M.G. Scullion, A.N.J. Scott, A. Curry, N.W. Ball, and J.A. Smyth. 2006. Detection of pigeon circovirus in cloacal swabs: implications for diagnosis, epidemiology and control. *Vet Rec*. 159:314–317.
134. Todd, D., A.N.J. Scott, E. Fringuelli, H.L. Shivaprasad, D. Gavier-Widen and J.A. Smyth. 2007. Molecular characterization of novel circoviruses from finch and gull. *Avian Pathol*. 36:75–81.
135. Todd, D., E. Fringuelli, A.N.J. Scott, B.J. Borghmans, H.L. Shivaprasad, S.R. Raidal, J.X. Abadie, M.P. Franciosini, and J.A. Smyth. 2008. Sequence comparison of pigeon circoviruses. *Res Vet Sci*. 84:311–319.
136. Tomasek, O., and V. Tukac. 2007. Psittacine circovirus infection in parakeets of the genus *Eunymphicus* and the treatment with β-(1,3/1,6)-D-glucan. *Avian Dis*. 51:989–991.
137. Twentyman, C.M., M.R. Alley, J. Meers, M.M. Cooke, and P.J. Duignan. 1999. Circovirus-like infection in a southern black backed gull (*Larus dominicanus*). *Avian Pathol*. 28:513–516.
138. Varsani, A., G.K. de Villiers, G.L. Regnard, R.R. Bragg, K. Kondiah, I.I. Hitzeroth, and E.P. Rybicki. 2010. A unique isolate of beak and feather disease virus isolated from budgerigars (*Melopsittacus undulates*) in South Africa. *Arch Virol*. 155:435–439.
139. Varsani, A., F.L. Regnard, R. Bragg, I.I. Hitzeroth, and E.P. Rybicki. 2011. Global genetic diversity and geographical and host-species distribution of beak and feather disease virus isolates. *J Gen Virol*. 92:752–767.
140. Wang, K., S. Xie, D. Zhang, G. Ma, X. Wang, and D. Zhang. 2011. Detection of duck circovirus in China: A proposal on genotype classification. *Vet Microbiol*. 147:410–415.
141. Woods, L.W., K.S. Latimer, B.C. Barr, F.D. Niagro, R.P. Campagnoli, R.W. Nordhausen, and A.E. Castro. 1993. Circovirus-like infection in a pigeon. *J Vet Diagn Invest*. 5:609–612.
142. Woods, L.W., K.S. Latimer, F.D. Niagro, C. Riddell, A.M. Crowley, M.L. Anderson, B.M. Daft, D.D. Moore, R.P. Campagnoli, and R.W. Nordhausen. 1994. A retrospective study of circovirus infection in pigeons: Nine cases (1986–1993). *J Vet Diagn Invest*. 6:156–164.
143. Woods, L.W., and K.S. Latimer. 2000. Circovirus infection of nonpsittacine birds. *J Avian Med Surg*. 14:154–163.
144. Wylie, S.L., and D.A. Pass. 1987. Experimental reproduction of psittacine beak and feather disease/French moult. *Avian Pathol*. 16:269–281.
145. Yilmaz, A., and E.F. Kaleta. 2004. Disinfectant tests at 20 and 10 degrees C to determine the virucidal activity against circoviruses. *Dtsch Tierarztl Wochenschr*. 111:248–251.
146. Ypelaar, I., M.R. Bassami, G.E. Wilcox, and S.R. Raidal. 1999. A universal polymerase chain reaction for the detection of psittacine beak and feather disease virus. *Vet Microbiol*. 68:141–148.
147. Yu, X.P., X.T. Zheng, S.C. He, J.L. Zhu, and Q.F. Shen. 2005. Cloning and analysis of the complete genome of a goose circovirus from Yongkang Zhejiang. *Wei Sheng Wu Xue Bao*. 45:860–864.
148. Yu, X., C. Zhu, X. Zheng, S. He, and X. Liu. 2007. Genome analysis and epidemiological investigation of goose circovirus detected in eastern China. *Virus Genes*. 35:605–609.
149. Yuasa, N. 1992. Effect of chemicals on the infectivity of chicken anaemia virus. *Avian Pathol*. 21:315–319.
150. Zhang, X., S. Jiang, J. Wu, Q. Zhao, Y. Sun, Y. Kong, X. Li, M. Yao, and T. Chai. 2009. An investigation of duck circovirus and co-infection in Cherry Valley ducks in Shandong Province, China. *Vet Microbiol*. 133:252–256.

Chapter 9

Adenovirus Infections

Introduction

Scott D. Fitzgerald

Adenoviruses are common infectious agents in poultry and wild birds worldwide. Many of the viruses replicate in healthy birds with little or no apparent signs of infection, although they can quickly take on the role of opportunistic pathogens when additional factors, particularly concurrent infections, adversely affect the health of the avian host. However, some adenoviruses (e.g., turkey hemorrhagic enteritis virus, quail bronchitis virus, and egg drop syndrome virus) are primary pathogens in their own right, and others continually turn up in specific disease situations, indicating a degree of guilt by association, although the results of experimental infections to elucidate pathogenic intent have not always been successful.

The first avian adenovirus was isolated in 1949 when material from a case of lumpy skin disease in cattle was inoculated into embryonating chicken eggs (12). Other early unintentional isolates of chicken adenoviruses were the chicken embryo lethal orphan (CELO) isolates made in embryonating eggs (13) and the Gallus adeno-like (GAL) viruses from chicken cell cultures (4). The first isolate of an avian adenovirus from diseased birds was from an outbreak of respiratory disease in bobwhite quail (*Colinus virginianus*) by Olson (11). Human adenoviruses were isolated in 1954 during investigations of respiratory disease (8) and initially were called adenoidal-pharyngeal-conjunctival agents, but the name adenoviruses subsequently was adopted (7).

Most of the viruses replicate readily in avian cell cultures derived from tissues, such as liver or kidney. Replication takes place in the nucleus and is accompanied by the development of intranuclear inclusions, which may aid histopathological diagnosis (9). The general properties required for classifying an isolate as an adenovirus have been defined by the International Committee on Taxonomy of Viruses (ICTV) (3). This report recognized two genera, *Mastadenovirus* and *Aviadenovirus*, within the adenovirus family, with human adenovirus type 2 and CELO virus as the respective type species (Table 9.1). The aviadenoviruses are serologically distinct from mastadenoviruses (10) and also differ in their

Table 9.1. Classification of adenoviruses.

Genus	Old classification	Species of host affected	Disease examples from this Chapter
Mastadenovirus	*Mastadenovirus*	Human, simian, bovine, equine, murine, porcine, ovine, caprine, etc.	• None
Aviadenovirus	Group I avian adenoviruses	Chickens, turkeys, ducks, geese, pigeons, various wild bird species	• Inclusion body hepatitis • Quail bronchitis virus • Hydropericardium syndrome • Gizzard erosions
Siadenovirus	Group II avian adenoviruses	Chickens, turkeys, pheasants, frogs, raptors	• Hemorrhagic enteritis (turkeys) • Marble spleen disease (pheasants) • Splenomegaly (chickens)
Atadenovirus	Group III avian adenoviruses	Ducks, bovine, ovine, deer, possums, snakes	• Egg drop syndrome
Ichtdenovirus		White sturgeon (fish)	• None

Diseases of Poultry, Thirteenth Edition. David E. Swayne.
© 2013 John Wiley & Sons, Inc. Published 2013 by John Wiley & Sons, Inc.

Table 9.2. Members of *Adenoviridae* affecting birds.*

Genus Aviadenovirus
Fowl adenovirus *A*
Serotypes: Fowl adenovirus 1 (FAdV-1) (CELO, 112, QBV, Ote, H1)
Fowl adenovirus *B*
Serotypes: Fowl adenovirus 5 (FAdV-5) (340, TR-22, Tipton, M2)
Fowl adenovirus *C*
Serotypes: Fowl adenovirus 4 (FAdV-4) (506, J2, KR5, H2, K31, 61)
Fowl adenovirus 10 (FAdV-10) (C-28, M11, CFA20, SA2)
Fowl adenovirus *D*
Serotypes: Fowl adenovirus 2 (FAdV-2) (GAL-1, 685, SR48, H3, P7)
Fowl adenovirus 3 (FAdV-3) (SR-49, 75, H5)
Fowl adenovirus 9 (FAdV-9) (A2, 90, CFA19)
Fowl adenovirus 11 (FAdV-11) (380, UF71)
Fowl adenovirus *E*
Serotypes: Fowl adenovirus 6 (FAdV-6) (CR-119, 168)
Fowl adenovirus 7 (FAdV-7) (YR36, X-11, 122)
Fowl adenovirus 8a (FAdV-8a) (58, TR-59, T-8, CFA40)
Fowl adenovirus 8b (FAdV-8b) (764, B3, VRI-33)
Turkey adenovirus B (Turkey adenovirus 1, 2)
Falcon adenovirus A
Goose adenovirus A
Genus Atadenovirus
Duck adenovirus A (Duck adenovirus 1, egg drop syndrome)
Genus Siadenovirus
Turkey adenovirus A (Turkey adenovirus 3, TAdV-3)
Raptor adenovirus A
Great tit adenovirus A

*http://ictvonline.org/virusTaxonomy.asp?version=2009&bhcp=1

genome organization (3). The genus contains most of the characterized adenoviruses isolated from chickens, turkeys, and geese (see Aviadenovirus Infections). These viruses often were previously referred to as group 1 avian adenoviruses in the literature (9).

However, two of the most important adenoviruses causing significant disease in avian species, namely hemorrhagic enteritis (see Hemorrhagic Enteritis and Related Infections) and egg drop syndrome virus (see Atadenovirus [Egg Drop Syndrome and Related Infections]), show substantial differences at the molecular level. Currently, hemorrhagic enteritis (HE) virus, along with the related viruses of marble spleen disease (MSD) virus of pheasants and splenomegaly virus of chickens, and a recently isolated virus from a frog form the genus *Siadenovirus* named to reflect one of their unique genome characteristics, namely the presence of a gene coding for sialidase (5, 6). Egg drop syndrome (EDS) virus, along with certain related adenoviruses isolated from ruminants, marsupials, and reptiles, are now classified as members of the genus *Atadenovirus*, reflecting their high adenine-thymidine (AT) content (1, 2, 3, 6) (Table 9.2). In addition, a recently characterized adenovirus from a fish appears unrelated to currently recognized genera and represents a fifth adenovirus genus *Ichtadenovirus* (1, 3).

Acknowledgement

The author wishes to acknowledge John Brian McFerran, who authored the "Adenovirus Infections: Introduction" in the 12th and earlier editions of *Diseases of Poultry*, for his substantial contributions to the current subchapter.

Aviadenovirus Infections

Michael Hess

Introduction

Definition and Synonyms

The genus *aviadenovirus* within the adenovirus family includes the important chicken adenoviruses (FAdV) which are separated into 5 species (A-E) (61). Aviadenoviruses from geese (GoAdV-1, 2, 3) and turkeys (TAdV-1, 2) are compiled in other species. Related viruses that have not been approved yet as species are a duck adenovirus (DAdV-2), a pigeon adenovirus (PiAdV-1), and some viruses from psittacines and parrots. In older literature such viruses are combined as group/subgroup I of the avian adenoviruses, which is no longer the official designation. In contrast to the turkey hemorrhagic enteritis and related viruses which belong to the *siadenoviruses* and the egg drop syndrome which is a member of the a*tadenoviruses* (Table 9.2), the role of most aviadenoviruses as pathogens was not that well defined in the past but recent data strengthen the role of some FAdV strains as primary pathogens, mainly in chickens. This could be demonstrated for some FAdV-1 strains (species A) causing gizzard erosion (GE) and some FAdV-4 strains (species C) which play a major role in the etiology of hydropericardium syndrome (HS). In addition, other strains, mainly those belonging to species D and E, can cause severe liver damage leading to the condition known as inclusion body hepatitis (IBH). Finally, quail bronchitis (see Quail Bronchitis) is caused by FAdV-1. In recent years different non-virulent FAdVs were modified to be used as viral vectors. Several reviews on aviadenoviruses are available highlighting different subjects (16, 62, 93, 97, 102, 108).

Economic Significance

With such variability in disease association, it is very difficult at present to assess the overall economic importance of

aviadenoviruses, especially FAdV. However, the high mortality noticed in flocks infected with very virulent FAdV-4 isolates and the growth retardation in connection with IBH and GE result in very substantial economic losses (16, 126).

Public Health Significance

There is no evidence of productive infection of human cells by aviadenoviruses, and therefore any public health implications are likely to be minimal. However, there is growing interest in the use of FAdV as a gene transfer vehicle for use in humans and possibly other species. Two different viruses belonging to two different serotypes (FAdV-1 and FAdV-9) have been shown to be able to transduce human cell lines without productive replication (29, 106). Another avian adenovirus, SMAM-1, may play a role in human obesity, although this remains controversial (38).

History

In the decades following the first report of the isolation of an avian adenovirus in 1949, a number adenoviruses were isolated from healthy and diseased birds in geographically different regions and typed by cross neutralization tests (19, 78, 98). In the period afterward it was demonstrated that infectious bursal disease virus (IBDV) and chicken infectious anemia virus (CIAV) are capable of enhancing the virulence of FAdV (45, 169). Later, experimental and field data demonstrated the primary role of FAdV in certain diseases, arguing to reassess the virulence of FAdV (42, 51, 92, 126).

Etiology

Classification

Within the adenovirus family, species designation depends on at least 2 of a number of key criteria that include calculated phylogenetic distance, restriction enzyme fragmentation, host range, pathogenicity, cross neutralization, and possibility of recombination (61). Within the genus *aviadenovirus*, five species, designated with the letters A–E, are recognized, based largely on molecular criteria in particular restriction enzyme fragmentation patterns and sequencing data (Table 9.2). So far the complete nucleotide sequences are available for the genomes of FAdV-A (CELO virus), FAdV-D (strain A-2A), FAdV-C (strains ON1 and KR5), and FAdV-E (strain HG), enabling more comprehensive phylogenetic studies with nucleotide identity values of 52%–72% between viruses belonging to different species (22, 53, 54, 88, 119). Viruses within each species also can be further subdivided into serotypes based largely on the results of cross neutralization tests or into genotypes.

Morphology

Ultrastructure and Symmetry

Details on morphology have been reviewed previously (93, 96). The virion is composed of 252 capsomeres, surrounding a core 60–65 nm in diameter. Capsomeres are arranged in triangular faces with six capsomeres along each edge. There are 240 non-vertex capsomeres (hexons) of 8–9.5 nm diameter and 12 vertex capsomeres (penton bases). Vertex capsomeres carry projections known as fibers (144). Mammalian adenoviruses have one fiber on each penton base, and FAdV have two (49). In most cases, both fibers are of similar length because they are probably transcribed from a single gene. In contrast, members of species FAdV-A and FAdV-C have two fiber genes (88). FAdV-1 possesses 2 fibers of different lengths (i.e., 46 and 10 nm). How the vertex capsomere is assembled to accommodate 2 fibers is not fully understood (63). The fiber proteins are of high importance for virus-cell interaction as demonstrated for FAdV-1 (162). This also might explain the importance of the fiber protein as virulence factor (89, 91, 122, 128).



Figure 9.1. Adenovirus-infected chick liver cell culture (48 hours post-infection). Adenovirus particles almost fill the nucleus.

Ultrastructural studies demonstrate accumulation of virus particles in the nucleus of infected cells, and these often form crystalline arrays which differ in morphology and density depending on the content of viral protein and DNA (Figure 9.1) (4, 5). Large intranuclear inclusions are also clearly visible in tissues from infected birds or in infected cell cultures by cytochemical or immunostaining methods (Figures 9.2 and 9.3), and these may be useful in diagnosis of adenovirus infections.

Size and Density

The adenovirus virion is a nonenveloped, icosahedral structure 70–90 nm in diameter (144). Densities between 1.32 and 1.37 g/mL in cesium chloride (CsCl) have been estimated for aviadenoviruses. Similar differences in density, which have been attributed to differences in DNA content and base composition in different isolates, also have been found in human adenoviruses.

Chemical Composition

The nucleic acid is double-stranded DNA, which accounts for 17.3% of the FAdV-1 virion, with the remainder being protein (82). The guanine-cytosine (G-C) content of fully sequenced

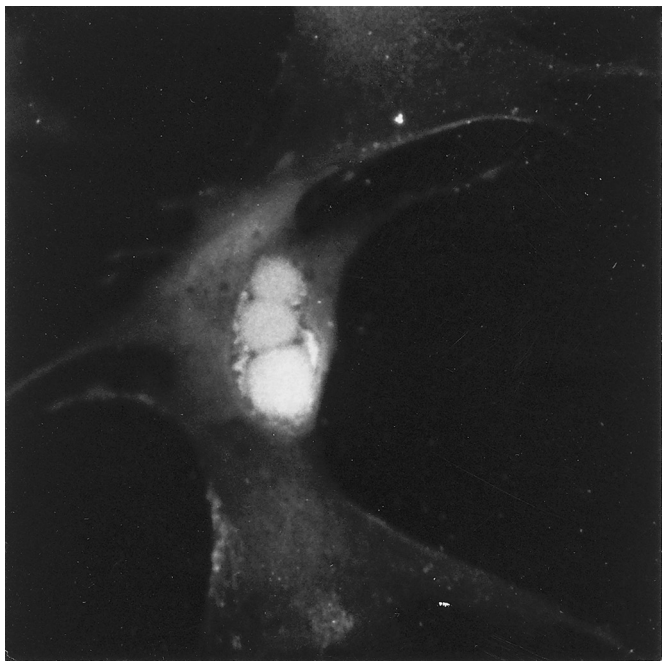

Figure 9.2. Growth of FAdV-8 (764) in chick kidney cell cultures. Intranuclear inclusions stained by direct immunofluorescence.

genomes varies between 54% and 58%. Between 11 and 14 structural polypeptides have been described for FAdV-1, with hexon as the most abundant.

Virus Replication

Adenovirus replication is divided into 2 well-defined phases. The early phase involves the entry of virus into the host cell and the transfer of the virus DNA to the nucleus, which is followed by the transcription and translation of the so-called early (E) genes (61). Afterward, proteins coded by the early genes redirect cellular functions to facilitate replication of the virus DNA and the consequent transcription and translation of the late (L) genes, coding for the virus structural proteins. Assembly of the viral proteins into complete virions is completed in the nucleus, and this is followed by disruption of the nuclear membrane and release of virus by destruction of the cell. However, these data were mainly gained from mammalian adenoviruses, because left and right hand regions, coding for early genes, of FAdV vary substantially from other adenoviruses.

Susceptibility to Chemical and Physical Agents

All avian adenoviruses tested so far have shown typical adenovirus properties (93, 96, 102, 108). They are resistant to lipid solvents such as ether and chloroform, sodium deoxycholate, trypsin, 2% phenol, and 50% alcohol. They are resistant to variations in pH between 3 and 9 but are inactivated by a 1:1,000 concentration of formaldehyde. They are inhibited by the DNA inhibitors IUdR and BUdR.

Although it is accepted that adenoviruses in general are inactivated in aqueous solution after exposure to 56 °C for 30 minutes and that heat stability is reduced by divalent ions, FAdV show more variability and are apparently more heat resistant. Some strains survive 60 °C and even 70 °C for 30 minutes. The infectivity titer of one FAdV-1 virus fell rapidly after 180 minutes at 56 °C, and another FAdV-1 strain apparently survived 18 hours at 56 °C. Even strains tested in the same laboratory have shown differences in thermostability, suggesting that the differences were not due to variation in technique. Although most workers found that divalent cations destabilize adenoviruses, some have found no effect, emphasizing the need to standardize procedures.

Hemagglutination

Hemagglutination has been reviewed by McFerran (96). Hemagglutination is a unique feature of FAdV-1 which hemagglutinates rat erythrocytes between pH 6 and 9 at temperatures between 20° and 45 °C. Apart from rat erythrocytes agglutination of sheep erythrocytes is reported for one FAdV-1 strain, indicating some strain variation. The hemagglutinin is stable to treatment with trypsin, RNase, DNase, and neuraminidase. A single report describes hemagglutination of sheep erythrocytes by a FAdV strain (Indiana C). No evidence exists for hemagglutination by any of the other chicken serotypes or by the turkey or duck aviadenoviruses (18).

Strain Classification

Antigenicity

The adenovirus hexon is the major capsid protein and contains type-, group-, and subgroup-specific antigenic determinants against which antibodies are produced (61, 97). The group-specific determinants are shared by all aviadenoviruses, but are not present in the *siadenoviruses* or *atadenoviruses* (although EDS virus appears to show some partial cross reactivity with aviadenoviruses, which has been demonstrated by indirect means). Despite its low sensitivity, the double immunodiffusion (DID) test can be used to differentiate viruses of the three genera.

Type-specific determinants give rise to antibodies that neutralize viral infectivity, and, therefore, the neutralization test has been widely used to separate isolates into serotypes (62, 97).

Immunogenicity and Protective Characteristics

Neutralizing antibodies produced against the type-specific epitopes should provide protection, but there are only very limited data available about the contribution of individual epitopes and the duration of protection.

Molecular Characteristics

Restriction enzyme (RE) analysis was used to differentiate 12 recognized serotypes into 5 genotypes designated A–E (175), which are now recognized as separate adenovirus species (61). PCR has been applied for detection of FAdV, with primer sequences mainly based on the hexon gene (48, 90, 104, 133, 135, 171). Sequencing of variable regions of the hexon gene can be used to allocate viruses to species A–E and to establish

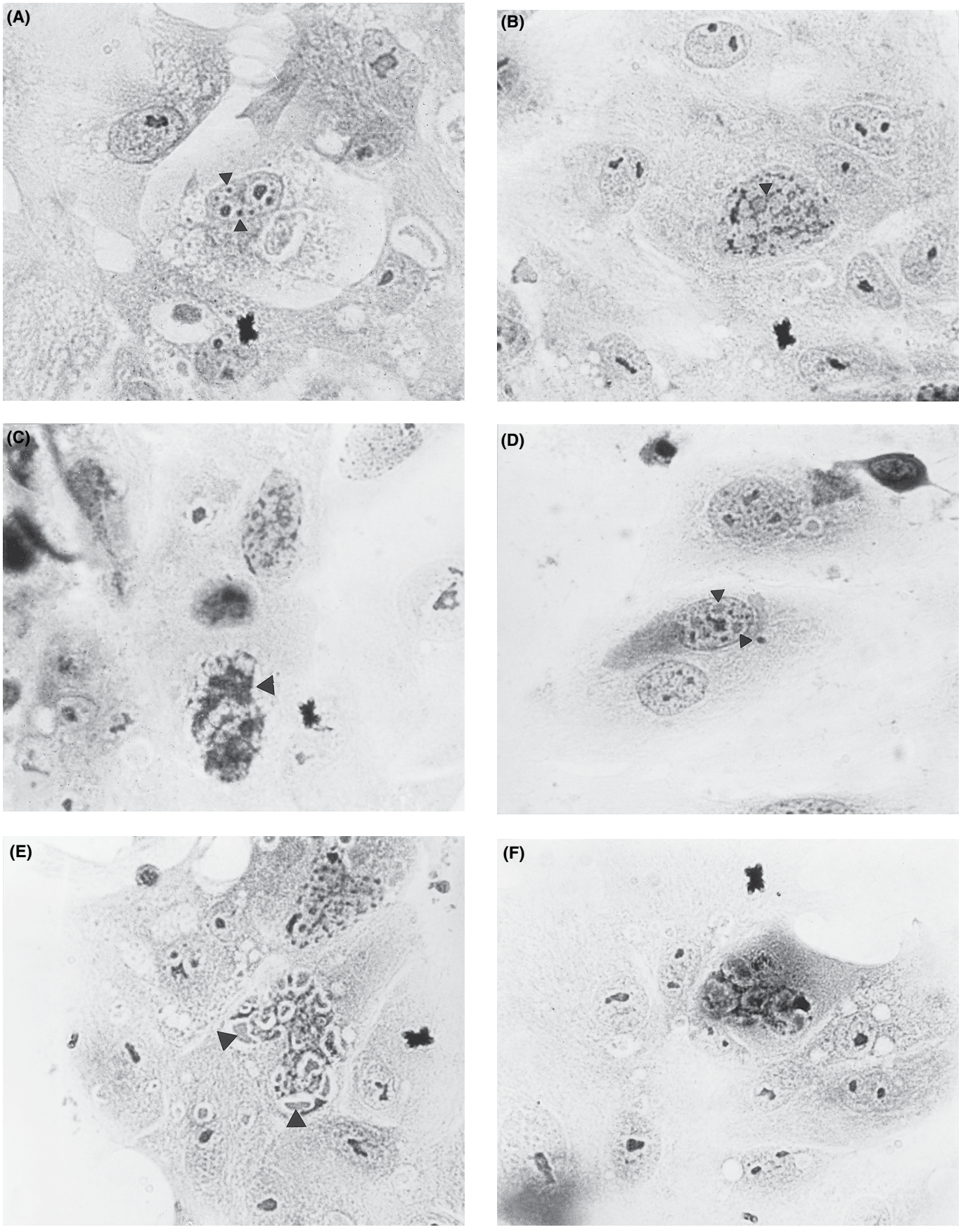

Figure 9.3. H&E staining of chick kidney cells infected with FAdV-8 (768) showing basophilic inclusions in the nucleus.

genotypes within species which is now frequently carried out (87, 105). Variation within loop 1 of the hexon gene also can be used for differentiation of viruses by high resolution melting curve analysis or pyrosequencing (129, 159).

Laboratory Host Systems

Most chicken isolates have been made in chick kidney (CK) or chicken embryo liver (CEL) cells. A chicken hepatoma cell line (LMH cells) also can be used for isolation and propagation of FAdV (11, 118). In addition, chicken tracheal organ cultures and chicken embryo fibroblasts appear to be less sensitive than other cells, and adaptation and attenuation of virulent FAdV-4 to a quail fibroblast cell line (QT35) was reported (97, 150).

Aviadenoviruses have been isolated from turkeys, geese, ducks, and pigeons (18, 64, 151, 175). Numerous reports describe the presence of FAdV in different species of birds, including psittacines, raptors, and other wild birds. If more avian species are examined using homologous cell systems, an extended range of viruses could be recognized.

Although it is probable that all aviadenoviruses multiply in the embryonating egg, not all chicken or turkey isolates cause recognizable lesions. Considering lesions and mortality, great variation exists between different strains of FAdV following embryo propagation (32). Yolk sac, in comparison to the allantoic cavity, was found most susceptible, reaching the highest virus titers. In another investigation allantoic cavity was found less susceptible than CAM, which also can be used to demonstrate the high susceptibility of the chicken embryo for FAdV-1 (78). Signs and lesions produced in the embryo were death, stunting, curling, hepatitis, splenomegaly, congestion, and hemorrhage of body parts, with urate accumulations in the kidneys. Hepatocytes usually contained basophilic or eosinophilic intranuclear inclusion bodies (10). No correlation could be found between high embryo mortality and clinical signs in experimentally infected day-old specific pathogen free (SPF) birds (92, 103).

Pathogenicity

Because the role of most FAdV as primary pathogens is not clearly established, factors determining pathogenicity are not yet clear. Different serotypes, and even strains of the same serotype, can vary in their ability to produce illness and death (27, 42, 92, 169). Variation in the ability to grow and persist in embryo tendon explants also has been noted (50). With some isolates, a relationship has been found between genotype and virulence but not between serotype and virulence (42). In comparison to other strains, FAdV-1 produces a variety of tumors when inoculated into hamsters and will transform human and hamster cells (96).

In many studies, the route of inoculation, the age of birds, and the virus dose has been extremely important in producing disease. Many isolates have failed to cause disease when inoculated by natural routes or by direct spread but were highly pathogenic when given by parenteral inoculation. Inducing high mortality via oral or eye/nostril infection is a distinctive feature of very virulent FAdV (42, 92). Coinfection with IBDV or CIAV enhanced the pathogenicity of some FAdV (45, 142, 169). In contrast, presence of an adenovirus-associated parvovirus may reduce the growth of FAdV in cell cultures as well as pathogenicity and oncogenicity (108).

Pathobiology and Epidemiology

Incidence and Distribution

FAdV are distributed widely throughout the world, and domestic avian species of all ages are susceptible. Other avian species appear to be susceptible to infection with FAdV as well as their own adenoviruses, but this has not been fully investigated.

Natural and Experimental Hosts

It is a widespread belief that FAdV are ubiquitous in chicken populations, independent of the health status of the birds. However, this assumption is mainly based on surveys performed some decades ago (31, 55, 100). In addition to infecting chickens, FAdV serotypes have been recovered from turkeys, psittacines, ostriches, guinea fowl, and a mallard duck (20, 23, 41, 52, 99).

Particles that resemble adenoviruses have been observed by electron microscopy in thin sections of tissue taken from wild birds or those kept in captivity. Without further characterization of the viruses they can't be attributed to the genus *aviadenovirus*.

Turkeys are also infected with TAdV-1,2, which grow in cells of turkey origin but either do not grow or grow poorly in cells of chicken origin (40, 151). Several reports describe less well defined adenoviruses in turkeys (33, 59, 156). Another separate species are goose adenoviruses (GAdV-1,2,3), detected and isolated from geese (40, 70, 140, 175). These viruses are unrelated in cross-neutralization tests to the recognized chicken serotypes but grow in cells of both goose and chicken origin. An aviadenovirus has been isolated from a Muscovy duck (18). This virus was unrelated to recognized chicken or turkey serotypes but did grow in chicken as well as duck cells. It is now classified as duck adenovirus type-2 (DAdV-2), with the egg drop syndrome (EDS) virus being duck adenovirus type-1 (DAdV-1) (Table 9.2).

A virus serologically different from FAdV was isolated from pigeons, in addition to different FAdV obtained from pigeons suffering from IBH and HS (64, 101, 161).

Attempts to grow avian adenoviruses in mammals have met with very limited success. FAdV-1 has produced fibrosarcomas, hepatomas, ependymomas, and adenocarcinomas when injected into hamsters (96), and another isolate has produced hepatitis in hamsters (108).

Age of Host Commonly Affected

Some viruses cause mortality in day-old chicks, following inoculation, but not in 10-day-old birds (27). Virulence could be associated with the strain of virus, the route of application, the age of birds, and the infectivity titer.

Transmission, Carriers, and Vectors

Vertical transmission is important in the spread of FAdV, and consequently, in induction of disease (166). In the embryonating egg viral antigens can be detected in egg yolk and the albumen and virus is often reactivated in cell cultures prepared from embryos and young chicks taken from infected flocks (97, 146). This has been one of the strongest motivations for establishing SPF flocks. There is evidence that adenovirus infection can remain latent and undetected in SPF flocks at least for one generation (43).

Although FAdV can be isolated from day 1 following infection onward, viruses normally are excreted from week 3 onward. In broilers, peak excretion occurred between 4 and 6 weeks of age (96). In layer replacements, virus excretion was at a maximum level from 5–9 weeks following infection but was still at 70% after 14 weeks, and six adenovirus serotypes were isolated from samples taken from four farms (173). In a study beginning with 8-week-old birds (31), excretion continued at a high level until 14 weeks of age, and eight different serotypes were isolated from samples from seven farms. It is not uncommon to isolate two or even three strains from one bird, suggesting that there is little cross protection despite the presence of high levels of neutralizing antibody to a single serotype. There appears to be a second period, around peak egg production, when FAdV are often detected. Presumably, the stress associated with egg production or the increased levels of sex hormones at this time caused reactivation of the virus, ensuring maximum egg transmission to the next generation.

Horizontal spread of virus is also important. Virus is present in feces, the tracheal and nasal mucosa, and kidneys. Therefore, virus could be transmitted in all excretions, but highest titers are found in the feces. Virus also may be present in the semen, presenting a potential risk where artificial insemination is used. Following oral infection of day-old or 4-week-old birds resulted in a different excretion pattern (25). Older birds showed lower peak titer of adenovirus present in the feces with an earlier decline in virus titer, and excretion persisted for a shorter time. Horizontal spread within a flock seemed to take place mainly by direct fecal contact but was also achieved by aerial contact over short distances, with infection spreading at a very slow rate for several weeks (28). This pattern also has been seen in experimentally infected and in adventitiously infected SPF flocks and contrasts markedly with the normal pattern usually found in commercial flocks in which most birds in a flock are often excreting adenoviruses. In these circumstances, it is probable that many foci of infection exist due to reactivation of latent viruses. Commercial broiler flocks are often derived from a number of parent flocks, each of which may harbor their own range of FAdV serotypes. Consequently, cross infections resulting in the mixing of several serotypes take place when the birds are brought together. Aerial spread between farms does not appear to be important, except when cleaning of depopulated houses takes place, when the dust created can transmit infection between farms. Spread by personnel, transport, and fomites (e.g., egg trays/trolleys) also can be important.

Incubation Period

The incubation period is short (24–48 hours) following infection by natural routes.

Clinical Signs

Inclusion Body Hepatitis (IBH)

IBH is characterized by sudden onset of mortality peaking after 3–4 days and usually stopping on day 5 but occasionally continuing for 2–3 weeks. Morbidity is low; sick birds adopt a crouching position with ruffled feathers and die within 48 hours or recover (68, 84, 101). Mortality may reach 10% and occasionally as high as 30% (24, 51, 138). IBH normally is seen in meat-producing birds and it may start in birds as young as 7 days old. There is evidence that in an integrated broiler operation, disease occurs in chickens from certain breeder flocks (84).

Many different serotypes have been associated with naturally occurring outbreaks of IBH. Considering the differences in nomenclature and the applied reference viruses in laboratory diagnosis the assignment of certain seroytpes could be misleading and limits the comparison between individual studies. In the last 10 years reported viruses inducing IBH in geographically different regions belong mainly to species D or E, in which serotypes 2, 3, 6, 7, 8a, 8b, 9, and 11 are combined (12, 42, 87, 118, 160).

Some workers have been successful in reproducing liver lesions with intranuclear inclusions (12, 57, 94, 147) (Figure 9.4), and additional lesions in other organs (145), following parenteral inoculation of very young chicks with adenovirus. When 12-month-old birds were inoculated intravenously with an FAdV-1 virus (76), no clinical signs were seen, but there was degeneration, necrosis, and a cellular response in the liver, with a mild response in the trachea and lungs. Liver lesions have developed following natural routes of infection in birds of different ages (44, 137), but sometimes no disease results are seen even when unnatural routes of exposure are used (95)).

Outbreaks of IBH in chickens less than 3 weeks of age with mortality up to 30% have occurred in Australia in the 1980s. IBH has been reproduced by inoculating day-old chicks by nasal and ocular routes with 24 isolates belonging to FAdV species E (serotypes 6, 7, and 8) (42). At the same time, viruses of the same serotype were reported from New Zealand but restriction enzyme analysis demonstrated differences to the Australian isolates (147). These isolates produced focal hepatitis in 2-day-old birds infected orally. In contact birds did not develop IBH but showed severe growth retardation (145). In addition to FAdV-E viruses, some of the most recent outbreaks in Australia where traced back to FAdV-D isolates, in agreement with reports from Canada and Europe (87, 118, 160).

Earlier studies indicated that immunosuppression induced by IBDV infection appears to facilitate adenoviruses in producing IBH (45, 142). Furthermore, when birds were infected with both CIAV and adenovirus, there was increased incidence of hepatitis and death (169). In India IBH was often

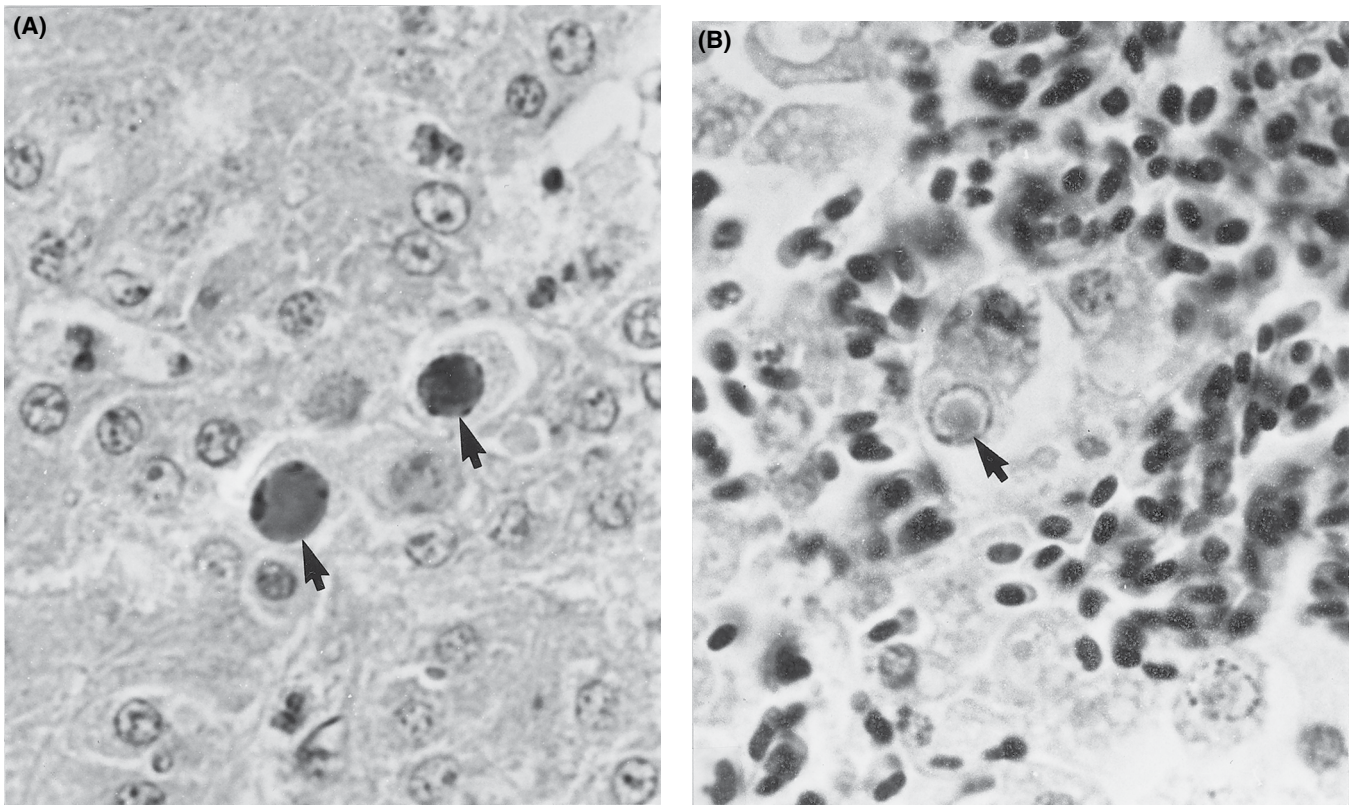

Figure 9.4. (A) Large basophilic intranuclear inclusion bodies in liver of a chicken experimentally infected with FAdV-8. (B) Eosinophilic intranuclear inclusion body in hepatocyte of a chicken with naturally occurring inclusion body hepatitis.

associated with the presence of aflatoxins in the feed (158). However, in New Zealand, IBH occurred in chickens before IBDV was present in the country (24), and recent outbreaks in different parts of the world confirmed the primary etiology of FAdV in causing IBH (12, 51, 160).

Inclusion Body Hepatitis in Other Birds

Even though IBH was described in day-old turkeys due to an infection with TAdV-2 (58), it seems to be a rare disease in turkeys (156).

A number of outbreaks of IBH have been recorded in pigeons, mainly by different FAdV serotypes (65, 161, 168). Inclusion bodies in the liver due to adenoviruses were reported in connection with sudden appearance of vomiting and diarrhea and with sudden death in pigeon lofts. Inclusion body hepatitis has been diagnosed in a group of eclectus parrots (132), kestrels (157), a merlin (148), and in psittacines (20).

Hydropericardium Syndrome (HS)

In 1987, a new condition, hydropericardium syndrome (HS), or Angara disease, was recognized in Pakistan, and within one year it had devastated the national broiler industry (14, 71). The disease subsequently was recognized in India, Kuwait, Iraq, Japan, Korea, and Russia (1, 2, 15, 66, 79, 83). A very severe form of IBH was diagnosed in South and Central America and Mexico (66, 167). This disease was similar to HS, underlining the close relationship between HS and IBH. Therefore, the disease is sometimes named hepatitis-hyrodpericardium syndrome. It appears that the only difference between HS and IBH is that the mortality rate and incidence of hydropericardium is higher in the former disease. It causes between 20% and 80% mortality, which starts at 3 weeks, peaks for 4–8 days in weeks 4 and 5, and then declines (14, 16, 152). HS also occurs in breeding and laying flocks, with lower mortality rates (2). In different countries the disease could be attributed due to an infection with an FAdV-C virus, serotype 4 (FAdV-4) (2, 17, 66, 79, 83, 91). In one study, a species D virus typed as FAdV-12 was detected from outbreaks in India (130). Some workers have claimed that other agents also may be involved (7, 155, 164). However, inducing high mortality in SPF birds with purified virus after oral infection, together with the ability to induce mortality in intramuscularly infected older birds, underlines the high virulence of these viruses (92, 113, 114).

The virus spreads well laterally among birds, and personnel appear to be important mechanical vectors (8, 9). The possibility that the initial massive spread throughout Pakistan was the result of a contaminated vaccine has been raised (8). In common with other aviadenoviruses this virus is also spread vertically (16, 167).

The disease also has been seen in pigeons and quails (110, 143). In both cases the virus also was typed as FAdV-4 and it was possible to reproduce the disease in broilers using liver suspensions from infected pigeons or quails. The disease in pigeons was controlled using the poultry vaccine.

Gizzard Erosions (GE)

There have been several reports over the last decade describing outbreaks of GE in broilers in Japan and Europe (3, 39, 85, 89, 126). Based on these reports the disease is caused by an FAdV-1 virus, although one report has identified FAdV-8 (121). Reduced weight gain and mortality are reported but very often the disease is diagnosed in the slaughterhouse. Gizzards are distended with hemorrhagic fluid and contain multiple black patchy erosions within the koilin layer (3). A number of experimental inoculation studies using oral or nasal/ocular inoculation in young broilers or leghorns at day-old or up to 53 days of age reproduced the gizzard erosions in 3 to 18 days post-inoculation (39, 115, 121, 123, 125). In some experiments, investigators also found pancreatitis, hepatitis, cholecystitis, and cholangitis, indicating infection spread through a number of digestive organs beyond the gizzard (121, 123). High mortality was reported in one experimental study which is controversial to other reports (39).

Aviadenovirus Infection in Chickens

Egg Production. Some workers have reported FAdV-1 tracheal infection resulting in a 10% fall in egg production (26). However, no effect on egg quality was demonstrated following experimental infection of birds with four strains of FAdV, and only one virus strain had a minimal effect on the number of eggs produced, in coincidence with a reduced feed intake (30). FAdV can be isolated from commercial flocks, even when exceptionally high levels of production and fertility exist, and adenovirus infections of SPF flocks in lay are often associated with little or no effect on either egg production or shell quality.

Feed Conversion and Growth. There have been reports of FAdV infection resulting in decreased food consumption (30). Although birds inoculated with various FAdV strains may have depressed body weights and even high mortality (27, 56, 103, 147), there is little evidence to suggest that naturally occurring infection causes either reduced food utilization or growth. Chickens inoculated with adenovirus had reduced weight gain accompanied by excess fat deposition and depressed cholesterol and triglyceride levels (37). However, a study in Denmark was unable to detect any effect on broiler flock performance (74). An adenovirus-like agent described as chicken proventricular necrosis virus causing poor feed conversion and impaired feed digestion was recently identified as birnavirus (60).

Respiratory Disease. Aviadenoviruses frequently have been isolated from both the upper and lower respiratory tract of birds with respiratory disease (40, 75, 77, 100). Despite these frequent findings there is no strong evidence about the involvement of aviadenoviruses in a respiratory disease, even though some lesions could be induced experimentally, sometimes in combination with an E. coli infection (26, 35, 95). However, the listed reports date back to times when respiratory diseases caused by infectious bronchitis virus (IBV) and Mycoplasma spp. were less well controlled. Exceptional to this is FAdV-1, the etiological agent of quail bronchitis.

Tenosynovitis. Adenoviruses have been isolated from chickens with tenosynovitis, but experimental work has not confirmed their involvement (73).

Aviadenovirus Infection in Turkeys

In addition to IBH induced by TAdV (see above), there are reports describing the involvement of aviadenoviruses in outbreaks of respiratory disease (33, 40) without data of experimental reproduction. No evidence was found in studies investigating the influence of aviadenoviruses in growth performance.

Aviadenovirus Infection in Geese and Ducks

Three genetically different aviadenoviruses comprising the species goose adenovirus (GoAdV) were isolated from geese (174). One of these viruses was isolated during an outbreak of the HS syndrome in 8-day-old goslings in two different farms in Hungary. The disease lasted for about three weeks and the cumulative mortality reached 6% (70). Less well defined adenovirus-like particles were reported twice in the liver or the trachea of goslings facing high mortality (139, 140). An adenovirus was isolated from 5-week-old Muscovy ducks with increased mortality over a 10-day period (18). Because the virus was serologically different from other avian adenoviruses it is classified as duck adenovirus 2 (DAdV-2). Similarly, an adenovirus was isolated from wild ducks and it was possible to reproduce the noticed lesions, e.g., enteritis and IBH (67).

Aviadenovirus Infection in Pigeons

A serologically and genetically different adenovirus is actually listed as a tentative species within the genus *aviadenovirus*, and named pigeon adenovirus (PiAdV) (64). In addition to IBH, two clinical diseases in pigeons in Belgium, described as adenovirus type I (classical adenovirus) and type II (necrotizing hepatitis), were described (168). Classical adenovirus occurs in pigeons under 1 year of age, whereas necrotizing hepatitis occurs in pigeons of all ages. Morbidity in case of type I disease can be up to 100% and secondary bacterial infections can increase mortality, which is in type 2 infections between 30%–100%. In both disease types, watery diarrhea and vomiting can be seen due to viral replication in epithelial cells of the intestinal tract. Necrotizing hepatitis is also characterized by massive hepatic necrosis.

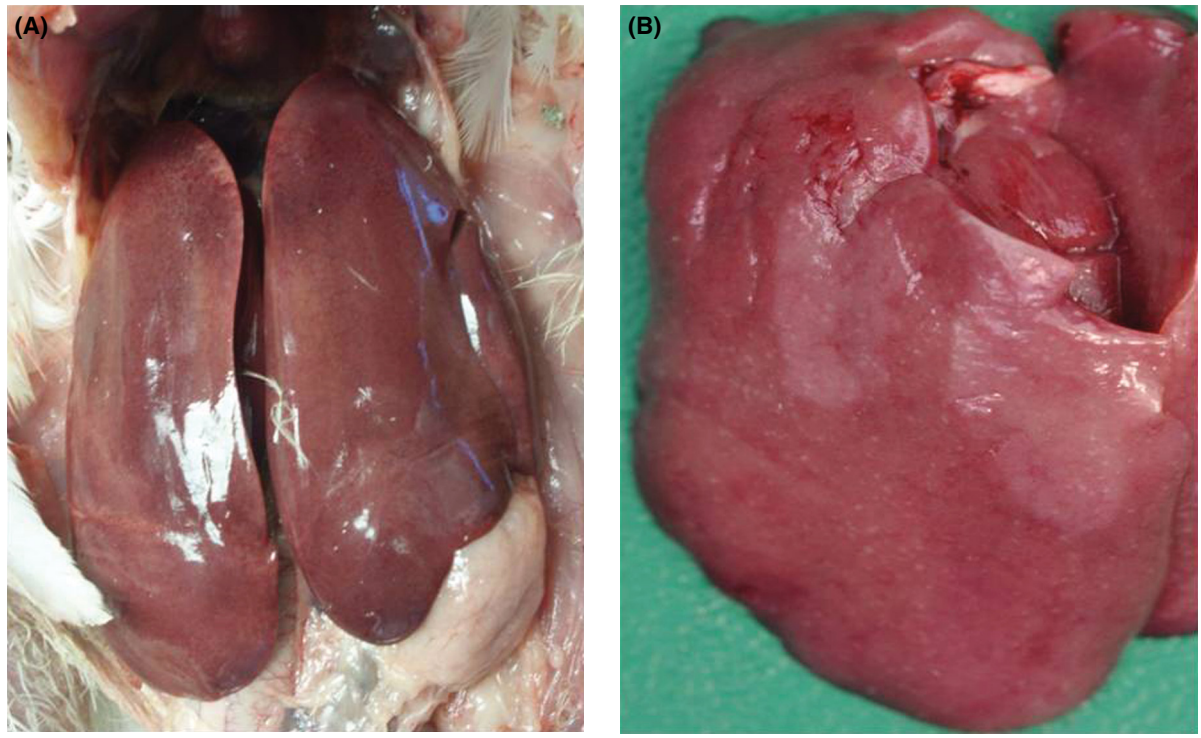

Figure 9.5. Livers from birds showing inclusion body hepatitis (A) from an outbreak in broilers (B) from experimentally infected SPF birds. (M. Hess)

Aviadenovirus Infection in Guinea Fowl

So far it appears that there are no adenoviruses characterized specifically for guinea fowl and adenovirus confirmation is mainly based on electron microscopy or less discriminative serology. An FAdV-A isolate was obtained from a 57-week-old bird during a broader survey (117). An aviadenovirus was reported in connection with excessive mortality in a flock of guinea fowl (21). Pancreatitis and ventriculitis together with splenomegaly and pulmonary edema were noticed during necropsy. Pancreatitis due to an aviadenovirus could be successfully reproduced (80). Other disease reports and described lesions reflect the picture of an infection with a virus belonging to the genus *siadenovirus*.

Aviadenovirus Infection in Ostriches

Adenoviruses have been associated with illness, death, and poor hatchability on ostrich farms (41, 131), and an isolate from an ostrich caused pancreatitis in guinea fowl. In a study in which 3-day-old ostrich chicks were inoculated with an ostrich-derived FAdV-A isolate, all birds died (41). Applying restriction enzyme analysis, five FAdV-E isolates and one FAdV-D isolate, obtained from intestinal or tracheal samples from diseases birds, could be classified (52).

Pathology

Inclusion Body Hepatitis (IBH)

In the literature there are several descriptions of a disease primarily affecting the liver and also one in which the primary lesions appeared to be present in the hemopoietic system. It is probable that the aplastic anemia described was due to infection with CIAV (Chapter 8). The main lesions of IBH are pale, friable, swollen livers. Small white foci can be seen on the liver, and petechial or ecchymotic hemorrhages may be present in the liver (Figure 9.5) and skeletal muscles (68, 84, 101).

Inclusion bodies are seen in the hepatocytes. These can be eosinophilic, large, round, or irregularly shaped with a clear pale halo or occasionally basophilic (57, 69, 156) (Figure 9.4B). Virus particles were detected only in cells with basophilic inclusions, and the eosinophilic inclusions were composed of a fibrillar, granular material (69). Lesions including atrophy of the cloacal bursa and thymus, aplastic bone marrow, and hepatitis were described in natural outbreaks and experimental studies (24, 103, 137, 145).

Glomerulonephritis determined by histomorphometric evaluation was noticed during an outbreak of IBH (170).

Hydropericardium Syndrome (HS)

In cases of HS, there is an accumulation of clear, straw-colored fluid in the pericardial sac, pulmonary edema, swollen and discolored liver, and enlarged kidneys with distended tubules showing degenerative changes (2, 79). Petechial hemorrhages and multiple areas of focal necrosis exist with mononuclear infiltration in the heart and liver (70, 113). Basophilic inclusions are present in the hepatocytes (14). One report describes multifocal pancreatic necrosis and gizzard erosions associated with HS (116). Following experimental infection the virus could induce

Figure 9.6. Experimentally induced gizzard erosion in SPF broilers. (M Hess).

severe immunosuppression with depletion of B and T cells in lymphoid organs (112, 150).

Respiratory Disease

In naturally occurring infections, mild to moderate catarrhal tracheitis with excess mucus were the only gross lesions noted (34). Hyperemia of the lungs with thickened trachea were described after experimental infection (36). Microscopically, the main lesions were loss of cilia, necrosis of some epithelial cells, intranuclear inclusion bodies, and infiltration of mononuclear cells into the lamina propria. Multifocal or occasionally diffuse interstitial pneumonia was found (33, 36).

Necrotizing Pancreatitis and Gizzard Erosions

Focal pancreatitis and gizzard erosions (Figure 9.6) have been described in broiler chickens in both natural outbreaks and experimental studies in Japan (121, 124). Intranuclear inclusion bodies containing adenovirus antigen in glandular epithelial cells were associated with necrosis of the koilin layer, and infiltration of the lamina propria, submucosa, and muscle layers by macrophages and lymphocytes (3, 39, 85, 116, 124, 125, 126, 127). Intranuclear inclusions also have been shown in necrotic pancreatic acinar cells (116, 124, 163). Pancreatitis and gizzard erosions associated with adenoviral infection have been recorded in guinea fowl (21).

Immunity

Aviadenoviruses have a common group-specific antigen that is distinct from that of *siadenoviruses* and *atadenoviruses* (61).

Following infection, birds rapidly developed neutralizing (type-specific) antibodies that were detectable after 1 week and reached peak titers after 3 weeks (107).

It has been found that birds were resistant to reinfection with the same serotype 45 days after primary infection, whereas birds were successfully reinfected with the same strain after 8 weeks, eliciting a secondary response of both neutralizing and precipitating antibodies (172). Virus excretion also occurred, despite the presence of humoral antibodies. Peaks of virus excretion were found when birds were 2.5, 4.5, and 7.5 months of age, consistent with the theory that local immunity lasts about 8 weeks. Therefore, it is possible that the resistance to challenge found after infection is due to short-lived local immunity while circulating antibodies protect mainly against invasion of the internal organs. The apparent correlation between appearance of circulating antibodies and cessation of virus excretion is more likely due to concurrent development of both local immunity, which is more transient, and humoral immunity, which is more persistent. Support for this hypothesis is provided by the finding that maternal antibody do not protect against natural routes of infection but does protect against intra-abdominal infection (56). With regard to protection, neutralizing antibodies are obviously not solely responsible for protection, determined in a severe challenge model (149).

The capability of some FAdV strains to induce immunosuppression needs special attention in designing of vaccination programs.

Diagnosis

Isolation and Identification of aviadenoviruses

Specimens of choice for virus isolation are feces, cecal tonsils, pharynx, kidney, and affected organs (e.g., liver, in cases of IBH). A 10% suspension of tissue in medium is prepared, and in case of FAdV, inoculated onto either chick embryo liver cells, chick kidney cells, or LMH cells. If attempting to isolate adenoviruses from other avian species, it is preferable to use cells from the species being investigated, although chicken cells can be used. Embryonating eggs are insensitive for primary isolation of most aviadenoviruses, although yolk sac or CAM infection was demonstrated for some FAdV isolates, leaving it as an alternative in laboratories lacking cell culture technology.

Confirmation of a virus isolate as an adenovirus can be carried out by electron microscopy. Immunocytochemistry can be used to detect adenoviruses in infected cells by immunofluorescence staining with avian adenovirus

antiserum (Figure 9.2). To identify the serotype of a virus that has been isolated, virus neutralization tests with the isolate against standard reference antisera to all known serotypes have to be applied (62). For FAdV, this laborious procedure is now mostly substituted by PCR combined with other procedures applying nucleotide differences within the loop 1 region of the hexon gene to allocate isolates to individual genotypes, which correlate mostly with serotypes (47, 87, 105, 129, 159). To achieve this, primers hybridize to conserved parts of the hexon gene. Developing primers for other regions allows extension of the PCR beyond aviadenoviruses but prevents further subtyping of FAdV genotypes (171). Primers that detect individual species or serotypes also can be developed, (134) and FTA papers were reported as an appropriate source for viral DNA (109). Nested and real-time PCRs were found beneficial to increase sensitivity in comparison to virus isolation (141).

Detection of adenovirus DNA in tissue samples by *in situ* hybridization (ISH) has been reported (62). Probe design has a severe influence on sensitivity and specificity (81). If these techniques are not available, then H&E staining of infected cell monolayers, or tissue sections, and demonstration of intranuclear basophilic inclusions provides a nonspecific indication of the presence of DNA containing virus (Figure 9.3).

Serology

Group-specific antibodies can be detected by DID following infection but were often transient. The enzyme-linked immunosorbent assay (ELISA) or indirect immunofluorescence is much more sensitive than DID and should be preferred, considering that results depend on the used antigen. ELISA has been used to detect group-specific antibodies, and it is inexpensive and sensitive (62). Type-specific antibodies normally have been detected using the serum-neutralization test, but ELISA also can be used for this purpose; however, presence of multiple serotypes complicates interpretation (107).

The presence of humoral antibody gives no indication of the state of local immunity at mucosal surfaces.

Intervention Strategies

Management Procedures

Aviadenoviruses are resistant to inactivation but it is possible to eliminate them from most environmentally controlled houses with impervious floors and walls that can be made airtight. Because FAdV are effectively transmitted vertically through the embryonating egg, effective control would have to start at primary breeder level. However, experience with SPF flocks has indicated that horizontal spread is also a major problem, and it takes some efforts to keep a commercial flock free from FAdV infection. Because both IBDV and CIAV can potentiate the pathogenicity of FAdV, control of these two viruses is also important.

Vaccination

As evidence mounts that certain genotypes may be primary pathogens, the possibility of vaccination is more appealing. Considering vertical transmission breeders are within the focus of vaccination and a certain level of antibody is required for protection of progeny (145).

Complete protection against IBH could be induced in progeny obtained up to 50 weeks of life of a grandparent stock, vaccinating at 10 and 17 weeks of life with an inactivated vaccine containing isolates of species FAdV-D and FAdV-E (12). Vaccination of breeders with a live vaccine, containing an FAdV-8b strain, is reported from Australia to protect progeny (160).

Soon after the first reports about HS appeared, a vaccine prepared by inactivating homogenates of liver from infected birds was used extensively with apparent success in Pakistan to control HS (6, 13). Vaccines prepared on tissue culture or in embryonating eggs were later developed (86, 111). Adaptation of a virulent FAdV-4 isolate to QT35 cells resulted in attenuation and protection of subsequently vaccinated birds (149). The lack of neutralizing antibodies prior to challenge underlines the importance of the cellular immunity for protection. One study has shown enhanced protection of progeny against HS by vaccinating broiler breeders against both CIAV and FAdV-4, compared to lesser protection achieved by vaccinating against either disease alone (165).

Contrary to IBH and HS, maternal antibodies seem to be less protective to prevent GE, as commercial broilers with antibodies, infected at 1 week of age, displayed severe lesions (125).

The genomes of FAdV-1 (CELO) and strains belonging to species FAdV-C and FAdV-E have been shown to have substantial capacity for insertion of foreign DNA sequences, and consequently there is substantial interest in the development of such viruses as a vaccine vector for use in mammalian and avian species (29, 106, 120). Anti-cancer activity in human cells was demonstrated by incorporating the herpes simplex virus type 1 thymidine kinase (TK) gene into the FAdV-1 genome (153). Experiments in which the VP2 gene of IBDV was incorporated into FAdV genomes demonstrated efficient expression and protection of challenged birds (46, 154). Furthermore, the S1 gene of IBV and chicken interferon gamma were successfully expressed in such vectors (72, 136). Altogether, these developments reflect the broad range of FAdV, from severe primary pathogens to viral vectors.

Acknowledgement

The author would like to acknowledge the contribution of J.B. McFerran, who originally authored this chapter, and B.M. Adair, who co-authored the chapter in the previous edition.

Atadenovirus (Egg Drop Syndrome and Related Infections)

Joan A. Smyth

Introduction

Definition and Synonyms

The egg drop syndrome (EDS) virus was originally designated as the sole member of the subgroup 3 avian adenoviruses, but it was reclassified as a member of the genus *Atadenovirus* (12) of the Adenoviridae family (Table 9.2). Its species name is Duck adenovirus A, and its strain name is duck adenovirus 1 or egg drop syndrome virus (EDSV).

History

EDS was first described by Dutch workers in 1976 (69). Hemagglutinating adenoviruses, which were later shown to be the cause of the disease, were isolated (47). No antibody to these viruses was found in chickens prior to 1974 (47), but antibody was present in many duck flocks (9). EDSV was isolated from normal ducks (19) and showed optimal growth in duck cells, so it is thought it was probably a duck adenovirus, which may have been introduced into chickens through a contaminated vaccine.

Economic Significance

Outbreaks of EDS in laying birds will cause significant loss of saleable eggs which may have been destined either for human consumption or for hatching purposes, although figures are not available. The disease has been well controlled in many countries for many years by vaccination and/or eradication programs. It is critically important that live virus is not introduced into layer breeders or elite or grandparent stock of any type, because the virus can be vertically transmitted. The European Pharmacopoeia, for example, requires that all avian viral vaccines are tested to ensure freedom from EDSV.

Public Health Significance

The virus affects only avian species; therefore, it has no public health significance.

Etiology

Classification

EDSV is classified as an adenovirus on the basis of its morphology, replication, and chemical composition. The virus is not related to 11 fowl aviadenoviruses nor 2 turkey prototype and 1 duck prototype aviadenoviruses in serum neutralization (SN) or hemagglutination inhibition (HI) tests (3, 15). Although the aviadenovirus group specific antigen is not detected by immunodiffusion or immunofluorescence tests in EDSV preparations, presence of common antigenic determinants were indicated in experiments in which aviadenovirus group-specific antibodies, which had developed in chickens after inoculation with an aviadenovirus, were restimulated following a subsequent inoculation with EDSV (48).

Sequencing of the genome of EDSV indicated significant differences from the subgroup I aviadenoviruses (33). These included smaller genome size (33.2 kb compared to 43.8 kb for FAdV-1) and high AT content (33). Also, some aviadenovirus early genes appear to be missing in EDSV, and other genes were identified that have no obvious homology with known aviadenovirus proteins (33). EDSV was shown to have similarities in its genetic characteristics to ovine adenovirus type D (strains 287 and goat adenovirus 1), bovine adenoviruses 4, 5, and 8, and a possum adenovirus. These viruses are all sufficiently different from the mammalian adenoviruses (mastadenoviruses) and from the aviadenoviruses and siadenoviruses to warrant classification as a separate adenovirus genus. This genus is called Atadenovirus, reflecting the high AT content of the viral DNA (11, 12, 32). Although initial isolates of EDSV were from chickens (49), the virus is now recognized as having originated from ducks; its species designation is duck adenovirus type A, and its strain name is duck adenovirus type 1 (DAdV-1) or EDSV (12). It is currently the only recognized atadenovirus from avian species (32). Only one serotype is recognized, although variations have been demonstrated by restriction endonuclease analysis of isolates (58, 63, 67). A 2004 study of Japanese isolates from chickens showed no evidence of change of the virus after two decades of the virus circulating in chickens (68).

Morphology

Ultrastructure

Purified virus preparations from cesium chloride (CsCl) gradients showed typical adenovirus morphology with triangular faces having six capsomeres on the edge and a single 25-nm fiber projecting from each vertex (40). In contrast, aviadenoviruses have 2 fibers. In non-purified preparations, the detail of the surface structure is not obvious (49, 74). Although EDSV particles are clearly adenoviruses with well-defined capsomeres with hollow centers, it is possible to distinguish them from conventional adenoviruses in some electron microscope preparations (Figure 9.7). In thin sections of infected chick embryo liver cells, virus particles of 70–75 nm are seen in the nucleus (3). Particles of 68–80 nm in diameter also have been described in the nuclei of epithelial cells of the oviduct (65).

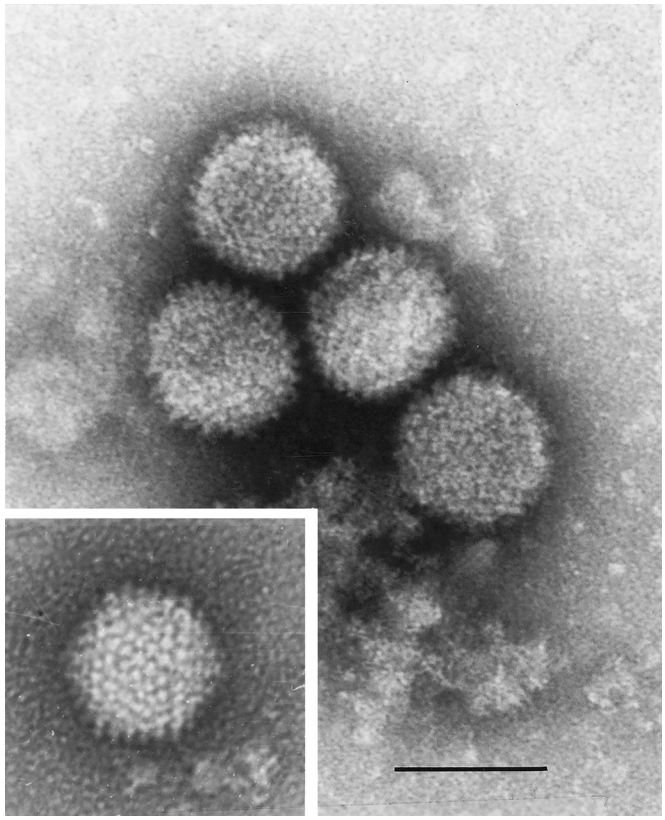

Figure 9.7. Four particles of egg drop syndrome (EDS) virus. Although individual capsomeres are well resolved, typical adenovirus morphology is not apparent. Inset: Fowl adenovirus type 8 (FAdV-8) particle showing well-defined, triangular faces. Bar = 80 nm.

Size and Density

The size of EDSV particles in negatively stained preparations has been reported to range from 76 nm (49) to 80 nm (40). These sizes are within the range acceptable for adenoviruses (73).

There are differences in the reported density of EDSV in CsCl. Todd and McNulty (66) found that infectious virus particles banded at densities of 1.32 and 1.30 g/mL. The heavier particles, however, did not agglutinate chicken erythrocytes and appeared by electron microscopy to be slightly damaged. Particles with a density of 1.30 g/mL hemagglutinated and appeared undamaged. A band of empty, disrupted, noninfectious hemagglutinating particles was present at a density of 1.28 g/mL. In contrast, Kraft et al. (40) reported presence of 2 bands of infectious, hemagglutinating particles at 1.32 g/mL, with noninfectious disrupted particles banding at 1.30 g/mL. Yamaguchi et al. (74) reported hemagglutinating particles banding at 1.30 g/mL and infectious particles with a density of 1.33 g/mL, and Takai et al. (64) found infectivity and hemagglutinin associated with a band at 1.33 g/mL and hemagglutinin in a band at 1.29. This discrepancy was explained, at least in part, by Zsak and Kisary (79), who reported that density and hemagglutinating ability of EDSV particles depended on the method used for virus purification and whether the virus was grown in cell cultures or embryonating eggs.

Chemical Composition

Labeling with H^3-thymidine and inhibition with iododeoxyuridine showed that EDSV contained DNA (3, 40, 66, 74). The molecular weight of the DNA was estimated at 22.6×10^6 Da compared with 28.9×10^6 Da for FAdV-1 (Phelps), and restriction endonuclease patterns indicated no relationship between these 2 viruses (79). The EDSV has 13 structural polypeptides, at least 7 of which correspond with polypeptides of FAdV-1 (66, 76). EDSV, like other members of atadenovirus, has a gene for a unique structural protein (p32k) (12) and has an F-box motif which is very rare among viral proteins (14)

Hemagglutination

EDSV agglutinated erythrocytes of chickens, ducks, turkeys, geese, pigeons, and peacocks but did not agglutinate rat, rabbit, horse, sheep, cattle, goat, or pig erythrocytes (3, 43).

The hemagglutinin (HA) is resistant to heating at 56 °C. An initial 4-fold fall in HA titer was reported after 16 hours at 56 °C, and thereafter the titer remained stable for 4 days; however, no HA activity was detected after 8 days at 56 °C. The HA also survived heating at 60 °C but was destroyed by heating to 70 °C for 30 minutes. The HA activity was stable for long periods at 4 °C (3, 50) and was resistant to treatment with trypsin, 2-mercaptoethanol, ethylenediaminetetraacetic acid (EDTA), papain, ficin, and 0.5% formaldehyde at 37 °C for 1 hour, but the titer was greatly reduced by treatment with potassium periodate and 0.5% glutaraldehyde (64). Purified soluble HA was destroyed by trypsin treatment (66). Alpha-chymotrypsin destroyed the virus receptor on chicken erythrocytes, whereas trypsin and neuraminidase had no effect (64).

Virus Replication

EDSV replicates in the nucleus of infected cells in a similar fashion to aviadenoviruses (1, 2, 3). Intranuclear inclusions were observed in hematoxylin and eosin stained preparations of virus-infected cell cultures (3) and in epithelial cells of the infundibulum, tubular shell gland, pouch shell gland, isthmus; and in nasal mucosa and spleen of experimentally infected chickens (62, 65). In ultrathin sections of EDSV-infected cells, adenovirus particles and type I inclusions similar to those produced by other avian adenoviruses were present in the nucleus (2, 3).

Susceptibility to Chemical and Physical Agents

EDSV was stable to treatment with chloroform and variations in pH between 3 and 10. The virus was inactivated by heating for 30 minutes at 60 °C, survived for 3 hours at 56 °C, and was stable in the presence of monovalent but not divalent cations (3, 74). Infectivity was not demonstrated after treating with 0.5% formaldehyde or 0.5% glutaraldehyde (64).

Strain Classification

Only one serotype of EDSV has been recognized (24, 74). However, by restriction endonuclease analysis, it was possible to divide isolates into four genotypes (58, 67). One group included isolates made over an 11-year period from European chickens, and a second group included viruses isolated from

ducks in the United Kingdom. A virus isolated from chickens in Australia formed the third group and a virus isolated from a duck in India represented a fourth group.

Although all isolates of EDSV from chickens and from ducks in Europe appeared to be of similar virulence (7), isolates from ducks in the United States produced no effect on egg production in chickens (70) or affected only the egg size (18).

Laboratory Host Systems

EDSV replicated to high titers in duck kidney, duck embryo liver, and duck embryo fibroblast cell cultures and grew well in chick embryo liver cells, less well in chick kidney cells, and rather poorly in chicken embryo fibroblast cells and turkey cells. No replication was detected in a range of mammalian cell cultures (3). The virus grew to high titers in goose cell cultures (79). In chick liver cell cultures, peak virus and intracellular HA titers were reached after 48 hours, with peak extracellular HA titers being achieved after 72 hours (74). The virus also grew very well when inoculated into the allantoic sac of embryonating duck or goose eggs producing HA titers of 1/16,000–1/32,000. No growth was detected in embryonating chicken eggs (3, 75).

Pathobiology and Epizootiology

Incidence and Distribution

EDSV has been isolated from chickens in Australia (27), Belgium (50), China (78), France (53), Great Britain (9), Hungary (79), India (41), Israel (45), Italy (77), Japan (74), Northern Ireland (49), Singapore (59), South Africa (16), and Taiwan (43). Serologic evidence of infection has been found in chickens in Brazil (36), Denmark (5), Mexico (55), New Zealand (35), and Nigeria (51). To date however, EDS has not been reported in the United States.

Natural and Experimental Hosts

Although disease outbreaks have been recorded mostly in laying hens, it is probable that the natural hosts for EDSV are ducks and geese. HI antibody to EDSV is widespread in domesticated ducks (5, 8, 9, 19, 27, 44, 45) and domestic geese (8, 80). In a study of Atlantic flyway birds in the United States, antibody was found in ruddy, ring-necked, wood, bufflehead, lesser scaup, mallard, northern shoveler, and gadwall ducks, and in mergansers, coots, and grebes (30, 52). Antibody also was detected in Muscovy ducks and cattle egrets (45), Canada geese (56), herring gulls (8), owls, a stork, and a swan (38).

The virus has been isolated from healthy domestic ducks (9, 70) and diseased ducks (6, 17, 26, 28), and it has been suggested that EDSV may cause rough, thin shells and decreased egg production in ducks (26, 42). With the exception of the Canadian ducklings with proliferative tracheitis in which intralesional adenoviral inclusions were confirmed (17), it remains possible that the viruses recovered from diseased ducks were incidental, because the virus can be found commonly in healthy ducks.

Infection also was shown to be common in geese (38, 44, 80), but goslings and geese experimentally infected with the virus showed neither illness nor change in egg production (80). However, in 2001 a severe respiratory disease outbreak was reported in young goslings, in which adenoviral inclusion bodies were found in the trachea and bronchial epithelium of affected birds. EDSV was recovered from affected geese and the disease was reproduced experimentally in 1-day-old goslings (37).

Quail (*Coturnix coturnix japonica*) are susceptible to infection and develop classic signs of EDS (25). There is no evidence of naturally occurring infection of pheasants, although they can be infected experimentally (8, 52, 77). There is one report of naturally occurring infection in turkeys associated with egg production problems (13). Guinea fowl may be infected naturally or experimentally, and soft-shelled eggs may be produced (29). However, in one study, guinea fowl became infected but remained clinically normal following exposure to a chicken isolate of EDSV (71).

A wide range of chicken breeds have been shown to be equally susceptible to experimental infection, although analysis of naturally occurring outbreaks suggests that broiler breeders and heavy breeds producing brown eggs are more severely affected than white-egg producers. When two brown and one white-egg layer strains were infected (34), egg production was depressed in the white layer strain. There was little depression in egg production of the brown layers, but more eggs were produced with shell defects. One brown egg-laying strain produced almost three times as many affected eggs as the white egg-laying strain.

Chickens of all ages are susceptible to EDSV infection. Introduction of EDSV into a laying site affected egg production in all ages of laying hens. The appearance of disease at around peak egg production (49) may be due to reactivation of latent virus.

Transmission, Carriers, and Vectors

EDS outbreaks could be divided into 3 types; i.e., classical, enzootic (or endemic) and sporadic. In the initially observed classic form of the disease, primary breeders were infected, and the main method of spread was vertically through the embryonating egg (49). Although the number of infected embryos was probably low (10), later lateral spread of virus was very efficient. In many cases, chicks infected *in ovo* did not excrete virus or develop HI antibody until the flock had achieved greater than 50% egg production. At this stage, the virus was reactivated and excreted, resulting in rapid lateral spread due to multiple foci of infection.

The virus has become established in commercial egg-laying flocks in some areas, e.g. in India, 32.6% of poultry flocks were found to be infected (41). This enzootic form of disease was often associated with a common egg-packing station, probably due to contamination of egg trays. Both normal- and abnormal-shelled eggs produced during the period of virus growth in the shell gland contained virus on their exterior and interior (61). Droppings also contained virus, but

such excretion was intermittent, and the virus was often present only at low titer (21). In the adult bird, presence of virus in the feces probably arises from contamination by oviduct exudate (62). There is evidence that spread can occur when birds are transported in inadequately cleaned trucks or when unused food has been moved between sites. There is also evidence that needles or blades used for vaccination or bleeding of viremic birds, if not properly sterilized, can transmit infection. Lateral spread of virus is slow and intermittent, taking up to 11 weeks to spread through a cage house; in one case, spread to an adjoining pen was prevented by a wire fence. Spread of virus between birds on litter is usually faster (21, 69).

Spread of EDSV from domestic or wild ducks, geese, and possibly other wild birds to hens through drinking water contaminated by droppings appears to give rise to a third type of disease outbreak. While very important in some areas, such cases tend to be sporadic. However, there is always the danger of such an infected flock becoming the focus for establishing endemic infection.

Clinical Signs

Following experimental infection, most workers detected the first signs of EDS after 7–9 days (22, 46, 75), but in some experiments, disease signs did not appear until 17 days post inoculation (PI) (50).

The first sign was loss of eggshell pigment. This was quickly followed by production of thin-shelled, soft-shelled, or shell-less eggs (Figure 9.8). Thin-shelled eggs were often rough, with a sandpaper-like texture, or had a granular roughening of the shell at one end of the egg. If the abnormal eggs were discarded, there was no effect on fertility or hatchability and no long-term effect on egg quality. If birds were infected in the late stages of egg production, forced molting of the flock appeared to restore egg production to normal. The fall in egg production was very rapid or extended over several weeks. EDS outbreaks usually lasted 4–10 weeks, and egg production was reduced by up to 40%; however, there was often compensation later in lay, so that the total number of eggs lost was typically 10–16/bird. If the disease resulted from reactivation of latent virus, the fall usually occurred when production was



Figure 9.8. Eggs from hens infected with egg drop syndrome (EDS) virus. Changes range from normal brown egg (N), to loss of shell pigment (1 and 2), thinning at the pole (1), and thin-shelled (2), soft-shelled (3), and shell-less eggs (4). Eggs may be eaten or broken, but many membranes (5) may be found.

between 50% and peak level. Small eggs have been described in naturally occurring outbreaks (49), but no effect on egg size was found in experimental infections (46). Watery albumen has been described (50, 69), although no effect on albumen was reported by other workers (24, 46, 75). Age at time of infection may be important. Birds infected at 1 day of age produced apparently normal eggs except for impaired albumen quality and smaller size (22).

An apparently different clinical syndrome is seen if some birds have acquired antibody before latent virus is reactivated. There may be failure to achieve predicted egg production, and onset of lay may be delayed. If a careful examination is made, it can often be established that there has been a series of small clinical episodes of classic EDS. Presumably, presence of EDS-specific antibodies slows down the spread of the virus between the birds. A similar picture often has been observed in birds housed in caged units, where spread of the virus can be slow and EDS not suspected.

Inappetence and dullness have been described in some affected flocks, but these are not consistent findings. The transient diarrhea described by some authors is probably due to secretions from the oviduct mixing with the droppings (62). EDSV does not cause clinical disease in growing chickens in the field. Oral infection of susceptible day-old chicks resulted in increased mortality in the first week of life (22), but there was no increase in mortality in many flocks of chickens produced by virus-infected parent flocks.

Pathology

Gross Lesions

Following experimental infection with EDSV, edema of the uterine folds and presence of exudate in the pouch shell gland commonly occurred within 9–14 days PI (60, 65). Mild splenomegaly, flaccid ovules, and eggs in various stages of formation in the abdominal cavity also were observed (65). In naturally occurring outbreaks of EDS, inactive ovaries and atrophied oviducts were sometimes present. In one outbreak, uterine edema was observed (43).

Microscopic Lesions

The major pathologic changes occurred in the pouch shell gland (Figure 9.9). Virus replication occurs in the nuclei of surface epithelial cells, and intranuclear inclusion bodies were detectable from 7 days PI onward (Figure 9.10) (60, 65). Many affected cells were sloughed into the lumen, and there was a rapid and severe inflammatory response with heterophilic infiltration of the epithelium and lamina propria and mucosal edema, together with macrophages, plasma cells, and lymphocytes, in the lamina propria (Figures 9.9, 9.10). Inclusion bodies were not seen after the third day of abnormal egg production, but viral antigen persisted for up to 1 week (60). As the lesions progressed, heterophils were less common and the mononuclear cells dominated. The sloughed surface epithelium was replaced initially by squamous to cuboidal epithelium, with rapid return to the normal pseudostratified, ciliated columnar epithelium. In some recovering and recovered birds which were producing normal eggs, a few areas of cuboidal surface epithelium and a few lymphoid aggregates or minimal loose infiltrates of lymphocytes and plasma cells persisted.

Most descriptions of the pathology of birds from naturally occurring disease outbreaks do not include the finding of inclusion bodies or the acute inflammatory and necrotizing phase of the disease. This is due to the transient nature of these lesions and the difficulty in finding acutely affected birds among the thousands of birds which may be present in an affected flock, where not all birds will have been infected simultaneously.

Lesions at the ultrastructural level have not been reported in detail. Adenovirus particles were found in uterine epithelial cells, macrophages in the lamina propria, and desquamated epithelial cells (65).

Pathogenesis of the Infectious Process

Experimental oral infection of adult hens with EDSV resulted in a viremia with limited virus replication in the nasal mucosa (62). At 3–4 days PI, virus replication occurred in lymphoid tissue throughout the body, particularly in spleen and thymus. The oviduct was consistently affected. At 7–20 days PI, evidence of substantial virus replication was detected in the pouch shell gland (Figure 9.9) with lower levels of replication in other parts of the oviduct. Replication in the shell gland was associated with a pronounced inflammatory response and production of eggs with abnormal shells (62, 65, 75).

Unlike the aviadenoviruses and siadenoviruses of birds, EDSV does not appear to replicate in the intestinal mucosa, and presence of virus in the feces of laying birds is probably due to contamination with oviduct exudate (62).

Immunity

Following experimental infection with EDSV, antibody was detectable by indirect fluorescent antibody test (IFA), enzyme-linked immunosorbent assay (ELISA), and SN and HI tests 5 days after infection and by double immunodiffusion (DID) test after 7 days (4). Antibodies reached a peak after 4–5 weeks; immunoprecipitating antibodies were more transient.

Birds excreted EDSV in the presence of high levels of HI antibody, but some birds that excreted the virus failed to develop antibody (22).

Antibody was transferred to the embryos through the yolk sac, and young chicks had high EDS HI titers (geometric mean titers, 6–9 $\log_2$). This antibody had a half-life of 3 days (24). Active antibody production was not stimulated until the chicks reached 4–5 weeks of age, when maternal antibodies were almost undetectable (24). Some chicks which became infected *in ovo* developed a latent infection and failed to develop antibody. With the onset of egg production, the virus was apparently reactivated and virus excretion took place. It is not known if all of these chicks developed antibody at this point.

If a flock as a whole develops antibody to EDSV before coming into lay, they will not develop EDS (10).

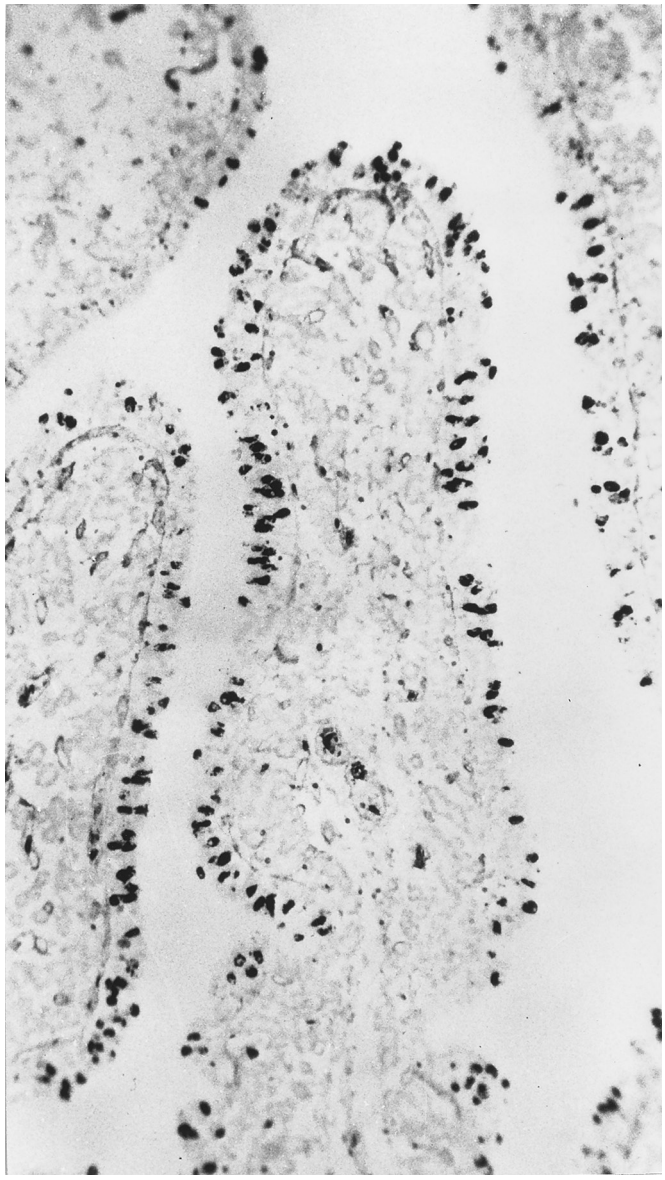

Figure 9.9. Pouch shell gland from a hen experimentally infected with egg drop syndrome virus. Note the viral nucleic acid in the surface epithelial layer, demonstrated by a biotinylated purified virus genome probe. (Allan)

Diagnosis

Selection of Specimens

A major problem for diagnosis of EDS is the selection of suitable birds for examination. The absence of obvious clinical signs in affected birds, the often slow spread of infection, and the transient nature of virus replication and associated lesions makes it difficult to select the most suitable birds from among the thousands that may be in the flock. The finding that abnormal eggs contained virus and that these eggs were produced after the bird had developed EDS antibodies has allowed a rational approach to diagnosis (61). To isolate the virus, abnormal eggs may be fed to antibody-negative adult laying hens. At the first appearance of abnormal eggs, the hens may be euthanized and virus isolation attempted from the pouch shell gland. For serological diagnosis, all the birds in cages where abnormal eggs are being produced should be blood sampled. If the birds are housed on litter, then birds throughout the house should be sampled, because it is usually not possible to determine which birds are producing abnormal eggs in these circumstances.

Identification of EDSV in Tissue Samples

The successful use of antigen capture ELISA and PCR-based tests has been described for use on field specimens (23, 54, 55, 58, 68), but these do not appear to be in widespread use. This may reflect a lack of cases submitted for laboratory diagnosis.

Virus Isolation

The most sensitive medium for EDSV isolation is either allantoic inoculation of embryonating duck or goose eggs derived from a flock free of EDSV infection, or duck or goose cell cultures. These systems have the added advantage that they do not support the growth of many chicken viruses. If they are unavailable, chicken cells should be used. Chicken embryo liver cells were more sensitive than chicken kidney cells, and chicken embryo fibroblasts were insensitive (3). Embryonating chicken eggs are not suitable.

In addition to observing for embryo death or cytopathic effect, allantoic fluid from inoculated goose or duck eggs or supernatant from infected cell cultures should be checked after each passage for presence of EDSV HA, using avian erythrocytes (a 0.8% chick erythrocyte suspension is suitable). Alternatively, immunofluorescence, using a labeled EDSV antiserum, can be used to detect the presence of the virus in the cells. Antiserum conjugated to aviadenoviruses will not detect EDSV. In theory, real time PCR could be used to detect increasing amounts of virus, but development and application of such an assay has not yet been reported.

If duck cells are used for isolation, a minimum of 2 passes are required, and with chick cells, 2–5 passes are necessary before declaring a specimen negative. The need for extensive passage is partly due to poor growth of the virus on primary isolation in chick cells, and partly because virus titers in the tissues can vary, particularly if the bird submitted to the laboratory is not at the stage of the disease process at which virus titers are maximal.

Serology

Presence of antibodies in nonvaccinated laying flocks indicates infection, but obviously does not indicate when infection occurred. The HI, ELISA, SN, DID, and IFA tests may be used to detect antibody, and are of similar sensitivity (4). While ELISA tests in general are popular and have the advantage of potential automation, nonspecific reactions can occur with ELISA tests for EDS. When birds were infected with a number of adenovirus serotypes, however, there were positive reactions in the ELISA, IFA, or DID tests for EDSV, but not in the HI or SN tests (4).

Therefore, HI is still considered the test of choice for serological diagnosis. Antigen for HI test can be prepared in either embryonating duck eggs or in cell culture. Higher HA titers are obtained if duck eggs are used, but high HA titers also can be obtained using chick embryo liver cell cultures. A suitable HI test uses 4 HA units of antigen, an initial 1:4 serum dilution, and 0.8% chicken erythrocytes. The EDSV agglutinates erythrocytes from chickens, geese, turkeys, and ducks, but not mammalian erythrocytes. There is no hemolysin. If nonspecific hemagglutinins are present in the serum, they can be removed by pre-adsorption of the serum with a 10% erythrocyte suspension. The SN test, using 100 $TCID_{50}$ of EDSV, 1-hour reaction time at 37 °C, and duck or chick cell cultures as the indicator system, is sensitive and specific. When using chick cell cultures, it often helps if the endpoints are read by presence of hemagglutinins in the supernatant fluid rather than by cytopathology. The SN test is really required only in diagnostic situations to confirm an unusual HI test result e.g. in an eradication program or to confirm a positive HI result in species in which EDS has not previously been recognized.

Many flocks containing birds that had been infected with EDSV *in ovo* did not develop antibodies during the growing period; antibody only became apparent immediately following the development of clinical signs of the disease. Therefore, even a negative serological test of all birds in a flock, at around 20 weeks of age, gives no guarantee of freedom from infection.

Differential Diagnosis

Egg drop syndrome should be suspected whenever there is failure to achieve predicted egg production levels or if there are falls in egg production, especially if birds are healthy and eggshell changes precede or are concurrent with the decline. Shell-less eggs are usually a feature of EDS but are often missed because they may be trampled into the litter, be consumed by the birds, or fall through the wire mesh of

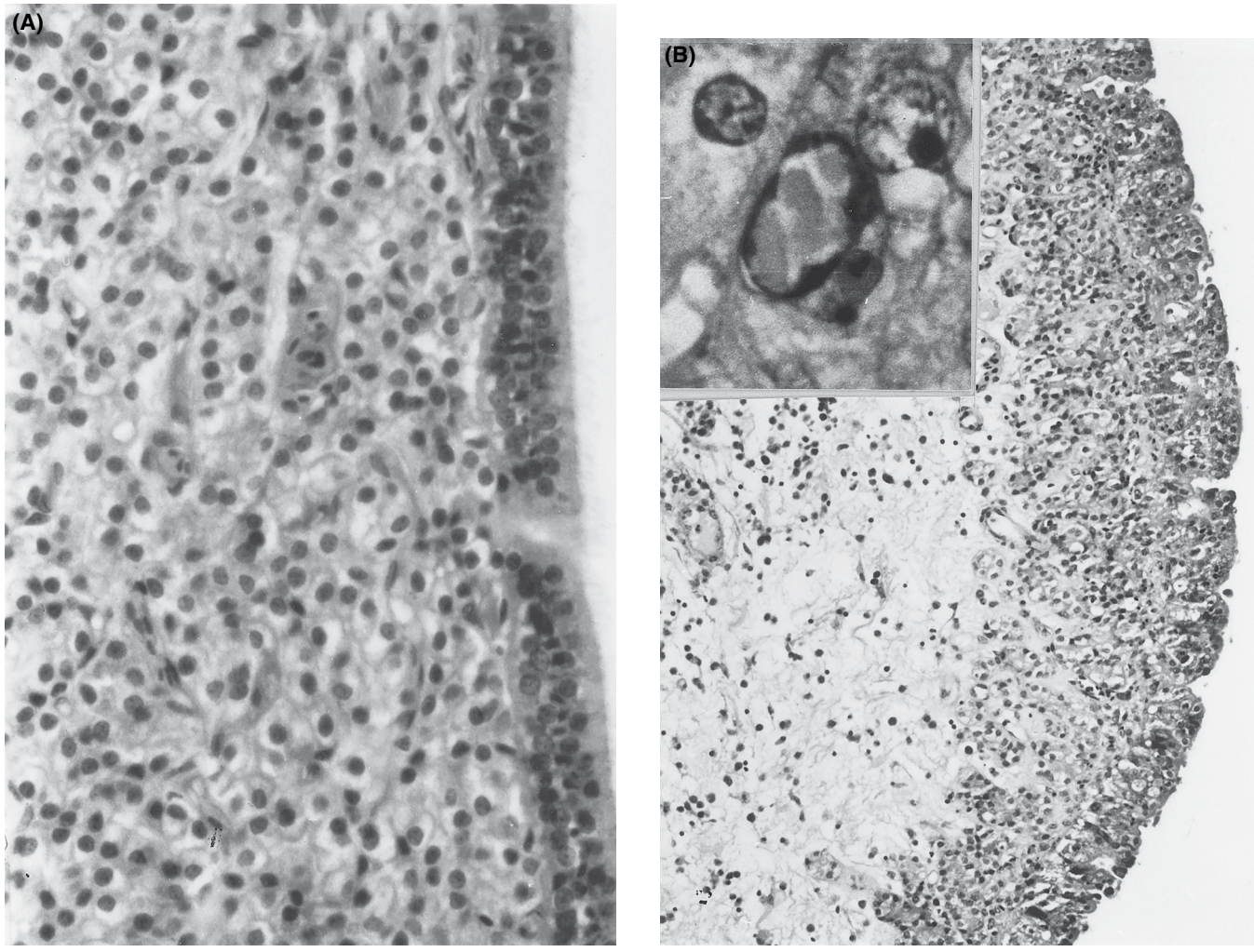

Figure 9.10. (A) Normal uterine mucosa. Surface epithelium consists of a single layer of columnar cells, many of which are ciliated; underlying these are tubular glands. (B) Pronounced edema of uterine submucosa, atrophy of tublar glands, and infiltration of entire mucosa by mononuclear cells are present at 8 days post inoculation. Inset: Intranuclear inclusion body in superficial epithelial cell. Note margination of nuclear chromatin and three eosinophilic inclusions in the nucleus.

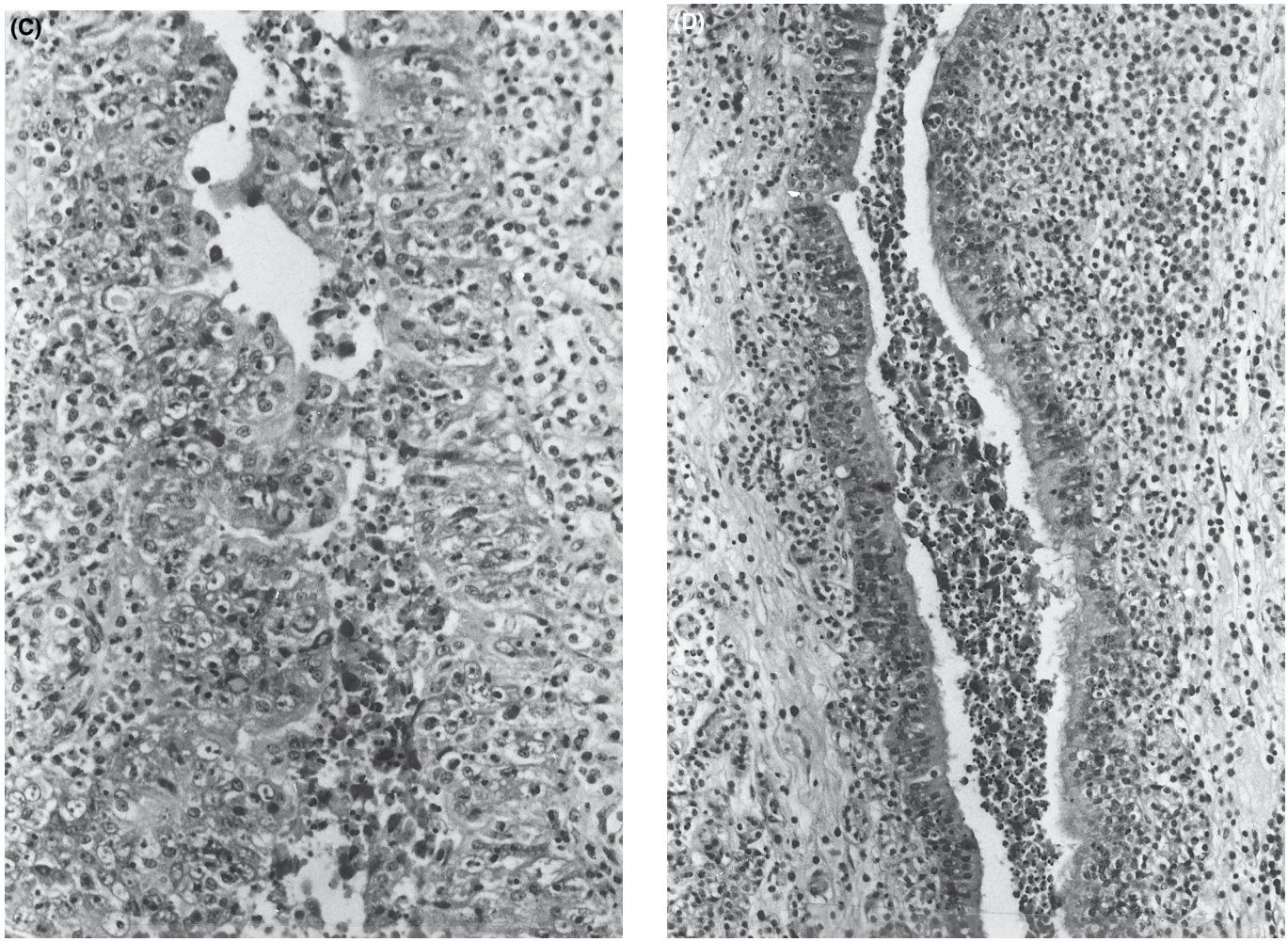

Figure 9.10. (*continued*) (C) Uterine surface epithelium is markedly hyperplastic 11 days PI; there is complete loss of cilia. (J. Smyth) (D) Exudate in uterine lumen consists of degenerating epithelial cells and heterophils mixed with mucus. Epithelium is devoid of cilia, tubular glands are almost absent, and uterine wall is infiltrated with lymphocytes and heterophils. (J. Smyth)

cage floors. Therefore, an inspection should take place early after the lights come on, before the eggs can be eaten. If the birds are housed on litter, a careful search will reveal egg membranes. Shell-less, soft-shelled, and thin-shelled eggs are characteristic of EDS; misshapen and ridged eggs are not a feature. In an infected flock in which vertical transmission of EDSV has occurred, most if not all cases occur around peak egg production, but any age of flock can be infected by lateral spread.

Although signs of EDS are quite characteristic, diagnosis must not be made on the clinical picture alone but should be confirmed before vaccination is considered.

Intervention Strategies

Management Procedures

Because classical EDS spreads primarily by vertical transmission through the egg, replacement birds should be derived from uninfected flocks. Endemic EDS often has been associated with a common egg-packing station, where contaminated egg trays have been a major factor in the spread of the disease. Virus is also present in droppings, and lateral spread is possible because the virus is resistant to inactivation. Circumstantial evidence exists for spread by personnel and transport, and therefore sensible hygienic precautions are required.

The infected birds develop a viremia, and thus it is important that bleeding needles, needles for inoculating vaccines, and other equipment should be sterilized between birds.

If infected and uninfected breeding flocks exist within the same organization, separate hatcheries, staff, and transport should be used. If this is not possible, separate setters and hatchers should be used, and hatches should be scheduled to take place on different days of the week. Although not recommended, minimum possible precautions are to use separate hatchers and to sex, vaccinate, and dispatch the clean stock before handling potentially infected chicks. It is particularly important to keep breeding stock from an infected breed separate from non-infected birds of another breed, and the eggs should never be incubated in the same hatchery.

In certain areas of the world, particularly where the drinking water for the birds is derived from dams, lakes, or rivers, EDSV infection has been common. These outbreaks have been controlled either by using water from wells or by chlorination of the water. Units where ducks or geese are kept should be carefully segregated from the chickens. If possible, all housing should be made wild bird-proof, because it is well documented that wild ducks and wild geese are often infected with EDSV, and it is not known how widespread infection is in other avian species.

It was possible to eradicate the virus from infected breeding stock before vaccines were developed (see earlier editions of this book).

Vaccination

Types of Vaccine

Oil-adjuvant inactivated vaccines are widely used and give good protection against EDS. The birds are vaccinated between 14 and 16 weeks of age. If uninfected birds are vaccinated, EDS HI titers of 8–9 $\log_2$ can be expected. If the flock has been exposed previously to EDSV, HI titers of 12–14 $\log_2$ may be found. An HI antibody response can be detected by the seventh day after vaccination, with peak titers achieved between the second and fifth weeks. Vaccinal immunity lasts at least 1 year (10, 22, 39, 63). Although properly vaccinated birds are protected against disease and do not appear to excrete EDSV, improperly vaccinated birds with low EDS HI titers excreted the virus following challenge (20). A recombinant subunit vaccine induced good antibody responses (31) but does not appear to have been tested against disease challenge.

Field Vaccination

When vertical or lateral transmission of EDSV is a possibility, at-risk flocks can be protected by vaccination in the growing period. If one or more houses on a multi-age laying site become infected due to lateral spread of the virus, the cost of vaccination, combined with costs and effects of the handling birds in lay in order to administer the inactivated vaccine, must be carefully weighed against the economic returns achieved from the protection. It is possible to limit the spread of virus on a site by good hygiene. It is particularly important to remember that the infected egg is potentially the most dangerous source of virus.

Treatment

Various treatments have been tried (e.g., vitamins and increasing calcium or protein in the ration), but in controlled trials, no effect could be demonstrated. Therefore, no successful treatment is available.

Acknowledgement

The author would like to acknowledge the contribution of J.B. McFerran who originally authored this chapter, and B.M. Adair who co-authored the chapter in the previous edition.

Hemorrhagic Enteritis and Related Infections

F. William Pierson and Scott D. Fitzgerald

Introduction

Definitions and Synonyms

Hemorrhagic enteritis (HE) is an acute viral disease of turkeys 4 weeks of age and older characterized by depression, bloody droppings, and death. Clinical disease usually persists in affected flocks for 7–10 days. Due to the immunosuppressive nature of the virus, secondary bacterial infections may extend losses for an additional 2–3 weeks.

Marble spleen disease (MSD) is a condition affecting confinement-reared pheasants 3–8 months of age. The virus is serologically indistinguishable from HEV and varies only slightly at the genomic level. However, the clinical presentation is predominantly respiratory, i.e., lung edema, congestion, dyspnea, and death. A similar, albeit milder disease referred to as avian adenovirus splenomegaly (AAS) has been described in broiler breeders.

Evidence of infection in other birds of the orders Galliformes, Passeriformes, Psittaciformes, Falconiformes, and Strigiformes exists.

Economic Significance

Financial losses due to HE within the United States are purported to have exceeded $3 million/year prior to development of a vaccine (20). Related losses due to colibacillosis were estimated to be $40 million/year (113). Today, due to the extensive use of vaccines, highly pathogenic outbreaks of HE are rare and typically associated with lack of vaccination or poor vaccination response. The economic impacts of MSD in pheasants and AAS in chickens have not been formally assessed.

Public Health Significance

The viruses responsible for HE, MSD, and AAS are not known to cause illness in humans. A recent study comparing industry personnel regularly exposed to HE virus (live vaccine) with non-exposed controls showed no serologic evidence of infection (66).

History

HE was first observed in Minnesota and described by Pomeroy and Fenstermacher (104). The disease commonly known as

"bankruptcy gut" reached epidemic proportions in Texas and Virginia in the 1960s (49). It was seen in confinement and range turkey operations and exhibited a strong tendency to reoccur on the same premises. In 1966, MSD in ring-necked pheasants was described by Mandelli et al. (75). AAS was identified in broiler breeders by Domermuth et al. in 1979 (27).

Experimental transmission of HE using unfiltered and filtered intestinal contents from turkeys was first described in 1967 (49) and by the mid-1970s, the causative agent was definitively identified as an adenovirus (8, 43, 48, 60). Studies of MSD yielded similar results (56, 57, 58, 59, 60).

Etiology

Classification

Morphologic, histologic, immunologic, and chloroform-resistance studies indicate that HE virus (HEV), MSD virus (MSDV), and AAS virus (AASV) are members of the family Adenoviridae (8, 25, 43, 48, 57, 61, 121).

The viruses were originally assigned to the genus *Aviadenovirus* and designated as avian adenovirus group (type) 2 (28) to distinguish them from the other members (fowl adenoviruses, group 1; EDS 76, group 3). This grouping was based on the observation that convalescent serum from HE-infected turkeys protected pheasants against MSD (25) and that MSDV and AASV were indistinguishable from HEV in agar-gel immunodiffusion tests (25, 27, 28, 29). The group was shown to be serologically distinct from CELO virus and other turkey adenovirus isolates (28, 63). DNA sequence homologies indicated that HEV and MSDV were different enough from other aviadenoviruses (4, 14, 64, 102) to warrant reclassification. They have since been reassigned to a new genus *Siadenovirus* (Table 9.2) and been given one species name, turkey adenovirus A (turkey adenovirus 3, TAdV-3). Other members of the genus include frog adenovirus A (13) and raptor adenovirus A with additional candidate species: great tit adenovirus 1, psittacine adenovirus 2, and Silawesi tortoise adenovirus 1 (68). The genus name is derived from an open reading frame in the early transcription region (E1) that has a high sequence homology with bacterial genes coding for sialidase. There are also several other putative genus-specific genes that share no sequence similarity with other adenoviruses (14). The origins of the genus, the functional significance of the sialidase homolog, and other genus-specific genes have yet to be determined.

Morphology

Ultrastructure

Thin-section tissue preparations examined by electron microscopy reveal that HE and MSD viral particles are non-enveloped icosahedrons with a total capsomere count of 252. They occur in empty and dense forms and are arranged intranuclearly in loosely packed aggregates or crystalline arrays (8, 43, 57, 61, 121, 130). Unlike the aviadenoviruses, only one penton fiber is present at each vertex (78, 127).

Size, Density

Electron microscopy of intranuclear inclusion bodies and cesium chloride-purified preparations reveal virions to be 60–90 nm in diameter (9, 57, 60, 61, 121). Buoyant densities are reported to be between 1.32 and 1.34 g/mL (8, 56, 58, 127, 130).

Chemical Composition

HEV, MSDV, and AASV are linear, double-stranded DNA viruses (14, 56). Complete sequences (Genbank Accession Numbers AF074946, AY849321) and maps of the HEV genome have been published for both virulent and avirulent strains (5, 102). The genome length is approximately 26.6 kb, which ranks it as one of the shorter adenovirus genomes (15). Guanine and cytosine comprise 34.9% of the bases, which is low by comparison with other adenoviruses (4, 102). However, 16 genes appear to be conserved based on comparative analysis with a variety of DNA sequences from other members of the family Adenoviridae (15).

An extensive list of putative HEV proteins has been published (14). Polyacrylamide gel electrophoresis and western blotting techniques suggest that HEV and MSDV have at least 11 distinct structural polypeptides with molecular weights ranging between 14 and 97 kD (87) and 9.5 and 96 kD (127). Six of these proteins have been further characterized: a 96-kD polypeptide believed to be the hexon, 51- to 52-kD and 29-kD polypeptides believed to be the vertex penton base and fiber, a 57-kD homologue of human adenovirus group 2 IIIa protein, and 2 core nucleoproteins of 12.5 kD and 9.5 kD (127).

Virus Replication

Macrophages and B lymphocytes are believed to be the primary target cells (116, 117). The spleen appears to be the major site of viral replication (20, 111). However, enzyme-linked immunosorbent assays (ELISA), immunohistochemistry, and polymerase chain reaction (PCR) assays have revealed the presence of infected cells in a variety of other tissues including intestine, cloacal bursa (bursa of Fabricius), cecal tonsils, thymus, liver, kidney, peripheral blood leukocytes, and lung (6, 35, 40, 53, 98, 113, 117, 122).

The replication strategy at the cellular level is presumed to be similar to that of other adenoviruses. Infection begins by viral attachment facilitated by the penton fiber. Receptor-mediated endocytosis occurs and DNA transcription utilizing host RNA polymerase II takes place in the nucleus. Genome replication also occurs in the nucleus and involves virus-encoded DNA-dependent DNA polymerase and the formation of a pan-handle intermediate with base pairing occurring at inverted terminal repeats. Virions are assembled in the nucleus and released upon cell disintegration (14).

Susceptibility to Chemical and Physical Agents

HEV remains stable under a variety of harsh conditions: heating at 65 °C (149 °F) for 1 hour, liquid at 37 °C (99 °F) for 4 weeks or 4 °C (40 °F) for 6 months, frozen at –20 °C

(–4 °F) for 4 years, and at low pH (20). Infectivity can be destroyed by heating at 70 °C (158 °F) for 1 hour and drying at 37 °C (99 °F) or 25 °C (77 °F) for 1 week (17). Chlorine and iodine based disinfectants are known to be effective against HEV (17, 18) and quaternary ammoniums should also be useful due to their efficacy against non-enveloped viruses (46). As with all disinfectants, pre-cleaning to remove organic material is critical.

Strain Classification

Traditionally, HEV, MSDV, and AASV strains have been classified according to their host source i.e., turkeys, pheasants, or chickens. Antigenic differences have been reported based on monoclonal antibody affinity (125, 132) but strains are considered to be serologically indistinct and provide cross protection (22, 25, 26, 27, 30, 59). A comparison of the genomes for virulent and avirulent strains of HEV indicates that they are 99.9% identical. However, the occurrence of mutations in the penton fiber, open reading frame 1 (ORF1), and/or E3 genes may account for variations in virulence (5). Finally, it is not uncommon for HEV isolates to be referred to as avirulent or virulent based on the severity of lesions they produce, i.e., splenomegaly in the former and splenomegaly, gastrointestinal hemorrhage, and death in the latter.

Laboratory Host Systems

HEV can be propagated in 6-week-old turkeys via intravenous (IV) or oral inoculation with splenic tissue from infected birds diluted 1:1 v/v with phosphate buffered saline (PBS). Spleens from these birds can then be harvested 3 or 5 days post inoculation (DPI) respectively, to yield significant amounts of virus (20). Inoculation of specific-pathogen-free turkey eggs with MSDV on day 24 of incubation also results in infection with peak viral loads in the spleen, intestine, and liver occurring 6 DPI (1). *In vitro* propagation of HEV in splenocyte culture has been unsuccessful (35, 94). However, Nazerian and Fadly (84) were able to demonstrate serial passage of HEV and MSDV in an immortalized lymphoblastoid B-cell line derived from a Marek's disease virus-induced tumor of turkey origin. The cell line known as MDTC-RP19 has since become the standard system for *in vitro* HE vaccine production. An *in vitro* method using purified peripheral blood leukocytes from turkeys also has been described (126).

Pathogenicity

In the field, mortality due to HE is reported to vary from more than 60% to less than 0.1% (49). It appears that virulence is a stable characteristic because 30 years of continuous vaccine use in the field has yet to produce a verifiable reversion.

Mortality rates in pheasants naturally infected with MSDV are reported to range between 5 and $20% (77). However, birds experimentally infected with cell culture propagated MSDV or virulent and avirulent strains of HEV failed to develop lung lesions or mortality despite the appearance of typical splenic lesions (30). Therefore, other factors may be necessary to replicate the disease observed in the field (30) or the strains used may have become cell culture adapted.

Pathobiology and Epidemiology

Incidence and Distribution

Hemorrhagic enteritis is observed wherever turkeys are raised. MSDV has been documented in confinement pheasant operations throughout the U.S., Canada, Europe, Australia, and Korea (6, 73, 74, 77, 105, 115, 118, 119, 120). Seroprevalence data suggests a wide distribution of AASV in mature chickens (29).

Natural and Experimental Hosts

Natural infection has been documented in turkeys (100), pheasants (74, 75), chickens (27), guinea fowl (11, 76), and chukar partridges (112). With regard to wild birds, an early serologic survey of 42 different species native to the U.S. revealed no evidence of infection outside the order Galliformes (16). Even wild populations of turkeys appear to be at little risk (52), probably due to their elusive nature. Outside the U.S., closely related viruses have been isolated from raptors (67, 68), psittacines (45, 65, 131), and a songbird (69).

Experimentally, HEV will infect ring-necked pheasants, and MSDV (26) and AASV (27, 28, 29) will infect turkeys. However, host genetics appear to influence the severity of clinical disease and lesion formation in both (70, 72). HEV also produces lesions in golden pheasants and peafowl, but without mortality (20).

Age of Host Most Commonly Affected

Primarily due to the protection afforded by maternal antibody (32), HE is not typically seen in turkeys until about 6 weeks of age, with most field cases occurring between 6 and 11 weeks of age (44, 104). However, a single case in 2.5-week-old turkeys has been reported with the predisposing factor thought to be a lack of maternal antibody (50). Newly hatched, seronegative turkeys are susceptible to infection, but refractory to intestinal lesion formation (31, 84), suggesting that target cell maturation may be necessary for the development of fulminate disease (32).

Marble spleen disease occurs naturally in pheasants 3–8 months of age (7, 77). Those younger than 4 weeks of age appear to be less susceptible to infection either due to maternal antibody or insufficient numbers of mature target cells (39).

In chickens, field infection with AASV has been observed in broiler breeders 20–45 weeks of age (27, 29).

Transmission, Carriers, and Vectors

HEV can be transmitted by oral or cloacal inoculation of susceptible turkeys with infectious feces (49, 62). Virus can remain viable for several weeks in carcasses protected from drying or in wet fecal material and litter, with the disease commonly reoccurring on infected premises (20). Recent data indicate that persistent infection can occur in recovered birds

Figure 9.11. Three spleens from pheasants experimentally infected with marble spleen disease virus. These spleens are enlarged 2 to 4 x the normal size, and diffusely mottled or marbled.

(6), possibly resulting in latent shedding. However, there is no epidemiologic evidence of egg transmission or other biological vectors (20). Therefore, the most probable route of transmission for HEV is fecal-oral/cloacal. MSDV and AASV are likely transmitted in the same manner, although due to the presence of respiratory lesions, aerosols cannot be ruled out.

Incubation Period

In turkeys, clinical signs and mortality begin 5–6 days after oral or cloacal inoculation and 3–4 days after IV inoculation with infectious splenic homogenate (24). The incubation period following oral inoculation with MSDV in pheasants (25) and AASV in chickens (27, 129) appears to be similar.

Clinical Signs

HE is characterized by a rapid progression of clinical signs over a 24-hour period (103). These include depression, bloody droppings, and death. Fecal material containing dark blood is often present around the vent. It also may be expressed from the vent if pressure is applied to the abdomen (20). In naturally infected flocks, signs of disease tend to subside 6–10 days after the appearance of bloody droppings. In pheasants with MSD, death is often peracute. Depression, weakness, dyspnea, and nasal discharge are noted in acute cases (37). The presentation for AASV in chickens is similar to that of pheasants, but generally less severe (27, 29).

Morbidity and Mortality

In field outbreaks of HE, morbidity approaches 100% based on serology and resistance to subsequent experimental challenge (24). Turkeys exhibiting clinical signs usually die within 24 hours or recover completely. Mortality ranges from less than 1% to greater than 60% and averages 10%–15% (49). Up to 80% mortality has been observed in experimental infections (20). Morbidity associated with MSD and AAS is similar to that of HE. Mortality associated with MSD in penreared ring-necked pheasants averages 2%–3%, but may reach 5%–20% over a 2- to 3-week period (9, 63, 77). In mature chickens with AAS, mortality as high as 8.9% has been reported (29).

Pathology

Gross Lesions

Following virulent HEV infection, dead turkeys routinely appear pale due to blood loss, but are typically in good flesh and have feed in their crops. The small intestine is commonly distended, grossly discolored, and filled with bloody contents (see Figure 9.14F in the Quail Bronchitis section). The intestinal mucosa is congested and in some cases, covered with a yellow fibrinonecrotic membrane. Lesions are usually more pronounced in the duodenum, but can extend distally. Spleens are characteristically enlarged, friable, and mottled in appearance (see Figure 9.14G in the Quail Bronchitis section); however, those of dead birds tend to be smaller due to contraction of the spleen in response to blood loss. Lungs may be congested, but other organs are generally pale. Hepatomegaly and petechiae in various tissues also have been reported (8, 43, 44, 47, 61, 104). Lesion formation with virulent strains appears to be dose dependent (85, 93).

Lesions associated with MSDV infection in pheasants include enlarged, mottled (marbled) spleens (Figure 9.11) and edematous congested lungs (7, 77). Intestinal hemorrhage has not been noted. In broiler breeders infected with AASV, lesions resemble those of MSD (27, 29).

Microscopic Lesions

Characteristic histopathologic changes associated with HE are most pronounced in the immune and gastrointestinal systems. Splenic lesions present at death include hyperplasia of white pulp and lymphoid necrosis. Basophilic Cowdry type B intranuclear inclusions (INI) can be found within mononuclear cells, i.e., macrophages and lymphocytes (Figure 9.12) (80, 111, 117). Proliferation of white pulp surrounding splenic ellipsoids is evident as early as 3 DPI. This leads to large, irregular, confluent islands of white pulp which are grossly visible 4–5 DPI (111). Hematoxylin and eosin staining reveals numerous INI in these zones between 3 and 5 DPI. By 4–5 DPI, the white pulp begins to undergo necrosis and by 6–7 DPI it has completely involuted with only occasional plasma cells appearing in the red pulp. In addition to splenic changes, lymphoid depletion is also noted

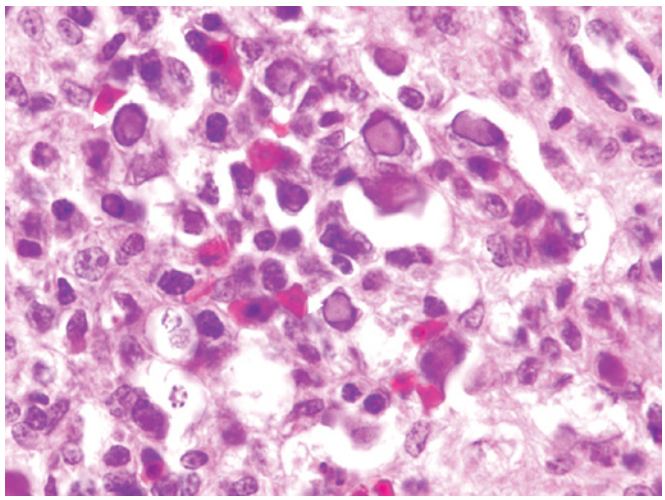

Figure 9.12. Section of spleen from a turkey affected with hemorrhagic enteritis. Nuclei of infected macrophages contain characteristic pale eosinophilic inclusions, with marginated chromatin and eccentric nucleoli. H&E, ×550.

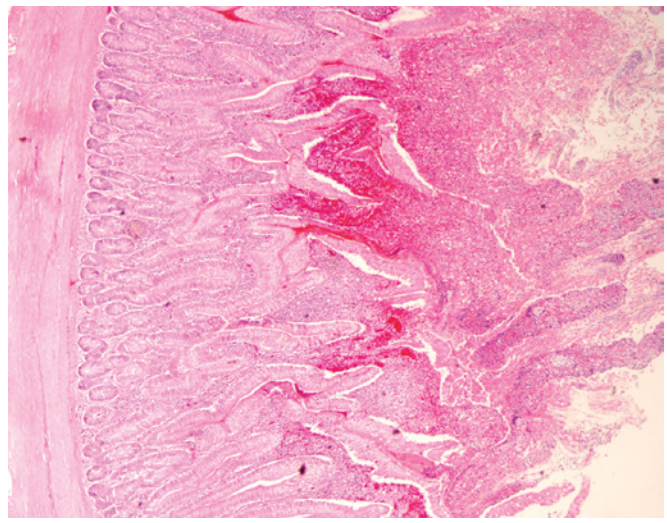

Figure 9.13. Section of small intestine from a turkey affected with hemorrhagic enteritis. Lesions include severe mucosal congestion, sloughing of epithelial cells at tip of villi, and hemorrhage into the intestinal lumen. H&E, ×550.

3–9 DPI in both the cortical and medullary areas of the thymus (53) and cloacal bursa (bursa of Fabricius) (53, 111).

Typical lesions in the intestinal tract include mucosal congestion, hemorrhage in the villus tips, and epithelial necrosis (Figure 9.13). Hemorrhage and necrosis are thought to be the result of endothelial disruption rather than destruction because blood vessels in the lamina propria appear intact and diapedesis of red cells is observed (111). Increased numbers of mononuclear cells with INI are observed in the lamina propria (53) in addition to mast cells (91), plasma cells, and heterophils (111). These changes are most pronounced in the duodenum just posterior to the pancreatic ducts, but similar, less severe lesions also may occur in the proventriculus, gizzard, distal small intestine, ceca, cecal tonsils, and cloacal bursa (20). Additionally, INI can be seen in the liver, bone marrow, peripheral blood leukocytes, lung, pancreas, brain, and renal tubular epithelium (43, 47, 53, 61, 80, 122).

MSDV and AASV produce splenic lesions similar to those of HEV, but intestinal lesions are absent. In naturally occurring cases of MSDV and AASV, vascular congestion of the lung as well as flooding of the pulmonary atria and tertiary bronchi with fibrin and red cells are observed (7, 29, 40). Large numbers of mononuclear cells with typical INI can be found in the atria and to a lesser extent in the liver, kidney, bursa, and bone marrow (37, 40).

Pathogenesis

HEV, MSDV, and AASV are considered to be lymphotropic and lymphocytopathic (38, 53, 111, 126) with IgM bearing B lymphocytes being the primary target (109, 117). Macrophages also appear to support viral replication (116, 126). This is consistent with the fact that bursectomy impairs viral replication and lesion formation (31, 38, 116) and that marked depletion of IgM bearing cells in the spleen and peripheral blood occurs during the acute phase of HEV infection (109, 116). HEV and MSDV also are known to produce transient inhibition of antibody responses to sheep erythrocytes (36, 81) and Newcastle disease virus (82) as well as suppression of *in vitro* mitogenic responses in B and T cells harvested from infected birds (36, 81, 82, 83).

Multiple hypotheses regarding the immunopathogenesis of HEV and related viruses have been proposed (31, 53, 79, 91, 92, 97, 107, 110, 111, 116, 117). Rautenschlein and Sharma (108) have suggested that after oral exposure, HEV either undergoes an initial round of replication in B lymphocytes located in the intestine and cloacal bursa or it travels directly to the spleen via the peripheral blood. There it infects more B cells and macrophages, replicating to high numbers. This results in an influx of CD4+ T cells and macrophages into the white pulp, presumably in an attempt to clear the virus, and accounts for the hyperplasia observed during the acute phase of infection. Once activated, macrophages produce a variety of cytokines including interleukin (IL)-6 and tumor necrosis factor (TNF). Interferon (IFN) production is subsequently induced. Type II IFN activates the macrophage population, stimulating production of nitric oxide, which has antiviral, immunosuppressive properties. Type I IFN is also produced in an attempt to limit viral replication. As infection progresses, HEV replication induces apoptosis and necrosis of target cells, thus depleting the IgM bearing B cell population. Cytokine-mediated apoptosis of by-stander cells also occurs (110). The cumulative effect is a transient period of immunosuppression.

The presence of increased numbers of mast cells in the intestine associated with HEV infection suggests that histamine and prostaglandin may play a role in intestinal lesion formation (90, 91). Other findings, e.g., the presence of few infected cells in the intestine (117) and the ability of cyclosporin A, a T cell inhibitor, to abrogate intestinal hemorrhage, also strongly suggest an immune-mediated pathogenic mechanism (116).

Conceivably, the lung lesions associated with MSD and AAS may also be immune-mediated if differences in the primary shock-response organs exist among species.

HEV alone (71, 114) or in conjunction with other agents such as *Bordetella avium*, avian paramyxovirus 1(APMV-1), and *Mycoplasma meleagridis* appears to predispose turkeys to secondary infection with *Escherichia coli* in the field (96). Observations suggest that colibacillosis following HE vaccination almost always requires prior or concomitant infection, even subclinical, to one of the other primary agents. Similar results have been observed experimentally (71, 88, 100). Combined infections with avian paramyxovirus 2 and *Chlamydophila psittaci* have also been reported (2).

Surprisingly, improved weight gains and reduced oocyst shedding have been found in turkeys co-infected with HEV or MSDV and *Eimeria meleagrimitis* (89). Likewise, simultaneous vaccination with APMV-1 and HEV appears to have a peculiar effect, i.e., APMV-1 antibody production is enhanced while HEV antibody production is suppressed. Spleens also exhibit more pronounced hyperplasia of the white pulp and an increase in apoptosis (107).

Finally, it is important to note that transient immunosuppression occurs with virulent as well as avirulent strains of HEV (71, 79, 95); the effect being more pronounced with the former. Therefore, although virulent strains should certainly be considered pathogenic, avirulent strains should not be considered apathogenic.

Immunity

Active

Turkeys recovering from natural or experimental infections with HEV are refractory to challenge. Protection does not appear to be strain specific. Strains that cause less than 1% mortality induce sufficient immunity to prevent infection with those producing much greater mortality (22). Antibodies against HEV may be detected as early as 3 DPI by ELISA (124). Immunity appears to be long lasting if not life-long. One breeder flock monitored over a 4-year period demonstrated a seroconversion rate of 100% at 4 weeks post-inoculation and was still 83% positive 40 months later (21). The occurrence of life-long immunity is believed to be the result of persistent infection since viral DNA can be detected in numerous tissues up to 70 DPI despite high levels of circulating antibody (6).

Cell-mediated immunity undoubtedly plays a role in active protection against infection and lesion formation, but its role is not fully understood. Inoculation of turkeys with HEV causes an increase in splenic CD4 bearing T cells 4–6 DPI (108, 116) and in circulating (95) and splenic (116) CD8+ bearing T cells 8–10 and 16 DPI, respectively. Selective *in vivo* T cell depletion with cyclosporin A seems to enhance splenic lesion formation and viral replication in MSDV-infected pheasants (42), but the same effect has not been observed in turkeys (116).

Passive

Maternal antibody can provide protection from the development of clinical HE up to 6 weeks of age and interfere with vaccination using cell culture products up to 5 weeks of age (32). However, in a commercial setting maternal antibody typically declines enough by 3.5–4 weeks-of-age to permit vaccination with splenic HEV vaccines. Passive immunity also can be conferred by injection of birds with serum obtained from recovered flocks. Experimentally and in the field, subcutaneous administration of 0.5–1.0 mL of antiserum prior to challenge or during an outbreak has been shown to prevent disease (19).

Diagnosis

Isolation and Identification of Causative Agent

Large concentrations of HEV can be found in bloody intestinal contents or splenic tissue obtained from dead or moribund turkeys (49). Splenic material from MSDV-infected pheasants and AASV-infected chickens is also a suitable source of virus. All three agents can be propagated in naïve turkeys, preferably 6 weeks of age or older, by inoculating per os (PO) with intestinal contents or PO or IV with a splenic homogenate (1:1 v/v spleen:PBS). With virulent isolates, mortality often begins 3 days after IV or 5–6 days after PO inoculation (20). Alternatively, MDTC-RP19 cells (American Type Culture Collection, Manassas, VA) grown in 65% McCoy's 5A and Lebowitz L-15 media supplemented with L-glutamine (combined 1:1 v/v), 5% tryptose phosphate broth, 20% chicken serum (HEV negative), and 10% fetal bovine serum with 100,000 IU of penicillin/streptomycin/L can be inoculated with filtrates (22 μm) of splenic material to isolate and propagate the viruses (84, 85).

Positive identification of HEV, MSD, and AASV can easily and inexpensively be accomplished through the use of an agar gel immunodiffusion (AGID). Briefly, splenic tissue (fresh or frozen) is diluted 1:1 v/v with PBS and precipitated against polyclonal turkey anti-HEV serum (23, 24, 99). Viral antigen can also be identified in thin sectioned (4–6 μm) frozen or formalin fixed tissues using immunofluorescent (35) or immunoperoxidase staining methods (40, 41, 54, 111). Standard (4, 51, 98, 102), nested (6), and real time (4) polymerase chain reaction (PCR) assays for detection of viral DNA in fresh or frozen tissues have been developed. Drying of crude splenic material or DNA extracts on filter paper also has been shown to be an adequate method of storage (102). For standard PCR, DNA extraction can be performed using commercially available kits. DNA polymerase, $MgCL_2$, deoxynucleotide triphosphates (dNTPs), oligonucleotide primers, sterile de-ionized water, and sample DNA are combined in a total reaction volume of 25–50 μL. Primers which amplify a 270 base pair region of the highly conserved hexon gene have been found to be reliable (nHEVL, 59-gtg gtt cag cag aaa gtt ctt-39; nHEVR, 59-cag tag act cat aag caa cta t-39). A standard 3-step thermocycler program is run for 35 cycles (4). Less commonly used methods for antigen detection include antigen-capture ELISA (55, 86, 113, 124) and *in sit*u DNA hybridization (117).

Serology

HEV antibodies can be detected in plasma or serum of recovered birds 2–3 weeks PI by AGID using known positive splenic material diluted 1:1 v/v with PBS as the test antigen (23, 24, 99). It is advisable to run both acute and convalescent sera if

a diagnosis is to be made based on serology. Maternal antibody may be detected using AGID, but this method generally lacks sufficient sensitivity beyond 1 week of age (124). More sensitive ELISA techniques have been developed (12, 55, 85, 86, 124) and are commercially available. Maternal antibody can be detected in turkeys up to 4–6 weeks of age, although most birds in the field are sero-negative by 3 weeks of age (33, 124). An active immune response can be detected as early as 3 DPI (124). Commercial kits are not available for MSDV or AASV antibody detection.

Differential Diagnosis

In turkeys, an enlarged mottled spleen without demonstrable evidence of HEV proteins (AGID) or DNA (PCR) or intestinal bleeding warrants consideration of lymphoid neoplasia, i.e., reticuloendotheliosis or lymphoproliferative disease. Enlarged, congested spleens in turkeys are often mistakenly attributed to HEV, but commonly result from bacteremia associated with organisms such as *Escherichia coli*, *Salmonella* spp., *Pasteurella multocida*, and *Erysipelothrix rhusiopathiae*. Additional signs and lesions usually accompany infections with these agents. Gastrointestinal bleeding and mucosal hyperemia may be associated with acute viral (highly pathogenic avian influenza, Newcastle disease), bacterial (endotoxemia, ileus induced intestinal autointoxication), parasitic (coccidiosis), or toxic (heavy metals, sulfa drugs) conditions. However, these would rarely be observed without other signs, lesions, or a history consistent with the etiology. Finally, it is important to note that mucosal hemorrhage and sloughing is commonly seen as a result of rapid post-mortem autolysis of the intestinal tract. Therefore, time of death must always be considered.

Pheasants and chickens that die acutely with signs of respiratory distress but without enlarged mottled spleens should be tested for other respiratory diseases including highly pathogenic avian influenza, Newcastle disease, *Syngamus trachea* infestation, and specifically in the case of chickens, infectious laryngotracheitis and infectious bronchitis. Respiratory signs with splenic enlargement and congestion should prompt consideration of bacterial pathogens such as *Escherichia coli*, *Salmonella* spp., and *Pasteurella multocida*. Carbon monoxide, carbon dioxide, and natural gas also should be considered in confinement operations. Splenic enlargement and mottling without demonstration of MSDV or AASV proteins (AGID) or DNA (PCR) should warrant histopathologic evaluation for neoplastic diseases such as Marek's disease, lymphoid leukosis, or reticuloendotheliosis. Adult chickens with hepatomegaly and/or splenomegaly without mottling should be tested for hepatitis E virus if AASV is ruled out.

Intervention Strategies

Management Procedures

Effective prevention and control of HE, MSD, and AAS begins with adherence to best management practices, especially biosecurity protocols, because movement of infectious litter or feces from one flock to another is the most common means of transmission. To eliminate HEV, MSDV, or AASV from confinement facilities with concrete floors, all organic material should first be removed followed by thorough cleaning with a detergent and rinsing. An approved chlorine, iodine, or quaternary ammonium-based disinfectant should then be applied and rinsed after allowing adequate contact time. Finally, the facility should be allowed to dry for 1 week at 25 °C (77 °F) (17, 18). In multi-stage/multi-age commercial operations, total elimination of the virus is considered impractical. In such cases, vaccination remains the only effective means of disease control and prevention.

Vaccination

Types of Vaccine

Avirulent isolates of HEV and MSDV have been successfully used as live, water-administered vaccines (22). Two forms of vaccine are currently in widespread use for turkeys. The first is a crude homogenate prepared from spleens (1:1 v/v spleen:PBS) obtained from 6-week-old turkeys inoculated PO or IV with a splenic homogenate containing the Domermuth strain (Virginia Avirulent 1). The second is a commercially available cell culture product (33) which contains an adapted/attenuated virus originally derived from the Domermuth strain. Both vaccines appear to produce adequate seroconversion and protection (3) and are used extensively in the United States. Of the two, only the cell culture vaccine is recommended for use in turkey breeders. A third method of vaccine production involving the propagation of avirulent HEV in peripheral blood leukocytes also has been described (126) and was temporarily used in Canada. Others, including a purified hexon subunit vaccine (128) and a recombinant penton fiber-knob subunit vaccine, have been developed (101). The latter is commercially available where live vaccines are not permitted.

Field Vaccination Protocols and Regimes

Water vaccination of healthy turkeys is currently the method of choice and is usually performed between 3.5 and 6 weeks of age. The elimination of any water line disinfectants, especially chlorine-based, 24 hours prior to vaccination and the addition of a vaccine stabilizer with colorant is essential to ensure successful vaccination. Water starvation prior to vaccination is not recommended in large flocks because some birds may not receive an adequate dose. Interestingly, stress applied on the day of vaccination, e.g., disruption of social structure through the movement of birds, appears to enhance the response to vaccination, either because it stimulates cell-mediated immunity or permits more efficient viral replication (79). Based on experience, a seroconversion rate of 60% or higher (AGID or ELISA) 3 weeks after vaccination with splenic homogenate is a good indication of 100% protection. A second vaccination 1 week after the first should be used on farms where seroconversion rates have been historically low, especially if cell culture vaccine is used. This phenomenon is likely due to differences between vaccine types in terms of shed rate and subsequent auto-vaccination. No roll-over effect relative to virulence has been noted. The most common cause of vaccine failure is residual disinfectant in the water line. However, turkeys exposed to immunosuppressive agents such as avian metapneumovirus prior to vaccination exhibit a reduced response (10).

Live avirulent water-administered vaccines are also effective for controlling MSD of pheasants (26, 30), but none are commercially available in the U.S. Vaccines for AAS of chickens have not been developed due to the sporadic, subclinical nature of the disease.

Treatment

Prior to the advent of effective vaccines, HE was treated by subcutaneous or intramuscular injection of 0.5–1.0 mL of convalescent antiserum obtained from healthy flocks at slaughter (19). Vaccination during the early stages of a farm outbreak of virulent HE has been found to be effective in reducing mortality. Also, due to the immunosuppressive nature of HEV and the potential for multi-agent interactions, treatment for secondary bacterial infections such as colibacillosis often must be considered. Selection of an appropriate antibiotic based on culture and sensitivity is always advised. For subsequent flocks on the same premises, correction of management deficiencies and vaccination for other primary agents that may interact with HE vaccine e.g., *Bordetella avium* and APMV-1, must be considered. Specific treatments have not been described for MSD of pheasants or AAS of chickens.

Acknowledgement

The authors are greatly indebted to C.H. Domermuth, W.B. Gross, and B.S. Pomeroy for their contributions to earlier editions of this subchapter.

Quail Bronchitis

Willie M. Reed and Sherman W. Jack

Introduction

Quail bronchitis (QB) is a naturally occurring, acute, highly contagious, fatal respiratory disease of young bobwhite quail (*Colinus virginianus*). The disease is of major economic significance to game bird breeders and has a worldwide distribution (1, 2). QB is characterized by rapid onset and high morbidity and mortality, and mainly affects captive-reared birds. The etiologic agent is quail bronchitis virus (QBV). QBV and chicken embryo lethal orphan (CELO) virus, both aviadenoviruses (Table 9.2), are considered to be the same agent and are not distinguishable using conventional techniques (3, 20). Both viruses produce similar disease and lesions in bobwhite quail and chicken embryos.

Few type I avian adenoviruses, other than QBV and CELO, have been evaluated for pathogenicity in bobwhite quail, with the exception of Indiana C adenovirus. Recent studies (11) have demonstrated that young bobwhite quail are susceptible to infection with Indiana C adenovirus, and the clinical disease and pathologic manifestations are indistinguishable from both naturally occurring and experimental infection with QBV.

QBV is infectious for domestic poultry, including chickens and turkeys, as well as other avian species. The infection is generally asymptomatic, although there is evidence of seroconversion. Although QB/CELO virus has induced neoplasms in laboratory animals, there is no known public health significance (15).

History, Incidence, and Distribution

QB was first described by Olson (16) from a 1949 outbreak in West Virginia. A similar disease in quail had been reported as early as 1933 by Levine, however, and an agent similar to QBV was isolated by Beaudette in 1939. Following Olson's report, several outbreaks were reported in Texas in 1956–1957 and in Virginia in 1959 (4, 5). Infection occurred in 3-week-old to mature bobwhite quail, with mortality in some pens reaching 80%. Chukar partridges on the game bird farm did not develop the disease. Circumstantial evidence indicated transmission of QBV from inapparently infected chickens or captive game birds other than quail to the affected bobwhite quail.

Since the early descriptions, QB has been frequently diagnosed as the cause of mortality in captive-reared bobwhite quail. The true incidence and distribution of infection are unknown, but asymptomatic infection in older birds is believed to be widespread. Infection had not been identified in wild bobwhite quail until 1981, when King et al. (14) reported antibodies against serotype 1 avian adenovirus in 23% of mature, free-ranging bobwhite quail collected from a research station.

Etiology

QB is caused by an avian adenovirus. It contains a DNA genome and is icosahedral and nonenveloped, and ranges in size from 69–75 nm in diameter (6). Based on virus neutralization, QBV is Fowl adenovirus A species in the genus Aviadenovirus (Table 9.2) and is indistinguishable from the Phelps strain of CELO virus (8, 15, 20). QBV/CELO serves as the type strain for Fowl Adenovirus A. Other techniques have been used to classify avian adenoviruses (e.g., physicochemical properties, hemagglutination, and restriction endonuclease mapping), but they have failed to further clarify the taxonomy of these agents. As with other adenoviruses, avian adeno-associated virus (AAAV) may occur with QBV (23).

Laboratory Hosts and Pathogenicity

QB virus is readily propagated in embryonating chicken eggs and in cultures of chicken kidney or liver cells. Although QBV will grow in chicken fibroblasts, this system is less suitable for cultivation because virus multiplication is poor. Propagation may be interfered with by concurrent AAAV infection (15, 23) or by maternal antibodies in the yolk of embryonating eggs (21, 22).

In most diagnostic laboratories, initial isolation is performed in embryonating chicken eggs, sometimes requiring several blind passages before typical lesions and mortality patterns develop. A common and proven route of inoculation is via the allantoic cavity. High yields of virus can be detected in allantoic fluid 48–96 hours post infection (PI). Isolation and propagation of QBV using the yolk sac route in antibody-free embryonating eggs is also an effective method. Infection of the embryo by the yolk sac or allantoic cavity results in dwarfing, curling, and stunting of the embryo in 2–4 days. Examination of affected embryos reveals widespread congestion and hemorrhage and enlargement of the liver, with varying degrees of necrosis and hepatitis with intranuclear inclusion bodies.

Experimental inoculation of hamsters leads to various kinds of neoplasms, depending primarily on the route of inoculation. Subcutaneous inoculation results in fibrosarcomas, hepatomas, or hepatic carcinomas, and intracranial inoculation leads to the development of ependymomas (1, 15). QB virus/CELO has not been found to be oncogenic in mice or chickens (15).

Pathogenesis and Epidemiology

Natural and Experimental Hosts

Bobwhite quail are the principal species that develop clinical signs and mortality due to infection with QBV. Clinical disease has been reported in Japanese quail. Chickens and turkeys may be experimentally infected but develop few or only mild clinical signs. Inapparent infections of chickens are suggested by serologic evidence (19, 20).

Transmission, Carriers, and Vectors

QB is highly contagious, as demonstrated by explosive morbidity and mortality in susceptible flocks. Most signs are seen in quail younger than 6 weeks of age. Although not experimentally documented, transmission is probably by aerosol. However, fecal-oral or mechanical transmission has been documented for other avian adenovirus, and QBV has been isolated from cecal tonsil during experimental infections (12). Serologic evidence of infection of other gallinaceous birds may suggest that even though they fail to develop clinical signs, these species may serve as a vector for QBV.

Incubation Period, Signs, Morbidity, and Mortality

QB is often a catastrophic disease of captive-reared bobwhite quail, which is manifested by respiratory distress that leads to death in young quail. Morbidity and mortality from field cases frequently exceed 50% and may be much higher in flocks affected at younger than 3 weeks of age. In experimental infections of 1-week-old quail, mortality began 2 days following intratracheal infection and subsided by day 9 (7). Mortality in quail inoculated at 3 weeks of age occurred between 6 and 11 days PI. Death is uncommon in birds older than 6 weeks of age.

Frequently, the first reported sign in the flock is a sudden increase in mortality. Closer inspection, however, frequently reveals sick birds that demonstrate decreased feed consumption, ruffled feathers, huddling under brooders, wing droop, open-mouthed breathing, "snicks," and nasal-ocular discharge. Following infection, signs may develop as early as 2 days but generally develop in 3–7 days. Severity of infection varies depending on the age at which the bird is infected. QB is most severe in quail less than 3 weeks of age. Older birds frequently are asymptomatic but develop antibodies to group I/serotype 1 adenovirus. This suggests that survivors may be immune to subsequent virus exposure, but the persistence of these antibodies and the level of immunity have not been investigated. Antibodies against QBV have been identified in recently hatched quail that did not exhibit adverse signs of infection. These antibodies were lost at between 4 and 6 weeks of age, suggesting that there were maternal antibodies.

Gross Lesions and Histopathology

The principal lesions of QB are in the respiratory tract (9). Nasal-ocular discharge also may be noted. Opacity and filling of the trachea by pale, moist, necrotic, and sometimes hemorrhagic exudate is common (Figure 9.14A). On cross section, the mucosa is markedly thickened (Figure 9.14B). Similar exudate may be found in the anterior air sacs. Histologically, tracheal lesions may include epithelial deciliation, cell swelling, karyomegaly, necrosis, desquamation, and leukocyte infiltration (Figure 9.14C). Basophilic, intranuclear viral inclusions are common in intact or desquamated tracheal epithelium. Electron microscopic changes are similar to those seen histologically but also demonstrate phagocytosed viral particles.

In the lungs, red, consolidated areas surround the bronchial hilus (Figure 9.14D). On section, bronchi frequently contain exudate similar to that in the trachea, indicative of a necrotizing, proliferative bronchitis. Inflammatory exudates consisting of lymphocytes, heterophils, and fluid may extend into the surrounding pulmonary parenchyma, but the intensity of the leukocyte response varies and may be confounded by secondary bacterial infections. Histologically, bronchial changes are similar to those in the trachea, except that bronchi may demonstrate more epithelial proliferation. Most lesions are associated with large basophilic intranuclear inclusions (Figure 9.14E).

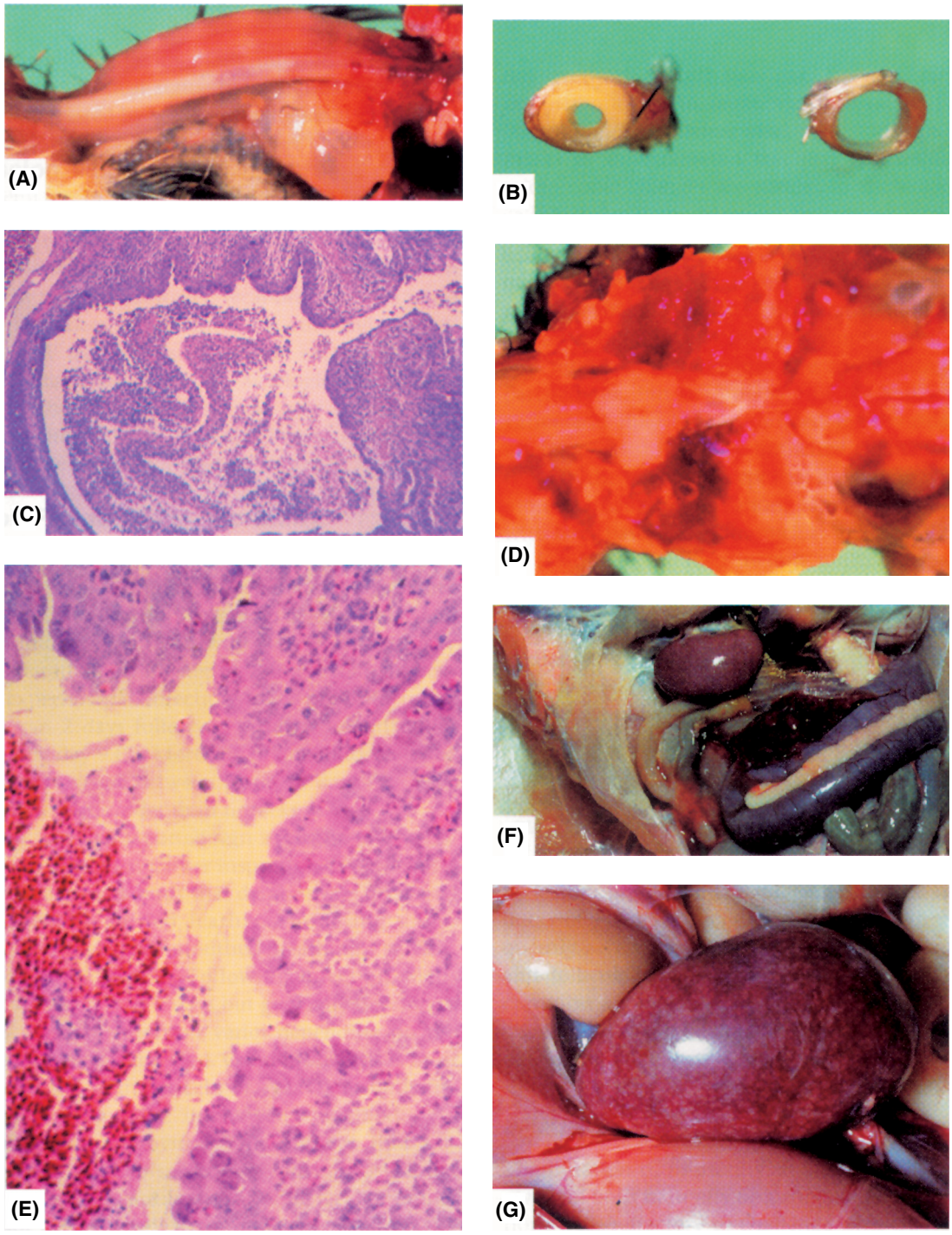

Figure 9.14. (A–E) Quail bronchitis. 9A) Trachea from a young quail chick infected with quail bronchitis virus (QBV). There is opacity of the trachea due to the presence of necrotic exudate. (B) Cross section of the trachea from a young quail chick infected with QBV. The mucosa of the section on the left is extremely thickened, causing partial obstruction, and the section on the right is minimally affected. (C) Microscopic section of trachea from QBV-infected quail. There is epithelial deciliation, cell swelling, necrosis, desquamation, and leukocyte infiltration. (D) Quail chick infected with QBV. The lungs are congested and contain red consolidated areas surrounding the bronchial hilus. (E) Microscopic section of pulmonary bronchus from a quail infected with QBV. There is epithelial cell proliferation, leukocyte infiltration, and luminal exudate. Basophilic intranuclear inclusions are within epithelial cells. (F and G) Hemorrhagic enteritis. (F) Turkey, 7 weeks old. Duodenal loop is dark because of bloody contents (one section opened to show contents). Note splenic enlargement and mottling. There is also inflammation of a thoracic air sac (left) typical of acute colisepticemia, which often follows hemorrhagic enteritis virus (HEV) infection. (G) Markedly enlarged and mottled spleen in turkey with HEV infection. (Barnes)

Lesions in the liver include multifocal pale, pinpoint to 3-mm necrotic foci. Histologically, these foci are characterized by hepatocellular necrosis, infiltrated to varying degrees by lymphocytes and fewer heterophils. Inclusion bodies are occasionally seen in hepatocytes adjacent to necrotic foci and/or biliary epithelium.

Lesions occur in the spleen and cloacal bursa but can be difficult to identify in quail less than 3 weeks of age. The spleen may be mottled and slightly enlarged. Histologically, affected spleens have multifocal, often extensive zones of necrosis, characterized by lymphocytolysis with increased fibrillar eosinophilic intercellular material, with minimal leukocyte infiltration. Adenoviral inclusions are rare in the spleen. Histologic lesions of the cloacal bursa include necrosis of lymphocytes, frequently accompanied by generalized lymphoid depletion and follicular atrophy. Intranuclear viral inclusions are common in bursal epithelium. Experimentally, some quail also develop necrotizing pancreatitis associated with adenoviral inclusions.

Immunity

The duration of immunity in QB is not known, but survivors of both naturally occurring and experimental infections were refractory to challenge with QBV for at least 6 months, and significant antibody levels developed in serum of quail following infection (2, 3, 16). Young chicks with maternal antibody also are refractory to challenge with QBV, but maternal antibody is not believed to prevent virus multiplication.

Diagnosis

In quail chicks, sudden onset of rales, sneezing, or coughing that spreads rapidly through the flock and results in mortality suggests QB. Excess mucus in the trachea, bronchi, and air sacs is added evidence of the disease. Severity of signs, rapidity of spread, and the presence of lesions are less marked in older quail. Isolation and identification of an agent indistinguishable from QBV (or CELO virus) confirms the diagnosis. Inoculation of 9– to 11-day embryonating chicken eggs via the chorioallantoic sac with suspensions of trachea, air sacs, or lungs has been used for isolation of the virus. Yates et al. (23) recommended suspensions of fecal samples or homogenates of the posterior small intestine (ileum) or colon. Jack et al. (12, 13) reported good success in isolating QBV from the liver of naturally infected birds and from the cloacal bursa and cecal tonsils of experimentally infected birds. Three to five blind passages are made with allantoamnionic fluid harvested from chilled eggs up to 6 days or more PI or earlier from embryos that died 24 hours PI or later or that exhibit signs of stunting in daily candling. According to Yates et al. (23), a few strains seem to require inoculation via the yolk sac in 5- to 7-day-old embryos.

Embryo mortality (increasing with number of passages), stunting, thickening of the amnion, necrotic foci, or mottling of the liver, and accumulation of urates in the mesonephros are typical changes caused by QBV or CELO virus. Neutralization of the isolated virus by specific QBV or CELO virus antiserum confirms identification of the virus and the diagnosis.

In general, information pertaining to isolation, propagation, and identification of CELO or any group I/serotype 1 avian adenovirus would be applicable to QBV. Yates et al. (23) noted preference for chick embryo kidney or kidney cell cultures, and Jack and Reed (10, 11) have described propagation of QBV in chicken embryo liver tissue. The agar gel immunodiffusion (AGID) test may be used to place an isolated virus in the avian adenovirus group, but it does not identify the serotype. Serotype classification is based on virus neutralization (10). In the absence of virus isolation or with failure to isolate a virus, the AGID test, using stock antigen on paired sets of serum samples, may be of value. A markedly higher percentage of positive precipitin tests among samples collected during convalescence (2–4 weeks after initial signs) than among sera collected during the acute phase (first few days of signs) should add weight to a presumptive diagnosis of QB based on clinical observations.

Pulmonary aspergillosis may be differentiated from pox by the presence of caseous plugs in lungs or deposits in air sacs with pockets of grayish or greenish spore accumulations. Although bacterial infections might complicate the disease, none is known to cause rapid development of signs, lesions, and mortality typical of QB. DuBose (2) suggested that Newcastle disease might present a clinical picture similar in part to QB, but clinical Newcastle disease has not been described in bobwhite quail. Histologic identification of intranuclear inclusion bodies morphologically characteristic of adenovirus in tracheal or bronchial epithelium is highly suggestive of infection with QBV (9).

Treatment, Prevention, and Control

No specific treatment exists for QB. Increased warmth in the brooder house, adequate ventilation but no drafts, and avoidance of crowding are suggested supportive measures during an outbreak. Prevention is based on protecting susceptible quail from all possible sources of QBV or CELO virus. In addition to the usual sanitation procedures and measures to prevent entry of infectious agents onto the premises, care should be taken to keep adult quail, as well as other avian species, away from young quail. Control measures on a farm should be started immediately, when even a tentative diagnosis of QB has been made. In addition to general measures to prevent transmission from group to group, hatching operations may need to be deferred until 2 weeks after signs have disappeared to prevent an outbreak in the presence of highly susceptible young quail.

Attempted eradication of QBV from bobwhite quail on a large game bird farm was unsuccessful but may have been responsible for preventing losses and clinical QB over a 2-year period (3). In that effort, 80% of the 10,000 quail hatched during the previous year died from the disease. In addition to measures described previously, older quail were marketed, and only survivors from hatches that had been affected at less than 4 weeks of age were kept for breeders. Virus-neutralization antibody at a high level was detected in 3-month-old quail hatched 2 years later, but no signs of QB were detected in the intervening period up to the time the farm closed the following

winter. Winterfield and Dhillon (17) used a type 1 adenovirus serotype in quail chicks as a vaccine against QB. The isolate, designated Indiana C virus, was isolated from chickens (18). It proved non-pathogenic for quail in a laboratory trial and was subsequently used on a farm where QB was endemic and losses were extensive. It was reported that the disease quickly subsided. In recent studies (11), however, experimental inoculation of quail at 1 or 3 weeks of age resulted in mortality rates of 33%–100%. In quail inoculated at 6 or 9 weeks of age, mortality ranged from 0%–10%. Gross and histologic lesions included necrotizing tracheitis and bronchitis with pneumonia, necrotizing hepatitis and splenitis, and lymphoid depletion of the cloacal bursa. Based on these findings, Indiana C appears to be highly pathogenic for bobwhite quail and is not recommended for use as a vaccine to prevent QB. More studies on potential use of vaccines to prevent QB are needed.

References

Introduction

1. Benko, M., P. Elo, K. Ursu, W. Ahne, S.E. LaPatra, D. Thomon, and B. Harrach. 2002. First molecular evidence for the existence of distinct fish and snake adenoviruses. *J Virol.* 76:10056–10059.
2. Benko, M., and B. Harrach. 1998. A proposal for a new (third) genus within the family Adenoviridae. *Arch Virol*. 143/4:829–837.
3. Harrach B., M. Benkö, G.W. Both, M. Brown, A.J. Davison, M. Echavarria, M. Hess, M.S. Jones, A. Kajon, H.D. Lehmkuhl, V. Mautner, S.K. Mittal, and G. Wadell. 2012. Family Adenoviridae. In: A.M.Q. King, M.J. Adams, E.B. Carstens, and E.J. Lefkowitz, eds. *Virus Taxonomy: Ninth Report of the International Committee on Taxonomy of Viruses*, 9th ed. Elsevier Academic Press, New York 125–41.
4. Burmester, B.R., G.R. Sharpless, and A.K. Fontes. 1960. Virus isolated from avian lymphomas unrelated to lymphomatosis virus. *J Natl Cancer Inst.* 24:1443–1447.
5. Davison, A., and B. Harrach. 2002. Genus Siadenovirus. In: C. A. Tidona, G. Darai, eds. *The Springer Index of Viruses*. Springer Verlag: Heidelberg. 29–33.
6. Davison, A.J., M. Benko, and B. Harrach. 2003. Genetic content and evolution of adenoviruses. *J Gen Virol.* 84:2895–2908.
7. Enders, J.F., J.A. Bell, J.H. Dingle, T. Francis, H.R. Hilleman, R.J. Huebner, and A.M. Payne. 1956. Adenoviruses: Group name proposed for the new respiratory tract viruses. *Science.* 124:119–120.
8. Huebner, R.J., W.P. Rowe, T.G. Ward, R.J. Parrott, and J.A. Bell. 1954. Adenoidal-pharyngeal-conjunctival agents. *New Engl J Med.* 257:1077–1086.
9. McFerran, J.B., and J. Smyth. 2000. Avian adenoviruses. *Rev Sci Tech Int Epiz.* 19:589–601.
10. McFerran, J.B., B. Adair, and T.J. Connor. 1975. Adenoviral antigens (CELO, QBV, GAL). *Am J Vet Res.* 36:527–529.
11. Olson, N.O. 1950. A respiratory disease (bronchitis) of quail caused by a virus. Proc 54th Annual Meet US Livestock Sanit Assoc., 171–174.
12. Van den Ende, M.P., P.A. Don, and A. Kipps. 1949. The isolation in eggs of a new filterable agent which may be the cause of bovine lumpy skin disease. *J Gen Microbiol.* 3:174–182.
13. Yates, V.J., and D.E. Fry. 1957. Observations on a chicken embryo lethal orphan (CELO) virus. *Am J Vet Res.* 18:657–660.

Aviadenovirus Infections

1. Abdul-Aziz, T.A., and M.A. Al-Attar. 1991. New syndrome in Iraqi chicks. *Vet Rec.* 129(12):272.
2. Abe, T., K. Nakamura, H. Tojo, M. Mase, T. Shibahara, S. Yamaguchi, and N. Yuasa. 1998. Histology, immunohistochemistry, and ultrastructure of hydropericardium syndrome in adult broiler breeders and broiler chicks. *Avian Dis.* 42(3):606–12.
3. Abe T, K. Nakamura, T. Tojo, and N. Yuasa. 2001. Gizzard erosion in broiler chicks by group I avian adenovirus. *Avian Dis.* 45(1):234–9.
4. Adair, B.M. 1978. Studies on the development of avian adenoviruses in cell cultures. *Avian Pathol.* 7(4):541–50.
5. Adair, B.M., W.L. Curran, and J.B. McFerran. 1979. Ultrastructural studies of the replication of fowl adenoviruses in primary cell cultures. *Avian Pathol.* 8(2):133–44.
6. Afzal, M., and I. Ahmad. 1990. Efficacy of an inactivated vaccine against hydropericardium syndrome in broilers. *Vet Rec.* 126(3):59–60.
7. Afzal, M., R. Muneer, and G. Stein. 1991. Studies on the aetiology of hydropericardium syndrome (Angara disease) in broilers. *Vet Rec.* 128(25):591–3.
8. Ahmad, K., M. Ahmad, M.A. Akram-Muneer, and M. Ajmal. 2011. Experimental transmission of Angara disease in broiler fowls. *Stud Res Vet Med.* 1:53–5.
9. Akhtar, S., S. Zahid, and M.I. Khan. 1992. Risk factors associated with hydropericardium syndrome in broiler flocks. *Vet Rec.* 131(21):481–4.
10. Alemnesh, W., M. Hair-Bejo, I. Aini, and A.R. Omar. 2011. Pathogenicity of fowl adenovirus in specific pathogen free chicken embryos. *J Comp Pathol.* 146(2–3):223–9.
11. Alexander, H.S., P. Huber, J. Cao, P.J. Krell, and E. Nagy. 1998. Growth characteristics of fowl adenovirus type 8 in a chicken hepatoma cell line. *J Virol Methods.* 74(1):9–14.
12. Alvarado, I.R., P. Villegas, J. El-Attrache, E. Jensen, G. Rosales, F. Perozo, and L.B. Purvis. 2007. Genetic characterization, pathogenicity, and protection studies with an avian adenovirus isolate associated with inclusion body hepatitis. *Avian Dis.* 51(1):27–32.
13. Anjum, A.D. 1990. Experimental transmission of hydropericardium syndrome and protection against it in commercial broiler chickens. *Avian Pathol.* 19:655–60.
14. Anjum, A.D., M.A. Sabri, and Z. Iqbal. 1989. Hydropericarditis syndrome in broiler chickens in Pakistan. *Vet Rec.* 124(10):247–8.
15. Asrani, R.K., V.K. Gupta, S.K. Sharma, S.P. Singh, and R.C. Katoch. 1997. Hydropericardium-hepatopathy syndrome in Asian poultry. *Vet Rec*. 1997 141(11):271–3.
16. Balamurugan, V., and J.M. Kataria. 2004. The hydropericardium syndrome in poultry—a current scenario. *Vet Res Commun.* 28(2):127–48.
17. Balamurugan, V., J.M. Kataria, R.S. Kataria, K.C. Verma, and T. Nanthakumar. 2002. Characterization of fowl adenovirus serotype-4 associated with hydropericardium syndrome in chicken. *Comp Immunol Microbiol Infect Dis.* 25(3):139–47.
18. Bouquet, J.F., Y. Moreau, J.B. McFerran, and T.J. Connor. Isolation and characterisation of an adenovirus isolated from Muscovy ducks. *Avian Pathol*. 11(2):301–7.

19. Calnek, B.W., and B.S. Cowen. 1975. Adenoviruses of chickens: serologic groups. *Avian Dis*. 1975 19(1):91–103.
20. Capua, I., L. Liberti, R.E. Gough, C. Casaccia, and G. Asdrubali. 1995. Isolation and characterization of an adenovirus associated with inclusion body hepatitis in psittacine birds. *Avian Pathol.* 24(4):717–22.
21. Charlton, B.R., and A.A. Bickford. 1995. Gross and histologic lesions of adenovirus group I in guinea fowl. *J Vet Diagn Invest.* 7(4):552–4.
22. Chiocca, S., R. Kurzbauer, G. Schaffner, A. Baker, V. Mautner, and M. Cotten. 1996. The complete DNA sequence and genomic organization of the avian adenovirus CELO. *J Virol.* 70(5):2939–49.
23. Cho, B.R. 1976. An adenovirus from a turkey pathogenic to both chicks and turkey poults. *Avian Dis.* 20(4):714–23.
24. Christensen, N.H., and M. Saifuddin. 1989. A primary epidemic of inclusion body hepatitis in broilers. *Avian Dis.* 33(4): 622–30.
25. Clemmer, D.I. 1972. Age-associated changes in fecal excretion patterns of strain 93 chick embryo lethal orphan virus in chicks. *Infect Immun.* 5(1):60–4.
26. Cook, J.K. 1972. Avian adenovirus alone or followed by infectious bronchitis virus in laying hens. *J Comp Pathol.* 82(2):119–28.
27. Cook, J.K. 1974. Pathogenicity of avian adenoviruses for day-old chicks. *J Comp Pathol.* 84(4):505–15.
28. Cook, J.K. 1974. Spread of an avian adenovirus (CELO virus) to uninoculated fowls. *Res Vet Sci.* 16(2):156–61.
29. Corredor, J.C., and E. Nagy. 2010. The non-essential left end region of the fowl adenovirus 9 genome is suitable for foreign gene insertion/replacement. *Virus Res.* 149(2):167–74.
30. Cowen, B., B.W. Calnek, N.A. Menendez, and R.F. Ball. 1978. Avian adenoviruses: effect on egg production, shell quality, and feed consumption. *Avian Dis.* 22(3):459–70.
31. Cowen, B., G.B. Mitchell, and B.W. Calnek. 1978. An adenovirus survey of poultry flocks during the growing and laying periods. *Avian Dis.* 22(1):115–21.
32. Cowen, B.S. 1988. Chicken embryo propagation of type I avian adenoviruses. *Avian Dis.* 32:282–97.
33. Crespo, R., H.L. Shivaprasad, R. Droual, R.P. Chin, P.R. Woolcock, and T.E. Carpenter. 1998. Inclusion body tracheitis associated with avian adenovirus in turkeys. *Avian Dis.* 42(3):589–96.
34. Dhillon, A.S., and F.S. Kibenge. 1987. Adenovirus infection associated with respiratory disease in commercial chickens. *Avian Dis* 31(3):654–7.
35. Dhillon, A.S., and R.W. Winterfield. 1984. Pathogenicity of various adenovirus serotypes in the presence of Escherichia coli in chickens. *Avian Dis.* 28(1):147–53.
36. Dhillon, A.S., R.W. Winterfield, H.L. Thacker, and D.S. Feldman. 1982. Lesions induced in the respiratory tract of chickens by serologically different adenoviruses. *Avian Dis.* 26(3):478–86.
37. Dhurandhar, N.V., P. Kulkarni, S.M. Ajinkya, and A. Sherikar. 1992. Effect of adenovirus infection on adiposity in chicken. *Vet Microbiol.* 31(2–3):101–7.
38. Dhurandhar, N.V., P.R. Kulkarni, S.M. Ajinkya, A.A. Sherikar, and R.L. Atkinson. 1997. Association of adenovirus infection with human obesity. *Obes Res.* 5(5):464–9.
39. Domanska-Blicharz, K., G. Tomczyk, K. Smietanka, W. Kozaczynski, and Z. Minta. 2011. Molecular characterization of fowl adenoviruses isolated from chickens with gizzard erosions. *Poult Sci.* 90(5):983–9.
40. Easton, G.D., and D.G. Simmons. 1977. Antigenic analysis of several turkey respiratory adenoviruses by reciprocal-neutralization kinetics. *Avian Dis.* 21(4):605–11.
41. El-Attrache, J., P. Villegas, B. O'Connor, J.R. Buhr, and G.N. Rowland. 2001. Adenovirus pathogenicity in immature ostriches. *Avian Dis.* 45(2):442–6.
42. Erny, K.M., D.A. Barr, and K.J. Fahey. 1991. Molecular charcterization of highly virulent fowl adenoviruses associated with outbreaks of inlcusion body hepatitis. *Avian Pathol.* 20(597):606.
43. Fadly, A.M., B.J. Riegele, K. Nazerian, and E.A. Stephens. 1980. Some observations on an adenovirus isolated from specific pathogen free chickens. *Poult Sci.* 59:21–7.
44. Fadly, A.M., and R.W. Winterfield. 1973. Isolation and some characteristics of an agent associated with inclusion body hepatitis, hemorrhages, and aplastic anemia in chickens. *Avian Dis.* 17(1):182–93.
45. Fadly, A.M., R.W. Winterfield, and H.J. Olander. 1976. Role of the bursa of Fabricius in the pathogenicity of inclusion body hepatitis and infectious bursal disease virus. *Avian Dis.* 20: 467–72.
46. Francois, A., C. Chevalier, B. Delmas, N. Eterradossi, D. Toquin, G. Rivallan, and P. Langlois. 2004. Avian adenovirus CELO recombinants expressing VP2 of infectious bursal disease virus induce protection against bursal disease in chickens. *Vaccine.* 22(17–18):2351–60.
47. Ganesh, K., V. Suryanarayana, R. Raghavan, and S. Gowda. 2001. Nucleotide sequence of L1 and part of P1 of hexon gene of fowl adenovirus associated with hydropericardium hepatitis syndrome differs with the corresponding region of other fowl adenoviruses. *Vet Microbiol.* 78(1):1–11.
48. Ganesh, K., V.V. Suryanarayana, and R. Raghavan. 2002. Detection of fowl adenovirus associated with hydropericardium hepatitis syndrome by a polymerase chain reaction. *Vet Res Commun.* 26(1):73–80.
49. Gelderblom, H., and I. Maichle-Lauppe. 1982. The fibers of fowl adenoviruses. *Arch Virol.* 72(4):289–98.
50. Georgiou, K., R.C. Jones, and J.R. Guneratne. 1983. Organ culture studies on adenoviruses isolated from tenosynovitis in chickens. *Avian Pathol.* 12(2):199–212.
51. Gomis, S., A.R. Goodhope, A.D. Ojkic, and P. Willson. 2006. Inclusion body hepatitis as a primary disease in broilers in Saskatchewan, Canada. *Avian Dis.* 50(4):550–5.
52. Gough, R.E., S.E. Drury, I. Capua, A.E. Courtenay, M.W. Sharp, and A.C. Dick. 1997. Isolation and identification of adenoviruses from ostriches (*Struthio camelus*). *Vet Rec.* 140(15):402–3.
53. Grgic, H., D.H. Yang, and E. Nagy. 2011. Pathogenicity and complete genome sequence of a fowl adenovirus serotype 8 isolate. *Virus Res.* 156(1–2):91–7.
54. Griffin, B.D., and E. Nagy. 2011. Coding potential and transcript analysis of fowl adenovirus 4: insight into uORFs as common sequence features in adenoviral transcripts. *J Gen Virol.* 92(Pt 6):1260–72.
55. Grimes, T.M., D.H. Culver, and D.J. King. 1977. Virus-neutralizing antibody titers against 8 avian adenovirus serotypes in breeder hens in Georgia by a microneutralization procedure. *Avian Dis.* 21(2):220–9.
56. Grimes, T.M., and D.J. King. 1977. Effect of maternal antibody on experimental infections of chickens with a type-8 avian adenovirus. *Avian Dis.* 21(1):97–12.

57. Grimes, T.M., D.J. King, S.H. Kleven, and O.J. Fletcher. 1977. Involvement of a type-8 avian adenovirus in the etiology of inclusion body hepatitis. *Avian Dis.* 21(1):26–38.
58. Guy, J.S., and H.J. Barnes. 1997. Characterization of an avian adenovirus associated with inclusion body hepatitis in day-old turkeys. *Avian Dis.* 41(3):726–31.
59. Guy, J.S., J.L. Schaeffer, and H.J. Barnes. 1988. Inclusion-body hepatitis in day-old turkeys. *Avian Dis.* 32(3):587–90.
60. Guy, J.S., M.A. West, F.J. Fuller, et al. 2011. Detection of chicken proventricular necrosis virus (R11/3 virus) in experimental and naturally occurring cases of transmissible viral proventriculitis with the use of a reverse transcriptase-PCR procedure. *Avian Dis.* 55(1):70–5.
61. Harrach, B., M. Benkö, G.W. Both, M. Brown, A.J. Davison, M. Echavarria, M. Hess, M.S. Jones, A. Kajon, H.D. Lehmkuhl, V. Mautner, S.K. Mittal, and G. Wadell. 2012. Family Adenoviridae. In: *Virus Taxonomy: Ninth Report of the International Committtee on Taxonomy of Viruses*, 9th ed. A.M.Q. King, M.J. Adams, E.B. Carstens, E.J. Lefkowitz, eds. Elsevier Academic Press, New York. 125–41.
62. Hess, M. 2000. Detection and differentiation of avian adenoviruses: a review. *Avian Pathol.* 29(3):195–206.
63. Hess, M., A. Cuzange, R.W. Ruigrok, J. Chroboczek, and B.Jacrot. 1995. The avian adenovirus penton: two fibres and one base. *J Mol Biol.* 252(4):379–85.
64. Hess, M., C. Prusas, and G. Monreal. 1998. Growth analysis of adenoviruses isolated from pigeons in chicken cells and serological characterization of the isolates. *Avian Pathol.* 27(2): 196–9.
65. Hess, M., C. Prusas, M. Vereecken, and H.P. De. 1998. Isolation of fowl adenoviruses serotype 4 from pigeons with hepatic necrosis. *Berl Munch Tierarztl Wochenschr.* 111(4):140–2.
66. Hess, M., R. Raue, and C. Prusas. 1999. Epidemiological studies on fowl adenoviruses isolated from cases of infectious hydropericardium. *Avian Pathol.* 28(5):433–9.
67. Hollmén,T.E., J.C. Franson, P.L. Flint, J.B. Grand, R.B. Lanctot, D.E. Docherty, and H.M. Wilson. 2003. An adenovirus linked to mortality and disease in long-tailed ducks (*Clangula hyemalis*) in Alaska. *Avian Dis.* 47(4):1434–40.
68. Howell, J., D.W. MacDonald, and R.G. Christian. 1970. Inclusion body hepatitis in chickens. *Can Vet J.* 11(5):99–101.
69. Itakura, C., M. Yasuba, and M. Goto. 1974. Histopathological studies on inclusion body hepatitis in broiler chickens. *Nihon Juigaku Zasshi.* 36(4):329–40.
70. Ivanics, E., V. Palya, B. Markos, A. Dán, K. Ursu, B. Harrach, G.Kaján, and R. Glávits. 2010. Hepatitis and hydropericardium syndrome associated with adenovirus infection in goslings. *Acta Vet Hung.* 58(1):47–58.
71. Jaffery, M.S. 1988. A treatise on Angara disease (hydropericardium-pulmonary oedema-hepatonephritis syndrome. *J Pakistan Vet Med Assoc.* 34:1–34.
72. Johnson, M.A., C. Pooley, J. Ignjatovic, and S.G. Tyack. 2003. A recombinant fowl adenovirus expressing the S1 gene of infectious bronchitis virus protects against challenge with infectious bronchitis virus. *Vaccine.* 21(21–22):2730–6.
73. Jones, R.C., and K. Georgiou. 1984. Experimental infection of chickens with adenoviruses isolated from tenosynovitis. *Avian Pathol.* 13(1):13–23.
74. Jorgensen, P.H., L. Otte, O.L. Nielsen, and M. Bisgaard. 1995. Influence of subclinical virus infections and other factors on broiler flock performance. *Br Poult Sci.* 36(3):455–63.
75. Kajan, G.L., R. Stefancsik, K. Ursu, V. Palya, and M. Benko. 2010. The first complete genome sequence of a non-chicken aviadenovirus, proposed to be turkey adenovirus 1. *Virus Res.* 153(2):226–33.
76. Kawamura, H., and T. Horiuchi. 2011. Pathological changes in chickens inoculated with CELO virus. *Natl Inst Anim Health Q (Tokyo).* 4:31–9.
77. Kawamura, H., H. Sato, H. Tsubahara, and S. Isogai. 1963. Isolation of CELO virus from chicken trachea. *Natl Inst Anim Health Q (Tokyo).* 3:1–10.
78. Kawamura, H., F. Shimizu, and H. Tsubahara. 1964. Avian adenovirus: Its properties and serological classification. *Natl Inst Anim Health Q (Tokyo).* 4:183–93.
79. Kim, J.N., S.H. Byun, M.J. Kim, J. Kim, H.W. Sung, and I.P. Mo. 2008. Outbreaks of hydropericardium syndrome and molecular characterization of Korean fowl adenoviral isolates. *Avian Dis.* 52(3):526–30.
80. Kles, V., M. Morin, G. Plassiart, M. Guittet, and G. Bennejean. 1991. Isolation of an adenovirus responsible for a case of pancreatitis in guinea fowl. *Zentralbl Veterinarmed B.* 38(8):610–20.
81. Latimer KS, Niagro FD, Williams OC, Ramis A, Goodwin MA, Ritchie BW, Campagnoli RP. 1997. Diagnosis of avian adenovirus infections using DNA in situ hybridization. *Avian Dis.* 41(4):773–82.
82. Laver, W.G., H.B. Younghusband, and N.G. Wrigley. 1971. Purification and properties of chick embryo lethal orphan virus (an avian adenovirus). *Virology.* 45(3):598–614.
83. Lobanov, V.A., V.V. Borisov, A.V. Borisov, V.V. Drygin, A.A. Gusev, M.M. Shmarov, T.A. Akopian, and B.S. Naroditskiĭ. 2000. Sequence analysis of hexon gene from adenovirus KR95 inducing hydropericardium syndrome in chickens. *Mol Gen Mikrobiol Virusol.* 1:30–6.
84. Macpherson, I., J.S. McDougall, and A.P. Laursen-Jones. 1974. Inclusion body hepatitis in a broiler integration. *Vet Rec.* 95(13):286–9.
85. Manarolla, G., G. Pisoni, P. Moroni, D. Gallazzi, G. Sironi, and T. Rampin. 2009. Adenoviral gizzard erosions in Italian chicken flocks. *Vet Rec.* 164(24):754–6.
86. Mansoor, M.K., I. Hussain, M. Arshad, and G. Muhammad. 2011. Preparation and evaluation of chicken embryo-adapted fowl adenovirus serotype 4 vaccine in broiler chickens. *Trop Anim Health Prod.* 43(2):331–8.
87. Marek, A., A. Gunes, E. Schulz, and M. Hess. 2010. Classification of fowl adenoviruses by use of phylogenetic analysis and high-resolution melting-curve analysis of the hexon L1 gene region. *J Virol Methods.* 170(1–2):147–54.
88. Marek, A., V. Nolte, A. Schachner, E. Berger, C. Schlotterer, and M. Hess. 2011. Two fiber genes of nearly equal lengths are a common and distinctive feature of Fowl adenovirus C members. *Vet Microbiol.* 156(3–4):411–7.
89. Marek, A., E. Schulz, C. Hess, and M. Hess. 2010. Comparison of the fibers of Fowl adenovirus A serotype 1 isolates from chickens with gizzard erosions in Europe and apathogenic reference strains. *J Vet Diagn Invest.* 22(6):937–41.
90. Mase, M., H. Mitake, T. Inoue, and T. Imada. 2009. Identification of group I-III avian adenovirus by PCR coupled with direct sequencing of the hexon gene. *J Vet Med Sci.* 71(9):1239–42.
91. Mase, M., K. Nakamura, and T. Imada. 2010. Characterization of Fowl adenovirus serotype 4 isolated from chickens with hydropericardium syndrome based on analysis of the short fiber protein gene. *J Vet Diagn Invest.* 22(2):218–23.

92. Mazaheri, A., C. Prusas, M. Voß, and M. Hess. 1998. Some strains of serotype 4 fowl adenovirues cause inclusion body hepatitis and hydropericardium syndrome in chickens. *Avian Pathol.* 27:269–76.
93. McCracken, R.M., and B.M. Adair. 1993. Avian adenoviruses. In: *Viral Infections of Vertebrates*, Vol. 4. Viral Infections of Birds, Chapter 7. J.B. McFerran, M.S. McNulty, eds. Elsevier Scientific Publishing Company, Amsterdam. 123–44.
94. McCracken, R.M., J.B. McFerran, R.T. Evans, and T.J. Connor. 1976. Experimental studies on the aetiology of inclusion body hepatitis. *Avian Pathol.* 5(4):325–39.
95. McDougall, J.S., and R.W. Peters. 1974. Avian adenoviruses: a study of 8 field isolates. *Res Vet Sci.* 16(1):12–8.
96. McFerran, J.B. 1981. Adenoviruses of vertebrate animals. In: *Comparative Diagnosis of Viral Diseases III*. E. Kurstak and C. Kurstak, eds. Academic Press, New York. 102–65.
97. McFerran, J.B., and B.M. Adair. 1977. Avian adenoviruses—a review. *Avian Pathol.* 6(3):189–217.
98. McFerran, J.B., J.K. Clarke, and T.J. Connor. 1972. Serological classification of avian adenoviruses. *Arch Gesamte Virusforsch.* 39(1):132–9.
99. McFerran, J.B., T.J. Connor, and R.M. McCracken. 1976. Isolation of adenoviruses and reoviruses from avian species other than domestic fowl. *Avian Dis.* 20(3):519–24.
100. McFerran, J.B., W.A. Gordon, S.M. Taylor, and P.J. McParland. 1971. Isolation of viruses from 94 flocks of fowls with respiratory disease. *Res Vet Sci.* 12(6):565–9.
101. McFerran, J.B., R.M. McCracken, T.J. Connor, and R.T. Evans. 1976. Isolation of viruses from clinical outbreaks of inclusion body hepatitis. *Avian Pathol.* 5(4):315–24.
102. McFerran, J.B., and J.A. Smyth. 2000. Avian adenoviruses. *Rev Sci Tech.* 19:589–601.
103. Mendelson, C., H.B. Nothelfer, and G. Monreal. 1995. Identification and characterization of an avian adenovirus isolated from a 'spiking mortality syndrome' field outbreak in broilers on the Delmarva Peninsula, USA. *Avian Pathol.* 24(4):693–706.
104. Meulemans, G., M. Boschmans, T.P. Berg, and M. Decaesstecker. 2001. Polymerase chain reaction combined with restriction enzyme analysis for detection and differentiation of fowl adenoviruses. *Avian Pathol.* 30(6):655–60.
105. Meulemans, G., B. Couvreur, M. Decaesstecker, M. Boschmans, and T.P. Van Den Berg. 2004. Phylogenetic analysis of fowl adenoviruses. *Avian Pathol.* 33(2):164–70.
106. Michou, A.I., H. Lehrmann, M. Saltik, and M. Cotten. 1999. Mutational analysis of the avian adenovirus CELO, which provides a basis for gene delivery vectors. *J Virol.* 73(2):1399–410.
107. Mockett, A.P., and J.K. Cook. 1983. The use of an enzyme-linked immunosorbent assay to detect IgG antibodies to serotype-specific and group-specific antigens of fowl adenovirus serotypes 2, 3 and 4. *J Virol Methods.* 7(5–6):327–35.
108. Monreal, G. 1992. Adenoviruses and adeno-associated viruses of poultry. *Poult Sci.* 4:1–27.
109. Moscoso, H., J.J. Bruzual, H. Sellers, and C.L. Hofacre. 2007. FTA (R) liver impressions as DNA template for detecting and genotyping fowl adenovirus. *Avian Dis.* 51(1):118–21.
110. Naeem, K., and H.S. Akram. 1995. Hydropericardium syndrome outbreak in a pigeon flock. *Vet Rec.* 136(12):296–7.
111. Naeem, K., T. Niazi, S.A. Malik, and A.H. Cheema. 1995. Development of cell culture vaccine against HPS in poultry. *Pakistan Vet J.* 15:150–1.
112. Naeem, K., T. Niazi, S.A. Malik, and A.H. Cheema. 1995. Immunosuppressive potential and pathogenicity of an avian adenovirus isolate involved in hydropericardium syndrome in broilers. *Avian Dis.* 39(4):723–8.
113. Nakamura, K., M. Mase, S. Yamaguchi, T. Shibahara, and N. Yuasa. 1999. Pathologic study of specific-pathogen-free chicks and hens inoculated with adenovirus isolated from hydropericardium syndrome. *Avian Dis.* 43(3):414–23.
114. Nakamura, K., M. Mase, S. Yamaguchi, and N. Yuasa. 2000.Induction of hydropericardium in one-day-old specific-pathogen-free chicks by adenoviruses from inclusion body hepatitis. *Avian Dis.* 44(1):192–6.
115. Nakamura, K., T. Ohyama, M. Yamada, T. Abe, H. Tanaka, and M. Mase. 2002. Experimental gizzard erosions in specific-pathogen-free chicks by serotype 1 group I avian adenoviruses in broilers. *Avian Dis.* 46:893–900.
116. Nakamura, K., H. Tanaka, M. Mase, T. Imada, and M. Yamada. 2002. Pancreatic necrosis and ventricular erosion in adenovirus-associated hydropericardium syndrome of broilers. *Vet Pathol.* 39(3):403–6.
117. Ojkic, D., P.J. Krell, T. Tuboly, and E. Nagy. 2008. Characterization of fowl adenoviruses isolated in Ontario and Quebec, Canada. *Can J Vet Res.* 72(3):236–41.
118. Ojkic, D., E. Martin, J. Swinton, J.P. Vaillancourt, M. Boulianne, and S. Gomis. 2008. Genotyping of Canadian isolates of fowl adenoviruses. *Avian Pathol.* 37(1):95–100.
119. Ojkic, D., and E. Nagy. 2000. The complete nucleotide sequence of fowl adenovirus type 8. *J Gen Virol.* 81(Pt 7):1833–7.
120. Ojkic, D., and E. Nagy. 2003. Antibody response and virus tissue distribution in chickens inoculated with wild-type and recombinant fowl adenoviruses. *Vaccine.* 22(1):42–8.
121. Okuda, Y., M. Ono, I. Shibata, and S. Sato. 2004. Pathogenicity of serotype 8 fowl adenovirus isolated from gizzard erosions of slaughtered broiler chickens. *J Vet Med Sci.* 66(12):1561–6.
122. Okuda, Y., M. Ono, I. Shibata, S. Sato, and H. Akashi. 2006. Comparison of the polymerase chain reaction-restriction fragment length polymorphism pattern of the fiber gene and pathogenicity of serotype-1 fowl adenovirus isolates from gizzard erosions and from feces of clinically healthy chickens in Japan. *J Vet Diagn Invest.* 18(2):162–7.
123. Okuda, Y., M. Ono, S. Yazawa, I. Shibata, and S. Sato. 2001. Experimental infection of specific-pathogen-free chickens with serotype-1 fowl adenovirus isolated from a broiler chicken with gizzard erosions. *Avian Dis.* 45(1):19–25.
124. Ono, M., Y. Okuda, I. Shibata, S. Sato, and K. Okada. 2004. Pathogenicity by parenteral injection of fowl adenovirus isolated from gizzard erosion and resistance to reinfection in adenoviral gizzard erosion in chickens. *Vet Pathol.* 41(5):483–9.
125. Ono, M., Y. Okuda, S. Yazawa, Y. Imai, I. Shibata, S. Sato, and K. Okada. 2003. Adenoviral gizzard erosion in commercial broiler chickens. *Vet Pathol.* 40(3):294–303.
126. Ono, M., Y. Okuda, S. Yazawa, I. Shibata, S. Sato, and K. Okada. 2003. Outbreaks of adenoviral gizzard erosion in slaughtered broiler chickens in Japan. *Vet Rec.* 153(25):775–9.
127. Ono, M., Y. Okuda, S. Yazawa, I. Shibata, N. Tanimura, K. Kimura, M. Haritani, M. Mase, and S. Sato. 2001. Epizootic outbreaks of gizzard erosion associated with adenovirus infection in chickens. *Avian Dis.* 45(1):268–75.
128. Pallister, J., P.J. Wright, and M. Sheppard. 1996. A single gene encoding the fiber is responsible for variations in virulence in the fowl adenoviruses. *J Virol.* 70(8):5115–22.

129. Pizzuto, M.S., C. DeBattisti, S. Marciano, I. Capua, and G. Cattoli. 2010. Pyrosequencing analysis for a rapid classification of fowl adenovirus species. *Avian Pathol.* 39:391–8.
130. Rahul, S., J.M. Kataria, N. Senthilkumar, K. Dhama, S.A. Sylvester, and R. Uma. 2005. Association of fowl adenovirus serotype 12 with hydropericardium syndrome of poultry in India. *Acta Virol.* 49(2):139–43.
131. Raines, A.M., A. Kocan, and R. Schmidt. 1997. Experimental inoculation of adenovirus in ostrich chicks (*Struthio camelus*). *J Avian Med Surg.* 11:255–9.
132. Ramis, A., M.J. Marlasca, N. Majo, and L. Ferrer. 1992. Inclusion body hepatitis (IBH) in a group of eclectus parrots (*Eclectus roratus*). *Avian Pathol.* 21(1):165–9.
133. Raue, R., H. Gerlach, and H. Muller. 2005. Phylogenetic analysis of the hexon loop 1 region of an adenovirus from psittacine birds supports the existence of a new psittacine adenovirus (PsAdV). *Arch Virol.* 150(10):1933–43.
134. Raue, R., H.M. Hafez, and M. Hess. 2002. A fiber gene-based polymerase chain reaction for specific detection of pigeon adenovirus. *Avian Pathol.* 31(1):95–9.
135. Raue, R., and M. Hess. 1998. Hexon based PCRs combined with restriction enzyme analysis for rapid detection and differentiation of fowl adenoviruses and egg drop syndrome virus. *J Virol Methods.* 73(2):211–7.
136. Rauw, F., B. Lambrecht, A. Francois, P. Langlois, and B.T. Van Den. 2007. Kinetic and biologic properties of recombinant ChIFN-gamma expressed via CELO-virus vector. *J Interferon Cytokine Res.* 27(2):111–8.
137. Reece, R.L., D.A. Barr, and D.C. Grix. 1987. Pathogenicity studies with a strain of fowl adenovirus serotype 8 (VRI-33) in chickens. *Aust Vet J.* 64(12):365–7.
138. Reece, R.L., D.A. Barr, D.C. Grix, W.M. Forsyth, R.J. Condron, and M. Hindmarsh. 1986. Observations on naturally occurring inclusion body hepatitis in Victorian chickens. *Aust Vet J.* 63(6):201–2.
139. Riddell, C. 1984. Viral hepatitis in domestic geese in Saskatchewan. *Avian Dis.* 28(3):774–82.
140. Riddell, C., J.V. den Hurk, S. Copeland, and G. Wobeser. 1992. Viral tracheitis in goslings in Saskatchewan. *Avian Dis.* 36(1):158–63.
141. Romanova, N., J.C. Corredor, and E.E. Nagy. 2009. Detection and quantitation of fowl adenovirus genome by a real-time PCR assay. *J Virol Methods.* 159(1):58–63.
142. Rosenberger, J.K., S. Klopp, R.J. Eckroade, and W.C. Krauss. 1975. The roles of the infectious bursal agent and several avian adenoviruses in the hemorrhagic-aplastic-anemia syndrome and gangrenous dermatitis. *Avian Dis.* 19(4):717–29.
143. Roy, P., S. Vairamuthu, S.M. Sakthivelan, and V. Purushothaman. 2004. Hydropericardium syndrome in Japanese quail (*Coturnix coturnix japonica*). *Vet Rec.* 155(9):273–4.
144. Russell, W.C. 2009. Adenoviruses: update on structure and function. *J Gen Virol.* 90(Pt 1):1–20.
145. Saifuddin, M., and C.R. Wilks. 1990. Reproduction of inclusion body hepatitis in conventionally raised chickens inoculated with a New Zealand isolate of avian adenovirus. *N Z Vet J.* 38(2):62–5.
146. Saifuddin, M., and C.R. Wilks. 1991. Vertical transmission of avian adenovirus associated with inclusion body hepatitis. *N Z Vet J.* 39(2):50–2.
147. Saifuddin, M., C.R. Wilks, and A. Murray. 1992. Characterisation of avian adenoviruses associated with inclusion body hepatitis. *N Z Vet J.* 40(2):52–5.
148. Schelling, S.H., D.S. Garlick, and J. Alroy. 1989. Adenoviral hepatitis in a merlin (*Falco columbarius*). *Vet Pathol.* 26(6):529–30.
149. Schonewille, E., R. Jaspers, G. Paul, and M. Hess. 2010. Specific-pathogen-free chickens vaccinated with a live FAdV-4 vaccine are fully protected against a severe challenge even in the absence of neutralizing antibodies. *Avian Dis.* 54(2):905–10.
150. Schonewille, E., A. Singh, T.W. Gobel, W. Gerner, A. Saalmuller, and M. Hess. 2008. Fowl adenovirus (FAdV) serotype 4 causes depletion of B and T cells in lymphoid organs in specific pathogen-free chickens following experimental infection. *Vet Immunol Immunopathol.* 2121(1–2):130–9.
151. Scott, M., and J.B. McFerran. 1971. Isolation of adenoviruses from turkeys. *Avian Dis.* 16:413–20.
152. Shane, S.M. 1996. Hydropericardium-hepatitis syndrome—the current world situation. *Zootec Internat.* 18:20–7.
153. Shashkova, E.V., L.V. Cherenova, D.B. Kazansky, and K.K. Doronin. 2005. Avian adenovirus vector CELO-TK displays anticancer activity in human cancer cells and suppresses established murine melanoma tumors. *Cancer Gene Ther.* 12:617–26.
154. Sheppard, M., W. Werner, E. Tsatas, R. McCoy, S. Prowse, and M. Johnson. 1998. Fowl adenovirus recombinant expressing VP2 of infectious bursal disease virus induces protective immunity against bursal disease. *Arch Virol.* 143(5):915–30.
155. Shivachandra, S.B., R.L. Sah, S.D. Singh, J.M. Kataria, and K. Manimaran. 2003. Immunosuppression in broiler chicks fed aflatoxin and inoculated with fowl adenovirus serotype-4 (FAV-4) associated with hydropericardium syndrome. *Vet Res Commun.* 27(1):39–51.
156. Shivaprasad, H.L., P.R. Woolcock, and M.D. McFarland. 2001. Group I avian adenovirus and avian adeno-associated virus in turkey poults with inclusion body hepatitis. *Avian Pathol.* 30(6):661–6.
157. Sileo, L., J.C. Franson, D.L. Graham, C.H. Domermuth, B.A. Rattner, and O.H. Pattee. 1983. Hemorrhagic enteritis in captive American kestrels (*Falco sparverius*). *J Wildl Dis.* 19(3):244–7.
158. Singh, A., M.S. Oberoi, S.K. Jand, and B. Singh. 1996. Epidemiology of inclusion body hepatitis in poultry in northern India from 1990 to 1994. *Rev Sci Tech.* 15(3):1053–60.
159. Steer, P.A., N.C. Kirkpatrick, D. O'sourke, and A.H. Noormohammadi. 2009. Classification of fowl adenovirus serotypes by use of high-resolution melting-curve analysis of the hexon gene region. *J Clin Microbiol.* 47(2):311–21.
160. Steer, P.A., D. O'sourke, S.A. Ghorashi, and A.H. Noormohammadi. 2011. Application of high-resolution melting curve analysis for typing of fowl adenoviruses in field cases of inclusion body hepatitis. *Aust Vet J.* 89(5):184–92.
161. Takase, K., N. Yoshinaga, T. Egashira, T. Uchimura, and M. Yamamoto. 1990. Avian adenovirus isolated from pigeons affected with inclusion body hepatitis. *Nippon Juigaku Zasshi.* 52(2):207–15.
162. Tan, P.K., A.I. Michou, J.M. Bergelson, and M. Cotten. 2001. Defining CAR as a cellular receptor for the avian adenovirus CELO using a genetic analysis of the two viral fibre proteins. *J Gen Virol.* 82(Pt 6):1465–72.
163. Tanimura, N., K. Nakamura, K. Imai, M. Maeda, T. Gobo, S. Nitta, T. Ishihara, and H. Amano. 1993. Necrotizing pancreatitis and gizzard erosion associated with adenovirus infection in chickens. *Avian Dis.* 37(2):606–11.
164. Toro, H., C. Gonzalez, L. Cerda, M. Hess, E. Reyes, and C. Geissea. 2000. Chicken anemia virus and fowl adenoviruses:

association to induce the inclusion body hepatitis/ hydropericardium syndrome. *Avian Dis.* 44(1):51–8.
165. Toro, H., C. Gonzalez, L. Cerda, M.A. Morales, P. Dooner, and M. Salamero. 2002. Prevention of inclusion body hepatitis/ hydropericardium syndrome in progeny chickens by vaccination of breeders with fowl adenovirus and chicken anemia virus. *Avian Dis.* 46(3):547–54.
166. Toro, H., O. Gonzalez, C. Escobar, L. Cerda, M.A. Morales, and C. Gonzalez. 2001. Vertical induction of the inclusion body hepatitis/hydropericardium syndrome with fowl adenovirus and chicken anemia virus. *Avian Dis.* 45(1):215–22.
167. Toro, H., C. Prusas, R. Raue, L. Cerda, C. Geisse, C. González, and M. Hess. 1999. Characterization of fowl adenoviruses from outbreaks of inclusion body hepatitis/hydropericardium syndrome in Chile. *Avian Dis.* 43(2):262–70.
168. Vereecken, M., H.P. De, and R. Ducatelle. 1998. Adenovirus infections in pigeons: A review. *Avian Pathol* 27(4):333–8.
169. von Bülow, V., R. Rudolph, and B. Fuchs. 1986. Folgen der Doppelinfektion von Küken mit Adenovirus oder Reovirus und dem Erreger der Aviären Infektiösen Anämie (CAA). *J Vet Med B.* 33:717–26.
170. Wilson, F.D., R.E. Wills, C.G. Senties-Cue, W.R. Maslin, P.A. Stayer, and D.L. Magee. 2010. High incidence of glomerulonephritis associated with inclusion body hepatitis in broiler chickens: routine histopathology and histomorphometric studies. *Avian Dis.* 54(3):975–80.
171. Xie, Z., A.A. Fadl, T. Girshick, and M.I. Khan. 1999. Detection of avian adenovirus by polymerase chain reaction. *Avian Dis.* 43(1):98–105.
172. Yates, V.J., Y.O. Rhee, and D.E. Fry. 1977. Serological response of chickens exposed to a type 1 avian adenovirus alone or in combination with the adeno-associated virus. *Avian Dis.* 21(3):408–14.
173. Yates, V.J., Y.O. Rhee, D.E. Fry, A.M. El Mishad, and K.J. McCormick. 1976. The presence of avian adenoviruses and adeno-associated viruses in healthy chickens. *Avian Dis.* 20(1):146–52.
174. Zsak, L., and J. Kisary. 1984. Characterisation of adenoviruses isolated from geese. *Avian Pathol.* 13:253–64.
175. Zsak, L., and J. Kisary. 1984. Grouping of fowl adenoviruses based upon the restriction patterns of DNA generated by BamHI and HindIII. *Intervirology.* 22(2):110–4.

Atadenovirus (Egg Drop Syndrome and Related Infections)

1. Adair, B.M. 1978. Studies on the development of avian adenoviruses in cell cultures. *Avian Pathol.* 7:541–550.
2. Adair, B.M., W.L. Curran, and J.B. McFerran. 1979a. Ultrastructural studies of the replication of fowl adenovirus in primary cell cultures. *Avian Pathol.* 8:133–144.
3. Adair, B.M., J.B. McFerran, T.J. Connor, M.S. McNulty, and E.R. McKillop. 1979b. Biological and physical properties of a virus (strain 127) associated with the egg drop syndrome 1976. *Avian Pathol.* 8:249–264.
4. Adair, B.M., D. Todd, J.B. McFerran, and E.R. McKillop. 1986. Comparative serological studies with egg drop syndrome virus. *Avian Pathol.* 15:677–685.
5. Badstue, P.B., and B. Smidt. 1978. Egg drop syndrome 76 in Danish poultry. *Nord Vet Med.* 30:498–505.
6. Bartha, A. 1984. Dropped egg production in ducks associated with adenovirus infection. *Avian Pathol.* 13:119–126.
7. Bartha, A., and J. Meszaros. 1985. Experimental infection of laying hens with an adenovirus isolated from ducks showing EDS symptoms. *Acta Vet Hung.* 33:125–127.
8. Bartha, A., J. Meszaros, and J. Tanyi. 1982. Antibodies against EDS 76 avian adenovirus in bird species before 1975. *Avian Pathol.* 11:511–513.
9. Baxendale, W. 1978. Egg drop syndrome 76. *Vet Rec.* 102:285–286.
10. Baxendale, W., D. Lutticken, R. Hein, and I. McPherson. 1980. The results of field trials conducted with an inactivated vaccine against the egg drop syndrome 76 (EDS 76). *Avian Pathol.* 9:77–91.
11. Benko, M., and B. Harrach. 1998. A proposal for a new (third) genus within the family Adenoviridae. *Arch Virol.* 143/4: 829–837.
12. Benko, M., B. Harrach, G.W. Both, W.C. Russell, B.M. Adair, E. Adam, J.C. de Jong, M. Hess, M. Johnson, A. Kajon, A.H. Kidd, H.D. Lehmkuhl, Q-G. Li, V. Mautner, P. Pring-Akerblom, and G. Wadell, G. 2005. Adenoviridae. In C.M. Fauquet, M.A. Mayo, J. Maniloff, U. Desselberger, and L.A. Ball, eds. Virus Taxonomy: Classification and Nomenclature of Viruses; 8th Report of the International Committee on Taxonomy of Viruses. 213–228.
13. Bidin, Z., I. Lojkic, M. Mikec, and B. Pokric. 2007. Naturally occurring egg drop syndrome infection in turkeys. *Acta Vet. BRNO* 76:415–421.
14. Both, G.W. 2002. Identification of a unique family of F-box proteins in Atadenoviruses. *Virology.* 304:425–433
15. Bouquet, J.F., Y. Moreau, J.B. McFerran, and T.J. Connor 1982. Isolation and characterisation of an adenovirus isolated from muscovy ducks, *Avian Pathol.* 11:301–307.
16. Bragg, R.R., D.M. Allwright, and L. Coetzee. 1991. Isolation and identification of adenovirus 127, the causative agent of egg drop syndrome (EDS), from commercial laying hens in South Africa. *Onderstepoort J Vet Res.* 58:309–310.
17. Brash, M.L., J.N. Swinton, A. Weisz, and D. Ojkić. 2009. Isolation and identification of duck adenovirus 1 in ducklings with proliferative tracheitis in Ontario. *Avian Dis.* 53:317–320.
18. Brugh, M., C.W. Beard, and P. Villegas. 1984. Experimental infection of laying chickens with adenovirus 127 and with a related virus isolated from ducks. *Avian Dis.* 28:168–178.
19. Calnek, B.W. 1978. Hemagglutination-inhibition antibodies against an adenovirus (virus-127) in white Pekin ducks in the United States. *Avian Dis.* 22:798–801.
20. Cook, J.K.A. 1983. Egg drop syndrome 1976 (EDS-76) virus infection in inadequately vaccinated chickens. *Avian Pathol.* 12:9–16.
21. Cook, J.K.A., and J.H. Darbyshire. 1980. Epidemiological studies with egg drop syndrome 1976 (EDS-76) virus. *Avian Pathol.* 9:437–443.
22. Cook, J.K.A., and J.H. Darbyshire. 1981. Longitudinal studies on the egg drop syndrome 1976 (EDS 76) in the fowl following experimental infection at 1-day old. *Avian Pathol.* 10:449–459.
23. DaCheng, L., Z. WeiGuang, G. PingYuan, and Z. XiaoRong. 2004. Development of PCR method for detection of egg drop syndrome virus. *Chin J Vet Sci Technol.* 34:56–59.
24. Darbyshire, J.H., and R.W. Peters. 1980. Studies on EDS 76 virus infection in laying chickens. *Avian Pathol.* 9:277–290.

25. Das, B.B., and H.K. Pradhan. 1992. Outbreaks of egg drop syndrome due to EDS-76 virus in quail (*Coturnix coturnix japonica*). *Vet Rec.* 131:264–265.
26. Der Tyan, L., L. YaFang, and H. TienLai. 2002. A serological survey and viral isolation of egg drop syndrome in domestic laying ducks in Taiwan. *Taiwan Vet J.* 28:32–37.
27. Firth, G.A., M.J. Hall, and J.B. McFerran. 1981. Isolation of a hemagglutinating adeno-like virus related to virus 127 from an Australian poultry flock with an egg drop syndrome. *Aust Vet J.* 57:239–242.
28. Gough, R.E., M.S. Collins, and D. Spackman. 1982. Isolation of a haemagglutinating adenovirus from commercial ducks. *Vet Rec.* 110:275–276.
29. Guittet, M., J.P. Picault, and G. Bennejean. 1981. Experimental soft-shelled eggs disease (EDS 76) in guinea fowl (*Numida meleagridis*). *Proc 7th Int Cong World Vet Poult Assoc*, Oslo, Norway, 22.
30. Gulka, C.M., T.H. Piela, V.J. Yates, and C. Bagshaw. 1984. Evidence of exposure of waterfowl and other aquatic birds to the hemagglutinating duck adenovirus identical to EDS 76 virus. *J Wildl Dis.* 20:1–5.
31. Gutter, B.E. Fingerut, G. Gallili, D. Eliahu, B. Perelman, A. Finger, and J. Pitcovski. (2008). Recombinant egg drop syndrome subunit vaccine offers an alternative to virus propagation in duck eggs. *Avian Pathol.* 37:33–37
32. Harrach B., M. Benkő, G.W. Both, M. Brown, A.J. Davison, M. Echavarría, M. Hess, M.S. Jones, A. Kajon, H.D. Lehmkuhl, V. Mautner, S.K Mittal, and G. Wadell. 2011. Family Adenoviridae. In: *Virus Taxonomy: Classification and Nomenclature of Viruses. Ninth Report of the International Committee on Taxonomy of Viruses*. A.M.Q King, M.J. Adams, E.B. Carstens, and E.J. Lefkowitz, eds. Elsevier, San Diego. 95–111
33. Hess, M., H. Blocker, and P. Brandt. 1997. The complete nucleotide sequence of the egg drop syndrome virus: An intermediate between mastadenoviruses and aviadenoviruses. *Virology.* 238:145–156.
34. Higashihara, M., M. Hiruma, T. Houdatsu, S. Takai, and M. Matumoto. 1987. Experimental infection of laying chickens with egg drop syndrome 1976 virus. *Avian Dis.* 31:193–196.
35. Howell, J. 1982. Egg drop syndrome in ross brown hens: An interim report. *Surveillance.* 9:10–11.
36. Hwang, M.H., J.M. Lamas, O. Hipolito, and E.N. Silva. 1980. Egg drop syndrome 1976 a serological survey in Brazil. *Proc 6th European Poultry Conf*, Hamburg, Germany, 371–378.
37. Ivanics, E., V. Palya, R. Glavits, A. Dan, V. Palfi, T. Revesz, and M. Benko. 2001. The role of egg drop syndrome virus in acute respiratory disease of goslings. *Avian Pathol.* 30:201–208.
38. Kaleta, E.F., S.E.D. Khalaf, and O. Siegmann. 1980. Antibodies to egg drop syndrome 76 virus in wild birds in possible conjunction with egg-shell problem. *Avian Pathol.* 9:587–590.
39. Khalaf, S.E.D., E.F. Kaleta, and O. Siegmann. 1982. Comparative studies on the kinetics of hemagglutination inhibition and virus neutralising antibodies following vaccination of chickens against egg drop syndrome 1976 (EDS 76). *Dev Biol Stand.* 51:127–137.
40. Kraft, V., S. Grund, and G. Monreal. 1979. Ultrastructural characterisation of isolate 127 of egg drop syndrome 1976 virus as an adenovirus. *Avian Pathol.* 8:353–361.
41. Kumar, R., G.C. Mohanty, K.C. Verma, and Ram-Kumar. 1992. Epizootiological studies on egg drop syndrome in poultry. *Indian J Anim Sci.* 62:497–501.
42. Liu, M.R.S. 1986. Occurrence and pathology of rough and thin shelled eggs in ducks. *J Chin Soc Vet Sci.* 12:65–76.
43. Lu, Y.S., D.F. Lin, H.J. Tsai, Y.L. Lee, S.Y. Chui, C. Lee, and S.T. Huang. 1985a. Outbreaks of egg drop syndrome 1976 in Taiwan and isolation of the etiological agent. *J Chin Soc Vet Sci.* 11:157–165.
44. Lu, Y.S., H.J. Tsai, D.F. Lin, S.Y. Chiu, Y.L. Lee, and C. Lee. 1985b. Survey on antibody against egg drop syndrome 1976 virus among bird species in Taiwan. *J Chin Soc Vet Sci.* 11:151–156.
45. Malkinson, M., and Y. Weisman. 1980. Serological survey for the prevalence of antibodies to egg drop syndrome 1976 virus in domesticated and wild birds in Israel. *Avian Pathol.* 9:421–426.
46. McCracken, R.M., and J.B. McFerran. 1978. Experimental reproduction of the egg drop syndrome 1976 with a hemagglutinating adenovirus. *Avian Pathol.* 7:483–490.
47. McFerran, J.B., H.M. Rowley, M.S. McNulty, and L.J. Montgomery. 1977. Serological studies on flocks showing depressed egg production. *Avian Pathol.* 6:405–413.
48. McFerran, J.B., T.J. Connor, and B.M. Adair. 1978a. Studies on the antigenic relationship between an isolate (127) from the egg drop syndrome 1976 and a fowl adenovirus. *Avian Pathol.* 7:629–636.
49. McFerran, J.B., R.M. McCracken, E.R. McKillop, M.S. McNulty, and D.S. Collins. 1978b. Studies on a depressed egg production syndrome in Northern Ireland. *Avian Pathol.* 7:35–47.
50. Meulemans, G., D. Dekegel, J. Peeters, E. Van Meirhaeghe, and P. Halen. 1979. Isolation of an adeno-like virus from laying chickens affected by egg drop syndrome 1976. *Vlaams Diergeneeskd Tijdschr.* 2:151–157.
51. Nawathe, D.R., and A. Abegunde. 1980. Egg drop syndrome 76 in Nigeria: Serological evidence in commercial farms. *Vet Rec.* 107:466–467.
52. Parsons, D.G, C.D. Bracewell, and G. Parsons. 1980. Experimental infection of turkeys with egg drop syndrome 1976 virus and studies on the application of the haemagglutination inhibition test. *Res Vet Sci.* 29:89–92.
53. Picault, J.P. 1978. Chutes de ponte associees a la production d'oeufs sans coquille ou a coquille fragile: Proprietes de l'agent infectieuts isole au cours de la maladie. *L'Aviculteur.* 379:57–60.
54. Raj, G.D., S. Sivakumar, K. Matheswaran, M. Chandrasekhar, V. Thiagarajan, and K. Nachimuthu. 2003. Detection of egg drop syndrome virus antigen or genome by enzyme-linked immunosorbent assay or polymerase chain reaction. *Avian Pathol.* 32:545–550.
55. Rosales, G., A. Antillon, and C. Morales. 1980. Reporte en Mexico sobre la presencia de anticuerpos contra el adenovirus causante del sindrome de la baja en postura (CEPA BC-14) en parvadas de gallinas domesticas. Proc 29th West Poult Dis Conf., 192–196.
56. Schloer, G.M. 1980. Frequency of antibody to adenovirus 127 in domestic ducks and wild waterfowl. *Avian Dis.* 24:91–98.
57. Senthilkumar, N., J.M. Kataria, K. Dhama, and K. Madhuri. 2004. Development of antigen capture ELISA for the detection of egg drop syndrome-76 virus in chickens. 2004. *Indian J Poult Sci.* 39: 90–94.
58. Senthilkumar, N., J.M. Kataria, M. Koti, K. Dhama, and B.B. Dash. 2004. Restriction enzyme analysis of Indian isolates of egg drop syndrome 1976 virus recovered from chicken, duck and quail. *Vet Res Comm.* 28: 447–453.
59. Singh, K.Y., and M. Chew-Lim. 1981. Breeder farm egg drop syndrome 1976 (EDS 76) in Singapore. *Singapore Vet J.* 5:8–13.
60. Smyth, J.A. 1988. A study of the pathology and pathogenesis of egg drop syndrome (EDS) virus infection in fowl. PhD

Thesis. The Queen's University of Belfast, Belfast, Northern Ireland.
61. Smyth, J.A., and B.M. Adair. 1988. Lateral transmission of egg drop syndrome 76 virus by the egg. *Avian Pathol.* 17:193–200.
62. Smyth, J.A., M.A. Platten, and J.B. McFerran. 1988. A study of the pathogenesis of egg drop syndrome in laying hens. *Avian Pathol.* 17:653–666.
63. Solyom, F., M. Nemesi, A. Forgacs, E. Balla, and T. Perenyi. 1982. Studies on EDS vaccine. *Dev Biol Stand.* 51:105–121.
64. Takai, S., M. Higashihara, and M. Matumoto. 1984. Purification and hemagglutinating properties of egg drop syndrome 1976 virus. *Arch Virol.* 80:59–67.
65. Taniguchi, T., S. Yamaguchi, M. Maeda, H. Kawamura, and T. Horiuchi. 1981. Pathological changes in laying hens inoculated with the JPA-1 strain of egg drop syndrome 1976 virus. *Natl Inst Anim Health Q (Tokyo).* 21:83–93.
66. Todd, D., and M.S. McNulty. 1978. Biochemical studies on a virus associated with egg drop syndrome 1976. *J Gen Virol.* 40:63–75.
67. Todd, D., M.S. McNulty, and J.A. Smyth. 1988. Differentiation of egg drop syndrome virus isolates by restriction endonuclease analysis of virus DNA. *Avian Pathol.* 17:909–919.
68. Tsukamoto, K., M. Kuwabara, M. Kaneko, M. Mase and K. Imai. 2004. *Avian Dis.* 48: 220–223.
69. Van Eck, J.H.H., F.G. Davelaar, T.A.M. Van den Heuvel-Plesman, N. Van Kol, B. Kouwenhoven, and F.H.M. Guldie. 1976. Dropped egg production, soft shelled and shell-less eggs associated with appearance of precipitins to adenovirus in flocks of laying fowl. *Avian Pathol.* 5:261–272.
70. Villegas, P., S.H. Kleven, C.S. Eidson, and D. Trampel 1979. Isolation of a hemagglutinating adenovirus serologically related to adenovirus 127. *Avian Dis.* 23:507–514.
71. Watanabe, T., and H. Ohmi. 1983. Susceptibility of guinea fowls to the virus of infectious laryngotracheitis and egg drop syndrome 1976. *J Agric Sci (Japan).* 28:193–200.
72. WenGui, L., Y. NaiSheng, and S. JianLing. 2000. Study on a nested polymerase chain reaction for detecting egg drop syndrome virus. *Chin J Vet Sci Technol.* 30:5–8.
73. Wigand, R., A. Bartha, R.S. Dreizin, H. Esche, H.S. Ginsberg, M. Green, S.S. Hierholzer, S.S. Kalter, J.B. McFerran, U. Pettersson, W.C. Russell, and G. Wadell. 1982. Adenoviridae: Second report. *Intervirology.* 18:169–176.
74. Yamaguchi, S., H. Imada, H. Kawamura, T. Taniguchi, H. Saio, and K. Shimamatsu. 1981a. Outbreaks of egg drop syndrome 1976 in Japan and its etiological agent. *Avian Dis.* 25:628–641.
75. Yamaguchi, S., T. Imada, H. Kawamura, T. Taniguchi, and M. Kawakami. 1981b. Pathogenicity and distribution of egg drop syndrome 1976 virus (JPA-1) in inoculated laying hens. *Avian Dis.* 25:642–649.
76. Zakharchuk, A.N., V.A. Kruglyak, T.A. Akopian, B.S. Naroditsky, and T.I. Tikchonenko. 1993. Physical mapping and homology studies of egg drop syndrome (EDS-76) adenovirus DNA. *Arch Virol.* 128:171–176.
77. Zanella, A., A. Di Donato, A. Nigrelli, and G. Poli. 1980. Egg drop syndrome (EDS 76). Etiopathogenesis, epidemiology, immunology and control of the disease. *Clin Vet*. 103:459–469.
78. Zhu, G.Q., and Y.K. Wang. 1994. Study on egg drop syndrome 1976 (EDS-76) and its control. *J Jiangsu Agric Coll.* 15:5–13.
79. Zsak, L., and J. Kisary. 1981. Some biological and physico-chemical properties of egg drop syndrome (EDS) avian adenovirus strain B8/78. *Arch Virol.* 68:211–219.
80. Zsak, L., A. Szekely, and J. Kisary. 1982. Experimental infection of young and laying geese with egg drop syndrome 1976 adenovirus strain B8/78. *Avian Pathol.* 11:555–562.

Hemorrhagic Enteritis and Related Infections

1. Ahmad, J., and J.M. Sharma. 1993. Protection against hemorrhagic enteritis and Newcastle disease in turkeys by embryo vaccination with monovalent and bivalent vaccines. *Avian Dis.* 37:485–491.
2. Andral, B., M. Metz, D. Toquin, J. LeCoz, and J. Newman. 1985. Respiratory disease (rhinotracheitis) of turkeys in Brittany, France. III. Interaction of multiple infecting agents. *Avian Dis.* 29:233–243.
3. Barbour, E.K., P.E. Poss, M.K. Brinton, J.B. Johnson, and N.H. Nabbut. 1993. Evaluation of cell culture propagated and *in vivo* propagated hemorrhagic enteritis vaccines in turkeys. *Vet Immunol Immunopathol.* 35:375–383.
4. Beach, N.M., 2006. *Characterization of avirulent turkey hemorrhagic enteritis virus: a study of the molecular basis for variation in virulence and the occurrence of persistent infection*. PhD diss., Virginia Polytechnic Institute and State University, Blacksburg, VA.
5. Beach, N.M., R.B. Duncan, C.T. Larsen, X.J. Meng, N. Sriranganathan, and F.W. Pierson 2009a. Comparison of 12 turkey hemorrhagic enteritis virus isolates allows prediction of genetic factors affecting virulence. *J Gen Virol.* 90:1978–1985.
6. Beach, N.M., R.B. Duncan, C.T. Larsen, X. Meng, N. Sriranganathan, and F.W. Pierson. 2009b. Persistent infection in turkeys with an avirulent strain of turkey hemorrhagic enteritis virus. *Avian Dis.* 53:370–375.
7. Bygrave, A.C., and M. Pattison. 1973. Marble spleen disease in pheasants (*Phasianus colchicus*). *Vet Rec.* 92:534–535.
8. Carlson, H.C., F. Al-Sheikhly, J.R. Pettit, and G.L. Seawright. 1974. Virus particles in spleens and intestines of turkeys with hemorrhagic enteritis. *Avian Dis.* 18:67–73.
9. Carlson, H.C., J.R. Pettit, R.V. Hemsley, and W.R. Mitchell. 1973. Marble spleen disease of pheasants in Ontario. *Can J Comp Med.* 37:281–286.
10. Chary, P., S. Rautenschlein, and J.M. Sharma. 2002. Reduced efficacy of hemorrhagic enteritis virus vaccine in turkeys exposed to avian pneumovirus. *Avian Dis.* 46:353–359.
11. Cowen, B.S., H. Rothenbacher, L.D. Schwartz, M.O. Braune, and R.L. Owen. 1988. A case of acute pulmonary edema, splenomegaly, and ascites in guinea fowl. *Avian Dis.* 32:151–156.
12. Davidson, I., A. Aronovici, Y. Weisman, and M. Malkinson. 1985. Enzyme immunoassay studies on the serological response of turkeys to hemorrhagic enteritis virus. *Avian Dis.* 29:43–52.
13. Davison, A.J., K.M. Wright, and B. Harrach. 2000. DNA sequence of frog adenovirus. *J Gen Virol.* 10:2431–2439.
14. Davison, A.J., and B. Harrach. 2012. Siadenovirus. In: *The Springer Index of Viruses*, Part 1. C.A. Tidona and G. Darai, eds. Springer-Verlag, Berlin. 49–566.
15. Davison, A.J., M. Benko, and B. Harrach. 2003. Genetic content and evolution of adenoviruses. *J Gen Virol.* 84:2895–2908.
16. Domermuth, C.H., D.J. Forrester, D.O. Trainer, and W.J. Bigler. 1977. Serologic examination of wild birds for hemorrhagic enter-

itis of turkey and marble spleen disease of pheasants. *J Wildl Dis.* 13:405–408.
17. Domermuth, C.H., and W.B. Gross. 1971. Effect of disinfectants and drying on the virus of hemorrhagic enteritis of turkeys. *Avian Dis.* 15:94–97.
18. Domermuth, C.H., and W.B. Gross. 1972. Effect of chlorine on the virus of hemorrhagic enteritis of turkeys. *Avian Dis.* 16:952–953.
19. Domermuth, C.H., and W.B. Gross. 1975. Hemorrhagic enteritis of turkeys. Antiserum—efficacy, preparation and use. *Avian Dis*. 19:657–665.
20. Domermuth, C.H., and W.B. Gross. 1984. Hemorrhagic enteritis and related infections. In: *Diseases of Poultry*, 8th ed. M.S. Hofstad, H.J. Barnes, B.W. Calnek, W.M. Reid, and H.W. Yoder, Jr., eds. Iowa State University Press, Ames, IA. 511–516.
21. Domermuth, C.H., and W.B. Gross. 1991. Hemorrhagic enteritis and related infections. In: *Diseases of Poultry*, 9th Ed. B.W. Calnek, H.J. Barnes, C.W. Beard, W.M. Reid, and H.W. Yoder, Jr., eds. Iowa State University Press, Ames, IA. 567–572.
22. Domermuth, C.H., W.B. Gross, C.S. Douglass, R.T. DuBose, J.R. Harris, and R.B. Davis. 1977. Vaccination for hemorrhagic enteritis of turkeys. *Avian Dis.* 21:557–565.
23. Domermuth, C.H., W.B. Gross, and R.T. DuBose. 1973. Microimmunodiffusion test for hemorrhagic enteritis of turkeys. *Avian Dis.* 17:439–444.
24. Domermuth, C.H., W.B. Gross, R.T. DuBose, C.S. Douglass, and C.B. Reubush, Jr. 1972. Agar gel diffusion precipitin test for hemorrhagic enteritis of turkeys. *Avian Dis.* 16:852–857.
25. Domermuth, C.H., W.B. Gross, R.T. DuBose, and E.T. Mallinson. 1975. Experimental reproduction and antibody inhibition of marble spleen disease of pheasants. *J Wildl Dis.* 11:338–342.
26. Domermuth, C.H., W.B. Gross, L.D. Schwartz, E.T. Mallinson, and R. Britt. 1979. Vaccination of ring-necked pheasant for marble-spleen disease. *Avian Dis.* 23:30–38.
27. Domermuth, C.H., J.R. Harris, W.B. Gross, and R.T. DuBose. 1979. A naturally occurring infection of chickens with a hemorrhagic enteritis/marble spleen disease type of virus. *Avian Dis.* 23:479–484.
28. Domermuth, C.H., C.R. Weston, B.S. Cowen, W.M. Colwell, W.B. Gross, and R.T. DuBose. 1980. Incidence and distribution of avian adenovirus group II splenomegaly of chickens. *Avian Dis.* 24:591–594.
29. Domermuth, C.H., L. van der Heide, and G.P. Faddoul. 1982. Pulmonary congestion and edema (marble spleen disease) of chickens produced by group II avian adenovirus. *Avian Dis.* 26:629–633.
30. Fadly, A.M., B.S. Cowen, and K. Nazerian. 1988. Some observations on the response of ring-necked pheasants to inoculation with various strains of cell-culture-propagated type II avian adenovirus. *Avian Dis.* 32:548–552.
31. Fadly, A.M., and K. Nazerian. 1982. Evidence for bursal involvement in the pathogenesis of hemorrhagic enteritis of turkeys. *Avian Dis.* 26:525–533.
32. Fadly, A.M., and K. Nazerian. 1989. Hemorrhagic enteritis of turkeys: Influence of maternal antibody and age at exposure. *Avian Dis.* 33:778–786.
33. Fadly, A.M., K. Nazerian, K. Nagaraja, and G. Below. 1985. Field vaccination against hemorrhagic enteritis of turkeys by a cell-culture live-virus vaccine. *Avian Dis.* 29:768–777.
34. Fasina, S.O., and J. Fabricant. 1982. *In vitro* studies of hemorrhagic enteritis virus with immunofluorescent antibody technique. *Avian Dis.* 26:150–157.
35. Fasina, S.O., and J. Fabricant. 1982. Immunofluorescence studies on the early pathogenesis of hemorrhagic enteritis virus infection in turkeys and chickens. *Avian Dis.* 26:158–163.
36. Fitzgerald, S.D., A.L. Fitzgerald, W.M. Reed, and T. Burnstein. 1992. Immune function in pheasants experimentally infected with marble spleen disease virus. *Avian Dis.* 36:410–414.
37. Fitzgerald, S.D., and W.M. Reed. 1989. A review of marble spleen disease of ring-necked pheasants. *J Wildl Dis.* 25: 455–461.
38. Fitzgerald, S.D., and W.M. Reed. 1991. Pathogenesis of marble spleen disease in bursectomized and non-bursectomized ring-necked pheasants following oral inoculation with cell-culture-propagated virus. *Avian Dis.* 35:579–584.
39. Fitzgerald, S.D., W.M. Reed, and T. Burnstein. 1991. The influence of age on the response of ring-necked pheasants to infection with marble spleen disease virus. *Avian Dis.* 35:960–964.
40. Fitzgerald, S.D., W.M. Reed, and T. Burnstein. 1992. Detection of type II avian adenoviral antigen in tissue sections using immunohistochemical staining. *Avian Dis.* 36:341–347.
41. Fitzgerald, S.D., and A. Richard. 1995. Comparison of four fixatives for routine splenic histology and immunohistochemical staining for group II avian adenovirus. *Avian Dis.* 39: 425–431.
42. Fitzgerald, S.D., W.M. Reed, A.M. Furukawa, E. Zimels, and L. Fung. 1995. Effect of T-lymphocyte depletion on the pathogenesis of marble spleen disease virus infection in ring-necked pheasants. *Avian Dis.* 39:68–73.
43. Fujiwara, H., S. Tanaami, M. Yamaguchi, and T. Yoshiro. 1975. Histopathology of hemorrhagic enteritis in turkeys. *Natl Inst Anim Hlth Quart.* 15:68–75.
44. Gale, C., and J.W. Wyne. 1957. Preliminary observations on hemorrhagic enteritis of turkeys. *Poult Sci.* 36:1267–1270.
45. Gomez-Villamandos, J.C., J.M. Martin de las Mulas, J. Hervas, F. Chancon, M. de Lara, J. Perez, and E. Mozos. 1995. Splenoenteritis caused by adenovirus in psittacine birds: A pathological study. *Avian Pathol.* 24:553–563.
46. Gordon, J.C., and T.Y. Morishita, 2002. Cleaning and disinfection of poultry facilities. http://ohioline.osu.edu/vme-fact/0013.html. 1 November, 2012.
47. Gross, W.B. 1967. Lesions of hemorrhagic enteritis. *Avian Dis.* 11:684–693.
48. Gross, W.B., and C.H. Domermuth. 1976. Spleen lesions of hemorrhagic enteritis of turkeys. *Avian Dis.* 20:455–466.
49. Gross, W.B., and W.E.C. Moore. 1967. Hemorrhagic enteritis of turkeys. *Avian Dis.* 11:296–307.
50. Harris, J.R., and C.H. Domermuth. 1977. Hemorrhagic enteritis in two-and-one-half-week-old turkey poults. *Avian Dis.* 21:120–122.
51. Hess, M., R. Raue, and H.M. Hafez. 1999. PCR for specific detection of haemorrhagic enteritis of turkeys, an avian adenovirus. *J Virol Meth.* 81:199–203.
52. Hopkins, B.A., J.K. Skeeles, G.E. Houghten, D. Slagle, and K. Gardner. 1990. A survey of infectious diseases in wild turkeys (*Meleagridis gallopavo silvestris*) from Arkansas. *J Wildl Dis.* 26:468–472.
53. Hussain, I., C.U. Choi, B.S. Rings, D.P. Shaw, and K.V. Nagaraja. 1993. Pathogenesis of hemorrhagic enteritis virus infection in turkeys. *J Vet Med.* 40:715–726.

54. Hussain, I., and, K.V. Nagaraja. 1993. A monoclonal antibody-based immunoperoxidase method for rapid detection of haemorrhagic enteritis virus of turkeys. *Res Vet Sci.* 55:98–103.
55. Ianconescu, M., E.J. Smith, A.M. Fadly, and K. Nazerian. 1984. An enzyme-linked immunosorbent assay for detection of hemorrhagic enteritis virus and associated antibodies. *Avian Dis.* 28:677–692.
56. Iltis, J.P. 1976. Experimental transmission of marble spleen disease in turkeys and pheasants with demonstration, characterization and classification of the causative virus. *Diss Abstr.* 36:4890B.
57. Iltis, J.P., S.B. Daniels, and D.S. Wyand. 1977. Demonstration of an avian adenovirus as the causative agent in marble spleen disease. *Am J Vet Res.* 38:95–100.
58. Iltis, J.P., and S.B. Daniels. 1977. Adenovirus of ring-necked pheasants: purification and partial characterization of marble spleen disease virus. *Infect Immun.* 16:701–705.
59. Iltis, J.P., R.M. Jakowski, and D.S. Wyand. 1975. Transmission of marble spleen disease in turkeys and pheasants. *Am J Vet Res.* 36:97–101.
60. Iltis, J.P., and D.S. Wyand. 1974. Indications of a viral etiology for marble spleen disease in pheasants. *J Wildl Dis.* 10: 272–278.
61. Itakura, C., and H.C. Carlson. 1975. Electron microscopic findings of cells with inclusion bodies in experimental hemorrhagic enteritis of turkeys. *Can J Com Med.* 39:299–304.
62. Itakura, C., H.C. Carlson, and G.N. Lang. 1974. Experimental transmission of hemorrhagic enteritis of turkeys. *Avian Pathol.* 3:279–292.
63. Jakowski, R.M., and D.S. Wyand. 1972. Marble spleen disease in ring-necked pheasants: demonstration of agar gel precipitin antibody in pheasants from an infected flock. *J Wildl Dis.* 8:261–263.
64. Jucker, M.T., J.R. McQuiston, J.V. van den Hurk, S.M. Boyle, and F.W. Pierson. 1996. Characterization of the haemorrhagic enteritis virus genome and the sequence of the putative penton base and core protein genes. *J Gen Virol.* 77:469–479.
65. Katoh, H., K. Ohya, M. Kubo, K. Murata, T. Yanai, and H. Fukushi. 2009. A novel budgerigar-adenovirus belonging to group II avian adenovirus of Siadenovirus. *Virus Res.* 144:294–297
66. Kayali, G., E.J. Ortiz, M.L. Chorazy, and G.C. Gray. 2009. Lack of evidence of avian adenovirus infection among turkey workers. *J Agromedicine.* 14:299–305.
67. Kovacs, E.R., and M. Benko. 2009. Confirmation of a novel siadenovirus species detected in raptors: partial sequence and phylogenetic analysis. *Virus Res.* 140:64–70.
68. Kovacs, E.R., and M. Benko. 2011. Complete sequence of raptor adenovirus 1 confirms the characteristic genome organization of siadenoviruses. *Infect Gen Evol.* 11:1058–1065.
69. Kovacs, E.R., M. Janoska, A. Dan, B. Harrach, and M. Benko. 2010. Recognition and partial genome characterization by non-specific DNA amplification and PCR of a new siadenovirus species in a sample originating from *Parus major*, a great tit. *J Virol Meth.* 163:262–268.
70. Kunze, L.S., S.D. Fitzgerald, A. Richard, R. Balander, and W.M. Reed. 1996. Variations in response of four lines of ring-necked pheasants to infection with marble spleen disease virus. *Avian Dis.* 40:306–311.
71. Larsen, C.T., C.H. Domermuth, D.P. Sponenberg, and W.B. Gross. 1985. Colibacillosis of turkeys exacerbated by hemorrhagic enteritis virus–laboratory studies. *Avian Dis.* 29: 729–732.
72. Le Gros, F.X., D. Toquin, M. Guittet, and G. Bennejean. 1989. Sensibilite comparee de quatre varietes genetiques de dinde a des souches virulentes ou attenuees du virue de l'enterite hemorragique. *Avian Pathol.* 18:147–160.
73. Lee, J.K., J.H. Choi, D.W. Lee, S.J. Kim, S.D. Fitzgerald, Y.S. Lee, and D.Y. Kim. 2001. Marble spleen disease in pheasants in Korea. *J Vet Med Sci.* 63:699–701.
74. Lucientes, J., J.F. Garcia-Marin, and J.J. Badiola. 1984. Outbreak of marble spleen disease in Spain. *Med Vet.* 1: 59–61.
75. Mandelli, G., A. Rinaldi, and G. Cervio. 1966. A disease involving the spleen and lungs in pheasants: Epidemiology, symptoms, and lesions. *Clin Vet (Milano).* 89:129–138.
76. Massi, P., D. Gelmett, G. Sironi, M. Dottori, A. Lavazza, and S. Pascucci. 1995. Adenovirus-associated haemorrhagic disease in guinea fowl. *Avian Pathol.* 24:227–237.
77. Mayeda, B., G.B. West, A.A. Bickford, and B.R. Cho. 1982. Marble spleen disease in pen-raised pheasants in California. *Proc Am Assoc Vet Lab Diag.* 25:261–270.
78. McFerran, J.B. 1997. Group I adenovirus infections. In: *Diseases of Poultry*, 10th Ed. B.W. Calnek, H.J. Barnes, C.W. Beard, L.R. McDougald, and Y.M. Saif, eds. Iowa State University Press, Ames, IA. 608–620.
79. Meade, S.M. 2004. *The effect of social stress and vitamin C on immunity and response to vaccination with hemorrhagic enteritis virus in turkeys*. PhD diss., Virginia Polytechnic Institute and State University, Blacksburg, VA.
80. Meteyer, C.U., H.O. Mohammed, R.P. Chin, A.A. Bickford, D.W. Trampel, and P.N. Klein. 1992. Relationship between age of flock seroconversion to hemorrhagic enteritis virus and appearance of adenoviral inclusions in the enteric and renal tubule epithelia of turkeys. *Avian Dis.* 36:88–96.
81. Nagaraja, K.V., D.J. Emery, B.L. Patel, B.S. Pomeroy, and J.A. Newman. 1982. *In vitro* evaluation of B-lymphocyte function in turkeys infected with hemorrhagic enteritis virus. *Am J Vet Res.* 43:502–504.
82. Nagaraja, K.V., S.Y. Kang, and J.A. Newman. 1985. Immunosuppressive effects of virulent strain of hemorrhagic enteritis virus in turkeys vaccinated against Newcastle disease. *Poult Sci.* 64:588–590.
83. Nagaraja, K.V., B.L. Patel, D.A. Emery, B.S. Pomeroy, and J.A. Newman. 1982. *In vitro* depression of the mitogenic response of lymphocytes from turkeys infected with hemorrhagic enteritis virus. *Am J Vet Res.* 43:134–136.
84. Nazerian, K., and A. Fadly. 1982. Propagation of virulent and avirulent turkey hemorrhagic enteritis virus in cell culture. *Avian Dis.* 26:816–827.
85. Nazerian, K., and A.M. Fadly. 1987. Further studies on *in vitro* and *in vivo* assays of hemorrhagic enteritis virus (HEV). *Avian Dis.* 31:234–240.
86. Nazerian, K., L.F. Lee, and W.S. Payne. 1990. A double-antibody enzyme-linked immunosorbent assay for the detection of turkey hemorrhagic enteritis virus antibody and antigen. *Avian Dis.* 34:425–432.
87. Nazerian, K., L.F. Lee, and W.S. Payne. 1991. Structural polypeptides of type II avian adenoviruses analyzed by monoclonal and polyclonal antibodies. *Avian Dis.* 35:572–578.
88. Newberry, L.A., J.K. Skeeles, D.L. Kreider, J.N. Beasley, J.D. Story, R.W. McNew, and B.R. Berridge. 1993. Use of virulent hemorrhagic enteritis virus for the induction of colibacillosis in turkeys. *Avian Dis.* 37:1–5.

89. Norton, R.A., J.K. Skeeles, and L.A. Newberry. 1993. Evaluation of the interaction of Eimeria meleagrimitis with hemorrhagic enteritis virus or marble spleen disease virus in turkeys. *Avian Dis.* 37:290–294.
90. Opengart, K.N. 1991. *Studies on the immunopathologic mechanisms of intestinal lesion formation in turkey poults infected with hemorrhagic enteritis virus*. PhD diss., Virginia Polytechnic Institute and State University, Blacksburg, VA.
91. Opengart, K., P. Eyre, and C.H. Domermuth. 1992. Increased numbers of duodenal mucosal mast cells in turkeys inoculated with hemorrhagic enteritis virus. *Am J Vet Res.* 53:814–819.
92. Ossa, I.E., J. Alexander, and G.G. Schurig. 1982. Role of splenectomy in prevention of hemorrhagic enteritis and death from hemorrhagic enteritis virus in turkeys. *Avian Dis.* 27:1106–1111.
93. Ossa, I.E., R.C. Bates, and G.G. Schurig. 1983. Hemorrhagic enteritis in turkeys: purification and quantification of the virus. *Avian Dis.* 27:235–245.
94. Perrin, G., C. Louzis, and D. Toquin. 1981. L'enterite hemorragique du dindon: Culture du virus in vitro. *Bull Acad Vet Fr.* 54:231–235.
95. Pierson, F.W. 1993. *The roles of multiple infectious agents in the predisposition of turkeys to colibacillosis*. PhD diss., Virginia Polytechnic Institute and State University Blacksburg, VA.
96. Pierson, F.W., V.D. Barta, D. Boyd, and W.S. Thompson. 1996. The association between exposure to multiple infectious agents and the development of colibacillosis in turkeys. *J Appl Poult Res.* 5:347–357.
97. Pierson, F.W., and C.H. Domermuth. 1997. Hemorrhagic enteritis, marble spleen disease, and related infections. In: *Diseases of Poultry*, 10th ed. B.W. Calnek, H.J. Barnes, C.W. Beard, L.R. McDougald, and Y.M. Saif, eds. Iowa State University Press, Ames, IA 624–632.
98. Pierson, F.W., R.B. Duncan, Jr., and D. Wise. 1998. Tissue distribution of hemorrhagic enteritis virus over time as determined by PCR. *Proceedings of the 70th Northeastern Conference on Avian Diseases*, June 10–12, Guelph, Ontario, Canada.
99. Pierson, F.W., and S.D. Fitzgerald, 2008. Hemorrhagic enteritis of turkeys, marble spleen disease of pheasants. In: *A Laboratory Manual for the Isolation and Identification of Avian Pathogens*, 5th Ed. L. Dufour-Zavala, D.E. Swayne, J.R. Glisson, J.E. Pearson, W.M. Reed, M.W. Jackwood, and P.R. Woolcock, eds. American Association of Avian Pathologists, Athens, GA. 90–93.
100. Pierson, F.W., C.T. Larsen, and C.H. Domermuth. 1996. The production of colibacillosis in turkeys following sequential exposure to Newcastle disease virus or *Bordetella avium*, avirulent hemorrhagic enteritis and *Escherichia coli*. *Avian Dis.* 40:837–840.
101. Pitcovski, J., E. Fingerut, G. Gallili, D. Eliahu, A. Finger, and B. Gutter. 2005. A subunit vaccine against hemorrhagic enteritis adenovirus. *Vaccine.* 23:4697–4702.
102. Pitcovski, J., M. Mualem, Z. Rei-Koren, S. Krispel, E. Shmueli, Y. Peretz, B. Gutter, G.E. Gallili, A. Michael, and D. Goldberg. 1998. The complete DNA sequence and genome organization of the avian adenovirus, hemorrhagic enteritis virus. *Virol.* 249:307–315.
103. Pomeroy, B.S. 1972. Hemorrhagic enteritis. In: *Diseases of Poultry*, 6th Ed. M.S. Hofstad, B.W. Calnek, C.F. Helmboldt, W.M. Reid, and H.W. Yoder, Jr., eds. Iowa State University Press, Ames, IA. 235–255.
104. Pomeroy, B.S., and R. Fenstermacher. 1937. Hemorrhagic enteritis in turkeys. *Poult Sci.* 16:378–382.
105. Rachac, V., and K. Marjankova. 1983. Occurrence of marble spleen disease in pheasants in southern Bohemia. *Veterinarstvi.* 33:359–361.
106. Rautenschlein, S., R.L. Miller, and J.M. Sharma. 2000. The inhibitory effect of imidazoquinolinamine S-28828 on the pathogenesis of type II adenovirus in turkeys. *Antiviral Res.* 46:195–205.
107. Rautenschlein, S., and J.M. Sharma. 1999. Response of turkeys to simultaneous vaccination with hemorrhagic enteritis and Newcastle disease viruses. *Avian Dis.* 43:286–292.
108. Rautenschlein, S., and J.M. Sharma. 2000. Immunopathogenesis of haemorrhagic enteritis virus (HEV) in turkeys. *Devel Comp Immno.* 24:237–246.
109. Rautenschlein, S., M. Suresh, U. Newmann, and J.M. Sharma. 1998. Comparative pathogenesis of haemorrhagic enteritis virus (HEV) infection in turkeys and chickens. *J Comp Path.* 119:251–261.
110. Rautenschlein, S., M. Suresh, and J.M. Sharma. 2000. Pathogenic avian adenovirus type II induces apoptosis in turkey spleen cells. *Arch Virol.* 145:1671–1683.
111. Saunders, G.K., F.W. Pierson, and J.V. van den Hurk. 1993. Haemorrhagic enteritis virus infection in turkeys: A comparison of virulent and avirulent virus infections, and a proposed pathogenesis. *Avian Pathol.* 22:47–58.
112. Shivaprasad, H.L., 2008. Adenovirus groupie-like infection in chukar partridges (*Alectoris chukar*). *Avian Dis.* 52:353–356.
113. Silim, A., and J. Thorsen. 1981. Hemorrhagic enteritis: Virus distribution and sequential development of antibody in turkeys. *Avian Dis.* 25:444–453.
114. Sponenberg, D.P., C.H. Domermuth, and C.T. Larsen. 1985. Field outbreaks of colibacillosis of turkeys associated with hemorrhagic enteritis virus. *Avian Dis.* 29:838–842.
115. Stoikov, V., and I. Nikiforov. 1983. Clinical features, epidemiology and pathology of marble spleen disease in pheasants. *Veterinarnomed Nauk.* 20:89–97.
116. Suresh, M., and J.M. Sharma. 1995. Hemorrhagic enteritis virus induced changes in the lymphocyte subpopulations in turkeys and the effect of experimental immunodeficiency on viral pathogens. *Vet Immunol Immunopathol.* 45:139–150.
117. Suresh, M., and J.M. Sharma. 1996. Pathogenesis of type II avian adenovirus infection in turkeys: *in vivo* immune cell tropism and tissue distribution of the virus. *J Virol.* 70:30–36.
118. Szankowska, Z., E. Kubissa, M. Piotrowska, H. Panufnik. 1982. Outbreak of marble spleen disease in pheasants in Poland. *Med Wet.* 38:288–290.
119. Sztojkov, V., F. Ratz, and E. Saghy. 1978. Marble spleen disease of pheasants in Hungary. *Magy Alltorvosok Lapja.* 33: 223–226.
120. Tham, V.L., and N.F. Thies. 1988. Marble spleen disease of pheasants. *Aust Vet J.* 65:130–131.
121. Tolin, S.A., and C.H. Domermuth. 1975. Hemorrhagic enteritis of turkeys: electron microscopy of the causal virus. *Avian Dis.* 19:118–125.
122. Trampel, D.W., C.U. Meteyer, and A.A. Bickford. 1992. Hemorrhagic enteritis virus inclusions in turkey renal tubular epithelium. *Avian Dis.* 36:1086–1091.
123. van den Hurk, J. 1985. Propagation of hemorrhagic enteritis virus in normal (nontumor derived) cell culture. *J Am Vet Med Assoc.* 187:307.

124. van den Hurk, J.V. 1986. Quantitation of hemorrhagic enteritis virus antigen and antibody using enzyme-linked immunosorbent assays. *Avian Dis.* 30:662–671.
125. van den Hurk, J. 1988. Characterization of group II avian adenoviruses using a panel of monoclonal antibodies. *Can J Vet Res.* 52:458–467.
126. van den Hurk, J.V. 1990. Efficacy of avirulent hemorrhagic enteritis virus propagated in turkey leukocyte cultures for vaccination against hemorrhagic enteritis in turkeys. *Avian Dis.* 34:26–35.
127. van den Hurk, J.V. 1992. Characterization of the structural proteins of hemorrhagic enteritis virus. *Arch Virol.* 126:195–213.
128. van den Hurk, J.V., and S. van Drunen Littel-van den Hurk. 1993. Protection of turkeys against hemorrhagic enteritis by monoclonal antibody and hexon immunization. *Vaccine.* 11:329–335.
129. Veit, H.P., C.H. Domermuth, and W.B. Gross. 1981. Histopathology of avian adenovirus group II splenomegaly of chickens. *Avian Dis.* 25:866–873.
130. Wyand, D.S., R.M. Jakowski, and C.N. Burke. 1972. Marble spleen disease in ring-necked pheasants–histology and ultrastructure. *Avian Dis.* 16:319–329.
131. Wellenham, J.F.X., C.B. Greenacre, G.J. Fleming, M.D. Stetter, A.L. Childress, and S.P. Terrell, 2009. Siadenovirus infection in two psittacine bird species. *Avian Pathol.* 38:413–417.
132. Zhang, C.L., K.V. Nagaraja, V. Sivanandan, and J.A. Newman. 1991. Identification and characterization of viral polypeptides from type-II avian adenoviruses. *Am J Vet Res.* 52:1137–1141.

Quail Bronchitis

1. Aghakhan, S.M. 1974. Avian adenoviruses. *Vet Bull.* 44:531–552.
2. DuBose, R.T. 1967. QB. *Bull Wildl Dis Assoc.* 3:10–13.
3. DuBose, R.T., and L.C. Grumbles. 1959. The relationship between QB virus and chicken embryo lethal orphan virus. *Avian Dis.* 3:321–344.
4. DuBose, R.T., L.C. Grumbles, and A.I. Flowers. 1958. The isolation of a nonbacterial agent from quail with a respiratory disease. *Poult Sci.* 37:654–658.
5. DuBose, R.T., L.C. Grumbles, and A.I. Flowers. 1960. Differentiation of QB virus and infectious bronchitis virus by heat stability. *Am J Vet Res.* 21:740–743.
6. Dutta, S.K., and B.S. Pomeroy. 1967. Electron microscopic studies of QB virus. *Am J Vet Res.* 28:296–299.
7. Jack, S.W., and W.M. Reed. 1989. Experimentally-induced QB. *Avian Dis.* 34:433–437.
8. Hess, M. 2000. Detection and differentiation of avian adenoviruses: a review. *Avian Pathol.* 29:195–206.
9. Jack, S.W., and W.M. Reed. 1990. Pathology of QB. *Avian Dis.* 34:44–51.
10. Jack, S.W., and W.M. Reed. 1990. Further characterization of an avian adenovirus associated with inclusion body hepatitis in bobwhite quail. *Avian Dis.* 34:526–530.
11. Jack, S.W. and W.M. Reed. 1994. Experimental infection of bobwhite quail with Indiana C adenovirus. *Avian Dis.* 38: 325–328.
12. Jack, S.W., W.M. Reed, and T.A. Bryan. 1987. Inclusion body hepatitis in bobwhite quail (*Colinus virginianus*). *Avian Dis.* 31:662–665.
13. Jack, S.W., W.M. Reed, and T. Burnstein. 1994. Pathogenesis of QB. *Avian Dis.* 38:548–556.
14. King, D.J., S.R. Pursglove Jr., and W.R. Davidson. 1981. Adenovirus isolation and serology from wild bobwhite quail (*Colinus virginianus*). *Avian Dis.* 25:678–682.
15. Monreal, G. 1992. Adenoviruses and adeno-associated viruses of poultry. *Poult Sci Rev.* 4:1–27.
16. Olson, N.O. 1950. A respiratory disease (bronchitis) of quail caused by a virus. Proc 54th Annu Meet US Livest Sanit Assoc. 171–174.
17. Winterfield, R.W., and A.S. Dhillon. 1980. Unpublished data.
18. Winterfield, R.W., A.M. Fadly, and A.M. Gallina. 1973. Adenovirus infection and disease. I. Some characteristics of an isolate from chickens in Indiana. *Avian Dis.* 17:334–342.
19. Yates, V.J. 1960. *Characterization of the chicken-embryo-lethal-orphan (CELO) virus*. PhD dissertation, University of Wisconsin, Madison, WI.
20. Yates, V.J., and D.E. Fry. 1957. Observations on a chicken embryo lethal orphan (CELO) virus. *Am J Vet Res.* 18:657–660.
21. Yates, V.J., P.W. Chang, A.H. Dardiri, and D.E. Fry. 1960. A study in the epizootiology of the CELO virus. *Avian Dis.* 4: 500–505.
22. Yates, V.J., D.V. Ablashi, P.W. Chang, and D.E. Fry. 1962. The chicken-embryo-lethal-orphan (CELO) virus as a tissue-culture contaminant. *Avian Dis.* 6:406–411.
23. Yates, V.J., Y.O. Rhee, and D.E. Fry. 1975. Comments on adenoviral antigens (CELO, QBV, GAL). *Am J Vet Res.* 36: 530–531.

Chapter 10

Pox

Deoki N. Tripathy and Willie M. Reed

Introduction

Definition and Synonyms

Pox is a common viral disease of commercial poultry (chickens and turkeys) as well as of pet and wild birds. Of the approximately 9,000 bird species, about 232 in 23 orders have been reported to have acquired a natural pox virus infection (9). Fowlpox is an economically important disease of commercial poultry because it can cause a drop in egg production, slow growth, and mortality. Pox is a slow-spreading disease characterized by the development of discrete nodular proliferative lesions on the non-feathered parts of the body (cutaneous form) or fibrino-necrotic and proliferative lesions in the mucous membrane of the upper respiratory tract, mouth, and esophagus (diphtheritic form). Concurrent systemic infections also may occur.

Synonyms that have been used for avipox infections are contagious epithelioma, avian diphtheria, variole aviaire (France), difteria aviar (Spain), bouba aviaria (Portugal), Geflugelpocken (Germany), virula aviar, and variola gallinarum.

Economic Significance

Mortality in flocks exhibiting the mild cutaneous form of the disease is usually low. However, it may become high with generalized infection, especially when lesions are primarily diphtheritic or when the disease is complicated by other infections or poor environmental conditions. Under those conditions the economic losses can be significant. The systemic form of disease in canaries causes high mortality.

Public Health Significance

Avianpox is not of public health significance. It does not cause productive infection in mammalian species. However, a pox virus isolated from a rhinoceros (45) was characterized as fowlpox virus (FPV).

History

Pox has long been observed in several avian species. The term fowlpox initially included all pox virus infections of birds, but now it is primarily used to refer to the disease in chickens. Initially, Woodruff and Goodpasture (98, 99, 100) presented evidence that the virus particles (Borrell bodies) within the inclusion bodies (Bollinger bodies) were the etiologic agent of fowlpox. Later, Ledingham and Aberd (41) demonstrated that antisera produced against FPV after immunization or following recovery from infection agglutinated suspensions of elementary bodies of FPV.

Etiology

Avianpox viruses infecting various avian species (canary, fowl, junco, mynah, pigeon, psittacine, quail, sparrow, starling, turkey, crow, peacock, penguin, alala, apapane, condor) are recognized within the Avipoxvirus genus in the family Poxviridae by the International Committee on taxonomy of viruses (http://ictvonline.org/virusTaxonomy.asp?version/) (3, 84, 85). FPV is the type species of the genus. Because of its economic importance, more basic and applied studies have been done on it than on any other member of this genus.

Morphology

As is the case with the members of other genera of the Poxviridae family, all avianpox viruses have a similar morphology. The mature virus (elementary body) is brick-shaped and measures about 330 x 280 x 200 nm. The outer coat is composed of random arrangements of surface tubules (Figure 10.1A). FPV and other avianpox viruses consist of an electron-dense centrally located biconcave core or nucleoid and 2 lateral bodies in each concavity, and are surrounded by an envelope (Figure 10.1B).

Chemical Composition

The main components of FPV are protein, DNA, and lipid. The virus has a particle weight of 2.04×10^{-14} g and contains 7.51×10^{-15} g protein, 4.03×10^{-16} g DNA, and 5.54×10^{-15} g lipid; nearly one-third of FPV is lipid. Squalene as a major lipid component and elevation of cholesterol esters were detected in virus preparation from infected chick scalp epithelium (43, 95). The average weight of the inclusion body is about 6.1×10^{-7} mg, 50% of which is extractable lipids. The

Diseases of Poultry, Thirteenth Edition. David E. Swayne.
© 2013 John Wiley & Sons, Inc. Published 2013 by John Wiley & Sons, Inc.

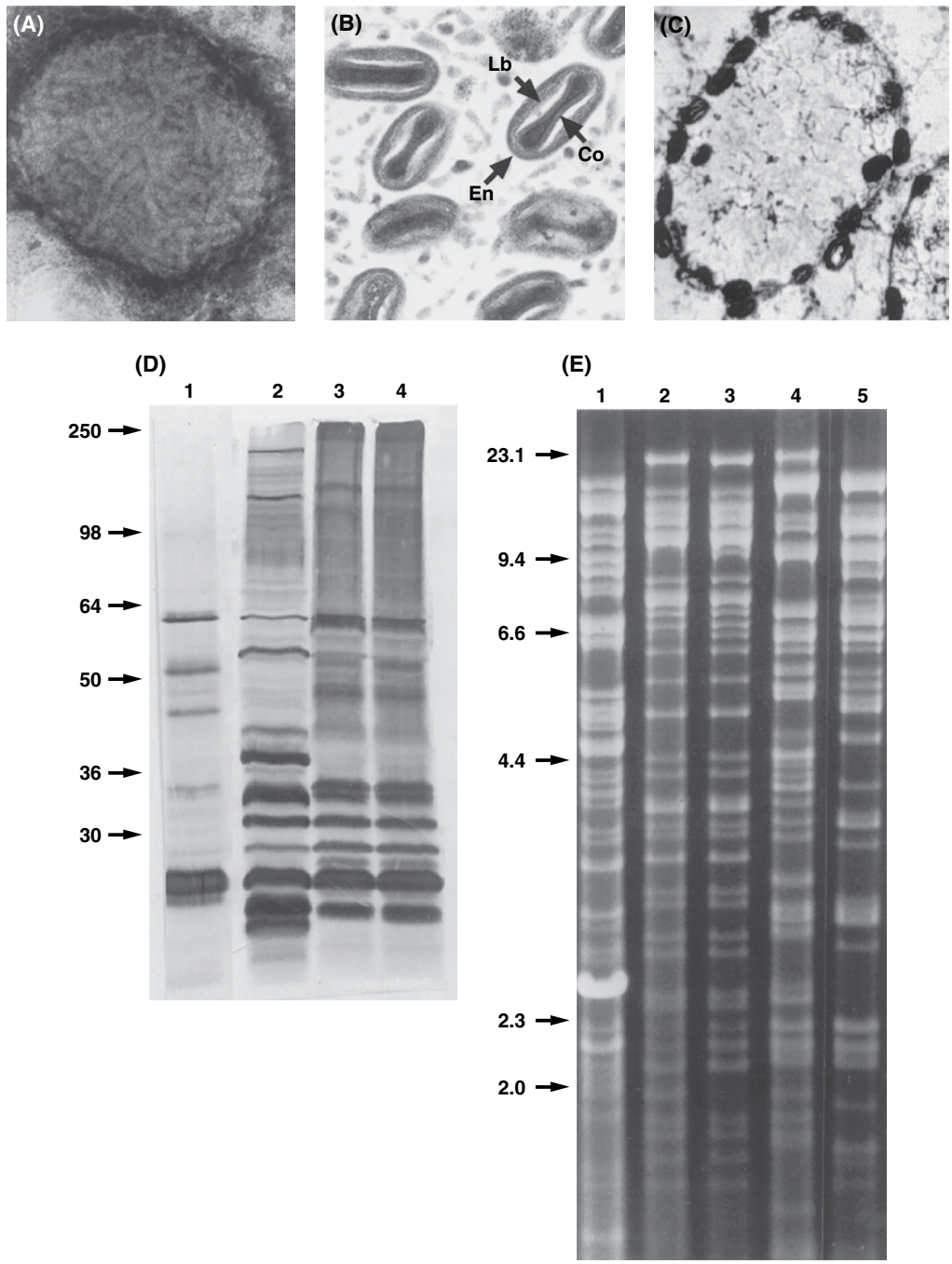

Figure 10.1. (A) Negatively stained FPV showing random distribution of surface tubules. (B) Ultrathin section of cutaneous pox lesion from a naturally infected dove showing virus particles of typical pox virus morphology. Co=core, Lb=lateral bodies, En=envelope. (Basgall) (C) Ultrathin section of diphtheritic fowl pox lesion from a chicken showing an A-type inclusion body in which virus particles of typical pox virus morphology are distributed around the periphery of the inclusion body. (D) Strain variation in antigenic composition by immunoblotting of soluble antigens of avianpox viruses. Antigens prepared from cells infected with FPV strains: 101 (lane 1), Ceva (lane 2), Minnesota (lane 3), and Nebraska (lane 4). Proteins were separated by sodium dodecyl sulfate polyacrylamide gel electrophoresis (SDS-PAGE) and transferred to nitrocellulose. Viral antigens were detected by reaction with chicken anti-FPV serum. (E) Agarose gel electrophoretic analysis of the genomes of a field isolate of (1) mynah pox, (2 and 3) a vaccine and field isolate of fowl pox, respectively, (4) a field isolate of canary pox, and (5) a vaccine isolate of quail pox virus after cleavage with HindIII. The scale on the left-hand side of the gel represents the position of the l HindIII fragments (kb).

protein content/inclusion body is 7.69×10^{-8} mg, and the average weight of DNA/inclusion is 6.64×10^{-9} mg (53, 54).

Virus Replication

The cytoplasmic site of DNA synthesis and packaging within the infectious virus particle are characteristics of pox viruses. Related information on replication of pox viruses may be found elsewhere (11, 50).

FPV contains genes that encode for a DNA ligase, ATP-GTP binding protein, uracil DNA glycosylase, DNA polymerase, DNA topoisomerase, DNA processing factor, and replication-essential protein kinase (2). In addition, FPV possesses a gene that encodes for the DNA repair enzyme, CPD photolyase that repairs UV-induced damage to the DNA by using visible light as a source of energy. It is assumed that the presence of this enzyme helps the virus prolong its survival in external lesions in poultry and in the environment (68, 70).

Replication of avianpox viruses appears to be similar in dermal or follicular epithelium of chickens, ectodermal cells of the chorioallantoic membrane (CAM) of developing chicken embryos, and embryonic skin cells. Differences in the host cell and virus strain, however, may be reflected in the time scale of replication and virus output.

Biosynthesis of FPV in dermal epithelium involves 2 distinct phases: a host response characterized by marked cellular hyperplasia during the first 72 hours and synthesis of infectious virus from 72–96 hours post infection (PI) (15, 16).

The replication of viral DNA in dermal epithelium begins between 12 and 24 hours PI and is followed by the appearance of infectious virus later. Epithelial hyperplasia between 36–48 hours PI ends in a 2.5-fold increase in cell numbers by 72 hours PI. The rate of viral DNA synthesis is low during the first 60 hours of infection. Enhancement in the rate of viral DNA synthesis occurs between 60 and 72 hours PI concomitantly with a sharp decline of cellular DNA synthesis. Between 72 and 96 hours PI, the synthesis of viral DNA becomes progressively more prominent, and no further hyperplasia is observed (15, 16). The genome of FPV contains 6 genes with putative protein modification functions. These include 3 serine/threonine protein kinase (PK), 1 tyrosine PK, a metalloprotease, and a tyrosine/serine protein phosphatase. These are involved in phosphorylation of virus proteins during virion assembly, viral protein processing, and virion morphogenesis (2).

Based upon the sequence analysis, FPV encodes homologues of at least 31 known vaccinia virus structural proteins (2), and the majority of them are associated with the intracellular mature virus particle (IMV). Of these proteins, 12 are located within the core and 7 are associated with the membrane. Three proteins also are associated with extra-cellular enveloped virions (EEVs). In addition, homologues of 5 proteins, which represent 2 conserved pox virus gene families and have putative structural functions, are present in FPV. Also, FPV contains homologues of pox virus A-type inclusion (ATI) proteins. These inclusions protect mature virions from environmental insults and assist in prolonged survival in nature. Stability of the virus in the environment may be further supported by the presence of photolyase and glutathione peroxidase (2, 68).

Ultrastructural studies have focused on the morphogenesis of the virus in various developmental stages that lead to mature virions (4, 5). After adsorption to and penetration of the cell membrane by FPV, and within 1 hour after infection of dermal epithelium or 2 hours after infection of CAM, there is uncoating of the virus before synthesis of new virus from the precursor material. Few small virus factories containing crescents and few isolated immature viruses (IV) are observed at 12 hours PI. The virus factories increase in size and contain more IV by 16 hours PI. Although the majority of viral particles appear as IV between 16 and 66 hours PI, all subsequent steps of morphogenesis also may be observed. Only a few isolated intracellular mature viruses (IMV) are detected by 47 hours PI, some of which appear completely or partially wrapped and in the process of becoming intracellular enveloped virus (IEV). IMV particles are also found in clusters associated with membranes. Accumulation of viral particles near the plasma membrane suggests that FPV exits the cell mostly by budding (11). Inclusion bodies are present at 72 hours after infection of dermal epithelium and at 96 hours after infection of the CAM (5). The A-type inclusions may contain virions within or toward the periphery (Figure 10.1C). Similar inclusions have been observed in cells infected with fowlpox, canarypox, and pigeonpox viruses, and perhaps are made by all avianpox viruses.

Susceptibility to Chemical and Physical Agents

Resistance to ether treatment is listed as a axonomic criterion for pox viruses. However, strains that were sensitive or resistant to both ether and chloroform have been reported. FPV is known to withstand 1% phenol and 1:1,000 formalin for 9 days but is inactivated by 1% caustic potash when freed from its matrix. Heating at 50°C for 30 minutes or 60°C for 8 minutes also inactivates the virus (3). Trypsin has no effect on the DNA or whole virus. When desiccated, the virus shows marked resistance. It can survive in dried scabs for months or even years.

Strain Classification

A nucleoprotein precipitinogen is common to all pox viruses (98). Avianpox viruses are antigenically and immunologically distinguishable from each other, but varying degrees of cross relationships exist. Attempts have been made to differentiate strains by immunologic methods (e.g., complement fixation, passive hemagglutination, agar gel precipitation, immunoperoxidase, enzyme-linked immunosorbent assay [ELISA], virus neutralization, and immunofluorescence) and cross protection studies (10, 55, 56). Antigenic characterization of immunogenic proteins by immunoblotting (Figure 10.1D) and genomic characterization by restriction fragment length polymorphism (RFLP) of DNA (Figure 10.1E) have been useful to some extent in detecting minor differences among the strains tested.

A monoclonal antibody has been used to differentiate FPV strains. Several major and minor immunogenic polypeptides

of FPV strains have been resolved by immunoblotting, which reveals antigenic differences among the vaccine and field strains of FPV. Similar differences are observed between FPV and viruses isolated from the wild birds. In this regard, quailpox virus showed distinct antigenic differences from FPV based on immunoblotting, although some common proteins also were detected. A pox virus isolated from the spleen of a condor was shown to be genetically, antigenically, and biologically different from FPV (34). Similarly, antigenic profiles of avianpox viruses isolated from endangered Hawaiian forest birds show differences from those of FPV (35, 36).

Genomic Differences in Avianpox Viruses

Similar to other pox viruses, the FPV genome is composed of a single linear double-stranded DNA molecule with a hairpin loop at each end. Although the overall genomic organization of FPV appears to be similar to that of other members of the Poxviridae family, some genomic rearrangement has occurred. The electrophoretic profiles of restriction enzyme-digested FPV and vaccinia virus DNAs are distinct. Although the DNA of fowlpox, pigeonpox, and juncopox virus have similar genomic profiles in the RFLP analysis , restriction endonuclease analysis profiles of quailpox, canarypox, and mynahpox virus DNA reveal marked differences from those of FPV.

Two strains of avianpox viruses from endangered Hawaiian forest birds—alala pox isolated from Hawaiian crows (*Corvus hawaiiansis*) and apapane pox isolated from an Apapane species (*Himatoine sanguinea*)—are genetically and biologically different from FPV (86). Similarly, avianpox virus strains isolated from endangered Hawaiian forest birds (palila and Hawaiian goose) were biologically different from FPV (86). Availability of nucleotide sequence of FPV and canarypox virus (2, 91) genomes has been useful in determining the phylogenetic relationship of new isolates.

The FPV genome contains a central coding region and 2 identical, inverted terminal repeat (ITR) regions of 9,520 bp at both termini. The complete sequence of the genome of a vaccine-like strain of FPV has been determined (2). It contains 288,539 bp, which is slightly smaller than some previous estimates and encodes for 260 putative genes of 60–1,949 amino acids in length. The genome of a tissue culture passaged FPV strain FP9 is approximately 260 kb in size (39). Based upon homologies with other viral or cellular genes, 101 open reading frames (ORFs) of FPV have been assigned similar or putative functions. The nucleotide composition of FPV is 69% A+T, which is uniformly distributed over the entire length of the genome. Six small regions with higher G+C content (50%) are located in the terminal genomic regions. Because of the presence of multiple and in some cases large gene families, the genome of FPV is larger than other completely sequenced pox virus genomes except the canarypox virus genome, which has a larger genome than that of FPV. In this regard, 32% of the FPV genome is composed of 31 genes in the ankyrin repeat family, 10 genes in the N1R/p28 family, and 6 genes in the B22R family. The B22R ORFs alone comprise 12% of the viral genome. Because fewer ankyrin genes were found in the genome of FPV after extensive passage in tissue culture, it is likely that in other avianpox viruses the number of ankyrin repeat genes also may vary. Since pox virus ankyrin repeat genes have been associated with host range functions, loss or disruption of many of these genes may be associated with the narrowing of host range.

Interestingly, the genomes of the majority of field isolates causing outbreaks of fowlpox in vaccinated flocks contain an integrated, nearly intact provirus copy of reticuloendotheliosis virus (REV) (Chapter 15). In contrast, only variable-length, REV long terminal repeat (LTR) remnants are present in the genome of all FPV vaccine strains (48, 65). These remnants are also retained, presumably after the loss of the REV provirus, by a minor proportion of each field strain population. Although an ubiquitin gene has been identified and sequenced in the genome of an avianpox virus isolated from Hawaiian forest birds, only fragmented remains of this gene were observed in the FPV genome. The 365-kbp canarypox virus genome (91) contains 328 potential genes in the central region and in the 6.5-kbp inverted terminal repeats.

Nucleotide sequence analysis reveals many similarities as well as genomic differences with FPV. For example, canarypox virus encodes 39 genes for which any homologue is absent from or fragmented in FPV. An intact and highly conserved homologue of cellular ubiquitin gene is disrupted in FPV, for instance. While the gene encoding for CPD-photolyase in FPV is also present in the canarypox virus genome, the REV sequences present in the FPV genome are absent in canarypox virus (19, 33, 48, 62, 65, 66).

Comparative analysis of the nucleotide sequence of a 4.5-kb HindIII fragment of condorpox virus DNA with a corresponding region of FPV genome showed marked differences. In FPV, 11 ORFs are confined in this region, including sequences related to REV integration. Condorpox virus, however, contains only 8 ORFs and does not have any REV sequences. Similarly, nucleotide sequences of a 5.3-kb Pst-HindIII fragment of the genome of an avianpox virus from a Hawaiian goose revealed very high homology with canarypox virus and homologs of 3 FPV ORFs including REV sequences were not present in its genome (34, 35). With the exception of FPV and canarypox virus, the complete nucleotide sequences of the genomes of other members of the avipox virus genus are not available at this time. However, based upon RFLP comparisons and nucleotide sequence analysis of selected genomic fragments, it is clear that genetically different strains of pox viruses infect domestic, pet, and wild birds. In this regard, the genomic profiles of canarypox, mynahpox, alalapox, apapanepox, condorpox, goosepox, and quailpox viruses determined by RFLP are markedly different from those of FPV (28, 34, 35).

Immunomodulatory and Non-Essential Genes

The functions of the proteins encoded for by more than half of the genes of FPV are not known. Some putative genes and the probable functions of their encoded proteins are briefly described here:

- A homologue of the eukaryotic transforming growth factor β (TGFβ), a multifunctional peptide that stimulates connective tissue growth and differentiation, is encoded within the FPV genome. Because TGFβ also exhibits a range of immunomodulatory effects, including suppression of cellular and humoral immune mechanisms, the FPV version may have a role in suppression of the host immune response and/or cell growth and differentiation.
- Two ORFs encoding proteins similar to the cellular β nerve growth factor (β-NGF) have been identified in the FPV genome. These proteins may play some part in inhibiting antiviral immune responses in virus-infected cutaneous and respiratory tract infections.
- Four ORFs of FPV show similarity to the CC (beta) class of small soluble chemokines. CC chemokines are known to attract T lymphocytes and natural killer (NK) cells to sites of infection. These CC chemokine homologues could function as antagonists and cause a broad-range inhibition of normal CC chemokine function during host antiviral immune responses.
- Three genes encoding proteins homologous to G-protein-coupled receptors are present in the FPV genome. It is likely that the encoding proteins may bind to chemokines involving cell signaling that affect viral replication and pathogenesis in the host.
- An ORF of FPV encodes a putative IL-18 binding protein. Because IL-18 homologues have been found to inhibit IL-18 dependent gamma interferon production, it may have an anti-inflammatory function during FPV infection.
- An ORF of FPV with homology to semaphorins is likely to be associated with immunomodulatory function.
- The FPV genome has 8 ORFs that encode proteins similar to C-type lectins NKG2 and CD94 proteins present on NK cells and CD69 located on the surface of lymphocytes. C-type lectin cellular NK cell receptors bind class I major histocompatibility complex antigens and promote or inhibit immune activity through intracellular signaling pathways. It is likely that the expression of these proteins in FPV-infected cells interferes with normal immune surveillance or host responses.
- Five homologues of serine proteinase inhibitors (serpins) encoded by FPV may be associated with host-range functions involving anti-inflammatory activity and/or regulation of cellular apoptosis in specific cells (2).

One of the characteristic features of avianpox virus infection is cellular hyperplasia of affected tissue. In this regard, a gene encoding a protein similar to epidermal growth factor (EGF) is present in the genome of FPV. Although this virus protein is not essential for virus replication, it may influence virulence, stimulate cell proliferation, and contribute to the hyperplasia observed in infected tissues. Furthermore, a homologue of the T10 gene that encodes a protein expressed at high levels in epithelial cells in the trachea, esophagus, and lung of vertebrates is present in the FPV genome. This T10 homologue may be required to extend the virus's host range to epithelial cells of the respiratory tract (2).

The FPV genome contains an ORF that encodes for a putative protein with similarity to the protein encoded by Marek's disease virus and fowl adenovirus, indicating its role in avian host range function. Interestingly, a natural dual viral infection of trachea by FPV and herpesvirus has been reported previously (25). Because homologues of FPV open reading frames were detected in the genome of Marek's disease virus (13), the likelihood of exchange of genetic material from one virus to another and emergence of a genetically and antigenically different virus is possible. In this regard, integration of full-length REV in the field isolates of the FPV genome indicates an event of natural genetic engineering in viruses. The FPV genome also contains a homologue of the glutathione peroxidase gene whose product may provide protection from oxidative stress, allowing efficient replication of virus under environmental conditions. Interaction of this enzyme with other proteins (e.g., photolyase) may have a synergistic effect on prolonging the survival of the virus in the poultry environment.

Hemagglutination (HA) activity has been detected in a few strains of pigeonpox virus and in 1 strain of FPV (27). Although such HA activity was not detected in most avianpox viruses, the nucleotide sequence of a putative HA gene has been identified in the genome of FPV. A similar nucleotide sequence is also present in the DNA of other strains of FPV, but functional HA activity could not be demonstrated when using chicken red blood cells. In preliminary studies, the HA gene appears to be nonessential for virus replication in tissue culture, but its functional role is not known at this time. Similarly, the thymidine kinase (TK) gene is nonessential for virus replication. Consequently, it has often been used for insertion of foreign genes to create recombinant FPV. Because TK has been associated with virulence, the resulting TK-deleted recombinants are less virulent than the parent FPV.

Laboratory Host Systems

Birds

Avianpox viruses affect a wide range of birds of various families by naturally occurring or artificial infection. These viruses productively infect only avian species, indicating a significant degree of adaptation to the avian host. In this regard, a number of genes showing similarity to cellular genes have been found in the genome of FPV.

A substantial degree of host specificity exists among avianpox viruses, especially those that infect wild birds. For example, a pox virus from a flicker (*Colaptes auratus*) revealed strict host specificity (37) when several species of wild and domestic birds were tested for susceptibility. Similarly, avianpox virus strains isolated from various species of thrushes (Turdidae) did not protect chickens against FPV. Differences in host susceptibility also were observed when a pox virus isolated from parrots was inoculated into susceptible parrots and chickens. Although it was more pathogenic for parrots than chickens, it did not provide protection

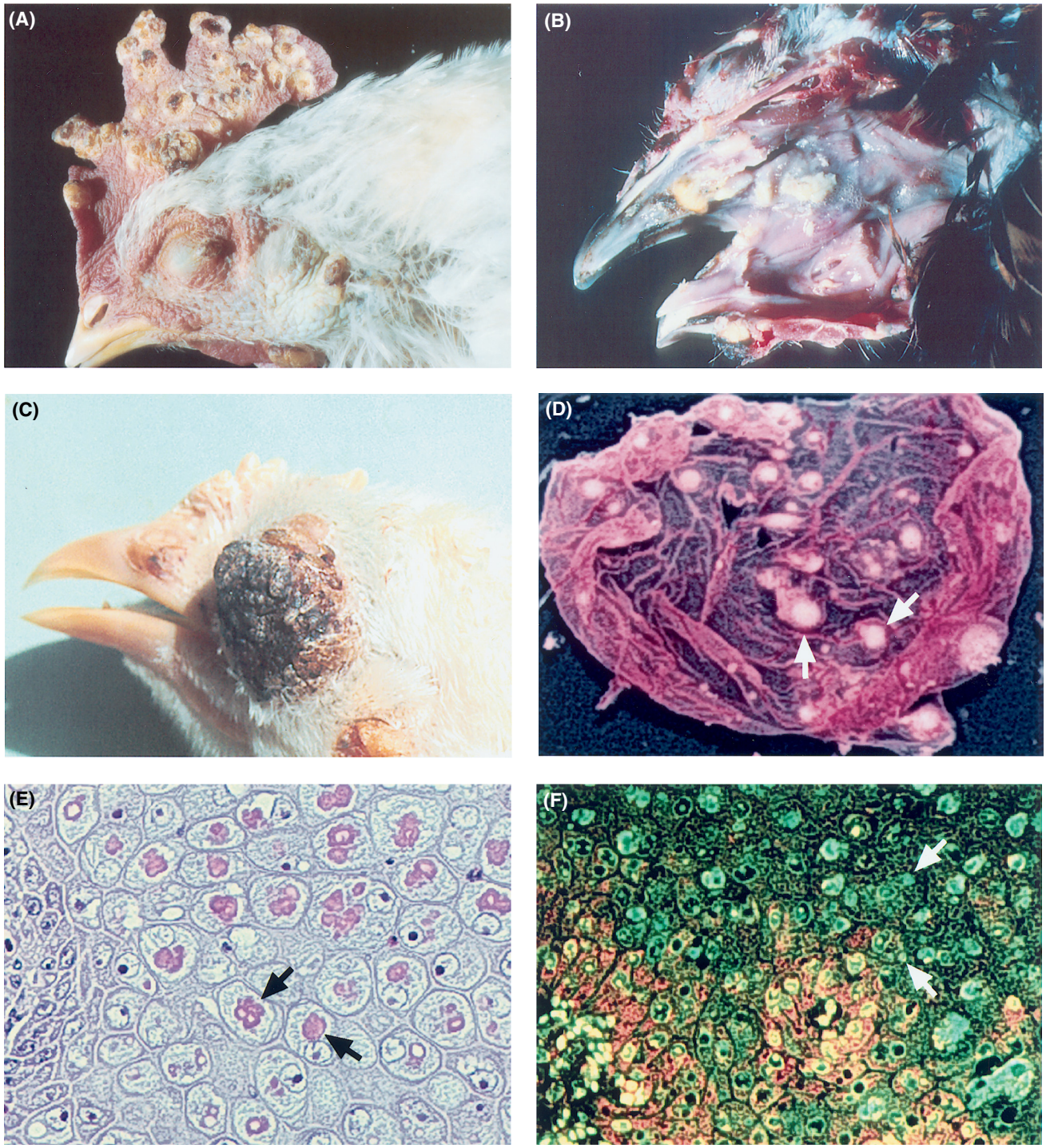

Figure 10.2. (A) Cutaneous FPV lesions on the comb of a chicken (Shivprasad). (B) Diphtheritic FPV lesions in the mouth of a chicken (Shivprasad). (C) Cutaneous FPV lesion on the eye and nostrils of an experimentally infected chicken. (D) Pocks (arrows) produced by FPV on the chorioallantoic membrane of developing chicken embryo. (E) Microscopic examination of a cutaneous lesion produced by canarypox virus. Eosinophilic cytoplasmic inclusion bodies (arrows) are present in most of the infected cells. Infected cells are enlarged, and some infected cells have lost their nuclei. (F) Microscopic examination of a section of "pock" (as seen in D) stained with acridine orange (AO). Cytoplasmic inclusion bodies containing DNA stain green (arrows) with AO.

against FPV. Furthermore, vaccination of chickens with either fowlpox or pigeonpox virus vaccine did not provide protection against challenge with psittacinepox virus (10).

A pox virus from a Canada goose (*Branta canadensis*) could be transmitted to domestic geese but not to chickens or domestic ducks. Sparrows and canaries were highly susceptible to a pox virus isolated during an outbreak in sparrows but produced a mild, local cutaneous reaction in chickens, turkeys, and pigeons (29). Chickens and pigeons were found to be refractory to infection with an avianpox virus isolated from a buzzard (*Accipiter nisus*). In an aviary housing more than 100 birds of a variety of species, only Rothchild's mynahs (*Leucospar rothchildii*) were infected with an avianpox virus. The virus, however, was pathogenic for starlings in the surrounding area but did not infect chickens. Mynahs and starlings are members of the family Sturnidae, and starlingpox has been reported to be specific for birds in that family (40). Pox virus strains isolated from magpies (*Pica pica*) and great tits (*Parus major*) did not infect young chickens. On the other hand, pox virus strains from various species of grouse, when used to immunize chickens, protected against an FPV challenge (38). An isolate of pox virus from previously vaccinated turkeys was antigenically different from FPV. Pox virus isolated from cutaneous proliferative lesions of greater hill mynah (*Gracula religiosa*) produced severe necrotizing and proliferative lesions in chickens and bobwhite quail previously vaccinated with fowlpox, pigeonpox, or quailpox viruses (55, 56). In an outbreak of avianpox, canaries and house sparrows were affected, although 10 species of passerine birds were housed within the facility (20).

Avianpox virus infections have been considered to be important factors in limiting the population of Hawaiian forest birds. In this regard, 3 isolates of pox viruses from Hawaiian forest birds (alala and apapane species) produced mild lesions in chickens, and only 2 of them could be adapted to chicken cell lines. A comparison of their genomic profile by RFLP revealed that the 2 Hawaiian bird pox viruses were more related to each other than to FPV, indicating that genetically distinct pox viruses exist in Hawaiian forest birds. Two avianpox viruses from endangered Hawaiian forest birds (Hawaiian goose and Palila) produced only a localized lesion in susceptible chickens. The lesion persisted for a short duration and the birds were not protected against challenge with FPV (36).

Studies on the differentiation of fowl, canary, turkey, and pigeonpox viruses based on pathogenicity for chickens, turkeys, pigeons, ducks, and canaries have been summarized (44). Canaries are highly susceptible to canarypox virus but show resistance to turkeypox, fowlpox, and pigeonpox viruses. Pigeonpox virus produces a mild infection in chickens and turkeys but is very pathogenic for pigeons. Susceptibility of ducks to turkeypox virus and not to FPV has been suggested for differentiation of these 2 closely related viruses.

Avian Embryos

Developing chicken embryos from a specific pathogen free (SPF) supply are commonly used for initial isolation and propagation of avianpox viruses by inoculation of the chorioallantoic membrane (CAM). Nine- to 12-day-old developing chicken embryos are appropriate for virus isolation. Duck and turkey embryos have been used, as well as embryos of other avian species. The inoculated embryos are incubated at 37°C for 5–7 days. Typically, infection of chicken embryo CAM results in compact, proliferative pock lesions that may be focal or diffuse (Figure 10.2D). Quantitative assay of viral infectivity may be performed by using the embryo infective dose-50% (EID_{50}) method or by the pock counting enumerative dose response. Rarely, some isolates from wild birds fail to grow on the CAM of chicken embryos.

Cell Culture

Avianpox viruses can be propagated in cell cultures of avian origin (e.g., chicken embryo fibroblasts, chicken embryo dermis and kidney cells, and duck embryo fibroblasts). A permanent cell line QT35 of Japanese quail origin as well as the chicken liver cell line LMH (32) can support growth of some avianpox viruses after adaptation. However, some isolates, especially from turkeys and wild birds, fail to grow in these cell lines even after repeated passages. While avianpox virus infections of mammalian cells are believed to be abortive, in a study, Syrian baby hamster kidney (BHK-21) cells (93) were found permissive for 3 avianpox virus strains.

Cytopathic Effects

Characteristic cytopathic effect (CPE) produced by the avianpox viruses in chicken embryo fibroblasts and QT35 cells is characterized by an initial phase of rounding of the cells followed by a second phase of degeneration and necrosis. Quantitative assay is by the cell culture dose-50% method based on CPE.

Plaque Formation

Differences in the plaque-forming ability of avianpox viruses have been observed. Plaques are evident by 3–4 days PI in quail cells with certain avianpox viruses after adaptation. Adaptation of the virus in cell culture is necessary because not all strains produce plaques.

Pathobiology and Epidemiology

Incidence and Distribution

Pox has been reported in more than 200 avian species (9). Fowlpox is worldwide in distribution in commercial chickens. The incidence, however, is variable. In high-density areas where multiple-age birds are raised under confined conditions, the disease tends to persist for a long time despite preventive vaccinations. In recent years, FPVs have been isolated in all regions of the United States from previously vaccinated chicken flocks experiencing high mortality due to the diphtheritic form and/or cutaneous form of pox. Cross-protection studies revealed that some of these isolates

have a limited immunologic relationship to strains of pox viruses used in commercial vaccines, indicating that currently available vaccines may not be fully effective in providing adequate protective immunity against challenge with these variant pox viruses (23).

Natural and Experimental Hosts

Fowlpox and turkeypox virus infections are economically important diseases in domestic poultry. Among companion birds, avianpox virus infections most often occur in blue-fronted Amazon parrots and in large aviaries of canaries where the disease is likely to be enzootic because of intimate contact. Therefore, canarypox and psittacinepox are especially significant for aviculturists because the disease can result in high losses in a short time. Severe outbreaks of quailpox in pen-raised quails have been reported.

Because of convenience, reasonable cost, and ready availability, susceptible chickens of various ages are used widely as experimental hosts in biological characterization of avianpox virus isolates. Most of the pathogenesis studies, however, have been conducted with FPV. Pathogenesis of FPV infection in chickens inoculated intradermally or intratracheally was similar with only minor differences. In chickens infected intradermally, the virus was first detected in the skin at the inoculation site on day 2 and in lungs on day 4, followed by detectable viremia on day 5 PI. In chickens infected intratracheally, the virus was first detected in the lungs on day 2, followed by viremia on day 4 PI. The virus was recovered from the liver, spleen, kidney, and brain of birds of both groups (61). In chickens inoculated intravenously, miliary nodules were observed in the kidneys at 10–18 days PI in addition to cutaneous lesions and diphtheritic lesions on the mucous membrane of the upper respiratory tract. Characteristic microscopic changes including inclusion bodies were observed in the epithelial cells of renal tubules 4–14 days PI, and in the epithelial reticular cells of the thymic medulla 4–10 days PI (77).

Transmission

Pox virus infection occurs through mechanical transmission of the virus to the injured or lacerated skin. Individuals handling birds at the time of vaccination may carry the virus on their hands and clothing and may unknowingly deposit the virus in the eyes of susceptible birds. Mechanical transmission of turkeypox virus from infected toms to turkey hens through artificial insemination has been reported. Insects also serve as mechanical vectors of the virus, resulting in ocular infection. The virus may reach the laryngeal region via the lacrimal duct to cause infection of the upper respiratory tract (22). In a contaminated poultry environment, the aerosol generated by feathers and dried scabs containing pox virus particles provide suitable conditions for both cutaneous and respiratory infection. Cells of the mucosa of the upper respiratory tract and mouth appear to be highly susceptible to the virus as initiation of infection may occur in the absence of apparent trauma or injury.

Mosquitoes can infect a number of different birds after a single feeding on a bird infected with avianpox virus. Eleven species of Diptera have been reported as vectors of avianpox virus. The mite (*Dermanyss gallinae*) also has been implicated in the spread of FPV.

In some flocks, the virus may persist for extended periods. This is common in large multiple-age complexes. Kirmse observed persistent cutaneous lesions of avianpox virus infection in a yellow-shafted flicker over a period of 13 months during which intracytoplasmic inclusions were demonstrable in the lesions (37). In an experimental study, Duran-Reynals and Bryan showed that cutaneous treatment of chickens and pigeons with methylcholanthrene can activate latent FPV infection (21).

Incubation Period

The incubation period of the naturally occurring disease varies from about 4–10 days in chickens, turkeys, and pigeons and is about 4 days in canaries.

Clinical Signs

The disease may occur in 1 of the 2 forms, cutaneous or diphtheritic, or both. In addition, a systemic form of infection with high mortality is usually seen in canaries. The signs vary depending upon the susceptibility of the host, virulence of the virus, distribution of the lesions, and other complicating factors. The cutaneous form of the disease is characterized by the appearance of nodular lesions on the comb, wattle, eyelids, and other nonfeathered areas of the body (Figure 10.2A, C). Cutaneous eye lesions interfere with the bird's ability to find food and water. In the diphtheritic form (wet pox), cankers or diphtheritic yellowish lesions (Figure 10.2B) occur on the mucous membranes of the mouth, esophagus, or trachea with accompanying coryza-like mild or severe respiratory signs similar to those caused by infectious laryngotracheitis virus infection of the trachea (Chapter 5) . Lesions in the corner of the mouth and on the tongue, throat, and upper part of the trachea interfere with eating, drinking, and breathing. In pullets coming into lay and in older birds, the disease often runs a slow course accompanied by unthriftiness and reduced egg production. In canaries, clinical signs include respiratory distress; loss of feathers and or/scaly skin on the head, neck, and back; weight loss; and high mortality.

Morbidity and Mortality

The morbidity rate of pox in chickens and turkeys varies from a few birds being infected to involvement of the entire flock if a virulent virus is present and no preventive measures have been taken. Birds affected with the cutaneous form of the disease are more likely to recover than those with the diphtheritic form involving oral mucosa and the respiratory tract.

The effects of pox in chickens usually include emaciation and poor weight gain; egg production is temporarily retarded if layers are infected. The course of the mild cutaneous form of disease is about 3–4 weeks, but if complications are present, the duration may be considerably longer. With virulent strains

of FPV, both primary and secondary cutaneous lesions may persist for more than 4 weeks. In such cases, cutaneous lesions around the eyes or diphtheritc lesions in the mouth and upper respiratory tract interfere with normal functions resulting in significant mortality.

In turkeys, the retardation of growth development of market birds is of greater financial importance than mortality. Blindness due to cutaneous eye lesions and starvation cause most of the losses. If pox occurs in breeding birds, decreased egg production and impaired fertility may result. In uncomplicated mild infections, the course of the disease in a flock may be 2–3 weeks. Severe outbreaks often last 6, 7, or even 8 weeks.

Flock mortality in chickens and turkeys is usually low, but in severe cases it may be high. In pigeons and psittacines, morbidity and mortality rates are similar to those in chickens. Pox in canaries can cause mortality as high as 80%–100%. In a natural outbreak of canarypox virus mortality in excess of 65% occurred in a flock of 450 canaries. Significant mortality has been observed in quail infected with quailpox virus. Pox virus infections have been considered as a population-limiting factor for endangered Hawaiian forest birds.

Pathology

Gross

The characteristic lesion of the cutaneous form of pox in chickens is epithelial hyperplasia involving the epidermis and underlying feather follicles, with formation of nodules that first appear as small white foci and then rapidly increase in size and become yellow. In chickens infected intradermally, a few primary lesions appear by the fourth day. Papules are formed by the fifth or sixth day. This is followed by the vesicular stage, with formation of extensive thick lesions (47). Adjoining lesions may coalesce and become rough and gray or dark brown. After about 2 weeks or sometimes sooner, lesions have areas of inflammation at the base and become hemorrhagic. Formation of a scab, which may last for another 1–2 weeks, ends with desquamation of the degenerated epithelial layer. If the scab is removed early in its development, there is a moist, seropurulent exudate underneath covering a hemorrhagic granulating surface. When the scab drops off naturally, a smooth scar may be present; in mild cases, there may be no noticeable scar. Attenuated vaccine viruses produce localized lesions, which are mild in comparison to the severe ones due to pathogenic strains. The secondary lesions produced by pathogenic strains may persist for several weeks (81).

In the diphtheritic form, slightly elevated, white opaque nodules or yellowish patches develop on the mucous membranes of mouth, esophagus, tongue, or upper trachea. Nodules rapidly increase in size and often coalesce to become a yellow, cheesy, necrotic, pseudodiphtheritic, or diphtheritic membrane (Figure 10.2B). If the membranes are removed, they leave bleeding erosions. The inflammatory process may extend into sinuses, particularly the infraorbital sinus (resulting in swelling) and also into the pharynx and larynx (resulting in respiratory disturbances) and esophagus. It is not uncommon to find cutaneous infection characterized by the development of lesions on the comb and wattles as well as diphtheritic lesions in the mouth and/or respiratory tract of the same bird. Often involvement of the comb and eyelids may accompany the formation of lesions in other areas of skin as well as diphtheritic lesions. In canarypox virus infection, gross lesions may include thickened eyelids and small nodules on the skin of the head and neck, enlarged thymus, mild to severe consolidation of the lungs, and exudates in the sinuses and trachea (60).

The first indication of pox in turkeys is appearance of minute yellowish eruptions on the dewlap, snood, and other head parts. They are soft and easily removed in this pustular stage, leaving an inflamed area covered with a sticky serous exudate. The corners of the mouth, eyelids, and oral membranes are commonly affected. Lesions enlarge and become covered with a dry scab or a yellow-red or brown wart-like mass. In young poults, the head, legs, and feet may be completely covered with lesions, which may even spread to the feathered parts of the body. In an unusual outbreak of pox virus in breeding turkeys, proliferative lesions occurred in the oviduct, cloaca, and skin surrounding the vent.

In some cases, avianpox virus infection may be characterized by cutaneous, diphtheritic, systemic and oncogenic manifestations (90), while in others the infection may be localized and characterized by the presence of small, pale, firm nodules in some internal organs. For example, in a natural pox virus infection in Galapagos doves (*Nesopelia g. galapagoensis*) small (1–6 mm), pale, firm nodules in the lungs (46) were characterized by lobulated and nonlobulated nodular foci, located mainly in the airways, originating from primary and secondary bronchi. Similarly, in a 3-month-old fledging Andean condor no lesions were found on the entire skin. However, the oral cavity, esophagus, and crop had multifocal raised yellow plaques. Most internal organs including heart, lungs, liver, kidney, small intestine, pancreas, and spleen had single to multiple soft white nodules ranging in size from 0.2–0.8 cm in diameter (34).

Microscopic

The most important feature of infection (whether the lesion is cutaneous, diphtheritic, systemic, or from infected CAM) is hyperplasia of the epithelium with enlargement and ballooning of infected cells, as well as associated inflammatory changes. Characteristic eosinophilic A-type cytoplasmic inclusion bodies (Bollinger bodies) are observed by light microscopy (Figure 10.2E) in infected cells (101). Because pox viruses are the largest among viruses, the elementary bodies can be observed in smears prepared from the lesions after staining by the Gimenez method (83) or with Wright's stain.

Histopathologic changes of tracheal mucosa include initial hypertrophy and hyperplasia of mucus-producing cells, with subsequent enlargement of epithelial cells that contain eosinophilic cytoplasmic inclusion bodies (Figure 10.2E). These inclusion bodies stain green with acridine orange, indicating

DNA in the inclusions (Figure 10.2F). Inclusion bodies may be present in various stages of development, depending on the time after infection, and may occupy almost the entire cytoplasm, with resulting cell degeneration. Often, clusters of epithelial cells resembling a papilloma may be observed (76).

Ultrastructure

Ultrastructural features of avianpox viruses are briefly described in the virus replication and diagnostic sections. Because of their large size, typical morphology, and characteristic ultrastructural details, diagnosis of avianpox viruses is relatively easy both under electron microscopy by negative staining or in ultrathin sections (Figure 10.1A, B, C).

Diagnosis

Natural avianpox virus infections have been reported both in domestic poultry and wild birds. In spite of antigenic, genetic, and biological differences, pathogenesis of these viruses presents many similarities, which help in rapid diagnosis of the disease. Tentative diagnosis based on clinical signs and lesions, supported by histopathology, is the method of choice to confirm the diagnosis in many laboratories. Details on various diagnostic methods are available elsewhere (84, 85).

Microscopy

Histopathology provides sound evidence of poxvirus infection in birds clinically infected with pox-like lesions. Tissue sections from cutaneous or diphtheritic lesions are processed by conventional methods or by using a solution that fixes and dehydrates the tissues simultaneously followed by hematoxylin-eosin staining for detection of cytoplasmic inclusions (Figure 10.2E). Cutaneous lesions typical of avianpox (Figure 10.2A, C) and diphtheritic lesions in upper respiratory and oral mucosa (Figure 10.2B) must be confirmed by either histopathology (presence of cytoplasmic inclusions as shown in Figure 10.2E) or by virus isolation (101). Histopathological examination is also a widely used method for the diagnosis of avianpox virus infection.

Electron microscopy can be used for the demonstration of virus particles in lesions and exudate by negative staining or in ultrathin sections (Figure 10.1A, B, C).

Isolation and Identification of Virus

Bird Inoculation

Avianpox viruses can be transmitted to susceptible birds by applying a suspension of the lesion material from infected birds to their scarified comb or denuded feather follicles of the thigh, or by the wing-web stick method. FPV can be transmitted readily to susceptible chicken, with typical cutaneous lesions developing in 5–7 days.

Avian Embryo Inoculation

The virus is released from the sample (e.g., cutaneous or diphtheritic lesion) in sterile broth or Hank's balanced salt solution by grinding with pestle and mortar or a glass grinder. After slow-speed centrifugation, appropriate concentration of antibiotics (penicillin and streptomycin) is added and the solution is incubated for 1 hour at 37°C. The antibiotic-treated solution is centrifuged and the supernatant is collected for inoculation. It is advisable to inoculate a blood agar and a McConkey agar plate with the antibiotic-treated sample to ensure that the sample is free of any remaining bacterial contamination. The plates should be incubated for 24 hours and examined for the presence of any bacterial growth. If none is observed, the sample is ready for inoculation of chicken embryos. Further treatment of the sample may be required if any bacterial colonies are observed on the plates. Alternatively, the sample can be passed through a sterile disposable filter that will retain the bacteria while allowing the poxvirus particles pass in the filtrate. The contamination-free suspension of a pox virus-suspected specimen is inoculated on the CAM of 9- to 12-day-old developing chicken embryos from an SPF flock. Five to 7 days after inoculation, the CAM is examined for pock lesions (Figure 10.2D). In some cases the pock lesions may be very minute or there may be slight thickness of the CAM due to very low concentration of the virus in the inoculum. In such cases a second embryo passage is advisable. Occasionally, some isolates fail to grow on the CAM of chicken embryos.

Cell Culture

Primary cell cultures of chicken embryo or kidney or secondary cell cultures of avian origin can be used for virus isolation. In this regard, secondary cell lines, e.g., QT35 and LMH, will support the growth of some strains. Adaptation of the virus to this host system is sometimes necessary because not all strains produce CPE on initial inoculation. For antigenic and genetic characterization of an isolate, propagation in cell culture is more convenient than the use of CAM.

Serology and Protection Tests

Actively acquired immunity against avianpox viruses results after recovery from naturally occurring infection or following vaccination. Both cell-mediated and humoral immunity following vaccination or naturally occurring infection provides protection (49, 64, 82). Cell-mediated immunity develops earlier than the humoral antibody response.

Immune responses against avianpox viruses can be determined by serological tests such as ELISA, immunoprecipitation, virus neutralization, or cross-protection tests. Cell-mediated immunity evaluations are not done routinely because the measurement of humoral immune responses is simple and convenient to perform. ELISA is the test of choice for evaluation of immune response to monitor the vaccination response of birds. Cross-protection tests generally are used to determine immunogenicity of fowl and pigeonpox vaccines. For this purpose, at least 20 SPF chickens are vaccinated according to manufacturer's directions. An additional 20 nonvaccinated and isolated birds of the same source and age are kept as controls. At 3 weeks after vaccination, vaccinated and control birds are challenged with a different strain of FPV capable of causing clinical signs of

pox in the control birds. The challenge virus may be applied to the skin of denuded feather follicles of the thigh, to scarified comb, or by the wing-web method at a site opposite that was used for vaccination. The birds should be examined for takes (see Immunization). For satisfactory immunization, at least 90% of the controls should have lesions and at least 90% of the vaccinated birds should not.

Cross-protection tests for the antigenic relationship of the avianpox viruses generally are not practical for routine diagnosis but may be necessary for their biological characterization (12, 35, 56, 62, 97). Other tests that have been used are briefly described below.

Immunodiffusion

Immunodiffusion has been used for the identification of fowlpox and pigeonpox viruses and to differentiate antibody responses due to fowlpox and from those of other avian viral diseases. Although the test is simple to perform, its sensitivity is low and because of cross-reacting antigens differential diagnosis of strains may not be easy. Because precipitating antibodies are detectable for only a short duration after infection, serum must be collected at the appropriate time, usually within 15–20 days after onset of infection.

Passive Hemagglutination

A passive hemagglutination test (79) detects antibodies in the serum of FPV-infected chickens earlier than the immunodiffusion test. Although this test is very sensitive, its use has been limited because it requires sheep or horse red blood cells for sensitization with soluble pox virus antigens. Furthermore, differentiation of viruses is not possible because of cross-reacting antigens.

Neutralization

Virus neutralization in cell culture or chicken embryos may be used; however, this procedure is not convenient as a routine diagnostic test.

Fluorescent Antibody, Immunoperoxidase, and ELISA

Direct or indirect immunofluorescence or immunoperoxidase tests reveal specific staining of intracytoplasmic inclusions in virus-infected cells. In this regard, immunoperoxidase reaction (80) can be done conveniently with the formalin-fixed infected tissue sections. Such stained slides can be stored for several days without loss of staining. Currently, ELISA is the test of choice to determine humoral antibody responses. An antibody response is detectable in 7–10 days PI.

Immunoblotting

Immunogenic proteins of vaccine and field strains of FPV can be compared by immunoblotting. Although common antigens are detected (Figure 10.1D), strains can be differentiated to some extent by the presence or absence of unique proteins of differing electrophoretic mobilities (25, 57, 59). Monoclonal antibodies also have been used to characterize field isolates and vaccine strains of FPV (63).

Molecular Methods

Current molecular methods can uncover the pathways needed by the pathogens to infect the host to produce disease. Using these techniques, it is possible to identify and evaluate the functions of the genes associated with virulence and protection. Furthermore, these techniques allow rapid diagnosis of the etiologic agents and their differentiation with vaccine strains that have been used for prevention of the disease. Most of the currently available molecular techniques used in the diagnosis of poxvirus infections and genetic differentiation have been described elsewhere. Following are some of the methods used.

Restriction Endonuclease Analysis of Avianpox Virus DNA

Restriction fragment length polymorphism (RFLP) can be used for comparing the genomes of avianpox viruses by examination of the relative mobilities of restriction endonuclease-generated fragments of their DNAs. The genetic profiles of FPV strains are similar, with a high proportion of comigrating fragments, although most strains could still be distinguished by the presence or absence of 1 or 2 DNA fragments (Figure 10.1E). The characteristic electrophoretic profile of restriction endonuclease-digested DNA has facilitated comparison of other members of the Avipoxvirus genus. In this regard, genomic profiles of fowlpox, quailpox, canarypox, and mynahpox viruses are distinct. Similarly, the Hawaiian bird pox viruses, alalapox and apapanepox, have genetic differences that distinguish them from each other as well as from FPV (18, 35, 36, 86).

Genomic Fragments as Diagnostic Probes

Selected genomic fragments or oligonucleotides designed from the published sequences of FPV have been used as probes in detecting FPV-specific DNA in the test samples. Crude DNA isolated from the skin or diphtheritic lesion is transferred to a solid surface (e.g., nitrocellulose membrane) and then hybridized with either a cloned fragment or an oligonucleotide which has been radioactively labeled (usually with ^{32}P dCTP) or with a nonradioactive substance (e.g., digoxigenin). This procedure is sensitive and specific and can be used in mixed infections. For example, a dual FPV and infectious laryngotyracheitis virus infection was confirmed using virus-specific genomic probes (25).

Polymerase Chain Reaction (PCR)

Genomic DNA sequences of various sizes can be amplified by polymerase chain reaction (PCR) using specific primers from FPV or canarypox virus nucleotide sequences. This technique is useful when an extremely small amount of virus is present in the sample. In the case of mixed infections, fragments of different sizes can be amplified in a single PCR, using pathogen-specific primers. For example, the diphtheritic form of fowlpox and infectious laryngotracheitis produce similar clinical signs and tracheal lesions and natural dual infections. Using virus-specific primers, either of these infections could be detected.

Currently, PCR is being used to differentiate vaccine and field strains of FPV because the majority of the latter contain intact REV provirus, whereas the vaccine strains contain only REV LTR sequences (1, 8, 14, 30, 31, 33, 42, 52, 67, 73, 74, 75, 88). In this regard, formalin-fixed tissue sections of avianpox virus-infected samples (e.g., CAM, skin) can be used to isolate the viral genome (87). Such DNA is used to amplify specific genomic fragments in a PCR reaction. Nucleotide sequences of the amplified fragments can be determined for differentiation of strains and evaluation of their phylogenetic relationships. In considering a virus strain as a putative vaccine, its antigenic, genetic, and biologic evaluation may be required. Because antigenic and biologic characterizations are time consuming, genetic evaluation could be done rather easily. In this regard, to determine the genetic relationship of a vaccine strain of fowlpox vaccine strain, selected genomic fragments were amplified by PCR; the nucleotide sequence of the amplicons was determined and compared with other respective sequences (89). PCR amplification of selected genomic fragments of new isolates, especially from the wild birds, is being used widely in the diagnosis and phylogenetic analysis of pox viruses.

Differential Diagnosis

Because fowlpox and infectious laryngotracheitis virus can produce similar tracheal lesions in chickens, the diphtheritic form of fowlpox in chickens with associated respiratory signs must be differentiated from infectious laryngotracheitis. In the case of infectious laryngeotracheitis (Chapter 5), intranuclear inclusions are detected in the tracheal epithelium. Cutaneous lesions caused by pantothenic acid or biotin deficiency in young chicks or by T-2 toxin (17, 102) could be mistaken for pox lesions. Similarly, diphtheritic pox lesions in doves and pigeons may be mistaken for lesions caused by *Trichomonas gallinae*, which are diagnosed by microscopic examination of smears or by culture.

Intervention Strategies

Management Procedures

Because of its genetic make-up and inherent stability, FPV can persist in scabs in the poultry environment and become a source of infection for young susceptible replacement birds. The greater frequency of the disease is perhaps due to closer confinement of chickens, especially in large multiple-age complexes. Such conditions provide opportunity for the transmission of FPV from bird to bird as well as through aerosol. Close confinement and unclean houses increase the opportunity for spreading the disease.

Immunization

The FPV vaccine was one of the earliest available vaccines for protection against fowlpox. Live FPV vaccines have been used for immunization of birds against pox for more than 70 years. Vaccines of fowlpox and pigeonpox virus origin are routinely used for vaccination of chickens and turkeys in areas where the disease is endemic. These should contain a minimum concentration of 10^5 EID_{50}/ml to establish satisfactory takes for good immunity (96). Fowlpox and pigeonpox virus vaccines labeled "chick embryo origin" are prepared from infected CAM. FPV vaccine labeled "tissue culture origin" is prepared from infected chicken embryo fibroblast cultures.

The success of a vaccination program depends on the potency and purity of the vaccine and its application under conditions for which it is specifically intended. Vaccination essentially produces a mild form of the disease. Directions for use of vaccine as supplied by the producer should be followed explicitly. Vaccine should not be used in a flock affected with other diseases or in generally poor condition. All birds within a house should be vaccinated on the same day. Other susceptible birds on the premises should be isolated from those being vaccinated. If pox appears in a flock in an initial outbreak with only a few birds affected, nonaffected birds should be vaccinated.

A vaccine vial should be opened immediately before use. Only 1 vial should be opened at a time, and the entire contents should be used within 2 hours. After the vaccine is prepared, the vaccinator's hands should be washed thoroughly. Vaccine should contact the bird only at the site of immunization. Extreme precautions should be taken not to contaminate other parts of the bird, the premises, or miscellaneous equipment.

All contaminated vaccine equipment, unused vaccine, empty vials, etc., should be decontaminated, preferably by incineration. No prepared vaccine should be saved for later use.

Fowlpox Vaccine

The chick embryo origin vaccine contains live FPV capable of producing serious disease in a flock if used improperly.

Fowlpox vaccine is commonly applied by the wing-web method to 4-week-old chickens and to pullets about 1–2 months before egg production is expected to start. It is also used to revaccinate chickens held for the second year of egg production. The vaccine is not to be used on hens while they are laying.

Attenuated FPV vaccines of cell culture origin can be used effectively on chicks as young as 1 day of age and have been used at times in combination with Marek's disease and other vaccines.

In one study, oral vaccination with an attenuated cell culture vaccine was reported to be effective in Germany. In another study, comparative immunity of FPV vaccines by intramuscular, feather follicle, oral, and intranasal routes in chickens of different age groups indicated that oral vaccination did not provide protection over 50%, while other methods provided 80%–100% protection. To be effective, oral administration requires a high concentration of the virus in the vaccine (51, 58). Turkeys may be vaccinated by the wing-web method, but the virus may spread and infect the head region. The site of choice for vaccination is about midway on the thigh. Initially, turkeys are vaccinated when they are 2–3 months old, but those to be used as breeders should be revaccinated before production. Revaccination at 3- to

4-month intervals during the laying season might be of some advantage, depending on the level of risk. Fowlpox vaccine is not to be used on pigeons.

In recent years, outbreaks of fowlpox have occurred in all regions of the United States and other countries (62, 75) in chickens that had been vaccinated with either fowlpox or pigeonpox virus vaccines, indicating their inability to provide adequate immunity. Often combined fowlpox and pigeonpox virus vaccines have been used in chicken flocks with variable results. In this regard, field isolates of FPV from vaccinated flocks show variable pathogenicity in chickens. Most of the virus strains isolated during outbreaks in previously vaccinated chicken flocks contain full-length REV in their genome. A comparison *in vivo* of a field strain of FPV, its genetically modified progeny (in which all REV sequences were deleted), and a rescue mutant (in whose genome the REV provirus was inserted in its previous location) indicated that elimination of the provirus sequences correlated with reduced virulence (66).

Pigeonpox Vaccine

Pigeonpox vaccine contains live nonattenuated, naturally occurring virus from pigeons. If used improperly, the vaccine can cause a severe reaction in these birds. The virus is less pathogenic for chickens and turkeys.

Pigeonpox vaccine may be applied by the wing-web method and can be used on chickens of any age. It is generally applied to chickens at 4 weeks of age and about 1 month before egg production is expected to start. When birds younger than 4 weeks are vaccinated, they should be revaccinated before the start of production. Birds held for the second year of production should be revaccinated.

Turkeys can be vaccinated at any age by the wing-web or thigh stick methods. Day-old poults can be vaccinated if necessary, but it is better to wait until they are about 8 weeks old so that a better immune response is obtained. Revaccination may be necessary and advisable during the growing period. Turkeys retained as breeders should be revaccinated.

Pigeons can be vaccinated by the wing-web method. The vaccine can be applied by the feather follicle method, but this is not generally employed. Differences in the immunizing properties of pigeonpox vaccines have been observed.

Canarypox Vaccine

A modified live canarypox virus vaccine to be administered cutaneously by the wing-web method has been available commercially for some time in the United States. Vaccination of birds at weaning age is suggested, and booster vaccinations are recommended every 6–12 months and 4 weeks prior to laying or vector season.

Quailpox Vaccine

A live vaccine of quailpox virus origin is available commercially. It does not appear to provide adequate protection against FPV infection (24, 97).

Vaccine Takes

The flock should be examined about 7–10 days after vaccination for evidence of takes. A "take" consists of swelling of the skin or a scab at the site where the vaccine was applied and is evidence of successful vaccination. Immunity normally develops 10–14 days after vaccination. If the vaccine is properly applied to susceptible birds, the majority of the birds should have takes. In large flocks, at least 10% of the birds should be examined for takes. The lack of a take could be the result of the vaccine being applied to an immune bird, use of a vaccine of inadequate potency (after the expiration date or subjected to deleterious influences), or improper application.

Prophylactic Vaccination

Immunization against pox consists of vaccinating susceptible birds prior to the time the disease is likely to occur. Usually this is done during spring and summer in areas where the disease occurs in fall and winter. However, in large complexes containing multiple-age birds and in tropical climates, where the disease may occur throughout the year, vaccination may be performed at any time when warranted without regard to the season.

In ovo *Vaccination*

Studies on *in ovo* administration of FPV vaccines to 18-day-old chicken embryos have provided encouraging results (6). Furthermore, recombinant FPV vaccines expressing protective antigens of other viruses have shown effectiveness of the *in ovo* vaccination method. With increasing use of *in ovo* vaccination, the cost of vaccination and stresses associated with handling the birds will be reduced significantly.

Recombinant FPV Vaccines

Potential of FPV as a Polyvalent Vaccine

Avianpox viruses have contributed significantly in the development of virology, immunology, vaccinology, and vectorology. The pox viruses have some unique features (e.g., cytoplasmic site of multiplication, large genome, and unique viral enzymes and transcription system), which allow the expression of foreign genes in a faithful manner. Thus, a large variety of genes encoding antigenic proteins of specific pathogens have been inserted into the genome of FPV. Because of its large genome size with several nonessential loci, genes from more than 1 pathogen can be inserted into its genome to create a polyvalent vaccine.

To develop a live recombinant FPV, it is important to stably insert the foreign gene(s) of interest from a poultry pathogen into its genome, express the gene(s) optimally, and still maintain the infectivity of the virus. Thus, the generation of an FPV (or other avianpox virus) expression vector requires (1) the identification of a suitable nonessential region in its genome for insertion of foreign genetic material so that virus replication is not disrupted, (2) a foreign gene that encodes for a protective antigen of a poultry pathogen, (3) a strong pox virus promoter that will optimally regulate the expression

of the inserted foreign gene(s), (4) a donor plasmid that incorporates these 3 features, and (5) a method for the selection and/or detection of recombinant progeny virus.

Several nonessential regions, including some in the terminal inverted repeats, have been identified in the FPV genome and have been used in the generation of recombinant viruses. Pox virus promoters are relatively conserved and, thus, are recognized by heterologous pox viruses. Initially, therefore, vaccinia virus promoters were used in lieu of FPV transcription regulatory elements in creating recombinant FPV. Although homologous FPV promoters have since been identified (69, 71) and a synthetic, early-late transcriptional regulatory element has been used, 2 vaccinia virus promoters, the early-late P7.5 and the late P11, have been used for the construction of recombinant avianpox viruses (7). Several homologous FPV promoters, including a bidirectional one, have been evaluated. Because some of these promoters appear to be as strong as the vaccinia virus ones, it is believed that their availability will assist in the development of a new generation of polyvalent FPV-vectored vaccines. Experiments with a recombinant FPV coexpressing Newcastle Disease virus (NDV) fusion and hemagglutinin neuraminidase genes and infectious laryngotracheitis virus (ILT) glycoprotein B gene indicated that this vaccine could be used as a potential vaccine for prevention of NDV and ILT by a single immunization (72). With available genetic information only on FPV and canarypox virus, development of polyvalent recombinant vaccines for prevention of poultry disease appears feasible. In spite of limited genetic information and antigenic information available on other avianpox viruses, their genomes also can be manipulated toward the development of a new generation of effective poultry vaccines.

Commercially Available Recombinant FPV Vaccines

Several live FPV-vectored vaccines, e.g., Newcastle disease-fowlpox vaccine for subcutaneous or wing-web stab immunization of 1-day-old chickens, is available commercially. Similarly, a recombinant FPV vaccine expressing genes of infectious laryngotracheitis (ILT) virus also has become available. Two recombinant FPV vaccines expressing H5 hemagglutinin gene of avian influenza virus have been used by the poultry industry for several years in Mexico with highly encouraging results. Details on avianpox virus-vectored vaccines have been reviewed by Weli and Tryland (94).

There has been a concern that immunity generated against FPV after initial vaccination may prevent the subsequent use of the same recombinant virus containing gene(s) of different pathogens as an immunizing agent. To circumvent this problem, other antigenically distinct avianpox viruses can be considered as vaccine vectors for re-immunization. Although FPV and canarypox virus have been used as vectors for recombinant vaccines, other avipoxviruses, e.g., quailpox, psittacinepox, sparrowpox, and condorpox, as well as those isolated from Hawaiian endangered birds, also can be considered as potential vectors. Studies with avianpox viruses from endangered Hawaiian forest birds show that these viruses are genetically, antigenically, and biologically different because they produce only mild localized lesions in chickens.

Avianpox Viruses as Expression Vectors for Genes from Mammalian Pathogens

The natural host range of avianpox viruses is limited to avian species. However, these viruses can initiate an abortive infection *in vitro* in cell lines of nonavian origin. Although infectious progeny virus is not produced, foreign antigens are synthesized authentically, processed, and presented on the cell surface. In this regard, expression of the rabies virus glycoprotein in recombinant FPV and canarypox viruses (78) provided a great impetus toward the use of avianpox viruses for the development of vaccines for both man and animals. A canarypox virus-vectored vaccine expressing rabies virus glycoprotein G for use in cats and canarypox virus-vectored distemper vaccine for dogs is currently available commercially. Similarly, a recombinant canarypox virus vaccine expressing antigens of West Nile virus has been licensed for equines.

Treatment

No specific treatment exists for birds infected with avianpox viruses.

References

1. Arathy, D.S., D.N. Tripathy, G.P. Sabrinath, M.I. Bhaiyat, A. Chikweto, V. Matthew, and R.N. Sharma. 2010. Preliminary molecular characterization of a fowl poxvirus isolate in Grenada. *Avian Dis.* 54:1081–1085.
2. Afonso, C.L., E.R. Tulman, Z. Lu, L. Zsak, G.F.L. Kutish, and D.L. Rock. 2000. The genome of FPV. *J Virol.* 74:3815–3831.
3. Andrews, C., H.G. Pereira, and P. Wildy. 1978. *Viruses of Vertebrates*, 4th ed. Bailliere Tindall, London. 356–389.
4. Arhelger, R.B., and C.C. Randall. 1964. Electron microscopic observations on the development of FPV in chorioallantoic membrane. *Virol.* 22:59–66.
5. Arhelger, R.B., R.W. Darlington, L.G. Gafford, and C.C. Randall. 1962. An electron microscopic study of fowl pox infection in chick scalps. *Lab Invest.* 11:814–825.
6. Avakian, A., B. Singbeil, R. Poston, D. Grosse, C. Klein, C. Whitfill, and D. Tripathy. 1999. Safety and efficacy of fowl and pigeon pox vaccines administered *in ovo* to SPF and broiler embryos. Proc. 48th WPDC. 56–60.
7. Beard, C.W., W.M. Schnitzlein, and D.N. Tripathy. 1991. Protection of chickens against highly pathogenic avian influenza virus (H5N2) by recombinant FPVes. *Avian Dis.* 35:356–359.
8. Biswas S.K., C. Jana, K. Chand, W. Rehman, and B. Mondal. 2011. Detection of fowl poxvirus integrated with reticuloendotheliosis virus sequences from an outbreak in backyard chickens in India. *Vet Ital.* 47:147–53.
9. Bolte, A.L., J. Meurer, and E.F. Kaleta. 1999. Avian host spectrum of avipox viruses. *Avian Pathol.* 28:415–432.
10. Boosinger, T.R., R.W. Winterfield, D.S. Feldman, and A. S. Dhillon. 1982. Psittacine pox virus: Virus isolation and identification, transmission and cross-challenge studies in parrots and chickens. *Avian Dis.* 26:437–444.

11. Boulanger, D., T. Smith, and M.A. Skinner. 2000. Morphogenesis and release of FPV. *J Gen Virol.* 81:675–687.
12. Boyle, D.B., and B.E.H. Couper. 1997. Comparison of field and vaccine strains of Australian FPVes. *Arch Virol.* 142:737–748.
13. Brunovskis, P., and L.F. Velicer. 1995. The Marek's disease virus (MDV) unique short region: Alphaherpesvirus-homologous, fowl pox-virus-homologous, and MDV-specific genes. *Virol.* 206:324–338.
14. Carulei, O., N. Douglass, and A.L. Williamson. 2009. Phylogenetic analysis of three genes of Penguin pox virus corresponding to Vaccinia virus G8R (VLTF-1), A3L (P4b) and H3L reveals that it is most closely related to turkeypox virus, ostrichpox virus and pigeonpox virus. *Virol J.* 6:52.
15. Cheevers, W.P., and C.C. Randall. 1968. Viral and cellular growth and sequential increase of protein and DNA during fowl pox infection *in vivo*. *Proc Soc Exp Biol Med.* 127:401–405.
16. Cheevers, W.P., D.J. O'Callaghan, and C.C. Randall. 1968. Biosynthesis of host and viral deoxyribonucleic acid during hyperplastic fowl pox infection *in vivo*. *J Virol.* 2:421–429.
17. Chi, M.S., and C.J. Mirocha. 1978. Necrotic oral lesions in chickens fed diacetoxyscirpenol, T-2 toxin, and crotocin. *Poult Sci.* 57:807–808.
18. Coupar, B.E.H., T. Teo, and D.B. Boyle. 1990. Restriction endonuclease mapping of the FPV genome. *Virology.* 179:159–167.
19. Davidson, I. I. Shkoda, and S. Perk. 2008. Integration of the reticuloendotheliosis virus envelope gene into the poultry FPV genome is not universal. *J Gen Virol.* 89:2456–2460.
20. Donnelly, T.M., and L.A. Crane. 1984. An epornitic of avian pox in a research aviary. *Avian Dis.* 28:517–525.
21. Duran-Reynals, F., and E. Bryan. 1952. Studies on the combined effects of FPV and methylcholanthrene in chickens. *Ann NY Acad Sci.* 54:977–991.
22. Eleazer, T. H., J.S. Harrel, and H.G. Blalock. 1983. Transmission studies involving a wet fowl pox isolate. *Avian Dis.* 27:542–544.
23. Fatunmbi, O.O., and W.M. Reed. 1996. Evaluation of a commercial modified live virus fowl pox vaccine for the control of "variant" FPV infections. *Avian Dis.* 40:582–587.
24. Fatunmbi, O.O., and W.M. Reed. 1996. Evaluation of a commercial quail pox vaccine (Bio-Pox QTM) for the control of "variant" FPV infections. *Avian Dis.* 40:792–797.
25. Fatunmbi, O.O., W.M. Reed, D.L. Schwartz, and D.N. Tripathy. 1995. Dual infection of chickens with pox and infectious laryngotracheitis (ILT) confirmed with specific pox and ILT DNA DOT-BLOT hybridization assays. *Avian Dis.* 39:925–930.
26. Garcia M., N. Narang, W.M. Reed, and A.M. Fadly. 2003. Molecular characterization of reticuloendotheliosis virus insertions in the genome of field and vaccine strains of FPV. *Avian Dis.* 47:343–354.
27. Garg, S.K., M.S. Sethi, and S.K. Negi. 1967. Hemagglutinating property of pigeon pox virus strains. *Ind J Microbiol.* 7:101–102.
28. Ghildyal, N., W. Schnitzlein, and D.N. Tripathy. 1989. Genetic and antigenic differences between fowl pox and quailpox viruses. *Arch Virol.* 106:85–92.
29. Giddens, W.E., L.J. Swago, J.D. Handerson, Jr., R.A. Lewis, D.S. Farner, A. Carlos, and W.C. Dolowy. 1971. Canary pox in sparrows and canaries (Fringillidae) and in Weavers (Ploceidae). *Vet Pathol.* 8:260–280.
30. Jarmin, S., R. Manvell, R.E. Gough, S.M. Laidlow, and M.A. Skinner. 2006. Avipoxvirus phylogenetics: identification of a PCR length polymorphism that discriminates between the two major clades. *J Gen Virol.* 87:2191–2201.
31. Jarvi, S.I., D. Triglia, A. Giannoulis, M. Farias, K. Bianchi, and C.T. Atkinson. 2008. Diversity, origins and virulence of avipoxviruses in Hawaiian forest birds. *Conserv Genet* 9:339–348.
32. Kawaguchi, T., K. Nomura, Y. Hirayama, and T. Kitagawa, 1987. Establishment and characterization of a chicken hepato-cellular carcinoma cell line, LMH. *Cancer Res.* 47:4460–4464.
33. Kim, T.J., and D.N. Tripathy. 2001. Reticuloendotheliosis virus integration in the FPV genome: Not a recent event. *Avian Dis.* 45:663–669.
34. Kim, T.J., W.M. Schnitzlein, D. McAloose, A.P. Pessier, and D.N. Tripathy. 2003. Characterization of an avian pox virus isolated from an Andean condor (*Vultur gryphus*). *Vet Microbiol.* 96:237–246.
35. Kim, T.J., and D.N. Tripathy. 2006. Antigenic and genetic characterization of an avian pox virus isolated from an endangered Hawaiian goose (*Branta sandvicensis*). *Avian Dis.* 50: 15–21.
36. Kim, T.J., and D.N. Tripathy. 2006. Evaluation of pathogenicity of avian pox virus isolates from endangered Hawaiian wild birds in chickens. *Avian Dis.* 50:288–291.
37. Kirmse, P. 1967. Host specificity and long persistence of pox infection in the flicker (*Colaptes auratus*). *Bull Wildl Dis Assoc.* 3:14–20.
38. Kirmse, P. 1969. Host specificity and pathogenicity of pox viruses from wild birds. *Bull Wildl Dis Assoc.* 5:376–386.
39. Laidlaw, S.M., and M.A. Skinner. 2004. Comparison of the genome sequence of FP9, an attenuated, tissue culture-adapted European strain of FPV, with those of virulent American and European viruses. *J Gen Virol.* 85:305–322.
40. Landolt, M., and R.M. Kocan. 1976. Transmission of avian pox from starlings to Rothchild's mynahs. *J Wildl Dis.* 12:353–356.
41. Ledingham, J.C.G., and M.B. Aberd. 1931. The aetiological importance of the elementary bodies in vaccinia and fowl pox. *Lancet.* 221:525–526.
42. Luschow, D., T.A. Hoffmann, and H.M. Hafez. 2004. Strains on the basis of nucleotide sequences of 4b gene fragment. *Avian Dis.* 48:453–462.
43. Lyles, D.S., C.C. Randall, L.G. Gafford, and H.B. White, Jr. 1976. Cellular fatty acids during FPV infection of three different host systems. *Virol.* 70:227–229.
44. Mayr, A. 1963. Neue Verfahren für die Differenzierung der Geflügelpokenviren. *Berl Munch Tierarztl Wochenschr.* 76: 316–324.
45. Mayr, A., and H. Mahnel. 1970. Charakteisierung eines Vom Rhino zeros isolierten Hühnerpockenvirus. *Arch Gesamte Virusforsch.* 31:51–60.
46. Mete, A., G.H.A. Borst, and G.M. Dorrestein. 2001. Atypical pox virus lesions in two Galapagos doves (*Nesopelia g. galapagoensis*). *Avian Pathol.* 30:159–162.
47. Minbay, A., and J.P. Kreier. 1973. An experimental study of the pathogenesis of fowl pox infection in chickens. *Avian Dis.* 17:532–539.
48. Moore, K.M., J.R. Davis, T. Sato, and A. Yasuda. 2000. Reticuloendotheliosis virus (REV) long terminal repeats incorporated in the genomes of commercial FPV vaccines and pigeon pox viruses without indication of the presence of infectious REV. *Avian Dis.* 44:827–841.
49. Morita, C. 1973a. Role of humoral and cell-mediated immunity on the recovery of chickens from FPV infection. *J Immunol.* 111:1495–1501.
50. Moss, B. 1996. Poxviridae: The viruses and their replication. In: *Fields Virology*, 3rd ed. B.N. Fields, D.M. Knipe, P.M. Hawley,

R.M. Chanock, J.L. Melnick, T.P. Monath, B. Roizman, and S.E. Straus, eds. Lippincott-Raven Publishers, New York. 2637–2671.
51. Nagy, E., A.D. Maeda-Machang'u, P.J. Krell, and J.B. Derbshire. 1990. Vaccination of 1-day-old chicks with FPV by the aerosol, drinking water, or cutaneous routes. *Avian Dis.* 34:677–682.
52. Perez-Tris, J., R.A.J. Williams, E. Abel-Fernandez, J. Barreiro, J.J. Coresa, J. Figuerola, M. Martinez-Martinez, A. Ramirez, and L. Benitez. 2011. A multiplex PCR for detection of poxvirus and papillomavirus in cutaneous warts from live birds and museum skins. *Avian Dis.* 55:545–553.
53. Randall, C.C., and L.G. Gafford. 1962. Histochemical and biochemical studies of isolated viral inclusions. *Am J Pathol.* 40:51–62.
54. Randall, C.C., L.G. Gafford, R.W. Darlington, and J. Hyde. 1964. Composition of FPV and inclusion matrix. *J Bacteriol.* 87:939–944.
55. Reed, W.M., and D.L. Schrader. 1989. Immunogenicity and pathogenicity of mynah pox virus. *Poult Sci.* 68:631–638.
56. Reed, W.M., and O.O. Fatunmbi. 1993. Pathogenicity and immunological relationship of quail and mynah pox viruses to fowl and pigeon pox viruses. *Avian Pathol.* 22:395–400.
57. Schnitzlein, W.M., N. Ghildyal, and D.N. Tripathy. 1988. Genomic and antigenic characterization of avipoxviruses. *Virus Res.* 10:65–76.
58. Sharma, D.K., and S.N. Sharma. 1988. Comparative immunity of FPV vaccines. *J Vet Med B.* 35:19–23.
59. Shivprasad H.L., T.J. Kim, P.R. Woolcock, and D.N. Tripathy. 2002. Genetic and antigenic characterization of a pox virus isolate from ostriches. *Avian Dis.* 46:429–436.
60. Shivprasad, H.L., T. Kim, D. Tripathy, P.R. Woolcock, and F. Uzal. 2009. Unusual pathology of canarypox virus infection associated with high mortality in young and adult breeder canaries (*Serinus canaria*). *Avian Pathol.* 38:311–316.
61. Singh, G.K., N.P. Singh, and S.K. Garg. 1987. Studies on pathogenesis of fowl pox: Virological study. *Acta Virol.* 31:417–423.
62. Singh, P., T.J. Kim, and D.N. Tripathy. 2000. Re-emerging fowl pox: evaluation of isolates from vaccinated flocks. *Avian Pathol.* 29:449–455.
63. Singh, P., T.J. Kim, and D.N. Tripathy. 2003. Identification and characterization of FPV strains utilizing monoclonal antibodies *J Vet Diagn Invest*. 15:50–54.
64. Singh, P., and D.N. Tripathy. 2003. FPV infection causes a lymphoproliferative response in chickens. *Viral Immunol.* 16:223–227.
65. Singh, P., W.M. Schnitzlein, and D.N. Tripathy. 2003. Reticuloendotheliosis virus sequences within the genomes of field strains of FPV display variability. *J Virol.* 77:5855–5862.
66. Singh, P., W.M. Schnitzlein, and D.N. Tripathy, 2005. Construction and characterization of a FPV field isolate whose genome lacks reticuloendotheliosis provirus nucleotide sequences. *Avian Dis.* 49:401–408.
67. Smits, J.E. J.L. Tella, M. Carrete, D. Serrano, and G. Lopez. 2005. An epizootic of avian pox in endemic short-toed larks (*Calandrella rufescens*) and Berthelot's Pipits (*Anthus berthelotti*) in the Canary Islands, Spain. *Vet Pathol*. 42:59–65.
68. Srinivasan, V., W.M. Schnitzlein, and D.N. Tripathy. 2001. Fowl pox virus encodes a novel DNA repair enzyme, CPD-photolyase, that restores infectivity of UV light-damaged virus. *J Virol.* 75:1681–1688.
69. Srinivasan, V., W.M. Schnitzlein, and D.N. Tripathy. 2003. A consideration of previously uncharacterized 2FPV unidirectional and bidirectional late promoters for inclusion in homologous recombinant vaccines. *Avian Dis.* 47:286–295.
70. Srinivasan, V., and D.N. Tripathy. 2005. The DNA repair enzyme, CPD-photolyase, restores the infectivity of UV-damaged FPV isolated from infected scabs of chickens. *Vet Microbiol.* 108:215–223.
71. Srinivasan, V., W.M. Schnitzlein, and D.N. Tripathy. 2006. Genetic manipulation of two FPV late transcriptional regulatory elements influences their ability to direct expression of foreign genes. *Virus Res.* 116:85–90.
72. Sun, H.L., Y.F. Wang, G.Z Tong, P.J. Zhang, D.Y. Miao, H.D. Zhi, M. Wang, and M. Wang. 2008. Protection of chickens from Newcastle disease and infectious laryngotracheitis with a recombinant FPV co-expressing the F. HN genes of Newcastle disease virus the GB gene of infectious laryngotracheitis virus. *Avian Dis*. 52:111–117.
73. Tadese T., and W.M. Reed. 2003. Use of restriction fragment length polymorphism, immunoblotting and polymerase chain reaction in the differentiation of avian pox viruses. *J Vet Diagn Invest.* 15:141–150.
74. Tadse, T., and W.M. Reed. 2003. Detection of specific reticuloendotheliosis virus sequences and protein from REV-integrated FPV strains. *J Virol Methods.* 110:99–104.
75. Tadese, T., S. Fitzgerald, and W.M. Reed. 2008. Detection and differentiation of re-emerging fowl pox (FPV) strains carrying integrated reticuloendotheliosis virus (FPV-REV) by real-time PCR. *Vet Microbiol.* 127:39–49.
76. Tanizaki, E., T. Kotani, and Y. Odagiri. 1986. Pathological changes of tracheal mucosa in chickens infected with FPV. *Avian Dis.* 31:169–175.
77. Tanizaki, E., T. Kotani, Y. Odagiri, and T. Horiuchi. 1989. Pathologic changes in chickens caused by intravenous inoculation with FPV. *Avian Dis.* 33:333–339.
78. Taylor, J., R. Weinberg, B. Languet, P. Desmettre, and E. Paoletti. 1988. Recombinant FPV inducing protective immunity in non-avian species. *Vaccine.* 6:497–503.
79. Tripathy, D.N., L.E. Hanson, and W.L. Myers. 1970. Passive hemagglutination test with FPV. *Avian Dis.* 14:29–38.
80. Tripathy, D.N., L.E. Hanson, and A.H. Killinger. 1973. Immunoperoxidase technique for detection of fowl pox antigen. *Avian Dis.* 17:274–278.
81. Tripathy, D.N., L.E. Hanson, and Killinger, A.H. 1974. Atypical fowl pox in a poultry farm in Illinois. *Avian Dis.* 18:84–90.
82. Tripathy, D.N., and L.E. Hanson. 1975. Immunity to fowl pox. *Am J Vet Res.* 36:541–544.
83. Tripathy, D.N., and L.E. Hanson. 1976. A smear technique for staining elementary bodies of fowl pox. *Avian Dis.* 20:609–610.
84. Tripathy, D.N., and W.M. Reed. 2008. Pox. In: *Diseases of Poultry*, 12th ed. Y.M. Saif, A.M. Fadly, J.R. Glisson, L.R. McDougald, L.K. Nolan, and D.E. Swayne, eds. Blackwell Publishing, Ames, Iowa. 291–307.
85. Tripathy, D.N., and W.M. Reed. 2008. Pox. In: *A Laboratory Manual for the Isolation, Identification and Characterization of Avian Pathogens*, 5th ed. Zavala, L.D., D.E. Swayne, J.R. Glisson, J.E. Pearson, W.M. Reed, M.W. Jackwood, and P.R. Woolcock, eds. In: American Association of Avian Pathologists. Jacksonville, Florida. 116–119.
86. Tripathy, D.N., W.M. Schnitzlein, P.J. Morris, D.L. Janssen, J.K. Zuba, G. Messy, and C.T. Atkinson. 2000. Characterization of pox viruses from forest birds in Hawaii. *J Wildl Dis.* 36:225–230.

87. Tripathy, D.N., and A.F.A Bahaa. 2009. Genetic characterization of avianpox viruses using DNA isolated from formalin fixed tissue sections. AAAP, AVMA Conference, Seattle, WA, July, 2009.
88. Tripathy, D.N., and A.F.A. Bahaa. 2010. Differentiation of Avianpox viruses by PCR amplification of specific genes. AAAP, AVMA Conference, Atlanta, GA, July, 2010.
89. Tripathy, D.N., A.F.A Bahaa, and G.J.F Robles. Genetic characterization of a vaccine strain of FPV. AAAP/PSA (Poultry Science Association) combined meeting, at AVMA conference, St. Louis, MO, July 16-19, 2011.
90. Tsai, S.S., T.C. Chang, S.F. Yang, Y.C. Chi, R.S. Cher, M.S. Chien, and C. Itakura, 1997. Unusual lesions associated with avian pox virus infection in rosy-faced lovebirds (*Agapornis roseicollis*). *Avian Pathol.* 26:75–82.
91. Tulman, E.R., C.L. Afonso, Z. Lu, G.F. Kutish, and D.L. Rock. 2004. The genome of canarypox virus. *J Virol.* 78:353–366.
92. Wang, J., J. Meers, P.B. Spradbrow, and W.F. Roibinson. 2006. Evaluation of immune effects of fowl pox vaccine strains and field isolates. *Vet Microbiol.* 116:106–119.
93. Weli, S.C., O. Nilssen, and T. Traavik. 2005. Avian pox virus multiplication in a mammalian cell line. *Virus Res.* 109:39–49.
94. Weli, S.C., and M. Tryland. 2011. Avianpoxviruses: infection biology and their use as vaccine vectors. *Virology J.* 8:49.
95. White, H.B., S.S. Powell, L.G. Gafford, and C.C. Randall. 1968. The occurrence of squalene in lipid of FPV. *J Biol Chem.* 243:4517–4525.
96. Winterfield, R.W., and S.B. Hitchner. 1965. The response of chickens to vaccination with different concentrations of pigeon pox and FPVes. *Avian Dis.* 9:237–241.
97. Winterfield, R.W., and W. Reed. 1985. Avian pox: Infection and immunity with quail, psittacine, fowl, and pigeon pox viruses. *Poult Sci.* 64:65–70.
98. Woodroofe, G.M., and F. Fenner. 1962. Serological relationship within the pox virus group: An antigen common to all members of the group. *Virol.* 16:334–341.
99. Woodruff, A.M., and E.W. Goodpasture. 1931. The susceptibility of the chorio-allantoic membrane of chick embryo to infection with the FPV. *Am J Pathol.* 7:209–222.
100. Woodruff, C.E., and E.W. Goodpasture. 1929. The infectivity of isolated inclusion bodies of fowl pox. *Am J Pathol.* 5:1–10.
101. Woodruff, C.E., and E.W. Goodpasture. 1930. The relation of the virus of fowl-pox to the specific cellular inclusions of the disease. *Am J Pathol.* 6:713–720.
102. Wyatt, R.D., B.A. Weeks, P.B. Hamilton, and H.R. Brumeister. 1972. Severe oral lesions in chickens caused by ingestion of dietary fusariotoxin T-2. *Appl Microbiol.* 24:251–257.

Chapter 11

Reovirus Infections

Richard C. Jones

Introduction

Avian reoviruses are members of the Orthoreovirus genus, one of 12 genera of the Reoviridae family. In turn they are assigned the species Spinareovirinae, one of the five recognized species of the genus Orthoreovirus, which also contains the non-fusogenic mammalian reoviruses, the two fusogenic mammalian reoviruses Nelson Bay virus (bat) and baboon reovirus, as well as fusogenic reoviruses isolated from reptilian species. Avian and mammalian reoviruses are the two principal groups of the genus and while they share many biological characteristics, they differ in host range, pathogenicity, coding capacity, and other biological properties (3, 4, 5, 6, 7, 8, 9, 11, 12, 13, 14, 15, 16). Unlike their mammalian counterparts, the avian reoviruses cause fusion of host cells (see Diagnosis) but lack hemagglutinating activity. Avian reovirus structure and biology have been reviewed in detail by Benavente and Martinez-Costas (1).

The double-stranded RNA (dsRNA) genome consisting of 10 segments packaged into a non-enveloped icosahedral double-shelled capsid of approximately 80 nm diameter (Figure 11.1). The name "reovirus" derives from "respiratory, enteric orphan," because they were first isolated from these sites in humans with initially no apparent association with disease. The term "avian reovirus" (ARV) is widely used to distinguish these viruses from their mammalian counterparts, although because recent work has shown that reoviruses of turkeys (TRV), ducks (DRV), and geese (GRV) have distinct molecular differences from chicken strains, the use of ARV is often used for chicken-derived reoviruses whereas TRV, DRV, and GRV are used for strains from the other domesticated species.

Although they are considered to be ubiquitous in commercial poultry and for the most part appear harmless, avian reoviruses have been isolated from a variety of tissues and organs in chickens affected by assorted disease conditions, including viral arthritis/tenosynovitis, stunting syndrome, respiratory disease, enteric disease, immunosuppression, and malabsorption syndrome (10, 12, 13, 15, 16). Reoviruses have recently been identified as the cause of viral arthritis in turkeys in the USA (14). They are frequently and easily isolated from chickens and turkeys that are clinically normal. The nature of the disease that occurs following reovirus infection is very much dependent upon host age, immune status, virus pathotype, and route of exposure. Interactions with other infectious agents have been documented (12, 15, 16) and may result in differences in both the nature and severity of reovirus-induced disease expression.

Figure 11.1. Avian reovirus particles under the electron microscope. Diameter of the double-shelled virions is 70–80 nm. Phosphotungstic acid negative stain (R.C. Jones)

Reoviruses also have been associated with diseases in turkeys, ducks, and geese, and infection has been detected in several wild species of birds. These are dealt with in a separate section later in this chapter.

In young meat-type chickens, economic losses related to reovirus infections are frequently associated with increased mortality, viral arthritis/tenosynovitis (4, 12), and a general lack of performance including diminished weight gains, poor feed conversions, uneven growth rates, and reduced marketability

Diseases of Poultry, Thirteenth Edition. David E. Swayne.
© 2013 John Wiley & Sons, Inc. Published 2013 by John Wiley & Sons, Inc.

of affected birds due to downgrading at slaughter (2). Breeder flocks that develop viral arthritis just prior to the onset of or during egg production may be characterized by lameness as well as increased mortality, decreased egg production, suboptimal hatchability/fertility, and vertical transmission of virus to progeny. All of these can contribute to increased costs for poultry producers.

The best defined and most readily diagnosed reovirus-associated disease in chickens is viral arthritis (12), now also recognized in turkeys (14) and sometimes referred to as tenosynovitis (10). The disease has been recognized in virtually all major poultry-producing areas worldwide, mainly as a disease of heavy meat-type chickens, but also in light breeds. Other disease conditions associated with reovirus infections can sometimes be demonstrated experimentally or are inferred by isolation from clinical accessions. However, these conditions are often difficult to recognize and conclusively diagnose in the commercial setting. Furthermore, experimental reproduction of the clinical condition is often difficult or impossible, so the reovirus-disease association is frequently tenuous. Because of the clear association between virus and disease and differences in disease expression, viral arthritis will be described separately in this chapter from other reovirus-associated diseases in poultry and other species.

Viral Arthritis

Introduction

Viral arthritis is an economically important disease of chickens that can be caused by different serotypes and pathotypes of avian reovirus (37, 47, 56, 103, 106). The disease is considered to be most important in meat-type chickens but has from time to time been diagnosed in commercial layers (54, 117). Although viral arthritis has been reported in turkeys (1, 25, 85, 93), experimental reproduction of joint lesions has not always been successful (1, 5). However, a recent report by Trites et al. (122) shows a clear link between reoviruses and viral arthritis in the turkey.

The disease in chickens typically is controlled by vaccination with live attenuated and/or inactivated whole virus vaccines. Derivatives of the S1133 strain of reovirus are most commonly used as vaccines and have proven to be efficacious in most parts of the world. However, antigenically different reoviruses can break through vaccinal immunity. Autogenous vaccines can be used to provide protection against different serotypes (109). Turkeys and other avian species have not been routinely vaccinated for viral arthritis.

Public Health Significance

No implications of public health significance have been reported.

History

In 1954, Fahey and Crawley (23) made what was later confirmed by Petek et al. (95) to be the initial isolation of avian reovirus from the respiratory tract of chickens with chronic respiratory disease. The Fahey-Crawley virus, when inoculated into susceptible chickens, produced a moderate respiratory disease, liver necrosis, and an inflammation of the tendons and synovial membranes.

Olson et al. in 1957 (91) described a naturally occurring synovitis in chickens from which they were able to isolate an agent insensitive to chlortetracycline and furazolidone and serologically unrelated to either *Mycoplasma gallisepticum* or *M. synoviae*. This agent, later named the "viral arthritis agent" by Olson and Kerr (87, 88), eventually was identified as a reovirus by Walker et al. in 1972 (137). Dalton and Henry (15) used the term tenosynovitis (sometimes used synonymously with viral arthritis) to define the changes in the tendons and tendon sheaths associated with a condition they considered different from that caused by *M. synoviae*. This difference was substantiated by Olson and Solomon (90, 92) when they reported tenosynovitis in commercially produced chickens that had been derived from *M. synoviae*-free broiler chickens. An isolate obtained from these birds had characteristics identical to those described for the "viral arthritis agent" and was shown to be antigenically similar to the Fahey-Crawley virus (91). Since the first reports of tenosynovitis in the United States and England, the disease has been described in many other countries. Several reviews document the incidence of reovirus-induced tenosynovitis (61, 64, 100, 130).

Control of viral arthritis was greatly facilitated by recognition of the role of maternal antibodies in conferring protection to progeny (129, 133). Both viable and inactivated vaccines were subsequently developed to induce antibodies in breeder flocks for the protection of progeny from contact and transovarian transmission (134). The first commercially available live vaccines were developed by van der Heide et al. (127, 131) from the S1133 strain of avian reovirus. This same strain has been extensively used as an inactivated vaccine alone or in combination with other reovirus pathotypes.

Reoviruses that cause viral arthritis also have the potential to induce other pathological changes in chickens, particularly if introduced via the transovarian route or shortly after hatch (48, 55, 77, 80, 103). Disease conditions associated with some reoviruses that have arthrotropic characteristics include ruptured gastrocnemius tendons, pericarditis, myocarditis, hydropericardium, uneven growth, and mortality (38, 54, 61, 127, 132). The recently described turkey viral arthritis (122)

appears to have strikingly similar gross and microscopic lesions to the disease in chickens.

Incidence and Distribution

Reovirus infections are prevalent worldwide in chickens, turkeys, and other avian species. Viral arthritis is observed primarily in meat-type chickens but can be found in lighter breeds (54, 112, 117) and turkeys (1, 5, 36, 85, 93, 122, 130). It should be recognized, however, that reoviruses are commonly found in the digestive and respiratory tracts of clinically normal chickens and turkeys (19, 93, 114, 130, 145). It is estimated that greater than 80% of reoviruses isolated from chickens are non-pathogenic (123). This fact has implications in relation to diagnosis of reovirus infections.

Etiology

Virus Morphology and Structure

Avian reoviruses contain 10 double-stranded RNA (dsRNA) genome segments divided into three size classes—L1-L3 (large), M1-M3 (medium), and S1-S4 (small)—on the basis of electrophoretic mobility. The avian reovirus genome expresses at least 12 primary translation products, of which 8 are structural proteins, incorporated into the virion. Several non-structural proteins are also expressed which are detected in the cytoplasm of infected cells. Their functions have been reviewed by Benavente and Martinez-Costas (8).

Protein λA, encoded by the L1 gene, is thought to form the inner core shell of the virus, while λB, encoded by L3, is a minor component of the viral core. Protein λC, encoded by L3, extends from the inner core to the outer capsid of the virion. Of the proteins encoded by the M segments, μA (M1) is a minor inner capsid component, μB (M2) forms part of the outer capsid, and μNS (M3) is a non-structural protein. The S gene segment encoding is as follows: σA (S2) is a component of the inner core shell which is considered to play a key role in the resistance to the antiviral activity of interferon and in virus morphogenesis, σB (S3) is a major component of the outer capsid, although its properties are uncertain, and σC (S1) is a minor capsid protein but is the viral cell attachment protein and elicits reovirus-specific neutralizing antibodies. S1 segment also codes for proteins p10 and p17 while S1 encodes a further non-structural protein, σNS.

Goldenberg et al. (29) classified avian reoviruses from all over the world into four groups on the basis of the most highly variable σC protein sequences. The authors point out the importance of such information in formulating wide-ranging vaccines.

Sequence analysis of selected S genes has led several authors to confirm that turkey (111) and duck reoviruses should be ascribed to separate subgroups of avian reovirus from the chicken types, while the goose reoviruses have similarities with those of the duck (6, 24).

Replication

The replication of avian reoviruses has been reviewed by Benavente and Martinez-Costas (9). Avian reoviruses enter cells by receptor-mediated endocytosis, and acidification of virus-containing endosomes is necessary for the virus to uncoat and release transcriptionally active cores into the cytosol. They replicate within cytoplasmic inclusions of globular morphology, termed viral factories, which are not microtubule-associated, and which are formed by the nonstructural protein NS. This protein also mediates the association of some viral proteins (but not of others) with inclusions, suggesting that the recruitment of viral proteins into avian reovirus factories has specificity. Avian reovirus morphogenesis is a complex and temporally controlled process that takes place exclusively within viral factories of infected cells. Core assembly takes place within the first 30 minutes after the synthesis of their protein components, and fully formed cores are then coated by outer-capsid polypeptides over the next 30 minutes to generate mature infectious reovirions.

Several reports confirm the ability of avian reoviruses to readily undergo reassortment, resulting in considerable variability in molecular type and biological nature (7, 119). Interferon induction is a feature of avian reovirus replication (141).

In the chicken in particular, replication of avian reoviruses has been described in various tissues but the chief targets appear to be the intestine (56), the tibiotarsal-tarsometatarsal (hock) joint (54), and the liver (62).

Biophysical Factors

Reoviruses are heat resistant; they are able to withstand 60°C for 8–10 hours, 56°C for 22–24 hours, 37°C for 15–16 weeks, 22°C for 48–51 weeks, 4°C for more than 3 years, −20°C for more than 4 years, and -63°C for more than 10 years (78). The titer of semi-purified virus at 60°C is reduced, but not completely inactivated, in 5 hours. Heat treatment in the presence of magnesium chloride results in increased titers. The ability of avian reoviruses to survive on or in materials associated with the poultry house has been studied by Savage and Jones (110). They found that reoviruses survived for at least 10 days on feathers, wood shavings, egg shells, and in feed but in drinking water virus was detectable for at least 10 weeks with little loss of infectivity.

Reoviruses are not sensitive to ether but are slightly sensitive to chloroform. They are resistant to pH 3; hydrogen peroxide when incubated for 1 hour at room temperature; 2% lysol; 3% formalin; and the DNA metabolic inhibitors actinomycin D, cytosine arabinoside, and 5-fluoro-2-deoxyuridine. They are inactivated by 70% ethanol, 0.5% organic iodine, and a 5% solution of hydrogen peroxide (84). Vegetable extracts from chestnut and quebracho wood have been shown to have anti-reovirus activity (75).

Sensitivity of avian reovirus to trypsin varies but is not related to antigenic configuration or species of origin (50). The significance of trypsin sensitivity to relative pathogenicity is unclear, but reoviruses sensitive to trypsin replicate poorly in the intestine following oral exposure and are not readily disseminated to other tissues sites (59, 83). Interestingly, S1133-derived vaccine viruses are inactivated by trypsin treatment.

Avian reoviruses induce cell fusion, which differentiates them phylogenetically from most other animal reoviruses (17). Syncytia formation in cell culture increases the rate of reovirus-associated cytopathogenicity and virus released from infected cells but is not essential for either activity (18).

Despite two early reports to the contrary (19, 20), it is generally accepted that avian reoviruses, unlike their mammalian counterparts, do not demonstrate hemagglutination.

Strain Classification

Reoviruses have been traditionally classified using serologic procedures or grouped according to their relative pathogenicity for chickens. Kawamura and Tsubahara and Kawamura et al. (60, 61) identified five serotypes of reovirus from 77 isolates originally obtained from feces, cloacal swabs, and tracheas. Sahu and Olson (108) found four serotypes from intestines, respiratory tract, and synovial isolates. Wood et al. (143) calculated the relatedness of reoviruses originating from the United States, the United Kingdom, Germany, and Japan, and found at least 11 serotypes, although there was considerable cross neutralization among heterologous types. Hieronymus et al. (38) grouped five reovirus isolates into three serotypes, and Robertson and Wilcox (99) assigned 10 Australian isolates into three groups with considerable cross-reactivity. It is apparent that reoviruses may frequently exist as antigenic subtypes, rather than distinct serotypes, and reassortment can occur (99).

Rosenberger et al. (105) and Sterner et al. (118) inoculated specific pathogen free (SPF) chickens by various routes with plaque-purified, antigenically similar viruses and demonstrated clear strain differences based on relative pathogenicity and virus persistence.

More recently avian reoviruses are characterized routinely by molecular methods, in particular by sequencing of σ proteins (28, 47). The recently described arthrotropic viruses of the turkey (122) await detailed characterization.

Laboratory Host Systems

Reoviruses grow readily in the embryonating chicken egg following inoculation via yolk sac or chorioallantoic membrane (CAM). The yolk sac is preferred for original isolation and generally results in embryo mortality 3–5 days after inoculation, with affected embryos exhibiting a purplish discoloration due to massive subcutaneous hemorrhage. Mortality in CAM-inoculated embryos usually occurs on day 7–8 post inoculation (PI); embryos are slightly dwarfed with occasional enlargement of the liver and spleen. Necrotic foci may occur in both the liver and spleen, particularly in embryos that survive longer than 7 days PI. Embryo mortality is less consistent following inoculation via the chorioallantoic sac.

The virus grows in primary chicken cell cultures of embryo, lung, kidney, liver, macrophages, and testicle. Primary chicken kidney cells from 2- to 6-week-old chickens are satisfactory, but for plaques and isolation, primary embryo liver cells are preferred (32). Chicken embryo fibroblasts are suitable for reovirus growth, but the virus often requires adaptation (8, 31, 56). Chicken-origin cell cultures infected with reoviruses are characterized by the formation of syncytia, which may occur as early as 24–48 hours, followed by degeneration, leaving holes in the monolayer and giant cells floating in the medium. Infected cells exhibit intracytoplasmic inclusions that may appear either eosinophilic or basophilic (99). Of many established cell lines tested, virus has been grown successfully, usually after adaptation, on Vero, BHK 21/13, 1TT, feline kidney (CRFK), Georgia bovine kidney (GBK), rabbit kidney (RK), porcine kidney (PK) (8), a Japanese quail cell line (QT35) derived from an induced fibrosarcoma (14), chicken lymphoblastoid cells (113), and subpopulations of chicken lymphocytes (82).

Pathogenicity

Although normally associated with arthritis, reoviruses have been strongly associated with other disease conditions in chickens as well, including growth retardation, pericarditis, myocarditis, hydropericardium, enteritis, hepatitis, bursal and thymic atrophy, osteoporosis, and acute and chronic respiratory syndromes (23, 25, 48, 69, 85, 86, 101, 108, 118, 130). The pathogenicity of selected reovirus isolates was shown to be enhanced by coinfection with *Eimeria tenella* or *E. maxima* (106, 107). Exposure to infectious bursal disease virus or particular dietary regimes increased the severity of tenosynovitis resulting from infections with the WVU-2937 isolate (12, 13, 117). Reoviruses also may exacerbate disease conditions caused by other pathogens including chicken anemia virus (22, 79), *Escherichia coli*, and common respiratory viruses (98, 105). The increased susceptibility to other infectious agents following or concomitant with reovirus exposure may result from immune system compromise (98, 101, 106, 107).

Pathogenesis and Epidemiology

Natural and Experimental Hosts

Although reoviruses have been found in many avian species, chickens are the only recognized natural or experimental hosts for reovirus-induced arthritis. The situation with turkeys has been unclear until recently. Reoviruses have been isolated from turkeys with arthritis (93), and Van der Heide et al. (130) found a turkey isolate to be pathogenic for chickens. The turkey isolate was neutralized by chicken reovirus S1133 antiserum. High mortality in turkey poults also has been associated with reovirus (114), although turkeys were shown by Al-Afaleq et al. (1) to be more resistant than chickens to reovirus-induced tenosynovitis. However, viral arthritis in turkeys has now been reported in the USA with clinical signs identical to those in the chicken, but caused by a different, possibly turkey-specific reovirus (122).

Reoviruses have been detected in several non-domesticated avian species and these are described in the final section of this chapter (Other Reovirus Infections). Phillips et al. (96) reported liver lesions in neonatal mice after oral and nasal infection, and Nersessian et al. (85) produced stunted growth and incoordination in suckling mice inoculated intracerebrally with several turkey isolates. Al-Afaleq et al. (3) showed that arthrotropic

reovirus R2 caused nervous signs and oiliness of the coat in mice, resembling the effect of mammalian reoviruses.

Age-Associated Resistance

Kerr and Olson (62) were the first to report an age-related resistance to reovirus-induced arthritis. The disease can be readily reproduced in 1-day-old chickens free of maternal antibody (51, 127), whereas older chickens are infected, but the disease is generally less severe, and the incubation period is longer. Similar results were reported by Rosenberger (105) with reoviruses isolated from birds with an apparent stunting syndrome and arthritis. Jones and Georgiou (51) infected chicks at intervals up to nine weeks and considered that the age-associated susceptibility is related to the inability of young birds to develop an effective immune response.

Transmission

Horizontal transmission of reovirus has been extensively documented (86, 100, 125). There is considerable variation, however, among strains of virus in their ability to spread laterally. Although reovirus may be excreted from both the intestinal and respiratory tracts for at least 10 days PI, virus generally appears to be shed from the intestine for longer periods, suggesting fecal contamination as a primary source of contact infection (51, 76). Roessler et al. (102) demonstrated that 1-day-old chickens are more susceptible to reovirus introduced via the respiratory route than orally. Virus may persist for long periods in the cecal tonsils and hock joints, particularly in birds infected at a young age (51, 77), implicating carrier birds as potential sources of infection for contacts.

Menendez et al. (80), Van der Heide and Kalbac (126), and Al-Mufarrej et al. (4) have clearly demonstrated that avian reoviruses can be vertically transmitted. Menendez et al. (80) showed that following oral, tracheal, and nasal inoculation of 15-month-old breeders, virus was present in chicks from eggs laid 17, 18, and 19 days PI. Reoviruses also were isolated from chicken embryo fibroblast cell cultures prepared from embryonating eggs derived from experimentally infected hens (81). Al-Mufarrej et al. (4) reported that infected eggs were laid by virus-infected SPF hens between 5 and 17 days PI, and virus was isolated from the liver, intestine, and hock joints of hatched chicks. Despite this, virus was never isolated from cloacal swabs taken from the hens. All reports suggest that the rate of egg transmission is low.

The possibility of avian reoviruses entering through broken skin in the foot and localizing in the hock joint was demonstrated using a trypsin-sensitive strain (2).

Incubation Period

The incubation period differs depending upon the virus pathotype, age of host, and route of exposure (100, 120). For inoculated 2-week-old chickens, the incubation period varied from 1 day (foot pad inoculation) to 11 days (intramuscular, intravenous, intrasinus inoculation). The incubation period following intratracheal inoculation and contact exposure was 9 and 13 days, respectively (89).

Often, infections are inapparent and demonstrable only by serology or virus isolations. Mature birds inoculated by oral and respiratory routes with the FDO isolate had virus in all organs tested at 4 days PI. The number of virus isolations was greatly reduced by 2 weeks, and no virus was present 20 days PI. There was frequent localization of virus in the flexor and extensor tendons of the pelvic limb, although gross lesions were not evident (77). Foot pad inoculation of 1-day-old chickens with an arthrotropic reovirus (R2) produced a more rapid progression of disease than either the oral, subcutaneous, or articular routes (45). When infected by the oral route, which appears to be a likely mode of naturally transmitted virus, the initial site of viral replication, which occurred within 2 to 12 hours post exposure, was the epithelium of the intestine and the cloacal bursa (bursa of Fabricius). This was followed by virus distribution in a wide range of tissues, including the hock joint, within 24–48 hours (58). Many reoviruses cause microscopic inflammatory changes in the digital flexor and metatarsal extensor tendons without development of gross lesions (88).

Chicks are most susceptible to reovirus infection when they are very young and the development of joint lesions is a slow process. When viral arthritis does result from naturally occurring infection, it is usually not seen in young birds before 4–7 weeks old but may be seen in much older chickens as well (124). In view of the increased resistance with age, the development of lesions at maturity is difficult to explain, unless persistent virus is reactivated by the stress of sexual activity. Morbidity can be as high as 100%, and mortality is generally less than 6%. The virus can persist in the tendons for at least 22 weeks (101). While the lesions of the recent turkey viral arthritis have been predominantly seen in males of 14 weeks or older (122), it remains to be determined if there is a similar age-linked resistance to infection to that in the chicken.

Clinical Signs

In chickens, typically, signs of lameness are unlikely to be seen before 4–5 weeks of age, even though infection may have occurred soon after hatching or transovarially. In acute infections, some chickens also may be stunted. With chronic infection, lameness is more pronounced. As the joint disease develops, the most severely affected birds with both hocks swollen are immobilized and may be recumbent close to drinkers. The mortality in a flock may typically be low (some sick birds may be trampled by their litter hatchmates) but morbidity may be as high as 100%.

In a typically affected flock of approximately 15,000 broilers, approximately 5% of the birds had enlargement in the area of the gastrocnemius or digital flexor tendons when observed at slaughter. At 9 weeks, birds from this flock had an average weight of only 3.66 lbs.; feed conversion was 2.45; mortality totaled 5%; and the condemnation rate was 2.6%. Virus was isolated from two birds condemned for toxemia; of 80 serum samples obtained from this flock, 89% had reovirus antibodies detected in a precipitin test. This inapparent infection probably caused the poor performance of these broilers.

Similar observations have been made by other workers (48). Rupture of the gastrocnemius tendon, especially in male roaster birds 12–16 weeks old and sometimes at point of lay, occurs in extreme cases and is often associated with reovirus

infection and increased bird weight (48, 57). This also has been produced by experimental infection. A similar lesion has been seen in 5– to 8-week-old turkeys (93). The typical uneven gait in bilateral rupture of the tendon results from the inability of the bird to mobilize the metatarsus. The latter is often accompanied by ruptured blood vessels.

Recent accounts of viral arthritis in turkeys in Iowa, Minnesota, and North and South Dakota (122) describe effects in males of 14 weeks or older. Affected birds had swollen hock joints and were lame. Morbidity varied from 5%–7% and mortality, including culling, was between 2 and 30%. Hens were less severely affected but marketed before signs became severe.

Gross Lesions

In naturally infected chickens, gross lesions in chickens are observed as swellings of the gastrocnemius, digital flexor, and metatarsal extensor tendons. The first lesion is evident by palpation just above the hock and may be readily observed when feathers are removed (Figure 11.2). The affected joints usually feel warm. If the gastrocnemius tendon is ruptured, this can often be perceived as a greenish discoloration of the skin due to extravasation of blood (Figure 11.3). Removal of the skin at autopsy will reveal the broken end of the tendon (54). This "greening" with the joint swelling can be an important cause of downgrading at slaughter.

Enlargement of the shank below the hock may suggest swelling of the digital flexor tendons; however, necropsy usually reveals that the swelling is due to sigmoid folding of the flexor tendons which have ruptured at the level of the hock itself (Figure 11.4), together with gelatinous fluid. Swellings of the foot pad and hock joint are less frequent.

The hock usually contains a small amount of straw-colored or blood-tinted exudate; in a few cases, there is a considerable amount of purulent exudate resembling that seen with mycoplasma synovitis. Early in the infection, there is marked edema of the tarsal and metatarsal tendon sheaths (Figure 11.4). Petechial hemorrhages are frequent in the synovial membranes above the hock (Figure 11.5A).

Figure 11.2. Marked edema of digital flexor tendon sheaths (left); normal (right).

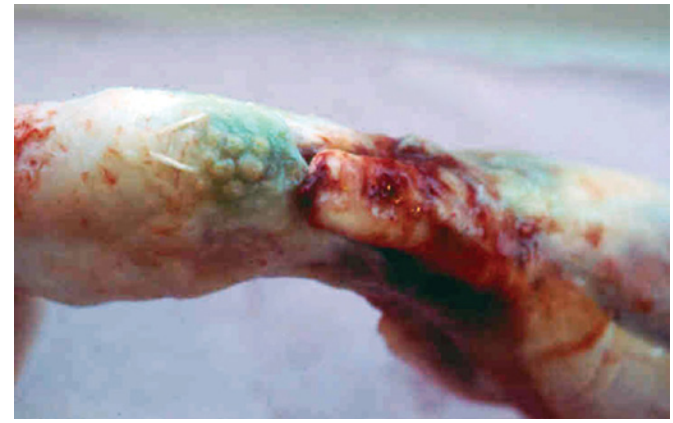

Figure 11.3. Hock joint of a 6-week old broiler with skin removed showing rupture of the gastrocnemius tendon. Experimental infection with reovirus at day old. (R.C. Jones)

Figure 11.4. Shank of a 6-week old broiler showing three digital flexor tendons, all having ruptured at the level of the hock joint. Reovirus was isolated from this joint. (R.C. Jones)

Inflammation of tendon areas progresses to a chronic-type lesion characterized by hardening and fusion of tendon sheaths. Small pitted erosions develop in the articular cartilage of the distal tibiotarsus. These erosions enlarge, coalesce, and extend into underlying bone (Figure 11.5B, C). An overgrowth of fibrocartilaginous pannus develops on the articular surface. Condyles and epicondyles are frequently involved (63). In inoculated chickens, the diaphysis of the proximal metatarsal of the affected limb is enlarged.

Gross lesions in naturally infected turkeys are virtually identical to those in the chicken (122).

Histopathology

Histologic changes have been described by Kerr and Olson (62). In general, they are the same for natural and experimental infections. During the acute phase (7–15 days following foot pad inoculation), edema, coagulation necrosis, heterophil accumulation, and perivascular infiltration are seen. There also are hypertrophy and hyperplasia of synovial cells, infiltration of lymphocytes and macrophages, and a proliferation of reticular cells. These latter lesions cause parietal and visceral layers of the tendon sheaths to become markedly thickened. The synovial cavity is filled with heterophils, macrophages, and sloughed synovial cells. Periostitis characterized by increased osteoclasts develops. During the chronic phase (starting by 15 days PI), the synovial membrane develops villous processes, and lymphoid nodules are seen. After 30 days, inflammatory changes become more chronic with an increase in fibrous connective tissue and a pronounced infiltration or proliferation of reticular cells, lymphocytes, macrophages, and plasma cells.

Similar inflammatory changes develop in the tarsometatarsal and hock joint areas. Development of sesamoid bones in the tendon of the affected limb is inhibited. Some tendons are replaced completely by irregular granulation tissue. At 54 days PI, orally infected birds showed chronic fibrosis of tendon sheaths, with fibrous tissues invading tendons and resulting in ankylosis and immobility.

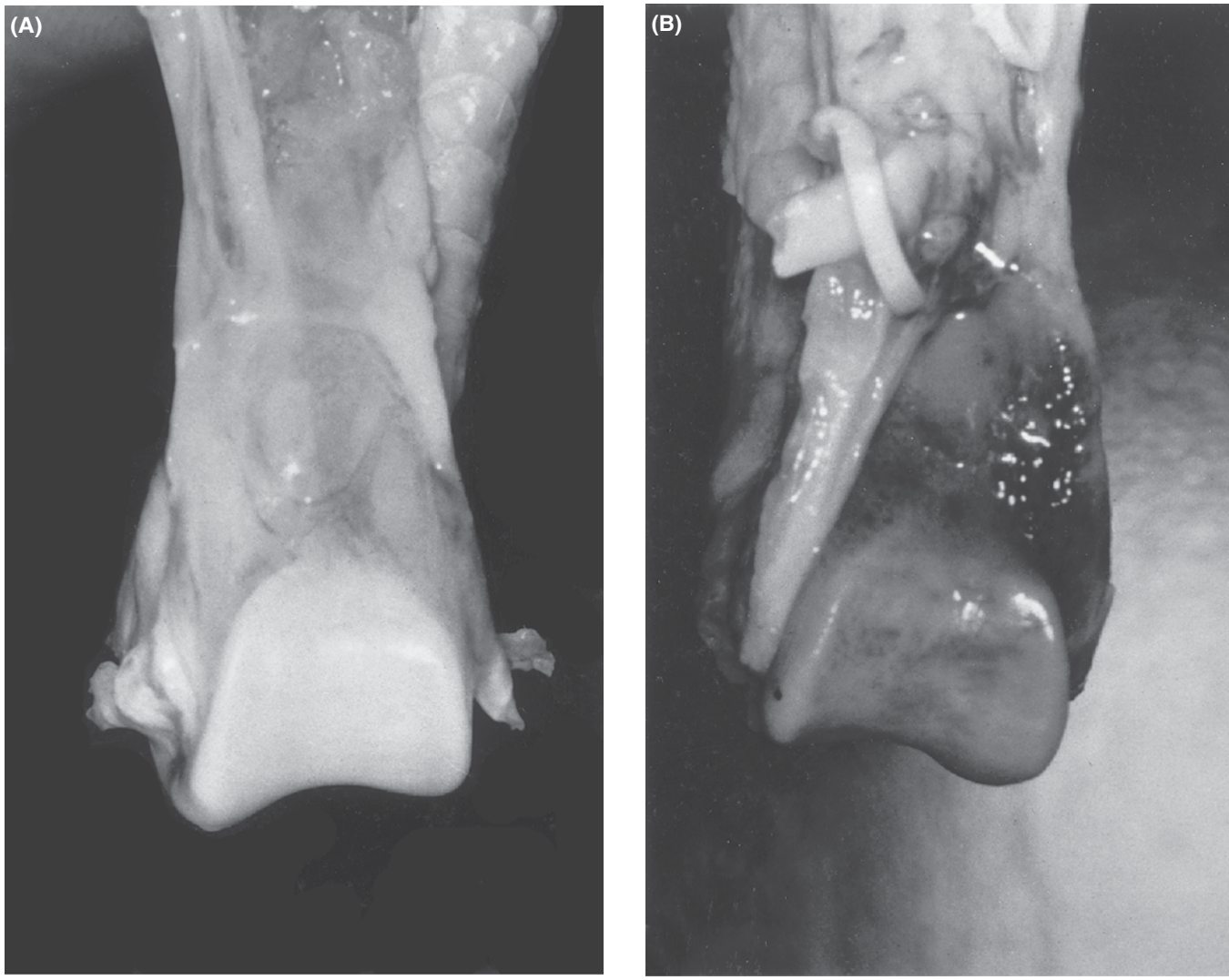

Figure 11.5. Viral arthritis lesions in distal posterior tibia of inoculated chickens. (A) Normal. (B) Cartilage erosions and hemorrhages of synovial membrane 35 days post inoculation.

Figure 11.5. (*continued*) (C) Erosions of cartilage and marked thickening of synovial membrane 212 days PI.

Linear growth of cartilage cells in the proximal tarsometatarsal bone becomes narrow and irregular. Erosions on the hock joint cartilage are accompanied by a granulation pannus. Osteoblasts become active and lay down a thickened layer of bone beneath the erosion. Osteoblastic activity is present on the condyles, epicondyles, and accessory tibia, producing osteoneogenesis and subsequent exostosis (62).

Ultrastructurally, the gastrocnemius tendon and sheath in broilers infected with reovirus at 1 day of age by the oral route were characterized by degenerative changes in fibroblasts including cytoplasmic vacuolization, membrane disruption, loss of ribosomes from the endoplasmic reticulum, and generalized mitochondrial and cellular disruption (40).

Lesions found in the heart have been described in detail (62, 90). An infiltration of heterophils between myocardial fibers is a constant finding, but it is not clear whether this is pathognomonic of reovirus infection. The pathogenicity of avian reoviruses for day-old chicks revealed the arthrogenic potential for many strains and ability to cause marked hepatic necrosis (53).

Immunity

In the relatively few reports on the mechanisms of immunity to avian reoviruses, both joint and enteric effects have been studied.

Humoral Antibodies

Avian reoviruses possess a group-specific antigen discernible with gel diffusion techniques (142) and a serotype-specific antigen demonstrable with neutralizing antibody in plaque-reduction or chicken embryo assays (99). Neutralizing antibodies can be detected 7–10 days following infection, and precipitating antibodies at approximately 2 weeks. Neutralizing antibody appears to persist longer than precipitating antibody, but this may be a reflection of assay sensitivity. The importance of antibody in establishing protection is not well understood, because birds may become persistently infected in the presence of high levels of circulating antibody (55). It is clear, however, that maternal antibody can afford a degree of protection to 1-day-old chickens against naturally occurring and experimental challenges (134, 136). In this case it is likely that circulating antibodies prevent virus in the gut from reaching the joints. Relative protection afforded by antibody appears to be related to serotype homogeneity, virus virulence, host age, and antibody titer (97, 129, 140).

Local Antibodies

Induction of intestinal virus-specific IgA, which may be important in limiting the pathogenic potential and dissemination of reovirus, is affected by route of exposure, age, and sensitivity to trypsin (83). Chickens infected at 1 day of age or with trypsin-sensitive reovirus by the oral route do not have a detectable intestinal IgA response.

Cell-Mediated Immunity

Kibenge et al. (65), using immunosuppression by bursectomy and/or thymectomy of chicks, showed that recovery from reovirus infection involves both B and T cell systems but that protection is predominantly B cell-mediated. In birds treated with both, virus infection appeared more persistent. Hill et al. (39) reported that the suppression of T cell-mediated immunity by cyclosporin A resulted in increased mortality in reovirus-infected birds, but the relative severity of tendon lesions was unaffected. Hill et al. (39) reported similar results.

In a study of the enteric activity of several strains of reovirus, Songserm et al. (116) showed that CD8+ T cells may play a major role in the pathogenesis and/or reovirus clearance in the small intestine. van Loon et al. (134) showed that in B cell immunosuppressed chicks, challenge virus is controlled in the absence of actively produced antibodies, and is independent of B lymphocytes. This suggests that cellular immunity is sufficient for protection of broilers with maternal antibodies against reovirus infection following early age vaccination with live reoviral vaccine.

Pertile et al. (94) used monoclonal antibodies specific for B and T lymphocytes to study the development of reovirus arthritis. T cells and plasma cells were the predominant inflammatory cells in the synovium. In the acute phase, T cell, mostly $CD8^+$, were present in low numbers. Most activity was in the subacute phase with increased numbers of $CD4^+$ and $CD8^+$. Aggregates of cells, IgM-positive B cells and plasma cells, were also present. The chronic stage was characterized by large numbers of predominantly $CD4^+$ cells. These changes were considered similar to those seen in rheumatoid arthritis in humans. These results indicated that a potential consequence of macrophage priming following virus infection is the protection of cells against virus-induced replication and cytopathic effects, and this protection may be mediated by the cytostatic effects of nitrous oxide on the host cell. Further studies on spleen cells from reovirus-infected birds indicated that reovirus infection in chickens does not compromise the functional capabilities of T cells directly but induces suppressor macrophages that do (94). Supporting evidence for the rheumatoid arthritis comparison was provided by the detection of anti-nuclear and anti-collagen antibodies in some reovirus-infected birds (46).

Interferon production by avian reoviruses has been demonstrated *in vitro* and *in vivo*. The S1133 attenuated strain induced interferon in chick embryo cell cultures, and *in vivo* it was detected in the lungs but not in other tissues (20, 21). A more pathogenic reovirus elicited the production of interferon detectable in serum samples (20, 21).

Diagnosis

A presumptive diagnosis of viral arthritis may be made on the basis of signs and lesions. However, the signs and gross and histologic lesions of viral arthritis are not pathognomonic and some joint lesions may resemble those caused by *Mycoplasma synoviae*, staphylococci, or other bacteria. Involvement primarily of the metatarsal extensor and digital flexor tendons (Figure 11.4), and sometimes heterophil infiltration in the heart, assist in differentiating reovirus arthritis from similar disease caused by these other agents. However, demonstration of virus in clinical material is required to confirm the cause. Hitherto, this has meant virus isolation, but more recently, more rapid molecular methods and especially the reverse-transcriptase polymerase chain reaction (RT-PCR) are used widely.

Detection of Virus

Virus Isolation

Avian reoviruses are normally among the easiest of viruses to grow, so it is often tempting to consider them as the cause of a clinical condition from which they are isolated, when they may actually play little or no part in it.

For isolation from the joints, tissue samples are more likely to yield virus than swabs (52). Pieces of hypotarsal sesamoid bone with the tendons that pass through it, synovial membrane, and articular cartilage are the tissues of choice. Joint material should be taken from apparently normal birds in addition to those that are affected, because the number of clinically affected birds in a flock at any one time may be relatively small and virus may be present before lesions have developed. Also, virus isolation may be impossible from joints in advanced stages of degeneration. It should be remembered that because avian reoviruses are ubiquitous and for the most part, harmless, isolation of virus from the intestine alone is likely to be meaningless in interpreting the cause of joint lesions. Specimens should be sent to the laboratory in transport medium even though the virus is relatively resistant. If a delay occurs, specimens can be stored at 4°C temporarily or for longer periods at –20°C or below.

Virus isolation is best achieved from hock joint tissues in chick embryos after 5–7 days of incubation inoculated via the yolk sac or chicken embryo liver cells (100). Reoviruses typically kill the embryos within 5–6 days, and in cell cultures, syncytium formation on the cell sheet is the typical cytopathic effect (Figure 11.6). More than one passage in eggs or cell cultures may be needed.

Reoviruses can be readily differentiated from other viruses by their typical morphology by electron microscopy, the presence of a group-specific antigen demonstrable with the agar gel precipitin (AGP) test, or by precise identification using RT-PCR (see below). For preparation of the AGP antigen, 9- to 11-day-old embryonating chicken eggs are inoculated via the CAM route, and CAMs are harvested from dead or affected embryos after 7 days incubation. The CAMs then are homogenized and used as antigen (142). The precipitin test can be used to identify isolates as reovirus with known positive antiserum, or it can be used as an indication of antibody status in affected flocks. Isolated virus also can be identified by immunofluorescence staining of infected cell sheets.

An alternative approach has been to use specific anti-σC monoclonal antibodies to detect avian reovirus isolates (41).

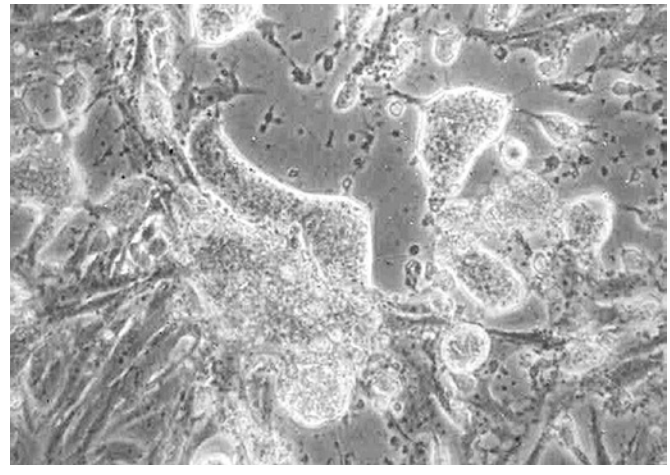

Figure 11.6. Cytopathic effect caused by avian reovirus in chick embryo liver cells. Note large well-circumscribed syncytia. Phase contrast microscopy. ×500. (R.C. Jones)

Molecular Methods

Molecular approaches to identification of avian reoviruses in infected tissues have been described by several authors. These included dot-blot hybridization, but now RT-PCR has become universally used (63, 73, 149). Liu et al. (69, 71, 73) contended that RT-PCR followed by restriction enzyme fragment length polymorphism (RFLP) provides a simple and rapid approach for characterization of ARV isolates. Frequently the σ4 gene is the one examined. Also, it is possible to determine whether a new variant strain has been introduced into a flock or a given virus strain has spread from one flock to another. Caterina et al. (11) developed a multiplex PCR for reovirus, adenovirus, infectious bursal disease virus, and chicken anemia virus. RT-PCRs also have been found useful for screening poultry vaccines for extraneous avian reoviruses in the quality control of biologicals used in veterinary medicine (10). Guo et al. (35) have described a TaqMan real-time RT-PCR which is claimed to be some 150 times more sensitive than the traditional RT-PCR. The test employed a primer-probe set from the conserved region of σ4 genome segment and is rapid, specific, and sensitive.

Undoubtedly, the molecular methods, and especially RT-PCR, are rapid, and combined with RFLP, enable molecular epidemiology to be investigated for tracing movement of infections. However, for the routine examination of field material, it also should be remembered that RT-PCR diagnosis does not provide the live virus, so isolation needs to be done if a new isolate is to be investigated further for pathogenicity/tropism or vaccine development.

Location of Virus in Tissues

Lesion-associated reovirus proteins or nucleic acid can be detected in formalin-fixed tissue using immunoperoxidase procedures (121). Demonstration of reovirus antigens in cryostat sections of snap-frozen tendon sheaths and other tissues by fluorescent antibody staining (55) is a rapid alternative method of diagnosis, but immunostaining is probably useful only in the early stages of infection. Liu and Giambrone (70) described the use of *in situ* hybridization for tracing avian reovirus strain S1133 in tissues of infected chickens. They were able to detect virus in wax-embedded sections of liver, pancreas, heart, and tendon, thus confirming the target sights for these viruses. Both immunostaining and *in situ* hybridization may be used to determine the tissue tropism of a new isolate.

In spite of extensive molecular studies, there are no recognized markers for pathogenicity of avian reoviruses, so experimental infections are required. For a reovirus obtained from an affected joint, its arthrotropic potential can be confirmed by inoculation into the foot pad of susceptible 1-day-old chicks. If pathogenic, the virus will induce a pronounced inflammation of the foot pad within 72 hours PI. A more natural but prolonged effect may be achieved after oral infection.

Serology

Reovirus group-specific antibodies have traditionally been detected with the agar gel precipitin test (60, 98, 142) or sometimes, indirect fluorescent antibody (IFA) assay (43). The latter is more sensitive, and therefore better suited for quantitative evaluations. Virus neutralization, based on plaque reduction in chicken kidney or chicken embryo liver cell cultures and several cell lines, has been routinely used for determining serotype differences with rabbit or chicken antiserum and monoclonal antibodies (61, 67, 120, 143). However, none of these tests is suitable for large-scale screening.

For commercial purposes, the above tests have been superseded by ELISA as the serological method of choice, allowing automation and rapid testing of many samples. Slaght et al. (115) were the first to describe an ELISA for detecting avian reovirus antibody. The S1133 strain was used as antigen and found to react with antibodies to the Reo-25 and WVU-2937 isolates, although homologous antibody gave the highest titer. Islam and Jones (43) found a significant correlation between ELISA and virus neutralizing antibodies. The ELISA systems now available from commercial sources are used widely for assessing reovirus antibody levels on a flock basis (72). Recently reported refinements have included the use of bacterially or yeast-expressed σC and σB proteins (68, 148) as ELISA antigens to improve assessment of flock immune status and monoclonal antibody-based competitive ELISA (68). Goldenberg et al. (28) have described an ELISA for differentiating between infected and vaccinated animals (DIVA). The test employed the variable σC protein as antigen, the main protein inducing neutralizing antibodies, from four prototypes of avian reovirus. This ELISA enabled vaccine antibodies to be distinguished from those to field virus, identifying the infection source and determining the level of vaccinal antibodies. A similar approach was used successfully by Xie et al. (147) using two non-structural protein genes cloned into an expression plasmid. They too were able to distinguish between vaccinated and infected chickens under experimental conditions.

Because reovirus infections are widespread among commercial flocks, the diagnostic value of serological profiling is often difficult to interpret with the currently available ELISA kits, although it is of course a useful indicator of immunity following vaccination. However, the novel developments outlined above may improve this situation.

Prevention and Control

Biosecurity

Avian reovirus infections (but not necessarily disease) are ubiquitous. The virus can be transmitted both vertically and horizontally, and because of its resistance to inactivation away from the host, may be frequently carried by mechanical means. In view of these properties, maintaining freedom from infection in modern intensively housed chicken flocks appears to be virtually impossible. Following the removal of an infected flock from the premises, thorough cleaning and disinfection of poultry house can prevent infection with pathogenic virus in subsequent groups. Because of the relative stability of the avian reovirus group, commercially available disinfectants should be validated for efficacy before use. Multi-component disinfectants and 0.5% organic iodine solutions are considered

to be effective inactivating agents. Commercial data are available showing efficacy. Though the main approach to control of reovirus infections in chickens is vaccination, good management and biosecurity procedures which reduce infections, especially in young birds, are essential.

Vaccination

Chickens are most susceptible to pathogenic reoviruses at 1 day of age and then develop an age-associated resistance beginning as early as 2 weeks. Because of this period of acute susceptibility, vaccination programs are designed to provide protection to chicks as soon as they hatch. This is best achieved by vaccinating the parent flock to provide chicks with high levels of maternal antibodies which will minimize transovarian transmission of the reovirus as well as prevent any virus contracted after hatch that is replicating in the gut from reaching the joints and inducing arthritis.

Induction of maternal antibodies is best achieved by the use of inactivated vaccines administered by injection at 12 weeks of age or older, although live vaccine may sometimes be used. Inactivated vaccines are likely to induce higher levels of maternal antibodies in the progeny if the parent flock has already been vaccinated with live vaccine (133, 144). The vaccines are commonly prepared from the S1133 strain as a water-in-oil preparation together with an adjuvant. Killed vaccines may be given in monovalent form or in combination with one or two others, such as strains 1733 and 2408, claimed to protect not only against tenosynovitis but also malabsorption syndrome.

Active immunization in young chicks can be achieved by vaccination with viable attenuated reovirus that is usually applied by the subcutaneous route, although immunization by coarse-spray application of vaccine also has been used (27). Protection from subsequent challenge can be demonstrated, but the S1133-derived reovirus vaccines may interfere with Marek's disease vaccination if administered simultaneously (103). The interference is most pronounced with herpes virus of turkeys (HVT)-derived Marek's disease vaccines.

A reovirus vaccine derived from a naturally apathogenic strain of reovirus (2177) isolated in the United States (127) may be more suitable for simultaneous day-of-age administration with Marek's disease vaccine than are several S1133 derivatives (139). The vaccine should be used with caution if Marek's disease vaccine titers are low and/or Marek's disease virus challenge is significant.

If a live vaccine is used, it should be administered prior to the onset of egg production to prevent transovarian transmission of the vaccine virus (26). The advantages of this type of immunization program include immediate protection of 1-day-old progeny provided by maternal antibody and a limitation of the potential for vertical transmission that has been shown to be economically significant (16). Vaccination of breeders is an efficacious method of controlling viral arthritis and other pathogenic reoviruses, but it should be recognized that protection is assured against homologous serotypes only (97, 109). When the field virus is clearly different from that included in commercially available vaccines, an autogenous vaccine may prove effective (97, 109). Recent work in Israel suggested using a live combination of four different genotypic groups to give broad protection against a range of field viruses (74).

In ovo vaccination has been investigated. Guo et al. (33, 34) reported that the reovirus vaccine alone should not be given to chicks without maternal antibodies but this immunosuppression could be overcome if the vaccine was given in an antibody complex.

Several novel approaches to reovirus vaccination have been reported and have shown varying degrees of promise. These include expressing σC proteins in yeast (146), alfalfa (42), and thale grass (*Arabidopsis thaliana*) (139). These developments suggest that edible vaccines may be possible. Other approaches have included the expression of σC and σB genes in a baculovirus (69) and a reovirus DNA vaccine delivered orally by attenuated *Salmonella typhimurium* (138).

The generally accepted method of assessing efficacy of live reovirus vaccines has been to vaccinate birds, and 3–4 weeks later challenge them with virulent virus via footpad inoculation. Results are based on interpretation of the footpad swellings. This causes suffering in the challenged birds and results can sometimes be difficult to interpret. van Loon et al. (136) have described an alternative challenge model which involves isolation of the challenge virus from selected tissue of vaccinated or control birds, and using monoclonal antibodies, discriminating challenge virus from vaccine virus.

Methods of attempting to control the recently described turkey viral arthritis (122) are being evaluated.

Other Reovirus Infections

Introduction

Reoviruses are recognized as a cause of tenosynovitis/viral arthritis in chickens and recently in turkeys (see preceding section, Viral Arthritis), but they also have been isolated from several other disease conditions in chickens and turkeys and from time to time, from a variety of other healthy or diseased avian species. In many cases, attempts to demonstrate that the reoviruses were the cause of the condition have been unsuccessful, or, especially in the case of wild species, experimental work has not been possible. Thus, their association with disease has not always been established. On other occasions, serological surveys have shown the presence of antibodies to at least the

avian group antigens in other avian species. In these cases, the role of reovirus infection is completely unknown.

There is increasing molecular evidence that reoviruses from chickens ("avian reoviruses," ARV) and turkeys show sequence differences from each other and from those from ducks and geese. Reoviruses from non-domesticated species have been little investigated. The role of these other species as carriers and reservoirs of infection for domestic poultry remains to be established.

The Viruses

In almost all cases in which reoviruses have been isolated, cultivation has been achieved using methods described for the viral arthritis strains—namely, fertile chicken eggs inoculated via the yolk sac, or chick embryo fibroblasts, liver or kidney cells, or chicken kidney cells. These systems may not be ideal for detection of viruses from non-domesticated species. Isolates usually have been identified by cultural characteristics and typical reovirus morphology under the electron microscope and more recently by molecular identification and sequencing.

Rekik et al. (66), examining many viruses from commercial chickens by virus neutralization, asserted that arthritis and non-arthritis reoviruses were different, while Heffels-Redmann et al. (31), using immunoprecipitation and virus neutralization, showed that two duck viruses were grouped in one serotype and unrelated to the S1133 chicken serotype. Lozano et al. (48), using polyacrylamide gel electrophoresis, compared profiles from 60 turkey, 8 chicken, and single canary and cockatiel reoviruses. They found greater heterogeneity among the turkey isolates than the chickens, but the canary and cockatiel strains showed similar migration patterns.

However, more work on molecular sequencing of the σC gene by Day et al. (12) of different strains has shown that turkey reoviruses (TRV) are different from chicken reoviruses, and duck (DRV) and goose (GRV) reoviruses belong to a different species, again in the subgroup 2 of orthoreoviruses (6, 90). Recently, it has been shown that an African grey parrot reovirus clustered with the Nelson Bay virus from bats (86), further demonstrating the diversity among avian reoviruses.

Diseases in Chickens

Reoviruses have been isolated from a wide range of disease conditions in commercial chickens other than tenosynovitis. They include respiratory disease, enteric disease, inclusion body hepatitis, hydropericardium, hepatitis in young chicks, generalized disease, blue wing disease, and the runting/malabsorption syndrome. At the same time, they can be isolated easily from the intestines of apparently healthy chickens. In addition to differences in tissue tropism between strains, a range of virulence exists, from high to virtually harmless. Several reports describe varying degrees of reduced weight gain due to reovirus infection, presumably indicating varying effects on function of the gastrointestinal tract.

A study by Robertson et al. (68) investigated the presence of reoviruses in healthy commercial chickens and in other flocks affected with the runting syndrome or tenosynovitis. The viruses could be isolated from almost all fecal samples from healthy flocks of 3 weeks of age or older, from several tissues of chicks aged 2 weeks or more with the runting syndrome, and from older birds with tenosynovitis. In addition, all broiler breeder flocks examined had antibodies to avian reovirus. The finding of widespread reovirus infection, apparently in the absence of disease, strongly suggests that isolation of reovirus from tissue specimens does not necessarily imply that they are causing disease.

Kant et al. (39) sequenced part of the S1 segment of the σC protein of avian reoviruses from chickens isolated from a variety of disease conditions in Germany and the Netherlands between 1998 and 2000. They were unable to correlate σC sequences with different disease conditions and did not establish temporal or geographic differences, either. Thus, the underlying markers that identify pathotype or tissue tropism are still to be investigated.

Reports of reoviruses being associated with conditions in chickens other than joint disease include the following diseases.

Respiratory Disease

The so-called Fahey-Crawley virus (20), whose identity was later confirmed as the first avian reovirus (65), caused a mild respiratory disease of baby chicks (81), but older chicks were resistant. Another respiratory isolate (UGA) was unable to cause respiratory disease alone, but in combination with a strain of *Mycoplasma gallisepticum* of low pathogenicity, respiratory signs and lesions were observed (76). However, reoviruses generally are not regarded as primary agents of respiratory disease in poultry.

Enteric Disease and Systemic Infections

Several descriptions exist of reovirus-associated enteric disease. An agent characterized as a reovirus was isolated from young chicks suffering from ulcerative enteritis by Krauss and Ueberschar (43), but it was not confirmed that this virus was the cause of the disease. Further early reports described enteric disease (16) and cloacal pasting and mortality (18) in young chicks.

A commercial farm with a history of poor feed conversion and chronic feed-passage problems was investigated (3). Abnormal tissue pathology was seen in broilers from 9 days of age. Avian adenoviruses and reoviruses were isolated, and although SPF chicks were inoculated with isolated reoviruses, their relationship to the initial problem was inconclusive.

Adenoviruses and reoviruses isolated from commercial broiler chickens were tested for gastrointestinal pathogenicity in day-old chicks by Lenz et al. (46). Chickens in inoculated groups developed wet unformed fecal droppings, but although adenoviruses caused marked gizzard erosions, necrotizing pancreatitis, and proventriculitis, reovirus effects were mild and included hyperplasia of lymphoid aggregates and mild gizzard erosions.

Some reports highlight the synergistic effect of reovirus in dual infection with other pathogens. For example, reovirus and *Cryptosporidium baileyi* produced a systemic infection (29), and Ruff and Rosenberger (72) showed that reoviruses can potentiate coccidial infection, although the outcome depends on the reovirus strain used.

Other reports record more generalized infections, with several organs affected. Four outbreaks of disease in broiler chickens in Victoria, Australia, were examined by Bagust and Westbury (4). Affected flocks ranged from 4–38 days. Sudden deaths and starvation were variously associated with hepatitis, ascites, hydropericardium, pale kidneys, and depleted bursas. Reoviruses were isolated consistently from the tissues of the affected birds. Inoculation of these viruses into day-old SPF chicks intraperitoneally or orally induced sporadic deaths but no clinical syndromes. It was speculated that other factors may interact with the reoviruses to induce these problems.

Blue wing disease is a condition affecting broilers characterized by mortalities of 10%; subcutaneous and intramuscular hemorrhages; and atrophy of the thymus, spleen, and bursa. Engstrom et al. (19) showed that it was caused by a synergistic effect between chicken anemia virus and a reovirus. Avian reoviruses also have been shown to enhance the pathogenicity of other infectious agents of chickens such as *Escherichia coli* (70) and infectious bursal disease virus (51).

Inclusion Body Hepatitis; Hepatitis in Young Chicks

The liver of the chicken is considered to be one of the target organs for reovirus infection. It has been shown experimentally that reoviruses can cause hepatitis immunosuppressed chicks (41). McFerran et al. (50) isolated reoviruses and adenoviruses from outbreaks of inclusion body hepatitis. However, it is now recognized that adenoviruses rather than reoviruses play an important role in the pathogenesis of this disease.

Mortality in broiler chicks up to 10 days of age has been reported in Poland and attributed to reoviruses (Z. Minta, personal communication). Van Loon et al. (84) characterized these viruses and called them "enteric reovirus strains" (ERS). The pathogenicity, dissemination, induction of malabsorption syndrome (MAS), unusual reaction pattern with different monoclonal antibodies to more common reoviruses, and serotype properties were reported. Screening of reoviruses in the field showed that these reovirus strains also were present in other countries and usually were isolated from birds with MAS.

Hydropericardium

Bains et al. (5) described serious mortalities (10%–18%) in broiler chicks in Queensland, which occurred in birds less than 14 days old. At necropsy, hydropericardium, with up to 3 ml fluid in some cases, was a consistent feature together with small spleens. Reoviruses were isolated from the hearts of these birds in fertile eggs or cell cultures, but there was no attempt to show that reoviruses were the cause of the condition. Jones (36) described a similar investigation but showed that intravenous inoculation of the isolated reovirus induced hydropericardium in experimentally infected chicks. The pathogenesis of this condition in relation to reoviruses has never been studied.

The Runting-Stunting/Brittle Bone Disease/ Malabsorption Syndrome in Broilers

A disease syndrome with several names that first appeared in broilers in the late 1970s and is chiefly characterized by lowered body weights and variously described as the runting-stunting, pale bird, MAS, brittle bone, and helicopter wing syndrome has been linked with several possible causative agents, including reoviruses (13, 25, 58, 63, 69, 84, 85). However, several studies have suggested that reoviruses probably play a secondary role in these conditions rather than a primary one. Montgomery et al. (53) attempted to reproduce the syndrome using various infectious agents isolated from affected Mississippi broilers. These included an infectious bronchitis virus (IBV) isolate and a reovirus. Although IBV with the reovirus caused weight depression, it was concluded that none of the isolated agents was the ultimate cause.

The enteropathogencity of avian reoviruses isolated from chickens with malabsorption syndrome from the Netherlands and Germany was studied by Songserm et al. (78). Despite replicating in the intestinal epithelium and causing small intestine lesions including denuding of the villi, none of the viruses caused weight gain depression. The authors concluded that reovirus alone cannot induce intestinal lesions as found in malabsorption syndrome. However, this group (77) had previously shown that a combination of enteropathogenic reovirus with other agents or substances present in an intestinal homogenate from affected and healthy chickens can induce MAS in broilers.

So, although several reports indicate that isolated reoviruses are sometimes capable of causing varying degrees of enteritis (66, 75) or simply reduced weight gain (71, 82), the consensus view appears to be that the most important pathogen is a small virus that can be seen in the enterocytes but which has escaped cultivation (53).

Nonetheless, some commercial reovirus vaccines are produced, which are claimed to have beneficial effects against the stunting or malabsorption syndrome. However, the vaccines are unlikely to protect against the primary cause(s).

Diseases in Turkeys

Tenosynovitis

Reoviruses have been isolated from tenosynovitis in turkeys (47, 59), but the relationship of the viruses with this disease has been unclear until recently. Al-Afaleq and Jones (1) examined three chicken and three turkey reoviruses, each isolated from hock joints. All viruses induced microscopic tenosynovitis lesions in chicks, but none produced them in turkey poults. Even when reovirus was given together with *Mycoplasma synoviae*, only minimal joint lesions were induced in experimentally infected turkeys (2). However, recently Trites et al. (83) have reported outbreaks of tenosynovitis in the USA

which are clearly due to reovirus infection and clinically virtually identical with disease in the chicken.

Enteric Disease

For turkey reoviruses, most attention has been paid to their role in enteric disease. Reoviruses have been isolated from the intestines of normal turkeys and turkeys with enteric disorders (14, 23, 56, 57, 75). When such strains have been tested *in vivo*, effects have been variable. Some have been found to be pathogenic, and others non-pathogenic or of low pathogenicity. Dees et al. (14) compared different isolates and found that although strain BC-7 was non-pathogenic, BC-3 induced enteritis, involving destruction of the intestinal villi. Goodwin et al. (24), using a brilliant red powder in the diet, found that gastrointestinal transit time in reovirus-infected turkeys was significantly longer than in normal turkeys.

In the USA, a condition in young turkeys called poult enteritis and mortality syndrome (PEMS) caused major losses to the turkey industry, especially in the 1990s. Little is known about its incidence outside the USA but is has recently been reported in the United Kingdom (10). PEMS was originally called "poult enteritis complex" (8), and its main features include stunting and poor feed utilization that result from enteritis. In the more severe forms, runting, immune dysfunction, and up to 100% morbidity and mortality are reported. Gross microscopic lesions of enteritis are present in all forms but tend to be non-specific. The etiology of the disease is not completely understood, but it appears to be multifactorial. While the agents thought to be most important are enteropathogenic *E. coli*, turkey coronaviruses (30) and turkey astroviruses (42) and reoviruses (32) also have been isolated. Heggen-Peay et al. (32) experimentally showed that while PEMS reovirus isolate ARV-CU98 did not induce fulminating PEMS in turkey poults, it was able to cause some of the typical clinical signs including intestinal alterations and significantly lowered liver and bursa weights. The authors considered that it could also contribute indirectly to the syndrome by increasing susceptibility to opportunistic pathogens that facilitate clinical PEMS. The implied involvement of the three types of virus in PEMS led to the development of a multiplex real-time RT-PCR by Spackman et al. (79) for turkey coronavirus astrovirus and reovirus, which is claimed to be as sensitive as isolation for each of the viruses.

In a study of enteric viruses in commercial chickens and turkeys between 2005 and 2006, (61) RT-PCR detected reoviruses, rotaviruses, astroviruses and coronaviruses. Reoviruses were present in 62.8% of turkey and 45.5% of chicken flocks. Based on the S4 gene segment, the chicken and turkey viruses assorted separately and were distinct from all previously reported avian reoviruses.

In an electron microscopic study of viruses associated with PEMS in turkeys in California from 1993 to 2003, Woolcock and Shivaprasad (87) found reoviruses, birnaviruses, and adenoviruses less common than rota-like and small round viruses alone or in combination. However, these visual observations do not always reflect pathogenic capability.

Various combinations of turkey astrovirus, rotavirus, and reovirus infections were examined in 3-day old poults (80). The most marked signs of enteric disease were found when all three agents were present, with the reovirus being the least pathogenic component. Field evidence reported by Jindal et al. (35), from virus detection of the same viruses plus coronavirus, supported the experimental findings that the presence of two or three viruses in combination are likely to affect the dynamics of turkey health and disease.

Immunosuppression

The potential for reoviruses to cause immunosuppression in turkeys has been described by Pantin-Jackwood et al. (62). Following infection of groups of poults with four reoviruses of turkey-origin there were variable degrees of cloacal bursal atrophy and lymphoid depletion, depending on the strain. Importantly, no such lesions were produced with virulent chicken strains, although viral antigen was detected in the intestine.

Myocarditis

A retrospective study of cases of myocarditis associated with reovirus from 1991 to 2009 concluded that reovirus was a likely cause, with vitamin E deficiency also contributing to the condition (21).

Reoviruses in Ducks and Geese

Several early reports describe the isolation of reoviruses from different species of ducks, including mallards (49), healthy Pekin ducks (37), and diseased ornamental ducks (26). All shared a common group antigen with chicken reoviruses, but their relationship with disease in ducks was not determined. However, the strains from Pekin ducks (37) were able to cause microscopic lesions of tenosynovitis in specific pathogen free chicks. Heffels Redmann et al. (31) considered that the two duck strains they examined were antigenically distinct from standard chicken strains.

Muscovy duck reovirus is the cause of a disease first described in South Africa and then France (22). It typically affects young ducklings 2–4 weeks of age, causing diarrhea and difficulty in movement, high morbidity, and mortality of 10% or higher. Malkinson et al. (51) isolated a reovirus from affected ducks in which they found necrotic foci in the liver, spleen, and kidneys. Intramuscular inoculation of the reovirus caused mortality without clinical signs within two days and necrotic foci in the liver and spleen. Kuntz-Simon et al. (44) and Zhang et al. (88) suggested separate classification for Muscovy duck reoviruses based on sequencing of the σC encoding gene. No satisfactory vaccines have been marketed for these viruses, but Kuntz-Simon et al. (45) have shown that a baculovirus-expressed σC alone or with expressed σB appeared to be a good candidate for vaccination of ducks against the reovirus infection.

In a die-off of common eiders (*Somateria molissima*) in the Western Gulf of Finland, Hollmen et al. (34) isolated a reovirus in cell cultures from Pekin duck but not chick embryo

fibroblasts from several tissues of affected birds. High prevalence of neutralizing antibodies in flocks corresponded to mortalities, questioning their role as the cause.

Serological evidence of reovirus infection in geese has been recorded in two reports. Kaleta et al. (38) detected neutralizing antibodies to a virus originating from Muscovy ducks and the standard chicken strain S1133 in sera of domestic geese (*Anser anser domesticus*). Hlinak et al. (33) examined sera from bean geese (*Anser fabalis*) and white-fronted geese (*Anser albifrons*) in Germany. Avian reovirus antibodies were detected in 29% of blood samples, and there was no difference in seroprevalence between the two species. The authors indicate that although the role and significance of wild geese in the epidemiology of avian diseases remains to be determined, it is possible that they could be of some importance as reservoirs and carriers of some diseases of domestic poultry.

The first description of reovirus as a cause of arthritis in geese was that of Palya et al. (60). The disease was characterized by splenitis with miliary necrotic foci during the acute phase, and epicarditis, arthritis, and tenosynovitis during the subacute/chronic phase. Clinical signs usually appeared at 2–3 weeks of age and persisted for 3–6 weeks. The reovirus was isolated from several organs and the disease was reproduced in young goslings.

The sequence and structural similarities between the genome segment encoding σC in goose and duck reoviruses lead Banyai et al., (6) to suggest that these viruses belong to a species distinct from other established avian reovirus species within subgroup 2 of orthoreoviruses. Kunz-Simon et al. (45) and Zhang et al. (88) also have suggested separate classification for Muscovy duck reoviruses based on sequencing of the σC encoding gene. It is now established by sequence and phylogenetic analysis of the S-class genome segments that the duck and goose reoviruses are quite distinct from chicken reoviruses (88), although they share a recent common ancestor.

Specific ELISAs for detecting antibodies to duck reoviruses have been developed, including a σB-σC test in which proteins are expressed in *E. coli* (90).

Reoviruses in Other Avian Species

Several reports describe detection of reoviruses in other avian species but their relationship to disease is often unknown. McFerran et al. (49) isolated reoviruses from pigeons and Gough et al. (26) from diseased pigeons, pheasants, parrots, and other exotic avian species. Jones and Guneratne (37) isolated a reovirus from the feces of a zoo wedge-tailed eagle (*Aquila andax*). This virus caused microscopic lesions of tenosynovitis in SPF chicks but was not further classified. All of these reoviruses shared a common group antigen with chicken reoviruses, but their importance as pathogens in the host species was not determined.

Graham (27) isolated a reovirus from the liver of an African grey parrot submitted for necropsy with subcutaneous hemorrhages; multiple foci; and necrosis in the liver, spleen, bone marrow, intestinal lamina propria, airsacculitis, and epicarditis. Experimental inoculation of two African grey parrots with the isolate was fatal and reproduced the hemorrhages and necrotic lesions of the original condition. Sanchez-Cordon et al. (74), describing disease in the same species involving 80% morbidity and 30% mortality, considered that the reovirus they isolated probably triggered the subsequent herpesvirus (Pacheco's disease) and mycosis that caused the illness.

Budgerigars suffering from emaciation and splenomegaly, hepatomegaly, or both were found to have *Chlamydia psittaci* and reovirus in the tissues by PCR (64). The reovirus was sequenced and had 100% homology with a reovirus found in an African grey parrot which in turn has been shown to be more closely related to the Nelson Bay bat virus than ARV (15).

A virus associated with mortalities in American woodcock (*Scolopax minor*) was identified as a reovirus by Doherty et al. (17). A consistent necropsy finding was emaciation of the carcass. The authors considered that the reovirus infection was systemic and responsible for the deterioration in bodily condition of the birds. Transmission was thought to be by the fecal-oral route, but again, the true association with the disease was not confirmed.

An enteric disease in bobwhite quail (*Colinus virginianus*), which resulted in increased mortality in birds from 5 days to 5 weeks, was described by Ritter et al. (67). A reovirus was isolated from the feces, and intestinal cryptosporidia were also present. In attempts to reproduce the condition experimentally, the reovirus induced subclinical infection, but the cryptosporidium caused changes resembling the natural disease. Infection of quail with both agents produced systemic infection (28).

An outbreak of disease in pheasants in Turkey attributed to reovirus infection was described by Mutlu et al. (55). Twenty-seven of a flock of 100 were affected between 3 and 5 months of age. In addition to being in poor condition, affected birds were short of breath, had greenish diarrhea, and died within a week. Pathological findings comprised fibrinous tracheitis, catarrhal inflammation of the gut, severe hepatic necrosis, and fibrinous perihepatitis. A reovirus was isolated from several organs, but whether this was the only agent involved was not investigated.

Curtis et al. (11) reported tenosynovitis in 6- to 7-week-old pheasants. *Staphylococcus aureus* and an avian reovirus related antigenically to strain S1133 were isolated from the swollen hock joints of lame birds. The association between the reoviruses as a cause of the disease was presumed but not confirmed.

The first report of a reovirus isolated from an ostrich (*Struthio camelus*) was made in Japan. Sakai et al. (73) reported that phylogenetic analysis showed that the virus was closely related to a chicken reovirus.

Antibodies to avian reoviruses have been detected in ostriches (*Struthio camelus*) in Zimbabwe (9), rockhopper penguins (*Eudyptes chrysocomes*) in Argentina (40), and bean geese (*Anser fabalis*) and white-fronted geese (*Anser albifrons*) in Germany (33). Again, the significance of these findings is unknown.

Conclusions

Reoviruses are very common among domestic poultry and are probably common in other avian species. They are viruses that are relatively easy to cultivate, and when they are looked for, serum antibodies are often found, so there is a temptation to implicate them as a cause of several conditions from which they have been isolated. Apart from tenosynovitis in chickens and more recently in the turkey, where a clear relationship occurs between reovirus infection and the clinical disease, the role of reoviruses in avian disease is frequently unclear. In exotic birds, reports of reoviruses have been sporadic. There appears to be a wide range of pathogenicity among isolates, but most are probably harmless. Because of the inconsistency of disease associated with reoviruses in species other than the chicken, vaccines have not been developed.

There may be differences in tissue tropism, although all appear to replicate in the gut, and pathogenic strains affect the liver. In most cases, the serologic or molecular relationship of reoviruses from exotic species to the tenosynovitis strains is unknown. Where exotic strains have been tested in chickens, a predilection exists for the hock joints or tendons, suggesting the potential for cross-species infection. The sudden appearance of reoviral arthritis in turkeys in several American states (83) may have been due to reassortment of strains which produced an arthrotropic virus specific for the turkey. This remains to be investigated.

The wider use of molecular methods is now demonstrating that viruses from chickens, turkeys, ducks, and geese show characteristic differences, and further work in this area will probably show that reoviruses from non-domestic species are different again, such as that from the African grey parrot. Conventionally, "avian reovirus" or ARV has been used either for all reoviruses from avian species, or just those from the chicken. Now the abbreviations TRV, DRV, and GRV are used for those from turkeys, ducks, and geese. It is probably time now to name reoviruses of chicken origin separately, perhaps as ChRV.

References

Introduction

1. Benavente, J., and J. Martínez-Costas 2007. Avian reovirus: structure and biology. *Virus Res*. 123:105–1019.
2. Dobson, K.N., and J.R. Glisson. 1992. Economic impact of a documented case of reovirus infection in broiler breeders. *Avian Dis*. 36:788–791.
3. Jones, R.C. 2000. Avian reovirus infections. *Rev Sci Tech*. 19: 614–625.
4. Jones, R.C., A. Al-Afaleq, C.E. Savage, and M.R. Islam. 1994. Early pathogenesis in chicks of infection with a trypsin-sensitive avian reovirus. *Avian Pathol*. 23:683–692.
5. Jones, R.C., and K. Georgiou. 1984. Reovirus-induced tenosynovitis in chickens: The influence of age at infection. *Avian Pathol*. 13:441–457.
6. Kawamura, H., and H. Tsubahara. 1966. Common antigenicity of avian reoviruses. *Natl Inst Anim Health Q (Tokyo)*. 6:187–193.
7. Kawamura, H., F. Shimizu, M. Maeda, and H. Tsubahara. 1965. Avian reovirus: Its properties and serological classification. *Natl Inst Anim Health Q (Tokyo)*. 5:115–124.
8. Mathews, R.E.F. 1982. Classification and nomenclature of viruses. *Intervirology* 17:1–200.
9. Nibert, M.L., R.L. Margraf, and K.M. Coombs. 1996. Nonrandom segregation of parental alleles in reovirus reassortants. *J Virol*. 70:7295–7300.
10. Olson, N.O., and K.M. Kerr. 1966. Some characteristics of an avian arthritis viral agent. *Avian Dis*. 10:470–476.
11. Roessler, D.E., and J.K. Rosenberger. 1989. *In vitro* and *in vivo* characterization of avian reoviruses. III. Host factors affecting virulence and persistence. *Avian Dis*. 33:555–565.
12. Rosenberger, J.K., and N.O. Olson. 1997. Viral arthritis. In: B.W. Calnek, H.J. Barnes, C.W. Beard, L.R. McDougald, and Y.M. Saif, eds. Diseases of Poultry, 10th ed. Iowa State University Press; Ames, IA. 711–718.
13. Sterner, F.J., J.K. Rosenberger, A. Margolin, and M.D. Ruff. 1989. *In vitro* and *in vivo* characterization of avian reoviruses. II. Clinical evaluation of chickens infected with two avian reovirus pathotypes. *Avian Dis*. 22:545–554.
14. Trites, J., D. Mills, and J.K. Rosenberger. 2011. Reovirus and turkey tenosynovitis. Proceedings: 'North Carolina Industry Days' North Carolina State University, October 5–6, Wilmington North Carolina.
15. Van der Heide, L. 1996. Introduction on avian reovirus. Proceedings International Symposium on Adenovirus and Reovirus Infections in Poultry, Rauischholzhausen, Germany, 138–142.
16. Van der Heide, L. 2000. The history of avian reovirus. *Avian Dis*. 44:638–641.

Viral Arthritis

1. Al Afaleq, A., and R.C. Jones. 1989. Pathogenicity of three turkey and three chicken reoviruses for poults and chicks with particular reference to arthritis/tenosynovitis. *Avian Pathol*. 18:433–440.
2. Al-Afaleq, A.I., and R.C. Jones. 1990. Localisation of avian reovirus in the hock joints of chicks after entry through broken skin. *Res Vet Sci*. 48:381–382.
3. Al-Afaleq, A.I., C.E. Savage, C. Payne-Johnson, and R.C. Jones. 1997. Experimental inoculation of mice with trypsin-resistant and trypsin-sensitive avian reoviruses. *J Comp Path*. 117: 253–259.
4. Al-Mufarrej, S.I., C.E. Savage, and R.C. Jones. 1996. Egg transmission of avian reoviruses in chickens: comparison of a trypsin-sensitive and a trypsin-resistant strain. *Avian Pathol*. 25:469–480.
5. Back, A., and K.V. Nagaraja. 1996. Pathogenicity of chickens reovirus strains S1133 and 1733 for turkeys. Proceedings International Symposium on Adenovirus and Reovirus Infections in Poultry, Rauischholzhausen, Germany. 245–250.
6. Banyai, K., V. Palya, M. Benko, J. Bene, V. Havasi, B. Melegh, and G. Szucs. 2005. The goose reovirus genome segment encoding the minor outer capsid protein 1/ C is bicistronic and shares structural similarities with its counterpart in Muscovy duck reovirus. *Virus Genes*. 31:285–291.
7. Bányai K., E. Dandár, K.M. Dorsey, T. Mató, and V. Palya. 2011. The genomic constellation of a novel avian orthoreovirus strain associated with runting-stunting syndrome in broilers. *Virus Genes*. 42:82–9.
8. Barta, V., W.T. Springer, and D.L. Miller. 1984. A comparison of avian and mammalian cell cultures for the propagation of avian reovirus WVU 2937. *Avian Dis*. 28:216–223.

9. Benavente, J., and J. Martínez-Costas. 2007. Avian reovirus: structure and biology. *Virus Res*. 123:105–1019.
10. Bruhn, S., L. Bruckner, and H. P. Ottiger. 2005. Application of RT-PCR for the detection of avian reovirus contamination in avian viral vaccines. *J Virol. Methods*. 123:179–186.
11. Caterina, K.M., S. Frasca Jr., T. Girshick, and M.I. Khan. 2004. Development of a multiplex PCR for detection of avian adenovirus, avian reovirus, infectious bursal disease virus, and chicken anemia virus. *Mol Cell Probes*. 18:293–308.
12. Cook, M.E., W.T. Springer, K.M. Kerr, and J.A. Herbert. 1984. Severity of tenosynovitis in reovirus-infected chickens fed various dietary levels of choline, folic acid, manganese, biotin, or niacin. *Avian Dis*. 28:562–573.
13. Cook, M.E., W.T. Springer, and J.A. Herbert. 1984. Enhanced incidence of leg abnormalities in reovirus WVU 2937-infected chickens fed various dietary levels of selected vitamins. *Avian Dis*. 28:548–561.
14. Cowen, B.S., and M.O. Braune. 1988. The propagation of avian viruses in a continuous cell line (QT35) of Japanese quail origin. *Avian Dis*. 32:282–297.
15. Dalton, P.J., and R. Henry. 1967. Tenosynovitis in poultry. *Vet Rec*. 80:638.
16. Dobson, K.N., and J.R. Glisson. 1992. Economic impact of a documented case of reovirus infection in broiler breeders. *Avian Dis*. 36:788–791.
17. Duncan R. 1999. Extensive sequence divergence and phylogenetic relationships between the fusogenic and nonfusogenic orthoreoviruses: A species proposal. *Virol*. 260:316–328.
18. Duncan R., A. Chen, S. Walsh, and S. Wu. 1996. Avian reovirus induced syncytium formation is independent of infectious progeny virus production and enhances the rate, but is not essential for virus-induced cytopathology and virus egress. *Virol*. 224:453–464.
19. Dutta, S.K., and B.S. Pomeroy. 1967. Isolation and characterization of an enterovirus from baby chicks having an enteric infection. I. Isolation and pathogenicity. *Avian Dis*. 11:1–9.
20. Ellis, M.N., C.S. Eidson, J. Brown, and S.H. Kleven. 1983. Studies on interferon induction and interferon sensitivity of avian reoviruses. *Avian Dis*. 27:927–936.
21. Ellis, M.N., C.S. Eidson, O.J. Fletcher, and S.H. Kleven. 1983b. Viral tissue tropisms and interferon production in white leghorn chickens infected with two reovirus strains. *Avian Dis*. 27:644–651.
22. Engstrom, B.E., O. Fossum, and M. Luthman. 1988. Blue wing disease of chickens: Experimental infection with Swedish isolate of chicken anemia agent and an avian reovirus. *Avian Pathol*. 17:33–50.
23. Fahey, J.E., and J.F. Crawley. 1954. Studies on chronic respiratory disease of chickens. II. Isolation of a virus. *Can J Comp Med*. 18:13–21.
24. Gaudry, D., J. Tektoff, and J.M. Charles. 1972. A propos d'un nouveau virus isole chez le canard de Barbarie. *Bull Soc Sci Vet Med Comp Lyon*. 74:137–143.
25. Gershowitz, A., and R.E. Wooley. 1973. Characterization of two reoviruses isolated from turkeys with infectious enteritis. *Avian Dis*. 17:406–414.
26. Giambrone, J.J., T.L. Hathcock, and S.B. Lockaby. 1991. Effect of a live reovirus vaccine on reproductive performance of broiler breeder hens and development of viral tenosynovitis in progeny. *Avian Dis*. 35:380–383.
27. Giambrone, J.J., T. Dormitorio, and S.B. Lockaby. 1992. Coarse-spray immunization of one-day-old broilers against enteric reovirus infections. *Avian Dis*. 36:364–368.
28. Goldenberg, D., A. Lublin, E. Rosenbluth, E.D. Heller, and Pitcovski J. 2011. Differentiating infected from vaccinated animals, and among virulent prototypes of reovirus. *J Virol Methods*. 177:80-6.
29. Goldenberg, D., M. Pasmanik-Chor, M. Pirak, N. Kass, A. Lublin, A. Yeheskel, D.E. Heller, and J. Pitcovski. 2010. Genetic and antigenic characterization of sigma C protein from avian reovirus. *Avian Pathol*. 39:189–99.
30. Gouvea, V.S., and T.J. Schnitzer. 1982. Polymorphism of the genomic RNAs among the avian reoviruses. *J Gen Virol*. 61:87–91.
31. Gouvea, V., and T.J. Schnitzer. 1982b. Pathogenicity of avian reoviruses: examination of six isolates and a vaccine strain. *Infect Immun*. 38:731–738.
32. Guneratne, J.R.M., R.C. Jones, and K. Georgiou. 1982. Some observations on the isolation and cultivation of avian reoviruses. *Avian Pathol*. 11:453–462.
33. Guo, Z.Y., J.J. Giambrone, Z. Liu, T.V. Dormitorio, and H. Wu. 2004. Effect of *in ovo* administered reovirus vaccines on immune responses of specific-pathogen-free chickens. *Avian Dis*. 48:224–228.
34. Guo, Z.Y., J.J. Giambrone, H. Wu, and T. Dormitorio. 2003. Safety and efficacy of an experimental reovirus vaccine for in ovo administration. *Avian Dis*. 47:1423–1428.
35. Guo, K., T.V. Dormitorio, S.C. Ou, and J.J. Giambrone. 2011. Development of TaqMan real-time RT-PCR for detection of avian reoviruses. *J Virol Methods*. 177:75–9.
36. Heggen-Peay, C.L., M.A. Qureshi, F.W. Edens, B. Sherry, P.S. Wakenell, P.H. O'Connell, and K.A. Schat, 2002. Isolation of a reovirus from poult enteritis and mortality syndrome and its pathogenicity in turkey poults. *Avian Dis*. 46:32–47.
37. Hemzani, E., M. Meroz, A. Weisz, G. Ayali, N. Kass, S. Mikhlin, E. Berman, and Y. Samberg. 1996. Isolation of an avian reovirus with unique antigenicity from a tenosynovitis outbreak. Proceedings International Symposium on Adenovirus and Reovirus Infections in Poultry. Rauischholzhausen, Germany. 269–278.
38. Hieronymus, D.R.K., P. Villegas, and S.H. Kleven. 1983. Identification and serological differentiation of several reovirus strains isolated from chickens with suspected malabsorption syndrome. *Avian Dis*. 27:246–254.
39. Hill, J.E., G.N. Rowland, K.S. Latimer, and J. Brown. 1989. Effects of cyclosporin A on reovirus-infected broilers. *Avian Dis*. 33:86–92.
40. Hill, J.E., G.N. Rowland, W.L. Steffens, and M.B. Ard. 1989. Ultrastructure of the gastrocnemius tendon and sheath from broilers infected with reovirus. *Avian Dis*. 33:79–85.
41. Hsu, C.J., C.Y. Wang, L.H. Lee, W.L. Shih, C.I. Chang, H.L. Cheng, J.L. Chulu, W.T. Ji, and H.J. Liu. 2006. Development and characterization of monoclonal antibodies against avian reovirus sigma C protein and their application in detection of avian reovirus isolates. *Avian Pathol*. 35:320-6.
42. Huang, L.K., S.C. Liao, C.C. Chang, and H.J. Liu. 2006. Expression of avian reovirus C protein in transgenic plants. *J Virol Methods*. 134:217–222.
43. Ide, P.R. 1982. Avian reovirus antibody assay by indirect immunofluorescence using plastic microculture plates. *Can J Comp Med*. 46:39–42.
44. Islam, M.R., and R.C. Jones 1988. An enzyme-linked immunosorbent assay for measuring antibody titers against avian reovirus using a single dilution of serum. *Avian Pathol*. 17:411–425.

45. Islam, M.R., R.C. Jones, and D.F. Kelly. 1988. Pathogenesis of experimental reovirus tenosynovitis in chickens: influence of the route of infection. *J Comp Pathol*. 98:325–336.
46. Islam, M.R., R.C. Jones, D.F. Kelly, and A.I. Al-Afaleq. 1990. Studies on the development of autoantibodies in chickens following experimental reovirus infection. *Avian Pathol*. 13:409–416.
47. Jindal N., D.P. Patnayak, Y. Chander, A.F. Ziegler, and S.M. Goyal. 2010. Detection and molecular characterization of enteric viruses in breeder turkeys. *Avian Pathol*. 39:53–61.
48. Johnson, D.C., and L. Van der Heide. 1971. Incidence of tenosynovitis in Maine broilers. *Avian Dis*. 15:829–834.
49. Jones, R.C. 2000. Avian reovirus infections. *Rev Sci Tech*. 19:614–625.
50. Jones, R.C., A. Al-Afaleq, C.E. Savage, and M.R. Islam. 1994. Early pathogenesis in chicks of infection with a trypsin-sensitive avian reovirus. *Avian Pathol*. 23:683–692.
51. Jones, R.C., and K. Georgiou. 1984. Reovirus-induced tenosynovitis in chickens: The influence of age at infection. *Avian Pathol*. 13:441–457.
52. Jones, R.C., and K. Georgiou. 1985. The temporal distribution of an arthrotropic avian reovirus in the leg of the chicken after oral infection. *Avian Pathol*. 14:75–85.
53. Jones, R.C., and J.R.M. Guneratne. 1984. The pathogenicity of some avian reoviruses with particular reference to tenyosynovitis. *Avian Pathol*. 13:173–189.
54. Jones, R.C., and F.S.B. Kibenge. 1984. Reovirus-induced tenosynovitis in chickens: The effect of breed. *Avian Pathol*. 13:511–528.
55. Jones, R.C., and B.N.C. Nwajei. 1985. Reovirus-induced tenosynovitis: persistence of homologous challenge virus in broiler chicks after vaccination of parents. *Res Vet Sci*. 39:39–41.
56. Jones, R.C., and O. Onunkwo. 1978. Studies on experimental tenosynovitis in light hybrid chickens. *Avian Pathol*. 7:171–181.
57. Jones, R.C., F.T.W. Jordan, and S. Lioupis. 1975. Characteristics of reovirus isolated from ruptured gastrocnemius tendons of chickens. *Vet Rec*. 96:153–154.
58. Jones, R.C., M.R. Islam, and D.F. Kelly. 1989. Early pathogenesis of experimental reovirus infection in chickens. *Avian Pathol*. 18:239–253.
59. Kaschula, V.R. 1950. A new virus disease of the Muscovy duck (*Cairina moschata*) present in Natal. *J S Afr Vet Med Assoc*. 21:18–26.
60. Kawamura, H., and H. Tsubahara. 1966. Common antigenicity of avian reoviruses. *Natl Inst Anim Health Q (Tokyo)*. 6:187–193.
61. Kawamura, H., F. Shimizu, M. Maeda, and H. Tsubahara. 1965b. Avian reovirus: its properties and serological classification. *Natl Inst Anim Health Q (Tokyo)*. 5:115–124.
62. Kerr, K.M., and N.O. Olson. 1964. Control of infectious synovitis. The effect of age of chickens on the susceptibility to three agents. *Avian Dis*. 8:256–263.
63. Kerr, K.M., and N.O. Olson. 1969. Pathology of chickens experimentally inoculated or contact-infected with an arthritis producing virus. *Avian Dis*. 13:729–745.
64. Kibenge, F.S.B., and G.E. Wilcox. 1983. Tenosynovitis in chickens. *Vet Bull*. 53:431–444.
65. Kibenge, F.S.B., R.C. Jones, and C.E. Savage. 1987. Effects of experimental immunosuppression on tenosynovitis in light hybrid chickens. *Avian Pathol*. 16:73–92.
66. Lee, L.H., J.H. Shien, and H.K. Shieh. 1998. Detection of avian reovirus RNA and comparison of a portion of genome segment S3 by polymerase chain reaction and restriction enzyme fragment length polymorphism. *Res Vet Sci*. 65:11–15.
67. Li, L., J.J. Giambrone, U.S. Ponongala, and F.J. Hen. 1996. Production and characterization of monoclonal antibodies against avian reovirus strain S1133. *Avian Dis*. 40:349–357.
68. Lin, Y.L., J.H. Shien, and L.H. Lee. 2006. A monoclonal antibody-based competitive enzyme-linked immunosorbent assay for detecting antibody production against avian reovirus proteins. *J Virol Methods*. 136:71–77.
69. Lin, Y.H., L.H. Lee, W.L. Shih, Y.C. Hu, and H.J. Liu. 2008. Baculovirus surface display of sigmaC and sigmaB proteins of avian reovirus and immunogenicity of the displayed proteins in a mouse model. *Vaccine*. 26:6361–7.
70. Liu, H.J., and J.J. Giambrone. 1997. *In situ* detection of reovirus in formalin-fixed paraffin-embedded tissues using a digoxigenin-labelled cDNA probe. *Avian Dis*. 41:447–451.
71. Liu, H.J., J.H. Chen, M.H. Liao, M.Y. Lin, and G.N. Chang. 1999. Identification of the C-encoded gene of avian reovirus by nested PCR and restriction endonuclease analysis. *J Virol Methods*. 81:83–90.
72. Liu, H.J., L.C. Kuo, Y.C. Hu, M.H. Liao, and Y.Y. Lien. 2002. Development of an ELISA for detection of antibodies to avian reovirus in chickens. *J Virol Methods*. 102:129–38.
73. Liu, H.J., L.H. Lee, W.L. Shih, Y.J. Li, and H.Y. Su. 2004. Rapid characterization of avian reoviruses using phylogenetic analysis, reverse transcription-polymerase chain reaction and restriction enzyme fragment length polymorphism. *Avian Pathol*. 33:171–180.
74. Lublin, A., D. Goldenberg, E. Rosenbluth, E.D. Heller, and J. Pitcovski. 2011. Wide-range protection against avian reovirus conferred by vaccination with representatives of four defined genotypes. *Vaccine*. 29:8683–8.
75. Lupini, C., M. Cecchinato, A. Scagliarini, R. Graziani, and E. Catelli. 2009. *In vitro* antiviral activity of chestnut and quebracho woods extracts against avian reovirus and metapneumovirus. *Res Vet Sci*. 87:482–7.
76. Macdonald, J.W., C.J. Randall, M.D. Dagless, and D.A. McMartin. 1978. Observations on viral tenosynovitis (viral arthritis) in Scotland. *Avian Pathol*. 7:471–482.
77. Marquardt, J., W. Herrmanns, L.C. Schulz, and W. Leibold. 1983. A persistent reovirus infection of chickens as a possible model of human rheumatoid arthritis (RA). *Zentralbl Veterinaermed*. 30B:274–282.
78. Mathews, R.E.F. 1982. Classification and nomenclature of viruses. *Intervirology*. 17:1–200.
79. McNeilly, F., J.A. Smyth, B.M. Adair, and M.S. McNulty. 1995. Synergism between chicken anemia virus (CAV) and avian reovirus following dual infection of 1-day-old chicks by a natural route. *Avian Dis*. 39:32–537.
80. Menendez, N.A., B.W. Calnek, and B.S. Cowen. 1975. Experimental egg-transmission of avian reovirus. *Avian Dis*. 19:104–111.
81. Menendez, N.A., B.W. Calnek, and B.S. Cowen. 1975. Localization of avian reovirus (FDO isolate) in tissues of mature chickens. *Avian Dis*. 19:112–117.
82. Mills, J.N., and G.E. Wilcox. 1993. Replication of four antigenic types of avian reovirus in subpopulations of chicken leukocytes. *Avian Pathol*. 22:353–361.
83. Mukiibi-Muka, G., and R.C. Jones. 1999. Local and systemic IgA and IgG responses of chicks to avian reoviruses: effects of age of chick, route of infection and virus strain. *Avian Pathol*. 28:54–60.

84. Neighbor, N.K., L.A. Newberry, G.R. Baygori, J.K. Skeeles, J.N. Beasly, and R.W. McNew. 1994. The effect of microaerosolized hydrogen peroxide on bacterial and viral poultry pathogens. *Poult Sci*. 73:1511–1516.
85. Nersessian, B.N., M.A. Goodwin, R.K. Rage, S.H. Kleven, and J. Brown. 1986. Studies on orthoreoviruses isolated from young turkeys. III. Pathogenic effects in chicken embryos, chicks, poults, and suckling mice. *Avian Dis*. 30:585–592.
86. Ni, Y., and M.C. Kemp. 1995. A comparative study of avian reovirus pathogenicity: virus spread and replication and induction of lesions. *Avian Dis*. 39:554–566.
87. Olson, N.O., and K.M. Kerr. 1966. Some characteristics of an avian arthritis viral agent. *Avian Dis*. 10:470–476.
88. Olson, N.O., and K.M. Kerr. 1967. The duration and distribution of synovitis-producing agents in chickens. *Avian Dis*. 11:578–585.
89. Olson, N.O., and M.A. Khan. 1972. The effect of intranasal exposure of chickens to the Fahey-Crawley virus on the development of synovial lesions. *Avian Dis*. 16:1073–1078.
90. Olson, N.O., and D.P. Solomon. 1968. A natural outbreak of synovitis caused by the viral arthritis agent. *Avian Dis*. 12:311–316.
91. Olson, N.O., and R. Weiss. 1972. Similarity between arthritis virus and Fahey-Crawley virus. *Avian Dis*. 16:535–540.
92. Olson, N.O., D.C. Shelton, and D.A. Munro. 1957. Infectious synovitis control by medication-effect of strain differences and pleuropneumonia-like organisms. *Am J Vet Res*. 18:735–739.
93. Page, R.K., O.J. Fletcher, and P. Villegas. 1982. Infectious tenosynovitis in young turkeys. *Avian Dis*. 26:924–927.
94. Pertile, T.L., K. Karaka, M.M. Walser, and J.M. Sharma. 1996. Suppressor macrophages mediate depressed lymphoproliferation in chickens infected with avian reovirus. *Vet Immunol Immunopath*. 53; 129–145.
95. Petek, M., B. Felluga, G. Borghi, and A. Baroni. 1967. The Crawley agent: An avian reovirus. *Arch Gesamte Virusforsch*. 21:413–424.
96. Phillips, P.A., N.F. Stanley, and M. Walters. 1970. Murine disease induced by avian reovirus. *Aust J Exp Biol Med Sci*. 48:277–284.
97. Rau, W.E., L. Van der Heide, M. Kalbac, and T. Girshick. 1980. Onset of progeny immunity against viral arthritis/tenosynovitis after experimental vaccination of parent breeder chickens and cross immunity against six reovirus isolates. *Avian Dis*. 24:648–657.
98. Rinehart, C.L., and J.K. Rosenberger. 1983. Effects of avian reoviruses on the immune responses of chickens. *Poult Sci*. 62:1488–1489.
99. Robertson, M.D., and G.E. Wilcox. 1984. Serological characteristics of avian reoviruses of Australian origin. *Avian Pathol*. 13:585–594.
100. Robertson, M.D., and G.E. Wilcox. 1986. Avian reovirus. *Vet Bull*. 56:155–174.
101. Roessler, D.E. 1986. Studies on the pathogenicity and persistence of avian reovirus pathotypes in relation to age resistance and immunosuppression. PhD Thesis. University of Delaware, Newark.
102. Roessler, D.E., and J.K. Rosenberger. 1989. *In vitro* and *in vivo* characterization of avian reoviruses. III. Host factors affecting virulence and persistence. *Avian Dis*. 33:555–565.
103. Rosenberger, J.K. 1983. Reovirus interference with Marek's disease vaccination. Proceedings 32nd West Poult Dis Conf, 50–51.
104. Rosenberger, J.K. 1983. Characterization of reoviruses associated with runting syndrome in chickens. Proceedings No 66. International Union of the Immunological Society: Sydney, Australia, 141–152.
105. Rosenberger, J.K., P.A. Fries, S.S. Cloud, and R.A. Wilson. 1986. *In vitro* and *in vivo* characterization of *Escherichia coli*. II. Factors associated with pathogenicity. *Avian Dis*. 29:1094–1107.
106. Ruff, M.D., and J.K. Rosenberger. 1985. Concurrent infections with reoviruses and coccidia in broilers. *Avian Dis*. 29:465–478.
107. Ruff, M.D., and J.K. Rosenberger, 1985. Interaction of low-pathogenicity reoviruses and low levels of infection with several coccidia species. *Avian Dis*. 29:1057–1065.
108. Sahu, S.P., and N.O. Olson. 1975. Comparison of the characteristics of avian reoviruses isolated from the digestive and respiratory tract, with viruses isolated from the synovia. *Am J Vet Res*. 36:847–850.
109. Samberg, Y., and M. Meroj. 1996. Experiments with an autogenous reovirus oil emulsion vaccine. Proceedings International Symposium on Adenovirus and Reovirus Infections in Poultry: Rauischholzhausen, Germany, 305–311.
110. Savage, C.E., and R.C. Jones. 2003. The survival of avian reoviruses on materials associated with the poultry house. *Avian Pathol.* 32: 419–425.
111. Sellers, H.S., E.G. Linneman, L. Periera, and D.R. Kapczynski. 2004. Phylogenetic analysis of the s2 protein gene of turkey reoviruses. *Avian Dis*. 48:651–7.
112. Schwartz, L.D., R.F. Gentry, H. Rothenbacher, and L. Van der Heide. 1976. Infectious tenosynovitis in commercial white leghorn chickens. *Avian Dis*. 20:769–773.
113. Shapouri, M.R.S., S.K. Reddy, and A. Silim. 1994. Interaction of avian reovirus with chicken lymphoblastoid cell lines. *Avian Pathol*. 23:287–296.
114. Simmons, D.G., W.M. Colwell, K.E. Muse, and C.E. Brewer. 1972. Isolation and characterization of an enteric reovirus causing high mortality in turkey poults. *Avian Dis*. 16:1094–1102.
115. Slaght, S.S., T.J. Yang, L. Van der Heide, and T.N. Fredrickson. 1978. An enzyme-linked immunosorbent assay (ELISA) for detecting chicken anti-reovirus antibody at high sensitivity. *Avian Dis*. 22:802–805.
116. Songserm, T., D. van Roozelaar, A. Kant, J. Pol, A. Pijpers, and A. ter Huurne. 2003. Enteropathogenicity of Dutch and German avian reoviruses in SPF white leghorn chickens and broilers. *Vet Res*. 34:285–295.
117. Springer, W.T., N.O. Olson, K.M. Kerr, and C.J. Fabacher. 1983. Responses of specific-pathogen-free chicks to concomitant infections of reovirus (WVU-2937) and infectious bursal disease virus. *Avian Dis*. 27:911–917.
118. Sterner, F.J., J.K. Rosenberger, A. Margolin, and M.D. Ruff. 1989. *In vitro* and *in vivo* characterization of avian reoviruses. II. Clinical evaluation of chickens infected with two avian reovirus pathotypes. *Avian Dis*. 22:545–554.
119. Su, Y.P., B.S. Su, J.H. Shien, H.J. Liu, and L.H. Lee. 2006. The sequence and phylogenetic analysis of avian reovirus genome segments M1, M2, and M3 encoding the minor core protein muA, the major outer capsid protein muB, and the nonstructural protein muNS. *J Virol Methods*. 133:146-57.
120. Takase, K., H. Fujikawa, and S. Yamada. 1996. Correlation between neutralizing antibody titre and protection from tenosynovitis in avian reovirus infections. *Avian Pathol*. 25:807–815.
121. Tang, K., and O.J. Fletcher. 1987. Application of the avidin-biotin-peroxidase complex (ABC) techniques for detecting avian reovirus in chickens. *Avian Dis*. 31:591–596.

122. Trites, J., D. Mills, and J.K. Rosenberger. 2011. Reovirus and turkey tenosynovitis. Proceedings: 'North Carolina Industry Days' North Carolina State University, October 5-6, Wilmington North Carolina.
123. Van der Heide, L. 1977. Viral arthritis/tenosynovitis: A review. *Avian Pathol*. 6:271–284.
124. Van der Heide, L. 1996. Introduction on avian reovirus. Proceedings International Symposium on Adenovirus and Reovirus Infections in Poultry, Rauischholzhausen, Germany. 138–142.
125. Van der Heide, L. 2000. The history of avian reovirus. *Avian Dis*. 44:638–641.
126. Van der Heide, L., and M. Kalbac. 1975. Infectious tenosynovitis (viral arthritis): characterization of a Connecticut viral isolant as a reovirus and evidence of viral egg transmission by reovirus-infected broiler breeders. *Avian Dis*. 19:683–688.
127. Van der Heide, L., and R.K. Page. 1980. Field experiments with viral arthritis/tenosynovitis vaccination of breeder chickens. *Avian Dis*. 24:493–497.
128. Van der Heide, L., J. Geissler, and E.S. Bryant. 1974. Infectious tenosynovitis: Serologic and histopathologic response after experimental infection with a Connecticut isolate. *Avian Dis*. 18:289–296.
129. Van der Heide, L., M. Kalbac, and W.C. Hall. 1976. Infectious tenosynovitis (viral arthritis): Influence of maternal antibodies on the development of tenosynovitis lesions after experimental infection by day-old chickens with tenosynovitis virus. *Avian Dis*. 20:641–648.
130. Van der Heide, L., M. Kalbac, M. Brustolon, and M.G. Lawson. 1980. Pathogenicity for chickens of a reovirus isolated from turkeys. *Avian Dis*. 24:989–997.
131. Van der Heide, L., M. Kalbac, and M. Brustolon. 1983. Development of an attenuated apathogenic reovirus vaccine against viral arthritis/tenosynovitis. *Avian Dis*. 27:698–706.
132. Van de Zande, S., and E.M. Kuhn. 2007. Central nervous system signs in chickens caused by a new avian reovirus strain: a pathogenesis study. *Vet Microbiol*. 120:42–9.
133. van Loon, A.A.W.M., A.M. Braber, and D. Roessler. 1996. Vaccination of one-day-old chickens with a new live avian reovirus vaccine (strain 2177). Proceedings International Symposium on Adenovirus and Reovirus Infections in Poultry, Rauischholzhausen, Germany. 318–323.
134. van Loon, A.A., W. Kosman, H.I. van Zuilekom, S. van Riet, M. Frenken, and E.J. Schijns. 2003. The contribution of humoral immunity to the control of avian reoviral infection in chickens after vaccination with live reovirus vaccine (strain 2177) at an early age. *Avian Pathol*. 32:15–23.
135. van Loon, A.A., H.C. Koopman, W. Kosman, J. Mumczur, O. Szeleszczuk, E. Karpinska, G. Kosowska, and D. Lutticken. 2001a. Isolation of a new serotype of avian reovirus associated with malabsorption syndrome in chickens. *Vet Quart*. 23:129–133.
136. van Loon, A.A., B. Suurland, and P. van der Marel. 2002. A reovirus challenge model applicable in commercial broilers after live vaccination. *Avian Pathol*. 31:13–21.
137. Walker, E.R., M.H. Friedman, and N.O. Olson. 1972. Electron microscopic study of an avian reovirus that causes arthritis. *J Ultrastruct Res*. 41:67–79.
138. Wan, J., C. Wang, X. Wen, X. Huang, S. Ling, Y. Huang, and S. Cao. 2010. Immunogenicity of a DNA vaccine of avian reovirus orally delivered by attenuated *Salmonella typhimurium*. *Res Vet Sci*. 91:382–3.
139. Wu, H., K. Scissum-Gunn, N.K. Singh, and J.J. Giambrone. 2009. Toward the development of a plant-based vaccine against reovirus. *Avian Dis*. 53:376–81.
140. Wickramasinghe, R., J. Meonger, C.E. Enriquez, and G.E. Wilcox. 1993. Avian reovirus proteins associated with neutralization of virus infectivity. *Virol*. 194:688–696.
141. Winship, T.R., and P.I. Marcus. 1980. Interferon induction by viruses. VI. Reovirus: Virion genome dsRNA as the interferon inducer in aged chick embryo cells. *J Interferon Res*. 1:155–167.
142. Woernle, H., A. Brunner, and K.F. Kussaul. 1974. Nachweis aviären Reo-Viren im Agar-Gel-Präzipitationstest. *Tieraerztl Umsch*. 29:307–312.
143. Wood, G. W., R.A.J. Nicholas, C.N. Hebert, and D.H. Thornton. 1980. Serological comparisons of avian reoviruses. *J Comp Pathol*. 90:29–38.
144. Wood, G.W., J.C. Muskett, and D.H. Thorton. 1986. Observations on the ability of avian reovirus vaccination of hens to protect their progeny against the effects of challenge with homologous and heterologous strains. *J Comp Pathol*. 96:125–129.
145. Wooley, R.E., T.A. Dees, A.S. Cromack, and J.B. Gratzek. 1972. Infectious enteritis of turkeys: characterization of two reoviruses isolated by sucrose density gradient centrifugation from turkeys with infectious enteritis. *Am J Vet Res*. 33:157–164.
146. Wu H., Y. Williams, K.S. Gunn, N.K. Singh, R.D. Locy, and J.J. Giambrone. 2005. Yeast-derived sC protein-induced immunity against avian reovirus. *Avian Dis*. 49:281–284.
147. Xie, Z., C. Qin, L. Xie, J. Liu, Y. Pang, X. Deng, Z. Xie, and M.I. Khan. 2010. Recombinant protein-based ELISA for detection and differentiation of antibodies against avian reovirus in vaccinated and non-vaccinated chickens. *J Virol Methods*. 165:108-11.
148. Yang, Z.J., C.Y. Wang, L.H. Lee, K.P. Chuang, Y.Y. Lien, H.S. Yin, D.W. Tong, X.G. Xu, and H.J. Liu. 2010. Development of ELISA kits for antibodies against avian reovirus using the sigmaC and sigmaB proteins expressed in the methyltropic yeast *Pichia pastoris*. *J Virol Methods*. 163:169–74.
149. Yin, H.S. and L.H. Lee. 1998. Development and characterization of a nucleic acid probe for avian reoviruses. *Avian Pathol*. 27:423–426.

Other Reovirus Infections

1. Al-Afaleq, A.I., and R.C. Jones. 1989. Pathogenicity of three turkey and three chicken reoviruses for poults and chicks with particular reference to arthritis/tenosynovitis. *Avian Pathol*. 18:433–440.
2. Al-Afaleq, A.I., J.M. Bradbury, R.C. Jones, and A.M. Metwali. 1989. Mixed infection of turkeys with *Mycoplasma synoviae* and reovirus: field and experimental observations. *Avian Pathol*. 18:441–453.
3. Apple, R.O., J.K. Skeeles, G.E. Houghten, J.N. Beesley, and K.S. Kim. 1991. Investigation of a chronic feed-passage problem in a broiler farm in Northwest Arkansas. *Avian Dis*. 35:422–425.
4. Bagust, T.J., and H.A. Westbury. 1975. Isolation of reoviruses associated with diseases of chickens in Victoria. *Aust Vet J*. 51:406–407.
5. Bains, B.S., M. Mackenzie, and P. Spradbrow. 1974. Reovirus-associated mortality in broiler chickens in Victoria. *Avian Dis*. 18:472–476.

6. Banyai, K., V. Palya, M. Benko, J. Bene, V. Havasi, B. Melegh and G. Szucs. 2005. The goose reovirus genome segment encoding the minor outer capsid protein s1/sC is bicistronic and shares structural similarities with its counterpart in Muscovy duck reovirus. *Virus Genes*. 31:285–291.
7. Bányai, K., E. Dandár, K.M. Dorsey, T. Mató, and V. Palya. 2011. The genomic constellation of a novel avian orthoreovirus strain associated with runting-stunting syndrome in broilers. *Virus Genes*. 42:82–9.
8. Barnes, H.J., J.S. Guy, and J.P. Vallaincourt. 2000. Poult enteritis complex. *Rev Sci Tech*. 19:565–88.
9. Cadman, H.F., P.J. Kelly, R. Zhou, F. Davelaar, and P.R. Mason. 1994. A serosurvey using enzyme-linked immunosorbent assay for antibodies against poultry pathogens in ostriches (*Struthio camelus*) from Zimbabwe. *Avian Dis*. 38:621–625.
10. Culver, F., F. Dziva, D. Cavanagh, and M.P. Stevens. 2006. Poult enteritis and mortality syndrome in turkeys in Great Britain. *Vet Rec*. 159: 209–210.
11. Curtis, P.E., S.I. Al-Mufarrej, R.C. Jones, J. Morris, and P.M. Sutton. 1992. Tenosynovitis in young pheasants associated with reovirus, staphylococci and environmental factors. *Vet Rec*. 131:293.
12. Day, J.M., M.J. Pantin-Jackwood, and E. Spackman. 2007. Sequence and phylogenetic analysis of the S1 genome segment of turkey-origin reoviruses. *Virus Genes*. 35:235–42.
13. Decaesstecker, M., G. Charlier, and G. Meulemans. 1986. Significance of parvoviruses, entero-like viruses and reoviruses in the aetiology of chicken malabsorption syndrome. *Avian Pathol*. 15:769–782.
14. Dees, T.A., R.E. Wooley, and J.B. Gratzek. 1972. Pathogenicity of bacteria-free filtrates and a viral agent isolated from turkeys with infectious enteritis. *Am J Vet Res*. 33:165–170.
15. de Kloet, S.R. 2008. Sequence analysis of four double-stranded RNA genomic segments reveals an orthoreovirus with a unique genotype infecting psittaciformes. *Avian Dis*. 52(3):480-6.
16. Desmukh, D.R., and B.S. Pomeroy. 1969. Avian reoviruses. II. Physiochemical characterisation and classification. *Avian Dis*. 13:243–251.
17. Doherty, D.E., K.A. Converse, W.R. Hansen, and G.W. Norman. 1994. American woodcock (*Scolopax minor*) mortality associated with a reovirus. *Avian Dis*. 38:899–904.
18. Dutta, S.K., and B.S. Pomeroy. 1967. Isolation and characterisation of an enterovirus from baby chicks having an enteric infection. II. Physical and chemical characteristics and ultrastructure. *Avian Dis*. 11:9–15.
19. Engstrom, B.E., O. Fossum, and M. Luthman. 1988. Blue wing disease of chickens. Experimental infection with a Swedish isolate of chicken anaemia agent and an avian reovirus. *Avian Pathol*. 17:33–50.
20. Fahey, J.E., and J.F. Crawley. 1954. Studies on chronic respiratory disease of chickens. II. Isolation of a virus. *Can J Comp Med*. 18:13–21.
21. França, M., R. Crespo, R. Chin, P. Woolcock, and H.L. Shivaprasad. 2010. Retrospective study of myocarditis associated with reovirus in turkeys. *Avian Dis*. 54:1026–31.
22. Gaudry, D., J. Tecktoff, and J.M. Charles. 1972. A propos d'un nouveau virus isole chez le canard the Barbarie. *Bull Soc Sci Vet Med Comp Lyon*. 74:137.
23. Gershowitz, A., and R.E. Wooley. 1973. Characterisation of two reoviruses isolated from turkeys with infectious enteritis. *Avian Dis*. 17:406–414.
24. Goodwin. M.A., B.N. Nersessian, J. Brown, and O.J. Fletcher. 1985. Gastrointestinal transit times in normal and reovirus-infected turkeys. *Avian Dis*. 29:920–928.
25. Goodwin, M.A., J.F. Davis, M.S. McNulty, J. Brown, and E.C. Player. 1993. Enteritis (so-called runting-stunting syndrome) in Georgia broiler chicks. *Avian Dis*. 37:451–458.
26. Gough, R.E., D.J. Alexander, M.S. Collins, S.A. Lister, and W.J. Cox. 1988. Routine virus isolation or detection in the diagnosis of diseases in birds. *Avian Pathol*. 17:893–907.
27. Graham, D.L. 1987. Characterisation of a reo-like virus from and pathogenicity for parrots. *Avian Dis*. 31:411–419.
28. Guy, J.S., M.G. Levy, D.H. Ley, H.J. Barnes, and T.M. Gerig. 1987. Experimental reproduction of enteritis in bobwhite quail (*Colinus virginianus*) with Cryptosporidium and reovirus. *Avian Dis*. 31:713–722.
29. Guy, J.S., M.G. Levy, D.H. Ley, H.J. Barnes, and T.M. Gerig. 1988. Interaction of reovirus and *Cryptosporidium baileyi* in experimentally infected chickens. *Avian Dis*. 32:381–390.
30. Guy, J.S., L.G. Smith, J.J. Breslin, J.P. Vaillancourt, and H.J. Barnes. 2000. High mortality and growth depression experimentally produced in young turkeys by dual infection with enteropathogenic *Escherichia coli* and turkey coronavirus. *Avian Dis*. 44:105–13.
31. Heffels-Redmann, U., H. Muller, and E.F. Kaleta. 1992. Structural and biological characteristics of reoviruses isolated from Muscovy ducks (*Cairina moschata*). *Avian Pathol*. 21:481–491.
32. Heggen-Peay, M.A., F.W. Qureshi, B. Edens, P.S. Sherry, P. H. Wakenell, C.L. O'Connell, and K.A. Schat 2002. Isolation of a reovirus from poult enteritis and mortality syndrome and its pathogenicity in turkey poults. *Avian Dis*. 46:360–369.
33. Hlinak, A., T. Muller, M. Kramer, R.U. Muhle, H. Liebherr, and K. Ziedler. 1998. Serological survey of viral pathogens in bean and white-fronted geese from Germany. *J Wildl Dis*. 34:479–486.
34. Hollmen, T., J.C. Franson, M. Kilpi, D.E. Docherty, W.R. Hanson, and M. Hario. 2002. Isolation and characterization of a reovirus from common eiders (*Somateria mollissima*) from Finland. *Avian Dis*. 46:478–484.
35. Jindal, N., D.P. Patnayak, Y. Chander, A.F. Ziegler, and S.M. Goyal. 2010. Detection and molecular characterization of enteric viruses in breeder turkeys. *Avian Pathol*. 39:53–61.
36. Jones, R.C. 1975. Reoviruses from chickens with hydropericardium. *Vet Rec*. 99:458.
37. Jones, R.C., and J.R.M. Guneratne. 1984b. The pathogenicity of some avian reoviruses with particular reference to tenosynovitis. *Avian Pathol*. 13:441–457.
38. Kaleta, E.F., H. Will, E. Bernius, W. Kruse, and A.L. Bolte. 1998. Serological detection of viral-induced infections in the domestic goose (*Anser anser domesticus*). *Tierarzt Prax Ausg Grobt Nutz*. 26:234–238.
39. Kant, A., F. Balk, L. Born, D. van Roozelaar, J. Heijmans, A. Gielkens, and A. ter Huurne. 2003. Classification of Dutch and German avian reoviruses by sequencing the sC protein. *Vet Res*. 34:203–12.
40. Karesh W.B., M.M. Uhart, E. Frere, P. Gandini, W.E. Braselton, H. Puche, and R.A. Cook. 1999. Health evaluation of free-ranging rockhopper penguins (*Eudyptes chrysocomes*) in Argentina. *J Zoo Wildl Med*. 30:25–31.
41. Kibenge, F., R.C. Jones, and C.E. Savage. 1987. Effects of experimental immunosuppression on reovirus-induced tenosynovitis in light hybrid chickens. *Avian Pathol*. 16: 73–92.

42. Koci, M.D., and S. Schulz-Cherry. 2002. Avian astroviruses. *Avian Pathol*. 31: 213–227.
43. Krauss, H., and S. Ueberschar. 1966. Zur Structur eines neuen Geflugel-Orphanvirus. *Zentral Vet B*. 13:239–249.
44. Kuntz-Simon, G., G. Le Gall-Recule, C. de Boisseson, and V. Jestin. 2002. Muscovy duck reovirus sC protein is atypically encoded by the smallest genome segment. *J Gen Virol*. 83:1189–2002.
45. Kuntz-Simon G., P. Blanchard, M. Cherbonnel, A. Jestin, and V. Jestin. 2002. Baculovirus-expressed Muscovy duck reovirus sC protein induces serum-neutralising antibodies and protection against challenge. *Vaccine*. 20:3113–3122.
46. Lenz, S.D., F.J. Hoerr, A.C. Ellis, M.A. Toivio-Kinnucan, and M. Yu. 1998. Gastrointestinal pathogenicity of adenoviruses and reoviruses isolated from broiler chickens in Alabama. *Avian Dis*. 10:145–151.
47. Levisohn, S., A. Gur-Lavi, and J. Weisman. 1980. Infectious synovitis in turkeys: isolation of a tenosynovitis virus-like agent. *Avian Pathol*. 9:1–4.
48. Lozano, L.F., S. Hammami, A.E. Castro, and B.I. Osburn. 1992. Interspecies polymorphism of double-stranded RNA extracted from reoviruses of turkeys and chickens. *J Vet Diag Invest*. 4:74–77.
49. McFerran, J.B., T.J. Connor, and R.M. McCracken. 1976. Isolation of adenoviruses and reoviruses from avian species other than the domestic fowl. *Avian Dis*. 20:519–524.
50. McFerran, J.B., R.M. McCracken, T.J. Connor, and R.T. Evans. 1976. Isolation of viruses from clinical outbreaks of inclusion body hepatitis. *Avian Pathol*. 5:315–324.
51. McNeilly, F., J.A. Smyth, B.M. Adair, and M.S. McNulty. 1995. Synergism between chicken anaemia virus (CAV) and avian reovirus following dual infection of 1-day-old chicks by a natural route. *Avian Dis*. 39:532–537.
52. Malkinson, M., K. Perk, and Y. Weisman. 1981. Reovirus infection in young Muscovy ducks. *Avian Pathol*. 10:440–443.
53. Montgomery, R.D., C.R. Boyle, W.R. Maslin, and D.L. Magee. 1997. Attempts to reproduce a runting/stunting-type syndrome using infectious agents isolated from affected Mississippi broilers. *Avian Dis*. 41:80–92.
54. Moradian, A., J. Thorsen, and R.J. Julian. 1991. Single and combined infection of specific-pathogen-free chickens with infectious bursal disease virus and an intestinal isolate of reovirus. *Avian Dis*. 34:63–72.
55. Mutlu, O.F., C. Grund, and F. Coven. 1998. Reovirus infection of pheasants (*Phasianus colchicus*). *Tierartzl Prax Ausg Grobti Nutz*. 26:104–107.
56. Nersessian, B.N., M.A. Goodwin, R.K. Page, and S.H. Kleven. 1985. Studies on orthoreoviruses isolated from young turkeys. II. Virus distribution in organs and serological response of poults inoculated orally. *Avian Dis*. 29:963–969.
57. Nersessian, B.N., M.A. Goodwin, R.K. Page, S.H. Kleven, and J. Brown. 1986. Studies on orthoreoviruses isolated from young turkeys. III. Pathogenic effects in chicken embryos, chicks, poults and suckling mice. *Avian Dis*. 29:963–969.
58. Page, R.K., O.J. Fletcher, G.N. Rowland, D. Gaudry, and P. Villegas. 1982. Malabsorption syndrome in broiler chickens. *Avian Dis*. 26:618–624.
59. Page, R.K., O.J. Fletcher, and P. Villegas. 1982. Infectious synovitis in young turkeys. *Avian Dis*. 26:924–927.
60. Palya, V., R. Glavits, M. Dobos-Kovacs, E. Ivanics, E. Nagy, K. Banyai, G. Reuter, G. Szucs, A. Dan, and M. Benko. 2003. Reovirus identified as cause of disease in young geese. *Avian Pathol*. 32:129–138.
61. Pantin-Jackwood, M.J., J.M. Day, M.W. Jackwood, and E. Spackman. 2008. Enteric viruses detected by molecular methods in commercial chicken and turkey flocks in the United States between 2005 and 2006. *Avian Dis*. 252:235–44.
62. Pantin-Jackwood, M.J., E. Spackman, and J.M. Day. 2007. Pathology and virus tissue distribution of Turkey origin reoviruses in experimentally infected turkey poults. *Vet Pathol*. 44:185–95.
63. Pass, D.A., D.M. Robertson, and G.E. Wilcox. 1982. Runting syndrome in broiler chickens in Australia. *Vet Rec*. 110:386–387.
64. Perpiñán, D., M.M. Garner, J.F. Wellehan, and D.L. Armstrong. 2010. Mixed infection with reovirus and chlamydophila in a flock of budgerigars (*Melopsittacus undulatus*). *J Avian Med Surg.* 24:316–21.
65. Petek, M., B. Felluga, G. Borghi, and A. Baroni. 1967b. The Crawley agent: an avian reovirus. *Arch Ges Virusforsch*. 21:413–424
66. Rekik, M.R., A. Silim, and G. Bernier. 1991. Serological and pathogenic characterisation of avian reoviruses isolated in Quebec. *Avian Pathol*. 20:607–617.
67. Ritter, D.G., D.H. Ley, M. Levy, J.J. Guy, and Barnes, H.J. 1986. Intestinal cryptosporidiosis and reovirus isolation from bobwhite quail (*Colinus virginianus*) with enteritis. *Avian Dis*. 30:603–608.
68. Robertson, M.D., G.E. Wilcox, and F.S.B. Kibenge. 1984. Prevalence of reoviruses in commercial chickens. *Aus Vet J*. 61:319–322.
69. Rosenberger, J.K. 1983. Characterisation of reoviruses associated with stunting syndrome in chickens. In International Union of Immunological Societies Proceedings 66. University of Sydney, New South Wales, 141–152.
70. Rosenberger, J.K., P.A. Fries, S.S. Cloud, and R.A. Wilson. 1985. *In vitro* and *in vivo* characterization of avian *Escherichia coli*. II. Factors associated with pathogenicity. *Avian Dis*. 29:1094–1107.
71. Rosenberger, J.S., F.J. Sterner, S. Botts, K.P. Lee, and A. Margolin. 1989. *In vitro* and *in vivo* characterization of avian reoviruses. I. Pathogenicity and antigenic relatedness of several avian reovirus isolates. *Avian Dis*. 33:535–544.
72. Ruff, M.D., and J.K. Rosenberger. 1985. Concurrent infections with reoviruses and coccidia in broilers. *Avian Dis*. 29:465–478.
73. Sakai, K., Y. Ueno, S. Ueda, K. Yada, S. Fukushi, M. Saijo, I. Kurane, K. Mutoh, K. Yoshioka, M. Nakamura, K. Takehara, S. Morikawa, and T. Mizutani. 2009. Novel reovirus isolation from an Ostrich (*Struthio camelus*) in Japan. *Vet Microbiol*. 134:227–32.
74. Sanchez-Cordon, P.J., J. Hervas, F. Chacon de Lara, J. Jahn, F.J. Salguero, and J.C. Gomez-Villamandos. 2002. Reovirus infection in psittacine birds (*Psittacus erythacus*): morphological and immunohistochemical study. *Avian Dis*. 46:485–492.
75. Simmons, D.G., W.M. Colwell, K.E. Muse, and C.E. Brewer. 1972. Isolation and characterization of an enteric reovirus causing high mortality in turkey poults. *Avian Dis*. 16:1094–1102.
76. Simmons, D. G., and P.D. Lukert. 1972. Isolation, identification and characterization of an avian respiratory reovirus. *Bull G Acad Sci*. 30:1–10.
77. Songserm, T., B. Zekarias, D.J. van Roozelar, R.S. Kok, J.M. Pol, A.A. Pijpers, and A.A. ter Huurne. 2002. Experimental reproduction of malabsorption syndrome with different combinations of reovirus, *Escherichia coli and treated homogenates obtained from broilers. Avian Dis*. 46: 87–94.
78. Songserm, T., D.J. van Roozelar, A. Kant, J.M. Pol, A.A. Pijpers, and A.A. ter Huurne. 2003. Enteropathogenicity of Dutch and German avian reoviruses in SPR white leghorn chickens and broilers. *Vet Res*. 34: 285–295.

79. Spackman, E., M. Pantin-Jackwood, J.M. Day, and H. Sellers. 2005. The pathogenesis of turkey origin reoviruses in turkeys and chickens. *Avian Pathol*. 34:291–296.
80. Spackman, E., J.M. Day, and M.J. Pantin-Jackwood. 2010. Astrovirus, reovirus, and rotavirus concomitant infection causes decreased weight gain in broad-breasted white poults. *Avian Dis*. 54:16–21.
81. Subramanyam, P., and B.S. Pomeroy. 1960. Studies on the Fahey-Crawley virus. *Avian Dis*. 4:165–175.
82. Tang, K.N., O.J. Fletcher, and P. Villegas. 1987. Comparative study on the pathogenicity of avian reoviruses. *Avian Dis*. 31:577–583.
83. Trites, J., D. Mills, and J.K. Rosenberger. 2011. Reovirus and turkey tenosynovitis. Proceedings: 'North Carolina Industry Days' North Carolina State University, October 5-6, Wilmington North Carolina.
84. van Loon, A.A., H.C. Koopman, W. Kosman, J. Mumczur, O. Szeleszczuk, E. Karpinska, G. Kosowska, and D. Lutticken. 2001. Isolation of a new serotype of avian reovirus associated with malabsorption in chickens. *Vet Quart* 23: 129–133.
85. Vertommen, M., J.H.H. van Eck, B. Kouwenhoven, and K. van Nol. 1980. Infectious stunting and leg weakness in broilers. I. Pathology and biochemical changes in blood plasma. *Avian Pathol*. 9:133–142.
86. Wellehan, J.F. Jr., A.L. Childress, R.E. Marschang, A.J. Johnson, E.W. Lamirande, J.F. Roberts, M.L. Vickers, J.M. Gaskin, and E.R. Jacobson. 2009. Consensus nested PCR amplification and sequencing of diverse reptilian, avian, and mammalian orthoreoviruses. *Vet Microbiol*. 133:34-42.
87. Woolcock, P.R., and Shivaprasad, H.L. 2003. Electron microscopic identification of viruses associated with poult enteritis in turkeys grown in California 1993-2003. *Avian Dis*. 52:209–13.
88. Zhang, Y., M. Liu, Q. Hu, S. Ouyang, and G. Tong. 2006. Characterization of the sC encoding gene from Muscovy duck reovirus. *Virus Genes*. 32:165–170.
89. Zhang, Y., D. Guo, H. Geng, M. Liu, Q. Hu, J. Wang, G. Tong, X. Kong, N. Liu, and C. Liu. 2007. Characterization of M-class genome segments of muscovy duck reovirus S14. *Virus Res*. 125:42–53.
90. Zhang, Y., D. Guo, M. Liu, H. Geng, Q. Hu, Y. Liu, N. Liu. 2007. Characterization of the sigmaB-encoding genes of muscovy duck reovirus: sigmaC-sigmaB-ELISA for antibodies against duck reovirus in ducks. *Vet Microbiol* 121:231–41.

Chapter 12

Viral Enteric Infections

Introduction

Y.M. Saif

Our knowledge of enteric viruses has increased substantially in the last 3 decades. Several factors have contributed to this progress. The realization that pathogens other than bacteria must be an important component of the etiology of enteric disease has fueled the search for other infectious agents with specific emphasis on viruses. The availability of diagnostic tools was another incentive. Most useful among these tools was direct and immune electron microscopy.

The morphologic identification of these viruses by electron microscopy from gut contents paved the way for attempts to purify, cultivate, and develop diagnostic reagents and to further characterize these agents. Another technique that was used successfully earlier to identify some viruses in fecal samples is electropherotyping of genomic RNA. This technique is useful for detection and differentiation of double-stranded RNA viruses, such as rotaviruses and reoviruses.

A significant finding reported in the earlier studies was the presence of a variety of viral species that could be present in different combinations in the gastrointestinal (GI) tract of young commercial poultry. That necessitated attempts to separate these viruses to facilitate the study of their role in enteric disease. The availability of specific pathogen free (SPF) poultry was of major value in studies on these viruses. In the last decade, more diagnostic technologies such as reverse transcriptase-polymerase chain reaction (RT-PCR) became available and are used routinely in some laboratories to detect enteric viruses in gut contents. Removal of inhibitors from fecal material has increased the utility of the test. In addition, the use of internal controls has improved the test specificity.

Most enteric viral infections occur in the first 3 weeks of life, but some occur later. The clinical signs and lesions induced by the different viruses have similarities; hence, it is difficult to attribute a specific enteric disease to a given virus unless laboratory studies are initiated to identify the causative agent(s). In addition, the presence of different combinations of viruses could result in varied disease presentations. In general, high morbidity and low mortality exist when only 1 virus is detected, but mortality could be high when several viruses are present. An example of the significant economic impact of these combinations is the condition that was designated poult enteritis and mortality syndrome that was identified in the United States.

Different terms have been used in the literature to describe different conditions/syndromes of enteric disease. Unfortunately such descriptions are not instructive and are confusing at best because these descriptions do not refer to a specific etiology or etiologies. Because diagnostic tools are available for most enteric viral infections, it is preferable to designate these conditions as enteritis with reference, when available, to the specific infectious agents involved.

Diarrhea is a common manifestation of the disease, and the GI tract is usually distended with gas and liquid/frothy contents. Different viruses replicate at different parts of the GI tract and at different sites on the villi. Epidemiologic studies indicated that most of these viruses do not persist for long in the birds. Unfortunately, many of the enteric viruses are uncultivable, which hampers research and diagnostics.

No evidence of egg transmission of enteric viruses exists, and there are gaps in our knowledge of the epidemiology of the infections. Active immunity apparently plays a role in limiting the disease, but the benefits of passive immunity are limited to the first few days of life. No commercial vaccines are available for most of these infections.

Enteric viruses are commonly the cause of most of the primary insults to the GI tract of young poultry. This provides other agents, especially bacteria, with the milieu to replicate, attach, and penetrate cells, leading to further damage. It has been shown that during the course of several enteric viral infections, bacteria adhere and form a membrane on the surface of the villi. Counteracting secondary bacterial involvement is probably the reason for the reported effectiveness of antibiotic treatment of some cases of enteric disease initiated by viruses in young birds.

Most of the early knowledge about enteric viruses was derived from studies on turkeys because of the economic significance of the disease caused by enteric viruses in commercial turkey poults. Lately, there has been renewed interest in studying enteric viral infections in young broilers because

Diseases of Poultry, Thirteenth Edition. David E. Swayne.
© 2013 John Wiley & Sons, Inc. Published 2013 by John Wiley & Sons, Inc.

of the emergence of enteric disease as an economically significant problem in broiler operations. It is interesting to note that most of the enteric viruses detected earlier in turkey poults are currently reported in chicks with similar characteristics.

The GI tract has the most extensive exposed surface in the body, and it is continually exposed to a variety of insults and stimulations. In food animals, the integrity of the GI tract is of paramount importance. Efficient utilization of nutrients depends on a healthy GI tract, and this is especially true for the young of the species. Damage to the GI tract early in life could result in irreversible damage to the flock.

The progress made in the last 3 decades has been remarkable, but gaps remain in our knowledge of enteric viruses and new enteric viruses continue to be detected as evidenced by the recognition of parvoviruses in chickens and turkeys in this chapter. Further information that could lead to novel methods for control of these infections should be significant.

Significant new information has been reported since the last edition of *Diseases of Poultry* for coronaviruses, rotaviruses, reoviruses, astroviruses, and enteroviruses, which has necessitated updating these subchapters. However, no new information or cases of toroviruses have been reported and the reader is referred to the 12th edition of *Diseases of Poultry* for information.

Turkey Coronavirus Enteritis

James S. Guy

Introduction

Turkey coronavirus (TCV) is the cause of an acute highly contagious enteric disease of turkeys characterized by depression, anorexia, diarrhea, and decreased weight gain. Bluecomb disease, transmissible enteritis, and coronaviral enteritis are synonyms of TCV enteritis of turkeys.

History

In 1951, Peterson and Hymas (61) described an enteric disease of turkeys that later became known as bluecomb disease. Severe economic losses were attributed to bluecomb disease in the United States and Canada in the 1950s and 1960s (52, 60). In 1971, Adams and Hofstad (1) successfully propagated a virus from bluecomb disease-affected turkeys in embryonating chicken and turkey eggs, and experimentally reproduced the disease using this embryo-propagated virus. A coronavirus was identified as the etiology in 1973 (57, 66). Additional information on historical aspects of this disease may be found in prior editions of *Diseases of Poultry*.

Etiology

Classification

Turkey coronavirus is classified as a member of the Coronaviridae (73). The Coronaviridae comprise a large family of RNA-containing viruses that infect a wide variety of avian and mammalian species (69). The *Coronaviridae* is in the order *Nidovirales*, an order composed of viruses having linear, nonsegmented, positive-sense, single-stranded RNA genomes with similar genomic organization and nested sets of subgenomic mRNAs (69, 73). The coronavirus genome consists of an RNA molecule that is approximately 28 kilobases in size (69). Coronaviruses possess 4 major structural proteins referred to as spike (surface) glycoprotein (90–180 kilodaltons [kDa]), integral membrane protein (20–35 kDa), small envelope protein (12.5 kDa), and nucleocapsid protein (50–60 kDa) (69). Some coronaviruses also contain a fifth major structural protein, the hemagglutinin-esterase (120–140 kDa) (69).

Coronaviruses have been subdivided into 3 major antigenic groups based on antigenic differences identified by serological analyses, and these findings have been substantiated by nucleotide sequence analyses (69). Infectious bronchitis virus (IBV) and TCV comprise the antigenic group 3 (12, 13, 14, 27).

Turkey coronavirus has been shown to be closely related to IBV based on antigenic and nucleotide sequence analyses (4, 5, 6, 8, 14, 22, 29, 36, 39, 40, 41, 42, 74). Studies have indicated a high degree of sequence identity between the integral membrane protein, nucleocapsid protein, and polymerase (ORF1b) genes of TCV and IBV, but only limited sequence identity between TCV and IBV spike glycoproteins (4, 5, 6, 8, 14, 36, 40, 41, 74).

Laboratory studies have shown that bovine coronavirus can replicate in intestinal tissues of inoculated turkey poults; however, only mild or inapparent disease was observed in infected turkeys (18, 35). Naturally occurring infection of turkeys with BCV has not been reported.

Morphology

Coronaviruses are roughly spherical, pleomorphic, enveloped particles, with diameters of 60–200 nm (69). They possess a characteristic surface structure composed of long (12–24 nm), widely spaced, club-shaped peplomers (Figure 12.1). These peplomers give virions the distinctive appearance of a solar corona, hence the name coronavirus.

Chemical Composition

The turkey coronavirus genome consists of a linear, nonsegmented, single-stranded RNA molecule that is approximately 28 kilobases (8, 22). Turkey coronavirus, like IBV, possesses spike (surface) glycoprotein, integral membrane, small envelope, and

nucleocapsid proteins (5, 6, 8, 14, 22, 40, 41). However, the size and structural properties of these proteins have not been determined. The virus lacks a hemagglutinin-esterase protein (22).

Virus Replication

Turkey coronavirus replicates primarily in enterocytes in the jejunum and ileum (7, 58, 64) and epithelium of the cloacal bursa (bursa of Fabricius) (29, 55). Viral antigens in intestinal enterocytes were found predominately in enterocytes lining the upper one-half to two-thirds of intestinal villi (Figure 12.2) (7, 29, 64). In the cloacal bursa, viral antigens are found in both follicular and interfollicular epithelium of the cloacal bursa (Figure 12.3); viral antigens are not found in bursal lymphoid follicles (29). In inoculated embryos, virus replication occurs exclusively in intestinal epithelial cells and cloacal bursa (64); virus replication has not been detected in allantoic, yolk, or amniotic membranes.

Thin-section electron microscopy of intestines from TCV-infected embryos and poults (3, 64) has shown that TCV replication occurs in the cytoplasm. Turkey coronavirus acquires its envelope by a process of budding through membranes of the endoplasmic reticulum and Golgi apparatus; virus particles accumulate in cisternae of the endoplasmic reticulum.

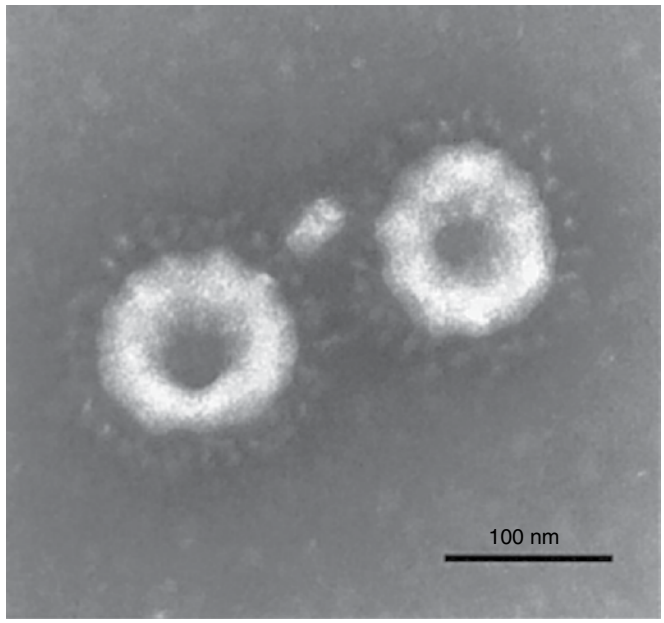

Figure 12.1. Negative contrast electron micrograph of turkey coronavirus.

Susceptibility to Chemical and Physical Agents

Turkey coronavirus was shown to be stable at pH 3 at 22°C for 30 minutes, and resistant to 50°C for 1 hour, even in the presence of 1 M magnesium sulfate (19). Chloroform treatment at 4°C for 10 minutes readily inactivated the virus.

Turkey coronavirus was shown to remain viable in intestinal tissues stored at –20°C or lower for more than 5 years. The virus was shown to survive in buildings and ranges for extended periods of time even after turkeys were removed from these premises (52). Saponified cresol and formaldehyde were shown to be effective disinfectants for eliminating TCV from contaminated buildings (60).

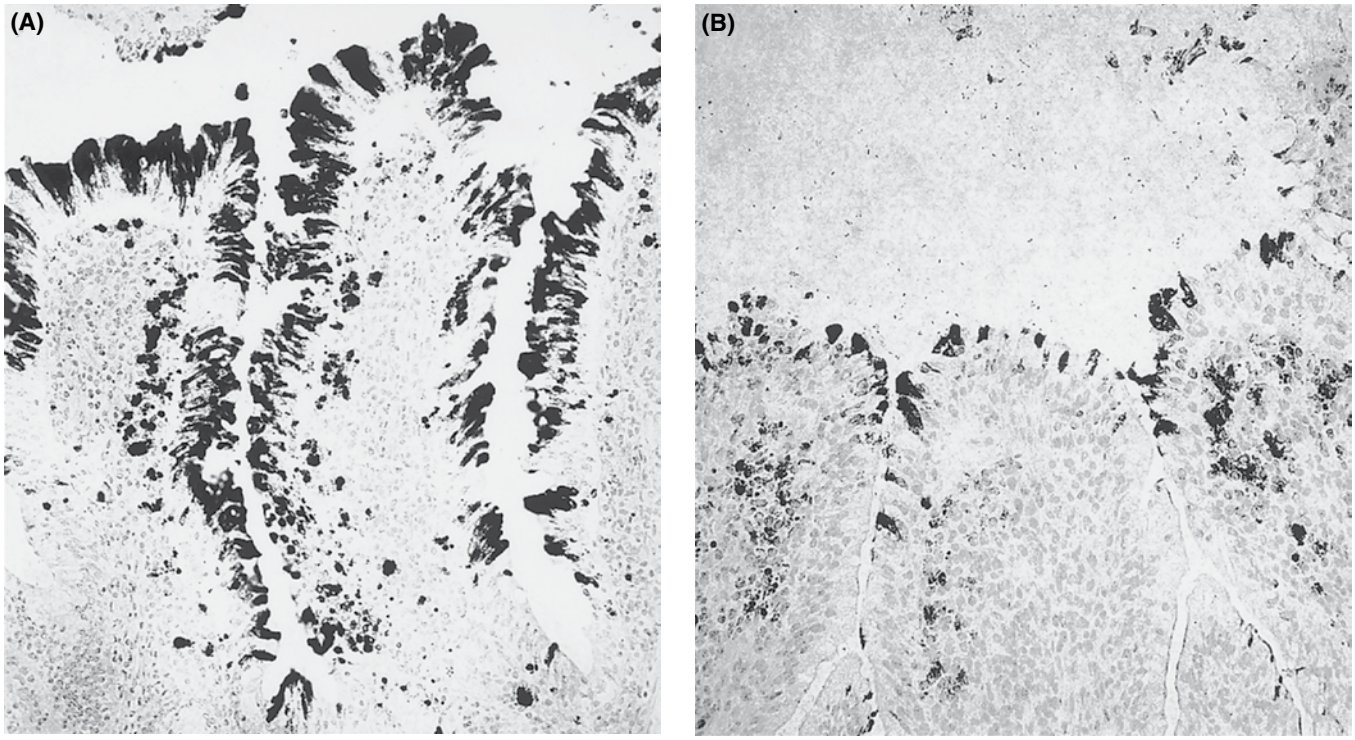

Figure 12.2. Immunoperoxidase staining of intestinal tissues from TCV-infected turkey. (A) Cecum, 1 day PI. (B) Ileum, 14 days PI. ×350.

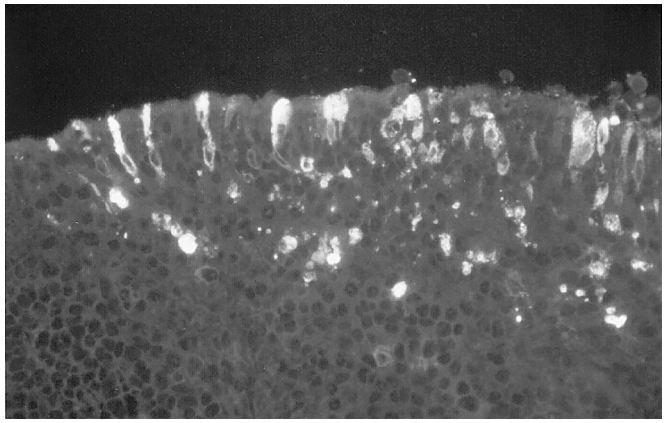

Figure 12.3. Immunofluorescent staining of cloacal bursa of TCV-infected turkey, 2 days PI. Note that staining is localized to bursal epithelium. ×240.

Strain Classification

Antigenic analyses based on cross-protection studies, cross-immunofluorescence, and enzyme-linked immunosorbent assays indicate close antigenic relationships between TCV isolates obtained from different geographical locations (29, 36, 39). Similarly, nucleotide sequence analyses of TCV proteins of different isolates have demonstrated that these viruses are genetically very similar (5, 6, 36, 38, 41, 47).

Antigenic differences between TCV strains recently were demonstrated based on serum-virus neutralization studies (38). Three TCV isolates were selected for antigenic analyses based on differences within their spike glycoprotein genes; cross-neutralization assays indicated that these isolates comprised distinctly different serotypes.

Studies have not been done to examine differences in virulence among different isolates of TCV.

Laboratory Host Systems

Turkey coronavirus strains can be propagated in embryonating chicken eggs (more than 16 days of incubation) and embryonating turkey eggs (more than 15 days of incubation) by inoculation of the amniotic cavity (1, 28). In inoculated embryos, virus is recovered only from intestines and cloacal bursa (52).

Attempts to propagate TCV in a variety of avian and mammalian cell cultures generally have been unsuccessful (20, 52). Cell culture propagation of TCV using a human rectal adenocarcinoma (HRT) cell line has been reported; however, this has not been corroborated by other investigators (17, 29, 35).

Pathobiology and Epizootiology

Incidence and Distribution

Turkey coronavirus has been identified in turkeys in the United States, Canada, Brazil, Italy, United Kingdom, France, Poland, and Australia (13, 14, 16, 47, 52, 75). The virus has been identified in most turkey-producing regions of the United States.

Natural and Experimental Hosts

Turkey coronavirus affects turkeys of all ages; however, clinical disease most commonly is observed in young turkeys during the first few weeks of life. Turkeys are believed to be the only natural host for TCV. Pheasants, sea gulls, coturnix quail, and hamsters are refractory to infection (33, 52). Chickens once were believed to be refractory to TCV infection (62, 71); however, recent studies indicate otherwise (30, 37). In 2 separate studies, SPF chickens did not exhibit clinically apparent disease after experimental inoculation with TCV; however, susceptibility to TCV infection was demonstrated by seroconversion and detection of virus and viral antigens in intestinal tissues and cloacal bursa (30), and by detection of virus is intestinal contents (37). Turkey coronavirus was not detected in other tissues (30).

Transmission, Carriers, Vectors

Turkey coronavirus is shed in feces of infected birds and spread horizontally through ingestion of feces and feces-contaminated materials. Turkey coronavirus generally spreads rapidly through a flock and from flock to flock on the same or neighboring farms. Mechanical movement of the virus may occur by people, equipment, vehicles, and insects. Darkling beetle larvae and domestic house flies have been shown to be potential mechanical vectors of TCV (9, 78). Wild birds, rodents, and dogs also may serve as mechanical vectors. There is no evidence that TCV is egg transmitted; however, poults may become infected in the hatchery via contaminated personnel and fomites such as egg boxes from infected farms.

Turkey coronavirus is shed in droppings of turkeys for several weeks after recovery from clinical disease (7). The virus was detected in intestinal contents of experimentally inoculated turkeys for up to 6 weeks post-inoculation (PI) by virus isolation, and up to 7 weeks PI by a reverse transcriptase-polymerase chain reaction (RT-PCR) procedure (7).

Incubation Period

The incubation period may vary from 1–5 days, but typically is 2–3 days.

Clinical Signs

In field cases, clinical signs occur suddenly, usually with high morbidity (52, 53). Birds exhibit depression, anorexia, decreased water consumption, watery diarrhea, dehydration, hypothermia, and weight loss. Droppings typically are green to brown, watery, and frothy, and may contain mucus and urates. Flocks infected with TCV experience increased mortality, growth depression, and poor feed conversion compared with uninfected flocks. Mortality is variable in affected flocks. High mortality may occur depending on the age of the birds, concurrent infection, and management practices.

Experimental studies using egg-adapted strains of TCV indicate that TCV infection results only in mild disease and moderate growth depression; mortality generally is negligible (31, 37, 53, 56).

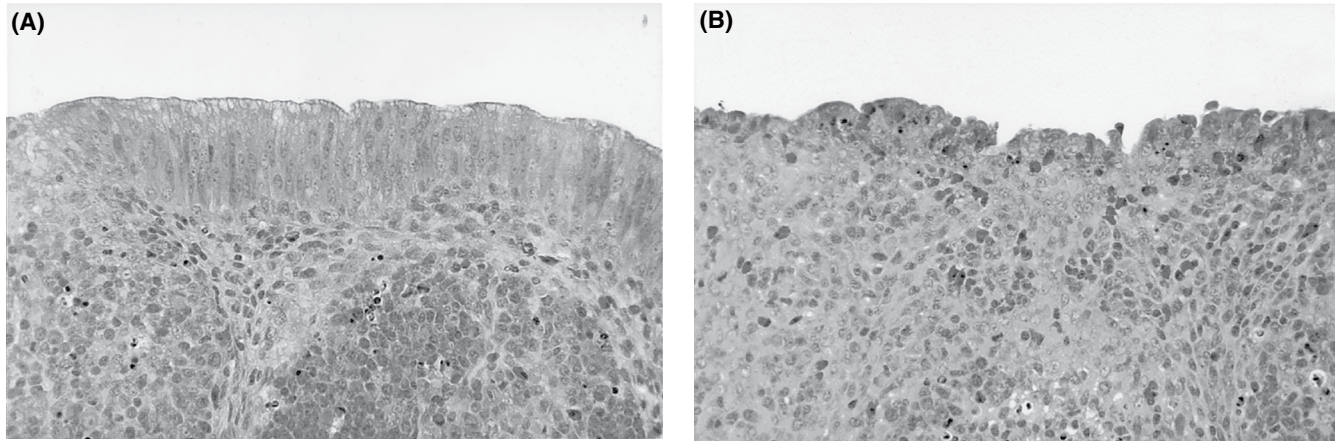

Figure 12.4. Histopathologic changes observed in cloacal bursa of TCV-infected turkey. (A) Sham-inoculated control. Note that epithelium consists of pseudostratified columnar epithelium. (B) TCV-infected turkey, 4 days PI. Note epithelial cell necrosis and hyperplasia with heterophilic inflammation. ×240.

Turkey coronavirus infection of turkey breeder hens during production results in a rapid drop in egg production (52). Egg quality also is affected. Hens produce eggs that lack normal pigmentation.

Pathology

Gross Pathology

Gross lesions are seen primarily in intestines and cloacal bursa. Duodenum and jejunum generally are pale and flaccid, and ceca are distended and filled with watery contents. Emaciation, dehydration, and atrophy of the cloacal bursa may be observed.

Microscopic Pathology

Microscopic lesions are observed in intestines and cloacal bursa of TCV-infected turkeys. In intestines, microscopic lesions in experimentally infected turkeys consist of decreased villous length, increased crypt depth, and decreased intestinal diameter (2, 25). The columnar epithelium of intestinal villi change to a cuboidal epithelium and these cells exhibit a loss of microvilli. There is a decrease in number of goblet cells, separation of enterocytes from lamina propria, and infiltration of lamina propria with heterophils and lymphocytes. Epithelial repair is evident beginning at 5 days PI and is complete by 21 days PI (2, 25). By 5 days PI, columnar epithelium with microvilli begins to replace cuboidal cells, and goblet cells begin to reappear (25).

In the cloacal bursa, changes in epithelial cells are evident by 2 days PI and consist of epithelial necrosis and hyperplasia (31). The normal pseudostratified columnar epithelium of the cloacal bursa is replaced by a stratified squamous epithelium (Figure 12.4). Intense heterophilic inflammation is observed within and subjacent to the epithelium. Moderate lymphoid atrophy of bursal follicles is observed.

Ultrastructural Pathology

Ultrastructural changes in intestines of TCV-infected turkeys are confined to epithelial cells (3, 64). Ultrastructural changes include loss of microvilli, disruption of the terminal web region, degeneration of mitochondria, dilation of cisternae in the endoplasmic reticulum, increases in intracellular lipid, excessive sloughing of cells at villous tips, and shortening of villi. Coronavirus particles (80–140 nm in diameter) are observed within cisternae of the endoplasmic reticulum (64).

Pathogenesis of the Infectious Process

Turkey coronavirus replicates preferentially in enterocytes lining the apical portions of intestinal villi and in epithelium of the cloacal bursa (20, 31, 64). The site of intestinal TCV infection suggests that the virus may cause diarrhea in a manner similar to other enteric coronaviruses (48, 67). Malabsorption, maldigestion, and diarrhea likely result from TCV-induced destruction of villous epithelium; however, the virus may exert its effects in a more subtle manner through alterations in the physiology of these cells (64). Turkey coronavirus also may exert its effects by altering the normal intestinal flora (54).

Severe disease characterized by high mortality was a common feature of early descriptions of TCV infection (bluecomb disease) and early experimental studies using inocula composed of crude fecal/intestinal homogenates (52). More recent experimental studies using embryo-propagated TCV indicate that mortality due to TCV infection usually is negligible, at least under laboratory conditions (31, 37, 53, 56). Management practices, crowding, and secondary infections may exacerbate the effects of TCV infection and result in increased losses. Antibiotics have been shown to reduce mortality in TCV-infected flocks, most likely because they control secondary bacterial infections (61, 70).

Experimental studies with TCV and an enteropathogenic strain of *Escherichia coli* provide evidence suggesting an

interaction between TCV and bacteria in the development of severe clinical disease (31, 56). In these experiments, young turkeys inoculated with only TCV developed moderate growth depression without significant mortality, and turkeys inoculated with only enteropathogenic *Escherichia coli* did not develop clinically apparent disease. However, turkeys dually inoculated with TCV and enteropathogenic *Escherichia coli* developed severe growth depression and high mortality.

Immunity

Active Immunity

Turkeys that recover from TCV infection are resistant to subsequent challenge (24, 52, 63). Turkeys that survived experimental TCV infection at 4 days of age showed no clinical signs when challenged at 11 and 22 weeks of age (63). Field observations indicate that flocks that recover from TCV infection are resistant to subsequent infection (62).

The nature of protective immunity in recovered birds is not fully understood. Specific secretory IgA and humoral and T cell-mediated immunity have been demonstrated in recovered turkeys (24, 43, 44, 49, 50, 51, 52). Specific secretory IgA was shown to persist in intestinal secretions and bile of recovered turkeys for at least 6 months (49). Concentrations of specific secretory IgA antibodies in feces of TCV-infected turkeys peaked at 3–4 weeks PI and disappeared at approximately 6 weeks PI (44).

Passive Immunity

Poults passively immunized against TCV by subcutaneous inoculation of serum from immune birds were not protected from challenge (63). Poults from immune and nonimmune breeder hens were equally susceptible to TCV challenge (76).

Diagnosis

Isolation and Identification of Causative Agent

Diagnosis of TCV infection generally requires laboratory assistance because other enteric pathogens of turkeys may cause similar clinical signs and lesions. Laboratory diagnosis may be achieved based on virus isolation, electron microscopy, serology, detection of viral antigens, or detection of viral RNA.

Virus isolation may be accomplished by inoculation of embryonating chicken or turkey eggs (see Laboratory Host Systems) with suspensions of intestinal contents, dropping samples, or tissues (intestines, cloacal bursa) from suspect infected turkeys (28). Clinical samples should be homogenized in an appropriate diluent, such as minimal essential medium, clarified by centrifugation, and filtered through a 0.45-μm filter. Embryonating chicken eggs (more than 16 days of incubation) or turkey eggs (more than 15 days of incubation) are inoculated by the amniotic route and returned to the incubator. Embryonating turkey eggs are the preferred substrate because the relative sensitivity of chicken embryos to TCV has not been determined. After incubation for 2–5 days, the presence of TCV in embryo intestines is determined by immunohistochemical detection of viral antigen or RT-PCR detection of viral RNA.

Diagnosis based on electron microscopy requires the identification of virus particles having typical coronavirus morphology. However, coronaviruses must be distinguished from cell membrane fragments in feces that may resemble coronaviruses. Definitive identification may be accomplished by immune electron microscopy (65).

Immunohistochemical diagnosis is based on detection of TCV antigens in tissues using either immunofluorescent antibody (FA) or immunoperoxidase (IP) procedures. Both direct and indirect FA procedures have been described for detection of TCV antigens using frozen tissue sections (7, 58, 59, 60, 64). The direct FA procedure is an excellent diagnostic approach with respect to simplicity and speed of diagnosis. However, sensitivity and specificity of this procedure depend upon the quality of the antiserum used to prepare the fluorochrome-conjugated antibody, and once this reagent is produced it has a relatively short shelf life. The direct FA procedure was shown to detect TCV antigens in experimentally infected turkeys from 1–28 days PI (60).

Indirect FA and indirect IP procedures have been described for detection of TCV antigens in tissues of infected turkeys (7); these procedures utilized TCV-specific monoclonal antibodies (MAb) and frozen tissue sections. These MAb-based immunohistochemical procedures detected TCV antigens in intestines and cloacal bursa of experimentally infected turkeys as early as 1 day PI and as late as 42 days PI. They were shown to have high specificity (greater than 92%), but low sensitivity (61%–69%) compared with virus isolation.

Recently, a direct IP procedure was described for detection of TCV antigens in formalin-fixed paraffin-embedded tissues (10). This procedure used a biotin-conjugated antibody prepared using antibodies from hyperimmunized chickens. The direct IP procedure was shown to be highly specific (93%) and highly sensitive (85%) compared with detection by indirect FA.

Reverse transcriptase polymerase chain reaction procedures (RT-PCR) have been developed for detection of TCV RNA in dropping samples and intestinal contents of infected turkeys (7, 77). These RT-PCR procedures have been shown to be highly sensitive and highly specific. In 1 study, RT-PCR was shown to detect TCV RNA in experimentally infected turkeys as early as 1 day PI and as late as 49 days PI; sensitivity and specificity of the RT-PCR procedure were 93% and 92%, respectively, compared with virus isolation (7). Multiplex RT-PCR procedures also have been developed that allow simultaneous detection of TCV and other enteric viruses (46, 68, 72).

A real-time RT-PCR procedure recently was described for detection and quantitation of TCV RNA in infected turkeys (15). Additionally, a reverse-transcriptase loop-mediated isothermal amplification procedure for detection of TCV RNA has been described (11). These detection procedures were demonstrated to be rapid, highly sensitive, and specific methods for TCV detection (11, 15).

Serology

Detection of TCV-specific antibodies most commonly is accomplished using the indirect FA procedure. Antigen for this procedure consists of either frozen sections of TCV-infected embryo intestines (58) or epithelium exfoliated from cloacal bursae of infected turkeys (26). Frozen tissue sections are prepared from intestinal tissues of TCV-infected turkey embryos 24–48 hours after inoculation with embryo-adapted TCV strains (58). Antigen preparation by this method is slow and labor intensive. However, an advantage of this serological method is that it allows discrimination of false positive staining based on determining the site of intestinal staining (i.e., TCV preferentially infects apical villous epithelium). Alternatively, antigen slides may be prepared using exfoliated epithelial cells collected from cloacal bursae of 2-week-old turkeys 4 days PI (26). Bursae are harvested from infected turkeys, rinsed in cell culture media, and incubated at 4°C for 18–24 hours with gentle stirring to exfoliate epithelial cells. Cells are concentrated by low-speed centrifugation and then spotted onto glass slides. TCV-specific antibodies may be detected in experimentally infected turkeys as early as 7 days PI using either of the indirect FA methods described above. In a study using indirect FA serology, turkeys infected early in the brooder house remained serologically positive throughout the grow-out period (34).

Enzyme-linked immunosorbent assays (ELISA) have been described for detection of TCV-specific antibodies in turkeys (23, 32, 42, 45). TCV-specific antibodies may be detected in turkey sera using commercially available, IBV-coated ELISA plates (42). In addition, ELISAs based on recombinant TCV nucleoproteins have been developed (32, 45). The IBV ELISA and the recombinant TCV nucleoprotein-based ELISAs were shown to be highly sensitive and highly specific compared with the indirect FA procedure (32, 42). The TCV nucleoprotein-based ELISAs failed to discriminate between IBV- and TCV-specific antibodies (32, 42, 45). However, this is unlikely to be an impediment to specific detection of TCV infection in turkeys because turkeys are not believed to be susceptible to IBV, and experimental attempts to infect turkeys with IBV have not been successful (27).

More recently, a TCV spike protein-specific ELISA was developed based on a recombinant TCV spike protein (23). This ELISA was highly sensitive and highly specific for TCV, and cross-reactivity with IBV-specific antibodies was not observed.

Differential Diagnosis

Enteric disease caused by TCV must be distinguished from other enteric diseases of turkeys, particularly those caused by other viruses, bacteria, and protozoa.

Intervention Strategies

Management Procedures

Prevention is the preferred method for controlling TCV. Turkeys infected with TCV have been shown to shed virus in feces for prolonged periods of time after recovery (7, 58); these turkeys, their feces, and the materials that their feces contact are potential sources of infection for other susceptible turkeys. Feces from TCV-infected turkeys can be carried on a variety of fomites including clothing, boots, equipment, feathers, and trucks. Other potential vectors such as wild birds, rodents, dogs, and flies also may be involved in transmission from infected to susceptible flocks.

Elimination of TCV from contaminated premises may be accomplished by depopulation followed by thorough cleaning and disinfection of houses and equipment (60). Following cleaning and disinfection procedures, premises should remain free of birds for a minimum of 3–4 weeks.

Vaccination

No licensed vaccine is available.

Treatment

At present, there is no specific treatment for TCV enteritis. Antibiotic treatment has been shown to reduce mortality, most likely by controlling secondary bacterial infections (52, 61, 70). No beneficial effect was observed when glucose, electrolytes, or calf milk replacer was added to drinking water (21). Management procedures that have been effective in reducing mortality include raising brooder house temperatures and avoiding crowded conditions.

Rotavirus Infections

J. Michael Day

Introduction

Rotaviruses are recognized as the chief etiologic agent of viral enteritis and diarrhea in humans (mainly young children and infants) and in the young of numerous other mammalian species (26, 29, 115). Rotaviruses also infect numerous species of birds, including many species of domesticated birds (32, 34, 35, 42, 86, 99, 101, 126, 131, 137, 142). Rotavirus infection in avian species is frequently associated with outbreaks of diarrhea and general flock depression, and is often found in association with a recognized enteric syndrome in poultry (9, 52, 54, 97, 98). The economic impact of rotavirus-associated enteric disease to the poultry industry is not clear, but nonspecific enteric disease with a probable

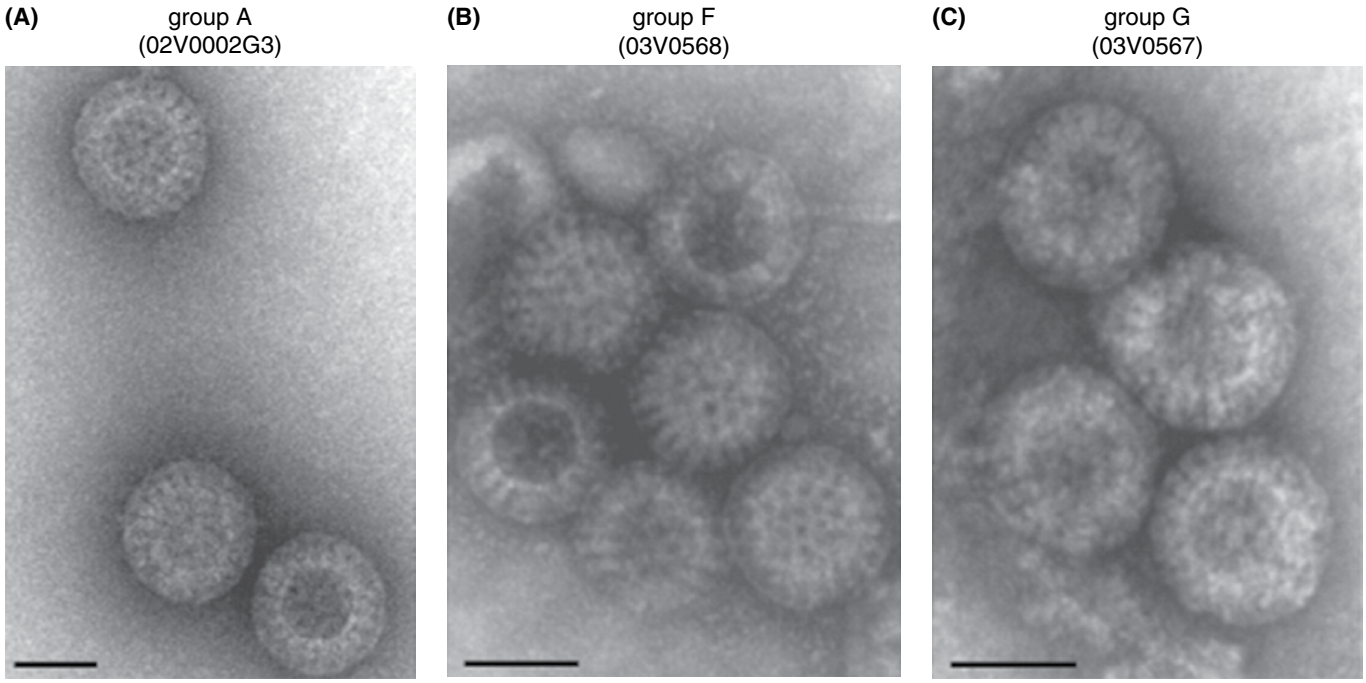

Figure 12.5. Identification of avian rotaviruses in intestinal samples by negative staining electron microscopy. (A) group A rotavirus 02V0002G3, (B) group F rotavirus 03V0568 and (C) group G rotavirus 03V0567. The bar corresponds to 100 nm. (*Virology* 412:384–391, 2011 ref. 55)

viral etiology is an ongoing industry burden (9, 54). There is evidence that certain avian rotaviruses are not strictly species specific, because rotaviruses from turkeys and pheasants can infect older SPF chickens (143). There is a report on the isolation of an avian-like group-A rotavirus from a calf with diarrhea in Germany, and a recent report out of southern Brazil of the isolation of rotavirus with a typical bovine genotype from diarrheic turkeys (3, 12); gene sequences and other data provide convincing evidence that the German virus originated from pigeons (112, 113, 114). An experimental infection of suckling mice with the pigeon rotavirus PO-13 caused microscopic intestinal lesions, whereas inoculation of a turkey rotavirus in the same suckling mouse model did not lead to virus replication and infection (92). Furthermore, a mammalian-like group-A rotavirus has been detected in chickens with diarrhea in India (141). Despite experimental and field evidence of interspecies transmission of rotaviruses between birds and mammals and vice versa, this is believed to be a rare event (68). Thus, avian rotaviruses do not appear to cause disease in humans and have no known public health significance.

In this section, the term rotavirus includes those viruses formerly described as atypical rotaviruses, pararotaviruses, antigenically distinct rotaviruses, and rotavirus-like viruses (RVLVs).

Etiology

Classification

The avian rotaviruses are members of the *Reoviridae* family, which is characterized by virions that contain 10–12 linear double-stranded RNA (dsRNA) segments. The *Reoviridae* consists of 15 genera which can be placed into 2 recognized subfamilies based upon the presence or absence of structural "turrets" located at the outer capsid vertices; the genus *Rotavirus* is in the non-turreted subfamily, the *Sedoreovirinae*, while the turreted genera comprise the subfamily *Spinareovirinae* (14, 62). The members of the *Reoviridae* family infect vertebrates, invertebrates, plants, and fungi; however, the members of the genus *Rotavirus* can infect only vertebrates and are transmitted via the fecal-oral route. The rotavirus genome consists of 11 segments of dsRNA with conserved 5' and 3' ends, and each genome segment codes for a single protein with the exception of segment 11, which codes for 2 (20, 50). The genome is enclosed by a triple-layered capsid with a characteristic wheel-like appearance (*rota* = wheel) when viewed via electron microscopy (Figure 12.5). The replication of rotaviruses involves the production of transiently enveloped particles in the endoplasmic reticulum, and the coinfection of cells with 2 different rotavirus strains can result in genetic reassortants containing a mixture of genome segments from each parent virus (20, 62).

Morphology

Mature rotavirus virions are nonenveloped, triple-layered icosahedrons and have an overall diameter of approximately 1,000Å (100 nm), including the VP4 cell attachment protein spikes (50, 105, 107). The diameter of the outer shell of the rotavirus virion, the so-called triple-layered particle (TLP), excluding the protruding spikes is approximately 750Å (62, 106, 108, 148). It is the smooth appearance of the outer protein shell that distinguishes the rotaviruses from other members of

the *Reoviridae* when viewed via electron microscopy (Figure 12.5). The subviral double-layered particle (DLP) has a maximum diameter of approximately 710Å and is the transcriptionally active form of the virus in the infected cell (20, 23, 148). The viral core, which encloses the dsRNA genome, is approximately 500Å in diameter (62, 148). Turkey rotavirus TLPs were found to have a buoyant density in CsCl of 1.34 g/cm^3 while DLPs had a density of 1.36 g/cm^3; subviral cores had a density greater than 1.40 g/cm^3 (58). Group D rotaviruses isolated from the intestinal contents of pheasant chicks had TLPs and DLPs with densities in CsCl of 1.35 and 1.37 g/cm^3, respectively. The pheasant Group D TLPs and DLPs had diameters of 800Å and 700Å, respectively, which is larger than the reported diameter of group A TLP and DLPs from turkeys, at 730Å and 600Å, respectively (21).

Each of the 2 outer layers of the rotavirus virion is distinguished by a T = 13 icosahedral lattice symmetry. A distinguishing morphological feature of the mature rotavirus virion is the presence of 60 protein spikes that extend approximately 100Å from the outer capsid shell (50, 108, 148). The rotavirus capsid core is formed from a T = 1 icosahedral shell approximately 30Å thick; this T = 1 architecture of the innermost shell has only been observed in the dsRNA viruses (50, 64).

Chemical Composition

The rotavirus dsRNA genome is contained within the capsid core and consists of 11 linear segments; avian rotaviruses have genome segments ranging from approximately 3.3 kb–700 bp, with a total genome size of approximately 19 kb (48, 134, 135).

Turkey rotavirus propagated in rhesus monkey kidney cells (MA104 cell line) expressed 10 major polypeptides starting at 6 hours PI. Of these 10 polypeptides, 3 structural proteins (designated VP1, VP2, and VP6) appeared to be associated with both viral DLP and TLPs, while 4 additional structural proteins (designated VP3, VP4, VP5s, and VP7) were only found in intact TLPs. The 37kD VP7 structural protein was also found to be glycosylated, as were 2 additional nonstructural proteins (57).

Rotavirus 993/83, a group A rotavirus which closely resembles avian rotaviruses despite its bovine origin, contained the polypeptides VP1, VP2, VP3, VP5* (a proteolytic cleavage product of VP4), VP6, and VP7 in purified, MA104-propagated TLPs. The migration pattern of these viral proteins via sodium dodecyl sulfate polyacrylamide gel electrophoresis (SDS-PAGE) was similar to the patterns obtained with the PO-13 rotavirus. The VP5* and VP7 bands of 993/83 were lost after ethylenediaminetetraacetic acid (EDTA) treatment, indicating they were associated with the outer layer of the TLPs, as is the case with other mammalian rotaviruses (12, 13, 50).

Virus Replication

Rotavirus-infected cells display characteristic electron-dense cytoplasmic inclusion bodies called viroplasms. These viroplasms are essentially viral factories in which genome replication and initial packaging of the viral genome segments occur, and their formation appears to be directed by the affinity of certain rotavirus structural proteins for newly translated positive-sense RNA [(+)RNA] (103). The self-assembly of virion structural proteins that takes place in the viroplasms ensures the association of the newly translated (+)RNA genome segment precursors with the viral core structure. The replication of the full dsRNA genome takes place fully within the newly formed viral cores, which are comprised of 120 copies of the structural protein VP2 as well as smaller amounts of VP1 (the viral RNA-dependent RNA-polymerase, or RdRp) and VP3 (the viral methyltransferase and guanylyltransferase). The dsRNA genome segments are thus never exposed to the interior of the cell (50, 103). The association of the rotavirus RdRp, or transcriptase complex, with the intact viral core also allows the transcription of each genome segment to occur without complete uncoating of the dsRNA genome. Rotavirus DLPs emerge from the viroplasm after acquiring the structural protein VP6, and appear to bud into the endoplasmic reticulum (ER) through VP7-rich membrane patches; the maturing virion is transiently membrane-bound within the lumen of the ER, and matures to nonenveloped TLPs with the addition of the outer capsid proteins VP7 and VP4. However, this final maturation process is poorly understood (104).

Evidence from studies with avian-origin rotaviruses suggests rotavirus replication and morphogenesis proceeds largely as has been observed in mammals. A group D rotavirus produced electron-dense viroplasms and mature viral particles in pheasant chick duodenal enterocytes by 7 days post infection (DPI), while viroplasm and mature viral particles in rough ER were observed by 8 DPI in chicken villous epithelial cells infected with an antigenically novel rotavirus (41, 78). Similarly, PO-13 rotavirus produced DLPs and TLPs in the rough ER of mammalian cells (MA-104 cell culture) (86).

Susceptibility to Chemical and Physical Agents

Some studies have looked specifically at the stability or inactivation of avian rotaviruses. Two different turkey rotavirus isolates (AvRV-1 and AvRV-3) propagated in MA-104 cells had no change in viral titers after a 30-minute treatment with chloroform; treatment at pH 3.0 reduced the titer of both isolates approximately 100-fold by 8 hours of treatment, but showed no effect on titers with a 2-hour treatment at pH 3.0. Titers were reduced by about 100-fold after treatment at 56°C for 30 minutes, but neither virus was completely inactivated with an extended (8 hour) incubation at 56°C (58). A turkey rotavirus strain, Ro/1145/08, was completely inactivated after incubation at 82.2°C for 140 seconds in Dulbecco's modified Eagle medium (DMEM), but was initially resistant to heating in an anisothermic heating gradient (thermal cycler) from 25°C–50°C. Viral titers for Ro/1145/08 quickly fell as the temperature increased from 50°C–82.2°C. Turkey rotavirus strain Ro/996/07 was similarly inactivated after a 6-hour, 82.2°C incubation in an effluent decontamination system (EDS) tank designed to treat effluent from a BSL-2 and BSL-3 (enhanced)

laboratory facility (16). Duck rotavirus strain F-29 also was resistant to chloroform treatment and treatment at pH 3.0 had no effect on viral titers. Heating to 50°C reduced the titer of F-29 10 times and heating to 50°C in the presence of 1 M $MgCl_2$ further reduced titers 1,000 times (124). The infectivity in cell culture of pigeon rotavirus (PO-13) was resistant to 20% ether, 10% chloroform, and 0.1% sodium deoxycholate (DOC) (86).

Strain Classification

Antigenicity

In general, the antigenicity of the rotaviruses is determined by 3 major structural proteins that comprise the middle (intermediate) and outer layers of the viral capsid: VP4, VP6, and VP7, with multiple serotypes recognized within each serogroup. Seven recognized serogroups comprise the rotaviruses (groups A–G), with groups A–E each formally recognized as species within the genus *Rotavirus*. Groups F and G do not have formal species recognition, nor does an additional group, novel adult diarrhea rotavirus (NADRV or ADRV-N), which has been tentatively placed in a new group, H (4, 26, 49, 72).

Most mammalian rotaviruses share a group (serogroup) antigen, and have historically been termed group A rotaviruses, with members of the other groups termed atypical rotaviruses. Groups B, C, and E have only been described in mammals; group A has been described in both mammals and birds; and groups D, F, and G have only been described in birds (4). Some avian group A rotaviruses are antigenically related to the mammalian group A rotaviruses. However, there is evidence that some epitopes located on avian rotavirus group A VP6 are antigenically distinct from the group A antigen common to all group A mammalian rotaviruses. Monoclonal antibodies specific for the VP6 of the avian group A rotaviruses sometime cross react with their mammalian counterparts, but other avian rotavirus-specific monoclonal antibodies do not recognize the mammalian group A rotaviruses (61, 87). Furthermore, some mammalian rotavirus-specific monoclonal antibodies do not cross react with the avian group A rotaviruses (30, 37, 45).

Mapping of antigenic sites on VP6 has shown that the antigen common to mammalian and avian group A rotaviruses is located at amino acids 134–142 in the pigeon rotavirus PO-13. Furthermore, the amino acids 45–65 in VP6 represent an additional antigenic site common to numerous mammalian and avian rotaviruses, with the exception of Ch-1, a chicken isolate (46, 47). Rotavirus subgroup specificities also reside on the VP6 structural protein. Subgrouping has allowed a classification system for rotaviruses that share the common group A antigen, and places all rotaviruses into subgroups I or II, both I and II, or neither I nor II (4, 44).

Prototypical members of the groups D, F, and G rotaviruses have been described in chickens, and include the fully-sequenced rotavirus strain 05V0049 ("Ch-49", group D), rotavirus A4 (group F), and rotavirus 555 (group G) (4, 115, 135). Some rotaviruses detected and described in turkeys are antigenically related to another group D chicken rotavirus (strain 132) and the group D rotaviruses appear to be the most common rotaviruses in turkey poults with diarrhea (109, 111, 116, 128, 129). There is molecular- and cell culture-based evidence, however, that group A rotaviruses circulate in turkeys in Germany and the United States (119, 122).

VP4 and VP7 are both part of the rotavirus outer capsid layer and are therefore significant neutralizing antigens, which led to a dual classification system based upon the antigenic properties of each protein (4, 20). Serotypes based upon the VP4 protein are P serotypes (derived from VP4's protease sensitivity) and serotypes based upon the VP7 protein are G serotypes (VP7 is a glycoprotein). At least 15 G serotypes and 14 P serotypes have been identified based upon virus neutralization assays with hyperimmune sera and monoclonal antibody reactivities, but numerous additional P genotypes exist (at least 35 P genotypes total) based upon sequence data (4, 26, 70). Some data exist regarding avian rotavirus G serotypes in turkeys and chickens (79). Serotype G7 contains group A rotaviruses of chicken, turkey, pigeon, and bovine origin, although the bovine isolate (Bo/993/83) closely resembles avian group A rotaviruses (12, 13, 26, 45, 114). Sequence data for avian VP7 also suggests that novel G serotypes circulate in poultry (63, 70, 112). There is no data regarding avian rotavirus P serotypes, but sequence data for avian VP4 and VP8* (VP8* contains the antigenic sites that define the P serotypes) has revealed several P genotypes in poultry (114, 119, 134).

Genetic

Analysis of the rotavirus segmented dsRNA genome via polyacrylamide gel electrophoresis (PAGE, electropherogrouping) remains a robust method to distinguish rotaviruses in the laboratory (26, 97, 119, 133) and can be used tentatively to place newly characterized rotaviruses into their respective antigenic groups (Figure 12.6) (55, 132). Five electropherogroups have been established in turkeys and chickens (132), with group D chicken rotaviruses having dsRNA migration patterns similar to turkey and pheasant group D rotaviruses (21, 78, 82, 128, 132). As an extension of the genotype-based classification system of the rotaviruses based on VP7 and VP4, a uniform classification system for the group A rotaviruses based upon the nucleotide sequences of all 11 genome segments has been proposed by the Rotavirus Classification Working Group (RCWG) (69, 70, 71). Using this approach, an individual group A rotavirus strain is classified with the notation Gx-P[x]-Ix-Rx-Cx-Mx-Ax-Nx-Tx-Ex-Hx referring to the rotavirus genes VP7-VP4-VP6-VP1-VP2-VP3-NSP1-NSP2-NSP3-NSP4-NSP5/6, respectively, with each genome segment receiving a numbered genotype. Using this approach, the fully sequenced chicken group A rotavirus Ch-2G3 possesses the genotype constellation G19-P[30]-I11-R6-C6-M7-A16-N6-T8-E10-H8; the pigeon rotavirus PO-13 has been similarly classified at the full genome level, and avian rotaviruses from chickens, turkeys, and pheasants have been classified based

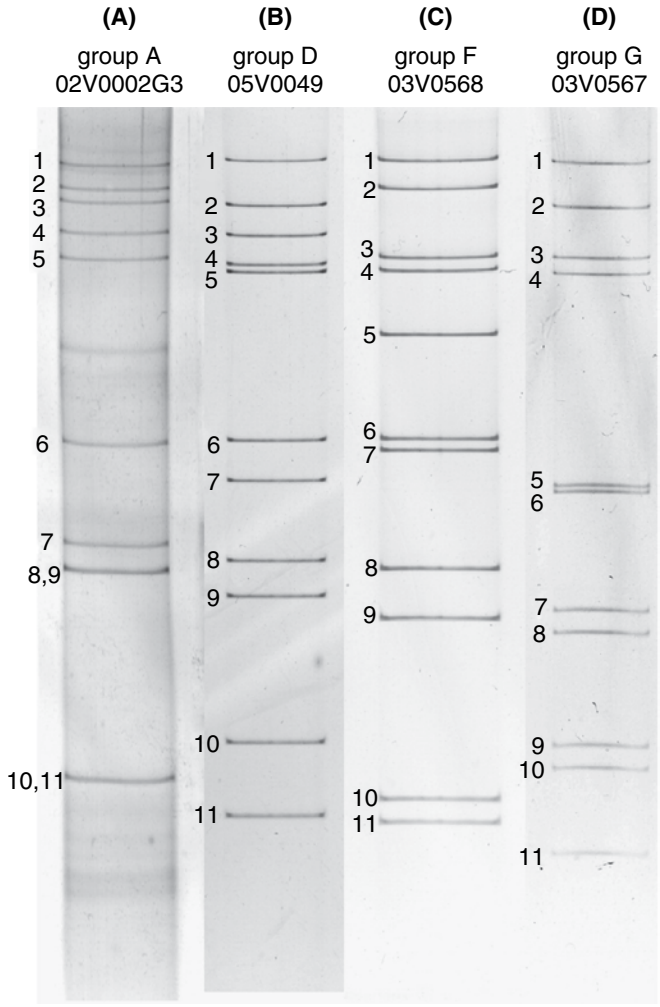

Figure 12.6. Analysis of the banding patterns of avian rotavirus dsRNA genomes after polyacrylamide gel electrophoresis followed by silver staining. RNA segments are numbered according to their mobility. (A) group A rotavirus 02V0002G3, (B) group D rotavirus 05V0049, (C) group F rotavirus 03V0568 and (D) group G rotavirus 03V0567. (*Virology* 412:384–391, 2011 ref. 55)

upon the genotype of at least 1 genome segment (70, 134, 136). This sort of uniform classification system will help to determine possible interspecies transmission and reassortment among the group A rotaviruses, including the avian rotaviruses (119). To facilitate the implementation of this classification system, a Web-based sequence analysis tool has been developed (http://rotac.regatools.be/) (67). In addition to the classification system for the group A rotaviruses, and building upon classification based upon serological approaches, a VP6-based sequence approach has been used to demarcate rotavirus species based upon phylogenetic analysis of novel avian rotavirus sequences (55, 72).

Laboratory Host Systems

Avian rotaviruses can be isolated directly from the feces or intestinal contents of turkeys, chickens, pheasants, ducks, and pigeons using primary cell culture (chick embryo liver cells and chick kidney cells) (34, 77, 78, 79, 124, 144). Avian rotaviruses from chickens, turkeys (including a rotavirus of apparent bovine origin), pheasants (group A), and pigeons also have been isolated using the fetal rhesus monkey kidney continuous cell line MA104 (3, 59, 65, 86, 95, 122, 129). Group D pheasant rotavirus could not be propagated in MA104 cells, even after multiple blind passages (21). Pigeon rotavirus also has been propagated successfully in Mardin-Darby bovine kidney cells (86). Group A avian rotaviruses also have been cultivated in normal chicken spleen cells as well as virus-transformed avian lymphoblastoid cell lines (both B and T cell lines) (118). The proteolytic cleavage of rotavirus VP4 into VP8* and VP5* by trypsin primes the virion for efficient infectivity (22, 23), thus the addition of trypsin to virus inocula and cell culture media generally facilitates isolation and propagation of avian rotaviruses in cell culture (73, 86). Interestingly, the majority of avian rotaviruses that have been successfully isolated and/or propagated in cell culture have been group A avian rotaviruses, with the exception of strain 132 (group D chicken, isolated in chick embryo liver cells) and duck rotavirus F29 (also isolated in chick embryo liver cells), both of which lacked a common rotavirus group antigen at the time of isolation (78, 124).

Certain rotaviruses have been isolated and propagated in embryonating chicken eggs. A rotavirus from a lovebird (*Agapornis* species) propagated in chick embryos via the yolk sac resulted in death 4–6 days after inoculation. Group A turkey rotaviruses inoculated into the yolk sac of embryonating chicken eggs also resulted in embryo death (15, 32).

Many avian rotavirus strains can be propagated successfully in their natural hosts (21, 41, 74, 143, 145, 146, 147), and in avian species other than their natural hosts (143, 144, 145, 147). Rotavirus P0-13 has been transmitted to suckling mice, and appeared to grow sporadically in the duodenum and ileum (92).

Pathogenicity

Although rotaviruses cause enteric disease in mammals and birds, rotaviruses are often detected in otherwise healthy flocks, particularly when sensitive molecular diagnostic assays are used (99, 101). In fact, a survey of turkey flocks (both healthy and affected by enteric disease) revealed that group A rotaviruses were found slightly more often in healthy flocks than in diseased flocks, while rotavirus-like viruses (RVLVs) were found more often in diseased flocks (110).

A retrospective look at cases involving poult enteritis in California from 1993–2003 revealed that RVLVs—along with "small round viruses"—were the most common viruses detected via electron microscopy during that time (142). In a similar retrospective study in Minnesota, turkey flocks diagnosed with poult enteritis syndrome (PES) were determined via electron microscopy to be infected with rotavirus 48% of the time ("small round viruses" were detected in 17% of these flocks) (54). Another molecular diagnostic study of PES in Minnesota turkeys revealed that 93% of PES cases studied (n=43) were positive for rotavirus via RT-PCR; electron

microscopy detected rotavirus particles in 25 of the 43 PES cases (52). A study of healthy turkey breeder flocks revealed 30.6% of samples (n=193) were positive for rotavirus via RT-PCR (51). Mammalian rotaviruses are known to have varying degrees of virulence (26), but the evidence for any variance in virulence among the avian rotaviruses is limited to indirect evidence.

Pathobiology and Epidemiology

Incidence and Distribution

Avian rotaviruses have been detected in and isolated from numerous avian species and likely have a worldwide distribution. Surveys employing molecular diagnostic assays and more traditional methods such as electron microscopy have detected rotaviruses in turkeys in the United States (51, 52, 54, 99, 101, 110, 116, 142), and rotaviruses have been directly isolated from poults in the United States (15, 122, 144). Rotaviruses have been detected in or isolated from chickens in the United States (99, 144), Argentina (10), Belgium (84), Brazil (2), China (140), Cuba (28), Germany (25, 98), India (85), the United Kingdom (76, 78, 79), and the former Soviet Union (5). Rotavirus has been detected in guinea fowl in Italy via electron microscopy and in the United States via RT-PCR (102, 131). Rotavirus has been detected in or isolated from pheasants in Italy (27, 65), the United Kingdom (31, 35, 36), Hungary (136), and the United States (111, 144).

Other reports of rotavirus in avian species include clinically normal ducks in Japan (124) and the United Kingdom (138), apparently normal feral pigeons in Japan (86) and diseased racing pigeons in the U.K. (34), and diseased partridges in the United Kingdom (31) and diseased partridges and Japanese quail in Italy (102). Rotaviruses have been detected in and isolated from wild birds including a velvet scoter (*Melanitta fusca*) in Japan (126), a lovebird (*Agapornis* species) in the United Kingdom (32), ratites in South Africa (ostrich) and the United States (emu chick) (24, 42), and healthy wild pheasant (*Phasianus colchicus*) and reed bunting (*Emberiza schoeniclus*) in Hungary (137). Antibody to rotavirus has been detected in chickens in Japan (117, 125), ducks in the United Kingdom (77), and pigeons in Belgium (139).

Natural and Experimental Hosts

Naturally occurring rotavirus infection in poultry (turkeys, chickens, pheasants, partridges, and ducks) and the associated enteric disease signs generally occur in birds that are young, less than about 6 weeks old (8, 9, 31, 99, 101, 111). This is in contrast to experimental infection of chicken and turkeys with rotavirus, where there is evidence that older birds (56–119 days for chickens, 112 days for turkeys) are more susceptible than younger birds (143, 147), and an outbreak of rotavirus-associated diarrhea has been reported in commercial laying hens between 32 and 92 weeks of age (56). A rotavirus of apparent bovine origin was isolated from 90- to 150-day-old turkeys presenting with diarrhea and low overall performance (3). There is evidence, however, that turkeys and chickens in the field are often exposed to and become infected with rotavirus at a young age (54, 99, 101). Natural infections with avian rotaviruses are often accompanied by simultaneous or sequential infections with other rotavirus electropherogroups and with other avian enteric viruses such as astrovirus and reovirus (83, 98, 99, 101, 110, 130, 132). The pigeon rotavirus PO-13 and avian rotavirus reassortants have been propagated using a suckling mouse model, although the infection of intestinal tissue was sporadic (89, 91, 92).

Transmission, Carriers, and Vectors

Rotaviruses are excreted in avian feces in very large numbers (147) and can be readily detected in cloacal swabs using molecular diagnostics (122). No information is available concerning survival of avian rotaviruses in feces, but by extrapolation from mammalian rotaviruses, environmental contamination is likely to be persistent. Horizontal transmission occurs readily between birds in direct and indirect contact, and rotavirus was the only enteric virus detected via RT-PCR in poults prior to placement on farms during a longitudinal field survey (101). Egg transmission of rotaviruses has not been demonstrated, but rotavirus detection in 3-day-old turkey poults prompted speculation that transmission occurs either in or on the egg (130). Furthermore, rotavirus has been detected in otherwise healthy breeder turkeys up to 9 weeks of age (51). Evidence demonstrates that larvae of the darkling beetle can act as a mechanical vector for turkey rotaviruses (19). No evidence exists for a carrier state in birds.

Incubation Period, Clinical Signs, Morbidity and Mortality

In experimentally infected 3-day-old turkeys, watery-to-soft droppings with orange-tinged mucus were passed 2–5 DPI. Rotavirus infection caused significant impairment of D-xylose absorption from the intestinal tract at 2 and 4 DPI. Inoculated turkeys were depressed with loss of appetite between 1 and 5 DPI. Pasting of the vents of experimentally infected poults also has been described. When inoculated orally into 3-day-old poults alone or in combination with turkey astrovirus and/or turkey reovirus, rotavirus could be detected via RT-PCR in cloacal swabs from 100% of poults by 2 DPI (40, 122, 145, 146). Similar clinical findings were reported in poults inoculated with crude intestinal homogenates that contained rotavirus, among other agents (53). In the majority of studies, no mortality occurred in experimentally infected turkeys or chickens, but in 1 series of experiments, 3 of 23 poults inoculated at 2 days of age died; in another experiment 1 of 12 poults inoculated with rotavirus at 3 days of age died at 4 DPI (121, 122). Mild (74) or no clinical signs (84, 143) were observed following experimental infection of

chickens. When signs occurred, their onset coincided with peak virus excretion about 3 DPI. Chicks had mild diarrhea (78) or passed increased quantities of cecal droppings (74). In a separate experiment, laying hens experimentally infected with rotavirus showed a drop in egg production 4–9 DPI (146). Rotavirus was detected in feces of experimentally infected chickens and turkeys from 24 hours PI, and in some birds, excretion continued for more than 16 days (53, 74, 122, 143, 145, 146).

Under field conditions, clinical signs associated with rotavirus infection in broilers have varied from subclinical infections to outbreaks of diarrhea severe enough to warrant attention to the wet litter, with associated dehydration, poor weight gains, and increased mortality (2, 10, 77, 79). In poults, variations in severity of clinical signs also have been observed, including very mild diarrhea in the first week of life, which caused mortality only if vent pecking occurred (43); a more severe disease in 12– to 21-day-old poults characterized by restlessness, litter eating, and watery droppings with mortality between 4 and 7% (11); and diarrhea in 2– to 5-week-old poults (76), with affected birds huddling together resulting in mortality from suffocation, and stunting of survivors. In other outbreaks, predominant signs have been diarrhea and wet litter.

Diarrhea and increased mortality also has been reported in 2– to 3-week-old pheasant chicks in the United States (111). In the United Kingdom, rotavirus infection was associated with stunting and increased mortality in pheasant chicks in the first week of life (35, 36). Six of twenty 2-day-old pheasants inoculated with intestinal contents containing rotaviruses from naturally occurring cases died 5–6 DPI (36); a high mortality rate was also observed in pheasant chicks inoculated with a group D rotavirus (41). In Italy, infected pheasants between 6 and 40 days of age showed depression, drooping wings, yellowish watery diarrhea, and dehydration; mortality was 20%–30% (27). Diarrhea, lethargy, and loss of appetite were associated with rotavirus infection in 3– to 4-month-old racing pigeons in the United Kingdom (34).

Variation in severity of clinical signs associated with rotavirus infections could be due to differences in virulence of avian rotavirus strains, as has been shown for mammalian rotaviruses (26), and/or interaction of rotavirus with additional factors such as other infectious agents (17, 99, 101, 122) or environmental stress. There is evidence that some avian rotaviruses may be transmitted from other agricultural animals (3), and that interspecies transmission of avian rotaviruses is possible (88, 92, 119, 141).

Pathology

Gross Pathology

The most common finding at necropsy is the presence of abnormal amounts of fluid and gas in the intestinal tract and ceca. Pallor of the intestinal tract accompanied by loss of tonicity may be evident. Secondary findings may include dehydration, stunting of growth, pasted vents, inflamed vents, anemia due to vent pecking, litter in the ventriculus (gizzard), and inflammation and encrustation with droppings of plantar surfaces of the feet (11, 40, 41, 43, 74, 79, 121, 122, 147). Hemorrhages were observed in the cecal walls of some experimentally infected pheasant chicks (36), and discrete, multifocal, superficial brownish-red erosions were found in the duodenum and jejunum of turkeys experimentally infected at 84 and 112 days of age (147).

Microscopic Pathology

Immunofluorescence (IF) studies using chickens and turkeys experimentally infected with rotavirus have demonstrated the principal site of virus replication to be the cytoplasm of mature villous absorptive epithelial cells in the small intestine. Infected cells were most numerous in the distal third of villi. Small numbers of infected cells were also detected in colon epithelium, ceca, cecal tonsils, and lamina propria of some villi. No IF-positive cells were observed in proventriculus, gizzard, spleen, liver, or kidney (74, 84, 143, 145, 147). Within the small intestine, different rotavirus strains may show preference for specific areas. One group A rotavirus grew best in the duodenum of experimentally infected chickens, and a group D rotavirus favored the jejunum and ileum (74). In general, experimental infections using chickens and turkeys of differing ages showed that increasing amounts of viral antigen were detected in birds of increasing age (146, 147).

Microscopic lesions in the small intestines of turkeys experimentally infected with group A rotaviruses consisted of basal vacuolation of enterocytes, separation of enterocytes from the lamina propria with subsequent desquamation, villous atrophy accompanied by widening of the lamina propria, scalloping of the villus surface, fusion of villi, and leukocytic infiltration of the lamina propria (121, 147). In general, mean villous lengths were decreased and crypt depths were increased following experimental infection, resulting in decreased villus-to-crypt ratios; morphometric changes were more pronounced in the duodenum and jejunum than in the ileum (40, 121, 147). There was infiltration of polymorphonuclear and mononuclear cells into the lamina propria of the cecum and colon in some birds. Scanning electron microscopy demonstrated roughened villus surfaces, irregularly shaped and sized villi, and loss of microvilli in enterocytes located at the tips of villi (40, 147). A group A rotavirus was detected via immunohistochemistry (IHC) in the distal portion of the villi in the jejunum of experimentally infected poults, and separation of enterocytes from the lamina propria was evident at 4 DPI (122) (Figures 12.7 and 12.8). In experimentally infected chickens, only minimal leukocytic infiltration of the lamina propria, with minimal loss of microvilli on cells at villus tips, was found in 1 study (147). Moderate villus atrophy, mainly in the ileum, also has been described by other workers in experimentally infected chickens (84).

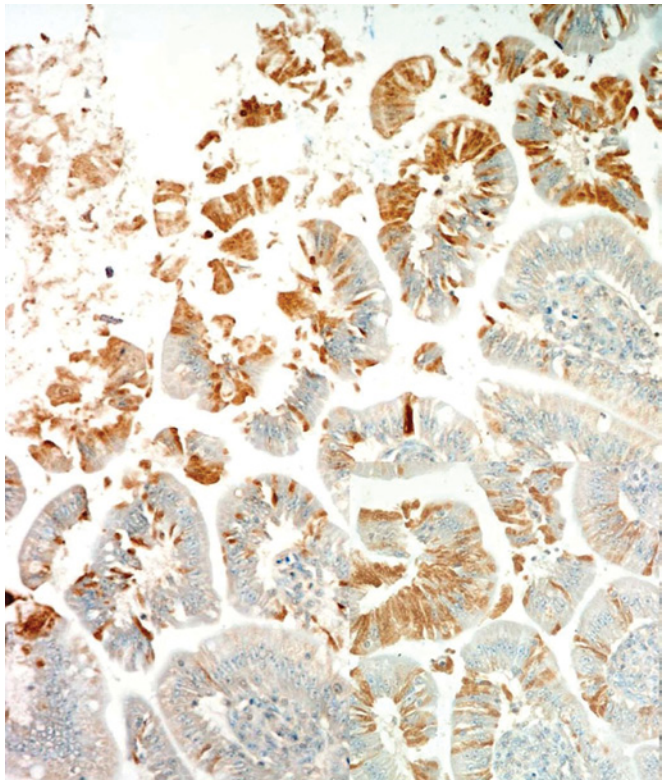

Figure 12.7. Photomicrograph of a section of the jejunum from a poult infected with rotavirus, 4 days PI. 1). Viral antigen staining present in the cytoplasm of the enterocytes at the distal section of the affected villi (brown staining). Primary antibody (hyperimmune serum) prepared from chickens inoculated with oil-emulsion rotavirus vaccine. Immunoperoxidase staining with haematoxylin counterstain, 400× magnification. (*Avian Dis*. 54:16–21, 2010 ref. 122)

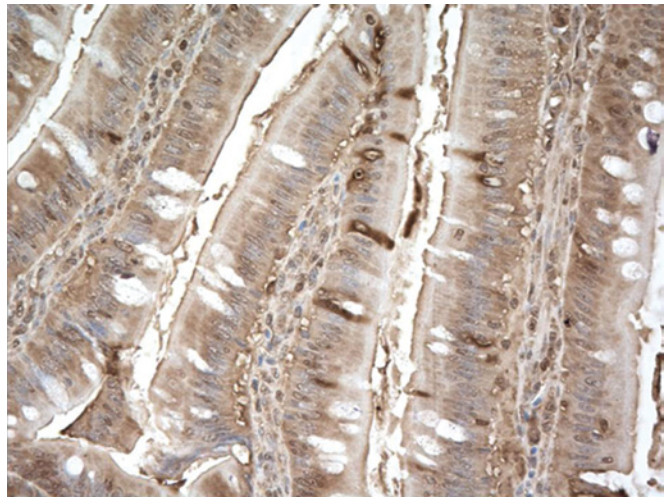

Figure 12.8. Photomicrograph of section of the jejunum from a poult infected with rotavirus, 6 days PI. Viral antigen staining present in the cytoplasm of the enterocytes (brown staining). Primary antibody (hyperimmune serum) prepared from chickens inoculated with VP6 rotavirus vaccine. Immunoperoxidase staining with haematoxylin counterstain. (M. Pantin-Jackwood)

Similar lesions to those found in turkeys were reported in pheasant chicks experimentally infected with a group D rotavirus. However, when microscopic lesions were most severe, at 7 DPI, viral antigen was detected along the entire length of villi and occasionally in the crypts. Lesions were most severe in the duodenum and jejunum (41).

The observed effects of avian rotavirus infections can be quite variable, and histopathological lesions may even be absent in poults with naturally acquired rotavirus infection (43). Degeneration and inflammation of villi of the duodenum (Figure 12.9) and jejunum also have been reported in poults with rotaviral enteritis (11). In broilers with naturally occurring rotaviral infections associated with runting-stunting syndrome (RSS), severe villous atrophy was noted in the jejunum, particularly in chicks with a group D rotavirus infection (98). No gross or microscopic lesions are pathognomonic for rotavirus infection, which underscores the general observation that rotaviruses can vary greatly in their ability to cause enteric disease signs and lesions, and are often detected via molecular methods during surveys of healthy poults and broilers (51, 100, 101). Furthermore, concomitant infection with other common enteric viruses in addition to rotavirus may exacerbate disease signs and lesions; these mixed infections are often not fully considered or investigated in reports of poultry enteric disease (122).

Ultrastructural

No detailed, sequential studies of the ultrastructural pathology associated with avian rotavirus infections have been published.

Pathogenesis of the Infectious Process

With both avian and mammalian rotaviruses, the target cells are mature columnar absorptive cells that are located in the villous epithelium. Studies with whole virus and with purified VP8 (VP8* is the natural cleavage product of VP4), the cell attachment protein, indicate that when initiating infection avian rotaviruses use sialic acid-containing molecules as receptors on the surface of MA104 cells (123). It is not known if a similar mechanism operates *in vivo*.

Specific information is lacking regarding the pathogenesis of avian rotaviruses, but some understanding of the process can be inferred from what is known about the mammalian rotaviruses. In rotavirus-infected piglets, infection and subsequent destruction of mature villous epithelial cells results in increased division and accelerated migration of crypt cells, so that the villi are clothed with immature, poorly differentiated cells, deficient in disaccharidases, alkaline phosphatase, and (Na^+-K^+)-ATPase. Glucose-stimulated sodium transport and the net absorption of sodium, potassium, chloride, and water are decreased, producing a rapid-onset, severe, watery diarrhea with loss of electrolytes in the feces (38, 39).

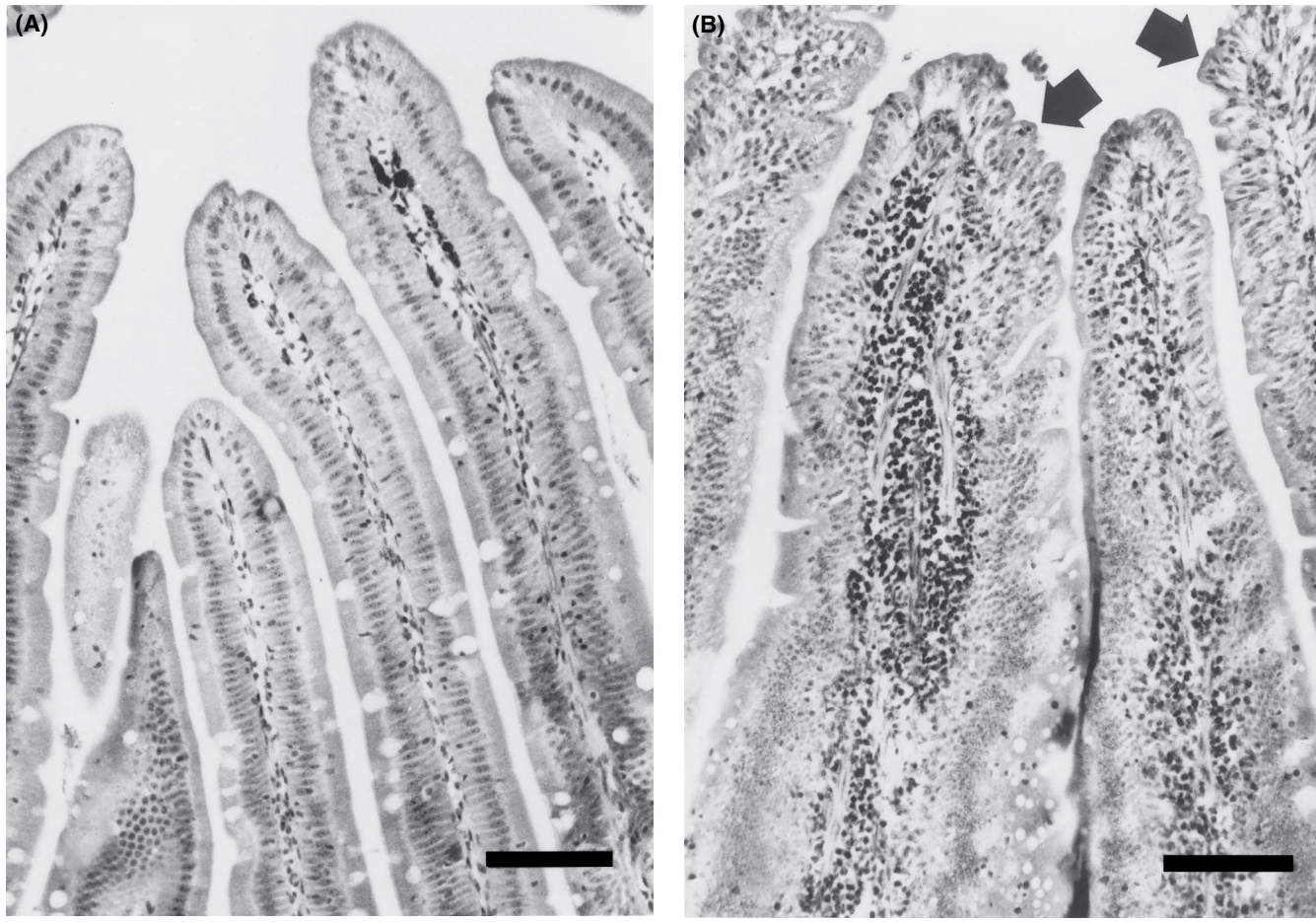

Figure 12.9. Duodenum of SPF turkey poults. (A) Normal villi of an uninfected control poult at 10 days of age. (B) Villi of a 10-day-old poult infected with Tu-2 rotavirus at 7 days of age. Note the remarkable hypercellularity in the lamina propria, scalloping of the villous surface, and basal vacuolation of the epithelial cells at the tips (arrows). H&E stain, bar=0.1 mm. (*Avian Pathol*. 15:421–35, 1986)

It can be inferred that broadly similar mechanisms operate in rotavirus-infected birds. Decreased absorption of D-xylose from the intestinal tract has been observed in experimentally infected turkeys (40, 121, 146). There is histological evidence that the rotavirus infection of enterocytes in the turkey jejunum leads to destruction of the distal portion of the villi (122) (Figure 12.8). However, shortening of the villi in experimentally infected turkeys (40, 121, 147) and chickens (147) was less severe than in infected calves and piglets. The differences in lesions between infected birds and mammals and the age-related susceptibility of turkeys and chickens may result from differences in the development of intestinal villi between mammals and birds (145, 146, 147). The frothy fluids found in the ceca of infected birds may result from impaired digestion and absorption of carbohydrates and sugars that lead to their fermentation by cecal bacteria, producing metabolites that draw water into the ceca by osmosis (145).

However, malabsorption may not be the only explanation for rotavirus-induced diarrhea. NSP4 proteins of mammalian rotaviruses are enterotoxins, causing diarrhea in suckling mice (6, 7, 26). Avian rotavirus NSP4 glycoproteins have similar biological activity, despite major differences in the amino acid sequences of avian and mammalian rotavirus NSP4 proteins. There are conserved structural regions in the NSP4 enterotoxin domain between avian and mammalian rotaviruses (88, 90, 92).

Immunity

Active Immunity

Chickens and turkeys inoculated orally with rotaviruses showed serum antibody responses as early as 4–6 DPI measured by indirect IF. In general, older birds developed higher antibody titers and responded more quickly than younger birds (143, 145, 146). Little is known about development or duration of protective immunity to rotaviruses following infection of birds. Using immunoglobulin class-specific ELISAs (96) to follow antibody responses in chickens experimentally infected with a group A rotavirus, rotavirus-specific IgM, IgG, and IgA were detected in serum, whereas the intestinal antibody response consisted almost entirely of IgA. Embryonic bursectomized chicks recovered from infection and developed resistance to a subsequent homotypic challenge more slowly than intact chicks (93), indicating that the intestinal IgA response is not the sole mediator of recovery from infection

and development of resistance to reinfection. Natural killer cell-like activity has been demonstrated in chick intraepithelial leukocytes against rotavirus-infected target cells, and this may be an important *in vivo* immune response (94).

Passive Immunity

Maternally derived antibodies to rotavirus are passively transferred to the avian embryo through the egg yolk. They progressively decline in titer in the serum and are undetectable at 3–4 weeks of age (145). Progeny of hyperimmunized turkey hens were more resistant to experimental infection with rotavirus at 2 or 5 days of age, but not at 12 days of age, compared with poults without circulating maternal IgG antibodies to rotavirus. It was suggested that circulating maternally derived IgG protects the intestinal mucosa against rotavirus infection during the first week of life and that this effect depends on the titer of antibodies (84, 121, 145). It was subsequently shown that during the first week of life, maternally derived anti-rotavirus IgG (rIgG) titers in intestinal washings of poults derived from hyperimmunized (vaccinated) hens were 200– to 500-fold less than rIgG titers in serum and that intestinal titers at 10 and 13 days of age were negligible. Evidence suggested that the rIgG had been transferred from the blood to the intestine. However, the presence of maternal antibody in the serum in 2 other studies had no apparent effect on susceptibility of chickens and turkeys to experimental group A rotavirus infection (84, 145). Maternally derived rIgG could not be detected in intestinal washings of progeny derived from naturally infected hens (120).

Similarly, an increase in serum-neutralizing antibodies was observed in pheasant hens vaccinated with an inactivated group A pheasant rotavirus vaccine, compared with mock-vaccinated controls. When challenged with a group A rotavirus at 1–2 days of age, mortality in the progeny of the vaccinated hens was 19.4% and mortality in the progeny of the controls was 48.3% (33). These results and those cited previously for the progeny of vaccinated turkeys suggest (1) that maternally derived antibodies in the progeny of unvaccinated turkeys and pheasants are unlikely to provide significant protection against a field challenge with rotavirus, and (2) that much higher titers of antibody would need to be produced by vaccination to completely protect young birds even for the first week of life.

Diagnosis

Isolation and Identification of Causative Agent

The classic way to diagnose avian rotavirus infections in the laboratory is to identify the virus in feces or intestinal contents by direct electron microscopy. This technique is relatively sensitive and detects rotaviruses of all serogroups, and the morphology of rotavirus is sufficiently distinct that experienced electron microscopists should have little difficulty identifying the virus with certainty. Rotaviruses can be confused with reoviruses, however, which are also frequently found in avian feces. The main distinguishing feature is the more clearly defined outer capsid shell of rotavirus (Figure 12.5). Material can be prepared in a variety of ways and has been described in detail (80, 81). Some workers use immune electron microscopy. Although this technique requires availability of specific antisera, it allows rotaviruses of different serogroups to be distinguished (116, 128).

Detection of rotavirus RNA in intestinal contents or feces provides an alternate means of diagnosis. Following extraction of RNA, electrophoresis on polyacrylamide gels, and silver staining, rotavirus RNA can be identified by the pattern of migration of the 11 genome segments. This technique is almost as sensitive as electron microscopic techniques (66, 83, 127, 128), provides provisional information on the serogroup(s) present, and is a convenient means of distinguishing between different isolates (55).

Using fecal samples collected from turkeys experimentally infected with a group A rotavirus, it was found that negative contrast electron microscopy was more sensitive than a staphylococcal protein-A co-agglutination test and a commercial ELISA developed for mammalian group A rotavirus detection; the latter two tests had approximately the same sensitivity (87% and 90%, respectively) and were slightly more sensitive than virus isolation in MA104 cells (60). Commercially available ELISAs are commonly used to detect group A rotaviruses in mammalian and avian feces. However no ELISAs are available to detect rotaviruses of groups D, F, and G.

Diagnosis of rotavirus infection by virus isolation in cell cultures is useful only for group A avian rotaviruses. It has proven extremely difficult to isolate other rotavirus serogroups in cell culture (21, 59, 83, 129). Because infections with nongroup A rotaviruses constitute the majority of infections in chickens (83, 132) and turkeys (110, 130), virus isolation in cell culture cannot be recommended as a diagnostic technique. The details of avian rotavirus isolation and propagation in continuous mammalian cell lines and in primary avian cells have been described elsewhere (59, 73, 81, 86, 95, 124, 129, 144).

Recently, a great deal of progress has been made in the design of molecular diagnostic assays specifically for the avian rotaviruses. A multiplex RT-PCR assay was designed and validated for the simultaneous identification of enteric viruses that are often found concomitantly in turkeys and chickens: avian astroviruses and avian rotaviruses (18). The assay has been used successfully for enteric virus surveys in both turkeys and chickens in different geographical regions of the United States (99, 101), and the NSP4 RT-PCR assay alone has been used for surveys of turkeys affected by poult enteritis syndrome (PES) (51, 52). A one-step RT-qPCR has been developed for the detection of turkey rotaviruses in fecal samples; the assay also targets the conserved NSP4 gene and is a real-time, quantitative assay that employs an internal control to monitor RT-PCR inhibitors in the sample (1). The highly conserved nature of the NSP4 target in these assays allows the screening of samples from different geographical regions and from different avian

species. A conventional RT-PCR assay targeting the rotavirus VP6 gene has been used successfully to amplify rotavirus RNA in field samples from pheasants and wild birds (136, 137). Individual RT-PCR assays targeting specific rotavirus genome segments have allowed in-depth sequence and phylogenetic based analyses of the avian rotaviruses (55, 72), and recent diagnostic RT-PCR assays have been used to detect and differentiate group A and D avian rotaviruses in field samples (97). The availability of novel molecular diagnostic assays will increase rapidly as more avian rotavirus genomes are fully sequenced and annotated (134, 135).

Serology

Serologic diagnosis of rotavirus infections is difficult and not recommended. The high prevalence of antibody (75, 86) makes results difficult to interpret. Few laboratories offer serologic tests for avian rotaviruses on a routine basis. Furthermore, the inability to adapt some avian serogroups to cell culture has resulted in gaps in the available battery of antigens. Serologic screening using indirect immunofluorescence (75) or ELISA (96) is useful for establishing and monitoring the status of SPF flocks.

Differential Diagnosis

Rotavirus infection must be differentiated from other conditions causing diarrhea. Because the clinical signs and pathology of rotavirus infection are not pathognomonic, laboratory diagnosis is necessary. It is important to remember, however, that rotavirus infection does not necessarily result in disease, as discussed previously. Furthermore, it is not unusual to find other potential viral enteropathogens, in addition to rotavirus, in flocks with enteric disease (31, 42, 99, 101, 102, 109, 116, 149).

Intervention Strategies

Management Procedures

The ubiquity of rotavirus infections in turkeys and chickens indicates that it is not practical to keep commercial flocks free from infection. At present, no specific treatment or means of control exists. The effect of diarrhea on the litter can be minimized by increasing ventilation rate and temperature and by adding fresh litter. Where litter is reused several times, infection will build up, and problems are likely to be more severe than in situations in which houses are cleaned and fumigated and fresh litter is used for each batch of birds. If severe problems arise, remove litter and thoroughly clean the house and equipment and fumigate with formaldehyde before restocking with a new flock.

Vaccination

Commercially available vaccines have not yet been developed. Given the extent of antigenic diversity that exists in avian rotaviruses and the difficulty in growing nongroup A rotaviruses in cell culture, obvious problems exist in vaccine development. Preliminary work on experimental group A rotavirus vaccines in turkeys (120) and pheasants (33) indicates that inactivated vaccines administered to the breeders are unlikely to protect the progeny against challenge for more than the first week of life, unless much higher titers of anti-rotavirus antibody can be produced.

Acknowledgement

The author gratefully acknowledges M.S. McNulty and D.L. Reynolds for their substantial contributions to this chapter.

Astrovirus Infections

Stacey L. Schultz-Cherry

Introduction

Astroviruses (AstVs) have been associated with acute gastroenteritis in a variety of mammals and birds including turkeys, chickens, and guinea fowl, as well as fatal hepatitis in ducks and nephritis in chickens (reviewed in 7). The identification of AstVs in poultry has greatly increased in recent years, likely due to enhanced surveillance and better diagnostic assays. To date, 6 different AstVs have been identified in poultry based on species of origin and the characteristics of the viral genome including 2 chicken-origin AstVs (avian nephritis virus [ANV] and chicken astrovirus [CAstV]), 2 turkey-origin AstVs (TAstV-1 and TAstV-2), and 2 duck-origin AstVs (DAstV-1 and DAstV-2) (Figure 12.10A). One must be careful when classifying newly identified AstVs from poultry by species as ANV has been detected in numerous species including turkeys (9) and ducks (3), and guinea fowl have been shown to be infected with TAstV-2 (4, 5). These data suggest that AstVs may be able to cross species barriers.

AstVs are among the most common viruses associated with poult enteritis complex (PEC), poult enteritis syndrome (PES), and poult enteritis and mortality syndrome (PEMS) in turkeys (13, 21, 27, 31), and runting stunting syndrome (RSS) in broilers (1, 8, 49). However, they also can be isolated from clinically healthy birds leading to questions about the role of particular AstV strains in disease pathogenicity (10, 21), a question that requires further investigation.

Incidence and Distribution

AstVs have been detected worldwide and are one of the most prevalent viral infections in poults 1–5 weeks old with enteric disease (31, 32, 33). Several studies demonstrated that

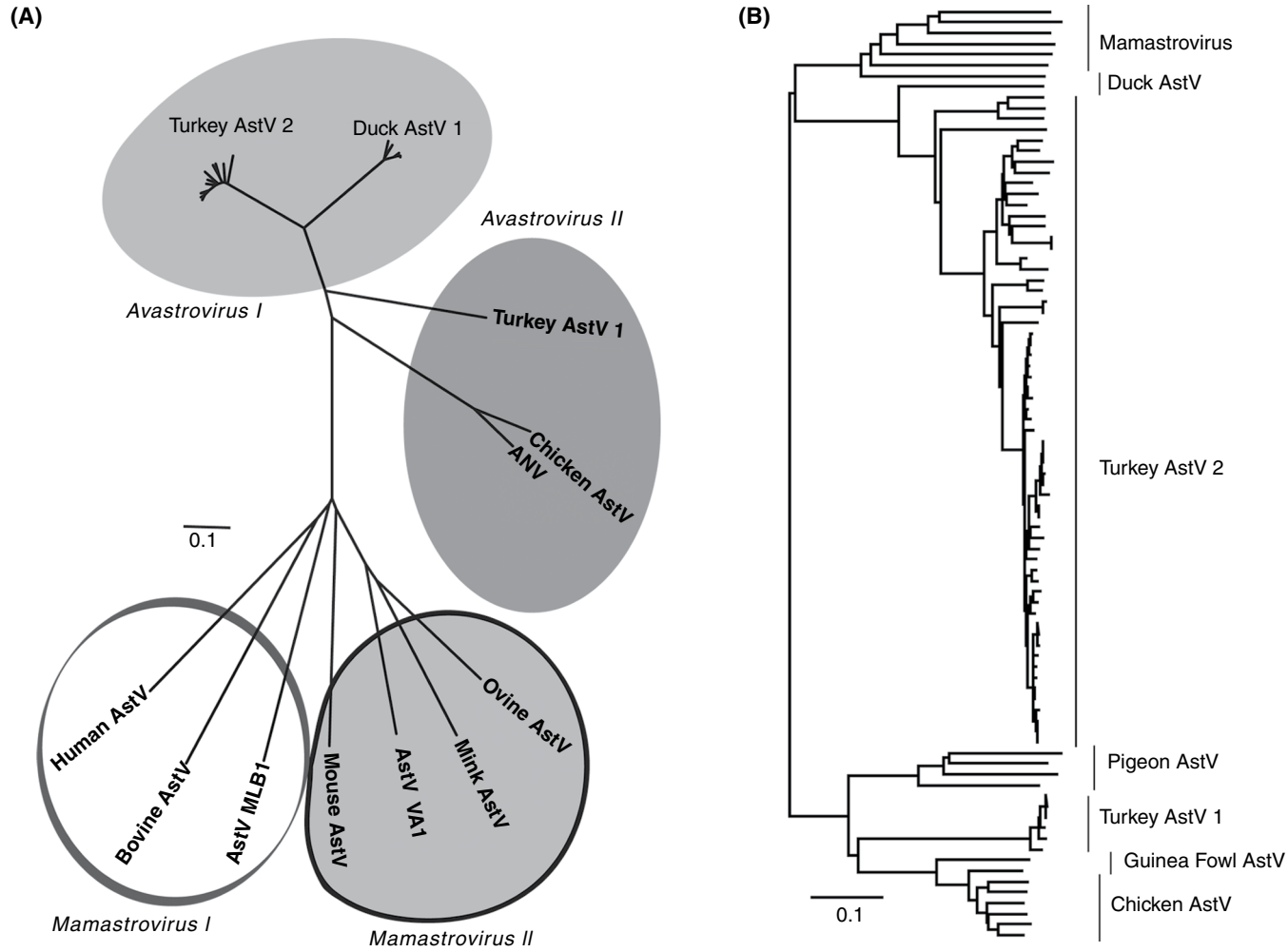

Figure 12.10. Phylogenetic trees of (A) whole genome and (B) capsid sequences of avian astroviruses. The complete nucleotide sequence of the astrovirus genome or an 800-nucleotide segment of the ORF2 capsid gene were aligned using MEGA4 software using the Neighbour-Joining method and a Kimura 2-parameter model with pair-wise deletion.

86%–100% of chicken flocks (25, 49) and up to 100% of turkey flocks (26) are infected with AstVs, frequently in association with other enteric viruses (25, 33). These infections typically occur within the first 4 weeks of life (32). When flocks were continuously monitored for enteric viral infections from 1 day of age until market, the first samples positive for viruses always contained AstVs, either alone or with other viruses (32).

Etiology

AstVs are small, round viruses typically 25–30 nm in diameter that are naturally spread via the fecal-oral route. The name *Astrovirus* arises from the 5 or 6 pointed star-like surface projections observed using transmission electron microscopy (TEM) (Figure 12.11) (30). However, only 10% of AstVs in a population may exhibit this morphology, and visualization depends on sample preparation leading to cautions about the use of TEM for diagnosis (7). AstVs are nonenveloped and composed of a positive-sense RNA genome 6.5–7.5 kilobase (kb) in length containing 3 open reading frames (ORF). These reading frames code for nonstructural proteins (ORF1a), a viral RNA-dependent RNA polymerase (ORF1b), and a capsid protein (ORF2). Their replication strategy is quite distinct from other enteric virus families in that they synthesize a subgenomic message during replication, contain a retrovirus-like frame shift signal sequence between ORF1a and ORF1b, and have a serine protease (18). Recently, several avian AstV genomes have been fully sequenced, supporting enhanced phylogenetic analysis. These analyses show that avian AstVs are molecularly distinct from mammalian AstVs and share little sequence similarity in the different gene segments (Figure 12.10A). For example, comparing the most conserved region of the genome, the RNA-dependent RNA polymerase (RDRP) from the human astrovirus type 1 (HAstV-1), to any of the avian viruses shows approximately 40% sequence identity. Among the different avian viruses there is great diversity ranging from only approximately 40% similarity (duck astrovirus-1 to other avian viruses) up to 95% (TAstV-1 to TAstV-2).

The prototype TAstV-1 strain was originally identified in the United States in 1985 and is genetically and antigenically

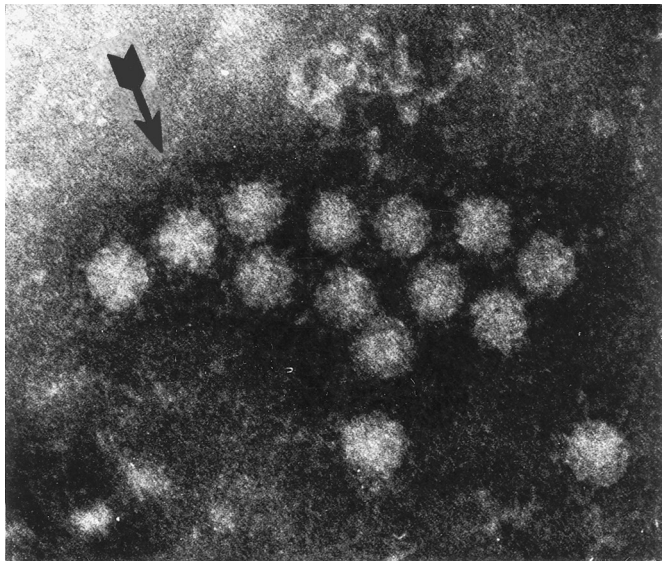

Figure 12.11. A star-shaped astrovirus particle (arrow) among an aggregate of astroviruses from intestinal samples of experimentally infected diarrheic poults, detected by immune electron microscopy. Average particle size is 29.6 nm. (*Avian Dis*. 30:728–735, 1986)

distinct from TAstV-2 isolates. Even within the more conserved polymerase gene, there is at least 10% nucleotide divergence among the TAstVs supporting the separation of isolates into 2 distinct groups (24). The diversity within the TAstV-2 capsid gene is staggering (7, 10, 25, 27) (Figure 12.10B) and there is increasing evidence that AstVs can undergo recombination (7, 24, 43). The existence of different sublineages of TAstV-2 has been confirmed by field studies (9, 11, 24, 43). Genetic analysis suggests that TAstV-1 and TAstV-2 should be reconsidered as subtypes instead of serotypes and that multiple serotypes of TAstV-2 exist (27, 43). In spite of the genetic diversity, the overall structure of the non-TAstV-2-avian AstV capsid proteins spike domain is predicted to be similar to the recently solved TAstV-2 structure (R. Dubois, personal communication, November 1, 2012). This structure may aid in the generation of avian AstV-specific tools, including antibodies and diagnostic assays that will be useful to fully understand the role of these different genotypes in poultry disease.

Given this diversity, a new taxonomy proposal for avian AstVs has been submitted to the International Committee on Taxonomy of Viruses (ICTV) for approval. This proposal, from members of the *Astroviridae* study group, states that a classification based on the genetic criteria is more appropriate than classifying the viruses into species within the genus *Avastrovirus* based only on the host of origin. This new classification establishes 3 new species within the genus: *Avastrovirus* GI.A, including TAstV-1; *Avastrovirus* GI.B, including ANV-1 and 2 and chicken AstV; and *Avastrovirus* GII.A, including TAstV-2 and duck AstV.

Susceptibility to Chemical and Physical Agents

AstVs are extremely stable and resistant to inactivation by phenolics, acidic pH, chloroform, a variety of detergents, heat, ambient temperatures, quarternary ammonia, most alcohols, and lipid solvents (35). Formaldehyde, b-propriolactone, 90% methanol, and a potassium peroxymonosulfate-containing disinfectant have been shown to eliminate AstV infectivity. TAstVs harvested from the intestines of embryos are very stable and infectivity can be maintained for several weeks at 4°C. To maintain long-term infectivity, virus can be stored at –20°C or –70°C. Inactivation of AstVs in the laboratory situation can be accomplished with 90% methanol or through the use of a potassium peroxymonosulfate-containing disinfectant (35).

Laboratory Host Systems

Virus isolation in embryonating eggs has been successful for most of the avian AstVs including TAstV and CAstV. TAstV can be propagated serially in the yolk sac of 20-day-old turkey embryos or by inoculating 24– to 25-day-old turkey embryos by the amnionic route (2, 15, 17, 30). TAstV infection does not result in embryo mortality. CAstVs can be propagated in SPF chick embryos following yolk sac inoculation. Infection can result in a variety of effects including early embryo death, dwarfing, and edema (40). Virus isolation in cell culture has been unsuccessful for TAstVs, but Baxendale and Mebastsion reported the successful isolation and propagation of CAstVs in primary chick embryo liver and LMH (chicken heptocellular carcinoma cell line) cells producing a marked cytopathic effect (CPE) after 4–5 passages (1). CAstVs replicate poorly in chick embryo fibroblasts and chick kidney cultures initially, but after several passages will replicate in chick kidney cells inducing CPE.

Pathogenesis and Epidemiology

TAstVs are commonly detected in 1- to 5-week-old commercial poults suffering from diarrhea (10, 11, 21, 31, 32, 33, 34) and have been associated with several enteric disease syndromes (13, 21, 27, 31). Clinical signs of disease usually develop between 1 and 3 weeks of age and generally last up to 2 weeks (30). Severity is usually mild to moderate and is characterized by diarrhea, listlessness, litter eating, and nervousness. Although the mortality rate is low, morbidity occurring as decreased growth (stunting) is of greatest concern (15, 34). TAstVs also can be detected in apparently healthy birds but at a lower frequency (10, 11).

Experimentally, TAstV-2-infected turkeys develop a profuse, watery diarrhea by 2 days post infection (dpi), which continued through 12 dpi (2, 23). Morphologically, intestines of infected poults are 3–5 times larger than their control counterparts and appeared dilated, distended, and fluid filled by 3 dpi (2). There is an overall growth depression in infected birds, possibly as a consequence of malabsorption (20, 47, 48). Recently, Spackman et al. (2010) evaluated the effect of TAstV-2, turkey rotavirus, and turkey reovirus coinfections in decreased weight gain in broad-breasted white turkey poults. They showed that poults exposed to all 3 viruses administered in combination had the lowest body weight, although the weights were not significantly different from control birds (41).

Much less is known about CAstVs. Experimental infection of SPF layer chicks resulted in a mild diarrhea and limited damage at the base of the small intestinal villi in some birds, and no histological changes outside the gut (1). However, these findings may be CAstV strain dependent because a separate group found the FP3 CAstV strain caused mild to moderate histological changes in the kidney, pancreas, and intestine (38). Unlike TAstV, it appears that CAstV is associated with only mild stunting (19).

Histological and Gross Changes

At necropsy, the characteristic pathologic changes associated with TAstV infection are dilated ceca containing yellow, frothy contents and gaseous fluid, loss of tone (gut thinness), and hyperemia of the intestinal tract. TAstV-1-infected poults exhibited histopathologic lesions of the small intestine characterized by mild crypt hyperplasia resulting in increased crypt depth and area beginning in the proximal jejunum as early as 1 dpi, with all portions of the small intestines affected by 5 dpi (47). Unlike some other intestinal viral infections, TAstV infections are not associated with villous atrophy.

A more extensive *in-situ* hybridization study with TAstV-2 demonstrated that replication was detected in the upper regions of the small intestine by 24 hours post-infection (2). Individual degenerating enterocytes were apparent along the basal edge of villi by 2 dpi and continued through day 4. By day 5, mild shortening of the villi was observed (2) as well as occasional clusters of necrotic enterocytes along the villous base, correlating with infection (15). TAstV-2 was localized primarily to the large intestine by day 7 pi. Replication peaked at 3–5 dpi and TAstV-2 was infrequently observed at later time points. There was little evidence of cell death. This lack of cellular damage is accompanied by a notable absence of an inflammatory response (12, 15). Several studies suggest that the combination of malabsorption and changes in paracellular permeability may be the cause of the diarrhea (20, 22). Although viral replication is likely an important player, it appears that the viral capsid protein can act as a novel enterotoxin leading to increased paracellular permeability *in vitro* (22) and *in vivo* (R. Dubois, personal communication, November 1, 2012). It may also explain the systemic spread in TAstV-2-infected poults (15).

Immune Response

The immune response to AstVs is not well characterized. A study with CAstV suggests that vaccination with a purified form of recombinant CAstV capsid protein leads to a partial protection from subsequent RSS challenge (36). There is no such information for TAstVs and neutralizing antibodies against TAstVs have not been isolated. The reason for this could be the reported dysregulation of the immune response by TAstV (30).

Specifically, the responsiveness of peripheral blood lymphocytes (PBLs), thymocytes, and splenocytes isolated from TAstV-2-infected poults was significantly reduced as compared to control birds (29). Functionally, macrophages and heterophils from TAstV-2-infected poults had reduced expression of several key proinflammatory cytokines (28) and upregulation of the immunosuppressive cytokine, TGF-beta (15), further supporting the hypothesis of an impaired innate response during infection.

In spite of this impaired immune response, the virus is cleared and clinical disease resolved within 12–14 dpi (15). Although the mechanism is still unknown, several studies suggest that the induction of nitric oxide (NO) during TAstV-2 infection may be important in halting viral replication in infected poults (14, 20, 28). However, much more work needs to be done to define the immune response to AstV infection, especially if vaccines are considered for control in commercial poultry.

Diagnosis

Commercial poultry appear to be endemically infected with a variety of divergent CAstV and TAstV strains. Thus, diagnostic assays need to be able to not only detect AstVs but also differentiate among different genotypes. Several groups have developed ELISA-based methodologies to detect either CAstV-specific antibodies using recombinant capsid protein (36) or the presence of TAstV-2 antigen in feces or intestinal homogenates (44, 45). However, given the increasing diversity of CAstV and TAstV viruses in commercial poultry, great care must be used in interpreting "negative" results.

There has been increasing use of molecular diagnostic tests for detecting avian AstVs. Several reports described conventional and/or real-time RT-PCR tests for detecting TAstV (16, 38, 42, 46) and CAstV (24, 39). This procedure is completed by pooling the feces or lower intestines from 3–5 birds/flock and either isolating RNA directly or passaging filtered fluids once through embryonating eggs. The RNA from the field sample or from the isolated embryo intestines then is subjected to RT-PCR using oligonucleotide primers specific to 2 different genes of the viral genome, a conserved region and a diverse region. However, given the diversity displayed by avian AstVs, it can be difficult to select primers that will detect all variants within 1 type. Chu et al. recently identified a set of degenerate primers within the highly conserved region of the ORF1a that has successfully detected AstVs from multiple mammalian and avian species (6, Schultz-Cherry unpublished). This reaction yields an approximately 400-nucleotide product that can be sequenced to initially identify the AstV genogroup. A positive finding needs to be followed with the use of genotype-specific primers to the capsid gene to identify the exact strain within the genogroup. However, because the majority of commercial poultry appear to become infected with avian AstVs at some point in their lifetimes, knowing that a flock is AstV positive may be of questionable importance. However, it is possible that future field studies using assays that differentiate among the many strains may point to a role for specific genotypes in disease, necessitating the need for specific testing.

Treatment, Prevention, and Control

No vaccines, chemotherapeutics, or other measures are reported to be efficacious for control and/or prevention of avian AstV infections. Sellers et al. demonstrated that breeders vaccinated multiple times with a recombinant form of the CAstV capsid protein offered some protection to progeny chicks challenged with RSS (36), suggesting that this approach may be worthy of further investigation. The widespread occurrence of AstVs in commercial poultry coupled with their environmental stability and resistance to inactivation by most widely used disinfectants makes elimination from affected areas difficult (35). It is likely that strict biosecurity, increased down time between flocks, and use of effective disinfectants could reduce the likelihood of AstV infections; however, this approach requires further investigation.

Acknowledgement

The author gratefully acknowledges Dr. Donald Reynolds, senior author of this chapter in 12th edition, and long-time contributor of to the astrovirus field.

Avian Enterovirus-Like Virus Infections

Christopher S. Hayhow

Introduction

A number of enterovirus-like viruses (ELVs) have been identified in avian species. The term enterovirus-like is applied to these viruses because they have not been fully characterized; definitive classification awaits further biologic, physicochemical, and molecular characterization. This section addresses ELVs identified in domestic poultry other than duck hepatitis virus types 1 and 3 (Chapter 13) and turkey viral hepatitis virus (Chapter 14).

The economic significance of avian ELVs is not yet known. No evidence suggests that they are transmissible from avian species to humans or other mammals. The extent, if any, to which they spread among different species of domesticated poultry is unknown.

Etiology

Classification

Enteroviruses are 1 of 12 within the family Picornaviridae (22). Members of Picornaviridae contain a single molecule of infectious, positive-sense, single-stranded RNA, 7–8.8 kb in size. Genera within the family Picornaviridae are distinguished *inter alia* by their sensitivity to acid, buoyant density of the virion in CsCl, and clinical manifestations in the affected host. Members of the genus *Enterovirus* are stable at acid pH, have a density of 1.30–1.34 g/mL in CsCl, and replicate primarily in the intestinal tract (21, 22). Most avian ELVs have been classified on the basis of size, morphology, cytoplasmic replication in enterocytes, and resistance to acid pH. However, it is emphasized that these biological criteria are insufficient for definitive classification. This is borne out by nucleotide sequence analyses of genomic RNA, and antigenic analyses, of some avian viruses that possess these biological criteria. Avian encephalomyelitis virus, a virus that initially was considered to be an enterovirus, has been shown to share a high level of deduced amino acid sequence identity with hepatitis A virus (25, 43). Based on the available information, avian encephalomyelitis virus has (Chapter 14) been classified as a species in the genus *Tremovirus* in the family Picornaviridae (22). Similarly, nucleic acid sequence analyses of other viruses—avian nephritis virus and 2 viruses initially thought to be turkey ELVs—have identified these viruses as members of the family Astroviridae (14, 15, 20, 22, 23, 33, 45, 46). Based on antigenic analyses, it is likely that several viruses initially identified as chicken ELVs will be reclassified in the future as astroviruses, because these viruses have been shown to share antigenic relationships with avian nephritis virus (4, 10, 30, 42).

Morphology

Picornavirus virions are icosahedral (T = 1), nonenveloped, and 22–30 nm in diameter. The virion lacks obvious surface structure, and no surface projections exist (21, 22) (Figure 12.12). The sizes described for most avian ELVs fall within a 22– to 30-nm range, although a range of 18–24 nm was described for a U.S. turkey ELV (41).

A turkey ELV isolate was determined to have a buoyant density of 1.33 g/mL in CsCl (18).

Chemical Composition

Only limited information is available regarding the chemical composition of avian ELVs. Information on the genome structure of ELVs is available only for a single U.S. isolate from turkeys (18). This virus was shown to possess a single-stranded RNA genome of approximately 7.5 kb. No information is available regarding avian ELV proteins.

Virus Replication

Replication of turkey ELVs has been investigated by both immunohistochemistry and transmission electron microscopy (TEM) (19). Virus replication was shown to occur in the cytoplasm of intestinal enterocytes. Crystalline arrays composed of small, round, virus-like particles approximately 23 nm in diameter were observed (Figure 12.13) (19); an

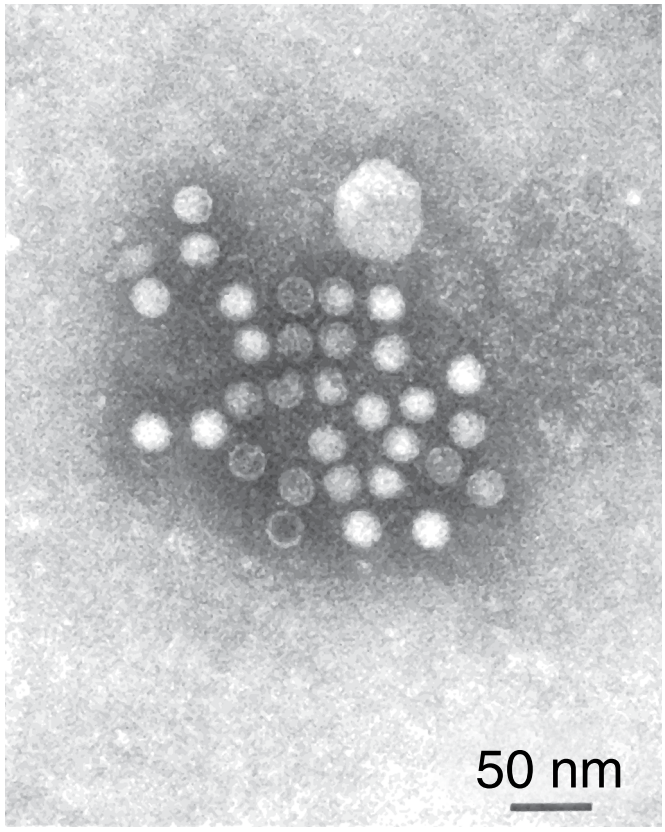

Figure 12.12. Spherical, 18- to 27-nm enterovirus-like viruses detected in feces of young turkeys with enteric disease. Sodium phosphotungstate.

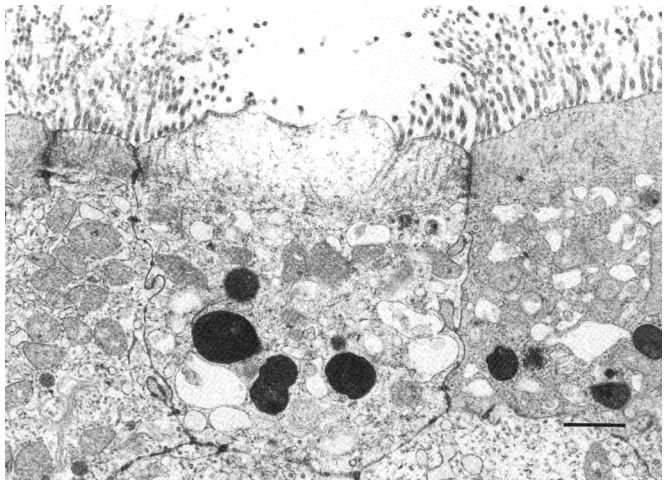

Figure 12.13. Degenerating enterocyte containing cytoplasmic crystalline arrays of enteroviruslike viruses (ELVs).

earlier study (41) described particles of 17.1 nm. Similar findings to the former were reported for chicken ELVs (6, 9, 26, 28). However, in 1 detailed study (9), membrane-bound cytoplasmic inclusions containing virus-like particles were detected more frequently in mesenchymal cells and macrophages in the lamina propria than in enterocytes. Some chicken ELVs also replicate in the kidney, and have been implicated in the etiology of baby chick nephropathy (38).

A U.S. turkey ELV was shown by immunofluorescence and immunoperoxidase staining procedures to replicate primarily in the jejunum and ileum of experimentally infected poults. The virus replicated preferentially in those enterocytes located halfway between the tip and base of the villus. Viral antigen was found most abundantly in enterocytes situated immediately above crypt openings (17); similarly, antigens of chicken ELVs were found mostly in cells at the base of the villi (6).

No information is available concerning transcription and translation of the RNA of avian ELVs.

Susceptibility to Chemical and Physical Agents

Avian ELVs that have been tested have been found to be stable at pH 3 and unaffected by solvents such as chloroform and ether (26, 28, 29, 40, 42). No information exists about their sensitivity to disinfectants.

Strain Classification

Because of the difficulties associated with growing avian ELVs in cell culture and other laboratory host systems, very little information is available concerning their antigenic relationships. Using cross immunofluorescence, 3 ELVs isolated from chickens, designated EF84/700 (29), FP3 (40), and 612 (26), were found to be antigenically distinct from each other and also from avian encephalomyelitis virus, avian nephritis virus, duck hepatitis virus type 1, and duck hepatitis virus type 3 (26, 30). Several ELVs isolated in Japan from chicks with baby chick nephropathy (38) and from broilers with a stunting syndrome (42) had biologic and physical properties similar to the G-4260 strain of avian nephritis virus but were antigenically distinct from avian nephritis virus (37, 38). Nucleotide sequence analyses of the genomes of these viruses are needed to determine whether these viruses are enteroviruses or a third serotype of avian nephritis virus (37, 38).

Two strains of turkey ELVs isolated in France were shown to be antigenically unrelated to avian encephalomyelitis and duck hepatitis viruses using cross-neutralization tests (1).

Laboratory Host Systems

Enterovirus-like viruses can be propagated in the laboratory by oral inoculation of neonatal birds of the same species from which they originally were recognized or isolated. Depending on the virus, inoculated birds may develop enteric disease and depressed growth rates. Intestinal contents examined by negative contrast TEM 1–3 days post infection (PI) normally contain the inoculated virus. Additionally, immune TEM can be used to assist identification of ELVs in intestinal contents of inoculated birds (34, 35, 41). However, caution must be exercised in propagating ELVs in this manner because even SPF birds may be infected with ELVs.

Most chicken ELVs will grow in the yolk sac of 6-day-old embryonating chicken eggs, with approximately 50% of embryos dying within 3–7 days PI. Dwarfing of embryos also may be observed (38). Some of these viruses also can be

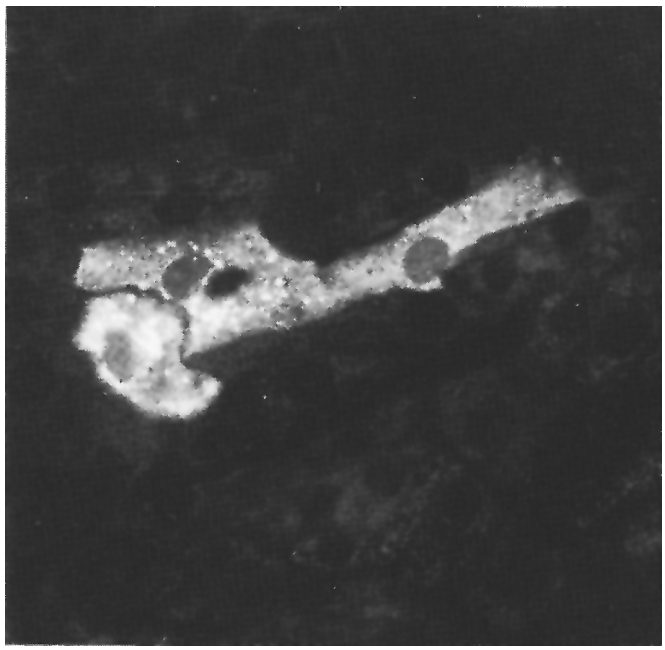

Figure 12.14. Immunofluorescent staining of chicken embryo liver cell culture infected with enteroviruslike virus (ELV) (612 isolate). ×450.

propagated in the chorioallantoic membrane of embryonating eggs. Immunofluorescent staining of impression smears of yolk sac membranes or cryostat sections of chorioallantoic membrane can be used to confirm virus growth. In addition, some ELVs, for example FP3 and 612, show limited growth in primary cultures of chicken embryo liver or chicken kidney cells. Growth of virus in cell cultures is best detected by immunofluorescent staining (Figure 12.14) because many of these viruses cause little, if any, cytopathology (4, 26, 30).

Samples of feces or intestinal contents that contain chicken or turkey ELVs also may contain reovirus. Reoviruses normally outgrow ELVs in embryos and cell cultures; thus, their presence interferes with attempts to isolate ELVs.

None of 4 turkey ELVs and 2 pheasant ELVs detected by negative contrast TEM in the feces and intestinal contents of birds with enteric disease in the United Kingdom produced a cytopathic effect in primary chicken embryo liver cell cultures. However, 1 turkey virus grew to low titers in embryonating chicken eggs inoculated via the yolk sac (12). Similarly, 2 isolates of ELVs were made in France from turkey intestinal contents following yolk sac inoculation of chicken embryos (1).

An ELV from guinea fowl with transmissible enteritis was propagated successfully following inoculation of 7-day-old guinea fowl embryos via the yolk sac; however, embryo mortality and lesions were inconsistent. This virus also grew in primary cultures of guinea fowl embryo brain cells; no cytopathic effect was evident, but the presence of virus was demonstrated by inoculation of guinea fowl embryos and 1-day-old guinea fowl (32).

Pathogenicity

The pathogenic role of avian ELVs requires further clarification. Although field and experimental evidence suggests that they may cause enteric disease in young turkeys, chickens, and guinea fowl, and nephropathy in baby chicks, additional studies are needed to define their importance.

Pathobiology and Epizootiology

Incidence and Distribution

Examination of feces using negative contrast TEM has led to the discovery of ELVs in a number of avian species. The presence of ELVs in intestinal contents of young turkeys and chickens was described in the United Kingdom in 1979 (27). Subsequently, ELVs were identified in the feces of turkey poults in the United States (34, 35, 36), Italy (32), and France (1); in chickens in Belgium (5), the United States (11), Malaysia (3), South Africa (26), Italy (32), Holland (39), and Germany (39); in guinea fowl with transmissible enteritis in Italy (24, 32) and France (2); and in partridges (13) and pheasants (12) in the United Kingdom. In addition, ELVs have been found in feces and enterocytes of cockatoos and galahs with enteric disease in Australia (31, 44) and in the gut contents of ostriches showing signs of enteritis in South Africa (8). Based on these findings, it is likely that avian ELVs have a worldwide distribution.

Natural and Experimental Hosts

Infections with ELVs have been described in turkeys, chickens, guinea fowl, partridges, pheasants, ostriches, and psittacine species. The majority of naturally occurring infections in domestic poultry have been identified in young birds during the first few weeks of life. However, a chicken ELV was isolated from the meconium of a dead-in-shell chicken embryo (40), indicating that infection with these viruses may occur in adulthood.

Transmission, Carriers, and Vectors

The principal site of replication of ELVs is the small intestinal epithelium (Figure 12.15); some chicken ELVs also replicate in the kidney (38). Thus, infection most likely is spread horizontally through ingestion of infected feces, but other routes of spread cannot be ruled out. Isolation of a chicken ELV from meconium of a dead-in-shell chicken embryo indicates that this virus is vertically transmitted (40); it is likely that other ELVs also are transmitted in this manner. Additionally, evidence indicates darkling beetle larvae may act as mechanical vectors for turkey ELVs (7).

Clinical Signs

The main clinical signs associated with naturally occurring ELV infections in domestic poultry are diarrhea, decreased feed efficiency, and uneven growth. Increased mortality also may occur. Disease is most frequently seen in birds in the first few weeks of life. Enteric disease has been reproduced experimentally in neonatal birds inoculated orally with ELVs.

In 3- or 4-day-old SPF turkeys experimentally infected with a U.S. turkey ELV, depression, watery droppings, and pasted

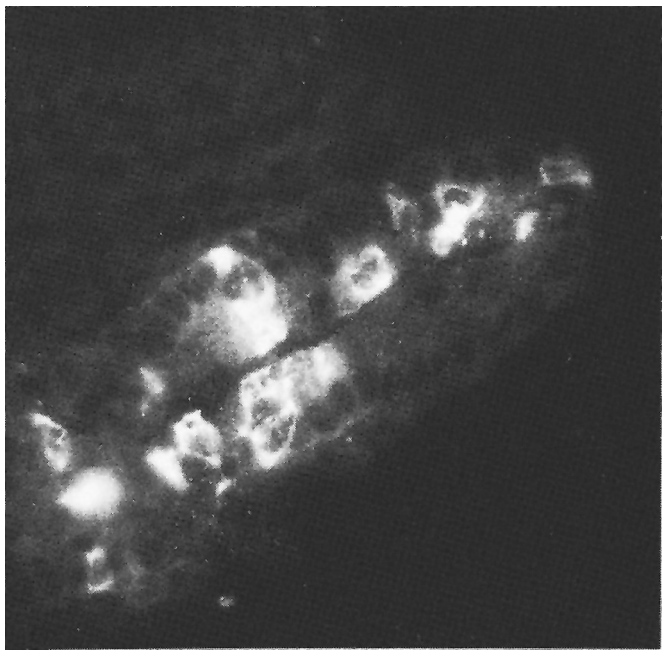

Figure 12.15. Specific immunofluorescence in epithelium of jejunal villus of chicken infected with enteroviruslike virus (ELV) (612 isolate). ×450.

vents were observed. Signs were first evident 3–4 days PI. Similar signs occurred in poults inoculated at 2, 3, and 4 weeks of age. Decreases in body weight gain also were observed. ELVs were detected in greatest numbers in the intestinal contents of inoculated turkeys at 3 and 4 days PI but were present in some birds up to 14 days PI (17, 19, 41).

Abnormal feces and transient stunting of growth of variable severity were observed in broiler chickens dosed orally with ELVs (5, 26, 30). SPF chicks inoculated orally with Japanese ELVs showed diarrhea and variable mortality (up to 53.3%), dying between 2 and 6 days PI (38).

An ELV isolated from guinea fowl with transmissible enteritis in Italy suppressed weight gains of commercial guinea fowl when they were inoculated orally at 1 day of age (32).

A naturally occurring syndrome associated with ELV infection in young galahs and sulfur-crested cockatoos was characterized by intractable profuse diarrhea, wasting, and death (31, 44).

Pathology

Gross lesions in turkeys experimentally infected with a U.S. turkey ELV consisted of thin-walled, dilated ceca filled with yellow, foamy fluid and extreme paleness of the serosa of the gastrointestinal tract; catarrhal secretions were detected in the small intestines. Morphometric studies indicated varying degrees of shortening of the villi and elongation of crypts along the length of the small intestine (17, 19, 41). In naturally occurring infections in turkeys, ELVs usually occur as a component of mixed infections. Interestingly, poults experimentally infected with a combined turkey ELV/group A rotavirus inoculum were more severely affected in terms of clinical signs, body weight gain, and lesion severity than poults that received either inoculum alone (17).

Chicks experimentally infected with Japanese ELVs and that died 2–6 days after inoculation showed microscopic changes characteristic of baby chick nephropathy (i.e., nephrosis and visceral urate deposition) (38). Chicks experimentally infected with ELVs from broilers in Belgium with a runting syndrome had pale small intestines with watery and sometimes filamentous contents of the small intestine and ceca (5).

In a naturally occurring syndrome associated with ELV infection in young galahs and sulfur crested cockatoos, the intestine was dilated with mucoid fluid and gas, and the walls appeared thickened. Microscopic lesions in the intestine consisted of villus atrophy and fusion, elongation of the crypts of Leiberkuhn, marked epithelial cell proliferation in the crypts and shortened villi, with inflammation of varying severity (31, 44).

Thin section TEM has revealed the presence of intracytoplasmic, crystalline arrays of particles resembling enteroviruses in the enterocytes of infected chickens (6, 28) and cockatoos (31, 44).

Pathogenesis of the Infectious Process

The nature of the microscopic lesions in the small intestine of affected birds suggests that infections with ELVs produce malabsorption and diarrhea due to destruction of small intestinal villus epithelial cells. Measurement of absorption of D-xylose from the intestines of experimentally infected turkey poults confirmed that a transient malabsorption was present in poults inoculated at 3 days of age, but not in poults inoculated at 2 weeks of age (17). However, it also has been suggested that the turkey ELV exerts its effects by altering the cellular physiology of the villus epithelial cells, altering the normal intestinal flora, or through a systemic mechanism (as evidenced by a transient lymphopenia) (41).

Replication in other organs, such as the kidneys, also may contribute to the pathogenesis of these viruses.

Immunity

The development of active immunity to ELV infections has not been investigated. Similarly, the extent to which passively acquired maternal antibodies provide protection from these infections is unknown.

Diagnosis

Isolation and Identification of Causative Agent

Diagnosis of ELV infections in avian species most commonly is accomplished by TEM examination of droppings or intestinal samples. ELVs have been identified using both direct and immune TEM procedures. For direct TEM, droppings or intestinal contents are prepared as suspensions (10%–20%) in phosphate-buffered saline and centrifuged at 800 × g for 20 minutes to remove large particulate material. The supernatant fluid subsequently is centrifuged at 15,000 × g for 20 minutes in a benchtop centrifuge, and the resultant pellet is resuspended in approximately 500 μL of distilled water and 100 μL of 2%

phosphotungstic acid. After mixing, the material either is sprayed onto formvar-filmed copper grids, or a drop of the material is placed on the grid for 1–3 minutes and removed by blotting on bibulous paper. ELVs also may be detected in droppings or intestinal contents using immune TEM (35); however, this procedure requires availability of specific antisera.

Confirmation that particles observed by TEM are animal viruses is achieved by isolating the viruses in turkey or chicken embryos or in cell cultures as described previously. Antigenic characterization of the isolate depends on the availability of serogroup-specific antisera. Yolk sac membranes or chorioallantoic membranes from inoculated embryos may be prepared as impression smears or cryostat sections and examined by immunofluorescent staining using serogroup-specific antisera. This serologic procedure distinguishes between isolates of known serogroups and aids in the identification of new serogroups.

An antigen-capture ELISA was described for detection of turkey ELV in turkey intestinal contents (16). The procedure was shown to be a rapid, highly sensitive, and specific method for diagnosis of the virus.

Serology

Antibodies to ELVs have been detected by serum neutralization and indirect immunofluorescence tests (6, 30, 38); however, because virus isolates and reference antisera are not widely distributed, routine serologic diagnosis is not recommended. Serology is, however, useful to determine the status of SPF birds with respect to ELV infections.

Differential Diagnosis

Enteric disease associated with ELVs needs to be distinguished from similar conditions caused by other enteric viruses, such as rotavirus, astrovirus, parovirus, and coronavirus; clinical signs and lesions are not pathognomonic. However, mixed infections of ELVs and other enteropathogens occur commonly, and it may be difficult to identify the relative importance of each constituent of mixed infections.

Intervention Strategies

The role of ELVs as avian pathogens has not yet been fully defined. Consequently, no specific therapeutic or prophylactic measures are available. Given the importance of some of the conditions with which avian ELVs have been associated, it would be prudent to develop better diagnostic methods for these viruses to investigate their epizootiology and pathogenicity more fully.

Acknowledgement

The contributions by J.S. Guy and M.S. McNulty to previous editions of this subchapter are gratefully acknowledged.

Enteric Parvovirus Infections of Chickens and Turkeys

Laszlo Zsak

Introduction

Chicken and turkey parvoviruses are members of the *Parvovirus* family. Comparative sequence analysis of their genome structure revealed that they should form a new genus within the vertebrate *Parvovirinae* subfamily (3). The first chicken and turkey parvoviruses were identified by transmission electron microscopy (TEM) (7, 27) during the early 1980s. Since then, parvoviruses have been detected in cases of enteric diseases of poultry (1, 17, 18, 24, 28), in association with cerebellar hypoplasia in day-old broilers (15), and in fecal samples of wild turkeys (5). In the past few years, the complete genome sequence of chicken and turkey parvoviruses has been determined (3), and diagnostic assays were developed and used to determine the prevalence of parvoviruses in the poultry industry (22, 30). It has been documented that parvoviruses can be frequently detected in chickens and turkeys from flocks that have been affected by enteric diseases (1, 17, 18, 24, 30). Pathogenicity studies indicate that chicken and turkey parvoviruses induce typical enteric diseases in susceptible young birds (8, 31, 32). Although the exact economic significance of parvovirus infections has not been determined, data suggest that they play a significant role in the etiology of enteric disease syndromes of poultry, including runting-stunting syndrome (RSS) of broilers and poult enteritis and mortality syndrome (PEMS) of turkey poults (1, 8, 17, 18, 24, 27). Chicken and turkey parvoviruses have no known public health significance.

Etiology

Classification

Classification of parvoviruses to reflect their evolutionary relationships initially was based on biological characteristics and structural properties of viruses. These criteria included whether the virus is capable of autonomous replication or is dependent upon a helper virus, whether the virion contains a single strand sense or packaged strands of both senses, and whether the virus has 1, 2, or 3 transcriptional promoters (25). As the sequences of more and more virus genomes became available, computer-based phylogenetic analysis has become the dominant method to classify parvoviruses. A genus now can be identified as a group of species that represents a single branch of a phylogenetic tree.

The use of a particle-associated nucleic acid sequencing technique has recently led to the identification and sequencing

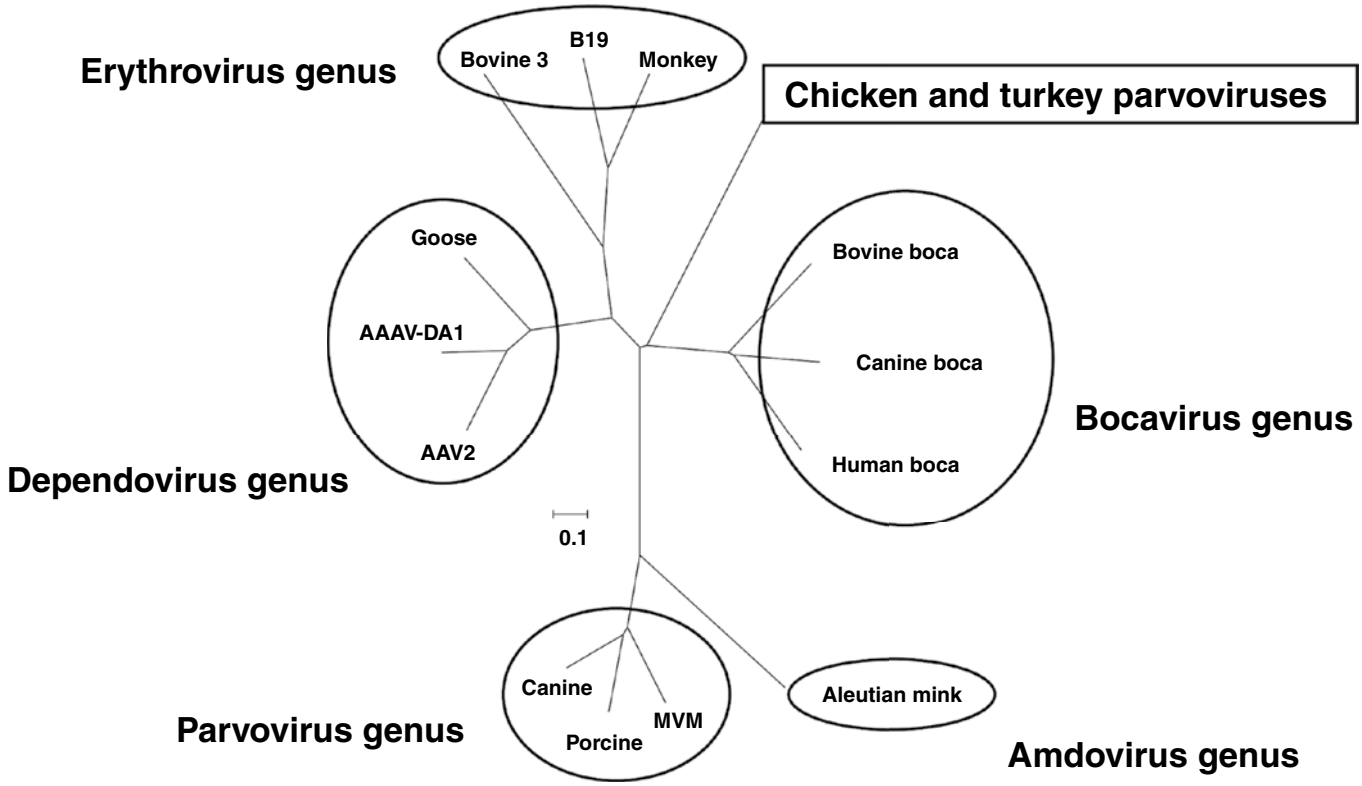

Figure 12.16. A phylogenetic tree prepared using the full coding sequence of the indicated parvoviruses. Representative genera within the *Parvovirinae* are indicated. The evolutionary relationships were inferred using the Neighbor-Joining method.

of the entire chicken parvovirus genome and the full-length coding region of the turkey parvovirus (3). Phylogenetic analysis of the complete coding sequence of chicken and turkey parvovirus genomes clearly indicates that these viruses are similar to each other, yet each differs significantly from other members of the *Parvovirus* subfamily within the family *Parvoviridae* (Figure 12.16). The high amino acid identities noted among the chicken and turkey isolates suggest that they diverged at some time in the recent past from a common ancestor. Based on the genome sequence analysis it is clear that the chicken and turkey parvoviruses represent distinct members of the *Parvovirinae* subfamily and should be recognized as the prototypical members of a novel genus within the *Parvovirinae*. A proposal to classify the chicken parvovirus (ChPV) and turkey parvovirus (TuPV) species is currently under consideration by the ICTV (26). The chicken and turkey parvoviruses are genetically distinct from the goose parvoviruses, which are in a different genus.

Morphology

Parvoviruses are small, isometric (icosahedral), nonenveloped DNA viruses that contain linear, single-stranded genomes (25). They are among the smallest of the isometric viruses with a virion diameter of about 25 nm (Figure 12.17). The virions contain a single genomic DNA molecule between 4 and 6 kilobases in length, which terminates in short palindromic sequences that can create duplex hairpin telomeres at both ends of the genome. In general, parvoviruses are extremely stable and are antigenically and structurally simple. Resistance to inactivation by organic solvents indicates that the virions lack essential lipids. None of the viral proteins are known to be glycosylated; the capsid shell is typically comprised of 60 copies of the 60-70 kDa structural virus protein VP2, which is encoded by the C terminal region of polypeptide VP1 (25).

Chicken parvoviruses were first detected using electron microscopy in samples taken from the gut of 10-day-old broilers, affected by stunting syndrome (7). The most typical particles measured 19–24 nm in diameter (Figure 12.17), and their buoyant density in CsCl ranged between 1.42 and 1.44 g/ml. Similarly, turkey parvoviruses were visualized in intestinal intranuclear inclusions of turkeys suffering from enteric disease (27). The individual particles had hexagonal profiles and were approximately 15–20 nm in diameter (Figure 12.17).

Chemical Composition

Further studies on the genome structure of the chicken parvovirus revealed that the virions contained a single genome which served as a template *in vitro* for second-strand synthesis in the presence of DNA polymerase and appropriate precursors (10). The converted double-stranded DNA migrated in agarose gels as a linear DNA of about 5,200 base pairs. The size and morphology of the virions together with their biochemical properties were characteristic to the members of the *Parvovirus* family. The fully assembled chicken parvovirus

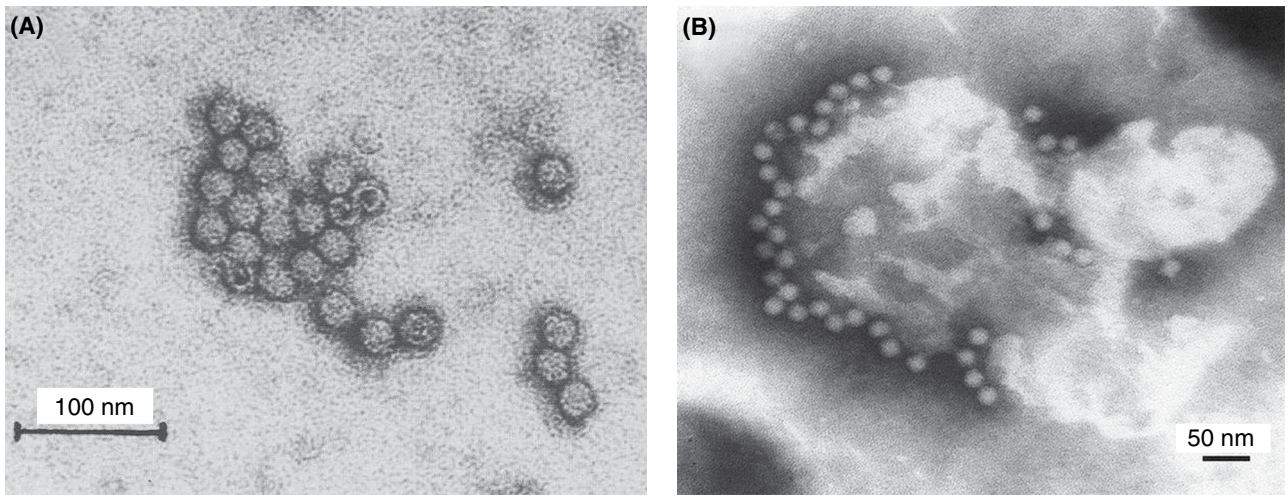

Figure 12.17. Electron micrograph of (A) purified chicken parvovirus (Janos Kisary) and (B) parvovirus from wild turkey fecal sample (Dallas Ingram).

genome is 5,275 nucleotides (nt) in length and has a basic organization similar to previously described members of the *Parvoviridae* (3). The genome is flanked on the 5^1 and 3^1 ends by 206-nt direct repeat sequences, each of which contains 39-nt inverted repeats presumed to form a hairpin structure similar to the structures common in other parvoviruses (4, 16, 23). The overall genomic organization of chicken and turkey parvoviruses is similar to that of other parvoviruses, with 2 major predicted open reading frames (ORFs). The 5^1 ORF is 2,095 nt long, and encodes for a nonstructural (NS1) protein. The deduced amino acid sequence of the NS1 protein contains highly conserved motifs important for the initiation of parvovirus replication and for pathogenesis (20). The major 3^1 ORF is 2,028 nt long, and encodes for the parvovirus capsid proteins VP1, VP2, and VP3. These 3 proteins together comprise the parvovirus virion (16) and are responsible for the induction of neutralizing antibodies during an infection (19).

Virus Replication

Chicken and turkey parvoviruses, like other autonomous parvoviruses, are able to replicate without helper viruses (11). TEM studies and immunohistochemistry (IHC) showed that the primary target cells for replication *in vivo* are located in the small intestine (7, 9, 18, 27, 29). The presence of parvovirus in the intestine of chickens showing stunting syndrome was first reported by Kisary et al. in 1984 (7). Negative contrast TEM revealed numerous parvovirus-like particles in the intestinal suspension taken from affected birds. In subsequent studies, specific nuclear fluorescence was seen in the epithelial cells in the small intestine of chickens infected experimentally with ChPV ABU strain at 1 day of age (9). Characteristic to parvovirus infection, brilliant nuclear staining was seen in the epithelial cells of the gut; the antigen filled up the whole nucleus. However, a more brilliant nuclear margin or granules scattered throughout the nucleus were more often seen. A similar finding was reported by Trampel et al. in 1983, who described the presence of turkey parvovirus-like particles in the epithelial cells of the small intestine (27). The size, shape, and intranuclear localization of the particles have been used to tentatively identify them as parvoviruses. Due to the failure to propagate chicken and turkey parvoviruses in cell culture or avian embryos, our knowledge about their replication mechanisms in infected cells is limited.

Susceptibility to Chemical and Physical Agents

Chicken parvovirus has been tested for stability in an effluent decontamination system (2). Although the nonenveloped parvoviruses are very resistant to inactivation, the study demonstrated that a standard treatment cycle of 82.2°C for 6 hours totally inactivated 6 $\log_{10}$/ml chicken infectious dose 50 of the chicken parvovirus ChPV-P1 strain.

Strain Classification

There is little information available about the antigenic relationships of chicken and turkey parvoviruses. ELISA using chicken parvovirus VP2 as antigen could successfully detect antibodies raised against various chicken and turkey isolates, indicating that these parvoviruses are closely related antigenically (22, 31, 32).

Although it is less reliable when applied at the species level, phylogenetic analysis is becoming the most frequently used technique for strain classification of parvoviruses (25). Comparative sequence analysis of full genome and partial genome sequences of chicken and turkey parvovirus strains in the United States, Hungary, and Croatia indicated that they are closely related, yet they represent different species within a putative new genus of *Parvovirinae* (1, 3, 17, 18, 30). Currently, strain classification is based on the phylogenetic analysis of a 561-bp polymerase chain reaction (PCR) amplicon from the highly conserved NS1 nonstructural viral gene (30). The phylogenetic tree constructed based on the nucleotide sequences of this NS1 gene segment revealed a dominant clustering of the virus strains of different species origin; however, occasionally parvoviruses from chickens grouped with turkey strains and vice versa (1, 18, 30).

Laboratory Host Systems

To date, chicken and turkey parvoviruses have not been isolated or propagated in embryonating chicken eggs or in cell culture. Although chicken parvovirus infection has been demonstrated in primary chicken fibroblast cell culture by indirect immunofluorescence (IF) staining of the nucleus with antiserum to the ChPV ABU strain, subsequent efforts to establish productive infection in cell cultures or in embryos were unsuccessful (11).

Pathogenicity

The pathogenic role of chicken and turkey parvoviruses in enteric disease syndromes of poultry requires further investigation. Although field and experimental data strongly suggest that they play a significant role in the etiology of enteric diseases, additional studies will be necessary to determine their exact pathogenic properties.

Pathobiology and Epizootiology

Incidence and Distribution

Recent surveys indicated that chicken and turkey parvoviruses are widely prevalent in poultry farms in the United States and several European countries, including Hungary, Poland, and Croatia (1, 17, 18, 24, 30). The first report was published in the United States, where a newly developed chicken and turkey parvovirus-specific diagnostic PCR assay was used to detect the parvoviruses in intestinal contents or in fecal materials of samples collected from commercial chicken and turkey flocks from different regions of the country (30). The data clearly showed that most, if not all, of the major poultry-producing states have poultry flocks in which parvovirus infection was detected. Like other parvovirus infections, chicken and turkey parvoviruses were present in young birds, as early as 4 days of age. Subsequent surveys demonstrated the presence of parvoviruses in several chicken and turkey flocks in Hungary (17, 18). It also has been shown that most of the virus-positive flocks experienced enteric disease syndromes and that the virus strains circulating in Hungary are genetically similar to those demonstrated in the United States. The presence of chicken and turkey parvoviruses in commercial poultry flocks experiencing enteric disease also has been reported in Croatia and Poland (1, 24).

Natural and Experimental Hosts

Commercial chickens and turkeys are the only natural hosts in which chicken and parvovirus infections were observed. Fast-growing broilers are the most susceptible to virus infection and clinical disease; however, productive virus replication has been documented in white leghorn chickens (8). Clinical disease could only be induced in broilers but not in white leghorns following experimental infection with the ChPV ABU strain (8).

Age of Host Commonly Affected

The susceptibility of birds to chicken and turkey parvovirus-induced enteric diseases is strongly age related (7, 18, 30). The most frequent infections occur within the first week of age and clinical signs appear between 7 and 28 days of life. Older birds do not show clinical signs but react to viral infection immunologically by producing virus-specific serum antibodies (31).

Transmission, Carriers, Vectors

Infected birds shed high concentrations of the virus in their feces as early as 4 days of age and this results in fast and efficient horizontal bird-to-bird transmission of the infection (31, 32). Because parvoviruses are very stable in the environment, infectious viruses can be easily detected in the litter, providing an additional source of productive infections to newly placed chicks. As with many other viruses, wild birds can be considered as potential carriers of avian parvoviruses. In fact, in a recent survey in the United States, TEM studies of wild turkey fecal samples showed the presence of parvovirus-like particles (5). PCR assay of the samples revealed chicken parvovirus-specific genomic sequences indicating that wild turkeys could play a direct or indirect role in virus transmission.

Clinical Signs

The main clinical signs associated with naturally occurring chicken and turkey parvovirus infections are described as infectious enteric disease syndrome of poultry and most often are called RSS of young broilers and PEMS of turkey poults. These syndromes are defined by rather nonspecific signs and are unlikely to be caused by a single disease agent. The commonly observed signs are: (1) impaired growth and poor feathering (because of this appearance of birds the syndrome is sometimes called "helicopter" disease) (7, 8, 13, 18); (2) intestinal malabsorption of nutrients such as carotenoids which results in the production of mucoid yellowish droppings and paleness of the birds, particularly in the shanks in affected broilers (8, 27); (2) watery diarrhea and mustard-yellow feces that can be observed as early as 4–7 days of age (13); and (4) osteoporosis that leads to bone deformation of the tibiae at the age of 2, 3, and 4 weeks (27). Case histories of parvovirus-associated enteropathy in turkeys included listlessness, depression, and stunting, and affected birds were reported to suffer from splayed legs (27). The economic significance of the enteric syndromes is primarily associated with poor production, failure of affected birds to grow, increased cost of therapy, poor feed conversion efficiency, and in severe forms immune dysfunction and increased mortality (3, 18).

Following experimental infection of young broiler chickens with chicken parvovirus, enteric disease syndrome was observed, characterized by serious growth retardation, poor feathering, and bone disorders (8). In the same study, similar signs were not seen in SPF white leghorn chickens, emphasizing that the syndrome is a typical "luxury disease" of the fast-growing chick (13). The broilers were infected at 1 day of age orally with the ABU parvovirus strain, which was purified from parvovirus-containing intestinal homogenates by sucrose and CsCl ultracentrifugation (8). The infected birds showed mild watery diarrhea and excreted light-yellow or mustard-yellow

feces for 7–10 days after infection. Importantly, by the fourth week of life the body weight gain of broiler chicks infected with the ABU parvovirus was nearly 40% lower than that of the controls. The difference was measurable by the seventh day of age and rapidly increased at subsequent weekly weighing. Retardation in growth was especially striking in the third and fourth weeks when there were considerable differences in body weight among infected birds. In addition to their retarded growth, the infected chicks showed disturbed feathering, their feathers being crumbled or absent from large areas of the body surface, and the metatarsal bones of poorly-developed birds were much more flexible than those of the uninfected controls. Similar results were obtained more recently in the United States with commercial and SPF broilers and turkey poults which were experimentally infected with chicken parvovirus ABU-P1 strain (a derivative of the ABU strain) and turkey parvovirus TuPV1078, respectively (31, 32). Following infection, 2-day-old SPF broiler chickens and turkey poults showed characteristic signs of enteric disease (watery diarrhea and growth retardation). Viral growth in the gut and shedding was detected at early times PI for 4–7 days, which was followed by viremia and generalization of infection. Chicken and turkey parvoviruses could be detected in most of the major tissues for at least 3 weeks PI. At the end of the study (35 days PI), the virus was still detectable at low levels in the intestine, spleen, and cloacal bursa.

When commercial broilers were used in experimental infections, a significant correlation was observed between the presence of parvovirus-specific maternal antibodies and disease outcome PI. In naturally acquired maternal antibody-positive birds, growth reduction (20% compared to controls) could be observed only during the first week PI, while in maternal antibody-negative chickens more significant and persistent impaired growth was detected. In the absence of parvovirus antibodies, infected birds showed 17%–42% weekly growth retardation for 4 consecutive weeks compared to the average weight of control uninfected chickens (31).

The effect of parvovirus infection on developing embryos is poorly understood. Trampel et al. reported in 1983 that poults showing parvovirus-associated enteropathy were known to have originated from eggs characterized by poor hatchability (27). Experimental infection of chicken embryos with the ABU parvovirus resulted in 15% death rate, the surviving embryos began to break through the egg shell 24–48 hours later than the uninfected controls, and on average, only 30%–40% of the embryos hatched (8). The chicks were poorly developed and 80%–90% of them died within 1 week post hatching. Prior to their death, the birds were reluctant to move, stayed close to the heat source, and had diarrhea with light mustard-yellow feces.

Pathology

The intestines are the major target organs in naturally occurring parvovirus-associated RSS and PEMS cases (7, 18, 27, 31, 32). In a recent study, naturally occurring parvovirus infections were described in Hungarian broiler flocks experiencing RSS and in young turkeys with PEMS (18). Examined birds from all of the flocks with clinical signs of enteric disease presented higher than normal daily mortality, stunted growth, and diarrhea. At necropsy, segments of the small intestine contained large amounts of gas and mucoid content. Histological examination revealed moderate to severe distension of the intestinal crypts and acute catarrhal enteritis in the jejunum and duodenum (Figure 12.18A). Nodular lymphohistiocytic pancreatitis also was observed (Figure 12.18C). TEM studies revealed the presence of parvovirus-like particles in the intestinal contents and positive nuclear staining was detected by indirect IHC in the epithelial cells and inflammatory cells from the lamina propria of the duodenum and jejunum in both chicken and turkey samples (Figure 12.18B). While the parvovirus specific staining was restricted to the small intestine in chickens, positive reactions were observed in the follicles of the cloacal bursa, liver, and exocrine pancreas in turkeys (Figure 12.18D).

Lesions observed at necropsy of turkeys affected with parvovirus-induced enteropathy also were restricted to the gastrointestinal tract (27). Gizzards contained large quantities of litter and grit but very little feed. The small intestines, and occasionally the ceca, were distended by mucus, gas, and fluid feces. In some flocks, the bones of several birds were extremely soft and pliable and would no longer break. Histopathological examination of tissues from poults disclosed the presence of intranuclear inclusion bodies within absorptive epithelial cells of the ileum. The inclusion bodies were round to oval, eosinophilic, and completely filled the nuclei, which were enlarged, and margination of chromatin was frequently observed around the periphery of the inclusion. Electron micrographs of ileal mucosa revealed that intranuclear inclusions were completely filled with loosely packed hexagonal virus particles of 15–20 nm in diameter. The size, morphology, and intranuclear location of turkey parvovirus particles within the inclusion bodies were consistent with other parvoviruses, including the goose parvovirus (21).

In experimental infections, parvovirus replication was detected by IHC in the small intestine of infected broilers and turkey poults (31, 32). Virus replication was most prevalent in the epithelial cells of the duodenal portions; however, PCR assays indicated the virus presence in different sections of the small intestine between 4 and 35 days PI. Generalization of infection occurred between 7 and 14 days PI and presence of parvovirus in liver, spleen, and thymus could be detected by PCR through the end of the study at 5 weeks of life.

Pathogenesis of the Infectious Process

It has been well documented that chicken and turkey parvoviruses or their DNA can be frequently detected from both healthy and diseased individuals, especially at an early age (17, 18, 30). Importantly, it was shown that maternally acquired virus-specific antibodies play a significant role in the epidemiology of clinical disease, and the level of passive immunity determines the susceptibility of the progeny following virus infection (31). Complex sero-epidemiological studies will be necessary to understand the exact mechanism(s) of the infectious process in parvovirus-induced enteric diseases.

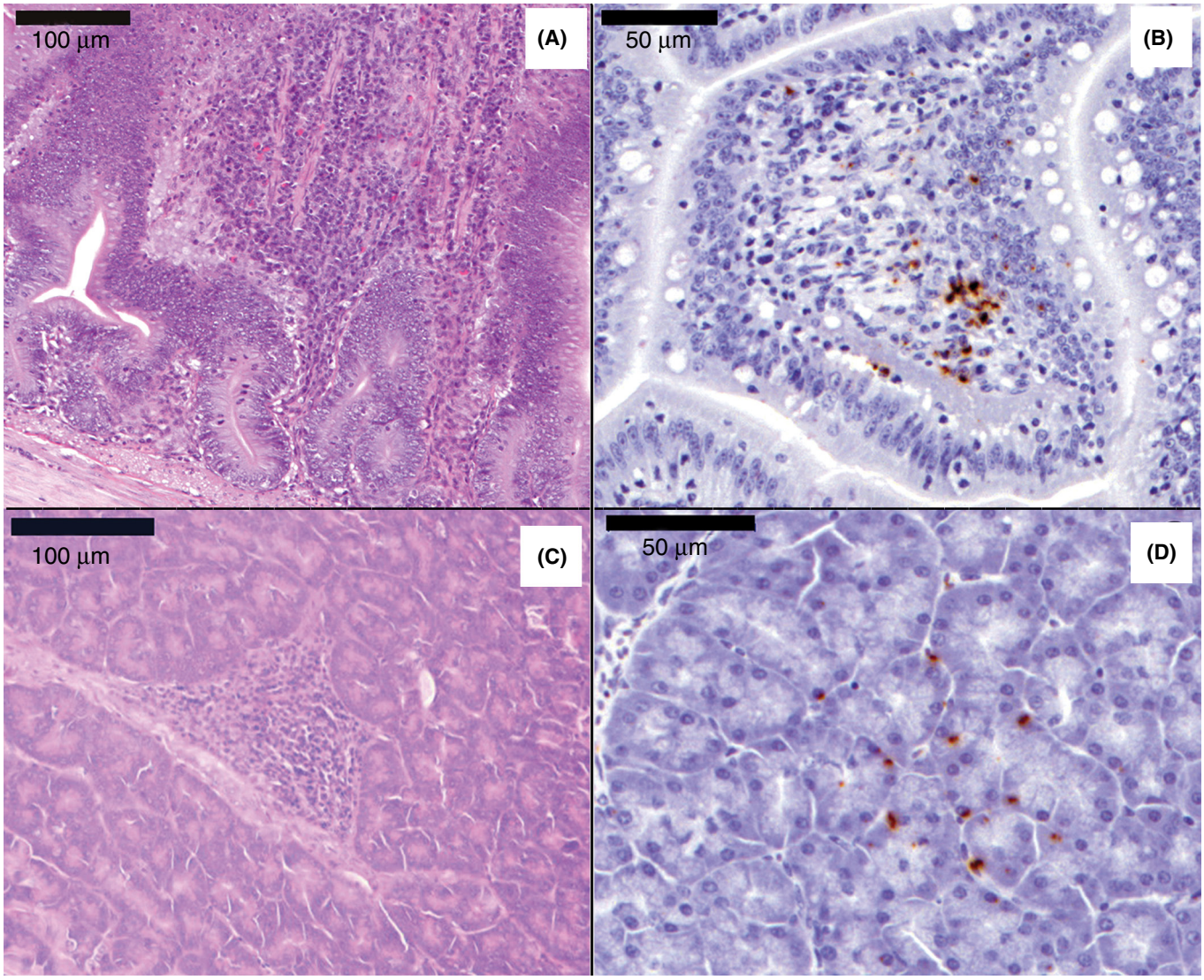

Figure 12.18. Distension of crypts with increased number of mononuclear leukocytes in the (A) jejunum and (B) nodular pancreatitis, with (C) lymphocytes and histiocytes in parvovirus-infected chickens. Indirect IHC staining shows parvovirus-positive nuclear staining in the inflammatory cells from the lamina propria of (B) jejunum and staining in the (D) exocrine pancreas. (Elena Alina Palade)

Immunity

Passive Immunity

Adult breeding chickens and turkeys that have been naturally infected with parvoviruses transfer maternal IgG type antibodies through the egg yolk to their progenies (22, 31). This passively acquired immunity progressively declines, halves at about 14 days of age, and cannot be detected after 3 weeks of life. The presence of maternally derived antibody has a significant correlation with protection against chicken parvovirus-induced enteric disease (31).

Active Immunity

Chickens and turkeys inoculated with parvoviruses developed antibody response as early as 4–7 days PI (22, 31). Using an immunoglobulin class-specific ELISA it has been shown that the primary antibody response was IgM type that subsequently converted into IgG type of serum antibodies (22). These antibodies could be detected for at least 35 days PI in experimental conditions. Similar serum antibody response was demonstrated in chickens following inoculation with a baculovirus vector that expressed chicken parvovirus VP2 protein (22, 31). The level and duration of antibody response, however, was somewhat lower than those observed following live virus infections.

Diagnosis

Electron microscopy was the main technique to identify parvovirus infections in chicken and turkey flocks during the early 1980s (7, 27). An indirect IF assay was developed by Kisary in 1985 for direct detection of viral antigens to monitor parvovirus infections in broiler flocks (9). Positive cells were detected in the intestinal tract of chicken parvovirus-infected birds and

no specific fluorescence was observed when anti-goose parvovirus antibody was used. These data agreed with previous observations, which indicated that goose parvovirus was not neutralized by serum against chicken parvovirus (9).

In more recent studies, comparative genome sequence analysis indicated a high level of homology of chicken and turkey parvovirus NS1 nonstructural genes, and a diagnostic PCR test targeting those regions was developed (30). This conventional PCR assay proved to be highly sensitive and specific to detecting parvoviruses of both chicken and turkey origin in clinical samples from experimentally infected birds and field samples (1, 17, 18, 30, 31, 32). For quick detection of chicken parvovirus in field samples a real time PCR also was developed and found to be more sensitive and less laborious than the previously described PCR test (24).

Serologic assays are frequently used as diagnostic tools to confirm the presence of parvoviral infections and to evaluate the immune status of parents and their progeny. To detect parvovirus-specific antibodies in chicken serum samples a capture ELISA was developed (22). A previously described approach was used to clone and express viral structural proteins in insect cells from recombinant baculovirus vectors (6, 12, 14). Baculovirus-expressed structural viral protein VP2 was then employed as antigen to develop an ELISA for detection of immunoglobulins directed against structural determinants in the viral particle. This ELISA demonstrated the presence of maternally derived parvovirus-specific antibodies in chicken serum samples and virus-specific antibodies in sera following experimental infection of birds (22).

Intervention Strategies

Management Procedures

The widespread occurrence of parvoviruses in poultry suggests that it is not practical to keep commercial flocks free from infections. Sound biosecurity measures are necessary to prevent accumulation of virus on the premises and control the spread of parvoviruses directly or indirectly by feces, litter, boots, or equipment. Parvoviruses are exceptionally stable and can survive for a long time in the environment (25). If litter is being reused several times combined with a short down time between placements, parvovirus infection will build up, and infection of newly placed birds will likely result in much more severe diseases compared to those flocks with which fresh litter is used more frequently.

Vaccination

At this time there is no commercial vaccine to prevent parvovirus-induced enteric diseases in poultry. Given the difficulties to propagate the viruses *in vitro* there are obvious challenges for vaccine development. It has been shown that maternal antibodies to chicken parvoviruses can reduce the severity of the disease (31), indicating that vaccination of breeder flocks would likely result in protection of the progeny during the most susceptible early days of their lives.

References

Turkey Coronavirus Enteritis

1. Adams, N.R., and M.S. Hofstad. 1971. Isolation of transmissible enteritis agent of turkeys in avian embryos. *Avian Dis*. 15:426–433.
2. Adams, N.R., R.A. Ball, and M.S. Hofstad. 1970. Intestinal lesions in transmissible enteritis of turkeys. *Avian Dis*. 14:392–399.
3. Adams, N.R., R.A. Ball, C.L. Annis, and M.S. Hofstad. 1972. Ultrastructural changes in the intestines of turkey poults and embryos affected with transmissible enteritis. *J Comp Pathol*. 82:187–192.
4. Akin, A., T.L. Lin, C.C. Wu, T.A. Bryan, T. Hooper, and D. Schrader. 2001. Nucleocapsid protein gene sequence analysis reveals close genomic relationship between turkey coronavirus and avian infectious bronchitis virus. *Acta Virol*. 45:31–38.
5. Breslin, J.J., L.G. Smith, F.J. Fuller, and J.S. Guy. 1999. Sequence analysis of the matrix/nucleocapsid gene region of turkey coronavirus. *Intervirology*. 42:22–29.
6. Breslin, J.J., L.G. Smith, F.J. Fuller, and J.S. Guy. 1999. Sequence analysis of the turkey coronavirus nucleocapsid protein gene and 3′ untranslated region identifies the virus as a close relative of infectious bronchitis virus. *Virus Res*. 65:187–193.
7. Breslin, J.J., L.G. Smith, H.J. Barnes, and J.S. Guy. 2000. Comparison of virus isolation, immunohistochemistry, and reverse transcriptase-polymerase chain reaction procedures for detection of turkey coronavirus. *Avian Dis*. 44:624–631.
8. Cao, J.C., C. Wu, and T.L. Lin. 2008. Complete nucleotide sequence of turkey coronavirus. *Virus Res*. 136:43–49.
9. Calibeo-Hayes, D., S.S. Denning, S.M. Stringham, J.S. Guy, L.G. Smith, and D.W. Watson. 2003. Mechanical transmission of turkey coronavirus by domestic house flies (*Musca domestica Linneaus*). *Avian Dis*. 47:149–153.
10. Cardoso, T.C., T.L. Castanheira, M.C. Teixeira, A.C. Rosa, K.Y. Hirata, R.D. Astolphi, and M.C. Luvizotto. 2008. Validation of an immunohistochemistry assay to detect turkey coronavirus: a rapid and simple screening tool for limited resource settings. *Poult Sci*. 87:1347–1352.
11. Cardoso, T.C., H.F. Ferrari, L.C. Bregano, C. Silva-Frade, A.C. Rosa, and A.L. Andrade. 2010. Visual detection of turkey coronavirus RNA in tissues and feces by reverse-transcriptional loop-mediated isothermal amplification (RT-LAMP) with hydroxynaphthol blue dye. *Mol Cell Probes*. 24:415–417.
12. Cavanagh, D. 2001. A nomenclature for avian coronavirus isolates and the question of species status. *Avian Pathol*. 30:109–115.
13. Cavanagh, D. 2005. Coronaviruses in poultry and other birds. *Avian Pathol* 34:439–448.
14. Cavanagh, D., K. Mawditt, M. Sharma, S.E. Drury, H.L. Ainsworth, P. Britton, and R.E. Gough. 2001. Detection of a coronavirus from turkey poults in Europe genetically related to infectious bronchitis virus of chickens. *Avian Pathol*. 30:355–368.
15. Chen, Y.N., C.C. Wu, T. Bryan, T. Hooper, D. Schrader, and T.L. Lin. 2010. Specific real-time reverse transcriptase-polymerase chain reaction for detection and quantitation of turkey corona-

virus RNA in tissues and feces of turkeys infected with turkey coronavirus. *J Virol Methods*. 163:452–458.
16. Dea, S., and P. Tijssen. 1988. Viral agents associated with outbreaks of diarrhea in turkey flocks in Quebec. *Can J Vet Res*. 52:53–57.
17. Dea, S., S. Garzon, and P. Tijssen. 1989. Isolation and trypsin-enhanced propagation of turkey enteric (bluecomb) coronaviruses in a continuous human rectal adenocarcinoma cell line. *Am J Vet Res*. 50:1310–1318.
18. Dea, S., A. Verbeek, and P. Tijssen. 1991. Transmissible enteritis of turkeys: experimental inoculation studies with tissue-culture-adapted turkey and bovine coronaviruses. *Avian Dis*. 35:767–777.
19. Deshmukh, D.R., and B.S. Pomeroy. 1974. Physicochemical characterization of a bluecomb coronavirus of turkeys. *Am J Vet Res*. 35:1549–1552.
20. Deshmukh, D.R., C.T. Larsen, and B.S. Pomeroy. 1973. Survival of bluecomb agent in embryonating turkey eggs and cell cultures. *Am J Vet Res*. 34:673–675.
21. Dziuk, H.E., G.E. Duke, and O.A. Evanson. 1970. Milk replacer, electrolytes, and glucose for treating bluecomb in turkeys. *Poult Sci*. 49:226–229.
22. Gomaa, M.H., D. Yoo, D. Ojkic, and J.R. Barta. 2008. Complete genomic sequence of turkey coronavirus. *Virus Res*. 135:237–246.
23. Gomaa, M.H., D. Yoo, D. Ojkic, and J.R. Barta. 2009. Use of a recombinant S1 spike polyprotein to develop a TCoV-specific antibody ELISA. *Vet Micro*. 138:281–288.
24. Gomaa, M.H., D. Yoo, D. Ojkic, and J.R. Barta. 2009. Virus shedding and serum antibody responses during experimental turkey coronavirus infections in young turkey poults. *Avian Pathol*. 38:181–186.
25. Gonder, E., B.L. Patel, and B.S. Pomeroy. 1976. Scanning electron, light, and immunofluorescent microscopy of coronaviral enteritis of turkeys (bluecomb). *Am J Vet Res*. 37:1435–1439.
26. Guy, J.S. 1998. New methods for diagnosis of turkey coronavirus infections. Proc 49th North Central Avian Dis. Conf, Indianapolis, Indiana. 8–10.
27. Guy, J.S. 2000. Turkey coronavirus is more closely related to avian infectious bronchitis virus than to mammalian coronaviruses: a review. *Avian Pathol*. 29:207–212.
28. Guy, J.S. 2008. Isolation and propagation of coronaviruses in embryonated eggs. *Methods Mol Biol*. 454:109–117.
29. Guy, J.S., H.J. Barnes, L.G. Smith, and J. Breslin. 1997. Antigenic characterization of a turkey coronavirus identified in poult enteritis and mortality syndrome-affected turkeys. *Avian Dis*. 41:583–590.
30. Guy, J.S., H.J. Barnes, L.G. Smith, and J.J. Breslin. 1999. Experimental infection of specific-pathogen-free chickens with turkey coronavirus. *Proc West Poult Dis Conf*. 48:91–92.
31. Guy, J.S., L.G. Smith, J.J. Breslin, J.P. Vaillancourt, and H.J. Barnes. 2000. High mortality and growth depression experimentally produced in young turkeys by dual infection with enteropathogenic *Escherichia coli* and turkey coronavirus. *Avian Dis*. 44:105–113.
32. Guy, J.S., L.G. Smith, J.J. Breslin, and S. Pakpinyo. 2002. Development of a competitive enzyme-linked immunosorbent assay for detection of turkey coronavirus antibodies. *Avian Dis*. 46:334–341.
33. Hofstad, M.S., N. Adams, and M.L. Frey. 1969. Studies on a filterable agent associated with infectious enteritis (bluecomb) of turkeys. *Avian Dis*. 13:386–393.
34. Hooper, T.A., and J.S. Guy. 1998. Identification of turkey coronavirus infections in commercial turkey flocks. *Proc West Poult Dis Conf*. 47:42.
35. Ismail, M.M., K.O. Cho, L.A. Ward, L.J. Saif, and Y.M. Saif. 2001. Experimental bovine coronavirus in turkey poults and young chickens. *Avian Dis*. 45:157–163.
36. Ismail, M.M., K.O. Cho, M. Hasoksuz, L.J. Saif, and Y.M. Saif. 2001. Antigenic and genomic relatedness of turkey-origin coronaviruses, bovine coronaviruses, and infectious bronchitis virus of chickens. *Avian Dis*. 45:978–984.
37. Ismail, M.M., Y. Tang, and Y.M. Saif. 2003. Pathogenicity of turkey coronavirus in turkeys and chickens. *Avian Dis*. 47:515–522.
38. Jackwood, M.W., T.O. Boynton, D.A. Hilt, E.T. McKinley, J.C. Kissinger, A.H. Paterson, J. Robertson, C. Lemke, A.W. McCall, S.M. Williams, J.W. Jackwood, and L.A. Byrd. 2010. Emergence of a group 3 coronavirus through recombination. *Virology*. 398:98–108.
39. Lin, T.L., C.C. Loa, C.C. Wu, T. Bryan, T. Hooper, and D. Schrader. 2002. Antigenic relationship of turkey coronavirus isolates from different geographic locations in the United States. *Avian Dis*. 46:466–467.
40. Lin, T.L., C.C. Loa, and C.C. Wu. 2002. Existence of gene 5 indicates close genomic relationship of turkey coronavirus to infectious bronchitis virus. *Acta Virol*. 46:107–116.
41. Lin, T.L., C.C. Loa, and C.C. Wu. 2004. Complete sequences of 3′ end coding region for structural genes of turkey coronavirus. *Virus Res*. 106:61–70.
42. Loa, C.C., T.L. Lin, C.C. Wu, T.A. Bryan, H.L. Thacker, T. Hooper, and D. Schrader. 2000. Detection of antibody to turkey coronavirus by antibody-capture enzyme-linked immunosorbent assay utilizing infectious bronchitis virus antigen. *Avian Dis*. 44:498–506.
43. Loa, C.C., T.L. Lin, C.C. Wu, T.A. Bryan, H.L. Thacker, T. Hooper, and D. Schrader. 2001. Humoral and cellular immune responses in turkey poults infected with turkey coronavirus. *Poult Sci*. 80:1416–1424.
44. Loa, C.C., T.L. Lin, C.C. Wu, T.A. Bryan, T. Hooper, and D. Schrader. 2002. Specific mucosal IgA immunity in turkey poults infected with turkey coronavirus. *Vet Immunol Immunopathol*. 88:57–64.
45. Loa, C.C., T.L. Lin, C.C. Wu, T.A. Bryan, and D. Schrader. 2004. Expression and purification of turkey coronavirus nucleocapsid protein in *Escherichia coli*. *J Virol Methods*. 116:161–167.
46. Loa, C.C., T.L. Lin, C.C. Wu, T.A. Bryan, T.A. Hooper, and D.L. Schrader. 2005. Differential detection of turkey coronavirus, infectious bronchitis virus, and bovine coronavirus by a multiplex polymerase chain reaction. *J Virol Methods*. 131:86–91.
47. Maurel, S., D. Toquin, F.X. Briand, M. Queguiner, C. Allee, J. Bertin, L. Ravillion, C. Retaux, V. Turblin, H. Morvan, and N. Eterradossi. 2011. First full-length sequences of the S gene of European isolates reveal further diversity among turkey coronavirus. *Avian Pathol*. 40:179–189.
48. Moon, H.W. 1978. Mechanisms in the pathogenesis of diarrhea. *J Am Vet Med Assoc*. 172:443–448.
49. Nagaraja, K.V., and B.S. Pomeroy. 1978. Secretory antibodies against turkey coronaviral enteritis. *Am J Vet Res*. 39:1463–1465.
50. Nagaraja, K.V., and B.S. Pomeroy. 1980. Cell-mediated immunity against turkey coronaviral enteritis (bluecomb). *Am J Vet Res*. 41:915–917
51. Nagaraja, K.V., and B.S. Pomeroy. 1980. Immunofluorescent studies on localization of secretory immunoglobulins in the

intestines of turkeys recovered from turkey coronaviral enteritis. *Am J Vet Res*. 41:1283–1284.
52. Nagaraja, K.V., and B.S. Pomeroy. 1997. Coronaviralenteritis of turkeys (bluecomb disease). In: *Diseases of Poultry*, 10th ed. B.W. Calnek, H.J. Barnes, C.W. Beard, L.R. McDougald, and Y.M. Saif, eds. Iowa State University Press, Ames, Iowa. 686–692.
53. Naqi, S.A. 1993. Coronaviral enteritis of turkeys. In: *Virus Infections of Birds*. J.B. McFerran and M.S. McNulty, eds. Elsiever Science Publishers, New York. 277–281.
54. Naqi, S.A., C.F. Hall, and D.H. Lewis. 1971. The intestinal microflora of turkeys: Comparison of apparently healthy and bluecomb-infected turkey poults. *Avian Dis*. 15:14–21.
55. Naqi, S.A., B. Panigrahy, and C.F. Hall. 1972. Bursa of Fabricius, a source of bluecomb infectious agent. *Avian Dis*. 16:937–939.
56. Pakpinyo, S., D.H. Ley, H.J. Barnes, J.P. Vaillancourt, and J.S. Guy. 2003. Enhancement of enteropathogenic *Escherichia coli* pathogenicity in young turkeys by concurrent turkey coronavirus infection. *Avian Dis*. 47:396–405.
57. Panigrahy, B., S.A. Naqi, and C.F. Hall. 1973. Isolation and characterization of viruses associated with transmissible enteritis (bluecomb) of turkeys. *Avian Dis*. 17:430–438.
58. Patel, B.L., D.R. Deshmukh, and B.S. Pomeroy. 1975. Fluorescent antibody test for rapid diagnosis of coronaviral enteritis of turkeys (bluecomb). *Am J Vet Res*. 36:1265–1267.
59. Patel, B.L., B.S. Pomeroy, E. Gonder, and C.E. Cronkite. 1976. Indirect fluorescent antibody test for the diagnosis of coronaviral enteritis of turkeys (bluecomb). *Am J Vet Res*. 37:1111–1112.
60. Patel, B.L., E. Gonder, and B.S. Pomeroy. 1977. Detection of turkey coronaviral enteritis (bluecomb) in field epiornithics, using the direct and indirect fluorescent antibody tests. *Am J Vet Res*. 38:1407–1411.
61. Peterson, E.H., and T.A. Hymas. 1951. Antibiotics in the treatment of unfamiliar turkey disease. *Poult Sci*. 30:466–468.
62. Pomeroy, B.S., and J.M. Sieburth. 1953. Bluecomb disease of turkeys. *Proc Ann Meet Am Vet Med Assoc*. 90:321–328.
63. Pomeroy, B.S., C.T. Larsen, D.R. Deshmukh, and B.L. Patel. 1975. Immunity to transmissible (coronaviral) enteritis of turkeys (bluecomb). *Am J Vet Res*. 36:553–555.
64. Pomeroy, K.A., B.L. Patel, C.T. Larsen, and B.S. Pomeroy. 1978. Combined immunofluorescence and transmission electron microscopic studies of sequential intestinal samples from turkey embryos and poults infected with turkey enteritis coronavirus. *Am J Vet Res*. 39:1348–1354.
65. Reynolds, D., and C.C. Wu. 2008. Enteric viruses. In: *Isolation and Identification of Avian Pathogens*, 5th ed. L. Dufour-Zavala, D. Swayne, J. Glisson, J. Pearson, W. Reed, M. Jackwood, and P. Woolcock, eds. American Association of Avian Pathologists, Kennett Square, Pennsylvania. 153–163.
66. Ritchie, A.E., D.R. Deshmukh, C.T. Larsen, and B.S. Pomeroy. 1973. Electron microscopy of coronavirus-like particles characteristic of turkey bluecomb disease. *Avian Dis*. 17:546–558.
67. Saif, L.J. 1989. Comparative aspects of enteric viral infections. In: *Viral Diarrheas of Man and Animals*. L.J. Saif and K.W. Thiel, eds. CRC Press, Inc., Boca Raton, Florida. 9–31.
68. Sellers, H.S., M.D. Koci, E. Linnemann, L.A. Kelley, and S. Schultz-Cherry. 2004. Development of a multiplex reverse transcriptase-polymerase chain reaction diagnostic test for turkey astrovirus and coronavirus. *Avian Dis*. 48:531–539.
69. Siddell, S.G. 1995. The Coronaviridae: an introduction. In: *Coronaviridae*. S. Siddell, ed. Plenum Press, Inc., New York. 1–9.
70. Sieburth, J.M., and B.S. Pomeroy. 1956. Bluecomb disease of turkeys. II. Antibiotic treatment of poults. *J Am Vet Med Assoc*. 128:509–513.
71. Sieburth, J.M., and E.P. Johnson. 1957. Transmissible enteritis of turkeys (bluecomb disease). I. Preliminary studies. *Poult Sci*. 36:256–261.
72. Spackman, E., D. Kapczynski, and H. Sellers. 2005. Multiplex real-time reverse transcription-polymerase chain reaction for the detection of three viruses associated with poult enteritis complex: turkey astrovirus, turkey coronavirus, and turkey reovirus. *Avian Dis*. 49:86–91.
73. Spaan, W., D. Brian, D. Cavanagh, R. de Groot, L. Enjuanes, A. Gorbalenya, K. Holmes, P. Masters, P. Rottier, F. Taguchi, and P. Talbot. 2005. Coronaviridae. In: *Virus Taxonomy: Eighth Report of the International Committee on Taxonomy of Viruses*. C. Fauquet, M. Mayo, J. Maniloff, U. Desselberger, and L. Ball, eds. Academic Press, San Diego. 947–964.
74. Stephensen, C.B., D.B. Casebolt, and N.N. Gangopadhyay 1999. Phylogenetic analysis of a highly conserved region of the polymerase gene from eleven coronaviruses and development of a consensus polymerase chain reaction assay. *Virus Res*. 60:181–189.
75. Teixera, M.C., M.C. Luvizotto, H.F. Ferrari, A.R. Mendes, S.E. da Silva, and T.C. Cardoso. 2007. Detection of turkey coronavirus in commercial turkey poults in Brazil. *Avian Pathol*. 36:29–33.
76. Tumlin, J.T., and B.S. Pomeroy. 1958. Bluecomb disease of turkeys. V. Preliminary studies on parental immunity and serum neutralization. *Am J Vet Res*. 19:725–728.
77. Velayudhan, B.T., H.J. Shin, V.C. Lopes, T. Hooper, D.A. Halvorson, and K.V. Nagaraja. 2003. A reverse transcriptase-polymerase chain reaction assay for the diagnosis of turkey coronavirus infection. *J Vet Diagn Invest*. 15:592–596.
78. Watson, D.W., J.S. Guy, and S.M. Stringham. 2000. Limited transmission of turkey coronavirus in young turkeys by adult *Alphitobius diapernius* (Coleoptera: Tenebrionidae). *J Med Entomol*. 37:480–483.

Rotavirus Infections

1. Akimkin, V., F. Bindel, M. Hoferer, R. Sting, B. Polley, A. Hanel, and H.M. Hafez. 2011. One-step RT-qPCR with an internal control system for the detection of turkey rotaviruses in faecal samples. *J Virol Methods*. 177:112–7.
2. Alfieri, A.F., M. Resende, J.S. Resende, and A.A. Alfieri. 1989. Atypical rotavirus infections among broiler chickens in Brazil. *Arq Bras Med Vet Zoot*. 41:81–82.
3. Asano, K.M., F. Gregori, S.P. Souza, D. Rotava, R.N. Oliveira, L.Y. Villarreal, L.J. Richtzenhain, and P.E. Brandao. 2011. *Bovine* rotavirus in turkeys with enteritis. *Avian Dis*. 55:697–700.
4. Attoui, H., P.P.C. Mertens, J. Becnel, S. Belaganahalli, S. Bergoin, C.P. Brussaard, J.D. Chappell, M. Ciarlet, M. del Vas, T.S. Dermody, P.R. Dormitzer, R. Duncan, Q. Fang, R. Graham, K.M. Guglielmi, R.M. Harding, B. Hillman, A. Makkay, C. Marzachi, J. Matthijnssens, R.G. Milne, F. Mohd Jaafar, H. Mori, A.A. Noordeloos, T. Omura, J.T. Patton, S. Rao, M. Maan, D. Stoltz, N. Suzuki, N.M. Upadhyaya, C. Wei, and H. Zhou. 2012. Reoviridae. In: *Virus Taxonomy: Ninth Report of the International Committee on Taxonomy of Viruses*. A.M.Q. King, M.J. Adams, E.B. Carstens, and E. Lefkowitz, eds. Elsevier, Amsterdam. 541–637.

5. Bakulin, V.A., A.S. Aliev, E.D. Dzhavadov, I.I. Tul'skaya, S.S. Vashukova, E.N. Gorbachev, and S.N. Verbov. 1991. Morphology of avian rotavirus and the lesions it produces in chicks. *Veterinariya (Moskva)*. 1:36–37.
6. Ball, J.M., D.M. Mitchell, T.F. Gibbons, and R.D. Parr. 2005. Rotavirus NSP4: a multifunctional viral enterotoxin. *Viral Immunol*. 18:27–40.
7. Ball, J.M., P. Tian, C.Q. Zeng, A.P. Morris, and M.K. Estes. 1996. Age-dependent diarrhea induced by a rotaviral nonstructural glycoprotein. *Science*. 272:101–104.
8. Barnes, H.J., and J.S. Guy. 2003. Poult enteritis mortality syndrome. In: *Diseases of Poultry*, 11th ed. Y.M. Saif, ed. Iowa State Press, Ames, Iowa. 1171–1180.
9. Barnes, H.J., J.S. Guy, and J.P. Vaillancourt. 2000. Poult enteritis complex. *Rev Sci Tech*. 19:565–588.
10. Bellinzoni, R., N. Mattion, L. Vallejos, J.L. La Torre, and E.A. Scodeller. 1987. Atypical rotavirus in chickens in Argentina. *Res Vet Sci*. 43:130–1.
11. Bergeland, M.E., J.P. McAdaragh, and I. Stotz. 1977. Rotaviral enteritis in turkey poults. *West Poult Dis Conf*. 26:129–130.
12. Brussow, H., O. Nakagomi, G. Gerna, and W. Eichhorn. 1992. Isolation of an avianlike group A rotavirus from a calf with diarrhea. *J Clin Microbiol*. 30:67–73.
13. Brussow, H., O. Nakagomi, N. Minamoto, and W. Eichhorn. 1992. Rotavirus 993/83, isolated from calf faeces, closely resembles an avian rotavirus. *J Gen Virol*. 73:1873–5.
14. Carstens, E.B. 2010. Ratification vote on taxonomic proposals to the International Committee on Taxonomy of Viruses (2009). *Arch Virol*. 155:133–146.
15. Castro, A.E., J. Moore, S. Hammami, R.B. Manalac, and R.P. Chin. 1992. Direct isolation of rotaviruses from turkeys in embryonating chicken eggs. *Vet Rec*. 130:379–80.
16. Chmielewski, R., J.M. Day, S. Spatz, Q. Yu, R. Gast, L. Zsak, and D.E. Swayne. 2011. Thermal inactivation of avian viral and bacterial pathogens in an effluent treatment system within a biosafety level 2 and 3 enhanced facility. *Appl Biosaf*. 16:206–217.
17. Ciarlet, M., M.E. Conner, M.J. Finegold, and M.K. Estes. 2002. Group A rotavirus infection and age-dependent diarrheal disease in rats: a new animal model to study the pathophysiology of rotavirus infection. *J Virol*. 76:41–57.
18. Day, J.M., E. Spackman, and M. Pantin-Jackwood. 2007. A multiplex RT-PCR test for the differential identification of turkey astrovirus type 1, turkey astrovirus type 2, chicken astrovirus, avian nephritis virus, and avian rotavirus. *Avian Dis*. 51:681–684.
19. Despins, J.L., R.C. Axtell, D.V. Rives, J.S. Guy, and M.D. Ficken. 1994. Transmission of enteric pathogens of turkeys by darkling beetle larvae (*Alphitobius diaperinus*). *J Appl Poult Res*. 3:61–65.
20. Desselberger, U. 2000. Rotaviruses: basic facts. In: *Rotaviruses: Methods and Protocols*. J. Gray and U. Desselberger, eds. Humana Press, Totowa, N.J. Series: Methods in Molecular Medicine 34:1–8.
21. Devitt, C.M., and D.L. Reynolds. 1993. Characterization of a group D rotavirus. *Avian Dis*. 37:749–55.
22. Dormitzer, P.R., E.B. Nason, B.V. Prasad, and S.C. Harrison. 2004. Structural rearrangements in the membrane penetration protein of a non-enveloped virus. *Nature*. 430:1053–1058.
23. Dormitzer, P.R. 2008. Rotavirus cell entry. In: *Segmented Double-Stranded RNA Viruses*. J.T. Patton, ed. Caister Academic Press, Norfolk, UK. 189–214.
24. Els, H.J., and D. Josling. 1998. Viruses and virus-like particles identified in ostrich gut contents. *J S African Vet Association*. 69:74–80.
25. Elschner, M., H. Hotzel, J. Reetz, R. Diller, and P. Otto. 2005. Isolation, identification and characterization of group A rotavirus from a chicken: the inner capsid protein sequence shows only a distant phylogenetic relationship to most other avian group A rotaviruses. *J Vet Med B*. 52:211–213.
26. Estes, M.K., and A.Z. Kapikian. 2007. Rotaviruses. In: *Fields Virology*, vol. 2. D.M. Knipe, P.M. Howley, D.E. Griffin, R.A. Lamb, M.A. Martin, B. Roizman, and S.E. Straus, eds. Lippincott Williams & Wilkins, Philadelphia. 1917–1974.
27. Foni, E., D. Gelmetti, A.D. Nigrelli, R. Gatti, and V. Carra. 1989. Transmissible enteritis syndrome in pheasants for restocking: experimental reproduction of the disease. *Selezione veterinaria*. 30:879–888.
28. Fraga, M., M.T. Frias, A. Moreno, and R. L'haridon. 1985. Diagnosis of rotavirus in broilers. *Revista de Salud Animal*. 1:13–18.
29. Franco, M.A., and H.B. Greenberg. 2009. Rotaviruses. In: *Clinical Virology*. D.D. Richman, R.J. Whitley, and F.G. Hayden, eds. American Society for Microbiology, Washington, D.C. 797–816.
30. Gary, G.W., Jr., D.R. Black, and E. Palmer. 1982. Monoclonal IgG to the inner capsid of human rotavirus. *Arch Virol*. 72:223–7.
31. Gough, R.E., M.S. Collins, D.J. Alexander, and W.J. Cox. 1990. Viruses and virus-like particles detected in samples from diseases game birds in Great Britain during 1988. *Avian Pathol*. 19:331–343.
32. Gough, R.E., M.S. Collins, G.W. Wood, and S.A. Lister. 1988. Isolation of a chicken embryo-lethal rotavirus from a lovebird (Agapornis species). *Vet Rec*. 122:363–4.
33. Gough, R.E., W.J. Cox, and C. Davis. 1999. Studies with an inactivated pheasant rotavirus vaccine. *Vet Rec*. 144:423–4.
34. Gough, R.E., W.J. Cox, and J. Devoy. 1992. Isolation and identification of rotavirus from racing pigeons. *Vet Rec*. 130:273.
35. Gough, R.E., G.W. Wood, M.S. Collins, D. Spackman, J. Kemp, and L.A. Gibson. 1985. Rotavirus infection in pheasant poults. *Vet Rec*. 116:295.
36. Gough, R.E., G.W. Wood, and D. Spackman. 1986. Studies with an atypical avian rotavirus from pheasants. *Vet Rec*. 118:611–2.
37. Greenberg, H., V. McAuliffe, J. Valdesuso, R. Wyatt, J. Flores, A. Kalica, Y. Hoshino, and N. Singh. 1983. Serological analysis of the subgroup protein of rotavirus using moloclonal antibodies. *Infect Immun*. 39:91–99.
38. Greenberg, H.B., H.F. Clark, and P.A. Offit. 1994. Rotavirus pathology and pathophysiology. *Curr Top Microbiol Immunol*. 185:255–283.
39. Hamilton, J.R., and D.G. Gall. 1982. Pathophysiological and clinical features of viral enteritis. In: *Virus Infections of the Gastrointestinal Tract*, A.J. Tyrell and A.Z. Kapikian, eds. Marcel Dekker, New York. 227–238.
40. Hayhow, C.S., and Y.M. Saif. 1993. Experimental infection of specific-pathogen-free turkey poults with single and combined enterovirus and group A rotavirus. *Avian Dis*. 37:546–57.
41. Haynes, J.S., D.L. Reynolds, J.A. Fagerland, and A.S. Fix. 1994. Morphogenesis of enteric lesions induced by group D rotavirus in ringneck pheasant chicks (*Phasianus colchicus*). *Vet Pathol*. 31:74–81.
42. Hines, M.E., E.L. Styer, C.A. Baldwin, and J.R. Cole, Jr. 1995. Combined adenovirus and rotavirus enteritis with *Escherichia coli* septicemia in an emu chick (*Dromaius novaehollandiae*). *Avian Dis*. 39:646–51.
43. Horrox, N.E. 1980. Some observations and comments on rotaviruses in turkey poults. *West Poult Dis Conf*. 29:162–164.

44. Hoshino, Y., and A.Z. Kapikian. 1994. Rotavirus antigens. *Curr Top Microbiol Immunol*. 185:179–227.
45. Hoshino, Y., R.G. Wyatt, H.B. Greenberg, J. Flores, and A. Z. Kapikian. 1984. Serotypic similarity and diversity of rotaviruses of mammalian and avian origin as studied by plaque-reduction neutralization. *J Infect Dis*. 149:694–702.
46. Ito, H., N. Minamoto, H. Goto, T.R. Luo, M. Sugiyama, and T. Kinjo. 1996. Mapping of antigenic sites on the major inner capsid protein of avian rotavirus using an *Escherichia coli* expression system. *Arch Virol*. 141:2129–38.
47. Ito, H., N. Minamoto, I. Sasaki, H. Goto, M. Sugiyama, T. Kinjo, and S. Sugita. 1995. Sequence analysis of cDNA for the VP6 protein of group A avian rotavirus: a comparison with group A mammalian rotaviruses. *Arch Virol*. 140:605–12.
48. Ito, H., M. Sugiyama, K. Masubuchi, Y. Mori, and N. Minamoto. 2001. Complete nucleotide sequence of a group A avian rotavirus genome and a comparison with its counterparts of mammalian rotaviruses. *Virus Res*. 75:123–38.
49. Jiang, S., S. Ji, Q. Tang, X. Cui, H. Yang, B. Kan, and S. Gao. 2008. Molecular characterization of a novel adult diarrhoea rotavirus strain J19 isolated in China and its significance for the evolution and origin of group B rotaviruses. *J Gen Virol*. 89:2622–2629.
50. Jiang, X., S.E. Crawford, M.K. Estes, and B.V.V. Prasad. 2008. Rotavirus structure. In: *Segmented Double-Stranded RNA Viruses: Structure and Molecular Biology*. J.T. Patton, ed. Caister Academic Press, Norfolk, UK. 45–60.
51. Jindal, N., D.P. Patnayak, Y. Chander, A.F. Ziegler, and S.M. Goyal. 2010. Detection and molecular characterization of enteric viruses in breeder turkeys. *Avian Pathol*. 39:53–61.
52. Jindal, N., D.P. Patnayak, Y. Chander, A.F. Ziegler, and S. M. Goyal. 2010. Detection and molecular characterization of enteric viruses from poult enteritis syndrome in turkeys. *Poult Sci*. 89:217–226.
53. Jindal, N., D.P. Patnayak, A.F. Ziegler, A. Lago, and S.M. Goyal. 2009. Experimental reproduction of poult enteritis syndrome: clinical findings, growth response, and microbiology. *Poult Sci*. 88:949–58.
54. Jindal, N., D.P. Patnayak, A.F. Ziegler, A. Lago, and S.M. Goyal. 2009. A retrospective study on poult enteritis syndrome in Minnesota. *Avian Dis*. 53:268–75.
55. Johne, R., P. Otto, B. Roth, U. Lohren, D. Belnap, J. Reetz, and E. Trojnar. 2011. Sequence analysis of the VP6-encoding genome segment of avian group F and G rotaviruses. *Virology*. 412:384–91.
56. Jones, R.C., C.S. Hughes, and R.R. Henry. 1979. Rotavirus infection in commercial laying hens. *Vet Rec*. 104:22.
57. Kang, S.Y., K.V. Nagaraja, and J.A. Newman. 1987. Characterization of viral polypeptides from avian rotavirus. *Avian Dis*. 31:607–21.
58. Kang, S.Y., K.V. Nagaraja, and J.A. Newman. 1988. Physical, chemical, and serological characterization of avian rotaviruses. *Avian Dis*. 32:195–203.
59. Kang, S.Y., K.V. Nagaraja, and J.A. Newman. 1986. Primary isolation and identification of avian rotaviruses from turkeys exhibiting signs of clinical enteritis in a continuous MA 104 cell line. *Avian Dis*. 30:494–9.
60. Kang, S.Y., K.V. Nagaraja, and J.A. Newman. 1985. Rapid coagglutination test for detection of rotaviruses in turkeys. *Avian Dis*. 29:640–8.
61. Kang, S.Y., and L.J. Saif. 1991. Production and characterization of monoclonal antibodies against an avian group A rotavirus. *Avian Dis*. 35:563–71.
62. King, A.M.Q., E. Lefkowitz, M.J. Adams, and E.B. Carstens 2012. *Virus Taxonomy: Ninth Report of the International Committee on Taxonomy of Viruses*. Academic Press, Waltham, MA. 1–1338.
63. Kool, D.A., and I.H. Holmes. 1993. The avian rotavirus Ty-1 Vp7 nucleotide and deduced amino acid sequences differ significantly from those of Ch-2 rotavirus. *Arch Virol*. 129:227–34.
64. Lawton, J.A., C.Q. Zeng, S.K. Mukherjee, J. Cohen, M.K. Estes, and B.V.V. Prasad. 1997. Three-dimensional structural analysis of recombinant rotavirus-like particles with intact and amino-terminal-deleted VP2: implications for the architecture of the VP2 capsid layer. *J Virol*. 71:7353–7360.
65. Legrottaglie, R., V. Rizzi, and P. Agrimi. 1997. Isolation and identification of avian rotavirus from pheasant chicks with signs of clinical enteritis. *Comp Immunol Microbiol Infect Dis*. 20:205–210.
66. Lozano, L.F., S. Hammami, A.E. Castro, and B. Osburn. 1992. Comparison of electron microscopy and polyacrylamide gel electrophoresis in the diagnosis of avian reovirus and rotavirus infections. *Avian Dis*. 36:183–8.
67. Maes, P., J. Matthijnssens, M. Rahman, and M. Van Ranst. 2009. RotaC: a web-based tool for the complete genome classification of group A rotviruses. *BMC Microbiol*. 9:238.
68. Martella, V., K. Banyai, J. Matthijnssens, C. Buonavoglia, and M. Ciarlet. 2010. Zoonotic aspects of rotaviruses. *Vet Microbiol*. 140:246–255.
69. Matthijnssens, J., M. Ciarlet, E. Heiman, I. Arijs, T. Delbeke, S.M. McDonald, E.A. Palombo, M. Iturriza-Gomara, P. Maes, J.T. Patton, M. Rahman, and M. Van Ranst. 2008. Full genome-based classification of rotaviruses reveals a common origin between human Wa-Like and porcine rotavirus strains and human DS-1-like and bovine rotavirus strains. *J Virol*. 82:3204–19.
70. Matthijnssens, J., M. Ciarlet, S.M. McDonald, H. Attoui, K. Banyai, J.R. Brister, J. Buesa, M.D. Esona, M.K. Estes, J.R. Gentsch, M. Iturriza-Gomara, R. Johne, C.D. Kirkwood, V. Martella, P.P.C. Mertens, O. Nakagomi, V. Parreno, M. Rahman, F.M. Ruggeri, L.J. Saif, N. Santos, A. Steyer, K. Taniguchi, J.T. Patton, U. Desselberger, and M. Van Ranst. 2011. Uniformity of rotavirus strain nomenclature proposed by the Rotavirus Classification Working Group (RCWG). *Arch Virol*. 156:1397–1413.
71. Matthijnssens, J., M. Ciarlet, M. Rahman, H. Attoui, K. Banyai, M.K. Estes, J.R. Gentsch, M. Iturriza-Gomara, C.D. Kirkwood, V. Martella, P.P.C. Mertens, O. Nakagomi, J.T. Patton, F.M. Ruggeri, L.J. Saif, N. Santos, A. Steyer, K. Taniguchi, U. Desselberger, and M. Van Ranst. 2008. Recommendations for the classification of group A rotaviruses using all 11 genomic RNA segments. *Arch Virol*. 153:16211629.
72. Matthijnssens, J., P.H. Otto, M. Ciarlet, U. Desselberger, M. Van Ranst, and R. Johne. 2012. VP6-sequence-based cutoff values as a criterion for rotavirus species demarcation. *Arch Virol*. 57(6):1177–82.
73. McNulty, M., G. Allan, D. Todd, and J. McFerran. 1979. Isolation and cell culture propagation of rotaviruses from turkeys and chickens. *Arch Virol*. 61:13–21.
74. McNulty, M.S., G.M. Allan, and R.M. McCracken. 1983. Experimental infection of chickens with rotaviruses: clinical and virological findings. *Avian Pathol*. 12:45–54.
75. McNulty, M.S., G.M. Allan, and J.B. McFerran. 1984. Prevalence of antibody to conventional and atypical rotaviruses in chickens. *Vet Rec*. 114:219.
76. McNulty, M.S., G.M. Allan, and J.C. Stuart. 1978. Rotavirus infection in avian species. *Vet Rec*. 103:319–20.

77. McNulty, M.S., G.M. Allan, D. Todd, and J.B. McFerran. 1979. Isolation and cell culture propagation of rotaviruses from turkeys and chickens. *Arch Virol*. 61:13–21.
78. McNulty, M.S., G.M. Allan, D. Todd, J.B. McFerran, and R.M. McCracken. 1981. Isolation from chickens of a rotavirus lacking the rotavirus group antigen. *J Gen Virol*. 55:405–13.
79. McNulty, M.S., G.M. Allan, D. Todd, J.B. McFerran, E.R. McKillop, D.S. Collins, and R.M. McCracken. 1980. Isolation of rotaviruses from turkeys and chickens: demonstration of distinct serotypes and RNA electropherotypes. *Avian Pathol*. 9:363–75.
80. McNulty, M.S., W.L. Curran, D. Todd, and J.B. McFerran. 1979. Detection of viruses in avian faeces by direct electron microscopy. *Avian Pathol*. 8:239–47.
81. McNulty, M.S., and D.L. Reynolds. 2008. Rotavirus infections. In: *Diseases of Poultry*, 12th ed. Y.M. Saif, ed. Blackwell, Ames, Iowa.
82. McNulty, M.S., D. Todd, G.M. Allan, J.B. McFerran, and J.A. Greene. 1984. Epidemiology of rotavirus infection in broiler chickens: recognition of four serogroups. *Arch Virol*. 81:113–21.
83. McNulty, M.S., D. Todd, G.M. Allan, J.B. McFerran, and J.A. Greene. 1984. Epidemiology of rotavirus infection in broiler chickens: recognition of four serogroups. *Arch Virol*. 81:113–121.
84. Meulemans, G., J.E. Peeters, and P. Halen. 1985. Experimental infection of broiler chickens with rotavirus. *Br Vet J*. 141:69–73.
85. Minakshi, G.P., G. Verma, and S. Dahiya. 2004. Detection of avian rotaviruses from diarrhoeic poultry in India. *Ind J Microbiol*. 44:205–210.
86. Minamoto, N., K. Oki, M. Tomita, T. Kinjo, and Y. Suzuki. 1988. Isolation and characterization of rotavirus from feral pigeon in mammalian cell cultures. *Epidemiol Infect*. 100:481–92.
87. Minamoto, N., O. Sugimoto, M. Yokota, M. Tomita, H. Goto, M. Sugiyama, and T. Kinjo. 1993. Antigenic analysis of avian rotavirus VP6 using monoclonal antibodies. *Arch Virol*. 131:293–305.
88. Mori, Y., M. Borgan, N. Ito, M. Sugiyama, and N. Minamoto. 2002. Diarrhea-inducing activity of avian rotavirus NSP4 glycoproteins, which differ greatly from mammalian rotavirus NSP4 glycoproteins in deduced amino acid sequence, in suckling mice. *J Virol*. 76:5829–5834.
89. Mori, Y., M.A. Borgan, N. Ito, M. Sugiyama, and N. Minamoto. 2002. Diarrhea-inducing activity of avian rotavirus NSP4 glycoproteins, which differ greatly from mammalian rotavirus NSP4 glycoproteins in deduced amino acid sequence in suckling mice. *J Virol* 76:5829–34.
90. Mori, Y., M.A. Borgan, N. Ito, M. Sugiyama, and N. Minamoto. 2002. Sequential analysis of nonstructural protein NSP4s derived from Group A avian rotaviruses. *Virus Res*. 89:145–51.
91. Mori, Y., M.A. Borgan, M. Takayama, N. Ito, M. Sugiyama, and N. Minamoto. 2003. Roles of outer capsid proteins as determinants of pathogenicity and host range restriction of avian rotaviruses in a suckling mouse model. *Virology*. 316:126–34.
92. Mori, Y., M. Sugiyama, M. Takayama, Y. Atoji, T. Masegi, and N. Minamoto. 2001. Avian-to-mammal transmission of an avian rotavirus: analysis of its pathogenicity in a heterologous mouse model. *Virology*. 288:63–70.
93. Myers, T.J., and K.A. Schat. 1990. Intestinal IgA response and immunity to rotavirus infection in normal and antibody-deficient chickens. *Avian Pathol*. 19:697–712.
94. Myers, T.J., and K.A. Schat. 1990. Natural killer cell activity of chicken intraepithelial leukocytes against rotavirus-infected target cells. *Vet Immunol Immunopathol*. 26:157–70.
95. Myers, T.J., and K.A. Schat. 1989. Propagation of avian rotavirus in primary chick kidney cell and MA104 cell cultures. *Avian Dis*. 33:578–81.
96. Myers, T.J., K.A. Schat, and A.P. Mockett. 1989. Development of immunoglobulin class-specific enzyme-linked immunosorbent assays for measuring antibodies against avian rotavirus. *Avian Dis*. 33:53–9.
97. Otto, P., M. Ahmed, H. Hotzel, P. Machnowska, J. Reetz, B. Roth, E. Trojnar, and R. Johne. 2011. Detection of avian rotaviruses of groups A, D, F and G in diseased chickens and turkeys from Europe and Bangladesh. *Vet Microbiol*. 156(1–2):8–15.
98. Otto, P., E.M. Liebler-Tenorio, M. Elschner, J. Reetz, U. Lohren, and R. Diller. 2006. Detection of rotaviruses and intestinal lesions in broiler chicks from flocks with runting and stunting syndrome (RSS). *Avian Dis*. 50:411–418.
99. Pantin-Jackwood, M., J.M. Day, M.W. Jackwood, and E. Spackman. 2008. Enteric viruses detected by molecular methods in commercial chicken and turkey flocks in the United States between 2005 and 2006. *Avian Dis*. 52:235–244.
100. Pantin-Jackwood, M.J., J.M. Day, M.W. Jackwood, and E. Spackman. 2008. Enteric viruses detected by molecular methods in commercial chicken and turkey flocks in the United States between 2005 and 2006. *Avian Dis*. 52:235–244.
101. Pantin-Jackwood, M.J., E. Spackman, J.M. Day, and D. Rives. 2007. Periodic monitoring of commercial turkeys for enteric viruses indicates continuous presence of astrovirus and rotavirus on the farms. *Avian Dis*. 51:674–680.
102. Pascucci, S., and A. Lavazza. 1994. A survey of enteric viruses in commercial avian species: experimental studies of transmissible enteritis of guinea fowl. In: *New and Evolving Virus Diseases of Poultry*. M.S. McNulty and J.B. McFerran, eds. Commission of the European Communities, Brussels. 225–241.
103. Patton, J.T., L.S. Silvestri, M.A. Tortorici, R. Vasquez-Del Carpio, and Z.F. Taraporewala. 2006. Rotavirus genome replication and morphogenesis: role of the viroplasm, In: *Reoviruses: Entry, Assembly, and Morphogeneisis*. P. Roy ed. Springer, Berlin. 169–187.
104. Pesavento, J.B., S.E. Crawford, M.K. Estes, and B.V. Prasad. 2006. Rotavirus proteins: structure and assembly. *Current Top Microbiol Immunol*. 309:189–219.
105. Pesavento, J.B., S.E. Crawford, M.K. Estes, and B.V.V. Prasad. 2006. Rotavirus proteins: Structure and assembly. *Curr Top Microbiol Immunol*. 309: 189–219.
106. Prasad, B.V.V., and W. Chiu. 1994. Structure of rotavirus. In: *Rotaviruses*. R.F. Ramig. ed. Springer-Verlag, New York. 9–29.
107. Prasad, B.V.V., and M.K. Estes. 2000. Electron cryomicroscopy and computer image processing techniques: Use in structure-function studies of rotavirus. In: *Rotaviruses: Methods and Protocols*. J. Gray and U. Desselberger, eds. Humana Press, Totowa, New Jersey. 9–31
108. Prasad, B.V.V., G.J. Wang, J.P.M. Clerx, and W. Chiu. 1988. Three-dimensional structure of rotavirus. *J Mol Biol*. 199:269–275.
109. Reynolds, D.L., Y.M. Saif, and K.W. Theil. 1987. A survey of enteric viruses of turkey poults. *Avian Dis*. 31:89–98.
110. Reynolds, D.L., Y.M. Saif, and K.W. Theil. 1987. A survey of enteric viruses of turkey poults. *Avian Dis*. 31:89–98.
111. Reynolds, D.L., K.W. Theil, and Y.M. Saif. 1987. Demonstration of rotavirus and rotavirus-like virus in the intestinal contents of diarrheic pheasant chicks. *Avian Dis*. 31:376–9.

112. Rohwedder, A., H. Hotop, N. Minamoto, H. Ito, O. Nakagomi, and H. Brussow. 1997. Bovine rotavirus 993/83 shows a third subtype of avian VP7 protein. *Virus Genes*. 14:147–51.
113. Rohwedder, A., H. Irmak, H. Werchau, and H. Brussow. 1993. Nucleotide sequence of gene 6 of avian-like group A rotavirus 993/83. *Virology*. 195:820–5.
114. Rohwedder, A., K.I. Schutz, N. Minamoto, and H. Brussow. 1995. Sequence analysis of pigeon, turkey, and chicken rotavirus VP8* identifies rotavirus 993/83, isolated from calf feces, as a pigeon rotavirus. *Virology*. 210:231–5.
115. Saif, L.J., and B. Jiang. 1994. Nongroup A rotaviruses of humans and animals, In: *Current Topics in Microbiology and Immunology: Rotaviruses*. R.F. Ramig, ed. Springer-Verlag, New York. 339–371.
116. Saif, L.J., Y.M. Saif, and K.W. Theil. 1985. Enteric viruses in diarrheic turkey poults. *Avian Dis*. 29:798–811.
117. Sato, K., Y. Inaba, T. Shinozaki, and M. Matumoto. 1981. Neutralizing antibody to bovine rotavirus in various animal species. *Vet Microbiol*. 6:259–261.
118. Schat, K.A., and T.J. Myers. 1987. Cultivation of avian rotaviruses in chicken lymphocytes and lymphoblastoid cell lines. *Arch Virol*. 94:205–213.
119. Schumann, T., H. Hotzel, P. Otto, and R. Johne. 2009. Evidence of interspecies transmission and reassortment among avian group A rotaviruses. *Virology*. 386:334–43.
120. Shawky, S.A., Y.M. Saif, and J. McCormick. 1994. Transfer of maternal anti-rotavirus IgG to the mucosal surfaces and bile of turkey poults. *Avian Dis*. 38:409–17.
121. Shawky, S.A., Y.M. Saif, and D.E. Swayne. 1993. Role of circulating maternal anti-rotavirus IgG in protection of intestinal mucosal surface in turkey poults. *Avian Dis*. 37:1041–50.
122. Spackman, E., J.M. Day, and M.J. Pantin-Jackwood. 2010. Astrovirus, reovirus, and rotavirus concomitant infection causes decreased weight gain in broad-breasted white poults. *Avian Dis*. 54:16–21.
123. Sugiyama, M., K. Goto, H. Uemukai, Y. Mori, N. Ito, and N. Minamoto. 2004. Attachment and infection to MA104 cells of avian rotaviruses require the presence of sialic acid on the cell surface. *J Vet Med Sci*. 66:461–3.
124. Takase, K., F. Nonaka, M. Sakaguchi, and S. Yamada. 1986. Cytopathic avian rotavirus isolated from duck faeces in chicken kidney cell cultures. *Avian Pathol*. 15:719–30.
125. Takase, K., T. Uchimura, N. Katsuki, and M. Yamamoto. 1990. A survey of chicken sera for antibody to atypical avian rotavirus of duck origin, in Japan. *Nihon Juigaku Zasshi*. 52:1319–21.
126. Takehara, K., H. Kiuchi, M. Kuwahara, F. Yanagisawa, M. Mizukami, H. Matsuda, and M. Yoshimura. 1991. Identification and characterization of a plaque forming avian rotavirus isolated from a wild bird in Japan. *J Vet Med Sci*. 53:479–86.
127. Theil, K.W. 1987. A modified genome electropherotyping procedure for detecting turkey rotaviruses in small volumes of intestinal contents. *Avian Dis*. 31:899–903.
128. Theil, K.W., D.L. Reynolds, and Y.M. Saif. 1986. Comparison of immune electron microscopy and genome electropherotyping techniques for detection of turkey rotaviruses and rotavirus-like viruses in intestinal contents. *J Clin Microbiol*. 23:695–9.
129. Theil, K.W., D.L. Reynolds, and Y.M. Saif. 1986. Isolation and serial propagation of turkey rotaviruses in a fetal rhesus monkey kidney (MA104) cell line. *Avian Dis*. 30:93–104.
130. Theil, K.W., and Y.M. Saif. 1987. Age-related infections with rotavirus, rotavirus-like virus, and atypical rotavirus in turkey flocks. *J Clin Microbiol*. 25:333–337.
131. Tilley, S., K.M. Robbins, J.M. Day, and H.J. Barnes. 2011. Enteritis and elevated mortality in young guinea fowl. Poster presentation, Annual meeting of American Association of Avian Pathologists, St. Louis, MO. July 16–19, 2011.
132. Todd, D., and M.S. McNulty. 1986. Electrophoretic variation of avian rotavirus RNA in polyacrylamide gels. *Avian Pathol*. 15:149–59.
133. Todd, D., M.S. McNulty, and G.M. Allan. 1980. Polyacrylamide gel electrophoresis of avian rotavirus RNA. *Arch Virol*. 63:87–97.
134. Trojnar, E., P. Otto, and R. Johne. 2009. The first complete genome sequence of a chicken group A rotavirus indicates independent evolution of mammalian and avian strains. *Virology*. 386:325–33.
135. Trojnar, E., P. Otto, B. Roth, J. Reetz, and R. Johne. 2010. The genome segments of a group D rotavirus possess group A-like conserved termini but encode group-specific proteins. *J Virol*. 84:10254–65.
136. Ursu, K., P. Kisfali, D. Rigo, E. Ivanics, K. Erdelyi, A. Dan, B. Melegh, V. Martella, and K. Banyai. 2009. Molecular analysis of the VP7 gene of pheasant rotaviruses identifies a new genotype, designated G23. *Arch Virol*. 154:1365–9.
137. Ursu, K., H. Papp, P. Kisfali, D. Rigo, B. Melegh, V. Martella, and K. Banyai. 2011. Monitoring of group A rotaviruses in wild-living birds in Hungary. *Avian Dis*. 55:123–7.
138. Varley, J., R.C. Jones, J.M. Bradbury, and F.T. Jordan. 1993. A survey of the viral flora of two commercial Pekin duck flocks. *Avian Pathol*. 22:703–714.
139. Vindevogel, H.U., L. Dagenais, B. Lansival, and P.P. Pastoret. 1981. Incidence of rotavirus, adenovirus and herpesvirus infection in pigeons. *Vet Rec*. 109:285–6.
140. Wang, Z.D., S.W. Lu, J.S. Huang, F.P. Zhang, and M.J. Liu. 1995. Investigation and identification of atypical rotavirus from animals and humans. *Chin J Virol*. 11:336–341.
141. Wani, S.A., M.A. Bhat, S.M. Ishaq, M.A. Ashrafi, A.S. Buchh, and M. Haq. 2003. Detection of a mammalian-like group A rotavirus in diarrhoeic chicken. *Vet Microbiol*. 94:13–8.
142. Woolcock, P.A., and H.L. Shivaprasad. 2008. Electron microscopic identification of viruses associated with poult enteritis in turkeys grown in California 1993–2003. *Avian Dis*. 52:209–213.
143. Yason, C.V., and K.A. Schat. 1986. Experimental infection of specific-pathogen-free chickens with avian rotaviruses. *Avian Dis*. 30:551–6.
144. Yason, C.V., and K.A. Schat. 1985. Isolation and characterization of avian rotaviruses. *Avian Dis*. 29:499–508.
145. Yason, C.V., and K.A. Schat. 1986. Pathogenesis of rotavirus infection in turkey poults. *Avian Pathol*. 15:421–35.
146. Yason, C.V., and K.A. Schat. 1987. Pathogenesis of rotavirus infection in various age groups of chickens and turkeys: clinical signs and virology. *Am J Vet Res*. 48:977–983.
147. Yason, C.V., B.A. Summers, and K.A. Schat. 1987. Pathogenesis of rotavirus infection in various age groups of chickens and turkeys: pathology. *Am J Vet Res*. 48:927–938.
148. Yeager, M., K.A. Dryden, N.H. Olson, H.B. Greenberg, and T. S. Baker. 1990. Three-dimensional structure of Rhesus Rotavirus by cryoelectron microscopy and image reconstruction. *J Cell Biol*. 110:2133–2144.
149. Yu, M., M.M. Ismail, M.A. Qureshi, R.N. Dearth, H.J. Barnes, and Y.M. Saif. 2000. Viral agents associated with poult enteritis and mortality syndrome: the role of a small round virus and a turkey coronavirus. *Avian Dis*. 44:297–304.

Astrovirus Infections

1. Baxendale, W., and T. Mebatsion. 2004. The isolation and characterisation of astroviruses from chickens. *Avian Pathol*. 33:364–370.
2. Behling-Kelly, E., S. Schultz-Cherry, M. Koci, L. Kelley, D. Larsen, and C. Brown. 2002. Localization of astrovirus in experimentally infected turkeys as determined by *in situ* hybridization. *Vet Path*. 39:595–598.
3. Bidin, M., I. Lojkic, Z. Bidin, M. Tisljar, D. Majnaric, and M. Mikec. 2011. Detection and characterization of avian nephritis virus in ducklings. *Avian Pathol*. 40:173–177.
4. Cattoli, G., C. De Battisti, A. Toffan, A. Salviato, A. Lavazza, M. Cerioli, and I. Capua. 2007. Co-circulation of distinct genetic lineages of astroviruses in turkeys and guinea fowl. *Arch Virol*. 152:595–602.
5. Cattoli, G., A. Toffan, C. De Battisti, A. Salviato, C. Terregino, and I. Capua. 2005. Astroviruses found in the intestinal contents of guinea fowl suffering from enteritis. *Vet Rec*. 156:220.
6. Chu, D.K., L.L. Poon, Y. Guan, and J.S. Peiris. 2008. Novel astroviruses in insectivorous bats. *J Virol*. 82:9107–9114.
7. De Benedictis, P., S. Schultz-Cherry, A. Burnham, and G. Cattoli. 2011. Astrovirus infections in humans and animals—molecular biology, genetic diversity, and interspecies transmissions. *Infect Genet Evol*. 11:1529–1544.
8. de Wit, J.J., G.B. Dam, J.M. de Laar, Y. Biermann, I. Verstegen, F. Edens, and C.C. Schrier. 2011. Detection and characterization of a new astrovirus in chicken and turkeys with enteric and locomotion disorders. *Avian Pathol*. 40:453–461.
9. Domanska-Blicharz, K., A. Seroka, and Z. Minta. 2011. One-year molecular survey of astrovirus infection in turkeys in Poland. *Arch Virol*. 156:1065–1072.
10. Jindal, N., D.P. Patnayak, Y. Chander, A.F. Ziegler, and S.M. Goyal. 2011. Comparison of capsid gene sequences of turkey astrovirus-2 from poult-enteritis-syndrome-affected and apparently healthy turkeys. *Arch Virol*. 156:969–977.
11. Jindal, N., D.P. Patnayak, Y. Chander, A.F. Ziegler, and S.M. Goyal. 2010. Detection and molecular characterization of enteric viruses from poult enteritis syndrome in turkeys. *Poult Sci*. 89:217–226.
12. Koci, M.D. 2005. Immunity and resistance to astrovirus infection. *Viral Immunol*. 18:11–16.
13. Koci, M.D., and S. Schultz-Cherry. 2002. Avian astroviruses. *Avian Pathol*. 31:213–227.
14. Koci, M.D., L.A. Kelley, and S. Schultz-Cherry. 2004. Astrovirus-induced synthesis of nitric oxide contributes to virus control during infection. *J Virol*. 78:1564–1574.
15. Koci, M.D., L.A. Moser, L.A. Kelley, D. Larsen, C.C. Brown, and S. Schultz-Cherry. 2003. Astrovirus induces diarrhea in the absence of inflammation and cell death. *J Virol*. 77:11798–11808.
16. Koci, M.D., B.S. Seal, and S. Schultz-Cherry. 2000. Development of an RT-PCR diagnostic test for an avian astrovirus. *J Virol Methods*. 90:79–83.
17. Koci, M.D., B.S. Seal, and S. Schultz-Cherry. 2000. Molecular characterization of an avian astrovirus. *J Virol*. 74:6173–6177.
18. Matsui, S.M., and H.B. Greenberg. 2001. Astroviruses. In: *Fields Virology*, 4th ed., vol. 1. D.M. Knipe and P.M. Howley, eds. Lippincott Williams & Wilkins, Philadelphia. 875–894.
19. McNeilly, F., T.J. Connor, V.M. Calvert, J.A. Smyth, W.L. Curran, A.J. Morley, D. Thompson, S. Singh, J.B. McFerran, B.M. Adair, and M.S. McNulty. 1994. Studies on a new enterovirus-like virus isolated from chickens. *Avian Pathol*. 23:313–327.
20. Meyerhoff, R.R., P.K. Nighot, R.A. Ali, A.T. Blikslager, and M.D. Koci. 2012. Characterization of turkey inducible nitric oxide synthase and identification of its expression in the intestinal epithelium following astrovirus infection. *Comp Immunol Microbiol Infect Dis*. 35:63–69.
21. Mor, S.K., M. Abin, G. Costa, A. Durrani, N. Jindal, S.M. Goyal, and D.P. Patnayak. 2011. The role of type-2 turkey astrovirus in poult enteritis syndrome. *Poult Sci*. 90:2747–2752.
22. Moser, L.A., M. Carter, and S. Schultz-Cherry. 2007. Astrovirus increases epithelial barrier permeability independently of viral replication. *J Virol*. 81:11937–11945.
23. Moser, L.A., and S. Schultz-Cherry. 2005. Pathogenesis of astrovirus infection. *Viral Immunol*. 18:4–10.
24. Pantin-Jackwood, M., E. Spackman, and P. Woolcock. 2006. Phylogenetic analysis of turkey astroviruses reveals evidence of recombination. *Virus Genes*. 32:187–192.
25. Pantin-Jackwood, M.J., J.M. Day, M.W. Jackwood, and E. Spackman. 2008. Enteric viruses detected by molecular methods in commercial chicken and turkey flocks in the United States between 2005 and 2006. *Avian Dis*. 52:235–244.
26. Pantin-Jackwood, M.J., E. Spackman, J.M. Day, and D. Rives. 2007. Periodic monitoring of commercial turkeys for enteric viruses indicates continuous presence of astrovirus and rotavirus on the farms. *Avian Dis*. 51:674–680.
27. Pantin-Jackwood, M.J., K.O. Strother, E. Mundt, L. Zsak, J.M. Day, and E. Spackman. 2011. Molecular characterization of avian astroviruses. *Arch Virol*. 156:235–244.
28. Qureshi, M.A., Y.M. Saif, C.L. Heggen-Peay, F.W. Edens, and G.B. Havenstein. 2001. Induction of functional defects in macrophages by a poult enteritis and mortality syndrome-associated turkey astrovirus. *Avian Dis*. 45:853–861.
29. Qureshi, M.A., M.Yu, and Y.M. Saif. 2000. A novel "small round virus" inducing poult enteritis and mortality syndrome and associated immune alterations. *Avian Dis*. 44:275–283.
30. Reynolds, D.L., and S. Schultz-Cherry. 2008. Astroviruses. In: *Diseases of Poultry*, 12th ed. Diseases Y.M. Saif, A.M. Fadly, J.R. Glisson, L.R. McDougald, L.K. Nolan, and D.E. Swayne, eds. Iowa State University Press, Ames, Iowa. 351–355.
31. Reynolds, D.L., and Y.M. Saif. 1986. Astrovirus: a cause of an enteric disease in turkey poults. *Avian Dis*. 30:728–735.
32. Reynolds, D.L., Y.M. Saif, and K.W. Theil. 1987. Enteric viral infections of turkey poults: incidence of infection. *Avian Dis*. 31:272–276.
33. Reynolds, D.L., Y.M. Saif, and K.W. Theil. 1987. A survey of enteric viruses of turkey poults. *Avian Dis*. 31:89–98.
34. Schultz-Cherry, S., D.R. Kapczynski, V.M. Simmons, M.D. Koci, C. Brown, and H.J. Barnes. 2000. Identifying agent(s) associated with poult enteritis mortality syndrome: importance of the thymus. *Avian Dis*. 44:256–265.
35. Schultz-Cherry, S., D.J. King, and M.D. Koci. 2001. Inactivation of an astrovirus associated with poult enteritis mortality syndrome. *Avian Dis*. 45:76–82.
36. Sellers, H., E. Linneman, A.H. Icard, and E. Mundt. 2010. A purified recombinant baculovirus expressed capsid protein of a new astrovirus provides partial protection to runting-stunting syndrome in chickens. *Vaccine*. 28:1253–1263.
37. Sellers, H.S., M.D. Koci, E. Linnemann, L.A. Kelley, and S. Schultz-Cherry. 2004. Development of a multiplex reverse transcription-polymerase chain reaction diagnostic test specific for turkey astrovirus and coronavirus. *Avian Dis*. 48:531–539.

38. Smyth, J.A., T.J. Connor, F. McNeilly, D.A. Moffet, V.M. Calvert, and M.S. McNulty. 2007. Studies on the pathogenicity of enterovirus-like viruses in chickens. *Avian Pathol*. 36:119–126.
39. Smyth, V.J., H.L. Jewhurst, B.M. Adair, and D. Todd. 2009. Detection of chicken astrovirus by reverse transcriptase-polymerase chain reaction. *Avian Pathol*. 38:293–299.
40. Spackman, D., R.E. Gough, M.S. Collins, and D. Lanning. 1984. Isolation of an enterovirus-like agent from the meconium of dead-in-shell chicken embryos. *Vet Rec*. 114:216–218.
41. Spackman, E., J.M. Day, and M.J. Pantin-Jackwood. 2010. Astrovirus, reovirus, and rotavirus concomitant infection causes decreased weight gain in broad-breasted white poults. *Avian Dis*. 54:16–21.
42. Spackman, E., D. Kapczynski, and H. Sellers. 2005. Multiplex real-time reverse transcription-polymerase chain reaction for the detection of three viruses associated with poult enteritis complex: turkey astrovirus, turkey coronavirus, and turkey reovirus. *Avian Dis*. 49:86–91.
43. Strain, E., L.A. Kelley, S. Schultz-Cherry, S.V. Muse, and M.D. Koci. 2008. Genomic analysis of closely related astroviruses. *J Virol*. 82:5099–5103.
44. Tang, Y., M.M. Ismail, and Y.M. Saif. 2005. Development of antigen-capture enzyme-linked immunosorbent assay and RT-PCR for detection of turkey astroviruses. *Avian Dis*. 49:182–188.
45. Tang, Y., M.V. Murgia, and Y.M. Saif. 2005. Molecular characterization of the capsid gene of two serotypes of turkey astroviruses. *Avian Dis*. 49:514–519.
46. Tang, Y., Q. Wang, and Y.M. Saif. 2005. Development of ssRNA internal control template reagent for a multiplex RT-PCR to detect turkey astroviruses. *J Virol Methods*. 126:81–86.
47. Thouvenelle, M.L., J.S. Haynes, and D.L. Reynolds. 1995. Astrovirus infection in hatchling turkeys: histologic, morphometric, and ultrastructural findings. *Avian Dis*. 39:328–336.
48. Thouvenelle, M.L., J.S. Haynes, J.L. Sell, and D.L. Reynolds. 1995. Astrovirus infection in hatchling turkeys: alterations in intestinal maltase activity. *Avian Dis*. 39:343–348.
49. Todd, D., D.S. Wilkinson, H.L. Jewhurst, M. Wylie, A.W. Gordon, and B.M. Adair. 2009. A seroprevalence investigation of chicken astrovirus infections. *Avian Pathol*. 38:301–309.

Avian Enterovirus-Like Virus Infections

1. Andral, B., and D. Toquin. 1984. Observations and isolation of pseudopicornavirus from sick turkeys. *Avian Pathol*. 13:377–388.
2. Andral, B., M. Lagadic, C. Louzis, J.P. Guillou, and J.M. Gourreau. 1987. Fulminating disease of guinea fowl: Aetiological studies. *Point Veterinaire*. 19:515–520.
3. Chooi, K.F., and U. Chulan. 1985. Broiler runting/stunting syndrome in Malaysia. *Vet Rec*. 116:354.
4. Decaesstecker, M., and G. Meulemans. 1989. Antigenic relationships between fowl enteroviruses. *Avian Pathol*. 18:715–723.
5. Decaesstecker, M., G. Charlier, and G. Meulemans. 1986. Significance of parvoviruses, entero-like viruses and reoviruses in the aetiology of the chicken malabsorption syndrome. *Avian Pathol*. 15:769–782.
6. Decaesstecker, M., G. Charlier, J. Peeters, and G. Meulemans. 1989. Pathogenicity of fowl enteroviruses. *Avian Pathol*. 18:697–713.
7. Despins, J.L., R.C. Axtell, D.V. Rives, J.S. Guy, and M.D. Ficken. 1994. Transmission of enteric pathogens of turkeys by darkling beetle larva (*Alphitobices diaperinus*). *J Appl Poultry Res*. 3:61–65.
8. Els, H.J., and D. Gosling. 1998. Viruses and virus-like particles identified in ostrich gut contents. *J S African Vet Assoc*. 69:74–80.
9. Frazier, J.A., and R.L. Reece. 1990. Infectious stunting syndrome of chickens in Great Britain: Intestinal ultrastructural pathology. *Avian Pathol*. 19:759–777.
10. Frazier, J.A., K. Howes, R.L. Reece, A.W. Kidd, and D. Cavanagh. 1990. Isolation of non-cytopathic viruses implicated in the aetiology of nephritis and baby chick nephropathy and serologically related to avian nephritis virus. *Avian Pathol*. 19:139–160.
11. Goodwin, M.A., J.F. Davis, M.S. McNulty, J. Brown, and E.C. Player. 1993. Enteritis (so-called runting stunting syndrome) in Georgia broiler chicks. *Avian Dis*. 37:451–458.
12. Gough, R.E., D.J. Alexander, M.S. Collins, S.A. Lister, and W.J. Cox. 1988. Routine virus isolation or detection in the diagnosis of diseases in birds. *Avian Pathol*. 17:893–907.
13. Gough, R.E., M.S. Collins, D.J. Alexander, and W.J. Cox. 1990. Viruses and virus-like particles detected in samples from diseased game birds in Great Britain during 1988. *Avian Pathol*. 19:331–343.
14. Guy, J.S., and H.J. Barnes. 1991. Partial characterization of a turkey enterovirus-like virus. *Avian Dis*. 35:197–203.
15. Guy, J.S., A.M. Miles, L.G. Smith, S. Schultz-Cherry, and F.J. Fuller. 2004. Antigenic and genomic characterization of turkey enterovirus-like virus (North Carolina, 1988 isolate): identification of the virus as turkey astrovirus 2. *Avian Dis*. 48:206–211.
16. Hayhow, C.S., and Y.M. Saif. 1993a. Development of an antigen-capture enzyme-linked immunosorbent assay for detection of enterovirus in commercial turkeys. *Avian Dis*. 37:375–379.
17. Hayhow, C.S., and Y.M. Saif. 1993b. Experimental infection of specific pathogen free turkey poults with single and combined enterovirus and group A rotavirus. *Avian Dis*. 37:546–557.
18. Hayhow, C.S., A.V. Parwani, and Y.M. Saif. 1993a. Single-stranded genomic RNA from turkey enterovirus-like virus. *Avian Dis*. 37:558–560.
19. Hayhow, C.S., Y.M. Saif, K.M. Kerr, and R.E. Whitmoyer. 1993b. Further observations on enterovirus infection in specific pathogen free turkey poults. *Avian Dis*. 37:124–134.
20. Imada, T., S. Yamaguchi, M. Mase, K. Tsukamoto, M. Kubo, and A. Morooka. 2000. Avian nephritis virus (ANV) as a new member of the family Astroviridae and construction of infectious ANV cDNA. *J Virol*. 74:8487–8493.
21. King, A.M.Q., F. Brown, P. Christian, T. Hovi, T. Hyypiä, N.J. Knowles, S.M. Lemon, P.D. Minor, A.C. Palmenberg, T. Skern, and G. Stanway. 2000. Picornaviridae. In: *Virus Taxonomy: Seventh Report of the International Committee on Taxonomy of Viruses*. M.H.V. van Regenmortel, C.M. Fauquet, D.H.L. Bishop, E.B. Carstens, M.K. Estes, S.M. Lemon, J. Maniloff, M.A. Mayo, D.J. McGeogh, C.R. Pringle, and R.B. Wickner, eds. Academic Press: San Diego. 657–678.
22. Knowles, N.J., T. Hovi, T. Hyypiä, A.M.Q. King, A.M. Lindberg, M.A. Pallansch, A.C. Palmenberg, P. Simmonds, T. Skern, G. Stanway, T. Yamashita, and R. Zell. 2012. Picornaviridae. In: *Virus Taxonomy: Ninth Report of the International Committee on Taxonomy of Viruses*. A.M.Q. King, M.J. Adams, E.B. Carstens, and E.J. Lefkowitz, eds. Academic Press: San Diego. 855–880.
23. Koci, M.D., B.S. Seal, and S. Schultz-Cherry. 2000. Molecular characterization of an avian astrovirus. *J Virol*. 74:6173–6177.

24. Lavazza, A., S. Pascucci, and D. Gelmetti. 1990. Rod-shaped virus-like particles in intestinal contents of three avian species. *Vet Rec*. 126:581.
25. Marvil, P., N.J. Knowles, A.P.A. Mockett, P. Britton, T.D.K. Brown, and D. Cavanagh. 1999. Avian encephalomyelitis virus is a picornavirus and is most closely related to hepatitis A virus. *J Gen Virol*. 80:653–662.
26. McNeilly, F., T.J. Connor, V.M. Calvert, J.A. Smyth, W.L. Curran, A.J. Morley, D. Thompson, S. Singh, J.B. McFerran, B.M. Adair, and M.S. McNulty. 1994. Studies on a new enterovirus-like virus isolated from chickens. *Avian Pathol*. 23:313–327.
27. McNulty, M.S., W.L. Curran, D. Todd, and J.B. McFerran. 1979. Detection of viruses in avian faeces by direct electron microscopy. *Avian Pathol*. 8:239–247.
28. McNulty, M.S., G.M. Allan, T.J. Connor, J.B. McFerran, and R.M. McCracken. 1984. An entero-like virus associated with the runting syndrome in broiler chickens. *Avian Pathol*. 13:429–439.
29. McNulty, M.S., G.M. Allan, and J.B. McFerran. 1987. Isolation of a novel avian entero-like virus. *Avian Pathol*. 16:331–337.
30. McNulty, M.S., T.J. Connor, F. McNeilly, and J.B. McFerran. 1990. Biological characterisation of avian enteroviruses and enterovirus-like viruses. *Avian Pathol*. 19:75–87.
31. McOrist, S., D. Madill, M. Adamson, and C. Philip. 1991. Viral enteritis in cockatoos (Cacatua spp). *Avian Pathol*. 20:531–539.
32. Pascucci, S., and A. Lavazza. 1994. A survey of enteric viruses in commercial avian species: Experimental studies of transmissible enteritis of guinea fowl. In: *New and Evolving Virus Diseases of Poultry*. M.S. McNulty and J.B. McFerran, eds. Commission of the European Communities: Brussels, Belgium. 225–241.
33. Qureshi, M.A., M. Yu, and Y.M. Saif. 2000. A novel "small round virus" inducing poult enteritis and mortality syndrome and associated immune functions. *Avian Dis*. 44:275–283.
34. Reynolds, D.L., Y.M. Saif, and K.W. Theil. 1987. A survey of enteric viruses of turkey poults. *Avian Dis*. 31:89–98.
35. Saif, L.J., Y.M. Saif, and K.W. Theil. 1985. Enteric viruses in diarrheic turkey poults. *Avian Dis*. 29:798–811.
36. Saif, Y.M., L.J. Saif, C.L. Hofacre, C. Hayhow, D.E. Swayne, and R.N. Dearth. 1990. A small round virus associated with enteritis in turkey poults. *Avian Dis*. 34:762–764.
37. Shirai, J., K. Nakamura, K. Shinohara, and H. Kawamura. 1991. Pathogenicity and antigenicity of avian nephritis isolates. *Avian Dis*. 35:49–54.
38. Shirai, J., N. Tanimura, K. Uramoto, M. Narita, K. Nakamura, and H. Kawamura. 1992. Pathologically and serologically different avian nephritis virus isolates implicated in etiology of baby chick nephropathy. *Avian Dis*. 36:369–377.
39. Songserm, T., J.M.A. Pol, D. van Roozelaar, G.L. Kok, F. Wagenaar, and A.A. ter Huurne. 2000. A comparative study of the pathogenesis of malabsorption syndrome in broilers. *Avian Dis*. 44:556–567.
40. Spackman, D., R.E. Gough, M.S. Collins, and D. Lanning. 1984. Isolation of an enterovirus-like agent from the meconium of dead-in-shell chicken embryos. *Vet Rec*. 114:216–218.
41. Swayne, D.E., M.J. Radin, and Y.M. Saif. 1990. Enteric disease in specific pathogen free turkey poults inoculated with a small round turkey-origin enteric virus. *Avian Dis*. 34:683–692.
42. Takase, K., K. Shinohara, M. Tsuneyoshi, M. Yamamoto, and S. Yamada. 1989. Isolation and characterization of cytopathic avian enteroviruses from broiler chicks. *Avian Pathol*. 18:631–642.
43. Todd, D., J.H. Weston, K.A. Mawhinney, and C. Laird. 1999. Characterization of the genome of avian encephalomyelitis virus with cloned cDNA fragments. *Avian Dis*. 43:219–226.
44. Wylie, S.L., and D.A. Pass. 1989. Investigations of an enteric infection of cockatoos caused by an enterovirus-like agent. *Aust Vet J*. 66:321–324.
45. Yu, M., M.M. Ismail, M.A. Qureshi, R.N. Dearth, H.J. Barnes, and Y.M. Saif. 2000a. Viral agents associated with poult enteritis and mortality syndrome: The role of a small round virus and a turkey coronavirus. *Avian Dis*. 44:297–304.
46. Yu, M., Y. Tang, M. Guo, Q. Zhang, and Y.M. Saif. 2000b. Characterization of a small round virus associated with the poult enteritis and mortality syndrome. *Avian Dis*. 44:600–610.

Enteric Parvovirus Infections of Chickens and Turkeys

1. Bidin, M., I. Lojkic, Z. Bidin, M. Tiljar, and D. Majnaric. 2011. Identification and phylogenetic diversity of parvovirus circulating in commercial chicken and turkey flocks in Croatia. *Avian Dis*. 55:693–696.
2. Chmielewski, R., J.M. Day, S. Spatz, Q. Yu, R. Gast, L. Zsak, and D. Swayne. 2011. Thermal inactivation of avian viral and bacterial pathogens in an effluent treatment system within a biosafety level 2 and 3 enhanced facility. *Appl Biosaf*. 16:206–217.
3. Day, J.M., and L. Zsak. 2010. Determination and analysis of the full-length chicken parvovirus genome. *Virology*. 399:59–64.
4. Farkas, S.L., Z. Zadori, M. Benko, S. Essbauer, B. Harrach and P. Tijssen. 2004. A parvovirus isolated from royal python (Python regius) is a member of the genus Dependovirus. *J Gen Virol*. 85:555–61.
5. Ingram, D., and L. Zsak. 2012. Unpublished data.
6. Kahn, J.S., D. Kesebir, S.F. Cotmore, A. D'Abramo, Jr., C. Cosby, C. Weibel, and P. Tattersall. 2008. Seroepidemiology of human bocavirus defined using recombinant virus-like particles. *J Infect Dis*. 198:41–50.
7. Kisary, J., B. Nagy, and Z. Bitay. 1984. Presence of parvoviruses in the intestine of chickens showing stunting syndrome. *Avian Pathol*. 13:339–343.
8. Kisary, J. 1985. Experimental infection of chicken embryos and day-old chickens with parvovirus of chicken origin. *Avian Pathol*. 14:1–7.
9. Kisary, J. 1985. Indirect immunofluorescence as a diagnostic tool for parvovirus infection of broiler chickens. *Avian Pathol*. 14:269–73.
10. Kisary, J., B. Avalosse, A. Miller-Faures, and J. Rommelaere. 1985. The genome structure of a new chicken virus identifies it as a parvovirus. *J Gen Virol*. 66:2259–2263.
11. Kisary, J., A. Miller-Faures, and J. Rommelaere. 1987. Presence of fowl parvovirus in fibroblast cell cultures prepared from uninoculated White Leghorn chicken embryos. *Avian Pathol*. 16:115–21.
12. Kisary, J. 1999. RecombiVac-S, the first Hungarian biosynthetic (recombinant) subunit vaccine. *Magy All Lap*. 121:243–247.
13. Kouwenhoven, B., M.H. Vertommen, and E. Goren. 1983. Runting and stunting syndrome in broilers: The disease with many names and faces. Proceeding of the Australian Veterinary Poultry Association Conference, Sydney, Australia. 73–93.
14. Le Gall-Recule, G., V. Jestin, P. Chagnaud, P. Blanchard, and A. Jestin. 1996. Expression of muscovy duck parvovirus capsid proteins (VP2 and VP3) in a baculovirus expression system and

demonstration of immunity induced by the recombinant proteins. *J Gen Virol*. 77:2159–2163.
15. Marusak, R.A., J.S. Guy, T.A. Abdul-Aziz, M.A. West, O.J. Fletcher, J.M. Day, L. Zsak, and H.J. Barnes. 2010. Parvovirus-associated cerebellar hypoplasia and hydrocephalus in day old broiler chickens. *Avian Dis*. 54:156–160.
16. Muzyczka, N., and K.I. Berns. 2001. Parvoviridae: the viruses and their replication. In: *Fields Virology*, 4th ed., Vol. 2. D.M. Knipe and P.M. Howley, eds. Lippincott, Williams & Wilkins, Philadelphia. 2327–2359.
17. Palade, E.A., Z. Demeter, A. Hornyak, C. Nemes, J. Kisary, and M. Rusvai. 2011. High prevalence of turkey parvovirus in turkey flocks from Hungary experiencing enteric disease syndromes. *Avian Dis*. 55:468–475.
18. Palade, E.A., J. Kisary, Z. Benyeda, M. Mandoki, G. Balka, C. Jakab, B. Vegh, Z. Demeter, and M. Rusvai. 2011. Naturally occurring parvoviral infection in Hungarian broiler flocks. *Avian Pathol*. 40:191–7.
19. Saikawa, T., S. Anderson, M. Momoeda, S. Kajigaya, and N.S. Young. 1993. Neutralizing linear epitopes of B19 parvovirus cluster in the VP1 unique and VP1-VP2 junction regions. *J Virol*. 67:3004–3009.
20. Saraste, M., P.R. Sibbald, and A. Wittinghofer. 1990. The P-loop—a common motif in ATP- and GTP-binding proteins. *Trends Biochem Sci*. 15:430–434.
21. Siegel, G. 1976. The parvoviruses. *Virology Monographs*. 4:15.
22. Strother, K.O., and L. Zsak. 2009. Development of an enzyme-linked immunosorbent assay to detect chicken parvovirus-specific antibodies. *Avian Dis*. 53:585–91.
23. Sukhumsirichart, W., P. Attasart, V. Boonsaeng, and S. Panyim. 2006. Complete nucleotide sequence and genomic organization of hepatopancreatic parvovirus (HPV) of Penaeus monodon. *Virology*. 346:266–277.
24. Tarasiuk, K., G. Wozniakowski, and E. Samorek-Salamonowicz. 2012. Occurrence of chicken parvovirus infection in Poland. *Open Virol J*. 6:7–11.
25. Tattersall, P. 2006. The evolution of parvovirus taxonomy. In: *Parvoviruses*. J.R. Kerr, S.F. Cotmore, M.E. Bloom, R.M. Linden, and C.R. Parish, eds. Hodder Arnold, London. 5–14.
26. Tijssen, P., M. Agbandje-McKenna, J.M. Almendral, M. Bergoin, T.W. Flegel, K. Hedman, J. Kleinschmidt, Y. Li, D.J. Pintel, and P. Tattersall. 2012. Family Parvoviridae. In: *Virus Taxonomy: Ninth Report of the International Committee on Taxonomy of Viruses*. A.M.Q. King, M.J. Adams, E.B. Carstens, and E.J. Lefkowitz, eds. Academic Press, Oxford. 405–425.
27. Trampel, D.W., D.A. Kinden, R.F. Solorzano, and P.L. Stogsdill. 1983. Parvovirus-like enteropathy in Missouri turkeys. *Avian Dis*. 27:49–54.
28. Zsak, L., K.O. Strother, and J. Kisary. 2008. Partial genome sequence analysis of parvoviruses associated with enteric disease in poultry. *Avian Pathol*. 37:435–41.
29. Zsak, L., J.M. Day, and K.O. Strother. 2009. Enteric disease in broiler chickens following experimental infection with chicken parvovirus. Proceedings of the American Association of Avian Pathologists Annual Meeting, Seattle, WA. abstract 7598.
30. Zsak, L., K.O. Strother, and J.M. Day. 2009. Development of a polymerase chain reaction procedure for detection of chicken and turkey parvoviruses. *Avian Dis*. 53:83–8.
31. Zsak, L., and J.M. Day. 2010. The pathogenicity of parvovirus in chickens. Proceedings of the American Association of Avian Pathologists Annual Meeting, Atlanta, GA. abstract 9293.
32. Zsak, L., and J.M. Day. 2010. Parvovirus-induced enteritis in young turkeys. Proceedings of the 59th Western Poultry Disease Conference, Vancouver, Canada. 22.

Chapter 13

Viral Infections of Waterfowl

Introduction

Peter R. Woolcock

The objective of this chapter is to bring together all of the viral diseases affecting waterfowl. This chapter has detailed subchapters on the following diseases:

- Duck hepatitis, a major disease of young ducklings, caused by up to five different viruses, three genotypes of duck hepatitis virus (DHV) type 1 (renamed Duck hepatitis A virus, DHAV), a picornavirus, and DHV 2 and DHV 3, both now classified as astroviruses.
- Duck virus enteritis (DVE), caused by a herpesvirus that poses a major threat to both commercially reared and wild waterfowl.
- Parvovirus infections of geese and Muscovy ducks. Molecular techniques have shown that although Muscovy duck parvovirus (MDPV) and goose parvovirus (GPV) are closely related, they are distinct and therefore, should be considered as causing separate diseases. MDPV has been recognized in the United States (94).
- Goose hemorrhagic polyomavirus (GHPV) is the cause of hemorrhagic nephritis enteritis of geese (HNEG) (31).

Other virus infections associated with waterfowl will be covered in this introduction. Viruses that are not necessarily associated with disease in waterfowl but still infect these species are included.

Interests in viral infections of waterfowl are more diverse than for poultry and focus on 3 different issues: (1) problems associated with raising birds commercially, (2) problems associated with wild waterfowl, and (3) problems created by migratory waterfowl in the transmission of infectious disease to commercially reared waterfowl and poultry.

RNA viruses associated with waterfowl include Picornaviridae (DHA, duck picornavirus [DPV]), Astroviridae (DHV II and III), Paramyxoviridae (avian metapneumovirus, avian paramyxoviruses 1, 4, 6, 8, and 9), Orthomyxoviridae (avian influenza), Flaviviridae (West Nile virus), and Reoviridae (Duck reovirus, Muscovy duck reovirus and goose reovirus); DNA viruses include Herpesviridae (DVE, goose herpes virus), Adenoviridae (duck adenovirus), Circoviridae (circovirus-like infection of ducks and geese), Hepadnaviridae (duck hepatitis B virus), Parvoviridae (MDPV and GPV), and Polyomaviridae (GHPV).

Oncogenic viruses of waterfowl are not included in this chapter.

Avian Paramyxoviruses

Avian paramyxoviruses (APMV) types 1, 4, 6, 8, and 9 have been associated with infections in waterfowl. Infections by these viruses have been demonstrated through virus isolation (14, 30, 32, 36, 68, 72, 75) or serology in various waterfowl species (10, 11, 27, 35, 55, 61). However, these viruses are generally considered to be apathogenic, and Chang et al. have reported the complete nucleotide sequence of an apathogenic APMV 6 isolate from ducks (15).

Exception to lack of pathogenicity are reports by Zou et al. (96) and Jinding et al.(45) of an APMV type 1 causing high mortality in geese in China. Shi et al. (74) reported an APMV type 1 isolated from Muscovy duck that was pathogenic for white feathered and black feathered Muscovy ducks and Pekin ducks.

APMVs are dealt with in detail in Chapter 3.

Avian Metapneumovirus

Avian metapneumoviruses (aMPV), members of the family Paramyxoviridae (67), were first isolated in 1980s (28). They have been of most concern to the turkey industry and were not detected in the United States until 1996 (73). The U.S. turkey isolate of aMPV is designated type C, because it is different from the types A and B found in Europe (71). Isolates from ducks in France (89) also have been assigned to subgroup C, and Toquin et al. (2006) have shown that the European and American subgroup C viruses belong to different genetic lineages (90).

In 1999, Toquin et al. (89) reported the isolation of a pneumovirus from 42-week-old Muscovy ducks exhibiting coughing for 7 days followed 2 weeks later by an egg drop. Mortality was

Diseases of Poultry, Thirteenth Edition. David E. Swayne.
© 2013 John Wiley & Sons, Inc. Published 2013 by John Wiley & Sons, Inc.

about 2%. Grossly, the birds showed general congestion and splenomegaly; histologically, tracheitis was also observed. The virus was isolated from tracheal swabs using Vero cells. After one passage, a cytopathic effect characterized by distended cells detaching from the monolayer and syncytia was observed. Indirect immunofluorescence staining of the culture was positive with a polyvalent anti-pneumovirus serum prepared in specific pathogen free (SPF) turkeys inoculated simultaneously with 4 aMPV strains. The isolate was confirmed as a pneumovirus by a reverse-transcriptase polymerase chain reaction (RT-PCR) on the N gene, a diagnostic test that detects aMPV isolates regardless of their subgroup. The authors also showed that using monospecific aMPV antisera in both an enzyme-linked immunosorbent assay (ELISA) and an indirect immunofluorescent assay (IFA), the Muscovy duck virus isolates reacted most strongly with the aMPV Colorado (type C) antiserum when compared with antisera against aMPV A, B, and non-A and non-B types. The closeness to the Colorado virus strain was confirmed by RT-PCR because the isolate did not react with primers specific to the G gene of subgroups A and B. The pathogenicity of the aMPV isolated required further investigation to determine its role in this syndrome because *Reimerella anatipestifer* also was recovered. Jestin et al. (44) subsequently has reported that experimental infection of 18-day-old SPF Muscovy ducklings with the aMPV isolate produced clinical signs that were correlated with tracheal swab virus isolation and preceded any seroconversion.

aMPV RNA has been isolated from the nasal turbinates or swabs of mallard ducks, wild geese, and sentinels captured in the north central U.S. (78). The nucleotide and amino acid sequences of the aMPV genes examined had 90%–95% identity with isolates from turkeys. It is not clear whether virus was isolated in all of these cases. The authors considered that wild birds may well be involved in the spread of the disease in turkeys. McComb et al. (59) reported the detection of aMPV viral RNA in choanal-tracheal swabs collected from 8-week-old sentinel ducks (mallards) that were allowed to mingle with wild waterfowl in central Minnesota. In one case, aMPV was isolated from the choanal-tracheal swabs, and the virus had more than 96% predicted amino acid identity with the MN/2A turkey aMPV isolate. The authors (59) also detected aMPV viral RNA in choanal swabs from Canada geese, blue winged teal, and snow geese; however, no viruses were isolated from these birds. They concluded that aMPVs may be more widespread in nature than previously thought.

In an experimental study (62), 10-day-old commercial ducklings were inoculated either orally or oculo-nasally with a Minnesota turkey isolate of aMPV. The birds remained clinically normal, but at 3–21 days post innoculation (PI), aMPV viral RNA was detected in tissues from inoculated birds. aMPV also was reisolated from the infected ducklings.

aMPV-negative mallard ducks placed next to a turkey farm experiencing a severe outbreak of aPMV infection did not develop clinical disease but infectious aMPV was recovered from choanal swabs after 2 weeks and anti-aMPV antibodies were detected after 4 weeks. This indicated that the aMPV isolates from different species can cross-infect (76).

Bennett et al. demonstrated the presence of aMPV in wild Canada geese (*Branta canadensis*) and blue winged teal (*Anas discors*) by RT-PCR (7), although virus could only be isolated from Canada geese, suggesting that RT-PCR may be more sensitive. Using Canada geese isolates, Bennett et al. (6) went on to investigate the genomic structure of the virus. All but one of the eight genes were similar to those of a turkey aMPV isolate in terms of size, sequence identity, and genome organization. However, the attachment gene (G) coding for the 585 amino acid-long protein is larger than for any pneumovirus or metapneumovirus. This was more than twice the size of G proteins for other subtype C viruses and human metapneumoviruses, and more than 170 amino acids longer than the G proteins from aMPV subtypes A, B, and D. Although this virus with the large insertion in the G gene was not detected in turkeys, it did replicate in the upper respiratory tract of experimentally challenged domestic turkeys with no clinical signs. This virus also could be horizontally transmitted to naïve turkeys and the infection induced specific antibody production. The authors suggested that this virus may be a safe and effective vaccine for commercial turkeys.

Shin et al. (77) considered that ducks could be suspected to play a role as nonclinical carriers of aMPV and serve as a potential source of infection for domestic turkeys.

Turpin et al. (92) surveyed wild birds for aMPV type C in Georgia, South Carolina, Arkansas, and Ohio. Among other species they obtained aMPV type C isolates from oral swabs of American coots and Canada geese, demonstrating that wild waterfowl can serve as reservoirs for the virus.

Avian Influenza Virus

Until relatively recently information on avian influenza in waterfowl was reported as follows: Waterfowl typically do not experience significant disease problems due to avian influenza viruses (AIVs), but infections in these birds are widespread (87). AIVs can be recovered from migratory waterfowl, particularly ducks; at least 30 of 149 species of ducks, geese, and swans have yielded virus but natural infections are usually considered asymptomatic (88).

The picture changed dramatically in late 2002 when HPAI (H5N1) occurred in geese, ducks, and swans, among other avian species, at two waterfowl parks in Hong Kong (23). The range of pathological changes present in the various waterfowl examined in this outbreak resembled those reported generally for HPAI viruses in chickens (88).

Since that outbreak in 2002, H5N1 HPAI, also referred to as "bird flu," has spread through Asia, Europe, and parts of Africa.

The role of migratory waterfowl in the spread of HPAI H5N1 has been questioned. Chen et al. (17) described an outbreak in bar headed geese (*Anser indicus*) at Qinghai Lake in Western China in May 2005; more than 1,500 birds died.

Hulse-Post et al. (40) reported that the H5N1 HPAI can revert to non-pathogenic forms in ducks. Thus, wild waterfowl may appear uninfected by the H5N1, but still may continue to circulate the virus. Similar findings were reported by Sturm-Ramirez et al. (84).

There are many reports about the H5N1 HPAI and the role of waterfowl in its transmission; this virus is covered in detail in Chapter 6.

West Nile Virus

West Nile virus (WNV) is a member of the Japanese encephalitis virus antigenic complex of arthropod-borne flaviviruses (Flaviviridae) that are transmitted through mosquitoes to a variety of mammals and birds (48). The notoriety of this virus has increased since 1999 when an epizootic causing death in wild American crows (*Corvus brachyrhynchus)* began in New York (64). This was the first time that WNV had been detected in North America. At the same time, WNV-positive cases occurred in a number of wild bird species, humans, and horses (48, 49, 83), and at zoological collections of mammals and birds in New York (13).

Outbreaks of WNV involving ducks and geese have been reported from Israel and Romania (49, 63, 70). In the New York outbreak, Steele et al. (83) examined birds from two wildlife facilities in the city, which had either died or were euthanized after suspected of being infected with WNV. Lesions in emaciated Anseriformes included brain hemorrhages, splenitis, splenomegaly, nephritis, and congestion in the kidneys. Three ducks were involved in this study—1 mallard and 2 bronze-winged ducks. In the mallard, abundant antigen was demonstrated by immunohistochemistry in the brain, heart, liver, kidney, and pancreas, and to a lesser extent in the adrenal gland and intestine. Virus in excess of 10^2 pfu/0.2 ml was isolated from brain, heart, spleen, liver, and kidney; virus also was demonstrated by RT-PCR in these same tissues. Only immunohistochemical testing was performed on the tissues from the bronze-winged ducks, but results obtained were not dissimilar to those in the mallard.

Calle et al. (13) reported that in the 1999 outbreak in New York an Abyssinian blue-winged goose (*Cyanochen cyanopterus*), a Roseybill duck (*Netta peposcaca*), and a domestic goose (*Anser anser*) showed asymptomatic seroconversion to WNV, and in the domestic goose and trumpeter swan (*Cygnus cygnus buccinator*) morbidity and recovery were recorded. No deaths were recorded in any of the birds.

The New York isolates of WNV yielded an E gene nucleotide sequence that was extremely homologous to that from the WNV isolated from a goose in Israel in 1998 and also from a 1996 Romanian isolate (49, 56).

In an experimental study, Swayne et al. (86) reported WNV replication in 2-week-old goslings following subcutaneous inoculation. Viremia was detected between 1 and 5 days PI; virus could be detected in plasma diluted up to $1{:}10^6$. All of the experimentally infected goslings developed clinical signs with depression, weight loss, and decreased activity; one bird developed neurological signs. Microscopic lesions seen in the infected birds were encephalitis and myocarditis. Virus was recovered from the brain and the heart. Viral antigen was demonstrated by immunohistochemistry in the heart, brain, pancreas, and kidney and in autonomic ganglion cells of the intestine (varied from bird to bird). These authors concluded that the disease was a threat to goslings; the high virus titers in the blood suggest that goslings could be an amplifying host, and thus infect permissive mosquito vectors; the virus was transmitted by contact between goslings in close association.

Bird-to-bird transmission of West Nile virus in geese has been proposed by Austin et al. 2004.(1) They investigated an outbreak on a multi-age farm with multi-age flocks in Manitoba, Canada. The level of seroconversion in these flocks exceeded that which would have been expected by mosquito transmission alone. In another study Banet-Noach et al. (4) showed direct (non-vector) transmission of WNV in geese. They mixed a group of 10 3-week-old s/c inoculated geese with 20 healthy geese of the same age in an insect-proof room. All geese in the inoculated group produced antibodies, 8 became viremic, and 5 died between 7 and 10 days PI. Virus was shed via the cloaca and oral cavity by 3 geese. Two of the contact birds died on days 10 and 17 PI and WNV was recovered from another 3 birds. The authors claim these findings strongly suggest that horizontal transmission can occur in commercial flocks and may be aggravated if cannibalism and feather picking of sick birds occurs.

RT-PCR procedures for detecting WNV have been described (8, 49, 70).

Jarvi et al. (43) have reported the successful use of a recombinant subunit WNV vaccine to protect geese.

Concern about the spread of WNV to Japan (69) and South Korea (95) have been raised as seropositive wild migratory ducks have been detected in both countries.

Duck, Muscovy Duck, and Goose Reoviruses

Muscovy duck reovirus infections have been described (46, 57). In France, it is considered to be a major virus disease of Muscovy ducks (50). In 2- to 4-week-old ducks, the disease is acute, morbidity is high, and mortality can reach 10%. Clinical signs include apathy, with diarrhea and difficulties in moving. Grossly, dead birds showed fibrinous pericarditis, marbled spleen, and enlarged friable livers (57, 58). Microscopically, the pericarditis consisted of an infiltration of mononuclear inflammatory cells in the serous membrane associated with a fibrinous exudate. In the liver, there were necrotic foci or infiltrations of lymphocytes and plasmacytes in the portal region. In the spleen, reticulosis, depletion of lymphoid nodules, and focal necrosis were evident. The synovial sheath of the leg tendons had an exudative inflammation (58).

Cross neutralization tests have demonstrated the Muscovy duck reovirus is antigenically distinct from the chicken reovirus S1133 (34).

Palya et al. (65) reported on a disease in young geese caused by a reovirus. The disease was characterized by splenitis and hepatitis with miliary necrotic foci during the acute phase, and epicarditis, arthritis, and tenosynovitis during the subacute/chronic phase. Although in earlier reports reoviruses had been repeatedly recovered from geese, they had never been associated with disease. The disease occurred most frequently in 2- to 20-week-old goslings and Banyai et al. (5) investigated the genetic variability among goose reoviruses (GRV). The S4 genome segment of 5 GRVs shared substantial structural similarity with Muscovy duck reovirus (DRV). The authors consider GRV and DRV to belong to a species distinct from others established within the subgroup 2 of orthoreoviruses.

Hollmen et al. (37) reported the isolation of a reovirus from common eider ducks (*Somateria mollissima)* in Finland. The virus was isolated from the cloacal bursa (bursa of Fabricius) in Muscovy duck embryo fibroblasts, but not in SPF chicken eggs. Mallard ducklings challenged with this virus seroconverted. No deaths were recorded but at necropsy focal hemorrhages were observed in the liver, spleen, and cloacal bursa of some of the birds. The polyvalent eider reovirus serum obtained from the experimental mallards did not inhibit the growth of avian arthritis virus (S1133) in Muscovy duck embryo fibroblasts. The relationship of this reovirus to DRV and GRV has not been reported. A reovirus also has been recovered from a mallard (60).

A reovirus causing duck viral swollen head hemorrhagic disease in Pekin ducks has been reported from China by Li et al. (51), who developed an indirect immunoperoxidase assay for detection of the virus. Liu et al. (53) report the isolation and characterization of a reovirus causing spleen necrosis in Pekin ducklings. The virus was isolated in the allantoic sac of 9-day-old Pekin duck embryos. DNA sequencing revealed that the isolate was closely related to Muscovy duck reoviruses. Liu et al. (52) characterized four monoclonal antibodies that react against the σB protein of Muscovy duck reovirus; the authors claim that the monoclonal antibodies are ideal for use in an antigen-capture ELISA.

Goose Herpesvirus (GHV)

In Australia, a herpesvirus has been implicated in a peracute disease of domestic geese that caused 97% mortality over a 24-day period (47). Clinical signs and gross pathology were similar to those seen with DVE infections. Histologically small button ulcers and large plaques overlying lymphocyte aggregates were present on the mucosa of the small intestine of affected birds. Small white foci of necrosis and focal hemorrhages were seen in the livers. Numerous intranuclear inclusion bodies were observed microscopically in the hepatocytes. A herpesvirus was isolated in various primary chicken and duck embryo cell cultures. This virus was not neutralized by antiserum to DVE virus. In experimental transmission studies, the virus caused 100% mortality in adult domestic geese, 50% mortality in 1-day-old commercial ducklings, and 25% mortality in 4- to 6-week-old commercial ducklings (47). However, Gough and Hansen (29) reported that Pekin ducks are not susceptible to GHV.

In cross-protection studies, Gough and Hansen (29) showed that mortality in DVE-vaccinated geese, Muscovy ducks, and Pekin ducks challenged with GHV was 100%, 50%, and 0%, respectively. Conversely, in geese, Muscovy ducks and Pekin ducks immunized with inactivated GHV, 100% mortality was recorded in the geese and Muscovy ducks and 80% in the Pekin ducks following challenge with DVE virus. Using cross-neutralization tests in cell cultures, they compared GHV with 5 other avian herpesviruses—namely, DVE/goose, DVE/Muscovy, infectious laryngotracheitis virus, Pacheco's herpesvirus, and falcon herpesvirus. No significant cross neutralization was reported, confirming that GHV is antigenically distinct from DVE viruses. Using restriction endonuclease analysis, a comparison of the genome of GHV with 3 different strains of DVE virus confirmed that GHV is completely different from the DVE viruses. By PCR using 2 different sets of DVE-specific primers, the GHV was shown to be different from 3 DVE virus strains.

Adenoviruses

Duck adenovirus 1 (DAdV-1) (previously known as group 3 avian adenovirus, egg drop syndrome-1976 virus [EDS], avian adenovirus EDS, and egg drop syndrome virus (41)) is a member of the genus *Atadenovirus, s*pecies Duck adenovirus A. Ducks and geese are assumed to be the natural hosts of this virus, but there is sparse evidence of disease in waterfowl associated with this virus. However, Ivanics et al. (42) reported in 2001 an acute respiratory disease in goslings in Hungary attributable to EDS virus. In 2009 Brash et al reported an outbreak in Canada of respiratory disease in 1-week-old Muscovy ducklings in Canada caused by DAdV-1.

Aviadenoviruses (41) also have been reported isolated from a mallard (60) and a Muscovy duck (12). In Muscovy ducks, mortality occurred, but there were no attempts to reproduce the disease with the isolated adenovirus tentatively named Duck adenovirus 2.

Unclassified Adenoviruses

Hollmen et al. (38) reported the isolation of an adenovirus from long-tailed ducks (*Clangula hyemalis)* collected during a die-off in the Beaufort Sea off the north coast of Alaska. The authors reproduced the disease experimentally in long tailed ducks inoculated with the isolated virus; no mortality was recorded but clinical signs included gastrointestinal disease including watery feces and blood in the feces. Challenged ducks seroconverted. The virus could not be neutralized by reference antisera to group 1, 2, or 3 avian adenoviruses and so may represent a new serotype.

Hollmen et al. (39) also reported on an adenovirus associated with impaction of the posterior small intestine with mucosal necrosis and the cause of death in 10 male common

eider ducks (*Somateria mollissima*) in the northern Baltic Sea near Finland. They isolated adenovirus from cloacal swabs from 6 of the birds. The adenovirus could not be neutralized with reference antisera to group 1, 2, or 3 avian adenoviruses. The virus caused clinical signs of illness and gastrointestinal pathology in an experimentally infected mallard duckling.

Cheng et al. (21) reported attempts to characterize a virus causing enteritis in goslings in China. They identified an adenovirus and named the virus new gosling viral enteritis virus (NGVEV). For further characterization information see (18, 19, 20). For more information on adenoviruses see Chapter 9.

Circovirus-Like Infection of Ducks and Geese

Soike et al. (82) first reported in 1999 the presence of circovirus-like particles, approximately 15 nm in diameter, by negative stain EM in cloacal bursa, splenic, and thymic tissues from a flock of Czech hybrid geese with a history of increased losses and runting. Since then a virus has been isolated from 2 female mulards showing characteristic signs of circovirus infection (81). This duck circovirus (DuCV) has been shown to be closely related phylogenetically to goose circovirus (GoCV), but is still distinct (33).

Avian circovirus infections which occur in the first months of life are characterized by developmental and/or feathering disorders. The virus invades the lymphoid tissues and leads to immunosuppression, growth retardation, and an increased probability of secondary infections, such as *Reimerella anatipestifer* and *Aspergillus* sp. In geese the only apparent gross lesions in 2-week-old and 9-week-old birds were a cloudiness of the air sacs (82). Histopathological changes were evident in the lymphoreticular tissue; lymphocytic depletion and histocytosis were most apparent in the cloacal bursa. Basophilic globular inclusions were found in the cytoplasm of medullar and cortical bursal follicular cells and bursal epithelial cells. Ultrastructural examination of these inclusions revealed paracrystalline or multilayered arrays or randomly arranged complexes of isometric viral particles approximately 14 nm in diameter. In naturally infected commercial Muscovy, mule, and Pekin ducks, and White Roman geese in Taiwan, the mainly 4- to 6-week-old birds had clinical signs of loss of wing and body feather, necrosis of feather follicles, and stunted growth. Grossly the most common lesion was polyserositis, particularly in the pericardial cavity and over the surface of the liver; a cheese-like mass within the air sacs was often observed (16).

Smyth et al. (79) investigated a circovirus infection in geese by *in situ* hybridization using a GoCV DNA probe that showed that circovirus DNA could be demonstrated in the cloacal bursa, spleen, thymus, bone marrow, liver, kidney, lung, and heart, indicating that the infection can be multi-systemic.

Diagnostic tests for GoCV and DuCV are mostly PCR based. Ball et al. (2) reported a PCR and dot blot hybridization test to diagnose GoCV in Hungarian geese. Fringuelli et al. (24) described the development of both conventional PCR and real time PCR to diagnose DuCV. Chen et al. 2006 (16) reported a PCR that could detect and differentiate duck and goose circovirus infections.

Liu et al. (54) have since reported the development of an indirect ELISA for the detection of DuCV infection in flocks using recombinant capsid protein as antigen.

Glavits et al. (26) investigated an outbreak of West Nile virus infection in a goose flock in Hungary; they found histologically that in addition to the changes attributable to WNV, changes more characteristic of a circovirus were identified. Both virus infections were diagnosed by molecular diagnostic tests (i.e., RT-PCR and PCR, respectively), but neither virus was isolated.

A duck circovirus (DuCV) was detected by PCR in bursal and thymic samples from Pekin ducks from New York. The birds exhibited bursal and thymic atrophy, as well as arthritis caused by *Staphylococcus aureus* (3). This is the first report involving Pekin ducks.

Phylogenetic analysis on the basis of genomic and open reading frame (ORF) C1 nucleotide and amino acid sequences showed that Chinese isolates of DuCV could be divided into two genotypes (93). Further diversity was reported by Fu et al. (25).

Miscellaneous Viral Infections

Tsai et al. (91) reported that 77.3% of 611 ducks and 70.9% of 542 geese in Taiwan were positive for antibodies to Japanese encephalitis virus.

Smyth and McNulty (80) reported on a transmissible disease of the cloacal bursa in ducks but could not identify a causative agent.

A virus causing an egg drop, feed decline, and ovary-oviduct disease in ducks has been reported from China. The disease was reproduced in healthy ducks and the virus has been identified as a flavivirus most closely related to Tembusu virus (85).

Bidin et al. (9) have reported the first evidence of avian nephritis virus (ANV) in ducks. The report from Croatia confirmed the diagnosis by RT-PCR; high nucleotide and amino acid identities were shared with other ANV polymerase (ORF 1b) genes.

Avian bornavirus (ABV) in association with non-suppurative inflammation in the central peripheral and autonomic nervous systems has been detected in wild free-ranging Canada geese and trumpeter swans (*Cygnus buccinator*) in Ontario, Canada. The virus was detected in brain tissue by immunohistochemistry and RT-PCR (22). ABV also has been detected in healthy Canada geese by RT-PCR; the virus was propagated in duck embryo fibroblast cells and detected by RT-PCR after two passages and indirect fluorescent antibody assay after three passages using a psittacine proventricular dilatation disease antibody (66).

Duck Hepatitis

Peter R. Woolcock and Hsiang-Jung Tsai

Introduction

Duck hepatitis (DH) is a highly fatal, rapidly spreading viral infection of young ducklings characterized primarily by hepatitis. The disease can be caused by at least five different viruses. The most pathogenic is a member of the newly proposed Picornavirus genus (*Avihepatovirus*) duck hepatitis A virus 1 (DHAV-1), formerly designated as duck hepatitis virus type 1 or DHV-1 (6, 14, 26, 74, 78). DHAV-2, isolated in Taiwan (123), and DHAV-3, isolated in South Korea (71) and China (39), are two newly described DHV genotypes, belonging to the same proposed *Avihepatovirus* genus; they can also cause high mortality in ducklings.

DHV types 2 and 3 were first recognized as separate entities because they induced hepatitis in DHAV-1–immune ducklings (6, 14, 38, 45, 46, 48, 53, 93, 117, 119). These two viruses are now reclassified and named Duck Astrovirus types 1 and 2, respectively (117). For other reviews of DHV types 1 and 3 see Calnek (14), and for DHV type 2 see Gough and Stuart (48).

Duck hepatitis is of economic importance to all duck-growing farms because of the high potential mortality if not controlled. The five virus types are not known to have any public health significance.

In addition to the five viruses that are etiologically associated with liver disease in ducks, a member of the hepadnavirus group (hepatitis B viruses; DHBV) is also found in wild and domestic ducks. Also duck picornavirus (DPV), a member of the newly proposed Picornavirus genus (provisionally named *Sapelovirus*), has been found in domestic ducks (124).

Duck Hepatitis Type 1

History

Duck hepatitis was first observed in Long Island in 1945 (79). The disease affected ducklings during the first week of age, and was characterized by enlarged livers mottled with hemorrhages. Affected birds showed rapid death after first clinical signs were observed. The causative pathogen DHAV-1 was first isolated in chicken embryos in 1950 (78) and was originally classified as an enterovirus (130) until the complete genome was determined in 2006 (74). Presently it is classified in the new genus *Avihepatovirus* in the family *Picornaviridae* (122). Now an additional two antigenically and genetically distinct viruses have been established: DHAV-2, isolated in Taiwan (122), and DHAV-3, isolated in South Korea and China (39, 71). For historical details of the disease, please refer to the previous edition of *Diseases of Poultry* (132).

Etiology

Classification

Analysis of the sequences of the three types of DHAV showed them to be closely related picornaviruses, but unrelated to any members of the currently defined genera. The Picornaviridae study group proposed the creation of the genus *Avihepatovirus*, containing the single species *Duck hepatitis A virus* (98) (http://ictvonline.org/virusTaxonomy.asp?version=2009&bhcp=1).

Morphology (Ultrastructure, Size, Density, Symmetry)

DHAV-1 is naked with an icosahedral capsid and has been estimated to be 20–40 nm in size (105, 106, 115), typical picornavirus morphology. The complete genome of DHAV-1 isolates from Korea (74), Taiwan (122), and China (26, 80) have been determined and shown to comprise a positive sense single-stranded RNA of 7,691 nucleotides in length, with a poly (A) tail at the 3′-end.

The genomic organization of DHAV-1 is typical of a picornavirus, with a single long open reading frame (ORF) flanked by 5′ and 3′ untranslated regions (UTRs). The ORF can be translated into a large polyprotein, 2,250 amino acids in size, which appears to be cleaved into 12 mature products, forming its structural (VP0, VP3, and VP1) and nonstructural proteins (2A1, 2A2, 2A3, 2B, 2C, 3A, 3B, 3C, and 3D). Three in-tandem 2A genes are unique features of DHAV-1. Among them, 2A1 protein is an aphthovirus-like 2A protein, and 2A3 protein is a human parechovirus-like 2A protein, whereas 2A2 protein is not related to any known picornavirus proteins (122). Analysis of the amino acid sequences of the three capsid proteins (VP1, VP0, and VP3) indicated the presence of conserved elements that form the 8-stranded β-barrel structures and intervening domains that vary in sequence between strains of different DHAV types, as seen in other picornaviruses (128).

Liu et al. (81) demonstrated that the 626-nucleotide-long 5′-UTR of the DHAV-1 genome contains an internal ribosome entry site (IRES) element that can direct translation initiation and is modulated by a viral coding sequence located downstream of the DHAV-1 5′-UTR. Also, the presence of conserved domains II and III at the 3′-end of the putative DHAV-1 IRES are essential for keeping the normal internal initiation of translation.

Chemical Composition

DHAV-1 has no hemagglutination activity (31, 115).

Susceptibility to Chemical and Physical Agents

DHAV-1 is resistant to ether and chloroform, is relatively heat stable, and is capable of survival for long periods under usual environmental conditions. DHAV-1 also resisted treatment with ether or fluorocarbon (99), chloroform, pH 3 and trypsin

(115), and 30% methanol or ammonium sulfate (54). Using cell culture-grown virus, Davis (21) reported that DHAV-1 resisted pH 3 for 9 hours, but longer exposure (48 hour) reduced virus titer. The virus was not inactivated by 2% lysol or 0.1% formalin (8); 15% creolin, naphthalysol, or xylonaphtha; or 20% anhydrous sodium carbonate (100). Complete inactivation was reported with 1% formaldehyde or 2% caustic soda within 2 hours at 15 °C–20 °C, 2% calcium hypochlorite within 3 hours at 15 °C–20 °C (100), 3% chloramine in 5 hours or 0.2% formalin in 2 hours (28), 5% phenol, undiluted inorganic iodine solution (Wescodyne, Steris Inc., Mentor, Ohio, USA), and undiluted sodium hypochlorite solution (Clorox, Clorox Company, Oakland, California, USA)(52, 57).

DHAV-1 survived for 21 days at 37 °C (99). Under more natural environmental conditions, the virus survived at least 10 weeks in uncleaned infected brooders and for longer than 37 days in moist feces stored in a cool shed (8). At 4 °C, the virus survived more than 2 years (8, 28) and at –20 °C for as long as 9 years (54).

Heating the virus at 50 °C for 1 hour had no effect on virus titer (115). Most of the virus was inactivated at 56 °C after 30 minutes (54). Asplin (8) reported, however, that it would survive at 56 °C for 60 minutes, but not at 62 °C for 30 minutes, and 23 hours were required for complete inactivation at 56 °C (28). Heat stability was unaffected by 1 M divalent cation (Mg^2) (118). Using cell culture-grown DHAV-1, the half-life of the virus was determined as 48 minutes at 50 °C, but in the presence of NaCl, Na_2SO_4, $MgCl_2$ or $MgSO_4$, the virus was protected from inactivation at that temperature (21). Tseng and Tsai (123) demonstrated that DHAV-2 is similar to DHAV-1 in several physic-chemical characteristics. Both are resistant to chloroform, formalin, pH 3.0, and 1 M Mg2+ treatment at 56 °C and 60 °C. Also, both viruses were sensitive to these temperatures in the absence of the cation, with DHAV-2 being more resilient.

Strain Classification

Viruses differing or serologically distinct from DHAV-1 have been recognized as causes of hepatitis in ducklings in India (103) and Egypt (112). The Indian isolate is known to be distinct from DHAV-l, but its relationships to the other DHV types are not known.

A variant strain of DHAV-1, named DHAV-1a, has been described (110). The origin of the virus is unknown, but all known isolates can be traced back to a single location. With the use of cross-neutralization tests in embryonating chicken eggs, the authors showed, with somewhat variable results, a partial cross-reaction between types 1 and 1a. They also showed partial cross-protection in passively immunized ducklings challenged with each of the viruses. Woolcock and Fabricant (141) also had reported differences between these two viruses in plaque-reduction assays in duck embryo kidney cells.

Both DHAV-2 and DHAV-3 have been shown to be distinct genetically and serologically from DHAV-1 (39, 71, 122). It is unknown whether DHAV-2 is serologically distinct from DHAV-3. However, the sequence difference (approximately 30% divergence in nucleotides) in capsid-coding regions suggested that they may belong to different serotypes (128). Sequence results have shown that mutations were distributed mainly in the VP1 (65, 80).

Laboratory Host Systems

Embryos. Levine and Fabricant (78) were the first to propagate the virus in the allantoic sac of 9-day-old chicken embryos. Ten percent to 60% of the embryos died by the 5th or 6th day and were stunted or edematous (Figure 13.1). Hwang and Dougherty (62) passaged a DHAV-1 strain as two lines in 10-day-old chicken embryos. The serially passaged lines became nonpathogenic for newly hatched ducklings at the 20th and 26th transfers. The virus titer in chicken embryos was 1–3 $\log_{10}$ lower than when grown in ducklings.

Goose embryos were found to be susceptible to the virus, and embryo deaths occurred 2–3 days after allantoic inoculation (4)

Cell Cultures. Various attempts to grow and assay DHAV-1 in cell cultures of duck and chicken embryo origin have been described (31, 33, 59, 66, 91, 99). Maiboroda (87) followed development of DHAV-1 in monolayers of duck kidney cells with a direct fluorescent antibody (FA) technique. Fluorescence was observed after 8 hours, reached a maximum after 2–4 days, and was confined to the cytoplasm. Cytopathic effects (CPE) characterized by rounding of cells with maximum virus titers occurred 2 days after infection. Goose embryo kidney and piglet kidney cell culture cells also produced CPE and virus growth (77, 88). Davis and Woolcock (24) showed that attenuated DHAV-1 grew in embryo cell cultures of goose, turkey, quail, pheasant, guinea fowl, and chicken origin, while virulent virus strains grew to varying degrees in only guinea fowl, quail, and turkey embryo cells. Golubnichi et al. (42) reported successful growth and extensive CPE in duck embryo fibroblasts inoculated with chick

Figure 13.1. Normal 15-day-old chick embryo (right). Fifteen-day-old chicken embryo inoculated 6 days previously with duck hepatitis A virus (DHAV) type 1 (left). Note small size, hemorrhage, and edema.

embryo-adapted DHAV-1. They recommended this procedure for vaccine production and virus neutralization (VN) tests.

Woolcock et al. (138) described a plaque assay for attenuated DHAV-1 in primary monolayers of duck embryo kidney (DEK) cells. The concentration of fetal calf serum in the overlay medium affected the plaque size, and several mammalian sera had non-specific inhibitory effects on the virus (17). The virus-inhibitory substance in fetal calf serum appeared to be in the albumin fraction.

There was no or minimal inhibitory effect in sera from ducks or chickens. Woolcock (133) reported plaque assays for both virulent and attenuated DHAV-1 in primary duck embryo liver (DEL) cells and compared the results of *in vitro* assays with those obtained *in ovo* and *in vivo*. Kaleta (67) described a microneutralization assay using attenuated DHAV-1 in primary DEK cells, which was used to monitor immune responses to vaccines (136).

Pathogenicity

Asplin (5) and Reuss (104) reported loss of pathogenicity of DHAV-1 for ducklings after chicken embryo passages. Hwang (56) found one virus strain to have lost its pathogenicity for ducklings after 20 or more passages in chicken embryos. He also found that the same strain had lost its pathogenicity for ducklings after the sixth passage in duck embryo fibroblasts, while retaining the pathogenicity for chicken embryos (58).

Hwang and Dougherty (62) reported that chicken embryo-passaged strains, while nonpathogenic for ducklings, multiplied in the tissues but at lower titers. Field strains were found in high concentrations in duckling brain, while chicken embryo-passaged strains could not be detected or were present in low titers.

A similar attenuation of pathogenicity has been reported when DHAV-1 was passaged in duck embryos (11). Embryo passage-attenuated DHAV-1 strains are still capable of causing very mild and transitory histologic changes after inoculation (109, 114), and reversion to virulence occurs after back-passage in young ducklings (139, 140).

Lu et al. (85) reported an outbreak of infectious-bill (beak)-atrophy syndrome in ducklings in Taiwan, which they believe was caused by a parvovirus infection in association with DHV. The exact role of DHV in this syndrome was not clearly defined.

Until recently, DHAV-I infection had only been associated with acute disease in mallard and Pekin ducklings; however, it has now been reported to cause pancreatitis and encephalitis in Muscovy ducks (50, 51).

Pathobiology and Epidemiology

Incidence and Distribution

DHAV-1 is worldwide in distribution (116, 131, 134). DHAV-2 was reported in Taiwan (123) and DHAV-3 was reported in South Korea (71) and China (39).

Natural and Experimental Hosts

Field observations indicated that chickens and turkeys were resistant. Rahn (102), however, found that day-old and week-old poults exposed to DHAV-1 developed signs, lesions, and neutralizing antibody. Poults, after either oral or intraperitoneal exposure, had mottled livers and enlarged gall bladders and spleens. DHAV-1 was isolated from livers up to 17 days after oral exposure of day-old poults. Schoop et al. (111) and Reuss (105) failed to infect chickens experimentally. Reuss could not transmit the disease to rabbits, guinea pigs, white mice, or dogs. Asplin (8) reported that young chickens can contract an inapparent infection and pass it on through contact with other chicks. Experimental infections in goslings (4) and mallard ducklings (36) have been reported. In experimentally exposed birds, no mortality occurred in chicks, Muscovy ducklings, or pigeon squabs; low mortality occurred in young turkeys and quail, while high mortality occurred in young pheasants, geese, and guinea fowl. All exposed birds became infected with DHAV-1 (61). In another experimentally exposed study, Tsiay duck (*Anas platyrhynchos* var. domestica) and Cherry Valley ducklings were highly sensitive, and Pekin ducklings and hybrid ducklings of Tsiay duck and Pekin duck were relatively sensitive. Muscovy ducklings were resistant, whereas mule ducklings showed intermediate sensitivity to infection (Tseng and Tsai, unpublished data).

In 2004, DHAV-2 was isolated in Taiwan from 1-week-old goslings in a white Roman goose flock experiencing mortality exceeding 70%. The affected goslings displayed liver hemorrhage typical of duck hepatitis (123). Recently DHAV-3 has been reported to cause a new disease in overfed geese in China characterized by hemorrhagic hepatitis. The flocks showed about 20%–40% morbidity and less than 5% mortality (82).

Age of Host Commonly Affected. In naturally occurring outbreaks, DHAV-1 has occurred only in young ducklings. Adult breeders on infected premises did not become clinically ill and continued in full production.

Transmission, Carriers, and Vectors

Under field conditions, DHAV-1 spreads rapidly to all susceptible ducklings in the flock. Although high mortality and rapid spread of the disease on farms indicate extreme contagiousness, occasional exceptions have been observed. In one pen, 65% of the ducks died, while in an adjoining pen separated only by a 14-inch curb, mortality was negligible (141).

Egg transmission presumably does not take place. Newly hatched ducklings produced by breeders on infected premises remained well when taken where no ducks were being kept (5).

Priz (101) found that aerosol infection of ducklings with Yagotinski strain of DHAV-1 was lethal. Hanson and Tripathy (55) reported successful infection with attenuated DHAV-1 by the oral route, although Toth and Norcross (120) suggested that the portal of entry was the pharynx or upper respiratory tract, because the virus administered in a capsule failed to produce infection.

Recovered ducks may excrete virus in feces for up to 8 weeks after infection (105). Asplin (8) reported that there is strong field evidence to incriminate wild birds as mechanical carriers

of the virus over short distances. He also suggested the possibility that an unknown host acting as a healthy carrier might be responsible for new outbreaks at great distances. However, no serologic evidence of DHAV-1 infection was found in 520 wild aquatic fowl of six species (7), or in four species of 36 wild ducks taken from ponds where DHAV type 1 had occurred in domestic ducks (125). In addition, all 153 wild duck embryonating eggs from an infected area were susceptible to experimental infection.

Of possible significance in the epizootiology of the disease is the report indicating that brown rats (*Rattus norvegicus*) could act as a reservoir host of DHAV-1(25). Ingested virus remained alive up to 35 days and the virus was excreted 18–22 days post inoculation (PI). Serum antibodies were also present 12–24 days PI. However, there has been no evidence of the involvement of any vectors in transmission of DHAV-1.

Incubation Period

The incubation period lasts 1–2 days.

Clinical Signs

Onset and spread of DHAV-1 are very rapid, with practically all mortality occurring within 3–4 days. Affected ducklings at first fail to keep up with the brood. Within a short time, they stop moving and squat down with eyes partially closed. Birds fall on their sides, kick spasmodically with both legs, and die with heads drawn back (Figure 13.2). Death occurs within an hour or so after signs are noted. During the height of severe outbreaks, the rapidity with which ducklings die is astonishing.

Morbidity and Mortality

Morbidity is 100% and mortality is variable in young ducklings infected with DHAV-1. In some broods less than 1-week-old, mortality may reach 95%. In ducklings 1–3 weeks of age, mortality may be 50% or less. In 4- to 5-week-old ducklings, morbidity and mortality are low or negligible.

Figure 13.2. Duckling dead from infection with DHAV type 1. Note typical opisthotonos.

Pathology

Gross Lesions. Principal lesions due to DHAV-1 are found in the liver, which is enlarged and contains punctate or ecchymotic hemorrhages (Figure 13.3). Frequent reddish discoloration or mottling of the liver surface is seen. The spleen is sometimes enlarged and mottled. In numerous cases, the kidneys are swollen and renal blood vessels congested.

Microscopic and Ultrastructural Lesions. Microscopic changes in uncomplicated, experimentally induced DHAV-1 infections have been studied (29). Primary changes in the acute disease consisted of necrosis of hepatic cells (Figure 13.4); survivors with more chronic lesions showed widespread bile duct hyperplasia (Figure 13.5). Varying degrees of inflammatory cell response and hemorrhage occurred. Regeneration of liver parenchyma was observed in

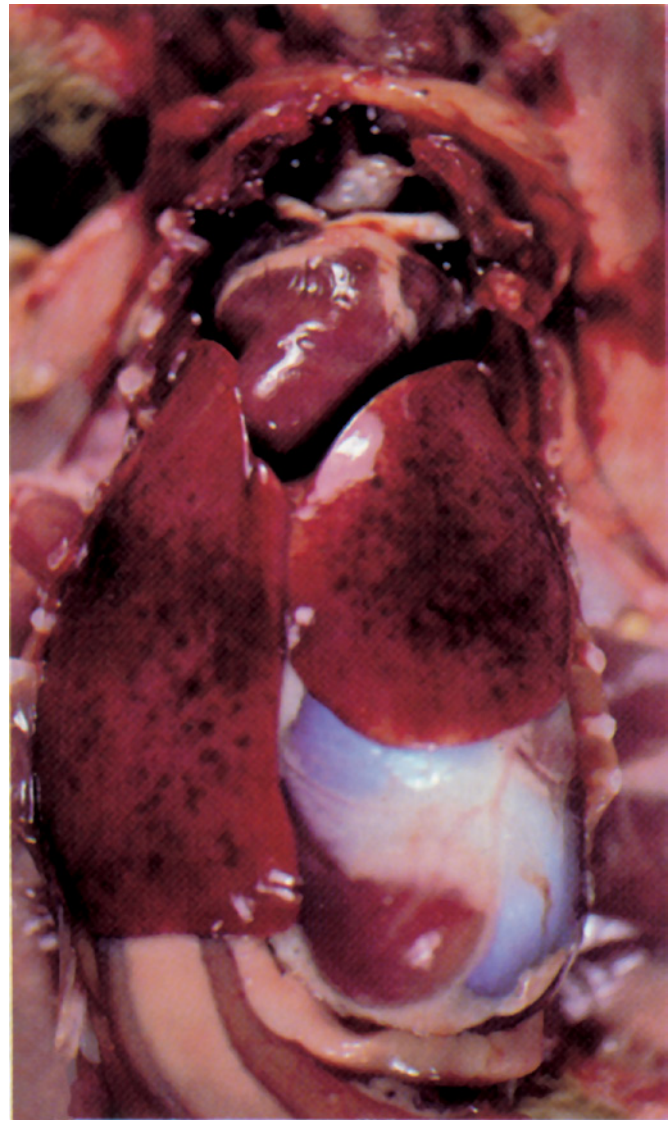

Figure 13.3. Liver with hemorrhagic lesions caused by DHAV type 1 infection.

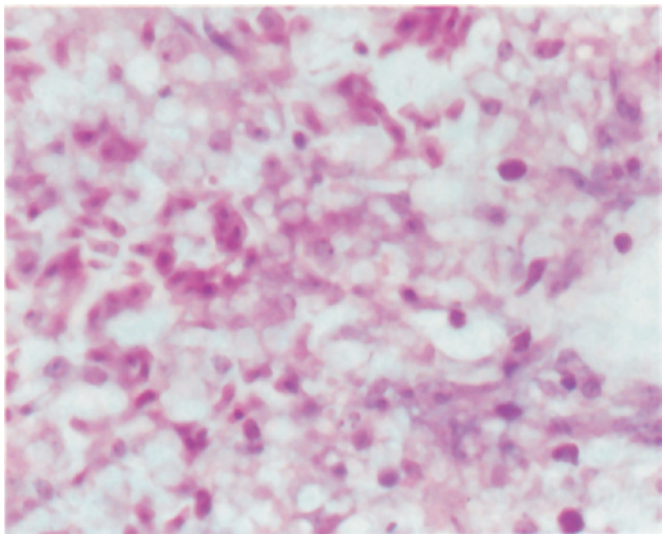

Figure 13.4. Microscopic lesions in liver of duckling 24 hours after infection. Note massive liver cell necrosis and hemorrhage. H and E, ×1000.

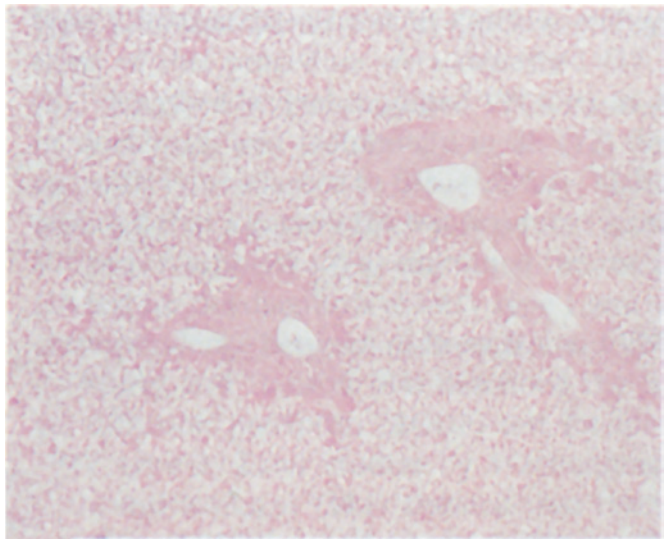

Figure 13.5. Microscopic lesions in liver of duckling 7 days after infection. Note extensive bile duct proliferation. H and E, ×250.

ducklings that did not die. Ten-day-old chicken embryos inoculated with DHAV-1 were killed and examined histologically at 12-hour intervals for periods up to 10 days PI (32). Histologic changes included proliferation of granulocytes in various organs, focal necrosis of the liver, bile duct hyperplasia, and subcutaneous edema. Inclusion bodies were not found. Six-day-old ducklings were infected intranasally and intramuscularly with DHAV-1 and killed 14–24 hours later; their livers were examined by electron microscopy (EM). One hour after infection, there was an occasional break-up of glycogen within the liver cells. Spherical particles with 100–300 nm diameter were visible. Changes seen in peracute cases were degenerative with extensive cell necrosis after 24 hours. Virus-like particles were detected at 1 hour and 18–20 hours PI (2). Large amounts of the DHAV-1 genomes were detected in the epithelium of bile ducts of naturally infected ducklings by *in situ* hybridization (Tu and Tsai, unpublished data).

Adamiker (1) examined spleen and muscle of ducks infected with DHAV-1 by EM. The spleen showed regressive changes from 6 hours PI and became necrotic by 24 hours. There were degenerative changes in the nuclei of plasma cells that may have been caused by the virus. Virus particles were not identified. Only slight changes were seen in muscles.

Pathogenesis—Biochemical Effects

Ahmed et al. (3) reported that in clinical cases of DHAV-1 infection, there were lower serum levels of total protein and albumen and elevated levels of alkaline phosphatase, glutamic pyruvic transaminase (GPT), bilirubin, and creatinine. The serum levels of GPT and glutamic oxaloacetic transaminase were increased in relation to severity of infection (92). Even in clinically inapparent DHAV-1 infection in mallards, liver enzyme patterns were altered, with a consequent alteration in metabolism of dichlorodiphenyltrichloroethane (DDT) (12, 13). This may partially explain the interrelationship between chlorinated hydrocarbons and DHAV-1 (34, 35, 37).

Liu et al. (84) reported that sublethal DHAV-1 infection significantly enhanced body weight gain and plasma T3 levels of ducklings, and that silymarin (extract of milk thistle seeds) could counteract this effect *in vivo*. This single study was based on a short observation period of about 10 days and did not measure the organ weight. More evaluation is needed to confirm this.

Immunity

Recovery from DHAV-1 results in solid immunity and VN antibodies in the serum. Active immunity can be induced in adult ducks by injection of certain strains of virus (5). Some strains require repeated injections to obtain high levels of antibody (96). Passive immunity can be conferred to ducklings by injection of serum from recovered or immunized birds. Passive antibodies also may be transferred through yolk to hatched ducklings to protect them. Malinovskaya (89), investigating the antibody response to DHAV-1 vaccine in breeder ducks and 7-day-old ducklings, showed by a passive hemagglutination (HA) test that duck serum contained more 7S antibodies (cysteine sensitive) than 19S antibodies (cysteine resistant). Decline of the 7S antibodies halved the hemagglutination-inhibition titers in 43% of serum samples taken 3–7 days PI. In ducklings experimentally infected between 3 and 21 days of age, the main type of antibody response was 19S during the ensuing 20 days; however, in ducklings infected at 30 days of age, 19S antibody was formed first, but 7S antibody began to appear after 15 days. Davis and Hannant (23) reported that VN antibody was present 4 days post vaccination of 2-day-old ducklings. The antibodies were shown to be in the macroglobulin and 7S fractions by Sephadex G200 chromatography and had γ or β_2 mobility by immunoelectrophoresis.

Diagnosis

Isolation and Identification of the Causative Agent

The presence of DHAV may be confirmed by one or more of the following procedures (131, 134):

- Inoculation, subcutaneously (SC) or intramuscularly (IM), of the isolate into 1- to 7-day-old DHAV susceptible ducklings. The characteristic clinical disease should follow, with deaths often occurring within 24 hours. Ducklings should show the gross pathology attributable to DHAV. The virus should be re-isolated from the livers to confirm the diagnosis.
- Inoculation of serial dilutions of the liver homogenate into the allantoic sacs of embryonating duck eggs (aged 10–14 days) from a DHAV-free flock, or chicken eggs (aged 8–10 days). DHAV infected duck embryos should die within 24–72 hours; chicken embryos are more variable and erratic in their response and usually take 5–8 days to die. The allantoic fluid is opalescent or a pale greenish-yellow. Gross pathological changes in the embryos include stunting and subcutaneous hemorrhages over the whole body, with edema, particularly of the abdominal and hind limb regions. The embryo livers may be swollen, red, and yellowish in color, and show necrotic foci. The liver lesions and embryo stunting become more apparent in embryos that take longer to die.
- Inoculation of primary cultures of duck embryo liver cells (133). Serial dilutions of the liver homogenate containing DHAV-I cause a cytopathic effect (CPE) that is characterized by cell rounding and necrosis. When overlaid with a maintenance medium containing 1% agarose (wt/vol), the CPE gives rise to plaques approximately 1 mm in diameter.

A rapid and accurate diagnosis of DHAV-1 can be made using the direct FA technique on livers of naturally occurring cases or inoculated duck embryos (87, 126). Virus isolation and identification procedures have been reviewed (52, 118).

Molecular Diagnostic Methods

Several reverse transcriptase polymerase chain reactions (RT-PCR) have been developed and are useful for identifying DHAV-1 infections (19, 39, 72). Chen et al. (19) reported the detection limit of RT-PCR DHAV-1 RNA as 3 pg/10 µl. They also demonstrated that RT-PCR was the most sensitive when the detection rates were compared on 185 clinically suspected DHAV-1-infected liver tissues by RT-PCR, ELISA, and virus isolation methods.

Multiplex PCR also has been developed for the simultaneous detection and differentiation of DHAV types (73).

Yang et al. (142) reported the development of a one-step real-time RT-PCR assay (rRT-PCR) for the detection of DHAV-1. A pair of specific primers, designed against the conserved region in the 3D gene that encodes the RNA-dependent RNA polymerase, and a single conserved TaqMan probe were used in the assay. The detection limit of this assay was 10 viral genomic copies per reaction.

Serology

Serologic tests have not been useful in diagnosing acute outbreaks of DHAV-1. However, from the time the virus was first recognized (78), the VN test has been used for other purposes: virus identification, titration of serologic response to vaccination, and epidemiologic surveys.

Hwang (57) described an accurate, reproducible DHAV-1 neutralization test in chicken embryos. Modifications of this procedure were described (47, 120), including those adapted to duck embryos or ducklings (52) and tissue culture (42). Malinovskaya (90) reported that a passive HA test was more sensitive than the VN test. Ivashhenko (64) examined the use of an indirect HA test for the diagnosis of DHAV-1 and showed a 90% correspondence between indirect HA and VN results.

Murty and Hanson (94) described the use of an agar gel diffusion precipitin (AGDP) test for identification of DHAV-1, although subsequent studies were unable to claim the specificity of the test (120, 127). Similarly, a comparative study of ELISA, VN, and AGDP has suggested that the ELISA and VN were comparable in sensitivity, although further studies are required to confirm this observation (143). Woolcock et al. (138) first described a plaque-reduction test for VN antibody. This assay was considerably more sensitive than VN assays in eggs. Chalmers and Woolcock (17) showed that sera collected from 16 uninfected ducks had 50% plaque reduction titers (VN_{50}) ranging between 1:12 and 1:250 with an average of 1:59. They suggested that the maximum VN_{50} titer for negative control serum should be taken as 1:250. Woolcock (133) reported a plaque reduction assay in DEL cells and showed that type 1 virus was only neutralized by type 1 antiserum and not by antisera to type 2 or type 3. He also reported that a VN_{50} of 1:64 in embryonating chicken eggs was equivalent to a VN_{50} in excess of 1:3200 in DEK cells. Microneutralization assay in DEK cells has been developed as a more practical, rapid, and economical alternative to other tests for the diagnosis of DHAV-1 (67), and has been adapted to monitor the VN antibody responses of ducks to vaccines in field and laboratory trials (136).

Liu et al. (83) described a VP1-ELISA using the expressed VP1 protein as a coating antigen for the detection of DHAV-1 antibodies in duck sera. It showed a specificity and sensitivity of 92.5% and 96.7%, respectively compared to VN test.

Differential Diagnosis

The sudden onset, rapid spread, and acute course of the disease caused by DHAV-1 are characteristic. Hemorrhagic lesions in liver of ducklings up to 3 weeks of age are pathognomonic. Occurrence of similar disease outbreaks caused by serologic variants of DHAV-1, -2 and -3 are the main problem in differential diagnosis.

Chalmers et al. (16) reported an outbreak of DHAV-1 associated with *Chlamydophyla psittaci* in 4- to 6-week-old birds, and suggested a possible synergistic effect as the cause of the persistent 15% mortality recorded. Similarly, Gough and Wallis (49) reported the association of DHAV-1 with

influenza virus in 2- to 5-week-old mallard ducks reared on a game farm. The DHAV-1 isolated was of low virulence, and it is suggested that the influenza virus may have exacerbated the hepatitis infection.

Other potential causes of acute mortality in ducklings include salmonellosis and aflatoxicosis. The latter disease may cause ataxia, convulsions, and opisthotonos as well as microscopic lesions of bile duct hyperplasia suggestive of DH, but does not cause the same characteristic liver hemorrhages. None of the other common lethal diseases of ducks occur frequently in this young age group.

Intervention Strategies

Management Procedures

Duck hepatitis type 1 can be prevented by strict isolation, particularly during the first 4–5 weeks of age. In areas where the disease is prevalent, however, it is very difficult to obtain the necessary degree of isolation.

Panikar (97) and Kaszanyitzky and Tanyi (69) demonstrated the feasibility of eradicating DHAV-1 in selected areas where isolation can be achieved. In both studies, vaccination of breeder ducks was used as part of the program.

Vaccination

Resistance against DHAV-1 may be conferred to ducklings by three methods: injection of immune serum or yolk as described under Treatment, immunization of breeding stock to ensure high levels of passively transferred antibody in the hatched ducklings, and direct active immunization of ducklings with live avirulent strains of DHAV-1.

Attenuated DHAV-1 strains suitable for vaccine use have been produced by passage in chicken embryos (5, 40, 41, 42, 63, 111) or duck embryos (108). Up to this time, various strains of chicken embryo-passaged DHAV-1 have been used most frequently as vaccines.

Davis (22) reported that triple plaque-purified strains of DHAV-1 vaccines could revert to virulence as readily as noncloned virus. This finding has been confirmed with various egg-passage levels of DHAV-1 (137). Davis suggested rapid passage as a method to increase genetic stability.

Kang et al. (68) developed a stabilizer for lyophilization of an attenuated DHAV-1 vaccine. This reduced the continuous need for freezer storage and transportation of the vaccine.

Breeders. Asplin (5) developed a chicken embryo-attenuated strain of virus for immunizing breeders. The method was to inoculate 0.5 mL undiluted egg-propagated virus intramuscularly 2–4 weeks before collecting hatching eggs. Reuss (104) found it necessary, with the strain of virus he used, to make repeated injections in breeders to obtain sufficient antibody levels to protect hatched ducklings against challenge with virulent virus. The optimum age, dosage, route of inoculation, strain of virus, and interval between initial and subsequent vaccinations are not known (8).

Rispens (108) recommended two doses of attenuated virus vaccine administered to breeders at least 6 week apart; passive immunity was transmitted to progeny for about 9 months after the second vaccination.

Hwang (60), Rinaldi et al. (107), Nikitin and Panikar (95), and Doroshko and Bezrukavaya (27) all confirmed that two or three doses of attenuated virus vaccine were necessary to secure satisfactory levels of protection of progeny. Bezrukavaya (11) secured effective protection by vaccination of breeders with duck embryo-attenuated vaccine.

The application of inactivated vaccines also has been investigated. Gough and Spackman (47) reported that effective levels of duckling protection can be secured by administering three doses of inactivated oil-emulsion vaccine. They also reported that live DHAV-1 vaccine at 2–3 days of age, followed by inactivated vaccine at 22 weeks, produced significantly higher VN antibody levels than did 3 doses of inactivated vaccine. Finally, they reported that inactivated vaccine prepared from virus grown in duck eggs gave a better antibody response than virus grown in chicken eggs. Woolcock (136), investigating the use of inactivated DHAV-1 vaccines in breeder ducks, showed that in order to ensure an adequate immune response to the inactivated virus, it was necessary to prime the ducks with modified live DHAV-1 (MLV). He showed that ducks primed with MLV at 12 weeks of age, and boosted with inactivated DHAV-1 vaccine at 18 weeks, developed VN antibody titers 16-fold higher than those in ducks that received only the MLV priming. This level of immunity was sufficient to protect ducklings hatched through a complete laying cycle (8 months), as demonstrated by challenging progeny with virulent DHAV-1. Inactivated vaccines prepared from MLV grown in embryos or from virulent type 1 virus grown in ducklings were both equally effective. Woolcock (136) also investigated various immunization schedules, using inactivated virus alone, and monitored the VN antibody response of individual ducks in a microtiter assay using primary DEL cells. Only 7 of 63 ducks (11%) developed titers of 6 $\log_2$ or greater, which was considered the minimum protective level, and these responses were only in birds given multiple inoculations of inactivated vaccine.

Ducklings. Asplin (5) used the chicken embryo-attenuated strain of DHAV-1 to vaccinate ducklings by the foot web-stab method. Reuss (104) also reported successful immunization with an attenuated strain.

Newly hatched ducklings injected intramuscularly with an attenuated DHAV-1 developed resistance in 3 days (60). Oral exposure required up to 6 days for protection to occur. There was evidence that vaccination would be of benefit even at the start of an outbreak. Sung et al. (113) reported that intramuscular administration of attenuated DHAV-1 vaccine showed more efficient protection than by the oral or eye-drop route of administration.

Attenuated strains of DHAV-1 induced a considerable degree of protection in day-old ducklings inoculated by the intramuscular, intranasal, or foot-web route (144). Crighton and Woolcock (20) and Gazdzinski (40) also reported successful immunization of ducklings by the subcutaneous and

intramuscular routes, respectively, with chicken embryo-passaged DHAV-1. Golubnichi et al. (42) used tissue culture-passaged DHAV-1 for duckling immunization. Effective mass vaccination of ducklings by the aerosol and drinking water routes have been reported (55, 75, 76, 96, 97, 121). Ducklings vaccinated orally at 2–3 days of age did not show an increased immune response when revaccinated at 17 days (9). Balla et al. (10) examined administration in the field of DHAV-1 vaccine by subcutaneous and drinking water routes. They reported that two doses given in the drinking water at 2–3 days of age were as effective as one dose given orally at 2 days of age.

Balla and Veress (9) examined the antibody response of ducklings of different immune status to subcutaneous and oral vaccination with live attenuated DHAV-1. They found that susceptible ducklings and those hatched with maternally derived immunity both responded to vaccination with 1,600–9,600 EID_{50} given during the first 3 weeks of life. The maternally immune birds responded only marginally less. They also showed that a dose of 300–600 EID_{50}/duckling given between 2 and 21 days and of 100 EID_{50} at 35 days was sufficient for seroconversion to occur irrespective of the ducklings' immune status. Exposure to an aerosol vaccine for 5–6 minutes at 2–5 days of age produced a good response in susceptible birds but not in maternally immune ducklings; 30-minute exposure to aerosol vaccine gave a good response, which was not boosted by re-exposure at 16 days. Luff and Hopkins (86) also looked at the effect of maternally derived immunity on vaccination of ducklings with live attenuated DHAV-1. Ducklings were vaccinated when about 12 hours old and were challenged with virulent DHAV-1 at 24 hours and 3 and 6 days. Their results suggested that partially protective levels of maternally derived antibody did not adversely affect either the speed of onset or the extent of protection afforded by the currently available live vaccine. Unfortunately, findings were limited to the first 6 days of life.

In contrast to the results reported by Luff and Hopkins, field experience has indicated that successful practical duckling vaccination depends on the absence of maternal antibodies and is influenced by time and severity of exposure to virulent virus. Vaccination is also less effective when ducklings are exposed to virulent virus early in life, especially in endemic areas and on heavily infected premises. Judicious application of good hygiene and sanitation methods could help to solve this problem.

Kim et al. (70) developed a live attenuated vaccine against DHAV-3 by repeated passages of a field virulent strain in SPF chicken embryos 100 times. The 100th passaged virus did not cause clinical sign and mortality in 1-day-old ducklings and did not show reversion to virulence after 6 back passages in 1-day-old ducklings. One-day-old ducklings vaccinated intramuscularly with the 100th passaged virus were fully protected from challenge with pathogenic virus 2–3 days post vaccination.

Treatment

As soon as the cause and nature of DHAV-1 were recognized (78), it became apparent that ducklings might be protected by administration of serum from immune ducks. This procedure proved to be highly successful in laboratory experiments and in the field. For many years, the Duck Research Laboratory (DRL), Cornell University at Eastport, Long Island, New York, kept a bank of antiserum processed from blood collected at the time of slaughter from recovered birds. Intramuscular injection of 0.5 ml DHAV-1 antiserum into each duckling of a brood at the time of the first deaths in an outbreak was an effective control method.

Rispens (108) suggested passive immunization by injection of yolk from eggs produced by hyperimmune breeder ducks. At the DRL, Long Island, New York, this procedure was modified by substituting yolk from eggs produced by SPF chickens hyperimmunized with DHAV-1.

Yolk antibody preparations with a minimum neutralizing index of 10^3 as determined by the constant-yolk/varying–virus method would be considered to be satisfactory (131).

Duck Hepatitis Type 2

Duck hepatitis type 2, although similar to the pathologic entity caused by DHAV, is caused by an entirely different agent, an astrovirus (48). The first report of an outbreak of DHV type 2 in ducklings was from Norfolk, England, in 1965 (6). The affected flock had been vaccinated with attenuated DHAV-1. An agent was isolated which was different from DHAV-1 by cross-protection studies in ducklings and was named DHV-2(6). The disease disappeared from commercial flocks by 1969 but reappeared in 1983-1984 on three farms, again in Norfolk, England (45). Losses in that outbreak varied between 10% and 25% in 3- to 6-week-old birds, and up to 50% in 6- to 14-day-old birds. Outbreaks on affected farms were often sporadic, affecting some batches of ducks. Since the outbreaks in the mid-1980s, there have been no additional outbreaks of the disease in that area (44). Outside England, a severe outbreak of duck hepatitis occurred in July 2008 in a commercial Cherry Valley duck flock in China, resulting in a mortality of about 50% in 1- to 2-week-old ducklings. The causative virus was shown to be a duck astrovirus (DAstV) as demonstrated by partial polymerase sequence comparison (38). DAstV-specific antibodies were also detected from a flock with no symptoms of duck hepatitis in China, indicating a possible wide distribution of subclinical infections caused by DAstV (129).

DHV type 2 particles with an astrovirus-like morphology and a diameter between 28 and 30 nm was seen by EM (46). Aggregates containing more than 1,000 virus particles have been observed in liver suspensions. On this basis, DHV type 2 has been classified as an astrovirus, and it has been suggested that it should be renamed duck astrovirus 1 (DAstV-1) (43, 93). Sequence analysis of a 391-nt ORF 1b from a DHV type 2 isolate M52 confirmed this observation (117). It has been compared with astrovirus isolates from chickens and turkeys by cross-protection and transmission studies, and found to be antigenically distinct (48). The virus is resistant to chloroform, pH 3.0, trypsin treatment, and heating at 50 °C for 60 minutes. Formaldehyde fumigation and standard

disinfection procedures have eliminated the infection from contaminated premises (48).

DHV type 2 replicated in embryonating chicken eggs following several blind passages in the amniotic sac (45). Few embryos died in less than 7 days, but infected embryos appeared stunted and had greenish necrotic livers in which astrovirus-like particles could be demonstrated by EM. Attenuation of pathogenicity occurred after serial passage in chicken embryos (45). Various duck and chicken cell cultures appear to be refractory to infection (45, 133).

DHV type 2 cannot be propagated efficiently in tissue culture (135); therefore, production of enough antigens for diagnostic tests is difficult.

Ducks appear to be the only species affected by DHV type 2, and no wildlife reservoirs or vectors have been detected. All recorded outbreaks have initially involved ducks kept on open fields; therefore, wildfowl, gulls, and other wild birds have been suspected as being vectors (43). Recently, Fu et al. (38) reported that the sequence comparisons and phylogenetic analyses revealed that DAstV was closely related to turkey astroviruses (TAstV-2, TAstV-3, and TAstV/MN/01) and suggest the possibility that DAstV may transmit across ducks and turkeys.

Infection occurs through oral, cloacal, and subcutaneous routes. Deaths occur within 1–4 days, usually within 1–2 hours after the appearance of clinical signs, which include polydypsia with loose droppings, excessive urate excretion, and sometimes convulsions and acute opisthotonos (48). Affected ducks usually die in good condition and both the time of death and the mortality rate (10%–50%) depend on the age of the ducks (45). Survivors excrete virus for at least 1 week after infection (48) and rear normally, with little evidence of retarded growth (45). Mature ducks are refractory to the disease (45).

The target organs for DHV type 2 appear to be liver and kidneys (45). Significantly more virus is present in the liver, which is usually pale pink with multiple, small punctate hemorrhages, often forming confluent bands. The spleen is invariably enlarged and "sago-like" in appearance due to scattered pale foci. Kidneys are often swollen with blood vessels injected and standing out from the pale kidney substance. The alimentary tract is usually devoid of food. Occasionally, small hemorrhages are seen in the intestinal wall and on the heart fat. Microscopic changes in the acute disease are characterized by extensive necrosis of the hepatocyte cytoplasm, and bile duct hyperplasia is widespread.

Gough and Stuart (48) found that survivors of DH type 2 were immune to further infection. Detectable antibody levels following infection were shown to be low, using a varying virus-constant serum neutralization test in embryonating chicken eggs (43). An indirect ELISA has been developed based on the expressed C-terminal ORF2 protein of duck astrovirus (129).

The most reliable diagnostic method for DHV type 2 is EM examination of liver homogenates for the detection of astrovirus-like particles. The virus can only be isolated, with difficulty, following repeated passage in the amniotic sac of embryonating chicken or duck eggs, but these are difficult and expensive processes because the embryos may respond erratically only after 4 passages and no deaths may be seen during earlier passages (45). Inoculation of susceptible ducklings with virus gives a variable response; mortality up to 20% may occur within 2–4 days PI (45, 131, 134). Inoculation of susceptible ducklings with convalescent serum obtained from DHV type 2-infected ducks has been used successfully to control the disease in the field (48). An experimental live attenuated virus vaccine also protected ducklings from challenge with virulent virus, but this vaccine has never been produced commercially (48).

Duck Hepatitis Type 3

Duck hepatitis type 3 was first reported by Toth (119), who observed hepatitis causing mortality and morbidity in ducklings immune to DHAV-1, on Long Island in the United States. The disease was less severe than DH type 1 and mortality rarely exceeded 30%. Based on differences from both DHAV-1 and DHV type 2, the agent was named DHV type 3 (53). The disease is only known to have occurred in the United States.

Haider and Calnek (53) reported that DHV type 3 contained RNA, based on insensitivity to IUdR, and was resistant to chloroform and pH 3.0 but sensitive to 50 °C irrespective of the presence of 1 M $MgCl_2$. Electron microscopy of cultured duck kidney (DK) cells infected with the virus revealed crystalline arrays containing particles about 30 nm in diameter in the cytoplasm. Based on these observations, they suggested that DHV type 3 be classified as a picornavirus but that it was unrelated to DHAV-1, because no common antigens could be demonstrated in VN and FA tests.

More recently, a 391-nucleotide-long, astrovirus-specific ORF1b sequence has been determined for DHV type 3 and indicates that it is an astrovirus and was named Duck Astrovirus type 2 DAstV-2 (117). Phylogenetic analyses based on the amplified ORF 1b sequences showed that DHV type 3 is more closely related to turkey astrovirus type 2 than DHV type 2 DAstV-1 (117).

Nine- to 10-day-old duck embryos inoculated onto the chorioallantoic membrane (CAM) were susceptible to DHV type 3 (53). During the first passages embryo deaths were erratic and did not occur until the 8th or 9th day PI, but this was reduced with higher passages. In severely affected embryos, the CAMs were discolored and the surface of the affected areas had a dry, crusty or cheesy appearance. Underneath, the CAM was edematous and thickened up to 10 times normal. Embryo lesions included stunting; edema; skin hemorrhages; flaccid appearance; gelatinous fluid accumulations; and enlargement of liver, kidneys, and spleen. Attenuation of pathogenicity for ducklings, accompanied by increased pathogenicity for duck embryos, occurred following serial passage in embryonating duck eggs inoculated by the CAM route. Chicken embryos were not susceptible to inoculation with DHV type 3.

Liver and kidney cell cultures of duck embryo or duckling origin were shown to support replication of the virus. This was demonstrated by a direct FA test to show foci of positively infected cells (53). Woolcock (133) reported that the type 3 virus failed to produce plaques in primary DEK and DEL cell monolayers.

DHV type 3 has a low pathogenicity for ducklings experimentally infected, and only ducklings appear to be affected by the virus. Subcutaneous or IM inoculation of liver homogenate from infected ducklings into susceptible day-old ducklings is unreliable. Intravenous inoculation may increase the effectiveness. Mortality and virus yields from liver could be increased if ducklings received 2 or 3 doses of cyclophosphamide (2 mg/dose) on days 1–3 and were challenged with virus on the 6th day of age (15).

Ducklings dying from DHV type 3 infection show the typical appearance of type 1 infection, i.e., outstretched legs and opisthotonos (119). Mortality rarely exceeds 30%, but gross pathologic changes are similar to those caused by DHAV-1.

An active immune response to DHV type 3 can be stimulated in adult ducks by inoculation of attenuated virus. This immunity may be passively transferred, via the yolk, to progeny.

DHV type 3 infection may be tentatively identified by inoculation of liver suspension onto the CAM of 10-day-old embryonating duck eggs if embryo lesions and mortality patterns develop as described above (131, 134). Alternatively, virus may be isolated and identified in DK or DEK cultures examined by immunofluorescence 48–72 hours PI using DHV type 3-specific antiserum. A direct FA test in duckling livers and DEK or DK cells has been described for DHV type 3 (131, 134). A serum neutralization test in embryonating duck eggs is possible.

Convalescent sera obtained from DHV type 3-infected ducks have been used effectively in the field to control outbreaks. A live attenuated vaccine has been used experimentally in breeder ducks to confer passive immunity to ducklings, but this vaccine has not been available commercially.

Duck Hepatitis B Virus Infection

Duck hepatitis B virus (DHBV) infection is widely distributed in domestic ducks and several species of migratory wild ducks. It is commonly found in the liver and serum. The virus is a small (40 nm diameter) DNA virus belonging to the hepadnavirus group which includes human and woodchuck hepatitis B viruses. In contrast to these mammalian hepadnaviruses, DHBV has not been associated with significant lesions or clinical disease in either chronic congenitally acquired infection or acute experimentally induced infection. For a detailed review of the characteristics of this virus see (30).

Chang et al. (18) reported a new avian hepadnavirus infecting snow geese (*Anser caerulescens*). Sequence analysis of the PCR-amplified genome revealed that this virus was distinct from other avian hepadnaviruses.

Duck Picornavirus

In 1990, several duck picornaviruses were isolated from a co-outbreak of duck parvovirus and DHAV-2 in Taiwan (85, 124). A duck picornavirus (DPV strain TW90A) isolated from the intestinal tracts of ducklings with duck hepatitis (DH) could not produce the typical hemorrhagic lesions of hepatitis and was not as deadly in day-old ducklings as DHAV, but DPV could apparently cause growth inhibition in day-old ducklings. It was then demonstrated that DPV TW90A was not antigenically or genetically related to DHAV-1 and DHAV-2 and was shown to share the same genome organization and a high percentage of sequence identity with porcine enterovirus serotype 8 (PEV-8) and several simian picornaviruses (SV-2, 16, 18, 42, 44, 45, and 49) in a new *Sapelovirus* genus in the family *Picornaviridae*. (98, 124).

Duck Virus Enteritis (Duck Plague)

Samia A. Metwally

Introduction

Definition and Synonyms

Duck virus enteritis (DVE) is an acute, contagious herpesvirus infection of ducks, geese, and swans, characterized by vascular damage, tissue hemorrhages, digestive mucosal eruptions, lesions of lymphoid organs, and degenerative changes in parenchymatous organs. Synonyms for the disease are duck plague, eendenpest (Dutch), peste du canard (French), Entenpest (German), and duck virus enteritis (98). Although Bos (4) first used the term duck plague, it was proposed as the official name by Jansen and Kunst in 1949 (42). Subsequently, DVE, based on principal features of the disease and to distinguish it from fowl plague, has become the preferred term.

Public Health Significance

DVE is primarily a disease of waterfowl. No known risk to human health has been reported.

Economic Significance

In duck-producing areas of the world where the disease has been reported, DVE has produced significant economic losses in domestic and wild waterfowl due to mortality, condemnations, and decreased egg production. The first outbreak in the United States was in 1967 and caused losses in excess of $1 million during a 1-year period for the small, but concentrated, duck industry of Long Island, New York (59).

History

In 1923, Baudet (2) reported an outbreak of an acute, hemorrhagic disease of domestic ducks in the Netherlands. DeZeeuw (20) showed that chickens, pigeons, and rabbits were refractory to experimental infection. DeZeeuw also suspected that wild waterfowl were carriers of the disease, because they were found within outbreak areas.

Bos (4) reexamined the earlier findings but was unable to reproduce the disease in chickens, pigeons, rabbits, guinea pigs, rats, or mice, and suggested that the disease was caused by a new distinct viral disease of ducks, which he termed "duck plague." These observations were further supported by more detailed studies on virus propagation, incidence and distribution, pathology, and immunity (37, 38, 39, 40, 41, 42, 43, 44).

Since the first reports of DVE in domestic and free-flying Anseriformes (ducks, geese, and swans) (54, 60), serious outbreaks in migratory waterfowl with high mortality have been reported (22). Outbreaks in zoos and game farm flocks also have been reported (35, 58, 69). The latest outbreak was reported in Germany (2007) in ducks and geese kept in captivity to prevent spread of highly pathogenic avian influenza (H5N1) (46).

Prior to the 1973 massive outbreak in migratory waterfowl in Lake Andes, South Dakota, the United States Department of Agriculture considered the disease exotic. Because of the high prevalence of DVE in North America, the disease is considered enzootic. For a review of the disease in North American waterfowl, see Brand (5).

DVE was delisted from the OIE Terrestrial Animal Health Code in 2010 due to its limited spread across country borders.

For details on the history of DVE, see prior editions of this book.

Etiology

Classification

The causative agent of DVE is a herpesvirus (Anatid herpesvirus 1), belonging to the Alphaherpesvirinae subfamily. Duck enteritis virus (DEV) is non-hemagglutinating (37) and non-hemadsorbing (17).

Morphology

Electron microscopy of virus-infected cells revealed virus particles in both nucleus and cytoplasm (Figure 13.6) (7).

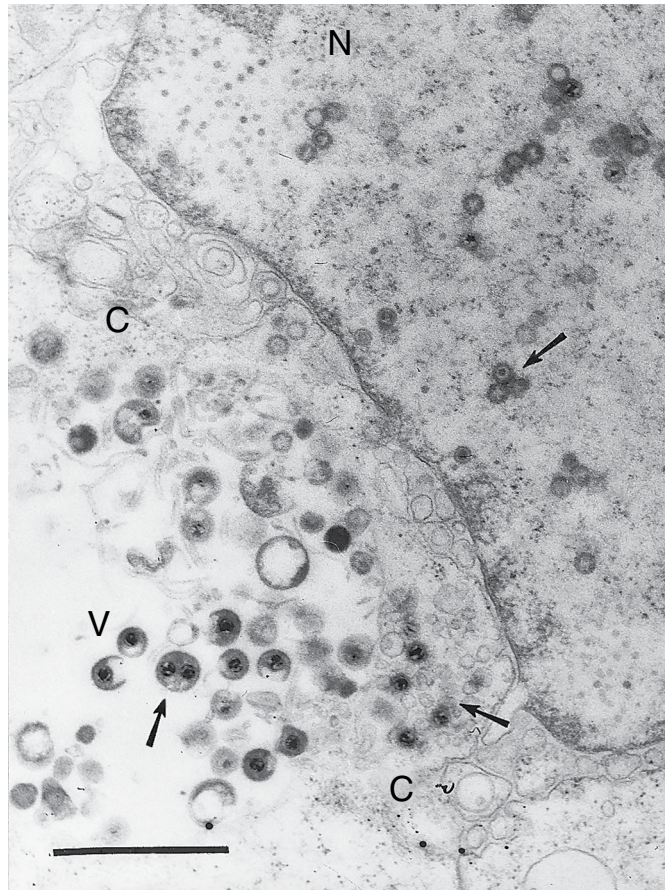

Figure 13.6. Thin section of Epon-embedded cells infected 48 hours with Long Island isolate of duck enteritis virus. Virus particles (arrows) appear in several forms in the nucleus (N), cytoplasm (C), and a cytoplasmic vacuole (V). Bar = 1 μm. (7).

Bergmann and Kinder (3) and Tantaswasdi et al. (94) studied structure and maturation of DEV in the cells of infected ducklings. They recorded spherical nucleocapsids about 91–93 nm in diameter with nucleoids (cores) approximately 61 nm in diameter in the nuclei of the host cells. Virus particles about 126–129 nm in diameter, probably the result of the envelopment of nucleocapsids by the nuclear membrane, were seen in the cytoplasm and perinuclear spaces. Larger mature particles varying in size from 156–384 nm in diameter were observed in the tubular system of the endoplasmic reticulum in the cytoplasm. These consisted of enveloped nucleocapsids encased in an osmiophilic matrix and surrounded by an additional membrane. These morphological structures differentiate DEV from other animal herpesviruses (3). In another study, four forms of nucleocapsids were identified in the tissues of infected ducks, which were found in the cytoplasm and nucleus, and measured 42–90 nm in diameter (108). Two types of nucleocapsids were associated with the intranuclear inclusion bodies: round or rod-shaped nucleocapsids containing an electron-dense internal core and nucleocapsids containing electron-dense particles in close proximity to the inner capsid wall, with an electron-lucent cross or pentagonal shape inside.

Many nucleocapsids, mature viruses, and viral inclusion bodies were observed in the nucleus and cytoplasm of infected cells of liver, small intestine, spleen, thymus, and cloacal bursa (bursa of Fabricius).

Chemical Composition

The virion contains DNA (7). RNase treatment on thin sections had no effect on ultrastructural morphology of the virus, and exposure to DNase led to the removal of the central core without affecting the envelope. Fluorescence of intranuclear inclusion bodies in cell cultures stained with acridine orange also was consistent with the presence of DNA (31). Inactivation by pancreatic lipase indicates that the virions contain an essential lipid (31).

Virus Replication

Development of the virus in cell cultures was studied by electron microscopy (EM) and growth curves of intracellular and extracellular virus (3, 7, 94). Examination of thin sections revealed development forms only in the nucleus 12 hours post inoculation (PI). By 24 hours, in addition to viral forms in the nucleus, larger particles with an envelope were observed in the cytoplasm. Virus titrations of similar cell cultures demonstrated new cell-associated virus 4 hours PI, with maximum titer at 48 hours. Extracellular virus was first detected 6–8 hours PI and reached maximum titer at 60 hours (7). Increased incubation temperatures of tissue cultures (39.5°C–41.5°C) favored viral replication, especially of less virulent strains (8).

In a susceptible host, virus replicates primarily in the mucosa of the digestive tract, especially in the esophagus, and then spreads to the cloacal bursa, thymus, spleen, and liver. The epithelial cells and macrophages of these organs are the principal sites of viral replication (32).

Susceptibility to Chemical and Physical Agents

The virus was found to be sensitive to ether and chloroform (31). Exposing virus for 18 hours at 37°C to trypsin, chymotrypsin, and pancreatic lipase markedly reduced or inactivated it, and papain, lysozyme, cellulase, DNase, and RNase had no effect. Cells treated with DNase showed intranuclear inclusions, but there was marked reduction in fluorescence when stained with acridine orange (31).

Thermal inactivation studies (31) revealed that infectivity was destroyed after heating for 10 minutes at 56°C or 90–120 minutes at 50°C. At room temperature (22°C), infectivity was lost after 30 days. Drying over calcium chloride at 22°C resulted in inactivation after 9 days.

Exposure of the virus for 6 hours at pH 7, 8, and 9 resulted in no loss of titer, but a measurable titer reduction was noted at pH 5, 6, and 10. At pH 3 and 11, the virus was rapidly inactivated. A marked difference in inactivation rates was noted between pH 10 and 10.5 (31).

Strain Classification

Although differences in virulence among DEV strains have been noted, all appear to be immunologically identical (31, 41, 92) and antigenically related (87). The virus is immunologically distinct from other avian viruses, including fowl plague, Newcastle disease, duck hepatitis (4, 17, 42, 61), and other herpesviruses (81).

A herpesvirus was isolated from domestic geese in Australia showing gross pathological and histopathological changes similar to those seen in DVE (47). The virus isolate was antigenically and genomically distinct from DEV as shown by protection, serological analysis, and genetic characterization by restriction endonuclease digestion and polymerase chain reaction (PCR) assays (26).

Full genomic analysis (62) demonstrated that the length of DEV genome is 158,091 base pairs encoding 78 putative proteins, consistent with genomic organization and gene composition of the members of the Alphaherpesvirinae. The genome is composed of a unique long (UL), a unique short (US), a unique short internal repeat (IRS), and a unique short terminal repeat (TRS) region. The genomic arrangement pattern (UL-IRS-US-TRS) corresponds to D-type herpesvirus and is consistent with the members of Varicellovirus and Iltovirus genera. The genome contains 67 genes inconsistent with most members of Alphaherpesvirinae. One of 67 genes is homologous to cercopithecine herpesvirus 8 of Betaherpesvirinae, 5 genes are homologous to avian herpesviruses, and 3 genes have unique identity. Like most members of the Alphaherpesvirinae, the genes in the UL region are well conserved, while the genomic arrangement of IRS-US is similar to that of Marek's disease virus and equine herpesvirus 1. Phylogenetic analysis of functional domains of UL24, thymidine kinase (TK), and glycoprotein H (gH) indicated closer identity to avian herpesviruses, except for infectious laryngotracheitis virus, than to other alphaherpesviruses (33). The genomic analysis (33, 62) suggested that DVE should be placed in a new genus of the Alphaherpesvirinae subfamily in the family Herpesviridae.

Laboratory Host Systems

DEV can be propagated in Pekin duck embryo fibroblasts (106) incubated at 39.5°C–41.5°C (8) in duck embryo liver or kidney primary cells (25), Muscovy duck embryo fibroblasts (49), and the chorioallantoic membrane (CAM) of 9- to 14-day-old embryonating duck eggs (37). The virus can be adapted to grow in embryonating chicken eggs (37) and chicken embryo cell cultures (17); however, they are unsatisfactory for primary isolation. The virus produces a cytopathogenic effect in inoculated cell cultures (17, 51), and intranuclear inclusions have been observed in infected chicken and duck embryo cell cultures (31) (Figure 13.7). Plaque assays have been used to measure virus and neutralizing antibody titers (17). In the presence of complement, antibodies to DEV are capable of lysing infected duck embryo fibroblasts (52).

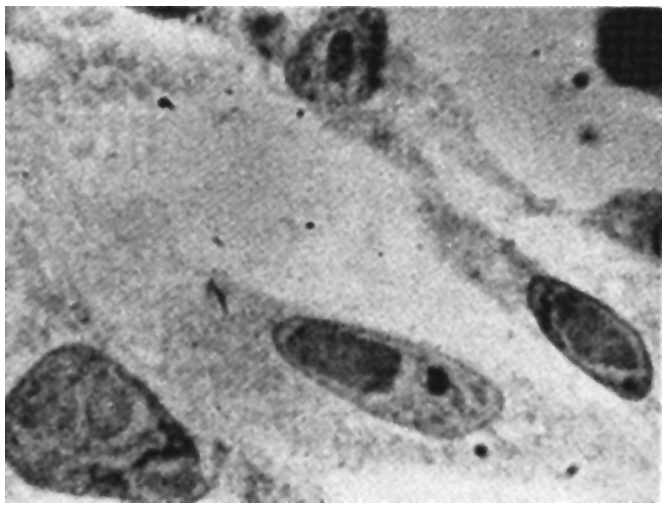

Figure 13.7. Inclusion bodies in duck embryo fibroblasts infected with duck virus enteritis. ×310,000 (Plum Island Animal Disease Laboratory)

Pathobiology and Epizootiology

Incidence and Distribution

In addition to the Netherlands, DVE has been reported in China (43) and confirmed in France (23, 66), Belgium (19), India (71, 72), Thailand (75), England (1, 28), Canada (30, 104), Hungary (100), Denmark (76), Austria (73), Vietnam (102), and Germany (46).

In 1967, the first reported outbreak in North America was observed in white Pekin ducks in the concentrated duck-producing area of Long Island (59). In addition, outbreaks in wild, free-flying waterfowl occurred at seven different locations on Long Island, New York (54, 60). The disease has been reported in 21 states, with repeated outbreaks in New York, Pennsylvania (34, 88), Maryland (70), California (91), Virginia, Wisconsin, and Texas. An extensive survey in North American wild waterfowl failed to detect the virus, indicating that the disease is not enzootic in them (6).

In the Netherlands, a higher incidence of DVE was noted in the spring (38); however, on Long Island, no seasonal increase was noted. In contrast, a higher incidence of DVE in wild, free-flying Anseriformes on Long Island was observed in the fall of 1967 (54).

Natural and Experimental Hosts

Natural susceptibility to DVE has been limited to members of the family Anatidae (ducks, geese, and swans) of the order Anseriformes, although the virus can be adapted by serial passage to grow in embryonating chicken eggs and chickens up to 2 weeks of age (40, 41). Natural infections have occurred in ducks ranging from 7 days of age to mature breeders. Naturally occurring outbreaks have occurred in a variety of domestic ducks (*Anas platyrhynchos*) including white Pekin, khaki Campbell, Indian runner, hybrids, and native ducks of mixed breeding. Outbreaks are quite common in Muscovy ducks (*Cairina moschata*) (37, 60). In an outbreak reported in Illinois (14), all 625 Muscovy ducks died in a flock of 650 waterfowl consisting of black ducks, rhumen ducks, Pekins, Muscovies, and geese. Naturally occurring infections also have been reported in domestic geese (*Anser anser*) (44) and mute swans (48). Gray call ducks have been found to be resistant to lethal infections (99). Outbreaks of DVE in domestic ducks are frequently associated with aquatic environments cohabited by wild waterfowl (20, 60).

Susceptibility of various species of Anseriformes to experimental DVE has been studied (99). In addition to domesticated species, mallards (*A. platyrhynchos*), Garganey teal (*A. quer quedula*), gadwall (*A. strepera*), European widgeon (*A. penelope*), wood ducks (*Aix sponsa*), shovelers (*Spatula clypeata*), common pochards (*Aythya ferina*), common eiders (*Somateria mollissima*), white-fronted geese (*Anser albifrons*), bean geese (*A. fabalis*), and mute swans (*Cygnus olor*) were susceptible to lethal infection. European teal (*A. crecca*) and pintails (*A. acuta*) were resistant but produced antibodies against DEV as a result of experimental exposure. Mallards were more resistant to lethal infections and were considered a possible natural reservoir of infection (104). An experimental study (103) showed blue-winged teal (*A. discors*) and Canada geese were extremely susceptible to DEV and experienced high mortalities. Blue-winged teal had few gross lesions at necropsy.

An outbreak was reported in common coots (*Fulica atra*) and crested coots (*Fulica cristata*) belonging to the family Rallidae order Gruiformes (82), but the virus was not isolated nor identified. Of the order Charadriiformes, herring gulls (*Larus argentatus*) and black-headed gulls (*L. ridibundus*) were not susceptible to experimental infection and failed to produce antibodies against DVE (99).

The first reported outbreaks of spontaneous DVE in wild waterfowl were diagnosed on Long Island, New York (54, 59). It was detected in mallards, black ducks (*A. rubripes*), a Canada goose (*Branta canadensis*), a bufflehead (*Bucephala albeola*), a greater scaup (*Aythya marila*), and a mute swan.

A major epornitic of DVE occurred at Lake Andes, South Dakota, in 1973, with an estimated loss of 43,000 ducks and geese out of a total population of 100,000 (22). DVE was diagnosed in black ducks, mallards, pintail-mallard hybrids, redheads (*Aythya americana*), common mergansers, common goldeneyes (*Bucephala clangula*), canvasbacks (*Aythya valisineria*), American widgeon (*Mareca americana*), wood ducks, and Canada geese. A study on susceptibility of waterfowl to Lake Andes strain showed that blue-winged teals, wood ducks, and redheads were highly susceptible; muscovies and gadwalls were moderately susceptible; mallards and Canada geese were less susceptible; and pintails were the least susceptible (93). An outbreak in captive ducks and geese reported in Germany in 2005 identified 14 additional susceptible Anseriform species that were collected by a hobbyist from different continents (46).

Transmission, Carriers, and Vectors

DVE can be transmitted by direct contact between infected and susceptible birds or indirectly by contact with a contaminated environment. Because waterfowl depend on an aquatic medium to provide a common vehicle for feeding, drinking, and body support, water appears to be the natural means of virus transmission from infected to susceptible individuals. Support for this concept is found in the history of new outbreaks in domestic ducks, which have been limited to birds having access to open bodies of water cohabited by free-flying waterfowl. After infection is established, it can be maintained in the absence of open water or infected birds if susceptible populations are moved onto recently contaminated premises.

New foci of infection may be established by movement of infected waterfowl into susceptible flocks or onto bodies of water previously free of virus contamination. Course and direction of the infection are defined by population densities and rate of transmission between infected and susceptible waterfowl. Population densities in concentrated duck-producing areas encourage rapid spread of DVE, with high mortality. Breeder ducks usually are selected and placed in a defined area and maintained in the same location for the balance of their productive lives. Once a breeder population is exposed, DVE infection is self-limiting. In contrast, market ducks are progressively moved as they mature and are relocated in areas formerly occupied by the next oldest age group. Infection in market ducklings tends to be a continuous recycling as susceptible birds are sequentially moved to contaminated environments.

Experimentally, DVE can be transmitted via oral, intranasal, intravenous, intraperitoneal, intramuscular, and cloacal routes. Although the intramuscular route of inoculation requires the least amount of virus to kill the inoculated birds, the intranasal and conjunctival routes require more virus, and the oral route requires the most virus (93). Potential transmission by bloodsucking arthropods may be possible during viremia. Although virus has been isolated from an egg removed from the cloaca of an infected domestic duck (40), it has not been recovered from eggs laid during a naturally occurring outbreak. Experimental vertical transmission has been reported in persistently infected waterfowl (9).

A carrier state has been suspected in wild ducks (12, 20, 90, 99). Recovered birds become carriers and shed the virus periodically (11). Like other herpesviruses, DEV latency and reactivation have been blamed for precipitating outbreaks in domestic and migrating waterfowl populations. The trigeminal ganglion has shown to be the latency site for the virus post infections with DEV (86). The virus was reactivated *in vitro* from trigeminal ganglia and lymphocytes. Immunosuppression with corticosteroid has been shown to reactivate the virus *in vivo*. Circumstantial evidence of virus reactivation is depicted in an outbreak in various Anseriform species of ducks and geese after being exposed to environmental stress as a result of housing in captivity to enforce biosecurity due to the threat of Avian influenza H5N1 virus (46).

Incubation Period

In domestic ducks, the incubation period ranges from 3–7 days. After overt signs appear, death usually follows within 1–5 days.

Clinical Signs

In domestic breeder ducks, sudden, high, persistent flock mortality is often the first observation. Mature ducks die in good flesh. Prolapse of the penis may be evident in dead mature males. In laying flocks, a marked drop in egg production may be noted during the period of highest mortality.

As infection progresses within a flock, more signs are observed. Photophobia, associated with half-closed pasted eyelids, inappetence, extreme thirst, droopiness, ataxia, ruffled feathers, nasal discharge, soiled vents, and watery diarrhea, appear. Affected ducks are unable to stand; they maintain a posture with drooping outstretched wings and head down suggesting weakness and depression. Sick ducks forced to move may show tremors of head, neck, and body.

Young ducklings 2–7 weeks of age show dehydration, loss of weight, blue beaks, conjunctivitis, lacrimation, nasal exudate, and often a blood-stained vent.

Morbidity and Mortality

Total mortality in domestic ducks may range from 5%–100%. Because the birds showing clinical signs usually die, morbidity closely approaches mortality. Adult breeder ducks tend to experience higher mortality than young ducks. No differences in mortality rates are found in mallard and white Pekin ducks experimentally infected with DVE and *Riemerella anatipestifer*, indicating that these pathogens do not act synergistically (68). However, mallards immunosuppressed with cyclophosphamide and challenged with a sublethal dose of DVE may increase mortality rate (24). Secondary bacterial infections with *Pasteurella multocida*, *Riemerella anatipestifer*, and *E. coli* are often seen in a natural outbreak of a low virulent strain in young ducklings as a result of immunosuppressive effect of the virus (88).

Pathology

The specific pathologic response to DVE depends on species affected (54), age, sex, stage of infection, and virulence and intensity of virus exposure (59, 60).

Gross Lesions

Lesions of DVE are associated with disseminated intravascular coagulopathy and necrotic degenerative changes in mucosa and submucosa of gastrointestinal tract in lymphoid and parenchymatous organs. These collective lesions, when present, are diagnostic of DVE.

Petechial, ecchymotic, or larger extravasations of blood may be found on or in the myocardium and other visceral organs and their supporting structures, including the mesentery and serous membranes. On the epicardium, especially within coronary grooves, closely packed petechiae give the surface a red "paintbrush" appearance (Figure 13.8). The

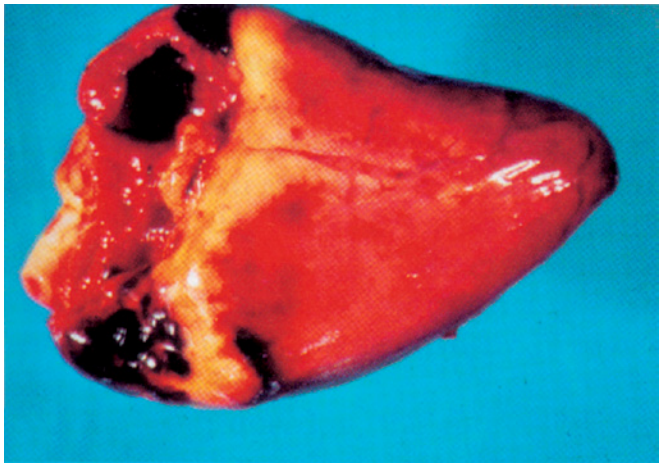

Figure 13.8. Petechial hemorrhages in the epicardium of duck infected with DVE virus (L. Munger)

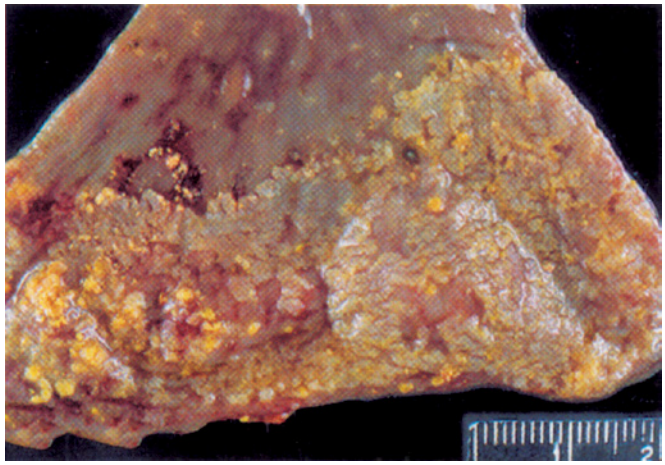

Figure 13.9. Extensive ulceration of esophageal mucosa from duck infected with DVE virus. (L. Munger)

latter lesion is observed more frequently in mature breeder ducks than in young ducklings. When heart chambers are exposed, endocardial mural and valvular hemorrhages also may be observed.

Surfaces of liver, pancreas, intestine, lungs, and kidney may be covered with petechiae. In mature laying females, hemorrhages may be observed in deformed, discolored ovarian follicles, and massive hemorrhage from the ovary may fill the abdominal cavity. Lumina of intestines and gizzard are often filled with blood. The esophageal-proventricular sphincter appears as a hemorrhagic ring.

Specific digestive mucosal lesions are found in the oral cavity (12), esophagus, ceca, rectum, and cloaca. Each of these lesions undergoes progressive alterations during the course of the disease. Initially, macular surface hemorrhages appear, which are later covered by elevated, yellow-white crusty plaques. Subsequently, the lesion becomes organized into a green superficial scab devoid of its former hemorrhagic base. Lesions range in size from approximately 1–10 mm in length.

Figure 13.10. Cloacal bursa lesions with DVE; hemorrhages (center) and cheesy exudates (right and left). (S.A. Shawky, T.S. Sandhu, H.L. Shivaprasad)

In the esophagus and cloaca, lesions may become confluent; however, close inspection will often reveal their composite structure. In the esophagus, macules occur parallel to longitudinal folds. When macular concentrations are numerous, small lesions may merge to form larger ones covered with a patchy diphtheritic membrane (Figure 13.9). In young ducklings, individual lesions in the esophagus are less frequent; sloughing of the entire mucosa is more common, and the lumen becomes lined with a thick yellow-white membrane. Oral erosions can be found at openings of sublingual salivary gland ducts in chronically infected waterfowl (12). Meckel's diverticulum may be hemorrhagic and contain a fibrinous core (79).

In ceca, macular lesions are singular, separated, and well defined between mucosal folds. The external surface of affected ceca often presents a barred, congested appearance.

Rectal lesions are usually few in number with greatest concentration at the posterior portion of the rectum, adjacent to the cloaca.

In the cloaca, macular lesions are densely packed; initially, the entire mucosa appears reddened. Later, individual plaque-like elevations become green and form a continuous scale-like band lining the lumen of the organ.

All lymphoid organs are affected. The spleen tends to be normal or smaller in size, dark, and mottled. The thymus is atrophied and has multiple petechiae (Figure 13.13) and necrotic focal areas on the surface and cut section and is surrounded by clear yellow fluid that infiltrates and discolors subcutaneous tissues of the adjacent cervical region from the thoracic inlet to the upper third of the neck. The latter lesion is of importance in meat inspection and is easily detected when the opened neck of the carcass is observed on the processing line. The bursa of Fabricius is intensely reddened during early infection (Figure 13.10). The exterior becomes surrounded by clear yellow fluid that discolors adjacent tissue of the pelvic cavity. When the lumen of the bursa is opened, pinpoint yellow areas are found in an intensely hemorrhagic surface. Later, walls of the bursa become thin and dark, and the bursal lumen is filled

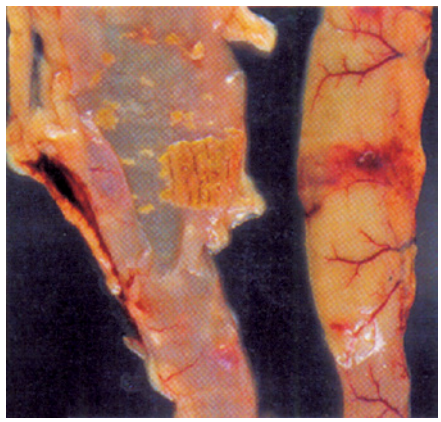

Figure 13.11. Multifocal necrosis of gut-associated lymphoid tissue resulting in ulceration covered by fibrinous pseudomembranes of DVE. Also note the reddened ring visible on the external surface of the intestine. (L. Munger)

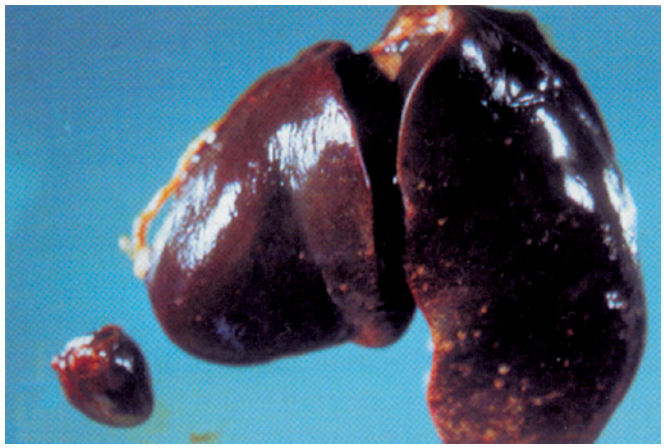

Figure 13.12. Multiple pale foci in liver and slightly smaller dark-colored spleen with DVE.

with white coagulated exudates (Figure 13.10). Intestinal annular bands appear as intensely reddened rings visible from external and internal surfaces. Yellow pinpoint areas can be observed on the mucosal surface. Later, the entire band becomes dark brown and tends to separate at its margins from the mucosal surface. The multifocal necrosis of gut-associated lymphoid tissue causes ulceration covered by fibrinous pseudomembranes (Figure 13.11).

During early stages of infection, the entire liver surface has a pale copper color with an admixture of irregularly distributed pinpoint hemorrhages and white foci (Figure 13.12), giving it a heterogeneous, speckled appearance. Late stages of infection are characterized by dark bronze or bile-stained livers without hemorrhages; the white foci are larger and appear more distinct on the darker background.

Although these lesions are consistent with DVE infection, each age group responds distinctively. In ducklings, tissue hemorrhages are less pronounced and lymphoid lesions are more prominent. In mature domestic ducks with naturally

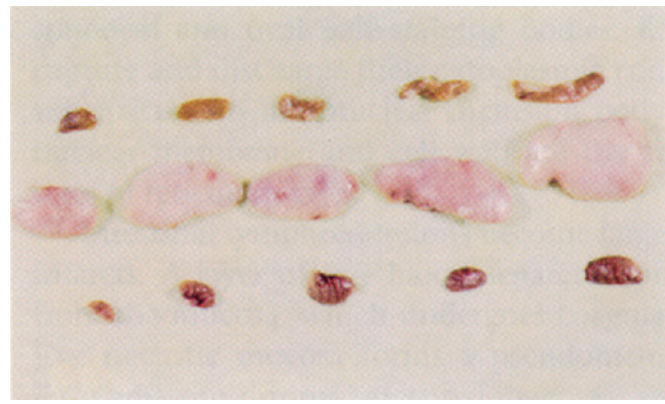

Figure 13.13. Normal thymus (middle) and thymus (DVE) showing hemorrhages and atrophy (top and bottom), 4 dpi with DVE virus. (Shawky, Sandhu, Shivaprasad)

regressed cloacal bursa and thymus, tissue hemorrhages and reproductive tract lesions predominate.

In geese, intestinal lymphoid disks (56) are analogous to annular bands in ducks. In a single Canada goose, lesions of the intestinal lymphoid disks resembled "button-like ulcers" (55). Similar intestinal lesions have been observed in an outbreak of DVE in Canada and Egyptian geese. In swans, diphtheritic esophagitis is a consistent lesion (48).

An outbreak caused by a low virulent strain of DVE in commercial 2– to 6-week-old white Pekin ducklings produced atypical gross lesions, including diphtheritic membranes under the tongue and in nasal and infraorbital sinuses. Esophageal mucosa had a few necrotic plaques, and cloacal mucosa was covered with necrotic greenish diphtheritic membranes. No lesions were seen in the intestines including annular bands. Thymus and bursa were atrophied and hemorrhagic, and the bursal lumen was filled with cheesy exudate. An experimental study showed that the bursal atrophy could last for at least 39 days post infection; however, the thymus recovered after 10 days of infection (88).

Microscopic Lesions

The initial lesion occurs in the walls of blood vessels. Smaller blood vessels, venules, and capillaries, instead of larger blood vessels, are more markedly involved. The endothelial lining is disrupted, and connective tissue of the wall becomes less compact, with visible separations at points where extravasations of blood pass from the lumen through the thin ruptured wall into surrounding tissues.

Hemorrhages are especially pronounced in certain locations: interlobular venules of the proventriculus, hepatic, and portal venules at the margins of liver lobules; venules in the spaces between lung parabronchi; capillaries within intestinal villi; and star-shaped intralobular renal hemorrhages.

As a result of vascular damage, affected tissues undergo progressive degenerative changes. Microscopic changes can be found in any visceral organs including those without gross lesions.

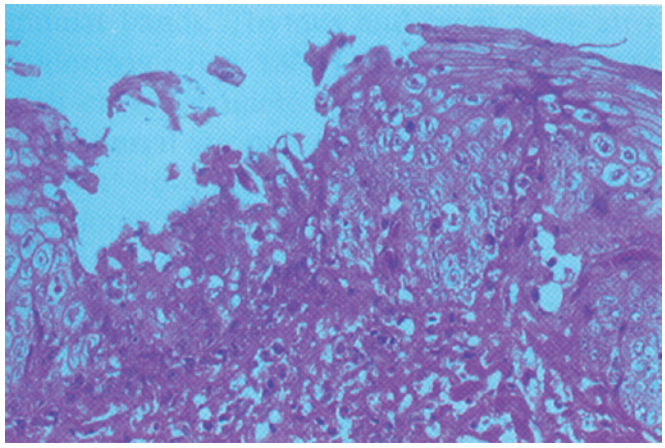

Figure 13.14. Microscopic appearance of esophageal ulcerations of DVE. Note the lack of inflammatory response and presence of intranuclear inclusion bodies. ×225. (L. Munger, H.J. Barnes)

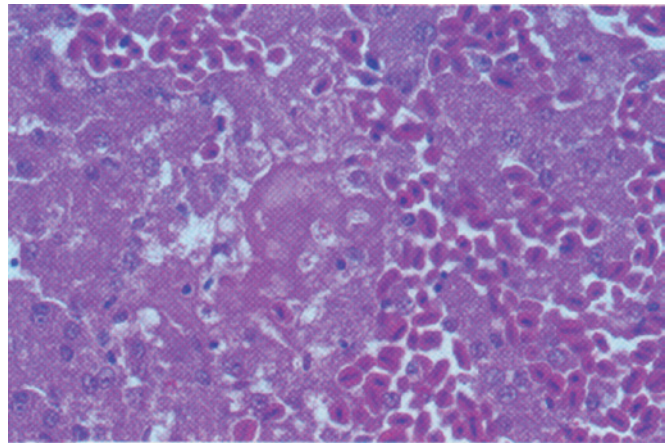

Figure 13.15. Microscopically, liver shows focal areas of necrosis filled with fibrin from DVE. Intranuclear inclusion bodies can be seen in hepatocytes near areas of necrosis. ×360. (L. Munger, H.J. Barnes)

Digestive lesions appear initially as hemorrhages of capillary arcades of submucosal papillae or folds. Hemorrhages become larger and confluent, elevating and separating the overlying mucosa. The affected epithelium above the hemorrhage becomes edematous, necrotic, and raised into the lumen above normal adjacent mucosal surfaces (Figure 13.14). Later, margins of necrotic epithelium separate to define the borders of elevated plaques. There is necrosis and degeneration of stratified squamous epithelium of the esophagus and cloaca (78). Eosinophilic intranuclear and cytoplasmic inclusions have been seen in epithelial cells (88, 94).

Hemorrhage from venules and capillaries fills lymphoid tissue within intestinal annular bands or lymphoid disks and lymphoid tissue of the esophageal-proventricular sphincter and spleen. Lymphocytes undergo karyorrhexis and pyknosis. Fragments of lymphocytes appear everywhere and are engulfed by phagocytes. In addition to cellular debris and hemorrhage within lymphoid follicles, marked swelling of reticulum cells occurs, and their cytoplasm becomes subdivided and condensed into spherical and oval pale-staining bodies. Reticulum cells rupture and discharge their cytoplasmic contents into tissue spaces. An intranuclear inclusion body and delicate nuclear membrane and cell wall are the remaining vestiges of reticulum cells.

Intestinal lymphoid lesions become large hemorrhagic infarcts. A layer of free blood separates lymphoid tissue from the mucosa, which undergoes coagulation necrosis. The necrotic mucosa forms a pseudomembrane higher than adjacent normal intestinal mucosa.

In the small intestines, sheets of epithelial cells are displaced from the surface of villi, many of which are broken and cast into the lumen. Abundant blood and cellular debris fill the lumen.

Within the cloacal bursa, submucosal and interfollicular capillary hemorrhages are found. There is a severe depletion of lymphocytes in the follicles, many of which have empty hollow cavities in the medulla. Corticomedullary epithelial cells, capillary networks, and large phagocytic cells containing fragmented lymphocytes form the circumference around these cavities. Severe depletion of lymphocytes in the follicles occurs, which is replaced by eosinophilic material mixed with heterophils. There are occasional mononuclear cells that contain intranuclear inclusions. Bursal epithelial cells are hypertrophied with vacuolated cytoplasm and contain both intranuclear and intracytoplasmic inclusions (88).

In the thymus, free blood fills interfollicular spaces. Coagulation necrosis of central medullary reticulum cells and destruction of cortical lymphocytes are pronounced.

In mature female breeder ducks, congestive, hemorrhagic, and necrotic alterations occur in the oviduct. Follicles may be misshapen and blood stained. In the ovary of immature female breeder ducks, focal intestinal hemorrhages from capillaries and venules may be found.

In mature breeder drakes, focal capillary hemorrhages occur in interstitial tissues between seminiferous tubules. In parenchymatous organs such as liver, pancreas, and kidneys, hemorrhages and focal necrosis are found surrounding blood vessels.

Within necrotic foci in the liver, hepatic cords show a variety of changes including detachment and disassociation of hepatocytes from each other and their surrounding structure. A few necrotic liver cells become swollen or subdivided and discharge their cytoplasmic contents through a ruptured cell surface and are represented only by intranuclear inclusion bodies. Focal areas of necrosis may be filled with fibrin (Figure 13.15). Similar, but more limited, changes occur in pancreas and kidney (57).

Immunity

Active Immunity

Active immunity has been demonstrated following the use of a modified live virus vaccine (40), inactivated tissue culture vaccine (87), and bivalent recombinant live attenuated vaccine (65). It is assumed that both humoral and cell-mediated

immunity are involved in protection (53, 97). Field observations suggest that recovered birds are immune to re-infection with DEV.

Passive Immunity

Maternal immunity has been reported in ducklings, but it declines rapidly. Progeny of breeder ducks vaccinated with a live-attenuated virus vaccine are fully susceptible. However, ducklings from breeders that had been vaccinated and challenged with a virulent virus were fully protected at 4 days of age, and less than 40% were protected at 13 days of age (96). In an experimental study (10), super-infection of persistently infected mallard ducks resulted in death, indicating that protection depends on the route of exposure, strain led to persistent infection, and strain of superinfecting virus.

Diagnosis

Isolation and Identification of DEV

Although a presumptive diagnosis can be made on the basis of gross and histopathologic lesions, isolation and identification of DEV confirm the diagnosis even in the absence of typical lesions. Samples recommended for virus isolation are liver, spleen, bursa, kidneys, peripheral blood lymphocytes (PBL), and cloacal swabs. Virus isolation is carried out by inoculation of susceptible 1-day-old Muscovy ducklings, white Pekin ducklings, or onto CAM of 9- to 14-day-old embryonating duck eggs. Characteristic lesions and mortality in inoculated ducklings are highly suggestive of DEV. Virus also can be isolated and propagated in white Pekin or Muscovy duck embryo fibroblasts, and primary cell culture of liver and kidney. Virus identification is carried out by virus neutralization assay in embryonating duck eggs or cell culture using DEV-specific antiserum.

Latex agglutination test was claimed to be as sensitive as duck embryo inoculation and virus neutralization in the detection of viral antigens (15). Antigen capture ELISA is rapid, specific, and sensitive for detection of DEV in tissue samples (36).

Conventional polymerase chain reaction (PCR) assay is used for detection of DEV DNA in tissue samples and in cell culture of virus isolation (29, 74, 77). A quantitative real-time PCR assay was developed to use for rapid diagnosis and detection of DEV DNA in acute and latent stages of infection (107). Recently, two quantitative TaqMan fluorescent real-time PCR assays have been developed with sensitivity 100 times higher than conventional PCR (27, 109). A simple, rapid, and cheap loop-mediated isothermal amplification (LAMP) assay has been developed for on-farm and laboratory diagnosis (45). Restriction endonuclease analysis could be a possible test for differentiation of DEV strains (101).

Serology

Increase in virus neutralization (VN) titers following convalescence from DEV will demonstrate progress of the disease within a flock. A VN index of 1.75 or more indicates infection with DEV (16). A VN index of 0–1.5 has been found in sera of domestic and wild waterfowl not exposed to the disease. The use of chicken embryo-adapted virus in chicken eggs for VN studies is safer and more convenient than the use of field-strain viruses inoculated onto the CAM of duck eggs (16).

Immunofluorescence tests can be used to detect viral antigens in cell cultures or tissue sections (21, 85). Other serologic procedures for detecting antibodies include a microtiter plate isolation and neutralization test using duck embryo fibroblasts (105), a reverse passive hemagglutination test (18), and ELISA (50, 84). A Dot-ELISA and passive hemagglutination assays have been developed for detection of DEV antibodies; however, the specificity and sensitivity of these two assays were shown to be moderate (67). An immunochromatographic strip test has been developed for use as a field test for monitoring flock immunity post vaccination and detection of exposure to DEV in unvaccinated flocks. This test is easy to perform, rapid (15 minutes), specific, and with equal sensitivity as the antibody ELISA (89).

Differential Diagnosis

Differential diagnosis requires consideration of other diseases producing hemorrhagic and necrotic lesions in Anseriformes. In domestic ducks, common diseases producing such changes are duck virus hepatitis, fowl cholera, necrotic enteritis, coccidiosis, and specific intoxications. Although Newcastle disease, fowl pox, and fowl plague are reported to produce similar changes in Anseriformes, these diseases have been infrequently reported.

Intervention Strategies

Management Procedures

Prevention is achieved by maintaining susceptible birds in environments free from exposure to the virus. These measures include the addition of stock known to be free from infection and avoiding direct and indirect contact with possibly contaminated material. Introduction of the disease by free-flying Anseriformes and contaminated aquatic environments must be prevented. All possible measures should be taken to prevent dissemination of virus by free-flowing water. After DEV has been introduced, control can be achieved by depopulation, removal of birds from the contaminated environments, sanitation, disinfection, and vaccination of all susceptible ducklings.

In countries where the disease is not enzootic and is truly exotic, measures should be taken to further prevent entry and dissemination into geographic areas known to be free from DEV. This includes specific examination to prevent importing infected Anseriformes. Accordingly, there is surveillance of ornamental bird collections, zoos, and domestic growers of Anseriformes. Efforts should be made to provide efficient detection of DEV by laboratory workers and waterfowl specialists so that its presence, status, and importance can be better defined.

Vaccination

Vaccination has been used as a preventive measure and also for controlling disease outbreaks.

Inactivated vaccines have been tried but have not been as efficacious as modified live virus vaccines (13). However, an inactivated tissue culture-grown virus vaccine has been shown to provide protection against the virulent strain (87). This vaccine could be used in domestic and captive waterfowl without the risk of introducing a live virus.

A chicken embryo-adapted DEV strain, avirulent for domestic ducks, has been developed and used extensively with good success in the Netherlands (40). This vaccine strain also has been used to prevent and control DVE outbreaks on commercial duck farms and captive waterfowl collections in the United States and Canada (69, 83). The vaccine can be used in the face of an outbreak, because it provides protection immediately after vaccination due to an interference phenomenon (39, 80). It should be noted, however, that birds in the period of incubation may not be protected. A naturally apathogenic and immunogenic strain of DVE was reported to be successful for active and passive immunization of ducks (63, 64).

Attenuated live virus vaccine is administered by subcutaneous or intramuscular routes in domestic ducklings more than 2 weeks of age. Normally, the breeding flocks are vaccinated. Flocks maintained for more than a year are revaccinated annually. Apparently, vaccinated ducklings do not excrete inoculated virus to a degree that would be sufficient to bring about contact immunization (41, 95).

Treatment

There is no specific treatment for infection with DVE.

Hemorrhagic Nephritis Enteritis of Geese

Jean-Luc Guérin

Introduction

Hemorrhagic nephritis enteritis of Geese (HNEG) is one of the major diseases of geese in Europe. HNEG had long been named "young geese disease" or "late form of Derzsy's disease" due to confusion with goose parvovirus infection. According to its etiology, a more relevant denomination should be "goose polyomavirosis." This systemic, frequently lethal disease is to date the only condition associated with a polyomavirus in a poultry species.

Public Health Significance

Polyomaviruses have a very narrow host range (8). This is supported by recent evidence of co-divergence of mammalian and avian polyomaviruses with their respective hosts (14). HNEG is thought to have no public health implications.

History

HNEG was first described in 1969 in Hungary (2), where occurrence of field cases was always associated with administration of serum—collected from convalescent flocks formerly affected by Derzsy's disease—to young geese to confer them with passive immunity. HNEG was described a few years later in Germany (19), then in France (18, 21), where it evolved with a sporadic pattern, except for epizootics in the late 1980s and since 1997 (7). For many years, HNEG was suspected to correspond to a late evolution of Derzsy's disease. Actually, because hyperimmune sera against goose parvovirus or duck hepatitis virus did not protect goslings from HNEG, it appeared clear that HNEG agent was a distinct virus (10). Etiology of HNEG was clarified lately by Guérin et al. (7), exactly 30 years after the first clinical report. More recently, it was shown that ducks are actually largely healthy carriers of the virus (4, 15).

Etiology

Classification

The agent of HNEG, namely *Goose hemorrhagic polyomavirus* (GHPV), is a member of the *Polyomaviridae* family and *Polyomavirus* genus (7). This virus is significantly divergent from *Budgerigar fledgling polyomavirus* (BFPyV), the prototype avian polyomavirus infecting psittacines, falconiforms, and passerines (3, 5, 8, 16).

Morphology

Virus particles are naked and spherical, and show icosahedral symmetry. Their size ranges from 40–50 nm in diameter (7). Buoyant density of virions is of 1.20 $g.cm^{-3}$ in sucrose gradient (7), which corresponds to 1.34–1.35 $g.cm^{-3}$ in CsCl.

Chemical Composition

GHPV genome is a circular, double stranded DNA of 5,256 base pairs (9). Genome organization of all polyomaviruses shares common features, with a set of early genes encoding polymerases (t and T antigens) and late genes, encoding structural proteins: VP1, the main capsid protein, and two other structural proteins, VP2 and VP3 (8, 9). As for Avian Polyomaviruses, an additional VP4 has been demonstrated, the precise functions of which still remain to be clarified (9).

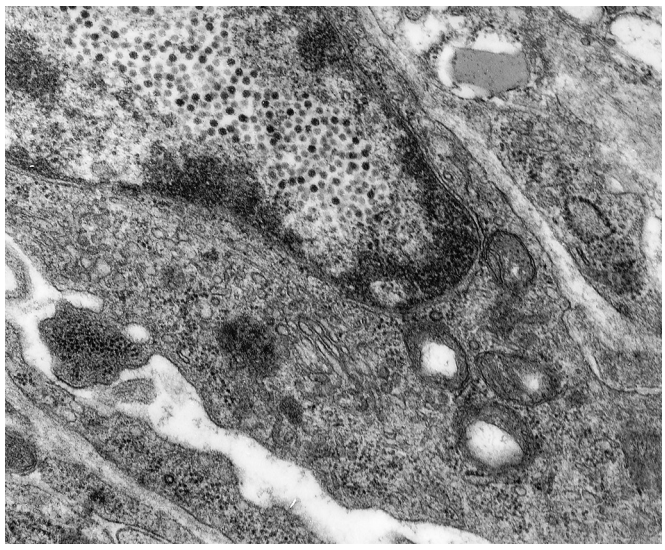

Figure 13.16. Electron micrograph of a GHPV-infected cell. Notice many naked virions in the nucleus and peripheral accumulation of chromatin. ×25,000.

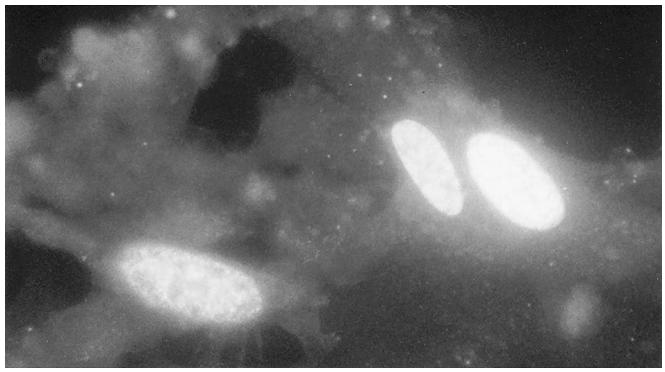

Figure 13.17. Immunostaining of goose polyomavirus in kidney cells culture. Intranuclear replication is demonstrated by indirect immunofluorescence, using isothiocyanate fluoresceine-labelled antibody.

Virus Replication

Replication of GHPV occurs in the nucleus (7). Infected cells show a huge concentration of viral material in the nucleus, both in cultured cells and tissues of infected goslings (Figure 13.16). Virus is easily detected in the nuclei by immunofluorescence, using serum of geese recovering from HNEG (Figure 13.17). Releasing of virions implicates disruption of cell membrane.

Susceptibility to Chemical and Physical Agents

GHPV shows a great resistance to heating: virus is still fully virulent even 2 hours after incubation at 55°C (7). The virus also resists freezing-thawing cycles and lipid solvents: treatment with 1% phenol has no effect on its viability (10). The other avian polyomavirus, BFPyV, is mostly sensitive to chloride-derived products (17).

Strain Classification

Genetic variability among field isolates has been poorly investigated so far. Nevertheless, polyomavirus genomes are generally highly conserved; all of the variants of BFPyV isolated from psittacines, falconiforms, or finches share more than 99% nucleotide identity (16). Phylogenic analysis of GHPV confirmed that VP1 is remarkably conserved among isolates from different countries (13). Moreover, duck GHPV strains do not show distinctive genetic features compared to the goose strains (4). No cross-neutralization experiment has been performed so far on GHPV field isolates.

Laboratory Host System

HNEG is successfully reproduced by parenteral inoculation on 1-day-old goslings. Clinical end points are reached between 6 and 8 days post-inoculation (PI), with peracute disease. Goslings are susceptible to inoculation either by subcutaneous or intraperitoneal routes. All attempts to adapt the HNEG virus to duck fibroblasts or embryos, as well as goose fibroblasts, remained unsuccessful (6, 7). Propagation of GHPV on goose embryos has been reported: 14-day-old goose embryos inoculated onto the chorioallantoic membrane (CAM) died from 8–10 days PI, with lesions similar to those described in goslings (1). Virus propagation can be accomplished by propagation on epithelial primary cells derived from 1-day-old gosling kidneys. Cytopathic effects appear by day 5 PI; granulations and vesicles are distinguished in the cytoplasm, followed by budding of the cell, and finally cell detachment from the monolayer (7). Cell-based dilution titration procedures are seldom done, because cytopathic effect appears late after infection. Alternatively, detection and quantification of virus yields from cell cultures or tissues can be determined by quantitative real-time PCR (4, 6).

Pathobiology and Epizootiology

Incidence and Distribution

Until now, HNEG has been mostly described in Hungary, Germany, and France (2, 7, 13, 18, 21). Occurrence of the disease in other countries seems likely, although there are no published reports confirming this. Cases are frequently observed in winter, probably due to climatic conditions or weakness of the goslings hatched from light-conditioned breeders.

Natural and Experimental Hosts

HNEG has only been described to date in growing geese. Subclinical infections have been reported in migrating wild geese (7). Other waterfowl species, such as mule or Muscovy ducklings, are clinically refractory to GHPV inoculation, but

can be infected at high replication levels (4, 15). Field surveys have suggested that ducks may constitute a significant subclinical reservoir of GHPV (4).

Transmission, Carriers, Vectors

Infected geese and ducks excrete significant amounts of virus in their droppings, resulting in dissemination of contagious material to the environment and easy direct and indirect contamination. Vertical transmission of the virus through the egg has never been confirmed, but cannot be excluded. The experimental infection of goose embryos has been shown, although this does not formally demonstrate the field occurrence of vertical transmission (1). No biologic vector seems to be involved in GHPV transmission.

Incubation Period

The incubation period is mostly age dependent. Inoculation of day-old goslings results in death within 6–8 days (11). In contrast, in 3-week-old goslings, the incubation period could last for up to 15 days (13). After 4 weeks, inoculation results mostly in non-clinical infection. Although clinical signs rarely start before 5 or 6 weeks of age, contamination from infected birds could possibly occur early in life, as observed for other polyomaviruses (14).

Clinical Signs, Morbidity, and Mortality

HNEG has been described in goslings from 4–10 weeks of age. In affected flocks, morbidity ranges from 10%–80% and death is the most common outcome (7). Clinical signs develop rapidly only a few hours before death; birds sit alone, away from the flock, stay in a coma, and die (2, 10). Nervous signs, such as opistothonos, are only observed after experimental or iatrogenic infections of goslings (11). Chronic evolution of the disease leads to urate deposits on viscera and in joints, resulting in lameness. In these late forms, mortality may be limited to a few birds every day up to the age of 12 weeks.

Pathology

Necropsic findings in goose include edema of subcutaneous connective tissues, gelatinous ascites, inflammation of the kidneys (Figure 13.18), and less frequently, hemorrhagic enteritis. Renal dysfunction leads to an increase of blood uric acid concentration (17). Geese that die after a chronic infection show visceral gout and deposition of urates in the joints (10, 11, 19). Histopathologically, the most obvious features are (1) an interstitial nephritis and necrosis of the kidney tubular epithelium (10, 11), and (2) a moderate to severe lymphocytosis in cortical and medullary regions of bursal follicles (Figure 13.19), suggestive of B-lymphocyte depletion (7, 11). Gross lesions of enteritis are associated with necrosis of intestinal epithelium. Hemorrhagic foci also are observed in most tissues, particularly in acute infections (11, 13). No inclusion could be detected in tissues of birds diagnosed with HNEG

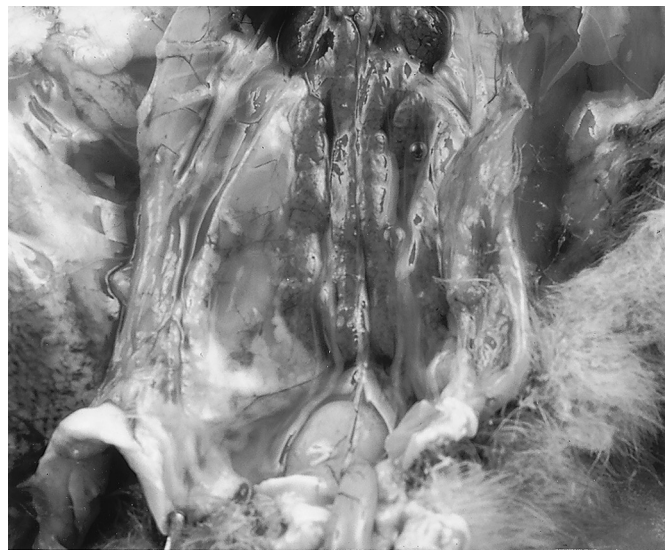

Figure 13.18. Necropsic appearance of a 10-day-old gosling infected with goose polyomavirus, showing edema, gelatinous ascites, and swelling of kidneys.

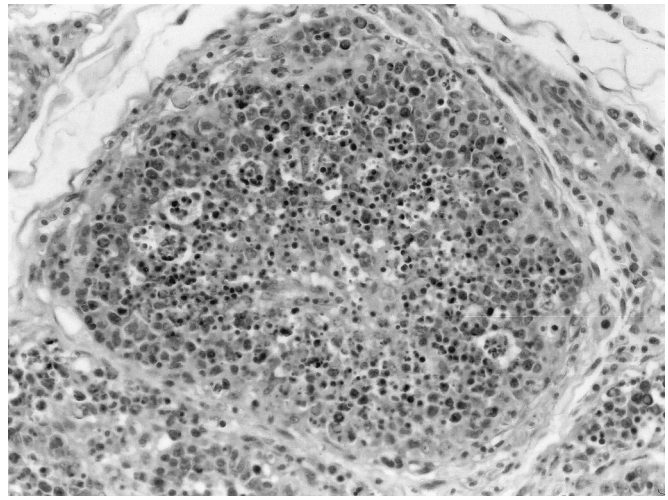

Figure 13.19. Microscopic lesions in a follicle of the bursa of Fabricius. Severe lympholysis is conspicuous in the center of the follicle and in cortical foci (arrow). H and E, ×150.

(7, 11). Electron microscopy examination of infected tissues shows aggregated virions in nuclei (Figure 13.16) and large vesicles of dense material, including optically clear centers, in the cytoplasm of about 20% of the infected cells (7). In infected ducks, no macroscopic or microscopic lesion has been observed (4).

Pathogenesis of the Infectious Process

During the course of infection, GHPV seems to replicate first in endothelial cells; nuclear enlargement of endothelial cells

and arteriolitis are the first lesions noticed (11, 13). These histological findings suggest a selective tropism for endothelial cells, which might be of great relevance in pathogenesis of HNEG. Endothelial cells are indeed known to play a critical role in many biological pathways, resulting in vascular dysfunctions as ascites or edema. Another main target of GHPV is lymphoid cells; virions are observed in many bursal lymphoid cells, and cloacal bursa (bursa of Fabricius) systematically shows significant lympholysis. However, thymic lymphoid cells are less or not affected. This feature is fairly relevant with the well documented tropism of polyomaviruses to B-lymphocytes (8), suggesting immunodepressive effects in subclinical infections.

Immunity

Immunological aspects of HNEG have so far received little attention. Neutralizing antibodies are detected in previously infected birds and their transmission to the progeny seems very efficient, because goslings hatched from infected breeders are refractory to experimental infections with huge viral load (7, 20). The duration of maternal immunity has not been fully determined, but serological monitoring assays on goslings from vaccinated breeders suggest a complete disappearance of maternal antibodies within 3 weeks of life (6).

Diagnosis

Isolation and Identification of Causative Agent

GHPV can be detected in clinical material from geese showing clinical disease, as well as from non-clinical carrier birds. Isolation could be based on either kidney cell culture (7) or goose embryo inoculation (1), but these methods are time consuming and seldom and can hardly be applied to routine diagnosis of HNEG. Detection of the GHPV genome is therefore a more reliable way to detect the virus; PCR detection of DNA extracted from infected tissues (liver, spleen, kidney) with primers designed on VP1 gene is efficient and reliable (4, 7, 11). In subclincally infected carriers, PCR assays can be advantageously performed on blood samples or spleen or cloacal swabs (4, 7). Serology appears of limited value to detect infection by a polyomavirus, because serologic response is greatly variable, while virus may persist in infected birds for months, if not years (17). ELISA has been developed using viral antigens (6) or recombinant VP1 (22).

Differential Diagnosis

Lesions of ascites, subcutaneous edema, visceral urate deposition, and nephritis in 4- to 10-week-old goslings are all suggestive of HNEG. However, similar lesions also may be associated with goose parvovirus infections. Histopathological, virological, or serological procedures may be helpful in confirming the etiology. HNEG is probably underdiagnosed because of the existing confusion with Derzsy's disease.

Intervention Strategies

Management Procedures

Goose polyomavirus spreads from carriers and clinically affected birds, mostly by fecal route (7, 10). Disinfection procedures should be thoroughly observed; i.e., complete removal of organic material, followed by the use of an appropriate disinfectant, is required to prevent or interrupt a disease outbreak. Chloride derived products are considered efficient to inactivate polyomaviruses, but are particularly sensitive to the presence of organic debris (17). Because infected birds have a viremia, needles used for administration of vaccines should be sterilized between uses. Though transmission of HNEG virus through the egg is not clarified, sanitary rules should be respected in the hatchery to limit potential early contamination of goslings before they reach the farm. When goslings are infected by the virus, occurrence of clinical signs may greatly depend on management factors such as cold and/or stress. Oil-adjuvant vaccines should be administered with extreme caution to flocks affected by the disease. Because ducks can be healthy carriers of GHPV, mixed goose and duck farming systems should be carefully reconsidered and biosecurity between these species enforced (4).

Vaccination

Management procedures are unlikely to be sufficient for the control of HNEG infection. Vaccination of breeders could be used to provide maternal immunity to goslings when they are critically sensitive to virus contamination (6). An inactivated vaccine, based on viral antigen produced by propagation on goose kidney cells, inactivated with β-propiolactone, and adjuvanted with carbopol, has been the subject of a trial on breeding geese and induced maternal antibodies, providing protection to goslings against a viral challenge (6). This vaccine, when administered to growing goslings, induced a significant serological response for several weeks.

A rational vaccination schedule could rely on (1) administration to breeders before each laying period and (2) vaccination of growing goslings to induce an active immunization covering the whole economic life of birds.

A subunit vaccine, based on recombinant VP1 protein produced in *E. coli*, also induced protection in goslings against a viral challenge, confirming that VP1 is the major antigenic determinant of polyomaviruses and can be expressed in subunit or vectored vaccines (12).

Parvovirus Infections of Waterfowl

Vilmos J. Palya

Introduction

Waterfowl parvoviruses can cause a highly contagious fatal disease affecting young geese and Muscovy ducks (*Cairina moschata*). The disease was described under different names depending on the major clinical-pathological features that were observed (27). To eliminate the discrepancies in nomenclature, the World Poultry Association in 1974 agreed to name the disease in goose as Derzsy's disease to acknowledge the pioneering work of the Hungarian researcher Domokos Derzsy. A syndrome associated with parvovirus infection causing short beak and dwarfism in mule duck was also reported (61). It has been shown that waterfowl parvoviruses can be divided into goose parvovirus (GPV) and duck parvovirus (DPV) species, the latter frequently referred to as Muscovy duck parvovirus (MDPV) (17, 50, 86).

Economic Significance

In countries where intensive farming of geese and Muscovy ducks is practiced, the disease has serious economic significance. Vaccination of breeding flocks and progeny has significantly reduced the impact of the disease recently.

Public Health Significance

There are no known public health risks associated with infection of waterfowl parvoviruses.

History

In the late 1950s and early 1960s a highly contagious and fatal disease of young goslings was reported in China and several European countries where intensive goose farming was present (27). During the following years the disease was reported as of great economic importance from all of the major goose and Muscovy duck farming countries (2, 11, 15, 48, 54, 80). In 1989, the occurrence of a new parvovirus strain, named Muscovy duck parvovirus, was reported in France (18); however, later study showed that MDPV-related virus had already been isolated in Taiwan in 1985 (5), which implies that MDPV might have been prevalent earlier than its first report in France. The syndrome of short beak and dwarfism (SBDS) occurred first in France (79).

Etiology

In early reports describing the disease several etiological agents have been proposed, including bacteria, reoviruses, and adenoviruses as they were frequently isolated or detected from diseased goslings (27). In subsequent studies, however, it has been confirmed that the etiological agent is a parvovirus (14, 46, 69).

Classification

Waterfowl parvoviruses are classified as autonomous members of the *Dependovirus* genus in the *Parvovirinae* subfamily of the *Parvoviridae* family, and belong to two species: GPV and DPV (17). DPV differ from GPV in pathogenicity and host range (19, 34). Using cross neutralization test, it has been demonstrated that DPV differs antigenically from GPV (34). Molecular analysis of the genomes of GPV and DPV also identified significant differences between the two viruses. Nucleotide sequence homology between GPV and DPV is approximately 80% (5, 7, 86). Phylogenetic analysis based on the structural proteins verified the existence of the two monophyletic groups (5, 77). A new DPV strain belonging to another branch was isolated in the USA, showing 85% identity with both GPV and DPV strains (63). Among the GPV strains, separate monophyletic subgroups can be differentiated based on the geographical origin and pathogenicity (77) (Figure 13.20). Strains isolated from SBDS cases belong to a distinct linage of GPV (61, http://www.ictvonline.org/virusTaxonomy.asp?bhcp=1).

Morphology

Waterfowl parvoviruses have small non-enveloped virions with icosahedral symmetry (Figure 13.21) and a diameter of 20-22 nm (27, 46).

Chemical Composition

The single-stranded DNA genome of GPV comprises of 5,106 nucleotides, and DPV is 5,132 nucleotides in length including the inverted terminal repeats with U-shaped hairpin structures at both ends. Both plus- and minus-strand genomes are encapsidated into virions. The genome contains two large open reading frames (ORF). The ORF in the left-hand side (5′-end) of the genome encodes REP1 and REP2 non-structural, regulatory proteins. The right-hand side of the genome encodes the capsid proteins VP1, VP2, and VP3 (50, 86, 87). These three proteins are generated from the same mRNA by alternative splicing in the case of VP1 and VP2 and by post-translational cleavage for VP3 (52). The virion predominately contains VP3 and varying amount of VP1 and VP2.

Virus Replication

The replication of GPV and DPV, similar to that of other parvoviruses, occurs in the nucleus of host cells by using the apparatus of the cells without the presence of helper virus (4, 42, 46). Parvoviruses in general can only replicate productively in actively mitotic host cell populations. Accordingly, pathogenic or lethal infections typically occur in fetal or neonatal hosts, which have many dividing cell populations, or involve adult tissues that remain actively dividing in later life (10). The RNA transcriptional profile of GPV proved to be a hybrid of the features of the Dependovirus and Parvovirus genus. (64).

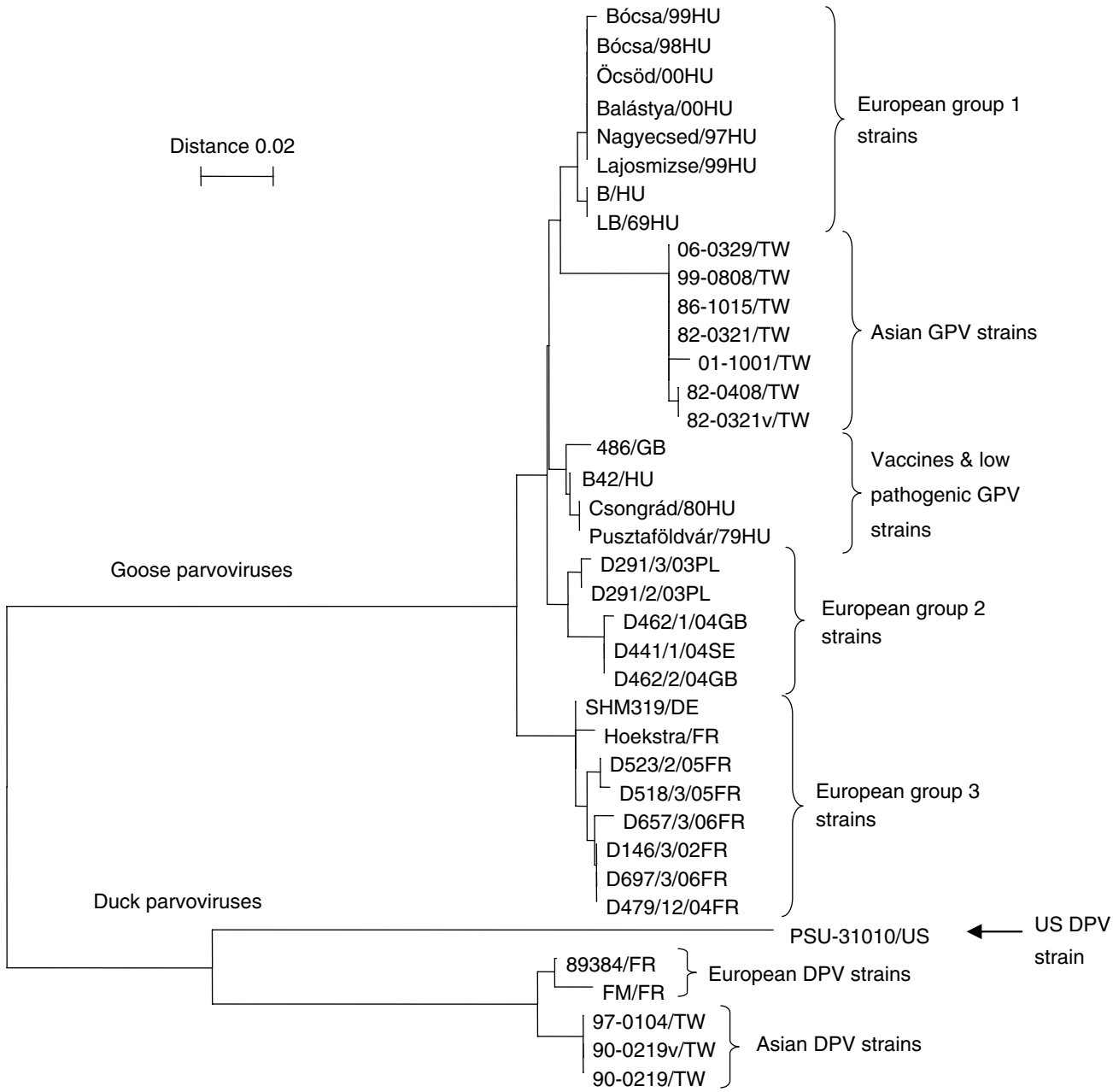

Figure 13.20. Phylogenetic relationship of goose and duck parvoviruses. The tree is based on a 493-bp-long region of the VP1 protein. GenBank accession numbers of the strains included: Bócsa/99HU (AY496898), Bócsa/98HU, Öcsöd/00HU, Balástya/00HU, Nagyecsed/97HU, and Lajosmizse/99HU had the same accession number (AY496897), B/HU (U25749), LB/69HU (AY496900), 06-0329 (EU583391), 99-0808 (AY382888), 86-1015 (AY382887), 82-0321 (AY382884), 01-1001 (AY382889), 82-0408 (AY382886), 82-0321v (AY382885), GPV486/GB (AY496904), B42 (AY496901), Csongrád/80HU and Pustaföldvár/79HU had the same accession number (AY496903), D291/2/03PL (DQ862009), D291/3/03PL (DQ862010), D441/1/04SE (DQ862008), D462/1/04GB (DQ86011), D462/2/04GB (DQ862012), SHM319/DE (U34761), Hoekstra/FR (AY496907), D146/3/02FR (AY496906), D479/12/04FR (EU938702), D518/3/05FR (EU938703), D523/2/05/FR (EU938704), D657/3/06FR (EU938705), D697/3/06FR (EU938706), PSU-31010 (DQ413026), 89384 (Z68272), FM (U22967), 97-0104 (AY382893), 90-0219 (AY382892) and 90-0219v (AY382890).

Susceptibility to Chemical and Physical Agents

Goose parvovirus is very resistant to chemical and physical inactivation (69). The virus is stable at 65°C for 30 minutes and at pH 3.0 for 1 hour at 37°C (25). However, treatment with 0.5% formaldehyde can destroy the infectivity of the virus (69).

Laboratory Host Systems

GPV and DPV can be propagated in embryonating goose or Muscovy duck eggs or young susceptible birds of the same species and primary cell cultures prepared from the embryos of these species. After a certain level of adaptation the virus can be grown in Pekin duck embryos as well (30).

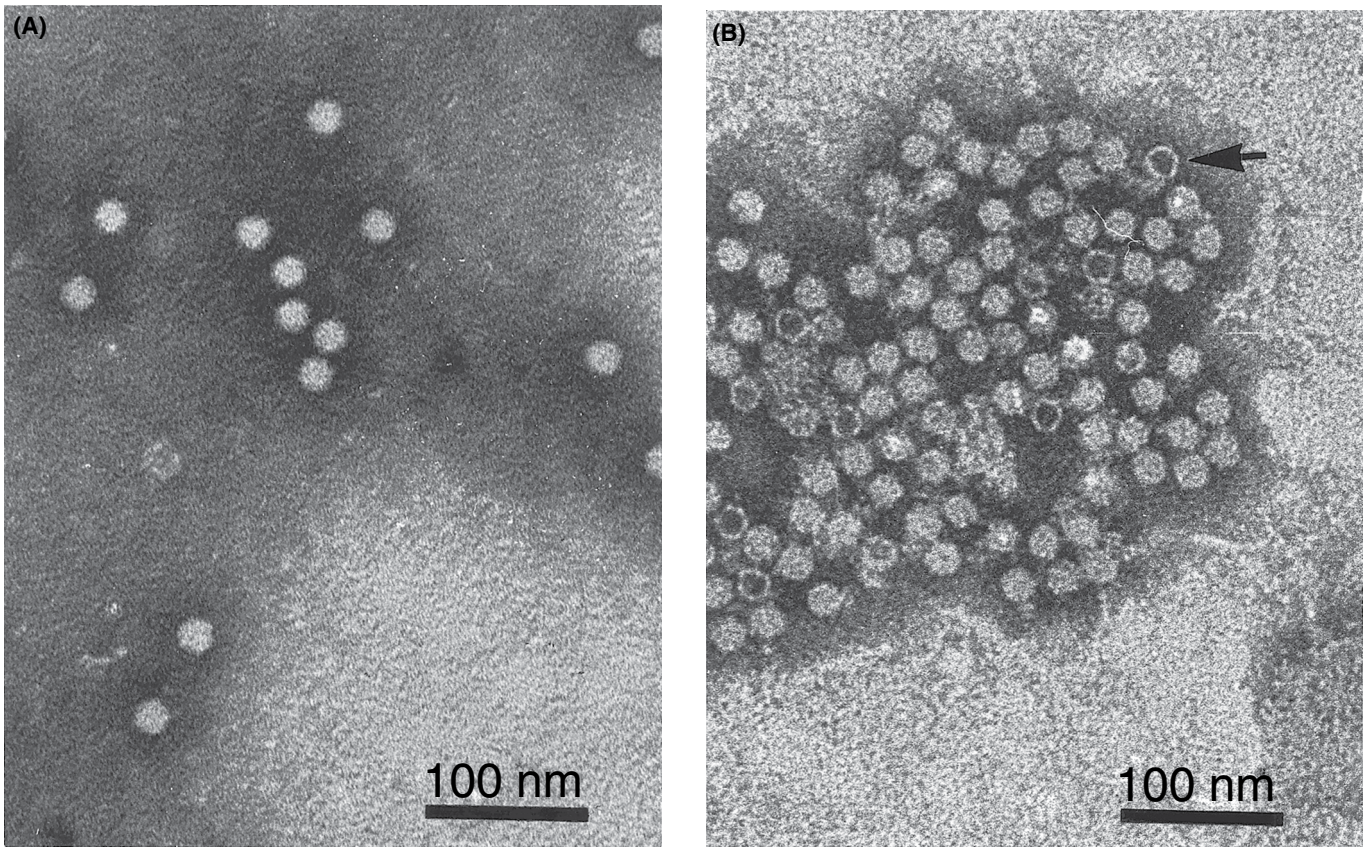

Figure 13.21. Electron micrograph of purified goose parvovirus. (A) Purified virions. (B) Virions in the feces of a naturally infected 10-day-old gosling showing intact and hollow particles (arrow).

GPV has been propagated in an embryonic goose fibroblast cell line (CGBQ) (64).

Pathobiology and Epidemiology

Incidence and Distribution

Waterfowl parvoviruses have been reported from all major goose and Muscovy duck farming countries of Europe and Asia (27). There have been reports of MDPV outbreaks in Muscovy ducks in the USA (63, 82) as well. SBDS of mule ducks has been reported from France, Poland, and Taiwan (55, 66, 79).

Natural and Experimental Hosts

Geese, Muscovy ducks, some hybrid breeds of duck, and some other members of the Anatidae family are the only species in which clinical disease has been observed (27, 67, 68). All breeds of domestic geese are susceptible. GPV can cause disease both in goslings and ducklings, whereas the antigenically distinct MDPV causes disease only in Muscovy ducks (21, 34). In a serological survey (29), some species of wild geese also tested positive for neutralizing antibody to GPV. Disease caused by GPV also has been reported in Canada geese (*Branta canadensis*) and snow geese (*Chen hypoborea atlantica*) as a consequence of accidental infection (68). The embryo-adapted virus given by parenteral route can infect young and adult Pekin ducks as well. Other breeds of domestic poultry appear refractory to experimental infection (25, 30).

Age of Host Commonly Affected

The diseases caused by waterfowl parvoviruses are strictly age dependent. In susceptible goslings and Muscovy ducklings less than 1 week of age, 100% mortality may occur. Losses decrease with age, reaching a negligible level when infection occurs in 5- to 6-week-old birds (15, 30, 34, 67). However, in birds with impaired immune systems, as a consequence of infection with immunosuppressive viruses (e.g., reovirus, circovirus) or due to nutritional (mycotoxins) and environmental factors, the infection may cause significant economic losses up to 6–10 weeks of age (12). Although older birds do not show clinical signs of infection, they respond immunologically (41).

Transmission, Carriers, Vectors

Infection of birds may occur both by vertical and horizontal routes. The most serious outbreaks occur in susceptible goslings following vertical transmission of the virus. In horizontal transmission, ingestion of virus-contaminated feed and water is of prime importance. Due to its high resistance to extreme physical and chemical effects (heat,

cold, dryness, disinfectants), the virus can remain infectious for long periods in the contaminated environment of animal houses. Birds that survive infection or those that are subclinically infected frequently become carriers and transmit the virus both horizontally and vertically. Latently infected breeders play an important role in the transmission of virus through their eggs to susceptible goslings or ducklings in the hatchery (8, 15, 67). Wild geese visiting the same pasture or water pond as domestic geese and Muscovy ducks also could be a source of infection and may play a role in the introduction of the infection to a disease-free country or flocks (33). No biological vectors have been identified.

Incubation Period

Infection of susceptible birds during the first week of life results in the appearance of clinical signs within 3–5 days. In 2- to 3-week-old birds, the incubation period may vary between 5 and 10 days (21, 30, 67). In general the older the birds at infection, the more time passes between infection and the appearance of clinical signs. In mule ducks the incubation period is considerably longer. Following infection of one-day-old mule ducklings, it can take 2–3 weeks before the characteristic signs of SBDS can be seen. (61).

Clinical Signs

Depending on the age and the immune status of goslings and Muscovy ducklings when infection occurs, the disease may be present in either acute, subacute, or chronic forms, representing multiple pathological features of the disease (11, 12, 15, 30, 31, 34, 67, 82). In the acute form, the course of the disease is usually rapid. The birds develop signs of illness with anorexia, polydipsia, weakness, and prostration, and die within a few days. Many birds show nasal and ocular discharge, conjunctivitis, profuse white diarrhea, and loss of natal down. Some of these birds have mucosal necrosis and a fibrinous pseudomembrane covering the tongue and oral cavity. In birds infected at an older age, between 1 and 3 weeks, the course of the disease can be either acute or a more prolonged. Deaths occur around 10 days post infection. In birds that survive the acute phase of the disease and in those that develop a more prolonged form of the disease as a consequence of infection at an older age, the clinical signs are characterized by reduced feed intake, profound growth retardation, and loss of feathers on the back and neck (Figure 13.22). Deaths may occur between the third and tenth weeks of age (12). In Muscovy ducks, locomotor problems including weakness, lateral recumbency, and inability to walk are usually evident.

In case of SBDS the main clinical signs are growth retardation, short beak (Figure 13.23), and the shortening of the leg bones, with a low morbidity rate. The heterogeneity within the flock due to the uneven growth is very significant. The age of mule ducks at infection influences the development of clinical signs; infection later than 3 weeks of age usually remains subclinical (61).

Figure 13.22. Gosling infected with GPV that survived the acute phase of the disease showing growth retardation and loss of feathers on the back and neck (natural case).

Figure 13.23. Mule duck infected with GPV at one day of age showing growth retardation and short beak characteristic of SBDS (experimental infection). For comparison, an uninfected duck of the same age is shown next to the diseased one.

Morbidity and Mortality

Infection in the hatcheries or at less than 1 week of age can result in 100% mortality in susceptible goslings and ducklings (15, 33, 67). Infection of susceptible birds during the first 2–3 weeks of life still results in almost 100% morbidity and high mortality (10%–60%). After that age, the level of morbidity and mortality decrease significantly with age. Goslings and ducklings over 4 weeks of age rarely show clinical signs; however, complicating factors such as poor management and concomitant viral infections causing immunosuppression may alter the course of the disease (43) and may extend the age of susceptibility leading to the "late form" of the disease (12).

Figure 13.24. Gross pathology of gosling got infected with GPV during the first week of life, showing enlarged and congested liver with fibrinous exudate on the surface, ascites, pale myocardium, and dilatation of heart (natural case).

The presence of maternally derived antibodies can considerably influence the course of the disease and consequently the rate of morbidity and mortality (30, 67).

Pathology

Gross Lesions

In acute cases, the lesions considered characteristic in geese include enlarged and congested liver with fibrinous exudate on the surface, pale myocardium, and dilatation of the heart. Typically, a serofibrinous perihepatitis with large volumes of straw-colored fluid in the abdominal cavity and pale dilated heart (Figure 13.24) are present (8, 11, 21, 67). In the acute enteric form of the disease, severe necrotic enteritis with diphtheritic lesion in the small intestine are the predominant postmortem findings (31). Diphtheritic and ulcerative lesions may be observed in the mouth and pharynx as well. In a more prolonged clinical course, the birds lose their feathers, especially on the back, neck, and wing, and have markedly reduced body weight (12).

In Muscovy ducks, the gross pathological lesions include pale thigh and heart muscles, increased pericardial fluid, serofibrinous perihepatitis, and ascites. In prolonged cases, the birds become stunted, have chronic congestion of liver, and ascites (20, 21, 34, 82).

Usually no gross lesions of the internal organs can be seen in SBDS (61). In a few cases, when the bird dies at a very young age following infection, fibrinous perihepatitis, hydropericardium, and ascites are observed (61).

Microscopic Lesions

Detailed descriptions of histopathological changes in the internal organs following GPV and MDPV infection have been reported by a number of researchers (3, 11, 21, 57, 58, 67). Both GPV and MDPV infection produce similar histological

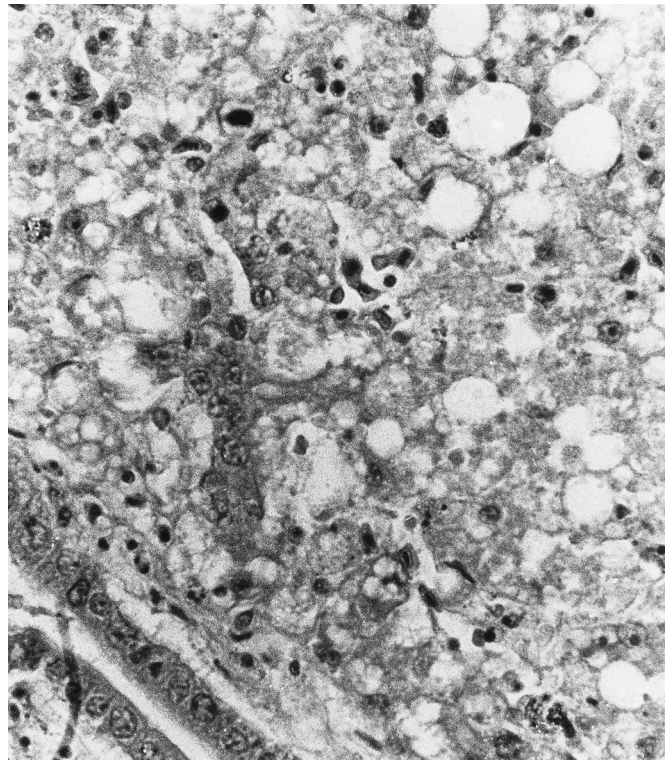

Figure 13.25. Liver section from a 10-day-old gosling infected with goose parvovirus showing widespread vacuolation and degeneration of hepatocytes.

lesions including extensive degenerative changes of myocardial cells, loss of striation of myocardial fibers, and the presence of scattered Cowdry type-A intranuclear inclusions. In liver, the predominant lesions are vacuolic degeneration of hepatocytes (Figure 13.25), multifocal single-cell necrosis, and occasional eosinophilic intranuclear inclusion bodies. In Muscovy ducklings, degeneration and necrosis of muscle fiber with lympho-histiocytic infiltration, together with mild sciatic neuritis and polioencephalomyelitis, are frequent findings (21, 82). The pathological features, however, vary depending on the clinical course of the disease.

In case of the predominantly enteric form of the disease, necrosis of intestinal epithelium, especially the crypt-lining epithelium, can be seen in the duodenum and proximal jejunum. Intranuclear inclusions may be found in the damaged epithelium cells (31).

Pathogenesis of the Infection Process

Detailed studies on the pathogenesis of waterfowl parvovirus are not available. The most accepted theory is that following infection, replication occurs in the intestinal wall. The virus enters the blood stream and reaches secondary target organs, including the liver and heart, where the most severe pathological changes occur (43). Another possibility is that the virus enters the blood stream through the nasopharyngeal lymphoid tissues and reaches the secondary target organs more rapidly (44). This latter theory is supported by recent

data obtained by quantification of GPV in different organs of experimentally infected goslings. GPV was first detected at 4 hours post infection in blood, heart, liver, spleen, kidney, and lymphoid organs, but not in any part of the gastrointestinal and respiratory system. From 8 hours to 9 days post infection, the virus was detected in all organs tested, with the highest amount in the liver, spleen, kidney, and lymphoid organs (84).

Immunity

Passive Immunity

In adult breeding geese and ducks that have been vaccinated or naturally infected with parvovirus, transfer of maternal antibody can occur via the egg yolk to their progeny (23, 30, 43). This passively acquired antibody may persist until about 2–3 weeks of age based on the starting level at hatch (22, 41).

Humoral Immunity

Following infection or vaccination, humoral immune response develops, which is characterized by the initial production of IgM and then IgY-type immunoglobulin (41). Using virus neutralization (VN) and agar gel precipitin (AGP) tests, high and persistent antibody level could be detected for several months after infection (23).

Cell-Mediated Immunity

Although much less is known about the role of cell-mediated immunity, it is not thought to play a significant role in immunity to waterfowl parvovirus.

Diagnosis

Isolation and Identification of the Causative Agent

Waterfowl parvovirus can be isolated from a variety of organs of affected animals using embryonated goose or Muscovy duck eggs or tissue cultures prepared from them (13, 24, 46, 69). 10- to 15-day-old embryonated goose or Muscovy duck eggs should be inoculated via the allantoic cavity. Embryo mortality occurs 5–10 days post inoculation with liver lesions and hemorrhages on the skin. Inoculation of goose or Muscovy duck embryo fibroblast cultures should be done before they reach confluency (46). The virus produces a well-defined cytopathic effect 3–5 days post infection, although several blind passages may be required before a detectable CPE is observed. In infected cultures Cowdry type-A intranuclear inclusions are often present (46). The presence of the virus can be confirmed by immune-staining or molecular methods.

Direct Detection of Viral Antigen

Immunofluorescence has been used to detect the presence of viral antigen in goslings, embryonated goose eggs, and infected cell cultures (1, 69). Flow cytometry assay has been used to detect virus-infected cells in the spleen (89). Other methods, including immunoperoxidase techniques, also have been developed (39, 65, 89).

Electron Microscopy

Electron microscopy (EM) and immune EM were used to detect parvovirus virions in the feces and organs of infected goslings as well as goose and duck embryos (1, 3).

Molecular Identification

Polymerase chain reaction (PCR) based methods have been developed for the detection and differentiation of waterfowl parvoviruses. Primers have been designed to amplify conserved regions of the capsid protein genes. Differentiation of GPV and DPV can be done by restriction fragment length polymorphism (RFLP) or nucleic acid sequencing, the latter being the most distinctive (5, 53, 63, 71, 77). Nucleotide sequence analysis of capsid protein genes of GPV allows the differentiation of vaccine and wild strains (70, 77, 78). Recently, a new loop-mediated isothermal amplification based method has been developed for simple, rapid detection of waterfowl parvoviruses, but this method cannot differentiate strains (36, 85). Real-time PCR method can be used for the detection and quantification of GPV in different organs (84).

Serology

Serology is useful for evaluating the immune status of breeding flocks and their progeny. It is widely used to confirm recent infection and determine the level of MDA in newly hatched birds.

A number of serological methods have been developed for detection of antibodies against GPV and DPV, including AGP, VN (22, 40) and plaque neutralization assay (74), ELISA using whole virus or recombinant antigens, and indirect fluorescent antibody test (39, 49, 76). Viral proteins expressed by *Escherichia coli* proved to be suitable antigens for western blotting or multiscreen western blotting assays (81). NS based serological tests may be used for differentiation of birds that have been vaccinated with subunit vaccines from those that are naturally infected (81).

Cross-reaction exists between GPV and DPV; depending on the serological method used it can detect antibodies against both viruses with varying sensitivity.

The VN test in embryonated goose or Muscovy duck eggs or primary fibroblast cell cultures is the most widely used method to detect the presence of antibodies (22, 24, 41). Cross neutralization tests can be used to differentiate between GPV and DPV antibodies (34).

The AGP test is less sensitive than the VN test and does not differentiate between antibodies against GPV and DPV, but is still a useful method for testing large numbers of sera for the presence of parvovirus antibodies (22, 24).

A number of ELISA have been developed to detect both GPV and DPV antibodies (34, 39, 88); however no commercial ELISA kit has reached the market.

Differential Diagnosis

GPV can be differentiated from DPV by using serological and molecular methods (5, 24, 34, 40, 86). Very few pathogens of geese and ducks exist that show the strict age-relatedness of waterfowl parvoviruses. These include duck virus enteritis, duck hepatitis, hemorrhagic nephritis enteritis of geese (HNEG), reovirus, adenovirus, circovirus, and Riemerella anatipestifer infections.

The herpesvirus of duck viral enteritis produces disease with high mortality in geese and ducks of all ages. Isolation and identification of the causal virus clearly differentiate it from parvoviruses. Duck hepatitis viruses also cause fatal diseases in ducks under the age of 6 weeks. However, these viruses are not pathogenic for geese or Muscovy ducks.

Hemorrhagic nephritis and enteritis of geese (HNEG) usually affects geese from 3 weeks of age; however, the virus can cause subclinical infection of ducks as well (9). Mortality ranges from a few percentage points to 50%–70%. On post mortem, apart from enteritis and nephritis, edema and hemorrhages of the subcutaneous connective tissue and hydropericardium and ascites can be seen (60). Diagnosis can be made on the basis of clinical signs and gross and histological lesions, and by the detection of HNEV with specific PCR (28, 60).

Reovirus diseases have been described in young, 2- to 6-week-old Muscovy duck and geese. The disease is characterized by splenitis with miliary necrotic foci during the acute phase and epicarditis, arthritis, and tenosynovitis during the subacute/chronic phase (56, 59).

Circovirus infection of geese and ducks may result in growth retardation and feathering disorders without causing significant mortality. Histopathological examination shows lymphocyte depletion, necrosis, and histiocytosis in the bursa of Fabricius. Globular or coarse granular inclusion bodies can be detected in the cells of bursa follicles (72, 73).

Recently an adenovirus infection causing hepatitis and hydropericardium in young (2–3 weeks old) geese was reported (32). The disease is characterized by the accumulation of clear fluid in the dilated pericardial sac and enlarged liver with multiple necrotic foci. Histologically, basophilic intranuclear inclusion bodies can be found in the liver cells around the necrotic foci.

Pasteurella anatipestifer also may cause high mortality in goslings and Muscovy ducklings. Treatment of birds with appropriate antibiotics and isolation of the etiologic agent in suitable media will enable differentiation from waterfowl parvovirus.

In most cases the course of the disease, clinical signs, and gross and histopathological lesions help to differentiate these diseases from those caused by waterfowl parvoviruses; however, in questionable cases molecular methods should be used to isolate and identify the causal agents (24).

Intervention Strategies

Management Procedures

Because outbreaks of waterfowl parvovirus are frequently attributed to transmission of the infection by congenitally infected birds during hatching, the practice of incubating and hatching eggs that have originated from different breeding flocks should be avoided. Only eggs from flocks with the same parvovirus status should be incubated together and good hatchery hygiene should be maintained. The practice of breeding from parent stocks that have survived the disease when young also should be discouraged, because these birds are potential carriers of the virus.

Vaccination Strategies

An optimal vaccination strategy must take into account the presence or absence of maternally derived (MDA) antibodies, their levels and heterogeneity within a flock, and the susceptible period of goslings and ducklings to the disease.

Breeder geese and Muscovy ducks that have been naturally infected or vaccinated transfer MDA to their progeny, which may persist until 2 to 4 weeks of age depending on the antibody levels of individual birds at hatch. Because the disease is confined to young age, control measures have been aimed at providing adequate immunity during the first 6 to 8 weeks of life. To achieve this, different methods have been applied during the last three decades. These include: passive immunization of newly hatched birds with convalescence or hyperimmune serum and the use of attenuated vaccine alone or in combination with an inactivated one for the active immunization of both adult and young animals.

Historically, hyperimmune or convalescence serum injected subcutaneously in day-old goslings was used to avoid heavy losses in flocks exposed to a parvovirus-contaminated environment (15, 30). This technique was effective but presented the risk of carrying over undetected infectious agents by the contaminated serum. Currently, prophylaxis based on vaccination is the preferred choice.

Live vaccines containing attenuated goose parvovirus can stimulate rapid immune response and protection in MDA-free birds (6, 16, 26, 35, 38, 47, 54, 83). MDA, even at a very low level, can neutralize the live vaccine, thus preventing from stimulating immune responses. Inactivated vaccines containing the whole parvovirus antigens, either in the monovalent (GPV) or bivalent (GPV and MDPV) forms, also have been developed (35, 62, 75). The disadvantage of the inactivated vaccine is the relatively slow immune response.

Immunization of breeders has two objectives: (1) protection of breeders from infection, and thus prevention of virus transmission to the progenies, and (b) supplying the progenies with passive immunity. An optimal vaccination strategy must protect goslings and ducklings against both the early and the late forms of the disease. Therefore, knowing the level of MDA in the day-old birds is fundamental to establishing an adequate vaccination strategy. In order to extend the protection after MDA declines to non-protective levels, the vaccination of goslings and ducklings around 1–2 weeks of age is essential to stimulate active immunity in face of still persisting maternal antibodies. This can be achieved only by the use of inactivated vaccine with high antigen content.

Future Developments

Recombinant subunit vaccines have been developed both from GPV and DPV using the baculovirus expression system (37, 45, 51). The structural protein(s) expressed were able to self-assemble into virus-like particles (VLP). Vaccines formulated from these VLPs in oil emulsion proved to be comparable to inactivated whole virus containing vaccines based on immunogenicity in young Muscovy ducks(51) or geese (37). Protection of the progeny from early infection with GPV after vaccination of goose and Muscovy duck breeders with adjuvanted VLP vaccine also has been demonstrated (45, 51).

Acknowledgement

Grateful acknowledgment is made to Dr. Richard E, Gough, the author of previous chapters, for his contributions included in this text.

References

Introduction

1. Austin, R.J., T.L. Whiting, R.A. Anderson, and M.A. Drebot. 2004. An outbreak of West Nile virus-associated disease in domestic geese (*Anser anser domesticus*) upon initial introduction to a geographic region, with evidence of bird to bird transmission. *Can Vet J.* 45:117–123.
2. Ball, N.W., J.A. Smyth, J.H. Weston, B.J. Borghmans, V. Palya, R. Glavits, E. Ivanics, A. Dan, and D. Todd. 2004. Diagnosis of goose circovirus infection in Hungarian geese samples using polymerase chain reaction and dot blot hybridization tests. *Avian Pathol.* 33:51–58.
3. Banda, A., R. Galloway-Haskins, T. Sandhu, and K.A. Schat. 2006. Detection by PCR and nucleotide sequence analysis of duck circovirus detected in Pekin ducks in the United States. In: Convention Notes, AAAP/AVMA. Honolulu, HI, AAAP.
4. Banet-Noach, C., L. Simanov, and M. Malkinson. 2003. Direct (non-vector) transmission of West Nile virus in geese. *Avian Pathol.* 32:489–494.
5. Banyai, K., V. Palya, M. Benko, J. Bene, V. Havasi, B. Melegh, and G. Szucs. 2005. The goose reovirus genome segment encoding the minor outer capsid protein, sigma1/sigmaC, is bicistronic and shares structural similarities with its counterpart in Muscovy duck reovirus. *Virus Genes.* 31:285–291.
6. Bennett, R.S., R. LaRue, D. Shaw, Q. Yu, K.V. Nagaraja, D.A. Halvorson, and M.K. Njenga. 2005. A wild goose metapneumovirus containing a large attachment glycoprotein is avirulent but immunoprotective in domestic turkeys. *J Virol.* 79:14834–14842.
7. Bennett, R.S., B. McComb, H.J. Shin, M.K. Njenga, K.V. Nagaraja, and D.A. Halvorson. 2002. Detection of avian pneumovirus in wild Canada (*Branta canadensis*) and blue-winged teal (*Anas discors*) geese. *Avian Dis.* 46:1025–1029.
8. Berthet, F.X., H.G. Zeller, M.T. Drouet, J. Rauzier, J.P. Digoutte, and V. Deubel. 1997. Extensive nucleotide changes and deletions within the envelope glycoprotein gene of Euro-African West Nile viruses. *J Gen Virol.* 78:2293–2297.
9. Bidin, M., I. Lojkic, Z. Bidin, M. Tisljar, D. Majnaric, and M. Mikec. 2011. Detection and characterization of avian nephritis virus in ducklings. *Avian Pathol.* 40:173–177.
10. Bolte, A.L., W. Lutz, and E.F. Kaleta. 2000. Investigation of the occurrence of infective agents among free living gray geese (*Anser anser* Linne, 1758). *Zeitschrift fuer Jagdwissenschaft.* 46:176–179.
11. Bolte, A.L., W. Lutz, and E.F. Kaleta. 1997. Investigations on the occurrence of ortho- and paramyxovirus infections among free living Greylag Geese (*Anser anser* Linne, 1758). *Zeitschrift fuer Jagdwissenschaft.* 43:48–55.
12. Bouquet, J.F., Y. Moreau, J.B. McFerran, and T.J. Connor. 1982. Isolation and characterisation of an adenovirus isolated from Muscovy ducks. *Avian Pathol.* 11:301–307.
13. Calle, P.P., G.V. Ludwig, J.F. Smith, B.L. Raphael, T.L. Clippinger, E.M. Rush, T. McNamarra, R. Manduca, M. Linn, M.J. Turell, R.J. Schoepp, T. Larsen, J. Mangiafico, K.E. Steele, and R.A. Cook. 2000. Clinical aspects of West Nile virus infection in a zoological collection. In: American Association of Zoo Veterinarians and International Association for Aquatic Animal Medicine Joint Conference, C.S. Baer and R.A. Patterson, eds. New Orleans, LA. 92–96.
14. Capua, I., R. De Nardi, M.S. Beato, C. Terregino, M. Scremin, and V. Guberti. 2004. Isolation of an avian paramyxovirus type 9 from migratory waterfowl in Italy. *Vet Rec.* 155:156.
15. Chang, P.C., M.L. Hsieh, J.H. Shien, D.A. Graham, M.S. Lee, and H.K. Shieh. 2001. Complete nucleotide sequence of avian paramyxovirus type 6 isolated from ducks. *J Gen Virol.* 82:2157–2168.
16. Chen, C.-L., P.-X. Wang, M.-S. Lee, J.-H. Shien, H.K. Shieh, S.-J. Ou, C.-H. Chen, and P.-C. Chang. 2006. Development of a polymerase chain reaction procedure for detection and differentiation of duck and goose circovirus. *Avian Dis.* 50:92–95.
17. Chen, H., G.J. Smith, S.Y. Zhang, K. Qin, J. Wang, K.S. Li, R.G. Webster, J.S. Peiris, and Y. Guan. 2005. Avian flu: H5N1 virus outbreak in migratory waterfowl. *Nature.* 436:191–192.
18. Chen, S., A. Cheng, M. Wang, D. Zhu, Q. Luo, F. Liu, and X. Chen. 2009. Immunohistochemical detection and localization of new type gosling viral enteritis virus in paraformaldehyde-fixed paraffin-embedded tissue. *Vet Immunol Immunopathol.* 130:226–235.
19. Chen, S., A.C. Cheng, and M.S. Wang. 2008. Morphologic observations of new type gosling viral enteritis virus (NGVEV) virulent isolate in infected duck embryo fibroblasts. *Avian Dis.* 52:173–178.
20. Chen, S., A.C. Cheng, M.S. Wang, D.K. Zhu, R.Y. Jia, Q.H. Luo, H.M. Cui, Y. Zhou, Y. Wang, Z.W. Xu, Z.L. Chen, X.Y. Chen, and X.Y. Wang. 2010. Histopathology, immunohistochemistry, *in situ* apoptosis, and ultrastructure characterization of the digestive and lymphoid organs of new type gosling viral enteritis virus experimentally infected gosling. *Poult Sci.* 89:668–680.
21. Cheng, A.C., M.S. Wang, X.Y. Chen, Y.F. Guo, Z.Y. Liu, and P.F. Fang. 2001. Pathogenic and pathological characteristic of new type gosling viral enteritis first observed in China. *World J Gastroenterol.* 7:678–684.
22. Delnatte P., C. Berkvens, M. Kummrow, D.A. Smith, D. Campbell, G. Crawshaw, D. Ojkic, and J. DeLay. 2011. New genotype of avian bornavirus in wild geese and trumpeter swans in Canada. *Vet Rec.* 169:108.

23. Ellis, T.M., R.B. Bousfield, L.A. Bissett, K.C. Dyrting, G.S. Luk, S.T. Tsim, K. Sturm-Ramirez, R.G. Webster, Y. Guan, and J.S. Malik Peiris. 2004. Investigation of outbreaks of highly pathogenic H5N1 avian influenza in waterfowl and wild birds in Hong Kong in late 2002. *Avian Pathol.* 33:492–505.
24. Fringuelli, E., A.N. Scott, A. Beckett, J. McKillen, J.A. Smyth, V. Palya, R. Glavits, E. Ivanics, A. Mankertz, M.P. Franciosini, and D. Todd. 2005. Diagnosis of duck circovirus infections by conventional and real-time polymerase chain reaction tests. *Avian Pathol.* 34:495–500.
25. Fu, G., S. Shi, Y. Huang, L. Cheng, C. Peng, C. Wan, H. Chen, F. Lin, and J. Lin. 2011. Genetic diversity and genotype analysis of duck circovirus. *Avian Dis.* 55:311–318.
26. Glavits, R., E. Ferenczi, E. Ivanics, T. Bakonyi, T. Mato, P. Zarka, and V. Palya. 2005. Co-occurrence of West Nile Fever and circovirus infection in a goose flock in Hungary. *Avian Pathol.* 34:408–414.
27. Goekjian, V.H., J.T. Smith, D.L. Howell, D.A. Senne, D.E. Swayne, and D.E. Stallknecht. 2011. Avian influenza viruses and avian paramyxoviruses in wintering and breeding waterfowl populations in North Carolina, USA. *J Wildl Dis.* 47:240–245.
28. Gough, R.E. 2003. Avian pneumoviruses. In: *Diseases of Poultry*, 11th ed. Y.M. Saif, H.J. Barnes, J.R. Glisson, A.M. Fadly, L.R. McDougald, and D.E. Swayne, eds. Iowa State Press, Ames, IA. 92–99.
29. Gough, R.E., and W.R. Hansen. 2000. Characterization of a herpesvirus isolated from domestic geese in Australia. *Avian Pathol.* 29:417–422.
30. Graves, I.L. 1996. Newcastle disease viruses in birds in the Atlantic flyway: Isolations, haemagglutination-inhibition and elution-inhibition antibody profiles. *Vet Res.* 27:209–218.
31. Guérin, J.-L., J. Gelfi, L. Dubois, A. Vuillaume, C. Boucraut-Baralon, and J.-L. Pingret. 2000. A novel polyomavirus (goose hemorrhagic polyomavirus) is the agent of hemorrhagic nephritis enteritis of geese. *J Virol.* 74:4523–4529.
32. Hanson, B.A., D.E. Swayne, D.A. Senne, D.S. Lobpries, J. Hurst, and D.E. Stallknecht. 2005. Avian influenza viruses and paramyxoviruses in wintering and resident ducks in Texas. *J Wildl Dis.* 41:624–628.
33. Hattermann, K., C. Schmitt, D. Soike, and A. Mankertz. 2003. Cloning and sequencing of Duck circovirus (DuCV). *Arch Virol.* 148:2471–2480.
34. Heffels-Redmann, U., H. Mueller, and E.F. Kaleta. 1992. Structural and biological characteristics of reoviruses isolated from Muscovy ducks Cairina-Moschata. *Avian Pathol.* 21:481–491.
35. Hlinak, A., T. Mueller, M. Kramer, R.U. Muehle, H. Liebherr, and K. Ziedler. 1998. Serological survey of viral pathogens in bean and white-fronted geese from Germany. *J Wildl Dis.* 34:479–486.
36. Hlinak, A., R.U. Muhle, O. Werner, A. Globig, E. Starick, H. Schirrmeier, B. Hoffmann, A. Engelhardt, D. Hubner, F.J. Conraths, D. Wallschlager, H. Kruckenberg, and T. Muller. 2006. A virological survey in migrating waders and other waterfowl in one of the most important resting sites of Germany. *J Vet Med B Infect Dis Vet Public Health.* 53:105–110.
37. Hollmen, T., J.C. Franson, M. Kilpi, D.E. Docherty, W.R. Hansen, and M. Hario. 2002. Isolation and characterization of a reovirus from common eiders (*Somateria mollissima*) from Finland. *Avian Dis.* 46:478–484.
38. Hollmen, T.E., J.C. Franson, P.L. Flint, J.B. Grand, R.B. Lanctot, D.E. Docherty, and H.M. Wilson. 2003. An adenovirus linked to mortality and disease in long-tailed ducks (*Clangula hyemalis*) in Alaska. *Avian Dis.* 47:1434–1440.
39. Hollmen, T.E., J.C. Franson, M. Kilpi, D.E. Docherty, and V. Myllys. 2003. An adenovirus associated with intestinal impaction and mortality of male common eiders (*Somateria mollissima*) in the Baltic Sea. *J Wildl Dis.* 39:114–120.
40. Hulse-Post, D.J., K.M. Sturm-Ramirez, J. Humberd, P. Seiler, E.A. Govorkova, S. Krauss, C. Scholtissek, P. Puthavathana, C. Buranathai, T.D. Nguyen, H.T. Long, T.S. Naipospos, H. Chen, T.M. Ellis, Y. Guan, J.S. Peiris, and R.G. Webster. 2005. Role of domestic ducks in the propagation and biological evolution of highly pathogenic H5N1 influenza viruses in Asia. *Proc Natl Acad Sci USA*. 102:10682–10687. Epub 12005 Jul 10619.
41. ICTV. 2006. Adenoviridae. http://ictvdb.bio-mirror.cn/Ictv/fs_adeno.htm.
42. Ivanics, E., V. Palya, R. Glavits, A. Dan, V. Palfi, T. Revesz, and M. Benko. 2001. The role of egg drop syndrome virus in acute respiratory disease of goslings. *Avian Pathol.* 30:201–208.
43. Jarvi, S.I., M.M. Lieberman, E. Hofmeister, V.R. Nerurkar, T. Wong, and C. Weeks-Levy. 2008. Protective efficacy of a recombinant subunit West Nile virus vaccine in domestic geese (*Anser anser*). *Vaccine* 26:5338–5344.
44. Jestin, V., D. Toquin, M.O. Le Bras, and N. Amenna. 2000. The new duck pneumovirus: Experimental assessment of the pathogenicity for the respiratory tract of Muscovy ducklings. In: 5th International Congress of the European Society for Veterinary Virology. Brescia, Italy. 341–342.
45. Jinding, C., L. Ming, R. Tao, and X. Chaoan. 2005. A goose-sourced paramyxovirus isolated from southern China. *Avian Dis.* 49:170–173.
46. Kaschula, V.R. 1950. A new virus disease of the Muscovy duck [*Cairina moschata* (Linn)] present in Natal. *J S Afr Vet Med Assoc.* 21:18–26.
47. Ketterer, P.J., B.J. Rodwell, H.A. Westbury, P.T. Hooper, A.R. Mackenzie, J.G. Dingle, and H.C. Prior. 1990. Disease of geese caused by a new herpesvirus. *Austral Vet J.* 67:446–448.
48. Komar, N. 2000. West Nile viral encephalitis. *Rev Sci Tech OIE.* 19:166–176.
49. Lanciotti, R.S., J.T. Roehrig, V. Deubel, J. Smith, M. Parker, K. Steele, B. Crise, K.E. Volpe, M.B. Crabtree, J.H. Scherret, R.A. Hall, J.S. MacKenzie, C.B. Cropp, B. Panigrahy, E. Ostlund, B. Schmitt, M. Malkinson, C. Banet, J. Weissman, N. Komar, H.M. Savage, W. Stone, T. McNamara, and D.J. Gubler. 1999. Origin of the West Nile virus responsible for an outbreak of encephalitis in the northeastern United States. *Science.* 286:2333–2337.
50. Le Gall-Recule, G., M. Cherbonnel, C. Arnauld, P. Blanchard, A. Jestin, and V. Jestin. 1999. Molecular characterization and expression of the S3 gene of muscovy duck reovirus strain 89026. *J Gen Virol.* 80:195–203.
51. Li, C., C. Shen, A. Cheng, M. Wang, N. Zhang, Y. Zhou, D. Zhu, R. Jia, Q. Luo, and X. Chen. 2010. Development and application of an indirect immunoperoxidase assay for the detection of Duck swollen head hemorrhagic disease virus antigen in Pekin ducks (*Anas platyrhynchos*). *J Vet Diagn Invest.* 22:10–19.
52. Liu, M., X. Chen, Y. Wang, Y. Zhang, Y. Li, N. Shen, and H. Chen. 2010. Characterization of monoclonal antibodies against Muscovy duck reovirus sigmaB protein. *Virol J.* 7:133.
53. Liu, Q., G. Zhang, Y. Huang, G. Ren, L. Chen, J. Gao, D. Zhang, B. Han, W. Su, J. Zhao, X. Hu, and J. Su. 2011. Isolation and

characterization of a reovirus causing spleen necrosis in Pekin ducklings. *Vet Microbiol.* 148:200–206.
54. Liu, S.N., X.X. Zhang, J.F. Zou, Z.J. Xie, Y.L. Zhu, Q. Zhao, E.M. Zhou, and S.J. Jiang. 2010. Development of an indirect ELISA for the detection of duck circovirus infection in duck flocks. *Vet Microbiol.* 145:41–46.
55. Liu, X., X. Wang, S. Wu, S. Hu, Y. Peng, and F. Xue. 2009. Surveillance for avirulent Newcastle disease viruses in domestic ducks (*Anas platyrhynchos* and *Cairina moschata*) at live bird markets in Eastern China and characterization of the viruses isolated. *Avian Pathol.* 38:377–391.
56. Malkinson, M., C. Banet, and Y. Weisman. 2000. West Nile fever—a reemerging zoonosis. In: 49th Western Poultry Disease Conference. Sacramento, CA. 24–25.
57. Malkinson, M., K. Perk, and Y. Weisman. 1981. Reovirus infection of young Muscovy ducks. *Avian Pathol.* 10:433–440.
58. Marius-Jestin, V., M. Lagadic, Y. Le Menec, and G. Bennejean. 1988. Histological data associated with Muscovy duck reovirus infection. *Vet Rec.* 123:32–33.
59. McComb, B., R. Bennett, H.J. Shin, K.V. Nagaraja, F.J. Jirjis, and D.A. Halvorson. 2001. Wild waterfowl as a source of avain pneumovirus (APV) infection in domestic poultry. In: 50th Western Poultry Disease Conference. Davis, CA. 76–77.
60. McFerran, J.B., T.J. Connor, and R.M. McCracken. 1976. Isolation of adenoviruses and reoviruses from avian species other than domestic fowl. *Avian Dis.* 20:519–524.
61. Mueller, T., A. Hlinak, R.U. Muehle, M. Kramer, H. Liebherr, K. Ziedler, and D.U. Pfeiffer. 1999. A descriptive analysis of the potential association between migration patterns of bean and white-fronted geese and the occurrence of Newcastle disease outbreaks in domestic birds. *Avian Dis.* 43:315–319.
62. Nagaraja, K.V., H.J. Shin, M. Njenga, D. Shaw, and D.A. Halvorson. 2001. Host range and epidemiology of avian pneumovirus infection. In: 50th Western Poultry Disease Conference. Davis, CA. 80–81.
63. Office International des Epizooties. 1999. West Nile fever in Israel: in geese. *Dis Inform.* 12:166–167.
64. Office International des Epizooties. 2000. West Nile fever in the United States of America. *Dis Inform.* 13.
65. Palya, V., R. Glavits, M. Dobos-Kovacs, E. Ivanics, E. Nagy, K. Banyai, G. Reuter, G. Szucs, A. Dan, and M. Benko. 2003. Reovirus identified as cause of disease in young geese. *Avian Pathol.* 32:129–138.
66. Payne S., L. Covaleda, G. Jianhua, S. Swafford, J. Baroch, P.J. Ferro, B. Lupiani, J. Heatley, and I. Tizard. 2011. Detection and characterization of a distinct bornavirus lineage from healthy Canada geese (*Branta canadensis*). *J Virol.* 85:12053–12056.
67. Pringle, C.R. 1998. Virus taxonomy—San Diego 1998. *Arch Virol.* 143:1449–1459.
68. Roy, P., A.T. Venugopalan, and R. Manvell. 2000. Characterization of Newcastle disease viruses isolated from chickens and ducks in Tamilnadu, India. *Vet Res Comm.* 24:135–142.
69. Saito, M., Y. Osa, and M. Asakawa. 2009. Antibodies to flaviviruses in wild ducks captured in Hokkaido, Japan: risk assessment of invasive flaviviruses. *Vector Borne Zoonotic Dis.* 9:253–258.
70. Savage, H.M., C. Ceianu, G. Nicolescu, N. Karabatsos, R. Lanciotti, A. Vladimirescu, L. Laiv, A. Ungureanu, C. Romanca, and T.F. Tsai. 1999. Entomologic and avian investigations of an epidemic of West Nile fever in Romania in 1996, with serologic and molecular characterization of a virus isolate from mosquitoes. *Amer J Trop Med Hyg.* 61:600–611.
71. Seal, B.S. 2000. Avian pneumoviruses and emergence of a new type in the United States of America. *Anim Health Res Rev.* 1:67–72.
72. Seal, B.S., M.G. Wise, J.C. Pedersen, D.A. Senne, R. Alvarez, M.S. Scott, D.J. King, Q. Yu, and D.R. Kapczynski. 2005. Genomic sequences of low-virulence avian paramyxovirus-1 (Newcastle disease virus) isolates obtained from live-bird markets in North America not related to commonly utilized commercial vaccine strains. *Vet Microbiol.* 106:7–16.
73. Senne, D.A., R.K. Edson, J.C. Pederson, and B. Panigrahy. 1997. Avian pneumovirus update. In: 134th American Association of Avian Pathologists/American Veterinary Medical Association. Reno, NV. 190.
74. Shi, S.H., Y. Huang, S.J. Cui, L.F. Cheng, G.H. Fu, X. Li, Z. Chen, C.X. Peng, F. Lin, J.S. Lin, and J.L. Su. 2011. Genomic sequence of an avian paramyxovirus type 1 strain isolated from Muscovy duck (*Cairina moschata*) in China. *Arch Virol.* 156:405–412.
75. Shihmanter, E., Y. Weisman, R. Manwell, D. Alexander, and M. Lipkind. 1997. Mixed paramyxovirus infection of wild and domestic birds in Israel. *Vet Microbiol.* 58:73–78.
76. Shin, H.J., K.V. Nagaraja, B. McComb, D.A. Halvorson, F.F. Jirjis, D.P. Shaw, B.S. Seal, and M.K. Njenga. 2002. Isolation of avian pneumovirus from mallard ducks that is genetically similar to viruses isolated from neighboring commercial turkeys. *Virus Res.* 83:207–212.
77. Shin, H.J., M.K. Njenga, D.A. Halvorson, D.P. Shaw, and K.V. Nagaraja. 2001. Susceptibility of ducks to avian pneumovirus of turkey origin. *Am J Vet Res.* 62:991–994.
78. Shin, H.J., M.K. Njenga, B. McComb, D.A. Halvorson, and K.V. Nagaraja. 2000. Avian pneumovirus (APV) RNA from wild and sentinel birds in the United States has genetic homology with RNA from APV isolates from domestic turkeys. *J Clin Microbiol.* 38:4282–4284.
79. Smyth, J., D. Soike, D. Moffett, J.H. Weston, and D. Todd. 2005. Circovirus-infected geese studied by *in situ* hybridization. *Avian Pathol.* 34:227–232.
80. Smyth, J.A., and M.S. McNulty. 1994. A transmissible disease of the bursa of Fabricius of ducks. *Avian Pathol.* 23:447–460.
81. Soike, D., K. Albrecht, K. Hattermann, C. Schmitt, and A. Mankertz. 2004. Novel circovirus in mulard ducks with developmental and feathering disorders. *Vet Rec.* 154:792–793.
82. Soike, D., B. Koehler, and K. Albrecht. 1999. A circovirus-like infection in geese related to a runting syndrome. *Avian Pathol.* 28:199–202.
83. Steele, K.E., M.J. Linn, R.J. Schoepp, N. Komar, T.W. Geisbert, R.M. Manduca, P.P. Calle, B.L. Raphael, T.L. Clippinger, T. Larsen, J. Smith, R.S. Lanciotti, N.A. Panella, and T.S. McNamara. 2000. Pathology of fatal West Nile virus infections in native and exotic birds during the 1999 outbreak in New York City, New York. *Vet Pathol.* 37:208–224.
84. Sturm-Ramirez, K.M., D.J. Hulse-Post, E.A. Govorkova, J. Humberd, P. Seiler, P. Puthavathana, C. Buranathai, T.D. Nguyen, A. Chaisingh, H.T. Long, T.S. Naipospos, H. Chen, T.M. Ellis, Y. Guan, J.S. Peiris, and R.G. Webster. 2005. Are ducks contributing to the endemicity of highly pathogenic H5N1 influenza virus in Asia? *J Virol.* 79:11269–11279.
85. Su, J., S. Li, X. Hu, X. Yu, Y. Wang, P. Liu, X. Lu, G. Zhang, D. Liu, X. Li, W. Su, H. Lu, N.S. Mok, P. Wang, M. Wang, K. Tian, and G.F. Gao. 2011. Duck egg-drop syndrome caused by BYD virus, a new Tembusu-related flavivirus. *PLoS One.* 6:e18106.

86. Swayne, D.E., J.R. Beck, C.S. Smith, W.J. Shieh, and S.R. Zaki. 2001. Fatal encephalitis and myocarditis in young domestic geese (*Anser anser domesticus*) caused by West Nile virus. *Emerg Inf Dis.* 7(4):751–3.
87. Swayne, D.E., and D.A. Halvorson. 2003. Influenza. In: *Diseases of Poultry*, 12th ed. Y.M. Saif, A.M. Fadly, J.R. Glisson, L.R. McDougald, L.K. Nolan, and D.E. Swayne, eds. Iowa State Press. Ames, Iowa. 153–184.
88. Swayne, D.E., and D.L. Suarez. 2000. Highly pathogenic avian influenza. *Rev Sci Tech OIE.* 19:463–482.
89. Toquin, D., M.H. Bayon-Auboyer, N. Eterradossi and V. Jestin. 1999. Isolation of a pneumovirus from a Muscovy duck. *Vet Rec.* 145:680.
90. Toquin, D., O. Guionie, V. Jestin, F. Zwingelstein, C. Allee, and N. Eterradossi. 2006. European and American subgroup C isolates of avian metapneumovirus belong to different genetic lineages. *Virus Genes.* 32:97–103.
91. Tsai, H.-J., M.-J. Pan, and Y.-K. Liao. 1999. A serological survey of ducks, geese, pigeons and cows for antibodies to Japanese B encephalitis virus in Taiwan. *J Chin Soc Vet Sci.* 25:104–112.
92. Turpin, E.A., D.E. Stallknecht, R.D. Slemons, L. Zsak, and D.E. Swayne. 2008. Evidence of avian metapneumovirus subtype C infection of wild birds in Georgia, South Carolina, Arkansas and Ohio, USA. *Avian Pathol.* 37:343–351.
93. Wang, D., X. Xie, D. Zhang, G. Ma, and X. Wang. 2011. Detection of duck circovirus in China: A proposal on genotype classification. *Vet Microbiol.* 147:410–415.
94. Woolcock, P.R., V. Jestin, H.L. Shivaprasad, F. Zwingelstein, C. Arnauld, M.D. McFarland, J.C. Pedersen, and D.A. Senne. 2000. Evidence of Muscovy duck parvovirus in Muscovy ducklings in California. *Vet Rec.* 146:68–72.
95. Yeh, J.Y., J.Y. Park, and E.N. Ostlund. 2011. Serologic evidence of West Nile virus in wild ducks captured in major inland resting sites for migratory waterfowl in South Korea. *Vet Microbiol.* 154(1–2):96–103.
96. Zou, J., S. Shan, N. Yao, and Z. Gong. 2005. Complete genome sequence and biological characterizations of a novel goose paramyxovirus-SF02 isolated in China. *Virus Genes.* 30:13–21.

Duck Hepatitis

1. Adamiker, D. 1970. Die Virushepatitis der EntenkUken im elektronenmikroskopischen Bild. Teil II: Befunde an der Milz und am Muskel. *Zentralbl Veterinaermed. (B)* 17:880–889.
2. Adamiker, D. 1969. Elektronenmikroskopische Untersuchungen zur Virushepatitis der EntenUken. *Zentralbl Veterinaermed. (B)* 16:620–636.
3. Ahmed, A.A., Y.Z. El-Abdin, S. Hamza, and F.E. Saad. 1975. Effect of experimental duck virus hepatitis infection on some biochemical constituents and enzymes in the serum of white Pekin ducklings. *Avian Dis.* 19:305–310.
4. Akulov, A.V., L.M. Kontrimavichus, and A.D. Maiboroda. 1972. [Sensitivity of geese to duck hepatitis virus]. *Veterinariia*. 48(3):47.
5. Asplin, F.D. 1958. An attenuated strain of duck hepatitis virus. *Vet Rec.* 70:1226–1230.
6. Asplin, F.D. 1965. Duck hepatitis: vaccination against two serological types. *Vet Rec.* 77:1529–1530.
7. Asplin, F.D. 1970. Examination of sera from wildfowl for antibodies against the viruses of duck plague, duck hepatitis and duck influenza. *Vet Rec.* 87:182–183.
8. Asplin, F.D. 1961. Notes on epidemiology and vaccination for virus hepatitis of ducks. *Off Int Epizoot Bull.* 56:793–800.
9. Balla, L., and T. Veress. 1984. Immunization experiments with a duck virus hepatitis vaccine. I Antibody response of ducklings of different immune status after subcutaneous, oral and aerosol vaccination. *Magy Allatorv Lapja*. 39:395–400.
10. Balla, L., T. Veress, E. Horvath, and G. Hegedus. 1984. Immunization experiments with a duck virus hepatitis vaccine. II. Efficacy of vaccination by drinking water in large duckling flocks. *Magy Allatorv Lapja.* 39:401–404.
11. Bezrukavaya, I.J. 1978. Vaccine against duck virus hepatitis from strain ZM. *Sborn Rab Puti Ob Vet Blago Prom Zivot (Kiev)*. 90–95 (Landwirtsch Zentralbl Abt IV 1981, p. 1061).
12. Buynitzky, S.J., G.J. Tritz, and W.L. Ragland. 1977. Correlation of induced drug metabolism with titer of duck hepatitis virus in chickens. *Res Commun Chem Pathol Pharmacol.* 17:275–282.
13. Buynitzky, S.J., G.O. Ware, and W.L. Ragland. 1978. Effect of viral infection on drug metabolism and pesticide disposition in ducks. *Toxicol Appl Pharmacol.* 46:267–278.
14. Calnek, B.W. 1993. Duck virus hepatitis. In: *Virus infections of Birds*, Vol. 4. J.B. McFerran and M.S. McNulty, eds. Elsevier Science Publishers B. V., Amsterdam. 485–495.
15. Calnek, B.W. 1988. Personal communication.
16. Chalmers, W.S., H. Farmer, and P.R. Woolcock. 1985. Duck hepatitis virus and Chlamydia psittaci outbreak (letter). *Vet Rec.* 116:223.
17. Chalmers, W.S.K., and P.R. Woolcock. 1984. The effect of animal sera on duck hepatitis virus. *Avian Pathol.* 13:727–732.
18. Chang, S.-F., H.J. Netter, M. Bruns, R. Schneider, K. Froelich, and H. Will. 1999. A new avian hepadnavirus infecting snow geese (*Anser caerulescens*) produces a significant fraction of virions containing single-stranded DNA. *Virology.* 262:39–54.
19. Cheng, A., M. Wang, H. Xin, D. Zhu, X. Li, H. Chen, R. Jia, and M. Yang. 2009. Development and application of a reverse transcriptase polymerase chain reaction to detect Chinese isolates of duck hepatitis virus type 1. *J Microbiol Methods.* 77:1–5.
20. Crighton, G.W., and P.R. Woolcock. 1978. Active immunisation of ducklings against duck virus hepatitis. *Vet Rec.* 102:358–361.
21. Davis, D. 1987. Temperature and pH stability of duck hepatitis virus. *Avian Pathol.* 16:21–30.
22. Davis, D. 1987. Triple plaque purified strains of duck hepatitis virus and their potential as vaccines. *Res Vet Sci.* 43:44–48.
23. Davis, D., and D. Hannant. 1987. Fractionation of neutralizing antibodies in serum of ducklings vaccinated with live duck hepatitis virus vaccine. *Res Vet Sci.* 43:276–277.
24. Davis, D., and P.R. Woolcock. 1986. Passage of duck hepatitis virus in cell cultures derived from avian embryos of different species. *Res Vet Sci.* 41:133–134.
25. Demakov, G.P., S.N. Ostashev, V.N. Ogordnikova, and M.A. Shilov. 1975. [Infection of brown rats with the duck hepatitus virus]. *Veterinariia.* 3:57–58.
26. Ding, C., and D. Zhang. 2007. Molecular analysis of duck hepatitis virus type 1. *Virology.* 361:9–17.
27. Doroshko, I.N., and I.Y. Bezrukavaya. 1975. Field trials of duck viral hepatitis vaccine. *Veterinariia.* 1:52–53.
28. Dvorakova, D., and Z. Kozusnik. 1970. The influence of temperature and some disinfectants on duck hepatitis virus. *Acta Brno.* 39:151–156.
29. Fabricant, J., C.G. Rickard, and P.P. Levine. 1957. The pathology of duck virus hepatitis. *Avian Dis.* 1:256–275.

30. Fernholz, D., H. Wetz, and H. Will. 1993. Hepatitis B viruses in birds. In: *Virus Infections of Birds*, Vol. 4. J.B. McFerran and M.S. McNulty, eds. Elsevier Science Publishers, B.V., Amsterdam. 111–119.
31. Fitzgerald, J.E., and L.E. Hanson. 1966. Certain properties of a cell-culture-modified duck hepatitis virus. *Avian Dis.* 10:157–161.
32. Fitzgerald, J.E., L.E. Hanson, and J. Simon. 1969. Histopathologic changes induced with duck hepatitis virus in the developing chicken embryo. *Avian Dis.* 13:147–157.
33. Fitzgerald, J.E., L.E. Hanson, and M. Wingard. 1963. Cytopathic effects of duck hepatitis virus in duck embryo kidney cell cultures. *Proc Soc Exp Biol Med.* 114:814–816.
34. Friend, M., and D.O. Trainer. 1974. Experimental DDT—duck hepatitis virus interaction studies in mallards. *J Wildl Manag.* 38:887–895.
35. Friend, M., and D.O. Trainer. 1974. Experimental dieldrin—duck hepatitis virus interaction studies in mallards. *J Wildl Manag.* 38:896–902.
36. Friend, M., and D.O. Trainer. 1972. Experimental duck virus hepatitis in the mallard. *Avian Dis.* 16:692–699.
37. Friend, M., and D.O. Trainer. 1970. Polychlorinated biphenyl: interaction with duck hepatitis virus. *Science.* 170:1314–1316.
38. Fu, Y., M. Pan, W. Wang, Y. Xu, X. Xie, N.J. Knowles, H. Yang, and D. Zhang. 2009. Complete sequence of a duck astrovirus associated with fatal hepatitis in ducklings. *J Gen Virol.* 90:1104–1108.
39. Fu, Y., M. Pan, X. Wang, Y. Xu, H. Yang, and D. Zhang. 2008. Molecular detection and typing of duck hepatitis A virus directly from clinical specimens. *Vet Microbiol.* 131:247–257.
40. Gazdzinski, P. 1979. Attenuation of duck hepatitis virus and evaluation of its usefulness for duckling immunization. I Studies on attenuation of the virus. Bull Vet Inst Pulawy. 23:80–89.
41. Gazdzinski, P. 1979. Attenuation of duck hepatitis virus and evaluation of its usefulness for duckling immunization. II. Studies on application of the attenuated strain of DVH for vaccination of ducklings. *Bull Vet Inst Pulawy.* 23:89–98.
42. Golubnichi, V.P., G.P. Tishchenko and V.I. Korolkov. 1976. Preparation of tissue culture antigens of duck hepatitis virus. *Vet Nauk Proiz Tr (Minsk).* 14:88–90.
43. Gough, R.E. 1986. Duck hepatitis type 2 associated with an astrovirus. In: *Acute Virus Infections of Poultry*. J.B. McFerran and M.S. McNulty, eds. Martinus Nijhoff, Dordrecht. 223–230.
44. Gough, R.E. 2001. Personal communication.
45. Gough, R.E., E.D. Borland, I.F. Keymer, and J.C. Stuart. 1985. An outbreak of duck hepatitis type II in commercial ducks. *Avian Pathol.* 14:227–236.
46. Gough, R.E., M.S. Collins, E. Borland, and L.F. Keymer. 1984. Astrovirus-like particles associated with hepatitis in ducklings. *Vet Rec.* 114:279.
47. Gough, R.E., and D. Spackman. 1981. Studies with inactivated duck virus hepatitis vaccines in breeder ducks. *Avian Pathol.* 10:471–479.
48. Gough, R.E., and J.C. Stuart. 1993. Astroviruses in ducks (duck virus hepatitis type II). In: *Virus Infections of Birds*, Vol. 4, J.B. McFerran and M.S. McNulty, eds. Elsevier Science Publishers, B.V., Amsterdam. 505–508.
49. Gough, R.E., and A.S. Wallis. 1986. Duck hepatitis type I and influenza in mallard ducks (*Anas platyrhynchos*). *Vet Rec.* 119:602.
50. Guérin, J.-L., O. Albaric, V. Noutary, and C. Boissieu. 2007. A duck hepatitis virus type 1 is agent of pancreatitis and encephalitis in Muscovy duckling. In: Proceedings of the 147th AVMA/50th American Association of Avian Pathologists Conference. Washington, DC. abs 4585.
51. Guérin, J.-L., V. Noutary, C. Boissieu, O. Albaric, and M. Wyers. 2005. Viral pancreatitis and encephalitis of Muscovy ducklings. *Vet Rec.* 157:328.
52. Haider, S.A. 1980. Duck virus hepatitis. In: *Isolation and Identification of Avian Pathogens*. S.B. Hitchner, C.H. Domermuth, H.G. Purchase, and J.E. Williams, eds. American Association of Avian Pathologists, Kennett Square, PA. 75–76.
53. Haider, S.A., and B.W. Calnek. 1979. *In vitro* isolation, propagation, and characterization of duck hepatitis virus type III. *Avian Dis.* 23:715–729.
54. Hanson, L.E., H.E. Rhoades, and R.L. Schricker. 1964. Properties of duck hepatitis virus. *Avian Dis.* 8:196–202.
55. Hanson, L.E., and D.N. Tripathy. 1976. Oral immunization of ducklings with attenuated duck hepatitis virus. *Dev Biol Stand.* 33:357–363.
56. Hwang, J. 1965. A chicken-embryo-lethel strain of duck hepatitis virus. *Avian Dis.* 9:417–422.
57. Hwang, J. 1969. Duck hepatitis virus-neutralization test in chicken embryos. *Am J Vet Res.* 30:861–864.
58. Hwang, J. 1965. Duck hepatitis virus in duck embryo fibroblast cultures. *Avian Dis.* 9:285–290.
59. Hwang, J. 1966. Duck hepatitis virus in duck embryo liver cell cultures. *Avian Dis.* 10:508–512.
60. Hwang, J. 1970. Immunizing breeder ducks with chicken embryo-propagated duck hepatitis virus for production of parental immunity in their progenies. *Am J Vet Res.* 31:805–807.
61. Hwang, J. 1974. Susceptibility of poultry to duck hepatitis viral infection. *Am J Vet Res.* 35:477–479.
62. Hwang, J., and I.E. Dougherty. 1964. Distribution and concentration of duck hepatitis virus in inoculated ducklings and chicken embryos. *Avian Dis.* 8:264–268.
63. Hwang, J., and I.E. Dougherty. 1962. Serial passage of duck hepatitis virus in chicken embryos. *Avian Dis.* 6:435–440.
64. Ivashhenko, V. 1982. The use of indirect hemagglutination reaction for the diagnosis of virus hepatitis of ducklings. *Eksp Inf Inst Ptits.* 109:32–34.
65. Jin, X., W. Zhang, W. Zhang, C. Gu, G. Cheng, and X. Hu. 2008. Identification and molecular analysis of the highly pathogenic duck hepatitis virus type 1 in Hubei province of China. *Res Vet Sci.* 85:595–598.
66. Kaeberle, M.L., J.W. Drake, and L.E. Hanson. 1961. Cultivation of duck hepatitis virus in tissue culture. *Proc Soc Exp Biol Med.* 106:755–757.
67. Kaleta, E.F. 1988. Duck viral hepatitis type 1 vaccination: Monitoring of the immune response with a microneutralization test in Pekin duck embryo kidney cell cultures. *Avian Pathol.* 17:325–332.
68. Kang, M.S., H. Jang, M.C. Kim, M.J. Kim, S.J. Joh, J.H. Kwon, and Y.K. Kwon. 2010. Development of a stabilizer for lyophilization of an attenuated duck viral hepatitis vaccine. *Poult Sci.* 89:1167–1170.
69. Kaszanyitzky, E.J., and J. Tanyi. 1980. Studies on the laboratory diagnosis and epizootiology of duck virus hepatitis. *Magy Allatorv Lapja.* 35:808–814.
70. Kim, M.C., M.J. Kim, Y.K. Kwon, A.M. Lindberg, S. Joh, H.M. Kwon, Y.J. Lee, and J.H. Kwon. 2009. Development of duck hepatitis A virus type 3 vaccine and its use to protect ducklings against infections. *Vaccine.* 27:6688–6694

71. Kim, M.C., Y.K. Kwon, S.J. Joh, S.J. Kim, C. Tolf, J.H. Kim, H.W. Sung, A.M. Lindberg, and J.H. Kwon. 2007. Recent Korean isolates of duck hepatitis virus reveal the presence of a new geno- and serotype when compared to duck hepatitis virus type 1 type strains. *Arch Virol.* 152:2059–2072.
72. Kim, M.C., Y.K. Kwon, S.J. Joh, J.H. Kwon, J.H. Kim, and S.J. Kim. 2007. Development of one-step reverse transcriptase-polymerase chain reaction to detect duck hepatitis virus type 1. *Avian Dis.* 51:540–545.
73. Kim, M.C., Y.K. Kwon, S.J. Joh, J.H. Kwon, and A.M. Lindberg. 2008. Differential diagnosis between type-specific duck hepatitis virus type 1 (DHAV-1) and Korean DHAV-1-like isolates using a multiplex polymerase chain reaction. *Avian Pathol.* 37:171–177.
74. Kim, M.C., Y.K. Kwon, S.J. Joh, A.M. Lindberg, J.H. Kwon, J.H. Kim, and S.J. Kim. 2006. Molecular analysis of duck hepatitis virus type 1 reveals a novel lineage close. *J Gen Virol.* 87:3307–3316.
75. Korolkov, V.I., V.P. Golubnichi, P.S. Khandogin, and M.A. Karvus. 1979. Aerosol vaccination method for virus hepatitis in ducklings. *Vet Nauk Proiz Tr (Minsk).* 17:82–83.
76. Korolkov, V.I., and G.P. Tishchenko. 1975. Laboratory trails of a duck hepatitis vaccine. *Tr Beloruss NI Vet Inst.* 13:79–83.
77. Kurilenko, A.N., and A.P. Strelnikov. 1976. Cytopathic effect of duck hepatitis virus in transplantable piglet kidney cell culture. *Sb Nauk Trud Moscow Vet Akad.* 85:122–124.
78. Levine, P.P., and J. Fabricant. 1950. A hitherto-undescribed virus disease of ducks in North America. *Cornell Vet.* 40:71–86.
79. Levine, P.P., and M.S. Hofstad. 1945. Duck disease investigation. *Annual Report of the New York State Veterinary College, Ithaca*. 55–56.
80. Liu, G., F. Wang, Z. Ni, T. Yun, B. Yu, J. Huang, and J. Chen. 2008. Genetic diversity of the VP1 gene of duck hepatitis virus type I (DHV-I) isolates from southeast China is related to isolate attenuation. *Virus Res.* 137:137–141.
81. Liu, G., E. Yángüez, Z. Chen, and C. Li. 2011. The duck hepatitis virus 5′-UTR possesses HCV-like IRES activity that is independent of eIF4F complex and modulated by downstream coding sequences. *Virol J.* 8:147.
82. Liu, M., Fanyi-Meng, X.J. Li, Z. Zhang, S. Liu, and Y. Zhang. 2011. Goose haemorrhagic hepatitis caused by a new subtype duck hepatitis type 1 virus. *Vet Microbiol.* 152(3–4):280–3.
83. Liu, M., T. Zhang, Y. Zhang, F. Meng, X. Li, Z. Hou, X. Feng, and X. Kong. 2010. Development and evaluation of a VP1-ELISA for detection of antibodies to duck hepatitis type 1 virus. *J Virol Methods.* 169:66–69.
84. Liu, W.M., B.-Y. Wang, J.H. Chen, J. Wang, H.-Q. Ji, S. Yuan, D.C. Huang, and and K.-L. Li. 2009. The potential of duck hepatitis virus (DHV-1) stimulating the body weight gain and the effects of Silymarin on it in duckling. *Agric Sci China.* 8:1403–1408.
85. Lu, Y.S., D.F. Lin, Y.L. Lee, Y.K. Liao, and H.J. Tsai. 1993. Infectious bill atrophy syndrome caused by parvovirus in a co-outbreak with duck viral hepatitis in ducklings in Taiwan. *Avian Dis.* 37:591–596.
86. Luff, P.R., and I.G. Hopkins. 1986. Live duck virus hepatitis vaccination of maternally immune ducklings. *Vet Rec.* 119:502–503.
87. Maiboroda, A.D. 1972. Formation of duck hepatitis virus in culture cells. *Veterinariia.* 48:50–52.
88. Maiboroda, A.D., and L.M. Kontrimavichus. 1968. Propagation of duck hepatitis virus in goose-embryo cells. *Byull Vses Inst Eksp Vet.* 4:5–7.
89. Malinovskaya, G.V. 1982. Formation of 19S and 7S antibodies during immunogenesis and pathogensis of duck viral hepatitis. *Vet Nauk Proiz (Minsk).* 19:68–70.
90. Malinovskaya, G.V. 1980. Use of passive hemagglutination reaction to determine antibodies in hyperimmune serum against virus hepatitis of ducklings. *Tr Beloruss Inst Eksp Vet Minsk.* 18:54–56.
91. Mason, R.A., N.M. Tauraso, and R.K. Ginn. 1972. Growth of duck hepatitis virus in chicken embryos and in cell cultures derived from infected embryos. *Avian Dis.* 16:973–979.
92. Mennella, G.R., and G. Mandelli. 1977. Glutamic-oxaloacetic (GOT) and glutamic-pyruvic (GPT) transaminases in the blood serum in experimental viral hepatitis of ducklings. *Arch Vet Ital.* 28:187–190.
93. Monroe, S.S., M.J. Carter, J. Herrmann, D.K. Mitchel, and A. Sanchez-Fauquier. 2005. Family Astroviridae. In: *Virus Taxonomy, Eighth Report of the International Committee on Taxonomy of Viruses*, C.M. Fauquet, M.A. Mayo, J. Maniloff, U. Desselberger, and L.A. Ball, eds. Elsevier Academic Press, London. 859–864.
94. Murty, D.K., and L.E. Hanson. 1961. A modified microgel diffusion method and its application in the study of the virus of duck hepatitis. *Am J Vet Res.* 22:274–278.
95. Nikitin, M.G., and I.I. Panikar. 1974. Specific prophylaxis of duck virus hepatitis. *Veterinariia.* 8:51–53.
96. Nikitin, M.G., I.I. Panikar, and V.V. Garkavaya. 1976. Aerosol immunization against duck virus hepatitis. *Vestn Skh Nauki.* 1:124–126.
97. Panikar, I., and V. Gostrik. 1981. Aerosol vaccination of ducklings against duck virus hepatitis. *Ptitsevodstvo.* 4:35–36.
98. Picornaviridae. 2011. http://www.picornaviridae.com/.
99. Pollard, M., and T.J. Starr. 1959. Propagation of duck hepatitis virus in tissue culture. *Proc Soc Exp Biol Med.* 101:521–524.
100. Polyakov, A.A., and G.D. Volkovskii. 1969. Survival of duckling hepatitis virus outside the host and methods of disinfection. *Vses Inst Vet Sanit.* 34:278–290.
101. Priz, N.N. 1973. Comparative study of virus hepatitis in animals (dogs and ducks) using different routes of influence. *Vopr Virusol.* 18(6):696–700.
102. Rahn, D.P. 1962. Susceptibility of turkeys to duck hepatitis virus and turkey hepatitis virus. University of Illinois.
103. Rao, S.B.V., and B.R. Gupta. 1967. Studies on a filterable agent causing hepatitis in ducklings, and biliary cirrhosis and blood dyscrasia in adults. *Indian J Poult Sci.* 2:18–30.
104. Reuss, U. 1959. Versuche zur aktiven und passiven Immunisierung bei der Virushepatitis der Entenkuken. *Zentralbl Veterinaermed.* 6:808–815.
105. Reuss, U. 1959. Virusbiologische untersuchungen bei der Entenhepatitis. *Zentralbl Veterinaermed.* 6:209–248.
106. Richter, W.R., E.J. Rozok, and S.M. Moize. 1964. Electron microscopy of virus-like particles associated with duck viral hepatitis. *Virology.* 24:114–116.
107. Rinaldi, A., G. Mandelli, G. Cervio, and A. Valeri. 1970. Immunization of the duck against viral hepatitis. *Atti Soc Ital Sci Vet.* 24:663–665.
108. Rispens, B.H. 1969. Some aspects of control of infectious hepatitis in ducklings. *Avian Dis.* 13:417–426.
109. Roszkowski, J., W. Kozaczynski, and P. Gazdzinski. 1980. Effect of attenuation on the pathogenicity of duck hepatitis virus, histopathological study. *Bull Vet Inst Pulawy.* 24:41–48.

110. Sandhu, T.S., B.W. Calnek, and L. Zeman. 1992. Pathologic and serologic characterization of a variant of duck hepatitis type I virus. *Avian Dis.* 36:932–936.
111. Schoop, G., H. Staub, and K. Erguney. 1959. Virus hepatitis of ducks. V. Attempted adaptation of the virus to chicken embryos. *Monatsh Tierheilkd.* 11:99–106.
112. Shalaby, M.A., M.N.K. Ayoub, and I.M. Reda. 1978. A study on a new isolate of duck hepatitis virus and its relationship to other duck hepatitis virus strains. *Vet Med J Cairo Univ.* 26:215–221.
113. Sung H.W., J.H. Kim, C.S. Song, M.K. Han, Y.J. Lee, and I.P. Mo. 2000. Development of a live vaccine strain of duck viral hepatitis using a Korean isolate. *Kor J Vet Res.* 40:106–110.
114. Syurin, V.N., I.I. Panikar, and I.M. Shchetinskii. 1977. Immunogenesis and pathogenesis of viral hepatitis of ducks. *Veterinariia.* 8:53–55.
115. Tauraso, N.M., G.E. Coghill, and M.J. Klutch. 1969. Properties of the attenuated vaccine strain of duck hepatitis virus. *Avian Dis.* 13:321–329.
116. Tempel, E., and J. Beer. 1968. Die virushepatitis der enten. In: *Handbuch der Virusinfektionen bei Tieren*, Vol. 3, H. Rohrer, ed. Gustav Fischer, Jena, Germany. 1019–1032.
117. Todd, D., V.J. Smyth, N.W. Ball, B.M. Donnelly, M. Wylie, C.H. Knowles, and B.M. Adair. 2009. Identification of chicken enterovirus-like viruses, duck hepatitis virus type 2 and duck hepatitis virus type 3 as astroviruses. *Avian Pathol.* 38:21–30.
118. Toth, T.E. 1975. Duck virus hepatitis. In: *Isolation and Identification of Avian Pathogens*, S.B. Hitchner, C.H. Domermuth, H.G. Purchase, and J.E. Williams, eds. American Association of Avian Pathologists, College Station, TX. 192–196.
119. Toth, T.E. 1969. Studies of an agent causing mortality among ducklings immune to duck virus hepatitis. *Avian Dis.* 13:834–846.
120. Toth, T.E., and N.L. Norcross. 1981. Humoral immune response of the duck to duck hepatitis virus: virus-neutralizing vs. virus-precipitating antibodies. *Avian Dis*. 25:17–28.
121. Tripathy, D.N., and L.E. Hanson. 1986. Impact of oral immunization against duck viral hepatitis in passively immune ducklings. *Prev Vet Med.* 4:355–360.
122. Tseng, C.H., C.H. Knowles, and H.J. Tsai. 2007. Molecular analysis of duck hepatitis virus type 1 indicates that it should be assigned to a new genus. *Virus Res.* 123:190–203.
123. Tseng, C.H., and H.J. Tsai. 2007. Molecular characterization of a new serotype of duck hepatitis virus. *Virus Res.* 126:19–31.
124. Tseng, C.H., and H.J. Tsai. 2007. Sequence analysis of a duck picornavirus isolate indicates that it together with porcine enterovirus type 8 and simian picornavirus type 2 should be assigned to a new picornavirus genus. *Virus Res.* 129:104–114.
125. Ulbrich, F. 1971. Significance of wild ducks in the transmission of duck viral hepatitis. *Monatsh Veterinaermed.* 26:629–631.
126. Vertinskii, K.I., B.F. Bessarabov, A.N. Kurilenko, A.P. Strelnikov, and P.M. Makhno. 1968. Pathogensis and diagnosis of duck viral hepatitis. *Veterinariia.* 7:27–30.
127. Wachendorfer, G. 1965. Das Agar-prazipitationsverfahren bei der Entenhepatitis, der Newcastle-Krankheit und besonders der klassischen Schweinepest-Seine Leistungsfahigkeit und Grenzen in der Virusdiagnostik. *Zentralbl Veterinaermed* 12:55–56.
128. Wang, L., M. Pan, Y. Fu, and D. Zhang. 2008. Classification of duck hepatitis virus into three genotypes based on molecular evolutionary analysis. *Virus Genes.* 37:52–59.
129. Wang, X., Y. Wang, X. Xie, B. Zhang, and D. Zhang. 2011. Expression of the C-terminal ORF2 protein of duck astrovirus for application in a serological test. *J Virol. Methods.* 171:8–12.
130. Wildy, P. 1971. Classification and nomenclature of viruses. *Monographs Virol.* 5:1–118.
131. Woolcock, P. 2010. Duck virus hepatitis. In: *Manual of Diagnostic Tests and Vaccines for Terrestrial Animals*. Office International des Epizooties, Paris, France.
132. Woolcock, P. 2008. Duck virus hepatitis. In: *Diseases of Poultry*, 12th ed. Y.M. Saif, A.M. Fadly, J.R. Glisson, L.R. McDougald, L.K. Nolan, and D.E. Swayne, eds. Blackwell, Ames, IA. 373–384.
133. Woolcock, P.R. 1986. An assay for duck hepatitis virus type I in duck embryo liver cells and a comparison with other assays. *Avian Pathol.* 15:75–82.
134. Woolcock, P.R. 2008. Duck hepatitis. In: *A Laboratory Manual for the Isolation, Identification and Characterization of Avian Pathogens*, 5th ed. L. Dufour-Zavala, D.E. Swayne, J.R. Glisson, J.E. Pearson, W.M. Reed, M.W. Jackwood, and P.R. Woolcock, eds. American Association of Avian Pathologists, Jacksonville, FL. 175–178.
135. Woolcock, P.R. 2003. Duck hepatitis. In: *Diseases of Poultry*, 11th ed. Y.M. Saif, H.J. Barnes, J.R. Glisson, A.M. Fadly, L.R. McDougald, and D.E. Swayne, eds. Iowa State Press. 343–354.
136. Woolcock, P.R. 1991. Duck hepatitis virus type I: Studies with inactivated vaccines in breeder ducks. *Avian Pathol.* 20:509–522.
137. Woolcock, P.R. 1995. Unpublished data.
138. Woolcock, P.R., W.S. K. Chalmers, and D. Davis. 1982. A plaque assay for duck hepatitis virus. *Avian Pathol.* 11:607–610.
139. Woolcock, P.R., and G.W. Crighton. 1979. Duck virus hepatitis: serial passage of attenuated virus in ducklings. *Vet Rec.* 105:30–32.
140. Woolcock, P.R., and G.W. Crighton. 1981. Duck virus hepatitis: The effect of attenuation on virus stability in ducklings. *Avian Pathol.* 10:113–119.
141. Woolcock, P.R., and J. Fabricant. 1991. Duck virus hepatitis. In: *Diseases of Poultry*, 9th ed. B.W. Calnek, H.J. Barnes, C.W. Beard, W.M. Reid, and H.W. Yoder, eds. Iowa State University Press, Ames, IA. 597–608.
142. Yang, M., A. Cheng, M. Wang, and H. Xing. 2008. Development and application of a one-step real-time Taqman RT-PCR assay for. *J Virol Meth.* 153:55–60.
143. Zhao, X., R.M. Phillips, G. Li, and A. Zhong. 1991. Studies on the detection of antibody to duck hepatitis virus by enzyme-linked immunosorbent assay. *Avian Dis.* 35:778–782.
144. Zubtsova, R.A. 1971. Laboratory trial of live vaccine against duck hepatitis containig GNKI attenuated strains. *Tr Gos Nauchn-Kontrol Inst Vet Prep.* 17:127–132.

Duck Virus Enteritis (Duck Plague)

1. Asplin, F. 1970. Examination of sera from wildfowl for antibodies against the viruses of duck plague, duck hepatitis and duck influenza. *Vet Rec.* 87:182–183.
2. Baudet, A.E.R.F. 1923. Mortality in ducks in the Netherlands caused by a filtrable virus; fowl plague. *Tijdschr Diergeneeskd.* 50:455–459.
3. Bergmann, V., and E. Kinder. 1982. Zu Morphologie, Reifung und Wirkung des Entenpestvirus im Wirtsgewebe-Eine Elektro nen mikroskopische studie. *Arch Exp Vet Med.* 36:455–463.

4. Bos, A. 1942. Some new cases of duck plague. *Tijdschr Diergeneeskd.* 69:372–381.
5. Brand, C.J. 1987. Chapter 11: Duck plague. In: *Field Guide to Wildlife Diseases (General Field Procedures and Disease of Migratory Birds)*. M. Friend, ed. United States Department of Interior Fish and Wildlife Services Resource Publication No. 167, Washington, DC.
6. Brand, C.J., and D.E. Docherty. 1984. A survey of North American migratory waterfowl for duck plague (duck virus enteritis) virus. *J Wildl Dis.* 20:261–266.
7. Breese, S.S., Jr., and A.H. Dardiri. 1968. Electron microscopic characterization of duck plague virus. *Virology.* 34:160–169.
8. Burgess, E.C., and T.M. Yuill. 1981a. Increased cell culture incubation temperatures for duck plague virus isolation. *Avian Dis.* 25:222–224.
9. Burgess, E.C., and T.M. Yuill. 1981b. Vertical transmission of duck plague virus (DPV) by apparently healthy DPV carrier waterfowl. *Avian Dis.* 25:795–800.
10. Burgess, E.C., and T.M. Yuill. 1982. Superinfection in ducks persistently infected with duck plague virus. *Avian Dis.* 26:40–46.
11. Burgess, E.C., and T.M. Yuill. 1983. The influence of seven environmental and physiological factors on duck plague virus shedding by carrier mallards. *J Wildl Dis.* 19:77–81.
12. Burgess, E.C., J. Ossa, and T.M. Yuill. 1979. Duck plague: A carrier state in waterfowl. *Avian Dis.* 23:940–949.
13. Butterfield, W.K., and A.H. Dardiri. 1969. Serologic and immunologic response of ducks to inactivated and attenuated duck plague virus. *Avian Dis.* 13:876–887.
14. Campagnolo, E.R., M. Banerjee, B. Panigrahy, and R.L. Jones. 2001. An outbreak of duck viral enteritis (duck plague) in domestic Muscovy ducks (*Cairina moschata*) in Illinois. *Avian Dis.* 45:522–528.
15. Chandrika, P., K. Kumanan, R. Jayakumar, and K. Nachimuthu. 1999. Latex agglutination test for the detection of duck plague viral antigen. *Indian Vet J.* 76:372–374.
16. Dardiri, A.H., and W.R. Hess. 1967. The incidence of neutralizing antibodies to duck plague virus in serums from domestic ducks and wild waterfowl in the United States of America. Proc 71st Annu Meet US Livest Sanit Assoc. 225–237.
17. Dardiri, A.H., and W.R. Hess. 1968. A plaque assay for duck plague virus. *Can J Comp Med Vet Sci.* 32:505–510.
18. Deng, M.Y., E.C. Burgess, and T.M. Yuill. 1984. Detection of duck plague virus by reverse passive hemagglutination test. *Avian Dis.* 28:616–628.
19. Devos, A., N. Viaene, and H. Staelens. 1964. Duck plague in Belgium. *Vlaams Diergeneeskd Tijdschr.* 33:260–266.
20. DeZeeuw, F.A. 1930. Nieuwe gevallen van eendenpest en de specificiteit van het virus. *Tijdschr Diergeneeskd.* 57:1095–1098.
21. Erickson, G.A., J.S. Proctor, J.E. Pearson, and G.A. Gustafson. 1974. Diagnosis of duck virus enteritis (duck plague). *Am Assoc Vet Lab Diag Proc.* 17:85–89.
22. Friend, M., and G.L. Pearson. 1973. Duck plague (duck virus enteritis) in wild waterfowl. US Dept Int Bur Sport Fish Wildl Bull. Washington, DC.
23. Gaudry, D., P. Precausta, G. de Saint-Aubert, J. Fontaine, J. Janson, R. Wemmenhove, and H. Kunst. 1970. Mise en evidence d'agents infectieux dans un elevage de Canards de Barbarie. *Rev Med Vet.* 121:317–331.
24. Goldberg, D.R., T.M. Yuill, and E.C. Burgess. 1990. Mortality from duck plague virus in immunosuppressed adult mallard ducks. *J Wildl Dis.* 26:299–306.
25. Gough, R.E., and D.J. Alexander. 1990. Duck virus enteritis in Great Britain, 1980 to 1989. *Vet Rec.* 126:595–597.
26. Gough, R.E., and W.R. Hansen. 2000. Characterization of a herpesvirus from domestic geese in Australia. *Avian Pathol.* 29:417–422.
27. Guo, A. Cheng, M. Wang, C. Shen, R. Jia, S. Chen, and N. Zhang. 2009. Development of TaqMan® MGB fluorescent real-time PCR assay for the detection of anatid herpesvirus 1. *Virol J.* 6:71–78.
28. Hall, S.A., and J.R. Simmons. 1972. Duck plague (duck virus enteritis) in Britain. *Vet Rec.* 90:691.
29. Hansen, W.R., S.W. Nashold, D.E. Docherty, S.E. Brown, and D.L. Knudson. 2000. Diagnosis of duck plague in waterfowl by polymerase chain reaction. *Avian Dis.* 44:266–274.
30. Hanson, J.A., and N.G. Willis. 1976. An outbreak of duck virus enteritis (duck plague) in Alberta. *J Wildl Dis.* 12:258–262.
31. Hess, W.R., and A.H. Dardiri. 1968. Some properties of the virus of duck plague. *Arch Gesamte Virusforsch.* 24:148–153.
32. Islam, M.R., and M.A. Khan. 1995. An immunocytological study on the sequential tissue distribution of duck plague virus. *Avian Pathol.* 24:189–194.
33. Li H., S. Liu, X. Kong. 2006. Characterization of the genes encoding UL24, TK and gH proteins from duck enteritis virus (DEV): a proof for the classification of DEV. *Virus Genes.* 33:221–227.
34. Hwang, J., E.T. Mallinson, and R.E. Yoxheimer. 1975. Occurrence of duck virus enteritis (duck plague) in Pennsylvania, 1968–74. *Avian Dis.* 19:382–384.
35. Jacobsen, G.S., J.E. Pearson, and T.M. Yuill. 1976. An epornitic of duck plague on a Wisconsin game farm. *J Wildl Dis.* 12:20–26.
36. Jia R., A. Cheng, M. Wang, X. Qi, D. Zhu, H. Ge, Q. Luo, F. Liu, Y. Guo, X. Chen. 2009. Development and evaluation of an antigen-capture ELISA for detection of the UL24 antigen of the duck enteritis virus, based on a polyclonal antibody against the UL24 expression protein. *J Virol Methods.* 161(1):38–43.
37. Jansen, J. 1961. Duck plague. *Br Vet J.* 117:349–356.
38. Jansen, J. 1963. The incidence of duck plague. *Tijdschr Diergeneeskd.* 88:1341–1343.
39. Jansen, J. 1964a. The interference phenomenon in the development of resistance against duck plague. *J Comp Pathol Ther.* 74:3–7.
40. Jansen, J. 1964b. Duck plague (a concise survey). *Indian Vet J.* 41:309–316.
41. Jansen, J. 1968. Duck plague. *J Am Vet Med Assoc.* 152:1009–1016.
42. Jansen, J., and H. Kunst. 1949. Is duck plague related to Newcastle disease or to fowl plague? *Proc 14th Int Vet Congr.* 2:363–365.
43. Jansen, J., and H. Kunst. 1964. The reported incidence of duck plague in Europe and Asia. *Tijdschr Diergeneeskd.* 89:765–769.
44. Jansen, J., and R. Wemmenhove. 1965. Duck plague in domesticated geese (*Anser anser*). *Tijdschr Diergeneeskd.* 90:811–815.
45. Ji J., L.Q. Du, Q.M. Xie, Y.C. Cao, K.J. Zuo, C.Y. Xue, J.Y. Ma, F. Chen, and Y.Z. Bee. 2009. Rapid diagnosis of duck plagues virus infection by loop-mediated isothermal amplification. *Res Vet Sci.* 87: 53–58.
46. Kaleta E.F., A. Kuczka, A. Kuhnhold, C. Bunzenthal, B.M. Bonner, K. Hanka, T. Redmann, and A. Yilmaz. 2007, Outbreak of duck plague (duck herpesvirus enteritis) in numerous species of captive ducks and geese in temporal conjunction with enforced biosecurity (in-house keeping) due to the threat of avian influenza

A virus of the subtype Asia H5N1. *Dtsch Tierarzt Wschr.* 114:3–11.
47. Ketterer, P.J., B.J. Rodwell, H.A. Westbury, P.T. Hooper, A.R. Mackenzie, J.G. Dingles, and H.C. Prior. 1990. Disease of geese caused by a new herpesvirus. *Austral Vet J.* 67:446–448.
48. Keymer, I.F., and R.E. Gough. 1986. Duck virus enteritis (Anatid herpesvirus infection) in mute swans (*Cygnus olor*). *Avian Pathol.* 15:161–170.
49. Kocan, R.M. 1976. Duck plague virus replication in Muscovy duck fibroblast cells. *Avian Dis.* 20:574–580.
50. Kumar, N.V., Y.R. Reddy, and M.V.S. Rao. 2004. Development of enzyme linked immunosorbent assay for the detection of antibodies to duck plague virus. *Indian Vet J.* 81:363–365.
51. Kunst, H. 1967. Isolation of duck plague virus in tissue cultures. *Tijdschr Diergeneeskd.* 92:713–714.
52. Lam, K.M. 1984. Antibody-and complement-mediated cytolysis against duck-enteritis-virus-infected cells. *Avian Dis.* 28:1125–1129.
53. Lam, K.M., and W. Lin. 1986. Antibody-mediated resistance against duck enteritis virus infection. *Can J Vet Res.* 50:380–383.
54. Leibovitz, L. 1968. Progress report: Duck plague surveillance of American Anseriformes. *Bull Wildl Dis Assoc.* 4:87–90.
55. Leibovitz, L. 1969a. The comparative pathology of duck plague in wild Anseriformes. *J Wildl Manag.* 33:294–303.
56. Leibovitz, L. 1969b. Duck plague. In: *Infectious and Parasitic Diseases of Wild Birds*. J.W. Davis, R.C. Anderson, L. Karstad, and D.O. Trainer, eds. Iowa State University Press: Ames, IA. 22–33.
57. Leibovitz, L. 1971. Gross and histopathologic changes of duck plague (duck plague enteritis). *Am J Vet Res.* 32:275–290.
58. Leibovitz, L. 1973. Necrotic enteritis of breeder ducks. *Am J Vet Res.* 34:1053–1061.
59. Leibovitz, L., and J. Hwang. 1968a. Duck plague on the American continent. *Avian Dis.* 12:361–378.
60. Leibovitz, L., and J. Hwang. 1968b. Duck plague in American Anseriformes. *Bull Wildl Dis Assoc.* 4:13–14.
61. Levine, P.P., and J. Fabricant. 1950. A hitherto-undescribed virus disease of ducks in North America. *Cornell Vet.* 40:71–86.
62. Li Y., B. Huang, M. Xiuli, J. Wu, F. Li, W. Ai, M. Song, and H. Yang. 2009. Molecular characterization of the genome of duck enteritis virus. *Virol.* 391: 151–161.
63. Lin, W., K.M. Lam, and W.E. Clark. 1984a. Active and passive immunization of ducks against duck viral enteritis. *Avian Dis.* 28:968–977.
64. Lin, W., K.M. Lam, and W.E. Clark. 1984b. Isolation of an apathogenic immunogenic strain of duck enteritis virus from waterfowl in California. *Avian Dis.* 28:641–650.
65. Liu J., P. Chen, Y. Jiang, L. Wu, X. Zeng, G. Tian, J. Ge, Y. Kawaoka, Z. Bu, H. Chen. 2011. A duck enteritis virus-vectored bivalent live vaccine provides fast and complete protection against H5N1 avian influenza virus infection in ducks. *J Virol.* 85(21):10989–98.
66. Lucam, F. 1949. La peste aviare en France. *Proc 14th Int Vet Congr*. 2:380–382.
67. Malmarugan, S., and S. Sulochana. 2002. Comparison of dot-ELISA passive haemagglutination test for the detection of antibodies to duck plague. *Indian Vet J.* 79:648–651.
68. Mo, C.L., and E.C. Burgess. 1987. Infection of duck plague carriers with *Pasteurella multocida* and *P. anatipestifer*. *Avian Dis*. 31:197–201.
69. Montali, R.J., M. Bush, and G.A. Greenwell. 1976. An epornitic of duck viral enteritis in a zoological park. *J Am Vet Med Assoc.* 169:954–958.
70. Montgomery, R.D., G. Stein, Jr., M.N. Novilla, S.S. Hurley, and R.J. Fink. 1981. An outbreak of duck virus enteritis (duck plague) in a captive flock of mixed waterfowl. *Avian Dis.* 25:207–213.
71. Mukerji, A., M.S. Das, B.B. Ghosh, and J.L. Ganguly. 1963. Duck plague in West Bengal. I and II. *Indian Vet J.* 40:457–462.
72. Mukerji, A., M.S. Das, B.B. Ghosh, and J.L. Ganguly. 1965. Duck plague in West Bengal. III. *Indian Vet J.* 42:811–815.
73. Pechan, V.P., H. Schweighardt, and E. Lauermann. 1985. Zum auftreten der Entenpest in Oberosterreich. *Wien Tierarztl Monatsschr.* 72:358–360.
74. Plummer, P.J., T. Alefantis, S. Kaplan, P. O'Connell, S. Shawky, and K.A. Schat. 1998. Detection of duck enteritis virus by polymerase chain reaction. *Avian Dis.* 42:554–564.
75. Poomvises, P. 1976. Personal communication.
76. Prip, M., B. Jylling, J. Flensburg, and B. Bloch. 1983. An outbreak of duck virus enteritis among ducks and geese in Denmark. *Nord Vet Med.* 35:385–396.
77. Pritchard, L.I., C. Morrissy, K. Van-Phuc, P.W. Daniels, and H.A. Westbury. 1999. Development of a polymerase chain reaction to detect Vietnamese isolates of duck virus enteritis. *Vet Microbiol.* 16:149–156.
78. Proctor, S.J. 1974. Pathogenesis of digestive tract lesions in duck plague. *Vet Pathol.* 12:349–361.
79. Proctor, S.J., G.L. Pearson, and L. Leibovitz. 1975. A color atlas of wildlife pathology. 2. Duck plague in free-flying water-fowl. Wildl Dis Color Fiche.67.
80. Richter, J.H.M., and M.C. Horzinek. 1993. Duck plague. In: *Virus Infections of Birds*. J.B. McFerran and M.S. McNulty, eds. Elsevier Science Publishing Company, New York. 77–90.
81. Roizman, B., L.E. Carmicheal, F. Deinhardt, G. de-Thé, A.J. Nahmias, W. Plowright, F. Rapp, P. Sheldrick, M. Takahashi, and K. Wolf. 1981. Herpesviridae: Definition, provisional nomenclature, and taxonomy. *Intervirology.* 16:201–217.
82. Salguero, F.J., P.J. Sanchez-Cordon, A. Nunez, and J.C. Gomez-Villamandos. 2002. Histopathological and ultrastructural changes associated with herpesvirus infection in waterfowl. *Avian Pathol.* 31:133–140.
83. Sandhu, T. 1992. Unpublished data.
84. Shawky, S. 1994. Unpublished data.
85. Shawky, S. 2000. Target cells for duck enteritis virus in lymphoid organs. *Avian Pathol.* 29:609–616.
86. Shawky, S., and K.A. Schat. 2002. Latency sites and reactivation of duck enteritis virus. *Avian Dis.* 46:461–466.
87. Shawky, S., and T.S. Sandhu. 1997. Inactivated vaccine for protection against duck virus enteritis. *Avian Dis.* 41:461–468.
88. Shawky S., T. Sandhu, and H.L. Shivaprasad. 2000. Pathogenicity of a low-virulence duck virus enteritis isolate with apparent immunosuppressive ability. *Avian Dis.* 44:590–599.
89. Shen, C., A. Cheng, M. Wang, K. Sun, R. Jia, T. Sun, N. Zhang, D. Zhu, Q. Luo, Y. Zhou, and X. Chen. 2010. Development and evaluation of an immunochromatographic strip test based on the recombinant UL51 protein for detecting antibody against duck enteritis virus. *Virol J.* 7:268–75.
90. Simpson. 2002. Review: Wild animals as reservoirs of infectious diseases in the UK. *Vet J.* 163:128–146.
91. Snyder, S.B., J.G. Fox, L.H. Campbell, K.F. Tam, and A.O. Soave. 1973. An epornitic of duck virus enteritis (duck plague) in California. *J Am Vet Med Assoc.* 163:647–652.

92. Spieker, J.O. 1977. Virulence assay and other studies of six North American strains of duck plague virus tested in wild and domestic waterfowl. PhD Dissertation. University of Wisconsin, Madison, WI.
93. Spieker, J.O., T.M. Yuill, and E.C. Burgess. 1996. Virulence of six strains of duck plague virus in eight waterfowl species. *J Wildl Dis.* 32:453–460.
94. Tantaswasdi, U., W. Wattanavijarn, S. Methiyapun, T. Kumagai, and M. Tajima. 1988. Light, immunofluorescent and electron microscopy of duck virus enteritis (duck plague). *Jpn J Vet Sci.* 50:1150–1160.
95. Toth, T.E. 1971a. Active immunization of white pekin ducks against duck virus enteritis (duck plague) with modified-live virus vaccine: Serologic and immunologic response of breeder ducks. *Am J Vet Res.* 32:75–81.
96. Toth, T.E. 1971b. Two aspects of duck virus enteritis: parental immunity, and persistence/excretion of virulent virus. Proc 74th Annu Meet US Anim Health Assoc. 1970–1971, 304–314.
97. Umamaheswararao, S., and B.V. Rao. 1993. Assay of cell mediated immune responses of ducks vaccinated against duck plague. *Indian J Poult Sci.* 28:256–258.
98. USDA. 1967. Duck virus enteritis. *Fed Reg.* 32:7012–7013.
99. Van Dorssen, C.A., and H. Kunst. 1955. Susceptibility of ducks and various other waterfowl to duck plague virus. *Tijdschr Diergeneeskd.* 80:1286–1295.
100. Vetesi, F., V. Palya, S. Levay, and P. Kapp. 1982. A kacsapestis (duck plague) elofordulasa kacsaallomanyokban. *Magy Allatorv Lapja.* 37:171–182.
101. Vijaysri, S., S. Sulochana, and K.T. Punnoose. 1997. Restriction endonuclease analysis of duck plague viral DNA. *J Vet Animal Sci.* 28:86–91.
102. Welling, R. 1993. Personal communication.
103. Wobeser, G. 1987. Experimental duck plague in blue-winged teal and Canada geese. *J Wildl Dis.* 23:368–375.
104. Wobeser, G., and D.E. Docherty. 1987. A solitary case of duck plague in a wild mallard. *J Wildl Dis.* 23:479–482.
105. Wolf, K., C.N. Burke, and M.C. Quimby. 1974. Duck viral enteritis: Microtiter plate isolation and neutralization test using the duck embryo fibroblast cell line. *Avian Dis.* 18:427–434.
106. Wolf, K., C.N. Burke, and M.C. Quimby. 1976. Duck viral enteritis: A comparison of replication by CCL-141 and primary cultures of duck embryo fibroblasts. *Avian Dis.* 20:447–454.
107. Yang, F., W. Jia, H. Yue, W. Luo, X. Chen, Y. Xie, W. Zen, and W. Yang. 2005. Development of quantitative real-time polymerase chain reaction for duck enteritis virus DNA. *Avian Dis.* 49:397–400.
108. Yuan, G., A. Cheng, M. Wang, F. Liu, X. Han, Y. Liao, and C. Xu. 2005. Electron microscopic studies of the morphogenesis of duck enteritis virus. *Avian Dis.* 49:50–55.
109. Zou Q., K. Sun, A. Cheng, M. Wang, C. Xu, D. Zhu, R. Jia, Q. Luo, Y. Zhou, Z. Chen, X. Chen. 2010. Detection of anatid herpesvirus 1 gC gene by TaqMan™ fluorescent quantitative real-time PCR with specific primers and probe. *Virol J.* 7:37–46.

Hemorrhagic Nephritis Enteritis of Geese

1. Bernath, S., A. Farsang, A. Kovacs, E. Nagy, and M. Dobos-Kovacs. 2006. Pathology of goose hemorrhagic polyomavirus infection in goose embryos. *Avian Pathol.* 35(1):49–52.
2. Bernath, S., and F. Szalai. 1970. Investigations for clearing the etiology of the disease appeared among goslings in 1969. *Magyar Alla Lap.* 25:531–536.
3. Bozeman, L.H., R.B. David, D. Gaudry P.D. Luckert, O.J. Fletcher, and M.J. Dykstra. 1981. Characterization of a papovavirus isolated from fledgling budgerigars. *Avian Dis.* 25:972–980.
4. Corrand, L., J. Gelfi, O. Albaric, M. Etievant, J-L. Pingret, and J-L. Guérin. 2011. Pathological and epidemiological significance of *Goose haemorrhagic polyomavirus* (GHPV) infection in ducks. *Avian Pathol.* 40(4):355–60.
5. Fauquet, C.M., M.A. Mayo, J. Maniloff, U. Desselberger, and L.A. Ball, ed. 2005. *Virus Taxonomy: VIIIth Report of the International Committee on Taxonomy of Viruses*. Academic Press.
6. Gelfi, J., M. Pappalardo, C. Claverys, B. Peralta, and J-L. Guérin. 2010. Safety and efficacy of an inactivated Carbopol-adjuvanted goose haemorrhagic polyomavirus vaccine for domestic geese. *Avian Pathol.* 39(2):111–6.
7. Guérin, J-L., J. Gelfi, L. Dubois, A. Vuillaume, C. Boucraut-Baralon, and J-L. Pingret. 2000. A novel polyomavirus *Goose* hemorrhagic polyomavirus is the agent of hemorrhagic nephritis enteritis of geese. *J Virol.* 74:4523–4529.
8. Imperiale, M., and E.O. Major. 2007. Polyomaviruses. In: *Fields Virology*, 5th ed. D.M. Knipe and P.M. Howley, eds. Lippincott Williams and Wilkins Publishers, Philadelphia. 2263–2298.
9. Johne, R., and H. Muller. 2003. The genome of goose hemorrhagic polyomavirus, a new member of the proposed subgenus *Avipolyomavirus*. *Virol.* 308(2):291–302.
10. Kisary, J. 1993. Haemorragic nephritis and enteritis of geese. In: *Virus Infections of Birds*. J-B. McFerran, M.S. McNulty, eds. Elsevier Edit., London. 513–514.
11. Lacroux, C., O. Andreoletti, B. Payre, J-L. Pingret, A. Dissais, and J-L. Guérin. 2004. Pathology of spontaneous and experimental infections by *Goose haemorrhagic polyomavirus*. *Avian Pathol.* 33(3):351–358
12. Mató T., Z. Pénzes, P. Rueda, C. Vela, V. Kardi, A. Zolnai, F. Misák, and V. Palya. 2009. Recombinant subunit vaccine elicits protection against goose haemorrhagic nephritis and enteritis. *Avian Pathol.* 38(3):233–7.
13. Palya, V., E. Ivanics, R. Glavits, A. Dan, T. Mato, and P. Zarka. 2004. Epizootic occurrence of haemorrhagic nephritis enteritis infections of geese. *Avian Pathol.* 33(2):244–250.
14. Perez-Losada, M., R.G. Christensen, D.A. McCellan, B.J. Adams, R.P. Viscidi, J.C. Demma, and K.A. Crandall. 2006. Comparing divergence between polyomaviruses and their hosts. *J Virol.* 80(12):5663–5669.
15. Pingret, J-L., C. Boucraut-Baralon, and J-L. Guérin. 2008. *Goose haemorrhagic polyomavirus (GHPV)* infection in ducks. *Vet Rec.* 162:5.
16. Phalen, N.L., V.G. Wilson, J.M. Gaskin, J.N. Derr, and D.L. Graham. 1999. Genetic diversity in twenty variants of the avian polyomavirus. *Avian Dis.* 43:207–218.
17. Ritchie, B.W., N. Pritchard, D. Pest, F.D. Niagro, K.S. Latimer, and P.D.. Lukert. 1993. Susceptibility of avian polyomavirus to inactivation. *J Assoc Avian Vet.* 7(4):193–195.
18. Schettler, C.H. 1977. Détection en France de la néphrite hémorragique et entérite de l'oie. *Rec Med Vet.* 153:353–355.
19. Schettler, C.H. 1980. Clinical picture and pathology of haemorragic and enteritis in geese. *Tier Prax.* 8:313–320.
20. Szalai, F., and S. Bernath.1971. Investigations for clearing the etiology of the disease appeared among goslings in 1969: II. The elaboration of passive immunization, the production of hyperimmune

serum. III. Pathohistological investigations. *Magyar Alla Lap*. 26:420–423.
21. Vuillaume, A., J. Tournut, and H. Banon. 1982. A propos de la maladie des oisons d'apparition tardive ou Néphrite Hémorragique-Entérite de l'Oie (N.H.E.O.). *Rev Med Vet*. 133:341–346.
22. Zielonka, A., A. Gedvilaite, R. Ulrich, D. Lüschow, K. Sasnauskas, H. Müller, and R. Johne. 2006. Generation of virus-like particles consisting of the major capsid protein VP1 of goose hemorrhagic polyomavirus and their application in serological tests. *Virus Res.* 120(1–2):128–37

Parvovirus Infections of Waterfowl

1. Alexandrov, M., R. Alexandrova, I. Alexandrov, S. Zacharieva, S. Lasarova, L. Doumanova, R. Pesher, and T. Donev. 1999. Fluorescent and electron-microscopy immunoassays employing polyclonal and monoclonal antibodies for detection of goose parvovirus infection. *J Virol Method.* 79:21–32.
2. Angelacev, A. 1966. Exudative septicaemia of geese-goose influenza. *Vet Sbir Sof.* 63:9–12.
3. Bergmann, V. 1987. Pathology and electron microscopical detection of virus in the tissues of goslings with Derzsy's disease (parvovirus infection). *Arch Exp Vet Med.* 41:212–221.
4. Brown, K.E., S.W. Green, and N.S. Young. 1995. Goose parvovirus—an autonomous member of the Dependovirus genus? *Virol.* 210:283–291.
5. Chang, P.C., J.H. Shien, M.S. Wang, and H.K. Shieh. 2000. Phylogenetic analysis of parvoviruses isolated in Taiwan from ducks and geese. *Avian Pathol.* 29:45–49.
6. Chen, B.L., B.H. Ye, and J.H. Li. 1985. Duck embryo adapted vaccine for gosling plague. *Acta Vet Zootech Sin.* 16:269–275.
7. Chu, C.Y., M.J. Pan, and J.T. Cheng. 2001. Genetic variation in the nucleocapsid genes of waterfowl parvovirus. *J Vet Med Sci.* 63:1165–1170.
8. Cleef, S.A.M. van, and J.T. Miltenburg. 1966. A serious virus disease with an acute course and high mortality in goslings. *Tijdschr Diergeneesk.* 91:372–382.
9. Corrand, L., J. Gelfi, O. Albaric, M. Etievant, J.L. Pingret, and J.L. Guerin. 2011. Pathological and epidemiological significance of Goose haemorrhagic polyomavirus infection in ducks. *Avian Pathol.* 40:355–360.
10. Cotmore, S.F., and P. Tattersall. 2007. Parvoviral host range and cell entry mechanisms. In: *Advances in Virus Research*. Elsevier, Amsterdam. 184–232.
11. Coudert, M., M. Fedida, G. Dannacher, M. Peillon, R. Labatut, and P. Ferlin. 1972. Viral disease of gosling. *Recl Med Vet.* 148:455–472
12. Coudert, M., M. Fedida, G. Dannacher, and M. Peillon. 1974. Parvovirus disease of goslings. Late form. *Recl Med Vet.* 150:899–906.
13. Dannacher, G., M. Coudert, M. Fedida, M. Peillon, and X. Fouillet. 1972. Etiology of the virus disease of geese. *Recl Med Vet.* 148:1333–1349.
14. Dannacher, G., X. Fouillet, M. Coudert, M. Fedida, and M. Peillon. 1974. Etiology of the virus disease of geese: The beta virus. *Recl Med Vet.* 150:49–58.
15. Derzsy, D. 1967. A viral disease of goslings. *Acta Vet Hung.* 17:443–448.
16. Fang, D.Y., and Y.K. Wang. 1981. Studies on the etiology and specific control of goose parvovirus infection. *Sci Agric Sin.* 4:1–8.
17. Fauquet C.M., M.A. Mayo, J. Maniloff, U. Desselberger, and L.A. Ball, eds. 2005. *Virus Taxonomy, Eighth Report of the ICTV*. Elsevier Academic Press, London. 353–363.
18. Fournier, D. 1991. Parvovirose du canard de Barbarie. Approche vaccinale et recherches en cours. *L'Aviculteur.* 521:55–58
19. Fournier D., and D. Gaudry. 1992. Muscovy duck parvovirosis (MDP) in France: field vaccination trials. In: Proceedings 9th International Symposium on Waterfowl. Pisa, Italy, 136–41.
20. Gaudry, D., J. Tetkoff, and J.M. Charles. 1972. A propos d'un nouveau virus isole chez le canard de Barbarie. *Bull Soc Sci Vet Med Lyon.* 74:137–143.
21. Glávits, R., A. Zolnai, E. Szabó, E. Ivanics, P. Zarka, T. Mató, and V. Palya. 2005. Comparative pathological studies on domestic geese and Muscovy ducks experimentally infected with parvovirus strains of goose and Muscovy duck origin. *Acta Vet Hung*. 53:73–89.
22. Gough, R.E. 1984. Application of the agar gel precipitin and virus neutralisation tests to the serological study of goose parvovirus. *Avian Pathol.* 13:501–509.
23. Gough, R.E. 1987. Persistence of parvovirus antibody in geese that have survived Derzsy's disease. *Avian Pathol.* 16:327–330.
24. Gough, R.E. 2008. Parvovirus of waterfowl. In: *Isolation, Identification, and Characterization of Avian Pathogens*, 5th ed. L. Dufour Zavala, ed. American Association of Avian Pathologists, Inc. Athens, Georgia. 191–194.
25. Gough, R.E., D. Spackman, and M.S. Collins. 1981. Isolation and characterisation of a parvovirus from goslings. *Vet Rec.* 108:399–400.
26. Gough, R.E., and D. Spackman. 1982. Studies with a duck embryo adapted goose parvovirus. *Avian Pathol.* 11:503–510.
27. Gough, R.E. 2008. Parvovirus infections. In: *Diseases of Poultry*, 12th ed. Y.M. Saif, ed. Blackwell Publishing, Ames, IA. 397–404.
28. Guérin, J.L., J. Gelfi, L. Dubois, A. Vuillaume, C. Boucraut-Baralon, and J.L. Pingret. 2000. A novel polyomavirus (Goose hemorrhagic polyomavirus) is the agent of hemorrhagic nephritis enteritis of geese. *J Virol.* 74:4523–4529.
29. Hlinak, A., T. Muller, M. Kramer, R.U. Muhle, H. Liebherr, and K. Ziedler. 1998. Serological survey of viral pathogens of bean and white-fronted geese from Germany. *J Wildl Dis.* 34:479–486.
30. Hoekstra, J., T. Smit, and C. van Brakel. 1973. Observations on the host range and control of goose virus hepatitis. *Avian Pathol.* 2:169–178.
31. Ivanics, É., R. Glávits, E-né Nagy, I-né Édes, T. Révész, and V. Pálfi. 1998. Predominantly enteral from of Derzsy's disease. *Magy Állatorv Lap* 120:744–752.
32. Ivanics, É., V. Palya, B. Markos, Á Dán, K. Ursu, Gy. Kaján, and R. Glávits 2010. Hepatitis and hydropericardium syndrome associated with adenovirus infection in goslings. *Acta Vet Hung.* 58:47–58.
33. Jansson, D.S., R. Feinstein, V. Kardi, T. Mató, and V. Palya. 2007. Epidemiologic investigation of an outbreak of Goose parvovirus infection in Sweden. *Avian Dis.* 51:609–613.
34. Jestin, V., M. Le Bras, M. Cherbonnel, G. Le Gall-Recule, and G. Bennejean. 1991. Demonstration of very pathogenic parvovirus (Derzsy's disease virus) in Muscovy duck farms. *Recl Med Vet.* 167:849–857.
35. Jestin, V., M.O. Le-Bras, and M. Cherbonnel. 1994. Control of Muscovy duck parvovirus. In: *New and Evolving Diseases of Poultry*. M.S. McNulty and J.B. McFerran, eds. Commission of the European Communities, Brussels, 167–181.

36. Ji J., Q.M. Xie, C.Y. Chen, S.W. Bai, L.S. Zou, K.J. Zuo, Y.C. Cao, C.Y. Xue, J.Y. Ma, and Y.Z. Bi. 2010. Molecular detection of muscovy duck parvovirus by loop-mediated isotermal amplification assay. *Poultry Sci.* 89:477–483.
37. Ju, H., N. Wei, Q. Wang, C. Wang, Z. Jing, L. Guo, D. Liu, M. Gao, B. Ma, and J. Wang. 2011. Goose parvovirus structural proteins expressed by recombinant baculoviruses self-assemble into virus-like particles with strong immunogenicity in goose. *Biochem Biophys Res Comm.* 409:131–136.
38. Kaleta, E.F. 1985. Immunisation of geese and Muscovy ducks against parvovirus hepatitis (Derzsy's disease). Report of a field trial with the attenuated live vaccine "Palmivax." Dt *Tirarztl Wschr*. 92:303–305.
39. Kardi, V., and E. Szegletes. 1996. Use of ELISA procedures for the detection of Derzsy's disease virus in geese and antibodies produced against it. *Avian Pathol.* 25:25–34.
40. Kisary, J. 1974. Cross-neutralisation tests on parvoviruses isolated from goslings. *Avian Pathol.* 3:293–296.
41. Kisary, J. 1977. Immunological aspects of Derzsy's disease in goslings. *Avian Pathol.* 6:327–334.
42. Kisary, J. 1979. Interaction in replication between the goose parvovirus strain B and duck plague herpesvirus. *Arch Virol.* 59:81–88.
43. Kisary, J. 1986. Diagnosis and control of parvovirus infection of geese (Derzsy's disease). In: *Acute Virus Infections of Poultry*. J.B. McFerran and M.S. McNulty, eds.) Martinus Nijhoff, Dordrecht, Netherlands. 239–242.
44. Kisary, J. 1989. Clinical and pathological features: Diagnosis of avian parvovirus infections. In: *CRC Handbook of Parvoviruses*, Volume II. P. Tijssen, ed. CRC Press Inc, Boca Raton, FL. 193–203.
45. Kisary, J. 1999. RecombiVac-S, the first Hungarian bio-synthetic (recombinant) subunit vaccine. *Magy Állatorv Lap*. 121: 243–247.
46. Kisary, J., and D. Derzsy. 1974. A viral disease of goslings. IV. Characterization of the causal agent in tissue culture systems. *Acta Vet Hung.* 24:287–292.
47. Kisary, J., D. Derzsy, and J. Meszaros. 1978. Attenuation of the goose parvovirus strain B. Laboratory and field trials of the attenuated mutant for vaccination against Derzsy's disease. *Avian Pathol.* 7:397–406.
48. Krauss, H. 1965. Eine Verlustreiche Aufzuchtkrankheit bei Gansekuken. *Berl Munch Tierarztl Wschr.* 78:372–375.
49. Kwang, M.J., H.J. Tsai, Y.S. Lu, A.C.Y. Fei, Y.L. Lee, D.F. Lin, and C. Lee. 1987. Detection of antibodies against goose parvovirus by an enzyme-linked immunosorbent assay (ELISA). *J Chin Soc Vet Sci.* 13:17–23.
50. Le Gall-Recule, G., and V. Jestin. 1994a. Biochemical and genomic characterisation of Muscovy duck parvovirus. *Arch Virol.* 139:121–131.
51. Le Gall-Reule, G., V. Jestin, P. Chagnaud, P. Blanchard, and A. Jestin. 1996. Expression of Muscovy duck parvovirus capsid proteins (VP2 and VP3) in baculovirus expression system and demonstration of immunity induced by the recombinant proteins. *J Gen Virol.* 77:2159–2163.
52. Li, L., J. Qiu, and D.J. Pintel. 2009. The choice of translation initiation site of Rep proteins from goose parvovirus P9-generated mRNA is governed by splicing and the Nature. of excised intron. *J Virol*. 83:10264–10268.
53. Limn, C.K., T. Yamada, M. Nakamura, and K. Takehara. 1996. Detection of goose parvovirus genome by polymerase chain reaction: distribution of goose parvovirus in Muscovy ducklings. *Virus Res.* 42:167–172.
54. Lu, Y.S., Y.L. Lee, D.F. Lin, H.J. Tsai, C. Lee, and T.H. Fuh. 1985. Control of parvoviral enteritis in goslings in Taiwan: The development and field application of immune serum and an attenuated vaccine. *Taiwan J Vet Med.* 46:43–50.
55. Lu, Y.S., D.F. Llin, Y.L. Lee, Y.K. Liao, and H.J. Tsai. 1993. Infectious bill atrophy syndrome caused by parvovirus in a co-outbreak with viral hepatitis in ducklings in Taiwan. *Avian Dis.* 37:591–596.
56. Malkinson, M., Perk, K., Weisman, Y. 1981. Reovirus infection of young Muscovy ducks (*Cairina Moschata*). *Avian Pathol.* 10:433–440.
57. Nadtochei, G.A., and E.V. Petelina. 1985. Ultrastructural changes in the liver and small intestine of geese infected with parvovirus. *Trudy Vses Inst Eksp Vet*. 62:103–112.
58. Nagy, Z., and D. Derzsy. 1968. A viral disease of goslings. II Microscopic lesions. *Acta Vet Hung.* 18:3–18.
59. Palya, V., R. Glávits, M. Dobos-Kovács, É. Ivanics, E. Nagy, K. Bányai, G. Reuter, G. Szűcs, Á. Dán, and M. Benkő 2003. Reovírus identified as cause of disease in young geese. *Avian Pathol.* 32:129–138.
60. Palya, V., É. Ivanics, R. Glávits, Á. Dán, T. Mató, and P. Zarka. 2004. Epizootic occurrence of haemorrhagic nephritis enteritis virus infection of geese. *Avian Pathol.* 33:244–250.
61. Palya, V., A. Zolnai, Z. Benyeda, E. Kovács, V. Kardi, and T. Mató. 2009. Short beak and dwarfism syndrome of mule duck is caused by a distinct lineage of goose parvovirus. *Avian Pathol.* 38:175–180.
62. Palya V. 2011. Unpublished data.
63. Poonia, B., P.A. Dunn, H. Lu, K.W. Jarosinski, and K.A. Schat. 2006. Isolation and molecular characterisation of a new parvovirus from Muscovy ducks in the USA. *Avian Pathol.* 35:435–441.
64. Qiu, J., F. Cheng, Y. Yoto, Z. Zádori, and D. Pintel. 2005. The expression strategy of goose parvovirus exhibits features of both the Dependovirus and Parvovirus genera. *J Virol.* 79:11035–11044.
65. Roszkowski, J., P. Gazdzinski, W. Kozaczynski, and M. Bartoszcze. 1982. Application of the immunoperoxidase technique for the detection of Derzsy's disease virus antigen in cell cultures and goslings. *Avian Pathol.* 11:571–578.
66. Samorek-Salamonowicz, E., J. Budzyk, and G. Tomczyk. 1995. Syndrom "karlowatoski I skróconego dzioba" u kaczek mulard. *Zycie Weterrynaryjne*, 2:56–57.
67. Schettler, C.H. 1971a. Virus hepatitis of geese. II. Host range of goose hepatitis virus. *Avian Dis.* 15:809–823.
68. Schettler, C.H. 1971b. Goose virus hepatitis in the Canada goose and snow goose. *J Wildl Dis.* 7:147–148.
69. Schettler, C.H. 1973. Virus hepatitis of geese. III. Properties of the causal agent. *Avian Pathol.* 2:179–193.
70. Shien, J.H., Y.S. Wang, C.H. Chen, H.K. Shieh, C.C. Hu, and P.C. Chang. 2008. Identification of sequence changes in live attenuated goose parvovirus vaccine strains developed in Asia and Europe. *Avian Pathol.* 37:499–505
71. Sirivan, P., M. Obayashi, M. Nakamura, U. Tantaswasch, and K. Takehara. 1998. Detection of goose and Muscovy duck parvoviruses using polymerase chain reaction—restriction fragment length polymorphism analysis. *Avian Dis.* 42:133–139.
72. Soike, D., B. Köhler, and K. Albrecht. 1999. A circovirus-like infection in geese related to a runting syndrome. *Avian Pathol.* 28:199–202.

73. Soike, D., K. Albrecht, K. Hattermann, C. Schmitt, and A. Mankertz. 2004. Novel circovirus in mulard ducks with developmental and feathering disorders. *Vet Rec.* 154:792–793.
74. Takehara, K., K. Hyakutake, T. Imamura, K. Mutoh, and M. Yeshimura. 1994. Isolation, identification and plaque titration of parvovirus from Muscovy ducks in Japan. *Avian Dis.* 38:810–815.
75. Takehara, K., T. Ohshiro, E. Matsuda, T. Nishio, T. Yamada, and M. Yoshimura. 1995. Effectiveness of an inactivated goose parvovirus vaccine in Muscovy ducks. *J Vet Med Sci.* 57:1093–1095.
76. Takehara, K., T. Nakata, K. Takizawa, C.K. Limn, K. Mutoh, and M. Nakamura. 1999. Expression of goose parvovirus VPI capsid protein by a baculovirus expression system and establishment of a fluorescent antibody test to diagnose goose parvovirus infection. *Arch Virol.* 144:1639–1645.
77. Tatár-Kis, T., T. Mató, B. Markos, and V. Palya. 2004. Phylogenetic analysis of Hungarian goose parvovirus isolates and vaccine strains. *Avian Pathol.* 33:438–444.
78. Tsai, H.J., C.H. Tseng, P.C. Chang, K. Mei, and S.C. Wang. 2004. Genetic variation of viral protein 1 genes of field strains of waterfowl parvoviruses and their attenuated derivatives. *Avian Dis.* 48:512–521.
79. Villatte, D. 1989. Maladie de Derzsy ou hepatonephrite-ascite de l'oison et du caneton de Barbarie (h.n.a.) ou parvovirose. In: *Manuel pratique des maladies des palmipedes*, 1st ed. Nouvelles Editions de Publications Agricoles. Paris 114–117.
80. Wachnik, Z., and J. Novaki 1962. Wirosowe zapaleine watroby u gesiat. *Medycyna Wet.* 18:344–347.
81. Wang, C.Y., H.K. Sheih, J.H. Shien, C.Y. Ko, and P.C. Chang. 2005. Expression of capsid proteins and non-structural proteins of waterfowl parvoviruses in *Escherichia coli* and their use in serological assays. *Avian Pathol.* 34:376–382.
82. Woolcock, P.R., V. Jestin, H.L. Shivaprasad, F. Zwingelstein, C. Arnauld, M.D. McFarland, J.C. Pedersen, and D.A. Senne. 2000. Evidence of Muscovy duck parvovirus in Muscovy ducklings in California. *Vet Rec.* 146:68–72.
83. Yadin, H., D.J. Roozelaar, and J. Hoekstra. 1977. Vaccines against viral hepatitis in geese. *Tijdschr Diergeneesk.* 102: 318–325.
84. Yang, J.L., A.C. Cheng, M.S. Wang, K.C. Pan, M. Li, Y.F. Guo, C.F. Li, D.K. Zhu, and X.Y Chen. 2009. Development of a fluorescent quantitative real-time polymerase chain reaction assay for the detection of Goose parvovirus *in vivo*. *Virol J.* 6:142.
85. Yang, J.L., R. Yang, A.C. Cheng, M.S. Wang, L.Z. Fu, S.Q. Yang, S.H. Zhang, L. Yang, and Z.Y. Xu. 2010. A simple and rapid method for detection of Goose parvovirus in field by loop-mediated isotermal amplification. *Virol J.* 7:14.
86. Zadori, Z., R. Stefancsik, T. Ranch, and J. Kisary. 1995. Analysis of the complete nucleotide sequences of goose and Muscovy duck parvovirus indicates common ancestral origin with adeno-associated virus 2. *Virol.* 212:562–573.
87. Zadori, Z., J. Erdei, J. Nagy, and J. Kisary. 1994. Characteristics of the genome of goose parvovirus. *Avian Pathol.* 23:359–364.
88. Zhang, Y., Y. Li, M. Liu, D. Zhang, D. Guo, C. Liu, H. Zhi, X. Wang, G. Li, N. Li, S. Liu, W. Xiang, and G. Tong. 2010. Development and evaluation of a VP3-ELISA for the detection of goose and Muscovy duck parvovirus antibodies. *J Virol Method.* 163:405–409.
89. Zhu, L.Q., X.Y. Ding, J. Tao, J.Y. Wang, X.J. Zhang, X.B. Wang, Y. Hu, H.F. Li, K.W. Chen, and G.Q. Zhu. 2010. Identification of target cells for Goose parvovirus infection in the immune system organs. *Acta Virologica* 54:211–215.

Chapter 14

Other Viral Infections

Introduction

Y.M. Saif

This chapter has traditionally included viral infections that did not fit into virus groupings used in a given edition of *Diseases of Poultry*. Yet, the grouping of viral infections into different chapters has changed in the different editions for a variety of reasons.

The etiology of some conditions such as proventriculitis and hypoglycemia-spiking mortality in chickens continue to be elusive and are presented in Chapter 33 in this edition. A viral etiology is suspected in both conditions.

Miscellaneous Herpesvirus Infections

Jean Pierre Duchatel and H. Vindevogel

Introduction

Herpesvirus infections have been described in several species of domestic and wild birds including pigeons (10, 40), psittacine birds (34), falcons (26), owls (4), cormorants (13), cranes (5), storks (21), and bobwhite quail (20).

All herpesvirus strains isolated from pigeons in Belgium, France, Australia, and Czechoslovakia have been found to be antigenically similar and to possess the same cultural characteristics (3, 19, 23, 40, 41). Therefore, only 1 pigeon herpesvirus type, pigeon herpesvirus 1 (PHV1), appears to exist. However, following Kaleta (19), various breeds of racing and show pigeons may harbor 2 serologically different herpesviruses and some isolates may contain small- and large-plaque variants.

PHV1 is antigenically different from turkey herpesvirus, Marek's disease virus, infectious laryngotracheitis virus, and duck virus enteritis herpesvirus (27, 29). It also can be clearly distinguished from the psittacine herpesvirus (Pacheco's disease virus) based on antigenic composition and plaque size in cell culture (51).

Conversely, PHV1 cannot be serologically distinguished from the falcon (FHV) and the owl (OHV) herpesviruses, and these viruses have almost identical DNA sequences for a fragment of the herpesviral DNA polymerase gene; thus, it is likely that these 3 herpesviruses are PHV1 (16, 26, 27). All other herpesviruses isolated from wild birds differ antigenically from each other and from other avian herpesviruses except for the bobwhite quail herpesvirus and the crane herpesvirus, which are serologically related (20).

This subchapter will cover PHV1 infections in pigeons and will briefly mention pseudorabies virus infections that can be experimentally induced in pigeons and young chickens.

History

The first observation of intranuclear inclusion bodies in the liver of pigeons, probably associated with PHV1 infection, was reported in 1945 (35). Since 1967, PHV1 has been isolated from diseased pigeons in numerous countries (9, 40).

Incidence and Distribution

The geographic distribution of PHV1 is worldwide (3, 8, 15, 18, 23, 24, 25, 29, 39, 40, 45, 52, 58). In Belgium, the presence of PHV1 was demonstrated in 60% of dovecotes where pigeons were permanently affected with respiratory disease, and PHV1 could be isolated from the pharynx of 82% of pigeons affected with acute coryza (40, 53).

Diseases of Poultry, Thirteenth Edition. David E. Swayne.
© 2013 John Wiley & Sons, Inc. Published 2013 by John Wiley & Sons, Inc.

Etiology

Belonging to the family of Herpesviridae (most probably alpha), PHV1 is called Columbid herpesvirus 1 in the new nomenclature. It possesses the morphology and has the physico-chemical properties of a typical herpesvirus (60).

All avian cell cultures tested to date were susceptible to PHV1, but the cytopathic effects varied (7, 44, 45, 46, 47). Virus multiplication in cell cultures is inhibited by trisodium phosphonoformate (30, 31, 40) and acycloguanosine (37). All of the other mammalian cell lines tested so far have been refractory to the virus except the baby hamster kidney cell line (BHK) (47). All details concerning the multiplication of the virus in chicken embryo fibroblast (CEF) cultures are given in the 12th edition of *Diseases of Poultry* (14)

Pathobiology and Epizootiology

Natural and Experimental Hosts

The pigeon seems to be the natural host of PHV1 with virus infection remaining latent (40). PHV1 has been isolated from budgerigars (*Nymphicus hollandicus*) accidentally infected after close contact with pigeons (48). Pigeons are susceptible to experimental infection by pharyngeal painting, which causes a mainly localized disease (44, 50), or by the intraperitoneal route, causing a systemic infection (10). Systemic infections also can be produced in budgerigars (*Melopsittacus undulates*) by intranasal inoculation of the virus (41). Chickens, ducks, canaries, and hamsters are resistant to infection (10, 40, 42).

Transmission

Susceptible pigeons can be infected through direct contact with infected birds. Egg transmission of PHV1 seems unlikely (43). Mature pigeons in infected flocks are asymptomatic carriers of the virus, and some of them may shed virus from time to time (50).

The vast majority of latently infected mature pigeons re-excrete virus in their throat during the breeding season and during squab gorging (62). Therefore, they are, able to directly transmit the infection to the squabs soon after hatching. Although the squabs become infected, they are protected from the disease by maternal antibodies acquired through the egg yolk. Therefore, most of the squabs themselves become asymptomatic carriers after this initial infection (43). The virus has been isolated from the cloacal bursae and the kidneys of 12-day-old pigeons (unpublished observation).

Incubation Period, Shedding, and Latency

Virus excretion begins 24 hours after inoculation and persists at a high titer for a minimum of 7–10 days in inoculated squabs. Typical lesions appear 1–3 days after infection when viral excretion reaches its peak. Mild episodes of recurrence, without clinical signs, occur spontaneously. High titers of specific antibodies do not prevent these recurrences, and, conversely, recurrent episodes are not more frequent when the animals are nearly devoid of specific antibodies. Pigeon herpesvirus 1 re-excretion also can be provoked by cyclophosphamide (Cy)-treatment of pigeons and this period of re-excretion may be accompanied by lesions (50).

Distribution of Pigeon Herpesvirus 1 in the Host

In classic PHV1 infection, virus generally remains localized in the upper respiratory and digestive tracts. However, naturally occurring experimental pharyngeal infection may be followed by viral dissemination throughout the body, with viral localization and development of lesions in organs such as trachea, spleen, liver, kidney, and brain (6, 8, 43, 44). Indeed, during the primary infection and during episodes of re-excretion following Cy-treatment, a transient viremia may occur (44). Moreover, PHV1 can be transmitted from cell to cell in the presence of high titers of specific antibodies (44). Thus, PHV1 can be spread either by tissue contiguity or by viremia, especially when pigeons are immunosuppressed (40).

Because about 65% of racing pigeons are infected with circovirus (11, 12, 36) and suffering from immunodeficiency, PHV1 is now a major viral infection associated with high morbidity. PHV1 DNA has been detected in 7 of 45 liver samples from pigeons with symptoms of circovirus infection from 5 of 15 lofts (28).

Signs

In the acute form of the disease, pigeons sneeze frequently and show conjunctivitis, and nostrils become obstructed with nasal mucus and moisture. Caruncles, which are normally white, turn yellow-gray.

In the chronic form, sinusitis and intense dyspnea may be observed if the primary viral infection is complicated by *Trichomonas columbae* or secondary mycoplasmal or bacterial invaders (*Mycoplasma columbinum, Mycoplasma columborale, Pasteurella multocida, Pasteurella hemolytica, Escherichia coli*, *Staphylococcus β-hemolysin, Streptococcus β-hemolytic*) (32, 40).

Morbidity and Mortality

Clinical disease is observed principally following primary infection of young pigeons not protected by maternal antibodies and in virus carriers in which the infection is complicated by virtue of debilitating factors (43).

Pathology

Gross Lesions

The mucous membranes of the mouth, pharynx, and larynx are congested, and in severe cases, covered with foci of necrosis and small ulcers. The mucous membrane of the pharynx may be coated with diptheric membranes. When the viral infection is generalized (viremia), foci of necrosis can be observed in the liver. If the initial infection becomes complicated by bacterial infections, the trachea may be obstructed by caseous material and some birds may show airsacculitis and pericarditis (pigeon chronic respiratory disease) (40).

Histopathology

Multiple foci of necrosis are observed in the pharyngeal stratified squamous epithelium and in the salivary glands. Foci contain cells at different stages of degeneration and necrosis, and intranuclear inclusions are present in adjacent epithelial cells. Large foci may extend and form ulcers. Similar foci of necrosis also can be observed in the laryngeal and tracheal epithelium (44).

In generalized infections, pigeons presenting with hepatitis consistently have intranuclear inclusion bodies in many hepatic cells widely spread throughout the organ (8, 44, 45). Lesions also have been described in the pancreas and the brain (6, 8, 10).

Immunity

Neutralizing antibodies appear in squabs at the end of the first week following infection. The importance of these antibodies is difficult to evaluate with regard to re-emergence of active infection (50), but when acquired passively in the form of maternally derived antibodies, they are protective for squabs (43). As a herpesvirus infection, it might be presumed that cell-mediated immunity is important in PHV1 infections.

Diagnosis

Isolation and Identification of Causative Agent

Pigeon herpesvirus 1 can be easily isolated in CEF cultures from pharyngeal swabs of infected pigeons; with more difficulty it also can be isolated from internal organs such as trachea, lungs, or liver. Isolates should be characterized by immunological means such as immunofluorescence (40, 49).

A PHV1 polymerase chain reaction (PCR) amplifying a 242 base pair product of the DNA-dependent DNA polymerase gene has been described (28).

Serology

Specific antibodies can be titrated by virus-neutralization tests or by indirect immunofluorescence and can be detected by counter immuno-electro-osmophoresis (40, 49).

Differential Diagnosis

Clinically, acute PHV1 infection disease may be confused with Newcastle disease virus infection (lentogenic pneumotropic paramyxovirus 1 strains), and chronic PHV1 infection complicated by secondary bacterial invaders must be distinguished from the diphteroid form of poxvirus infection (59, 61). A diagnosis of PHV1 infection requires virus isolation or serological evidence; however, both techniques may fail to demonstrate PHV1 infection in individual pigeons, the first because the animal may not be actively excreting virus and the second because of an absence of seroconversion in a latent carrier. For these reasons, several animals from the same dovecote must be simultaneously examined (40, 49).

Treatment, Prevention, and Control

After primary infection, pigeons become asymptomatic carriers and may re-excrete virus. Chemotherapy trials with trisodium phosphonoformate and acycloguanosine failed to prevent infection (30, 31, 37, 54). Vindevogel et al. (55, 56, 57), therefore, compared the ability of inactivated (in oil adjuvant) or attenuated vaccines to prevent clinical disease, the carrier state, and virus re-excretion. Both types of vaccine were able to reduce primary viral excretion and clinical signs of challenge. Nevertheless, neither attenuated nor inactivated vaccines were able to prevent the appearance of carriers because most of the pigeons re-excreted virus after Cy-treatment. Vaccination did, however, help to prevent viral re-excretion, thereby helping to control viral dissemination.

Pseudorabies Infection of Birds

Pseudorabies virus (Sus herpesvirus 1 [SHV1]) produces a generally mild disease in swine, its natural host, but a fatal disease in cattle. Other animals found infected in nature are dogs, cats, sheep, and rats (22, 25). The virus multiplies well in chicken embryo fibroblast cultures (2).

Experimentally, SHV 1 can infect chickens, chicken embryos, and pigeons (17, 22, 38). Chicken embryos succumb with encephalitis after inoculation on the chorioallantoic membrane, as do 2-day-old chicks after being inoculated subcutaneously (1). Adult chickens, however, are resistant to subcutaneous inoculation (33).

Toneva (38) attenuated a strain of SHV 1 by serial passages in pigeons combining intramuscular and subcutaneous routes of inoculation (pigeon strain 80). Inoculated pigeons developed classic symptoms of encephalitis (i.e., torticollis) and disordered balance. The SHV 1 pigeon strain 80 is avirulent for rabbits, mice, guinea pigs, and piglets after subcutaneous injection but remains lethal after intracerebral inoculation.

Avian Nephritis

Daniel Todd and Tadao Imada

Introduction

Avian nephritis is an acute, highly contagious, typically subclinical disease of young chickens that produces lesions in the kidneys. It is caused by avian nephritis virus (ANV), which was first isolated in chicken kidney (CK) cell cultures from the rectal contents of apparently normal 1-week-old broiler chickens in Japan in 1976 (57). ANV was characterized as an

astrovirus in 2000 on the basis of its genome sequence (19) and is classified as a member of the genus *Avastrovirus*, together with other avian astrovirus species including turkey astrovirus types 1 and 2 (TAstV-1, TAstV-2), duck astrovirus (DAstV), and chicken astrovirus (CAstV) (2). Recently CAstV also has been shown to cause nephritis in young chickens (Todd, unpublished results), but for the purposes of this review, the causal agent of avian nephritis is considered to be ANV and only information relating to ANV infections will be described.

ANVs vary in terms of their pathogenicity and their antigenicity, and this variation is consistent with the high level of capsid protein sequence diversity exhibited (56). Difficulties in isolating and propagating ANVs *in vitro* have restricted their biological characterization and inhibited the development of convenient diagnostic tests. As a consequence, the nature and extent of the disease problems caused by ANV are largely unknown. Although infections are prevalent and widespread in commercial chickens, there have been comparatively few reports describing ANV-associated nephritis in the field (23, 27, 51) and its economic importance is unknown, as is the public health significance of ANV infections. Recent detections in turkeys, ducks, pigeons, and guinea fowl suggest that ANV may have a wide host range, but it remains to be determined whether infections in other avian species result in nephritis (1, 3, 38, 60).

Etiology

Morphology, Physico-Chemical Properties, Classification, Sequence Diversity

ANV was originally considered to be a picornavirus on the basis of characteristics including particle size (28 nm in diameter), absence of surface structure, and cytoplasmic replication (57). Its infectivity is resistant to ethyl ether, chloroform, trypsin, and acid (pH 3.0), and is relatively heat labile, although it shows partial stabilization at 50°C by molar magnesium chloride (4, 19, 25, 57). However, based on genome sequence characteristics shared with mammalian astroviruses, it was later classified as a member of the genus *Avastrovirus* of the family *Astroviridae* (19). It has a positive sense RNA genome, approximately 7,000 nt in size, that contains small, untranslated regions (UTR) at the 5′ and 3′ termini and 3 open reading frames (ORFs), designated ORF 1a, 1b, and 2 (Figure 14.1) (20). ORF 1a and 1b encode the nonstructural 3C-like serine protease and RNA-dependent RNA polymerase respectively, while ORF 2, which adjoins the 3′-UTR, encodes the capsid precursor polyprotein. As is the case with human astroviruses, ORF 2 of ANV is expressed from a subgenomic RNA, which was detected in the ANV-infected cells, in addition to genomic RNA.

A recent taxonomic proposal submitted for approval to the International Committee for the Taxonomy of Viruses (ICTV) by members of the *Astroviridae* Study Group during the preparation of the 9th ICTV Report (2) states that a classification based on genetic criteria is more appropriate than classifying the viruses into species within the genus *Avastrovirus* based only on host of origin (http://talk.ictvonline.org/files/proposals/taxonomy_proposals_vertebrate1/m/vert01/2358.aspx). According to this proposal ANV would be assigned to a separate species, called G1b, while G1a would comprise TAstV-1, and G2a would comprise TAstV-2 and DAstV. The proteins encoded by the ANV ORFs share low-level amino acid identities with those of mammalian and other avian astroviruses. Thus, ORFs 1a, 1b, and 2 of ANV (G-4260 strain) display pairwise amino acid identities of 17%, 43%, and 23% with those of human astrovirus serotype 6 and 28%, 54%, and 29% with those of TAstV-2. Analyses of ANVs from the United Kingdom and Europe (56) and the United States (39) showed that the capsid proteins of ANVs exhibit substantial amino acid sequence diversity, with pairwise amino identities as low as 51% being observed.

A recent study comparing the capsid protein sequences of 27 ANVs from the United Kingdom, Europe, and Japan identified 6 different capsid groups (Figure 14.2) (56). Representative viruses from each of group, 2 of which were

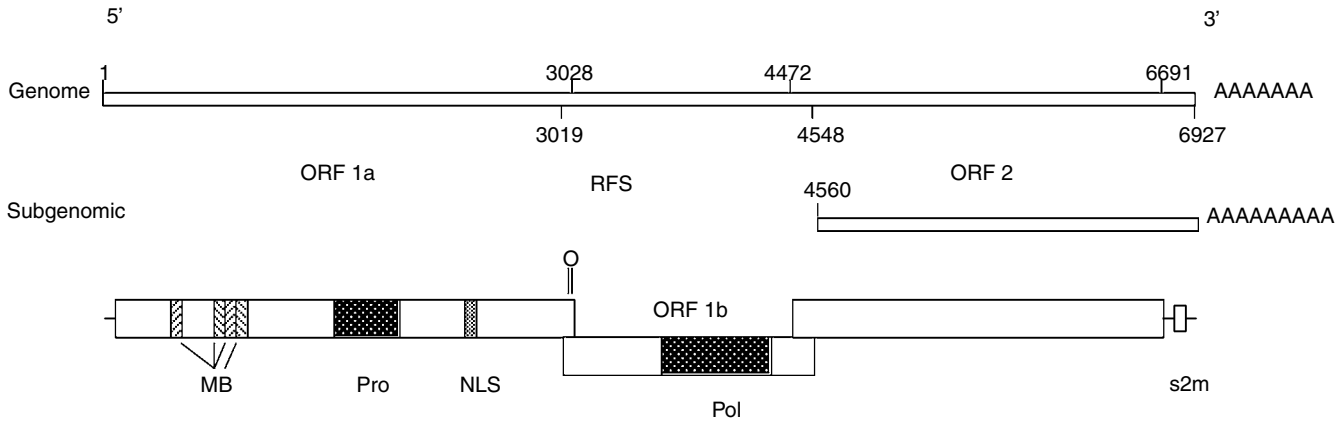

Figure 14.1. Schematic representation of the ANV (G-4260 strain) genome. Open boxes, ORFs. The locations of 3 ORFs, predicted transmembrane helices (MB), protease (Pro), nuclear localization signal (NLS), ribosomal frameshift structure (RFS), RNA-dependent RNA polymerase (Pol), and stem-loop II-like motif (s2m) are indicated. Numbering is according to the ANV genomic sequence (accession no. AB033998).

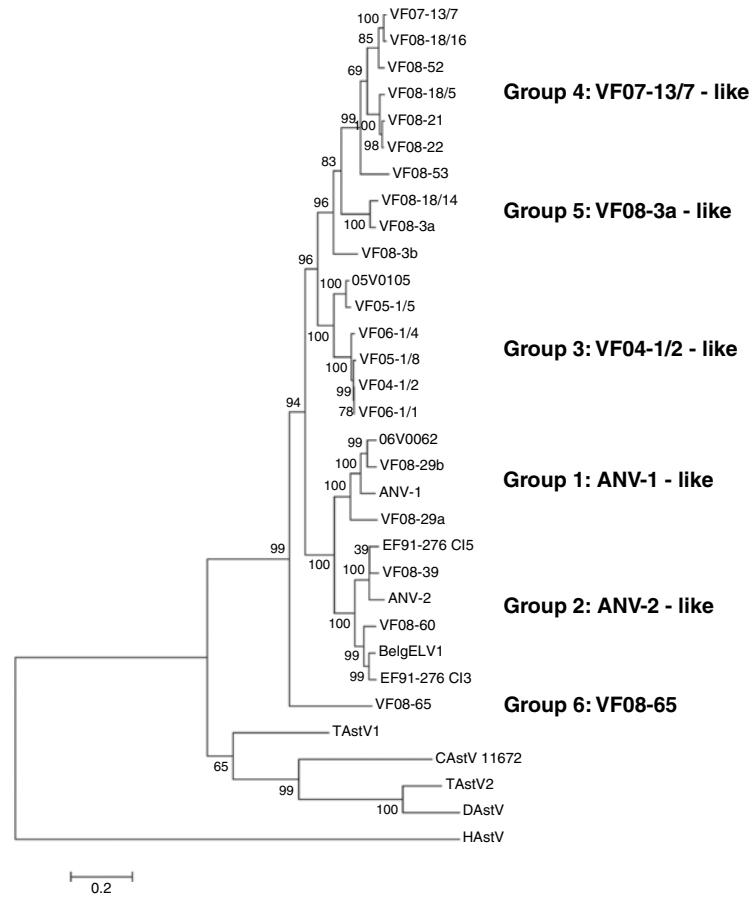

Figure 14.2. Phylogenetic tree of ANVs, other avian astroviruses, and human astrovirus (HAstV) based on capsid amino acid sequences. The tree was constructed using Mega 4 using the Neighbour-Joining method and 1,000 bootstrap replicates (bootstrap values are shown on the tree). Data relating to the origin of the ANVs, including the Genbank accession numbers, are described (56). The Genbank accession numbers of the other avian and human astroviruses are Y15936 (TAstV-1), HQ330506 (CAstV), NC_005790 (TAstV-1), FJ434664 (DAstV), and AAC60723 (HAstV serotype 1).

represented by the G-4260 serotype 1 ANV strain (hereafter designated ANV-1) and a serotype 2 ANV strain (ANV-2) from Japan, shared less than 80% amino acid identity (56). Further capsid sequence work supports the view that an ANV from healthy chicken flocks reared in China should be assigned to a seventh capsid group (58), making it likely that additional capsid sequence-based groups will be recognized in future. On the basis that the capsid proteins of the serotypically different ANV-1 and ANV-2 strains shared an amino acid identity of 71%, the low identity levels observed are likely to correlate with substantial antigenic variation and the existence of multiple serotypes (see Serology). The nonstructural proteins appear to be more highly conserved. For example, whereas the capsid proteins of the G-4260 ANV strain from Japan and the Sichuan 54 strain from China share 62% amino acid identity, identities of 86% and 94% were determined for their protease (ORF 1a) and RNA polymerase (ORF 1b) genes, respectively (58).

Laboratory Host Systems

Chicken Embryos

When inoculated with some ANVs by the yolk sac route, 6-day-old embryos died 3–14 days post inoculation (PI). They manifested hemorrhage and edema of the whole body at 3–6 days PI and stunting at 7–14 days PI. When inoculated by the chorioallantoic membrane (CAM) route, high virus doses killed all embryos, but low virus doses allowed some infected embryos to hatch normally. In these eggs, the CAM showed edematous thickening or pocks at the inoculation site, and the embryos were stunted. Embryos inoculated by the allantoic cavity route sometimes became infected, but no virus was detected in allantoic fluids (12, 17).

Cell Culture

ANV differs from previously described mammalian astroviruses in that trypsin is not required for growth in tissue culture. The ANV-1 strain grew in primary CK cells, producing a round cell-type cytopathic effect (CPE) and maximum virus titers at 24 hours PI (57). ANV also can be propagated in LMH cells, a chicken heptocellular carcinoma cell line, but it did not grow in duck embryo fibroblasts, duck embryo kidney cells, or some established mammalian cell lines (HeLa, Vero, MDBK, PK-15, and MDCK). The ability of ANV to replicate and to show CPE *in vitro* may depend on the conditions of the cell cultures and the ANV strain (5, 9, 12, 31, 51).

Pathogenicity

To date, young chickens are the only animals known to be affected clinically by ANV. The severity of clinical disease and kidney lesions following experimental infection of specific pathogen free (SPF) chickens at 1 day of age was greater

than that observed following infection at 14 days of age, suggesting that there may be increasing disease resistance with age of chicken (12, 16, 34). Field viruses exhibit different degrees of pathogenicity in chickens. There are indications that different serotypes, and even strains with the same serotype, can vary in their ability to produce illness and death (9, 10, 12, 14, 23, 41, 46, 47, 48, 51). Recently a novel ANV, typified by "isolate 19," which was isolated from chickens and turkeys affected by runting and stunting and/or locomotory problems, and which differs antigenically from ANV-1, produced stunting, mortality, and nephritis following inoculation of 3-wk-old SPF chickens. Histological lesions were detected in the pancreas, intestine, and kidney, but not in the joints (10). The Belgian PV2 isolate, originally recognized as an enterovirus-like virus (ELV), was shown to cause substantial growth retardation and severe and long-lasting intestinal lesions following experimental infection (9). Lesions were detected in the pancreas and proventriculus and were absent in the kidney tissue from chickens experimentally infected with PV2, suggesting that some ANV isolates such as PV2 may have different tissue tropisms.

ANV had no apparent effect on egg production or egg quality in laying hens (18). It had been reported that infectious bursal disease virus infection and cyclophosphamide treatment enhanced the pathogenicity of ANV in chickens (35, 36). The detection of ANV in hatched ducklings and dead-in-shell duck embryos has led to speculation that ANV infections may be associated with reduced hatchability in ducks (1).

Pathogenesis and Epidemiology

Incidence and Distribution

Accurate information about the incidence and distribution of avian nephritis is not known owing to the transient, usually subclinical nature of ANV infections and the absence of convenient methods for diagnosing disease. The diagnosis of ANV infections, achieved originally by virus isolation and serology and more recently by reverse transcriptase-polymerase chain reaction (RT-PCR), is easier than diagnosing ANV-associated nephritis, and evidence indicates that infections are highly prevalent in commercial chickens worldwide. Using serology, ANV has been shown to be widely distributed in chicken flocks in Japan (15, 52, 54) and in some European countries (5, 8, 37). Antibody to ANV also has been detected in SPF flocks and in turkeys (30). Enterovirus-like viruses, antigenically related to ANV, which, for the purposes of this review, are presumed to be ANVs, were reported in association with cases of runting and diarrhea in young chickens in some countries (7, 9, 11, 12, 26, 28, 29, 40, 48). Since 2007, ANV has been detected by RT-PCR in commercial chickens in numerous countries worldwide including the United States (6), China (58), several in Africa (Todd, unpublished results), Australia (13), and several within Europe (23, 56). ANV also has been detected in turkeys, ducks, pigeons, and guinea fowl (1, 3, 38, 60). The prevalences of ANV infections and ANV-related disease problems in other avian species are unknown.

Natural and Experimental Hosts

ANV has been detected by RT-PCR in chickens, turkeys, ducks, guinea fowl, and pigeons, including wood pigeons (1, 3, 21, 38, 60). It is therefore likely that it will be detected in other types of birds. Cross-infection is thought possible but the extent to which it occurs is unknown. An attempt to infect turkey poults with the chicken-derived G-4260 strain was unsuccessful (32) and attempts to establish active infection in other animals have not yet been reported.

Horizontal transmission readily occurs by direct or indirect contact (16), with the fecal-oral route thought to be predominant. Vertical transmission via the egg has been suggested on the basis of field observations (5, 51), and virus has been detected in dead embryos from ducks (1) and chickens (Todd, unpublished results). In chicks experimentally infected by the oral route, the virus was first detected in feces 2 days PI, with maximum virus shedding at 4–5 days PI. The virus is widely distributed, with maximum titers in the kidney and jejunum and lower titers in the cloacal bursa, spleen, and liver. The virus was consistently isolated from kidney, jejunum, and cloaca, but not from brain and trachea during the first 10 days PI (14).

Clinical Signs and Pathology

Following infection of 1-day-old chicks, the only clinical sign of ANV-1 infection is transient diarrhea, but not all chicks show this sign. Weight gain is depressed between 7 and 14 days PI. At necropsy at 4–21 days PI, mild to severe discoloration and swelling in the kidneys are observed, and in dead chicks within 2 weeks PI, visceral urate deposits are observed (Figure 14.3) (11, 14, 22, 33, 34, 41, 43, 45). It has been reported that the concentration of serum uric acid or plasma urate value of ANV-infected 1-day-old chicks is transiently higher than that of uninfected chicks (33, 34, 35, 36, 45, 47). Mortality may be influenced by the virulence of the ANV strain, strain of birds, and experimental conditions (12, 41, 47, 53).

Under field conditions, clinical signs associated with this virus infection in broiler chickens have varied from none (subclinical) to outbreaks of the so-called runting syndrome, baby chick nephropathy, and visceral gout (11, 15, 23, 26, 28, 44, 48, 50, 51, 57). Nothing is known about clinical signs in turkeys; however, there is some evidence suggesting that ANV infections may cause embryo deaths in ducks (1).

Histopathology

Histopathologic lesions in the kidneys of experimentally infected chickens have been studied (12, 16, 17, 18, 22, 33, 34, 35, 36, 41, 43, 45, 46, 48). The primary changes consisted of necrosis and degeneration of epithelial cells of the proximal convoluted tubules with infiltration of granulocytes.

Figure 14.3. Visceral urate deposits in a chick that died 10 days PI. Chalk-like urate crystals were deposited on the surface of the peritoneum and liver, although those on the surface of the liver were mostly removed during necropsy. The heart is white due to heavy urate deposits on the epicardium.

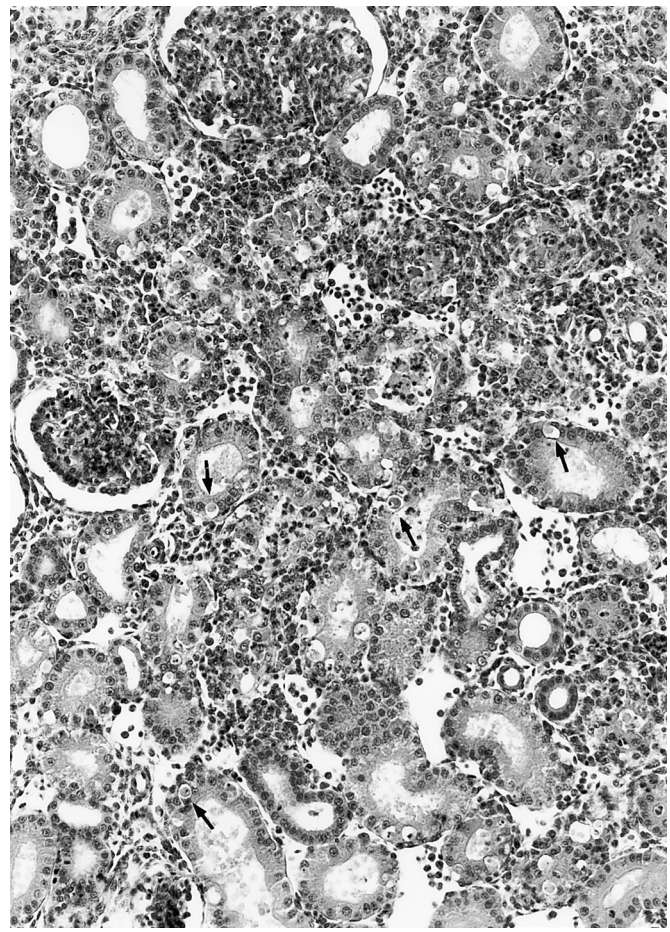

Figure 14.4. Degenerated proximal convoluted tubules containing acidophilic granules (arrows) in epithelial cell cytoplasm, and lymphocytic infiltration in interstitium, 5 days PI. H&E, x300.

The degenerating epithelial cells had acidophilic granules of various sizes in the cytoplasm (Figure 14.4). Also, there was interstitial lymphocyte infiltration and moderate fibrosis. In later stages, at 14–28 days PI, lymphoid follicles developed. ANV particles and viral antigens were demonstrated in the degenerating epithelium by electron microscopy (Figure 14.5) and immunofluorescence (IF), respectively. Virus-specific antigens also were recognized by IF in the jejunum, but distinct microscopic lesions were not observed in the small intestine. The chicks that died revealed many urate tophi in the serosa and parenchyma throughout the body, including the kidneys. Histological lesions that were characteristic of nephritis also have been detected in young chicks that were naturally infected with chicken astrovirus (CAstV), with CAstV-specific antigens being detected in association with the histological lesions (Todd, unpublished results).

Diagnosis

Because ANV infections are highly prevalent and usually subclinical, the diagnosis of nephritis caused by ANV is best achieved by demonstrating the presence of virus antigens by immunohistochemistry (IHC) or IF, or viral RNA by *in situ* hybridization (ISH) at the sites of histopathology within kidney tissue. Diagnosing ANV infections, as opposed to ANV-related disease, can be accomplished by several methods designed to detect either the presence of the virus or serum antibody specific to ANV. Methods for detecting the presence of the virus include virus isolation and identification, demonstration of virus antigen, and demonstration of virus RNA.

Isolation and Identification of ANV

Isolation of Virus

ANVs have been isolated in primary chicken-derived cell culture or embryonating SPF eggs from suspensions of kidney or rectal contents. In ANV-infected primary CK cells, a round cell-type CPE, without hemagglutinin, develops within 72 hours PI. Some ANV strains grow poorly or not at all, and can often be outgrown by other avian viruses, including fowl adenoviruses and reoviruses, which grow readily in cell culture and which occur commonly in clinical samples. ANVs also can be isolated by yolk-sac inoculation of 6-day-old embryonating eggs obtained from an SPF flock with no antibody to ANV (53, 57). Any viruses isolated from infected cell cultures or embryonating eggs need to be identified as ANV. This can be done by demonstrating the presence of virus antigen or virus RNA.

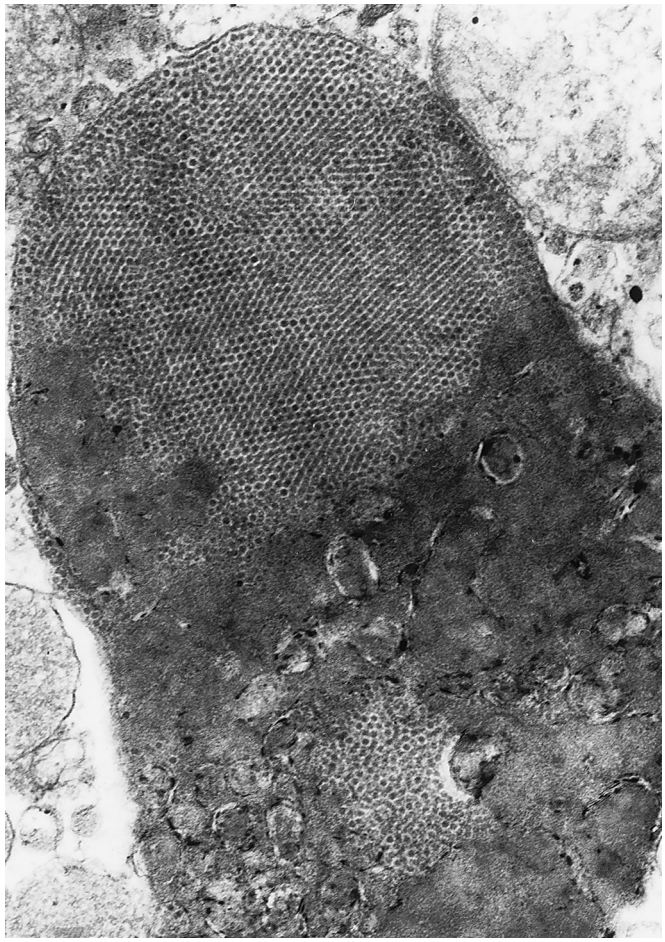

Figure 14.5. Crystalline array of virus particles in the cytoplasm of a kidney epithelial cell, 3 days PI. x30,000.

Demonstration of Virus Antigen

The IF technique can be used to detect the presence of virus antigen, provided that the virus-specific antiserum used is reactive with virus antigens (group antigens) that are common to all of the antigenically-diverse ANV strains. Viral antigens can be detected in the early acute phase of the disease by staining kidney tissue (frozen sections or impression smears). This technique also can be used to detect viral antigens in cell cultures and embryos. In primary CK cells infected with ANV, lumpy and granular antigens are seen in the cytoplasm as early as 12 hours PI.

Demonstration of Virus RNA

Reverse transcription PCR tests for detecting RNA viruses are sensitive, specific, and fast, and are being used increasingly for detecting avian astroviruses including ANV (6, 50). Because astroviruses display substantial levels of nucleotide sequence diversity, the selection and design of the oligonucleotide primers used for amplification should be based on comparisons of as large a number of virus sequences as possible if the developed test is to detect all virus strains, including those with very diverse capsid protein sequences. Four different RT-PCR tests have been described, each amplifying different regions of the ANV genome, including ORF 1a (protease, 24), ORF 1b (RNA polymerase, 6) and the 3′UTR (55, 50). The majority of intestinal content samples from growth-retarded broiler chickens and longitudinal surveys of broiler flocks were shown to be positive by a highly sensitive conventional RT-PCR test (55). Because most enteric samples and a large proportion of kidney samples from commercial broilers are ANV-positive, conventional RT-PCR may be useful for diagnosing infections, but is of questionable value for identifying cases in which the virus infection is causing disease. On the basis that the severity of the pathogenic effect produced by a virus infection is likely to increase with increasing levels of virus replication, a real-time RT-PCR (qRT-PCR) test, which is capable of quantifying the numbers of virus RNA copies present in the clinical sample, has been developed and may prove useful in differentiating cases in which ANV is having a pathogenic effect be it in the intestine or in kidney (50).

Serology

Natural and experimental infections with ANV elicit a virus-specific antibody response in chickens, which can be measured with a conventional virus neutralization test, an indirect IF test, and an enzyme-linked immunosorbent assay (ELISA) (8). Analysis of published data supports the view that there are at least 3 different serotypes, typified by the G-4260 (serotype 1, ANV-1), M8 (serotype 2), and WG3 (serotype 3) isolates (12, 46, 48, 51). The relatively low levels of indirect IF cross reactivity observed when isolates representing the 3 serotypes are compared indicates that an indirect IF test based on antigen specified by a serotype 1 strain, such as G-4260, will not be effective for detecting antibodies elicited by different ANV serotypes (48).

A recent capsid sequence diversity study supports the view that there may be multiple ANV serotypes (56). Because infections with ANVs representing the different capsid sequence groups appear to be common (56, 58), it is likely that many ANV infections will not be serologically diagnosed using an indirect IF test or an ELISA based on a single ANV strain, such as the commonly used ANV-1 strain. This view is supported by recent work by de Wit et al. (10), who showed that serum samples containing detectable antibodies to a novel ANV isolate (isolate 19) did not test positive using an IF test based on ANV-1. Because there may be difficulties in isolating and propagating antigenically-representative ANVs for use in serological tests, capsid protein antigens produced by recombinant DNA-based expression systems may be useful for this purpose. An ELISA based on part of the capsid protein specified by the Sichuan 54 ANV strain from China and produced by an *E. coli*.-based expression system was successfully used to detect antibody in field sera. (59).

Differential Diagnosis

Because certain nephrotoxic strains of infectious bronchitis virus (IBV) and CAstV (Todd, unpublished results) cause interstitial nephritis, it is difficult to differentiate the causal virus on the basis of the histologic lesions (49). The IBV-related cases

may be differentiated from ANV infections by the fact that with infectious bronchitis there are some changes in the trachea, and infections in kidneys are usually preceded by respiratory signs. Therefore, when nephritis is observed in young chickens, it is necessary to apply antigen-detecting methods such as IHC or IF to demonstrate the presence of ANV-specific antigen in kidney tissue showing histopathology. The importance of using an antiserum that is reactive with viral antigens common to all antigenically different ANV strains must be emphasized. The possibility that flocks may be infected simultaneously with ANV and CAstV, or ANV and IBV, or ANV, CAstV, and IBV should not be overlooked.

Treatment, Prevention, Control

There is no specific treatment. It has been possible to produce and maintain SPF flocks that are free of ANV infection as demonstrated by the absence of antibody. However, serological tests based on one ANV strain, such as ANV-1, may not be effective for detecting antibody to the broad range of antigenically different ANVs that are now known to exist (48, 56). If this is the case, then SPF flocks may be infected with undetected, antigenically-different ANVs.

The common and widespread occurrence of ANV in commercial poultry and in wild birds (21), when combined with its capacity for vertical transmission, strongly suggests that its eradication from commercial poultry is not feasible. In addition, astroviruses are very stable in the environment and may be resistant to inactivation by some routinely used disinfectants, and this may make virus elimination from infected premises more difficult (42). Strict biosecurity, increased down time between flocks, and effective disinfection of the premises help reduce the likelihood of exposing young chickens to substantial ANV challenges, which are likely to offer the greatest disease threat.

In theory, administration of an ANV vaccine to parent flocks should prevent or limit vertical transmission of virus that is likely to occur if parent flocks become infected during lay. However, on the basis of capsid sequence data, ANV will exhibit high levels of antigenic diversity, and this will make the prospect of developing an ANV vaccine capable of protecting against all ANV infections very difficult.

Arbovirus Infections

James S. Guy

Introduction

The term arbovirus, an abbreviation of arthropod-borne-virus, is used to describe a virus that replicates in a hematophagous (bloodsucking) arthropod and is transmitted by bite to a vertebrate host. This term has been used to group viruses that share the property of transmission by arthropod vectors. More than 100 arboviruses have been isolated from avian species or ornithophilic arthropod vectors.

Public Health Significance

Eastern equine encephalitis (EEE) virus, western equine encephalitis (WEE) virus, and West Nile (WN) virus are zoonotic agents and potential causes of significant neurological disease in human beings; these infections may progress to paralysis, convulsions, coma, and death. The case fatality rate for EEE virus in human beings is 50–75% (90). Western equine encephalitis virus and WN virus are less severe, with most infections being subclinical. The case-fatality rate in human beings for WEE virus and WN virus is approximately 3%–7% and 4-11%, respectively (68, 90). Human infection usually is acquired by mosquito bite; however, care should be taken to avoid contact or droplet exposure when handling suspect infected birds. Highlands J (HJ) virus and Israel turkey meningoencephalitis (IT) virus are not believed to be pathogenic for human beings.

Etiology

Classification

The arboviruses comprise a large, diverse group of viruses, with members in 12 different virus families. However, only the *Togaviridae* and *Flaviviridae* contain viruses that cause disease in poultry and game birds. The main characteristics of the *Togaviridae* and *Flaviviridae* are presented below.

Togaviridae

Togaviruses are spherical enveloped viruses approximately 70 nm in diameter (Figure 14.6). The genome consists of a single molecule of positive-sense, single-stranded RNA of 9.7–11.8 kb, enclosed within a 40-nm diameter icosahedral nucleocapsid (119). Virions are composed of 2 or 3 envelope proteins (E1, E2, and sometimes E3) that are usually glycosylated, and a fourth capsid (C) protein. The molecular weights of alphavirus E1 and E2 structural proteins are 45–58 kDa; that of E3, when present, is 10 kDa, and C is 30–33 kDa (119). Togaviruses replicate in the cytoplasm, and assembly involves budding of nucleocapsids through host-cell plasma membranes. Some togaviruses exhibit pH-dependent hemagglutinating activity.

Togaviridae comprise 2 genera, Alphavirus and Rubivirus, but only the *Alphavirus* genus contains arboviruses (119). The alphavirus genus includes 29 viruses, including EEE virus,

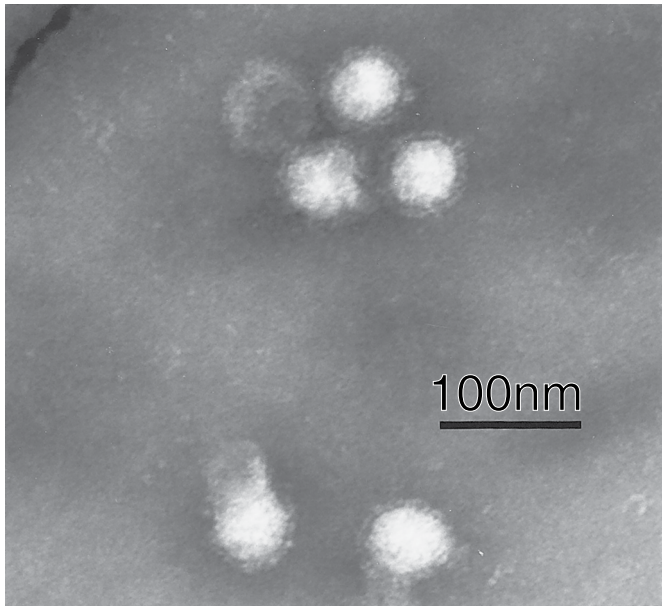

Figure 14.6. Negative-contrast electron micrograph of eastern equine encephalitis virus. x150,000.

WEE virus, Venezuelan equine encephalitis (VEE) virus, and HJ virus. Based on serologic cross reactivity and genetic similarity (61, 119), alphaviruses have been subdivided into 8 antigenic groups. The EEE antigenic group includes EEE virus; the WEE antigenic group includes WEE virus and HJ virus.

Flaviviridae

Flaviviruses resemble togaviruses, with the exception that they are somewhat smaller; they are spherical enveloped viruses approximately 50 nm in diameter (111). They replicate in the cytoplasm and acquire a lipid envelope by budding into cytoplasmic vesicles. The genome consists of a single molecule of positive-sense, single-stranded RNA of approximately 11 kb. Virions are composed of 3 structural proteins (64, 111): an envelope (E) glycoprotein with a molecular weight of 51–59 kDa, a core (C) protein of 13–16 kDa, and a membrane-like (prM or M) protein of 7–9 kDa. Flaviviruses exhibit pH-dependent hemagglutinating activity.

The *Flaviviridae* comprise 3 genera, *Flavivirus*, *Pestivirus*, and *Hepacivirus*, but only the *Flavivirus* genus contains arboviruses (111). The *Flavivirus* genus contains about 70 virus members grouped antigenically into 8 antigenic groups (18, 71). The Japanese encephalitis antigenic group includes WN virus, Japanese encephalitis virus, and St. Louis encephalitis virus (36, 120); the Ntaya antigenic group includes IT virus (18).

Laboratory Host Systems

Day-old chickens and newborn and baby mice are highly susceptible to arboviruses when inoculated by the intracerebral (IC) route and some are susceptible following inoculation by peripheral routes (88, 102). Intracerebral inoculation of newborn mice, 1–4 days of age, is the preferred method for isolation of these viruses. Arboviruses also may be propagated in embryonating chicken eggs and in a variety of vertebrate and arthropod cell cultures. Vero cells, BHK-21 cells, and primary cultures of chicken and duck cells are frequently used for virus propagation. Cytopathic effects are readily produced by arboviruses in vertebrate cell cultures; they are not always produced in arthropod cell cultures.

Arboviruses of Birds

Only 5 arboviruses—eastern equine encephalitis virus, western equine encephalitis virus, Highlands J virus, West Nile virus, and Israel turkey meningoencephalitis virus have been identified as causes of disease in domestic poultry and farm-reared game birds.

Eastern Equine Encephalitis

History

Eastern equine encephalitis virus was first isolated in 1933 from the brain of a horse with encephalitis (110). In 1938, the virus was identified by Tyzzer et al. (114) as the cause of an epornitic disease of penned pheasants. It was subsequently identified as a cause of disease in pigeons, chukar partridges, ducks, and turkeys (27, 34, 83, 104).

Pathobiology and Epizootiology

Incidence and Distribution

Eastern equine encephalitis is most commonly seen as a disease of horses. Many outbreaks of EEE in farm-raised ring-necked pheasants and chukar partridges have been identified, but it occurs only sporadically in other species of poultry and game birds. The disease occurs primarily in the eastern parts of North America, throughout Central America and the Caribbean, and in eastern parts of South America. In the United States, EEE has been identified in most states east of the Mississippi River, as well as Louisiana and Texas; it occurs most often in Atlantic seaboard states and Gulf Coast states. Reported isolations of EEE virus in Europe and Asia have not been confirmed.

Eastern equine encephalitis outbreaks most commonly occur in late summer and fall as a consequence of increasing numbers of mosquito vectors.

Natural and Experimental Hosts

Outbreaks of EEE in avian species have been reported primarily in pheasants (58, 114); however, outbreaks in pigeons (34), chukar partridges (83, 93), turkeys (32, 104, 116), and ducks (28) also have been reported. Episodes of clinical disease in chickens and quail have not been reported, but both species are highly susceptible to experimental infection (113, 114).

Transmission, Carriers, Vectors

Culiseta melanura, an ornithophilic mosquito, is the principal vector of EEE virus in North America (19, 51). The virus also has been identified in a variety of other mosquitoes including *Aedes sollicitans, Coquilletia perturbans, Culex (Cx) pancossa, Cx. dunni*, and *Cx. sacchettae*, as well as mites, lice,

simuliid flies, and culicoides (23, 117, 118). *C. melanura* is the likely vector responsible for transmission to poultry and game birds; transmission to mammalian species most likely occurs by other mosquitoes such as *Aedes* spp. and *Coquillettia* spp., which feed on birds but also have a propensity to bite mammals (82).

Wild birds, primarily the smaller species of Passeriformes, are the principal vertebrate hosts of EEE virus (66, 82, 122). These birds rarely become ill but serve as maintenance and amplifying hosts for the virus in the transmission cycle. In experimental studies, a variety of wild birds were shown to develop viremia lasting up to 4 days; small passeriform birds were shown to develop viremias with maximal lethal-dose-50% (LD_{50}) titers greater than 10^6/mL (66).

Although EEE virus is transmitted principally by mosquitoes, direct transmission has been shown to occur among pheasants as a result of feather picking and cannibalism (50). In addition, pheasants have been experimentally infected by oral inoculation (97). Epornitics of EEE virus infection in pheasants are believed to be initiated by mosquito-borne infection of 1 or more birds in a flock, with subsequent spread occurring as a result of feather picking and cannibalism.

Transmission of EEE virus by semen also has been demonstrated (41); virus was shed in the semen of experimentally infected tom turkeys on days 1 to 5 post infection (PI). Semen collected from infected tom turkeys at 1–2 days PI resulted in transmission to breeder hens after artificial insemination.

Clinical Signs and Pathology

Clinical disease produced by EEE virus in poultry and game birds usually is attributed to central nervous system (CNS) infection with or without involvement of viscera. However, EEE virus also may produce visceral infections with little or no involvement of CNS tissues.

Pheasants

Naturally infected pheasants develop signs of neurologic dysfunction consisting of listlessness, leg paralysis, torticollis, and tremors (8, 114). Clinical signs occurred in 40%–100% of experimentally infected pheasants with mortality of 25%–100% (43, 65, 97). Mortality rates up to 80% have been described for naturally occurring outbreaks.

Tyzzer et al. (114) and Jungherr et al. (60) described the pathology of EEE in pheasants. Gross lesions were not observed; however, histopathologic changes in the CNS consisted of vasculitis, patchy necrosis, neuronal degeneration, and meningeal inflammation.

Turkeys

Outbreaks of EEE in turkeys in Wisconsin were characterized by drowsiness, incoordination, progressive weakness, and paralysis of legs and wings (104). Mortality in affected flocks was low, generally less than 5%. Infected turkeys had neurologic lesions consisting primarily of calcification of blood vessel walls in the cerebral cortex, the cerebellar folia, and the basal part of the medulla. Central nervous system lesions in intracerebrally inoculated birds included lymphocytic perivascular infiltration, neuronal degeneration, and endothelial cell swelling. Calcification of blood vessel walls was not observed in intracerebrally inoculated birds that died before 6 days PI.

Ficken et al. (32) serologically identified EEE virus as the cause of high mortality in young (1- to 4-week-old) turkeys. Subsequent experimental studies demonstrated susceptibility of young turkeys to experimental infection (38). Two-week-old turkeys experimentally infected with EEE virus exhibited depression, somnolence, and high mortality. Viremia was detected in infected turkeys on days 1 and 2 PI, with peak viremia of $10^{5.5}$ plaque-forming units/ml (PFU/ml) detected on day 1 PI. Pathologic changes consisted of multifocal necrosis in heart (Figure 14.7A), kidney, and pancreas, and lymphoid necrosis and depletion in thymus (Figure 14.7B), spleen, and cloacal bursa (bursa of Fabricius) (Figure 14.7C). No lesions were detected in brains.

Acute drops in egg production in turkey breeder hens due to EEE virus infection were reported by Wages et al. in 1993 (116). Decreased egg production in affected flocks was characterized by sudden onset with production of white thin-shelled and shell-less eggs. No increase in mortality was observed, and acute ovarian regression was the only gross lesion observed. Experimental infection of turkey hens with EEE virus reproduced the disease observed in naturally affected flocks (40). Eastern equine encephalitis virus–infected turkey hens exhibited mild depression and inappetence, but only on day 1 PI. A precipitous decline in egg production began on day 2 PI, and production remained depressed for 15 days; no mortality was observed. Viremia of short duration (1–2 days), peaking at $10^{5.8}$ PFU/ml on day 1 PI, was detected in EEE virus–infected hens.

Chukar Partridges

Chukar partridges infected with EEE virus exhibited clinical signs of depression, somnolence, and high mortality (30%–80%) (93). Pale focal areas were present in hearts of affected birds, and spleens were mottled and enlarged. Microscopic lesions consisted of gliosis, satellitosis, and perivascular lymphocytic infiltration in brains, and myocardial necrosis with lymphocytic infiltration.

Ducks

White Pekin ducklings infected with EEE virus developed a paralytic disease characterized by sudden onset, posterior paresis, and paralysis (27). Mortality rates in EEE virus-affected flocks ranged from 2%–60%. Histopathologic lesions consisted of edema of spinal cord white matter, lymphocytic meningitis, and microgliosis.

Chickens

Newly hatched chickens are highly susceptible to EEE virus and succumb rapidly to infection, often without showing signs of CNS involvement. Byrne and Robbins (15) demonstrated that susceptibility of chickens to lethal EEE virus infection declined rapidly with age; chickens became refractory to lethal

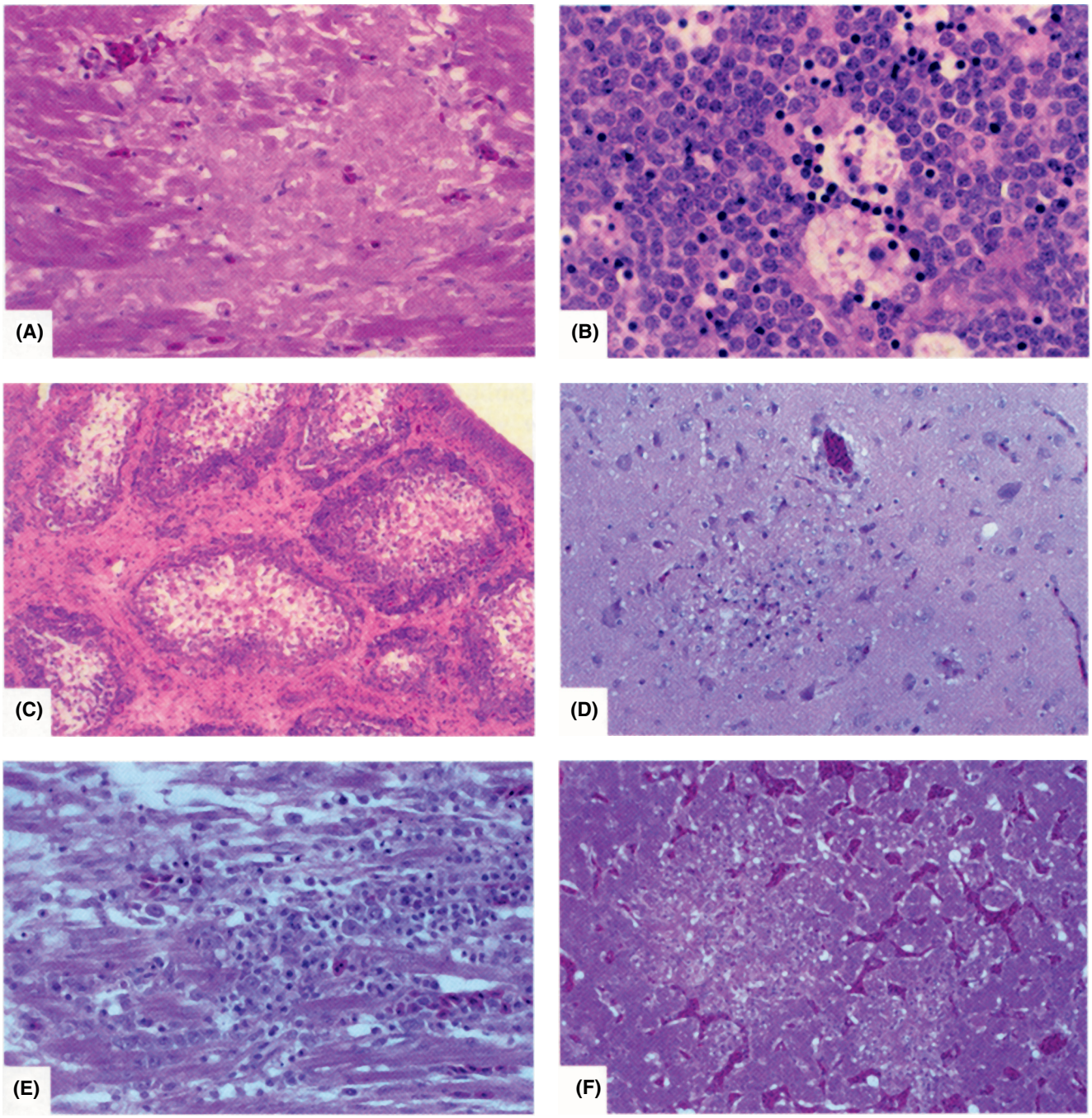

Figure 14.7. Microscopic lesions in turkeys and chickens experimentally infected with eastern equine encephalitis virus. (A) Heart of turkey, 3 days PI. A large focal area of myocardial necrosis is present, with no inflammatory reaction. (B) Thymus of turkey, 3 days PI. Aggregates of pyknotic nuclei within clear spaces indicate acute lymphocyte necrosis. (C) Cloacal bursa of turkey, 3 days PI. Atrophy of bursal follicles with marked lymphoid depletion is present. (D) Brain of chicken, 2 days PI. A focal area of necrosis is present with mild perivascular cuffing. Note emigration of mononuclear cells from an adjacent venule distended with erythrocytes. (E) Heart of chicken, 5 days PI. Myocardial degeneration and necrosis with a mononuclear cell infiltrate. (F) Liver of chicken, 5 days PI. Focal necrosis is present with minimal inflammatory cell response.

infection by 14 days of age. In contrast to their findings, susceptibility to lethal infection was demonstrated by Tyzzer and Sellards (113) in 3- to 13-day-old chickens and by Guy et al. (39) in 14-day-old chickens. The different findings from these studies have not been explained, but differences in age-dependent resistance may be due to differences in host genetics and/or differences in virulence of the EEE viruses used in these studies.

Experimental infection of young chickens, 1–14 days of age, caused depression, somnolence, and high mortality; paralysis was infrequently observed (39, 113). The principal lesion, and the presumed cause of death, was myocarditis.

Microscopic heart lesions consisted of multifocal necrosis with fragmentation of myocardial fibers, and infiltration with lymphocytes, plasma cells, and macrophages (Figure 14.7E). Central nervous system lesions in infected chickens were inconsistently observed (39, 113). In brains, microscopic lesions consisted of occasional small foci of necrosis and mild perivascular cuffing (Figure 14.7D). Multifocal necrosis of the liver (Figure 14.7F) and lymphoid depletion and necrosis in the thymus, spleen, and cloacal bursa also were observed in EEE virus–infected chickens (39). Ascites and right ventricular dilatation of the heart were observed in chickens that survived the acute effects of EEE virus infection; these effects likely occur due to myocardial damage (39).

Diagnosis

Diagnosis of EEE virus may be accomplished by isolation and identification of the virus, detection of viral antigens using antigen-capture ELISAs (47, 48, 98, 99), or immunohistochemistry (123), detection of viral RNA using reverse transcription-polymerase chain reaction (RT-PCR) procedures (115), and serologic testing (102). The virus can be isolated by inoculation of blood or tissue homogenates (brain, spleen, liver, heart) into newborn mice by the intracerebral route, day-old chickens by subcutaneous or intramuscular routes, and 5- to 7-day-old embryonating chicken eggs by the yolk sac route (88, 102). In addition, a variety of cell cultures may be used for virus isolation; Vero, BHK-21, and chicken or duck embryo cells are highly susceptible. Newborn mice and 1-day-old chickens generally die of encephalitis in 2–5 days. Chicken embryos generally die within 18–72 hours and have a hemorrhagic appearance. Cell cultures develop cytopathic effects (CPE) within 24–48 hours, and plaques develop under agar within 36–48 hours. Identification of EEE virus in inoculated animals, embryonating eggs, or cell cultures generally is accomplished by virus-neutralization (VN) tests or complement fixation (CF) tests.

Antigen-capture ELISA procedures for detection of EEE virus antigens have been described (13, 47, 48, 98, 99). These procedures have been shown to be highly sensitive, detecting EEE virus in experimentally infected birds as early as 12 hours PI and in pools of insects in which only 1% of the insects were infected (13, 47, 48, 98, 99). Commercially available antigen-capture ELISA tests recently have become available for detecting EEE virus in mosquitoes; these also are available for detection of WEE virus and WN virus (85).

Immunohistochemical (123) and RT-PCR procedures (115) were described for detection of EEE virus antigens and viral RNA, respectively, in tissues of infected birds. These procedures were shown to be rapid, sensitive, and specific methods for detection of EEE virus in tissues. Additionally, these diagnostic procedures, along with antigen-capture ELISA tests, reduce the human health risks inherent with virus isolation and identification procedures.

Serology

Serological diagnosis of EEE virus may be accomplished using VN, hemagglutination-inhibition (HI), ELISA, and CF. Of these, VN and HI tests are most commonly used. The HI test is rapid and relatively simple; it requires either goose or 1-day-old chicken erythrocytes and antigen prepared from infected suckling mouse brains by the sucrose–acetone extraction method (20, 102). Avian serum contains nonspecific inhibitors of hemagglutination and these must be removed by kaolin adsorption before use in HI tests. A presumptive serologic diagnosis may be obtained by detection of EEE virus antibodies in serum collected from recovered birds. A definitive diagnosis is achieved by demonstrating a rising antibody titer in serum samples collected soon after onset of clinical signs and 1–2 weeks later.

Guy et al. (40) demonstrated the value of serology for diagnosis of EEE virus–induced episodes of decreased egg production in turkey breeder hens. Serology was shown to be particularly important because the virus was found to be present in most tissues of experimentally infected breeder hens for only a very brief period (on days 1–2 PI) following experimental inoculation, yet marked drops in egg production became apparent only after day 2 PI.

Differential Diagnosis

Eastern equine encephalitis must be distinguished from other causes of neurologic disease in poultry and game birds such as HJ virus, Newcastle disease virus, avian encephalomyelitis virus, botulism, and listeriosis. In cases of egg-production drops in turkeys, EEE virus, WEE virus, HJ virus, Newcastle disease virus, avian influenza virus, avian encephalomyelitis virus, paramyxovirus type 3, turkey coronavirus, and turkey rhinotracheitis virus must be considered.

Intervention Strategies

Eastern equine encephalitis is best prevented and controlled by measures aimed at reducing vector populations. Such measures include reduction of vector habitats by modifications of the environment or by chemical spraying. If feasible, farms that raise susceptible avian species should be located away from wetlands and other areas that provide habitat for vectors.

Formalin-inactivated EEE vaccines, prepared for use in horses, have been used to protect pheasants against EEE epornitics (106), although their efficacy has been questioned (29).

Western Equine Encephalitis

Western equine encephalitis virus has many characteristics in common with EEE virus. The virus is rarely associated with disease in avian species; however, a few cases have been reported (22, 31, 93, 124). In 1957, WEE virus was identified by Woodring (124) as the cause of encephalitis and high mortality in turkeys in Wisconsin; affected turkeys exhibited somnolence, tremors, and leg paralysis. Faddoul and Fellows (31) reported the isolation of WEE virus from the brain of a pheasant in Massachusetts, and Ranck et al. (93) identified the virus as the cause of high mortality in chukar partridges in

Florida. However, the association of WEE virus with disease in these species, particularly pheasants (31) and chukar partridges (93), is tenuous. It is now generally accepted that WEE virus rarely occurs in the eastern United States, and that all WEE-related alphaviruses isolated in the eastern United States are strains of HJ virus (see below) (16, 112).

Recently, WEE was associated as a cause of decreased egg production in turkey breeder hens in California (21). Decreased egg production in affected flocks was characterized by sudden onset with production of small, white-shelled and shell-less eggs. No increase in mortality and no clinical signs were observed. A WEE virus isolated from affected breeder hens was evaluated for pathogenicity in 2-week-old turkeys (22). The isolate failed to produce clinically apparent disease in inoculated turkeys, but infection resulted in mild to moderate lymphoid necrosis in cloacal bursa and thymus.

Western equine encephalitis is identified mainly in western parts of the North America, Central America, and South America. It is transmitted principally by *Culiseta tarsalis*, a mosquito vector that is relatively common in the United States west of the Mississippi River (19). Laboratory diagnosis of WEE is accomplished using the same procedures that are used for EEE.

Highlands J Virus Infection

Highlands J virus initially was isolated in 1960 from blue jays in Florida (46). Since that time, the virus has been identified as a cause of disease in chukar partridges (30, 93) and turkeys (32, 38, 40, 116).

Ranck et al. (93) reported that WEE virus was the cause of mortality in chukar partridges in Florida in 1964; however, this virus most likely was HJ virus. Antigenically, HJ virus is closely related to WEE virus and for many years was considered to be a variant of that virus (44, 46, 62). However, serologic and oligonucleotide mapping studies have identified HJ virus as a distinct virus in the WEE antigenic group (16, 17, 61, 112). All viruses belonging to the WEE antigenic group that have been isolated in the eastern United states have been determined to be HJ virus (16).

Ranck et al. (93) experimentally reproduced the disease by subcutaneous inoculation of young chukars. Experimentally infected chukars exhibited somnolence, ruffled feathers, and recumbency prior to death; lesions primarily consisted of encephalitis and myocardial necrosis. Eleazer and Hill (30) described a more recent outbreak of HJ virus infection in chukar partridges. Chukars exhibited similar clinical signs and high mortality (35%); myocarditis was consistently observed in affected birds, but lesions in the brain were uncommon.

Wages et al. (116) found HJ virus to be the cause of acute drops in egg production in turkey breeder hens. In addition, these viruses were serologically associated with mortality in young turkeys (32). Experimental infection of breeder hens with HJ virus produced precipitous egg-production drops (40), but was only mildly pathogenic for young turkeys (38). The clinical and pathologic characteristics of HJ virus infection in turkeys closely resemble those of EEE virus infection (see above).

Laboratory diagnosis of HJ virus infection is accomplished using the same procedures used for EEE virus and WEE virus (32, 40, 121). Highlands J virus is readily distinguished from WEE virus by a variety of serologic procedures using polyclonal and monoclonal antibodies (63).

Israel Turkey Meningoencephalitis

History

Israel turkey meningoencephalitis (IT) was first described in Israel by Komarov and Kalmar in 1960 (70). In 1961, Porterfield (91) identified the etiologic agent as a new virus belonging to the *Flaviviridae*. The disease was identified in South Africa in 1978 (7).

Incidence and Distribution

Israel turkey meningoencephalitis has been reported only in Israel and South Africa. Outbreaks of the disease occur seasonally in Israel, corresponding with activity of arthropod vectors; outbreaks generally begin in late summer, peak in October, and disappear in early winter (52).

Pathogenesis and Epizootiology

Natural and Experimental Hosts

Israel turkey meningoencephalitis has been reported only in turkeys. Field cases of IT rarely are observed in turkeys less than 10 weeks of age, but younger birds are susceptible (95). Experimental infection of turkeys less than 10 weeks of age results in disease with an incubation period of 5–8 days (52). A viremia is detectable within 24 hours PI in experimentally infected turkeys and persists for 5–8 days (55).

Newly hatched poults (53), Japanese quail (*Coturnix coturnix japonica*) (56), and suckling mice (53) are highly susceptible to IT virus inoculated by the intracerebral and intramuscular routes. Chickens, ducks, geese, and pigeons are refractory to infection (70).

Transmission, Carriers, Vectors

The seasonal incidence of IT strongly suggests that this disease is transmitted by insect vectors. The virus has been isolated from unsorted pools of mosquitoes (*Aedes* spp. and *Culex pipiens*) and culicoides trapped near affected turkey flocks (11). Experimentally, IT virus has been shown to infect *Aedes aegypti* and *Culex molestus* mosquitoes (87). Field observations and experimental studies indicate that virus transmission does not occur by direct contact between infected and uninfected birds (55, 57).

Clinical Signs and Pathology

In field outbreaks, IT occurs with greatest incidence in turkeys 10–12 weeks of age. Affected turkeys exhibit neurologic dysfunction characterized by progressive paresis and paralysis, with variable mortality. Morbidity and mortality rates generally

average 15%–30% but may be as high as 80% (52). Affected birds initially exhibit incoordination and walk with 1 or both wings drooping. As the disease progresses, birds become reluctant or unable to walk, and rest on their breasts with legs extended forward and wings spread laterally. Turkey breeder hens exhibit a severe drop in egg production, but egg quality, fertility, and hatchability are unaffected. Egg production returns to normal after recovery from infection.

Gross lesions include splenomegaly or atrophy of the spleen, catarrhal enteritis, and myocarditis (6, 54, 70). Ovarian regression, ruptured ovarian follicles, and peritonitis are observed in affected breeder hens (6). The principal microscopic lesions are nonpurulent meningoencephalitis characterized by submeningeal and perivascular lymphocytic infiltration, and focal myocardial necrosis (54, 70).

Diagnosis

Diagnosis of IT virus may be accomplished by isolation and identification of the virus, detection of viral RNA using RT-PCR procedures (24), and serologic testing (7, 54, 55, 89). Brain, spleen, liver, serum, and ovary are the preferred materials for virus isolation (53, 55). Homogenates of tissue or undiluted serum are inoculated into 6- to 8-day-old embryonating chicken eggs by the yolk sac route, or onto monolayers of chicken embryo fibroblasts (CEF). One or more passages in embryonating chicken eggs may be required before embryo mortality is observed; embryos die 3–6 days PI and show a distinct cherry-red discoloration. Suckling mice inoculated by the intracerebral or intramuscular routes also may be used for virus isolation (53).

A readily recognizable CPE is produced in infected CEF cells by 3 days PI (54, 55); however, CEF cells are less sensitive than embryonating chicken eggs or suckling mice for isolation of IT virus. Identification of isolates usually is accomplished by VN tests.

A specific RT-PCR assay for IT virus has been described (25). This RT-PCR assay was shown to be a rapid method for diagnosis and possessed sensitivity comparable to virus isolation.

Serological diagnosis can be accomplished using HI or VN tests in CEF or BHK-21 cells (7, 54, 55, 89). The HI test requires either goose or day-old chicken erythrocytes and antigen prepared from infected suckling mouse brains by the sucrose–acetone extraction method (53).

Differential Diagnosis

Israel turkey meningoencephalitis must be differentiated from other causes of neurological disease in turkeys, particularly Newcastle disease virus, avian influenza virus, EEE virus, and HJ virus. The known geographic distribution of these viruses and the greater severity of paralysis that is observed with IT as compared with EEE and HJ are helpful in distinguishing these agents. Nervous signs may be observed with Newcastle disease, but paralysis generally does not occur. Nervous signs also may be caused by *Riemerella anatipestifer* infection and ionophore toxicity.

Control

Israel turkey meningoencephalitis is controlled by vaccination. Live attenuated vaccines have been prepared by serial passage of IT virus in embryonating chicken eggs (54), Japanese quail kidney cells (57), and BHK-21 cells (7). The Japanese quail kidney cell attenuated virus has been shown to be highly efficacious and is commercially available. Reduction of insect vector populations in the vicinity of turkey farms also is useful in controlling the disease.

West Nile Virus

History

West Nile (WN) virus was first isolated in 1937 from the blood of a febrile woman in Uganda (103). West Nile virus was identified as a significant cause of disease in domestic avian species in 1997, when the virus was identified as a cause of neurological disease in young geese (75). In August 1999, the disease was detected for the first time in avian species, horses, and human beings in North America (105).

Pathogenesis and Epizootiology

Incidence and Distribution

West Nile virus is now considered to be endemic in many countries in Europe, Asia, Africa, North America, and Central America (45, 105). Outbreaks affecting primarily human beings, horses, and geese occur sporadically and there is evidence for viral transmission bi-directionally between Africa and Europe by migrating birds (3, 35, 76, 79). Most outbreaks begin in late summer and fall and end when cold temperatures reduce mosquito vector activity.

West Nile viruses isolated from different parts of the world were shown to segregate into 2 distinct lineages based on complete genomic sequences (72) and sequence analyses of the E protein gene (9). Lineage I contained WN viruses isolated in Europe and Africa; lineage II contained viruses isolated in Africa, Madagascar, and most recently in Central Europe (4).

Natural and Experimental Hosts

Outbreaks of WN in poultry have been reported primarily in geese (3, 5, 35, 75, 79). In naturally infected flocks, mortality rates of 10% to 60% have been reported (4, 35). In experimentally infected geese, mortality was observed in birds inoculated by the intracerebral route beginning on day 5 PI, and on day 8 PI after inoculation by the intramuscular route.

Ducks, chukar partridges, and pheasants are susceptible to WN virus infection but episodes of naturally occurring disease are rare in these species (49, 125). Naturally occurring disease has been reported in young ducklings, chukar partridges, and pheasantss (49, 125); experimental infection of young Muscovy ducks and Aigamo ducks resulted in clinical signs and mortality (101).

Episodes of clinical disease in chickens and turkeys have not been reported, but both species are susceptible to experimental infection (100, 107).

A wide variety of feral and captive birds are known to be susceptible to WN virus infection (68). In a study examining the role of various feral birds as reservoirs of WN virus in the transmission cycle, 25 species were shown to be susceptible to experimental infection (69). Based on levels of viremia, the 5 most competent species were Passeriform birds: blue jay (*Cyanocitta cristata*), common grackle (*Quiscalus quiscula*), house finch (*Carpodacus mexicanus*), American crow (*Corvus brachyrhynchos*), and house sparrow (*Passer domesticus*).

Transmission, Carriers, Vectors

Culex (Cx) mosquitoes are the principal vectors of WN virus. The virus also has been identified in *Cx. pipiens* and *Cx. Restans* in the United States (37), *Cx. univittatus* in Africa and the Middle East, and *Cx. pipiens* and *Cx. Modestus* in Europe (80). West Nile virus has been isolated from at least 10 tick species belonging to *Amblyomma*, *Dermacentor*, *Hyalomma*, *Rhipicephalus*, *Argas*, and *Ornothodorus* genera (84).

Wild birds are the principal vertebrate hosts of WN virus (2, 78). These birds rarely become ill but serve as maintenance and amplifying hosts for the virus in the transmission cycle. The 1 exception to this rule is in the American crow, which has a high mortality rate after experimental infection and has evidence of natural disease outbreaks. The virus has been isolated from white storks, gulls, feral pigeons, crows, jays, doves, and hawks; these findings suggest that these species become infected and also transmit the virus over considerable distances as they migrate.

West Nile virus is transmitted principally by mosquitoes, but direct transmission has been suggested based on experimental studies (5, 78, 108). In geese, mortality during a WN epizootic was greater than expected if mosquito-borne transmission was the principal route of infection. Contact transmission was investigated experimentally as an alternative explanation (5). A group of 3-week-old geese was inoculated subcutaneously and placed in an insect-proof room with 20 geese of the same age. All geese in the inoculated group produced antibodies, 8 became viremic, and 5 died between 7 and 10 days after infection. Virus was shed from the cloaca and oral cavity by 3 geese. Two of the in-contact birds died on days 10 and 17 after infection, and WNV was recovered from another 3 birds. In another experiment involving 2-week-old goslings inoculated subcutaneously with WN virus, the virus was recovered from plasma of 1 in-contact gosling on day 10 PI and VN antibody was detected on days 14 and 21 PI (108). These findings suggest that direct transmission of WN virus can occur in commercial flocks and may be aggravated if cannibalism and feather-picking of sick geese occur.

Clinical Signs and Pathology

Geese

West Nile virus-infected geese show various degrees of neurological involvement ranging from recumbency to leg and wing paralysis (Figure 14.8) (35, 108). Affected birds are either reluctant or unable to move when disturbed. Signs of incoordination are pronounced; some birds may fall while attempting to stand. Torticollis and opisthotonus may be observed.

Figure 14.8. Six-week-old geese infected with West Nile virus. The bird on the left is unable to stand; the bird on right has spread its wings in attempt to retain its balance (Y. Weisman)

In 3- to 4-week-old geese experimentally infected by the subcutaneous or intramuscular route, viremia was detected in some birds as early as day 1 PI. Peak viremias of 10^4–10^6 tissue culture infectious doses/ml occurred on days 2–4 PI; viral titers declined or disappeared coincident with the appearance of neutralizing antibodies. Some geese had detectable VN antibodies by day 4 PI. Viral excretion from inoculated geese was determined to be from the oropharynx and not from feces. The high viremic levels in infected geese are sufficient to transmit virus to engorging mosquitoes; geese thereby act as reservoirs for further virus circulation.

Pathological changes in WN virus-infected geese include pallor of the myocardium and occasionally the kidneys, splenomegaly, and hepatomegaly, and engorgement of meningeal blood may be observed. Microscopic lesions were found mainly in the brain and consisted of lymphocytic perivascular infiltration and neuronal degeneration (Figure 14.9). Small necrotic foci were present in the heart muscle but lymphocytic infiltration was minimal.

Chickens

Day-old chickens develop neurological signs including tremors and paralysis following inoculation by a variety of routes; clinical signs appeared between 5 and 10 days PI (94). Chickens aged 1–11 days developed viremia of 10^4–$10^{6.3}$ mouse infectious doses/ml following infection by mosquito bite and were capable in turn of infecting mosquitoes (109). In endemic areas chickens may be naturally infected, and sentinel chickens may play an important role in serological surveillance programs (14, 67).

Experimentally infected 7-week-old chickens developed viremia of 10^5 tissue culture doses/ml on day 5 PI that persisted until day 7 PI; this level of viremia is enough to infect engorging mosquitoes. Some chickens shed virus in their feces on days 4 and 5 PI (100). However, no clinical signs or mortality were observed in birds infected subcutaneously with WN virus (100). Birds sacrificed on days 5 and 10 PI

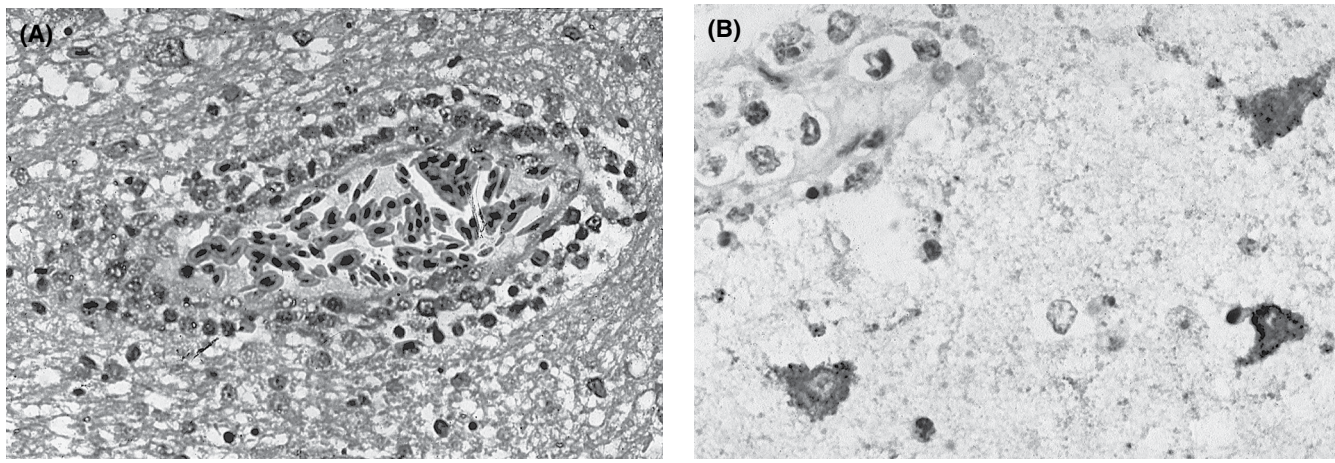

Figure 14.9. Microscopic lesions in the brain of west Nile virus-infected goose. (A) Perivascular cuffing by mononuclear cells. H&E stain. (S. Perl) (B), Immunohistochemistry. Three intensely stained neurons with viral antigen in the cytoplasm; the nuclei remain unstained. Stained granules are dispersed in the neuropil. Counter-staining with hematoxylin. (S. Perl)

showed myocardial necrosis, nephritis, and peritonitis, while at termination of the experiment on day 21 PI nonsuppurative encephalitis was found. No transmission to in-contact chickens was detected; they remained antibody and viremia negative for 21 days.

Turkeys

No morbidity or mortality has been reported in commercial turkey flocks. No clinical signs were observed in 3-week-old turkeys experimentally inoculated subcutaneously with WN virus; however, most of them became viremic for up to 10 days PI (107). Virus was recovered from feces on days 4–7 PI but in-contact poults were not infected.

Immunity

Geese rapidly develop high serum antibody titers to WN virus; however, these are not reliable indicators of protection (12). Cell-mediated immunity to WN virus has not been studied in geese; however, geese vaccinated with a live, attenuated IT vaccine were resistant to intracerebral challenge even though they failed to develop detectable VN antibodies (77). In a mouse model, B cells and antibody were shown to play critical roles in defense against disseminated infection (26).

Maternal antibodies have been detected in sera collected from 1- to 2-week-old goslings hatched from commercial geese flocks but these did not interfere with an active response to inactivated WN virus vaccine. Based on field observations, susceptibility of geese to natural infection appears to decline with increasing age; geese older than 12 weeks of age appear to be resistant to disease.

Diagnosis

Diagnosis of WN virus may be accomplished by isolation and identification of the virus, detection of viral antigens in tissues using immunohistochemistry (105), detection of viral RNA (9, 73, 105), and serologic testing (10, 42). Tissues of choice for isolating WN virus are brain, spleen, and kidneys. Tissue homogenates are inoculated into newborn mice by the intracerebral route, into embryonating eggs by yolk sac route, or onto monolayers of Vero cell cultures or mosquito cell cultures. Mice develop ataxia within 4–7 days; chick embryos die within 2–6 days PI and have a hemorrhagic appearance. Cell cultures develop a cytopathic effect within 48–72 hours. Virus may be identified in cell cultures by indirect immunofluorescence; monoclonal antibodies are commercially available for use in this procedure.

Reverse transcription-polymerase chain reaction procedures recently have been described (11, 73). These procedures allow rapid detection of WN virus in avian tissues, cell cultures, and field-collected mosquitoes. Immunohistochemistry and *in situ* hybridization have been described for detecting WN virus antigens and viral RNA, respectively, in tissues of infected birds (33, 59, 105). These diagnostic procedures minimize the human health risks inherent with virus isolation and identification procedures.

Serology

Serological diagnosis may be accomplished using HI, VN, or ELISA tests. For the HI test, antigen is prepared from infected suckling mouse brains by the sucrose–acetone extraction method (see EEE section).

Several different ELISA procedures have been described for serologic detection of WN virus infection (10, 28, 58, 59). Indirect ELISAs have been developed that use cell culture-propagated WN virus antigen to coat plates (28). Johnson et al. (58) reported the development of an ELISA to detect immunoglobulin M (IgM) antibodies against WN virus (IgM capture ELISA) in serum of chickens; however, the species specificity of the IgM capture procedure precludes application of this procedure to other avian species. The detection of WN virus-specific antibodies in multiple avian species is

possible by use of competitive ELISAs (10, 59); these ELISAs block antibody binding to specific WN virus epitopes.

Differential Diagnosis

Nervous signs in young geese may be caused by a variety of bacteria including *Riemerella anatipestifer*, *Streptococcus gallolyticus*, *Erysipelothrix spp*., *Listeria spp*., *Salmonella spp*., Newcastle disease virus, and avian influenza virus. Nervous signs also may be caused by *Aspergillus spp*. and ionophore intoxication.

Intervention Strategies

Disease caused by WN virus is best prevented and controlled by measures aimed at reducing vector populations. Such measures include reduction of vector habitats by modifications of the environment or by chemical spraying. If feasible, farms that raise susceptible avian species should be located away from wetlands and other areas that provide habitat for vectors.

West Nile vaccines are commercially available, and several types recently have been developed for use in birds and horses (81, 86, 96). Vaccination primarily is used to prevent infection in young goose flocks, especially those raised during late summer and fall when *Culex spp*. are most numerous. Because of age susceptibility, goslings should be immunized as young as possible and preferably at 3 weeks of age.

Field trials have been performed extensively with a formaldehyde-inactivated mouse brain-derived product (77, 96). This vaccine is produced based on the procedure described for production of Japanese encephalitis virus vaccine (1). More than 75% of geese vaccinated with a single dose of vaccine at 3 weeks of age were protected and 94% protection was achieved with 2 doses spaced 2 weeks apart. The duration of immunity was estimated to be approximately 12 weeks. Inactivated vaccines prepared from chick embryos or Vero cells are less protective, likely because of low antigenic mass.

WN virus has been attenuated by serial passage in mosquito cell cultures (74). A single dose of mosquito cell-passaged virus induced immunity to intracerebral challenge in young geese.

The use of IT virus vaccine has been investigated in commercial flocks (77). A single injection given at 3 weeks of age produced protection in geese challenged 2 weeks later. This is an example of cross protection that is known to exist within the flavivirus family (92). However, some birds vaccinated with IT virus vaccine developed a post-vaccination paralytic reaction causing losses of up to 10% in some flocks.

A DNA vaccine based on a recombinant plasmid that expresses the preM and E proteins has been developed (25). In initial experiments mice and horses were protected against infection and lethal challenge.

Acknowledgement

The author wishes to acknowledge M. Malkinson, who coauthored this chapter in previous editions of *Diseases of Poultry*, for his substantial contributions to this chapter.

Turkey Viral Hepatitis

James S. Guy

Introduction

Turkey viral hepatitis (TVH) is a highly contagious, generally subclinical disease of turkeys. It is characterized by multifocal hepatic necrosis with or without accompanying pancreatic necrosis.

The economic significance of TVH is not known. There is no evidence to suggest that TVH virus is transmissible to human beings or other mammalian species.

History

Turkey viral hepatitis (TVH) initially was described in 1959. A picornavirus was suggested as the likely etiology based on size, morphology, site of replication, and antigenic analyses (2, 3, 5, 8, 12). In 1982, MacDonald et al. (3) identified aggregates of 24-nm, picornavirus-like particles in the cytoplasm of hepatocytes in livers from TVH-affected turkeys. In 1991, Klein et al. (2) isolated a picornavirus-like virus, 26–28 nm in diameter, from affected turkeys and reproduced the disease with this isolate. In 2011, TVH virus was determined to be a picornavirus based on nucleotide sequence analyses (1).

Etiology

Turkey viral hepatitis virus recently was identified as a member of the Picornaviridae (1). The Picornaviridae comprise a large family of RNA viruses that infect a wide variety of avian and mammalian species (9). They are characterized by an approximately 22- to 30-nm, isocosahedral, nonenveloped capsid that encloses a single-stranded RNA genome, 7–8.8 kilobases in size (9). Picornaviruses presently are subdivided into 9 genera. Turkey viral hepatitis virus was determined to have sequence similarities with other known picornaviruses, but phylogenetic analyses indicated that this virus could not be classified within presently recognized picornavirus genera (1).

Chemical Composition

The TVH virus genome consists of a single-stranded RNA molecule that is approximately 9 kilobases in size (1). The structural properties of viral proteins have not been determined.

Susceptibility to Chemical and Physical Agents

The virus is resistant to ether, chloroform, phenol, and creoline, but not formalin. In yolk it survives 6 hours at 60°C, 14 hours at 56°C, and 4 weeks at 37°C. It survived for 1 hour at pH 2 but not at pH 12 (11).

Laboratory Host Systems

Turkey viral hepatitis virus can be propagated and assayed in embryonating chicken eggs, embryonating turkey eggs, and turkey poults. The virus has not been propagated in cell culture (12).

The virus may be propagated by yolk sac inoculation of 5- to 7-day-old embryonating chicken eggs (5, 7, 8). Virus was demonstrated in inoculated embryonating chicken eggs at 66 hours PI and peak virus titers of approximately $10^{3.5}$ EID_{50}/ml were detected at 90 hours PI (10). The virus also may be propagated by yolk sac inoculation of embryonating turkey eggs up to 10 days of incubation; however, embryonating chicken eggs have been shown to be a superior host system, possibly due to the presence of maternal antibody in turkey eggs (4).

Turkey poults are susceptible to infection by intraperitoneal, intravenous, and intramuscular routes of inoculation. Clinical signs seldom develop in experimentally infected poults, but infection may be demonstrated 5–10 days PI by necropsy and detection of characteristic lesions (6).

Pathogenesis and Epizootiology

Incidence and Distribution

Turkey viral hepatitis has been described in Canada, the United States, Italy, and Great Britain (3, 4, 5, 8). The disease is believed to be widely distributed in North America, but the true incidence and distribution is not known owing to the frequent subclinical nature of the disease and the absence of serological tests.

Natural and Experimental Hosts

Turkey viral hepatitis has been recognized only in turkeys. Chickens, pheasants, ducks, quail, mice, and rabbits have been shown to be refractory to infection (12).

Transmission, Carriers, Vectors

Transmission of TVH virus occurs readily by both direct and indirect contact. Feces from infected turkeys is believed to be the principal source for virus transmission; the virus could be consistently isolated from liver and feces of experimentally infected birds during the first 28 days PI, and less frequently from bile, blood, and kidney during this period. The virus could not be detected in tissues and feces after 28 days PI (10, 12). Vertical transmission via the egg has been suggested by field observations and by isolation of virus from an ovarian follicle of an experimentally infected hen (7).

Incubation Period

The incubation period in poults, as determined by the appearance of lesions, varied between 2 and 7 days in both intraperitoneally inoculated and in-contact poults (7, 10).

Clinical Signs

Turkey viral hepatitis is usually a subclinical infection of turkeys (3, 6). It is believed that the disease becomes apparent as a result of undefined factors such as concurrent infection and/or environmental stresses. Clinical signs in TVH-affected birds are not well defined. Variable degrees of depression may be observed in affected flocks, but more commonly field cases are characterized by sudden death of apparently normal birds. Turkey viral hepatitis virus has been suggested as a cause of decreased egg production, decreased fertility, and decreased hatchability in turkey breeder hen flocks, but an etiologic role for TVH virus has not been conclusively determined (6).

Morbidity and Mortality

Morbidity and mortality vary considerably among affected flocks. Usually morbidity and mortality are very low with mortality occurring during a 7- to 10-day period (6). However, morbidity rates of up to 100% have occurred in some flocks, and 25% mortality was reported in 1 flock (6). It is believed that severity of morbidity and mortality are influenced by other factors such as concurrent infection. Mortality in turkeys over 6 weeks of age has not been reported.

Pathology

Gross Lesions

Gross lesions attributable to TVH have been detected only in the liver and pancreas. Livers generally are enlarged, and lesions consist of focal, gray, sometimes depressed areas up to several millimeters in diameter (Figure 14.10). Lesion distribution is variable; birds that die usually exhibit very extensive lesions, which often coalesce and may be partially masked by vascular congestion and focal hemorrhage. Pancreatic lesions are less consistently observed than hepatic lesions. Lesions in the pancreas generally are roughly circular, gray-pink, and may extend across a lobe (Figure 14.11).

Microscopic Lesions

Vacuolation of hepatocytes occurs early in the course of infection with dense infiltration by mononuclear leukocytes and proliferation of bile ductules. Lesions progress to overt focal necrosis with pooling of blood around the focus; necrotic cells are scattered among infiltrating lymphocytes (Figure 14.12). Late in the course of infection lesions are comprised of proliferating reticuloendothelial cells which frequently form giant cells (Figure 14.12).

Pancreatic lesions exhibit the same general histopathological changes as those observed in livers. Acinar cell degeneration and necrosis are observed with infiltration of macrophages and lymphocytes.

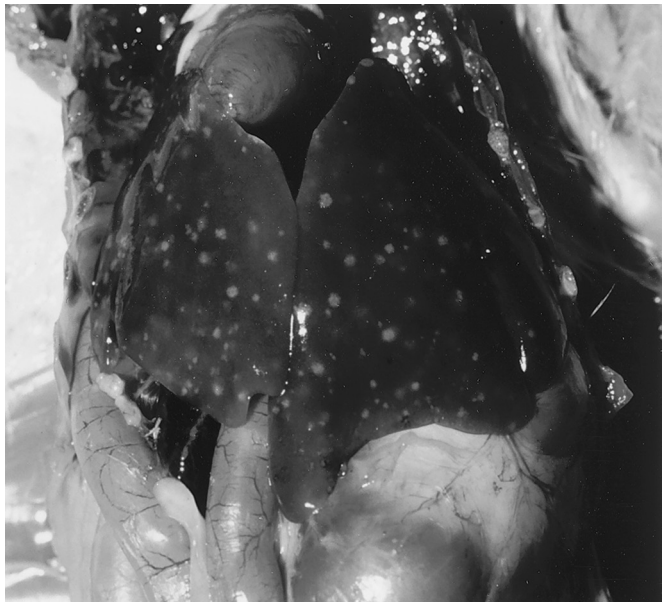

Figure 14.10. Multiple pale tan to gray foci in the liver of a poult with turkey viral hepatitis. Lesions vary from 1 to several mm. They are randomly scattered throughout the liver, and roughly circular, oval, or elliptical. Lesions often have an irregular, "frayed" border, and some have a darker, slightly depressed central area. (H.J. Barnes)

Immunity

Immunologic aspects of TVH have received little attention. Tzianabos and Snoeyenbos were unable to detect neutralizing antibodies in sera from recovered turkeys or hyperimmunized chickens (12). Immunity to reinfection was observed in previously infected turkeys, but the duration of immunity has not been determined (8).

Diagnosis

Diagnosis of TVH may be based on histopathology or virus isolation. Serological procedures currently are not available. Histopathology may be used to presumptively diagnose TVH because the presence of lesions in both the liver and pancreas of turkeys is highly suggestive of the disease. However, similar lesions may be produced in the liver by a variety of bacterial, viral, and protozoal agents. These include *Salmonella spp., Pasteurella multocida*, avian adenoviruses, reovirus, and *Histomonas meleagridis* (6, 7).

Isolation and Identification of Causative Agent

Virus isolation may be accomplished using a variety of tissues including liver, pancreas, spleen, kidney or feces, but liver is the preferred sample. Tissues or feces should be homogenized in an appropriate diluent such as minimal essential medium, and clarified by centrifugation; clarified fecal suspensions should be filtered through a 0.45-μm membrane filter. Homogenates of tissue or fecal suspensions are inoculated into 5- to 7-day-old embryonating chicken eggs by the yolk sac route. In TVH-positive cases, embryo mortality generally occurs 4–11 days PI (8). Embryo mortality is delayed if low virus titers are present and in some cases a second passage using yolk harvest may be required. Embryos exhibit cutaneous congestion and edema; dwarfing is observed in those embryos in which mortality is delayed, and less cutaneous congestion is observed in these embryos (8). Liver lesions containing necrotic foci are sometimes observed in embryos that survive to 11 days PI. Embryonic fluids do not hemagglutinate erythrocytes. Isolates may be further characterized by yolk sac or intraperitoneal inoculation of poults with yolk harvested from infected embryonating eggs; poults are examined for lesions 5–10 days PI.

Figure 14.11. Poult with turkey viral hepatitis showing prominent pancreatic foci. (H.J. Barnes)

Intervention Strategies

No specific therapeutic or prophylactic measures are available. Prevention of stress and other infections may be helpful in preventing normally subclinical disease from developing into TVH.

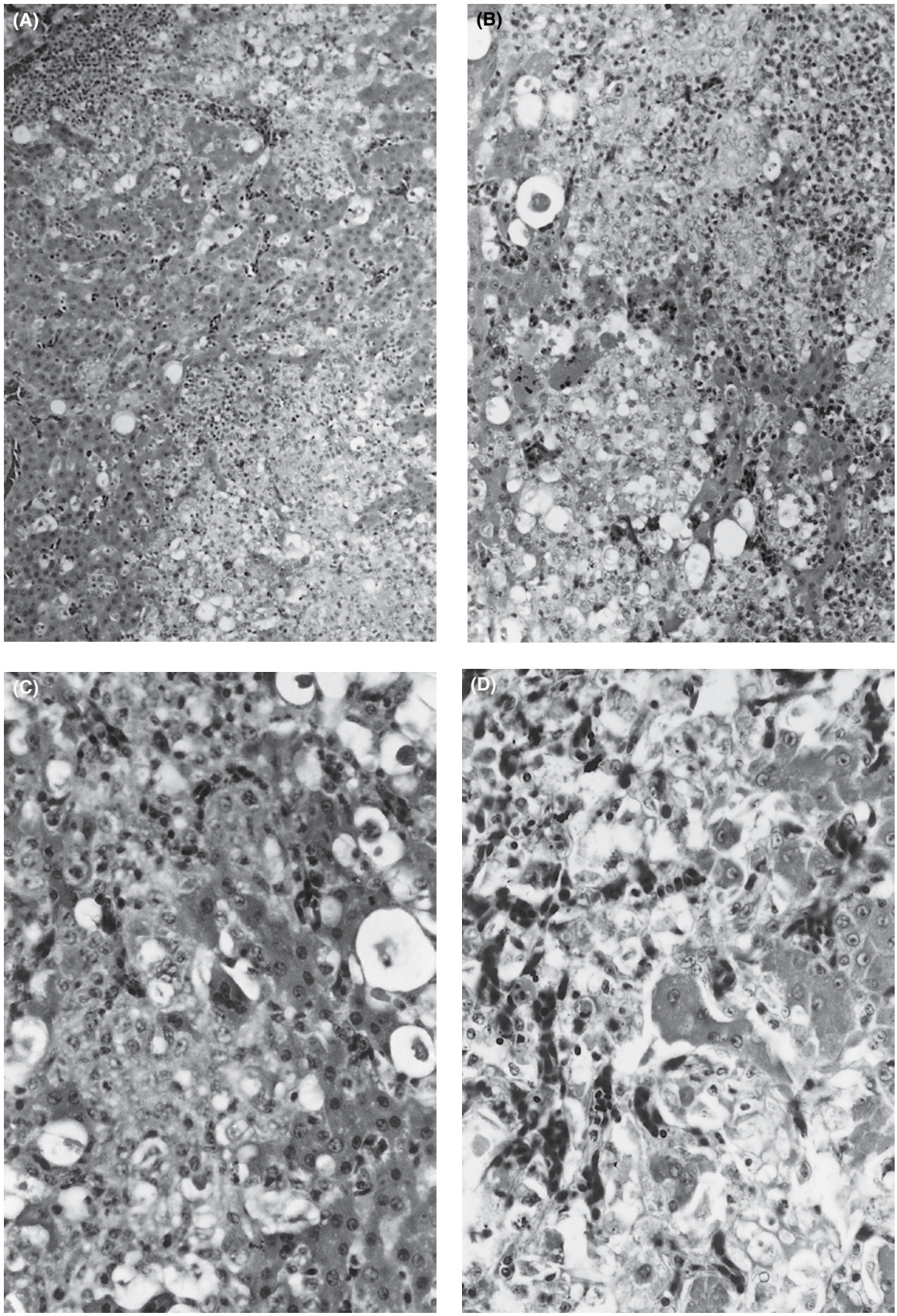

Figure 14.12. Microscopic lesions of turkey viral hepatitis. (H.J. Barnes). (A) Early lesions consist of multiple foci of vacuolar degeneration and coagulative necrosis. Cellular response primarily consists of lymphocytes and macrophages; heterophils are occasionally present but are not numerous. Pancreatic lesions are similar. In the liver, biliary hyperplasia generally is present, but the degree is highly variable among infected turkeys. (B) As lesions mature, they advance along sinusoids, often investing islands of liver cells, creating an irregular margin. (C) Frequently, liver cells within or adjacent to lesions fuse together to form syncytial cells. (D) Nuclear changes as seen here in hepatocytes adjacent to a lesion develop an appearance suggestive of inclusion bodies. Their nature is currently uncertain, but they are not believed to be of viral origin.

Avian Encephalomyelitis

David L. Suarez

Introduction

Avian encephalomyelitis (AE) is an infectious viral disease affecting young chickens, pheasants, quail, and turkeys. It is characterized by ataxia and rapid tremors, especially of the head and neck; because of the latter, it was often called epidemic tremor.

No public health significance has been attached to this disease. The disease was of great economic importance to the commercial poultry industries prior to the widespread use of vaccines in the early 1960s.

History

Jones (43, 44) first encountered AE in 1930 in 2-week-old commercial Rhode Island Red chicks showing tremors. In 1931, 2 additional outbreaks were observed in 1- and 4-week-old chicks raised on different farms but originating from the same breeding flock. During the next 2 years, additional outbreaks were observed in Connecticut, Maine, Massachusetts, and New Hampshire, which led to AE being tagged New England disease.

In 1934, Jones (44) reproduced the disease in susceptible chicks by intracerebral (IC) inoculation with filtrates of brain material from spontaneous cases. It was not until the mid-1950s, however, that Schaaf reported the first successful control of the disease by immunization (75). The epizootiology of AE was clarified by Calnek et al. in 1960 (19), and the development of an orally administered vaccine (20) soon followed. Historical accounts of the control of AE and other details are available from several authors (15, 85).

Etiology

Classification

Avian encephalomyelitis virus (AEV) is a member of the Picornaviridae family (57, 89) based on molecular characterization of the virus genome. It was tentatively placed in the Hepatovirus genus because it had some similarities to hepatitis A virus (57), but because of differences in the internal ribosome entry site (IRES)(3) and low homology of several proteins to hepatitis A virus, it has been reclassified as a unique virus and placed as the sole member of the *Tremorvirus* genus (48).

Morphology: Ultrastructure, Size, and Density

In purified preparations of AEV, virions are observed with hexagonal profiles lacking envelopes(30). Based on filtration studies, their size was found to range from 20–30 nm or 16–25 nm (11, 69). By transmission electron microscopic (TEM) examination of purified AEV, virions were 24–32 nm in diameter (30). Later EM studies determined the mean diameter to be 26.1 ± 0.4 nm (86). Intracytoplasmic crystalline arrays observed in Purkinje cells from the brains of infected chickens had particles with diameters estimated to be 22 nm (21) or 25 nm(32).

The virus has a buoyant density of 1.31 – 1.33 g/mL (12, 30, 86) and a sedimentation coefficient of 148 S (30).

Chemical Composition

The AEV RNA genome is a polyadenylated, single-stranded RNA, (89). Complete sequencing of the AEV genome determined a genome size of 7,032 nucleotides not including the poly A tail, and has a predicted open reading frame (ORF) of 6,405 nucleotides starting at nucleotide 495. The closest genetic relationship is with hepatitis A virus with a 39% overall amino acid identity to the polypeptide (57). One of the nonstructural proteins (2A) associated with AEV possessed conserved motifs shared with 2 other picornaviruses, human parechoviruses, and Aichi virus (35). The authors noted that these motifs are characteristic of a family of cellular proteins, 2 of which are involved in the control of cell growth.

Susceptibility to Chemical and Physical Agents

AEV is resistant to chloroform, acid, trypsin, pepsin, and DNase and is protected against effects of heat by divalent magnesium ions (8, 12). The virus was found susceptible to a single exposure to formaldehyde fumigation(36), and beta-propriolactone also inactivates the virus (18).

Strain Classification and Pathogenicity

Although all isolates of AEV are serologically similar, there are 2 distinct pathotypes of virus. One, represented by natural field strains, is enterotropic. These strains infect chickens readily via the oral route and are shed in the feces. They are relatively nonpathogenic except in susceptible chicks infected by vertical transmission or by early horizontal transmission, in which case they cause neurologic signs. Neurologic disease also occurs following experimental infection by intracerebral inoculation of susceptible chickens.

Embryo-adapted strains constitute the other pathotype. These viruses are highly neurotropic and cause severe neurologic signs following intracerebral inoculation (invariable incidence) or parenteral routes such as intramuscular or subcutaneous inoculation (variable incidence). They do not infect via the oral route except with very high doses, and they do not spread horizontally (17, 41, 42, 61, 77, 99). Adaptation may occur after multiple passages in antibody-free chicken embryos (20, 60, 103). The most commonly used adapted strain is the VR strain, which had been passaged repeatedly by intracerebral inoculation of chickens (93). The VR strain already had the phenotype of adapted strains when first inoculated into embryos after 150 chicken passages (82).

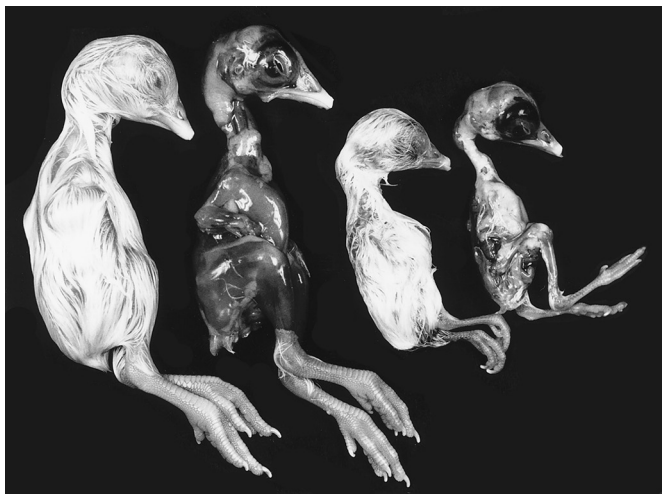

Figure 14.13 Chicken embryos on the right were inoculated via the yolk sac with the Van Roekel strain of avian encephalomyelitis virus on the sixth incubation day. Control embryos are on the left. The affected embryos, examined on the 18th incubation day, show extreme muscular dystrophy (most evident in the embryo with the skin removed) and rigidity of the legs.

Both pathotypes can replicate in embryos derived from a susceptible flock, but natural strains do not cause obvious signs or gross lesions. However, adapted strains are pathogenic for embryos, causing muscular dystrophy (Figure 14.13) and immobilization of skeletal muscles (46). The virus was detected in brains of inoculated embryos 3–4 days PI, and peak titers were found 6–9 days PI (9, 46). Histopathologic changes in embryos infected with egg-adapted virus have been described as uniform in character but variable in intensity and location and consisting of encephalomalacia and muscular dystrophy (46). Muscular changes consisted primarily of eosinophilic swelling and necrosis, fragmentation, and loss of striations of affected fibers with rare sarcolemmal proliferation and heterophil infiltration. Neural lesions were characterized by severe local edema, gliosis, vascular proliferation, and pyknosis.

Laboratory Host Systems

Virus may be propagated in the baby chick, chicken embryos from susceptible flocks, and a variety of cell culture systems. Chicks and embryos must be from a susceptible flock except in the case of intracerebral inoculation of chicks. Several routes of inoculation in embryos have been used (46, 82, 103), but inoculation via the yolk sac at 5–7 days of embryonation generally is considered the method of choice. Gross lesions (see previous section) are observed only with adapted strains. The first successful replication of the VR strain of AEV in chicken embryo brain cultures was in 1967 (56). Subsequently, fibroblasts, kidney cells, and neuroglial cells from chicken embryos and pancreatic cells from young chicks were used to cultivate both adapted and field strains of virus (85). Titers, particularly with natural strains, were generally low (rarely exceeding $10^{3.5}$ EID_{50}/mL), and cytopathic effects have not been described. Replication in cell cultures is detected by inoculation of embryos (adapted strains only) or by tests for antigen using immunofluorescence or ELISA. Chicken embryo neuroglial cells may provide an excellent substrate for production of AEV antigen suitable for serologic tests, such as immunodiffusion and ELISA, and cell cultures can be adopted as the method of choice for titration of AE vaccine (66, 67). In comparison of the VR strain, a field isolate, and a vaccine strain for the ability to grow in chicken embryo brain cultures, the titers with the VR strain, after a 2-day eclipse, were 8–10 times higher than those with the other strains, and virus was largely cell associated (77). Efforts to demonstrate replication of AEV in a variety of established mammalian cell lines have been unsuccessful (1).

Pathobiology and Epidemiology

Incidence and Distribution

Avian encephalomyelitis occurs virtually worldwide (85, 91). Nearly all chicken flocks eventually become infected with the virus, but the incidence of clinical disease is low unless a breeder flock is not vaccinated and becomes infected after the commencement of egg production. Turkey flocks apparently also experience high rates of natural infection based on serological surveys (23). The rate of infection in pheasants and quail is not known.

Natural and Experimental Hosts

Avian encephalomyelitis virus has a limited host range. Chickens, pheasants, coturnix quail, pigeons, and turkeys have all succumbed to naturally occurring infection (10, 90, 91, 98). Experimental infection of young quail chicks (31) caused clinical signs, and the infection spread to breeding quail in the same room. Infection of the adults resulted in reduced egg production and hatchability, and clinical AE developed in chicks hatched from eggs laid during the outbreak. The naturally occurring disease in turkeys is essentially the same as that in chickens (34). Ducklings, poults, young pigeons, and guinea fowl also have been infected experimentally. Mice, guinea pigs, rabbits, and monkeys were refractory to virus introduced intracerebrally (58, 65, 92). Naturally occurring AEV antibodies have been found in serum from partridge, pheasant, and turkeys but not in serum from finches, sparrows, starlings, pigeons, jackdaws, rooks, doves, or ducks (95). The latter 4 species also failed to develop antibodies after oral exposure to AEV. AEV antibodies were reported to be present in sera from ostriches (14), waved albatrosses (70), and penguins (47). A comparison of adult pheasants and red and gray partridges for sensitivity to intramuscular or oral-nasal inoculation with the VR strain of virus demonstrated infection in all 3 species, but the severity of disease based on signs and lesions was greatest in gray partridges and least in pheasants (5). Embryonating eggs from the 3 species also were susceptible to infection.

Transmission

The IC route of inoculation has given the most consistent results in reproducing AE in chickens. Other routes by which infection has been experimentally established are intraperitoneal, subcutaneous, intradermal, intravenous, intramuscular, intrasciatic, intraconjunctival sac, oral, and intranasal inoculation (11, 19, 24, 68, 75, 92).

Under natural conditions, AE is essentially an enteric infection (19). Ingestion is the usual portal of entry (19, 33); exposure via the respiratory tract may be unimportant other than through the coincident exposure of the alimentary tract (19). Virus is shed in the feces for a period of several days, and because it is quite resistant to environmental conditions, it remains infectious for long periods of time. The period during which virus is excreted in feces depends in part on the age of the bird when infected. Young chicks may excrete virus for more than 2 weeks, whereas those infected after 3 weeks of age may shed virus for only about 5 days (76, 102). Infected litter is a source of virus easily transmitted horizontally by tracking or fomites. Infection spreads rapidly from bird to bird within a pen or house once introduced and from pen to pen on farms where no special precautions are taken to prevent spread. Birds in isolated flocks of a single age group were found to be less likely to have encountered infection than chickens on farms with multiple-age groups. Virus spread was found to be less rapid among birds in cages than in those on the floor (19, 25).

Vertical transmission is an important means of virus dissemination based on both field evidence and experimental results (19, 45, 75, 88, 94). A serologic survey showed that 57% of breeder flocks tested in North America had been exposed to the virus by 5 months of age, and that by 13 months 96% were serologically positive (87). Although the source of infection for susceptible flocks is unknown, it is likely that it is carried from infected farms by people or fomites. When susceptible flocks are exposed after sexual maturity, the hens infect a variable proportion of their eggs, and experimentally infected embryos and chicks came from eggs laid during the period 5–13 days after infection of susceptible breeders (19). Conflicting reports on hatchability of eggs from infected flocks has been reported from no effect to a pattern of high embryo death during the last 3 days of incubation (45, 88). The percentage of embryos that hatched declined from a 78.6% preinfection level to 59.6% during the clinical stage and increased to 75.4% post infection. Eggs produced just prior to and during the period of depressed egg production showed decreased hatchability and increased embryo mortality during the last 3 days of incubation. Furthermore, only chicks from the group with depressed hatchability showed signs of AE; chicks hatched prior to and after the affected hatch appeared normal (88). Similar observations have been reported by other workers (19).

Virus transmission also can occur in the incubator(19). Chicks hatched from eggs inoculated at 6 days' incubation manifested signs on the first day of age; by the sixth day, 49 of 52 showed clinical evidence of AE. Chicks from uninoculated eggs hatched with the infected birds first manifested signs on the tenth day, and 15 of 18 chicks developed clinical signs. An isolated control group of 19 chicks remained negative. The possibility of a carrier status is unknown.

Incubation Period

The incubation period in chicks infected by embryo transmission was 1–7 days, whereas chicks infected by contact transmission or oral administration had a minimum incubation period of 10 days (19).

Clinical Signs

Avian encephalomyelitis presents an interesting syndrome. In naturally occurring outbreaks, it usually makes its appearance when chicks are 1–2 weeks of age, although affected chicks have been observed at the time of hatching. Affected chicks first show a slightly dull expression of the eyes, followed by a progressive ataxia from incoordination of the muscles, which may be detected readily by exercising the chicks. As the ataxia grows more pronounced, chicks show an inclination to sit on their hocks. When disturbed, they may move about, exhibiting little control over speed and gait. Finally, they come to rest or fall on their sides. Some may refuse to move or may walk on their hocks and shanks. The dull expression becomes more pronounced and is accompanied by a weakened cry. Fine tremors of the head and neck may become evident, the frequency and magnitude of which may vary. Exciting or disturbing the chicks may bring on the tremor, which may continue for variable periods and recur at irregular intervals. Ataxic signs usually, but not always, appear before the tremor. In some cases, only tremor has been observed. Ataxia usually progresses until the chick is incapable of moving about, and this stage is followed by inanition, prostration, and finally death. Chicks with marked ataxia and prostration are frequently trampled by their penmates.

Some chicks with definite signs of AE may survive and grow to maturity, and in some instances signs may disappear completely. Survivors may later develop blindness from an opacity giving a bluish discoloration to the lens (71).

There is a marked age resistance to clinical signs in birds exposed after they are 2–3 weeks of age (see Pathogenesis of the Infectious Process). Mature birds may experience a temporary drop in egg production (5%–10%) but do not develop neurologic signs.

Morbidity and Mortality

Morbidity from the naturally occurring disease has been observed only in young birds. The usual morbidity rate is 40%–60% if all of the chicks come from the infected flock. Mortality averages 25% and may exceed 50%. These rates are considerably lower if many of the chicks comprising the flock originate from breeder flocks of immune birds.

Pathology

Gross Lesions

The only gross lesions associated with AE in chicks are whitish areas (due to masses of infiltrating lymphocytes) in the muscularis of the ventriculus. These are subtle changes and

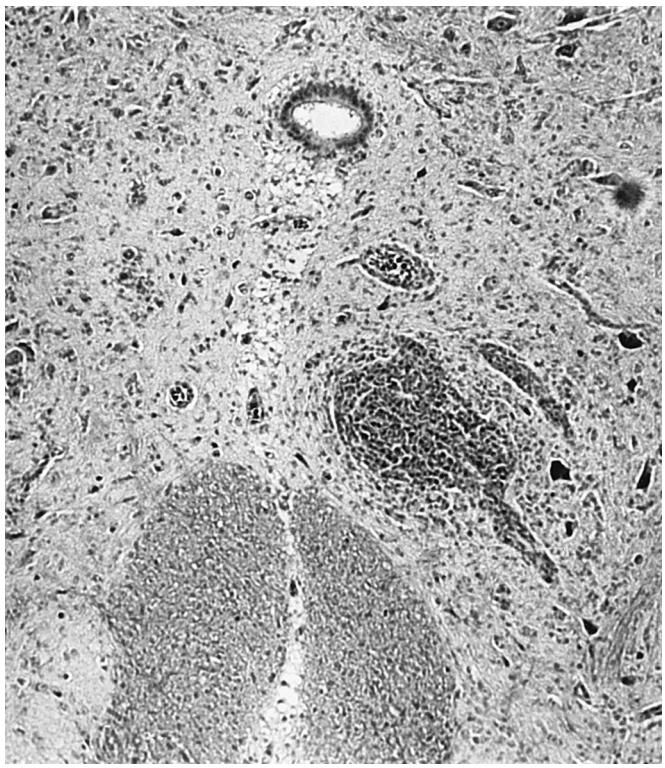

Figure 14.14. Spinal cord at the lumbar level of chick. Large glial nodule and several perivascular infiltrates of lymphocytes are in gray matter. The central canal is at the top. H&E. x75.

Figure 14.15. Perivascular infiltration and gliosis are seen in the nucleus cerebellaris. H&E, x363. (Jakowski)

require favorable conditions to be discerned. No changes have been described for infected adult birds, other than the lens opacities described in "Signs."

Microscopic

The principal changes are in the CNS and some viscera. The peripheral nervous system is not involved, a point of importance in differential diagnosis.

In the central nervous system (CNS), the lesions are those of a disseminated, non-purulent encephalomyelitis and a ganglionitis of the dorsal root ganglia. The most frequently encountered addition is a striking perivascular infiltrate seeming to occur in all portions of the brain and spinal cord (Figures 14.14 and 14.15), except the cerebellum, where it is confined to the nucleus (n.) cerebellaris. Infiltrating small lymphocytes may pile up several layers to form an impressive perivascular cuff.

Microgliosis occurs as diffuse and nodular aggregates. The glial lesion is seen chiefly in the cerebellar molecular layer, where it tends to be compact (Figure 14.16). A loose gliosis usually is found in the n. cerebellaris, brain stem, midbrain, and optic lobes, and less often in the corpus straita. In the midbrain, two nuclei, Cn. rotundus and n. ovoidalis, are invariably affected with a loose microgliosis that can be considered pathognomonic. Another lesion of pathognomonic significance is central chromatolysis (axonal reaction) of the neurons in the nuclei of the brain stem, particularly those of the medulla oblongata (Figure 14.17). This alteration can almost always be found if several sagittal sections are made. The dying neuron is surrounded by satellite oligodendroglia, and later, microglia phagocytize the remains; the central chromatolysis is never seen without an attending cellular reaction.

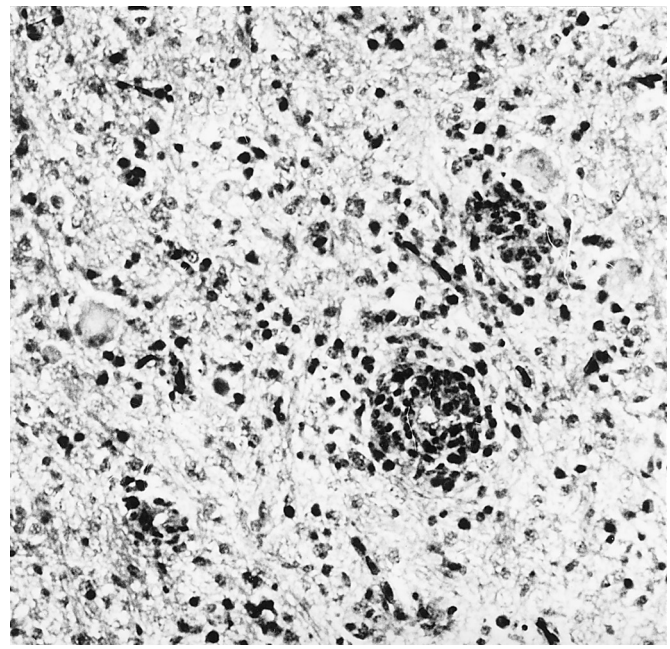

Figure 14.16. Cerebellum of a chick. Glial foci common in avian encephalomyelitis are in the molecular layer. H&E. x375.

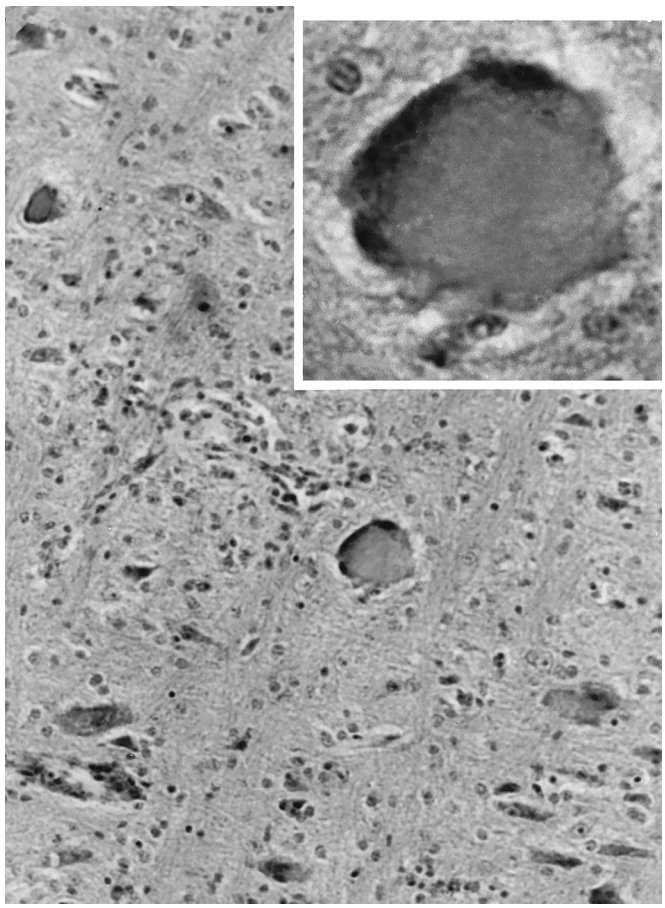

Figure 14.17. Medulla oblongata of chick. There is diffuse gliosis, and in the center a neuron is undergoing central chromatolysis. H&E. 3375. Inset shows tigrolysis and loss of nucleus. x3480.

Brain and spinal cord lesions from experimentally infected chicks on a sequential basis using light and electron microscopy and immunofluorescence techniques showed the most characteristic changes to be degeneration of Purkinje neurons in the cerebellum and motor neurons in the medulla oblongata and spinal cord (32). The central chromatolysis observed in the motor neurons was thought to be reversible, whereas affected Purkinje neurons always became necrotic. Purkinje neurons contained abundant viral antigen and cystalline arrays of virus particles in the cytoplasm (21). Degenerated neuronal cells showed dilatation of rough-surfaced endoplasmic reticulum, a reduction in ribosomes, and mitochondrial degeneration (21, 32, 105). Liu et al. (56, 57, 58), in a series of studies on the nonstructural virus protein 3A, have shed some light on the subject of cell death due to AEV infection. They showed that this membrane-interacting protein can result in membrane permeability and is capable of inducing apoptosis by activating the cytochrome caspace-9 pathway (49–51).

The dorsal root ganglia often contain rather tight aggregates of small lymphocytes amid the neurons. The lesion is always confined to the ganglion and never enters the nerves (Figure 14.18). In general, signs cannot be correlated with severity of lesions or distribution in the CNS.

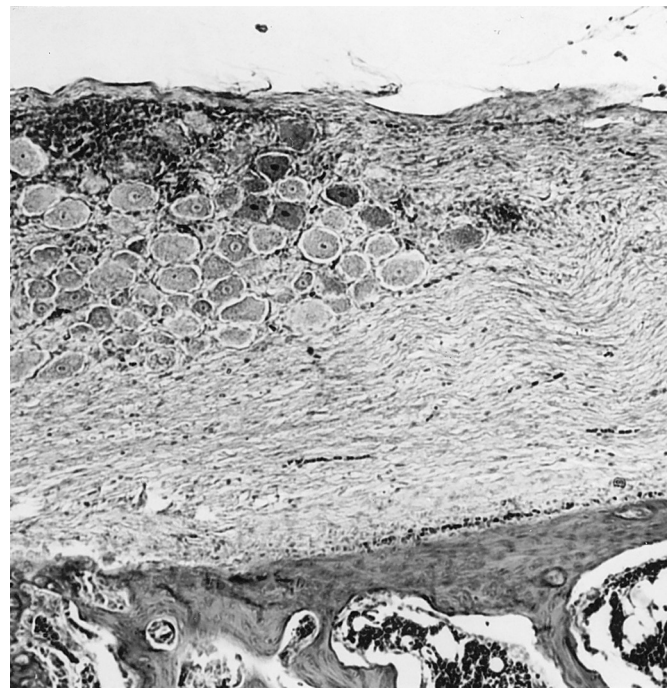

Figure 14.18. Dorsal root ganglion of lumbar level of a chick. Dense infiltrate of lymphocytes is confined to ganglion. The sciatic nerve is unaffected. H&E, x375.

Visceral lesions appear to be hyperplasia of the lymphocytic aggregates scattered in a random fashion throughout the bird. In the proventriculus, aggregates of a few small lymphocytes normally are within the muscular wall; in AE, these are obvious dense nodules that are certainly pathognomonic (Figure 14.19). Similar lesions occur in the ventriculus muscle, but unfortunately, they also occur in Marek's disease. In the pancreas, circumscribed lymphocytic follicles are normal (52), but in AE the number increases several times (Figure 14.20). In the myocardium and particularly the atrium, aggregates of lymphocytes are considered to be the result of AE (81). Lymphocytes in the myocardium of young chicks are not unusual; however, they may be considered a lesion only if they are widespread and accompanied by previously noted alterations.

There appears to be an excellent correlation between clinical signs and histologic lesions in the nervous system. In one study, 11% had signs but no lesions, and 8% had lesions but no signs (45). Later, Jungherr believed that all birds with clinical signs had histologic lesions. This was based on more intensive research that, in turn, was based on multiple sections of brain and viscera. Experimentally inoculated chicks killed in sequential fashion invariably yield lesions 1–2 days before clinical signs. Recovered birds free from clinical signs still have CNS lesions for at least 1 week and probably much longer.

Pathogenesis of the Infectious Process

Significant differences exist between embryo-adapted AEV and field strains of the virus in terms of pathogenesis. This

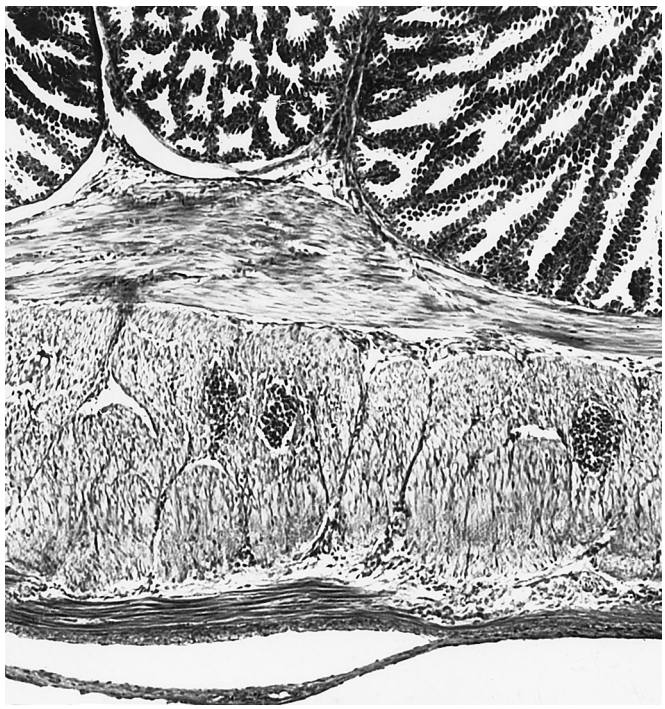

Figure 14.19. Proventriculus of a chick. Dense lymphocytic foci are in the muscular wall. This lesion is pathognomonic. H&E, x330.

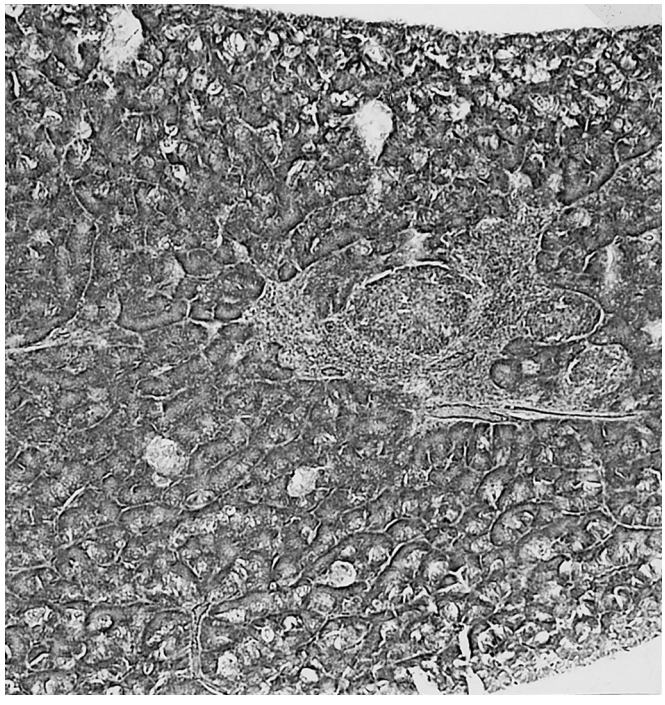

Figure 14.20. Pancreas of a young chick. Several follicles of lymphocytes are present. This lesion is significant only when abnormal numbers of follicles are present. H&E, x330.

is largely because the adapted strains generally lose the enterotropic properties that characterize the natural strains. Consequently, adapted strains are relatively noninfectious by the oral route of exposure, do not replicate in the intestine, and are not excreted in the feces following infection by parenteral inoculation (17, 19).

In young chicks exposed orally to field strains of AEV, primary infection of the alimentary tract, especially in the duodenum, is rapidly followed by a viremia and subsequent infection of the pancreas and other visceral organs (liver, heart, kidney, spleen) and skeletal muscle, and finally the central nervous system. Alimentary tract infections involve muscular layers, and pancreatic infections are found in both the acinar and islet cells, persisting more in the latter. Viral antigen is relatively abundant in the CNS where Purkinje neurons and the molecular layer of the cerebellum are apparently favored sites of virus replication (7, 39, 41, 62, 63, 64, 76, 77, 91). Neuroglial cells are probably also infected given the report of their susceptibility to AEV *in vitro* (66). Chicks with clinical signs at 10–30 days of age tend to have viral antigen mostly in the CNS and pancreas; lesser amounts of antigen have been seen in heart and kidney, and only small amounts have been seen in liver and spleen. Persistence of the virus infection is common in the CNS, alimentary tract, and pancreas. Interestingly, the CNS and the pancreas are the only sites uniformly infected by embryo-adapted strains of AEV, although small amounts of virus may be found transiently in other tissues including the liver, heart, and spleen.

In the intestinal tract of hens infected orally with a field strain of AEV, viral antigen was found in the epithelial tunica mucosa, circular muscle layer, and/or muscularis mucosa and in the tunica propria mucosa, but the detection rate was lower than has been reported for young chicks. No viral antigen was found in the CNS; presumably this lack of infection correlates with the absence of clinical disease in infected adults (63). As in young chicks, infection of older birds with embryo-adapted AEV has a more limited tissue distribution and/or lower titers of AEV in tissues other than those of the CNS, when compared with infection with field strains (39, 40).

Age at exposure is especially important for pathogenesis; birds that are infected at 1 day of age generally died, whereas those infected at 8 days developed paresis but usually recovered, and infection at 28 days caused no clinical signs (21, 99, 100, 101). Bursectomy but not thymectomy abrogated the age resistance (102). Westbury and Sinkovic (113) concluded that young birds with lower immunologic competence have an extended viremia, persistence of virus in the brain, and development of clinical disease. Presumably, the immune response of an immunologically competent bird would stop the spread of infection before it reached the CNS (21, 99). Age resistance was not expressed when experimental infection was induced by IC inoculation of virus.

Immunity

Birds that recover from naturally occurring and experimental infection develop circulating antibodies capable of neutralizing the virus (see 10, 85). Antibodies to the VP1 protein appear to be the most important neutralizing epitopes, with

only limited protection being induced from VP3 and VP0 proteins (96).

It has been clearly shown that humoral, but not cellular, immunity was important in curtailing infection. If the response is rapid, as is usual in birds greater than 21 days of age, the CNS infection apparently does not progress to the point where clinical signs may develop (21, 100).

Active

When chickens are immunologically competent, the serologic response can be relatively rapid with chicks from eggs laid as early as 11 days after exposure already carrying passively acquired antibodies because they were resistant to contact exposure after hatching (19). Also, positive VN tests (i.e., those with a neutralization index [NI] of 1.1 or greater), can be found after 11–14 days PI (20, 101), and positive immunodiffusion (ID) tests as early as 4–10 days PI (41). Flocks of chickens with positive serology rarely if ever have recurrent outbreaks of AE.

Passive

Antibodies are transferred to progeny from the dam via the embryo and can be demonstrated in egg yolk (83). Birds from immune dams were not fully susceptible to oral inoculation until 8–10 weeks of age, and antibodies were demonstrated in the serum until 4–6 weeks of age (20). Passively acquired antibodies can prevent development of disease and prevent or reduce the period of virus excretion in feces (19, 102). They also render embryonating eggs resistant to virus inoculated via the yolk sac, forming the basis for the embryo susceptibility test (see Diagnosis).

Diagnosis

Isolation and Identification of Causative Agents

The brain is an excellent source of virus for isolation, although other tissues and organs induce the disease when injected into chicks (44, 93). In addition to the brain, the pancreas and duodenum were especially reliable sources of virus (62).

The need to titrate vaccine virus makes a sensitive method for virus detection important. One system for assay of virus is to inoculate embryos (obtained from a susceptible flock) via the yolk sac when 5–7 days of age, allow these to hatch, and observe chicks for signs of disease during the first 10 days (33). When clinical signs appear, brain, proventriculus, and pancreas should be examined for lesions as described in Pathology. Additionally or alternatively, brain, pancreas, and duodenum from affected chicks can be examined for specific viral antigen by immunofluorescence (6, 7, 59, 61, 91) or ID (37) tests.

Infected chicken embryo brain cell cultures have been used with the indirect fluorescent antibody (FA) test to detect viral antigen and it was found to be more sensitive than the embryo inoculation method (4). Nicholas et al. (67) compared several methods for detection of AEV. In a comparison study of different diagnostic methods, inoculation of brain cell cultures followed by indirect FA test was found to be convenient, but inoculation of 2-week-old susceptible chicks followed by serologic tests such as ELISA or ID was slightly more sensitive (67). An RT-PCR test has been developed to detect AEV that appears sensitive to as little as 10 picograms of AEV RNA (104). This RT-PCR test was developed using only a single sequence of AEV and was evaluated with only 5 American AEV isolates, and the test cannot be considered validated. A sequence comparison of the primers to the 3 isolates available in GenBank identify several primer mismatches that could potentially affect test results.

Serology

Chickens exposed to AEV develop antibodies that can be measured with the standard virus neutralization (VN) test (16, 83), indirect fluorescent antibody (FA) test (22), immunodiffusion (ID) test (37, 53), ELISA (27, 79, 80) and passive hemagglutination test (2).

The VR embryo-adapted strain is recommended to determine the neutralizing capacity of the serum or plasma. Six-day-old embryos inoculated via the yolk sac with virus dilutions mixed with serum are examined for characteristic lesions 10–12 days PI. A neutralization index (NI) of 1.1 or greater is considered as positive evidence of previous exposure to AEV. Among samples from a recently exposed flock, the NI may vary from 1.5–3.0. Antibodies may be detected as early as the second week after exposure and remain at significant levels for at least several months. In many instances birds having no detectable VN antibodies (NI less than 1.1) would resist IC challenge with as many as 10,000 EID_{50} of virus (16).

Another method to determine immunity of a flock is the embryo susceptibility (ES) test (83). Fertile eggs from the flock to be tested are incubated, along with control eggs from a known susceptible flock. After six days, each embryo is inoculated via the yolk sac with 100 EID_{50} of egg-adapted virus. Embryos are examined 10–12 days PI for characteristic lesions. If 100% of embryos are affected, the flock is considered susceptible; less than 50% affected indicates immunity. Intermediate figures should be considered nondefinitive and may indicate recent exposure.

Titers in the indirect FA test appear to parallel those of the VN test and are as useful as the ES test for assessing immunity in turkey breeder flocks (22).

Standard procedures for ID tests used concentrated tissue extracts from infected embryos as the antigen (28, 37, 38). Antibodies could be found as early as 4–10 days post exposure, and these persisted for at least 28 months. Rare false-positives and false-negatives were reported when the ID test was compared with the VN test.

A passive hemagglutination test was developed that was reported to be more sensitive than the ID test and equal to the ES test in sensitivity(2).

An ELISA using purified viral antigen compared well with the VN test and was found more suitable than the ID test for evaluation of immunity (27, 55, 73, 84). Antibodies induced to the VP1 protein are the most important structural viral antigen for the detection of AE experimentally (96). The use of a negative-antigen-subtraction step may enhance the ability to discriminate between positive and negative sera (76). The ELISA also appears to correlate well with the ES test and was used to diagnose active infections with AEV by an increase in titer with sequential serum samples (80). ELISA titers in hens also have been correlated with the resistance of progeny embryos to challenge with AEV (26).

Differential Diagnosis

In spontaneous cases, a tentative and frequently definite diagnosis of disease can be made when a complete history of the flock and typical specimens are provided for histopathology.

Histopathologic evidence of gliosis, lymphocytic perivascular infiltration, axonal type of neuronal degeneration in the CNS, and hyperplasia of the lymphoid follicles in certain visceral tissues usually can be considered as a basis for a positive diagnosis. A nonradioactive digoxigenin probe to the VP1 gene also can provide a definitive diagnosis with histology samples (97). Virus isolation or a rise in titer with serologic tests gives a more specific diagnosis.

Avian encephalomyelitis should not be confused with other avian diseases manifesting similar clinical signs, such as Newcastle disease, equine encephalomyelitis infection, nutritional disturbances (rickets, encephalomalacia, riboflavin deficiency), and Marek's disease.

Avian encephalomyelitis is predominantly a disease of 1- to 3-week-old chicks. Because Newcastle disease may strike at this time, a problem of differential diagnosis can arise. Certain histological lesions are peculiar to AE: central chromatolysis as opposed to peripheral chromatolysis of Newcastle disease, gliosis in the n. rotundus and n. ovoidalis that is not observed in Newcastle disease, lymphocytic foci in the muscular wall of the proventriculus, and circumscribed lymphocytic follicles in the pancreas. Newcastle disease rarely causes an interstitial pancreatitis.

Nutritional encephalomalacia generally appears 2–3 weeks later than AE, and from the standpoint of clinical history, the signs should be no problem. Histologically, it causes severe degenerative lesions in no way similar to AE.

Marek's disease, which occurs still later, presents little difficulty. The peripheral nerve involvement and state of lymphomatosis of the viscera are 2 criteria not seen in AE.

Intervention Strategies

No satisfactory treatment is known for acute outbreaks in young chicks. Removal and segregation of affected chicks may be indicated under certain conditions, but they generally will not develop into profitable stock. After a flock has experienced an outbreak of AE, no further evidence of it is likely to be observed (75).

Vaccination

Control of AE is achieved by vaccination of breeder flocks during the growing period to ensure that they do not become infected after maturity, thereby preventing dissemination of the virus by the egg-borne route. Also, maternal antibodies protect progeny against contact to AEV during the critical first 2–3 weeks. Vaccination also may be used with commercial egg-laying flocks to prevent a temporary drop in egg production associated with AE. Vaccines used to control AE in chickens have been shown to be efficacious in turkeys as well (23).

The development of AE vaccination strategies has been detailed by Calnek (15). Inactivated vaccines have been developed (13, 18, 54, 74) and may be useful in flocks already in production or where the use of a live virus is contraindicated. Most flocks, however, are vaccinated with a live, embryo-propagated virus, such as strain 1143 (20), which can be administered by naturally occurring routes such as via drinking water or by spraying (20, 25). Live virus vaccines, which can be stored frozen or after lyophilization (8, 72), are similar to field virus in that they spread readily within a flock. This allows for administration *per os* to a small percentage of the birds in a flock, which then spread infection to others, although this method is generally unsatisfactory for birds in wire cages (25). The serologic responses to vaccine administered conjunctivally to 10% (but not 5%) of a flock were as good as those following drinking-water administration of virus to the entire flock (78). Vaccination by wing-web inoculation of AEV is also practiced in many flocks, but this method may carry some risk of clinical signs (29). Generally, vaccination is done after 8 weeks of age and at least 4 weeks before egg production.

It is important that embryo adaptation of strains used for live virus vaccines does not occur because (1) adapted virus loses its ability to infect via the intestinal tract and is, therefore, no longer efficacious when administered by naturally occurring routes (20); and (2) adapted virus, like field strains, can cause clinical disease when administered by the wing-web route (17). Adaptation is detected by careful monitoring of inoculated embryos used in the production of vaccine for characteristic signs (see Etiology), and any adapted virus can be eliminated from vaccine seed virus stocks by passage in susceptible chicks inoculated orally.

Acknowledgement

The author gratefully acknowledges Bruce W. Calnek for his substantial contributions to this chapter.

Avian Hepatitis E Virus Infections

X.J. Meng and H.L. Shivaprasad

Introduction

Hepatitis-splenomegaly (HS) syndrome is a disease of layer and broiler-breeder chickens characterized by increased mortality and decreased egg production and is caused by avian hepatitis E virus (avian HEV) (24, 43, 49, 50, 60). Dead birds have red fluid or clotted blood in their abdomens, and enlarged livers and spleens. Field veterinarians have recognized this disease since the mid 1980s in some parts of the United States. Although first described as HS syndrome, the disease is also referred to as big-liver-and-spleen (BLS) disease (38, 48, 68), necrotic hemorrhage hepatitis-splenomegaly syndrome (54), necrotic hemorrhagic hepatomegalic hepatitis (64), hepatitis-liver hemorrhage syndrome (31), and chronic fulminating cholangiohepatitis (32). Because there are only a few reports of HS syndrome outbreaks in Canada and the United States, the economic impact of this disease is not known, even though avian HEV infection is widespread in chicken flocks worldwide (2, 8, 36, 43, 51). In Australia, BLS was considered an economically significant disease of broiler breeders with estimated annual loss at 8 eggs/hen in 50% of broiler breeder flocks for approximately 2.8 million Australian dollars (43, 49, 50).

In addition to chickens, strains of hepatitis E viruses (HEV) also have been genetically identified in humans, swine, rabbit, deer, mongoose, rat, and fish (3, 12, 30, 39, 40, 42, 44, 45, 46, 47, 52, 71). Furthermore, antibodies to HEV have been detected in numerous other animal species including mice, dogs, cats, sheep, goats, cattle, and nonhuman primates, suggesting that these animal species have been infected by HEV of unknown classification (1, 41, 44, 45, 46, 47, 52). Unfortunately, the genotype of these infecting HEV in many of these seropositive animal species, with the exception of pigs, chickens, rabbit, deer, rat, mongoose, and fish, could not be identified. Swine HEV from pigs infects humans (40, 41, 42), and the HEV strains from rabbit, deer, and mongoose may be zoonotic as well (12, 45, 46, 71). However, human infections by avian HEV have not been reported (27, 43).

Etiology

Bacteria could not be routinely isolated from affected livers (29, 54, 56, 58, 60, 64), except in 1 outbreak in which *Campylobacter spp*. were isolated (32). Attempts to link the cause of HS syndrome to toxins or bacterins were unsuccessful (43, 54, 60, 64). It is now known that the primary causative agent of HS syndrome or BLS is a strain of HEV (24, 43, 49).

Classification

HEV is classified in the family of *Hepeviridae* (47). Currently there is a single genus, *Hepevirus*, and a floating species, Avian HEV, within the family (47). The viruses within the genus *Hepevirus* all infect mammals including strains of HEV from human, pig, mongoose, deer, rat, and rabbit (44, 45, 46, 47). The genus *Hepevirus* includes 4 recognized and 2 putative genotypes (46, 47): genotype 1 (Asian strains of human HEV), genotype 2 (a single Mexican strain and some African strains of human HEV), genotype 3 (human HEV strains from sporadic cases and animal strains of HEV from pig, deer, mongoose, and rabbit), genotype 4 (human strains of HEV from sporadic cases and swine HEV from pigs), putative genotype 5 (strains of HEV from rats in Germany and the United States) (30, 53), and putative genotype 6 (strains of HEV from wild boars in Japan) (65).

At least 3 genetically distinct genotypes of avian HEV have now been identified from chickens worldwide (8, 36, 47): genotype 1 from chickens in Australia (8, 36, 49, 50), genotype 2 from chickens in USA (24), and genotype 3 from chickens in Europe (8, 36) and China (15, 72). Avian HEV is distinct from mammalian *Hepeviruses*, sharing only approximately 50% nucleotide sequence identity. Therefore, it has been proposed that avian HEV should be classified as a separate genus, instead of a floating species, within the family *Hepeviridae* (8, 36, 47). Similarly, the HEV strain recently identified from fish also appears to be another new genus within the family (3).

Morphology

Human HEV is a spherical, nonenveloped, symmetrical virus particle of approximately 32–34 nm in diameter with cup-shaped depressions on the surface, similar to caliciviruses (52). The avian HEV particles revealed by negative staining electron microscopy (EM) of bile samples from chickens with HS syndrome are similar in size and morphology to human HEV (24) (Figure 14.21).

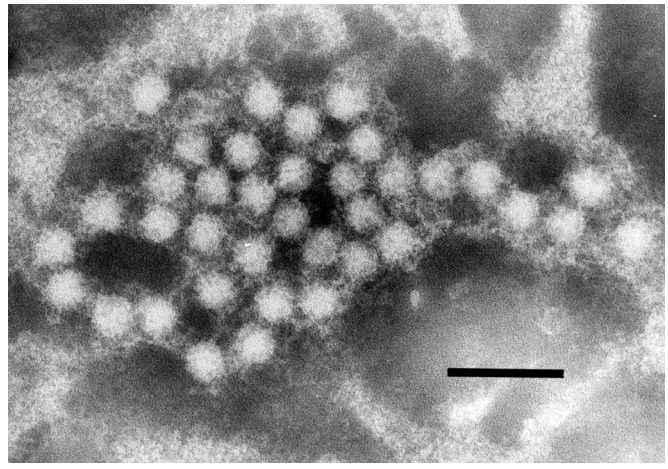

Figure 14.21. Electron micrograph of negatively stained 30- to 35-nm diameter avian hepatitis E virus particles in bile sample from a chicken with hepatitis-splenomegaly syndrome. Bar = 100 nm. (Used with permission (24))

Chemical Composition

The genome of avian HEV is a polyadenylated, single-stranded, positive-sense RNA molecule 6,654 bp in length excluding the poly (A) tail, which is approximately 600 bp shorter than that of mammalian HEVs (5, 8, 27, 36, 72). Similar to mammalian HEV genomes, the avian HEV genome consists of a short 5′ noncoding region (NCR) followed by 3 open reading frames (ORFs) and a 3′ NCR. ORF1, located at the 5′ end of the genome, encodes the nonstructural proteins. The polyprotein encoded by ORF1 of avian HEV contained several putative functional domains including methyltransferase, papain-like cysteine protease, helicase, and RNA-dependent RNA polymerase (RdRp) that are also present in mammalian HEVs (27, 34). The functional motifs typical of the helicase and methyltransferase found in the alpha-like virus supergroup were conserved between avian HEV and mammalian HEVs (27, 34). ORF2 encodes the immunogenic capsid protein, and a truncated version of the avian HEV capsid protein has been expressed in bacteria and used for serological diagnosis of avian HEV infection (25, 26). The ORF2 capsid protein elicits protective immunity in chickens (19). The avian HEV ORF3 encodes a small protein with unknown function, although the ORF3 protein of mammalian HEV is a multifunctional phosphoprotein that may be involved in virus replication and pathogenesis (70). Complete genomic sequence analyses revealed that avian HEV shares approximately 50% nucleotide sequence identity with mammalian HEV strains (5, 27).

Virus Replication

Due to the lack of a robust cell culture system for avian or mammalian HEVs, the life cycle of HEV replication is largely unknown. In SPF chickens experimentally infected with avian HEV, replicating virus was detected in livers as well as in several extrahepatic tissues including colon, cecum, jejunum, ileum, duodenum, and cecal tonsils (6), indicating that avian HEV replicates not only in the liver but in the gastrointestinal tissues as well. The initial site of avian HEV replication in chickens is still unknown but it is believed that prior to reaching liver, its target organ, the virus first replicates in the gastrointestinal tract following oral ingestion of the virus (10, 69). Avian HEV is excreted in large amount in feces (4, 7, 62).

Susceptibility to Chemical and Physical Agents

Liver suspensions containing avian HEV remained infectious after treatment with chloroform and ether (16, 50) but lost infectivity after incubating at 56°C for 1 hour or 37°C for 6 hours. Avian HEV infectivity in liver suspensions was reduced 1,000-fold after treatment with 0.05% Tween-20, 0.1% NP40, and 0.05% formalin (16, 43, 50). Human HEV is sensitive to CsCl gradient centrifugation and low-temperature storage (9, 52). Iodinated disinfectants and autoclaving destroy the virus (57). Human HEV virions are reportedly stable when exposed to trifluorotrichloroethane (52, 57). The fecal-oral route of transmission indicates that avian HEV is resistant to inactivation by acidic and mild alkaline conditions in the intestinal tract. It has recently been shown that human HEV is more heat labile than hepatitis A virus (HAV), another enterically transmitted hepatitis virus (17). HAV was only 50% inactivated at 60°C for 1 hour but was almost totally inactivated at 66°C. In contrast, human HEV was about 50% inactivated at 56°C and almost totally inactivated (96%) at 60°C (17). Incubation at 56°C for 1 hour of HEV-containing pig liver homogenates did not abolish the virus infectivity, although boiling or frying the HEV-infected liver for 5 minutes completely inactivated the virus (46).

Strain Classification

The virus isolated from chickens with BLS in Australia is a genetically variant strain of avian HEV (37, 38, 49, 68) with approximately 80% nucleotide sequence identity with the avian HEV strains from the United States and Canada (2, 24, 25, 26, 27, 63). An apparently avirulent strain of avian HEV was identified from healthy chickens in Virginia (63), and unique genetic differences between the strains from chickens with HS syndrome and from healthy chickens were identified (5). Subsequent comparative pathogenesis studies in SPF chickens demonstrated that the avian HEV strain recovered from a healthy chicken is only slightly attenuated when compared to the strain recovered from a chicken with HS syndrome (7, 35), indicating that other cofactors are likely required for the manifestation of the full spectrum of HS syndrome.

Avian HEV is not only genetically, but also antigenically, related to mammalian HEVs (18, 21, 22, 24, 25, 27). Common antigenic epitopes in the capsid protein between avian HEV and mammalian HEV have been identified (18, 25). It has been demonstrated that the avian HEV capsid protein reacted with antisera against a genotype 1 human HEV and genotype 3 human and swine HEVs. Convalescent sera from chickens experimentally infected with avian HEV also reacted with recombinant capsid proteins derived from genotype 3 swine HEV and genotype 1 human HEV (25).

Laboratory Host Systems

Avian HEV can be propagated in chicken embryos only when the virus is inoculated intravenously but not by other conventional inoculation methods (11, 48; Haqshenas and Meng, unpublished data). It has been demonstrated that leghorn male hepatoma (LMH) chicken liver cells (ATCC CRL-2117), when transfected with RNA transcripts from infectious cDNA clones of avian HEV, supported avian HEV replication (28, 35). Viral antigens were detected in transfected LMH cells by immunofluorescence assay with avian HEV antiserum, and the fluorescent signals were mainly in the cytoplasm. However the virus does not spread from cell to cell (28, 35).

Pathobiology and Epizootiology

Incidence and Distribution

First reported in western Canada in 1991 (56), HS syndrome has since been recognized in eastern Canada (2, 64), California (54),

and the Midwestern and eastern United States (32; Shivaprasad, unpublished data). Avian HEV infection has now been reported worldwide including Australia, United Kingdom, Hungary, Czech Republic, Ukraine, Germany, Spain, Poland, Israel, and China (8, 11, 13, 14, 15, 23, 36, 48, 49, 72). Leghorn hens in cages are typically affected and HS syndrome frequently reoccurs on some farms (54, 55, 56). The disease also has been recognized in broiler breeder hens (29, 58, 59), and may be associated with sporadic mortality in dual-purpose hens and in small flocks kept on litter (31).

In the United States, avian HEV infection is enzootic in chicken flocks. A serological survey of 1,276 chickens of different ages and breeds from 76 different chicken flocks in five states (California, Colorado, Connecticut, Virginia, and Wisconsin) was conducted to determine the seroprevalence of avian HEV (26). It was found that approximately 71% chicken flocks and 30% chickens in the United States were positive for antibodies to avian HEV (26). Approximately 17% of young chickens (less than 18 weeks of age) and about 36% of adult chickens were positive for avian HEV-specific antibodies. In Spain, approximately 90% of the chicken flocks and 20%–80% of chickens also tested seropositive for avian HEV antibodies (51).

Natural and Experimental Hosts

Under field conditions, chickens are the only known host for avian HEV infections. Under experimental conditions, chickens of all ages are susceptible to avian HEV infection (4, 6, 28, 48, 62). SPF chickens were experimentally infected with avian HEV via both intravenous and oronasal routes of inoculation (4). Under laboratory conditions, 8-week-old turkeys intravenously inoculated with an infectious stock of avian HEV also became infected as evidenced by seroconversion to avian HEV antibodies, viremia, and fecal virus shedding (62). However, attempts to experimentally infect rhesus monkeys (27) and mice (Sun and Meng, unpublished data) with avian HEV were unsuccessful.

Transmission, Carriers, Vectors

Transmission within and between flocks appears to occur readily. In a prospective study of natural avian HEV infection in a chicken flock in Virginia (63), all 14 chickens monitored in the study were seronegative at 12 weeks of age. The first chicken seroconverted at 13 weeks of age, and by 21 weeks of age all 14 chickens in the flock had seroconverted (63). Like human and swine HEVs, the transmission route for avian HEV is presumably fecal-oral, and experimental avian HEV infection has been successfully reproduced via oronasal route of inoculation of SPF chickens (4). Feces from infected chickens are likely the main source of virus for transmission as large amounts of virus are shed in feces in experimentally infected chickens (4, 62). Other routes of transmission cannot be ruled out at this time. Vertical transmission has been suggested during avian HEV infection of hens (9). Egg whites from eggs of chickens experimentally infected with avian HEV contain infectious virus, although experimental evidence of complete vertical transmission is lacking (20). Experimental aerosol transmission of avian HEV also was unsuccessful (14, 16). It has been demonstrated that uninoculated chickens housed in the same room with avian HEV-inoculated chickens became infected through direct contact (62). There is no known carrier or vector in the transmission of avian HEV, although rodents in the chicken farms might serve as a mechanical carrier (Sun and Meng, unpublished data).

Clinical Signs

The disease morbidity and mortality in the field are very low, and the majority of avian HEV infection is subclinical (26, 43, 63). No clinical signs has been recognized in birds with HS syndrome prior to death (54, 56, 58, 64). In some outbreaks, there has been a drop in egg production of up to 20% (54, 56), but in other outbreaks egg production has not been affected (64). HS syndrome is characterized by above-normal mortality in broiler breeder hens and laying hens of 30–72 weeks of age, with the highest incidence occurring between 40 and 50 weeks of age (55, 58). Weekly mortality increases to approximately 0.3% for several weeks during the middle of the production period and may sometimes exceed 1.0% (54, 56, 58, 64). The clinical signs for BLS in Australia also vary from subclinical infection to egg drops that may reach 20% and are accompanied by up to 1% mortality/week over a period of 3–4 weeks (13, 23). Diseased birds may have pale combs and wattles, depression, anorexia, and soiled vent feathers or pasty droppings (13, 14, 23, 43, 50, 55). Small eggs with thin and poorly pigmented shells are produced in affected flocks; however, the internal quality, fertility, and hatchability of the eggs are unaffected (50). Affected flocks in the United States and Europe appear to have milder or subclinical infections compared to those in Australia (50, 63).

Pathology

Under field conditions, dead chickens usually have regressive ovaries, red fluid in the abdomen, and enlarged liver and spleen (23, 55, 56, 58, 64). Prior to death, affected birds are usually in good condition, with pale combs and wattles (64), but some birds are in poor condition (56). Livers are enlarged with hemorrhage and/or clotted blood can be seen in the abdominal cavity (Figure 14.22). Livers can often be friable, mottled, and stippled with red, yellow, and/or tan foci, and may have subcapsular hematomas and attached blood clots on the surface (43, 55, 58). Spleens from affected birds are mild to severely enlarged (Figure 14.23), sometimes with white mottling (29, 54, 58, 64). Affected birds generally have regressive ovaries (54, 56), but some have active ovaries (64).

Microscopically, liver lesions varied from multifocal hemorrhage to extensive areas of necrosis and hemorrhage and infiltration of heterophils and mononuclear inflammatory cells around portal triads. There is often segmental infiltration of lymphocytes and a few plasma cells in and around portal veins. Also, accumulation of homogenous eosinophilic material, amyloid in the interstitium of the liver, and separation of hepatocytes are common. In severe cases, discrete granulomas and possible thrombosis of portal veins were

Figure 14.22. Enlarged and hemorrhagic liver from a 63-week-old chicken with hepatitis-splenomegaly syndrome. Note the liver is not fatty.

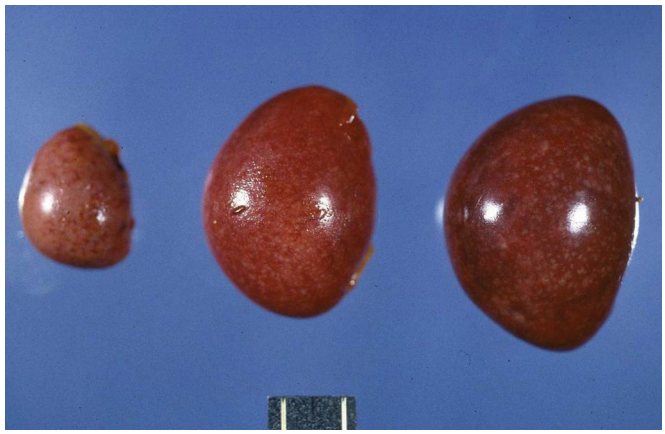

Figure 14.23. Two enlarged and mottled white spleens from 56-week-old chickens with hepatitis-splenomegaly syndrome. The spleen on the left is normal size.

recognized. Lesions in spleens consisted of lymphoid depletion accompanied by an increase in the cells of mononuclear phagocyte system in later stages. There is accumulation of homogenous eosinophilic material and amyloid in the walls of small arteries and arterioles and in the interstitium. Eosinophilic material in both livers and spleens was identified as amyloid using Congo red stain (43, 54, 58, 59, 60, 64) (Figure 14.24).

Under experimental conditions, gross lesions were observed primarily in the liver of SPF chickens experimentally infected with avian HEV (4). Subcapsular hemorrhages and slightly enlarged right intermediate lobe of the liver (Figure 14.25) were observed in some of the infected chickens (4).

Microscopically, lymphocytic periphlebitis and phlebitis foci were observed in liver sections (Figure 14.26). The severity of liver lesions peaked at 10 days PI in the intravenous inoculated chickens. Other liver lesions such as foci of hepatocellular necrosis, amyloid in the interstitium, and subcapsular hemorrhages also were observed in some chickens (Figure 14.26). Microscopic lesions also were observed in spleen (mild lymphoid hyperplasia), thymus (mild cortical hypoplasia), kidney (occasional mild lymphocytic interstitial nephritis), and lung (mild lymphocytic and heterophilic parabronchial and interstitial inflammation) of SPF chickens infected with avian HEV (4, 7, 35). There was no significant elevation of serum levels of liver enzymes AST, albumin/globulin (A/G) ratios, or bile acids (4). However, in intravenously inoculated chickens, LDH levels peaked at 1 week PI and then returned to baseline levels. The LDH levels in oronasally inoculated chickens remained elevated from 1–4 and 6 weeks PI prior to returning to baseline values at 7 weeks PI (4).

Pathogenesis of the Infectious Process

The pathogenesis of avian HEV infection in chickens is largely unknown. Like mammalian HEVs (52, 69), avian HEV enters the host through the fecal-oral route. In primates and pigs experimentally infected with human or swine HEV, virus replication in the liver has been demonstrated (22, 40). It is believed that after replication in the liver, HEV is released to the gallbladder from hepatocytes and then is excreted in feces. Billam et al. (6) reported that in addition to the liver, replicating avian HEV was also detected in colon tissues at 5, 16, 20, and 35 days PI; in cecum and jejunum tissues at 20 and 35 days PI; in ileum tissues at 7, 10, 20, and 35 days PI; in duodenum tissues at 20 days PI; and in cecal tonsils at 35 and 56 days PI of experimentally infected chickens (6). Thus, the gastrointestinal tissues appear to be the first site of avian HEV replication following oral inoculation, although the clinical and pathological significances of these extrahepatic sites of avian HEV replication remain unknown.

Immunity

The humoral antibody response in chickens infected with avian HEV appears at approximately 1–4 weeks PI (4, 62). The cell-mediated immunity in response to avian HEV infection in chickens is unknown. The capsid protein of avian HEV is immunogenic and induces protective immunity against

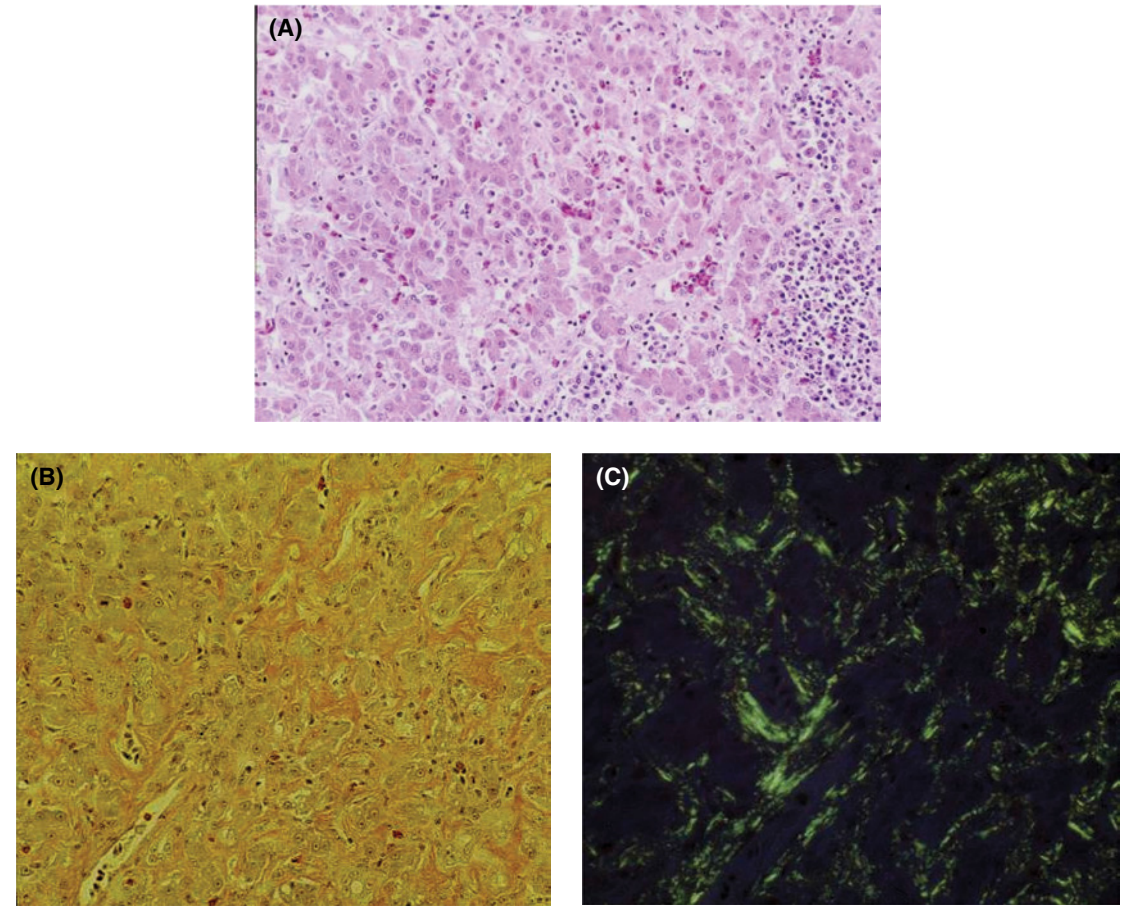

Figure 14.24. Photomicrographs of a liver from a chicken with spontaneous case of hepatitis-splenomegaly syndrome showing accumulation of homogeneous eosinophilic material, amyloid in the interstitium stained with (A) H&E, (B) Congo red stain positive amyloid, and (C) birefringence property of amyloid under polarizing filter.

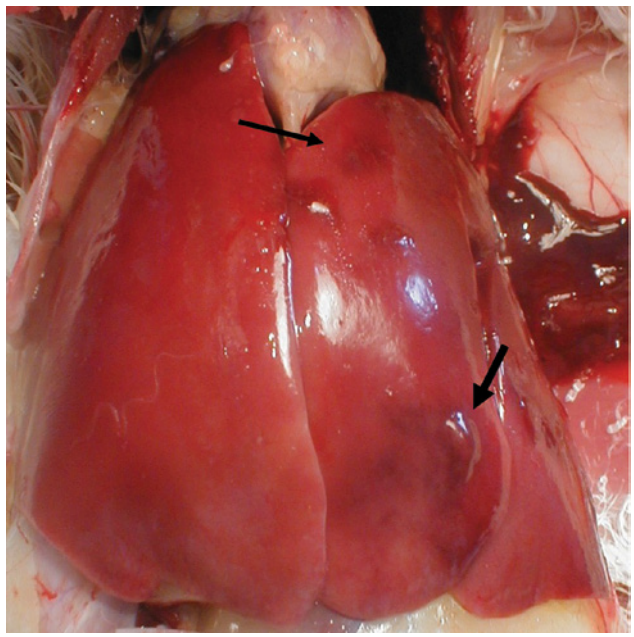

Figure 14.25. Gross lesion of a liver from an SPF chicken experimentally infected with avian HEV showing subcapsular hemorrhages (arrows). (Used with permission [4])

avian HEV infection (19). It has been demonstrated that the avian HEV capsid protein shares common antigenic epitopes and cross reacts with that of swine and human HEVs (18, 19, 21, 25). Avian HEV capsid protein reacted with antisera against human HEV (Sar-55 strain) and with convalescent antisera against swine HEV and the US2 strain of human HEV. Conversely, convalescent sera from chickens experimentally infected with avian HEV also reacted with the recombinant capsid proteins of swine and human HEVs (25). A total of 4 putative antigenic domains (I, II, III, IV) have been identified in the avian HEV capsid protein. Guo et al. (18) identified a B-cell epitope at the C-terminus of domain II (possibly between aa 477-492) that is unique for avian HEV; a B-cell epitope in domain I (aa 389-410) that is common to avian, human, and swine HEVs; and 1 or more B-cell epitopes in domain IV (aa 583-600) that are shared between avian and human HEVs. Immunodominant epitopes have been mapped in the capsid protein of avian HEV by synthetic peptides (21) and by monoclonal antibodies (15), and at least 2 neutralizing epitopes have been identified in the capsid protein of avian HEV (73). However, an animal challenge study showed that the immunodominant epitopes in the avian HEV capsid protein are nonprotective, suggesting that the protective neutralizing epitopes are likely not linear for avian HEV (21).

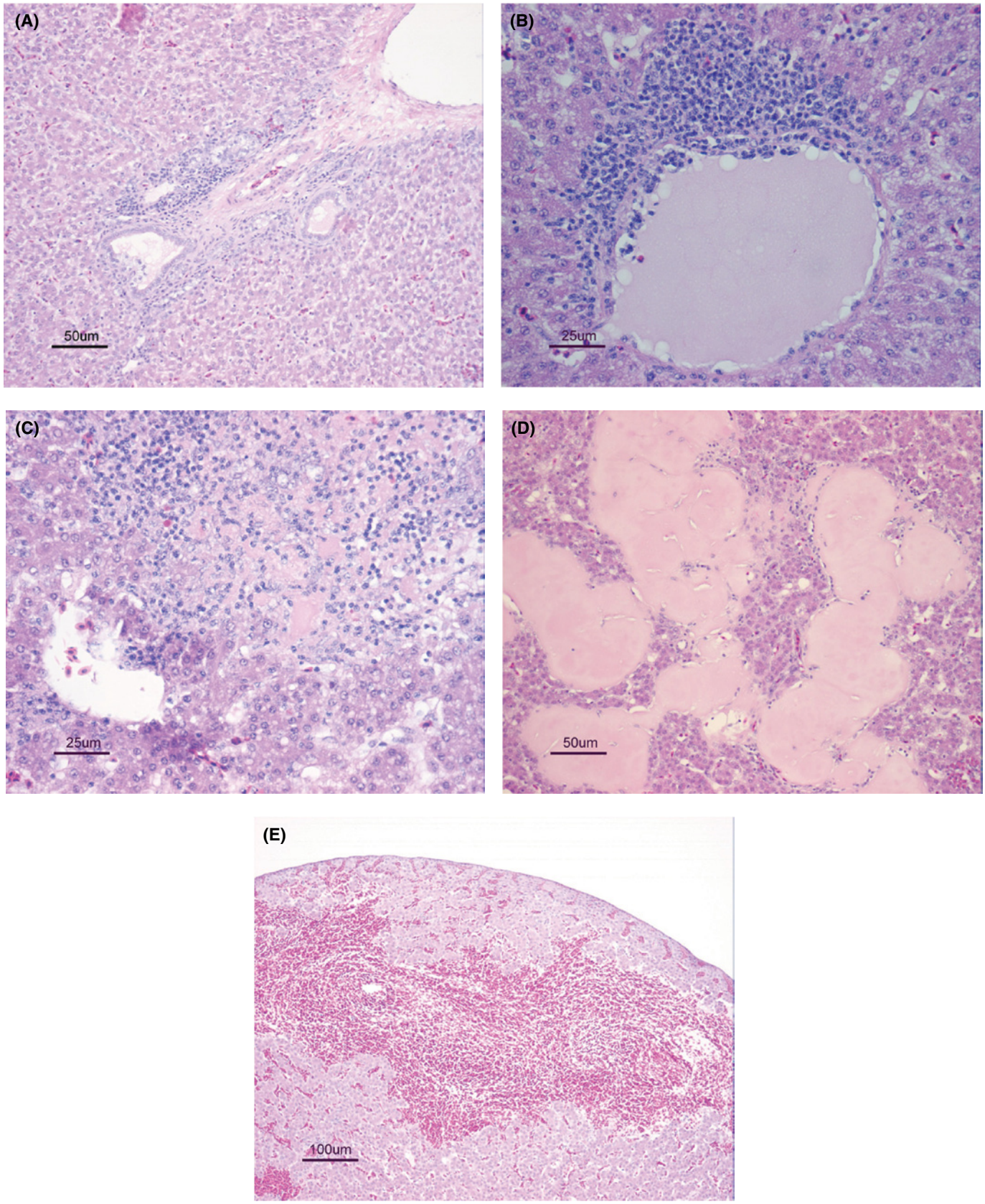

Figure 14.26. Microscopic lesions of the liver from chickens experimentally infected with avian HEV. (A) A liver section from an oronasally inoculated chicken, showing lymphocytic and scattered heterophilic portal vein periphlebitis. (B) A liver section from an IV-inoculated chicken showing focally intense lymphocytic venous phlebitis and periphlebitis. (C) A liver section from an IV-inoculated chicken showing locally extensive hepatocellular necrosis with lymphocytic inflammatory cell infiltration. (D) A liver section from an IV-inoculated chicken. Note architectural disruption and coalescing deposition of hypocellular homogenous eosinophilic matrix with displacement of hepatocellular cords. (E) A liver section from an oronasally inoculated chicken. Note large focus of acute hemorrhage with local architectural disruption of hepatocellular cords and hepatic sinusoids. H&E staining. (Used with permission [4])

Diagnosis

A presumptive diagnosis of HS syndrome can be made on the basis of clinical signs and pathological lesions. However, HS syndrome needs to be differentiated from hemorrhagic fatty liver syndrome (HFLS) due to the presence of clotted blood in the abdominal cavity and hemorrhages in the liver with HS syndrome. The livers in HS syndrome are not fatty as in HFLS. Clotted or unclotted blood in the abdominal cavity or around the liver sometimes can also be seen in cases of rodenticide (anticoagulant) toxicities. Virus particles of 30–35 nm may be detected in bile of chickens with HS syndrome by negative staining electron microscopy (24).

Avian HEV does not replicate in cell culture. Although embryonic chicken eggs can be experimentally infected with avian HEV via intravenous inoculation (48; Haqshenas and Meng, unpublished data), virus isolation with chicken embryos is not practical due to the technical difficulty and high mortality associated with the intravenous inoculation procedure. Currently, the diagnosis of avian HEV infection is primarily based on detection of avian HEV RNA by RT-PCR or detection of antibodies by ELISA (26, 62, 63, 66). A truncated version of the avian HEV capsid protein has been expressed and used in an ELISA to detect avian HEV antibodies in chickens (4, 25, 26, 62, 63).

Avian HEV-specific RT-PCR and real-time quantitative PCR assays have been successfully developed for the detection of avian HEV infections in chickens (4, 26, 33, 61, 62, 63, 67). However, the specificity of these PCR-based assays in detecting avian HEV strains in chickens from different geographic regions is not known because at least 3 distinct genotypes of avian HEV exist worldwide (8, 26, 36, 63, 72).

Intervention Strategies

A vaccine against avian HEV or mammalian HEVs is not yet available. Currently there is no treatment for avian HEV infection. Implementation of strict biosecurity in chicken farms may limit the spread of virus.

Acknowledgement

The authors acknowledge the contribution of Dr. Christine Payne in the 12th edition of the *Diseases of Poultry*, which was the basis of this 13th edition.

References

Miscellaneous Herpesvirus Infections

1. Bang, F.B. 1942. Experimental infection of the chick embryo with the virus of pseudorabies. *J Exp Med.* 76:263–270.
2. Beladi, I. 1962. Study on the plaque formation and some properties of the Aujeszky disease virus on chicken embryo cells. *Acta Vet Acad Sci Hung.* 12:417–422.
3. Boyle, D.B., and J.A. Binnington. 1973. Isolation of a herpesvirus from a pigeon. *Aust Vet J.* 49:54.
4. Burtscher, H. 1965. Die virubedingte Hepatosplenitis infectiosa strigum. 1. Mitteilung: Morphologishe Untersuchungen. *Pathol Vet*. 2:227–255.
5. Burtscher, H., and W. Grünberg. 1979. Herpesvirus-Hepatitis bei Kranichen (Aves Gruidae). *I. Pathomorphologische Befunde. Zen tralbl Veterinaermed B.* 26:561–569.
6. Callinan, R.B., B. Kefford, R. Borland, and R. Garrett. 1979. An outbreak of disease in pigeons associated with a herpesvirus. *Aust Vet J.* 55:339–341.
7. Cornwell, H.J.C., and A.R. Weir. 1970. Herpesvirus infection of pigeons. IV. Growth of the virus in tissue-culture and comparison of its cytopathogenicity with that of the viruses of laryngotracheitis and pigeon pox. *J Comp Pathol.* 80:517–523.
8. Cornwell, H.J.C., and N.G. Wright. 1970. Herpesvirus infection in pigeons. I. Pathology and virus isolation. *J Comp Pathol.* 80: 221–227.
9. Cornwell, H.J.C., A.R. Weir, and E.A.C. Follett. 1967. A herpes infection of pigeons. *Vet Rec.* 81:267–268.
10. Cornwell, H.J.C., N.G. Wright, and H.B. McCusker. 1970. Herpesvirus infection of pigeons. II. Experimental infections of pigeons and chicks. *J Comp Pathol.* 80:229–232.
11. Duchatel, J.P., T. Jauniaux, F. Vandersanden, G. Charlier, F. Coignoul, and H. Vindevogel. 1998. Première mise en evidence en Belgique de particules ressemblant à des circovirus chez le pigeon voyageur. *Ann Méd Vét*. 142:425–428.
12. Duchatel J.P., D. Todd, J.A. Smyth, J.C. Bustin, and H. Vindevogel. 2006. Observations on detection, excretion and transmission of pigeon circovirus in adult, young and embryonic pigeons. *Avian Pathol.* 35:30–34.
13. French, E.L., H.G. Purchase, and K. Nazerian. 1973. A new herpesvirus isolated from a nestling cormorant (*Pharmalacrocorax melanoleucos*). *Avian Pathol.* 2:3–15.
14. Duchatel J.P., and Vindevogel H. 2008. Miscellaneous Herpesvirus Infections. In: *Diseases of Poultry*, 12th ed. Y.M. Saif, ed. Blackwell Publishing, Ames, Iowa. 405-409.
15. Fritzche, K., U. Heffels, and E.F. Kaleta. 1981. Ubersichtreferat: Virusbedingte Infektionen der Taube. *Dtsch Tieraerztl Wochenschr.* 88:72–76.
16. Gailbreath, K.L., and J.L. Oaks. 2008. Herpesviral inclusion body disease in owls and falcons is caused by the pigeon herpesvirus (*columbid herpesvirus* 1). *J Wildl Dis.* 44:427–433.
17. Glover, R.E. 1939. Cultivation of the virus of Aujeszky's disease on the chorioallantoic membrane of the developing egg. *Br J Exp Pathol.* 20:150–158.
18. Heffels, U., K. Fritzche, E.F. Kaleta, and U. Neumann. 1981. Serologische Untersuchungen zum Nachweis virusbedingter Infektionen bei der Taube in der Bundesrepublik Deutschland. *Dtsch Tieraerztl Wochenschr.* 88:97–102.
19. Kaleta, E.F. 1990. Herpesviruses of birds. A review. *Avian Pathol.* 19:193–211.
20. Kaleta, E.F., H.J. Marschall, G. Glünder, and B. Stiburek. 1980. Isolation and serological differentiation of a herpesvirus from bobwhite quail (*Colinus virginianus*, L. 1758). *Arch Virol*. 66:359–364.

21. Kaleta, E.F., T.I. Mikami, H.J. Marschall, U. Heffels, M. Heidenreich, and B. Stiburek. 1980. A new herpesvirus isolated from black storks (*Ciconia nigra*). *Avian Pathol.* 9:301–310.
22. Kaplan, A.S., 1969. Herpesvirus simplex and pseudorabies viruses. In: *Virology Monographs.* S. Gard, C. Hallauer, and K.F. Meyer, eds. Springer-Verlag, Vienna/New York. 66–68, 80–82.
23. Krupicka, V., B. Smid, L. Valicek, and V. Pleva. 1970. Isolation of an herpesvirus from pigeons in the chorio-allantoic membrane of embryonated eggs. *Vet Med (Praha).* 15:609–612.
24. Landré, F., H. Vindevogel, P.P. Pastoret, A. Schwers, E. Thiry, and J. Espinasse. 1982. Fréquence d l'infection du pigeon par le Pigeonherpesvirus 1 et le virus de la maladie de Newcastle dans le Nord de la France. *Rec Med Vet.* 158:523–528.
25. Lautié, R. 1969. Les maladies animales à virus. La maladie d'Aujeszky. In: *Collection de monographies, direction scientifique*. P. Lépine and P. Goret, eds. L'expansion scientifique française Editeur, Paris.
26. Mare, C.J., and D.L. Graham. 1973. Falcon herpesvirus, the etiologic agent of inclusion body disease of falcons. *Infect Immun.* 8:118–126.
27. Purchase, H.G., C.J. Mare, and B.R. Burmester. 1972. Antigenic comparison of avian and mammalian herpesviruses and protection tests against Marek's disease. *Proc US Animal Health Assoc.* 76:484–492.
28. Raue, R., V. Schmidt, M. Freick, B. Reinhardt, R. Johne, L. Kamphausen, E.F., Kaleta, H. Müller, and M.E. Krautwald-Junghanns. 2005. A disease complex associated with pigeon circovirus infection, young pigeon disease syndrome. *Avian Pathol.* 34:418–425.
29. Saik, J.E., E.R. Weintraub, R.W. Diters, and M.A.E. Egy. 1986. Pigeon herpesvirus: Inclusion body hepatitis in a free-ranging pigeon. *Avian Dis.* 30:426–429.
30. Schwers, A., P.P. Pastoret, H. Vindevogel, P. Leroy, A. Aguilar-Setien, and M. Godart. 1980. Comparison of the effect of trisodium phosphonoformate on the mean plaque size of pseudorabies virus, infectious bovine rhinotracheitis virus and pigeon herpesvirus. *J Comp Pathol.* 90:625–633.
31. Schwers A., H. Vindevogel, P. Leroy, and P.P. Pastoret. 1981. Susceptibility of different strains of pigeon herpesvirus to trisodium phosphonoformate. *Avian Pathol.* 10:23–29.
32. Shimizu, T., H. Erno, and H. Nagatomo. 1978. Isolation and characterization of Mycoplasma columbinum and Mycoplasma columborale, two new species from pigeons. *Int J Syst Bact.* 28:538–546.
33. Shope, R.E. 1931. An experimental study of mad itch with special reference to its relationship to pseudorabies. *J Exp Med.* 45:233–248.
34. Simpsons, C.F., J.E. Hanley, and J.M. Gaskin. 1975. Psittacine herpesvirus resembling Pacheco's parrot disease. *J Infect Dis.* 131:390–396.
35. Smadel, J.E., E.B. Jackson, and J.W. Harman. 1945. A new virus of pigeons. I. Recovery of the virus. *J Exp Med*. 81:385–398.
36. Tavernier P., P. De Herdt, H. Thoonen, and R. Ducatelle. 2000. Prevalence and pathogenic significance of circovirus-like infections in racing pigeons (*Columba livia*). *Vlaams Diergeneeskd Tijdschr.* 69:338–341.
37. Thiry, E., H. Vindevogel, P. Leroy, P.P. Pastoret, A. Schwers, B. Brochier, Y. Anciaux, and P. Hoyois. 1983. *In vivo* and *in vitro* effect of acyclovir on pseudorabies virus, infectious bovine rhinotracheitis virus and pigeon herpesvirus. *Ann Rech Vét*. 14:239–245.
38. Toneva, V. 1961. Obtention d'une souche non-virulente du virus de la maladie d'Aujeszki au moyen de passages et de l'adaptation des pigeons. *C R Acad Bulgare Sci.* 14:187–190.
39. Vetesy, F., and J. Tanyi. 1975. Occurrence of a pigeon disease in Hungary caused by a herpesvirus. *Magyar Allotorv Lapja.* 30(3):193–197.
40. Vindevogel, H. 1981. Le coryza infectieux du pigeon. Thesis of "Agregation de l'Enseignement Supérieur." University of Liège, Fac Vet Med.
41. Vindevogel, H., and J.P. Duchatel. 1977. Réceptivité de la perruche au virus herpès du pigeon. *Ann Méd Vét*. 121:193–195.
42. Vindevogel, H., and J.P. Duchatel. 1979. 1. Etude de la réceptivité de différentes espèces animales au virus herpès du pigeon. 2. Résistance du pigeon au virus de la laryngotrachéite infectieuse aviaire. *Ann Méd Vét*. 123:63–65.
43. Vindevogel, H., and P.P. Pastoret. 1980. Pigeon herpes infection: Natural transmission of the disease. *J Comp Pathol.* 90:409–413.
44. Vindevogel, H., and P.P. Pastoret. 1981. Pathogenesis of pigeon herpes infection. *J Comp Pathol.* 91:415–426.
45. Vindevogel, H., P.P. Pastoret, G. Burtonboy, M. Gouffaux, and J.P. Duchatel. 1975. Isolement d'un virus herpes dans un élevage de pigeons de chair. *Ann Rech Vét*. 6:431–436.
46. Vindevogel, H., J.P. Duchatel, and M. Gouffaux. 1977. Pigeon herpesvirus. I. Pathogenesis of pigeon herpesvirus in chicken embryo fibroblasts. *J Comp Pathol.* 87:597–603.
47. Vindevogel, H., J.P. Duchatel, M. Gouffaux, and P.P. Pastoret. 1977. Pigeon herpesvirus. II. Susceptibility of avian and mammalian cell cultures to infection with pigeon herpesvirus. *J Comp Pathol*. 87:605–610.
48. Vindevogel, H., J.P. Duchatel, and G. Burtonboy. 1978. Infection herpétique de psittacidés. *Ann Méd Vét*. 122:167–169.
49. Vindevogel, H., A. Aguilar-Setien, L. Dagenais, and P.P. Pastoret. 1980. Diagnostic de l'infection herpétique du pigeon. *Ann Méd Vét*. 124:407–418.
50. Vindevogel, H., P.P. Pastoert, and G. Burtonboy. 1980. Pigeon herpes infection: Excretion and re-excretion of virus after experimental infection. *J Comp Pathol.* 90:401–408.
51. Vindevogel, H., P.P. Pastoret, P. Leroy, and F. Coignoul. 1980. Comparaison de trois souches de virus herpétique isolées de psittacidés avec le virus herpes du pigeon. *Avian Pathol.* 9:385–394.
52. Vindevogel, H., L. Dagenais, B. Lansival, and P.P. Pastoret. 1981. Incidence of rotavirus, adenovirus and herpesvirus infection in pigeons. *Vet Rec.* 109:285–286.
53. Vindevogel, H., A. Kaeckenbeeck, and P.P. Pastoret. 1981. Fréquence de l'ornithose-psittacose et de l'infection herpétique chez le pigeon voyageur et les psittacidés en Belgique. *Rev Méd de Liège*. 36:693–696.
54. Vindevogel, H., P.P. Pastoret, and A. Aguilar-Setien. 1982. Assays of phosphonoformate-treatment of pigeon herpesvirus infection in pigeons and budgerigars, and Aujesky's disease in rabbits. *J Comp Pathol.* 92:177–180.
55. Vindevogel, H., P.P. Pastoret, and P. Leroy. 1982. Vaccination trials against pigeon herpesvirus infection (Pigeon herpesvirus 1). *J Comp Pathol.* 93:484–494.
56. Vindevogel, H., P.P. Pastoret, and P. Leroy. 1982. Essais de vaccination contre l'infection herpétique du pigeon (Pigeon herpesvirus 1). *Dev Biol.* 52:429–436.
57. Vindevogel, H., P.P. Pastoret, and P. Leroy. 1982. Comportement d'une souche atténuée de pigeon herpesvirus 1 et de souches pathogènes lors d'infections successives chez le pigeon. *Ann Rech Vét*. 13:143–148.

58. Vindevogel, H., P.P. Pastoret, E. Thiry, and N. Peeters. 1982. Réapparition de formes graves de la maladie de Newcastle chez le pigeon. *Ann Méd Vét*. 126:5–7.
59. Vindevogel, H., E. Thiry, P.P. Pastoret, and G. Meulemans. 1982. Lentogenic strains of Newcastle disease virus in pigeons. *Vet Rec.* 110:497–499.
60. Vindevogel, H., P.P. Pastoret, and E. Thiry. 1983. Pigeon herpes virus 1. WHO collaborating Centre for Collection and Evaluation of Data on Comparative Virology. *Veterinärstr* 13, Munich, W. Germany.
61. Vindevogel, H., J.P. Duchatel, and P.P. Pastoret. 1984. Les dominantes pathologiques respiratoires chez le pigeon. *Rec Med Vet.* 160:1031–1036.
62. Vindevogel, H., H. Debruyne, and P.P. Pastoret. 1985. Observation of pigeon herpesvirus 1 re-excretion during the reproduction period in conventionally reared homing pigeons. *J Comp Pathol.* 95:105–112.

Avian Nephritis

1. Biđin M., I. Lojkić, Z. Biđin, M. Tisljar, D. Majnarić, and M. Mikec. 2011. Detection and characterization of avian nephritis virus in ducklings. *Avian Pathol*. 40:173–177.
2. Bosch, A., S. Guix, N.K. Krishna, E. Mendez, S.S. Monroe, M. Pantin-Jackwood, and S. Schultz-Cherry. 2009. Family *Astroviridae*. In: *Virus Taxonomy. Ninth Report of the International Committee on Taxonomy of Viruses*. C.M. Fauquet, M.A. Mayo, J. Maniloff, U. Desselberger, and L.A. Ball, eds. Elsevier/Academic Press, London. 859–864.
3. Canelli, E., C.P. Barbieri, I. Catella, A. Pennelli, D. Ceruti, R. Moreno, and A. Lavazza. 2012. Astroviruses as causative agents of poultry enteritis: genetic characterization and longitudinal studies on field conditions. *Avian Dis.* 56(1):173–82.
4. Carter, M.J., and M.M. Willcocks. 1996. The molecular biology of astroviruses. *Arch Virol Suppl.* 12:277–285.
5. Connor, T.J., F. McNeilly, J.B. McFerran, and M.S. McNulty. 1987. A survey of avian sera from Northern Ireland for antibody to avian nephritis virus. *Avian Pathol.* 16:15–20.
6. Day, J.M., E. Spackman, and M. Pantin-Jackwood. 2007. A multiplex RT-PCR test for the differential identification of turkey astrovirus type 1, turkey astrovirus type 2, chicken astrovirus, avian nephritis virus and avian rotavirus. *Avian Dis.* 51:681–684.
7. Decaesstecker, M. and G. Meulemans. 1989. Antigenic relationships between fowl enteroviruses. *Avian Pathol.* 18:715–723.
8. Decaesstecker, M., and G. Meulemans. 1991. An ELISA for the detection of antibodies to avian nephritis virus and related entero-like viruses. *Avian Pathol.* 20:523–530.
9. Decaesstecker, M., G. Charlier, J. Peeters, and G. Meulemans. 1989. Pathogenicity of fowl enteroviruses. *Avian Pathol.* 18:697–713.
10. de Wit, J.J., G.B. Dam, J.M. de Laar, Y. Biermann, I. Verstegen, F. Edens, and C.C. Schrier. Detection and characterization of a new astrovirus in chicken and turkeys with enteric and locomotion disorders. *Avian Pathol*. 40:453–61.
11. Frazier, J.A., and R.L. Reece. 1990. Infectious stunting syndrome of chickens in Great Britain: Intestinal ultrastructural pathology. *Avian Pathol.* 19:759–777.
12. Frazier, J.A., K. Howes, R.L. Reece, A.W. Kidd, and D. Cavanagh. 1990. Isolation of non-cytopathic viruses implicated in the aetiology of nephritis and baby chick nephropathy and serologically related to avian nephritis virus. *Avian Pathol.* 19:139–160.
13. Hewson, K.A., D. O'Rourke, and A.H. Noormohammadi. 2010. Detection of avian nephritis virus in Australian chicken flocks. *Avian Dis.* 54:990–993.
14. Imada, T., S. Yamaguchi, and H. Kawamura. 1979. Pathogenicity for baby chicks of the G-4260 strain of the picornavirus "Avian nephritis virus." *Avian Dis.* 23:582–588.
15. Imada, T., S. Yamaguchi, and H. Kawamura. 1980. Antibody survey against avian nephritis virus among chickens in Japan. *Natl Inst Anim Health Q (Jpn)*. 20:79–80.
16. Imada, T., T. Taniguchi, S. Yamaguchi, T. Minetoma, M. Maeda, and H. Kawamura. 1981. Susceptibility of chickens to avian nephritis virus at various inoculation routes and ages. *Avian Dis.* 25:294–302.
17. Imada, T., T. Taniguchi, S. Sato, S. Yamaguchi, and H. Kawamura. 1982. Pathogenicity of avian nephritis virus for embryonating hen's eggs. *Natl Inst Anim Health Q (Jpn)*. 22:8–15.
18. Imada, T., M. Maeda, K. Furuta, S. Yamaguchi, and H. Kawamura. 1983. Pathogenicity and distribution of avian nephritis virus (G-4260 stain) in inoculated laying hens. *Natl Inst Anim Health Q (Jpn)*. 23:43–48.
19. Imada, T., S. Yamaguchi, M. Mase, K. Tsukamoto, M. Kubo, and A. Morooka. 2000. Avian nephritis virus (ANV) as a new member of the family Astroviridae and construction of infectious ANV cDNA. *J Virol.* 74:8487–8493.
20. Koci, M.D., and S. Schultz-Cherry. 2002. Avian astroviruses. *Avian Pathol.* 31:213–227.
21. Kofstad T., and C.M. Jonassen. 2011. Screening of feral and wood pigeons for viruses harbouring a conserved mobile viral element: characterization of novel Astroviruses and Picornaviruses. *PLoS One.* 6(10):e25964.
22. Maeda, M., T. Imada, T. Taniguchi, and T. Horiuchi. 1979. Pathological changes in chicks inoculated with the picornavirus "Avian nephritis virus." *Avian Dis.* 23:589–596.
23. Mandoki, M., T. Bakonyi, E. Ivanics, C. Nemes, M. Dobos-Kovacs, and M. Rusvai. 2006. Phylogenetic diversity of avian nephritis virus in Hungarian chicken flocks. *Avian Pathol.* 35:224–229.
24. Mandoki, M., M. Dobos-Kovacs, T. Bakonyi, and M. Rusvai. 2006. Molecular diagnosis of avian nephritis: preliminary report. *Acta Veterinaria Hungarica.* 54:51–60.
25. Matsui, S.M., and H.B. Greenberg. 2001. Astroviruses. In: *Fields Virology*, Vol. 1, 4th ed.. D.M. Knipe and P.M. Howley, eds. Lippincott Williams and Wilkins, Baltimore. 875–893.
26. McFerran, J.B., and M.S. McNulty. 1986. Recent advances in enterovirus infections of birds. In: *Acute Virus Infections of Poultry*. J.B. McFerran and M.S. McNulty, eds. Martinus Nijhoff, Dordrecht, Netherlands. 195–202.
27. McNeilly, F., T.J. Connor, V.M. Calvert, J.A. Smyth, W.L. Curran, A.J. Morley, D. Thompson, S. Singh, J.B. McFerran, B.M. Adair, and M.S. McNulty. 1994. Studies on a new enterovirus-like virus isolated from chickens. *Avian Pathol.* 23:313–327.
28. McNulty, M.S., G.M. Allan, T.J. Connor, J.B. McFerran, and R.M. McCracken. 1984. An entero-like virus associated with the runting syndrome in broiler chickens. *Avian Pathol.* 13:429–439.
29. McNulty, M.S., G.M. Allan, and J.B. McFerran. 1987. Isolation of a novel avian entero-like virus. *Avian Pathol.* 16:331–337.
30. McNulty, M.S., T.J. Connor, and F. McNeilly. 1989. A survey of specific pathogen-free chicken flocks for antibodies to chicken anaemia agent, avian nephritis virus and group A rotavirus. *Avian Pathol.* 18:215–220.

31. McNulty, M.S., T.J. Connor, F. McNeilly, and J.B. McFerran. 1990. Biological characterisation of avian enteroviruses and enterovirus-like viruses. *Avian Pathol.* 19:75–87.
32. Mockett, A.P., M.B. Huggins, M. Woods, and S. Orbell. 1993. A comparison of three serological methods to detect chicken and turkey antibodies to avian nephritis virus and the use of virus-specific monoclonal antibodies. *Avian Pathol.* 4:751–70.
33. Narita, M., H. Kawamura, K. Nakamura, J. Shirai, K. Furuta, and F. Abe. 1990. An immunohistological study on the nephritis in chicks experimentally produced with avian nephritis virus. *Avian Pathol.* 19:497–509.
34. Narita, M., K. Ohta, H. Kawamura, J. Shirai, K. Nakamura, and F. Abe. 1990. Pathogenesis of renal dysfunction in chicks experimentally induced by avian nephritis virus. *Avian Pathol.* 19:571–582.
35. Narita, M., H. Kawamura, K. Furuta, J. Shirai, and K. Nakamura. 1990. Effects of cyclophosphamide in newly hatched chickens after inoculation with avian nephritis virus. *Am J Vet Res.* 51:1623–1628.
36. Narita, M., S. Umiji, K. Furuta, J. Shirai, and K. Nakamura. 1991. Pathogenicity of avian nephritis virus in chicks previously infected with infectious bursal disease virus. *Avian Pathol.* 20:101–111.
37. Nicholas, R.A.J., R.D. Goddard, and P.R. Luff. 1988. Prevalence of avian nephritis virus in England. *Vet Rec.* 123:398.
38. Pantin-Jackwood, M.J., E. Spackman, and P.R. Woolcock. 2006. Molecular characterization and typing of chicken and turkey astroviruses circulating in the United States: implications for diagnostics. *Avian Dis.* 50:397–404.
39. Pantin-Jackwood, M.J., K.O. Strother, E. Mindt, L. Zsak, J.M. Day, and E. Spackman. 2010. Molecular characterization of avian astroviruses. *Arch Virol.* 156(2):235–44.
40. Reece, R.L., and J.A. Frazier. 1990. Infectious stunting syndrome of chickens in Great Britain: Field and experimental studies. *Avian Pathol.* 19:723–758.
41. Reece, R.L., K. Howes, and J.A. Frazier. 1992. Experimental factors affecting mortality following inoculation of chickens with avian nephritis virus (G-4260). *Avian Dis.* 36:619–624.
42. Schultz-Cherry, S., D.J. King, and M.D. Koci. 2001. Inactivation of an astrovirus associated with poult enteritis mortality syndrome. *Avian Dis.* 45:76–82.
43. Shirai, J., K. Nakamura, M. Narita, K. Furuta, H. Hihara, and H. Kawamura. 1989. Visceral urate deposits in chicks inoculated with avian nephritis virus. *Vet Rec.* 124:658–661.
44. Shirai, J., H. Obata, K. Nakamura, K. Furuta, H. Hihara, and H. Kawamura. 1990. Experimental infection in SPF chicks with avian reo and avian nephritis viruses isolated from broiler chicks showing runting syndrome. *Avian Dis.* 34:295–303.
45. Shirai, J., K. Nakamura, M. Narita, K. Furuta, and H. Kawamura. 1990. Avian nephritis virus infection of chicks: Virology, pathology, and serology. *Avian Dis.* 34:558–565.
46. Shirai, J., K. Nakamura, K. Shinohara, and H. Kawamura. 1991. Pathogenicity and antigenicity of avian nephritis isolates. *Avian Dis.* 35:49–54.
47. Shirai, J., K. Nakamura, H. Nozaki, and H. Kawamura. 1991. Differences in the induction of urate deposition of specific-pathogen-free chicks inoculated with avian nephritis virus passaged by five different methods. *Avian Dis.* 35:269–275.
48. Shirai, J., N. Tanimura, K. Uramoto, M. Narita, K. Nakamura, and H. Kawamura. 1992. Pathologically and serologically different avian nephritis virus isolates implicated in etiology of baby chick nephropathy. *Avian Dis.* 36:369–377.
49. Siller, W.G. 1981. Renal pathology of the fowl—a review. *Avian Pathol.* 10:187–262.
50. Smyth, V.J., Jewhurst, H.L., Wilkinson, D.S., Adair, B.M., Gordon, A.W., and Todd, D. 2010. Development and evaluation of real-time TaqMan® RT-PCR assays for the detection of avian nephritis virus and chicken astrovirus in chickens. *Avian Pathol.* 39(6):467–474.
51. Takase, K., K. Shinohara, M. Tsuneyoshi, M. Yamamoto, and S. Yamada. 1989. Isolation and characterisation of cytopathic avian enteroviruses from broiler chicks. *Avian Pathol.* 18:631–642.
52. Takase, K., K. Matsuo, and M. Yamamoto. 1990. A survey of avian sera for avian nephritis virus, strain AAF in Japan. *J Jpn Vet Med Assoc.* 43:199–201.
53. Takase, K., T. Uchimura, M. Yamamoto, and S. Yamada. 1994. Susceptibility of embryos and chicks, derived from immunized breeding hens, to avian nephritis virus. *Avian Pathol.* 23:117–125.
54. Takase, K., Y. Murakawa, R. Ariyoshi, S. Eriguchi, T. Sugimura, and H. Fujikawa. 2000. Serological monitoring on layer farms with specific pathogen-free chickens. *J Vet Med Sci.* 62:1327–1329.
55. Todd, D., J. Trudgett, F. McNeilly, N. McBride, B. Donnelly, V.J. Smyth, H.J. Jewhurst, and B.M. Adair. 2010. Development and application of an RT-PCR test for detecting avian nephritis virus. *Avian Pathol.* 39:207–213.
56. Todd, D., J.S. Trudgett, V.J. Smyth, B. Donnelly, N. McBride, and M.D. Welsh. 2011. Capsid protein sequence diversity of avian nephritis virus. *Avian Pathol.* 40:249–259.
57. Yamaguchi, S., T. Imada, and H. Kawamura. 1979. Characterization of a picornavirus isolated from broiler chicks. *Avian Dis.* 23:571–581.
58. Zhao, W., X.G. Hua, L. Yuan, L. Cui, T.L. Shan, X.Q. Dai, A.L. Zhu, Y. Yu, C.X. Zhu, and Z.B. Yang. 2011. Sequence analyses of the representative Chinese-prevalent strain of avian nephritis virus in healthy chicken flocks. *Avian Dis.* 55(1):65–9.
59. Zhao, W., A.L. Zhu, Y. Yu, C.L. Yuan, C.X. Zhu, D.L. Lan, Z.B. Yang, L. Cui, and X.G. Hua. 2012. Segmentation expression of capsid protein as an antigen for the detection of avian nephritis virus infection in chicken flocks. *J Virol Methods.* 179(1):57–61.
60. Zhao, W., A.L. Zhu, C.L. Yuan, Y. Yu, C.X. Zhu, D.L. Lan, Z.B. Yang, L. Cui, and X.G. Hua. 2011. Detection of astrovirus infection in pigeons (*Columbia livia*) during an outbreak of diarrhoea. *Avian Pathol.* 40:361–365.

Arbovirus Infections

1. Aizawa, C., S. Hasegawa, C. Chih-Yuan, and I. Yoshioka. 1980. Large-scale purification of Japanese encephalitis virus from infected mouse brain for preparation of vaccine. *Appl Environ Microbiol.* 39:54–57.
2. Anderson J.F., T.G. Andreadis, C.R. Vossbrinck, S. Tirrel, E.M. Wakem, R.A. French, A.E. Garmendia, and H.J. Van Kruiningen. 1999. Isolation of West Nile virus from mosquitoes, crows and a Cooper's hawk in Connecticut. *Science.* 286:2331–2333.
3. Austin, R.J., T.L. Whiting, R.A. Anderson, and M.A. Drebot. 2004. An outbreak of West Nile virus-associated disease in domestic geese (*Anser anser domesticus*) upon initial introduction to a geographic region, with evidence of bird to bird transmission. *Can Vet J.* 45:117–23.
4. Bakonyi, T., E. Ivanics, K. Erdelyi, K. Ursu, E. Ferenczi, H. Weissenbock, and N. Nowotny. 2006. Lineage 1 and 2 strains of encephalitic West Nile virus, central Europe. *Emerg Infect Dis.* 12:618–23.

5. Banet-Noach, C., L. Simanov, and M. Malkinson. 2003. Direct (non-vector) transmission of West Nile virus in geese. *Avian Pathol.* 32:489–94.
6. Barnard, B.J.H., and H.J. Geyer. 1981. Attenuation of turkey meningo-encephalitis virus in BHK21 cells. *Onderstepoort J Vet Res.* 48:105–108.
7. Barnard, B.J.H., S.B. Buys, J.H. Du Preez, S.P. Greyling, and H.J. Venter. 1980. Turkey meningo-encephalitis in South Africa. *Onderstepoort J Vet Res.* 47:89–94.
8. Beaudette, F.R., J.J. Black, C.B. Hudson, and J.A. Bivens. 1952. Equine encephalomyelitis in pheasants from 1947 to 1951. *J Am Vet Med Assoc.* 121:478–483.
9. Berthet F.X., H.G. Zeller, M.T. Drouet, J. Rauzier, J.P. Digoutte, and V. Deubel. 1997. Extensive nucleotide changes and deletions within the envelope glycoprotein gene of Euro-African West Nile viruses. *J Gen Virol.* 78:2293–2297.
10. Blitvich, B.J., N.L. Marlenee, R.A. Hall, C.H. Calisher, R.A. Bowen, J.T. Roehrig, N. Komar, S.A. Langevin, and B.J. Beaty. 2003. Epitope-blocking enzyme-linked immunosorbent assays for the detection of serum antibodies to west Nile virus in multiple avian species. *J Clin Microbiol.* 41:1041–7.
11. Braverman, Y., M. Rubina, and K. Frish. 1981. Pathogens of veterinary importance isolated from mosquitoes and biting midges in Israel. *Insect Sci Appl.* 2:157–161.
12. Broom A.K., J. Charlick, S.J. Richards, and J.S. Mackenzie. 1987. An enzyme-linked immunosorbent assay for detection of flavivirus antibodies in chicken sera. *J Virol Meth.* 15:1–9.
13. Brown, T.M., C.J. Mitchell, R.S. Nasci, G.C. Smith, and J.T. Roehrig. 2001. Detection of eastern equine encephalitis virus in infected mosquitoes using a monoclonal antibody-based antigen-capture enzyme-linked immunosorbent assay. *Am J Trop Med Hyg.* 65:208–213.
14. Buckley, A., A. Dawson, and E.A. Gould. 2006. Detection of seroconversion to West Nile virus, Usutu virus and Sindbis virus in UK sentinel chickens. *Virol J.* 3:71.
15. Byrne, R.J., and M.L. Robbins. 1961. Mortality patterns and antibody response in chickens inoculated with eastern equine encephalitis virus. *J Immunol.* 86:13–16.
16. Calisher, C.H., T.P. Monath, D.J. Muth, J.S. Lazuick, D.W. Trent, D.B. Francy, G.E. Kemp, and F.W. Chandler. 1980. Characterization of Fort Morgan virus, an alphavirus of the western equine encephalitis virus complex in an unusual ecosystem. *Am J Trop Med Hyg.* 29:1428–1440.
17. Calisher, C.H., N. Karabotsos, J.S. Lazuick, T.P. Monath, and K.L. Wolff. 1988. Reevaluation of the western equine encephalitis antigenic complex of alphaviruses (family Togaviridae) as determined by neutralization tests. *Am J Trop Med Hyg.* 38:447–452.
18. Calisher, C.H., N. Karabatsos, J.M. Dalrymple, R.E. Shope, J.S. Porterfield, E.G. Westaway, and W.E. Brandt. 1989. Antigenic relationships between flaviviruses as determined by cross-neutralization tests with polyclonal antisera. *J Gen Virol.* 70:37–43.
19. Chamberlain, R.W. 1958. Vector relationships of the arthropod-borne encephalitides in North America. *Ann N Y Acad Sci.* 70:312–319.
20. Clarke, D.H., and J. Casals. 1958. Techniques for hemagglutination and hemagglutination-inhibition with arthropod-borne viruses. *Am J Trop Med Hyg.* 7:561–573.
21. Cooper, G.L., and H.A. Medina. 1999. Egg production drops in breeder turkeys associated with western equine encephalitis virus infection. *Avian Dis.* 43:136–141.
22. Cooper, G.L., H.A. Medina, P.R. Woolcock, M.D. McFarland, and B. Reynolds. 1997. Experimental infection of turkey poults with western equine encephalitis virus. *Avian Dis.* 41:578–582.
23. Crans, W.J., J. McNelly, T.L. Sulze, and A. Main. 1986. Isolation of eastern equine encephalitis virus from Aedes sollicitans during an epizootic in southern New Jersey. *J Am Mosq Control Assoc.* 2:68–72.
24. Davidson, I., R. Grinberg, M. Malkinson, S. Mechani, S. Pokamonski, and Y. Weisman. 2000. Diagnosis of turkey meningoencephalitis virus infection in field cases by RT-PCR compared to virus isolation in embryonated eggs and suckling mice. *Avian Pathol.* 29:35–39.
25. Davis, B.S., G.J. Chang, B. Cropp, J.T. Roehrig, D.A. Martin, C.J. Mitchell, R. Bowen, and M.L. Bunning. 2001. West Nile recombinant DNA vaccine protects mouse and horse from virus challenge and express *in vitro* a noninfectious recombinant antigen that can be used in enzyme-linked immunosorbent assays. *J Virol.* 75:4040–4047.
26. Diamond, M.S., B. Shrestha, A. Marri, D. Mahan, and M. Engle. 2003. B cells and antibody play critical roles in the immediate defense of disseminated infection by West Nile encephalitis virus. *J Virol.* 77:2578–86.
27. Dougherty, E., and J.I. Price. 1960. Eastern encephalitis in White Pekin ducklings on Long Island. *Avian Dis.* 4:247–258.
28. Ebel, G.D., A.P. Dupuis, D. Nicholas, D. Young, J. Maffei, and L.D. Kramer. 2002. Detection by enzyme-linked immunosorbent assay of antibodies to West Nile virus in birds. *Emerg Infect Dis.* 8:979–982.
29. Eisner, R.J., and S.R. Nusbaum. 1983. Encephalitis vaccination of pheasants: A question of efficacy. *J Am Vet Med Assoc.* 183:280–281.
30. Eleazer, T.H., and J.E. Hill. 1994. Highlands J virus-associated mortality in chukar partridges. *J Vet Diagn Invest.* 6:98–99.
31. Faddoul, G.P., and G.W. Fellows. 1965. Clinical manifestations of eastern equine encephalomyelitis in pheasants. *Avian Dis.* 9:530–535.
32. Ficken, M.D., D.P. Wages, J.S. Guy, J.A. Quinn, and W.H. Emory. 1993. High mortality of domestic turkeys associated with Highlands J virus and eastern equine encephalitis virus infections. *Avian Dis.* 37:585–590.
33. Foral, T.M.A., R.A. French, H.J. Van Kruiningen, and A.E. Garmendia. 2007. Fluorescent antibody test for rapid diagnosis of West Nile virus antigen in avian tissues. *Avian Dis.* 51:601–605.
34. Fothergill, G.P., and J.H. Dingle. 1938. A fatal disease of pigeons caused by the virus of the eastern variety of equine encephalomyelitis. *Science.* 88:549–50.
35. Glavits, R., E. Ferenczi, E. Ivanics, T. Bakonyi, T. Mato, P. Zarka, and V. Palya. 2005. Co-occurrence of West Nile Fever and circovirus infection in a goose flock in Hungary. *Avian Pathol.* 34:408–14.
36. Gould, E.A. 2002. Evolution of the Japanese encephalitis serocomplex viruses. *Curr Top Microbiol Immunol.* 267:391–404.
37. Granwehr, B.P., K.M. Lillibridge, S. Higgs, P.W. Mason, J.F. Aronson, G.A. Campbell, and A.D. Barrett. 2004. West Nile virus: where are we now? *Lancet Infect Dis.* 4:547–56.
38. Guy, J.S., M.D. Ficken, H.J. Barnes, D.P. Wages, and L.G. Smith. 1993. Experimental infection of young turkeys with eastern equine encephalitis virus and Highlands J virus. *Avian Dis.* 37:389–395.
39. Guy, J.S., H.J. Barnes, and L.G. Smith. 1994. Experimental infection of young broiler chickens with eastern equine encephalitis virus and Highlands J virus. *Avian Dis.* 38:572–582.

40. Guy, J.S., H.J. Barnes, M.D. Ficken, L.G. Smith, W.H. Emory, and D.P. Wages. 1994. Decreased egg production in turkeys experimentally infected with eastern equine encephalitis virus or Highlands J virus. *Avian Dis.* 38:563–571.
41. Guy, J.S., T.P. Siopes, H.J. Barnes, L.G. Smith, and W.H. Emory. 1995. Experimental transmission of eastern equine encephalitis virus and Highlands J virus via semen collected from infected tom turkeys. *Avian Dis.* 39:337–342.
42. Hall, R.A., A.K. Broom, A.C. Hartnett, M.J. Howard, and J.S. MacKenzie. 1995. Immunodominant epitopes on the NS1 protein of Murray valley encephalitis and Kunjin viruses serve as targets for a blocking ELISA to detect virus-specific antibodies in sentinel animal serum. *J Virol. Meth* 51:201–210.
43. Hanson, R.P., S. Vadlamudi, D.O. Trainer, and R. Anslow. 1968. Comparison of the resistance of different aged pheasants to eastern encephalitis virus from different sources. *Am J Vet Res.* 29:723–727.
44. Hayes, C.G., and R.C. Wallis. 1977. Ecology of western equine encephalitis virus in the eastern United States. *Adv Virus Res.* 21:37–83.
45. Hayes C.G. 1989. West Nile fever. In: *The Arboviruses: Epidemiology and Ecology*, Vol. 5. T.P. Monath, ed. CRC Press, Inc., Boca Raton, Florida. 59–88.
46. Henderson, J.R., N. Karabotsos, A.T.C. Bourke, R.C. Wallis, and R.M. Taylor. 1962. A survey of arthropod-borne viruses in south-central Florida. *Am J Trop Med Hyg.* 11:800–810.
47. Hildreth, S.W., and B.J. Beaty. 1984. Detection of eastern equine encephalitis virus and Highlands J virus antigens within mosquito pools by enzyme-linked immunoassay (EIA) 1. A laboratory study. *Am J Trop Med Hyg*. 33:965–972.
48. Hildreth, S.W., B.J. Beaty, H.K. Maxfield, R.F. Gilfillan, and B.J. Rosenau. 1984. Detection of eastern equine encephalitis virus and Highlands J virus antigens within mosquito pools by enzyme-linked immunoassay (EIA) 2. Retrospective field test of the EIA. *Am J Trop Med Hyg*. 33:973–980.
49. Himsworth, C.G., K.E.B. Gurney, A.S. Neimanis, G.A. Wobeser, and F.A. Leighton. 2009. An outbreak of West Nile infection in captive lesser scaup (*Aythya affinis*) ducklings. *Avian Dis.* 53:129–134.
50. Holden, P. 1955. Transmission of eastern equine encephalitis virus in ring-neck pheasants. *Proc Soc Exp Biol Med.* 88:607–610.
51. Howard, J.S., and R.C. Wallis. 1974. Infection and transmission of eastern equine encephalitis virus with colonized Culiseta melanura (Coquillett). *Am J Trop Med Hyg.* 23:522–525.
52. Ianconescu, M. 1976. Turkey meningo-encephalitis: A general review. *Avian Dis.* 20:135–138.
53. Ianconescu, M. 1989. Turkey meningo-encephalitis. In: *A Laboratory Manual for the Isolation and Identification of Avian Pathogens*, 3rd ed. H.G. Purchase, L.H. Arp, C.H. Domermuth, and J.E. Pearson, eds. American Association of Avian Pathologists, Kennett Square, Pennsylvania. 163–164.
54. Ianconescu, M., A. Aharonovici, Y. Samberg, M. Merdinger, and K. Hornstein. 1972. An aetiological and immunological study of the 1971 outbreak of turkey meningo-encephalitis. *Refu Vet.* 29:110–117.
55. Ianconescu, M., A. Aharonovici, Y. Samberg, K. Hornstein, and M. Merdinger. 1973. Turkey meningo-encephalitis: Pathologic and immunological aspects of the infection. *Avian Pathol.* 2:251–262.
56. Ianconescu, M., A. Aharonovici, and Y. Samberg. 1974. The Japanese quail as an experimental host for turkey meningo-encephalitis virus. *Refu Vet.* 31:100–108.
57. Ianconescu, M., K. Hornstein, Y. Samberg, A. Aharonovici, and M. Merdinger. 1975. Development of a new vaccine against turkey meningo-encephalitis using a virus passaged through Japanese quail (*Coturnix coturnix japonica*). *Avian Pathol.* 4:119–131.
58. Johnson, A.J., S. Langevin, K.L. Wolff, and N. Komar. 2003. Detection of anti-West Nile virus immunoglobulin M in chicken serum by an enzyme-linked immunosorbent assay. *J Clin Microbiol.* 41:2002–2007.
59. Jozam, M., R. Evans, R. McLean, R. Hall, B. Tangredi, L. Reed, and J. Scott. 2003. Detection of West Nile virus infection in birds in the United States by blocking ELISA and immunohistochemistry. *Vector Borne Zoonotic Dis.* 3:99–110.
60. Jungherr, E.L., C.F. Helmboldt, S.F. Satriano, and R.E. Luginbuhl. 1958. Investigation of eastern equine encephalomyelitis. III. Pathology in pheasants and incidental observations in feral animals. *Am J Hyg*. 67:10–20.
61. Karabotsos, N. 1975. Antigenic relationships of group A arboviruses by plaque-reduction neutralization testing. *Am J Trop Med Hyg.* 24:527–532.
62. Karabotsos, N., A.T.C. Burke, and J.R. Henderson. 1963. Antigenic variation among strains of western equine encephalomyelitis virus. *Am J Trop Med Hyg.* 12:408–412.
63. Karabotsos, N., A.L. Lewis, C.H. Calisher, A.R. Hunt, and J.T. Roehrig. 1988. Identification of Highlands J virus from a Florida horse. *Am J Trop Med Hyg.* 39:603–606.
64. Kaufmann, B., G.E. Nybakken, P.R. Chipman, W. Zhang, M.S. Diamond, D.H. Fremont, R.J. Kuhn, and M.G. Rossmann. 2006. West Nile virus in complex with the Fab fragment of a neutralizing monoclonal antibody. *Proc Natl Acad Sci.* 103:12400–12404.
65. Kissling, R.E. 1958. Eastern equine encephalomyelitis in pheasants. *J Am Vet Med Assoc.* 132:466–468.
66. Kissling, R.E. 1958. Host relationship of the arthropod-borne encephalitides. *Ann N Y Acad Sci.* 70:320–327.
67. Komar, N. 2001. West Nile virus surveillance using sentinel birds. *Ann N Y Acad Sci.* 951:58–73.
68. Komar, N. 2003. West Nile virus: epidemiology and ecology in North America. *Adv Virus Res.* 61:185–234.
69. Komar, N., S. Langevin, S. Hinten, N. Nemeth, E. Edwards, D. Hettler, B. Davis, R. Bowen, and M. Bunning. 2003. Experimental infection of North American birds with the New York 1999 strain of West Nile virus. *Emerg Infect Dis.* 9: 311–22.
70. Komarov, A., and E. Kalmar. 1960. A hitherto undescribed disease-turkey meningoencephalitis. *Vet Rec.* 72:257–261.
71. Kuno, G., G.J. Chang, K.R. Tsuchiya, N. Karabatsos, and C.B. Cropp. 1998. Phylogeny of the genus flavivirus. *J Virol.* 72:73–83.
72. Lanciotti, R.S., G.D. Ebel, V. Deubel, A.J. Kerst, S. Murri, R. Meyer, M. Bowen, N. McKinney, W.E. Morrill, M.B. Crabtree, L.D. Kramer, and J.T. Roehrig. 2002. Complete genome sequences and phylogenetic analysis of West Nile virus strains isolated from the United States, Europe, and the Middle East. *Virology.* 298:96–105.
73. Lanciotti R.S., A.J. Kerst, R.S. Nasci, M.S. Godsey, C.J. Mitchell, H.M. Savage, N. Komar, N.A. Panella, B.C. Allen, K.E. Volpe, B.S. Davis, and J.T. Roehrig. 2000. Rapid detection of West Nile virus from human clinical samples, field-collected mosquitoes and avian samples by a TaqMan reverse transcriptase–PCR assay. *J Clin Micro.* 38:4066–4071.
74. Lustig S., U. Olshevsky, D. Ben-Nathan, B.E. Lachmi, M. Malkinson, D. Kobiler, and M. Halevy. 2000. A live attenuated

West Nile virus strain as a potential veterinary vaccine. *Viral Immunol.* 13:401–410.
75. Malkinson M., C. Banet, S. Machany, Y. Weisman, A. Frommer, and R. Bock. 1998. Virus encephalomyelitis of geese: some properties of the viral isolate. *Israel J Vet Med.* 53:44–45.
76. Malkinson M., C. Banet, J. Weisman, S. Pokamonski, and R. King. 1999. West Nile fever: recent evidence for inter-continental dispersion of the virus by migratory birds. Proceedings 11th International Congress Virology, Sydney, Australia.
77. Malkinson M., C. Banet, Y. Khinich, I. Samina, S. Pokamonski, and Y. Weisman. 2002. Use of live and inactivated vaccines in the control of West Nile fever in domestic geese. *Ann NY Acad Sci.* 951:255–261.
78. McLean R.G., S.R. Ubico, D.E. Docherty, W.R. Hansen, and L. Sileo. 2001. West Nile virus transmission and ecology in birds. *Ann NY Acad Sci.* 951:54–57.
79. Meece, J.K., T.A. Kronenwetter-Koepel, M.F. Vandermause, and K.D. Reed. 2006. West Nile virus infection in commercial waterfowl operation, Wisconsin. *Emerg Infect Dis*. 451–453.
80. Miller B.R., R.S. Nasci, M.S. Godsey, H.M. Savage, J.J. Lutwama, R.S. Lanciotti, and C.J. Peters. 2000. First field evidence for natural vertical transmission of West Nile virus in Culex univittatus complex mosquitoes from Rift Valley Province, Kenya. *Am J Trop Med Hyg*. 62:240–246.
81. Minke, J.M., L. Siger, K. Karaca, L. Austgen, P. Gordy, R. Bowen, R.W. Renshaw, S. Loosmore, J.C. Audonnet, and B. Nordgren. 2004. Recombinant canarypoxvirus vaccine carrying the prM/E genes of West Nile virus protects horses against a West Nile virus-mosquito challenge. *Arch Virol Suppl.* 221–30.
82. Monath, T.P., and D.W. Trent. 1981. Togaviral diseases of domestic animals. In: *Comparative Diagnosis of Viral Diseases*, Vol. 4. E. Kurstak and C. Kurstak, eds. Academic Press, New York. 331–440.
83. Moulthrop, I.M., and B.A. Gordy. 1960. Eastern viral encephalomyelitis in chukar (*Alectoris graeca*). *Avian Dis.* 4:380–83.
84. Mumcuoglu, K.Y., C. Banet-Noach, M. Malkinson, U. Shalom, and R. Galun. 2005. Argasid ticks as possible vectors of West Nile virus in Israel. *Vector Borne Zoonotic Dis.* 5:65–71.
85. Nasci, R.S., K.L. Gottfried, J.R. Brukhalter, J.R. Ryan, E. Emmerich, and K. Dave. 2003. Sensitivity of the VecTest antigen assay for eastern equine encephalitis and western equine encephalitis viruses. *J Am Mosq Control Assoc.* 19:440–444.
86. Ng, T., D. Hathaway, N. Jennings, D. Champ, Y.W. Chiang, and H.J. Chu. 2003. Equine vaccine for West Nile virus. *Dev Biol (Basel)*. 114:221–227.
87. Nir, Y. 1972. Some characteristics of Israel turkey virus. *Arch ges Virusforsch.* 36:105–114.
88. Pearson, J.E. 1989. Arbovirus infections. In: *A Laboratory Manual for the Isolation and Identification of Avian Pathogens*, 3rd ed. H.G. Purchase, L.H. Arp, C.H. Domermuth, and J.E. Pearson, eds. American Association of Avian Pathologists, Kennett Square, Pennsylvania. 161–162.
89. Peleg, B.A. 1963. A small-scale serological survey of Israel turkey meningo-encephalitis. *Refu Vet.* 20:253–250.
90. Peters, C.J, and J.M. Dalrymple. 1990. Alphaviruses. In: *Virology*, 2nd ed., Vol. 1. B.N. Fields, D.M. Knipe, R.M. Chanock, M.S. Hirsch, J.L. Melnick, T.P. Monath, and B. Roizman, eds. Raven Press, Ltd., New York. 713–761.
91. Porterfield, J.S. 1961. Israel turkey meningoencephalitis virus. *Vet Rec.* 73:392–393.
92. Price, W.H., and I.S. Thind. 1972. The mechanism of cross-protection afforded by dengue virus against West Nile virus in hamsters. *J Hyg Cambridge.* 70:611–617.
93. Ranck, F.M., Jr., J.H. Gainer, J.E. Hanley, and S.L. Nelson. 1965. Natural outbreak of eastern and western encephalitis in pen-raised chukars in Florida. *Avian Dis.* 9:8–20.
94. Reagan R.L., W.C. Day, M.P. Harmon, and A.L. Brueckner. 1952. Response of the baby chick to West Nile virus. *Proc Soc Exp Biol Med.* 80:210–212.
95. Samberg, Y., M. Ianconescu, and K. Hornstein. 1972. Epizootiological aspects of turkey meningoencephalitis. *Refu Vet.* 29:103–110.
96. Samina, I., Y. Khinich, M. Simanov, and M. Malkinson. 2005. An inactivated West Nile virus vaccine for domestic geese-efficacy study and a summary of 4 years of field application. *Vaccine.* 23:4955–8.
97. Satriano, S.F., R.E. Luginbuhl, R.C. Wallis, E.L. Jungherr, and L.H. Williamson. 1958. Investigation of eastern equine encephalomyelitis. Susceptibility and transmission studies with virus of pheasant origin. *Am J Hyg.* 67:21–34.
98. Scott, T.W., and J.G. Olsen. 1986. Detection of eastern equine encephalitis viral antigen in avian blood by enzyme immunoassay: A laboratory study. *Am J Trop Med Hyg.* 35:611–618.
99. Scott, T.W., J.G. Olsen, T.E. Lewis, J.W. Carpenter, L.H. Lorenz, L.A. Lembeck, S.R. Joseph, and B.B. Pagac. 1987. A prospective field evaluation of an enzyme immunoassay: Detection of eastern equine encephalitis virus in pools of Culiseta melanura. *J Am Mosq Control Assoc.* 3:412–417.
100. Senne D.A., J.C. Pedersen, D.L. Hutto, W.D. Taylor, B.J. Schmitt, and B. Panigrahy. 2000. Pathogenicity of West Nile virus in chickens. *Avian Dis.* 44:642–649.
101. Shirafuji, H., K. Kanehira, M. Kubo, T. Shibahara, and T. Kamio. 2009. Experimental West Nile virus infection in Aigamo ducks, a cross between wild ducks (*Anas platyrhynchos*) and domestic ducks (Anas *platyrhynchos var domesticus*). *Avian Dis.* 53:239–244.
102. Shope, R.E., and G.E. Sather. 1979. Arboviruses. In: *Diagnostic Procedures for Viral, Rickettsial, and Chlamydial Infections*, 5th ed. E.H. Lennette and N.J. Schmidt, eds. American Public Health Service, Washington, DC. 767–814.
103. Smithburn K.C., T.P. Hughes, A.W. Burke, and J.H. Paul. 1940. A neurotropic virus isolated from the blood of a native in Uganda. *Am J Trop Med.* 20:471–493.
104. Spalatin, J., L. Karstad, J.R. Anderson, L. Lauerman, and R.P. Hanson. 1961. Natural and experimental infections in Wisconsin turkeys with the virus of eastern encephalitis. *Zoonoses Res.* 1:29–48.
105. Steele K.E., M.J. Linn, R.J. Schoepp, N. Komar, T.W. Geisbert, R.M. Manduca, P.P. Calle, B.L. Raphael, B.L. Clippinger, T. Larsen, J. Smith, R.S. Lanciotti, N.A. Panella, and T.S. McNamara. 2000. Pathology of fatal West Nile virus infections in native and exotic birds during the 1999 outbreak in New York City, New York. *Vet Pathol*. 37:208–234.
106. Sussman, O., D. Cohen, J.E. Gerende, and R.E. Kissling. 1958. Equine encephalitis vaccine studies in pheasants under epizootic and preepizootic conditions. *Ann N Y Acad Sci.* 70:328–340.
107. Swayne, D.E., J.R. Beck, and S. Zaki. 2000. Pathogenicity of West Nile virus for turkeys. *Avian Dis.* 44:932–937.
108. Swayne, D.E., J.R. Beck, C. Smith, and S. Zaki. 2001. Fatal encephalitis and myocarditis in young geese (*Anser anser*

domesticus) caused by West Nile virus infection. *Emerging Infect Dis.* 7:751–753.
109. Taylor, R.M., T.H. Work, H.S. Hurlbut, and F. Rizk. 1956. A study of the ecology of West Nile virus in Egypt. *Am J Trop Med Hyg.* 5:579–620.
110. TenBroeck, C., and M.H. Merrill. 1933. A serological difference between eastern and western equine encephalomyelitis virus. *Proc Soc Exp Med.* 31:217–220.
111. Thiel, H.J., M.S. Collett, E.A. Gould, F.X. Heinz, M. Houghton, G. Meyers, R.H. Purcell, and C.M. Rice. 2005. Flaviviridae. In: *Virus taxonomy: Eighth Report of the International Committee on Taxonomy of Viruses*. C.M. Fauquet, M.A. Mayo, J. Maniloff, U. Desselberger, and L.A. Ball, eds. Elsevier Academic Press, San Diego. 981–998.
112. Trent, D.W., and J.A. Grant. 1980. A comparison of New World alphaviruses in the western equine encephalomyelitis complex by immunochemical and oligonucleotide fingerprint techniques. *J Gen Virol.* 47:261–282.
113. Tyzzer, E.E., and A.W. Sellards. 1941. The pathology of equine encephalomyelitis in young chickens. *Am J Hyg.* 33:69–81.
114. Tyzzer, E.E., A.W. Sellards, and B.L. Bennett. 1938. The occurrence in nature of equine encephalomyelitis in the ring-necked pheasant. *Science.* 88:505–506.
115. Vodkin, M.H., G.L. McLaughlin, J.F. Day, R.E. Shope, and R.J. Novak. 1993. A rapid diagnostic assay for eastern equine encephalitis viral RNA. *Am J Trop Med Hyg.* 49:772–776.
116. Wages, D.P., M.D. Ficken, J.S. Guy, T.S. Cummings, and S.R. Jennings. 1993. Egg-production drop in turkeys associated with alphaviruses: Eastern equine encephalitis virus and Highlands J virus. *Avian Dis.* 37:1163–1166.
117. Walder, R., O.M. Suarez, and C.H. Calisher. 1984. Arbovirus studies in the Guajira region of Venezuela: Activities of eastern equine encephalitis and Venezuelan equine encephalitis viruses during an interepizootic period. *Am J Trop Med Hyg.* 33:699–707.
118. Wallis, R.C., and A.J. Main. 1974. Eastern equine encephalitis in Connecticut, progress and problems. *Mem Conn Entomol Soc.* 117–144.
119. Weaver, S.C., T.K. Frey, H.V. Huang, R.M. Kinney, C.M. Rice, J.T. Roehrig, R.E. Shope, and E.G. Strauss. 2005. Togaviridae. In: *Virus Taxonomy: Eighth Report of the International Committee on Taxonomy of Viruses*. C.M. Fauquet, M.A. Mayo, J. Maniloff, U. Desselberger, and L.A. Ball, eds. Elsevier Academic Press, San Diego. 999–1008.
120. Weissenbock, H., J. Kolodziejek, A. Url, H. Lussy, B. Rebel-Bauder, and N. Nowotny. 2002. Emergence of Usutu virus, an African mosquito-borne flavivirus of the Japanese encephalitis virus group, central Europe. *Emerg Infect Dis.* 8:652–656.
121. Whitehouse C.A., A. Guibeau, D. McGuire, T. Takeda, and T.N. Mather. 2001. A reverse transcriptase-polymerase chain reaction assay for detecting Highlands J virus. *Avian Dis.* 45:605–611.
122. Williams, J.E., O.P. Young, D.M. Watts, and T.J. Reed. 1971. Wild birds as eastern equine encephalitis and western equine encephalitis sentinels. *J Wildl Dis.* 7:188–194.
123. Williams, S.M., R.M. Fulton, J.S. Patterson, and W.M. Reed. 2000. Diagnosis of eastern equine encephalitis by immunohistochemistry in two flocks of Michigan ring-neck pheasants. *Avian Dis.* 44:1012–1016.
124. Woodring, F.R. 1957. Naturally occurring infection with equine encephalomyelitis virus in turkeys. *J Am Vet Med Assoc.* 130:511–512.
125. Wunschmann, A., and A. Ziegler. 2006. West Nile virus-associated mortality events in domestic chukar partridges (*Alectoris chukar*) and domestic Impeyan pheasants (*Lophophorus impeyanus*). *Avian Dis.* 50:456–459.

Turkey Viral Hepatitis

1. Honkavuori, K.S., H.L. Shivaprasad, T. Briese, C. Street, D.L. Hirschberg, S.K. Hutchinson, and W.I. Lipkin. 2011. Novel picornavirus in turkey poults with hepatitis, California, USA. *Emerg Infect Dis*. 17:480–487.
2. Klein, P.N., A.E. Castro, C.U. Meteyer, B. Reynolds, J.A. Swartzmann-Andert, G. Cooper, R.P. Chin, and H.L. Shivaprasad. 1991. Experimental transmission of turkey viral hepatitis to day-old poults and identification of associated viral particles resembling picornaviruses. *Avian Dis.* 35:115–125.
3. MacDonald, J.W., C.J. Randall, and M.D. Dagless. 1982. Picornaviruslike virus causing hepatitis and pancreatitis in turkeys. *Vet Rec.* 111:323.
4. Mandelli, G.A., A. Rinaldi, and G. Cervio. 1966. Gross and ultramicroscopic lesions in hepatopancreatitis in turkeys. *Atti Soc Ital Sci Vet.* 20:541–545.
5. Mongeau, J.D., R.B. Truscott, A.E. Ferguson, and M.C. Connell. 1959. Virus hepatitis in turkeys. *Avian Dis.* 3:388–396.
6. Snoyenbos, G.H. 1991. Turkey viral hepatitis. In: *Diseases of Poultry*, 9th ed. B.W. Calnek, H.J. Barnes, C.W. Beard, W.M. Reid, and H.W. Yoder, Jr., eds. 699–701.
7. Snoeyenbos, G.H., and H.I. Basch. 1960. Further studies of virus hepatitis in turkeys. *Avian Dis.* 4:477–485.
8. Snoeyenbos, G.H., H.I. Basch, and M. Sevoian. 1959. An infectious agent producing hepatitis in turkeys. *Avian Dis.* 3:377–388.
9. Stanway, G., F. Brown, P. Christian, T. Hovi, T. Hyypia, A. King, N. Knowles, S. Lemon, P. Minor, M. Pallansch, A. Palmberg, and T. Skern. 2005. Picornaviridae. In: *Virus Taxonomy: Eighth Report of the International Committee on Taxonomy of Viruses*. C. Fauquet, M. Mayo, J. Maniloff, U. Desselberger and L. Ball, eds. Academic Press, San Diego. 947–964.
10. Tzianabos, T. 1965. Turkey viral hepatitis. Some clinical, immunological, and physiochemical properties. PhD dissertation, University of Massachusetts, Amherst.
11. Tzianabos, T., and G.H. Snoeyenbos. 1965a. Some physiochemical properties of turkey hepatitis virus. *Avian Dis.* 9:152–156.
12. Tzianabos, T., and G.H. Snoeyenbos. 1965b. Clinical, immunological and serological observations on turkey virus hepatitis. *Avian Dis.* 9:578–595.

Avian Encephalomyelitis

1. Abe, T. 1968. A search for susceptible cells to avian encephalomyelitis (AE) virus. *Jap J Vet Res.* 16:88–89.
2. Ahmed, A.A., I.M. El-Azm, N.N. Ayoub, and B.I. El-Toukhi. 1982. Studies on the serological detection of antibodies to avian encephalomyelitis virus. *Avian Pathol.* 11:253–62.
3. Bakhshesh, M., E. Groppelli, M.M. Willcocks, E. Royall, G.J. Belsham, and L.O. Roberts. 2008. The picornavirus avian encephalomyelitis virus possesses a hepatitis C virus-like internal ribosome entry site element. *J Virol.* 82:1993–2003.
4. Berger, R.G. 1982. An *in vitro* assay for quantifying the virus of avian encephalomyelitis. *Avian Dis.* 26:534–41.

5. Bodin, R.G., J.L. Pellerin, A. Milon, M.F. Geral, X. Berthelot, and R. Lautie. 1981. Etude de la contamination experimentale du gibier a plumes (faisnas, perdrix rouges, perdix grises), par le virus de l'encephalomyelite infectieuse aviare. *Revue Med Vet.* 132:805–816.
6. Braune, M.O., and R.F. Gentry. 1971. Avian encephalomyelitis virus. I. Pathogenesis in chicken embryos. *Avian Dis.* 15:638–47.
7. Braune, M.O., and R.F. Gentry. 1971. Avian encephalomyelitis virus. II. Pathogenesis in chickens. *Avian Dis.* 15:648–53.
8. Bulow, V.V. 1964. Studies on the physico-chemical properties of the virus of avian encephalomyelitis (AE) with special reference to urification and preservation of virus suspensions. *Zentralbl Veterinarmed B.* 11:674–686.
9. Burke, C.N., H. Krauss, and R.E. Luginbuhl. 1965. The multiplication of avian encephalomyelitis virus in chicken embryo tissues. *Avian Dis.* 9:104–108.
10. Butterfield, W.K. 1975. Avian encephalomyelitis: the virus and immune response. *Am J Vet Res.* 36:557–9.
11. Butterfield, W.K., C.F. Helmboldt, and R.E. Luginbuhl. 1969. Studies on avian encephalomyelitis IV. Early incidence and longevity of histopathologic lesions in chickens. *Avian Dis.* 13:53–7.
12. Butterfield, W.K., R.E. Luginbuhl, and C.F. Helmboldt. 1969. Characterization of avian encephalomyelitis virus (an avian enterovirus). *Avian Dis.* 13:363–78.
13. Butterfield, W.K., R.E. Luginbuhl, C.F. Helmboldt, and F.W. Sumner. 1961. Studies on avian encephalomyelitis. III Immunization with an inactivated virus. *Avian Dis.* 5:445–450.
14. Cadman, H.F., P.J. Kelly, R. Zhou, F. Davelaar, and P.R. Mason. 1994. A serosurvey using enzyme-linked immunosorbent assay for antibodies against poultry pathogens in ostriches (*Struthio camelus*) from Zimbabwe. *Avian Dis.* 38:621–5.
15. Calnek, B.W. 1998. Control of avian encephalomyelitis: a historical account. *Avian Dis.* 42:632–47.
16. Calnek, B.W., and H. Jehnich. 1959. Studies on avian encephalomyelitis. I. The use of a serum neuralization test in the detection of immunity levels. *Avian Dis.* 3:95–104.
17. Calnek, B.W., and H. Jehnich. 1959. Studies on avian encephalomyelitis. II. Immune responses to vaccination procedures. *Avian Dis.* 3:225–239.
18. Calnek, B.W., and P.J. Taylor. 1960. Studies on avian encephalomyelitis. III. Immune responses to vaccination procedures. *Avian Dis.* 4:116–122.
19. Calnek, B.W., P.J. Taylor, and M. Sevoian. 1960. Studies on avian encephalomyelitis. IV. Epizootiology. *Avian Dis.* 4:325–347.
20. Calnek, B.W., P.J. Taylor, and M. Sevoian. 1961. Studies on the avian encephalomyelitis. V. Development and application of an oral vaccine. *Avian Dis.* 5:297–312.
21. Cheville, N.F. 1970. The influence of thymic and bursal lymphoid systems in the pathogenesis of avian encephalomyelitis. *Am J Pathol.* 58:105–25.
22. Choi, W.P., and S. Miura. 1972. Indirect fluorescent antibody technique for the detection of avian encephalomyelitis antibody in chickens. *Avian Dis.* 16:949–51.
23. Deshmukh, D.R., C.T. Larsen, T.A. Rude, and B.S. Pomeroy. 1973. Evaluation of live-virus vaccine against avian encephalomyelitis in turkey breeder hens. *Am J Vet Res.* 34:863–7.
24. Feibel, F., C.F. Helmboldt, E.L. Jungherr, and J.R. Carson. 1952. Avian encephalomyelitis—prevalence, pathogenicity of the virus, and breed susceptibility. *Am J Vet Res.* 13:260–6.
25. Folkers, C., D. Jaspers, M.E. Stumpel, and E.A. Wittevrongel. 1976. Vaccination against avian encephalomyelitis with special reference to the spray method. *Dev Biol Stand.* 33:364–9.
26. Garrett, J.K., R.B. Davis, and W.L. Ragland. 1985. Correlation of serum antibody titer for avian encephalomyelitis virus (AEV) in hens with the resistance of progeny embryos to AEV. *Avian Dis.* 29:878–80.
27. Garrett, J.K., R.B. Davis, and W.L. Ragland. 1984. Enzyme-linked immunosorbent assay for detection of antibody to avian encephalomyelitis virus in chickens. *Avian Dis.* 28:117–30.
28. Girshick, T., and C.K. Crary, Jr. 1982. Preparation of an agar gel precipitating antigen for avian encephalomyelitis and it use in evaluating the antibody status of poultry. *Avian Dis.* 26:798–804.
29. Glisson, J.R., and O.J. Fletcher. 1987. Clinical encephalitis following avian encephalomyelitis vaccination in broiler breeder pullets. *Avian Dis.* 31:383–5.
30. Gosting, L.H., B.W. Grinnell, and M. Matsumoto. 1980. Physiochemical and morphological characteristics of avian encephalomyelitis virus. *Vet Microbiol.* 5:87–100.
31. Hill, R.W., and R.G. Raymond. 1962. Apparent natural infection of Coturnix quail hens with the virus of avian encephalomyelitis. *Avian Dis.* 6:226–227.
32. Hishida, N., Y. Odagiri, T. Kotani, and T. Horiuchi. 1986. Morphological changes of neurons in experimental avian encephalomyelitis. *Nihon Juigaku Zasshi.* 48:169–72.
33. Hoekstra, J. 1964. Experiments with avian encephalomyelitis. *Br Vet J.* 120:322–335.
34. Hohlstein, W.M., D.R. Deshmukh, C.T. Larsen, J.H. Sautter, B.S. Pomeroy, and J.R. McDowel. 1970. An epiornithic of avian encephalomyelitis in turkeys in Minnesota. *Am J Vet Res.* 31:2233–4.
35. Hughes, P.J., and G. Stanway. 2000. The 2A proteins of three diverse picornaviruses are related to each other and to the H-rev107 family of proteins involved in the control of cell proliferation. *J Gen Virol.* 81:201–7.
36. Ide, P.R. 1979. The sensitivity of some avian viruses to formaldehyde fumigation. *Can J Comp Med.* 43:211–6.
37. Ikeda, S. 1977. Immunodiffusion test in avian encephalomyelitis. I. Standardization of procedure and detection of antigen in infected chickens and embryos. *Natl Inst Anim Health Q (Tokyo).* 17:81–7.
38. Ikeda, S. 1977. Immunodiffusion test in avian encephalomyelitis. II. Detection of precipitating antibody in infected chickens in comparison with neutralizing antibody. *Natl Inst Anim Health Q (Tokyo).* 17:88–94.
39. Ikeda, S., and K. Matsuda. 1976. Susceptibility of chickens to avian encephalomyelitis virus. IV. Behavior of the virus in laying hens. *Natl Inst Anim Health Q (Tokyo).* 16:83–9.
40. Ikeda, S. and K. Matsuda. 1976. Susceptibility of chickens to avian encephalomyelitis virus. V. Behavior of a field strain in laying hens. *Natl Inst Anim Health Q (Tokyo).* 16:90–6.
41. Ikeda, S., K. Matsuda, and K. Yonaiyama. 1976. Susceptibility of chickens to avian encephalomyelitis virus. II. Behavior of the virus in day-old chicks. *Natl Inst Anim Health Q (Tokyo).* 16:1–7.
42. Ikeda, S., K. Matsuda, and K. Yonaiyama. 1976. Susceptibility of chickens to avian encephalomyelitis virus. III. Behavior of the virus in growing chicks. *Natl Inst Anim Health Q (Tokyo).* 16:33–8.
43. Jones, E.E. 1932. An encephalomyelitis in the chicken. *Science.* 76:331–2.
44. Jones, E.E. 1934. Epidemic tremor, an encephalomyelitis affecting young chickens. *J Exp Med.* 59:781–98.
45. Jungherr, E., and E.L. Minard. 1942. The present status of avian encephalomyelitis. *J Am Vet Med Assoc.* 100:38–46.

46. Jungherr, E., F. Sumner, and R.E. Luginbuhl. 1956. Pathology of egg-adapted avian encephalomyelitis. *Science.* 124:80–1.
47. Karesh, W.B., M.M. Uhart, E. Frere, P. Gandini, W.E. Braselton, H. Puche, and R.A. Cook. 1999. Health evaluation of free-ranging rockhopper penguins (*Eudyptes chrysocomes*) in Argentina. *J Zoo Wildl Med.* 30:25–31.
48. King, A.M.Q., E. Lefkowitz, M.J. Adams, and E.B. Carstens 2012. *Virus Taxonomy: Ninth Report of the International Committee on Viral Taxonomy*. Academic Press, Waltham, MA.
49. Liu, J., T. Wei, and J. Kwang. 2002. Avian encephalomyelitis virus induces apoptosis via major structural protein VP3. *Virology.* 300:39–49.
50. Liu, J., T. Wei, and J. Kwang. 2004. Avian encephalomyelitis virus nonstructural protein 2C induces apoptosis by activating cytochrome c/caspase-9 pathway. *Virology.* 318:169–82.
51. Liu, J., T. Wei, and J. Kwang. 2004. Membrane-association properties of avian encephalomyelitis virus protein 3A. *Virology.* 321:297–306.
52. Lucas, A.M. 1951. Lymphoid tissue and its relationship to so-called normal lymphoid foci and to lymphomatosis. VI. A study of lymphoid areas in the pancreas of doves and chickens. *Poult Sci*. 30:116–124.
53. Lukert, P.D., and R.B. Davis. 1971. An antigen used in the agar-gel precipitin reaction to detect avian encephalomyelitis virus antibodies. *Avian Dis.* 15:935–8.
54. Macleod, A.J. 1965. Vaccination against avian encephalomyelitis with a betapropiolactone inactivated vaccine. *Vet Rec.* 77:335–7.
55. Malkinson, M., Y. Weisman, A. Stavinski, I. Davidson, U. Orgad, and M.S. Dison. 1986. Application of ELISA to study avian encephalomyelitis in a flock of turkeys. *Vet Rec.* 119:503–4.
56. Mancini, L.O., and V.J. Yates. 1967. Cultivation of avian encephalomyelitis virus *in vitro*. I. In chick embryo neuroglial cell culture. *Avian Dis*. 11:672–9.
57. Marvil, P., N.J. Knowles, A.P. Mockett, P. Britton, T.D. Brown, and D. Cavanagh. 1999. Avian encephalomyelitis virus is a picornavirus and is most closely related to hepatitis A virus. *J Gen Virol.* 80:653–62.
58. Mathey, W.J., Jr. 1955. Avian encephalomyelitis in pheasants. *Cornell Vet*. 45:89–93.
59. Miyamae, T. 1974. Ecological survey by the immunofluorescent method of virus in enzootics of avian encephalomyelitis. *Avian Dis.* 18:369–77.
60. Miyamae, T. 1976. Emergence pattern of egg-adapted avian encephalomyelitis virus by alternating passage in chickens and embryos. *Avian Dis.* 20:425–8.
61. Miyamae, T. 1977. Immunofluorescent study on egg-adapted avian encephalomyelitis virus infection in chickens. *Am J Vet Res.* 38:2009–12.
62. Miyamae, T. 1983. Invasion of avian encephalomyelitis virus from the gastrointestinal tract to the central nervous system in young chickens. *Am J Vet Res.* 44:508–10.
63. Miyamae, T. 1981. Localization of viral protein in avian-encephalomyelitis-virus-infected hens. *Avian Dis.* 25:1065–9.
64. Miyamae, T., and S. Miura. 1971. Patterns of virus multiplication in chickens infected orally with wild and egg adapted encephalomyelitis viruses. *Jpn J Vet Sci.* 33:40–41.
65. Mohanty, G.C., and J.L. West. 1968. Research note: some observations on experimental avian encephalomyelitis. *Avian Dis.* 12:689–93.
66. Nicholas, R.A., I.G. Hopkins, S.J. Southern, and D.H. Thornton. 1986. A comparison of titration methods for live avian encephalomyelitis virus vaccines. *Dev Biol Stand.* 64:207–12.
67. Nicholas, R.A., A.J. Ream, and D.H. Thornton. 1987. Replication of avian encephalomyelitis virus in chick embryo neuroglial cell cultures. Brief report. *Arch Virol*. 96:283–7.
68. Olitsky, P.K. 1939. Experimental studies of the virus of infectious avian encephalomyelitis. *J Exp Med.* 70:565–82.
69. Olitsky, P.K., and J.H. Bauer. 1939. Ultrafiltration of the virus of infectious avian encephalomyelitis. *Proc Soc Exp Biol Med.* 42:634–636.
70. Padilla, L.R., K.P. Huyvaert, J. Merkel, R.E. Miller, and P.G. Parker. 2003. Hematology, plasma chemistry, serology, and Chlamydophila status of the waved albatross (*Phoebastria irrorata*) on the Galapagos Islands. *J Zoo Wildl Med.* 34:278–83.
71. Peckham, M.C. 1957. Lens opacities in fowls possibly associated with epidemic tremors. *Avian Dis.* 1.
72. Polewaczyk, D.E., Z. Zolli Jr., and W.D. Vaughn. 1972. Efficacy studies for a freeze-dried avian encephalomyelitis vaccine. *Poult Sci.* 51:1851.
73. Richter, R., J. Kosters, and S. Kuhavanta-Kalkosol. 1985. [Comparative studies of the use of the enzyme-linked immunosorbent assay (ELISA) for the determination of antibodies against the avian encephalomyelitis agent]. *Zentralbl Veterinarmed B*. 32:116–27.
74. Schaaf, K. 1959. Avian encephalomyelitis immunization with inactivated virus. *Avian Dis.* 3:245–256.
75. Schaaf, K., and W.F. Lamoreux. 1955. Control of avian encephalomyelitis by vaccination. *Am J Vet Res.* 16:627–33.
76. Shafren, D.R., and G.A. Tannock. 1988. An enzyme-linked immunosorbent assay for the detection of avian encephalomyelitis virus antigens. *Avian Dis.* 32:209–14.
77. Shafren, D.R., and G.A. Tannock. 1991. Pathogenesis of avian encephalomyelitis viruses. *J Gen Virol.* 72:2713–9.
78. Shafren, D.R., G.A. Tannock, and P.J. Groves. 1992. Antibody responses to avian encephalomyelitis virus vaccines when administered by different routes. *Aust Vet J.* 69:272–5.
79. Smart, I.J., and D.C. Grix. 1985. Measurement of antibodies to infectious avian encephalomyelitis virus by ELISA. *Avian Pathol.* 14:341–52.
80. Smart, I.J., D.C. Grix, and D.A. Barr. 1986. The application of the ELISA to the diagnosis and control of avian encephalomyelitis. *Aust Vet J.* 63:297–9.
81. Springer, W.T., and S.C. Schmittle. 1968. Avian encephalomyelitis: a chronological study of the histopathogenesis in selected tissues. *Avian Dis.* 12:229–39.
82. Sumner, F.W., E.L. Jungherr, and R.E. Luginbuhl. 1957. Studies on avian encephalomyelitis. I. Egg adaption of the virus. *Am J Vet Res*. 18:717–723.
83. Sumner, F.W., R.E. Luginbuhl, and E.L. Jungherr. 1957. Studies on avian encephalomyelitis. II. Flock survey for embryo susceptibility to the virus. *Am J Vet Res*. 18:720–3.
84. Sytuo, B., and M. Matsumoto. 1981. Detection of chicken antibodies against avian encephalomyelitis virus by an enzyme-linked immunoassay. *Poult Sci.* 60:1742.
85. Tannock, G.A., and D.R. Shafren. 1994. Avian encephalomyelitis: a review. *Avian Pathol.* 23:603–20.
86. Tannock, G.A., and D.R. Shafren. 1985. A rapid procedure for the purification of avian encephalomyelitis viruses. *Avian Dis.* 29:312–21.
87. Taylor, J.R.E., and E.P. Schelling. 1960. The distribution of avian encephalomyelitis in North America as indicated by an immunity test. *Avian Dis.* 4:122–133.

88. Taylor, L.W., D.C. Lowry, and L.G. Raggi. 1955. Effects of an outbreak of avian encephalomyelitis (epidemic tremor) in a breeding flock. *Poult Sci.* 34:1036–1045.
89. Todd, D., J.H. Weston, K.A. Mawhinney, and C. Laird. 1999. Characterization of the genome of avian encephalomyelitis virus with cloned cDNA fragments. *Avian Dis.* 43:219–26.
90. Toplu, N., and G. Alcigir. 2004. Avian encephalomyelitis in naturally infected pigeons in Turkey. *Avian Pathol.* 33:381–6.
91. Van Der Heide, L. 1970. The flourescent antibody technique in the diagnosis of avian encephalomyelitis. *Univ Maine Tech Bull.* 44:1–79.
92. van Roekel, H., K.L. Bullis, and M.K. Clarke. 1939. Infectious avian encephalomyelitis. *Vet Med.* 34:754–755.
93. Van Roekel, H., K.L. Bullis, and M.K. Clarke. 1938. Preliminary report on infectious avian encephalomyelitis. *J Am Vet Med Assoc.* 93:372–375.
94. Van Roekel, H., K.L. Bullis, and M.K. Clarke. 1941. Transmission of avian encephalomyelitis. *J Am Vet Med Assoc.* 99:220.
95. Van Steenis, G. 1971. Survey of various avian species for neutralizing antibody and susceptibility to avian encephalomyelitis virus. *Res Vet Sci.* 12:308–311.
96. Wei, L., L.L. Chee, T. Wei, J. Kwang, J. Zhou, J. Wang, L. Shi, and J. Liu. 2008. The VP1 protein of avian encephalomyelitis virus is a major host-protective immunogen that serves as diagnostic potential. *J Virol Methods.* 149:56–62.
97. Wei, L., J. Zhou, J. Wang, L. Shi, and J. Liu. 2008. Development of a non-radioactive digoxigenin cDNA probe for the detection of avian encephalomyelitis virus. *Avian Pathol.* 37:187–91.
98. Welchman D. de B., W.J. Cox, R.E. Gough, A.M. Wood, V.J. Smyth, D. Todd, and D. Spackman. 2009. Avian encephalomyelitis virus in reared pheasants: a case study. *Avian Pathol*. 38:251–6.
99. Westbury, H.A., and B. Sinkovic. 1978. The pathogenesis of infectious avian encephalomyelitis. 1. The effect of the age of the chicken and the route of administration of the virus. *Aust Vet J*. 54:68–71.
100. Westbury, H.A., and B. Sinkovic. 1978. The pathogenesis of infectious avian encephalomyelitis. 2. The effect of immunosuppression on the disease. *Aust Vet J*. 54:72–5.
101. Westbury, H.A., and B. Sinkovic. 1978. The pathogenesis of infectious avian encephalomyelitis. 3. The relationship between viraemia, invasion of the brain by the virus, and the development of specific serum neutralising antibody. *Aust Vet J*. 54:76–80.
102. Westbury, H.A., and B. Sinkovic. 1978. The pathogenesis of infectious avian encephalomyelitis. 4. The effect of maternal antibody on the development of the disease. *Aust Vet J*. 54:81–5.
103. Wills, F.K., and I.M. Moulthrop. 1956. Propagation of avian encephalomyelitis virus in the chick embryo. *Southwest Vet.* 10:39–42.
104. Xie, Z., M.I. Khan, and T. Girshick. 2005. Reverse transcriptase-polymerase chain reaction to detect avian encephalomyelitis virus. *Avian Dis.* 49:227–30.
105. Yamagiwa, S., T. Yamashita, and C. Itakura. 1969. Poliomyelitis of newborn chicks (epidemic tremor of chickens, avian encephalomyelitis). II. Electron microscopic observations of degenerated nerve cells. *Nihon Juigaku Zasshi*. 31:173–7.

Avian Hepatitis E Virus Infections

1. Arankalle, V.A., M.V. Joshi, A.M. Kulkarni, S.S. Gandhe, L.P. Chobe, S.S. Rautmare, A.C. Mishra, and V.S. Padbidri. 2001. Prevalence of anti-hepatitis E virus antibodies in different Indian animal species. *J Viral Hepat.* 8:223–227.
2. Agunos, A.C., D. Yoo, S.A. Youssef, D. Ran, B. Binnington, and D.B. Hunter. 2006. Avian hepatitis E virus in an outbreak of hepatitis-splenomegaly syndrome and fatty liver haemorrhage syndrome in two flaxseed-fed layer flocks in Ontario. *Avian Pathol.* 35:404–12.
3. Batts, W., S. Yun, R. Hedrick, and J. Winton. 2011. A novel member of the family Hepeviridae from cutthroat trout (*Oncorhynchus clarkii*). *Virus Res.* 158(1–2):116–23.
4. Billam, P., F.F. Huang, Z.F. Sun, F.W. Pierson, R.B. Duncan, F. Elvinger, D.K. Guenette, T.E. Toth, and X.J. Meng. 2005. Systematic pathogenesis and replication of avian hepatitis E virus in specific-pathogen-free adult chickens. *J Virol.* 79:3429–37.
5. Billam, P., Z.F. Sun, and X.J. Meng. 2007. Analysis of the complete genomic sequence of an apparently avirulent strain of avian hepatitis E virus (avian HEV) identified major genetic differences compared with the prototype pathogenic strain of avian HEV. *J Gen Virol.* 88:1538–44.
6. Billam, P., F.W. Pierson, W. Li, T. LeRoith, R.B. Duncan, and X.J. Meng. 2008. Development and validation of a negative-strand-specific reverse transcription-PCR assay for detection of a chicken strain of hepatitis E virus: identification of nonliver replication sites. *J Clin Microbiol.* 46:2630–4.
7. Billam, P., T. LeRoith, R.S. Pudupakam, F.W. Pierson, R.B. Duncan, and X.J. Meng. 2009. Comparative pathogenesis in specific-pathogen-free chickens of two strains of avian hepatitis E virus recovered from a chicken with hepatitis-splenomegaly syndrome and from a clinically healthy chicken. *Vet Microbiol.* 139:253–61.
8. Bilic, I., B. Jaskulska, A. Basic, C.J. Morrow, and M. Hess. 2009. Sequence analysis and comparison of avian hepatitis E viruses from Australia and Europe indicate the existence of different genotypes. *J Gen Virol.* 90:863–73.
9. Bradley, D.W., K. Krawczynski, E.H. Cook, Jr., K.A. McCaustland, C.D. Humphrey, J.E. Spelbring, H. Myint, and J.E. Maynard. 1987. Enterically transmitted non-A, non-B hepatitis: serial passage of disease in cynomolgus macaques and tamarins and recovery of disease-associated 27- to 34-nm viruslike particles. *Proc Natl Acad Sci USA*. 84:6277–6681.
10. Choi, C., and C. Chae. 2003. Localization of swine hepatitis E virus in liver and extrahepatic tissues from naturally infected pigs by in situ hybridization. *J Hepatol.* 38:827–832.
11. Clarke, J.K., G.M. Allan, D.G. Bryson, W. Williams, D. Todd, D.P. Mackie, and J.B. McFerran. 1990. Big liver and spleen disease of broiler breeders. *Avian Pathol.* 19:41–50.
12. Cossaboom, C.M., L. Cordoba, B.A. Dryman, and X.J. Meng. 2011. Hepatitis E virus in rabbits, Virginia, USA. *Emerg Infect Dis.* 17(11):2047–9.
13. Crerar, S.K. and G.M. Cross. 1994a. The experimental production of big liver and spleen disease in broiler breeder hens. *Aust Vet J.* 71:414–7.
14. Crerar, S.K., and G.M. Cross. 1994b. Epidemiological and clinical investigations into big liver and spleen disease of broiler breeder hens. *Aust Vet J.* 71:410–3.
15. Dong, S., Q. Zhao, M. Lu, P. Sun, H. Qiu, L. Zhang, J. Lv, and E.M. Zhou. 2011. Analysis of epitopes in the capsid protein of avian hepatitis E virus by using monoclonal antibodies. *J Virol Methods.* 171(2):374–80.
16. Ellis, T.M., C.J. Payne, S.L. Plant, and A.R. Gregory. 1995. An antigen detection immunoassay for big liver and spleen disease agent. *Vet Microbiol.* 46:315–26.

17. Emerson, S.U., V.A. Arankalle, and R.H. Purcell. 2005. Thermal stability of hepatitis E virus. *J Infect Dis.* 192:930–3.
18. Guo, H., E.M. Zhou, Z.F. Sun, X.J. Meng, and P.G. Halbur. 2006. Identification of B-cell epitopes in the capsid protein of avian hepatitis E virus (avian HEV) that are common to human and swine HEVs or unique to avian HEV. *J Gen Virol.* 87:217–23.
19. Guo, H., E.M. Zhou, Z.F. Sun, and X.J. Meng. 2007a. Protection of chickens against avian hepatitis E virus (avian HEV) infection by immunization with recombinant avian HEV capsid protein. *Vaccine.* 25:2892–9.
20. Guo, H., E.M. Zhou, Z.F. Sun, and X.J. Meng. 2007b. Egg whites from eggs of chickens infected experimentally with avian hepatitis E virus contain infectious virus, but evidence of complete vertical transmission is lacking. *J Gen Virol.* 88:1532–7.
21. Guo, H., E.M. Zhou, Z.F. Sun, and X.J. Meng. 2008. Immunodominant epitopes mapped by synthetic peptides on the capsid protein of avian hepatitis E virus are non-protective. *Viral Immunol.* 21:61–7.
22. Halbur, P.G., C. Kasorndorkbua, C. Gilbert, D.K. Guenette, M.B. Potters, R.H. Purcell, S.U. Emerson, T.E. Toth, and X.J. Meng. 2001. Comparative pathogenesis of infection of pigs with hepatitis E viruses recovered from a pig and a human. *J Clin Microbiol.* 9:918–923.
23. Handlinger, J.H., and W. Williams. 1988. An egg drop associated with splenomegaly in broiler breeders. *Avian Dis.* 32:773–8.
24. Haqshenas, G., H.L. Shivaprasad, P.R. Woolcock, D.H. Read, and X.J. Meng. 2001. Genetic identification and characterization of a novel virus related to human hepatitis E virus from chickens with hepatitis-splenomegaly syndrome in the United States. *J Gen Virol.* 82:2449–62.
25. Haqshenas, G., F.F. Huang, M. Fenaux, D.K. Guenette, F.W. Pierson, C.T. Larsen, H.L. Shivaprasad, T.E. Toth, and X.J. Meng. 2002. The putative capsid protein of the newly identified avian hepatitis E virus shares antigenic epitopes with that of swine and human hepatitis E viruses and chicken big liver and spleen disease virus. *J Gen Virol.* 83:2201–9.
26. Huang, F.F., G. Haqshenas, H.L. Shivaprasad, D.K. Guenette, P.R. Woolcock, C.T. Larsen, F.W. Pierson, F. Elvinger, T.E. Toth, and X.J. Meng. 2002. Heterogeneity and seroprevalence of a newly identified avian hepatitis e virus from chickens in the United States. *J Clin Microbiol.* 40:4197–202.
27. Huang, F.F., Z.F. Sun, S.U. Emerson, R.H. Purcell, H.L. Shivaprasad, F.W. Pierson, T.E. Toth, and X.J. Meng. 2004. Determination and analysis of the complete genomic sequence of avian hepatitis E virus (avian HEV) and attempts to infect rhesus monkeys with avian HEV. *J Gen Virol.* 85:1609–18.
28. Huang, F.F., F.W. Pierson, T.E. Toth, and X.J. Meng. 2005. Construction and characterization of infectious cDNA clones of a chicken strain of hepatitis E virus (HEV), avian HEV. *J Gen Virol.* 86:2585–93.
29. Jeffrey, J.S., and H.L. Shivaprasad. 1998. Investigation of hemorrhagic hepatosplenomegaly syndrome in broiler breeder hens. *Proc West Poultry Dis Confer.* 47:46–48.
30. Johne, R., A. Plenge-Bönig, M. Hess, R.G. Ulrich, J. Reetz, and A. Schielke. 2010. Detection of a novel hepatitis E-like virus in faeces of wild rats using a nested broad-spectrum RT-PCR. *J Gen Virol.* 91:750–8.
31. Julian, R.J. 1995. Hepatitis-liver hemorrhage syndrome in laying hens. *Proc NE Conf Avian Dis.* 67:17.
32. Kerr, K.M., D.E. Swayne, and G.A. March. 1993. Chronic fulminating cholangiohepatitis associated with Campylobacter species in mature laying chickens. *Proc 130th Meet AVMA*. AVMA, Schaumburg, Illinois. 150.
33. Kasorndorkbua, C., P.G. Halbur, P.J. Thomas, D.K. Guenette, T.E. Toth, and X.J. Meng. 2002. Use of a swine bioassay and a RT-PCR assay to assess the risk of transmission of swine hepatitis E virus in pigs. *J Virol Methods.* 101:71–78.
34. Koonin, E.V., A.E. Gorbalenya, M.A. Purdy, M.N. Rozanov, G.R. Reyes, and D.W. Bradley. 1992. Computer-assisted assignment of functional domains in the nonstructural polyprotein of hepatitis E virus: delineation of an additional group of positive-strand RNA plant and animal viruses. *Proc Natl Acad Sci USA*. 89:8259–8263.
35. Kwon, H.M., T. LeRoith, R.S. Pudupakam, F.W. Pierson, Y.W. Huang, B.A. Dryman, and X.J. Meng. 2011. Construction of an infectious cDNA clone of avian hepatitis E virus (avian HEV) recovered from a clinically healthy chicken in the United States and characterization of its pathogenicity in specific-pathogen-free chickens. *Vet Microbiol.* 147(3–4):310–9.
36. Marek, A., I. Bilic, I. Prokofieva, and M. Hess. 2010. Phylogenetic analysis of avian hepatitis E virus samples from European and Australian chicken flocks supports the existence of a different genus within the Hepeviridae comprising at least three different genotypes. *Vet Microbiol.* 145(1–2):54–61.
37. McAlinden, V.A., A.J. Douglas, F. McNeilly, and D. Todd. 1995. The identification of an 18,000-molecular-weight antigen specific to big liver and spleen disease. *Avian Dis.* 39:788–95.
38. McFerran, J.B. 1994. Big liver and spleen disease. In: *New and Evolving Virus Diseases of Poultry*. M.S. McNulty and J.B. McFerran, eds. Commission of the European Communities, Brussels. 299–304.
39. Meng, X.J., R.H. Purcell, P.G. Halbur, J.R. Lehman, D.M. Webb, T.S. Tsareva, J.S. Haynes, B.J. Thacker, and S.U. Emerson. 1997. A novel virus in swine is closely related to the human hepatitis E virus. *Proc Natl Acad Sci USA*. 94:9860–9865.
40. Meng, X.J., P.G. Halbur, M.S. Shapiro, S. Govindarajan, J.D. Bruna, I.K. Mushahwar, R.H. Purcell, and S.U. Emerson. 1998. Genetic and experimental evidence for cross-species infection by swine hepatitis E virus. *J Virol.* 72:9714–9721.
41. Meng, X.J., B. Wiseman, F. Elvinger, D.K. Guenette, T.E. Toth, R.E. Engle, S.U. Emerson, and R.H. Purcell. 2002. Prevalence of antibodies to hepatitis E virus in veterinarians working with swine and in normal blood donors in the United States and other countries. *J Clin Microbiol.* 40:117–22.
42. Meng, X.J., and P.G. Halbur. 2005. Swine hepatitis E virus. In: *Diseases of Swine*, 9th ed. B.E. Straw, J.J. Zimmerman, S. D'Allaire, and D.J. Taylor, eds. Blackwell Publishing/Iowa State University Press, Ames, Iowa. 537–545.
43. Meng, X.J., H.L. Shivaprasad, and C.J. Payne. 2008. Hepatitis E virus infections. In: *Diseases of Poultry*, 12th ed. Y.M. Saif, A.M. Fadly, J.R. Glisson, L.R. McDougald, L.K. Nolan, and D.E. Swayne, eds. Blackwell Publishing Press, Ames, Iowa. 443–452.
44. Meng, X.J. 2010a. Recent advances in Hepatitis E virus. *J Viral Hepat.* 17(3):153–61.
45. Meng, X.J. 2010b. Hepatitis E virus: animal reservoirs and zoonotic risk. *Vet Microbiol.* 140:256–65.
46. Meng, X.J. 2011. From barnyard to food table: the omnipresence of hepatitis E virus and risk for zoonotic infection and food safety. *Virus Res.* 161:23–30.
47. Meng, X.J., D.A. Anderson, V.A. Arankalle, S.U. Emerson, T.J. Harrison, S. Jameel, and H. Okamoto. 2011. Hepeviridae.

In: *Virus Taxonomy, 9th Report of the ICTV*. M.A.E. Carstens and E. Lefkowitz, eds. Elsevier/Academic Press, London. 1021–1028.

48. Payne, C.J., S.L. Plant, T.M. Ellis, P.W. Hillier, and W. Hopkinson. 1993. The detection of big liver and spleen agent in infected tissues via intravenous chick embryo inoculation. *Avian Pathol.* 22:245–256.
49. Payne, C.J., T.M. Ellis, S.L. Plant, A.R. Gregory, and G.E. Wilcox. 1999. Sequence data suggests big liver and spleen disease virus (BLSV) is genetically related to hepatitis E virus. *Vet Microbiol.* 68:119–25.
50. Payne, C.J. 2003. Big liver and spleen disease. In: *Diseases of Poultry*, 11th ed. Y.M Saif, H.J. Barnes, J.R. Glisson, A.M. Fadly, L.R. McDougald, and D.E. Swayne, eds. Iowa State University Press, Ames, Iowa. 1183–1186.
51. Peralta, B., M. Biarnés, G. Ordóñez, R. Porta, M. Martín, E. Mateu, S. Pina, and X.J. Meng. 2009. Evidence of widespread infection of avian hepatitis E virus (avian HEV) in chickens from Spain. *Vet Microbiol.* 137:31–6.
52. Purcell, R.H., and S.U. Emerson. 2001. Hepatitis E virus. In: *Fields Virology*, 4th ed. D. Knipe, P. Howley, D. Griffin, R. Lamb, M. Martin, B. Roizman, and S. Straus, eds. Lippincott, Williams and Wilkins, Philadelphia. 3051–3061.
53. Purcell, R.H., R.E. Engle, M.P. Rood, Y. Kabrane-Lazizi, H.T. Nguyen, S. Govindarajan, M. St. Claire, and S.U. Emerson. 2011. Hepatitis E virus in rats, Los Angeles, California, USA. *Emerg Infect Dis.* 17(12):2216–22.
54. Reed, D.H., B.M. Daft, J.T. Barton, P.R. Woolcock, G. Cutler, and F. Galey. 1993. Necrotic hemorrhagic hepatitis-splenomegaly syndrome: An unsolved sudden death syndrome in layer leghorn chickens. *Proc Amer Assoc Vet Lab Diagn.* 36:8–9.
55. Riddell, C. 1997. Hepatitis-splenomegaly syndrome. In: *Diseases of Poultry*, 10th ed. B.W. Calnek, C.W. Beard, and L.R. McDougald, eds. Iowa State University Press, Ames, Iowa. 1041.
56. Ritchie, S.J., and C. Riddell. 1991. "Hepatitis-splenomegaly" syndrome in commercial egg laying hens. *Can Vet J.* 32:500–501.
57. Schlauder, G.G., and G.J. Dawson. 2003. Hepatitis E virus. In: *Manual of Clinical Microbiology*, vol. 2, 8th ed. P.R. Murray, E.J. Baron, J.H. Jorgensen, M.A. Pfaller, and R.H. Yolken, eds. ASM Press, Washington, DC. 1495–1911.
58. Shivaprasad, H.L., and P.R. Woolcock. 1995. Necrohemorrhagic hepatitis in broiler breeders. *Proc West Poult Dis Conf.* 44:6.
59. Shivaprasad, H.L., D.H. Read, P.R. Woolcock, J. Jeffrey, B. Daft, G. Haqshenas, and X.J. Meng. 2001. Hepatitis-splenomegaly syndrome in chickens associated with 30-35 nm virus particles. *Proc West Poult Dis Conf.* 60:55–56.
60. Shivaprasad, H.L. 2003. Hepatitis-splenomegaly syndrome. In: *Diseases of Poultry*, 11th ed. Y.M Saif, H.J. Barnes, J.R. Glisson, A.M. Fadly, L.R. McDougald, and D.E. Swayne, eds. Ames: Iowa State University Press, Ames, Iowa. 1186–1188
61. Sun, Z.F., F.F. Huang, P.G. Halbur, S.K. Schommer, F.W. Pierson, T.E. Toth, and X.J. Meng. 2003. Use of heteroduplex mobility assays (HMA) for pre-sequencing screening and identification of variant strains of swine and avian hepatitis E viruses. *Vet Microbiol.* 96:165–76.
62. Sun, Z.F., C.T. Larsen, F.F. Huang, P. Billam, F.W. Pierson, T.E. Toth, and X.J. Meng. 2004a. Generation and infectivity titration of an infectious stock of avian hepatitis E virus (HEV) in chickens and cross-species infection of turkeys with avian HEV. *J Clin Microbiol.* 42:2658–62.
63. Sun, Z.F., C.T. Larsen, A. Dunlop, F.F. Huang, F.W. Pierson, T.E. Toth, and X.J. Meng. 2004b. Genetic identification of avian hepatitis E virus (HEV) from healthy chicken flocks and characterization of the capsid gene of 14 avian HEV isolates from chickens with hepatitis-splenomegaly syndrome in different geographical regions of the United States. *J Gen Virol.* 85:693–700.
64. Tablante, N.L., J.P. Vaillancourt, and R.J. Julian. 1994. Necrotic, haemorragic, hepatomegalic hepatitis associated with vasculitis and amyloidosis in commercial laying hens. *Avian Pathol.* 23:725–732.
65. Takahashi, M., T. Nishizawa, H. Sato, Y. Sato, Jirintai, S. Nagashima, and H. Okamoto. 2011. Analysis of the full-length genome of a hepatitis E virus isolate obtained from a wild boar in Japan that is classifiable into a novel genotype. *J Gen Virol.* 92:902–8.
66. Todd, D., K.A. Mawhinney, V.A. McAlinden, and A.J. Douglas. 1993. Development of an enzyme-linked immunosorbent assay for the serological diagnosis of big liver and spleen disease. *Avian Dis.* 37:811–6.
67. Troxler, S., A. Marek, I. Prokofieva, I. Bilic, and M. Hess. 2011. TaqMan real-time reverse transcription-PCR assay for universal detection and quantification of avian hepatitis E virus from clinical samples in the presence of a heterologous internal control RNA. *J Clin Microbiol.* 49(4):1339–46.
68. William, W., P. Curtin, J. Handlinger, and J.B. McFerran. 1993. A new disease of broiler breeders—big liver and spleen disease. In: *Virus Infections of Birds*. J.B. McFerran and M.S. McNulty, eds. Elsevier Science Publishers, B.V., Amsterdam. 563–568.
69. Williams, T.P., C. Kasorndorkbua, P.G. Halbur, G. Haqshenas, D.K. Guenette, T.E. Toth, and X.J. Meng. 2001. Evidence of extrahepatic sites of replication of the hepatitis E virus in a swine model. *J Clin Microbiol.* 39:3040–3046.
70. Zafrullah, M., M.H. Ozdener, S.K. Panda, and S. Jameel. 1997. The ORF3 protein of hepatitis E virus is a phosphoprotein that associates with the cytoskeleton. *J Virol.* 71:9045–53.
71. Zhao, C., Z. Ma, T.J. Harrison, R. Feng, C. Zhang, Z. Qiao, J. Fan, H. Ma, M. Li, A. Song, and Y. Wang. 2009. A novel genotype of hepatitis E virus prevalent among farmed rabbits in China. *J Med Virol.* 81(8):1371–9.
72. Zhao, Q., E.M. Zhou, S.W. Dong, H.K. Qiu, L. Zhang, S.B. Hu, F.F. Zhao, S.J. Jiang, and Y.N. Sun. 2010. Analysis of avian hepatitis E virus from chickens, China. *Emerg Infect Dis.* 16(9):1469–72.
73. Zhou, E.M., H. Guo, F.F. Huang, Z.F. Sun, and X.J. Meng. 2008. Identification of two neutralization epitopes on the capsid protein of avian hepatitis E virus. *J Gen Virol.* 89:500–8.

Chapter 15

Neoplastic Diseases

Introduction

Venugopal Nair

Neoplastic diseases of poultry comprise a variety of conditions possessing a single common denominator: neoplasia involving one or more of the cell types. Neoplastic diseases can be of infectious or non-infectious origin. Unlike in human medicine where the vast majority of cancers are non-infectious (3, 16), most of the neoplastic diseases affecting poultry have a viral etiology. Indeed, studies on avian oncogenic viruses have contributed immensely to our current understanding of a number of molecular mechanisms of cancer (4). This chapter deals primarily with the three most economically important virus-induced transmissible neoplastic diseases of poultry, namely herpesvirus-induced Marek's disease (MD), and retrovirus-induced avian leukoses/sarcoma and reticuloendotheliosis, with a final section covering tumors of unknown etiology. These neoplastic diseases or disease complexes are described in separate sections because of their etiologic distinctness.

The first section describes MD, a T cell lymphoma induced in chickens by the highly cell-associated Marek's disease virus (MDV). MD lesions consist of CD4+ T cell lymphomas affecting a number of visceral organs and tissues, together with lymphoid cell infiltration into the peripheral nerves resulting in paralytic symptoms. Recent advances in MD research have provided significant insights into the molecular mechanisms of the disease, further strengthening its significance as an excellent biomedical model for T cell lymphomas (17, 20, 21, 32). MD is and has been controlled since the early 1970s by use of conventional vaccines. During the last four decades, research on MD has not only resulted in improved conventional vaccines and vaccination methods, but also has provided a greater understanding of the molecular mechanisms of the disease and factors affecting host genetic resistance (2). However, despite widespread use of vaccines and development of new methods of vaccination, MD still remains a major challenge to poultry health, particularly from the continuing increase in virulence of MDV strains (14, 29). Furthermore, the incidence of MD in other avian species such as turkeys and geese (6, 18) demonstrates the increasing host range and economic significance. Clearly, in the absence of control measures including vaccine failures, MD is capable of causing devastating losses in poultry (15, 30). As a disease occurring worldwide, with reports of vaccination breaks and probable emergence of more virulent pathotypes, MD poses severe threats to the poultry industry, and developing strategies for its control remains one of the great challenges today (2, 14, 19, 29). This section gives an up-to-date account of the scientific understanding of MD and its control strategies.

The second section describes a group of leukoses, sarcomas, and related neoplasms induced by a number of closely related groups of avian retroviruses termed the leukosis/sarcoma (L/S) viruses. The contributions of these retroviruses to tumor virology, such as the landmark study on transmissible tumors and the discovery of the oncogenes and the reverse transcriptase, have been hugely significant.

The term "leukosis" is used because a leukemic blood picture is not always present during the course of leukemia-like proliferative diseases of the hemopoietic system (7, 26, 27). The various forms of hemopoietic system neoplasia induced by the L/S group of avian retroviruses include the lymphopoietic, the erythropoietic, and the myelopoietic systems. Lymphoid leukosis (LL), a lymphoproliferative disease of chickens affecting primarily the cloacal bursa (bursa of Fabricius) and visceral organs, is the most common form of leukosis that arises from infection with avian leukosis virus (7, 25).

Other neoplasms of hematopoietic origin that also can be seen in ALV-infected chickens, albeit infrequently, include erythroblastosis, myeloblastosis, myelocytomatosis, and certain related neoplasms such as nephroblastoma and osteopetrosis (23). With the emergence of the ALV subgroup J in the late 1980s, myelocytomatosis became a major neoplasia, particularly in meat-type chickens (24, 26). The incidence of ALV-J has been significantly reduced in Europe and North America through the successful implementation of eradication programs. However, it is alarming that

Diseases of Poultry, Thirteenth Edition. David E. Swayne.
© 2013 John Wiley & Sons, Inc. Published 2013 by John Wiley & Sons, Inc.

Table 15.1. Transmissible neoplasms.

Virus type	Nucleic acid type	Virus classification of etiological agent	Neoplastic diseases
Retrovirus	RNA	Leukosis/sarcoma group	Leukoses
			Lymphoid leukosis
			Erythroblastosis
			Myeloloblastosis
			Sarcomas and other connective tissue tumors
			Fibrosarcoma, fibroma
			Myxosarcoma, myxoma
			Osteogenic sarcoma, osteoma
			Histiocytic sarcoma
			Related neoplasms
			Hemangioma
			Nephroblastoma
			Hepatocarcinoma
			Osteopetrosis
		Reticuloendotheliosis group	Reticuloendotheliosis
			Lymphoid leukosis
Herpesvirus	DNA	Marek's disease virus	Marek's disease

significant losses continue to occur in countries such as China, where in addition to the commercial meat-type chickens, commercial layers and native breeds of chickens are affected (5, 10, 11).

The section on leukoses/sarcoma viruses provides comprehensive coverage of the recent advances in our understanding of the pathogenic mechanisms, diagnosis, and eradication methods.

The third section describes reticuloendotheliosis (RE), a group of disease syndromes caused by a gammaretrovirus, reticuloendotheliosis virus (REV), unrelated to the leukoses/sarcoma group of viruses (8, 27, 28). The REV group includes different viruses associated with a number of disease syndromes. These consist of defective REV-T strain that induces rapid neoplastic transformation by virtue of the very potent virus-encoded oncogene v-*Rel*, an NFkB homolog (12, 13). The most common clinical diseases induced by REV include chronic lymphoma as well as immunosuppressive runting disease. REV infects chickens, turkeys, ducks, geese, pheasants, quail, and probably many other avian species. However, a major economic concern of REV arises from its potential as a contaminant of live vaccines produced in chicken embryo cells or tissues. REV also could be a barrier for the export of breeding stock to certain countries. The section gives a very detailed account of some of pathogenic mechanisms of REV and the recent developments in diagnosis and control.

The final section describes tumors of unknown etiology diagnosed on the basis of morphologic characteristics. Included are a wide variety of benign and malignant neoplasms derived from muscle, epithelial, and nerve tissues; serous membranes; and pigmented cells.

Lymphoproliferative disease (LPD), another neoplastic disease of turkeys reported in Europe and Israel, is also induced by another retrovirus (9, 22, 33). The incidence of LPD of turkeys has always been sporadic and hence not included in this chapter.

Because many of the avian tumor viruses appear to have multipotent characteristics, i.e., they can sometimes induce a variety of neoplasms, classification and nomenclature of virus-induced neoplasms present a problem. The dilemma is largely due to the fact that certain strains of these viruses induce some pathologic lesions difficult to distinguish from those induced by another unrelated virus. The two major lymphomatotic diseases, MD and lymphoid leukosis (LL), are particularly confusing. Although REV-induced lymphomas are infrequent and generally arise from contaminated vaccines, REV could also add to the problems in differential diagnosis of lymphomas. A practical and useful strategy for the differential diagnosis of viral lymphomas has been proposed (31). The choice of terminology for the neoplasia used in this chapter (Table 15.1) is based on that originally adopted by the World Veterinary Poultry Association (1) with suitable modifications.

Neoplastic diseases by these groups of viruses continue to cause serious disease and economic losses in many parts of the world. While diseases such as MD remain a major challenge in nearly all poultry-raising countries, the threats from retroviral diseases LL and RE have been significantly reduced thanks to the eradication procedures adopted by the poultry industry over the last several years. An exception to this is perhaps the diseases caused by ALV subgroup J, which continues to cause major health problems and economic significance in countries such as China.

Marek's Disease

Karel A. Schat and Venugopal Nair

Introduction

Marek's disease (MD) is a common lymphoproliferative disease of chickens, usually characterized by mononuclear cellular infiltrates in peripheral nerves and various other organs and tissues including iris and skin. The disease is caused by a herpesvirus, is transmissible, and can be distinguished etiologically from other lymphoid neoplasms of birds.

Because the literature on MD has greatly expanded, it is no longer feasible to cite all relevant publications that provide the scientific basis for our current knowledge of the disease. In this chapter, literature is cited selectively, and reviews are often substituted for original papers. Useful recent books on MD are *Marek's Disease* (250) and *Marek's Disease: An Evolving Problem* (174), as well as proceedings from the international symposia on MD.

Definition and Synonyms

The seminal description by József Marek (380) identified the disease as polyneuritis. Other common synonyms included neuritis, neurolymphomatosis gallinarum, and range paralysis. Jungherr and colleagues (297) proposed that the term lymphomatosis be subdivided into visceral, neural, and ocular forms. This nomenclature was widely applied for more than 20 years to all lymphoproliferative diseases of chickens, but masked the etiological distinctions between MD and LL. In retrospect, neural and ocular lymphomatosis were probably MD, whereas visceral lymphomatosis included both MD and LL. The term acute leukosis or acute Marek's disease was used in the 1960s to designate more virulent manifestations of MD characterized by visceral lymphomas. Lymphomatous lesions in the skin, which were common in broilers, were sometimes termed skin leukosis. In 1961, Biggs (51, 53) proposed the term Marek's disease to distinguish the condition clearly from etiologically different lymphoproliferative diseases. This term remains in common use.

MD also has been subdivided into acute and classical forms, where the latter term designates forms of the disease prevalent prior to the 1950s (51). MD virus (MDV) also can induce other clinically distinct disease syndromes such as transient paralysis, early mortality syndrome, cytolytic infection, atherosclerosis, and persistent neurological disease.

Economic Significance

Prior to the use of vaccines, MD constituted a serious economic threat to the poultry industry, causing up to 60% mortality in layer flocks and 10% condemnations in broiler flocks. Because vaccines are not 100% effective, sporadic losses still occur, but they are no longer as serious a problem. In 2004, Morrow and Fehler (401) quoted worldwide annual losses in the range of US $1 to $2 billion, but they indicated that these figures are impossible to verify. The disease remains a major concern for the poultry industry due to the unpredictability of outbreaks and the possibility that vaccines may ultimately fail as a consequence of the evolution of more virulent strains of MDV.

Public Health Significance

Although there are several reports suggesting a role for MDV in the etiology of multiple sclerosis, Tischer and Osterrieder (620) concluded that there is no evidence that MDV can infect humans. An earlier report (491) had already stated that no etiologic relationship exists between MDV or any of the MD vaccine viruses and human cancer.

Scientific Significance

Research on MD has contributed greatly to veterinary medicine, basic science, and comparative oncology. The disease is uncommonly complex, featuring an interplay of neoplasia and inflammation expressed as several distinct clinical syndromes, each modified in important ways by host genetic influences. MDV, an alphaherpesvirus with lymphotropic properties of gammaherpesviruses, is highly cell-associated but readily transmitted, and its virulence varies and evolves. It has 2 unique sister viruses, both nononcogenic, that naturally infect chickens and turkeys. Infection induces complex immune responses, usually resulting in high levels of protection. Vaccination for MD constitutes an outstanding example of successful disease control in veterinary medicine. Moreover, MD vaccines are the first effective vaccines against cancer in any species.

History

The seminal report by József Marek, published in 1907 (380), of paresis in 4 roosters is the first account of the disease named after him. Afterward, outbreaks were reported as early as 1914 in the USA, and subsequently in many other countries. Pappenheimer et al. (439) clarified the lymphoproliferative nature of the lesions in peripheral nerves and spinal ganglia and also described lymphoid neoplasms in the ovary and other visceral organs as part of the disease. A detailed history of MD research can be found in the 12th edition of *Diseases of Poultry* (540), a paper by Biggs (52), the videotape "Legacy of the 1960s," and the historical archives of the American Association of Avian Pathologists. A long view on the last 40 years of Marek's disease research has recently been published as part of the 40th anniversary of *Avian Pathology* (58).

Etiology

Classification

MDV is a cell-associated herpesvirus (citations in 521) with lymphotropic properties similar to those of gammaherpesviruses. However, its molecular structure and genomic

organization are similar to alphaherpesviruses (76, 344, 626). As per the recent classification by the International Committee on Taxonomy of Viruses (ICTV) (http://www.ictvonline.org/virusTaxonomy.asp?version=2009), all MDV serotypes are grouped together in the genus Mardivirus (321). Members of the genus Mardivirus, described previously as 3 serotypes, are now grouped as 3 species: Gallid herpesvirus 2 (serotype 1), Gallid herpesvirus 3 (serotype 2) and Meleagrid herpesvirus 1 (Herpesvirus of turkey [HVT], serotype 3). Serotype 1 MDV is the prototype virus for this group of avian viruses, and except where otherwise indicated MDV refers to serotype 1 virus. On the basis of their virulence, serotype 1 strains are further divided into pathotypes, which are often referred to as mild (m)MDV, virulent (v)MDV, very virulent (vv)MDV, and very virulent plus (vv+)MDV strains (651, 664). Non-oncogenic Gallid herpesvirus 2 isolated from chickens (56, 139, 531) and Meleagrid herpesvirus 1 isolated from turkeys (314, 673) belonging to the genus *Mardivirus* are also included in this chapter.

Morphology

The morphology and morphogenesis of MDV have been reviewed (35, 308, 521). Hexagonal nucleocapsids 85–100 nm in diameter and enveloped particles 150–160 nm in diameter may be seen in thin sections of infected cell cultures. Enveloped virus particles appearing as irregular amorphous structures and measuring 273–400 nm can be observed in negatively stained preparations of lysed feather follicle epithelium (FFE) (107). Thin-section preparations of the FFE revealed large numbers of cytoplasmic enveloped herpesvirus particles in keratinizing cells. The morphology of MD virions in cell cultures and FFE is shown in Figure 15.1A.

The morphology of serotype 2 and 3 strains resembles that of MDV serotype 1 (413, 454, 531). In thin sections, however, nucleocapsids of HVT commonly show a unique crossed appearance (413).

Chemical Composition

Viral DNA

Physical Properties. The complete sequence of several strains belonging to the 3 serotypes (15, 279, 323, 344, 588, 590, 626) confirmed that the genomes are very similar, consisting of linear, double-stranded DNA molecules of approximately 160–180 kb with a buoyant density in neutral CsCl of 1.706 g/mL for serotype 1 (338, 511). The guanine plus cytosine (GC) ratio is different for the 3 serotypes and ranges from 43.9%–53.6% in serotype 1 and 2, respectively, and 47.6% for HVT (279, 575). It is difficult to separate viral DNA from host cell DNA because its density is close to that of chicken DNA. Several methods have been described to obtain viral DNA (511). Pulse-field electrophoresis is probably the best way to obtain pure infectious viral DNA (646). However, the cloning of the complete MDV genome as bacterial artificial chromosomes (BAC) has greatly facilitated the production of MDV DNA (548, 705). Infectious BAC clones of a number of strains have been constructed, allowing rapid manipulation of MDV genomes to identify various determinants associated with MD biology (132, 320, 591). Similarly, the rescue of infectious MDV from overlapping cosmid clones of the Md5 strain of MDV also has been reported (499).

Structural Organization. The genomic structure of the 3 serotypes is typical for alphaherpesviruses, as previously suggested (130), with a unique long (U_L) and a unique short (U_S) sequence. These unique sequences are flanked by sets of inverted repeat sequences: the terminal repeat long (TR_L), internal repeat long (IR_L), internal repeat short (IR_S), and terminal repeat short (TR_S), respectively. Alpha (a)-like sequences, believed to be important for the cleavage and packaging of viral DNA into virions, are located at the terminal ends of the TR_L and IR_L and between the IRL and IRS regions (15, 279, 344, 590, 626).

The complete genome sequences of a number of serotype 1 MDV strains have now been determined. GenBank accession numbers of some of these strains are AF243438 (Md5), AF147806 (GA), AY510475 (Md11 clone), DQ530348 (CVI988 clone), JF742597 (814) and JQ314003 (LMS). All of these viruses show similar genome structure, although there were differences in the lengths caused by changes in the copy numbers of the direct repeats in the repeat regions of the genome. Comprehensive analysis of the sequence of the TR_L/IR_L regions in the genomes of 13 strains of varying virulence has identified several single nucleotide polymorphisms (SNPs) which loosely partition between attenuated and non-attenuated strains (587, 589).

The complete genome sequences of serotype 2 strains HPRS-24 (GenBank NC_002577) and SB-1 (GenBank HQ840738), and of the serotype 3 HVT strain Fc126 (GenBank AF291866, AF282130) also have been determined (15, 279, 323, 590). The genomes of the 3 serotypes demonstrated conservation in the genome structure and significant homology at the DNA level.

DNA Structure in Infected Cells. The structure of viral DNA in infected cells depends on the virus-cell interaction. Linear viral DNA can be found in nuclei of cells undergoing virus replication (130). It remains unknown how viral DNA is maintained in latently infected, nontransformed cells (90, 395), although there is some evidence on the role of epigenetic regulation of the viral genome (69). The status of DNA in transformed cells has been difficult to determine in part because a variable percentage of the transformed cells may undergo viral replication at any point in time, in which case linear DNA can be detected. In addition, most of the studies on the structure of viral DNA have been done using established cell lines, which may have undergone additional selection. Initial investigations into the status of the MDV genome have indicated an absence of integration (611); the MDV genome is now thought to exist as a mixture of integrated and episomal DNA (178, 179, 307, 400, 506, 509). MDV can be found integrated at multiple sites in the chromosomes of cells derived from MDV-related T cell lymphomas, suggesting a

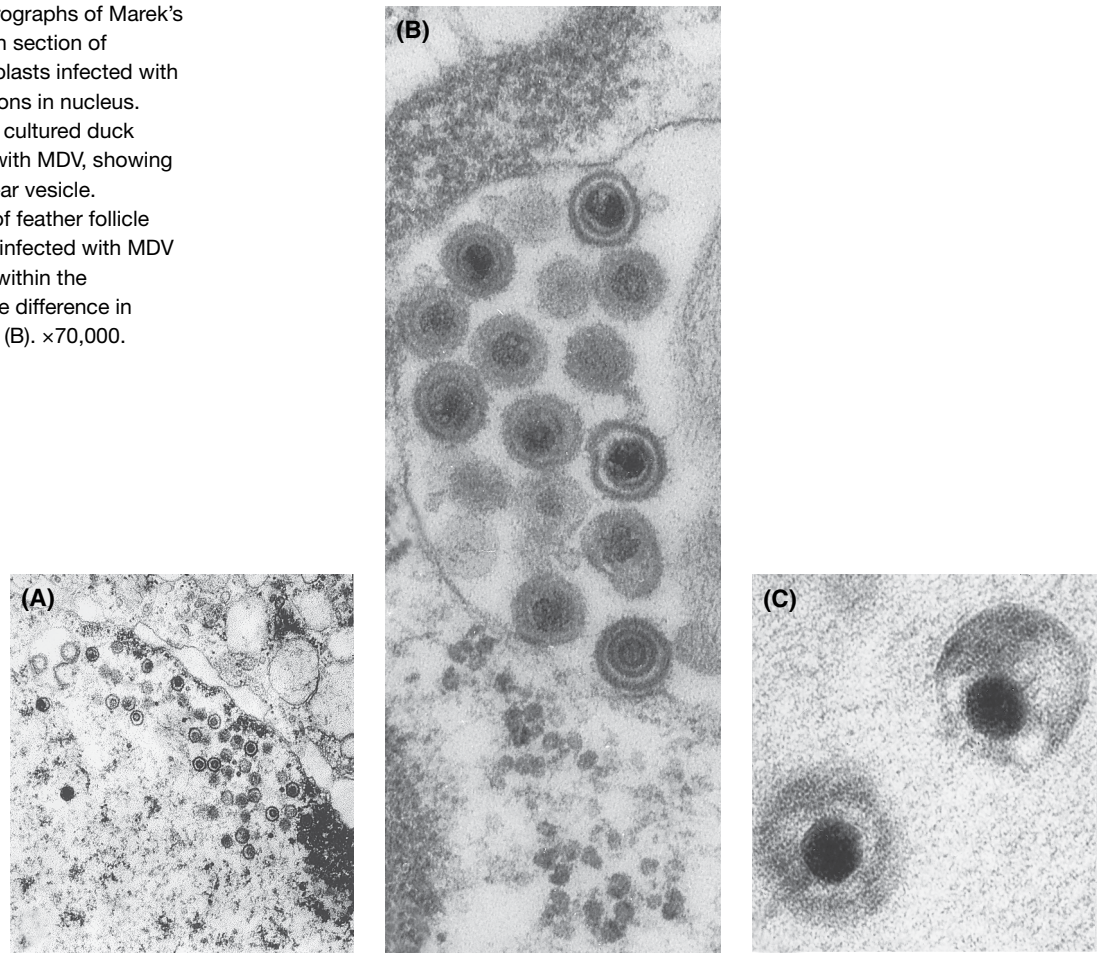

Figure 15.1. Electron micrographs of Marek's disease virus (MDV). (A) Thin section of cultured duck embryo fibroblasts infected with MDV showing scattered virions in nucleus. ×38,400. (B) Thin section of cultured duck embryo fibroblast infected with MDV, showing enveloped virions in a nuclear vesicle. ×360,000. (C) Thin section of feather follicle epithelium (FFE) of chicken infected with MDV showing enveloped virions within the cytoplasmic inclusions. Note difference in morphology compared with (B). ×70,000. (Nazerian)

correlation between integration and oncogenicity. The integration sites are preferentially located near the ends of the chromosomes within the telomeric region. The telomere-like sequences located at the terminal ends of the MDV genome (324) are thought to assist in the preferential integration of the viral DNA. Interestingly, MDV encodes an RNA telomerase subunit (viral TR [vTR]) that shares 88% sequence identity with the chicken TR (cTR) gene (208). It is speculated that vTR might play a role in MDV genome integration by aiding in the generation of telomeric elongations at the ends of the viral genome (209, 310).

Structural Changes by Recombination and/or Mutation. Spontaneous recombination among the 3 MDV serotypes under field conditions is probably a very rare occurrence, despite the fact that chickens vaccinated with all 3 serotypes frequently are superinfected with virulent MDV. Although concomitant infections in the same tissue or cells occur (136, 415), only one case of a recombination between 2 serotypes has been reported (253).

Serotype 1 strains quickly develop altered biologic characteristics upon serial passage *in vitro*, such as loss of oncogenicity, reduced expression of glycoprotein C (gC) (146), and decreased replication *in vivo* (535), indicating that spontaneous mutations may have occurred. Accumulations of such mutations after continuous cell culture passages and generations of mixed population of viruses have been recently demonstrated by sequence analysis (587, 589). The gradual evolution of pathotypes toward greater virulence and the changes in biologic properties of MDV during *in vivo* backpassage (655) further support the mutability of MDV.

These biological changes are accompanied by several molecular changes, although it is not clear which molecular change correlates with a specific biological change. An expansion was found within the Bam-HI D and H fragments that are commonly associated with cell culture passage and attenuation in serotype 1 strains (211, 251, 577). This expansion was caused by a tandem amplification of direct 132 bp repeat (260, 378, 513). Other changes also have been described, including the deletion of 400 bp in the Bam-HI A fragment of CVI988 clone C (988C) and 988C/R6 (260) and a deletion of 200 bp in the Bam-HI L fragment of the vvMDV strain Md11 (646). Additional changes have been reported for CVI988 in the meq gene (344, 588) and the ICP4 promoter/enhancer region of CVI988 (306). It is not clear whether these differences are a consequence of cell culture passage or if they reflect strain differences.

Serial passage of serotype 2 and serotype 3 strains can also lead to biological and structural changes. The biological changes are often associated with loss of *in vivo* replication and protective immunity (658, 674, 692). Other changes also have been reported such as the release of large quantities of cell-free HVT (692) or the development of resistance to inhibition by phosphonoacetate (342). *In vitro* co-cultivation of MDV or HVT with avian leukosis virus (ALV) or reticuloendotheliosis virus (REV) resulted in spontaneous insertion of long terminal repeats (LTR) of the retroviral provirus in the MDV genome (272, 294, 295), but full-length, infectious provirus occasionally can integrate (274). Integration of endogenous ALV sequences into MDV also has been reported (516). The integration occurs often at the border regions of the repeats and unique sequences of MDV and in the gD gene (72, 295). Davidson and Borenshtain (167, 168) reported the *in vivo* integration of retrovirus sequences into MDV in commercial poultry. The significance of the retrovirus integration for the MD pathogenesis is not fully known, although LTR insertions have been shown to induce increased transcription of MDV genes (272, 294, 320). More recently, direct effects of retroviral insertions on the increased potential for horizontal transmission of MDV have been demonstrated (164, 601).

Viral Genes and Proteins

Over the last 25 years, a number of individual genes of MDV-1 have been identified and sequenced, and the proteins have been characterized (515, 540). Comprehensive reviews based on the complete sequences for the 3 serotypes have been published including lists of open reading frames (ORFs) and their putative products (279, 373, 434, 435, 575). Table 15.2 summarizes the location of the ORFs and indicates the number of ORFs with homologues to herpes simplex virus (HSV), the number of ORFs with homologues shared among the 3 serotypes, and the number of unique genes for each serotype. Many of the genes in the U_L and the U_S regions have homologues with HSV and equine herpesvirus-1 and 4, and the genome organization is similar to these 2 alphaherpesviruses (373). For this chapter, the MDV genes are grouped into 2 general categories: genes with homologues in alphaherpesviruses and genes unique for MDV. Only the genes that are important for the pathogenesis and immune responses will be reviewed briefly. The reader is referred to the contemporary literature for additional information.

Genes with Homologues in Alphaherpesviruses. This broad category of genes can be divided into immediate early (IE), early, and late genes, which are with few exceptions important for virus replication.

IE and Early Genes with Homology to HSV. The IE genes are important transcriptional regulators. Four IE genes have been identified: intracellular protein (ICP)4, ICP0, ICP22, and ICP27. Anderson et al. (19) identified ICP4 as a 4245 bp ORF, but sequence data indicated the presence of an open reading frame (ORF) of 6969 bp. This is in agreement with the

Table 15.2. Number of tentative genes in the 3 serotypes of MDV in relation to other alphaherpesviruses[A].

Serotype	Gene classification	Location of expected functional ORFs[B]						
		TRL (R-LORF)	UL (L-ORF)	IRL (R-LORF)	IRS (RS)	US (S-ORF)	TRS(RS)	Total[C]
1	HSV Homolog[D]	0	57	0	1	7	1	*65*,**66**
	MDV-specific[E]	1	4	1	0	1	0	*6*,**7**
	Serotype-specific	13[H]	8	13	2	3[H]	2	*26*,**41**
	Total	14	69	14	3	11	3	*97*,**114**
2	HSV Homolog	0	59	0	1	7	1	*67*,**68**
	MDV-specific[F]	1	4	1	0	1	0	*6*,**7**
	Serotype-specific	9	4	9	1	4	1	*17*,**27**
	Total	10	66	10	2	12	2	*90*,**102**
3	HSV Homolog	0	59	0	1	8[I]	1	*68*,**69**
	MDV-specific[G]	0	6	0	0	1	0	*7*,**7**
	Serotype-specific	4	2	4	6	1	6	*13*,**23**
	Total	4	67	4	7	10[I]	7	*88*,**99**

[A] For reference see (15, 279, 344, 373).

[B] Based on the location of the start codon.

[C] The italic numbers indicate the number of single genes for each serotype; the bold figures give the total number of genes including the duplications in the repeat regions.

[D] Based on the sequence of the GA strain, nomenclature adapted from (340).

[E] Serotype-specific genes with homologues present in serotype 2 or 3.

[F] Serotype-specific genes with homologues present in serotype 1 or 3.

[G] Serotype-specific genes with homologues present in serotype 1 or 2.

[H] The sequence for Md5 has minor differences compared with GA.

[I] Includes 2 copies of US8.

finding that 2 functional promoter/enhancer regions are located upstream of the larger ORF and that the putative promoter/enhancer region for the short ORF was nonfunctional *in vitro* (306). Proof that ICP4 protein is a transactivator was provided by transfection of the MD cell line (MDCC) MSB-1 with the short form of ICP4, showing increased transcription of the endogenous ICP4, pp38, and pp24 genes (199, 482). The ICP4 protein also can transactivate the LTR of Rous sarcoma virus at low levels (41). Transcription of ICP4 may require the presence of VP16, a late protein coded for by UL48 and present in the tegument of MDV particles (63). However, Kaplan and Schat (306) were unable to confirm this observation, and the requirement for VP16 in a cell-associated virus may not be absolute.

The role of ICP22 (=US1) protein (73) in MDV replication is poorly understood. Deletion mutants lacking ICP22 replicate *in vitro* but to a lower degree than wild-type virus. ICP22 is not essential for *in vivo* infection, oncogenesis, and reisolation of virus (441, 442). The MDV ICP27 phosphoprotein (502) localizes in the nucleus, can transactivate pp38 and pp14 independently of ICP4, and represses the early thymidine kinase gene (503). Additionally, MDV ICP27 also interacts with SR proteins and inhibits splicing of cellular telomerase chTERT and viral vIL-8 transcripts (18). Recent reports on the role of HSV ICP27 in the mRNA export pathway (327, 627) and other functions (241, 517) suggest important roles for this protein in MDV biology, too. ICP0 (LORF1) has been identified as an ORF in the TR_L and IR_L, and a recent study using proteomic approaches has demonstrated that the ICP0 gene product is expressed in MDV-infected chicken embryo fibroblast (CEF) (366). However, it is currently unknown if the protein has similar functions as ICP0 in HSV.

The MDV genes MDV008 and MDV073 encoding the related phosphoproteins pp24 and pp38, respectively (626), with early expression kinetics are discussed separately.

LATE GENES. The late gene products include the nucleocapsid proteins, the tegument proteins, including VP16, and the glycoproteins (373). The glycoproteins (gB, gC, gD, gE, gH, gI, gK, gL, and gM) are presumed to be important for infection of cells, transfer of virus from cell to cell, and immune responses.

gB, encoded by UL27, consists of a complex of 3 glycoproteins with molecular weights of 100, 60, and 49 kD, and is important for cell attachment and/or penetration based on the production of gB-specific virus-neutralizing (VN) antibodies (reviewed in 373). Deletion of gB from MDV prevented cell-to-cell spread, demonstrating the essential nature of this protein for MDV replication (548). In a recent study examining the structural basis for membrane fusion of MDV, some of the peptides derived from gB showed antiviral properties, providing some insights into MDV entry into cells (643).

The UL44 gene encodes gC, a 57- to 65-kD glycoprotein identified in some early references as gA, which is extensively synthesized in productively infected cells and is expressed on the cell surface. In addition, gC is actively secreted by infected cells (157, 267, 273, 275) and is one of the major antigens to which the chicken immune system mounts a substantial serological response. The function of gC has not been elucidated; the production of gC in cell culture decreases with attenuation (146, 268, 647). It is suggested that the reduction of MDV replication due to overexpression of gC in cultured cells is possibly caused by the secreted forms of gC (622). Deletion of gC in RB-1B compromised the establishment of latency and tumor development, although the viral load in the peripheral blood was not affected, suggesting a major role for gC in MD pathogenesis (434). More recently, gC and UL13 were shown to be important in horizontal transmission (288, 291).

The importance of gD, coded by US6, is poorly understood. It is non-essential for horizontal transmission (20) and is expressed poorly *in vitro* (432, 610), probably as a consequence of no or limited transcription. Limited expression of gD compared to pp38 and gB has been described in FFE (418), suggesting that specific transcription factors in the FFE may be needed for the production of gD.

The functions of the other glycoproteins have not been studied in detail. The gI and gE proteins interact with each other based on immunoprecipitation assays (610). It is not clear whether the gE/gI complex functions as Fc receptors as described for other alphaherpesviruses. Associations of mutations in the gL with MDV pathogenesis and reduced immune responses have been reported (518, 613). Mutants constructed in a BAC clone carrying deletions in the gM, gI, or gE gene indicate that the encoded glycoproteins are essential for virus replication, because the deletion mutants are unable to transfer infectivity from infected to uninfected cells (549, 623).

Genes Unique for MDV. Several genes have been identified that are unique for MDV strains (Table 15.2). Some of these genes are present only in serotype 1, and others may have homologues in MDV serotype 2 and/or HVT.

LATENCY ASSOCIATED TRANSCRIPTS. The latency-associated transcripts (LATs) are a group of transcripts antisense to ICP4 and have been reviewed in detail (90, 395). These include a large 10-kb transcript as well as several spliced transcripts referred to as MSR (MDV small RNA) or SAR (small antisense RNA). The importance of LATs for latency or transformation is unclear. LATs are expressed in both lytically infected and transformed cells, including the MDV-positive QT35 cell line (693).

MEQ (MAREK'S ECOQ). The molecular biology of Meq (R-LORF7) has been reviewed (332, 395, 407, 440). The Meq protein of 339 amino acids contains a basic leucine zipper (bZIP) domain at the N terminal closely resembling the jun/fos oncogene family. The proline-rich repeat region at the C terminal resembles the WT-1 tumor suppressor gene (296). The Meq protein is expressed consistently in the nucleus of lymphoma cells and tumor cell lines (368, 493, 514) and can be expressed during the S-phase (367). Meq has a domain for dimerization with itself or the cellular oncoprotein Jun; the

complex can bind to two distinct sequences, MERE I and MERE II. MERE I is located in the promoter/enhancer region of meq, and a MERE II site has been located in the putative MDV origin of replication (492, 493). Several lines of evidence suggest that Meq is important for transformation. The expression of meq antisense RNA in MSB-1 cells reduced colony formation in soft agar (687). Overexpression of Meq in transfected rat cells resulted in morphological transformation, inhibition of apoptosis (368), and interactions with the cell cycle regulator CDK2 (369). Interestingly, CVI988 has a 178 bp insert resulting in a frame-shift encoding for the proline-rich domain (348), although the frame-shift in the protein sequence could not be confirmed in a subsequent study (467). Forms of large Meq (L-Meq) containing the insertion have a suppressive effect on the Meq expression on the basis of reporter assays (131). Variations in the sequence of the proline-rich domains also showed association with virulence (554).

Meq shows differential binding to different promoters depending on its dimerization status. As homodimers or heterodimers with leucine zipper proteins, Meq can transactivate different promoters (70, 357, 501, 598, 599), resulting in the upregulation of a number of genes including interleukin (IL)-2 and CD30, a member of the tumor necrosis factor receptor II (TNFR-II) family (86, 97). It is suggested that meq transforms chicken cells through the activation of genes such as JTAP-1, JAC, and HB-EGF, which are associated with the v-Jun transforming pathway (356). Together with the upregulation of anti-apoptotic factors such as Bcl-2 and c-Ski, the cellular homolog of the retrovirus-transduced oncogene v-Ski strongly indicates a converging pathway for transformation by oncogenic retroviruses and herpesviruses. Further evidence for a direct role for meq has come from a recent study in which an meq-deletion mutant of the vvMDV strain Md5 failed to induce tumors. However, this also may be caused by a significant reduction in the replication of the virus. A number of subsequent studies have demonstrated efficacy of meq-deleted viruses as efficient vaccines (339, 345, 573). The mechanism behind such improved immunogenicity is not fully understood; however, gene expression changes in meq-deleted viruses (345) and reduced immunosuppressive effects (361) are thought to contribute to this effect. Specific interaction between Meq and the transcriptional co-repressor protein CtBP was shown to be critical for MD oncogenicity, because specific mutations abolishing the interaction resulted in the total loss of oncogenicity of the virus (68).

Splice variants of Meq also have been identified, one of which has been named vIL-8, and the second one lacks the transactivator domain (462). The dynamic cellular properties and distribution of Meq and Meq/vIL8 proteins have indicated that these two forms may have fundamentally different functions in MDV-infected cells (22).

vIL-8. The vIL-8 gene (R-LORF2) is located in the long repeat region and originally was identified as a spliced meq variant (461, 462). The gene consists of 3 exons and is expressed late during cytolytic infection. IL-8 attracts T cells, especially after IL-8 receptors are upregulated by interferon-γ (IFN-γ), leading Schat and Xing (544) to hypothesize that vIL-8 may be important for the switch of infection from B to T lymphocytes (see Pathogenesis).

Viral Lipase. The 3 serotypes of MDV encode the viral lipase gene (vLIP) (15, 279, 323, 344, 626). vLIP, a soluble, glycosylated protein, is encoded by the LORF-2 gene consisting of 2 exons. The first exon codes for the signal peptide, and the second exon codes for the lipase activity. vLIP is probably an IE or early protein (301). The glycosylated protein is required for the efficient lytic replication in birds (302).

pp38/pp24. The MDV phosphorylated protein complex, often referred to as pp38/pp24, is coded by 2 genes located at opposite ends of the UL region (711). The pp24 gene (R-LORF14) is located partly in the TR_L and the U_L region, and the pp38 gene (R-LORF14a) is located in the IR_L and the U_L region. Homologues for pp24 and pp38 have been identified in serotype 2 strains (279, 433). The TR_L and IR_L of HVT contain a gene with homology to pp38, but the functional relationship to serotype 1 pp38 is unknown (15, 580). The presence of these homologues was expected because HVT and SB-1 induce cell-mediated immune response to pp38 (429, 483).

The function of the pp24/pp38 complex has not been elucidated. Originally, it was linked to oncogenicity because pp38 is expressed in the cytoplasm of a variable proportion of MDV-transformed, latently infected lymphocytes (162, 266). Expression of pp24/pp38 can be enhanced by activation (482, 693), suggesting that pp38 may play a role during reactivation and subsequent virus replication. The association of repressive histone modifications of H3K27 and H3K9 trimethylation (69) supported these observations. Recent observations of the association of pp38 with mitochondrial membrane transport support its suggested role in apoptosis (470, 515). Demonstration of two new splice variants that enhanced the metabolic activity suggested additional roles for pp38 in MDV latency and transformation (358). pp38 is essential for cytolytic infection of B cells and maintenance of the transformed state (499), although deletion did not affect the ability of the virus to spread horizontally (224). CVI988 also expresses pp38, but shows an amino acid mutation in an epitope defined by monoclonal antibody (MAb) H19 (163). The demonstration that vvMDV5 strain expressing the pp38 protein from CVI988 remains oncogenic indicates that the attenuation of CVI988 is not associated with pp38 (337).

The 1.8-kb Gene Family. The promoter/enhancer regions of pp38 and pp24 are part of a bidirectional promoter complex regulating the transcription of pp38/pp24, the 1.8-kb gene family, and the origin of replication (181, 569). Several IE transcripts originate from the 1.8-kb gene family containing 3 exons (395, 515). These transcripts are truncated in attenuated strains due to an expansion of a tandem 132-bp direct repeat (132-bp DR) (64, 513). The difference in the numbers of copies of these repeats between virulent and vaccine strains forms the

basis of their differentiation by polymerase chain reaction (PCR) assays (40, 572, 712). However, the 132-bp region per se appears not to be directly associated with oncogenicity because the deletion of the region did not appear to affect the pattern or the frequency of tumors (576). Furthermore, it was shown that viruses lacking the 132-bp repeats can still be attenuated by repeated cell culture passages (574).

So far, a 7-kDa (460) and a 14-kDa (259) protein have been associated with these transcripts. Both proteins can be detected in lytically infected and transformed cells, but the 7-kDa protein was not found after infection with attenuated virus. The function of these proteins has not been elucidated, although expression of 1.69-kb and 1.5-kb cDNAs derived from the 1.8-kb gene family in transfected CEF prolonged proliferation and reduced serum dependence, suggesting that one of the functions may involve the control of the cell cycle (459). In addition, expression of oligonucleotides antisense to the 132-bp DR transcripts inhibited proliferation of lymphoblastoid cell lines (315), further suggesting that the 1.8-kb gene family may be important for transformation. Deletion of the gene, although it can effect virus replication, did not stop the oncogenicity of the virus (600). More recently, the bicistronic nature of this transcript and its translation using internal ribosome entry site (IRES) elements were demonstrated (606, 607).

Telomerase RNA. The existence of a unique gene encoding the RNA telomerase subunit (vTR) was identified in the IR_L/TR_L region of the MDV genome (208). MDV vTR showed nearly 88% sequence identity to the chicken telomerase RNA (ChTR), indicating its transduction from the host genome. vTR, also regulated by the action of c-myc (570), can constitute telomerase activity by interacting with chicken telomerase reverse transcriptase (ChTERT) more efficiently than ChTR (208, 209). The direct association between MDV oncogenicity and vTR was demonstrated using MDV lacking either one or both copies of vTR (133, 625) that resulted in significantly impaired ability to induce lymphomas with reduced ability for dissemination (309, 310, 311).

MDV-encoded MicroRNAs. MicroRNAs (miRNAs) are a distinct class of small regulatory molecules of approximately 22 nucleotides affecting the gene expression in various cell types. These have been identified in a large range of organisms including several herpesviruses (408). A number of microRNAs have been identified in MDV (88, 89, 392, 393), many of which are expressed at very high levels (156, 619, 695, 698). Some of these microRNAs have been shown to have direct roles in the pathogenesis (709, 710). As more data on expression profiling of MDV-transformed cells and identification of targets becomes available, more insights will be gained into the functions of these microRNAs in MDV biology and pathogenesis.

Other Unique Genes. Proteins have not been identified for several unique ORFs that are transcribed in tumor cells. Most of these have not been further studied, with a few exceptions. RLOR5a [ORF-L1 (424)] is expressed in tumor cell lines, QT35 latently infected with MDV, and in a REV cell line latently infected with MDV (424, 463, 693). The function of RLORF5a remains unknown. Expression is not essential for reactivation from latency and virus replication (538) or tumor formation (289).

Jarosinski et al. (287) found that RLORF4 was expressed in MD tumor cell lines and that this ORF was deleted in a series of attenuated MDV strains. Deletion of both copies of RLORF4, but not one copy, in RB-1B resulted in an attenuated phenotype *in vitro* and resulted in a major reduction in tumor development, but early viral replication was not affected by the deletion (289). MDV also encodes the ubiquitin-specific protease domain within the major tegument protein-coding gene UL36 (283). Mutation analysis indicated that this protein has functional roles in replication and pathogenesis. Using a recombinant virus expressing UL47-EGFP fusion protein, it was shown that the UL47 tegument protein was expressed highly in the feather follicle epithelium (284), suggesting that UL47 has a potentially important function in the cell-free virus production in the FFE.

Viral Vectors. Several nonessential sites in the 3 serotypes of MDV can be used for the insertion and expression of foreign and specific MDV genes (reviewed in 252). The anticipated advantages of MDV-vectored vaccines are that these vaccines will protect simultaneously against MD and other pathogens, and reactivation from latency will reinforce immune responses against MD and the other pathogens (26, 75, 644). There has been significant progress in utilizing HVT-based vectors for the expression of protective antigens from a number of viruses (350, 360, 498). The presence of maternal antibodies against the expressed foreign protein may impede the development of active immunity against the inserted gene, although studies with recombinant IBD vaccine show limited interference (74).

Virus Replication

Replication of the 3 serotypes is typical of other cell-associated herpesviruses and has been reviewed extensively (52, 308, 511, 521, 540). For initial infection of cultures or chickens by cell-free virus, enveloped virions bind to cellular receptors, probably by gB, perhaps in combination with other glycoproteins. Heparan sulfate, a member of the glycosaminoglycans, has been identified as one of the cellular receptor molecules (347). In cell cultures, viral penetration occurs within 1 hour after attachment, which is enhanced for serotype 1 by chelators such as ethylenediaminetetraacetic acid (EDTA) (13). Subsequent spread of infection to other cells occurs by direct contact with infected cells, and virus transfer probably is accomplished through formation of intracellular bridges (300). This is presumed to be the principal mode of virus spread after initial infection *in vitro* and *in vivo*. Recent data demonstrate the role of the US3-encoded kinase in the morphogenesis as well as cell-to-cell spread of virions through the effect on stress fiber breakdown and polymerization of actin (551). The glycoproteins gE, gI, and gM play a role in the

transfer of virus from infected to uninfected cells (549, 623). Replication rates vary with serotype, passage level of the virus strain, cell type, and temperature of incubation.

The spread of virus *in vivo* from cell to cell requires intimate contact between infected and uninfected cells, which are most often lymphocytes, although epithelial also cells can be involved in this process. The precise interaction between these cells remains one of the important unsolved issues, although recent demonstration of epithelial-specific expression of the UL47 tegument protein (284) suggests distinct virus-host interactions in these cell types.

Virus-Cell Interactions

Three general types of virus-cell interactions are recognized: productive, latent, and transforming.

Productive Infection. During productive infection, replication of viral DNA occurs. Proteins are synthesized, and in some cases virus particles are produced. The number of genome copies/cell can increase 100-fold and exceed 1,200 in the case of HVT (307). Two types of productive infection exist. Fully productive infection in the FFE of chickens results in development of large numbers of enveloped, fully infectious virions (107). In productive-restrictive infection, most of the virions are non-enveloped and non-infectious. A variable number of the virions in cultured cells may be enveloped, which can be recovered as cell-free, infectious virus by disruption of cells. The use of an appropriate stabilizer such as sucrose-phosphate-glutamate-albumin (SPGA) buffer (113) will improve the yield of cell-free virus. A variant strain of HVT that releases large quantities of cell-free virus into the medium of infected cell cultures has been described. This strain is replication-defective in chickens (692). In all susceptible cells, productive infection leads to intranuclear inclusion body formation and lysis of the cell. A gene for the viral host shut-off protein has been identified, UL41 (373), that is probably responsible for the initiation of the lytic process. Lytic infection *in vivo* can cause frank necrobiotic lesion formation. Therefore, productive infection has been termed cytolytic, and the terms are used synonymously (101).

In productively infected fibroblasts, most of the MDV genome is transcribed (379, 530, 578). Differences in transcripts between productive infection with virulent and attenuated serotype 1 strains have been described (64, 513) and are mostly associated with transcripts in the repeat regions flanking U_L. Mass spectrometry-based proteomic approaches have provided insights into the changes in the proteomes including those in the phosphoproteins during cytolytic infection in CEF (135, 366, 497).

Productive infection in cell cultures is influenced by several factors. Inhibitors of viral DNA polymerase and thymidine kinase inhibit virus replication in productively infected cell cultures but do not influence the growth of lymphoblastoid cell lines (511, 521). The presence of nitric oxide (NO) in cell cultures reduces virus replication in a dose-dependent manner (182, 689). *In vitro* infection can change transcriptional regulation of cellular genes in infected and in neighboring cells. Microarrays have been used to determine which genes may be up- or downregulated by infection with MDV (394). For example, major histocompatibility complex (MHC) class I (MHC-I) and II (MHC-II) genes and two IFN-response elements were upregulated. The importance of these results needs to be further examined. Hunt et al. (262) reported that productive-restrictive MDV replication downregulated expression of MHC-I expression in OU2 cells and in lymphoblastoid cell lines, although the mechanisms remain elusive. As reported in varicelloviruses, MDV-encoded protein UL49.5 has been implicated in MHC-I downregulation (285), although the effect is thought to be small. However, upregulation of MHC genes can actually occur in non-infected cells (316), probably through IFN (355). IFN, probably IFN-α, may be produced at least by some MDV and HVT strains (258, 299).

Latent Infection. Latent herpesvirus infections have been defined as the presence of viral DNA in the absence of viral transcripts and proteins, although LATs have been described for many herpesviruses. This definition is appropriate for the nontransforming serotype 2 and 3 strains. For serotype 1 strains, the distinction between latency and transformation is often problematic. In both cases, the viral genome is present, but no information is available on differences in transcriptional regulation between latently infected and transformed cells, because it is impossible to separate latently infected, nontransformed cells from non-infected cells. As a consequence, studies on latency have often been done in MD-transformed cell lines.

MDV latency mostly is associated with $CD4^+$ T cells, although $CD8^+$ T cells and B cells also can be latently infected (121, 346, 406). Fewer than 5 copies of the viral genome are present in latently infected cells (511). MDV latency is maintained through various mechanisms including non-random *de novo* DNA methylation and histone modifications, with different genomic regions separated by chromatin boundary elements (69, 371). The MDV genome can be reactivated from latently infected cells and tumor cells by inoculation of susceptible chickens, co-cultivation with permissive cells, and *in vitro* cultivation of latently infected lymphocytes. The latter approach can be used to estimate the number of latently infected cells by enumeration of antigen-positive cells at 0 hours and 48 hours in culture (123). Upregulation of ICP4 transcripts and downregulation of LATs have been associated with reactivation of early and late genes in latently infected cells (11, 693). *In vitro* latent infections have been described in REV-transformed (484), OU2 (11), and QT35 cell lines (693). The usefulness of REV-transformed cells, from which MDV genomes can be reactivated in a manner similar to MDV-transformed cell lines for the study of MDV latency, also has been demonstrated (24, 25).

At least 2 cytokines produced by concanavalin A-stimulated spleen cell cultures can help maintain latency in cultured lymphocytes (91). Subsequently, 2 recombinant chicken (rCh) cytokines, rChIFN-α (633) and rChIFN-γ (239), have been shown to suppress production of IE, early, and late viral

antigens in latently infected lymphocytes. Curiously, IFN-α was more effective in the suppression of viral genes in later stages of latency than during early stages (633). *In vivo* selective reactivation of latently infected cells can be induced by treatment with cyclosporin or betamethazone (92), but not by infection with immunosuppressive viruses, such as infectious bursal disease (IBD) virus (IBDV) or REV. Chicken infectious anemia virus (CIAV) may influence latency in MD based on its influence on cytokine production and cytotoxic T lymphocytes (CTL) (522).

Transforming Infection. Transforming infections occur only in cells infected with serotype 1 MDV. Selection of transformed cells from the background of immunologically committed and non-committed cells (458) would facilitate comparative studies on transformed cells in tumors and tumor cell lines. The search for specific surface markers associated with tumors has identified antigens, broadly referred to as MD tumor-associated surface antigen (MATSA), detected on cells from MD lymphomas and lymphoblastoid cell lines but not on the surface of productively infected cells (476, 684). Another antigen, CD30, detected by the MAb AV37, has been associated with MD-transformed CD4+ T cells and MDV-infected cells during the cytolytic phase. However, this antigen also can be detected on B cells and REV-transformed cells (84, 514) and hence is not an MD-specific marker. Recent studies confirm that $CD30^{hi}$ expression is characteristic of MD lymphomas, suggesting that CD30 is a component of a critical intracellular signaling pathway perturbed in neoplastic transformation (86, 553). Both MATSA and CD30 can be used to enrich for transformed cells in tumor cell suspensions. Ross et al. (514) purified cells from lymphomas using CD4 and AV37 MAbs and found that meq and SAR transcripts were abundant in these populations. With the advances in a number of tools for the analysis of global gene expression, several studies have been carried out to determine the expression profiles of transcriptome, proteome, and miRNome in MDV-infected or transformed cell lines (134, 156, 366, 377, 581, 619, 690, 699). Although these studies have generated significant amounts of data on MDV-host cell interactions, detailed systematic analysis of these data will be needed to identify the molecular pathways and biomarkers of MDV-induced oncogenesis.

Virus Stock Production and Stability. Productively infected cell cultures are a common source of cell-associated virus stocks for all 3 viral serotypes and for cell-free HVT stocks. Techniques for the production and cryopreservation of cell-free and cell-associated virus stocks have been described (reviewed in 145). Cell-associated stocks of MDV or HVT are routinely stored at -196°C. The infectivity of such stocks, however, is directly related to viability of the cells contained in these preparations and also depends on optimal freezing and thawing techniques. Under ideal conditions, the half-life of diluted, cell-associated virus stocks or vaccines should be at least 2–6 hours (617).

Cell-free serotypes 1 and 2 virus stocks are best obtained from FFE (low-passage virus) or infected cell cultures (high-passage virus). Small quantities of low-passage virus can be obtained from infected cell cultures by lysing cells in SPGA (113). The production of cell-free HVT is best achieved by lysing heavily infected cell cultures. Cell-free MDV and HVT can be stored at -70°C or lyophilized (113). Potency of both cell-associated and cell-free vaccines can be affected adversely by storage temperature, reconstitution technique, choice of diluent, and holding time and temperature after reconstitution (234, 449).

Susceptibility to Chemical and Physical Agents

The stability of cell-associated MDV serotype 1 and 2 strains is completely dependent on the viability of the cells. Any treatment affecting cell viability will directly impact the infectivity of virus stocks.

Cell-free MDV obtained from the skin of infected chickens was inactivated when treated for 10 minutes at pH 3 or 11 and stored for 2 weeks at 4°C, 4 days at 25°C, 18 hours at 37°C, 30 minutes at 56°C, or 10 minutes at 60°C (106). Dander, litter, and feathers from infected chickens are infectious and presumably contain cell-free virus from the FFE bound to cellular debris. The infectivity of such materials was retained for 4–8 months at room temperature (255, 662) and for at least 10 years at 4°C (104). Virus infectivity was inactivated by a variety of common chemical disinfectants within a 10-minute treatment period (112, 254). Survival of virus in litter may be affected adversely by increased humidity (662).

Strain Classification

Serotypes

Von Bülow and Biggs (637, 638) classified the MDV herpesvirus group into 3 distinct groups that correlated with biologic properties. Type-specific monoclonal antibodies (264, 340) usually are used to determine virus serotype. The genomes of viruses belonging to each of these 3 serotypes have now been sequenced, which has allowed us to determine their precise relationships of the proteins encoded by these viruses. Cloning of their full-length genomes also has allowed application of functional genomics analysis on these viruses.

A number of biological characteristics are associated with viral serotypes (56, 521). Low-passage serotype 1 viruses grow best in duck embryo fibroblast (DEF) or chicken kidney cell (CKC) cultures, grow slowly, and produce small plaques. Serotype 2 viruses grow best in chicken embryo fibroblasts (CEF), grow slowly, and produce medium plaques with some large syncytia. HVT grow best in CEF, grow rapidly, and produce large plaques. More infectious virus can be extracted from HVT-infected cells than from cells infected with serotype 1 or 2 viruses.

Pathotypes

Virulence or oncogenicity is associated with only serotype 1 MDVs. Within this group, however, a wide variation in pathogenic potential is recognized and undoubtedly represents a

continuum from nearly avirulent to maximally virulent. Pathotypic classification schemes have evolved over the last 30 years with the continued increase in virulence. Current classification schemes recognize 4 groups of viruses. These groups are designated as mMDV, vMDV, vvMDV, and vv+MDV (651, 664). Pathotyping of virus isolates involves comparative pathogenicity tests in vaccinated and unvaccinated maternal antibody positive chickens with prototype viruses as controls (654, 660). Detailed reviews on the increasing virulence and the details of prototype viruses have been published (219, 540, 649, 653, 654). The evolution in the virulence of MDV strains is recognized, but the molecular basis for this evolution has not been elucidated, because genome sequence analyses of a number of these strains have not provided definite markers associated with the virulence phenotypes.

Certain biologic characteristics are associated with pathotypes of serotype 1 MDVs but are most pronounced between low-passage and high-passage (attenuated) strains. Serial passage *in vitro* (30–70 passages usually are required) results in attenuation of virulent isolates (507, 535, 657). Attenuated strains grow more readily *in vitro* but produce lower viremia titers *in vivo* (669), which may be associated with a marked decrease in their ability to infect and/or replicate in lymphocytes and spread between birds (176, 535, 655). There also could be incomplete attenuation resulting in minor lesions in susceptible chickens (471, 636) or over-attenuation resulting in low level *in vivo* replication and poor immune response (328, 674). The *in vivo* growth potential of attenuated serotype 1 isolates can be increased by backpassage in chickens (177, 655). The ability to generate molecularly defined MDV vaccines (339, 341) through genetic manipulation of MDV strains can help in alleviating some of the uncertainties of the phenotypes of vaccine strains with regard to their virulence of attenuation.

Laboratory Host Systems

MDV usually is propagated and assayed in tissue cultures, newly hatched chicks, and embryonating eggs. Lymphoblastoid cell lines from MD lymphomas also are an important laboratory host system.

Cell Cultures

The propagation of MDV serotypes *in vitro* has been reviewed (521, 523, 540). Isolation of low-passage MDV in CEF or embryonal CKC cultures is far less efficient than in CKC or DEF (523) because propagation in CEF leads to accelerated attenuation (535). In embryonal CKC, replication of serotype 1 MDV (but not HVT) is abortive, leading to loss of infectivity within 2 to 3 passages. Attenuated MDV and serotype 2 and 3 viruses can be isolated readily and propagated in CEF (531). Infected cultures usually develop discrete focal lesions, called foci or plaques, which consist of clusters of rounded, refractile degenerating cells when mature (Figure 15.2). Plaques are usually less than 1 mm in diameter and of variable cell density, although plaque size varies with viral strain, time, and other factors. Polykaryocytosis is seen in cultured fibroblasts and is a major component of the viral plaques or foci frequently used as a marker in virus assays. Affected cells may contain 2 to several hundred nuclei, and type A intranuclear inclusion bodies are commonly seen. Despite release of rounded cells into the medium as plaques mature, large areas of cell lysis are not seen.

Serotype 1 plaques develop in 5–14 days on primary isolation and in 3–7 days after adaptation to culture, and usually are enumerated by microscopic examination, but different staining techniques have been developed, allowing enumeration at a later time. Differences in development and morphology of serotype 1 plaques in chick and duck cells and in plaques induced by the 3 viral serotypes (521) have been described. Other cell culture systems such as chick embryo skin (480), tracheal explants (496), and embryo fibroblasts from several avian species including Japanese quail (489) also have been used.

A few avian cell lines such as OU2 (10, 12), quail muscle cell line QM7 constitutively expressing MDV-1 gE (550), and JBJ-1 (215) also have been used for the propagation of MDV strains with varying success. Recently developed quail cell lines free of MDV can be used to propagate serotype 1 MDV and HVT, but SB-1 did not replicate efficiently (359).

Serotype 1, but not serotype 2, MDVs also can be grown in chicken splenic lymphocytes *in vitro* (122). Passages are made by the addition of fresh spleen cells to the suspension cell cultures every 2 days, and infection is monitored by immunofluorescence. HVT may be similarly grown in turkey spleen cell cultures, but viral antigen is rarely seen, if at all.

Chickens

Newly hatched chicks inoculated with virulent, serotype 1 MDV develop gross lesions or lesions that can be detected histologically in ganglia, nerves, and certain viscera after 2–4 weeks. Response is greatly dependent on genetic susceptibility of the chicken and virulence of the MDV isolate. Presence of virus or antibody, which can be detected by *in vitro* tests, or the presence of virus-associated antigen detected by FA tests on tissues are also specific host responses of inoculated chickens to MD infection. All of these responses are markedly enhanced in chicks lacking maternal antibodies against MDV (98). The induction of virus-specific lesions in the wing web (114) or the feather pulp (396) constitutes alternate approaches that provide direct access to the site of lesion development.

Embryos

Virus pocks develop on the chorioallantoic membrane (CAM) of chicken embryos following yolk sac inoculation with cellular MDV preparations (57, 635). Embryos also have been used for MD vaccine evaluation, because *in ovo* vaccination is becoming increasingly common in the field (See Pathogenesis of *in ovo* Infection). Embryos also may be used to isolate MDV viruses that cannot be isolated directly in cell culture for unknown reasons. Yamaguchi et al. (693) reported the isolation of MDV from the QT35 cell line by using kidney cell

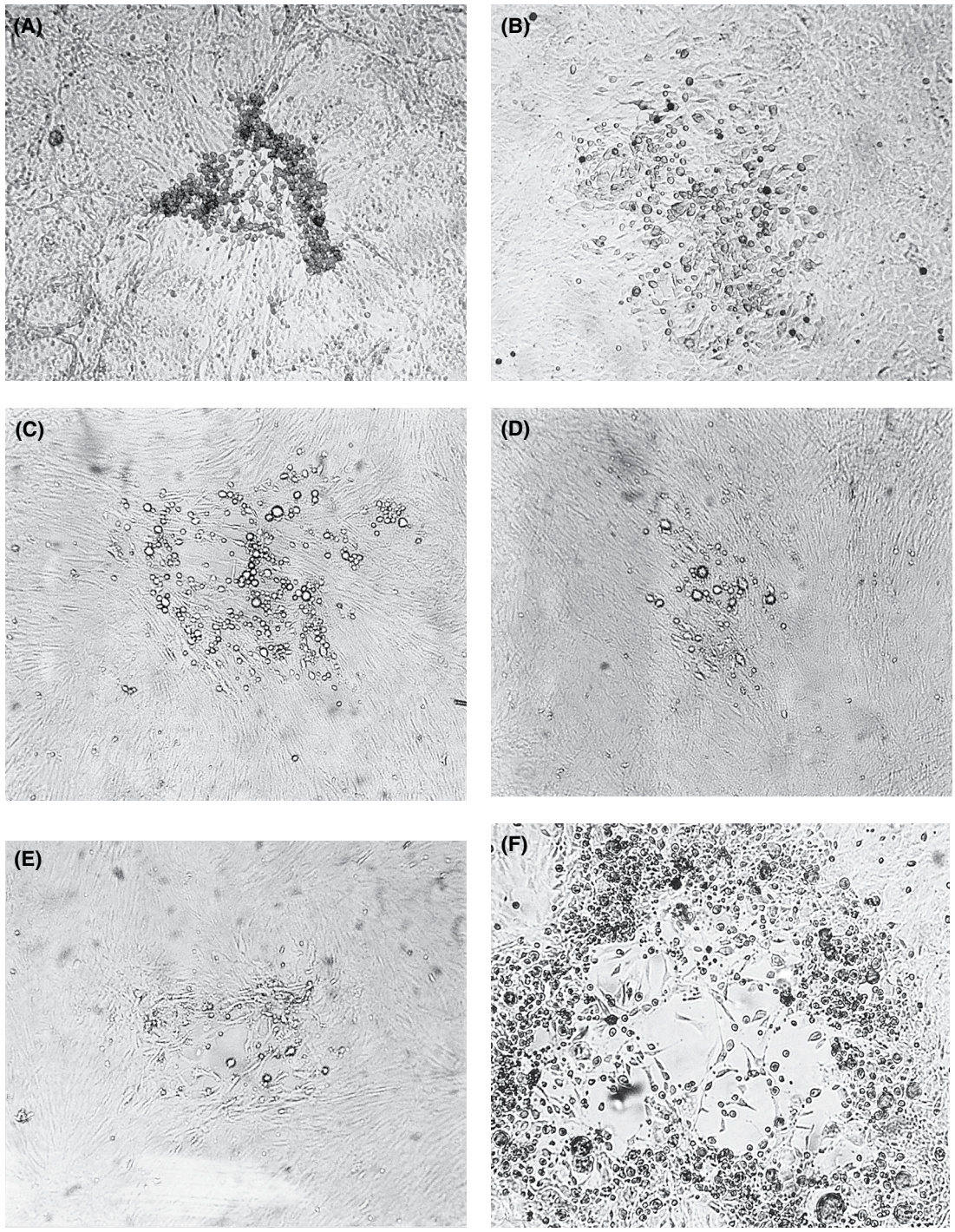

Figure 15.2. Focal lesions in cultured cells infected with various Marek's disease virus (MDV) serotypes. (A) Low-passage serotype 1 MDV in chicken kidney cells cultured from an infected chicken, 9 days. (B) Low-passage serotype 1 MDV in duck embryo fibroblasts (DEF), 5 days. (C) High-passage, attenuated serotype 1 MDV in chick embryo fibroblasts (CEF), 5 days. (D) Low-passage serotype 2 MDV in CEF, 8 days. (E) Low-passage HVT (serotype 3) in CEF, 4 days. (F) Low-passage turkey herpesviruses (HVT) in DEF, 12 days. All photos unstained, about ×40. (Witter)

cultures prepared from 4- to 7-day-old chicks that had been inoculated at embryo day (ED) 8 with QT35 cells.

Lymphoblastoid Cell Lines

Lymphoblastoid cell lines developed from MD lymphomas grow continuously in cell culture without attachment to the culture vessel. Success rates for establishing cell lines from MD lymphomas have improved because of better methodology (124, 455), but *in vitro* immortalization of lymphocytes has not been achieved with 2 exceptions (116, 265). Many cell lines are now available including several from MD lymphomas in turkeys (411). The majority of the chicken cell lines

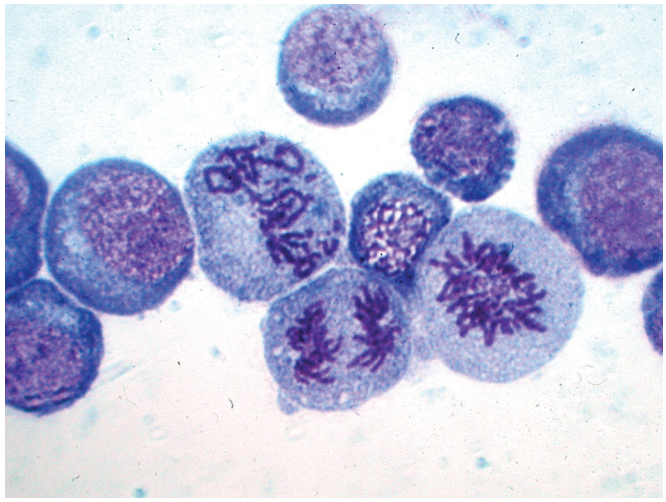

Figure 15.3. Smear from the MDCC-RP1 cell line. Note the characteristic lymphoblastoid morphology and the mitotic figures. Giemsa, ×1,500. (Nazerian)

established from lymphomas are $CD4^+/CD8^-$ T cells expressing MHC-II and T cell receptor (TCR) 2 or 3 (406, 443, 536). Lymphoblastoid cell lines also can be established from lymphocytes harvested from early (4–6 days post infection) lesions induced in the wing web or pectoral muscle by injection of a mixture of MDV and allogeneic kidney cells. The cell lines from early lesions may be $CD4^+/CD8^-$, $CD4^-/CD8^+$, or $CD4^-/CD8^-$ (536). Cells of the MDCC-RP1 line are illustrated in Figure 15.3.

Some transformed cells contain about 5–15 copies of viral genome, although the mean number may be considerably higher in different cell lines, perhaps in relation to the proportion of productively infected cells in the population (395, 511). Viral DNA can be highly methylated in cell lines, although methylation is not essential for maintaining the transformed state (303, 443). Methylation profiles of the viral genome in the cell lines are not very different from those in the primary tumors (69).

Most cell lines can be termed "producer" lines because a small proportion (1%–2%) of the cells enter into productive infection (124, 476). Most, but not all, MD cell lines established from lymphomas were found to display a chromosomal aberration in which an amplification of DNA resulted in an extra G-band and interband in the short arm of chromosome 1 (62, 180, 391). The aberration was found only infrequently in MD lines established from local MD lesions (391), and it remains to be determined whether any relationship exists between this change and neoplastic transformation.

MD cell lines have been used to analyze the potential interaction with tumor suppressor genes and cellular oncogenes. meq protein induces the transcription of the proto-oncogene bcl-2 in Rat-2 cells (368), although the transcription of Bcl-2 was not detected in 2 cell lines (423). Several mutations of p53, a tumor suppressor gene, also have been reported, but these mutations are not located in the traditional hot spots associated with loss of function of p53 (608–609).

The data generated from the systematic analysis of the gene expression from a number of MDV-induced tumors and transformed cell lines (377, 581, 617) will help to identify the molecular and biochemical pathways of transformation and the maintenance of the transformed phenotype in these cells.

Pathobiology and Epizootiology

Multiple Syndromes

MD consists of several distinct pathologic syndromes (102) with apparent differences among these syndromes typically seen in commercial flocks and those induced in the laboratory. Lymphoproliferative lesions, especially lymphomas, are most frequently associated with MD and have the most practical importance (Table 15.3A). However, skin leukosis in broilers, fowl paralysis, persistent neurological disease, and ocular lesions are additional clinical manifestations with lymphoproliferative components. Some of the lymphoproliferative syndromes also may have degenerative components. Several additional clinical syndromes characterized solely by degenerative and inflammatory lesions, often with accompanying immunosuppression, are induced by experimental infection (Table 15.3B). Nonneoplastic brain pathology, mainly vasogenic edema, is responsible for transient paralysis (226). Vascular lesions are manifested as atherosclerosis (202). Under laboratory conditions, young chicks inoculated with tumor cells may develop transplantable tumors (597, 616). Inoculation of MDV-infected, allogeneic CKC in the wing web may induce local tumor lesions (114). Some of the syndromes induced under laboratory conditions are rare or nonexistent in the field, probably because most commercial chickens are maternal antibody positive and vaccinated.

Subclinical syndromes also may occur but are more difficult to define. Vaccinated flocks produced more eggs than nonvaccinated flocks, indicating that MDV may depress productivity in otherwise normal appearing, non-vaccinated chickens (490).

Incidence and Distribution

MD exists in all poultry-producing countries. Probably every flock of chickens raised in areas where poultry is prevalent becomes infected, and many experience some loss. Reporting systems vary, however, and it is difficult to determine the true MD incidence. Even in susceptible chickens, infection does not always induce clinical disease, and in genetically resistant or vaccinated chickens, infection may rarely cause overt disease.

Historical data using broiler condemnation rates in the USA showed a biphasic pattern with maximum condemnation rates around April and minimum frequencies around

Table 15.3A. Clinical and pathologic syndromes associated with Marek's disease virus (part A).

	Lymphoproliferative syndromes[AB] (Marek's disease)			
Situation in which syndrome observed	**Lymphomas and nerve lesions**	**Fowl paralysis (nerve lesions)**	**Skin leukosis (integument)**	**Blindness and ocular lesions**
Experimental chickens (laboratory)				
Clinical signs	Depression, death, stunting, paralysis	Paralysis	Swollen feather follicles	Blindness, ocular lesions
Mortality	0–100%[C]	0–30%[CD]	None	Rare or none[C]
Age	Onset 2–8 wk PI	Growing birds	Young birds[E]	4–8 wk PI
Organ	Visceral organs+peripheral nerves	Mostly peripheral nerves	Skin	Eye (iris, cornea)
Layer/Breeder flocks (field)				
Clinical signs	Depression, death, paralysis	Paralysis, death	Swollen feather follicles	Blindness, gray eye
Prevalence	Common	Occasional[D]	Rare or none[E]	Rare
Mortality	0–60%	0–20%	None	None
Age	4–90 wk	8–20 wk	4–8 wk PI	>10 wk
Broiler flocks (field)				
Clinical signs	Depression, death, paralysis	Paralysis, death	Swollen feather follicles, red leg	Blindness, gray eye
Prevalence	Common	Rare or none[D]	Common[E]	Rare or none
Mortality	Minor		None	None
Age	At processing		At processing	

[A] Neoplastic lesions may include inflammatory components.
[B] Severity of syndrome usually less in vaccinated flocks.
[C] Depends on experimental conditions (virus strain, dose, chicken genotype, maternal antibody status, prior vaccination, etc.)
[D] Rarely induced by contemporary MDV strains, except in conjunction with visceral neoplastic lesions.
[E] Not usually recognized except at broiler processing or after feather removal.

Table 15.3B. Clinical and pathologic syndromes associated with Marek's disease virus (part B).

	Lymphodegenerative syndromes	CNS syndromes	Vascular syndromes	Other syndromes
Situation in which syndrome observed	**Early mortality syndrome, cytolytic infection, immunodepression**	**Transient paralysis and persistent neurological diseases**	**Atherosclerosis**	**Local lesions; transplants**
Experimental chickens (laboratory)				
Clinical signs	Depression, stunting, death, increased disease susceptibility	Transient paralysis, tics, torticollis, death	None	Swelling at inoculation site
Mortality	0–100%[AB]	0–100%[AB]	None	Yes (transpl.)
Age	9–20 days PI	9–28 days PI	Adult birds	Young birds
Organ	Bursa, thymus, spleen	Brain	Blood vessels	Web—local and many—transpl.
Layer/Breeder flocks (field)				
Clinical signs	Increased disease susceptibility	Transient paralysis, tics, torticollis		N/A: Only experimental
Prevalence	Rare[A]	Rare[A]	Rare or none	
Mortality		Rare		
Age		5–12 wk		
Broiler flocks (field)				
Clinical signs	Increased disease susceptibility	Transient paralysis, tics, torticollis		N/A: Only experimental
Prevalence	Rare[A]	Occasional[A]	None	
Mortality		Rare		
Age		5–7 wk		

[A] Not normally observed in chickens vaccinated for MD.
[B] Depends on experimental conditions (virus strain, dose, chicken genotype, maternal antibody status, prior vaccination, etc.).

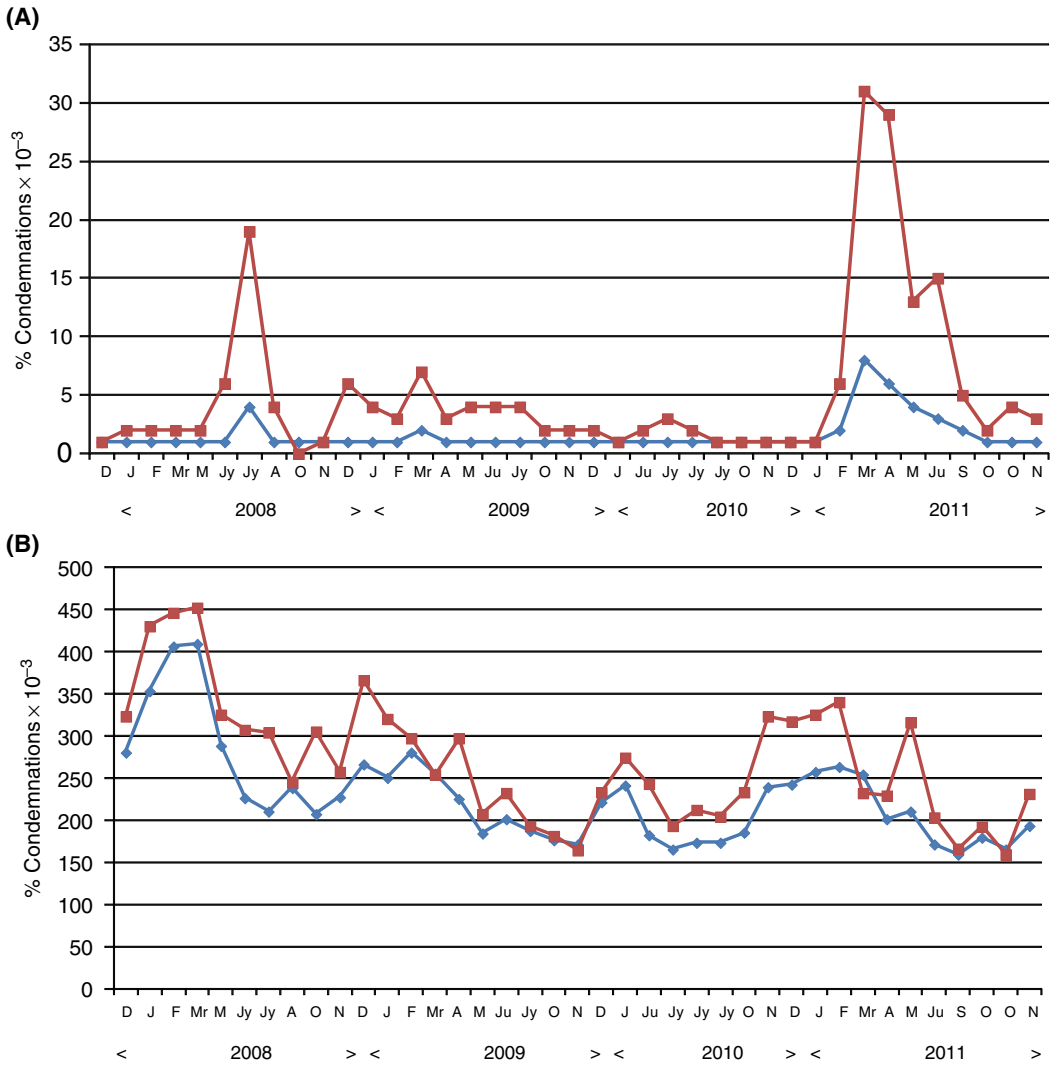

Figure 15.4. Condemnations in young broilers for the period December 2007 to November 2011. (A) Marek's disease for the average farm in the USA ♦ and the Mid-Atlantic region ■. (B) Total condemnations for the average farm in the USA ♦ and the Mid-Atlantic region ■. (Data from National Agricultural Statistics Service as reported in Poultry Informed Professional no 98-121). (Schat)

August (540). Using the condemnations rates from the USDA National Agricultural Statistics Service published in the Poultry Informed Professional numbers 98–121, Schat (527) analyzed the total and MD condemnation rates for the average company in the USA and the Mid-Atlantic region from December 2007 through November 2011 (Figure 15.4). The total condemnation rates were 0.23±0.6% and 0.271±0.75% and for MD 0.0016±0.0015% and 0.0052±0.007% for the USA and the Mid Atlantic region, respectively. Both differences are statistically significant (t-test: $p < 0.01$). Most of the total condemnation is caused by septicemia, and MD condemnations constitute a minor fraction.

Sporadic outbreaks of MD occur on individual farms or regions. Several reports lend credence to the implication of exceptionally virulent MDV isolates in vaccine failures (e.g., 42, 651), but it is important to exclude CIAV as a cofactor (387). It is usually difficult to associate increased virulence of MDV isolates with regional fluctuations in MD frequency, but layer outbreaks in Ohio in 1995 yielded isolates of unusual virulence (110, 651).

Natural and Experimental Hosts

Virtually all chickens including game fowl are susceptible to MDV infection and tumor development (540) and are by far the most important natural host. Quail, turkeys, pheasants, and some species of ducks and geese are also susceptible to infection and disease. Most other avian species including sparrows, partridge, pigeons, and peafowl are probably refractory (reviewed in 540). MD-like lymphoid tumors in passerines are frequently cited, but it is necessary to exclude lymphoma-like lesions caused by infection with Isospora, especially in captive populations (165). Mammals, including several species of primates, are refractory to experimental inoculation (reviewed in 540).

Quail

Natural outbreaks of MD in commercial flocks of Japanese quail are relatively common. Affected birds develop lymphomas in various visceral organs, but peripheral nerves are rarely affected. Mortality can reach 10%–20%, but deaths occur relatively late (271, 325, 464, 479). MDV antigens can be demonstrated in the FFE, and MDV occasionally can be isolated from blood, although with low titers (261, 271), or can be detected by PCR assays (464). Transmission of MDV from chickens to quail has been reported (189). MD can be induced in quail by experimental inoculation or contact exposure to MDV strains of both chicken and quail origin (159, 270, 319, 386, 642). Many commercial quail flocks are apparently protected after vaccination with HVT (325), but protective immunity could not be demonstrated after experimental challenge (313). Bobwhite quail are susceptible to infection, but perhaps less so than Japanese quail (477).

Turkeys

Between 1997 and 2002 severe outbreaks of MD were reported in commercial turkey flocks in Europe (155, 214, 465, 632) and Israel (170). In some of these cases, the affected turkey flocks were raised in proximity to broilers. Paralysis was noted in some birds, and peripheral nerves were occasionally infiltrated with lymphocytes (155). Mortality from tumors reached 40–80% between 8–30 weeks of age. PCR assays were positive for serotype 1 MDV and negative for retroviruses. Experimental infection of turkeys and chickens with blood or tumor cells from diseased turkeys resulted in the development of MD (155, 170). Horizontal transmission between turkeys and between turkeys and chickens was established (155). Vaccination of turkeys with CVI988 appears to offer protection (155), although Davidson et al. (170) failed to show protection by vaccination with CVI988. The disease has not yet become endemic within commercial turkey populations.

Earlier studies had shown that turkeys are susceptible to experimental infection with MDV resulting in mortality up to 70% (450, 683). Enlarged peripheral nerves were rare or absent in these studies. Immunosuppression was noted in tumor-bearing turkeys (195). Virus could be re-isolated from peripheral blood lymphocytes but less frequently and with lower titers than from chickens (195). Interestingly, vaccination with HVT provided no protection against MDV challenge (196). Turkey B cell (412) and T cell (475) lines have been established from MDV-induced lymphomas, suggesting that both cell types are susceptible to transformation.

Ducks and Geese

Ducks experimentally infected with MDV did not develop clinical disease, but antibodies were demonstrated and virus was re-isolated (46). Recently, a case of MD was reported in white-fronted geese (*Anser albifrons*) in Japan (403, 624). Subsequent analysis showed the presence of the meq gene in the feather tips of a high percentage of this species (403) and in several duck species (404). It is unknown if any of the duck species develop MD or if they play a role in the horizontal transmission of MDV to free-range chicken farms.

Other Species

Challenge of the common pheasant (*Phasianus colchicus*) with virulent MDV induced paralysis, visceral lymphomas, and precipitating antibodies within 75–85 days post inoculation (PI) (352). Unlike quail and turkeys, pheasants appear to be more susceptible to neurological lesions of MD. However, the disease has not been well characterized in this species. The older literature suggests that spontaneous disease may occur in pheasants and related species such as the black Francolin (540) but other viruses such as REV were not excluded. Recently a herpesvirus was isolated from 3 species of endangered pheasants causing hepatocellular necrosis. Based on sequence analysis of two genes, this virus is related to HVT and is proposed to be a new member of the genus Mardivirus (552).

Transmission, Carriers, Vectors

MDV is transmitted readily by direct or indirect contact between chickens by the airborne route (citations in 55). The FFE produces fully infectious virus (107). These cells present in feathers and dander form the major source of contamination of the environment and infection of chickens (48, 126). Contaminated poultry house dust remains infectious for at least several months at 20°C–25°C and for years at 4°C (citations in 101). Under commercial conditions, young chickens are most commonly exposed to MDV by contact with residual dust and dander in the growing house or by aerosolized dust from adjacent chicken houses, fomites, or personnel. After the virus is introduced into a chicken flock, regardless of vaccination status or genetic resistance, infection spreads quickly from bird to bird. Early studies, based on contact infection, demonstrated that virus excretion begins about 2 weeks post infection (317) and continues indefinitely (682). The development of qPCR assays for the 3 serotypes has provided measurements of virus load in feather pulp and dust (3, 37, 276, 505). These assays may measure cell-associated virus in the feather pulp and therefore do not necessarily provide a measure for the amount of infectious virus shed into the environment. The latter question is relevant because dust collected from poultry houses containing HVT-vaccinated flocks is positive for HVT DNA. It is possible that this DNA is derived from cell-associated HVT orginally present in feather pulp cells rather than true cell-free infectious virus. Older literature suggested that horizontal spread of HVT from vaccinated chickens is limited at best (540).

Vertical transmission of MDV does not occur (507, 585, 586). Transmission from dam to progeny as the result of external egg contamination is also unlikely because of poor virus survival at temperature and humidity levels used during incubation (112). Passive transmission by darkling beetles (*Alphitobius diaperinus*) has been reported, but free-living litter mites, mosquitoes, and coccidial oocysts do not transmit MDV (47, 65–66, 192).

Experimental transmission is commonly accomplished by parenteral inoculation of susceptible chickens with cell-associated virus from cell cultures, tumor cell suspensions, or blood cells from infected chickens. Exposure by direct or indirect contact with infected chickens also is effective. Cell-free but not cell-associated virus can be used for intratracheal instillation or inhalation exposure. Recently an aerosol-based exposure model was described (7), which may facilitate studies on the early events in the pathogenesis.

Incubation Period

The incubation period for experimentally induced MD is well established (see reviews in 35, 102). Mononuclear infiltrations containing $AV37^{+}CD4^{+}$ lymphocytes can be detected in nerves of maternal antibody-negative, genetically susceptible chickens as early as 5 days PI (83). Monoclonal antibody AV37 recognizes chicken $CD30^{hi}$, which is considered a marker for transformed lymphocytes (86). Clinical signs and gross lesions generally do not appear until between the third and fourth weeks PI.

The incubation periods can be short for several nonlymphomatous syndromes associated with MDV infection. Cytolytic infections occur at 3–6 days PI and are followed by degenerative lesions (atrophy) of the thymus and cloacal bursa (bursa of Fabricius) within 6–8 days PI (82). The early mortality syndrome (EMS) is characterized by deaths at 8–14 days PI (675). The clinical expression of both acute and classical forms of transient paralysis usually occurs from 8–18 days PI (318, 667) and can occur when specific pathogen free (SPF) birds are challenged with vv+MDV between 30 and 102 weeks of age (665). Field cases of transient paralysis are seen mainly between 6 and 12 weeks of age, probably reflecting MDV exposure 8–10 days prior to the onset of symptoms. Development of atherosclerosis requires 3–7 months (201). Induction of tumors within 10–14 days after inoculation of cellular material is suggestive of a transplantation response (597). Local lesions in the wing web are visible 3–4 days PI with allogeneic MDV-infected CKC. Cell lines have been established from these lesions, suggesting that transformed cells are present (114).

Under field conditions, MD outbreaks sometimes occur in unvaccinated layer chickens as young as 3–4 weeks. Most of the serious cases begin after 8–9 weeks but sometimes commence well after the onset of egg production, especially in broiler breeders (401) or subsequent to molting (658). Witter (658) differentiated the outbreaks in commercial, vaccinated chickens as "early" or "late" breaks. It is uncertain whether late breaks are caused by recent infections or that immunosuppressive conditions [e.g., infection with CIAV (543)] reactivate early infections. Witter and Gimeno (665) infected birds between 18 and 102 weeks of age and found that nonvaccinated birds developed MD within 68 days PI when challenged with highly virulent strains. In contrast, vaccinated birds of similar ages did not develop MD after challenge. The authors suggested that late breaks were not likely the result of recent infections alone and that additional factors are needed to cause the late breaks. The different manifestations of MD, including EMS (128), may occur in backyard flocks, which are often not vaccinated.

Clinical Signs

Signs associated with MD vary according to the specific syndrome (Tables 15.3A, 15.3B). Chickens with MD lymphoma or fowl paralysis syndromes may exhibit signs, but few are specific to MD (54). In general, signs related to peripheral nerve dysfunction are those associated with asymmetric progressive paresis, and later, complete spastic paralysis of one or more of the extremities. Involvement of the vagus nerve can result in paralysis and dilation of the crop and/or gasping. Because locomotory disturbances are easily recognized, incoordination or stilted gait may be the first observed sign. A particularly characteristic clinical presentation is a bird with one leg stretched forward and the other back as a result of unilateral paresis or paralysis of the leg (Figure 15.5). However, chickens with MD lymphomas may appear clinically normal but have extensive neoplastic involvement when euthanized, while other birds may become depressed and comatose prior to death. Non-specific signs such as weight loss, paleness, anorexia, and diarrhea may be observed, especially in birds in which the course is prolonged. Under commercial conditions, death often results from starvation and dehydration because of the inability to reach food and water or from trampling by penmates. Some birds develop nervous tics or torticollis 18–26 days PI, often after recovery from classical transient paralysis. This syndrome, termed persistent neurological disease (226), can be induced by partially attenuated MDVs that no longer induce transient paralysis (225). However, the central nervous system (CNS) signs are difficult to distinguish from those associated with MD nerve lesions.

Birds with ocular involvement may show evidence of blindness (205, 438, 594). Ficken et al.(205) isolated 2 MD strains from commercial flocks with more than 90% blindness. The blindness was reproduced in experimentally infected commercial chickens. Gross ocular lesions were not always present in blind birds. The blindness can be unilateral or bilateral,

Figure 15.5. Fowl paralysis. Spastic paralysis of limbs associated with peripheral nerve involvement in Marek's disease. (Witter)

Figure 15.6. Transient paralysis. Flaccid paralysis of neck of young chicken 9 days after inoculation with Marek's disease virus. (Courtesy of Avian Diseases). (Witter)

although recognition of clinical blindness requires careful observation. Affected eyes gradually lose their ability to accommodate to light intensity. Although ocular lesions sometimes have been associated with specific isolates (205, 594), many contemporary MDV strains induce ocular lesions as well (651).

EMS results in high mortality 8–16 days PI of young chickens with virulent MDV strains (629, 675). Chickens become depressed and comatose prior to death, which occurs within 48 hours of the onset of signs. Some affected chickens also may exhibit flaccid neck paralysis prior to death (667). Chickens undergoing acute cytolytic infection at 3–6 days PI may be depressed but rarely die during this period, although some may die later from EMS. Immunosuppressed chickens may succumb to ancillary infections, but some chickens die 20–40 days PI with few signs.

Classical and acute transient paralysis syndromes have been described in field flocks (702) and are associated with MDV infection (318). These syndromes have been observed infrequently in the field because vaccination for MD has become widespread, but may be encountered in non-vaccinated backyard flocks. In the classical form, affected chickens display varying degrees of ataxia and flaccid paralysis of the neck or limbs beginning 8–12 days PI (Figure 15.6). Signs typically last 1–2 days followed by a rapid and complete recovery, although recovered chickens may succumb a few weeks later with MD lymphomas. The acute (fatal) form results in death within 24–72 hours following the onset of paralytic signs (667).

Morbidity and Mortality

The incidence of MD is quite variable in commercial flocks and in general low since the world-wide introduction of vaccines, although problems are sometimes reported (401). Most birds developing clinical disease die. A few birds may apparently recover from the clinical disease (59, 83), but the recovery is rarely permanent. Prior to the use of vaccines, losses in affected flocks were estimated to range from a few birds to 30% and occasionally as high as 60% (401). In broilers, MD condemnations averaged 1% in 1970 with 10% or higher in individual flocks (487). The average condemnation rate for MD in the USA has decreased dramatically (see Incidence and Distribution).

Some flocks experience significant disease outbreaks despite vaccination. After the disease appears, mortality builds gradually and generally persists for 4–10 weeks. Outbreaks occur and abate spontaneously in isolated flocks or occasionally in several flocks in a region or in succeeding flocks on a farm. The reasons for these fluctuations are poorly understood.

Response rates or mortality approaching 100% for lymphomas, EMS, acute cytolytic infection, or transient paralysis can be achieved following inoculation or exposure of unvaccinated, susceptible chickens to MDV. Because the response frequency is influenced by many factors (see the following section), laboratory experiments can be designed to produce a wide range of specific clinical and pathologic responses.

Factors That Influence Mortality and Lesions

Virus Strain. The virulence of MDV strains varies widely and appears to have increased over time (651 and reviewed in 175, 529). Compared to the milder forms of the disease, which caused mainly peripheral nerve lesions, very virulent (vv) and vv+pathotypes frequently induce higher mortality and more visceral lymphomas, and have the tendency to more frequently break through genetic host resistance or immunity induced by vaccination (664). The extent of disease induced by a given strain depends in part on the genetic constitution of the host (534).

Virus Dose and Route. Dosage may influence disease frequency under natural conditions, although the MD response in genetically susceptible birds given virulent virus was found to be maximal even when a limiting dilution of virus was inoculated (582). Infection with cell-free MDV through intratracheal inoculation or by aerosol may enhance early virus replication and increase the development of lymphomas compared to parenteral inoculation (7, 27, 96).

Host Gender. Several studies indicated that females died earlier and experienced higher losses than males (376, 454), but the opposite also has been reported (383). The differences were apparently not due to sex hormones, varied with the genetic strain, and were most pronounced with genetically susceptible chickens and with viruses of higher virulence. In practice, the influence of gender is probably less important than other factors.

Maternal Antibodies. Maternal antibodies reduce and delay MD mortality (144), EMS (675), and transient paralysis (318), probably by limiting, but not preventing, the spread of virus in tissues during the first few days post exposure (98, 456). Thus, maternal antibodies do not provide a sterilizing immunity. Breeder stocks are vaccinated uniformly and exposed to virulent MDV and virtually all chickens are hatched with maternal antibodies against multiple serotypes. SPF flocks are a source of antibody-free chicks for laboratory studies.

Host Genetics and Age at Exposure. Genetic factors (see reviews 28, 79) and age at initial exposure are important determinants of MD susceptibility (see Genetic Resistance).

Following Calnek (102), age-related resistance is an expression of genetic resistance and develops after hatching paralleling the development of immune competence. Newly hatched chicks and older chickens are both susceptible to infection and cytolytic infection (102), but cytolytic infections are resolved more rapidly in older birds (92) and virus load is somewhat lower (172). The frequency of lymphomas is variable and often markedly reduced in older chickens compared to newly hatched chicks, especially in genetically resistant lines (540). However, nonvaccinated, SPF, older chickens may develop high rates of lymphomas and transient paralysis following challenge with vv and vv+strains (263, 665). Age-related resistance can be abrogated by neonatal thymectomy (567), suggesting that other immunosuppressive factors, e.g., CIAV (543), may increase the susceptibility of older chickens to disease. Lesion regression has been linked to age-related resistance (83, 566).

Prior Infection. Early studies had shown that mild, serotype 1 strains can induce protective immune responses against challenge (583). Recently, Dunn et al. (188) addressed the question of what the consequences are of superinfection using Md5, a vvMDV, in which the pp38 gene of CVI988 was inserted (Md5//38CVI). The pp38 gene of CVI988 has a single nucleotide polymorphism resulting in a difference of 1 amino acid with pp38 from oncogenic MDV strains. This difference can be detected by immunohistochemistry (IHC) and pyrosequencing. Challenge with the virulent JM strain or Md5 followed by Md5//38CVI or vice versa 2 days later resulted in a high incidence of dual infections. If the second challenge was given after 14 days, the superinfection was significantly reduced but not totally eliminated.

Environmental Factors and Stress. Various environmental factors and intercurrent infections appear to affect the incidence of MD, probably through interference with immune responses. Gross (229) observed increased incidence among chickens selected for high concentrations of plasma corticosterone or subjected to a high degree of social stress. The administration of corticosteroids to latently infected chickens precipitated the appearance of clinical MD (473). Feeding of corticosteroid inhibitors tended to increase resistance to MD (150). Restricted feed intake delayed and reduced incidence of MD (236), whereas high-protein diets (486) or the selection for fast growth rate were associated with increased susceptibility to MD (235).

Because MDV infection may depress host immune responses in its own right (see Immunosuppression), concurrent infections are often exacerbated. However, when the concurrent infection is itself immunosuppressive, the resulting immunosuppression usually will exacerbate both disease processes. Examples include IBDV, REV, and CIAV (293, 639, 670), although Buscaglia et al. (93) were unable to demonstrate an effect of REV or IBDV on reactivation of latent MDV infection. Unfortunately, MDV stocks occasionally have become contaminated with other viruses, especially when propagated in chickens. Problems with CIAV contamination invariably interfere with the evaluation of MDV stocks for relative virulence (388).

Pathology

Gross Pathology

Pathologic changes in MD have been reviewed (451, 454) and consist mainly of nerve lesions and visceral lymphomas. Macroscopic changes are not seen in the brain, but gross enlargements can be found in spinal ganglia.

Nerves. Severely affected peripheral nerves may show loss of cross-striations, gray or yellow discoloration, and sometimes an edematous appearance. Usually, plexi of the sciatic and brachial nerves are more enlarged than the respective trunks. Localized or diffuse enlargement causes the affected portion to be 2–3 times normal size, in some cases much more. Goodchild (227) reported that autonomic nerves and especially the celiac plexus are affected at a higher frequency than peripheral nerves, e.g., the sciatic and brachial nerves. Witter (656) found the cervical vagus to be of particular diagnostic importance. Because unilateral and or minimal enlargements may be important indicators of disease, it is helpful to examine opposite nerves, and in experimental infections, to compare with age-matched normal controls to detect changes. Careful examination of the various nerve ramifications may be necessary to expose gross lesions in some birds because enlargements can vary in both presence and degree from one portion of an affected nerve to another. Figure 15.7 illustrates unilateral gross enlargements in the sciatic plexus.

Visceral Organs. Lymphomas may occur in one or more of a variety of organs and tissues. Lymphomatous lesions can be found in the gonad (especially the ovary), lung, heart,

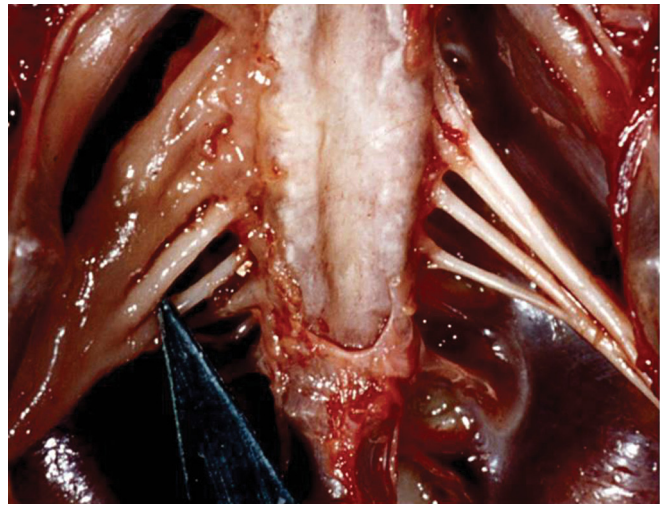

Figure 15.7. Enlarged sciatic plexus (left) and normal plexus (right). (Peckham)

mesentery, kidney, liver, spleen, bursa, thymus, adrenal gland, pancreas, proventriculus, intestine, iris, skeletal muscle, and skin. Probably no tissue or organ is without occasional involvement. Both the genetic strain of chicken and the virus strain can influence the organ distribution of lesions. Visceral lymphomas are common in more virulent forms of the disease (651). Visceral tumors can occur in the absence of gross nerve lesions, especially in certain strains of chickens. MD lymphomas in most viscera appear as diffuse enlargements, sometimes to several times the normal size, and a diffuse white or grayish discoloration is often present (Figure 15.8B). Alternatively, lymphomas may occur as focal, nodular growths of varying size (Figures 15.8E, F). Nodules are white or gray in color and are firm, and the cut surface is smooth. Necrosis is rare but may occur in the center of rapidly growing lesions.

Diffuse infiltration of the liver causes loss of normal lobule architecture and often gives the surface a coarse granular appearance. Nodular tumors also may be seen in the liver. Lesions in the immature ovary are observed as small to large grayish translucent areas (Figure 15.8B). With large tumors, the normal foliated appearance of the ovary is obliterated. Mature ovaries may retain function, even though some follicles are tumorous. Marked involvement is indicated by a cauliflower-like appearance. The proventriculus becomes thickened and firm as a result of focal leukotic areas within and between the glands, which may be seen through the serosal surface or, if involvement is diffuse, detected by palpation. Affected hearts are pale from diffuse infiltration or have single or multiple nodular tumors in the myocardium (Figure 15.8F). Pinpoint foci may be seen in the epicardium. Involvement of the lung (Figure 15.8E) may be indicated by increased firmness of the organ upon palpation. Muscle lesions may be present in both superficial and deep layers and are most common in the pectoral muscle (50). Gross changes vary from tiny whitish streaks to nodular tumors.

Integument. Skin lesions, probably the most important cause of condemnation in broiler chickens, usually are associated with feather follicles. The nodular lesions may involve few scattered follicles, or they may be numerous and coalesce. The distinct whitish nodules (Figure 15.8A), especially evident in dressed carcasses, may become scab-like with brownish crust formation in extreme cases (50). Lapen and Kenzy (333) found the highest incidences of lesions in external and internal crural and dorsal cervical tracts. Erythematous involvement of the shank integument is seen, especially in virulent forms of the disease in broiler chickens (190) and is commonly known as "Alabama redleg." Swelling of the comb or wattles may indicate lymphoma growth in underlying tissues (190, 193). Interestingly, FFE is not essential for virus production or development of skin tumors, because scaleless chickens produced cell-free infectious virus in epithelial cells and developed skin tumors (243).

Eye. Gross ocular changes, including loss of pigmentation in the iris ("gray eye") and irregularity of the pupil, are caused by mononuclear infiltration of the iris (Figure 15.8C). Nearly all field isolates can induce ocular lesions in non-vaccinated or HVT-vaccinated chickens (651). Conjunctivitis, occasionally with multifocal hemorrhages and corneal edema, also has been observed (205).

Other Syndromes. Gross lesions are associated with at least some of the other MDV-associated syndromes. The lymphodegenerative syndromes, related to intense cytolytic infections of lymphoid organs, usually are characterized by severe bursal and thymus atrophy. The cytolytic infection is first evident 3–6 days PI, but may persist, becoming more obvious at 8–14 days PI (110, 629, 675). After inoculation with highly virulent field strains, some chickens may die at 20–50 days without gross lesions except for severe bursal and thymic atrophy (651). Some chickens also develop a transient splenomegaly within 4–12 days PI (108). The splenomegaly is a non-neoplastic response to viral replication and is induced by all 3 serotypes. Vascular syndromes are manifested principally by occlusive atherosclerosis (202). Susceptible P-line chickens inoculated with the CU2 isolate of MDV developed grossly visible fatty atheromatous lesions in large coronary arteries, aortas, major aortic branches, and other arteries (Figure 15.8D). Lymphoid tumor transplants and local lesions are experimental syndromes characterized by nodular growths at the site of inoculation, although some transplantable tumors metastasize readily to the liver and spleen, causing diffuse enlargements (597).

Microscopic Pathology

Histopathologic changes associated with MD lymphoproliferative lesions have been described by numerous researchers who are in general agreement about the types of histologic lesions and the cells involved (reviewed in 451, 452, 454).

Nerves. In peripheral nerves, 2 main types of lymphoproliferative lesions are recognized, which are referred to as type A and B. Type A lesions consist mostly of $CD30^{+}CD4^{+}$ T cells (83) and some B cells; this type is considered neoplastic. In some cases, demyelination and Schwann cell proliferation are associated with A-type lesions. B-type lesions are essentially inflammatory and are characterized by diffuse, light-to-moderate infiltration by small lymphocytes and plasma cells, usually with edema, and sometimes with demyelination and Schwann cell proliferation. A few macrophages may be found. The 2 types may be observed in different nerves of the same bird or even in different areas of the same nerve. Lawn and Payne (334) observed cellular infiltrations as early as 5 days PI, which gradually increased in intensity until 3 weeks when severe proliferative, type-A lesions were seen in the absence of paralysis or demyelination. Coincident with initial neurologic signs seen at 4 weeks PI, areas of widespread demyelination could be found within the proliferative lesions. Finally, characteristic inflammatory, type-B lesions (edema, sparse infiltrations) appeared, suggesting the occurrence of regression of A type lesions. A third lesion, C-type, consists of light infiltration of lymphocytes and plasma cells. The sequence of events

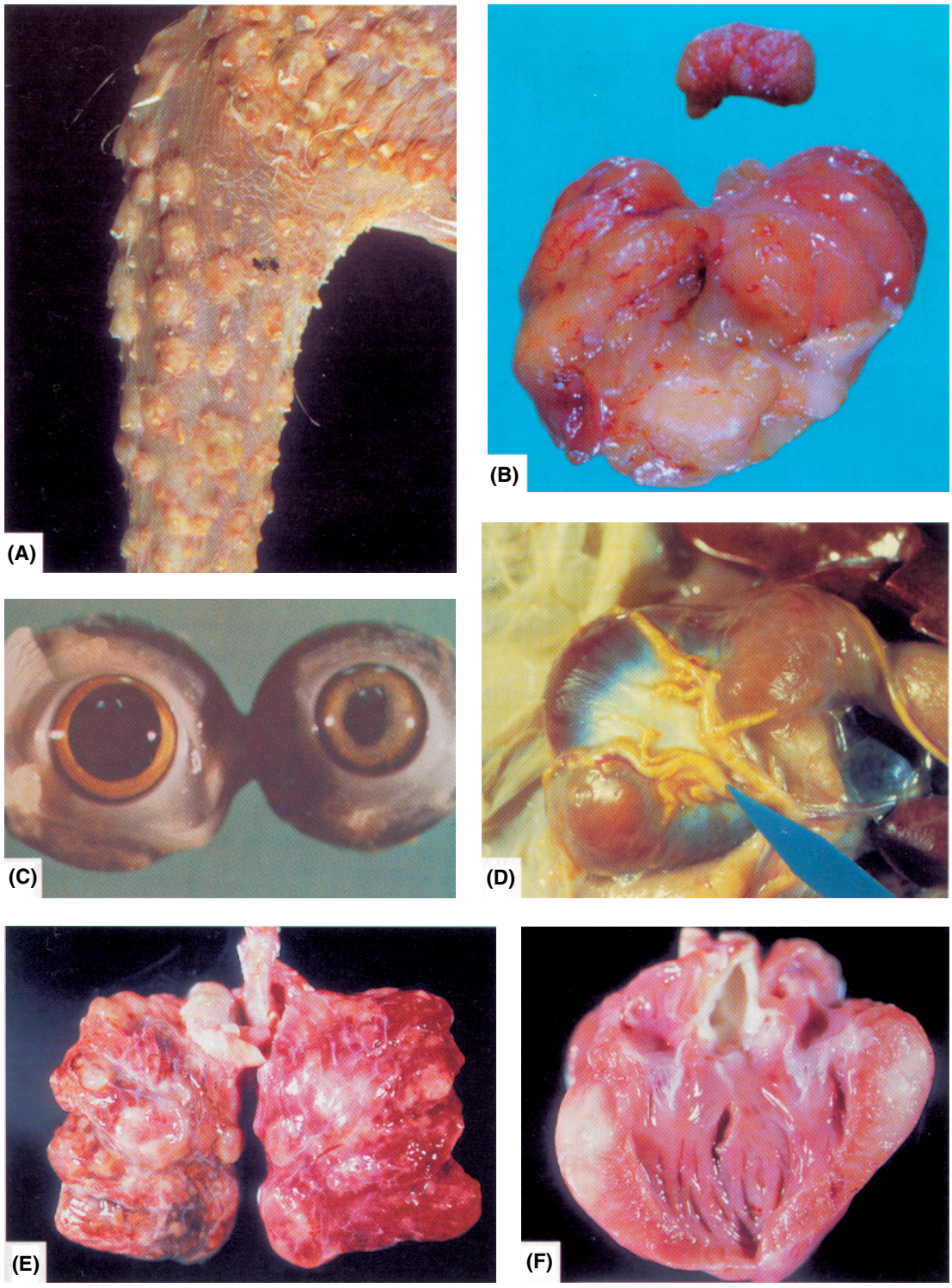

Figure 15.8. (A) Leukotic tumors involving feather follicles (skin leukosis). (Peckham) (B) Experimentally induced Marek's disease (MD) lymphoma in immature ovary (bottom) compared with normal ovary (top). (Witter) (C) Ocular lesions of MD. Note that the normal eye (left) has a sharply defined pupil and well-pigmented iris. Affected eye (right) has a discolored iris and very irregular pupil as a result of mononuclear cell infiltration. (Peckham) (D) Gizzard from a chicken infected with CU-2 isolate of MDV. Note the grossly obvious atherosclerotic change in the arteries. (C. Fabricant) Microscopic changes from similar arteries are shown in Figure 15.16B. (E) Multiple lymphomas in lungs. (F) Multiple lymphomas in heart. (Shivaprasad)

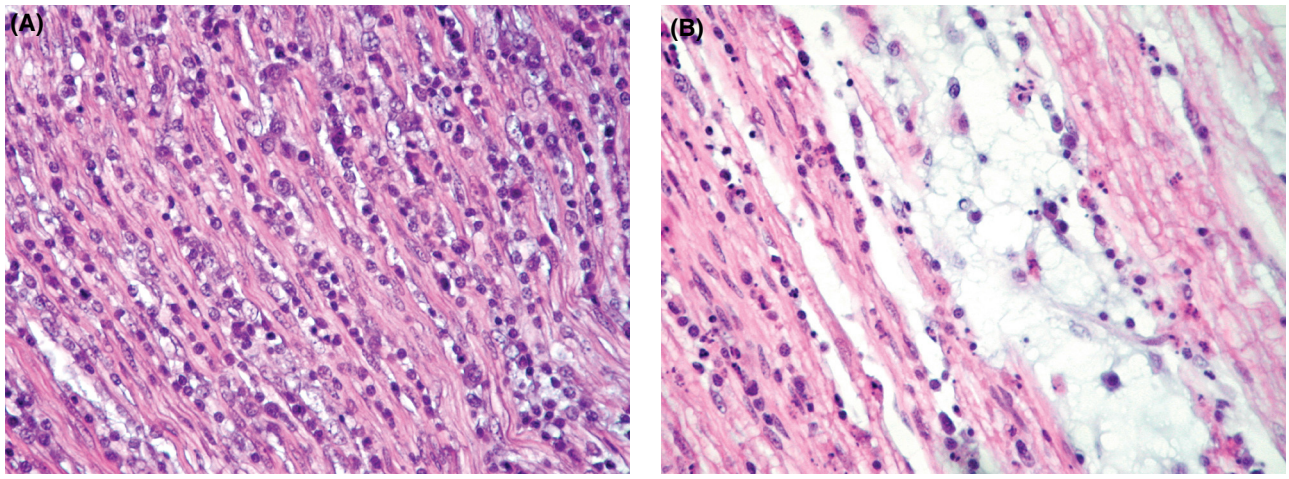

Figure 15.9. Microscopic lesions of Marek's disease in peripheral nerves. (A) Type A lesion characterized by marked cellular infiltration, numerous proliferating lymphoblastic cells, and no edema. H and E, ×550. (B) Type B lesion with edema, scattered infiltrating small and medium lymphocytes, and plasma cells. H&E, ×420. (Gimeno)

has been reviewed in detail by Payne et al. (454). Characteristic changes in nerves are illustrated in Figure 15.9.

Brain. The principal CNS lesion in MD consists of mild, but persistent, perivascular cuffing usually accompanied by gliosis but without primary demyelination as the principal CNS lesion in MD (226, 454). Experimental infection with less virulent MDV strains only resulted in transient, moderately severe inflammatory lesions as early as 7–10 days PI. In contrast, lesions induced by vv+MDV strains appeared earlier, were more extensive, and were followed by proliferative lesions (223). The initial lesions involve vascular elements; endotheliosis occurs at 6 days PI and is followed at 8–10 days PI by a moderate to severe infiltration of lymphocytes and macrophages around blood vessels and scattered throughout the neuropil (223). The vasculitis and edema disappear and may be followed by lymphoproliferative infiltrations of large lymphocytes and glial cells. These lesions tend to persist and are associated with persistent neurological disease. Severe lymphoblastic infiltration, often accompanied by extensive vacuolated areas that may correspond with secondary demyelination, has been shown to occur 4 weeks after inoculation with vv+MDV (223). Infection with 2 vv+strains (C12/130 and RK-1) showed infiltration with monocytes in addition to T cells in the perivascular cuffs. These monocytes were expressing pp38 after infection with C12/130 (44) but not with RK-1 (419). However, in RK-1-infected birds many of the monocytes were in mitosis and apoptotic cells were often observed first in the white matter and later in the gray matter. Cho et al. (140) reported severe necrotizing and non-necrotizing lesions in the brains of chickens up to 10 weeks PI with vvMDV. Thus, as in nerves, brain lesions are both inflammatory and lymphoproliferative. Severe lymphoid infiltration in the cerebellum is shown in Figure 15.10.

Visceral Organs. Lymphomatous lesions in visceral organs are more uniformly proliferative in nature than those in nerves

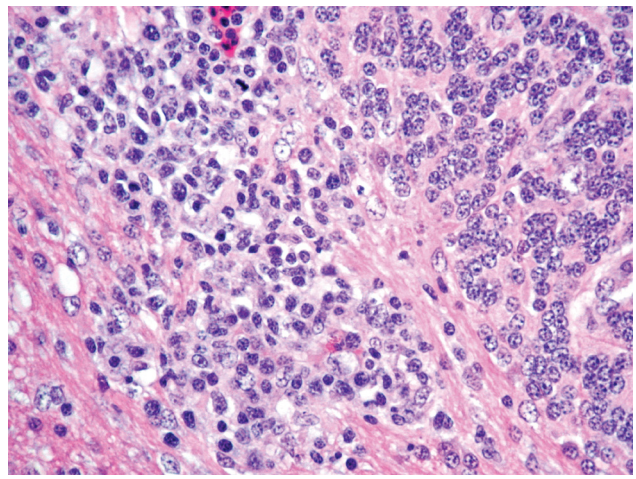

Figure 15.10. Extensive infiltration of lymphoblasts extending into the neuropil in the cerebellum of a Marek's disease virus-infected chicken 3 weeks PI. H&E, ×400. (Gimeno)

(Figure 15.11) and similar in appearance to A-type lesions consisting of diffusely proliferating small-to-medium T lymphocytes and lymphoblasts, natural killer (NK) cells, B cells, and macrophages, whereas plasma cells are rarely present (reviewed in 81, 454) (Figure 15.12). The cellular composition of tumors is similar from one organ to another, even though the gross pattern of involvement may vary. Tumor cells are characterized by large, pleomorphic nuclei with prominent nucleoli (185). The majority of transformed T cells express MHC-II and CD4, although $CD4^{-}CD8^{+}$, $CD4^{+}CD8^{+}$, and $CD4^{-}CD8^{-}$ T cells also can be transformed by MDV (536). In addition, the tumor cells express high levels of CD30 (84) and resemble Treg cells (553). Pradhan et al. (478) found immune complexes in the kidney, leading to glomerulopathy, in MDV-infected chickens. They suggested that these lesions might be one of the major causes of death in MD.

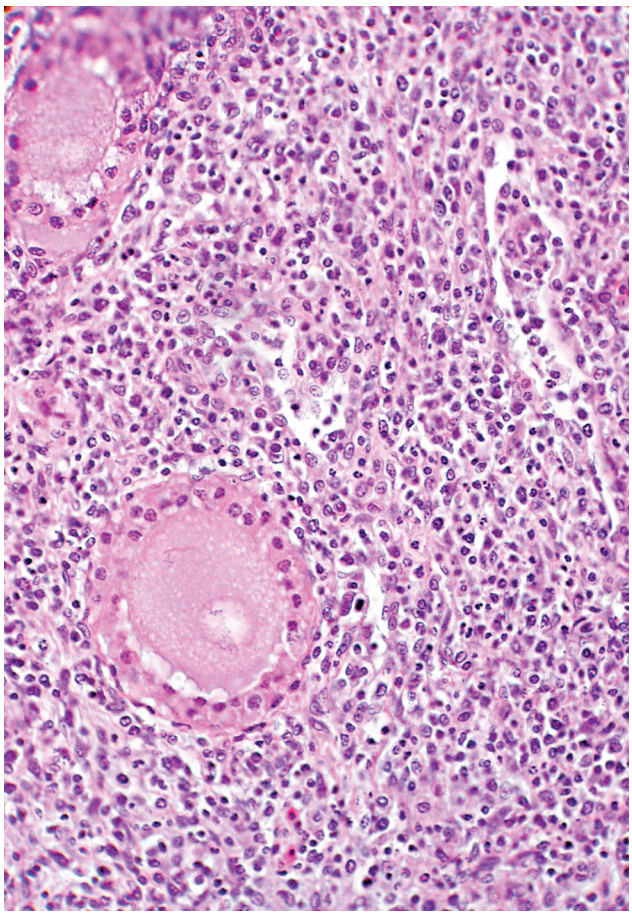

Figure 15.11. Lymphoid cell infiltration of ovary. Organ is composed largely of tumor cells, but a few ovarian follicles can be seen. H&E, ×116. (Witter)

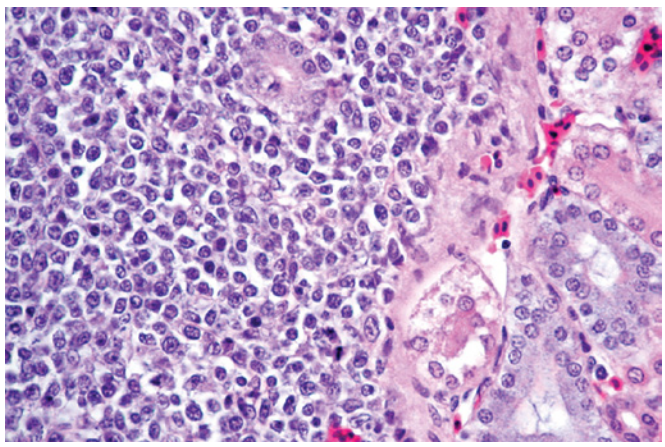

Figure 15.12. Higher magnification of a kidney lymphoma showing pleomorphic tumor cells. Kidney tubules (bottom) show degeneration caused by tumor cell pressure. H&E, ×450. (Gimeno)

Integument. Lymphoproliferative nodules often surround feather follicles that contain MDV viral antigens and intranuclear inclusions in the FFE (107, 142). These lesions in the skin appear largely inflammatory but also may be lymphomatous. Massive proliferative lesions may cause disruption of the epidermis, resulting in an ulcer. Similar lesions develop in the absence of feather follicles (243). Moriguchi et al. (396) described both inflammatory and lymphoproliferative lesions in the feather pulp; the latter were closely related to the incidence of MD and may be useful for antemortem diagnosis (143).

Eye. Smith et al. (584) and Pandiri et al. (437) examined the histology of eye lesions after experimental infection with the GA and Md5 strains, respectively. The former group found that apparently transformed cells could be detected as early as 11 days PI in the arachnoid layer of the optic nerve and subsequently in ciliary nerves and uvea. Pandiri et al. (437) distinguished early and late lesions. The early lesions, between 6–11 days PI, consisted of hypertrophy of endothelial cells, vasculitis, and infiltration of mostly $CD8^+$ T cells, plasma cells, heterophils, and macrophages. The cellular infiltration probably represented an immune response to MDV viral antigens such as pp38, which is recognized by CTL (429). The late lesions appeared between 26–56 days PI and consisted of uveitis, keratitis, and retinal necrosis. Infiltrating cells included $Cd4^+$ and $CD8^+$ T cells, macrophages, plasma cells, and granulocytes. Early and late lesions did not contain transformed lymphocytes based on the absence of meq expression.

The unusually severe ocular lesions described by Ficken et al. (205) include uveal changes with increased aqueous humor protein, vascular engorgement, mild hyperemia to severe swelling of the iris, severe inflammatory changes, and edema of the cornea, including intranuclear inclusion bodies.

Blood. Leukemia consisting of T lymphoblasts may occur occasionally (115, 457). Extravascular hemolytic anemia has been reported after infection with vvMDV strains in the absence of CIAV (217). The importance of this finding is not clear because hematocrit values are not routinely used as an MD parameter. Jakowski et al. (280) reported that MDV caused anemia as a consequence of bone marrow aplasia, but their MDV was later found to be contaminated with CIAV (543). Blood lymphocyte numbers may vary during the infection cycle: T cells may be elevated while B cells are decreased (457). However, Morimura et al. (397) reported an initial increase of $CD4^+TCR\alpha\beta1$ cells around 16 days PI followed by a decrease at 30 days. Infection with vv+C12/130 caused significant increases in the absolute number of blood monocytes around 8 days PI. B cells and $CD4^+$ and $CD8^+$ T cells decreased during the early cytolytic infection followed by an increase between 8–10 days PI, but these changes were also seen for T cells after infection with HPRS-16 (44). Circulating $CD4^+CD30^{hi}$ T cells are detected during the early cytolytic phase (84), suggesting that transformation or perhaps activation of T cells, as part of the immune response, causes expression of $C30^{hi}$.

Lymphodegenerative Syndromes. MDV replication in the cloacal bursa and thymus results in transient acute cytolytic changes accompanied by atrophy (citations in 101, 454). In experimental infections, bursal lesions consist of follicular

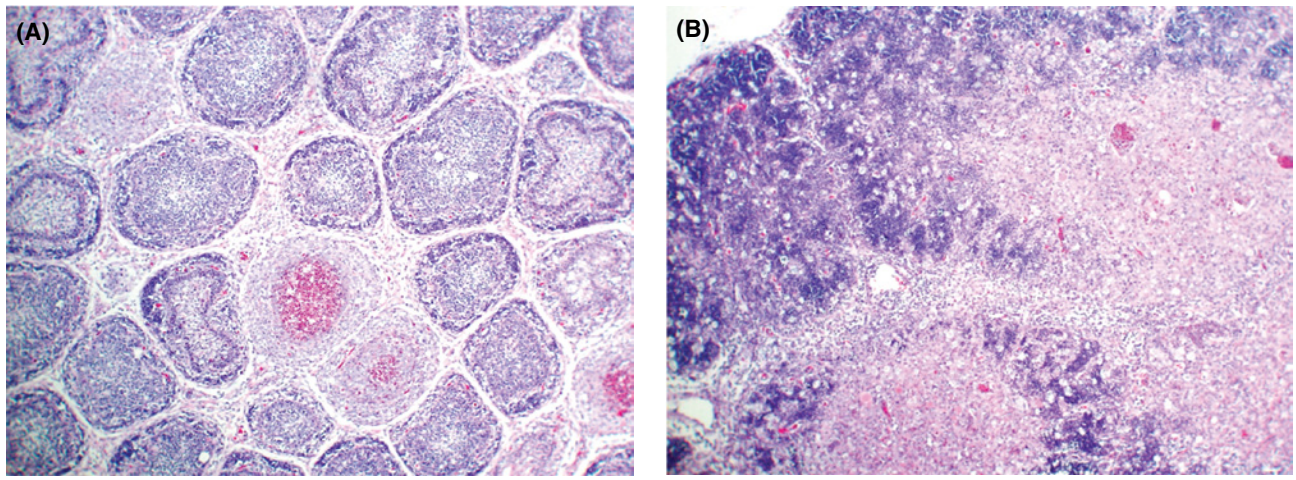

Figure 15.13. Degenerative lesions in cloacal bursa and thymus of chickens inoculated with the 648A (vv1) strain of Marek's disease virus. Bursa (A) at 10 days PI shows degeneration and atrophy of follicles. Thymus (B) at 6 days PI shows necrosis and lymphoid cell depletion. ×12 (Gimeno)

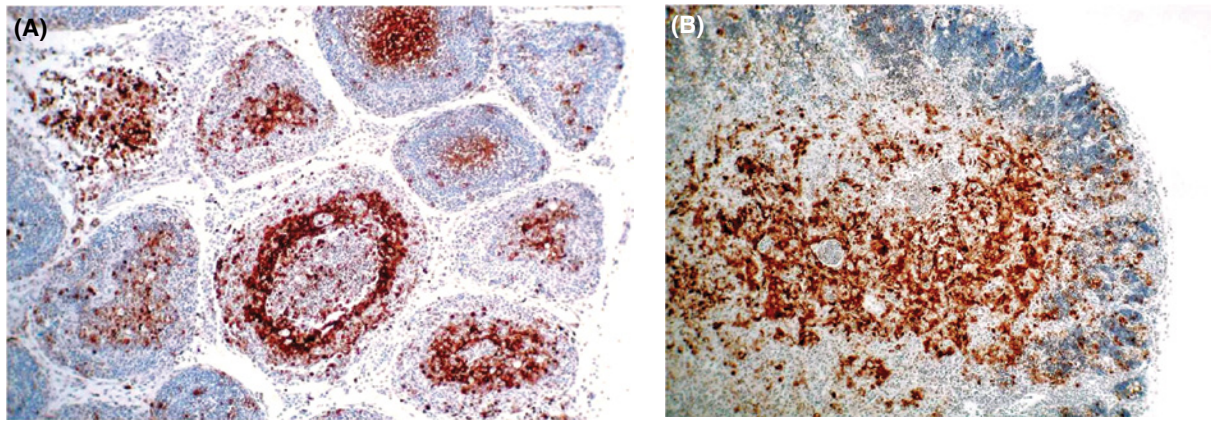

Figure 15.14. Acute cytolytic infection of lymphoid tissues 6 days PI with the 648A (vv+) strain of Marek's disease virus. The pp38 viral antigen is visualized by immunohistochemical staining (black). (A) Cloacal bursa. (B) Thymus. ×30 (Witter)

degeneration, lymphoid necrosis with depletion, and cyst formation (Figure 15.13A). Thymic atrophy is often severe, and lymphocytes are depleted in both cortex and medulla (Figure 15.13B). Intranuclear inclusions can sometimes be found in cells associated with degenerative lesions. Viral antigens can be abundant during the acute cytolytic phase, especially in the medullary regions of the thymus and in some but not all bursal follicles (Figure 15.14). Infection in the absence of maternal antibodies may cause focal or generalized necrosis in a variety of organs, including the kidney (98, 206). Following the acute cytolytic phase, antigen-positive cells disappear, and at least partial repopulation with lymphocytes occurs. Bursal and thymic atrophy, however, may persist for several weeks or longer. In the cloacal bursa, some interfollicular lymphoid infiltration with T cells may occur. EMS is characterized by severe lymphoid degeneration and death, often with enlarged, necrotic spleens (675). EMS has been linked with central nervous system (CNS) signs and transient paralysis (357, 667).

Central Nervous System Syndromes (Transient Paralysis). Lesions in classical and acute transient paralysis are very similar. The critical lesion in both types is vasculitis (Figure 15.15) leading to vasogenic brain edema (226, 605, 667). Leakage of albumin and IgG around affected vessels results in vacuolization. Edema and vasculitis develop coordinately with clinical flaccid paralysis and resolve in 2–3 days (603). Other, apparently unrelated, brain lesions (perivascular cuffing, lymphocytosis, and gliosis) may be observed after clinical recovery or in infected but clinically normal birds.

Vascular Syndromes. Arterial lesions associated with MDV-induced atherosclerosis include proliferative and fatty-proliferative changes in aortic, coronary, celiac, gastric, and

mesenteric arteries (Figure 15.16A, B) (202, 389, 614). Internal and medial foam cells, extracellular lipid, cholesterol clefts, and calcium deposits characterized the fatty-proliferative lesions. MDV antigens could be detected by immunofluorescence adjacent to the arterial lesions. An altered lipid metabolism is suggested by the findings of Fabricant et al. (203) and Hajjar et al. (232), that MDV infection of arterial smooth muscle cells *in vitro* and *in vivo* induced accumulation of phospholipids, free fatty acid, cholesterol, and cholesterol esters.

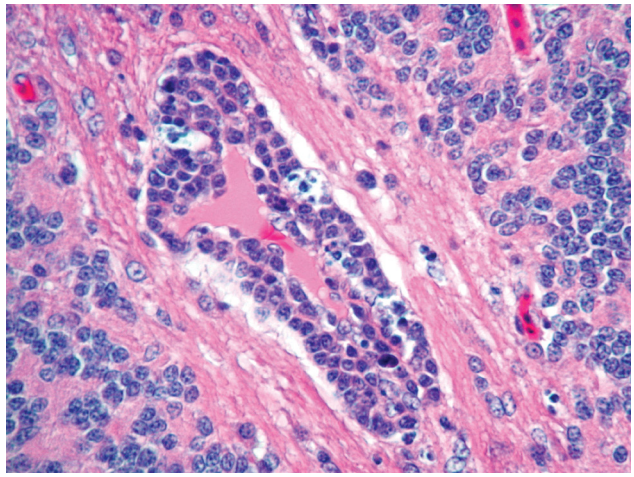

Figure 15.15. Transient paralysis lesions in the brain. Vasculitis in the cerebellum at 10 days PI showing endothelial cell necrosis, lymphoid cell accumulations, and vacuolization. Note intramural necrotic debris as well as infiltration of heterophils in the vessel wall. H&E, ×250. (Gimeno)

Tumor Transplants and Local Lesions. Tumor transplants are composed of uniform, lymphoblastic cells with few, if any, infiltrating host cells. In regressing tumor transplants, small lymphocytes, heterophils, vascular invasion, and necrosis may be present (207). Local lesions induced in the wing web or pectoral muscle by inoculation of MDV-infected, allogeneic CKC are inflammatory in nature, consisting of lymphocytes and macrophages and sometimes accompanied by hemorrhages and necrosis (114).

Pathogenesis

Several reviews on the pathogenesis of MD have been published (35, 102, 544), which also provide references for older reviews. The use of BACs and overlapping cosmid technologies has allowed the deletion of specific genes. Using these technologies, the importance of several genes for the pathogenesis has been established.

Four phases of infection *in vivo* can be delineated: (1) Early productive-restrictive virus infection causing primarily degenerative changes. The infection is productive–restrictive because the virus remains cell-associated and is only transferred by

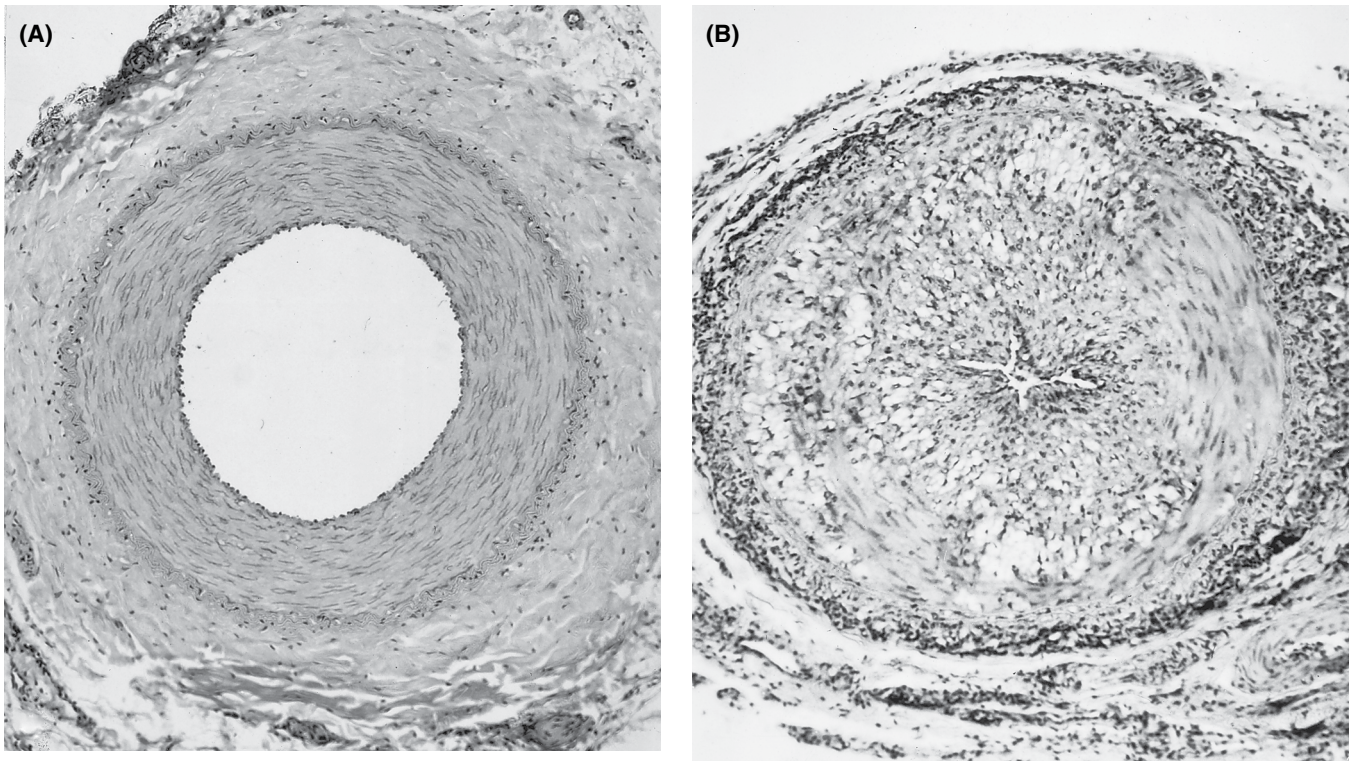

Figure 15.16. (A) Gastenic artery of normal chicken. (B) Atherosclerotic artery in gizzard of chicken infected with CU2 isolate of Marek's disease virus. Lumen is occluded by thickened intima, and atheromatous changes have occurred deep in the intima and media. H&E, ×24. (C. Fabricant)

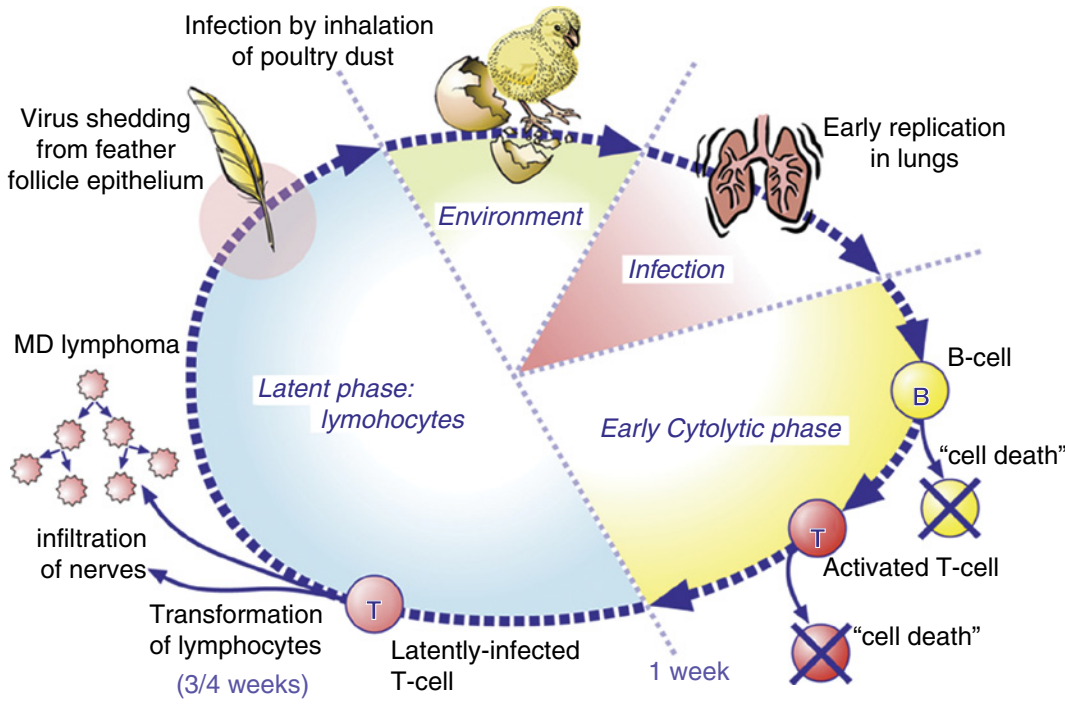

Figure 15.17. Schematic diagram showing the different stages of MD pathogenesis including the virus shedding from the feather follicle epithelium and the transformation of T lymphocytes in susceptible birds.

cell-to-cell contact. (2) Latent infection. (3) A second productive-restrictive infection phase coincident with permanent immunosuppression. (4) The proliferative phase involving nonproductively infected lymphoid cells that may or may not progress to the point of lymphoma formation (Figure 15.17). This division is somewhat arbitrary and phases 2–4 can coexist in different cells in the same bird. Infection with some of the vv + strains may not follow this general pattern, and mortality can occur without even entering into the latent phase. The next section describes the classical pathogenesis in lymphoid tissues, based mostly on studies in SPF chickens. The pathogenesis of infection in the FFE involves epithelial cells and is discussed in the section on cytolytic infection in FFE.

Early Productive-Restrictive Infection (Phase 1)

The virus enters the host via the respiratory tract, and cell-free virus reaches the lymphoid organs within 24–36 hours after intratracheal inoculation (7, 528). MDV is probably transferred to the lymphoid organs by phagocytic cells (102). Based on the presence of MDV proteins (43, 222) and transcripts (27), macrophages can become infected, but because virus particles could not be demonstrated, it is unsure whether this is an abortive or productive-restrictive infection.

Shortly after infection, either by inhalation of cell-free virus or by parenteral inoculation with cell-associated virus, cytolytic infection can be detected in the spleen, cloacal bursa, and thymus, peaking between 3 and 6 days. Splenectomy (526) and embryonal bursectomy (EBx) (533) delayed or reduced productive-restrictive infection and the development of lymphomas, suggesting a central role for these 2 organs in the pathogenesis of MD. In contrast, neonatal thymectomy enhanced the pathogenicity of the low-oncogenic CU-1 and CU-2 strains (109).

The explanation for these findings was provided by Shek et al. (568), discovering that the primary target cells in all 3 organs are B cells. Recently it has been shown that B cells are also infected in the lung 2 days after intratracheal inoculation (27). Infection of T cells requires activation based on the expression of MHC-II antigens, and activated but not resting T cells can undergo cytolytic infection (118, 120–121). Baigent and Davison (36) confirmed that the early cytolytic infection occurs mostly in B cells using dual staining techniques with MAb specific for B and T cell markers and MDV pp38. In addition, they demonstrated that a small percentage of $CD4^+$ and $CD8^+$ T cells expressing TCRαβ can become cytolytically infected during the early phase of the pathogenesis. The consequence is a transient atrophy of the lymphoid organs, especially the thymus and the bursa. Depending on the virulence of the challenge strain, birds may recover between 8 and 14 days PI, or the atrophy may become permanent (108, 110). The cytolysis is likely initiated by the activation of the host shut-off protein leading to cell death by apoptosis (398). Although MDV-infected cells in the thymus are mostly B cells (568), thymocytes undergo massive apoptosis possibly as the consequence of viral infection (36) or virus-induced cytokine changes.

During phase 1, hyperplasia of lymphoid and reticulum cells occurs (454), causing splenomegaly between 4 and 7 days PI, which is also observed after infection with MDV-2 and HVT (108). The level of infection is generally similar in genetically

resistant and susceptible strains during phase 1 (9, 298, 701). However, genetically resistant line 6 chickens have a significantly lower level of infected lymphocytes than susceptible line 7 chickens. Interestingly, line 6 has more B cells than line 7; thus, the difference is not caused by a lack of target cells in line 6 (36). In spleens of line 7 birds, dramatic changes occur with irregular patches of $pp38^+$ B cells becoming surrounded by $TCR\alpha\beta1^+$ $CD4^+$ and $CD8^+$ cells, thus providing optimal conditions for virus transfer from B to T cells. These data suggest that MDV may replicate and spread more efficiently in line 7 than line 6 chickens (36). Interestingly, Calnek et al. (120) reported that B cells from line 7 are more susceptible to *in vitro* infection than B cells from line 6.

Recently several studies have been conducted to analyze the changes in transcriptome and proteome in various tissues after MDV infection (reviewed in 238). Changes have been found for many genes and pathways, but additional studies will be needed before general conclusions can be drawn for the understanding of the pathogenesis and immune responses.

Changes in proinflammatory cytokine expression occur in splenocytes and elsewhere during the cytolytic phase. The initial changes are the consequence of activation of Toll-like receptors (TLRs) by pathogen-associated molecular patterns (PAMP). Thus far, upregulation of TLR3 and TLR7 in lungs of infected chickens (1) and TLR15 and TLR1B in cultured brain microglia cells (694) has been associated with MDV infection. The level of upregulation of cytokines may depend on interactions between the pathotype of the virus and the genotype of the host (286, 298). Several groups reported the upregulation of IFN-γ mRNA as early as 3 to 4 days PI in the spleen (e.g., 183, 292, 298, 688), cloacal bursa (2), brain (286), and feather pulp (8). Several other cytokines are also upregulated. Increased transcription of IL-1β, IL-6, IL-8, and IL-18 has been reported in spleen, bursa, lung, brain, and feather pulp (1, 2, 8, 286, 298). The degree of increased transcription depended on the combination of viral strain and genotype of the host and the results by the different authors were not always in agreement. The increased expression of some cytokines was attributed to specific subsets of T cells (448). In addition to the cytokines, inducible NO synthase (iNOS, officially named NOSII) is also upregulated during the cytolytic infection (688) (see Immunity).

Conflicting data have been reported on the upregulation of MHC-II antigens. As mentioned before, only activated T cells, which express MHC-II, are susceptible to infection. It is possible that IFN-γ upregulates MHC-II on T cells, although Niikura et al. (416) suggested that MDV-induced upregulation *in vitro* and *in vivo* was caused by replicating virus, probably by IE or early proteins. However, others reported the downregulation of MHC-II transcripts at 4 and 7 days PI (362, 614).

The early activation of IFN-γ also may be important for the upregulation of the IL-8 receptor on activated T cells, so that vIL-8 can attract activated T cells to lytically infected B cells and facilitate the transfer of virus to T cells (444, 544). Infection with vIL-8 deletion mutants resulted in a significant reduction in virus replication during the early lytic infection and a subsequent decrease in tumor incidence (154, 161, 290, 444). In addition to vIL-8, pp38 is also essential for the early cytolytic infection (224). The exact role of p38 has not been established, although the full length transcript alters the oxidative phosphorylation pathway resulting in decreased ATP production by mitochondria (470). Deletion of meq, RLORF4, RLORF5a, vLIP (LORF2), or viral telomerase (vTR) did not significantly impact phase 1, but does reduce tumor formation (133, 289, 302, 372).

Several factors can modify the early pathogenesis events. Prior vaccination or the presence of maternal antibodies reduce the cytolytic infection (102). The reduction in cytolytic infection also reduces the number of latently infected cells and reduces or delays tumor development. Exposure at 1 day of age prolongs the cytolytic infection compared to exposure at 2 or 7 weeks of age (92). Likewise, the pathogenicity of the virus strain may affect the severity of early infection. The vv and vv+strains can cause more severe lymphoid organ atrophy than the less oncogenic strains, resulting in an early mortality syndrome (110, 675).

The apoptosis of lymphocytes during the early cytolytic phase (398) may cause transient or permanent immunosuppression, depending on the virulence of the challenge strain. In addition, a transient suppression of mitogen stimulation has been reported, but this may actually represent a protective response (539, 544). The importance of these observations is discussed in the Immunosuppression section.

Latent Infection (Phase 2)

At about 6–7 days, the infection becomes latent when cytolytic infection can no longer be demonstrated, and tumors are not yet detectable. The development of latency coincides with the development of immune responses. The interactions between virus and cells during the induction of latency are incompletely understood. Impairment of cell-mediated immunity (CMI) (92) or infection with the more virulent pathotypes delays the onset of latency (701). Several soluble factors have been implicated in the induction of latency including IFN-α, IFN-γ, latency maintaining factor, and NO (91, 633, 689). Based on infection of CEF with RB-1B in the presence of IFN-containing supernatants, Levy et al. (353) suggested that IFN may block virus replication before translation of late genes. In one study IL-10 expression leading to a Th2 response was the only cytokine upregulated in splenocytes during latent infection (245), but this could not be confirmed in another study (447).

Most latently infected cells are activated $CD4^+$ T cells, although $CD8^+$ T cells and B cells can also be involved (121, 346, 568). Infection in genetically resistant birds often remains latent and can last for the lifetime of the bird aside from a persistent low-grade productive infection in the FFE (102). Apoptosis of T cells during latent infection has been described (397, 399), although it cannot be excluded that MDV was reactivated in these cells. Susceptible birds or resistant birds infected with vv or vv+strains may develop a second wave of

cytolytic infections after the second or third week, coincident with permanent immunosuppression.

The extent to which nonlymphoid cells are latently infected is not known, although apparent latent infection has been observed in Schwann cells and satellite cells in spinal ganglia (466).

Second Phase of Cytolytic Infection (Phase 3)

The second cytolytic infection phase has not been studied in great detail and does not always occur, depending on genetic resistance of the host and the virulence of MDV. If present, localized foci can be found in the lymphoid organs and in tissues of epithelial origin in various visceral organs (e.g., kidney, pancreas, adrenal gland, proventriculus, etc.). Focal cell death and inflammatory reactions develop around affected areas (14, 102). If the second cytolytic infection occurs, many of the cytokines upregulated during the first cytolytic phase are again upregulated (447).

Cytolytic Infection in FFE

Starting around 14 days PI, cytolytic infection occurs in the FFE (111), which is the only known site of complete virus replication. The replication occurs in genetically resistant as well as susceptible birds independently of the virulence of the MDV strain. MDV most likely is transferred to the FFE by infected lymphocytes. Viral DNA of all 3 serotypes can be detected in feather tips as early as 5–7 days PI by qPCR (see Transmission, Carriers, Vectors). It is not known if this really represents infectious cell-free virus or viral DNA inside feather tips, because MDV-positive peripheral blood lymphocytes (PBL) can be found in feather pulp as early as 4 days PI concomitant with increased IFN-γ transcription (5).

Lymphocyte aggregates consisting of small lymphocytes with nuclear inclusions can be detected in the perifollicular dermis as early as 7 days PI (141). The lymphoid aggregates can develop into either necrotic areas consisting of FFE cells and degenerating lymphocytes or into cutaneous tumors. The former is associated with strong expression of pp38, which is the first viral protein expressed in the FFE after reactivation followed by gB and gD (418). In contrast, the cutaneous tumors have only a few $pp38^+$ cells. It is likely that virus is reactivated from latency in the FFE, because mutant strains lacking vIL-8 (161) or pp38 (224) are able to produce virus in the FFE. Jarosinski et al. (288) found that U_L44 (gC) and the invariant lysine essential for U_L13 kinase activity are essential for the production of infectious cell-free virus. They speculated that the U_L13 product is important for cell entry and that gC may be needed to bind to glycosaminoglycans as previously suggested by Lee et al. (347).

Development of Lymphomas (Phase 4)

Lymphoproliferative changes, constituting the ultimate response in the disease, may progress to tumor development. Death from lymphomas may occur at any time from about 3 weeks onward. Regression of lesions has been reported after infection with vMDV strains and depends on the genetic resistance of the bird and the age at infection (83, 331, 566). However, it is not clear how important tumor regression is in commercial poultry.

The transformed T cells are mostly $CD4^+$ cells expressing TCRαβ1 or TCRαβ2 and MHC-II (536) with limited clonality (406). Other subsets (e.g., $CD8^+CD4^-$, $CD3^-CD4^-CD8^-$, and $CD3^+CD4^-CD8^-$) can be transformed under special conditions (114, 426, 536). Burgess and Davison (84) further characterized tumor cells using *ex vivo* lymphoma cells and tumor cell lines as MHC-I^{hi}, MHC-II^{hi}, $CD4^+$, TCRαβ1^+ or TCRαβ2^+, $CD25^+$, $CD28^-$, $CD30^{hi}$. This profile is compatible with Treg cells (446, 553). The expression of $CD30^{hi}$ suggests that MD could be a natural model for Hodgkin's disease (86). MD tumor cells also may express poorly characterized MATSA (684) and fetal antigens (474). In addition to tumor cells $CD8^+$ T cells are present and consist of oligoclonal expansions with public and private CDR3 sequences (406).

The infection in transformed cells is nonproductive *in vivo* and *in vitro*. $CD4^+$ and $CD30^{hi}$ express Meq and SAR (see Viral Proteins), but are negative for pp38 and gB (84, 514). Meq is the key protein involved in the transformation of lymphocytes, probably in conjunction with viral telomerase (see Genes Unique for MDV) (407, 625). Additional genes, for example RLORF4 (287) and RLORF5a (424), also may be expressed in tumor cells, but their functions remain unknown. Low numbers of tumor cells may express pp38, which probably represent cells in which a productive-restrictive infection has been initiated. Based on *in vitro* studies it is suggested that the expression of pp38 and late genes in tumor cells may be under control of IFN (353, 634).

The possibility that MD tumors are of clonal origin has been proposed based on observations of random MDV DNA integration into the genomes of lymphoma cells (178). Analyzing the TCRβ repertoire of tumors, Mwangi et al. (406) concluded that most of the tumors are clonal in origin, but that birds could have tumors originating from different clones. In addition, PBL can be positive for these clonal tumor cells a few weeks before the birds succomb. Earlier studies by Schat et al. (536) showed that different lymphomas in the same bird could yield cell lines representing different T cell phenotypes.

Studies of graft-versus-host reactions in different genetic strains led to the suggestion that low alloimmune competence and resistance to MD are very closely related through genetic linkage or functional dependence (370). This prompted speculation by Schat et al. (537) and Calnek (101) that activation of T cells in response to the lytic infection of B cells constitutes a significant event in the pathogenesis of MD by providing an abundant supply of cells that are the usual target cells for transformation. This hypothesis has been borne out by studies by Calnek et al. (144) showing that tumor induction at the site of inoculation with MDV is enhanced by provoking a CMI reaction against allogeneic cells at the site.

It is plausible that transformation requires (1) susceptibility to infection; (2) intrinsic or extrinsic control of virus replication (latency); (3) cell division to integrate virus genome; and (4) expression of viral oncogenes, activation of cellular oncogenes,

or repression of the induction of apoptosis. Activated T cells infected at the time that cytokines and/or CMI responses cause a switch to latency could fit this model. Interestingly, cells present as early as 4 days after inoculation of MDV-infected allogeneic CKC can be grown *in vitro* as MD cell lines (114). Thus, transformed cells, or at least transformation target cells, may be present during the early cytolytic phase. Subsequently, Burgess and Davison (84) supported this hypothesis by showing the presence $CD30^{hi}$ T cells during the early lytic infection.

One of the major problems in understanding the molecular basis for transformation is the lack of a reliable method for *in vitro* transformation of T cells. Calnek and Schat (116) used different approaches, but with very limited success. In a few instances "cell lines" were maintained until 100 to 140 days in culture, when the cells deteriorated.

Factors Influencing Pathogenesis

The pathogenesis of infection with oncogenic MDV, which has become attenuated by passage *in vitro*, has been studied by Bradley et al. (quoted in 454) and Schat et al. (535). Attenuated viruses failed to cause cytolytic infection and cell-associated viremia levels were low. Moreover, attenuated virus was not infectious for lymphocytes *in vitro*, perhaps explaining the *in vivo* observations.

The actual mechanism(s) by which pathogenesis is altered in the case of host resistance is not clear. Transcriptome and proteome studies have indicated many proteins that may interact with specific virus proteins. At least 1 gene linked to genetic resistance (IRG1) has 1 single-nucleotide polymorphism (SNP) difference between a resistant and susceptible line (581). CMI probably is also involved (see Immunity). Both age and genetic resistance depend on immunologic competence (100, 567). If the hypothesis is correct that tumor development is enhanced by a strong T cell response against the early cytolytic infection of B cells, then factors that limit that response should reduce tumor incidence. Vaccinal immunity, EBx, and splenectomy suppress the active viral infection (117, 526, 532, 533), thereby obviating an inflammatory response and reducing the incidence of tumors. Interestingly, some genetic strains with unusually strong CMI responses are especially susceptible to MD (citations in 99), although this is not true in all cases (105).

Virus strains differ in oncogenicity, but the molecular basis for differences in pathogenesis is not well defined. All cause similar early cytolytic infections, although the vv+ strains may cause a prolonged and more severe cytolytic infection (701). Some of the new strains are capable of infecting macrophages leading to increased death of macrophages (45). Murata et al. (405) suggested that point mutations in meq resulting in amino acid substitutions in the protein could change transactivation and hence change the pathogenicity.

The immune response itself may be responsible for some lesions characteristic of MD. Nerve lesions have some characteristics suggestive of an autoimmune disease (485, 546), although the presence of MDV was not positively shown. Additional evidence supporting an autoimmune component for MD comes from studies showing immune complexes in the kidneys of MDV-infected chickens and quail (312, 478).

The primary cytolytic infection is not an absolute prerequisite for tumor development. Schat et al. (533) found that MDV infection in EBx chickens resulted in the development of tumors in the absence of the primary cytolytic infection. These results are similar to the development of tumors in the absence of cytolytic infection during phase 1 of the pathogenesis after infection using vIL-8 and pp38 deletion mutants (123, 224, 291, 444). Apparently, enough activated T cells are available at the time of challenge to become infected. Thus, cytolytic infections are not absolutely essential for tumor development, which also may be the case in vaccinated, commercial chickens. However, stress and immunosuppressive infections may induce secondary cytolytic infections, reducing the benefits provided by vaccination.

Pathogenesis of in ovo *Infection*

An understanding of the pathogenesis of infection after *in ovo* injection of the 3 serotypes has become important in view of the widespread use of *in ovo* vaccination. HVT could be isolated from embryonal lung tissues at 1 day PI in the amniotic fluid at ED 17, whereas chorioallantoic membranes, embryonal spleen, and proventriculus remained negative. However, spleens were virus positive at 4 days post hatch (564). Studies using *in situ* hybridization confirmed these findings (596). The target cells for HVT in the lung are adherent fibroblastoid or epitheloid cells, but this did not result in a lytic infection (557, 595). It is possible that HVT did not replicate, and that rapid cell division of infected cells during embryonal development resulted in high titers and are the consequence of rapid cell division of infected cells during embryonal development. It is also possible that expression of the anti-apoptotic ORF in HVT (323) and/or the induction of high levels of IFN (558) are responsible for the lack of apoptosis and virus replication.

Low levels of SB-1, attenuated serotype 1 strain Md11/75C, and CVI988 could be recovered from embryonal lungs between 4 and 7 days after inoculation at ED 16-18 (556, 707). Intravenous inoculation of RB-1B, a vvMDV strain, at ED 16 resulted in active virus replication in the cloacal bursa at ED 21, while intra-amniotic inoculation resulted in the presence of viral DNA in lung and thymus tissue (556, 595, 596).

Pathogenesis of Non-Tumor Diseases

MDV infection can cause several non-neoplastic disease syndromes (Table 15.3B). The pathogenesis of MDV-induced atherosclerosis has not been elucidated. Microscopic lesions consisting of fatty proliferative lesions with alterations in lipid metabolism in arterial smooth muscle cells could be detected as early as 1 month after infection (201, 232). $CD4^+$ and $CD8^+$ T lymphocytes infiltrated into the intima as early as 2 weeks PI. In addition, endothelial cells expressed MHC-II antigen in infected chickens but not in normal chickens (420). These cells may have been responsible for the introduction of virus into the smooth muscle cells leading to occasional viral antigen expression and alterations in the lipid metabolism. In contrast to the

original work by Fabricant et al. (202–203), Njenga and Dangler (421) were unable to demonstrate arterial lipid accumulation without cholesterol supplementation. Cellular infiltrates were detected in the intima and serum cholesterol was increased significantly compared to non-infected control chickens.

The pathogenesis of the neurological lesion complex consisting of classical transient paralysis (TP), acute TP, persistent neurological syndrome (PND), and late paralysis (LP) (226) is not fully understood. The difference between classical and acute TP is somewhat arbitrary (667) and the early pathogenesis is probably similar. The development of both types of TP is influenced by the MHC and the virulence of the MDV strain with the more virulent strains causing acute rather than classical TP (545, 667). B cells are required for the induction of transient TP (445), probably because these cells are essential for the early cytolytic infection. The brain lesions start with vasculitis at 6–8 days followed by leakage of albumin from blood vessels into vacuoles (605). This vasogenic edema is transient and correlates with classical TP symptoms (604). Jarosinski et al. (286) noted that the development of neurological symptoms induced by the vv+RK-1 strain correlated with increased levels of iNOS mRNA in the cerebellum and NO in blood serum (see Nitric Oxide). NO can cause vasodilation and could be the cause of the edema. Chickens inoculated with the vMDV JM-16 strain did not show neurological signs or iNOS mRNA in the cerebellum.

The degree of virus replication in the brain may be related to the severity of the disease. The absence or low levels of virus replication correlated with the absence of neurological symptoms (4, 225), while high levels of replication in MHC-resistant and -susceptible chickens resulted in neural lesions (286). Attenuation of the vv+648A strain resulted in reduced induction of TP coordinately with a reduction in viral replication in lymphoid organs and FFE (225).

Endothelial cells expressed no viral antigens but became hyperplastic and hypertrophic soon after the virus reached the brain and showed upregulation of MHC-II as early as 6 days PI and downregulation of MHC-I at 10 days PI (223). Infection with RK-1 or RB-1B also caused upregulation of proinflammatory cytokine transcription in the cerebellum including IFN-γ, IL-1β, IL-6, IL-8, IL-12, and IL-18 (4, 286). The increased expression of IFN-γ, IL-6, and IL-18 was significantly higher in birds with RB-1B-induced classical TP than in asymptomatic MDV-infected chickens (4).

The clinical signs of PND are associated with a strong infiltration of lymphoblasts in the neuropil, many of which express meq protein. The later occurrence of PND after 3 weeks PI suggests that its pathogenesis may parallel that of lymphoma induction in other tissues. Moreover, PND was shown to be closely related with the onset of lymphoproliferative lesions in peripheral nerves and visceral organs (225).

Immunity

Infection with pathogenic MDV or vaccine strains not only results in the activation of innate or non-specific and acquired or specific immune responses but also may cause immunosuppressive effects, especially after infection with pathogenic serotype 1 strains. The importance of the interactions between immune responses and immunosuppression for the pathogenesis of MD cannot be overemphasized. A distortion in the balance toward immunosuppression will lead to disease. Immune responses and immunosuppressive features of MD have been extensively reviewed (173, 539, 544).

Immune Responses

The immune responses developing during the early cytolytic phase of infection are crucial for the outcome of infection. Impairment of immune responses during this phase delays establishment of latency, resulting in prolonging the lytic infection and the subsequent continued destruction of immune cells by virus-induced apoptosis. Impairments include infection at 1 day of age when the immune responses are not yet fully developed or treatment with cyclosporin or neonatal thymectomy combined with cyclophosphamide treatment (92). The importance of immune responses during latency is relevant for protection against the second cytolytic phase and depends on cell-mediated immunity. It has often been suggested that vaccine-induced immunity is an anti-tumor immune response because vaccination does not prevent superinfection with wild-type virus but does prevent tumor development. However, vaccination clearly reduces the early cytolytic infection (117, 532), thus preventing extensive damage to the immune system and reducing the number of latently infected T cells. Lesion regression, however, has been described (83, 566), suggesting that immune responses against tumor cells may occur. Burgess et al. (86) detected specific antibodies against CD30 in resistant line 6 but not in susceptible line 7 chickens after infection with the vMDV HPRS-16 strain. This important finding needs further study because there is no evidence that HPRS-16 induced $CD30^{hi}$ cells in line 6 birds (86).

Initiation of Immune Responses. Professional antigen-processing cells (APC), such as dendritic cells, encountering pathogens are activated by interactions between the PAMP and the pattern recognition receptors (PRR), e.g., TLR, on the APC. These interactions result in the activation of cytokines which direct both the innate and acquired immune responses. There is currently no information on PAMPs associated with any of the 3 MDV serotypes.

Although the distinction between innate and acquired immune responses has become less defined over the last few years, the innate and acquired responses will be discussed in separate sections.

Innate Immune Responses. Innate immune responses include changes in cytokine expression, natural killer (NK) cells, and macrophages.

Cytokine Responses. Infection with MDV results in the upregulation of a number of proinflammatory cytokines (See Early Productive-restrictive Infection) driving a Th1 immune response. It is interesting to note that a vv+strain caused

strong proinflammatory cytokine responses in spleen and cerebellum of MHC-susceptible and -resistant strains of chickens with significantly higher levels of IFN-γ, IL-1β, and IL-8 in the resistant line between 4 and 10 days PI without beneficial effects for the host (286). The authors speculated that a strong genetic-based response was actually detrimental for the host by inducing high levels of NO production.

IFN-γ is an important pleiotropic cytokine with many functions in antiviral immune responses, but few studies have been performed on the roles of IFN-γ in protective immunity to MD. *In vitro* studies indicate that IFN-γ is able to inhibit virus replication directly or indirectly through the induction of NO production and reactive oxygen intermediates (182, 689).

The importance of IFN-α for MD immunity has not been analyzed in detail. Xing and Schat (688) failed to show induction of INF-α mRNA in spleens of control and infected resistant chickens. Quéré et al. (495) found a decrease of INF-α mRNA in blood cells at 1 day PI in a resistant line of birds but not in a susceptible line. Stimulation of IFN-α mRNA by inoculation of infected chickens with NDV showed that MDV was able to block transcription at 1 day PI in susceptible birds but not in resistant birds. It will be interesting to determine if this result can be repeated in additional lines. Mixtures of IFNs containing IFN-α and –γ produced by stimulation of CEF with NDV were able to upregulate MHC-I expression in CEF and to counteract the decreased MHC-I expression induced by RB-1B (354).

Nitric Oxide. NO is synthesized by 3 isoforms of nitric oxide synthase (NOS) with iNOS (NOS II) being inducible in macrophages, glial cells, astrocytes, and perhaps other cells as well. The induction of iNOS occurs as part of the nonspecific inflammatory immune response to microorganisms. NO and other reactive nitrogen species are very versatile molecules with many functions. NO has been linked to beneficial effects by killing pathogens but also to neurodegenerative processes in humans (71, 187).

NO can inhibit MDV replication *in vitro* (182, 689). Increased transcription of iNOS has been reported between 6 and 12 days PI with MDV (688), resulting in increased levels of NO in the plasma of genetically resistant chickens but not in genetically susceptible chickens (183, 292). NO may be beneficial, because it can inhibit MDV replication *in vivo* when genetically resistant chickens were challenged with vMDV (689). However, pathology may be associated with very high levels of NO production, especially in genetically resistant birds challenged with vv+MDV (286).

NK Cells. NK cells are the first line of defense because these cells can lyse virus-infected and tumor cells without prior exposure to the pathogen. NK cells are also potent inducers of IFN-γ. In order to lyse target cells, NK cells must recognize the target cells as foreign (e.g., the MHC-I has been altered or downregulated). Thus, the downregulation of MHC-I during the lytic infection (262) supports a potential role for NK cells. Thus far functional NK cell assays have used total spleen cell populations and LSCC-RP9 as target cells in chromium release assays (CRA). The recent development of NK cell-specific MAb (282) will facilitate further examination of the importance of NK cells in MD immunity. Conflicting data have been published on the susceptibility of MD tumor cells to NK cell lysis. MSB1 cells are susceptible (563), but Heller and Schat (247) found that most MDCC lines are resistant to NK cell lysis. The resistance could be caused by fetal antigens interfering with NK cell lysis (422). This is compatible with the observation that tumor-bearing, genetically susceptible chickens had decreased NK cell activity in contrast to enhanced NK cell levels in tumor-free, genetically resistant, or vaccinated chickens (561). NK-like activity was demonstrated in genetically resistant N2a chickens for at least 14 days PI with RB-1B, but only for 8 days in susceptible P2a chickens (213).

Macrophages. Activated macrophages can restrict MDV replication and perhaps as a consequence reduce tumor incidence. These effects are probably the result of NO production (reviewed in 539, 544) or by reactive oxygen intermediates (182). Increased numbers of macrophages have been noted shortly after infection in the lung in conjunction with increased transcription of iNOS. Macrophages harvested shortly after MDV infection can inhibit proliferation of MD cell lines *in vitro*, which was considered to be a transient immunosuppressive effect (343, 559). This inhibition may actually be a protective response, because it may limit the number of activated T cells during the critical switch of MDV from B to T cells (539, 544).

Acquired Immunity

Humoral Immunity. Chickens infected with MDV develop precipitating and VN antibodies within 1–2 weeks; a transient IgM response is replaced by IgY (249). Due to the cell-associated nature of MDV, antibodies are of limited importance in MD immunity. VN antibodies are important only when cell-free virus infects chickens or when MDV proteins are expressed on the surface of cells. In the latter case, antibodies plus complement or antibody-dependent, cell-mediated cytotoxicity (ADCC) can lyse infected cells (326, 510). However, the target antigens and the effector cells involved in ADCC were not identified. *In vivo* VN has indeed been demonstrated using cell-free and cell-associated virus (87). Maternal antibodies reduce the cytolytic infection (98) and can reduce the efficacy of cell-associated vaccines with low titers or if cell-free HVT is used (e.g., 127, 322).

Few specific antigens involved in humoral immunity have been identified. Antibodies to gB neutralize cell-free MDV (269) and protect against MDV challenge (281, 431). Antibodies against other glycoproteins, such as gC, gE, and gI, are detected after infection. Inoculation with baculovirus-produced gC did not protect (281). Nazerian et al. (414) vaccinated chickens with rFPV expressing gB (rFPV-gB) or gC. The former produced VN antibodies and protected, while the latter did not protect against challenge. However, Omar et al.

(430) found also gB-specific cytotoxic T cells (CTL) after vaccination with rFPV-gB, raising questions about the mechanism of protection.

The possibility that surface antigens found on MDV-transformed cells could be involved in immunity was suggested by protection against challenge after immunization with anti-idiotype antibodies against MATSA (166). Similarly, antibodies against CD30 may provide protection against tumor cells (86).

Cell-Mediated Immunity. CTL recognize small peptide fragments of 8–12 amino acids presented in the context of MHC-I. These peptides are generated from *de novo* synthesized proteins through a complex process involving the proteasome and transporters associated with antigen-processing (TAP) 1 and 2. *In vitro* demonstration of antigen-specific CTL requires effector and target cells expressing the same MHC-I antigens (555).

Recently, Mwangi et al. (406) found a limited number of CD8+ clonal cell populations, which were generated shortly after infection suggesting that MDV infection results in a limited number of antigen-specific clones. Earlier, Pratt et al. (483) stably transfected and expressed MDV genes in REV-transformed cell lines with known MHC antigens. These cell lines were used to show that CTL from infected or vaccinated chickens recognize peptides derived from pp38, meq, ICP4, ICP27, gB, gC, gH, gI, and gE (381, 429, 544). The effector cells developed around 7 days PI and were characterized as typical CTL expressing CD3, CD8, and TCR$\alpha\beta$1 but not CD4 (428). Important differences were noted in the recognition of proteins by CTL from resistant and susceptible chicken lines. CTL from resistant N2a (MHC: $B^{21}B^{21}$) but not from susceptible P2a (MHC: $B^{19}B^{19}$) chickens recognized ICP4 (429). Effective killing of infected cells as soon as ICP4 is expressed, e.g., when latently infected cells are reactivated and before virus replication is completed, could be one of the contributing factors to MHC-based genetic resistance. Two glycoproteins, gB and gI, were recognized by CTL from both lines. N2a-derived CTL also lysed cells expressing gC and gK and to a lesser degree gH, gL, and gM. CTL from P2a chickens recognized cells expressing gE. Vaccination with rFPV-gI and rFPV-gB, but not rFPV-gE or rFPV-gH, conferred protection to MDV challenge (336, 414). It is likely that gB- and gI-specific CTL contributed to the protective immunity induced by rFPV-gI and rFPV-gB. CTL against pp38 are likely to be important for immunity based on the observation that vaccination with rFPV-pp38 transiently reduced viremia levels in the absence of VN antibodies (414).

CTL and NK cells can lyse target cells through the perforin/granzyme pathway. Increased transcription rates of Granzyme A have been reported between 4 and 15 days PI (244, 519, 520).

Vaccinal Immunity. HVT, attenuated MDV, and serotype 2 MDV protect against early replication of virulent viruses in the lymphoid organs of challenged birds and reduce the level of latent infection, but do not prevent superinfection (reviewed in 219, 539, 658). Based on current knowledge, the following sequence of events is proposed to explain vaccine-induced immunity with challenge occurring within 3 days after hatch, as is typical in the field. INF-γ is most likely a key cytokine for the initiation of vaccine-induced protection (304). Vaccination with CVI988 results in upregulation of IFN-γ, IL-8, IL-18, and iNOS in lung and spleen as early as 3 days PI (220), which is probably also the case after vaccination with HVT and SB-1. IFN-γ can reduce virus replication and stimulate macrophages to initiate the transcription of iNOS, producing NO between 3 and 7 days post vaccination, thus limiting the replication of challenge virus. Shortly afterward NK cells are activated (246, 561), probably producing more IFN-γ and killing virus-infected B cells. Antigen-specific CTL develop starting at 7 days post vaccination and may eliminate additional cells infected with challenge virus, perhaps in combination with ADCC and NK cells. The combination of these effector mechanisms will push the challenge virus into latency. Memory CTL will be able to quickly eliminate reactivated virus-infected cells. Kano et al. (305) reported that TCR$\gamma\delta$ as well as TCR$\alpha\beta$ T cells increased after vaccination with CVI988. The latter support the work by Omar and Schat (428) showing that vaccination with SB-1-induced antigen-specific CTL. The importance of the increase of TCR$\gamma\delta$ T cells is currently unknown.

Feather pulp can be used to examine temporal changes in immune responses in individual, vaccinated chickens. This will facilitate monitoring cytokine responses induced by different vaccines (6, 240). Vaccination with CVI988 showed a down regulation of RB-1B in the feather pulp (240). Challenge did not increase replication of CVI988 (40, 240), in contrast to the observation that HVT and SB-1 shedding increased after challenge with MDV (278).

Many factors can interfere with vaccine-induced immunity such as MDV-caused immunoevasion (see Immunoevasion). Differences between vaccines from different manufacturers have been noted, which probably relates to passage levels (339). Concurrent infections with immunosuppressive viruses, e.g., CIAV (382) or stress may interfere with vaccine-induced CMI responses. Deletion of humoral immunity by bursectomy and X-irradiation does not seem to have a major effect on protection conferred by attenuated MDV (197), although a similar treatment partially impairs vaccinal immunity from HVT (504).

Immunoevasion

Many viruses, including MDV (524), have developed strategies of immunoevasion interfering with the development of immune response. Schat and Skinner (542) defined immunoevasion as "Pathogen-initiated responses counteracting the immune responses to the specific pathogen". *In vitro* infection with MDV causes downregulation of MHC-I (262, 316, 354), probably through retention of the class I molecule in the endoplasmic reticulum (262). Gimeno et al. (223) reported that MHC-I also was downregulated in brain tissue, especially after infection with vv+MDV. Jarosinski et al. (285) suggested that the UL49.5 gene product was responsible for

the downregulation but Verweij et al. (630) were unable to confirm this result. Transcripts for CD8α and β chains are downregulated during the cytolytic infection and at later stages, resulting in a decreased expression of CD8 on CTL (397, 398) and perhaps NK cells. The downregulation of CD28 on MD tumor cells (84) may interfere with anti-tumor responses. Other antigens, such as chicken fetal antigens, may interfere with NK cell activity (422).

Immunosuppression

Suppression of the immune response by MDV infection is a critical feature of the disease, contributing to the virulence of MDV isolates and altering susceptibility of the host to other pathogens (reviewed in 524). Initial impairment of the immune response is the result of the lytic infection of lymphocytes during the first cytolytic infection (see Pathogenesis) (citations in 524). Permanent immunosuppression coincides with the second phase of cytolytic infection and tends to correlate with eventual tumor development (541, 615). It is difficult to distinguish between cause and effect because tumor cells might have suppressor activity (77, 494). Because immunocompetence is required for the maintenance of latency (92) it might be that immunosuppression associated with the appearance of transformed lymphoblasts results in additional reactivation of the lytic infection. This, in turn, will cause the loss of additional B and T cells, thus compounding the situation and resulting in the bursal and thymic atrophy seen in birds destined to succumb to MD. A possible association between immunosuppression, reactivation of cytolytic infection, and MD breaks during the laying cycle should be considered. However, immunosuppression may not be a prerequisite for the development of tumors. Witter et al. (671) found that the RM1 clone, containing a retroviral LTR, was no longer oncogenic, but caused a severe early cytolytic infection. It will be important to further analyze the relationship between virus-induced immunosuppression and oncogenicity. Although the two properties are not invariably linked, they are often expressed concurrently and, in such cases, immunosuppression may serve to augment oncogenic potential.

Humoral and cell-mediated immunity can be suppressed by MDV infection leading to reduced antibody responses to a variety of antigens and alterations in T cell functions, such as skin graft rejection, mitogen stimulation of lymphocytes, delayed hypersensitivity, reduced NK cell activity, primary and secondary infections with coccidia, and impaired Rous sarcoma regression (citations in 454).

Diagnosis

Techniques for diagnosis of infection with MDV are different from those needed for differential diagnosis of the disease. The infection is ubiquitous, but the disease is not. The principal methods to identify the presence of infection are isolation of the virus, demonstration of viral DNA or antigens in tissues, and detection of antibody. The applications of different diagnostic procedures have been recently reviewed (425, 704).

Virus Isolation

Virus isolation is performed to confirm its presence for diagnostic purposes and to secure the infectious virus for further study. Techniques for isolation of all serotypes have been reviewed (523, 560).

Source of Virus

MDV can be isolated as early as 1 or 2 days PI (469) or 5 days after contact exposure (14) and throughout the life of the chicken. Intact viable cells are the preferred inoculum because in most cases, infectivity is avidly cell-associated, although cell-free preparations from skin, dander, or feather tips of infected chickens may contain the virus (107). Inocula may consist of blood lymphocytes, heparinized whole blood, splenocytes, or tumor cells. MDV can often be recovered from infected cell suspensions following storage for 24 hours at 4°C, thus facilitating transport of samples (669).

Cell Culture Techniques

Probably the most widely used method for primary isolation of MDV is inoculation of susceptible cell cultures with blood lymphocytes or single-cell suspensions from lymphoid tissues of infected chickens. CKC and DEF cultures are preferred substrates for primary isolation of serotype 1 MDV; whereas CEF normally are used for isolation of viruses of serotypes 2 and 3 as well as for attenuated serotype 1 vaccine strains. Although CEF are less permissive for growth of low passage serotype 1 virus (reviewed in 523), some contemporary isolates may grow well in CEF, even on primary isolation. Cultures are inoculated with $1–2\times10^6$ cells, although some inhibition of viral plaque formation may be encountered with doses greater than 8×10^6 cells for some viruses (125).

Development of typical plaques (Figure 15.2) in inoculated cultures within 3–12 days and the absence of such changes in comparable uninoculated (or sham inoculated) control cultures are evidence for isolation of MDV. The plaques induced by serotype 1, 2, and 3 viruses can be distinguished, with practice, by morphologic criteria (521, 650), but immunofluorescent staining with serotype-specific monoclonal antibodies provides a more accurate differentiation. Optimal time for observation of plaques varies with the cell substrate and serotype of the virus. MDV also has been isolated by direct culture of kidney cells from infected chickens or by inoculation of normal kidney cultures with trypsinized kidney cells from infected chickens (681).

Isolate Identification

MDV serotype 1 isolates should be free of contaminating MD vaccine strains. It normally is useful for the isolate to be plaque purified or cloned at the earliest possible passage. Serotype identity and purity can be confirmed using staining techniques with serotype-specific monoclonal antibodies (340). Freedom from extraneous viruses is critical, because contamination with passenger viruses may alter the apparent pathogenicity of the isolate (293, 436). Propagation of MDV isolates for up to 6 passages in CEFs or CKC cultures appears

to exclude contaminants such as CIAV (700) and permits preparation of seed and working stocks, which can be more easily standardized and titrated. To preserve virulence, some workers have preferred to propagate serotype 1 viruses *in vivo*, preparing stocks of cryopreserved spleen or buffy coat cells from infected chickens. Pathotyping of serotype 1 MDVs, although not routine, may be accomplished by comparison of pathogenicity with that of prototype strains by inoculation of non-vaccinated chickens as well as chickens vaccinated with HVT or bivalent vaccines (664).

Virus Assay and Titration

Viruses of serotypes 1, 2, and 3 can be assayed by *in vitro* techniques similar to those described for virus isolation. Methods differ for different serotypes, but most rely on plaque induction in susceptible cell cultures. Enumeration should be done as soon as plaques become mature (time varies with isolate), because secondary plaques may occur when cultures are maintained with liquid medium. Procedures for titration of vaccine viruses have been reviewed (617) and are not fundamentally different from those for pathogenic isolates.

Viral Markers in Tissues

It is often desirable to detect the presence of viral infection in chickens without isolating the virus in culture. Such infection markers also have value for the identification of putative MDV isolates in cell cultures.

Viral Antigen Detection

MAb prepared against type-common and type-specific epitopes of all 3 MDV serotypes (340) are now used in preference to polyclonal antibodies for the detection of antigens in tissues. Viral antigens can be detected in feather tips and FFE, cytolytically infected lymphoid tissues, brain, or infected cell cultures with appropriate antibodies by fluorescent antibody tests (592), immunohistochemistry (129) and agar gel precipitin (AGP) tests (231, 351), and immunoassay (547). In MD lymphomas, pp38-positive cells occasionally are observed (224) and MD tumor cells are positive for Meq (514).

Polymerase Chain Reaction (PCR) Assays

The availability of the nucleotide sequences of different genes from a large number of viruses including the complete genome sequence of the 3 serotypes of MDV allows the use of PCR-based methods of specific detection of MDV. Primers designed to amplify 132-bp sequences specific to MDVs of serotype 1 have been described (49, 572, 712). However, PCR may not always be sensitive enough to detect latent infection due to the lower frequency of positive cells and the lower number of viral genomes/cell. qPCR assays using various primer sequences have been used to assay viral load in tissues from infected chickens (37, 80, 85, 277, 500) and are essential tools for diagnosis and epidemiological studies of MD. For example, qPCR assays have been adapted for the detection of related MD vaccine strains and PCR assays have been used to differentially detect MDV and HVT in both blood lymphocytes and feather tips of field chickens (237). More recently, qPCR assays were carried out to study different aspects of MD biology including replication kinetics of MDV in blood, feathers, and lymphoid tissues (40, 153, 276). qPCR tests for the absolute quantitation of serotype 2 and serotype 3 MDV also have been developed (276, 505). Furthermore, loop-mediated isothermal amplification (LAMP) methods for the rapid detection of MDV-1 genome at high sensitivity were developed for routine diagnosis of MD in less-equipped laboratories as well as under field conditions (21, 685).

DNA Probes

Methods using DNA-DNA dot-blot hybridization with DNA probes for the detection of MDV DNA in feather tip extracts (171) have been used for detection of MDV (402, 403, 404). Furthermore, localization of virus-infected cells has been accomplished by *in situ* hybridization for both MDV (199, 512) and HVT (257).

Antibody Detection

Tests for identifying the presence of specific antibodies in chicken sera are useful in studies of viral pathogenesis and for monitoring SPF flocks. A number of procedures including agar gel precipitin, fluorescent antibody, enzyme-linked immunosorbent assays (ELISA) (390, 706), and virus neutralization tests are in common use (560).

Diagnosis of the Disease

Despite long-established guidelines for the diagnosis of MD (571), diagnosis of the clinical disease remains difficult in practice because of the absence of truly pathognomonic gross lesions and the widespread nature, often with co-infection, of other pathogens such as ALV and REV (164, 169), complicating diagnostic efforts that depend on virological methods.

Diagnosis of MD must primarily be addressed by consideration of the characteristics of the proliferating cell populations that constitute the disease. Other disease-specific criteria, such as epidemiological factors, are also valuable. Virological criteria are less valuable but can help establish the presence of the causative agent or, more importantly, the absence of certain other agents. The process commences with the acquisition of a flock history and a sufficient number (5–10) of representative sick and dead chickens showing the lesions of the disease and proceeds as a series of steps (666).

Step 1: Clinical Data and Gross Pathology

Although enlarged peripheral nerves and visceral lymphomas are common in MD and one or both are invariably present, neither lesion occurs consistently nor is pathognomonic. Thus, other criteria, such as age and lesion distribution, must be considered in the postmortem diagnosis of MD. Chickens may be diagnosed provisionally as MD if at least one of the following conditions is met: (1) leukotic enlargement of peripheral nerves, (2) lymphoid tumors in various tissues (liver, heart, gonad, skin, muscle, and proventriculus) in birds

under 16 weeks of age, (3) visceral lymphoid tumors in birds 16 weeks or older that lack neoplastic involvement of the cloacal bursa, or (4) iris discoloration and pupil irregularity, as in Figure 15.8C. Proper examination of the bursa is particularly important and requires incision of the organ with close inspection of the epithelial surface. However, diagnoses based only on gross pathologic criteria are not definitive and additional steps are required.

Step 2: Histology, Cytology, and Histochemistry of Tumor Cells

Affected tissues, fixed in formalin or fresh-frozen, are used to prepare paraffin and cryostat sections, respectively. Impression smears of tumors also may be used. Essential diagnostic features may be seen in routine histologic sections stained with hematoxylin and eosin or touch preparations stained with methyl green pyronin or Shorr's stain (571). Cellular and viral antigens can be demonstrated in frozen or, in some cases, paraffin sections by immunohistochemistry. A mixed population of small to large lymphocytes, lymphoblasts, plasma cells, and macrophages are typically found in MD tumors and nerve lesions (221, 222, 226, 453). The proportion of cell types varies with the stage of the disease and virulence of the virus, and the most aggressive lymphomas may contain high numbers of lymphoblasts. MD tumors are a mixed population, and most cells express MHC-II antigen and T cell markers, especially CD4 (although $CD8^+$ cells also may be present) (536), but IgM is present on less than 5% of cells. CD30 also is commonly found in MD tumor cells (514). MATSA (684) can be demonstrated with polyclonal or monoclonal antibodies on 5–40% of MD tumor cells but is also present on activated T cells (384).

Step 3: Virologic Criteria

For tumors that satisfy MD criteria listed in steps 1 and 2, or for atypical tumors, the association of MDV with the tumor cell is a useful confirmation. Viral antigens such as pp38 or meq may be detected in tumor cells by *in situ* hybridization, immunohistochemistry, or fluorescent antibody tests (409, 514). PCR assays and virus isolation from buffy coat or spleen cells as well as detection of viral proteins demonstrate the virus in the bird but do little to associate the virus with the tumor cells. There may be a quantitative association between virus load and MD tumors. Low levels of virus or viral DNA may be detected in lymphocytes from non-tumor-bearing chickens, but most tumor-bearing chickens have high viremia titers (682) and PCR levels (39). Thus, the demonstration of high quantities of viral antigens or genome in tumor cells and the absence of other tumor viruses, along with the criteria in steps 1 and 2, is sufficient to establish MD diagnosis.

Pathotyping of MDV Strains

The concept of MDV pathotypes has arisen from the recognition of the existence of strains that are associated with increased virulence that show correlation with breaking of vaccinal immunity in the field (664). Different methods to differentiate between classical strains of MDV and the more virulent pathotypes have been examined. However, the Avian Disease and Oncology Laboratory (ADOL) method of pathotyping, based on induction of lymphoproliferative lesions in chickens vaccinated with different vaccination regimes, has been the most widely used. This method was used to characterize more than 45 isolates into distinct vMDV, vvMDV, or vv+MDV pathotype groups (651). Even though the ADOL method stipulates the use of line 15×7 chickens for pathotyping, experiments with other lines of birds have given similar results (94, 186, 664).

Differential Diagnosis

LL is a clonal, bursal lymphoma induced by ALV, and under some conditions, by REV in chickens older than 16 weeks of age. Chickens usually have gross tumors in the cloacal bursa, and tumor cells are uniform, blast-like, pyroninophilic and express B cell markers and IgM. Also, the tumor cells have clonal insertions of proviral DNA near the c-myc gene (see Leukosis/Sarcoma Group). Nerve enlargements, runting, and nonbursal T cell lymphomas can be induced by REV, but thus far have only been observed under experimental conditions or where chickens have been inoculated with contaminated vaccines. Lymphocytes obtained from REV-induced nerve lesions or tumors are not known to express pp38 or Meq. Cells from nonbursal RE lymphomas are negative for MHC-II and predominantly stain for CD8 antigen (152) (see Reticuloendotheliosis). Exclusion of ALVs or REVs, where possible, through negative PCR, histochemical assays on tumors, or antibody tests may provide strong support for a diagnosis of MD when other MD-related criteria are positive.

Peripheral neuropathy is a neurological disease of uncertain etiology that causes paralysis and nerve enlargement in a low proportion of commercial chickens 6–12 weeks of age (33, 60, 661) and is characterized by a Th1-to-Th2 shift (34). Affected chickens lack visceral lymphomas, the nerve lesions are uniformly B-type, and MDV is rarely, if ever, demonstrated. Other diseases that may present confusing gross lesions or paralytic signs are myelocytomatosis (myeloid leukosis), myeloblastosis, erythroblastosis, carcinoma of the ovary, various other nonviral neoplasms, riboflavin deficiency, tuberculosis, histomoniasis, genetic gray eye, Newcastle disease, avian encephalomyelitis, and joint infections or injuries. Myeloid leukosis is a common tumor in broiler breeder flocks that superficially resembles MD but can be differentiated histologically. The tumor cells are myeloid in nature and lack T cell and MD viral markers.

Diagnosis of Other MD Syndromes

Transient paralysis occasionally is observed in the field, especially in chickens not vaccinated against MD. Most cases represent the classical form in which chickens experience flaccid paralysis of neck or limbs for 1–43 days and then undergo a complete recovery. This syndrome can be differentiated from the neurological form of MD (fowl paralysis) by its transient nature and flaccid rather than spastic paralysis. Transient paralysis can be differentiated from peripheral neuropathy by

its transient nature and the absence of enlarged peripheral nerves with B-type lesions. Davidson et al. (171) differentiated transient paralysis from peripheral neuropathy on the basis of PCR tests for MDV on brain tissue. However, brains from MDV-infected chickens without transient paralysis also may be detected as positive by PCR assays (667). In contrast, detection of viral antigens in the brain appeared to correlate with the onset of paralytic signs (223).

Skin leukosis (the skin form of MD) can be differentiated from dermal squamous cell carcinoma, which is commonly observed in defeathered broiler chickens at processing (230, 410). MD lesions are nodular and contain lymphoid cells, whereas squamous cell carcinomas have a craterlike gross appearance and are composed of squamous epithelial cells.

Lymphodegenerative lesions of lymphoid organs characterized by organ atrophy and immunosuppression are difficult to diagnose, because many diseases produce similar changes. However, lymphoid organs atrophied consequent to productive infection with MDV also may contain MD viral antigens, such as pp38, at least for a short period.

Intervention Strategies

The development of successful vaccines for control of MD (147, 427, 507) was a significant achievement. Vaccination represents, for now and the foreseeable future, the central strategy for the prevention and control of MD. Genetic resistance and biosecurity, however, are critical adjuncts to properly executed vaccination procedures. No effective practical treatment exists for the disease in individual chickens or infected flocks. An integrated strategy to prevent early infection, slow the acquisition of virulence of field strains, and provide superior immune responses seems most likely to succeed. Recent reviews on MD vaccines and control procedures are available (75, 219, 529).

Vaccination

Types of Vaccines

Several different types of MD vaccines are in common use, both individually and in various combinations. The most widely used products are low-pathogenic serotype 1 MDV (507, 508), naturally avirulent HVT (427), and serotype 2 viruses (531, 678). The latter usually are combined with HVT to take advantage of the synergistic activity documented between serotypes 2 and 3 (532, 657). All vaccine types are protective but to varying degrees. HVT, mainly strain FC126 (673), is extensively used because it is effective and economical to produce and combines well with other products. Although both cell-free and cell-associated forms of HVT are available, the latter has been most widely used because it is more effective than cell-free virus in the presence of maternal antibodies (663). Bivalent vaccines consisting of HVT and SB-1 (531) or 301B/1 (678) strains of serotype 2 MDV were introduced in the mid-1980s. The CVI988 strain (507) used in The Netherlands (375) and other countries since the early 1970s was introduced to the United States in the early 1990s. Serotype 1 and 2 vaccines are available only as cell-associated products.

Vaccine Administration

MD vaccines are administered to chicks at hatch by subcutaneous or intramuscular inoculation or *in ovo* at ED18 (75, 562). *In ovo* vaccination is now performed by automated technology and is used in more than 90% of commercial broiler chickens in the USA (645), mainly because of reduced labor costs and greater precision of vaccine administration. Deposition of the vaccine by the amniotic or intraembryonic route is essential for optimal protection (641). Proper handling of vaccine during thawing and reconstitution is crucial to ensure that adequate doses are administered (216, 234).

Factors Affecting Efficacy

Vaccines typically are given at doses of 2,000–6,000 plaque-forming units (PFU) per chick, but these are often significantly reduced in broilers. The older literature suggests that increased doses of HVT above a threshold level of around 400 PFU offered little improvement (191). However, recent studies indicate that a substantially higher threshold is needed to protect against challenge with vv and vv+strains (221). Although the older literature does not provide evidence for improved protection (658), revaccination is often suggested to increase protection in breeders and layers. Recently, Wu et al. (686) showed improved protection in field trials when birds were vaccinated at 1 and 7 days of age with HVT+CVI988. In laboratory experiments it was shown that revaccination resulted in two replication phases of the vaccine viruses, and a lower secondary replication phase of the challenge virus RB-1B (686).

On the other hand, Le Galludec (335), using qPCR assays on feathers, found that revaccination at 7 days interfered with vaccine virus replication and concluded that revaccination is not recommended. Several other factors may influence vaccine efficacy such as the passage level of the vaccine viruses. Increased passage level may cause a decrease in vaccine replication resulting in decreased immunity (674). Unfortunately, passage levels of commercial vaccines generally are not available. Maternal antibodies against the 3 serotypes are typically present in commercial 1-day-old chicks. These antibodies may reduce the effectiveness of cell-associated vaccines but do not abrogate the protective effect (322) if sufficient PFU are administered.

In addition to improper vaccination techniques (401), early exposure is undoubtedly one of the most important causes of excessive MD in vaccinated flocks because field exposure usually occurs very soon after placement of chickens (672) and because at least 7 days are required to establish solid immunity after vaccination (reviewed in 544). The vaccine strain of virus also has a major influence on vaccine efficacy. Immunity induced by weaker vaccines such as HVT may be excellent against low virulence challenge but can be completely overwhelmed by early challenge with highly virulent strains (651). Although high virulence strains commonly are invoked to explain field outbreaks of disease, many alternate causes should be considered.

Stress appears to interfere with the maintenance of vaccinal immunity. In chickens properly vaccinated at hatch and well

protected following challenge, Powell and Davison (473) induced MD lesions and mortality by immunosuppressive treatment at 10 weeks of age. The onset of egg production deserves consideration as a stress factor precipitating vaccine breaks (658). Infection with other pathogens such as IBDV, REV, CIAV, and reoviruses have been reported to interfere with the induction of vaccinal immunity (reviewed in 542), although very specific conditions are sometimes required.

The strain of chicken is another important determinant of vaccine efficacy. Schat et al. (532) reported that HVT vaccine in genetically resistant chickens resulted in a stronger immunity than did the bivalent (HVT+SB-1) vaccine in susceptible chickens. Bacon and Witter (29) found that the B haplotype influences protective immunity in commercial chickens.

Vaccination Strategies

MD vaccines as a class are unusually effective, often achieving greater than 90% protection under commercial conditions (658). However, attention is often focused on flocks in which MD losses are perceived to be excessive (401). Causes for such vaccine failures are difficult to ascertain by retrospective analysis (401, 658). Improper vaccination techniques, early exposure, immunosuppression—especially by CIAV infection—and the emergence of new MDV strains with increased virulence need to be considered.

Efficacy data comparing certain groups of vaccines are available (citations in 525, 658). Bivalent serotype 2+3 vaccines are clearly more effective than HVT, but the original CVI988 vaccine seems to be the most effective (652), a result consistent with earlier reports from Europe (631).

The propensity of MDVs to evolve to greater virulence is critical to the strategic use of vaccines for MD control (218). Vaccination itself no doubt contributes to this virulence increase, which in turn, tends to make earlier vaccines obsolete. Kreager (330) noted that the useful life of an MD vaccine has been about 10 years under current management conditions. Although this is perhaps an overstatement, the implications are serious. Since CVI988 was introduced in the United States, some evidence already suggests that contemporary strains have increased their virulence in CVI988-vaccinated chickens (653).

Research continues to be directed toward the development of improved vaccines through recombinant DNA approaches, but thus far with limited practical success. The availability of BAC clones of all vaccine serotypes will facilitate the development of new vaccines by rational genome changes (434). DNA vaccination using pBAC20, derived from attenuated MDV, provided limited protection against challenge (621). MDV strains with mutations in the CtBP-interaction domain of meq (68) or lacking the vIL-8 (160) or meq (341) genes were protective against challenge with vv or vv+MDV. The meq deletion mutant using the vvMDV strain Md5 protected chickens to challenge with vv+strains at least as well as if not better than CVI988 (339). Unfortunately, the deletion mutant is causing severe thymus and bursa atrophy in maternal antibody-negative, 1-day-old chicks (23), preventing licensing in the USA under current regulations.

Incorporation of cytokines in vaccine strategies may improve vaccine efficacy. Inclusion of the avian myelomonocytic growth factor gene in FPV improved HVT-induced protection (184). However, the usefulness of recombinant FPV vaccines may be limited if birds have maternal antibodies against FPV (602). Insertion of IL-2 in HVT induced increased levels of neutralizing antibodies against HVT, but did not increase protection against challenge (612). Vaccination with HVT together with plasmids expressing IFN-γ improved protection (239), suggesting that incorporation of this gene in HVT may be useful.

Efforts to derive more efficacious serotype 1 vaccines through classical virological approaches (653) or retroviral insertion (671) yielded several promising candidates. However, these strains did not protect better than the best commercial CVI988 vaccines (668). Those authors questioned if the efficacy of MD vaccines is limited by some type of biological threshold.

The emergence of increasingly virulent viral strains, coupled with an apparent reduction of vaccine efficacy during the past 20 years, has prompted justifiable concern. This suggests that vaccination by itself does not provide a complete control program and is not the ultimate solution for MD. Strict biosecurity procedures to reduce early exposure and the presence of genetic resistance are essential adjuncts to a successful vaccination program.

Genetic Resistance

The well-known variation in susceptibility of different lines of chickens to MD challenge is determined by genetic factors (28, 79, 148) and provides a unique opportunity to include genetic approaches to control MD. Indeed, poultry breeders have included resistance to MD in selection programs for many years (385). However, genetic resistance can be overcome by challenge with highly virulent MDVs and is best applied in concert with vaccination and biosecurity to achieve optimal control. Genetics influences virtually every aspect of host response to MD. However, only those issues germane to disease control programs are considered here.

For successful incorporation of selection for resistance in breeding programs, several conditions need to be met (reviewed in 28). The heritability of resistance is relatively large; thus, selection has a considerable impact. Selection for resistance is at least neutral for production traits or is correlated positively with production traits (17). Sufficient heterogeneity exists in single-sire families to warrant selection for resistance in commercial chickens, which is still the case in recent commercial genetic stocks (198). Recently, Buscaglia et al. (95) used the heterogeneity in a broiler breeder line to select for the optimal level of NO production linked to MD resistance.

Selection Methods

Selection programs for resistance historically have been based on progeny testing or family selection (149) or reproduction from survivors of exposed nonvaccinated breeding flocks through mass selection (374). Bacon and Witter (31) found that resistance may better be determined in vaccinated stocks. Under

certain conditions acquisition of resistance can be obtained within 4 to 6 generations (149, 374). Family selection may be more appropriate than mass selection for commercial breeders in order to avoid high loss of genetic material on initial challenge exposure (28). Resistance has been considered dominant, although this varies to some extent (248). In most cases, resistance of crosses has been intermediate to that of the parent strains (61).

In addition to selection based on challenge with MDV, blood typing for MHC can be used based on the close relationship between MD resistance and certain alleles of the B-F region of the MHC, especially B^{21} (67, 79). However, the value of selection for MHC-associated markers may vary considerably among commercial lines and crosses (61, 242).

Several non-MHC genes also may be involved in resistance. For example, line 6 and line 7 chickens differ markedly in MD susceptibility, but both lines are homozygous for the MHC B^2 allele (158). Because non-MHC effects were considered more important than MHC effects in several commercial lines (228), the identification and mapping of map quantitative trait loci (QTL) have become important. These studies have identified 14 or more putative QTL associated with MD resistance (78, 628, 691). The rapid technological advances in complete genome sequencing and SNP analysis in combination with previous information based on QTL analysis, microarrays (364), and 2-hybrid screen approaches (417) will undoubtedly identify several specific genes associated with resistance to MD. Liu et al. (365) demonstrated that the chicken growth hormone peptide interacts with the MDV SORF2 gene. Moreover, polymorphism in the growth hormone gene is associated with the number of tumors in tissues. Using Affymetrix chicken whole-genome arrays combined with SNP analysis, Smith et al. (581) recently identified IRG1 as a new candidate gene for resistance.

Applications to Control

The knowledge that genetically resistant chickens are protected by vaccination to a greater extent than more susceptible strains (593) has fueled interest by commercial breeders to emphasize MD resistance in selection programs. However, synergy between host genetics and vaccines is complex. Some resistant B-haplotypes were demonstrated only by challenge of previously vaccinated chickens (31). However, the relative efficacy of MD vaccines is also influenced by B-haplotype, leading to the concept to select the most appropriate vaccine based on the predominant B-haplotypes in a particular strain (30). In practice, this issue has been either ignored or addressed through the use of vaccines containing multiple serotypes.

In light of the selection tools available, the absence of negative correlations, and the major benefits to be derived, it is not surprising that breeders place a high priority on this approach. Although selection for B-haplotype has been practiced with variable success and has proven to be complex, especially in meat strains (385), breeders acknowledge the value of improved genetic resistance to offset virulence increase by viral strains and the limitations of current vaccines (329).

Management Procedures

Strict biosecurity practices to limit the extent of early MDV exposure, although impractical as a primary control procedure, are a crucial and cost-effective adjunct to vaccination. MD control is compromised because modern poultry management decisions are often linked to cost analyses. As a consequence replacement flocks of different ages are placed in close proximity to each other, vaccine doses are reduced, and/or litter from previous broiler flocks is used (529). The failure to prevent early exposure is perhaps the most important single cause of vaccine failures. Improved hygiene has often appeared to play a key and cost-effective role in the elimination of excessive MD losses in vaccinated flocks. Relevant sanitation principles have been reviewed (449).

For SPF flocks, higher standards of biosecurity are required and become cost effective. Most SPF operations use filtered-air, positive-pressure houses, which, along with strict biosecurity measures, successfully can maintain large flocks free of MDV infection. In this case, biosecurity becomes a substitute for vaccination and provides a practical demonstration that MDV infection can be prevented, at least under specialized conditions.

Nononcogenic Avian Herpesviruses

As mentioned earlier, two additional groups of nononcogenic herpesviruses, MDV-2 (*Gallid herpesvirus 3*) and HVT (*Meleagrid herpesvirus 1*), isolated from chickens (56, 139) and turkeys (314, 673), respectively, are considered part of the Mardivirus genus. The classification of these two viruses as two distinct serotypes, originally based on the recognition of common and distinct antigenic epitopes (637, 638), has been justified from the data on the complete sequence for serotype 2 strains HPRS-24 and SB-1 (279, 590), and serotype 3 FC126 virus strains (15, 323).

Interest in MDV-2 and HVT derives mainly from their use as live vaccines against MD. However, both viruses occur in nature independent of vaccination, and it seems appropriate to also consider some aspects of their epizootology and pathogenesis in their natural or alternate avian hosts. Reviews providing additional details on pathogenesis of these infections may be consulted (102, 103).

Turkey Herpesvirus

HVT is endemic and ubiquitous in domestic turkeys (679) and has also been isolated from wild turkeys (151). In chickens, the virus also has become ubiquitous because of its widespread usage as vaccines (75). Increasingly, HVT is used successfully as recombinant live virus vectored vaccines against a number of diseases (212, 349, 350, 360).

The 160 Kb-long HVT genome encodes nearly 100 functional genes that include sets of homologous and unique genes (15, 323), as well as novel microRNAs (640, 696). The functions of HVT genes in relation to their distinct properties of high immunogenicity, lack of oncogenicity, and ability to produce cell-free virus are not fully understood. The availability

of infectious BAC clones of HVT (38) will be helpful in gaining further insights into HVT gene functions.

In turkeys, HVT spreads rapidly through exposed flocks by contact exposure as no evidence of vertical transmission has been demonstrated (680). Virtually all individual turkeys become viremic and develop antibodies within a few weeks (679). The virus appears to mature in the FFE, because cell-free skin extracts are infectious (680), although viral antigen was found only infrequently and at low levels in the FFE (204). HVT may be transmitted from turkeys to chickens under experimental conditions (680), although this is considered extremely rare. Only limited contact spread occurs among chickens, but transmission could not be demonstrated by the airborne route (137). Replication of virus in the FFE of infected chickens appears limited and transient (137, 481), although increased levels of HVT DNA were observed in FFE of HVT-vaccinated chickens after MDV challenge (278).

Fabricant et al. (204) studied the early pathogenesis of HVT infection in chickens and turkeys. Chickens had no cytolytic infections in any lymphoid organ. Turkeys infected with HVT had some viral antigen-positive cells at 4–14 days PI in the spleen, but no cytolytic infections in bursa or thymus were seen. In chickens, there was no depression of bursa or thymus size, although a transient splenomegaly was variably present (108, 204). Expression of gB was detected in spleen, with limited levels in thymus and cloacal bursa (256). B cells are rarely infected, but latent infection is probably established in MHC-II-positive T cells (103). NK cell activity was stimulated through at least 8 weeks PI (564). HVT can be recovered from infected chickens for long periods, and antibodies persist for life (488, 677). The virus is apparently nononcogenic in turkeys (659), but the possibility of fertility problems in HVT-infected toms has been raised (618). The virus generally causes no clinical disease in intact or immunosuppressed chickens (565, 673). However, transient B-lymphocyte dysfunction (210), atrophy of the bursa and thymus with high doses (233), and minor cellular infiltrations in nerves (204, 677) have been reported. In contrast, up to 19% of S-line chickens infected with HVT *in ovo* (ED 8) were reported to develop clinical paralysis and gross nerve enlargement due to inflammatory type lesions (117). Chickens exposed to HVT at ED 14 or earlier showed higher incidence of immunological tolerance resulting in a persistent HVT viremia (708). A possible role for HVT as a predisposing factor in autoimmune disease is suggested by its implied involvement in peripheral neuropathy (33) and autoimmune vitiligo (200); both syndromes are restricted to certain strains of chickens.

Serotype 2 Marek's Disease Virus

Apathogenic strains isolated from clinically normal chickens (56, 139) subsequently were determined to be a separate serotype based on antigenic properties (638) and genome sequences. The 166 Kb MDV-2 genome encodes several homologous and unique genes (279, 590) (see Table 15.2) as well as novel microRNAs (697). Availability of infectious BAC clones of SB-1 virus (468, 579) could facilitate functional analysis of MDV-2 genes.

Serotype 2 viruses are widespread, although not universal in commercial chicken flocks (56). The epizootology has been complicated by distribution of the virus through a seeder chick program (703) and widespread use of MDV-2 vaccines (119, 676). Other unique features of this virus group were further elucidated following the isolation of the SB-1 strain (531).

Serotype 2 viruses replicate in the FFE (136) and spread readily by contact (531, 678). Following inoculation of day-old chickens, the virus can be first isolated 5–6 days PI, reaching peak titers at 2–4 weeks, persisting thereafter for long periods (108, 678). A transient splenomegaly was induced between 4–12 days PI with SB-1, but no bursal atrophy and only occasional thymic atrophy was seen, and cytolytic infection of lymphoid organs was not observed (108). In contrast, Lin et al. (363) found viral antigens in spleen and bursal tissues 5–14 days PI, primarily in B cells, but no gross or microscopic changes were observed. Calnek (103) considered B cells and macrophages relatively refractory to infection, and the cells supporting latent infection lacked MHC-II antigens, thus differing from those in HVT infections. T cells also may not be very susceptible because of the poor re-isolation rates of SB-1 from $CD4^+$ and $CD8^+$ cells of infected chickens (346), although MDV-transformed MSB-1 cells can be dually infected with MDV-1 and MDV-2 viruses (697). SB-1 is not normally considered immunosuppressive (194), although a diminished response to a B lymphocyte-specific mitogen and decreased antibody responses to bovine serum albumen have been reported in chickens vaccinated with SB-1 strain in combination with HVT. However, because it has not been associated with neoplastic lesions in chickens or embryos, SB-1 is designated nononcogenic rather than apathogenic (531). The absence of lymphoma induction has been confirmed by other workers (56, 138, 678), although there was one report of visceral lymphomas in 2 of 48 chickens inoculated with the HPRS-24 strain (472).

Vaccination with serotype 2 viruses causes a pronounced enhancement of B cell lymphomas in certain genetic strains of chickens exposed at an early age to subgroup A ALV (32) or REV (16) (see Leukosis/Sarcoma Group). The ability of serotype 2 virus to enhance LL was attenuated without abrogation of its protective properties against MD challenge (648). ALV-A has now been eradicated from most of the chicken lines susceptible to serotype 2 enhancement, and field problems due to serotype 2 enhancement of LL are rare (see Leukosis/Sarcoma Group).

Acknowledgement

The authors are greatly indebted to Bruce W. Calnek and Richard L. Witter for their contributions to earlier editions of this chapter. Drs. Calnek and Witter were the co-authors of the previous 5 and 6 editions, respectively, of this chapter, encompassing a 25- to 30-year span. Their inspiration, along with many of their words, are reflected in the current chapter.

Leukosis/Sarcoma Group

Venugopal Nair and Aly M. Fadly

Introduction

Definition and Synonyms

The leukosis/sarcoma (L/S) group of diseases designates a variety of transmissible benign and malignant neoplasms of chickens caused by members that belong to the family Retroviridae (199). Due to the expansion of the literature on this disease, it is no longer feasible to cite all relevant publications that provide the scientific basis for our current knowledge of the disease. Hence, the literature is cited selectively, with reviews often used instead of original papers. For more detailed references to the literature, readers are advised to refer to the chapter in the previous edition (189).

Lymphoid leukosis (LL) has been the most common form of L/S group of diseases seen in field flocks, although myeloid leukosis also has become prevalent. The neoplasms and their synonyms are listed in Table 15.4. Members of this group of avian viruses, as are all members of the Retroviridae, are characterized by possession of an enzyme reverse transcriptase, which directs the synthesis of the proviral DNA form of the RNA virus that forms part of the retroviral life cycle and from which the family name is derived.

Because of the relationships between these viruses, they are discussed as a group in most parts of this chapter. Sections reflecting the host response (Pathology and Pathogenesis of the Infectious Process) are discussed under the pathologic

Table 15.4. Neoplasms caused by viruses of the leukosis/sarcoma group.

Neoplasm	Synonyms
Leukoses	
Lymphoid leukosis	Big liver disease, lymphatic leukosis, visceral lymphoma, lymphocytoma, lymphomatosis, visceral lymphomatosis, lymphoid leukosis
Erythroblastosis	Leukemia, intravascular lymphoid leukosis, erythroleukosis, erythromyelosis, erythroblastosis, erythroid leukosis
Myeloblastosis	Leukemic myeloid leukosis, leukomyelosis, myelomatosis, myeloblastosis, granuloblastosis, myeloid leukosis
Myelocytoma(tosis)	Myelocytoma, aleukemic myeloid leukosis, leukochloroma, myelomatosis
Connective tissue tumors	
Fibroma and fibrosarcoma	
Myxoma and myxosarcoma	
Histiocytic sarcoma	
Chondroma	
Osteoma and osteogenic sarcoma	
Epithelial tumors	
Nephroblastoma	Embryonal nephroma, renal adenocarcinoma, adenosarcoma, nephroblastoma, cystadenoma
Nephroma	Papillary cystadenoma, carcinoma of the kidney
Hepatocarcinoma	
Adenocarcinoma of the pancreas	
Thecoma	
Granulosa cell carcinoma	
Seminoma	Adenocarcinoma of the testis
Squamous cell carcinoma	
Endothelial tumors	
Hemangioma	Hemangiomatosis, endothelioma, hemangioblastomas, hemangioendotheliomas
Angiosarcoma	
Endothelioma	
Mesothelioma	
Related tumors	
Osteopetrosis	Marble bone, thick leg disease, sporadic diffuse osteoporostitis, osteopetrosis gallinarum
Meningioma	
Glioma	

entities without regard for the properties of the inducing virus(es) other than their inclusion in the L/S group.

Economic Significance

Infection of chickens with ALV is the most common L/S virus infection encountered in field flocks and is known to be of significant economic importance. Economic losses from ALV-induced diseases are attributed to two sources. First, tumor mortality commonly amounts to around 1–2% of birds, with occasional losses of up to 20% or more. Second, subclinical infection by ALV, to which most flocks are subject, produces a depressive effect on a number of important performance traits, including egg production and quality (216, 217, 219). Economic losses due to ALV tumor mortality and reduced productivity are estimated to be in the millions of U.S. dollars each year (189). During the 1990s, the broiler breeder industry identified an ALV-induced myeloid leukosis (383) as its highest disease priority, as losses due to this disease (487, 492) have threatened the economic viability of the entire broiler industry (531). Currently the virus is causing huge economic losses to the poultry industry in countries such as China (213, 395).

Public Health Significance

Recent studies have addressed the relationship between avian tumor viruses, particularly ALVs, and human health. Evidence for the presence of antibodies to ALVs in humans usually has been lacking or at best is presumptive (270). Endogenous and exogenous ALV also were detected in the albumen of commercial eggs using reverse transcription polymerase chain reaction (RT-PCR) (401, 402), but the public health significance was not determined. In a serological survey that included 549 human subjects, including groups exposed and not exposed to chickens, significant differences between men and women were found for the prevalence of antibodies to ALV but were not related to exposure to chickens (101). Robertson et al. (428) discussed the significance of detecting reverse transcriptase activity in vaccines derived from chicken cells. Reverse transcriptase activity was detected in all chicken cell-derived measles and mumps vaccines, suggesting the presence of endogenous ALV elements; however, no evidence of antibodies or proviral sequences of ALV was found in the vaccines or the sera from vaccine recipients (260, 262, 461, 523). Clearly, no strong unequivocal evidence suggests that ALV constitutes a danger to public health.

History

The earliest reports of leukotic diseases in fowl are those of Roloff (432), who described a case of "lymphosarcomatosis" in 1868, and of Caparini (88), who in 1896 described cases of "fowl leukemia." In 1905, Butterfield (81) diagnosed "aleukemic lymphadenosis" in the United States. In 1908, Ellermann and Bang (169), working in Copenhagen, founded the discipline of viral oncology when they transmitted erythroleukemia and myelogenous leukemia by inoculation of chickens with cell-free filtrates.

Ellermann also provided further classification of the pathological forms of avian leukosis that essentially still holds today (168). He described in his monograph *The Leucosis of Fowls and Leucemia Problems* (168) (1) "lymphatic leucosis," with lymphoblastic hyperplasia; (2) "myeloic leucosis," with leukemia and general hyperplasia of "myeloic" cells (myelocytes, "large mononuclear cells," and "poikilonuclear cells"); and (3) "intravascular lymphoid leucosis," involving "lymphoidocytes," which he concluded were erythrocytic cells and that this intravascular form was erythroleukosis.

Also in the early decades of the 20th century, Rous, working in New York, was undertaking studies on the transmissibility of avian sarcomas. In 1909, he succeeded in transplanting a spindle cell sarcoma from 1 hen to another (436) and soon after showed that the transplantable tumor could be transmitted by cell-free filtrates (435). Over the next two decades, some 20 transplantable tumors of fowl were shown by a number of workers to be filterable (102). In the 1920s and 1930s, many transmission studies also were conducted on the avian leukoses by notable workers including Furth (210) in the United States, Jarmai (269) in Hungary, Engelbreth-Holm (170, 171) in Denmark, and Oberling and Guérin (362) in France, and numerous strains of avian leukosis virus were isolated (76). An important question was whether the same or different agents caused the 3 forms of leukosis. In general, erythroid and myeloid leukosis were readily transmissible, either in pure or mixed forms, and lymphoid leukosis was not. Furth provided evidence of transmission of lymphoid leukosis with filtrates (210), and conclusive proof of the viral etiology of this form came from transmission experiments of Burmester and his coworkers in 1946-1947 (67, 69, 70).

Much of the early research on avian leukosis and sarcomas was motivated by basic scientific and medical interest. From 1920–1940, however, the expansion of the poultry industry in the United States and elsewhere brought increasing losses from the so-called "avian leukosis complex." Research was carried out particularly at land grant colleges and state agricultural stations in the United States, with the aim being practical control of these diseases (76). The disease picture was complicated by the inclusion in the leukosis complex of neurolymphomatosis (range or fowl paralysis), and visceral lymphomas associated with this disease, which were increasing in prevalence. There was much uncertainty and argument as to whether or not neurolymphomatosis (now termed Marek's disease) was caused by the agents that caused the leukoses (382). The use of the term "visceral lymphomatosis" (273) to cover both lymphoid leukosis and lymphomas associated with neurolymphomatosis did not help the debate (46, 85). In 1939, the U.S. Department of Agriculture established the Regional Poultry Research Laboratory at East Lansing, Michigan, (later renamed the Avian Disease and Oncology Laboratory) to study the cause and control of fowl paralysis and other neoplastic conditions. In 1959, a similar center, the Leukosis Experimental Unit of the Houghton Poultry Research Station, was established in England.

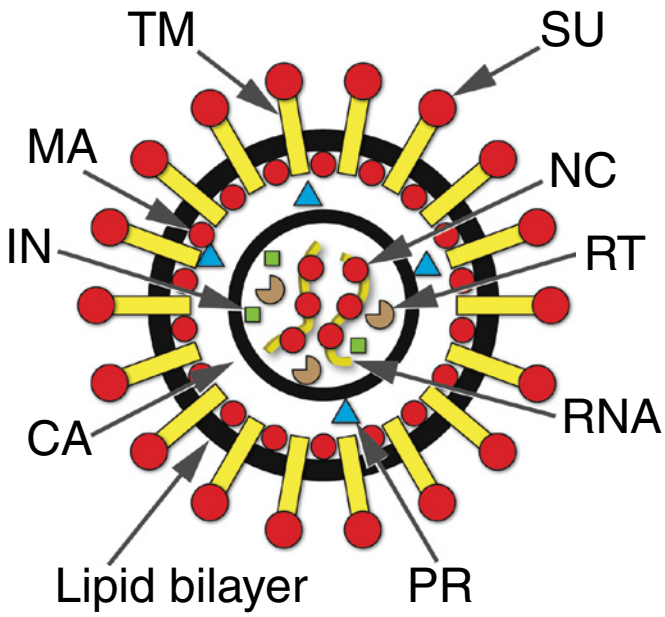

Figure 15.18. Schematic diagram of avian leukosis virus particle. The viral envelope is a lipid bilayer in which the gp37 transmembrane (TM) and the gp85 surface (SU) proteins, encoded by the env gene, are inserted. Internal components encoded by the gag/pro gene, are p19 matrix (MA) protein, p27 capsid (CA) protein, p12 nucleocapsid (NC) protein, and p15 protease (PR). The pol gene encodes the reverse transcriptase (RT) and p32 integrase (IN). The core of the particle contains 2 viral RNA strands.

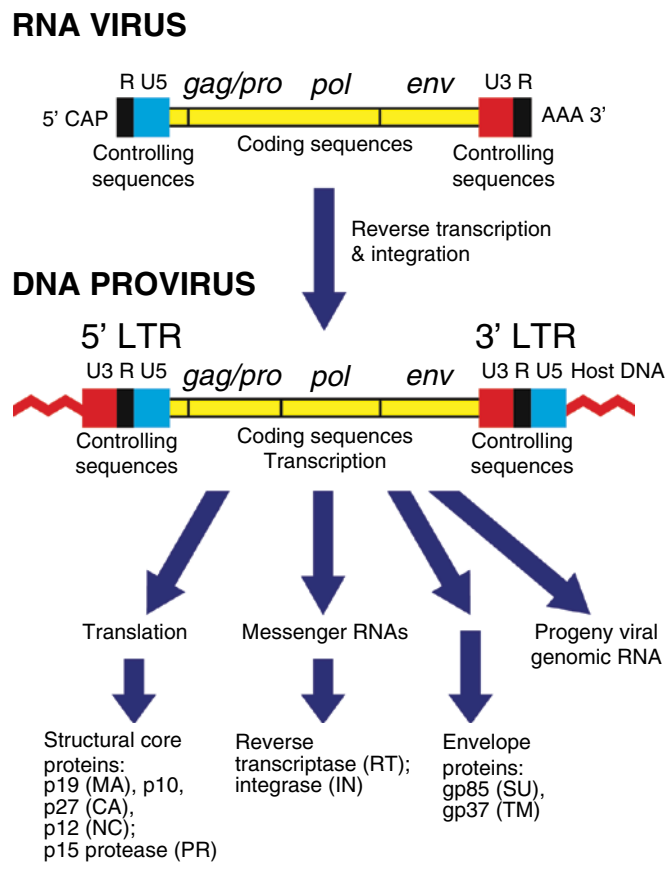

Figure 15.19. Key features of the viral RNA and proviral DNA forms of the genome of avian leukosis virus. CAP, 5′ end structure; AAA, polyadenylation of 3′ end; R, repeat sequence; U5, unique 5′ end sequence; U3, unique 3′ end sequence; LTR, long terminal repeat. For other abbreviations, see Figure 15.18 and the text.

Numerous other solid tumors have been associated with the avian leukoses occurring in the field and in transmission experiments, including connective tissue tumors, nephromas and nephroblastomas, various other epithelial tumors, endothelial tumors, and neural tumors (36, 192). Also included in the avian leukosis complex is a hypertrophic bone disorder, osteopetrosis, first reported by Pugh in 1927 (412) and described and reproduced in 1938 by Jungherr and Landauer (274). The latter workers, and later Burmester and co-workers (67, 203), noted the association of osteopetrosis with lymphoid leukosis.

Detailed reviews on the history of avian retrovirus research are available elsewhere (189, 380, 385, 395, 438, 538, 555).

Etiology

Classification

Viruses of the avian leukosis/sarcoma group are placed in the *Alpharetrovirus* genus of the family Retroviridae (http://ictvonline.org/virusTaxonomy.asp?version=2009&bhcp=1). Members of this family are RNA viruses characterized by the possession of the enzyme reverse transcriptase, which is necessary for the formation of a DNA provirus that is integrated in the host genome during virus replication. Under the new taxonomy, avian leukosis virus (ALV) is the type species of the genus (Figures 15.18 and 15.19). Other species in the genus include Rous sarcoma virus (RSV) and a number of replication defective viruses carrying various oncogenes.

Morphology

Ultrastructure

In thin-section electron microscopy, avian leukosis/sarcoma viruses (ALSV) have an inner, centrally located electron-dense core about 35–45 nm in diameter, an intermediate membrane, and an outer membrane. This appearance typifies the C-type retroviral morphology. The overall diameter of the virus particle is 80–120 nm, with an average of 90 nm. Immature virions budding from the cell membrane can be visualized (Figure 15.20).

Negatively stained preparations reveal essentially spherical particles that are readily distorted under certain conditions of drying (37). Characteristic knobbed spikes about 8 nm in diameter are present on the surface of the particles and comprise the viral envelope glycoproteins. These projections also can be seen in thin sections.

Size and Density

By filtration through membranes of graded pore size, ultracentrifugation, and electron microscopy, viruses have a diameter of 80–145 nm. The value of 1.15–1.17 g/mL for the

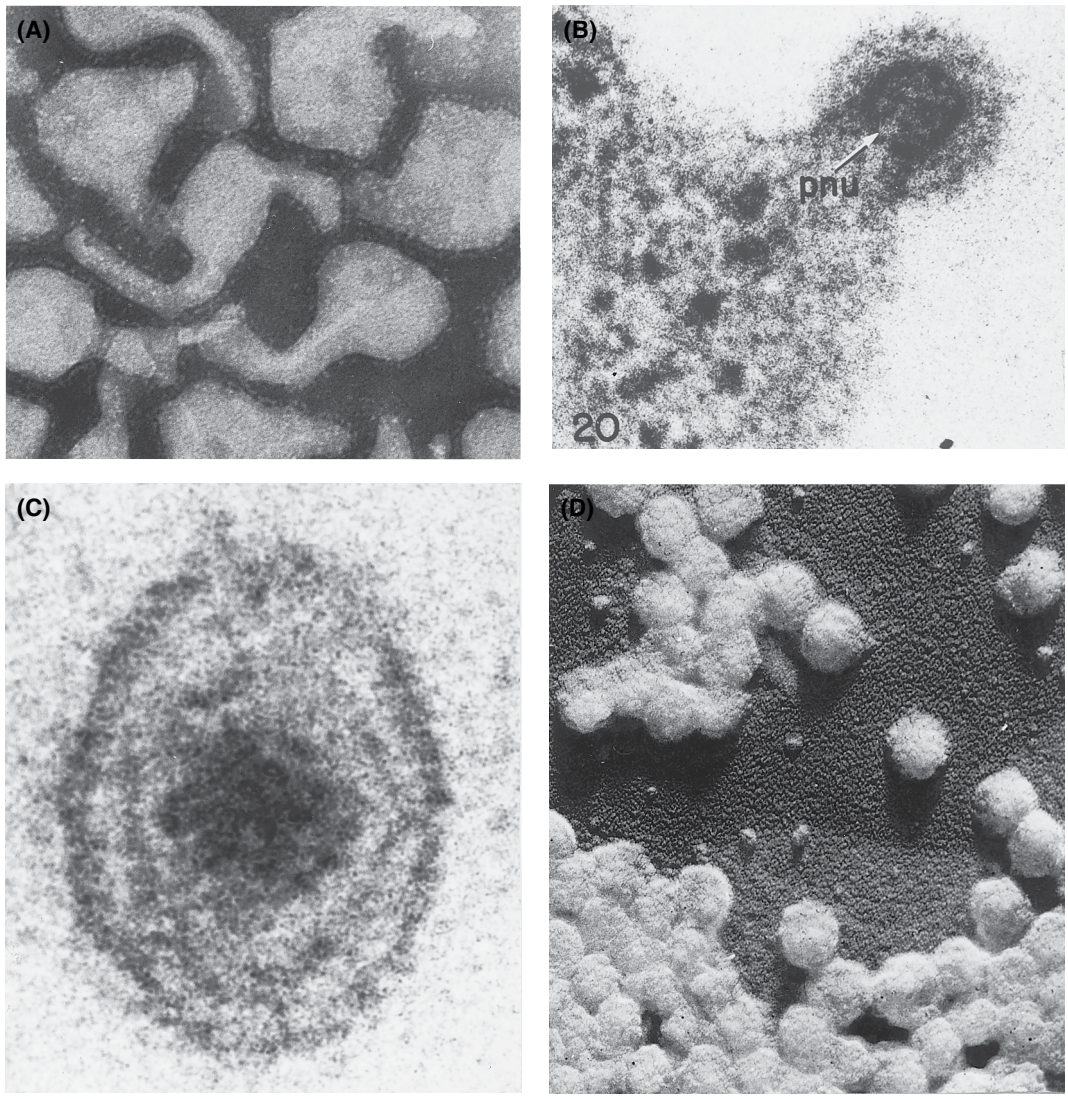

Figure 15.20. Ultrastructure of leukosis/sarcoma viruses. (A) BAI-A of avian myeloblastosis virus (AMV), unfixed, and negatively stained with neutralized phosphotungstic acid. Peripheral fringe about particles is resolved in some places into discrete "knobs." ×150,000. (B) Ultrastructure of leukosis/sarcoma virus release. Virus budding at cell membrane of a leukemic myeloblast. Surface of buds and particles peripheral to outer membrane is irregular and indistinct (pnu, dense prenucleoid). ×215,000. (C) Thin section of BAI-A of AMV sedimented from plasma, fixed in osmium tetroxide, and stained with lead subacetate. Inner and outer membranes and granular character of nucleoid can be seen. Impression of granules might be derived from sectioning of filaments. Some granules appear to be hollow. ×510,000. (D) Purified BAI-A of AMV fixed and shadowed with chromium. ×50,000. (Bonar and de Thé)

buoyant density in sucrose is characteristic for C-type retroviruses (31, 431).

Symmetry

Although the particle, and core, of ALSV show no obvious symmetrical features, the cores of some C-type retroviruses have icosahedral symmetry.

Chemical Composition

The overall composition of avian myeloblastosis virus (AMV), which has been studied extensively, is 30%–35% lipid and 60%–65% protein, of which 5%–7% is glycoprotein, 2.2% is RNA, and small amounts of DNA are present, apparently of cellular origin (32, 35, 541).

Viral Nucleic Acids

The major class sizes of RNA sediment at 60–70S, which is the viral genome, and at 4–5S, most of which is host tRNA, thought to be accidentally included in the virion and to play no role in viral replication. A tRNA is also associated with the 70S RNA and is a primer for the DNA polymerase during transcription of viral RNA to DNA. Small amounts of 18 and 28S RNA, viral and cellular mRNA, and DNA are also present. The 60–70S genomic RNA is a dimer and can be split into 2 subunits of about 34–38S, which are believed to represent the diploid genome. These subunits of genomic RNA are mRNAs, and their genes have been mapped for a number of avian retroviruses.

Table 15.5. Acutely transforming avian sarcoma and leukemia viruses classified according to viral oncogene.

Virus strain	Oncogene(s) carried	Oncogene product	Predominant neoplasm(s)	Cells transformed *in vitro*
RSV, B77, S1, S2	*src*	Nr ptk	Sarcoma	Fibroblast
FuSV, UR1, PCR II, PCR IV	*fps*	Nr ptk	Sarcoma	Fibroblast
Y73, ESV	*yes*	Nr ptk	Sarcoma	Fibroblast
UR2	*ros*	R ptk	Sarcoma	Fibroblast
RPL30	*eyk*	R ptk	Sarcoma	Fibroblast
ASV-17	*jun*	Tf	Sarcoma	Fibroblast
ASV-31	*qin*	Tf	Sarcoma	Fibroblast
AS42	*maf*	Tf	Sarcoma	Fibroblast
ASV-1	*crk*	Ap	Sarcoma	Fibroblast
AEV-ES4,	*erb*A, *erb*B	Tf, R ptk	Erythroblastosis, sarcoma	Erythroblast, fibroblast
AEV-R	*erb*A, *erb*B	Tf, R ptk	Erythroblastosis	Erythroblast
AEV-H	*erb*B	R ptk	Erythroblastosis, sarcoma	Erythroblast, fibroblast
S13	*sea*	R ptk	Erythroblastosis, sarcoma	Erythroblast, fibroblast
E26	*myb, ets*	Tf	Myeloblastosis, erythroblastosis	Myeloblast, erythroblast
AMV	*myb*	Tf	Myeloblastosis	Myeloblast
MC29	*myc*	Tf	Myelocytoma, endothelioma	Immature macrophage, fibroblast
CMII	*myc*	Tf	Myelocytoma	Immature macrophage, fibroblast
966 ALV-J	*myc*	Tf	Myelocytoma	Immature macrophage
OK10	*myc*	Tf	Endothelioma	Immature macrophage, fibroblast
MH2	*myc, mil*	Tf, S/tk	Endothelioma	Immature macrophage, fibroblast

Note: Ap 5 Adaptor protein; Nr ptk 5 Nonreceptor protein tyrosine kinase; R ptk 5 Receptor protein tyrosine kinase; S/tk 5 Serine/threonine kinase; and Tf 5 Transcription factor.

The sequence of the structural genes of ALV, from the 5′ end to the 3′ end of the RNA molecule, is gag/pro-pol-env; these genes encode, respectively, the proteins of the virion group-specific (gs) antigens and protease, RNA-dependent DNA polymerase (reverse transcriptase, or RT), and envelope glycoproteins (Figure 15.19). The structural genes are flanked by terminal genomic sequences with gene promoter and enhancer activities, and that, in the DNA provirus, form the long terminal repeat (LTR) regions. The viral genome is about 7.3 kb in size.

The so-called acutely transforming viruses possess additional viral oncogene sequences that initiate neoplastic transformation (320). Acquisition of a viral oncogene usually is accompanied by genetic defects elsewhere in the viral genome (see Pathogenicity). Non-defective RSV has the genetic composition gag/pro-pol-env-src. The additional gene, src, responsible for sarcomatous transformation, evidently was acquired originally from a normal cellular oncogene, cellular src. The gene cellular src is an example of a number of host cell genes, termed proto-oncogenes or onc genes, concerned with acute transformation (172, 545). Viral and cellular versions of onc genes, and of the specific varieties such as src, are distinguished by the prefixes "v-" and "c-." Specific v-onc genes, with c-onc counterparts in normal cells, are present in other acutely transforming viruses, as listed in Table 15.5.

Slow transformation, as in LL, is caused by an indirect mechanism independent of a v-onc but depends on activation of a c-onc, namely c-myc in LL, by adjacent integration of ALV provirus (295, 296). This mechanism is called insertional mutagenesis.

Viral Lipids

Viral lipids, mainly phospholipid, occur in the virion envelope and are of cellular origin. They have a bilayered structure similar to the outer cell membrane from which the virion envelope is derived (32, 49).

Viral Proteins

The nature, location, and synthesis of proteins that constitute avian retroviruses have been extensively studied (508) (Figures 15.18 and 15.19). The virion core contains 5 non-glycosylated proteins encoded by the gag/pro gene: MA (matrix, p19); p10; CA (capsid, p27), which is the major gs antigen (Gag) in the core shell; NC (nucleocapsid, p12), involved in RNA processing and packaging; and PR (protease, p15), involved in cleavage of protein precursors. Other minor polypeptides have been reported.

The pol gene encodes the enzyme reverse transcriptase (RT) present in the core. It is a complex consisting of the b subunit

(95 kD) and the a subunit (68 kD) derived from it and has RNA- and DNA-dependent polymerase and DNA:RNA hybrid-specific ribonuclease H activities. The b subunit also contains the IN domain (integrase, p32), the enzyme necessary for integration of viral DNA into the host genome. Recent structural studies on the catalytic core domain of the ALSV integrase suggested that it can dimerize in more than one state, allowing the flexibility for multifunctionality during different steps of retroviral life cycle (22).

The virion envelope contains 2 glycoproteins encoded by the env gene: SU (surface, gp85), the viral surface knob-like structures that determine viral envelope subgroup specificity of the ALSV, and TM (transmembrane, gp37), representing the transmembrane structure that attaches the knobs to the envelope. These 2 envelope (Env) proteins are linked to form a dimer, termed virion glycoprotein (VGP).

Enzymes and other proteins are found in virions and are considered to be cellular components incorporated during virus maturation (508). Of practical value is the presence in AMV obtained from blood of infected chickens, or from myeloblast cultures, of adenosine triphosphatase derived from the cell membrane and incorporated into the virus particle during maturation. This enzyme will dephosphorylate adenosine triphosphate, and this activity can be used for virus assay and purification. Cells without this enzyme, such as fibroblasts, release virus that is devoid of this activity.

Virus Replication

As with other retroviruses, replication of ALSV is characterized by the formation, under the direction of reverse transcriptase, of a DNA provirus that becomes linearly integrated into the host cell genome (Figure 15.19). Subsequently, the proviral genes are transcribed into viral RNAs, which are translated to produce precursor and mature proteins that constitute the virion. Great efforts have been made since the 1970s to elucidate these events, details of which have been reviewed extensively (314, 513). Only an outline of the main events is provided here.

Penetration of the Host Cell

Detailed reviews describing the recent understanding of the early ALV interactions with the host cells are available (29, 30). Although adsorption of the virion to the cell membrane is nonspecific, occurring even in cells resistant to infection, penetration of cells is dependent on the presence, in the cell membrane, of host gene-encoded receptors specific for particular virus envelope subgroups and on fusion of viral and cell membranes. Virions are taken into the cell in vacuoles and viral RNA in the nucleus within 120 minutes of attachment (137). In recent years, considerable progress has been made in understanding the nature of the receptors used by the different ALV subgroups (29). The receptor for subgroup A ALV, designated TVA, is related to the human low-density lipoprotein receptor (31, 234, 575). Binding of the virus to the receptor for subgroup A ALV triggers a conformational change in the viral envelope glycoprotein that allows viral fusion with the cell membrane and viral entry (222). Decreased susceptibility subgroup A ASLV *in vitro* and *in vivo* from intronic deletions in a close-bred line of domestic chickens resulting in inefficient splicing of the TVA mRNA has been reported (423). The receptors for ALV subgroups B, D, and E, designated TVB^{s3} and TVB^{s1}, resemble a receptor for cytokines of the tumor necrosis factor family (1, 2, 3, 290, 424), and the resistance to these viruses is due to a premature stop codon within this allele (288); molecular tests to evaluate TVB haplotypes have been developed (581).

The TVB receptors are functional death receptors capable of inducing death-signaling pathways leading to apoptosis (57, 289). The receptor for the subgroup C avian sarcoma and leukosis viruses, TVC, is related to mammalian butyrophilins, members of the immunoglobulin superfamily (167, 344). The host cell receptor used by the ALV subgroup J, which has a distinct envelope with limited homology to those of other subgroups, recently has been identified as the chicken Na(+)/H(+) exchanger type 1 (chNHE1) protein (91, 360).

Synthesis and Integration of Viral DNA

Detailed reviews on the synthesis and integration of viral DNA have been provided elsewhere (59, 95, 311). Major stages in formation of retroviral DNA are (1) synthesis of the first (minus) strand of viral DNA by reverse transcription of viral RNA by reverse transcriptase, forming an RNA:DNA hybrid, (2) removal of RNA from the hybrid by RNase-H and formation on the template of minus-strand DNA of second (plus) strands of viral DNA, giving rise to linear DNA duplexes (these duplex molecules are detectable in cytoplasm of the cell within a few hours of infection), and (3) migration of linear DNA to the cell nucleus.

Linear viral DNA is integrated into the host DNA through the action of the viral integrase. This integration can occur at many sites, and infected cells can contain up to 20 copies of viral DNA. The proviral genes occur in the same order as their RNA copies occur in the virion, and they are flanked on either side by the long terminal repeats (LTRs) (Figure 15.19). These sequences include promoter and enhancer sequences controlling transcription of viral DNA to RNA. The LTR promoters also may cause abnormal transcription of host genes, usually downstream of the proviral DNA, leading to oncogenesis.

Transcription

Formation of new virions in the infected cell is the result of transcription and translation of proviral DNA, the major events being as follows: (1) Transcription of viral RNA on a template of proviral DNA under the influence of a host RNA polymerase. Transcription of the pro sequence of the gag/pro gene to produce protease (PR) involves a frame shift. Viral RNA molecules give rise to mRNA in association with polyribosomes, and they also serve as genomic RNA in newly formed virions. New viral RNA is detectable within 24 hours of infection. (2) mRNA species, bound to polyribosomes, are translated to form the gag, pol, and env gene-coded proteins

Table 15.6. Phenotypic expression of representative endogenous avian leukosis viral (*ev*) genes in normal chicken cells.

Phenotype	Symbol	*ev* locus
No detectable viral product	gs^2chf^2	1, 4, 5
Expression of subgroup E envelope antigen	gs^2chf^1	9
Coordinate expression of group-specific and envelope antigens	gs^1chf^1	3
Spontaneous production of subgroup E virus	$V\text{-}E^1$	2

Source: Adapted from Smith (464)

that compose the virion. The gag-pol gene product is a large protein precursor, (180 kD) Pr180, which is cleaved to give a precursor polyprotein, Pr76 (76 kD), from which virion core proteins matrix (MA) (p19), capsid (CA) (p27), nucleocapsid (NC) (p12), protease (PR) (p15), and p10 are derived. The Pr180 polyprotein also gives rise to RT (p63 and p95) and integrase (IN, p32) enzymes. The env gene product is a precursor protein gPr92 (92 kD) from which the viral envelope proteins SU (gp85) and TM (gp37) are derived. Translation of env is from a spliced subgenomic RNA. The viral proteins localize at the plasma membrane of the cell, where crescent-shaped structures develop and virions that bud off from the cell may be visualized.

Defectiveness and Phenotypic Mixing

A number of avian retroviruses (Table 15.6) have been shown to have defective genomes and arise either spontaneously or as a result of experimental mutagenesis (249, 320). Some viruses (certain strains of RSV and acute leukemia viruses) are defective for genes required for replication and are termed replication-defective (rd) mutants. They will transform cells but require the presence of a helper leukosis virus to enable them to replicate (e.g., Bryan high-titer RSV (BH-RSV) and avian myeloblastosis virus (AMV) lack the env gene, and avian erythroblastosis virus (AEV) and MC29 lack the pol and env genes). Other acutely transforming viruses, such as certain strains of RSV, have lost their v-onc gene and ability to transform rapidly: They are called transformation defective (td) mutants and have an oncogenic potential similar to that of non-defective ALVs.

BH-RSV is the classic example of an *rd* mutant and is of practical importance in the non-producer (NP) cell activation test for ALVs (see Diagnosis). On single infection of chick embryo fibroblasts, the defective virus genome of BH-RSV functions to bring about replication of viral RNA, transformation of infected cells, and production of gs antigen. However, only non-infectious progeny particles are produced, which are unable to enter new host cells because of an alteration in their envelope glycoproteins. The morphologically altered cells are called NP cells. A non-defective ALV added to these cells acts as a helper virus by complementing the defective genome of BH-RSV and causes both infectious RSV and progeny ALV to be produced simultaneously. Thus, the presence of infectious RSV in the NP test denotes the presence of ALV in added test material. This RSV has envelope antigens identical to those of the helper virus, which, thus, determines infectivity and range of infectivity in genetically different cells, interference patterns among and between virus subgroups (see Strain Classification), and envelope antigenicity.

Stocks of rd mutant RSV must by their existence contain helper viruses; these originally were referred to as Rous-associated viruses (RAVs). Infectious RSVs formed in these circumstances are called pseudotypes, and their designation includes the helper virus when this is identified (e.g., BH-RSV [RAV-1] when RAV-1 strain ALV helper virus is used). This phenomenon is an example of the phenotyping mixing (PM) (48) that occurs readily when two related viruses infect the same cell, and in which virions with the genome of one virus may possess envelope and other structural proteins of the other parent, or both. The phenomenon of PM also is used in the PM test for detection of ALV (see Diagnosis). Use of defective strains of RSV enables tailor-made RSV to be produced with envelope properties of the helper ALV. Determinations of host range, interference pattern, and neutralization can be performed more easily with the appropriate RSV pseudotype than with the ALV, because the former can be readily quantified in cell culture.

These factors notwithstanding, infectious RSV may be generated with BH-RSV and other rd mutants following solitary infections in the absence of added helper viruses in certain types of chicken cells that carry endogenous ALV genomes (see Endogenous Leukosis Viruses). Such RSV has the subgroup E host range of the endogenous virus, however, and may be distinguished from helper viruses of other subgroups when NP tests are conducted.

Endogenous Leukosis Viruses

ALVs that are transmitted as infectious virus particles are termed exogenous viruses. The normal chicken genome also contains several classes or families of avian retrovirus-like elements (116) that are transmitted genetically and are termed endogenous viruses. These include the endogenous viral (ev) loci, recognized some 30 years ago, and the more recently discovered moderately repetitive elements EAV (endogenous avian virus) (54, 161) and ART-CH (avian retrotransposon from chicken genome) (51, 359, 445) and the highly repetitive elements CR1 (chicken repeat 1) elements (500, 501). Endogenous retroviruses in chickens are examples of the numerous retroelements present in eukaryotes. Certain retroelements are believed to represent stages in the evolution of retroviruses from cellular movable genetic elements (transposons); whereas others are thought to be degenerate proviral forms of exogenous retroviruses that have lost the ability to produce infectious virus due to mutations. The significance of these elements is currently the subject of much research.

The genetic sequences of the ev loci are related to subgroup E ALVs and are present as either complete or defective

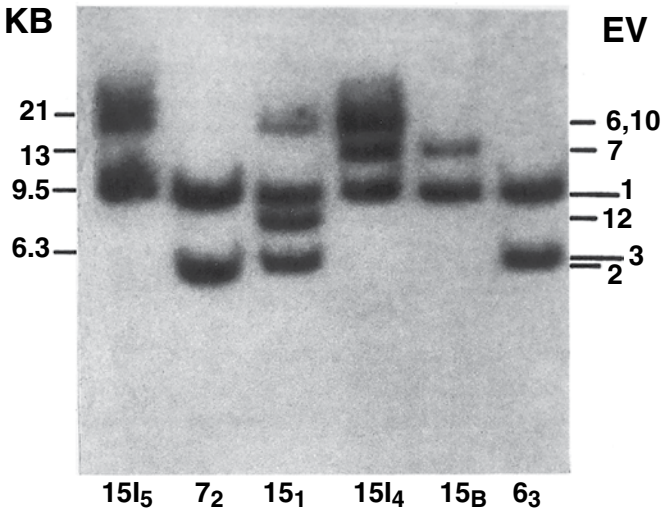

Figure 15.21. Endogenous viral (ev) loci detected in 6 inbred lines of white leghorns by restriction fragment polymorphisms generated after Sac-1 endonuclease digestion of red blood cell DNA and hybridized to ^{32}P-labeled RAV-2 genomic sequences. (469)

genomes in almost all normal chickens (reviewed in 115, 327, 395, 574) (Figure 15.21). The chromosomal locations of a number of ev loci have been determined (516) and the availability of the chicken genome sequence (107, 235) has enabled the identification of their genomic locations. They occur in somatic and germ line cells and are transmitted genetically in a Mendelian fashion to their progeny by both sexes (8, 125). At least 29 ev loci have been identified (237, 469) and locus-specific PCR tests for their identification have been described (41). Each chicken has been reported to carry on average about 5 ev loci (437). The phenotypic expressions of these loci vary, depending on the viral genes present and on poorly understood control mechanisms (Tables 15.6 and 15.7). When the complete endogenous viral genome is present, the cell may produce subgroup E ALV, either spontaneously or after induction by chemicals such as bromo-deoxyuridine (BrdU). When the endogenous virus is incomplete (defective), genes present may be expressed phenotypically in the cells, but infectious virus is not produced. This is because of the absence of the complete set of genes needed for infectious virion production (e.g., the defective ev3 locus possesses the gag and env genes of subgroup E ALV, and cells carrying this locus contain gs antigen and subgroup E viral envelope glycoproteins). However, the locus has a genetic deletion around the gag-pol junction, and infectious virions are not formed. The presence of ev genes in such cells is responsible for their positive reactions in the enzyme-linked immunosorbent assay (ELISA) test, the complement-fixation test for avian leukosis viruses (COFAL), and the chick helper factor (chf) test (see Diagnosis).

In the chf test, genetic defectiveness in the envelope of BH-RSV is complemented by endogenous envelope proteins, resulting in an infectious form of RSV with subgroup E host range and other properties. Genetic characteristics of ev loci

Table 15.7. Phenotypes of endogenous avian leukosis (*ev*) genes in inbred and commercial lines of white leghorn chickens.

ev	Phenotype	Line or Source[a]
1	gs^2chf^2	Most lines
2	V-E^1	RPRL72
3	gs^1chf^1	RPRL63
4	gs^2chf^2	SPAFAS
5	gs^2chf^2	SPAFAS
6	gs^2chf^1	RPRL151
7	V-E^1	RPRL15B
8	gs^2chf^2	K18
9	gs^2chf^1	K18
10	V-E^1	RPRL 15I4
11	V-E^1	RPRL 15I4
12	V-E^1	RPRL 151
14	V-E^1	H & N
15 (C)	None	K28 3K16
16 (D)	None	K28 3K16
17	gs^2chf^2	RC-P
18	V-E^1	RI
19	V-E^1(?)[b]	RW
20	V-E^1(?)[b]	RW
21	V-E^1	Hyline FP

Note: *Ev*13 is associated with the gs^2chf^2 phenotype, but restriction fragments have not been characterized.

[a] Not exclusive to line or source. K, Kimber; R, Reaseheath; H & N, Heisdorf and Nelson; for references see Smith (464).

[b] The presence of 5 *ev* loci in Reaseheath line w birds precludes definitive assignment with the V-E^1 phenotype. Definitive association requires further segregation of *ev* genes. Hyline FP birds also carry *ev*1, *ev*3, and *ev*6.

are described in detail (116, 469, 552, 553). The expression of endogenous ev genes is responsible for a dominant form of genetic resistance of chicken cells to infection by subgroup E ALV from a block of virus receptors by envelope protein (396, 429). Transmission of ev genes from parent to offspring has been called genetic transmission of ALV (551), distinguishing it from the vertical (congenital) and horizontal (contact) transmission of viruses in an infectious state. However, fully expressed infectious endogenous virus may sometimes also be transmitted vertically and horizontally (480). Related ev loci occur in several species of fowl, other than domestic chickens, including red jungle fowl and some strains of pheasant, partridges, and grouse, but the distribution does not support a phylogenetic relationship (207, 221). Rather, it is considered that the ALV genomes have become incorporated at various loci relatively recently in the history of *Gallus* and independent of integration in other genera. The presence of ALSV gag genes in 26 species of galliform birds recently was reported (147, 148). Evidence of congruence of ALSV and host phylogenies exists along with evidence of horizontal ALSV transmission between hosts of different phylogenies. It is not known whether endogenous viruses arise from exogenous viruses of other subgroups, from which they differ genomically at the env gene and the LTR region, or vice versa.

Subgroup E ALV, typified by the RAV-0 strain of ALV, has little or no oncogenicity (343), apparently because of the weak promoter activity of the LTR. Persistence of these viral loci suggests that birds carrying them are not at a great disadvantage, and they may be beneficial. Thus, Crittenden et al. have shown that the presence of ev2 or ev3 protects birds from a unique non-neoplastic syndrome caused by infection with an exogenous subgroup A ALV (120, 131). Endogenous viruses will have either beneficial or detrimental effects, perhaps by their induction of immunity or tolerance to tumor virus antigens, depending on when they are expressed. Long-term selection studies showed that only a few of the integrations contributed to the high ALVE expression which seemed to correlate with lower body weights for the females, indicating potential linkage to the loci regulating growth (275). Embryonic infection with endogenous ALV, RAV-0, caused more persistent viremia and more neoplasms following infection with exogenous ALV, apparently due to tolerant depression of specific humoral immunity (123). Similarly, subgroup E recombinants of endogenous and exogenous viruses have been reported to be capable of inducing neoplasm (121). Endogenous viruses of the ev family are not essential, because it has been possible to produce chickens free of ev genes (7). A line of such chickens has been produced, designated line 0 (119), that is of value in research studies and certain diagnostic tests in which birds or cells free from ev loci are needed. Other chickens lacking ev loci have been recognized (116), but the great majority have these endogenous sequences. More recently, methods of detecting and developing commercial chicken strains free of endogenous retroviruses have been described (14, 468).

Of particular importance is the ev21 locus, which is linked tightly in white leghorn stock to the dominant sex-linked gene, K, on the Z chromosome (15), which regulates slow feathering. It is possible that insertion of the ev21 sequence into a feather growth locus is responsible for the slow feathering mutation (116). Some breeders producing feather-sexed crosses have reported reduced egg production and higher leukosis mortality associated with an increased incidence of viremia with exogenous ALV in fast-feathering female progeny from dams carrying the K gene. The ev21 gene is expressed as an infectious endogenous ALV, EV21, in the dam, which is transmitted congenitally to the progeny, inducing immunological tolerance and, consequently, increased susceptibility to infection by exogenous ALV (15, 244, 471, 473). Strategies to overcome the ev21 locus effect have been studied (165, 475, 476, 478).

The biologic functions, if any, of the other endogenous elements described, namely EAV, ART-CH, and CR1, remain to be determined. Members of the EAV family are not expressed as infectious virus, but RT activity can be expressed and has been found in live virus vaccines (260, 262, 428, 523, 556). A member of the EAV family, EAV-HP (also termed ev/J), is believed to be the origin of the env gene of subgroup J ALV (20, 43, 44, 143, 443, 445, 483). The 5′ sequences of ART-CH and EAV-HP are almost identical (445). Embryonic expression of EAV-HP env has been suggested to be associated with the induction of immunological tolerance, a feature observed in a significant proportion of meat-type chickens infected with ALV-J. In support of this hypothesis, it was recently demonstrated that EAV-HP loci are still segregating within the chicken population (447). Recently the strongest evidence of the role of EAV-HP in the emergence of ALV-J by recombination was obtained from the identification of an intact chicken EAV-HP locus showing a uniquely close relationship to the ALV-J prototype clone HPRS-103 env region (446).

CR1 elements are non-LTR-containing retroelements (retroposons) possessing RT sequences. They are highly numerous and are considered ancient and primitive sequences, preceding the evolution of birds, and are not functionally expressed (309, 501, 550, 558).

Susceptibility to Chemical and Physical Agents

Lipid Solvents and Detergents

Avian retroviruses have high lipid content in the envelope, and their infectivity is abolished by ethyl ether (205). The detergent sodium dodecyl sulfate disrupts the virions and releases RNA and core proteins (431).

Thermal Inactivation

The half-life of various ALSVs at 37°C varies from 100–540 minutes (average, around 260 minutes), depending on the medium in which the virus is suspended, the tissue of origin, and the virus strain. ALSVs are inactivated rapidly at high temperatures; the half-life for RSV at 50°C is 8.5 minutes and at 60°C is 0.7 minutes (157).

Thermal lability of infectivity of these viruses is a critical factor in storage. Even at -15°C, the half-life of AMV is less than 1 week (164); it is only at temperatures below -60°C that avian retroviruses can be stored for several years without loss of infectivity (62). Freezing and thawing degrade the virus, and the gs antigen is released.

pH Stability

The stability of viruses of this group changes little between pH 5 and 9; outside this range, inactivation rates are markedly increased.

Ultraviolet Irradiation

RSV and field strains of ALV are relatively resistant to exposure to ultraviolet light (205, 440).

Strain Classification

Antigenicity

ALSVs that occur in chickens have been divided into 6 envelope subgroups, A, B, C, D, E, and J, on the basis of differences in their viral envelope glycoproteins, which determine antigenicity, viral interference patterns with members of the same and different subgroups, and host range in chicken embryo fibroblasts of different phenotypes (104, 395, 554).

The other subgroups, F, G, H, and I, represent endogenous ALVs occurring in pheasants, partridges, and quail (189, 379).

Viral interference patterns (Table 15.8) and host range patterns (Tables 15.9 and 15.10) are the most reliable methods for subgroup classification. Antigenicity, as determined by the production of neutralizing antibodies or neutralization by known subgroup-specific antibodies, also can also be used for strain classification, but is less dependable. Viruses within a subgroup usually cross-neutralize to varying extents, but with the exception of partial cross-neutralization between subgroup B and D viruses, viruses of different subgroups do not. However, antisera against particular isolates of subgroup J virus do not always cross-neutralize other J isolates, or they may show one-way cross-neutralization (181, 192, 371, 374, 535). Subgroup B viruses appear to be more heterogeneous than those of subgroup A, and subgroup J viruses are especially variable (212, 213, 302, 531, 535, 547).

Table 15.8. Interference patterns between ALV and RSV of subgroups A–E and J.

Subgroup of interfering ALV	Subgroup of challenge RSV					
	A	B	C	D	E	J
A	1	2	2	2	2	2
B	2	1	2	1	1	2
C	2	2	1	2	2	2
D	2	2	2	1	2	2
E	2	2	2	2	1	2
J	2	2	2	2	2	1

Note: Susceptible avian embryo fibroblast cultures are infected with ALV of each subgroup and challenged several days later with RSV of each subgroup. Reduction in RSV foci in infected cultures compared with uninfected controls is indicative of viral interference. 1, interference; 2, no interference.

Table 15.9. Examples of host range of subgroup A–E and J avian leukosis/sarcoma viruses in chicken embryo cells of different phenotypes.

Phenotype of cells	Examples (chicken or cell lines)	Subgroup of virus					
		A	B	C	D	E	J
C/0	15B1	S	S	S	S	S	S
C/AE	C, alv6	R	S	S	S	R	S
C/A,B,D,E	7_2	R	R	S	R	R	S
C/E	0, 15l, BrL	S	S	S	S	R	S
C/EJ	DF-1/J[a]	S	S	S	S	R	R

Note: S, susceptible; R, resistant. The cell phenotype designation denotes chicken (C) cells resistant to (/) the specified subgroup (0, no subgroup; AE, subgroups A and E; etc.).
[a] Cell line, Hunt et al. (265).

Table 15.10. Host range of different subgroups of Rous sarcoma virus (RSV) in embryo fibroblasts of various avian species.

Avian species	Subgroup of RSV					
	A	B	C	D	E	J
Red jungle fowl	S	S	R	R	R	S
Common pheasant	S	R	R	R	S	R
Japanese quail	S	R	R	R	S	R
Guinea fowl	S	S	S	S	S	R
Turkey	S	S	S	S	S	S
Peking duck	R	R	S	R	R	R
Goose	R	R	S	R	R	R

Note: Embryo fibroblast cultures from avian species are challenged with RSV and susceptibility to RSV focus formation determined. S, susceptible; R, resistant. Data from Payne et al. (389).

Molecular Characteristics

Sequence analysis of the gp85 encoding sequences of the *env* genes of ALVs of subgroups A–E have identified 2 hypervariable regions, hr1 and hr2, and 3 less variable regions, vr1, vr2 and vr3, in which differences between the subgroups are present (52, 53, 156). Studies of recombinants indicated that hr1 and hr2, and to a lesser extent vr3, play the major role in determining receptor tropism (155). However, the exact locations and nature of the differences that determine host range and antigenicity have not yet been identified. The gp85 sequence of the env gene of subgroup J ALVs differs more extensively from those of the other 5 subgroups, notably at hr1, hr2, vr2, and vr 3, and to a lesser extent also between these regions (20, 21). Different subgroup J isolates also vary at particular hypervariable regions of gp85 (212, 374, 578). Primers from the variable regions of the env gene of subgroups A–E and J have been used in PCR tests to identify subgroups of ALV isolates (215, 281, 466, 482, 577, 584). These tests have the potential to be used in strain classification, although more extensive studies are needed of multiple isolates within subgroups to fully evaluate their specificity.

Pathogenicity

Numerous strains of ALSVs exist, many of which were isolated from naturally occurring or experimentally induced neoplasms over many years. Many induce a predominant type of neoplasm and can be named accordingly; e.g., lymphoid leukosis virus (LLV), although ALV is most commonly used rather than LLV, avian erythroblastosis virus (AEV), avian myeloblastosis virus (AMV), and avian sarcoma virus (ASV) (Table 15.11). Commonly, however, the virus strains induce other neoplasms in addition to the predominant one, and the tumor spectrum can be wide. The oncogenic spectrum tends to be characteristic of a particular virus strain, but often overlaps with other strains. Thus, the RPL12 strain of ALV induces lymphoid leukosis, erythroblastosis, osteopetrosis, hemangiomas, and sarcomas; the BAI A strain of AMV induces myeloblastosis, lymphoid leukosis, osteopetrosis,

Table 15.11. Laboratory strains of avian leukosis/sarcoma viruses of the chicken classified according to predominant neoplasm induced and virus envelope subgroup.

Virus class according to neoplasm	Virus class according to envelope subgroup						No subgroup (defective virus)[a]
	A	B	C	D	E	J	
Lymphoid leukosis virus (LLV)	RAV-1 RIF-1 MAV-1 RPL12 HPRS-F42	RAV-2 RAV-6 MAV-2	RAV-7 RAV-49	RAV-50 CZAV	RAV-60		
Avian erythroblastosis virus (AEV)							AEV-ES4 AEV-R AEV-H
Avian myeloblastosis virus (AMV)							AMV-BAI-A
Avian sarcoma virus (ASV)	SR-RSV-A PR-RSV-A EH-RSV RSV29	SR-RSV-B PR-RSV-B HA-RSV	B77 PR-RSV-C	SR-RSV-D CZ-RSV	SR-RSV-E PR-RSV-E		BH-RSV BS-RSV FuSV PRCII PRCIV ESV Y73 UR1 UR2 S1 S2
Myelocytoma and endothelioma viruses						HPRS-103 ADOL-Hc1	MC29 966 MH2 CMII OK10 RAV-0
Endogenous virus (EV) (no neoplasm)					EV21 ILV-E		

[a] Defective viruses have the envelope subgroup of their helper virus.

nephroblastomas, sarcomas, hemangiomas, thecomas, granulosa cell tumors, and epitheliomas (36).

The spectra of tumors induced have several explanations. Some strains of virus consist of mixtures of viruses either fortuitously or because some may require coinfecting helper viruses for replication (see later discussion). However, clone-purified strains of ALV can cause a variety of neoplasms in addition to lymphoid leukosis, including erythroblastosis, osteopetrosis, and nephroblastomas (419), and clone-purified AEV can induce both erythroblastosis and sarcomas, irrespective of the helper virus (233). The relatively high mutation rate of retroviruses no doubt contributes to strain variability. The tumor spectrum of a virus strain also can be modified in passage experiments according to the type of neoplasm used to harvest virus.

Virus dose is an important factor in determining tumors induced. Thus, high doses of strain RPL12 of ALV mainly cause erythroblastosis, whereas low doses cause lymphoid leukosis (74). Factors that influence effective dose, including route of inoculation and age and genotype of the host, also influence the oncogenic spectrum.

Strains of ALSV also can be placed into 2 major classes in respect of rapidity of induction of tumors.

1. Acutely transforming viruses. These viruses can induce neoplastic transformation, *in vivo* or *in vitro*, within a few days or weeks. They cause various types of acute leukemia (leukosis) or solid tumors (usually sarcomas) (172, 174, 232, 295, 339). The acutely transforming viruses are those that carry viral oncogenes in their genome (Table 15.5). Details of viral oncogenes and the biochemical functions of their products have been reviewed elsewhere (104, 295, 320, 395, 539).
2. Slowly transforming viruses. These ALVs do not carry viral oncogenes. They induce tumors by a "promoter insertion" or a related mechanism that activates a cellular oncogene to bring about neoplastic transformation and development of tumors over many weeks or months (104, 174, 198, 295, 346).

Nomenclature

A variety of conventions, which reflect the classification methods outlined previously, are used in designating ALSVs; many of these are illustrated in Table 15.11. They are given a

full and an abbreviated designation based on the predominant neoplasm they induce, with an affix to indicate their origin with an individual (e.g., Rous sarcoma virus [RSV]) or a location (e.g., Regional Poultry Research Laboratory isolate 12 [RPL12 of ALV). Substrains of RSV are designated according to individuals who worked with them (e.g., Bryan's high-titer strain [BH-RSV]) or to location (e.g., Prague [PR-RSV]). Subgroups (e.g., subgroup A) also may be designated: PR-RSV-A. The general terms avian leukosis (or leukemia) virus (ALV) and avian sarcoma virus (ASV) are used widely to designate members of the group.

Helper viruses isolated from stocks of defective viruses are named, for example, as Rous-associated virus (RAV) or myeloblastosis-associated virus (MAV), and isolates are numbered (RAV-1, MAV-1, etc.). Where a helper virus is used for replication of a defective virus, this is indicated. Thus, BH-RSV grown with RAV-1 as a helper is designated BH-RSV(RAV-1). Endogenous ALV is abbreviated EV (e.g., EV21). Strains of ALV that act as resistance-inducing factors (see Diagnosis) were designated RIFs, but this term is now rarely used. Further details of the origins of the abbreviations (379) are given in Table 15.11.

Laboratory Host Systems

Chick Inoculation

Rous sarcoma and other sarcoma viruses produce tumors when injected by the subcutaneous (SC), intramuscular (IM), or intra-abdominal (IA) routes and at times by contact with inoculated chickens. Subcutaneous injection into the wing web or IM injection can be used for sarcoma virus isolation and propagation (337, 420), and SC inoculation has been used for TD_{50} assays of stocks of RSV (61). Following wing-web injection of high doses of RSV, tumors are first palpable at about 3 days. In susceptible chickens, these may grow rapidly, ulcerate, and metastasize; in resistant chickens, the sarcomas may regress (61).

ALVs may be inoculated IA or IV into day-old susceptible chicks to obtain a tumor response. Burmester and Gentry (73) inoculated strain RPL12 of ALV IA into day-old line 15I chicks and obtained a tumor response in 200–270 days. This procedure was used for initial isolation of virus from field cases (72). Time required for quantitative assay of certain strains passaged in the laboratory was shortened to 63 days by using the less sensitive erythroblastosis response (63). In these transmission experiments, all sources of virus that cause LL also caused erythroblastosis. Osteopetrosis, hemangiomas, and fibrosarcomas were also observed in chickens of certain strains and passages (71, 74).

AMV can be titrated in susceptible chicks by IV inoculation at 1–3 days of age (162, 163). AMV in chicken plasma can be assayed by its adenosine triphosphatase activity, a method useful for routine and large-scale studies (40).

Osteopetrosis-inducing activity of virus strains can be examined by IV or IM inoculation of day-old chicks (71, 254). Guinea fowl are particularly susceptible to MAV-2(O)-induced osteopetrosis (282, 283, 285, 286).

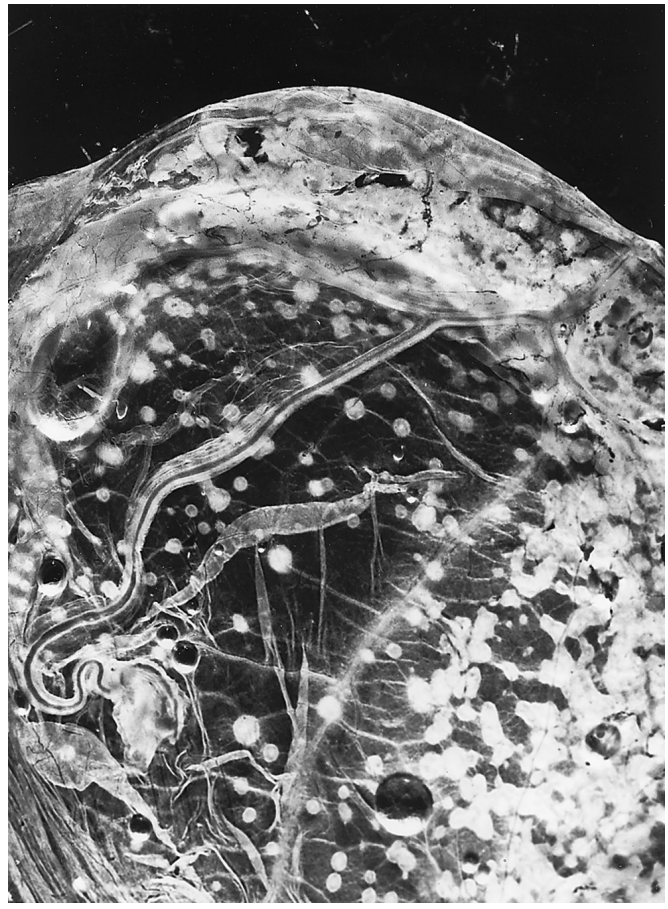

Figure 15.22. Pocks induced by BH-RSV on the chorioallantoic membrane (CAM) of a chicken embryo. (Piraino)

Embryo Inoculation

When RSV and other sarcoma viruses are inoculated onto the chorioallantoic membrane (CAM) of 11-day-old susceptible embryos, tumor pocks develop (Figure 15.22), which can be counted 8 days later and are related linearly to virus dose (159). This technique also is useful for detecting genetic resistance to infection.

ALVs have been quantitated by IV inoculation into 11-day-old susceptible chicken embryos. Depending on the virus, within 2 weeks of hatching, a high incidence of neoplasms (mainly erythroblastosis) can occur, although hemorrhages and solid tumors can develop including fibrosarcomas, endotheliomas, nephroblastomas, and chondromas. When chicks are held for a post inoculation (PI) period of 46 days, responses are higher by 1–2 $\log_{10}$ dilutions than those following chicken inoculation. Most chickens that survive the acute neoplasms develop LL after 100 days PI (404).

AMV produced a myeloblastosis response within a few weeks when injected by IV into susceptible embryos (23, 24, 25). When the HPRS-103 strain of subgroup J ALV was inoculated by IV into 11-day-old embryos, first death from tumor (myelocytoma) was not until 9 weeks of age, and median tumor mortality was at 20 weeks (388).

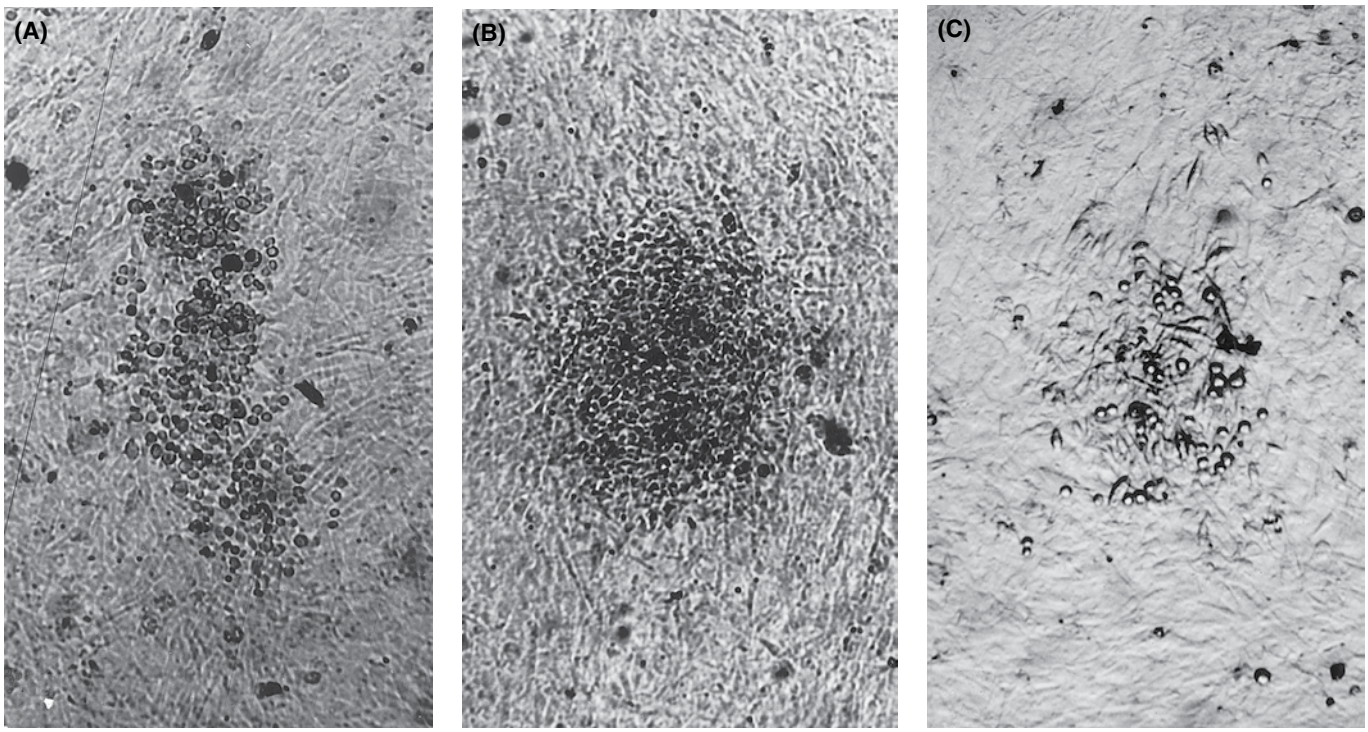

Figure 15.23. Foci induced by Rous sarcoma virus (RSV) in cell culture. (A) Unstained focus of transformed spherical, refractile chicken embryo cells infected 6 days previously with Bryan's standard strain of RSV. ×100. (B) Unstained focus of transformed, polygonal, opaque Rous sarcoma cells infected 6 days previously with Bryan's high-titer strain. ×100. (C) Unstained focus of transformed round and fusiform cells infected 6 days previously with Popken's preparation of RSV. ×100.

Cell Culture

RSV and other sarcoma viruses induce rapid neoplastic transformation of cells when inoculated onto monolayer cultures of chicken embryo fibroblasts (418). The transformed cells proliferate to produce within a few days discrete colonies or foci of transformed cells (Figure 15.23), which under agar can be used for quantitative assay of virus (515). Such cell culture methods are preferred for virus assay.

Most leukosis viruses replicate in fibroblast cultures without producing any obvious cytopathic effect. Their presence can be detected by a variety of tests (see Diagnosis). ALVs of subgroups B and D may induce cytopathic plaques that may be used for virus assay (231). The cytopathic effect of these 2 subgroups is explained by their use of the death receptor of the tumor necrosis factor receptor family (57, 100, 145, 146). Morphological alterations also have been reported after prolonged passage of ALV-infected fibroblasts (84).

Acutely transforming ALVs will transform hematopoietic cells *in vitro* (339). Yolk sac and bone marrow cells in culture are transformed to neoplastic myeloblasts on infection with AMV (340), and bone marrow cells transform to erythroblasts with AEV (230). Transformation of hematopoietic cells by MH2, MC29, and OK10 viruses was observed by Graf and Beug (232). Such acutely transforming ALVs have been used extensively to study avian hematopoietic cell lineages and differentiation (45, 325, 326). Acutely transforming variants of subgroup J ALV also can transform bone marrow cells and blood monocytes *in vitro* (96, 389). *In vitro* transformation of B-lymphocytes by non-defective ALV has not been reported, and bone marrow cultures were not transformed by non-defective subgroup J ALV (389).

Tumor cell lines derived from tumors induced *in vivo* by the ALVs have been developed, including LL (364, 463), myeloblastosis (304), erythroblastosis (230), and myelocytoma (305).

The properties of ALSVs in cell culture are described in more detail under Diagnosis.

Pathogenicity

As discussed previously (see Strain Classification), strains of ALVs may produce more than one type of neoplasm, and the oncogenic spectrum of each strain tends to be characteristic but often overlaps with responses to other strains. Viral factors, including the origin and dose, and host factors, such as route of inoculation, age, genotype, and sex, influence the oncogenic patterns of different virus strains.

Origin of Virus

Differences in tumor spectrum may be seen in virus strains newly isolated from the field (203). Fredrickson et al. (203, 204) observed that serial transfer from donors with LL resulted primarily in LL, and virus from donors with erythroblastosis predominantly caused erythroblastosis. In another instance, selection of virus donors with hemangiomas resulted in a larger proportion of birds with this tumor than in a previous passage (74).

In some situations, the outcome may be due to a virus-dose effect, but in other instances, an acutely transforming ALV with a transduced oncogene may have been generated (251).

Virus Subgroup

Usually no relationship has been observed between virus subgroup and oncogenicity except for endogenous E subgroup ALVs, such as RAV-0, which have little or no oncogenicity, thought to be due to the weak promoter activity of the subgroup E LTR (343). Subgroup J ALV induced myelocytomatosis (388), and the env as well as other elements are thought to be associated with the unique oncogenicity (96, 97, 98, 316, 317).

Virus Dose

High doses of RPL12 ALV mainly induced erythroblastosis, whereas doses close to the endpoint predominantly induced LL (74). Sarcomas, endotheliomas, and hemorrhages also were more common with high virus doses. Occurrence of osteopetrosis showed no dependency on dose (204).

Route of Inoculation

Responses obtained after virus administration by less efficient portals of entry into the host apparently reflect the decreased effective dose. Thus, exposure of susceptible birds by contact with birds inoculated with a high dose of strain RPL12 of ALV resulted in an LL response similar to that expected with 1/1,000 of the inoculated dose (74). Intramuscular inoculation of strain RPL26 of ALV favored sarcoma induction, whereas IV inoculation mainly produced erythroblastosis and hemorrhages (204). These differences may reflect variations in amounts of virus that reach the target cells by different routes.

Age of Host

In general, resistance of birds to the development of neoplasms increases with age, with the rate varying with route of inoculation. Resistance increases rapidly between 1 and 21 days of age with oral or nasal administration but relatively slowly when virus is inoculated intravenously (71). Types of tumors produced also reflect the decreased effective dose (74). However, the incidence of some tumors decreases more rapidly than expected from the dose effect alone. For example, certain preparations of strain RPL12 ALV given via IV at 1 day of age caused a high incidence of osteopetrosis; the proportion of chickens inoculated at 3 weeks of age and developing osteopetrosis was only one-tenth that of chickens inoculated at 1 day of age (71).

Genotype and Sex of Host

The genetic constitution of the host has a strong influence on response to ALSVs (see Pathobiology and Epizootiology). Females are more susceptible to LL than males. Castration increases the incidence of disease, and treatment with testosterone increases resistance of males and capons (75). These effects are probably a consequence of hormonal effects influencing regression and, hence, target cell numbers in the cloacal bursa (bursa of Fabricius).

Pathobiology and Epidemiology

Incidence and Distribution

ALVs are still considered ubiquitous in commercial chickens. However, implementation of the eradication programs by most of the primary breeding companies has resulted in significant decreases in the incidence, and most of the descriptions given here are from past reports.

Incidence of Disease

Although sporadic cases of ALV-induced neoplasia occur in most flocks, it is only occasionally that even the most common neoplasm, LL, produces heavy losses (184, 189, 192, 385, 398). De Boer (139, 140) reported LL mortality in the Netherlands as 2.18% of 11,220 white layers and 0.57% of 7,920 brown layers, recorded in random sample tests from 1973–1979. The incidence of LL in chickens may be reduced by the widespread occurrence of infectious bursal disease virus (133, 415, 417). Conversely, serotype 2 MDV was found to enhance the development of LL in certain lines of chickens following exposure to ALV after hatch (18, 183, 186, 195). Also, an increased frequency of spontaneous bursal lymphoma (135) in white leghorn chickens inoculated with serotype 2 MDV has been reported (449). Molecular and *in situ* hybridization analysis of the bursa from chickens co-infected with ALV and serotype 2 MDV proved that MDV was closely associated with transformed, but not with nontransformed, bursa cells (211, 322). *In vitro* studies also showed that serotype 2 MDV can increase ALV and RSV gene expression (26, 413, 520).

Under field conditions, erythroblastosis occurs less frequently than LL (414). However, a rare epizootic of erythroblastosis has been reported in 5-week-old birds (243). Very few reports have been made of natural occurrence of myeloblastosis, but cases occur sporadically.

Until recently, and before the recognition of subgroup J ALV (386, 398), myelocytomatosis was mainly a sporadic disease seen among young and adult birds (414). An overall incidence of 27% myelocytomatosis was reported in meat-type chickens inoculated with strain HPRS-103 of ALV-J (388). High incidence of ALV-J tumors has been reported in many countries (19, 212, 213, 371, 519, 531) with mortalities up to 1.5% in excess of normal levels/week in some commercial broiler breeder flocks (194). ALV-J-induced disease in China is characterized by the occurrence of the disease in meat-type as well as layer populations including the native breeds (312, 503) and is characterized by a high incidence of hemangiomas (302, 582). Earlier studies on the type of tumors also showed that apart from the leukotic tumors, hemangiomas make up 25% and 19%, and nephroblastomas 19% and 3–10%, in broilers (87) and layers (414), respectively.

Connective tissue tumors, which are often not the primary cause of death, make up about 20% of nonlymphoid tumors in broilers (87). The incidence of connective tissue tumors in chickens is probably less than 1 in 1,000 (414), but epizootics

have occurred. Outbreak of histiocytic sarcomas was reported in a flock of 600 1-year-old hens, during which tumors were found in 90% of 400 birds examined during a 4-month period (399). Low incidence of histiocytic sarcomatosis also has been associated with ALV-J (4).

Osteopetrosis occurs much less frequently than LL, and epizootics occur sporadically in broilers. In all types of chicken, males are more frequently affected than females. Examination of a 1986 outbreak of osteopetrosis revealed ALV sequences (27).

Incidence of Virus Infection

ALV belonging to the subgroup A are the most common viruses isolated from field outbreaks of LL. In one study (83), 1.6%–12.5% of the embryos from 8 commercial flocks representing a variety of sources contained subgroup A ALV, and there was significant shedding in every flock. In contrast, viruses belonging to the subgroup B were relatively rare and shed in eggs much less frequently. In general, fewer studies of the prevalence of ALV in meat lines have been made compared with those in egg lines. Antibodies to the novel subgroup J ALV were found in 3 of 5 meat-type chicken lines, but not in 7 layer lines examined in the United Kingdom (393). Using virological and serological assays, the incidence of ALV-J infection in affected broiler breeder flocks was reported to be as high as 87% (194). Similar high levels of ALV-J infection also have been reported in other countries (19, 303, 321, 519, 531, 572). The incidence of infection with subgroup ALV-J also was influenced by other factors such as age at exposure (562, 563).

Subgroups A, B, C, and D of ALV have been isolated from commercial flocks in Finland; 5 of 10 flocks surveyed had antibody to all 4 subgroups (450).

Antibodies to subgroups A and B are common among wildfowl and domestic chickens in Kenya and Malaysia, and some evidence exists of antibody to subgroup D viruses in Kenya. Subgroup F viruses have been found in ring-necked and green pheasants, and subgroup G viruses in Ghinghi, silver, and golden pheasants. Subgroup H virus has been isolated from Hungarian partridges and subgroup I virus from Gambel's quail (see Virus Subgroups). Viruses that do not fit within known subgroups have been isolated from Mongolian and Swinhoe pheasants, Chinese quail, and chickens. However, none was found in Japanese quail, pigeons, geese, and Pekin and Muscovy ducks (94).

In most vertebrate species, endogenous retroviral genomes are inherited in a Mendelian fashion and occur at distinct chromosomal loci. DNA sequences related to RAV-0, the endogenous avian retrovirus, occur in the germ lines of most domestic chickens and several species of galliform birds. For example, partridges, true pheasants, grouse, and jungle fowl contain sequences complementary to RAV-0, whereas guinea fowl, quail, peafowl, ruffed pheasants, gallo-pheasants, and turkeys do not (206). The structure, function, and regulation of endogenous retroviruses in the genome of the chicken have been reviewed (116).

Natural and Experimental Hosts

Chickens are the natural hosts for all viruses of the L/S group (381); these viruses have not been isolated from other avian species except pheasants, partridges, and quail (see Virus Subgroups). Experimentally, however, some members of the L/S group of avian retroviruses have a wide host range and can be adapted to grow in unusual hosts by passage in very young animals or through the induction of immunologic tolerance prior to inoculation of the virus. RSV has the widest host range; it will cause tumors in chickens, pheasants, guinea fowl, ducks, pigeons, Japanese quail, turkeys, and rock partridges. Ducks were shown to be an ideal experimental system for studying persistence of ALV because the virus appeared to persist even up to 3 years with no viremia or neutralizing antibodies after embryonic infection (351). However, ducks infected as embryos with subgroup C showed wasting disease soon after hatching (497, 507, 522). There has been one report of lymphoid leukosis in ostriches (214). Some strains of RSV induce tumors in mammals (537), including monkeys (291, 292, 293, 294). Osteopetrosis can be produced in turkeys by inoculation of fresh whole blood from affected chickens (254). Also, turkeys were susceptible to ALV-J infection and tumors induced by the acute form of strain HPRS-103 of ALV-J (534).

Transmission

Exogenous ALVs are transmitted in 2 ways: vertically from hen to progeny through the egg and horizontally from bird to bird by direct or indirect contact (reviewed in 189, 380, 395) (Figure 15.24). Although usually only a small percentage of chicks are infected vertically, this route of transmission is important epizootiologically because it affords a means of maintaining the infection from one generation to the next. Most chickens become infected by close contact with congenitally infected birds. Although vertical transmission is important in the maintenance of the infection, horizontal infection also may be necessary to maintain a rate of vertical transmission sufficient to prevent the infection from dying out (387). The infection does not spread readily through indirect contact, probably because of the relatively short life of the virus outside the birds (see Thermal Inactivation). However, contact exposure at hatch was shown to be an effective method of spread of ALV-J among broiler breeder chickens (194, 564, 565) and was prevented by small group rearing (568).

Four classes of ALV infection are recognized in mature chickens: (1) no viremia, no antibody (V-A-); (2) no viremia, with antibody (V-A+); (3) viremia, with antibody (V+A+); and (4) viremia, no antibody (V+A-) (reviewed in 178, 189, 380, 395). Birds in an infection-free flock and genetically resistant birds in a susceptible flock fall into the category V-A-. Genetically susceptible birds in an infected flock fall into one of the other three categories. Most are V-A+, and a minority, usually less than 10%, is V+A-. Most V+A- hens transmit ALV to a varying but relatively high proportion of their progeny (380, 395). A small proportion of V-A+hens transmit the virus congenitally and do so more intermittently; the tendency for congenital transmission of ALV in this category was found

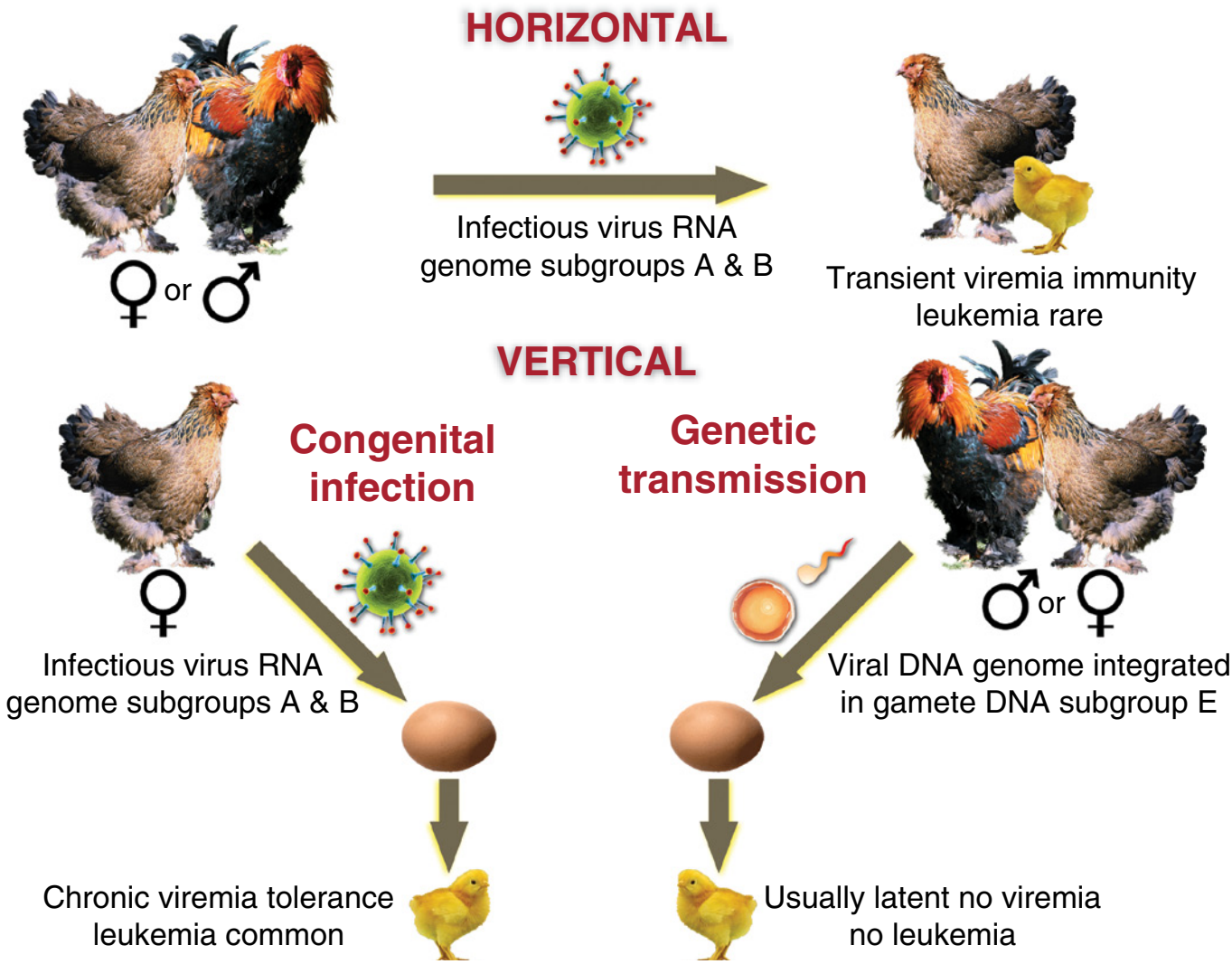

Figure 15.24. Horizontal and vertical transmission of exogenous ALV (e.g., subgroups A and B) and genetic transmission of endogenous (subgroup E) virus with potential outcomes. (115)

to be more frequent in hens with low antibody titer (525). Congenitally infected embryos develop immunologic tolerance to the virus and after hatching make up the V+A- class, with high levels of virus in the blood and tissues and an absence of antibodies. By 22 weeks of age, up to 25% of meat-type chickens exposed to ALV-J at hatch were found to be V+A-, although this could be affected by a number of factors including the virus strain (375).

The role of males in the transmission of ALV is at best equivocal. Infection of the cock apparently does not influence the rate of congenital infection of progeny (441, 491). The genetics of the host and the strain of ALV influence shedding and congenital transmission after horizontal infection (131). With electron microscopy, virus budding has been seen on all structures of reproductive organs of cocks except germinal cells (144), indicating that the virus does not multiply in germ cells. The cock, therefore, is likely to act only as a virus carrier and source of contact of venereal infection to other birds (460, 474, 490). Congenital infection of embryos is strongly associated with shedding by the hen of ALV into egg albumen and with presence of virus in the vagina of hens (391, 488). These traits are also highly correlated with viremia. Witter et al. (565) reported on the association between various infection profiles of subgroup J ALV in broiler breeders and transmission to progeny.

Shedding of ALV into egg albumen and transmission to the embryo is a consequence of virus production by albumen-secreting glands of the oviduct. In most hens congenitally transmitting ALV, the highest titers of virus were found in the ampulla of the oviducts, suggesting that embryo infection is closely related with ALV produced at the oviduct but not with ALV transferred from other parts of the body (524). Electron

microscopy studies have revealed a high degree of virus replication in the magnum of the oviduct (149). Virus budding also occurs in various cell types in the ovary but not in the follicular cells or ovum, and transovarial infection does not seem to be important (391). Not all eggs that have ALV in the albumen give rise to infected embryos or chicks; in the studies of Spencer et al. (488), Payne et al. (391), and Tsukamoto et al. (525), only about one-half to one-eighth of embryos were infected from eggs with virus in the albumen. This intermittent congenital transmission may be a consequence of neutralization of virus by antibody in the yolk and of loss because of thermal inactivation. Congenital transmission of ALV has been found in the absence of detectable shedding of group-specific antigen (263).

Electron microscopy has revealed virus particles in many organs from infected chicken embryos, and virus has been observed to bud and accumulate in large amounts in pancreatic acinar cells of embryos (585). These particles, which are highly infectious, are shed in droppings of newly hatched chicks (66). Infectious virus also is present in saliva and feces of older birds that provide a source of horizontal infection to other birds (66).

In flocks infected with subgroup A ALV, only a minority of the infected birds develops LL, while the others remain as carriers and shedders. Viremic-tolerant (V+A-) birds are reported to be several times more likely to die of LL than those with antibody (V-A+) (441). Incidence of leukosis decreases rapidly if infection by natural routes occurs after the first few weeks of age (71); there are well-established genetic differences in susceptibility to LL development in chickens that are equally susceptible to virus infection (129).

Endogenous ALVs (see "Etiology") usually are transmitted genetically in germ cells of both sexes (Figure 15.24). Many are genetically defective and incapable of giving rise to infectious virions, but some are not and may be expressed in an infectious form in either embryos or hatched birds. In this form, they then are transmitted similarly to exogenous viruses, although most chickens are genetically resistant to such exogenous infection. Endogenous viruses have little or no oncogenicity (343) but may influence response of the bird to infection by exogenous ALV (120, 473). Immunodepression induced by infectious bursal disease virus increased the rate of shedding of ALV (197); in addition, the strain of virus can influence the incidence of tolerantly infected chickens (185).

Incubation Period

Members of the L/S group of viruses are multipotent viruses capable of inducing a variety of neoplastic diseases. The incubation period for these diseases depends on strain and dose of virus, route of and age at exposure, and genetic constitution of the host. Susceptible chicks inoculated as embryos or at 1–14 days of age with a standard strain of ALV-RPL12 (74), B15, F42 (47), or RAV-1 developed LL between 14 and 30 weeks of age. It is very seldom that LL cases occur in chickens under 14 weeks. Certain laboratory recombinant viruses have been shown to cause LL within 5–7 weeks (277), although such short incubation periods are not found in field outbreaks. In field outbreaks, LL cases can occur any time after 14 weeks of age; however, incidence is usually highest at about sexual maturity.

Another determining factor is whether the virus strain lacks or possesses a viral oncogene. For example, diseases such as erythroblastosis, induced by slowly transforming viruses lacking oncogene, usually develop after a long latent period (97, 208, 295). After IA inoculation of the slowly transforming RPL12 strain virus into susceptible day-old chicks, the incubation period varies from 21–110 days (74). On IV inoculation of 11-day-old embryos, chicks occasionally have been found to have erythroblastosis on hatching. Strain R virus produces a much more rapid response, and in some experiments, birds inoculated with high doses have all died between 7 and 12 days PI (35). Field strains and viruses passaged in cell culture induce erythroblastosis after a longer incubation period (72). Passage from donors with erythroblastosis shortens the incubation period (203).

Other strains of virus including F42 (47), ES4, and strain 13 (35) also produce erythroblastosis. Field cases usually occur in birds older than 3 months of age. RPL12 and F42 viruses are non-defective and slowly transforming, whereas ES4 and R are defective and acutely transforming (232).

Strain BAI-A of ALV predominantly induces myeloblastosis. Virus stocks are defective and contain helper viruses of both A and B subgroups (267). After inoculation of susceptible day-old chicks with large doses of virus, changes in the blood can be observed in 10 days, and birds die a few days thereafter. Mortality continues for about 1 month, and only a few deaths occur after this (78, 162). The virus E26 (232) also mostly induces myeloblastosis.

Virus-induced myelocytomatosis generally has a longer incubation period than erythroblastosis and myeloblastosis induced by the acutely transforming virus strains, but it is shorter than LL. On IV injection of MC29 into young chicks, myelocytomas were obtained in 3–11 weeks (335). The incubation period in field cases is unknown, but most cases are observed in immature birds. The virus CMII also induces myelocytomas (232). Myelocytomatosis induced by the HPRS-103 strain of ALV, which lacks a viral oncogene, had a long (median time to death was 20 weeks) latent period (388). However, median time to death with the acutely transforming 879-strain variant of HPRS-103, believed to carry a viral oncogene, was 9 weeks (389). Field cases of subgroup J-induced myelocytomatosis were reported in broiler breeder chickens as young as 4 weeks of age (194).

Most strains of ALV have been found to cause hemangiomas (67, 204). These tumors can be found in birds of various ages. In naturally occurring outbreaks, most mortality from hemangiosarcomas occurred at 6–9 months (79, 80). Induction of lung angiosarcomas by subgroup F ALVs is reported (467). Experimental inoculation of young chicks

with field strains of virus induced hemangiomas in 3 weeks to 4 months (203).

In field cases, ALV-induced renal tumors are rarely seen in chickens younger than 5 weeks; most cases are seen in birds between 2 and 6 months of age. Nephroblastomas induced by strain BAI-A may reach an incidence of 60–85% in birds not dying of myeloblastosis (78). Renal carcinomatous lesions induced by strain MC29 are found as soon as 18 days or as late as 7 weeks PI. Incidence in inoculated chickens may be 60% or more, but incidence in field flocks is not known.

Osteopetrosis may develop any time after 1 month following experimental inoculation of day-old chicks with strain RPL12-L29 of ALV (451) or other viruses (252, 254, 411); it is most commonly seen in birds 8–12 weeks of age. The disease probably has a similar incubation period in the field. MAV-2(O) virus will induce palpable osteopetrosis 7–10 days after hatching in chicks inoculated at 1 day of age or as 11–12-day-old embryos (202).

Sarcomas may occur any time after inoculation with ALVs but are most frequently observed in the first 2–3 months (77). In field flocks, connective tissue tumors may occur in birds at any age (580). Sarcomas also develop readily and are palpable within 3 days after inoculation of chicks with high doses of acutely transforming RSV.

Clinical Signs

Outward signs of the leukotic diseases are mostly non-specific. They include inappetance, weakness, diarrhea, dehydration, and emaciation. In LL especially, there may be abdominal enlargement. The comb may be pale, shrivelled, or occasionally cyanotic. In erythroblastosis and myeloblastosis, hemorrhage from feather follicles also may occur. After clinical signs develop, the course is usually rapid, and birds die within a few weeks. Other affected birds may die without showing obvious signs.

In myelocytomatosis, skeletal myelocytomas may cause protuberances on the head, thorax, and shanks. Myelocytomas may occur in the orbit of the eye, causing hemorrhage and blindness. Hemangiomas may occur in the skin, appearing as "blood blisters," and these may rupture, causing hemorrhage. Renal tumors may cause paralysis due to pressure on the sciatic nerve. Sarcomas and other connective tissue tumors may be seen in the skin and musculature. When advanced, these various other tumors may be accompanied by the nonspecific signs given previously. Benign tumors may follow a long course, malignant tumors a rapid one.

In osteopetrosis, the long bones of the limbs are commonly affected. Uniform or irregular thickening of the diaphyseal or metaphyseal regions can be detected by inspection or palpation. The affected areas are often unusually warm. Birds with advanced lesions have characteristic "bootlike" shanks. Affected birds usually are stunted and pale and walk with a stilted gait or limp.

ALV also has been shown to be associated with the so called fowl glioma(363), associated with cerebellar hypoplasia and myocarditis (245, 246, 247, 268, 350, 521).

Pathology

Introduction

One or more specific neoplasms induced by ALSVs may occur in a given flock of chickens, and more than one type of neoplasm may occur in an individual bird. This is particularly true in flocks infected with subgroup J ALV. The presence of a tumor similar to that produced experimentally is only provisional evidence that a bird was infected with a virus of this group. Firmer evidence is provided by ALSV detection or isolation, and if appropriate by experimental reproduction of tumors by a virus isolate.

In this section, the pathology of the different neoplasms is discussed without regard for virological properties of the inducing agent(s). Only entities that have been reproduced with ALSVs are described.

Nonneoplastic Conditions

The clinical consequences of infection of chickens with exogenous ALV vary. Some chickens, principally those with a tolerant viremic infection (arising from congenital or early neonatal infection, see the Immunity section), may show a variety of clinical signs, as detailed later in this chapter, including depression of body weight and of other production traits. Birds with tolerant viremic infections are also those most likely to develop neoplasia. Ultrastructural and virological studies of congenitally or neonatally infected birds have shown the virus to be widespread in most tissues and organs of the body (5, 6, 150, 158, 310, 430, 496, 521). Dougherty and DiStefano (151, 158) observed virus budding in cells of every type of tissue examined, except germ cells and neurons.

ALV infection in the absence of overt disease can adversely affect the productivity of egg-laying chickens. Compared with non-shedders, hens that shed virus produced 20–35 fewer eggs/hen housed to 497 days of age, matured later sexually (i.e., age at first egg), and produced smaller eggs (487) at a lower rate and with thinner shells. Mortality from causes other than neoplasms was 5%–15% higher, fertility was 2.4% lower, and hatchability was 12.4% lower in shedders than non-shedders (219). Shedders are mostly viremic birds, whereas non-shedders are immune, possessing ALV antibody. ALV infection has similar effects on broiler breeders and causes a consistent, although often small, reduction in broiler growth rate (128, 218). However, these effects are more marked in meat-type chickens infected with subgroup J ALV (492, 493, 495, 496). In broiler breeder flocks affected by myeloid leukosis caused by subgroup J ALV, smaller eggs were associated with the presence of gs antigen in allantoic fluid and virus in the embryo (487). The most critical time for the immunosuppressive effects of ALV-J infection in experimental studies was the 3- to 4-week period after infection (544). Other studies on reduced productivity in chickens with ALV infections and the genetic consequences have been reviewed (217, 265, 486). The presence of ALV in semen was not associated with reduced semen production, but some evidence suggested an effect on semen quality and fertility (460).

A number of other nonneoplastic effects of ALV infection have been observed, mostly in experimental infections.

Chickens, turkeys, and jungle fowl exposed when young to certain ALVs (RAV-1, RAV-60, MAV-2(O), and ALVs of subgroup B and D, develop anemia, hepatitis, immunodepression, and wasting; some may die (120, 484). A myocarditis and chronic circulatory syndrome was reported in chickens inoculated with RAV-1 ALV (223). Intracytoplasmic viral matrix inclusion bodies have been observed in the myocardium of adult ALV-infected chickens (225, 348). Chickens inoculated with RAV-7 develop neurologic signs including ataxia, lethargy, and imbalance resulting from a nonsuppurative meningoencephalomyelitis (557). A persistent infection of the central nervous system, with inflammatory lesions and clinical signs, followed *in ovo* infection with RAV-1 (175). Fowl glioma-associated virus also shows involvement of brain with cerebellar hypoplasia (350, 521).

In MAV-2(O) infection, anemia occurs due to an aplastic crisis in the bone marrow in which erythrocytes fail to incorporate iron into hemoglobin and exhibit a decreased survival time (136). Administration of antiviral antibody will prevent anemia (411). The immunodepression may involve atrophy of lymphoid organs, hypergammaglobulinemia, decreased mitogen-induced blastogenesis, and decreased antibody response (484). The changes in the immune system are likely a result of cessation of B cell maturation and a block in the development of T-suppressor cells, possibly due to interference with the functional IL-2 synthesis (252, 299).

In addition to stunting and atrophy of the lymphoid organs, RAV-7 caused obesity, high triglyceride and cholesterol levels, reduced thyroxine levels (hypothyroidism), and increased insulin levels. The frequent occurrence of stunting may relate to the suppression of thyroid function by the virus. Stunting of chicks with congenital subgroup J ALV infection also was associated with hypothyroidism, mediated via effects on the pituitary (60) or other factors (492, 493, 495).

Lymphoid Leukosis

Gross. Fully developed LL occurs in chickens of about 4 months of age and older. Grossly visible tumors almost invariably involve the liver (Figures 15.25 and 15.30A), spleen, and cloacal bursa (Figures 15.26 and 15.30G). Other organs often grossly involved include kidney, lung, gonad, heart, bone marrow, and mesentery.

Tumors are soft, smooth, and glistening; a cut surface appears grayish to creamy white and seldom has areas of necrosis. Tumor growth may be nodular (Figure 15.25), miliary, diffuse (Figure 15.30A), or a combination of these forms. In the nodular form, the lymphoid tumors vary from 0.5–5 cm in diameter and may occur singly or in large numbers. They are usually spherical but may be flattened when they are close to the surface of an organ. The miliary form, which is most obvious in the liver, consists of numerous small nodules less than 2 mm in diameter uniformly distributed throughout the parenchyma. In the diffuse form, the organ is uniformly enlarged, slightly grayish in color, and usually very friable. Occasionally, the liver is firm, fibrous, and almost gritty.

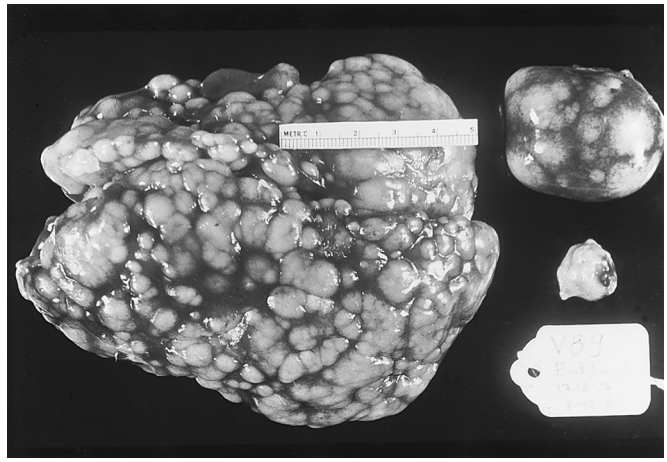

Figure 15.25. Nodular lesions in liver and spleen of bird with LL inoculated at 1 day of age with RPL12 virus. Bursa also has a small tumor.

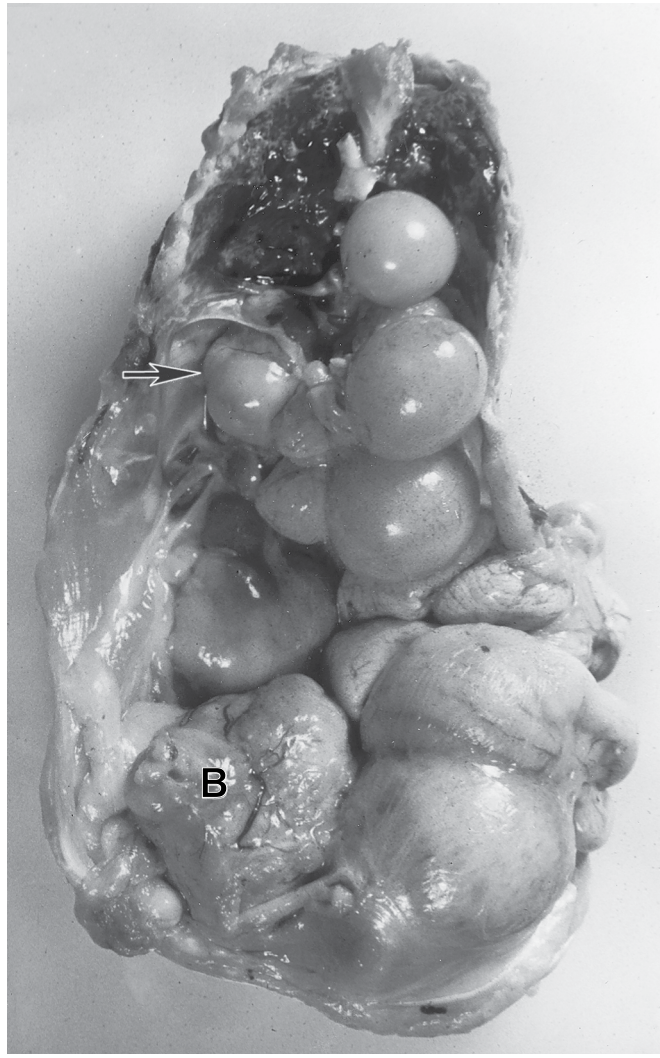

Figure 15.26. Large tumor of bursa of Fabricius (B) and kidneys (arrow) in a naturally occurring case of lymphoid leukosis in the adult hen.

Microscopic

All tumors are focal and multicentric in origin. Even in organs appearing diffusely involved when examined grossly, the microscopic pattern is one of coalescing foci. As tumor cells proliferate, they displace and compress cells of the organ rather than infiltrate between them (Figure 15.27). Nodules in the liver usually are surrounded by a band of fibroblast-like cells that have been shown to be remnants of sinusoidal endothelial cells (236). In the bursa, a follicular pattern of tumor growth usually can be seen.

Tumors consist of aggregates of large lymphoid cells (lymphoblasts) that may vary slightly in size but are all at the same early developmental stage. They have a poorly defined cytoplasmic membrane, much basophilic cytoplasm, and a vesicular nucleus in which there are margination and clumping of the chromatin and one or more conspicuous acidophilic nucleoli (379).

The cytoplasm of most tumor cells contains a large amount of RNA, which stains red with methyl green pyronin, indicating that the cells are immature and rapidly dividing (108, 109, 110). Characteristic features of the cell can best be seen in wet-fixed impression smears that have been stained with May-Grunwald-Giemsa, methyl green pyronin, or other cytological stains. The tumor cells have B cell antigen markers and produce and carry surface IgM (112, 397).

No consistent or significant changes occur in cellular elements of circulating blood. Rarely, lymphoblasts predominate in frank leukemic cases.

Ultrastructural. Vacuoles are found infrequently in lymphoid cells of birds with LL, but some virus particles have been observed budding from the plasma membranes of lymphoblasts (152, 153, 154, 158). Inclusion bodies in enteric smooth muscle and virions resembling avian retroviruses in the adjacent intercellular spaces were reported in a bird positive for ALV-J PCR (240).

Pathogenesis. ALVs multiply in most tissues and organs of the body (158). Transitory lymphoid foci may occur in various tissues and are considered to be inflammatory in nature (82) (Figure 15.28). The infection persists longer in bursal lymphocytes than in other hematopoietic tissues (9, 10), and cells of the cloacal bursa are the target cells that neoplastically transform. The target cells must be resident in the bursa, because surgical bursectomy up to 5 months of age and other treatments

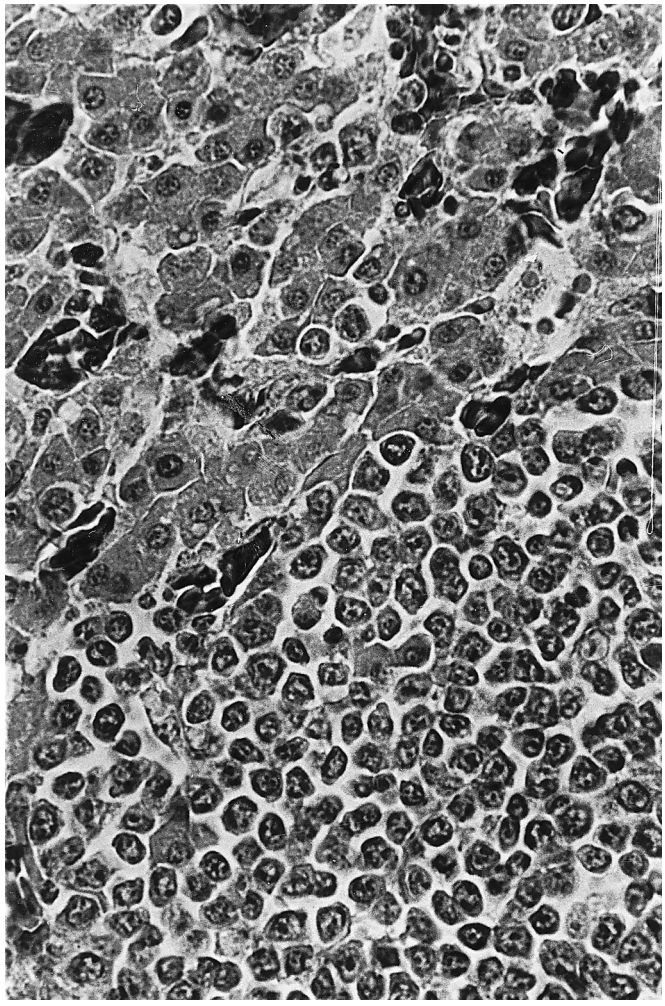

Figure 15.27. Liver tumor from a 20-week-old chicken inoculated at 1 day of age with RAV-1 ALV. Note displacement and compression of hepatic parenchyma. ×700.(179)

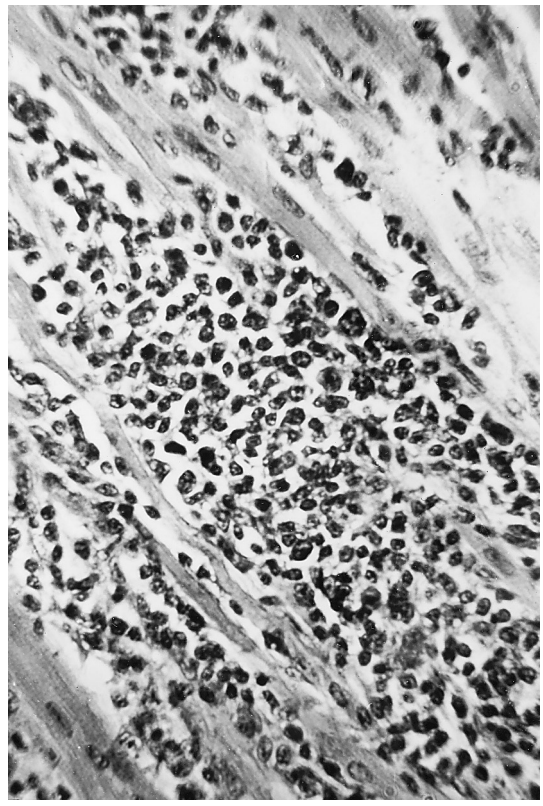

Figure 15.28. Lesions in young chickens induced by leukosis virus. Heart from a 4-week-old RIF3-infected chick showing diffuse accumulations of lymphoid cells among myocardial fibers. ×430. (Calnek)

that destroy the cloacal bursa will eliminate the disease (65, 99, 276, 400, 415, 417, 433).

Medullary macrophages appear to be the principal bursal cells for virus replication and may be important in transmitting infection to the lymphoid cells (224). At a variable time after infection, which can be as short as 4 weeks in experimental studies, a proliferation of lymphoblasts occurs in one or more lymphoid follicles in the bursa. These altered bursal follicles are termed transformed follicles (9, 354, 414), and the change is regarded as a focal preneoplastic hyperplasia (255, 256) (Figure 15.29). The transformed follicle is a consequence of insertional activation of the c-myc gene by ALV. This places the c-myc gene under the control of the enhancers of the viral LTR, resulting in over-expression of myc, causing a maturation arrest and proliferation of bursal stem cells, associated with changes in global gene expression profiles and genomic instability (355, 356).

Arrest of maturation of the transformed B cells results in interference of the normal intraclonal switch of immunoglobulin production from IgM to IgG, hence the surface IgM that characterizes LL cells. The cells grow within the confines of the bursal follicle and are not neoplastic. Sometimes, many follicles are transformed, but the majority of these appear to regress, and only a few continue to grow to give rise to nodular tumors in the bursa, which are visible grossly from about 14 weeks of age (111, 354). Progression of the transformed follicle to the fully neoplastic state requires additional genetic changes, and other putative oncogenes, Blym-1 (229, 352) Mtd/Bok (58), and c-bic (103, 509), have been implicated. The oncogenicity associated with the non-coding c-bic transcript is due to a novel microRNA designated miR-155 (510). Oncogenicity assays demonstrated that bic can cooperate with c-myc in lymphomagenesis and erythroleukemogenesis, providing direct evidence for the involvement of untranslated RNAs in oncogenesis (511).

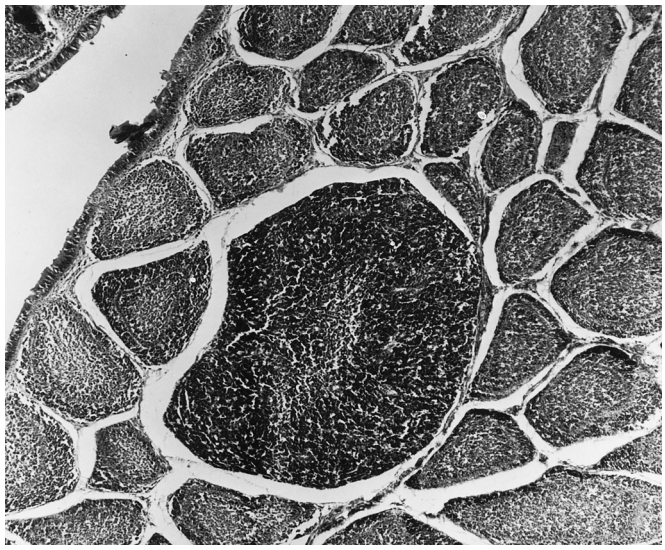

Figure 15.29. Lymphoblastic transformation in single bursal follicle in chicken with lymphoma leukosis (LL). All surrounding follicles are histologically normal in this and other sections from a 16-day-old chicken infected with RPL12 virus at hatching. Methyl green pyronin. ×40. (Dent)

Genome-wide analysis also has shown that myc-induced genomic instability from palindrome formation in many sites including the c-bic/miR-155 locus is a major factor triggering the bursal lymphoma (353). Analysis of the proviral integration sites in B cell lymphomas showed that the telomerase reverse transcriptase (TERT) promoter/enhancer region was a common integration site, suggesting that upregulation of cellular TERT by insertional activation is a factor initiating or enhancing B cell lymphomas (573). Evidence also suggests that apoptosis of neoplastic bursal cells is inhibited by an antagonist of apoptotic cell death, NR-13, related to the Bcl-2 proto-oncogene (308, 361). Induction of angiogenic factors from the transformed cells also contributes to the generation of myc-induced lymphomas (56). From about 12 weeks of age, cells in the clonal bursal tumors metastasize to other organs and tissues and result in the terminal disease. Metastatic tumors in the viscera usually have the same DNA fragments as bursal tumors, supporting their clonal origin (122), but multiple bursal tumors can give rise to polyclonal metastatic disease (479).

Experimentally, B cell lymphomas also have been induced by c-myb activation, following embryonic infection with ALV (277, 405). The tumors were unusual in that metastatic disease occurred within 7 weeks of infection, and preneoplastic and primary bursal neoplasms were not detected. Spontaneous bursal lymphomas of unknown etiology also have been observed in lines of chickens free of exogenous ALV and including line 0 free of ev loci (134, 135). REV (see Reticuloendotheliosis) also can induce LL associated with c-myc activation.

Transplantable LL tumors can be developed from ALV-induced tumors. The RPL12 transplantable tumor, from which the RPL12 strain of ALV was isolated, is a well-known example. Several other new LL transplantable tumors have been described (368). Transplantable LL tumors grow to a palpable size within 5–10 days and become widely disseminated, inducing rapid mortality.

Erythroblastosis

Gross Lesions. Natural cases of erythroblastosis (erythroid leukosis) usually occur in birds between 3 and 6 months of age. The liver and kidney are moderately swollen, and the spleen often is greatly enlarged. The enlarged organs are usually cherry red to dark mahogany (Figure 15.30B) and are soft and friable. The marrow is hyperplastic, semi-liquid, and red in color. Petechial hemorrhages occur in various organs such as muscles, subcutis, and viscera. Thrombosis, infarction, and rupture of the liver or spleen may be observed. Edema of the lungs, hydropericardium, and a fibrinous clot on the liver may occur.

With severe anemia, atrophy usually is seen in visceral and lymphoid organs, particularly the spleen.

Changes in the blood reflect those in other organs, such as liver, spleen, and bone marrow, and depend largely on the

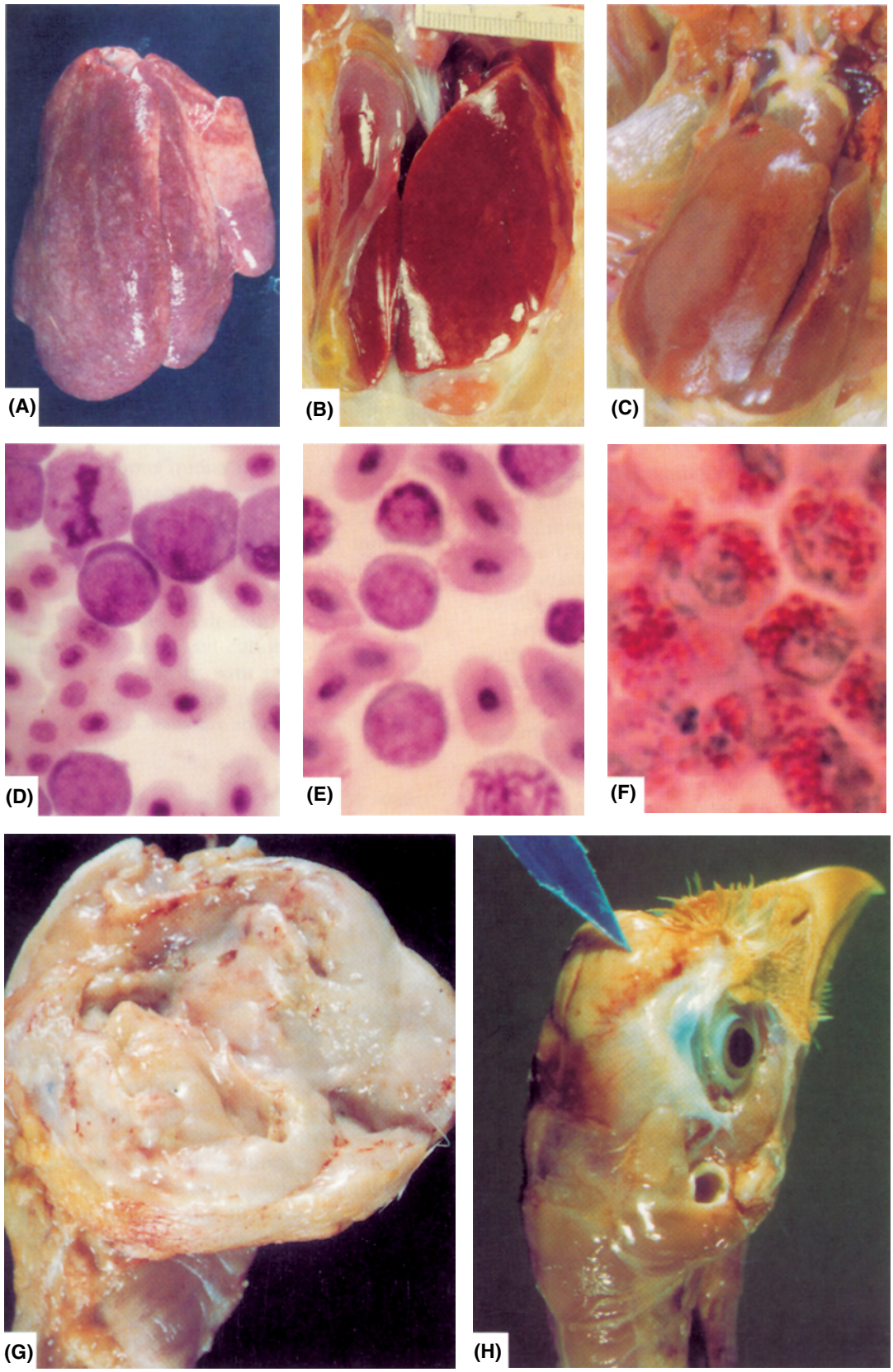

Figure 15.30. Comparison of leukosis. (A) Lymphoid leukosis (LL) Diffuse form affecting the liver. Lesion is grossly indistinguishable from those in Marek's disease. (B) Erythroblastosis. Enlarged cherry red liver and spleen; note the fibrinous exudates. (C) Myeloblastosis, with enlarged gray-red liver. (D) Erythroblastosis; note the basophilic cytoplasm and perinuclear halo, blood smear, Giemsa stain. ×975. (E) Myeloblastosis. Myeloblasts are slightly smaller than erythroblasts; cytoplasm is not as basophilic, nucleus is less vesicular, and nucleoli are as not frequent or conspicuous, blood smear. Giemsa stain, ×975. (F) Myelocytomatosis; note myelocytes are packed with acidophilic granules, section of tumor. Giemsa, ×975. (Beard) (G) LL tumors in the bursa of Fabricius (from the same bird with the liver tumor shown in (A). (H) Myeloid leukosis tumor on the surface of the skull. (Peckham)

extent of anemia or leukemia. When severe anemia exists, the blood is watery and light red and clots slowly. In contrast, acute cases may show no grossly apparent changes, although the blood appears dark red with a smoky overcast.

Microscopic Lesions. Examination of the marrow in early cases reveals blood sinusoids filled with rapidly proliferating erythroblasts that fail to mature. In advanced cases, marrow consists of sheets of homogeneous erythroblasts with small islands of myelopoietic activity and little or no adipose tissue. With concurrent anemia, the number of erythropoietic cells may be reduced.

Alterations in visceral organs are primarily due to hemostasis, resulting in an accumulation of erythroblasts in the blood sinusoids and capillaries (Figure 15.31). The liver sinusoids, splenic red pulp, bone marrow, and sinusoids of other organs are filled with proliferating erythroblasts.

The sinusoids become greatly distended, resulting in pressure atrophy of the parenchyma. Although accumulations of erythroblasts may be extensive, they always remain intravascular, unlike those in LL and myeloblastosis.

Varying degrees of anemia may occur. Sometimes erythroblastosis occurs, and there may be only severe anemia. Extramedullary erythropoiesis is common.

The primary cell involved is the erythroblast. The cell has a large, round nucleus with very fine chromatin, 1 or 2 nucleoli, and a large amount of cytoplasm that is basophilic. A perinuclear halo, vacuoles, and occasionally fine granules are present. The cell is irregular in shape and often has pseudopodia. Erythroblasts have cell markers that identify them as members of the erythrocytic series.

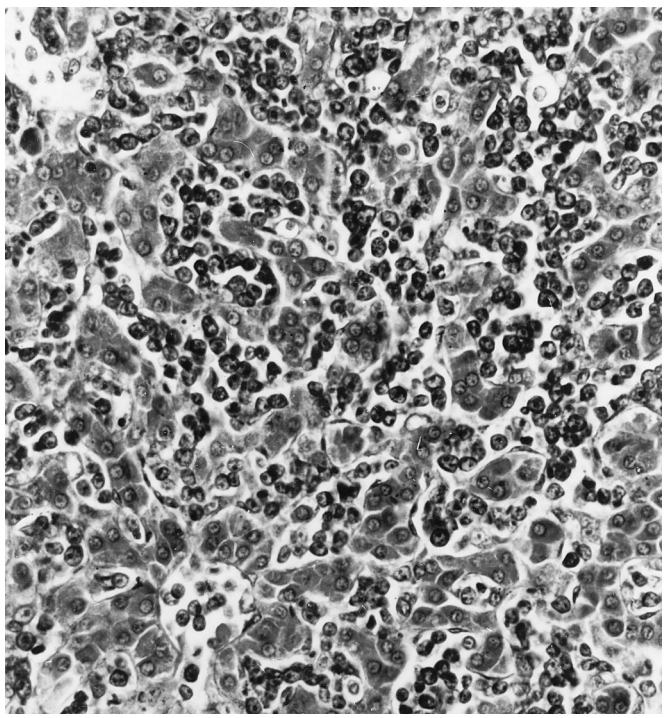

Figure 15.31. Erythroblastosis. Liver sinuses permeated with erythroblasts in bird 40 days after inoculation with strain MC29 leukosis virus. ×280. (Beard)

Stained blood smears reveal a variable number of erythroblasts (Figure 15.30D). These vary in maturity from the early erythroblast, which is the dominant cell, to the various stages of polychrome erythrocytes. The more mature cells often appear early in the course of the disease or during remission, if it occurs. The thrombocytic series of cells may be somewhat increased in number and immaturity. Similarly, in most naturally occurring cases, immature cells of the myelocytic series appear in the peripheral circulation. Occasionally, they are as prominent as the erythroblasts. Cases of mixed erythroblastosis and myelocytomatosis may occur.

Ultrastructural Studies. Numerous studies have been made of the primitive cells in erythroblastosis induced by different strains of ALV (37, 38, 241) and RPL12 (154). Neoplastic erythroblasts are for the most part indistinguishable from corresponding cells in the normal bird, except that virus particles may be present in extracellular spaces and within vacuoles inside cells. In erythroblasts in the circulating blood, as in cell culture, there is a great increase in membrane activity, with vacuolization of the cytoplasm and budding of virus particles from the cell membrane. Only occasionally are aberrant structures seen in erythroblasts (154).

Pathogenesis. Inoculation of slowly transforming strains of ALV such as RPL12 into 11-day-old chick embryos induces erythroblastosis from the first week of age (404). When day-old chicks are inoculated, the incubation period varies from 21 days to more than 100 days (74). Induction of erythroblastosis by slowly transforming ALV involves activation of the cellular oncogene c-erbB by LTR insertion (97, 209, 298), and new acutely transforming AEV strains with transduced c-erbB genes may arise (251, 331). Whether such acutely transforming viruses spread naturally and induce more erythroblastosis is not clear.

Experimentally, acutely transforming AEV strains, such as ES4 and R, cause mortality from erythroblastosis 7–14 days after inoculation (232). ES4 carries the gene v-erbA, which blocks erythroid precursor cell differentiation, in addition to the v-erbB oncogene (138, 172, 313, 326). Two subgroup J ALV isolates, 1B and 4B, have been shown to be acutely transforming and to induce erythroblastosis as well as myelocytomatosis and other tumors (533). Their viral oncogenes have not yet been identified.

When birds are exposed to an acutely transforming AEV, the first alterations are found in 3 days as foci of proliferating erythroblasts in bone marrow sinusoids. By day 7, the primitive cells reach the circulating blood, and some foci of erythroid proliferation are present in sinusoids of the liver and spleen. Erythroblasts continue to accumulate in hepatic sinusoids and elsewhere until death of the host and transplantable erythroblastosis tumors can be developed (407).

Myeloblastosis

Gross Lesions. Natural cases of myeloblastosis (myeloblastic myeloid leukosis) are uncommon and usually occur in adult chickens. The liver is greatly enlarged and firm with diffuse grayish tumor infiltrates, which give a mottled or granular ("Morocco leather") appearance (Figure 15.30C). The spleen and kidneys are also diffusely infiltrated and moderately enlarged. The bone marrow is replaced by a solid, yellowish-gray tumor cell infiltration.

A severe leukemia exists, with myeloblasts comprising up to 75% of peripheral blood cells and forming a thick buffy coat and usually an anemia and thrombocytopenia.

Microscopic Lesions. Parenchymatous organs, notably the liver, show a massive intravascular and extravascular accumulation of myeloblasts with a variable proportion of promyelocytes (Figure 15.32). In the spleen, these tumor cells accumulate in the red pulp. In the bone marrow, myeloblastic activity is confined to extrasinusoidal areas.

Myeloblasts in leukemic blood smears are large cells with slightly basophilic clear cytoplasm and a large nucleus containing 1–4 acidophilic nucleoli, which do not stain prominently (Figure 15.30E). Often, promyelocytes and myelocytes are also present; they easily can be identified by their specific granulation, which in the early forms is primarily basophilic. The disease may result in a secondary anemia, with the presence of polychrome erythrocytes and reticulocytes. Such a secondary anemia is distinguished easily from the conditions in which erythroblastosis and myeloblastosis occur together, because then blast cells of both cell series are present in the circulating blood.

Ultrastructural Studies. In circulating myeloblasts from birds with myeloblastosis induced by BAI-A AMV, virus particles are only rarely found and then in small numbers in clear vacuoles (35, 154, 241, 242). However, reticular and phagocytic elements of the spleen and bone marrow frequently are packed with virus particles. Myeloblasts show large numbers of lysosomes in the cytoplasm when transferred to cell culture. Virus particles can be seen in lysosomes, in vacuoles, and budding at the cell membrane of myeloblasts.

Pathogenesis. The v-myb gene of AMV is responsible for neoplastic transformation of the target myeloblasts (172). Experimental infection is followed within a few days by the appearance of multiple foci of proliferating myeloblasts in the extrasinusoidal areas of the bone marrow, followed rapidly by leukemia and infiltration of the liver, spleen, and other organs (300, 301). The v-myb oncogene acts as a transcription factor that transforms myelomonocytic cells by deregulating the expression of specific target genes and through alterations of the nucleosomal organization (559).

Myelocytomatosis

Gross Lesions. Tumors of myelocytomatosis (myelocytic myeloid leukosis) are distinctive and can be recognized on gross examination with some degree of certainty. Characteristically, they occur on the surface of bones in association with the periosteum and near cartilage, although any tissue or organ can be affected. Myelocytomas often develop at the costochondral junctions of the ribs, on the inner sternum, pelvis, and the cartilaginous bones of the mandible and nares. Flat bones of the skull also are commonly affected (Figure 15.30H).

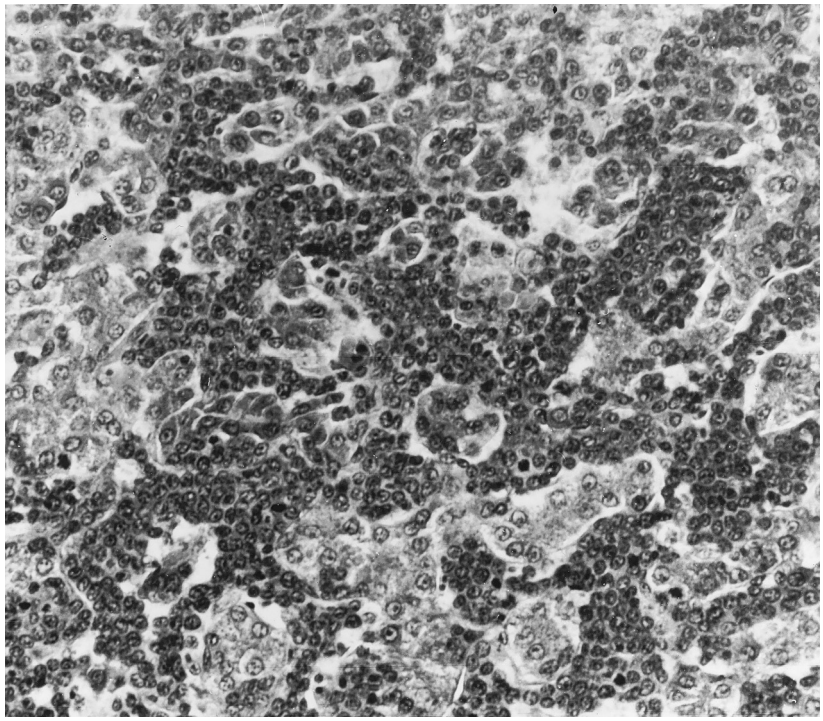

Figure 15.32. Myeloblastosis. Distribution of myeloblasts in liver of bird with myeloblastic leukemia 19 days after inoculation with BAI-A virus. ×280. (Langlois)

Tumors may be seen in the oral cavity, trachea, and in and around the eye (408). The tumors are usually nodular and multiple, with a soft, friable consistency and creamy color. In the disease caused by subgroup J ALV, myelocytomatous infiltration often causes enlargement of the liver and other organs, in addition to skeletal tumors (561) and myelocytic leukemia (386).

Microscopic Lesions. Tumors consist of masses of uniform, usually well-differentiated, myelocytes. Their nuclei are large, vesicular, and usually eccentrically located, and a distinct nucleolus is usually present. The cytoplasm is usually tightly packed with acidophilic granules, which are usually spherical. When imprint preparations of fresh tumors are stained with May-Grunwald Giemsa, granules appear brilliant red (Figure 15.30F). Areas of less well-differentiated myelocytes are not uncommon within the myelocytomas, and areas of undifferentiated cells, which may be stem cells of the myelocyte-monocyte series, also may be found. In the liver, accumulations of neoplastic myelocytes occur around blood vessels and in the parenchyma. In the spleen, tumor cells are present in the red pulp. In the marrow, the extrasinusoidal myelopoietic areas are greatly expanded by uniform neoplastic myelocytes. Detailed description of bone and bone marrow lesions in myelocytomatosis associated with subgroup J ALV is provided elsewhere (349).

Although the naturally occurring disease has been stated to be usually aleukemic, myelocytomatosis induced by subgroup J ALV frequently is accompanied by a marked leukemia of myeloid cells. Laboratory strains of myelocytomatosis-inducing virus, such as MC29, also cause leukemia (Figure 15.33).

Ultrastructural Studies. Ultrastructural features of myelocytoma cells vary from those of well-differentiated myelocytes to those of undifferentiated, nongranulated myeloid cells (335).

Pathogenesis. Acutely transforming strains of ALV that induce myelocytomatosis, such as MC29 and CMII, carry the v-myc oncogene (172, 339). Slowly transforming strains of subgroup J ALV that also induce myelocytomatosis, such as HPRS-103 and ADOL-Hc1, do not carry an oncogene, but molecular studies of HPRS-103-induced myelocytomatosis indicate that c-myc is activated (96, 97, 98). The acutely transforming strain 966 ALV, derived from myelocytoma and induced by strain HPRS-103 of subgroup J ALV, has been shown to carry v-myc (96, 389). Studies on HPRS-103 and 966 showed that they have a tropism for the myelomonocytic cell lineage, which may relate to their ability to cause myelocytomas (5, 6). Recently, a recombinant ALV with an envelope of subgroup B and LTR of subgroup J (ALV-B/J) was isolated from a field outbreak of myeloid leukosis in commercial layers (226). However, inoculation of experimental and commercial strains of white leghorn chickens with this recombinant ALV-B/J resulted in primarily LL, but not myeloid leukosis, suggesting that differences in the genetic makeup of the commercial layers from which ALV-B/J was originally isolated and lines of chickens used in experimental inoculations studies may be responsible for the differences in pathogenicity (315).

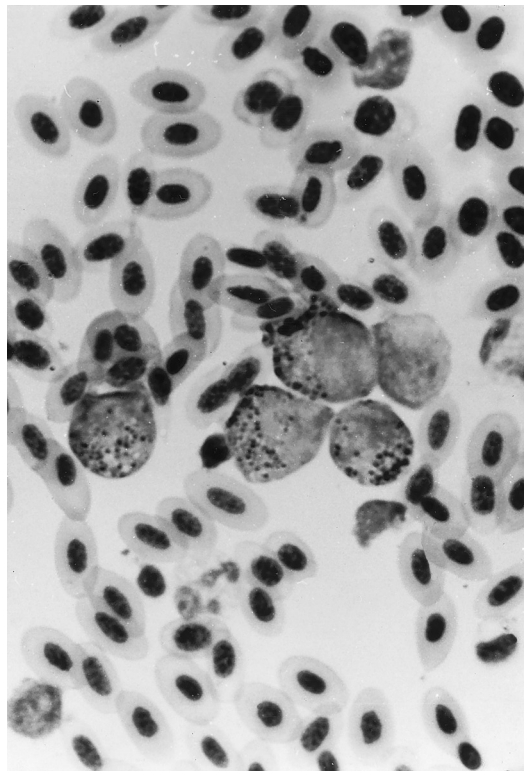

Figure 15.33. Myelocytomatosis. Granulated myelocytes in blood smear from bird 23 days after inoculation with strain MC29 leukosis virus, ×750. (Beard)

The earliest alterations occur in bone marrow in which there is crowding of intrasinusoidal spaces, principally by myelocytes, and destruction of sinusoid walls. The spaces may contain 2 types of cell—the primitive hemocytoblast-like cell (myeloid stem cell) and the neoplastic myelocyte. The latter appears to arise directly from the stem cell, and differentiation is arrested both at the nongranulated and granulated myelocyte level (335). Myelocytes proliferate and soon overgrow the bone marrow. Tumors form by expansion of marrow growth and may crowd through the bone and periosteum. Extramedullary tumors may also arise by blood-borne metastasis.

Hemangioma

Gross Lesions. These tumors are found in the skin or in visceral organs in chickens of various ages. They appear as blood-filled cystic masses or blood blisters (Figure 15.34) or more solid tumors and consist of distended blood-filled spaces lined by endothelium or as more cellular, proliferative, lesions (86). They are often multiple and may rupture, causing fatal hemorrhage (485). More recently, many workers have reported the incidence of hemangiomas in layer chickens infected with ALV-J in China (302, 372, 582).

Microscopic Lesions. The cavernous form is characterized by greatly distended blood spaces with thin walls composed

Figure 15.34. Hemangioma of gizzard serosa of RPL12 virus-inoculated bird. Note the dark circumscribed and raised tumor nodules.(236)

Figure 15.35. Cavernous hemangioendothelioma of mesentery. (Feldman and Olson)

of endothelial cells (Figure 15.35). Capillary hemangiomas are solid masses in which endothelium may proliferate into dense masses (hemangioendothelioma), leaving mere clefts for blood channels (Figure 15.36). They develop into a lattice with capillary spaces or grow into collagen-supported cords with larger interspersed blood spaces. Solid and papillary forms have also been described (345).

Ultrastructural Studies. Ultrastructural studies have shown that the hemangiomas consisted mainly of undifferentiated mesenchymal cells and had an alveolar structure (323).

Pathogenesis. Sequence analysis of an avian hemangioma-inducing virus isolated from layer hens revealed unique elements in both the env gene and LTR (80). This virus was cytocidal and had an affinity for endothelial cells (425, 426). Although several sequence changes have been reported in the genomes of hemangioma-inducing ALV-J strains isolated from layers (372, 571), the precise molecular mechanisms are unknown.

Hemangiomas are tumors of the vascular system and as such usually involve all layers of blood vessels. In some instances, the endothelium may proliferate more than the supporting tissue. Hemangiosarcomas have been associated with subgroup J ALV infection (228, 383).

Nephroma and Nephroblastoma

Gross Lesions. Two types of renal tumor occur: nephroblastomas (Wilms' tumor) and adenomas and carcinomas. Nephroblastomas vary from small, pinkish gray nodules embedded in the kidney parenchyma to large, yellowish gray lobulated masses that replace most of the kidney tissue (Figure 15.37). Tumors may be pedunculated and connected to the kidney by a thin fibrous vascular stalk. Large tumors are often cystic and may involve both kidneys. Adenomas and carcinomas vary in size and appearance, similar to nephroblastomas. They are often multiple and within cysts.

Microscopic Lesions. In nephroblastomas, the histologic variation between different tumors or areas of the same tumor is striking. There is usually neoplastic proliferation of both epithelial and mesenchymal elements, although their proportion and differentiation vary widely. Epithelial structures vary from enlarged tubules with invaginated epithelium and malformed glomeruli, through irregular masses of distorted tubules, to groups of large, irregular, cuboidal, undifferentiated cells with little tubular organization (Figure 15.38). The growth may be embedded in a loose mesenchymal or sarcomatous stroma. There may be islands of keratinizing stratified squamous epithelial structures (epithelial pearls), cartilage, or

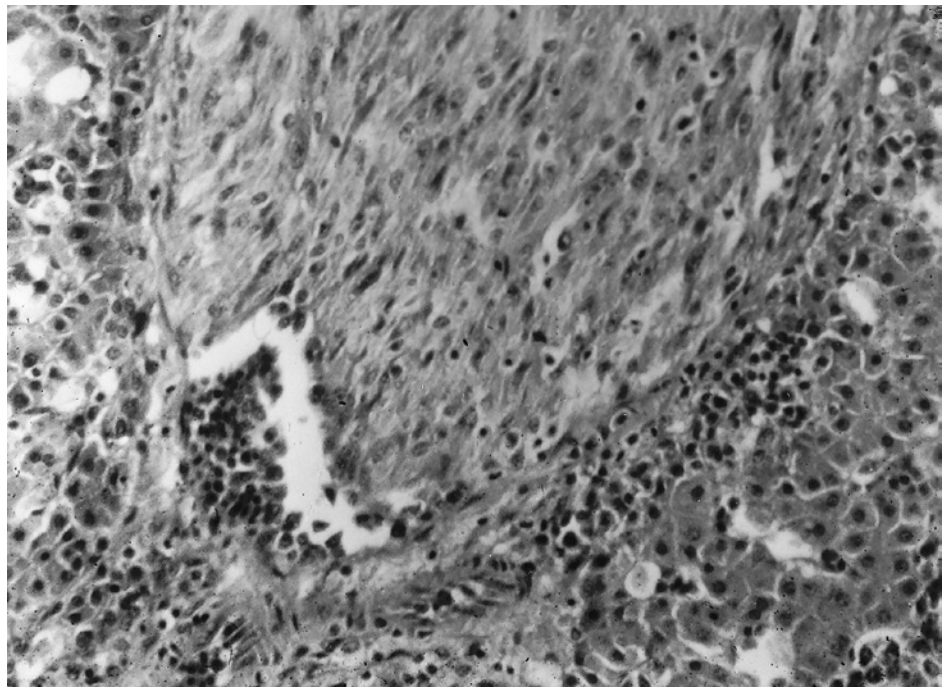

Figure 15.36. Endothelioma in liver of bird inoculated with RPL30 leukosis virus. Occlusion of portal vein by inward-growing spindle cells from blood vessel. ×250. (Fredrickson)

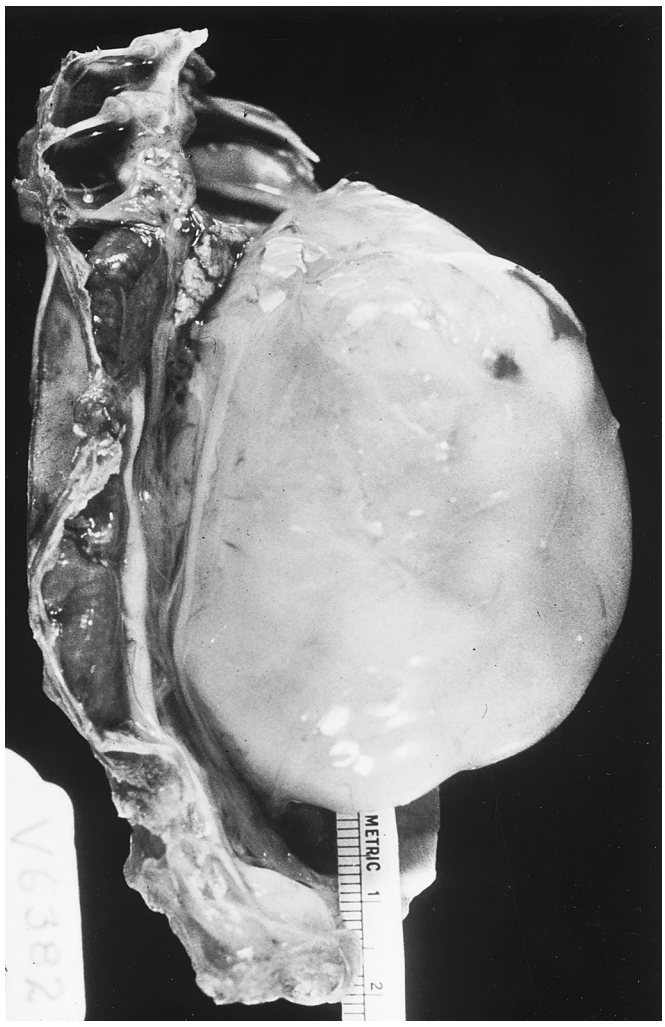

Figure 15.37. Nephroblastoma. Bird was inoculated at 1 day of age with avian myeloblastosis virus BAI-A strain.

Figure 15.38. Nephroblastoma. Bird was inoculated at 1 day of age with cloned preparation of avian myeloblastosis virus BAI-A strain. Note primary multiplicity of tumors of two distinct types in different areas (arrows). ×20.

bone (142, 250, 266). Primary multiplicity of tumors may occur, but metastases are rare.

Adenomatous or carcinomatous growths also vary greatly in microscopic appearance. In tubular adenocarcinomas, primitive abnormal glomeruli frequently occur in large numbers among abnormal tubules. Papillary cyst adenocarcinomas are frequent. At times, solid carcinomas with little evidence of renal tubules develop (39, 335). Rarely is there cartilage and never are there other mesenchymal tumor tissues. A trabecular fibrous tissue stroma may separate masses of epithelial tumor tissue.

Ultrastructural Studies. In the epithelial nephronic elements of nephroblastomas induced by strain BAI-A of ALV (35), cytoplasmic aberrant structures occasionally are seen in large or small aggregates. Virus particles bud from cell membranes of epithelial cells, fibroblastic elements of the stroma, and chondrocytes. Sarcomatous elements consist of cells similar in morphology to those in other avian sarcomas. Virus particles have been observed budding from epithelial cells in cystadenomas and adenocarcinomas induced by strain MC29 myelocytomatosis virus (337). Large accumulations of particles in spaces in the cysts and tubules probably were related to a lack of tubule and glomerular drainage.

Pathogenesis. Infrequent involvement of c-fos has been observed in ALV-induced nephroblastoma (105). More recently, new proto-oncogenes such as nov, (272) and twist (369) were identified as common integration sites in nephroblastomas (370).

Nephroblastomas originate from nephrogenic blastema (embryonic nephrons and embryonal rests) (86, 266). This blastema tissue is present in the metanephros (functional kidney) at hatching until at least 6 weeks of age and appears as wedge-shaped foci of immature renal tissue, particularly beneath the capsule. These epithelial structures enlarge and become neoplastic. The supporting stroma of mesenchymal elements also proliferates and, in turn, may be altered. There is extensive multiplication of tumor cells (usually convoluted tubules and/or stroma) and varying degrees of differentiation, some abnormal. In the most differentiated form, nephrogenic cells form glomeruli, tubules, or keratinized epithelium, whereas cells of the stroma form sarcomas, cartilage, and bone. Anaplasia of kidney cells can result in sheets of large epithelioid cells with almost no tubular organization. Malformed and blocked tubules result in cysts. Nephroblastomas have been induced by BAI-A strain AMV (36, 78, 543), MAV-2(N) (445), MAV-2-O (50), and subgroup J-related strain 1911 (388). Transplantable nephroblastomas have been developed (543).

Carcinomatous growths originate only from the epithelial part of the embryonal blastema and not from mesenchymal elements. Depending on the degree of anaplasia of epithelial elements, tumors formed may be adenomas, adenocarcinomas, or solid carcinomas (36). These tumors have been induced by MC29 (36), ES4 (90), and MH2 (89) virus strains and by various field isolates (204). Renal adenomas and carcinomas can be caused by slowly and acutely transforming subgroup J ALV (386, 388).

Fibrosarcoma and Other Connective Tissue Tumors

Gross Lesions. A variety of benign and malignant connective tissue tumors occur naturally, usually sporadically, in young and mature chickens, and transmission of many of these by cell-free filtrates has been demonstrated. These tumors include fibromas and fibrosarcomas, myxomas and myxosarcomas, histiocytic sarcomas, osteomas and osteosarcomas, and chondromas and chondrosarcomas. The benign tumors grow slowly, are localized, and are non-infiltrative. The malignant counterparts grow more rapidly, infiltrate surrounding tissue, and may metastasize.

Fibromas arise as firm fibrous lumps attached to the skin, subcutaneous tissues, muscles, and occasionally other organs; fibrosarcomas are of a softer consistency. In the skin, they may ulcerate. Myxomas and myxosarcomas are softer and contain tenacious slimy material. They occur mainly in the skin and muscles. Histiocytic sarcomas are firm, fleshy tumors occurring mainly in the viscera. Osteomas and osteosarcomas are uncommon and occur as hard tumors that may arise from the periosteum of any bone. Chondromas and chondrosarcomas are rare. They occur where cartilage is present and sometimes within fibrosarcomas and myxosarcomas. Ganglioneurosarcoma was reported associated with subgroup J ALV infection (228).

Microscopic Lesions. Fibromas in their simplest forms consist of mature fibroblasts interspersed with collagen fibers arranged in wavy parallel bands or whorls. Slowly growing tumors are more differentiated and contain more collagen and fewer cells than those growing more rapidly. Some fibromas may have edematous areas and should not be confused with myxomas and myxosarcomas. If necrosis, ulceration, and secondary infection have occurred, various inflammatory and necrotic alterations may be observed in the tumor. Inflammatory changes may be so prominent that the tumor may be confused with a granuloma.

Aggressive and destructive growth, cellular composition, and the immaturity of constituent cells (Figure 15.39) characterize fibrosarcomas. Large, irregular, and hyperchromic fibroblasts are abundant, and mitosis is common. Tumors contain less collagen than fibromas, and this is concentrated in and near irregular septa that subdivide the tumor. Regions of necrosis often occur in rapidly growing tumors. Edema is sometimes present. Multiple undifferentiated pulmonary sarcomas associated with subgroup J ALV infection have been reported (239).

Myxomas consist of stellate or spindle-shaped cells surrounded by a homogeneous, slightly basophilic, mucinous matrix. In the malignant form (myxosarcoma), the mucinous matrix is less abundant, and fibroblasts are proportionally more numerous and immature than in myxomas (Figure 15.40). Myxosarcomas associated with ALV-A infection have been reported in fancy breed chickens (560).

Histiocytic sarcomas are derived from cells of the monocyte and macrophage lineage, and the cellular constituents are highly variable both within a tumor and between tumors (Figure 15.41). They have been reported in infection by subgroup J ALV (4, 238), particularly in persistently viremic but not immunotolerized meat-type chickens (373).

Figure 15.39. Fibrosarcoma in musculature of breast. ×120. (Feldman and Olson)



Figure 15.41. Histiocytic sarcoma of the heart. Note the varied character of cellular components. ×240. (Helmboldt)

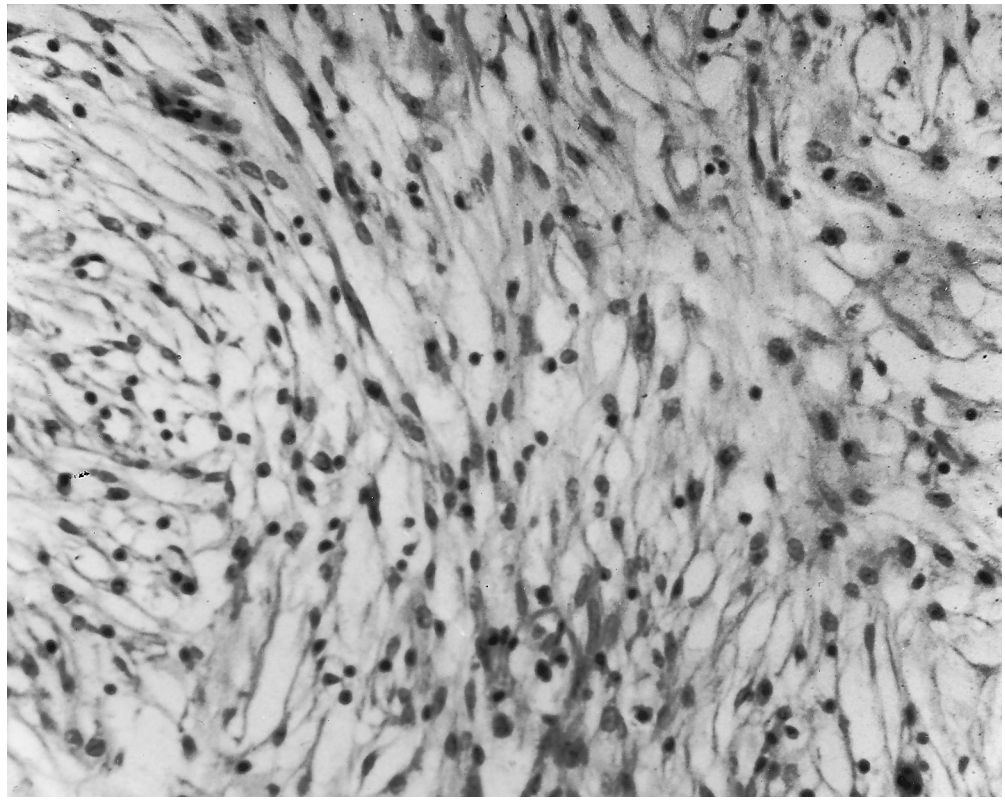

Figure 15.40. Myxosarcoma induced by Rous sarcoma virus. ×240. (Helmboldt)

The cells may be spindle-shaped, usually appearing in groups or bundles as in fibrosarcomas; stellate reticulum-producing elements; and/or large phagocytic cells or macro-phages. Tumors apparently derived from stem cells of the myelomonocytic lineage also may be considered to be histiocytic sarcomas. The so-called endotheliomas induced by MH2 and MC29 may be tumors of this lineage (173). In primary tumors, spindle-shaped cells usually predominate, whereas in metastatic foci, primitive histiocytic forms are more numerous.

Osteomas are structurally similar to bone except that much of the inner histologic detail is lacking. They consist of a homogenous acidophilic matrix of osseomucin containing collections of osteoblasts at irregular intervals. Osteosarcomas are usually very cellular infiltrative growths that invade and destroy surrounding tissues. The cells are spindle-shaped, ovoid, or polyhedral, and many are in mitosis. Nuclei are prominent, and cytoplasm is basophilic. Multinucleated giant cells may be quite numerous. Although very cellular and rapid growing, some areas usually have sufficient differentiation for the production of osseomucin, which is usually sufficient to identify these tumors.

Chondromas have a typical and unique structure (i.e., groups of 2 or more chondrocytes lying in a matrix of chondromucin). In chondrosarcomas, considerable cellular variation exists, ranging from the most immature to the fully mature chondrocyte.

Ultrastructural Studies. Only the sarcomas produced by RSV have been examined in detail. The morphology of fibroblasts, macrophage-like cells, and mast cells, found in Rous sarcomas, have been described (35, 241).

Pathogenesis. Induction of sarcomas and other connective tissue tumors in the field is likely to be by activation of a cellular oncogene by a slowly transforming ALV, occurring up to several months after infection (506). ALV related to MAV-1 has been implicated in a field outbreak of sarcomas in commercial layers; inoculation of susceptible white leghorn chickens with new isolate resulted in sarcomas and myelocytomas (580).

Viral oncogenes that have been associated with sarcoma induction include src, fps, yes, ros, eyk, jun, qin, maf, crk, sea, and erbB (104, 172, 539) (Table 15.5). These reflect the cellular oncogenes that are activated by insertional mutagenesis and that may undergo mutation. These cellular oncogenes control a variety of functions in the cell (their products are generally growth factors, growth factor receptors, signal transducers, or DNA transcription factors), and it is their altered expression that results in the loss of regulation of cell proliferation or differentiation that causes neoplasia.

Osteopetrosis

Gross Lesions. The first grossly visible changes occur in the diaphysis of the tibia and/or tarsometatarsus. Alterations soon are seen in other long bones and bones of the pelvis, shoulder girdle, and ribs, but not the digits. Lesions are usually bilaterally symmetric; they first appear as distinct pale yellow foci against the gray-white translucent normal bone. The periosteum is thickened, and the abnormal bone is spongy and at first easily cut. The lesion is commonly circumferential and advances to the metaphysis, giving the bone a fusiform appearance (Figures 15.42 and 15.43). Occasionally, the lesion remains focal or is eccentric. Severity of the lesion varies from a slight exostosis to a massive asymmetric enlargement with almost complete obliteration of the marrow cavity. In long-standing cases, the periosteum is not as thickened as it was earlier; when it is removed, the porous irregular surface of the very hard osteopetrotic bone is revealed.

Figure 15.42. Osteopetrosis. A 24-week-old chicken, injected with RPL12 at 1 day of age, with advanced osteopetrotic lesions of the shanks. (Sanger)

Early in the disease, the spleen may be slightly enlarged. Later, severe splenic atrophy occurs as well as premature bursal and thymic atrophy. LL often occurs in individual birds with osteopetrosis.

Microscopic Lesions. The periosteum over the lesion is greatly thickened from an increase in number and size of basophilic osteoblasts. The number of osteoclasts/tibia increases, but the density of osteoclasts (i.e., the number/unit volume of bone) decreases (458). Affected bones differ from normal bones in the following ways. Spongy bone converges centripetally toward the center of the shaft (Figure 15.44). An increase occurs in size and irregularity of the Haversian canals, and there is an increase in number and size, and an alteration in position, of lacunae. Osteocytes are more numerous, large, and eosinophilic; the new bone is basophilic and fibrous.

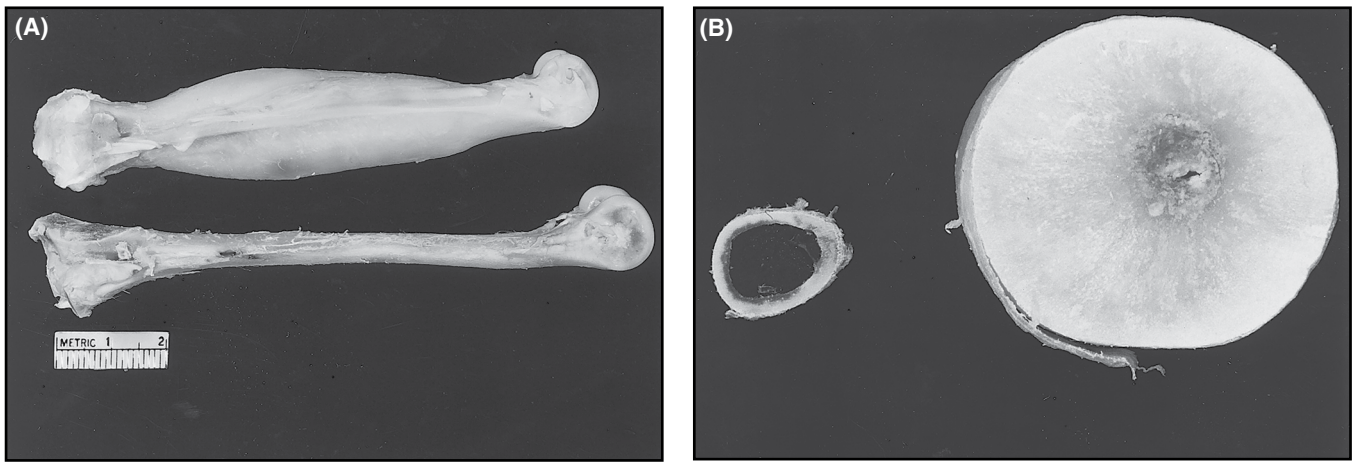

Figure 15.43. Osteopetrosis of tibia in 10-week-old chicken. (A) Shorter length of bone is due to reduced growth. Lower tibia is from control bird of same age. (B) Cross-section of middle of shaft of bones in (A). (451)

Figure 15.44. Osteopetrosis. Cross-section of humerus from 8-week-old chicken. Six separate osteopetrotic foci are present, two of which extend from endosteum to periosteum. ×18 (451)

The blood picture is ordinarily aleukemic, and a secondary anemia often exists. There may be active erythropoiesis in remaining bone marrow and sometimes in focal areas in the liver. Experimentally, viruses that cause osteopetrosis can induce an aplastic anemia and an increased corpuscular fragility (252, 411).

Ultrastructural Studies. Virus particles bud transiently from osteoblasts and continuously from osteocytes and accumulate in the periosteocytic space. With calcification of the bone, the particles become incorporated in the bone trabeculae. No virus production is observed from osteoclasts (201).

Pathogenesis. Osteopetrosis is a polyclonal disease of the bone and is thought to be caused by high levels of virus infection perturbing the growth and differentiation of osteoblasts. Much higher levels of virus infection were found in diseased bones than in cultured osteoblasts infected with the Br21 strain of an osteopetrosis-inducing ALV (200). Severe cases of osteopetrosis contained 10 times more viral DNA, 30 times more gag precursor protein, and 2–3 times more env protein than the infected osteoblast cultures The osteopetrotic lesion is basically proliferative or hypertrophic (87, 451) and may be neoplastic (55, 458). Lesions of the lymphoid organs and bone marrow are degenerative or anaplastic (252). The propensity for certain ALVs to induce osteopetrosis depends on sequences in the gag-pol-5′env region of the viral genome (462). Env proteins also have been implicated in osteopetrosis induction (271). Exogenous ALV sequences most similar to the envelope of myeloblastosis associated virus type 1 (MAV-1) were identified from archived bones of an outbreak of osteopetrosis in commercial birds (27).

Other Tumors

Apart from renal tumors, epithelial tumors caused by ALV are uncommon. They mainly have been reported following experimental infections with acutely transforming viruses, although some have occurred in natural and experimental infections with subgroup J ALV. Strains BAI-A (36) and HPRS-103 (388) of ALV have induced thecomas and granulosa cell tumors of the ovary. A seminoma in the testis occurred in a bird inoculated with strain MH2 (36) and possibly in birds inoculated with subgroup J ALV isolates (398). Adenocarcinomas of the pancreas have been induced in chickens by strains MC29,

MH2, and HPRS-103 of ALV (36, 336, 388). The Pts-56 strain of osteopetrosis virus produced pancreatic adenomas and adenocarcinomas and duodenal papillomas in guinea fowl (284, 286, 287). Squamous cell carcinomas have been observed in a few chicks with strains MC29 and MH2 (36). The MC29 and MH2 strains have induced hepatocarcinomas (36, 306). Other epithelial tumors induced by subgroup J ALV include cholangioma and ovarian carcinoma (388).

Strains MC29 (36) and HPRS-103 of ALV (388) have been shown to induce mesotheliomas.

Immunity

Active Immunity

Immune responses to oncogenic viruses including ALV have been reviewed (347). Under natural conditions, most chicks become infected by exogenous ALV from penmates or their surroundings, and after a transient viremia, develop virus-neutralizing antibodies directed against virus envelope antigens that rise to a high titer and persist throughout the life of the bird. The virus-neutralizing antibodies serve to restrict the amount of virus in the bird, which in turn will limit neoplasia, but they generally are considered to have little direct influence on tumor growth. After inoculation of birds with ALV at 4 weeks of age or older, transient viremia was detectable at 1 week and was followed by antibodies at 3 weeks and later (319). In a study of birds naturally infected after hatching, antibodies were first detected at 9 weeks of age, with a marked increase in the proportion with antibodies between 14 and 18 weeks, when 80% were positive (442).

Antibodies against gs-antigen also may occur in ALV-infected birds, but these apparently have no influence on tumor growth (434, 464).

Knowledge of the occurrence of, and the part played by, cell-mediated immunity in ALSV infections is still incomplete, but it is likely to be directed against both the virus infection and tumor formation. The presence of cytotoxic lymphocytes against viral envelope antigens has been shown in birds immunized with ALV or RSV (33, 34, 297), and cell-mediated immunity and the MHC are clearly implicated in the regression of Rous sarcomas (455, 456). Viral proteins expressed on the surface of tumor cells appear to be important targets for the cell-mediated immunity, and transformation-specific cell surface antigens also may be implicated. Thacker and coworkers (518) have reported on a new system for studying MHC-restricted cytotoxic lymphocyte responses to ALV infection, which should be of value in determining the role of this type of cell-mediated immunity in ALV infections. Whether cell-mediated immune responses are directed against tumor cells in lymphoid and other forms of leukosis has yet to be determined.

Chickens that are infected congenitally by ALV do not develop immune responses to the virus. Instead, they become immunologically tolerant to the virus and develop a persistent viremia in the absence of neutralizing antibodies (329, 442). Inoculating chickens up to 2 weeks of age with ALV also may induce tolerant infection. Early infection with subgroup J ALV is particularly likely to induce a tolerant infection (194, 564, 566). Birds with a tolerant viremic infection are more likely to develop neoplasms than are immune-infected birds, because of the greater virus load in viremics.

Infection by ALV can depress primary and secondary antibody responses and cell-mediated immunity (444) to unrelated antigens, although these effects have been variable in different studies. Fadly et al. (188), in a study of congenital infection with an A subgroup ALV, RAV-1, failed to detect effects on B and T cell function during the early and late stages of infection, and they reported no histological damage to the cloacal bursa, thymus, or spleen. In contrast, subgroup B ALVs have been reported to induce a marked suppression of the humoral immune response to several antigens and decreased responsiveness to several mitogens (549). Evidence that subgroup J ALV is immunosuppressive appears to be equivocal (303, 494, 495, 579). ALV-J infection induced a strong immune response at 2 weeks of age, but after 4 weeks of age, the response decreased quickly, suggesting that approximately 3–4 weeks post-infection is the critical time at which the ALV-J virus exerts its immunosuppressive effects on the host (544). Nucleotide sequence analysis of consecutive isolates from V+A+infection profile suggested viral evolution to escape the host immune response, thereby contributing to ALV J persistence (374).

Passive Immunity

Serum antibodies, which are mainly in the IgG fraction (330), are passed on by the hen to her progeny via the egg yolk and provide a passive immunity that lasts 3–4 weeks. Passive antibody delays infection by ALV (567), reduces the incidence of viremia and shedding of ALV (177), and reduces the incidence of tumors (64). Level and persistence of antibody in the chick is related to the titer of antibody in the dam's serum.

Genetic Resistance

Two levels of genetic resistance to leukosis or sarcoma virus-induced tumors are recognized: cellular resistance to virus infection and resistance to tumor development (12, 29, 113, 403).

Inheritance of cellular resistance to infection is of a simple Mendelian type (Table 15.12). Independent autosomal loci control responses to infection by ALSVs of subgroups A, B, and C and are designated tva (tumor virus A subgroup), tvb, and tvc, respectively (116). At each tv locus, alleles for susceptibility and resistance exist that are designated tva^s, tva^r; tvb^s, tvb^r; and tvc^s tvc^r, respectively, and the susceptibility alleles are dominant over the resistance alleles. These genes usually are abbreviated to a^s, a^r, etc. It is probable that multiple alleles occur at each locus, encoding different levels of susceptibility (166, 574).

Mutations in the tvb receptor gene account for the resistance to subgroups B, D, or E infections (29, 257, 290, 424). Similarly, intronic deletions that disrupt mRNA splicing of the tva receptor gene were shown to result in decreased susceptibility to subgroup A ALV infection (423).

Genetic resistance to infection by subgroup J virus has not been recognized in chickens, although a number of other avian species are resistant (386, 394, 395). There is no evidence of

Table 15.12. Genes controlling cellular susceptability to leukosis and sarcoma viruses.

	Locus		Alleles		
Virus subgroup	**Old**	**New**	**Old**	**New**	**Dominant trait**
A	*tva*	*TVA*	tva^s tva^r	TVA*S TVA*R	Susceptibility
B and D	*tvb*	*TBV*	tvb^{s1} tvb^r	TVS*S1, S3 TVB*R	Susceptibility
C	*tvc*	*TVC*	tvc^s tvc^r	TVC*S TVC*R	susceptibility
E	*tved*	*TVE*	tve^s tve^r	TVE*S TVC*R	Susceptibility
	ie		I^e i^e		Resistance

Note: The locus designation is adapted from Crittenden (117). The new locus designation is that agreed by the Poultry Committee of the USDA National Animal Genome Research Program, 1994. The allele previously designated tvb^{s2} now is considered to be identical to tvb^{S1}. The existence of a *tve* locus is not settled. The i^e locus is now considered to be an *ev* locus, with blocking of the subgroup E virus receptor by endogenous virus ENV glycoprotein expression.

the segregation of the ALV-J cell receptor, Na+/H+ exchange type I molecule (91), in the chicken population (360).

Cellular susceptibility phenotypes associated with these genes are designated according to a convention that recognizes the virus subgroups to which the chicken (C) cell is resistant (/) (e.g., C/AE denotes a cell resistant to A and E subgroups but susceptible to B, C, D, and J subgroups); C/0 denotes a cell resistant to no subgroup (i.e., susceptible to A, B, C, D, E, and J).

Resistance or susceptibility conferred by these genes is expressed by all cells, whether by cells cultured *in vitro*, such as chicken embryo fibroblasts; by chicken embryo cells, such as those of the CAM; or by chickens after hatching. These responses are applicable to ALSVs sharing the same envelope glycoproteins, and, thus, viral subgroup, but most genetic studies are undertaken with appropriate subgroups of RSV, because infection of the cell is expressed within a few days by visible growth of tumor cells. Thus, the phenotype of an individual may be determined by inoculation of a standard dose of RSV into chicken embryo fibroblasts in culture, with the production of foci of transformed cells in susceptible embryo cells but not in resistant cells (439). Similarly, RSV can be inoculated onto the CAM of the chicken embryo, with or without the production of tumor pocks (127), or intracranially into day-old chicks, with death or survival as the response criterion (548) (see Prevention and Control Procedures). The phenotype of individual birds may be determined by culturing fibroblasts from plucked pin feather pulp and by challenging these cultures with RSV (132, 393, 489).

Genetically resistant chicks are resistant to infection and tumor induction by ALSVs of the subgroups concerned, and they usually fail to develop antibodies (117, 126). Genetic resistance to tumor development has been studied mainly with the Rous sarcoma (459, 512), regression of which is determined by a dominant gene, R-RS-1, that lies within the major histocompatibility complex (MHC locus) of the chicken and is located in the BBL region (106, 220, 410, 457). Conserved peptide motifs of the RSV proteins that bind to the MHC have been identified and shown to be immunoprotective against Rous sarcoma growth in chickens with Class I allele B-F12 (253), and peptide motifs of the single dominantly expressed class I molecule explain the MHC-determined responses to RSV (542). The MHC (Ea-B) locus also influences incidence of erythroblastosis and, to a lesser extent, LL (17). Some influence of the lymphocyte Bu-1 locus on Rous sarcoma regression and of the Th-1 locus on LL is reported (13). Structural analysis of the MHC alleles in RSV tumor regression has ruled out the DMA1, DMA2, BRD2, TAPBP, and BLB2 genes in regression in B6 haplotype (504, 505).

Diagnosis

Isolation and Identification of Causative Agent

Because ALV is widespread among chickens, virus isolation and the demonstration of antigen or antibody have limited or no value in diagnosing field cases of lymphomas. However, assays for the detection of ALV are very useful in identification and classification of new isolates, safety testing of vaccines, and testing pathogen-free and other breeder flocks for freedom from virus infection. Samples most commonly used for detection of ALV include blood, plasma, serum, meconium, cloacal and vaginal swabs, oral washings, egg albumen, embryos, and tumors (181, 189, 196). Virus also can be isolated from albumen of newly laid eggs or the 10-day-old embryo of eggs laid by hens that are transmitting virus vertically, from feather pulp, and from semen. All ALSVs are very thermolabile and can be preserved for long periods only at temperatures below –60°C. Thus, materials used for biological assays for infectious virus should be collected and placed on melting ice or stored at –70°C until assayed. However, samples for detection of ALV gs antigens by direct assays can be stored at –20°C (196).

Because most strains of ALV produce no visible morphologic changes in cell culture, assays for ALV are based on the following: (a) detection of specific proteins or glycoproteins coded for by 1 or more of the 3 major ALV genes, namely gag, pol, and env (Figure 15.18), or (b) detection of specific proviral DNA or viral RNA sequences of ALV by the polymerase chain reaction (PCR) and reverse transcription (RT)-PCR, respectively.

The presence of virus is determined by the detection of ALV p27 by indirect biologic assays, such as complement

fixation (CF) for avian leukosis (COFAL), ELISA for ALV, phenotypic mixing (PM), resistance-inducing factor (RIF), and non-producer cell activation (NP). The biological assays require CEF with specific host range (Table 15.9). CEFs that are resistant to infection with endogenous ALV (C/E) are desirable to use in tests for detection and isolation of exogenous ALV. Other cells, such as those resistant to subgroup A (C/A) and resistant to subgroup J ALV (C/J) (259), also can be used to confirm the subgroup of isolated ALV. Testing samples on CEFs that are susceptible to all subgroups of ALV (C/O), and those that are resistant to subgroup E (C/E), can be used in differentiating exogenous and endogenous ALV. If a positive test is obtained from using C/O but not C/E CEFs, the sample is positive for endogenous ALV. Positive tests using both C/E and C/O indicate the presence of exogenous ALV. A flow cytometry method using a highly specific alloantibody termed R2 has been described for detection of endogenous ALV envelope in chicken plasma (11, 16). It should be noted that some tests such as CF and ELISA and possibly NP, PM, R(-)Q cell, and FA can be suitable for all leukosis and sarcoma viruses. The RIF test can be performed only on ALVs that are not rapidly cytopathogenic. Rapid transformation of fibroblast cultures is produced only by certain RSV and of hematopoietic cell cultures only by defective ALV. The adenosine triphosphatase activity is a test specific for avian myeloblastosis virus. Various procedures that are most widely used have been reviewed (181, 196).

RIF Test

In general, most ALVs do not induce alterations in cultured cells except after prolonged passage. When CEFs are infected with an ALV, however, they become resistant to superinfection by a sarcoma virus of the same subgroup. Only viruses of the same subgroup interfere with one another in this way. The property of interference has been used for assay of ALVs by the RIF test (437) and also in delineating virus subgroups (540). In the RIF test, known susceptible chicken embryo fibroblast cultures are inoculated with material suspected of containing an ALV. Cells are subcultured at least 3 times at 3- to 4-day intervals, and at each passage, a sample of the cells is tested for susceptibility to RSVs of different subgroups. Alternatively, supernatant fluids may be transferred to new cell cultures every 4 days. In this case, cells may be challenged without subculture 4–6 days PI. Control cultures infected with known ALVs and uninfected cultures are always included to establish validity of the tests. Presence of ALV in a cell culture is indicated by a 10-fold or greater reduction in number of foci produced by a standard stock of RSV when compared with the number of foci on similarly challenged control cells. Several different challenge viruses, one for each subgroup, must be used to detect ALVs belonging to different subgroups; each requires a separate cell culture plate for testing.

Tests for Viral-Internal, Group-Specific (gs) Antigens

Detection of the major antigen (p27) forms the basis of several diagnostic tests for virus.

The COFAL test can be used to detect the gs antigen in cultures of fibroblasts that have been inoculated with virus. Cells must be susceptible to infection with the virus sought; to obtain a suitable antigen from low-titer inoculate, inoculated fibroblasts must be cultivated for 14 days before they are harvested. The harvested cells are adjusted to a standard concentration, frozen, thawed, and then used as antigen in the test. Various controls are necessary, including uninoculated fibroblasts, because these may contain gs antigen derived from endogenous ALV. Titration of complement-fixing activity of extracts of the control and inoculated cultures allows differentiation between endogenous and exogenous viral antigen, because the titer of the latter is much higher. Fibroblasts that do not express endogenous antigens (e.g., line 0) are preferred.

Because of the difficulty in distinguishing between gs antigens of endogenous and exogenous viruses, direct CF tests of infected materials, without tissue culture passage, are of limited value. Nevertheless, direct tests may be done in certain circumstances (e.g., on egg albumen) (see Eradication).

Complement-fixing antiserum against gs antigen can be obtained from hamsters bearing sarcomas induced by RSV such as the Schmidt-Ruppin strain (453). Rabbit and other mammalian antisera prepared against purified gs antigens derived from avian myeloblastosis virus also can be used (470, 498, 499). Antisera also have been raised in pigeons bearing RSV-induced tumors (452, 454).

Highly sensitive ELISA tests for gs antigens are widely used directly for the assay of test material or indirectly using cell cultures inoculated with test material. These antigens also may be detected in cells by fluorescent-labeled antibody (FA) techniques (280, 378). Using indirect FA tests, monoclonal antibodies to ALV-J proved useful in the detection of ALV-J-infected cell cultures (193, 421, 502, 532). A variety of samples can be tested by ELISA for the presence of ALV; however, serum has been shown to be unsuitable for the detection of exogenous ALV by direct ELISA (390). For the detection of exogenous ALV, samples are inoculated on CEFs that are genetically resistant to subgroup E ALV. Seven to 9 days later, cell lysates are tested for the presence of ALV gs antigen by ELISA (182, 196, 472). Rabbit anti-p27 antibody, which is used to coat ELISA plates and rabbit anti-p27 conjugate, as well as complete kits for running ELISA for detection of ALV gs antigen, are available commercially. An indirect ELISA using a recombinant capsid protein also has been reported (422).

Tests Based on Phenotypic Mixing of Viruses

CEFs can be infected with envelope-defective strains of RSV (e.g., BH-RSV) to produce transformed cells that are nonproducers of infectious RSV of subgroups A, B, and D. Superinfection of a culture of NP cells by a leukosis helper virus results in production of infectious RSV, which is detectable in supernatant fluid by assays in susceptible CEF cultures and forms the basis of the NP cell activation test. Several variants of the test are described. Non-producer cell activation is an example of phenotypic mixing of viruses (see Etiology). Non-producer cells from embryos with endogenous subgroup

E ALV may spontaneously produce a subgroup E RSV from complementation of the defective RSV by subgroup E envelope. In assaying for RSV production following activation, it is then necessary to use fibroblast cultures resistant to subgroup E but susceptible to subgroups A, B, C, D, and J (C/E cells).

A useful modified NP cell activation test uses Japanese quail cells that have been transformed with envelope-defective BH-RSV. Those nonproducing R(-)Q cells can be activated to produce infectious RSV by cocultivation with C/E cells infected with the exogenous ALV under test, thus providing the R(-)Q cell test (118).

Another variant of the NP cell test is the PM test (366, 416), for which cultures of C/O fibroblasts (i.e., cells susceptible to all virus subgroups) pretreated with diethylaminoethanol (DEAE) dextran are infected heavily with subgroup E RSV(RAV-0), producing RSV-transformed cells. About 24 hours later, the supernatant fluid is discarded, and cultures are infected with test material. Cultures are incubated for 7 days, and the culture fluid is harvested, frozen, thawed, centrifuged, and assayed for infectious RSV on C/E fibroblasts. Because E subgroup RSV is excluded, the presence of RSV foci indicates presence of exogenous ALV in the test material. Various controls must be included in the test.

Variants of these tests also have been developed to detect infectious endogenous ALV, as well as expression in chick cells of subgroup E envelope glycoprotein termed chick helper factor (chf) encoded by the endogenous virus (118).

Comparison of Tests

In vivo and *in vitro* cell culture tests for detection or assay of exogenous ALVs are compared in Table 15.13.

All of the *in vitro* tests require a standard source of chicken embryos free from exogenous ALSVs and of known phenotype for use in cell culture. The following reagents are also required: for the RIF test, stocks of challenge RSV of each subgroup; for the COFAL and ELISA tests, specific antiserum; for the NP test, quantities of NP cells; and for the PM test, stocks of RSV with endogenous helper, RSV(RAV-0). Cells obtained from embryos of unknown genetic origin should not be used in RIF, COFAL, and indirect ELISA tests because the results may be confused by genetic resistance. Both COFAL and indirect ELISA tests require either prolonged maintenance of culture or several subcultures to propagate the virus sufficiently; therefore, much more work is involved than in the NP or PM tests.

The indicator systems for each test are different. In the RIF test, the number and appearance of RSV foci after challenge are highly dependent on the physiologic condition of the cells. Thus, when cell cultures are not in optimal condition, an RIF test cannot be performed and cell extract is used in the COFAL and ELISA tests; however, and the extracts can be

Table 15.13. Comparison of methods for assaying exogenous avian leukosis viruses.

Method	Requirements	Response measured	Additional requirements for subgroup determination	Time required (days)[c]
In vivo				
Chick inoc 1 day IA	LL susceptible[a]	LL	Genetically resistant chickens	270
Chick inoc 1 day IA	Erythro susceptible[b]	Erythro	Genetically resistant chickens	63
Embryo inoc 11 days IV	Erythro susceptible	Erythro	Genetically resistant chickens	43
Cell culture	RSV pseudotypes, C/E cells	Resistance to formation of RSV foci in CC[d]	Challenge virus of known subgroup	12+6
RIF				
COFAL	Hamster antiserum, C/E cells	Complement fixation	Genetically resistant cells	14+1
ELISA	Enzyme-linked antisera C/E cells	Color change of substrate	Genetically resistant cells	14+1
NP	NP cells (chicken or quail)	RSV foci in CC	Genetically resistant cells of RIF test with leukosis virus of known subgroup	8+6
PM	RSV (RAV-0), C/O, and C/E cells	RSV foci in CC	Genetically resistant cells of RIF test with leukosis virus of known subgroup	5+6

Note: C/E, cells, genetically resistent to infection with viruses of E subgroup, but susceptible to viruses of other subgroups; C/O, cells phenotypically susceptible to infection by viruses of all subgroups; COFAL, complement fixation for avian leukosis viruses; CC, cell culture; ELISA, enzyme-linked immunoabsorbent assay; erythro, erythroblastosis; IA, intraabdominal; IV, intravenous; LL, lymphoid leukosis; NP, nonproducer; RIF, resitance-inducing factor; RSV, Rous sarcoma virus; RSV (RAV-0), Rous sarcoma virus with endogenous helper.

[a] Chickens susceptible to LL tumor formation (e.g., line 15I chickens).

[b] Chickens susceptible to virus infection and to development of erythroblastosis (or myeloblastosis).

[c] Approximate number of days necessary to cultivate the virus plus the number of days to indicate the presence of virus.

[d] Cell culture.

stored frozen and tested on more than one occasion if necessary. Similarly, in the NP and PM tests, the supernatant fluid of cell cultures can be stored and tested for virus by the cell culture technique. Results are usually more clear-cut in the NP and PM tests than in the RIF, COFAL, or ELISA tests. ALV infectivity and titer could be determined by ELISA within 7 days after cultivation, but after 19 days and 3 subcultures by the RIF test (526).

The subgroup of an infecting ALV can be determined by any of the tests. In the RIF test, only RSV belonging to the same subgroup as the ALV is subjected to interference. In COFAL and ELISA tests, genetically resistant cells can be used; thus, an ALV of subgroup A will not produce CF antigens in cells of the C/A phenotype (resistant to subgroup A viruses). In the NP test, genetically resistant NP cells can be prepared, and in the PM test, genetically resistant cells can be used in the mixing phase. In NP and PM tests, supernatant from the activation or mixing phase, which contains RSV of the same subgroup as the ALV, can be placed on genetically resistant cells or embryos or used in an interference test with an ALV of known subgroup.

Immunohistochemical Tests

Direct (280) and indirect (378) FA tests as well as flowcytometry (258, 259) have been used to detect viral antigen in CEF cultures; flow cytometry also has been shown to be a very useful tool in identifying the subgroup of ALV strains contaminating commercial Marek's disease vaccines (28, 176, 466).

Enzyme Assays

Avian myeloblastosis virus has on its surface an enzyme (ATPase) that dephosphorylates adenosine triphosphate. This activity can be used as a quantitative assay to determine the amount of virus present in the plasma of infected chickens or in supernatants of myeloblast cultures (40).

Assays for RT activities have been used for the detection of oncogenic RNA viruses including all ALSVs (514). Detection of this enzyme, either directly when the correct template is used (279, 517) or indirectly when the radioimmunoassay is used (376), is an indication of presence of virus. Most recently, a highly sensitive PCR-based RT assay has been used to screen human vaccines that are produced in CEF or embryonating eggs for freedom from avian retroviruses (261, 318, 523, 536).

Detection of Viral Nucleic Acids

The PCR is the most common DNA-based test used for detection and identification of ALV including subgroup E viruses (Figure 15.45). RT-PCR also has been used to detect several subgroups of ALV (248, 584). A specific PCR for ALV subgroup A can be used to detect proviral DNA and viral RNA in various tissues from ALV-infected chickens (530). A reverse transcriptase nested PCR (RT-nested PCR) test that amplifies a fragment of the LTR of exogenous ALV subgroups A, B, C, D, and J, but not endogenous retroviral sequences, has been described (215). Several primers specific for the detection of the most commonly isolated ALVs, particularly subgroup A (316),

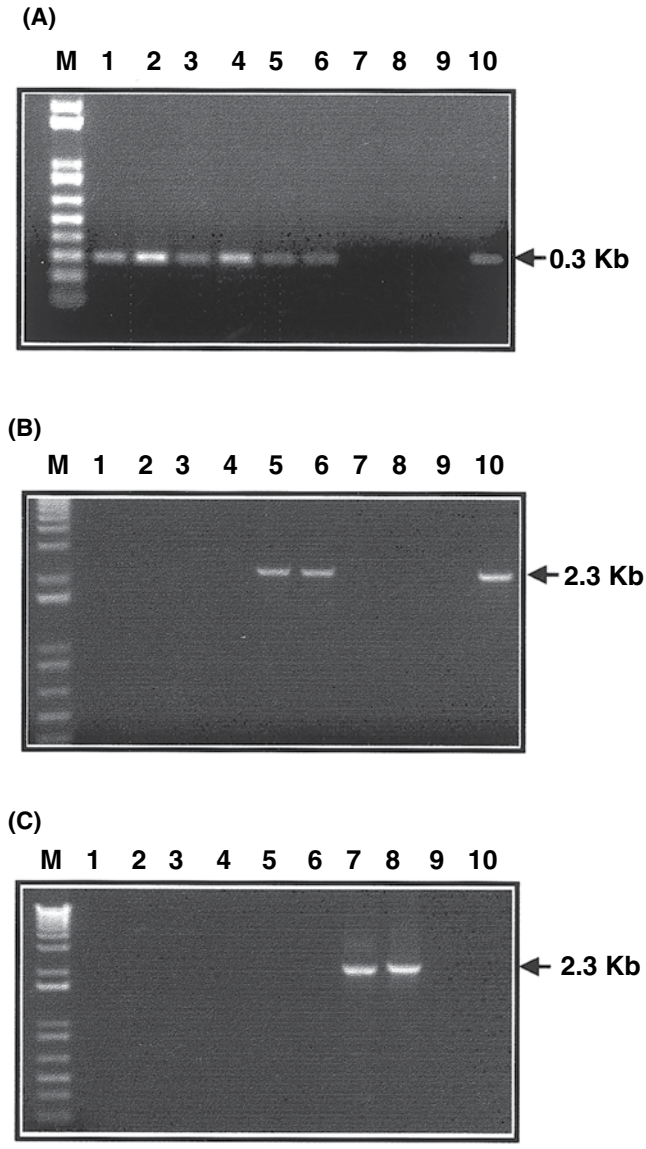

Figure 15.45. PCR analysis of DNA isolated from line 0 CEF uninfected and infected with RAV-1 (ALV-A), RAV-2 (ALV-B), RAV-49 (ALV-C), RAV-50 (ALV-D), ADOL-HC-1 (ALV-J), and ADOL-R5-4 (ALV-J), and 15B1 cells uninfected and infected with RAV-0 (ALV-E) and EV21 (ALV-E). (A) PCR analysis using primers specific for ALV-A-E. (B) PCR analysis using primers specific for ALV-E. (C) PCR analysis using primers specific for ALV-J Lanes: M, 1 Kb plus DNA ladder; 1, RAV-1; 2, RAV-2; 3, RAV-49; 4, RAV-50; 5, RAV-0; 6, EV21; 7, ADOL-HC-1; 8, ADOL-R5-4; 9 line 0 CEF; 10, 15B1 CEF (481, 482). (B. Lupiani)

and the new subgroup ALV-J (465, 481, 482) have been developed. Other primers specific for endogenous subgroup E ALV also can be used to detect cell culture infected with endogenous ALV-E, but not those infected with exogenous ALV of subgroups A, B, C, D, and J (196). As further modification of the PCR test, loop-mediated isothermal amplification (LAMP) method for the detection of ALV subgroups has been developed (546, 583).

Hematopoietic Transformation

Avian myeloblastosis virus, an acutely transforming strain of ALV, harboring an oncogene, can infect and transform cultures of avian myeloblasts. Assays usually are based on a quantal response in which individual cultures are scored as positive or negative (23, 338). Focus assays for myeloblastosis, erythroblastosis, and other defective ALVs have been developed (230, 232, 340). Cultured bone marrow cells and blood monocytes are useful in isolation and propagation of acutely transforming viruses from cases of myeloid leukosis induced by strain HPRS-103 ALV-J (389).

Transformation of Fibroblasts and Cytopathology

Avian sarcoma viruses transform spindle-shaped flat CEFs into spherical and refractile foci (418, 515) that can be seen microscopically after 4–5 days (Figure 15.23). Genetically susceptible cultures are inoculated with test material. The next day, medium is decanted and is replaced with an agar overlay (196). Inoculated cultures should be examined daily for RSV-induced foci, which usually develop within 4–7 days PI.

Sarcoma viruses also activate NP cells, produce the complement-fixing gs antigen, and can be detected by the FA technique. A number of defective acute ALVs also can transform CEFs (232). ALVs of subgroups B and D induce cytopathic effects in cell culture (231, 278). Because this property is restricted to a few viruses, it cannot be used as an assay for field viruses.

Serology

Plasma, serum, and egg yolk are suitable samples for the detection of antibodies to ALSVs.

Tests

Antibody to ALV can be measured by its reaction with RSV or ALV; a virus of one subgroup will not be neutralized by antibodies provoked by a virus of a different subgroup. Usually, a 1:5 dilution of heat-inactivated (56°C for 30 minutes) serum is mixed with an equal quantity of a standard preparation of RSV of a known pseudotype; after incubation, the residual virus is quantitated by any one of many procedures, the cell culture assay being most commonly used. A microneutralization test to assay for residual virus can be used for detection of ALV antibody (196). The test can be conducted in 96-well microtiter plates, and the neutralization of the virus is determined by an ELISA on culture fluids (187).

An indirect immunoperoxidase absorbance test (332, 333), ELISA tests (334, 477, 524, 527), and flow cytometry (258, 259) have been described for the detection of antibodies. ELISA kits for the detection of antibodies to ALV subgroups A and B are available commercially. Also, molecularly cloned, baculovirus-expressed envelope glycoproteins of ALV-J now are being used in commercial ELISA kits specific for the detection of antibody to ALV-J (307, 532).

Serotypes

Based on host range, interference spectrum, and viral envelope antigens, viruses of L/S group occurring in chickens are divided into 6 subgroups: A, B, C, D, E, and J. Viruses of different subgroups can be distinguished by the ability of monovalent antiserums to neutralize them. Even though some cross-neutralization usually exists between viruses belonging to the same subgroup, the kinetics of neutralization vary, and slopes of curves for heterologous systems differ from those of homologous systems. No common neutralization antigens are among the viruses of different subgroups, except for a relationship between subgroups B and D. The diagnosis of infection by serologic means requires that representatives of all serotypes be employed. ALVs themselves may be used, but more commonly, RSV pseudotypes are employed in the neutralization tests (196).

Differential Diagnosis

Lymphoid Leukosis

Differential diagnosis of lymphomas in chickens can be difficult. The 2 most common lymphoid neoplasms, namely Marek's disease (MD) and LL, are particularly confusing (569). Lymphoid tumors observed in REV-infected chickens, although only infrequently in cases of use of REV-contaminated vaccines, or under experimental conditions (see Reticulendotheliosis), may also add to the confusion. LL cannot be differentiated from REV-induced bursal lymphomas on the basis of pathology, immunohistochemistry, and molecular changes in the c-myc region. Virologic, serologic, or PCR tests may be helpful in establishing infection for one virus and exclusion for the other. However, such assays are not particularly helpful in the diagnosis of virus-induced lymphomas of chickens including LL, as avian oncogenic viruses are widespread, and infection in the absence of tumor formation is common. Detection of proviral DNA and integration junctions by PCR assays (97, 227, 406) also are useful for tumor diagnosis.

Because LL tumors should contain ALV proviral DNA sequences inserted near the c-myc gene, differentiation between LL and REV-induced bursal lymphomas can be made by Southern blots and hybridization analysis of tumor DNA for clonal insertion of ALV.

Lymphomas in which bursal tumors are lacking, or in which the latent period is too short for that of LL, can be confused primarily with MD; however, under certain circumstances, REV-induced lymphoma also should be ruled out (see Reticuloendotheliosis). In cases in which bursal tumors are lacking, LL and MD can be differentiated only with difficulty, because similar lymphoid tumors may occur in both diseases in the same visceral organs during the same age period. Visceral lesions of these 2 diseases cannot be distinguished by gross examination. Diagnosis is possible in most instances on careful microscopic examination; however, considerable experience is necessary. In coming to a decision, history, signs, gross and microscopic lesions, and cytology should all be considered. Ordinarily, LL does not occur before 14 weeks of age, and most of the mortality occurs between 24 and 40 weeks. MD, however, may occur as early as 4 weeks, and the mortality peak varies from 10–20 weeks. Occasionally, losses continue and may reach a peak after 20 weeks.

Nodular tumors of the bursa can often be palpated through the cloaca in birds infected with ALV. Paralysis associated with gross lesions in autonomic and peripheral nervous systems and gross lesions of the iris ("gray eye") are specific for MD.

As stated previously, the cloaca plays a central role in development of LL. When distinct focal or nodular lymphoid tumors are present in the bursa, a diagnosis of LL can be made; however, REV-induced bursal lymphomas must be ruled out. Such tumors are sometimes quite small and may be overlooked. In some birds, MD induces a premature atrophy of the bursa. In others, the bursa may be tumorous, in which case the walls and the plica may be thickened from interfollicular infiltration with pleomorphic lymphocytes. In contrast, intrafollicular tumors of the bursa consisting of uniform large lymphocytes are usual with LL.

Microscopic lymphoid infiltrations in nerves, cuffing around small arterioles in the white matter of the cerebellum, and the feather follicular pattern of lymphoid cell infiltration in the skin, which are characteristic of MD, are not seen with LL.

Cytologically, LL tumors generally are composed of a homogeneous population of lymphoblasts (Figure 15.27). In contrast, tumors of MD usually contain lymphoid cells varying in size and maturity from lymphoblasts to small lymphocytes, and plasma cells also may be present. Special stains such as methyl green pyronin are helpful for cytology. Immature lymphoblasts characteristic of LL tumors are highly pyroninophilic, whereas the medium and small lymphocytes that predominate in tumors of MD do not stain with pyronin.

LL tumors are composed almost entirely of B cells and have surface IgM markers, whereas 60%–90% of MD tumor cells are T cells that lack IgM markers and only about 3%–25% are B cells. In addition, from 0.5%–35% of MD tumor cells have a tumor-associated cell surface antigen (MATSA), which is absent from LL tumor cells (160, 357, 358, 409). Recently, Witter et al. (569) introduced a diagnostic strategy for the differential diagnosis of viral lymphomas in chickens.

Other diseases that may be confused with LL are erythroblastosis, myeloblastosis, myelocytomatosis, pullorum disease, tuberculosis, enterohepatitis, Hjarre's disease, and fatty degeneration of the liver.

Erythroblastosis

Although gross lesions of liver, spleen, and bone marrow provide the basis for a presumptive diagnosis, a firm diagnosis must be based on finding large numbers of erythroblasts by microscopic examination of a blood smear and sections or smears of liver and bone marrow. Chickens in early stages of disease or without obvious signs may be missed easily unless microscopic examination is made.

Erythroblastosis with concurrent anemia is often difficult to differentiate from anemia resulting from non-neoplastic causes. In erythroblastosis, there is usually a defect in maturation of erythroblasts, resulting in the presence of large numbers of them and very few polychrome erythrocytes. In anemia, the reverse usually occurs. Extramedullary erythropoiesis and stasis of erythroblasts in the sinusoids are usually more prominent in erythroblastosis than in anemia.

Erythroblastosis can be distinguished from myeloblastosis on the following grounds. In myeloblastosis, the liver is usually pale red and the marrow is whitish, whereas in erythroblastosis, the liver and marrow are usually cherry red (Figure 15.30B, C). In myeloblastosis, the cells accumulate intravascularly and extravascularly, whereas in erythroblastosis they are always intravascular. The erythroblast and myeloblast may be difficult to distinguish. Erythroblasts have a basophilic cytoplasm and perinuclear halo; myeloblasts often have some granules (Figure 15.30D, E).

Erythroblasts are cells of the erythropoietic system and can be differentiated from cells of the myelopoietic system on the basis of the presence of certain markers. Thus, erythroblasts have erythroid markers including hemoglobin, chicken erythrocyte-specific histone H5, and chicken erythrocyte-specific cell surface antigens detected by immunofluorescence. Myeloblasts and myelocytes have myeloid markers including adherence and phagocytic capacity, Fc receptors as determined by rosette formation, macrophage- and granulocyte-specific cell surface antigen as detected by immunofluorescence, and dependence of colony formation on colony-stimulating factor (232, 341).

Erythroblastosis can be distinguished from LL by the nature and distribution of lesions. Microscopically, the cytoplasm of lymphoblasts is somewhat less basophilic than that of erythroblasts, and there is also a larger nuclear-cytoplasmic ratio than in the latter cells. Lymphoblasts are more variable in size and shape than erythroblasts, but they are all at the same primitive developmental stage. Lymphoblasts tend to have an ovoid rather than spherical nucleus and a finer, more delicate-looking chromatin network.

Myelocytomas and erythroblastosis can be easily distinguished histologically.

Myeloblastosis

As in erythroblastosis, a tentative diagnosis may be based on gross lesions; however, these are often so similar to those of LL that specific diagnosis cannot be made without examination of a blood smear. Examination of liver or bone marrow sections is helpful when identity of the cell type is in doubt. The myeloblast is, on average, smaller than the erythroblast or lymphoblast; its cytoplasm is more acidophilic and is polygonal or angular. The nucleus is less vesicular; the nucleolus, while present, is not nearly so frequently seen or conspicuous as in the other 2 leukoses. Myeloblasts also have physiologic markers that identify them as members of the myeloid series.

Myelocytomatosis

The distinctive character and location of the tumor (see the previous discussion) provide the basis for diagnosis, which can be verified by examination of a stained smear or

tumor section. Gross tumors must be differentiated from myeloblastosis, LL, osteopetrosis, and necrotic and/or purulent processes occurring in tuberculosis, pullorum disease, and mycotic infections. In recent outbreaks of ALV-J-induced tumors, myelocytomatosis was diagnosed primarily on the basis of presence of characteristic microscopic features of tumor cells (189).

Hemangioma

Hemangiomas on the skin should be differentiated from wounds, bleeding feather follicles, and cannibalism. Those in the visceral organs should be differentiated from hemorrhages and sarcomas.

Renal Tumors

Renal tumors should be suspected when tumor nodules or large masses are found only in the kidney or are encountered suspended from the lumbar region. Diagnosis can be verified by microscopic examination. Tumors should be differentiated from other causes of kidney enlargement including hematomata, LL, and accumulation of urates.

Osteopetrosis

Bone lesions of advanced cases are sufficiently distinctive to present no difficulty in diagnosis. Cross and longitudinal sectioning of long bones is helpful in detecting slight exostoses and endostoses, particularly in early stages.

Among other osteopathies (412), rickets and osteoporosis can be differentiated from osteopetrosis by their epiphyseal formation of osteoid or porous bone. In perosis, there is twisting and flattening of the shank while the bone structure itself remains normal.

Connective Tissue Tumors

These tumors are usually easy to distinguish from the leukoses. They should not be confused with granulomas (Hjarre's disease, tuberculosis, pullorum disease), results of trauma, myelocytomas, or leiomyomas.

Intervention Strategies

Vaccination

No commercial vaccine is available for the protection of chickens from infection with ALV. However, the idea of using vaccines to increase host resistance to ALV infection is very attractive (448). In a series of attempts to inactivate ALV by various means, however, Burmester (68) demonstrated that ability of these virus preparations to induce antibody was destroyed almost concurrently with inactivation. Attempts to produce attenuated strains of ALV that do not induce disease also have failed (367). Results of experimental vaccination with live ALV on shedding and congenital transmission of the virus are equivocal. Some success has been obtained in attempts to increase the resistance of the host to RSV by immunization with viral or cellular antigens (42, 384). The use of experimental recombinant ALSVs as vaccines may prove to be a valuable adjunct to current programs for reduction or eradication of ALV infection. Recombinant ALVs expressing subgroup A (92, 180, 324, 570) and ALV-J (307, 532) envelope glycoproteins have been produced that could have potential as vaccines to protect against horizontal transmission. It is worth noting that congenitally infected chicks are immunologically tolerant, and thus, cannot be immunized even if a suitable vaccine was available. These chickens constitute the major source of ALV transmission and are the most likely to develop neoplasms.

Treatment

No practical measures have been found for treatment of the various forms of the avian leukosis complex. In general, all attempts to treat virus-induced neoplasia have resulted in negative or nonreproducible results. RNAi (RNA interference)-based methods of inhibiting ALV replication have been demonstrated experimentally (93, 328), although its value in future treatment cannot be predicted.

Prevention and Control Procedures

Eradication

Eradication of ALV from primary breeding stocks is the most effective means for controlling ALV infection in chickens. Primary breeding companies of layer-type and meat-type stock have made significant progress in reducing or eradicating ALV of subgroups A, B, and J from their elite breeding lines (395).

Programs for eradication of ALV infection depend on breaking the vertical transmission of virus from dam to progeny. Breeder hens are tested by various methods for the presence of ALV, and those that test positive are discarded. In order to establish an ALV-free flock, it is necessary to hatch, rear, and maintain in isolation a group of chickens free from congenital infection. To achieve this, embryos must be obtained from dams that are not transmitting virus to their progeny. In earlier work on development of ALV-free flocks, several methods for selecting dams were used. The dams selected to produce the next generation and hoped to be a virus-free generation were (1) immune, nonvirus shedders. Hens with antibody were selected on the assumption that they were less likely to shed virus than hens without antibody. Chicks were hatched from those that did not transmit virus to their embryos, based on tests on at least 3 embryos/hen. (2) Non-immune, non-virus shedders. Hens without antibody were selected on the assumption that they had not ever been infected and were less likely to become intermittent shedders. (3) Non-viremic hens regardless of immune status. These were used to provide replacements; however, up to 4 generations of testing were needed to establish freedom, and even then infection could not be ruled out (576).

Application of eradication programs of ALV to commercial flocks has depended on associations between virus infections in hens, eggs, embryos, and chicks (488): (1) Egg

albumen may contain exogenous ALV and gs antigen, and both are usually present together. (2) A strong association exists between ALV or gs antigen in egg albumen and ALV in vaginal swabs. (3) An association exists between ALV in vaginal swabs or egg albumen and ALV in chicken embryos and newly hatched chicks. Consequently, hens with a low probability of producing infected embryos are hens negative for virus (or gs antigen) by the vaginal swab test, or hens that produce eggs with albumen free from virus or gs antigen. Commonly, virus in vaginal or cloacal swabs may be detected by ELISA, NP, or PM tests and in egg albumen by ELISA or direct COFAL tests. It is unlikely that a single test will detect all potential shedder hens. A problem that arises in applying the ELISA test to albumen or swabs is the need to differentiate positive reactions due to the presence of gs antigen derived from endogenous ALV or loci from the reactions due to the presence of exogenous ALV infection (264). Reactions due to the latter are usually markedly higher, but the setting of the boundary between endogenous and exogenous virus infections is sometimes difficult and somewhat arbitrary. High reactions due to exogenous virus are clearer with albumen samples than with swabs (130). The use of monoclonal antibodies and PCR tests that can differentiate between endogenous and exogenous infections could prove useful in the future.

A procedure for eradication of ALV involves (1) selection of fertile eggs from hens negative in the egg albumen or vaginal swab test (reviewed in 139, 189, 392, 398); (2) hatching of chicks in isolation in small groups (25–50) in wire-floored cages, avoidance of manual vent sexing (191), and vaccination with a common needle (141) to prevent mechanical spread of any residual infection; (3) testing of chicks for ALV by a biologic assay or PCR on blood, and discarding reactors and contact chicks (190, 191, 364); and (4) rearing ALV-free groups in isolation (191, 568). In practice, selection of hens with a low shedding rate is a simpler requirement to fulfill than the subsequent chick testing and isolation rearing needed to achieve complete eradication. Consequently, some commercial breeder organizations are concentrating only on reduction of infection rate by hen testing. Small group hatching and rearing procedures allowed identification and removal of groups containing chickens infected prior to hatching and prevented horizontal transmission of ALV-A in egg-type chickens and ALV-J in meat-type chickens (568).

Chicks are most susceptible to contact infection by ALVs during the period immediately after hatching. Although congenitally infected hatchmates are likely to be the main source of such infection, several procedures can reduce or eliminate infection remaining from previous populations. Incubators, hatchers, brooding houses, and all equipment should be thoroughly cleaned and disinfected between each use. Chick boxes should not be reused, and each farm ideally should have only one age group of chickens. The danger of introducing strains of virus not already present in the population can be eliminated if eggs or chicks from different sources are not mixed, and if chicks are reared under isolation, conditions that will prevent cross-contamination of flocks.

Experimental vaccination of chickens with virulent ALV at 8 weeks of age is reported to prevent virus shedding to eggs and to facilitate eradication of ALVs (427), but this could not be confirmed by Okazaki et al. (365). Chicks vaccinated at 8 weeks of age or older usually do not shed virus to their eggs; they may harbor it, particularly in white blood cells and the spleen (319).

Selection for Genetic Resistance

The frequencies of the alleles that encode cellular susceptibility and resistance to infection by exogenous ALSVs (see Genetic Resistance) vary greatly among commercial lines of chickens (124, 342). In some lines, high frequencies of a resistant allele may be found naturally. In others, frequencies of the resistant alleles can be increased by artificial selection. In practice, emphasis is placed on resistance to the predominating A subgroup ALV and sometimes to the B subgroup as well. With the emergence of ALV-J infection in meat-type chickens, the value of developing lines that are resistant to ALV-J should be determined.

In artificial selection, genotypes of unknown parents may be determined in a progeny test by mating them to recessive tester birds of the subgroup in question (e.g., $a^r a^r$ for A subgroup virus) (377). Depending on the segregation of susceptible and resistant progeny in a particular mating, the genotype of the unknown parent may be determined. The phenotypic identification of progeny in the test may be determined by inoculation of RSV onto the CAM, the embryo being scored as susceptible or resistant on the basis of pock count (127) or intracranial inoculation of RSV into hatched chicks, with chicks being scored on the basis of death or survival. The former method is preferable and has many advantages.

Crittenden (114, 117) discussed some of the problems raised by this approach. Mutant viruses are more likely to overcome resistance from a single gene than that related to a multiple gene effect, and mutant subgroups then may be favored. In a host population resistant to virus penetration, there can be no effective selection for resistance to the development of neoplasms; for this reason, mutant viruses may take over. It is probable that past selection for host viability has increased the resistance of infected birds to the development of neoplasms. This type of resistance is poorly defined but may be controlled by a number of genes and is, consequently, more difficult to overcome by viral mutation. A prospect suggests that it will become possible to control ALV infections by the development of resistant stock by transgenesis (116). Recent methods of developing commercial chicken strains free of endogenous retroviruses (14) and the new methodologies of transgenesis using genetically modified primordial germ cells (528, 529) point toward the feasibility of using these approaches for generating resistant stock.

Reticuloendotheliosis

Venugopal Nair, Guillermo Zavala, and Aly M. Fadly

Introduction

Definition and Synonyms

Reticuloendotheliosis (RE) designates a group of pathologic syndromes caused by the reticuloendotheliosis virus (REV) group of retroviruses in several avian species. In consideration of the increasing amounts of new literature on this virus and the disease, it has not been possible to cite all publications in this chapter. Hence the literature is cited selectively, and readers are advised to refer to other reviews (13, 29, 65, 82, 172, 178, 250).

Representative strains of the REV group include the replication-defective T strain and the non-defective A strain. A number of other REV strains also have been isolated from various avian species, including from some of the endangered species. The disease syndromes associated with RE include (1) a runting disease syndrome, (2) chronic neoplasia of lymphoid and other tissues, and (3) acute reticulum cell neoplasia. Disease manifestations are less common despite the widespread nature infection. Both runting disease and the chronic neoplastic disease are caused by the non-defective REV strains, and occur in nature. The acute reticulum cell neoplasia is induced only by strain T and is not known to occur in nature.

Economic Significance

Prevalence of the virus and the incidence of the disease with associated losses vary between countries. Dramatic economic loss from runting syndrome or chronic neoplasia also can occur when REV-contaminated vaccines are administered to very young chickens (81, 111, 124). However, such events are rare, and on the basis of reported clinical disease, the economic importance of RE in turkeys and chickens is relatively minor. Progeny of seropositive flocks are prohibited from export to certain countries, causing economic losses to certain breeding companies. Significant costs also are incurred by vaccine companies and producers of specific pathogen free (SPF) flocks who must routinely monitor their products for REV contamination. Potential problems such as the immunosuppressive effects from environmental exposure or contaminated vaccines, or of infection becoming endemic in valuable breeding stocks, have raised the level of concern on this disease (252).

Public Health Significance

REV has a wide host range, which includes certain mammalian cells (1, 245). In addition, characteristics suggesting an evolutionary linkage with mammalian retroviruses (16, 123, 184), supported by some serological evidence (112, 113), have raised the possibility of human infection. However, other workers have considered the evidence for human REV infection as insufficient to warrant concern (65, 89).

Scientific Significance

The acute and chronic neoplastic diseases seen in RE represent a third distinct etiological group of avian viral neoplasms, after Marek's disease and lymphoid leukosis. REV has a wider host range than other avian tumor viruses and can infect or transform a variety of cell types (16, 246). The various REV-induced neoplastic syndromes in chickens resemble both lymphoid leukosis and Marek's disease. REV also can integrate into the host genome, as well as that of large DNA viruses such as Marek's disease and fowlpox with significant biological consequences (99, 108), including viral recombination (61). REVs also have been used as expression vectors to insert foreign genes into chicken and mammalian cells (168). Such vectors may have diverse uses from transgenesis (31) to gene therapy (66).

History

The initial REV isolate, strain T, was obtained in 1957 from a turkey with visceral lymphomas and was serially passaged over 300 times in turkeys and chickens by Twiehaus and colleagues at Kansas State University with cellular and cell-free inocula. Although these authors obtained considerable experimental data on this virus during the period from 1958–1960, the work was published much later (187). In the meantime, Sevoian obtained the isolate from Twiehaus and found it acutely oncogenic, causing death of young chicks 6–21 days post-inoculation (PI) (202). The acute oncogenicity of the REV T strain also was demonstrated in turkeys and Japanese quail, where the virus produced acute reticulum cell neoplasia (227). The disease was designated reticuloendotheliosis on the basis of the prominent cell in these neoplastic lesions and the T strain of the virus as REV (30). The antigenic relationships between strain T and the previously characterized but non-oncogenic chicken syncytial (CSV), spleen necrosis (SNV) and duck infectious anemia viruses (DIAV) was demonstrated, thus establishing the concept of an REV group (177). Thus, the nomenclature for the disease and the virus originated from the atypical pathology induced by the defective strain T and was extended to all viruses in the group, although reticuloendothelial cell lesions are rarely, if ever, induced by non-defective strains.

Etiology

The laboratory-derived strain T is defective for replication in chicken fibroblast tissue cultures and possesses a unique oncogene of cellular origin (v-rel) that is responsible for

its acute oncogenicity (100, 101). Stocks of T strain also contain a non-defective helper REV that replicates in chicken fibroblast cultures but lacks acute oncogenic properties (100). The helper virus has been variously designated as REV-A (100) or as non-defective strain T (263). Many other non-defective strains have been isolated from a variety of avian species including turkeys, chickens, ducks, pheasants, geese, and prairie chickens (82). Non-defective strains are a single serotype, but have been differentiated into 3 antigenic subtypes (43, 82). The non-defective REVs are responsible for the runting disease and the chronic neoplastic disease, both of which occur in nature. The acute reticulum cell neoplasia is induced only by strain T and is not known to occur in nature.

Classification

REVs are retroviruses immunologically, morphologically, and structurally distinct from the leukosis/sarcoma group of avian retroviruses (reviewed in 178). The International Committee on Taxonomy of Viruses (http://ictvonline.org/virusTaxonomy.asp?version/) has recently classified REVs within the genus Gammaretrovirus in family Retroviridae, with a phylogenetic relationship with mammalian C-type retroviruses (119, 150).

Morphology

Viral particles are typical of retroviruses (Figure 15.46); they are about 100 nm in diameter (272) and are covered with surface projections about 6 nm long and 10 nm in diameter (114). Virions have a density of 1.16–1.18 g/ml in sucrose density gradients (23), but can be differentiated from avian leukosis viruses by morphology in thin sections (149, 272).

Chemical Composition

Nucleic Acid

Genomic single stranded RNA of REV consists of a 60–70 S complex containing two 30–40 S RNA subunits, each having a size of about 3.9×10^6 d (25, 139). The non-defective REV has a genome of about 9.0 kb, while the replication-defective REV T strain genome is only about 5.7 kb due principally to a large deletion in the gag-pol region and a smaller deletion in the env region (47). Moreover, the REV T genome contains a substitution of 0.8–1.5 kb in the env region that represents the transforming gene, identified as v-rel (42, 48, 264). The v-rel is not present in non-defective REVs nor other avian or mammalian retroviruses. Related sequences (c-rel) are present in the DNA of normal avian cells, including turkey cells from where the oncogene was thought to have been transduced (42, 249). No endogenous REV sequences in host DNA have been recognized. The long terminal repeats (LTRs), 569 base-pairs in length, are efficient promoters in a variety of cell types (185, 205). In addition to those of the prototype viruses, the complete genome sequence of a number of REV strains including the Chinese isolate HA9901 (GenBank NC006934), the US isolate APC-566 (GenBank DQ387450) from the endangered Attwater's prairie chickens (17), and the isolate 3410/06 (GenBank FJ439119) from geese (135) have been published.

Oncogene

The v-rel oncogene is transcribed in strain T-transformed lymphoid cells and produces a phosphoprotein product identified as $pp59^{v\text{-}rel}$. The v-rel protein is a member of the rel/dorsal family of proteins, which are related to nuclear factor kappa B (NFkB) and function as DNA-binding transcription factors (27, 190). It differs from the c-rel protein both in

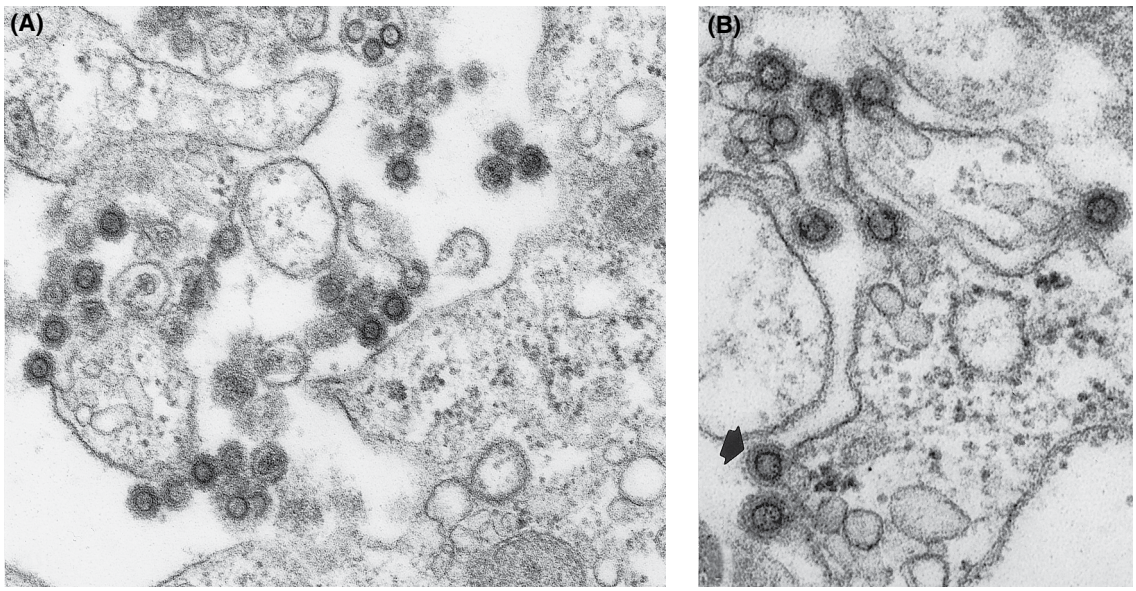

Figure 15.46. Electron micrographs of thin sections of chicken embryo fibroblasts infected with REV. (A) Typical virus particles in the extracellular spaces. ×40,000. (B) REV particles budding from the plasma membrane of infected cells (arrow). ×60,000. (Nazerian)

structure and transforming ability (91, 92, 93), and unlike most other oncogene products, can be detected in both the cytoplasm and nucleus of transformed cells (29). The v-rel protein can complex with a number of cellular proteins (71, 122, 134). In several cases, REV isolates other than strain T have induced neoplastic disease within very short latent periods (68, 69, 179, 181). Examination of such strains for viral oncogenes of cellular origin may be of interest.

Viral Proteins

Like other retroviruses, REV encodes genes that express structural proteins, an envelope protein, and a polymerase. The RNA-directed DNA polymerase (reverse transcriptase) differs structurally and immunologically from the comparable enzyme of leukosis/sarcoma viruses (22, 149). The preference of REV polymerase for Mn^{2+} ions is a characteristic by which it can be differentiated from enzymes of other avian retroviruses (149, 199). The envelope protein is composed of 2 peptides, the gp90 surface unit (SU) and the gp20 transmembrane unit (TU) (234, 236). The C-terminal epitope of gp90 is located on the surface of infected cells (237). The gp90 protein is considered the immunodominant protein of the virus (59). Glycoprotein expression results in interference with superinfection (83). The 2 glycoproteins and 2 other proteins were located on the surface of the virions (152). The receptor binding regions have been mapped and structural differences compared to other retroviruses were noted (141). Recently, recombinant gp90 protein expressed in insect cells was shown to be immunogenic and reacted with specific antibodies (131, 132). There are five gag gene-encoded structural proteins, p12, pp18, pp20, p30, and p10 (235). The 30-kD (p30) protein constitutes the major group-specific antigen that plays a role in viral particle assembly (247). Antiserum to p30 cross-reacted with p30 of other REVs, demonstrating its group specific nature (140).

Replication

Non-Defective Strains

The cycle of replication *in vitro* is similar to that of other retroviruses (reviewed in 65). A full-length infectious clone of REV has been valuable in studying viral replication (63). Virus entry involves binding of the envelope glycoprotein to a specific receptor on the cell surface that has not yet been identified, although a sodium-dependent neutral-amino-acid transporter molecule has been suggested as a shared receptor (218). Entry of virions into cells is probably accomplished by direct membrane fusion. Integration of the DNA provirus proceeds by different mechanisms in chicken and D17 cells. Viral RNA transcription and translation are initiated through promoter and enhancer sequences in the LTR. Two polyproteins are encoded, gag-pol and env; the gag precursor protein is myristylated. The encapsidation sequence is located in the gag gene. The final stage is budding of viral particles from the plasma membrane. Virus production is thought to occur in 24 hours, peaking at 2–4 days after infection in chicken cells (30, 116, 223).

Defective Strain

The replication-defective strain T virus requires a non-defective helper REV for replication (100). Oncogenicity of this strain is maintained during passage *in vivo* (187) or during culture of infected hematopoietic cells (100), but is rapidly lost during passage in chicken fibroblast cultures (227, 260) and dog thymus cells (1). This apparent attenuation in chick embryo fibroblast cultures is due to the loss of the replication-defective, acutely oncogenic virus, which was completely absent after 3 passages; however, the non-defective helper REV continued to replicate (32).

Cytopathology

Replication of REV in avian fibroblast cultures is accompanied in some cases by subtle cytopathic changes (227). Syncytial cell formation has been reported in infected cultures but degenerative changes are more commonly seen (223). Temin et al. (225) proposed the following model: Infected cells synthesize unintegrated viral DNA, a part of which is integrated at multiple sites in the cellular genome. Superinfection of the progeny virus then leads to an accumulation of unintegrated viral DNA. Cells with large amounts of unintegrated DNA die, while those cells able to prevent early superinfection have few copies of unintegrated viral DNA and survive. The acute phase of cell killing (Figure 15.47A, B) lasts 2–10 days after infection and is followed by a state of chronic infection with reduced cytopathology (Figure 15.47C) but continued virus production (223, 224).

Host Range

Cultured avian cells from many species, but especially chicken embryo fibroblasts, are susceptible to infection. However, certain mammalian cells support at least limited viral replication. Non-defective REV has been grown in D17 dog sarcoma cells (16, 245), dog thymus cells (206), normal rat kidney cells (118), mink lung cells (1), and bovine cells (15). D17 cells are susceptible and constitute a useful host system for virus propagation (245, 246), although REVs require some adaptation before high titers are obtained. Rat and mouse cells were only semipermissive for replication of REV, with blocks at different replication steps (72, 73). A wide range of avian species support REV replication *in vivo* but there is little evidence for *in vivo* replication of REV in any of the non-avian species. Detection of antibodies to REV have been reported in humans, monkeys, horses, and goats, although it needs further confirmation (113). Although REV-A-based vectors could infect human cells (123), recent evidence indicates that REVs did not infect human cells due to the inability to bind to a cell surface receptor (89, 168). Further, some batches of a commonly used D17.2G packaging cell line may be contaminated with murine retroviruses that produce, when infected with REV, pseudotyped virions that can infect human cells (89).

Pseudotypes

The envelope component of non-defective REV forms pseudotypes with Rous sarcoma virus (195, 238) and with vesicular



Figure 15.47. Acute (cytopathic) and chronic (noncytopathic) infection of chicken embryo fibroblasts inoculated with nondefective REV strain. (A) Mild cytopathic changes 13 days after infection. Unstained, ×55. (B) Cytopathic changes and viral antigens 13 days after infection demonstrated by indirect immunofluorescent staining. (C) Chronically infected cultures 48 days after infection showing relatively normal-appearing cells, most of which contain cytoplasmic viral antigens. ×360.

stomatitis virus (115). The pseudotyped virus can be neutralized by antiserum to REV and this has been used to detect REV antibodies (52).

Insertional Mutagenesis

Similar to other retroviruses, replication of REV requires integration of proviral DNA into the host cell genome. However, REV proviral DNA also can integrate into the genomes of large DNA viruses including Marek's disease virus (108) and fowlpox virus (99). Insertions apparently result from co-infections of REV and a recipient DNA virus, and occur both *in vitro* and *in vivo* (61). Most insertions consist of a solitary LTR, sometimes with partial deletions (54, 151, 265). However, full-length, infectious REV genomes have been detected in herpesviruses (110). Retroviral insertions into herpesviruses can affect biological functions of the viruses (54, 212). This effect is thought to be due to the influence of the REV LTR on the MDV genes (120). In fowlpox virus, a nearly full-length, infectious REV provirus has been detected in certain strains (4, 26, 86, 99, 121, 207). Such proviral insertions have been detected in some fowlpox virus stocks (60, 97, 217), sometimes from materials kept lyophilized for more than 50 years (121). As REV insertions have the potential to change the biological properties of the recipient organism, infectious clones of REV packaged in other viruses may provide a novel and important mechanism for transfer of infection (see section on Horizontal Transmission).

Strain Classification

The different isolates of REV are remarkably uniform in antigenicity (33, 177, 260), and except for defective strain T, have similar structural and chemical properties (22, 116) and close sequence similarity (17, 135). Nevertheless, subtypes based on differences in neutralization tests and reactivity with monoclonal antibodies have been identified (43, 55). Viruses of subtype 1 and 2 could not be differentiated by receptor interference (83), thus confirming the absence of major differences between subtypes. REV isolates also differ in certain biologic properties, including pathogenicity (178) and replication *in vivo* (57), but such differences have not been the basis for strain classification.

Laboratory Host Systems

Cell Cultures

Fibroblasts from several avian species and certain cell lines, such as QT35 quail sarcoma cells (46, 50) and D17 dog osteosarcoma cells (16, 245), are susceptible to infection with non-defective REV strains. In infected cultures, antigens (Figure 15.47B,C), virus particles, proviral DNA, cytopathology, and reverse transcriptase may be detected and serve as criteria for virus assay. When the cultures are grown under agar, foci of cells containing antigens can be localized and used as the basis for a quantitative fluorescent focus assay (177). Duck embryo fibroblasts may be preferred for demonstration of cytopathic effects (14). However, chicken bone marrow-derived macrophages appear resistant to infection (239).

Embryos and Birds

Other laboratory host systems for REV include chicken embryos (202) and a variety of avian species including young chickens, Japanese quail, ducks, geese, turkeys, pheasants, and guinea fowl (181, 227). Embryos and animals may respond to infection by development of specific lesions, viremia, or antibodies.

Cell Lines

Hematopoietic cells transformed *in vivo* or *in vitro* by the replication-defective REV have been developed into continuous cell lines; the cell types and surface markers vary based on the strain of helper virus and whether transformation occurred *in vivo* or *in vitro* (29, 104). A line of transformed chicken embryo fibroblasts also has been developed (85). Non-producer clones can be isolated that produce pseudotypes when infected with non-defective REV strains (101). The cells possess surface viral antigens that co-cap with antigens of the major histocompatibility complex (138). Cell lines also have been derived from chronic lymphomas induced by non-defective strains of REV (163, 179). Cell lines induced by *in vitro* transformation of spleen cells with defective REV can serve as useful expression systems for transfected foreign genes (176, 198) or as substrates for the propagation of other viruses (182). Some of these transformed cell lines elaborate growth factors or cytokines (87, 90).

Pathobiology and Epidemiology

Incidence and Distribution

REV infection is common, but not ubiquitous, in flocks of turkeys, ducks, chickens, and certain other avian species such as geese (135), partridges (45), and Attwater's prairie chickens (18, 67, 142). Mixed infections with other retroviruses such as the subgroup J avian leukosis virus (ALV-J) also are being recognized (53). The prevalence of seropositive flocks and the proportion of seropositive birds both increase with the age of the flock. Different studies have established the presence of REV antibodies (or virus) in a number of countries (5, 14, 44, 241). Antibody levels of chicken flocks in some countries such as Korean Peninsula or Egypt were as high as 34%–75%, with seropositive chicken flocks still common in the USA (reviewed in 82).

In contrast, the incidence of REV-associated clinical disease in commercial poultry varies from sporadic to negligible. Acute reticulum cell neoplasia is not seen in the field. The runting disease syndrome has been primarily seen following vaccination of young chickens with REV-contaminated vaccines (111, 117, 268). In such cases, a high proportion of chickens are typically affected.

Chronic neoplasia associated with REV infection also is rare. Field cases of lymphomas in turkeys have been described in the United States (51, 170, 211, 256, 261), England (143), and Israel (106). Losses from mortality and condemnation at slaughter in affected flocks could be as high as 16%–20% (143, 170). Lymphomas associated with REV infection also have been reported in wild turkeys (98, 129). REV-associated lymphomas in chickens have been reported (58, 106, 146, 167) but are rare. Chronic neoplasia associated with REV has been occasionally observed in ducks (95, 171, 173), quail (38, 193, 197, 240), pheasants (69), geese (68), peafowl (148), and prairie chickens (17, 18, 70, 271). Administration of REV-contaminated vaccines to chickens may induce chronic lymphomas (11, 74, 77, 81, 151, 180, 220).

Natural and Experimental Hosts

Natural hosts for REV infection include turkeys, chickens, ducks, geese, pheasants, Japanese quail, peafowl, and Attwater's prairie chickens. Experimental hosts include all of the above species, as well as guinea fowl (18, 45, 82, 135). Chickens and turkeys have been most frequently employed as experimental hosts.

Transmission, Vectors, and Carriers

Horizontal Transmission

Experimentally, REV can be transmitted by direct physical contact with infected chickens, turkeys, and ducks (127, 155, 169). Horizontal transmission may be influenced by the host species (177) and the virus strain (257, 269), and was not detected when chickens were separated by wire mesh (12). In nature, many flocks develop REV infection at older ages (257) where direct contact with infected birds can be excluded. Environmental sources of infection may include contaminated poultry houses, insects, and other biological reservoirs. Poultry house environments can become contaminated with virus shed by infected birds because REV has been detected in feces and cloacal swabs (10, 174, 263, 269), other body fluids, and litter (12, 244). Virus present in poultry house environments transported on fomites or insufficiently disinfected could potentially serve as a source of infection for other flocks. However, this does not seem to explain the high rates of flock infection because in flocks infected at later ages, virus is difficult to isolate (257) and the quantity of shed virus is probably limited. Furthermore, REVs, like all retroviruses, are quickly degraded outside the host at ambient temperatures (37).

Insect transmission is another possible source of horizontal transmission of REV. Virus could be recovered for brief periods in *Triatoma infestans* and *Ornithodoros moubata* after feeding on infected chickens (228, 229). REV was isolated from 7 of 39 batches of mosquitoes (*Culex annulirostris*) in contact with viremic chickens, demonstrating the potential for mechanical transmission of the infection to chickens (157). Mosquitoes fed on infected blood for 96 hours retained infectious virus for an additional 5 hours (59). Mosquito transmission has been proposed to explain why flocks seroconvert more commonly during summer months (161) and why there is a high prevalence of infection in Southern US states (257, 259). However, if insects are to be an important mode of infection for older poultry flocks, an ample reservoir of infected donor animals would be required, but the proportion of viremic chickens in field flocks at any given time appears too low to constitute the necessary biological reservoir. Novel viral

reservoirs such as fowlpox virus that may contain infectious clones of REV (86, 99, 207) . In addition to these vectors, the transmission by mosquitoes could also be considered. Thus, mechanisms for horizontal transmission among commercial flocks and the identity of biological reservoirs of infection are poorly understood.

Vertical Transmission

Chickens, turkeys, and ducks with persistent viremias may transmit infectious REV to progeny, although usually at low frequency. REV was isolated from 2 of 25 embryos from tolerantly infected turkey hens (144). Similar low rates of viral shedding and transmission were documented for tolerantly infected chickens (10, 12, 241, 263), although Motha and Egerton (160) reported transmission to more than 50% of chicks in an experiment in which eggs were incubated within 24 hours of lay. Albumen samples from tolerantly infected hens frequently contained RE viral gs antigen, although at low levels; infectious virus was rarely isolated (263). Vertical transmission may occur at higher rates in ducks, because virus was isolated from 87% of embryos derived from tolerantly infected females (155). Vertical transmission from non-tolerantly infected chickens is even less common, but one exceptional antibody-positive, virus-positive turkey hen transmitted virus to 6 of 21 progeny (261). Although semen from tolerantly infected turkeys contains infectious virus (145, 261), the role of the tom in vertical transmission is not clear. Turkey hens inseminated with infected semen produced infected progeny (144), but, in contrast, the frequency of vertical transmission was no greater from hens mated with viremic males than with hens mated with non-viremic males (261). Furthermore, they found no evidence in turkey breeders or congenitally infected progeny of clonal insertions of proviral DNA that would be indicative of genetic transmission (261). Male transmission has received less attention in chickens, but REV proviral DNA has been detected in chicks from matings of viremic males and non-viremic females (191, 192). The role for the male in vertical transmission of REV has not been excluded.

Contaminated Biological Materials

Accidental contamination of virus and vaccine stocks with REV has been observed on a variety of occasions. The use of REV-contaminated fowlpox (6, 81) or Marek's disease (111, 269) vaccines has been documented, sometimes resulting in major economic consequences. Standard assays of quality control may not detect REV contamination in vaccines such as fowlpox (77). REV continues to be found in some (6, 64, 86, 99, 207) but not all fowlpox virus vaccines (60, 151). REV also has been detected in stocks of *Plasmodium lophurae*, which was serially passed in ducks (137, 233). The occurrence of such problems points to a further mechanism for increasing the distribution of this virus in nature.

Incubation Period

The runting disease syndrome includes a number of non-neoplastic disease processes that are not coordinately expressed and vary depending on virus strain and several other factors. Atrophic changes in the cloacal bursa and thymus can be seen as early as 3 days after infection (162). Weight depression in infected chicks can be detected as early as 6 days of age (153). By the second week PI, chickens developed microscopic nerve lesions and depressed immune response (258, 260).

Chronic neoplastic responses occur after moderate or long incubation periods. Chickens developed bursal-derived B cell lymphomas 17–43 weeks PI (263). Chronic non-bursal lymphomas with latent periods as short as 6 weeks have been described in line 6_3 and line 0 chickens following experimental infection with the spleen necrosis or chick syncytial strains of non-defective REV (262). REV-associated lymphomas in turkeys occurred between 15 and 20 weeks of age (143, 170). In transmission studies, lymphomas were induced after 8–11 or 11–12 weeks (143, 169). Chronic lymphomas occur between 20 and 30 weeks in the domestic goose (68), and at 4–24 weeks in ducks (95, 171, 173). Experimental inoculation of newly hatched ducks induced lymphomas and other neoplasms between 8 and 30 weeks (130, 155). Because of the short latent period and high mortality, defective REV strain T is referred to as the most virulent of all retroviruses (29).

Clinical Signs

Chickens with runting disease syndrome may be notably stunted and pale (162). Weights of infected chickens may be 20%–50% lower than those of controls by 3–5 weeks after infection (258, 260). Weight depression also has been seen in infected ducks (177). Some chickens may have abnormal feather development, termed Nakanuke, i.e., wing feathers with adhesion of the barbs to a localized section of the shaft (126). Lameness or paralysis is rare even in birds with gross nerve lesions. Mortality is rare in chickens (258), but affected birds in commercial flocks are usually culled prior to death, with cull rates as high as 50% between 5 and 8 weeks reported (221). Birds developing chronic lymphomas become depressed prior to death, but show few specific clinical signs. Similarly, newly hatched chickens or turkeys that develop acute reticulum cell neoplasia following inoculation with defective strain T show few clinical signs due to the rapid onset of the disease, and mortality rates often reach 100% (203, 227).

Pathology

Runting Disease Syndrome

In chickens, the principal lesions include runting (162, 260), atrophy of the thymus and cloacal bursa (162), enlarged peripheral nerves (260), abnormal feather development (124, 125), proventriculitis (111), enteritis (143), anemia (117, 137), and necrosis of the liver and spleen (233). These are often accompanied by depression of cellular and humoral immune responses (33, 39, 106, 117, 258). The acute hemorrhagic or chronic ulcerative proventriculitis observed in field cases (111) could not be reproduced with a similar isolate (11).

It is unclear whether the proliferative lesions in enlarged peripheral nerves are neoplastic or inflammatory; however, nerve lesions often occur in the absence of other neoplasms (260). Grossly, nerves are only modestly enlarged with the

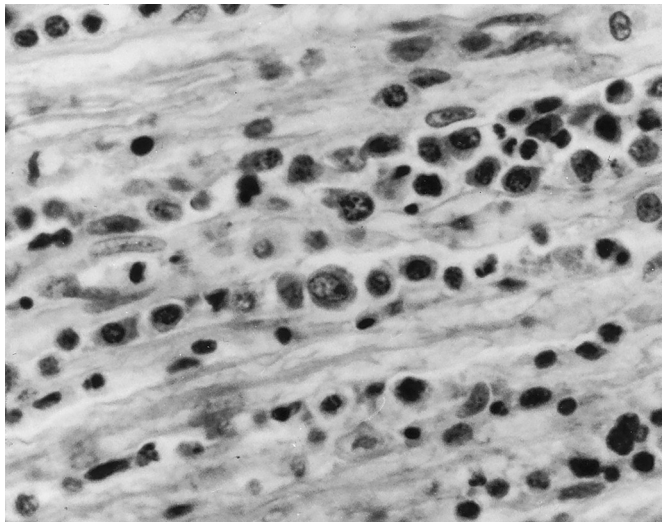

Figure 15.48. Microscopic lesions in a peripheral nerve of a chicken inoculated with nondefective REV strain. Infiltrating cells consist of mature and immature lymphocytes and plasma cells.

infiltrating lymphocytes and plasma cells (Figure 15.48). Parts of the runting disease syndrome occur in ducks inoculated with the spleen necrosis or duck infectious anemia strains of REV (137, 233). Hematocrit values in ducks inoculated with spleen necrosis strain can be as low as 20%, compared to 35% for control ducks (233). Affected turkeys showed enlarged nerves (169, 170), and enteritis (143) has been observed in turkeys with RE-related chronic lymphomas. Genetic differences in susceptibility have not yet been described; chicks from lines of different susceptibility to Marek's disease were equally susceptible to the development of nerve lesions following inoculation with REV (260). Most non-defective REV strains, when inoculated at hatch, induce high frequencies of gross lesions (177, 258), but others, such as chick syncytial strain, may induce few, if any, lesions (258).

Chicken Bursal Lymphoma

Chickens inoculated with the non-defective chick syncytial or T strains developed B cell lymphomas, involving principally the liver and cloacal bursa (253, 263). The gross lesions were nodular or diffuse lymphoid lesions in the liver and other visceral organs, including nodular lesions in the cloacal bursa, which were indistinguishable from lymphoid leukosis (Figure 15.49). A few birds may develop sarcomas or adenocarcinomas. The frequency of lymphomas was influenced by virus strain and whether a tolerant infection had been induced (263). Interestingly, co-infection of chickens with serotype 2 Marek's disease virus enhanced the incidence of REV bursal lymphomas as reported for lymphoid leukosis (3, 7).

The tumor cells, which appeared histologically as uniform populations of lymphoblasts, were identified as B cells by IgM and other B cell-specific markers (163, 263). The bursal dependency of this tumor was confirmed by the finding that chemically or surgically bursectomized chickens were refractory to tumor development (79). Bursal lymphomas may not always be present in field cases (94), although typical bursal lymphomas were observed in chicken flocks following administration of a REV-contaminated fowlpox vaccine (81).

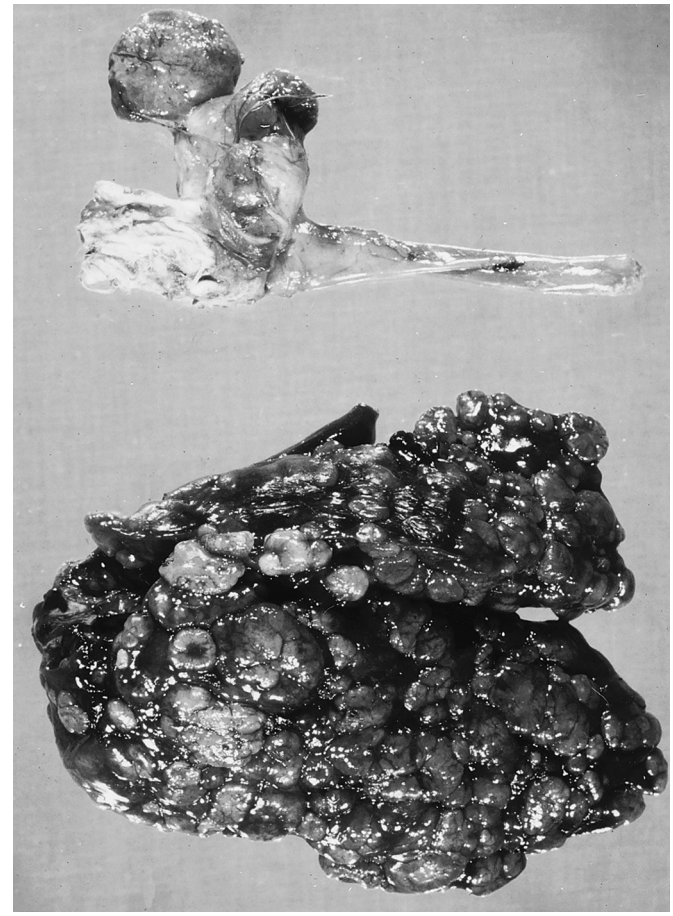

Figure 15.49. Bursal lymphoma in a chicken. Gross lymphomas in the liver and bursa of a chicken 25 weeks after inoculation with the nondefective chick syncytial strain of REV.

Chicken Non-Bursal Lymphoma

Chicken non-bursal lymphomas have been observed in certain lines of chickens following experimental infection with the spleen necrosis or chick syncytial strains of non-defective REV (262). Grossly, these lymphomas appear as focal or diffuse lymphoid infiltrations, usually producing enlargements of the thymus, liver, and spleen or focal lesions of the myocardium (Figure 15.50). The cloacal bursa is not involved. Nerve enlargements, probably from concomitant expression of the runting disease syndrome, may be seen. Histologically, the tumors appear to be a uniform, immature lymphoreticular cell that lacked B cell markers and MATSA, a cellular antigen seen in Marek's disease tumors (262).

Turkey Lymphoma

Chronic lymphomas in turkeys are characterized by gross lymphoid infiltrations in the liver, intestine, spleen, and other visceral organs. Lymphomatous lesions can be seen in the

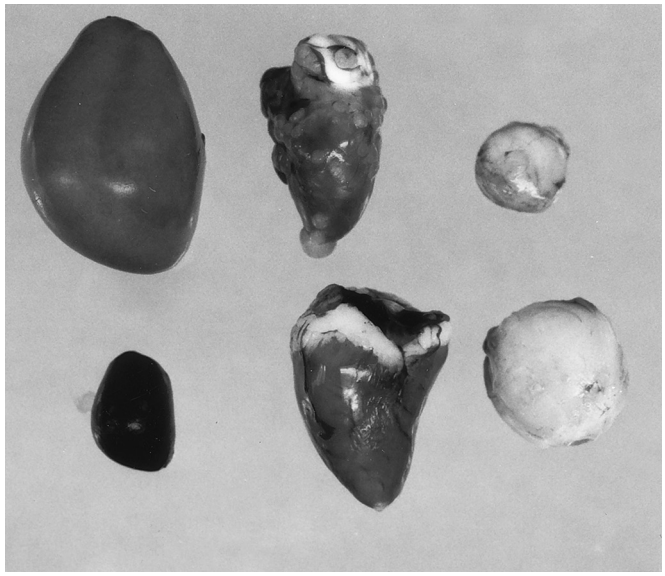

Figure 15.50. Nonbursal lymphoma in a chicken 48 days post-inoculation with the nondefective spleen necrosis strain of REV. Note enlargement of spleen, nodular lymphomas on heart, and bursal atrophy of infected chicken (top row). Organs from age-matched controls in the bottom row.(262)

cloacal bursa, although this lesion was not common (143, 169). Grossly, liver and spleen show enlargement, with the latter also showing focal lesions. Intestines show thickened annular lesions. Histologically, the lesions were composed of uniform populations of lymphoreticular cells (51, 143).

Lymphomas of Other Species

Various other species develop chronic lymphomatous lesions associated with REV infections. Gross lesions are not very different for those described for chickens and turkeys. Lesions reported in ducks include enlarged livers and spleens with diffuse or focal involvement, intestinal lesions, and infiltrations in skeletal muscle, pancreas, kidneys, heart, and other tissues (95, 130, 155). An outbreak in ducks characterized by generalized leukemia in addition to visceral lymphomas has also been reported (173). Similar tumors were described in geese, and also included occasional lymphoproliferative lesions in the cloacal bursa (68). Outbreaks in both pheasants and prairie chickens were characterized by cutaneous lesions on the head and mouth in addition to nodular lymphomas in visceral organs (18, 69, 70, 271). Outbreaks in quail, attributed to REV, were characterized by liver and spleen enlargements (197) or intestinal lesions (38), while infected partridges demonstrated liver tumors (45, 243). Histologically, tumors from all of these species generally resembled those described for chickens and turkeys, although the identity of the target cell has not been determined.

Acute Reticulum Cell Neoplasia

The pathology of the acute reticulum cell neoplasia has been well described (187, 203, 227). The affected birds develop large livers and spleens with infiltrative focal or diffuse lesions.

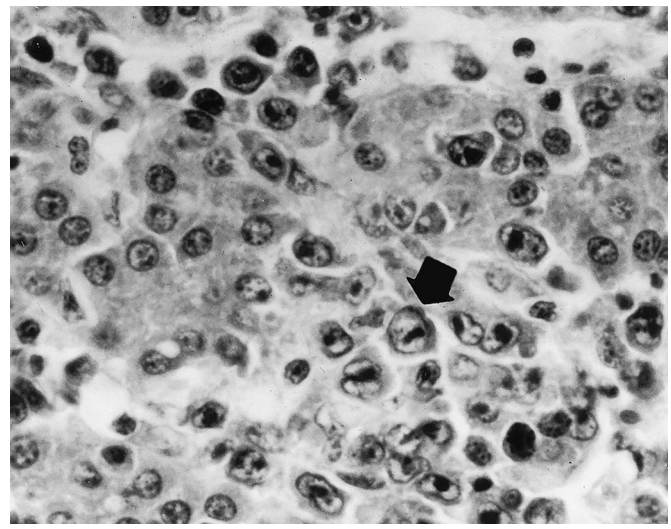

Figure 15.51. Microscopic lesions of acute reticulum cell neoplasia (reticuloendotheliosis) in the liver of a chicken inoculated with replication-defective, acutely transforming strain T REV. The liver is infiltrated with large primitive reticular cells (arrow).

Lesions also are common in the pancreas, gonads, heart, and kidney. The blood shows a decrease in heterophils and an increase in lymphocytes (222), leading to leukemia a few hours before death (204). The serum transferrin and globulin level was elevated, whereas albumin concentration was reduced (204, 232). Histopathological changes are generally characterized by the infiltration and proliferation of large vesicular cells of the reticuloendothelial system or primitive mesenchymal cells (187, 203, 227). Some lesions are composed almost solely of such cells, whereas others also include a moderate to heavy population of smaller lymphoid elements (Figure 15.51), probably indicating a host immunologic response to the primary lesion. Areas of necrosis in association with the neoplastic lesions are also frequent.

Multiple Syndromes

Lesions of the different types can be observed in the same experiment, or even in the same bird. Nondefective REV strains may first induce lesions of the runting disease syndrome and lymphomas may occur later in the survivors, sometimes accompanied by nerve enlargements. Chickens inoculated with replication-defective, acutely transforming strain T, especially those surviving the acute disease, may develop lesions associated with the non-defective strain T helper virus.

Pathogenesis

Virus Infection

Once REV infection is established in a susceptible host animal, it proceeds on 1 of 2 paths, which to a large extent determine pathologic outcomes.

Tolerant infection, i.e., persistent viremia in the absence of antibody, is induced readily in chickens by embryo inoculation (106, 263) and by vertical transmission of virus from infected dams (12). Persistent infections occur rarely, following

inoculation at hatching (10, 144, 263). Persistent infections also occur in turkeys (144, 261). Some birds with persistent infections develop antibody responses. Tolerant infection is associated with higher rates of vertical transmission and tumor development, and birds are typically stunted and immunodepressed.

In birds exposed at hatching or later, however, a transient viremia followed by the development of antibodies is the most common consequence of infection (10, 258). Persistence of non-infectious REV antigens in the blood for several weeks following the disappearance of infectious virus has been observed (10). Transient infection, particularly of older birds, only rarely results in vertical transmission, immunosuppression, or tumor development (174, 177, 257, 269), except, perhaps, in turkeys, in which lymphomas have been observed following contact exposure (144, 145, 169).

Various other factors influence susceptibility of avian hosts to infection or disease. No genetic cellular resistance has been recognized. However, some differences in the pathologic response of lines or families have been recognized in chickens (78, 201, 204, 262) and quail (226). Differences were not apparent in infections with replication-defective strain T (202).

Runting Disease Syndrome

The pathogenesis of the various lesions associated with the runting disease syndrome has not been elucidated. Stunted chickens did not consume less food, but had marked reduction of phosphoenolpyruvate carboxykinase, a key gluconeogenic enzyme in the liver (88). The adherence of feather barbules to the shaft (Nakanuke) is apparently due to REV-induced necrosis of feather-forming cells early after inoculation (219). Although the microscopic lesions of chicks with runting syndrome have been suggested to resemble graft-versus-host reaction (162), a specific autoimmune component has not been identified.

Chronic Lymphomas

In REV-induced bursal lymphomas, DNA proviral genome of REV was integrated adjacent to c-myc, a cellular oncogene important in the induction of lymphoid leukosis by avian leukosis virus (166). The molecular mechanism by which c-myc is activated by insertion of REV proviral DNA has been described (186, 216). The proviral insert often contains major deletions that prevent the expression of infectious virus (215). Based on pathology, proviral insertional activation of c-myc, and enhancement by serotype 2 Marek's disease virus, bursal lymphomas induced by REV and avian leukosis virus appear indistinguishable–a rare case in which the same disease is caused by two unrelated viruses. However, some subtle differences have been noted. For example, chickens of lines resistant and susceptible to lymphoid leukosis were uniformly less susceptible to lymphoma induction by REV than by avian leukosis virus (78), and the REV lymphomas usually require longer latent periods than those induced by avian leukosis virus. For non-bursal lymphomas, the molecular mechanism of oncogenesis also involves insertional activation of c-myc, but differs from that in bursal lymphomas; the strong tendency for the provirus to be oriented in the same direction as c-myc in bursal lymphomas was not observed in non-bursal tumor (109).

Critical comparisons between chronic lymphomas in turkeys and chickens have not been made and there is no evidence that a common mechanism of oncogenesis exists. In ducks, the frequency of experimentally induced REV lymphomas was not affected by embryonal bursectomy (130), indicating that these tumors may not be of B cell origin.

Acute Reticulum Cell Neoplasia

The target cell transformed *in vivo* by replication-defective strain T (with REV-A helper virus) expresses T lymphoid and myeloid markers (19). These cells also express surface MHC class I and II antigens, as well as interleukin-2 receptor (102), and are immunoglobulin M (IgM) negative but vary in expression of CT3 (19). Similar tumors were induced in chemically bursectomized chickens (19). Inoculation directly into the thymus induced thymomas composed of T and B cells (29). On the other hand, defective strain T, when associated with chick syncytial virus helper virus instead of REV-A, induces IgM-positive B cell lymphomas with rearrangements of the heavy- and light-chain immunoglobulin loci (20, 21). Thus, cell tropism appears to be determined, in part, by differential effects of the helper viruses on lymphoid populations.

Neoplastic transformation in acute reticulum cell neoplasia is mediated by the oncogene, v-rel, contained within the replication-defective strain T virus. Transformation does not require the presence of a helper virus (128). Lymphoid cells transformed by strain T *in vitro*, but which produce no infectious virus, will produce typical RE when transplanted into syngeneic recipients (128, 189). Significant insights into the molecular mechanisms of v-rel-mediated transformation are available (for recent reviews, see 91, 92, 93). For example, recent data have demonstrated that the activation of TGF-β/Smad signaling is required for the transforming ability of v-rel (231). More recently, the roles of microRNAs in v-rel function have been shown. For example, miR-155 has been shown to be associated with v-rel transformation through the downregulation of factors such as JARID2 (28) or in driving the NFkB-CD10 pathway by downregulating the target protein PU.1 (230). Downregulation of miR-26a in v-rel-transformed cells also suggested roles for tumor suppressor miRNAs in transformation (266).

Immunity

Humoral Responses

Birds with non-tolerant infections develop robust antibody responses. Antibodies have been detected as early as 16–21 days PI in chickens (33, 156), but 6–10 weeks may be required in contact-exposed birds (127, 144). Antibody titers may decline with age (11, 33, 263), but they have been detected at high frequency in experimentally infected turkeys through 40 weeks (144). Most birds that develop tolerant infections do not develop humoral immune responses, although a few may

ultimately develop antibodies (153). The presence of antibodies may influence tumor susceptibility because chemically bursectomized quail were more susceptible to infection with a field isolate compared to the control quails (181).

Cellular Responses

MHC-restricted cytotoxicity against lymphoblastoid cell lines transformed with defective REV has been described in chickens within 7 days PI with defective or non-defective REV strains (138, 248). This response appears to be mediated by activated (MHC class II+) CD8+ T cells (123). However, NK cells were not activated (196). The induction of cytotoxic T cells by REV has been used as a general indicator of immune response in the study of other avian viruses (182).

Immunodepression

Humoral and cellular immune responses are frequently depressed in chickens infected with non-defective REV strains. Depressed antibody responses to Marek's disease virus and turkey herpesvirus (33, 117), Newcastle disease virus (106, 268), as well as to sheep erythrocytes and Brucella abortus (258) are documented. The magnitude of antibody depression is influenced by the dose and strain of virus, and primary responses are more severely affected than secondary responses (258). Barth and Humphries (20) found that different strains of non-defective REV varied in ability to induce bursal atrophy and in suppression of B cell populations available for transformation by v-rel. Studies on chimeric viruses derived from REV-A and CSV showed that regions in both gag and env genes were associated with the strong immunodepressive ability of REV-A (84).

Spleen cells from chickens infected with replication-defective strain T were suppressed in their ability to respond to the mitogen phytohemagglutinin (39, 200). This effect is associated with the non-defective helper virus in strain T stocks (41) and is mediated through a population of suppressor cells (40, 188). The suppressor cells could be demonstrated only through the third week after infection (189). REV also has been shown to inhibit mixed lymphocyte reaction and allograft rejection (242).

Witter et al. (258, 263) found depression of humoral responses and mitogen responsiveness was transient following infection with the CSV, but persisted through 10–19 weeks in chickens tolerantly infected with non-defective strain T. Infected chickens were more susceptible to the development of a Marek's disease tumor transplant (34), to reactions from infectious laryngotracheitis vaccine (156, 208), to natural fowlpox virus infection (159), to infectious bronchitis virus (208), and to mortality induced by *Eimeria tenella* (158) and *Salmonella typhimurium* (157). Protective efficacy of vaccination against highly pathogenic avian influenza was dramatically suppressed by early infection of chickens with reticuloendotheliosis virus (214). Humoral immunodepression was also seen in ducks infected with a field isolate of REV (130). In the field, immunodepression is probably the most important consequence of embryo- or vaccine-derived REV infections rather than contact infections (257), and has not commonly been associated with seropositive flocks. For a review on REV-induced immunosuppression, see (270).

Tumor Immunity

A protective immune response against the acute neoplasia induced by strain T has been described. Regression of strain T-induced wing-web tumors was partially abrogated by bursectomy, thymectomy, and bursectomy-thymectomy (136). Serum from hyperimmunized chickens was protective against tumor development even after absorption to remove antiviral antibodies (103), thus suggesting the existence of tumor-specific transplantation antigens on RE tumor cells. Chickens immunized with purified or inactivated preparations of non-defective strain T helper virus were resistant to challenge with acutely transforming strain T preparations (24). However, immunization with empty virions (147) did not provide protection.

Diagnosis

A diagnosis of RE requires not only the presence of typical gross and microscopic lesions, but also the demonstration of REV. Because REV, unlike avian leukosis and Marek's disease viruses, is not yet as ubiquitous, the demonstration of infectious virus, viral antigens, and proviral DNA in tumor cells has diagnostic value. The application of various techniques in the diagnosis of RE has been reviewed (74, 80).

Isolation and Identification

REV titers in blood are typically low and transient, except following congenital transmission or embryo inoculation that leads to tolerant infection. Virus may be isolated by inoculation of susceptible tissue cultures with tissue suspensions, whole blood, plasma, or other inocula. In general, cellular inocula are preferred over cell-free inocula, because the former usually contain higher titers of virus than the latter. Because cytopathic effects in cell cultures may not be seen on primary isolation, cultures should be maintained through at least 2 blind 7-day passages. The presence of REV is confirmed by the demonstration of viral antigen in infected cell culture using polyclonal or monoclonal antibodies (55), immunofluorescence (260), immunoperoxidase staining (35), complement fixation (209), or enzyme immunoassay (56, 107). In comparative studies, enzyme immunoassays were more sensitive than complement fixation tests (56) and indirect immunofluorescence was more sensitive than indirect immunoperoxidase or immunoelectron microscopy (165). A convenient and sensitive indirect immunofluorescent assay conducted in 96-well plates (43) has been used for virus isolation from field samples (261). More recently, an indirect ELISA for serological detection of REV using the gp90 protein expressed in *Pichia pastoris* has been reported (131). Virus isolated by this procedure may be identified by reproduction of the typical disease in experimental animals and by further neutralization tests. Virus isolates may be assigned to antigenic subtypes by the differential reactivity of monoclonal antibodies in immunofluorescent assays (43).

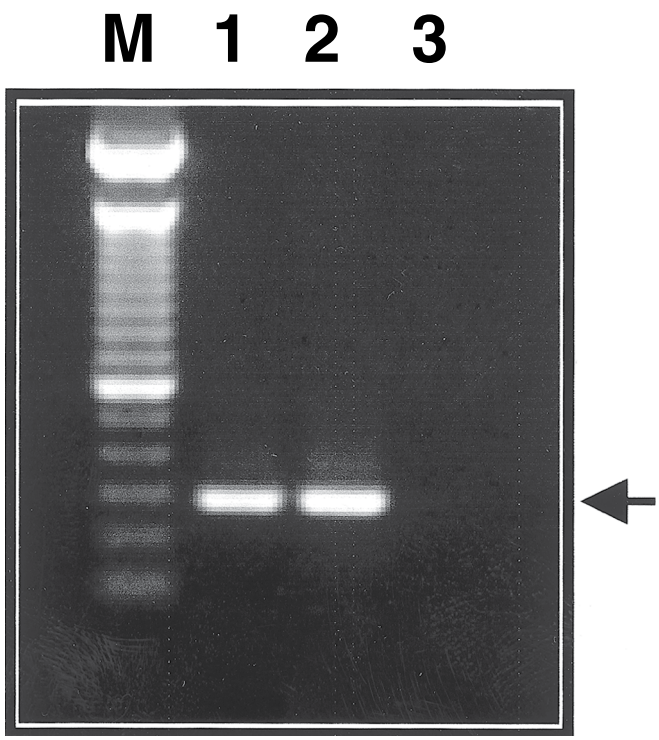

Figure 15.52. PCR analysis of DNA isolated from chicken lymphomas using primers specific for REV. Lanes: M, 100 bp ladder; 1, experimentally induced REV lymphoma (positive control); 2, unknown lymphoma (test sample); 3, uninfected chicken embryo fibroblasts. The expected 291 bp PCR product (arrow) is indicated. (Lupiani)

Detection of proviral DNA by polymerase chain reaction (PCR) assays that amplifies the 291 base pairs product of REV LTR (Figure 15.52) has been shown to be a sensitive and specific method for detection of various strains of REV in infected chicken embryo fibroblasts as well as in blood and tumors of infected chickens (2). This procedure appears useful for tumor diagnosis (57, 58) and for the evaluation of vaccines for possible REV contamination (74, 75, 77, 81, 99, 133, 183, 213, 220). Assays amplifying REV envelope and REV 3′ LTR sequences provided a more accurate assessment of REV provirus than PCR assays that amplify the REV 5′ LTR region (86). A highly specific and sensitive loop-mediated isothermal amplification (LAMP) method for rapid detection of REV using a set of 2 pairs that amplify the pol gene also has been reported (62).

Serology

Confirmation of REV infection by serologic procedures involves the detection of antibodies in sera from chickens. Antibodies are induced with various frequencies and persist for varied periods. The most sensitive test for detection of antibodies to REV is virus neutralization; briefly, samples of plasma or serum are reacted with REV and the neutralization of REV is determined by assay for residual virus using enzyme immunoassay or immunofluorescence. Immunoperoxidase plaque assay (35) also has been shown to be a sensitive and reliable method for detection of REV antibody. Specific antibody may be detected in the serum or egg yolk from exposed birds by indirect immunofluorescence (260), virus neutralization (144, 177), agar gel precipitin (105, 154), enzyme immunoassay (164, 210), and pseudotype neutralization tests (52). Enzyme immunoassay kits for antibody detection are commercially available. Antibody tests are particularly useful in ascertaining the absence of viral exposure in SPF breeder flocks or flocks producing progeny for export.

Differential Diagnosis

The pathology of REV-induced tumors, particularly those of lymphoproliferative nature, can be confused with that of tumors seen in Marek's disease and lymphoid leukosis (76, 80, 255). Because avian tumor viruses are widespread and infection in the absence of tumor formation is common, in most cases virologic and serologic criteria rarely provide a definitive diagnosis. However, as previously stated, diagnoses of RE should be supported by virologic evidence of REV infection, because REV is not as ubiquitous as Marek's disease and avian leukosis viruses. Techniques based on immunocytochemistry (193) with monoclonal antibodies to cellular, tumor, and viral antigens, or molecular hybridization can be used in the differential diagnosis of avian viral lymphomas including RE.

Avian retroviral lymphomas in chickens originate from either B cells (RE, lymphoid leukosis) or T cells (RE), whereas Marek's disease lymphomas are of T cell origin (see subchapters on Marek's Disease and Leukosis/Sarcoma Group). The characteristics of target cells provide the basis for tests that distinguish among B and T cell lymphomas using monoclonal antibodies specific for cell surface antigens of B and T lymphocytes. Non-defective strains of REV have been shown to transform chicken B or T cells by integration within cellular oncogenes such as c-myc (109, 216). These molecular changes are the bases for testing tumor DNA for the definitive diagnosis of REV-induced lymphomas.

Non-quantitative PCR assays detecting viral genomes are probably of little value for diagnosis of Marek's disease, because of the potential to detect MDV DNA in the absence of lymphomas. Also, PCR has been shown to detect REV-LTR sequences from lymphomas and brains of REV-infected chickens, but not from DNA from Marek's disease or lymphoid leukosis lymphomas (2). However, diagnosticians should always keep in mind that PCR assays demonstrate the presence or absence of the respective virus and thus have the same limitations for tumor diagnosis as virus isolation.

Chronic neoplasia in the chicken where the tumors are of bursal origin usually cannot be differentiated from lymphoid leukosis on pathologic criteria (253); virologic, serologic, or PCR tests demonstrating infection can be established for 1 virus, thus excluding the other. In addition, RE or lymphoid leukosis tumors should contain proviral DNA sequences of the respective virus integrated near major oncogenes such as c-myc, which could permit differentiation of lymphomas by molecular hybridization using appropriate probes for viral genome or oncogenes, respectively.

Chronic neoplasia in which bursal tumors are lacking or are in the latent period is too short for that of lymphoid leukosis must be differentiated from Marek's disease. Here too, pathologic criteria are insufficient and virologic assays may be helpful. The pp38 antigen of Marek's disease virus, occasionally expressed in Marek's disease lymphomas, is not present in RE lymphomas. Also, MHC class II (Ia) antigens are reported to be present on Marek's disease lymphoma cells (196) but absent on RE non-bursal lymphoma cells (49). A diagnostic strategy for the differential diagnosis of virus-induced lymphomas in chickens has been developed (254).

The acute reticulum cell neoplasia syndrome is not known to occur in the field and is unlikely to require differential diagnosis. A syndrome of broiler chickens characterized by reticuloendothelial proliferation in the spleen and liver resulting in condemnation loss at processing has been confused with RE (96), but can be distinguished by the absence of REV antigens and proviral DNA (251).

The runting disease syndrome must be distinguished from Marek's disease, especially when nerve lesions are also evident. Differences between REV-induced and Marek's disease virus-induced nerve lesions are not consistent (258, 260). Both types of nerve lesions must be distinguished from spontaneous neuropathy, a probable autoimmune lesion of peripheral nerves (8, 9). Other immunodepressive diseases such as infectious bursal disease and infection with chicken anemia virus also may resemble the runting disease syndrome. Chronic RE neoplasia in the turkey must be differentiated from lesions of lymphoproliferative disease; differences in pathology and in properties of the viral reverse transcriptases can be helpful (199, 267). PCR assays for lymphoproliferative disease (194) should aid the differentiation of these diseases.

In summary, naturally occurring RE lesions in the chicken can be confused with Marek's disease, lymphoid leukosis, and various other lymphoproliferative or immunodepressive conditions, and in the turkey, with lymphoproliferative disease virus-induced neoplasms and Marek's disease. An increasing awareness of REV-related syndromes, the increasing prevalence of REV infection, and the availability of improved diagnostic techniques should facilitate the inclusion of RE in the differential diagnosis of these avian neoplasms.

Intervention Strategies

Vaccination

Although vaccines have not been seriously proposed for control of RE, some candidate vaccines have been described. Vaccination of chickens with a recombinant fowlpox virus expressing the env gene of REV (36), or empty REV particles produced by transfected QT35 quail cells (147), provided some protection. Use of defective REV particles produced by infection of the D17 transformed canine cell line (245) also has been shown to induce neutralizing antibody in inoculated chickens. A baculovirus construct expressing the env gene of REV (244) or the recombinant gp90 expressed in *Pichia pachoris* (132) induced REV antibody in inoculated chickens.

Prevention and Control Procedures

In the absence of any specific treatments, prevention of RE is currently accomplished through quality assurance of poultry biologics, and in SPF flocks, by strict biosecurity (252). Although it is desirable to prevent environmental exposure and seroconversion of breeder flocks where progeny are destined for export, this is difficult to accomplish because knowledge of the important natural reservoirs of infection is incomplete. Control of insect vectors and virulent fowlpox virus infections could be important in prevention programs (252).

Procedures for the control of RE have rarely been applied in commercial practice, mainly because the disease has been sporadic and self-limiting, but also because the necessary techniques and knowledge have not been available. Studies on a flock of naturally infected breeder turkeys showed that REV has the potential to be a major economic problem, and provided an evaluation of some techniques for identification of shedder hens (261). Enzyme immunoassay to detect RE viral antigen in albumen samples seems to be the procedure of choice (107, 261). It would be necessary to eliminate vertical transmission through removal of infected hens, and to rear progeny under isolated conditions whereby horizontal infection could be precluded. Many of these principles have successfully been applied to the control of avian leukosis virus in chickens. Such control procedures could be considered if REV infection becomes endemic in especially valuable breeding stock, as is the case with the endangered Attwater's prairie chickens (70, 175).

Other Tumors

Scott Hafner, Rodney L. Reece, and Susan M. Williams

Introduction

Other tumors refers to tumors of poultry (chickens, turkeys, quail, pigeons, ducks, geese, guinea fowl, pheasants, and ratites) in which a known etiology does not exist. Avian tumors often exhibit distinctive microscopic appearances that may be difficult to extrapolate from similar mammalian tumors. The most detailed examination of chicken tumors remains that of Campbell (25), whose definition of a tumor as "an abnormal tissue mass…which usually persists independent of initiating

factors…whose excessive, often uncoordinated growth threatens the host through compression, infiltration, or remote spread" still suits our purposes. Detailed information on the prevalence of different tumor types in poultry exists, but most early reports are skewed by a large number of virally induced "leukotic" tumors and the reproductive tumors that are common in adult hens.

Tumor prevalence in poultry not only depends on species, breed, age, and sex, but also various intrinsic (hormonal, genetic/developmental) and extrinsic (viral, chemical, and other environmental) factors (25). Some indications of the proportion of different tumors to be expected in aged chickens unaffected by exogenous viruses are available in the surveys of tumors in specific pathogen free (SPF) flocks (45, 46, 112). Information on the classification and histologic appearance of some of the less common tumors of poultry is available from detailed reports by poultry pathologists, zoo surveys, and examinations of the tumors of non-commercial birds. Examinations of tumors present in poultry at slaughter are particularly useful because the sheer numbers of poultry slaughtered may provide multiple examples of even very rare tumors, and slaughtered birds are conveniently separated by age and species. Radical deviations from the "normal" prevalence, distribution, and/or type of these tumors may indicate changes in etiology or other factors that require further elucidation.

Immunohistochemical techniques that use antibodies to lineage-specific cell markers have found increasing applications as an aid to identification of tumor cells in both poultry and other avian species. Extended formalin fixation may reduce the avidity of some antibodies for their designated tissue epitopes; this at times may be reversed by heated acid solutions or applications of proteases. Some studies have used antibodies to vimentin for detecting mesenchymal cells, cytokeratin for epithelial cells, actin for smooth and skeletal muscles, and neurofilament for nerves. Some other antibodies may exhibit different avidity in avian tumors compared to that in mammalian species, for instance S100 proteins may stain normal nerves, but not label tumor cells derived from those tissues (85). Neuron-specific enolase often will intensely stain neural tissues, but may also stain other tissues, particularly muscle. Careful evaluation of the particular antibody in both normal and neoplastic tissues of the affected species, including both positive and negative controls, is important for accurate interpretation of immunohistochemical findings.

Public Health Significance

There is no known public health significance for other tumors.

Urogenital System

Ovary

Despite the considerable differences between avian and mammalian ovaries, particularly with regard to histologic appearance and physiology, attempts are made to characterize avian ovarian tumors using criteria developed for mammals, particularly humans. Even with the difficulty of categorizing avian neoplasms by mammalian criteria, classifying ovarian tumors as derived from surface mesothelium (adenocarcinomas), sex cord tissues (granulosa cell tumors and arrhenoblastomas), germ cells (teratomas and dysgerminomas), or other supportive tissues provides clues to both expected behavior and possible etiology, in addition to differentiating these tumors from metastatic disease. In particular, ovarian adenocarcinomas of white leghorn hens have recently been investigated as an animal model for ovarian cancer of women, with potential for this research to yield insight into the development of this neoplasm in both species (9, 16, 67).

Adenocarcinoma

Early tumors are small, firm, white nodules that occur on the surface of the ovary; these may be mistaken for atretic follicles, but are less symmetric (45). Nodules coalesce into a gray-white, cauliflower-like mass that commonly seeds serosal surfaces with transcoelomic metastases. Ascitic fluid often develops with growth of the metastases and terminally affected hens may assume an upright, penguin-like posture. Ovarian adenocarcinomas must be differentiated from oviductal adenocarcinomas because both may be widely metastatic and oviductal tumors may metastasize to the ovary. Failure to detect tumors in the lining of the oviduct suggests tumors are of ovarian rather than oviductal origin.

Tumors are assumed to arise from the mesothelial covering of the ovary (germinal epithelium), including its invaginations into the ovary, but other suggested tissues include sex cord remnants, thecal cells, interstitial cells, or even the mesonephros. Small tumors appear to be located in the theca externa of small follicles (Figure 15.53) or in the ovarian stroma; a few may originate in the ovarian stalk. Multiple tumors may be present. Smaller tumors contain predominantly epithelial cells and little stroma, while larger tumors are often scirrhous. In advanced cases, ovarian follicles fail to mature and oviducts are often atrophied. Ovarian adenocarcinomas are not associated with increased production of steroid hormones (45, 46). Occasionally, ovaries affected by adenocarcinomas are covered with small cysts filled with yellow fluid; these may be dilated lymphatics or ovarian stromal lacunae (97).

Histologically, ovarian adenocarcinomas are often composed of acini lined by cuboidal to low columnar non-ciliated epithelial cells. These epithelial cells are often arranged around lumina that are at times filled with intensely eosinophilic periodic acid-Schiff (PAS) positive material (Figure 15.54). In other, more densely cellular tumors, acini may be compressed into cords or islands of epithelial cells or papillary proliferations of the lining epithelium may be invaginated into dilated acini (Figure 15.55). The mitotic rate is variable, and in many cases mitoses are not prominent. In larger tumors, acini are often surrounded by a marked scirrhous response (Figure 15.56), and in some serosal implants there may be a proliferative response of the underlying muscularis (98). Similar ovarian adenocarcinomas have been described in turkey hens (140).

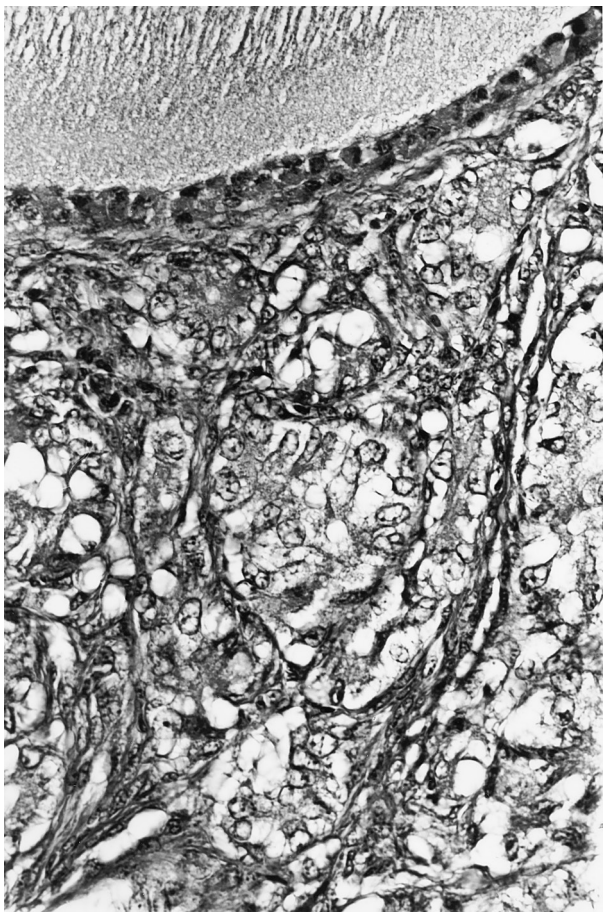

Figure 15.53. Ovarian adenocarcinoma in the theca region demonstrating delicate trabeculae and round nuclei; note the granulosa cells and yolk of the developing ova (top). H&E, ×360.

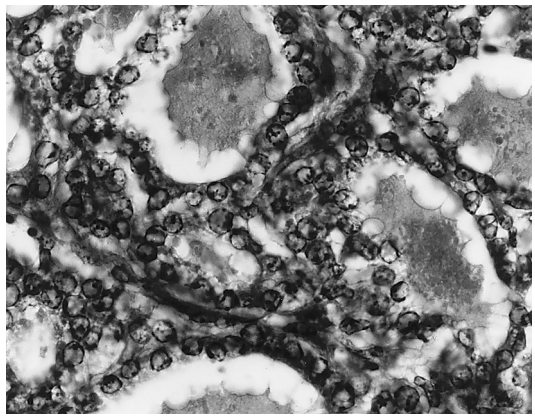

Figure 15.54. Acinar structures, typical of ovarian adenocarcinoma filled with eosinophilic material and lined by cuboidal cells containing round nuclei with condensed chromatin and sparse eosinophilic cytoplasm. H&E, ×600.

Granulosa-Theca Cell Tumor

Granulosa-theca cell tumors are irregularly round to multilobular and encapsulated by a smooth, glistening membrane. Tumors occasionally exhibit peripheral thin-walled cysts filled with fluid; sectioned tumors are yellow and friable and some contain hemorrhages. These tumors enlarge while remaining attached by the thin ovarian pedicle. Tumors may become quite large without metastasizing, but metastases to visceral organs and serosal surfaces can occur (25, 45). Granulosa-theca cell tumors are by far the most common ovarian tumor of the young broiler chicken. In these birds, there is often marked precocious glandular hyperplasia of the oviduct (66). Histologically, tumor cells are polyhedral to fusiform with pale eosinophilic to vacuolated cytoplasm (Figure 15.57). Nuclei are generally irregularly round to ovoid. The arrangement of tumor cells varies widely from the formation of follicular structures to solid sheets composed of tightly packed thin cords (Figure 15.58) separated by a fine fibrovascular stroma, more elaborate gyriform arrangements (Figure 15.59), or rosettes arranged around small central spaces. The mitotic rate is variable but often low, and the stroma may be prominent.

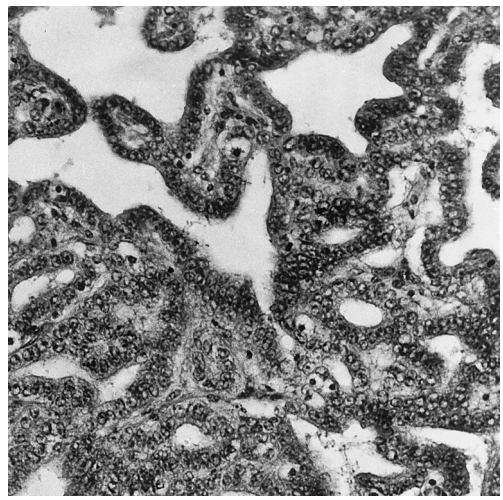

Figure 15.55. Ovarian adenocarcinoma with papillary structures projecting into dilated acini. H&E, ×160.

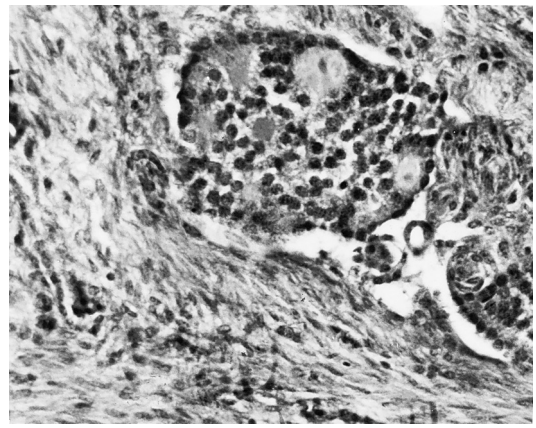

Figure 15.56. Another form of ovarian adenocarcinoma with dense bands of stromal cells enclosing clusters of neoplastic acinar cells with intensely basophilic nuclei. H&E, ×160.

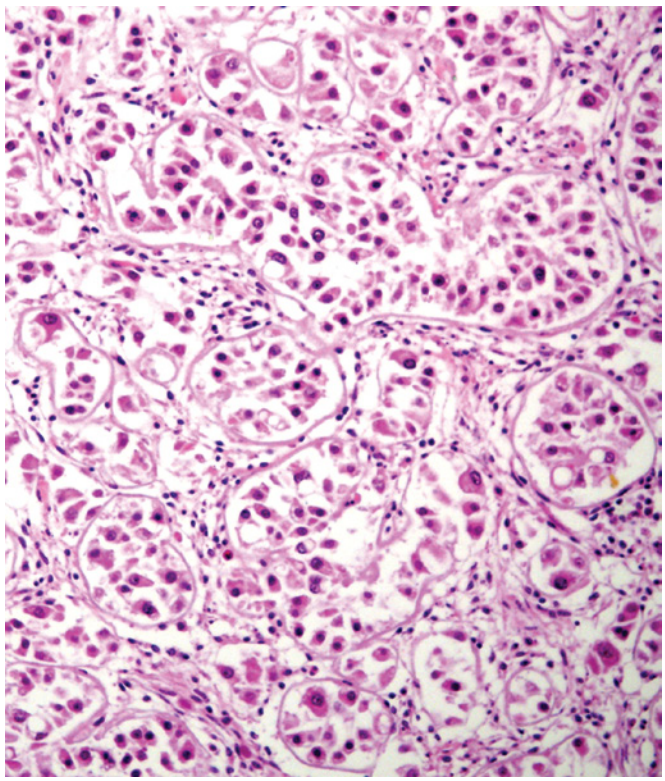

Figure 15.57. Lobules of vacuolated cells separated by moderate trabeculae in a granulosa-theca cell tumor. H&E, ×200.

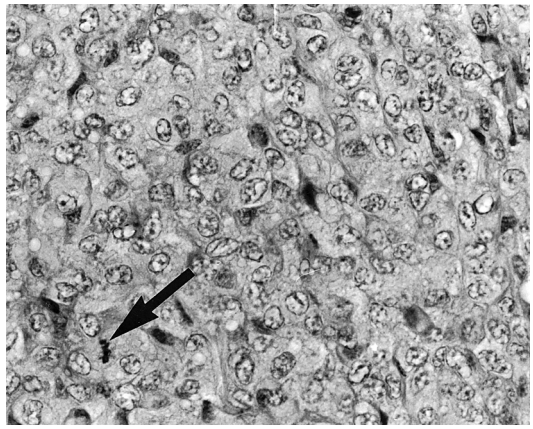

Figure 15.58. Granulosa-theca cell tumor composed of a uniform population of tightly packed tumor cells with plentiful, pale eosinophilic cytoplasm and uniform, round vesicular nuclei. Note the mitotic figure (arrow). H&E, ×600.

Ultrastructurally, tumor cells are identified by transosomes, a structure specific to avian granulosa cells and those of some other lower vertebrates (45). Transosomes (lining bodies) are dense structures of the lateral and apical plasma membranes of granulosa cells that are taken up by the oocyte becoming associated with primordial yolk granules. These structures are involved in the transport of vitellogenin (a yolk precursor)

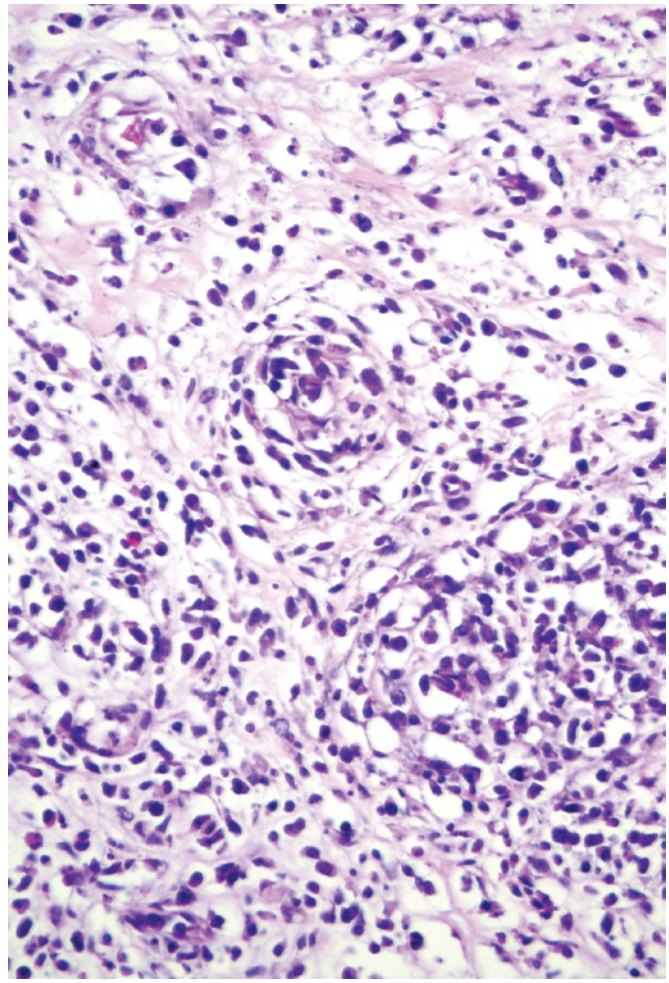

Figure 15.59. Gyriform arrangements of cells in one area of an ovary with a granulosa-theca cell tumor. H&E, ×400.

into the oocyte (90). Although granulosa cells from normal avian follicles produce progesterone, theca interna cells produce testosterone, and theca externa cells estrogen (106): hens with large granulosa-theca cell tumors exhibit markedly elevated plasma levels of estrogen (45). Oviducts of affected hens are the same size as those of hens in lay, but eggs are not produced. A significant thecal cell component may be present in granulosa-theca cell tumors; the presence of numerous vacuolated theca-like cells may lead to characterization of a granulosa cell tumor as "luteinized" or even as a "luteoma" (25). Campbell (25) also includes a tumor composed primarily of thecal cells that he designated a thecoma. A metastatic granulosa-theca cell tumor has been described in a duck (19). A very low incidence of granulosa-theca cell tumors has been induced in meat-type chickens inoculated as embryos with ALV-J (105).

Arrhenoblastoma (Arrhenoma)

Arrhenoblastomas are associated with formation of seminiferous tubules within the ovarian stroma and are accompanied

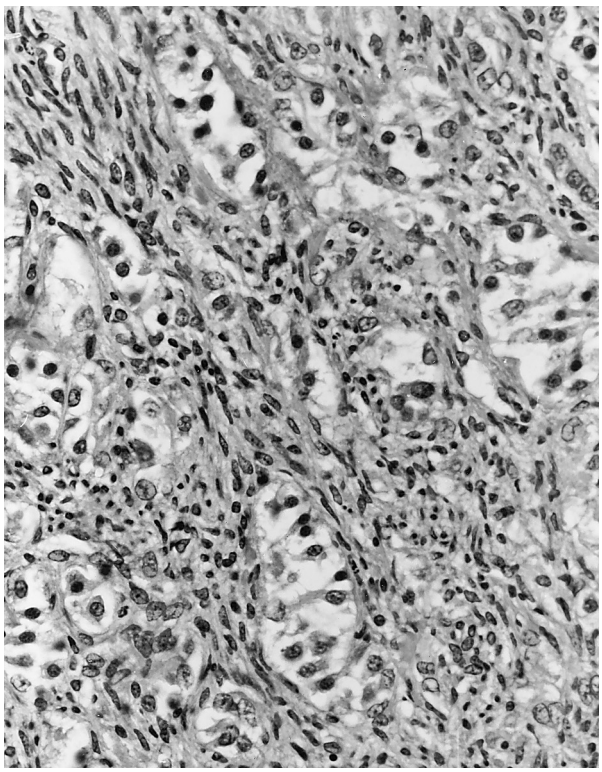

Figure 15.60. Arrhenoma from a hen that showed sex reversal. Network of epithelial cells arranged as ill-defined cords and tubules. H&E, ×350. (C.J. Randall)

by evidence of sex reversal (virilism). Sex reversal in domestic fowl was well recognized in ancient times. Most cases of sex reversal in poultry are due to destruction of the functional left ovary and formation of an ovotestis in the remnants of the rudimentary right gonad rather than hormone production by ovarian tumors (25, 44). In birds, the male is the neutral sex and the young female is demasculinized by the production of her ovarian hormones (102). Well-differentiated arrhenoblastomas are histologically composed of branching cords of columnar epithelium that are often two cells thick; these resemble primitive seminiferous tubules. There is little, if any spermatogenesis. In less differentiated tumors, epithelial cells may be arranged in cords, nests, and rosettes that form incomplete tubules (Figure 15.60) separated by a prominent interstitium that may contain interstitial (Leydig) cells (115). Large tumors may be hemorrhagic. Arrhenoblastomas have been induced by the injection of radioactive isotopes into the left ovary (142).

Ovarian Sertoli Cell Tumors

Ovarian Sertoli cell tumors in the chicken seem to be limited to the 5 cases described by Fredrickson (46). These tumors were composed of compact masses of seminiferous tubules lying under the ovarian capsule. The tubules were lined by a single, radially arranged layer of tall columnar Sertoli cells (Figure 15.61); variable numbers of interstitial cells were present between tubules. There was no obvious sex reversal or alteration in circulating hormones.

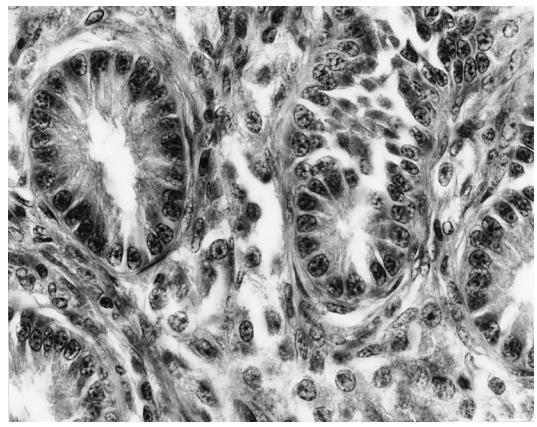

Figure 15.61. Ovarian Sertoli cell tumor composed of well-defined seminiferous-like tubules lined by Sertoli cells. Stroma contains interstitial cells. H&E, ×600.

Dysgerminoma

Dysgerminomas are the equivalent of mammalian ovarian seminomas, and have been detected in a few intersex (pseudohermaphroditic) pullets (145, 146). There was no overt sex reversal, but there was masculinization of the comb and plumage of the head. Tumor cells were round to polygonal and contained round to occasionally reniform nuclei. Some tumors had metastasized to the liver or peritoneum.

Mesosalpinx

Leiomyoma

Leiomyomas (at times termed fibroleiomyomas or even fibroids) are common in the ventral ligament of the oviduct and the oviductal wall in domestic fowl, including SPF hens (8, 21, 91, 112). The prevalence of these tumors is variable, but may affect up to 60% of hens in the first egg laying cycle (8). Similar tumors were present in the oviduct ligaments in some rapidly growing Japanese quail (43). Leiomyomas of the ventral ligament of the oviduct are usually solitary. Unless tumors are quite large, there is little effect on oviductal function, but there may be increased egg yolk peritonitis (91). In hens affected by these tumors, there were elevated serum concentrations of estradiol, and oviductal leiomyomas were induced in hens treated with both diethylstilbestrol and progesterone (7, 8). Some reports (21) also have demonstrated that the tumor cells contain receptors for both estrogen and progesterone, suggesting steroid hormones are likely to be involved in the etiology of these tumors. Many tumors are discrete, pale, solid masses less than 1 cm in diameter, but some may be several centimeters in diameter and heavily vascularized (91, 115). Tumor cells are well-differentiated, interlaced, smooth muscle cells bundled by variable amounts of connective tissue (Figure 15.62). Mitotic figures are rare. These tumor cells are immunolabeled by α-smooth muscle actin, desmin, and vimentin (91).

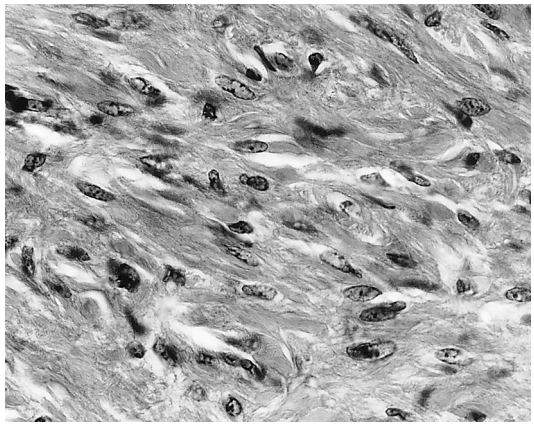

Figure 15.62. Leiomyoma of mesosalpinx composed of smooth muscle fibers arranged in compact whorls. Mitoses are absent from this field, and the nuclear/cytoplasmic ratio is low. H&E, ×600.

Oviduct

Adenocarcinoma

Adenocarcinomas originating in the oviduct most commonly arise in the upper magnum, with occasional tumors seen in the uterus (shell gland) or infundibulum. These tumors, like ovarian carcinomas, are often metastatic to the mesentery and serous surfaces of abdominal organs, especially to the pancreas and duodenum, but also to the ovary and occasionally to the surface of the liver and spleen. Tumor cells may be spread transcoelomically in the ascitic fluid accumulating in the intestinal peritoneal cavity. In contrast, metastases to the lung may be hematogenous (2, 80). The prevalence of oviductal adenocarcinomas as determined by examining the oviductal mucosa for tumors varied widely (5%–81%) in one survey (54). In some studies (6), a positive correlation existed between egg weight and body weight, and prevalence of tumors.

Oviductal adenocarcinomas in both chickens and turkeys may begin as small (2- to 10-mm) nodular areas of mucosal dysplasia, typically discovered during close examination of the mucosa of the oviduct (18, 131). Histologically, these nodules are well-demarcated from adjacent glands and are composed of concentrically arranged columnar epithelial cells with acidophilic cytoplasmic secretory granules and pale enlarged nuclei (Figure 15.63). Adenocarcinomas are grossly evident as small pink to gray, firm masses that protrude into the lumen of the oviduct and may invade through the muscularis. There is often a distinct border between the normal magnal mucosa and tumor cells (Figure 15.64). Metastases are often well-encapsulated (Figure 15.65) and may be composed of well-differentiated cells. Implants on the enteric serosa are often anaplastic cells embedded in dense connective tissue (Figure 15.66), while implants on the oviduct serosa lack this intense scirrhous response (Figure 15.67). The metastases of oviductal adenocarcinomas may in some cases be histologically quite similar to those of ovarian adenocarcinomas, and because the ovary is also a common site for metastasis, differentiating the tumors may be difficult. The ultrastructural

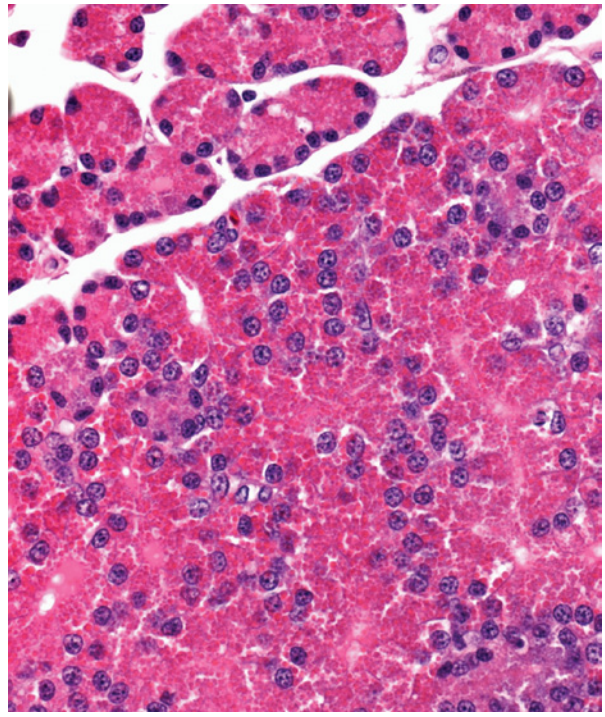

Figure 15.63. Dysplastic adenomatous focus in a fold in the magnum showing clear demarcation from surrounding normal glands. The columnar epithelial cells are densely packed and oriented concentrically. H&E, ×400.

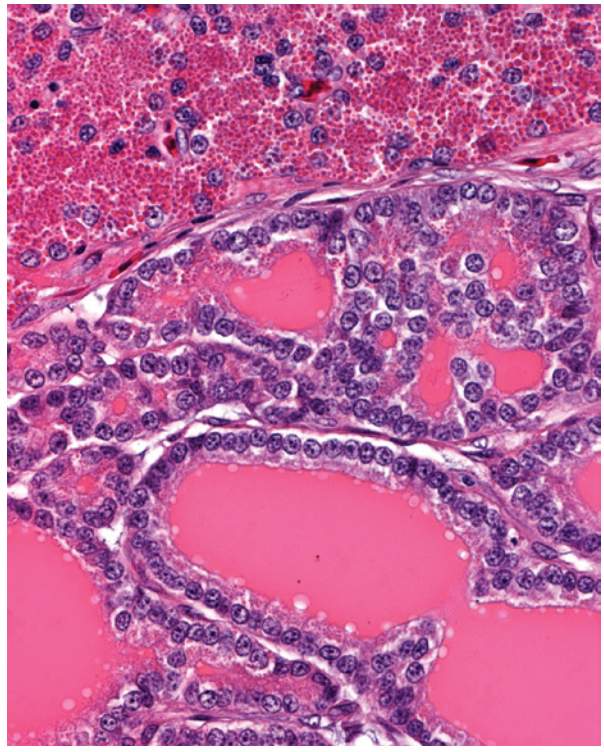

Figure 15.64. Magnal adenocarcinoma showing the well-defined margin between normal secretory tissue with cellular cytoplasm containing eosinophilic granules of ovalbumin (above) and very lightly granular tumor cells (below). H&E, ×400.

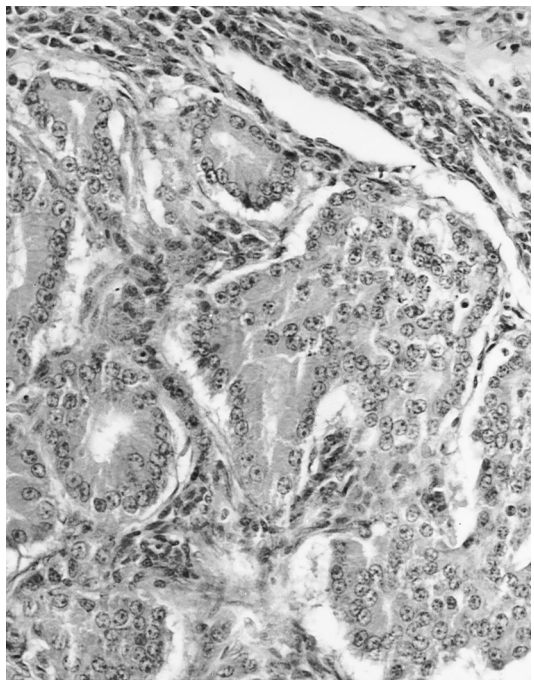

Figure 15.65. Implant of magnal adenocarcinoma deep in the ovary showing capsule around adenocarcinomatous cells. Despite the apparent aggressiveness of this tumor, mitotic figures are not prominent. H&E, ×200.

characteristics of oviductal adenocarcinomas have been described (74). Immunohistochemical studies have demonstrated that the cells of oviductal adenocarcinomas contain ovalbumin (70), but more recent studies (51) have also identified ovalbumin in ovarian adenocarcinomas; the latter finding was attributed to cellular dedifferentiation or return of the cell to a less differentiated state. Cells of oviductal adenocarcinomas retain receptors for estrogen and progesterone (7) and the growth of these cells *in vitro* is stimulated by estrogen (6). In a recent study, few oviductal adenocarcinomas displayed immunostaining for v-erbB, the chicken oncogenic form of the epidermal growth factor homologous to human HER-2/neu, but it was present in many ovarian adenocarcinomas, especially those which were large (67). The organ or tissue of origin of many metastatic adenocarcinomas observed in the abdomens of poultry cannot be determined and these are best described as "of undetermined origin."

Testis

Sertoli cell tumor

Sertoli cell tumors are rare in chickens (25) and a few have been reported in Japanese quail (56), a duck (29), and a pigeon (109). There is a single case report of a tumor arising in the testicular remnants of an incompletely surgically caponized chicken (126). Elongated Sertoli cells are commonly intratubular (Figure 15.68) and arranged at right angles to tubular basement membranes, while in other cases there may be areas with solid sheets of cells. Nuclei are hyperchromatic and often there is a high mitotic rate.

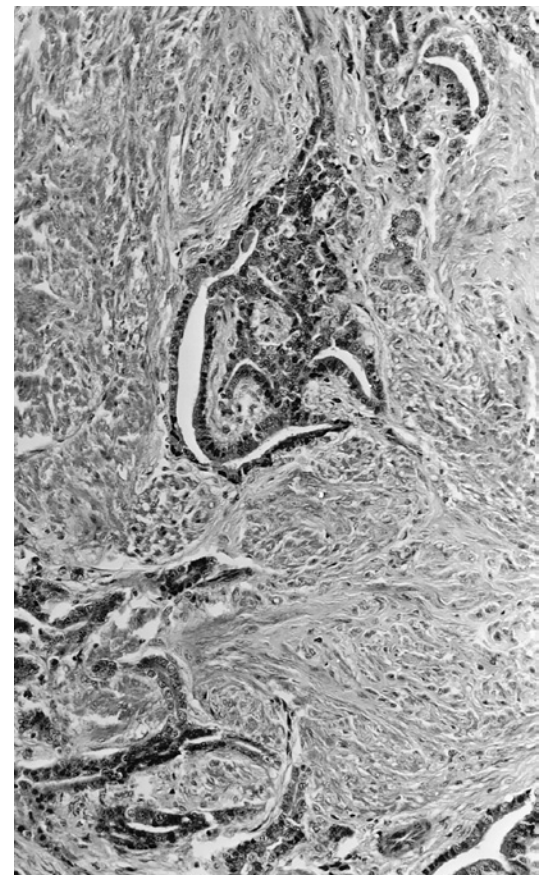

Figure 15.66. Compacted acini lined by cuboidal epithelium surrounded by dense drifts of fibrous tissue in this cirrhotic implant in duodenal serosa of a magnal adenocarcinoma. H&E, ×175.

Figure 15.67. Magnal adenocarcinoma implanted on the serosa of the isthmus is surrounded by little fibrous tissue. The dilated acinar lumina are lined by cuboidal epithelium. H&E, ×200.

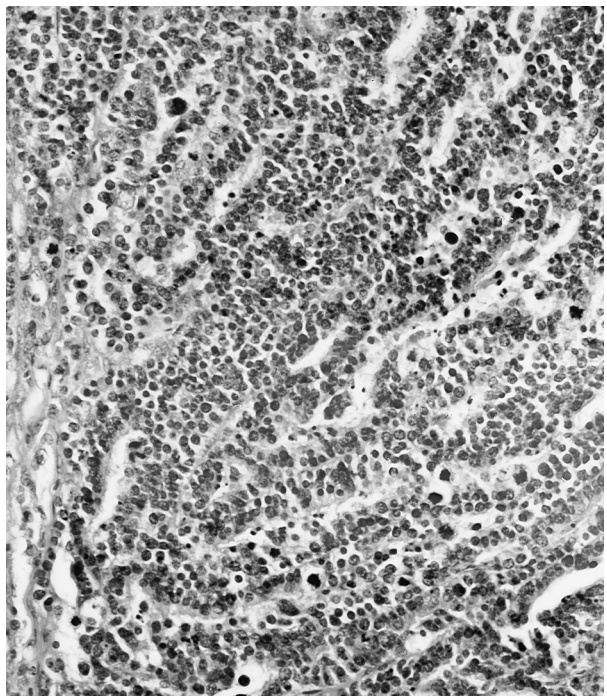

Figure 15.68. Sertoli cell tumor in a quail. The tubule-like structures are lined by cells 2 layers deep. H&E, ×360.

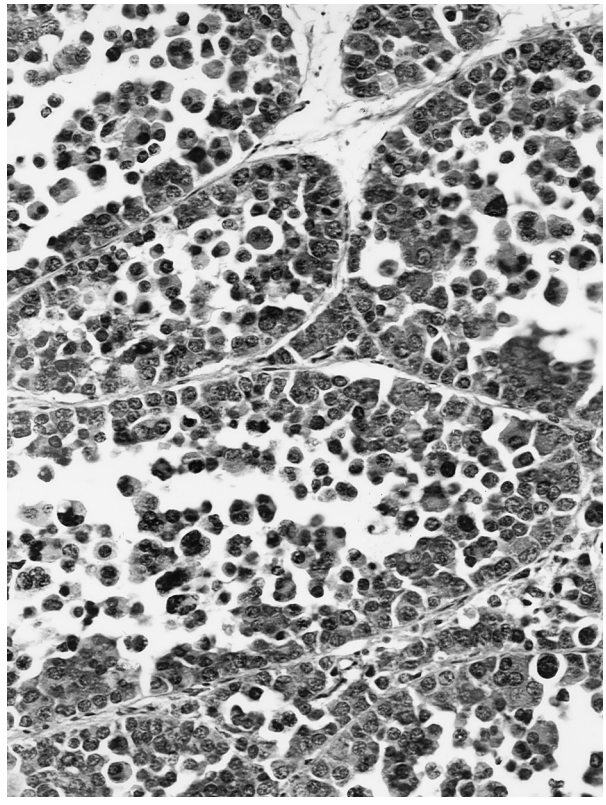

Figure 15.69. Seminoma in a duck. Lobules of pleomorphic polyhedral cells with finely granular cytoplasm; some multinucleated cells. Delicate stroma. H&E, ×180.

Seminoma

Seminomas have been reported in chickens (25), ducks (47, 94, 110), quail (110), guinea fowl (52, 84), and pigeons (37, 137). These tumors are commonly unilateral and consist of intratubular or broad sheets of round to polyhedral cells (Figure 15.69) with eosinophilic cytoplasm and irregularly round, eccentrically placed nuclei. Multinucleated syncytia may be present. Some tumors have been metastatic.

Interstitial (Leydig) Cell Tumors

Interstitial cell proliferations may be present in seminomas of chickens (25), but interstitial cell tumors have not been described in poultry. Interstitial cells were a component of a mixed cell tumor affecting both testes of a duck, but only the Sertoli cell component was present in a metastatic site (86).

Renal

Renal nephroblastomas and adenocarcinomas occur in chickens. Some are associated with infections with avian leukosis/sarcoma viruses (see Leukosis/Sarcoma Group).

Digestive System

Alimentary Tract

Squamous cell carcinomas have been most commonly reported from the oropharynx, esophagus, and crop of chickens (3, 30, 72, 107, 120, 139). Both humans and chickens from certain regions of northern China exhibit an increased prevalence of esophageal squamous cell carcinoma (107, 124, 141, 151), suggesting that common etiologic factors could play a role as chickens and humans may have common exposures to drinking water, food, and other environmental factors. However, detailed epidemiologic studies have not identified a specific cause (141, 154). Such tumors were often superficially ulcerated and composed of cords and islands of anaplastic squamous epithelial cells, some of which surrounded keratin (Figure 15.70).

Multiple papillomas have been described in the esophagus and crop of chickens, but that report lacks histological characterization (101).

In chickens, proventricular adenomas (26) and adenocarcinomas (25, 112) have been described, along with adenocarcinomas (25, 26, 115) of the gizzard (Figure 15.71). A proventricular adenoma was described in a duck (12).

Adenocarcinomas of the small intestine have been described in chickens (5, 25, 59, 112, 136) and ducks (119); some of these involved the ileocecal junction. Primary adenocarcinomas affecting the intestinal tract must be differentiated from metastatic adenocarcinomas of the reproductive tract, which readily and rapidly metastasize to involve the intestine (25).

Enterogenous cysts that are lined by mucosa derived from the gastrointestinal tract have been described in young chickens. These usually present as fluid-filled cysts partially replacing the spleen and the lining mucosa often resembles that of the ventriculus (82).

Leiomyomas and leiomyosarcomas have been described affecting the gastrointestinal tract (see Musculoskeletal

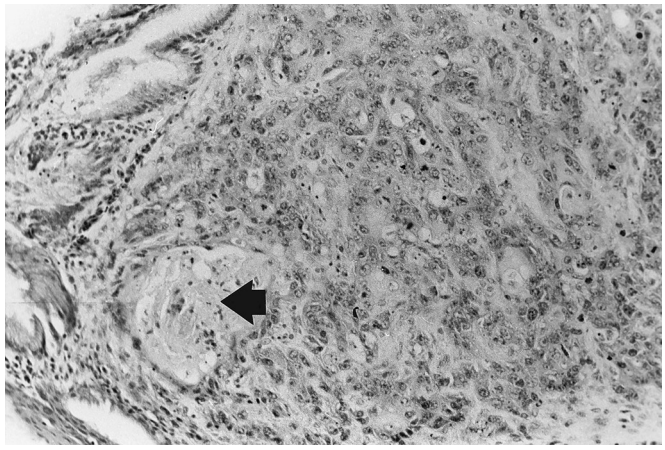

Figure 15.70. Oro-pharyngeal squamous cell carcinoma in an adult noncommercial chicken. Cords and islands of epithelial cells with some central keratin pearls (arrow). Mucosal gland is shown at top left. H&E, ×200.

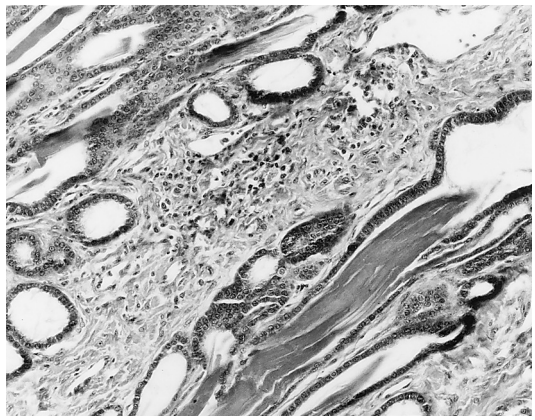

Figure 15.71. Adenocarcinoma of gizzard with growth of darkly staining cuboidal tumor cells downward into muscularis. The keratinous product of these cells is shown at lower right. H&E, ×200. (K. Langheinrich)

System). Pheasants are affected by a nodular typhlitis caused by infection with *Heterakis isolonche* with larval migration producing pseudoneoplastic submucosal nodules that are composed of fibrocytes and histiocytes (58).

Liver

Hepatocellular Tumors

Hepatocellular adenomas (hepatomas) and hepatocellular carcinomas are uncommonly reported in chickens (25, 31, 101, 112). Adenomas consist of masses of large polygonal, well-differentiated hepatocytes that are compactly arranged in cords that are several cells thick and separated by connective tissue septa (Figure 15.72); however, portal triads and central veins lacking in these masses and there is a low mitotic rate. Hepatocellular carcinomas often multifocally replace the liver and there may be metastases to the lung. In carcinomas, the tumor cells are less well differentiated, often exhibit

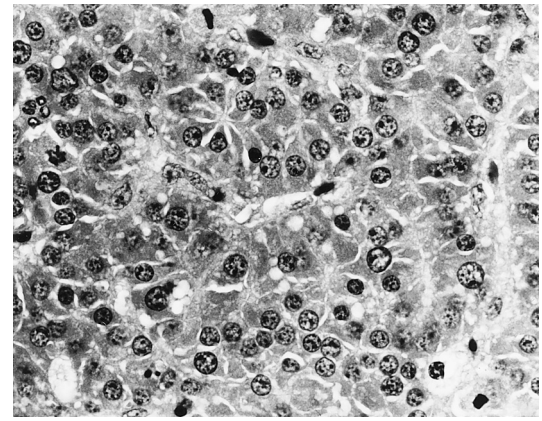

Figure 15.72. Hepatoma composed of large eosinophilic neoplastic cells, some in mitosis, forming irregular plates. H&E, ×600.

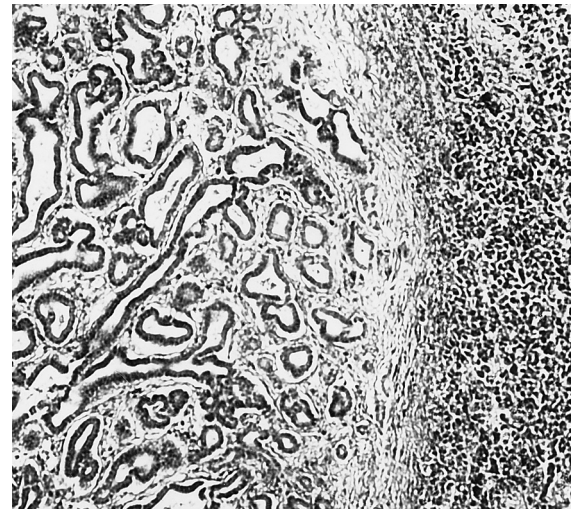

Figure 15.73. Cholangioma composed of dilated ducts in a loose fibrocytic stroma. H&E, ×75.

mitoses, and may be multinucleated (25, 108). Hepatocellular tumors in chickens have been induced with some oncogenic avian retroviruses (17) or by administration of diethyl-nitrosamine (81). These tumors appear to be common in ducks (88, 119) and some have been induced by feeding aflatoxin (28). Duck hepatitis B virus has been suggested to be involved in the development of hepatocellular carcinomas in Chinese ducks (38, 152), but aflatoxins also were suspected.

Cholangiocellular Tumors

Cholangiomas and cholangiocellular carcinomas are uncommon in poultry, with only a few cases being described in chickens, ducks, and pigeons (26, 46, 110, 112, 119, 143). Tumors of bile ducts must be differentiated from the proliferation that accompanies chronic toxic damage to the liver due to the ingestion of hepatotoxins. Cholangiomas consist of clusters of dilated and often distorted ducts that are lined by well-differentiated epithelial cells; these ducts are separated by fibrous connective tissue (Figure 15.73). In cholangiocarcinomas,

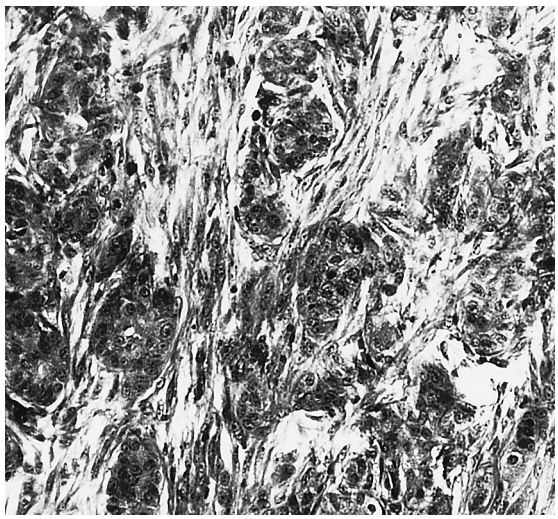

Figure 15.74. Cholangiocarcinoma composed of small clusters of epithelial cells in a fibroblastic stroma. H&E, ×190.

Figure 15.75. Pancreatic adenocarcinoma, probably of ductule cell origin, composed of columnar cells forming tubular structures among a few remnant acinar cells (arrow). ×160.

epithelial cells less commonly form defined ducts and are separated by fibroblasts (Figure 15.74).

Pancreas

Adenocarcinoma

Tumors of pancreatic epithelial cells are often difficult to distinguish from metastases of ovarian or oviductal tumors, because those tumors commonly implant upon the duodenal serosa and surface of the pancreas. Pancreatic tumors may arise from ducts (100, 110) or exocrine cells (46). Most probably arise from ductal epithelium and are composed of columnar epithelial cells with lightly basophilic cytoplasm (Figure 15.75). Tumors derived from exocrine

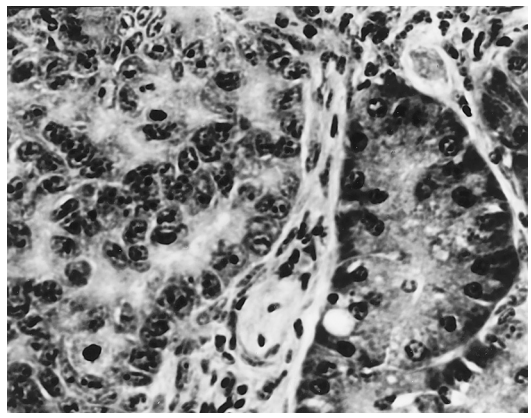

Figure 15.76. Pancreatic acinar cell adenocarcinoma with normal exocrine tissue (right) and agranular neoplastic cells (left). H&E, ×600.

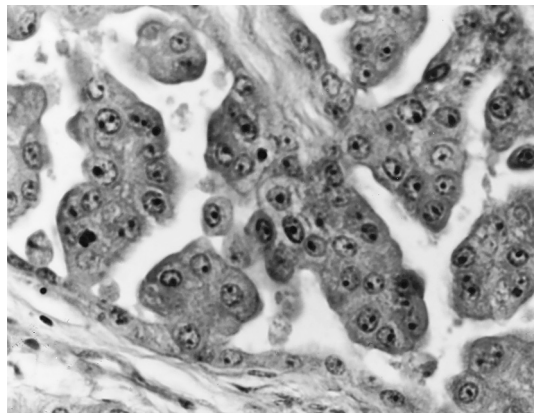

Figure 15.77. Mesothelioma with prominent neoplastic epithelial cells supported on a delicate stalk. H&E, ×600.

cells morphologically resemble acini (Figure 15.76) and may or may not have cytoplasmic bodies resembling zymogen granules (46).

Peritoneum

Mesothelioma

Mesotheliomas have been reported in chickens (25, 46, 59, 101) and ducks (87). Multiple papilliform abdominal nodules in which mesothelial cells and anaplastic fibrocytes were seen have been described in an aged female ostrich (110). Often there is ascites, and tumors invest serosal surfaces of abdominal organs. Histologically, papillae are covered by cuboidal mesothelial cells supported on delicate stalks (Figure 15.77).

Respiratory System

Infraorbital Sinus

Reece (115) reported two chickens with pea-sized cystic adenomas that extended into the infraorbital sinuses and were filled with mucin.

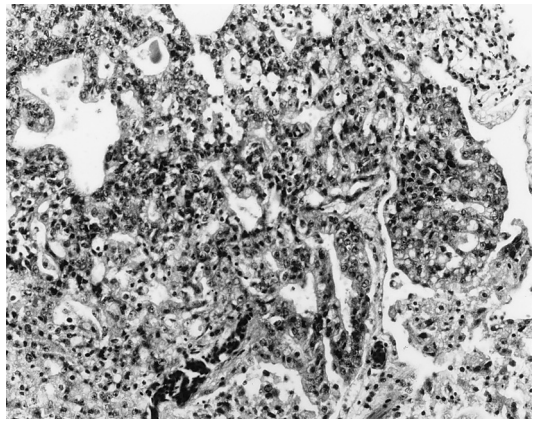

Figure 15.78. Adenocarcinoma of lung composed of a papillary growth of epithelial cells that have replaced most of the normal lung. H&E, ×200.

Lung

Adenocarcinoma

In chickens, primary adenocarcinomas of the lung appear to be extremely rare (10, 25). Campbell described three cases characterized by small nodules located near the primary bronchi and Fredrickson and Helmboldt described a papillary adenocarcinoma arising multifocally from parabronchi (46). In that case, cuboidal epithelial cells replaced most of the lung (Figure 15.78) and there were metastases in the thorax and abdomen. Primary tumors of the lung, especially in mature chickens, need to be differentiated from metastases of ovarian or oviductal adenocarcinomas, hepatocellular carcinomas, or metastases of other tumors (25, 112). Reports of pulmonary adenocarcinomas are more common in ducks (89, 129, 153), particularly those maintained in zoos, than in other avian species. There are rare descriptions in pigeons (129).

Nervous System

Central Nervous System

Astrocytoma

Both sporadic and epizootic cases of astrocytoma (fowl glioma) have been described, commonly as multiple tumors in aged hens (22, 76, 78, 112, 148), and one case has been described in a domestic duck (110). These small masses are often near the thalamus or the base of the cerebellum (46). There frequently are perivascular accumulations of lymphocytes adjacent to the tumor, but no hemorrhage, giant cells, or areas of pressure necrosis (Figure 15.79). Masses are composed of astrocytes with extended cytoplasmic fibrillar processes (Figure 15.80). Similar masses in some breeds of chickens have been shown to be caused by infections with a specific subgroup A avian leukosis virus (71, 99, 135).

The small ependymoma described by Wight and Campbell (147) was discovered in the right cerebral hemisphere of a 60-day-old chicken affected by Marek's disease; the mass was within or adjacent to the lateral ventricle and consisted of vacuolated cells that occasionally formed palisades or rosettes. In the same report, two subdural angioblastic meningiomas were described in pullets displaying neurological signs: both were located near the cerebellum and consisted of multiple congested vascular

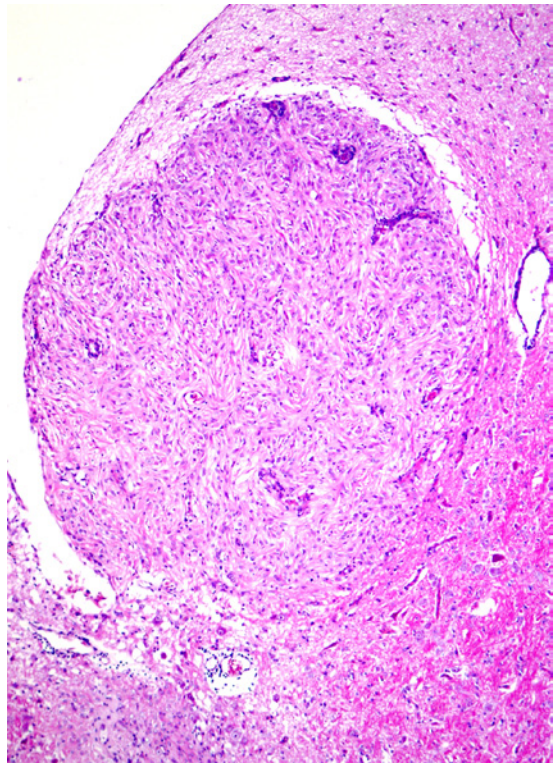

Figure 15.79. One of several clearly demarcated, but unencapsulated astrocytomas composed of fibrillar astrocytes in anterior brain stem. There is a significant lymphocytic infiltrate around the blood vessels within the tumor and the adjacent tissue. H&E, ×100.

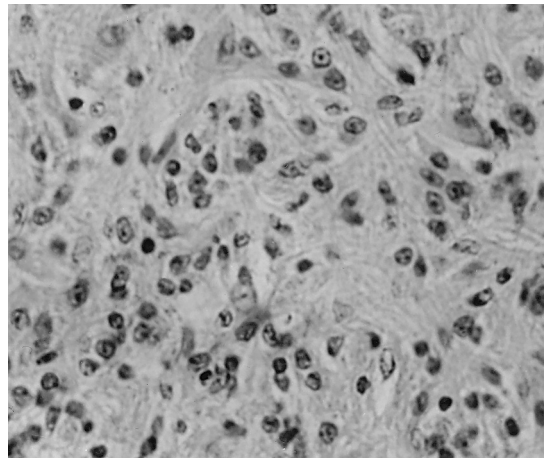

Figure 15.80. Astrocytoma composed of uniform astrocytes with extended cytoplasmic processes. H&E, ×190.

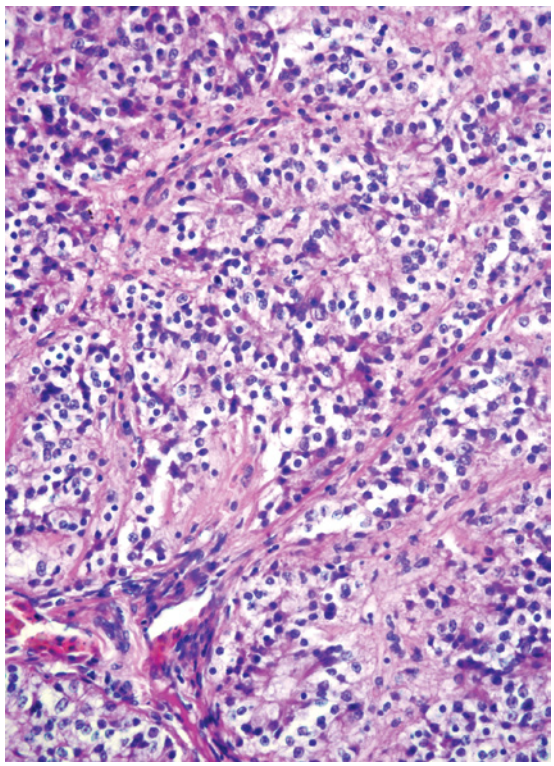

Figure 15.81. Lobules of a pineal body tumor separated by fine trabeculae. Palisaded low columnar epithelial cells with large vesicular nuclei are surrounded by smaller parafollicular cells. H&E, ×200.

sinuses that were lined by enlarged endothelial cells and separated by a prominent reticulin network.

Pineal Body Tumor

There are a few reports of pineal body tumors in chickens (25, 112, 132). In the young hen described by Swayne (132), the mass was somewhat similar to a normal pineal gland, but was greatly enlarged (3×) and displaced adjacent cerebellar tissue, and cells exhibited an increased mitotic rate. These characteristics, in addition to a relatively decreased number of follicular cells, identified this as a tumor rather than pineal gland hyperplasia. In the cases reported by Reece (112), there were clinical histories that included neurologic symptoms such as fine tremors and head pressing. In each bird, there was a large mass between the cerebrum and cerebellum that extended into or impinged upon the cerebellum. Tumors were composed of lobular masses of low columnar epithelial cells (Figure 15.81) surrounding a central lumen. These cells were surrounded by parafollicular cells.

Peripheral Nervous System

Neurofibromas

The term neurofibroma is often used interchangeably with Schwannoma (neurilemmoma); however, Schwannomas are relatively homogenous proliferations of Schwann cells,

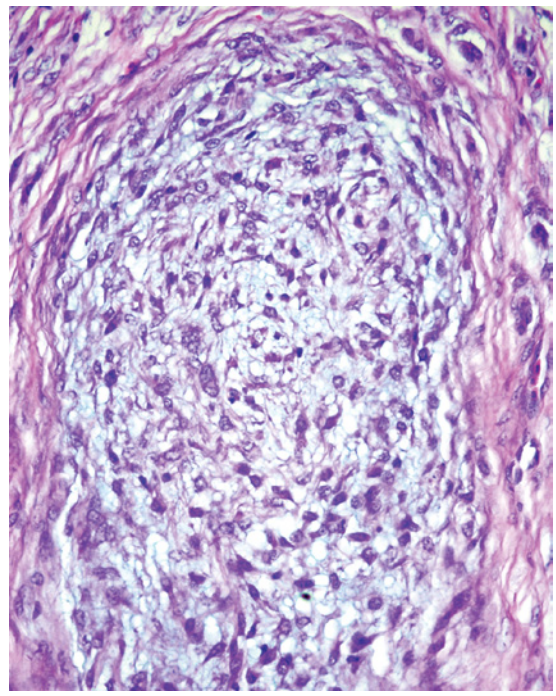

Figure 15.82. Schwannoma of the sciatic plexus showing a whorling pattern of spindle-shaped cells with central nuclei. H&E, ×400.

whereas neurofibromas contain a mixture of nerve elements including Schwann cells. Separation of these tumors is not always possible in poultry, and similar tumors have been referred to by some authors as neurogenic sarcomas (101). Tumors of the nerve sheath are well recognized in young broiler chickens (26) but also occur in older birds, often originating in major nerves or near dorsal root ganglia. Neurofibromas are often solitary masses, but multiple tumors have been described (4). Tumors are composed of fibroblast-like spindle cells that may form concentric whorls resembling nerve sheaths (Figure 15.82). In tumors with predominantly Schwann cell proliferation, there may be nuclear palisading or structures resembling sensory nerve endings (Wagner-Meissner corpuscles or Pacinian corpuscles) (25).

Neuromas

Post-traumatic neuromas commonly occur when afferent nerves attempting to regenerate become obstructed by, then entrapped within, densely collagenous scar tissue, resulting in tangled masses of poorly myelinated axons, Schwann cells, and perineurial cells separated by bands of connective tissue (Figure 15.83). These neuromas are not true neoplasms and are a well-recognized, although relatively rare, sequela to beak-trimming or toe amputation (48, 49). When young chicks or turkey poults are partially beak-trimmed, the resultant dermal scar tissue is less dense, which may partially explain the relative absence of neuroma development in birds treated when they were young (35, 50).

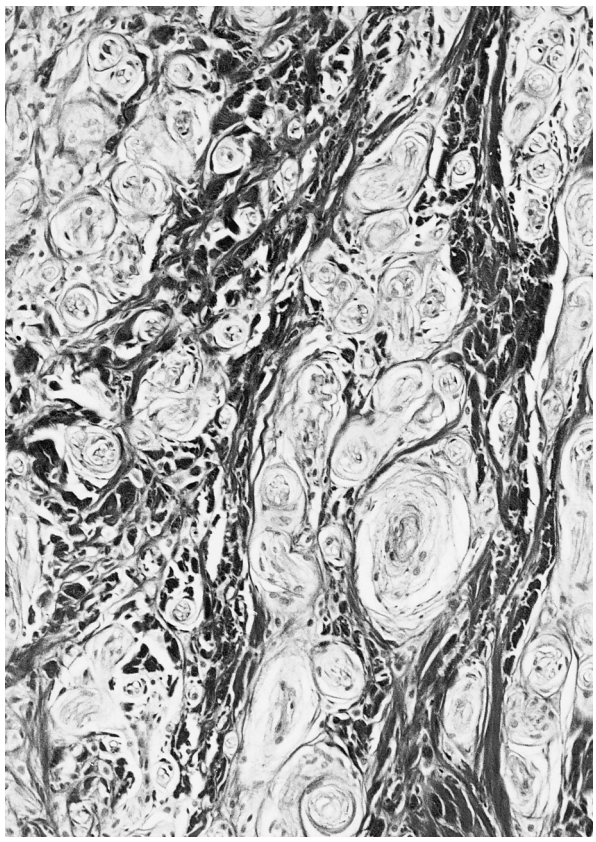

Figure 15.83. Post-traumatic neuroma in beak tip showing dense collagenous scar tissue and multiple whorls of nervous tissue composed of poorly myelinated axons, Schwann cells, and associated connective tissue. Martius scarlet blue, ×360. (C. J. Randall)

Melanoma

Melanomas, including some described as originating in the ovary with metastasis to other organs, have been described in the chicken (25). Multifocal melanomas with the appearance of malignancy have been seen affecting the skin, visceral organs, musculature, and other tissues in young broiler chickens and a 16-week-old pullet (112). Some authors described similar tumors as malignant melanomas and demonstrated that unbleached tumor cells and tumor cells bleached by potassium permanganate or hydrogen peroxide were not immunoreactive with antibodies specific for S100 proteins, but did react with antibodies to neuron specific enolase, vimentin, and Melan-A (149). Melanocytes in avian melanocytic tumors often do not react with antibodies to S100 proteins even though normal nerves are S100 immunopositive (64, 85). These cells may be spindloid or there may be closely packed masses of polyhedral melanocytes reminiscent of epithelial tissue (Figure 15.84). Malignant melanomas also have been described in ducks (15, 36, 110, 118) and a pheasant (36), and melanomas, some of which were amelanotic, have been seen in the skin of pigeons (79, 110, 113). Benign melanomas have been seen within the eye of chickens (14, 39, 123). A small number of cases of multifocal melanomas were noted in young adult Japanese quail from one inbred commercial strain (114).

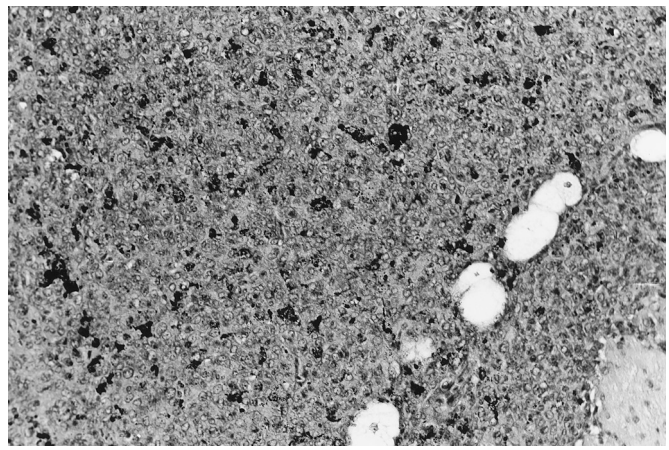

Figure 15.84. Subcutaneous melanoma of the wing of a pigeon. There is melanin pigment in many polyhedral cells. Mitotic figures are rare. The cells are densely packed, clearly demarcated from the surrounding tissue, and penetrate between muscle fibers and adipocytes (lower right). H&E, ×200.

Special Senses

Eye

Intraorbital rhabdomyosarcomas, thought to originate from the striated muscle of the iris, have been described in chickens (39). Retinoblastomas (25, 33) and melanomas involving the eye have been described.

Endocrine System

Adrenal Gland

The avian adrenal gland is composed of intermingled cords of cortical cells and enterochromaffin (medullary) cells rather than a defined cortex and medulla. Two adrenal cortical adenomas have been described, one in a young chicken and one in an SPF hen (26, 112). The well-differentiated cells comprising these neoplasms contained abundant eosinophilic cytoplasm that was occasionally vacuolated. The close anatomic relationship between the ovary and adrenal glands makes it imperative to eliminate markedly luteinized ovarian carcinomas when the ovary is also involved (25). A pheochromocytoma has been described in a 14-week-old pullet (25).

Pituitary Gland

Pituitary tumors of poultry appear to be limited to the two chickens reported by Campbell (25). One was described as a tumor of chromophobe cells that compressed the brain stem, and the second was an infiltrative acidophil adenoma.

Thymus

Thymomas have most commonly been described in chickens (13, 26, 41, 59, 101), and one has been described in a duck (150). These have primarily been masses in the neck that are histologically characterized by sheets of epithelial cells lacking distinct cytoplasmic borders. Immunostaining of tumor cells with cytokeratin has been used to verify epithelial origin (13). There may be accompanying myoid cells (25).

Thyroid and Parathyroid Glands

Adenomas of the thyroid have been described in a 24-week-old pullet (101) and a 2-year-old hen (25). Both affected the left thyroid glands, contained multiple cysts, and were described as containing relatively undifferentiated epithelium resembling embryonic thyroid. Microscopic cysts lined by ciliated epithelium are occasionally seen in the thyroid and are thought to be derived from thyroglossal duct remnants (25). Tumors of the parathyroid gland of chickens seem to be limited to an adenoma and a parathryoid carcinoma (59).

Integument

Subcutis

Of the various sarcomas, fibromas, and myxomas that are encountered in subcutaneous tissues of chickens, many may be induced by avian leukosis viruses (see Leukosis/Sarcoma Group), although some of these tumors are reported from SPF hens and other poultry species. Chickens systemically infected by some retroviruses may produce tumors in response to the inflammation associated with wounds, as postulated to be the cause of some mesenchymal tumors observed near the trimmed beak of hens (112).

Hemangiopericytoma

A few hemangiopericytomas have been described in chickens (46, 128). They were all benign and occurred as subcutaneous nodules in the cervical region. Histologically, they were arranged as concentric rings around blood vessels, and were composed of uniform spindle-shaped cells with a fusiform nucleus. The intervening reticulin fibers could be demonstrated by a silver stain (Figure 15.85).

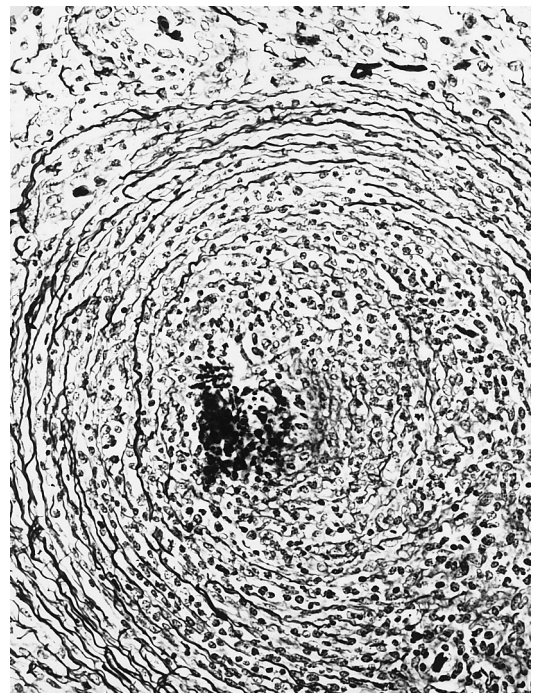

Figure 15.85. Hemangiopericytoma with concentric rings of pericytes clearly defined. Silver, ×90.

Lipoma and Liposarcoma

Subcutaneous lipomas are not common in chickens (25, 110). They are generally benign, encapsulated and delicately trabeculated, and may exhibit necrosis and/or hemorrhage. These tumors are composed of large mature vacuolated adipocytes with a pale displaced nucleus. Mitotic figures are rare. Liposarcomas of chickens are rare and may be locally invasive or metastasize (111); in some cases, the predominant cells are elongate and may be mistaken for fibrocytes except for the presence of small cytoplasmic fat vacuoles. Others are composed of more typical immature adipocytes. Myelolipomas and erythrolipomas have not been reported in chickens.

Cutis

Squamous Cell Carcinoma

The true squamous cell carcinoma of the skin of birds originates from the surface epidermis, forming infiltrating cords of anaplastic keratinocytes that invade downward into the underlying dermis. Epithelial cells are separated by intercellular bridges and resemble cells of the stratum spinosum. Because it is likely that some of these tumors, like those of other species, are induced by years of sun exposure, many have occurred on the feet and shanks of aged birds (25, 27). Although these tumors are locally invasive, only a few have been metastatic (1). The tumors originally described as dermal squamous cell carcinomas in young broiler chickens have been redesignated as avian keratoacanthomas, due in part due to origin from feather follicle epithelium rather than surface epidermis (125). Oropharyngeal, esophageal, and ingluvial squamous cell carcinomas also have been recognized, especially in chickens (see Digestive System).

Avian Keratoacanthoma

Avian keratoacanthomas are most commonly found in the skin of carcasses of young chickens at slaughter (20, 23, 62, 117, 138), although some have been identified in live broiler chickens (61, 112) and a few have been seen in older chickens (77, 130). These tumors were formerly designated as "dermal

squamous cell carcinoma," but avian keratoacanthoma was selected as a more descriptive term because tumors unaltered by the processing artifacts of de-feathering and scalding have the distinctive tissue architecture of keratoacanthomas, originate from feather follicle epithelium rather than the surface epidermis, are not metastatic, and, in live birds, regress (61). Carcasses with extensive lesions are condemned at slaughter, while less affected carcasses undergo trimming. The prevalence of broiler carcasses with multiple lesions commonly varies from 0.01% to 0.05%, but may be 0.09% or higher in individual flocks (62, 138, 144). In some studies, chickens slaughtered at less than 48 days of age exhibited more tumors than older birds, and tumor prevalence was cyclic, being lowest in summer months (62, 144). In other surveys, an increased number of condemnations due to these tumors were associated with dusty houses, birds placed in new houses, or certain farms (53).

The etiology of this condition remains unknown. Some authors have suggested an association with fowlpox because some studies by nested PCR detected DNA sequences specific for fowlpox virus in lesions (40), but other studies failed to detect evidence of fowlpox (95). In one study of these lesions, type C retroviruses were identified (125), but in other studies, viral particles were not seen ultrastructurally and evidence of avian leukosis viruses was not detected (61, 95). Carcasses most commonly exhibit crater-shaped ulcers with raised margins within feather tracts (Figure 15.86), but both nodular and ulcerative lesions may be present. Smaller circular ulcers average 5 mm in diameter, but larger, irregular, coalescing ulcers are present on some carcasses. In live chickens, these ulcers are filled with keratin and cell debris (Figure 15.87). Nodules are generally smaller (averaging 3 mm in one study) and appear grossly as enlarged feather follicles (Figure 15.88). Microscopically, nodular lesions appear as proliferative outgrowths of feather follicle epithelium (Figure 15.89), cysts originating from dysplastic feather follicles, or hyperplastic feather follicles that contain hyperkeratotic feathers. Ulcers are composed of a central cup-shaped cavity lined by epithelium and filled with keratin, bacteria, and cell debris. Epithelial lips overhang this central mass of keratin and cell debris. The lining epithelium keratinizes toward the central cavity and extends thin stands of keratinocytes into the surrounding dermal fibroplasia (Figure 15.90). Carcass lesions are often

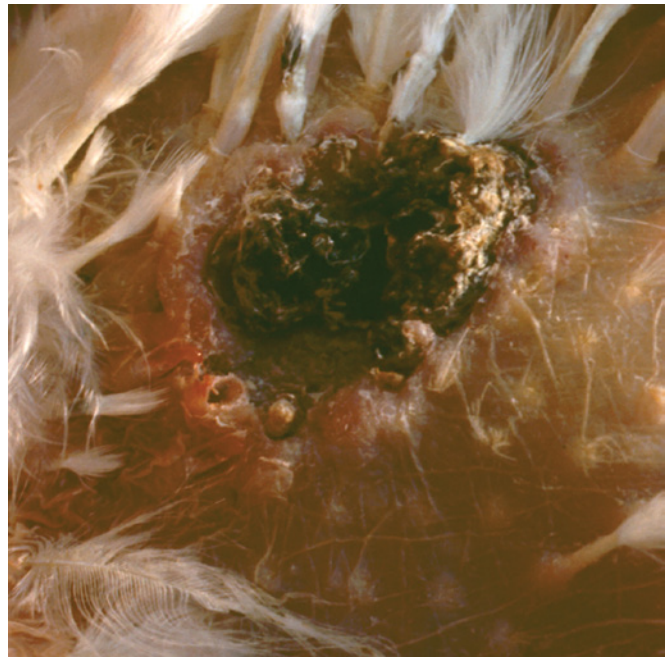

Figure 15.87. In live chickens with keratoacanthomas, ulcerative lesions contain central masses that are mixtures of keratin, cell debris, and bacteria.

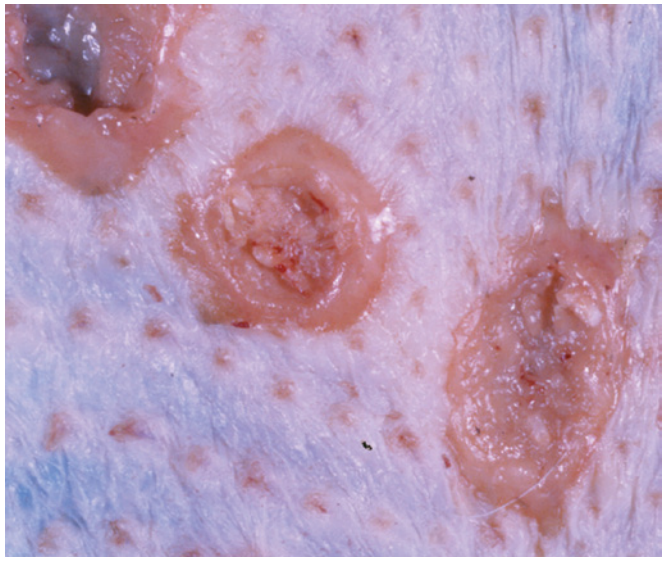

Figure 15.86. Typical carcass lesions of avian keratoacanthomas are craterous ulcers within feather tracts.

Figure 15.88. Early keratoacanthoma lesions in the skin of live chickens are nodules in the base of feather follicles.

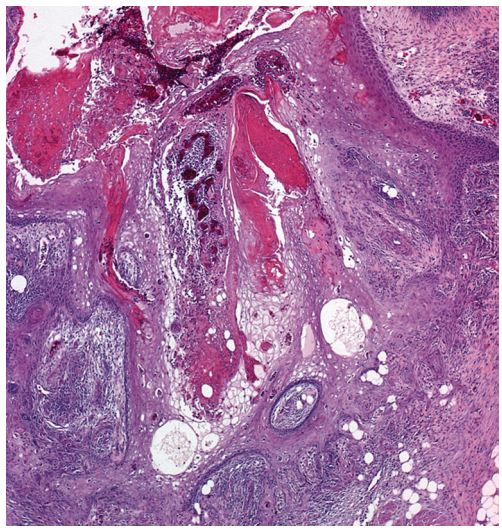

Figure 15.89. Microscopically, nodular lesions of avian keratoacanthoma are expansions of feather follicle epithelium. H&E, ×40.

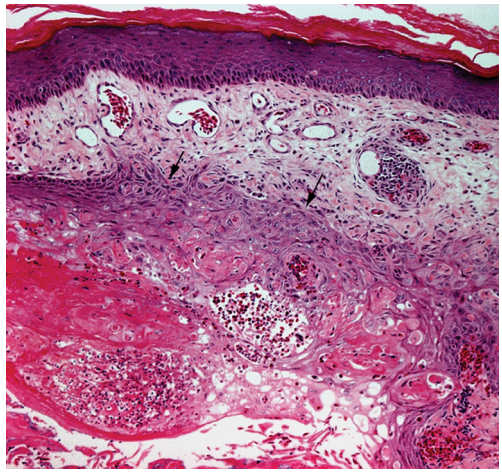

Figure 15.90. A section through the epithelial lip of an ulcerative keratoacanthoma from a live chicken shows the centrally keratinizing and peripherally invasive lining epithelium (arrows) adjacent to the central keratin and cell debris. H&E, ×100.

extensively altered by post slaughter de-feathering with loss of the central keratin core and much of the lining epithelium. In affected live chickens, nodules progressed to ulcers and all lesions eventually regressed (61).

Feather Folliculoma

Multiple cystic structures found on the medial surfaces of the wings of adult hens have been described (112). These cysts were filled with keratin and feather remnants, and were lined by squamous epithelial cells. In some areas, there was abrupt keratinization of the lining epithelium, while in other areas, there was disorganized feather follicle epithelium (Figure 15.91). There was an intense inflammatory reaction in the adjacent dermis. Similar cysts have been described in turkeys (34).

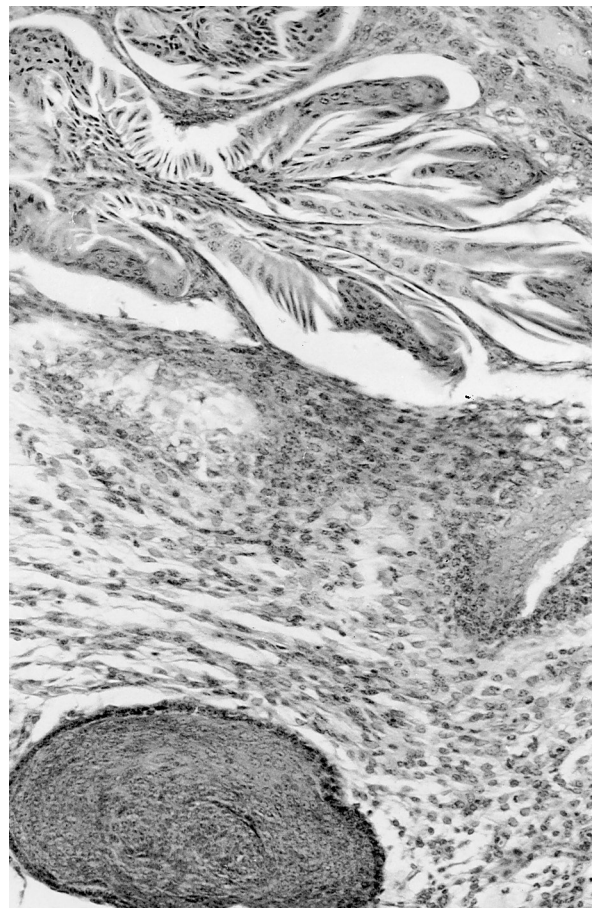

Figure 15.91. Edge of a feather folliculoma showing dysplastic specialized feather-forming epithelium and an adjacent cord of basal cells. The lumen was lined by stratified cuboidal to squamous epithelium with abrupt keratinization and contained keratin and feather remnants. H&E, ×180.

Intracutaneous Keratinizing Epithelioma

These benign masses were characterized by multiple nodules in the facial skin of adult hens, each marked by a central pore. These cysts were lined by stratified squamous epithelium with orderly maturation from a peripheral basal layer. The cyst lumen contained lamellated keratin (Figure 15.92) but no feather remnants. Little inflammation surrounded these cysts unless there was rupture of the cyst wall (112).

Other Tumors of the Cutis

Acanthomas. Acanthomas are firm, often conical masses that protrude from the scaled epithelium on the plantar surface of the tarso-metatarsus. Tumors are composed of keratin whorls on a base of fibrous connective tissue that contains islets of squamous epithelium with central basal epithelial cells (25).

Mast Cell Tumors. Mast cell tumors are extremely rare in poultry, but have been described in a few adult chickens (63, 68, 104). In one, there was a solitary lesion of the eyelid, while in the other two birds, there were multiple dermal tumors

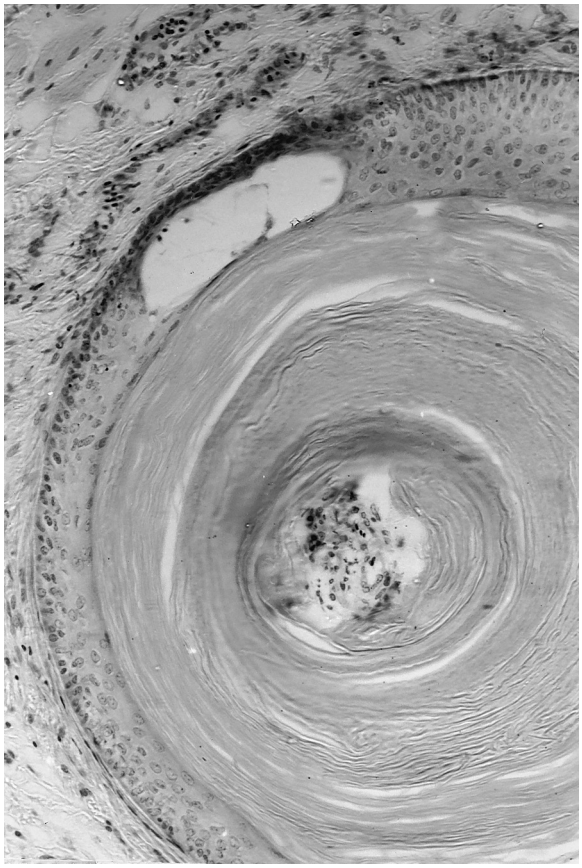

Figure 15.92. The lumen of this intracutaneous keratinizing epithelioma contains lamellated keratin. The epithelium shows basal cells aligned on a distinct basal lamina and progression to polyhedral cells with abrupt keratinization. Note the small intraepithelial bulla. H&E, ×190. (Courtesy of Avian Pathology (112) and with permission of Taylor and Francis, Ltd., www.tandfonline.com)

composed of solid sheets of round to ovoid mast cells. In one hen, there was metastasis to the lung (63).

Xanthomas. Xanthomas are not true neoplasms, but are masses of foamy macrophages and multinucleated giant cells that surround cholesterol clefts. The multiple xanthomas seen in chickens in the 1950s were attributed to chlorinated hydrocarbons contaminating the fat added to rations. The masses were considered to possibly be a reaction to metabolites of this material accumulating in dermal fat (121).

Musculoskeletal

Leiomyoma and Leiomyosarcoma

Leiomyomas of the ventral ligament of the oviduct are common in domestic fowl and Japanese quail (see Urogenital System). Other smooth muscle tumors are more rarely reported. Leiomyomas have been described in the intestine of ducks (115); the trachea of broiler chickens (26, 113, 115) (Figure 15.93); attached to the pancreas (110) or in the liver of pigeons (32); and in the muscularis of chicken proventriculus, ventriculus (gizzard), and duodenum (26, 112). Leiomyosarcomas have been described in chicken tracheal muscle (25), chicken ventriculus (gizzard) (122), hen ovary (75), and chicken intestine (4). Leiomyosarcomas also have been described in the lung and skin of pigeons (93, 96).

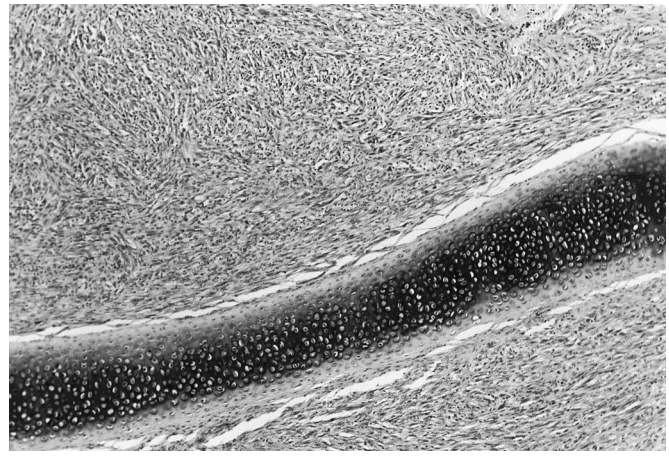

Figure 15.93. Leiomyoma of the trachea of a broiler chicken. Bundles and whorls of smooth muscle fibers in the lamina propria (upper portion) penetrate between the cartilagenous rings and extend into the adjacent adventitia (lower right). H&E, ×100.

Rhabdomyoma and Rhabdomyosarcoma

Rhabdomyomas and rhabdomyosarcomas have been primarily seen affecting the skeletal muscle of the breast and legs and less commonly the musculature of the hearts of young chickens (25, 26, 101), and a rhabdomyoma also has been described in the eyelid of a racing pigeon (110). A rhabdomyosarcoma originating in cranial muscle and invading the brain occurred in a 7-month-old hen (57), and rhabdomyosarcomas metastatic to the lung of chickens also have been described (83, 112). Two intraocular rhabdomyosarcomas have been described in chickens (39). These muscle cell tumors are generally histologically characterized by spindle, strap, flame, or racquet cells and multinucleated cells (Figure 15.94). Cross striations may be present only in rare cells; even examinations with polarized light or phosphotungstic acid-stained sections may not detect striations in the intensely eosinophilic cytoplasm of anaplastic myoblasts. Immunohistochemical examinations for vimentin, myoglobin, muscle-specific actin, and desmin have been useful in some avian rhabdomyosarcomas (42).

Osteoma and Osteosarcoma

Osteomas have been described in the feet of ducks (110) and affecting various sites in a few chickens (25, 26, 112). These osteomas were well circumscribed and were composed of disorganized bone trabeculae (Figure 15.95). Several osteosarcomas, some of which were metastatic, were described affecting long bones, ribs, and vertebrae of young chickens (26). Another osteosarcoma affecting an aged hen also was metastatic (127). An osteosarcoma also has been described affecting the tibiotarsus of a Japanese quail (110) and the foot of a goose (92).

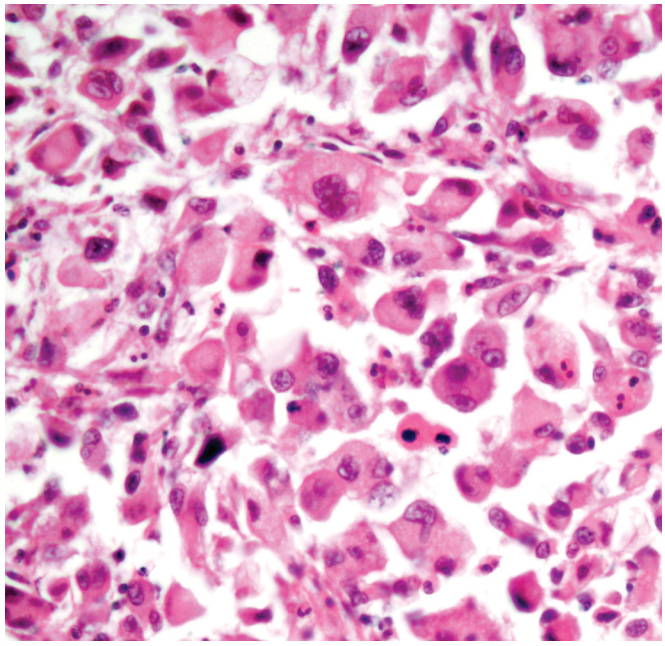

Figure 15.94. Rhabdomyosarcoma. Some cells are strap-like, whereas others are large and polyhedral. The cytoplasm is eosinophilic and some cells contain multiple nuclei. H&E, ×400.

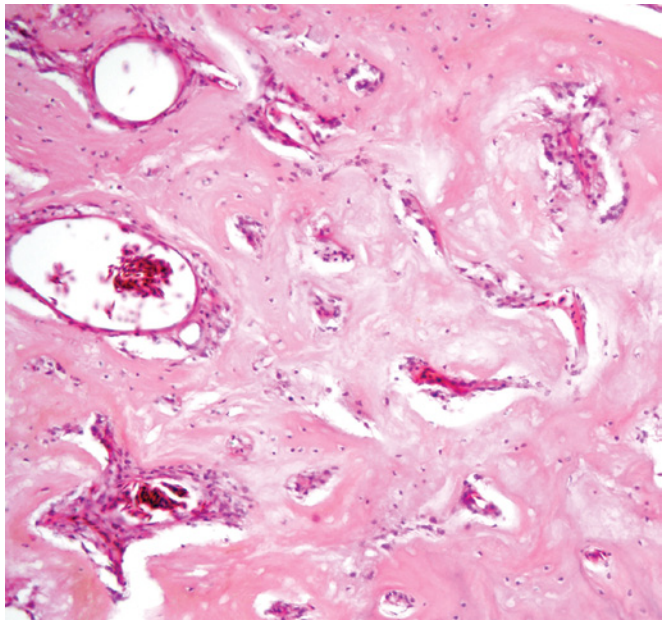

Figure 15.95. Osteoma showing thick irregular trabeculae. H&E, ×100.

Chondroma and Chrondrosarcoma

A single chondroma has been described as originating at a costochondral junction in a young chicken (25). Multifocal chondromas have been described in the footpads of geese and ducks (110). These tumors were characterized by lobules of chondrocytes separated by trabeculae (Figure 15.96). Chondrosarcomas in poultry are exceedingly rare.

Figure 15.96. Multifocal chondroma of the footpad of a goose showing lobules of cartilage that are separated by fibrovascular trabeculae. H&E, ×100.

Other Tumors

Teratoma

Teratomas are composed of tissues arising from more than one germinative layer and commonly contain a disorganized mixture of variously differentiated epithelial cells, bone, cartilage, smooth muscle, fat, or other tissues including nervous tissue, melanocytes, or cardiac muscle. Often, ciliated columnar epithelial cells with goblet cell differentiation line tubules or cysts. Other epithelial islands may be composed of squamous epithelial cells that surround keratin (resembling primitive feather follicles). Some tumors are described simply as abdominal masses (73). In chickens, teratomas are reported to arise more commonly in the testis than ovary (25, 26, 73). Teratomas may also arise at other sites (25, 26, 59, 119). Teratomas also have been induced in chickens by the injection of various metallic ions into the testis (25, 60). Teratomas have been observed in several ducks and a goose (24, 69, 116, 118).

In contrast to teratomas, hamartomas are a focal overgrowth of mature tissue indigenous to the organ or location in which it is found; these have not been reported in poultry.

Multicentric Histiocytosis

Multicentric histiocytosis (histiocytic sarcomatosis, systemic spindle-cell proliferative disease) primarily affects young broiler chickens, producing hepatomegaly and splenomegaly. Numerous small (0.5 to 2mm) white masses are grossly evident in the spleen, liver, and kidneys. Some diseased birds are pale (anemic) and smaller than flock mates. Microscopically, nodules of spindle-shaped cells replace the spleen (Figure 15.97), liver,

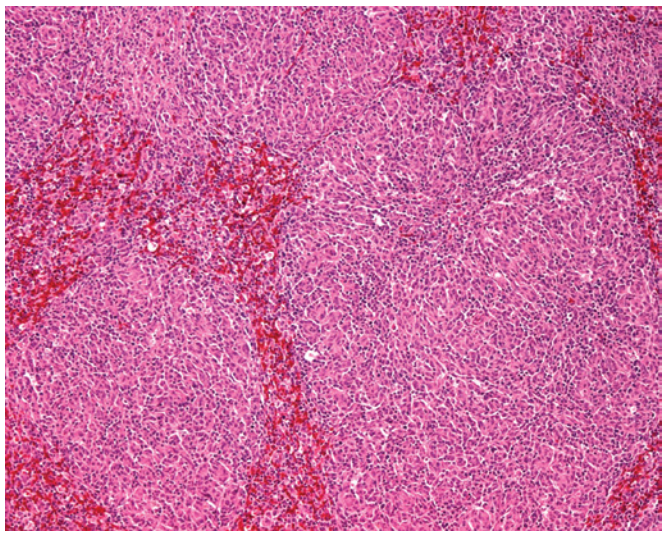

Figure 15.97. In multicentric histiocytosis, nodular masses of spindle-shaped cells multifocally replace the spleen. H&E, ×100.

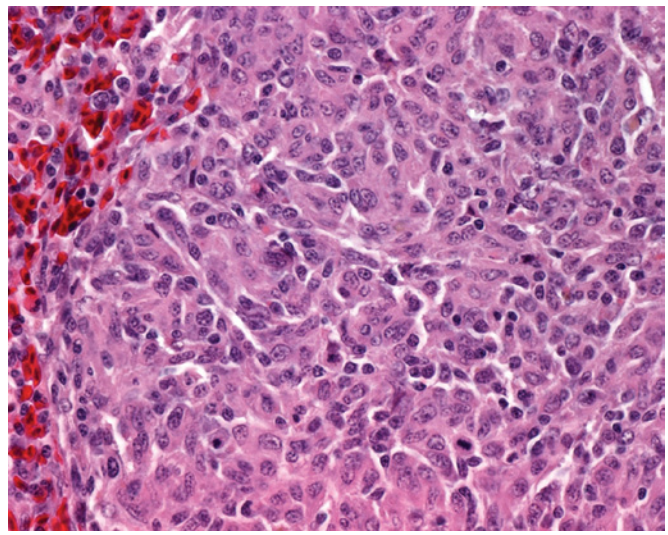

Figure 15.98. Histiocytic spindle-shaped cells in the spleen of a chicken with multicentric histiocytosis contain elongated and pleomorphic nuclei. H&E, ×400.

kidneys, and other organs, most commonly including bone marrow, pancreas, intestine, proventriculus, and lungs (11, 55, 65, 103, 133, 134). Germinal centers may be present within these nodules, especially in the spleen; liver nodules may contain a more heterogeneous population of cells, including plasma cells and some typically bulge into portal vessels. Lesions are not accompanied by myeloid leukosis (myelocytomatosis). Spindle cells contain abundant eosinophilic cytoplasm and elongated ovoid to more pleomorphic nuclei (Figure 15.98). Mitoses are common, but there are no multinucleated cells. Spindle cells are immunohistochemically positive for markers characteristic of antigen-presenting tissue macrophages or dendritic cells (11, 103). Infection of meat-type chickens at day of hatch with strains of subgroup J avian leukosis virus have reproduced these lesions, but only in birds that are persistently viremic with an ineffective antibody response (103).

References

Introduction

1. Biggs, P.M. 1962. Some observations on the properties of cells from lesions of Marek's disease and lymphoid leucosis. In: 13th Symposium of Colston Research Society.
2. Biggs, P.M., and V. Nair. 2012. The long view: 40 years of Marek's disease research and Avian Pathology. *Avian Pathol.* 41:3–9.
3. Braoudaki, M., and F. Tzortzatou-Stathopoulou. 2011. Tumorigenesis related to retroviral infections. *J Infect Dev Ctries.* 5:751–758.
4. Calnek, B.W. 1992. Gordon Memorial Lecture. Chicken neoplasia—a model for cancer research. *Br Poult Sci.* 33:3–16.
5. Cui, Z., Y. Du, Z. Zhang, and R.F. Silva. 2003. Comparison of Chinese field strains of avian leukosis subgroup J viruses with prototype strain HPRS-103 and United States strains. *Avian Dis.* 47:1321–1330.
6. Davidson, I., M. Malkinson, and Y. Weisman. 2002. Marek's disease in turkeys. I. A seven-year survey of commercial flocks and experimental infection using two field isolates. *Avian Dis.* 46:314–321.
7. Fadly, A.M., and V. Nair. 2008. Leukosis/sarcoma Group. In: *Diseases of Poultry*, 12th ed. Y.M. Saif, A.M. Fadly, J.R. Glisson, L.R. McDougald, L.K. Nolan, and D.E. Swayne, eds. Blackwell Publishing Ltd, Ames, Iowa. 514–568.
8. Fadly, A.M., G. Zavala, and R.L. Witter. 2008. Reticuloendotheliosis. In: *Diseases of Poultry*, 12th ed. Y.M. Saif, A.M. Fadly, J.R. Glisson, L.R. McDougald, L.K. Nolan, and D.E. Swayne, eds. Blackwell Publishing Ltd, Ames, Iowa. 568–588.
9. Gak, E., A. Yaniv, L. Sherman, M. Ianconescu, S.R. Tronick, and A. Gazit. 1991. Lymphoproliferative disease virus of turkeys: sequence analysis and transcriptional activity of the long terminal repeat. *Gene.* 99:157–162.
10. Gao, Y., B. Yun, L. Qin, W. Pan, Y. Qu, Z. Liu, Y. Wang, X. Qi, H. Gao, and X. Wang. 2012. Molecular epidemiology of avian leukosis virus subgroup J in layer flocks in China. *J Clin Microbiol.* 50:953–960.
11. Gao, Y.L., L.T. Qin, W. Pan, Y.Q. Wang, X. Le Qi, H.L. Gao, and X.M. Wang. 2010. Avian leukosis virus subgroup J in layer chickens, *China. Emerg Infect Dis.* 16:1637–1638.
12. Gilmore, T.D., and S. Gerondakis. 2011. The c-Rel transcription factor in development and disease. *Genes Cancer.* 2:695–711.
13. Gilmore, T.D., and F.S. Wolenski. 2012. NF-κB: where did it come from and why? *Immunol Rev.* 246:14–35.
14. Gimeno, I.M. 2008. Marek's disease vaccines: a solution for today but a worry for tomorrow? *Vaccine.* 26 Suppl 3:C31–41.
15. Gimeno, I.M., R.L. Witter, A.L. Cortes, and W.M. Reed. 2011. Replication ability of three highly protective Marek's disease vaccines: implications in lymphoid organ atrophy and protection. *Avian Pathol.* 40:573–579.
16. Javier, R.T., and J.S. Butel. 2008. The history of tumor virology. *Cancer Res.* 68:7693–7706.
17. Kaufer, B.B., S. Arndt, S. Trapp, N. Osterrieder, and K.W. Jarosinski. 2011. Herpesvirus telomerase RNA (vTR) with a

mutated template sequence abrogates herpesvirus-induced lymphomagenesis. *PLoS Pathog.* 7:e1002333.
18. Murata, S., K.S. Chang, Y. Yamamoto, T. Okada, S.I. Lee, S. Konnai, M. Onuma, Y. Osa, M. Asakawa, and K. Ohashi. 2007. Detection of the virulent Marek's disease virus genome from feather tips of wild geese in Japan and the Far East region of Russia. *Arch Virol.* 152:1523–1526.
19. Nair, V. 2005. Evolution of Marek's disease—A paradigm for incessant race between the pathogen and the host. *Vet J.* 170:175–183.
20. Osterrieder, N., J.P. Kamil, D. Schumacher, B.K. Tischer, and S. Trapp. 2006. Marek's disease virus: from miasma to model. *Nat Rev Micro.* 4:283–294.
21. Parcells, M., J. Burnside, and R. Morgan. 2012. Marek's disease virus-induced T cell lymphomas. In: *Cancer Associated Viruses—Current Research*. E.S. Robertson, ed. Springer Science+Business Media, New York. 307–335.
22. Patel, J.R., and R.W. Shilleto. 1987. Characterisation of lymphoproliferative disease virus of turkeys. Structural polypeptides of the C-type particles. *Arch Virol*. 95:159–176.
23. Payne, L.N. 1992. Biology of avian retroviruses. In: *The Retroviridae*, vol. 1. J. Levy, ed. Plenum Press, New York. 299–404.
24. Payne, L.N. 2000. History of ALV-J. Proceedings, International Symposium on ALV-J and Other Avian Retroviruses. E.F. Kaleta, L.N. Payne, and U. Heffels-Redmann, eds. *Rauischholzhausen, Germany*. 3–12.
25. Payne, L.N. 1998. Retrovirus-induced disease in poultry. *Poult Sci.* 77:1204–1212.
26. Payne, L.N., and V. Nair. 2012. The long view: 40 years of avian leukosis research. *Avian Pathol*. 41:1–9.
27. Payne, L.N., and K. Venugopal. 2000. Neoplastic diseases: Marek's disease, avian leukosis and reticuloendotheliosis. *Rev Sci Tech.* 19:544–564.
28. Purchase, H.G., and R.L. Witter. 1975. The reticuloendotheliosis viruses. *Curr Top Microbiol Immunol.* 71:103–124.
29. Witter, R.L. 2001. Marek's disease vaccines—past, present and future (Chicken vs virus—a battle of the centuries). In: *Current Progress on Marek's Disease Research*, K.A. Schat, R.W. Morgan, M.S. Parcells, and J.L. Spencer, eds. American Association of Avian Pathologists, Kennett Square, PA. 1–9.
30. Witter, R.L., B.W. Calnek, C. Buscaglia, I.M. Gimeno, and K.A. Schat. 2005. Classification of Marek's disease viruses according to pathotype—philosophy and methodology. *Avian Pathol.* 34:75–90.
31. Witter, R.L., I.M. Gimeno, and A.M. Fadly 2005. Differential diagnosis of lymphoid and myeloid tumors in the chicken. American Association of Avian Pathologists Athens, GA 27.
32. Zhao, Y., H. Xu, Y. Yao, L.P. Smith, L. Kgosana, J. Green, L. Petherbridge, S.J. Baigent, and V. Nair. 2011. Critical role of the virus-encoded microRNA-155 ortholog in the induction of Marek's disease lymphomas. *PLoS Pathog.* 7:e1001305.
33. Zimber, A., K. Perk, M. Ianconescu, Y. Yegana, A. Gazit, and A. Yaniv. 1983. Lymphoproliferative disease of turkeys: pathogenesis, viraemia and serum protein analysis following infection. *Avian Pathol.* 12:101–116.

Marek's Disease

1. Abdul-Careem, M.F., K. Haq, S. Shanmuganathan, L.R. Read, K.A. Schat, M. Heidari, and S. Sharif. 2009. Induction of innate host responses in the lungs of chickens following infection with a very virulent strain of Marek's disease virus. *Virology.* 393: 250–257.
2. Abdul-Careem, M.F., B.D. Hunter, L.F. Lee, J.H. Fairbrother, H.R. Haghighi, L.R. Read, P. Parvizi, M. Heidari, and S. Sharif. 2008. Host responses in the bursa of Fabricius of chickens infected with virulent Marek's disease virus. *Virology.* 379: 256–265.
3. Abdul-Careem, M.F., B.D. Hunter, E. Nagy, L.R. Read, B. Sanei, J.L. Spencer, and S. Sharif. 2006. Development of a real-time PCR assay using SYBR Green chemistry for monitoring Marek's disease virus genome load in feather tips. *J Virol Methods.* 133:34–40.
4. Abdul-Careem, M.F., B.D. Hunter, A.J. Sarson, A. Mayameei, H. Zhou, and S. Sharif. 2006. Marek's disease virus-induced transient paralysis is associated with cytokine gene expression in the nervous system. *Viral Immunol.* 19:167–176.
5. Abdul-Careem, M.F., B.D. Hunter, A.J. Sarson, P. Parvizi, H.R. Haghighi, L.R. Read, M. Heidari, and S. Sharif. 2008. Host responses are induced in feathers of chickens infected with Marek's disease virus. *Virology.* 370:323–332.
6. Abdul-Careem, M.F., D.B. Hunter, S. Shanmuganathan, H.R. Haghighi, L. Read, M. Heidari, and S. Sharif. 2008. Cellular and cytokine responses in feathers of chickens vaccinated against Marek's disease. *Vet Immunol Immunopathol.* 126:362–366.
7. Abdul-Careem, M.F., A. Javaheri-Vayeghan, S. Shanmuganathan, H.R. Haghighi, L.R. Read, K. Haq, D.B. Hunter, K.A. Schat, M. Heidari, and S. Sharif. 2009. Establishment of an aerosol-based Marek's disease virus infection model. *Avian Dis.* 53: 387–391.
8. Abdul-Careem, M.F., L.R. Read, P. Parvizi, N. Thanthrige-Don, and S. Sharif. 2009. Marek's disease virus-induced expression of cytokine genes in feathers of genetically defined chickens. *Dev Comp Immunol.* 33:618–623.
9. Abplanalp, H., K.A. Schat, and B.W. Calnek. 1985. Resistance to Marek's disease of congenic lines differing in major histocompatibility haplotypes to 3 virus strains. In: *Proceedings International Symposium on Marek's Disease*, B.W. Calnek and J.L. Spencer, eds. American Association of Avian Pathologists, Kennett Square, PA. 347–358.
10. Abujoub, A., and P.M. Coussens. 1995. Development of a sustainable chick cell line infected with Marek's disease virus. *Virology.* 214:541–549.
11. Abujoub, A.A., and P.M. Coussens. 1997. Evidence that Marek's disease virus exists in a latent state in a sustainable fibroblast cell line. *Virology.* 229:309–321.
12. Abujoub, A.A., D.L. Williams, and J.D. Reilly. 1999. Development of a cell line system susceptible to infection with vaccine strains of MDV. *Acta Virol.* 43:186–191.
13. Adldinger, H.K., and B.W. Calnek. 1972. Effect of chelators on the *in vitro* infection with Marek's disease virus. In: *Oncogenesis and Herpesviruses*. P.M. Biggs, G. de Thé, and L.N. Payne, eds. IARC, Lyon, France. 99–105.
14. Adldinger, H.K., and B.W. Calnek. 1973. Pathogenesis of Marek's disease: early distribution of virus and viral antigens in infected chickens. *J Natl Cancer Inst.* 50:1287–1298.
15. Afonso, C.L., E.R. Tulman, Z. Lu, L. Zsak, D.L. Rock, and G.F. Kutish. 2001. The genome of turkey herpesvirus. *J Virol.* 75:971–978.
16. Aly, M.M., R.L. Witter, and A.M. Fadly. 1996. Enhancement of reticuloendotheliosis virus-induced bursal lymphomas by serotype 2 Marek's disease virus. *Avian Pathol.* 25:81–94.
17. Ameli, H., J.S. Gavora, J.L. Spencer, and R.W. Fairfull. 1992. Genetic resistance to two Marek's disease viruses and its relationship to production traits in chickens. *Can J Anim Sci.* 72:213–225.

18. Amor, S., S. Strassheim, G. Dambrine, S. Remy, D. Rasschaert, and S. Laurent. 2011. ICP27 protein of Marek's disease virus interacts with SR proteins and inhibits the splicing of cellular telomerase chTERT and viral vIL8 transcripts. *J Gen Virol.* 92:1273–1278.
19. Anderson, A.S., A. Francesconi, and R.W. Morgan. 1992. Complete nucleotide sequence of the Marek's disease virus ICP4 gene. *Virology.* 189:657–667.
20. Anderson, A.S., M.S. Parcells, and R.W. Morgan. 1998. The glycoprotein D (US6) homolog is not essential for oncogenicity or horizontal transmission of Marek's disease virus. *J Virol.* 72: 2548–2553.
21. Angamuthu, R., S.S. Baskaran, D.R. Gopal, J. Devarajan, and K. Kathaperumal. 2012. Rapid detection of the Marek's disease viral genome in chicken feathers by loop-mediated isothermal amplification. *J Clin Microbiol.* 50:961–965.
22. Anobile, J.M., V. Arumugaswami, D. Downs, K. Czymmek, M. Parcells, and C.J. Schmidt. 2006. Nuclear localization and dynamic properties of the Marek's disease virus oncogene products Meq and Meq/vIL8. *J Virol.* 1160–1166.
23. Anonymous. 2010. Discussion. In: *5th International Workshop on the Molecular Pathogenesis of Marek's disease*. Athens, GA.
24. Arumugaswami, V., P.M. Kumar, V. Konjufca, R.L. Dienglewicz, S.M. Reddy, and M.S. Parcells. 2009. Latency of Marek's disease virus (MDV) in a reticuloendotheliosis virus-transformed T cell line. I: Uptake and structure of the latent MDV genome. *Avian Dis*. 53:149–155.
25. Arumugaswami, V., P.M. Kumar, V. Konjufca, R.L. Dienglewicz, S.M. Reddy, and M.S. Parcells. 2009. Latency of Marek's disease virus (MDV) in a reticuloendotheliosis virus-transformed T cell line. II: Expression of the latent MDV genome. *Avian Dis*. 53:156–165.
26. Avakian, A.P., R.M. Poston, F.K. Kong, K.R. Van Kampen, and D.C. Tang. 2007. Automated mass immunization of poultry: the prospect for nonreplicating human adenovirus-vectored in ovo vaccines. *Expert Rev Vaccines.* 6:457–465.
27. Baaten, B.J., K.A. Staines, L.P. Smith, H. Skinner, T.F. Davison, and C. Butter. 2009. Early replication in pulmonary B cells after infection with Marek's disease herpesvirus by the respiratory route. *Viral Immunol.* 22:431–444.
28. Bacon, L.D., H.D. Hunt, and H.H. Cheng. 2001. Genetic resistance to Marek's disease. *Curr Top Microbiol Immunol.* 255: 121–141.
29. Bacon, L.D., and R.L. Witter. 1994. B haplotype influence on the relative efficacy of Marek's disease vaccines in commercial chickens. *Poult Sci.* 73:481–487.
30. Bacon, L.D., and R.L. Witter. 1995. Efficacy of Marek's disease vaccines in Mhc heterozygous chickens: Mhc congenic x inbred line F1 matings. *J Hered.* 86:269–273.
31. Bacon, L.D., and R.L. Witter. 1992. Influence of turkey herpesvirus vaccination on the B-haplotype effect on Marek's disease resistance in 15.B-congenic chickens. *Avian Dis*. 36:378–385.
32. Bacon, L.D., R.L. Witter, and A.M. Fadly. 1989. Augmentation of retrovirus-induced lymphoid leukosis by Marek's disease herpesviruses in white leghorn chickens. *J Virol.* 63:504–512.
33. Bacon, L.D., R.L. Witter, and R.F. Silva. 2001. Characterization and experimental reproduction of peripheral neuropathy in white leghorn chickens. *Avian Pathol.* 30:487–499.
34. Bader, S.R., S. Kothlow, S. Trapp, S.C. Schwarz, H.C. Philipp, S. Weigend, A.R. Sharifi, R. Preisinger, W. Schmahl, B. Kaspers, and K. Matiasek. 2010. Acute paretic syndrome in juvenile White Leghorn chickens resembles late stages of acute inflammatory demyelinating polyneuropathies in humans. *J Neuroinflammation.* 7:7.
35. Baigent, S., and F. Davison. 2004. Marek's disease virus: biology and life cycle. In: *Marek's Disease, an Evolving Problem*. F. Davison and V. Nair, eds. Academic Press, London. 62–77.
36. Baigent, S.J., and T.F. Davison. 1999. Development and composition of lymphoid lesions in the spleens of Marek's disease virus-infected chickens: association with virus spread and the pathogenesis of Marek's disease. *Avian Pathol.* 28:287–300.
37. Baigent, S.J., L.J. Petherbridge, K. Howes, L.P. Smith, R.J. Currie, and V.K. Nair. 2005. Absolute quantitation of Marek's disease virus genome copy number in chicken feather and lymphocyte samples using real-time PCR. *J Virol Methods.* 123:53–64.
38. Baigent, S.J., L.J. Petherbridge, L.P. Smith, Y. Zhao, P.M. Chesters, and V.K. Nair. 2006. Herpesvirus of turkey reconstituted from bacterial artificial chromosome clones induces protection against Marek's disease. *J Gen Virol.* 87:769–776.
39. Baigent, S.J., L.P. Smith, R.J. Currie, and V.K. Nair. 2007. Correlation of Marek's disease herpesvirus vaccine virus genome load in feather tips with protection, using an experimental challenge model. *Avian Pathol.* 36:467–474.
40. Baigent, S.J., L.P. Smith, L.J. Petherbridge, and V.K. Nair. 2011. Differential quantification of cloned CVI988 vaccine strain and virulent RB-1B strain of Marek's disease viruses in chicken tissues, using real-time PCR. *Res Vet Sci.* 91:167–174.
41. Banders, U.T., and P.M. Coussens. 1994. Interactions between Marek's disease virus encoded or induced factors and the Rous sarcoma virus long terminal repeat promoter. *Virology.* 199:1–10.
42. Barrow, A., and K. Venugopal. 1999. Molecular characteristics of very virulent European MDV isolates. *Acta Virol.* 43:90–93.
43. Barrow, A.D., S.C. Burgess, S.J. Baigent, K. Howes, and V.K. Nair. 2003. Infection of macrophages by a lymphotropic herpesvirus: a new tropism for Marek's disease virus. *J Gen Virol.* 84: 2635–2645.
44. Barrow, A.D., S.C. Burgess, K. Howes, and V.K. Nair. 2003. Monocytosis is associated with the onset of leukocyte and viral infiltration of the brain in chickens infected with the very virulent Marek's disease virus strain C12/130. *Avian Pathol.* 32:183–191.
45. Barrow, A.D., S.C. Burgess, K. Howes, and K. Venugopal. 2001. Invasion of avian macrophages by highly virulent Marek's disease virus strain C12/130 represents a "tropic" shift in the pathogenesis. In: *Current Progress on Marek's Disease Research*. K.A. Schat, R.M. Morgan, M.S. Parcells, and J.L. Spencer, eds. American Association of Avian Pathologists, Kennett Square, PA. 63–67.
46. Baxendale, W. 1969. Preliminary observations on Marek's disease in ducks and other avian species. *Vet Rec.* 85:341–342.
47. Beasley, J.N., and J.L. Lancaster. 1971. Studies on the role of arthropods as vectors of Marek's disease. *Poult Sci.* 50:1552–1552.
48. Beasley, J.N., L.T. Patterson, and D.H. McWade. 1970. Transmission of Marek's disease by poultry house dust and chicken dander. *Am J Vet Res.* 31:339–344.
49. Becker, Y., Y. Asher, E. Tabor, I. Davidson, M. Malkinson, and Y. Weisman. 1992. Polymerase chain reaction for differentiation between pathogenic and non-pathogenic serotype 1 Marek's disease viruses (MDV) and vaccine viruses of MDV-serotypes 2 and 3. *J Virol Methods.* 40:307–322.
50. Benton, W.J., and M.S. Cover. 1957. The increased incidence of visceral lymphomatosis in broiler and replacement birds. *Avian Dis.* 1:320–327.

51. Biggs, P.M. 1966. Avian leukosis and Marek's disease. In: *Thirteenth World's Poultry Congress Symposium Papers*. 91–118.
52. Biggs, P.M. 2001. The history and biology of Marek's disease virus. *Curr Top Microbiol Immunol.* 255:1–24.
53. Biggs, P.M. 2004. Marek's disease–long and difficult beginnings. In: *Marek's Disease, an eEvolving Problem*. F. Davison and V. Nair, eds. Elsevier Academic Press, London. 8–16.
54. Biggs, P.M. 1968. Marek's disease. Current state of knowledge. *Curr Top Microbiol Immunol*. 43:93–125.
55. Biggs, P.M. 1985. Spread of Marek's disease. In: *Marek's Disease, Scientific Basis and Methods of Control*. L.N. Payne, ed. Martinus Nijhoff, Boston, MA. 329–340.
56. Biggs, P.M., and B.S. Milne. 1972. Biological properties of a number of Marek's disease virus isolates. In: *Oncogenesis and Herpesviruses*. P.M. Biggs, G. de Thé, and L.N. Payne, eds. IARC, Lyon, France. 88–94.
57. Biggs, P.M., and B.S. Milne. 1971. Use of the embryonating egg in studies on Marek's disease. *Am J Vet Res.* 32:1795–1809.
58. Biggs, P.M., and V. Nair. 2012. The long view: 40 years of Marek's disease research and avian pathology. *Avian Pathol.* 41:3–9.
59. Biggs, P.M., and L.N. Payne. 1967. Studies on Marek's disease. I. Experimental transmission. *J Natl Cancer Inst*. 39:267–280.
60. Biggs, P.M., R.F.W. Shilleto, A.M. Lawn, and D.M. Cooper. 1982. Idiopathic polyneuritis in SPF chickens. *Avian Dis.* 11:163–178.
61. Blankert, J.J., G.A. Albers, W.E. Briles, M. Vrielink-van Ginkel, A.J. Groot, G.P. te Winkel, M.G. Tilanus, and A.J. van der Zijpp. 1990. The effect of serologically defined major histocompatibility complex haplotypes on Marek's disease resistance in commercially bred White Leghorn chickens. *Avian Dis.* 34:818–823.
62. Bloom, S.E. 1981. Detection of normal and aberrant chromosomes in chicken embryos and in tumor cells. *Poult Sci.* 60:1355–1361.
63. Boussaha, M., W. Sun, R. Pitchyangkura, S. Triezenberg, and P.M. Coussens. 1996. Marek's disease virus (MDV) UL48 (VP16) contains multiple functional domains and transactivates both homologous and heterologous immediate early gene promoters. In: *Current Research on Marek's Disease*. R.F. Silva, H.H. Cheng, P.M. Coussens, L.F. Lee, and L.F. Velicer, eds. American Association of Avian Pathologists, Kennett Square, PA. 182–188.
64. Bradley, G., M. Hayashi, G. Lancz, A. Tanaka, and M. Nonoyama. 1989. Structure of the Marek's disease virus BamHI-H gene family: Genes of putative importance for tumor induction. *J Virol.* 63:2534–2542.
65. Brewer, R.N., W.M. Reid, H. Botero, and S.C. Schmittle. 1968. Studies on acute Marek's disease. 2. The role of coccidia in transmission and induction. *Poult Sci*. 47:2003–2012.
66. Brewer, R.N., W.M. Reid, J. Johnson, and S.C. Schmittle. 1969. Studies on the acute Marek's disease. VIII. The role of mosquitoes in transmission under experimental conditions. *Avian Dis*. 13: 83–88.
67. Briles, W.E., R.W. Briles, R.E. Taffs, and H.A. Stone. 1983. Resistance to a malignant lymphoma in chickens is mapped to subregion of major histocompatibility (B) complex. *Science.* 219: 977–979.
68. Brown, A.C., S.J. Baigent, L.P. Smith, J.P. Chattoo, L.J. Petherbridge, P. Hawes, M.J. Allday, and V. Nair. 2006. Interaction of MEQ protein and C-terminal-binding protein is critical for induction of lymphomas by Marek's disease virus. *Proc Natl Acad Sci USA*. 103:1687–1692.
69. Brown, A.C., V. Nair, and M.J. Allday. 2012. Epigenetic regulation of the latency-associated region of Marek's disease virus (MDV) in tumour-derived T cell lines and primary lymphoma. *J Virol.* 86:1683–1695.
70. Brown, A.C., L.P. Smith, L. Kgosana, S.J. Baigent, V. Nair, and M.J. Allday. 2009. Homodimerization of the Meq viral oncoprotein is necessary for induction of T cell lymphoma by Marek's disease virus. *J Virol.* 83:11142–11151.
71. Bruckdorfer, R. 2005. The basics about nitric oxide. *Mol. Aspects Med.* 26:3–31.
72. Brunovskis, P., and H.J. Kung. 1996. Retrotransposition and herpesvirus evolution. *Virus Genes.* 11:259–270.
73. Brunovskis, P., and L.F. Velicer. 1995. The Marek's disease virus (MDV) unique short region; alphaherpesvirus-homologous, fowlpox virus-homologous, and MDV- specific genes. *Virology.* 206:324–338.
74. Bublot, M., N. Pritchard, F.X. Le Gros, and S. Goutebroze. 2007. Use of a vectored vaccine against infectious bursal disease of chickens in the face of high-titred maternally derived antibody. *J Comp Pathol.* 137:S81–84.
75. Bublot, M., and J. Sharma. 2004. Vaccination against Marek's disease. In: *Marek's Disease, an Evolving Problem*. F. Davison and V. Nair, eds. Elsevier Academic Press, London. 168–185.
76. Buckmaster, A.E., S.D. Scott, M.J. Sanderson, M.E.G. Boursnell, L.J.N. Ross, and M.M. Binns. 1988. Gene sequence and mapping data from Marek's disease virus and herpesvirus of turkeys implications for herpesvirus classification. *J Gen Virol.* 69:2033–2042.
77. Bumstead, J.M., and L.N. Payne. 1987. Production of an immune suppressor factor by Marek's disease lymphoblastoid cell lines. *Vet Immunol Immunopathol.* 16:47–66.
78. Bumstead, N. 1998. Genomic mapping of resistance to Marek's disease. *Avian Pathol.* 27:S78–S81.
79. Bumstead, N., and J. Kaufman. 2004. Genetic resistance to Marek's disease. In: *Marek's Disease, an Evolving Problem*. F. Davison and V. Nair, eds. Elsevier Academic Press, London. 112–125.
80. Bumstead, N., J. Sillibourne, M. Rennie, N. Ross, and F. Davison. 1997. Quantification of Marek's disease virus in chicken lymphocytes using the polymerase chain reaction with fluorescence detection. *J Virol Methods.* 65:75–81.
81. Burgess, S.C. 2004. Marek's disease lymphomas. In: *Marek's Disease, an Evolving Problem*. F. Davison and V. Nair, eds. Elsevier Academic Press, London. 98–111.
82. Burgess, S.C. 2004. Proteomics in the chicken: tools for understanding immune responses to avian diseases. *Poult Sci.* 83: 552–573.
83. Burgess, S.C., B.H. Basaran, and T.F. Davison. 2001. Resistance to Marek's disease herpesvirus-induced lymphoma is multiphasic and dependent on host genotype. *Vet Pathol.* 38:129–142.
84. Burgess, S.C., and T.F. Davison. 2002. Identification of the neoplastically transformed cells in Marek's disease herpesvirus-induced lymphomas: recognition by the monoclonal antibody AV37. *J Virol.* 76:7276–7292.
85. Burgess, S.C., and T.F. Davison. 1999. A quantitative duplex PCR technique for measuring amounts of cell-associated Marek's disease virus: differences in two populations of lymphoma cells. *J Virol Methods.* 82:27–37.
86. Burgess, S.C., J.R. Young, B.J.G. Baaten, L. Hunt, L.N.J. Ross, M.S. Parcells, P.M. Kumar, C.A. Tregaskes, L.F. Lee, and T.F. Davison. 2004. Marek's disease is a natural model for

lymphomas overexpressing Hodgkin's disease antigen (CD30). *Proc Natl Acad Sci USA*. 101:13879–13884.
87. Burgoyne, G.H., and R.L. Witter. 1973. Effect of passively transferred immunoglobulins on Marek's disease. *Avian Dis.* 17:824–837.
88. Burnside, J., E. Bernberg, A. Anderson, C. Lu, B.C. Meyers, P.J. Green, N. Jain, G. Isaacs, and R.W. Morgan. 2006. Marek's disease virus encodes microRNAs that map to meq and the latency-associated transcript. *J Virol.* 80:8778–8786.
89. Burnside, J., and R. Morgan. 2011. Emerging roles of chicken and viral microRNAs in avian disease. *BMC Proc*. 5:Suppl 4:S2.
90. Burnside, J., and R.W. Morgan. 2007. Genomics and Marek's disease virus. *Cytogenet Genome Res.* 117:376–387.
91. Buscaglia, C., and B.W. Calnek. 1988. Maintenance of Marek's disease herpesvirus latency *in vitro* by a factor found in conditioned medium. *J Gen Virol.* 69:2809–2818.
92. Buscaglia, C., B.W. Calnek, and K.A. Schat. 1988. Effect of immunocompetence on the establishment and maintenance of latency with Marek's disease herpesvirus. *J Gen Virol.* 69:1067–1077.
93. Buscaglia, C., B.W. Calnek, and K.A. Schat. 1989. Effect of reticuloendotheliosis virus and infectious bursal disease virus on Marek's disease herpesvirus latency. *Avian Pathol.* 18:265–281.
94. Buscaglia, C., P. Nervi, and M. Risso. 2004. Characterization of four very virulent Argentinian strains of Marek's disease virus and the influence of one of those isolates on synergism between Marek's disease virus. *Avian Pathol.* 33:190–195.
95. Buscaglia, C., P.H. O'Connell, K.W. Jarosinski, I. Pevzner, and K.A. Schat. 2009. Selection for increased nitric oxide production does not increase resistance to Marek's disease in a primary broiler breeder line. *Avian Dis.* 53:336–340.
96. Butter, C., K. Staines, B. Baaten, L. Smith, and T.F. Davison. 2007. Route of challenge is critical in determining the clinical outcome of infection with a very virulent oncogenic herpesvirus, Marek's disease virus. *Avian Pathol*. 36:93–99.
97. Buza, J.J., and S.C. Burgess. 2007. Modeling the proteome of a Marek's disease transformed cell line: a natural animal model for CD30 overexpressing lymphomas. *Proteomics.* 7:1316–1326.
98. Calnek, B.W. 1972. Effects of passive antibody on early pathogenesis of Marek's disease. *Infect Immun.* 6:193–198.
99. Calnek, B.W. 1985. Genetic resistance. In: *Marek's Disease, Scientific Basis and Methods of Control*. L.N. Payne, ed. Martinus Nijhoff, Boston, MA. 293–328.
100. Calnek, B.W. 1973. Influence of age at exposure on the pathogenesis of Marek's disease. *J Natl Cancer Inst.* 51:929–939.
101. Calnek, B.W. 1986. Marek's disease–a model for herpesvirus oncology. *CRC Crit Rev Microbiol.* 12:293–320.
102. Calnek, B.W. 2001. Pathogenesis of Marek's disease virus infection. *Curr Top Microbiol Immunol.* 255:25–55.
103. Calnek, B.W. 1985. Pathogenesis of Marek's disease: A review. In: *Proceedings of the International Symposium on Marek's* Disease. B.W. Calnek and J.L. Spencer, eds. American Association of Avian Pathologists, Kennett Square, PA. 374–390.
104. Calnek, B.W. 1979. Personal communication.
105. Calnek, B.W., D.F. Adene, K.A. Schat, and H. Abplanalp. 1989. Immune response versus susceptibility to Marek's disease. *Poult Sci.* 68:17–26.
106. Calnek, B.W., and H.K. Adldinger. 1971. Some characteristics of cell-free preparations of Marek's disease virus. *Avian Dis.* 15:508–517.
107. Calnek, B.W., H.K. Adldinger, and D.E. Kahn. 1970. Feather follicle epithelium: A source of enveloped and infectious cell-free herpesvirus from Marek's disease. *Avian Dis.* 14:219–233.
108. Calnek, B.W., J.C. Carlisle, J. Fabricant, K.K. Murthy, and K.A. Schat. 1979. Comparative pathogenesis studies with oncogenic and nononcogenic Marek's disease viruses and turkey herpesvirus. *Am J Vet Res.* 40:541–548.
109. Calnek, B.W., J. Fabricant, K.A. Schat, and K.K. Murthy. 1977. Pathogenicity of low-virulence Marek's disease viruses in normal versus immunologically compromised chickens. *Avian Dis.* 21:346–358.
110. Calnek, B.W., R.W. Harris, C. Buscaglia, K.A. Schat, and B. Lucio. 1998. Relationship between the immunosuppressive potential and the pathotype of Marek's disease virus isolates. *Avian Dis.* 42:124–132.
111. Calnek, B.W., and S.B. Hitchner. 1969. Localization of viral antigen in chickens infected with Marek's disease herpesvirus. *J Natl Cancer Inst.* 43:935–949.
112. Calnek, B.W., and S.B. Hitchner. 1973. Survival and disinfection of Marek's disease virus and the effectiveness of filters in preventing airborne dissemination. *Poult Sci.* 52:35–43.
113. Calnek, B.W., S.B. Hitchner, and H.K. Adldinger. 1970. Lyophilization of cell-free Marek's disease herpesvirus and a herpesvirus from turkeys. *Appl Microbiol.* 20:723–726.
114. Calnek, B.W., B. Lucio, K.A. Schat, and H.S. Lillehoj. 1989. Pathogenesis of Marek's disease virus-induced local lesions. 1. Lesion characterization and cell line establishment. *Avian Dis*. 33:291–302.
115. Calnek, B.W., K.K. Murthy, and K.A. Schat. 1978. Establishment of Marek's disease lymphoblastoid cell lines from transplantable versus primary lymphomas. *Int J Cancer* 21:100–107.
116. Calnek, B.W., and K.A. Schat. 1991. Proliferation of chicken lymphoblastoid cells after *in vitro* infection with Marek's disease virus. *Avian Dis.* 35:728–737.
117. Calnek, B.W., K.A. Schat, and J. Fabricant. 1980. Modification of Marek's disease pathogenesis by in ovo infection or prior vaccination. In: *Viruses in Naturally Occurring Cancers*. M. Essex, G. Todaro, and H. zur Hausen, eds. Cold Spring Harbor, New York. 185–197.
118. Calnek, B.W., K.A. Schat, E.D. Heller, and C. Buscaglia. 1985. *In vitro* infection of T-lymphoblasts with Marek's disease virus. In: *Proceedings of the International Symposium on Marek's Disease*. B.W. Calnek and J.L. Spencer, eds. American Association of Avian Pathologists, Kennett Square, PA. 173–187.
119. Calnek, B.W., K.A. Schat, M.C. Peckham and J. Fabricant. 1983. Field trials with a bivalent vaccine (HVT and SB-1) against Marek's disease. *Avian Dis.* 27:844–849.
120. Calnek, B.W., K.A. Schat, L.J. Ross, and C.L. Chen. 1984. Further characterization of Marek's disease virus-infected lymphocytes. II. *In vitro* infection. *Int J Cancer*. 33:399–406.
121. Calnek, B.W., K.A. Schat, L.J. Ross, W.R. Shek, and C.L. Chen. 1984. Further characterization of Marek's disease virus-infected lymphocytes. I. *In vivo* infection. *Int J Cancer*. 33:389–398.
122. Calnek, B.W., K.A. Schat, W.R. Shek, and C.L.H. Chen. 1982. *In vitro* infection of lymphocytes with Marek's disease virus. *J Natl Cancer Inst.* 69:709–713.
123. Calnek, B.W., W.R. Shek, and K.A. Schat. 1981. Latent infections with Marek's disease virus and turkey herpesvirus. *J Natl Cancer Inst.* 66:585–590.
124. Calnek, B.W., W.R. Shek, and K.A. Schat. 1981. Spontaneous and induced herpesvirus genome expression in Marek's disease tumor cell lines. *Infect Immun.* 34:483–491.

125. Calnek, B.W., W.R. Shek, K.A. Schat, and J. Fabricant. 1982. Dose-dependent inhibition of virus rescue from lymphocytes latently infected with turkey herpesvirus or Marek's disease virus. *Avian Dis.* 26:321–331.
126. Calnek, B.W., T. Ubertini, and H.K. Adldinger. 1970. Viral antigen, virus particles, and infectivity of tissues from chickens with Marek's disease. *J Natl Cancer Inst*. 45:341–351.
127. Calnek, W., and M.W. Smith. 1972. Vaccination against Marek's disease with cell-free turkey herpesvirus: interference by maternal antibody. *Avian Dis.* 16:954–957.
128. Carvallo, F.R., R.A. French, K. Gilbert-Marcheterre, G. Risatti, J.R. Dunn, F. Forster, M. Kiupel, and J.A. Smyth. 2011. Mortality of one-week-old chickens during naturally occurring Marek's disease virus infection. *Vet Pathol.* 48:993–998.
129. Cauchy, L. 1974. The detection of viral antigens in Marek's disease by immunoperoxidase. In: *Viral Immunodiagnosis*. E.K Kurstak, and R. Morisett, ed. Academic Press, New York. 77–87.
130. Cebrian, J., C. Kaschka-Dierich, N. Berthelot, and P. Sheldrick. 1982. Inverted repeat nucleotide sequences in the genomes of Marek's disease virus and the herpesvirus of the turkey. *Proc Natl Acad Sci USA*. 79:555–558.
131. Chang, K.S., K. Ohashi, S.I. Lee, M. Takagi, and M. Onum. 2005. Detection of the meq gene in the T cell subsets from chickens infected with Marek's disease virus serotype 1. *Jpn J Vet Res.* 53:3–11.
132. Chattoo, J.P., M.P. Stevens, and V. Nair. 2006. Rapid identification of non-essential genes for *in vitro* replication of Marek's disease virus by random transposon mutagenesis. *J Virol Methods.* 135:288–291.
133. Chbab, N., A. Egerer, I. Veiga, K.W. Jarosinski, and N. Osterrieder. 2010. Viral control of vTR expression is critical for efficient formation and dissemination of lymphoma induced by Marek's disease virus (MDV). *Vet Res.* 41:56.
134. Chen, C., H. Li, Q. Xie, H. Shang, J. Ji, S. Bai, Y. Cao, Y. Ma, and Y. Bi. 2011. Transcriptional profiling of host gene expression in chicken liver tissues infected with oncogenic Marek's disease virus. *J Gen Virol.* 92:2724–2733.
135. Chien, K.Y., H.C. Liu, and M.B. Goshe. 2011. Development and application of a phosphoproteomic method using electrostatic repulsion-hydrophilic interaction chromatography (ERLIC), IMAC, and LC-MS/MS analysis to study Marek's disease virus infection. *J Proteome Res.* 10:4041–4053.
136. Cho, B.R. 1977. Dual virus maturation of both pathogenic and apathogenic Marek's disease herpesvirus (MDHV) in the feather follicles of dually infected chickens. *Avian Dis.* 21:501–507.
137. Cho, B.R. 1975. Horizontal transmission of turkey herpesvirus to chickens. IV. Viral maturation in the feather follicle epithelium. *Avian Dis*. 19:136–141.
138. Cho, B.R. 1976. A possible association between plaque type and pathogenicity of Marek's disease herpesvirus. *Avian Dis.* 20:324–331.
139. Cho, B.R., and S.G. Kenzy. 1972. Isolation and characterization of an isolate (HN) of Marek's disease virus with low pathogenicity. *Appl Microbiol.* 24:299–306.
140. Cho, K.-O., D. Endoh, J.-F. Qian, K. Ochiai, M. Onuma, and C. Itakura. 1998. Central nervous system lesions induced experimentally by a very virulent strain of Marek's disease virus in Marek's disease resistant chickens. *Avian Pathol.* 27:512–517.
141. Cho, K.-O., M. Mubarak, T. Kimura, K. Ochiai, and C. Itakura. 1996. Sequential skin lesions in chickens experimentally infected with Marek's disease virus. *Avian Pathol.* 25:325–343.
142. Cho, K.-O., K. Ochiai, Y. Fukikawa, and C. Itakura. 1997. Cutaneous lesions in broiler chickens spontaneously affected with Marek's disease. *Avian Pathol.* 26:277–291.
143. Cho, K.O., N.Y. Park, D. Endoh, K. Ohashi, C. Sugimoto, C. Itakura, and M. Onuma. 1998. Cytology of feather pulp lesions from Marek's disease (MD) virus-infected chickens and its application for diagnosis and prediction of MD. *J Vet Med Sci.* 60:843–847.
144. Chubb, R.C., and A.E. Churchill. 1969. Effect of maternal antibody on Marek's disease. *Vet Rec.* 85:303–305.
145. Churchill, A.E. 1985. Production of vaccines. In: *Marek's Disease, Scientific Basis and Methods of Control*. L.N. Payne, ed. Martinus Nijhoff, Boston, MD. 251–266.
146. Churchill, A.E., R.C. Chubb, and W. Baxendale. 1969. The attenuation, with loss of oncogenicity of the herpes-type virus of Marek's disease (strain HPRS-16) on passage in cell culture. *J Gen Virol.* 4:557–564.
147. Churchill, A.E., L.N. Payne, and R.C. Chubb. 1969. Immunization against Marek's disease using a live attenuated virus. *Nature.* 221:744–747.
148. Cole, R.K. 1985. Natural resistance to Marek's disease: A review. In: *Proceedings of the International Symposium on Marek's Disease*. B.W. Calnek and J.L. Spencer, eds. American Association of Avian Pathologists, Kennett Square, PA. 318–329.
149. Cole, R.K. 1968. Studies on genetic resistance to Marek's disease. *Avian Dis.* 12:9–28.
150. Colmano, G., and W.B. Gross. 1971. Effect of metyrapone and DDD on infectious diseases. *Poult Sci.* 50:850–854.
151. Colwell, W.M., C.F. Simpson, L.E. Williams, Jr., and D.J. Forrester. 1973. Isolation of a herpesvirus from wild turkeys in Florida. *Avian Dis.* 17:1–11.
152. Cooper, M.D., C.-L.H. Chen, R.P. Bucy, and C.B. Thompson. 1991. Avian T cell ontogeny. *Adv Immunol.* 50:87–117.
153. Cortes, A.L., E.R. Montiel, S. Lemiere, and I.M. Gimeno. 2011. Comparison of blood and feather pulp samples for the diagnosis of Marek's disease and for monitoring Marek's disease vaccination by real time-PCR. *Avian Dis.* 55:302–310.
154. Cortes, P.L., and C.J. Cardona. 2004. Pathogenesis of a Marek's disease virus mutant lacking vIL-8 in resistant and susceptible chickens. *Avian Dis.* 48:50–60.
155. Coudert, F., A. Vuillaume, M. Wyers, and A.M. Chaussé. 1997. Marek's disease in turkeys. *World Poultry.* S28–29.
156. Coupeau, D., G. Dambrine, and D. Rasschaert. 2012. Kinetic expression analysis of the cluster mdv1-mir-M9~M4, genes meq and vIL-8 differs between the lytic and latent phases of Marek's disease virus infection. *J Gen Virol*. 93:1519–1529.
157. Coussens, P.M., and L.F. Velicer. 1988. Structure and complete nucleotide sequence of the Marek's disease herpesvirus gp57–65 gene. *J Virol.* 62:2373–2379.
158. Crittenden, L.B., R.L. Muhm, and B.R. Burmester. 1972. Genetic control of susceptibility to the avian leukosis complex. 2. Marek's disease. *Poult Sci*. 51:261–267.
159. Crucillo, K.L., K.A. Schat, Y.H. Schukken, A.E. Brown, and P.S. Wakenell. 2010. Pathogenicity of a quail (*Coturnix coturnix japonica*) derived Marek's disease virus rescued from the QT35 cell line. *Avian Dis.* 54:126–130.
160. Cui, X., L.F. Lee, H.D. Hunt, W.M. Reed, B. Lupiani, and S.M. Reddy. 2005. A Marek's disease virus vIL-8 deletion mutant has

attenuated virulence and confers protection against challenge with a very virulent plus strain. *Avian Dis.* 49:199–206.
161. Cui, X., L.F. Lee, W.M. Reed, H.J. Kung, and S.M. Reddy. 2004. Marek's disease virus-encoded vIL-8 gene is involved in early cytolytic infection but dispensable for establishment of latency. *J Virol.* 78:4753–4760.
162. Cui, Z.-Z., Y. Ding, and L.F. Lee. 1990. Marek's disease virus gene clones encoding virus-specific phosphorylated polypeptides and serological characterization of fusion proteins. *Virus Genes.* 3:309–322.
163. Cui, Z., A. Qin, L.F. Lee, P. Wu, and H.J. Kung. 1999. Construction and characterization of a H19 epitope point mutant of MDV CVI988/Rispens strain. *Acta Virol.* 43: 169–173.
164. Cui, Z., G. Zhuang, X. Xu, A. Sun, and S. Su. 2010. Molecular and biological characterization of a Marek's disease virus field strain with reticuloendotheliosis virus LTR insert. *Virus Genes.* 40:236–243.
165. Cushing, T.L., K.A. Schat, S.L. States, J.L. Grodio, P.H. O'Connell, and E.L. Buckles. 2011. Characterization of the host response in systemic isosporosis (atoxoplasmosis) in a colony of captive American goldfinches (*Spinus tristis*) and house sparrows (*Passer domesticus*). *Vet Pathol.* 48:985–992.
166. Dandapat, S., H.K. Pradhan, and G.C. Mohanty. 1994. Anti-idiotype antibodies to Marek's disease-associated tumour surface antigen in protection against Marek's disease. *Vet Immunol Immunopathol.* 40:353–366.
167. Davidson, I., and R. Borenshtain. 2001. *In vivo* events of retroviral long terminal repeat integration into Marek's disease virus in commercial poultry: detection of chimeric molecules as a marker. *Avian Dis.* 45:102–121.
168. Davidson, I., R. Borenshtain, H.-J. Kung, and R.L. Witter. 2002. Molecular indications for *in vivo* integration of the avian leukosis virus, subgroup J-long terminal repeat into the Marek's disease virus in experimentally dually-infected chickens. *Virus Genes.* 24:173–180.
169. Davidson, I., and R. Borenstein. 1999. Multiple infection of chickens and turkeys with avian oncogenic viruses: prevalence and molecular analysis. *Acta Virol.* 43:136–142.
170. Davidson, I., M. Malkinson, and Y. Weisman. 2002. Marek's disease in turkeys. I. A seven-year survey of commercial flocks and experimental infection using two field isolates. *Avian Dis.* 46:314–321.
171. Davidson, I., Y. Weisman, S. Perl, and M. Malkinson. 1998. Differential diagnosis of two paralytic conditions affecting young birds with emphasis on PCR findings. *Avian Pathol.* 27:417–419.
172. Davison, F., S. Baigent, M. Rennie, and N. Bumstead. 1998. Age-and strain-related differences in the quantity of Marek's disease virus in different sub-populations of lymphocytes. *Avian Pathol.* 27:S88.
173. Davison, F., and P. Kaiser. 2004. Immunity to Marek's disease. In: *Marek's Disease, an Evolving Problem*. F. Davison and V. Nair, eds. Elsevier Academic Press, London. 126–141.
174. Davison, F., and V. Nair. 2004. *Marek's Disease, an Evolving Problem*. Elsevier Academic Press, London 1–212.
175. Davison, F., and V. Nair. 2005. Use of Marek's disease vaccines: could they be driving the virus to increasing virulence? *Expert Rev Vaccines.* 4:77–88.
176. de Boer, G.F., J. Pol, and H. Oei. 1987. Biological characteristics of Marek's disease vaccine CVI-988 clone C. *Vet. Q.* 9: 16S–28S.
177. de Boer, G.F., J.M.A. Pol, and S.H.M. Jeurissen. 1989. Marek's disease vaccination strategies using vaccines made from three avian herpesvirus serotypes. In: *Advances in Marek's Disease Research*. S. Kato, T. Horiuchi, T. Mikami, and K. Hirai, eds. Japanese Association on Marek's Disease, Osaka, Japan. 405–413.
178. Delecluse, H.-J., and W. Hammerschmidt. 1993. Status of Marek's disease virus in established lymphoma cell lines: Herpesvirus integration is common. *J Virol.* 67:82–92.
179. Delecluse, H.-J., S. Schüller, and W. Hammerschmidt. 1993. Latent Marek's disease virus can be activated from its chromosomally integrated state in herpesvirus-transformed lymphoma cells. *Eur Mol Biol Organ J.* 12:3277–3286.
180. Di Bucchianico, S., M.F. Giardi, P. De Marco, L. Ottaviano and D. Botti. 2011. Cytogenetic stability of chicken T cell line transformed with Marek's disease virus: atomic force microscope, a new tool for investigation. *J Mol Recognit.* 24:608–618.
181. Ding, J., Z. Cui, S. Jiang, and Y. Li. 2008. Study on the structure of heteropolymer pp38/pp24 and its enhancement on the bi-directional promoter upstream of pp38 gene in Marek's disease virus. *Sci China Series C Life Sci.* 51:821–826.
182. Djeraba, A., N. Bernardet, G. Dambrine, and P. Quere. 2000. Nitric oxide inhibits Marek's disease virus replication but is not the single decisive factor in interferon-gamma-mediated viral inhibition. *Virology.* 277:58–65.
183. Djeraba, A., E. Musset, N. Bernardet, Y. Le Vern, and P. Quere. 2002. Similar pattern of iNOS expression, NO production and cytokine response in genetic and vaccination-acquired resistance to Marek's disease. *Vet Immunol Immunopathol*. 85:63–75.
184. Djeraba, A., E. Musset, J.W. Lowenthal, D.B. Boyle, A.M. Chausse, M. Peloille, and P. Quere. 2002. Protective effect of avian myelomonocytic growth factor in infection with Marek's disease virus. *J Virol.* 76:1062–1070.
185. Doak, R.L., J.F. Munnell, and W.L. Ragland. 1973. Ultrastructure of tumor cells in Marek's disease virus- infected chickens. *Am J Vet Res.* 34:1063–1069.
186. Dudnikova, E., S. Norkina, A. Vlasov, A. Slobodchuk, L.F. Lee, and R.L. Witter. 2007. Evaluation of Marek's disease field isolates by the "best fit" pathotyping assay. *Avian Pathol.* 36:135–143.
187. Duncan, A.J., and S.J.R. Heales. 2005. Nitric oxide and neurological disorders. *Mol Aspects Med.* 26:67–96.
188. Dunn, J.R., R.L. Witter, R.F. Silva, L.F. Lee, J. Finlay, B.A. Marker, J.B. Kaneene, R.M. Fulton, and S.D. Fitzgerald. 2010. The effect of the time interval between exposures on the susceptibility of chickens to superinfection with Marek's disease virus. *Avian Dis.* 54:1038–1049.
189. Dutton, R.L., S.G. Kenzy, and W.A. Becker. 1973. Marek's disease in the Japanese quail (*Coturnix coturnix japonica*). *Poult Sci.* 52:139–143.
190. Eidson, C.S., O.J. Fletcher, and D.P. Anderson. 1971. Characterization of Ala-1 isolate of acute Marek's disease. *Poult Sci.* 50:693–699.
191. Eidson, C.S., R.K. Page, and S.H. Kleven. 1978. Effectiveness of cell-free or cell-associated turkey herpesvirus vaccine against Marek's disease in chickens as influenced by maternal antibody, vaccine dose, and time of exposure to Marek's disease virus. *Avian Dis.* 22:583–597.
192. Eidson, C.S., S.C. Schmittle, R.B. Goode, and J.B. Lai. 1966. Induction of leukosis tumors with the beetle *Alphitobius diaperinus*. *Am J Vet Res.* 27:1053–1057.

193. Ekperigin, H.E., A.M. Fadly, L.F. Lee, X. Liu, and R.H. McCapes. 1983. Comb lesions and mortality patterns in white leghorn layers affected by Marek's disease. *Avian Dis.* 27:503–512.
194. Ellis, M.N., C.S. Eidson, J. Brown, O.J. Fletcher, and S.H. Kleven. 1981. Serological responses to mycoplasma synoviae in chickens infected with virulent or avirulent strains of Marek's disease virus. *Poult Sci.* 60:1344–1347.
195. Elmubarak, A.K., J.M. Sharma, R.L. Witter, K. Nazerian, and V.L. Sanger. 1981. Induction of lymphomas and tumor antigen by Marek's disease virus in turkeys. *Avian Dis.* 25:911–926.
196. Elmubarak, A.K., J.M. Sharma, R.L. Witter, and V.L. Sanger. 1982. Marek's disease in turkeys: Lack of protection by vaccination. *Am J Vet Res.* 43:740–742.
197. Else, R.W. 1974. Vaccinal immunity to Marek's disease in bursectomized chickens. *Vet Rec.* 95:182–187.
198. Emara, M.G., M.A. Abdellatif, D.L. Pollock, M. Sadjadi, S.S. Cloud, C.R. Pope, J.K. Rosenberger, and H. Kim. 2001. Genetic variation in susceptibility to Marek's disease in a commercial broiler population. *Avian Dis.* 45:400–409.
199. Endoh, D. 1996. Enhancement of gene expression by Marek's disease virus homologue of the herpes simplex virus-1 ICP4. *Jpn J Vet Res.* 44:136–137.
200. Erf, G.F., T.K. Bersi, X.L. Wang, G.P. Sreekumar, and J.R. Smyth. 2001. Herpesvirus connection in the expression of autoimmune vitiligo in Smyth line chickens. *Pigment Cell Res.* 14:40–46.
201. Fabricant, C.G. 1985. Atherosclerosis: The consequence of infection with a herpesvirus. *Adv Vet Sci Comp Med.* 30:39–66.
202. Fabricant, C.G., J. Fabricant, M.M. Litrenta, and C.R. Minick. 1978. Virus-induced atherosclerosi. *J Exp Med.* 148:335–340.
203. Fabricant, C.G., D.P. Hajjar, C.R. Minick, and J. Fabricant. 1981. Herpesvirus infection enhances cholesterol and cholesteryl ester accumulation in cultured arterial smooth muscle cells. *Am J Pathol.* 105:176–184.
204. Fabricant, J., B.W. Calnek, and K.A. Schat. 1982. The early pathogenesis of turkey herpesvirus infection in chickens and turkeys. *Avian Dis.* 26:257–264.
205. Ficken, M.D., M.P. Nasisse, G.D. Boggan, J.S. Guy, D.P. Wages, R.L. Witter, J.K. Rosenberger, and R.M. Nordgren. 1991. Marek's disease virus isolates with unusual tropism and virulence for ocular tissues: Clinical findings, challenge studies and pathological features. *Avian Pathol.* 20:461–474.
206. Fletcher, O.J., C.S. Eidson, and R.K. Page. 1971. Pathogenesis of Marek's disease induced in chickens by contact exposure to GA isolate. *Am J Vet Res.* 32:1407–1416.
207. Fletcher, O.J., and L.W. Schierman. 1985. Variation in histology and growth characteristics of transplantable Marek's disease lymphomas. *Cancer Res.* 45:1762–1765.
208. Fragnet, L., M.A. Blasco, W. Klapper, and D. Rasschaert. 2003. The RNA subunit of telomerase is encoded by Marek's disease virus. *J Virol.* 77:5985–5996.
209. Fragnet, L., E. Kut, and D. Rasschaert. 2005. Comparative functional study of the viral telomerase RNA based on natural mutations. *J Biol Chem.* 280:23502–23515.
210. Friedman, A., E. Shalem-Meilin, and E.D. Heller. 1992. Marek's disease vaccines cause temporary B-lymphocyte dysfunction and reduced resistance to infection in chicks. *Avian Pathol.* 21:621–631.
211. Fukuchi, K., A. Tanaka, L.W. Schierman, R.L. Witter, and M. Nonoyama. 1985. The structure of Marek's disease virus DNA: the presence of unique expansion in nonpathogenic viral DNA. *Proc Natl Acad Sci USA*. 82:751–754.
212. Gao, H., H.Y. Cui, X. Cui, X.M. Shi, Y. Zhao, X. Zhao, Y. Quan, S. Yan, W. Zeng, and Y. Wang. 2011. Expression of HA of HPAI H5N1 virus at US2 gene insertion site of turkey herpesvirus induced better protection than that at US10 gene insertion site. *Plos One.* 6:e22549.
213. Garcia-Camacho, L., K.A. Schat, R.J. Brooks, and D.I. Bounous. 2003. Early cell-mediated immune responses to Marek's disease virus in two chicken lines with defined major histocompatibility complex antigens. *Vet Immunol Immunopathol.* 95:145–153.
214. Gawel, A., E. Samorek-Salamonowicz, M. Mazurkiewicz and W. Kozdrun. 1998. Przebieg choroby Mareka u indyków rzeźnych. *Nowa Weterynaria.* 3:1–3.
215. Geerligs, H., S. Quanz, B. Suurland, I.E. Spijkers, J. Rodenberg, F.G. Davelaar, B. Jongsma, and M. Kumar. 2008. Efficacy and safety of cell associated vaccines against Marek's disease virus grown in a continuous cell line from chickens. *Vaccine.* 26: 5595–5600.
216. Geerligs, H.J., and A. Hoogendam. 2007. Determination of optimal conditions for thawing and diluting cell-bound CVI 988 Marek's disease vaccine and stability of the diluted vaccine. *Avian Dis.* 51:969–973.
217. Gilka, F., and J.L. Spencer. 1995. Extravascular hemolytic anemia in chicks infected with highly pathogenic Marek's disease viruses. *Avian Pathol.* 24:393–410.
218. Gimeno, I.M. 2004. Future strategies for controlling Marek's disease. In: *Marek's Disease: An Evolving Problem*. F. Davison and V. Nair, eds. Elsevier Academic Press, London. 186–199.
219. Gimeno, I.M. 2008. Marek's disease vaccines: a solution for today but a worry for tomorrow? *Vaccine.* 26:C31–41.
220. Gimeno, I.M., and A.L. Cortes. 2011. Chronological study of cytokine transcription in the spleen and lung of chickens after vaccination with serotype 1 Marek's disease vaccines. *Vaccine.* 29:1583–1594.
221. Gimeno, I.M., A.L. Cortes, E.R. Montiel, S. Lemiere, and A.K.R. Pandiri. 2011. Effect of diluting Marek's disease vaccines on the outcomes of Marek's disease virus infection when challenged with highly virulent Marek's disease viruses. *Avian Dis.* 55:263–272.
222. Gimeno, I.M., R.L. Witter, A.L. Cortes, and W.M. Reed. 2011. Replication ability of three highly protective Marek's disease vaccines: implications in lymphoid organ atrophy and protection. *Avian Pathol.* 40:573–579.
223. Gimeno, I.M., R.L. Witter, H.D. Hunt, L.F. Lee, S.M. Reddy and U. Neumann. 2001. Marek's disease virus infection in the brain: virus replication, cellular infiltration, and major histocompatibility complex antigen expression. *Vet Pathol.* 38:491–503.
224. Gimeno, I.M., R.L. Witter, H.D. Hunt, S.M. Reddy, L.F. Lee, and R.F. Silva. 2005. The pp38 gene of Marek's disease virus (MDV) is necessary for cytolytic infection of B cells and maintenance of the transformed state but not for cytolytic infection of the feather follicle epithelium and horizontal spread of MDV. *J Virol.* 79:4545–4549.
225. Gimeno, I.M., R.L. Witter, H.D. Hunt, S.M. Reddy, and U. Neumann. 2001. Differential attenuation of the induction by Marek's disease virus of transient paralysis and persistent neurological disease: a model for pathogenesis studies. *Avian Pathol.* 30:397–410.
226. Gimeno, I.M., R.L. Witter, and W.M. Reed. 1999. Four distinct neurologic syndromes in Marek's disease: effect of viral strain and pathotype. *Avian Dis.* 43:721–737.

227. Goodchild, W.M. 1969. Some observations on Marek's disease (fowl paralysis). *Vet Rec.* 84:87–89.
228. Groot, A.J.C., and G.A.A. Albers. 1992. The effect of MHC on resistance to Marek's disease in White Leghorn crosses. In: *Proceedings of the 4th International Symposium on Marek's Disease*. G. de Boer and S.H.M. Jeurissen, eds. Ponsen and Looijen, Wageningen, Amsterdam, The Netherlands. 185–188.
229. Gross, W.B. 1972. Effect of social stress on occurrence of Marek's disease in chickens. *Am J Vet Res.* 33:2275–2279.
230. Hafner, S., B.G. Harmon, G.N. Rowland, R.G. Stewart, and J.R. Glisson. 1991. Spontaneous regression of "dermal squamous cell carcinoma" in young chickens. *Avian Dis.* 35:321–327.
231. Haider, S.A., R.F. Lapen, and S.G. Kenzy. 1970. Use of feathers in a gel precipitation test for Marek's disease. *Poult Sci.* 49:1654–1165.
232. Hajjar, D.P., C.G. Fabricant, C.R. Minick, and J. Fabricant. 1986. Virus-induced atherosclerosis. Herpesvirus infection alters aortic cholesterol metabolism and accumulation. *Am J Pathol.* 122:62–70.
233. Halouzka, R., and V. Jurajda. 1992. Pathological lesions in the organs of chicks after infection with turkey herpesvirus THV-BI0-I. *Vet Med (Praha).* 37:463–470.
234. Halvorson, D.A., and D.O. Mitchel. 1979. Loss of cell-associated Marek's disease vaccine titer during thawing, reconstitution and use. *Avian Dis.* 23:848–853.
235. Han, P.F., and J.R. Smyth, Jr. 1972. The influence of growth rate on the development of Marek's disease in chickens. *Poult Sci.* 51:975–985.
236. Han, P.F., and J.R. Smyth, Jr. 1972. The influence of restricted feed intake on the response of chickens to Marek's disease. *Poult Sci.* 51:986–991.
237. Handberg, K.J., O.L. Nielsen, and P.H. Jorgensen. 2001. The use of serotype 1- and serotype 3-specific polymerase chain reaction for the detection of Marek's disease virus in chickens. *Avian Pathol.* 30:243–249.
238. Haq, K., J.T. Brisbin, N. Thanthrige-Don, M. Heidari, and S. Sharif. 2010. Transcriptome and proteome profiling of host responses to Marek's disease virus in chickens. *Vet Immunol Immunopathol.* 138:292–302.
239. Haq, K., I. Elawadli, P. Parvizi, A.I. Mallick, S. Behboudi and S. Sharif. 2011. Interferon-γ influences immunity elicited by vaccines against very virulent Marek's disease virus. *Antiviral Res.* 90:218–226.
240. Haq, K., T. Fear, A. Ibraheem, M.F. Abdul-Careem, and S. Sharif. 2012. Influence of vaccination with CVI988/Rispens on load and replication of a very virulent Marek's disease virus strain in feathers of chickens. *Avian Pathol.* 41:69–76.
241. Hargett, D., S. Rice, and S.L. Bachenheimer. 2006. Herpes simplex virus type 1 ICP27-dependent activation of NFκβ. *J Virol.* 80:10565–10578.
242. Hartmann, W., K. Hala, and G. Heil. 1992. The B blood group system of the chicken and resistance to Marek's disease: Effect of B blood group genotypes in leghorn crosses. *Arch Tierzucht.* 35:169–180.
243. Heidari, M., S.D. Fitzgerald, H.M. Zhang, R.F. Silva, L.F. Lee, and J.R. Dunn. 2007. Marek's disease virus-induced skin leukosis in scaleless chickens: tumor development in the absence of feather follicles. *Avian Dis.* 51:713–718.
244. Heidari, M., A.J. Sarson, M. Huebner, S. Sharif, D. Kireev, and H. Zhou. 2010. Marek's disease virus-induced immunosuppression: array analysis of chicken immune response gene expression profiling. *Viral Immunol.* 23:309–319.
245. Heidari, M., H.M. Zhang, and S. Sharif. 2008. Marek's disease virus induces Th2 activity during cytolytic infection. *Viral Immunol.* 21:203–214.
246. Heller, E.D., and K.A. Schat. 1987. Enhancement of natural killer cell activity by Marek's disease vaccines. *Avian Pathol.* 16:51–60.
247. Heller, E.D., and K.A. Schat. 1985. Inhibition of natural killer activity in chickens by Marek's disease virus-transformed cell lines. In: *Proceedings of the International Symposiuim on Marek's Disease*. American Association of Avian Pathologists, Kennett Square, PA, B.W. Calnek and J.L. Spencer, eds. 286–294.
248. Hepkema, B.G., J.J. Blankert, G.A. Albers, M.G. Tilanus, E. Egberts, A.J. van der Zijpp, and E.J. Hensen. 1993. Mapping of susceptibility to Marek's disease within the major histocompatibility (B) complex by refined typing of White Leghorn chickens. *Anim Genet.* 24:283–287.
249. Higgins, D.A., and B.W. Calnek. 1975. Fowl immunoglobulins: Quantitation in birds genetically resistant and susceptible to Marek's disease. *Infect Immun.* 12:360–363.
250. Hirai, K. 2001. *Marek's Disease*. *Springer-Verlag, Berlin.* 1–294.
251. Hirai, K., K. Ikuta, and S. Kato. 1981. Structural changes of the DNA of Marek's disease virus during serial passage in cultured cells. *Virology.* 115:385–389.
252. Hirai, K., and M. Sakaguchi. 2001. Polyvalent recombinant Marek's disease virus vaccine against poultry diseases. *Curr Top Microbiol Immunol.* 255:261–287.
253. Hirai, K., M. Yamada, Y. Arao, S. Kato, and S. Nii. 1990. Replicating Marek's disease virus (MDV) serotype 2 DNA with inserted MDV serotype 1 DNA sequences in a Marek's disease lymphoblastoid cell line MSB1-41C. *Arch Virol.* 114:153–165.
254. Hlozanek, I., V. Jurajda, and V. Benda. 1977. Disinfection of Marek's disease virus in poultry dust. *Avian Pathol.* 6:241–250.
255. Hlozanek, I., O. Mach, and V. Jurajda. 1973. Cell-free preprations of Marek's disease virus from poultry dust. *Folia Biol (Praha).* 19:118–123.
256. Holland, M.S., C.D. Mackenzie, R.W. Bull, and R.F. Silva. 1996. A comparative study of histological conditions suitable for both immunofluorescence and *in situ* hybridization in the detection of herpesvirus and its antigens in chicken tissues. *J Histochem Cytochem.* 44:259–265.
257. Holland, M.S., C.D. Mackenzie, R.W. Bull, and R.F. Silva. 1998. Latent turkey herpesvirus infection in lymphoid, nervous, and feather tissues of chickens. *Avian Dis.* 42:292–299.
258. Hong, C.C., and M. Sevoian. 1971. Interferon production and host resistance to type II avian (Marek's) leukosis virus (JM strain). *Appl Microbiol.* 22:818–820.
259. Hong, Y., M. Frame, and P.M. Coussens. 1995. A 14-kDa immediate-early phosphoprotein is specifically expressed in cells infected with oncogenic Marek's dsiease virus strains and their attenuated derivatives. *Virology.* 206:695–700.
260. Hooft van Iddekinge, B.J., L. Stenzler, K.A. Schat, H. Boerrigter, and G. Koch. 1999. Genome analysis of Marek's disease virus strain CVI-988: effect of cell culture passage on the inverted repeat regions. *Avian Dis.* 43:182–188.
261. Horiuchi, T., A. Horinouchi, T. Kotani, Y. Odagiri, S. Kato, K. Imai, and S. Kobayashi. 1988. Isolation of serotype 1 Marek's disease virus from a quail. In: *Advances in Marek's Disease Research*. S. Kato, T. Horiuchi, T. Mikami, and

K. Hirai, eds. Japanese Association on Marek's Disease, Osaka, Japan. 367–371.
262. Hunt, H.D., B. Lupiani, M.M. Miller, I. Gimeno, L.F. Lee, and M.S. Parcells. 2001. Marek's disease virus down-regulates surface expression of MHC (B Complex) Class I (BF) glycoproteins during active but not latent infection of chicken cells. *Virology.* 282:198–205.
263. Ikezawa, M., M. Goryo, J. Sasaki, M. Haridy, and K. Okada. 2010. Late Marek's disease in adult chickens inoculated with virulent Marek's disease virus. *J Vet Med Sci.* 72:1539–1545.
264. Ikuta, K., H. Honma, K. Maotani, S. Ueda, S. Kato, and K. Hirai. 1982. Monoclonal antibodies specific to and cross-reactive with Marek's disease virus and herpesvirus of turkeys. *Biken J.* 25:171–175.
265. Ikuta, K., K. Nakajima, A. Kanamori, K. Maotani, J.S. Mah, S. Ueda, S. Kato, M. Yoshida, S. Nii, M. Naito, C. Nishida-Umehara, M. Saski, and K. Hirai. 1987. Establishment and characterization of a T-lymphoblastoid cell line MDCC-MTB1 derived from chick lymphocytes infected *in vitro* with Marek's disease serotype 1. *Int J Cancer.* 39:514–520.
266. Ikuta, K., K. Nakajima, M. Naito, S.H. Ann, S. Ueda, S. Kato, and K. Hirai. 1985. Identification of Marek's disease virus-specific antigens in Marek's disease lymphoblastoid cell lines using monoclonal antibody against virus-specific phosphorylated polypeptides. *Int. J. Cancer.* 35:257–264.
267. Ikuta, K., K. Nakajima, S. Ueda, S. Kato, and K. Hirai. 1985. Differences in the processing of secreted glycoprotein A induced by Marek's disease virus and herpesvirus of turkeys. *J Gen Virol.* 66:1131–1137.
268. Ikuta, K., S. Ueda, S. Kato, and K. Hirai. 1983. Most virus-specific polypeptides in cells productively infected with Marek's disease virus or herpesvirus of turkeys possess cross-reactive determinants. *J Gen Virol.* 64:961–965.
269. Ikuta, K., S. Ueda, S. Kato, and K. Hirai. 1984. Processing of glycoprotein gB related to neutralization of Marek's disease virus and herpesvirus of turkeys. *Microbiol Immunol.* 28:923–933.
270. Imai, K., N. Yuasa, K. Furuta, M. Narita, H. Banba, S. Kobayashi, and T. Horiuchi. 1991. Comparative studies on pathogenical, virological and serological properties of Marek's disease virus isolated from Japanese quail and chicken. *Avian Pathol.* 20:57–65.
271. Imai, K., N. Yuasa, S. Kobayashi, K. Nakamura, K. Tsukamoto, and H. Hihara. 1990. Isolation of Marek's disease virus from Japanese quail with lymphoproliferative disease. *Avian Pathol.* 19:119–129.
272. Isfort, R., D. Jones, R. Kost, R. Witter, and H.-J. Kung. 1992. Retrovirus insertion into herpesvirus *in vitro* and in *vivo*. *Proc Natl Acad Sci USA*. 89:991–995.
273. Isfort, R., H. Kung, and L. Velicer. 1987. Identification of the gene encoding Marek's disease herpesvirus A antigen. *J Virol.* 61:2614–2620.
274. Isfort, R.J., Z. Qian, D. Jones, R.F. Silva, R. Witter, and H. Kung. 1994. Integration of multiple chicken retroviruses into multiple chicken herpesviruses: Herpesviral gD as a common target of integration. *Virology.* 203:125–133.
275. Isfort, R.J., R.A. Stringer, H.-J. Kung, and L.F. Velicer. 1986. Synthesis, processing, and secretion of the Marek's disease herpesvirus A antigen glycoprotein. *J Virol.* 57:464–474.
276. Islam, A., B.F. Cheetham, T.J. Mahony, P.L. Young, and S.W. Walkden-Brown. 2006. Absolute quantitation of Marek's disease virus and herpesvirus of turkeys in chicken lymphocyte, feather tip and dust samples using real-time PCR. *J Virol Methods.* 132:127–134.
277. Islam, A., B. Harrison, B.F. Cheetham, T.J. Mahony, P.L. Young, and S.W. Walkden-Brown. 2004. Differential amplification and quantitation of Marek's disease viruses using real-time polymerase chain reaction. *J Virol Methods.* 119:103–113.
278. Islam, A., and S.W. Walkden-Brown. 2007. Quantitative profiling of the shedding rate of the three Marek's disease virus (MDV) serotypes reveals that challenge with virulent MDV markedly increases shedding of vaccinal viruses. *J Gen Virol.* 88:2121–2128.
279. Izumiya, Y., H.K. Jang, M. Ono, and T. Mikami. 2001. A complete genomic DNA sequence of Marek's disease virus type 2, strain HPRS24. *Curr Top Microbiol Immunol.* 255:191–221.
280. Jakowski, R.M., T.N. Fredrickson, T.W. Chomiak, and R.E. Luginbuhl. 1970. Hematopoietic destruction in Marek's disease. *Avian Dis.* 14:374–385.
281. Jang, H.-K., T. Kitazawa, M. Ono, Y. Kawaguchi, K. Maeda, N. Yokoyama, Y. Tohya, M. Niikura and T. Mikami. 1996. Protection studies against Marek's disease using baculovirus-expressed glycoproteins B and C of Marek's disease virus type 1. *Avian Pathol.* 25:5–24.
282. Jansen, C.A., P.M. van de Haar, D. van Haarlem, P. van Kooten, t.S. de Wi, W. van Eden, B.C. Viertlböck, T.W. Göbel, and L. Vervelde. 2010. Identification of new populations of chicken natural killer (NK) cells. *Dev Comp Immunol.* 34:759–767.
283. Jarosinski, K., L. Kattenhorn, B. Kaufer, H. Ploegh, and N. Osterrieder. 2007. A herpesvirus ubiquitin-specific protease is critical for efficient T cell lymphoma formation. *Proc Natl Acad Sci USA*. 104:20025–29930.
284. Jarosinski, K.W., S. Arndt, B.B. Kaufer, and N. Osterrieder. 2012. Fluorescently tagged pUL47 of Marek's disease virus reveals differential tissue expression of the tegument protein in vivo. *J Virol.* 86:2428–2436.
285. Jarosinski, K.W., H.D. Hunt, and N. Osterrieder. 2010. Down-regulation of MHC class I by the Marek's disease virus (MDV) UL49.5 gene product mildly affects virulence in a haplotype-specific fashion. *Virology.* 405:457–463.
286. Jarosinski, K.W., B.L. Njaa, P.H. O'Connell, and K.A. Schat. 2005. Pro-inflammatory responses in chicken spleen and brain tissues after infection with very virulent plus Marek's disease virus. *Viral Immunol.* 18:148–161.
287. Jarosinski, K.W., P.H. O'Connell, and K.A. Schat. 2003. Impact of deletions within the Bam HI-L fragment of attenuated Marek's disease virus on vIL-8 expression and the newly identified transcript of open reading frame LORF4. *Virus Genes* 26:255–269.
288. Jarosinski, K.W., and N. Osterrieder. 2010. Further analysis of Marek's disease virus horizontal transmission confirms that U(L)44 (gC) and U(L)13 protein kinase activity are essential, while U(S)2 is nonessential. *J Virol.* 84:7911–7916.
289. Jarosinski, K.W., N. Osterrieder, V.K. Nair, and K.A. Schat. 2005. Attenuation of Marek's disease virus by deletion of open reading frame RLORF4 but not RLORF5a. *J Virol.* 79: 11647–11659.
290. Jarosinski, K.W., and K.A. Schat. 2007. Multiple alternative splicing to exons II and III of viral interleukin-8 (vIL-8) in the Marek's disease virus genome: the importance of vIL-8 exon I. *Virus Genes.* 34:9–22.
291. Jarosinski, K.W., B.K. Tischer, S. Trapp, and N. Osterrieder. 2006. Marek's disease virus: lytic replication, oncogenesis and control. *Expert Rev Vaccines.* 5:761–772.

292. Jarosinski, K.W., R.W. Yunis, P.H. O'Connell, C.J. Markowski-Grimsrud, and K.A. Schat. 2002. Influence of genetic resistance of the chicken and virulence of Marek's disease virus (MDV) on nitric oxide responses after MDV infection. *Avian Dis.* 46:636–649.
293. Jeurissen, S.H., and G.F. de Boer. 1993. Chicken anaemia virus influences the pathogenesis of Marek's disease in experimental infections, depending on the dose of Marek's disease virus. *Vet Q.* 15:81–84.
294. Jones, D., P. Brunovskis, R. Witter, and H.J. Kung. 1996. Retroviral insertional activation in a herpesvirus: transcriptional activation of US genes by an integrated long terminal repeat in a Marek's disease virus clone. *J Virol.* 70:2460–2467.
295. Jones, D., R. Isfort, R. Witter, R. Kost, and H.-J. Kung. 1993. Retroviral insertions into a herpesvirus are clustered at the junctions of the short repeat and short unique sequences. *Proc Natl Acad Sci USA*. 90:3855–3859.
296. Jones, D., L. Lee, J.L. Liu, H.J. Kung, and J.K. Tillotson. 1992. Marek's disease virus encodes a basic-leucine zipper gene resembling the fos/jun oncogenes that is highly expressed in lymphoblastoid tumors. *Proc Natl Acad Sci USA*. 89:4042–4046.
297. Jungherr, E., L.P. Doyle, and E.P. Johnson. 1941. Tentative pathologic nomenclature for the disease and/or for the disease complex variously designated as fowl leukemia, fowl leucosis, etc. *Am J Vet Res.* 2:116.
298. Kaiser, P., G. Underwood, and F. Davison. 2003. Differential cytokine responses following Marek's disease virus infection of chickens differing in resistance to Marek's disease. *J Virol.* 77:762–768.
299. Kaleta, E.F., and R.A. Bankowski. 1972. Production of interferon by the Cal-1 and turkey herpesvirus strains associated with Marek's disease. *Am J Vet Res.* 33:567–571.
300. Kaleta, E.F., and U. Neumann. 1977. Investigations on the mode of transmission of the herpesvirus of turkeys *in vitro*. *Avian Pathol.* 6:33–39.
301. Kamil, J., D. Robinson, L.F. Lee, and H.J. Kung. 2001. Marek's disease virus encodes a secreted lipase. In: *Current Progress on Marek's Disease Research*. K.A. Schat, R.M. Morgan, M.S. Parcells, and J.L. Spencer, eds. American Association of Avian Pathologists, Kennett Square, PA. 209–213.
302. Kamil, J.P., B.K. Tischer, S. Trapp, V.K. Nair, N. Osterrieder, and H.J. Kung. 2005. vLIP, a viral lipase homologue, is a virulence factor of Marek's disease virus. *J Virol.* 79:6984–6996.
303. Kanamori, A., K. Ikuta, S. Ueda, S. Kato, and K. Hirai. 1987. Methylation of Marek's disease virus DNA in chicken T-lymphoblastoid cell lines. *J Gen Virol.* 68:1485–1490.
304. Kano, R., S. Konnai, M. Onuma, and K. Ohashi. 2009. Cytokine profiles in chickens infected with virulent and avirulent Marek's disease viruses: interferon-gamma is a key factor in the protection of Marek's disease by vaccination. *Microbiol Immunol.* 53:224–232.
305. Kano, R., S. Konnai, M. Onuma, and K. Ohashi. 2009. Microarray analysis of host immune responses to Marek's disease virus infection in vaccinated chickens. *J Vet Med Sci.* 71: 603–610.
306. Kaplan, S.K., and K.A. Schat 2001. Unpublished data.
307. Kaschka-Dierich, C., K. Nazerian, and R. Thomssen. 1979. Intracellular state of Marek's disease virus DNA in two tumour-derived chicken cell lines. *J Gen Virol.* 44:271–280.
308. Kato, S., and K. Hirai. 1985. Marek's disease virus. *Adv Virus Res.* 30:225–277.
309. Kaufer, B.B., S. Arndt, S. Trapp, N. Osterrieder, and K.W. Jarosinski. 2011. Herpesvirus telomerase RNA (vTR) with a mutated template sequence abrogates herpesvirus-induced lymphomagenesis. *PLoS Pathog.* 7:e1002333.
310. Kaufer, B.B., K.W. Jarosinski, and N. Osterrieder. 2011. Herpesvirus telomeric repeats facilitate genomic integration into host telomeres and mobilization of viral DNA during reactivation. *J Exp Med.* 208:605–615.
311. Kaufer, B.B., S. Trapp, K.W. Jarosinski, and N. Osterrieder. 2010. Herpesvirus telomerase RNA(vTR) dependent lymphoma formation does not require interaction of vTR with telomerase reverse transcriptase (TERT). *Plos Pathog.* 6:e1001073.
312. Kaul, L., and H.K. Pradhan. 1991. Immunopathology of Marek's disease in quails: presence of antinuclear antibody and immune complex. *Vet Immunol Immunopathol.* 28:89–96.
313. Kaul, L., and H.K. Pradhan. 1991. Vaccination trial of quail with herpes virus of turkey. *Prev Vet Med.* 11:69–73.
314. Kawamura, H., D.J. King, Jr, and D.P. Anderson. 1969. A herpesvirus isolated from kidney cell culture of normal turkeys. *Avian Dis.* 13:853–886.
315. Kawamura, M., M. Hayashi, T. Furuichi, M. Nonoyama, E. Isogai, and S. Namioka. 1991. The inhibitory effects of oligonucleotides, complementary to Marek's Disease virus mRNA transcribed from the BamHI-H region, on the proliferation of transformed lymphoblastoid cells, MDCC- MSB1. *J Gen Virol.* 72:1105–1111.
316. Kent, J., E. Bernberg, and R. Morgan. 2001. Major histocompatibility complex (MHC) expression is down-regulated on the surface of Marek's disease (MDV) infected chicken embryo fibroblasts but up-regulated on the surface of adjacent uninfected CEF. In: *Current Progress on Marek's Disease Research*. K.A. Schat, R.M. Morgan, M.S. Parcells, and J.L. Spencer, eds. American Association of Avian Pathologists, Kennett Square. 163–166.
317. Kenzy, S.G., and P.M. Biggs. 1967. Excretion of the Marek's disease agent by infected chickens. *Vet Rec.* 80:565–568.
318. Kenzy, S.G., B.R. Cho, and Y. Kim. 1973. Oncogenic Marek's disease herpesvirus in avian encephalitis (temporary paralysis). *J Natl Cancer Inst.* 51:977–982.
319. Khare, M.L., J. Grun, and E.V. Adams. 1975. Marek's disease in Japanese quail—a pathological, virological and serological study. *Poult Sci.* 54:2066–2068.
320. Kim, T., J. Mays, A. Fadly, and R. Silva. 2011. Artificially inserting a reticuloendotheliosis virus long terminal repeat into a bacterial artificial chromosome clone of Marek's disease virus (MDV) alters expression of nearby MDV genes. *Virus Genes.* 42:369–376.
321. King, A.M.Q., M.J. Adams, E.B. Carstens, and E.J. Lefkowitz. 2011. Ninth Report of the International Committee on Taxonomy of Viruses. Elsevier Academic Press, San Diego.
322. King, D., D. Page, K.A. Schat, and B.W. Calnek. 1981. Difference between influences of homologous and heterologous maternal antibodies on response to serotype-2 and serotype-3 Marek's disease vaccines. *Avian Dis.* 25:74–81.
323. Kingham, B.F., V. Zelnik, J. Kopacek, V. Majerciak, E. Ney, and C.J. Schmidt. 2001. The genome of herpesvirus of turkeys: comparative analysis with Marek's disease viruses. *J Gen Virol.* 82:1123–1135.
324. Kishi, M., H. Harada, M. Takahashi, A. Tanaka, M. Hayashi, M. Nonoyama, S.F. Josephs, A. Buchbinder, F. Schachter, D.V. Ablashi, F. Wong-Staal, S.Z. Salahuddin, and R.C. Gallo. 1988.

A repeat sequence, GGGTTA, is shared by DNA of human herpesvirus 6 and Marek's disease virus. *J Virol.* 62:4824–4827.
325. Kobayashi, S., K. Kobayashi, and T. Mikami. 1986. A study of Marek's disease in Japanese quails vaccinated with herpesvirus of turkeys. *Avian Dis.* 30:816–819.
326. Kodama, H., C. Sugimoto, F. Inage, and T. Mikami. 1979. Antiviral immunity against Marek's disease virus-infected chicken kidney cells. *Avian Pathol.* 8:33–44.
327. Koffa, M.D., J.B. Clements, E. Izaurralde, S. Wadd, S.A. Wilson, I.W. Mattaj, and S. Kuersten. 2001. Herpes simplex virus ICP27 protein provides viral mRNAs with access to the cellular mRNA export pathway. *EMBO J.* 20:5769–5778.
328. Konobe, T., T. Ishikawa, K. Takaku, K. Ikuta, N. Kitamoto, and S. Kato. 1979. Marek's disease virus and herpesvirus of turkey noninfective to chickens, obtained by repeated in vitro passages. *Biken J.* 22:103–107.
329. Kreager, K. 1997. A global perspective on Marek's disease control in layers and layer breeders. *World Poultry.* S14–15.
330. Kreager, K.S. 1998. Chicken industry strategies for control of tumor virus infections. *Poult Sci.* 77:1213–1216.
331. Kumar, S., J.J. Buza, and S.C. Burgess. 2009. Genotype-dependent tumor regression in Marek's disease mediated at the level of tumor immunity. *Cancer Microenviron.* 2:23–31.
332. Kung, H.J., L. Xia, P. Brunovskis, D. Li, J.L. Liu, and L.F. Lee. 2001. Meq: an MDV-specific bZIP transactivator with transforming properties. *Curr Top Microbiol Immunol.* 255:245–260.
333. Lapen, R.F., and S.G. Kenzy. 1972. Distribution of gross cutaneous Marek's disease lesions. *Poult Sci.* 51:334–336.
334. Lawn, A.M., and L.N. Payne. 1979. Chronological study of ultrastructural changes in the peripheral nerves in Marek's disease. *Neuropathol Appl Neurobiol.* 5:485–497.
335. Le Galludec, H. 2008. Clinical application of diagnostics (PCR) in the management of Marek's disease: The ultimate goals. In: *Marek's Disease Symposium CP Group*. Chengdu, China, Fort Dodge Animal Health Asia Pacific.
336. Lee, L.E., R.L. Witter, S.M. Reddy, P. Wu, N. Yanagida, and S. Yoshida. 2003. Protection and synergism by recombinant fowl pox vaccines expressing multiple genes from Marek's disease virus. *Avian Dis.* 47:549–558.
337. Lee, L.F., X. Cui, Z. Cui, I. Gimeno, B. Lupiani, and S.M. Reddy. 2005. Characterization of a very virulent Marek's disease virus mutant expressing the pp38 protein from the serotype 1 vaccine strain CVI988/Rispens. *Virus Genes.* 31:73–80.
338. Lee, L.F., E.D. Kieff, S.L. Bachenheimer, B. Roizman, P.G. Spear, B.R. Burmester, and K. Nazerian. 1971. Size and composition of Marek's disease virus deoxyribonucleic acid. *J Virol.* 7:289–294.
339. Lee, L.F., K.S. Kreager, J. Arango, A. Paraguassu, B. Beckman, H. Zhang, A. Fadly, B. Lupiani, and S.M. Reddy. 2010. Comparative evaluation of vaccine efficacy of recombinant Marek's disease virus vaccine lacking Meq oncogene in commercial chickens. *Vaccine* 28:1294–1299.
340. Lee, L.F., X. Liu, and R.L. Witter. 1983. Monoclonal antibodies with specificity for three different serotypes of Marek's disease viruses in chickens. *J Immunol.* 130:1003–1006.
341. Lee, L.F., B. Lupiani, R.F. Silva, H.-J. Kung, and S.M. Reddy. 2008. Recombinant Marek's disease virus (MDV) lacking the Meq oncogene confers protection against challenge with a very virulent plus strain of MDV. *Vaccine.* 26:1887–1892.
342. Lee, L.F., K. Nazerian, R.L. Witter, S.S. Leinbach, and J.A. Boezi. 1978. A phosphonoacetate-resistant mutant of herpesvirus of turkeys. *J Natl Cancer Inst.* 60:1141–1146.
343. Lee, L.F., J.M. Sharma, K. Nazerian, and R.L. Witter. 1978. Suppression of mitogen-induced proliferation of normal spleen cells by macrophages from chickens inoculated with Marek's disease virus. *J Immunol.* 120:1554–1559.
344. Lee, L.F., P. Wu, D. Sui, D. Ren, J. Kamil, H.J. Kung, and R.L. Witter. 2000. The complete unique long sequence and the overall genomic organization of the GA strain of Marek's disease virus. *Proc Natl Acad Sci USA*. 97:6091–6096.
345. Lee, L.F., H. Zhang, M. Heidari, B. Lupiani, and S.M. Reddy. 2011. Evaluation of factors affecting vaccine efficacy of recombinant Marek's disease virus lacking the Meq oncogene in chickens. *Avian Dis.* 55:172–179.
346. Lee, S.I., K. Ohashi, T. Morimura, C. Sugimoto, and M. Onuma. 1999. Re-isolation of Marek's disease virus from T cell subsets of vaccinated and non-vaccinated chickens. *Arch Virol.* 144:45–54.
347. Lee, S.I., K. Ohashi, C. Sugimoto, and M. Onuma. 2001. Heparin inhibits plaque formation by cell-free Marek's disease viruses in vitro. *J Vet Med Sci.* 63:427–432.
348. Lee, S.I., M. Takagi, K. Ohashi, C. Sugimoto, and M. Onuma. 2000. Difference in the meq gene between oncogenic and attenuated strains of Marek's disease virus serotype 1. *J Vet Med Sci.* 62:287–292.
349. Lemiere, S., R. Fernandez, N. Pritchard, J. Cruz-Coy, F. Rojo, S.Y. Wong, A.L. Saint-Gerand, J.C. Gauthier, and F. Perozo. 2011. Concomitant turkey herpesvirus-infectious bursal disease vector vaccine and oil-adjuvanted inactivated Newcastle disease vaccine administration: consequences for vaccine intake and protection. *Avian Dis.* 55:642–649.
350. Lemiere, S., S.Y. Wong, A.L. Saint-Gerand, S. Goutebroze, and F.X. Le Gros. 2011. Compatibility of turkey herpesvirus-infectious bursal disease vector vaccine with Marek's disease Rispens vaccine injected into day-old pullets. *Avian Dis.* 55:113–118.
351. Lesnik, F., D. Chudy, J. Bogdan, O.J. Vrtiak, and M. Rudic. 1978. Testing the immunogenicity of the dermal antigen of Marek's disease virus. *Vet Med (Praha).* 23:421–430.
352. Lesnik, F., T. Paauer, O.J. Vrtiak, M. Danihel, A. Gdovinova, and M. Gergely. 1981. Transmission of Marek's disease to wild feathered game. *Vet Med (Praha).* 26:623–630.
353. Levy, A.M., S.C. Burgess, I. Davidson, G. Underwood, G. Leitner, and E.D. Heller. 2003. Interferon-containing supernatants increase Marek's disease herpesvirus genomes and gene transcription levels, but not virion replication *in vitro*. *Viral Immunol.* 16:501–509.
354. Levy, A.M., I. Davidson, S.C. Burgess, and E.D. Heller. 2003. Major histocompatibility complex class I is downregulated in Marek's disease virus infected chicken embryo fibroblasts and corrected by chicken interferon. *Comp. Immunol Microbiol Infect Dis.* 26:189–198.
355. Levy, A.M., I. Davidson, S.C. Burgess, G. Underwood, G. Leitner, and E.D. Heller. 2001. Quantifying the effect induced by native chicken interferon on the RB1B strain of Marek's disease virus. In: *Current Progress on Marek's Disease Research*. K.A. Schat, R.M. Morgan, M.S. Parcells, and J.L. Spencer, eds. American Association of Avian Pathologists, Kennett Square, PA. 237–239.
356. Levy, A.M., O. Gilad, L. Xia, Y. Izumiya, J. Choi, A. Tsalenko, Z. Yakhini, R. Witter, L. Lee, C.J. Cardona, and H.J. Kung. 2005. Marek's disease virus Meq transforms chicken cells via the v-Jun transcriptional cascade: A converging transforming pathway for avian oncoviruses. *Proc Natl Acad Sci USA*. 102:14831–14836.

357. Levy, A.M., Y. Izumiya, P. Brunovskis, L. Xia, M.S. Parcells, S.M. Reddy, L.F. Lee, H.W. Chen, and H.J. Kung. 2003. Characterization of the chromosomal binding sites and dimerization partners of the viral oncoprotein Meq in Marek's disease virus-transformed T cells. *J Virol.* 77:12841–12851.
358. Li, X., K.W. Jarosinski, and K.A. Schat. 2006. Expression of Marek's disease virus phosphorylated polypeptide pp38 produces splice variants and enhances metabolic activity. *Vet Microbiol.* 117:154–168.
359. Li, X., and K.A. Schat. 2004. Quail cell lines supporting replication of Marek's disease virus serotype 1 and 2 and herpesvirus of turkeys. *Avian Dis.* 48:803–812.
360. Li, Y., K. Reddy, S.M. Reid, W.J. Cox, I.H. Brown, P. Britton, V. Nair, and M. Iqbal. 2011. Recombinant herpesvirus of turkeys as a vector-based vaccine against highly pathogenic H7N1 avian influenza and Marek's disease. *Vaccine.* 29:8257–8266.
361. Li, Y., A. Sun, S. Su, P. Zhao, Z. Cui, and H. Zhu. 2011. Deletion of the Meq gene significantly decreases immunosuppression in chickens caused by pathogenic Marek's disease virus. *Virol J.* 8:2.
362. Lian, L., L.J. Qu, J.X. Zheng, C.J. Liu, Y.P. Zhang, Y.M. Chen, G.Y. Xu, and N. Yang. 2010. Expression profiles of genes within a subregion of chicken major histocompatibility complex B in spleen after Marek's disease virus infection. *Poult Sci.* 89:2123–2129.
363. Lin, J.A., H. Kodama, M. Onuma, and T. Mikami. 1991. The early pathogenesis in chicken inoculated with non-pathogenic serotype 2 Marek's disease virus. *J. Vet. Med. Sci.* 53:269–273.
364. Liu, H.C., H.H. Cheng, V. Tirunagaru, L. Sofer, and J. Burnside. 2001. A strategy to identify positional candidate genes conferring Marek's disease resistance by integrating DNA microarrays and genetic mapping. *Anim Genet.* 32:351–359.
365. Liu, H.C., H.J. Kung, J.E. Fulton, R.W. Morgan, and H.H. Cheng. 2001. Growth hormone interacts with the Marek's disease virus SORF2 protein and is associated with disease resistance in chicken. *Proc Natl Acad Sci USA*. 98:9203–9208.
366. Liu, H.C., E.J. Soderblom, and M.B. Goshe. 2006. A mass spectrometry-based proteomic approach to study Marek's disease virus gene expression. *J Virol Methods.* 135:66–75.
367. Liu, J.L., L.F. Lee, Y. Ye, Z. Qian, and H.J. Kung. 1997. Nucleolar and nuclear localization properties of a herpesvirus bZIP oncoprotein, MEQ. *J Virol*. 71:3188–3196.
368. Liu, J.L., Y. Ye, L.F. Lee, and H.J. Kung. 1998. Transforming potential of the herpesvirus oncoprotein MEQ: morphological transformation, serum-independent growth, and inhibition of apoptosis. *J Virol.* 72:388–395.
369. Liu, J.L., Y. Ye, Z. Qian, Y. Qian, D.J. Templeton, L.F. Lee, and H.J. Kung. 1999. Functional interactions between herpesvirus oncoprotein MEQ and cell cycle regulator CDK2. *J Virol.* 73:4208–4219.
370. Longenecker, B.M., F. Pazderka, J.S. Gavora, J.L. Spencer, and R.F. Ruth. 1976. Lymphoma induced by herpesvirus: Resistance associated with a major histocompatibility gene. *Immunogenetics* 3:401–407.
371. Luo, J., Y. Yu, H.M. Zhang, F. Tian, S. Chang, H.H. Cheng, and J. Song. 2011. Down-regulation of promoter methylation level of CD4 gene after MDV infection in MD-susceptible chicken line. *BMC Proc*. 5: Suppl 4:S7.
372. Lupiani, B., L.F. Lee, X. Cui, I. Gimeno, A. Anderson, R.F. Silva, R.L. Witter, H.J. Kung, and S.M. Reddy. 2004. Marek's disease virus-encoded Meq gene is involved in transformation of lymphocytes but is dispensable for replication. *Proc Natl Acad Sci USA*. 101:11815–11820.
373. Lupiani, B., L.F. Lee, and S.M. Reddy. 2001. Protein-coding content of the sequence of Marek's disease virus serotype 1. *Curr Top Microbiol Immunol.* 255:159–190.
374. Maas, H.J.L., H.W. Antonisse, V.D.A.J. Zypp, J.E. Groenendal, and G.L. Kok. 1981. The development of two white plymouth rock lines resistant to Marek's disease by breeding from survivors. *Avian Pathol.* 10:137–115.
375. Maas, H.J.L., B.H. Rispens, and J.E. Groenendal. 1974. Control of Marek's disease in the Netherlands: Large scale field trials with the avirulent cell-associated Marek's disease vaccine virus (strain CVI988). *Tijdschr Diergeneeskd.* 99:1273–1288.
376. Maas, H.J.L., A.J. van der Zijpp, J.E. Groenendal, and G.L. Kok. 1982. Evaluation of resistance to Marek's disease in three white plymouth rock lines and in two reciprocal crosses. *Avian Pathol.* 11:1–9.
377. MacEachern, S., W.M. Muir, S. Crosby, and H.H. Cheng. 2011. Genome-wide identification of allele-specific expression (ASE) in response to Marek's disease virus infection using next generation sequencing. *BMC Proc.* 5:S14.
378. Maotani, K., A. Kanamori, K. Ikuta, S. Ueda, S. Kato, and K. Hirai. 1986. Amplification of a tandem direct repeat within inverted repeats of Marek's disease virus DNA during serial in vitro passage. *J Virol.* 58:657–660.
379. Maray, T., M. Malkinson, and Y. Becker. 1988. RNA transcripts of Marek's disease virus (MDV) serotype 1 in infected and transformed cells. *Virus Genes.* 2:49–68.
380. Marek, J. 1907. Multiple Nervenentzuendung (Polyneuritis) bei Huehnern. *Dtsch Tierarztl Wochenschr.* 15:417–421.
381. Markowski-Grimsrud, C.J., and K.A. Schat. 2002. Cytotoxic T lymphocyte responses to Marek's disease herpesvirus-encoded glycoproteins. *Vet Immunol Immunopathol.* 90:133–144.
382. Markowski-Grimsrud, C.J., and K.A. Schat. 2003. Infection with chicken anemia virus impairs the generation of antigen-specific cytotoxic T lymphocytes. *Immunology.* 109: 283–294.
383. Martin, A., E.A. Dunnington, W.E. Briles, R.W. Briles, and P.B. Siegel. 1989. Marek's disease and major histocompatibility complex haplotypes in chickens selected for high or low antibody response. *Anim Genet.* 20:407–414.
384. McColl, K., B.W. Calnek, W.V. Harris, K.A. Schat, and L.F. Lee. 1987. Expression of a putative tumor-associated antigen on normal versus Marek's disease virus-transformed lymphocytes. *J Natl Cancer Inst.* 79:991–1000.
385. McKay, J.C. 1998. A poultry breeder's approach to avian neoplasia. *Avian Pathol.* 27:S74–S77.
386. Mikami, T., M. Onuma, T.T. Hayashi, M. Narita, and K. Okada. 1975. Pathogenic and serologic studies of Japanese quail infected with JM strain of Marek's disease herpesvirus. *J Natl Cancer Inst.* 54:607–614.
387. Miles, A.M., A.S. Anderson, E.L. Bernberg, J. Kent, J.K. Rosenberger, C.R. Pope, and R.W. Morgan. 1999. Comparison of two serotype 1 MDV isolates. *Acta Virol.* 43:102–105.
388. Miles, A.M., S.M. Reddy, and R.W. Morgan. 2001. Coinfection of specific-pathogen-free chickens with Marek's disease virus (MDV) and chicken infectious anemia virus: effect of MDV pathotype. *Avian Dis.* 45:9–18.
389. Minick, C.R., C.G. Fabricant, J. Fabricant, and M.M. Litrenta. 1979. Atheroarteriosclerosis induced by infection with a herpesvirus. *Am J Pathol.* 96:673–706.

390. Mohammadi, A., J.L. Spencer, M. Chan, and M. Ansari Lari. 2007. Antibody response of chickens to serotype 1, 2, or 3 Marek's disease vaccines based on ELISA with infected cells as antigen. *Avian Dis.* 51:982–985.
391. Moore, F.R., B.W. Calnek, and S.E. Bloom. 1994. Cytogenetic studies of cell lines derived from Marek's disease virus-induced local lesions. *Avian Dis.* 38:797–779.
392. Morgan, R., A. Anderson, E. Bernberg, S. Kamboj, E. Huang, G. Lagasse, G. Isaacs, M. Parcells, B.C. Meyers, P.J. Green, and J. Burnside. 2008. Sequence conservation and differential expression of Marek's disease virus microRNAs. *J Virol.* 82:12213–12220.
393. Morgan, R.W., and J. Burnside. 2011. Roles of avian herpesvirus microRNAs in infection, latency, and oncogenesis. *Biochim Biophys Acta.* 1809:654–659.
394. Morgan, R.W., L. Sofer, A.S. Anderson, E.L. Bernberg, J. Cui, and J. Burnside. 2001. Induction of host gene expression following infection of chicken embryo fibroblasts with oncogenic Marek's disease virus. *J Virol.* 75:533–539.
395. Morgan, R.W., Q. Xie, J.L. Cantello, A.M. Miles, E.L. Bernberg, J. Kent, and A. Anderson. 2001. Marek's disease virus latency. *Curr Top Microbiol Immunol.* 255:223–243.
396. Moriguchi, R., M. Oshima, F. Mori, I. Umezawa, and C. Itakura. 1989. Chronological change of feather pulp lesions during the course of Marek's disease virus-induced lymphoma formation in field chickens. In: *Advances in Marek's Disease Research*. S. Kato, T. Horiuchi, T. Mikami, and K. Hirai, eds. Japanese Association on Marek's Disease, Osaka, Japan. 338–343.
397. Morimura, T., M. Hattori, K. Ohashi, C. Sugimoto, and M. Onuma. 1995. Immunomodulation of peripheral T cells in chickens infected with Marek's disease virus: involvement in immunosuppression. *J Gen Virol.* 79:2979–2985.
398. Morimura, T., K. Ohashi, Y. Kon, M. Hattori, C. Sugimoto, and M. Onuma. 1996. Apoptosis and CD8-down-regulation in the thymus of chickens infected with Marek's disease virus. *Arch Virol.* 141:2243–2249.
399. Morimura, T., K. Ohashi, Y. Kon, M. Hattori, C. Sugimoto, and M. Onuma. 1997. Apoptosis in peripheral CD4+T cells and thymocytes by Marek's disease virus-infection. *Leukemia.* 11 S3:206–208.
400. Morissette, G., and L. Flamand. 2010. Herpesviruses and chromosomal integration. *J Virol.* 84:12100–12109.
401. Morrow, C., and F. Fehler. 2004. Marek's disease: a worldwide problem. In: *Marek's Disease: An Evolving Problem*. F. Davison and V. Nair, eds. Elsevier Academic Press, London. 49–61.
402. Murata, S., K.-S. Chang, S.-I. Lee, S. Konnai, M. Onuma, and K. Ohashi. 2007. Development of a nested polymerase chain reaction method to detect oncogenic Marek's disease virus from feather tips. *J Vet Diagn Invest.* 19:471–478.
403. Murata, S., K.S. Chang, Y. Yamamoto, T. Okada, S.I. Lee, S. Konnai, M. Onuma, Y. Osa, M. Asakawa, and K. Ohashi. 2007. Detection of the virulent Marek's disease virus genome from feather tips of wild geese in Japan and the Far East region of Russia. *Arch Virol.* 152:1523–1526.
404. Murata, S., Y. Hayashi, A. Kato, M. Isezaki, S. Takasaki, M. Onuma, Y. Osa, M. Asakawa, S. Konnai, and K. Ohashi. 2012. Surveillance of Marek's disease virus in migratory and sedentary birds in Hokkaido, Japan. *Vet J.* 192:538–540.
405. Murata, S., T. Okada, R. Kano, Y. Hayashi, T. Hashiguchi, M. Onuma, S. Konnai, and K. Ohashi. 2011. Analysis of transcriptional activities of the Meq proteins present in highly virulent Marek's disease virus strains, RB1B and Md5. *Virus Genes.* 43:66–71.
406. Mwangi, W.N., L.P. Smith, S.J. Baigent, R.K. Beal, V. Nair, and A.L. Smith. 2011. Clonal structure of rapid-onset MDV-driven CD4+ lymphomas and responding CD8+ T cells. *PLoS Pathog.* 7:e1001337.
407. Nair, V., and H.J. Kung. 2004. Marek's disease virus oncogenicity: molecular mechanisms. In: *Marek's Disease: An Evolving Problem*. F. Davison and V. Nair, eds. Elsevier Academic Press, London. 32–48.
408. Nair, V., and M. Zavolan. 2006. Virus-encoded microRNAs: novel regulators of gene expression. *Trends Microbiol.* 14: 169–175.
409. Naito, M., K. Nakajima, N. Iwa, K. Ono, I. Yoshida, T. Konobe, K. Ikuta, S. Ueda, S. Kato, and K. Hirai. 1986. Demonstration of a Marek's disease virus-specific antigen in tumour lesions of chickens with Marek's disease using monoclonal antibody against a virus phosphorylated protein. *Avian Pathol.* 15: 503–510.
410. Nakamura, K., M. Ito, K. Fujino, Y. Yamamoto, M. Mase, M.Yamada, H. Kobayashi, and T. Harada. 2010. Pathology and microbiology of dermal squamous cell carcinoma in young brown chickens reared on reused litter. *Avian Dis.* 54: 1120–1124.
411. Nazerian, K. 1987. An updated list of avian cell lines and transplantable tumours. *Avian Pathol.* 16:527–544.
412. Nazerian, K., A. Elmubarak and J.M. Sharma. 1982. Establishment of B-lymphoblastoid cell lines from Marek's disease virus-induced tumors in turkeys. *Int J Cancer.* 29:63–68.
413. Nazerian, K., L.F. Lee, R.L. Witter, and B.R. Burmester. 1970. Ultra-structural studies of a herpesvirus of turkeys antigenically related to Marek's disease virus. *Virology.* 43:442–452.
414. Nazerian, K., L.F. Lee, N. Yanagida, and R. Ogawa. 1992. Protection against Marek's disease by a fowlpox virus recombinant expressing the glycoprotein B of Marek's disease virus. *J Virol.* 66:1409–1413.
415. Nii, S., M. Yamada, M. Yoshida, Y. Arao, F. Uno, T. Ishikawa, M. Hayashi, K. Ono, and K. Hirai. 1989. Growth of MDV II in MDCC-MSB1-41C. In: *Advances in Marek's Disease Research*. S. Kato, T. Horiuchi, T. Mikami, and K. Hirai, eds. Japanese Association of Marek's Disease, Osaka, Japan. 197–203.
416. Niikura, M., T. Kim, H.D. Hunt, J. Burnside, R.W. Morgan, J.B. Dodgson, and H.H. Cheng. 2007. Marek's disease virus up-regulates major histocompatibility complex class II cell surface expression in infected cells. *Virology.* 359:212–219.
417. Niikura, M., H.-C. Liu, J.B. Dodgson, and H.H. Cheng. 2004. A comprehensive screen for chicken proteins that interact with proteins unique to virulent strains of Marek's disease virus. *Poult Sci.* 83:1117–1123.
418. Niikura, M., R.L. Witter, H.K. Jang, M. Ono, T. Mikami, and R.F. Silva. 1999. MDV glycoprotein D is expressed in the feather follicle epithelium of infected chickens. *Acta Virol.* 43:159–163.
419. Njaa, B.L., K.W. Jarosinski, and K.A. Schat. 2004. Identification of mitotically active macrophages in perivascular cuffs in chickens infected with vv+Marek's disease virus. Unpublished data.
420. Njenga, M.K., and C.A. Dangler. 1995. Endothelial MHC class II antigen expression and endarteritis associated with Marek's disease virus infection in chickens. *Vet Pathol.* 32:403–411.

421. Njenga, M.K., and C.A. Dangler. 1996. Intimal lipid accretion and elevated serum cholesterol in Marek's disease virus-inoculated chickens. *Vet Pathol.* 33:704–708.
422. Ohashi, K., T. Mikami, H. Kodama, and H. Izawa. 1987. Suppression of NK activity of spleen cells by chicken fetal antigen present on Marek's disease lymphoblastoid cell line cells. *Int J Cancer.* 40:378–382.
423. Ohashi, K., T. Morimura, M. Takagi, S.I. Lee, K.O. Cho, H. Takahashi, Y. Maeda, C. Sugimoto, and M. Onuma. 1999. Expression of bcl-2 and bcl-x genes in lymphocytes and tumor cell lines derived from MDV-infected chickens. *Acta Virol.* 43:128–132.
424. Ohashi, K., W. Zhou, P.H. O'Connell, and K.A. Schat. 1994. Characterization of a Marek's disease virus BamHI-L specific cDNa clone obtained from a Marek's disease lymphoblastoid cell line. *J Virol.* 68:1191–1195.
425. OIE. 2010. Marek's Disease. In: *Manual of Diagnostic Tests and Vaccines for Terrestrial Animals*. World Organization for Animal Health (OIE), Paris.
426. Okada, K., Y. Tanaka, K. Murakami, S. Chiba, T. Morimura, M. Hattori, M. Goryo, and M. Onuma. 1997. Phenotype analysis of lymphoid cells in Marek's disease of CD4+ or CD8+ T cell-deficient chickens: occurrence of double negative T cell turnout. *Avian Pathol.* 26:525–534.
427. Okazaki, W., H.G. Purchase, and B.R. Burmester. 1970. Protection against Marek's disease by vaccination with a herpesvirus of turkeys. *Avian Dis.* 14:413–429.
428. Omar, A.R., and K.A. Schat. 1997. Characterization of Marek's disease herpesvirus-specific cytotoxic T lymphocytes in chickens inoculated with a non-oncogenic vaccine strain of MDV. *Immunology.* 90:579–585.
429. Omar, A.R., and K.A. Schat. 1996. Syngeneic Marek's disease virus (MDV)-specific cell-mediated immune responses against immediate early, late, and unique MDV proteins. *Virology.* 222: 87–99.
430. Omar, A.R., K.A. Schat, L.F. Lee, and H.D. Hunt. 1998. Cytotoxic T lymphocyte response in chickens immunized with a recombinant fowlpox virus expressing Marek's disease herpesvirus glycoprotein B. *Vet Immunol Immunopathol.* 62:73–82.
431. Ono, K., M. Takashima, T. Ishikawa, M. Hayashi, T. Konobe, K. Ikuta, K. Nakajima, S. Ueda, S. Kato, K. Hirai, and I. Yoshida. 1985. Partial protection against Marek's disease in chickens immunized with glycoproteins gB purified from turkey-herpesvirus-infected cells by affinity chromatography coupled with monoclonal antibodies. *Avian Dis.* 29:533–539.
432. Ono, M., H.K. Jang, K. Maeda, Y. Kawaguchi, Y. Tohya, M. Niikura, and T. Mikami. 1996. Detection of Marek's disease virus serotype 1 (MDV1) glycoprotein D in MDV1-infected chick embryo fibroblasts. *J Vet Med Sci.* 58:777–780.
433. Ono, M., Y. Kawaguchi, K. Maeda, N. Kamiya, Y. Tohya, C. Kai, M. Niikura, and T. Mikami. 1994. Nucleotide sequence analysis of Marek's disease virus (MDV) serotype 2 homolog of MDV serotype 1 pp38, an antigen associated with transformed cells. *Virology.* 201:142–146.
434. Osterrieder, N., J.P. Kamil, D. Schumacher, B.K. Tischer, and S. Trapp. 2006. Marek's disease virus: from miasma to model. *Nat Rev Micro.* 4:283–294.
435. Osterrieder, N., and D. Vautherot. 2004. The genome content of Marek's disease-like viruses. In: *Marek's Disease: An Evolving Problem*. F. Davison and V. Nair, eds. Elsevier Academic Press, Oxford. 17–31.
436. Ottiger, H.P. 2010. Development, standardization and assessment of PCR systems for purity testing of avian viral vaccines. *Biologicals.* 38:381–388.
437. Pandiri, A.K., A.L. Cortes, L.F. Lee, and I.M. Gimeno. 2008. Marek's disease virus infection in the eye: chronological study of the lesions, virus replication, and vaccine-induced protection. *Avian Dis.* 52:572–580.
438. Pappenheimer, A.M., L.C. Dunn, and V. Cone. 1929. Studies on fowl paralysis (neurolymphomatosis gallinarum). I. Clinical features and pathology. *J Exp Med.* 49:63–86.
439. Pappenheimer, A.M., L.C. Dunn, and V. Cone. 1926. A study of fowl paralysis (neuro-lymphomatosis gallinarum). *Bulletin Storrs Agricultural Experiment Station.* 143:187–289.
440. Parcells, M., J. Burnside, and R. Morgan. 2012. Marek's disease virus-induced T cell lymphomas. In: *Cancer Associated Viruses—Current Research*. E.S. Robertson, ed. Springer Science, Heidelberg. 307–335.
441. Parcells, M.S., A.S. Anderson, J.L. Cantello, and R.W. Morgan. 1994. Characterization of Marek's disease virus insertion and deletion mutants that lack US1 (ICP22 homolog), US10, and/or US2 and neighboring short-component open reading frames. *J Virol.* 68:8239–8253.
442. Parcells, M.S., A.S. Anderson, and R.W. Morgan. 1995. Retention of oncogenicity by a Marek's disease virus mutant lacking six unique short region genes. *J Virol.* 69: 7888–7898.
443. Parcells, M.S., R.L. Dienglewicz, A.S. Anderson, and R.W. Morgan. 1999. Recombinant Marek's disease virus (MDV)-derived lymphoblastoid cell lines: regulation of a marker gene within the context of the MDV genome. *J Virol.* 73: 1362–1373.
444. Parcells, M.S., S.F. Lin, R.L. Dienglewicz, V. Majerciak, D.R. Robinson, H.C. Chen, Z. Wu, G.R. Dubyak, P. Brunovskis, H.D. Hunt, L.F. Lee, and H.J. Kung. 2001. Marek's disease virus (MDV) encodes an interleukin-8 homolog (vIL-8): characterization of the vIL-8 protein and a vIL-8 deletion mutant MDV. *J Virol.* 75:5159–5173.
445. Parker, M.A., and L.W. Schierman. 1983. Suppression of humoral immunity in chickens prevents transient paralysis caused by a herpesvirus. *J Immunol.* 130:2000–2001.
446. Parvizi, P., K. Andrzejewski, L.R. Read, S. Behboudi, and S. Sharif. 2010. Expression profiling of genes associated with regulatory functions of T cell subsets in Marek's disease virus-infected chickens. *Avian Pathol.* 39:367–373.
447. Parvizi, P., L.R. Read, M.F. Abdul-Careem, C. Lusty, and S. Sharif. 2009. Cytokine gene expression in splenic CD4(+) and CD8(+) T cell subsets of chickens infected with Marek's disease virus. *Viral Immunol.* 22:31–38.
448. Parvizi, P., L.R. Read, M.F. Abdul-Careem, A.J. Sarson, C. Lusty, M. Lambourne, N. Thanthrige-Don, S.C. Burgess, and S. Sharif. 2009. Cytokine gene expression in splenic CD4+ and CD8+ T cell subsets of genetically resistant and susceptible chickens infected with Marek's disease virus. *Vet Immunol Immunopathol.* 132:209–217.
449. Pattison, M. 1985. Control of Marek's disease by the poultry industry: Practical considerations. In: *Marek's Disease, Scientific Basis and Methods of Control*. L.N. Payne, ed. Martinus Nijhoff, Boston, MA. 341–349.
450. Paul, P.S., J.H. Sautter, and B.S. Pomeroy. 1977. Susceptibility of turkeys to Georgia strain of Marek's disease virus of chicken origin. *Am J Vet Res.* 38:1653–1656.

451. Payne, L.N. 2004. Pathological responses to infection. In: *Marek's Disease: An Evolving Problem*. F. Davison and V. Nair, eds. Elsevier Academic Press, London. 78–97.
452. Payne, L.N. 1985. Pathology. In: *Marek's Disease, Scientific Basis and Methods of Control*. L.N. Payne, ed. Martinus Nijhoff, Boston, MA. 43–75.
453. Payne, L.N., and P.M. Biggs. 1967. Studies on Marek's disease. II. Pathogenesis. *J Natl Cancer Inst*. 39:281–302.
454. Payne, L.N., J.A. Frazier, and P.C. Powell. 1976. Pathogenesis of Marek's disease. *Int Rev Exp Pathol.* 16:59–154.
455. Payne, L.N., K. Howes, M. Rennie, J.M. Bumstead, and A.W. Kidd. 1981. Use of an agar culture technique for establishing lymphoid cell lines from Marek's disease lymphomas. *Int J Cancer.* 28:757–766.
456. Payne, L.N., and M. Rennie. 1973. Pathogenesis of Marek's disease in chicks with and without maternal antibody. *J Natl Cancer Inst.* 51:1559–1573.
457. Payne, L.N., and M. Rennie. 1976. Sequential changes in the numbers of B and T lymphocytes and other leukocytes in the blood in Marek's disease. *Int J Cancer.* 18:510–520.
458. Payne, L.N., and J. Roszkowski. 1972. The presence of immunologically uncommitted bursa and thymus dependent lymphoid cells in the lymphomas of Marek's disease. *Avian Pathol.* 1:27–34.
459. Peng, F., J. Donovan, S. Specter, A. Tanaka, and M. Nonoyama. 1993. Prolonged proliferation of primary chicken embryo fibroblasts transfected with cDNAs from the BamHI-H gene family of Marek's disease virus. *Int J Oncology.* 3:587-591.
460. Peng, F., S. Specter, A. Tanaka, and M. Nonoyama. 1994. A 7 kDa protein encoded by the BamHI-H gene family of Marek's disease virus is produced in lytically and latently infected cells. *Int J Oncology.* 4:799–802.
461. Peng, Q., and Y. Shirazi. 1996. Characterization of the protein product encoded by a splicing variant of the Marek's disease virus Eco-Q gene (Meq). *Virology.* 226:77–82.
462. Peng, Q., and Y. Shirazi. 1996. Isolation and characterization of Marek's disease virus (MDV) cDNAs from a MDV-transformed lymphoblastoid cell line: identification of an open reading frame antisense to the MDV Eco-Q protein (Meq). *Virology.* 221:368–374.
463. Peng, Q., M. Zeng, Z.A. Bhuiyan, E. Ubukata, A. Tanaka, M. Nonoyama, and Y. Shirazi. 1995. Isolation and characterization of Marek's disease virus (MDV) cDNAs mapping to the BamHI-I2, BamHI-Q2, and BamHI-L fragments of the MDV genome from lymphoblastoid cells transformed and persistently infected with MDV. *Virology.* 213:590–599.
464. Pennycott, T.W., G. Duncan, and K. Venugopal. 2003. Marek's disease, candidiasis and megabacteriosis in a flock of chickens (*Gallus gallus domesticus*) and Japanese quail (*Coturnix japonica*). *Vet Rec.* 153:293–297.
465. Pennycott, T.W., and K. Venugopal. 2002. Outbreak of Marek's disease in a flock of turkeys in Scotland. *Vet Rec.* 150:277–279.
466. Pepose, J.S., J.G. Stevens, M.L. Cook, and P.W. Lampert. 1981. Marek's disease as a model for the Landry-Guillain-Barr Syndrome: Latent viral infection in nonneuronal cells is accompanied by specific immune responses to peripheral nerve and myelin. *Am J Pathol.* 103:309–332.
467. Petherbridge, L., K. Howes, S.J. Baigent, M.A. Sacco, S. Evans, N. Osterrieder, and V. Nair. 2003. Replication-competent bacterial artificial chromosomes of Marek's disease virus: Novel tools for generation of molecularly defined herpesvirus vaccines. *J Virol.* 77:8712–8718.
468. Petherbridge, L., H. Xu, Y. Zhao, L.P. Smith, J. Simpson, S. Baigent, and V. Nair. 2009. Cloning of Gallid herpesvirus 3 (Marek's disease virus serotype-2) genome as infectious bacterial artificial chromosomes for analysis of viral gene functions. *J Virol Methods.* 158:11–17.
469. Phillips, P.A., and P.M. Biggs. 1972. Course of infection in tissues of susceptible chickens after exposure to strains of Marek's disease virus and turkey herpesvirus. *J Natl Cancer Inst.* 49: 1367–1137.
470. Piepenbrink, M.S., X. Li, P.H. O'Connell, and K.A. Schat. 2009. Marek's disease virus phosphorylated polypeptide pp38 alters transcription rates of mitochondrial electron transport and oxidative phosphorylation genes. *Virus Genes.* 39:102–112.
471. Pol, J.M., G.L. Kok, H.L. Oei, and G.F. de Boer. 1986. Pathogenicity studies with plaque-purified preparations of Marek's disease virus strain CVI-988. *Avian Dis.* 30:271–275.
472. Pol, J.M.A., G.L. Kok, and G.F. de Boer. 1985. Studies on the oncogenic properties of various Marek's disease virus strains. In: Proceedings of the International Symposium on Marek's Disease. B.W. Calnek and J.L. Spencer, eds. American Association of Avian Pathologists, Kennett Square, PA. 469–479.
473. Powell, P.C., and T.F. Davison. 1986. Induction of Marek's disease in vaccinated chickens by treatment with betamethasone or corticosterone. *Israel J Vet Med.* 42:73–78.
474. Powell, P.C., K.J. Hartley, B.M. Mustill, and M. Rennie. 1983. The occurrence of chicken foetal antigen after infection with Marek's disease virus in three strains of chicken. *Oncodev Biol Med.* 4:261–271.
475. Powell, P.C., K. Howes, A.M. Lawn, B.M. Mustill, L.N. Payne, M. Rennie, and M.A. Thompson. 1984. Marek's disease in turkeys: The induction of lesions and the establishment of lymphoid cell lines. *Avian Pathol.* 13:201–214.
476. Powell, P.C., L.N. Payne, J.A. Frazier, and M. Rennie. 1974. T lymphoblastoid cell lines from Marek's disease lymphomas. *Nature.* 251:79–80.
477. Powell, P.C., and M. Rennie. 1984. The expression of Marek's disease tumor-associated surface antigen in various avian species. *Avian Pathol.* 13:345–349.
478. Pradhan, H.K., G.C. Mohanty, W.Y. Lee, L. Kaul, and J.M. Kataria. 1988. Immune complex-mediated glomerulopathy in Marek's disease. *Vet Immunol Immunopathol.* 19:165–171.
479. Pradhan, H.K., G.C. Mohanty, and A. Mukit. 1985. Marek's disease in Japanese quails (*Coturnix coturnix japonica*): A study of natural cases. *Avian Dis.* 29:575–558.
480. Prasad, L.B.M., and P.B. Spradbrow. 1977. Multiplication of turkey herpes virus and Marek's disease virus in chick embryo skin cell cultures. *J Comp Pathol.* 87:515–520.
481. Prasad, L.M.B., and P.B. Spradbrow. 1980. Ultrastructure and infectivity of tissue from normal and immunodepressed chickens inoculated with turkey herpesvirus *J Comp Pathol*. 90: 47–56.
482. Pratt, W.D., J. Cantello, R.W. Morgan and K.A. Schat. 1994. Enhanced expression of the Marek's disease virus-specific phosphoproteins after stable transfection of MSB-1 cells with the Marek's disease virus homolog of ICP4. *Virology.* 201: 132–136.
483. Pratt, W.D., R. Morgan, and K.A. Schat. 1992. Cell-mediated cytolysis of lymphoblastoid cells expressing Marek's disease virus-specific phosphoproteins. *Vet. Microbiol.* 33:93–99.
484. Pratt, W.D., R.W. Morgan, and K.A. Schat. 1992. Characterization of reticuloendotheliosis virus-transformed

avian T-lymphoblastoid cell lines infected with Marek's disease virus. *J Virol.* 66:7239–7244.
485. Prineas, J.W., and R.G. Wright. 1972. The fine structure of peripheral nerve lesions in a virus-induced demyelinating disease in fowl (Marek's disease). *Lab Invest.* 26:548–557.
486. Proudfoot, F.G., and J.R. Aitken. 1969. The effect of diet on mortality attributed to Marek's disease among leghorn genotype. *Poult Sci.* 48:1457–1459.
487. Purchase, H.G. 1985. Clinical disease and its economic impact. In: *Marek's Disease, Scientific Basis and Methods of Control*. L.N. Payne, ed. Martinus Nijhoff, Boston, MA. 17–24.
488. Purchase, H.G. 1972. Recent advances in the knowledge of Marek's disease. *Adv Vet Sci Comp Med.* 16:223–258.
489. Purchase, H.G., B.R. Burmester, and C.H. Cunningham. 1971. Responses of cell cultures from various avian species to Marek's disease virus and herpesvirus of turkeys. *Am J Vet Res.* 32: 1811–1823.
490. Purchase, H.G., W. Okazaki, and B.R. Burmester. 1972. Long-term field trials with the herpesvirus of turkeys vaccine against Marek's disease. *Avian Dis.* 16:57–71.
491. Purchase, H.G., and R.L. Witter. 1986. Public health concerns from human exposure to oncogenic avian herpesviruses. *JAVMA.* 189:1430–1436.
492. Qian, Z., P. Brunovskis, L. Lee, P.K. Vogt, and H.J. Kung. 1996. Novel DNA binding specificities of a putative herpesvirus bZIP oncoprotein. *J Virol.* 70:7161–7170.
493. Qian, Z., P. Brunovskis, F. Rauscher, 3rd, L. Lee, and H.J. Kung. 1995. Transactivation activity of Meq, a Marek's disease herpesvirus bZIP protein persistently expressed in latently infected transformed T cells. *J Virol.* 69:4037–4044.
494. Quéré, P. 1992. Suppression mediated *in vitro* by Marek's disease virus-transformed T-lymphoblastoid cell lines: Effect on lymphoproliferation. *Vet Immunol Immunopathol.* 32:149–164.
495. Quéré, P., C. Rivas, K. Ester, R. Novak, and W.L. Ragland. 2005. Abundance of IFN-alpha and IFN-gamma mRNA in blood of resistant and susceptible chickens infected with Marek's disease virus (MDV) or vaccinated with turkey herpesvirus; and MDV inhibition of subsequent induction of IFN gene transcription. *Arch Virol.* 150:507–519.
496. Ramachandra, R.N., R. Raghavan, and B.S. Keshavamurthy. 1978. Propagation of Marek's disease virus in chicken tracheal explants. *Indian J Anim Sci.* 48:525–528.
497. Ramaroson, M.F., J. Ruby, M.B. Goshe, and H.C. Liu. 2008. Changes in the *Gallus gallus* proteome induced by Marek's disease virus. *J Proteome Res.* 7:4346–4358.
498. Rauw, F., V. Palya, S. Van Borm, S. Welby, T. Tatar-Kis, Y. Gardin, K.M. Dorsey, M.M. Aly, M.K. Hassan, M.A. Soliman, B. Lambrecht, and T. van den Berg. 2011. Further evidence of antigenic drift and protective efficacy afforded by a recombinant HVT-H5 vaccine against challenge with two antigenically divergent Egyptian clade 2.2.1 HPAI H5N1 strains. *Vaccine.* 29:2590–2600.
499. Reddy, S.M., B. Lupiani, I.M. Gimeno, R.F. Silva, L.F. Lee, and R.L. Witter. 2002. Rescue of a pathogenic Marek's disease virus with overlapping cosmid DNAs: use of a pp38 mutant to validate the technology for the study of gene function. *Proc Natl Acad Sci USA*. 99:7054–7059.
500. Reddy, S.M., R.L. Witter, and I. Gimeno. 2000. Development of a quantitative-competitive polymerase chain reaction assay for serotype 1 Marek's disease virus. *Avian Dis.* 44:770–775.
501. Reinke, A.W., G. Grigoryan, and A.E. Keating. 2010. Identification of bZIP interaction partners of viral proteins HBZ, MEQ, BZLF1, and K-bZIP using coiled-coil arrays. *Biochemistry.* 49:1985–1997.
502. Ren, D., L.F. Lee, and P.M. Coussens. 1994. Identification and characterization of Marek's disease virus genes homologous to ICP27 and glycoprotein K of herpes simplex virus-1. *Virology.* 204:242–250.
503. Ren, D., L.F. Lee, and P.M. Coussens. 1996. Regulatory function of the Marek's disease virus ICP27 gene product. In: *Current Research on Marek's Disease*. R.F. Silva, H.H. Cheng, P.M. Coussens, L.F. Lee, and L.F. Velicer, eds. American Association of Avian Pathologists, Kennett Square, PA. 170–175.
504. Rennie, M., P.C. Powell, and B.M. Mustill. 1980. The effect of bursectomy on vaccination against Marek's disease with the herpesvirus of turkeys. *Avian Pathol.* 9:557–566.
505. Renz, K.G., A. Islam, B.F. Cheetham, and S.W. Walkden-Brown. 2006. Absolute quantification using real-time polymerase chain reaction of Marek's disease virus serotype 2 in field dust samples, feather tips and spleens. *J Virol Methods.* 135:186–191.
506. Rhiza, H.-J., and B. Bauer. 1984. Persistence of viral DNA in Marek's disease virus-transformed lymphoblastoid cell lines. In: *Latent Herpesvirus Infections in Veterinary Medicine*. G. Wittman, R.M. Gaskell, and H.-J. Rhiza, eds. Martinus Nijhoff, Boston. 481–488.
507. Rispens, B.H., H. van Vloten, N. Mastenbroek, H.J. Maas, and K.A. Schat. 1972. Control of Marek's disease in the Netherlands. I. Isolation of an avirulent Marek's disease virus (strain CVI 988) and its use in laboratory vaccination trials. *Avian Dis*. 16:108–125.
508. Rispens, B.H., H. van Vloten, N. Mastenbroek, J.L. Maas, and K.A. Schat. 1972. Control of Marek's disease in the Netherlands. II. Field trials on vaccination with an avirulent strain (CVI 988) of Marek's disease virus. *Avian Dis*. 16:126–138.
509. Robinson, C.M., H.D. Hunt, H.H. Cheng, and M.E. Delany. 2010. Chromosomal integration of an avian oncogenic herpesvirus reveals telomeric preferences and evidence for lymphoma clonality. *Herpesviridae.* 1:1–5.
510. Ross, L.J.N. 1980. Mechanism of protection conferred by HVT. In: *Resistance and Immunity to Marek's Disease*. P.M. Biggs, ed. Commission of the European Communities, Luxembourg. 289–297.
511. Ross, L.J.N. 1985. Molecular biology of the virus. In: *Marek's Disease, Scientific Basis and Methods of Control*. L.N. Payne, ed. Martinus Nijhoff, Boston, MA. 113–150.
512. Ross, L.J.N., W. Delorbe, H.E. Varmus, J.M. Bishop, and M. Brahic. 1981. Persistence and expression of Marek's disease virus DNA in tumour cells and peripheral nerves studied by *in situ* hybridization. *J Gen Virol.* 57:285–296.
513. Ross, N., M.M. Binns, M.J. Sanderson, and K.A. Schat. 1993. Alterations in DNA sequence and RNA transcription of the Bam HI-H fragment accompany attenuation of oncogenic Marek's disease herpesvirus. *Virus Genes.* 7:33–51.
514. Ross, N., G. O'sullivan, C. Rothwell, G. Smith, S.C. Burgess, M.Rennie, L.F. Lee, and T.F. Davison. 1997. Marek's disease virus EcoRI-Q gene (meq) and a small RNA antisense to ICP4 are abundantly expressed in CD4+ cells and cells carrying a novel lymphoid marker, AV37, in Marek's disease lymphomas. *J Gen Virol*. 78 2191–2198.
515. Ross, N.L. 1999. T cell transformation by Marek's disease virus. *Trends Microbiol.* 7:22–29.

516. Sakaguchi, M., K. Sonoda, K. Matsuo, G.S. Zhu, and K. Hirai. 1997. Insertion of tandem direct repeats consisting of avian leukosis virus LTR sequences into the inverted repeat region of Marek's disease virus type 1 DNA. *Virus Genes.* 14:157–162.
517. Sandri-Goldin, R.M. 2011. The many roles of the highly interactive HSV protein ICP27, a key regulator of infection. *Future Microbiol.* 6:1261–1277.
518. Santin, E.R., C.E. Shamblin, J.T. Prigge, V. Arumugaswami, R.L. Dienglewicz, and M.S. Parcells. 2006. Examination of the effect of a naturally occurring mutation in glycoprotein L on Marek's disease virus pathogenesis. *Avian Dis.* 50:96–103.
519. Sarson, A.J., M.F. Abdul-Careem, L.R. Read, J.T. Brisbin, and S. Sharif. 2008. Expression of cytotoxicity-associated genes in Marek's disease virus-infected chickens. *Viral Immunol.* 21: 267–272.
520. Sarson, A.J., P. Parvizi, D. Lepp, M. Quinton, and S. Sharif. 2008. Transcriptional analysis of host responses to Marek's disease virus infection in genetically resistant and susceptible chickens. *Animal Gen.* 39:232–240.
521. Schat, K.A. 1985. Characteristics of the virus. In: *Marek's Disease, Scientific Basis and Methods of Control*. L.N. Payne, ed. Martinus Nijhoff, Boston, MA. 77–112.
522. Schat, K.A. 2003. Chicken infectious anemia. In: *Diseases of Poultry*, 11th ed. Y.M. Saif, H.J. Barnes, A.M. Fadly, J.R. Glisson, L.R. McDougald, and D.E. Swayne, eds. Iowa State Press, Ames, IA. 182–202.
523. Schat, K.A. 2005. Isolation of Marek's disease virus: revisited. *Avian Pathol.* 34:91–95.
524. Schat, K.A. 2004. Marek's disease immunosuppression. In: *Marek's Disease: An Evolving Problem*. F. Davison and V. Nair, eds. Academic Press, London. 142–155.
525. Schat, K.A. 1997. Prevention of Marek's disease. *World Poultry.* S15–17.
526. Schat, K.A. 1980. Role of the spleen in the pathogenesis of Marek's disease. *Avian Pathol.* 10:171–182.
527. Schat, K.A. 2012. Unpublished data.
528. Schat, K.A. 1979. Unpublished data.
529. Schat, K.A., and E. Baranowski. 2007. Animal vaccination and the evolution of viral pathogens. *Rev Sci Tech Off Int Epiz.* 26:327–338.
530. Schat, K.A., A. Buckmaster, and L.J.N. Ross. 1989. Partial transcription map of Marek's disease herpesvirus in lytically infected cells and lymphoblastoid cell lines. *Int J Cancer.* 44:101–109.
531. Schat, K.A., and B.W. Calnek. 1978. Characterization of an apparently nononcogenic Marek's disease virus. *J Natl Cancer Inst.* 60:1075–1082.
532. Schat, K.A., B.W. Calnek, and J. Fabricant. 1982. Characterisation of two highly oncogenic strains of Marek's disease virus. *Avian Pathol.* 11:593–605.
533. Schat, K.A., B.W. Calnek, and J. Fabricant. 1981. Influence of the bursa of Fabricius on the pathogenesis of Marek's disease. *Infect Immun.* 31:199–207.
534. Schat, K.A., B.W. Calnek, J. Fabricant, and H. Abplanalp. 1981. Influence of oncogenicity of Marek' disease virus on evaluation of genetic resistance. *Poult Sci.* 60:2559–2566.
535. Schat, K.A., B.W. Calnek, J. Fabricant, and D.L. Graham. 1985. Pathogenesis of infection with attenuated Marek's disease virus strains. *Avian Pathol.* 14:127–146.
536. Schat, K.A., C.-L.H. Chen, B.W. Calnek, and D. Char. 1991. Transformation of T-lymphocyte subsets by Marek's disease herpesvirus. *J Virol.* 65:1408–1413.
537. Schat, K.A., C.-L.H. Chen, W.R. Shek, and B.W. Calnek. 1982. Surface antigens on Marek's disease lymphoblastoid tumor cell lines. *J Natl Cancer Inst.* 69:715–720.
538. Schat, K.A., B.J. Hooft van Iddekinge, H. Boerrigter, P.H. O'Connell, and G. Koch. 1998. Open reading frame L1 of Marek's disease herpesvirus is not essential for *in vitro* and *in vivo* virus replication and establishment of latency. *J Gen Virol.* 79:841–849.
539. Schat, K.A., and C.J. Markowski-Grimsrud. 2001. Immune responses to Marek's disease virus infection. *Curr Top Microbiol Immunol.* 255:91–120.
540. Schat, K.A., and V. Nair. 2008. Marek's disease. In: *Diseases of Poultry*, 12th ed. Y.M. Saif, A.M. Fadly, J.R. Glisson, L.R. McDougald, L.K. Nolan, and D.E. Swayne, eds. Blackwell Publishing, Ames. 452–514.
541. Schat, K.A., R.D. Schultz, and B.W. Calnek. 1978. Marek's disease: Effect of virus pathogenicity and genetic susceptibility on response of peripheral blood lymphocytes to concanavalin-A. In: *Advances Comparative Leukosis Research*. P. Bentvelzen, J. Hilgers, and D.S. Yohn, eds. Elsevier, Amsterdam, The Netherlands. 183–185.
542. Schat, K.A., and M.A. Skinner. 2008. Avian immunosuppressive diseases and immune evasion. In: *Avian Immunology*. F. Davison, B. Kaspers, and K.A. Schat, eds. AP Academic Press, London. 299–322.
543. Schat, K.A., and V.L. van Santen. 2013. Chicken infectious anemia. In: *Diseases of Poultry*, 13th ed. D.E. Swayne, J.R. Glisson, L.R. McDougald, V. Nair, L.K. Nolan, and D.L. Suarez, eds. Wiley-Blackwell, Ames, IA. 248–275.
544. Schat, K.A., and Z. Xing. 2000. Specific and nonspecific immune responses to Marek's disease virus. *Dev Comp Immunol.* 24:201–221.
545. Schierman, L.W., and O.J. Fletcher. 1980. Genetic control of Marek's disease virus-induced transient paralysis: Association with the major histocompatibility complex. In: *Resistance and Immunity to Marek's Disease*. P.M. Biggs, ed. Commission European Communities, Luxembourg. 429–442.
546. Schmahl, W., G. Hoffmann-Fezer and R. Hoffmann. 1975. [Pathogenesis of neural lesions in Marek's disease. I. Allergic skin reaction against myelin of the peripheral nerves (author's transl)]. *Z Immunitatsforsch Exp Klin Immunol*. 150:175–183.
547. Scholten, R., L.A.T. Hilgers, S.H.M. Jeurissen, and M.W. Weststrate. 1990. Detection of Marek's disease virus antigen in chicken by a novel immunoassay. *J Virol Methods.* 27:221–226.
548. Schumacher, D., B.K. Tischer, W. Fuchs, and N. Osterrieder. 2000. Reconstitution of Marek's disease virus serotype 1 (MDV-1) from DNA cloned as a bacterial artificial chromosome and characterization of a glycoprotein B-negative MDV-1 mutant. *J Virol.* 74:11088-11098.
549. Schumacher, D., B.K. Tischer, S.M. Reddy, and N. Osterrieder. 2001. Glycoproteins E and I of Marek's disease virus serotype 1 are essential for virus growth in cultured cells. *J Virol.* 75: 11307–11318.
550. Schumacher, D., B.K. Tischer, J.P. Teifke, K. Wink, and N. Osterrieder. 2002. Generation of a permanent cell line that supports efficient growth of Marek's disease virus (MDV) by constitutive expression of MDV glycoprotein E. *J Gen Virol.* 83:1987–1992.
551. Schumacher, D., B.K. Tischer, S. Trapp, and N. Osterrieder. 2005. The protein encoded by the US3 orthologue of Marek's disease virus is required for efficient de-envelopment of perinuclear

virions and involved in actin stress fiber breakdown. *J Virol.* 79: 3987–3997.
552. Seimon, T.A., D. McAloose, B. Raphael, K.S. Honkavuori, T. Chang, D.L. Hirschberg, and W.I. Lipkin. 2012. A novel herpesvirus in 3 species of pheasants: mountain peacock pheasant (Polyplectron inopinatum), Malayan peacock pheasant (Polyplectron malacense), and Congo peafowl (Afropavo congensis). *Vet Pathol*. 49:482–491.
553. Shack, L.A., J.J. Buza, and S.C. Burgess. 2008. The neoplastically transformed (CD30hi) Marek's disease lymphoma cell phenotype most closely resembles T-regulatory cells. *Cancer Immunol Immunother.* 57:1253–1262.
554. Shamblin, C.E., N. Greene, V. Arumugaswami, R.L. Dienglewicz, and M.S. Parcells. 2004. Comparative analysis of Marek's disease virus (MDV) glycoprotein-, lytic antigen pp38- and transformation antigen Meq-encoding genes: association of meq mutations with MDVs of high virulence. *Vet Microbiol.* 102:147–167.
555. Sharma, J.M. 2008. The avian immune system. In: *Diseases of Poultry*. 12th ed, Y.M. Saif, A.M. Fadly, J.R. Glisson, L.R. McDougald, L.K. Nolan and D.E. Swayne, eds. Blackwell Publishing, Ames, IA. 47–58.
556. Sharma, J.M. 1987. Delayed replication of Marek's disease virus following *in ovo* inoculation during late stages of embryonal development. *Avian Dis.* 31:570–576.
557. Sharma, J.M. 1987. Embryo vaccination of chickens with turkey herpesvirus: characteristics of the target cell of early viral replication in embryonic lung. *Avian Pathol.* 16:567–579.
558. Sharma, J.M. 1989. *In situ* production of interferon in tissues of chickens exposed as embryos to turkey herpesvirus and Marek's disease virus. *Am J Vet Res.* 50:882–886.
559. Sharma, J.M. 1980. *In vitro* suppression of T cell mitogenic response and tumor cell proliferation by spleen macrophages from normal chickens. *Infect Immun.* 28:914–922.
560. Sharma, J.M. 2008. Marek's disease. In: *A Laboratory Manual for the Isolation and Identification of Avian Pathogens*, 5th ed. L. Dufour-Zavala, D.E. Swayne, J.R. Glisson, J.E. Pearson, W.M. Reed, M.W. Jackwood, and P.R. Woolcock, eds. American Association of Avian Pathologists, Jacksonville, FL. 99–105.
561. Sharma, J.M. 1981. Natural killer cell activity in chickens exposed to Marek's disease virus: inhibition of activity in susceptible chickens and enhancement of activity in resistant and vaccinated chickens. *Avian Dis.* 25:882–893.
562. Sharma, J.M., and B.R. Burmester. 1982. Resistance to Marek's disease at hatching in chickens vaccinated as embryos with the turkey herpesvirus. *Avian Dis.* 26:134–149.
563. Sharma, J.M., and B.D. Coulson. 1979. Presence of natural killer cells in specific-pathogen-free chickens. *J Natl Cancer Inst.* 63:527–531.
564. Sharma, J.M., L.F. Lee, and P.S. Wakenell. 1984. Comparative viral, immunologic, and pathologic responses of chickens inoculated with herpesvirus of turkeys as embryos or a hatch. *Am J Vet Res.* 45:1619–1623.
565. Sharma, J.M., L.F. Lee, and R.L. Witter. 1980. Effect of neonatal thymectomy on pathogenesis of herpesvirus of turkeys in chickens. *Am J Vet Res.* 40:761–764.
566. Sharma, J.M., R.L. Witter, and B.R. Burmester. 1973. Pathogenesis of Marek's disease in old chickens: lesion regression as the basis for age-related resistance. *Infect Immun.* 8: 715–724.
567. Sharma, J.M., R.L. Witter, and H.G. Purchase. 1975. Absence of age-resistance in neonatally thymectomised chickens as evidence for cell-mediated immune surveillance in Marek's disease. *Nature.* 253:477–479.
568. Shek, W.R., B.W. Calnek, K.A. Schat, and C.-L.H. Chen. 1983. Characterization of Marek's disease virus-infected lymphocytes: Discrimination between cytolytically and latently infected cells. *J Natl Cancer Inst.* 70:485–491.
569. Shigekane, H., Y. Kawaguchi, M. Shirakata, M. Sakaguchi, and K. Hirai. 1999. The bi-directional transcriptional promoters for the latency-relating transcripts of the pp38/pp24 mRNAs and the 1.8 kb-mRNA in the long inverted repeats of Marek's disease virus serotype 1 DNA are regulated by common promoter-specific enhancers. *Arch Virol*. 144:1893–1907.
570. Shkreli, M., G. Dambrine, D. Soubieux, E. Kut, and D. Rasschaert. 2007. Involvement of the oncoprotein c-Myc in viral telomerase RNA gene regulation during Marek's disease virus-induced lymphomagenesis. *J Virol.* 81:4848–4857.
571. Siccardi, F.J., and B.R. Burmester. 1970. The differential diagnosis of lymphoid leukosis and Marek's disease. *USDA Tech Bull*. 1412, Washington, DC.
572. Silva, R.F. 1992. Differentiation of pathogenic and nonpathogenic serotype 1 Marek's disease viruses (MDVs) by the polymerase chain reaction amplification of the tandem direct repeats within the MDV genome. *Avian Dis.* 36:521–528.
573. Silva, R.F., J.R. Dunn, H.H. Cheng, and M. Niikura. 2010. A MEQ-deleted Marek's disease virus cloned as a bacterial artificial chromosome is a highly efficacious vaccine. *Avian Dis.* 54:862–869.
574. Silva, R.F., and I. Gimeno. 2007. Oncogenic Marek's disease viruses lacking the 132 base pair repeats can still be attenuated by serial *in vitro* cell culture passages. *Virus Genes.* 34:87–90.
575. Silva, R.F., L.F. Lee, and G.F. Kutish. 2001. The genomic structure of Marek's disease virus. *Curr Top Microbiol Immunol.* 255:143–158.
576. Silva, R.F., S.M. Reddy, and B. Lupiani. 2004. Expansion of a unique region in the Marek's disease virus genome occurs concomitantly with attenuation but is not sufficient to cause attenuation. *J Virol.* 78:733–740.
577. Silva, R.F., and R.L. Witter. 1985. Genomic expansion of Marek's disease virus DNA is associated with serial in vitro passage. *J Virol.* 54:690–696.
578. Silver, S., A. Tanaka, and M. Nonoyama. 1979. Transcription of the Marek's disease virus genome in a nonproductive chicken lymphoblastoid cell line. *Virology.* 93:127–133.
579. Singh, S.M., S.J. Baigent, L.J. Petherbridge, L.P. Smith, and V.K. Nair. 2010. Comparative efficacy of BAC-derived recombinant SB-1 vaccine and the parent wild type strain in preventing replication, shedding and disease induced by virulent Marek's disease virus. *Res Vet Sci.* 89:140–145.
580. Smith, G.D., V. Zelnik, and L.J.N. Ross. 1995. Gene organization in herpesvirus of turkeys: Identification of a novel open reading frame in the long unique region and a truncated homolog of pp38 in the internal repeat. *Virology.* 207:205–216.
581. Smith, J., J.-R. Sadeyen, I.R. Paton, P.M. Hocking, N. Salmon, M. Fife, V. Nair, D.W. Burt, and P. Kaiser. 2011. Systems analysis of immune responses in Marek's disease virus-infected chickens identifies a gene involved in susceptibility and highlights a possible novel pathogenicity mechanism. *J Virol.* 85: 11146–11158.
582. Smith, M.W., and B.W. Calnek. 1974. Comparative features of low-virulence and high-virulence Marek's disease virus infections. *Avian Pathol.* 3:229–246.

583. Smith, M.W., and B.W. Calnek. 1974. High virulence Marek's disease virus infection in chickens previously infected with low-virulence virus. *J Natl Cancer Inst.* 52:1595–1603.
584. Smith, T.W., D.M. Albert, N. Robinson, B.W. Calnek, and O. Schwabe. 1974. Ocular manifestations of Marek's disease. *Invest Ophthalmol.* 13:586–592.
585. Solomon, J.J., and R.L. Witter. 1973. Absence of Marek's disease in chicks hatched from eggs containing blood or meat spots. *Avian Dis.* 17:141–144.
586. Solomon, J.J., R.L. Witter, H.A. Stone, and L.R. Champion. 1970. Evidence against embryo transmission of Marek's disease virus. *Avian Dis.* 14:752–762.
587. Spatz, S.J. 2010. Accumulation of attenuating mutations in varying proportions within a high passage very virulent plus strain of Gallid herpesvirus type 2. *Virus Res.* 149:135–142.
588. Spatz, S.J., L. Petherbridge, Y. Zhao, and V. Nair. 2007. Comparative full-length sequence analysis of oncogenic and vaccine (Rispens) strains of Marek's disease virus. *J Gen Virol.* 88:1080–1096.
589. Spatz, S.J., C. Rue, D. Schumacher, and N. Osterrieder. 2008. Clustering of mutations within the inverted repeat regions of a serially passaged attenuated gallid herpesvirus type 2 strain. *Virus Genes.* 37:69–80.
590. Spatz, S.J., and K.A. Schat. 2011. Comparative genomic sequence analysis of the Marek's disease vaccine strain SB-1. *Virus Genes.* 42:331–338.
591. Spatz, S.J., L.P. Smith, S.J. Baigent, L. Petherbridge, and V. Nair. 2011. Genotypic characterization of two bacterial artificial chromosome clones derived from a single DNA source of the very virulent gallid herpesvirus-2 strain C12/130. *J Gen Virol.* 92:1500–1507.
592. Spencer, J.L., and B.W. Calnek. 1970. Marek's disease: Application of immunofluorescence for detection of antigen and antibody. *Am J Vet Res.* 31:345–358.
593. Spencer, J.L., J.S. Gavora, A.A. Grunder, A. Robertson, and G.W. Speckmann. 1974. Immunization against Marek's disease: influence of strain of chickens, maternal antibody, and type of vaccine. *Avian Dis.* 18:33–44.
594. Spencer, J.L., F. Gilka, J.S. Gavora, R.J. Hampson, and D.J. Caldwell. 1992. Studies with a Marek's disease virus that caused blindness and high mortality in vaccinated flocks. In: Proceedings 4th International Symposium on Marek's Disease. G. de Boer and S.H.M. Jeurissen, eds. Ponsen and Looijen, Wageningen, Amsterdam, The Netherlands. 199–201.
595. St. Hill, C.A., and J.M. Sharma. 1999. Response of embryonic chicken lymphocytes to in ovo exposure to lymphotropic viruses. *Am J Vet Res.* 60:937–941.
596. St Hill, C.A., R.F. Silva, and J.M. Sharma. 2004. Detection and localization of avian alphaherpesviruses in embryonic tissues following in ovo exposure. *Virus Res.* 100:243–248.
597. Stephens, E.A., R.L. Witter, K. Nazerian, and J.M. Sharma. 1980. Development and characterization of a Marek's disease transplantable tumor in inbred line 72 chickens homozygous at the major (B) histocompatibility locus. *Avian Dis.* 24:358–374.
598. Suchodolski, P.F., Y. Izumiya, B. Lupiani, D.K. Ajithdoss, O. Gilad, L.F. Lee, H.J. Kung, and S.M. Reddy. 2009. Homodimerization of Marek's disease virus-encoded Meq protein is not sufficient for transformation of lymphocytes in chickens. *J Virol.* 83:859–869.
599. Suchodolski, P.F., Y. Izumiya, B. Lupiani, D.K. Ajithdoss, L.F. Lee, H.J. Kung, and S.M. Reddy. 2010. Both homo and heterodimers of Marek's disease virus encoded Meq protein contribute to transformation of lymphocytes in chickens. *Virology.* 399:312–321.
600. Sun, A., Y. Li, J. Wang, S. Su, H. Chen, H. Zhu, J. Ding, and Z. Cui. 2010. Deletion of 1.8-kb mRNA of Marek's disease virus decreases its replication ability but not oncogenicity. *Virol. J.* 7:294.
601. Sun, A.J., X.Y. Xu, L. Petherbridge, Y.G. Zhao, V. Nair, and Z.Z. Cui. 2010. Functional evaluation of the role of reticuloendotheliosis virus long terminal repeat (LTR) integrated into the genome of a field strain of Marek's disease virus. *Virology.* 397:270–276.
602. Swayne, D.E., J.R. Beck, and N. Kinney. 2000. Failure of a recombinant fowl poxvirus vaccine containing an avian influenza hemagglutinin gene to provide consistent protection against influenza in chickens preimmunized with a fowl pox vaccine. *Avian Dis.* 44:132–137.
603. Swayne, D.E., O.J. Fletcher, and L.W. Schierman. 1989. Marek's disease virus-induced transient paralysis in chickens. 1. Time course association between clinical signs and histological brain lesions. *Avian Pathol.* 18:385–396.
604. Swayne, D.E., O.J. Fletcher, and L.W. Schierman. 1988. Marek's disease virus-induced transient paralysis in chickens: Alterations in brain density. *Acta Neuropathol.* 76:287–291.
605. Swayne, D.E., O.J. Fletcher, and L.W. Schierman. 1989. Marek's disease virus-induced transient paralysis in chickens: Demonstration of vasogenic brain oedema by an immunohistochemical method. *J Comp Pathol.* 101:451–462.
606. Tahiri-Alaoui, A., D. Matsuda, H. Xu, P. Panagiotis, L. Burman, L.S. Lambeth, L. Petherbridge, W. James, V. Mauro and V. Nair. 2009. The 5′ leader of the mRNA encoding the Marek's disease virus serotype 1 pp14 protein contains an intronic internal ribosome entry site with allosteric properties. *J Virol.* 83:12769–12778.
607. Tahiri-Alaoui, A., L.P. Smith, S. Baigent, L. Kgosana, L.J. Petherbridge, L.S. Lambeth, W. James, and V. Nair. 2009. Identification of an intercistronic internal ribosome entry site in a Marek's disease virus immediate-early gene. *J Virol.* 83:5846–5853.
608. Takagi, M., K. Ohashi, T. Morimura, C. Sugimoto, and M. Onuma. 1998. Analysis of tumor suppressor gene p53 in chicken lymphoblastoid tumor cell lines and field tumors. *J Vet Med Sci.* 60:923–929.
609. Takagi, M., K. Ohashi, T. Morimura, C. Sugimoto, and M. Onuma. 2006. The presence of the p53 transcripts with truncated open reading frames in Marek's disease tumor-derived cell lines. *Leukemia Res.* 30:987–992.
610. Tan, X., P. Brunovskis, and L.F. Velicer. 2001. Transcriptional analysis of Marek's disease virus glycoprotein D, I, and E genes: gD expression is undetectable in cell culture. *J Virol.* 75: 2067–2075.
611. Tanaka, A., S. Silver, and M. Nonoyama. 1978. Biochemical evidence of the nonintegrated status of Marek's disease virus DNA in virus-transformed lymphoblastoid cells of chickens. *Virology.* 88:19–24.
612. Tarpey, I., P.J. Davis, P. Sondermeijer, C. van Geffen, I. Verstegen, V.E. Schijns, J. Kolodsick, and R. Sundick. 2007. Expression of chicken interleukin-2 by turkey herpesvirus increases the immune response against Marek's disease virus but fails to increase protection against virulent challenge. *Avian Pathol.* 36:69–74.

613. Tavlarides-Hontz, P., P.M. Kumar, J.R. Amortegui, N. Osterrieder, and M.S. Parcells. 2009. A deletion within glycoprotein L of Marek's disease virus (MDV) field isolates correlates with a decrease in bivalent MDV vaccine efficacy in contact-exposed chickens. *Avian Dis.* 53:287–296.
614. Thanthrige-Don, N., L.R. Read, M.F. Abdul-Careem, H. Mohammadi, A.I. Mallick, and S. Sharif. 2010. Marek's disease virus influences the expression of genes associated with IFN-gamma-inducible MHC class II expression. *Viral Immunol.* 23:227–232.
615. Theis, G.A., R.A. McBride, and L.W. Schierman. 1975. Depression of *in vitro* responsiveness to phytohemagglutinin in spleen cells cultured from chickens with Marek's disease. *J Immunol.* 115:848–853.
616. Theis, G.A., L.W. Schierman and R.A. McBride. 1974. Transplantation of a Marek's disease lymphoma in syngeneic chickens. *J Immunol.* 113:1710–1715.
617. Thornton, D.H. 1985. Quality control and standardization of vaccines. In: *Marek's Disease, Scientific Basis and Methods of Control*. L.N. Payne, ed. Martinus Nijhoff, Boston, MA. 267–291.
618. Thurston, T.J., R.A. Hess, H.K. Adldinger, R.F. Solorzano, and H.V. Biellier. 1975. Ultrastructural studies of semen abnormalities and herpesvirus associated with cultured testis cells from domestic turkeys. *J Reprod Fertil.* 45:507–514.
619. Tian, F., J. Luo, H. Zhang, S. Chang, and J. Song. 2012. MiRNA expression signatures induced by Marek's disease virus infection in chickens. *Genomics.* 99:152–159.
620. Tischer, B.K., and N. Osterrieder. 2010. Herpesviruses–A zoonotic threat? *Vet Microbiol.* 140:266–270.
621. Tischer, B.K., D. Schumacher, M. Beer, J. Beyer, J.P. Teifke, K. Osterrieder, K. Wink, V. Zelnik, F. Fehler, and N. Osterrieder. 2002. A DNA vaccine containing an infectious Marek's disease virus genome can confer protection against tumorigenic Marek's disease in chickens. *J Gen Virol.* 83:2367–2376.
622. Tischer, B.K., D. Schumacher, D. Chabanne-Vautherot, V. Zelnik, J.-F. Vautherot, and N. Osterrieder. 2005. High-level expression of Marek's disease virus glycoprotein C is detrimental to virus growth in vitro. *J Virol.* 79:5889–5899.
623. Tischer, B.K., D. Schumacher, M. Messerle, M. Wagner, and N. Osterrieder. 2002. The products of the UL10 (gM) and the UL49.5 genes of Marek's disease virus serotype 1 are essential for virus growth in cultured cells. *J Gen Virol*. 83:997–1003.
624. Tomikawa, T., K. Ohashi, and M. Onuma. 2001. Incidence of Marek's disease virus infection of a white-fronted goose (*Anser albifrons*) at Lake Miyajima-numa, Hokkaido. *Zoo Wildlife News*. 13:28–29.
625. Trapp, S., M.S. Parcells, J.P. Kamil, D. Schumacher, B.K. Tischer, P.M. Kumar, V.K. Nair, and N. Osterrieder. 2006. A virus-encoded telomerase RNA promotes malignant T cell lymphomagenesis. *J Exp Med.* 203:1307–1317.
626. Tulman, E.R., C.L. Afonso, Z. Lu, L. Zsak, D.L. Rock, and G.F. Kutish. 2000. The genome of a very virulent Marek's disease virus. *J Virol.* 74:7980–7988.
627. Tunnicliffe, R.B., G.M. Hautbergue, P. Kalra, B.R. Jackson, A. Whitehouse, S.A. Wilson, and A.P. Golovanov. 2011. Structural basis for the recognition of cellular mRNA export factor REF by herpes viral proteins HSV-1 ICP27 and HVS ORF57. *PLoS Pathog.* 7:e1001244.
628. Vallejo, R.L., L.D. Bacon, H.C. Liu, R.L. Witter, M.A. Groenen, J. Hillel, and H.H. Cheng. 1998. Genetic mapping of quantitative trait loci affecting susceptibility to Marek's disease virus induced tumors in F2 intercross chickens. *Genetics.* 148: 349–360.
629. Venugopal, K., A.P. Bland, L.J.N. Ross, and L.N. Payne. 1996. Pathogenicity of an unusual highly virulent Marek's disease virus isolated in the United Kingdom. In: *Current Research on Marek's Disease*, R.F. Silva, H.H. Cheng, P.M. Coussens, L.F. Lee, and L.F. Velicer, eds. American Association of Avian Pathologists, Kennett Square, PA. 119–124.
630. Verweij, M.C., A.D. Lipińska, D. Koppers-Lalic, W.F. van Leeuwen, J.I. Cohen, P.R. Kinchington, I. Messaoudi, K. Bieńkowska-Szewczyk, M.E. Ressing, F.A.M. Rijsewijk, and E.J.H.J. Wiertz. 2011. The capacity of UL49.5 proteins to inhibit TAP is widely distributed among members of the genus Varicellovirus. *J Virol*. 85:2351–2363.
631. Vielitz, E., and H. Landgraf. 1986. Protection against Marek's disease with different vaccines, determination of PD50 and duration of vaccinal immunity. *Dtsch Tierarztl Wochenschr.* 93:53–55.
632. Voelckel, K., E. Bertram, I. Gimeno, U. Neumann, and E.F. Kaleta. 1999. Evidence for Marek's disease in turkeys in Germany: detection of MDV-1 using the polymerase chain reaction. *Acta Virol.* 43:143–147.
633. Volpini, L.M., B.W. Calnek, M.J. Sekellick, and P.I. Marcus. 1995. Stages of Marek's disease virus latency defined by variable sensitivity to interferon modulation of viral antigen expression. *Vet Microbiol.* 47:99–109.
634. Volpini, L.M., B.W. Calnek, B. Sneath, M.J. Sekellick, and P.I. Marcus. 1996. Interferon modulation of Marek's disease virus genome expression in chicken cell lines. *Avian Dis.* 40:78–87.
635. von Bülow, V. 1971. Diagnosis and certain biological properties of the virus of Marek's disease. *Am J Vet Res.* 32:1275–1288.
636. von Bülow, V. 1977. Further characterisation of the CVI 988 strain of Marek's disease virus. *Avian Pathol.* 6:395–403.
637. von Bülow, V., and Biggs. 1975. Precipitating antigens associated with Marek's disease viruses and a herpesvirus of turkeys. *Avian Pathol.* 4:147–162.
638. von Bülow, V., and P.M. Biggs. 1975. Differentiation between strains of Marek's disease virus and turkey herpesvirus by immunofluorescence assays. *Avian Pathol.* 4:133–146.
639. von Bülow, V., R. Rudolph, and B. Fuchs. 1986. Erhöhte Pathogenität des Erregers der aviären infektiösen Anämia bei Hühnerküken (CAA) bei simultaner Infektion mit Virus der Marekschen Krankheit (MDV), Bursitisvirus (IBDV) oder Reticuloendotheliosevirus (REV). *Zentralbl Veterinarmed. [B]* 33:93–116.
640. Waidner, L.A., R.W. Morgan, A.S. Anderson, E.L. Bernberg, S. Kamboj, M.T. Garcia, S.M. Riblet, M. Ouyang, G.K. Isaacs, M. Markis, B.C. Meyers, P.J. Green, and J. Burnside. 2009. MicroRNAs of Gallid and Meleagrid herpesviruses show generally conserved genomic locations and are virus-specific. *Virology.* 388:128–136.
641. Wakenell, P.S., T. Bryan, J. Schaeffer, A. Avakian, C. Williams, and C. Whitfill. 2002. Effect of *in ovo* vaccine delivery route on herpesvirus of turkeys/SB-1 efficacy and viremia. *Avian Dis.* 46:274–280.
642. Wakenell, P.S., P. O'Connell, C. Blackmore, S.P. Mondal, and K.A. Schat. 2010. Role of Marek's disease herpesvirus in the induction of tumours in Japanese quail (*Coturnix coturnix japonica*) by methylcholanthrene. *Avian Pathol.* 39:183–188.

643. Wang, X., X. Chi, and M. Wang. 2011. Structural characteristics and antiviral activity of multiple peptides derived from MDV glycoproteins B and H. *Virol J.* 8:190.
644. Weli, S.C., and M. Tryland. 2011. Avipoxviruses: infection biology and their use as vaccine vectors. *Virol J.* 8:49.
645. Williams, C.J., and A.S. Zedek. 2010. Comparative field evaluations of in ovo applied technology. *Poult Sci.* 89:189–193.
646. Wilson, M.R., and P.M. Coussens. 1991. Purification and characterization of infectious Marek's disease virus genomes using pulsed field electrophoresis. *Virology.* 185:673–680.
647. Wilson, M.R., R.A. Southwick, J.T. Pulaski, V.L. Tieber, Y. Hong, and P.M. Coussens. 1994. Molecular analysis of the glycoprotein C-negative phenotype of attenuated Marek's disease virus. *Virology.* 199:393–402.
648. Witter, R.L. 1995. Attenuation of lymphoid leukosis enhancement by serotype 2 Marek's disease virus. *Avian Pathol.* 24: 665–678.
649. Witter, R.L. 1998. The changing landscape of Marek's disease. *Avian Pathol.* 27:S46–S53.
650. Witter, R.L. 1983. Characteristics of Marek's disease viruses isolated from vaccinated commercial chicken flocks: Association of viral pathotype with lymphoma frequency. *Avian Dis.* 27: 113–132.
651. Witter, R.L. 1997. Increased virulence of Marek's disease virus field isolates. *Avian Dis.* 41:149–163.
652. Witter, R.L. 1992. Influence of serotype and virus strain on synergism between Marek's disease vaccine viruses. *Avian Pathol.* 21:601–614.
653. Witter, R.L. 2001. Marek's disease vaccines—past, present and future (Chicken vs virus—a battle of the centuries). In: *Current Progress on Marek's Disease Research*. K.A. Schat, R.W. Morgan, M.S. Parcells, and J.L. Spencer, eds. American Association of Avian Pathologists, Kennett Square, PA. 1–9.
654. Witter, R.L. 2005. Marek's disease: The continuing struggle between pathogen and host. *Vet J.* 170:149-150.
655. Witter, R.L. 1987. New serotype 2 and attenuated serotype 1 Marek's disease vaccine viruses: Comparative efficacy. *Avian Dis.* 31:752–765.
656. Witter, R.L. 1995. Personal communication.
657. Witter, R.L. 1982. Protection by attenuated and polyvalent vaccines against highly virulent strains of Marek's Disease virus. *Avian Pathol.* 11:49–62.
658. Witter, R.L. 2001. Protective efficacy of Marek's disease vaccines. *Curr Top Microbiol Immunol.* 255:57–90.
659. Witter, R.L. 1972. Turkey herpesvirus: lack of oncogenicity for turkeys. *Avian Dis.* 16:666–670.
660. Witter, R.L. 1989. Very virulent Marek's disease viruses: Importance and control. *World's Poult Sci. J.* 45:60–65.
661. Witter, R.L., and L.D. Bacon. 1995. A naturally occurring neuropathy of chickens not associated with Marek's disease. In: 132th Annual Meeting of the American Veterinary Medical Association. 140.
662. Witter, R.L., G.H. Burgoyne and B.R. Burmester. 1968. Survival of Marek's disease agent in litter and droppings. *Avian Dis.* 12:522–530.
663. Witter, R.L., and B.R. Burmester. 1979. Differential effect of maternal antibodies on efficacy of cellular and cell-free Marek's disease vaccines. *Avian Pathol.* 8:145–156.
664. Witter, R.L., B.W. Calnek, C. Buscaglia, I.M. Gimeno and K.A. Schat. 2005. Classification of Marek's disease viruses according to pathotype: philosophy and methodology. *Avian Pathol.* 34:75–90.
665. Witter, R.L., and I. Gimeno. 2006. Susceptibility of adult chickens, with and without prior vaccination, to challenge with Marek's disease virus. *Avian Dis.* 50:354–365.
666. Witter, R.L., I.M. Gimeno, A.R. Pandiri and A.M. Fadly. 2010. Tumor diagnosis manual: The differential diagnosis of lymphoid and myeloid tumors in the chicken. American Association of Avian Pathologists, Jacksonville, FL.
667. Witter, R.L., I.M. Gimeno, W.M. Reed and L.D. Bacon. 1999. An acute form of transient paralysis induced by highly virulent strains of Marek's disease virus. *Avian Dis.* 43:704–720.
668. Witter, R.L., and K.S. Kreager. 2004. Serotype 1 viruses modified by backpassage or insertional mutagenesis: Approaching the threshold of vaccine efficacy in Marek's disease. *Avian Dis.* 48:768–782.
669. Witter, R.L., and L.F. Lee. 1984. Polyvalent Marek's disease vaccines: Safety, efficacy and protective synergism in chickens with maternal antibodies. *Avian Pathol.* 13:75–92.
670. Witter, R.L., L.F. Lee, L.D. Bacon and E.J. Smith. 1979. Depression of vaccinal immunity to Marek's disease by infection with reticuloendotheliosis virus. *Infect Immun.* 26:90–98.
671. Witter, R.L., D. Li, D. Jones, L.F. Lee and H.J. Kung. 1997. Retroviral insertional mutagenesis of a herpesvirus: a Marek's disease virus mutant attenuated for oncogenicity but not for immunosuppression or in vivo replication. *Avian Dis.* 41:407–421.
672. Witter, R.L., J.I. Moulthrop Jr., G.H. Burgoyne and H.C. Connell. 1970. Studies on the epidemiology of Marek's disease herpesvirus in broiler flocks. *Avian Dis.* 14:255–267.
673. Witter, R.L., K. Nazerian, H.G. Purchase and G.H. Burgoyne. 1970. Isolation from turkeys of a cell-associated herpesvirus antigenically related to Marek's disease virus. *Am J Vet Res.* 31:525–538.
674. Witter, R.L., and L. Offenbecker. 1979. Nonprotective and temperature-sensitive variants of Marek's disease vaccine viruses. J. Natl Cancer Inst. 62:143–151.
675. Witter, R.L., J.M. Sharma and A.M. Fadly. 1980. Pathogenicity of variant Marek's disease virus isolants in vaccinated and unvaccinated chickens. *Avian Dis.* 24:210–232.
676. Witter, R.L., J.M. Sharma, L.F. Lee, H.M. Opitz and C.W. Henry. 1984. Field trials to test the efficacy of polyvalent Marek's disease vaccines in broilers. *Avian Dis.* 28:44–60.
677. Witter, R.L., J.M. Sharma and L. Offenbecker. 1976. Turkey herpesvirus infection in chickens: Induction of lymphoproliferative lesions and characterization of vaccinal immunity against Marek's disease. *Avian Dis.* 20:676–692.
678. Witter, R.L., R.F. Silva and L.F. Lee. 1987. New serotype 2 and attenuated serotype 1 Marek's disease vaccine viruses: selected biological and molecular characteristics. *Avian Dis.* 31:829–840.
679. Witter, R.L., and J.J. Solomon. 1971. Epidemiology of a herpesvirus of turkeys: Possible sources and spread of infection in turkey flocks. *Infect Immun.* 4:356–361.
680. Witter, R.L., and J.J. Solomon. 1972. Experimental infection of turkeys and chickens with a herpesvirus of turkeys (HVT). *Avian Dis.* 16:34–44.
681. Witter, R.L., J.J. Solomon and G.H. Burgoyne. 1969. Cell culture techniques for primary isolation of Marek's disease-associated herpesvirus. *Avian Dis.* 13:101–118.
682. Witter, R.L., J.J. Solomon, L.R. Champion and K. Nazerian. 1971. Long term studies of Marek's disease infection in individual chickens. *Avian Dis.* 15:346–365.

683. Witter, R.L., J.J. Solomon and J.M. Sharma. 1974. Response of turkeys to infection with virulent Marek's disease viruses of turkey and chicken origins. *Am J Vet Res.* 35:1325–1332.
684. Witter, R.L., E.A. Stephens, J.M. Sharma and K. Nazerian. 1975. Demonstration of a tumor-associated surface antigen in Marek's disease. *J. Immunol.* 115:177–183.
685. Woźniakowski, G.J., E. Samorek-Salamonowicz and W. Kozdruń. 2011. Rapid detection of Marek's disease virus in feather follicles by loop-mediated amplification (LAMP). *Avian Dis.* 55:462–467.
686. Wu, C., J. Gan, Q. Jin, C. Chen, P. Liang, Y. Wu, X. Liu, L. Ma, and F. Davison. 2009. Revaccination with Marek's disease vaccines induces productive infection and superior immunity. *Clin Vaccine Immunol.* 16:184–193.
687. Xie, Q., A.S. Anderson, and R.W. Morgan. 1996. Marek's disease virus (MDV) ICP4, pp38, and meq genes are involved in the maintenance of transformation of MDCC-MSB1 MDV-transformed lymphoblastoid cells. *J Virol.* 70:1125–1131.
688. Xing, Z., and K.A. Schat. 2000. Expression of cytokine genes in Marek's disease virus-infected chickens and chicken embryo fibroblast cultures. *Immunology.* 100:70–76.
689. Xing, Z., and K.A. Schat. 2000. Inhibitory effects of nitric oxide and gamma interferon on *in vitro* and *in vivo* replication of Marek's disease virus. *J Virol.* 74:3605–3612.
690. Xu, M., H. Zhang, L. Lee, H. Gao, S. Sharif, R.F. Silva, and M.Heidari. 2011. Gene expression profiling in rMd5- and rMd5deltameq-infected chickens. *Avian Dis.* 55:358–367.
691. Xu, S., N. Yonash, R.L. Vallejo, and H.H. Cheng. 1998. Mapping quantitative trait loci for binary traits using a heterogeneous residual variance model: an application to Marek's disease susceptibility in chickens. *Genetica.* 104:171–178.
692. Yachida, S., T. Kondo, K. Hirai, H. Izawa, and T. Mikami. 1986. Establishment of a variant type of turkey herpesvirus which releases cell-free virus into the culture medium in large quantities. *Arch Virol.* 91:183–192.
693. Yamaguchi, T., S.L. Kaplan, P. Wakenell, and K.A. Schat. 2000. Transactivation of latent Marek's disease herpesvirus genes in QT35, a quail fibroblast cell line, by herpesvirus of turkeys. *J Virol.* 74:10176–10186.
694. Yang, Q.L., H. Chen, and P. Wei. 2011. Marek's disease virus can infect chicken brain microglia and promote the transcription of toll-like receptor 15 and 1LB genes [Article in Chinese]. *Bing Du Xue Bao.* 27:18–25.
695. Yao, Y., Y. Zhao, L.P. Smith, C.H. Lawrie, N.J. Saunders, M. Watson, and V. Nair. 2009. Differential expression of microRNAs in Marek's disease virus-transformed T-lymphoma cell lines. *J Gen Virol.* 90:1551–1559.
696. Yao, Y., Y. Zhao, L.P. Smith, M. Watson, and V. Nair. 2009. Novel microRNAs (miRNAs) encoded by herpesvirus of turkeys: evidence of miRNA evolution by duplication. *J Virol.* 83:6969–6973.
697. Yao, Y., Y. Zhao, H. Xu, L.P. Smith, C.H. Lawrie, A. Sewer, M. Zavolan, and V. Nair. 2007. Marek's disease virus type 2 (MDV-2)-encoded microRNAs show no sequence conservation to those encoded by MDV-1. *J Virol.* 81:7164–7170.
698. Yao, Y., Y. Zhao, H. Xu, L.P. Smith, C.H. Lawrie, M. Watson, and V. Nair. 2008. MicroRNA profile of Marek's disease virus-transformed T cell line MSB-1: Predominance of virus-encoded microRNAs. *J Virol.* 82:4007–4015.
699. Yu, Y., J. Luo, A. Mitra, S. Chang, F. Tian, H. Zhang, P. Yuan, H. Zhou, and J. Song. 2011. Temporal transcriptome changes induced by MDV in Marek's disease-resistant and -susceptible inbred chickens. *BMC Genomics.* 12:501.
700. Yuasa, N. 1983. Propagation and infectivity titration of the GIFU-1 strain of chicken anemia agent in a cell line (MDCC-MSB1) derived from Marek's disease lymphoma. *Natl Inst Anim Hlth Q.* 23:13–20.
701. Yunis, R., K.W. Jarosinski, and K.A. Schat. 2004. Association between rate of viral genome replication and virulence of Marek's disease herpesvirus strains. *Virology.* 328:142–150.
702. Zander, D.V. 1959. Experiences with epidemic tremor control. In: Proceedings of the 8th Annual Western Poultry Disease Conference. Davis, CA. 18–23.
703. Zander, D.V., R.W. Hill, R.G. Raymond, R.K. Balch, R.W. Mitchell, and J.W. Dunsing. 1972. The use of blood from selected chickens as an immunizing agent for Marek's disease. *Avian Dis.* 16:163–178.
704. Zelnik, V. 2004. Diagnosis of Marek's disease. In: *Marek's Disease: An Evolving Problem*. F. Davison and V. Nair, eds. Elsevier Academic Press, Oxford. 157–167.
705. Zelnik, V. 2003. Marek's disease virus research in the post-sequencing era: new tools for the study of gene functions and virus-host interactions. *Avian Pathol.* 32:323–334.
706. Zelnik, V., O. Harlin, F. Fehler, B. Kaspers, T.W. Gobel, V.K. Nair, and N. Osterrieder. 2004. An enzyme-linked immunosorbent assay (ELISA) for detection of Marek's disease virus-specific antibodies and its application in an experimental vaccine trial. *J Vet Med B Infect Dis Vet Public Health.* 51:61–67.
707. Zhang, Y., and J.M. Sharma. 2001. Early posthatch protection against Marek's disease in chickens vaccinated *in ovo* with a CVI988 serotype 1 vaccine. *Avian Dis.* 45:639–645.
708. Zhang, Y., and J.M. Sharma. 2003. Immunological tolerance in chickens hatching from eggs injected with cell-associated herpesvirus of turkey (HVT). *Dev Comp Immunol.* 27:431–438.
709. Zhao, Y., H. Xu, Y. Yao, L.P. Smith, L. Kgosana, J. Green, L. Petherbridge, S.J. Baigent, and V. Nair. 2011. Critical role of the virus-encoded microRNA-155 ortholog in the induction of Marek's disease lymphomas. *PLoS Pathog.* 7:e1001305.
710. Zhao, Y., Y. Yao, H. Xu, L. Lambeth, L.P. Smith, L. Kgosana, X. Wang, and V. Nair. 2009. A functional MicroRNA-155 ortholog encoded by the oncogenic Marek's disease virus. *J Virol.* 83:489–492.
711. Zhu, G.S., A. Iwata, M. Gong, S. Ueda, and K. Hirai. 1994. Marek's disease virus type 1-specific phosphorylated proteins pp38 and pp24 with common amino acid termini are encoded from the opposite junction regions between the long unique and inverted repeat sequences of viral genome. *Virology.* 200:816–820.
712. Zhu, G.S., T. Ojima, T. Hironaka, T. Ihara, N. Mizukoshi, A. Kato, S. Ueda, and K. Hirai. 1992. Differentiation of oncogenic and nononcogenic strains of Marek's disease virus type 1 by using polymerase chain reaction DNA amplification. *Avian Dis.* 36:637–645.

Leukosis/Sarcoma Group

1. Adkins, H.B., S.C. Blacklow, and J. A. Young. 2001. Two functionally distinct forms of a retroviral receptor explain the nonreciprocal receptor interference among subgroups B, D, and E avian leukosis viruses. *J Virol.* 75:3520–3526.
2. Adkins, H.B., J. Brojatsch, J. Naughton, M.M. Rolls, J.M. Pesola, and J. A. Young. 1997. Identification of a cellular receptor for

subgroup E avian leukosis virus. *Proc Natl Acad Sci USA*. 94:11617–11622.
3. Adkins, H.B., J. Brojatsch, and J.A. Young. 2000. Identification and characterization of a shared TNFR-related receptor for subgroup B, D, and E avian leukosis viruses reveal cysteine residues required specifically for subgroup E viral entry. *J Virol.* 74: 3572–3578.
4. Arshad, S.S., A.P. Bland, S.M. Hacker, and L.N. Payne. 1997. A low incidence of histiocytic sarcomatosis associated with infection of chickens with the HPRS-103 strain of subgroup J avian leukosis virus. *Avian Dis.* 41:947–956.
5. Arshad, S.S., K. Howes, G.S. Barron, L.M. Smith, P.H. Russell, and L.N. Payne. 1997. Tissue tropism of the HPRS-103 strain of J subgroup avian leukosis virus and of a derivative acutely transforming virus. *Vet Pathol.* 34:127–137.
6. Arshad, S.S., L.M. Smith, K. Howes, P.H. Russell, K. Venugopal, and L.N. Payne. 1999. Tropism of subgroup J avian leukosis virus as detected by *in situ* hybridization. *Avian Pathol.* 28: 163–169.
7. Astrin, S.M., E.G. Buss, and W.S. Haywards. 1979. Endogenous viral genes are non-essential in the chicken. *Nature.* 282: 339–341.
8. Astrin, S.M., H.L. Robinson, L.B. Crittenden, E.G. Buss, J. Wyban, and W.S. Hayward. 1979. Ten genetic loci in the chicken that contain structural genes for endogenous avian leukosis viruses. *Cold Spring Harb Symp Quant Biol.* 44:1105–1109.
9. Baba, T.W., and E.H. Humphries. 1985. Formation of a transformed follicle is necessary but not sufficient for development of an avian leukosis virus-induced lymphoma. *Proc Natl Acad Sci USA*. 82:213–216.
10. Baba, T.W., and E.H. Humphries. 1986. Selective integration of avian leukosis virus in different hematopoietic tissues. *Virology.* 155:557–566.
11. Bacon, L.D. 2000. Detection of endogenous avian leukosis virus envelope in chicken plasma using R2 antiserum. *Avian Pathol.* 29:153–164.
12. Bacon, L.D. 1987. Influence of the major histocompatability complex on disease resistance and productivity. *Poult Sci.* 66: 802–811.
13. Bacon, L.D., T.L. Fredericksen, D.G. Gilmour, A.M. Fadly, and L.B. Crittenden. 1985. Tests of association of lymphocyte alloantigen genotypes with resistance to viral oncogenesis in chickens. 2. Rous sarcoma and lymphoid leukosis in progeny derived from $6(3) \times 15(1)$ and $100 \times 6(3)$ crosses. *Poult Sci*. 64:39–47.
14. Bacon, L.D., J.E. Fulton, and G.B. Kulkarni. 2004. Methods for evaluating and developing commercial chicken strains free of endogenous subgroup E avian leukosis virus. *Avian Pathol.* 33: 233–243.
15. Bacon, L.D., E. Smith, L.B. Crittenden, and G.B. Havenstein. 1988. Association of the slow feathering (K) and an endogenous viral (ev21) gene on the Z chromosome of chickens. *Poult Sci.* 67:191–197.
16. Bacon, L.D., E.J. Smith, A.M. Fadly, and L.B. Crittenden. 1996. Development of an alloantiserum (R2) that detects susceptibility of chickens to subgroup E endogenous avian leukosis virus. *Avian Pathol.* 25:551–568.
17. Bacon, L.D., R.L. Witter, L.B. Crittenden, A. Fadly, and J. Motta. 1981. B-haplotype influence on Marek's disease, Rous sarcoma, and lymphoid leukosis virus-induced tumors in chickens. *Poult Sci.* 60:1132–1139.
18. Bacon, L.D., R.L. Witter, and A.M. Fadly. 1989. Augmentation of retrovirus-induced lymphoid leukosis by Marek's disease herpesviruses in White Leghorn chickens. *J Virol.* 63:504–512.
19. Bagust, T.J., S.P. Fenton, and M.R. Reddy. 2004. Detection of subgroup J avian leukosis virus infection in Australian meat-type chickens. *Aust Vet J.* 82:701–706.
20. Bai, J., K. Howes, L.N. Payne, and M.A. Skinner. 1995. Sequence of host-range determinants in the env gene of a full-length, infectious proviral clone of exogenous avian leukosis virus HPRS-103 confirms that it represents a new subgroup (designated J). *J Gen Virol.* 76 (Pt 1):181–187.
21. Bai, J., L.N. Payne, and M.A. Skinner. 1995. HPRS-103 (exogenous avian leukosis virus, subgroup J) has an env gene related to those of endogenous elements EAV-0 and E51 and an E element found previously only in sarcoma viruses. *J Virol.* 69:779–784.
22. Ballandras, A., K. Moreau, X. Robert, M.P. Confort, R. Merceron, R. Haser, C. Ronfort, and P. Gouet. 2011. A crystal structure of the catalytic core domain of an avian sarcoma and leukemia virus integrase suggests an alternate dimeric assembly. *PLoS One.* 6:e23032.
23. Baluda, M.A. 1963. Conversion of cells by avian myeloblastosis virus. *Perspect Virol.* 3:118–137.
24. Baluda, M.A. 1962. Properties of cells infected with avian myeloblastosis virus. *Cold Spring Harb Symp Quant Biol.* 27:415–425.
25. Baluda, M.A., and P.P. Jamieson. 1961. *In vivo* infectivity studies with avian myeloblastosis virus. *Virology*. I 14:33–45.
26. Banders, U.T., and P.M. Coussens. 1994. Interactions between Marek's disease virus encoded or induced factors and the Rous sarcoma virus long terminal repeat promoter. *Virology.* 199: 1–10.
27. Barbosa, T., M. Ramirez, S. Hafner, S. Cheng, and G. Zavala. 2010. Forensic investigation of a 1986 outbreak of osteopetrosis in commercial brown layers reveals a novel avian leukosis virus-related genome. *Avian Dis.* 54:981–989.
28. Barbosa, T., G. Zavala, and S. Cheng. 2008. Molecular characterization of three recombinant isolates of avian leukosis virus obtained from contaminated Marek's disease vaccines. *Avian Dis.* 52:245–252.
29. Barnard, R.J., D. Elleder, and J.A. Young. 2006. Avian sarcoma and leukosis virus-receptor interactions: from classical genetics to novel insights into virus-cell membrane fusion. *Virology.* 344:25–29.
30. Barnard, R.J., and J.A. Young. 2003. Alpharetrovirus envelope-receptor interactions. *Curr Top Microbiol Immunol.* 281:107–136.
31. Bates, P., J.A. Young, and H.E. Varmus. 1993. A receptor for subgroup A Rous sarcoma virus is related to the low density lipoprotein receptor. *Cell*, 74:1043–1051.
32. Bauer, H. 1974. Virion and tumor cell antigens of C-type RNA tumor viruses. *Adv Cancer Res.* 20:275–341.
33. Bauer, H., and B. Fleischer. 1981. Immunobiology of avian RNA tumor virus-induced cell surface antigens. In: *Mechanisms of Immunity to Virus-Induced Tumors*. J.W. Blasecki, ed. Marcel Dekker: New York. 69–118.
34. Bauer, H., R. Kirth, L. Rohrschneider, and H. Gelderblum. 1976. Immune response to oncornaviruses and tumor-associated antigens in the chicken. *Cancer Res.* 36:598–602.
35. Beard, J.W. 1963. Avian virus growths and their etiological agents. *Adv Cancer Res.* 7:1–127.
36. Beard, J.W. 1980. Biology of avian oncornaviruses. In: *Viral Oncology*. G. Klein, ed. Raven Press, New York. 55–87.

37. Beard, J.W. 1973. Oncornaviruses. I. The avian tumor viruses. In: *Ultrastructure in Biological Systems, vol. 5. Ultrastructure of Animal Viruses and Bacteriophages*. A.J. Dalton and F. Haguenau, eds. Academic Press: New York. 261–281.
38. Beard, J.W. 1963. Viral tumors of chickens with particular reference to the leukosis complex. *Ann N Y Acad Sci.* 108: 1057–1085.
39. Beard, J.W., J.F. Chabot, D. Beard, U. Heine, and G.E. Houts. 1976. Renal neoplastic response to leukosis virus strains BAI A (avian myeloblastosis virus) and MC29. *Cancer Res.* 36:339–353.
40. Beaudreau, G.S., and C. Becker. 1958. Virus of avian myeloblastosis. X. Photometric microdetermination of adenosinetriphosphatase activity. *J Natl Cancer Inst*. 20:339–349.
41. Benkel, B.F. 1998. Locus-specific diagnostic tests for endogenous avian leukosis-type viral loci in chickens. *Poult Sci.* 77: 1027–1035.
42. Bennett, D.D., and S.E. Wright. 1987. Immunization with envelope glycoprotein of an avian RNA tumor virus protects against sarcoma virus tumor induction: Role of subgroup. *Virus Res.* 8:73–77.
43. Benson, S.J., B.L. Ruis, A.M. Fadly, and K.F. Conklin. 1998. The unique envelope gene of the subgroup J avian leukosis virus derives from ev/J proviruses, a novel family of avian endogenous viruses. *J Virol.* 72:10157–10164.
44. Benson, S.J., B.L. Ruis, A.L. Garbers, A.M. Fadly, and K.F. Conklin. 1998. Independent isolates of the emerging subgroup J avian leukosis virus derive from a common ancestor. *J Virol.* 72:10301–10304.
45. Beug, H., A.V. Kirchbach, G. Döderlein, J.F. Conscience, and T. Graf. 1979. Chicken hematopoietic cells transformed by seven strains of defective avian leukemia virus display three distinct phenotypes. *Cell.* 18:375–390.
46. Biggs, P.M. 1961. A discussion on the classification of the avian leucosis complex and fowl paralysis. *Br Vet J.* 117:326–334.
47. Biggs, P.M., and L.N. Payne. 1964. Relationship of Marek's disease (neural lymphomatosis) to lymphoid leukosis. *Natl Cancer Inst Monogr.* 17:83–98.
48. Boettiger, D. 1979. Animal virus pseudotypes. *Prog Med Virol.* 25:37–68.
49. Bolognesi, D.P. 1974. Structural components of RNA tumor viruses. *Adv Virus Res.* 19:315–359.
50. Boni-Schnetzler, M., J. Boni, F.J. Ferdinand, and R.M. Franklin. 1985. Developmental and molecular aspects of nephroblastomas induced by avian myeloblastosis-associated virus 2-O. *J Virol.* 55:213–222.
51. Borisenko, L., and A.V. Rynditch. 2004. Complete nucleotide sequences of ALV-related endogenous retroviruses available from the draft chicken genome sequence. *Folia Biol (Praha)* 50:136–141.
52. Bova, C.A., J.P. Manfredi, and R. Swanstrom. 1986. env genes of avian retroviruses: nucleotide sequence and molecular recombinants define host range determinants. *Virology.* 152:343–354.
53. Bova, C.A., J.C. Olsen, and R. Swanstrom. 1988. The avian retrovirus env gene family: molecular analysis of host range and antigenic variants. *J Virol.* 62:75–83.
54. Boyce-Jacino, M.T., K. O'Donoghue, and A.J. Faras. 1992. Multiple complex families of endogenous retroviruses are highly conserved in the genus Gallus. *J Virol.* 66:4919–4929.
55. Boyde, A., A.J. Banes, R.M. Dillaman, and G.L. Mechanic. 1978. Morphological study of an avian bone disorder caused by myeloblastosis-associated virus. *Metab Bone Dis Relat Res.* 1:235–242.
56. Brandvold, K.A., P. Neiman, and A. Ruddell. 2000. Angiogenesis is an early event in the generation of myc-induced lymphomas. *Oncogene.* 19:2780–2785.
57. Brojatsch, J., J. Naughton, H.B. Adkins, and J.A. Young. 2000. TVB receptors for cytopathic and noncytopathic subgroups of avian leukosis viruses are functional death receptors. *J Virol.* 74:11490–11494.
58. Brown, C.Y., S.J. Bowers, G. Loring, C. Heberden, R.M. Lee, and P.E. Neiman. 2004. Role of Mtd/Bok in normal and neoplastic B cell development in the bursa of Fabricius. *Dev Comp Immunol.* 28:619–634.
59. Brown, P.O. 1997. Integration. In: *Retroviruses*. J.M. Coffin, S.H. Hughes, and H.E. Varmus, eds. Cold Spring Harbor, New York. 161–240.
60. Brown, T.P., N. Stedman, and M. Pantin-Vera. 2000. Proceedings, International Symposium on ALV-J and Other Avian Retroviruses. Rauischholzhausen, Germany. E.F. Kaleta, L.N. Payne, and U. Heffels-Redmann, eds. 63–66.
61. Bryan, W.R. 1956. Biological studies on the Rous sarcoma virus. IV. Interpretation of tumor-response data involving one inculation site per chicken. *J Natl Cancer Inst*. 16:843–863.
62. Bryan, W.R., J.B. Moloney, and D. Calnan. 1954. Stable standard preparations of the Rous sarcoma virus preserved by freezing and storage at low temperatuRes *J Natl Cancer Inst*. 15: 315–329.
63. Burmester, B.R. 1956. Bioassay of the virus of visceral lymphomatosis. I. Use of short experimental period. *J Natl Cancer Inst*. 16:1121–1127.
64. Burmester, B.R. 1955. Immunity to visceral lymphomatosis in chicks following injection of virus into dams. *Proc Soc Exp Biol Med*. 88::153–155.
65. Burmester, B.R. 1969. The prevention of lymphoid leukosis with androgens. *Poult Sci.* 48:401–408.
66. Burmester, B.R. 1956. The shedding of the virus of visceral lymphomatosis in the saliva and feces of individual normal and lymphomatous chickens. *Poult Sci.* 35:1089–1099.
67. Burmester, B.R. 1947. Studies on the transmission of avian visceral lymphomatosis. II. Propagation of lymphomatosis with cellular and cell-free preparations. *Cancer Res*. 7:786-797.
68. Burmester, B.R. 1968. Unpublished data.
69. Burmester, B.R., and G.E. Cottral. 1947. The propagation of filtrable agents producing lymphoid tumors and osteopetrosis by serial passage in chickens. *Cancer Res*. 7::669–675.
70. Burmester, B.R., and E.M. Denington. 1947. Studies on the transmission of avian visceral lymphomatosis. I. Variation in transmissibility of naturally occurring cases. *Cancer Res*. 7: 779–785
71. Burmester, B.R., A.K. Fontes, and W.G. Walter. 1960. Pathogenicity of a viral strain (RPL 12) causing avian visceral lymphomatosis and related neoplasms III. Influence of host age and route of inoculation. *J Natl Cancer Inst*. 24:1423–1442.
72. Burmester, B.R., and T.N. Fredrickson. 1964. Transmission of virus from field cases of avian lymphomatosis. I. Isolation of virus in line 151 chickens. *J Natl Cancer Inst*. 32:37–63.
73. Burmester, B.R., and R.F. Gentry. 1956. The response of susceptible chickens to graded doses of the virus of visceral lymphomatosis. *Poult Sci.* 35:17–26.
74. Burmester, B.R., M.A. Gross, W.G. Walter, and A.K. Fontes. 1959. Pathogenicity of a viral strain (RPL 12) causing avian

visceral lymphomatosis and related neoplasms. II. Host-virus interrelations affecting response. *J Natl Cancer Inst*. 22:103–127.
75. Burmester, B.R., and N. M. Nelson. 1945. The effect of castration and sex hormones upon the incidence of lymphomatosis in chickens. *Poult Sci.* 24.
76. Burmester, B.R., and H.G. Purchase. 1979. The history of avian medicine in the United States. V. Insights into avian tumor virus research. *Avian Dis*. 23:1–29.
77. Burmester, B.R., and W.G. Walter. 1961. Occurrence of visceral lymphomatosis in chickens inoculated with Rous sarcoma virus. *J Natl Cancer Inst.* 26:511–518.
78. Burmester, B.R., W.G. Walter, M.A. Gross, and A.K. Fontes. 1959. The oncogenic spectrum of two `pure' strains of avian leukosis. *J Natl Cancer Inst.* 23:277–291.
79. Burstein, H., M. Gilead, U. Bendheim, and M. Kotler. 1984. Viral aetiology of haemangiosarcoma outbreaks among layer hens. *Avian Pathol.* 13:715–726.
80. Burstein, H., N. Resnick-Roguel, J. Hamburger, G. Arad, M. Malkinson, and M. Kotler. 1990. Unique sequences in the env gene of avian hemangioma retrovirus are responsible for cytotoxicity and endothelial cell perturbation. *Virology.* 179:512–516.
81. Butterfield, E.E. 1905. Aleukaemic lymphadenoid tumors of the hen. *Folia Haematol.* 2:649–657.
82. Calnek, B.W. 1968. Lesions in young chickens induced by lymphoid leukosis virus. *Avian Dis.* 12:111–129.
83. Calnek, B.W. 1968. Lymphoid leukosis virus: a survey of commercial breeding flocks for genetic resistance and incidence of embryo infection. *Avian Dis.* 12:104–111.
84. Calnek, B.W. 1964. Morphological alteration of RIF-infected chick embryo fibroblasts. *Natl Cancer Inst Monogr.* 17:425–447.
85. Campbell, J.G. 1961. A proposed classification of the leucosis complex and fowl paralysis. *Br Vet J.* 117:316–325.
86. Campbell, J.G. 1969. *Tumours of the Fowl*. William Heinemann Medical Books: London.
87. Campbell, J.G., and E.C. Appleby. 1966. Tumours in young chickens bred for rapid body growth (broiler chickens). A study of 351 cases. *J Pathol Bacteriol*. 92:77–90.
88. Caparini, U. 1896. Fetati leucemici nei polli. *Clin Vet (Milan).* 19:433–435.
89. Carr, J.G. 1960. Kidney carcinomas of the fowl induced by the MH2 reticuloendothelioma virus. *Br J Cancer.* 14:77–82.
90. Carr, J.G. 1956. Renal adenocarcinoma induced by fowl leukemia virus. *Br J Cancer.* 10:379–383.
91. Chai, N., and P. Bates. 2006. Na+/H+exchanger type 1 is a receptor for pathogenic subgroup J avian leukosis virus. *Proc Natl Acad Sci USA*. 103:5531–5536.
92. Chebloune, Y., J. Rulka, F.L. Cosset, S. Valsesia, C. Ronfort, C. Legras, A. Drynda, J. Kuzmak, V.M. Nigon, and G. Verdier. 1991. Immune response and resistance to Rous sarcoma virus challenge of chickens immunized with cell-associated glycoproteins provided with a recombinant avian leukosis virus. *J Virol.* 65:5374–5380.
93. Chen, M., A.J. Granger, M.W. Vanbrocklin, W.S. Payne, H. Hunt, H. Zhang, J.B. Dodgson, and S.L. Holmen. 2007. Inhibition of avian leukosis virus replication by vector–based RNA interference. *Virology.* 365:464–472.
94. Chen, Y.C., and P.K. Vogt. 1977. Endogenous leukosis viruses in the avian family Phasianidae. *Virology.* 76:740–750.
95. Cherepanov, P., G.N. Maertens, and S. Hare. 2011. Structural insights into the retroviral DNA integration apparatus. *Curr Opin Struct Biol.* 21:249–256.
96. Chesters, P.M., K. Howes, J.C. McKay, L.N. Payne, and K. Venugopal. 2001. Acutely transforming avian leukosis virus subgroup J strain 966: defective genome encodes a 72-kilodalton Gag-Myc fusion protein. *J Virol.* 75:4219–4225.
97. Chesters, P.M., K. Howes, L. Petherbridge, S. Evans, L.N. Payne and K. Venugopal. 2002. The viral envelope is a major determinant for the induction of lymphoid and myeloid tumours by avian leukosis virus subgroups A and J, respectively. *J Gen Virol* 83:2553–2561.
98. Chesters, P.M., L.P. Smith, and V. Nair. 2006. E (XSR) element contributes to the oncogenicity of Avian leukosis virus (subgroup J). *J Gen Virol.* 87:2685–2692.
99. Cheville, N.F., W. Okazaki, P.D. Lukert, and H.G. Purchase. 1978. Prevention of avian lymphoid leukosis by induction of bursal atrophy with infectious bursal disease viruses. *Vet Pathol.* 15:376–382.
100. Chi, Y., F. Diaz-Griffero, C. Wang, J.A. Young, and J. Brojatsch. 2002. An NF-kappa B-dependent survival pathway protects against cell death induced by TVB receptors for avian leukosis viruses. *J Virol.* 76:5581–5587.
101. Choudat, D., G. Dambrine, B. Delemotte, and F. Coudert. 1996. Occupational exposure to poultry and prevalence of antibodies against Marek's disease virus and avian leukosis retroviruses. *Occup Environ Med.* 53:403–410.
102. Claude, A., and J.G. Murphy. 1933. Transmissible tumors of the fowl. *Physiol Rev.* 13:246–275.
103. Clurman, B.E., and W.S. Hayward. 1989. Multiple proto-oncogene activations in avian leukosis virus-induced lymphomas: evidence for stage-specific events. *Mol Cell Biol.* 9:2657–2664.
104. Coffin, J.M., S.H. Hughes, and H.E. Varmus, eds. 1997. *Retroviruses*. Cold Spring Harbor Laboratory Press: Cold Spring Harbor, New York.
105. Collart, K.L., R. Aurigemma, R.E. Smith, S. Kawai, and H.L. Robinson. 1990. Infrequent involvement of c-fos in avian leukosis virus-induced nephroblastoma. *J Virol.* 64:3541–3544.
106. Collins, W.H., W.E. Briles, R.M. Zsigray, W.R. Dunlop, A.C. Corbett, K.K. Clark, J.L. Marks, and T.P. McGrail. 1977. The B locus (MHC) in the chicken: Association with the fate of RSV-induced tumors. *Immunogenetics.* 5:333–343.
107. Consortium, I.C.G.S. 2004. Sequence and comparative analysis of the chicken genome provide unique perspectives on vertebrate evolution. *Nature.* 432:695–716.
108. Cooper, G.M. 1982. Cellular transforming genes. *Science.* 217:801–806.
109. Cooper, G.M. 1982. Transforming genes of chicken bursal lymphomas. *J Cell Physiol Suppl.* 1:209–212.
110. Cooper, M.D., L.N. Payne, P.B. Dent, B.R. Burmester, and R.A. Good. 1968. Pathogenesis of avian lymphoid leukosis. I. Histogenesis. *J Natl Cancer Inst*. 41:373–378.
111. Cooper, M.D., H.G. Purchase, D.E. Bockman, and W.E. Gathings. 1974. Studies on the nature of the abnormality of B cell differentiation in avian lymphoid leukosis: production of heterogeneous IgM by tumor cells. *J Immunol.* 113:1210–1222.
112. Cottral, G.E., B.R. Burmester, and N.F. Waters. 1954. Egg transmission of avian lymphomatosis. *Poult Sci.* 33:1174–1184.
113. Crittenden, L.B. 1975. Two levels of genetic resistance to lymphoid leukosis. *Avian Dis.* 19:281–292.
114. Crittenden, L.B. 1968. Avian tumor viruses: Prospects for control. *World's Poult Sci J.* 24:18–36.
115. Crittenden, L.B. 1981. Exogenous and endogenous leukosis virus genes-a review. *Avian Pathol.* 10:101–112.

116. Crittenden, L.B. 1991. Retroviral elements in the genome of the chickens: Implications for poultry genetics and breeding. *Crit Rev Poultry Biol.* 3:73–109.
117. Crittenden, L.B. 1975. Two levels of genetic resistance to lymphoid leukosis. *Avian Dis.* 19:281–292.
118. Crittenden, L.B., D.A. Eagen, and F.A. Gulvas. 1979. Assays for endogenous and exogenous lymphoid leukosis viruses and chick helper factor with RSV(-) cell lines. *Infect Immun.* 24: 379–386.
119. Crittenden, L.B., and A.M. Fadly. 1985. Responses of chickens lacking or expressing endogenous avian leukosis virus genes to infection with exogenous virus. *Poult Sci.* 64:454–463.
120. Crittenden, L.B., A.M. Fadly, and E.J. Smith. 1982. Effect of endogenous leukosis virus genes on response to infection with avian leukosis and reticuloendotheliosis viruses. *Avian Dis.* 26: 279–294.
121. Crittenden, L.B., W.S. Hayward, H. Hanafusa, and A.M. Fadly. 1980. Induction of neoplasms by subgroup E recombinants of exogenous and endogenous avian retroviruses (Rous-associated virus type 60). *J Virol.* 33:915–919.
122. Crittenden, L.B., and H.J. Kung. 1984. Mechanism of induction of lymphoid leukosis and related neoplasms by avian leukosis viruses. In: *Mechanisms of Viral Leukaemogenesis*. J.M. Goldman and O. Jarrett eds. Churchill Livingstone: Edinburgh, Scotland. 64–88.
123. Crittenden, L.B., S. McMahon, M.S. Halpern, and A.M. Fadly. 1987. Embryonic infection with the endogenous avian leukosis virus Rous-associated virus-0 alters responses to exogenous avian leukosis virus infection. *J Virol.* 61:722–725.
124. Crittenden, L.B., and J.V. Motta. 1969. A survey of genetic resistance to leukosis-sarcoma viruses in commercial stocks of chickens. *Poult Sci.* 48:1751–1757.
125. Crittenden, L.B., J.V. Motta, and E.J. Smith. 1977. Genetic control of RAV-0 production in chickens. *Virology.* 76:90–97.
126. Crittenden, L.B., and W. Okazaki. 1966. Genetic influence of the Rs locus on susceptibility to avian tumor viruses. II. Rous sarcoma virus antibody production after strain RPL12 virus inoculation. *J Natl Cancer Inst*. 36:299–303.
127. Crittenden, L.B., W. Okazaki, and R. Reamer. 1963. Genetic resistance to rous sarcoma virus in embryo cell cultures and embryos. *Virology.* 20:541–544.
128. Crittenden, L.B., W. Okazaki, and E.J. Smith. 1983. Incidence of avian leukosis virus infection in broiler stocks and its effect on early growth. *Poult Sci.* 62:2383–2386.
129. Crittenden, L.B., H.G. Purchase, J.J. Solomon, W. Okazaki, and B.R. Burmester. 1972. Genetic control of susceptibility to the avian leukosis complex. I. The leukosis-sarcoma virus group. *Poult Sci*. 51:242–261.
130. Crittenden, L.B., and E.J. Smith. 1984. A comparison of test materials for differentiating avian leukosis virus group-specific antigens of exogenous and endogenous origin. *Avian Dis.* 28: 1057–1070.
131. Crittenden, L.B., E.J. Smith, and A.M. Fadly. 1984. Influence of endogenous viral (ev) gene expression and strain of exogenous avian leukosis virus (ALV) on mortality and ALV infection and shedding in chickens. *Avian Dis.* 28:1037–1056.
132. Crittenden, L.B., E.J. Wendel, Jr., and D. Ratzsch. 1971. Genetic resistance to the avian leukosis-sarcoma virus group: determining the phenotype of adult birds. *Avian Dis.* 15:503–507.
133. Crittenden, L.B., and R.L. Witter. 1978. Studies of flocks with high mortality from lymphoid leukosis. *Avian Dis.* 22:16–23.
134. Crittenden, L.B., R.L. Witter, and A.M. Fadly. 1979. Low incidence of lymphoid tumors in chickens continuously producing endogenous virus. *Avian Dis.* 23:646–653.
135. Crittenden, L.B., R.L. Witter, W. Okazaki, and P.E. Neiman. 1979. Lymphoid neoplasms in chicken flocks free of infection with exogenous avian tumor viruses. *J Natl Cancer Inst.* 63: 191–200.
136. Cummins, T.J., and R.E. Smith. 1988. Analysis of hematopoietic and lymphopoietic tissue during a regenerative aplastic crisis induced by avian retrovirus MAV-2(O). *Virology.* 163:452–461.
137. Dales, S., and H. Hanafusa. 1972. Penetration and intracellular release of the genomes of avian RNA tumor viruses. *Virology.* 50:440–458.
138. Danielsen, A.J., T.A. Christensen, C.A. Lovejoy, M.A. Adelsman, D.C. Connolly, and N.J. Maihle. 2004. Membrane localization of v-ErbB is required but not sufficient for ligand-independent transformation. *Exp Cell Res.* 296:285–293.
139. de Boer, G.F. 1987. Approaches to control of avian lymphoid leukosis. In: *Avian Leukosis*. G.F. de Boer, ed. *Martinus Nijhoff*: Boston, MA. 261–286.
140. de Boer, G.F., O.J.H. Devos, and H.J.L. Maas. 1981. The incidence of lymphoid leukosis in chickens in the Netherlands. *Zootechnica Int.* 10:32–35.
141. de Boer, G.F., J.v. Vloten, and D.v. Zaane. 1980. Possible horizontal spread of lymphoid leukosis virus during vaccination against Marek's disease. In: *Resistance and Immunity to Marek's Disease*. P.M. Biggs, ed. C.E.C. Luxembourg. 552–565.
142. De The, G., U. Heine, H. Ishiguro, J.R. Sommer, D. Beard, and J.W. Beard. 1962. Biologic response of nephrogenic cells to avian myeloblastosis virus. *Fed Proc.* 21:919–929.
143. Denesvre, C., D. Soubieux, G. Pin, D. Hue, and G. Dambrine. 2003. Interference between avian endogenous ev/J 4.1 and exogenous ALV-J retroviral envelopes. *J Gen Virol*. 84: 3233–3238.
144. Di Stefano, H.S., and R.M. Dougherty. 1968. Multiplication of avian leukosis virus in the reproductive system of the rooster. *J Natl Cancer Inst.* 41:451–464.
145. Diaz-Griffero, F., S.A. Hoschander, and J. Brojatsch. 2003. Bystander killing during avian leukosis virus subgroup B infection requires TVB(S3) signaling. *J Viro.* 77:12552–12561.
146. Diaz-Griffero, F., A.P. Jackson, and J. Brojatsch. 2005. Cellular uptake of avian leukosis virus subgroup B is mediated by clathrin. *Virology.* 337:45–54.
147. Dimcheff, D.E., S.V. Drovetski, M. Krishnan, and D.P. Mindell. 2000. Cospeciation and horizontal transmission of avian sarcoma and leukosis virus gag genes in galliform birds. *J Virol.* 74:3984–3995.
148. Dimcheff, D.E., M. Krishnan, and D.P. Mindell. 2001. Evolution and characterization of tetraonine endogenous retrovirus: a new virus related to avian sarcoma and leukosis viruses. *J Virol.* 75:2002–2009.
149. DiStefano, H.S., and R.M. Dougherty. 1966. Mechanisms for congenital transmission of avian leukosis virus. *J Natl Cancer Inst.* 37:869–883.
150. DiStefano, H.S., and R.M. Dougherty. 1969. Multiplication of avian leukosis virus in endocrine organs of congenitally infected chickens. *J Natl Cancer Inst.* 42:147–154.
151. DiStefano, H.S., and R.M. Dougherty. 1968. Multiplication of avian leukosis virus in the reproductive system of the rooster. *J Natl Cancer Inst.* 41:451–464.

152. Dmochowski, L. 1970. Comparison of leukemogenic and sarcomagenic viruses at the ultrastructural level. *Bibl Haematol.* 62–82.
153. Dmochowski, L. 1963. The electron microscopic view of virus-host relationship in neoplasia. *Prog Exp Tumor Res.* 25:35–147.
154. Dmochowski, L., C.E. Grey, F. Padgett, P.L. Langford, and B.R. Burmester. 1964. Submicroscopic morphology of avian neoplasms. VI. Comparative dtudies on Rous sarcoma, visceral lymphomatosis, erythroblastosis, myeloblastosis, and nephroblastoma. *Tex Rep Biol Med*. 22:20–60.
155. Dorner, A.J., and J.M. Coffin. 1986. Determinants for receptor interaction and cell killing on the avian retrovirus glycoprotein gp85. *Cell.* 45:365–374.
156. Dorner, A.J., J.P. Stoye, and J.M. Coffin. 1985. Molecular basis of host range variation in avian retroviruses. *J Virol.* 53:32–39.
157. Dougherty, R.M. 1961. Heat inactivation of Rous sarcoma virus. *Virology.* 14:371–372.
158. Dougherty, R.M., and H.S. DiStefano. 1967. Sites of avian leukosis virus multiplication in congenitally infected chickens. *Cancer Res.* 27:322–332.
159. Dougherty, R.M., J.A. Stewart, and H.R. Morgan. 1960. Quantitative studies of the relationships between infecting dose of Rous sarcoma virus, antiviral immune response, and tumor growth in chickens. *Virology.* 11:349–370.
160. Dren, C.N., and I. Nemeth. 1987. Demonstration of immunoglobulin M on avian lymphoid leukosis lymphoma cells by the unlabelled antibody peroxidase-antiperoxidase method. *Avian Pathol.* 16:253–268.
161. Dunwiddie, C.T., R. Resnick, M. Boyce-Jacino, J.N. Alegre, and A.J. Faras. 1986. Molecular cloning and characterization of gag-, pol-, and env-related gene sequences in the ev- chicken. *J Virol.* 59:669–675.
162. Eckert, E.A., D. Beard, and J.W. Beard. 1954. Dose-response relations in experimental transmission of avian erythromyeloblastic leukosis III. Titration of the virus. *J Natl Cancer Inst*. 14:1055–1066.
163. Eckert, E.A., D. Beard, and J.W. Beard. 1953. Dose response relations in experimental transmission of avian myeloblastic leukosis. II. Host response to whole blood and to washed primitive cells. *J Natl Cancer Inst*. 13:1167–1184.
164. Eckert, E.A., I. Green, D.G. Sharp, D. Beard, and J.W. Beard. 1955. Virus of avian erythromyeloblastic leukosis. VII. Thermal stability of virus infectivity; of the virus particle; and of the enzyme dephosphorylating adenosinetriphosphate. *J Natl Cancer Inst*. 153–161.
165. Elferink, M.G., A.A. Vallee, A.P. Jungerius, R.P. Crooijmans, and M.A. Groenen. 2008. Partial duplication of the PRLR and SPEF2 genes at the late feathering locus in chicken. *BMC Genomics.* 9:391.
166. Elleder, D., D.C. Melder, K. Trejbalova, J. Svoboda, and M.J. Federspiel. 2004. Two different molecular defects in the Tva receptor gene explain the resistance of two tvar lines of chickens to infection by subgroup A avian sarcoma and leukosis viruses. *J Virol.* 78:13489–13500.
167. Elleder, D., V. Stepanets, D.C. Melder, F. Senigl, J. Geryk, P. Pajer, J. Plachy, J. Hejnar, J. Svoboda, and M.J. Federspiel. 2005. The receptor for the subgroup C avian sarcoma and leukosis viruses, Tvc, is related to mammalian butyrophilins, members of the immunoglobulin superfamily. *J Virol.* 79:10408–10419.
168. Ellermann, V. 1921. *The Leucosis of Fowls and Leukemia Problems*. Gyldendal: London.
169. Ellermann, V., and O. Bang. 1908. Experimentelle leukamie bei huhnern. *Zentralbl Bakteriol Parasitenkd Infektionskr Hyg Abt I Orig.* 46:595–609.
170. Engelbreth-Holm, J. 1931/2. Bericht über einen neuen stamm Hühnerleukose. *Z Immunitätsforsch*. 73:126–136.
171. Engelbreth-Holm, J., and A. Rothe-Meyer. 1932. II. Ueber den Zusammenhangzwischendenverschiedenen Huhnerleukosefornen (Anamie-erythroblastose-myelose). *Acta Pathol Microbiol Scand.* 312–332.
172. Enrietto, P., and M. Hayman. 1987. Structure and virus-associated oncogenes of avian sarcoma and leukaemia viruses. In: *Avian Leukosis*. G.F. De Boer, ed. Martinus Nijhoff, Boston. 29–46.
173. Enrietto, P.J., M.J. Hayman, G.M. Ramsay, J.A. Wyke, and L.N. Payne. 1983. Altered pathogenicity of avian myelocytomatosis (MC29) viruses with mutations in the v-myc gene. *Virology.* 124:164–172.
174. Enrietto, P.J., and J.A. Wyke. 1983. The pathogenesis of oncogenic avian retroviruses. *Adv Cancer Res.* 39:269–314.
175. Ewert, D.L., I. Steiner, and J. Duttadaway. 1990. *In ovo* infection with the avian retrovirus RAV-1 leads to persistent infection of the central nervous system. *Lab Invest.* 62:156–116.
176. Fadly, A., R. Silva, H. Hunt, A. Pandiri, and C. Davis. 2006. Isolation and characterization of an adventitious avian leukosis virus isolated from commercial Marek's disease vaccines. *Avian Dis.* 50:380–385.
177. Fadly, A.M. 1988. Avian leukosis virus (ALV) infection, shedding, and tumors in maternal ALV antibody-positive and -negative chickens exposed to virus at hatching. *Avian Dis.* 32:89–95.
178. Fadly, A.M. 1997. Avian retroviruses. *Vet Clin North Am Food Anim Pract*. 13:71–85.
179. Fadly, A.M. 1987. Differential diagnosis of lymphoid leukosis. In: *Avian Leukosis*. G.F de Boer, ed. *Martinus Nijhoff: Boston, MA*. 197–211.
180. Fadly, A.M. 1993. Induction of antibodies to avian leukosis and reticuloendotheliosis viruses using defective retroviral particles. *Proceedings, 130th AVMA Convention, Minneapolis, MN*. (abstract).
181. Fadly, A.M. 2000. Isolation and identification of avian leukosis viruses: A review. *Avian Pathol.* 29:529–535.
182. Fadly, A.M. 1989. Leukosis and sarcoma. In: *A Laboratory Manual for the Isolation and Identification of Avian Pathogens*. H.G. Purchase, L.H. Arp, C.H. Domermuth, J.E. Pearson, eds. American Association of Avian Pathologists: Kennett Square, PA. 135–142.
183. Fadly, A.M. 1992. Some observations on the enhancement of avian leukosis virus-induced lymphomas byserotype 2 Marek's disease virus. Proceedings XIX World's Poultry Congress. Ponsen and Looijen, Wageningen. 281–285.
184. Fadly, A.M., and L.B. Crittenden. 1987. Hemolymphatic neoplasms, sarcomas and related conditions, Part VIII. Poultry. In: *Veterinary Cancer Medicine*, 2nd ed. G.H. Theilen and B.R. Madwell, eds. Lea and Febiger: Philadelphia. 442–453.
185. Fadly, A.M., L.B. Crittenden, and E.J. Smith. 1987. Variation in tolerance induction and oncogenicity due to strain of avian leukosis virus. *Avian Pathol.* 16:665–677
186. Fadly, A.M., and D.L. Ewert. 1994. *Enhancement of Avian Retrovirus-Induced B Cell Lymphoma by Marek's Disease Herpesvirus*. World Scientific, Singapore. 1–9.
187. Fadly, A.M., T.F. Davison, L.N. Payne, and K. Howes. 1989. Avian leukosis virus infection and shedding in brown leghorn

chickens treated with corticosterone or exposed to various stressors. *Avian Pathol.* 18:283–298.
188. Fadly, A.M., L.F. Lee, and L.D. Bacon. 1982. Immunocompetence of chickens during early and tumorigenic stages of Rous-associated virus-1 infection. *Infect Immun.* 37:1156–1161.
189. Fadly, A.M., and V. Nair. 2008. Leukosis/sarcoma group. In: *Diseases of Poultry*, 12th ed. Y.M. Saif, A.M. Fadly, J.R. Glisson, L.R. McDougald, L.K. Nolan, and D.E. Swayne, eds. Blackwell Publishing Ltd., Ames. 514–568.
190. Fadly, A.M., W. Okazaki, E.J. Smith, and L.B. Crittenden. 1981. Relative efficiency of test procedures to detect lymphoid leukosis virus infection. *Poult Sci.* 60:2037–2044.
191. Fadly, A.M., W. Okazaki, and R.L. Witter. 1981. Hatchery-related contact transmission and short-term small-group-rearing as related to lymphoid-leukosis-virus-eradication programs. *Avian Dis.* 25:667–677.
192. Fadly, A.M., and L.N. Payne. 2003. Leukosis/sarcoma group. In: *Diseases of Poultry*, 11th ed. Y.M. Saif, ed. Iowa State Press, Ames. 465–516.
193. Fadly, A.M., R.F. Silva, and L.F. Lee. 2000. *Antigenic Characterisation of Selected Field Isolates of Subgroup J Avian Leukosis Virus*. Rauischholzhausen, Germany. 13–22.
194. Fadly, A.M., and E.J. Smith. 1999. Isolation and some characteristics of a subgroup J-like avian leukosis virus associated with myeloid leukosis in meat-type chickens in the United States. *Avian Dis.* 43:391–400.
195. Fadly, A.M., and R.L. Witter. 1993. Effects of age at infection with serotype 2 Marek's disease virus on enhancement of avian leukosis virus-induced lymphomas. *Avian Pathol.* 22: 565–576.
196. Fadly, A.M., and R.L. Witter. 1998. Oncornaviruses: Leukosis/sarcoma and reticuloendotheliosis. In: *A Laboratory Manual for the Isolation and Identification of Avian Pathogens*, 4th ed. J.R. Glisson, D.J. Jackwood, J.E. Pearson, W.M. Reed, and D.E. Swayne eds. Am Assoc Avian Pathologists: Kennet Square, PA. 185–196.
197. Fadly, A.M., R.L. Witter, and L.F. Lee. 1985. Effects of chemically or virus-induced immunodepression on response of chickens to avian leukosis virus. *Avian Dis.* 29:12–25.
198. Fan, H., and C. Johnson. 2011. Insertional oncogenesis by non-acute retroviruses: implications for gene therapy. *Viruses.* 3: 398–422.
199. Fauquet, C.M., M.A. Mayo, J. Maniloff, U. Desselberger, and L.A. Ball. 2005. *Virus Taxonomy: VIIIth Report of the International Committee on Taxonomy of Viruses*. Elsevier-Academic Press.
200. Foster, R.G., J.B. Lian, G. Stein, and H.L. Robinson. 1994. Replication of an osteopetrosis-inducing avian leukosis virus in fibroblasts, osteoblasts, and osteopetrotic bone. *Virology.* 205: 179–187.
201. Frank, R.M., and R.M. Franklin. 1982. Electron microscopy of avian osteopetrosis induced by retrovirus MAV.2-0. *Calcif Tissue Int*. 34:382–390.
202. Franklin, R.M., and M.T. Martin. 1980. *In ovo* tumorigenesis induced by avian osteopetrosis virus. *Virology.* 105:245–249.
203. Fredrickson, T.N., B.R. Burmester, and W. Okazaki. 1965. Transmission of virus from field cases of avian lymphomatosis. II. Development of strains by serial passage in line 15I chickens. *Avian Dis*. 9:82–103.
204. Fredrickson, T.N., H.G. Purchase, and B.R. Burmester. 1964. Transmission of virus from field cases of avian lymphomatosis. III. Variation in the oncogenic spectra of passaged virus isolates. *Natl Cancer Inst Monogr*. 17:1–29.
205. Friesen, B., and H. Rubin. 1961. Some physicochemical and immunological properties of an avian leucosis virus (RIF). *Virology.* 15:387–396.
206. Frisby, D., R. MacCormick, and R. Weiss. 1980. Origin of RAV-0. The endogenous retrovirus of chickens. *Cold Spring Harb Conf Cell Prolifer.* 7:509–517.
207. Frisby, D.P., R.A. Weiss, M. Roussel, and D. Stehelin. 1979. The distribution of endogenous chicken retrovirus sequences in the DNA of galliform birds does not coincide with avian phylogenetic relationships. *Cell.* 17:623–634.
208. Fung, Y.K., L.B. Crittenden, A.M. Fadly, and H.J. Kung. 1983. Tumor induction by direct injection of cloned v-src DNA into chickens. *Proc Natl Acad Sci USA*. 80:353–357.
209. Fung, Y.K., W.G. Lewis, L.B. Crittenden, and H.J. Kung. 1983. Activation of the cellular oncogene c-erbB by LTR insertion: molecular basis for induction of erythroblastosis by avian leukosis virus. *Cell.* 33:357–368.
210. Furth, J. 1933. Lymphomatosis, myelomatosis, and endothelioma of chickens caused by a filterable agent. *J Exp Med.* 58:253–275.
211. Fynan, E., T.M. Block, J. DuHadaway, W. Olson, and D.L. Ewert. 1992. Persistence of Marek's disease virus in a subpopulation of B cells that is transformed by avian leukosis virus, but not in normal bursal B cells. *J Virol.* 66:5860–5866.
212. Gao, Y., B. Yun, L. Qin, W. Pan, Y. Qu, Z. Liu, Y. Wang, X. Qi, H. Gao, and X. Wang. 2012. Molecular epidemiology of avian leukosis virus subgroup J in layer flocks in China. *J Clin Microbiol.* 50:953–960.
213. Gao, Y.L., L.T. Qin, W. Pan, Y.Q. Wang, X. Le Qi, H.L. Gao, and X.M. Wang. 2010. Avian leukosis virus subgroup J in layer chickens, China. *Emerg Infect Dis*. 16:1637–1638.
214. Garcia-Fernandez, R.A., C. Perez-Martinez, J. Espinosa-Alvarez, A. Escudero-Diez, J.F. Garcia-Marin, A. Nunez, and M.J. Garcia-Iglesias. 2000. Lymphoid leukosis in an ostrich (*Struthio camelus*). *Vet Rec.* 146:676–677.
215. Garcia, M., J. El-Attrache, S.M. Riblet, V.R. Lunge, A.S. Fonseca, P. Villegas, and N. Ikuta. 2003. Development and application of reverse transcriptase nested polymerase chain reaction test for the detection of exogenous avian leukosis virus. *Avian Dis.* 47:41–53.
216. Gavora, J., J. Spencer, and J. Chambers. 1982. Performance of meat-type chickens test-positive and -negative for lymphoid leukosis virus infection. *Avian Pathol.* 11:29–38.
217. Gavora, J.S. 1987. Influences of avian leukosis virus infection on production and mortality and the role of genetic selection in the control of lymphoid leukosis. In: *Avian Leukosis*. G.F. de Boer, ed. Martinus Nijhoff: Boston. 241–260.
218. Gavora, J.S., J.L. Spencer and J.A. Chambers. 1982. Performance of meat-type chickens test-positive and -negative for lymphoid leukosis virus infection. *Avian Pathol.* 11:29–38.
219. Gavora, J.S., J.L. Spencer, R.S. Gowe, and D.L. Harris. 1980. Lymphoid leukosis virus infection: effects on production and mortality and consequences in selection for high egg production. *Poult Sci.* 59:2165–2178.
220. Gebriel, G.M., and A.W. Nordskog. 1983. Genetic linkage of subgroup C Rous sarcoma virus-induced tumour expression in chickens to the IR-GAT locus of the B complex. *J Immunogenet.* 10:231–235.
221. Gifford, R., and M. Tristem. 2003. The evolution, distribution and diversity of endogenous retroviruses. *Virus Genes.* 26:291–315.

222. Gilbert, J.M., L.D. Hernandez, J.W. Balliet, P. Bates, and J.M. White. 1995. Receptor-induced conformational changes in the subgroup A avian leukosis and sarcoma virus envelope glycoprotein. *J Virol.* 69:7410–7415.
223. Gilka, F., and J.L. Spencer. 1990. Chronic myocarditis and circulatory syndrome in a White Leghorn strain induced by an avian leukosis virus: light and electron microscopic study. *Avian Dis.* 34:174–184.
224. Gilka, F., and J.L. Spencer. 1987. Importance of the medullary macrophage in the replication of lymphoid leukosis virus in the bursa of Fabricius of chickens. *Am J Vet Res.* 48:613–620.
225. Gilka, F., and J.L. Spencer. 1985. Viral matrix inclusion bodies in myocardium of lymphoid leukosis virus-infected chickens. *Am J Vet Res.* 46:1953–1960.
226. Gingerich, E., R.E. Porter, B. Lupiani, and A.M. Fadly. 2002. Diagnosis of myeloid leukosis induced by a recombinant avian leukosis virus in commercial white leghorn egg laying flocks. *Avian Dis.* 46:745–748.
227. Gong, M., H.L. Semus, K.J. Bird, B.J. Stramer, and A. Ruddell. 1998. Differential selection of cells with proviral c-myc and c-erbB integrations after avian leukosis virus infection. *J Virol.* 72:5517–5525.
228. Goodwin, M.A., S. Hafner, D.I. Bounous, and J. Brown. 1998. "Myeloid leukosis" is a misnomer: multiple and diverse tumor morphotypes are found in broiler breeder chickens that are infected with subgroup J avian leukosis/sarcoma viruses (J-ALSV). Proceedings, 135th AVMA Convention. Baltimore. 189 (Abstract).
229. Goubin, G., D.S. Goldman, J. Luce, P.E. Neiman, and G.M. Cooper. 1983. Molecular cloning and nucleotide sequence of a transforming gene detected by transfection of chicken B cell lymphoma DNA. *Nature.* 302:114–119.
230. Graf, T. 1975. *In vitro* transformation of chicken bone marrow cells with avian erythroblastosis virus. *Z Naturforsch [C].* 30:847–849.
231. Graf, T. 1972. A plaque assay for avian RNA tumor viruses. *Virology.* 50:567–578.
232. Graf, T., and H. Beug. 1978. Avian leukemia viruses: interaction with their target cells *in vivo* and *in vitro*. *Biochim Biophys Acta.* 516:269–299.
233. Graf, T., D. Fink, H. Beug, and B. Royer-Pokora. 1977. Oncornavirus-induced sarcoma formation obscured by rapid development of lethal leukemia. *Cancer Res.* 37:59–63.
234. Gray, E.R., C.J. Illingworth, J.M. Coffin, and J.P. Stoye. 2011. Binding of more than one Tva800 molecule is required for ASLV-A entry. *Retro Virology.* 8:96.
235. Groenen, M.A., H.J. Megens, Y. Zare, W.C. Warren, L.W. Hillier, R.P. Crooijmans, A. Vereijken, R. Okimoto, W.M. Muir, and H.H. Cheng. 2011. The development and characterization of a 60K SNP chip for chicken. *BMC Genomics.* 12:274.
236. Gross, M.A., B.R. Burmester, and W.G. Walter. 1959. Pathogenicity of a viral strain (RPL12) causing avian visceral lymphomatosis and related neoplasms. I. Nature of the lesions. *J Natl Cancer Inst*. 22:83–101.
237. Gudkov, A.V., E. Korec, M.V. Chernov, A.T. Tikhonenko, I. B. Obukh, and I. Hlozanek. 1986. Genetic structure of the endogenous proviruses and expression of the gag gene in Brown Leghorn chickens. *Folia Biol (Praha).* 32:65–72.
238. Hafner, S., M.A. Goodwin, E.J. Smith, D.I. Bounous, M. Puette, L.C. Kelley, K.A. Langheinrich, and A.M. Fadly. 1996. Multicentric histiocytosis in young chickens. Gross and light microscopic pathology. *Avian Dis*. 40:202–209.
239. Hafner, S., M.A. Goodwin, E.J. Smith, A. Fadly, and L.C. Kelley. 1998. Pulmonary sarcomas in a young chicken. *Avian Dis.* 42:824–828.
240. Hafner, S., S.M. Williams, and M.T. Sutton. 2007. Retroviral inclusions in the enteric smooth muscle of a tumor-bearing young chicken. *Avian Dis.* 51:133–136.
241. Haguenau, F., and J.W. Beard. 1962. The avian sarcoma-leukosis complex: Its biology and ultrastructure. In: *Tumors Induced by Viruses*. A.J. Dalton and F. Haguenau, eds. Academic Press, New York. 1–59.
242. Haguenau, F., H. Febvre, and J. Arnoult. 1960. [Ultrastructure of Rous sarcoma virus cultivated in vitro.] *C R Hebd Seances Acad Sci*. 250:1747–1749.
243. Hamilton, C.M., and C.E. Sawyer. 1939. Transmission of erythroleukosis in young chickens. *Poult Sci.* 18:388–393.
244. Harris, D.L., V.A. Garwood, P.C. Lowe, P.Y. Hester, L.B. Crittenden, and A.M. Fadly. 1984. Influence of sex-linked feathering phenotypes of parents and progeny upon lymphoid leukosis virus infection status and egg production. *Poult Sci.* 63:401–413.
245. Hatai, H., K. Ochiai, M. Murakami, S. Imanishi, Y. Tomioka, T. Toyoda, K. Ohashi, and T. Umemura. 2008. Prevalence of fowl glioma-inducing virus in chickens of zoological gardens in Japan and nucleotide variation in the env gene. *J Vet Med Sci.* 70:469–474.
246. Hatai, H., K. Ochiai, K. Nagakura, S. Imanishi, A. Ochi, R. Kozakura, M. Ono, M. Goryo, K. Ohashi, and T. Umemura. 2008. A recombinant avian leukosis virus associated with fowl glioma in layer chickens in Japan. *Avian Pathol.* 37:127–137.
247. Hatai, H., K. Ochiai, Y. Tomioka, T. Toyoda, K. Hayashi, M.Anada, M. Kato, A. Toda, K. Ohashi, E. Ono, T. Kimura, and T. Umemura. 2005. Nested polymerase chain reaction for detection of the avian leukosis virus causing so-called fowl glioma. *Avian Pathol.* 34:473–479.
248. Hauptli, D., L. Bruckner, and H.P. Ottiger. 1997. Use of reverse transcriptase polymerase chain reaction for detection of vaccine contamination by avian leukosis virus. *J Virol Methods.* 66: 71–81.
249. Hayward, W.S., and B.G. Neel. 1981. Retroviral gene expression. *Curr Top Microbiol Immunol.* 19:217–276.
250. Heine, U., G. De The, H. Ishiguro, J.R. Sommer, D. Beard, and J.W. Beard. 1962. Multiplicity of cell response to the BAI strain A (myeloblastosis) avian tumor virus. II. Nephroblastoma (Wilms' tumor): ultrastructure. *J Natl Cancer Inst*. 29:41–105.
251. Hihara, H., H. Yamamoto, H. Shimohira, K. Arai, and T. Shimizu. 1983. Avian erythroblastosis virus isolated from chick erythroblastosis induced by lymphatic leukemia virus subgroup A. *J Natl Cancer Inst.* 70:891–897.
252. Hirota, Y., M.T. Martin, M. Viljanen, P. Toivanen, and R.M. Franklin. 1980. Immunopathology of chickens infected *in ovo* and at hatching with the avian osteopetrosis virus MAV.2-0. *Eur J Immunol.* 10:929–936.
253. Hofmann, A., J. Plachy, L. Hunt, J. Kaufman, and K. Hala. 2003. v-src oncogene-specific carboxy-terminal peptide is immunoprotective against Rous sarcoma growth in chickens with MHC class I allele B-F12. *Vaccine.* 21:4694–4699.
254. Holmes, J.R. 1964. Avian osteopetrosis. *Natl Cancer Inst Monogr*. 17:63–79.
255. Humphries, E.H., and T.W. Baba. 1984. Follicular hyperplasia in the prelymphomatous avian bursa: relationship to the incidence of B cell lymphomas. *Curr Top Microbiol Immunol.* 113:47–55.

256. Humphries, E.H., and T.W. Baba. 1986. Restrictions that influence avian leukosis virus-induced lymphoid leukosis. *Curr Top Microbiol Immunol.* 132:215–220.
257. Hunt, H., A. Fadly, R. Silva, and H. Zhang. 2008. Survey of endogenous virus and TVB* receptor status of commercial chicken stocks supplying specific-pathogen-free eggs. *Avian Dis.* 52:433–440.
258. Hunt, H., B. Lupiani, and A.M. Fadly. 2000. Recombination between ALV-J and endogenous subgroup E viruses. In E.F. Kaleta, L.N. Payne, and U. Heffels-Redmann eds. Proceedings, International Symposium on ALV–J and Other Avian Retroviruses. Rauischholzhausen, Germany. 50–60.
259. Hunt, H.D., L.F. Lee, D. Foster, R.F. Silva, and A.M. Fadly. 1999. A genetically engineered cell line resistant to subgroup J avian leukosis virus infection (C/J). *Virology.* 264:205–210.
260. Hussain, A.I., J.A. Johnson, M. Da Silva Freire, and W. Heneine. 2003. Identification and characterization of avian retroviruses in chicken embryo-derived yellow fever vaccines: investigation of transmission to vaccine recipients. *J Virol.* 77:1105–1111.
261. Hussain, A.I., V. Shanmugam, W.M. Switzer, S.X. Tsang, A. Fadly, D. Thea, R. Helfand, W. Bellini, T.M. Folks, and W. Heneine. 2001. Lack of evidence of endogenous avian leukosis virus and endogenous avian retrovirus transmission to measles, mumps and rubella vaccine recipients. *Emerg Infect Dis.* 7: 66–72.
262. Hussain, A.I., V. Shanmugam, W.M. Switzer, S.X. Tsang, A. Fadly, D. Thea, R. Helfand, W.J. Bellini, T.M. Folks, and W. Heneine. 2001. Lack of evidence of endogenous avian leukosis virus and endogenous avian retrovirus transmission to measles, mumps, and rubella vaccine recipients. *Emerg Infect Dis.* 7:66–72.
263. Ignjatovic, J. 1990. Congenital transmission of avian leukosis virus in the absence of detectable shedding of group specific antigen. *Aust Vet J.* 67:299–301.
264. Ignjatovic, J. 1986. Replication-competent endogenous avian leukosis virus in commercial lines of meat chickens. *Avian Dis.* 30:264–270.
265. Ignjatovic, J., R.A. Fraser, and T.J. Bagust. 1986. Effect of lymphoid leukosis virus on performance of layer hens and the identification of infected chickens by tests on meconia. *Avian Pathol.* 15:63–74.
266. Ishiguro, H., D. Beard, J.R. Sommer, U. Heine, d. Thé, and J.W. Beard. 1962. Multiplicity of cell response to the BAI strain A (myeloblastosis) avian tumor virus. I. Nephroblastoma (Wilms' tumor): Gross and microscopic pathology. *J Natl Cancer Inst*. 29:1–39.
267. Ishizaki, R., A.J. Langlois, and D.P. Bolognesi. 1975. Isolation of two subgroup-specific leukemogenic viruses from standard avian myeloblastosis virus. *J Virol.* 15:906–912.
268. Iwata, N., K. Ochiai, K. Hayashi, K. Ohashi, and T. Umemura. 2002. Nonsuppurative myocarditis associated with so-called fowl glioma. *J Vet Med Sci.* 64:395–399.
269. Jármai, K. 1933. Infektioseversuche bebrüteter Eier mit dem 'Virus' der Hühnererythroleukose. *Dtsch Tierarztl Wschr.* 41: 418–420.
270. Johnson, E.S., Y. Zhou, C.L. Yau, V. Sarda, N. Preacely, S. Bankuru, S. Bangara, M. Felini, and H. Ndetan. 2011. Update of cancer and non-cancer mortality in the Missouri poultry cohort. *Am J Ind Med.* 54:49–54.
271. Joliot, V., K. Boroughs, F. Lasserre, J. Crochet, G. Dambrine, R.E. Smith, and B. Perbal. 1993. Pathogenic potential of myeloblastosis-associated virus: implication of env proteins for osteopetrosis induction. *Virology.* 195:812–819.
272. Joliot, V., C. Martinerie, G. Dambrine, G. Plassiart, M. Brisac, J. Crochet, and B. Perbal. 1992. Proviral rearrangements and overexpression of a new cellular gene (nov) in myeloblastosis-associated virus type 1-induced nephroblastomas. *Mol Cell Biol.* 12:10–21.
273. Jungherr, E.L. 1941. Tentative pathologic nomenclature for the disease complex variously designated as fowl leucemia, fowl leucosis, etc. *Am J Vet Res.* 2:116.
274. Jungherr, E.L., and W. Landauer. 1938. Studies on fowl paralysis. III. A condition resembling osteopetrosis (marble bone) in the common fowl. *Storrs Agric Exp Stn Bull 222*.
275. Ka, S., S. Kerje, L. Bornold, U. Liljegren, P.B. Siegel, L. Andersson and F. Hallbook. 2009. Proviral integrations and expression of endogenous avian leucosis virus during long term selection for high and low body weight in two chicken lines. *Retro Virology.* 6:68.
276. Kakuk, T.J., F.R. Frank, and T.E. Weddon. 1977. Avian lymphoid leukosis prophylaxis with mibolerone. *Avian Dis.* 21: 280–289.
277. Kanter, M.R., R.E. Smith, and W.S. Hayward. 1988. Rapid induction of B cell lymphomas: insertional activation of c-myb by avian leukosis virus. *J Virol.* 62:1423–1432.
278. Kawai, S., and H. Hanafusa. 1972. Plaque assay for some strains of avian leukosis virus. *Virology.* 48:126–135.
279. Kelloff, G., M. Hatanaka. and R.V. Gilden. 1972. Assay of C-type virus infectivity by measurement of RNA-dependent DNA polymerase activity. *Virology.* 48:266–269.
280. Kelloff, G., and P.K. Vogt. 1966. Localization of avian tumor virus group-specific antigen in cell and virus. *Virology.* 29:377–384
281. Kim, Y., and T.P. Brown. 2004. Development of quantitative competitive-reverse transcriptase-polymerase chain reaction for detection and quantitation of avian leukosis virus subgroup J. *J Vet Diagn Invest.* 16:191–196.
282. Kirev, T., R.A. Woutersen and A. Kiril. 1999. Effects of long term feeding of raw soya bean flour on virus-induced pancreatic carcinogenesis in guinea fowl. *Cancer Lett.* 135:195–202.
283. Kirev, T., R.A. Woutersen, and A. Kril. 2002. Effects of dietary fat on virus-induced pancreatic carcinogenesis in guinea fowl. *Nutr Cancer.* 42:98–104.
284. Kirev, T.T. 1988. Neoplastic response of guinea fowl to osteopetrosis virus strain MAV-2(0). *Avian Pathol.* 17:101–112.
285. Kirev, T.T., I.A. Toshkov, and Z.M. Mladenov. 1989. Pathogenic effect of osteopetrosis virus strain MAV-2(0) on guinea fowl pancreas. *Int J Pancreatol.* 5:29–34.
286. Kirev, T.T., I.A. Toshkov, and Z.M. Mladenov. 1986. Virus-induced pancreatic cancer in guinea fowl: a morphologic study. *J Natl Cancer Inst.* 77:713–720.
287. Kirev, T.T., T.A. Toshkov, and Z.M. Mladenov. 1987. Virus-induced duodenal adenomas in guinea fowl. *J Natl Cancer Inst.* 79:1117–1121.
288. Klucking, S., H.B. Adkins, and J.A. Young. 2002. Resistance to infection by subgroups B, D, and E avian sarcoma and leukosis viruses is explained by a premature stop codon within a resistance allele of the tvb receptor gene. *J Virol.* 76:7918–7921.
289. Klucking, S., A.S. Collins, and J.A. Young. 2005. Avian sarcoma and leukosis virus cytopathic effect in the absence of TVB death domain signaling. *J Virol.* 79:8243–8248.
290. Klucking, S., and J.A. Young. 2004. Amino acid residues Tyr-67, Asn-72, and Asp-73 of the TVB receptor are important for subgroup E avian sarcoma and leukosis virus interaction. *Virology.* 318:371–380.

291. Kumanishi, T. 1967. Brain tumors induced with Rous sarcoma virus, Schmidt-Ruppin strain. I. Induction of brain tumors in adult mice with Rous chicken sarcoma cells. *Jpn J Exp Med*. 37:461–474.
292. Kumanishi, T., F. Ikuta, K. Nishida, K. Ueki, and T. Yamamoto. 1973. Brain tumors induced in adult monkeys by Schmidt-Ruppin strain of Rous sarcoma virus. *Gann.* 64:641–643.
293. Kumanishi, T., F. Ikuta and T. Yamamoto. 1973. Brain tumors induced by Rous sarcoma virus, Schmidt-Ruppin strain. 3. Morphology of brain tumors induced in adult mice. *J Natl Cancer Inst*. 50:95–109.
294. Kumanishi, T., and T. Yamamoto. 1970. Brain tumors induced with Rous sarcoma virus, Schmidt-Ruppin strain. 2. Rous tumor specific transplantation antigen in subcutaneously passaged mouse brain tumors. *Jpn J Exp Med*. 40:79–86.
295. Kung, H.J., and J.L. Liu. 1997. Retroviral oncogenesis. In: *Viral Pathogenesis*. N. Nathanson, ed. Lippincott-Raven Publishers, Philadelphia. 235–266.
296. Kung, H.J., and N.J. Maihle. 1987. Molecular basis of oncogenesis by non-acute avian retroviruses. In: *Avian Leukosis*, G.F. De Boer, ed. Martinus Nijhoff, Boston. 77–100.
297. Kurth, R., and H. Bauer. 1972. Cell-surface antigens induced by avian RNA tumor viruses: Detection by a cytotoxic microassay. *Virology.* 47:426–433.
298. Kurth, R., E.M. Fenyo, E. Klein, and M. Essex. 1979. Cell-surface antigens induced by RNA tumour viruses. *Nature.* 279:197–201.
299. Labat, M.L. 1986. Retroviruses, immunosuppression and osteopetrosis. *Biomed Pharmacother.* 40:85–90.
300. Lagerloef, B., and P. Sundelin. 1963. Variations in the pathogenic effect of myeloid fowl leukaemia virus. *Acta Pathol Microbiol Scand.* 59:129–144.
301. Lagerlof, B., and P. Sundelin. 1963. The histogenesis and haematology of virus-induced myeloid leukemia in the fowl. *Acta Haematol.* 30:111–122.
302. Lai, H., H. Zhang, Z. Ning, R. Chen, W. Zhang, A. Qing, C. Xin, K. Yu, W. Cao, and M. Liao. 2011. Isolation and characterization of emerging subgroup J avian leukosis virus associated with hemangioma in egg-type chickens. *Vet MicroBiol.* 151:275–283.
303. Landman, W.J., J. Post, A.G. Boonstra-Blom, J. Buyse, A.R. Elbers, and G. Koch. 2002. Effect of an *in ovo* infection with a Dutch avian leukosis virus subgroup J isolate on the growth and immunological performance of SPF broiler chickens. *Avian Pathol.* 31:59–72.
304. Langlois, A.J., R. Ishizaki, G.S. Beaudreau, J.F. Kummer, J.W. Beard, and D.P. Bolognesi. 1976. Virus-infected avian cell lines established *in vitro*. *Cancer Res.* 36:3894–3904.
305. Langlois, A.J., K. Lapis, R. Ishizaki, J.W. Beard, and D.P. Bolognesi. 1974. Isolation of a transplantable cell line induced by the MC29 avian leukosis virus. *Cancer Res.* 34:1457–1464.
306. Lapis, K. 1979. Histology and ultrastructural aspects of virus-induced primary liver cancer and transplantable hepatomas of viral origin in chickens. *J Toxicol Environ Health.* 5:469–501.
307. Lee, L.F., A.M. Fadly, and H.D. Hunt. 2000. Avian leukosis virus subgroup J envelope gene product for diagnosis and immunogenic composition. United States Patent. #6:146,641.
308. Lee, R.M., G. Gillet, and P. Neiman. 1998. Molecular events in avian neoplasia: regulation of cell death in development of B cell lymphomas in the chicken bursa of Fabricius. *Avian Pathol.* 27:S16–S20.
309. Lee, S.-H., P. Eldi, S.-Y. Cho and D. Rangasamy. 2009. Control of chicken CR1 retrotransposons is independent of Dicer-mediated RNA interference pathway. *BMC Biology* 7:53.
310. Li, N., B. Xu, W. Dong, S. Qiao, L.F. Lee, H.M. Zhang, M. Li and N. Du. 2007. Detection and localization of naturally transmitted avian leukosis subgroup J virus in egg-type chickens by in situ PCR hybridization. *J Vet Med A Physiol Pathol Clin Med* 54:553–558.
311. Li, X., L. Krishnan, P. Cherepanov and A. Engelman. 2011. Structural biology of retroviral DNA integration. *Virology.* 411:194–205.
312. Liu, C., S. Zheng, Y. Wang, L. Jing, H. Gao, Y. Gao, X. Qi, L. Qin, W. Pan, and X. Wang. 2011. Detection and molecular characterization of recombinant avian leukosis viruses in commercial egg-type chickens in China. *Avian Pathol.* 40:269–275.
313. Lobmayr, L., T. Sauer, I. Killisch, M. Schranzhofer, R.B. Wilson, P. Ponka, H. Beug, and E.W. Mullner. 2002. Transferrin receptor hyperexpression in primary erythroblasts is lost on transformation by avian erythroblastosis virus. *Blood.* 100:289–298.
314. Luciw, P.A., and N.J. Leung. 1992. Mechanisms of retroviral replication. In: *The Retroviridae*, Vol. 1. J.A. Levy, ed. Plenum Press, New York. 159–298.
315. Lupiani, B., A. Pandiri, J. Mays, H. Hunt, and A. Fadly. 2006. Molecular and biological characterization of a naturally occurring recombinant subgroup B avian leukosis virus (ALV) with a subgroup J like long terminal repeat (LTR). *Avian Dis.* 50(4): 572–8.
316. Lupiani, B., H. Hunt, R. Silva, and A. Fadly. 2000. Identification and characterization of recombinant subgroup J avian leukosis viruses (ALV) expressing subgroup A ALV envelope. *Virology.* 276:37–43.
317. Lupiani, B., S.M. Williams, R.F. Silva, H.D. Hunt, and A.M. Fadly. 2003. Pathogenicity of two recombinant avian leukosis viruses. *Avian Dis.* 47:425–432.
318. Ma, Y.K., and A.S. Khan. 2009. Evaluation of different RT enzyme standards for quantitation of retroviruses using the single-tube fluorescent product-enhanced reverse transcriptase assay. *J Virol Methods.* 157:133–140.
319. Maas, H.J.L., G.F. d. Boer, and J.E. Groenendal. 1982. Age related resistance to avian leukosis virus. III. Infectious virus, neutralising antibody, and tumours in chickens inoculated at various ages. *Avian Pathol*. 11:309–327.
320. Maeda, N., H. Fan, and Y. Yoshikai. 2008. Oncogenesis by retroviruses: old and new paradigms. *Rev Med Virol.* 18:387–405.
321. Malkinson, M., C. Banet-Noach, I. Davidson, A.M. Fadly, and R.L. Witter. 2004. Comparison of serological and virological findings from subgroup J avian leukosis virus-infected neoplastic and non-neoplastic flocks in Israel. *Avian Pathol.* 33:281–287.
322. Marsh, J.D., L.D. Bacon, and A.M. Fadly. 1995. Effect of serotype 2 and 3 Marek's disease vaccines on the development of avian leukosis virus-induced pre-neoplastic bursal follicles. *Avian Dis.* 39:743–751.
323. Masegi, T., Y. Inoue, T. Yanai, and K. Ueda. 1993. An ultrastructural study of cutaneous hemangioma in two chickens. *J Vet Med Sci.* 55:185–188.
324. McBride, M.A.T., and R.M. Shuman. 1988. Immune response of chickens inoculated with a recombinant avian leukosis virus. *Avian Dis.* 32:96–102.
325. McNagny, K.M., and T. Graf. 1996. Acute avian leukemia viruses as tools to study hematopoietic cell differentiation. *Curr Top Microbiol Immunol.* 212:143–162.

326. McNagny, K.M., and T. Graf. 2003. E26 leukemia virus converts primitive erythroid cells into cycling multilineage progenitors. *Blood.* 101:1103–1110.
327. McNally, M.M., K.J. Wahlin, and M.V. Canto-Soler. 2010. Endogenous expression of ASLV viral proteins in specific pathogen free chicken embryos: relevance for the developmental biology research field. *BMC Dev Biol* 10:106.
328. Meng, Q.W., Z.P. Zhang, W. Wang, J. Tian, and Z.G. Xiao. 2011. Enhanced inhibition of Avian leukosis virus subgroup J replication by multi-target miRNAs. *Virol J.* 8:556.
329. Meyers, P. 1976. Antibody response to related leukosis viruses induced in chickens tolerant to an avian leukosis virus. *J Natl Cancer Inst.* 56:381–386.
330. Meyers, P., and R.M. Dougherty. 1972. Analysis of immunoglobulins in chicken antibody to avian leucosis viruses. *Immunology.* 23:1–6.
331. Miles, B.D., and H.L. Robinson. 1985. High-frequency transduction of c-erbB in avian leukosis virus-induced erythroblastosis. *J Virol.* 54:295–303.
332. Mizuno, Y., and K. Arai. 1981. Assay of avian leukosis viruses by indirect immunoperoxidase method. *Natl Inst Anim Health Q (Tokyo)*. 21:63–67.
333. Mizuno, Y., and H. Hatakeyama. 1983. Detection of antibodies against avian leukosis viruses with indirect immunoperoxidase absorbance test. *Nippon Juigaku Zasshi* 45:31–37.
334. Mizuno, Y., and S. Itohara. 1986. Enzyme-linked immunosorbent assay to detect subgroup-specific antibodies to avian leukosis viruses. *Am J Vet Res.* 47:551–556.
335. Mladenov, Z., U. Heine, D. Beard, and J.W. Beard. 1967. Strain MC29 avian leukosis virus. Myelocytoma, endothelioma, and renal growths: pathomorphological and ultrastructural aspects. *J Natl Cancer Inst*. 38:251–285.
336. Mladenov, Z., S. Nedyalkov, I. Ivanov, and I. Toshkov. 1980. Neoplastic growths in chickens treated with cell and cell-free material from transplantable hepatoma induced by virus strain MC-29. *Neoplasma.* 27:175–182.
337. Moloney, J.B. 1956. Biological studies on the Rous sarcoma virus. V. Preparation of improved standard lots of the virus for use in quantitative investigations. *J Natl Cancer Inst.* 16:877–888.
338. Moscovici, C. 1975. Leukemic transformation with avian myeloblastosis virus: present status. *Curr Top Microbiol Immunol.* 71:79–101.
339. Moscovici, C., and L. Gazzolo. 1987. Virus-cell interactions of avian sarcoma and defective leukemia viruses. In: *Avian Leukosis*. G.F. De Boer, ed. Martinus Nijhoff, Boston. 153–170.
340. Moscovici, C., L. Gazzolo, and M.G. Moscovici. 1975. Focus assay and defectiveness of avian myeloblastosis virus. *Virology.* 68:173–181.
341. Moscovici, M.G., and C. Moscovici. 1980. AMV-induced transformation of hemopoietic cells: Growth patterns of producers and nonproducers. In: *In Vivo* and *In Vitro* Erythropoiesis: The Friend System. G.B. Rossi, ed. Elsevier/North Holland Biomedical Press: Amsterdam, The Netherlands. 503–514.
342. Motta, J.V., L.B. Crittenden, and W.O. Pollard. 1973. The inheritance of resistance to subgroup C leukosis-sarcoma viruses in New Hampshire chickens. *Poult Sci.* 52:578–586.
343. Motta, J.V., L.B. Crittenden, H.G. Purchase, H.A. Stone, and R.L. Witter. 1975. Low oncogenic potential of avian endogenous RNA tumor virus infection or expression. *J Natl Cancer Inst.* 55:685–689.
344. Munguia, A., and M.J. Federspiel. 2008. Efficient subgroup C avian sarcoma and leukosis virus receptor activity requires the IgV domain of the Tvc receptor and proper display on the cell membrane. *J Virol.* 82:11419–11428.
345. Murase, A., N. Tamura, N. Matsui, and M. Nakamura. 1997. Histopathological studies on hemangioma in broilers at meat inspection. *J Jpn Soc Poult Dis.* 33:228–232.
346. Nair, V. 2008. Retrovirus-induced oncogenesis and safety of retroviral vectors. *Curr Opin Mol Ther.* 10:431–438.
347. Nair, V. 2008. Tumors of the avian immune system. In: *Avian Immunology*. T.F. Davison, B. Kaspers, and K.A. Schat, eds., Academic Press, London. 359–372.
348. Nakamura, K., F. Abe, H. Hihara, and T. Taniguchi. 1988. Myocardial cytoplasmic inclusions in chickens with hemangioma and lymphoid leukosis. *Avian Pathol.* 17:3–10.
349. Nakamura, K., M. Ogiso, K. Tsukamoto, N. Hamazaki, H. Hihara, and N. Yuasa. 2000. Lesions of bone and bone marrow in myeloid leukosis occurring naturally in adult broiler breeders. *Avian Dis.* 44:215–221.
350. Nakamura, S., K. Ochiai, H. Hatai, A. Ochi, Y. Sunden, and T. Umemura. 2011. Pathogenicity of avian leukosis viruses related to fowl glioma-inducing virus. *Avian Pathol.* 40: 499–505.
351. Nehyba, J., J. Svoboda, I. Karakoz, J. Geryk, and J. Hejnar. 1990. Ducks: a new experimental host system for studying persistent infection with avian leukaemia retroviruses. *J Gen Virol.* 71 (Pt 9):1937–1945.
352. Neiman, P. 1985. The Blym oncogenes. *Adv Cancer Res*. 45:107–123.
353. Neiman, P.E., K. Elsaesser, G. Loring, and R. Kimmel. 2008. Myc oncogene-induced genomic instability: DNA palindromes in bursal lymphomagenesis. *PLoS Genet.* 4:e1000132.
354. Neiman, P.E., L. Jordan, R.A. Weiss, and L.N. Payne. 1980. Malignant lymphoma of the bursa of Fabricius: Analysis of early transformation. In: *Cold Spring Harbor Conference Cell Proliferation*. Cold Spring Harbor Laboratory, New York. 519–528.
355. Neiman, P.E., R. Kimmel, A. Icreverzi, K. Elsaesser, S.J. Bowers, J. Burnside, and J. Delrow. 2006. Genomic instability during Myc-induced lymphomagenesis in the bursa of Fabricius. *Oncogene.* 25(47):6325–35
356. Neiman, P.E., A. Ruddell, C. Jasoni, G. Loring, S.J. Thomas, K.A. Brandvold, R. Lee, J. Burnside, and J. Delrow. 2001. Analysis of gene expression during myc oncogene-induced lymphomagenesis in the bursa of Fabricius. *Proc Natl Acad Sci USA*. 98:6378–6383.
357. Neumann, U., and R.L. Witter. 1979. Differential diagnosis of lymphoid leukosis and Marek's disease by tumor-associated criteria. I. Studies on experimentally infected chickens. *Avian Dis*. 23::417–425.
358. Neumann, U., and R.L. Witter. 1979. Differential diagnosis of lymphoid leukosis and Marek's disease by tumor-associated criteria. II. Studies on field cases. *Avian Dis*. 23:426–433.
359. Nikiforov, M.A., and A.V. Gudkov. 1994. ART-CH: a VL30 in chickens? *J Virol.* 68:846–853.
360. Ning, Z.Y., Y.F. An, W.B. Qi, H. Wang, J.Q. Pan, X.T. Wu, and M. Liao. 2012. Na(+)/H (+) exchanger 1 gene expression in tissues of yellow chicken. *Biochem Genet.* 50:227–234.
361. Nouvion, A.L., J. Thibaut, O.D. Lohez, S. Venet, P. Colas, G. Gillet, and P. Lalle. 2007. Modulation of Nr-13 antideath activity by peptide aptamers. *Oncogene.* 26:701–710.

362. Oberling, C., and M. Guérin. 1933. Lesions tumorales en rapport avec la leucémie transmissible des poules. *Bull Cancer.* 22.
363. Ochiai, K., K. Ohashi, T. Mukai, T. Kimura, T. Umemura, and C. Itakura. 1999. Evidence of neoplastic nature and viral aetiology of so-called fowl glioma. *Vet Rec.* 145:79–81.
364. Okazaki, W., B.R. Burmester, A. Fadly, and W.B. Chase. 1979. An evaluation of methods for eradication of avian leukosis virus from a commercial breeder flock. *Avian Dis.* 23:688–697.
365. Okazaki, W., A. Fadly, B.R. Burmester, W.B. Chase, and L.B. Crittenden. 1980. Shedding of lymphoid leukosis virus in chickens following contact exposure and vaccination. *Avian Dis.* 24:474–480.
366. Okazaki, W., H.G. Purchase, and B.R. Burmester. 1975. Phenotypic mixing test to detect and assay avian leukosis viruses. *Avian Dis.* 19:311–317.
367. Okazaki, W., H.G. Purchase, and L.B. Crittenden. 1982. Pathogenicity of avian leukosis viruses. *Avian Dis.* 26:553–559.
368. Okazaki, W., R.L. Witter, C. Romero, K. Nazerian, J.M. Sharma, A.M. Fadly, and D. Ewert. 1980. Induction of lymphoid leukosis transplantable tumours and the establishment of lymphoblastoid cell lines. *Avian Pathol.* 9:311–329.
369. Pajer, P., V. Pecenka, V. Karafiat, J. Kralova, Z. Horejsi and M. Dvorak. 2003. The twist gene is a common target of retroviral integration and transcriptional deregulation in experimental nephroblastoma. *Oncogene.* 22:665–673.
370. Pajer, P., V. Pecenka, J. Kralova, V. Karafiat, D. Prukova, Z. Zemanova, R. Kodet, and M. Dvorak. 2006. Identification of potential human oncogenes by mapping the common viral integration sites in avian nephroblastoma. *Cancer Res.* 66:78–86.
371. Pan, W., Y. Gao, L. Qin, W. Ni, Z. Liu, B. Yun, Y. Wang, X. Qi, H. Gao, and X. Wang. 2012. Genetic diversity and phylogenetic analysis of glycoprotein GP85 of ALV-J isolates from Mainland China between 1999 and 2010: Coexistence of two extremely different subgroups in layers. *Vet MicroBiol.* 156:205–212.
372. Pan, W., Y. Gao, F. Sun, L. Qin, Z. Liu, B. Yun, Y. Wang, X. Qi, H. Gao, and X. Wang. 2011. Novel sequences of subgroup J avian leukosis viruses associated with hemangioma in Chinese layer hens. *Virol J.* 8:552.
373. Pandiri, A.R., I.M. Gimeno, W.M. Reed, S.D. Fitzgerald, and A.M. Fadly. 2009. Subgroup J avian leukosis virus-induced histiocytic sarcomatosis occurs only in persistently viremic but not immunotolerized meat-type chickens. *Vet Pathol.* 46:282–287.
374. Pandiri, A.R., J.K. Mays, R.F. Silva, H.D. Hunt, W.M. Reed, and A.M. Fadly. 2010. Subgroup J avian leukosis virus neutralizing antibody escape variants contribute to viral persistence in meat-type chickens. *Avian Dis.* 54:848–856.
375. Pandiri, A.R., W.M. Reed, J.K. Mays, and A.M. Fadly. 2007. Influence of strain, dose of virus, and age at inoculation on subgroup J avian leukosis virus persistence, antibody response, and oncogenicity in commercial meat-type chickens. *Avian Dis.* 51:725–732.
376. Panet, A., D. Baltimore, and T. Hanafusa. 1975. Quantitation of avian RNA tumor virus reverse transcriptase by radioimmunoassay. *J Virol.* 16:146–152.
377. Pani, P.K., and P.M. Biggs. 1973. Genetic control of susceptibility to an A subgroup sarcoma virus in commercial chickens. *Avian Pathol.* 2:27–41.
378. Payne, F.E., J.J. Solomon, and H.G. Purchase. 1966. Immunofluorescent studies of group-specific antigen of the avian sarcoma-leukosis viruses. *Proc Natl Acad Sci USA*. 55:341–349.
379. Payne, L.N. 1992. Biology of avian retroviruses. In: *The Retroviridae*, Vol. 1. J.A. Levy, ed. Plenum Press, New York. 299–404.
380. Payne, L.N. 1992. Biology of avian retroviruses. In: J. Levy (ed.). *The Retroviridae, Plenum Press: New York*. vol 1:299–404.
381. Payne, L.N. 1987. Epizootiology of avian leukosis virus infections. In: *Avian Leukosis*. G.F. De Boer, ed. Martinus Nijhoff, Boston. 47–76.
382. Payne, L.N. 1985. Historical review. In: *Marek's Disease*. L.N. Payne, ed. Martinus Nijhoff, Boston, MA. 1–15.
383. Payne, L.N. 2000. History of ALV-J. In: *International Symposium on ALV-J and Other Avian Retroviruses*. E.F. Kaleta, L.N. Payne, U. Heffels-Redmann, eds. Rauischholzhausen, Germany. 3–12.
384. Payne, L.N. 1981. Immunity to lymphoid leukosis, Rous sarcoma, and reticuloendotheliosis. In: *Avian Immunology*. M.E. Rose, L.N. Payne, B. M. Freeman, eds. British Poultry Science: Edinburgh. 285–299.
385. Payne, L.N. 1998. Retrovirus-induced disease in poultry. *Poult Sci.* 77:1204–1212.
386. Payne, L.N., S.R. Brown, N. Bumstead, K. Howes, J.A. Frazier, and M.E. Thouless. 1991. A novel subgroup of exogenous avian leukosis virus in chickens. *J Gen Virol.* 72 (Pt 4):801–807.
387. Payne, L.N., and N. Bumstead. 1982. Theoretical considerations on the relative importance of vertical and horizontal transmission for the maintenance of infection by exogenous avian lymphoid leukosis virus. *Avian Pathol.* 11:547–553.
388. Payne, L.N., A.M. Gillespie, and K. Howes. 1992. Myeloid leukaemogenicity and transmission of the HPRS-103 strain of avian leukosis virus. *Leukemia.* 6:1167–1176.
389. Payne, L.N., A.M. Gillespie, and K. Howes. 1993. Recovery of acutely transforming viruses from myeloid leukosis induced by the HPRS-103 strain of avian leukosis virus. *Avian Dis.* 37:438–450.
390. Payne, L.N., A.M. Gillespie, and K. Howes. 1993. Unsuitability of chicken sera for detection of exogenous ALV by the group-specific antigen ELISA. *Vet Rec.* 132:555–557.
391. Payne, L.N., A.E. Holmes, K. Howes, M. Pattison, D.L. Pollock, and D.E. Waters. 1982. Further studies on the eradication and epizootiology of lymphoid leukosis virus infection in a commercial strain of chickens. *Avian Pathol.* 11:145–162.
392. Payne, L.N., and K. Howes. 1991. Eradication of exogenous avian leukosis virus from commercial layer breeder lines. *Vet Rec.* 128:8–11.
393. Payne, L.N., K. Howes, and D.F. Adene. 1985. A modified feather pulp culture method for determining the genetic susceptibility of adult chickens to leukosis-sarcoma viruses. *Avian Pathol.* 14:261–265.
394. Payne, L.N., K. Howes, A.M. Gillespie, and L.M. Smith. 1992. Host range of Rous sarcoma virus pseudotype RSV (HPRS-103) in 12 avian species: Support for a new avian retrovirus envelope subgroup, *designated* J. *J Gen Virol.* 2995–2997.
395. Payne, L.N., and V. Nair. 2012. The long view: 40 years of avian leukosis research. *Avian Pathol.* 41:1–9.
396. Payne, L.N., P.K. Pani, and R.A. Weiss. 1971. A dominant epistatic gene which inhibits cellular susceptibility to RSV(RAV-0). *J Gen Virol.* 13:455–462.
397. Payne, L.N., and M. Rennie. 1975. B cell antigen markers on avian lymphoid leukosis tumour cells. *Vet Rec.* 96:454–456.
398. Payne, L.N., and K. Venugopal. 2000. Neoplastic diseases: Marek's disease, avian leukosis and reticuloendotheliosis. *Rev Sci Tech.* 19:544–564.

399. Perek, M. 1960. An epizootic of histiocytic sarcomas in chickens induced by a cell-free agent. *Avian Dis.* 4:85–94.
400. Peterson, R.D., H.G. Purchase, B.R. Burmester, M.D. Cooper, and R.A. Good. 1966. Relationships among visceral lymphomatosis, bursa of Fabricius, and bursa-dependent lymphoid tissue of the chicken. *J Natl Cancer Inst.* 36:585–598.
401. Pham, T.D., J.L. Spencer, and E.S. Johnson. 1999. Detection of avian leukosis virus in albumen of chicken eggs using reverse transcription polymerase chain reaction. *J Virol Methods.* 78:1–11.
402. Pham, T.D., J.L. Spencer, V.L. Traina-Dorge, D.A. Mullin, R.F. Garry, and E.S. Johnson. 1999. Detection of exogenous and endogenous avian leukosis virus in commercial chicken eggs using reverse transcription polymerase chain reaction assay. *Avian Pathol.* 28:382–389.
403. Pinard-van der Laan, M.H., D. Soubieux, L. Merat, D. Bouret, G. Luneau, G. Dambrine, and P. Thoraval. 2004. Genetic analysis of a divergent selection for resistance to Rous sarcomas in chickens. *Genet Sel Evol.* 36:65–81.
404. Piraino, F., W. Okazaki, B.R. Burmester, and T.N. Fredrickson. 1963. Bioassay of fowl leukosis virus in chickens by the inoculation of 11-day-old embryos. *Virology.* 21:396–401.
405. Pizer, E., and E.H. Humphries. 1989. RAV-1 insertional mutagenesis: disruption of the c-myb locus and development of avian B cell lymphomas. *J Virol.* 63:1630–1640.
406. Plachy, J., J. Kotab, P. Divina, M. Reinisova, F. Senigl, and J. Hejnar. 2010. Proviruses selected for high and stable expression of transduced genes accumulate in broadly transcribed genome areas. *J Virol.* 84:4204–4211.
407. Ponten, J. 1962. Transmission *in vivo* of chicken erythroblastosis by intact cells. *J Cell Comp Physiol.* 60:209–215.
408. Pope, C.R., E.M. Odor, and M. Salem. 1999. Unusual eye lesions associated with ALV-J virus. Proceedings, 28th Western Poultry Disease Conference. 96–97.
409. Powell, P.C., L.N. Payne, J.A. Frazier, and M. Rennie. 1974. T lymphoblastoid cell lines from Marek's disease lymphomas. *Nature.* 251:79–80.
410. Praharaj, N., C. Beaumont, G. Dambrine, D. Soubieux, L. Merat, D. Bouret, G. Luneau, J.M. Alletru, M.H. Pinard-Van der Laan, P. Thoraval, and S. Mignon-Grasteau. 2004. Genetic analysis of the growth curve of Rous sarcoma virus-induced tumors in chickens. *Poult Sci.* 83:1479–1488.
411. Price, J.A., and R.E. Smith. 1981. Influence of bursectomy on bone growth and anemia induced by avian osteopetrosis viruses. *Cancer Res.* 41:752–759.
412. Pugh, L.P. 1927. Sporadic diffuse osteoperiostitis in fowls. *Vet Rev.* 7:189–190.
413. Pulaski, J.T., V.L. Tieber, and P.M. Coussens. 1992. Marek's disease virus-mediated enhancement of avian leukosis virus gene expression and virus production. *Virology.* 186:113–121.
414. Purchase, H.G. 1987. Pathogenesis and pathology of neoplasms caused by avian leukosis viruses. In: *Avian Leukosis*. G.F. De Boer, ed. Martinus Nijhoff, Boston. 171–196.
415. Purchase, H.G., and N.F. Cheville. 1975. Infectious bursal agent of chickens reduces the incidence of lymphoid leukosis. *Avian Pathol.* 4:239–245.
416. Purchase, H.G., and A.M. Fadly. 1980. Leukosis and sarcomas. In: *Isolation and Identification of Avian Pathogens*. S.B. Hitchner, C.H. Domermuth, H.G. Purchase, and J.E. Williams eds. *American Association of Avian Pathologists: Kennett Square, PA*. 54–58.
417. Purchase, H.G., and D.G. Gilmour. 1975. Lymphoid leukosis in chickens chemically bursectomized and subsequently inoculated with bursa cells. *J Natl Cancer Inst.* 55:851–855.
418. Purchase, H.G., and W. Okazaki. 1964. Morphology of foci produced by standard preparation of Rous sarcoma virus. *J Natl Cancer Inst.* 32:579–586.
419. Purchase, H.G., W. Okazaki, P.K. Vogt, H. Hanafusa, B.R. Burmester, and L.B. Crittenden. 1977. Oncogenicity of avian leukosis viruses of different subgroups and of mutants of sarcoma viruses. *Infect Immun.* 15:423–428.
420. Purchase, H.G., and J.M. Sharma 1973. *The Differential Diagnosis of Lymphoid Leukosis and Marek's Disease: Slide Study Set 3*. American Association of Avian Pathologists. Kennett Square, PA.
421. Qin, A., L.F. Lee, A. Fadly, H. Hunt, and Z. Cui. 2001. Development and characterization of monoclonal antibodies to subgroup J avian leukosis virus. *Avian Dis.* 45:938–945.
422. Qiu, Y., K. Qian, H. Shen, W. Jin, and A. Qin. 2011. Development and validation of an indirect enzyme-linked immunosorbent assay for the detection of avian leukosis virus antibodies based on a recombinant capsid protein. *J Vet Diagn Invest.* 23:991–993.
423. Reinisova, M., J. Plachy, K. Trejbalova, F. Senigl, D. Kucerova, J. Geryk, J. Svoboda, and J. Hejnar. 2012. Intronic deletions that disrupt mRNA splicing of the tva receptor gene result in decreased susceptibility to infection by avian sarcoma and leukosis virus subgroup A. *J Virol.* 86:2021–2030.
424. Reinisova, M., F. Senigl, X. Yin, J. Plachy, J. Geryk, D. Elleder, J. Svoboda, M.J. Federspiel, and J. Hejnar. 2008. A single-amino-acid substitution in the TvbS1 receptor results in decreased susceptibility to infection by avian sarcoma and leukosis virus subgroups B and D and resistance to infection by subgroup E in vitro and in vivo. *J Viro.* 82:2097–2105.
425. Resnick-Roguel, N., H. Burstein, J. Hamburger, A. Panet, A. Eldor, I. Vlodavsky, and M. Kotler. 1989. Cytocidal effect caused by the envelope glycoprotein of a newly isolated avian hemangioma-inducing retrovirus. *J Virol.* 63:4325–4330.
426. Resnick-Roguel, N., A. Eldor, H. Burstein, E. Hy-Am, I. Vlodavsky, A. Panet, M.A. Blajchman, and M. Kotler. 1990. Envelope glycoprotein of avian hemangioma retrovirus induces a thrombogenic surface on human and bovine endothelial cells. *J Virol.* 64:4029–4032.
427. Rispens, B.H., G.F. d. Boer, A. Hoogerbrugge, and J.V. Vloten. 1976. A method for the control of lymphoid leukosis in chickens. *J Natl Cancer Inst.* 57:1151–1156.
428. Robertson, J.S., C. Nicolson, A.M. Riley, M. Bentley, G. Dunn, T. Corcoran, G.C. Schild, and P. Minor. 1997. Assessing the significance of reverse transcriptase activity in chick cell-derived vaccines. *Biologicals* 25:403–414.
429. Robinson, H.L., S.M. Astrin, A.M. Senior, and F.H. Salazar. 1981. Host susceptibility to endogenous viruses: defective, glycoprotein-expressing proviruses interfere with infections. *J Virol.* 40:745–751.
430. Robinson, H.L., L. Ramamoorthy, K. Collart, and D.W. Brown. 1993. Tissue tropism of avian leukosis viruses: analyses for viral DNA and proteins. *Virology.* 193:443–445.
431. Robinson, W.S., and P.H. Duesberg. 1968. The chemistry of RNA tumor viruses. In: *Molecular Basis of Virology*. H. Fraenkel-Conrat, ed. Reinhold Book, New York. 306–331.
432. Roloff, F. 1868. Mag Ges Thierheilkd 34:190 (cited by Chubb, L.G., and R.F. Gordon. 1957). *Vet Rev Annot*. 32:97–120.
433. Romero, C.H., H.G. Purchase, F. Frank, L.B. Crittenden, and T.S. Chang. 1978. The prevention of natural and experimental

avian lymphoid leukosis with the androgen analogue Mibolerone. *Avian Pathol.* 7:87–103.
434. Roth, F.K., P. Meyers, and R.M. Dougherty. 1971. The presence of avian leukosis virus group-specific antibodies in chicken sera. *Virology.* 45:265–274.
435. Rous, P. 1911. A sarcoma of the fowl transmissible by an agent separable from tumor cells. *J Exp Med*. 13:397–411.
436. Rous, P. 1910. A transmissible avian neoplasm. (Sarcoma of the common fowl). *J Exp Med*. 12:696–705.
437. Rovigatti, V.G., and S.M. Astrin. 1983. Avian endogenous viral genes. *Curr Top Microbiol Immunol.* 103:1–21.
438. Rubin, H. 2011. The early history of tumor virology: Rous, RIF, and RAV. *Proc Natl Acad Sci USA*. 108:14389–14396.
439. Rubin, H. 1965. Genetic control of cellular susceptibility to pseudotypes of Rous sarcoma virus. *Virology.* 26:270–276.
440. Rubin, H. 1960. Growth of Rous sarcoma virus in chick embryo cells following irradiation of host cells or free virus. *Virology.* 11:28–47.
441. Rubin, H., A. Cornelius, and L. Fanshier. 1961. The pattern of congenital transmission of an avian leukosis virus. *Proc Natl Acad Sci USA* 47:1058–1060.
442. Rubin, H., L. Fanshier, A. Cornelius, and W.F. Huges. 1962. Tolerance and immunity in chickens after congenital and contact infection with an avian leukosis virus. 17:143–156. *Virology.* 17:143–156.
443. Ruis, B.L., S.J. Benson, and K.F. Conklin. 1999. Genome structure and expression of the ev/J family of avian endogenous viruses. *J Virol.* 73:5345–5355.
444. Rup, B.J., J.D. Hoelzer, and H.R. Bose, Jr. 1982. Helper viruses associated with avian acute leukemia viruses inhibit the cellular immune response. *Virology.* 116:61–71.
445. Sacco, M.A., D.M. Flannery, K. Howes, and K. Venugopal. 2000. Avian endogenous retrovirus EAV-HP shares regions of identity with avian leukosis virus subgroup J and the avian retrotransposon ART-CH. *J Virol.* 74:1296–1306.
446. Sacco, M.A., K. Howes, L.P. Smith, and V.K. Nair. 2004. Assessing the roles of endogenous retrovirus EAV-HP in avian leukosis virus subgroup J emergence and tolerance. *J Virol.* 78:10525–10535.
447. Sacco, M.A., and K. Venugopal. 2001. Segregation of EAV-HP ancient endogenous retroviruses within the chicken population. *J Virol.* 75:11935–11938.
448. Salter, D.W., A. Fadly, E. Smith, K. Nazerian, N. Yanagida, R. Silva, D. Reilly, D. Marshall, L. Bacon, and L. Crittenden. 1991. The use of vaccines and genetic resistance (natural and transgenic) to control avian leukosis. In: *Proceedings Avian Tumor Virus Symposium*. D. Swayne and D. Zander, eds. 9–14.
449. Salter, D.W., W. Payne, H.J. Kung, D. Robinson, D. Ewert, W. Olson, L.B. Crittenden, and A.M. Fadly. 1999. Enhancement of spontaneous bursal lymphoma frequency by serotype 2 Marek's disease vaccine, SB-1, in transgenic and non-trangenic line 0 white leghorn chickens. *Avian Pathol.* 28:147–154.
450. Sandelin, K., and T. Estola. 1974. Occurrence of different subgroups of avian leukosis virus in Finnish poultry. *Avian Pathol.* 3:159–168.
451. Sanger, V.L., T.N. Fredrickson, C.C. Morrill and B.R. Burmester. 1966. Pathogenesis of osteopetrosis in chickens. *Am J Vet Res.* 27:1735–1744.
452. Sarma, P.S., T.S. Log, R.J. Huebner, and H.C. Turner. 1969. Studies of avian leukosis group-specific complement-fixing serum antibodies in pigeons. *Virology.* 37:480–483.
453. Sarma, P.S., H.C. Turner, and R.J. Huebner. 1964. An avian leucosis group-specific complement fixation reaction. Application for the detection and assay non-cytopathogenic leucosis viruses. *Virology*. 23.
454. Sazawa, H., T. Sugimori, Y. Miura, and T. Shimizu. 1966. Specific complement fixation test of Rous sarcoma with pigeon serum. *Natl Inst Anim Health Q (Tokyo)*. 6:208–215.
455. Schat, K.A. 1987. Immunity in Marek's disease and other tumors. In: *Avian Immunology: Basis and Practice*, Vol. IIA. Toivanen and P. Toivanen, eds. CRC Press, Boca Raton, FL. 101–128.
456. Schat, K.A. 1996. Immunity to Marek's disease, lymphoid leukosis and reticuloendotheliosis. In: *Poultry Immunology*. T.F. Davison, T.R. Morris, L.N. Payne, eds. Carfax Publishing Company: Abingdon. 209–233.
457. Schierman, L.W., and W.M. Collins. 1987. Influence of the major histocompatibility complex on tumor regression and immunity in chickens. *Poult Sci.* 66:812–818.
458. Schmidt, E.V., and R.E. Smith. 1981. Avian osteopetrosis virus induces proliferation of cultured bone cells. *Virology.* 111: 275–282.
459. Schulten, E.S., W.E. Briles. and R.L. Taylor, Jr. 2009. Rous sarcoma growth in lines congenic for major histocompatibility (B) complex recombinants. *Poult Sci.* 88:1601–1607.
460. Segura, J.C., J.S. Gavora, J.L. Spencer, R.W. Fairfull, R.S. Gowe. and R.B. Buckland. 1988. Semen traits and fertility of White Leghorn males shown to be positive or negative for lymphoid leukosis virus in semen and feather pulp. *Br Poult Sci.* 29:545–553.
461. Shahabuddin, M., J.F. Sears. and A.S. Khan. 2001. No evidence of infectious retroviruses in measles virus vaccines produced in chicken embryo cell cultures. *J Clin Microbiol.* 39:675–684.
462. Shank, P.R., P.J. Schatz, L.M. Jensen, P.N. Tsichlis, J.M. Coffin. and H.L. Robinson. 1985. Sequences in the gag-pol-5′env region of avian leukosis viruses confer the ability to induce osteopetrosis. *Virology.* 145:94–104.
463. Siegfried, L.M., and C. Olson. 1972. Characteristics of avian transmissible lymphoid tumor cells maintained in culture. *J Natl Cancer Inst.* 48:791–795.
464. Sigel, M.M., P. Meyers, and H.T. Holden. 1971. Resistance to Rous sarcoma elicited by immunization with live virus. *Proc Soc Exp Biol Med.* 137:142–146.
465. Silva, R.F., A.M. Fadly, and H.D. Hunt. 2000. Hypervariability in the envelope genes of subgroup J avian leukosis viruses obtained from different farms in the United States. *Virology.* 272:106–111.
466. Silva, R.F., A.M. Fadly, and S.P. Taylor. 2007. Development of a polymerase chain reaction to differentiate avian leukosis virus (ALV) subgroups: detection of an ALV contaminant in commercial Marek's disease vaccines. *Avian Dis.* 51:663–667.
467. Simon, M.C., W.S. Neckameyer, W.S. Hayward, and R.E. Smith. 1987. Genetic determinants of neoplastic diseases induced by a subgroup F avian leukosis virus. *J Virol.* 61:1203–1212.
468. Smith, A., and B.F. Benkel. 2009. Novel avian leukosis virus-related endogenous proviruses from layer chickens: characterization and development of locus-specific assays. *Poult Sci.* 88:1580–1585.
469. Smith, E.J. 1987. Endogenous avian leukemia viruses. In: *Avian Leukosis*. G.F. De Boer, ed. Martinus Nijhoff, Boston. 101–120.

470. Smith, E.J. 1977. Preparation of antisera to group-specific antigens of avian leukosis-sarcoma viruses: an alternate approach. *Avian Dis.* 21:290–299.
471. Smith, E.J., and L.B. Crittenden. 1988. Genetic cellular resistance to subgroup E avian leukosis virus in slow-feathering dams reduces congenital transmission of an endogenous retrovirus encoded at locus ev21. *Poult Sci.* 67:1668–1673.
472. Smith, E.J., A. Fadly, and W. Okazaki. 1979. An enzyme-linked immunosorbent assay for detecting avian leukosis-sarcoma viruses. *Avian Dis.* 23:698–707.
473. Smith, E.J., and A.M. Fadly. 1988. Influence of congenital transmission of endogenous virus-21 on the immune response to avian leukosis virus infection and the incidence of tumors in chickens. *Poult Sci.* 67:1674–1679.
474. Smith, E.J., and A.M. Fadly. 1994. Male-mediated venereal transmission of endogenous avian leukosis virus. *Poult Sci.* 73:488–494.
475. Smith, E.J., A.M. Fadly, and L.B. Crittenden. 1990. Interactions between endogenous virus loci ev6 and ev21. 1. Immune response to exogenous avian leukosis virus infection. *Poult Sci*. 69:1244–1250.
476. Smith, E.J., A.M. Fadly, and L.B. Crittenden. 1990. Interactions between endogenous virus loci ev6 and ev21. 2. Congenital transmission of EV21 viral product to female progency from slow-feathering dams. *Poult Sci*. 69:1251–1256.
477. Smith, E.J., A.M. Fadly, and L.B. Crittenden. 1986. Observations on an enzyme-linked immunosorbent assay for the detection of antibodies against avian leukosis-sarcoma viruses. *Avian Dis.* 30:488–493.
478. Smith, E.J., A.M. Fadly, I. Levin, and L.B. Crittenden. 1991. The influence of ev6 on the immune response to avian leukosis virus infection in rapid-feathering progeny of slow- and rapid-feathering dams. *Poult Sci.* 70:1673–1678.
479. Smith, E.J., U. Neumann, and W. Okazaki. 1980. Immune response to avian leukosis virus infection in chickens: Sequential expression of serum immunoglobulins and viral antibodies. *Comp Immunol Microbiol Infect Dis.* 2:519–529.
480. Smith, E.J., D.W. Salter, R.F. Silva, and L.B. Crittenden. 1986. Selective shedding and congenital transmission of endogenous avian leukosis viruses. *J Virol.* 60:1050–1054.
481. Smith, E.J., S.M. Williams, and A.M. Fadly. 1998. Detection of avian leukosis virus subgroup J using the polymerase chain reaction. *Avian Dis.* 42:375–380.
482. Smith, L.M., S.R. Brown, K. Howes, S. McLeod, S.S. Arshad, G.S. Barron, K. Venugopal, J.C. McKay, and L.N. Payne. 1998. Development and application of polymerase chain reaction (PCR) tests for the detection of subgroup J avian leukosis virus. *Virus Res.* 54:87–98.
483. Smith, L.M., A.A. Toye, K. Howes, N. Bumstead, L.N. Payne and K. Venugopal. 1999. Novel endogenous retroviral sequences in the chicken genome closely related to HPRS-103 (subgroup J) avian leukosis virus. *J Gen Virol.* 80 (Pt 1):261–268.
484. Smith, R.E. 1987. Immunology of avian leukosis virus infections. In: *Avian Leukosis*. G.F. De Boer, ed. Martinus Nijhoff, Boston. 121–130.
485. Soffer, D., N. Resnick-Roguel, A. Eldor, and M. Kotler. 1990. Multifocal vascular tumors in fowl induced by a newly isolated retrovirus. *Cancer Res.* 50:4787–4793.
486. Spencer, J.L. 1984. Progress towards eradication of lymphoid leukosis viruses—a review. *Avian Pathol.* 13:599–619.
487. Spencer, J.L., M. Chan, and S. Nandin-Davis. 2000. Relationship between egg size and subgroup J avian leukosis virus in eggs from broiler breeders. *Avian Pathol.* 29:617–622.
488. Spencer, J.L., L.B. Crittenden, B.R. Burmester, W. Okazaki, and R.L. Witter. 1977. Lymphoid leukosis: interrelations among virus infections in hens, eggs, embryos, and chicks. *Avian Dis.* 21:331–345.
489. Spencer, J.L., J.S. Gavora, and F. Gilka. 1987. Feather pulp organ cultures for assessing host resistance to infection with avian leukosis-sarcoma viruses. *Avian Pathol.* 16:425–438.
490. Spencer, J.L., J.S. Gavora, and R.S. Gowe. 1980. Lymphoid leukosis virus: Natural transmission and nonneoplastic effects. *Cold Spring Harb Conf Cell Prolifer.* 7:553–564.
491. Spencer, J.L., J.S. Gavora, and R.S. Gowe. 1980. *Lymphoid leukosis virus: Natural transmission and nonneoplastic effects*. In: Cold Spring Harbor Conference on Cell Proliferation. Cold Spring Harbor, New York. 553–564.
492. Stedman, N.L., and T.P. Brown. 1999. Body weight suppression in broilers naturally infected with avian leukosis virus subgroup J. *Avian Dis.* 43:604–610.
493. Stedman, N.L., and T.P. Brown. 2002. Cardiomyopathy in broiler chickens congenitally infected with avian leukosis virus subgroup J. *Vet Pathol.* 39:161–164.
494. Stedman, N.L., T.P. Brown, and D.I. Bounous. 2000. Functions of heterophils, macrophages, and lymphocytes isolated from broilers naturally infected with avian leukosis virus subgroup J. In: *Proceedings, International Symposium on ALV-J and Other Avian Retroviruses*. E.F. Kaleta, L.N. Payne, U. Heffels-Redmann, eds. Rauischholzhausen, Germany. 111–114.
495. Stedman, N.L., T.P. Brown, R.L. Brooks, Jr., and D.I. Bounous. 2001. Heterophil function and resistance to staphylococcal challenge in broiler chickens naturally infected with avian leukosis virus subgroup J. *Vet Pathol.* 38:519–527.
496. Stedman, N.L., T.P. Brown, and C.C. Brown. 2001. Localization of avian leukosis virus subgroup J in naturally infected chickens by RNA *in situ* hybridization. *Vet Pathol.* 38:649–656.
497. Stepanets, V., Z. Vernerova, M. Vilhelmova, J. Geryk, J. Plachy, J. Hejnar, F.F. Weichold, and J. Svoboda. 2003. Intraembryonic avian leukosis virus subgroup C (ALV-C) inoculation producing wasting disease in ducks soon after hatching. *Folia Biol (Praha)*. 49:100–109.
498. Stephenson, J.R., E.J. Smith, L.B. Crittenden, and S.A. Aaronson. 1975. Analysis of antigenic determinants of structural polypeptides of avian type C tumor viruses. *J Virol.* 16:27–33.
499. Stephenson, J.R., R.E. Wilsnack, and S.A. Aaronson. 1973. Radioimmunoassay for avian C-type virus group-specific antigen: Detection in normal and virus-transformed cells. *J Virol.* 11:893–899.
500. Stumph, W.E., C.P. Hodgson, M.J. Tsai, and B.W. O'Malley. 1984. Genomic structure and possible retroviralorigin of the chicken CR1 repetitive DNA sequence family. *Proc Natl Acad Sci USA*. 81:6667–6671.
501. Suh, A., M. Paus, M. Kiefmann, G. Churakov, F.A. Franke, J. Brosius, J.O. Kriegs, and J. Schmitz. 2011. Mesozoic retroposons reveal parrots as the closest living relatives of passerine birds. *Nat Commun.* 2:443.
502. Sun, M., D. Yu, H. Mo, H. Cao, C. Chen, and F. Chen. 2012. Epitope mapping of a monoclonal antibody against the gp85 of avian leukosis virus subgroup J. *J Vet Med Sci* 74(6):693–7.

503. Sun, S., and Z. Cui. 2007. Epidemiological and pathological studies of subgroup J avian leukosis virus infections in Chinese local "yellow" chickens. *Avian Pathol.* 36:221–226.
504. Suzuki, K., E. Kobayashi, H. Yamashita, H. Uenishi, I. Churkina, G. Plastow, N. Hamasima, and T. Mitsuhashi. 2012. Structural analysis of MHC alleles in an RSV tumour regression chicken using a BAC library. *Anim Genet.* 43:348–351.
505. Suzuki, K., T. Matsumoto, E. Kobayashi, H. Uenishi, I. Churkina, G. Plastow, H. Yamashita, N. Hamasima, and T. Mitsuhashi. 2010. Genotypes of chicken major histocompatibility complex B locus associated with regression of Rous sarcoma virus J-strain tumors. *Poult Sci.* 89:651–657.
506. Svoboda, J. 2008. Foundations in cancer research. The turns of life and science. *Adv Cancer Res*. 99:1–32.
507. Svoboda, J., J. Hejnar, J. Geryk, D. Elleder, and Z. Vernerova. 2000. Retroviruses in foreign species and the problem of provirus silencing. *Gene.* 261:181–188.
508. Swanstrom, R., and J.W. Wills. 1997. Synthesis, assembly and processing of viral proteins. In: *Retroviruses*. J.M. Coffin, S.H. Hughes, H.E. Varmus, eds. Cold Spring Harbor, New York. 263–334.
509. Tam, W., D. Ben-Yehuda, and W.S. Hayward. 1997. bic, a novel gene activated by proviral insertions in avian leukosis virus-induced lymphomas, is likely to function through its noncoding RNA. *Mol Cell Biol*. 17:1490–1502.
510. Tam, W., and J.E. Dahlberg. 2006. miR-155/BIC as an oncogenic microRNA. *Genes Chromosomes Cancer*. 45:211–212.
511. Tam, W., S.H. Hughes, W.S. Hayward, and P. Besmer. 2002. Avian bic, a gene isolated from a common retroviral site in avian leukosis virus-induced lymphomas that encodes a noncoding RNA, cooperates with c-myc in lymphomagenesis and erythroleukemogenesis. *J Virol.* 76:4275–4286.
512. Taylor, R.L., Jr. 2004. Major histocompatibility (B) complex control of responses against Rous sarcomas. *Poult Sci.* 83:638–649.
513. Telesnitsky, A., and S.P. Goff. 1997. Reverse transcriptase and the generation of retroviral DNA. In: *Retroviruses*. J.M. Coffin, S.H. Hughes, H.E. Varmus, eds. Cold Spring Harbor, New York. 121–160.
514. Temin, H.M. 1974. The cellular and molecular biology of RNA tumor viruses, especially avian leukosis-sarcoma viruses, and their relatives. *Adv Cancer Res.* 19:47–104.
515. Temin, H.M., and H. Rubin. 1958. Characteristics of an assay for Rous sarcoma virus and Rous sarcoma cells in tissue culture. *Virology.* 6:669–688.
516. Tereba, A., L.B. Crittenden, and S.M. Astrin. 1981. Chromosomal localization of three endogenous retrovirus loci associated with virus production in White Leghorn chickens. *J Virol.* 39:282–289.
517. Tereba, A., and K.G. Murti. 1977. A very sensitive biochemical assay for detecting and quantitating avian oncornaviruses. *Virology.* 80:166–176.
518. Thacker, E.L., J.E. Fulton, and H.D. Hunt. 1995. *In vitro* analysis of a primary, major histocompatibility complex (MHC)-restricted, cytotoxic T-lymphocyte response to avian leukosis virus (ALV), using target cells expressing MHC class I cDNA inserted into a recombinant ALV vector. *J Virol.* 69:6439–6444.
519. Thapa, B.R., A.R. Omar, S.S. Arshad, and M. Hair-Bejo. 2004. Detection of avian leukosis virus subgroup J in chicken flocks from Malaysia and their molecular characterization. *Avian Pathol.* 33:359–363.
520. Tieber, V.L., L.L. Zalinskis, R.F. Silva, A. Finkelstein, and P.M. Coussens. 1990. Transactivation of the Rous sarcoma virus long terminal repeat promoter by Marek's disease virus. *Virology.* 179:719–727.
521. Toyoda, T., K. Ochiai, H. Hatai, M. Murakami, E. Ono, T. Kimura, and T. Umemura. 2006. Cerebellar hypoplasia associated with an avian leukosis virus inducing fowl glioma. *Vet Pathol.* 43:294–301.
522. Trejbalova, K., K. Gebhard, Z. Vernerova, L. Dusek, J. Geryk, J. Hejnar, A.T. Haase, and J. Svoboda. 1999. Proviral load and expression of avian leukosis viruses of subgroup C in long-term persistently infected heterologous hosts (ducks). *Arch Virol.* 144:1779–1807.
523. Tsang, S.X., W.M. Switzer, V. Shanmugam, J.A. Johnson, C. Goldsmith, A. Wright, A. Fadly, D. Thea, H. Jaffe, T.M. Folks, and W. Heneine. 1999. Evidence of avian leukosis virus subgroup E and endogenous avian virus in measles and mumps vaccines derived from chicken cells: investigation of transmission to vaccine recipients. *J Virol.* 73:5843–5851.
524. Tsukamoto, K., M. Hasebe, S. Kakita, H. Hihara, and Y. Kono. 1991. Identification and characterization of hens transmitting avian leukosis virus (ALV) to their embryos by ELISAs for detecting infectious ALV, ALV antigens and antibodies to ALV. *J Vet Med Sci*. 53:859–864.
525. Tsukamoto, K., M. Hasebe, S. Kakita, Y. Taniguchi, H. Hihara, and Y. Kono. 1992. Sporadic congenital transmission of avian leukosis virus in hens discharging the virus into the oviducts. *J Vet Med Sci.* 54:99–103.
526. Tsukamoto, K., H. Hihara, and Y. Kono. 1991. Detection of avian leukosis virus antigens by the ELISA and its use for detecting infectious virus after cultivation of samples and partial characterization of specific pathogen free chicken lines maintained at this laboratory. *J Vet Med Sci.* 53:399–408.
527. Tsukamoto, K., Y. Kono, and K. Arai. 1985. An enzyme linked immunosorbent assay for detection of antibodies to exogenous avian leukosis virus. *Avian Dis.* 29:1118–1129.
528. van de Lavoir, M.C., J.H. Diamond, P.A. Leighton, C. Mather-Love, B.S. Heyer, R. Bradshaw, A. Kerchner, L.T. Hooi, T.M. Gessaro, S.E. Swanberg, M.E. Delany, and R.J. Etches. 2006. Germline transmission of genetically modified primordial germ cells. *Nature.* 441:766–769.
529. van de Lavoir, M.C., C. Mather-Love, P. Leighton, J.H. Diamond, B.S. Heyer, R. Roberts, L. Zhu, P. Winters-Digiacinto, A. Kerchner, T. Gessaro, S. Swanberg, M.E. Delany, and R.J. Etches. 2006. High-grade transgenic somatic chimeras from chicken embryonic stem cells. *Mech Dev.* 123:31–41.
530. Van Woensel, P.A.M., A.V. Blaaderen, R.J.M. Mooman, and G.F. d. Boer. 1992. Detection of proviral DNA and viral RNA in various tissues early after avian leukosis virus infection. *Leukemia 6*. (Suppl 3).
531. Venugopal, K. 1999. Avian leukosis virus subgroup J: a rapidly evolving group of oncogenic retroviruses. *Res Vet Sci.* 67: 113–119.
532. Venugopal, K., K. Howes, G.S. Barron, and L.N. Payne. 1997. Recombinant env-gp85 of HPRS-103 (subgroup J) avian leukosis virus: antigenic characteristics and usefulness as a diagnostic reagent. *Avian Dis.* 41:283–288.

533. Venugopal, K., K. Howes, D.M.J. Flannery, and L.N. Payne. 2000. Isolation of acutely transforming subgroup J avian leukosis viruses that induce erythroblastosis and myelocytomatosis. *Avian Pathol.* 29:327–332.
534. Venugopal, K., K. Howes, D.M.J. Flannery, and L.N. Payne. 2000. Subgroup J avian leukosis virus infection in turkeys: induction of rapid onset tumours by acutely transforming virus strain 966. *Avian Pathol.* 29:319–326.
535. Venugopal, K., L.M. Smith, K. Howes, and L.N. Payne. 1998. Antigenic variants of J subgroup avian leukosis virus: sequence analysis reveals multiple changes in the env gene. *J Gen Virol.* 79 (Pt 4):757–766.
536. Victoria, J.G., C. Wang, M.S. Jones, C. Jaing, K. McLoughlin, S. Gardner, and E.L. Delwart. 2010. Viral nucleic acids in live-attenuated vaccines: detection of minority variants and an adventitious virus. *J Virol.* 84:6033–6040.
537. Vogt, P.K. 1965. Avian tumor viruses. *Adv Virus Res.* 11: 293–385.
538. Vogt, P.K. 2010. Oncogenes and the revolution in cancer research: homage to hidesaburo hanafusa (1929–2009). *Genes Cancer.* 1:6–11.
539. Vogt, P.K., A.G. Bader, and S. Kang. 2006. Phosphoinositide 3-kinase: from viral oncoprotein to drug target. *Virology.* 344:131–138.
540. Vogt, P.K., and R. Ishizaki. 1966. Criteria for the classification of avian-tumor viruses. In: Viruses Inducing Cancer: W.J. Burdett, ed. *University of Utah Press, Salt Lake City UT*. 71–90.
541. Vogt, V.M., and M.N. Simon. 1999. Mass determination of Rous sarcoma virus virions by scanning transmission electron microscopy. *J Virol.* 73:7050–7055.
542. Wallny, H.J., D. Avila, L.G. Hunt, T.J. Powell, P. Riegert, J. Salomonsen, K. Skjodt, O. Vainio, F. Vilbois, M.V. Wiles, and J. Kaufman. 2006. Peptide motifs of the single dominantly expressed class I molecule explain the striking MHC-determined response to Rous sarcoma virus in chickens. *Proc Natl Acad Sci USA*. 103:1434–1439.
543. Walter, W.G., B.R. Burmester, and C.H. Cunningham. 1962. Studies on the transmission and pathology of a viral-induced avian nephroblastoma (embryonal nephroma). *Avian Dis.* 6:455–477.
544. Wang, F., X. Wang, H. Chen, J. Liu, and Z. Cheng. 2011. The critical time of avian leukosis virus subgroup J-mediated immunosuppression during early stage infection in specific pathogen-free chickens. *J Vet Sci.* 12:235–241.
545. Wang, L.H., and H. Hanafusa. 1988. Avian sarcoma viruses. *Virus Res.* 9:159–203.
546. Wang, Y., Z. Kang, Y. Gao, L. Qin, L. Chen, Q. Wang, J. Li, H. Gao, X. Qi, H. Lin, and X. Wang. 2011. Development of loop-mediated isothermal amplification for rapid detection of avian leukosis virus subgroup A. *J Virol Methods.* 173:31–36.
547. Wang, Z., and Z. Cui. 2006. Evolution of gp85 gene of subgroup J avian leukosis virus under the selective pressure of antibodies. *Sci China C Life Sci.* 49:227–234.
548. Waters, N.F., and B.R. Burmester. 1961. Mode of inheritance of resistance to Rous sarcoma virus in chickens. *J Natl Cancer Inst.* 27:655–661.
549. Watts, S.L., and R.E. Smith. 1980. Pathology of chickens infected with avian nephoblastoma virus MAV-2(N). *Infect Immun.* 27:501–512.
550. Webster, M.T., E. Axelsson, and H. Ellegren. 2006. Strong regional biases in nucleotide substitution in the chicken genome. *Mol Biol Evol.* 23:1203–1216.
551. Weiss, R.A. 1975. Genetic transmission of RNA tumor viruses. *Perspect Virol.* 9:165–205.
552. Weiss, R.A. 1981. Retrovirus receptors. In: *Virus Receptors. Pt. 2: Receptors and Recognition, series B*, Vol. 8. K. Longberg-Holm, L. Philipson, eds. Chapman and Hall, London. 187–202.
553. Weiss, R.A., and D.P. Frisby. 1981. Are avian endogenous viruses pathogenic. 10th International Symposium for Comparative Research on Leukosis and Related Diseases. D.S. Yohn, ed. Elsevier/North Holland, New York.
554. Weiss, R.A., N. Teich, H. Varmus, and J. Coffin. 1982. RNA tumor viruses. In: *RNA Tumor Viruses*. Cold Spring Harbor Laboratory, New York,
555. Weiss, R.A., and P.K. Vogt. 2011. 100 years of Rous sarcoma virus. *J Exp Med.* 208:2351–2355.
556. Weissmahr, R.N., J. Schupbach, and J. Boni. 1997. Reverse transcriptase activity in chicken embryo fibroblast culture supernatants is associated with particles containing endogenous avian retrovirus EAV-0 RNA. *J Virol.* 71:3005–3012.
557. Whalen, L.R., D.W. Wheeler, D.H. Gould, S.A. Fiscus, L.C. Boggie, and R.E. Smith. 1988. Functional and structural alterations of the nervous system induced by avian retrovirus RAV-7. *Microb Pathog.* 4:401–416.
558. Wicker, T., J.S. Robertson, S.R. Schulze, F.A. Feltus, V. Magrini, J.A. Morrison, E.R. Mardis, R.K. Wilson, D.G. Peterson, A.H. Paterson, and R. Ivarie. 2005. The repetitive landscape of the chicken genome. *Genome Res.* 15:126–136.
559. Wilczek, C., O. Chayka, A. Plachetka, and K.H. Klempnauer. 2009. Myb-induced chromatin remodeling at a dual enhancer/promoter element involves non-coding rna transcription and is disrupted by oncogenic mutations of v-myb. *J Biol Chem.* 284:35314–35324.
560. Williams, S.M., T. Barbosa, S. Hafner, and G. Zavala. 2010. Myxosarcomas associated with avian leukosis virus subgroup A infection in fancy breed chickens. *Avian Dis.* 54:1319–1322.
561. Williams, S.M., S.D. Fitzgerald, W.M. Reed, L.F. Lee, and A.M. Fadly. 2004. Tissue tropism and bursal transformation ability of subgroup J avian leukosis virus in White Leghorn chickens. *Avian Dis.* 48:921–927.
562. Williams, S.M., W.M. Reed, L.D. Bacon, and A.M. Fadly. 2004. Response of white leghorn chickens of various genetic lines to infection with avian leukosis virus subgroup J. *Avian Dis.* 48:61–67.
563. Williams, S.M., W.M. Reed, and A.M. Fadly 2000. Influence of age of exposure on the response of line 0 and line 63 chickens to infection with subgroup J avian leukosis virus. Proceedings, International Symposium on ALV-J and Other Avian Retroviruses. E.F. Kaleta, L.N. Payne, U. Heffels-Redmann, eds. Rauischholzhausen, Germany. 67–76.
564. Witter, R.L. 2000. Determinants of early transmission of ALV-J in commercial broiler breeder chickens. Proceedings, International, Symposiumon ALV-J and Other Avian Retroviruses. E.F. Kaleta, L.N. Payne, U. Heffels-Redmann, eds. Rauischholzhausen, Germany. 216–225.
565. Witter, R.L., L.D. Bacon, H.D. Hunt, R.E. Silva, and A.M. Fadly. 2000. Avian leukosis virus subgroup J infection profiles in broiler breeder chickens: association with virus transmission to progeny. *Avian Dis.* 44:913–931.
566. Witter, R.L., L.D. Bacon, H.D. Hunt, R.E. Silva, and A.M. Fadly. 2001. Avian leukosis virus subgroup J infection profiles in broiler breeder chickens: Associations with virus transmission to progeny. *Avian Dis.* 44:913–931.

567. Witter, R.L., B.W. Calnek, and P.P. Levine. 1966. Influence of naturally occurring parental antibody on visceral lymphomatosis virus infection in chickens. *Avian Dis.* 10:43–56.
568. Witter, R.L., and A.M. Fadly. 2001. Reduction of horizontal transmission of avian leukosis virus subgroup J in broiler breeder chickens hatched and reared in small groups. *Avian Pathol.* 30:641–654.
569. Witter, R.L., I.M. Gimeno, and A.M. Fadly 2005 Differential diagnosis of lymphoid and myeloid tumors in the chicken. AAAP Slide Study Set #27 American Association of Avian Pathologists, Athens, GA (Electronic media), 1–49.
570. Wright, S.E., and D.D. Bennett. 1992. Avian retroviral recombinant expressing foreign envelope delays tumour formation of ASV-A-induced sarcoma. *Vaccine.* 10:375–378.
571. Wu, X., K. Qian, A. Qin, H. Shen, P. Wang, W. Jin, and Y.M. Eltahir. 2010. Recombinant avian leukosis viruses of subgroup J isolated from field infected commercial layer chickens with hemangioma and myeloid leukosis possess an insertion in the E element. *Vet Res Commun.* 34:619–632.
572. Xu, B., W. Dong, C. Yu, Z. He, Y. Lv, Y. Sun, X. Feng, N. Li, L.F. Lee, and M. Li. 2004. Occurrence of avian leukosis virus subgroup J in commercial layer flocks in China. *Avian Pathol.* 33:13–17.
573. Yang, F., R.R. Xian, Y. Li, T.S. Polony, and K.L. Beemon. 2007. Telomerase reverse transcriptase expression elevated by avian leukosis virus integration in B cell lymphomas. *Proc Natl Acad Sci USA*. 104:18952–18957.
574. Yang, J., Y. Yu, J. Yao, Y. Chen, G. Xu, N. Yang, D. Sun, and Y. Zhang. 2011. Molecular identification of avian leukosis virus subgroup E loci and tumor virus B locus in Chinese indigenous chickens. *Poult Sci.* 90:759–765.
575. Young, J.A., P. Bates, and H.E. Varmus. 1993. Isolation of a chicken gene that confers susceptibility to infection by subgroup A avian leukosis and sarcoma viruses. *J Virol.* 67:1811–1816.
576. Zander, D.V., R.G. Raymond, C.F. McClary, and K. Goodwin. 1975. Eradication of subgroups A and B lymphoid leukosis virus from commercial poultry breeding flocks. *Avian Dis.* 19:403–423.
577. Zavala, G., and S. Cheng. 2006. Detection and characterization of avian leukosis virus in Marek's disease vaccines. *Avian Dis.* 50:209–215.
578. Zavala, G., S. Cheng, and M.W. Jackwood. 2007. Molecular epidemiology of avian leukosis virus subgroup J and evolutionary history of its 3′ untranslated region. *Avian Dis.* 51:942–953.
579. Zavala, G., L. Dufour-Zavala, P. Villegas, J. El-Attrache, D.A. Hilt, and M.W. Jackwood. 2002. Lack of interaction between avian leukosis virus subgroup J and fowl adenovirus (FAV) in FAV-antibody-positive chickens. *Avian Dis.* 46:979–984.
580. Zavala, G., B. Lucio-Martinez, S. Cheng, and T. Barbosa. 2006. Sarcomas and myelocytomas induced by a retrovirus related to myeloblastosis-associated virus type 1 in White Leghorn egg layer chickens. *Avian Dis.* 50:201–208.
581. Zhang, H.M., L.D. Bacon, H.H. Cheng, and H.D. Hunt. 2005. Development and validation of a PCR-RFLP assay to evaluate TVB haplotypes coding receptors for subgroup B and subgroup E avian leukosis viruses in White Leghorns. *Avian Pathol.* 34:324–331.
582. Zhang, H.N., H.Z. Lai, Y. Qi, X.T. Zhang, Z.Y. Ning, K.J. Luo, C.A. Xin, W.S. Cao, and M. Liao. 2011. An ALV-J isolate is responsible for spontaneous haemangiomas in layer chickens in China. *Avian Pathol.* 40:261–267.
583. Zhang, X., M. Liao, P. Jiao, K. Luo, H. Zhang, T. Ren, G. Zhang, C. Xu, C. Xin, and W. Cao. 2010. Development of a loop-mediated isothermal amplification assay for rapid detection of subgroup J avian leukosis virus. *J Clin Microbiol.* 48:2116–2121.
584. Zhou, G., W. Cai, X. Liu, C. Niu, C. Gao, C. Si, W. Zhang, L. Qu, and L. Han. 2011. A duplex real-time reverse transcription polymerase chain reaction for the detection and quantitation of avian leukosis virus subgroups A and B. *J Virol Methods.* 173:275–279.
585. Ziegel, R.F. 1961. Morphological evidence of the association of virus particles with the pancreatic acinar cells of the chick. *J Natl Cancer Inst.* 26:1011–1039.

Reticuloendotheliosis

1. Allen, P.T., J.A. Mullins, C.L. Harris, A. Hellman, R.F. Garry, and M.R.F. Waite. 1979. Replication of reticuloendotheliosis virus in mammalian cells (Abstract). American Society for Microbiology Annual Meeting. S100, p256. 256–256.
2. Aly, M.M., E.J. Smith, and A.M. Fadly. 1993. Detection of reticuloendotheliosis virus infection using the polymerase chain reaction. *Avian Pathol.* 22:543–554.
3. Aly, M.M., R.L. Witter, and A.M. Fadly. 1996. Enhancement of reticuloendotheliosis virus-induced bursal lymphomas by serotype 2 Marek's disease virus. *Avian Pathol.* 25:81–94.
4. Arathy, D.S., D.N. Tripathy, G.P. Sabarinath, M.I. Bhaiyat, A. Chikweto, V. Matthew, and R.N. Sharma. 2010. Preliminary molecular characterization of a fowl poxvirus isolate in Grenada. *Avian Dis.* 54:1081–1085.
5. Aulisio, C.G., and A. Shelokov. 1969. Prevalence of reticuloendotheliosis in chickens: immunofluorescence studies. *Proc Soc Exp Biol Med.* 130:178–181.
6. Awad, A.M., H.S. Abd El-Hamid, A.A. Abou Rawash, and H.H. Ibrahim. 2010. Detection of reticuloendotheliosis virus as a contaminant of fowl pox vaccines. *Poult Sci.* 89:2389–2395.
7. Bacon, L.D., R.L. Witter, and A.M. Fadly. 1989. Augmentation of retrovirus-induced lymphoid leukosis by Marek's disease herpesviruses in White Leghorn chickens. *J Virol.* 63:504–512.
8. Bacon, L.D., R.L. Witter, and R.F. Silva. 2001. Characterization and experimental reproduction of peripheral neuropathy in White Leghorn chickens. *Avian Pathol.* 30:487–499.
9. Bader, S.R., S. Kothlow, S. Trapp, S.C. Schwarz, H.C. Philipp, S. Weigend, A.R. Sharifi, R. Preisinger, W. Schmahl, B. Kaspers, and K. Matiasek. 2010. Acute paretic syndrome in juvenile White Leghorn chickens resembles late stages of acute inflammatory demyelinating polyneuropathies in humans. *J Neuroinflammation.* 7:7.
10. Bagust, T.J., and T.M. Grimes. 1979. Experimental infection of chickens with an Australian strain of reticuloendotheliosis virus. 2. Serological responses and pathogenesis. *Avian Pathol*. 8:375–389.
11. Bagust, T.J., T.M. Grimes, and D.P. Dennett. 1979. Infection studies on a reticuloendotheliosis virus contaminant of a commercial Marek's disease vaccine. *Aust Vet J.* 55:153–157.
12. Bagust, T.J., T.M. Grimes, and N. Ratnamohan. 1981. Experimental infection of chickens with an Australian strain of reticuloendotheliosis virus 3. persistent infection and transmission by the adult hen. *Avian Pathol*. 10:375–385.
13. Bagust, T.J., J. Ignjatovic, L.A. Corner, and T.J. Bagust. 1993. Avian Reticuloendotheliosis: Virology., and Serology. In:

Australian Standard Techniques for Animal Diseases. East Melbourne, Australia.
14. Bagust, T.J., J.B. McFerran, and M.S. McNulty. 1993. Reticuloendotheliosis virus. In: *Virus Infections of Vertebrates: Virus Infections of Birds,* Vol. 4. Elsevier, Amsterdam. 437–454.
15. Ban, J., N.L. First, and H.M. Temin. 1989. Bovine leukaemia virus packaging cell line for retrovirus-mediated gene transfer. *J Gen Virol.* 70 (Pt 8):1987–1993.
16. Barbacid, M., E. Hunter, and S.A. Aaronson. 1979. Avian reticuloendotheliosis viruses: evolutionary linkage with mammalian type C retroviruses. *J Virol.* 30:508–514.
17. Barbosa, T., G. Zavala, S. Cheng, and P. Villegas. 2007. Full genome sequence and some biological properties of reticuloendotheliosis virus strain APC-566 isolated from endangered Attwater's prairie chickens. *Virus Res.* 124:68–77.
18. Barbosa, T., G. Zavala, S. Cheng, and P. Villegas. 2007. Pathogenicity and transmission of reticuloendotheliosis virus isolated from endangered prairie chickens. *Avian Dis.* 51:33–39.
19. Barth, C.F., D.L. Ewert, W.C. Olson, and E.H. Humphries. 1990. Reticuloendotheliosis virus REV-T(REV-A)-induced neoplasia: development of tumors within the T-lymphoid and myeloid lineages. *J Virol.* 64:6054–6062.
20. Barth, C.F., and E.H. Humphries. 1988. Expression of v-rel induces mature B cell lines that reflect the diversity of avian immunoglobulin heavy- and light-chain rearrangements. *Mol Cell Biol.* 8:5358–5368.
21. Barth, C.F., and E.H. Humphries. 1988. A nonimmunosuppressive helper virus allows high efficiency induction of B cell lymphomas by reticuloendotheliosis virus strain T. *J Exp Med.* 167:89–108.
22. Bauer, G., and H.M. Temin. 1980. Specific antigenic relationships between the RNA-dependent DNA polymerases of avian reticuloendotheliosis viruses and mammalian type C retroviruses. *J Virol.* 34:168–177.
23. Baxter-Gabbard, K.L., W.F. Campbell, F. Padgett, A. Raitano-Fenton, and A.S. Levin. 1971. Avian reticuloendotheliosis virus (strain T). II. Biochemical and biophysical properties. *Avian Dis*. 15:850–862.
24. Baxter-Gabbard, K.L., D.A. Peterson, A.S. Levine, P. Meyers, and M.M. Sigel. 1973. Reticuloendotheliosis virus (strain T). VI. An immunogen versus reticuloendotheliosis and Rous sarcoma. *Avian Dis*. 17:145–150.
25. Beemon, K.L., A.J. Faras, A.T. Hasse, P.H. Duesberg, and J.E. Maisel. 1976. Genomic complexities of murine leukemia and sarcoma, reticuloendotheliosis, and visna viruses. *J Virol.* 17:525–537.
26. Biswas, S.K., C. Jana, K. Chand, W. Rehman, and B. Mondal. 2011. Detection of fowl poxvirus integrated with reticuloendotheliosis virus sequences from an outbreak in backyard chickens in India. *Vet Ital.* 47:147–153.
27. Blank, V., P. Kourilsky, and A. Israel. 1992. NF-kappa B and related proteins: Rel/dorsal homologies meet ankyrin-like repeats. *Trends Biochem Sci.* 17:135–140.
28. Bolisetty, M.T., G. Dy, W. Tam, and K.L. Beemon. 2009. Reticuloendotheliosis virus strain T induces miR-155, which targets JARID2 and promotes cell survival. *J Virol.* 83: 12009–12017.
29. Bose, H.R., Jr. 1992. The Rel family: models for transcriptional regulation and oncogenic transformation. *Biochim Biophys Acta* 1114:1–17.
30. Bose, H.R., Jr., and A.S. Levine. 1967. Replication of the reticuloendotheliosis virus (strain T) in chicken embryo cell culture. *J Virol.* 1:1117–1121.
31. Bosselman, R.A., R.Y. Hsu, T. Boggs, S. Hu, J. Bruszewski, S. Ou, L. Souza, L. Kozar, F. Martin, M. Nicolson, W. Rishell, J.A. Schultz, K.M. Semon and R.G. Stewart. 1989. Replication-defective vectors of reticuloendotheliosis virus transduce exogenous genes into somatic stem cells of the unincubated chicken embryo. *J Virol.* 63:2680–2689.
32. Breitman, M.L., M.M. Lai, and P.K. Vogt. 1980. Attenuation of avian reticuloendotheliosis virus: loss of the defective transforming component during serial passage of oncogenic virus in fibroblasts. *Virology.* 101:304–306.
33. Bulow, V.V. 1977. Immunological effects of reticuloendotheliosis virus as potential contaminant of Marek's disease vaccines. *Avian Pathol.* 6:383–393.
34. Bulow, V.V., and F. Weiland. 1980. Stimulation of local solid tumour development of the nonproducer Marek's disease tumour transplant JMV by virus-induced immunosuppression. *Avian Pathol.* 9:93–108.
35. Calvert, J.G., and K. Nazerian. 1994. An immunoperoxidase plaque assay for reticuloendotheliosis virus and its application to a sensitive serum neutralization assay. *Avian Dis.* 38:165–171.
36. Calvert, J.G., K. Nazerian, R.L. Witter, and N. Yanagida. 1993. Fowlpox virus recombinants expressing the envelope glycoprotein of an avian reticuloendotheliosis retrovirus induce neutralizing antibodies and reduce viremia in chickens. *J Virol.* 67: 3069–3076.
37. Campbell, W.F., K.L. Baxter-Gabbard, and A.S. Levine. 1971. Avian reticuloendotheliosis virus (strain T). I. Virological characterization. *Avian Dis*. 15:837–849.
38. Carlson, H.C., G.L. Seawright, and J.R. Pettit. 1974. Reticuloendotheliosis in Japanese quail. *Avian Pathol.* 3: 169–175.
39. Carpenter, C.R., H.R. Bose, and A.S. Rubin. 1977. Contact-mediated suppression of mitogen-induced responsiveness by spleen cells in reticuloendotheliosis virus-induced tumorigenesis. *Cell Immunol.* 33:392–401.
40. Carpenter, C.R., K.E. Kempf, H.R. Bose, and A.S. Rubin. 1978. Characterization of the interaction of reticuloendotheliosis virus with the avian lymphoid system. *Cell Immunol.* 39:307–315.
41. Carpenter, C.R., A.S. Rubin, and H.R. Bose, Jr. 1978. Suppression of the mitogen-stimulated blastogenic response during reticuloendotheliosis virus-induced tumorigenesis: investigations into the mechanism of action of the suppressor. *J Immunol.* 120:1313–1320.
42. Chen, I.S., T.W. Mak, J.J. O'Rear, and H.M. Temin. 1981. Characterization of reticuloendotheliosis virus strain T DNA and isolation of a novel variant of reticuloendotheliosis virus strain T by molecular cloning. *J Virol.* 40:800–811.
43. Chen, P.Y., Z. Cui, L.F. Lee, and R.L. Witter. 1987. Serologic differences among nondefective reticuloendotheliosis viruses. *Arch Virol.* 93:233–245.
44. Cheng, W.H., Y. P. Huang, and C.H. Wang. 2006. Serological and virological surveys of reticuloendotheliosis in chickens in Taiwan. *J Vet Med Sci.* 68:1315–1320.
45. Cheng, Z., Y. Shi, L. Zhang, G. Zhu, X. Diao, and Z. Cui. 2007. Occurrence of reticuloendotheliosis in Chinese partridge. *J Vet Med Sci.* 69:1295–1298.
46. Cho, B.R. 1984. Improved focus assay of reticuloendotheliosis virus in a quail fibroblast cell line (QT35). *Avian Dis.* 28:261–265.
47. Coffin, J.M., B.M. Fields, D.M. Knipe, and P.M. Howley. 1996. Retroviridae: The viruses and their replication. In: *Fields Virology*. Lippincott-Raven Publishers, Philadelphia. 1767–1846.

48. Cohen, R.S., T.C. Wong, and M.M. Lai. 1981. Characterization of transformation- and replication-specific sequences of reticuloendotheliosis virus. *Virology.* 113:672–685.
49. Cooper, M.D., C.L. Chen, R.P. Bucy, and C.B. Thompson. 1991. Avian T cell ontogeny. *Adv Immunol.* 50:87–117.
50. Cowen, B.S., and M.O. Braune. 1988. The propagation of avian viruses in a continuous cell line (QT35) of Japanese quail origin. *Avian Dis.* 32:282–297.
51. Crespo, R., P.R. Woolcock, A.M. Fadly, C. Hall, and H.L. Shivaprasad. 2002. Characterization of T cell lymphomas associated with an outbreak of reticuloendotheliosis in turkeys. *Avian Pathol.* 31:355–361.
52. Crittenden, L.B., A.M. Fadly, and E.J. Smith. 1982. Effect of endogenous leukosis virus genes on response to infection with avian leukosis and reticuloendotheliosis viruses. *Avian Dis.* 26:279–294.
53. Cui, Z., S. Sun, Z. Zhang, and S. Meng. 2009. Simultaneous endemic infections with subgroup J avian leukosis virus and reticuloendotheliosis virus in commercial and local breeds of chickens. *Avian Pathol.* 38:443–448.
54. Cui, Z., G. Zhuang, X. Xu, A. Sun, and S. Su. 2010. Molecular and biological characterization of a Marek's disease virus field strain with reticuloendotheliosis virus LTR insert. *Virus Genes.* 40:236–243.
55. Cui, Z.Z., L.F. Lee, R.F. Silva, and R.L. Witter. 1986. Monoclonal antibodies against avian reticuloendotheliosis virus: identification of strain-specific and strain-common epitopes. *J Immunol.* 136:4237–4242.
56. Cui, Z.Z., L.F. Lee, E.J. Smith, R.L. Witter, and T.S. Chang. 1988. Monoclonal-antibody-mediated enzyme-linked immunosorbent assay for detection of reticuloendotheliosis viruses. *Avian Dis.* 32:32–40.
57. Davidson, I., R. Alphandary, M. Novoseler, and M. Malkinson. 1997. Replication of non-defective reticuloendotheliosis viruses in the avian embryo assayed by PCR and immunofluorescence. *Avian Pathol.* 26:579–593.
58. Davidson, I., A. Borovskaya, S. Perl, and M. Malkinson. 1995. Use of the polymerase chain reaction for the diagnosis of natural infection of chickens and turkeys with Marek's disease virus and reticuloendotheliosis virus. *Avian Pathol.* 24:69–94.
59. Davidson, I., and M. Malkinson. 1996. A non-radioactive method for identifying enzyme-amplified products of the reticuloendotheliosis proviral *env* and LTR genes using psoralen-biotin labelled probes. *J Virol Methods.* 59:113–119.
60. Davidson, I., I. Shkoda, and S. Perk. 2008. Integration of the reticuloendotheliosis virus envelope gene into the poultry fowlpox virus genome is not universal. *J Gen Virol.* 89:2456–2460.
61. Davidson, I., and R.F. Silva. 2008. Creation of diversity in the animal virus world by inter-species and intra-species recombinations: lessons learned from poultry viruses. *Virus Genes.* 36:1–9.
62. Deng, X., X. Qi, Y. Gao, Y. Wang, L. Qin, H. Gao, L. Gao, and X. Wang. 2010. Development of a loop-mediated isothermal amplification method for rapid detection of reticuloendotheliosis virus. *J Virol Methods.* 168:82–86.
63. Deng, X., X. Qi, G. Wu, Y. Gao, L. Qin, Y. Wang, H. Gao, and X. Wang. 2012. Construction and characterization of the infectious clone of Reticuloendotheliosis virus carrying a genetic marker. *Virus Res.* 167(2):146–51.
64. Diallo, I.S., M.A. Mackenzie, P.B. Spradbrow, and W.F. Robinson. 1998. Field isolates of fowlpox virus contaminated with reticuloendotheliosis virus. *Avian Pathol.* 27:60–66.
65. Dornburg, R. 1995. Reticuloendotheliosis viruses and derived vectors. *Gene Ther.* 2:301–310.
66. Dornburg, R. 2003. Reticuloendotheliosis viruses and derived vectors for human gene therapy. *Front Biosci.* 8:d801–817.
67. Drechsler, Y., R.L. Bohls, R. Smith, N. Silvy, H. Lillehoj, and E.W. Collisson. 2009. An avian, oncogenic retrovirus replicates *in vivo* in more than 50% of CD4+ and CD8+ T lymphocytes from an endangered grouse. *Virology.* 386:380–386.
68. Dren, C.N., I. Nemeth, I. Sari, F. Ratz, R. Glavits, and P. Somogyi. 1988. Isolation of a reticuloendotheliosis-like virus from naturally occurring lymphoreticular tumours of domestic goose. *Avian Pathol.* 17:259–277.
69. Dren, C.N., E. Saghy, R. Glavits, F. Ratz, J. Ping, and V. Sztojkov. 1983. Lymphoreticular tumour in pen-raised pheasants associated with a reticuloendotheliosis like virus infection. *Avian Pathol.* 12:55–71.
70. Drew, M.L., W.L. Wigle, D.L. Graham, C.P. Griffin, N.J. Silvy, A.M. Fadly, and R.L. Witter. 1998. Reticuloendotheliosis in captive greater and Attwater's prairie chickens. *J Wildl Dis.* 34:783–791.
71. Dutta, J., G. Fan, and C. Gelinas. 2008. CAPERalpha is a novel Rel-TAD-interacting factor that inhibits lymphocyte transformation by the potent Rel/NF-kappaB oncoprotein v-Rel. *J Virol.* 82:10792–10802.
72. Embretson, J.E., and H.M. Temin. 1987. Lack of competition results in efficient packaging of heterologous murine retroviral RNAs and reticuloendotheliosis virus encapsidation-minus RNAs by the reticuloendotheliosis virus helper cell line. *J Virol.* 61:2675–2683.
73. Embretson, J.E., and H.M. Temin. 1986. Pseudotyped retroviral vectors reveal restrictions to reticuloendotheliosis virus replication in rat cells. *J Virol.* 60:662–668.
74. Fadly, A., and M.C. Garcia. 2006. Detection of reticuloendotheliosis virus in live virus vaccines of poultry. *Dev Biol (Basel).* 126:301–305; discussion 327.
75. Fadly, A., R. Silva, H. Hunt, A. Pandiri, and C. Davis. 2006. Isolation and characterization of an adventitious avian leukosis virus isolated from commercial Marek's disease vaccines. *Avian Dis.* 50:380–385.
76. Fadly, A.M. 1987. Differential diagnosis of lymphoid leukosis. In: *Avian Leukosis*. G.F. de Boer, ed. *Martinus Nijhoff: Boston, MA*.197–211.
77. Fadly, A.M., and R.L. Witter. 1997. Comparative evaluation of *in vitro* and *in vivo* assays for the detection of reticuloendotheliosis virus as a contaminant in a live virus vaccine of poultry. *Avian Dis.* 41:695–701.
78. Fadly, A.M., and R.L. Witter. 1986. Resistance of line 6(3) chickens to reticuloendotheliosis-virus-induced bursa-associated lymphomas. *Int J Cancer.* 38:139–143.
79. Fadly, A.M., and R.L. Witter. 1983. Studies of reticuloendotheliosis virus-induced lymphomagenesis in chickens. *Avian Dis.* 27:271–282.
80. Fadly, A.M., R.L. Witter, and H.D. Hunt. 2008. Oncornaviruses: leukosis/sarcomas and reticuloendotheliosis. In: *A Laboratory Manual for the Isolation, Identification and Characterization of Avian Pathogens*. L. Dufour-Zavala, D.E. Swayne, J.R. Glisson, J.E. Pearson, W.M. Reed, M.W. Jackwood, and P.R. Woolcock, eds. American Association of Avian Pathologists, Jacksonville, FL. 164–172.
81. Fadly, A.M., R.L. Witter, E.J. Smith, R.F. Silva, W.M. Reed, F.J. Hoerr, and M.R. Putnam. 1996. An outbreak of lymphomas in

commercial broiler breeder chickens vaccinated with a fowlpox vaccine contaminated with reticuloendotheliosis virus. *Avian Pathol.* 25:35–47.
82. Fadly, A.M., G. Zavala, and R.L. Witter. 2008. Reticuloendotheliosis. In: *Diseases of Poultry*, 12th ed. Y.M. Saif, A.M. Fadly, J.R. Glisson, L.R. McDougald, L.K. Nolan, and D.E. Swayne, eds. Blackwell Publishing Ltd., Ames, IA. 568–588.
83. Federspiel, M.J., L.B. Crittenden, and S.H. Hughes. 1989. Expression of avian reticuloendotheliosis virus envelope confers host resistance. *Virology.* 173:167–177.
84. Filardo, E.J., M.F. Lee, and E.H. Humphries. 1994. Structural genes, not the LTRs, are the primary determinants of reticuloendotheliosis virus A-induced runting and bursal atrophy. *Virology.* 202:116–128.
85. Franklin, R.B., C.Y. Kang, K. Min-Min Wan, and H.R. Bose, Jr. 1977. Transformation of chick embryo fibroblasts by reticuloendotheliosis virus. *Virology.* 83:313–321.
86. Garcia, M., N. Narang, W.M. Reed, and A.M. Fadly. 2003. Molecular characterization of reticuloendotheliosis virus insertions in the genome of field and vaccine strains of fowl poxvirus. *Avian Dis.* 47:343–354.
87. Garry, R.F., and H.R. Bose, Jr. 1988. Autogenous growth factor production by reticuloendotheliosis virus-transformed hematopoietic cells. *J Cell Biochem.* 37:327–338.
88. Garry, R.F., G.M. Shackleford, L.J. Berry, and H.R. Bose, Jr. 1985. Inhibition of hepatic phosphoenolpyruvate carboxykinase by avian reticuloendotheliosis viruses. *Cancer Res.* 45:5020–5026.
89. Gautier, R., A. Jiang, V. Rousseau, R. Dornburg, and T. Jaffredo. 2000. Avian reticuloendotheliosis virus strain A and spleen necrosis virus do not infect human cells. *J Virol.* 74:518–522.
90. Genovese, K.J., R.B. Moyes, L.L. Genovese, V.K. Lowry, and M.H. Kogut. 1998. Resistance to Salmonella enteritidis organ invasion in day-old turkeys and chickens by transformed T cell line-produced lymphokines. *Avian Dis.* 42:545–553.
91. Gilmore, T.D., and M.R. Garbati. 2011. Inhibition of NF-kappaB signaling as a strategy in disease therapy. *Curr Top Microbiol Immunol.* 349:245–263.
92. Gilmore, T.D., and S. Gerondakis. 2011. The c-Rel transcription factor in development and disease. *Genes Cancer.* 2:695–711.
93. Gilmore, T.D., and F.S. Wolenski. 2012. NF-κB: where did it come from and why? *Immunol Rev.* 246:14–35.
94. Grimes, T.M., T.J. Bagust and C.K. Dimmock. 1979. Experimental infection of chickens with an australian strain of reticuloendotheliosis virus. I. Clinical, pathological and haematological effects. *Avian Pathol*. 8:57–68.
95. Grimes, T.M., and H.G. Purchase. 1973. Reticuloendotheliosis in a duck. *Aust Vet J.* 49:466–471.
96. Hafner, S., M.A. Goodwin, L.C. Kelley, D.I. Bounous, M. Puette, W.B. Steffens, K.A. Langheinrich, and J. Brown. 1994. Multicentric histiocytosis mimicking reticuloendotheliosis in broiler chickens. Proceedings of the 66th Northeastern Conference of Avian Diseases. 266.
97. Hauck, R., C. Prusas, H.M. Hafez, and D. Luschow. 2009. Quantitative PCR as a tool to determine the reticuloendotheliosis virus-proviral load of fowl poxvirus. *Avian Dis.* 53:211–215.
98. Hayes, L.E., K.A. Langheinrich, and R.L. Witter. 1992. Reticuloendotheliosis in a wild turkey (*Meleagris gallopavo*) from coastal Georgia. *J Wildl Dis.* 28:154–158.
99. Hertig, C., B.E. Coupar, A.R. Gould, and D.B. Boyle. 1997. Field and vaccine strains of fowlpox virus carry integrated sequences from the avian retrovirus, reticuloendotheliosis virus. *Virology.* 235:367–376.
100. Hoelzer, J.D., R.B. Franklin, and H.R. Bose, Jr. 1979. Transformation by reticuloendotheliosis virus: development of a focus assay and isolation of a nontransforming virus. *Virology.* 93:20–30.
101. Hoelzer, J.D., R.B. Lewis, C.R. Wasmuth, and H.R. Bose, Jr. 1980. Hematopoietic cell transformation by reticuloendotheliosis virus: characterization of the genetic defect. *Virology.* 100:462–474.
102. Hrdlickova, R., J. Nehyba, and E.H. Humphries. 1994. v-rel induces expression of three avian immunoregulatory surface receptors more efficiently than c-rel. *J Virol*. 68:308–319.
103. Hu, C., and T.J. Linna. 1976. Serotherapy of avian reticuloendotheliosis virus-induced tumors. *Ann N Y Acad Sci.* 277:634–646.
104. Humphries, E.H., and G. Zhang. 1992. V-rel and C-rel modulate the expression of both bursal and non-bursal antigens on avian B cell lymphomas. *Curr Top Microbiol. Immunol.* 182:475–483.
105. Ianconescu, M. 1977. Reticuloendotheliosis antigen for the agar gel precipitation test. *Avian Pathol.* 6:259–267.
106. Ianconescu, M., and A. Aharonovici. 1978. Persistent viraemia in chickens subsequent to *in ovo* inoculation of reticuloendotheliosis virus. *Avian Pathol.* 7:237–247.
107. Ignjatovic, J., K.J. Fahey, and T.J. Bagust. 1987. An enzyme-linked immunosorbent assay for detection of reticuloendotheliosis virus infection in chickens. *Avian Pathol.* 16:609–621.
108. Isfort, R., D. Jones, R. Kost, R. Witter, and H.J. Kung. 1992. Retrovirus insertion into herpesvirus *in vitro* and *in vivo*. *Proc Natl Acad Sci USA* 89:991–995.
109. Isfort, R., R.L. Witter, and H.J. Kung. 1987. *C-myc* activation in an unusual retrovirus-induced avian T-lymphoma resembling Marek's disease: proviral insertion 5′ of exon one enhances the expression of an intron promoter. *Oncogene Res* 2:81–94.
110. Isfort, R.J., Z. Qian, D. Jones, R.F. Silva, R. Witter, and H.J. Kung. 1994. Integration of multiple chicken retroviruses into multiple chicken herpesviruses: herpesviral gD as a common target of integration. *Virology.* 203:125–133.
111. Jackson, C.A., S.E. Dunn, D.I. Smith, P.T. Gilchrist, and P.A. Macqueen. 1977. Proventriculitis, "nakanuke" and reticuloendotheliosis in chickens following vaccination with herpesvirus of turkeys (HVT). *Aust Vet J.* 53:457–459.
112. Johnson, E.S., L.G. Nicholson, and D.T. Durack. 1995. Detection of antibodies to avian leukosis/sarcoma viruses (ALSV) and reticuloendotheliosis viruses (REV) in humans by ELISA. *Cancer Detect Prev.* 19:394–404.
113. Johnson, E.S., L. Overby, and R. Philpot. 1995. Detection of antibodies to avian leukosis/sarcoma viruses and reticuloendotheliosis viruses in humans by western blot assay. *Cancer Detect Prev.* 19:472–486.
114. Kang, C.Y. 1975. Characterization of endogenous RNA-directed DNA polymerase activity of reticuloendotheliosis viruses. *J Virol.* 16:880–886.
115. Kang, C.Y., and P. Lambright. 1977. Pseudotypes of vesicular stomatitis virus with the mixed coat of reticuloendotheliosis virus and vesicular stomatitis virus. *J Virol.* 21:1252–1255.
116. Kang, C.Y., T.C. Wong, and K.V. Holmes. 1975. Comparative ultrastructural study of four reticuloendotheliosis viruses. *J Virol.* 16:1027–1038.
117. Kawamura, H., T. Wakabayashi, S. Yamaguchi, T. Taniguchi, and N. Takayanagi. 1976. Inoculation experiment of Marek's

disease vaccine contaminated with a reticuloendotheliosis virus. *Natl Inst Anim Health Q (Tokyo)*. 16:135–140.
118. Keshet, E., and H.M. Temin. 1979. Cell killing by spleen necrosis virus is correlated with a transient accumulation of spleen necrosis virus DNA. *J Virol.* 31:376–388.
119. Kewalramani, V.N., A.T. Panganiban, and M. Emerman. 1992. Spleen necrosis virus, an avian immunosuppressive retrovirus, shares a receptor with the type D simian retroviruses. *J Virol.* 66:3026–3031.
120. Kim, T., J. Mays, A. Fadly, and R.F. Silva. 2011. Artificially inserting a reticuloendotheliosis virus long terminal repeat into a bacterial artificial chromosome clone of Marek's disease virus (MDV) alters expression of nearby MDV genes. *Virus Genes.* 42:369–376.
121. Kim, T.J., and D.N. Tripathy. 2001. Reticuloendotheliosis virus integration in the fowl poxvirus genome: not a recent event. *Avian Dis.* 45:663–669.
122. Kochel, T., and N.R. Rice. 1992. v-rel- and c-rel-protein complexes bind to the NF-kappa B site *in vitro*. *Oncogene.* 7: 567–572.
123. Koo, H.M., J. Gu, A. Varela-Echavarria, Y. Ron, and J.P. Dougherty. 1992. Reticuloendotheliosis type C and primate type D oncoretroviruses are members of the same receptor interference group. *J Virol.* 66:3448–3454.
124. Koyama, H., T. Sasaki, Y. Ohwada, and Y. Saito. 1980. The relationship between feathering abnormalities ("nakanuke") and tumour production in chickens inoculated with reticuloendotheliosis virus. *Avian Pathol.* 9:331–340.
125. Koyama, H., Y. Suzuki, Y. Ohwada, and Y. Saito. 1976. Relationships between reticuloendothelial virus of chickens and an agent isolated from a duck embryo cell culture of turkey herpesvirus. *Kitasato Arch Exp Med.* 49:93–105.
126. Koyama, H., Y. Suzuki, Y. Ohwada, and Y. Saito. 1976. Reticuloendotheliosis group virus pathogenic to chicken isolated from material infected with turkey herpesvirus (HVT). *Avian Dis.* 20:429–434.
127. Larose, R.N., and M. Sevoian. 1965. Avian lymphomatosis. IX. Mortality and serological response of chickens of various ages to graded doses of T strain. *Avian Dis*. 9:604–610.
128. Lewis, R.B., J. McClure, B. Rup, D.W. Niesel, R.F. Garry, J.D. Hoelzer, K. Nazerian, and H.R. Bose, Jr. 1981. Avian reticuloendotheliosis virus: identification of the hematopoietic target cell for transformation. *Cell.* 25:421–431.
129. Ley, D.H., M.D. Ficken, D.T. Cobb, and R.L. Witter. 1989. Histomoniasis and reticuloendotheliosis in a wild turkey (*Meleagris gallopavo*) in North Carolina. *J Wildl Dis.* 25: 262–265.
130. Li, J., B.W. Calnek, K.A. Schat, and D.L. Graham. 1983. Pathogenesis of reticuloendotheliosis virus infection in ducks. *Avian Dis.* 27:1090–1105.
131. Li, K., H. Gao, L. Gao, X. Qi, Y. Gao, L. Qin, Y. Wang, and X. Wang. 2012. Development of an indirect ELISA for serological detection of reticuloendotheliosis virus using the gp90 protein expressed in Pichia pastoris. *J Virol Methods.* 180:43–48.
132. Li, K., H. Gao, L. Gao, X. Qi, Y. Gao, L. Qin, Y. Wang, and X. Wang. 2012. Recombinant gp90 protein expressed in Pichia pastoris induces a protective immune response against reticuloendotheliosis virus in chickens. *Vaccine.* 30:2273–2281.
133. Li, K., H. Gao, L. Gao, X. Qi, L. Qin, Y. Gao, Y. Xu, and X. Wang. 2012. Development of TaqMan real-time PCR assay for detection and quantitation of reticuloendotheliosis virus. *J Virol Methods.* 179:402–408.
134. Lim, M.Y., N. Davis, J.Y. Zhang, and H.R. Bose, Jr. 1990. The v-rel oncogene product is complexed with cellular proteins including its proto-oncogene product and heat shock protein 70. *Virology.* 175:149–160.
135. Lin, C.Y., C.L. Chen, C.C. Wang, and C.H. Wang. 2009. Isolation, identification, and complete genome sequence of an avian reticuloendotheliosis virus isolated from geese. *Vet Microbiol.* 136:246–249.
136. Linna, T.J., C.P. Hu, and K.D. Thompson. 1974. Development of systemic and local tumors induced by avian reticuloendotheliosis virus after thymectomy or bursectomy. *J Natl Cancer Inst.* 53:847–854.
137. Ludford, C.G., H.G. Purchase, and H.W. Cox. 1972. Duck infectious anemia virus associated with Plasmodium lophurae. *Exp Parasitol.* 31:29–38.
138. Maccubbin, D.L., and L.W. Schierman. 1986. MHC-restricted cytotoxic response of chicken T cells: expression, augmentation, and clonal characterization. *J Immuno.* 136:12–16.
139. Maldonado, R.L., and H.R. Bose. 1971. Separation of reticuloendotheliosis virus from avian tumor viruses. *J Virol.* 8: 813–815.
140. Maldonado, R.L., and H.R. Bose, Jr. 1976. Group-specific antigen shared by the members of the reticuloendotheliosis virus complex. *J Virol.* 17:983–990.
141. Martinez, I., and R. Dornburg. 1996. Mutational analysis of the envelope protein of spleen necrosis virus. *J Virol.* 70:6036–6043.
142. Mays, J.K., R.F. Silva, L.F. Lee, and A.M. Fadly. 2010. Characterization of reticuloendotheliosis virus isolates obtained from broiler breeders, turkeys, and prairie chickens located in various geographical regions in the United States. *Avian Pathol.* 39:383–389.
143. McDougall, J.S., P.M. Biggs, and R.W. Shilleto. 1978. A leukosis in turkeys associated with infection with reticuloendotheliosis virus. *Avian Pathol.* 7:557–568.
144. McDougall, J.S., R.W. Shilleto, and P.M. Biggs. 1980. Experimental infection and vertical transmission of reticuloendotheliosis virus in the turkey. *Avian Pathol.* 9:445–454.
145. McDougall, J.S., R.W. Shilleto, and P.M. Biggs. 1981. Further studies on vertical transmission of reticuloendotheliosis virus in turkeys. *Avian Pathol.* 10:163–169.
146. Meroz, M. 1992. Reticuloendotheliosis and 'pullet disease' in Israel. *Vet Rec.* 130:107–108.
147. Meyers, N.L. 1993. Antibody response elicited against empty reticuloendotheliosis virus particles in two inbred lines of chicken. *Vet Microbiol.* 36:317–332.
148. Miller, P.E., J. Paul-Murphy, R. Sullivan, A.J. Cooley, R. R. Dubielzig, C.J. Murphy, and A.M. Fadly. 1998. Orbital lymphosarcoma associated with reticuloendotheliosis virus in a peafowl. *J Am Vet Med Assoc.* 213:377–380.
149. Moelling, K., H. Gelderblom, G. Pauli, and R. Friis. 1975. A comparative study of the avian reticuloendotheliosis virus: relationship to murine leukemia virus and viruses of the avian sarcoma-leukosis complex. *Virology.* 65:546–557.
150. Moore, B.E., and H.R. Bose, Jr. 1988. Expression of the v-rel oncogene in reticuloendotheliosis virus-transformed fibroblasts. *Virology.* 162:377–387.
151. Moore, K.M., J.R. Davis, T. Sato, and A. Yasuda. 2000. Reticuloendotheliosis virus (REV) long terminal repeats incorporated in the genomes of commercial fowl poxvirus vaccines and pigeon poxviruses without indication of the presence of infectious REV. *Avian Dis.* 44:827–841.

152. Mosser, A.G. 1975. Polypeptide composition of spleen necrosis virus, a reticuloendotheliosis virus. *J Virol.* 15:1088–1095.
153. Motha, M.X. 1987. Clinical effects, virological and serological responses in chickens following *in-ovo* inoculation of reticuloendotheliosis virus. *Vet Microbiol.* 14:411–417.
154. Motha, M.X. 1987. Demonstration of precipitating antibodies to reticuloendotheliosis virus in egg yolk. *Aust Vet J.* 64: 259–260.
155. Motha, M.X. 1984. Distribution of virus and tumour formation in ducks experimentally infected with reticuloendotheliosis virus. *Avian Pathol.* 13:303–319.
156. Motha, M.X. 1982. Effects of reticuloendotheliosis virus on the response of chickens to infectious laryngotracheitis virus. *Avian Pathol.* 11:475–486.
157. Motha, M.X., and J.R. Egerton. 1983. Effect of reticuloendotheliosis virus on the response of chickens to Salmonella typhimurium infection. *Res Vet Sci.* 34:188–192.
158. Motha, M.X., and J.R. Egerton. 1984. Influence of reticuloendotheliosis on the severity of Eimeria tenella infection in broiler chickens. *Vet Microbiol.* 9:121–129.
159. Motha, M.X., and J.R. Egerton. 1987. Outbreak of atypical fowlpox in chickens with persistent reticuloendotheliosis viraemia. *Avian Pathol.* 16:177–182.
160. Motha, M.X., and J.R. Egerton. 1987. Vertical transmission of reticuloendotheliosis virus in chickens. *Avian Pathol.* 16: 141–147.
161. Motha, M.X., J.R. Egerton, and A.W. Sweeney. 1984. Some evidence of mechanical transmission of reticuloendotheliosis virus by mosquitoes. *Avian Dis.* 28:858–867.
162. Mussman, H.C., and M.J. Twiehaus. 1971. Pathogenesis of reticuloendothelial virus disease in chicks–an acute runting syndrome. *Avian Dis.* 15:483–502.
163. Nazerian, K., R.L. Witter, L.B. Crittenden, M.R. Noori-Dalloii, and H.J. Kung. 1982. An IgM-producing B lymphoblastoid cell line established from lymphomas induced by a non-defective reticuloendotheliosis virus. *J Gen Virol.* 58: 351–360.
164. Nicholas, R.A., and D.H. Thornton. 1987. An enzyme-linked immunosorbent assay for the detection of antibodies to avian reticuloendotheliosis virus using whole cell antigen. *Res Vet Sci.* 43:403–404.
165. Nicholas, R.A., and D.H. Thornton. 1983. Relative efficiency of techniques for detecting avian reticuloendotheliosis virus as a vaccine contaminant. *Res Vet Sci.* 34:377–379.
166. Noori-Daloii, M.R., R.A. Swift, H.J. Kung, L.B. Crittenden and R.L. Witter. 1981. Specific integration of REV proviruses in avian bursal lymphomas. *Nature.* 294:574–576.
167. Okoye, J.O., W. Ezema, and J.N. Agoha. 1993. Naturally occurring clinical reticuloendotheliosis in turkeys and chickens. *Avian Pathol.* 22:237–244.
168. Parveen, Z., M. Mukhtar, and R.J. Pomerantz. 2010. Generation of retroviral particles for the spleen necrosis virus (SNV)-based vector system and their use in transduction of various cell types. *Cold Spring Harb Protoc*. 2010:pdb prot5435.
169. Paul, P.S., K.H. Johnson, K.A. Pomeroy, B.S. Pomeroy, and P.S. Sarma. 1977. Experimental transmission of reticuloendotheliosis in turkeys with the cell-culture-propagated reticuloendotheliosis viruses of turkey origin. *J Natl Cancer Inst.* 58:1819–1824.
170. Paul, P.S., K.A. Pomeroy, P.S. Sarma, K.H. Johnson, D.M. Barnes, M.C. Kumar, and B.S. Pomeroy. 1976. Naturally occurring reticuloendotheliosis in turkeys: transmission. *J Natl Cancer Inst.* 56:419–422.
171. Paul, P.S., R.E. Werdin, and B.S. Pomeroy. 1978. Spontaneously occurring lymphoproliferative disease in ducks. *Avian Dis.* 22:191–195.
172. Payne, L.N., and K. Venugopal. 2000. Neoplastic diseases: Marek's disease, avian leukosis and reticuloendotheliosis. *Rev Sci Tech.* 19:544–564.
173. Perk, K., M. Malkinson, A. Gazit, A. Yaniv, and A. Zimber. 1981. Reappearance of an acute undiferentialed leukema in a flock of Musocy ducks. 10th International Symposium on Comparative Leukemia and Related Diseases. 99–100.
174. Peterson, D.A., and A.S. Levine. 1971. Avian reticuloendotheliosis virus (strain T). IV. Infectivity and transmissibility in day-old cockerels. *Avian Dis*. 15:874–883.
175. Peterson, M.J., P.J. Ferro, M.N. Peterson, R.M. Sullivan, B.E. Toole, and N.J. Silvy. 2002. Infectious disease survey of lesser prairie chickens in north Texas. *J Wildl Dis.* 38:834–839.
176. Pratt, W.D., R.W. Morgan, and K.A. Schat. 1992. Characterization of reticuloendotheliosis virus-transformed avian T-lymphoblastoid cell lines infected with Marek's disease virus. *J Virol.* 66:7239–7244.
177. Purchase, H.G., C. Ludford, K. Nazerian and H.W. Cox. 1973. A new group of oncogenic viruses: reticuloendotheliosis, chick syncytial, duck infectious anemia, and spleen necrosis viruses. *J Natl Cancer Inst.* 51:489–499.
178. Purchase, H.G., and R.L. Witter. 1975. The reticuloendotheliosis viruses. *Curr Top Microbiol Immunol.* 71:103–124.
179. Ratnamohan, N., T.J. Bagust, and P.B. Spradbrow. 1982. Establishment of a chicken lymphoblastoid cell line infected with reticuloendotheliosis virus. *J Comp Pathol.* 92:527–532.
180. Ratnamohan, N., T.M. Grimes, T.J. Bagust, and P.B. Spradbrow. 1980. A transmissible chicken tumour associated with reticuloendotheliosis virus infection. *Aust Vet J.* 56:34–38.
181. Ratnamohan, R., T.J. Bagust, T.M. Grimes and P.B. Spradbrow. 1979. Transmission of an Australian strain of reticuloendotheliosis virus to adult Japanese quail. *Aust Vet J.* 55:506.
182. Reddy, S.K., M.J. Ratcliffe, and A. Silim. 1993. Flow cytometric analysis of the neutralizing immune response against infectious bursal disease virus using reticuloendotheliosis virus-transformed lymphoblastoid cell lines. *J Virol Methods.* 44:167–177.
183. Reimann, I., and O. Werner. 1996. Use of the polymerase chain reaction for the detection of reticuloendotheliosis virus in Marek's disease vaccines and chicken tissues. *Zentralbl Veterinarmed B.* 43:75–84.
184. Rice, N.R., T.I. Bonner, and R.V. Gilden. 1981. Nucleic acid homology between avian and mammalian type C viruses: relatedness of reticuloendotheliosis virus cdna to cloned proviral DNA of the endogenous Colobus virus CPC-1. *Virology.* 114:286–290.
185. Ridgway, A.A. 1992. Reticuloendotheliosis virus long terminal repeat elements are efficient promoters in cells of various species and tissue origin, including human lymphoid cells. *Gene.* 121:213–218.
186. Ridgway, A.A., R.A. Swift, H.J. Kung, and D.J. Fujita. 1985. *In vitro* transcription analysis of the viral promoter involved in *c-myc* activation in chicken B lymphomas: detection and mapping of two RNA initiation sites within the reticuloendotheliosis virus long terminal repeat. *J Virol.* 54:161–170.
187. Robinson, F.R., and M.J. Twiehaus. 1974. Isolation of the avian reticuloendothelial virus (strain T). *Avian Dis.* 18:278–288.

188. Rup, B.J., J.D. Hoelzer, and H.R. Bose, Jr. 1982. Helper viruses associated with avian acute leukemia viruses inhibit the cellular immune response. *Virology.* 116:61–71.
189. Rup, B.J., J.L. Spence, J.D. Hoelzer, R.B. Lewis, C.R. Carpenter, A.S. Rubin, and H.R. Bose, Jr. 1979. Immunosuppression induced by avian reticuloendotheliosis virus: mechanism of induction of the suppressor cell. *J Immunol.* 123:1362–1370.
190. Rushlow, C., and R. Warrior. 1992. The rel family of proteins. *Bioessays.* 14:89–95.
191. Salter, D.W., E.J. Smith, S.H. Hughes, S.E. Wright, and L.B. Crittenden. 1987. Transgenic chickens: insertion of retroviral genes into the chicken germ line. *Virology.* 157:236–240.
192. Salter, D.W., E.J. Smith, S.H. Hughes, S.E. Wright, A.M. Fadly, R.L. Witter, and L.B. Crittenden. 1986. Gene insertion into the chicken germ line by retroviruses. *Poult Sci.* 65:1445–1458.
193. Santos, V.L., S.M. Williams, G. Zavala, T. Barbosa, J. Zhang, S. Cheng, H.L. Shivaprasad, S. Hafner, A. Fadly, R.L. Santos, and C.C. Brown. 2008. Detection of reticuloendotheliosis virus by immunohistochemistry and *in situ* hybridization in experimentally infected Japanese quail embryos and archived formalin-fixed and paraffin-embedded tumours. *Avian Pathol.* 37:451–456.
194. Sarid, R., A. Chajut, M. Malkinson, S.R. Tronick, A. Gazit, and A. Yaniv. 1994. Diagnostic test for lymphoproliferative disease virus infection of turkeys, using the polymerase chain reaction. *Am J Vet Res.* 55:769–772.
195. Sawyer, R.C., and H. Hanafusa. 1977. Formation of reticuloendotheliosis virus pseudotypes of Rous sarcoma virus. *J Virol.* 22:634–639.
196. Schat, K.A. 1991. Importance of cell-mediated immunity in Marek's disease and other viral tumor diseases. *Poult Sci.* 70:1165–1175.
197. Schat, K.A., J. Gonzalez, A. Solorzano, E. Avila, and R.L. Witter. 1976. A lymphoproliferative disease in Japanese Quail. *Avian Dis.* 20:153–161.
198. Schat, K.A., W.D. Pratt, R. Morgan, D. Weinstock, and B.W. Calnek. 1992. Stable transfection of reticuloendotheliosis virus-transformed lymphoblastoid cell lines. *Avian Dis.* 36:432–439.
199. Schwarzbard, Z., A. Yaniv, M. Ianconescu, K. Perk, and A. Zimber. 1980. A reverse transcriptase assay for the diagnosis of lymphoproliferative disease (LPD) of turkeys. *Avian Pathol.* 9:481–487.
200. Scofield, V.L., and H.R. Bose, Jr. 1978. Depression of mitogen response in spleen cells from reticuloendotheliosis virus-infected chickens and their suppressive effect on normal lymphocyte response. *J Immunol.* 120:1321–1325.
201. Scofield, V.L., J.L. Spence, W.E. Briles, and H.R. Bose, Jr. 1978. Differential mortality and lesion responses to reticuloendotheliosis virus infection in Marek's disease-resistant and susceptible chicken lines. *Immunogenetics.* 7:169–172.
202. Sevoian, M., R.N. Larose, and D.M. Chamberlain. 1964. Avian lymphamatosis VI. A virus of unusual potency and pathogenicity. *Avian Dis*. 3:336–347.
203. Sevoian, M., R.N. Larose, and D.M. Chamberlain. 1964. Avian lymphamatosis VII. Pathological response of the chicken embryos to T virus. *J Natl Cancer Inst*. 17:99–119.
204. Shen, P.F. 1981. Immunological, hematological, pathological and ultrastructural studies of chickens with reticuloendotheliosis. PhD.
205. Shimotohno, K., S. Mizutani, and H.M. Temin. 1980. Sequence of retrovirus provirus resembles that of bacterial transposable elements. *Nature.* 285:550–554.
206. Simek, S., and N.R. Rice. 1980. Analysis of the nucleic acid components in reticuloendotheliosis virus. *J Virol* 33:320–329.
207. Singh, P., T.J. Kim, and D.N. Tripathy. 2000. Re-emerging fowlpox: evaluation of isolates from vaccinated flocks. *Avian Pathol.* 29:449–455.
208. Sinkovic, B. 1981. *In vivo* interactions between reticuloendotheliosis virus and some other infectious agents of chickens. Proceedings of the 4th Australasian Poultry Stock and Feed Convention. 114–118.
209. Smith, E.J., J.J. Solomon, and R.L. Witter. 1977. Complement-fixation test for reticuloendotheliosis viruses: limits of sensitivity in infected avian cells. *Avian Dis.* 21:612–622.
210. Smith, E.J., and R.L. Witter. 1983. Detection of antibodies against reticuloendotheliosis viruses by an enzyme-linked immunosorbent assay. *Avian Dis.* 27:225–234.
211. Solomon, J.J., R.L. Witter, and K. Nazerian. 1976. Studies on the etiology of lymphomas in turkeys: isolation of reticuloendotheliosis in virus. *Avian Dis.* 20:735–747.
212. Sun, A.J., X.Y. Xu, L. Petherbridge, Y.G. Zhao, V. Nair and Z.Z. Cui. 2010. Functional evaluation of the role of reticuloendotheliosis virus long terminal repeat (LTR) integrated into the genome of a field strain of Marek's disease virus. *Virology.* 397:270–276.
213. Sun, F., P.J. Ferro, B. Lupiani, J. Kahl, M.E. Morrow, J.P. Flanagan, C. Estevez, and A. Clavijo. 2011. A duplex real-time polymerase chain reaction assay for the simultaneous detection of long terminal repeat regions and envelope protein gene sequences of Reticuloendotheliosis virus in avian blood samples. *J Vet Diagn Invest.* 23:937–941.
214. Sun, S., Z. Cui, J. Wang, and Z. Wang. 2009. Protective efficacy of vaccination against highly pathogenic avian influenza is dramatically suppressed by early infection of chickens with reticuloendotheliosis virus. *Avian Pathol.* 38:31–34.
215. Swift, R.A., C. Boerkoel, A. Ridgway, D.J. Fujita, J.B. Dodgson, and H.J. Kung. 1987. B-lymphoma induction by reticuloendotheliosis virus: characterization of a mutated chicken syncytial virus provirus involved in *c-myc* activation. *J Virol.* 61: 2084–2090.
216. Swift, R.A., E. Shaller, R.L. Witter, and H.J. Kung. 1985. Insertional activation of *c-myc* by reticuloendotheliosis virus in chicken B lymphoma: nonrandom distribution and orientation of the proviruses. *J Virol.* 54:869–872.
217. Tadese, T., S. Fitzgerald, and W.M. Reed. 2008. Detection and differentiation of re-emerging fowlpox virus (FWPV) strains carrying integrated reticuloendotheliosis virus (FWPV-REV) by real-time PCR. *Vet Microbio.* 127:39–49.
218. Tailor, C.S., A. Nouri, Y. Zhao, Y. Takeuchi, and D. Kabat. 1999. A sodium-dependent neutral-amino-acid transporter mediates infections of feline and baboon endogenous retroviruses and simian type D retroviruses. *J Virol.* 73:4470–4474.
219. Tajima, M., T. Nunoya, and Y. Otaki. 1977. Pathogenesis of abnormal feathers in chickens inoculated with reticuloendotheliosis virus. *Avian Dis.* 21:77–89.
220. Takagi, M., K. Ishikawa, H. Nagai, T. Sasaki, K. Gotoh, and H. Koyama. 1996. Detection of contamination of vaccines with the reticuloendotheliosis virus by reverse transcriptase polymerase chain reaction (RT-PCR). *Virus Res.* 40:113–121.
221. Taniguchi, T., N. Yuasa, S. Sato, and T. Horiuchi. 1977. Pathologicalchangesinchickensinoculatedwithreticuloendotheliosis-virus-contaminated Marek's disease vaccine. *Natl Inst Anim Health Q (Tokyo)*. 17:141–150.

222. Taylor, H.W., and L.D. Olson. 1973. Chronologic study of the T-virus in chicks. II. Development of hematologic changes. *Avian Dis*. 17:794–802.
223. Temin, H.M., and V.K. Kassner. 1974. Replication of reticuloendotheliosis viruses in cell culture: acute infection. *J Virol.* 13:291–297.
224. Temin, H.M., and V.K. Kassner. 1975. Replication of reticuloendotheliosis viruses in cell culture: chronic infection. *J Gen Virol.* 27:267–274.
225. Temin, H.M., E. Keshet, and S.K. Weller. 1980. Correlation of transient accumulation of linear unintegrated viral DNA and transient cell killing by avian leukosis and reticuloendotheliosis viruses. *Cold Spring Harb Symp Quant Biol.* 44 Pt 2:773–778.
226. Terada, N., T. Kuramoto, and T. Ino. 1977. Comparison of susceptibility to T strain of reticuloendotheliosis virus among families of Japanese quail. *Jap Journal of Poult Sci.* 14: 259–265.
227. Theilen, G.H., R.F. Zeigel, and M.J. Twiehaus. 1966. Biological studies with RE virus (strain T) that induces reticuloendotheliosis in turkeys, chickens, and Japanese quail. *J Natl Cancer Inst.* 37:731–743.
228. Thompson, K.D., R.G. Fischer, and D.H. Luecke. 1968. Determination of the viremic period of avian reticuloendotheliosis virus (strain T) in chicks and virus viability in Triatoma infestans (Klug) [Hemiptera: Reduviidae]. *Avian Dis.* 12: 354–360.
229. Thompson, K.D., R.G. Fischer, and D.H. Luecke. 1971. Quantitative infectivity studies of avian reticuloendotheliosis virus (strain T) in certain hematophagous arthropods. *J Med Entomol.* 8:486–490.
230. Thompson, R.C., M. Herscovitch, I. Zhao, T.J. Ford, and T.D. Gilmore. 2011. NF-kappaB down-regulates expression of the B-lymphoma marker CD10 through a miR-155/PU.1 pathway. *J Biol Chem*. 286:1675–1682.
231. Tiwari, R., W. Bargmann, and H.R. Bose, Jr. 2011. Activation of the TGF-beta/Smad signaling pathway in oncogenic transformation by v-Rel. *Virology.* 413:60–71.
232. Torres-Medina, A., H.C. Mussman, M.B. Rhodes, and M.J. Twiehaus. 1973. Chicken transferrin: high levels in chickens with reticuloendothelial virus disease. *Poult Sci.* 52:747–754.
233. Trager, W. 1959. A new virus of ducks interfering with development of malaria parasite (Plasmodium lophurae). *Proc Soc Exp Biol Med.* 101:578–582.
234. Tsai, W.P., T.D. Copeland, and S. Oroszlan. 1986. Biosynthesis and chemical and immunological characterization of avian reticuloendotheliosis virus *env* gene-encoded proteins. *Virology.* 155:567–583.
235. Tsai, W.P., T.D. Copeland, and S. Oroszlan. 1985. Purification and chemical and immunological characterization of avian reticuloendotheliosis virus gag-gene-encoded structural proteins. *Virology.* 140:289–312.
236. Tsai, W.P., and S. Oroszlan. 1988. Novel glycosylation pathways of retroviral envelope proteins identified with avian reticuloendotheliosis virus. *J Virol.* 62:3167–3174.
237. Tsai, W.P., and S. Oroszlan. 1988. Site-directed cytotoxic antibody against the C-terminal segment of the surface glycoprotein gp90 of avian reticuloendotheliosis virus. *Virology.* 166:608–611.
238. Vogt, P.K., J.L. Spencer, W. Okazaki, R.L. Witter, and L.B. Crittenden. 1977. Phenotypic mixing between reticuloendotheliosis virus and avian sarcoma viruses. *Virology.* 80:127–135.
239. von Bulow, V., and A. Klasen. 1983. Effects of avian viruses on cultured chicken bone-marrow-derived macrophages. *Avian Pathol.* 12:179–198.
240. von dem Hagen, D., and H.C. Lliger. 1978. Studies into Epizootiology of quail leukosis. *Mh Vet Med.* 33:591–593.
241. Wakabayashi, T., and H. Kawamura. 1977. Serological survey of reticuloendotheliosis virus infection among chickens in Japan. *Natl Inst Anim Health Q (Tokyo)*. 17:73–74.
242. Walker, M.H., B.J. Rup, A.S. Rubin, and H.R. Bose, Jr. 1983. Specificity in the immunosuppression induced by avian reticuloendotheliosis virus. *Infect Immun.* 40:225–235.
243. Wang, G., Y. Wang, L. Yu, Y. Jiang, J. Liu, and Z. Cheng. 2012. New pathogenetic characters of reticuloendotheliosis virus isolated from Chinese partridge in specific-pathogen-free chickens. *Microb Pathog.* 53:57–63.
244. Wang, X.L., Z. Zhang, S.J. Jiang, and Z.Z. Cui. 2005. Immunogenicity of envelope glycoprotein gene of reticuloendotheliosis virus expressed in insect cell. *Wei Sheng Wu Xue Bao.* 45:593–597.
245. Watanabe, S., and H.M. Temin. 1983. Construction of a helper cell line for avian reticuloendotheliosis virus cloning vectors. *Mol Cell Biol.* 3:2241–2249.
246. Watanabe, S., and H.M. Temin. 1982. Encapsidation sequences for spleen necrosis virus and avian retrovirus are between the 59 long terminal repeat and the start of the gag gene. *Proc of the Natl Acad Sci USA*. 79:5986–5990.
247. Weaver, T.A., K.J. Talbot, and A.T. Panganiban. 1990. Spleen necrosis virus gag polyprotein is necessary for particle assembly and release but not for proteolytic processing. *J Virol.* 64: 2642–2652.
248. Weinstock, D., K.A. Schat, and B.W. Calnek. 1989. Cytotoxic T lymphocytes in reticuloendotheliosis virus-infected chickens. *Eur J Immunol.* 19:267–272.
249. Wilhelmsen, K.C., K. Eggleton, and H.M. Temin. 1984. Nucleic acid sequences of the oncogene v-rel in reticuloendotheliosis virus strain T and its cellular homolog, the proto-oncogene c-rel. *J Virol.* 52:172–182.
250. Witter, R.L. 1997. Avian tumor viruses: persistent and evolving pathogens. *Acta Vet Hung* 45:251–266.
251. Witter, R.L. 1994. Control of Marek's disease. Proceedings of the International Seminar on Avian Pathol. 201–208.
252. Witter, R.L. 2006. Prevention and control of reticuloendotheliosis virus infection: rationale and strategies. Proceedings of the AAAP Avian Tumor Virus Symposium, Honolulu, HI. 81–89.
253. Witter, R.L., and L.B. Crittenden. 1979. Lymphomas resembling lymphoid leukosis in chickens inoculated with reticuloendotheliosis virus. *Int J Cancer.* 23:673–678.
254. Witter, R.L., I.M. Gimeno, and A.M. Fadly 2005. Differential diagnosis of lymphoid and myeloid tumors in the chicken. Athens. GA, American Association of Avian Pathologists.
255. Witter, R.L., I.M. Gimeno, A.R. Pandiri, and A.M. Fadly. 2010. The differential diagnosis of lymphoid and myeloid tumors in the chicken. In: *Tumor Diagnosis Manual*, 1st ed. American Association of Avian Pathologists, Inc., Jacksonville, FL. 1–84.
256. Witter, R.L., and S.E. Glass. 1984. Reticuloendotheliosis in breeder turkeys. *Avian Dis.* 28:742–750.
257. Witter, R.L., and D.C. Johnson. 1985. Epidemiology of reticuloendotheliosis virus in broiler breeder flocks. *Avian Dis.* 29:1140–1154.
258. Witter, R.L., L.F. Lee, L.D. Bacon, and E.J. Smith. 1979. Depression of vaccinal immunity to Marek's disease by

infection with reticuloendotheliosis virus. *Infect Immun.* 26:90–98.
259. Witter, R.L., I.L. Peterson, E.J. Smith, and D.C. Johnson. 1982. Serologic evidence in commercial chicken and turkey flocks of infection with reticuloendotheliosis virus. *Avian Dis.* 26:753–762.
260. Witter, R.L., H.G. Purchase, and G.H. Burgoyne. 1970. Peripheral nerve lesions similar to those of Marek's disease in chickens inoculated with reticuloendotheliosis virus. *J Natl Cancer Inst.* 45:567–577.
261. Witter, R.L., and D.W. Salter. 1989. Vertical transmission of reticuloendotheliosis virus in breeder turkeys. *Avian Dis.* 33:226–235.
262. Witter, R.L., J.M. Sharma, and A.M. Fadly. 1986. Nonbursal lymphomas induced by nondefective reticuloendotheliosis virus. *Avian Pathol.* 15:467–486.
263. Witter, R.L., E.J. Smith, and L.B. Crittenden. 1981. Tolerance, viral shedding, and neoplasia in chickens infected with nondefective reticuloendotheliosis viruses. *Avian Dis.* 25:374–394.
264. Wong, T.C., and M.M. Lai. 1981. Avian reticuloendotheliosis virus contains a new class of oncogene of turkey origin. *Virology.* 111:289–293.
265. Wozniakowski, G., E. Samorek-Salamonowicz, and W. Kozdrun. 2011. Molecular characteristics of Polish field strains of Marek's disease herpesvirus isolated from vaccinated chickens. *Acta Vet Scand.* 53:10.
266. Xu, H., Y. Yao, L.P. Smith, and V. Nair. 2010. MicroRNA-26a-mediated regulation of interleukin-2 expression in transformed avian lymphocyte lines. *Cancer Cell Int.* 10:15.
267. Yaniv, A., A. Gazit, M. Ianconescu, K. Perk, B. Aizenberg, and A. Zimber. 1979. Biochemical characterization of the type C retrovirus associated with lymphoproliferative disease of turkeys. *J Virol.* 30:351–357.
268. Yoshida, I., M. Sakata, K. Fujita, T. Noguchi, and N. Yuasa. 1981. Modification of low virulent Newcastle disease virus infection in chickens infected with reticuloendotheliosis virus. *Natl Inst Anim Health Q (Tokyo).* 21:1–6.
269. Yuasa, N., I. Yoshida, and T. Taniguchi. 1976. Isolation of a reticuloendotheliosis virus from chickens inoculated with Marek's disease vaccine. *Natl Inst Anim Health Q (Tokyo).* 16:141–151.
270. Zavala, G. 2006. Immunodepression induced by reticuloendotheliosis virus. Proceedings of the AAAP Avian Tumor Virus Symp. Honolulu, HI. 70–80.
271. Zavala, G., S. Cheng, T. Barbosa, and H. Haefele. 2006. Enzootic reticuloendotheliosis in the endangered Attwater's and greater prairie chickens. *Avian Dis.* 50:520–525.
272. Zeigel, R.F., G.H. Theilen, and M.J. Twiehaus. 1966. Electron microscopic observations on RE virus (strain T) that induces reticuloendotheliosis in turkeys, chickens, and Japanese quail. *J Natl Cancer Inst.* 37:709–729.

Other Tumors

1. Abels, H. Die Geschwulste der Vogelhaut. 1929. *Z Krebsforsch.* 29:207–210.
2. Alfonso, M., L. Adochiles, V.M. Hendrickson, D.K. Carver, G.C. Rodriguez, and H.J. Barnes. 2005. Metastatic adenocarcinoma in the lungs of older laying hens. *Avian Dis.* 49: 430–432.
3. Anderson, W.I., and H. Steinberg. 1989. Primary glossal squamous-cell carcinoma in a Spanish Cochin hen. *Avian Dis.* 33:827–828.
4. Anderson, W.I., P.C. McCaskey, K.A. Langheinrich, and A.E. Dreesen. 1985. Neurofibrosarcoma and leiomyosarcoma in slaughterhouse broilers. *Avian Dis*. 29:521–527.
5. Andreasen, J.R., Jr., and C. B. Andreasen. 1992. Intestinal adenocarcinoma of the ileocecal junction in a chicken. *Avian Dis*. 36:799–802.
6. Anjum, A.D. 1987. Adenocarcinoma of the oviduct of the domestic fowl (*Gallus domesticus*) and its relationship to steroid sex hormones. PhD Thesis. Royal Veterinary College: London, United Kingdom, 1–356.
7. Anjum, A.D., and L.N. Payne. 1988. Concentration of steroid sex hormones in the plasma of hens in relation to oviduct tumours. *Br Poult Sci*. 29:729–734.
8. Anjum, A.D., L.N. Payne, and E.C. Appleby. 1988. Spontaneous occurrence and experimental induction of leiomyoma of the ventral ligament of the oviduct of the hen. *Res Vet Sci*. 45: 341–348.
9. Ansenberger, K., C. Richards, Y. Zhuge, A. Barua, J.M. Bahr, J.L. Luborsky, and D.B. Hales. 2010. Decreased severity of ovarian cancer and increased survival in hens fed a flaxseed-enriched diet for 1 year. *Gynecol Oncol*. 117:341–347.
10. Apperly, F.L. 1935. Primary carcinoma of the lung in the domestic fowl. *Am J Cancer*. 23:556–557.
11. Arshad, S.S., A.P. Bland, S.M. Hacker, and L.N. Payne. 1997. A low incidence of histiocytic sarcomatosis associated with infection of chickens with the HPRS-103 strain of subgroup J avian leukosis virus. *Avian Dis*. 41:947–956.
12. Baker, J.R. 1980. A proventricular adenoma in a Brazilian teal (*Amazonetta brasiliensis*). *Vet Rec*. 107:63–64.
13. Balaquer, L., J. Romano, and A. Mora. 1995. A poorly-differentiated squamous cell thymoma in a chicken with lymphoma. *Avian Pathol*. 24:737–741.
14. Ball, R. 1945. Two unusual neoplasms in the chicken iris. *Cornell Vet*. 35:383–386.
15. Barlow, A.M., and T.R. Girling. 2004. Malignant melanoma in a merlin (*Falco columbarius*). *Vet Rec*. 154:696–697.
16. Barua, A., P. Bitterman, J.S. Abramowicz, A.L. Dirks, J.M. Bahr, D.B. Hales, M.J. Bradaric, S.L. Edassery, J. Rotmenxch, and J.L. Luborsky. 2009. Histopathology of ovarian tumors in laying hens: a preclinical model of human ovarian cancer. *Int J Gynecol Cancer*. 19:531–539.
17. Beard, J.W., E.A. Hillman, D. Beard, K. Lapis, and U. Heine. 1975. Neoplastic response of the avian liver to host infection with strain MC29 leukosis virus. *Cancer Res*. 35:1603–1627.
18. Beasley, J.N., S. Klopp, and B. Terry. 1986. Neoplasms in the oviducts of turkeys. *Avian Dis*. 30:433–437.
19. Beer, J.V., and G.W. Storey. 1961. An ovarian tumour in a Mallard. *Bull Brit Ornith Club*. 81:153–156.
20. Bergmann, V. von, A. Valentin, and J. Scheer. 1986. Hartzkarzinomatose bei Broilern. *Monatsh Veterinaermed*. 41:815–817.
21. Berry, W., A. Doernte, M. Conner, M. Barnes, and S. Oates. 2006. Spontaneously occurring fibroid tumors of the laying hen oviduct. *Poult Sci*. 85:1969–1974.
22. Biering-Sorensen, U. 1956. On disseminated, focal gliomatosis ("multiple gliomas") and cerebral calcifications in hens. A study of pathogenesis. *Nord Vet Med*. 8:887–901.
23. Blandford, T.B., A.S. Bremner, and C.J. Randall. 1979. Squamous cell carcinomas in broilers [letter]. *Vet Rec*. 105:334–335.
24. Bolte, A.L., and E. Burkhardt. 2000. A teratoma in a Muscovy duck (*Cairina moschata*). *Avian Pathol*. 29:237–239.

25. Campbell, J.G. 1969. *Tumours of the Fowl*. Lippincott, Philadelphia. 1–292.
26. Campbell, J.G., and E.C. Appleby. 1966. Tumours in young chickens bred for rapid body growth (broiler chickens): A study of 351 cases. *J Pathol Bacteriol*. 92:77–90.
27. Cardona, C.J., A.A. Bickford, and K. Emanuelson. 1992. Squamous cell carcinoma on the legs of an Aracauna chicken. *Avian Dis*. 36:474–479.
28. Carnaghan, R.B.A. 1965. Hepatic tumours in ducks fed a low level of toxic groundnut meal. *Nature (Lond)*. 208:308.
29. Childs-Sanford, S.E., K.M. Rassnick, and A. Alcaraz. 2006. Carboplatin for treatment of a sertoli cell tumor in a mallard (*Anas platyrhynchos*). *Vet Comp Oncol*. 4:51–56.
30. Chin, R.P., and B.C. Barr. 1990. Squamous cell carcinoma of the pharyngeal cavity in a Jersey black giant rooster. *Avian Dis*. 34:775–778.
31. Christopher, J., J.V. Narayana, and G.A. Sastry. 1966. Primary neoplasms of the liver of the domestic fowl. *Ceylon Vet J*. 14:61–64.
32. Christopher, J., P. Rama Rao, J.V. Narayana, and G.A. Sastry. 1965. A case of leiomyoma in the liver of a pigeon. *Indian Vet J*. 42:754–755.
33. Cole, R.K. 1946. An avian retinoblastoma. *Cornell Vet*. 36:350–353.
34. Couvillion, C.E., W.A. Maslin, and R.M. Montgomery. 1990. Multiple feather follicle cysts in a wild turkey. *J Wildl Dis*. 26:122–124.
35. Desserich, M., D.W. Folsch, and V. Ziswiler. 1984. Das Schnabelkupieren bei Huhnern. *Tier Praxis*. 12: 191–202.
36. Dillberger, J.E., S.B. Citino, and N.H. Altman. 1987. Four cases of neoplasia in captive wild birds. *Avian Dis*. 31:206–213.
37. Dillehay, D.L., and N.D. Lehner 1990. Diagnostic exercise: abdominal mass in a male pigeon. *Lab Anim Sci*. 40:202–203.
38. Duflot, A., R. Mehrotra, S-Z. Yu, L. Barraud, C. Trepo, and L. Cova. 1995. Spectrum of liver disease and duck hepatitis B virus infection in a large series of Chinese ducks with hepatocellular carcinoma. *Hepatology*. 21:1483–91.
39. Dukes, T.W., and J.R. Pettit. 1983. Avian ocular neoplasia—a description of spontaneously occurring cases. *Can J Comp Med*. 47:33–36.
40. Fallavena, L.C.B., C.W. Canal, C.T.P. Salle, H.L.S. Moraes, S.L.S. Rocha, R.A. Pereira, and A.B. da Silva. 2002. Presence of avipoxvirus DNA in avian dermal squamous cell carcinoma. *Avian Pathol*. 31:241–246.
41. Feldman, W.H. 1936. Thymoma in a chicken (*Gallus domesticus*). *Am J Cancer*. 26:576–580.
42. Fernandez-Bellon, H., J. Martorell, R. Rabanal, and A. Ramis. 2003. Rhabdomyosarcoma in a racing pigeon (*Columba livia*). *Avian Pathol*. 32:613–616.
43. Foster, D.N., K.E. Nestor, Y.M. Saif, W.L. Bacon, and P.D. Moorhead. 1989. Influence of selection for increased body weight on the incidence of leiomyomas and leiomyosarcomas in Japanese quail. *Poult Sci*. 68:1447–1453.
44. Frankenhuis, M.T. 1987. Sex reversal in poultry. *Poultry (Misset)*. 32:46–47.
45. Fredrickson, T.N. 1987. Ovarian tumors of the hen. *Environ Health Perspect*. 73:35–51.
46. Fredrickson, T.N., and C.F. Helmboldt. 1991. Tumors of unknown etiology. In: *Diseases of Poultry*, 9th ed. B.W. Calnek, H.J. Barnes, C.W. Beard, W.M. Reid, and H.W. Yoder Jr., eds. Iowa State University Press, Ames, Iowa. 459–470.
47. Ganorkar, A.G., and N.V. Kurkure. 1998. Bilateral seminoma in a duck (*Anas platyrhynchos*). *Avian Pathol*. 27:644–645.
48. Gentle, M.J. 1986. Neuroma formation following partial beak amputation (beak trimming) in the chicken. *Res Vet Sci*. 41:383–85.
49. Gentle, M.J., and L.H. Hunter. 1988. Neural consequences of partial toe amputation in chickens. *Res Vet Sci*. 45:374–376.
50. Gentle, M.J., B.H. Thorp, and B.O. Hughes. 1995. Anatomical consequences of partial beak amputation (beak trimming) in turkeys. *Res Vet Sci*. 58:158–162.
51. Giles, J.R., H.L. Shivaprasad, and P.A. Johnson. 2004. Ovarian tumor expression of an oviductal protein in the hen: a model for human serous ovarian adenocarcinoma. *Gynecol Oncol*. 95: 530–533.
52. Golbar, H.M., T. Izawa, M. Kuwamura, M. Yonezawa, S. Ito, and J. Yamate. 2009. Malignant seminoma with multiple visceral metastases in a guinea fowl (*Numida meleagris*) kept in a zoo. *Avian Dis*. 53:143–145.
53. Good, R.E. 1991. The importance of squamous cell carcinoma in broilers. Proceedings of the Avian Tumor Virus Symposium. American Association of Avian Pathologists, Kennett Square, PA. 56–57.
54. Goodchild, W.M. 1969. Adenocarcinoma of the oviduct in laying hens. *Vet Rec*. 84:122.
55. Goodwin, M.A., S. Hafner, D.I. Bounous, J. Brown, E. Smith, and A. Fadly. 1999. Multi-centric histiocytosis: Experimental induction in broiler and specific pathogen-free leghorn chickens. *Avian Pathol* 28:273–278.
56. Gorham, S.L., and M.A. Ottinger. 1986. Sertoli cell tumors in Japanese quail. *Avian Dis.* 30:337–339.
57. Grewel, G.S., and H.S. Patel. 1985. An unusual case of rhabdomyosarcoma in a fowl. *Avian Pathol.* 14:177–180.
58. Griner, L.A., G. Migaki, L.R. Penner, and A.E. McKee Jr. 1977. Heterakidosis and nodular granulomas caused by Heterakis isolonche in the ceca of Gallinaceous birds. *Vet Pathol.* 14: 582–590.
59. Guerin, M. 1954. Tumeurs spontanees de la poule. In: *Tumeurs Spontanees des Animaux de Laboratoire*. Legrand, Paris, France. 153–180.
60. Guthrie, J. 1967. Specificity of the metallic ion in the experimental induction of teratomas in fowl. *Br J Cancer.* 21:619–622.
61. Hafner, S., B.G. Harmon, G.N. Rowland, R.G. Stewart, and J.R. Glisson. 1991. Spontaneous regression of "dermal squamous cell carcinoma" in young chickens. *Avian Dis.* 35:321–327.
62. Hafner, S., B.G. Harmon, R.G. Stewart, and G.N. Rowland. 1993. Avian keratoacanthoma (dermal squamous cell carcinoma) in broiler chicken carcasses. *Vet Pathol.* 30:265–270.
63. Hafner, S., and K. Latimer. 1997. Cutaneous mast cell tumours with pulmonary metastasis in a hen. *Avian Pathol.* 26:657–663.
64. Hafner, S., K. Latimer, L.C. Kelley, K. Wortham, and M. Puette. 1995. Malignant melanocytic neural crest tumor in a young chicken. *Vet Pathol.* 32:535–537.
65. Hafner, S., M.A. Goodwin, E.J. Smith, D.I. Bounous, M. Puette, L.C. Kelley, K.A. Langheinrich, and A.M. Fadly. 1996. Multicentric histiocytosis in young chickens. Gross and light microscopic pathology. *Avian Dis.* 40:202–209.
66. Hafner, S. 2011. Unpublished observations.
67. Hakim, A.A., C.P. Barry, H.J. Barnes, K.E. Anderson, J. Petitte, R. Whitaker, J.M. Lancaster, R.M. Wenham, D.K. Carver, J. Turbov, A. Berchuck, L. Kopelovich, and G.C.

Rodriguez. 2009. Ovarian adenocarcinomas in the laying hen and women share similar alterations in p53, ras, and Her-2/neu. *Cancer Prev Res* 2:114–121.
68. Hall, S.M., D. Mosier, and M.M. Degraw. 1994. Histological and ultrastructural characterization of a cutaneous mast cell tumor in a chicken. Proceedings of the 43rd Western Poultry Disease Conference, University of California, Davis, California. 6–7.
69. Hamir, A.N. 1985. Teratoma in a duck. *Vet Rec.* 117:314.
70. Haritani; M., H. Kajigaya, T. Akashi, M. Kamemura, N. Tanahara, M. Umeda, M. Sugiyama, M. Isoda, and C. Kato. 1984. A study on the origin of adenocarcinoma in fowls using immunohistological technique. *Avian Dis.* 28:1130–1134.
71. Hatai, H., K. Ochiai, and T. Umemura. 2009. Detection of Avian leukosis virus genome by a nested polymerase chain reaction using DNA and RNA from dried feather shafts. *J Vet Diagn Invest.* 21:519–522.
72. Hatkin, J., E. Styer, D. Miller. 2002. Ingluvial squamous cell carcinoma in a game chicken. *Avian Dis.* 46:1070–1075.
73. Helmboldt, C.F., G. Migaki, K.A. Langheinrich, and R.M. Jakowski. 1974. Teratoma in domestic fowl (*Gallus gallus*). *Avian Dis.* 18:142–148.
74. Ilchmann, G., and V. Bergmann. 1975. Histologische and elektronenmikroskopische Untersuchungen zu Adenokarzinomatose der Legehennen. *Arch Exp Veterinaermed.* 29:897–907.
75. Jackson, C. 1936. The incidence and pathology of tumors of domesticated animals in South Africa. *Onderstepoort J Vet Res.* 6:1–460.
76. Jackson, C. 1954. Gliomas of the domestic fowl: Their pathology with special reference to histogenesis; and pathogenesis and their relationship to other diseases. *Onderstepoort J Vet Res.* 26:501–592.
77. James, C. 1968. Neoplasms of the chicken. *Ceylon Vet J.* 16:59–61.
78. Jungherr, E.L., and A. Wolf. 1939. Gliomas in animals. A report of two astrocytomas in the common fowl. *Am J Cancer* 37: 493–509.
79. Kajigaya, H., K. Konagaya, H. Ejima, Z. Usuda, S. Kodama, and J. Thone. 2010. Metastatic melanoma appearing to originate from the beak of a racing pigeon (*Columba livia*). *Avian Dis.* 54:958–960.
80. Kajigaya, H., M. Kamemura, N. Tanahara, A. Ohta, H. Suzuki, M. Sugiyama, and M. Isoda. 1987. The influence of celomic membranes and a tunnel between celomic cavities on cancer metastasis in poultry. *Avian Dis.* 31:176–186.
81. Kawaguchi, T., K. Nomura, Y. Hirayama, and T. Kitagawa. 1987. Establishment and characterization of a chicken hepatocellular carcinoma cell line, LMH. *Cancer Res*. 47:4460–4464.
82. Kelley, L., J. Hill, S. Hafner, and K. Langheinrich. 1993. Enterogenous cysts in chickens. *Vet Pathol.* 30:376–378.
83. Krogh, G. 1953. Two cases of rhabdomyosarcoma in chickens. *Nord Vet Med* 5:232–236.
84. Kurkure, N.V., V.V. Pande, F. Thomas, and A.G. Bhandarkar. 2006. A seminoma in a monorchid guinea fowl (*Numida meleagris*). *J Vet Med A Physiol Pathol Clin Med.* 53:22–23.
85. Kusewitt, D.F., R.L. Reece, and K.B. Miska. 1997. S–100 immunoreactivity in melanomas of two marsupials, a bird, and a reptile. *Vet Pathol.* 43:615–618.
86. Leach, S., J.J. Heatley, R.R. Pool, Jr., and K. Spaulding. 2008. Bilateral testicular germ cell-sex cord-stromal tumor in a pekin duck (*Anas platyrhynchos domesticus*). *J Avian Med Surg.* 22:315–319.
87. Ling, Y.S., and Y.Q. Guo. 1985. Pathological study of spontaneous mesothelioma in ducks. *Chin J Vet Sci Technol.* 9:15–16.
88. Ling, Y.S., Y.J. Guo, and L.K. Yang. 1993. Pathological observations of hepatic tumours in ducks. *Avian Pathol.* 22:131–140.
89. Lombard, L.S., and E.J. Witte. 1959. Frequency and types of tumors in mammals and birds of the Philadelphia Zoological Garden. *Cancer Res.* 19:127–141.
90. Madekurozwa, M.-C., and W.H. Kimaro. 2008. An ultrastructural characterization of the ooplasm in ovarian follicles of the immature Ostrich (*Struthio camelus*). *Anat Histol Embryol.* 37:214–218.
91. Manarolla, G., S. Caserio, G. Sironi, and T. Rampin. 2011. Morphological and immunohistochemical observations on leiomyoma of the ventral ligament of the oviduct of the hen. *J Comp Pathol.* 144:180–186.
92. Mawdesley-Thomas, L.E., and D.H. Solden. 1967. Osteogenic sarcoma in a domestic goose (*Anser anser*). *Avian Dis.* 11: 365–370.
93. Movassaghi, A.R., and K. Sardari. 2008. Cutaneous leiomyosarcoma in a pigeon. *Vet Rec.* 162:250–251.
94. Mutinelli, F., M. Vascellari, and E. Bozzato. 2006. Unilateral seminoma with multiple visceral metastases in a duck (*Anas platyrhynchos*). *Avian Pathol.* 35:327–329.
95. Nakumura, K., M. Ito, K. Fujino, Y. Yamamoto, M. Mase, M. Yamada, H. Kobayashi, and T. Harada. 2010. Pathology and microbiology of dermal squamous cell carcinoma in young Brown chickens reared on reused litter. *Avian Dis.* 54:1120–1124.
96. Newman, S.J., and K. West. 2001. Pulmonary leiomyosarcoma in a White Carneau pigeon (*Columba livia*). 2001. *J Avian Med Surg*. 15:293–296.
97. Nili, H., and W.R. Kelly. 1996. Form and function of lacunae in the ovary of the laying hen. *Anat Rec.* 244:165–174.
98. Nobel, T.A., F. Neumann, and M.S. Dison. 1964. A histological study of peritoneal carcinomatosis in the laying hen. *Avian Dis.* 8:513–522.
99. Ochiai, K., K. Ohashi, T. Mukai, T. Kimura, T. Umemura, C. Itakura. Evidence of neoplastic nature and viral aetiology of so-called fowl glioma. 1999. *Vet Rec*. 145:79–81.
100. Okoye, J.O.A., and C.C. Ilochi. 1993. Pancreatic adenocarcinoma in Guinea fowl. *Avian Pathol.* 22:401–406.
101. Olson, C., and K.L. Bullis. 1942. A survey of spontaneous neoplastic diseases in chickens. *Massachusetts Agric Exp Stat Bull.* 391:1–25.
102. Ottinger, M.A., E. Adkins-Regan, J. Buntin, M.F. Cheng, T. de Voogd, C. Harding, and H. Opel. 1984. Hormonal mediation of reproductive behaviour. *J Exp Zool.* 232:605–616.
103. Pandiri, A.R., I.M. Gimeno, W.M. Reed, S.D. Fitzgerald, A.M. Fadly. 2009. Subgroup J avian leukosis virus–induced histiocytic sarcomatosis occurs only in persistently viremic but not immunotolerized meat-type chickens. *Vet Pathol.* 46:282–287.
104. Patnaik, G.M., and D. Mohanty. 1970. A case of avian mastocytoma. *Indian Vet J.* 47:298–300.
105. Payne, L.N., A.M. Gillespie, and K. Howes. 1992. Myeloid leukaeomogenicity and transmission of the HPRS-103 strain of avian leukosis virus. *Leukaemia.* 6:1167–1176.
106. Porter, T.E., B.M. Hargis, J.L. Silsby, and M.E. El-Halawani. 1989. Differential steroid production between theca interna and theca externa cells: A three cell model for follicular steroidogenesis in avian species. *Endocrinology.* 125:109–116.

107. Priester, W.A. 1975. Esophageal cancer in North China; high rates in human and poultry populations in the same areas. *Avian Dis.* 19:213–215.
108. Purvulov, B., and S. Bozhkov. 1984. Pathology of some spontaneous neoplasms of fowls. *Obshch i Stravnitelna Patologiya.* 16:55–58.
109. Razmyar, J., O. Dezfoulian, B. Shojadoost, M. Masoudifard, S.M. Peighambari. 2005. Sertoli cell tumor in a pigeon (*Columba livia*). *J Avian Med Surg.* 19:286–288.
110. Reece, R.L. 1992. Observations on naturally occurring neoplasms in birds in the state of Victoria, Australia. *Avian Pathol*. 21:3–32.
111. Reece, R.L. 1995. Unpublished observations.
112. Reece, R.L. 1996. Some observations on naturally occurring neoplasms in domestic fowl in the state of Victoria, Australia. *Avian Pathol*. 25:407–447.
113. Reece, R.L. 2001. Unpublished observations.
114. Reece, R.L. 2011. Unpublished observations.
115. Reece, R.L. 2008. Other tumors of unknown etiology. In: *Diseases of Poultry*, 12th ed. Y.M. Saif, A.M. Fadly, J.R. Glisson, L.R. McDougald, L.K. Nolan, and D.E. Swayne, eds. Blackwell Publishing, Ames, Iowa. 593–616.
116. Reece, R.L., and S.A. Lister. 1993. An abdominal teratoma in a domestic goose (Anseriformes, *Anser anser domesticus*). *Avian Pathol.* 22:193–196.
117. Riddell, C., and P.T. Shettigara. 1980. Dermal squamous cell carcinoma in broiler chickens in Saskatchewan. *Can Vet J.* 21:287–289.
118. Rigdon, R.H. 1967. Neoplasms in sterile hybrid ducks–a melanoma and two teratomas. *Avian Dis.* 11:79–89.
119. Rigdon, R.H. 1970. Spontaneous-occurring tumors in the duck: Review of the literature and report of three cases. *Avian Dis.* 14:431–444.
120. Rubio, C.A., and F-S. Liu. 1989. Spontaneous squamous carcinoma of the esophagus in chickens. *Cancer.* 64: 2511–2514.
121. Sanger, V.L., and A. Lagace. 1966. Avian xanthomatosis. Etiology and pathogenesis. *Avian Dis*. 10:103–113.
122. Sato, T., E. Nosaka, H. Shibuya, E. Momotani, Y. Fujii, J. Inoue, and K. Tezuka. 2002. Myxoid leiomyosarcoma of the gizzard in a broiler chicken. *Avian Dis.* 46:256–259.
123. Saunders, L.Z., and C.N. Barron. 1958. Primary pigmented intraocular tumours in animals. *Cancer Res.* 18:234–245.
124. She, R.P. 1987. Epidemiology and pathology of oropharyngo-esophageal carcinoma in chickens from different areas in Zhongxian county, Hubei province. *Acta Vet Zootech Sinica*. 18:195–200.
125. Sievert, Rabea. 2002. Pathomophologische Untersuchungen zur Charakterisierung der Hautkarzinomatose (Keratoakanthom) von Jungmasthühnern. Diss., Freien Universität, Berlin.
126. Siller, W.G. 1956. A Sertoli cell tumour causing feminization in a brown leghorn capon. *J Endocrinol.* 14:197–203.
127. Siller, W.G. 1959. An osteogenic sarcoma in the fowl. *Br J Cancer.* 13:642–646.
128. Sokkar, S.M., M.A. Mohammed, A.J. Zubaidy, and A. Mutalib. 1979. Study of some non-leukotic avian neoplasms. *Avian Pathol.* 8:69–75.
129. Stewart, H.L. 1966. Pulmonary cancer and adenomatosis in captive wild mammals and birds from the Philadelphia Zoo. *J Natl Cancer Inst.* 36:117–138.
130. Sugiyama, M., H. Yamashina, T. Kanbara, H. Kajigaya, K. Konagaya, M. Umeda, M. Isoda, and T. Sakai. 1987. Dermal squamous cell carcinoma in a laying hen. *Jpn J Vet Sci.* 49:1129–1130.
131. Swarbrick, 0., J.G. Campbell, and D.M. Berry. 1968. An outbreak of oviduct adenocarcinoma in laying hens. *Vet Rec.* 82:57–59.
132. Swayne, D.E., G.N. Rowland, and O.J. Fletcher. 1986. Pinealoma in a broiler breeder. *Avian Dis.* 30:853–855.
133. Takami S., M. Goryo, T. Masegi, and K. Okada. 2004. Microscopic characteristics of spindle-cell proliferative disease in broiler chickens and its experimental reproduction in specific pathogen-free chickens. *J Vet Med Sci.* 66:231–235.
134. Takami S., M. Goryo, T. Masegi, and K. Okada. 2005. Systemic spindle-cell proliferative disease in broiler chickens. *J Vet Med Sci.* 67:13–18.
135. Tomioka, Y., K. Ochiai, K. Ohashi, T. Kimura, and T. Umemura. 2003. *In ovo* infection with an avian leukosis virus causing fowl glioma: viral distribution and pathogenesis. *Avian Pathol.* 32:617–624.
136. Turk, J.R., A.L. Forar, and A.M. Gallina. 1980. Intestinal adenocarcinoma in a chicken. *Avian Dis.* 24:507–509.
137. Turk, J.R., J. Kim, and A.M. Gallina. 1981. Seminoma in a pigeon. *Avian Dis.* 25:752–755.
138. Turnquest, R.U. 1979. Dermal squamous cell carcinoma in young chickens. *Am J Vet Res.* 40:1628–1633.
139. Vázquez, S., M.I. Quiroga, N. Alemań, J.C. Garcia, M. López-Peńa, and J.M. Nieto. 2003. Squamous cell carcinoma of the oropharynx and esophagus in a Japanese Bantam rooster. *Avian Dis*. 47:215–217.
140. Walser, M.M., and P.S. Paul. 1979: Ovarian adenocarcinomas in domestic turkeys. *Avian Pathol.* 8:335–339.
141. Wang, Z., L. Tang, G. Sun, Y. Tang, Y. Xie, S. Wang, X. Hu, W. Gao, S.B. Cox, and J.S. Wang. 2006. Etiologic study of esophageal squamous cell carcinoma in an endemic region: a population-based case control study in Huaian, China. *BMC Cancer*. 6:287.
142. Warner, N.E., N.B. Friedman, B.J. Bomze, and F. Masin. 1960. Comparative pathology of experimental and spontaneous androblastomas and gynoblastomas of the gonads. *Am J Obstet Gynecol.* 79:971–988.
143. Webster, W.S., B.C. Bullock, and R.W. Prichard. 1969. A report of three bile duct carcinomas occurring in pigeons. *J Am Vet Med Assoc.* 155:1200–1205.
144. Weinstock, D., M.T. Correa, D.V. Rives, and D.P. Wages. 1995. Histopathology and epidemiology of condemnations due to squamous cell carcinoma in broiler chickens in North Carolina. *Avian Dis.* 39:676–686.
145. Wight, P.A.L. 1962. Gonadal maldevelopment in a flock of Rhode Island red fowls. *J Endocrino1*. 23:341–349.
146. Wight, P.A.L. 1965. Neoplastic sequelae of gonadal maldevelopment in a flock of domestic fowls. *Avian Dis.* 9:327–335.
147. Wight, P.A.L., and J.G. Campbell. 1976. Three unusual intracranial tumours of the domesticated fowl. *Avian Pathol.* 5: 201–214.
148. Wight, P.A.L., and R.H. Duff. 1964. The histopathology of epizootic gliosis and astrocytomata of the domestic fowl. *J Comp Pathol.* 74:373–380.
149. Williams, S.M., G. Zavala, S. Hafner, S.R. Collett, and S. Cheng. 2012. Metastatic melanomas in young broiler chickens (*Gallus gallus domesticus*). *Vet Pathol.* 49:288–291.

150. Worms, G., and H.P. Klotz. 1934. Contribution a l'etude des tumeurs thymiques. A propos d'un cas d'epitheliome thymique chez un canard. *Bull Assoc Fr Etude Cancer*. 23:420–432.
151. Yang, C.S. 1980. Research on esophageal cancer in China: a review. *Cancer Res.* 40:2633–2644.
152. Yokosuka, 0., M. Omata, Y.Z. Zhou, F. Imazeki, and K. Okuda. 1985. Duck hepatitis B virus DNA in liver and serum of Chinese ducks: Integration of viral DNA in a hepatocellular carcinoma. *Proc Natl Acad Sci USA*. 82:5180–5184.
153. Zhang, J.L., F.C. Liang, and Y.J. Chen. 1985. Primary pulmonary tumours in Pekin ducks: Pathological analysis of 16 cases. *Chin J Vet Sci Tech.* 4:32–33.
154. Zheng, S., L. Vuitton, I. Sheyhidin, D.A. Vuitton, Y. Zhang, and X. Lu. 2010. Northwestern China: a place to learn more on oesophageal cancer. Part one: behavioural and environmental risk factors. *Eur J Gastroenterol Hepatol*. 22:917–925.

III Bacterial Diseases

Chapter 16	Salmonella Infections	677
Chapter 17	Campylobacteriosis	737
Chapter 18	Colibacillosis	751
Chapter 19	Pasteurellosis and Other Respiratory Bacterial Infections	807
Chapter 20	Infectious Coryza and Related Bacterial Infections	859
Chapter 21	Mycoplasmosis	875
Chapter 22	Clostridial Diseases	943
Chapter 23	Other Bacterial Diseases	971
Chapter 24	Avian Chlamydiosis	1055

Chapter 16

Salmonella Infections

Introduction

Richard K. Gast

Infections with bacteria of the genus *Salmonella* are responsible for both acute and chronic poultry diseases. These diseases cause economically significant losses for poultry producers in many nations and absorb large investments of public and private resources in testing and control efforts. Infected poultry flocks are also among the most important reservoirs of salmonellae which are transmitted through the food chain to humans. Poultry producers face continually intensifying pressures from public health and regulatory authorities to protect consumers from illness due to contaminated poultry meat or eggs. Poultry and poultry products are among the most frequently implicated animal sources for salmonellae entering the human food supply. This association is a consequence of both a high prevalence of *Salmonella* infections in poultry and very high levels of consumption of poultry products throughout the world. Widespread and intensive programs for identifying infected poultry flocks and products have increased the likelihood of detecting and reporting infection or contamination. The increasingly international scope of the modern poultry industry has created new and more complex opportunities for the global dissemination of *Salmonella*.

The genus *Salmonella* (of the family Enterobacteriaceae), named for USDA veterinary bacteriologist Daniel E. Salmon (1850–1914), includes more than 2,500 antigenically distinguishable variants (serovars or serotypes) which have often been named for the place of initial isolation. Although recent taxonomic refinements have indicated that all salmonellae associated with poultry are members of a single genetically defined species, *Salmonella enterica*, the distinctions between the various serotypes are often epidemiologically significant. Accordingly, *Salmonella* isolates are still most often described by reference to their traditional serotype nomenclature.

Infections of poultry with salmonellae can be grouped into 3 categories, each of which is the subject of a separate section of this chapter. The first section discusses infections with the 2 nonmotile serotypes, *S*. Pullorum and *S*. Gallinarum, which are generally host-specific for avian species. Pullorum disease, caused by *S*. Pullorum, is an acute systemic disease of chicks or poults. Fowl typhoid, caused by *S*. Gallinarum, is an acute or chronic septicemic disease that most often affects mature birds. Both of these diseases have been responsible for serious economic losses since the inception of commercial poultry production, and have been addressed by the implementation of extensive testing and eradication programs. Nevertheless, both diseases remain widely prevalent in some nations.

The second section of this chapter discusses infections with the numerous motile and nonhost-adapted serotypes referred to collectively as paratyphoid salmonellae. Found nearly ubiquitously in wild and domestic animals, this diverse group of organisms is principally of concern as a cause of food-borne disease in humans. Although paratyphoid infections of poultry are very common, they seldom cause acute systemic disease except in highly susceptible young birds subjected to stressful conditions. More often, paratyphoid *Salmonella* infections of poultry are characterized by asymptomatic and sometimes persistent colonization of the intestinal tract and internal organs, potentially leading to contamination of finished carcasses. Some serotypes, especially *S*. Enteritidis, are deposited inside the contents of eggs laid by systemically infected hens. Because there are so many potential sources for the introduction of paratyphoid salmonellae into poultry flocks, effective strategies for controlling these important zoonotic pathogens require the combined and sustained implementation of comprehensive risk reduction practices throughout the production continuum.

The third section of this chapter discusses infections with *S. enterica* subspecies *arizonae*, a motile serotype which was formerly designated *Arizona hinshawii*. This organism, although biochemically distinct, causes an acute septicemic disease that is not clinically distinguishable from other *Salmonella* infections. Arizonosis has re-emerged as an economically significant disease of young turkeys in recent years.

Diseases of Poultry, Thirteenth Edition. David E. Swayne.
© 2013 John Wiley & Sons, Inc. Published 2013 by John Wiley & Sons, Inc.

Pullorum Disease and Fowl Typhoid

H.L. Shivaprasad and Paul A. Barrow

Introduction

In terms of history, clinical signs, epizootiology, lesions, and control and eradication procedures, pullorum disease and fowl typhoid have many similarities. However, differences have been reported for these 2 diseases, which are caused by these 2 different serovars (i.e., *Salmonella* Pullorum and *S*. Gallinarum, respectively). These 2 bacterial taxa are generally regarded as separate serovars, namely *S. enterica* subsp. *enterica* serovar Gallinarum (*S*. Gallinarum) or *S*. Pullorum, but debate continues as to whether they are single or different taxa within the same serovar.

Pullorum disease (PD) and fowl typhoid (FT) are septicemic diseases affecting primarily chickens and turkeys, but other birds such as quail, pheasants, ducks, peacocks, and guinea fowl are also susceptible. Both diseases can be transmitted through the egg by transovarian infection. The serovars are highly host adapted and seldom cause significant clinical signs, morbidity, or mortality in nonavian hosts.

Definition and Synonyms

Bacillary white diarrhea was a term used to designate PD before 1929, but the term pullorum disease has since gained universal acceptance.

Economic Significance

The elimination of PD and FT from commercial flocks in the United States in the mid 1900s was largely a result of the pullorum-typhoid control program, the National Poultry Improvement Plan (NPIP), instituted by a voluntary organization (10). Similar government-backed approaches contributed to reductions in Europe. Even though PD is rare in commercial chickens in the United States and Europe, the disease still occurs in backyard flocks and where more extensive and outdoor rearing has become popular (9, 57, 148, 175). The major economic cost from PD over the last 20 years has been the cost involved in testing breeding flocks of chickens and turkeys to ensure that they are free of the infection. Both diseases remain of considerable economic significance in those countries which have only recently begun to intensify their industries and where extensive breeding remains important or where the ambient conditions are such that environmental infection is difficult to control through improvements in housing.

Public Health Significance

The pathogenesis of infection is such that in adult birds the alimentary tract is rarely affected unless clinical disease occurs. Therefore the pathogens seldom enter the human food chain. Rare cases of PD in humans have resulted from massive exposure following the ingestion of contaminated foods or experimental challenge (115, 120). The clinical signs are characterized by a rapid onset of acute enteritis followed by prompt recovery in survivors without treatment. *S*. Gallinarum is rarely isolated from humans and is of little public health significance (9, 129). According to a Centers for Disease Control and Prevention report (8), 18 S. Pullorum isolates and 8 S. Gallinarum isolates were reported out of a total of 458,081 *Salmonella* isolates from humans between 1982 and 1992. Experimental reproduction of salmonellosis with 4 strains of S. Pullorum in humans with large numbers (billions) of bacteria produced only transient clinical signs followed by prompt recovery (120).

History

Only the salient features of these 2 diseases are provided here. Further information on the history of these diseases can be found in previous editions of this book, as well as in a historical review by Bullis (40). A recent review by Barrow and Freitas Neto (22) provides new thoughts on various aspects of PD and FT including prevalence of infection and antibiotic resistance in different countries, taxonomy, recent information on genomics, virulence and motility, immunity, diagnosis, and current and novel opportunities for control.

The etiologic agent of PD was described by Rettger in 1899 as a fatal septicemia of young chicks (133). The disease was designated as bacillary white diarrhea to distinguish it from other diseases of chicks (129). At that time PD was widespread in the United States and in many other countries throughout the world. Mortality associated with this disease in chicks ranged up to 100% (134), seriously threatening the chicken industry. Between 1900 and 1910, PD was shown to be an egg-borne infection. In 1913, the practical application of the macroscopic tube agglutination antibody test for detection of carriers of the organism was described (89). Standard methods of diagnosis of PD in barnyard fowl were formulated by the Conference of Research Workers in Animal Diseases of North America and later adopted by the USA Livestock Association, now the United States Animal Health Association (USAHA), in 1932 (5, 6). A modified whole blood test method in which stained antigen is used was developed in 1931 (142). It has been widely used because of its simplicity.

The NPIP, established in 1935, is administered by state agencies cooperating with the USDA, and was designed in part to control PD in chickens. Pullorum disease was first recognized in turkeys in 1928 (77), and by 1940, the disease was widespread in turkeys and responsible for severe economic losses. A National Turkey Improvement Plan, similar to NPIP, was organized in 1943. A series of modifications of these plans over a number of years has helped eradicate PD in commercial poultry.

Fowl typhoid, a disease very similar to PD, was first recognized in 1888, even before PD (96). Initially, the causative agent was named *Bacillus gallinarum*, later changed to *B. sanguinarium* and then later to *S. gallinarum*. The name fowl typhoid was applied in 1902, and it was soon used in other parts of the world such as Germany and The Netherlands. Control of FT was included in the NPIP in 1954. This resulted in the inclusion of FT in the same category as PD and is one of the main reasons for the eradication of FT in commercial poultry and its low incidence in all poultry.

The control and reduction of FT and PD have been suggested to be among the reasons for the emergence of *S*. Enteritidis in the 1980s (131). Whether this is true or not, given the temporal gap between these 2 events, remains to be seen.

Etiology

Classification

Pullorum disease and FT are caused by *S*. Pullorum and *S*. Gallinarum, respectively. However, these 2 bacteria are currently placed in a single serovar, *S. enterica* subsp. *enterica* serovar Pullorum-Gallinarum of the family Enterobacteriaceae, which is highly host adapted to birds. It is 1 of the few members of the genus that is nonmotile and belongs to the serogroup D according to the Kauffman White scheme. Classification of the etiology of PD and FT has been confusing and has changed in the last few years from separate species of *S. pullorum* and *S. gallinarum* to be member serovars of *S. enterica* subsp. *enterica*. In some classification schemes, the 2 serovars are also referred to as *S. enterica* serovar Gallinarum biovars gallinarum and pullorum because of biochemical differences and epizootiology. For simplicity in this chapter, the etiology of PD will be termed *S*. Pullorum, and the etiology of FT will be termed *S*. Gallinarum.

These 2 nonmotile serovars are monophyletic, and the most recent common ancestor is thought to be a common nonmotile derivative of *S*. Enteritidis (107). Since diverging from this ancestor, the Pullorum lineage has evolved more rapidly than the Gallinarum lineage as shown by multilocus enzyme electrophoresis and estimation of the chromosomal genotypic diversity (162). Using multilocus enzyme electrophoresis, it was shown that *S*. Enteritidis, a polyphyletic serotype, is closely related to *S*. Pullorum and *S*. Gallinarum (162). Genetic differences also were found between isolates of *S*. Pullorum isolated prior to the 1980s and isolates of *S*. Pullorum isolated during the 1990s based on random amplified polymorphic DNA assay (53). This has been supported more recently by microarray comparisons of whole genomic DNA (44, 130), and full analysis of the recently sequenced genomes (www.sanger.ac.uk/Projects/Salmonella, 170) will enable extensions of these comparisons. Chromosomal rearrangements also have been observed in these serovars, which, it has been speculated, are related to host adaptation (108, 192). Some differences also exist between the 2 taxa including deletions in both organisms in the trimethylamine N-oxide TMAO reductase (tor) system and in the *std* fimbriae and chemotaxis genes in Gallinarum strains (130), and more unusual strains with large deletions were also seen.

Gallinarum strains also can be differentiated from Pullorum strains by polymerase chain reaction- (PCR-) based assays reflecting local genomic sequence differences such as those in the *rfbS* (146) and *glgC* genes (116).

Morphology and Staining

The organisms are Gram-negative, nonsporogenic, and facultatively anaerobic. They are slender rods measuring 0.3–1.5 mm in width and 1–2.5 mm in length. The bacilli mostly occur singly, but occasionally 2 or more can be found to be united. Both *S*. Pullorum and *S*. Gallinarum are considered as nonmotile. However, motility and flagellation have been shown in *S*. Pullorum grown on special types of solid media (46, 71, 80). Nevertheless, other workers were unable to induce motility in *S*. Pullorum when grown on Hektoen agar (44).

S. Gallinarum and *S*. Pullorum are nonmotile although there has been considerable speculation on the reversibility of this phenotype in *S*. Pullorum (46, 80). The *fli*C gene in *S*. Gallinarum, responsible for flagellin expression, is entire. However, this serovar carries mutations in 5 genes (*cheM*, *flh*A, *flh*B, *flg*K and *flg*I) distributed in 2 loci involved in the synthesis of the flagellar structure. Why more mutations have not accumulated in more than 5 of the 50 genes responsible in *Salmonella* for motility remains to be seen.

Growth Requirements

S. Pullorum and *S*. Gallinarum grow readily on beef agar, broth, or other nutrient media. They are aerobic or facultatively anaerobic and grow well at 37ºC. The organisms will grow in selective enrichment media such as selenite-F and tetrathionate broths, and differential plating media such as MacConkey, bismuth sulfite, and brilliant green agars. It has been shown that some strains of *S*. Pullorum may fail to grow on certain selective media such as brilliant green or salmonella-shigella agar but grow satisfactorily on bismuth sulfite and MacConkey agars (42). *S*. Pullorum appears to grow slower than *S*. Gallinarum, and this has been attributed to its inability to oxidatively assimilate a variety of amino acids (163).

Colony Morphology

Colonies of *S*. Pullorum and *S*. Gallinarum on meat extract or infusion agar (pH 7.0–7.2) appear as small, discrete, smooth, blue-gray or grayish white, glistening, homogenous, and entire. The growth of both strains is luxuriant and markedly translucent on liver infusion agar. Confluent colonies remain small (1 mm or less), but isolated colonies may have a diameter of 3–4 mm or more. Surface markings may appear as the colonies increase in size and age, but as a rule, young colonies in a heavily seeded plate change little with age. Occasionally, morphologically abnormal strains are encountered. Inoculation of gelatin slants yields grayish-white surface growth with filiform growth in the stab and no liquefaction. Growth in broth is turbid with heavy flocculent sediment.

Biochemical Properties

More similarities than differences exist between the biochemical properties of *S*. Pullorum and *S*. Gallinarum (34, 51, 171). Both organisms can ferment arabinose, dextrose, galactose, mannitol, mannose, rhamnose, and xylose to produce acid, with or without gas production. Substances not fermented include lactose, sucrose, and salicin. One important biochemical difference between these 2 organisms is that *S*. Gallinarum ferments dulcitol, whereas *S*. Pullorum does not. Also, *S*. Pullorum only occasionally ferments maltose. The major difference between the 2 organisms is, that *S*. Pullorum cultures produce rapid decarboxylation of ornithine, whereas cultures of *S*. Gallinarum do not. In addition, *S*. Gallinarum uses citrate, D(2) sorbitol, L(2) fucose, D(2) tartrate, and cysteine hydrochloride gelatin (171). Some of these differences are helpful in differentiating the 2 organisms; however, variation in the characteristics of some strains can be observed occasionally, especially in regard to gas production, and strains with intermediate characteristics also exist.

S. Gallinarum carries a mutation in *speC* encoding ornithine decarboxylase, making the 1 remaining intact arginine catabolic pathway, involving arginine decarboxylase (ADC), an essential biosynthetic route for putrescine (170). The mutation in *speC* could explain the inability of *S*. Gallinarum to decarboxylate ornithine, a defining feature of this *Salmonella* serovar.

Unlike other *Salmonella* serovars, *S*. Gallinarum and *S*. Pullorum are both unable to produce glycogen. In *S*. Gallinarum there are extensive mutations in *glgA, B*, and *C*; *S*. Pullorum does not possess the same deletion in *glgC* but the nature of other mutations is currently unknown.

Molecular techniques have increasingly been introduced for rapid, accurate, cost-effective diagnoses of multiple serotypes of *Salmonellae* including SP and SG. Ribotyping by the use of the enzyme *Eco*RI has been suggested as an important tool to differentiate between *S*. Pullorum and *S*. Gallinarum (50). Also, profiles of whole-cell fatty acid methyl ester have been helpful for separation and identification of *S*. Pullorum and *S*. Gallinarum (138). More recently it has been demonstrated that *S*. Pullorum can be differentiated from *S*. Gallinarum by the analysis of the phase 1 flagellin C gene (flic) by single-strand conformational polymorphism (103).

In 1 study using multiplex PCR (m-PCR) rapid identification of 7 *Salmonella enterica* serovars—Enteritidis, Typhimurium, Hadar, Choleraesuis, Dublin, Infantis, and Gallinarum—were identified with considerable specificity. Multilocus sequence typing (MLST) and multi-locus enzyme electrophoresis (MLEE) have been used to differentiate strains and identify the relationships between these serovars and *S*. Enteritidis and *S*. Dublin (154).

A highly accurate biovar-specific duplex PCR assay has been performed for the rapid identification and discrimination of biovars Gallinarum and Pullorum from field isolated (92).

Another method which has been used is multilocus variable number tandem-repeat analysis (MLVA) that can subtype S. Gallinarum isolates and is useful for epidemiological investigations of fowl typhoid (93). MLVA was better than pulsed-field gel electrophoresis (PFGE) because it discriminated strains having the same PFGE pattern. In cases where the *S*. Gallimarum live vaccine strain 9R has been used to control fowl typhoid, a triplex PCR assay has been used to differentiate wild-type Gallinarum, Pullorum, and the 9R vaccine.

The availability of the whole genome sequences for *S*. Gallinarum and *S*. Pullorum, along with the availability of chicken genome, will enhance studies on pathogenesis (see below) and genetic resistance to disease (22, 60, 170).

Susceptibility to Chemical and Physical Agents

In general, the susceptibility of *S*. Pullorum and *S*. Gallinarum is similar to that of members of the paratyphoid group (128, 159). They may survive for several years in a favorable environment, but they are less resistant than paratyphoid strains to heat, chemicals, and adverse environmental factors. For example, *S*. Gallinarum was killed within 10 minutes at 60ºC; within a few minutes by direct exposure to sunlight; in 3 minutes by 1:1000 phenol, 1:20,000 dichloride of mercury, or 1% potassium permanganate; and in 1 minute by 2% formalin (159). *S*. Gallinarum grown on agar cultures may rapidly lose their virulence. Orr and Moore (122) found that *S*. Gallinarum retained viability up to 43 days when subjected to daily freezing and thawing. Organisms in liver survived more than 148 days at –20ºC, even though they were accidentally thawed twice. *S*. Gallinarum can survive in feces from infected chickens up to 10.9 days when kept in a range house and 2 days less in the open (155).

Antigenic Structure

Both *S*. Pullorum and *S*. Gallinarum possess the O antigens 1, 9, and 12. Variation involving antigen 12 occurs in *S*. Pullorum strains based on serologic testing, but there is no evidence for such strain variation in *S*. Gallinarum. However, DNA fingerprint analysis has raised doubts regarding such variation in the major somatic antigen 12 of *S*. Pullorum (189).

The first serologic evidence of antigenic variation in *S*. Pullorum strains was discovered when progeny infected with a new strain were negative for antibodies using a standard agglutination test. Sera from infected chicks agglutinated homologous-strain antigen but not standard-strain antigens. This antigenic variation, characteristic of *S*. Pullorum, was studied extensively (55, 56, 187, 193). The antigenic composition of *S*. Pullorum was shown to contain O antigens 9, 12_1, 12_2, and 12_3, but the quantity of antigens 12_2 and 12_3 varies with strains. Standard strains contain a large amount of 12_3 and a very small amount of 12_2, but in variant strains, the content of the 2 antigens is reversed. Extensive examination of individual colonies, sometimes through successive transfers, has been necessary to determine accurately the antigenic form of a culture. Most isolates tend to stabilize during passage on artificial media. Standard-form cultures usually contain a small percentage of 12_2 predominant colonies even after long artificial cultivation. Variant forms of cultures are

often pure or nearly pure for 12_2 and 12_3 factors. Colonies of intermediate strains are usually mixtures of 12_{2-} and 12_{3-} predominant colonies or rarely are uniform and contain appreciable amounts of both factors in individual colonies. Strains also may vary in content of the O–1 antigen.

Early reports indicated that as many as one-third of the *S*. Pullorum isolates from some areas of the United States were of the variant type; by 1950, only 13% of total isolates were of that type (186), a reduction believed to be the result of the extensive use of polyvalent testing antigens.

Tests to differentiate standard, intermediate, and variant types of S. Pullorum have been described (183, 184). Phage typing of S. Pullorum can be used for type identification, epidemiologic investigations, and genetic studies (51, 172, 173).

Virulence Factors

S. Pullorum and *S*. Gallinarum, being Gram-negative bacteria, have endotoxin. S. Pullorum contains a thermostable toxin to which rodents, but not chicks, are susceptible. Similarly, *S*. Gallinarum contains a toxin that was lethal to rabbits (158). Endotoxins from *S*. Gallinarum can cause clinical signs within a few hours after intravenous injection in chicks (158). Most of the clinical signs subsided within 24–48 hours. Storing *S*. Gallinarum at 275ºC or 220ºC did not have any effect on the subsequent pathogenicity test results (158). Other toxins produced by *Salmonella* serovars continue to be reported. Among these are a hemolysin (1) now considered to be a regulatory gene rather than a structural toxin. The genes *sly*A and *cly*A have been found to encode cytolysin production in *S*. Typhi and *S*. Paratyphi A. The *cly*A gene was not detectable by PCR in 95 *S*. Gallinarum strains. The *sly*A gene was detectable in 94 *S*. Gallinarum strains but its presence did not correlate with hemolytic activity. The significance of these results remains to be seen. SlyA is an important regulatory component in a signalling cascade controlling *Salmonella* Pathogenicity Island 2 (SPI-2) gene expression in *S*. Typhimurium.

Like most pathogenic microorganisms, *S*. Gallinarum, and probably *S*. Pullorum, may lose virulence rapidly during propagation and passage on artificial media; hence, cultures should be passaged serially in their natural host, the chicken, before testing the pathogenicity of the organisms. Pathogenicity of such cultures is best maintained in the lyophilized or frozen state. Passage on artificial media by different investigators have found wide variation in virulence among cultures of *S*. Gallinarum.

An 85-kb plasmid plays a role in the virulence of *S*. Pullorum and *S*. Gallinarum in chickens (18, 21, 51, 117). Plasmids of sizes other than 85 kb, either alone or in combination, or isolates absent in plasmids also have been reported in *S*. Gallinarum (4, 117). The virulence plasmid *spvRABCD* genes are present in both *S*. Gallinarum and *S*. Pullorum (137) and are essential for clinical disease. Given the fact that so many chromosomal genes are known to contribute to systemic disease it is tempting to regard the virulence plasmid genes as no more than a molecular switch with a close regulatory relationship to key chromosomal genes, possibly SPI-2 genes. Although it is essential for systemic disease, the virulence plasmid contributes little to host specificity because the plasmids of *S*. Gallinarum, *S*. Pullorum, and *S*. Typhimurium appear to be fully interchangeable without affecting the virulence phenotype of the recipient strain (Barrow and Lovell, 1989).

As might be expected from *Salmonella* serovars causing systemic typhoid-like diseases, *Salmonella*SPI-2 is essential to virulence and survival and multiplication intracellularly (90, 182, 145), although the contribution of *Salmonella* Pathogenicity Island 1 (SPI-1) encoding genes required for invasion of nonprofessional phagocytes is unclear. Other virulence gene clusters also can be identified but have not yet been fully characterized.

Certain genes are responsible for efficient adherence and entry of various salmonellae into cultured epithelial cells (2). When a mutated version of 1 of these genes, *invH*, was introduced into different *Salmonella* strains, some, including *S*. Gallinarum, were rendered deficient for adherence and invasion of cultured cells. In 1 study, significant variability was observed among *S*. Pullorum isolates in their ability to invade avian epithelial cells despite the presence of *Salmonella* invasion genes *spvB* and *invA* (53). However, the relative role of the various fimbriae expressed by these and other *Salmonella* species has not been fully assessed. Genes homologous to K88 genes *faeH* and *faeI* have been demonstrated on the virulence plasmid of *S*. Gallinarum, which may influence intestinal invasion (137) and which may be equivalent to the *Pef* fimbriae of *S*. Typhimurium. *Sef* fimbriae are also produced (132).

Genomic analysis is beginning to reveal information which may contribute to our understanding of host adaptation and evolutionary aspects of pathogenicity (see 22).

The genome of *S*. Gallinarum is slightly smaller at 4.659 Mbp compared with 4.686 Mbp for *S*. Enteritidis but carries 309 pseudogenes compared with 113 in Enteritidis (204 and 25 in *S*. Typhi and *S*. Typhimurium, respectively) (170). The presence of a reduced genome indicates the relatively favorable environment within the phagosome of the infected macrophage and that fewer genes are required for systemic virulence than for the production of enteric disease. It is expected that the gene complement of the more host-adapted *S*. Pullorum will be even smaller. The absence of motility, at least, has been postulated to be an adaptation to the avian host. The biological and molecular basis of host adaptation in any of these host-specific serovars is not understood. Several studies indicate that for *S*. Gallinarum virulence and host specificity correlate with *in vivo* multiplication in the tissues but not with intestinal colonization or with invasion from the gut (17). The relatively high apparent rate of accumulation of mutations suggests a rapid rate of evolution associated with the host adaptation event, particularly in the development of *S*. Pullorum, suggesting that host adaptation may have developed independently in *S*. Gallinarum and *S*. Pullorum.

In the case of *S*. Gallinarum several metabolic pathways have been lost, which must have a bearing on its intracellular lifestyle (170). These include the inability to use long chain maltodextrins, (D)-glucarate and hydrogenase 1. Importantly, there is an inability to utilize 1, 2-propanediol through mutations in the

pdu operons in addition to *ttr* (tetrathionate) and *cbi* (cobalamin), which are required for its oxidation. However, it may also relate to the poor intestinal colonization ability in *S*. Gallinarum and *S*. Pullorum in addition to *S*. Typhi, and recent unpublished evidence suggests that it is important during colonization of the chicken intestine in *S*. Typhimurium (Barrow et al., unpublished results).

The SPI3 genes *shd*A and *rat*B, associated with intestinal colonization, also have been lost functionally by *S*. Pullorum and *S*. Gallinarum. Other genes associated with colonization and lost by these 2 serovars include those encoding the ability to use alternative electron acceptors dimethyl sulphoxide (*dms*A1, *dms*A2 in *S*. Gallinarum and *dms*A2, *dms*B2 in *S*. Typhi) and trimethylamine N-oxide (*tor*S in *S*. Gallinarum and *tor*R, *tor*C in *S*. Typhi) (170). The *bcs*G gene in *S*. Enteritidis contributes to biofilm production and extracellular survival. A mutation in *bcs*G in *S*. Gallinarum (170) might contribute to its poorer survival outside the host.

Although the virulence plasmid of *S*. Typhimurium does not appear to play a role in the initial intestinal phase of *S*. Typhimurium infection in mice, the plasmid of *S*. Gallinarum does contribute to the initial intestinal colonization, transient though it is, associated with the production of K88-like fimbriae in the same plasmid location as the *pef* locus in *S*. Enteritidis (137).

Flagellin, the main protein of the flagellar filament, is an important pathogen-associated molecular pattern (PAMP) responsible for alerting the host of early infection, in this case through stimulation of an inflammatory response via toll-like receptor 5 (TLR5) signalling following invasion. As a result of the absence of flagella, *S*. Gallinarum and *S*. Pullorum are able to invade from the alimentary tract without provoking a strong inflammatory response, perhaps favoring systemic infection and which might be a specific adaptation to avian hosts (85, 94). Additionally, there is some evidence for the role of flagella in colonization and invasion in *S*. Typhimurium and *S*. Enteritidis.

Genes such as *sop*A, *pip*B2, and *sif*B, which encodes TTSS effector proteins involved in intestinal inflammation and enteritis, are truncated in *S*. Gallinarum; an attempt to detect secreted SopA in this serovar was not successful (170). It also has been found that SopB was not detectable in *S*. Gallinarum, in contrast to most other serovars, but SopE could be. Other deleted genes involved in cellular interactions, including *big*A, have been lost in *S*. Gallinarum, suggesting that the enteropathogenic ability may be affected accordingly.

Of the 13 fimbrial operons possessed by *S*. Enteritidis, *std* is not present in *S*. Gallinarum and there are mutations in several genes of the other fimbriae, leaving only *fim*, *bcf*, *csg*, and *ste* undisrupted (170). The 5 genes of the *pef* operon present in *S*. Enteritidis virulence plasmid are replaced by 3 encoding fimbrial genes in *S*. Gallinarum (137, 170).

It is thought that intracellular bacterial multiplication takes place largely through the activities of homologous/orthologous genes in *S*. Gallinarum that have been found to contribute to virulence in *S*. Typhimurium. These include SPI-2 genes, whereas SPI-1 appears to contribute little to disease in poultry (90). As with *S*. Typhimurium in mice, SPI-2 does not appear to contribute to invasiveness after oral infection. SPI-2 contributes to persistent infection in *S*. Pullorum; however, it is unclear to what extent this is simply a reflection of initial survival or not in macrophages rather than a specific association with long-term persistence (182). The exact manner in which the 19 SPIs, 13 fimbrial gene sets, and several metabolic traits all combine to contribute to virulence and host adaptation of *S*. Gallinarum and *S*. Pullorum remains to be determined. *S*. Gallinarum also carries mutations in genes involved in drug resistance, protective responses, and DNA restriction/modification (170).

Acute and chronic disease is also characterized by hemolysis and the presence of necrotic lesions in the heart and alimentary tract (155). These are correlated with bacterial multiplication (49). The cardiac lesions are characterized by myofibrillar necrosis with heterophils, lymphocytes, and plasma cells being replaced by histiocytes. They occur as disease progresses into a more chronic phase of infection, both with *S*. Gallinarum and with *S*. Pullorum; how extensive of a response the provide to bacterial antigens or a form an auto-immune reaction is unclear. It is thought that they do not contain viable bacteria (Christensen and Barrow, unpublished).

Although the full genome sequence for *S*. Pullorum is not yet available, microarray studies comparing the gene content with *S*. Enteritidis indicate the absence of the *torRS* regulatory system, which is also found to be absent in *S*. Abortusovis but present in all other serovars, and a hydrolase also absent for a variety of other *Salmonella* strains. One *S*. Pullorum strain appeared to be intermediate with *S*. Gallinarum in possessing the *torRS* and hydrolase not possessed by most other strains of this biotype but it lacked other RODs normally associated with *S*. Gallinarum (130). A study using suppression subtractive hybridization also has identified a number of putative virulence genes in *S*. Pullorum that differ from *S*. Enteritidis and *S*. Gallinarum. These included *ipaJ* gene (an invasion plasmid antigen gene of *Shigella*), a gene for Colicin Y production (an antimicrobial protein encoded by a *E. coli* plasmid), fimbrial plasmid genes *faeH* and *faeI*, and *traG* which encodes a couple protein with TraJ (involved in DNA translocation).

Pathobiology and Epidemiology

Incidence and Distribution

Pullorum disease and FT are worldwide in distribution (15, 33, 37, 48, 81, 87, 103, 109, 111, 114, 117, 121, 141, 152, 157, 193, 194). Pullorum disease is rare in commercial poultry in the United States and perhaps in other parts of the world such as Canada, Australia, Japan, and Western Europe. Pullorum disease is also less commonly reported from backyard chickens in the United States (9). Except for 1 epizootic of PD in commercial chickens in the United States during 1990–1991, there have been no recent outbreaks (88, 139). This epizootic involved a

single integrated broiler operation in 5 states (Delaware, Maryland, North Carolina, Alabama, and Florida). The outbreak involved 18 breeder flocks and more than 261 broiler rearing facilities.

No outbreaks of FT in commercial poultry in the United States have been reported since 1980 (7, 126). Canada and several European countries have a low incidence or absence of FT. Mexico, Central and South America, Africa, China, and the Indian subcontinent continue to report PD and FT in poultry flocks (16, 33, 37, 87, 109, 111, 1114, 117, 141, 151, 152). Recently, a few outbreaks of FT have been reported in commercial poultry in Denmark and Germany as a result of importation from Eastern Europe (52).

Natural and Experimental Hosts

Chickens are the natural hosts for both *S*. Pullorum and *S*. Gallinarum; however, naturally occurring outbreaks of PD and FT have been described in turkeys, guinea fowl, quail, pheasants, sparrows, and parrots (125, 128, 149, 160). In addition, naturally occurring outbreaks of PD have been described in canaries and bullfinches, and FT has been described in ring doves, ostriches, and peafowl. The susceptibility of ducks, geese, and pigeons to *S*. Gallinarum is variable, but most breeds used currently appear resistant to this pathogen. Ducks were found to be resistant to experimental infection with *S*. Pullorum and *S*. Gallinarum (19, 39).

Significant differences in susceptibility to PD among breeds of chickens have been described (41, 143). The lighter breeds, particularly leghorns, appear to be more resistant than the heavy breeds. PD-resistant and PD-susceptible lines of Rhode Island reds, New Hampshires, and crosses between the 2 were developed based on the selection for high and low body temperature during the first 6 days of life (84). Enormous differences in resistance to *S*. Pullorum and *S*. Gallinarum have also been shown in inbred lines of white leghorn chickens (36), much of which can be attributed to 1 locus, designated SAL1, although TLR4 and NRAMP1 also contribute (83, 106, 112). It appears that a greater percentage of females than males stay as reactors, probably due to local infection being sequestered in the ovarian follicles.

PD has been described as a naturally occurring or experimental infection in mammals including chimpanzees, rabbits, guinea pigs, chinchillas, pigs, kittens, foxes, dogs, swine, mink, cows, and wild rats. *S*. Gallinarum was able to be cultured for up to 121 days from the feces of experimentally infected rats (13). Human salmonellosis caused by *S*. Pullorum occasionally has been reported (8, 115, 120).

Age of Hosts Commonly Infected

Mortality from PD usually is confined to the first 2–3 weeks of age. Acute infections in older chickens, particularly among brown egg-producing strains, have been reported occasionally. Similarly, mortality due to PD in semi-mature and mature turkeys has been observed. A certain percentage of chickens and turkeys that survive the initial infection become carriers with or without the presence of lesions.

Although FT is frequently referred to as a disease of adult birds, there have been reports of high mortality in young chicks (26, 102, 113, 191, 223). Fowl typhoid can cause mortality as high as 26% in chicks during the first month of life. Mortalities of 65% and 100% within 11 days after inoculation of 1-day-old broiler chicks with 10^4 CFU and 10^8 CFU/ml of *S*. Gallinarum, respectively, have been reported (184). As in PD, FT losses begin at hatching time; however, in FT they also continue into laying age. Certain strains of *S*. Gallinarum produce lesions in chicks indistinguishable from those associated with PD (161). Therefore, as a result of experimental and field observations we can conclude that chicks and poults are highly susceptible to *S*. Pullorum and *S*. Gallinarum, whereas adults are more susceptible to *S*. Gallinarum.

Transmission

Like many other bacterial diseases, PD and FT can be transmitted in several ways. The infected bird (reactor and carrier) is by far the most important means of perpetuation and spread of the organism. Birds may infect not only their own generation by horizontal transmission, but also succeeding ones through egg transmission. Egg transmission may result from contamination of the ovum following ovulation (23, 26), but localization of *S*. Pullorum or *S*. Gallinarum in the ovules before ovulation is likely and probably constitutes the chief mode of vertical transmission. The relative contribution of vertical transmission in the 2 organisms is unclear because it is easy to establish persistent infections and egg transmission with *S*. Pullorum (32) but much less easy with *S*. Gallinarum, and it may be that horizontal transmission is more important in this highly virulent organism in which experimental infection generally either results in clinical disease and mortality or no infection depending on the genetic background of the host. Egg transmission has been influenced by levels of antibodies in the yolk (177). Maternal antibodies against *S*. Pullorum may be critical in the prevention of embryonic mortality in infected eggs, thus allowing successful egg transmission.

The exact mechanism surrounding persistent infection and carriage which results in infection of the reproductive tract is still unclear. However, it is known that *S*. Pullorum persists within macrophages in the spleen during the carrier state (178). Although numbers gradually reduce they are not eliminated (32) and at sexual maturity the numbers increase as a result of reduced capacity of T cells to respond specifically and nonspecifically to antigens (179), probably following increases in sex hormones. The reduced immune responsiveness enables the bacteria to spread to the reproductive tract.

Transmission through shell penetration and feed contamination by *S*. Pullorum has been reported but appears to be of minor importance (185). The number of eggs infected with *S*. Pullorum or *S*. Gallinarum can be as high as 33% of the total laid by an infected hen. Contact transmission of infected chicks or pullets can be an important route of dissemination of *S*. Pullorum and *S*. Gallinarum. This can happen in the hatcher and can be partially prevented only by formaldehyde fumigation (78). Mortality as high as 60.9% of the exposed

flock due to *S*. Gallinarum has been reported (69). Transmission also may occur within a flock as a result of cannibalism of infected birds, eating infected eggs, and through wounds on the skin. Feces from infected birds are also a source of bacteria. Contaminated feed, water, and litter can be sources of both *S*. Pullorum and *S*. Gallinarum. Attendants, feed dealers, chicken buyers, and visitors who move from house to house and from farm to farm may spread these diseases unless precautions are taken to disinfect footwear, hands, and clothing. Similarly, trucks, crates, and feed sacks may be contaminated. Wild birds, mammals, and flies may be important mechanical spreaders of the organisms.

Clinical Signs

PD and FT are primarily diseases of chicks and poults. However, FT is a more significant disease in growing and adult chickens and turkeys than PD. The signs noted in young chicks and poults associated with both diseases are very similar as a result of the transovarian transmission of these diseases. Occasional cases of PD can be subclinical, even though the disease may originate by egg transmission.

Chicks and Poults

If birds are hatched from *S*. Pullorum- or *S*. Gallinarum-infected eggs, moribund and dead birds may be observed in the incubator or within a short time after hatching. The birds can manifest somnolescence, weakness, depressed appetite, poor growth, and adherence of chalky white material to the vent. Death may soon follow. In some cases, evidence of PD is not observed until 5–10 days after hatching, but the disease gains momentum during the following 7–10 days. Mortality usually peaks during the second or third week of life. In these situations, the birds exhibit lassitude and an inclination to huddle together under heaters, having droopy wings, and distorted body appearance.

Labored breathing or gasping may be observed as a result of extensive involvement of the lungs due to PD. Survivors may be greatly retarded in their growth and appear underdeveloped and poorly feathered. These birds may not mature into vigorous or well-developed laying or breeding birds. Flocks that have passed through a serious outbreak usually have a high percentage of carriers at maturity.

Blindness, as well as swelling of the tibiotarsal and the humero-radial and ulnar articulations, due to *S*. Pullorum infection in chicks has been described (27, 59, 61, 88, 114, 139). In certain instances, a relatively high incidence of infection in the joints, which can produce lameness and obvious joint enlargement, can occur in chicks. In the 1990–1991 outbreaks of PD in the eastern part of the United States, swelling of the hock joint, due to synovitis, was commonly seen (139). Similar lesions in turkey poults also have been reported. This may suggest that some strains of *S*. Pullorum may have a tropism for these sites.

Growing and Mature Fowl

Infected birds may not exhibit any signs and cannot be detected by their physical appearance, especially in the case of PD. Acute outbreaks of FT in chickens may begin by a sudden drop in feed consumption, with birds being droopy and showing ruffled feathers and pale and shrunken combs. Other signs, such as a drop in egg production, decreased fertility, and diminished hatchability, can sometimes be observed in both PD and FT, depending upon the severity of infection. Death may occur within 4 days of exposure, but usually occurs after 5–10 days. There may be an increase in body temperature of 1°F–3°F 2–3 days after exposure. In some cases of PD in semi-mature and mature flocks, the predominant clinical signs include anorexia, diarrhea, depression, and dehydration (57).

Clinical signs due to PD and FT in turkeys may consist of thirst, inappetence, listlessness, a tendency to separate from healthy birds, and green to greenish-yellow diarrhea. However, deaths may occur with no prior clinical signs, but body temperature may increase several degrees initially. The first outbreak on a farm usually causes the highest mortality followed by intermittent recurrence and less severe losses (79).

Morbidity and Mortality

Both morbidity and mortality are highly variable in chickens and are influenced by age, strain of bird, nutrition, flock management, concurrent diseases, and route and dose of exposure. Mortality from PD may vary from 0% to 100%. The greatest losses usually occur during the second week after hatching, with a rapid decline between the third and fourth week of age in PD. Mortality ranging from 10%–93% due to FT have been reported in chicks (72). One hundred percent mortality in 11 days was reported in broiler chicks after they were inoculated at 1 day of age with 10^8 CFU/ml of *S*. Gallinarum (184).

Morbidity is often much higher than mortality with some of the affected birds recovering spontaneously. Birds hatched from an infected flock and reared on the same premises exhibit less mortality than those subjected to the stress of shipping. Losses may be as severe in turkeys as in chickens.

Pathology

Gross Pathology

Descriptions of gross and microscopic lesions associated with PD and FT are sporadic. Some of the earliest descriptions were those by Rettger (134, 139). Since then, there have been many reports in various species of birds, primarily involving chickens and turkeys, but also pheasants, quail, and guinea fowl (23, 28, 47, 54, 57, 58, 68, 75, 76, 77, 78, 100, 101, 113, 114, 125, 147, 148, 149, 167, 191, 193).

Chicks. In peracute cases of PD and FT, birds that die suddenly in the early stages of brooding may show no gross lesions. In acute cases, enlarged and congested liver, spleen, and kidneys may be seen (Figure 16.1). Livers may have white foci of 2–4 mm in diameter (Figure 16.2). The yolk sac and its contents may or may not reveal any abnormalities, but in protracted cases, interference with yolk absorption may occur. In such cases, the yolk sac contents may be of creamy or caseous consistency. Occasionally, birds with respiratory signs may have white nodules in the lung (Figure 16.3), and

Figure 16.1. *S. pullorum* infection. Enlarged and congested spleen and liver with pale yellow fibrinonecrotic cast in the lumen of cecum in a 10-day-old chick.

white nodules, resembling Marek's disease tumors, may be present in the cardiac muscle (Figure 16.4) or pancreas. Occasionally, nodules in the heart may become so large they distort the shape of the heart (Figure 16.5). This, in turn, may lead to chronic passive congestion of the liver and ascites. The pericardium may be thickened, and the pericardial sac may contain yellow serous or fibrinous exudate. Similar nodules may be present in the muscle of the ventriculus (gizzard) (Figure 16.6) and occasionally in the wall of the ceca and rectum. The ceca may contain caseous cores. Some birds may exhibit swollen joints containing yellow viscous fluid (27) (Figure 16.7); this was one of the most commonly reported gross lesions in the 1990–1991 outbreak of PD in commercial broilers in the United States (139). Among the joints, the hock joint is most commonly involved, but other joints such as the wing joint and the footpad may be affected. Other changes that can be seen include exudate in the peritoneal cavity, thickening of the wall of the intestine, and exudate in the anterior chamber of the eye.

Splenomegaly, gray necrotic foci with petechial hemorrhages in lungs, and pale or discolored livers were observed in Bobwhite quail inoculated with *S*. Pullorum (39). In young-pheasants, yolk sac infection, pneumonia, hepatitis, and typhlocolitis were the most common lesions associated with PD (125).

Figure 16.2. *S. pullorum* infection. Enlarged liver showing pale foci of necrosis. (Glass)

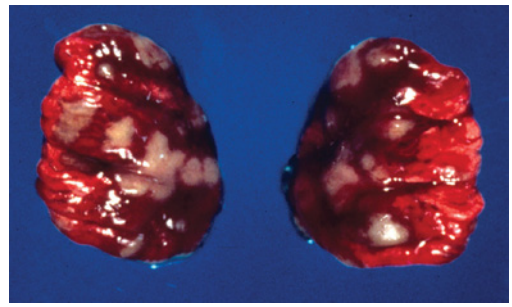

Figure 16.3. *S. pullorum* infection. Lungs with pale exudates due to chronic infection. (Peckham)

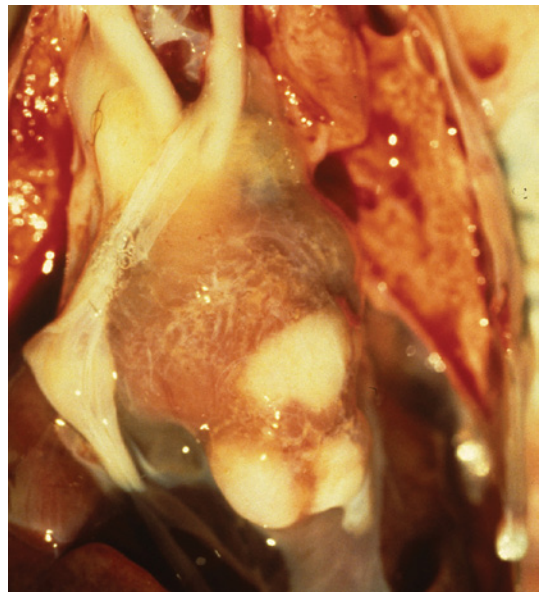

Figure 16.4. *S. pullorum* infection. Heart from young chick with white nodules representing myocarditis. Such nodules can be confused for tumors, such as Marek's disease. (Chin)

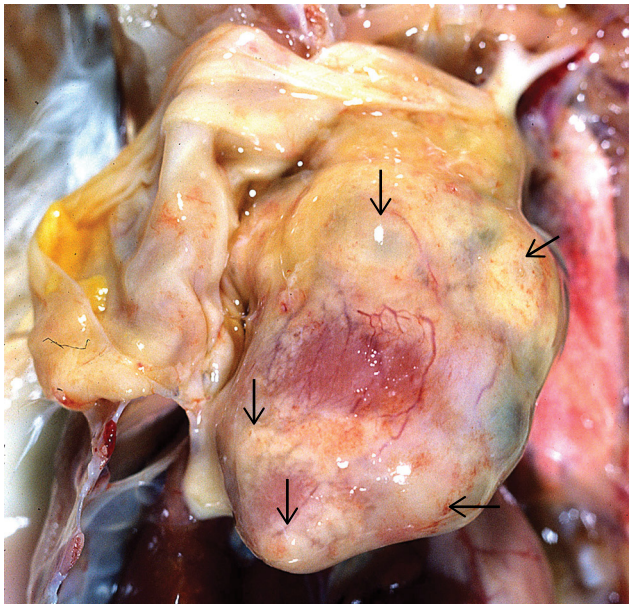

Figure 16.5. *S. pullorum* infection. Nodular lesions in the heart due to chronic infection; note the thickened yellow pericardium (arrows) (reflected).

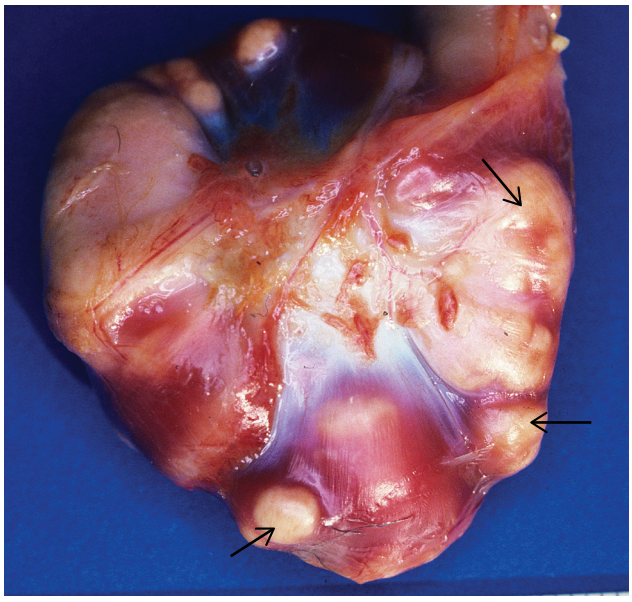

Figure 16.6. *S. pullorum* infection. Gizzard with yellow nodules of various sizes (arrows) on the serosa in a 6-week-old chick.

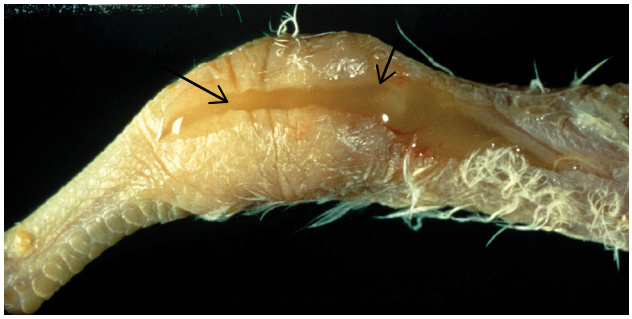

Figure 16.7. *S. pullorum* infection. Swollen hock joint containing yellow viscous fluid (arrows).

Adult Chickens. Lesions due to PD may be minimal in some birds, even though they may be active serologic reactors. Sometimes, only a minimal lesion, such as a small nodular or regressing ovarian follicle, can be found. However, the lesions found most frequently in chronic carrier hens with PD and FT are a few misshapen, discolored cystic or nodular ova among a few normal-appearing ovules (Figures 16.8 and 16.9). The involved ova may contain oily and caseous material enclosed in a thickened capsule. These degenerative ovarian follicles may be closely attached to the ovary, but frequently they are pedunculated and may become detached from the ovarian mass. In such cases, they may become embedded in the inner lining of the peritoneal cavity. Often, the oviduct contains caseous exudate in the lumen. Ovary and oviduct dysfunction may lead to peritoneal ovulation or oviduct impaction, which in turn may bring about extensive peritonitis and adhesions of the abdominal viscera. Fibrinous peritonitis and perihepatitis, with or without involvement of the reproductive tract, may sometimes be seen. Ascites also may develop, especially in turkeys. However, it may be difficult to culture *Salmonella* from advanced chronic lesions.

Frequently, pericarditis is observed. Changes in the pericardium, epicardium, and pericardial fluid depend on the duration of the disease. In some cases, the pericardium exhibits only a slight translucency, and the pericardial fluid may be increased in volume and turbid. In the more advanced stages, the pericardial sac is thickened and opaque, and the pericardial fluid is greatly increased in amount, containing considerable exudate. More advanced cases have chronic thickening of the pericardium and epicardium and partial obliteration of the pericardial cavity by adhesions. Occasionally, small cysts

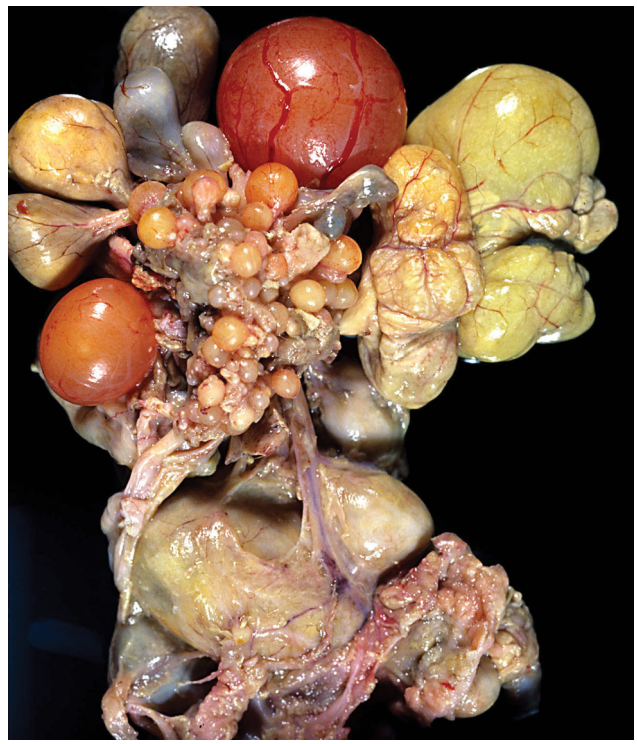

Figure 16.8. *S. pullorum* infection. Ovarian lesions, salpingitis, and peritonitis.

Figure 16.9. *S. pullorum* infection. Ovary with multiple misshapen gray nodules.

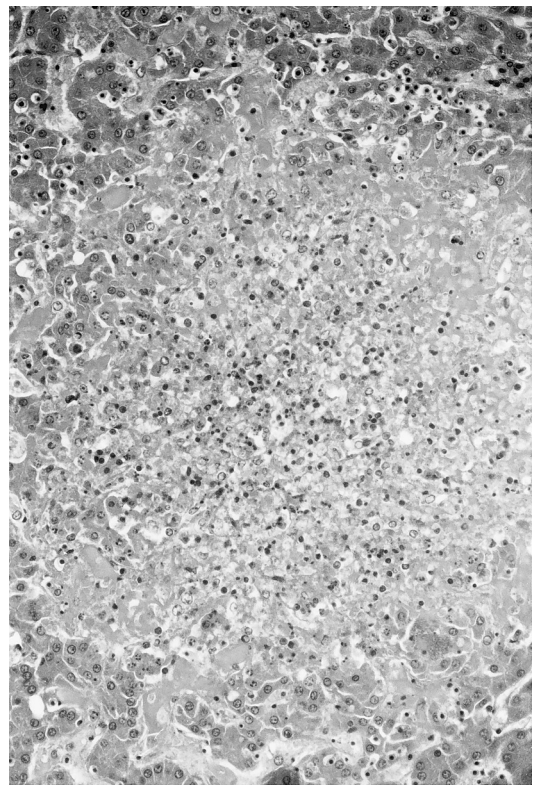

Figure 16.10. *S. pullorum* infection. Liver revealing focal degeneration and necrosis. ×51.

containing amber, caseous material may be found embedded in the abdominal fat or attached to the ventriculus and intestine. Frequently, the pancreas may have white foci or nodules.

In the male, testes may have white foci or nodules (68). Occasionally, caseous granulomas can be found in the lungs and air sacs (57).

Turkeys. Lesions due to PD and FT in turkeys are similar to those observed in chickens (77). Enlarged mahogany or brown-streaked livers, splenomegaly, areas of necrosis in the heart, and grayish lungs are characteristic lesions of FT in turkey poults. Ulceration throughout the small intestine and ceca is a common type of lesion in turkeys but is uncommon in chickens. In adult carriers, there is a predilection of infection for the reproductive organs similar to that seen in chickens.

Ducks and Guinea Fowl. Lesions due to FT in ducklings and adult ducks are similar to those in chickens. In guinea fowl, FT lesions involve the respiratory tract and are characterized by congested lungs and increased mucus in the nasal cleft and trachea.

Histopathology

A very limited amount of information on microscopic lesions is available for PD or FT. Most of the PD lesions described are from field cases, which might have been complicated by other bacterial and/or viral agents (54, 167). There is 1 report on experimental pathology of FT in chicks (191).

In peracute cases of PD and FT, only severe vascular congestion in various organs, especially liver, spleen, and kidney, can be identified. In acute to subacute cases, there is multifocal necrosis of hepatocytes (Figure 16.10) with accumulation of fibrin and infiltration of heterophils in the hepatic parenchyma. Periportal infiltration of heterophils mixed with a few lymphocytes and plasma cells also can be seen in the liver. In chronic cases, especially in cases in which there are large nodules in the heart, the liver will have chronic passive congestion with interstitial fibrosis. The spleen may have severe congestion or fibrin exudation of vascular sinuses in acute stages, and severe hyperplasia of the mononuclear phagocytic system cells in later stages. The ceca in young chicks may have extensive necrosis of the mucosa and submucosa, with an accumulation of necrotic debris mixed with fibrin and heterophils in the lumen.

However, the most characteristic microscopic lesions are in the heart and ventriculus. In the heart, they begin as necrosis of myofibers with infiltration of heterophils mixed with lymphocytes and plasma cells. In later stages, these cells are replaced by massive numbers of uniform histiocytes (Figure 16.11). These cells are fairly large, with irregular vesicular nuclei and faintly staining, foamy eosinophilic cytoplasm. They may be arranged in solid sheets, forming nodules that often protrude from the epicardial surface. These nodules, both grossly and histologically, can be confused with lymphoid tumors caused by Marek's disease virus and possibly retroviruses. A similar process can be seen in the ventriculus and pancreas. The lesions in the pancreas can be so severe that the normal architecture is obliterated.

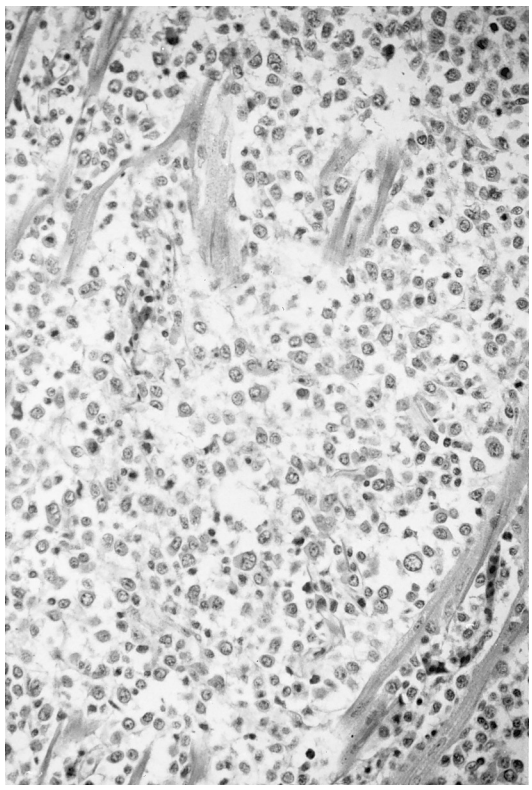

Figure 16.11. *S. pullorum* infection. Myocardium from a S. Pullorum-infected chick showing infiltration with histiocytic-type cells. ×62.

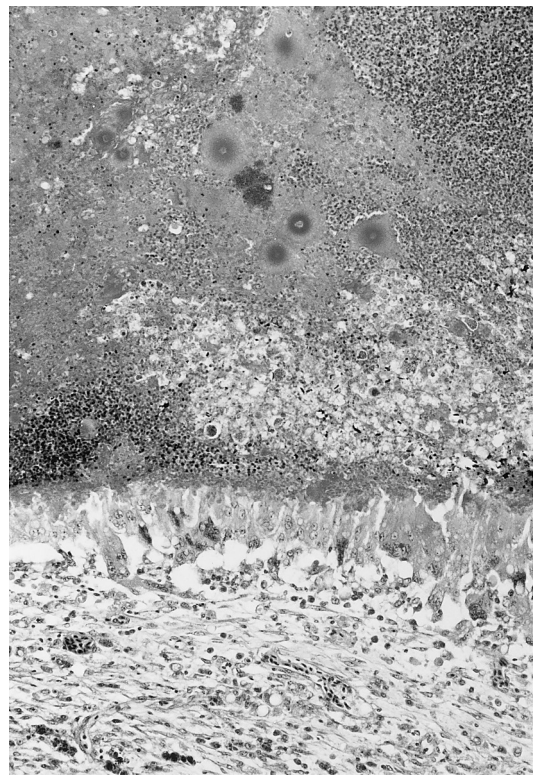

Figure 16.12. *S. pullorum* infection. Ovule from an adult hen with pullorum disease showing fibrinosuppurative inflammation and bacterial colonies. ×20.

Other changes such as serositis of various organs including the pericardium, pleuroperitoneum, synovium, and serosa of the intestinal tract and mesentery can be seen in a high percentage of cases (167). In acute stages, these lesions can be associated with heterophils and fibrin, but in later stages, only lymphocytes, plasma cells, and histiocytes will be found.

Microscopic lesions in the ovary range from acute fibrinosuppurative inflammation to severe pyogranulomatous inflammation of the ovules (Figure 16.12). The pyogranulomatous inflammation is characterized by infiltration of heterophils mixed with fibrin and bacterial colonies in the coagulated yolk material. In turn, the core is surrounded by successive layers of multinucleated giant cells and a mixed population of inflammatory cells that can include macrophages, plasma cells, heterophils, and lymphocytes. In males, degeneration, necrosis, and inflammation of the epithelial cells lining the seminiferous tubules can be seen (96). Other, but less common, changes are catarrhal bronchitis, catarrhal enteritis, and interstitial inflammation of the lungs and kidneys. Minimal and nonspecific changes in endocrine glands, such as the hypoplasia of thyroid and hypertrophy of adrenal and pituitary glands due to FT, have been described (64).

Pathogenesis of Infectious Process

Differences in the ability of various salmonellae, including *S*. Pullorum and *S*. Gallinarum, to survive and multiply in visceral organs (especially in spleen and liver) have been attributed to an unknown mechanism involving the mononuclear phagocyte system (MPS) of the host (17). Ducks may be resistant to *S*. Gallinarum due to the inherent inability of the bacteria to multiply in the MPS of ducks (19). Because of the ability of these bacteria to infect and multiply within the cells of the MPS of chickens and turkeys, it is probable that cell-mediated immunity to *S*. Pullorum and *S*. Gallinarum may play a role in recovery and resistance to infection in chickens and turkeys (179).

In 1 study, it was found that an *S*. Gallinarum infection of primary chicken cells caused a reduction in IL-1β and no change in IL-6 (94). Modest increases in IL-β were also found *in vivo* following vaccination with the 9R vaccine (180). The reduction in IL-1β was interpreted as a lack of an inflammatory response resulting in systemic infection of *S*. Gallinarum (92). This, it was argued, was a strategic approach to facilitate invasion without stimulating the strong inflammatory responses associated with infection with most *Salmonella* strains (190, 191). Because signaling via TLR5 with flagella may be important, the absence of flagella in these species may be highly significant (85). It is likely that these early responses are largely mediated through heterophilic granulocytes (97) which are not induced by these serovars, unlike *S*. Enteritidis. In another study it was demonstrated that *S*. Pullorum preferentially targeted the cloacal bursa prior to eliciting inflammation in the intestine (73). In a study with *S*. Gallinarum in chickens, leucocytosis was observed on the third day PI but

was followed by leukopenia that lasted for 10 days (98). This was followed by a leucocytosis as late as 21 days PI, and it was associated with heterophilia but a relative lymphopenia (98). Infection with *S*. Gallinarum may cause anemia (49) and an increase in sialic acid content in serum (99).

In most cases of FT, the organism is disseminated via intestinal lesions although the nature of this process and the cells involved are not understood.

Immunity

Very little information regarding immunity to PD and FT is available, due in part to the great success in the eradication of these diseases in commercial poultry. Chicks orally infected at 4 days of age did not produce detectable agglutinating antibodies until 20–40 days of age, but mature birds produced agglutinating antibodies within 3–10 days following infection. In chicks, maximum antibody production was not reached until 100 days after infection. The possible role of agglutinating antibodies in affecting the course of infection in the host is poorly understood.

It seems likely that with systemic diseases cell-mediated immunity is likely to be of major importance in clearance (59). Little information is available specifically on *S*. Pullorum and *S*. Gallinarum. With *S*. Typhimurium, clearance is correlated with IFN-γ levels (24) and a strong T cell response (23). A recent study has also shown high IFN-γ levels following vaccination with the live 9R vaccine and strong lymphoproliferative responses (181). Although it is assumed that a strong Th1–type response is responsible for immunity, the absence of studies involving Th2–type responses restricts analysis. It is thought that *S*. Pullorum induces a stronger Th2–type response which is responsible for the persistent infection and it is known that SPI2 secreted proteins are involved (182).

In a detailed study of gene expression of chickens, macrophages and chicken kidney cells (CKC) infected with *S*. Pullorum, *S*. Gallinarium, and other salmonellae including *S*. Enteritidis (SE), the macrophages infected with *S*. Pullorum showed decreased expression of CXCLi2, IL-6, and iNOS when compared to *S*. Enteritidis-infected cells (144). CKC-infected cells had lower expression of pro-inflammatory cytokine IL-6, chemokines CXCLi1 and CXCLi2, and iNOS genes in *S*. Pullorum and *S*. Gallinarium groups while increased significant changes were detected in the SE-infected cells (144).

Diagnosis

A definitive diagnosis of PD or FT requires the isolation and identification of *S*. Pullorum or *S*. Gallinarum, respectively. A tentative diagnosis, however, can be made based on flock history, clinical signs, mortality, and lesions. Positive serologic findings also can be of major value in detecting infection; however, negative results should not be considered adequate for a definite diagnosis because of the delay of 3–10 days in the appearance of agglutinating antibodies following infection. Similarly, positive results should be interpreted with caution because of cross reactions with other serogroup D *Salmonellae* such as *S*. Enteritidis (64, 65, 150, 173).

Isolation and Identification of Causative Agent

Acute PD and FT are characteristically systemic infections; causative organisms can be isolated from most internal organs. The liver, spleen, and ceca usually are involved and are the preferred organs to culture. Lesions may occur in lungs, heart, ventriculus, pancreas, or yolk sac, and these are also dependable samples for culturing. In mature birds, if lesions are present in the reproductive organs, ovarian follicles and testes can be cultured. Other sites for culturing are the peritoneum, synovial fluid, and the interior of the eye. Beef extract or infusion, or tryptose agar, in tubes or petri dishes, are all satisfactory for primary isolation. Enrichment broths or selective media also may be used if tissues are decomposed.

Birds with chronic PD or FT that are detected by serologic tests may or may not have gross lesions. If such birds are submitted to the laboratory as carriers, thorough culturing of internal organs is necessary. A detailed outline for testing such specimens is provided in the procedures manual of the NPIP (10). This procedure is summarized as follows.

Grossly normal or diseased internal organs should be cultured directly on veal infusion (VI) and brilliant green (BG) agar plates and incubated for 48 hours at 37ºC. In addition, portions of the internal organs should be pooled, ground, or blended in 10 times their volume of VI broth; 10 ml aliquots of the suspension are transferable to 100 mL of both VI and tetrathionate BG (TBG) broth and incubated for 24 hours at 37ºC. The broths then are plated on VI and BG agar and incubated and examined after 24 and 48 hours. If contamination with proteus or pseudomonas is a problem, platings can be done on BG sulfapyridine (BGS) agar.

The digestive tract should be cultured using individual cotton swabs for the upper, middle, and lower intestinal tract, including both the ceca and the rectum-cloaca area. The swabs should be deposited in 10 mL TBG broth, incubated, and plated as previously described for the internal organs. In addition, portions of the gut should be pooled, ground, or blended in 10 times their volume of TBG broth. Ten mL of the suspension from the digestive tract are transferred to 100 mL TBG broth and incubated at 42ºC or 37ºC for 24 hours. The higher incubation temperatures for TBG broth reduce populations of competitive flora common in gut tissue.

Suspect colonies are transferred to triple sugar-iron (TSI) agar and lysine-iron (LI) agar and incubated at 37ºC for 24 hours. Cultures revealing typical reactions of salmonellae or arizonae on TSI or LI agar slants should be identified by appropriate biochemical and other tests. All *Salmonella* cultures should be serologically typed.

Use of nonselective media demands careful aseptic techniques but has the advantage of more dependably ensuring the isolation of *S*. Pullorum and *S*. Gallinarum. Also, other bacteria capable of producing cross reactions with pullorum-typhoid antigen may be more dependably isolated.

Identification of Cultures

The colonies of *S*. Pullorum may appear small, smooth, and translucent on nutrient media after 24 hours of incubation. With *S*. Gallinarum, colonies are smooth, blue-gray, moist, circular, and entire. Careful initial culture of tissues on nonselective media usually should result in pure cultures. If pure cultures are not secured, or if an enriched medium has been used, it is often advantageous to transfer individual colonies to TSI agar slants for preliminary differentiation. *S*. Pullorum and *S*. Gallinarum produce a red slant with a yellow butt that shows delayed blackening from H_2S production. Reactions listed in Table 16.1, which can be determined within 24 hours, provide identification of a number of other common pathogens and allow differentiation between the 2 organisms.

Additional differentiation tests described under Etiology may be necessary to identify isolates that produce nontypical reactions (chiefly fermentation of maltose or no gas production). Decarboxylation of ornithine by *S*. Pullorum is the single most dependable test for differentiating maltose-fermenting *S*. Pullorum strains from *S*. Gallinarum. Polymerase chain reaction also has been used to identify isolates of *S*. Pullorum and *S*. Gallinarum (91, 94, 174).

Serology

Serologic tests to detect PD and FT include the macroscopic tube agglutination (TA) test, rapid serum (RS) test, stained antigen whole blood (WB) test, and the microagglutination (MA) test using tetrazolium-stained antigens (65, 89, 128, 136, 142, 160, 169, 188). The standard procedure in the United States for detecting breeding flocks chronically infected with *S*. Pullorum and *S*. Gallinarum is to use the standard strains of S. Pullorum (O–1, 9, 12_3) for tube and serum plate antigens and both standard (O–1, 9, 12_3) and variant (O–1, 9, 12_2) strains of *S*. Pullorum for the polyvalent rapid whole blood plate antigens. These antigens detect flocks infected with either *S*. Pullorum or *S*. Gallinarum. Hens infected with antigenically intermediate or variant strains of *S*. Pullorum were detected as seropositive less often than were hens infected with antigenically standard strains with 2 commercially available plate test antigens (65).

The techniques and procedures for official testing of chicken and turkey breeding flocks and the interpretation of tests are described in detail in the latest version of the NPIP (10).

Enzyme-linked immunosorbent assays (ELISA) for detecting *S*. Pullorum and *S*. Gallinarum antibodies have been developed by using lipopolysaccharides or whole cell antigen from these *Salmonellae* (16, 31, 118, 119). This technique can be used for screening large numbers of blood or egg yolk samples and can be adapted to differentiate vaccinated birds from those infected with wild-type strains (16, 118, 119). Infection with both serovars also can be differentiated serologically from *S*. Enteritidis infection using flagella as an antigen (16, 31, 67). Another test, a dot immunobinding assay (DIA), was found to be more sensitive compared to the tube agglutination test for detecting high titers of antibodies in birds challenged with *S*. Gallinarum (109). This test also detected antibodies to *S*. Gallinarum in vaccinated birds that failed to react by TA.

Table 16.1. Biochemical reactions useful in differentiating *S. gallinarum* and *S. Pullorum*.

Reactant or characterstic	*S. gallinarum*	*S. pullorum*
Dextrose	Fermented with no gas	Fermented with gas
Lactose	Not fermented	Not fermented
Sucrose	Not fermented	Not fermented
Mannitol	Fermented with no gas	Fermented with gas
Maltose	Fermented with no gas	Usually not fermented
Dulcitol	Fermented with no gas	Not fermented
Ornithine	Not fermented	Fermented
Indole	Not produced	Not produced
Urea	Not hydrolyzed	Not hydrolyzed
Motility	Nonmotile	Nonmotile
Agglutination	Positive with group D	Positive with group D

Differential Diagnosis

The clinical signs and lesions produced by PD or FT are not pathognomonic. Other *Salmonella* infections may produce similar lesions in the liver, spleen, and intestine, which cannot be distinguished grossly or microscopically from those produced by PD or FT. Aspergillus or other fungi may produce similar lesions in the lungs.

S. Pullorum and *S*. Gallinarum can localize in major joints and tendon sheaths of chicks. Such signs and lesions resemble those produced by organisms such as *Mycoplasma synoviae*, *Staphylococcus aureus*, *Pasteurella multocida*, or *Erysipelothrix rhusiopathiae*. Sometimes the white nodules in the heart of young chicks may resemble Marek's disease tumors and those in the liver resemble those produced by *Yersinia pseudotuberculosis* with which it shares some antigenic relationships. Local infections with *S*. Pullorum and *S*. Gallinarum in adult carriers, particularly of the ovary, may appear identical to those produced by other bacterial infections such as coliforms, staphylococci, *P. multocida*, streptococci, and other *Salmonellae*. Birds of any age may be infected with *S*. Pullorum or *S*. Gallinarum but fail to show grossly discernible lesions. A definitive diagnosis of PD and FT can be made only following the isolation and identification of *S*. Pullorum and *S*. Gallinarum, respectively.

Intervention Strategies

It has long been established that chicken and turkey flocks can be developed and maintained free of PD and FT by adhering to well-defined procedures. Both PD and FT are good examples of diseases that have decreased in incidence over the years by the application of basic management procedures. In the simplest sense, the only requirement is to establish breeding flocks free of *S*. Pullorum and *S*. Gallinarum and to hatch and rear their progeny under conditions that preclude direct or indirect contact with infected chickens or turkeys.

Management Procedures

Methods of management broadly designed to prevent the introduction of infectious agents are applicable to preventing the introduction of *S*. Pullorum and *S*. Gallinarum. Because of egg transmission, only eggs from flocks known to be free of PD and FT should be used in hatcheries. Under the NPIP, chicken and turkey breeding flocks and their progeny may be recognized as free of PD and FT.

Management practices should be broadly applied to prevent the introduction of PD or FT. If PD or FT is encountered, elimination of carriers must be carried out regularly until the breeder flocks are free of PD and FT.

1. Chicks and poults should be obtained from sources free of PD and FT.
2. Pullorum-free and typhoid-free stock should not be mixed with other poultry or confined birds.
3. Chicks and poults should be placed in an environment that can be cleaned and sanitized to eliminate any residential *Salmonellae* from previous flocks (see Susceptibility to Chemical and Physical Agents).
4. Chicks and poults should receive pelletized, crumbled feed to minimize the introduction of *S*. Pullorum and *S*. Gallinarum and other *Salmonellae* through contaminated feed ingredients. Use of feed ingredients free of *Salmonellae* is essential.
5. Introduction of salmonellae from outside sources must be minimized by the use of a sound biosecurity program.
   a. Free-flying birds are commonly found to be carriers of other salmonellae, although rarely with *S*. Pullorum or *S*. Gallinarum. Poultry houses should be bird proof.
   b. Rats, mice, rabbits, cats, dogs, and pests may be carriers of other *Salmonellae*, but they are rarely infected with *S*. Pullorum or *S*. Gallinarum. Nevertheless, poultry houses should be vermin proof.
   c. Insect control is important, particularly against flies, poultry mites, and the lesser mealworm. These pests may provide a means of survival for salmonellae and other avian pathogens in the environment.
   d. Potable drinking water must be used, or chlorinated water should be provided. In some areas, a danger is posed by surface water collected in open ponds for use as drinking water for livestock and poultry.
   e. Mechanical carriers of the organism include footwear and clothing of humans, as well as poultry equipment, processing trucks, and poultry crates. Every precaution should be made to prevent the introduction of *S*. Pullorum or *S*. Gallinarum by fomites.
   f. Proper disposal of dead birds is essential.

Elimination of Carriers

The foundation of the PD control program was established in 1913 by use of TA for detecting infected chickens (86). The test was promptly applied in state programs to eliminate the disease from flocks by the detection and removal of reactors.

Early field testing results indicated that removal of reactors following a single test usually was not sufficient for the complete elimination of infected birds from a flock. Such results may be expected because of three possible intercurrent characteristics: (1) serum agglutinin titers of infected birds tend to fluctuate and may for brief periods fail to produce significant agglutination at the usual dilution of 1:25 or 1:50, (2) a delay of at least several days exists between infection and the development of agglutinins, and (3) following the removal of reactors, environmental contamination may serve as a source of infection for other birds at a later date.

Serologic Tests

As noted previously, in addition to the TA test, other serologic tests such as the RS, WB, and MA tests have been developed (136, 142, 188). All of these are effective in detecting carriers. The MA test is as dependable as the TA test and offers an important advantage in lower cost. The NPIP (10), which details testing methods, accepts 4 tests for testing chickens: standard TA test, WB test, RS test, and MA test. Of the 4, only the WB test is not satisfactory for turkeys. Testing for accreditation is allowed after chickens and turkeys reach approximate immunologic maturity at 16 weeks of age.

In contrast to requirements in the United States for producing antigen from cells grown on the surface of appropriate agar, a different WB test antigen was developed in Japan, where it is officially used (168). This antigen is prepared from cultures grown in a continuous-flow, broth-culture system, in which it is necessary to blend sublots to secure desired agglutinability. An ELISA test is also available for screening of flocks for PD and FT (16, 119, 120).

Serologic evidence of infection should be confirmed by bacteriologic examination of 1 or more reactors. If only suspicious reactions are observed in a flock, the birds reacting most strongly should be submitted to a laboratory for retesting and a thorough bacteriologic examination. In routine testing, flocks should not be interpreted as infected solely on the basis of doubtful or atypical reactions, because such reactions may result from infections other than *S*. Pullorum or *S*. Gallinarum (66, 67, 150, 176).

Nonpullorum/Nongallinarum Reactors

Nonpullorum, and possibly nongallinarum, reactions occasionally cause problems in interpretation (61, 176). A variety of bacteria possessing antigens in common with, or closely related to, those of *S*. Pullorum may infect birds and produce an agglutinin response. It was reported that nonpullorum reactions occur more frequently with variant than with standard-form antigen. Infections with coliforms, micrococci, and streptococci, particularly those belonging to the Lancefield group D, were found to be responsible for a large percentage of nonpullorum reactions in chickens. Infections with other bacteria such as Staphylococcus epidermidis; *Micrococcus* spp.; *Aerobacter aerogenes*; *Y. pseudotuberculosis*; *Proteus* spp.; *E. coli*; and species of *Arizona, Providentia*, and *Citrobacter* were responsible for many nonpullorum reactions. Other salmonellae, particularly

those in group D, such as S. Enteritidis, also may produce cross reactions. Nonpullorum reactors range from a few birds in a flock to as high as 30%–40%. The character of the agglutination may be variable. Thorough bacteriologic examination of representative reactors is often the only dependable method of determining the infection status of a flock, and it is usually the only method of distinguishing between infections by *S*. Pullorum and *S*. Gallinarum.

National Control Program

The NPIP (10) details specific criteria for establishing and maintaining official U.S. pullorum-typhoid-clean flocks and hatcheries. These criteria are based on farm and hatchery management practices that prevent direct or indirect contact with infected stock and annual testing of all, or a representative portion, of the birds in the flocks.

If an attempt is made to free a flock of infection, retesting of the infected flock should be done at 2- to 4-week intervals until 2 consecutive negative tests of the entire flock are secured at not less than a 21-day interval. In the majority of cases, infection can be eliminated from the flock through short-interval testing. Two or 3 retests are often sufficient to detect all infected birds; occasionally, however, infection continues to spread within a flock. In some situations, the disease may not be eliminated through repeated testing.

Area Eradication

The following are the essentials of an eradication program for an area:

1. PD and FT must be mandatory reportable diseases.
2. Outbreaks must be placed under quarantine, and infected flocks marketed under supervision.
3. All reports of PD and FT must be investigated by an authorized state or federal official.
4. Importation regulations must require shipments of poultry and hatching eggs to be from sources considered free of PD and FT.
5. Regulations must require poultry going to public exhibition to be from flocks free from PD and FT.
6. Total participation of poultry breeding flocks and hatcheries must be required in a pullorum-typhoid control program, such as NPIP programs or the equivalent.

Forty-three states in the United States had qualified under the preceding program as pullorum-typhoid-clean states by 2000; however, a reservoir of PD still exists in small backyard and hobby flocks. This reservoir of infection may be larger than indicated, because not all states have a program to test noncommercial and exhibition poultry. Experience indicates that the usual separation of commercial and noncommercial poultry is quite effective in preventing the transmission of *S*. Pullorum and *S*. Gallinarum between these populations. Nevertheless, infected backyard flocks pose some danger to commercial flocks. It is necessary to continue to test commercial breeding flocks to enable earlier identification of accidental infections from noncommercial poultry.

Vaccination

Because PD has been mostly eradicated from commercial flocks over the years and the eradication program is in place, very little incentive exists for the production of vaccines to control PD. Fowl typhoid, however, continues to be a problem in some parts of the world. No federally licensed *S*. Gallinarum killed bacterin is produced in the United States, and live modified vaccines used in other countries are not permitted in the United States. Various investigators have evaluated killed and modified live vaccines as well as virulence plasmid-cured derivatives (11, 20, 29, 38, 72, 73, 74, 124, 153, 156, 195, 196). With the upsurge of FT in many countries, studies on the use of the 9R strain (156) as live oral or injectable vaccine, with or without oil adjuvants, have been reported with variable results (11, 72, 73, 74, 124, 153). Similarly, outer membrane proteins from *S*. Gallinarum have been reported to offer better protection than the 9R live vaccine in terms of clearance of the pathogenic strain from internal organs (30, 32). More recently, immunization against FT by the use of mutant strains of *S*. Gallinarum and a virulence plasmid-cured derivative of *S*. Gallinarum and other types appear to be promising in protecting birds challenged with *S*. Gallinarum (14, 15, 20, 70, 196).

Use of attenuated *S*. Gallinarum (SG) mutant strain with deletion of genes *cob*S and *cbi*A as a vaccine resulted in protection against infection with wild strain of SG (60).

Other Approaches

Incorporation of commercial formic acid preparations in the feed has been found to significantly reduce the experimental incidence and severity of FT (B29).

Competitive exclusion using gut flora preparations also has been reported to be effective against FT (123).

Treatment

Reasonably effective prophylactic and therapeutic drugs have been developed against PD and FT. In Canada and the United States, every effort has been made to eradicate these diseases so treatment is neither feasible nor desired.

Various sulfonamides, nitrofurans, chloramphenicol, tetracyclines, and aminoglycosides have been found to be effective in reducing mortality from PD and FT; however, no drug or combination of drugs has been found capable of eliminating infection from a treated flock. Sulfonamides, in particular, frequently suppress growth and may interfere with feed and water intake and egg production. Sulfonamides that have been used in the treatment of PD and FT include sulfadiazine, sulfamerazine, sulfathiazole, sulfamethazine, and sulfaquinoxaline (3, 35, 127).

Most of the studies have indicated, however, that appreciable numbers of infected birds remain among medicated survivors (30, 108). Spraying eggs with neomycin sulfate prior to incubation has been helpful in controlling PD in chicks (164).

Dipping contaminated eggs in antibiotic solution containing 400 ppm and 800 ppm of gentamicin was helpful in controlling *S*. Gallinarum in eggs (12). In addition, variable resistance to chlortetracycline and nitrofurazone has been reported among isolates of *S*. Pullorum (95, 140). Similar drug resistance to furazolidone (75, 157, 165, 166), quinolones (104), and other antibiotics (105) by certain strains of *S*. Gallinarum has been reported.

Paratyphoid Infections

Richard K. Gast

Introduction

The numerous motile members of the bacterial genus *Salmonella* are collectively referred to as paratyphoid (PT) salmonellae. Found throughout the world, these organisms infect a wide variety of hosts (including invertebrate and vertebrate wildlife, domestic animals, and humans) to yield either asymptomatic intestinal carriage or clinical disease. First reported in avian species in an 1895 infectious enteritis outbreak in pigeons, PT infections have a long history of association with significant disease losses in young poultry. PT salmonellae also have emerged as leading agents of food-borne human disease, and contaminated poultry meat and eggs are frequently implicated as vehicles for *Salmonella* transmission. Advances in poultry production practices, changes in consumer lifestyles and preferences, and heightened nutritional awareness have all helped to establish poultry products among the principal sources of animal protein for much of the world. Accordingly, preventing (or at least controlling) PT infections in poultry flocks has become an important objective from both economic and public health perspectives.

Economic Significance

Human illnesses resulting from the consumption of poultry products contaminated by *Salmonella* can be expensive for the poultry industry, governments, and affected individuals. The total combined costs of medical care, lost productivity, and premature deaths resulting from food-borne *Salmonella* infections of humans in the USA are estimated to exceed $2.7 billion annually (421). Widely circulated media reports regarding *Salmonella* contamination of particular foods can significantly affect consumer demand for those items. International markets for poultry products are increasingly subject to restrictions based on food safety considerations.

Poultry producers also face many direct expenses from *Salmonella* infections in their flocks. Infections acquired vertically from parents or horizontally in the hatchery can cause significant growth depression or even mortality in young chicks or poults. Other diseases or stressful conditions can predispose mature poultry to severe *Salmonella* infections. Likewise, infection with *Salmonella* can increase the susceptibility of birds to other pathogens. Preventing the transmission of salmonellae to progeny or to humans also can be expensive for producers. For example, risk reduction practices for controlling *S*. Enteritidis infections in laying flocks (including biosecurity, cleaning and disinfection of facilities, rodent control, vaccination, and testing) have been estimated to cost nearly 1 cent/dozen eggs produced (314).

Public Health Significance

PT salmonellae are consistently reported to be among the leading international sources of food-borne human disease. The incidence of laboratory-confirmed human *Salmonella* infections in the United States in 2010 (17.6/100,000 population) was higher than any other food-borne pathogen and was not significantly different from the corresponding incidence in 1996–1998 (67). Poultry products are often identified as prominent sources of salmonellae which cause human illness. More than 70% of human *Salmonella* infections in the United States have been attributed to the consumption of contaminated chicken, turkey, or eggs (198). Throughout much of the world, eggs and egg-containing foods have been implicated as the principal vehicles for the transmission of *S*. Enteritidis infections (193). Many of the serotypes that are most prevalent in humans (notably *S*. Enteritidis and *S*. Typhimurium) are similarly common in poultry.

Etiology

Classification and Nomenclature

The genus *Salmonella* is a member of the family Enterobacteriaceae and consists of 2 genetically distinct species, 1 of which *(S. enterica)* includes 6 subspecies determined by patterns of biochemical reactions (296). Only 1 of these subspecies (*S. enterica* subspecies *enterica*) is associated with disease in warm-blooded animals, and includes more than 2,500 motile and nonhost-adapted PT serotypes such as *S. enterica* subspecies *enterica* serovar Enteritidis and *S. enterica* subspecies *enterica* serovar Typhimurium. The traditional serotype designations (*S*. Enteritidis, *S*. Typhimurium, and so forth) are still often employed for concise diagnostic classification and epidemiologic analysis.

Morphology and Staining

*Salmonella*e are straight, nonspore-forming rods, measuring about 0.7–1.5 × 2.0–5.0 μm. *Salmonella*e are Gram-negative, but cells can readily be stained with common dyes such as methylene blue or carbolfuchsin. PT salmonellae are usually

peritrichously flagellated and motile, although naturally occurring nonmotile mutants are occasionally encountered.

Growth Requirements

*Salmonella*e are facultatively anaerobic and can grow well under both aerobic and anaerobic conditions. The optimum temperature to support *Salmonella* multiplication is 37ºC, but some growth is observed over a range from about 5ºC–45ºC. *Salmonella*e can grow within a pH range of 4.0–9.0, with an optimum pH around 7.0, although cellular components such as flagella and fimbria may not be expressed under extreme pH conditions. The nutritional requirements of salmonellae are relatively simple, and most culture media that supply sources of carbon and nitrogen can support their growth. The viability of *Salmonella* cultures can be maintained for many years in simple media, such as peptone agar or nutrient agar, which have been stab-inoculated, sealed, and held at room temperature.

Colony Morphology

Typical *Salmonella* colonies on agar media are 2–4 mm in diameter, round with smooth edges, slightly raised, and glistening.

Biochemical Properties

Typical PT salmonellae ferment glucose (to produce both acid and gas), dulcitol, mannitol, maltose, and mucate, but do not ferment lactose, sucrose, malonate, or salicin. They can produce hydrogen sulfide on many types of media, decarboxylate ornithine and lysine, utilize citrate as a sole source of carbon, and reduce nitrates to nitrites. PT salmonellae do not hydrolyze urea or gelatin and do not produce indole.

Most PT salmonellae can be readily distinguished from the avian host-adapted serotypes, *S*. Pullorum and *S*. Gallinarum, on the basis of the inability of *S*. Pullorum strains to ferment mucate or dulcitol and the inability of *S*. Gallinarum strains to decarboxylate ornithine or produce gas from glucose fermentation. In addition, PT salmonellae are usually motile but *S*. Pullorum and *S*. Gallinarum are typically nonmotile. Strains of *S. enterica* subspecies arizonae, a clinically important pathogen of young turkeys, are differentiated from PT salmonellae by their ability to ferment malonate and their inability to ferment dulcitol.

Susceptibility to Chemical and Physical Agents

Physical Agents: Heat and Irradiation

Except for a few distinctively thermoresistant strains such as *S*. Senftenberg 775 W, salmonellae are generally susceptible to destruction by heat. Thermal decontamination (during cooking or pasteurization) is critical for ensuring the microbial safety of poultry products, but heat disinfection has fewer applications during live poultry production. Steam pelleting treatment of poultry feed under precisely defined conditions inactivates salmonellae in a manner dependent on temperature, time, and moisture (217). Heating to at least 60ºC (at 100% relative humidity) reportedly decontaminated laying houses (192). Irradiation also has been considered for eliminating salmonellae from poultry feeds and environmental surfaces. Gamma radiation was successfully applied to diminish *Salmonella* levels in poultry feeds (276). Ultraviolet radiation has reduced *Salmonella* contamination on hatching eggs (18) and egg belts (158).

Chemical Disinfectants

Diverse chemical treatments have shown efficacy for reducing the levels of salmonellae associated with hatching eggs, feed, and poultry facilities. However, recontamination after disinfection can diminish any potential benefits (43). Sublethal chemical treatment has been reported to induce bacterial thermotolerance (378) and antibiotic resistance (8), but exposure to disinfectants also may suppress the ability of salmonellae to infect chickens (361).

Significant reductions of salmonellae on hatching eggs have been achieved using a variety of disinfectants, including formaldehyde (451), hydrogen peroxide (323), ozone (18), lactic acid (94), peroxidase catalyzed compounds (269), and biguanides (97). Disinfectants can be applied to hatching eggs by fumigating, spraying, or dipping. Significant *Salmonella* reductions in contaminated poultry feeds have been reported following the inclusion of ethyl alcohol (201) or organic acids such as zinc acetate and zinc propionate (344). However, a study of 12 potential antagonists of salmonellae in poultry feed (including organic acids) found that only formalin was consistently effective (395).

Chemical disinfectants (especially phenolic and quaternary ammonium compounds) are also widely used in poultry housing facilities. However, poultry houses sometimes remain contaminated with *Salmonella* after cleaning and disinfection (59, 318). Heavily contaminated areas of poultry houses, including floors, dropping boards or belts, and nest boxes, can be especially difficult to disinfect completely (61, 318). Disinfectants may not be effective against all bacterial strains (379), especially those which form biofilms (299). The presence of chick fluff, feces, feed, or wood shavings can interfere with disinfectants (38). Some disinfectants may be less potent when used with well, stream, or pond water (116). Improper performance of cleaning and disinfection protocols or recontamination of the environment by infected rodents can compromise disinfectant efficacy (112, 114). Formalin disinfection (61, 318) or formaldehyde fumigation (449) can be highly effective for decontaminating poultry facilities, but safety considerations have limited their use. Ozone fumigation has been considered as a safer (although less effective) alternative (449).

Environmental Factors

Environmental persistence by PT salmonellae creates continuous opportunities for horizontal transmission of infection within and between flocks. *S*. Enteritidis has been observed to survive in litter and feed for 26 months after removal of an infected flock (107). *S*. Senftenberg persisted for more than 2 years in a poultry house despite depopulation, cleaning, disinfection, drying, and

numerous intervening negative environmental tests (348). High moisture levels are particularly important risk factors for *Salmonella* persistence. The numbers of viable *Salmonella* in poultry litter are directly related to water activity (143) and accordingly tend to increase in regions of houses with reduced airflow (325). Reducing water activity or manipulating pH to antibacterial extremes has reduced *Salmonella* populations in poultry litter (37, 347).

Antigenic Structure

The traditional Kauffmann-White classification of salmonellae into serotypes is based on both somatic and flagellar antigens. Somatic O antigens are determined by polysaccharides associated with the cell body and are identified by Arabic numerals. Serogroups (designated with uppercase letters) are defined by somatic antigens unique to members of that group. Most *Salmonella* isolates found in poultry belong to serogroups B, C, or D. The H antigens are determined by flagellar proteins and are usually identified by lowercase letters. Flagellar antigens sometimes occur in 2 different phases. The serotype of a particular *Salmonella* isolate is determined by the combination of its O and H antigens. Serotyping of isolates is generally accomplished using agglutination tests with batteries of specific antisera.

Strain Classification

Phage Typing

Differentiation of epidemiologically relevant strains within serotypes is often based on their patterns of lysis with a defined set of bacteriophages. Phage typing has sometimes provided better strain discrimination than antimicrobial susceptibility testing, plasmid analysis, ribotyping, or pulsed field gel electrophoresis (423). The various phage types of *S*. Enteritidis have provided the foundation for establishing relationships between isolates from different sources (220). However, the dependability of phage typing is limited by the potential for the conversion of isolates to different phage types by mutation (355) or by the introduction of plasmids (52) or temperate phages (363).

Molecular and Antibiotic Susceptibility Typing

Diverse genetic analyses have been evaluated for discriminating *Salmonella* isolates within and between serotypes and phage types according to their source or epidemiological relevance. However, no single approach is demonstrably superior for all applications. The relative discriminatory abilities of methods often differ between serotypes (284). Moreover, the genetic homogeneity within serotypes such as *S*. Enteritidis has limited the meaningful differentiation of epidemiologically relevant strains (339, 342). Pulsed field gel electrophoresis of chromosomal DNA (235), ribotyping (80), random amplification of polymorphic DNA (290), plasmid profiling (283), and repetitive extragenic pallindromic-polymerase chain reaction (10) are among the most widely used molecular typing methods for *Salmonella* isolates. These techniques have distinguished between outbreak-related strains of salmonellae and unrelated strains (78) and between strains from different geographic locations (235). They also have been used to link isolates obtained from diverse sources within integrated commercial poultry enterprises (284) and to establish relationships between isolates from poultry flocks and human disease outbreaks (287). The combined use of 2 or more typing methods can provide the most detailed differentiation of *Salmonella* strains (281). The pattern of resistance to antimicrobial agents often has been used for strain differentiation in conjunction with molecular analyses (196).

Virulence Factors

Toxins

Two general categories of toxins play roles in the pathogenicity of PT salmonellae. Endotoxin is associated with the lipid A portion of *Salmonella* cell wall lipopolysaccharide (LPS). If released into the bloodstream of an infected animal upon lysis of bacterial cells, endotoxin can produce fever. Intravenously administered *S*. Enteritidis endotoxin caused liver and spleen lesions in 2-week-old chickens (419). LPS also contributes to the resistance of the bacterial cell wall to attack and digestion by host phagocytes. Loss of the ability to synthesize complete LPS impairs the ability of *S*. Typhimurium to colonize the ceca and invade to the spleen in broiler chicks (100).

Several proteinaceous toxins also have been identified in *Salmonella*. Enterotoxin activity induces a secretory response by epithelial cells that results in fluid accumulation in the intestinal lumen (267). The heat-labile cytotoxin causes structural damage to intestinal epithelial cells, perhaps by inhibiting protein synthesis (264).

Adherence and Invasion

Adherence to intestinal epithelial cells is the pivotal first step in the sequence of events by which PT salmonellae cause disease. Inefficient colonization of the intestinal tracts of chicks by *Salmonella* strains correlates with severely attenuated virulence (420). Several characterized *Salmonella* virulence genes are up-regulated in the high-osmolarity intestinal environment (128). Both flagella and fimbria have been identified as mediators of intestinal attachment, although neither is absolutely essential (130, 359). Mutants of *S*. Enteritidis lacking flagella exhibited reduced adherence to cultured avian intestinal cells (7) and competed poorly with wild-type strains to colonize the ceca of chicks (6). Strains of *S*. Enteritidis lacking fimbria were isolated less often than fimbriated strains from the ceca of inoculated chicks (409). LPS also may play a role in gastrointestinal attachment by salmonellae (62).

Salmonella virulence also requires mucosal invasion following adherence. Adherence and invasion appear to be separately regulated activities. The expression of important virulence genes in *Salmonella* pathogenicity island 1 strongly influences invasion of internal tissues such as livers and spleens, but has much less effect on initial cecal colonization (122, 131). Mutations affecting intestinal colonization and lethality after oral inoculation of chicks did not have similar effects after intraperitoneal administration (354). Flagella and

some types of fimbria may play roles in *S*. Enteritidis invasion and dissemination to internal organs of chicks (130). Flagella-deficient (but not fimbria-deficient) mutants were less able to invade to the livers and spleens of chicks (5). Type 1 fimbria appear to mediate the colonization of tubular gland cells in the upper oviduct (118). However, other researchers were unable to identify any significant effect on the invasion of enterocytes, ingestion by macrophages, or virulence for chickens when fimbrial genes were inactive (359, 411).

Plasmids

Plasmids are transmissible extrachromosomal DNA elements which are often associated with bacterial pathogenicity. Serotype-specific plasmids of characteristic molecular weights have been directly linked with virulence in salmonellae, although considerable homology has been demonstrated between virulence-associated plasmids of different serotypes (79). The acquisition of a plasmid by a widely prevalent clone of *S*. Kentucky was hypothesized to confer increased ability to colonize chicken ceca and cause extra-intestinal disease (246). Plasmid-mediated virulence among *S*. Typhimurium and *S*. Enteritidis isolates has been associated with survival and multiplication in serum (73). *Salmonella* strains cured of their virulence-associated plasmids are less persistent in the ceca of chicks (436). However, pathogenicity among salmonellae does not always require the presence of serotype-specific plasmids. For example, curing a serotype-specific plasmid of *S*. Enteritidis reduced its virulence in mice but did not affect colonization and invasion of internal tissues in chickens (202).

Pathogenicity Differences of Strains, Serotypes, and Phage Types

Salmonella strains can differ greatly in characteristic pathological effects in poultry. Differences between serotypes have been reported in the frequencies of mortality in chicks (376) and systemic infection in mature hens (334). Significantly higher frequencies of invasion of cecal lamina propria (41) and reproductive organs (157) have been attributed to *S*. Enteritidis isolates than to other serotypes, as well as significantly more frequent deposition inside eggs (173). Conversely, widely prevalent but avirulent *S*. Sofia isolates were impaired in adherence, invasion, and intracellular survival in comparison to other serotypes (155). Diverse aspects of *Salmonella* infections, including colonization of the intestinal tract and invasion to internal tissues, can also vary tremendously within individual serotypes (50). Differences between strains of *S*. Enteritidis, crossing phage-type boundaries, have been noted in both lethality for chicks (167) and egg contamination by hens (390). Even within the same clonal genomic lineage, *S*. Enteritidis strains may not have entirely identical virulence properties (338), and considerable dissimilarity in metabolic properties has been found within phage types (313). Pathogenicity differences between *S*. Enteritidis phage types have been extensively investigated, with phage type 4 sometimes associated with higher invasiveness (27) and lethality (167) for newly hatched chicks. However, in mature hens, infection with phage type 4 strains has caused intestinal colonization, systemic invasion, horizontal transmission, and egg contamination at frequencies similar to strains of other phage types (168, 177).

Although some virulence-associated genes are distributed widely in *Salmonella* isolates from diverse sources (402), genetic regions associated with specific attributes have accumulated differentially in individual strains (85). Particular genes, notably those of the type III protein secretion systems of *Salmonella* pathogenicity islands 1 and 2, are demonstrably important for invasion and survival in macrophages and internal organs (279, 387, 452). Alternatively, egg contamination by *S*. Enteritidis has been linked to the aggregate occurrence of a large number of single-nucleotide polymorphisms (195, 312). The complex series of events from initial intestinal colonization to eventual systemic consequences may be orchestrated by sequential expression of complementary phenotypic properties, relevant at different stages of infection, by distinct bacterial subpopulations (194, 195). The changing environmental conditions to which enteric pathogens are exposed before and during the course of infection may induce corresponding changes in the expression of virulence-related genes (139). Many *Salmonella* genes are differentially expressed in response to environmental stress (444). Stress-induced responses have been postulated to mediate persistent oviduct contamination and survival in egg white by *S*. Enteritidis (430). Sequential passage of *S*. Enteritidis isolates through reproductive tissues of laying hens induced a higher ability to cause egg contamination, although no similar effect was associated with passage through livers or spleens (171). In *S*. Enteritidis clones found in both oviducts and eggs from infected hens, genes for amino acid and nucleic acid metabolism, motility, cell wall integrity, and stress responses were all highly expressed (156).

Pathobiology and Epizootiology

Incidence of PT Salmonellae in Poultry

Numerous and varied estimates have been made of the incidence of *Salmonella* in poultry and poultry house environments around the world. Recent surveys of the incidence of *Salmonella* infection among turkey flocks have ranged from 16%–54%, with 1.5% of breeding flocks also testing positive in 1 study (12, 14). Likewise, recent surveys of the incidence of *Salmonella* infection among broiler chicken flocks have ranged from 9%–57% (275, 293). Incidences of infection can differ substantially across national borders, even within the same geographic region (350), and national *Salmonella* isolation rates can sometimes change considerably from year to year (145). The actual prevalence of infection or contamination within *Salmonella*-positive flocks also can vary widely. For example, within turkey flocks, salmonellae were isolated from 13% of litter samples and 11% of cecal samples in 1 study and 79% of litter samples and 70% of fecal samples in

another (331, 381). Moreover, the incidence of infection or contamination among flocks does not necessarily correlate with either the prevalence of infection within flocks (437) or the quantitative level of contamination within poultry facilities (95).

Recent surveys for the incidence of *Salmonella* in egg-type poultry in various nations have similarly generated a diversity of results, ranging from 12%–65% of flocks (364, 399). The frequency of *Salmonella*-positive samples within egg-laying flocks is often far less than the overall incidence among flocks (341). The within-flock *Salmonella* prevalence for laying hens in five European nations was reported to range from 0%–27.5% (429). The distribution of salmonellae within contaminated laying houses is not necessarily uniform, as illustrated by a study which reported that 10.5% of laying houses, but only 1% of individual cage rows within these houses, were positive for *S*. Enteritidis (65). The number of *Salmonella* found in individual environmental samples from laying houses is typically relatively low, although somewhat higher levels can be present at the beginning of egg production and molting (370).

Distribution of Salmonella *Serotypes*

Only about 10% of the known PT *Salmonella* serotypes have ever been found in poultry, and an even smaller subset of these are common. The distribution of *Salmonella* serotypes from poultry sources varies geographically and changes over time, although several serotypes are consistently found at a high incidence. Among clinical and environmental isolates submitted in the United States in 2009, the most frequently identified PT serotypes were *S*. Enteritidis, *S*. Kentucky, *S*. Heidelberg, *S*. Senftenberg, and *S*. Mbandaka in chickens, and *S*. Senftenberg, *S*. Hadar, *S*. Worthington, *S*. Muenster, and *S*. Saintpaul in turkeys (142). The important epidemiological connection between poultry and human reservoirs of salmonellae is sometimes evident in similarities in their respective serotype distributions. Of the 10 serotypes most often reported in the USA in 2009 (*S*. Enteritidis and *S*. Typhimurium were most common), 5 appeared on similar lists for either chickens or turkeys in that same year (66, 142). Similar associations between the distributions of *Salmonella* serotypes among poultry and human isolates have been reported in many countries (77, 149). The implementation of new food safety regulations in Australia changed the relative incidences of *Salmonella* serotypes, but not the linkage between the serotypes found in poultry and those causing human illness (401).

Reports of the frequencies at which *Salmonella* serotypes are isolated from poultry sources around the world vary widely, although several serotypes are of continuing international significance. The unique epidemiologic association of *S*. Enteritidis with disease transmission via contaminated eggs (67) has made the prevalence of this serotype a topic of special interest. *S*. Enteritidis is often the most common serotype found in surveys of egg-producing chickens in many nations (375, 407), and has been reported as the most common serotype present in eggs even when other serotypes are predominant in associated laying flocks (341). *S*. Enteritidis also has become a prominent isolate from broilers in some countries (291, 298, 350). Several other serotypes are highly prevalent in particular types of poultry or certain geographic regions. A rapidly increasing prevalence of *S*. Kentucky has been observed in both egg-type and meat-type poultry in the United States (154, 280, 380). *S*. Infantis has been common in both layers and broilers in Japan (244, 245). *S*. Sofia has predominated for a number of years in Australian poultry (305, 351). Other highly prevalent serotypes in broiler chickens include *S*. Typhimurium (343), *S*. Heidelberg (154), *S*. Hadar (293), *S*. Mbandaka (200), and *S*. Anatum (274).

Natural and Experimental Hosts

Paratyphoid Infections in Young Poultry

PT infections often have far different consequences for newly hatched poultry than for older birds. In very susceptible young chicks and poults, *Salmonella* infection can sometimes lead to illness and death at high frequencies. For example, oral doses of 10^9 *S*. Typhimurium cells were lethal for 50% of broiler chicks at 1 day of age and 20% at 3 days, but for 0% at 7 days (147). Mortality associated with naturally occurring PT infections in poultry often reaches peak levels at 3–7 days of age (316). Older birds are much less susceptible to the lethal effects of PT salmonellae and may experience intestinal colonization and even systemic dissemination without significant morbidity or mortality. The development of resistance to salmonellae in young birds is mostly attributable to the acquisition of protective microflora which compete with salmonellae for intestinal receptor sites or produce inhibitory factors (400). Such resistance may begin developing as early as 36 hours after hatching (32). Significantly more orally administered *S*. Typhimurium cells adhered in the ceca of chicks at 2 days of age than at 3–7 days (162). Naturally exposed birds can be heavily infected on their first day of life (299), and the frequency of fecal shedding of salmonellae in broiler flocks has been reported to peak at 14 days of age (300). Only 4% of cecal samples collected from naturally infected turkey poults were *Salmonella*-positive at 1 day of age, but 55% were positive at 9 days (448).

PT infection has been experimentally established by oral, intracloacal, intratracheal, intraocular, navel, and aerosol administration to chicks (91). The usual outcomes of PT infections in chicks and poults involve 3 stages. Orally introduced salmonellae first establish intestinal colonization, often resulting in persistent fecal shedding. *Salmonella* levels in the intestinal contents of colonized chicks may greatly exceed intracellular levels in the intestinal epithelium (392). Second, invasion beyond the gastrointestinal tract can lead to *Salmonella* multiplication in the macrophage-phagocyte system of the liver and spleen (31), and eventual dissemination to colonize a variety of internal tissue sites. Third, extensive bacteremia sometimes occurs, resulting in high mortality. The incidence of both intestinal colonization (377) and mortality (147) in chicks correlate strongly with the dose of orally administered salmonellae. Infectious doses of salmonellae may vary between different avian species (460).

PT intestinal colonization (377), invasion to internal organs (125), and persistence in colonized tissues (123, 134) are all higher in newly hatched chicks than in older birds. Intestinal persistence was far greater following oral inoculation of chicks with *S*. Typhimurium or *S*. Enteritidis at 1 day of age than at 7 days (39, 162). After oral inoculation of 1-day-old chicks, *S*. Enteritidis was shed in the feces of nearly half of these birds at 6 months of age (176). PT infection has been reported to persist for as long as 64 weeks after the exposure of young chicks (349). Administering 10^2 *S*. Enteritidis cells to 1-day-old chicks led to more persistent intestinal infection than administering 10^9 cells to 1-week-old birds (432). Some internal tissues reportedly remained *Salmonella*-positive for as long as 1 year after inoculation of 1-day-old chicks (393).

Paratyphoid Infections in Mature Poultry

Morbidity or mortality are not consistently associated with PT infections in mature poultry. Experimental infections of adult chickens with large oral doses of PT salmonellae may result in extensive intestinal colonization, bacteremia, and systemic dissemination to diverse internal organs, but they rarely cause any evident signs of clinical illness (237, 412). During the first 2–4weeks following experimental oral infection of chickens or turkeys, salmonellae are typically isolated from intestinal tracts and voided feces at high frequencies (163). Although the incidence of gut colonization and fecal shedding steadily decline thereafter, some *S*. Enteritidis strains can persist in the intestines of chickens for several months after oral inoculation (164, 390). *Salmonella* was isolated from 42% of commercial broilers at 6–8 weeks of age (98). The frequency of fecal shedding of salmonellae by commercial layers peaked at 18 weeks of age and then declined steadily (280).

Gut colonization by salmonellae is usually followed by invasion through the intestinal epithelium and dissemination to colonize internal tissues. In commercial broilers, 35% of sampled spleens, livers, and gall bladders were *Salmonella*-positive at 6–8 weeks of age (98). Various serotypes (including *S*. Typhimurium, *S*. Heidelberg, and *S*. Infantis) are known to be invasive for poultry, but the patterns and consequences of systemic invasion have been documented most extensively for *S*. Enteritidis. After experimental oral inoculation of laying hens, *S*. Enteritidis has been isolated from numerous internal tissues, including the liver, spleen, ovary, oviduct, heart blood, and peritoneum (164, 412). Dissemination of *S*. Enteritidis to diverse internal organs, including the ovary and oviduct, has also been recorded following intravenous (170), intratracheal (326), conjunctival (238), intravaginal (310), or intracloacal (310) inoculation; exposure to contaminated aerosols (170); or insemination with contaminated semen (366). The magnitude of internal organ colonization is directly related to the infecting dose (172). *S*. Enteritidis also has been isolated from a wide range of internal organs in naturally infected poultry (234).

The production of contaminated eggs is an aspect of *Salmonella* infections in mature chickens which has unique public health ramifications. Among egg-transmitted human salmonellosis outbreaks, 74% have been caused by *S*. Enteritidis and 15% by *S*. Typhimurium (193). Investigations of egg-laying flocks implicated in human disease outbreaks have sometimes found *S*. Enteritidis isolates of the same phage types, plasmid profiles, or chromosomal DNA profiles found in affected people (211). Internal contamination of eggs with *S*. Enteritidis is a consequence of invasion to the ovary and oviduct (250). *S*. Enteritidis can colonize diverse regions of the reproductive tract of chickens, although the relationship between the colonization site and the frequency or location of egg contamination is uncertain (174). *S*. Heidelberg (169) and multiple antibiotic-resistant *S*. Typhimurium DT104 (450) have also been found inside eggs laid by experimentally infected hens. The reported incidence of *S*. Enteritidis contamination of eggs from infected commercial flocks has usually been extremely low, even when laying house environments are contaminated (140, 211, 383), but transiently higher incidences may lead to human disease outbreaks (44). After oral inoculation of hens, *S*. Enteritidis can be deposited in both yolk and albumen, although usually at very low initial concentrations (163, 177). Naturally contaminated eggs also typically contain very small numbers of *S*. Enteritidis cells (241), but these populations can expand to more dangerous levels if eggs are held at growth-promoting temperatures (178).

Predisposing Factors

A number of factors can increase the likelihood or severity of PT infections in poultry. Several other infectious agents are known to influence the course of *Salmonella* infections. Prior infection with coccidia such as *Eimeria tenella* can increase *Salmonella* colonization of the intestinal tracts of chickens (356), and *E. tenella* exposure may cause recrudescence of an earlier *Salmonella* infection (357). Coccidial infection decreases intestinal levels of *Salmonella*-inhibiting volatile fatty acids (15). However, *E. tenella* infection diminished the frequency at which subsequently administered *S*. Enteritidis invaded to the internal organs of chicks, possibly by thickening the intestinal lamina propria (406). Infections with immunosuppressive viruses or bacteria also can affect the outcome of *Salmonella* infections in poultry. Exposure to reticuloendotheliosis virus or bursal disease virus at 1 day of age increased mortality among chicks inoculated subsequently with salmonellae (317, 457). Suppression of cell-mediated immunity by *Corynebacterium parvum* led to increased morbidity in chicks after *Salmonella* infection (90). Perhaps via protection against compromising infections, both coccidial and viral vaccines have been associated with reduced *Salmonella* detection in broiler flocks (438).

Environmental and management factors also influence the susceptibility of poultry to PT salmonellae. Stressful conditions facilitate or exacerbate infections. Housing inoculated chicks at a high density in unsanitary conditions increased cecal carriage of *S*. Enteritidis (13). Lowering the brooding temperature of chicks by 5ºC–8ºC increased mortality among newly hatched chicks inoculated with *S*. Worthington (408). Water deprivation before inoculation of 7-week-old chickens increased the duration of fecal shedding of *S*. Typhimurium

(53). Stress from the onset of egg laying can increase susceptibility to *Salmonella* infection (335). The incidence of *Salmonella* isolation from broiler chickens sometimes increases after they are transported for slaughter (300).

Feed withdrawal from broiler chickens before slaughter has been linked to increased *Salmonella* contamination of crops (87). Both feed withdrawal and exposure to heat alter intestinal morphology and microbial communities, and increase *Salmonella* attachment to intestinal cells (55). Inducing molting by feed restriction has been identified as a highly significant risk factor for *S*. Enteritidis infection in laying flocks (159). Feed deprivation lowers crop levels of protective lactobacilli and volatile fatty acids while increasing pH (138). In experimental infection studies, feed restriction of hens increased intestinal colonization and fecal shedding (223, 229), intestinal lesions (353), invasion to livers and spleens (229), recurrence of prior infections (231), and horizontal (222) or airborne (230) transmission of *S*. Enteritidis infection. Molting also can be induced via alternatives, such as alfalfa diets, without increasing the susceptibility of hens to *Salmonella* (132, 136).

Housing systems for laying hens have been intensively investigated as potential *S*. Enteritidis risk factors. Some European studies have attributed increased risk to conventional cages (242, 429), but others report less transmission of infection in conventional cages (126). The age of housing may be a more important risk factor than the type of housing (428). The likelihood of *Salmonella* infection appears to increase with both flock size and age (329, 398).

Sources, Vectors, and Transmission

PT salmonellae can be introduced into poultry flocks from many sources. Feeds containing contaminated animal proteins, vegetable proteins, or cereals, or contaminated by vermin or wildlife, are potential sources of *Salmonella* in both chickens and turkeys (102, 111, 374). Chicks can be infected by very low levels of PT salmonellae in feed (219). *Salmonella* contamination was found in 28% of finished feed samples from commercial broiler farms (4). Meal or mash feeds are more often contaminated with salmonellae than pelleted feeds (102, 374). *Salmonella*e can survive for 2 years in inoculated feeds (113). *Salmonella* isolates from feedstuffs have had matching genetic profiles with isolates found on poultry meat products (54). *S*. Enteritidis isolates with similar chromosomal DNA patterns were found in both feed given to a commercial laying flock and eggs they laid (389).

The wide PT host range creates numerous reservoirs of infection for poultry. Biologic vectors introduce, disseminate, and amplify salmonellae in flocks. In United Kingdom egg-laying farms, molecular fingerprinting linked *S*. Enteritidis isolates from wildlife, farm environments, mice, hens, and eggs (282). Insects and other invertebrates, including flies (441), darkling (litter) beetles (394), ground beetles (107), cockroaches (265), red mites (315), and centipedes (107) can carry *Salmonella* organisms externally (and sometimes internally). *Salmonella* infection has been transmitted by feeding contaminated flies or darkling beetles to chickens (228, 371). Mice (60) and roof rats (273) are important vectors for *S*. Enteritidis in laying flocks. A study of commercial laying flocks in the USA reported a *S*. Enteritidis prevalence in mice from environmentally positive poultry houses which was 4 times that of negative houses (159). A single mouse fecal pellet can contain 10^5 *S*. Enteritidis cells (212). Wild birds and other wildlife are sometimes identified as *Salmonella* risk factors for poultry (113, 299, 440). Humans can also transmit *Salmonella* infection into poultry flocks (256).

Vertical transmission of salmonellae to the progeny of infected breeding flocks can result in internal or external contamination of eggs. Egg shells can be contaminated with feces during oviposition. *Salmonella* penetration into or through shells and shell membranes can either directly transmit infection to developing embryos or allow exposure of chicks to infection when the shell structure is disrupted during hatching. *S*. Enteritidis can be deposited in the contents of eggs before oviposition (163, 250). The resulting transovarian transmission of infection to progeny is an important aspect of *S*. Enteritidis epidemiology in chickens.

The same *Salmonella* serotypes responsible for mortality in naturally infected chicks or poults are often also found in their parent flocks (316). The *Salmonella* status of newly hatched chicks is a leading risk factor for infection in mature commercial layer and broiler flocks (298, 330). Any salmonellae carried in or on eggs can spread extensively in hatcheries. As chicks or poults pip through egg shells, salmonellae are released into the air and circulated around hatching cabinets on contaminated fluff and other hatching debris (437). Samples of egg fragments, belting materials, and paper pads from broiler hatcheries have been *Salmonella*-contaminated (92). Newly hatched birds, lacking protective intestinal microflora, are highly susceptible to intestinal colonization by salmonellae. Chicks from uncontaminated eggs became infected with *S*. Typhimurium when hatched along with surface-contaminated eggs (64).

Salmonella prevalence in broiler hatcheries is reportedly greater than at later production stages, and the serotypes isolated from hatcheries sometimes correlate with those found on finished carcasses (20). *Salmonella* serotypes carried from hatcheries by chicks may predominate in broiler flocks (271).

Horizontal transmission of *Salmonella* occurs both within and between flocks. Infection spreads via direct bird-to-bird contact or ingestion of contaminated feed, water, feces, or litter. Circulation of personnel, equipment, aerosols, and dust throughout houses facilitates transmission. *Salmonella* spread rapidly among chicks reared on litter (396). *S*. Enteritidis was found in the feces and internal organs of uninoculated laying hens housed in cages adjacent to orally inoculated birds (163, 164). Poultry environments are often implicated as principal sources of salmonellae. Serotypes present in broiler houses during the rearing period are likely to appear on processed carcasses (270).

Studies in Dutch and Japanese laying flocks suggested that *S*. Enteritidis infection was more often acquired from farm environments than from breeders (425, 458). Infection in

previous flocks is a significant risk factor for *Salmonella* in both broiler and layer flocks (242, 330). Dust levels are also important risk factors for salmonellae in poultry (298, 299). *S*. Enteritidis persisted for at least 1 year in dust in an empty poultry house, even after cleaning and disinfection (113). Air samples collected inside and outside of commercial laying houses were *Salmonella*-positive (115). Airborne transmission of *Salmonella* has been reported, apparently mediated by contaminated dust (182, 369). Levels of airborne salmonellae in broiler houses have been linked to levels in litter (76).

Clinical Signs

PT infections of poultry typically cause clinical disease only in very young birds. *Salmonella* contamination within eggs may lead to embryo mortality or rapid death among newly hatched birds before clinical signs are observed. Morbidity and mortality can be high during the first 2 weeks of life, with significant body weight loss or growth retardation (129), but signs of disease are infrequent in older birds. The course of illness is normally relatively brief in individual birds. Signs of severe PT infection in young poultry are generally similar to those observed with other avian *Salmonella* infections (pullorum disease and fowl typhoid) and with other bacteria which cause acute septicemia. Although clinical disease is not characteristic of PT infections in mature poultry, some *S*. Enteritidis strains have caused anorexia, diarrhea, and reduced egg production in experimentally infected laying hens (163, 390).

Typical signs of PT infection in chicks and poults include progressive somnolence with closed eyes, drooping wings, ruffled feathers, shivering and huddling near heat sources, anorexia, emaciation, and profuse watery diarrhea (often resulting in dehydration and pasting of the vent area). Blindness and lameness are occasionally observed.

Pathology

In severe outbreaks of PT infection in newly hatched poultry, rapidly developing septicemia can cause high mortality with few apparent lesions. When the course of disease is longer, severe enteritis is often accompanied by focal necrotic lesions in the mucosa of the small intestine, sometimes with cheesy cecal cores. Spleens and livers are commonly swollen and congested, with evident hemorrhagic streaks or necrotic foci. Kidneys may be enlarged and congested. Fibrinopurulent perihepatitis and pericarditis are frequently reported. Slight inflammatory processes with heterophil infiltration ranging from focal to diffuse in distribution were observed in ovaries and oviducts from infected laying flocks (234). Unabsorbed, coagulated material may be present in the yolk sac. Other occasionally observed lesions include peritonitis, pneumonia, hypopyon, panophthalmitis, purulent arthritis, polyserositis, serous typhlitis, airsacculitis, and omphalitis (333, 376).

Pathogenesis of the Infectious Process

Although salmonellae invade epithelial cells throughout the intestinal tract, the ceca and ileocecal junction are sites of particular affinity (419). After oral inoculation of chicks, *S*. Enteritidis adhered to epithelial cells at the tips of villi (124). *Salmonella* invasion changes the density and morphology of intestinal epithelial cells (148), affecting intestinal fluid and electrolyte regulation, and ultimately causing cell death and diarrhea. Oral inoculation of laying hens with *S*. Enteritidis produces inflammation of the epithelium and lamina propria of the ceca and colon due to heterophilic infiltration (210). Epithelial invasion also may allow removal of salmonellae through the basement membrane into the lamina propria by macrophages (51). *S*. Enteritidis was recovered from several internal organs of laying hens within 1 hour after oral infection (239). *S*. Enteritidis numbers peaked at 24–36 hours after oral inoculation of chicks (207). The ability of salmonellae to survive and multiply in internal organs, particularly livers and spleens, correlates with their virulence (30). The spleen may provide a protected site for intracellular *Salmonella* multiplication without exposure to host defense mechanisms (137). Many *S*. Enteritidis strains are invasive for cells of the reproductive tract (117).

Immunity and Resistance

The immune response of poultry to PT salmonellae minimizes the duration and severity of infection and protects against re-infection (205). This response also serves as the basis for protecting birds against infection by vaccination and permits serologic detection of infected flocks. Administering immunosuppressive agents to chicks increased mortality associated with PT infection (141). *Salmonella* infection of chickens can cause lymphocyte depletion, atrophy of lymphoid organs, and immunosuppression, thereby facilitating the establishment of a persistent carrier state (204).

PT salmonellae can elicit strong antibody responses in infected poultry. In a naturally infected broiler breeder flock, 70% of the birds were found to be positive for antibodies to *S*. Enteritidis (86). Experimental infection of chicks with *S*. Typhimurium induced strong IgG, IgA, and IgM responses (205). When laying hens were orally infected with *S*. Enteritidis, serum antibodies were produced by most birds by 1 week post inoculation (PI), reached peak values at 2 weeks, and remained at high levels for more than 6 months (165, 179). Serologic positivity to *Salmonella* persisted among infected chickens throughout a 1-year period (393). *S*. Enteritidis infection of laying hens induces antibody production by lymphoid cells in the crop, ceca, and small intestine (232, 434). Antibodies to *S*. Enteritidis have been found in the yolks of eggs laid by naturally infected hens (86). Specific antibodies were found as early as 9 days PI and reached peak levels at 3–5 weeks in eggs from experimentally infected hens (166). The progeny of immune breeding hens can acquire partially protective immunity via transfer of maternal antibodies in egg yolks (39).

Cell-mediated immunity to salmonellae is also important in poultry. Avian heterophils are phagocytic and bactericidal (447), and may play a vital role in restricting organ invasion during early phases of *Salmonella* infection (263). Stimulating the immune responses of heterophils increased the resistance

of chicks to *S*. Enteritidis colonization (208). Cytokines produced by sensitized T lymphocytes expand the pool of circulating phagocytic heterophils (261) and recruit them to the site of infection (262). Various intestinal cytokines and antimicrobial peptides were sequentially expressed during the course of *S*. Enteritidis infection in chickens (101). *S*. Enteritidis infection in chicks also induced the expression of chemokines, which recruit macrophages and monocytes (74). Proliferation of chicken granulosa cells, which recruit mediators of innate immunity, is suppressed by *S*. Enteritidis infection (418).

Both humoral cell-mediated immune responses appear to play important roles in protecting poultry against *Salmonella* infection. Strong antigen-specific cellular and humoral immune responses were both temporally linked to the clearance of *S*. Typhimurium infection in chickens (34). Likewise, a decline in *S*. Enteritidis isolation from reproductive tissues of laying hens during the second week of infection was associated with the proliferation of both T and B lymphocytes (453). Both the opsonic activity of specific antibodies and the phagocytic and lytic activity of cellular effectors may be necessary for the full expression of immunity (304). In addition to antigen-specific adaptive immune responses, innate host phagocytic capabilities also contribute significantly to resistance against infection by salmonellae. Chicken macrophages can internalize higher numbers of *S*. Enteritidis cells and clear intracellular salmonellae more rapidly than lymphocytes (268). Innate responses are especially critical in newly hatched poultry which are immunologically immature and unable to mount fully protective adaptive immune responses to infection (227).

Selection for genetically based differences in the innate resistance or immunity of lines of chickens to *Salmonella* infection has been considered as a potential protective strategy. Chicks from distinct lines can vary in *Salmonella*-associated mortality (197). Different incidences of fecal shedding, organ invasion, and egg contamination have been observed for lines of mature chickens infected with *S*. Enteritidis (135, 190). Lines of chickens differing in *Salmonella* resistance also have differed in T cell responses (33) and the expression of cytokines (82), antimicrobial peptides (121), and pathogen-specific cellular receptors (1). However, effective selection for *Salmonella*-resistant lines of chickens is complicated by negative genetic correlations between resistance in chicks and adults (35) and between resistance traits and production traits (365, 414).

Diagnosis

Although clinical observations may suggest a PT infection, final diagnosis depends on the isolation and identification of causative organisms. Using conventional culture methods, this requires 48–96 hours (and even longer for some protocols). A concise summary of traditional methods for isolating *Salmonella* from poultry was provided previously (442). Numerous faster alternative strategies for detecting and identifying salmonellae have been proposed and studied. Serologic detection of specific antibodies is sometimes employed as a rapid preliminary screening test to identify flocks that have been exposed to salmonellae.

Isolation and Identification of Causative Agent

Sample Selection

Samples from a variety of sources, including tissues, eggs, voided feces, and poultry house environments, are collected and tested to identify PT infection in flocks. The number of samples which must be processed to achieve a predetermined level of confidence of accurate detection is directly related to flock size and inversely related to the prevalence of infection (3). In very large flocks estimated to have low *Salmonella* prevalence, multiple samples are often pooled together before culturing to improve the likelihood of detection within the limitations of existing laboratory resources.

Many *Salmonella* serotypes are highly invasive and can spread systemically to numerous internal tissues, so a diversity of sites (including liver, spleen, ovary, oviduct, testes, yolk sac, heart, heart blood, kidney, gall bladder, pancreas, synovia, and eye) can provide samples for diagnostic culturing. Because lesions do not reliably indicate infected tissues, several different organs should be cultured from each bird (separately or together). Egg culturing is often applied to assess the potential threat to public health posed by laying flocks infected with highly invasive serotypes, particularly *S*. Enteritidis, which are deposited in the contents of eggs before oviposition.

Because PT infections in poultry almost invariably involve intestinal tract colonization, samples of intestinal tissues and contents are frequently a focus for testing. In a diagnostic survey, salmonellae were found exclusively in intestinal samples in 78% of chickens and 70% of turkeys (146). In experimentally infected laying hens, *S*. Enteritidis was recovered more often from the intestinal tract than from any other sampled tissue (164). The caudal ileum, ceca, cecal tonsils, and cecal contents are often recommended for *Salmonella* recovery. No specific sample ensures detection of all infected birds (364), but cecal contents may be positive at the highest frequency (392, 407). Cloacal swabs or fecal samples can provide sensitive indicators of persistent intestinal colonization in individual birds (160), but their diagnostic reliability is diminished by the intermittent shedding of salmonellae in the feces of infected birds (427).

Fecal shedding of *Salmonella* into poultry house environments by infected birds makes culturing environmental samples a useful diagnostic tool. Environmental samples provide opportunities to monitor the introduction of salmonellae into poultry houses by feed, vectors, personnel, and equipment. Sampling floor litter has provided a level of detection comparable to fecal samples (336, 382). Dragging moistened gauze pads across floors in poultry houses has detected salmonellae with high sensitivity (257). Swabs dragged through wet areas of manure are more productive than dry areas (373). Foot covers worn in poultry houses also can provide effective samples for detecting environmental salmonellae (319). Nest boxes, egg belts, dropping belts or scrapers, fan blades, and

dust are particularly productive sources for *Salmonella* sampling in laying houses (104, 255). Dust samples provide higher sensitivity than feces, but combined testing of both optimizes detection (11). Air sampling detected *Salmonella* in both hatching cabinets and rooms housing infected chickens (42, 183). Hatcher fluff and hatched eggshell membranes are frequently contaminated with salmonellae, offering opportunities for early detection of infection (71, 309).

Standard Culture Methods for Salmonella *Detection*

Although diverse culture conditions are applied to isolate and identify PT salmonellae, most standard methods follow a general scheme involving 4 principal stages. First, nonselective pre-enrichment encourages the growth of very small numbers of salmonellae or resuscitates injured cells. Pre-enrichment is not recommended when testing samples (such as intestinal contents or feces) with large numbers of competing organisms that might overgrow salmonellae in nonselective media. Second, selective enrichment allows additional expansion of the *Salmonella* population while suppressing the growth of other organisms. Third, plating on selective agar media yields isolated colonies, each derived from a single cell. Nonselective agar plating media are also sometimes used with swabs from internal organs. Fourth, colonies with appearances characteristic of salmonellae are subjected to biochemical and serologic tests to confirm their genus and serotype identity. Virtually all proposed methods require the last 2 of these steps, but enrichment requirements vary according to the nature of the sample.

Internal organs (except for intestinal samples) from infected birds ordinarily contain relatively few competing organisms. Swab or loop samples taken from internal tissues are often transferred directly to plates of both selective and nonselective agar media, without broth enrichment. Excised tissue samples, and any samples derived from the intestinal tract, are generally transferred initially into selective enrichment broth.

Because fecal contamination may result in the presence of diverse flora, eggshells are usually sampled for *Salmonella* without pre-enrichment (unless detecting the presence of other bacterial contaminants is also of interest). The surface of eggshells can be sampled by immersion or rinsing in broth media or the entire shell (including interior structures and shell membranes) can be sampled by aseptic breaking to release the contents followed by manual crushing and the addition of enrichment broth. In a study of commercially produced eggs, similar frequencies of *Salmonella* recovery were obtained via shell rinse and crush methods (324). Before culturing egg contents for contamination by salmonellae, shell exteriors must be disinfected to prevent the transfer of fecal contaminants to the contents during breaking.

Salmonella contaminants inside eggs are typically present at both very low prevalences and in very small numbers, so theentire liquid contents of 10–20 eggs are often pooled together for sampling to minimize demands on laboratory resources. Egg contents pools are usually incubated before further culturing to allow *Salmonella* populations to expand to consistently detectable levels (175). Supplementation of whole egg pools with iron can increase *Salmonella* multiplication during incubation (75, 175). Pre-enrichment of egg contents leads to more sensitive *Salmonella* detection than direct selective enrichment (161), perhaps by allowing expansion of small initial levels of bacteria before they are exposed to harsh selective enrichment conditions. Direct plating of incubated egg pools onto selective agar media reduces time, media, and labor requirements, but results in significantly poorer detection sensitivity (161, 175).

Environmental samples are typically collected in sterile plastic bags and subsequently cultured by transfer into selective enrichment broth. Moistened gauze pads can be used to sample environmental surfaces or can be dragged across floor litter or dropping pits. Transporting environmental swab samples in double-strength skim milk or buffered peptone water may improve *Salmonella* detection (58). Feed should be tested by collecting several representative samples from each lot and transferring into selective enrichment broth. Pre-enrichment of poultry feed samples may be unnecessary or even counterproductive (93).

Culture media are generally incubated for 24 hours at 37ºC–41ºC. Longer (48-hour) incubation in nonselective media has been useful for recovering small numbers of *S*. Enteritidis from egg contents (163, 240). Shorter (6-hour) selective enrichment is inadequate to suppress competing microflora in heavily contaminated samples (103). Incubation of selective enrichment cultures at elevated temperatures (42ºC–43ºC) has been recommended to restrict the growth of competing organisms, especially in intestinal samples or samples containing fecal material (103).

Culture Media

A broad assortment of media has been developed and evaluated for isolating and identifying salmonellae. Although some evidence suggests that proper selection of culture media is contingent on the type of sample being tested, several commercially available formulations have been consistently effective for a variety of applications. Suggested broth media to pre-enrich samples for salmonellae include buffered peptone water and trypticase soy broth. The selective broth media most often used for *Salmonella* detection in recent years are tetrathionate broth and Rappaport-Vassiliadis broth. Modified semisolid Rappaport-Vassiliadis (MSRV) medium has sometimes performed better than broth media for selectively enriching *Salmonella* from poultry samples (439).

Numerous agar media are available for isolating PT salmonellae. Among the most commonly used plating media are brilliant green, xylose-lysine-deoxycholate (XLD), xylose-lactose-tergitol 4 (XLT4), Rambach, bismuth sulfite, and Hektoen enteric agars. Brilliant green agar has been widely and successfully applied for *Salmonella* isolation from diverse poultry sources, including tissue, environmental, egg, feed, and air samples (183, 443). Both XLT4 (308) and Rambach (57) agars have been effectively employed for detecting salmonellae in poultry house environmental samples. Novobiocin

addition to media improves *Salmonella* recovery by suppressing the growth of competitors such as *Proteus*. Samples should always be plated on 2 different agar media, preferably with dissimilar indicator systems for differentiating salmonellae from other organisms.

Confirmation of Genus and Serotype

Characteristic *Salmonella* colonies on selective agar plates must be tested further to confirm their genus identity and determine their serotype. Combined use of triple sugar iron agar and lysine iron agar provides an effective presumptive test for salmonellae. The observed pattern of fermentation with a battery of six carbohydrates can provide further differentiation of PT isolates from other organisms (99). The serogroup of isolates can be determined by agglutination tests with polyvalent antisera for somatic O antigens, and the serotype can then be determined by slide agglutination tests with monovalent antisera to specific O antigens and tube agglutination tests with antisera to flagellar H antigens. Serotype-specific primers have facilitated the development and application of molecular typing methods (199).

Rapid Detection Technologies

Obtaining *Salmonella*-negative results using conventional culturing methods requires several days for most types of samples, and confirming positive results adds even more time. Considerably faster techniques are available and are increasingly becoming accepted as standard practices, although rapid methods have not altogether supplanted traditional culturing for most applications. Rapid methods typically reduce time requirements for testing by 1 or more days, and many are adaptable to some degree of automation. The principal limitations of rapid methods are high cost and poor sensitivity. Rapid methods nearly always require at least 1 enrichment step to achieve detectable cell densities (180). Most efforts to develop rapid *Salmonella*-detection methods have centered on the use of specific antibodies or DNA probes.

Specific antibodies have been used in a variety of enzyme immunoassay (EIA) methods to detect *Salmonella* antigens. Polyclonal antibodies to LPS or flagella detected salmonellae in eggs, tissues, cloacal swabs, environmental drag swabs, litter, and feed (206, 295). Assays using monoclonal antibodies to outer membrane proteins or flagella have been applied to specifically detect *S*. Enteritidis in eggs, tissues, and environmental samples (249, 251). Antibody-based methods are characteristically less sensitive than standard culture methods (403, 405), and usually require 1 or more initial enrichment steps to support expansion of the *Salmonella* population to detection threshold values of 10^5–10^7 cells/ml (206, 249). EIA tests are also prone to false-positive results from competing flora, which grow in enrichment media (36). Other antibody-based detection formats have demonstrated similar sensitivities (46, 181).

Another application of antibodies for *Salmonella* detection is immunomagnetic separation (IMS), which employs small magnetic beads coated with specific antibodies to bind *Salmonella* target antigens in samples and remove them when a magnetic field is applied. IMS offers a faster alternative to broth enrichment for concentrating salmonellae without adversely affecting sublethally injured cells (388). IMS concentration of salmonellae before plating on selective agar detected *Salmonella* contamination in poultry environmental samples at a similar frequency as traditional selective enrichment (292). IMS supported detection of small numbers of *S*. Enteritidis contaminants in egg contents pools by both culturing and EIA (225). IMS concentration plus an EIA detected *Salmonella* from poultry environmental swabs with 98% of the sensitivity of traditional culturing, but required only 48 hours for testing (277).

An increasingly prominent approach to rapid testing for *Salmonella* is based on detecting genus-specific or even serotype-specific genetic sequences by hybridization of specific probes with target DNA extracted from samples. DNA hybridization typically detects salmonellae at sensitivity thresholds similar to EIA, and thus requires 1 or more preliminary enrichment culturing steps (289, 413). Moreover, DNA hybridization assays are procedurally complex and are more expensive than other available methods. The development of PCR technology has allowed amplification of specific target segments of DNA, thereby enabling hybridization reactions with probes to detect salmonellae in tissues, environmental swabs, feces, and eggs with a high level of sensitivity (72, 294, 386). After enrichment culturing, PCR methods have detected initial contamination loads of less than 10 *Salmonella* cells in eggs and poultry environmental samples (254, 288). Carefully chosen DNA probes can be used with PCR to detect salmonellae with particular characteristics, such as genes for virulence factors (272), biochemical properties (285), or surface structures such as fimbria (455). Multiplex PCR assays can simultaneously detect the presence of several serotypes (233, 340).

Serologic Diagnosis of Infection

Specific antibodies to PT salmonellae can be found in infected poultry with high sensitivity using diverse agglutination and EIA methods. Detectable serum antibody titers are often present long after clearance of all salmonellae from tissues and cessation of fecal shedding (203). Because antibody tests only document prior *Salmonella* exposure, and do not provide unequivocal evidence of ongoing infection in flocks, positive serologic results must be followed by bacteriologic culturing for confirmation. Serology also yields positive results much later after infection than bacteriologic culturing (247). Other serologic testing limitations include subclinical infections which lead to fecal shedding without eliciting detectable antibody responses (336), immunologic unresponsiveness in very young birds (445), cross reactions between antibodies to similar PT serotypes (45, 185), and vaccine-induced antibody responses which confound serologic differentiation of vaccinated and infected birds (311).

Agglutination tests have detected both natural and experimental infections of chickens with PT salmonellae (165, 234).

Agglutination assays are performed on both whole blood and serum in plate, tube, and microwell formats. All of these tests rely on the ability of specific antibodies to visibly agglutinate killed whole *Salmonella* cells, which are stained (except in tube tests) to improve visualization of agglutination reactions.

Salmonella infections in poultry can be detected using diverse EIA approaches. An international survey reported a high degree of correspondence in the performance of a wide assortment of EIA formats and antigens for detecting *S*. Enteritidis infections (29). EIA using LPS, flagella, or outer membrane protein antigens has identified chickens infected naturally or experimentally with *S*. Typhimurium or *S*. Enteritidis (28, 44, 253). Screening for serum antibodies using a flagella-based EIA was applied successfully for controlling *S*. Enteritidis in Dutch breeder flocks (433). By using very precisely defined antigens, EIA often achieves a high degree of specificity and thus produces fewer false-positive cross reactions between serotypes than agglutination reactions (203, 253). Assays employing fimbrial antigens have shown especially high specificity for identifying *S*. Enteritidis infections in chickens (360).

Antibodies deposited in egg yolks by infected hens offer uniquely convenient samples for *Salmonella* testing. Both EIA and agglutination tests have found antibodies to salmonellae in eggs from naturally and experimentally infected chickens, correlating directly with the incidence of fecal shedding and organ invasion (166, 184, 410, 426). Antibodies were detected by flagella-based EIA in egg yolks from hens inoculated orally with as few as 10^3 *S*. Enteritidis cells (187). Egg yolk antibody detection predicted *S*. Enteritidis contamination of eggs slightly more accurately than culturing voided feces in experimentally infected hens (186). Egg yolk antibody testing and culturing environmental swabs have been estimated to have very similar abilities to prevent the release of egg contaminated with *S*. Enteritidis (258).

Intervention Strategies

Risk Reduction

The diversity of sources for *Salmonella* introduction into flocks or houses complicates the identification of critical control points for preventing infection of poultry. Nevertheless, epidemiological calculations confirm the potent positive influence that risk reduction at the production level can have on human illness due to *S*. Enteritidis (127). Effective prevention and control programs must involve coordinated and sustained implementation of risk reduction practices throughout the production continuum. Financial analysis has indicated that the costs of intensive *Salmonella* control efforts in poultry are justified by even greater savings in public health costs (248).

Eggs and chicks (or poults) should be obtained only from demonstrably *Salmonella*-free breeding flocks. Hatching eggs should be properly disinfected and hatched under stringent sanitation standards. Poultry houses should be thoroughly cleaned and disinfected by recommended procedures between flocks. Rodent and insect control measures should be incorporated into house design and management and verified by periodic testing. Rigidly enforced biosecurity practices should be implemented to restrict movement of personnel and equipment onto poultry housing premises and between houses. Only pelleted feed or feed containing no animal protein should be used. Water provided to poultry should come only from sources treated to ensure purity. Treatments such as gastrointestinal colonization control or vaccination can be applied to reduce the susceptibility of birds to infection. Finally, the *Salmonella* status of poultry and their environment should be monitored by periodic testing to verify the effectiveness of risk reduction practices.

Multifaceted risk reduction programs in breeding and laying flocks have been internationally associated with significant reductions in both the prevalence of *S*. Enteritidis infection in poultry and egg-association human illness (266, 320, 352), and were incorporated into a recently implemented *S*. Enteritidis control plan for laying flocks in the United States (422).

Gastrointestinal Colonization Control

Newly hatched chicks and poults are highly susceptible to *Salmonella* infection, but quickly become more resistant as they acquire protective intestinal microflora from the environment. The ability of the normal bacterial flora of the gastrointestinal tract to inhibit colonization by pathogens is the basis for a diverse group of treatments often referred to collectively as competitive exclusion (CE). Defined or undefined CE cultures are administered to poultry to diminish *Salmonella* colonization. Various nonmicrobial manipulations of gastrointestinal biochemistry also have been explored as colonization control options. CE treatment reduces the incidence and magnitude of *Salmonella* colonization in poultry, but rarely prevents it altogether. Accordingly, CE treatment can make a valuable contribution toward controlling salmonellae, but it cannot entirely supplant comprehensive risk reduction programs.

The efficacy of CE treatment has been demonstrated in both chickens and turkeys using intestinal or fecal material from mature birds or undefined anaerobic cultures derived from such material. CE cultures have diminished both intestinal colonization and subsequent invasion to internal tissues by various PT salmonellae (332). In commercial broiler flocks, CE treatment significantly reduced the incidence of salmonellae both in live birds and on carcasses (25). CE administration to egg-type pullets before transfer into a contaminated laying house reduced subsequent *Salmonella* isolation from fecal and environmental samples (106). Treatment with CE cultures has sometimes enhanced the clearance of concurrent or preexisting *Salmonella* infections (88, 213). Only live CE preparations exert protective effects (215), but their efficacy can be maintained by continuous flow culturing (221). CE cultures are effective when administered via oral gavage, spraying, or addition to drinking water (89, 454). The protective efficacy of CE can be overcome by severe *Salmonella* challenges (397). Disruption of the normal intestinal microflora by feed or water deprivation, or by antibiotic administration, can interfere with the activities of

CE cultures (17, 446). Because CE cultures are most effective when administered before exposure to pathogens, infection during hatching can compromise the value of subsequent treatment (19). Individual CE preparations may not be equally protective in different avian species (306).

Efforts to identify the microflora constituents responsible for CE effects have indicated that cultures of diverse bacterial genera, including *Lactobacillus* (424), *Bifidobacterium* (152), *Bacillus* (435), *Escherichia* (456), *Pediococcus* (9), and *Streptococcus* (461), and the yeast *Saccharomyces* (286), exhibit protective (probiotic) activity against salmonellae in chickens. Defined mixtures of microorganisms potentially perform with greater consistency and more assurance of safety than undefined cultures of unknown organisms. The protective efficacy of defined CE preparations is often higher for mixtures of greater diversity or complexity (214, 367).

Protection by CE cultures is attributed both to direct steric interference with *Salmonella* attachment to the intestinal epithelium and inhibition of intestinal *Salmonella* growth via lowered pH and increased levels of undissociated volatile fatty acids (384). Some probiotic cultures also influence gene expression by salmonellae (216). Diverse "prebiotic" additives either directly inhibit pathogen colonization or support the growth of protective microflora. Feed or water supplementation with various complex carbohydrates (including lactose, glucose, mannose, and fructooligosaccharide) can reduce crop or cecal colonization of chickens by salmonellae (70). Supplementing feed with formic, propionic, butyric, caprylic, or caproic acids is also associated with lower frequencies of *Salmonella* isolation (351, 431). Adding chlorate, lactic acid, or sucrose to the drinking water of broilers has reduced isolation of salmonellae from crops after preslaughter feed withdrawal (56, 218). Incorporating *Salmonella*-specific bacteriophages or antibodies into drinking water has decreased intestinal colonization of chickens (49, 358).

Vaccination

Vaccination with either killed or live preparations can reduce the susceptibility of poultry to PT infection. Decreased incidences of human *S*. Enteritidis infections followed the widespread vaccination of egg-laying hens in Belgium and the United Kingdom (83, 84). Vaccination of laying flocks has reduced the frequency of egg contamination with *S*. Enteritidis even in the presence of ongoing poultry house environmental contamination (108). Both killed and live vaccines have been associated with significant protection against salmonellae (24), although neither type of vaccine has consistently provided an impenetrable barrier against infection, especially when high *Salmonella* challenge doses are involved (188, 372). Feed or water deprivation and environmental stresses such as heat can compromise vaccine efficacy (327). Vaccines do not consistently confer protection against heterologous serotypes (459). Vaccination did not provide any clear advantage in a comparison of 2 Irish programs for controlling egg-borne transmission of *S*. Enteritidis (322). Like competitive exclusion, vaccination is most effectively used as a component within comprehensive risk reduction programs.

Interest in killed vaccines (bacterins) for poultry has been renewed by ongoing concerns about *S*. Enteritidis. Subcutaneous or intramuscular vaccination of laying hens with adjuvanted bacterins induces long-lasting antibody responses (417) and has significantly reduced *S*. Enteritidis isolation from feces, internal tissues, and eggs following subsequent oral challenge (81, 188). Bacterin administration to laying hens moderated the effects of induced molting by feed restriction on fecal shedding of *S*. Enteritidis (328). Killed vaccines were associated with decreased incidences of *S*. Enteritidis infection in Dutch broiler breeder flocks (150) and *S*. Enteritidis contamination in eggs from Japanese laying flocks (415). Consistently negative *S*. Enteritidis testing results were obtained from a vaccinated laying flock transferred into previously contaminated facilities (105). Progeny of breeding flocks vaccinated with *Salmonella* bacterins may display some degree of maternally acquired protective immunity to infection (40, 243). Multivalent bacterins, prepared from a mixture of serotypes or strains, can provide an expanded spectrum of protection (120). Immunization of chickens with subunit vaccines composed of outer-membrane, fimbrial, or flagellar proteins has conferred significant protection against *S*. Enteritidis colonization (119, 252, 416).

Live attenuated vaccines must persist in tissues long enough to induce protective immune responses, but should be avirulent and cleared from vaccinated birds within a few weeks of administration. A wide variety of *Salmonella* vaccine strains have been evaluated for protective efficacy in poultry, often incorporating multiple deletion mutations to ensure irreversible attenuation. Mutant strains unable to synthesize or utilize essential metabolites, produce flagella, express virulence-related proteins, or multiply at poultry body temperatures have all reduced *Salmonella* colonization after administration to chicks or poults by spraying or addition to drinking water (47, 68, 307). Nonflagellated mutants may elicit protective immunity without preventing serologic detection of PT-infected flocks (2, 151). Live vaccine strains can induce both humoral and cellular immune responses (63). Attenuated vaccines have been useful for protecting hens against increased susceptibility to *S*. Enteritidis infection following induced molting by feed deprivation (226) and for enhancing protection by maternal antibodies in chicks from bacterin-vaccinated hens (23)

Evidence for cross protection by live vaccine strains against other *Salmonella* serotypes has been inconsistent. For example, an attenuated *S*. Typhimurium vaccine reduced intestinal colonization by *S*. Enteritidis, but was less effective in preventing organ invasion (345). Even antigenically unrelated *Salmonella* strains sometimes generate a degree of protection against subsequent *S*. Enteritidis challenge, perhaps via a combination of immunological and competitive exclusion mechanisms (224). Safety concerns have sometimes been raised about live *Salmonella* vaccines based on evidence that some vaccine strains may be genetically unstable (26) or can be detected for longer than anticipated in vaccinated hens if sufficiently sensitive culturing methods are used (404).

Live *Salmonella* vaccines have sometimes been associated with more complete protection of poultry, perhaps due to more persistent presentation of relevant antigens to the host immune system or because these antigens are adversely affected during the preparation of killed vaccines (16). Bacterins also may fail to fully elicit the cell-mediated portion of the protective immune response (321). However, killed vaccines frequently stimulate protection of greater duration (22). Protection against infection following the combined application of both live and killed vaccines often has exceeded the performance of either product administered separately (133, 153).

Prophylactic administration of lymphokines from immunized chickens can protect chicks against organ invasion following subsequent *S*. Enteritidis challenge (301). This effect is associated with increased phagocytosis and killing of *Salmonella* by avian heterophils (124). Various routes of administering immune lymphokines to poultry have provided some protection against *S*. Enteritidis challenge (259, 302), but this effect may be of relatively transient duration (189). Cross protection against other *Salmonella* serotypes also has been observed (462). Feeding cationic peptides to chicks has similarly increased protection against *Salmonella* colonization by stimulating functional activities of heterophils and monocytes (260).

Treatment

The efficacy and wisdom of medicating with antibiotics to prevent or treat PT infections in poultry have been debated for many years. Antibiotics have a long history of widespread use in poultry at both therapeutic and sub-therapeutic (growth-promoting) levels (391). Their usefulness for these purposes has been extensively documented in both experimental and commercial settings. A variety of antibiotics have demonstrated either prophylactic or therapeutic activity against salmonellae in poultry (69, 191), in some instances leading to decreased fecal shedding when used as feed additives (48, 96). Antibiotics were employed effectively for *S*. Enteritidis control in broiler and broiler breeder flocks in Northern Ireland (303). Treatment with a fluoroquinolone antibiotic, followed by provision of a competitive exclusion culture to restore protective normal microflora, reduced fecal shedding of *S*. Enteritidis in broiler breeders (368), egg-type pullets, (109) and molted laying hens (385). *In ovo* administration of gentamicin controlled *Salmonella* infection without affecting the viability of competitive exclusion cultures given to the hatched chicks (21).

However, current control practices for poultry salmonellosis in many nations no longer regularly rely on antibiotics because of both inconsistent performance of these drugs in eliminating *Salmonella* colonization and concerns that indiscriminate veterinary and agricultural use could promote microbial resistance (209, 391). Limited efficacy of antibiotics for controlling *Salmonella* infections in poultry has been documented on numerous occasions (236, 337). In some instances, antibiotic administration has actually increased susceptibility to *Salmonella* infection, perhaps by suppressing the growth of other competitive or inhibitory microflora (13, 297). Discontinuing antimicrobial use for growth promotion in Denmark was followed by decreased *Salmonella* prevalence in broilers (144). Both therapeutic and subtherapeutic antibiotic administration can select for drug-resistant strains of salmonellae (110, 362), thereby imperiling the medicinal usefulness of those (and related) agents for animals and humans. Drug resistance determinants can accumulate over time in salmonellae present in poultry flocks (380). Very high incidences of antibiotic resistance have been reported among *Salmonella* isolates from both poultry production facilities and poultry products (244, 346), with a large proportion of these strains often displaying resistance to multiple antimicrobials (278).

Arizonosis

H.L. Shivaprasad

Introduction

Arizonosis is a septicemic disease of young turkey poults caused by the bacterium *Salmonella enterica* subsp. *arizonae* (*S. arizonae*). Other species of birds such as chickens, ducks and wild birds, canaries, and parrots are also susceptible. *S. arizonae* was formerly one of the most frequently identified *Salmonella* serotypes in turkeys in the United States (30) and is related to significant morbidity and mortality. Sporadic and serious outbreaks still occur throughout the United States (11, 31, 81, 96, 97). The disease is clinically indistinguishable from salmonellosis caused by other serotypes of salmonellae such as *S*. Typhimurium and *S*. Heidelberg.

S. arizonae represents an antigenically diverse group of bacteria (more than 300 serotypes have been identified), which can be distinguished biochemically from other species in the genus *Salmonella*. Historically, the organisms now classified as *S. enterica arizonae* were included in the genus Arizona, and have commonly been referred to as the arizona group, arizonas, and paracolons. In 1982, the International Subcommittee on Taxonomy of Enterobacteriaceae decided that the arizona group should be classed as 2 subspecies of the genus *Salmonella* based on the relatedness of their DNA with that of *Salmonella* spp. Earlier reviews on the arizona group and arizonosis have been published (3, 4, 46).

Definition and Synonyms

Arizona infection or avian arizonosis (AA) is an acute or chronic egg-transmitted disease of primarily young turkey poults characterized by septicemia and neurological signs and blindness and increased mortality. In the past disease caused by *Salmonella enterica* arizonae was called paracolon infection, and members of the genus *Arizona* once were referred as paracolons, *Arizona arizonae*, and *Arizona hinshawii*.

Economic Significance

Avian arizonosis has considerable economic significance to the turkey industry of North America and certain parts of the world through increased morbidity and mortality in young turkey poults and decreased egg production in turkey breeders and decreased hatchability (18, 19, 39, 51, 63, 94, 96, 100). The cost incurred in testing carrier birds and eggs, supplies such as swabs, culling of birds, dipping eggs, and cleaning and disinfection, use of antibiotics for treatment of breeders and poults, and labor adds substantially to the cost of eradicating the disease.

Public Health Significance

Infection in people due to *S. enterica arizonea* associated with birds, and turkeys in particular, has not been reported. However, arizonosis associated with reptiles has been reported numerous times in humans (for example, 8, 32, 60, 89, 103,).

History

Caldwell and Ryerson were the first to isolate the *Salmonella*-like organisms from diseased reptiles from the semiarid regions surrounding Tucson, Arizona (9). It is probable, however, that the bacteria were isolated earlier from poultry. Lewis and Hitchner (68) had previously reported recovery of slow lactose-fermenting bacteria from a disease of chicks resembling salmonellosis. This infection was probably due to a member of the arizona group, and may represent the first report of AA. In Great Britain, the first report of avian arizonosis in poultry was in 1968 (57).

Etiology

Classification

Since 1939, many attempts have been made to find a generally acceptable taxonomic position for this group of bacteria; several classification systems have been used and a wide variety of names and designations has been applied to the organisms.

Edwards and associates (cited in 72), established the biochemical and antigenic similarity of the arizonae and salmonellae. Enough differences were found between the groups, however, to justify classification of the arizonae in a separate genus. Kauffmann and Edwards (59) first employed the name *Arizona arizonae*, which was also used by Ewing (23) for members of the genus *Arizona* (genus II of the tribe *Salmonella*e). A new type species name *Arizona hinshawii* had been proposed by Ewing (25) to pay honor to the pioneering work of W.R. Hinshaw on AA in turkeys, reptiles, and other animals. Kauffmann (58) subsequently included the arizonae in his subgenus III of the genus *Salmonella*, designating them *S. enterica arizonae* and listing their antigenic formulas only in the simplified Kauffmann-White scheme. According to the recent Kauffmann-White scheme, the Arizona group, formerly known as the genus *Arizona*, contains 2 phylogenetically distinct groups, *Salmonella enterica* subsp. *arizonae* (IIIa) and *Salmonella enterica* subsp. *diarizonae* (IIIb) (6).

Ewing and his colleagues (24, 27, 28, 29, 72) have further clarified the definition by which the biochemical and antigenic characteristics of members of the genus Arizona may be readily differentiated from other Enterobacteriaceae. The terminology used by the Centers for Disease Control and Prevention will be followed in this subchapter, e.g., *S. enterica arizonae*, 18:Z4, Z32 (see Antigenic Structure).

Morphology and Staining

The *S. enterica arizonae* resemble other enteric organisms. They are Gram-negative nonsporogenic bacilli that are motile by peritrichous flagella.

Growth Requirements

Members can be readily cultivated on ordinary liquid and solid laboratory media, revealing abundant growth similar to that of the salmonellae. Most cultures grow very well on *Salmonella*-Shigella and brilliant green (BG) agars, as well as other solid media recommended for isolation of salmonellae. On initial isolation, colonies usually resemble those of salmonellae but may develop an indicator change typical of lactose fermenters after incubation for several days or weeks. Rapid lactose-fermenting strains, rare in poultry, cannot be distinguished from normal coliforms, which are usually inhibited by these media. Routine use of bismuth sulfite plating medium was recommended (21, 46, 72) to aid in preliminary recognition of lactose-fermenting Arizona strains before they are possibly discarded as coliforms.

Colony Morphology

Colonies of *S. enterica arizonae* appear similar to other salmonellae and do not have any special characteristics that distinguish them. On blood agar they appear as dull white with round, convex, butyrous colonies. On XLT4 media they appear as round, convex to flat, butyrous colonies with a black center or completely black, and on BG agar round, convex to flat, butyrous colonies pink to pinkish red in color.

Biochemical Properties

Cultures possessing the biochemical characteristics shown in Table 16.2 are almost invariably classifiable serologically as members of *S. enterica arizonae* (14, 26, 28).

Table 16.2. Typical biochemical characteristics of *S. enterica arizonae*.

Dextrose	Fermented with gas
Lactose	Fermented, as a rule, slowly or promptly
Sucrose	Not fermented, as a rule
Mannitol	Fermented with gas
Maltose	Fermented with gas
Dulcitol	Not fermented
Inositol	Not fermented
Indole	Not produced, as a rule
Methyl red	Positive
Voges-Proskauer	No reaction
Hydrogen sulfide	Positive
Urea	Not hydrolyzed
Gelatin	Liquified slowly
Potassium cyanide	Negative, as a rule
Nitrates	Reduced
Motility	Positive
Betagalactosidase	Positive
Decarboxylases	
Lysine	Positive
Arginine	Positive, usually delayed
Ornithine	Positive
Malonate	Positive
Phenylalanine deaminase	Negative

Most isolates from poultry, unlike other salmonellae, ferment lactose, usually within 7–10 days' incubation. Failure of cultures to ferment dulcitol and inositol or to use D-tartrate, their slow liquefaction of gelatin, and their positive reactions in sodium malonate and β-galactosidase are most useful in distinguishing them from other members of the *Salmonella* group.

Citrobacter

For purposes of classification and identification, the *S. enterica arizonae* must be differentiated not only from other salmonellae, but also from the antigenically related genus *Citrobacter* of the tribe *Salmonella*e. Members of this genus are not known to be pathogenic for poultry, but from a diagnostic standpoint they may be confused with *Salmonella* cultures on initial isolation from fecal specimens. The former Bethesda-Ballerup paracolons (*P. intermedium*) are included in the genus *Citrobacter* along with cultures previously classified as *Escherichia freundii*.

Resistance to Chemical and Physical Agents

Arizonae are readily destroyed by heat and common disinfectants, but have survived in contaminated water for 5 months, in contaminated feed for 17 months, in soil on turkey ranges for 6–7 months, and for 5–25 or more weeks on materials and utensils in poultry houses (2, 35, 62, 63, 86, 91). Resistance properties are very similar to those of salmonellae.

Antigenic Structure

S. enterica arizonae strains are related serologically to the salmonellae and other Enterobacteriaceae, and procedures for study and identification of their antigenic structure are identical to those for paratyphoid organisms. Thirty-four somatic (O) and 43 flagellar (H) antigens have been demonstrated.

The serotype nomenclature system used in designating members of the genus *Salmonella* has been applied to *S. enterica arizonae*. In writing antigenic formulas, commas are used to separate O antigen factors, a colon to distinguish the O and H antigens, commas to separate H antigenic factors within a single phase, and a hyphen or dash to separate the first phase from the second and the second from the third, etc. Thus, the monophasic type species would be designated *S. enterica arizonae* 18:Z4, Z32.

Evolution of the nomenclature for salmonellae has resulted in some confusion over the identification of strains. Two serotypes that were previously designated as 7:1,7,8 and 7:1,2,6 are now recognized as 18:Z4,Z32 and 18:Z4,Z23, respectively. Confusion also exists because even though there are only 34 O and 43 H antigens, sometimes an isolate is designated as 65:Z52,Z53. The latter is the designation that conforms to the system recognized by the Centers for Disease Control and Prevention and the World Health Organization.

Pathogenesis and Epidemiology

Incidence and Distribution

Avian arizonosis occurs worldwide wherever poultry is raised. At one time, *S. enterica arizonae* 18:Z4, Z32 was endemic in turkey flocks of North America. Very high rates of isolation were reported in California in 1968 and 1969, but decreased considerably by 1972 (73). However, a resurgence of AA in the form of serious outbreaks occurred in California between 1999 and 2006 (11, 96). The most common serotype isolated was *S. enterica arizonae* 18:Z4, Z23 followed by 18:Z4, Z32 (11). *S. enterica arizonae* has been eliminated from the turkey industry in Great Britain (5, 57, 101).

Natural and Experimental Hosts

S. enterica arizonae recognize no host barriers and are widely distributed in nature in a variety of avian, mammalian, and reptilian species (10, 17, 18, 19, 72, 82, 95, 110, 111).

Among poultry, AA is most frequently encountered in turkeys. Greenfield (43) noted that AA in chickens does not appear to be economically important, although chickens are affected by AA both naturally and experimentally (17, 68, 99). Dougherty (12) isolated *S. enterica arizonae* from duck livers, revealing lesions very similar to those produced by paratyphoid infections.

For a review of AA as a human disease causing gastroenteritis and frequently more serious enteric fever and focal infections, see (49, 56, 60, 72, 103, 104, 108).

Transmission

The transmission cycle of AA in poultry is identical to that established for motile salmonellae (see Paratyphoid Infections). Infected adult birds are frequently intestinal carriers and spreaders of *S. enterica arizonae* for long periods (16). Wild birds (75), rats and mice (39), and reptiles (50, 52) have been cited as common sources of the organisms for poultry flocks but reptiles are probably the primary source of *S. enterica arizonae*.

Intestinal infections have been reported (51, 93), and Adler and Rosenwald (1) reported that AA in adult turkeys is confined primarily to the intestinal tract.

Transmission of AA through eggs has been reported by many workers (7, 16, 17, 18, 19, 41, 51), and recovery of *S. enterica arizonae* from ovaries and oviducts of adult turkeys (33, 51, 94, 96) suggests that transovarian transmission can occur. This can result in eggs contaminated with the bacteria and as a consequence there is decreased hatchability and increased mortality during the first week in the hatched poults. Direct contamination of the ovary by systemic infection can follow ingestion of the organisms (64, 94, 98). Perek et al. (84) isolated *S. enterica arizonae* from semen of cockerels.

S. enterica arizonae from fecal contamination have a penetration pattern through the shell and shell membranes of chicken eggs very similar to that of *S.* Typhimurium when incubated at 37.2°C, resulting in frequent presence of the organisms in chicken and turkey eggs (16, 41, 94, 107). Fecal contamination may spread the infection from other animal species to poultry. Goetz (39) found an AA infection rate of 90% in rats and 50% in mice on the premises of a turkey farm where the infection was a problem in poults. Various types of wild birds, reptiles, and many common animal species also can infect poultry flocks.

AA is transmitted in the incubator and brooder by direct contact and through contaminated feed and water (22, 63).

Clinical Signs

Although signs of AA in poultry are not specific, infected poults and chicks may appear listless, depressed, and weak, and develop anorexia, diarrhea, leg paralysis, and twisted necks (Figure 16.13). There may be blindness due to corneal opacity and/or caseous material in the anterior chamber and vitreous of the eye (Figure 16.14) (10, 63, 93, 96, 99). Infected birds tend to sit on their hocks and huddle together. Nervous signs, including paralysis, torticollis, opisthotonus, and convulsions, may follow brain and internal ear infection in poults (Figure 16.13) (55, 82, 96). Sato and Adler (93) noted that clinical signs of AA are rarely seen in adult turkeys and they seldom die from this infection.

Mortality due to AA in poults and chicks is variable. Lewis and Hitchner (68) recorded mortality of 32%–50% from the infection in chicks. In 1 study mortalities of 70% by 7 days and 60% by 23 days after hatching were reported (96). Mortality can be exacerbated by secondary or concurrent infections such as colibacillosis, poult enteritis, aspergillosis, coccidiosis, paratyphoid infections, crop mycosis, etc. (96).

Figure 16.13. Two-week-old turkey poults exhibiting depression and neurological signs due to arizonosis.

Others have observed mortality generally between 10% and 50% in chicks or poults, which are especially susceptible within the 1st few days after hatching, and with mortality continuing for up to 3–5 weeks (1, 17, 48, 63, 85, 96, 100). Geissler and Youssef (34) inoculated or dipped chicken eggs with *S. enterica arizonae*; 100% and 40%–79% of embryos in the respective groups died during the incubation period. Hatchability for the latter group varied from 0% to 21%–70%, with evidence that the organisms penetrated to the inner structures of the eggs.

Worcester (112) noted that *S. enterica arizonae* can penetrate the wall of the intestinal tract and stay there indefinitely.

Pathology

Gross Lesions

Gross and microscopic lesions due to AA in poults have been well described (11, 40, 90, 96, 99, 105). Lesions in poults, either naturally or experimentally infected with *S. enterica arizonae*, are comparable to lesions induced by paratyphoid organisms. In natural outbreaks there are retained yolk sacs, yolk sacs with watery or caseous yellow contents (Figure 16.15), prominent yolk stalks (navel buttons), cores in the ceca, and exudate on the meninges of the brain. Livers may be enlarged and mottled with white foci; there may be caseous exudate in the abdominal cavity, and discolored hearts. Pericardium and air sacs can be cloudy and there may be swollen joints (96). One of the most frequently noted pathologic changes in somewhat protracted cases is the presence of pale white or yellow exudate in the anterior chamber and vitreous of one or both eyeballs in poults (Figure 16.14). However, lesions in the eye and brain develop in slightly later stages of the disease.

Lesions typical of generalized septicemia, including peritonitis, retained yolk sacs, enlarged, yellowish mottled livers, and discolored hearts, also were described in experimentally infected chicks by Lewis and Hitchner (68). Goetz and Quortrup (40) and Shivaprasad et al. (96) have described caseous cores (Figure 16.16) in the ceca similar to those seen in pullorum disease. Hinshaw and McNeil (51) observed that

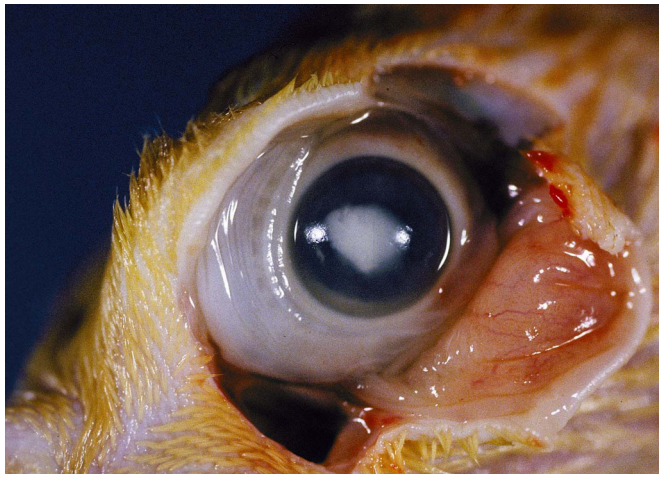

Figure 16.14. *Salmonella enterica* arizonae infection. Eye of a 3-week-old turkey poult with severe ophthalmitis.

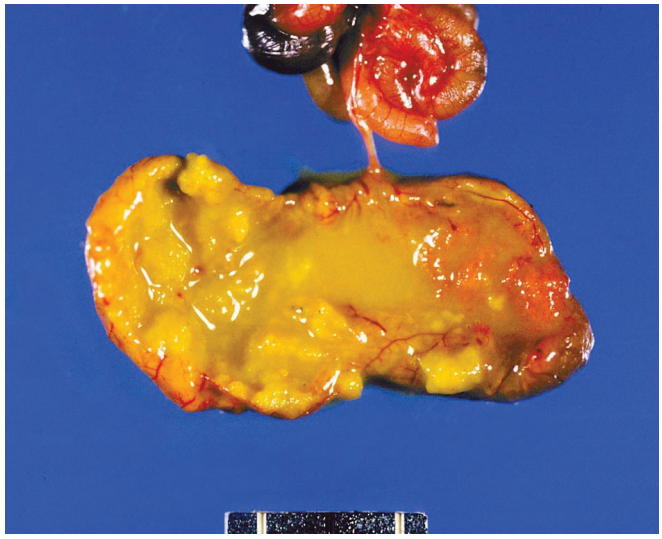

Figure 16.15. *Salmonella enterica* arizonae infection. Severe yolk sac infection in a 5-day-old poult.

Figure 16.16. *Salmonella enterica* arizonae infection. Ceca from a 5-day-old turkey poult with a core in the lumen.

S. enterica arizonae-infected adult turkeys had a small amount of caseous exudate in the abdominal cavity and cystic ovules.

Histopathology

Microscopically, there is moderate to severe fibrinosuppurative inflammation associated with Gram-negative bacteria in the yolk sac and yolk stalk. In the brain, there is severe meningitis with infiltration of heterophils mixed with fibrin and bacterial colonies (Figure 16.17). Similar exudate also can be seen in the ventricles of the brain, and there is malacia, inflammation, and vascular thrombosis in the cerebral cortex. Interestingly, changes in other organs are minimal, such as necrosis of hepatocytes and infiltration with mononuclear inflammatory cells, increased numbers of mononuclear phagoctyic system cells in the spleen, and vascular congestion in various organs. Occasionally inflammation of the pericardium, air sacs, synovium, and intestine, especially the ceca due to *S. arizona enterica*, can be seen (96).

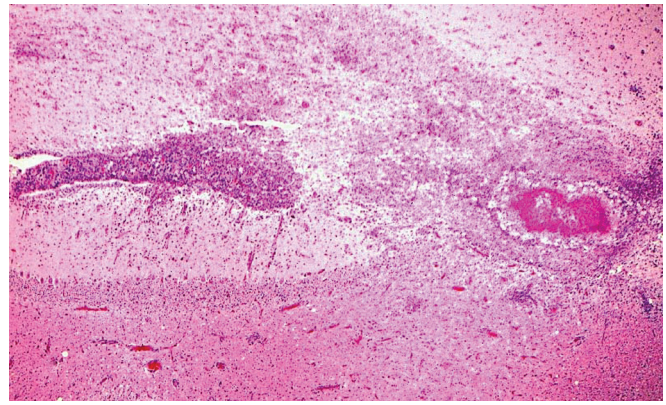

Figure 16.17. Histopathology of brain with meningitis and encephalitis due to *Salmonella enterica* arizonae infection. ×300.

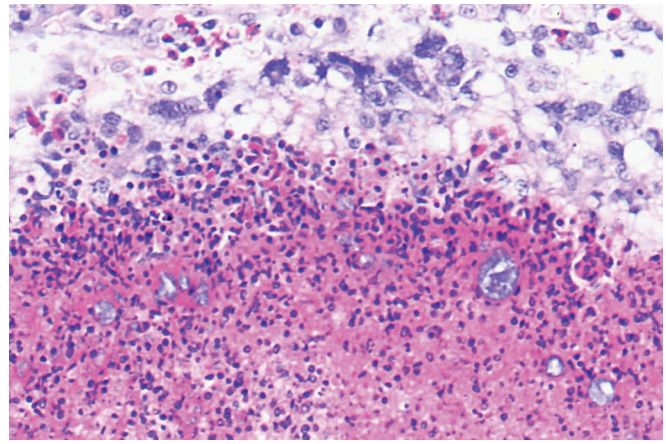

Figure 16.18. Histopathology of internal ear with severe otitis and bacteria of *Salmonella enterica* arizonae infection. ×500.

Otitis interna with bacteria (Figure 16.18) and neuritis and ganglionitis of the vestibulocochlear nerve (VIIIth cranial nerve), most likely due to spread of *S. enterica arizonae* from the brain meninges in 9- to 21-day-old turkey poults, have been described (97).

Pathogenesis of the Infectious Process

There is little or no information available regarding the pathogenesis of *S. enterica arizonae* but it can be assumed that it causes disease similar to other salmonellae. As a Gram-negative bacteria it can elaborate endotoxins, causing inflammation in various organs, most notably in the yolk sac, ceca, brain, eye, etc. *S. enterica arizonae* can invade the bloodstream, especially of young fowl, resulting in high mortality (18).

Virulence Factors

The virulence factors of *S. enterica arizonae* are poorly understood. However, a recent study has shown that the spv virulence locus is present in *S. enterica arizonae* and that it was found to be located on the chromosome (69). Sequence analysis of the spv locus revealed that it contains homologues of spv^{RABC} but lacks spv^{D}. The Spv^{B} protein is an ADP ribosyltransferase that modifies actin and destabilizes the cytoskeleton of infected cells. This may explain the ability of *S. enterica arizonae* to cause disseminated infection in various species of animals, including humans (69).

Diagnosis

High mortality, neurologic signs, and blindness coupled with gross lesions in turkey poults can be used for a presumptive diagnosis of AA. However, these clinical signs, as well as lesions, can be seen in other *Salmonella* infections, including those of paratyphoid organisms. The organisms can usually be recovered from liver, spleen, heart blood, unabsorbed yolk sac, intestine, lung, kidney, brain, and eye.

Isolation and Identification of Causative Agent

Cultural procedures identical to those outlined and discussed under Paratyphoid Infections are employed for isolation and identification of arizonae. Standard methods for isolation and biochemical or serologic identification of *S. enterica arizonae* from poultry tissues, eggs and embryos, and environmental samples have been described (21, 26, 101, 109). Bismuth sulfite medium can be used for plating enrichment broths in addition to BG sulfa if desired. The 2 serotypes of *S. enterica arizonae* common in turkeys are slow lactose fermenters; therefore, they are identical to paratyphoids on initial isolation on BG agar.

Selenite cysteine broth may be used in enrichment of fecal and organic tissue cultures (63, 93, 94). Selenite broth incubated at 43ºC yielded fewer isolations of arizonae than did tetrathionate or selenite F broth at 35ºC (44).

Forty-nine strains of *S. enterica arizonae* isolated from turkeys all had similar cultural and biochemical characteristics, varying only in use of citrate and melibiose (102). Most *S. enterica arizonae* strains were sensitive only to chloramphenicol and nalidixic acid among the antibiotics tested. Kumar et al. (65) found that selenite BG with sulfapyridine (SBGS) and tetrathionate BG broths gave comparable results with *S. arizonae*, but at 48 hours there was considerable reduction in recovery of arizonae from SBGS in tubes initially inoculated with high numbers of organisms. Littell (70) described a differential plating medium for isolation of *S. arizonae* that produces a uniform reaction of both lactose-negative and lactose-positive *S. arizonae*, and differentiates them from other salmonellae.

Snoeyenbos and Smyser (100) believed that litter culturing may aid epidemiologic studies and identify infected turkey flocks as part of a control program. Greenfield and Bigland (45) noted that culture of turkey litter might be a useful means of detecting insidious AA.

Culture of turkey shell membranes and shells is recommended over yolk material for rapid detection of arizonae-contaminated eggs (13, 47, 87).

Serology

Serologic analysis of cultures is essential in epizootiologic studies of AA of fowl; cultures can be submitted to the *Salmonella* Serotyping Laboratory, National Veterinary Services Laboratories, P.O. Box 844, Ames, IA 50010, for biochemical characterization and antigenic typing.

Edwards and Galton (15) noted that it is essential to use a polyvalent *S. enterica arizonae* antiserum in preliminary examination of cultures because arizona types may not be agglutinated by *Salmonella* polyvalent antiserum. Kowalski and Stephens (63) employed formalinized broth cultures and *S. enterica arizonae* polymonophasic antiserum in serologic identification of arizonae cultures. Snoeyenbos and Smyser (100) used *S. enterica arizonae* flagellar polyvalent, *Salmonella* flagellar Z32, and *Salmonella* somatic 18 antisera in screening cultures suspected to be *S. enterica arizonae*.

Differential Diagnosis

The clinical signs as well as lesions of AA can be seen in other *Salmonella*e infections, including those of paratyphoid organisms. Neurologic signs also can be caused by Newcastle disease, aspergillosis, and vitamin E deficiency (encephalomalacia). Blindness in turkey poults can be due to aspergillosis or other causes such as cataracts. Therefore, AA must be confirmed by isolation and identification of the causative bacteria.

Intervention Strategies

Management Procedures

Because *S. enterica arizonae* is egg transmitted, primary breeding stock must be developed free of *S. enterica arizonae*. The control program at the multiplier breeder level depends on

having available *S. enterica arizonae*-free stock. Management procedures outlined under Paratyphoid Infections are applicable for the control and reduction of AA. The program outlined by Ghazikhanian et al. (38) for the primary breeder level is applicable to the multiplier level except for the treatment of hatching eggs with antibiotics. Total confinement, with bird-proof and rodent-proof buildings that can be cleaned and disinfected, quality feed and feed ingredients, and microbiologic monitoring at the hatchery and breeder farm levels are essential.

Ghazikhanian et al. (38) reviewed the program of a primary breeder to reduce and eliminate *S. enterica arizonae* from a basic breeding operation. A combination antibiotic hatching-egg treatment (dipped and injected) was successful in producing *S. arizonae*-free pedigree stock (37, 74). In addition to the egg treatment program, an autogenous oil-emulsion, *S. enterica arizonae* bacterin, was used on infected flocks to reduce transmission. Because of contamination of ranges, a new capital building program was initiated (total confinement, paved floors, bird proof). A cleaning and disinfecting program was initiated after each depopulation and the facilities were monitored to determine the effectiveness of the program. Finally, special emphasis was placed on frequent egg-collection practices. Only pelleted feed containing no animal or poultry by-products was used. The program has been highly successful.

Serologic Testing

Serologic tests have not been entirely effective in detecting or controlling AA in turkeys (1, 86, 112).

Methods for preparing and using *S. enterica arizonae* antigens for serologic testing of chickens and turkeys have been outlined (4).

Timms (101) found that the most reliable and satisfactory methods for detecting *S. enterica arizonae* at various stages of infection in adult turkeys were the rapid serum plate (SP) test and the somatic tube agglutination (TA) test. The rapid whole-blood (WB) test was found to be a useful tool in testing large numbers of birds in the field, but it required confirmation by the TA test. Uses of the agar gel diffusion, indirect hemagglutination, immunofluorescence, and H agglutination tests in providing supporting evidence of infection were discussed. Lamont and Timms (67) reported use of O and H TA tests, rapid WB test, and agar gel precipitin tests for detection of AA in turkeys. They also found the rapid WB test particularly useful for flock screening.

Sato and Adler (93, 94) used a formalin-treated broth culture of actively motile arizona strains in preparing H antigen, and ethanol-treated cell suspension from beef heart infusion agar for O antigen. They found that naturally infected turkeys had positive O agglutination reactions at some time during the period they were observed; however, some of the same birds were negative when tested with H antigen. The H agglutinins disappeared earlier than O agglutinins. Not all infected birds revealed positive O agglutination tests at time of necropsy. There was little correlation between serologic results and persistence of infection.

Kumar et al. (66) developed a tetrazolium-stained micro-agglutination (MA) test antigen for detection of *S. arizonae* infections in turkeys. The MA test was demonstrated to be far more sensitive and superior to the TA and SP tests in detecting turkeys infected with *S. enterica arizonae*. Attempts to detect infection with the microantiglobulin test were unsuccessful.

Adult carriers may lack detectable antibodies 12–14 weeks after exposure, and infected turkey hens go through an antibody-negative phase at 16–20 weeks of age when most breeder flocks are tested (66, 101). When the ovary becomes activated following a lighting regime at 28–32 weeks of age, antibodies may be detectable. At that stage in the breeding cycle, it is too late to eliminate the flocks. Greenfield (42) noted that antibody titers do not persist for lengthy periods and may not be detectable in birds with subclinical infections.

An ELISA using outer-membrane proteins extracted from *S. enterica arizonae* as antigens was found by Nagaraja et al. to be sensitive and specific for the detection of *S. enterica arizonae* infection in breeder flocks of turkeys (77, 79). It was considered to be a valuable tool to determine which breeder flock is infected, allowing the hatchery program to be adjusted to reduce *S. enterica arizonae* dissemination at the time of hatching.

Vaccination

Several types of bacterins have been applied to turkey breeding stock. Holte (54) found that vaccinated breeders exposed to *S. arizonae* 18:Z4,Z32 had reduced shedding and were protected from systemic infection, thus preventing egg transmission of arizonae. Parental immunity was found to be transmitted to poults of vaccinated hens.

Sato and Adler (92) found varying degrees of protection afforded by arizona bacterins in both mice and turkeys. A formalin-treated whole culture in aluminum hydroxide gel provided the best protection, based on the number of organisms that migrated to the spleen following intramuscular challenge. In turkeys, a chrome-alum-treated arizona bacterin provided protection against both oral and intraperitoneal challenge (76). Fecal shedding for the first 3 weeks after challenge may be reduced by immunization with bacterins (1).

Gerlach et al. (36) found serum from nonimmunized turkey hens had both bacteriostatic and bactericidal effects on cultures of *S. arizonae* 18:Z4,Z32, but there was no inhibitory activity in the serum of birds vaccinated with arizona bacterin or in serum from naturally infected breeders. Inhibition of growth was not associated with presence of agglutinating antibodies; in fact, the opposite appeared to be true. In contrast, a bactericidal substance in the albumen of eggs from vaccinated turkeys was reported (1).

Ghazikhanian et al. (38) reported encouraging results using oil-emulsion bacterins; egg transmission following challenge was reduced from 12% in nonvaccinated controls to 2% in vaccinated turkeys. Vaccination against *S. arizonae* infection with a mineral oil-adjuvant vaccine was evaluated in turkey breeder flocks under laboratory and field situations by Nagaraja et al. (78, 80). The results were encouraging; it was possible to obtain *S. arizonae*-free progeny from vaccinated breeder flocks held in infected environments.

Lowry et al. (71) reported that immunoprophylactic administration of *S*. Enteritidis-immune lymphokines in turkey poults significantly reduced the horizontal transmission and organ invasion of *S. enterica arizonae*.

Treatment

Chemotherapy may reduce losses in acute outbreaks of AA and may be recommended to prevent spread of the disease in market flocks. Williams (106) reviewed various treatments for AA. In the United States, the only drugs approved by the Food and Drug Administration for treatment of AA are antibiotic injectables, gentamicin and spectinomycin. These injectables, given at the hatchery, have dramatically controlled the acute losses and morbidity that may occur during the first 3 weeks of age. Isolates of *S. enterica arizonae* resistant to gentamicin have been reported (20, 53). Addition of 30 ppm of zinc from zinc-methionine to the diet of young turkeys increased the reduction of intravenously administered *S. arizonae* from the spleen (61).

References

Pullorum Disease and Fowl Typhoid

1. Agrawal, R.K., Singh, B.R., Babu, N., and Chandra, M. 2005. Novel haemolysins of *Salmonella enterica* spp. Enterica serovar Gallinarum. *Indian J Exp Biol*. 43:626–630.
2. Altmeyer, R.M., J.K. McNern, J.C. Bossio, I. Rosenshine, B.B. Finlay, and J.E. Galan. 1993. Cloning and molecular characterization of a gene involved in salmonella adherence and invasion of cultured epithelial cells. *Mol Microbiol*. 7:89–98.
3. Anderson, G.W., J.B. Cooper, J.C. Jones, and C.L. Morgan. 1948. Sulfonamides in the control of pullorum disease. *Poult Sci*. 27: 172–175.
4. Anjanappa, M., P.C. Harbola, and J.C. Verma. 1994. Plasmid profile analysis of field strains of *Salmonella gallinarum*. *Indian Vet J*. 71:417–421.
5. Anonymous. 1930. Eastern states conference on laboratory workers in pullorum disease control. *J Am Vet Med Assoc*. 77: 259–263.
6. Anonymous. 1933. Report of the conference of official research workers in animal diseases of North America on standard methods of pullorum disease in barnyard fowl. *J Am Vet Med Assoc*. 82:487–491.
7. Anonymous. 1987. 1986 Summary of commercial poultry disease reports. *Avian Dis*. 31:926–978.
8. Anonymous. 1992. *Salmonella* Surveillance, Annual Summary. Centers for Disease Control and Prevention, Atlanta, GA.
9. Anonymous. 1994. *Salmonella* Serotyping Results. Iowa State University Press, Ames, IA.
10. Anonymous. 1997. The National Poultry Improvement Plan and Auxiliary Provisions. United States Department of Agriculture, Animal and Plant Health Inspection Service, Hyattsville, MD.
11. Arora, A.K., K.S. Sandhu, and S.S. Sodhi. 1998. Comparative studies on efficacy of different vaccines against fowl typhoid in chickens. *Ind J Ani Sci*. 68:297–299.
12. Aziz, N.S.A., K.C. Satija, and D.N. Garg. 1997. The efficacy of gentamicin for the control of egg-borne transmission of *Salmonella gallinarum*. *Indian Vet J*. 74:731–733.
13. Badi, M.A., N. Iliadis, and K. Sarris. 1992. Natural and experimental infection of rodents (*Rattus norvegicus*) with *Salmonella gallinarum*. *Berl Munch Tierarztl Wochenschr*. 105:264–267.
14. Barrow, P.A. 1990. Immunity to experimental fowl typhoid in chickens induced by a virulence plasmid-cured derivative of *Salmonella gallinarum*. *Infect Immunol*. 58:2283–2288.
15. Barrow, P.A. 1992. *In-vitro* and *in-vivo* characteristics of TnphoA mutant strains of *Salmonella* serotype gallinarum not invasive for tissue culture cells. *J Med Microbiol* 36:389–397.
16. Barrow, P.A., J.A. Berchieri, and O. Al-Haddad. 1992. Serological response of chickens to infection with *Salmonella gallinarum-S. pullorum* detected by enzyme-linked immunosorbent assay. *Avian Dis*. 36:227–236.
17. Barrow, P.A., M.B. Huggins, and M.A. Lovell. 1994. Host specificity of *Salmonella* infection in chickens and mice is expressed *in vivo* primarily at the level of the reticuloendothelial system. *Infect Immunol*. 62:4602–4610.
18. Barrow, P.A., and M.A. Lovell. 1988. The association between a large molecular mass plasmid and virulence in a strain of *Salmonella pullorum*. *J Gen Microbiol*. 134:2307–2316.
19. Barrow, P.A., M.A. Lovell, C.K. Murphy, and K. Page. 1999. *Salmonella* infection in a commercial line of ducks: Experimental studies in virulence, intestinal colonization and immune protection. *Epidemiol Infect*. 123:121–132.
20. Barrow, P.A., M.A. Lovell, and B.A.D. Stocker. 2000. Protection against experimental fowl typhoid by parenteral administration of live SL5828, an aroA-serC (aromatic dependent) mutant of a wild-type *Salmonella Gallinarum* strain made lysogenic for P22 site. *Avian Pathol*. 29:423–431.
21. Barrow, P.A., J.M. Simpson, M.A. Lovell, and M.M. Binns. 1987. Contribution of *Salmonella gallinarum* large plasmid toward virulence in fowl typhoid. *Infect Immunol*. 55:388–392.
22. Barrow, P.A., and O.C. Freitas Neto. 2011. Pullorum disease and fowl typhoid—new thoughts on old diseases: a review. *Avian Pathol*. 40:1–13.
23. Beach, J.R., and D.E. Davis. 1927. Acute infection in chicks and chronic infection of the ovaries of hens caused by the fowl typhoid organisms. *Hilgardia*. 2:411–424.
24. Beal, R.K., C. Powers, P. Wigley, P.A. Barrow, P. Kaiser, and A.L. Smith. 2005. A strong antigen-specific T-cell response is associated with age and genetically dependent resistance to avian enteric salmonellosis. *Infect Immun*. 73:7509–7516.
25. Beal, R.K., C. Powers, P. Wigley, P.A. Barrow, and A.L. Smith. 2004. Temporal dynamics of the cellular, humoral and cytokine responses in chickens during primary and secondary infection with *Salmonella enterica* serovar Typhimurium. *Avian Pathol*. 33:25–33.
26. Beaudette, F.R. 1925. The possible transmission of fowl typhoid through the egg. *J Am Vet Med Assoc*. 67:741–745.
27. Beaudette, F.R. 1930. Fowl typhoid and bacillary white diarrhea. *Int Vet Congr*. 11:705–723.
28. Beaudette, F.R. 1936. Arthritis in a chick caused by *Salmonella pullorum*. *J Am Vet Med Assoc*. 89:89–91.
29. Bebora, L.C., P.N. Nyaga, and C.O. Kimoro. 1965. Comparison of immune responses of two *Salmonella gallinarum* strains viewed as possible vaccines for fowl typhoid in Kenya. *Onderstepoort J Vet Res*. 65:67–73.
30. Berchieri, A. Jr., and P.A. Barrow. 1996. Reduction in incidence of experimental fowl typhoid by incorporation of a commercial

formic acid preparation (Bio-Add™) into poultry feed. *Poult Sci*. 75:339–341.
31. Berchieri, A., A.M. Iba, and P.A. Barrow. 1995. Examination by ELISA of sera obtained from chicken breeder and layer flocks showing evidence of fowl typhoid or pullorum disease. *Avian Pathol*. 24:411–420.
32. Berchieri, A. Jr., C.K. Murphy, K. Marston, and P.A. Barrow. 2001. Observations on the persistence and vertical transmission of *Salmonella enterica* serovars Pullorum and Gallinarum in chickens: effect of bacterial and host genetic background. *Avian Pathol*. 30:229–239.
33. Bhattacharyya, H.M., G.C. Chakraborty, D. Chakraborty, D. Bhattacharyya, U.N. Goswami, and A. Chaterjee. 1984. Broiler chick mortality due to pullorum disease and brooder pneumonia in West Bengal. *Indian J Anim Health*. 23:85–88.
34. Blaxland, J.D., W.J. Sojka, and A.M. Smither. 1956. A study of *Salmonella pullorum* and *Salmonella gallinarum* strains isolated from field outbreaks of disease. *J Comp Pathol Ther*. 66:270–277.
35. Bottorff, C.A., and J.S. Kiser. 1947. The use of sulfonamides in the control of pullorum disease. *Poult Sci*. 26:335–339.
36. Bouzoubaa, K. 1988. Membrane proteins from *Salmonella gallinarum* for protection against fowl typhoid. PhD, Institute of Agronomy and Veterinary Medicine, Hassan II.
37. Bouzoubaa, K., and K.V. Nagaraja. 1984. Epidemiological studies on the incidence of salmonellosis in chicken breeder/hatchery operations in Morocco. *Int Symp Salmonella*. 337.
38. Bouzoubaa, K., K.V. Nagaraja, J.A. Newman, and B.S. Pomeroy. 1987. Use of membrane proteins from *Salmonella gallinarum* for prevention of fowl typhoid infection in chickens. *Avian Dis*. 31: 699–704.
39. Buchholz, P.S., and A. Fairbrother. 1992. Pathogenicity of *Salmonella pullorum* in northern bobwhite quail and mallard ducks. *Avian Dis*. 36:304–312.
40. Bullis, K. 1977. The history of avian medicine in the U.S. II. Pullorum disease and fowl typhoid. *Avian Dis*. 21:422–435.
41. Bumstead, N., and P. Barrow. 1993. Resistance to *Salmonella gallinarum, S. pullorum*, and *S. enteritidis* in inbred lines of chickens. *Avian Dis*. 37:189–193.
42. Carlson, V.L., and G.H. Snoeyenbos. 1974. Comparative efficacies of selenite and tetrathionate broths for the isolation of salmonella serotypes. *Am J Vet Res*. 35:711–718.
43. Chadfield, M.S., D.J. Brown, S. Aabo, J.P. Christensen, and J.E. Olsen. 2003. Comparison of intestinal invasion and macrophage response of *Salmonella Gallinarum* and other host-adapted *Salmonella enterica* serovars in the avian host. *Vet Microbiol*. 92: 49–64.
44. Chan, K., S. Baker, C.C. Kim, C.S. Detweiler, G. Dougan, and S. Falkow. 2003. Genomic comparison of *Salmonella enterica* serovars and *Salmonella bongori* by use of an *S. enterica* serovar Typhimurium DNA microarray. *J Bacteriol*. 2185:553–563.
45. Chart, H., and B. Rowe. 1998. Growth of *Salmonella enteritidis* and *S. pullorum* on Hektoen agar and the expression of lipopolysaccharide or flagella. *FEMS Microbiol Lett*. 163:181–184.
46. Chaubal, L.H., and P.S. Holt. 1999. Characterization of swimming motility and identification of flagellar proteins in *Salmonella pullorum* isolates. *Am J Vet Res*. 60:1322–1327.
47. Chishti, M.A., M.Z. Khan, and M. Irfan. 1985. Pathology of liver and spleen in avian salmonellosis. *Pakistan Vet J*. 5:157–160.
48. Chishti, M.A., M.Z. Khan, and M. Siddique. 1985. Incidence of salmonellosis in chicken in and around Faisalabad (Pakistan). *Pakistan Vet J*. 5:79–82.
49. Christensen, J.P., P.A. Barrow, J.E. Olsen, J.S.D. Poulsen, and M. Bisgaard. 1996. Correlation between viable counts of *Salmonella* gallinarum in spleen and liver and the development of anaemia in chickens as seen in experimental fowl typhoid. *Avian Pathol*. 25:769–783.
50. Christensen, J.P., J.E. Olsen, and M. Bisgaard. 1993. Ribotypes of *Salmonella enterica* serovar gallinarum biovars gallinarum and pullorum. *Avian Pathol*. 22:725–738.
51. Christensen, J.P., J.E. Olsen, H.C. Hansen, and M. Bisgaard. 1992. Characterization of *Salmonella enterica* serovar gallinarum biovars gallinarum and pullorum by plasmid profiling and biochemical analysis. *Avian Pathol*. 21:461–470.
52. Christensen, J.P., M.N. Skov, K.H. Hinz, and M. Bisgaard. 1994. *Salmonella enterica* serovar gallinarum biovar gallinarum in layers: Epidemiological investigations of a recent outbreak in Denmark. *Avian Pathol*. 23:489–501.
53. Dodson, S.V., J.J. Maurer, P.S. Holt, and M.D. Lee. 1999. Temporal changes in the population genetics of *Salmonella pullorum*. *Avian Dis*. 43:685–695.
54. Doyle, L.P., and F.P. Mathews. 1928. The pathology of bacillary white diarrhea in chicks. *Purdue Univ Agric Exp Stn Res Bull*. 323.
55. Edwards, P.R., and D.W. Bruner. 1946. Form variation in *Salmonella pullorum* and its relation to X strains. *Cornell Vet*. 36:318–324.
56. Edwards, P.R., D.W. Bruner, E.R. Doll, and G.S. Hermann. 1948. Further notes on variation in *Salmonella pullorum*. *Cornell Vet*. 38:257–262.
57. Erbeck, D.H., B.G. McLaughlin, and S.N. Singh. 1993. Pullorum disease with unusual signs in two backyard chicken flocks. *Avian Dis*. 37:895–897.
58. Evans, W.M., D.W. Bruner, and M.C. Peckham. 1955. Blindness in chicks associated with salmonellosis. *Cornell Vet*. 45:239–247.
59. Farnell, M.B., M. El Halawani, S. You, A.P. McElroy, B.M. Hargis, and D.J. Caldwell. 2001. *In vivo* biologic effects of recombinant-turkey interferon-gamma in neonatal leghorn chicks: protection against *Salmonella enteritidis* organ invasion. *Avian Dis*. 45:473–478.
60. Feng Y,, H.F. Xu, Q.H. Li S.Y. Zhang, C.X. Wang, D.L. Zhu, F.L. Cao, Y.G. Li, R.N. Johnston, J. Zhou, G.R. Liu, and S.L. Liu. 2012. Complete genome sequence of Salmonella enterica serovar pullorum RKS5078. *J Bacteriol*. 194:744.
61. Ferguson, A.E., M.C. Connell, and B. Truscott. 1961. Isolation of *Salmonella pullorum* from the joints of broiler chicks. *Can Vet J*. 2:143–145.
62. Filho, R.A.C.P., J.B. de Paiva, M.D. da Silva, A.M. de Almeida, and A. Berchieri Jr. 2010. Control of *Salmonella* Enteritidis and *Salmonella* Gallinarum by using live vaccine. Candidate containing attenuated *Salmonella* Gallinarum mutant strain. *Vaccine*. 28:2853–2859.
63. Garrard, E.H., W.H. Burton, and J.A. Carpenter. 1948. Non-pullorum agglutination reactions. *World's Poult Congr*. 8:626–631.
64. Garren, H.W., and C.W. Barber. 1955. Endocrine and lymphatic gland changes occurring in young chickens with fowl typhoid. *Poult Sci*. 34:1250–1258.
65. Gast, R.K. 1997. Detecting infections of chickens with recent *Salmonella pullorum* isolates using standard serological methods. *Poult Sci*. 76:17–23.
66. Gast, R.K., and C.W. Beard. 1990. Serological detection of experimental *Salmonella enteritidis* infections in laying hens. *Avian Dis*. 34:721–728.

67. Gast, R.K., and P.S. Holt. 1998. Application of flagella-based immunoassays for serologic detection of *Salmonella pullorum* infection in chickens. *Avian Dis*. 42:807–811.
68. Gauger, H.C. 1934. A chronic carrier of fowl typhoid with testicular focalization. *J Am Vet Med Assoc*. 84:248–251.
69. Gordeuk, S.J., P.J. Glantz, E.W. Callenbach, and W.T.S. Thorp. 1949. Transmission of fowl typhoid. *Poult Sci*. 28:385–391.
70. Griffin, H.G., and P.A. Barrow. 1993. Construction of an aroA mutant of *Salmonella* serotype gallinarum: Its effectiveness in immunization against experimental fowl typhoid. *Vaccine*. 11: 457–462.
71. Guard-Petter, J. 1997. Induction of flagellation and a novel agar-penetrating flagellar structure in *Salmonella enterica* grown on solid media: Possible consequences for serological identification. *FEMS Microbiol Lett*. 149:173–180.
72. Gupta, B.R., and B.B. Mallick. 1976. Immunization against fowl typhoid. 1. Live oral vaccine. *Indian J Anim Sci*. 46:502–505.
73. Gupta, B.R., and B.B. Mallick. 1976. Immunization against fowl typhoid. 2. Live adjuvant vaccine. *Indian J Anim Sci*. 46:546–551.
74. Gupta, B.R., and B.B. Mallick. 1977. Use of 9R strain of *S. gallinarum* as vaccine. against *S. pullorum* infection in chicks. *Indian Vet J*. 54:331–333.
75. Hall, W.J., D.H. Legenhausen, and A.D. McDonald. 1949. Studies on fowl typhoid. 1. Nature and dissemination. *Poult Sci*. 28:344.
76. Henderson, S.C., D.I. Bounos, and M.D. Lee. 1999. Early events in the pathogenesis of avian salmonellosis. *Infect Immunol*. 67: 3580–3586.
77. Hewitt, E.A. 1928. Bacillary white diarrhea in baby turkeys. *Cornell Vet*. 18:272–276.
78. Hinshaw, W.R. 1930. Fowl typhoid of turkeys. *Vet Med*. 25: 514–517.
79. Hinshaw, W.R., C.W. Upp, and J.M. Moore. 1926. Studies on transmission of bacillary white diarrhea in incubators. *J Am Vet Assoc*. 68:631–641.
80. Holt, P.S., and L.H. Chaubal. 1997. Detection of motility and putative synthesis of flagellar proteins in *Salmonella* pullorum cultures. *J Clin Microbiol*. 35:1016–1020.
81. Hoop, R.K., and P. Albicker-Rippinger. 1997. The infection with *Salmonella gallinarum-pullorum* in poultry: Experience from Switzerland. *Schweizer Archiv fuer Tierheilkunde*. 139:485–489.
82. Hoque, M.M., H.R. Biswas, and L. Rahman. 1997. Isolation, identification and production of *Salmonella pullorum* coloured antigen in Bangladesh for the rapid whole blood test. *Asian-Australasian J Anim Sci*. 10:141–146.
83. Hu, J., N. Bumstead, P.A. Barrow, G. Sebastiani, L. Olien, K.Morgan, and D. Malo. 1997. Resistance to salmonellosis in the chicken is linked to NRAMP1 and TNC. *Genome Res*. 7:693–704.
84. Hutt, F.B., and R.D. Crawford. 1960. On breeding chicks resistant to pullorum disease without exposure thereto. *Can J Genet Cytol*. 2:357–370.
85. Iqbal, M., V.J. Philbin, G.S.K. Withanage, P. Wigley, R.K. Beal, M.J. Goodchild, P.A. Barrow, I. McConnell, D.J. Maskell, J.R. Young, N. Bumstead, Y. Boyd, and A.L. Smith. 2005. Identification and functional characterization of chicken TLR5 reveals a fundamental role in the biology of infection with *Salmonella enterica* serovar Typhimurium. *Infect Immun*. 73:2344–2350.
86. Itoh, Y., K. Hirose, M. Miyake, A.Q. Khan, Y. Hashimoto, and T. Ezaki. 1997. Amplification of rfbE and fliC genes by polymerase chain reaction for identification and detection of *Salmonella* serovar enteritidis, dublin and gallinarum-pullorum. *Microbiol Immunol*. 41:791–794.
87. Javed, T., A. Hameed, and M. Siddique. 1990. Status of salmonella in indigenous (domestic) chickens in Pakistan. *Veterinarski Arhiv*. 60:251.
88. Johnson, D.C., M. David, and S. Goldsmith. 1992. Epizootiological investigation of an outbreak of pullorum disease in an integrated broiler operation. *Avian Dis*. 36:770–775.
89. Jones, F.S. 1913. The value of the macroscopic agglutination test in detecting fowls that are harboring *Bacterium pullorum*. *J Med Res*. 27:481–495.
90. Jones, M.A., P. Wigley, K.L. Page, S.D. Hulme, and P.A. Barrow. 2001. *Salmonella enterica* serovar Gallinarum requires the *Salmonella* pathogenicity island 2 type III secretion system but not the *Salmonella* pathogenicity island 1 type III secretion system for virulence in the chicken. *Infect Immun*. 69:5471–5476.
91. Joseph, T., P. Chaudhuri, V.P. Singh, and B. Sharma. 1997. Randomly cloned chromosomal fragments for fingerprinting *Salmonella gallinarum* isolates. *Indian Vet J*. 74:191–194.
92. Kang M.S., Y.K. Kwon, B.Y. Jung, A. Kim, K.M. Lee, B.K. An, E.A. Song, J.H. Kwon, and G.S. Chung. 2011. Differential identification of Salmonella enterica subsp. enterica serovar Gallinarum biovars Gallinarum and Pullorum based on polymorphic regions of glgC and speC genes. *Vet Microbiol*. 147:181–185.
93. Kang M.S, Y.K. Kwon, J.Y. Oh, D.R. Call, B.K. An, E.A. Song, J.Y. Kim, E.G. Shin, M.J. Kim, J.H. Kwon, and G.S. Chung. 2011. Multilocus variable-number tandem-repeat analysis for subtyping *Salmonella enterica* subsp. enterica serovar Gallinarum. *Avian Pathol*. 40:559–564.
94. Kaiser, P., L. Rothwell, E.E. Galyov, P.A. Barrow, J. Burnside, and P. Wigley. 2000. Differential cytokine expression in avian cells in response to invasion by *Salmonella typhimurium, Salmonella enteritidis* and *Salmonella gallinarum*. *Microbiology* 146:3217–3226.
95. Karyagin, V.W. 1964. Development of resistance of *Salmonella pullorum*. I. To biomycin. II. To furazolidone. *Nauchn Tr*. 31–49.
96. Klein, E. 1889. Über eine epidemische Krankheit der Hühner, verursacht durch einer Bacillus-*Bacillus gallinarum*. *Zentralbl Bakteriol Parasitenkd Abt I Orig*. 5:689–693.
97. Kogut, M.H., G.I. Tellez, B.M. Hargis, D.E. Corrier, and J.R. DeLoach. 1993. The effect of 5-fluorouracil treatment of chicks: a cell depletion model for the study of avian polymorphonuclear leukocytes and natural host defenses. *Poult Sci*. 72:1873–1880.
98. Kokosharov, T. 1998. Changes in the white blood cells and specific phagocytosis in chicken with acute fowl typhoid. *I Veterinarski Arhiv*. 68:33–38.
99. Kokosharov, T. 2000. Sialic acids in the serum of poultry with experimental acute fowl typhoid. *Indian Vet J*. 77:1–3.
100. Kokosharov, T., H. Hristov, and L. Belchev. 1997. Clinical, bacteriological and pathological studies on experimental fowl typhoid. *Indian Vet J*. 74:547–549.
101. Kokosharov, T., I. Petkov, and I. Dzhurova. 1984. Cocks with experimentally induced acute typhoid. *Vet Med Nauki*. 21: 18–26.
102. Komarov, A. 1932. Fowl typhoid in baby chicks. *Vet Rec*. 12:1455–1457.
103. Kwon, H.J., K.Y. Park, H.S. Yoo, J.Y. Park, Y.H. Park, and S.J. Kim. 2000. Differentiation of *Salmonella enterica* serotype gallinarum biotype pullorum from biotype gallinarum by analysis of phase 1 flagellin C gene (fliC). *J Microbiol Methods*. 40:33–38.
104. Lee, Y.J., K.S. Kim, J.H. Kim, and R.B. Tak. 2004. *Salmonella gallinarum* gyrA mutations associated with fluoroquinolone resistance. *Avian Pathol*. 33:251–257.

105. Lee, Y.J., K.S. Kim, Y.K. Kwon, and R.B. Tak. 2003. Biochemical characteristics and antimicrobial susceptibility of *Salmonella gallinarum* isolated in Korea. *J Vet Sci*. 4: 161–166.
106. Leveque, G., V. Forgetta, S. Morroll, A.L. Smith, N. Bumstead, P.A. Barrow, J.C. Loredo-Osti, K. Morgan, and D. Malo. 2003. Allelic variation in TLR4 is linked to susceptibility to *Salmonella enterica* serovar Typhimurium infection in chickens. *Infect Immun*. 71:1116–1124.
107. Li, J., N.H. Smith, K. Nelson, P.B. Crichton, D.C. Old, T.S. Whittam, and R.K. Selander. 1993. Evolutionary origin and radiation of the avian-adapted non-motile salmonellae. *J Med Microbiol*. 38:129–139.
108. Liu, G.R., A. Rahn, W.Q. Liu, K.E. Sanderson, R.N. Johnston, and S.L. Liu. 2002. The evolving genome of *Salmonella enterica* serovar Pullorum. *J Bacteriol*. 184:2626–2633.
109. Lucio, B., M. Padron, and A. Mosqueda. 1984. Fowl typhoid in Mexico. *Int Symp Salmonella*. 382–383.
110. Madhur, D., P. Chaud, and J.R. Sadana. 1999. Comparison of a dot immunobinding assay and the serum agglutination test for detecting serological responses in vaccinated and unvaccinated chickens following challenge with *Salmonella gallinarum*. *Avian Pathol*. 28:98–101.
111. Majid, A., M. Siddique, and M.Z. Khan. 1991. Prevalence of salmonellosis in commercial chicken layers in and around Faisalabad. *Pakistan Vet J*. 11:37–41.
112. Mariani, P., P. Barrow, H.H. Cheng, M.A.M. Groenen, R. Negrini, and N. Bumstead. 1998. A major quantitative trait locus determining resistance to salmonellosis is located on chicken chromosome 5. *Anim Genet*. 29:73–74.
113. Martinaglia, G. 1929. A note on *Salmonella gallinarum* infection of ten-day-old chicks and adult turkeys. *J S Afr Vet Med Assoc*. 1:35–36.
114. Mayahi, M., R.N. Sharma, and S. Maktabi. 1995. An outbreak of blindness in chicks associated with *Salmonella pullorum* infection. *Indian Vet J*. 72:922–925.
115. McCullough, N.B., and C.W. Eisele. 1951. Experimental human salmonellosis. IV. Pathogenicity of strains of *Salmonella pullorum* obtained from spray-dried whole egg. *J Infect Dis*. 89:259–265.
116. McMeechan, A., M.A. Lovell, T.A. Cogan, K.L. Marston, T.J. Humphrey, and P.A. Barrow. 2005. Glycogen production by different *Salmonella enterica* serotypes: contribution of functional glgC to virulence, intestinal colonization and environmental survival. *Microbiology*. 151:3969–3977.
117. Mdegela, R.H., M.G.S. Yongolo, U.M. Minga, and J.E. Olsen. 2000. Molecular epidemiology of *Salmonella gallinarum* in chickens in Tanzania. *Avian Pathol*. 29:457–463.
118. Minga, U.M., and C. Wray. 1992. A disc ELISA for the detection of *Salmonella* group D antibodies in poultry. *Res Vet Sci*. 52:384–386.
119. Minga, U.M., C. Wray, and P.S. Gwakisa. 1992. Serum, disc and egg ELISA for the serodiagnosis of *Salmonella gallinarum* and *S. enteritidis* infections in chickens. *Scand J Immunol*. 11: 157–159.
120. Mitchell, R.B., F.C. Garlock, and R.H. Broh-Kahn. 1946. An outbreak of gastro-enteritis presumably caused by *Salmonella pullorum*. *J Infect Dis*. 79:57–62.
121. Nabbut, N. 1993. The salmonella problem in Lebanon and its role in acute gastroenteritis. *J Food Protect*. 56:270–272.
122. Orr, B.B., and E.N. Moore. 1953. Longevity of *Salmonella gallinarum*. *Poult Sci*. 32:800–805.
123. Nisbet, D.J., G.I. Tellez, V.K. Lowry, R.C. Anderson, G. Garcia, G. Nava, M.H. Kogut, D.E. Corrier, and L.H. Stanker. 1998 Effect of a commercial competitive exclusions culture (Preempt) on mortality and horizontal transmission of *Salmonella gallinarum* in broiler chickens. *Avian Dis*. 42:651–656.
124. Padmanaban, V.D., K.R. Mittal, and B.R. Gupta. 1981. Cross protection against fowl typhoid: Immunization trials and humoral immune response. *Dev Comp Immunol*. 5:301–312.
125. Pennycott, T.W., and G. Duncan. 1999. *Salmonella pullorum* in the common pheasant (*Phasianus colchicus*). *Vet Rec*. 144: 283–287.
126. Pomeroy, B.S. 1984. Fowl typhoid. In: *Diseases of Poultry*, 8th ed. M.S. Hofstad, B.W. Calnek, W.M. Reid, and H.W. Yoder, Jr., eds. Iowa State University Press, Ames, IA. 79–91.
127. Pomeroy, B.S., R. Fenstermacher, and M.H. Roepke. 1948. Sulfonamides in the control of salmonellosis of chicks and poults. *J Am Vet Med Assoc*. 112:296–303.
128. Pomeroy, B.S., and K.V. Nagaraja. 1991. Fowl typhoid. In: *Diseases of Poultry*, 9th ed. B.W. Calnek, H.J. Barnes, C.W. Beard, W.M. Reed, and J.H.W. Yoder, eds. Iowa State University Press, Ames, IA. 87–99.
129. Popp, L. 1947. Fowl typhoid organisms as the cause of gastroenteritis in man [abst]. *J Am Vet Med Assoc*. 111:314.
130. Porwollik, S., C.A. Santiviago, P. Cheng, L. Florea, S. Jackson, and M. McClelland. 2005. Differences in gene content between *Salmonella enterica* serovar Enteritidis isolates and comparison to closely related serovars Gallinarum and Dublin. *J Bacteriol*. 187:6545–6555.
131. Rabsch, W., B.M. Hargis, R.M. Tsolis, R.A. Kingsley, K.H. Hinz, H. Tschape, and A.J. Baumler. 2000 Competitive exclusion of *Salmonella enteritidis* by *Salmonella gallinarum* in poultry. *Emer Infect Dis*. 6:443–448.
132. Rahman, H., Prager, R., and Tschape, H. 2000. Occurrence of sef and pef genes among different serovars of *Salmonella*. *Indian J Med Res*. 111:40–42.
133. Rettger, L.F. 1900. Septicemia among young chickens. *NY Med J*. 71:803–805.
134. Rettger, L.F. 1909. Further studies on fatal septicemia in young chickens or "white diarrhea." *J Med Res*. 21:115–123.
135. Rettger, L.F., and W.N. Plastridge. 1932. Pullorum disease of domestic fowl. *Monogr Storrs Agric Exp Stn Bull*. 178.
136. Runnels, R.A., C.J. Coon, H. Farley, and F. Thorp. 1927. An application of the rapid-method agglutination test to the diagnosis of bacillary white diarrhea infection. *J Am Vet Med Assoc*. 70:660–662.
137. Rychlik, I., M.A. Lovell, and P.A. Barrow. 1998. The presence of genes homologous to the K88 genes faeH and faeI on the virulence plasmid of *Salmonella gallinarum*. *FEMS Microbiol Lett*. 159:255–260.
138. Ryll, M., M. Bisgaard, J.P. Christensen, and K.H. Hinz. 1996. Differentiation of *Salmonella gallinarum* and *Salmonella pullorum* by their whole-cell fatty acid methyl ester profiles. *J Vet Med Series*. 43:357–363.
139. Salem, M., E.M. Odor, and C. Pope. 1992. Pullorum disease in Delaware roasters. *Avian Dis*. 36:1076–1080.
140. Sarkisov, A.K., and E.T. Trishkina. 1966. Antibiotic sensitivity of *Salmonella pullorum* isolated from chicks on farms where antibiotics have been used over a long period. *Tr Vses Inst Eksp Vet*. 32:224–230.
141. Sato, Y., G. Sato, L. Tuchili, G.S. Pandy, A. Nakajima, H. Chimana, and H. Sinsungwe. 1997. Status of *Salmonella*

gallinarum-pullorum infections in poultry in Zambia. *Avian Dis*. 41:490–495.
142. Schaffer, J.M., A.D. MacDonald, W.J. Hall, and H. Bunyea. 1931. A stained antigen for the rapid whole blood test for pullorum disease. *J Am Vet Med Assoc*. 79:236–240.
143. Setta, A., P.A. Barrow, P. Kaiser, and M.A. Jones. 2012. Immune dynamics following infection of avian macrophages and epithelial cells with typhoidal and non-typhoidal Salmonella enterica serovars: bacterial invasion and persistence, nitric oxide and oxygen production, differential host gene expression, NF-κB signalling and cell cytotoxicity. *Vet Immunol Immunopathol*. 146:212–224.
144. Severens, J.M., E. Roberts, and L.E. Card. 1944. A study of the defense mechanism involved in hereditary resistance to pullorum disease of the domestic fowl. *J Infect Dis*. 75:33–46.
145. Shah, D.H., M.J. Lee, J.H. Park, J.H. Lee, S.K. Eo, J.T. Kwon, and J.S. Chae. 2005. Identification of *Salmonella gallinarum* virulence genes in a chicken infection model using PCR-based signature tagged mutagenesis. *Microbiology*. 151:3957–3968.
146. Shah, D.H., J.H. Park, M.R. Cho, M.C. Kim, and J.S. Chae. 2005. Allele-specific PCR method based on rfbS sequence for distinguishing *Salmonella gallinarum* from *Salmonella pullorum*: serotype-specific rfbS sequence polymorphism. *J Microbiol Methods*. 60:169–177.
147. Sharp, M.W., and P.W. Laing. 1993. *Salmonella pullorum* infection and pheasants. *Vet Rec*. 133:460.
148. Shivaprasad, H.L. 2008. Unpublished data.
149. Shivaprasad, H.L. 2000. Fowl typhoid and pullorum disease. *Rev Sci Tech Off Int Epiz*. 19:405–424.
150. Shivaprasad, H.L., J.F. Timoney, S. Morales, B. Lucio, and R.C. Baker. 1990. Pathogenesis of *Salmonella enteritidis* infection in laying chickens. I. Studies on egg transmission, clinical signs, fecal shedding, and serologic responses. *Avian Dis*. 34:548–557.
151. Siddique, M., T. Javed, and M.A. Sabri. 1987. Incidence and pathology of various poultry diseases prevalent in Faisalabad (Pakistan) and surrounding districts. *Pakistan Vet J*. 7:148–154.
152. Silva, E.N. 1984. The *Salmonella gallinarum* problem in Central and South America. *Int Symp Salmonella*. 150–156.
153. Silva, E.N., G.H. Snoeyenbos, O.M. Weinack, and C.F. Smyser. 1981. Studies on the use of 9R strain of *Salmonella gallinarum* as a vaccine in chickens. *Avian Dis*. 25:38–52.
154. Singh, P., S.L. Foley, R. Nayak, and Y.M. Kwon. 2012. Multilocus sequence typing of *Salmonella* strains by high-throughput sequencing of selectively amplified target genes. *J Microbiol Methods*. 88:127–133.
155. Smith, H.W. 1955. The longevity of *Salmonella*rum in the faeces of infected chickens. *J Comp Pathol Ther*. 65:267–270.
156. Smith, H.W. 1956. The use of live vaccines in experimental *Salmonella gallinarum* infection in chickens with observations on their interference effect. *J Hyg*. 54:419–432.
157. Smith, H.W., J.F. Tucker, and M. Lovell. 1981. Furazolidone resistance in *Salmonella gallinarum*: The relationship between *in vitro* and *in vivo* determinations of resistance. *J Hyg (Camb)*. 87:71–81.
158. Smith, I.M., S.T. Licence, and R. Hill. 1978. Haematological, serological and pathological effects in chicks of one or more intravenous infections of *Salmonella gallinarum* endotoxin. *Res Vet Sci*. 24:154–160.
159. Smith, T.H., and C.T. Broeck. 1915. Agglutination affinities of a pathogenic bacillus from fowls (fowl typhoid) (*Bacterium sanguinarium* Moore) with the typhoid bacillus of man. *J Med Res*. 31:503–521.
160. Snoeyenbos, G.H. 1991. Pullorum disease. In: *Diseases of Poultry*, 9th ed.B.W. Calnek, H.J. Barnes, C.W. Beard, W.M. Reed, and J.H.W. Yoder, eds. Iowa State University Press, Ames, IA. 73–86.
161. St. John-Brooks, R., and M. Rhodes. 1923. The organisms of the fowl typhoid group. *J Pathol Bacteriol*. 26:433–439.
162. Stanley, J., and N. Baquar. 1994. Phylogenetics of *Salmonella enteritidis*. *Int J Food Microbiol*. 21:79–87.
163. Stokes, J.L., and H.G. Bayne. 1961. Oxidative assimilation of amino acids by salmonellae in relation to growth rates. *J Bacteriol*. 81:118–125.
164. Stuart, E.E., and R.D. Keenum. 1970. Preincubation treatment of chicken hatching eggs infected with *Salmonella pullorum*. *Avian Dis*. 14:87–95.
165. Stuart, E.E., R.D. Keenum, and H.W. Bruins. 1962. Experimental studies on an isolate of *Salmonella gallinarum* apparently resistant to furazolidone. *Avian Dis*. 7:294–303.
166. Stuart, E.E., R.D. Keenum, and H.W. Bruins. 1967. The emergence of a furazolidone-resistant strain of *Salmonella gallinarum*. *Avian Dis*. 11:139–145.
167. Suganuma, Y. 1960. Histopathological studies of serositis of pullorum disease. *Jpn J Vet Sci*. 22:175–182.
168. Tanaka, S. 1975. Production of pullorum antigen by continuous submerged culture. *Jpn Agric Res Q*. 9:60–65.
169. Thain, J.A., and T.B. Blandford. 1981. A long-term serological study of a flock of chickens naturally infected with *Salmonella pullorum*. *Vet Rec*. 109:136–138.
170. Thomson, N.R., D.J. Clayton, D. Windhorst, G. Vernikos, S. Davidson, C. Churcher, M.A. Quail, M. Stevens, M.A. Jones, M. Watson, A. Barron, A. Layton, D. Pickard, R.A. Kingsley, A. Bignell, L. Clark, B. Harris, D. Ormond, Z. Abdellah, K. Brooks, I. Cherevach, T. Chillingworth, J. Woodward, H. Norberczak, A. Lord, C. Arrowsmith, K. Jagels, S. Moule, K. Mungall, M. Sanders, S. Whitehead, J.A. Chabalgoity, D. Maskell, T. Humphrey, M. Roberts, P.A. Barrow, G. Dougan, and J. Parkhill. 2008. Comparative genome analysis of *Salmonella* Enteritidis PT4 and *Salmonella* Gallinarum 287/91 provides insights into evolutionary and host adaptation pathways. *Genome Res*. 18:1624–1637.
171. Trabulsi, L.R., and P.R. Edwards. 1962. The differentiation of *Salmonella pullorum* and *Salmonella gallinarum* by biochemical methods. *Cornell Vet*. 52:563–569.
172. Tsubokura, M. 1965. Studies of *Salmonella pullorum* phage. I. Isolation of phages and their properties. *Jpn J Vet Sci*. 27:179–188.
173. Tsubokura, M. 1966. Studies on *Salmonella pullorum* phage. V. Conversion of subtypes of *S. pullorum* by phage. *Jpn J Vet Sci*. 28:35–40.
174. Tuchili, L.M., H. Kodama, Y. Izumoto, M. Mukamoto, T. Fukata, and T. Baba. 1995. Detection of *Salmonella gallinarum* and S. *typhimurium* DNA in experimentally infected chicks by polymerase chain reaction. *J Vet Med Sci*. 57:59–63.
175. Van Buskirk, M.A. 1987. A pullorum disease outbreak in a pullorum-free state. *Northeast Conf Avian Dis*. 59:40–42.
176. Waltman, W.D., and A.M. Horne. 1993. Isolation of salmonella from chickens reacting in the pullorum-typhoid agglutination test. *Avian Dis*. 37:805–810.
177. Watanabe, S., T. Nagai, K. Hashimoto, T. Kume, and R. Sakazaki. 1960. Studies on *Salmonella* infection in hens' eggs during incubation. VII. Transmission to eggs of agglutinins and immunity from hens infected with *S. pullorum*. *Bull Natl Inst Anim Health (Tokyo)*. 39:37–41.

178. Wigley, P., A. Berchieri, K.L. Page, A.L. Smith, and P.A. Barrow. 2001. *Salmonella enterica* Serovar pullorum persists in splenic macrophages and in the reproductive tract during persistent, disease-free carriage in chickens. *Infect Immun*. 69: 7873–7879.
179. Wigley, P., S.D. Hulme, C. Powers, R.K. Beal, A. Berchieri, A. Smith, and P. Barrow. 2005. Infection of the reproductive tract and eggs by *Salmonella enterica* serovar Pullorum in the chicken is associated with suppression of cellular immunity at sexual maturity. *Infect Immun*. 73:2986–2990.
180. Wigley, P., S.D. Hulme, C. Powers, R. Beal, A.L. Smith, and P.A. Barrow. 2005. Oral infection with the *Salmonella enterica* serovar Gallinarum 9R attenuated live vaccine as a model to characterise immunity to fowl typhoid in the chicken. *BMC Vet Res*. 1:2.
181. Wigley, P., M.A. Jones, and P.A. Barrow. 2002. *Salmonella enterica* serovar Pullorum requires the *Salmonella* pathogenicity island 2 type III secretion system for virulence and carriage in the chicken. *Avian Pathol*. 31:501–6.
182. Williams, J.E. 1953. Antigenic studies using ammonium sulfate. I. The relative sedimentation effect of ammonium sulfate on the various antigenic types of *Salmonella pullorum*. *Am J Vet Res*. 14:458–462.
183. Williams, J.E. 1953. Antigenic studies using ammonium sulfate. II. The macroscopic ammonium sulfate sedimentation test for distinguishing the antigenic forms of *Salmonella pullorum*. *Am J Vet Res*. 14:465–470.
184. Williams, J.E., L.H. Dillard, and G.O. Hall. 1968. The penetration patterns of *Salmonella typhimurium* through the outer structures of chicken eggs. *Avian Dis*. 12:445–466.
185. Williams, J.E., and A.D. MacDonald. 1955. The past, present, future of salmonella antigens for poultry. *Annu Meet Am Vet Med Assoc*. 92:333–339.
186. Williams, J.E., B.S. Pomeroy, R. Fenstermacher, and A. Holland. 1949. The incidence of variant pullorum in Minnesota. *Cornell Vet*. 39:129–135.
187. Williams, J.E., and A.D. Whittemore. 1971. Serological diagnosis of pullorum disease with the microagglutination system. *Appl Microbiol*. 21:394–399.
188. Wilson, M.A., and G.E. Nordholm. 1995. DNA fingerprint analysis of standard, intermediate and variant antigenic types of *Salmonella enterica* subspecies enterica serovar gallinarum biovar pullorum. *Avian Dis*. 39:594–598.
189. Withanage, G.S.K., P. Kaiser, P. Wigley, C. Powers, P. Mastroeni, H. Brooks, P.A. Barrow, A. Smith, D.J. Maskell, and I. McConnell. 2004. Rapid expression of chemokines and pro-inflammatory cytokines in newly hatched chickens infected with *Salmonella enterica* serovar Typhimurium. *Infect Immun*. 72:2152–2159.
190. Withanage, G.S., P. Wigley, P. Kaiser, P. Mastroeni, H. Brooks, C. Powers, R.K. Beal, P.A. Barrow, D.J. Maskell, and I. McConnell. 2005. Cytokine and chemokine response associated with clearance of a primary *Salmonella enterica* serovar Typhimurium infection in the chicken and in protective immunity to rechallenge. *Infect Immun*. 73:5173–5182.
191. Wong, R.A., G.I. Tellez, J. Valladares, and B.M. Hargis. 1996. Pathogenicity of *Salmonella gallinarum* on an experimental infection of one-day-old broiler chicks. *Poultry Sci* 75:44.
192. Wu, K.Y., G.R. Liu, A.O. Wang, S. Zhan, K.E. Sanderson, R.N. Johnston, and S.L. Liu. 2005. The genome of *Salmonella enterica* serovar Gallinarum: distinct insertions/deletions and rare rearrangements. *J Bacteriol*. 187:4720–4727.
193. Younie, A.R. 1941. Fowl infection like pullorum disease. *Can J Comp Med Vet Sci*. 5:164–167.
194. Zhang, D., J.J. Yuan, G.S. Zhang, D.L. Zhang, J.Y. Jia, and G.S. Zhang. 1996. An investigation of poultry diseases in Gansu. *Chinese J Vet Med*. 22:6–27.
195. Zhang-Barber, L., A.K. Turner, and P.A. Barrow. 1999. Vaccination for control of *Salmonella* in poultry. *Vaccine*. 17:2538–2545.
196. Zhang-Barber, L., A.K. Turner, G. Dougan, and P.A. Barrow. 1998. Protection of chickens against experimental fowl typhoid using a nuoG mutant of *Salmonella* serotype Gallinarum. *Vaccine*. 16:899–903.

Paratyphoid Infections

1. Abasht, B., M.G. Kaiser, J. van der Poel, and S.J. Lamont. 2009. Genetic lines differ in Toll-like receptor gene expression in spleens of chicks inoculated with *Salmonella enterica* serovar Enteritidis. *Poult Sci*. 88:744–749.
2. Adriaensen, C., H. De Greve, J.Q. Tian, S. De Craeye, E. Gubbels, V. Eeckhaut, F. Van Immerseel, R. Ducatelle, M. Kumar, and J.P. Hernalsteens. 2007. A live *Salmonella enterica* serovar Enteritidis vaccine allows serological differentiation between vaccinated and infected animals. *Infect Immun*. 75:2461–2468.
3. Aho, M. 1992. Problems of *Salmonella* sampling. *Int J Food Microbiol*. 15:225–235.
4. Alali, W.Q., S. Thakur, R.D. Berghaus, M.P. Martin, and W.A. Gebreyes. Prevalence and distribution of *Salmonella* in organic and conventional broiler poultry farms. *Foodborne Pathog Dis*. 7:1363–1371.
5. Allen-Vercoe, E., A.R. Sayers, and M.J. Woodward. 1999. Virulence of *Salmonella enterica* serotype Enteritidis aflagellate and afimbriate mutants in a day-old chick model. *Epidemiol Infect*. 122:395–402.
6. Allen-Vercoe, E., and M.J. Woodward. 1999. Colonisation of the chicken caecum by afimbriate and aflagellate derivatives of *Salmonella enterica* serotype Enteritidis. *Vet Microbiol*. 69:265–275.
7. Allen-Vercoe, E., and M.J. Woodward. 1999. The role of flagella, but not fimbriae, in the adherence of *Salmonella enterica* serotype Enteritidis to chick gut explant. *J Med Microbiol*. 48:771–780.
8. Alonso-Hernando, A., R. Capita, M. Prieto, and C. Alonso-Calleja. 2009. Comparison of antibiotic resistance patterns in Listeria monocytogenes and *Salmonella enterica* strains pre-exposed and exposed to poultry decontaminants. *Food Control*. 20:1109–1111.
9. Al-Zenki, S.F., A.Y. Al-Nasser, A.E. Al-Saffar, F.K. Abdullah, M.E. Al-Bahouh, A.S. Al-Haddad, H. Alomirah, and M. Mashaly. 2009. Effects of using a chicken-origin competitive exclusion culture and probiotic cultures on reducing *Salmonella* in broilers. *J Appl Poult Res*. 18:23–29.
10. Anderson, P.N., M.E. Hume, J.A. Byrd, C. Hernandez, S.M. Stevens, K. Stringfellow, and D.J. Caldwell. 2010. Evaluation of repetitive extragenic pallindromic-polymerase chain reaction and denatured gradient gel electrophoresis in identifying *Salmonella* serotypes isolated from processed turkeys. *Poult Sci*. 89: 1293–1300.
11. Arnold, M.E., J.J. Carrique-Mas, I. McLaren, and R.H. Davies. 2011. A comparison of pooled and individual bird sampling for detection of *Salmonella* in commercial egg laying flocks. *Prev Vet Med*. 99:176–184.

12. Arsenault, J., A. Letellier, S. Quessy, V. Normand, and M. Boulianne. 2007. Prevalence and risk factors for *Salmonella* spp., and Campylobacter spp. Caecal colonization in broiler chicken and turkey flocks slaughtered in Quebec, Canada. *Prevent Vet Med*. 81:250–264.
13. Asakura, H., O. Tajima, M. Watarai, T. Shirahata, H. Kurazono, and S. Makino. 2001. Effects of rearing conditions on the colonization of *Salmonella* enteritidis in the cecum of chicks. *J Vet Med Sci*. 63:1221–1224.
14. Aury, K., M. Chemaly, I. Petetin, S. Rouxel, M. Picherot, V. Michel, and S. Le Bouquin. 2010. Prevalence and risk factors for *Salmonella enterica* subsp. enterica contamination in French breeding and fattening turkey flocks at the end of the rearing period. *Prev Vet Med*. 94:84–93.
15. Baba, E., T. Fukata, and A. Arakawa. 1985. Factors influencing enhanced *Salmonella typhimurium* infection in Eimeria tenella-infected chickens. *Am J Vet Res*. 46:1593–1596.
16. Babu, U., R.A. Dalloul, M. Okamura, H.S. Lillehoj, H. Xie, R.B. Raybourne, D. Gaines, and R.A. Heckert. 2004. *Salmonella* enteritidis clearance and immune responses in chickens following *Salmonella* vaccination and challenge. *Vet Immunol Immunopathol*. 101:251–257.
17. Bailey, J.S., L.C. Blankenship, N.J. Stern, N.A. Cox, and F. McHan. 1988. Effect of anticoccidial and antimicrobial feed additives on prevention of *Salmonella* colonization of chicks treated with anaerobic cultures of chicken feces. *Avian Dis*. 32: 324–329.
18. Bailey, J.S., R.J. Buhr, N.A. Cox, and M.E. Berrang. 1996. Effect of hatching cabinet sanitation treatments on *Salmonella* cross-contamination and hatchability of broiler eggs. *Poult Sci*. 75: 191–196.
19. Bailey, J.S., J.A. Cason, and N.A. Cox. 1998. Effect of *Salmonella* in young chicks on competitive exclusion treatment. *Poult Sci*. 77:394–399.
20. Bailey, J.S., N.A. Cox, S.E. Craven, and D.E. Cosby. 2002. Serotype tracking of *Salmonella* through integrated broiler chicken operations. *J Food Prot*. 65:742–745.
21. Bailey, J.S., and E. Line. 2001. *In ovo* gentamicin and mucosal starter culture to control *Salmonella* in broiler production. *J Appl Poult Res*. 10:376–379.
22. Bailey, J.S., A. Rolón, P.S. Holt, C.L. Hofacre, J.L. Wilson, D.E. Cosby, L.J. Richardson, and N.A. Cox. 2007. Humoral and mucosal-humoral immune response to a *Salmonella* vaccination program in broiler breeders. *Int J Poult Sci*. 6:172–181.
23. Bailey, J.S., A. Rolón, C.L. Hofacre, P.S. Holt, J.L. Wilson, D.E. Cosby, L.J. Richardson, and N.A. Cox. 2007. Intestinal humoral immune response and resistance to *Salmonella* challenge or progeny from breeders vaccinated with killed antigen. *Int J Poult Sci*. 6:417–423.
24. Bailey, J.S., A. Rolón, C.L. Hofacre, P.S. Holt, J.L. Wilson, D.E. Cosby, L.J. Richardson, and N.A. Cox. 2007. Resistance to challenge of breeders and their progeny with and without competitive exclusion treatment to *Salmonella* vaccination programs in broiler breeders. *Int J Poult Sci*. 6:386–392.
25. Bailey, J.S., N.J. Stern, and N.A. Cox. 2000. Commercial field trial evaluation of Mucosal Starter Culture to reduce *Salmonella* incidence in processed broiler carcasses. *J Food Prot*. 63:867–870.
26. Barbezange, C., G. Ermel, C. Ragimbeau, F. Humbert, and G. Salvat. 2000. Some safety aspects of *Salmonella* vaccines for poultry: *in vivo* study of the genetic stability of three *Salmonella typhimurium* live vaccines. *FEMS Microbiol Lett*. 192:101–106.
27. Barrow, P.A. 1991. Experimental infection of chickens with *Salmonella* enteritidis. *Avian Pathol*. 20:145–153.
28. Barrow, P.A. 1992. Further observations on the serological response to experimental *Salmonella typhimurium* in chickens measured by ELISA. *Epidemiol Infect*. 108:231–241.
29. Barrow, P.A., M. Desmidt, R. Ducatelle, M. Guittet, H.M.J.F. van der Heijden, P.S. Holt, J.H.J. Huis in't Velt, P. McDonough, K.V. Nagaraja, R.E. Porter, K. Proux, F. Sisak, C. Staak, G. Steinbach, C.J. Thorns, C. Wray, and F. van Zijderveld. 1996. World Health Organisation-supervised interlaboratory comparison of ELISAs for the serological detection of *Salmonella enterica* serotype Enteritidis in chickens. *Epidemiol Infect*. 117:69–77.
30. Barrow, P.A., M.B. Huggins, and M.A. Lovell. 1994. Host specificity of *Salmonella* infection in chickens and mice is expressed *in vivo* primarily at the level of the reticuloendothelial system. *Infect Immun*. 62:4602–4610.
31. Barrow, P.A., M.B. Huggins, M.A. Lovell, and J.M. Simpson. 1987. Observations on the pathogenesis of experimental *Salmonella typhimurium* infection in chickens. *Res Vet Sci*. 42:194–199.
32. Barrow, P.A., M.A. Lovell, C.K. Murphy, and K. Page. 1999. *Salmonella* infection in a commercial line of ducks; experimental studies on virulence, intestinal colonization and immune protection. *Epidemiol Infect*. 123:121–132.
33. Beal, R.K., C. Powers, P. Wigley, P.A. Barrow, P. Kaiser, and A.L. Smith. 2005. A strong antigen-specific T-cell response is associated with age and genetically dependent resistance to avian enteric salmonellosis. *Infect Immun*. 73:7509–7515.
34. Beal, R.K., C. Powers, P. Wigley, P.A. Barrow, and A.L. Smith. 2004. Temporal dynamics of the cellular, humoral and cytokine responses in chickens during primary and secondary infection with *Salmonella enterica* serovar Typhimurium. *Avian Pathol*. 33:25–33.
35. Beaumont, C., H. Chapuis, J. Protais, N. Sellier, P. Menanteau, P. Fravalo, and P. Velge. 2010. Resistance to *Salmonella* carrier state: selection may be efficient but response depends on animal's age. *Genet Res Camb*. 91:161–169.
36. Beckers, H.J., P.D. Tips, P.S.S. Soentoro, E.H.M. Delfgou-Van Asch, and R. Peters. 1988. The efficacy of enzyme immunoassays for the detection of salmonellas. *Food Microbiol*. 5:147–156.
37. Bennett, D.D., S.E. Higgins, R.W. Moore, R. Beltran, D.J. Caldwell, J.A. Byrd II, and B.M. Hargis. 2003. Effects of lime on *Salmonella enteritidis* survival *in vitro*. *J Appl Poult Res*. 12:65–68.
38. Berchieri, A., Jr., and P.A. Barrow. 1996. The antibacterial effects for *Salmonella* Enteritidis phage type 4 of different chemical disinfectants and cleaning agents tested under different conditions. *Avian Pathol*. 25:663–673.
39. Berchieri, A., Jr., P. Wigley, K. Page, C.K. Murphy, and P.A. Barrow. 2001. Further studies on vertical transmission and persistence of *Salmonella enterica* serovar Enteritidis phage type 4 in chickens. *Avian Pathol*. 30:297–310.
40. Berghaus, R.D., S.G. Thayer, J.J. Maurer, and C.L. Hofacre. 2011. Effect of vaccinating breeder chickens with a killed *Salmonella* vaccine on *Salmonella* prevalences and loads in breeder and broiler chicken flocks. *J Food Prot*. 74:727–734.
41. Berndt, A., A. Wilhelm, C. Jugert, J. Pieper, K. Sachse, and U. Methner. 2007. Chicken cecum immune response to *Salmonella enterica* serovars of different levels of invasiveness. *Infect Immun*. 75:5993–6007.
42. Berrang, M.E., N.A. Cox, and J.S. Bailey. 1995. Measuring airborne microbial contamination of broiler hatching cabinets. *J Appl Poult Res*. 4:83–87.

43. Berrang, M.E., J.F. Frank, R.J. Buhr, J.S. Bailey, N.A. Cox, and J.M. Mauldin. 1997. Microbiology of sanitized broiler hatching eggs through the egg production period. *J Appl Poult Res*. 6:298–305.
44. Betancor, L., M. Pereira, A. Martinez, G. Glossa, M. Faces, K. Flores, P. Barrios, V. Repiso, R. Vignoli, N. Cordeiro, G. Algorta, N. Thomson, D. Maskell, F. Schelotto, and J.A. Chabalgoity. 2010. Prevalence of *Salmonella enterica* in poultry and eggs in Uruguay during an epidemic due to *Salmonella enterica* serovar Enteritidis. *J Clin Microbiol*. 48:2413–2423.
45. Biswas, D., P. Herrera, L. Fang, R.R. Marquardt, and S.C. Ricke. 2010. Cross-reactivity of anti-*Salmonella* egg yolk antibodies to *Salmonella* serovars. *J Environ Sci Health B*. 45:790–795.
46. Blais, B.W., and A. Martinez-Perez. 2008. Detection of group D salmonellae including *Salmonella* Enteritidis in eggs by polymyxin-based enzyme-linked immunosorbent assay. *J Food Prot*. 71:392–396.
47. Bohez, L., R. Ducatelle, F. Pasmans, F. Haesebrouck, and F. Van Immerseel. 2007. Long-term colonisation-inhibition studies to protect broilers against colonisation with *Salmonella* Enteritidis, using *Salmonella* pathogenicity island 1 and 2 mutants. *Vaccine*. 25:4235–4243.
48. Bolder, N.M., J.A. Wagenaar, F.F. Putirulan, K.T. Veldman, and M. Sommer. 1999. The effect of flavophospholipol (Flavomycin®) and salinomycin sodium (Sacox®) on the excretion of *Clostridium perfringens*, *Salmonella enteritidis*, and *Campylobacter jejuni* in broilers after experimental infection. *Poult Sci*. 78:1681–1689.
49. Borie, C., I. Albala, P. Sánchez, S. Ramírez, C. Navarro, M.A. Morales, J. Retamales, and J. Robeson. 2008. Bacteriophage treatment reduces *Salmonella* colonization of infected chickens. *Avian Dis*. 52:64–67.
50. Borsoi, A., E. Santin, L.R. Santos, C.T.P. Salle, H.L.S. Moraes, and V.P. Nascimento. 2009. Inoculation of newly hatched broiler chicks with two Brazilian isolates of *Salmonella heidelberg* strains with different virulence gene profiles, antimicrobial resistance, and pulsed field gel electrophoresis patterns to intestinal changes evaluation. *Poult Sci*. 88:750–758.
51. Brito, J.R.F., Y. Xu, M. Hinton, and G.R. Pearson. 1995. Pathological findings in the intestinal tract and liver of chicks after exposure to *Salmonella* serotypes typhimurium or kedougou. *Brit Vet J*. 151: 311–323.
52. Brown, D.J., D.L. Baggesen, D.J. Platt, and J.E. Olsen. 1999. Phage type conversion in *Salmonella enterica* serotype Enteritidis caused by the introduction of a resistance plasmid of incompatibility group X (IncX). *Epidemiol Infect*. 122:19–22.
53. Brownell, J.R., W.W. Sadler, and M.J. Fanelli. 1969. Factors influencing the intestinal infection of chickens with *Salmonella typhimurium*. *Avian Dis*. 13:804–816.
54. Bucher, O., R.A. Holley, R. Ahmed, H. Tabor, C. Nadon, L.K. Ng, and J.Y. D'Aoust. 2007. Occurrence and characterization of *Salmonella* from chicken nuggets, strips, and pelleted broiler feed. *J Food Prot*. 70:2215–2258.
55. Burkholder, K.M., K.L. Thompson, M.E. Einstein, T.J. Applegate, and J.A. Patterson. 2008. Influence of stressors on normal intestinal microbiota, intestinal morphology, and susceptibility to *Salmonella* Enteritidis colonization in broilers. *Poult Sci*. 87:1734–1741.
56. Byrd, J.A., M.R. Burnham, J.L. McReynolds, R.C. Anderson, K.J. Genovese, T.R. Callaway, L.F. Kubena, and D.J. Nisbet. 2008. Evaluation of an experimental chlorate product as a preslaughter feed supplement to reduce *Salmonella* in meat-producing birds. *Poult Sci*. 87:1883–1888.
57. Carrique-Mas, J.J., S. Barnes, I. McLaren, and R. Davies. 2009. Comparison of three plating media for the isolation of *Salmonella* from poultry environmental samples in Great Britain using ISO 6579:2002 (Annex D). *J Appl Microbiol*. 107:1976–1983.
58. Carrique-Mas, J.J., M. Breslin, A.R. Sayers, I. McLaren, M. Arnold, and R.H. Davies. 2008. Comparison of environmental sampling methods for detecting *Salmonella* in commercial laying flocks in the UK. *Lett Appl Microbiol*. 47:514–519.
59. Carrique-Mas, J.J., M. Breslin, L. Snow, M.E. Arnold, A. Wales, I. McLaren, and R.H. Davies. 2008. Observations related to the *Salmonella* EU layer baseline survey in the United Kingdom: follow-up of positive flocks and sensitivity issues. *Epidemiol Infect*. 136:1537–1546.
60. Carrique-Mas, J.J., M. Breslin, L. Snow, I. McLaren, A.R. Sayers, and R.H. Davies. 2009. Persistence and clearance of different *Salmonella* serovars in buildings housing laying hens. *Epidemiol Infect*. 137:837–846.
61. Carrique-Mas, J.J., C. Marín, M. Breslin, I. McLaren, and R.H. Davies. 2009. A comparison of the efficacy of cleaning and disinfection methods in eliminating *Salmonella* spp. From commercial egg laying houses. *Avian Pathol*. 38:419–424.
62. Carroll, P., R.M. La Ragione, A.R. Sayers, and M.J. Woodward. 2004. The O-antigen of *Salmonella enterica* serotype Enteritidis PT4: a significant factor in gastrointestinal colonisation of young but not newly hatched chicks. *Vet Microbiol*. 102:73–85.
63. Carvajal, B.G., U. Methner, J. Pieper, and A. Berndt. 2008. Effects of *Salmonella enterica* serovar Enteritidis on cellular recruitment and cytokine gene expression in caecum of vaccinated chickens. *Vaccine*. 26:5423–5433.
64. Cason, J.A., J.S. Bailey, and N.A. Cox. 1994. Transmission of *Salmonella typhimurium* during hatching of broiler chicks. *Avian Dis*. 38:583–588.
65. Castellan, D.M., H. Kinde, P.H. Kass, G. Cutler, R.E. Breitmeyer, D.D. Bell, R.A. Ernst, D.C. Kerr, H.E. Little, D. Willoughby, H.P. Riemann, A. Ardans, J.A. Snowdon, and D.R. Kuney. 2004. Descriptive study of California egg layer premises and analysis of risk factors for *Salmonella enterica* serotype enteritidis as characterized by manure drag swabs. *Avian Dis*. 48:550–561.
66. Centers for Disease Control and Prevention. 2011. National *Salmonella* surveillance data. http://www.cdc.gov/ncidod/dbmd/phlisdata/salmonella.htm. Accessed March 7, 2013.
67. Centers for Disease Control and Prevention. 2011. Vital signs: incidence and trends of infection with pathogens transmitted commonly through food—foodborne diseases active surveillance network, 10 U.S. sites, 1996–2010. *Morbid Mortal Weekly Rep*. 60:749–755.
68. Cerquetti, M.C., and M.M. Gherardi. 2000. Orally administered attenuated *Salmonella enteritidis* reduces chicken cecal carriage of virulent *Salmonella* organisms. *Vet Microbiol*. 76:185–192.
69. Chadfield, M.S., and M.H. Hinton. 2003. Evaluation of treatment and prophylaxis with nitrofurans and comparison with alternative antimicrobial agents in experimental *Salmonella enterica* serovar enteritidis infection in chicks. *Vet Res Commun*. 27: 257–273.
70. Chambers, J.R., J.L. Spencer, and H.W. Modler. 1997. The influence of complex carbohydrates on *Salmonella typhimurium* colonization, pH, and density of broiler ceca. *Poult Sci*. 76:445–451.
71. Chao, M.R., C.H. Hsien, C.M. Yeh, S.J. Chou, C. Chu, Y.C. Su, and C.Y. Yu. 2007. Assessing the prevalence of *Salmonella enterica* in poultry hatcheries by using hatched eggshell membranes. *Poult Sci*. 86:1651–1655.

72. Charlton, B.R., R.L. Walker, H. Kinde, C.R. Bauer, S.E. Channing-Santiago, and T.B. Farver. 2005. Comparison of a *Salmonella* Enteritidis-specific polymerase chain reaction assay to delayed secondary enrichment culture for the detection of *Salmonella* Enteritidis in environmental drag swab samples. *Avian Dis*. 49:418–422.
73. Chart, H., E.J. Threlfall, N.G. Powell, and B. Rowe. 1996. Serum survival and plasmid possession by strains of *Salmonella enteritidis, S. typhimurium* and *S. virchow*. *J Appl Bacteriol*. 80:31–36.
74. Cheeseman, J.H., N.A. Levy, P. Kaiser, H.S. Lillehoj, and S.J. Lamont. 2008. *Salmonella* Enteritidis-induced alteration of inflammatory CXCL chemokine messenger-RNA expression and histologic changes in the ceca of infected chicks. *Avian Dis*. 52:229–234.
75. Chen, H., R.C. Anantheswaran, and S.J. Knabel. 2001. Optimization of iron supplementation for enhanced detection of *Salmonella* Enteritidis in eggs. *J Food Prot*. 64:1279–1285.
76. Chinivasagam, H.N., T. Tran, L. Maddock, A. Gale, and P. Blackall. Mechanically ventilated broiler sheds: a possible source of aerosolized *Salmonella*, *Campylobacter*, and *Escherichia coli*. *Appl Environ Microbiol*. 75:7417–7425.
77. Chiu, L.H., C.H. Chiu, Y.M. Horn, C.S. Chiou, C.Y. Lee, C.M. Yeh, C.Y. Yu, C.P. Wu, C.C. Chang, and C. Chu. 2010. Characterization of 13 multi-drug resistant *Salmonella* serovars from different broiler chickens associated with those of human isolates. *BMC Microbiol*. 10:86.
78. Christensen, J.P., D.J. Brown, M. Madsen, J.E. Olsen, and M. Bisgaard. 1997. Hatchery-borne *Salmonella enterica* serovar Tennessee infections in broilers. *Avian Pathol*. 26:155–168.
79. Chu, C., S.F. Hong, C. Tsai, W.S. Lin, T.P. Liu, and J.T. Ou. 1999. Comparative physical and genetic maps of the virulence plasmids of *Salmonella enterica* serovars Typhimurium, Enteritidis, Choleraesuis, and Dublin. *Infect Immun*. 67:2611–2614.
80. Clark, C.G., T.M.A.C. Kruk, L. Bryden, Y. Hirvi, R. Ahmed, and F.G. Rodgers. 2003. Subtyping of *Salmonella enterica* serotype Enteritidis strains by manual and automated PstI-SphI ribotyping. *J Clin Microbiol*. 41:27–33.
81. Clifton-Hadley, F.A., M. Breslin, L.M. Venables, K.A. Sprigings, S.W. Cooles, S. Hougton, and M.J. Woodward. 2002. A laboratory study of an inactivated bivalent iron restricted *Salmonella enterica* serovars Enteritidis and Typhimurium dual vaccine against Typhimurium challenge in chickens. *Vet Microbiol*. 89:167–179.
82. Coble, D.J., S.B. Redmond, B. Hale, and S.J. Lamont. 2011. Distinct lines of chickens express different splenic cytokine profiles in response to *Salmonella* Enteritidis challenge. *Poult Sci*. 90:1659–1663.
83. Cogan, T.A., and T.J. Humphrey. 2003. The rise and fall of *Salmonella* Enteritidis in the UK. *J Appl Microbiol*. 94:114S-119S.
84. Collard, J.M., S. Bertrand, K. Dierick, C. Godard, C. Wildemauwe, K. Vermeersch, J. Duculot, F. Van Immerseel, F. Pasmans, H. Imberechts, and C. Quinet. 2007. Drastic decrease of *Salmonella* Enteritidis isolated from humans in Belgium in 2005, shift in phage types and influence on foodborne outbreaks. *Epidemiol Infect*. 136:771–781.
85. Conner, C.P., D.M. Heithoff, S.M. Julio, R.L. Sinsheimer, and M.J. Mahan. 1998. Differential patterns of acquired virulence genes distinguish *Salmonella* strains. *Proc Natl Acad Sci USA*. 95:4641–4645.
86. Corkish, J.D., R.H. Davies, C. Wray, and R.A.J. Nicholas. 1994. Observations on a broiler breeder flock naturally infected with *Salmonella enteritidis* phage type 4. *Vet Rec*. 134:591–594.
87. Corrier, D.E., J.A. Byrd, B.M. Hargis, M.E. Hume, R.H. Bailey, and L.H. Stanker. 1999. Presence of *Salmonella* in the crop and ceca of broiler chickens before and after preslaughter feed withdrawal. *Poult Sci*. 78:45–49.
88. Corrier, D.E., J.A. Byrd II, M.E. Hume, D.J. Nisbet, and L.H. Stanker. 1998. Effect of simultaneous or delayed competitive exclusion treatment on the spread of *Salmonella* in chicks. *J Appl Poult Res*. 7:132–137.
89. Corrier, D.E., A.G. Hollister, D.J. Nisbet, C.M. Scanlan, R.C. Beier, and J.R. DeLoach. 1994. Competitive exclusion of *Salmonella enteritidis* in Leghorn chicks: Comparison of treatment by crop gavage, drinking water, spray, or lyophilized alginate beads. *Avian Dis*. 38:297–303.
90. Corrier, D.E., and R.L. Ziprin. 1989. Suppression of resistance to *Salmonella typhimurium* in young chickens inoculated with Corynebacterium parvum. *Avian Dis*. 33:787–791.
91. Cox, N.A., J.S. Bailey, and M.E. Berrang. 1996. Alternative routes for *Salmonella* intestinal tract colonization of chicks. *J Appl Poult Sci*. 5:282–288.
92. Cox, N.A., J.S. Bailey, J.M. Mauldin, and L.C. Blankenship. 1990. Presence and impact of *Salmonella* contamination in commercial broiler hatcheries. *Poult Sci*. 69:1606–1609.
93. Cox, N.A., J.S. Bailey, and J.E. Thomson. 1982. Effect of various media and incubation conditions on recovery of inoculated Salmonellae from poultry feed. *Poult Sci*. 61:1314–1321.
94. Cox, N.A., M.E. Berrang, J.S. Bailey, and N.J. Stern. 2002. Bactericidal treatment of hatching eggs. V: Efficiency of repetitive immersions in hydrogen peroxide or phenol to eliminate *Salmonella* from hatching eggs. *J Appl Poult Res*. 11:328–331.
95. Cox, N.A., M.E. Berrang, and J.M. Mauldin. 2002. Extent of salmonellae contamination in primary breeder hatcheries in 1998 as compared to 1991. *J Appl Poult Res*. 10:202–205.
96. Cox, N.A., S.E. Craven, M.T. Musgrove, M.E. Berrang, and N.J. Stern. 2003. Effect of sub-therapeutic levels of antimicrobials in feed on the intestinal carriage of *Campylobacter* and *Salmonella* in turkeys. *J Appl Poult Res*. 12:32–36.
97. Cox, N.A., L.J. Richardson, R.J. Buhr, M.T. Musgrove, M.E. Berrang, and W. Bright. 2007. Bactericidal effect of several chemicals on hatching eggs inoculated with *Salmonella* serovar Typhimurium. *J Appl Poult Res*. 16:623–627.
98. Cox, N.A., L.J. Richardson, R.J. Buhr, J.K. Northcutt, J.S. Bailey, P.F. Cray, and K.L. Hiett. 2007. Recovery of *Campylobacter* and *Salmonella* serovars from the spleen, liver and gallbladder, and ceca of six- and eight-week-old commercial broilers. *J Appl Poult Res*. 16:477–480.
99. Cox, N.A., and J.E. Williams. 1976. A simplified biochemical system to screen salmonella isolates from poultry for serotyping. *Poult Sci*. 55:1968–1971.
100. Craven, S.E. 1994. Altered colonizing ability for the ceca of broiler chicks by lipopolysaccharide-deficient mutants of *Salmonella typhimurium*. *Avian Dis*. 38:401–408.
101. Crhanova, M., H. Hradecka, M. Faldynova, M. Matulova, H. Havlickova, F. Sisak, and I. Rychlik. 2011. Immune response of chicken gut to natural colonization by gut microflora and to *Salmonella enterica* serovar Enteritidis infection. *Infect Immun*. 79:2755–2763.
102. Danguy des Déserts, J., R.H. Davies, K. Vaughan, I. McLaren, P. Canning, A. Wintrip, D. Mueller-Doblies, and J.J. Carrique-Mas. 2011. A longitudinal study of *Salmonella* infection in different types of turkey flocks in Great Britain. *Zoonoses Public Hlth*. 58:200–208.

103. D'Aoust, J.Y., A.M. Sewell, and E. Daley. 1992. Inadequacy of small transfer volume and short (6 h) selective enrichment for the detection of foodborne *Salmonella*. *J Food Prot*. 55:326–328.
104. Davies, R., and M. Breslin. 2001. Environmental contamination and detection of *Salmonella enterica* serovar enteritidis in laying flocks. *Vet Rec*. 149:699–704.
105. Davies, R., and M. Breslin. 2003. Effects of vaccination and other preventive methods for *Salmonella* Enteritidis on commercial laying chicken farms. *Vet Rec*. 153:673–677.
106. Davies, R.H., and M.F. Breslin. 2003. Observations on the distribution and persistence of *Salmonella enterica* serovar Enteritidis phage type 29 on a cage layer farm before and after the use of competitive exclusion. *Brit Poult Sci*. 44:551–557.
107. Davies, R.H., and M. Breslin. 2003. Persistence of *Salmonella* Enteritidis phage type 4 in the environment and arthropod vectors on an empty free-range chicken farm. *Environ Microbiol*. 5:79–84.
108. Davies, R., and M. Breslin. 2004. Observations on *Salmonella* contamination of eggs from infected commercial laying flocks where vaccination for *Salmonella enterica* serovar Enteritidis had been used. *Avian Pathol*. 33:133–144.
109. Davies, R., E. Liebana, and M. Breslin. 2003. Investigation of the distribution and control of *Salmonella enterica* serovar Enteritidis PT6 in layer breeding and egg production. *Avian Pathol*. 32:227–237.
110. Davies, R.H., C.J. Teale, C. Wray, I.M. McLaren, Y.E. Jones, S. Chappell, and S. Kidd. 1999. Nalidixic acid resistance in salmonellae isolated from turkeys and other livestock in Great Britain. *Vet Rec*. 144:320–322.
111. Davies, R.H., and A.D. Wales. 2010. Investigations into *Salmonella* contamination in poultry feedmills in the United Kingdom. *J Appl Microbiol*. 109:1430–1440.
112. Davies, R.H., and C. Wray. 1995. Observations on disinfection regimens used on *Salmonella enteritidis* infected poultry units. *Poult Sci*. 74:638–647.
113. Davies, R.H., and C. Wray. 1996. Persistence of *Salmonella enteritidis* in poultry units and poultry food. *Br Poult Sci*. 37:589–596.
114. Davies, R.H., and C. Wray. 1996. Studies of contamination of three broiler breeder houses with *Salmonella enteritidis* before and after cleansing and disinfection. *Avian Dis*. 40:626–633.
115. Davis, M., and T.Y. Morishita. 2005. Relative ammonia concentrations, dust concentrations, and presence of *Salmonella* species and *Escherichia coli* inside and outside commercial layer facilities. *Avian Dis*. 49:30–35.
116. Davison, S., C.E. Benson, and R.J. Eckroade. 1996. Evaluation of disinfectants against *Salmonella enteritidis*. *Avian Dis*. 40: 272–277.
117. Dawoud, T.M., P. Hererra, I. Hanning, Y.M. Kwon, and S.C. Ricke. 2011. *In vitro* invasion of laying hen ovarian follicles by *Salmonella* Enteritidis strains. *Poult Sci*. 90:1134–1137.
118. De Buck, J., F. Pasmans, F. Van Immerseel, F. Haesebrouck, and R. Ducatelle. 2004. Tubular glands of the isthmus are the predominant colonization site of *Salmonella* Enteritidis in the upper oviduct of laying hens. *Poult Sci*. 83:352–358.
119. De Buck, J., F. Van Immerseel, F. Haesebrocuk, and R. Ducatelle. 2005. Protection of laying hens against *Salmonella* Enteritidis by immunization with type 1 fimbriae. *Vet Microbiol*. 105:93–101.
120. Deguchi, K., E. Yokoyama, T. Honda, and K. Mizuno. 2009. Efficacy of a novel trivalent inactivated vaccine against the shedding of *Salmonella* in a chicken challenge model. *Avian Dis*. 53:281–286.
121. Derache, C.E., C. Esnault, C. Bonsergent, Y. Le Vern, P. Quéré, and A.C. Lalmanach. 2009. Differential modulation of β-defensin gene expression by *Salmonella* Enteritidis in intestinal epithelial cells from resistant and susceptible chicken inbred lines. *Develop Compar Immunol*. 33:959–966.
122. Desin, T.S., P.K. Lam, B. Koch, C. Mickael, E. Berberov, A.L.S. Wisner, H.G.G. Townsend, A.A. Potter, and W. Köster. 2009. *Salmonella enterica* serovar Enteritidis pathogenicity island 1 is not essential for but facilitates rapid systemic spread in chickens. *Infect Immun*. 77:2866–2875.
123. Desmidt, M., R. Ducatelle, and F. Haesebrouck. 1997. Pathogenesis of *Salmonella enteritidis* phage type four after experimental infection of young chickens. *Vet Microbiol*. 56:99–109.
124. Desmidt, M., R. Ducatelle, and F. Haesebrouck. 1998. Immunohistochemical observations in the ceca of chickens infected with *Salmonella enteritidis* phage type four. *Poult Sci*. 77:73–74.
125. Desmidt, M., R. Ducatelle, and F. Haesebrouck. 1998. Serological and bacteriological observations on experimental infection with *Salmonella hadar* in chickens. *Vet Microbiol*. 60:259–269.
126. De Vylder, J. Dewulf, J., S. Van Hoorebeke, F. Pasmans, F. Haesebrouck, R. Ducatelle, and F. Van Immerseel. 2011. Horizontal transmission of *Salmonella* Enteritidis in groups of experimentally infected hens housed in different housing systems. *Poult Sci*. 90:1391–1396.
127. DeWinter, L.M., W.H. Ross, H. Couture, and J.F. Farber. 2011. Risk assessment of shell eggs internally contaminated with *Salmonella* Enteritidis. *Int Food Risk Anal J*. 1:40–81.
128. Dhawi, A.A., A. Elazomi, M.A. Jones, M.A. Lovell, H. Li, R.D. Emes, and P.A. Barrow. 2011. Adaptation to the chicken intestine in *Salmonella* Enteritidis PT4 studies by transcriptional analysis. *Vet Microbiol*. 153:198–204.
129. Dhillon, A.S., H.L. Shivaprasad, P. Roy, B. Alisantosa, D. Schaberg, D. Bandli, and S. Johnson. 2001. Pathogenicity of environmental origin *Salmonella*s in specific pathogen-free chicks. *Poult Sci*. 80:1323–1328.
130. Dibb-Fuller, M.P., and M.J. Woodward. 2000. Contribution of fimbriae and flagella of *Salmonella enteritidis* to colonization and invasion of chicks. *Avian Pathol*. 29:295–304.
131. Dieye, Y., K. Ameiss, M. Mellata, and R. Curtiss III. 2009. The *Salmonella* pathogenicity island (SPI) 1 contributes more than SPI2 to the colonization of the chicken by *Salmonella enterica* serovar Typhimurium. *BMC Microbiol*. 9:3.
132. Donalson, L.M., J.L. McReynolds, W.K. Kim, V.I. Chalova, C.L. Woodward, L.F. Kubena, D.J. Nisbet, and S.C. Ricke. 2008. The influence of a fructooligosaccharide prebiotic combined with alfalfa molt diets on the gastrointestinal tract fermentation, *Salmonella* Enteritidis infection, and intestinal shedding in laying hens. *Poult Sci*. 87:1253–1262.
133. Dórea, F.C., D.J. Coyle, C. Hofacre, K. Zamperini, D. Mathis, M.P. Doyle, M.D. Lee, and J.J. Maurer. 2010. Effect of *Salmonella* vaccination of breeder chickens on contamination of broiler chicken carcasses in integrated poultry operations. *Appl Environ Microbiol*. 76:7820–7825.
134. Duchet-Suchaux, M., P. Léchopier, J. Marly, P. Bernardet, R. Delaunay, and P. Pardon. 1995. Quantification of experimental *Salmonella enteritidis* carrier state in B13 Leghorn chicks. *Avian Dis*. 39:796–803.
135. Duchet-Suchaux, M., F. Mompart, F. Berthelot, C. Beaumont, P. Léchopier, and P. Pardon. 1997. Differences in frequency,

level, and duration of cecal carriage between four outbred chicken lines infected orally with *Salmonella enteritidis*. *Avian Dis*. 41:559–567.
136. Dunkley, K.D., J.L. McReynolds, M.E. Hume, C.S. Dunkley, T.R. Callaway, L.F. Kubena, D.J. Nisbet, and S.C. Ricke. 2007. Molting in *Salmonella* Enteritidis-challenged laying hens fed alfalfa crumbles. I. *Salmonella* Enteritidis colonization and virulence gene hilA response. *Poult Sci*. 86:1633–1639.
137. Dunlap, N.E., W.H. Benjamin, Jr., A.K. Berry, J.H. Eldridge, and D.E. Briles. 1992. A 'safe-site' for *Salmonella typhimurium* is within splenic polymorphonuclear cells. *Microb Pathogen*. 13:181–190.
138. Durant, J., D.E. Corrier, J.A. Byrd, L.H. Stanker, and S.C. Ricke. 1999. Feed deprivation affects crop environment and modulates *Salmonella enteritidis* colonization and invasion of leghorn hens. *Appl Environ Microbiol*. 65:1919–1923.
139. Durant, J.A., D.E. Corrier, L.H. Stanker, and S.C. Ricke. 2000. Expression of the hilA *Salmonella typhimurium* gene in a poultry *S*. Enteritidis isolate in response to lactate and nutrients. *J Appl Microbiol*. 89:63–69.
140. Ebel, E., and W. Schlosser. 2000. Estimating the annual fraction of eggs contaminated with *Salmonella enteritidis* in the United States. *Int J Food Microbiol*. 61:51–62.
141. Elissalde, M.H., R.L. Ziprin, W.E. Huff, L.F. Kubena, and R.B. Harvey. 1994. Effect of Ochratoxin A on *Salmonella*-challenged broiler chicks. *Poult Sci*. 73:1241–1248.
142. Erdman, M.M., B.R. Morningstar-Shaw, D.A. Barker, T.A. Mackie, M.I. Munoz, E.A. Palmer, M.A. Kane, and L.K. Cox. 2011. *Salmonella* serotypes isolated from animals in the United States: January 1–December 31, 2009. *Proc U.S. Anim Health Assoc*. 114:462–473.
143. Eriksson de Rezende, C.L., E.T. Mallinson, N.L. Tablante, R. Morales, A. Park, L.E. Carr, and S.W. Joseph. 2001. Effect of dry litter and airflow in reducing *Salmonella* and *Escherichia coli* populations in the broiler production environment. *J Appl Poult Res*. 10:245–251.
144. Evans, M.C., and H.C. Wegener. 2003. Antimicrobial growth promoters and *Salmonella* spp., *Campylobacter* spp. in poultry and swine, Denmark. *Emerging Infect Dis*. 9:489–492.
145. Eyigor, A., G. Goncagul, E. Gunyadin, and K.T. Carli. 2005. *Salmonella* profile in chickens determined by real-time polymerase chain reaction and bacteriology from years 2000 to 2003 in Turkey. *Avian Pathol*. 32:101–105.
146. Faddoul, G.P., and G.W. Fellows. 1966. A five-year survey of the incidence of Salmonellae in avian species. *Avian Dis*. 10:296–304.
147. Fagerberg, D.J, C.L. Quarles, J.A. Ranson, R.D. Williams, L.P. Williams, Jr., C.B. Hancock, and S.L. Seaman. 1976. Experimental procedure for testing the effects of low level antibiotic feeding and therapeutic treatment on *Salmonella typhimurium* var. copenhagen infection in broiler chicks. *Poult Sci*. 55:1848–1857.
148. Fasina, Y.O., F.J. Hoerr, S.R. McKee, and D.E. Conner. 2010. Influence of *Salmonella enterica* serovar Typhimurium infection on intestinal goblet cells and villous morphology in broiler chicks. *Avian Dis*. 54:841–847.
149. Fearnley, E., J. Raupach, F. Lagal, and S. Cameron. 2011. *Salmonella* in chicken meat, eggs and humans: Adelaide, South Australia, 2008. *Int J Food Microbiol*. 146:219–227.
150. Feberwee, A., T.S. de Vries, A.R.W. Elbers, and W.A. de Jong. 2000. Results of a *Salmonella enteritidis* vaccination field trial in broiler-breeder flocks in the Netherlands. *Avian Dis*. 44:249–255.
151. Feberwee, A., T.S. de Vries, E.G. Hartman, J.J. de Wit, A.R.W. Elbers, and W.A. de Jong. 2001. Vaccination against *Salmonella enteritidis* in Dutch commercial layer flocks with a vaccine based on a live *Salmonella gallinarum* 9R strain: evaluation of efficacy, safety, and performance of serological *Salmonella* tests. *Avian Dis*. 45:83–91.
152. Fernandez, F., M. Hinton, and B. Van Gils. 2002. Dietary mannan-oligosaccharides and their effect on chicken caecal microflora in relation to *Salmonella* Enteritidis colonization. *Avian Pathol*. 31:49–58.
153. Filho, R.A.C.P., J.B. de Paiva, Y.M.S. Argüello, M.D. da Silva, Y. Gardin, F. Resende, A. Berchieri Jr., and L. Sesti. 2009. Efficacy of several vaccination programmes in commercial layer and broiler breeder hens against experimental challenge with *Salmonella enterica* serovar Enteritidis. *Avian Pathol*. 38:367–375.
154. Foley, S.L., R. Nayak, I.B. Hanning, T.J. Johnson, J. Han, and S.C. Ricke Population dynamics of *Salmonella enterica* serotypes in commercial egg and poultry production. *Appl Environ Microbiol*. 77:4273–4279.
155. Gan, E., F.J. Baird, P.J. Coloe, and P.M. Smooker. 2011. Phenotypic and molecular characterization of *Salmonella enterica* serovar Sofia, an avirulent species in Australian poultry. *Microbiol*. 157:1056–1065.
156. Gantois, I., R. Ducatelle, F. Pasmans, F. Haesebrouck, and F. Van Immerseel. 2008. *Salmonella enterica* serovar Enteritidis genes induced during oviduct colonization and egg contamination in laying hens. *Appl Environ Microbiol*. 74:6616–6622.
157. Gantois, I., V. Eeckhaut, F. Pasmans, F. Haesebrouck, R. Ducatelle, and F. Van Immerseel. 2008. A comparative study on the pathogenesis of egg contamination by different serotypes of *Salmonella*. *Avian Pathol*. 37:399–406.
158. Gao, F., L.E. Stewart, S.W. Joseph, and L.E. Carr. 1997. Effectiveness of ultraviolet irradiation in reducing the numbers of *Salmonella* on eggs and egg belt conveyor materials. *Appl Eng Agric*. 13:355–359.
159. Garber, L., M. Smeltzer, P. Fedorka-Cray, S. Ladely, and K. Ferris. 2003. *Salmonella enterica* serotype *enteritidis* in table egg layer house environments and in mice in U.S. layer houses and associated risk factors. *Avian Dis*. 47:134–142.
160. García, J., M. Soriano, V. Benítez, and P. Catalá-Gregori. 2011. Assessment of *Salmonella* spp. in feces, cloacal swabs, and eggs (eggshell and content separately) from a laying hen farm. *Poult Sci*. 90:1581–1585.
161. Gast, R.K. 1993. Evaluation of direct plating for detecting *Salmonella enteritidis* in pools of egg contents. *Poult Sci*. 72: 1611–1614.
162. Gast, R.K., and C.W. Beard. 1989. Age-related changes in the persistence and pathogenicity of *Salmonella typhimurium* in chicks. *Poult Sci*. 68:1454–1460.
163. Gast, R.K., and C.W. Beard. 1990. Production of *Salmonella enteritidis*-contaminated eggs by experimentally infected hens. *Avian Dis*. 34:438–446.
164. Gast, R.K., and C.W. Beard. 1990. Isolation of *Salmonella enteritidis* from internal organs of experimentally infected hens. *Avian Dis*. 34:991–993.
165. Gast, R.K., and C.W. Beard. 1990. Serological detection of experimental *Salmonella enteritidis* infections in laying hens. *Avian Dis*. 34:721–728.
166. Gast, R.K., and C.W. Beard. 1991. Detection of *Salmonella* serogroup D-specific antibodies in the yolks of eggs laid by hens infected with *Salmonella enteritidis*. *Poult Sci*. 70:1273–1276.
167. Gast, R.K., and S.T. Benson. 1995. The comparative virulence for chicks of *Salmonella enteritidis* phage type 4 isolates and

isolates of phage types commonly found in poultry in the United States. *Avian Dis*. 39:567–574.
168. Gast, R.K., and S.T. Benson. 1996. Intestinal colonization and organ invasion in chicks experimentally infected with *Salmonella enteritidis* phage type 4 and other phage types isolated from poultry in the United States. *Avian Dis*. 40:853–857.
169. Gast, R.K., J. Guard-Bouldin, and P.S. Holt. 2004. Colonization of reproductive organs and internal contamination of eggs after experimental infection of laying hens with *Salmonella* heidelberg and *Salmonella enteritidis*. *Avian Dis*. 48:863–869.
170. Gast, R.K., J. Guard-Petter, and P.S. Holt. 2002. Characteristics of *Salmonella enteritidis* contamination in eggs after oral, aerosol, and intravenous inoculation of laying hens. *Avian Dis*. 46:629–635.
171. Gast, R.K., J. Guard-Petter, and P.S. Holt. 2003. Effect of prior serial *in vivo* passage on the frequency of *Salmonella enteritidis* contamination in eggs from experimentally infected laying hens. *Avian Dis*. 47:633–639.
172. Gast, R.K., R. Guraya, J. Guard, and P.S. Holt. 2011. Frequency and magnitude of internal organ colonization following exposure of laying hens to different oral doses of *Salmonella enteritidis*. *Int J Poult Sci*. 10:325–331.
173. Gast, R.K., R. Guraya, J. Guard, and P.S. Holt. 2011. The relationship between the numbers of *Salmonella* Enteritidis, *Salmonella* Heidelberg, or *Salmonella* Hadar colonizing reproductive tissues of experimentally infected laying hens and deposition inside eggs. *Avian Dis*. 55:243–247.
174. Gast, R.K., R. Guraya, J. Guard-Bouldin, P.S. Holt, and R.W. Moore. 2007. Colonization of specific regions of the reproductive tract and deposition at different locations inside eggs by hens infected with *Salmonella* Enteritidis or *Salmonella* Heidelberg. *Avian Dis*. 51:40–44.
175. Gast, R.K., and P.S. Holt. 1995. Iron supplementation to enhance the recovery of *Salmonella enteritidis* from pools of egg contents. *J Food Prot*. 58:268–272.
176. Gast, R.K., and P.S. Holt. 1998. Persistence of *Salmonella enteritidis* from one day of age until maturity in experimentally infected layer chickens. *Poult Sci*. 77:1759–1762.
177. Gast, R.K., and P.S. Holt. 2000. Deposition of phage type 4 and 13a *Salmonella enteritidis* strains in the yolk and albumen of eggs laid by experimentally infected hens. *Avian Dis*. 44:706–710.
178. Gast, R.K., and P.S. Holt. 2001. Assessing the frequency and consequences of *Salmonella enteritidis* deposition on the egg yolk membrane. *Poult Sci*. 80:997–1002.
179. Gast, R.K., and P.S. Holt. 2001. The relationship between the magnitude of the specific antibody response to experimental *Salmonella enteritidis* infection in laying hens and their production of contaminated eggs. *Avian Dis*. 45:425–431.
180. Gast, R.K., and P.S. Holt. 2003. Incubation of supplemented egg contents pools to support rapid detection of *Salmonella enterica* serovar Enteritidis. *J Food Prot*. 66:656–659.
181. Gast, R.K., P.S. Holt, M.S. Nasir, M.E. Jolley, and H.D. Stone. 2003. Detection of *Salmonella enteritidis* in incubated pools of egg contents by fluorescence polarization and lateral flow immunodiffusion. *Poult Sci*. 82:687–690.
182. Gast, R.K., B.W. Mitchell, and P.S. Holt. 1998. Airborne transmission of *Salmonella enteritidis* infection between groups of chicks in controlled-environment isolation cabinets. *Avian Dis*. 42:315–320.
183. Gast, R.K., B.W. Mitchell, and P.S. Holt. 2004. Detection of airborne *Salmonella enteritidis* in the environment of experimentally infected laying hens by an electrostatic sampling device. *Avian Dis*. 48:148–154.
184. Gast, R.K., M.S. Nasir, M.E. Jolley, P.S. Holt, and H.D. Stone. 2002. Detection of experimental *Salmonella enteritidis* and S. *typhimurium* infections in laying hens by fluorescence polarization assay for egg yolk antibodies. *Poult Sci*. 81:1128–1131.
185. Gast, R.K., M.S. Nasir, M.E. Jolley, P.S. Holt, and H.D. Stone. 2002. Serologic detection of experimental *Salmonella enteritidis* infections in laying hens by fluorescence polarization and enzyme immunoassay. *Avian Dis*. 46:137–142.
186. Gast, R.K., R.E. Porter, Jr., and P.S. Holt. 1997. Applying tests for specific yolk antibodies to predict contamination by *Salmonella enteritidis* in eggs from experimentally infected laying hens. *Avian Dis*. 41:195–202.
187. Gast, R.K., R.E. Porter, Jr., and P.S. Holt. 1997. Assessing the sensitivity of egg yolk antibody testing for detecting *Salmonella enteritidis* infections in laying hens. *Poult Sci*. 76:798–801.
188. Gast, R.K., H.D. Stone, P.S. Holt, and C.W. Beard. 1992. Evaluation of the efficacy of an oil-emulsion bacterin for protecting chickens against *Salmonella enteritidis*. *Avian Dis*. 36: 992–999.
189. Genovese, L.L., V.K. Lowry, K.J. Genovese, and M.H. Kogut. 2000. Longevity of augmented phagocytic activity of heterophils in neonatal chickens following administration of *Salmonella enteritidis*-immune lymphokines to chickens. *Avian Pathol*. 29: 117–122.
190. Girard-Santosuosso, O., P. Menanteau, M. Duchet-Suchaux, F. Berthelot, F. Mompart, J. Protais, P. Colin, J.F. Guillot, C. Beaumont, and F. Lantier. 1998. Variability in the resistance of four chicken lines to experimental intravenous infection with *Salmonella enteritidis* phage type 4. *Avian Dis*. 42:462–469.
191. Goodnough, M.C., and E.A. Johnson. 1991. Control of *Salmonella enteritidis* infections in poultry by polymyxin B and trimethoprim. *Appl Environ Microbiol*. 57:785–788.
192. Gradel, K.O., J. Chr. Jørgensen, J.S. Andersen, and J.E.L. Corry. 2004. Monitoring the efficacy of steam and formaldehyde treatment of naturally *Salmonella*-infected layer houses. *J Appl Microbiol*. 96:613–622.
193. Greig, J.D., and A. Ravel. 2009. Analysis of foodborne outbreak data reported internationally for source attribution. *Int J Food Microbiol*. 130:77–87.
194. Guard, J., R.K. Gast, and R. Guraya. 2010. Colonization of avian reproductive-tract tissues by variant subpopulations of *Salmonella* Enteritidis. *Avian Dis*. 54:857–861.
195. Guard, J., D. Shah, C.A. Morales, and D. Call. 2011. Evolutionary trends associated with niche specialization as modelled by whole genome analysis of egg-contaminating *Salmonella enterica* serovar Enteritidis. In: *Salmonella: From Genome to Function*. S. Porwollik, ed. Caister Academic Press, Norfolk, United Kingdom. 91–106.
196. Guard-Bouldin, J., C.A. Morales, J.G. Frye, R.K. Gast, and M. Musgrove. 2007. Detection of *Salmonella enterica* subpopulations by phenotype microarray antibiotic resistance patterns. *Appl Environ Microbiol*. 73:7753–7756.
197. Guillot, J.F., C. Beaumont, F. Bellatif, C. Mouline, F. Lantier, P. Colin, and J. Protais. 1995. Comparison of resistance of various poultry lines to infection by *Salmonella enteritidis*. *Vet Res*. 26:81–86.
198. Guo, C., R.M. Hoekstra, C.M. Schroeder, S.M. Pires, K.L. Ong, E. Hartnett, A. Naugle, J. Harman, P. Bennett, P. Cieslak, E. Scallan, B. Rose, K.G. Holt, B. Kissler, E. Mbandi, R.

Roodsari, F.J. Angulo, and D. Cole. 2011. Application of Bayesian techniques to model the burden of human salmonellosis attributable to U.S. food commodities at the point of processing: adaptation of a Danish model. *Foodborne Pathog Dis*. 8:509–516.

199. Gürakan, G.C., C. Aksoy, Z.B. Ögel, and N.G. Ören. 2008. Differentiation of *Salmonella* Typhimurium from *Salmonella* Enteritidis and other *Salmonella* serotypes using random amplified polymorphic DNA analysis. *Poult Sci*. 87:1068–1074.
200. Gutierrez, M., J. Fanning, A. Murphy, G. Murray, M. Griffin, A. Flack, N. Leonard, and J. Egan. 2009. *Salmonella* in broiler flocks in the Republic of Ireland. *Foodborne Pathog Dis*. 6:111–120.
201. Ha, S.D., K.G. Maciorowski, and S.C. Ricke. 1997. Ethyl alcohol reduction of *Salmonella typhimurium* in poultry feed. *J Rap Meth Automat Microbiol*. 5:75–85.
202. Halavatkar, H., and P.A. Barrow. 1993. The role of a 54-kb plasmid in the virulence of strains of *Salmonella* Enteritidis of phage type 4 for chickens and mice. *J Med Microbiol*. 38:171–176.
203. Hassan, J.O., P.A. Barrow, A.P.A. Mockett, and S. McLeod. 1990. Antibody response to experimental *Salmonella typhimurium infection in chickens measured by ELISA*. *Vet Rec*. 126: 519–522.
204. Hassan, J.O., and R. Curtiss III. 1994. Virulent *Salmonella typhimurium*-induced lymphocyte depletion and immunosuppression in chickens. *Infect Immun*. 62:2027–2036.
205. Hassan, J.O., A.P.A. Mockett, D. Catty, and P.A. Barrow. 1991. Infection and reinfection of chickens with *Salmonella typhimurium*: Bacteriology and immune responses. *Avian Dis*. 35:809–819.
206. Hassan, J.O., A.P.A. Mockett, S. McLeod, and P.A. Barrow. 1991. Indirect antigen-trap ELISAs using polyclonal antisera for detection of group B and D *Salmonella*s in chickens. *Avian Pathol*. 20:271–282.
207. He, G.Z., W.Y. Tian, N. Qian, A.C. Cheng, and S.X. Deng. 2010. Quantitative studies of the distribution pattern for *Salmonella* Enteritidis in the internal organs of chicken after oral challenge by a real-time PCR. *Vet Res Commun*. 34:669–676.
208. He, H., K.J. Genovese, C.L. Swaggerty, D.J. Nisbet, and M.H. Kogut. 2007. *In vivo* priming heterophil innate immune functions and increasing resistance to *Salmonella enteritidis* infection in neonatal chickens by immune stimulatory CpG oligodeoxynucleotides. *Vet Immunol Immunopathol*. 117:275–283.
209. Helmuth, R. 2000. Antibiotic resistance in *Salmonella*. In: *Salmonella in Domestic Animals*. C. Wray and A. Wray, eds. CABI Publishing, Oxon, United Kingdom. 89–106.
210. Henderson, S.C., D.I. Bounous, and M.D. Lee. 1999. Early events in the pathogenesis of avian salmonellosis. *Infect Immun*. 67:3580–3586.
211. Henzler, D.J., D.C. Kradel, and W.M. Sischo. 1998. Management and environmental risk factors for *Salmonella enteritidis* contamination of eggs. *Am J Vet Res*. 59:824–829.
212. Henzler, D.J., and H.M. Opitz. 1992. The role of mice in the epizootiology of *Salmonella enteritidis* infection on chicken layer farms. *Avian Dis*. 36:625–631.
213. Higgins, J.P., S.E. Higgins, J.L. Vicente, A.D. Wolfenden, G. Tellez, and B.M. Hargis. 2007. Temporal effects of lactic acid bacteria probiotic culture on *Salmonella* in neonatal broilers. *Poult Sci*. 86:1662–1666.
214. Higgins, J.P., S.E. Higgins, A.D. Wolfenden, S.N. Henderson, A. Torres-Rodriguez, J.L. Vicente, B.M. Hargis, and G. Tellez. 2010. Effect of lactic acid bacteria probiotic culture treatment timing on *Salmonella* Enteritidis in neonatal broilers. *Poult Sci*. 89:243–247.
215. Higgins, S.E., J.P. Higgins, A.D. Wolfenden, S.N. Henderson, A. Torres-Rodriguez, G. Tellez, and B. Hargis. 2008. Evaluation of a Lactobacillus-based probiotic culture for the reduction of *Salmonella* Enteritidis in neonatal broiler chicks. *Poult Sci*. 887:27–31.
216. Higgins, S.E., A.D. Wolfenden, G. Tellez, B.M. Hargis, and T.E. Porter. 2011. Transcriptional profiling of cecal gene expression in probiotic- and *Salmonella*-challenged neonatal chicks. *Poult Sci*. 90:901–913.
217. Himathongkham, S., M.G. Pereira, and H. Riemann. 1996. Heat destruction of *Salmonella* in poultry feed: effect of time, temperature, and moisture. *Avian Dis*. 40:72–77.
218. Hinton, A., Jr., R.J. Buhr, and K.D. Ingram. 2002. Carbohydrate-based cocktails that decrease the population of *Salmonella* and *Campylobacter* in the crop of broiler chickens subjected to feed withdrawal. *Poult Sci*. 81:780–784.
219. Hinton, M. 1988. *Salmonella* infection in chicks following the consumption of artificially contaminated feed. *Epidemiol Infect*. 100:247–256.
220. Hogue, A., P. White, J. Guard-Petter, W. Schlosser, R. Gast, E. Ebel, J. Farrar, T. Gomez, J. Madden, M. Madison, A.M. McNamara, R. Morales, D. Parham, P. Sparling, W. Sutherlin, and D. Swerdlow. 1997. Epidemiology and control of egg-associated *Salmonella* Enteritidis in the United States of America. *Rev Sci Tech Off Int Epiz*. 16:542–553.
221. Hollister, A.G., D.E. Corrier, D.J. Nisbet, and J.R. DeLoach. 1999. Effects of chicken-derived cecal microorganisms maintained in continuous culture on cecal colonization by *Salmonella typhimurium* in turkey poults. *Poult Sci*. 78:546–549.
222. Holt, P.S. 1995. Horizontal transmission of *Salmonella enteritidis* in molted and unmolted laying chickens. *Avian Dis*. 39: 239–249.
223. Holt, P.S., R.J. Buhr, D.L. Cunningham, and R.E. Porter, Jr. 1994. Effect of two different molting procedures on a *Salmonella enteritidis* infection. *Poult Sci*. 73:1267–1275.
224. Holt, P.S., and R.K. Gast. 2004. Effects of prior coinfection with different *Salmonella* serovars on the progression of a *Salmonella enterica* serovar *enteritidis* infection in hens undergoing induced molt. *Avian Dis*. 48:160–166.
225. Holt, P.S., R.K. Gast, and C.R. Greene, 1995. Rapid detection of *Salmonella enteritidis* in pooled liquid egg samples using a magnetic bead-ELISA system. *J Food Prot*. 58:967–972.
226. Holt, P.S., R.K. Gast, and S. Kelly-Aehle. 2003. Use of a live attenuated *Salmonella typhimurium* vaccine to protect hens against S. *enteritidis* infection while undergoing molt. *Avian Dis*. 47:656–661.
227. Holt, P.S., R.K. Gast, R.E. Porter, Jr., and H.D. Stone. 1999. Hyporesponsiveness of the systemic and mucosal humoral immune systems in chickens infected with *Salmonella enterica* serovar *enteritidis* at one day of age. *Poult Sci*. 78: 1510–1517.
228. Holt, P.S., C.J. Geden, R.W. Moore, and R.K. Gast. 2007. Isolation of *Salmonella enterica* serovar Enteritidis from houseflies (*Musca domestica*) found in rooms containing *Salmonella* serovar Enteritidis-challenged hens. *Appl Environ Microbiol*. 73:6030–6035.
229. Holt, P.S., N.P. Macri, and R.E. Porter, Jr. 1995. Microbiological analysis of the early *Salmonella enteritidis* infection in molted and unmolted hens. *Avian Dis*. 39:55–63.

230. Holt, P.S., B.W. Mitchell, and R.K. Gast. 1998. Airborne horizontal transmission of *Salmonella enteritidis* in molted laying chickens. *Avian Dis*. 42:45–52.
231. Holt, P.S., and R.E. Porter, Jr. 1993. Effect of induced molting on the recurrence of a previous *Salmonella enteritidis* infection. *Poult Sci*. 72:2069–2078.
232. Holt, P.S., L.E. Vaughn, and R.K. Gast. 2011. Changes in Peyer's patch and cecal tonsil B lymphocytes in laying hens following challenge with *Salmonella enterica* serovar Enteritidis. *Int J Poult Sci*. 10:231–237.
233. Hong, Y., T. Liu, M.D. Lee, C.L. Hofacre, M. Maier, D.G. White, S. Ayers, L. Wang, R. Berghaus, and J. Maurer. 2009. A rapid screen of broth enrichments for *Salmonella enterica* serovars Enteritidis, Hadar, Heidelberg, and Typhimurium by using an allelotyping multiplex PCR that targets O- and H-antigen alleles. *J Food Prot*. 72:2198–2201.
234. Hoop, R.K., and A. Pospischil. 1993. Bacteriological, serological, histological and immunohistochemical findings in laying hens with naturally acquired *Salmonella enteritidis* phage type 4 infection. *Vet Rec*. 133:391–393.
235. Hudson, C.R., M. Garcia, R.K. Gast, and J.J. Maurer. 2001. Determination of close genetic relatedness of the major *Salmonella enteritidis* phage types by pulsed-field gel electrophoresis and DNA sequence analysis of several *Salmonella* virulence genes. *Avian Dis*. 45:875–886.
236. Humbert, F., J.J. Carramiñana, F. Lalande, and G. Salvat. 1997. Bacteriological monitoring of *Salmonella enteritidis* carrier birds after decontamination using enrofloxacin, competitive exclusion and movement of birds. *Vet Rec*. 141:297–299.
237. Humphrey, T.J., A. Baskerville, H. Chart, and B. Rowe. 1989. Infection of egg-laying hens with *Salmonella enteritidis* PT4 by oral inoculation. *Vet Rec*. 125:531–532.
238. Humphrey, T.J., A. Baskerville, H. Chart, B. Rowe, and A. Whitehead. 1992. Infection of laying hens with *Salmonella enteritidis* PT4 by conjunctival challenge. *Vet Rec*. 131:386–388.
239. Humphrey, T.J., A. Baskerville, A. Whitehead, B. Rowe, and A. Henley. 1993. Influence of feeding patterns on the artificial infection of laying hens with *Salmonella enteritidis* phage type 4. *Vet Rec*. 132:407–409.
240. Humphrey, T.J., and A. Whitehead. 1992. Techniques for the isolation of salmonellas from eggs. *Brit Poult Sci*. 33:761–768.
241. Humphrey, T.J., A. Whitehead, A.H.L. Gawler, A. Henley, and B. Rowe. 1991. Numbers of *Salmonella enteritidis* in the contents of naturally contaminated hens' eggs. *Epidemiol Infect*. 106:489–496.
242. Huneau-Salaün, A., C. Marianne, S. Le Bouquin, F. Lalande, I. Petetin, S. Rouxel, M. Virginie, P. Fravalo, and N. Rose. 2009. Risk factors for *Salmonella enterica* subsp. Enterica contamination in 519 French laying hen flocks at the end of the laying period. *Prev Vet Med*. 89:51–58.
243. Inoue, A.Y., A. Berchieri, Jr., A. Bernardino, J.B. Paiva, and E.V. Sterzo. 2008. Passive immunity of progeny from broiler breeder vaccinated with oil-emulsion bacterin against *Salmonella* Enteritidis. *Avian Dis*. 52:567–571.
244. Iwabuchi, E., N. Maruyama, A. Hara, M. Nishimura, M. Muramatsu, T. Ochiai, and K. Hirai. 2010. Nationwide survey of *Salmonella* prevalence in environmental dust from layer farms in Japan. *J Food Prot*. 73:1993–2000.
245. Iwabuchi, E., S. Yamamoto, Y. Endo, T. Ochiai, and K. Hirai. 2011. Prevalence of *Salmonella* isolates and antimicrobial resistance patterns in chicken meat throughout Japan. *J Food Prot*. 74:270–273.
246. Johnson, T.J., J.L. Thorsness, C.P. Anderson, A.M. Lynne, S.L. Foley, J. Han, W.F. Fricke, P.F. McDermott, D.G. White, M. Khatri, A.L. Stell, C. Flores, and R.S. Singer. 2010. Horizontal gene transfer of a ColV plasmid has resulted in a dominant avian clonal type of *Salmonella enterica* serovar Kentucky. *PloS One*. 5:e15524.
247. Jouy, E., K. Proux, F. Humbert, V. Rose, F. Lalande, C. Houdayer, U.P. Picault, and G. Salvat. 2005. Evaluation of a French ELISA for the detection of *Salmonella* Enteritidis and *Salmonella* Typhimurium in flocks of laying and breeding hens. *Prev Vet Med*. 71:91–103.
248. Kangas, S., T. Lyytikäinen, J. Peltola, J. Ranta, and R. Maijala. 2007. Costs of two alternative *Salmonella* control policies in Finnish broiler production. *Acta Vet Scand*. 49:35.
249. Keller, L.H., C.E. Benson, V. Garcia, E. Nocks, P. Battenfelder, and R.J. Eckroade. 1993. Monoclonal antibody-based detection system for *Salmonella enteritidis*. *Avian Dis*. 37:501–507.
250. Keller, L.H., C.E. Benson, K. Krotec, and R.J. Eckroade. 1995. *Salmonella enteritidis* colonization of the reproductive tract and forming and freshly laid eggs of chickens. *Infect Immun*. 63:2443–2449.
251. Kerr, S., H.J. Ball, D.P. Mackie, D.A. Pollock, and D.A. Finlay. 1992. Diagnostic application of monoclonal antibodies to outer membrane proteins for rapid detection of salmonella. *J Appl Bacteriol*. 72:302–308.
252. Khan, M.I., A.A. Fadl, and K.S. Venkitanarayanan. 2003. Reducing colonization of *Salmonella* Enteritidis in chicken by targeting outer membrane proteins. *J Appl Microbiol*. 95:142–145.
253. Kim, C.J., K.V. Nagaraja, and B.S. Pomeroy. 1991. Enzyme-linked immunosorbent assay for the detection of *Salmonella enteritidis* infection in chickens. *Am J Vet Res*. 52:1069–1074.
254. Kim, J.S., M.S. Jahng, G.G. Lee, K.J. Lee, H.K. Chae, J.H. Lee, J.H. Lee, and M.H. Kim. 2011. Rapid and simple detection of the invA gene in *Salmonella* spp. by isothermal target and probe amplification (iTPA). *Lett Appl Microbiol*. 52:399–405.
255. Kinde, H., D.M. Castellan, D. Kerr, J. Campbell, R. Breitmeyer, and A. Ardans. 2005. Longitudinal monitoring of two commercial layer flocks and their environments for *Salmonella enterica* serovar Enteritidis and other Salmonellae. *Avian Dis*. 49: 189–194.
256. Kinde, H., D.H. Read, A. Ardans, R.E. Breitmeyer, D. Willoughby, H.E. Little, D. Kerr, R. Gireesh, and K.V. Nagaraja. 1996. Sewage effluent: likely source of *Salmonella enteritidis*, phage type 4 infection in a commercial chicken layer flock in southern California. *Avian Dis*. 40:672–676.
257. Kingston, D.J. 1981. A comparison of culturing drag swabs and litter for identification of infections with *Salmonella* spp. in commercial chicken flocks. *Avian Dis*. 25:513–516.
258. Klinkenberg, D., E. Thomas, F.F.C. Artavia, and A. Bouma. 2011. *Salmonella* Enteritidis surveillance by egg immunology: impact of the sampling scheme on the release of contaminated table eggs. *Risk Anal*. 31:1260–1270.
259. Kogut, M.H., K. Genovese, R.B. Moyes, and L.H. Stanker. 1998. Evaluation of oral, subcutaneous, and nasal administration of *Salmonella enteritidis*-immune lymphokines on the potentiation of a protective heterophilic inflammatory response to *Salmonella enteritidis* in day-old chickens. *Can J Vet Res*. 62:27–32.
260. Kogut, M.H., H. He, K.J. Genovese, and Y.W. Jiang. 2010. Feeding the BT cationic peptides to chickens at hatch reduces cecal colonization by *Salmonella enterica* serovar Enteritidis

and primes innate immune cell functional activity. *Foodborne Pathog Dis*. 7:23–30.
261. Kogut, M.H., E.D. McGruder, B.M. Hargis, D.E. Corrier, and J.R. DeLoach. 1994. Dynamics of avian inflammatory response to *Salmonella*-immune lymphokines: Changes in avian blood leukocyte populations. *Inflammation*. 18:373–388.
262. Kogut, M.H., E.D. McGruder, B.M. Hargis, D.E. Corrier, and J.R. DeLoach. 1995. Characterization of the pattern of inflammatory cell influx in chicks following the intraperitoneal administration of live *Salmonella enteritidis* and *Salmonella enteritidis*-immune lymphokines. *Poult Sci*. 74:8–18.
263. Kogut, M.H., G.I. Tellez, E.D. McGruder, B.M. Hargis, J.D. Williams, D.E. Corrier, and J.R. DeLoach. 1994. Heterophils are decisive components in the early responses of chickens to *Salmonella enteritidis* infections. *Microb Pathog*. 16:141–151.
264. Koo, F.C., J.W. Peterson, C.W. Houston, and N.C. Molina. 1984. Pathogenesis of experimental salmonellosis: Inhibition of protein synthesis by cytotoxin. *Infect Immun*. 43:93–100.
265. Kopanic, R.J., Jr., B.W. Sheldon, and C.G. Wright. 1994. Cockroaches as vectors of *Salmonella*: Laboratory and field trials. *J Food Prot*. 57:125–132.
266. Korsgaard, H., M. Madsen, N.C. Feld, J. Mygind, and T. Hald. 2009. The effects, costs and benefits of *Salmonella* control in the Danish table-egg sector. *Epidemiol Infect*. 137:828–836.
267. Koupal, L.P., and R.H. Deibel. 1975. Assay, characterization, and localization of an enterotoxin produced by *Salmonella*. *Infect Immun*. 11:14–22.
268. Kramer, J., A.H. Visscher, J.A. Wagenaar, and S.H.M. Jeurissen. 2003. Entry and survival of *Salmonella enterica* serotype Enteritidis PT4 in chicken macrophage and lymphocyte lines. *Vet Microbiol*. 91:147–155.
269. Kuo, F.L., J.B. Carey, S.C. Ricke, and S.D. Ha. 1996. Peroxidase catalyzed chemical dip, egg shell surface contamination, and hatching. *J Appl Poult Res*. 5:6–13.
270. Lahellec, C., and P. Colin. 1985. Relationship between serotypes of salmonellae from hatcheries and rearing farms and those from processed poultry carcasses. *Brit Poult Sci*. 26:179–186.
271. Lahellec, C., P. Colin, G. Bennejean, J. Pacquin, A. Guillerm, and J.C. Debois. 1986. Influence of resident *Salmonella* on contamination of broiler flocks. *Poult Sci*. 65:2034–2039.
272. Lampel, K.A., S.P. Keasler, and D.E. Hanes. 1996. Specific detection of *Salmonella enterica* serotype Enteritidis using the polymerase chain reaction. *Epidemiol Infect*. 116:137–145.
273. Lapuz, R., H. Tani, J. Sasai, K. Shirota, H. Katoh, and E. Baba. 2008. The role of roof rats (*Rattus rattus*) in the spread of *Salmonella* Enteritidis and S. Infantis contamination in layer farms in eastern Japan. *Epidemiol Infect*. 136:1235–1243.
274. Lay, K.S., Y. Vuthy, P. Song, K. Phol, and J.L. Sarthou. 2011. Prevalence, numbers and antimicrobial susceptibilities of *Salmonella* serovars and *Campylobacter* spp. in retail poultry in Phnom Penh, Cambodia. *J Vet Med. Sci* 73:325–329.
275. Le Bouquin, S., V. Allain, S. Rouxel, I. Petetin, M. Picherot, V. Michel, and M. Chemaly. 2010. Prevalence and risk factors for *Salmonella* spp. contamination in French broiler-chicken flocks at the end of the rearing period. *Prev Vet Med*. 97:245–251.
276. Leeson, S., and M. Marcotte. 1993. Irradiation of poultry feed I. Microbial status and bird response. *World's Poult Sci J*. 49:19–33.
277. Leon-Valarde, C.G., L. Zosherafatein, and J.A. Odumeru. 2009. Application of an automated immunomagnetic separation-enzyme immunoassay for the detection of *Salmonella enterica* subspecies enterica from poultry environmental swabs. *J Microbiol Meth*. 79:13–17.
278. Lestari, S.I., F. Han, F. Wang, and B. Ge. 2009. Prevalence and antimicrobial resistance of *Salmonella* serovars in conventional and organic chickens from Louisiana retail stores. *J Food Prot*. 72:1165–1172.
279. Li, S., Z. Zhang, L. Pace, H. Lillehoj, and S. Zhang. 2009. Functions exerted by the virulence-associated type-three secretion systems during *Salmonella enterica* serovar Enteritidis invasion into and survival within chicken oviduct epithelilal cells and macrophages. *Avian Pathol*. 38:97–106.
280. Li, X., J.B. Payne, F.B. Santos, J.F. Levine, K.E. Anderson, and B.W. Sheldon. 2007. *Salmonella* populations and prevalence in layer feces from commercial high-rise houses and characterization of the *Salmonella* isolates by serotyping, antibiotic resistance analysis, and pulsed field gel electrophoresis. *Poult Sci*. 86:591–597.
281. Liebana, E., L. Garcia-Migura, M.F. Breslin, R.H. Davies, and M.J. Woodward. 2001. Diversity of strains of *Salmonella enterica* serotype Enteritidis from English poultry farms assessed by multiple genetic fingerprinting. *J Clin Microbiol*. 39:154–161.
282. Liebana, E., L. Garcia-Migura, C. Clouting, F.A. Clifton-Hadley, M.F. Breslin, and R.H. Davies. 2003. Molecular fingerprinting evidence of the contribution of wildlife vectors in the maintenance of *Salmonella* Enteritidis infection in layer farms. *J App Microbiol*. 94:1024–1029.
283. Liebana, E., L. Garcia-Migura, C. Clouting, F.A. Clifton-Hadley, E. Lindsay, E.J. Threlfall, S.W.J. McDowell, and R.H. Davies. 2002. Multiple genetic typing of *Salmonella enterica* serotype Typhimurium isolates of different phage types (DT104, U302, DT204b, and DT49) from animals and humans in England, Wales, and Northern Ireland. *J Clin Microbiol*. 40: 4450–4456.
284. Liebana, E., D. Guns, L. Garcia-Migura, M.J. Woodward, F.A. Clifton-Hadley, and R.H. Davies. 2001. Molecular typing of *Salmonella* serotypes prevalent in animals in England: assessment of methodology. *J Clin Microbiol*. 39:3609–3616.
285. Lin, J.S., and H.Y. Tsen. 1999. Development and use of polymerase chain reaction for the specific detection of *Salmonella* Typhimurium in stool and food samples. *J Food Prot*. 62: 1103–1110.
286. Line, J.E., J.S. Bailey, N.A. Cox, N.J. Stern, and T. Tompkins. 1998. Effect of yeast-supplemented feed on *Salmonella* and Campylobacter populations in broilers. *Poult Sci*. 77:405–410.
287. Liu, F., S. Kariyawasam, B.M. Jayarao, R. Barrangou, P. Gerner-Smidt, E.M. Ribot, S.J. Knabel, and E.G. Dudley. 2011. Subtyping *Salmonella enterica* serovar Enteritidis isolates from different sources by using sequence typing based on virulence genes and clustered regularly interspaced short palindromic repeats (CRISPRs). *Appl Environ Microbiol*. 77:4520–4526.
288. Liu, T., K. Liljebjelke, E. Bartlett, C. Hofacre, S. Sanchez, and J.J. Maurer. 2002. Application of nested polymerase chain reaction to detection of *Salmonella* in poultry environment. *J Food Prot*. 65:1227–1232.
289. Löfström, C., F. Hansen, and J. Hoorfar. 2010. Validation of a 20–h real-time PCR method for screening of *Salmonella* in poultry faecal samples. *Vet Microbiol*. 144:511–514.
290. Lopes, V.C., B.T. Velayudhan, D.A. Halvorson, D.C. Lauer, R.K. Gast, and K.V. Nagaraja. 2004. Comparison of methods for differentiation of *Salmonella enterica* serovar Enteritidis phage type 4 isolates. *Am J Vet Res*. 65:538–543.

291. Lu, Y., C.M. Wu, G.J. Wu, H.Y. Zhao, T. He, X.Y. Cao, L. Dai, L.N. Xia, S.S. Qin, and J.Z. Shen. 2011. Prevalence of antimicrobial resistance among *Salmonella* isolates from chicken in China. *Foodborne Pathog Dis*. 8:45–53.
292. Lynch, M.J.B., C.G. Leon-Velarde, S. McEwen, and J.A. Odumeru. 2004. Evaluation of an automated immunomagnetic separation method for the rapid detection of *Salmonella* species in poultry environmental samples. *J Microbiol Meth*. 58:285–288.
293. Mainali, C., G. Gensler, M. McFall, R. King, R. Irwin, and A. Senthilselvan. 2009. Evaluation of associations between feed withdrawal and other management factors with *Salmonella* contamination of broiler chickens at slaughter in Alberta. *J Food Prot*. 72:2202–2207.
294. Mainali, C., M.E. McFall, and R.K. King. 2011. Validation of a real-time polymerase chain reaction assay for the detection of *Salmonella* in crops of broiler chickens. *Poult Sci*. 90:660–664.
295. Mallinson, E.T., C.R. Tate, R.G. Miller, B. Bennett, and E. Russek-Cohen. 1989. Monitoring poultry farms for *Salmonella* by drag-swab sampling and antigen-capture immunoassay. *Avian Dis*. 33:684–690.
296. Malorny, B., E. Hauser, and R. Dieckmann. 2011. New approaches in subspecies-level *Salmonella* classification. In: *Salmonella: From Genome to Function*. S. Porwollik ed. Caister Academic Press, Norfolk, United Kingdom. 1–23.
297. Manning, J.G., B.M. Hargis, A. Hinton, Jr., D.E. Corrier, J.R. DeLoach, and C.R. Creger. 1994. Effect of selected antibiotics and anticoccidials on *Salmonella enteritidis* cecal colonization and organ invasion in Leghorn chicks. *Avian Dis*. 38:256–261.
298. Marin, C., S. Balasch, S. Vega, and M. Lainez. 2011. Sources of *Salmonella* contamination during broiler production in Eastern Spain. *Prev Vet Med*. 98:39–45.
299. Marin, C., A. Hernandiz, and M. Lainez. 2009. Biofilm development capacity of *Salmonella* strains isolated in poultry risk factors and their resistance against disinfectants. *Poult Sci*. 88:424–431.
300. Marin, C., and M. Lainez. 2009. *Salmonella* detection in feces during broiler rearing and after live transport to the slaughterhouse. *Poult Sci*. 88:1999–2005.
301. McGruder, E.D., M.H. Kogut, D.E. Corrier, J.R. DeLoach, and B.M. Hargis. 1995. Comparison of prophylactic and therapeutic efficacy of *Salmonella enteritidis*-immune lymphokines against *Salmonella enteritidis* organ invasion in neonatal leghorn chicks. *Avian Dis*. 39:21–27.
302. McGruder, E.D., G.A. Ramirez, M.H. Kogut, R.W. Moore, D.E. Corrier, J.R. DeLoach, and B.M. Hargis. 1995. *In ovo* administration of *Salmonella enteritidis*-immune lymphokines confers protection to neonatal chicks against *Salmonella enteritidis* organ infectivity. *Poult Sci*. 74:18–25.
303. McIlroy, S.G., R.M. McCracken, S.D. Neilland, and J.J. O'brien. 1989. Control, prevention and eradication of *Salmonella enteritidis* infection in broiler and broiler breeder flocks. *Vet Rec*. 125:545–548.
304. McSorley, S.J., and M.K. Jenkins. 2000. Antibody is required for protection against virulent but not attenuated *Salmonella enterica* serovar Typhimurium. *Infect Immun*. 68:3344–3348.
305. Mellor, G.E., L.L. Duffy, G.A. Dykes, and N. Fegan. 2010. Relative prevalence of *Salmonella sofia* on broiler chickens pre- and postprocessing in Australia. *Poult Sci*. 89:1544–1548.
306. Menconi, A., A.D. Wolfenden. S. Shivaramaiah, J.C. Terraes, T. Urbano, J. Kuttel, C. Kremer, B.M. Hargis, and G. Tellez. 2011. Effect of lactic acid bacteria probiotic culture for the treatment of *Salmonella enterica* serovar Heidelberg in neonatal broiler chickens and turkey poults. *Poult Sci*. 90:561–565.
307. Methner, U., P.A. Barrow, A. Berndt, and I. Rychlik. 2011. *Salmonella* Enteritidis with double deletion in phoPfliC—a potential live *Salmonella* vaccine candidate with novel characteristics for use in chickens. *Vaccine*. 29:3248–3253.
308. Miller, R.G., C.R. Tate, E.T. Mallinson, and J.A. Scherrer. 1991. Xylose-lysine-tergitol 4: An improved selective agar medium for the isolation of *Salmonella*. *Poult Sci*. 70:2429–2432.
309. Miura, S., G. Sato, and T. Miyamae. 1964. Occurrence and survival of *Salmonella* organisms in hatcher chick fluff from commercial hatcheries. *Avian Dis*. 8:546–554.
310. Miyamoto, T., T. Horie, T. Fukata, K. Sasai, and E. Baba. 1998. Changes in microflora of the cloaca and oviduct of hens after intracloacal or intravaginal inoculation with *Salmonella enteritidis*. *Avian Dis*. 42:536–544.
311. Mizumoto, N., Y. Toyota-Hanatani, K. Sasai, H. Tani, T. Ekawa, H. Ohta, and E. Baba. 2004. Detection of specific antibodies against deflagellated *Salmonella* Enteritidis and S. Enteritidis FliC-specific 9 kDa polypeptide. *Vet Microbiol*. 99:113–120.
312. Morales, C.A., M. Musgrove, T.J. Humphrey, C. Cates, R. Gast, and J. Guard-Bouldin. 2007. Pathotyping of *Salmonella enterica* by analysis of single-nucleotide polymorphisms in cyaA and flanking 23S ribosomal sequences. *Environ Microbiol*. 9:1047–1059.
313. Morales, C.A., S. Porwollik, J.G. Frye, H. Kinde, M. McClelland, and J. Guard-Bouldin. 2005. Correlation of phenotype with the genotype of egg-contaminating *Salmonella enterica* serovar Enteritidis. *Appl Environ Microbiol*. 71:4388–4399.
314. Morales, R.A., and R.M. McDowell. 1999. Economic consequences of *Salmonella enterica* serovar Enteritidis infection in humans and the U. S. egg industry. In: *Salmonella enterica Serovar Enteritidis in Humans and Animals*. A.M. Saeed, R.K. Gast, M.E. Potter, and P.G. Wall, eds. Iowa State University Press, Ames, IA. 271–290.
315. Moro, C.V., P. Fravalo, M. Amelot, C. Chauve, L. Zenner, and G. Salvat. 2007. Colonization and organ invasion in chicks experimentally infected with *Dermanyssus gallinae* contaminated by *Salmonella* Enteritidis. *Avian Pathol*. 36:307–311.
316. Morris, G.K., B.L. McMurray, M.M. Galton, and J.G. Wells. 1969. A study of the dissemination of salmonellosis in a commercial broiler chicken operation. *Am J Vet Res*. 30:1413–1421.
317. Motha, M.X.J., and J.R. Egerton. 1983. Effect of reticuloendotheliosis virus on the response of chickens to *Salmonella typhimurium* infection. *Res Vet Sci*. 34:188–192.
318. Mueller-Doblies, D., J.J. Carrique-Mas, A.R. Sayers, and R.H. Davies. 2010. A comparison of the efficacy of different disinfection methods in eliminating *Salmonella* contamination from turkey houses. *J Appl Microbiol*. 109:471–479.
319. Mueller-Doblies, D., A.R. Sayers, J.J. Carrique-Mas, and R.H. Davies. 2009. Comparison of sampling methods to detect *Salmonella* infection of turkey flocks. *J Appl Microbiol*. 107:635–645.
320. Mumma, G.A., P.M. Griffin, M.I. Meltzer, C.R. Braden, and R.V. Tauxe. 2004. Egg quality assurance programs and egg-associated *Salmonella* Enteritidis infections, United States. *Emerg Infect Dis*. 10:1782–1789.
321. Muotiala, A., M. Hovi, and P.H. Makela. 1989. Protective immunity in mouse salmonellosis: Comparison of smooth and rough live and killed vaccines. *Microb Pathog*. 6:51–60.

322. Murchie, L., P. Whyte, B. Xia, S. Horrigan, L. Kelly, and R.H. Madden. 2007. Prevalence of *Salmonella* in Grade A whole shell eggs in the island of Ireland. *J Food Prot*. 70:1238–1240.
323. Musgrove, M.T., N.A. Cox, M.E. Berrang, R.J. Buhr, L.J. Richardson, and J.M. Mauldin. 2010. Effect of inoculation and application methods on the performance of chemicals used to disinfect *Salmonella*-contaminated broiler hatching eggs. *J Appl Poult Res*. 19:387–392.
324. Musgrove, M.T., D.R. Jones, J.K. Northcutt, M.A. Harrison, N.A. Cox, K.D. Ingram, and A.J. Hinton, Jr. 2005. Recovery of *Salmonella* from commercial shell eggs by shell rinse and shell crush methodologies. *Poult Sci*. 84:1955–1958.
325. Myint, M.S., Y.J. Johnson, S.L. Branton, and E.T. Mallinson. 2005. Airflow pattern in broiler houses as a risk factor for growth of enteric pathogens. *Int J Poult Sci*. 4: 947–954.
326. Nakamura, M., N. Nagamine, T. Takahashi, M. Norimatsu, S. Suzuki, and S. Sato. 1995. Intratracheal infection of chickens with *Salmonella enteritidis* and the effect of feed and water deprivation. *Avian Dis*. 39:853–858.
327. Nakamura, M., N. Nagamine, T. Takahashi, S. Suzuki, and S. Sato. 1994. Evaluation of the efficacy of a bacterin against *Salmonella enteritidis* infection and the effect of stress after vaccination. *Avian Dis*. 38:717–724.
328. Nakamura, M., T. Nagata, S. Okamura, K. Takehara, and P.S. Holt. 2004. The effect of killed *Salmonella enteritidis* vaccine prior to induced molting on the shedding of *S. enteritidis* in laying hens. *Avian Dis*. 48:183–188.
329. Namata, H., E. Méroc, M. Aerts, C. Faes, J. Cortiñas, H. Imberechts, and K. Mintiens. 2008. *Salmonella* in Belgian laying hens: an identification of risk factors. *Prevent Vet Med*. 83:323–336.
330. Namata, H., S. Welby, M. Aerts, C. Faes, J.C. Abrahantes, H. Imberechts, K. Vermeersch, J. Hooyberghs, E. Méroc, and K. Mintiens. 2009. Identification of risk factors for the prevalence and persistence of *Salmonella* in Belgian broiler chicken flocks. *Prev Vet Med*. 90:211–222.
331. Nayak, R., P.B. Kenney, J. Keswani, and C. Ritz. 2003. Isolation and characterisation of *Salmonella* in a turkey production facility. *Brit Poult Sci*. 44:192–202.
332. Nuotio, L., C. Schneitz, U. Halonen, and E. Nurmi. 1992. Use of competitive exclusion to protect newly-hatched chicks against intestinal colonisation and invasion by *Salmonella enteritidis* PT4. *Brit Poult Sci*. 33:775–779.
333. Oh, J.Y., M.S. Kang, B.K. An, E.A. Song, J.H. Kwon, and Y.K. Kwon. 2010. Occurrence of purulent arthritis broilers vertically infected with *Salmonella enterica* serovar Enteritidis in Korea. *Poult Sci*. 89:2116–2122.
334. Okamura, M., Y. Kamijima, T. Miyamoto, H. Tani, K. Sasai, and E. Baba. 2001. Differences among six *Salmonella* serovars in abilities to colonize reproductive organs and to contaminate eggs in laying hens. *Avian Dis*. 45:61–69.
335. Okamura, M., M. Sonobe, S. Obara, T. Kubo, T. Nagai, M. Noguchi, K. Takehara, and M. Nakamura. 2010. Potential egg contamination by *Salmonella enterica* serovar Typhimurium definitive type 104 following experimental infection of pullets at the onset of lay. *Poult Sci*. 89:1629–1634.
336. Olesiuk, O.M., V.L. Carlson, G.H. Snoeyenbos, and C.F. Smyser. 1969. Experimental *Salmonella typhimurium* infection in two chicken flocks. *Avian Dis*. 13:500–508.
337. Olesiuk, O.M., G.H. Snoeyenbos, and C.F. Smyser. 1973. Chemotherapy studies of *Salmonella typhimurium* in chickens. *Avian Dis*. 17:379–389.
338. Olsen, J.E., T. Tiainen, and D.J. Brown. 1999. Levels of virulence are not determined by genomic lineage of *Salmonella enterica* serotype Enteritidis strains. *Epidemiol Infect*. 123:423–430.
339. Olson, A.B., A.K. Andrysiak, D.M. Tracz, J. Guard-Bouldin, W. Demczuk, L.K. Ng, A. Maki, F. Jamieson, and M.W. Gilmour. 2007. Limited genetic diversity in *Salmonella enterica* serovar Enteritidis PT13. *BMC Microbiol* 7:87.
340. O'Regan, E., E. McCabe, C. Burgess, S. McGuinness, T. Barry, G. Duffy, P. Whyte, and S. Fanning. 2008. Development of a real-time multiplex PCR assay for the detection of multiple *Salmonella* serotypes in chicken samples. *BMC Microbiology*. 8:156.
341. Otomo, Y., K. Abe, K. Odagiri, A. Shiroto, K. Takatori, and Y. Hara-Kudo. 2007. Detection of *Salmonella* in spent hens and eggs associated with foodborne infections. *Avian Dis*. 51: 578–583.
342. Pang, J.C., T.H. Chiu, R. Helmuth, A. Schroeter, B. Guerra, and H.Y. Tsen. 2007. A pulsed-field gel electrophoresis (PFGE) study that suggests a major world-wide clone of *Salmonella enterica* serovar Enteritidis. *Int J Food Microbiol*. 116:305–312.
343. Papadopoulou, C., R.H. Davies, J.J. Carrique-Mas, and S.J. Evans. 2009. *Salmonella* serovars and their antimicrobial resistance in British turkey flocks in 1995 to 2006. *Avian Pathol*. 38:349–357.
344. Park, S.Y., S.G. Birkhold, L.F. Kubena, D.J. Nisbet, and S.C. Ricke. 2004. Survival of a *Salmonella typhimurium* poultry marker strain added as a dry inoculum to zinc and sodium organic acid amended feeds. *J Food Safety*. 23:263–274.
345. Parker, W.D., B. Lungu, R.D. Berghaus, H.S. Sellers, I.R. Alvarado, and C.L. Hofacre. 2011. Comparison of real-time PCR with conventional PCR and culture to assess the efficacy of a live attenuated *Salmonella enterica* serovar Typhimurium vaccine against *Salmonella enterica* serovar Enteritidis in commercial leghorn chicks vaccinated under field and laboratory conditions. *Avian Dis*. 55:248–254.
346. Parveen, S., M. Taabodi, J.G. Schwarz, T.P. Oscar, J. Harter-Dennis, and D.G. White. 2007. Prevalence and antimicrobial resistance of *Salmonella* recovered from processed poultry. *J Food Prot*. 70:2466–2472.
347. Payne, J.B., J.A. Osborne, P.K. Jenkins, and B.W. Sheldon. 2007. Modeling the growth and death kinetics of *Salmonella* in poultry litter as a function of pH and water activity. *Poult Sci*. 86: 191–201.
348. Pedersen, T.B., J.E. Olsen, and M. Bisgaard. 2008. Persistence of *Salmonella* Senftenberg in poultry production environments and investigation of its resistance to desiccation. *Avian Pathol*. 37:421–427.
349. Phillips, R.A., and H.M. Opitz. 1995. Pathogenicity and persistence of *Salmonella enteritidis* and egg contamination in normal and infectious bursal disease virus-infected leghorn chicks. *Avian Dis*. 39:778–787.
350. Pieskus, J., M.P. Franciosini, P.C. Proietti, F. Reich, E. Kazeniauskas, C. Butrimaite-Ambrozeviciene, M. Mauricas, and N. Bolder. 2008. Preliminary investigations on *Salmonella* spp. incidence in meat chicken farms in Italy, Germany, Lithuania and the Netherlands. *Int J Poult Sci*. 7:813–817.
351. Pointon, A., M. Sexton, P. Dowsett, T. Saputra, A. Kiermeier, M. Lorimer, G. Holds, G. Arnold, D. Davos, B. Combs,

S.Fabiansson, G. Raven, H. McKenzie, A. Chapman, and J. Sumner. 2008. A baseline survey of the microbiological quality of chicken portions and carcasses at retail in two Australian states (2005 to 2006). *J Food Prot*. 71:1123–1134.

352. Poirier, E., L. Watier, E. Espie, F.X. Weill, H. De Valk, and J.C. Desenclos. 2008. Evaluation of the impact on human salmonellosis of control measures targeted to *Salmonella* Enteritidis and Typhimurium in poultry breeding using time-series analysis and intervention models in France. *Epidemiol Infect*. 136:1217–1224.
353. Porter, R.E., Jr., and P.S. Holt. 1993. Effect of induced molting on the severity of intestinal lesions caused by *Salmonella enteritidis* infection in chickens. *Avian Dis*. 37:1009-1016.
354. Porter, S.B., and R. Curtiss III. 1997. Effect of inv mutations on *Salmonella* virulence and colonization in 1-day-old white leghorn chicks. *Avian Dis*. 41:45–57.
355. Powell, N.G., E.J. Threlfall, H. Chart, S.L. Schofield, and B. Rowe. 1995. Correlation of change in phage type with pulsed field profile and 16S rrn profile in *Salmonella enteritidis* phage types 4, 7, and 9a. *Epidemiol Infect*. 114:403–411.
356. Qin, A.R., T. Fukata, E. Baba, and A. Arakawa. 1995. Effect of *Eimeria tenella* infection on *Salmonella enteritidis* infection in chickens. *Poult Sci*. 74:1–7.
357. Qin, Z.R., A. Arakawa, E. Baba, T. Fukata, T. Miyamoto, K. Sasai, and G.S.K. Withanage. 1995. *Eimeria tenella* infection induces recrudescence of previous *Salmonella enteritidis* infection in chickens. *Poult Sci*. 74:1786–1792.
358. Rahimi, S., Z.M. Shiraz, T.Z. Salehi, M.A.K. Torshizi, and J.L. Grimes. 2007. Prevention of *Salmonella* infection in poultry by specific egg-derived antibody. *Int J Poult Sci*. 6:230–235.
359. Rajashekara, G., S. Munir, M.F. Alexeyev, D.A. Halvorson, C.L. Wells, and K.V. Nagaraja. 2000. Pathogenic role of SEF14, SEF17, and SEF21 fimbriae in *Salmonella enterica* serovar Enteritidis infection of chickens. *Appl Environ Microbiol*. 66: 1759–1763.
360. Rajashekara, G., S. Munir, C.M. Lamichhane, A. Back, V. Kapur, D.A. Halvorson, and K.V. Nagaraja. 1998. Application of recombinant fimbrial protein for the specific detection of *Salmonella enteritidis* infection in poultry. *Diagn Microbiol Infect Dis*. 32:147–157.
361. Randall, L.P., M.C. Bagnall, K.A. Karatzas, N.C. Coldham, L.J.V. Piddock, and M.J. Woodward. 2008. Fitness and dissemination of disinfectant-selected multiple-antibiotic (MAR) strains of *Salmonella enterica* serovar Typhimurium in chickens. *J Antimicrob Chemother*. 61:156–162.
362. Randall, L.P., D.J. Eaves, S.W. Cooles, V. Ricci, A. Buckley, M.J. Woodward, and L.J.V. Piddock. 2005. Fluoroquinolone treatment of experimental *Salmonella enterica* serovar Typhimurium DT104 infections in chickens selects for both gyrA mutations and changes in efflux pump gene expression. *J Antimicrob Chemother*. 56:297–306.
363. Rankin, S., and D.J. Platt. 1995. Phage conversion in *Salmonella enterica* serotype Enteritidis: implications for epidemiology. *Epidemiol Infect*. 114:227–236.
364. Rasschaert, G., K. Houf, J. Van Hende, and L. De Zutter. 2007. Investigation of the concurrent colonization with *Campylobacter* and *Salmonella* in poultry flocks and assessment of the sampling site for status determination at slaughter. *Vet Microbiol*. 123:104–109.
365. Redmond, S.B., P. Chuammitri, C.B. Andreasen, D. Palić, and S.J. Lamont. 2009. Chicken heterophils from commercially selected and non-selected genetic lines express cytokines differently after *in vitro* exposure to *Salmonella enteritidis*. *Vet Immunol Immunopathol*. 132:129–134.
366. Reiber, M.A., D.E. Conner, and S.F. Bilgili. 1995. *Salmonella* colonization and shedding patterns of hens inoculated via semen. *Avian Dis*. 39:317–322.
367. Revolledo, L., C.S.A. Ferriera, and A.J.P. Ferreira. 2009. Prevention of *Salmonella* Typhimurium colonization and organ invasion by combination treatment in broiler chicks. *Poult Sci*. 88:734–743.
368. Reynolds, D.J., R.H. Davies, M. Richards, and C. Wray. 1997. Evaluation of combined antibiotic and competitive exclusion treatment in broiler breeder flocks infected with *Salmonella enterica* serovar Enteritidis. *Avian Pathol*. 26:83–95.
369. Richardson, L.J., C.L. Hofacre, B.W. Mitchell, and J.L. Wilson. 2003. Effect of electrostatic space charge on reduction of airborne transmission of *Salmonella* and other bacteria in broiler breeders in production and their progeny. *Avian Dis*. 47:1352–1361.
370. Riemann, H., S. Himathongkham, D. Willoughby, R. Tarbell, and R. Breitmeyer. 1998. A survey for *Salmonella* by drag swabbing manure piles in California egg ranches. *Avian Dis*. 42: 67–71.
371. Roche, A.J., N.A. Cox, L.J. Richardson, R.J. Buhr, J.A. Cason, B.D. Fairchild, and N.C. Hinkle. 2009. Transmission of *Salmonella* to broilers by contaminated larval and adult lesser mealworms, *Alphitobius diaperinus* (Coleoptera: Tenebrionidae). *Poult Sci*. 88:44–48.
372. Roland, K., S. Tinge, E. Warner, and D. Sizemore. 2004. Comparison of different attenuation strategies in development of a *Salmonella hadar* vaccine. *Avian Dis*. 48:445–452.
373. Rolfe, D.L., H.P. Riemann, T.B. Farver, and S. Himathongkham. 2000. Drag swab efficiency factors when sampling chicken manure. *Avian Dis*. 44:668–675
374. Rose, N., F. Beaudeau, P. Drouin, J.Y. Toux, V. Rose, and P. Colin. 1999. Risk factors for *Salmonella enterica* subsp. enterica contamination in French broiler-chicken flocks at the end of the rearing period. *Prevent Vet Med*. 39:265–277.
375. Rousi, V., S. Madouvalou, M. Pasiotou, X. Diamantis, and A.R. Burriel. 2010. Investigating *Salmonella* serotypes colonizing laying hen housing across southern Greece: implications to public health. *J Anim Vet Adv*. 9:841–843.
376. Roy, P., A.S. Dhillon, H.L. Shivaprasad, D.M. Schaberg, D. Bandli, and S. Johnson. 2001. Pathogenicity of different serogroups of avian *Salmonella*e in specific-pathogen-free chickens. *Avian Dis*. 45:922–937.
377. Sadler, W.W., J.R. Brownell, and M.J. Fanelli. 1969. Influence of age and inoculum level on shed pattern of *Salmonella typhimurium* in chickens. *Avian Dis*. 13:793–803.
378. Sampathkumar, B., G.G. Khachatourians, and D.R. Korber. 2004. Treatment of *Salmonella enterica* serovar Enteritidis with a sublethal concentration of trisodium phosphate or alkaline pH induces thermotolerance. *Appl Environ Microbiol*. 70: 4613–4620.
379. Sander, J.E., C.L. Hofacre, I.H. Cheng, and R.D. Wyatt. 2002. Investigation of resistance of bacteria from commercial poultry sources to commercial disinfectants. *Avian Dis*. 46:997–1000.
380. Santos, F.B.O., D.H. D'Souza, L. Jaykus, P.R. Ferket, and B.W. Sheldon. 2007. Genotypes, serotypes, and antibiotic resistance profiles of *Salmonella* isolated from commercial North Carolina turkey farms. *J Food Prot*. 70:1328–1333.
381. Santos, F.B.O., X. Li, J.B. Payne, and B.W. Sheldon. 2005. Estimation of most probable number *Salmonella* populations

on commercial North Carolina turkey farms. *J Appl Poult Res*. 14:700–708.
382. Sato, G., S. Matsubara, S. Etoh, and H. Kodama. 1971. Cultivation of samples of hatcher chick fluff, floor litter and feces for the detection of *Salmonella* infection in chicken flocks. *Jpn J Vet Res*. 19:73–80.
383. Schmid, D., A. Luckner-Hornishcer, G. Holzhammer, D. Rokita, M. Federspiel, H. Lassnig, A.M. Pichler, I. Lederer, A. Beranek, C. Kornschober, C. Berghold, and F. Allerberger. 2007. Lessons learned from a *Salmonella* Enteritidis phage type 4 outbreak in Austria, 2005. *J Food Prot*. 70:35–39.
384. Schneitz, C., and G. Mead. 2000. Competitive exclusion. In: *Salmonella in Domestic Animals*. C. Wray and A. Wray, eds. CABI Publishing, Oxon, United Kingdom. 301–322.
385. Seo, K.H, P.S. Holt, R.K. Gast, and C.L. Hofacre. 2000. Combined effect of antibiotic and competitive exclusion treatment on *Salmonella* Enteritidis fecal shedding in molted laying hens. *J Food Prot*. 63:545–548.
386. Seo, K.H., I.E. Valentin-Bon, R.E. Brackett, and P.S. Holt. 2004. Rapid, specific detection of *Salmonella* Enteritidis in pooled eggs by real-time PCR. *J Food Prot*. 67:864–869.
387. Shah, D.H., X. Zhou, T. Addwebi, M.A. Davis, L. Orfe, D.R. Call, J. Guard, and T.E. Besser. 2011. Cell invasion of poultry-associated *Salmonella enterica* serovar Enteritidis isolates is associated with pathogenicity, motility and proteins secreted by the type III secretion system. *Microbiol*. 157:1428–1445.
388. Shaw, S.J., B.W. Blais, and D.C. Nundy. 1998. Performance of the Dynabeads anti-*Salmonella* system in the detection of *Salmonella* species in foods, animal feeds, and environmental samples. *J Food Prot*. 61:1507–1510.
389. Shirota, K., H. Katoh, T. Murase, T. Ito, and K. Otsuki. 2001. Monitoring of layer feed and eggs for *Salmonella* in eastern Japan between 1993 and 1998. *J Food Prot*. 64:734–737.
390. Shivaprasad, H.L., J.F. Timoney, S. Morales, B. Lucio, and R.C. Baker. 1990. Pathogenesis of *Salmonella enteritidis* infection in laying chickens. I. Studies on egg transmission, clinical signs, fecal shedding, and serologic responses. *Avian Dis*. 34: 548–557.
391. Singer, R.S., and C.L. Hofacre. 2006. Potential impacts of antibiotic use in poultry production. *Avian Dis*. 50:161–172.
392. Sivula, C.P., L.M. Bogomolnaya, and H.L. Andrews-Polymenis. 2008. A comparison of cecal colonization of *Salmonella enterica* Typhimurium in white leghorn chicks and *Salmonella* resistant mice. *BMC Microbiol*. 8:182.
393. Skov, M.N., N.C. Feld, B. Carstensen, and M. Madsen. 2002. The serologic response to *Salmonella enteritidis* and *Salmonella typhimurium* in experimentally infected chickens, followed by an indirect lipopolysaccharide enzyme-linked immunosorbent assay and bacteriologic examinations through a one-year period. *Avian Dis*. 46:265–273.
394. Skov, M.N., A.G. Spencer, B. Hald, L. Petersen, B. Nauerby, B. Carstensen, and M. Madsen. 2004. The role of litter beetles as potential reservoir for *Salmonella enterica* and thermophilic *Campylobacter* spp. between broiler flocks. *Avian Dis*. 48: 9–18.
395. Smyser, C.F., and G.H. Snoeyenbos. 1979. Evaluation of organic acids and other compounds as *Salmonella* antagonists in meat and bone meal. *Poult Sci*. 58:50–54.
396. Snoeyenbos, G.H., V.L. Carlson, C.F. Smyser, and O.M. Olesiuk. 1969. Dynamics of *Salmonella* infection in chicks reared on litter. *Avian Dis*. 13:72–83.
397. Snoeyenbos, G.H., O.M. Weinack, and C.F. Smyser. 1978. Protecting chicks and poults from Salmonellae by oral administration of "normal" gut microflora. *Avian Dis*. 22:273–287.
398. Snow, L.C., R.H. Davies, K.H. Christiansen, J.J. Carrique-Mas, A.J.C. Cook, and S.J. Evans. 2010. Investigation of risk factors for *Salmonella* on commercial egg-laying farms in Great Britain, 2004–2005. *Vet Rec*. 166:579–586.
399. Snow, L.C., R.H. Davies, K.H. Christiansen, J.J. Carrique-Mas, A.D. Wales, J.L. O'Connor, A.J.C. Cook, and S.J. Evans. 2007. Survey of the prevalence of *Salmonella* species on commercial laying farms in the United Kingdom. *Vet Rec*. 161:471–476.
400. Stavric, S., T.M. Gleeson, B. Blanchfield, and H. Pivnick. 1987. Role of adhering microflora in competitive exclusion of *Salmonella* from young chicks. *J Food Prot*. 50:928–932.
401. Sumner, J., G. Raven, and R. Givney. 2004. Have changes to meat and poultry food safety regulation in Australia affected the prevalence of *Salmonella* or of salmonellosis? *Int J Food Microbiol*. 92:199–205.
402. Swamy, S.C., H.M. Barnhart, M.D. Lee, and D.W. Dreesen. 1996. Virulence determinants invA and spvC in salmonellae isolated from poultry products, wastewater, and human sources. *Appl Environ Microbiol*. 62:3768–3771.
403. Tan, S., C.L. Gyles, and B.N. Wilkie. 1997. Comparison of an LPS-specific competitive ELISA with a motility enrichment culture method (MSRV) for detection of *Salmonella typhimurium* and S. *enteritidis* in chickens. *Vet Microbiol*. 56:79–86.
404. Tan, S., C.L. Gyles, and B.N. Wilkie. 1997. Evaluation of an aroA mutant *Salmonella typhimurium* vaccine in chickens using modified semisolid Rappaport Vassiliadis medium to monitor faecal shedding. *Vet Microbiol*. 54:247–254.
405. Tate, C.R., R.G. Miller, and E.T. Mallinson. 1992. Evaluation of two isolation and two nonisolation methods for detecting naturally occurring *Salmonella*e from broiler flock environmental drag-swab samples. *J Food Prot*. 55:964–967.
406. Tellez, G.I., M.H. Kogut, and B.M. Hargis. 1994. *Eimeria tenella* or *Eimeria adenoeides*: Induction of morphological changes and increased resistance to *Salmonella enteritidis* infection in leghorn chicks. *Poult Sci*. 73:396–401.
407. Temelli, S., S. Kahya, A. Eyigor, and K.T. Carli. 2010. Incidence of *Salmonella* Enteritidis in chicken layer flocks in Turkey: results by real-time polymerase chain reaction and International Organization for Standardization culture methods. *Poult Sci*. 89:1406–1410.
408. Thaxton, P., R.D. Wyatt, and P.B. Hamilton. 1975. The effect of environmental temperature on paratyphoid infection in the neonatal chicken. *Poult Sci*. 53:88–94.
409. Thiagarajan, D., H.L. Thacker, and A.M. Saeed. 1996. Experimental infection of laying hens with *Salmonella enteritidis* strains that express different types of fimbriae. *Poult Sci*. 75:1365–1372.
410. Thomas, M.E., D. Klinkenberg, A.A. Bergwerff, E. van Erden, J.A. Stegeman, and A. Bouma. 2010. Evaluation of suspension array analysis for detection of egg yolk antibodies against *Salmonella* Enteritidis. *Prev Vet Med*. 95:137–143.
411. Thorns, C.J., C. Turcotte, C.G. Gemmell, and M.J. Woodward. 1996. Studies into the role of the SEF14 fimbrial antigen in the pathogenesis of *Salmonella enteritidis*. *Microb Pathogenesis*. 20:235–246.
412. Timoney, J.F., H.L. Shivaprasad, R.C. Baker, and B. Rowe. 1989. Egg transmission after infection of hens with *Salmonella enteritidis* phage type 4. *Vet Rec*. 125:600–601.

413. Tomás, D., A. Rodrigo, M. Hernández, and M.A. Ferrús. 2009. Validation of real-time PCR and enzyme-linked fluorescent assay-based methods for detection of *Salmonella* spp. in chicken feces samples. *Food Anal Methods*. 2:180–189.
414. Toscano, M.J., L. Sait, F. Jørgensen, C.J. Nicol, C. Powers, A.L. Smith, M. Bailey, and T.J. Humphrey. 2010. Sub-clinical infection with *Salmonella* in chickens differentially affects behaviour and welfare in three inbred strains. *Brit Poult Sci*. 51:703–713.
415. Toyota-Hanatani, T. Ekawa, H. Ohta, S. Igimi, Y. Hara-Kudo, K. Sasai, and E. Baba. 2009. Public health assessment of *Salmonella enterica* serovar Enteritidis inactivated-vaccine treatment in layer flocks. *Appl Environ Microbiol*. 75:1005–1010.
416. Toyota-Hanatani, Y., Y. Kyoumoto, E. Baba, T. Ekawa, H. Ohta, H. Tani, and K. Sasai. 2009. Importance of subunit vaccine antigen of major Fli C antigenic site of *Salmonella* Enteritidis II: a challenge trial. *Vaccine*. 27:1680–1684.
417. Tran, T.Q.L., S. Quessy, A. Letellier, A. Desrosiers, and M. Boulianne. 2010. Immune response following vaccination against *Salmonella* Enteritidis using 2 commercial bacterins in laying hens. *Can J Vet Res*. 74:185–192.
418. Tsai, H.J., C.H. Chiu, C.L. Wang, and C.H. Chou. A time-course study of gene responses of chicken granulosa cells to *Salmonella* Enteritidis infection. *Vet Microbiol*. 144:325–333.
419. Turnbull, P.C.B., and G.H. Snoeyenbos. 1974. Experimental salmonellosis in the chicken. 1. Fate and host response in alimentary canal, liver, and spleen. *Avian Dis*. 18:153–177.
420. Turner, A.K., M.A. Lovell, S.D. Hulme, L. Zhang-Barber, and P.A. Barrow. 1998. Identification of *Salmonella typhimurium* genes required for colonization of the chicken alimentary tract and for virulence in newly hatched chicks. *Infect Immun*. 66:2099–2106.
421. U.S. Department of Agriculture, Economic Research Service. 2011. Foodborne illness cost calculator: *Salmonella*. http://www.ers.usda.gov/data/foodborneillness/salm_intro.asp. Accessed March 8, 2013.
422. U.S. Food and Drug Administration. 2009. Prevention of *Salmonella* Enteritidis in shell eggs during production, storage, and transportation; final rule. *Fed Reg*. 74:33030–33101.
423. Valdezate, S., A. Echeita, R. Díez, and M.A. Usera. 2000. Evaluation of phenotypic and genotypic markers for characterisation of the emerging gastroenteritis pathogen *Salmonella hadar*. *Eur J Clin Microbiol*. 19:275–281.
424. Van Coillie, E., J. Goris, I. Cleenwerck, K. Grijspeerdt, N. Botteldoorn, F. Van Immerseel, J. De Buck, M. Vancanneyt, J. Swings, L. Herman, and M. Heyndrickx. 2007. Identification of lactobacilli isolated from the cloaca and vagina of laying hens and characterization for potential use as probiotics to control *Salmonella* Enteritidis. *J Appl Microbiol*. 102:1095–1106.
425. van de Giessen, A.W., A.J.H.A. Ament, and S.H.W. Notermans. 1994. Intervention strategies for *Salmonella enteritidis* in poultry flocks: A basic approach. *Int J Food Microbiol*. 21:145–154.
426. van de Giessen, A.W., J.B. Dufrenne, W.S. Ritmeester, P.A.T.A. Berkers, W.J. van Leeuwen, and S.H.W. Notermans. 1992. The identification of *Salmonella enteritidis*-infected poultry flocks associated with an outbreak of human salmonellosis. *Epidemiol Infect*. 109:405–411.
427. Van Hoorebeke, S., F. Van Immerseel, J. De Vylder, R. Ducatelle, F. Haesebrouck, F. Pasmans, A. de Kruif, and J. Dewulf. 2009. Faecal sampling underestimates the actual prevalence of *Salmonella* in laying hen flocks. *Zoonoses Public Hlth*. 56:471–476.
428. Van Hoorebeke, S., F. Van Immerseel, J. De Vylder, R. Ducatelle, F. Haesebrouck, F. Pasmans, A. de Kruif, and J. Dewulf. 2010. The age of production system and previous *Salmonella* infections in laying hen flocks. *Poult Sci*. 89:1315–1319.
429. Van Hoorebeke, S., F. Van Immerseel, J. Schulz, J. Hartung, M. Harisberger, L. Barco, A. Ricci, G. Theodoropoulos, E. Xylouri, J. De Vylder, R. Ducatelle, F. Haesebrouck, F. Pasmans, A. de Kruif, and J. Dewulf. 2010. Determination of the within and between flock prevalence and identification of risk factors for *Salmonella* infections in laying hen flocks housed in conventional and alternative systems. *Prev Vet Med*. 94:94–100.
430. Van Immerseel, F. 2010. Stress-induced survival strategies enable *Salmonella* Enteritidis to persistently colonize the chicken oviduct tissue and cope with antimicrobial factors in egg white: a hypothesis to explain a pandemic. *Gut Pathogens*. 2:23.
431. Van Immerseel, F., J. De Buck, F. Boyen, L. Bohez, F. Pasmans, J. Volf, M. Sevcik, I. Rychlik, F. Haesbrouck, and R. Ducatelle. 2004. Medium-chain fatty acids decrease colonization and invasion through hilA suppression shortly after infection of chickens with *Salmonella enterica* serovar Enteritidis. *Appl Environ Microbiol*. 70:3582–3587.
432. Van Immerseel, F., J. De Buck, I.F. Pasmans, L. Bohez, F. Boyen, F. Haesbrouck, and R. Ducatelle. 2004. Intermittent long-term shedding and induction of carrier birds after infection of chickens early posthatch with a low or high dose of *Salmonella* Enteritidis. *Poult Sci*. 83:1911–1916.
433. van Zijderveld, F.G., A.M. van Zijderveld-van Bemel, R.A.M. Brouwers, T.S. de Vries, W.J.M. Landman, and W.A. de Jong. 1993. Serological detection of chicken flocks naturally infected with *Salmonella enteritidis*, using an enzyme-linked immunosorbent assay based on monoclonal antibodies against the flagellar antigen. *Vet Quart*. 15:135–137.
434. Vaughn, L.E., P.S. Holt, R.W. Moore, R.K. Gast, and K.E. Anderson. 2008. Crop immune response post-*Salmonella* Enteritidis challenge in eight commercial egg-layer strains and specific-pathogen-free white leghorn chickens. *Avian Dis*. 52: 79–87.
435. Vilá, B., A. Fontgibell, I. Badiola, E. Esteve-Garcia, G. Jiménez, M. Castillo, and J. Brufau. 2009. Reduction of *Salmonella enterica* var. Enteritidis colonization and invasion by *Bacillus cereus* var. toyoi inclusion in poultry feeds. *Poult Sci*. 88:975–979.
436. Virlogeux-Payant, I., F. Mompart, P. Velge, E. Bottreau, and P. Pardon. 2003. Low persistence of a large-plasmid-cured variant of *Salmonella enteritidis* in ceca of chicks. *Avian Dis*. 47:163–168.
437. Volkova, V.V., R.H. Bailey, S.A. Hubbard, D. Magee, J.A. Byrd, and W.W. Robert. 2011. Risk factors associated with *Salmonella* status of broiler flocks delivered to grow-out farms. *Zoonoses Public Hlth*. 58:284–298.
438. Volkova, V.V., R.W. Wills, S.A. Hubbard, D. Magee, J. Byrd, and R.H. Bailey. 2011. Associations between vaccinations against protozoal and viral infections and *Salmonella* in broiler flocks. *Epidemiol Infect*. 139:206–215.
439. Voogt, N., M. Raes, W.J.B. Wannet, A.M. Henken, and A.W. van de Giessen. 2001. Comparison of selective enrichment media for the detection of *Salmonella* in poultry faeces. *Lett Appl Microbiol*. 32:89–92.
440. Wales, A., M. Breslin, B. Carter, R. Sayers, and R. Davies. 2007. A longitudinal study of environmental salmonella contamination in caged and free-range layer flocks. *Avian Pathol*. 36: 187–197.
441. Wales, A.D., J.J. Carrique-Mas, M. Rankin, B.B. Thind, and R.H. Davies. 2010. Review of the carriage of zoonotic bacteria

by arthropods, with special reference to *Salmonella* in mites, flies and litter beetles. *Zoonoses Public Hlth*. 57:299–314.
442. Waltman, W.D., and R.K. Gast. 2008. Salmonellosis. In: *A Laboratory Manual for the Isolation and Identification of Avian Pathogens*, 5th ed. L. Dufour-Zavala, D.E. Swayne, J.R. Glisson, J.E. Pearson, W.M. Reed, M.W. Jackwood, and P.R. Woolcock, eds. American Association of Avian Pathologists, Athens, GA. 3–9.
443. Waltman, W.D., A.M. Horne, C. Pirkle, and T. Dickson. 1991. Use of delayed secondary enrichment for the isolation of *Salmonella* in poultry and poultry environments. *Avian Dis*. 35:88–92.
444. Wang, S., A.M. Phillippy, K. Deng, X. Rui, Z. Li, M.L. Tortorello, and W. Zhang. 2010. Transcriptomic responses of *Salmonella enterica* serovars Enteritidis and Typhimurium to chlorine-based oxidative stress. *Appl Environ Microbiol*. 76: 5013–5024.
445. Weinack, O.M., C.F. Smyser, and G.H. Snoeyenbos. 1979. Evaluation of several methods of detecting *Salmonella*e in groups of chickens. *Avian Dis*. 23:179–193.
446. Weinack, O.M., G.H. Snoeyenbos, A.S. Soerjadi-Liem, and C.F. Smyser. 1985. Therapeutic trials with native intestinal microflora for *Salmonella typhimurium* infections in chickens. *Avian Dis*. 29:1230–1234.
447. Wells, L.L., V.K. Lowry, J.R. DeLoach, and M.H. Kogut. 1998. Age-dependent phagocytosis and bactericidal activities of the chicken heterophil. *Dev Comp Immunol*. 22:103–109.
448. Wesley, I.V., and W.T. Muraoka. 2011. Time of entry of *Salmonella* and *Campylobacter* into the turkey brooder house. *Food Bioprocess Technol*. 4:616–623.
449. Whistler, P.E., and B.W. Sheldon. 1989. Comparison of ozone and formaldehyde as poultry hatchery disinfectants. *Poult Sci*. 68:0345–1350.
450. Williams, A., A.C. Davies, J. Wilson, P.D. Marsh, S. Leach, and T.J. Humphrey. 1998. Contamination of the contents of intact eggs by *Salmonella typhimurium* DT104. *Vet Rec*. 143:562–563.
451. Williams, J.E. 1970. Effect of high-level formaldehyde fumigation on bacterial populations on the surface of chicken hatching eggs. *Avian Dis*. 14:386–392.
452. Wisner, A.L.S., T.S. Desin, B. Koch, P.K.S. Lam, E.M. Berberov, C.S. Mickael, A.A. Potter, and W. Köster. 2010. *Salmonella enterica* subspecies enterica serovar Enteritidis *Salmonella* pathogenicity island 2 type III secretion system: role in intestinal colonization of chickens and systemic spread. *Microbiol*. 156:2770–2781.
453. Withanage, G.S.K., K. Sasai, T. Fukata, T. Miyamoto, H.S. Lillehoj, and E. Baba. 2003. Increased lymphocyte subpopulations and macropohages in the ovaries and oviducts of laying hens infected with *Salmonella enterica* serovar Enteritidis. *Avian Pathol*. 32:583–590.
454. Wolfenden, A.D., C.M. Pixley, J.P. Higgins, S.E. Higgins, J.L. Vicente, A. Torres-Rodriguez, B.M. Hargis, and G. Tellez. 2007. Evaluation of spray application of a Lactobacillus-based probiotic on *Salmonella enteritidis* colonization in broiler chickens. *Int J Poult Sci*. 6:493–496.
455. Woodward, M.J., and S.E.S. Kirwan. 1996. Detection of *Salmonella enteritidis* in eggs by the polymerase chain reaction. *Vet Rec*. 138:411–413.
456. Wooley, R.E., P.S. Gibbs, and E.B. Shotts, Jr. 1999. Inhibition of *Salmonella typhimurium* in the chicken intestinal tract by a transformed avirulent avian *Escherichia coli*. *Avian Dis*. 43:245–250.
457. Wyeth, P.J. 1975. Effect of infectious bursal disease on the response of chickens to S. *typhimurium* and *E. coli* infections. *Vet Rec*. 96:238–243.
458. Yamane, Y., J.D. Leonard, R. Kobatake, N. Awamura, Y. Toyota, H. Ohta, K. Otsuki, and T. Inoue. 2000. A case study on *Salmonella enteritidis* (SE) origin at three egg-laying farms and its control with an S. *enteritidis* bacterin. *Avian Dis*. 44:519–526.
459. Young, S.D., O. Olusanya, K.H. Jones, T. Liu, K.A. Liljebjelke, and C.L. Hofacre. 2007. *Salmonella* incidence in broilers from breeders vaccinated with live and killed *Salmonella*. *J Appl Poult Res*. 16:521–528.
460. Yu, C.Y., C. Chu, S.J. Chou, M.R. Chao, C.M. Yeh, D.Y. Lo, Y.C. Su, Y.M. Horng, B.C. Weng, J.G. Tsay, and K.C. Huang. 2008. Comparison of the association of age with the infection of *Salmonella* and *Salmonella enterica* serovar Typhimurium in Pekin ducks and Roman geese. *Poult Sci*. 87:1544–1549.
461. Zhang, G., L. Ma, and M.P. Doyle. 2007. *Salmonella*e reduction in poultry by competitive exclusion bacteria *Lactobacillus salivarius* and *Streptococcus cristatus*. *J Food Prot*. 70:874–878.
462. Ziprin, R.L., and M.H. Kogut. 1997. Efficacy of two avian *Salmonella*-immune lymphokines against liver invasion in chickens by *Salmonella* serovars with different O-group antigens. *Avian Dis*. 41:181–186.

Arizonosis

1. Adler, H.E., and A.S. Rosenwald. 1968. Paracolon control—What we know and need to know. *Turkey World*. 43:18.
2. Anonymous. 1967. *Salmonella* and *Arizona* group of infections of avian origin. 1966 Annual Report of the Food Protein Toxicology Center. University of California, Davis. 24–29.
3. Anonymous. 1976. *Proc Salmonella Symp. American* Association of the Avian Pathologists, Kennett Square, PA.
4. Anonymous. 1984. *Proc Int Symp Salmonella*, New Orleans. G.H. Snoyenbos, ed. American Association of Avian Pathologists, Kennett Square, PA.
5. Anonymous. 1986. Animal salmonellosis. Annual summaries, survey of drug resistance in salmonellae. Ministry of Agriculture Fisheries and Food. Welsh Office Agriculture Department. Department of Agriculture and Fisheries for Scotland.
6. Bales, J.A., E.M. de Pinna, E.J. Threlfall, and L.R. Ward. 2007. Kauffmann-White Scheme—2007. *Salmonella* identification—serotypes and antigenic formulae. Health Protection Agency, London.
7. Bruner, D.W., and M.C. Peckham. 1952. An outbreak of paracolon infection in turkey poults. *Cornell Vet*. 42:22–24.
8. Buck, J.J., and S.W. Nicholls. 1997. *Salmonella* arizona enterocolitis acquired by an infant from a pet snake. *J Ped Gastro and Nutri*. 25:248–249.
9. Caldwell, M.E., and D.L. Ryerson. 1939. Salmonellosis in certain reptiles. *J Infect Dis*. 65:242–245.
10. Cambre, R.C., D.E. Green, E.E. Smith, R.J. Montali, and M. Bush. 1980. Salmonellosis and arizonosis in the reptile collection at the National Zoological Park. *J Am Vet Med Assoc*. 177:800–803.
11. Crespo, R., J. Jeffrey, R.P. Chin, G. Senties-Cue and H.L. Shivaprasad. 2004. Genotypic and phenotypic characterization of *Salmonella arizonae* from an integrated turkey operation. *Avian Dis*. 48:344–350.
12. Dougherty, E. 1953. Disease problems confronting the duck industry. *Proc Annu Meet Am Vet Med Assoc*. 90:359–365.
13. Dovadola, E., and F. Carlotto. 1969. Bacteriological survey for arizona infection in turkey eggs. Results and discussion. *Vet Ital*. 20:304–311.

14. Edwards, P.R., and W.H. Ewing. 1972. Identification of Enterobacteriaceae. Burgess Publishing, Minneapolis, MN.
15. Edwards, P.R., and M.M. Galton. 1967. Salmonellosis. *Adv Vet Sci*. 11:1–63.
16. Edwards, P.R., W.B. Cherry, and D.W. Bruner. 1943. Further studies on coliform bacteria serologically related to the genus *Salmonella*. *J Infect Dis*. 73:229–238.
17. Edwards, P.R., M.G. West, and D.W. Bruner. 1947. *Arizona* group of paracolon bacteria. *Ky Agric Exp Stn Bull*. 499.
18. Edwards P.R., A.C. McWhorter, and M.A. Fife. 1956. The *Arizona* group of Enterobacteriaceae in animals and man. *Bull WHO*. 14:511–528
19. Edwards, P.R., M.A. Fife, and C.H. Ramsey. 1959. Studies on the arizona group of Enterobacteriaceae. *Bacteriol Rev*. 23: 155–174.
20. Ekperigin, H.E., S. Jang, and R.H. McCapes. 1983. Effective control of a gentamicin-resistant *Salmonella* arizonae infection in turkey poults. *Avian Dis*. 27:822–829.
21. Ellis, E.M., J.E. Williams, E.T. Mallinson, G.H. Snoeyenbos, and W.J. Martin. 1976. *Culture Methods for the Detection of Animal Salmonellosis and Arizonosis*. Iowa State University Press, Ames, Iowa. 9–87.
22. Erwin, L.E. 1955. Examination of prepared poultry feeds for the presence of *Salmonella* and other enteric organisms. *Poult Sci*. 34:215–216.
23. Ewing, W.H. 1963. An outline of nomenclature for the family Enterobacteriaceae. *Int Bull Bacteriol Nomencl Taxon*. 13:95–110.
24. Ewing, W.H. 1967. *Revised Definitions for the Family Enterobacteriaceae, its Tribes and Genera*. U.S. Department of Health Education and Welfare, NCDC, Atlanta, GA.
25. Ewing, W.H. 1969. *Arizona hinshawii*. *Int J Syst Bacteriol*. 19:1.
26. Ewing, W.H. 1986. *Edwards and Ewing's Identification of Enterobacteriaceae*. Elsevier Science, New York.
27. Ewing, W.H., and M.M. Ball. 1966. *The Biochemical Reactions of Members of the Genus Salmonella*. U.S. Department of Health Education and Welfare, NCDC, Atlanta, GA.
28. Ewing, W.H., and M.A. Fife. 1966. A summary of the biochemical reactions of Arizona arizonae. *Int J Syst Bacteriol*. 16: 427–433.
29. Ewing, W.H., M.A. Fife, and B.R. Davis. 1965. *The Biochemical Reactions of Arizona arizonae*. U.S. Department of Health Education and Welfare, NCDC, Atlanta, GA.
30. Ferris, K., and W.M. Frerichs. 1987. *Salmonella* serotypes from animals and related sources reported during the fiscal year 1987. *Proc Annu Meet US Anim Health Assoc*. 92:349–362.
31. Ferris, K., and E.D.A. Miller. 1997. Annual *Salmonella*e Report, October 1, 1996–September 30, 1997. Bacterial Identification section. Nat Vet Sci Lab. USDA/APHIS, Ames Iowa.
32. Foster, N., and K. Kerr. 2005. The snake in the grass—*Salmonella* arizonae gastroenteritis in a reptile handler. *Acta Paediatr*. 94:1165–1166.
33. Gauger, H.C. 1946. Isolation of a type 10 paracolon bacillus from an adult turkey. *Poult Sci*. 25:299–300.
34. Geissler, H., and Y.I. Youssef. 1979. The effect of infection with *Arizona hinshawii* on chicken embryos. *Avian Pathol*. 8:157–161.
35. Geissler, H., and Y.I. Youssef. 1981. Persistence of *Arizona hinshawii* in or on materials used in poultry houses. *Avian Pathol*. 10:359–363.
36. Gerlach, H., H.E. Adler, and A.S. Rosenwald. 1968. Research Note: Observations on immune factors associated with arizona group infection in turkeys. *Avian Dis*. 12:681–686.
37. Ghazikhanian, G.Y., R. Yamamoto, R.H. McCapes, W.M. Dungan, and H.B. Ortmayer. 1980. Combination dip and injection of turkey eggs with antibiotics to eliminate *Mycoplasma meleagridis* infection from a primary breeding stock. *Avian Dis*. 24:57–70.
38. Ghazikhanian, G.Y., B.J. Kelly, and W.M Dungan. 1984. *Salmonella* arizonae control program. *Proc Int Symp on Salmonella*. G.H. Snoeyenbos, ed. American Association of Avian Pathologists, Kennett Square, PA. 142–149.
39. Goetz, M.E. 1962. The control of paracolon and paratyphoid infections in turkey poults. *Avian Dis*. 6:93–99.
40. Goetz, M.E., and E.R. Quortrup. 1953. Some observations of the problem of *Arizona paracolon* infections in poults. *Vet Med*. 48:58–60.
41. Goetz, M.E., E.R. Quortrup, and J.E. Dunsing. 1954. Investigations of *Arizona paracolon* infections in poults. *J Am Vet Med Assoc*. 124:120–121.
42. Greenfield, J. 1972. Studies on *Arizona* in turkeys: Isolation and antibiotic control. *Diss Abstr Int B*. 489–490.
43. Greenfield, J. 1976. *Proc Salmonella Symposium*. American Association of Avian Pathologists, Kennett Square, PA. 70–78.
44. Greenfield, J., and J.C. Bankier. 1969. Isolation of *Salmonella* and *Arizon*a using enrichment media incubated at 35 and 43 C. *Avian Dis*. 13:864–871.
45. Greenfield, J., and C.H. Bigland. 1971b. Isolation of *Arizona* from specimens grossly contaminated with competitive bacteria. *Avian Dis*. 15:604–608.
46. Greenfield, J., C.H. Bigland, and T.W. Dukes. 1971a. The genus *Arizona* with special reference to Arizona disease in turkeys. *Vet Bull*. 41:605–612.
47. Greenfield, J., C.H. Bigland, and H.D. McCausland. 1971b. Culture of shell and shell membranes for efficient isolation of *Arizona* from turkey hatching eggs. *Avian Dis*. 15:82–88.
48. Greenfield, J., C.H. Bigland, H.D. McCausland, and C.W. Wood. 1972. Control of Arizona disease in turkeys by poult injection. *Poult Sci*. 51:523–526.
49. Guckian, J.E., E.H. Byers, and J.E. Perry. 1967. *Arizona* infection of man. *Arch Int Med*. 119:170–175.
50. Hinshaw, W.R., and E. McNeil. 1944. Gopher snakes as carriers of salmonellosis and paracolon infections. *Cornell Vet*. 34:248–254.
51. Hinshaw, W.R., and E. McNeil. 1946a. The occurrence of type 10 paracolon in turkeys. *J Bacteriol*. 51:281–286.
52. Hinshaw, W.R., and E. McNeil. 1947. Lizards as carriers of salmonella and paracolon bacteria. *J Bacteriol*. 53:715–718.
53. Hirsh, D.C., J.S. Ikeda, L.D. Martin, B.J. Kelly, and G.Y. Ghazikhanian. 1983. R plasmid-mediated gentamicin resistance in *Salmonella* isolated from turkeys and their environment. *Avian Dis*. 27:766–772.
54. Holte, R.J.A. 1965. Paracolon arizona immunization trials in turkeys. *Proc Annu Meet US Livest Sanit Assoc*. 69:539–542.
55. Jamison, S.L. 1956. Paracolon infections. *Pac Poult*. 62:40–42.
56. Johnson, R.H., L.I. Lutwick, G.A. Huntley, and K.L. Vosti. 1976. *Arizona hinshawii* infections. New cases, antimicrobial sensitivities and literature review. *Ann Intern Med*. 85:587–592.
57. Jordan, F.T.W., P.H. Lamont, L. Timms, and D.A.P. Grattan. 1976. The eradication of *Arizona* 7:1,7,8 from a turkey breeding flock. *Vet Rec*. 99:413–415.
58. Kauffmann, F. 1966. The Bacteriology of Enterobacteriaceae. Williams & Wilkins, Baltimore, MD.
59. Kauffmann, F., and P.R. Edwards. 1952. Classification and nomenclature of Enterobacteriaceae. *Int Bull Bacteriol Nomencl Taxon*. 2:2–8.

60. Kelly, J., R. Hopkin, and M.E. Rimsza. 1995. Rattlesnake meat ingestion and *Salmonella* Arizona infection in children: case report and review of the literature. *Pediatr Infect Dis J*. 14: 320–322.
61. Kidd, M.T., M.A. Quereshi, P.R. Ferket, and L.N. Thomas. 1994. Dietary zinc-methionine enhances mononuclear-phagoctyi function in young turkeys, Zinc-methionine, immunity, and *Salmonella*. *Biol Trace Elem Res*. 42:217–219.
62. Kowalski, L.M., and J.F. Stephens. 1967. Persistence of *Arizona paracolon* 7:1,7,8 in feed and water. *Poult Sci*. 46:1586–1587.
63. Kowalski, L.M., and J.F. Stephens. 1968. *Arizona* 7:1,7,8 infection in young turkeys. *Avian Dis*. 12:317–326.
64. Kumar, M.C., S.C. Nivas, A.K. Bahl, M.D. York, and B.S. Pomeroy. 1974. Studies on natural infection and egg transmission of *Arizona hinshawii* 7:1,7,8 in turkeys. *Avian Dis*. 18: 416–426.
65. Kumar, M.C., M.D. York, and B.S. Pomeroy. 1976. Comparison of tetrathionate and selenite enrichment broth for isolations of *Arizona hinshawii* 7:1,7,8 and various serotypes of *Salmonella*. *Proc Annu Meet Am Assoc Vet Lab Diagn*. 19:179–188.
66. Kumar, M.C., M.D. York, and B.S. Pomeroy. 1977. Development of microagglutination test for detecting *Arizona hinshawii* 7:1,7,8 infection in turkeys. *Am J Vet Res*. 38:255–257.
67. Lamont, P.H., and L. Timms. 1972. Experimental infection of turkey poults with *Arizona* serotype 7:1,7,8. *Br Vet J*. 128: 129–137.
68. Lewis, K.H., and E.R. Hitchner. 1936. Slow lactose fermenting bacteria pathogenic for baby chicks. *J Infect Dis*. 59:225–235.
69. Libby, S.I., M. Lesnick, P. Hasegawa, M. Kurth, C. Belcher, J. Fierer, and D.G. Guiney. 2002. Characterization of the spv locus in *Salmonella enterica* Serovar Arizona. *Infect Immun*. 70: 3290–3294.
70. Littell, A.M. 1977. Plating medium for differentiation of *Salmonella arizonae* from other salmonellae. *Appl Environ Microbiol*. 33:485–487.
71. Lowry, V.K., G.I. Tellez, D.J. Nisbet, G. Garcia, O. Urquiza, L.H. Stanker, and M.H. Kogut. 1999. Efficacy of *Salmonella enteritidis*-immune lymphokines on horizontal transmission of *S. arizonae* in turkeys and *S. gallinarum* in chickens. *Int J of Food Micro*. 48:130–148.
72. Martin, W.J., M.A. Fife, and W.H. Ewing. 1967. *The Occurrence and Distribution of the Serotypes of Arizona*. U.S. Department of Health Education and Welfare, NCDC, Atlanta, GA.
73. Mayeda, B., R.H. McCapes, and W.F. Scott. 1978. Protection of day-old poults against *Arizona hinshawii* challenge by preincubation streptomycin egg treatment. *Avian Dis*. 22:61–70.
74. McCapes, R.H., R. Yamamoto, H.B. Ortmayer, and W.F. Scott. 1975. Injecting antibiotics into turkey hatching eggs to eliminate *Mycoplasma meleagridis* infection. *Avian Dis*. 19:506–514.
75. McClure, H.E., W.C. Eveland, and A. Kase. 1957. The occurrence of certain Enterobacteriaceae in birds. *Am J Vet Res*. 18: 207–209.
76. Miyamae, T., and H.E. Adler. 1967. Comparative studies on immunogenicity of *Arizona* (7:1,7,8) adjuvant bacterins in mice and turkeys. *Avian Dis*. 11:380–392.
77. Nagaraja, K.V., D.A. Emery, L.F. Sherlock, J.A. Newman, and B.S. Pomeroy. 1984. Detection of *Salmonella* arizonae in turkey flocks by ELISA. *Proc Am Assoc Vet Lab Diag*. 27:185–203.
78. Nagaraja, K.V., M.C. Kumar, J.A. Newman, and B.S. Pomeroy. 1985. Control of *Salmonella arizonae* infection in turkey breeder flocks by immunization. *J Am Vet Med Assoc*. 187:309.
79. Nagaraja, K.V., L.T. Ausherman, D.A. Emery, and B.S. Pomeroy. 1986. Update on enzyme-linked immunosorbent assay for its field application in the detection of *Salmonella arizonae* infection in breeder flocks of turkeys. *Proc Am Assoc Vet Diag*. 29: 347–356.
80. Nagaraja, K.V., C.J. Kim, and B.S. Pomeroy. 1988. Prophylactic vaccines for the control and reduction of salmonella in turkeys. *Proc Annu Meet US Anim Health Assoc*. 92:347–348.
81. Opengart, K.N., C.R. Tate, R.G. Miller, and E.T. Mallinson. 1991. The use of drag-swab technique and improved selective plating media in the recovery of *Salmonella arizona* (7:1,7,8) from turkey breeder hens. *Avian Dis*. 35:228–230.
82. Oros, J., J.L. Rodriguez, A. Fernandez, P. Herraez, A. Espinosa de los Monteros, and E.R. Jacobson. 1998. Simultaneous occurrence of *Salmonella* arizonae in a sulfur crested cockatoo (*Cacatua galerita galerita*) and iguanas. *Avian Dis*. 42:818–23.
83. Perek, M. 1957. Isolation of a paracolobactrum organism pathogenic to chickens. *J Infect Dis*. 101:8–10.
84. Perek, M., M. Elian, and E.D. Heller. 1969. Bacterial flora of semen and contamination of the reproductive organs of the hen following artificial insemination. *Res Vet Sci*. 10:127–132.
85. Renault, L., J. Vaissaire, C. Maire, and P. Motte. 1972. Identification of *Arizona arizonae* from turkeys in France. *Bull Acad Vet Fr*. 45:53–55.
86. Rosenwald, A.S. 1965. New facts on paracolon control. *Poult Meat*. 2:25.
87. Saif, Y.M., L.C. Ferguson, and K.E. Nestor. 1971. Treatment of turkey hatching eggs for control of *Arizona* infection. *Avian Dis*. 15:448–461.
88. Sambyal, D.S., and V.K. Sharma. 1972. Screening of free-living animals and birds for *Listeria*, *Brucella* and *Salmonella* infections. *Br Vet J*. 128:50–55.
89. Sanyal, D., T. Douglas, and R. Roberts. 1997. *Salmonella* infection acquired from reptilian pets. *Arch Dis Child*. 77:345–346
90. Sari, I., M. Lakatos, S. Toth, Z. Nemes, and G. Szeifert. 1979. Arizona salmonellosis of turkeys in Hungary. II. Aetiology and histopathology. *Magy Allatorv Lapja*. 34:610–615.
91. Sato, G. 1967. Detection of *Salmonella* and *Arizona* organisms from soil of empty turkey yards. *Jpn J Vet Res*. 15:53–55.
92. Sato, G., and H.E. Adler. 1966a. A study on the efficacy of *Arizona* bacterin in turkeys. *Avian Dis*. 10:239–246.
93. Sato, G., and H.E. Adler. 1966b. Bacteriological and serological observations on turkeys naturally infected with *Arizona* 7:1,7,8. *Avian Dis*. 10:291–295.
94. Sato, G., and H.E. Adler. 1966c. Experimental infection of adult turkeys with *Arizona* group organisms. *Avian Dis*. 10:329–336.
95. Sharma, V.K., Y.K. Kaura, and I.P. Singh. 1970. *Arizona* infection in snakes, rats and man. *Indian J Med Res*. 58:409–412.
96. Shivaprasad, H.L., R. Crespo, R.P. Chin, G. Senties-Cue and P. Cortes. 2004. *Salmonella arizonae* outbreaks in turkey poults. *Proc. American Association of Avian Pathologists Conference*. Philadelphia. 38.
97. Shivaprasad, H.L., P. Cortes, and R. Crespo. 2006. Otitis interna (Labyrinthitis) associated with *Salmonella enterica* arizonae in turkey poults. *Avian Dis*. 50:135–138.
98. Silva, E.N., and O. Hipólito. 1978. *Salmonella* strains isolated from the digestive tract of breeding chickens and apparently normal turkeys and in chick embryos. *Proc World's Poult Congr*. 16:701–706.
99. Silva, E.N., O. Hipolito, and R. Grecchi. 1980. Natural and experimental *Salmonella arizonae* 18:z4,z32 (Ar. 7:1,7,8) infection in

broilers. Bacteriological and histological survey of eye and brain lesions. *Avian Dis*. 24:631–636.
100. Snoeyenbos, G.H., and C.F. Smyser. 1969. Research note—Isolation of *Arizona* 7:1,7,8 from litter of pens housing infected turkey. *Avian Dis*. 13:223–224.
101. Timms, L. 1971. *Arizona* infection in turkeys in Great Britain. *J Med Lab Technol Br*. 28:150–156.
102. Valeri, A., C. Marenzi, F. Enice, and T. Rampin. 1976. Study of biochemical characteristics of *Salmonella arizonae* isolates from turkeys. *Clin Vet*. 99:422–429.
103. Waterman, S.H., G. Juarej, S.J. Carr, and L. Kilman. 1990. *Salmonella arizona* infections in Latinos associated with rattlesnake folk medicine. *Am J Pub Health*. 80:286–289.
104. Weiss, S.H., M.J. Blaser, F.P. Paleologo, R.E. Black, A.C. McWhorter, M.A. Asbury, G.P. Carter, R.A. Feldman, and D.J. Brenner. 1986. Occurrence and distribution of serotypes of the *Arizona* subgroup of *Salmonella* strains in the United States from 1967 to 1976. *J Clin Microbiol*. 23:1056–1064.
105. West, J.L., and G.C. Mohanty. 1973. *Arizona hinshawii* infection in turkey poults: Pathologic changes. *Avian Dis*. 17:314–324.
106. Williams, J.E. 1984. Avian Arizonosis. In: *Diseases of Poultry*, 8th ed. M.S. Hofstad, H.J. Barnes, B.W. Calnek, W.M. Reid, and H.W. Yoder, Jr., eds. Iowa State University Press, Ames, IA. 130–140.
107. Williams, J.E., and L.H. Dillard. 1968. Penetration of chicken egg shells by members of the *Arizona* group. *Avian Dis*. 12: 645–649.
108. Williams, L.P., and B.C. Hobbs. 1975. Enterobacteriaceae infections. In: *Diseases Transmitted from Animals to Man*. W.T. Hubbert, W.F. McCulloch, and P.R. Schnurrenberger, eds. Charles C. Thomas, Springfield, IL. 33–109.
109. Williams, J.E., E.T. Mallinson, and G.H. Snoeyenbos. 1980. Salmonellosis and arizonosis. In: *Isolation and Identification of Avian Pathogens*. S.B. Hitchner, C.H. Domermuth, H.G. Purchase, and J.E. Williams, eds. American Association of Avian Pathologists, Kennett Square, PA. 1–8.
110. Windingstad, R.W., D.O. Trainer, and R. Duncan. 1977. *Salmonella enteritidis* and *Arizona hinshawii* isolated from wild sandhill cranes. *Avian Dis*. 21:704–707.
111. Winsor, D.K., A.P. Bloebaum, and J.J. Mathewson. 1981. Gram-negative aerobic, enteric pathogens among intestinal microflora of wild turkey vultures (*Cathartes aura*) in west central Texas. *Appl Environ Microbiol*. 42:1123–1124.
112. Worcester, W.W. 1965. Californian report results of test on paracolon control. *Feedstuffs* 37:6.

Chapter 17

Campylobacteriosis

Qijing Zhang and Orhan Sahin

Introduction

Avian species, especially domestic poultry including chickens, turkeys, ducks, and geese, are frequently infected with the members of thermophilic *Campylobacter*, primarily *Campylobacter jejuni* and *Campylobacter coli* (157, 163, 180). As enteric organisms, *C. jejuni* and *C. coli* are well adapted to the avian host and reside in the intestinal tract of birds. Despite extensive colonization, *Campylobacter* infections produce minimal or no disease in poultry (33, 97, 129). However, vibrionic hepatitis associated with *C. coli* and *C. jejuni* has been reported in laying hens and ostriches, causing high morbidity and mortality (22, 178). A recent experimental study suggested that *Campylobacter* alone is not sufficient to cause vibrionic hepatitis and a predisposing factor in chickens might be required for the development of the disease (79).

Although thermophilic campylobacters are not significant pathogens for poultry, they are important to food safety and public health, with *C. jejuni* being responsible for the majority of human campylobacteriosis, followed by *C. coli*, and rarely by *C. lari*. *Campylobacter* has now emerged as a leading bacterial cause of foodborne gastroenteritis in humans around the world (115). Most of *Campylobacter*-related illnesses in humans are sporadic and characterized by self-limiting watery and/or bloody diarrhea, abdominal cramps, and possible fever; however, severe conditions may occur in immunocompromised patients, requiring antibiotic treatment (51, 115). In addition, *Campylobacter* infection is associated with Guillain-Barre syndrome, a postinfectious autoimmune disease characterized by acute and progressive neuromuscular paralysis (91, 123).

Etiology

Classification

At present, the genus *Campylobacter* contains 18 species, with *Campylobacter fetus* being the type species (98, 133). The family *Campylobacteraceae* represents a diverse but phylogenetically distinct group, rRNA superfamily VI, within the group of Gram-negative bacteria (133, 199). This lineage is also known as the epsilon division of the *Proteobacteria*, and comprises rRNA homology groups I (*Campylobacter* and *Bacteroides ureolyticus*), II (*Arcobacter*), and III (*Helicobacter* and *Wolinella succinogenes*). Members of this lineage are characterized by their low chromosomal G+C content, inability to ferment carbohydrates, and microaerobic growth requirements.

The members of the genus *Campylobacter* are associated with a wide variety of diseases in humans and animals although they are commensals in poultry (173). Within the genus, 3 species (*C. jejuni*, *C. coli*, and *C. lari*) known as thermophilic *Campylobacter* are of clinical significance because they are the dominant causative agents of human campylobacteriosis (51, 124).

Growth Requirements

Thermophilic *Campylobacter* spp. grow optimally at 42°C on artificial media (124, 163). They are slow-growing fastidious organisms, and require a microaerobic atmosphere for optimal growth (124, 142, 190). In general, *Campylobacter* is sensitive to oxygen, desiccation, osmotic stress, low pH, and high temperatures (48, 135). *Campylobacter* cells are S-shaped spirally curved rods that range from 0.2–0.8 μm wide and 0.5–6.0 μm long, although cells may transform to spherical or coccoid forms in response to stress or deleterious conditions (124, 163). The members of the genus are Gram-negative and non-spore forming, and possess a single polar flagellum, mediating a characteristic corkscrew-like or darting motility (124, 163). *Campylobacter* spp. are typically unable to ferment or oxidize carbohydrates, and thus energy is mainly derived from the degradation of amino acids or tricarboxylic acid cycle intermediates (85). However, recent studies indicate that some *C. jejuni* strains can use L-fucose as a substrate for growth (120, 175).

Pathobiology and Epizootiology

Incidence and Distribution

C. jejuni and C. coli are widespread in avian hosts (33, 128, 157, 180). Generally, the carriage rate of *Campylobacter* in domestic poultry is found to be much higher than that in wild birds (163, 180, 191, 212). This is probably due to the high bird density in commercial poultry houses, which facilitates

Diseases of Poultry, Thirteenth Edition. David E. Swayne.
© 2013 John Wiley & Sons, Inc. Published 2013 by John Wiley & Sons, Inc.

the spread of *Campylobacter* between birds. The numbers of *Campylobacter*-positive poultry flocks are generally high, but vary by regions, seasons, and the production stages and types (conventional, free range, or organic). It appears that the prevalence of *Campylobacter* is lower in Scandinavian countries (e.g., Norway, Sweden, Finland, and Iceland) than in other European countries, North America, and developing countries (129). Many prevalence studies have been conducted in Europe and the United States, which reported *Campylobacter*-positive flocks ranging from 3%–97% (7, 9, 12, 18, 46, 58, 62, 67, 73, 138, 148, 182, 195, 206, 210). Despite the fact that the majority of on-farm surveys were conducted with broiler chickens, breeder flocks and laying hens are also commonly infected by *Campylobacter* (76, 155, 163).

Seasonal variations were observed in the prevalence of *Campylobacter* flocks with a peak in warm months (9, 18, 148, 182, 206). The exact reason(s) for this seasonal variation is unknown, but it is proposed that the peaking prevalence of *Campylobacter* in warm months is due to increased fly population and fly-mediated transmission (56). On commercial poultry farms, *Campylobacter* is rarely detected in birds less than 3 weeks of age. Typically, the prevalence of *Campylobacter* increases as the birds grow and reaches the peak at the slaughter age for boiler chickens. There is a general trend that *Campylobacter* is more prevalent in organic and free-range flocks than in conventional production (44, 67, 108, 150, 198, 210). For organic and free-range operations, birds have free access to the outside environment and are slaughtered at an older age, both of which may account for the increased prevalence of *Campylobacter*. Once a broiler flock is infected with *Campylobacter*, the majority of the birds within that flock can become colonized in a short time (9, 12, 26, 53, 182).

With respect to species distribution of campylobacters isolated from chickens, *C. jejuni* accounts for the majority of isolates, followed by *C. coli*, and rarely by *C. lari* (12, 18, 21, 26, 46, 67, 73, 108, 148, 151, 163, 170). However, a higher or even sometimes predominant proportion of *Campylobacter* isolates from turkeys or organic and free range productions are *C. coli* (67, 108, 151, 210). The isolation of other *Campylobacter* spp. including *C. upsaliensis* and *C. hyointestinalis* in poultry is at a low rate (163, 206). Poultry *Campylobacter* isolates are of multiple genotypes and great genetic diversities. Chicken flocks can be colonized by single or multiple genotypes of *Campylobacter* (12, 21, 45, 70, 129, 136, 151, 183, 210). Even during a single rearing cycle, a broiler flock can be infected by different species or genotypes of *Campylobacter* at different times (21, 62, 151, 157), reflecting the dynamic changes of *Campylobacter* populations on poultry farms.

Transmission, Carriers, Vectors

Horizontal Transmission

Many farm-based studies have indicated that horizontal transmission from the environment to poultry houses is the most common mode of transmission of Ca*mpylobacter* on poultry farms. Potential sources of infection include old litter, untreated drinking water, other farm animals, domestic pets, wildlife species, house flies, insects, equipment and transport vehicles, and farm workers. Because *Campylobacter* growth is very sensitive to oxygen and temperature, the organism is usually unable to grow in feed, litter, or water under normal ambient conditions (73, 75, 84). The organism is usually absent in fresh litter or feed before broilers are infected. Used litter may become contaminated by *Campylobacter* and may play a role in maintaining *Campylobacter* in the farm environment (104, 118). Due to its low moisture content, feed is unlikely to be an original source for the introduction of *C. jejuni* into the poultry houses (78, 196). However, feed can be contaminated by feces in chicken houses (53), which may facilitate the spread of *Campylobacter* within production facilities.

Unchlorinated water supplies have been implicated as a source of *Campylobacter* infection in broiler chickens (83, 137). Due to its requirement for microaerobic conditions and its inability to grow below 31°C–32°C (59), *C. jejuni* is unlikely to propagate in environmental water. The presence of this organism in water systems is probably a sign of a recent contamination by feces of livestock or wild birds (81, 176). Therefore, it is likely that contaminated water serves as a passive carrier of *Campylobacter* rather than a niche for growth of *Campylobacter*. Also, drinking water on poultry farms usually becomes positive with *C. jejuni* only after chickens are colonized (12, 196, 216), making questionable the role of drinking water in transmitting *Campylobacter* on poultry farms. Water supplies of intensively reared broilers are often inhabited by protozoa. It was shown that *Campylobacter* could enter into protozoan cells and was able to survive for prolonged periods inside the protozoan cells (8, 174). The same studies also found that *Campylobacter* was more resistant to disinfectants (e.g., chlorine) when co-cultured with protozoa than when cultured alone. These results suggest that protozoa in the aquatic environments could serve as a potential reservoir for *Campylobacter* and may facilitate the survival and transmission of *Campylobacter* in animal reservoirs.

Insects (house flies, darkling beetles, cockroaches, mealworms, etc.) can act as mechanical vectors, and may transmit *Campylobacter* to poultry houses (78, 148, 152). Several studies reported that identical serotypes and genotypes of *Campylobacter* were isolated from both broilers and insects within broiler houses (11, 78, 153). There also were reports indicating that insects in poultry houses were not positive for *C. jejuni* until the organism was isolated from broiler chickens in the same houses (11, 127). A recent study in Denmark by Hald et al. (56) reported that in summer months about 10% of flies around a broiler house were contaminated with *Campylobacter* and that hundreds of flies could enter a poultry house through the ventilation system. Furthermore, the same study demonstrated that *Campylobacter* isolates from the broiler chickens and from flies captured in the environment were of the same genotypes. These findings suggest that flies serve as a vector for transmitting *Campylobacter* on farms, especially during the summer months.

Several studies have shown that rodents and other small wild animals such as raccoons harbor *Campylobacter* in their intestines, and thus these wild animals can potentially introduce *Campylobacter* into grow-out houses (6, 83, 127). In the study reported by Petersen and Wedderkopp (140), the persistence of some *C. jejuni* clones during successive broiler flock rotations was suggested to be a result of survival of the organism in such reservoirs as rodents and insects that were able to evacuate the house during cleaning and disinfection and then return. However, no direct evidence existed to prove this theory (53, 78, 196). In addition, other studies found that *Campylobacter* was not isolated from rodents in the vicinity of broiler houses (53, 80). Considering the fact that vermin control programs are implemented in most commercial poultry production facilities, rodents and other small animals are unlikely a common source of *Campylobacter* infection for broiler flocks.

Campylobacter has a wide distribution in wild birds (100, 147, 203). Wild birds in the vicinity of poultry production facilities are often found to be infected with *C. jejuni*; however, the *Campylobacter* isolates from wild birds are usually different from those of chicken origin (53, 127, 153). Because wild birds often carry *Campylobacter* in their intestines, and owing to their great mobility, wild birds may spread *Campylobacter* to domestic poultry through fecal contamination of pastures, forage, surface water, or feed.

Presence of other farm animals on broiler farms including pigs, cattle, sheep, and poultry other than chickens has been found to be associated with an increased risk of *Campylobacter* infection in broiler chickens (12, 18, 83, 196). In the study by Gregory et al., cattle and chickens on the surveyed farms were found to be concurrently infected with *C. jejuni* (53). In a follow up study, *C. jejuni* isolates from these cattle were shown to have the same *flaA* type as the isolates from the broilers on the same farm (183). Identical genotypes between cattle and broiler isolates from the same farm were observed in another study, and cattle were suggested to be a source of infection to the broilers on the farm (196). However, as was indicated by the authors (196), the direction of the transmission was unknown, and the vectors/carriers mediating the transmission between cattle and chickens were not revealed. In other studies, *C. jejuni* isolated from cattle was found to be different from the isolates recovered from the broilers on the same farm (21, 77, 78, 127, 153), suggesting that cattle and broilers were infected by *Campylobacter* from different sources. Pigs also are frequently colonized by *Campylobacter* (6, 53, 127). Tending pigs before entering broiler houses was indicated as a risk factor for *Campylobacter* colonization of chickens (83). However, pigs are usually infected with *C. coli* instead of *C. jejuni* (14, 189), whereas poultry (especially chickens) are frequently colonized by *C. jejuni* (180, 196).

Farm workers may carry *Campylobacter* into poultry houses (12). *Campylobacter* was isolated from footbath water, farmer's boots, and transport crates (21, 182, 196). Therefore, it is possible that *Campylobacter* may spread between broiler flocks or farms by the movement of personnel or farm equipment.

In summary, it appears that poultry houses can be invaded by *Campylobacter* in many different ways from various sources. The complexity of *Campylobacter* transmission and the widespread presence of *Campylobacter* in the production system greatly undermine the success in controlling *Campylobacter* on poultry farms by using management-based strategies.

Vertical Transmission

There was a major debate regarding whether vertical transmission plays a role in introducing *Campylobacter* to poultry flocks, but the current understanding is that vertical transmission of *Campylobacter* does not occur or occurs very rarely on poultry farms. This argument is supported by the following evidence. First, young broiler chickens usually lack *Campylobacter* before 2 or 3 weeks of age even though they are hatched from eggs originated from breeder flocks infected by *Campylobacter* (9, 11, 21, 166, 194, 196). Second, progeny broiler flocks are frequently infected with strains different from those of their breeder flocks (21, 29, 139, 140, 196). Third, a well-conceived large-scale longitudinal study conducted in Iceland reported the lack of vertical transmission of *Campylobacter* in poultry production (9). Finally, isolation of *Campylobacter* from eggs and hatchings has been scarce (40, 69, 74, 155, 166), and to date there has been only one report on isolation of live *Campylobacter* cells from hatcheries or young hatchlings (23).

Evidence suggesting vertical transmission of *Campylobacter* is as follows. Some earlier studies showed that *C. jejuni* could be isolated from both the outer and inner surface of egg shells laid by naturally infected commercial layers or broiler breeders (40, 164, 166). Furthermore, *C. jejuni* has been isolated from the reproductive tract of healthy hens (20, 25, 68, 77) and from semen of commercial broiler breeder roosters (36). However, these findings do not necessarily indicate vertical transmission because *Campylobacter* needs to survive in eggs and the hatching process for transmission to young chicks. Several studies using molecular detection methods demonstrated the presence of *Campylobacter* DNA in embryos and newly hatched chicks (30, 31, 74) and in hatcheries (69), but these methods do not allow for differentiation of dead and live *Campylobacter*.

Incubation Period

Experimental studies demonstrated that *Campylobacter* colonization could occur as early as 1 day after inoculation (10, 90, 156, 167, 181, 214). In a few cases in which diarrhea was observed, the incubation time ranged from 2–5 days (154, 160, 207). The minimal infective dose to establish colonization in day-old chicks was shown to be as low as 2 cfu (90), although other studies indicated higher infectious doses (167, 181, 214). Once *Campylobacter* colonization is established, it can persist in the intestinal tract for multiple weeks (3, 90, 157), but a gradual decrease in the level of colonization usually occurs after a prolonged plateau period (109, 156, 180).

On poultry farms, *Campylobacter* is rarely detected in birds less than 2–3 weeks of age. The reason for this lack of infection

in young birds is unclear and may be related to multiple factors including the presence of maternally derived antibodies (28, 156, 158) or differences in environmental or host-related factors. Once a flock is infected, *Campylobacter* spreads rapidly within the flock, leading to colonization of the majority of the birds within a few days (12, 46, 53, 169). Despite the fact that *Campylobacter* infection rarely occurs in young flocks on poultry farms, newly hatched chickens can be readily infected experimentally with *Campylobacter* (157, 163, 167).

Clinical Signs and Pathology

Campylobacter infections in poultry usually produce no clinical signs of disease under natural conditions. However, it has been reported that in ostriches natural *Campylobacter* infection can cause clinical illness and lesions in liver and intestines (128, 178). Vibrionic hepatitis was prevalent during the 1950s and 1960s in commercial laying hens, but is only occasionally reported today (22, 37). It was suspected that *Campylobacter* might be the cause of the disease, but the etiologic agent(s) for vibrionic hepatitis was not formally identified (165).

Some studies reported that experimental challenge of young chickens with *Campylobacter* can induce clinical signs including watery/mucoid/bloody diarrhea, weight loss, or even mortality (154, 160, 207). In an early report, 3-day old chickens inoculated with a high dose of *C. jejuni* developed diarrhea within 72 hours, which lasted for 10 days and resulted in considerable weight loss as well as a mortality of 32% (154). Welkos (207) reported that almost one-third of the day-old chicks and nearly all of the newly-hatched chicks, but none of the 3-day old chickens, developed signs of gastroenteritis after oral challenge with *C. jejuni*. Similarly, Sanyal et al. (160) observed watery/mucoid diarrhea in 81% of 36- to 72-hour-old birds 5 days after inoculation with *C. jejuni*, and also found that the Starbro strain of broiler chickens was more likely to develop diarrhea than the white leghorns strain. *Campylobacter* infection in commercial broilers of less than 2 weeks of age (a rare event) was found to be associated with diarrhea, decreased weight gain, and excess mortality (126). Another study using newly hatched or 4-day old turkey poults also observed reduced weight gain and transient watery diarrhea in the birds after inoculation with *Campylobacter* (93). Oral inoculation of 3-week-old Japanese quails with *C. jejuni* resulted in diarrhea that lasted for 2 weeks (111). Despite these isolated reports, many other studies did not observe any clinical signs associated with *Campylobacter* infections in poultry (10, 90, 156, 167, 181).

Gross lesions associated with *Campylobacter* infection in experimentally infected chicks are minimal and mainly confined to the gastrointestinal tract. Due to accumulation of fluid, gas, or excess mucus, distention of intestines including ceca with watery/foamy material may be a common finding (160, 207). Blood and mucus in the lumen of small intestine and petechial hemorrhages in the ventricular (gizzard) mucosa of chicks can be seen occasionally (207). There is a report that *Campylobacter* was isolated more frequently (21% of 223 livers) from broiler chicken livers with necrotic lesions than from normal livers (12% of 50 livers) obtained from slaughter plants in Canada (17); however, there was no evidence that *Campylobacter* directly contributed to the lesion.

Microscopic lesions following experimental infection of chicks are mostly inapparent or minimal, but exceptions occur in birds with severe clinical signs and gross pathological changes. Usually examination of gastrointestinal tissue reveals no necrosis or invasion of the epithelium or any other pathological changes; however, a mild edema of the lamina propria and submucosa of the intestines, mostly in ceca, was reported with *Campylobacter* infections in chickens (10, 90, 160, 167, 181). In some cases, *Campylobacter* cells can be seen attaching to the brush borders on enterocytes, within intestinal epithelial cells, and inside or outside the cells of lamina propria with minimal tissue or cell damage (154, 160, 207). Mononuclear infiltration in the submucosa and villous atrophy resulting in accumulation of red blood cells and leucocytes in small and large intestinal lumen may occur in more severe cases (90, 207).

Pathogenesis of the Infectious Process

Birds become infected with campylobacters via the fecal-oral route. As enteric organisms, *Campylobacter* spp. are able to survive the harsh conditions in the acidic proventriculus and ventriculus (gizzard) as well as in the small intestine, and eventually reach the lower intestine, where they establish colonization in cecal and cloacal crypts (2, 10, 157). To a lesser extent, the organism can also be recovered from the small intestine and the ventriculus (gizzard), and infrequently from the liver, spleen, blood, and gall bladder (2, 82, 143, 160). Several distinct features are associated with colonization of *Campylobacter* in chickens. First, it appears that *Campylobacter* does not adhere directly to intestinal epithelial cells, but mainly localizes in the mucous layer of the crypts (10, 117). Second, usually no gross or microscopic lesions are induced in the chickens. Third, invasion of the intestinal epithelium occasionally occurs with *Campylobacter* (101, 197). Even when the invasion of internal organs occurs, no clinical signs of illness are observed (10, 79, 90, 214). A recent study suggests that *C. jejuni* establish colonization by using a strategy that involves transient invasion of intestinal epithelium to avoid mucosal clearance combined with rapid replication in the intestinal mucus (197). Once a broiler chicken becomes infected, large numbers of the organism (up to 10^9 cfu/g feces) can be detected in ceca and excreted in feces for a prolonged period (157).

Many bacterial factors contribute to the colonization of *Campylobacter* in poultry. These include flagella, DnaJ (heat shock protein), CiaB (*Campylobacter* invasin antigen B), PldA (phospholipase A), CadF (*Campylobacter* adhesin to fibronectin), CmeABC (multidrug efflux pump), CmeR (a pleiotropic regulator), MCP (a methyl-accepting chemotaxis protein), RpoN (sigma factor), the Kps locus (capsule biosynthesis proteins), the Pgl locus (protein glycosylation system), SOD (superoxide dismutase), Fur (ferric uptake regulator), an unnamed lipoprotein encoding gene, FucP (a fucose permease), and CbrR (a bile resistance response regulator) (52, 60, 92, 103, 120, 125, 131, 145, 192, 205, 217, 218). A comprehensive review of the colonization

factors in chickens was published recently (64) and the list of genes contributing to the infection likely will continue to grow with the advance of genomics and functional genomics.

Immunity

Despite the commensal relationship between *Campylobacter* and the avian host, the infection indeed elicits a mild pro-inflammatory innate response in the intestinal mucosa (63) as well as both systemic and mucosal humoral responses (27, 122, 130, 149, 208). Following experimental infection of day-old chickens via oral gavage, production of *Campylobacter*-specific IgM and IgA antibodies in serum reached significant levels within 1–2 weeks of infection and peaked at weeks 4–6 post infection, followed by gradual decreases as birds age (27, 122). In contrast, detectable levels of IgG responses develop later than IgM and IgA responses, peaked at weeks 8–9 of the infection, and persist for a longer period (27, 122). Naturally occurring *Campylobacter* colonization in chickens also elicits overt immune responses, and anti-*Campylobacter* antibodies readily transfer from hens to their progenies as maternally derived (158, 213). Maternal antibody plays a partial role in protecting young chickens from infection by *Campylobacter* (28, 156). A wide variety of *Campylobacter* antigens are recognized by chicken sera (27, 149, 158, 168, 209). There is a trend that with the development of specific anti-*Campylobacter* antibodies, the level of *Campylobacter* colonization diminishes and some infected chickens eventually clear the infection (2, 82, 129, 156, 181). However, the nature of protective immunity has not been elucidated, and it is unknown if humoral immunity or cellular immunity (or both) contributes to the clearance of *Campylobacter* from the host.

Diagnosis

Culture-Based Isolation and Detection Methods

Thermophilic campylobacters are fastidious and slow growing, requiring microaerobic atmosphere (containing 5% O_2, 10% CO_2, 85% N_2) and elevated temperature (42°C) for optimal growth under laboratory conditions (34, 42, 159, 172). Thus, culturing *Campylobacter* spp. from fecal or environmental materials with a high level of background flora requires the use of selective culture media and special culture conditions. The first selective medium for culturing *C. jejuni* and *C. coli* was developed in 1977 by Skirrow (172). Since then, more than 40 solid and liquid selective media for culturing of *Campylobacter* from clinical and food samples have been reported, which have been reviewed by Corry et al. (34, 88, 95, 141). Some of the most commonly used are Skirrow, Preston, Karmali, modified charcoal cefoperazone deoxycholate agar (mCCDA), cefoperazone amphotericin teicoplanin (CAT) agar, Campy-CVA (cefoperazone vancomycin amphotericin), Campy-Cefex agar (CCA), modified CCA (mCCA), Campy-Line agar (CLA), *Campylobacter* agar plates (CAP), and a recently developed *Campylobacter* selective chromogenic medium CASA. The selective media contain a variety of different combinations of antibiotics to which thermophilic campylobacters are intrinsically resistant, such as polymyxin, vancomycin, trimethoprim, rifampicin, cefoperazone, cephalothin, colistin, cycloheximide, and nystatin. The multidrug efflux pump CmeABC in *Campylobacter* contributes, at least partly, to the intrinsic resistance to these selective agents (102). Use of these antibiotics inhibits the growth of many background microbial flora present in samples and allows the isolation of slow-growing *Campylobacter* spp.

Since *Campylobacter* spp. are sensitive to oxygen levels above 5%, *Campylobacter* selective media often contain various oxygen-quenching agents to neutralize the toxic effect of oxygen radicals (34). The commonly used oxygen quenching agents include blood (e.g., Skirrow and Campy-CVA media), a combination of ferrous sulfate, sodium metabisulfite and sodium pyruvate (e.g., Campy-Cefex agar), charcoal (e.g., mCCDA agar), and hematin (as in Karmali agar).

Depending on the type of specimen, selective media can be used either for direct plating or for an enrichment step followed by plating for isolation of *Campylobacter*. An enrichment step in liquid medium followed by plating on solid agar plates is usually superior to direct plating alone for isolation of *Campylobacter* from processed foods in which bacteria are usually in relatively low numbers and/or in an "injured" state (34, 75). However, the enrichment step may not always perform better than direct plating when culturing fecal samples. Musgrove et al. (121) compared enrichment and direct plating for isolation of *Campylobacter* from ceca and crops, which showed that direct plating of cecal samples on selective media resulted in a significantly higher recovery rate than the enrichment method. However, enrichment was slightly better than direct plating for the recovery of *Campylobacter* spp. from crop samples. When an enrichment step is used, it should be controlled for less than 24 hours because a prolonged incubation in enrichment broth may actually decrease the isolation rate.

To isolate thermophilic campylobacters from environmental water, two methods can be used to increase the detection sensitivity. A large volume of water can be filtered through a single membrane with a pore size of 0.2 μm. Subsequently the membrane can either be placed directly on a selective agar plate, or first cultured in an enrichment broth followed by selective plating (134, 137). Alternatively, water samples can be concentrated by high-speed centrifugation from which the supernatant is discarded and the pellet is cultured by direct plating or enriched in broth followed by plating.

Usually typical *Campylobacter* colonies are visible on solid media after 48 hours of incubation (16, 34), but it may take up to 72–96 hours to observe some slow-growing strains (34, 124, 159). Depending on the media used, colonies of *Campylobacter* spp. may appear differently. If the agar is moist, the colonies may appear gray, flat, irregular, and thinly spreading. Round, convex, or glistening colonies may be formed when plates are dry (34). Presumptive identification of thermophilic *Campylobacter* spp. can be made according to colony morphology, typical cellular shapes (spiral or curved rods), and

characteristic rapid darting motility as observed under phase-contrast microscope. The most commonly used phenotypic tests for identification of *Campylobacter* to genus or species level include biochemical tests (catalase, oxidase, nitrate reduction, hippurate hydrolysis, indoxyl acetate hydrolysis), antibiotic susceptibility patterns (nalidixic acid, cephalothin), and growth characteristics at different temperatures (25°C, 37°C, and 42°C) (132, 177). Differentiation between *C. jejuni* (hippurate-positive) and *C. coli* can be done with the hippurate test. However, hippurate-negative *C. jejuni* isolates have been reported (177), emphasizing the need for further testing of hippurate-negative strains with other methods when species identification is considered important.

Immunology-Based Diagnostic Methods

Enzyme immunoassays (EIA), based on antigen-antibody interaction, have been developed for direct detection of *Campylobacter* spp. in animal feces or processed food. These EIA assays are commercially available in a very similar format to sandwich-enzyme-linked immunosorbent assay (ELISA) assays, which use two different antibodies, to detect *Campylobacter* spp. directly in crude samples (71) or after a selective enrichment step (99, 159). Some examples of these commercial kits include VIDAS *Campylobacter* (bioMerieux), EIA-Foss *Campylobacter* (Foss Electric), ProSpecT *Campylobacter* EIA (Remel), Premier CAMPY EIA (Meridian Bioscience), ImmunoCard STAT! CAMPY test (Meridian Bioscience), and RidaScreen *Campylobacter* test (R-Biopharm AG). Most of these assays have been evaluated with humans stool samples, but their utility for detection of *Campylobacter* in chicken feces remains to be determined. Given that *Campylobacter* isolates from poultry are genetically and antigenically diverse, an effective immunoassay should have a broad and specific reactivity to different strains.

Nucleic Acid-Based Diagnostic Methods

DNA-based methods have been widely used for detection and identification of *Campylobacter* spp. The majority of the methods are designed in the formats of polymerase chain reaction (PCR) tests, which can be used for culture confirmation or for direct detection of *Campylobacter* from environmental or clinical samples. Depending on the purposes, PCR primers can be designed from either variable or conserved gene sequences of *Campylobacter* spp. PCR primers directed to conserved sequences are usually used for general detection, while primers designed from variable sequences can be used for differentiation of species or strains. A variety of PCR assays targeting genus- or species-specific sequences have been developed to detect and identify *Campylobacter* spp. from poultry feces and environmental samples (31, 66, 146, 159, 186, 200). When applied to crude samples, PCR-based tests tend to have a low sensitivity due to the presence of PCR inhibitors in feces and food matrices and are unable to differentiate dead bacteria from live cells. However, PCR assays can be used in conjunction with conventional culture methods to improve the speed and accuracy of *Campylobacter* detection and identification. Additionally, improvement of DNA purification from complex samples also should increase the utility of PCR-based detection methods (13, 96).

In addition to PCR, DNA microarray also has been reported for detection of *Campylobacter* from chicken feces and retail chicken samples (86, 144). With the use of multiple probes, DNA microarray allows simultaneous detection and differentiation of different species (and potentially strains). Many DNA-based methods have been developed for molecular typing of *Campylobacter* isolates from chickens and other animal reservoirs. These include pulsed-field gel electrophoresis (PFGE), random amplified polymorphic DNA (RAPD), amplified fragment length polymorphism (AFLP), ribotyping, and sequence-based methods [reviewed in reference (204)]. Sequence-based typing methods target the variable region of the *fla* gene (encoding the flagellin subunit), several house-keeping genes (multilocus sequence typing, MLST), or the *cmp* gene (encoding the major outer membrane protein) (72, 110, 116, 215). Comprehensive reviews on various typing tools have been published previously (49, 89, 204). It should be pointed out that these molecular typing methods are used for pure *Campylobacter* cultures and are not suitable for direct detection from feces and other complex samples.

Intervention Strategies

Poultry houses can be contaminated by *Campylobacter* in many different ways from various environmental sources, making the control of flock colonization by *Campylobacter* a very challenging task. In general, on-farm control strategies that have been examined for control of *Campylobacte*r in poultry can be broadly divided into two approaches: (1) prevention of flock colonization by use of biosecurity-based interventions, and (2) prevention and/or reduction of *Campylobacter* colonization by non-biosecurity based measures such as vaccination, bacteriocins, feed additives, bacteriophages, and competitive exclusion (41, 50, 65, 101). At present no single measure is completely effective in controlling *Campylobacter* infections on poultry farms.

Biosecurity

Several epidemiological investigations have found a correlation between decreased *Campylobacter* infection in broiler flocks and the employment of stringent biosecurity measures and hygienic practices on farms (12, 26, 46, 73, 83, 151, 196). In most of these studies, adherence to biosecurity measures either reduced the colonization level or delayed the onset time of colonization of birds by *Campylobacter*, but was largely unsuccessful in preventing introduction of *Campylobacter* into broiler flocks (12, 73, 128, 151, 169). Although on-farm biosecurity measures appear to be effective in reducing the incidence of *Campylobacter* infection in northern European countries such as Norway, Sweden, and Finland, these measures have met limited success in other countries such as the UK, the Netherlands, and Denmark (1, 195, 206). Because *Campylobacter* spp. are commonly present in the poultry farm environment and poultry flocks can be infected by multiple

sources, it is rather difficult to eliminate *Campylobacter* from poultry houses by biosecurity practices alone. So far, use of fly screens on poultry houses has been found to be a consistently effective measure to reduce the introduction of *Campylobacter* into broiler houses during summer in some European countries (54, 57), but their use in other countries such as the U.S. remains to be examined due to prominent differences in the rearing practices (e.g., horizontal [tunnel] ventilation systems in the U.S. vs. vertical ventilation shafts in Europe).

Competitive Exclusion

A number of studies investigated competitive exclusion as a means of preventing *Campylobacter* colonization in broiler chickens (41, 113, 202). These studies used fecal or cecal mucus suspensions, intestinal homogenates, undefined cecal mucus culture, or defined flora from cecal mucus. Although some level of protection was observed in chickens challenged under laboratory conditions, the degree of reduction was inadequate for practical purposes (113). Ideally, competitive exclusion should use pure (defined) cultures instead of crude intestinal mucus suspensions. However, the effect of defined competitive exclusion flora on *Campylobacter* was variable and inconsistent (114, 161, 162, 179). Also, treatment of broiler chickens with pure cultures of *Saccharomyces boulardii* (105, 113) or *Lactobacillus acidophilus* and *Streptococcus faecium* (119) was only partially successful in reducing *Campylobacter* colonization. In several studies assessing the effectiveness of the competitive exclusion product Broilact, substantial reduction in *Campylobacte*r colonization was observed in one study, but was not reproduced by others (4, 55, 113). In general, the currently available competitive exclusion products are of low effectiveness and are poorly reproducible under production conditions (35, 65, 101, 112).

Vaccination

Currently there are no commercial vaccines available for control of C*ampylobacter* in poultry (38, 65, 101). The commensal nature of *Campylobacter* colonization and the great genetic/antigenic diversity among different *Campylobacter* strains create a great challenge for developing effective vaccines that can confer broad-spectrum protection. The reported immunization studies used killed whole cells, live-attenuated cells, flagellin-based subunit vaccines, genetically engineered live vectors expressing *Campylobacter*-specific antigens, and chitosan-encapsulated DNA vaccine, most of which showed some protective effect in chickens (19, 38, 65, 87, 94, 101, 128, 149, 208, 211). These encouraging results suggest the possibility of using vaccination to control *Campylobacter* infection on poultry farms. However, significant efforts are needed to develop vaccines that elicit protective immune responses and can be delivered on poultry farm in a practical and economically viable manner.

Other Intervention Strategies

Several other potential intervention strategies have been evaluated to reduce *Campylobacter* colonization in chickens, including phage therapy, bacteriocin-based treatment, and feed/water additives (39, 41, 65, 107, 184, 185, 201). *Campylobacter*-specific bacteriophages are commonly recovered from broiler chickens and the farm environment. Experimental challenge studies, in which broiler chickens were used to assess the prophylactic or therapeutic effect of bacteriophages against *Campylobacter* colonization, showed a significant decrease in *Campylobacter* numbers in chickens treated with phages (32, 107, 201). However, the level of reduction was variable and was affected by the phage types and doses. At present, there are still several hurdles for phage therapy to become a practical intervention; these include the narrow spectrum of phages, the rapid development of resistance, and the low efficiency of phage production in *Campylobacter*.

Several feed additives (including short- and medium-chain fatty acids, plant-derived additives, egg yolk powder, etc.) were evaluated for their effects on *Campylobacter* colonization in broiler chickens (47, 193). Although some effects were observed, they were inconsistent and biologically insignificant (43, 65). Similarly, fermented or acidified feed (61) or organic acid- or chlorine-treated drinking water (24, 65) did not significantly reduced the level and rate of *Campylobacter* colonization in chickens. Interestingly, a recent study in Norway reported that addition of formic acid and sorbate in feed totally prevented *Campylobacter* colonization in broilers (171), suggesting that combination of organic acids might be effective way to reduce *Campylobacter*. Supplementation of feed with prebiotics (e.g., lactose, fructooligosaccharide, mannose-oligosaccharide), immune response stimulators (selenium, beta-glucan), activated charcoal, and other compounds had limited success in reducing *Campylobacter* colonization in chickens (5, 15, 41, 65).

Several bacteriocins purified from *Paenibacillus polymyxa*, *Lactobacillus salivarius*, and *Enterococcus* spp. have been evaluated for controlling *Campylobacter* colonization in chickens (184, 185, 187, 188). When given to chickens as feed supplements, these bacteriocins were highly effective in reducing *C. jejuni* infections. Notably, the bacteriocins had broad anti-*Campylobacter* activities and were effective against different strains of *C. jejuni* when tested in chickens. Also, treatment of market-age broiler chickens naturally colonized by *Campylobacter* with bacteriocins in feed or water a few days before slaughter significantly reduced intestinal colonization (106, 187, 188). These findings suggest that bacteriocin supplements are promising approaches for control of *Campylobacter* in poultry, but it is unknown if these bacteriocins can be produced in a cost-effective manner for commercial use and if they will meet regulatory approval (101, 188).

Acknowledgement

A large number of published studies are available on *Campylobacter* in poultry, and it is impossible to cite every relevant reference due to the space limit. The authors regret not being able to include many other excellent publications in the reference list.

References

1. 2004. Advisory Committee on the Microbiological Safety of Food. UK(htpp://food.gov.uk).
2. Achen, M., T.Y. Morishita, and E.C. Ley. 1998. Shedding and colonization of *Campylobacter jejuni* in broilers from day- of-hatch to slaughter age. *Avian Dis*. 42:732–737.
3. Adler-Mosca, H., and M. Altwegg. 1991. Fluoroquinolone resistance in *Campylobacter jejuni* and *Campylobacter coli* isolated from human faeces in Switzerland. *J Infect.* 23:341–342.
4. Aho, M., L. Nuotio, E. Nurmi, and T. Kiiskinen. 1992. Competitive exclusion of campylobacters from poultry with K-bacteria and Broilact. *Int J Food Microbiol.* 15:265–275.
5. Anderson, R.C., R.B. Harvey, J.A. Byrd, T.R. Callaway, K.J. Genovese, T.S. Edrington, Y.S. Jung, J.L. McReynolds, and D.J. Nisbet. 2005. Novel preharvest strategies involving the use of experimental chlorate preparations and nitro-based compounds to prevent colonization of food-producing animals by foodborne pathogens. *Poult Sci.* 84:649–654.
6. Annan-Prah, A., and M. Janc. 1988. The mode of spread of *Campylobacter jejuni/coli* to broiler flocks. *J Vet Med. B* 35:11–18.
7. Atanassova, V., and C. Ring. 1999. Prevalence of *Campylobacter* spp. in poultry and poultry meat in Germany. *Int J Food Microbiol*. 51:187–190.
8. Axelsson-Olsson, D., J. Waldenstrom, T. Broman, B. Olsen, and M. Holmberg. 2005. Protozoan Acanthamoeba polyphaga as a potential reservoir for *Campylobacter jejuni*. *Appl Environ Microbiol.* 71:987–992.
9. Barrios, P.R., J. Reiersen, R. Lowman, J.R. Bisaillon, P. Michel, V. Fridriksdottir, E. Gunnarsson, N. Stern, O. Berke, S. McEwen, and W. Martin. 2006. Risk factors for *Campylobacter* spp. colonization in broiler flocks in Iceland. *Prev Vet Med*. 74:264–278.
10. Beery, J.T., M.B. Hugdahl, and M.P. Doyle. 1988. Colonization of gastrointestinal tracts of chicks by *Campylobacter jejuni*. *Appl Environ Microbiol.* 54:2365–2370.
11. Berndtson, E., M.L. Danielsson-Tham, and A. Engvall. 1996. *Campylobacter* incidence on a chicken farm and the spread of *Campylobacter* during the slaughter process. *Int J Food Microbiol.* 32:35–47.
12. Berndtson, E., U. Emanuelson, A. Engvall, and M.L. Danielsson-Tham. 1996. A 1-year epidemiological study of campylobacters in 18 Swedish chicken farms. *Prev Vet Med.* 26:167–185.
13. Bessede, E., A. Delcamp, E. Sifre, A. Buissonniere, and F. Megraud. 2011. New methods for detection of Campylobacters in stool samples in comparison to culture. *J Clin Microbiol.* 49:941–944.
14. Boes, J., L. Nersting, E.M. Nielsen, S. Kranker, C. Enoe, H. C. Wachmann, and D.L. Baggesen. 2005. Prevalence and diversity of *Campylobacter jejuni* in pig herds on farms with and without cattle or poultry. *J Food Prot.* 68:722–727.
15. Bolder, N.M., J.A. Wagenaar, F.F. Putirulan, K.T. Veldman, and M. Sommer. 1999. The effect of flavophospholipol (Flavomycin) and salinomycin sodium (Sacox) on the excretion of *Clostridium perfringens, Salmonella enteritidis*, and *Campylobacter jejuni* in broilers after experimental infection. *Poult Sci.* 78:1681–1689.
16. Bolton, F.J., D. Coates, P.M. Hinchliffe, and L. Robertson. 1983. Comparison of selective media for isolation of *Campylobacter jejuni/coli*. *J Clin Pathol.* 36:78–83.
17. Boukraa, L., S. Messier, and Y. Robinson. 1991. Isolation of *Campylobacter* from livers of broiler chickens with and without necrotic hepatitis lesions. *Avian Dis.* 35:714–717.
18. Bouwknegt, M., A.W. van de Giessen, W.D. Dam-Deisz, A.H. Havelaar, N. J. Nagelkerke, and A.M. Henken. 2004. Risk factors for the presence of *Campylobacter* spp. in Dutch broiler flocks. *Prev Vet Med*. 62:35–49.
19. Buckley, A.M., J.H. Wang, D.L. Hudson, A.J. Grant, M.A. Jones, D. J. Maskell, and M.P. Stevens. 2010. Evaluation of live-attenuated *Salmonella* vaccines expressing *Campylobacter* antigens for control of *C. jejuni* in poultry. *Vaccine.* 28:1094–1105.
20. Buhr, R.J., N.A. Cox, N.J. Stern, M.T. Musgrove, J.L. Wilson, and K.L. Hiett. 2002. Recovery of *Campylobacter* from segments of the reproductive tract of broiler breeder hens. *Avian Dis.* 46:919–924.
21. Bull, S.A., V.M. Allen, G. Domingue, F. Jorgensen, J.A. Frost, R. Ure, R. Whyte, D. Tinker, J.E. Corry, J. Gillard-King, and T.J. Humphrey. 2006. Sources of *Campylobacter* spp. colonizing housed broiler flocks during rearing. *Appl Environ Microbiol*. 72:645–652.
22. Burch, D. 2005. Avian vibrionic hepatitis in laying hens. *Vet Rec.* 157:528.
23. Byrd, J., R.H. Bailey, R. Wills, and D. Nisbet. 2007. Recovery of *Campylobacter* from commercial broiler hatchery trayliners. *Poultry Science.* 86:26–29.
24. Byrd, J.A., B.M. Hargis, D.J. Caldwell, R.H. Bailey, K.L. Herron, J.L. McReynolds, R.L. Brewer, R.C. Anderson, K.M. Bischoff, T.R. Callaway, and L.F. Kubena. 2001. Effect of lactic acid administration in the drinking water during preslaughter feed withdrawal on *Salmonella* and *Campylobacter* contamination of broilers. *Poult Sci.* 80:278–283.
25. Camarda, A., D.G. Newell, R. Nasti, and G. Di Modugnoa. 2000. Genotyping *Campylobacter jejuni* strains isolated from the gut and oviduct of laying hens. *Avian Dis.* 44:907–912.
26. Cardinale, E., F. Tall, E.F. Gueye, M. Cisse, and G. Salvat. 2004. Risk factors for *Campylobacter* spp. infection in Senegalese broiler-chicken flocks. *Prev Vet Med*. 64:15–25.
27. Cawthraw, S., R. Ayling, P. Nuijten, T. Wassenaar, and D.G. Newell. 1994. Isotype, specificity, and kinetics of systemic and mucosal antibodies to *Campylobacter jejuni* antigens, including flagellin, during experimental oral infections of chickens. *Avian Dis.* 38:341–349.
28. Cawthraw, S.A., and D.G. Newell. 2010. Investigation of the presence and protective effects of maternal antibodies against *Campylobacter jejuni* in chickens. *Avian Dis.* 54:86–93.
29. Chuma, T., K. Makino, K. Okamoto, and H. Yugi. 1997. Analysis of distribution of *Campylobacter jejuni* and *Campylobacter coli* in broilers by using restriction fragment length polymorphism of flagellin gene. *J Vet Med Sci.* 59:1011–1015.
30. Chuma, T., T. Yamada, K. Yano, K. Okamoto, and H. Yugi. 1994. A survey of *Campylobacter jejuni* in broilers from assignment to slaughter using DNA-DNA hybridization. *J Vet Med Sci.* 56:697–700.
31. Chuma, T., K. Yano, H. Omori, K. Okamoto, and H. Yugi. 1997. Direct detection of *Campylobacter jejuni* in chicken cecal contents by PCR. *J Vet Med Sci.* 59:85–87.
32. Connerton, P.L., A.R. Timms, and I.F. Connerton. 2011. *Campylobacter* bacteriophages and bacteriophage therapy. *J Appl Microbiol.* 111:255–265.
33. Corry, J.E., and H.I. Atabay. 2001. Poultry as a source of *Campylobacter* and related organisms. *J Appl Microbiol*. 96S-114S.
34. Corry, J.E., D.E. Post, P. Colin, and M.J. Laisney. 1995. Culture media for the isolation of campylobacters. *Int J Food Microbiol.* 26:43–76.

35. Cox, J.M., and A. Pavic. 2010. Advances in enteropathogen control in poultry production. *J Appl Microbiol.* 108:745–755.
36. Cox, N.A., N.J. Stern, J.L. Wilson, M.T. Musgrove, R.J. Buhr, and K.L. Hiett. 2002. Isolation of *Campylobacter* spp. from semen samples of commercial broiler breeder roosters. *Avian Dis*. 46:717–720.
37. Crawshaw, T., and S. Young. 2003. Increased mortality on a free-range layer site. *Vet Rec.* 153:664.
38. de Zoete, M.R., J.P.M. van Putten, and J.A. Wagenaar. 2007. Vaccination of chickens against *Campylobacter*. *Vaccine* 25:5548–5557.
39. DeSantis, T.Z., C.E. Stone, S.R. Murray, J.P. Moberg, and G.L. Andersen. 2005. Rapid quantification and taxonomic classification of environmental DNA from both prokaryotic and eukaryotic origins using a microarray. *FEMS Microbiol Letts.* 245:271–278.
40. Doyle, M.P. 1984. Association of *Campylobacter jejuni* with laying hens and eggs. *Appl Environ Microbiol.* 47:533–536.
41. Doyle, M.P., and M.C. Erickson. 2006. Reducing the carriage of foodborne pathogens in livestock and poultry. *Poult Sci.* 85:960–973.
42. Doyle, M.P., and D.J. Roman. 1981. Growth and survival of C*ampylobacter fetus* subsp. *jejuni* as a function of temperature and pH. *J Food Prot*. 44:596–601.
43. EFSA. 2011. Panel on Biological Hazards (BIOHAZ); Scientific opinion on *Campylobacter* in broiler meat production: control options and performance objectives and/or targets at different stages of the food chain. *EFSA Journal.* 9:2105.
44. Engvall, A. 2001. May organically farmed animals pose a risk for *Campylobacter* infections in humans? *Acta Vet Scand. Suppl* 95:85–87.
45. Ertas, H.B., B. Cetinkaya, A. Muz, and H. Ongor. 2004. Genotyping of broiler-originated *Campylobacter jejuni* and *Campylobacter coli* isolates using fla typing and random amplified polymorphic DNA methods. *Int J Food Microbiol.* 94:203–209.
46. Evans, S.J., and A.R. Sayers. 2000. A longitudinal study of campylobacter infection of broiler flocks in Great Britain. *Prev Vet Med.* 46:209–223.
47. Fernandez, F., R. Sharma, M. Hinton, and M.R. Bedford. 2000. Diet influences the colonisation of *Campylobacter jejuni* and distribution of mucin carbohydrates in the chick intestinal tract. *Cell Mol Life Sci.* 57:1793–1801.
48. Fernandez, H., M. Vergara, and F. Tapia. 1985. Dessication resistance in thermotolerant *Campylobacter* species. *Infection.* 13:197.
49. Foley, S.L., A.M. Lynne, and R. Nayak. 2009. Molecular typing methodologies for microbial source tracking and epidemiological investigations of Gram-negative bacterial foodborne pathogens. *Infect Genet Evol.* 9:430–440.
50. Food Standards Agency. 2008. A critical review of interventions and strategies (both biosecurity and non-biosecurity) to reduce *Campylobacter* on the poultry farm.
51. Friedman, C.R., J. Neimann, H.C. Wegener, and R.V. Tauxe. 2000. Epidemiology of *C. jejuni* infections in the United States and other industrialized nations. In: *Campylobacter*, 2nd ed. I. Nachamkin, M.J. Blaser, eds. American Society for Microbiology, Washington, D.C. 121–138.
52. Grant, A.J., C. Coward, M.A. Jones, C.A. Woodall, P.A. Barrow, and D.J. Maskell. 2005. Signature-tagged transposon mutagenesis studies demonstrate the dynamic nature of cecal colonization of 2-week-old chickens by *Campylobacter jejuni*. *Appl Environ Microbiol.* 71:8031–8041.
53. Gregory, E., H. Barnhart, D.W. Dreesen, N.J. Stern, and J.L. Corn. 1997. Epidemiological study of *Campylobacter* spp. in broilers: source, time of colonization, and prevalence. *Avian Dis*. 41:890–898.
54. Guerin, M. T., W. Martin, J. Reiersen, O. Berke, S.A. Mcewen, J.R. Bisaillon, and R. Lowman. 2007. A farm-level study of risk factors associated with the colonization of broiler flocks with *Campylobacter* spp. in Iceland, 2001-2004. *Acta Vet Scand*. 49:18–29.
55. Hakkinen, M., and C. Schneitz. 1999. Efficacy of a commercial competitive exclusion product against *Campylobacter jejuni*. *Br. Poult Sci.* 40:619–621.
56. Hald, B., H. Skovgard, D.D. Bang, K. Pedersen, J. Dybdahl, J.B. Jespersen, and M. Madsen. 2004. Flies and *Campylobacter* infection of broiler flocks. *Emerg Infect Dis.* 10:1490–1492.
57. Hald, B., H.M. Sommer, and H. Skovgard. 2007. Use of fly screens to reduce *Campylobacter* spp. introduction in broiler houses. *Emerg Infect Dis*. 13:1951–1953.
58. Hansson, I., E.O. Engvall, J. Lindblad, A. Gunnarsson, and I. Vagsholm. 2004. Surveillance programme for *Campylobacter* species in Swedish broilers, July 2001 to June 2002. *Vet Rec.* 155:193–196.
59. Hazeleger, W.C., J.A. Wouters, F.M. Rombouts, and T. Abee. 1998. Physiological activity of *Campylobacter jejuni* far below the minimal growth temperature. *Appl Environ Microbiol.* 64:3917–3922.
60. Hendrixson, D.R., and V.J. DiRita. 2004. Identification of *Campylobacter jejuni* genes involved in commensal colonization of the chick gastrointestinal tract. *Mol Microbiol.* 52:471–484.
61. Heres, L., B. Engel, H.A. Urlings, J.A. Wagenaar, and F. van Knapen. 2004. Effect of acidified feed on susceptibility of broiler chickens to intestinal infection by *Campylobacter* and *Salmonella*. *Vet Microbiol.* 99:259–267.
62. Herman, L., M. Heyndrickx, K. Grijspeerdt, D. Vandekerchove, I. Rollier, and L. de Zutter. 2003. Routes for *Campylobacter* contamination of poultry meat: epidemiological study from hatchery to slaughterhouse. *Epidemiol Infect.* 131:1169–1180.
63. Hermans, D., F. Pasmans, M. Heyndrickx, F. van Immerseel, A. Martel, K. van Deun, and F. Haesebrouck. 2011. A tolerogenic mucosal immune response leads to persistent *Campylobacter jejuni* colonization in the chicken gut. *Crit Rev. Microbiol*. Epub ahead of print.
64. Hermans, D., K. Van Deun, A. Martel, F. Van Immerseel, W. Messens, M. Heyndrickx, F. Haesebrouck, and F. Pasmans. 2011. Colonization factors of *Campylobacter jejuni* in the chicken gut. *Vet Res.* 42:82.
65. Hermans, D., K. van Deun, W. Messens, A. Martel, F. van Immerseel, F. Haesebrouck, G. Rasschaert, M. Heyndrickx, and F. Pasmans. 2011. *Campylobacter* control in poultry by current intervention measures ineffective: Urgent need for intensified fundamental research. *Vet Microbiol.* 152:219–228.
66. Hernandez, J., A. Fayos, M.A. Ferrus, and R.J. Owen. 1995. Random amplified polymorphic DNA fingerprinting of *Campylobacter jejuni* and *C. coli* isolated from human faeces, seawater and poultry products. *Res Microbiol*. 146:685–696.
67. Heuer, O.E., K. Pedersen, J.S. Andersen, and M. Madsen. 2001. Prevalence and antimicrobial susceptibility of thermophilic *Campylobacter* in organic and conventional broiler flocks. *Lett Appl Microbiol.* 33:269–274.
68. Hiett, K.L., N.A. Cox, R.J. Buhr, and N.J. Stern. 2002. Genotype analyses of *Campylobacter* isolated from distinct segments of the

reproductive tracts of broiler breeder hens. *Curr Microbiol.* 45:400–404.
69. Hiett, K.L., N.A. Cox, and N.J. Stern. 2002. Direct polymerase chain reaction detection of *Campylobacter* spp. in poultry hatchery samples. *Avian Dis*. 46:219–223.
70. Hiett, K.L., N.J. Stern, P. Fedorka-Cray, N.A. Cox, M.T. Musgrove, and S. Ladely. 2002. Molecular subtype analyses of *Campylobacter* spp. from Arkansas and California poultry operations. *Appl Environ Microbiol*. 68:6220–6236.
71. Hindiyeh, M., S. Jense, S. Hohmann, H. Benett, C. Edwards, W. Aldeen, A. Croft, J. Daly, S. Mottice, and K.C. Carroll. 2000. Rapid detection of *Campylobacter jejuni* in stool specimens by an enzyme immunoassay and surveillance for *Campylobacter upsaliensis* in the greater Salt Lake City area. *J Clin Microbiol.* 38:3076–3079.
72. Huang, S., T. Luangtongkum, T.Y. Morishita, and Q. Zhang. 2005. Molecular typing of *Campylobacter* strains using the *cmp* gene encoding the major outer membrane protein. *Foodborne Pathog Dis.* 2:12–23.
73. Humphrey, T.J., A. Henley, and D.G. Lanning. 1993. The colonization of broiler chickens with *Campylobacter jejuni*: some epidemiological investigations. *Epidemiol Infect.* 110:601–607.
74. Idris, U., J. Lu, M. Maier, S. Sanchez, C.L. Hofacre, B.G. Harmon, J.J. Maurer, and M.D. Lee. 2006. Dissemination of fluoroquinolone-resistant *Campylobacter* spp. within an integrated commercial poultry production system. *Appl Environ Microbiol*. 72:3441–3447.
75. Jacobs-Reitsma, W., U. Lyhs, and J. Wagenaar. 2008. *Campylobacter* in the food supply. In: *Campylobacter*, 3rd ed. I. Nachamkin, M.J. Blaser, eds. American Society for Microbiology, Washington, D.C. 467–481.
76. Jacobs-Reitsma, W.F. 1995. *Campylobacter* bacteria in breeder flocks. *Avian Dis.* 39:355–359.
77. Jacobs-Reitsma, W.F. 1997. Aspects of epidemiology of *Campylobacter* in poultry. *Vet Q.* 19:113–117.
78. Jacobs-Reitsma, W.F., A.W. van de Giessen, N.M. Bolder, and R.W. Mulder. 1995. Epidemiology of *Campylobacter* spp. at two Dutch broiler farms. *Epidemiol Infect*. 114:413–421.
79. Jennings, J.L., L.C. Sait, C.A. Perrett, C. Foster, L.K. Williams, T.J. Humphrey, and T.A. Cogan. 2011. *Campylobacter jejuni* is associated with but not sufficient to cause vibrionic hepatitis in chickens. *Vet Microbiol.* 149:193–199.
80. Jones, F.T., R.C. Axtell, D.V. Rives, S.E. Scheideler, F.R. Tarver, R.I. Walker, and M.J. Wineland. 1991. A survey of *Campylobacter jejuni* contamination on modern broiler production and processing plants. *J Food Prot.* 54:259–262.
81. Jones, K. 2001. Campylobacters in water, sewage and the environment. *J Appl Microbiol.* 90:S68–S79.
82. Kaino, K., H. Hayashidani, K. Kaneko, and M. Ogawa. 1988. Intestinal colonization of *Campylobacter jejuni* in chickens. *Jpn J Vet Sci.* 50:489–494.
83. Kapperud, G., E. Skjerve, L. Vik, K. Hauge, A. Lysaker, I. Aalmen, S.M. Ostroff, and M. Potter. 1993. Epidemiological investigation of risk factors for *Campylobacter* colonization in Norwegian broiler flocks. *Epidemiol Infect.* 111:245–255.
84. Kazwala, R.R., J.D. Collins, J. Hannan, R.A. Crinion, and H. O'Mahony. 1990. Factors responsible for the introduction and spread of *Campylobacter jejuni* infection in commercial poultry production. *Vet Rec.* 126:305–306.
85. Kelly, D.J. 2001. The physiology and metabolism of *Campylobacter jejuni* and *Helicobacter pylori*. *J Appl Microbiol.* 30:S16S–S24.
86. Keramas, G., D.D. Bang, M. Lund, M. Madsen, H. Bunkenborg, P. Telleman, and C.B. Christensen. 2004. Use of culture, PCR analysis, and DNA microarrays for detection of *Campylobacter jejuni* and *Campylobacter coli* from chicken feces. *J Clin Microbiol.* 42:3985–3991.
87. Khry, C.A., and R.J. Meinersmann. 1995. A genetic hybrid of the *Campylobacter jejuni* flaA gene with LT-B of *Escherichia coli* and assessment of the efficacy of the hybrid protein as an oral chicken vaccine. *Avian Dis.* 39:812–820.
88. Kiess, A.S., H.M. Parker, and C.D. McDaniel. 2010. Evaluation of different selective media and culturing techniques for the quantification of *Campylobacter* ssp. from broiler litter. *Poult Sci*. 89:1755–1762.
89. Klena, J.D., and M.E. Konkel. 2005. Methods for epidemiological analysis of *Campylobacter jejuni*. In: *Campylobacter: Molecular and Cellular Biology*, 1st ed. J.M. Ketley and M.E. Konkel, eds. Horizon Bioscience, Norfolk, U.K., 165–179.
90. Knudsen, K.N., D.D. Bang, L.O. Andresen, and M. Madsen. 2006. *Campylobacter jejuni* strains of human and chicken origin are invasive in chickens after oral challenge. *Avian Dis.* 50:10–14.
91. Komagamine, T., and N. Yuki. 2006. Ganglioside mimicry as a cause of Guillain-Barre syndrome. *CNS Neurol Disord Drug Targets.* 5:391–400.
92. Konkel, M.E., B.J. Kim, J.D. Klena, C.R. Young, and R. Ziprin. 1998. Characterization of the thermal stress response of *Campylobacter jejuni*. *Infect Immun.* 66:3666–3672.
93. Lam, K.M., A.J. DaMassa, T.Y. Morishita, H.L. Shivaprasad, and A.A. Bickford. 1992. Pathogenicity of *Campylobacter jejuni* for turkeys and chickens. *Avian Dis.* 36:359–363.
94. Layton, S.L., M.J. Morgan, K. Cole, Y.M. Kwon, D.J. Donoghue, B.M. Hargis, and N.R. Pumford. 2011. Evaluation of *Salmonella*-Vvctored *Campylobacter* peptide epitopes for reduction of *Campylobacter jejuni* in broiler chickens. *Clin Vac Immuno.* 18:449–454.
95. Le, B.H., S. Kayal, M. Bonnaure-Mallet, and J. Minet. 2011. CASA chromogenic medium for enteric *Campylobacter* species. *J Clin Microbiol.* 49:3675–3677.
96. Leblanc-Maridor, M., F. Beaudeau, H. Seegers, M. Denis, and C. Belloc. 2011. Rapid identification and quantification of *Campylobacter coli* and *Campylobacter jejuni* by real-time PCR in pure cultures and in complex samples. *Bmc Microbiol.* 11:113.
97. Lee, M.D., and D.G. Newell. 2006. *Campylobacter* in poultry: filling an ecological niche. *Avian Dis.* 50:1–9.
98. Lefebure, T., and M.J. Stanhope. 2009. Pervasive, genome-wide positive selection leading to functional divergence in the bacterial genus *Campylobacter*. *Genome Res.* 19:1224–1232.
99. Lilja, L., and M.-L. Hanninen. 2001. Evaluation of a commecial automated ELISA and PCR-method for rapid detection and identification of *Campylobacter jejuni* and *C. coli* in poultry products. *Food Microbiol*. 18:205–209.
100. Lillehaug, A., J.C. Monceyron, B. Bergsjo, M. Hofshagen, J. Tharaldsen, L.L. Nesse, and K. Handeland. 2005. Screening of feral pigeon (*Colomba livia*), mallard (*Anas platyrhynchos*) and graylag goose (*Anser anser*) populations for *Campylobacter* spp., *Salmonella* spp., avian influenza virus and avian paramyxovirus. *Acta Vet Scand*. 46:193–202.
101. Lin, J. 2009. Novel approaches for *Campylobacter* control in poultry. *Foodborne Pathog Dis.* 6:755–765.
102. Lin, J., L.O. Michel, and Q. Zhang. 2002. CmeABC functions as a multidrug efflux system in *Campylobacter jejuni*. *Antimicrob Agents Chemother.* 46:2124–2131.

103. Lin, J., O. Sahin, L.O. Michel, and Q. Zhang. 2003. Critical role of multidrug efflux pump CmeABC in bile resistance and *in vivo* colonization of *Campylobacter jejuni*. *Infect Immun.* 71:4250–4259.
104. Line, J.E. 2002. *Campylobacter* and *Salmonella* populations associated with chickens raised on acidified litter. *Poult Sci.* 81:1473–1477.
105. Line, J.E., J.S. Bailey, N.A. Cox, N.J. Stern, and T. Tompkins. 1998. Effect of yeast-supplemented feed on Salmonella and *Campylobacter* populations in broilers. *Poult Sci.* 77:405–410.
106. Line, J.E., E.A. Svetoch, B.V. Eruslanov, V.V. Perelygin, E.V. Mitsevich, I.P. Mitsevich, V.P. Levchuk, O.E. Svetoch, B.S. Seal, G.R. Siragusa, and N.J. Stern. 2008. Isolation and purification of enterocin E-760 with broad antimicrobial activity against gram-positive and gram-negative bacteria. *Antimicrob Agent Chemother.* 52:1094–1100.
107. Loc Carrillo C., R.J. Atterbury, A. el-Shibiny, P.L. Connerton, E. Dillon, A. Scott, and I.F. Connerton. 2005. Bacteriophage therapy to reduce *Campylobacter jejuni* colonization of broiler chickens. *Appl Environ Microbiol.* 71:6554–6563.
108. Luangtongkum, T., T.Y. Morishita, A.J. Ison, S. Huang, P. F. McDermott, and Q. Zhang. 2006. Effect of conventional and organic production practices on the prevalence and antimicrobial resistance of *Campylobacter* spp. in poultry. *Appl Environ Microbiol*. 72:3600–3607.
109. Luo, N., S. Pereira, O. Sahin, J. Lin, S. Huang, L. Michel, and Q. Zhang. 2005. Enhanced in vivo fitness of fluoroquinolone-resistant *Campylobacter jejuni* in the absence of antibiotic selection pressure. *Proc Natl Acad Sci USA*. 102:541–546.
110. Manning, G., C.G. Dowson, M.C. Bagnall, I.H. Ahmed, M. West, and D.G. Newell. 2003. Multilocus sequence typing for comparison of veterinary and human isolates of *Campylobacter jejuni*. *Appl Environ Microbiol.* 69:6370–6379.
111. Maruyama, S., and Y. Katsube. 1988. Intestinal colonization of *Campylobacter jejuni* in young Japanese quails (*Coturnix coturnix japonica*). *Jpn J Vet Sci.* 50:569–572.
112. Mead, G.C. 2000. Prospects for 'competitive exclusion' treatment to control salmonellas and other foodborne pathogens in poultry. *Vet J.* 159:111–123.
113. Mead, G.C. 2002. Factors affecting intestinal colonization of poultry by campylobacter and role of microflora in control. *World Poult Sci J.* 58:169–178.
114. Mead, G.C., M.J. Scott, T.J. Humphrey, and K. McAlpine. 1996. Observations on the control of *Campylobacter jejuni* infection of poultry by 'competitive exclusion.' *Avian Pathol.* 25:69–79.
115. Mead, P.S., L. Slutsker, V. Dietz, L.F. McCaig, J.S. Bresee, C. Shapiro, P.M. Griffin, and R.V. Tauxe. 1999. Food-related illness and death in the United States. *Emerg Infect Dis.* 5:607–625.
116. Meinersmann, R.J., L.O. Helsel, P.I. Fields, and K.L. Hiett. 1997. Discrimination of *Campylobacter jejuni* isolates by fla gene sequencing. *J Clin Microbiol.* 35:2810–2814.
117. Meinersmann, R.J., W E. Rigsby, N.J. Stern, L.C. Kelley, J.E. Hill, and M.P. Doyle. 1991. Comparative study of colonizing and noncolonizing *Campylobacter jejuni*. *Am J Vet Res.* 52:1518–1522.
118. Montrose, M.S., S.M. Shane, and K.S. Harrington. 1985. Role of litter in the transmission of *Campylobacter jejuni*. *Avian Dis.* 29:392–399.
119. Morishita, T.Y., P.P. Aye, B.S. Harr, C.W. Cobb, and J.R. Clifford. 1997. Evaluation of an avian-specific probiotic to reduce the colonization and shedding of *Campylobacter jejuni* in broilers. *Avian Dis.* 41:850–855.
120. Muraoka, W.T., and Q. Zhang. 2011. Phenotypic and genotypic evidence for L-fucose utilization by *Campylobacter jejuni*. *J Bacteriol.* 193:1065–1075.
121. Musgrove, M.T., M.E. Berrang, J.A. Byrd, N.J. Stern, and N.A. Cox. 2001. Detection of *Campylobacter* spp. in ceca and crops with and without enrichment. *Poult Sci*. 80:825–828.
122. Myszewski, M.A., and N.J. Stern. 1990. Influence of *Campylobacter jejuni* cecal colonization on immunoglobulin response in chickens. *Avian Dis.* 34:588–594.
123. Nachamkin, I., B.M. Allos, and T. Ho. 1998. *Campylobacter* species and Guillain-Barre syndrome. *Clin Microbiol Rev.* 11:555–567.
124. Nachamkin, I., J. Engberg, and F.M. Aarestrup. 2000. Diagnosis and antimicrobial susceptibility of *Campylobacter* species. In: *Campylobacter*, second ed. I. Nachamkin, M.J. Blaser, eds. American Society for Microbiology, Washington, D.C. 45–66.
125. Nachamkin, I., X.H. Yang, and N.J. Stern. 1993. Role of *Campylobacter jejuni* flagella as colonization factors for three-day-old chicks: analysis with flagellar mutants. *Appl Environ Microbiol.* 59:1269–1273.
126. Neill, S.D., J.N. Campbell, and J.J. O'Brien. 1984. *Campylobacter* spp. in broiler chickens. *Avian Pathol*. 13:313–320.
127. Nesbit, E.G., P. Gibbs, D.W. Dreesen, and M.D. Lee. 2001. Epidemiologic features of *Campylobacter jejuni* isolated from poultry broiler houses and surrounding environments as determined by use of molecular strain typing. *Am J Vet Res.* 62:190–194.
128. Newell, D.G., and J.A. Wagenaar. 2000. Poultry infections and their control at the farm level. In: *Campylobacter*, 2nd ed. I. Nachamkin, M.J. Blaser, eds. American Society for Microbiology, Washington, D.C. 497–509.
129. Newell, D.G., and C. Fearnley. 2003. Sources of *Campylobacter* colonization in broiler chickens. *Appl Environ Microbiol.* 69:4343–4351.
130. Noor, S.M., A.J. Husband, and P.R. Widders. 1995. *In ovo* oral vaccination with *Campylobacter jejuni* establishes early development of intestinal immunity in chickens. *Br Poult Sci.* 36:563–573.
131. Oakland, M., B. Jeon, O. Sahin, Z.Q. Shen, and Q.J. Zhang. 2011. Functional characterization of a lipoprotein-encoding operon in *Campylobacter jejuni*. *Plos One.* 6:e20084.
132. On, S.L. 1996. Identification methods for campylobacters, helicobacters, and related organisms. *Clin Microbiol Rev.* 9:405–422.
133. On, S.L.W. 2001. Taxonomy of *Campylobacter, Arcobacter, Helicobacter* and related bacteria: current status, future prospects and immediate concers. *J Appl Microbiol.* 90:S1–S15.
134. Oyofo, B.A., and D.M. Rollins. 1993. Efficacy of filter types for detecting *Campylobacter jejuni* and *Campylobacter coli* in environmental water samples by polymerase chain reaction. *Appl Environ Microbiol.* 59:4090–4095.
135. Park, S.F. 2002. The physiology of *Campylobacter* species and its relevance to their role as foodborne pathogens. *Int J Food Microbiol.* 74:177–188.
136. Payne, R.E., M.D. Lee, D.W. Dreesen, and H.M. Barnhart. 1999. Molecular epidemiology of *Campylobacter jejuni* in broiler flocks using randomly amplified polymorphic DNA-PCR and 23S rRNA-PCR and role of litter in its transmission. *Appl Environ Microbiol.* 65:260–263.
137. Pearson, A.D., M. Greenwood, T.D. Healing, D. Rollins, M. Shahamat, J. Donaldson, and R.R. Colwell. 1993. Colonization of broiler chickens by waterborne *Campylobacter jejuni*. *Appl Environ Microbiol.* 59:987–996.

138. Perko-Makela, P., M. Hakkinen, T. Honkanen-Buzalski, and M.L. Hanninen. 2002. Prevalence of campylobacters in chicken flocks during the summer of 1999 in Finland. *Epidemiol Infect.* 129:187–192.
139. Petersen, L., E.M. Nielsen, and S.L. On. 2001. Serotype and genotype diversity and hatchery transmission of *Campylobacter jejuni* in commercial poultry flocks. *Vet Microbiol.* 82:141–154.
140. Petersen, L., and A. Wedderkopp. 2001. Evidence that certain clones of *Campylobacter jejuni* persist during successive broiler flock rotations. *Appl Environ Microbiol.* 67:2739–2745
141. Potturi-Venkata, L.P., S. Backert, A.J. Lastovica, S.L. Vieira, R.A. Norton, R.S. Miller, S. Pierce, and O.A. Oyarzabal. 2007. Evaluation of different plate media for direct cultivation of *Campylobacter* species from live broilers. *Poult Sci.* 86:1304–1311.
142. Prescott, J.F., and D.L. Munroe. 1982. *Campylobacter jejuni* enteritis in man and domestic animals. *J Am Vet Med Assoc.* 181:1524–1530.
143. Przondo-Mordarska, A., G. Gosciniak, B. Sobieszczanska, D. Dzierzanowska, and G. Mauff. 1989. Serological diagnosis of *Campylobacter jejuni* infections. *Med Dosw Mikrobiol.* 41:160–165.
144. Quinones, B., C.T. Parker, J.M. Janda, Jr., W.G. Miller, and R.E. Mandrell. 2007. Detection and genotyping of *Arcobacter* and *Campylobacter* isolates from retail chicken samples by use of DNA oligonucleotide arrays. *Appl Environ Microbiol.* 73:3645–3655.
145. Raphael, B.H., S. Pereira, G.A. Flom, Q. Zhang, J.M. Ketley, and M.E. Konkel. 2005. The *Campylobacter jejuni* response regulator, CbrR, modulates sodium deoxycholate resistance and chicken colonization. *J Bacteriol.* 187:3662–3670.
146. Rasmussen, H.N., J.E. Olsen, K. Jorgensen, and O.F. Rasmussen. 1996. Detection of *Campylobacter jejuni* and Camp. coli in chicken faecal samples by PCR. *Lett Appl Microbiol*. 23:363–366.
147. Reed, K.D., J.K. Meece, J.S. Henkel, and S.K. Shukla. 2003. Birds, migration and emerging zoonoses: west Nile virus, lyme disease, influenza A and enteropathogens. *Clin Med Res.* 1:5–12.
148. Refregier-Petton, J., N. Rose, M. Denis, and G. Salvat. 2001. Risk factors for *Campylobacter* spp. contamination in French broiler-chicken flocks at the end of the rearing period. *Prev Vet Med*. 50:89–100.
149. Rice, B.E., D.M. Rollins, E.T. Mallinson, L. Carr, and S.W. Joseph. 1997. *Campylobacter jejuni* in broiler chickens: colonization and humoral immunity following oral vaccination and experimental infection. *Vaccine.* 15:1922–1932.
150. Ring, M., M.A. Zychowska, and R. Stephan. 2005. Dynamics of *Campylobacter* spp. spread investigated in 14 broiler flocks in Switzerland. *Avian Dis*. 49:390–396.
151. Rivoal, K., C. Ragimbeau, G. Salvat, P. Colin, and G. Ermel. 2005. Genomic diversity of *Campylobacter coli* and *Campylobacter jejuni* isolates recovered from free-range broiler farms and comparison with isolates of various origins. *Appl Environ Microbiol.* 71:6216–6227.
152. Rosef, O., and G. Kapperud. 1983. House flies (*Musca domestica*) as possible vectors of *Campylobacter fetus* subsp. *jejuni*. *Appl Environ Microbiol*. 45:381–383.
153. Rosef, O., G. Kapperud, S. Lauwers, and B. Gondrosen. 1985. Serotyping of *Campylobacter jejuni*, *Campylobacter coli*, and *Campylobacter laridis* from domestic and wild animals. *Appl Environ Microbiol.* 49:1507–1510.
154. Ruiz-Palacios, G.M., E. Escamilla, and N. Torres. 1981. Experimental *Campylobacter* diarrhea in chickens. *Infect Immun.* 34:250–255.
155. Sahin, O., P. Kobalka, and Q. Zhang. 2003. Detection and survival of *Campylobacter* in chicken eggs. *J Appl Microbiol.* 95:1070–1079.
156. Sahin, O., N. Luo, S. Huang, and Q. Zhang. 2003. Effect of *Campylobacter*-specific maternal antibodies on *Campylobacter jejuni* colonization in young chickens. *Appl Environ Microbiol.* 69:5372–5379.
157. Sahin, O., T. Morishita, and Q. Zhang. 2002. *Campylobacter* colonization in poultry: sources of infection and modes of transmission. *Anim. Health Res Rev.* 3:95–105.
158. Sahin, O., Q. Zhang, J.C. Meitzler, B.S. Harr, T.Y. Morishita, and R. Mohan. 2001. Prevalence, antigenic specificity, and bactericidal activity of poultry anti-*Campylobacter* maternal antibodies. *Appl Environ Microbiol.* 67:3951–3957.
159. Sahin, O., Q. Zhang, and T.Y. Morishita. 2003. Detection of *Campylobacter*. In: *Microbial Food Safety in Animal Agriculture*, 1st ed. M.E. Torrence, R.E. Isaacson, eds. Iowa State Press, Ames, IA. 183–193.
160. Sanyal, S.C., K.M. Islam, P.K. Neogy, M. Islam, P. Speelman, and M.I. Huq. 1984. *Campylobacter jejuni* diarrhea model in infant chickens. *Infect Immun.* 43:931–936.
161. Schoeni, J.L., and M.P. Doyle. 1992. Reduction of *Campylobacter jejuni* colonization of chicks by cecum- colonizing bacteria producing anti-*C. jejuni* metabolites. *Appl Environ Microbiol*. 58:664–670.
162. Schoeni, J.L., and A.C. Wong. 1994. Inhibition of *Campylobacter jejuni* colonization in chicks by defined competitive exclusion bacteria. *Appl Environ Microbiol.* 60:1191–1197.
163. Shane, S.M. 1992. The significance of *C. jejuni* infection in poultry: a review. *Avian Pathol*. 21:189–213.
164. Shane, S.M., D.H. Gifford, and K. Yogasundram. 1986. *Campylobacter jejuni* contamination of eggs. *Vet Res Commun.* 10:487–492.
165. Shane, S.M., and N.J. Stern. 2003. *Campylobacter* infection. In: *Diseases of Poultry*. 11th ed. Y.M. Saif, H.J. Barnes, A. Fadly, J.R. Glisson, L.R. McDougald, and D.E. Swayne, eds. Iowa State Press, Ames, IA. 615–630.
166. Shanker, S., A. Lee, and T.C. Sorrell. 1986. *Campylobacter jejuni* in broilers: the role of vertical transmission. *J Hyg (Lond)*. 96:153–159.
167. Shanker, S., A. Lee, and T.C. Sorrell. 1988. Experimental colonization of broiler chicks with *Campylobacter jejuni*. *Epidemiol Infect.* 100:27–34.
168. Shoaf-Sweeney, K.D., C.L. Larson, X.T. Tang, and M.E. Konkel. 2008. Identification of *Campylobacter jejuni* proteins recognized by maternal antibodies of chickens. *App Environ Microbiol.* 74:6867–6875.
169. Shreeve, J.E., M. Toszeghy, M. Pattison, and D.G. Newell. 2000. Sequential spread of *Campylobacter* infection in a multipen broiler house. *Avian Dis.* 44:983–988.
170. Siragusa, G.R., J.E. Line, L.L. Brooks, T. Hutchinson, J.D. Laster, and R.O. Apple. 2004. Serological methods and selective agars to enumerate *Campylobacter* from broiler carcasses: data from inter- and intralaboratory analyses. *J Food Prot.* 67:901–907.
171. Skanseng, B., M. Kaldhusdal, B. Moen, A.G. Gjevre, G.S. Johannessen, M. Sekelja, P. Trosvik, and K. Rudi. 2010. Prevention of intestinal *Campylobacter jejuni* colonization in

broilers by combinations of in-feed organic acids. *J Appl Microbio* 109:1265–1273.
172. Skirrow, M.B. 1977. *Campylobacter* enteritis: a "new" disease. *Br Med J.* 2:9–11.
173. Skirrow, M.B. 1994. Diseases due to *Campylobacter, Helicobacter* and related bacteria. *J Comp Pathol*. 111:113–149.
174. Snelling, W.J., J.P. McKenna, D.M. Lecky, and J.S. Dooley. 2005. Survival of *Campylobacter jejuni* in waterborne protozoa. *Appl Environ Microbiol.* 71:5560–5571.
175. Stahl, M., L.M. Friis, H. Nothaft, X. Liu, J.J. Li, C.M. Szymanski, and A. Stintzi. 2011. L-Fucose utilization provides *Campylobacter jejuni* with a competitive advantage. *Proc Natl Acad Sci USA*. 108:7194–7199.
176. Stanley, K., R. Cunningham, and K. Jones. 1998. Isolation of *Campylobacter jejuni* from groundwater. *J Appl Microbiol.* 85:187–191.
177. Steinbrueckner, B., G. Haerter, K. Pelz, and M. Kist. 1999. Routine identification of *Campylobacter jejuni* and *Campylobacter coli* from human stool samples. *FEMS Microbiol Lett.* 179:227–232.
178. Stephens, C.P., S.L. On, and J.A. Gibson. 1998. An outbreak of infectious hepatitis in commercially reared ostriches associated with *Campylobacter coli* and *Campylobacter jejuni*. *Vet Microbiol.* 61:183–190.
179. Stern, N., M.P. Doyle, and R.J. Meinersmann. 1993. Influence of defined antagonistic flora on *Campylobacter jejuni* in broiler chicks. *Poult Sci*. 72 Supp.:5.
180. Stern, N.J. 1992. Reservoirs for *C. jejuni* and approaches for intervention in poultry. In: *Campylobacter jejuni: Current Status and Future Trends*. I. Nachamkin, M.J. Blaser, L.S. Tompkins, eds. American Society for Microbiology, Washington, D.C. 49–60.
181. Stern, N.J., J.S. Bailey, L.C. Blankenship, N.A. Cox, and F. McHan. 1988. Colonization characteristics of *Campylobacter jejuni* in chick ceca. *Avian Dis.* 32:330–334.
182. Stern, N.J., P. Fedorka-Cray, J.S. Bailey, N.A. Cox, S.E. Craven, K.L. Hiett, M.T. Musgrove, S. Ladely, D. Cosby, and G.C. Mead. 2001. Distribution of *Campylobacter* spp. in selected U.S. poultry production and processing operations. *J Food Prot*. 64:1705–1710.
183. Stern, N.J., M.A. Myszewski, H.M. Barnhart, and D.W. Dreesen. 1997. Flagellin A gene restriction fragment length polymorphism patterns of *Campylobacter* spp. isolates from broiler production sources. *Avian Dis*. 41:899–905.
184. Stern, N.J., E.A. Svetoch, B.V. Eruslanov, Y.N. Kovalev, L.I. Volodina, V.V. Perelygin, E.V. Mitsevich, I.P. Mitsevich, and V.P. Levchuk. 2005. *Paenibacillus polymyxa* purified bacteriocin to control *Campylobacter jejuni* in chickens. *J Food Prot.* 68:1450–1453.
185. Stern, N.J., E.A. Svetoch, B.V. Eruslanov, V.V. Perelygin, E.V. Mitsevich, I.P. Mitsevich, V.D. Pokhilenko, V.P. Levchuk, O.E. Svetoch, and B.S. Seal. 2006. Isolation of a *Lactobacillus salivarius* strain and purification of its bacteriocin, which is inhibitory to *Campylobacter jejuni* in the chicken gastrointestinal system. *Antimicrob Agents Chemother.* 50:3111–3116.
186. Studer, E., J. Luthy, and P. Hubner. 1999. Study of the presence of *Campylobacter jejuni* and *C. coli* in sand samples from four Swiss chicken farms. *Res Microbiol*. 150:213–219.
187. Svetoch, E.A., B.V. Eruslanov, V.P. Levchuk, V.V. Perelygin, E.V. Mitsevich, I.P. Mitsevich, J. Stepanshin, I. Dyatlov, B.S. Seal, and N.J. Stern. 2011. Isolation of *Lactobacillus salivarius* 1077 (NRRL B-50053) and characterization of its bacteriocin, including the antimicrobial activity spectrum. *Appl Environ Microbiol.* 77:2749–2754.
188. Svetoch, E.A., and N.J. Stern. 2010. Bacteriocins to control *Campylobacter* spp. in poultry—A review. *Poult Sci*. 89:1763–1768.
189. Thakur, S., and W.A. Gebreyes. 2005. Prevalence and antimicrobial resistance of *Campylobacter* in antimicrobial-free and conventional pig production systems. *J Food Prot.* 68:2402–2410.
190. Thompson, J.S., D.S. Hodge, D.E. Smith, and Y.A. Yong. 1990. Use of tri-gas incubator for routine culture of *Campylobacter* species from fecal specimens. *J Clin Microbiol.* 28:2802–2803.
191. Tsai, H.J., and P.H. Hsiang. 2005. The prevalence and antimicrobial susceptibilities of *Salmonella* and *Campylobacter* in ducks in Taiwan. *J Vet Med Sci.* 67:7–12.
192. Tsubokura, K., E. Berndtson, A. Bogstedt, B. Kaijser, M. Kim, M. Ozeki, and L. Hammarstrom. 1997. Oral administration of antibodies as prophylaxis and therapy in *Campylobacter jejuni*-infected chickens. *Clin Exp Immunol.* 108:451–455.
193. Udayamputhoor, R.S., H. Hariharan, T.A. Van Lunen, P.J. Lewis, S. Heaney, L. Price, and D. Woodward. 2003. Effects of diet formulations containing proteins from different sources on intestinal colonization by *Campylobacter jejuni* in broiler chickens. *Can J Vet Res.* 67:204–212.
194. van de Giessen A., S.I. Mazurier, W. Jacobs-Reitsma, W. Jansen, P. Berkers, W. Ritmeester, and K. Wernars. 1992. Study on the epidemiology and control of *Campylobacter jejuni* in poultry broiler flocks. *Appl Environ Microbiol.* 58:1913–1917.
195. van de Giessen, A.W., M. Bouwknegt, W.D. Dam-Deisz, W. van Pelt, W.J. Wannet, and G. Visser. 2006. Surveillance of *Salmonella* spp. and *Campylobacter* spp. in poultry production flocks in the Netherlands. *Epidemiol Infect*. 134:1–10.
196. van de Giessen, A.W., J.J. Tilburg, W.S. Ritmeester, and J. van der Plas. 1998. Reduction of *Campylobacter* infections in broiler flocks by application of hygiene measures. *Epidemiol Infect.* 121:57–66.
197. Van Deun, K., F. Pasmans, R. Ducatelle, B. Flahou, K. Vissenberg, A. Martel, W. Van den Broeck, F. Van Immerseel, and F. Haesebrouck. 2008. Colonization strategy of *Campylobacter jejuni* results in persistent infection of the chicken gut. *Vet Microbiol.* 130:285–297.
198. Van Overbeke, I., L. Duchateau, L. De Zutter, G. Albers, and R. Ducatelle. 2006. A comparison survey of organic and conventional broiler chickens for infectious agents affecting health and food safety. *Avian Dis.* 50:196–200.
199. Vandamme, P. 2000. Taxonomy of the family *Campylobacteraceae*. In: *Campylobacter*. I. Nachamkin and M. J. Blaser, eds. American Society for Microbiology, Washington D.C. 3–26.
200. Waegel, A., and I. Nachamkin. 1996. Detection and molecular typing of *Campylobacter jejuni* in fecal samples by polymerase chain reaction. *Mol Cell Probes.* 10:75–80.
201. Wagenaar, J.A., M.A. Van Bergen, M.A. Mueller, T.M. Wassenaar, and R.M. Carlton. 2005. Phage therapy reduces *Campylobacter jejuni* colonization in broilers. *Vet Microbiol.* 109:275–283.
202. Wagner, R.D. 2006. Efficacy and food safety considerations of poultry competitive exclusion products. *Mol Nut Food Res.* 50:1061–1071.
203. Waldenstrom, J., D. Mevius, K. Veldman, T. Broman, D. Hasselquist, and B. Olsen. 2005. Antimicrobial resistance profiles of *Campylobacter jejuni* isolates from wild birds in Sweden. *Appl Environ Microbiol.* 71:2438–2441.
204. Wassenaar, T. M., and D.G. Newell. 2000. Genotyping of *Campylobacter* spp. *Appl Environ Microbiol.* 66:1–9.

205. Wassenaar, T.M., B.A. van der Zeijst, R. Ayling, and D.G. Newell. 1993. Colonization of chicks by motility mutants of *Campylobacter jejuni* demonstrates the importance of flagellin A expression. *J Gen Microbiol.* 139:1171–1175.
206. Wedderkopp, A., K.O. Gradel, J.C. Jorgensen, and M. Madsen. 2001. Pre-harvest surveillance of *Campylobacter* and *Salmonella* in Danish broiler flocks: a 2-year study. *Int J Food Microbiol.* 68:53–59.
207. Welkos, S.L. 1984. Experimental gastroenteritis in newly-hatched chicks infected with *Campylobacter jejuni*. *J Med Microbiol.* 18:233–248.
208. Widders, P.R., R. Perry, W.I. Muir, A.J. Husband, and K.A. Long. 1996. Immunisation of chickens to reduce intestinal colonisation with *Campylobacter jejuni*. *Br Poult Sci.* 37:765–778.
209. Widders, P.R., L.M. Thomas, K.A. Long, M.A. Tokhi, M. Panaccio, and E. Apos. 1998. The specificity of antibody in chickens immunised to reduce intestinal colonisation with *Campylobacter jejuni*. *Vet Microbiol.* 64:39–50.
210. Wittwer, M., J. Keller, T.M. Wassenaar, R. Stephan, D. Howald, G. Regula, and B. Bissig-Choisat. 2005. Genetic diversity and antibiotic resistance patterns in a *Campylobacter* population isolated from poultry farms in Switzerland. *Appl Environ Microbiol.* 71:2840–2847.
211. Wyszynska, A., A. Raczko, M. Lis, and E.K. Jagusztyn-Krynicka. 2004. Oral immunization of chickens with avirulent *Salmonella* vaccine strain carrying *C. jejuni* 72Dz/92 cjaA gene elicits specific humoral immune response associated with protection against challenge with wild-type *Campylobacter*. *Vaccine.* 22:1379–1389.
212. Yogasundram, K., S.M. Shane, and K.S. Harrington. 1989. Prevalence of *Campylobacter jejuni* in selected domestic and wild birds in Louisiana. *Avian Dis.* 33:664–667.
213. Yoshida, S., K. Kaneko, M. Ogawa, and T. Takizawa. 1987. Serum agglutinin titers against somatic and flagellar antigens of *Campylobacter jejuni* and isolation of *Campylobacter* spp in chickens. *Am J Vet Res.* 48:801–804.
214. Young, C.R., R.L. Ziprin, M.E. Hume, and L.H. Stanker. 1999. Dose response and organ invasion of day-of-hatch Leghorn chicks by different isolates of *Campylobacter jejuni*. *Avian Dis.* 43:763–767.
215. Zhang, Q., J.C. Meitzler, S. Huang, and T. Morishita. 2000. Sequence polymorphism, predicted secondary structures, and surface-exposed conformational epitopes of *Campylobacter* major outer membrane protein. *Infect Immun.* 68:5679–5689.
216. Zimmer, M., H. Barnhart, U. Idris, and M.D. Lee. 2003. Detection of *Campylobacter jejuni* strains in the water lines of a commercial broiler house and their relationship to the strains that colonized the chickens. *Avian Dis.* 47:101–107.
217. Ziprin, R.L., C.R. Young, J.A. Byrd, L.H. Stanker, M.E. Hume, S.A. Gray, B.J. Kim, and M.E. Konkel. 2001. Role of *Campylobacter jejuni* potential virulence genes in cecal colonization. *Avian Dis.* 45:549–557.
218. Ziprin, R.L., C.R. Young, L.H. Stanker, M.E. Hume, and M.E. Konkel. 1999. The absence of cecal colonization of chicks by a mutant of *Campylobacter jejuni* not expressing bacterial fibronectin-binding protein. *Avian Dis.* 43:586–589.

Chapter 18

Colibacillosis

Lisa K. Nolan, H. John Barnes, Jean-Pierre Vaillancourt, Tahseen Abdul-Aziz, and Catherine M. Logue

Introduction

Definition and Synonyms

Colibacillosis refers to any localized or systemic infection caused entirely or partly by avian pathogenic *Escherichia coli* (APEC), including colisepticemia, hemorrhagic septicemia, coligranuloma (Hjarre's disease), air sac disease (chronic respiratory disease, CRD), swollen-head syndrome, venereal colibacillosis, coliform cellulitis (inflammatory or infectious process, IP), peritonitis, salpingitis, orchitis, osteomyelitis/synovitis (including turkey osteomyelitis complex), panophthalmitis, omphalitis/yolk sac infection, and enteritis. Lesions alone should not be used to infer an *E. coli* infection without the descriptor "coli" or "coliform" being added, because other opportunistic bacteria can behave similarly to *E. coli* in secondary infections. Colibacillosis in mammals is most often a primary enteric or urinary tract disease, whereas colibacillosis in poultry is typically a localized or systemic disease occurring secondarily when host defenses have been impaired or overwhelmed by virulent *E. coli* strains (34). Strains of *E. coli* that cause disease outside the intestinal tract of any species share common characteristics and are called extraintestinal pathogenic *E. coli* (ExPEC) (275, 504). Most APEC are ExPEC and share characteristics with mammalian ExPEC.

Several reviews on APEC and colibacillosis in poultry have been published (36, 123, 137, 150, 202, 325, 491, 588). Earlier information on colibacillosis can be found in previous editions of *Diseases of Poultry*.

Economic Significance

There is general agreement that colibacillosis is the most common infectious bacterial disease of poultry and that collectively, *E. coli* infections in their various forms are responsible for significant economic losses. Often colibacillosis is among the most frequently reported diseases in surveys of poultry health or condemnations at processing. For example, 43% of broiler carcasses condemned for disease at processing had lesions consistent with colisepticemia (621), and colibacillosis was the major cause of infections causing condemnation of processed chickens in Switzerland (267). Flocks with airsacculitis at processing had, in general, lower average body weights of 84 g/bird, and more processing errors, fecal contamination, and *Campylobacter* contamination (502). *E. coli* was isolated from 88.2% of chickens with airsacculitis from flocks in Jordan (143). In Greece, colibacillosis was the most frequent respiratory disease of broilers over a 10-year period (1992–2001) and caused considerable economic losses (176). APEC infections were identified as a major factor in poultry disease in Belgium. Data collected at the East-Flanders regional laboratory between 1997 and 2000 on groups of healthy and sick broilers, layers, and breeders showed the incidence of APEC infection to be 17.7%, 38.6%, and 26.9%, respectively. Resistance to antibiotics was also found to be high (590). The most frequent cause of mortality in a study of organic layer flocks and confined flocks on deep litter in Denmark was *E. coli*. It was the only pathogen isolated from dead birds in all flocks. Coinfections with *Pasteurella multocida, Erysipelothrix rhusiopathiae*, other bacteria, and *Histomonas meleagridis* resulted in higher mortality. Colisepticemia, airsacculitis, salpingitis, oophoritis, and peritonitis were seen (549).

Colibacillosis was second only to enteritis as a disease of turkey flocks in California, affecting 6 of 26 flocks (84). However, in spite of its recognized importance, no studies accurately defining the economic significance of colibacillosis in poultry appear to have been done.

Public Health Significance

Though poultry has not been a significant source of shigatoxin producing *E. coli* (STEC) in human disease, continued vigilance is recommended because STEC, including *E. coli* O157:H7, an important enterohemorrhagic pathogen of humans, has been isolated from various types of birds and poultry products (46, 118, 130, 199, 211, 213, 235, 395, 454, 467, 512, 517, 541, 545, 559). More concerning is the possibility that APEC-contaminated poultry is a foodborne reservoir of extraintestinal pathogenic *E. coli* (ExPEC) that cause human urinary tract infections, meningitis, and other extraintestinal diseases. This hypothesis is based on the remarkable similarities that some APEC and human ExPEC share in their genomic sequences, serogroups, virulence genotypes, phylogenetic types, plasmid content, antimicrobial resistance patterns, and abilities

Diseases of Poultry, Thirteenth Edition. David E. Swayne.
© 2013 John Wiley & Sons, Inc. Published 2013 by John Wiley & Sons, Inc.

to cause disease in various *in vitro* and *in vivo* models of human disease (2, 279, 280, 282, 290, 300, 338, 382, 385, 396, 402, 490, 495, 533, 571). Support for this hypothesis is also found in the fact that retail poultry meat harbors *E. coli* that are more like APEC and human ExPEC than commensal *E. coli* from the feces of birds at slaughter. These similarities are especially notable in regard to the virulence plasmid content of these organisms (282). Though ExPEC causing human urinary tract infections may harbor virulence plasmids (290), APEC and human neonatal meningitis *E. coli* are defined in great part by their presence (289, 351, 491). These plasmids have been shown to contribute to the pathogenesis of colibacillosis, urinary tract infection, and meningitis (279, 533) and are transmissible by conjugation from APEC to other pathogens of human health significance (283). Evidence that such transfer occurs in poultry production may be found in the emergence of a highly virulent strain of *Salmonella* var *enterica* Kentucky, which contains APEC-like plasmids (287).

Also concerning is the fact that in APEC, these virulence plasmids may harbor multidrug-resistance (MDR)-encoding islands or co-transfer with large MDR-encoding R plasmids (283, 288). Such MDR islands or R plasmids encode resistance to silver-, mercury- and/or copper- compounds; certain disinfectants such as quaternary ammonium compounds; and various antibiotics. Though resistance of chicken *E. coli* isolates to antimicrobials used mainly in people is minimal (8, 581), the potential for spread of resistance genes from APEC to organisms of human health importance must be considered. *S. enterica* subsp. enterica serovar Newport, a disease-producing organism in people, and another *E. coli* serotype readily acquired antibiotic resistance in the absence of antibiotic selection pressure through transfer of a large conjugative resistance plasmid from antibiotic-resistant *E. coli* in the intestine of turkey poults. The plasmid was transferred to more than 25% of *Salmonella* serovar Newport strains following co-infection (468). Antibiotic resistance of fecal *E. coli* was greater in broilers and turkeys that received antibiotics relatively frequently compared to layers, which had little exposure to antibiotics (581). Similar antibiotic resistance patterns were present in *E. coli* isolated from people who worked with these birds, and in some instances specific strains were shared among the birds and workers, indicating that transmission of resistant organisms and/or plasmids from poultry to people occurs commonly.

Thus, it may be prudent to consider poultry a reservoir of bacterial strains and/or plasmid-linked virulence and resistance genes contributing to the pathogenesis and outcome of disease caused by ExPEC or other human pathogens.

History

Mortality of fowl and isolation of a bacterium from heart, liver, and spleen that was consistent with *E. coli* was first reported by Lignieres in 1894 (451). Following experimental inoculation, the isolate was virulent for pigeons, variably virulent for chickens depending on dose and route of administration, and not virulent for guinea pigs or rabbits. Subsequently diseases in grouse, pigeons, swans, turkeys, quail, and additional chicken flocks associated with a similar organism were documented between 1894 and 1922 (451).

The first description of colisepticemia was published in 1907 based on chickens dying from a cholera-like disease while being transported. It was concluded that "*Bacterium* (*Escherichia*) *coli*" may, under certain conditions, take on the ability to leave the intestines, become virulent, and cause a septicemia in hens, especially if their resistance has been weakened by hunger, thirst, cold, or lack of good ventilation" (451).

Infectious enteritis characterized by birds "going light" (infectious asthenia) and paralysis from which *E. coli* could be isolated was described in 1923 (451). In 1938, a pullorum-like disease caused losses of 15%–40% in chicks less than 10 days of age that came from the same hatchery. The chicks had pericarditis, perihepatitis, and white spots on the liver. *E. coli* was isolated from tissues. Poor incubation resulting in weak chicks was identified as the reason for their susceptibility to infection (105).

Between 1938 and 1965, coligranuloma (Hjarre's disease) and the role of *E. coli* in a variety of lesions including air sac disease, arthritis, plantar abscesses (bumblefoot), omphalitis, panophthalmitis, peritonitis, and salpingitis were identified and described. The presence of *E. coli* in eggs (172) and *E. coli* infections following vaccination or natural virus infections were also documented (537).

Etiology

The etiology of colibacillosis is avian pathogenic *Escherichia coli* (APEC). Other infectious agents and noninfectious factors usually predispose a bird to infection or contribute to the severity of the disease. Two additional *Escherichia* species, *E. fergusonii* and *E. albertii*, have been isolated from birds and are capable of causing disease or are of public health significance.

E. fergusonii is a closely related species that has been isolated from poultry (155, 158), shown to cause disease in day-old chicks (158) and acute death in adult ostriches (233), and exhibit a broad range of antimicrobial resistances (158, 327, 515). Whole genomic sequencing of a strain of *E. fergusonii*, isolated from a broiler chicken, localized a number of antimicrobial resistance genes and known and putative virulence genes to the chromosome or 1 of 5 plasmids. The similarities of 1 of its large plasmids to well-described APEC virulence plasmids is especially notable, because these plasmids are the defining characteristic of APEC and neonatal meningitis *E. coli* pathotypes (289, 290, 351, 490) and contribute to the pathogenesis of colibacillosis in poultry and meningitis, urinary tract infection, and sepsis in murine models of human disease (279). This report plus descriptions of the emergence of an APEC plasmid-containing strain of *Salmonella* var enterica Kentucky (161, 287) suggests that acquisition of APEC plasmids by commensal or pathogenic bacteria in poultry production may enhance their virulence and/or resistance and lead to the emergence of new disease problems among poultry.

Table 18.1. Diagnostic characteristics of *Escherichia coli* (*Ec*), *E. fergusonii* (*Ef*), and *E. albertii* (*Ea*) (3, 431).

Gram-negative, rod (bacillus) shape, nonspore forming, oxidase negative, facultative anaerobe			
	Ec	***Ef***	***Ea***
MacConkey agar	+ Pink colonies, precipitate	Clear colonies	Clear colonies
Tergitol-7 agar	+ Yellow colonies	Red colonies	Red colonies
EMB agar	+ Dark colonies, metallic sheen	Clear colonies	Clear colonies
Motility	+	+	–
Catalase	+	+	+
Nitrates → nitrites	+	+	+
Gelatin	–	–	–
Hydrogen sulfide	–	–	–
Indole	+	+	–/+*
Methyl red	+	+	+
Voges-Proskauer	–	–	–
Citrate (Simmons)	–	–	–
Urease	–	–	–
KCN medium	–	–	–
Lysine decarboxylase	+	+	+/–*
Ornithine decarboxylase	v	+	+
Adonitol	–	+	–
Arabitol	–	+	–
Cellobiose	–	+	–
Dulcitol	v	v	–
Glucose	+	+	+
Inositol	–	–	–
Lactose	+	–	–
Malonate	–	v	–/+*
Mannitol	+	+	+
Xylose	+	+	–
Salicin	v	v	–
Sorbitol	+	–	–/+*
Sucrose	v	–	–

[+] Growth or reaction occurs

[–] Growth or reaction does not occur

[v] Reaction or character is variable among isolates

***** Biogroup 1 (human-origin)/biogroup 2, formerly *Shigella boydii* 13, (human- and animal-origin)

E. albertii is a recently described new species that ferments d-mannitol but not lactose or d-xylose. Phenotypic and molecular tests are used to identify *E. albertii*, but conventional identification systems often incorrectly identify the organism as *E. coli, Hafnia alvei*, or other enteric bacteria (3). *E. albertii* causes gastroenteritis in people. In birds, infections range from asymptomatic to severe intestinal disease and mortality. Virulence factors include intimin (responsible for attaching-effacing lesions in the intestinal tract) and cytolethal distending toxin, also a cause of diarrheal disease (442, 443). *E. albertii* may be increasingly identified as a cause of intestinal disease in birds as better methods to identify it become available.

Classification

Escherichia is the type genus of the family Enterobacteriaceae, which is composed of organisms that can grow aerobically or anaerobically and utilize simple carbon and nitrogen sources (52, 152). *E. coli* is the type species of the genus *Escherichia*. Additional species have been assigned to the genus but *E. coli* occurs most commonly and is most important as a pathogen. Although *Shigella* is still recognized as a genus with 4 species, they actually group genetically with *E. coli* (431).

Name and Synonyms

Escherichia coli was initially named *Bacterium* (*Bacillus*) *coli* commune, which was shortened and modified to *B. coli* before being given its present name by Castellani and Chalmers in 1919 (152). The genus is named for Theodor Escherich, a pediatrician who first identified and described the organism, which appeared in the feces of infants soon after they began nursing. It is typical of bacterial species within the family Enterobacteriaceae (431). Diagnostic characteristics of *E. coli, E. fergusonii*, and *E. albertii* are presented in Table 18.1.

Table 18.2. Effect of temperature on generation time and numbers of *Escherichia coli* that could develop within 24 hours in the absence of limits on growth (nutrition, accumulation of inhibitory substances, etc.).

Temperature		Generation	
(°F)	(°C)	Time (hours)	No. of *E. coli* in 24 hours
32	0	20	2
40	4.4	6	8
50	10.0	3	128
60	15.6	2	2,048
70	21.1	1	8,388,608
80	26.7	0.75	3,435,973,800
90	32.2	0.50	24,073,749,000,000
100	37.8	0.30	236,118,320,000,000,000,000

Morphology and Staining

Escherichia coli is a Gram-negative, nonacid-fast, uniform staining, nonspore-forming bacillus, usually –3×0.6 μm. Organisms grown in culture are more variable in size and shape. Intracellular organisms are often smaller than extracellular bacteria. Most strains are motile and have peritrichous flagella.

Growth Requirements

Escherichia coli grow aerobically or anaerobically on ordinary nutrient media at temperatures of 18ºC–44ºC. It ferments carbohydrates, often producing gas. Generation time and number of organisms during a specific time period are related to temperature (see Table 18.2).

Colony Morphology

On agar plates incubated for 24 hours at 37ºC, colonies are low, convex, smooth, and colorless. Colonies are bright pink and surrounded by a precipitate on MacConkey's agar, have a dark green-black metallic sheen on eosin-methylene blue (EMB) agar, and are yellow on tergitol-7 agar. Although colony morphology may vary, they are usually 1–3 mm in diameter with granular structure and an entire margin. Rough colonies are larger with irregular margins. Mucoid colonies are raised, larger, appear wet, and are sticky when probed. In contrast to the frequent occurrence of hemolysis by mammalian pathogenic *E. coli* on blood agar, hemolysis is not a common characteristic of APEC. *E. coli* rapidly produces diffuse turbidity in broth cultures.

Biochemical Properties

Acid and gas are produced from fermentation of glucose, maltose, mannitol, xylose, glycerol, rhamnose, sorbitol, and arabinose, but not dextrin, starch, or inositol. Substituting sorbitol for lactose in MacConkey agar is useful for distinguishing *E. coli* O157:H7 from other *E. coli* because O157:H7 typically does not ferment sorbitol and will not appear as pink colonies in contrast to typical *E. coli* isolates. Most *E. coli* isolates ferment lactose, but negative strains, which must be differentiated from *Salmonella*, are occasionally isolated. Fermentation of adonitol, sucrose, salicin, raffinose, and dulcitol is variable. Isolates that fermented raffinose and sorbose produced high mortality in an embryo lethality test (392). *E. coli* produces indole, a positive methyl red reaction, and reduces nitrate to nitrite. Voges-Proskauer and oxidase reactions are negative and hydrogen sulfide is not produced in Kligler's iron medium. *E. coli* does not grow in the presence of potassium cyanide, hydrolyze urea (urease negative), liquefy gelatin, or grow in citrate medium. Biochemical tests can be used to distinguish *E. coli* from other *Escherichia* species (52) and bacteria in the family Enterobacteriaceae (152). *E. fergusonii* does not ferment lactose, sucrose, raffinose, or sorbitol, which helps distinguish it from *E. coli* (Table 18.1). *E. albertii* does not ferment lactose, sorbitol, or xylose, which helps distinguish it from *E. coli* (Table 18.1).

Susceptibility to Chemical and Physical Agents

Escherichia coli possess no unique resistance capabilities and have a susceptibility pattern to chemical and physical agents typical of vegetative, Gram-negative bacteria. Inactivation of most strains occurs at temperatures ranging from 60ºC for 30 minutes to 70ºC for 2 minutes. Thorough pre-cleaning and/or presence of a germicide enhance thermal inactivation. The organism survives freezing and persists for extended periods at cold temperatures. Thermal inactivation in litter to achieve a 90% reduction in the number of bacteria depends on time and temperature ranging from 1–2 days at 37ºC to 6–22 weeks at 4ºC. Inactivation in litter is slower in the presence of high moisture, but more rapid when free ammonia is present (236).

Reproduction of most strains is inhibited by a pH of less than 4.5 or greater than 9, but the organism is not killed. Some virulent strains (e.g., O157:H7) are acid tolerant, which permits them to pass through the stomach without being killed. Organic acids are more effective than inorganic acids at inhibiting growth. Treatment with citric, tartaric, or salicylic acids significantly reduces coliform counts in poultry litter (266). Certain plasmids may also contribute to APEC's acid and bile tolerance, affecting survival of APEC in the bird or elsewhere (380). A salt concentration of 8.5% prevents growth but does not inactivate the organism (47).

Stabilized chlorine dioxide is highly effective when used as a water disinfectant (456). Chlorate in feed selectively reduces the number of *E. coli* and related bacteria in the digestive tract by converting relatively nontoxic chlorate to highly toxic chlorite via the same pathway *E. coli* uses to convert nitrate to nitrite (17). Solar disinfection of water through the action of ultraviolet light and temperature is a low-cost method of treating drinking water for people that may have application in the poultry industry (48).

Drying is detrimental to the organism. When samples of flooring from broiler transport coops were contaminated with *E. coli* and allowed to dry for 24 or 48 hours, only very

few organisms were still viable (49). Washing before drying completely eliminated the organism.

Resistance to Heavy Metals, Disinfectants, and Antibiotics

Escherichia coli have the ability to acquire resistance to a broad range of heavy metals (arsenic, copper, mercury, silver, tellurium, zinc) and disinfectants (chlorhexidine, formaldehyde, hydrogen peroxide, quaternary ammonium compounds). Specific strains can vary substantially in their susceptibility to heavy metals and disinfectants (1, 513). Strains develop resistance to disinfectants when subjected to environmental selection pressures, and such resistances are often encoded by large R plasmids (279, 281, 283, 288). In addition to antibiotic resistance, the APEC IncHI2 plasmid, p-APEC-O1-R, conferred resistance to potassium tellurite, silver nitrate, copper sulfate, and benzalkonium chloride following transfer of the plasmid to a recipient strain by conjugation (288). Similarly, the APEC IncF plasmid, pAPEC-O2-R, encoded resistance to quaternary ammonium compounds, silver, and other heavy metals, as well as several antibiotics (279, 283). Such plasmids are readily transferred to other APEC, avian fecal commensal *E. coli*, *Salmonella* spp., and uropathogenic *E. coli* of humans via conjugation (283), suggesting the possibility that APEC's R plasmids could be reservoirs of resistance genes for other bacteria of animal and human health importance.

Antigenic Structure and Toxins

Serotypes of *E. coli* are classified according to the Kauffmann scheme (152). Currently there are approximately 180 O, 60 H and 80 K antigens (547); the numbers change as new ones are identified and previous ones that are duplicated or attributable to another bacterial species are removed. In most serologic typing schemes only the O and H antigens are determined (e.g., O157:H7). The O antigen determines serogroup; addition of the H antigen and sometimes K antigen determines serotype (295). Rough strains autoagglutinate and cannot be serotyped. Additional serotypes with O antigens that have not been recognized also are found in most surveys. Fimbrial (pilus) antigens are included in serotyping when considered important. Recent innovations have enabled assignment of *E. coli* to "serogroups" using polymerase chain reaction-(PCR-)-based schemes (115).

O (Somatic) Antigen

Lipopolysaccharide (LPS) in the cell wall, also known as endotoxin, is a polysaccharide-phospholipid complex that is released when the cell undergoes lysis. O antigen is the antigenic portion of LPS, whereas the toxic portion of the molecule is lipid A. O antigen is resistant to boiling. Methods to prepare and use anti-sera, which typically agglutinate O antigen at high titers (usually over 1:2,560) when antigen-antibody mixtures are incubated at 50ºC for 24 hours, have been described (611).

H (Flagellar) Antigen

H antigens are proteins found in the different types of flagellin that comprise the flagella. To examine for H antigens, isolates must be grown under conditions that promote motility. Heating to 100ºC destroys them. Tube agglutination tests are read after incubation at 50ºC for 2 hours (611).

K (Capsular) Antigen

K antigens are polymeric acids containing 2% reducing sugars, are associated with virulence, are on the surface of the cell, interfere with O agglutination, and can be removed by heating for 1 hour at 100ºC. A few strains require heating for 2.5 hours at 121ºC. On the basis of heat stability, K antigens are subdivided into L, A, and B forms. Antisera are prepared in rabbits by inoculating live organisms intravenously. Tube agglutination titers are determined by incubating antigen-antibody mixtures at 37ºC for 2 hours and overnight at 4ºC. Titers are low (1:100–1:400). Most of these antigens can be identified by the slide agglutination test using appropriately diluted serum (611). Presently K antigens are not commonly included in serotyping.

F (Pilus) Antigen

F antigens are involved in attachment to cells. They are variably expressed depending on the environment in which the organism is growing, both *in vitro* and *in vivo*. Pili are classified as being mannose sensitive or mannose resistant depending on whether or not agglutination is inhibited or unaffected, respectively, when mannose is present. A variety of tests has been developed for detecting fimbrial antigens (611).

Toxins

APEC are much less toxigenic than pathogenic *E. coli* in mammals and humans. While APEC do not commonly produce enterotoxins, other toxins are elaborated, but their roles in diseases of poultry are currently uncertain (see Virulence Factors: Toxins). Pigeons can be a source of shiga-toxin producing *E. coli* strains (see Public Health Significance).

Strain Classification

Antigenicity

Even though molecular methods for identifying specific virulence genes are available, serotyping remains a useful tool for epidemiologic studies. Serotyping provides a means of relating previous work with new work. Also, it is important to know the serotype of an APEC strain because the immune response in poultry primarily is directed against O antigens. Numerous surveys have been made in many parts of the world to determine serotypes most frequently associated with diseases in poultry caused by *E. coli* (496, 523, 565). Variations according to geographic region occur, but in most studies the common serotypes have been O1, O2, O18, O35, O36, O78, and O111 (231, 537). Many other serotypes have been found less frequently, while some APEC do not belong to known serotypes or are untypeable (626). Some outbreaks are consistently associated with a specific serotype (e.g., O111

causing mortality, septicemia, and polyserositis in egg-laying chickens) (625).

Sixty-two different O types were found among typeable strains in a study comparing serotypes of 458 *E. coli* isolates from chickens with colibacillosis to 167 isolates from healthy chickens. Only 15% of the strains belonged to the serogroups O1, O2, O35, O36, or O78, which previously had been associated with avian colibacillosis. Several isolates from diseased birds belonged to 5 serogroups (O18, O81, O115, O116, O132), which had not previously been associated with colibacillosis. Although serotypes from diseased birds were significantly different from those from healthy birds, intestinal infection of healthy birds with serotypes isolated from diseased birds still occurred frequently (60).

Molecular Typing

In addition to phenotyping and serotyping, isolates of *E. coli* can be further characterized by antimicrobial susceptibility patterns, toxigenicity, presence of various virulence factors, cell attachment, invasiveness, hemagglutination, lysogeny (phage typing), plasmid profiling, phylogenetic typing, and virulence genotyping. DNA probes and polymerase chain reactions (PCRs) have been developed to detect specific genes important in virulence (314, 322, 349, 611). Detection of multiple genes that encode virulence factors by multiplex PCR is an efficient method for identifying several characteristics of APEC and commensal strains simultaneously (149, 491, 532).

Methods of "fingerprinting" isolates including pulsed-field gel electrophoresis (PFGE), amplified fragment length polymorphism (AFLP), restriction fragment length polymorphism (RFLP), and random amplification of polymorphic DNA (RAPD) can be used in epidemiological studies (274, 371). PFGE permitted fingerprinting of *E. coli* isolates from chickens with cellulitis. Specific types of the organism were found consistently associated with farms and successive flocks (529, 530).

RAPD is a rapid, cost-effective procedure for determining clonal types of *E. coli* in epidemiologic studies (77, 371). It is less costly and quicker than molecular fingerprinting using RFLP (371). RAPD analysis of 55 isolates revealed 50 subtypes in 3 clusters. It was not helpful for discriminating between pathogenic and nonpathogenic isolates (77). Sixteen different RAPD types were identified in a collection of isolates from diseased and healthy poultry in Georgia. Differences in the types were discovered but, with the exception of 1 RAPD type that occurred only in diseased chickens and accounted for 23% of the isolates, the differences were not absolute. Also, RAPD types did not correlate with antimicrobial resistance profiles (371).

Multilocus enzyme electrophoresis (MLEE) identified specific genotypes, which demonstrated that relatively few clonal types are responsible for different forms of colibacillosis in chickens and turkeys in widespread geographic areas. Virulence varied little among isolates within a clonal group but varied considerably between clonal groups (604). MLEE applied to a large number of *E. coli* isolates showed that they could all be placed into 1 of 4 clonal groups designated A, B1, B2, and D. Several clonal groups were identified among isolates from chickens with omphalitis, swollen head syndrome, septicemia, and intestines of healthy chickens in Brazil. MLEE permitted better discrimination of the isolates than ribotyping; most pathogenic isolates clustered together in 2 clonal subgroups while most commensal isolates occurred in other clonal groups (103). Multilocus sequence typing (MLST) is based on the principles of MLEE but relies on nucleotide sequencing of alleles at each target locus. MLST can be used to construct phylogenetic trees, providing insight into the evolution of APEC and its zoonotic potential (394, 401, 571). Assignment of APEC to phylogenetic types also can be accomplished with a multiplex PCR-based method (89). This method assigns isolates to A, B1, B2, and D phylogenetic groups. Clonal groups B2 and D are considered to contain most of the pathogenic isolates. However, Rodriguez-Siek et al. (490) found that the majority of 524 APEC isolates fell into so-called nonpathogenic clonal groups.

Genomes of *E. coli* contain multiple sequences, which can be identified by PCR and used to characterize individual isolates of the organism and determine their relatedness to each other. The procedure is known as enterobacterial repetitive intergenic consensus (ERIC). ERIC can be combined with repetitive extragenic palindromic (REP) PCR, which determines repetitive sequences outside of the genome. Using these methods dendrograms based on the different patterns revealed extensive genetic diversity among avian *E. coli* strains. Pathogenic and nonpathogenic isolates tended to group in different clonal groups whereas serotypes were distributed among all groups. No specific genotype or serotype could be identified as being the cause of colibacillosis (110). In a subsequent study, commensal and omphalitis isolates grouped together while APEC from poultry with septicemia or swollen head syndrome occurred in different clonal groups, indicating the opportunistic nature of the omphalitis isolates (102).

Comparative genomic analysis (136, 280, 291), signature-tagged transposon mutagenesis (STM) (342), selective capture of transcribed sequences (SCOTS) (131), genomic suppression subtractive hybridization (104, 299), virulence genotyping (149, 289, 290, 491), transcriptomics (343), proteomics (338), and recombination-based *in vivo* expression technology (RIVET) (577) are methods that have been useful in identifying previously unknown putative virulence genomic sequences in APEC (67, 299, 385, 518, 548). The newly recognized genetic sequences did not occur in commensal strains, suggesting their importance in virulence. Mutant strains lacking the putative novel virulence factors were less virulent than the APEC strains from which they originated. Furthermore, these novel virulence factors were more frequent in other avian and mammalian pathogenic strains than commensal strains. The specific nature of the genes, and their roles in the pathogenesis of colibacillosis in poultry, remain to be determined.

When 2 virulent avian strains (O2 and O78) from colisepticemia cases were compared, they were found to be very different with only a few shared genes. Analysis of

additional strains of each serogroup of human and animal origin showed similar genetic diversity, leading to a mix-and-match theory (i.e., different virulence factors can combine to provide an ability to cause septicemia) (385).

Presence of *E. coli* in water indicates fecal pollution, as the organism does not normally live outside of the intestinal tract and is present in high numbers in feces. To determine the source of the pollution, *E. coli* isolates can be classified as to species of origin by ribotyping (71, 212). Riboprints of fecal *E. coli* provided the most accurate determination of source when comparisons were made among no more than 3. For example, the source of *E. coli* from geese, turkeys, or chickens was correctly determined for approximately 96% of the isolates by the procedure (71).

Pathogenicity

Ability to cause mortality in embryos or chicks differentiates APEC from commensal *E. coli* strains (179, 180 ,181, 392, 438). An embryo lethality test can be used to test avian *E. coli* isolates for virulence. Eleven 12-day-old chicken embryos are inoculated via the allantoic cavity with 100 cfu of the test organism. Two-day mortality is less than 10% for nonvirulent strains, 10%–29% for intermediate strains, and greater than 29% for virulent strains (610). Extending the post inoculation observation time resulted in higher mortality, but the pattern of mortality among various strains remained essentially unchanged (392). Intravenous and subcutaneous inoculation of chicks correlated with embryo lethality, whereas intratracheal inoculation did not (180). Compared to the embryo lethality test, virulence of an isolate correlated with complement resistance and presence of ColV plasmid, but neither of these tests conclusively identified all isolates as virulent strains. Efforts to differentiate APEC from commensal *E. coli* using *in vitro* tests show promise (149, 289, 519, 532).

Virulence Factors

The ideas that avian colibacillosis is a secondary disease and APEC are opportunists are widely accepted. However, increasing evidence indicates that most APEC are well equipped for a pathogenic lifestyle, suggesting that APEC infections might not always be opportunistic or secondary to some predisposing condition. Certainly APEC, like other pathogenic *E. coli*, have acquired genes by horizontal transfer that encode virulence factors, which serve to distinguish APEC from commensal strains (126, 280, 289, 291, 491, 548). These virulence genes may be clustered into chromosomal- or plasmid-located pathogenicity islands (PAIs). As APEC frequently cause extraintestinal disease, they are commonly classified as a subpathotype of the extraintestinal pathogenic *E. coli* (ExPEC) pathotype (295, 504). The ExPEC pathotype also includes uropathogenic *E. coli* (UPEC) and neonatal meningitis *E. coli* (NMEC), which cause disease in humans and other hosts (295). ExPEC share certain virulence attributes, enabling their extraintestinal lifestyle, including adhesins, toxins, protectins, iron acquisition mechanisms, and invasins (295, 490, 491). Identification of these traits among APEC has fostered development of a rudimentary definition of an APEC pathotype (491) and led to interest in APEC's zoonotic potential (280, 290, 402, 490, 495, 533, 571).

Despite the fact that most APEC infections are extraintestinal, some APEC contain traits associated with intestinal *E. coli* pathotypes, including enteropathogenic *E. coli* (EPEC) (296, 322), enterotoxigenic *E. coli* (ETEC) (296, 325), enteroinvasive *E. coli* (EIEC) (496, 497), enterohemorrhagic *E. coli* (EHEC) (325, 541), and enteroaggregative *E. coli* (EAEC, EAggEC) (269, 446). Furthermore, APEC strains causing the same disease may differ substantially in their genetic content (385). In view of this high level of genomic plasticity, it is not surprising that no single virulence factor has been identified that will distinguish all APEC from all commensal *E. coli* strains. However, APECs' plasmid PAIs occur so commonly among APEC that they are considered a defining trait of the APEC pathotype (491), whose presence in an avian *E. coli* isolate has been used diagnostically (289). Genes encoding virulence factors in APEC are summarized in Table 18.3.

Adhesins

Adhesins may be fimbrial or nonfimbrial. The role of fimbriae in the pathogenesis of avian colibacillosis is unclear, although it seems likely that these virulence factors would be important in APEC's colonization of the host (28). Fimbriae can undergo phase variation depending on the types present on the organism and tissue being colonized. Several fimbrial types have been described among APEC, including AC/I (avian *E. coli* I) (28, 432, 620), P (F11) (325), type 1 (F1) (22, 325), Stg (352), curli (193, 319, 322), and ExPEC adhesion I (18). Also, a ColV plasmid, encoding type 4 pili, has been found in an APEC O78 strain. Although type 4 pili are known to contribute to host cell adherence of some bacteria, their roles in APEC adherence and virulence, if any, are unknown (195).

F1 fimbriae are expressed during initial colonization of tracheal epithelial cells, whereas P fimbriae are expressed later when the organism is in the lower respiratory tract or body tissues. Bacteria are rapidly killed by macrophages when they express F1 fimbriae (470, 472). Although the F1 fimbrial adhesin, FimH, is required for adhesion to cultured chicken epithelial pharyngeal or tracheal cells, lack of FimH favors *in vivo* colonization of the trachea of chickens (22). Curli may contribute to bacterial invasion of eukaryotic cells (193) and APEC's persistence in the cecum (319).

Intimin is a non-fimbrial adhesin encoded by the *E. coli* attaching and effacing (*eae*) gene, which is found in EHEC and EPEC. It permits the bacterial cell to adhere to the surface of the enterocyte, which initiates a characteristic attaching and effacing (AE) lesion. Several genetic variants of intimin, identified by letters of the Greek alphabet, have been identified. The most common type in APEC is β-intimin followed by l-intimin (314, 550). A highly virulent APEC (O86:K61) that caused mass mortality of passerine birds in Britain

Table 18.3. Putative APEC virulence and virulence-associated genes and regions. Modified from 276a, 295, 491.

Gene, Operon or Region	Description
Iron-Related Genes	
feoB	Primary gene mediating ferrous (Fe^{2+}) iron uptake
ireA[1]	Iron regulated, siderophore receptor, outer membrane protein
Yersiniabactin operon[1]	
irp2	Encodes iron repressible gene associated with yersiniabactin synthesis
fyuA	Encodes ferric yersiniabactin uptake receptor
Sit operon[1,2]	
sitA	Putative iron transport operon
Aerobactin operon[2]	
iutA	Ferric aerobactin outer membrane receptor gene
iucC	Involved in aerobactin synthesis
	Aerobactin operon is involved in iron uptake and transport
Salmochelin operon[2]	
iroN	Catecholate siderophore receptor gene
Eit operon[2]	
eitA	ABC iron transporter; periplasmic-binding protein
Toxin/Bacteriocin-Related Genes	
stx1, stx2[3]	Shiga toxins; inhibit protein synthesis
hlyD	Transport gene of the α-hemolysin operon
hlyF[2]	Avian *E. coli* hemolysin
cdtB	Cytolethal distending toxin; DNase I activity; blocks mitosis
vat[1]	Vacuolating autotransporter toxin
cnf1	Cytotoxic necrotizing factor 1; altered cytoskeleton, necrosis
usp	Uropathogenic-specific protein (bacteriocin)
ColV operon[2]	
cvaC	Structural gene of the ColV operon
ColB operon[2]	
cbi	Immunity gene of the ColB operon
ColM operon[2]	
cma	Structural gene for ColM activity
Adhesins	
Type 1 fimbrial adhesin operon (Fim)	
fimH	D-mannose-specific adhesin of Type 1 fimbriae
Pap pilus operon[1]	
papC	Acts as a molecular usher in P pilus assembly
papA	Encodes the major structural subunit
papG	Encodes the pilus tip adhesin
S fimbrial operon	
S fimbrial family of adhesins differ in receptor specificity	
S fimbriae (Sfa)	
sfaS	Encodes pilus tip adhesin of S fimbriae; S fimbriae interact with glycoproteins containing sialic acid
F1C-fimbriae (Foc)	
focG	Encodes a component of F1C fimbriae
focA	Encodes the major fimbrial subunit
S/F1C-related fimbriae (Sfr)	
AC/I fimbriae (Fac)	
facA	Encodes major subunit of avian *E. coli* I (AC/I) fimbriae
Curli operon	
crl	Gene cluster encoding for curli fibers; involved in cell adhesion and internalization
iha	IrgA homologue adhesin
afa	Afimbrial adhesin, a member of the Dr family of adhesins
gafD	G fimbrial adhesin
bmaE	Blood group M-specific adhesin
Stg operon	
stgA	On the C-terminus of the Stg fimbrial operon
tsh[2]	Temperature-sensitive hemagglutinin gene
bfp	Bundle-forming pilus, initiates attaching and effacing lesions in typical AEEC isolates
eae	*E. coli* attaching and effacing gene that encodes intimin
Protectins	
iss[2]	Encodes an outer membrane protein involved in increased serum survival and surface exclusion
traT[2]	Encodes an outer membrane protein involved in serum resistance and surface exclusion
bor	Virulence determinant encoded by λ bacteriophage; involved in serum resistance
ompA	Outer membrane protein A is involved in serum resistance
kps cluster	Involved in encoding capsular (K) antigens
Invasins	
ibeA[1]	Promotes invasion of brain micro-vascular endothelial cells
ipa	Cell penetration and intracellular survival
tia[1]	Tia invasion determinant
Miscellaneous	
ompT[1,2]	Encodes a protease able to cleave colicin
malX	Pathogenicity island marker from UPEC CFT073
fliC (H7)	Produces flagellin protein associated with the H7 antigen group
Ets operon[2]	
etsA	Encodes ABC transporter, efflux pump protein

[1] localized to an APEC chromosomal PAI

[2] localized to APEC plasmid-linked PAIs

[3] encoded by phage

produced l-intimin (322). This organism has recently been reclassified as *E. albertii* (442).

Organisms producing AE lesions are known as attaching and effacing *E. coli* (AEEC). In mammals, a specific pilus (BFP, bundle-forming pilus) occurs together with intimin to cause the AE lesion. AEEC that do not have BFP are referred to as "atypical AEEC." Avian AEEC are usually atypical AEEC as isolates usually lack BFP. AEEC either are absent or found infrequently in most surveys of poultry (314, 550) except for pigeons infected with shigatoxin strains (211, 541). However, high percentages of *eae*+isolates were obtained from dead-in-shell embryos and chicks with yolk sac infections in Mexico (30%) (496) and feces of healthy chicks in Kenya (60%) (296), suggesting there may be certain geographic areas where AEEC commonly infect chickens. A novel avian respiratory soluble lectin, distinct from pulmonary collectins and ficolins, which binds with surface polysaccharides of pathogenic *E. coli* (serogroups O2 and O78), has been discovered in air sac fluids of turkeys. Its role, if any, in colibacillosis has yet to be defined (598).

Also, temperature-sensitive hemagglutinin (Tsh), the first described serine protease autotransporter of the Enterobacteriaceae (SPATE) (474), is secreted by some APEC strains. It is a bifunctional protein that acts as an adhesin and protease (311) and mediates colonization of the host's respiratory tract during early infection (132). The contribution of Tsh to the pathogenesis of colisepticemia appears to be restricted to the early stages of infection, as *tsh*$^-$ mutants cause less severe and less frequent lesions in air sacs. Tsh does not appear to be required for high levels of APEC virulence (570). Reports of its prevalence among different APEC populations vary widely (12, 109, 116, 117, 148, 149, 269, 369, 375, 490, 491, 587, 618, 626). Another autotransporter, AatA, which has a role in APEC adherence and virulence, has recently been described (340). *aatA* is strongly associated with *E. coli* from avian sources but not with *E. coli* from human hosts. In some APEC, *aatA* is plasmid-linked (340), but in others, it is chromosomally encoded (104). Also, a Type VI secretion system has been described in APEC, which contributes to APEC adherence, invasion of cultured HeLa cells, biofilm formation on abiotic surfaces, motility, survival within macrophages, and virulence (111, 112).

Toxins

APEC tend to be less toxigenic than mammalian pathogenic *E. coli* (59, 269, 378). This difference may be due to the lack of toxin production or that toxins produced by avian strains are not detectable with tests for toxins produced by mammalian strains. In addition to endotoxin, a structural component of the organism's cell wall, APEC can elaborate several toxins that are important in disease (454, 455, 509, 510, 511); low-level occurrence of certain toxin genes among APEC has been reported. These genes include those encoding cytolethal distending toxin (325, 490, 491, 496), cytotoxic necrotizing factor 1 (490, 491), and various hemolysins (12, 278, 285, 375, 396, 410, 485, 490, 491, 612).

Some of the genes encoding toxins occur in a substantial number of APEC. A *Salmonella* virulence homologue, *hlyF*, was first described in an avian *E. coli* isolate in 2004 (396). It shares significant homology with the *E. coli* K12 "silent" hemolysin gene, *she*, and occurs commonly among APEC. The gene is found within a virulence cluster of large, conjugative ColV and ColBM plasmids (278, 285). Its role in APEC virulence is unknown.

Vacuolating autotransporter toxin (Vat), which is encoded by the *vat* gene, also occurs commonly among APEC (148). Vat is a 148.3-kDa protein, which has a structure typical of SPATE. It causes cytotoxic effects in cultured cells similar to those caused by *Helicobacter pylori* VacA toxin. Vat appears to be a virulence factor for APEC, as deletion of the *vat* gene results in attenuation of virulence (453).

Iron Acquisition Mechanisms

The ability of APEC to obtain iron is well documented and likely due to various iron-acquisition mechanisms (aerobactin, yersiniabactin, *sit*, and *iro* systems) (72, 73, 124, 131, 194, 326, 506, 607). Genes of these operons occur frequently among APEC, but are significantly less common in commensal *E. coli* strains (491). APEC frequently contain several of these operons, 1 or more of which may be found on large plasmids (127, 131, 182, 263, 277, 285, 288, 490, 491, 506, 570). This apparent redundancy in iron acquisition mechanisms and widespread distribution of these systems among APEC suggest that the ability to obtain iron is important in the pathogenesis of avian colibacillosis.

The *sit* operon was originally described in a *Salmonella enterica* serovar Typhimurium isolate (628) and more recently identified in APEC using genomic subtractive hybridization and signature-tagged mutagenesis (342, 518). The *sit* operon encodes an ABC transport system involved in metabolism of iron and manganese and resistance to hydrogen peroxide (506). In at least 1 APEC, this operon occurs in both chromosomal and plasmid-located PAIs (278, 280). In its plasmid location, *sit* is closely associated with the aerobactin siderophore operon and *iro* locus (278). The yersiniabactin operon in at least 1 APEC is found in a chromosomal PAI (GenBank accession no. NC 008563).

Protectins

The ability to resist complement is a common characteristic of APEC, regardless of the syndrome or avian host species of origin (439). Resistance of *E. coli* to complement is related to several structural factors including K1 capsule (98, 99, 175, 379) or other capsule type (505, 552), a smooth lipopolysaccharide (LPS) layer (99, 188) or particular LPS type (379), and certain outer membrane proteins (OMPs), including TraT, Iss, and OmpA (54, 85, 86, 386, 601). When 294 APEC were compared with 75 fecal *E. coli* isolates from clinically healthy birds for possession of a capsule, smooth LPS layers, *ompA*, *traT*, and *iss*, only *iss* was found to occur significantly more often in APEC relative to commensal strains (464).

The increased serum survival gene (*iss*), first described by Binns and co-workers in 1979 for its role in complement resistance associated with a ColV plasmid, increased the virulence of an *E. coli* 100-fold for day-old chicks (53) and its complement resistance more than 20-fold (37, 85, 86). The gene *iss* encodes Iss, a lipoprotein exposed on the outer membranes of *E. coli* (354). It occurs frequently among APEC (490, 491, 618, 626) compared to a low rate of occurrence in commensal strains. Although it has been proposed that the substantial difference in distribution of *iss* between APEC and commensal strains might reflect its importance in APEC virulence (439), Mellata et al. (379) reported that *iss* did not play a major role in resistance of APEC strain χ7122 to serum. In contrast, Tivendale et al. (570) found a strong association between APEC virulence and carriage of *iss* and/or *iucA*, a gene of the aerobactin operon. From such disparate observations, it is evident that much remains unknown about complement resistance in APEC, its mediators, and its role in disease pathogenesis. Recently, Li et al. (339) used a global microarray approach to assess serum resistance in APEC O1. The organism quickly adapted to growth in serum by significantly upregulating 311 genes and downregulating 299 genes. The extent of these changes demonstrates the complexity of APEC's response to serum. Upregulated genes were involved in biosynthesis of cofactors, prosthetic groups, and carriers, and downregulated genes were involved in energy metabolism. Of the upregulated genes, only 39 were localized to chromosomal islands, while most were found in APEC O1's 3 plasmids with 56 of these localized to APEC O1's large virulence plasmid, pAPEC-O1-ColBM.

The ability of APEC to resist the detrimental effects of heterophils and macrophages is likely another important determinant that contributes to successful infection. Resistance to phagocytosis or its effects may be related to complement resistance or possession of other traits. Kottom et al. (312) reported that a complement-sensitive mutant bound significantly more C3 subunits and was phagocytosed significantly more often than the wild-type APEC strain from which it had been derived. It was hypothesized that the mutant's decreased virulence resulted from its increased sensitivity to complement-mediated bacteriolysis or enhanced susceptibility to complement-opsonized phagocytosis. However, subsequent studies by Mellata et al. (379) showed that nonopsonized APEC were eliminated by phagocytes to the same or greater extent than serum-opsonized bacteria.

Phagocytosis of APEC by avian phagocytes is promoted by presence of type 1 fimbriae and absence of P fimbriae, K1 capsule, O78 antigen, and an uncharacterized pathogen-specific chromosomal region. Presence of type 1 and P fimbriae, O78 antigen, and the 0-minute chromosomal region contributed to protection of APEC against the bactericidal effect of phagocytes, in particular, heterophils (379).

Certain strains of APEC can survive within macrophages and cause their destruction through apoptosis (41, 489). Caspases, enzymes essential for apoptosis, were activated by a strain of APEC (APEC17), which resulted in cytotoxicity within 8 hours of infection (41).

Invasins

The *ibeA* gene contributes to invasion of brain microvascular endothelial cells (BMEC) by neonatal meningitis ExPEC. It is significantly more likely to be found in APEC than in avian commensal strains (177, 299, 490, 491). The abilities of APEC strain BEN2908 to invade human BMEC, adhere to BMEC, and cause avian colibacillosis are significantly reduced when *ibeA* is inactivated (95, 177). These results indicate that *ibeA* is a virulence attribute of APEC. *ibeA* occurs in 14%–20% of APEC (177, 490, 491). *ibeA* and *ibeT*, which is located downstream of *ibeA* in APEC BEN2908, may affect adherence by modulation of type 1 fimbrial expression (95). *ibeA* is found in chromosomal PAIs (APEC O1). APEC BEN2908 also usurps cellular endocytic pathways to invade cultured human pneumocytes and avian hepatocytes (78).

Other

Formation and residence within a biofilm could enhance the ability of APEC to resist cleaning and disinfection and to acquire virulence and resistance genes by horizontal gene transfer. When 105 APEC and 103 avian commensal *E. coli* strains were compared for their ability to form biofilms on plastic surfaces, formation of biofilms by APEC was induced by nutrient-poor conditions. In contrast, commensals formed biofilms in both nutrient-poor and -rich conditions (535). The intracellular multiplication factor (IcmF) protein, which is a component of APEC's Type VI secretion system, may contribute to biofilm formation on abiotic surfaces (111).

Genomic Location of Virulence Genes

Much progress has been made in localizing various virulence genes in the APEC genome, providing insight into their organization, regulation, and evolution. These insights have been accelerated with the completion of the first genomic sequence of an APEC strain, APEC O1 (280), as genomic sequences are often starting points for high-throughput studies of APEC pathogenesis and gene function under host conditions (339, 341, 343). Such studies will be greatly enhanced with public release of additional genomic sequences (136, 360, 492) because APEC are highly diverse in their genomic composition (491).

Sequences of several APEC chromosomal PAIs and at least 5 APEC virulence (PAI-containing) plasmids are currently available.

Common features of most PAIs include encoding 1 or more virulence factors, being between 10 and 200 kb in size, usually being flanked by small direct repeat sequences, and bearing traces of their introduction into the genome via horizontal transfer, including deviation of G-C ratios and codon usage from the organism's typical pattern (294). PAIs may contain mobility elements, such as integrons, transposons, and insertion sequences. If they move they are likely carried on plasmids, conjugative transposons, or phages, whose loss may spontaneously convert a virulent organism into an avirulent one (294).

Several chromosomal PAIs have been identified among APEC including the VAT-PAI (453), PAI $I_{APEC-O1}$ (298), AGI-3 (83), the *tkt1*-containing PAI (341), and several other putative PAIs found in APEC O1 (280, 291). VAT-PAI is a 22-kb PAI that includes the *vat* gene, which encodes Vat (see Virulence Factors: Toxins). Another chromosomally located APEC PAI, PAI $I_{APEC-O1}$ (298), is 56 kb in size and harbors the complete *pap* operon and other *E. coli* genes (*tia* and *ireA*). Also, PAI $I_{APEC-O1}$ lies immediately upstream of the *kps* gene cluster, which is required for biosynthesis of polysialic acid capsule. Although the role of this PAI in virulence has yet to be elucidated, study of 95 APEC and 95 avian commensal isolates for possession of 6 genes of this PAI revealed that they occurred more often in APEC of high and intermediate virulence than in isolates of low virulence. None of the commensals contained all 6 of these targets, whereas 7.2% of APEC strains had all of the genes (297). Another chromosomal PAI, AGI-3 (83), is 49.6 kb in size and is arranged in 5 modules. Deletion analysis of module 1 demonstrated its contributions to APEC's carbohydrate uptake and virulence for chickens. Studies of its prevalence among 249 ExPEC strains, including 205 APEC and 36 nonpathogenic strains of avian origin, showed that about 12% of all strains tested contained this region. Also, all 15 APEC strains of the O5 serogroup contained this PAI, suggesting that it might be serogroup-associated. The 16-kb *tkt1*-containing PAI, found in the chromosome of APEC O1, is strongly associated with human and avian ExPEC of the B2 phylogenetic group but not avian fecal commensal *E. coli*. Tkt1 seems to contribute to APEC's bipeptide metabolism (341).

APEC PAIs also have been found on large transmissible virulence plasmids, 5 of which have been sequenced to date. These plasmids, and more specifically, their PAIs, are the defining trait of the APEC subpathotype (491). APEC plasmid PAIs share remarkable similarity in their conserved regions (278, 279, 285, 381, 569). However, these plasmids also may have important differences allowing their host bacteria to exploit various niches. For instance pAPEC-O2-ColV harbors the ColV operon (285); whereas, pAPEC-O1-ColBM contains only remnants of the ColV operon and has ColBM operons (278). Still other APEC virulence plasmids may contain a multidrug-resistance (MDR)-encoding island in addition to the PAI (279). As more APEC plasmid sequences are released, added "variations on the theme" are likely to be identified because genotyping of large collections of APEC has suggested that these plasmids are very diverse (151, 289, 290, 490, 491).

A 180-kb ColV plasmid known as pAPEC-O2-ColV, found in an APEC O2 strain, was shown to harbor many of the genes associated with APEC virulence and be similar in genetic make-up to a plasmid and chromosomal PAI of human uropathogenic *E. coli* (533). When transferred by conjugation along with a large R plasmid into a commensal avian *E. coli* strain, the resulting transconjugant showed enhanced virulence for chick embryos and abilities to grow in human urine and cause urinary tract infection in the murine model of human disease. pAPEC-O2-ColV was sequenced and analyzed (285), and its role in virulence was further evaluated (534). In addition to regions devoted to plasmid transfer, maintenance, and replication, pAPEC-O2-ColV contained a 94-kb cluster of putative virulence traits, including *hlyF*, *ompT*, *iss*, *tsh*, the ColV operon, and several iron-related systems. The iron-related systems included those encoding aerobactin and salmochelin, and the *sit* ABC transport system. Also, this PAI contained another putative ABC transport system known as *ets*. A study of the distribution of these PAI genes in 595 APEC and 199 avian fecal commensal *E. coli* isolates revealed that a portion of this PAI was highly conserved among APEC and that the genes of the conserved region occurred more often in APEC than in commensal strains. This conserved portion, which occurred in nearly 80% or more of APEC examined, included the *sit*, *salmochelin*, *aerobactin*, and *ets* operons; *hlyF*; *iss*; *ompT*; the RepFIB replicon; and the 5' end of the ColV operon. The variable portion of this PAI contained the 5' end of the ColV operon, *tsh*, and the *eit* operon. The split between conserved and variable portions occurred within the *cvaB* gene of the ColV operon with the 5' end of *cvaB* and many of its upstream genes occurring significantly more often among APEC than the 3' end of *cvaB* and many of its downstream genes. This difference in prevalence between conserved and variable portions of the PAI among APEC suggested that there must be an alternative location for the conserved portion in APEC. Indeed, a very similar PAI was found in a 174-kb ColBM-encoding APEC plasmid, known as pAPEC-O1-ColBM (278), which was isolated from an APEC O1 strain. This F-type plasmid shares remarkable similarities with pAPEC-O2-ColV, except that it encodes for production of colicins B and M rather than ColV. Similarly, Tivendale et al. (572) described the sequence of a 151-kb plasmid, pVM01, whose conserved PAI region contributed to the virulence of its host APEC, an O nontypeable: H28 APEC field isolate. Mellata et al. (381) also described the complete sequences of several APEC plasmids, found in an APEC O78:K80:H9 strain, and their contributions to APEC virulence and fitness (377, 380, 381), again confirming the importance of these plasmids in the pathogenesis of avian colibacillosis. Johnson et al.(279) sequenced pAPEC-O103-ColBM, a 124.7-kb hybrid RepFIIA/FIB plasmid harboring components of the ColV PAI and an MDR-encoding island. Acquisition of this plasmid conferred the abilities to cause colisepticemia in chickens, bacteremia resulting in meningitis in the rat model of human disease, and resistance to the bacteriostatic or killing effects of human serum, streptomycin, sulfisoxazole, tetracycline, erythromycin, and trimethoprim-sulfamethoxazole.

At least portions of these plasmid-linked PAIs appear to occur widely among APEC isolated from different parts of the world (12, 116, 117, 148, 269, 369, 375, 490, 491, 587, 618, 626), various avian host species (12, 375, 490, 491), and different syndromes (109, 491). These observations suggest that the conserved region of these plasmid-linked PAIs is a defining characteristic of the APEC pathotype (289, 491)

that could be exploited in colibacillosis control. Protocols for rapid characterization of APEC, based on detection of certain virulence genes, including some from this cluster, show promise (149, 289, 532).

During conjugation, these virulence plasmids may co-transfer from donor to recipient strains with large MDR-encoding R plasmids (284, 288), and, as noted above, genes encoding virulence and resistance can be found on the same APEC plasmids (279). This close association between resistance and virulence genes in APEC suggests that use of any of a number of antibiotics, heavy metal compounds, or disinfectants used in poultry production may select for APEC with enhanced ability to cause disease, resist therapy and disinfection, and persist in the environment (286).

Thus, APEC virulence plasmids are found in most APEC (289, 491) and are the defining trait of the APEC subpathotype, whose presence can be exploited in colibacillosis control. They contribute to the fitness of *E. coli* for different environments and enhance its abilities to cause colibacillosis in avian hosts, and urinary tract infection (UTI), sepsis, and meningitis in murine models of human disease. They also are found in the *E. coli* that contaminate retail poultry meat (282), suggesting the possibility that retail poultry could be a foodborne reservoir of plasmid-linked virulence or resistance genes in human disease. Though APEC-like virulence plasmids occur at relatively low prevalence in human uropathogenic *E. coli*, they occur in a majority of human neonatal meningitis *E. coli* (NMEC) and are considered a defining characteristic of the NMEC subpathotype (351).

Regulation of APEC Virulence

Mutational analysis of the specific phosphate transport system (Pst) operon of an APEC strain resulted in deregulation of phosphate sensing and changes in the composition of the bacterial surface. These changes were accompanied by increased susceptibility to serum, acid shock, and polymyxin, and resulted in decreased virulence, suggesting that a functional Pst system is required for full virulence of APEC O78 strain χ7122 (328). Also, the Pho regulon in APEC is controlled by the 2-component regulatory system PhoBR and modulated by the PsT system (50). In addition, the BarA-UvrY 2-component system has been shown to regulate APEC virulence. Mutants lacking *barA* or *uvrY* had impaired adherence, invasiveness, persistence in tissues, survival in macrophages, and serum resistance (234). It is likely that completion of the APEC genome will facilitate experimentation that will provide insight into the critical issue of virulence regulation.

Pathobiology and Epidemiology

Incidence and Distribution

Escherichia coli have a cosmopolitan distribution. The various serotypes of *E. coli* are normal intestinal inhabitants and occur in high numbers in most animals, including humans. The presence of *E. coli* in the lower intestinal tract is beneficial, aiding in growth and development (516) and inhibiting other bacteria, including *Salmonella* (168, 370, 469). *E. coli* likely occur in most mammals and birds, although healthy psittacines may be an exception (30, 551). It is a common inhabitant in the intestinal tracts of poultry at concentrations up to 10^6 *E. coli*/gram of intestinal contents. Higher numbers are found in younger birds, birds without an established normal flora, and in the lower intestinal tract (129, 333, 609). A diversity of *E. coli* serotypes colonize the cecal mucosa, which may shift abruptly as birds age (273). *E. coli* strains that persist over time are considered resident strains, whereas those that are present for a limited period are considered transient strains. Among normal chickens, 10%–15% of intestinal coliforms may belong to potentially pathogenic serotypes (225), although intestinal strains may not be the same serotype as those from extraintestinal sites in the same bird. Intestinal *E. coli* provide a reservoir for virulence and antimicrobial resistance factors (437).

Egg transmission of pathogenic *E. coli* is common and can be responsible for high chick mortality (184, 347, 462, 496). Fluoroquinolone-resistant *E. coli* were vertically transmitted from clinically normal breeders and caused high mortality in chicks (462). Pathogenic coliforms are more frequent in the intestine of newly hatched chicks than in the eggs from which they hatched (226), suggesting rapid spread after hatching. The most important source of egg infection is fecal contamination of the egg surface with subsequent penetration of the shell and membranes.

Coliform bacteria can be found in litter and fecal matter. However, *E. coli* accounts for only a small number of total bacteria in litter (427). Environmental isolates often constitute a distinctly different population from APEC occurring in the birds (270). Dust in poultry houses may contain 10^5–10^6 *E. coli*/g. Dust concentrations are higher immediately outside of power-ventilated houses than they are within the houses. *E. coli* are present in the air inside of the houses and up to 40 feet outside of the houses (106). These bacteria persist for long periods, particularly under dry conditions (224). Wetting dust inside houses with water resulted in an 84%–97% reduction within 7 days. Feed and feed ingredients are often contaminated with pathogenic coliforms and are a common source for introducing new serotypes into a flock (362). Rodent droppings frequently contain pathogenic coliforms. The intestinal tract of the mouse is a suitable environment for transfer of genes from resistant to susceptible strains. Exposure of mice to an antibiotic accelerates the process (227). Pathogenic serotypes also can be introduced into poultry flocks through contaminated well water (413). Presence of *E. coli* in drinking water indicates fecal contamination and serves as an indicator for the possible presence of any infectious agent that can be transmitted by the fecal-oral route.

Natural and Experimental Hosts

Most, if not all, avian species are susceptible to colibacillosis. Clinical disease is reported most often in commercial chicken, turkey, and duck flocks. Collectively, the various forms of

colibacillosis are considered to be the most common infectious bacterial disease of broiler chickens and turkeys. Natural infections of other avian species occur including quail (21, 70, 160, 627), pheasants (558), pigeons (63, 482), guinea fowl (221, 350), waterfowl (39, 55, 97, 265, 383, 477, 595, 596), ostriches (93, 307, 430, 602), emus (237, 608), peacocks (32, 531), and partridges (125), especially if they are kept intensively in confined conditions. The disease is less common in wild birds, but can cause morbidity and mortality (240).

Age of Host Commonly Affected

All ages are susceptible to colibacillosis, but young birds are more frequently affected and disease severity is greater in young birds, including developing embryos (196, 222, 276, 390). Outbreaks can occur in caged layers (587, 625) and coliform salpingitis/peritonitis is a common cause of mortality in breeders (292). Colibacillosis in older birds is often manifested as an acute septicemia.

Host Susceptibility Factors

Compared with bacterial virulence factors, host susceptibility and resistance factors are probably an equal or greater determinant of colibacillosis occurrence (Tables 18.4, 18.5). Normal, healthy birds with intact defenses are remarkably resistant to naturally occurring *E. coli* exposure, including virulent strains. Infection occurs when skin or mucosal barriers are compromised (e.g., unhealed navel; wounds; mucosal damage from viral, bacterial, or parasitic infections; lack of normal flora; etc.), the mononuclear-phagocytic system is impaired (e.g., viral infections, toxins, nutritional deficiencies), there is immunosuppression (e.g., viral infections, toxins), exposure is overwhelming (e.g., environmental contamination, poor ventilation, contaminated water), and/or birds are exposed to abnormal stress or have an inappropriate response to stress. Effective control of colibacillosis depends on identifying and eliminating the predisposing cause(s) of the disease.

Colibacillosis often occurs concurrently with other diseases, making it difficult to determine the contribution of each agent to the overall clinical disease. For example, colibacillosis, paratyphoid, and histomoniasis caused high mortality in a broiler flock maintained free of antibiotics where high ambient temperatures and humidity may have been additional factors contributing to the disease (171). High mortality in Japanese quail with signs of respiratory disease was associated with *Mycoplasma gallisepticum*, *Pasteurella multocida*, *Staphylococcus sp*., *Streptococcus sp*., *Cryptosporidium sp*., and *E. coli*; relatively high ammonia levels likely also contributed to the clinical disease (403). Coliform peritonitis was more severe in commercial layers challenged with *Mycoplasma synoviae* and *E. coli* than in those challenged with *E. coli* alone (483).

Infection with infectious bronchitis virus (IBV) in chickens (92, 183, 419, 536), infection with hemorrhagic enteritis virus in turkeys (433, 466, 582), and exposure of avian species to ammonia (412, 447) are the most commonly reported factors that predispose to colibacillosis. Interactions between IBV and *E. coli* have been studied extensively and used to determine virulence of both organisms, efficacy of IBV vaccination programs, and effect of IBV vaccination on subsequent colibacillosis (91, 366, 367, 416). IBV vaccination by spray of chicks at 1 day of age reduced the occurrence and severity of airsacculitis following challenge with virulent IBV and *E. coli*. In contrast, IBV vaccination by eye drop reduced systemic infection and improved uniformity, but did not protect against airsacculitis (366).

Moderate stress increases resistance, possibly resulting from development of immunity following contact of organisms with the immune system (333), or because of developing and exercising defense mechanisms and maintaining them in a state of readiness (204). Similarly, provoking mild, nonspecific inflammation of the respiratory system increases resistance to subsequent respiratory *E. coli* infection (573). Resistance to intra-air sac *E. coli* challenge was observed following primary NDV vaccination with the Roakin strain, which was prevented when the chickens were given corticosterone (241). Individual survival is likely promoted by diversion of feed-derived nutrients from growth and development to antibacterial defenses (208). Protein does not accumulate at the same rate in muscles of infected birds once they recover, and they do not match the weight-for-age of uninfected birds (566). Inhibition of prostaglandin E2 by naproxen restored normal growth (567), which is consistent with the earlier finding that inhibition of prostaglandins with aspirin and vitamin E decreased the severity of disease resulting from *E. coli* challenge (346).

Genetic lines of chickens and turkeys vary in their resistance to *E. coli* infections (26, 526, 527, 624). Variations among genotypes in growth rate, nutritional interactions, and immune responsiveness that relate to *E. coli* susceptibility also have been identified. Consistent among studies in both chickens and turkeys is an inverse relationship between growth rate and resistance to colibacillosis (210, 243, 249, 526, 622, 624). Selection for rapid growth is believed to require redirection of nutrients toward growth at the expense of bacterial resistance (208, 481). However, no correlation between body weight at market for broilers or chick production of breeders with high early antibody response to *E. coli* vaccine was found, indicating the feasibility to select for both immune responsiveness and desirable production traits (335). Immune responses to other vaccines and antigens paralleled response to *E. coli* vaccine in selected lines (623). In general, chickens and turkeys that are more immunologically responsive (e.g., high early antibody lines) are more susceptible to colibacillosis unless they have been vaccinated or otherwise exposed prior to challenge (42, 135, 622). Genetic lines may be more resistant to colibacillosis if the challenge method uses a predisposing agent such as infectious bronchitis virus because of resistance to the predisposing agent rather than *E. coli* (69).

When 5 broiler lines, a slow-growing line, and 2 line crosses were examined using a standardized pure *E. coli* challenge, substantial differences in mortality, lesion occurrence, and growth depression were found. These results indicated that

Table 18.4. Factors known or suspected to increase host susceptibility to *Escherichia coli* infections in poultry. See also 28.

Factor	References	Factor	References
Viruses		*Eimeria brunetti*	(230, 413)
Adenovirus (Type 1)	(120, 122, 237, 499, 594)	*Eimeria tenella*	(313, 425)
Avian influenza virus	(6, 31, 310, 435, 475, 560)	*E. tenella/whole wheat diet*	(170)
Avian metapneumovirus	(9, 272, 359, 578, 580)	*Cryptosporidium baileyi*	(99a)
Chicken infectious anemia virus	(480)	*Histomonas meleagridis*	(66, 373, 542, 549)
Duck enteritis virus (low virulent)	(524)	**Toxins**	
Hemorrhagic enteritis virus	(433, 466, 582)	Ammonia	(412, 447)
Infectious bronchitis virus	(92, 183, 366, 367, 419, 536)	Cyclophosphamide	(119, 140, 417)
Infectious bursal disease virus	(426, 428, 499)	Iron—parenteral	(64)
Infectious laryngotracheitis virus	(348, 419)	Mycotoxins	
Marek's disease virus	(165)	Ochratoxin	(315, 316)
Newcastle disease virus	(144, 145, 207, 424, 465, 466)	Fumonison/Moniliformin	(344, 345)
Pigeon paramyxovirus 1	(615)	**Physiologic**	
Reovirus	(499)	Age—young	(196, 276, 390)
Turkey coronavirus	(214, 429)	Stress—minimal or severe	(245, 364)
Pigeon circovirus	(482, 500)	Sex—male	(248)
"Stunting syndrome"	(162)	Fast-growing strains	(624)
Bacteria		Obesity	(441)
Bordetella avium	(156, 238, 466, 579)	High antibody response	(210)
Erysipelothrix rhusiopathiae	(549)	High inflammatory response	(42)
Pasteurella multocida	(549, 551)	**Environmental**	(224, 414)
Campylobacter jejuni	(187)	Contaminated water	
Clostridium perfringens (?)	(404)	Dry, dusty conditions	
Mycoplasma gallisepticum	(207, 424)	Feed/water restriction	
M. meleagridis	(393, 435, 465, 507)	Inadequate ventilation	
M. synoviae	(357, 483, 543, 556)	Overcrowding	
Chlamydiophila psittaci	(583)	Poor litter conditions	
Parasites		Temperature extremes	
Ascaridia (larvae)		**Nutrition**	
A. dissimilis	(440)	Hypervitaminosis E	(163)
A. galli	(461)	Hypervitaminosis A	(164)
		Vitamin A deficiency	(164)
		Other	
		Trauma (bruising)	(217)

Table 18.5. Factors known or suspected to decrease host susceptibility to *Escherichia coli* infections in poultry. See also (28).

Factor	Nutrition
Immunity	Protein
Passive	Vitamin A
Active	Vitamin C
Immunostimulants	Vitamin D
Phagocyte priming	Vitamin E
Physiologic	ß-carotene
Genetics	High iron—oral
Age—older	Selenium
Sex—Female	
Moderate stress	
Socialization	
Deoxycorticosterone	
Short heat stress	
Intestinal flora	

selection for resistance would be feasible, but that heterosis was either negative or negligible, making test crossings essential (26, 27). Evaluation of 4 broiler strains for their response to endotoxin revealed differences in weight gain and changes in bone breaking strength. Response of the strains to endotoxin with regard to changes in liver size and bone breaking strength were highly correlated with mortality prior to endotoxin exposure. Strains that had a greater loss of bone breaking strength because of inflammation were more likely to have higher overall mortality (249, 384). Variations in physiological and behavioral responses to endotoxin also occur among egg-laying strains (81).

Transmission, Carriers, Vectors

Escherichia coli are present in the intestinal tracts of most animals and shed in the feces, often in high numbers. Direct or indirect contact with other animals or feces can introduce

new strains into the poultry flock. Free-living birds are especially important because they are colonized with strains that are already adapted to avian species. *E. coli* is readily isolated from free-living waterfowl, especially ducks (90, 153, 154), and passerine birds, especially European starlings (173, 398). A particularly virulent O86 APEC, recently reclassified as *E. albertii* (442), caused significant mortality in free-living finches in Britain, but has yet to be found in poultry (159, 460).

Trachea, ceca, and oviduct of recovered laying hens remained persistently colonized for at least 21 weeks after either oral or intra-air sac inoculation with pathogenic *E. coli*. Hens with colonized oviducts continued to lay eggs, of which 2.7% contained the organism. Interestingly, *E. coli* was not isolated from the shell surface, even when the oviduct was heavily colonized (20).

Larval and adult darkling beetles (*Alphitobius diaperinus*) likely contribute to *E. coli* transmission and its spread among poultry houses and farms following consumption of infected larvae or beetles or contact with their feces by the birds (192). Following exposure, larvae and adults were positive for *E. coli* both externally and internally for up to 12 days. The organism was shed in their feces for 6–10 days. Chicks became colonized with *E. coli* after eating infected larvae or adults, but the number of infected chicks was higher when the birds ate larvae (372).

Adult houseflies (*Musca domestica*) serve as mechanical vectors of *E. coli*, and fly larvae develop digestive tract infections with *E. coli* following ingestion of bacteria-laden material. Ingested bacteria can serve as a food source for flies; larvae have a high survival rate when experimentally fed solely *E. coli*. Once infected, *E. coli* persists through the pupal and adult stages, making it possible for flies to serve as a reservoir for virulent strains (487, 488). The gut of the housefly provides a suitable environment for horizontal transfer of *E. coli* antibiotic resistance and virulence genes (463).

Incubation Period

The time between infection and onset of clinical signs varies with the specific type of disease produced by *E. coli*. The incubation period is short, generally between 1 and 3 days, in experimental studies in which birds are exposed to high numbers of virulent organisms. In the field, it is more common to see colisepticemia 5–7 days after infection with a predisposing agent such as infectious bronchitis virus in chickens or hemorrhagic enteritis virus in turkeys.

Clinical Signs

Clinical signs vary from inapparent to total unresponsiveness just prior to death depending on the specific type of disease produced by *E. coli*. Localized infections generally result in fewer and milder clinical signs than systemic diseases. Coliform cellulitis is typically not detected until the birds are processed. Lameness and retarded growth are seen in birds with skeletal lesions that develop as a sequel to sepsis. Affected birds are typically undersized for the flock and found at the ends of the house, along the side walls, or under feeders or waterers. They may be victims of persecution ("cannibalism") by other birds. When joints or bones of 1 leg are affected, birds walk with a characteristic hopping motion to keep weight off the affected leg. Birds with lesions in both legs are either nonambulatory or have great difficulty in standing and walking. When the thoracolumbar spine is affected, the birds have an arched back, sit on their hocks, and bear little or no weight on their feet. Occasionally they will sit back on their tail and hocks with their feet elevated off the ground. Birds with chronic lameness have caking of droppings around the vent and on abdominal feathers. Feces are green with white to yellow urates because of anorexia and dehydration. Young birds with omphalitis and infected yolk sacs also may have difficulty in walking because of abdominal distention, which alters weight distribution and impairs balance.

Birds with colisepticemia are often terminally moribund or very lethargic. Decreased water consumption is associated with a poor prognosis. Severely affected individual birds are unresponsive when approached, do not react to stimuli, and are easily caught and handled. They sit with their eyes closed in a hunched position with drooping of the head, neck, and wings. The beak may be inserted into the litter to support the head. Dehydration is indicated by dark dry skin, which is especially noticeable in the shanks and feet. Dehydrated young chicks typically have prominent raised folds of skin along the medial and lateral sides of the shanks and toenails that appear black. Although, technically, death is not a clinical sign, this may be the main indication of an outbreak of colibacillosis in a flock.

Clinical signs of predisposing or compounding factors often are seen concurrently with signs of *E. coli* infections.

Morbidity and Mortality

Both morbidity and mortality are highly variable, depending on the type of disease produced by *E. coli*. It is probable that most, if not all, commercial flocks experience some degree of morbidity, mortality, or condemnation due to *E. coli* infections.

Mortality occurring during the day indicates a more severe disease outbreak than when birds are only found dead in the morning. In flocks with highly virulent colisepticemia, it is occasionally possible to watch a bird sicken and die within a few hours. A flock that appears clinically normal when examined during the day, but has an excess number of dead birds the following morning, is a common finding in mildly affected flocks. This pattern is typical for egg layer and breeder flocks experiencing coliform salpingitis/peritonitis.

Pathology

Several localized and systemic types of colibacillosis affect poultry. Often the name is based on the tissue(s) affected or disease process (Table 18.6). APEC responsible for different forms of colibacillosis (septicemia, omphalitis, swollen head syndrome) form subgroups with different pathogenic, genotypic, and phenotypic traits (368).

Table 18.6. Classification of the different types of pathological manifestations of colibacillosis (adapted from (34)).

Manifestation
Localized infections
Coliform omphalitis/yolk sac infection
Coliform cellulitis (inflammatory process)
Swollen head syndrome
Diarrheal disease
Venereal colibacillosis (acute vaginitis)
Coliform salpingitis/peritonitis/salpingo-peritonitis (adult)
Coliform orchitis/epididymitis/epididymo-orchitis
Systemic infections
Colisepticemia
Respiratory-origin (air sac disease, chronic respiratory disease, CRD)
Enteric-origin
Hemorrhagic septicemia
Neonatal
Layer
Duck
Colisepticemia sequelae
Meningitis/encephalitis
Panophthalmitis
Osteomyelitis
Spondylitis
Arthritis/polyarthritis
Synovitis/tenosynovitis
Sternal bursitis
Chronic fibrosing pericarditis
Salpingitis (juvenile)
Coligranuloma

Localized Forms of Colibacillosis

Coliform Omphalitis/Yolk Sac Infection. Omphalitis is an inflammation of the navel (umbilicus). In birds, the yolk sac is also usually involved (yolksacculitis) because of its close anatomic relationship to the umbilicus. Infection follows contamination of the unhealed navel with APEC. Fecal contamination of the egg shell and unsanitary conditions in the hatchery are considered the most important sources of infection. Bacteria may be acquired *in ovo* if the hen has oophoritis or salpingitis or via contamination following artificial insemination (223, 390). Yolksacculitis also can result from translocation of bacteria from the chick's intestine or from the bloodstream. In these cases the navel is not affected. Similarly, peritonitis can occur without involvement of the umbilicus.

It is common to recover low numbers of *E. coli* from normal yolk sacs. Between 0.5% and 6% of eggs from normal hens contain *E. coli*. Experimentally inoculated hens may shed *E. coli* in up to 26% of their eggs. Pathogenic strains accounted for 43 of 245 isolates from dead embryos (222). About 70% of chicks with "mushy chick disease" had *E. coli* in their yolk sacs (222). Other types of bacteria also can cause omphalitis, although *E. coli* is most common. *E. coli* and *Enterococcus faecalis* infections accounted for approximately half of the mortality that occurred in layer chicks during the first week after hatching. First week mortality was significantly correlated with total mortality in the flock but not flock uniformity. A variety of *E. coli* genotypes indicated different sources of infection. For good flock performance, first week mortality needs to be less than 1% (445).

Adhesin factors characterizing omphalitis isolates of *E. coli* include type 1 (F) fimbriae in 96%, P fimbriae in 8%, and afimbrial adhesins in 16%. Afimbrial adhesin occurred more frequently in omphalitis isolates compared to isolates from cases of salpingitis, swollen head syndrome, or respiratory disease (308). When genotyped, omphalitis isolates tended to be more similar to commensal isolates than they were to isolates from swollen head syndrome or septicemia (14, 102). A high percentage of *E. coli* isolates from eggs, dead embryos, and chicks that died between placement and 7 days of age possessed the virulence genes *ipaH* (invasion and persistence in cells), *eae* (attaching and effacing lesions), and *cdt* (cell distension and death) compared to other APEC (496).

Some embryos may die before hatching, particularly late in incubation, whereas others die at or shortly after hatching. Surviving infected chicks can be a source of *E. coli* for other chicks in the same hatch (390). The incidence of birds with omphalitis increases after hatching and declines after about 6 days with occasional losses continuing up to 3 weeks. As few as 10 organisms of serotype O1a:K1:H7 caused 100% mortality in day-old chicks following yolk sac injection (525). When birds become infected with low virulent strains there may be no embryo or chick mortality or some may survive, although hatchability, chick livability, and relative yolk weights may be affected (390); the only pathologic finding is retention of infected yolk sacs containing caseated yolk (209).

Swelling, edema, redness, and possibly small abscesses characterize acute inflammation of the navel. The abdomen is often distended and blood vessels are hyperemic (Figures 18.1A, 18.1B). In severe cases, the body wall and overlying skin undergo lysis and are wet and dirty, leading to the term "mushy" chicks or poults. Other nonspecific changes such as dehydration, visceral gout, emaciation, vent pasting, and enlarged gall bladder may be seen. The yolk sac is typically distended because yolk has not been absorbed and inflammatory products have been added. Yolk is abnormal in color, consistency, and smell, and may contain visible exudate. Blood vessels of the yolk sac are often prominent. Chicks or poults with infected yolk sacs that live more than 4 days also may have peritonitis, pericarditis, or perihepatitis, indicating local and systemic spread of the organism from the yolk sac.

Microscopically, the wall of the infected yolk sac is edematous with mild inflammation. There is an outer connective tissue zone adjacent to a layer of inflammatory cells containing heterophils and macrophages, a layer of giant cells, a zone of necrotic heterophils and masses of bacteria, and then the inner, abnormal yolk contents. A few plasma cells may be found in some yolk sacs.

Omphalitis and yolk sac infection have been experimentally reproduced in ducks by exposing eggs to *E. coli* broth cultures. Dipping eggs at 18 days of incubation resulted in a higher

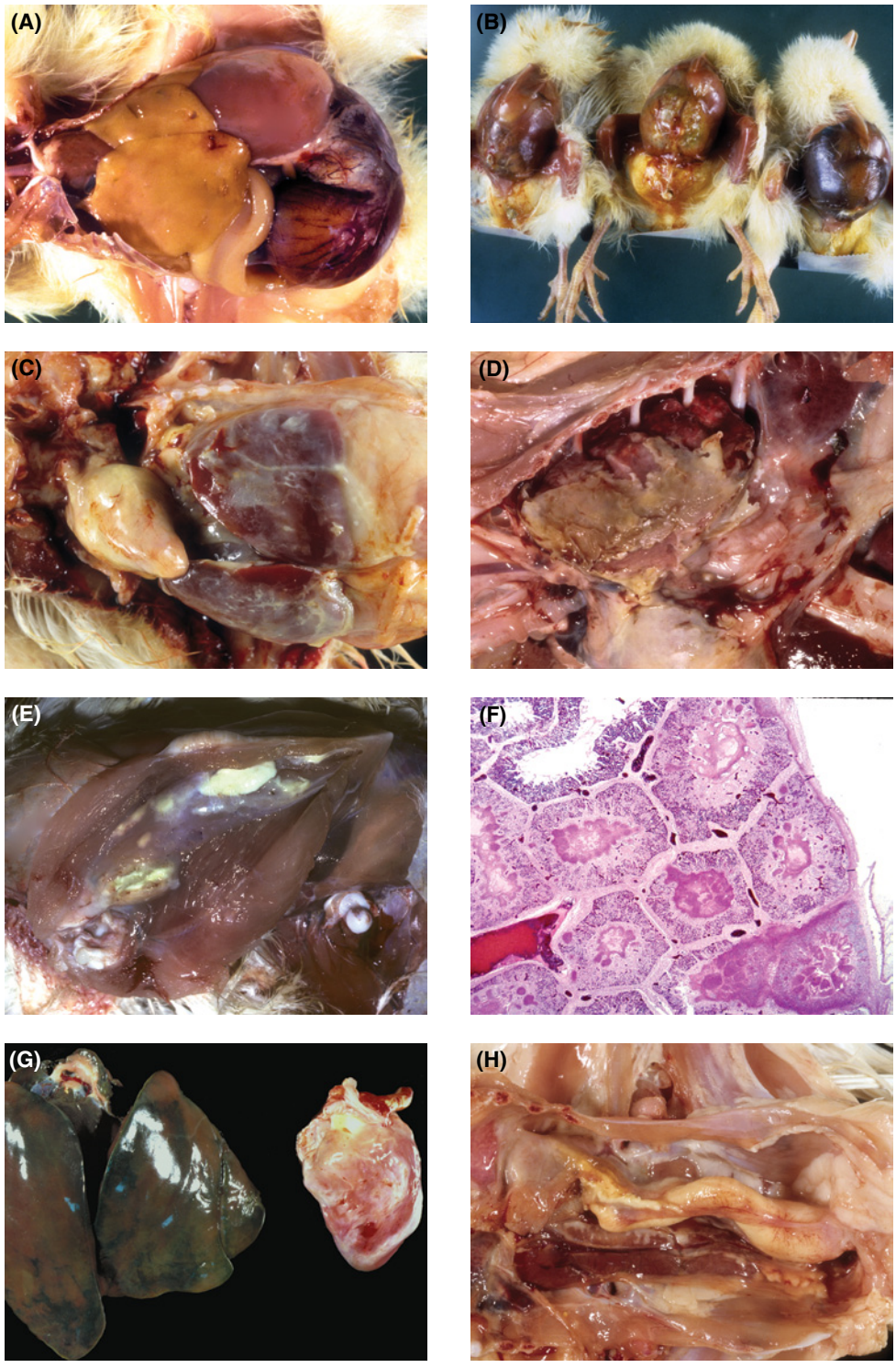

Figure 18.1. Colibacillosis. (A) Yolk sac infection in a 4-day-old leghorn chick. Yolk sac is distended, hyperemic (note prominent vessels), and filled with abnormal brown, watery contents. (B) Omphalitis and yolk sac infection in a group of 3-day-old leghorn chicks. Navels are inflamed and yolk sacs are distended with abnormal contents. (C) Advanced air sac disease in a 20-day-broiler chicken. Polyserositis (pericarditis, perihepatitis, peritonitis, airsacculitis) have occurred as a result of systemic spread of *Escherichia coli*. (D) Pleuropneumonia and airsacculitis in a broiler chicken caused by *E. coli* infection.(E) Experimental colibacillosis in a turkey. Extension of inflammation between superficial and deep pectoral muscles from airsacculitis involving the interclavicular air sac. Detecting this type of lesion is important during inspection at processing. (F) Microscopic appearance of pneumonia caused by *E. coli* in a broiler chicken. Exudate fills the lumen of several affected parabronchi (compare with unaffected parabronchi at the top left of the figure). Exudate has expanded some atria. Some atria have ruptured, permitting extension of the inflammatory process through the air capillary bed into the interstitium. The process involves almost all of 1 lobule with extension to the adjacent pleural surface. ×10. (G) Pericarditis and green discoloration of the liver in a turkey that survived the acute septic phase of colibacillosis. Pericardium is thickened and exudate in the pericardial sac is beginning to undergo fibrosis. Green discoloration of the liver can indicate inflammation elsewhere in the bird, especially in turkeys. (H) Salpingitis in a young bird caused by *E. coli*. This lesion occurs infrequently but is often associated with airsacculitis involving the left abdominal air sac. (Figures A–C courtesy of L. Munger)

incidence of infection than dipping at 1 day. Low brooding temperature or fasting after hatching increased the incidence of infection and mortality (514).

Consequences of yolk sac infection include deprivation of nutrients and maternal antibodies, absorption of toxins, and spread of *E. coli* by extension into the body cavity (peritonitis) or systemically to produce colisepticemia and its sequelae (polyserositis, arthritis). Survivors are usually stunted and do poorly. Birds that survive the acute infection have small, firm, persistent yolk sacs (often referred to as "retained" yolk sacs) that contain inspissated exudate and yolk material. *E. coli* persists in these chronically inflamed yolk sacs and can be isolated from them for weeks to months after hatching. There is some thought that persistence of the organism in the chronically affected yolk sacs may permit it to escape later during periods of increased susceptibility to cause localized or systemic *E. coli* infections, but evidence for this theory is lacking. Adhesions to intestines, especially the tip of the duodenal loop, or other visceral organs are common. Rarely the elongated stalk of the yolk sac will wind around the intestine and cause strangulation.

Coliform Cellulitis (Avian Cellulitis, Inflammatory Process, Infectious Process, IP). Coliform cellulitis is caused by *Escherichia coli* and characterized by sheets of serosanguineous to caseated, fibrinoheterophilic exudate in subcutaneous tissues. Lesions, often referred to as "plaques," are located in the skin over the abdomen or between the thigh and midline. Other colibacillosis lesions, or reduced productivity, occasionally accompany coliform cellulitis (14, 20, 44, 58), but usually lesions are discovered at processing when inspectors open the thickened yellow abdominal body wall of an otherwise normal carcass.

Coliform cellulitis has emerged as a significant disease since its description in 1984 (48) because of increased condemnations, downgrading at processing, and higher labor costs to process affected flocks. Between 1986 and 1996, condemnations for coliform cellulitis increased almost 12-fold in Canada. In 1996, 0.568% of all birds processed and approximately 30% of total condemnations were classified as cellulitis (29). In an Ontario study conducted in 2001, 1.11% of birds processed in federally inspected slaughter plants were condemned for cellulitis (57). Estimated annual losses to the U.S. broiler industry due to coliform cellulitis have increased from $20 million in 1991 to more than $80 million in 1998 (54).

Escherichia coli are the most frequently isolated organisms from cellulitis lesions and the cause of coliform cellulitis in chickens. Other bacteria that have been isolated from cellulitis lesions include *Pseudomonas aeruginosa, Proteus vulgaris, Enterobacter agglomerans, Pasteurella multocida, Streptococcus dysgalactiae, Aeromonas spp., Staphylococcus aureus, Actinomyces pyogenes*, etc.), but they are not considered significant (4, 15, 34, 48, 56, 59). Cellulitis isolates of *E. coli* belong to the same serogroups as those that cause other forms of colibacillosis. They usually produce colicin and aerobactin (46). Virulence properties and molecular characteristics are similar among isolates from cellulitis and colisepticemia lesions and normal birds (16, 24, 35). However, isolates from cellulitis lesions have a greater ability to produce cellulitis in experimentally exposed birds than *E. coli* isolates from airsacculitis lesions or feces of healthy chickens (7, 26, 47). Cellulitis-type and systemic-type strains of avian pathogenic *E. coli* can be selected that cause a predominance of either cellulitis or septicemic lesions, respectively (25). A possible explanation for the high cellulitis prevalence in affected flocks is that cellulitis strains of *E. coli* may have greater capacity to adhere to deep tissue layers (30).

A vacuolating cytotoxin produced by cellulitis *E. coli* isolates is also produced by isolates from chickens with colisepticemia and swollen head syndrome but not by isolates from healthy chickens. The cytotoxin is similar to one produced by *Helicobacter pylori*, except that *H. pylori* cytotoxin is specific for mammalian cells while the avian *E. coli* cytotoxin is specific for avian cells (51).

Initially, isolates of *E. coli* from litter and lesions could not be differentiated based on biotyping, suggesting that litter was the source of *E. coli* in cellulitis lesions (13). However, genotyping has shown that the prevalence of pathogenic *E. coli* in a broiler house is independent of the prevalence of other *E. coli* in the environment (23). DNA fingerprinting identified the presence of endemic populations of specific cellulitis-associated *E. coli* existing in the broiler house environment. These organisms persist for at least 6 months, irrespective of partial or complete cleaning and disinfection, and cause coliform cellulitis in successive flocks (56, 57).

Regional differences in the prevalence of coliform cellulitis emphasize the important roles of environmental and management factors in occurrence of the disease. Increased condemnation rates due to coliform cellulitis during the past 25 years indicate that changes have occurred in either the occurrence or characteristics of risk factors associated with coliform cellulitis. The most notable change during this time has been in the genotype and phenotype of the bird being raised, so it is not surprising that bird-related factors contribute significantly to the increased incidence of scratches and subsequent coliform cellulitis.

Fast-growing, heavy broiler strains are more likely to have an increased prevalence and severity of skin scratches, which predispose to coliform cellulitis (Figure 18.3). Several reasons may explain this association. The strength of the skin in broilers is related to genetics. The lack of association between scratches and abdominal circumference suggests that strain of bird *per se* could be a better predictor than body characteristics (12). Aggressiveness or nervousness of chickens also may be strain dependent. Birds from a more nervous strain could be more active, increasing the chances of being injured or scratched. If aggressiveness is a problem, the source could be farm dependent (e.g., behavioral studies have demonstrated the importance of socialization of the flock by the grower on the birds' behavior) (8).

Rapid growth by modern broiler breeds results in a higher stocking density sooner in the life of the flock, at a time when feathering is not well developed. Poor feathering and crowded conditions could have a significant impact on the

incidence of coliform cellulitis. The major histocompatibility complex affects the likelihood of an individual chicken developing cellulitis, although not the severity of the lesion (36). Commercial broilers with MHC type B21 are more susceptible to cellulitis than those with MHC type B13; however, the severity of lesions was not related to their MHC (355). Breed differences in immune response, feathering, and body conformation are known to exist, but their possible contribution to the occurrence of coliform cellulitis requires further studies.

Feather cover helps to protect the skin from damage. A positive association exists between scratches and poor feathering (10). Although little is known about nutritional and environmental factors that affect feather growth and development, birds kept in warm temperatures tend to feather less rapidly than birds kept in cooler temperatures.

Coliform cellulitis occurs more frequently in males than females (9, 58). The gene responsible for sexing regulates feather growth. Slower feathering males may be more vulnerable to skin injuries because of greater exposure of the skin to potential physical damage. Sex also may contribute to coliform cellulitis because of its association with weight, aggressiveness, or management practices. In addition, production time is longer for roasters than for broilers.

Stocking density plays a dual role as a risk factor. It leads to an increase in skin scratches (10) and stress, but it also contributes by increasing the level of contact between birds. Cellulitis lesions occurred more readily when birds were palpated daily to simulate close contact among birds (34).

Flocks grown on straw were 2.8 times more likely to experience coliform cellulitis than flocks grown on shavings (9). Physically, straw consists of sharp, pointed pieces that may inflict minor injuries to the skin. Straw also may provide a good medium for growth and multiplication of *E. coli* because of its ability to hold more moisture than shavings. Similarly, in Brazil, occurrence of coliform cellulitis was greatest in broilers on *Brachiaria* grass litter compared to corncob, rice shells, or sawdust litter (613). A positive association also exists between the number of flocks raised on the same litter and cellulitis (53). However, this association could not be explained by an increase in litter bacterial load. Furthermore, litter environmental variables (water activity, pH, moisture content, and ammonia levels), as measured in this study, also were not significant. Nevertheless, litter quality should be considered an important factor by those working on reducing this condition in the field. Total down time is negatively associated with coliform cellulitis (i.e., the longer the down time, the lower the incidence of the disease) (1, 53). This supports the hypothesis that the bacterial load in the environment is associated with disease prevalence.

In a prospective study, a positive association between ambient temperature during early grow-out and cellulitis was found. The predictive model, after controlling for other significant variables, indicated a 40%–60% increase in cellulitis as temperatures increased over a range of approximately 60°F (15.5°C) from 29°F (–1.7°C) to 94°F (34.4°C). Low-cellulitis-prevalence flocks would increase from 0.5%–0.8%, while high-prevalence flocks would increase from 1.2%–1.9%. Similar to ambient temperature, increased relative humidity at mid–grow-out correlated with increased occurrence of cellulitis. An increase in relative humidity from 36%–93% was predicted to increase cellulitis from 0.3%–0.9% in low-prevalence flocks and from 1%–1.9% in high-prevalence flocks (53).

A positive association was observed between coliform cellulitis and feed company in a prospective study (9). The effect of nutrition on the pathogenesis of the disease is not well known. Amino acid levels in the feed may be important. Feed deficient in cysteine and methionine can cause nervousness and affect feathering (45, 52). A relative deficiency occurs in feeds with high energy to total protein ratios. High-energy feeds also may contribute to coliform cellulitis by increasing fat deposition in the skin, which may result in the skin being more susceptible to scratches and injuries (52).

Occurrence of coliform cellulitis was higher in vegetarian broilers compared to broilers fed feeds containing animal products. Condemnation rates for birds fed a standard diet, which contained growth promotants, antibiotics, and anticoccidials, was substantially lower (0.26%) than for birds fed a vegetarian or organic feed without additives (1.18%) (22).

Providing vitamin E at 300 mg/kg or vitamin A at 60,000 IU/kg improved the resistance of 6-week-old broilers against *E. coli* infection (55). Supplementation with vitamin E had a variable impact on development of coliform cellulitis. Intermediate levels were superior to both lower and higher levels of the vitamin (33). Birds fed both vitamin E at 48 IU/kg and a zinc-protein complex at 40 ppm of zinc decreased the occurrence of coliform cellulitis (43). Improved wound healing and immune system potentiation by the supplements were considered responsible for the beneficial effect.

Older chickens are more likely to develop lesions of cellulitis following inoculation of scratches or subcutaneous injection than young chickens, which tend to develop systemic disease and experience high mortality (17, 26, 27, 31, 39, 41, 47). Recently, a case in quail was described (1). Cellulitis in turkeys is more similar to gangrenous dermatitis and differs from coliform cellulitis in chickens (87).

Cellulitis lesions are primarily unilateral and located on the abdomen or thigh. Skin color varies from normal to yellow or red-brown, and the skin may be swollen at the site of inflammation (Figure 18.3). The size of the lesion normally varies between 1 and 10 cm (14). Scratches and scabs on the skin overlying the lesions often can be identified (Figure 18.4). Beneath the skin, there is subcutaneous edema, exudate, and muscle hemorrhage. A fibrinous to caseous plaque between the muscle and subcutis is the characteristic lesion (Figure 18.2H).

Lesions develop rapidly. Exudate is visible as early as 6 hours post infection, and the caseous plaque could be experimentally produced within 18–24 hours post infection. Rapid lesion development suggests that events occurring late in the life of the flock could be important in the development of lesions found at processing (17, 39). When birds were inocu-

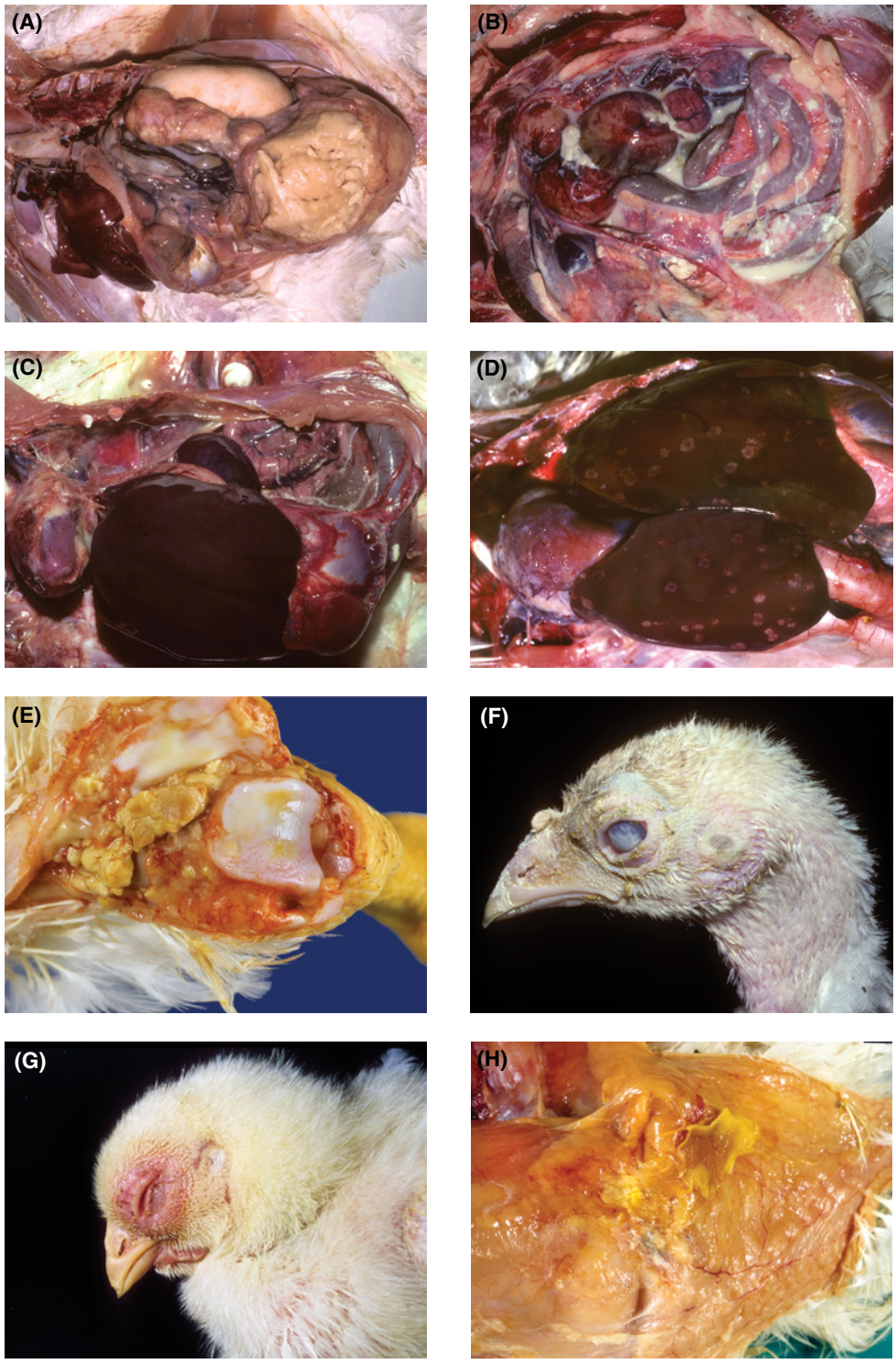

Figure 18.2. Colibacillosis. (A) Large caseated masses distending the oviduct of this mature laying hen are characteristic of salpingitis caused by *Escherichia coli*. Salpingitis in the adult female most likely results from an ascending infection from the cloaca. (B) Goose breeder with acute peritonitis. Yolk was demonstrated in the peritoneum and *E. coli* was isolated. (C) Acute *E. coli* septicemia in a turkey. Spleen is markedly enlarged and congested. Note that it is approximately the same size as the proventriculus. Liver is also enlarged and congested, and there is evidence of early pericarditis and peritonitis. (D) Experimental colibacillosis in a turkey. Liver from a bird that survived the acute septicemic phase has multiple pale foci, which were determined microscopically to be focal areas of early heterophilic, granulomatous hepatitis. (E) Advanced tenosynovitis/arthritis involving the hock joint and flexor tendons of a lame commercial broiler. *E. coli* and *Staphylococcus* spp. were isolated from the lesion. (F) Panophthalmitis affecting the eye of a turkey that survived an earlier episode of colisepticemia. This lesion is uncommon and typically unilateral. The organism can be isolated from the eye for an extended period after it is no longer present in other tissues. (G) Swollen-head syndrome in a broiler chicken. There is conjunctival inflammation and periorbital swelling due to cellulitis. Evidence of exposure to high ammonia levels and infection with infectious bronchitis virus and *E. coli* were found in this flock. (H) Avian coliform cellulitis (inflammatory process). Subcutaneous yellow, caseous exudate is present over the abdomen of this affected bird. (Figures E and G courtesy of L. Munger)

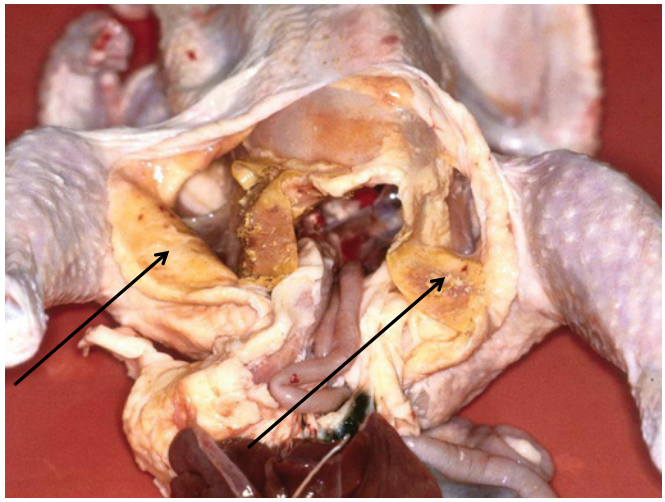

Figure 18.3. Coliform cellulitis lesion at processing. A caseous sheet of exudate, often referred to as a plaque, is located in the subcutaneous tissues beneath an area of thickened, yellow discolored skin (arrows).

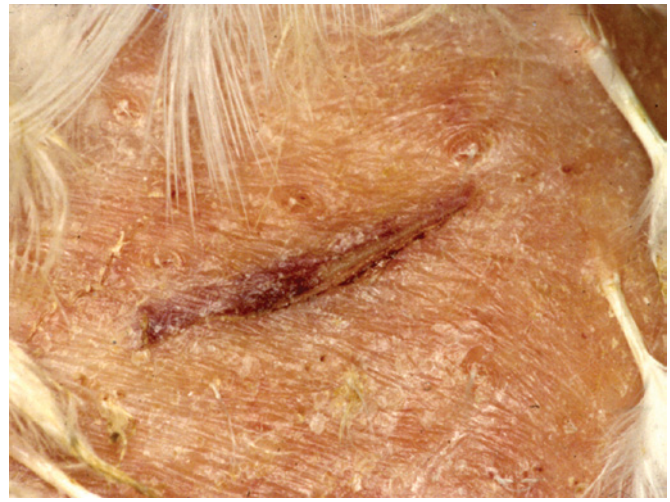

Figure 18.4. Five-week old broiler chicken with a skin laceration (scratch). Scratches often go unrecognized, but are the most important risk factor for development of coliform cellulitis. Taking measures to reduce scratches reduces cellulitis condemnations at processing.

lated experimentally with *E. coli* strains isolated from coliform cellulitis lesions, the highest percentage of birds developing typical lesions had been challenged only 3 days prior to processing (38). Lesions were still present 3 weeks post inoculation (39).

High coliform cellulitis condemnation rates are not of hatchery origin. Scratching the dorsal skin surface of older birds and inoculating them with *E. coli* produces lesions referred to as type I coliform cellulitis, which have been thought to originate from navel infections in the hatchery. Bacteria and inflammatory exudate gravitate from the area where it originates to around the navel, producing the so-called type I lesion (40). In Canada, only 1.7% of coliform cellulitis lesions were consistent with a primary navel infection (14).

Experimental exposure of young chickens to cellulitis isolates of *E. coli* results in septicemia, death, or marked stunting, indicating that most birds affected by *E. coli* in the hatchery would either die or be culled before reaching the processing plant (26, 27, 41). No association between cellulitis and the source of eggs, age of parent flocks, total bacterial count, and coliform count in the hatchers was found (13).

Skin trauma, especially scratches, provides the main portal of entry into the host for specific cellulitis-type *E. coli* present in the litter. Applying bacteria to feather follicles from which the feather had been pulled did not cause coliform cellulitis. Oral feeding or swabbing the navel of young chickens did not produce cellulitis but did result in mortality, depressed growth, and other types of colibacillosis, which was dose dependent (27). The disease is reproduced readily by swabbing damaged skin with broth cultures or subcutaneous inoculation (17, 26, 27, 31, 39, 41, 47).

When a fast-growing strain of broiler chicken was compared to a strain of leghorns, the broiler strain was more predisposed to cellulitis because of an inferior first line of defense of their skin. In the broilers, wound-healing was slower, lesions were more severe and covered a larger area, and mobilization and functionality of phagocytic cells were inferior (42).

Usually, an affected bird has only skin lesions, but concurrent lesions of systemic colibacillosis occasionally can be found, suggesting that cellulitis may result from systemic spread or, conversely, that localized lesions in the skin can be a source for systemic disease. The latter is inversely correlated with age (i.e., the younger the bird, the more likely it is to develop systemic disease) (17, 26). Lesions have been correlated with other categories of condemnation in which *E. coli* would be expected to play a significant role (septicemia, airsacculitis, etc.) (13, 14, 16, 20, 58).

A positive association between cellulitis and ascites has been shown (13, 58). Ascites is a common condition in broiler chickens characterized by an abnormally large abdomen. Because most cellulitis lesions are located in the abdominal area, it may be that ascites is a biological predisposing factor for cellulitis. It also is possible that both conditions may share common risk factors such as rapid growth.

Valgus-varus leg deformity, characterized by lateral or medial deviation of the distal tibiotarsus with a corresponding deviation of the tarsometatarsus, occurred more frequently in carcasses condemned for cellulitis (13, 58). Valgus-varus deformity is considered to be the most frequent cause of leg weakness and lameness in broiler chickens (49). However, the association between valgus-varus deformity and coliform cellulitis needs to be interpreted with caution due to potential confounding with sex and breed. Most valgus-varus deformity affects male birds, and the incidence of coliform cellulitis can vary with breed. Birds with valgus-varus leg deformity spend more time lying on the floor (28), which results in greater

contact exposure between the skin and the *E. coli* present in the litter. Prolonged resting by lame birds also may result in skin damage as other birds tread on them (13).

Cellulitis lesions are identified readily at processing, normally making it possible to use condemnation results to assess control strategies. However, an epidemiological study in Ontario has found that 30% of the variation in cellulitis prevalence depended on the slaughter plant (57). Therefore, the possibility of misclassification may exist, and should be considered in an investigation. Lesions should be cultured aseptically to determine the presence of *E. coli*. There is no treatment for coliform cellulitis, and eradication of the disease is not possible because of the ubiquitous occurrence of *E. coli*. Advances in the development of immunoprotective agents or immunomodulators suggest that a molecular approach to cellulitis control is possible, although not currently practical or economical (2). However, by carefully managing the environment and nutrition of the modern, fast-growing, heavy broiler, it is possible to substantially reduce the incidence and impact of the disease. A key aspect of any control strategy is its cost-benefit. Adequate monitoring to ensure implementation and compliance of control strategies is needed to determine what is feasible. The following are some recommendations.

Very early lesions consist mainly of serosanguineous fluid in contrast to the caseous lesions observed after 24 hours post infection. A high prevalence of acute lesions indicates that events occurring just prior to or during transportation should be investigated, especially if at least 10 hours exists between load-out and processing. In contrast, a majority of chronic lesions indicates the need to focus on earlier events that occurred during the grow-out period.

Problem flocks should be compared with flocks that did well during the same time period within the same company and determine the risk factors for each type of flock. Any management or environmental factors that affect the bird's resistance or contribute to skin scratches should be identified. Special attention should be paid to stocking density, feeder and waterer space (effective space—i.e., in some houses, the space is available, but the drinkers or feeders are not all functional), migration fencing, type of litter, quality of litter, and feed restriction and lighting programs. Any intervention must first focus on improving the environment of the birds. This includes good sanitation to reduce the bacterial load of the environment.

Swollen Head Syndrome. Swollen head syndrome (SHS) is an acute to subacute cellulitis involving the periorbital and adjacent subcutaneous tissues of the head (Figure 18.2G). SHS was first described in broilers in South Africa associated with *E. coli* and an unidentified coronavirus infection (400). The disease has subsequently been described in most intense poultry-producing areas of the world. The disease also affects turkeys and guinea fowl (350, 580).

Swelling of the head is caused by inflammatory exudate beneath the skin that accumulates in response to bacteria, usually *E. coli*, following upper respiratory viral infections (e.g., avian metapneumovirus, infectious bronchitis virus). Ammonia aggravates the disease (134). The portal of entry is considered to be the conjunctiva or inflamed mucous membranes of the sinuses or nasal cavity (421). Possible infection via the Eustachian tube also has been suggested (134). Microscopic lesions include fibrinoheterophilic inflammation and heterophilic granulomas in the air spaces of the cranial bones, middle ear, and facial skin. Lymphoplasmacytic conjunctivitis and tracheitis with formation of germinal centers also have been observed (264).

Although the pathogenesis of SHS has not been established, conjunctival-associated lymphoid tissue inflamed from virus infection and/or ammonia irritation may serve as the site through which bacteria gain access to subcutaneous tissues. Periorbital inflammation is typically seen early in the disease and hyperplastic lymphoid tissue has been shown to be a site where *E. coli* penetrates mucosal surfaces (207). Scarifying the conjunctival mucosa and instilling a pure culture of *E. coli* (400), or inoculation of *E. coli* into submucosal or subcutaneous tissues (422), will reproduce the disease. Intranasal inoculation of avian metapneumovirus and *E. coli* failed to reproduce the disease (422). Swollen head syndrome did not occur when day-old chicks were inoculated supraconjunctivally with either avian metapneumovirus or *E. coli*, but they did develop clinical disease, which was most severe when the chicks received both agents (9).

Escherichia coli isolates from SHS cases possess several virulence factors including fimbrial adhesins, colicin production, aerobactin, and complement resistance. In general, SHS isolates have virulence attributes similar to isolates from cases of septicemia (102), except colicin production and iron-acquisition siderophores were more frequent in SHS isolates. The colicins produced by SHS strains often differed from ColV (101). The majority of strains were motile, but presence of K1 capsule was infrequent (452). Similar results were found in a subsequent study in which SHS isolates were more similar to isolates that cause septicemia than isolates that cause omphalitis or commensal isolates except type 1 and curli fimbriae, and temperature-sensitive hemagglutinin (*tsh*) were more frequent in SHS isolates (14). A transferable 60 MDa plasmid from an SHS *E. coli* isolate contained genes for cell adhesion, colicin production, and *tsh* (546). Adhesin factors occurring in SHS *E. coli* isolates included type 1 in 94% and P fimbriae in 28%. The P-fimbrial adhesin factor occurred more frequently in SHS isolates compared to isolates from cases of salpingitis, omphalitis, or respiratory disease (308). A unique Shiga toxin (VT2y) (510) that may be involved in the pathogenesis of SHS was identified in a high percentage of SHS *E. coli* isolates (455). Additionally another toxin, similar to one produced by *Bacillus cereus* that is highly lethal for mice following injection, was identified in SHS isolates (509).

Diarrheal Disease. Primary enteritis is a common manifestation of *E. coli* infections in mammals including humans, but is considered rare in poultry. Diarrhea results from infections

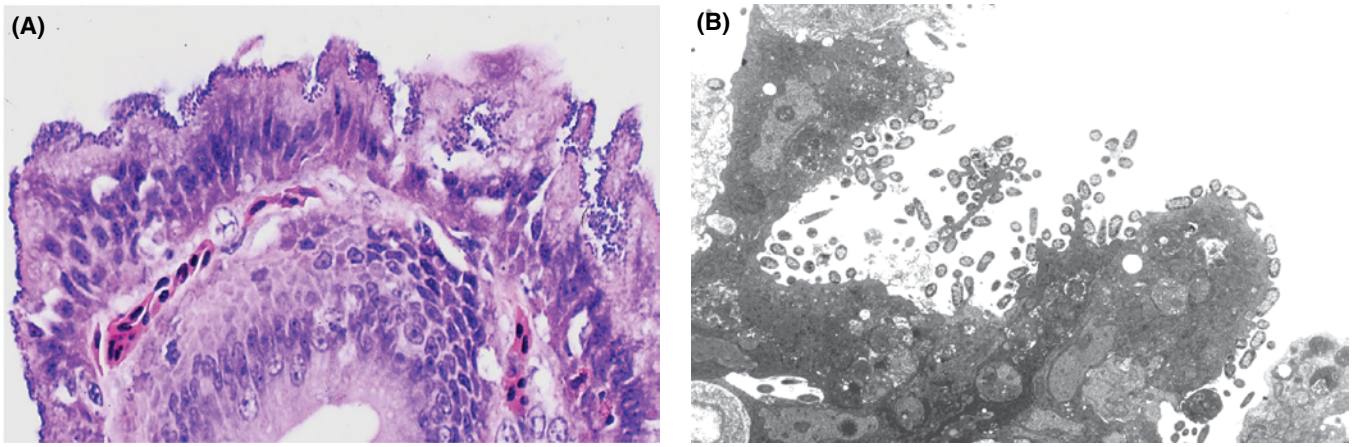

Figure 18.5. Attaching effacing *E. coli* bind tightly to the apical surface of enterocytes, destroying the normal brush border. (A) On light microscopy the surface epithelium appears irregular and numerous bacteria can be seen attached to affected cells. (B). By electron microscopy the organisms characteristically occupy small pits in the cell surface or are on pedestals. The number of bacteria and extent of brush border effacement is apparent. (Courtesy of H.L. Shivaprasad)

with enterotoxigenic (ETEC), enterohemorrhagic (EHEC), enteropathogenic (EPEC), or enteroinvasive *E. coli* (EIEC); each type possesses certain virulence factors that determine the characteristics for each type of enteric disease (see Virulence Factors). EHEC and EPEC strains produce attaching and effacing lesions on intestinal mucosal surfaces. Collectively, these strains are called attaching and effacing *E. coli* (AEEC). Similar lesions are also produced by the closely related species *E. albertii* (442, 443). Intestinal *E. coli* in poultry have been poorly studied, except as commensal strains for comparison with APEC or reservoirs of virulence genes that occur in human strains, so our knowledge of the role that *E. coli* may play in intestinal disease is limited.

Enterotoxigenicity caused by ETEC strains is uncommon in APEC. Most surveys for heat-stable and heat-labile enterotoxins either fail to find any positive isolates or identify only a few (146). ETEC that elaborated toxins capable of causing fluid accumulation in ligated intestinal loops of chickens were recovered from chickens with diarrhea (7, 293), and an O15 APEC strain that produced heat-labile toxin II was isolated from ostrich chicks experiencing severe diarrhea and high mortality (430).

Natural and experimental infections with AEEC or presence of *eae* gene have been reported in chickens (169, 296, 314, 496, 550, 553), turkeys (449, 450, 550), pigeons (594), ducks (550), psittacines (520), and other avian species (159, 320). Infections with infectious bursal disease virus in chickens and adenovirus infection in pigeons were considered possible predisposing factors to AEEC infection. In turkey poults, coinfection of EPEC and turkey coronavirus (TCV) resulted in severe stunting and very high mortality (214). Clinical disease was most severe when poults were infected with TCV prior to inoculation with EPEC (449). Ten of 12 commercial turkey flocks experiencing high mortality because of poult enteritis mortality syndrome (PEMS) were infected with EPEC, confirming the importance of natural EPEC infection as a cause of mortality in young turkeys (449).

Birds infected with AEEC may be clinically normal or have diarrhea and be dehydrated. In clinically affected birds, the intestines are pale and distended with fluid, which may contain visible flecks of mucus and exudate. Ceca are often the most obviously affected part of the digestive tract. They are typically distended with pale brown fluid and gas. Bacteria intimately attach to the surface of enterocytes, causing effacement of microvilli, pitting, and pedestal formation, which are best seen by electron microscopy (Figure 18.5). Lesions are most common in the ceca. Organisms are readily identified in tissue sections using Giemsa stain or by immunohistochemical methods.

Experiments to define a role for *E. coli* in malabsorption syndrome of chickens have not successful (391, 539, 540). In contrast, specific strains of *E. coli* have been associated with PEMS (140, 141). Turkey astrovirus, an agent involved in PEMS, impairs macrophage function, which could explain the enhanced susceptibility of affected poults to secondary bacterial infections such as colibacillosis (476).

Diseases resulting from infection with EIEC have not been described but are likely, especially in the case of neonatal septicemia. EIEC possess genes such as *ipa*, which encodes a virulence factor that provides the organism with the ability to penetrate and survive within cells. The most frequently identified virulence gene in *E. coli* isolated from eggs, dead embryos, and chicks with omphalitis/yolk sac infections was *ipaH*. Most of the *ipaH*$^+$ isolates (62 of 80; 77.5%) came from liver or yolk sac of chicks that died between 3 and 7 days of age, which corresponded to a period of increased mortality (496). Further characterization of the *ipaH*$^+$ isolates revealed properties that did not match those of typical EIEC and the existence of specific EIEC clone complexes among avian isolates. Cell invasion was confirmed *in vitro* (496).

Venereal Colibacillosis (Acute Vaginitis). Venereal colibacillosis is an acute and frequently fatal vaginitis that affects

turkey breeder hens shortly after they are first inseminated. Puncturing the hymen of young turkey hens can lead to a severe localized *E. coli* infection characterized by vaginitis, cloacal and intestinal prolapse, peritonitis, egg binding, and internal laying. The affected mucosa is markedly thickened, ulcerated, and covered with a diphtheritic, caseonecrotic membrane, which causes obstruction of the lower reproductive tract. The marked tissue changes can lead to egg binding. The upper oviduct is grossly and histologically normal. Flocks can have losses of up to 8% because of increased mortality and culling. Egg production is decreased and there is an increased number of cull eggs due to small size. No other infectious agents have been identified as contributing to the disease (174). Anecdotal reports indicate a similar disease can affect young broiler breeders as they come into production.

Coliform Salpingitis/Peritonitis/Salpingoperitonitis (Adult). Inflammation of the oviduct caused by *E. coli* results in decreased egg production and sporadic mortality. It is one of the most common causes of mortality in commercial layer and breeder chickens (56, 57, 292) and also affects other female birds, especially ducks, geese (55), and quail. Accumulations of caseating exudate in the body cavity resemble coagulated yolk, which is the reason for the common name egg peritonitis. Yolk peritonitis is a mild to moderate diffuse peritonitis without exudate resembling coagulated yolk that results from free yolk in the body cavity. Yolk peritonitis is usually associated with bursting atresia that occurs during acute ovarian regression. Marked exudation, extensive inflammation, and positive cultures characterize coliform peritonitis and serve to distinguish it from yolk peritonitis.

Salpingitis and egg binding may occur concurrently, which can cause confusion because both result in an obstructive mass within the oviduct. If an egg is not grossly visible, cutting through the mass in the oviduct and finding a shelled egg in the center indicates egg binding.

Infection occurs when *E. coli* ascends the oviduct from the cloaca (576). Injecting large (10^9) numbers of bacteria into the reproductive tract reproduces the disease. Mucosal infections with viruses (e.g., infectious bronchitis virus) or mycoplasmas also may predispose a bird to salpingitis. *Mycoplasma synoviae* infection increased the occurrence of coliform peritonitis (483). Co-infection with *E. coli* and *Tetratrichomonas* occurred in Pekin duck breeders with salpingitis (97). Heavy egg production and associated estrogenic activity predispose hens to salpingitis by relaxing the sphincter between the vagina and cloaca. Spread of *E. coli* to the oviduct from an airsacculitis is also possible, but this form of salpingitis occurs more frequently in young birds as part of a systemic infection.

Isolates of APEC from birds with salpingitis have similar virulence characteristics to those that cause airsacculitis. In a study of 30 isolates, 11 belonged to serogroups O2 and O78, while 10 were untypeable. Twenty-seven of the isolates were of either high or intermediate virulence in a day-old chick assay. Most isolates possessed type 1 fimbriae and adhered to oviductal epithelium, especially from adult breeders, and they had the ability to acquire iron when grown in iron-deficient medium. Isolates were resistant to serum from young breeders, but sensitive to serum from older breeders (389). In a separate study, type 1 fimbriae also were identified in 49 of 50 isolates from broiler breeders with salpingitis; few isolates possessed other fimbrial types (308). Presence of type 1 fimbriae can be considered a characteristic of APEC salpingitis isolates.

Escherichia coli was isolated from the cloacae of clinically normal birds and dead birds with peritonitis, and from the oviducts and peritoneal cavities of birds with peritonitis, but not from these sites in clinically normal birds. *E. coli* from the oviducts and peritoneal cavities of each of the dead birds had identical characteristics. Isolates from 1 flock belonged to serogroup O78, phyologentic group A, and contained virulence genes *iroN*, *sitA*, *iutA*, *tsh*, and *iss*. Isolates from a second flock belonged to serogroup 111, phylogenetic group D, and contained virulence genes *iroN*, *sitA*, *iutA*, *traT*, *iss*, and *ompT*. The similarity among isolates from hens in each flock indicated that a single clone of *E. coli* affected that specific flock (576). Molecular characteristics of *E. coli* isolated from layers with salpingitis, peritonitis, and salpingoperitonitis (292) also were clonal and possessed several of the same virulence factors including *iss*, *sfa*, *tsh*, *iucC*, *ibeA*, and *sitA* (568). Specific clones caused colibacillosis in free-range layer flocks, indicating they were primary pathogens that did not require predisposing factors to cause disease (446).

In chronic cases the oviduct is markedly distended and thin-walled with single or multiple masses of caseous exudate in the general form of the oviduct (Figure 18.2A). The mass of exudate may expand to the point that it fills most of the body cavity (107). Rupture of the oviduct is possible. Exudate is laminated; often contains a central egg, shells, and/or membranes; and is malodorous. Spread of the organism into the body cavity through the compromised oviduct wall or the open end of the infundibulum leads to concurrent peritonitis, which is termed salpingoperitonitis when there is involvement of both the oviduct and peritoneum. Peritonitis in the absence of salpingitis also can occur, but is uncommon. Acute cases have less exudate in the oviduct or peritoneum that tends to be soft and not as caseated (Figure 18.2B). Affected birds are incapable of laying eggs although they typically continue to ovulate. Repeated ovulations and albumen secretion are responsible for the laminated appearance of the oviductal masses. Abdominal laying and misovulated ova may accompany salpingitis and contribute to peritonitis.

Microscopically, the tissue reaction in the oviduct is surprisingly mild in view of the marked gross lesions. It primarily consists of multifocal to diffuse heterophil accumulations subjacent to the epithelium and caseous exudate in the lumen, which often contains bacterial colonies. Lymphoid foci develop in the mucosa with time and indicate chronicity.

Coliform Orchitis/Epididymitis/Epididymo-Orchitis. An ascending *E. coli* infection of the male reproductive tract, analogous to

that resulting in salpingitis in the hen, occurs infrequently in roosters. Testicles are swollen, firm, inflamed, irregularly shaped, and have a mosaic of necrotic and viable tissue when opened. Heavy growth of *E. coli* can be obtained from the testicle and epididymis (388).

Systemic Forms of Colibacillosis

Colisepticemia. Presence of virulent *E. coli* in the bloodstream defines colisepticemia. Virulence and number of organisms balanced against efficacy of host defenses determine duration, degree, and outcome of the disease, as well as the pattern and severity of lesions (470, 471). Colisepticemia progresses through the following stages: acute septicemia, subacute polyserositis, and chronic granulomatous inflammation (82). While lesions are typical of colisepticemia, other bacteria capable of producing septicemia also can cause similar changes. Characteristic features of colisepticemia at necropsy are tissues that develop a green discoloration following exposure to air and a characteristic odor, possibly related to indole produced by the organism. The bursa of Fabricius is often atrophic or inflamed as a result of colisepticemia. It should not be interpreted that a small bursa is evidence of a prior immune-suppressing disease such as infectious bursal disease (128, 418, 420).

Pericarditis is common and is a characteristic of colisepticemia. It is usually associated with myocarditis, which results in marked changes in the electrocardiogram (205), often before gross lesions appear. Vessels in the pericardium become increasingly prominent because of hyperemia, and the pericardium becomes cloudy and edematous. Initially fluid and soft masses of pale exudate accumulate within the pericardial sac followed by fibrinous exudate (Figure 18.1C). Exudate can be seen loosely adhering to the epicardium when the pericardial sac is opened. As the disease progresses exudate increases, becomes more cellular (fibrinoheterophilic), and undergoes caseation. The pericardial sac adheres to the epicardium with chronicity.

Microscopically, the same progression of lesion development is seen. Serous and serofibrinous exudate is seen initially followed by increasing numbers of heterophils and subsequently macrophages. Within the myocardium, particularly close to the epicardium, there are accumulations of lymphoid cells and by 7–10 days there also are many plasma cells. Subsequently, exudate in the pericardial sac undergoes organization (Figure 18.1G), which, in survivors, eventually results in constrictive pericarditis and liver fibrosis due to chronic passive congestion. Cardiac lesions reduce arterial blood pressure from a norm of about 150 mmHg to about 40 mmHg just before death.

Several distinct clinical forms of colisepticemia can be distinguished depending on how the organism gains access to the circulation and the age and type of bird.

Respiratory-Origin Colisepticemia. Respiratory-origin colisepticemia affects both chickens and turkeys and is the most common type of colisepticemia. *E. coli* gains access to the circulation following damage to the respiratory mucosa by infectious or noninfectious agents (183, 201). Infectious bronchitis virus (IBV) and Newcastle disease virus (NDV), including vaccine strains, mycoplasmas, and ammonia, are the most common predisposing agents. Avian metapneumovirus infection increases susceptibility of turkeys to colisepticemia (9, 272, 578, 580). Severity of the resulting disease, which is commonly referred to as air sac disease, chronic respiratory disease (CRD), or multi-causal respiratory disease (238), is directly related to the number of agents that are involved. A diversity of *E. coli* serotypes can be identified in a disease outbreak. Those in the tissues are usually different from those in the intestinal tract of the same bird but can be found in the intestinal tracts of other birds and the environment.

Susceptibility is increased when only IBV or NDV infection occurs. Five days after administration of a vaccine strain of NDV, clearance of aerosol-administered *E. coli* is reduced. Microscopically, 3–8 layers of immature, nonciliated cells replace the pseudostratified, columnar epithelium of the trachea (157). Mixed IBV-*E. coli* infections are more severe than those caused by either agent alone (419, 536). Antibodies against *E. coli* produced by chickens infected with infectious bursal disease virus and/or IBV had a significant decrease in opsonizing ability compared to antibodies produced by normal chickens. Reduced opsonization of the organism resulted in decreased macrophage function, which may help explain the frequent infection with *E. coli* that follows IBV infection (428).

Mycoplasmal infection increases susceptibility to *E. coli* about 12–16 days post inoculation, and susceptibility persists for at least 30 days. Co-infection with IBV or NDV in addition to mycoplasma further decreases resistance to *E. coli* and the period of increased susceptibility begins earlier and persists longer.

Inhaled coliform-contaminated dust has been implicated as one of the most important sources for infecting air sacs of susceptible birds. Exposure to chicken-house dust and ammonia results in deciliation of the upper respiratory tract of birds (412, 447), permitting inhaled *E. coli* to colonize and cause respiratory infection.

Lesions are prominent in respiratory tissues (trachea, lungs, air sacs), pericardial sac, and peritoneal cavities, and are typical of the subacute polyserositis stage of colibacillosis (82, 471) (Figures 18.1C, 18.1D, 18.1F). Infected air sacs are thickened and often have caseous exudate on the respiratory surface. Microscopically, the earliest changes consist of edema and heterophil infiltration. Mononuclear phagocytes are frequently seen 12 hours after inoculation. Later, macrophages become common, with giant cells along margins of necrotic areas. There is fibroblast proliferation and accumulation of vast numbers of necrotic heterophils in caseous exudate. Bacterial colonies are often present in caseous exudate and contain numerous organisms. *E. coli* colonies have a typical appearance in histologic sections. They are usually circular with concentrated bacilli forming a distinct smooth perimeter with fewer bacilli and spaces centrally. They stain negative with tissue Gram stain. Lesions of predisposing respiratory

disease are usually present in the trachea and lungs and consist of lymphoid follicles, epithelial hyperplasia, and epithelium-lined air passages that may contain heterophils. Pneumonia and pleuropneumonia are more common in turkeys, while chickens usually have pleuritis or pleuropneumonia with less lung involvement. Extension of the disease process into the oviduct from the left abdominal air sac may occur and cause salpingitis in juvenile birds (Figure 18.1H).

Inoculating pathogenic *E. coli* or bacteria-free culture filtrates into the air sac readily reproduces lesions of uncomplicated coliform infection (27, 119). Airsacculitis occurs within 1.5 hours. Bacteremia and pericarditis develop within 6 hours. In birds that survive, lesions are well-developed by 48 hours post inoculation. Most mortality occurs during the first 5 days. Recovery is usually rapid if birds survive the initial infection, although a few with persistent anorexia become emaciated and die. Ask et al. (27) have developed a defined method for determining susceptibility to colibacillosis that is reproducible and has been used to determine the relative innate (genetic) susceptibility of various broiler chicken genotypes to the disease (26).

Enteric-Origin Colisepticemia. Enteric-origin colisepticemia is most common in turkeys. *E. coli* gain access to the circulation and tissues following damage to the intestinal mucosa by infectious agents. The most common predisposing agent is hemorrhagic enteritis virus (433, 466, 582). Usually only 1 or 2 types of *E. coli* are involved in the disease outbreak, and those in the tissues and intestinal tract of each bird tend to be the same.

Lesions are typical of the acute septicemic stage of colibacillosis (82). Affected birds are in good physical condition and often have full crops containing feed and water. The most characteristic lesions are congestion or green discoloration of the liver, marked enlargement and congestion of the spleen, and congested muscles (Figure 18.2C). Microscopically, the spleen is congested with proteinaceous fluid in sinuses and has multifocal necrosis, often containing intralesional bacteria. Fibrin thrombi are present in liver sinusoids and occasionally renal glomeruli. In some cases, multiple, pale foci in the liver are seen. Microscopically, these are initially areas of acute necrosis, but with time they evolve into granulomatous hepatitis in survivors (Figure 18.2D). After a few days birds eventually develop lesions similar to those of respiratory-origin colisepticemia.

Hemorrhagic Septicemia. The hemorrhagic septicemia form of colibacillosis occurs in turkeys and is characterized by generalized circulatory disturbances, discoloration of subserosal fat, bloody fluid on serosal surfaces, pulmonary edema and hemorrhage, and enlargement of the liver, spleen, and kidneys. Generalized necrosis of the liver and multifocal necrosis of the spleen are seen on cut surfaces. Pure cultures of *E. coli* are obtained from the liver, spleen, and pericardium. Characterization of isolates from 7 affected flocks showed they belonged to multiple serogroups (O1, O2, O18, O78, and O111). For each flock, isolates were clonal based on serotype, plasmid profiling, ribotyping, and MLST. Virulence factors were similar among all isolates in spite of differences in serotype and phenotype, and included F11 pili, *iucD*, *iss*, *vat*, *tsh*, and colicin V (444).

Neonatal Colisepticemia. Chicks are affected within the first 24–48 hours after hatching. Mortality remains elevated for 2–3 weeks and usually totals 10%–20%. Up to 5% of the flock may be stunted and require culling. Unaffected birds grow normally and the disease does not appear to spread. Initial lesions consist of congested lungs, edematous serous membranes, and splenomegaly. The proventriculus and lungs develop a dark color that can approach black as the interval between death and necropsy increases. Microscopically, bacteria are numerous in affected tissues and easily identified. After a few days the typical pattern of acute, fibrinoheterophilic polyserositis involving the pericardial sac, pleura, air sacs, and peritoneum becomes evident. Lesions are often extensive and severe in birds that survive into the second week. Occasionally birds with arthritis or osteomyelitis may be found late in the disease. Most affected birds have yolk sac abscesses, suggesting the navel is the portal of entry. Alternatively, *in ovo* infection may be responsible (390).

Layer Colisepticemia. Colisepticemia is usually a disease of young birds, but occasional outbreaks of acute *E. coli* infection resembling fowl typhoid or fowl cholera occur in mature chickens and turkeys (36, 121, 584, 625). Acute colibacillosis in layers is being seen with increasing frequency (584). The majority of outbreaks are associated with onset of egg production, but less frequently they occur at an older age, or may continue as the flock ages and potentially spread to older flocks on the same farm. The disease may reoccur in the same flock or subsequent flocks placed on farms or in houses where affected flocks had been previously (584). Death usually occurred suddenly without premonitory signs, although depression and/or dirty vents were observed in some affected hens in approximately half of the flocks. Weekly mortality was significantly higher in affected flocks than age-matched control flocks (0.26%–1.71% vs. 0.0%–0.30%). Cumulative mortality ranged up to 10% and mortality remained elevated for 3–10 weeks. Polyserositis (perihepatitis, pericarditis) and peritonitis associated with free yolk in the peritoneal cavity were present in most birds at necropsy. Oophoritis and salpingitis occurred less frequently.

Isolates of *E. coli* from outbreaks in Italy were lactose negative and nonmotile, and belonged to serogroup O111. Intramuscular inoculation of the O111 APEC reproduced the disease, whereas it developed in only a few birds following oro-nasal administration (625). In contrast, the majority of isolates from outbreaks in Belgium were serogroup O78. Outbreak isolates were more likely to have P fimbriae (F11), especially if they were serogroup O78 and recovered from the heart. Serogroup O78 isolates also had the lowest percentage of motile strains (584). A number of virulence factors were

significantly more frequent in outbreak isolates compared to control isolates. However, when cecal isolates and extra-intestinal isolates within either the outbreak or control groups were compared, they were not significantly different. Collectively, no virulence factors or combination of factors were found only in outbreak isolates (587).

The pathogenesis of the disease is unknown, but stress associated with onset of egg production is believed to be an important contributing factor (625). Ascending infections via the oviduct have been suggested as a means by which *E. coli* gain access to systemic tissues, but in a recent study, higher colonization rates of the trachea, but not the oviduct, in affected flocks suggests layer colisepticemia may be aerogenous (584). Lack of recognized stressors or indications of diseases known to predispose chickens to colisepticemia suggest layer colisepticemia results from a primary *E. coli* infection (584, 586).

Risk factors for developing layer colisepticemia include close proximity to other poultry farms and higher stocking density (585). Control has been through chlorination of water or treatment of the flock with appropriate antibiotics.

Coliform Septicemia of Ducks. Coliform septicemia of ducks is characterized by moist, granular to curd-like exudate of variable thickness causing pericarditis, perihepatitis, and airsacculitis. A characteristic odor is often noted at necropsy. Liver is frequently swollen, dark, and bile stained, and spleen is swollen and dark. *E. coli* (usually O78) can be recovered from any internal organ (332, 383). *Riemerella anatipestifer* causes similar lesions, but it can be identified by appropriate cultural procedures.

Coliform septicemia occurs throughout the growing season but is most frequent in late fall and winter. All ages of ducklings are susceptible. Distribution of losses suggests individual farms, rather than hatcheries, are the source of infection (332). Poor husbandry and marked contamination of pond water used by ducklings were contributing factors to an outbreak of colisepticemia in captive mallards (383).

Colisepticemia Sequelae. Death is the usual outcome of colisepticemia, but some birds may completely recover or recover with residual sequelae. If the bird does not control *E. coli*, it can localize in poorly protected ("immunologically privileged") sites including the brain, eyes, synovial tissues (joints, tendon sheaths, sternal bursa), and bones. In immature females, salpingitis can occur when there is involvement of nearby air sacs. IBV infection of the oviduct also may be an important predisposing factor in juvenile salpingitis. After *E. coli* is no longer present, constrictive pericarditis develops as exudate in the pericardial sac undergoes organization, and liver becomes fibrotic (Figure 18.1G). Ascites may develop because of residual pulmonary damage from combined *E. coli*–IBV infection (574, 617). It also is possible for ascites to develop from the direct action of endotoxin on the pulmonary vascular system. Endotoxin causes vasoconstriction leading to pulmonary hypertension and the potential to develop ascites (pulmonary hypertension syndrome) (79).

Meningitis/meningoencephalitis. *Escherichia coli* localization in the brain is uncommon. Meninges are affected (meningitis) but in some birds there also is involvement of the brain (encephalitis) and ventricles (ventriculitis). Meningeal lesions are evident at necropsy as areas of discoloration, often adjacent to major blood vessels. Fibrinoheterophilic to heterophilic exudate is seen microscopically early in the infection; the lesion becomes more granulomatous with time. Bacteria are usually numerous within lesions but may not form distinct colonies.

Panophthalmitis. As with the brain, involvement of the eye is uncommon. However, if it is infected the resulting panophthalmitis is severe (206, 415). Typically there is hypopyon and hyphema, and infection is unilateral (Figure 18.2F). The eye is swollen, cloudy to opaque, and may be hyperemic initially. Later the eye shrinks as it undergoes atrophy. Fibrinoheterophilic exudate and numerous bacterial colonies are present throughout the eye. Inflammation, especially adjacent to necrotic tissue, becomes granulomatous with time. Varying degrees of retinal detachment, retinal atrophy, and lysis of the lens also may be seen. The organism persists in the diseased eye for long periods of time.

Osteoarthritis and Synovitis. Localization of *E. coli* in bones and synovial tissues is a common sequel to colisepticemia (Figure 18.2E). The term osteoarthritis is used when a joint is inflamed and 1 or more bones making up that joint have osteomyelitis. Polyarthritis refers to involvement of more than 1 joint. Bacterial chondronecrosis with osteomyelitis (BCO) is another name that has been used (374).

Affected birds likely have insufficient resistance to clear bacteria completely. Hematogenous spread of *E. coli* following hemorrhagic enteritis virus infection of turkeys resulted in synovitis, osteomyelitis, and green liver discoloration (133). Intravenous inoculation to simulate hematogenous spread to bones and joints has been used to reproduce the lesions, but mortality from the initial septicemia is often high (42). A preferable method is to inoculate the air sac of birds with low numbers of *E. coli* after a pretreatment with dexamethasone (252).

Mild to severe lameness and poor growth are seen clinically and affected birds are more likely to be victims of persecution (cannibalism). Often multiple sites are involved. Bacteria colonize the vascular sprouts that invade the physis of a growing bone, provoking an inflammatory response that results in osteomyelitis. Transphyseal blood vessels in birds serve as conduits for the process to spread into the joint and surrounding soft tissues. Compared to clinically normal turkeys, lame turkeys had the following: higher splenic and liver weights; lower body and bursal weights; decreased cellular immunity; normal to increased humoral immunity; decreased circulating lymphocytes; increased circulating total leukocytes, monocytes, and heterophils; normal to marginally depressed phagocyte function; increased serum protein, uric acid, and blood urea nitrogen (BUN); and decreased

hemoglobin, iron, alkaline phosphatase, and gamma-glutamyltransferase (44).

Bones most often affected are the tibiotarsus, femur, thoracolumbar vertebra, and humerus (407). Proximal physes of long bones are more frequently affected than distal physes. Lesions typically form where endochondral ossification is occurring and extend proximally to involve the adjacent physeal cartilage. It is common to find both osteomyelitis and tibial dyschondroplasia together, but this is most likely due to their occurrence at the same location rather than a cause-and-effect relationship. Osteomyelitis is easily recognized on gross examination of bones opened to expose the physes, but small lesions that can only be seen microscopically also occur (374).

Hock, stifle, hip, and wing joints and articulations of the free thoracic vertebra are sites where arthritis is most likely to occur (407). Lesions in other joints are less common. Trauma to joints and growing bones may predispose to the development of lesions. Tenosynovitis frequently accompanies arthritis. Less commonly, spread of the inflammatory process from a joint into the periarticular tissues occurs. An infectious sternal bursitis also is common but must be distinguished from traumatic sternal bursitis in which fluid, but not exudate, is seen. When inflammatory lesions involve the shoulder joint or proximal humerus, extensive exudate can accumulate between the superficial and deep pectoral muscles (Figure 18.1E). Lesions that develop in joint spaces of the articulating free thoracic vertebra are characterized by spondylitis, which results in progressive paresis and paralysis (166) (Figure 18.6). Lesions in the distal articulation of the free thoracic vertebra occur more commonly than lesions in its proximal articulation or both articulations.

Figure 18.6. Spondylitis involving articulating free thoracic vertebrae of 2 lame turkeys (fixed tissues). Pressure from the lesion on the spinal cord has caused demyelination of the ventral tracts. *Escherichia coli* is a common cause, but the lesion also can result from infection with other bacteria that can localize in bones and synovial tissues.

Turkey Osteomyelitis Complex. Turkeys with turkey osteomyelitis complex (TOC) have infectious, inflammatory lesions in bones, joints, or periarticular soft tissues and enlarged, green discolored livers that are used at processing to indicate the possible presence of intraosseous lesions (88, 133, 246, 252). Green liver discoloration is rarely identified in the field, even in lame turkeys. Most often green discolored livers are detected at processing and result in downgrading and, depending on severity, partial or whole bird condemnation. It is likely green discoloration of the liver is more evident in processed birds because they have bled out, in contrast to birds in flocks that either die naturally or are euthanized.

In TOC, osteomyelitis and arthritis occur as described above. Spondylitis of the articulating free thoracic vertebra can be associated with green liver discoloration (35). Not all birds with green discolored livers have TOC, but generally birds with TOC have discolored livers (88). Feed and water withdrawal do not cause green liver discoloration (254), but infection with *Mycoplasma synoviae* can be associated with a high percentage of carcasses with green discolored livers in the absence of TOC (35). The Food Safety Inspection Service (FSIS) in the United States uses green discoloration of the liver at processing to identify carcasses that may have TOC so that any abnormal tissue can be removed from the food chain. Osteomyelitis lesions also can be detected by ultrasonography (406). Tom turkeys are more affected than hens and affected birds have decreased cell-mediated immunity (44, 252).

Escherichia coli are frequently isolated from the lesions (133), but other bacteria also may cause TOC lesions, especially *Staphylococcus aureus*, or *S. hyicus* (561) (see Staphylococcosis). Culturing bones and livers from affected and unaffected birds in 2 turkey flocks resulted in recovery of pleomorphic, Gram-variable bacteria consistent with L-forms (cell-wall-deficient forms). Positive cultures were obtained more frequently from affected birds and bones than from unaffected birds or livers. The significance of these organisms in the disease is unknown, but the high number of isolates suggests that these bacterial forms may be more common in turkeys than has been generally realized (43).

A laboratory model of TOC based on injecting turkeys with dexamethasone followed by inoculation of low numbers of *E. coli* into an air sac has been developed and used to study

Figure 18.7. Coligranuloma in a market-age turkey. Numerous nodular lesions are located in gastrointestinal tissues including liver, but they do not involve the spleen. A mucoid *Escherichia coli* was isolated.

the pathogenesis of the disease (244, 245, 247, 248, 252). Dexamethasone injections alone will reproduce the lesions of TOC by increasing susceptibility of the birds to opportunistic bacteria, particularly *S. aureus*. Exposure of turkeys to low levels of *E. coli* via air sac inoculation increases the occurrence of TOC (252). The current hypothesis is that TOC is related less to the virulence of the infecting bacteria than it is to an inappropriate response of a subpopulation of male turkeys to stress, which increases their susceptibility to opportunistic bacterial infections. The greater susceptibility of turkeys selected for rapid growth and higher body weights to experimental TOC further supports the concept of genetic susceptibility that is most likely mediated by how the birds respond to stress (243). The protective effect of vitamin D_3 (246) also suggests a possible genetic basis for TOC susceptibility related to vitamin D receptors and their function (252). However, when vitamin D metabolites were administered, TOC was reduced as with vitamin D treatment, but there were toxic effects in dexamethasone-treated turkeys challenged with *E. coli* (251).

Coligranuloma (Hjarre's Disease). Coligranuloma of chickens and turkeys is characterized by multiple granulomas in liver, ceca, duodenum, and mesentery, but not spleen (Figure 18.7). The disease also has been described in quail (100). Coligranuloma is an uncommon form of systemic colibacillosis that usually occurs sporadically in individual birds, but can cause mortality as high as 75% when a flock is affected. Serosal lesions resemble leukosis tumors. Early in the disease there is confluent coagulation necrosis involving as much as half the liver. Only scattered heterophils are seen, and at the edge of the necrotic areas there are a few giant cells. Subsequently, typical heterophilic granulomas are present in the affected tissues. Pyogranulomatous typhlitis and hepatitis, which may be related to coligranuloma, have been described in turkeys with cecal cores and ruptured ceca (399).

Pathogenesis

Escherichia coli enters host tissues following mucosal colonization or directly through breaks or openings in the skin. Mucosal colonization depends on adhesin factors that

permit the bacterium to attach to receptors and subsequently reproduce. A variety of fimbrial and nonfimbrial adhesins are produced by *E. coli*, which facilitates their attachment to host cells (see Virulence Factors). There is good evidence that 2 fimbriae—Type 1 (F) and P fimbriae—are important in the initial stages of infection. Type 1 fimbriae are expressed by *E. coli* that attach to upper tracheal epithelium (472), oviductal epithelium (389), and digestive tract mucosa (121). P fimbriae are expressed in deeper tissues (422). Type 1 fimbriae bind to mucus in the digestive tract but not to goblet cells producing the mucus. In contrast, AC/I fimbriae bind poorly to mucus but attach to goblet cells (138). Flagella aid in penetrating the mucous layer to reach the cell surface, and curli, another adhesin factor, aids in attachment to the cell surface (321, 324).

Virulent strains are capable of traversing the mucosa, especially if an injurious agent has compromised it, and surviving within the internal milieu of the body. Exactly how *E. coli* crosses mucosal barriers is poorly understood. Bacteria may penetrate between damaged cells. Air sac epithelial cells round up and become vacuolated following exposure to virulent strains, which causes them to separate from each other, providing bacteria access to systemic tissues (119, 471). The ability of APEC to bind with fibronectin and laminin, 2 components of basement membranes, aid in penetration through the damaged mucosa into host tissues (479). Toxins in cell-free culture filtrates, most likely endotoxin, produce the same acute inflammatory response as the living organism (119).

Alternatively, the initial portal of entry into the host's tissues, an essential first step in colisepticemia, may be transcellular through nonphagocytic cells. Certain strains of APEC have the ability to invade fibroblasts, much like virulent *Salmonella typhimurium* (365). *E. coli* have been identified within air sac epithelial cells by electron microscopy (471). An APEC strain was able to readily adhere to and invade tracheal epithelial cells in primary cell culture and tracheal explants (478). Factors involved in cell penetration remain to be identified.

Once *E. coli* becomes extra-mucosal, the environment it has entered is extremely hostile. Unless the organism is equipped with survival capabilities (e.g., virulence factors), it is rapidly destroyed by phagocytic cells such as heterophils, thrombocytes, and macrophages (219, 220, 606). Macrophages located primarily in the spleen and liver phagocytize bacteria that gain access to the circulation (25). Complement and antibodies to O antigens (endotoxin), outer-membrane proteins (siderophores), and fimbriae serve as opsonins to promote phagocytosis and destruction of the organism (23, 24). Endotoxin also decreases the bacteriocidal ability of pulmonary macrophages (147), which may aid in survival and dissemination.

Immediately after *E. coli* contacts host tissues, there is an acute inflammatory response. Acute phase proteins produced in the liver and cytokines IL-1, IL-6, and tumor necrosis factor increase rapidly following exposure to endotoxin or *E. coli*, which can serve as nonspecific indicators of early disease (76, 423, 614). Acute phase effects of endotoxemia include hypothermia followed by hyperthermia; hypotension; decreased circulating heterophils associated with increased apoptosis and sequestration in the lung; and increased inflammatory mediators; TL1A, IL-1β, and IL-6 (108). Increasing amounts of endotoxin in the circulation cause decreased feed consumption and efficiency; body weight and breast meat yield; tibial bone size, weight, calcium content, and breaking strength; and increased mortality, liver weight, plasma ionized calcium, and antibody responses (384). Vascular permeability increases, leading to the accumulation of fluid and protein in the tissues. Serous membranes become wet and edematous and liquid begins to accumulate in body cavities. Chemotactic factors attract heterophils, which marginate in post capillary venules and emigrate into surrounding tissues (358). Between 6 and 12 hours, soft, gelatinous exudate becomes grossly visible. Heterophils can kill *E. coli* extra-cellularly by substances such as β-defensins released as they degranulate and die (219, 554, 555). After 12 hours there is a progressive shift in inflammatory cells from heterophils to macrophages and lymphocytes.

Exudate continues to accumulate and eventually undergoes caseation to form a firm, dry, yellow, irregular, cheese-like mass. Microscopically, caseous exudate consists of heterophilic granulomatous exudate containing variable numbers of embedded bacterial colonies. A palisade of multinucleated giant cells and macrophages surrounds the exudate (82). Depending on the size of the mass of exudate, an extended period of time is required for the exudate to be slowly eroded away by the action of the surrounding phagocytic cells. Viable bacteria persist as microcolonies within the exudate. Epithelial tissue may be restored if damage has not been too severe, but usually there is some degree of fibrosis, which may be complete (scarring) if tissue destruction has been extensive. Exudate containing fibrin undergoes organization and is eventually converted to scar tissue.

Gross lesions are inversely related to virulence. Highly virulent strains cause mortality so quickly that gross lesions have little time to develop, whereas birds infected with less virulent strains survive longer and develop more extensive lesions.

Infections with APEC serve as a model for studying the molecular aspects of host-pathogen interactions of extraintestinal *E. coli* (ExPEC) infections. Both pulmonary and systemic infection models have been established using a serogroup O2 strain (19).

Diagnosis

Isolation and Identification of Causative Agent

Diagnosis is based on isolation and identification of *E. coli* from lesions typical of colibacillosis. Care must be taken to avoid fecal contamination of samples. Isolation of the organism from visceral organs of birds undergoing decomposition must be interpreted cautiously because *E. coli* rapidly spreads from the intestinal tract into surrounding tissues of dead birds. Bone marrow cultures are easy to obtain and are generally free of

contaminating bacteria. The brain is another site to culture, but it is less easily accessed compared to bone marrow.

Material should be streaked on eosin-methylene blue (EMB), MacConkey, or tergitol-7 agar, as well as noninhibitory media. A presumptive diagnosis of *E. coli* infection can be made if most of the colonies are characteristically dark with a metallic sheen on EMB agar, bright pink, with a precipitate surrounding colonies on MacConkey agar, or yellow on tergitol-7 agar. Strains of *E. coli* can be slow or nonlactose fermenters and appear as nonlactose-fermenting colonies. Definitive identification of *E. coli* is based on the organism's characteristics (see Etiology). A flow chart for the isolation and identification of *E. coli* has been published (331). A number of manual and automated systems are available for identification of bacteria, including *E. coli*.

Antigenic identification, determination of virulence factors, or fingerprinting of the isolate might be helpful, particularly when done as part of an epidemiologic investigation. The correlation between virulence and complement resistance suggests that this may be a good method for screening isolates for possible disease association. A relatively simple rapid turbidimetric assay has been described (458). Also, analysis of the results of an extensive virulence genotyping assay identified 5 genes that typified a large majority of APEC (289). From these data, a pentaplex PCR quick test was designed to distinguish APEC from commensal *E. coli* isolated from the feces of healthy poultry without having to resort to *in vivo* virulence models (289). Also, a recent and extensive study identified 4 patterns of virulence genes for identifying APEC (519) that could be exploited diagnostically. Despite the promise of these *in vitro* predictors of APEC identity, it may be unrealistic to expect them to identify all *E. coli* capable of causing avian colibacillosis. Most APEC are well equipped for a pathogenic lifestyle and are easily identified by their constellation of virulence genes; however, a few strains are not. Such minority isolates are likely opportunistic, causing disease in immunocompromised hosts and lacking the traits that gene-based assays target (289).

Serology has not been used as a diagnostic method. However, survival after challenge correlated better with antibody titers detected by an enzyme-linked immunosorbent assay (ELISA) than by the standard indirect hemagglutination procedure (334). Procedures to detect acute phase proteins (76, 384, 423, 614) or shifts in the heterophil/lymphocyte ratio (203) can serve as nonspecific markers of the inflammation and stress that accompany colibacillosis.

Differential Diagnosis

Acute septicemic diseases may result from pasteurellae (*Pasteurella*, *Ornithobacterium*, *Riemerella*), salmonellae, streptococci, and other organisms. *Chlamydophila*, pasteurellae, or streptococci (*Streptococcus*, *Enterococcus*) can cause pericarditis or peritonitis, and other bacteria, mycoplasmas, and *Chlamydophila* can cause airsacculitis. Many organisms including viruses, mycoplasmas, and other bacteria can cause synovial lesions similar to those resulting from *E. coli* infection. A variety of organisms including *Aerobacter* spp., *Klebsiella* spp., *Proteus* spp., salmonellae, *Bacillus* spp., staphylococci, enterococci, or clostridia are frequently isolated (often as mixed cultures) from yolk sacs of embryos and chicks (222). Liver granulomas have many causes, including anaerobic bacteria belonging to the genera Eubacterium and Bacteroides.

Intervention Strategies

Management Procedures

Biosecurity is essential to the control of colibacillosis. Keeping *E. coli* out of the flock is not the goal because intestinal colonization is universal. However, reducing the numbers of *E. coli* through water, feed, environmental sanitation, and good air quality, and protecting the flock from factors, especially viral infections, that decrease host resistance will sharply reduce the likelihood of colibacillosis.

Fecal contamination of hatching eggs is the most important way that *E. coli* are transmitted between flocks. Collecting eggs frequently, keeping nest material clean, not using floor eggs, discarding cracked eggs or those with obvious fecal contamination, and fumigating or disinfecting eggs within 2 hours after they are laid can reduce transmission. *E. coli* on the shell surface can be reduced or eliminated with sanitizers (522). Application of sanitizers by electrostatic spraying improves efficacy (503). Ultraviolet irradiation can reduce or eliminate *E. coli* and other bacteria on the surface of hatching eggs without altering conductance or hatchability (96). If infected eggs are broken during incubation or hatching, the contents are a serious source of infection to other chicks, especially when personnel and egg-handling equipment are contaminated. Eggs are particularly susceptible just before hatching. Methods for preventing incubator and hatcher dissemination are unknown. However, venting incubators and hatchers to the outside and having as few breeder flocks as possible represented in each unit will help reduce cross contamination and losses. Chicks and poults are colonized by strains of *E. coli* that they are exposed to in the hatchery from people or the environment, and they take the organisms with them when they are placed on the farm. Contaminated chicks survive better if kept warm and are not deprived of food for an extended period of time.

Survival tends to be better in birds fed high-protein diets, increased selenium (330), and increased vitamins A and E (250, 436, 562, 563). However, high levels of vitamin E can be detrimental to resistance to coliform cellulitis, colibacillosis, and antibody production (163, 337, 356, 521). Response to vitamin E is likely interrelated with the genotype of the bird (526, 619). Feeding can have an impact on severity of colibacillosis. Chickens fed on alternate days were more resistant to *E. coli* challenge than full-fed chickens (61, 473).

There are no known methods for reducing the level of pathogenic *E. coli* in the intestinal tract and feces, although that the following considerations should not be overlooked: (1) pelleted feed has fewer *E. coli* than mash, (2) rodent droppings

are a source of pathogenic *E. coli*, and (3) contaminated water can contain high numbers of the organism. Hot pelleting processes destroy *E. coli* (142), but care must be taken not to recontaminate finished feed. Adding 5%–10% egg yolk powder to feed effectively reduced or eliminated *E. coli*, and other bacterial foodborne illness pathogens in layers (303). Commercial broiler chickens and breeders were less productive when their water contained *E. coli* and nitrates (200). Chlorination of drinking water and use of closed (nipple) watering systems have decreased the occurrence of colibacillosis and condemnations for airsacculitis (62, 121, 456). Pathogenic strains of *E. coli* can be competitively excluded from intestines of chicks by seeding them with native microflora from resistant chickens (600), commercial competitive exclusion products (216, 239), or *Bacillus subtilis* spores (318, 564). A similar effect was achieved following *in ovo* inoculation of *Lactobacillus reuteri* (139). Food and water deprivation increased the occurrence of spontaneous bacteremia (336).

Infections with *M. gallisepticum* or IBV overcome the protective effect of native flora colonization (599). Raising mycoplasma-free birds and reducing exposure of birds to viruses causing respiratory diseases can reduce *E. coli* infection of the respiratory tract of birds. Effective vaccination to protect against respiratory tract pathogens and immunosuppressive agents that predispose to colibacillosis reduces occurrence of the disease (366).

Birds acquire nonspecific resistance to colibacillosis following moderate stress and socialization with people. Nonspecific resistance is short-lived and can be minimized by cold stress or corticosterone (364).

Maintaining good air and litter quality is fundamental to reducing the risk of a flock developing colibacillosis (106). Fluctuating between cool and warm temperatures and modulating airflow have been used experimentally to produce colibacillosis in commercial chickens (271). Proper ventilation minimizes respiratory tract damage from ammonia and reduces the levels of bacterial and aerial endotoxin exposure. Ammonia, even at levels below those that can be detected by human smell, impairs mucociliary clearance of inhaled particulates (412, 447). Degree of damage to the respiratory mucosa correlates with the level of ammonia exposure (411). Dust also increases the risk of colibacillosis (224). Bacteria preferentially adhere to dust particles because of electrostatic charges. The combination of dust and ammonia results in birds inhaling high numbers of bacteria and being unable to clear them from their respiratory tract.

Wet litter provides an excellent environment for *E. coli* to persist and reach high numbers. Higher numbers of *E. coli* and *Salmonella* were found in litter that had water activity greater than 0.9% and moisture content above 35%. Air velocities across the surface of the litter of at least 100 feet/minute produce drier litter and decrease the number of *E. coli* (486). Airflow across litter may not be uniform throughout a commercial broiler house. Low airflow correlated with high coliform counts in litter and litter with high numbers of coliforms was 16 times more likely to be in a low airflow area of the house (409). The incidence and severity of footpad dermatitis at processing can be used as an indicator of litter condition and air quality that were present during the production cycle (228). Maintenance of waterers is essential in eliminating wet spots in the house. Daily raking of soiled litter that builds up around feeders and waterers, removing heavily soiled litter, and tilling and replacing or covering wet litter with fresh dry litter are useful procedures for maintaining good litter quality.

Vaccination

Types of Vaccines

A variety of vaccines and vaccination methods have been developed, including passive and active immunization, use of inactivated and live products, recombinant and subunit vaccines, and immunization against specific virulence factors. Most have not gone beyond the experimental investigation phase. No vaccination procedure has proved to be highly efficacious in commercial production and no product is used widely in the industry at the present time. A commercial vaccine containing F11 (PapA) fimbrial antigen and flagellar antigen (FT) is licensed in Europe for use in broiler breeders to provide natural passive immunity to progeny of vaccinated hens (Noblis *E. coli* Inac, Intervet). Total mortality did not differ between vaccinated and unvaccinated breeder flocks, but mortality attributable to *E. coli* infection was 3 times higher in the unvaccinated flocks. Production parameters for broilers from vaccinated breeders were not significantly different from those for broilers from unvaccinated breeders. All *E. coli* isolates belonged to phylogenetic group B2, but were genetically diverse (198).

Inactivated Vaccines. Effective inactivated vaccines against various serotypes including O2:K1 and O78:K80 have been produced (24, 74, 113, 114, 575). They provide protection against homologous serogroups, but no cross protection against heterologous serogroups. An inactivated O78 vaccine protected ducks (514). Both homologous and heterologous protection was provided by a vaccine prepared by ultrasonic inactivation of the organism followed by irradiation (376). A vaccine containing bacterial membrane vesicles was effective in protecting turkey poults against challenge with pathogenic *E. coli* by stimulating antibody production, bacterial-lysis activity of complement, T cell proliferation, and cytotoxic T cell activity (75). Use of a liposomal inactivated vaccine given by either eye drop or coarse spray stimulated humoral and mucosal antibodies. The number of bacteria in the blood was decreased and clinical signs were less severe in vaccinated birds following APEC challenge (616).

Live Vaccines. A live vaccine prepared from a naturally occurring, nonpathogenic, piliated *E. coli* strain (BT-7) was efficacious when used in chickens older than 14 days of age. Protection against both homologous and heterologous strains was demonstrated (167). *E. coli* J5, a mutant strain

that has incomplete endotoxin in the cell wall exposing Gram-negative core antigen, was both safe and effective for protecting chicks (4, 5). Antibody titers to Gram-negative core antigens that develop in commercial chickens peak during the pullet period (501).

Recombinant and Mutant Vaccines. A *carAB* mutation of a virulent O2 serotype caused defective utilization of arginine and pyrimidines, increasing the requirements by the mutant. Because low levels of these substances are generally available *in vivo*, the organism was unable to sustain itself, which resulted in a self-limiting infection. The mutant strain was found to be stable, immunogenic, and attenuated. Turkeys orally vaccinated with the mutant were protected against colibacillosis in a hemorrhagic enteritis virus-parent wild-type strain challenge model (317). Mutant O2 and O78 APEC with deletions of the genes *cya* or *crp*, which are involved in energy production, were used as a spray vaccine to immunize broiler chickens. The mutants were safe and immunogenic but provided only limited protection against airsacculitis following challenge (457). Similarly, strain O78 mutants with deletions of *galE*, *purA*, and *aroA* genes were found to be safe and immunogenic, but provided only moderate protection against homologous challenge with no protection against heterologous challenge (301).

In contrast to high mortality caused by the parent and wild-type strains, attenuated streptomycin-dependent (str-dependent) mutants derived from a virulent APEC did not cause mortality in challenged birds. No protection against cellulitis or systemic lesions resulted when birds were vaccinated with high numbers of the mutant strains by aerosol and oral routes. However, systemic lesions were significantly reduced when birds were given 3 vaccinations on days 1 (aerosol), 14 (oral), and 28 (oral) (13).

A recombinant vaccine using *Salmonella typhimurium* was constructed to produce homologous group B determinants and *E. coli* O78 antigen. Vaccinated birds seroconverted and were protected against subsequent challenge with a pathogenic *E. coli* O78 strain (493). A similar vaccine constructed to express *E. coli* type 1 fimbrial antigen in addition to O78 LPS provided protection against homologous challenge. The O78 LPS was responsible for most of the efficacy of the vaccine, although presence of the fimbrial antigen decreased the severity of air sac lesions. The fimbrial antigen did not provide cross protection following challenge with O1 and O2 APEC serogroups (494).

A modified-live vaccine containing an *aroA* gene deleted *E. coli*, type O78, is licensed in the United States for use in chickens and turkeys by administration via drinking water or coarse spray (Poulvac *E. coli*, Pfizer). The vaccine significantly reduces mortality and lesions associated with *E. coli*, and provides cross protection for airsacculitis caused by *E. coli* serotypes O1, O2, and O18. A small study done in Thailand did not find differences in mortality or morbidity between vaccinated and unvaccinated chickens, but lesions were significantly reduced in the vaccinated birds (484).

Molecular Vaccines. Immunization of chickens with Iss, a surface protein common to APEC, but not commensal *E. coli*, is important in complement resistance, suggesting the potential to achieve cross protection among different serotypes(353). Chickens immunized with Iss produced humoral and mucosal antibody responses and provided good protection against colibacillosis following challenge with O1, O2, and O78 APEC serotypes. Challenged birds had significantly lower lesion scores compared to unvaccinated, challenged controls (353).

Multivalent vaccines made from pili containing low levels (180 μg) of protein/dose reduced the severity of challenge infection (215). Absorbed sera indicate pili of serotypes O1, O2, and O78 are antigenically different (557).

Fimbrial vaccines containing FimH, the adhesin of F1A (type 1) fimbriae, or PapGII, the highly conserved portion of P fimbrial adhesion, were immunogenic but did not provide protection against APEC challenge (589, 591). The results of PapGII immunization differ from the finding that passive immunization with PapG yolk-derived antibodies was protective (see Passive Immunization).

Passive Immunization. Passive immunization results in increased resistance to aerosol challenge and clearance of bacteria from blood (408). Use of inactivated vaccines in breeders provided passive protection against homologous challenge in progeny, which was complete for 2 weeks and partial for several additional weeks post hatch (232, 498).

Antiserum prepared in rabbits against iron-regulated outer membrane proteins of *E. coli* protected turkeys against mortality following challenge. Frequency of bacteremia at 96 hours after challenge, recovery of *E. coli* from air sacs, and severity of gross lesions were significantly reduced in immunized birds compared with control birds given normal rabbit serum or saline solution (65).

Antibodies extracted from the yolk of eggs laid by immunized hens provided homologous protection against an O78 APEC. Partial protection against heterologous challenge with O1 and O2 serotypes was provided by immunizing hens with P pilus adhesin (PapG) or the aerobactin outer membrane receptor IutA. Immunizing with PapG provided the best overall protection. Breeder hens immunized by this method may provide immunity to their progeny (302).

Immunopotentiation. A problem with recombinant vaccines is low immunogenicity, which could potentially be solved by using effective immunopotentiators. Inoculation of chickens by intramuscular or subcutaneous routes and chicks by intramuscular or *in ovo* routes with cytosine-phosphodiester-guanine (CpG) oligodeoxynucleotides improved livability and reduced cellulitis lesion size following challenge with APEC (189, 191). Use of CpG as an adjuvant in an inactivated *E. coli* vaccine improved the efficacy of the vaccine (190). CpG motifs are present in high numbers in bacterial DNA and enhance innate immune responses (29, 189).

Modification of *E. coli* heat-labile enterotoxin (LT) resulted in a nontoxic protein (nLT) that stimulated antibody production in chickens following either oral or parenteral co-administration of an antigen to chickens (592).

Mixtures of antimicrobial/host defense peptides and gamma-amino-butyric acid promoted production of pro-inflammatory cytokines following subcutaneous injection. Chickens challenged with a virulent O2 APEC 24 hours after receiving the mixture had lower mortality and bacteremia, but there was no effect on cellulitis lesions. Intramuscular administration was less effective (11).

Treatment

Antimicrobial Drugs

Antimicrobial drugs have been used extensively for reducing losses from colibacillosis since their first introduction for treatment of poultry in the mid 1950s. Occurring in parallel with use of an antimicrobial has been a progressive development of resistance, which was initially identified following introduction of tetracyclines (538). Antimicrobial resistance is determined genetically and is usually transferable within a species or between different types of bacteria via mobile genetic elements—plasmids, integrons, and transposons (40, 329, 618). The greatest reservoir for transferable antimicrobial resistance factors in the poultry flock environment is not *E. coli*, or even Gram-negative bacteria, but Gram-positive bacteria that comprise over 85% of the bacteria in poultry litter (427). The intestinal tract of the chicken is a suitable environment for transfer of genes from tetracycline-resistant to susceptible *E. coli* strains. Adding tetracycline to the chick's drinking water accelerates the process. Resistance to other antimicrobials is co-transferred along with tetracycline resistance (227).

Growing concern over antibiotic resistance, especially multidrug resistance, and the potential of bacterial strains affecting people acquiring transmissible resistance factors from bacteria in animals (see Public Health Significance), has led to changes in the way antimicrobials are used to treat colibacillosis in poultry (528). Additionally, new antimicrobials are not being developed for use in poultry, and the ones that have been used previously have lost much of their efficacy due to acquired resistance. Recently, fluoroquinolones became available in the United States and elsewhere for treatment of colibacillosis in poultry, which generally proved to be highly efficacious (186). However, resistance to fluoroquinolones has developed in parallel with their use in both chickens and turkeys (197), and societal concerns about resistance in pathogenic bacteria (45, 185, 274, 305, 605), development of cross resistance among different quinolones, and importance of this class of antibiotics for treating people have led to their withdrawal for use in poultry in many countries, including the United States. For a review of antimicrobial resistance of avian *E. coli* see (603).

When selecting an antimicrobial, it is important to determine the susceptibility of the isolate involved in the disease outbreak so that ineffective drugs can be avoided. APEC frequently are resistant to tetracyclines, sulfonamides, ampicillin, and streptomycin (382, 590, 603, 618). Multidrug resistance is common (590), may be linked to transmissible plasmids (284, 288), and may occur in conjunction with virulence factors (279, 286). Numerous recent studies on antimicrobial resistance of *E. coli* isolates from chickens (15, 58, 178, 242, 306, 329, 382, 392, 434, 448, 581, 618, 626), turkeys (13, 94, 508, 581), ducks (387, 597), eggs (405), and poultry feed and ingredients (362) have been done in different geographic areas. All showed some level of resistance in APEC and commensal strains, but there were regional variations. Most *E. coli* isolates from eggs were susceptible to all antibiotics (405). Occasionally resistance is higher among commensal strains compared to APEC, (e.g., ampicillin resistance in turkeys) (13), but in general, resistance tends to be greatest in APEC strains. A high percentage of *E. coli* isolates from turkeys are resistant to gentamicin, which has been attributed to the widespread use of day-old gentamicin injection (13). Gentamicin resistance among chicken-origin *E. coli* was associated with significantly greater virulence in an embryo lethality assay (392).

Even a highly effective drug may not result in improvement of the flock if too little is used or it is incapable of reaching the site of infection. Therefore, underdosing may promote development of resistance. Chicks given feeds with increasingly lower concentrations of ampicillin (1.7 and 5 g/ton) developed resistance that was directly correlated to the amount of antibiotic in the feed (10). Paradoxically, certain antimicrobials and anticoccidials commonly used at subtherapeutic levels in poultry for growth promotion and coccidiosis control inhibited transfer of a plasmid that is responsible for multiresistance in *E. coli*. The basis for the inhibition was attributed to the ion-binding properties of the drugs and interference with DNA uptake channels in the organism (363). Selective pressure from exposure to an antibiotic is not always essential for resistance to develop (80). Although resistance generally occurs following prior contact with an antimicrobial, it can occur naturally in the absence of previous exposure. Resistance to florfenicol and chloramphenicol, which had never been used in poultry in the United States, was found in *E. coli* isolates from chickens in the southeastern United States (304).

Water administration of apramycin proved effective in reducing the numbers of organisms in the digestive tract and preventing bacteremia in chickens (336). Neomycin reduced mortality in turkey poults exposed naturally to litter from flocks with colibacillosis (361).

Anticoccidials also have antimicrobial activity that may be beneficial in the prevention and treatment of coliforms. Monensin reduced colonization of chickens with *E. coli* O157:H7 to undetectable levels 14 days post exposure compared with nonmedicated controls and chickens receiving other coccidiostats (544). In a recent study TAMUS 2032, a cationic amphipathic peptide antibiotic produced by *Brevibacillus texasporus*, improved performance and reduced mortality when added to the feed of commercial broilers with

or without monensin following natural environmental challenge. Improved livability and productivity also resulted from adding monensin with or without bacitracin. Bacitracin alone provided no protection against colibacillosis (271).

Other Treatments

The declining use of antibiotics for prevention and treatment of colibacillosis has stimulated interest in alternative methods including prebiotics, probiotics, enzymes, digestive acidifiers, vitamins, immune enhancers, anti-inflammatory drugs, and other antimicrobial products. Although prebiotics and probiotics are widely available for use in poultry, few studies on their effect on colibacillosis have been published. Colonization with *E. coli* begins immediately after hatching, making early administration of probiotics essential (139). Administration of a bacteriocin-producing strain of *Lactobacillus plantarum* F1 or the purified bacteriocin provided chicks with protection against challenge with an O2 APEC. Fermentation of coarsely ground wheat with a mixture of *L. plantarum* and *Pediococcus pentosaceus* completely eliminated *E. coli* when the pH of the mixture was less than 4.0 for at least 24 hours (397). *L. johnsonii* significantly reduced colonization of the small intestine with *E. coli*, but had no effect on colonization of the ceca or large intestine (323).

In addition to lactobacilli, other microbes can inhibit colonization with *E. coli*. Specific strains of *Bacillus* spp. inhibit *E. coli* colonization in the digestive tract and have potential use as probiotics (33, 318). Formation of highly resistant spores simplifies administration of these bacteria to commercial flocks through feed. Extracts prepared from Bifidobacterium enhanced resistance to colibacillosis following oral administration. Cell-mediated immunity was enhanced in the treated chickens (309). Inoculating young birds with nonspecific competitive exclusion products derived from healthy adults reduced intestinal colonization by APEC (239).

Essential oils often have a substantial inhibitory effect on *E. coli in vitro* (218, 459) and in the lower intestinal tract of chickens (268). A commercial oregano oil product has been used in organic poultry production, but there are no studies on its effect on colibacillosis. Isopathic (immune enhancing) and homeopathic treatments with multiple products were unsuccessful in modifying the response of 8-day-old broilers challenged intratracheally with an O78 APEC strain (593). A Chinese herbal mixture ("XQT") significantly lowered plasma inflammatory mediators and reduced mortality when it was given orally prior to challenge (229).

Bacteriophage administration provides another possible alternative to antibiotic medication for controlling colibacillosis (38, 68). Two bacteriophages isolated from municipal wastewater that lysed an O2 APEC were effective in reducing mortality from experimental colibacillosis caused by the homologous APEC strain when high numbers of phage were mixed with the inoculum, given as a spray up to 3 days prior to challenge, or inoculated intramuscularly up to 48 hours post infection (255, 256, 257, 258, 260, 261). Combination of bacteriophage treatment with enrofloxacin had a synergistic beneficial effect (259). Prior exposure to bacteriophage results in antibodies that interfere with subsequent exposure to bacteriophage and reduces their effectiveness (262). While bacteriophage treatment has been shown to be efficacious, several challenges remain before a commercial product might be realized (255).

Several studies have shown vitamin E supplementation to have both prophylactic and therapeutic benefits for *E. coli* infections (250), but not all studies support this conclusion (see Management Procedures). Differences in results likely are due to differences in experimental designs, especially severity of challenge and the timing and manner in which vitamin E is administered. Use of aspirin or sodium salicylate reduced the impact of experimental colibacillosis in turkeys (250) and chickens (346), respectively. However, if used in high levels or in combination with other products that impair the inflammatory response, a reverse response can occur (250). Feeding a beta-glucan product obtained from yeast cell walls improved the response of chickens to *E. coli* challenge, but also depressed growth of unchallenged controls (253).

Acknowledgement

The authors wish to acknowledge the contribution of Dr. W.B. ("Bernie") Gross to this chapter in previous editions of *Diseases of Poultry* and to recognize his pioneering work on this disease in poultry.

References

1. Aarestrup, F.M., and H. Hasman. 2004. Susceptibility of different bacterial species isolated from food animals to copper sulphate, zinc chloride and antimicrobial substances used for disinfection. *Veterinary Microbiology*. 100:83–89.
2. Aarestrup, F.M., and H.C. Wegener. 1999. The effects of antibiotic usage in food animals on the development of antimicrobial resistance of importance for humans in Campylobacter and Escherichia coli. *Microbes and Infection/Institut Pasteur*. 1:639–644.
3. Abbott, S.L., J. O'Connor, T. Robin, B.L. Zimmer, and J.M. Janda. 2003. Biochemical properties of a newly described Escherichia species, *Escherichia albertii. Journal of Clinical Microbiology*. 41:4852–4854.
4. Abdul Aziz, T.A., and S.N. El Sukhon. 1998. Chickens hyperimmunized with *Escherichia coli* J5 strain are protected against experimental challenge with *Escherichia coli* O78 serotype. *Vet Res Comm*. 22:7–9.
5. Abdul Aziz, T.A., and S.N. El Sukhon. 1996. Serum sensitivity and apathogenicity for chickens and chick embryos of *Escherichia coli* J5 strain. *Vet Res*. 27:267–271.
6. Abolnik, C., G.H. Gerdes, M. Sinclair, B.W. Ganzevoort, J.P. Kitching, C.E. Burger, M. Romito, M. Dreyer, S. Swanepoel, G.S. Cumming and A.J. Olivier. 2010. Phylogenetic analysis of influenza A viruses (H6N8, H1N8, H4N2, H9N2, H10N7) isolated from wild birds, ducks, and ostriches in South Africa from 2007 to 2009. *Avian Diseases*. 54:313–322.
7. Akashi, N., S. Hitotsubashi, H. Yamanaka, Y. Fujii, T. Tsuji, A. Miyama, J.E. Joya, and K. Okamoto. 1993. Production of heat-stable enterotoxin II by chicken clinical isolates of Escherichia coli. *FEMS Microbiology Letters*. 109:311–316.

8. Al-Ghamdi, M.S., F. El-Morsy, Z.H. Al-Mustafa, M. Al-Ramadhan, and M. Hanif. 1999. Antibiotic resistance of *Escherichia coli* isolated from poultry workers, patients and chicken in the eastern province of Saudi Arabia. *Trop Med Int Health*. 4:278–283.
9. Al Ankari, A.R., J.M. Bradbury, C.J. Naylor, K.J. Worthington, C. Payne Johnson, and R.C. Jones. 2001. Avian pneumovirus infection in broiler chicks inoculated with *Escherichia coli* at different time intervals. *Avian Pathology: Journal of the WVPA*. 30:257–267.
10. Al Sam, S., A.H. Linton, P.M. Bennett, and M. Hinton. 1993. Effects of low concentrations of ampicillin in feed on the intestinal *Escherichia coli* of chicks. *J Appl Bacteriol*. 75:108–112.
11. Allan, B., R.M. Buchanan, S. Hauta, J. van den Hurk, and H.L. Wilson. 2012. Innate cocktail partially protects broilers against cellulitis and septicemia. *Avian Diseases*. 56:659–669.
12. Altekruse, S.F., F. Elvinger, C. DebRoy, F.W. Pierson, J.D. Eifert, and N. Sriranganathan. 2002. Pathogenic and fecal *Escherichia coli* strains from turkeys in a commercial operation. *Avian Diseases*. 46:562–569.
13. Altekruse, S.F., F. Elvinger, K.Y. Lee, L.K. Tollefson, E.W. Pierson, J. Eifert, and N. Sriranganathan. 2002. Antimicrobial susceptibilities of *Escherichia coli* strains from a turkey operation. *J Am Vet Med Assoc*. 221:411–416.
14. Amabile de Campos, T., E.G. Stehling, A. Ferreira, A.F. Pestana de Castro, M. Brocchi, and W. Dias da Silveira. 2005. Adhesion properties, fimbrial expression and PCR detection of adhesin-related genes of avian *Escherichia coli* strains. *Veterinary Microbiology*. 106:275–285.
15. Amara, A., Z. Ziani, and K. Bouzoubaa. 1995. Antibioresistance of *Escherichia coli* strains isolated in Morocco from chickens with colibacillosis. *Veterinary Microbiology*. 43:325–330.
16. Amoako, K.K., T. Prysliak, A.A. Potter, S.K. Collinson, W.W. Kay, and B.J. Allan. 2004. Attenuation of an avian pathogenic *Escherichia coli* strain due to a mutation in the rpsL gene. *Avian Diseases*. 48:19–25.
17. Anderson, R.C., R.B. Harvey, J.A. Byrd, T.R. Callaway, K.J. Genovese, T.S. Edrington, Y.S. Jung, J.L. McReynolds, and D.J. Nisbet. 2005. Novel preharvest strategies involving the use of experimental chlorate preparations and nitro-based compounds to prevent colonization of food-producing animals by foodborne pathogens. *Poultry Science*. 84:649–654.
18. Antao, E.M., C. Ewers, D. Gurlebeck, R. Preisinger, T. Homeier, G. Li, and L.H. Wieler. 2009. Signature-tagged mutagenesis in a chicken infection model leads to the identification of a novel avian pathogenic *Escherichia coli* fimbrial adhesin. *PloS One*. 4:e7796.
19. Antao, E.M., S. Glodde, G. Li, R. Sharifi, T. Homeier, C. Laturnus, I. Diehl, A. Bethe, H.C. Philipp, R. Preisinger, L.H. Wieler, and C. Ewers. 2008. The chicken as a natural model for extraintestinal infections caused by avian pathogenic *Escherichia coli* (APEC). *Microbial Pathogenesis*. 45:361–369.
20. Ardrey, W.B., C.F. Peterson, and M. Haggart. 1968. Experimental colibacillosis and the development of carriers in laying hens. *Avian Diseases*. 12:505–511.
21. Arenas, A., S. Vicente, I. Luque, J.C. Gomez-Villamandos, R. Astorga, A. Maldonado, and C. Tarradas. 1999. Outbreak of septicaemic colibacillosis in Japanese quail (*Coturnix coturnix japonica*). *Zentralbl Veterinarmed [B]*. 46:399–404.
22. Arne, P., D. Marc, A. Bree, C. Schouler, and M. Dho-Moulin. 2000. Increased tracheal colonization in chickens without impairing pathogenic properties of avian pathogenic *Escherichia coli* MT78 with a fimH deletion. *Avian Diseases*. 44:343–355.
23. Arp, L.H. 1985. Effect of antibodies to type 1 fimbriae on clearance of fimbriated *Escherichia coli* from the bloodstream of turkeys. *American Journal of Veterinary Research*. 46:2644–2647.
24. Arp, L.H. 1982. Effect of passive immunization on phagocytosis of blood-borne *Escherichia coli* in spleen and liver of turkeys. *American Journal of Veterinary Research*. 43:1034–1040.
25. Arp, L.H., and N.F. Cheville. 1981. Interaction of blood-borne *Escherichia coli* with phagocytes of spleen and liver in turkeys. *American Journal of Veterinary Research*. 42:650–657.
26. Ask, B., E.H. van der Waaij, J.A. Stegeman, and J.A. van Arendonk. 2006. Genetic variation among broiler genotypes in susceptibility to colibacillosis. *Poultry Science*. 85:415–421.
27. Ask, B., E.H. van der Waaij, J.H. van Eck, J.A. van Arendonk, and J.A. Stegeman. 2006. Defining susceptibility of broiler chicks to colibacillosis. *Avian Pathology: Journal of the WVPA*. 35:147–153.
28. Babai, R., B.E. Stern, J. Hacker, and E.Z. Ron. 2000. New fimbrial gene cluster of S-fimbrial adhesin family. *Infection and Immunity*. 68:5901–5907.
29. Babiuk, L.A., S. Gomis, and R. Hecker. 2003. Molecular approaches to disease control. *Poultry Science*. 82:870–875.
30. Bangert, R.L., B.R. Cho, P.R. Widders, E.H. Stauber, and A.C. Ward. 1988. A survey of aerobic bacteria and fungi in the feces of healthy psittacine birds. *Avian Diseases*. 32:46–52.
31. Bano, S., K. Naeem, and S.A. Malik. 2003. Evaluation of pathogenic potential of avian influenza virus serotype H9N2 in chickens. *Avian Diseases*. 47:817–822.
32. Barbieri, N.L., T.M. Tejkowski, A.L. d. Oliveira, B.G. d. Brito, and F. Horn. 2012. Characterization of extraintestinal *Escherichia coli* isolated from a peacock (*Pavo cristatus*) with colisepticemia. *Avian Diseases*. 56:436–440.
33. Barbosa, T.M., C.R. Serra, R.M. La Ragione, M.J. Woodward, and A.O. Henriques. 2005. Screening for bacillus isolates in the broiler gastrointestinal tract. *Applied and Environmental Microbiology*. 71:968–978.
34. Barnes, H.J. 2000. Pathological manifestation of colibacillosis in poultry. Proc 21st World's Poultry Congress, Montréal, Canada, Aug. 20–24.
35. Barnes, H.J. 2001. Unpublished data.
36. Barnes, H.J., and F. Lozano. 1994. *Colibacillosis in Poultry*. Pfizer Animal Health, Lee's Summit, MO. 45.
37. Barondess, J.J., and J. Beckwith. 1990. A bacterial virulence determinant encoded by lysogenic coliphage lambda. *Nature*. 346:871–874.
38. Barrow, P., M. Lovell, and A. Berchieri, Jr. 1998. Use of lytic bacteriophage for control of experimental *Escherichia coli* septicemia and meningitis in chickens and calves. *Clin Diag Lab Immunol*. 5:294–298.
39. Baruah, K.K., P.K. Sharma, and N.N. Bora. 2001. Fertility, hatchability and embryonic mortality in ducks. *Indian Vet J*. 78:529–530.
40. Bass, L., C.A. Liebert, M.D. Lee, A.O. Summers, D.G. White, S.G. Thayer, and J.J. Maurer. 1999. Incidence and characterization of integrons, genetic elements mediating multiple-drug resistance, in avian *Escherichia coli*. *Antimicrobial Agents and Chemotherapy*. 43:2925–2929.
41. Bastiani, M., M.C. Vidotto, and F. Horn. 2005. An avian pathogenic *Escherichia coli* isolate induces caspase 3/7 activation in J774 macrophages. *FEMS Microbiology Letters*. 253:133–140.

42. Bayyari, G.R., W.E. Huff, J.M. Balog, and N.C. Rath. 1997. Variation in toe-web response of turkey poults to phytohemagglutinin-P and their resistance to *Escherichia coli* challenge. *Poultry Science*. 76:791–797.
43. Bayyari, G.R., W.E. Huff, R.A. Norton, J.K. Skeeles, J.N. Beasley, N.C. Rath, and J.M. Balog. 1994. A longitudinal study of green-liver osteomyelitis complex in commercial turkeys. *Avian Diseases*. 38:744–754.
44. Bayyari, G.R., W.E. Huff, N.C. Rath, J.M. Balog, L.A. Newberry, J.D. Villines, and J.K. Skeeles. 1997. Immune and physiological responses of turkeys with green-liver osteomyelitis complex. *Poultry Science*. 76:280–288.
45. Bazile-Pham-Khac, S., Q.C. Truong, J.P. Lafont, L. Gutmann, X.Y. Zhou, M. Osman, and N.J. Moreau. 1996. Resistance to fluoroquinolones in *Escherichia coli* isolated from poultry. *Antimicrobial Agents and Chemotherapy*. 40:1504–1507.
46. Beery, J.T., M.P. Doyle, and J L. Schoeni. 1985. Colonization of chicken cecae by *Escherichia coli* associated with hemorrhagic colitis. *Applied and Environmental Microbiology*. 49:310–315.
47. Bell, C., and A. Kyriakides. 1998. *E. coli. A Practical Approach to the Organism and Its Control in Foods*. Blackie Academic & Professional, London. 200.
48. Berney, M., H.-U. Weilenmann, A. Simonetti, and T. Egli. 2006. Efficacy of solar disinfection of *Escherichia coli*, *Shigella flexneri, Salmonella typhimurium and Vibrio cholerae. Journal of Applied Microbiology*. 101:828–836.
49. Berrang, M.E., and J.K. Northcutt. 2005. Use of water spray and extended drying time to lower bacterial numbers on soiled flooring from broiler transport coops. *Poultry Science*. 84:1797–1801.
50. Bertrand, N., S. Houle, G. LeBihan, E. Poirier, C.M. Dozois, and J. Harel. 2010. Increased Pho regulon activation correlates with decreased virulence of an avian pathogenic *Escherichia coli* O78 strain. *Infection and Immunity*. 78:5324–5331.
51. Best, A., R.M. La Ragione, A.R. Sayers and M.J. Woodward. 2005. Role for flagella but not intimin in the persistent infection of the gastrointestinal tissues of specific-pathogen-free chicks by shiga toxin-negative *Escherichia coli* O157:H7. *Infection and Immunity*. 73:1836–1846.
52. Bettelheim, K.A. 1994. Biochemical characteristics of *Escherichia coli*. In: *Escherichia coli in Domestic Animals and Humans*. C.L. Gyles, ed. CAB Int'l, Wallingford, UK. 3–30.
53. Binns, M.M., D.L. Davies, and K.G. Hardy. 1979. Cloned fragments of the plasmid ColV,I-K94 specifying virulence and serum resistance. *Nature*. 279:778–781.
54. Binns, M.M., J. Mayden, and R.P. Levine. 1982. Further characterization of complement resistance conferred on *Escherichia coli* by the plasmid genes traT of R100 and iss of ColV,I-K94. *Infection and Immunity*. 35:654–659.
55. Bisgaard, M. 1995. Salpingitis in web-footed birds: prevalence, aetiology and significance. *Avian Pathology: Journal of the W.V.P.A*. 24:443–452.
56. Bisgaard, M., and A. Dam. 1980. Salpingitis in poultry. I. Prevalence, bacteriology and possible pathogenesis in broilers. *Nord Vet*. 32:361–368.
57. Bisgaard, M., and A. Dam. 1981. Salpingitis in poultry. II. Prevalence, bacteriology, and possible pathogenesis in egg-laying chickens. *Nord Vet*. 33:81–89.
58. Blanco, J.E., M. Blanco, A. Mora, and J. Blanco. 1997. Prevalence of bacterial resistance to quinolones and other antimicrobials among avian Escherichia coli strains isolated from septicemic and healthy chickens in Spain. *Journal of Clinical Microbiology*. 35:2184–2185.
59. Blanco, J.E., M. Blanco, A. Mora, and J. Blanco. 1997. Production of toxins (enterotoxins, verotoxins, and necrotoxins) and colicins by *Escherichia coli* strains isolated from septicemic and healthy chickens: relationship with *in vivo* pathogenicity. *Journal of Clinical Microbiology*. 35:2953–2957.
60. Blanco, J.E., M. Blanco, A. Mora, W.H. Jansen, V. Garcia, M.L. Vazquez, and J. Blanco. 1998. Serotypes of *Escherichia coli* isolated from septicaemic chickens in Galicia (northwest Spain). *Veterinary Microbiology*. 61:229–235.
61. Boa Amponsem, K., A. Yang, N.K. Praharaj, E.A. Dunnington, W.B. Gross, and P.B. Siegel. 1997. Impact of alternate-day feeding cycles on immune and antibacterial responses of White Leghorn chicks. *J Appl Poult Res*. 6:123–127.
62. Boado, E., A. Gonzalez, V. Masdeu, C. Fonseca, O. Viamontes and Y.J. Camejo. 1988. Chlorination of drinking water against coli septicaemia in fowls. *Revista Avicultura*. 32:45–58.
63. Boado, E., L. Zaldivar, and A. Gonzalez. 1992. Diagnosis, report and incidence of diseases of the pigeon (*Columba livia*) in Cuba. *Rev Cubana Ciencia Avicola*. 19:74–78.
64. Bolin, C.A. 1986. Effects of exogenous iron on *Escherichia coli* septicemia of turkeys. *American Journal of Veterinary Research*. 47:1813–1816.
65. Bolin, C.A., and A.E. Jensen. 1987. Passive immunization with antibodies against iron-regulated outer membrane proteins protects turkeys from Escherichia coli septicemia. *Infection and Immunity*. 55:1239–1242.
66. Bradley, R.E., and W.M. Reid. 1966. Histomonas meleagridis and several bacteria as agents of infectious enterohepatitis in gnotobiotic turkeys. *Experimental Parasitology*. 19:91–101.
67. Brown, P.K., and R. Curtiss, 3rd. 1996. Unique chromosomal regions associated with virulence of an avian pathogenic *Escherichia coli* strain. *Proc Natl Acad Sci USA*. 93: 11149–11154.
68. Brussow, H. 2005. Phage therapy: the *Escherichia coli* experience. *Microbiol*. 151:2133–2140.
69. Bumstead, N., M.B. Huggins, and J.K. Cook. 1989. Genetic differences in susceptibility to a mixture of avian infectious bronchitis virus and Escherichia coli. *Br Poult Sci*. 30:39–48.
70. Burns, K.E., R. Otalora, J.R. Glisson and C.L. Hofacre. 2003. Cellulitis in Japanese quail (*Coturnix coturnix japonica*). *Avian Diseases*. 47:211–214.
71. Carson, C.A., B.L. Shear, M.R. Ellersieck, and A. Asfaw. 2001. Identification of fecal *Escherichia coli* from humans and animals by ribotyping. *Applied and Environmental Microbiology*. 67:1503–1507.
72. Caza, M., F. Lepine, and C.M. Dozois. 2011. Secretion, but not overall synthesis, of catecholate siderophores contributes to virulence of extraintestinal pathogenic *Escherichia coli*. *Molecular Microbiology*. 80:266–282.
73. Caza, M., F. Lepine, S. Milot, and C.M. Dozois. 2008. Specific roles of the iroBCDEN genes in virulence of an avian pathogenic *Escherichia coli* O78 strain and in production of salmochelins. *Infection and Immunity*. 76:3539–3549.
74. Cessi, D. 1979. Prophylaxis of *Escherichia coli* infection in fowls with emulsified vaccines. *Clinica Veterinaria*. 102:270–278.
75. Chaffer, M., B. Schwartsburd, and E.D. Heller. 1997. Vaccination of turkey poults against pathogenic *Escherichia coli*. *Avian Pathology: Journal of the W.V.P.A*. 26:377–390.
76. Chamanza, R., L. v. Veen, M.T. Tivapasi, M.J.M. Toussaint, and L. van Veen. 1999. Acute phase proteins in the domestic fowl. *World's Poult Sci J*. 55:61–71.

77. Chansiripornchai, N., P. Ramasoota, J. Sasipreeyajan, and S. B. Svenson. 2001. Differentiation of avian pathogenic *Escherichia coli* (APEC) strains by random amplified polymorphic DNA (RAPD) analysis. *Veterinary Microbiology*. 80:75–83.
78. Chanteloup, N.K., G. Porcheron, B. Delaleu, P. Germon, C. Schouler, M. Moulin-Schouleur, and P. Gilot. 2011. The extra-intestinal avian pathogenic *Escherichia coli* strain BEN2908 invades avian and human epithelial cells and survives intracellularly. *Veterinary Microbiology*. 147:435–439.
79. Chapman, M.E., W. Wang, G.F. Erf, and R.F. Wideman, Jr. 2005. Pulmonary hypertensive responses of broilers to bacterial lipopolysaccharide (LPS): evaluation of LPS source and dose, and impact of pre-existing pulmonary hypertension and cellulose micro-particle selection. *Poultry Science*. 84:432–441.
80. Chaslus-Dancla, E., G. Gerbaud, M. Lagorce, J.P. Lafont, and P. Courvalin. 1987. Persistence of an antibiotic resistance plasmid in intestinal *Escherichia coli* of chickens in the absence of selective pressure. *Antimicrobial Agents and Chemotherapy*. 31:784–788.
81. Cheng, H.W., R. Freire, and E.A. Pajor. 2004. Endotoxin stress responses in chickens from different genetic lines. 1. Sickness, behavioral, and physical responses. *Poultry Science*. 83:707–715.
82. Cheville, N.F., and L.H. Arp. 1978. Comparative pathologic findings of *Escherichia coli* infection in birds. *J Am Vet Med Assoc*. 173:584–587.
83. Chouikha, I., P. Germon, A. Bree, P. Gilot, M. Moulin-Schouleur, and C. Schouler. 2006. A selC-associated genomic island of the extraintestinal avian pathogenic *Escherichia coli* strain BEN2908 is involved in carbohydrate uptake and virulence. *Journal of Bacteriology*. 188:977–987.
84. Christiansen, K.H., D.W. Hird, K.P. Snipes, C. Danaye-Elmi, C.W. Palmer, M.D. McBride, and W.W. Utterback. 1996. California National Animal Health Monitoring System for meat turkey flocks—1988–89 pilot study: management practices, flock health, and production. *Avian Diseases*. 40:278–284.
85. Chuba, P.J., M.A. Leon, A. Banerjee, and S. Palchaudhuri. 1989. Cloning and DNA sequence of plasmid determinant iss, coding for increased serum survival and surface exclusion, which has homology with lambda DNA. *Mol Gen Genet*. 216:287–292.
86. Chuba, P.J., S. Palchaudhuri, and M.A. Leon. 1986. Contribution of traT and iss genes to the serum resistance phenotype of plasmid ColV-K94. *FEMS Microbiology Letters*. 37:135–140.
87. Clark, S., R. Porter, B. McComb, R. Lippert, S. Olson, S. Nohner, and H.L. Shivaprasad. 2010. Clostridial dermatitis and cellulitis: an emerging disease of turkeys. *Avian Diseases*. 54:788–794.
88. Clark, S.R., H.J. Barnes, A.A. Bickford, R.P. Chin, and R. Droual. 1991. Relationship of osteomyelitis and associated soft-tissue lesions with green liver discoloration in tom turkeys. *Avian Diseases*. 35:139–146.
89. Clermont, O., J.R. Johnson, M. Menard, and E. Denamur. 2007. Determination of *Escherichia coli* O types by allele-specific polymerase chain reaction: application to the O types involved in human septicemia. *Diagn Microbiol Infect Dis*. 57:129–136.
90. Cole, D., D.J. Drum, D.E. Stalknecht, D.G. White, M.D. Lee, S. Ayers, M. Sobsey, and J.J. Maurer. 2005. Free-living Canada geese and antimicrobial resistance. *Emerg Infect Dis*. 11:935–938.
91. Cook, J.K.A., M.B. Huggins, and M.M. Ellis. 1991. Use of an infectious bronchitis virus and *Escherichia coli* model infection to assess the ability to vaccinate successfully against infectious bronchitis in the presence of maternally-derived immunity. *Avian Pathology: Journal of the W.V.P.A*. 20:619–626.
92. Cook, J.K.A., H.W. Smith, and M.B. Huggins. 1986. Infectious bronchitis immunity: its study in chickens experimentally infected with mixtures of infectious bronchitis virus and *Escherichia coli*. *J Gen Virol*. 67:1427–1434.
93. Cooper, R.G. 2005. Bacterial, fungal and parasitic infections in the ostrich (Struthio camelus var. domesticus). *An Sci J*. 76:97–106.
94. Cormican, M., V. Buckley, G. Corbett-Feeney, and F. Sheridan. 2001. Antimicrobial resistance in *Escherichia coli* isolates from turkeys and hens in Ireland. *The Journal of Antimicrobial Chemotherapy*. 48:587–588.
95. Cortes, M.A., J. Gibon, N.K. Chanteloup, M. Moulin-Schouleur, P. Gilot, and P. Germon. 2008. Inactivation of ibeA and ibeT results in decreased expression of type 1 fimbriae in extraintestinal pathogenic *Escherichia coli* strain BEN2908. *Infection and Immunity*. 76:4129–4136.
96. Coufal, C.D., C. Chavez, K.D. Knape, and J.B. Carey. 2003. Evaluation of a method of ultraviolet light sanitation of broiler hatching eggs. *Poultry Science*. 82:754–759.
97. Crespo, R., R.L. Walker, R. Nordhausen, S.J. Sawyer, and R.B. Manalac. 2001. Salpingitis in Pekin ducks associated with concurrent infection with Tetratrichomonas sp., and *Escherichia coli*. *J Vet Diagn Invest*. 13:240–245.
98. Cross, A.S., P. Gemski, J.C. Sadoff, F. Orskov, and I. Orskov. 1984. The importance of the K1 capsule in invasive infections caused by *Escherichia coli*. *The Journal of Infectious Diseases*. 149:184–193.
99. Cross, A.S., J.C. Sadoff, P. Gemski, and K.S. Kim. 1988. The relative role of lipopolysaccharide and capsule in the virulence of *E. coli*. In: *Bacteria, Complement and the Phagocytic Cell*, Vol. H2., F. Cabello and C. Pruzzo, eds. Springer-Verlag, Berlin. 319–334.
99a. Current, W.L., M.N. Novilla, and D.B. Snyder. 1987. Cryptosporidiosis in poultry: An update (Are Cryptosporidium spp. primary pathogens?). *Proc Nat Meet Poult Health Condemn*. 22:17–29.
100. da Silva, P.L., H.E. Coelho, S.C. Ribeiro, and P.R. Oliveira. 1989. Occurrence of coligranulomatosis in coturnix quail in Uberlandia, Minas Gerais, Brazil. *Avian Diseases*. 33:590–593.
101. da Silveira, W.D., A. Ferreira, M. Brocchi, L.M.D. Hollanda, A.F.P. d. Castro, A.T. Yamada, M. Lancellotti, W.D. da Silveira, L.M. de Hollanda, and A.F.P. de Castro. 2002. Biological characteristics and pathogenicity of avian Escherichia coli strains. *Veterinary Microbiology*. 85:47–53.
102. da Silveira, W.D., A. Ferreira, M. Lancellotti, I.A.G.C.D. Barbosa, D.S. Leite, A.F.P. de Castro, and M. Brocchi. 2002. Clonal relationships among avian *Escherichia coli* isolates determined by enterobacterial repetitive intergenic consensus (ERIC)-PCR. *Veterinary Microbiology*. 89:323–328.
103. da Silveira, W.D., M. Lancellotti, A. Ferreira, V.N. Solferini, A.F. de Castro, E.G. Stehling, and M. Brocchi. 2003. Determination of the clonal structure of avian *Escherichia coli* strains by isoenzyme and ribotyping analysis. *J Vet Med [B]*. 50:63–69.
104. Dai, J., S. Wang, D. Guerlebeck, C. Laturnus, S. Guenther, Z. Shi, C. Lu, and C. Ewers. 2010. Suppression subtractive hybridization identifies an autotransporter adhesin gene of *E. coli* IMT5155 specifically associated with avian pathogenic *Escherichia coli* (APEC). *BMC Microbiology*. 10:236.
105. Davis, C.R. 1938. Colibacillosis in young chicks. *J Am Vet Med Assoc*. 92:518–522.

106. Davis, M., and T.Y. Morishita. 2005. Relative ammonia concentrations, dust concentrations, and presence of Salmonella species and *Escherichia coli* inside and outside commercial layer facilities. *Avian Diseases*. 49:30–35.
107. Davis, M.F., G.M. Ebako, and T.Y. Morishita. 2003. A golden comet hen (*Gallus gallus forma domestica*) with an impacted oviduct and associated colibacillosis. *J Avian Med Surg*. 17:91–95.
108. De Boever, S., S. Croubels, E. Meyer, S. Sys, R. Beyaert, R. Ducatelle, and P. De Backer. 2009. Characterization of an intravenous lipopolysaccharide inflammation model in broiler chickens. *Avian Pathology: Journal of the W.V.P.A*. 38:403–411.
109. de Brito, B.G., L.C. Gaziri, and M.C. Vidotto. 2003. Virulence factors and clonal relationships among *Escherichia coli* strains isolated from broiler chickens with cellulitis. *Infection and Immunity*. 71:4175–4177.
110. de Moura, A.C., K. Irino, and M.C. Vidotto. 2001. Genetic variability of avian *Escherichia coli* strains evaluated by enterobacterial repetitive intergenic consensus and repetitive extragenic palindromic polymerase chain reaction. *Avian Diseases*. 45:173–181.
111. de Pace, F., J. Boldrin de Paiva, G. Nakazato, M. Lancellotti, M.P. Sircili, E. Guedes Stehling, W. Dias da Silveira, and V.Sperandio. 2011. Characterization of IcmF of the type VI secretion system in an avian pathogenic *Escherichia coli* (APEC) strain. *Microbiology*. 157:2954–2962.
112. de Pace, F., G. Nakazato, A. Pacheco, J.B. de Paiva, V. Sperandio, and W.D. da Silveira. 2010. The type VI secretion system plays a role in type 1 fimbria expression and pathogenesis of an avian pathogenic *Escherichia coli* strain. *Infection and Immunity*. 78:4990–4998.
113. Deb, J.R., and E.G. Harry. 1978. Laboratory trials with inactivated vaccines against *Escherichia coli* (O2:K1) infection in fowls. *Research in Veterinary Science*. 24:308–313.
114. Deb, J.R., and E.G. Harry. 1976. Laboratory trials with inactivated vaccines against *Escherichia coli* (O78 K80) infection in fowls. *Research in Veterinary Science*. 20:131–138.
115. DebRoy, C., E. Roberts, and P.M. Fratamico. 2011. Detection of O antigens in *Escherichia coli*. *Anim Health Res Rev*. 12:169–185.
116. Delicato, E.R., B.G. de Brito, L.C. Gaziri, and M.C. Vidotto. 2003. Virulence-associated genes in *Escherichia coli* isolates from poultry with colibacillosis. *Veterinary Microbiology*. 94:97–103.
117. Delicato, E.R., B.G. de Brito, A.P. Konopatzki, L.C. Gaziri, and M.C. Vidotto. 2002. Occurrence of the temperature-sensitive hemagglutinin among avian *Escherichia coli*. *Avian Diseases*. 46:713–716.
118. Dell' Omo, G., S. Morabito, R. Quondam, U. Agrimi, F. Ciuchini, A. Macri, and A. Caprioli. 1998. Feral pigeons as a source of verocytotoxin-producing *Escherichia coli*. *The Veterinary Record*. 142:309–310.
119. DeRosa, M., M.D. Ficken, and H.J. Barnes. 1992. Acute airsacculitis in untreated and cyclophosphamide-pretreated broiler chickens inoculated with *Escherichia coli* or *Escherichia coli* cell-free culture filtrate. *Vet Pathol*. 29:68–78.
120. Dhillon, A.S. 1986. Pathology of avian adenovirus serotypes in the presence of *Escherichia coli* in infectious-bursal-disease-virus-infected specific-pathogen-free chickens. *Avian Diseases*. 30:81–86.
121. Dhillon, A.S., and O.K. Jack. 1996. Two outbreaks of colibacillosis in commercial caged layers. *Avian Diseases*. 40:742–746.
122. Dhillon, A.S., and F.S. Kibenge. 1987. Adenovirus infection associated with respiratory disease in commercial chickens. *Avian Diseases*. 31:654–657.
123. Dho-Moulin, M., and J.M. Fairbrother. 1999. Avian pathogenic *Escherichia coli* (APEC). *Vet Res*. 30:299–316.
124. Dho, M., and J.P. Lafont. 1984. Adhesive properties and iron uptake ability in *Escherichia coli* lethal and nonlethal for chicks. *Avian Diseases*. 28:1016–1025.
125. Díaz-Sánchez, S., S. Sánchez, C. Ewers, and U. Höfle. 2012. Occurrence of avian pathogenic *Escherichia coli* and antimicrobial-resistant E. coli in red-legged partridges (*Alectoris rufa*): sanitary concerns of farming. *Avian Pathology*. 41:337–344.
126. Dobrindt, U. 2005. (Patho-)Genomics of *Escherichia coli*. *International Journal of Medical Microbiology*. 295:357–371.
127. Doetkott, D.M., L.K. Nolan, C.W. Giddings, and D.L. Berryhill. 1996. Large plasmids of avian *Escherichia coli* isolates. *Avian Diseases*. 40:927–930.
128. Dominick, M.A. 1985. Pathologic response of gnotobiotic turkeys following oral challenge with highly and weakly virulent strains of *Escherichia coli*. *Dissertation Abstracts International, B*. 45:2067.
129. Dominick, M.A., and A.E. Jensen. 1984. Colonization and persistence of *Escherichia coli* in axenic and monoxenic turkeys. *American Journal of Veterinary Research*. 45:2331–2335.
130. Doyle, M.P., and J.L. Schoeni. 1987. Isolation of *Escherichia coli* O157:H7 from retail fresh meats and poultry. *Applied and Environmental Microbiology*. 53:2394–2396.
131. Dozois, C.M., F. Daigle, and R. Curtiss, 3rd. 2003. Identification of pathogen-specific and conserved genes expressed *in vivo* by an avian pathogenic *Escherichia coli* strain. *Proceedings of the National Academy of Sciences of the United States of America*. 100:247–252.
132. Dozois, C.M., M. Dho-Moulin, A. Bree, J.M. Fairbrother, C. Desautels, and R. Curtiss, 3rd. 2000. Relationship between the Tsh autotransporter and pathogenicity of avian *Escherichia coli* and localization and analysis of the tsh genetic region. *Infection and Immunity*. 68:4145–4154.
133. Droual, R., R.P. Chin, and M. Rezvani. 1996. Synovitis, osteomyelitis, and green liver in turkeys associated with Escherichia coli. *Avian Diseases*. 40:417–424.
134. Droual, R., and P. Woolcock. 1994. Swollen head syndrome associated with E. coli and infectious bronchitis virus in the Central Valley of California. *Avian Pathology: Journal of the W.V.P.A*. 23:733–742.
135. Dunnington, E.A., P.B. Siegel, and W.B. Gross. 1991. *Escherichia coli* challenge in chickens selected for high or low antibody response and differing in haplotypes at the major histocompatibility complex. *Avian Diseases*. 35:937–940.
136. Dziva, F., H. Hauser, T.R. Connor, P.M. van Diemen, G. Prescott, G.C. Langridge, S. Eckert, R.R. Chaudhuri, C. Ewers, M. Mellata, S. Mukhopadhyay, R. Curtiss, 3rd, G. Dougan, L.H. Wieler, N.R. Thomson, D.J. Pickard, and M.P. Stevens. 2012. Sequencing and functional annotation of avian pathogenic *Escherichia coli* serogroup O78 strains reveals the evolution of *E. coli* lineages pathogenic for poultry via distinct mechanisms. *Infection and Immunity*.
137. Dziva, F., and M.P. Stevens. 2008. Colibacillosis in poultry: unravelling the molecular basis of virulence of avian pathogenic *Escherichia coli* in their natural hosts. *Avian Pathology: Journal of the W.V.P.A*. 37:355–366.

138. Edelman, S., S. Leskela, E. Ron, J. Apajalahti, and T.K. Korhonen. 2003. *In vitro* adhesion of an avian pathogenic *Escherichia coli* O78 strain to surfaces of the chicken intestinal tract and to ileal mucus. *Veterinary Microbiology*. 91:41–56.
139. Edens, F.W., C.R. Parkhurst, I.A. Casas, and W.J. Dobrogosz. 1997. Principles of *ex ovo* competitive exclusion and *in ovo* administration of *Lactobacillus reuteri*. *Poultry Science*. 76:179–196.
140. Edens, F.W., C.R. Parkhurst, M.A. Qureshi, I.A. Casas, and G.B. Havenstein. 1997. Atypical *Escherichia coli* strains and their association with poult enteritis and mortality syndrome. *Poultry Science*. 76:952–960.
141. Edens, F.W., R.A. Qureshi, C.R. Parkhurst, M.A. Qureshi, G.B. Havenstein, and I.A. Casas. 1997. Characterization of two *Escherichia coli* isolates associated with poult enteritis and mortality syndrome. *Poultry Science*. 76:1665–1673.
142. Ekperigin, H.E., R.H. McCapes, R. Redus, W.L. Ritchie, W.J. Cameron, K.V. Nagaraja, and S. Noll. 1990. Microcidal effects of a new pelleting process. *Poultry Science*. 69:1595–1598.
143. El-Sukhon, S.N., A. Musa, and M. Al-Attar. 2002. Studies on the bacterial etiology of airsacculitis of broilers in northern and middle Jordan with special reference to *Escherichia coli, Ornithobacterium rhinotracheale, and Bordetella avium*. *Avian Diseases*. 46:605–612.
144. El Tayeb, A.B., and R.P. Hanson. 2001. The interaction between Newcastle disease virus and *Escherichia coli* endotoxin in chickens. *Avian Diseases*. 45:313–320.
145. El Tayeb, A.B., and R.P. Hanson. 2002. Interactions between *Escherichia coli* and Newcastle disease virus in chickens. *Avian Diseases*. 46:660–667.
146. Emery, D.A., K.V. Nagaraja, D.P. Shaw, J.A. Newman, and D.G. White. 1992. Virulence factors of *Escherichia coli* associated with colisepticemia in chickens and turkeys. *Avian Diseases*. 36:504–511.
147. Emery, D.A., K.V. Nagaraja, V. Sivanandan, B.W. Lee, C.L. Zhang, and J.A. Newman. 1991. Endotoxin lipopolysaccharide from *Escherichia coli* and its effects on the phagocytic function of systemic and pulmonary macrophages in turkeys. *Avian Diseases*. 35:901–909.
148. Ewers, C., T. Janssen, S. Kiessling, H.C. Philipp, and L.H. Wieler. 2004. Molecular epidemiology of avian pathogenic *Escherichia coli* (APEC) isolated from colisepticemia in poultry. *Veterinary Microbiology*. 104:91–101.
149. Ewers, C., T. Janssen, S. Kiessling, H.C. Philipp, and L.H. Wieler. 2005. Rapid detection of virulence-associated genes in avian pathogenic *Escherichia coli* by multiplex polymerase chain reaction. *Avian Diseases*. 49:269–273.
150. Ewers, C., T. Janssen, and L.H. Wieler. 2003. Aviare pathogene *Escherichia coli* (APEC). *Berl Munch Tierarztl Wochenschr*. 116:381–395.
151. Ewers, C., G. Li, H. Wilking, S. Kiessling, K. Alt, E.M. Antao, C. Laturnus, I. Diehl, S. Glodde, T. Homeier, U. Bohnke, H. Steinruck, H.C. Philipp, and L.H. Wieler. 2007. Avian pathogenic, uropathogenic, and newborn meningitis-causing *Escherichia coli*: how closely related are they? *International Journal of Medical Microbiology*. 297:163–176.
152. Ewing, W.H. 1986. *Edwards and Ewing's Identification of Enterobacteriaceae*, 4th ed. Elsevier, Amsterdam. 1–536.
153. Fallacara, D.M., C.M. Monahan, T.Y. Morishita, C.A. Bremer, and R.F. Wack. 2004. Survey of parasites and bacterial pathogens from free-living waterfowl in zoological settings. *Avian Diseases*. 48:759–767.
154. Fallacara, D.M., C.M. Monahan, T.Y. Morishita, and R.F. Wack. 2001. Fecal shedding and antimicrobial susceptibility of selected bacterial pathogens and a survey of intestinal parasites in free-living waterfowl. *Avian Diseases*. 45:128–135.
155. Farmer, J.J., 3rd, G.R. Fanning, B.R. Davis, C.M. O'Hara, C. Riddle, F.W. Hickman-Brenner, M.A. Asbury, V.A. Lowery, 3rd, and D.J. Brenner. 1985. *Escherichia fergusonii* and *Enterobacter taylorae*, two new species of Enterobacteriaceae isolated from clinical specimens. *Journal of Clinical Microbiology*. 21:77–81.
156. Ficken, M.D., J.F. Edwards, and J.C. Lay. 1986. Clearance of bacteria in turkeys with Bordetella avium-induced tracheitis. *Avian Diseases*. 30:352–357.
157. Ficken, M.D., J.F. Edwards, J.C. Lay, and D.E. Tveter. 1987. Tracheal mucus transport rate and bacterial clearance in turkeys exposed by aerosol to La Sota strain of Newcastle disease virus. *Avian Diseases*. 31:241–248.
158. Forgetta, V., H. Rempel, F. Malouin, R. Vaillancourt, Jr., E. Topp, K. Dewar, and M.S. Diarra. 2012. Pathogenic and multidrug-resistant *Escherichia fergusonii* from broiler chicken. *Poultry Science*. 91:512–525.
159. Foster, G., H.M. Ross, T.W. Pennycott, G.F. Hopkins, and I.M. McLaren. 1998. Isolation of *Escherichia coli* O86:K61 producing cyto-lethal distending toxin from wild birds of the finch family. *Lett Appl Microbiol*. 26:395–398.
160. Franchesi, M.D., S. Viora, and H. Barrios. 1995. *Escherichia coli* infections in layer quails. *Rev Med Vet Buenos Aires*. 76:416–420.
161. Fricke, W.F., P.F. McDermott, M.K. Mammel, S. Zhao, T.J. Johnson, D.A. Rasko, P.J. Fedorka-Cray, A. Pedroso, J.M. Whichard, J.E. Leclerc, D.G. White, T.A. Cebula, and J. Ravel. 2009. Antimicrobial resistance-conferring plasmids with similarity to virulence plasmids from avian pathogenic *Escherichia coli* strains in Salmonella enterica serovar Kentucky isolates from poultry. *Applied and Environmental Microbiology*. 75:5963–5971.
162. Friedman, A., I. Aryeh, D. Melamed, and I. Nir. 1998. Defective immune response and failure to induce oral tolerance following enteral exposure to antigen in broilers afflicted with stunting syndrome. *Avian Pathology: Journal of the W.V.P.A*. 27:518–525.
163. Friedman, A., I. Bartov, and D. Sklan. 1998. Humoral immune response impairment following excess vitamin E nutrition in the chick and turkey. *Poultry Science*. 77:956–962.
164. Friedman, A., A. Meidovsky, G. Leitner, and D. Sklan. 1991. Decreased resistance and immune response to *Escherichia coli* infection in chicks with low or high intakes of vitamin A. *J Nutrition*. 121:395–400.
165. Friedman, A., E. Shalem Meilin, and E.D. Heller. 1992. Marek's disease vaccines cause temporary B-lymphocyte dysfunction and reduced resistance to infection in chicks. *Avian Pathology: Journal of the W.V.P.A*. 21:621–631.
166. Friedman, J., M.S. Dison, S. Perl, and Y. Weisman. 1988. Spondylosis in turkeys. *Israel J Vet Med*. 44:97–102.
167. Frommer, A., P.J. Freidlin, R.R. Bock, G. Leitner, M. Chaffer, and E.D. Heller. 1994. Experimental vaccination of young chickens with a live, non-pathogenic strain of *Escherichia coli*. *Avian Pathology: Journal of the W.V.P.A*. 23:425–433.
168. Fukata, T., E. Baba, and A. Arakawa. 1989. Population of Salmonella typhimurium in the cecum of gnotobiotic chickens. *Poultry Science*. 68:311–314.

169. Fukui, H., M. Sueyoshi, M. Haritani, M. Nakazawa, S. Naitoh, H. Tani, and Y. Uda. 1995. Natural infection with attaching and effacing *Escherichia coli* (O 103:H-) in chicks. *Avian Diseases*. 39:912–918.
170. Gabriel, I., S. Mallet, M. Leconte, G. Fort, and M. Naciri. 2006. Effects of whole wheat feeding on the development of coccidial infection in broiler chickens until market-age. *An Feed Sci Tech*. 129:279–303.
171. Ganapathy, K., M.H. Salamat, C.C. Lee, and M.Y. Johara. 2000. Concurrent occurrence of salmonellosis, colibacillosis and histomoniasis in a broiler flock fed with antibiotic-free commercial feed. *Avian Pathology: Journal of the W.V.P.A*. 29:639–642.
172. Garrard, E.H. 1946. Coliform contamination of eggs. *Cand J Res*. 24:121–125.
173. Gaukler, S.M., G.M. Linz, J.S. Sherwood, N.W. Dyer, W.J. Bleier, Y.M. Wannemuehler, L.K. Nolan, and C.M. Logue. 2009. *Escherichia coli*, Salmonella, and Mycobacterium avium subsp. paratuberculosis in wild European starlings at a Kansas cattle feedlot. *Avian Diseases*. 53:544–551.
174. Gazdzinski, P., and H.J. Barnes 2004. Venereal colibacillosis (acute vaginitis) in turkey breeder hens. *Avian Diseases* 48:681–685.
175. Gemski, P., S. Cross, and J.C. Sadoff. 1980. K1 antigen-associated resistance to the bactericidal activity of serum. *FEMS Microbiology Letters*. 9:193–197.
176. Georgopoulou, J., P. Lordanidis, and P. Bougiouklis. 2005. The frequency of respiratory diseases in broiler chickens during 1992–2001. *Deltion tes Ellenikes Kteniatrikes Etaireias (J Hellenic Vet Med Soc)*. 56:219–227.
177. Germon, P., Y.H. Chen, L. He, J.E. Blanco, A. Bree, C. Schouler, S.H. Huang, and M. Moulin-Schouleur. 2005. ibeA, a virulence factor of avian pathogenic *Escherichia coli*. *Microbiol*. 151:1179–1186.
178. Gholamreza, S., and H. Abbass-Zadeh. 2006. Prevalence of bacterial resistance to commonly used antimicrobials among *Escherichia coli* isolated from chickens in Kerman Province of Iran. *J Med Sci (Pakistan)*. 6:99–102.
179. Gibbs, P.S., J.J. Maurer, L.K. Nolan, and R.E. Wooley. 2003. Prediction of chicken embryo lethality with the avian *Escherichia coli* traits complement resistance, colicin V production, and presence of the increased serum survival gene cluster (iss). *Avian Diseases*. 47:370–379.
180. Gibbs, P.S., S.R. Petermann, and R.E. Wooley. 2004. Comparison of several challenge models for studies in avian colibacillosis. *Avian Diseases*. 48:751–758.
181. Gibbs, P.S., and R.E. Wooley. 2003. Comparison of the intravenous chicken challenge method with the embryo lethality assay for studies in avian colibacillosis. *Avian Diseases*. 47:672–680.
182. Ginns, C.A., M.L. Benham, L.M. Adams, K.G. Whithear, K.A. Bettelheim, B.S. Crabb, and G.F. Browning. 2000. Colonization of the respiratory tract by a virulent strain of avian *Escherichia coli* requires carriage of a conjugative plasmid. *Infection and Immunity*. 68:1535–1541.
183. Ginns, C.A., G.F. Browning, M.L. Benham, and K.G. Whithear. 1998. Development and application of an aerosol challenge method for reproduction of avian colibacillosis. *Avian Pathology: Journal of the W.V.P.A*. 27:505–511.
184. Giovanardi, D., E. Campagnari, L.S. Ruffoni, P. Pesente, G. Ortali, and V. Furlattini. 2005. Avian pathogenic *Escherichia coli* transmission from broiler breeders to their progeny in an integrated poultry production chain. *Avian Pathology: Journal of the W.V.P.A*. 34:313–318.
185. Giraud, E., S. Leroy-Setrin, G. Flaujac, A. Cloeckaert, M. Dho-Moulin, and E. Chaslus-Dancla. 2001. Characterization of high-level fluoroquinolone resistance in *Escherichia coli* O78:K80 isolated from turkeys. *The Journal of Antimicrobial Chemotherapy*. 47:341–343.
186. Glisson, J.R., C.L. Hofacre, and G.F. Mathis. 2004. Comparative efficacy of enrofloxacin, oxytetracycline, and sulfadimethoxine for the control of morbidity and mortality caused by *Escherichia coli* in broiler chickens. *Avian Diseases*. 48:658–662.
187. Glunder, G., and A. Wieliczko 1990. Pathogenicity of *Campylobacter jejuni* as a monoinfection and as a mixed infection with *Escherichia coli* O78:K80 in broilers. [Zur Pathogenitat von Campylobacter jejuni als Monoinfektion und als Mischinfektion mit Escherichia coli O78:K80 bei Broilern.] *Berl Munch Tierarztl Wochenschr* 103:302–305.
188. Goldman, R.C., K. Joiner, and L. Leive. 1984. Serum-resistant mutants of *Escherichia coli* O111 contain increased lipopolysaccharide, lack an O antigen-containing capsule, and cover more of their lipid A core with O antigen. *Journal of Bacteriology*. 159:877–882.
189. Gomis, S., L. Babiuk, B. Allan, P. Willson, E. Waters, N. Ambrose, R. Hecker, and A. Potter. 2004. Protection of neonatal chicks against a lethal challenge of *Escherichia coli* using DNA containing cytosine-phosphodiester-guanine motifs. *Avian Diseases*. 48:813–822.
190. Gomis, S., L. Babiuk, B. Allan, P. Willson, E. Waters, R. Hecker, and A. Potter. 2007. Protection of chickens against a lethal challenge of *Escherichia coli* by a vaccine containing CpG oligodeoxynucleotides as an adjuvant. *Avian Diseases*. 51:78–83.
191. Gomis, S., L. Babiuk, D.L. Godson, B. Allan, T. Thrush, H. Townsend, P. Willson, E. Waters, R. Hecker, and A. Potter. 2003. Protection of chickens against *Escherichia coli* infections by DNA containing CpG motifs. *Infection and Immunity*. 71:857–863.
192. Goodwin, M.A., and W.D. Waltman. 1996. Transmission of Eimeria, viruses, and bacteria to chicks: darkling beetles (*Alphitobius diaperinus*) as vectors of pathogens. *J Appl Poult Res*. 5:51–55.
193. Gophna, U., M. Barlev, R. Seijffers, T.A. Oelschlager, J. Hacker, and E.Z. Ron. 2001. Curli fibers mediate internalization of *Escherichia coli* by eukaryotic cells. *Infection and Immunity*. 69:2659–2665.
194. Gophna, U., T.A. Oelschlaeger, J. Hacker, and E.Z. Ron. 2001. Yersinia HPI in septicemic *Escherichia coli* strains isolated from diverse hosts. *FEMS Microbiology Letters*. 196:57–60.
195. Gophna, U., A. Parket, J. Hacker, and E.Z. Ron. 2003. A novel ColV plasmid encoding type IV pili. *Microbiol*. 149:177–184.
196. Goren, E. 1978. Observations on experimental infection of chicks with *Escherichia coli*. *Avian Pathology: Journal of the W.V.P.A*. 7:213–224.
197. Gosling, R.J., C.S. Clouting, L.P. Randall, R.A. Horton, and R.H. Davies. 2012. Ciprofloxacin resistance in *E. coli* isolated from turkeys in Great Britain. *Avian Pathology*. 41:83–89.
198. Gregerson, R.H., H. Christensen, C. Ewers, and M. Bisgaard. 2010. Impact of *Escherichia coli* vaccine on parent stock mortality, first week mortality of broilers and population diversity of *E. coli* in vaccinated flocks. *Avian Pathology: Journal of the W.V.P.A*. 39:287–295.

199. Griffin, P.M., and R.V. Tauxe. 1991. The epidemiology of infections caused by *Escherichia coli* O157:H7, other enterohemorrhagic *E. coli*, and the associated hemolytic uremic syndrome. *Epidemiol Rev*. 13:60–98.
200. Grizzle, J.M., T.A. Armbrust, M.A. Bryan, and A.M. Saxton. 1997. Water quality III: the effect of water nitrate and bacteria on broiler breeder performance. *J Appl Poult Res*. 6:56–63.
201. Gross, W.B. 1961. The development of "air sac disease." *Avian Diseases.* 5:431–439.
202. Gross, W.B. 1994. Diseases due to *Escherichia coli* in poultry. In: *Escherichia coli in Domestic Animals and Humans*. C.L. Gyles, ed. CAB Int'l, Wallingford, UK. 237–260.
203. Gross, W.B. 1984. Effect of a range of social stress severity on *Escherichia coli* challenge infection [fowl]. *American Journal of Veterinary Research*. 45:2074–2076.
204. Gross, W.B. 1992. Effect of short-term exposure of chickens to corticosterone on resistance to challenge exposure with *Escherichia coli* and antibody response to sheep erythrocytes. *American Journal of Veterinary Research*. 53:291–293.
205. Gross, W.B. 1966. Electrocardiographic changes of *Escherichia coli*-infected birds. *American Journal of Veterinary Research*. 27:1427–1436.
206. Gross, W.B. 1957. *Escherichia coli* infection of the chicken eye. *Avian Diseases*. 1:37–41.
207. Gross, W.B. 1990. Factors affecting the development of respiratory disease complex in chickens. *Avian Diseases*. 34:607–610.
208. Gross, W.B. 1995. Relationship between body-weight gain after movement of chickens to an unfamiliar cage and response to *Escherichia coli* challenge infection. *Avian Diseases*. 39:636–637.
209. Gross, W.B. 1964. Retained caseous yolk sacs caused by *Escherichia coli*. *Avian Diseases*. 8:438–441.
210. Gross, W.G., P.B. Siegel, R.W. Hall, C.H. Domermuth, and R.T. DuBoise. 1980. Production and persistence of antibodies in chickens to sheep erythrocytes. 2. Resistance to infectious diseases. *Poultry Science*. 59:205–210.
211. Grossmann, K., B. Weniger, G. Baljer, B. Brenig, and L.H. Wieler. 2005. Racing, ornamental and city pigeons carry shiga toxin producing *Escherichia coli* (STEC) with different Shiga toxin subtypes, urging further analysis of their epidemiological role in the spread of STEC. *Berl Munch Tierarztl Wochenschr*. 118:456–463.
212. Guan, S., R. Xu, S. Chen, J. Odumeru, and C. Gyles. 2002. Development of a procedure for discriminating among *Escherichia coli* isolates from animal and human sources. *Applied and Environmental Microbiology*. 68:2690–2698.
213. Guo, W., C. Ling, F. Cheng, W.Z. Guo, C.S. Ling, and F.H. Cheng. 1998. Preliminary investigation on enterohaemorrhagic *Escherichia coli* O157 from domestic animals and fowl in Fujian province. *Chinese J Zoonoses*. 14:3–6.
214. Guy, J.S., L.G. Smith, J.J. Breslin, J.P. Vaillancourt, and H.J. Barnes. 2000. High mortality and growth depression experimentally produced in young turkeys by dual infection with enteropathogenic *Escherichia coli* and turkey coronavirus. *Avian Diseases*. 44:105–113.
215. Gyimah, J.E., B. Panigrahy, and J.D. Williams. 1986. Immunogenicity of an *Escherichia coli* multivalent pilus vaccine in chickens. *Avian Diseases.* 30:687–689.
216. Hakkinen, M., and C. Schneitz. 1996. Efficacy of a commercial competitive exclusion product against a chicken pathogenic *Escherichia coli* and *E. coli* O157:H7. *The Veterinary Record*. 139:139–141.
217. Hamdy, M.K., and N.D. Barton. 1966. *Escherichia coli* in normal and traumatized tissues. *Proc Soc Exp Biol Med*. 122:661–665.
218. Hammer, K.A., C.F. Carson, and T.V. Riley. 1999. Antimicrobial activity of essential oils and other plant extracts. *Journal of Applied Microbiology*. 86:985–990.
219. Harmon, B.G. 1998. Avian heterophils in inflammation and disease resistance. *Poultry Science*. 77:972–977.
220. Harmon, B.G., and J.R. Glisson. 1989. *In vitro* microbicidal activity of avian peritoneal macrophages. *Avian Diseases*. 33:177–181.
221. Harpreet, S., B.B. Dash, P.K. Dash, K. Sanjeev, H. Singh, and S. Kumar. 1993. Mortality pattern in indigenous guinea fowl under confinement rearing. *Indian J Poult Sci*. 28:56–62.
222. Harry, E.G. 1957. The effect on embyonic and chick mortality of yolk contaminated with bacteria from the hen. *The Veterinary Record*. 69:1433–1439.
223. Harry, E.G. 1963. Some observations on the bacterial content of the ovary and oviduct of the fowl. *Br Poult Sci*. 4:63–70.
224. Harry, E.G. 1964. The survival of *E. coli* in the dust of poultry houses. *The Veterinary Record*. 76:466–470.
225. Harry, E.G., and L.A. Hemsley. 1965. The association between the presence of septicaemia strains of *Escherichia coli* in the respiratory and intestinal tracts of chickens and the occurrence of coli septicaemia. *The Veterinary Record*. 77:35–40.
226. Harry, E.G., and L.A. Hemsley. 1965. The relationship between environmental contamination with septicaemia strains of *Escherichia coli* and their incidence in chickens. *The Veterinary Record*. 77:241–245.
227. Hart, W.S., M.W. Heuzenroeder, and M.D. Barton. 2006. A study of the transfer of tetracycline resistance genes between *Escherichia coli* in the intestinal tract of a mouse and a chicken model. *J Vet Med [B]*. 53:333–340.
228. Haslam, S.M., S.N. Brown, L.J. Wilkins, S.C. Kestin, P.D. Warriss, and C.J. Nicol. 2006. Preliminary study to examine the utility of using foot burn or hock burn to assess aspects of housing conditions for broiler chicken. *Br Poult Sci*. 47:13–18.
229. He, C.L., B.D. Fu, H.Q. Shen, X.L. Jiang, C.S. Zhang, S.C. Wu, W. Zhu, and X.B. Wei. 2011. Xiang-qi-tang increases avian pathogenic *Escherichia coli*-induced survival rate and regulates serum levels of tumor necrosis factor alpha, interleukin-1 and soluble endothelial protein C receptor in chicken. *Biol Pharm Bull*. 34:379–382.
230. Hein, H., and L. Timms. 1972. Bacterial flora in the alimentary tract of chickens infected with *Eimeria brunetti* and in chickens immunized with *Eimeria maxima* and cross-infected with *Eimeria brunetti*. *Experimental Parasitology*. 31:188–193.
231. Heller, E.D., and N. Drabkin. 1977. Some characteristics of pathogenic *E. coli* strains. *Br Vet J*. 133:572–578.
232. Heller, E.D., G. Leitner, N. Drabkin, and D. Melamed. 1990. Passive immunisation of chicks against *Escherichia coli*. *Avian Pathology: Journal of the W.V.P.A*. 19:345–354.
233. Herraez, P., A.F. Rodriguez, A. Espinosa de los Monteros, A.B. Acosta, J.R. Jaber, J. Castellano, and A. Castroa. 2005. Fibrinonecrotic typhlitis caused by *Escherichia fergusonii* in ostriches (*Struthio camelus*). *Avian Diseases*. 49:167–169.
234. Herren, C.D., A. Mitra, S.K. Palaniyandi, A. Coleman, S. Elankumaran, and S. Mukhopadhyay. 2006. The BarA-UvrY two-component system regulates virulence in avian pathogenic *Escherichia coli* O78:K80:H9. *Infection and Immunity*. 74:4900–4909.

235. Heuvelink, A.E., J.T. Zwartkruis-Nahuis, F.L. van den Biggelaar, W.J. van Leeuwen, and E. de Boer. 1999. Isolation and characterization of verocytotoxin-producing *Escherichia coli* O157 from slaughter pigs and poultry. *Int J Food Microbiol*. 52:67–75.
236. Himathongkham, S., H. Riemann, S. Bahari, S. Nuanualsuwan, P. Kass, and D.O. Cliver. 2000. Survival of S*almonella typhimurium* and *Escherichia coli* O157:H7 in poultry manure and manure slurry at sublethal temperatures. *Avian Diseases*. 44:853–860.
237. Hines, M.E., II, E.L. Styer, C.A. Baldwin, and J.R. Cole, Jr. 1995. Combined adenovirus and rotavirus enteritis with *Escherichia coli* septicemia in an emu chick (*Dromaius novaehollandiae*). *Avian Diseases*. 39:646–651.
238. Hinz, K.H., M. Ryll, U. Heffels Redmann, and M. Poppel. 1992. Multicausal infectious respiratory disease of turkey poults. *Dtsch Tierarztl Wochenschr*. 99:75–78.
239. Hofacre, C.L., A.C. Johnson, B.J. Kelly, and R. Froyman. 2002. Effect of a commercial competitive exclusion culture on reduction of colonization of an antibiotic-resistant pathogenic *Escherichia coli* in day-old broiler chickens. *Avian Diseases*. 46:198–202.
240. Hoque, M.A., G.W. Burgess, A.R. Greenhil, R. Hedlefs, and L.F. Skerratt. 2012. Causes of morbidity and mortality of wild aquatic birds at Billabong Sanctuary, Townsville, North Queensland, Australia. *Avian Diseases*. 56:249–256.
241. Huang, H.J., and M. Matsumoto. 2000. Nonspecific innate immunity against *Escherichia coli* infection in chickens induced by vaccine strains of Newcastle disease virus. *Avian Diseases*. 44:790–796.
242. Huang, T.M., T.L. Lin, and C.C. Wu. 2009. Antimicrobial susceptibility and resistance of chicken *Escherichia coli*, Salmonella spp., and Pasteurella multocida isolates. *Avian Diseases*. 53:89–93.
243. Huff, G., W. Huff, N. Rath, J. Balog, N.B. Anthony, and K. Nestor. 2006. Stress-induced colibacillosis and turkey osteomyelitis complex in turkeys selected for increased body weight. *Poultry Science*. 85:266–272.
244. Huff, G.R., W.E. Huff, J.M. Balog, and N.C. Rath. 2001. Effect of early handling of turkey poults on later responses to a dexamethasone-*Escherichia coli* challenge. 1. Production values and physiological response. *Poultry Science*. 80:1305–1313.
245. Huff, G.R., W.E. Huff, J.M. Balog, and N.C. Rath. 2001. Effect of early handling of turkey poults on later responses to multiple dexamethasone-*Escherichia coli* challenge. 2. Resistance to air sacculitis and turkey osteomyelitis complex. *Poultry Science*. 80:1314–1322.
246. Huff, G.R., W.E. Huff, J.M. Balog, and N.C. Rath. 2000. The effect of vitamin D3 on resistance to stress-related infection in an experimental model of turkey osteomyelitis complex. *Poultry Science*. 79:672–679.
247. Huff, G.R., W.E. Huff, J.M. Balog, and N.C. Rath. 1998. The effects of dexamethasone immunosuppression on turkey osteomyelitis complex in an experimental *Escherichia coli* respiratory infection. *Poultry Science*. 77:654–661.
248. Huff, G.R., W.E. Huff, J.M. Balog, and N.C. Rath. 1999. Sex differences in the resistance of turkeys to *Escherichia coli* challenge after immunosuppression with dexamethasone. *Poultry Science*. 78:38–44.
249. Huff, G.R., W.E. Huff, J.M. Balog, N.C. Rath, N.B. Anthony, and K.E. Nestor. 2005. Stress response differences and disease susceptibility reflected by heterophil to lymphocyte ratio in turkeys selected for increased body weight. *Poultry Science*. 84:709–717.
250. Huff, G.R., W.E. Huff, J.M. Balog, N.C. Rath, and R.S. Izard. 2004. The effects of water supplementation with vitamin E and sodium salicylate (Uni-Sol) on the resistance of turkeys to *Escherichia coli* respiratory infection. *Avian Diseases*. 48:324–331.
251. Huff, G.R., W.E. Huff, J.M. Balog, N.C. Rath, H. Xie, and R.L. Horst. 2002. Effect of dietary supplementation with vitamin D metabolites in an experimental model of turkey osteomyelitis complex. *Poultry Science*. 81:958–965.
252. Huff, G.R., W.E. Huff, N.C. Rath, and J.M. Balog. 2000. Turkey osteomyelitis complex. *Poultry Science*. 79:1050–1056.
253. Huff, G.R., W.E. Huff, N.C. Rath, and G. Tellez. 2006. Limited treatment with beta-1,3/1,6-glucan improves production values of broiler chickens challenged with *Escherichia coli*. *Poultry Science*. 85:613–618.
254. Huff, W.E., G.R. Bayyari, N.C. Rath, and J.M. Balog. 1996. Effect of feed and water withdrawal on green liver discoloration, serum triglycerides, and hemoconcentration in turkeys. *Poultry Science*. 75:59–61.
255. Huff, W.E., G.R. Huff, N.C. Rath, J.M. Balog, and A.M. Donoghue. 2005. Alternatives to antibiotics: utilization of bacteriophage to treat colibacillosis and prevent foodborne pathogens. *Poultry Science*. 84:655–659.
256. Huff, W.E., G.R. Huff, N.C. Rath, J.M. Balog, and A.M. Donoghue. 2003. Bacteriophage treatment of a severe *Escherichia coli* respiratory infection in broiler chickens. *Avian Diseases*. 47:1399–1405.
257. Huff, W.E., G.R. Huff, N.C. Rath, J.M. Balog, and A.M. Donoghue. 2003. Evaluation of aerosol spray and intramuscular injection of bacteriophage to treat an *Escherichia coli* respiratory infection. *Poultry Science*. 82:1108–1112.
258. Huff, W.E., G.R. Huff, N.C. Rath, J.M. Balog, and A.M. Donoghue. 2002. Prevention of *Escherichia coli* infection in broiler chickens with a bacteriophage aerosol spray. *Poultry Science*. 81:1486–1491.
259. Huff, W.E., G.R. Huff, N.C. Rath, J.M. Balog, and A.M. Donoghue. 2004. Therapeutic efficacy of bacteriophage and Baytril (enrofloxacin) individually and in combination to treat colibacillosis in broilers. *Poultry Science*. 83:1944–1947.
260. Huff, W.E., G.R. Huff, N.C. Rath, J.M. Balog, H. Xie, P.A. Moore, Jr., and A.M. Donoghue. 2002. Prevention of *Escherichia coli* respiratory infection in broiler chickens with bacteriophage (SPR02). *Poultry Science*. 81:437–441.
261. Huff, W.E., G.R. Huff, N.C. Rath, and A.M. Donoghue. 2006. Evaluation of the influence of bacteriophage titer on the treatment of colibacillosis in broiler chickens. *Poultry Science*. 85:1373–1377.
262. Huff, W.E., G.R. Huff, N.C. Rath, and A.M. Donoghue. 2010. Immune interference of bacteriophage efficacy when treating colibacillosis in poultry. *Poultry Science*. 89:895–900.
263. Ike, K., K. Kawahara, H. Danbara, and K. Kume. 1992. Serum resistance and aerobactin iron uptake in avian *Escherichia coli* mediated by conjugative 100-megadalton plasmid. *J Vet Med Sci*. 54:1091–1098.
264. Ishii, E., M. Goryo, S. Kikuchi, and K. Okada. 1997. Pathology of swollen head syndrome in broiler chickens. *J Japan Vet Med Assoc*. 50:214–219.
265. Islam, M.T., M.A. Islam, M.A. Samad, and S.M.L. Kabir. 2004. Characterization and antibiogram of *Escherichia coli* associated with mortality in broilers and ducklings in Bangladesh. *Bangladesh J Vet Med*. 2:9–14.

266. Ivanov, I.E. 2001. Treatment of broiler litter with organic acids. *Research in Veterinary Science*. 70:169–173.
267. Jakob, H.P., R. Morgenstern, P. Albicker, and R.K. Hoop. 1998. Reasons for condemnation of slaughtered broilers from two large Swiss producers. *Schweiz Arch Tierheilkd*. 140:60–64.
268. Jang, I.S., Y.H. Ko, S.Y. Kang, and C.Y. Lee. 2007. Effect of a commercial essential oil on growth performance, digestive enzyme activity and intestinal microflora population in broiler chickens. *An Feed Sci Tech*. 134:304–315.
269. Janssen, T., C. Schwarz, P. Preikschat, M. Voss, H.C. Philipp, and L.H. Wieler. 2001. Virulence-associated genes in avian pathogenic *Escherichia coli* (APEC) isolated from internal organs of poultry having died from colibacillosis. *Intl J Med Microbiol*. 291:371–378.
270. Jeffrey, J.S., R.S. Singer, R. O'Connor, and E.R. Atwill. 2004. Prevalence of pathogenic *Escherichia coli* in the broiler house environment. *Avian Diseases*. 48:189–195.
271. Jiang, Y.W., M.D. Sims, and D.P. Conway. 2005. The efficacy of TAMUS 2032 in preventing a natural outbreak of colibacillosis in broiler chickens in floor pens. *Poultry Science*. 84:1857–1859.
272. Jirjis, F.F., S.L. Noll, D.A. Halvorson, K.V. Nagaraja, F. Martin, and D.P. Shaw. 2004. Effects of bacterial coinfection on the pathogenesis of avian pneumovirus infection in turkeys. *Avian Diseases*. 48:34–49.
273. Joerger, R.D., and T. Ross. 2005. Genotypic diversity of *Escherichia coli* isolated from cecal content and mucosa of one- to six-week-old broilers. *Poultry Science*. 84:1902–1907.
274. Johnson, J.R., M.A. Kuskowski, M. Menard, A. Gajewski, M. Xercavins, and J. Garau. 2006. Similarity between human and chicken *Escherichia coli* isolates in relation to ciprofloxacin resistance status. *The Journal of Infectious Diseases*. 194:71–78.
275. Johnson, J.R., and T.A. Russo. 2002. Extraintestinal pathogenic *Escherichia coli*: "the other bad E coli." *J Lab Clin Med*. 139:155–162.
276. Johnson, L.C., S.F. Bilgili, F.J. Hoerr, B.L. McMurtrey, and R.A. Norton. 2001. The influence of *Escherichia coli* strains from different sources and the age of broiler chickens on the development of cellulitis. *Avian Pathology: Journal of the W.V.P.A*. 30:475–479.
276a. Johnson, J.R., P. Delavari, A.L. Stell, T.S. Whittam, U. Carlino, and T.A. Russo. 2001. Molecular comparison of extraintestinal *Escherichia coli* isolates of the same electrophoretic lineages from humans and domestic animals. *J Infect Dis*. 183:154–159.
277. Johnson, T.J., C.W. Giddings, S.M. Horne, P.S. Gibbs, R.E. Wooley, J. Skyberg, P. Olah, R. Kercher, J.S. Sherwood, S.L. Foley, and L.K. Nolan. 2002. Location of increased serum survival gene and selected virulence traits on a conjugative R plasmid in an avian *Escherichia coli* isolate. *Avian Diseases*. 46:342–352.
278. Johnson, T.J., S.J. Johnson, and L.K. Nolan. 2006. Complete DNA sequence of a ColBM plasmid from avian pathogenic *Escherichia coli* suggests that it evolved from closely related ColV virulence plasmids. *Journal of bacteriology*. 188:5975–5983.
279. Johnson, T.J., D. Jordan, S. Kariyawasam, A.L. Stell, N.P. Bell, Y.M. Wannemuehler, C.F. Alarcon, G. Li, K.A. Tivendale, C.M. Logue, and L.K. Nolan. 2010. Sequence analysis and characterization of a transferable hybrid plasmid encoding multidrug resistance and enabling zoonotic potential for extraintestinal *Escherichia coli*. *Infection and Immunity*. 78:1931–1942.
280. Johnson, T.J., S. Kariyawasam, Y. Wannemuehler, P. Mangiamele, S.J. Johnson, C. Doetkott, J.A. Skyberg, A.M. Lynne, J.R. Johnson, and L.K. Nolan. 2007. The genome sequence of avian pathogenic *Escherichia coli* strain O1:K1:H7 shares strong similarities with human extraintestinal pathogenic *E. coli* genomes. *Journal of Bacteriology*. 189:3228–3236.
281. Johnson, T.J., C.M. Logue, J.R. Johnson, M.A. Kuskowski, J.S. Sherwood, H.J. Barnes, C. DebRoy, Y.M. Wannemuehler, M. Obata-Yasuoka, L. Spanjaard, and L.K. Nolan. 2012. Associations between multidrug resistance, plasmid content, and virulence potential among extraintestinal pathogenic and commensal *Escherichia coli* from humans and poultry. *Foodborne Pathogens and Disease*. 9:37–46.
282. Johnson, T.J., C.M. Logue, Y. Wannemuehler, S. Kariyawasam, C. Doetkott, C. DebRoy, D.G. White, and L.K. Nolan. 2009. Examination of the source and extended virulence genotypes of *Escherichia coli* contaminating retail poultry meat. *Foodborne Pathogens and Disease*. 6:657–667.
283. Johnson, T.J., K.E. Siek, S.J. Johnson, and L.K. Nolan. 2005. DNA sequence and comparative genomics of pAPEC-O2-R, an avian pathogenic *Escherichia coli* transmissible R plasmid. *Antimicrobial Agents and Chemotherapy*. 49:4681–4688.
284. Johnson, T.J., K.E. Siek, S.J. Johnson, and L.K. Nolan. 2005. DNA sequence and comparative genomics of pAPEC-O2-R, an avian pathogenic *Escherichia coli* transmissible R plasmid. *Antimicrobial Agents and Chemotherapy*. 49:4681–4688.
285. Johnson, T.J., K.E. Siek, S.J. Johnson, and L.K. Nolan. 2006. DNA sequence of a ColV plasmid and prevalence of selected plasmid-encoded virulence genes among avian *Escherichia coli* strains. *Journal of Bacteriology*. 188:745–758.
286. Johnson, T.J., J. Skyberg, and L.K. Nolan. 2004. Multiple antimicrobial resistance region of a putative virulence plasmid from an *Escherichia coli* isolate incriminated in avian colibacillosis. *Avian Diseases*. 48:351–360.
287. Johnson, T.J., J.L. Thorsness, C.P. Anderson, A.M. Lynne, S.L. Foley, J. Han, W.F. Fricke, P.F. McDermott, D.G. White, M. Khatri, A.L. Stell, C. Flores, and R.S. Singer. 2010. Horizontal gene transfer of a ColV plasmid has resulted in a dominant avian clonal type of Salmonella enterica serovar Kentucky. *PloS One*. 5:e15524.
288. Johnson, T.J., Y.M. Wannemeuhler, J.A. Scaccianoce, S.J. Johnson, and L.K. Nolan. 2006. Complete DNA sequence, comparative genomics, and prevalence of an IncHI2 plasmid occurring among extraintestinal pathogenic *Escherichia coli*. *Antimicrobial Agents and Chemotherapy*. 50:3929–3933.
289. Johnson, T.J., Y. Wannemuehler, C. Doetkott, S.J. Johnson, S.C. Rosenberger, and L.K. Nolan. 2008. Identification of minimal predictors of avian pathogenic *Escherichia coli* virulence for use as a rapid diagnostic tool. *Journal of Clinical Microbiology*. 46:3987–3996.
290. Johnson, T.J., Y. Wannemuehler, S.J. Johnson, A.L. Stell, C. Doetkott, J.R. Johnson, K.S. Kim, L. Spanjaard, and L.K. Nolan. 2008. Comparison of extraintestinal pathogenic *Escherichia coli* strains from human and avian sources reveals a mixed subset representing potential zoonotic pathogens. *Applied and Environmental Microbiology*. 74:7043–7050.
291. Johnson, T.J., Y. Wannemuehler, S. Kariyawasam, J.R. Johnson, C.M. Logue, and L.K. Nolan. 2012. Prevalence of avian-pathogenic *Escherichia coli* strain O1 genomic islands among extraintestinal and commensal *E. coli* isolates. *Journal of Bacteriology*. 194:2846–2853.

292. Jordan, F.T.W., N.J. Williams, A. Wattret, and T. Jones. 2005. Observations on salpingitis, peritonitis and salpingoperitonitis in a layer breeder flock. *Vet Rec*. 157:573–577.
293. Joya, J.E., T. Tsuji, A.V. Jacalne, M. Arita, T. Tsukamoto, T. Honda, and T. Miwatani. 1990. Demonstration of enterotoxigenic *Escherichia coli* in diarrheic broiler chicks. *Eur J Epidemiol*. 6:88–90.
294. Kaper, J.B., and J. Hacker. 1999. The concept of pathogenicity islands and other mobile virulence elements. In: *Pathogenicity Islands and Other Mobile Virulence Elements*. J.B. Kaper and J. Hacker, eds. Am Soc Microbiol, Washington, D.C. 1–11.
295. Kaper, J.B., J.P. Nataro, and H.L. Mobley. 2004. Pathogenic *Escherichia coli*. *Nat Rev Microbiol*. 2:123–140.
296. Kariuki, S., C. Gilks, J. Kimari, J. Muyodi, B. Getty, and C.A. Hart. 2002. Carriage of potentially pathogenic *Escherichia coli* in chickens. *Avian Diseases*. 46:721–724.
297. Kariyawasam, S., T.J. Johnson, C. DebRoy, and L.K. Nolan. 2006. Occurrence of pathogenicity island IAPEC-O1 genes among *Escherichia coli* implicated in avian colibacillosis. *Avian Diseases*. 50:405–410
298. Kariyawasam, S., T.J. Johnson, and L.K. Nolan. 2006. The pap operon of avian pathogenic *Escherichia coli* strain O1:K1 is located on a novel pathogenicity island. *Infection and Immunity*. 74:744–749.
299. Kariyawasam, S., T.J. Johnson, and L.K. Nolan. 2006. Unique DNA sequences of avian pathogenic *Escherichia coli* isolates as determined by genomic suppression subtractive hybridization. *FEMS Microbiology Letters*. 262:193–200.
300. Kariyawasam, S., J.A. Scaccianoce, and L.K. Nolan. 2007. Common and specific genomic sequences of avian and human extraintestinal pathogenic *Escherichia coli* as determined by genomic subtractive hybridization. *BMC Microbiology*. 7:81.
301. Kariyawasam, S., B.N. Wilkie, and C.L. Gyles. 2004. Construction, characterization, and evaluation of the vaccine potential of three genetically defined mutants of avian pathogenic *Escherichia coli*. *Avian Diseases*. 48:287–299.
302. Kariyawasam, S., B.N. Wilkie, and C.L. Gyles. 2004. Resistance of broiler chickens to *Escherichia coli* respiratory tract infection induced by passively transferred egg-yolk antibodies. *Veterinary Microbiology*. 98:273–284.
303. Kassaify, Z.G., and Y. Mine. 2004. Nonimmunized egg yolk powder can suppress the colonization of *Salmonella typhimurium, Escherichia coli* O157:H7, and *Campylobacter jejuni* in laying hens. *Poultry Science*. 83:1497–1506.
304. Keyes, K., C. Hudson, J.J. Maurer, S. Thayer, D.G. White, and M.D. Lee. 2000. Detection of florfenicol resistance genes in *Escherichia coli* isolated from sick chickens. *Antimicrobial Agents and Chemotherapy*. 44:421–424.
305. Khan, A.A., M.S. Nawaz, C. Summage West, S.A. Khan, and J. Lin. 2005. Isolation and molecular characterization of fluoroquinolone-resistant *Escherichia coli* from poultry litter. *Poultry Science*. 84:61–66.
306. Klein, L.K., R.J. Yancey, Jr., C.A. Case, and S.A. Salmon. 1996. Minimum inhibitory concentrations of selected antimicrobial agents against bacteria isolated from 1–14-day-old broiler chicks. *J Vet Diag Invest*. 8:494–495.
307. Knobl, T., M.R. Baccaro, A.M. Moreno, T.A.T. Gomes, M.A.M. Vieira, C.S.A. Ferreira, and A.J.P. Ferreira. 2001. Virulence properties of *Escherichia coli* isolated from ostriches with respiratory disease. *Veterinary Microbiology*. 83:71–80.
308. Knobl, T., T.A.T. Gomes, M.A.M. Vieira, J.A. Bottinoa, and A.J.P. Ferreira. 2004. Detection of pap, sfa, afa and fim adhesin-encoding operons in avian pathogenic *Escherichia coli*. *J Appl Res Vet Med*. 2:135–141.
309. Kobayashi, C., H. Yokoyama, S.V. Nguyen, T. Hashi, M. Kuroki, and Y. Kodama. 2002. Enhancement of chicken resistance against *Escherichia coli* infection by oral administration of Bifidobacterium thermophilum preparations. *Avian Diseases*. 46:542–546.
310. Kodihalli, S., V. Sivanandan, K.V. Nagaraja, D. Shaw, and D.A. Halvorson. 1994. Effect of avian influenza virus infection on the phagocytic function of systemic phagocytes and pulmonary macrophages of turkeys. *Avian Diseases*. 38:93–102.
311. Kostakioti, M., and C. Stathopoulos. 2004. Functional analysis of the Tsh autotransporter from an avian pathogenic *Escherichia coli* strain. *Infection and Immunity*. 72:5548–5554.
312. Kottom, T.J., L.K. Nolan, M. Robinson, J. Brown, T. Gustad, S.M. Horne, and C.W. Giddings. 1997. Further characterization of a complement-sensitive mutant of a virulent avian *Escherichia coli* isolate. *Avian Diseases*. 41:817–823.
313. Koynarski, V., T. Mircheva, S. Stoev, V. Urumova, D. Zapryanova, E. Dishlyanova, T.S. Koynarski, and R.S. Karov. 2010. Pathoanatomical and blood biochemical investigations in chicks, challenged with *Escherichia coli* on the background of a pre-existing *Eimeria* infection. *Revue Med Vet*. 161:133–140.
314. Krause, G., S. Zimmermann, and L. Beutin. 2005. Investigation of domestic animals and pets as a reservoir for intimin- (eae) gene positive *Escherichia coli* types. *Veterinary Microbiology*. 106:87–95.
315. Kumar, A., N. Jindal, C.L. Shukla, R.K. Asrani, D.R. Ledoux, and G.E. Rottinghaus. 2004. Pathological changes in broiler chickens fed ochratoxin A and inoculated with *Escherichia coli*. *Avian Pathology: Journal of the W.V.P.A*. 33:413–417.
316. Kumar, A., N. Jindal, C.L. Shukla, Y. Pal, D.R. Ledoux, and G.E. Rottinghaus. 2003. Effect of ochratoxin A on *Escherichia coli*-challenged broiler chicks. *Avian Diseases*. 47:415–424.
317. Kwaga, J.K., B.J. Allan, J.V. van der Hurk, H. Seida, and A.A. Potter. 1994. A carAB mutant of avian pathogenic *Escherichia coli* serogroup O2 is attenuated and effective as a live oral vaccine against colibacillosis in turkeys. *Infection and Immunity*. 62:3766–3772.
318. La Ragione, R.M., G. Casula, S.M. Cutting, and M.J. Woodward. 2001. Bacillus subtilis spores competitively exclude *Escherichia coli* O78:K80 in poultry. *Veterinary Microbiology*. 79:133–142.
319. La Ragione, R.M., R.J. Collighan, and M.J. Woodward. 1999. Non-curliation of *Escherichia coli* O78:K80 isolates associated with IS1 insertion in csgB and reduced persistence in poultry infection. *FEMS Microbiology Letters*. 175:247–253.
320. La Ragione, R.M., W.A. Cooley, D.D. Parmar, and H.L. Ainsworth. 2004. Attaching and effacing *Escherichia coli* O103:K+:H– in red-legged partridges. *The Veterinary Record*. 155:397–398.
321. La Ragione, R.M., W.A. Cooley, and M.J. Woodward. 2000. The role of fimbriae and flagella in the adherence of avian strains of *Escherichia coli* O78:K80 to tissue culture cells and tracheal and gut explants. *Journal of Medical Microbiology*. 49:327–338.
322. La Ragione, R.M., I.M. McLaren, G. Foster, W.A. Cooley, and M.J. Woodward. 2002. Phenotypic and genotypic characterization of avian *Escherichia coli* O86:K61 isolates possessing a

gamma-like intimin. *Applied and Environmental Microbiology*. 68:4932–4942.
323. La Ragione, R.M., A. Narbad, M.J. Gasson, and M.J. Woodward. 2004. *In vivo* characterization of *Lactobacillus johnsonii* FI9785 for use as a defined competitive exclusion agent against bacterial pathogens in poultry. *Lett Appl Microbiol*. 38:197–205.
324. La Ragione, R.M., A.R. Sayers, and M.J. Woodward. 2000. The role of fimbriae and flagella in the colonization, invasion and persistence of *Escherichia coli* O78:K80 in the day-old-chick model. *Epidemiol Infect*. 124:351–363.
325. La Ragione, R.M., and M.J. Woodward. 2002. Virulence factors of *Escherichia coli* serotypes associated with avian colisepticaemia. *Research in Veterinary Science*. 73:27–35.
326. Lafont, J.-P., M. Dho, H.M. D'Hauteville, A. Bree, and P.J. Sansonetti. 1987. Presence and expression of aerobactin genes in virulent avian strains of *Escherichia coli*. *Infection and Immunity*. 55:193–197.
327. Lagace-Wiens, P.R., P.J. Baudry, P. Pang, and G. Hammond. 2010. First description of an extended-spectrum-beta-lactamase-producing multidrug-resistant *Escherichia fergusonii* strain in a patient with cystitis. *Journal of Clinical Microbiology*. 48:2301–2302.
328. Lamarche, M.G., C.M. Dozois, F. Daigle, M. Caza, R. Curtiss, 3rd, J.D. Dubreuil, and J. Harel. 2005. Inactivation of the pst system reduces the virulence of an avian pathogenic *Escherichia coli* O78 strain. *Infection and Immunity*. 73:4138–4145.
329. Lanz, R., P. Kuhnert, and P. Boerlin. 2003. Antimicrobial resistance and resistance gene determinants in clinical *Escherichia coli* from different animal species in Switzerland. *Veterinary Microbiology*. 91:73–84.
330. Larsen, C.T., F.W. Pierson, and W.B. Gross. 1997. Effect of dietary selenium on the response of stressed and unstressed chickens to *Escherichia coli* challenge and antigen. *Biol Trace Element Res*. 58:169.
331. Lee, M.D., and L.K. Nolan. 2008. Colibacillosis. In: *A Laboratory Manual for the Isolation, Identification and Characterization of Avian Pathogens*, 5th ed. L. Dufour-Zavala, D.E. Swayne, J.R. Glisson, J.E. Pearson, W.M. Reed, M.W. Jackwood, and P.R. Woolcock, eds. Am Assoc Avian Pathologists, Athens, GA. 10–11.
332. Leibovitz, L. 1972. A survey of the so-called "anatipestifer syndrome." *Avian Diseases*. 16:836–851.
333. Leitner, G., and E.D. Heller. 1992. Colonization of *Escherichia coli* in young turkeys and chickens. *Avian Diseases*. 36:211–220.
334. Leitner, G., D. Melamed, N. Drabkin, and E.D. Heller. 1990. An enzyme-linked immunosorbent assay for detection of antibodies against *Escherichia coli*: association between indirect hemagglutination test and survival. *Avian Diseases*. 34:58–62.
335. Leitner, G., Z. Uni, A. Cahaner, M. Gutman, and E.D. Heller. 1992. Replicated divergent selection of broiler chickens for high or low early antibody response to *Escherichia coli* vaccination. *Poultry Science*. 71:27–37.
336. Leitner, G., R. Waiman, and E.D. Heller. 2001. The effect of apramycin on colonization of pathogenic *Escherichia coli* in the intestinal tract of chicks. *Vet Q*. 23:62–66.
337. Leshchinsky, T.V., and K.C. Klasing. 2001. Relationship between the level of dietary vitamin E and the immune response of broiler chickens. *Poultry Science*. 80:1590–1599.
338. Li, G., W. Cai, A. Hussein, Y.M. Wannemuehler, C.M. Logue, and L.K. Nolan. 2012. Proteome response of an extraintestinal pathogenic *Escherichia coli* strain with zoonotic potential to human and chicken sera. *Journal of Proteomics*. 75:4853–4862.
339. Li, G., W. Cai, A. Hussein, Y.M. Wannemuehler, C.M. Logue, and L.K. Nolan. 2012. Proteome response of an extraintestinal pathogenic *Escherichia coli* strain with zoonotic potential to human and chicken sera. *Journal of Proteomics*. 75:4853–4862.
340. Li, G., Y. Feng, S. Kariyawasam, K.A. Tivendale, Y. Wannemuehler, F. Zhou, C.M. Logue, C.L. Miller, and L.K. Nolan. 2010. AatA is a novel autotransporter and virulence factor of avian pathogenic *Escherichia coli*. *Infection and Immunity*. 78:898–906.
341. Li, G., S. Kariyawasam, K.A. Tivendale, Y. Wannemuehler, C. Ewers, L.H. Wieler, C.M. Logue, and L.K. Nolan. 2012. tkt1, located on a novel pathogenicity island, is prevalent in avian and human extraintestinal pathogenic *Escherichia coli*. *BMC Microbiology*. 12:51.
342. Li, G., C. Laturnus, C. Ewers, and L.H. Wieler. 2005. Identification of genes required for avian *Escherichia coli* septicemia by signature-tagged mutagenesis. *Infection and Immunity*. 73:2818–2827.
343. Li, G., K.A. Tivendale, P. Liu, Y. Feng, Y. Wannemuehler, W. Cai, P. Mangiamele, T.J. Johnson, C. Constantinidou, C.W. Penn, and L.K. Nolan. 2011. Transcriptome analysis of avian pathogenic *Escherichia coli* O1 in chicken serum reveals adaptive responses to systemic infection. *Infection and Immunity*. 79:1951–1960.
344. Li, Y.C., D.R. Ledoux, A.J. Bermudez, K.L. Fritsche and G.E. Rottinghaus. 1999. Effects of fumonisin B1 on selected immune responses in broiler chicks. *Poultry Science*. 78:1275–1282.
345. Li, Y.C., D.R. Ledoux, A.J. Bermudez, K.L. Fritsche, and G.E. Rottinghaus. 2000. The individual and combined effects of fumonisin B1 and moniliformin on performance and selected immune parameters in turkey poults. *Poultry Science*. 79:871–878.
346. Likoff, R.O., D.R. Guptill, L.M. Lawrence, C.C. McKay, M.M. Mathias, C.F. Nockels, and R.P. Tengerdy. 1981. Vitamin E and aspirin depress prostaglandins in protection of chickens against *Escherichia coli* infection. *The American Journal of Clinical Nutrition*. 34:245–251.
347. Lin, J.A., C. Shyu, and C.L. Shyu. 1996. Studies on egg transmission of colibacillosis in chicks. *Taiwan J Vet Med An Husb*. 66:199–205.
348. Linares, J.A., A.A. Bickford, G.L. Cooper, B.R. Charlton, and P.R. Woolcock. 1994. An outbreak of infectious laryngotracheitis in California broilers. *Avian Diseases*. 38:188–192.
349. Lior, H. 1994. Classification of *Escherichia coli*. In: *Escherichia coli in Domestic Animals and Humans*. C.L. Gyles, ed. CAB Int'l, Wallingford, UK. 31–72.
350. Litjens, J.B., F.C. van Willigen, and M. Sinke. 1989. A case of swollen head syndrome in a flock of guinea fowl. *Tijdschr Diergeneeskd*. 114:719–720.
351. Logue, C.M., C. Doetkott, P. Mangiamele, Y.M. Wannemuehler, T.J. Johnson, K.A. Tivendale, G. Li, J.S. Sherwood, and L.K. Nolan. 2012. Genotypic and phenotypic traits that distinguish neonatal meningitis-associated *Escherichia coli* from fecal *E. coli* isolates of healthy human hosts. *Applied and Environmental Microbiology*. 78:5824–5830.
352. Lymberopoulos, M.H., S. Houle, F. Daigle, S. Leveille, A. Bree, M. Moulin-Schouleur, J.R. Johnson, and C.M. Dozois. 2006. Characterization of Stg fimbriae from an avian pathogenic *Escherichia coli* O78:K80 strain and assessment of their contri-

bution to colonization of the chicken respiratory tract. *Journal of Bacteriology*. 188:6449–6459.
353. Lynne, A.M., S. Kariyawasam, Y. Wannemuehler, T.J. Johnson, S.J. Johnson, A.S. Sinha, D.K. Lynne, H.W. Moon, D.M. Jordan, C.M. Logue, S.L. Foley, and L.K. Nolan. 2012. Recombinant Iss as a potential vaccine for avian colibacillosis. *Avian Diseases*. 56:192–199.
354. Lynne, A.M., J.A. Skyberg, C.M. Logue, and L.K. Nolan. 2007. Detection of Iss and Bor on the surface of *Escherichia coli*. *Journal of Applied Microbiology*. 102:660–666.
355. Macklin, K.S., R.A. Norton, and S.J. Ewald. 2009. Effect of the major histocompatibility complex on the inhibition of induced cellulitis development in a broiler chicken model. *Avian Diseases*. 53:297–300.
356. Macklin, K.S., R.A. Norton, J.B. Hess, and S.F. Bilgili. 2000. The effect of vitamin E on cellulitis in broiler chickens experiencing scratches in a challenge model. *Avian Diseases*. 44:701–705.
357. MacOwan, K.J., C.J. Randall, H.G.R. Jones, and T.F. Brand. 1982. Association of Mycoplasma synoviae with respiratory disease of broilers. *Avian Pathology: Journal of the W.V.P.A*. 11:235–244.
358. Madhu, S., A.K. Katiyar, J.L. Vegad, and M. Swamy. 2001. Bacteria-induced increased vascular permeability in the chicken skin. *Indian J An Sci*. 71:621–622.
359. Majo, N., X. Gibert, M. Vilafranca, C.J. O'Loan, G.M. Allan, L. Costa, A. Pages, and A. Ramis. 1997. Turkey rhinotracheitis virus and *Escherichia coli* experimental infection in chickens: histopathological, immunocytochemical and microbiological study. *Veterinary Microbiology*. 57:29–40.
360. Mangiamele, P., B. Nicholson, Y. Wannemuehler, T. Seemann, C.M. Logue, G. Li, K.A. Tivendale, and L.K. Nolan. 2013. Complete genome sequence of the avian pathogenic Escherichia coli strain APEC O78. *Genome Announcements*. 1:e00026–13
361. Marrett, L.E., E.J. Robb, and R.K. Frank. 2000. Efficacy of neomycin sulfate water medication on the control of mortality associated with colibacillosis in growing turkeys. *Poultry Science*. 79:12–17.
362. Martins da Costa, P., M. Oliveira, A. Bica, P. Vaz-Pires, and F. Bernardo. 2006. Antimicrobial resistance in Enterococcus spp., and *Escherichia coli* isolated from poultry feed and feed ingredients. *Veterinary Microbiology*. 120:122–131.
363. Mathers, J.J., S.R. Clark, D. Hausmann, P. Tillman, V.R. Benning, and S.K. Gordon. 2004. Inhibition of resistance plasmid transfer in *Escherichia coli* by ionophores, chlortetracycline, bacitracin, and ionophore/antimicrobial combinations. *Avian Diseases*. 48:317–323.
364. Matsumoto, M., H. Huang, and H.J. Huang. 2000. Induction of short-term, nonspecific immunity against *Escherichia coli* infection in chickens is suppressed by cold stress or corticosterone treatment. *Avian Pathology: Journal of the W.V.P.A*. 29:227–232.
365. Matter, L.B., N.L. Barbieri, M. Nordhoff, C. Ewers, and F. Horn. 2011. Avian pathogenic *Escherichia coli* MT78 invades chicken fibroblasts. *Veterinary Microbiology*. 148:51–59.
366. Matthijs, M.G., J.H. van Eck, J.J. de Wit, A. Bouma, and J.A. Stegeman. 2005. Effect of IBV-H120 vaccination in broilers on colibacillosis susceptibility after infection with a virulent Massachusetts-type IBV strain. *Avian Diseases*. 49:540–545.
367. Matthijs, M.G., J.H. van Eck, W.J. Landman, and J.A. Stegeman. 2003. Ability of Massachusetts-type infectious bronchitis virus to increase colibacillosis susceptibility in commercial broilers: a comparison between vaccine and virulent field virus. *Avian Pathology: Journal of the W.V.P.A*. 32:473–481.
368. Maturana, V.G., F. de Pace, C. Carlos, M. Mistretta Pires, T. Amabile de Campos, G. Nakazato, E. Guedes Stheling, C.M. Logue, L.K. Nolan, and W. Dias da Silveira. 2011. Subpathotypes of avian pathogenic *Escherichia coli* (APEC) exist as defined by their syndromes and virulence traits. *Open Microbiol J*. 5:55–64.
369. Maurer, J.J., T.P. Brown, W.L. Steffens, and S.G. Thayer. 1998. The occurrence of ambient temperature-regulated adhesins, curli, and the temperature-sensitive hemagglutinin tsh among avian *Escherichia coli*. *Avian Diseases*. 42:106–118.
370. Maurer, J.J., C.L. Hofacre, R.E. Wooley, P. Gibbs, and R. Froyman. 2002. Virulence factors associated with *Escherichia coli* present in a commercially produced competitive exclusion product. *Avian Diseases*. 46:704–707.
371. Maurer, J.J., M.D. Lee, C. Lobsinger, T. Brown, M. Maier, and S.G. Thayer. 1998. Molecular typing of avian *Escherichia coli* isolates by random amplification of polymorphic DNA. *Avian Diseases*. 42:431–451.
372. McAllister, J.C., C.D. Steelman, J.K. Skeeles, L.A. Newberry, and E.E. Gbur. 1996. Reservoir competence of Alphitobius diaperinus (Coleoptera: Tenebrionidae) for Escherichia coli (Eubacteriales: Enterobacteriaceae). *J Med Entomol*. 33:983–987.
373. McDougald, L.R. 2005. Blackhead disease (histomoniasis) in poultry: a critical review. *Avian Diseases*. 49:462–476.
374. McNamee, P.T., and J.A. Smyth. 2000. Bacterial chondronecrosis with osteomyelitis ('femoral head necrosis') of broiler chickens: A review. *Avian Pathology: Journal of the W.V.P.A*. 29:253–270.
375. McPeake, S.J., J.A. Smyth, and H.J. Ball. 2005. Characterisation of avian pathogenic *Escherichia coli* (APEC) associated with colisepticaemia compared to faecal isolates from healthy birds. *Veterinary Microbiology*. 110:245–253.
376. Melamed, D., G. Leitner, and E.D. Heller. 1991. A vaccine against avian colibacillosis based on ultrasonic inactivation of *Escherichia coli*. *Avian Diseases*. 35:17–22.
377. Mellata, M., K. Ameiss, H. Mo, and R. Curtiss, 3rd. 2010. Characterization of the contribution to virulence of three large plasmids of avian pathogenic *Escherichia coli* chi7122 (O78:K80:H9). *Infection and Immunity*. 78:1528–1541.
378. Mellata, M., R. Bakour, E. Jacquemin, and J.G. Mainil. 2001. Genotypic and phenotypic characterization of potential virulence of intestinal avian *Escherichia coli* strains isolated in Algeria. *Avian Diseases*. 45:670–679.
379. Mellata, M., M. Dho-Moulin, C.M. Dozois, R. Curtiss, 3rd, B. Lehoux, and J.M. Fairbrother. 2003. Role of avian pathogenic *Escherichia coli* virulence factors in bacterial interaction with chicken heterophils and macrophages. *Infection and Immunity*. 71:494–503.
380. Mellata, M., J.T. Maddux, T. Nam, N. Thomson, H. Hauser, M.P. Stevens, S. Mukhopadhyay, S. Sarker, A. Crabbe, C.A. Nickerson, J. Santander, and R. Curtiss, 3rd. 2012. New insights into the bacterial fitness-associated mechanisms revealed by the characterization of large plasmids of an avian pathogenic *E. coli*. *PloS One*. 7:e29481.
381. Mellata, M., J.W. Touchman, and R. Curtiss. 2009. Full sequence and comparative analysis of the plasmid pAPEC-1 of avian pathogenic *E. coli* chi7122 (O78:K80:H9). *PloS One*. 4:e4232.

382. Miles, T., W. McLaughlin, and P. Brown. 2006. Antimicrobial resistance of *Escherichia coli* isolates from broiler chickens and humans. *BMC Veterinary Research*. 2:7.
383. Miller, D.L., J. Hatkin, Z.A. Radi, and M.J. Mauel. 2004. *An Escherichia coli* epizootic in captive mallards (*Anas platyrhynchos*). 3:206.
384. Mireles, A.J., S.M. Kim, and K.C. Klasing. 2005. An acute inflammatory response alters bone homeostasis, body composition, and the humoral immune response of broiler chickens. *Poultry Science*. 84:553–560.
385. Mokady, D., U. Gophna, and E.Z. Ron. 2005. Extensive gene diversity in septicemic *Escherichia coli* strains. *Journal of Clinical Microbiology*. 43:66–73.
386. Moll, A., P.A. Manning, and K.N. Timmis. 1980. Plasmid-determined resistance to serum bactericidal activity: a major outer membrane protein, the traT gene product, is responsible for plasmid-specified serum resistance in *Escherichia coli*. *Infection and Immunity*. 28:359–367.
387. Mondal, D., and B.N. Mukherjee. 1996. Isolation, serotyping and antimicrobial drug sensitivity of *E. coli* strains from dead and diseased ducklings. *Indian J An Hlth*. 35:95–99.
388. Monleon, R., M.P. Martin, and H.J. Barnes. 2008. Bacterial orchitis and epididymo-orchitis in broiler breeders *Avian Pathology: Journal of the W.V.P.A*. 37:613–617.
389. Monroy, M.A., T. Knobl, J.A. Bottino, C.S. Ferreira, and A.J. Ferreira. 2005. Virulence characteristics of *Escherichia coli* isolates obtained from broiler breeders with salpingitis. *Comparative Immunology, Microbiology and Infectious Diseases*. 28:1–15.
390. Montgomery, R.D., C.R. Boyle, T.A. Lenarduzzi, and L.S. Jones. 1999. Consequences to chicks hatched from *Escherichia coli*-inoculated embryos. *Avian Diseases*. 43:553–563.
391. Montgomery, R.D., C.R. Boyle, W.R. Maslin, and D.L. Magee. 1997. Attempts to reproduce a runting/stunting-type syndrome using infectious agents isolated from affected Mississippi broilers. *Avian Diseases*. 41:80–92.
392. Montgomery, R.D., L.S. Jones, C.R. Boyle, Y. Luo, and J.A. Boyle. 2005. The embryo lethality of *Escherichia coli* isolates and its relationship to various *in vitro* attributes. *Avian Diseases*. 49:63–69.
393. Moorhead, P.D., and Y.M. Saif. 1970. Mycoplasma meleagridis and *Escherichia coli* infections in germfree and specific-pathogen-free turkey poults: pathologic manifestations. *American Journal of Veterinary Research*. 31:1645–1653.
394. Mora, A., C. Lopez, G. Dabhi, M. Blanco, J.E. Blanco, M.P. Alonso, A. Herrera, R. Mamani, S. Bonacorsi, M. Moulin-Schouleur, and J. Blanco. 2009. Extraintestinal pathogenic *Escherichia coli* O1:K1:H7/NM from human and avian origin: detection of clonal groups B2 ST95 and D ST59 with different host distribution. *BMC Microbiology*. 9:132.
395. Morabito, S., G. Dell'Omo, U. Agrimi, H. Schmidt, H. Karch, T. Cheasty, and A. Caprioli. 2001. Detection and characterization of Shiga toxin-producing *Escherichia coli* in feral pigeons. *Veterinary Microbiology*. 82:275–283.
396. Morales, C., M.D. Lee, C. Hofacre, and J.J. Maurer. 2004. Detection of a novel virulence gene and a Salmonella virulence homologue among *Escherichia coli* isolated from broiler chickens. *Foodborne Pathogens and Disease*. 1:160–165.
397. Moran, C.A., R.H. Scholten, J.M. Tricarico, P.H. Brooks, and M.W. Verstegen. 2006. Fermentation of wheat: effects of backslopping different proportions of pre-fermented wheat on the microbial and chemical composition. *Archives of Animal Nutrition*. 60:158–169.
398. Morishita, T.Y., P.P. Aye, E.C. Ley, and B.S. Harr. 1999. Survey of pathogens and blood parasites in free-living passerines. *Avian Diseases*. 43:549–552.
399. Morishita, T.Y., and A.A. Bickford. 1992. Pyogranulomatous typhlitis and hepatitis of market turkeys. *Avian Diseases*. 36:1070–1075.
400. Morley, A.J., and D.K. Thomson. 1984. Swollen-head syndrome in broiler chickens. *Avian Diseases*. 28:238–243.
401. Moulin-Schouleur, M., M. Reperant, S. Laurent, A. Bree, S. Mignon-Grasteau, P. Germon, D. Rasschaert, and C. Schouler. 2007. Extraintestinal pathogenic *Escherichia coli* strains of avian and human origin: link between phylogenetic relationships and common virulence patterns. *Journal of Clinical Microbiology*. 45:3366–3376.
402. Moulin-Schouleur, M., C. Schouler, P. Tailliez, M.R. Kao, A. Bree, P. Germon, E. Oswald, J. Mainil, M. Blanco, and J. Blanco. 2006. Common virulence factors and genetic relationships between O18:K1:H7 *Escherichia coli* isolates of human and avian origin. *Journal of Clinical Microbiology*. 44:3484–3492.
403. Murakami, S., M. Miyama, A. Ogawa, J. Shimada, and T. Nakane. 2002. Occurrence of conjunctivitis, sinusitis and upper region tracheitis in Japanese quail (*Coturnix coturnix japonica*), possibly caused by Mycoplasma gallisepticum accompanied by Cryptosporidium sp. infection. *Avian Pathology: Journal of the W.V.P.A*. 31:363–370.
404. Murakami, S., Y. Okazaki, T. Kazama, T. Suzuki, I. Iwabuchi, and K. Kirioka. 1989. A dual infection of *Clostridium perfringens* and *Escherichia coli* in broiler chicks. *J Japan Vet Med Assoc*. 42:405–409.
405. Musgrove, M.T., D.R. Jones, J.K. Northcutt, N.A. Cox, M.A. Harrison, P.J. Fedorka-Cray, and S.R. Ladely. 2006. Antimicrobial resistance in Salmonella and *Escherichia coli* isolated from commercial shell eggs. *Poultry Science*. 85:1665–1669.
406. Mutalib, A., M. Holland, H.J. Barnes, and C. Boyle. 1996. Ultrasound for detecting osteomyelitis in turkeys. *Avian Diseases*. 40:321–325.
407. Mutalib, A., B. Miguel, T. Brown, and W. Maslin. 1996. Distribution of arthritis and osteomyelitis in turkeys with green liver discoloration. *Avian Diseases*. 40:661–664.
408. Myers, R.K., and L.H. Arp. 1987. Pulmonary clearance and lesions of lung and air sac in passively immunized and unimmunized turkeys following exposure to aerosolized *Escherichia coli*. *Avian Diseases*. 31:622–628.
409. Myint, M.S., Y J. Johnson, S.L. Branton, and E.T. Mallinson 2005. Airflow pattern in broiler houses as a risk factor for growth of enteric pathogens. *International Journal of Poultry Science*. 4:947–954.
410. Nagai, S., T. Yagihashi, and A. Ishihama. 1998. An avian pathogenic *Escherichia coli* strain produces a hemolysin, the expression of which is dependent on cyclic AMP receptor protein gene function. *Veterinary Microbiology*. 60:227–238.
411. Nagaraja, K.V., D.A. Emery, K.A. Jordan, J.A. Newman, and B.S. Pomeroy. 1983. Scanning electron microscopic studies of adverse effects of ammonia on tracheal tissues of turkeys. *American Journal of Veterinary Research*. 44:1530–1536.
412. Nagaraja, K.V., D.A. Emery, K.A. Jordan, V. Sivanandan, J.A. Newman, and B.S. Pomeroy. 1984. Effect of ammonia on the quantitative clearance of *Escherichia coli* from lungs, air sacs,

and livers of turkeys aerosol vaccinated against *Escherichia coli*. *American Journal of Veterinary Research*. 45:392–395.
413. Nagi, M.S., and W.J. Mathey. 1972. Interaction of *Escherichia coli* and *Eimeria brunetti* in chickens. *Avian Diseases*. 16:864–873.
414. Nagi, M.S., and L.G. Raggi. 1972. Importance to 'airsac' disease of water supplies contaminated with pathogenic *Escherichia coli*. *Avian Diseases*. 16:718–723.
415. Nakamura, K., and F. Abe. 1987. Ocular lesions in chickens inoculated with *Escherichia coli*. *Can J Vet Res*. 51:528–530.
416. Nakamura, K., J.K. Cook, J.A. Frazier, and M. Narita. 1992. *Escherichia coli* multiplication and lesions in the respiratory tract of chickens inoculated with infectious bronchitis virus and/or *E. coli*. *Avian Diseases*. 36:881–890.
417. Nakamura, K., Y. Imada, and F. Abe. 1987. Effect of cyclophosphamide on infections produced by *Escherichia coli* of high and low virulence in chickens. *Avian Pathology: Journal of the W.V.P.A*. 16:237–252.
418. Nakamura, K., Y. Imada, and M. Maeda. 1986. Lymphocytic depletion of bursa of Fabricius and thymus in chickens inoculated with *Escherichia coli*. *Vet Pathol*. 23:712–717.
419. Nakamura, K., K. Imai, and N. Tanimura. 1996. Comparison of the effects of infectious bronchitis and infectious laryngotracheitis on the chicken respiratory tract. *J Comp Pathol*. 114:11–21.
420. Nakamura, K., M. Maeda, Y. Imada, T. Imada, and K. Sato. 1985. Pathology of spontaneous colibacillosis in a broiler flock. *Vet Pathol*. 22:592–597.
421. Nakamura, K., M. Mase, N. Tanimura, S. Yamaguchi, M. Nakazawa, and N. Yuasa. 1997. Swollen head syndrome in broiler chickens in Japan: its pathology, microbiology and biochemistry. *Avian Pathology: Journal of the W.V.P.A*. 26:139–154.
422. Nakamura, K., M. Mase, N. Tanimura, S. Yamaguchi, and N. Yuasa. 1998. Attempts to reproduce swollen head syndrome in specific pathogen-free chickens by inoculating with *Escherichia coli* and/or turkey rhinotracheitis virus. *Avian Pathology: Journal of the W.V.P.A*. 27:21–27.
423. Nakamura, K., Y. Mitarai, M. Yoshioka, N. Koizumi, T. Shibahara, and Y. Nakajima. 1998. Serum levels of interleukin-6, alpha1-acid glycoprotein, and corticosterone in two-week-old chickens inoculated with *Escherichia coli* lipopolysaccharide. *Poultry Science*. 77:908–911.
424. Nakamura, K., H. Ueda, T. Tanimura, and K. Noguchi. 1994. Effect of mixed live vaccine (Newcastle disease and infectious bronchitis) and Mycoplasma gallisepticum on the chicken respiratory tract and on *Escherichia coli* infection. *J Comp Pathol*. 111:33–42.
425. Nakamura, K., T. Usobe, and M. Narita. 1990. Dual infections of *Eimeria tenella* and *Escherichia coli* in chickens. *Research in Veterinary Science*. 49:125–126.
426. Nakamura, K., N. Yuasa, H. Abe, and M. Narita. 1990. Effect of infectious bursal disease virus on infections produced by *Escherichia coli* of high and low virulence in chickens. *Avian Pathology: Journal of the W.V.P.A*. 19:713–721.
427. Nandi, S., J.J. Maurer, C. Hofacre, and A.O. Summers. 2004. Gram-positive bacteria are a major reservoir of Class 1 antibiotic resistance integrons in poultry litter. *Proc Natl Acad Sci USA*. 101:7118–7122.
428. Naqi, S., G. Thompson, B. Bauman, and H. Mohammed. 2001. The exacerbating effect of infectious bronchitis virus infection on the infectious bursal disease virus-induced suppression of opsonization by *Escherichia coli* antibody in chickens. *Avian Diseases*. 45:52–60.
429. Naqi, S.A., C.F. Hall, and D.H. Lewis. 1971. The intestinal microflora of turkeys: comparison of apparently healthy and bluecomb-infected turkey poults. *Avian Diseases*. 15:14–21.
430. Nardi, A.R.M., M.R. Salvadori, L.T. Coswig, M.S.V. Gatti, D.S. Leite, G.F. Valadares, M. Garcia Neto, R.P. Shocken-Iturrino, J.E. Blanco, and T. Yano. 2005. Type 2 heat-labile enterotoxin (LT-II)-producing *Escherichia coli* isolated from ostriches with diarrhea. *Veterinary Microbiology*. 105:245–249.
431. Nataro, J.P., C.A. Bopp, P.I. Fields, J.B. Kaper and N.A. Strockbine. 2011. *Escherichia, Shigella*, and *Salmonella*. In: *Manual of Clinical Microbiology*, 10th ed. vol. 1. J. Versalovic, K.C. Carroll, G. Funk, J.H. Jorgensen, M.L. Landry, and D.W. Warnock, eds. ASM Press, Washington, D.C. 603–626.
432. Naveh, M.W., T. Zusman, E. Skutelsky, and E.Z. Ron. 1984. Adherence pili in avian strains of *Escherichia coli*: effect on pathogenicity. *Avian Diseases*. 28:651–661.
433. Newberry, L.A., J.K. Skeeles, D.L. Kreider, J.N. Beasley, J.D. Story, R.W. McNew, and B.R. Berridge. 1993. Use of virulent hemorrhagic enteritis virus for the induction of colibacillosis in turkeys. *Avian Diseases*. 37:1–5.
434. Ngeleka, M., L. Brereton, G. Brown, and J.M. Fairbrother. 2002. Pathotypes of avian *Escherichia coli* as related to tsh-, pap-, pil-, and iuc-DNA sequences, and antibiotic sensitivity of isolates from internal tissues and the cloacae of broilers. *Avian Diseases*. 46:143–152.
435. Nivas, S.C., A.C. Peterson, M.D. York, B.S. Pomeroy, L.D. Jacobson, and K.A. Jordan. 1977. Epizootiological investigations of colibacillosis in turkeys. *Avian Diseases*. 21:514–530.
436. Nockels, C.F. 1979. Protective effects of supplemental vitamin E against infection. *Fed Proc*. 38:2134–2138.
437. Nogrady, N., J. Paszti, H. Piko, and B. Nagy. 2006. Class 1 integrons and their conjugal transfer with and without virulence-associated genes in extra-intestinal and intestinal Escherichia coli of poultry. *Avian Pathology: Journal of the W.V.P.A*. 35:349–356.
438. Nolan, L.K., C.W. Giddings, S.M. Horne, C. Doetkott, P.S. Gibbs, R.E. Wooley, and S.L. Foley. 2002. Complement resistance, as determined by viable count and flow cytometric methods, and its association with the presence of iss and the virulence of avian *Escherichia coli*. *Avian Diseases*. 46:386–392.
439. Nolan, L.K., S.M. Horne, C.W. Giddings, S.L. Foley, T.J. Johnson, A.M. Lynne, and J. Skyberg. 2003. Resistance to serum complement, iss, and virulence of avian *Escherichia coli*. *Veterinary Research Communications*. 27:101–110.
440. Norton, R.A., B.A. Hopkins, J.K. Skeeles, J.N. Beasley, and J.M. Kreeger. 1992. High mortality of domestic turkeys associated with *Ascaridia dissimilis*. *Avian Diseases*. 36:469–473.
441. O'Sullivan, N.P., E.A. Dunnington, E.J. Smith, W.B. Gross, and P.B. Siegel. 1991. Performance of early and late feathering broiler breeder females with different feeding regimens. *Br Poult Sci*. 32:981–995.
442. Oaks, J.L., T.E. Besser, S.T. Walk, D.M. Gordon, K.B. Beckmen, K.A. Burek, G.J. Haldorson, D.S. Bradway, L. Ouellette, F.R. Rurangirwa, M.A. Davis, G. Dobbin, and T.S. Whittam. 2010. Escherichia albertii in wild and domestic birds. *Emerg Infect Dis*. 16:638–646.
443. Oh, J.Y., M.S. Kang, H.T. Hwang, B.K. An, J.H. Kwon, and Y.K. Kwon. 2011. Epidemiological investigation of eaeA-positive

Escherichia coli and *Escherichia albertii* strains isolated from healthy wild birds. *J Microbiol*. 49:747–752.
444. Olsen, R.H., M.S. Chadfield, J.P. Christensen, F. Scheutz, H. Christensen, and M. Bisgaard. 2011. Clonality and virulence traits of *Escherichia coli* associated with haemorrhagic septicaemia in turkeys. *Avian Pathology*. 40:587–595.
445. Olsen, R.H., C. Frantzen, H. Christensen, and M. Bisgaard. 2012. An investigation on first-week mortality in layers. *Avian Diseases*. 56:51–57.
446. Olsen, R.H., N.M. Stockholm, A. Permin, J.P. Christensen, H. Christensen, and M. Bisgaard. 2011. Multi-locus sequence typing and plasmid profile characterization of avian pathogenic *Escherichia coli* associated with increased mortality in free-range layer flocks. *Avian Pathology*. 40:437–444.
447. Oyetunde, O.O.F., R.G. Thomson, and H.C. Carlson. 1978. Aerosol exposure of ammonia, dust and *Escherichia coli* in broiler chickens. *Can Vet J*. 19:187–193.
448. Ozawa, M., K. Harada, A. Kojima, T. Asai, and T. Sameshima. 2008. Antimicrobial susceptibilities, serogroups, and molecular characterization of avian pathogenic E*scherichia coli* isolates in Japan. *Avian Diseases*. 52:392–397.
449. Pakpinyo, S., D.H. Ley, H.J. Barnes, J.P. Vaillancourt, and J.S. Guy. 2003. Enhancement of enteropathogenic *Escherichia coli* pathogenicity in young turkeys by concurrent turkey coronavirus infection. *Avian Diseases*. 47:396–405.
450. Pakpinyo, S., D.H. Ley, H.J. Barnes, J.P. Vaillancourt, and J.S. Guy. 2002. Prevalence of enteropathogenic *Escherichia coli* in naturally occurring cases of poult enteritis-mortality syndrome. *Avian Diseases*. 46:360–369.
451. Palmer, C.C., and H.R. Baker. 1923. Studies on infectious enteritis of poultry caused by Bacterium coli communis. *J Am Vet Med Assoc*. 63:85–96.
452. Parreira, V.R., C.W. Arns, and T. Yano. 1998. Virulence factors of avian *Escherichia coli* associated with swollen head syndrome. *Avian Pathology: Journal of the W.V.P.A*. 27:148–154.
453. Parreira, V.R., and C.L. Gyles. 2003. A novel pathogenicity island integrated adjacent to the thrW tRNA gene of avian pathogenic *Escherichia coli* encodes a vacuolating autotransporter toxin. *Infection and Immunity*. 71:5087–5096.
454. Parreira, V.R., and C.L. Gyles. 2002. Shiga toxin genes in avian *Escherichia coli*. *Veterinary Microbiology*. 87:341–352.
455. Parreira, V.R., and T. Yano. 1998. Cytotoxin produced by *Escherichia coli* isolated from chickens with swollen head syndrome (SHS). *Veterinary Microbiology*. 62:111–119.
456. Pedersen, K., and N. Jahromi. 1993. Inactivation of bacteria with SMAC—a stable solution of chlorine dioxide in water. *Vatten*. 49:264–270.
457. Peighambari, S.M., D.B. Hunter, P.E. Shewen, and C.L. Gyles. 2002. Safety, immunogenicity, and efficacy of two *Escherichia coli* cya crp mutants as vaccines for broilers. *Avian Diseases*. 46:287–297.
458. Pelkonen, S., and J. Finne. 1987. A rapid turbidometric assay for the study of serum sensitivitiy of *Escherichia coli*. *FEMS Microbiology Letters*. 42:53–57.
459. Penalver, P., B. Huerta, C. Borge, R. Astorga, R. Romero, and A. Perea. 2005. Antimicrobial activity of five essential oils against origin strains of the Enterobacteriaceae family. *Apmis*. 113:1–6.
460. Pennycott, T.W., H.M. Ross, I.M. McLaren, A. Park, G.F. Hopkins, and G. Foster. 1998. Causes of death of wild birds of the family Fringillidae in Britain. *The Veterinary Record*. 143:155–158.
461. Permin, A., J.P. Christensen, and M. Bisgaard. 2006. Consequences of concurrent *Ascaridia galli* and *Escherichia coli* infections in chickens. *Acta Vet Scand*. 47:43–54.
462. Petersen, A., J.P. Christensen, P. Kuhnert, M. Bisgaard, and J.E. Olsen. 2006. Vertical transmission of a fluoroquinolone-resistant *Escherichia coli* within an integrated broiler operation. *Veterinary Microbiology*. 116:120–128.
463. Petridis, M., M. Bagdasarian, M.K. Waldor, and E. Walker. 2006. Horizontal transfer of Shiga toxin and antibiotic resistance genes among *Escherichia coli* strains in house fly (Diptera: Muscidae) gut. *J Med Entomol*. 43:288–295.
464. Pfaff-McDonough, S.J., S.M. Horne, C.W. Giddings, J.O. Ebert, C. Doetkott, M.H. Smith, and L.K. Nolan. 2000. Complement resistance-related traits among *Escherichia coli* isolates from apparently healthy birds and birds with colibacillosis. *Avian Diseases*. 44:23–33.
465. Pierson, F.W., V.D. Barta, D. Boyd, and W.S. Thompson. 1996. Exposure to multiple infectious agents and the development of colibacillosis in turkeys. *J Appl Poult Res*. 5:347–357.
466. Pierson, F.W., C.T. Larsen, and C.H. Domermuth. 1996. The production of colibacillosis in turkeys following sequential exposure to Newcastle disease virus or Bordetella avium, avirulent hemorrhagic enteritis virus, and *Escherichia coli*. *Avian Diseases*. 40:837–840.
467. Pilipcinec, E., L. Tkacikova, H.T. Naas, R. Cabadaj, and I. Mikula. 1999. Isolation of verotoxigenic *Escherichia coli* O157 from poultry. *Folia Microbiol*. 44:455–456.
468. Poppe, C., L.C. Martin, C.L. Gyles, R. Reid-Smith, P. Boerlin, S.A. McEwen, J.F. Prescott, and K.R. Forward. 2005. Acquisition of resistance to extended-spectrum cephalosporins by Salmonella enterica subsp. enterica serovar Newport and Escherichia coli in the turkey poult intestinal tract. *Applied and Environmental Microbiology*. 71:1184–1192.
469. Portrait, V., S. Gendron Gaillard, G. Cottenceau, and A.M. Pons. 1999. Inhibition of pathogenic Salmonella enteritidis growth mediated by *Escherichia coli* microcin J25 producing strains. *Canadian Journal of Microbiology*. 45:988–994.
470. Pourbakhsh, S.A., M. Boulianne, B. Martineau-Doize, and J. M. Fairbrother. 1997. Virulence mechanisms of avian fimbriated *Escherichia coli* in experimentally inoculated chickens. *Veterinary Microbiology*. 58:195–213.
471. Pourbakhsh, S.A., M. Boulianne, B. Martineau Doize, C.M. Dozois, C. Desautels, and J.M. Fairbrother. 1997. Dynamics of *Escherichia coli* infection in experimentally inoculated chickens. *Avian Diseases*. 41:221–233.
472. Pourbakhsh, S.A., M. Dho-Moulin, A. Bree, C. Desautels, B. Martineau-Doize, and J.M. Fairbrother. 1997. Localization of the *in vivo* expression of P and F1 fimbriae in chickens experimentally inoculated with pathogenic *Escherichia coli*. *Microbial Pathogenesis*. 22:331–341.
473. Praharaj, N.K., W.B. Gross, E.A. Dunnington, and P.B. Siegel. 1996. Feeding regimen by sire family interactions on growth, immunocompetence, and disease resistance in chickens. *Poultry Science*. 75:821–827.
474. Provence, D.L., and R. Curtiss, 3rd. 1994. Isolation and characterization of a gene involved in hemagglutination by an avian pathogenic *Escherichia coli* strain. *Infection and Immunity*. 62:1369–1380.
475. Pu, J., Y.L. Fan, Z. Wang, B. Ma, E.G. Brown, and J.H. Liu. 2012. Pathogenicity of H3N8 influenza viruses isolated from

domestic ducks in chickens with or without *Escherichia coli* coinfections. *Avian Diseases*. 56:597–600.
476. Qureshi, M.A., Y.M. Saif, C.L. Heggen-Peay, F.W. Edens, and G.B. Havenstein. 2001. Induction of functional defects in macrophages by a poult enteritis and mortality syndrome-associated turkey astrovirus. *Avian Diseases*. 45:853–861.
477. Rajeswari, S., B.R. Shome, S. Senani, S.K. Saha, R.B. Rai and S.P.S. Ahlawat. 2002. Bacterial enteritis of ducks due to *E. coli* infection: a report from Andaman. *Indian Vet J*. 79:606–607.
478. Ramirez, R.M., Y. Almanza, S. Garcia, and N. Heredia. 2009a. Adherence and invasion of avian pathogenic *Escherichia coli* to avian tracheal epithelial cells. *World Journal of Microbiology and Biotechnology*. 25:1019–1023.
479. Ramirez, R.M., Y. Almanza, R. Gonzalez, S. Garcia, and N. Heredia. 2009b. Avian pathogenic *Escherichia coli* bind fibronectin and laminin. *Veterinary Research Communications*. 33:379–386.
480. Randall, C.J., W.G. Siller, A.S. Wallis, and K.S. Kirkpatrick. 1984. Multiple infections in young broilers. *The Veterinary Record*. 114:270–271.
481. Rao, S.V.R., N.K. Praharaj, M.R. Reddy, and A.K. Panda. 2003. Interaction between genotype and dietary concentrations of methionine for immune function in commercial broilers. *Br Poult Sci*. 44:104–112.
482. Raue, R., V. Schmidt, M. Freick, B. Reinhardt, R. Johne, L. Kamphausen, E.F. Kaleta, H. Muller, and M.E. Krautwald-Junghanns. 2005. A disease complex associated with pigeon circovirus infection, young pigeon disease syndrome. *Avian Pathology: Journal of the W.V.P.A*. 34:418–425.
483. Raviv, Z., N. Ferguson-Noel, V. Laibinis, R. Wooten, and S.H. Kleven. 2007. Role of Mycoplasma synoviae in commercial layer *Escherichia coli* peritonitis syndrome. *Avian Diseases*. 51:685–690.
484. Rawiwet, V., and N. Chansiripornchai. 2009. The efficacy of *Escherichia coli* AroA-live vaccine in broilers against avian *E. coli* serotype O78 infection. *Thai J Vet Med*. 39:337–342.
485. Reingold, J., N. Starr, J. Maurer, and M.D. Lee. 1999. Identification of a new *Escherichia coli* She haemolysin homolog in avian *E. coli*. *Veterinary Microbiology*. 66:125–134.
486. Rezende, C.L.E. d., E.T. Mallinson, N.L. Tablante, R. Morales, A. Park, L.E. Carr, and S.W. Joseph. 2001. Effect of dry litter and airflow in reducing Salmonella and *Escherichia coli* populations in the broiler production environment. *J Appl Poult Res*. 10:245–251.
487. Rochon, K., T.J. Lysyk, and L.B. Selinger. 2004. Persistence of *Escherichia coli* in immature house fly and stable fly (Diptera: Muscidae) in relation to larval growth and survival. *J Med Entomol*. 41:1082–1089.
488. Rochon, K., T.J. Lysyk, and L.B. Selinger. 2005. Retention of *Escherichia coli* by house fly and stable fly (Diptera: Muscidae) during pupal metamorphosis and eclosion. *J Med Entomol*. 42:397–403.
489. Rodrigues, V.S., M.C. Vidotto, I. Felipe, D.S. Santos, and L.C.J. Gaziri. 1999. Apoptosis of murine peritoneal macrophages induced by an avian pathogenic strain of *Escherichia coli*. *FEMS Microbiology Letters*. 179:73–78.
490. Rodriguez-Siek, K.E., C.W. Giddings, C. Doetkott, T.J. Johnson, M.K. Fakhr, and L.K. Nolan. 2005. Comparison of *Escherichia coli* isolates implicated in human urinary tract infection and avian colibacillosis. *Microbiol*. 151:2097–2110.
491. Rodriguez-Siek, K.E., C.W. Giddings, C. Doetkott, T.J. Johnson, and L.K. Nolan. 2005. Characterizing the APEC pathotype. *Vet Res*. 36:241–256.
492. Rojas, T.C., L.P. Parizzi, M.R. Tiba, L. Chen, G.A. Pereira, V. Sangal, J. Yang, J. Yu, and W. Dias da Silveira. 2012. Draft genome of a Brazilian avian-pathogenic *Escherichia coli* strain and in silico characterization of virulence-related genes. *Journal of Bacteriology*. 194:3023.
493. Roland, K., R. Curtiss, 3rd, and D. Sizemore. 1999. Construction and evaluation of a delta cya delta crp *Salmonella typhimurium* strain expressing avian pathogenic *Escherichia coli* O78 LPS as a vaccine to prevent airsacculitis in chickens. *Avian Diseases*. 43:429–441.
494. Roland, K., K. Karaca, and D. Sizemore. 2004. Expression of *Escherichia coli* antigens in Salmonella typhimurium as a vaccine to prevent airsacculitis in chickens. *Avian Diseases*. 48:595–605.
495. Ron, E.Z. 2006. Host specificity of septicemic *Escherichia coli*: human and avian pathogens. *Curr Opin Microbiol*. 9:28–32.
496. Rosario, C.C., A.C. Lopez, I.G. Tellez, O.A. Navarro, R.C. Anderson, and C.C. Eslava. 2004. Serotyping and virulence genes detection in *Escherichia coli* isolated from fertile and infertile eggs, dead-in-shell embryos, and chickens with yolk sac infection. *Avian Diseases*. 48:791–802.
497. Rosario, C.C., J.L. Puente, A. Verdugo-Rodriguez, R.C. Anderson, and C.C. Eslava. 2005. Phenotypic characterization of ipaH+*Escherichia coli* strains associated with yolk sac infection. *Avian Diseases*. 49:409–417.
498. Rosenberger, J.K., P.A. Fries, and S.S. Cloud. 1985. *In vitro* and *in vivo* characterization of avian *Escherichia coli*. III. Immunization. *Avian Diseases*. 29:1108–1117.
499. Rosenberger, J.K., P.A. Fries, S.S. Cloud, and R.A. Wilson. 1985. *In vitro* and *in vivo* characterization of avian *Escherichia coli*. II. Factors associated with pathogenicity. *Avian Diseases*. 29:1094–1107.
500. Roy, P., A.S. Dhillon, L. Lauerman, and H.L. Shivaprasad. 2003. Detection of pigeon circovirus by polymerase chain reaction. *Avian Diseases*. 47:218–222.
501. Ruble, R.P., P.S. Wakenell, and J.S. Cullor. 2002. Seroprevalence of antibodies specific for Gram-negative core antigens in chickens on the basis of an *Escherichia coli* J5 enzyme-linked immunosorbent assay. *Avian Diseases*. 46:453–460.
502. Russell, S.M. 2003. The effect of airsacculitis on bird weights, uniformity, fecal contamination, processing errors, and populations of Campylobacter spp., and *Escherichia coli*. *Poultry Science*. 82:1326–1331.
503. Russell, S.M. 2003. Effect of sanitizers applied by electrostatic spraying on pathogenic and indicator bacteria attached to the surface of eggs. *J Appl Poult Res*. 12:183–189.
504. Russo, T.A., and J.R. Johnson. 2000. Proposal for a new inclusive designation for extraintestinal pathogenic isolates of *Escherichia coli*: ExPEC. *The Journal of Infectious Diseases*. 181:1753–1754.
505. Russo, T.A., M.C. Moffitt, C.H. Hammer, and M.M. Frank. 1993. TnphoA-mediated disruption of K54 capsular polysaccharide genes in *Escherichia coli* confers serum sensitivity. *Infection and Immunity*. 61:3578–3582.
506. Sabri, M., S. Leveille, and C.M. Dozois. 2006. A SitABCD homologue from an avian pathogenic *Escherichia coli* strain mediates transport of iron and manganese and resistance to hydrogen peroxide. *Microbiol*. 152:745–758.

507. Saif, Y.M., P.D. Moorhead, and E.H. Bohl. 1970. Mycoplasma meleagridis and E*scherichia coli* infections in germfree and specific-pathogen-free turkey poults: production of complicated airsacculitis. *American Journal of Veterinary Research*. 31:1637–1643.
508. Salmon, S.A., and J.L. Watts. 2000. Minimum inhibitory concentration determinations for various antimicrobial agents against 1570 bacterial isolates from turkey poults. *Avian Diseases*. 44:85–98.
509. Salvadori, M.R., A.M. Chudzinski-Tavassi, M.R. Baccaro, C.S. Ferreira, A.J. Ferreira, J. Prado-Franceschi, and T. Yano. 2002. Lethal factor to mice produced by *Escherichia coli* isolated from chickens with swollen head syndrome. *Microbiol Immunol*. 46:773–775.
510. Salvadori, M.R., A.T. Yamada, and T. Yano. 2001. Morphological and intracellular alterations induced by cytotoxin VT2y produced by *Escherichia coli* isolated from chickens with swollen head syndrome. *FEMS Microbiology Letters*. 197:79–84.
511. Salvadori, M.R., T. Yano, H.F. Carvalho, V.R. Parreira, and C.L. Gyles. 2001. Vacuolating cytotoxin produced by avian pathogenic *Escherichia coli*. *Avian Diseases*. 45:43–51.
512. Samadpour, M., J. Stewart, K. Steingart, C. Addy, J. Louderback, M. McGinn, J. Ellington, and T. Newman. 2002. Laboratory investigation of an *E. coli* O157:H7 outbreak associated with swimming in Battle Ground Lake, Vancouver, Washington. *J Environ Health*. 64 (10):16–20.
513. Sander, J.E., C.L. Hofacre, I.H. Cheng, and R.D. Wyatt. 2002. Investigation of resistance of bacteria from commercial poultry sources to commercial disinfectants. *Avian Diseases*. 46:997–1000.
514. Sandhu, T.S., and H.W. Layton. 1985. Laboratory and field trials with formalin-inactivated *Escherichia coli* (O78)-Pasteurella anatipestifer bacterin in White Pekin ducks. *Avian Diseases*. 29:128–135.
515. Savini, V., C. Catavitello, M. Talia, A. Manna, F. Pompetti, M. Favaro, C. Fontana, F. Febbo, A. Balbinot, F. d. Berardino, G. d. Bonaventura, S. d. Zacomo, F. Esattore, and D. D'Antonio. 2008. Multidrug-resistant *Escherichia fergusonii*: a case of acute cystitis. *Journal of Clinical Microbiology*. 46:1551–1552.
516. Schmidt, G.P., C.H. Domermuth, and L.M. Potter. 1988. Effect of oral *Escherichia coli* inoculation on performance of young turkeys. *Avian Diseases*. 32:103–107.
517. Schmidt, H., J. Scheef, S. Morabito, A. Caprioli, L.H. Wieler, and H. Karch. 2000. A new Shiga toxin 2 variant (Stx2f) from *Escherichia coli* isolated from pigeons. *Applied and Environmental Microbiology*. 66:1205–1208.
518. Schouler, C., F. Koffmann, C. Amory, S. Leroy-Setrin, and M. Moulin-Schouleur. 2004. Genomic subtraction for the identification of putative new virulence factors of an avian pathogenic Escherichia coli strain of O2 serogroup. *Microbiol*. 150:2973–2984.
519. Schouler, C., B. Schaeffer, A. Bree, A. Mora, G. Dahbi, F. Biet, E. Oswald, J. Mainil, J. Blanco, and M. Moulin-Schouleur. 2012. Diagnostic strategy for identifying avian pathogenic *Escherichia coli* based on four patterns of virulence genes. *Journal of Clinical Microbiology*. 50:1673–1678.
520. Schremmer, C., J.E. Lohr, U. Wastlhuber, J. Kosters, K. Ravelshofer, H. Steinruck, and L.H. Wieler. 1999. Enteropathogenic *Escherichia coli* in Psittaciformes. *Avian Pathology: Journal of the W.V.P.A*. 28:349–354.
521. Sell, J.L., D.W. Trampel, and R.W. Griffith. 1997. Adverse effects of *Escherichia coli* infection of turkeys were not alleviated by supplemental dietary vitamin E. *Poultry Science*. 76:1682–1687.
522. Shane, S.M., and A. Faust. 1996. Evaluation of sanitizers for hatching eggs. *J Appl Poult Res*. 5:134–138.
523. Sharada, R., G. Krishnappa, and H.A. Upendra. 2001. Serological 'O' grouping and drug susceptibility of *Escherichia coli* strains from chicken. *Indian Vet J*. 78:78–79.
524. Shawky, S., T. Sandhu, and H.L. Shivaprasad. 2000. Pathogenicity of a low-virulence duck virus enteritis isolate with apparent immunosuppressive ability. *Avian Diseases*. 44:590–599.
525. Siccardi, F.J. 1966. Identification and disease producing ability of *Escherichia coli* associated with *E. coli* infection of chickens and turkeys. St. Paul, MN, University of Minnesota.
526. Siegel, P.B., M. Blair, W.B. Gross, B. Meldrum, C. Larsen, K. Boa-Amponsem, and D.A. Emmerson. 2006. Poult performance as influenced by age of dam, genetic line, and dietary vitamin E. *Poultry Science*. 85:939–942.
527. Siegel, P.B., C.T. Larsen, D.A. Emmerson, P.A. Geraert, and M. Picard. 2000. Feeding regimen, dietary vitamin E, and genotype influences on immunological and production traits of broilers. *J Appl Poult Res*. 9:269–278.
528. Singer, R.S., and C.L. Hofacre. 2006. Potential impacts of antibiotic use in poultry production. *Avian Diseases*. 50:161–172.
529. Singer, R.S., J.S. Jeffrey, T.E. Carpenter, C.L. Cooke, E.R. Atwill, W.O. Johnson, and D.C. Hirsh. 2000. Persistence of cellulitis-associated *Escherichia coli* DNA fingerprints in successive broiler chicken flocks. *Veterinary Microbiology*. 75:59–71.
530. Singer, R.S., J.S. Jeffrey, T.E. Carpenter, C.L. Cooke, R.P. Chin, E.R. Atwill, and D.C. Hirsh. 1999. Spatial heterogeneity of *Escherichia coli* DNA fingerprints isolated from cellulitis lesions in chickens. *Avian Diseases*. 43:756–762.
531. Sivaseelan, S., P.G. Edwin, R.U. Rani, D. Kathiresan, and V. Purushothaman. 2005. A report on the outbreak of colibacillosis in peacocks. *Indian Veterinary Journal*. 82:95–96.
532. Skyberg, J.A., S.M. Horne, C.W. Giddings, R.E. Wooley, P.S. Gibbs, and L.K. Nolan. 2003. Characterizing avian *Escherichia coli* isolates with multiplex polymerase chain reaction. *Avian Diseases*. 47:1441–1447.
533. Skyberg, J.A., T.J. Johnson, J.R. Johnson, C. Clabots, C.M. Logue, and L.K. Nolan. 2006. Acquisition of avian pathogenic *Escherichia coli* plasmids by a commensal *E. coli* isolate enhances its abilities to kill chick embryos, grow in human urine, and colonize the murine kidney. *Infection and Immunity*. 74:6287–6292.
534. Skyberg, J.A., T.J. Johnson, and L.K. Nolan. 2008. Mutational and transcriptional analyses of an avian pathogenic *Escherichia coli* ColV plasmid. *BMC Microbiology*. 8:24.
535. Skyberg, J.A., K.E. Siek, C. Dotkott, and L.K. Nolan. 2007. Biofilm formation by avian *Escherichia coli* in relation to media, source and phylogeny. *Journal of Applied Microbiology*. 102:548–554.
536. Smith, H.W., J.K.A. Cook, and Z.E. Parsell. 1985. The experimental infection of chickens with mixtures of infectious bronchitis virus and *Escherichia coli*. *J Gen Virol*. 66:777–786.
537. Sojka, W.J. 1965. *Escherichia coli* in Domestic Animals and Poultry. Commonwealth Agricultural Bureau, Farnham Royal, England. 1–231.
538. Sojka, W.J., and R.B.A. Carnaghan. 1961. *Escherichia coli* infections in poultry. *Research in Veterinary Science*. 2:340–352.

539. Songserm, T., J.M. Pol, D. van Roozelaar, G.L. Kok, F. Wagenaar, and A.A. ter Huurne. 2000. A comparative study of the pathogenesis of malabsorption syndrome in broilers. *Avian Diseases*. 44:556–567.
540. Songserm, T., B. Zekarias, D.J. van Roozelaar, R.S. Kok, J. M. Pol, A.A. Pijpers, and A.A. ter Huurne. 2002. Experimental reproduction of malabsorption syndrome with different combinations of reovirus, *Escherichia coli*, and treated homogenates obtained from broilers. *Avian Diseases*. 46:87–94.
541. Sonntag, A.K., E. Zenner, H. Karch, and M. Bielaszewska. 2005. Pigeons as a possible reservoir of Shiga toxin 2f-producing *Escherichia coli* pathogenic to humans. *Berl Munch Tierarztl Wochenschr*. 118:464–470.
542. Springer, W.T., J. Johnson, and W.M. Reid. 1970. Histomoniasis in gnotobiotic chickens and turkeys: biological aspects of the role of bacteria in the etiology. *Experimental Parasitology*. 28:383–392.
543. Springer, W.T., C. Luskus, and S.S. Pourciau. 1974. Infectious bronchitis and mixed infections of *Mycoplasma synoviae* and *Escherichia coli* in gnotobiotic chickens. I. Synergistic role in the airsacculitis syndrome. *Inf Immun*. 10:578–589.
544. Stanley, V.G., S. Woldesenbet, C. Gray, and A. Hinton, Jr. 1996. Sensitivity of *Escherichia coli* O157:H7 strain 932 to selected anticoccidial drugs in broiler chicks. *Poultry Science*. 75:42–46.
545. Stavric, S., B. Buchanan, and T.M. Gleeson. 1993. Intestinal colonization of young chicks with *Escherichia coli* O157:H7 and other verotoxin-producing serotypes. *J Appl Bacteriol*. 74:557–563.
546. Stehling, E.G., T. Yano, M. Brocchi, and W.D. da Silveira. 2003. Characterization of a plasmid-encoded adhesin of an avian pathogenic *Escherichia coli* (APEC) strain isolated from a case of swollen head syndrome (SHS). *Veterinary Microbiology*. 95:111–120.
547. Stenutz, R., A. Weintraub, and G. Widmalm. 2006. The structures of *Escherichia coli* O-polysaccharide antigens. *FEMS Microbiol Rev*. 30:382–403.
548. Stocki, S.L., L.A. Babiuk, N.A. Rawlyk, A.A. Potter, and B.J. Allan. 2002. Identification of genomic differences between *Escherichia coli* strains pathogenic for poultry and *E. coli* K-12 MG1655 using suppression subtractive hybridization analysis. *Microbial Pathogenesis*. 33:289–298.
549. Stokholm, N.M., A. Permin, M. Bisgaard, and J.P. Christensen. 2010. Causes of mortality in commercial organic layers in Denmark. *Avian Diseases*. 54:1241–1250.
550. Stordeur, P., D. Marlier, J. Blanco, E. Oswald, F. Biet, M. Dho-Moulin, and J. Mainil. 2002. Examination of *Escherichia coli* from poultry for selected adhesin genes important in disease caused by mammalian pathogenic *E. coli*. *Veterinary Microbiology*. 84:231–241.
551. Styles, D.K., and K. Flammer. 1991. Congo red binding of *Escherichia coli* isolated from the cloacae of psittacine birds. *Avian Diseases*. 35:46–48.
552. Suerbaum, S., S. Friedrich, H. Leying, and W. Opferkuch. 1994. Expression of capsular polysaccharide determines serum resistance in *Escherichia coli* K92. *Zentralbl Bakteriol*. 281:146–157.
553. Sueyoshi, M., H. Fukui, S. Tanaka, M. Nakazawa, and K. Ito. 1996. A new adherent form of an attaching and effacing *Escherichia coli* (eaeA+, bfp–) to the intestinal epithelial cells of chicks. *J Vet Med Sci*. 58:1145–1147.
554. Sugiarto, H., and P. Yu. 2004. Avian antimicrobial peptides: the defense role of beta-defensins. *Biochem Biophy Res Comm*. 323:721–727.
555. Sugiarto, H., and P. Yu. 2006. Identification of three novel ostricacins: an update on the phylogenetic perspective of beta-defensins. *Intl J Antimicrob Agents*. 27:229–235.
556. Sumano, L.H., C.L. Ocampo, G.W. Brumbaugh, and R.E. Lizarraga. 1998. Effectiveness of two fluoroquinolones for the treatment of chronic respiratory disease outbreak in broilers. *Br Poult Sci*. 39:42–46.
557. Suwanichkul, A., B. Panigrahy, and R.M. Wagner. 1987. Antigenic relatedness and partial amino acid sequences of pili of *Escherichia coli* serotypes O1, O2, and O78 pathogenic to poultry. *Avian Diseases*. 31:809–813.
558. Swarbrick, O. 1985. Pheasant rearing: associated husbandry and disease problems. *The Veterinary Record*. 116:610–617.
559. Synge, B.A. 2000. Recent epidemiological studies of verocytotoxin-producing *E. coli* O157 in cattle in Scotland. *Cattle Practice*. 8:341–343.
560. Tantaswasdi, U., A. Malayaman, and K.F. Shortridge. 1986. Influenza A virus infection of a pheasant. *The Veterinary Record*. 119:375–376.
561. Tate, C.R., W.C. Mitchell, and R.G. Miller. 1993. Staphylococcus hyicus associated with turkey stifle joint osteomyelitis. *Avian Diseases*. 37:905–907.
562. Tengerdy, R.P., and J.C. Brown. 1977. Effect of vitamin E and A on humoral immunity and phagocytosis in *E. coli* infected chicken. *Poultry Science*. 56:957–963.
563. Tengerdy, R.P., and C.F. Nockels. 1975. Vitamin E or vitamin A protects chickens against *E. coli* infection. *Poultry Science*. 54:1292–1296.
564. Teo, A.Y.L., and H.M. Tan. 2006. Effect of Bacillus subtilis PB6 (CloSTAT) on broilers infected with a pathogenic strain of *Escherichia coli*. *J Appl Poult Res*. 15:229–235.
565. Thangapandian, E., K. Vijayarani, P. Ramadass, and A.M. Nainar. 2006. Distribution of virulence associated genes in avian pathogenic *Escherichia coli* isolates from Tamil Nadu. *Indian J An Sci*. 76:284–287.
566. Tian, S., and V. E. Baracos. 1989. Effect of Escherichia coli infection on growth and protein metabolism in broiler chicks (Gallus domesticus). *Comp Biochem Physiol A*. 94:323–331.
567. Tian, S., and V.E. Baracos. 1989. Prostaglandin-dependent muscle wasting during infection in the broiler chick (*Gallus domesticus*) and the laboratory rat (*Rattus norvegicus*). *The Biochemical Journal*. 263:485–490.
568. Timothy, S., K. Shafi, A.H. Leatherbarrow, F.T.W. Jordan, and P. Wigley. 2008. Molecular epidemiology of a reproductive tract-associated colibacillosis outbreak in a layer breeder flock associated with atypical avian pathogenic *Escherichia coli*. *Avian Pathology*. 37:375–378.
569. Tivendale, K.A., J.L. Allen, and G.F. Browning. 2009. Plasmid-borne virulence-associated genes have a conserved organization in virulent strains of avian pathogenic *Escherichia coli*. *Journal of Clinical Microbiology*. 47:2513–2519.
570. Tivendale, K.A., J.L. Allen, C.A. Ginns, B.S. Crabb, and G.F. Browning. 2004. Association of iss and iucA, but not tsh, with plasmid-mediated virulence of avian pathogenic *Escherichia coli*. *Infection and Immunity*. 72:6554–6560.
571. Tivendale, K.A., C.M. Logue, S. Kariyawasam, D. Jordan, A. Hussein, G. Li, Y. Wannemuehler, and L.K. Nolan. 2010. Avian-pathogenic *Escherichia coli* strains are similar to neonatal meningitis *E. coli* strains and are able to cause meningitis in the rat model of human disease. *Infection and Immunity*. 78:3412–3419.

572. Tivendale, K.A., A.H. Noormohammadi, J.L. Allen, and G.F. Browning. 2009. The conserved portion of the putative virulence region contributes to virulence of avian pathogenic *Escherichia coli*. *Microbiology*. 155:450–460.
573. Toth, T.E., H. Veit, W.B. Gross, and P.B. Siegel. 1988. Cellular defense of the avian respiratory system: Protection against *Escherichia coli* airsacculitis by Pasteurella multocida-activated respiratory phagocytes. *Avian Diseases*. 32:681–687.
574. Tottori, J., R. Yamaguchi, Y. Murakawa, M. Sato, K. Uchida, and S. Tateyama. 1997. Experimental production of ascites in broiler chickens using infectious bronchitis virus and *Escherichia coli*. *Avian Diseases*. 41:214–220.
575. Trampel, D.W., and R.W. Griffth. 1997. Efficacy of aluminum hydroxide-adjuvanted *Escherichia coli* bacterin in turkey poults. *Avian Diseases*. 41:263–268.
576. Trampel, D.W., Y. Wannemuehler, and L.K. Nolan. 2007. Characterization of *Escherichia coli* isolates from peritonitis lesions in commercial laying hens. *Avian Diseases*. 51:840–844.
577. Tuntufye, H.N., S. Lebeer, P.S. Gwakisa, and B.M. Goddeeris. 2012. Identification of avian pathogenic *Escherichia coli* genes that are induced *in vivo* during infection in chickens. *Applied and Environmental Microbiology*. 78:3343–3351.
578. Turpin, E.A., L.E. Perkins, and D.E. Swayne. 2002. Experimental infection of turkeys with avian pneumovirus and either Newcastle disease virus or *Escherichia coli*. *Avian Diseases*. 46:412–422.
579. Van Alstine, W.G., and L.H. Arp. 1987. Influence of Bordetella avium infection on association of *Escherichia coli* with turkey trachea. *American Journal of Veterinary Research*. 48:1574–1576.
580. Van de Zande, S., H. Nauwynck, and M. Pensaert. 2001. The clinical, pathological and microbiological outcome of an *Escherichia coli* O2:K1 infection in avian pneumovirus infected turkeys. *Veterinary Microbiology*. 81:353–365.
581. van den Bogaard, A.E., N. London, C. Driessen, and E.E. Stobberingh. 2001. Antibiotic resistance of faecal *Escherichia coli* in poultry, poultry farmers and poultry slaughterers. *The Journal of Antimicrobial Chemotherapy*. 47:763–771.
582. van den Hurk, J.V., B.J. Allan, C. Riddell, T. Watts, A.A. Potter, and J.V. Van den Hurk. 1994. Effect of infection with hemorrhagic enteritis virus on susceptibility of turkeys to *Escherichia coli*. *Avian Diseases*. 38:708–716.
583. Van Loock, M., K. Lootsa, M. Van Heerden, D. Vanrompay, and B.M. Goddeeris. 2006. Exacerbation of Chlamydophila psittaci pathogenicity in turkeys superinfected by *Escherichia coli*. *Vet Res*. 37:745–755
584. Vandekerchove, D., P. De Herdt, H. Laevens, and F. Pasmans. 2004. Colibacillosis in caged layer hens: characteristics of the disease and the aetiological agent. *Avian Pathology: Journal of the W.V.P.A*. 33:117–125.
585. Vandekerchove, D., P. De Herdt, H. Laevens, and F. Pasmans. 2004. Risk factors associated with colibacillosis outbreaks in caged layer flocks. *Avian Pathology: Journal of the W.V.P.A*. 33:337–342.
586. Vandekerchove, D., P.D. Herdt, H. Laevens, P. Butaye, G. Meulemans, and F. Pasmans. 2004. Significance of interactions between *Escherichia coli* and respiratory pathogens in layer hen flocks suffering from colibacillosis-associated mortality. *Avian Pathology: Journal of the W.V.P.A*. 33:298–302.
587. Vandekerchove, D., F. Vandemaele, C. Adriaensen, M. Zaleska, J.P. Hernalsteens, L. De Baets, P. Butaye, F. Van Immerseel, P. Wattiau, H. Laevens, J. Mast, B. Goddeeris, and F. Pasmans. 2005. Virulence-associated traits in avian *Escherichia coli*: comparison between isolates from colibacillosis-affected and clinically healthy layer flocks. *Veterinary Microbiology*. 108:75–87.
588. Vandemaele, F., A. Assadzadeh, J. Derijcke, M. Vereecken, and B.M. Goddeeris. 2002. Aviaire pathogene *Escherichia coli* (APEC). *Tijdschr Diergeneeskd*. 127:582–588.
589. Vandemaele, F., N. Bleyen, O. Abuaboud, E. vanderMeer, A. Jacobs, and B.M. Goddeeris. 2006. Immunization with the biologically active lectin domain of PapGII induces strong adhesion-inhibiting antibody responses but not protection against avian pathogenic *Escherichia coli*. *Avian Pathology: Journal of the W.V.P.A*. 35:238–249.
590. Vandemaele, F., M. Vereecken, J. Derijcke, and B.M. Goddeeris. 2002. Incidence and antibiotic resistance of pathogenic *Escherichia coli* among poultry in Belgium. *The Veterinary Record*. 151:355–356.
591. Vandemaele, F., C. Ververken, N. Bleyen, J. Geys, C. D'Hulst, T. Addwebi, P. van Empel, and B.M. Goddeeris. 2005. Immunization with the binding domain of FimH, the adhesin of type 1 fimbriae, does not protect chickens against avian pathogenic *Escherichia coli*. *Avian Pathology: Journal of the W.V.P.A*. 34:264–272.
592. Vasserman, Y., and J. Pitcovski. 2006. Genetic detoxification and adjuvant-activity retention of *Escherichia coli* enterotoxin LT. *Avian Pathology: Journal of the W.V.P.A*. 35:134–140.
593. Velkers, F.C., A.J. te Loo, F. Madin, and J.H. van Eck. 2005. Isopathic and pluralist homeopathic treatment of commercial broilers with experimentally induced colibacillosis. *Research in Veterinary Science*. 78:77–83.
594. Wada, Y., H. Kondo, M. Nakazawa, and M. Kubo. 1995. Natural infection with attaching and effacing *Escherichia coli* and adenovirus in the intestine of a pigeon with diarrhea. *J Vet Med Sci*. 57:531–533.
595. Wang, L., J. Wang, F. Wu, Z. Wu, C. Fu, H. You, W. Lin, L.C. Wang, J.Q. Wang, F.D. Wu, Z.J. Wu, C.S. Fu, H. You, and W.Q. Lin. 1998. Serotyping of *Escherichia coli* isolates from waterfowl in Guangdong. *Poult Husb Dis Contrl*. No. 11:6–7.
596. Wang, Y., C. Tang, X. Yu, M. Xia, and H. Yue. 2010. Distribution of serotypes and virulence-associated genes in pathogenic *Escherichia coli* isolated from ducks. *Avian Pathology*. 39:297–302.
597. Watts, J.L., S.A. Salmon, R.J. Yancey, Jr., B. Nersessian, and Z.V. Kounev. 1993. Minimum inhibitory concentrations of bacteria isolated from septicemia and airsacculitis in ducks. *J Vet Diag Invest*. 5:625–628.
598. Weebadda, W.K., G.J. Hoover, D.B. Hunter, and M.A. Hayes. 2001. Avian air sac and plasma proteins that bind surface polysaccharides of *Escherichia coli* O2. *Comp Biochem Physiol B Biochem Mol Biol*. 130:299–312.
599. Weinack, O.M., G.H. Snoeyenbos, C.F. Smyser, and A.S. Soerjadi-Liem. 1984. Influence of Mycoplasma gallisepticum, infectious bronchitis, and cyclophosphamide on chickens protected by native intestinal microflora against *Salmonella typhimurium* or *Escherichia coli*. *Avian Diseases*. 28:416–425.
600. Weinack, O.M., G.H. Snoeyenbos, C.F. Smyser, and A.S. Soerjadi. 1981. Competitive exclusion of intestinal colonization of *Escherichia coli* in chicks. *Avian Diseases*. 25:696–705.
601. Weiser, J.N., and E.C. Gotschlich. 1991. Outer membrane protein A (OmpA) contributes to serum resistance and pathogenicity of *Escherichia coli* K-1. *Infection and Immunity*. 59:2252–2258.

602. Welsh, R.D., R.W. Nieman, S.L. Vanhooser, and L.B. Dye. 1997. Bacterial infections in ratites. *Vet Med*. 92:992–998.
603. White, D.G. 2006. Antimicrobial resistance in pathogenic *Escherichia coli* from animals. In: *Antimicrobial Resistance in Bacteria of Animal Origin*. F.M. Aarestrup, ed. ASM Press, Washington, DC. 145–166.
604. White, D.G., M. Dho-Moulin, R.A. Wilson, and T.S. Whittam. 1993. Clonal relationships and variation in virulence among *Escherichia coli* strains of avian origin. *Microbial Pathogenesis*. 14:399–409.
605. White, D.G., L.J. Piddock, J.J. Maurer, S. Zhao, V. Ricci, and S.G. Thayer. 2000. Characterization of fluoroquinolone resistance among veterinary isolates of avian *Escherichia coli*. *Antimicrobial Agents and Chemotherapy*. 44:2897–2899.
606. Wigley, P., S.D. Hulme and P.A. Barrow. 1999. Phagocytic and oxidative burst activity of chicken thrombocytes to Salmonella, *Escherichia coli* and other bacteria. *Avian Pathology: Journal of the W.V.P.A*. 28:567–572.
607. Wittig, W., R. Prager, E. Tietze, G. Seltmann, and H. Tschape. 1988. Aerobactin-positive *Escherichia coli* as causative agents of extra-intestinal infections among animals. *Arch Exp Veterinarmed*. 42:221–229.
608. Woolcock, P.R., H.L. Shivaprasad and M. De Rosa. 2000. Isolation of avian influenza virus (H10N7) from an emu (*Dromaius novaehollandiae*) with conjunctivitis and respiratory disease. *Avian Diseases*. 44:737–744.
609. Wooley, R.E., J. Brown, P.S. Gibbs, L.K. Nolan, and K.R. Turner. 1994. Effect of normal intestinal flora of chickens on colonization by virulent colicin V-producing, avirulent, and mutant colicin V-producing avian *Escherichia coli*. *Avian Diseases*. 38:141–145.
610. Wooley, R.E., P.S. Gibbs, T.P. Brown, and J.J. Maurer. 2000. Chicken embryo lethality assay for determining the virulence of avian *Escherichia coli* isolates. *Avian Diseases*. 44:318–324.
611. Wray, C., and M.J. Woodward. 1994. Laboratory diagnosis of *Escherichia coli* infections. In: *Escherichia coli in Domestic Animals and Humans*. C.L. Gyles, ed. CAB Int'l, Wallingford, UK. 595–628.
612. Wyborn, N.R., A. Clark, R.E. Roberts, S.J. Jamieson, S. Tzokov, P.A. Bullough, T.J. Stillman, P.J. Artymiuk, J.E. Galen, L. Zhao, M.M. Levine, and J. Green. 2004. Properties of haemolysin E (HlyE) from a pathogenic *Escherichia coli* avian isolate and studies of HlyE export. *Microbiol*. 150:1495–1505.
613. Xavier, D.B., D.M. Broom, C.M.P. McManus, C. Torres, and F.E.M. Bernal. 2010. Number of flocks on the same litter and carcase condemnations due to cellulitis, arthritis and contact footpad dermatitis in broilers. *British Poultry Science*. 51:586–591.
614. Xie, H., L. Newberry, F.D. Clark, W.E. Huff, G.R. Huff, J.M. Balog, and N.C. Rath. 2002. Changes in serum ovotransferrin levels in chickens with experimentally induced inflammation and diseases. *Avian Diseases.* 46:122–131.
615. Xu, F.Y., S.P. Yu, X.F. Shan, T.S. Li, and G.X. Hu. 2006. Diagnosis and cure of mixed infection of paramyxovirus type I and *E. coli* in pigeon. *J Econ An*. 10:22–24.
616. Yaguchi, K., T. Ohgitani, T. Noro, T. Kaneshige, and Y. Shimizu. 2009. Vaccination of chickens with liposomal inactivated avian pathogenic *Escherichia coli* (APEC) vaccine by eye drop or coarse spray administration. *Avian Diseases*. 53:245–249.
617. Yamaguchi, R., J. Tottori, K. Uchida, S. Tateyama, and S. Sugano. 2000. Importance of *Escherichia coli* infection in ascites in broiler chickens shown by experimental production. *Avian Diseases*. 44:545–548.
618. Yang, H., S. Chen, D.G. White, S. Zhao, P. McDermott, R. Walker, and J. Meng. 2004. Characterization of multiple-antimicrobial-resistant *Escherichia coli* isolates from diseased chickens and swine in China. *Journal of Clinical Microbiology*. 42:3483–3489.
619. Yang, N., C.T. Larsen, E.A. Dunnington, P.A. Geraert, M. Picard, and P.B. Siegel. 2000. Immune competence of chicks from two lines divergently selected for antibody response to sheep red blood cells as affected by supplemental vitamin E. *Poultry Science*. 79:799–803.
620. Yerushalmi, Z., N.I. Smorodinsky, M.W. Naveh, and E.Z. Ron. 1990. Adherence pili of avian strains of *Escherichia coli* O78. *Infection and Immunity*. 58:1129–1131.
621. Yogaratnam, V. 1995. Analysis of the causes of high rates of carcase rejection at a poultry processing plant. *The Veterinary Record*. 137:215–217.
622. Yunis, R., A. Ben-David, E.D. Heller, and A. Cahaner. 2002. Antibody responses and morbidity following infection with infectious bronchitis virus and challenge with E*scherichia coli*, in lines divergently selected on antibody response. *Poultry Science*. 81:149–159.
623. Yunis, R., A. Ben-David, E.D. Heller, and A. Cahaner. 2002. Genetic and phenotypic correlations between antibody responses to *Escherichia coli*, infectious bursa disease virus (IBDV), and Newcastle disease virus (NDV), in broiler lines selected on antibody response to *Escherichia coli*. *Poultry Science*. 81:302–308.
624. Yunis, R., A. Ben-David, E.D. Heller, and A. Cahaner. 2000. Immunocompetence and viability under commercial conditions of broiler groups differing in growth rate and in antibody response to *Escherichia coli* vaccine. *Poultry Science*. 79:810–816.
625. Zanella, A., G.L. Alborali, M. Bardotti, P. Candotti, P.F. Guadagnini, P.A. Martino, and M. Stonfer. 2000. Severe *Escherichia coli* O111 septicaemia and polyserositis in hens at the start of lay. *Avian Pathology: Journal of the W.V.P.A*. 29:311–317.
626. Zhao, S., J.J. Maurer, S. Hubert, J.F. De Villena, P.F. McDermott, J. Meng, S. Ayers, L. English, and D.G. White. 2005. Antimicrobial susceptibility and molecular characterization of avian pathogenic *Escherichia coli* isolates. *Veterinary Microbiology*. 107:215–224.
627. Zhou, B., Y. Li, T. Wu, B.T. Zhou, Y.M. Li, and T. Wu. 1995. Colibacillosis in quails. *Chinese J Vet Sci Tech*. 25:34–35.
628. Zhou, D., W.D. Hardt, and J.E. Galan. 1999. Salmonella typhimurium encodes a putative iron transport system within the centisome 63 pathogenicity island. *Infection and Immunity*. 67:1974–1981.

Chapter 19

Pasteurellosis and Other Respiratory Bacterial Infections

Introduction

John R. Glisson

A number of distinct respiratory diseases are caused by small Gram-negative bacteria in commercial poultry. These diseases may have very similar clinical presentations. Many of the etiologic agents of bacterial respiratory diseases are classified as members of the family Pasteurellaceae but have in recent years been redesignated to new genera. Recent reclassifications included changing the name of *Pasteurella haemolytica* to *Gallibacterium anatis* biovar *haemolytica*, *Pasteurella gallinarum* to *Avibacterium gallinarum*, and *Haemophilus paragallinarum* to *Avibacterium paragallinarum*. The current taxonomy reflects advancements in techniques for determining genetic relatedness among bacteria. The new taxonomy is used in this text.

Four distinct diseases are included in this chapter: fowl cholera caused by *Pasteurella multocida*, *Riemerella anatipestifer* infection, *Ornithobacterium rhinotracheale* infection, and bordetellosis. These diseases are grouped together because they are caused by organisms that are genotypically and phenotypically related and because they induce diseases in commercial poultry that may present in a clinically similar way. Other diseases of poultry caused by members of the family Pasteurellaceae, such as fowl coryza caused by Avibacterium paragallinarum, are presented elsewhere in this text because the disease produced by infection with these organisms presents distinctly differently from the diseases included in this chapter.

In diagnostic poultry medicine, definitive diagnosis of fowl cholera, *Riemerella anatipestifer* infection, *Ornithobacterium rhinotracheale* infection, and bordetellosis depends upon the isolation and identification of the causative organism. Several organisms, such as *Avibacterium gallinarum*, which are less important as disease agents, may be isolated and must be differentiated from the more important disease agents included in this chapter. A clinical diagnostic text will be helpful in this regard (1).

Fowl Cholera

John R. Glisson, Charles L. Hofacre, and Jens P. Christensen

Introduction

Fowl cholera (FC) (avian cholera, avian pasteurellosis, or avian hemorrhagic septicemia) is a contagious disease affecting domesticated and wild birds. It usually appears as a septicemic disease associated with high morbidity and mortality, but chronic or benign conditions often occur. This disease historically important because of its role in the early development of bacteriology and because it was 1 of 4 diseases the Veterinary Division of the United States Department of Agriculture (USDA) was created to investigate.

History

Several epornitics among fowl occurred in Europe during the latter half of the 18th century. The disease was studied in France in 1782 by Chabert and in 1836 by Mailet, who first used the term fowl cholera. Huppe in 1886 referred to hemorrhagic septicemia, and Lignieres in 1900 used the term avian pasteurellosis. Benjamin in 1851 gave a good description of the disease and demonstrated that it could be spread by cohabitation. With this knowledge of the disease, he formulated procedures for its prevention. At about the same time,

Diseases of Poultry, Thirteenth Edition. David E. Swayne.
© 2013 John Wiley & Sons, Inc. Published 2013 by John Wiley & Sons, Inc.

Renault, Reynal, and Delafond demonstrated its transmissibility to various species by inoculation. In 1877 and 1878, Perroncito of Italy and Semmer of Russia observed in tissues of affected birds a bacterium that had a rounded form and occurred singly or in pairs. In 1879, Toussaint isolated the bacterium and proved it was the sole cause of the disease (52).

Pasteur (126) isolated the organism and grew pure cultures in chicken broth. In further studies, Pasteur (127, 128) used the FC organism to perform his classic experiments in attenuation of bacteria for use in producing immunity. Salmon (153) appears to have been the first to study the disease in the United States. A good description of disease signs was reported, however, as early as 1867 in Iowa, where losses of chickens, turkeys, and geese had occurred (4).

Etiology

Classification

Pasteurella multocida is the causative agent of FC. When pronouncing multocida, the accent should be on the "ci" (16) rather than on the "to" as given in the 7th and 8th editions of *Bergey's Manual*. In the past, the bacterium has been given many names, including *Micrococcus gallicidus*, 1883; *M. cholerae gallinarum*, 1885; *Octopsis cholerae gallinarum*, 1885; *Bacterium cholerae gallinarum*, 1886; *Bacillus cholerae gallinarum*, 1886; *P. cholerae-gallinarum*, 1887; *Coccobacillus avicidus*, 1888; *P. avicida*, 1889; *Bacterium multicidum*, 1899; *P. avium*, 1903; *Bacillus avisepticus*, 1903; *Bacterium avisepticum*, 1903; *Bacterium avisepticus*, 1912; and *P. aviseptica*, 1920 (16, 19).

For a while, each isolate of *P. multocida* was named according to the animal from which it was isolated, such as *P. avicida* or *P. aviseptica*, *P. muricida* or *P. muriseptica*. In 1929, it was suggested that all isolates be referred to as *P. septica* (170). This name was used mainly in the United Kingdom and can be found in recent literature. *Pasteurella multocida*, proposed by Rosenbusch and Merchant (151), is now accepted as the official name in *Bergey's Manual* and is used exclusively throughout the world.

Morphology and Staining

P. multocida is a Gram-negative, nonmotile, nonspore-forming rod occurring singly, in pairs, and occasionally as chains or filaments. It measures 0.2–0.4 × 0.6–2.5 mm but tends to become pleomorphic after repeated subculture. A capsule can be demonstrated in recently isolated cultures using indirect methods of staining (Figure 19.1). In tissues, blood, and recently isolated cultures, the organism stains bipolar (Figure 19.2). Pili have been reported (49, 135).

Growth Requirements

P. multocida grows aerobically or anaerobically. The optimal growth temperature is 37°C. The optimal pH range is 7.2–7.8, but growth can occur in the range 6.2–9.0, depending upon composition of the medium. In liquid media, maximum growth is obtained in 16–24 hours. The broth becomes cloudy, and in a few days, a sticky sediment collects. With some isolates, a flocculent precipitate occurs.

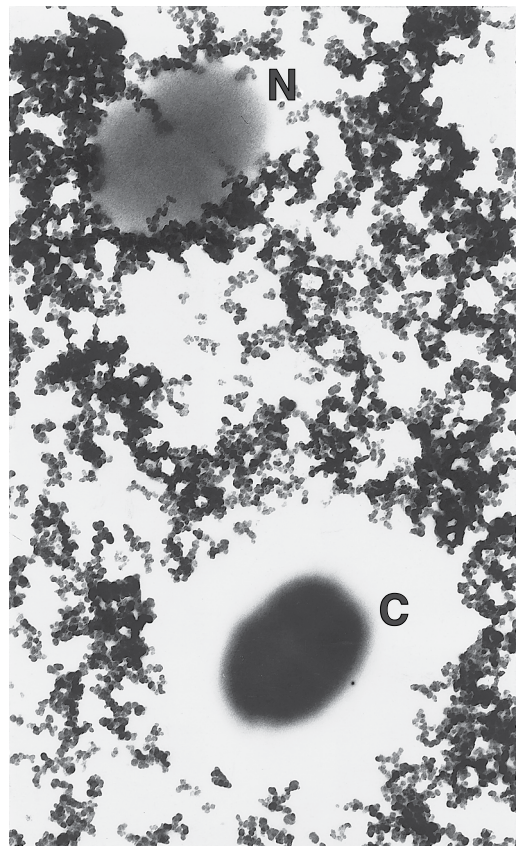

Figure 19.1. Electron photomicrograph of *Pasteurella multocida*-encapsulated cell (C) and nonencapsulated cell (N) suspended in India ink. ×19,000.

The bacterium will grow on meat infusion media; growth is enhanced when the medium is enriched with peptone, casein hydrolysate, or avian serum. Blood or serum from some animals inhibits growth of *P. multocida*. Inhibition is greatest from blood of horses, cattle, sheep, and goats; blood of chickens, ducks, swine, and water buffalo has little or no inhibitory action (152). Several selective media for isolation have been described (27, 28, 44, 99, 111, 160). Chemically defined media have been described by Jordan (92), Watko (167), Wessman and Wessman (169), and Flossmann et al. (42). Berkman (8) found that pantothenic acid and nicotinamide are essential for growth. Dextrose starch agar with 5% avian serum is an excellent medium for isolating and growing *P. multocida*.

Colonial Morphology and Related Properties

Colonial morphology observed with obliquely transmitted light is one of the most useful characteristics in the study of *P. multocida*. On primary isolation from birds with FC, colonies may be iridescent, sectored with various intensities of iridescence, or blue with little or no iridescence (Figure 19.3). Iridescence is related to the presence of a capsule. The term

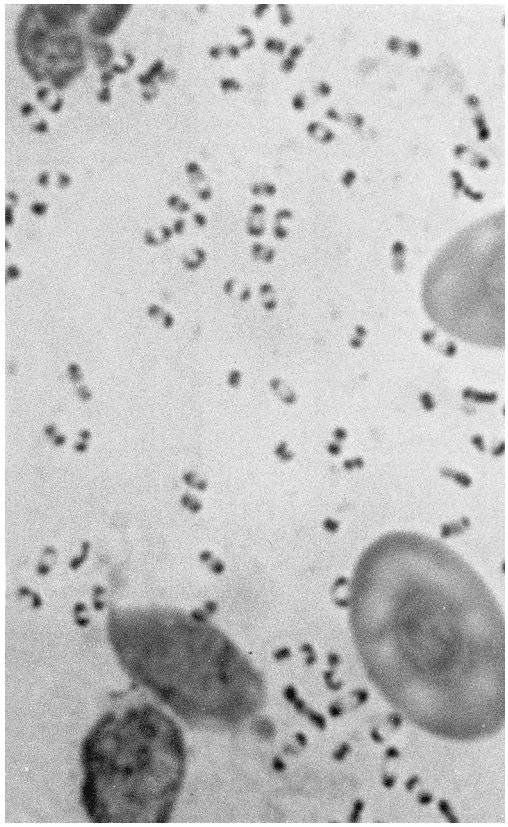

Figure 19.2. *Pasteurella multocida* in liver imprint from chicken with acute FC (note bipolarity). Wright's stain, ×2,500.

fluorescent used to describe colonies in older literature should be considered synonymous with the term iridescent; the latter is the appropriate term.

The composition of the medium determines to a certain extent the degree and type of iridescence. Occasionally, an isolate produces blue colonies; when serum is added to the medium, sectored or iridescent colonies are sometimes produced. Examination of 18- to 24-hour colonies with a stereomicroscope using obliquely transmitted light (Figure 19.4) is helpful when observing colonial morphology (77). Iridescent colonies on primary isolation from acute cases of FC are circular (2–3 mm), smooth, convex, translucent, glistening, and butyrous, and show a tendency to coalesce. As the colony ages, it usually loses these distinguishing properties, becomes larger and viscous, and may adhere to the medium when picked with an inoculating needle. Blue colonies often isolated from birds with the chronic type of cholera or derived by dissociation of iridescent colonies are circular (1–2 mm), smooth, slightly convex or flat, translucent, butyrous, and discrete. The watery mucoid colonies produced by encapsulated strains from the respiratory tract of cattle, swine, sheep, rabbits, and humans are not iridescent but gray (75).

Anderson et al. (3) observed that a highly virulent isolate, which produced smooth colonies, later dissociated on subculture and produced rough colonies. Organisms from the smooth colonies were approximately 3–4 million times more virulent for pigeons than those from rough colonies. Hughes (82) studied the colonial morphology of 210 cultures from cases of FC and distinguished 3 types. The iridescent type was associated with outbreaks of acute FC

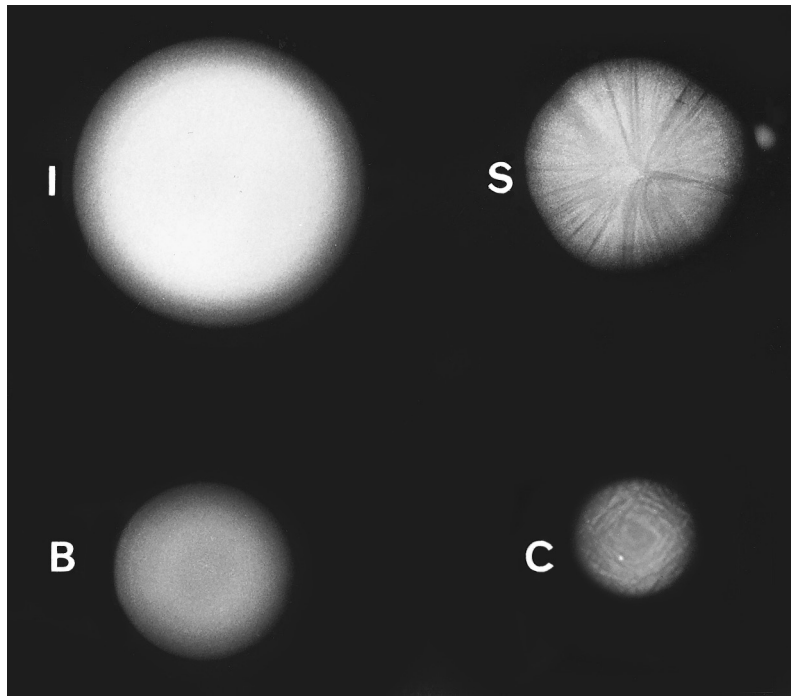

Figure 19.3. *Pasteurella multocida* 20-hour colonies on dextrose starch agar viewed with obliquely transmitted lighting (see Figure 19.4). I, iridescent; S, sectored; B, blue; C, rough. ×20.

Figure 19.4. Arrangement of stereomicroscope with obliquely transmitted light for evaluation of colonial morphology.

and was highly virulent. The blue type was of low virulence and occurred in flocks in which cholera was enzootic. The third type was intermediate in its properties of iridescence and virulence.

Heddleston et al. (72) reported that a virulent isolate of *P. multocida* of avian origin produced iridescent colonies that dissociated *in vitro* and produced blue colonies. Organisms from blue colonies also mutated and produced gray colonies, which have not been reported in primary cultures from birds. Cells from iridescent colonies occurred singly or in pairs, did not agglutinate in immune serum, were encapsulated, and were virulent for chickens, turkeys, rabbits, and mice when administered on mucous membranes of the upper air passages. Cells from blue colonies occurred singly or in pairs, were agglutinated by immune serum, were unencapsulated, and were avirulent when applied to mucous membranes of chickens and mice but were virulent for rabbits and slightly virulent for turkeys. Cells from gray colonies occurred only as chains and were unencapsulated and avirulent. Killed organisms from all 3 colonial forms induced immunity in chickens. Antigens extracted with hot saline from highly virulent encapsulated cells of iridescent colonies by Yaw and Kakavas (173) actively immunized chickens and mice, whereas less virulent unencapsulated cells from blue colonies immunized chickens more effectively than mice.

Physiologic Properties

The physiologic properties of *P. multocida* are used for identification. *P. multocida* does not produce gas but produces oxidase, catalase, peroxidase, and a characteristic odor. Unlike most Gram-negative bacteria, it is sensitive to penicillin. The results of 29 other physiologic tests with 948 cultures of avian origin are shown in Table 19.1.

Significant differential characteristics are listed in Table 19.2.

Table 19.1 Physiologic properties of 948 *Pasteurella multocida* cultures of avian origin.

Test	% Positive
Arabinose	7.4
Dextrin	0.6
Dulcitol	2.6
Fructose	100.0
Galactose	99.8
Gelatin	0.0
Glucose	100.0
Glycerol	93.3
Hemolysis	0.0
Hydrogen sulfide	97.5
Indol	99.6
Inositol	0.0
Inulin	0.0
Lactose	1.6
Litmus milk	0.7
MacConkey agar	0.1
Maltose	0.0
Mannitol	99.5
Mannose	99.6
Motility	0.0
Nitrate reduction	100.0
Raffinose	2.7
Rhamnose	0.0
Salicin	0.0
Sorbitol	97.6
Sucrose	100.0
Trehalose	4.1
Urease	0.0
Xylose	7.4

Source: From Hacking, W. C. and J. R. Pettit. 1974. *Pasteurella hemolytica* in pullets and laying hens. *Avian Dis* 18: 483–486.

Table 19.2. Differential tests for *Pasteurella multocida, Gallibacterium anatis biovar haemolytica*, and *Avibacterium gallinarum*.

Test	*P. multocida*	*G. anatis biovar haemolytica*	*Av. gallinarum*
Hemolysis	–	+	–
MacConkey agar	–	+U	–
Indol	+	–	–
Motility	–	–	–
Gelatin	–	–	–
Catalase	+	+U	–
Oxidase	+	+	+
Urease	–	–	–
Glucose	+	+	+
Lactose	–U	+U	–
Sucrose	+	+	+
Maltose	–U	–U	+

Note: U = usually.

Resistance to Chemical and Physical Agents

P. multocida is destroyed easily by ordinary disinfectants, sunlight, drying, or heat; it is killed within 15 minutes at 56ºC and 10 minutes at 60ºC. A 1% solution of formaldehyde, phenol, sodium hydroxide, betapropiolactone, or glutaraldehyde and a 0.1% solution of benzalkonium chloride killed within 5 minutes 4.4×10^8 organisms of P. multocida/ml suspended in 0.85% saline solution at 24ºC.

Das (27) observed that cotton swabs saturated with blood from infected mice contained viable organisms after 118 hours but not after 166 hours (at which time the swabs were completely dry); films of blood on glass contained viable organisms after 24 hours but not 30 hours. Das also reported that infected blood sealed in glass tubes and held in a cold room contained viable organisms after 221 days. Skidmore (159) observed that the organism survived in dried turkey blood on glass for 8 days but not 30 days at room temperature. In studies of environmental influence on the incidence of FC, Van Es and Olney (164) found the infection hazard had apparently disappeared from a poultry yard 2 weeks after occurrence of the last death and removal of birds.

Influence of temperature on viability and virulence of *P. multocida* was studied by Nobrega and Bueno (119), who observed that broth cultures stored in sealed tubes at an average room temperature of 17.6ºC were still virulent after 2 years; at 2ºC–4ºC, they were nonviable after 1 year. With controlled experiments, Dimov (32) observed that *P. multocida* died rapidly in soils with moisture content of less than 40%. At a moisture content of 50% and temperature of 20ºC, it survived for 5–6 days at pH 5.0, 15–100 days at pH 7.0, and 24–85 days at pH 8.0. A culture survived without loss of virulence for 113 days in soil with 50% moisture at 3ºC and pH 7.15.

Cultures may be maintained without dissociation or loss of virulence in the lyophilized state or sealed in glass tubes and stored at 4ºC or colder (168). Lyophilized cultures tested after 26 years were still virulent for chickens, and a culture sealed in a rubber-stoppered bottle containing beef infusion broth with 50% horse serum and held at room temperature was virulent after 26 years (64).

Subgrouping of P. multocida

Based upon DNA homology studies *P. multocida* has been divided into 3 subspecies, namely *P. multocida* subspecies *multocida*, *P. multocida* subspecies *septica*, and *P. multocida* subspecies *gallicida* (115). The subspecies can be differentiated by their physiologic properties (115). Important differential characteristics are listed in Table 19.3. However, this approach cannot be recommended because variation in fermentation patterns may complicate the interpretation of results. By the use of full phenotypic characterization, Fegan et al. (40) were able to identify 10 biotypes among a strain collection including all 3 subspecies of *P. multocida* (40). All 3 subspecies of *P. multocida* have been isolated from outbreaks of fowl cholera (40, 78, 161). However, it appears that subspecies *multocida* is the most common subspecies isolated from chickens and turkeys and that only a minor percentage of isolations is made up by strains of subspecies *septica* (40, 113, 161). *P. multocida* subspecies *multocida* also seems to represent the predominant type of raptors and psittacines (109, 110). Subspecies *gallicida* is mainly associated with web-footed birds (50, 78, 112). The most recent taxonomic investigations of *P. multocida* include multi-locus sequence typing (MLST) (162) and single gene sequences analysis of 16S rRNA and housekeeping genes and indicate that subspecies *multocida* and *gallicida* belong to the same phylogenetic lineage and that subspecies *septica* makes up a separate lineage. Phenotypic criteria for separation of these 2 lineages, however, remain to be identified (12, 24).

Table 19.3. Characters used for identification of subspecies of *Pasteurella multocida.*

	P. multocida		
Characters	**ssp. *multocida***	**ssp. *septica***	**ssp. *gallicida***
L(+) arabinose	d	–	+
D(–) arabinose	d	d	–
Dulcitol	–	–	+
D(–) sorbitol	+	–	+
L(–) fucose	d	d	–
Trehalose	d	+	–
α-glucosidase (p-nitrophenyl-beta-D-glucopyranoside [pNPG])	+	+	–

+: 90% or more of the strains positive within 1–2 days
– : 90% or more of the strains negative
d: different

Conventional subgrouping of *P. multocida* entails serological determination of capsular and somatic antigens. Specific capsule serogroup antigens are recognized using passive hemagglutination tests (21). Five capsular types (A, B, D, E, and F) are currently recognized (147). Carter (21) studied numerous isolates from various animals and found capsular types A and D were isolated from fowl and other animals. In a study of isolates representing a variety of avian hosts, Rhoades and Rimler (138) found organisms belonging to A, B, D, and F. Presumptive identification of capsular types A, D, and F can be determined by capsule depolymerization with specific mucopolysaccharidases (145).

However, a highly specific multiplex capsular polymerase chain reaction (PCR) assay has been developed which enables less laborious and more specific capsular typing than conventional tests (163).

Somatic serotyping has been done by tube agglutination test (116) and gel diffusion precipitin methods (74). Comparative studies by Brogden and Packer (17) indicated that a serotype determination by 1 method did not correlate with a serotype determination by the other method. Often, cultures that represented a single somatic serotype in a particular test represented more than 1 serotype in the other test. Because of its simplicity, the gel diffusion precipitin test is used routinely in

the United States, and its popularity is increasing throughout the world. The test uses antisera prepared in chickens and heat-stable antigens extracted from formalinized saline suspensions of the bacteria. The heat-stable antigens form lines of identity with lipopolysaccharide-protein complexes from culture supernatants (74). Somatic serotype specificity seems to be determined by the lipopolysaccharide component of a complex (143). Heddleston et al. (74) found there was good, though not absolute, correlation between the gel precipitin test and the immune response in chickens and turkeys. Rimler and Phillips (146) showed that lipopolysaccharide combined with carrier protein protected chickens against FC. To date, 16 somatic serotypes have been described (18). However, conventional serotyping suffers from major problems with reproducibility and reliability just as the methods are quite laborious.

Recently, an alternative to serological typing has been developed (59). The lipopolysaccharide (LPS) structures expressed by different *P. multocida* Heddleston type strains and the genes responsible for LPS assembly have been identified. This information has been used to design a multiplex PCR assay that can differentiate between different Heddleston serotypes (59, 60, 61). Such a method will have a major impact on diagnostic procedures as well as being a strong tool in future vaccine development.

All of these somatic serotypes have been isolated from avian hosts. Correlation between subspecies and serovars of *P. multocida* obtained by traditional serotyping systems has not been demonstrated (13). Over the years, somatic serotyping has provided useful information regarding the diversity of avian *P. multocida* strains; however, some particular serovars predominate in certain geographical regions, making detailed conclusions concerning the epizootiology of *P. multocida* difficult. Thus, Snipes et al. (161) found that more than 60% of clinical *P. multocida* isolates from turkeys in California belonged to serovar 3,4 (78) and according to Gunawardana et al., serovar 1 dominates in Vietnam (54). In Australia, serovar 3 appears to dominate (13). In addition, phenotypic and genotypic variation within a given serovar has been demonstrated several times and underlines the limitations of serotyping as a method for strain differentiation (12, 14, 20, 97).

Other phenotypic methods of grouping strains of *P. multocida* have included phagetyping and multi-locus enzyme electrophoresis (MLEE). Phage sensitivity as a basis for grouping *P. multocida* has been investigated. Rifkind and Pickett (142) found that 84 of 118 isolates from various hosts were sensitive to 1 or more of 16 bacteriophages. Kirchner and Eisenstarck (98) examined 25 cultures of avian origin and found that 11 were lysogenic. They divided the 11 bacteriophages into 5 groups based on their host range, and into 3 groups based on plaque morphology. Karaivanov and Mraz (95) identified 87% of 77 cultures of *P. multocida* using 1 strain of bacteriophage. Saxena and Hoerlein (154) demonstrated lysogeny in 63 of 112 cultures from various hosts. One phage caused lysis of 8 different cultures; many were lysogenic for only 1 or 2 cultures. Gadberry and Miller (43) showed that 32 of 61 isolates were sensitive to 1 or more of 3 phages. Isolates of *Gallibacterium anatis*, *Avibacterium gallinarum*, *Actinobacillus ureae*, *P. pneumotropica*, and 3 species of the genus *Yersinia* were resistant to lysis. Results of these investigations demonstrated the possibility of a phage grouping system for *P. multocida*.

The analysis of isoenzymes (i.e., enzymes with the same functional activity but encoded by different alleles) has been used for many years in the study of eukaryotic population genetics (101), and has more recently been applied to prokaryotic organisms (155). Recently, Blackall et al. used MLEE to investigate the population structure of Australian *P. multocida* isolates obtained from poultry (14). Although the 81 field isolates of *P. multocida* investigated were diverse, being divided into 56 electrophoretic types (ETs), the overall population structure was shown to form a clonal population in which little horizontal gene flow apparently had been occurring. No obvious correlation between serotype or subspecies and particular ETs was found.

Among phenotypically based methods used for grouping strains of *P. multocida*, MLEE has provided the highest discriminatory power and has been suggested as a tool for elucidating the complex epizootiology of *P. multocida* infections (14). Data published on antibiotic resistance profiling do not seem to provide enough discriminatory power to allow its use for epidemiological investigations (121).

A number of nucleic-acid-based typing methods have been introduced for differentiation of avian strains of *P. multocida*. In favor of these methods, they do not depend on expression of phenotypic properties, all strains are typeable, and the discriminatory power is generally high (121). Bacterial genomes can be compared by electrophoretic separation of DNA fragments generated *in vitro* by digestion with restriction enzymes. To simplify the reading of results, the DNA fragments may be transferred to hybridization membranes and hybridized with a labeled hybridization probe (restriction fragment length polymorphism, RFLP) in which case the strain comparison is only based on restriction fragments that show homology to the probe. Strains that are of the same origin are anticipated to have the same genome and therefore both the same number and the same position of recognition sites for a restriction enzyme. Restriction enzyme analysis (REA) and RFLP of *P. multocida* have been used extensively to obtain knowledge about routes of transmission and about strain diversity in outbreak situations (20, 23, 109, 110, 161, 172). The restriction enzymes HpaII and HhaI are most frequently used (23).

Recently, amplified fragment length polymorphism (AFLP) also has proved useful for epidemiological purposes (38). This method is based on amplification of genomic fragments by the use of nonspecific primers following restriction endonuclease digestion and ligation of appropriate adaptors. In addition, RFLP analysis results have supported the population structure data on *P. multocida* obtained by MLEE (14). Pulsed field gel electrophoresis (PFGE), using rare cutting restriction enzymes, allows the resolution of large DNA fragments reflecting restriction fragment length polymorphism throughout the entire genome. Gunawardana et al. (54) demonstrated a very high discriminatory power of PFGE using the technique on avian isolates of *P. multocida* originating from Australia and Vietnam.

A multi-locus sequence typing (MLST) scheme for avian isolates of *P. multocida* recently has been developed (162). MLST is commonly used to study the population structure of groups of organisms, and for *P. multocida*, MLST has revealed a population structure closely matching the population structure recognized by MLEE and ribotyping (162). MLST also has proved to be an excellent molecular typing method suitable for epidemiological studies. In fact, MLST has been suggested to be the new "gold standard" typing method (162).

In recent years, PCR-based methods have been used for differentiation of avian *P. multocida* isolates. Hopkins et al. successfully used arbitrary primed PCR (AP-PCR) to distinguish the Clemson University (CU) vaccine strain from fowl cholera outbreak strains (80). Repetitive extragenic palindromic sequence PCR (REP-PCR) and enterobacterial repetitive intergenic consensus (ERIC-PCR) also have been shown to be valuable in identifying epidemiologically related and unrelated strains from Australia, Vietnam, and Hungary (54, 156).

The use of plasmid profiling in subtyping of *P. multocida* has been of limited use due to a low number of plasmid carrying strains. Most investigations using this technique have shown that only approximately 20% of the isolates carry plasmids (22, 161).

Pathogenicity

Pathogenicity or virulence of *P. multocida* in relation to FC is complex and variable, depending on the strain, host species, and variations within the strain or host and conditions of contact between the 2. The ability of *P. multocida* to invade and reproduce in the host is enhanced by the presence of a capsule that surrounds the organism (104). Loss of ability of a virulent strain to produce the capsule results in loss of virulence (72). Many isolates from cases of fowl cholera have large capsules but are of low virulence. Therefore, virulence is apparently related to some chemical substance associated with the capsule, rather than with its physical presence.

P. multocida usually enters tissues of birds through mucous membranes of the pharnyx or upper air passages, but it also may enter through the conjunctiva or cutaneous wounds. Hughes and Pritchett (83) were unable to infect chickens by placing a culture in a gelatin capsule and inserting it into the esophagus, but chickens were infected when the culture was dropped on the roof of the nasal cleft. Arsov (5) infected birds by mouth, using ^{35}P-labeled culture, and observed that the portal of infection was the mucous membrane of the mouth and pharnyx but not the esophagus, crop, or proventriculus. The Eustachian tube was suggested by Olson and McCune (122) as the most likely route of infection because the infection localizes in air spaces of the cranial bone, middle ear, and meninges.

Turkeys are much more susceptible than chickens to infection with *P. multocida*, and mature chickens are more susceptible than young ones (63). Hungerford (84) observed heavy losses in mature chickens, but no losses in birds up to 16 weeks of age in a case involving 90,000 birds. When testing infectivity of an isolate or susceptibility of a host, cohabitation is the most natural method of exposure. Unless the host is highly susceptible and the isolate highly invasive, however, results may be slow. Therefore, it is often advantageous to swab the nasal cleft with cotton saturated with the culture; if a more severe exposure is required, the culture can be injected parenterally.

Toxicity

A dried culture filtrate of *P. multocida* was first demonstrated to produce signs of toxicity in chickens by Pasteur (126). Salmon (153) repeated this work and described signs resulting from toxicity similar to those observed in cases of acute FC. Kyaw (100), using the developing chick embryo in the study of pathogenesis, suggested that a toxin was produced *in vivo* by *P. multocida*. Rhoades (137) observed severe general passive hyperemia in chickens that died from acute FC. This lesion was considered to be indicative of shock and was attributed to the action of endotoxin.

Endotoxins

Endotoxins are produced by all *P. multocida*, both virulent and nonvirulent. They may contribute to virulence; however invasion and multiplication of a strain are necessary for the production of sufficient quantities of endotoxin *in vivo* to contribute to pathologic processes.

Pirosky (131) obtained an endotoxin from *P. multocida* of avian origin by the trichloroacetic acid extraction procedure of Boivin. Heddleston and Rebers (68) demonstrated that a loosely bound endotoxin could be washed from *P. multocida* with cold formalinized saline solution. This endotoxin was a nitrogen-containing phosphorylated lipopolysaccharide, readily inactivated under mild acid conditions. Signs of acute FC were induced in chickens by injection of fractional amounts of endotoxin. The LD_{50} for chicken embryos was 5.2 mg via the chorioallantoic membrane; the LD_{50} for mice was 194 mg via the peritoneal cavity. One dose of 1.9 mg injected intravenously killed 5 of 6 19-day-old turkeys; the median death time was only 3 hours. The endotoxin was present in the vascular system of turkeys with FC and could be detected with the *Limulus* lysate test and antiserum in the gel diffusion precipitin test. The serologic specificity of the endotoxin was associated with the lipopolysaccharide. Free endotoxin induced active immunity.

Purified lipopolysaccharides of each of the Heddleston serotypes were prepared by Rimler et al. (148). The lipopolysaccharides were similar to those of other Gram-negative bacteria. Week-old poults were relatively resistant to the lethal effects of purified lipopolysaccharides from 2 highly pathogenic FC strains of *P. multocida* (139). In poults, the lipopolysaccharides did not provoke a dermal Shwartzman reaction, and lethality was not enhanced by a liver-damaging substance, a histamine-releasing substance, or a surgical bursectomy.

Protein Toxins

Heat-labile protein toxins have been found in serogroup A and D strains isolated from different animal species. Nielsen et al. (118) found 6 of 10 turkey strains produced heat-labile protein toxins; the strains were not serotyped. Four serogroup D

strains isolated from turkeys were found to contain a heat-labile toxin (140). Sonicated suspensions of these strains produced necrotic lesions in turkey skin and were lethal to poults. Antiserum prepared against the heat-labile toxin from a swine strain neutralized the ability of the avian strain sonicated material to produce skin necrosis (141). Baba and Bito (6) chemically purified a protein toxin from an avian strain.

Pathogenesis and Epizootiology

Incidence and Distribution

Normal fowl cholera is more prevalent in late summer, fall, and winter. This seasonal occurrence is one of circumstance rather than lowered resistance, except that chickens become more susceptible as they reach maturity.

Natural and Experimental Hosts

Most reported outbreaks of FC affected chickens, turkeys, ducks, or geese. However, this disease also affects other types of poultry, game birds raised in captivity, companion birds, birds in zoos, and wild birds. The wide range of avian hosts in which FC has been reported suggests that all types of birds are susceptible.

Among types of poultry, turkeys are most affected. Most or all in an infected flock may die within a few days. The disease usually occurs in young mature turkeys, but all ages are highly susceptible. Under experimental conditions, 90%–100% of mature turkeys may die within 48 hours when exposed to a highly virulent strain of *P. multocida* by swabbing the palatine cleft or by contact with infected birds.

The disease in turkeys was first reported in detail by DeVolt and Davis (31), who described an outbreak in a flock of 175 turkeys in Maryland, where the mortality was 17%. Alberts and Graham (1) described outbreaks in 4 flocks of turkeys in which mortality was 17%–68%. They emphasized that environmental stressors such as changes in climate, nutrition, injury, and excitement may have influenced the incidence and course of the disease.

Death losses from FC in chickens usually occur in laying flocks, because birds of this age are more susceptible than younger chickens. Chickens less than 16 weeks of age generally are quite resistant. Fowl cholera in young chickens usually is caused by serotype 1 and often occurs in conjunction with some other malady. Recent outbreaks of FC in 6 flocks of 20- to 46-day-old broilers, however, resulted from infections with serotypes 3; 1,3; and 3,4. Experimental challenge of 5-week-old broilers with 2 representative strains (serotypes 3 and 1,3) resulted in mortality and lameness.

In naturally infected chickens, mortality usually ranges from 0%–20%, but greater losses have been reported. Reduced egg production and persistent localized infection often occur. Chickens are more susceptible to FC after withdrawal of feed and water or after an abrupt change of diet (15). Heat or rough treatment on a shaking machine increased the incidence in chickens exposed experimentally (93, 94).

Under experimental conditions, 90%–100% of mature chickens exposed by swabbing the palatine cleft may die within 24–48 hours, depending on the strain of *P. multocida* used, but only 10%–20% usually die within a 2-week period when exposed by contact with infected birds. Pritchett et al. (133) observed mortality of 35%–45% in 3 houses of pullets. In 1 house, 45% of the birds died within 4 weeks. In a flock of 45 birds that had survived an acute outbreak the previous year, no losses were observed, but the number of birds with localized lesions increased during winter. In South Carolina and adjoining areas, FC existed mainly as a persistent, subacute chronic disease that clinically resembles avian monocytosis (10).

Domestic geese and ducks are also highly susceptible to FC. Curtice (26) reported the disease in geese in Rhode Island, where about 3,200 of a flock of 4,000 died in a short period. Van Es and Olney (164) recognized the marked susceptibility of geese to FC, in using them to test for persistence of viable organisms in lots after removal of infected chickens. Fowl cholera in ducks has been a serious problem on Long Island, where it was diagnosed on 32 of 68 commercial duck farms. Losses usually occur in ducks greater than 4 weeks of age, and mortality may reach 50% (37).

Birds of prey, waterfowl, and other birds kept in zoologic gardens occasionally succumb to infection; *P. multocida* has been isolated from more than 50 species of feral birds. During a 2.5-year survey, Faddoul et al. (39) isolated *P. multocida* from 13 (7 species) of 248 feral birds submitted to the diagnostic laboratory. Jaksic et al. (90) described an acute epornitic among pheasants, in which 1,700 died. An outbreak in the San Francisco Bay area was reported to have been responsible for an estimated loss of 40,000 waterfowl (150). Gershman et al. (45) observed a serious outbreak among eider ducks (*Somateria mollissima*) in their nesting area 6 miles off the coast of Maine, where more than 200 birds died and more than 100 nests were lost. More than 60,000 waterfowl died of FC during the winter of 1956–1957 at the Muleshoe National Wildlife Refuge in Texas (91). Rosen (149) reported that there are 2 areas in the United States where fowl cholera is enzootic in waterfowl: the Muleshoe National Wildlife Refuge and the north central area of California. Both locations have had periodic outbreaks since 1944.

P. multocida from birds with FC usually kills rabbits and mice, but other mammals are resistant to infection. According to Heddleston and Watko (70), rabbits, mice, pigeons, and sparrows died of acute septicemia when exposed intranasally to an isolate of *P. multocida* from an acute case of FC; rats, ferrets, guinea pigs, a sheep, a pig, and a calf did not show any clinical response to the same organism. One of 5 rats, 1 of 2 mink, and 11 of 19 mice fed viscera of infected chickens developed nasal infection, pneumonia, and fatal septicemia, respectively. A calf died of acute septicemia less than 18 hours after intramuscular (IM) exposure. Guinea pigs exposed by IM inoculation developed necrosis at the inoculation site; those exposed intraperitoneally usually died.

Horses, cattle, sheep, pigs, dogs, and cats are refractory to oral inoculation, and subcutaneous (SC) inoculation results in

localized abscesses. All of these animals, however, may succumb to intravenous inoculation.

Transmission, Carriers, Vectors

How FC is introduced into a flock is often impossible to determine. Chronically infected birds are considered to be a major source of infection. The only limit to the duration of the chronic carrier state is the life span of the infected bird. Free-flying birds having contact with poultry may be a source of FC organisms. Transmission of the organism through the egg seldom, if ever, occurs. A study of more than 2,000 fresh and embryonating eggs from chickens infected with chronic FC yielded no evidence that *P. multocida* was transmitted through the egg (158).

Pritchett et al. (133, 134) and Pritchett and Hughes (132) examined 3 infected commercial flocks of white leghorns for *P. multocida* and found that many birds harbored the organism in nasal clefts. Presence of the bacterium was related to severity of upper respiratory infection in the flocks. They concluded that the enzootic focus of infection was healthy nasal carriers. These studies, as well as those of Van Es and Olney (164) and Hall et al. (56), proved that survivors of an epornitic of FC may be reservoirs of infection. Dorsey and Harshfield (36) reported a higher incidence of FC during late summer and fall in South Dakota. Carrier birds among the older flock, held over for a second year, provided a reservoir of infection for young susceptible pullets housed with them.

Most species of farm animals may be carriers of P. multocida. Generally, these organisms, except for those from swine and possibly those from cats, are avirulent for fowl. Iliev et al. (87) isolated *P. multocida* from tonsils of 34 of 75 slaughtered cattle, 14 of 27 sheep, and 102 of 162 pigs. Isolates from cattle and sheep were not pathogenic for fowl, but all 18 isolates from pigs in areas where FC was common were highly pathogenic for fowl. Only 2 of 47 isolates from pigs in areas having low incidence of FC were pathogenic. Iliev et al. (88) also reported that healthy pigs that were carriers of *P. multocida* transmitted infection to fowl in the same enclosure. Two isolates, serotypes 1:A and 5:A, from lungs of pigs with pneumonia, were studied by Murata et al. (114). Serotype 5:A was highly virulent for chickens, and sero type 1:A was avirulent. They found no cross-immunity in chickens between the 2 serotypes.

Gregg et al. (53) isolated 2 cultures from raccoons that were pathogenic for turkeys. They suggested that raccoons are a reservoir of *P. multocida*, and the organisms may be transmitted to turkeys via the raccoon bite. Contaminated crates, feed bags, or any equipment used previously for poultry may serve in introducing FC into a flock. Organisms are disseminated throughout the carcasses of birds that die of acute FC and may serve as an infection source, especially because fowl tend to consume such carcasses. Hendrickson and Hilbert (76) were able to isolate *P. multocida* from the blood of a naturally infected chicken for 49 days preceding death. They noticed a rapid increase in the number of organisms immediately preceding and following death and that the organisms remained viable for 2 months at 5ºC–10ºC. Serdyuk and Tsimokh (157) demonstrated experimentally that sparrows, pigeons, and rats could become infected with *P. multocida* when exposed to chickens with FC and that they in turn could infect susceptible chickens. Sparrows and pigeons carried organisms without showing clinical signs, but 10% of infected rats developed acute pasteurellosis.

The possibility that insects may serve as vectors of FC has been investigated. Skidmore (159) experimentally transmitted FC to turkeys by feeding them flies that had previously fed on infected blood. He pointed out that under natural conditions, ingestion of flies might be a means of introducing the disease into a flock. Transmission by flies, however, is probably not common, as indicated by studies of Van Es and Olney (164). Although FC was maintained in 2 lots of chickens during the height of the fly season, no spread of the disease occurred to adjoining lots separated only by poultry netting. Iovcev (89) observed that larvae, nymphs, and adult ticks (*Argas persicus*) contained *P. multocida* after feeding on infected hens. Petrov (129) demonstrated that the red mite (*Dermanyssus gallinae*) became infected with *P. multocida* after feeding on infected birds, but the mite did not transmit the organism.

Heddleston and Wessman (71) showed that 27 cultures of *P. multocida* from the upper respiratory tract of humans were not pathogenic for turkeys. Humans can become infected, however, and may infect poultry via excretion from the nose or mouth.

Dissemination of *P. multocida* within a flock is primarily by excretions from the mouth (Figure 19.5), nose, and conjunctiva of diseased birds that contaminate their environment, particularly feed and water. Feces very seldom contain viable *P. multocida*; however, Reis (136) found the organism in feces from 1 of 9 birds just before death. In the remaining 8 birds, the organisms were isolated only in feces collected from the cloacae of dead birds. Iliev et al. (88) demonstrated that *P. multocida* labeled with ^{32}P was inactivated in the proventriculus, and feces contained no viable *P. multocida*. Turkeys drinking from the same water trough with those experimentally infected with *P. multocida* developed FC (124).

Clinical Signs

Acute

Signs of infection in acute FC are often present for only a few hours before death (Figure 19.5). Unless infected birds are observed during this period, death may be the first indication of disease. Signs that often occur are fever, anorexia, ruffled feathers, mucous discharge from the mouth, diarrhea, and increased respiratory rate. Cyanosis often occurs immediately prior to death and is most evident in unfeathered areas of the head, such as comb and wattles. Fecal material associated with the diarrhea is initially watery and whitish in color but later becomes greenish and contains mucus. Birds that survive the initial acute septicemic stage may later succumb to the debilitating effects of emaciation and dehydration, may become chronically infected, or may recover.

Figure 19.5. Acute FC; mucous excretion from the mouth contains large numbers of *Pasteurella multocida* that can contaminate feed and water.

Chronic

Chronic FC may follow an acute stage of the disease or result from infection with organisms of low virulence. Signs generally are related to localized infections. Wattles (Figure 19.6), sinuses, leg or wing joints, foot pads, and sternal bursae often become swollen. Exudative conjunctival (Figure 19.7) and pharyngeal lesions may be observed, and torticollis (Figure 19.8) sometimes occurs. Tracheal rales and dyspnea may result from respiratory tract infections. In the past, the term roup was used to indicate a condition in which signs were associated with chronic infections of cephalic mucous membranes. The term was not limited to FC, but included other diseases as well. Chronically infected birds may succumb, remain infected for long periods, or recover.

Gross and Microscopic Pathology

Lesions of FC are not constant but vary in type and severity. The greatest variation is related to the course of the disease, whether acute or chronic. Although it is convenient for descriptive purposes to refer to either acute or chronic FC, it is sometimes difficult to categorize the disease in this manner. Signs of infection and lesions that occur may be intermediate to those described for acute and chronic forms.

Acute Disease

When the course of the disease is acute, most of the postmortem lesions are associated with vascular disturbances. General

Figure 19.6. Chronic FC. Swollen wattle resulting from localized infection.

hyperemia usually occurs, is most evident in veins of the abdominal viscera, and may be quite pronounced in small vessels of the duodenal mucosa (Figure 19.9). Large numbers of bacteria usually can be observed microscopically in the hyperemic vessels. Petechial and ecchymotic hemorrhages are frequently found and may be widely distributed. Subepicardial (Figure 19.10A) and subserosal hemorrhages are common, as are hemorrhages in the lung, abdominal fat, and intestinal mucosa. Increased amounts of pericardial and peritoneal fluid frequently occur. Disseminated intravascular clotting or fibrinous thrombosis has been observed in chickens and ducks that died from acute experimentally induced FC (85, 125).

Livers of acutely affected birds may be swollen and usually contain multiple small focal areas of coagulative necrosis (Figure 19.10B) and heterophilic infiltration (Figure 19.11). Some of the less virulent *P. multocida* do not produce necrotic foci in the liver. Heterophilic infiltration also occurs in lungs

Figure 19.7. Chronic FC. Serous inflammation of conjunctiva.

Figure 19.8. Chronic FC. Torticollis resulting from meningeal infection.

and certain other parenchymatous organs (137). Lungs of turkeys are affected more severely than those of chickens, with pneumonia being a common sequela. Large amounts of viscid mucus may be observed in the digestive tract, particularly in the pharynx, crop, and intestine.

Ovaries of laying hens are commonly affected. Mature follicles often appear flaccid; thecal blood vessels, which are usually easily observed, are less evident (Figure 19.10E). Yolk

Figure 19.9. Acute FC. Hyperemia of chicken duodenum.

material from ruptured follicles may be found in the peritoneal cavity. Immature follicles and ovarian stroma are often hyperemic.

Chronic Disease

Chronic FC is characterized by localized infections, in contrast to the septicemic nature of the acute disease. These generally become suppurative and may be widely distributed anatomically. They often occur in the respiratory tract and may involve any part, including sinuses and pneumatic bones (Figure 19.12). Pneumonia (Figure 19.10C, D) is an especially common lesion in turkeys. Infections of the conjunctiva and adjacent tissues occur (see Figure 19.7), and facial edema may be observed. Localized infections also may involve the hock joints (Figure 19.10F), foot pads, peritoneal cavity, and oviduct.

Chronic localized infections can involve the middle ear and cranial bones and have been reported to result in torticollis. In turkeys, torticollis and eventual death can be associated with infections of the cranial bones, middle ear, and meninges. In a study of naturally infected turkeys exhibiting torticollis, Olson (120) described lesions at these sites. The outstanding gross lesion was yellowish caseous exudate in air spaces of the calvarial bones. Heterophilic infiltration and fibrin were consistently observed in the air spaces, middle ear, and meninges. Multinuclear giant cells often were associated with necrotic masses of heterophils in air spaces. Similar lesions were found in experimentally exposed turkeys (122). Localized meningeal infections (Figure 19.13), without involvement of cranial bones or the middle ear, have been observed in turkeys exhibiting torticollis, as have cerebellar infections (41).

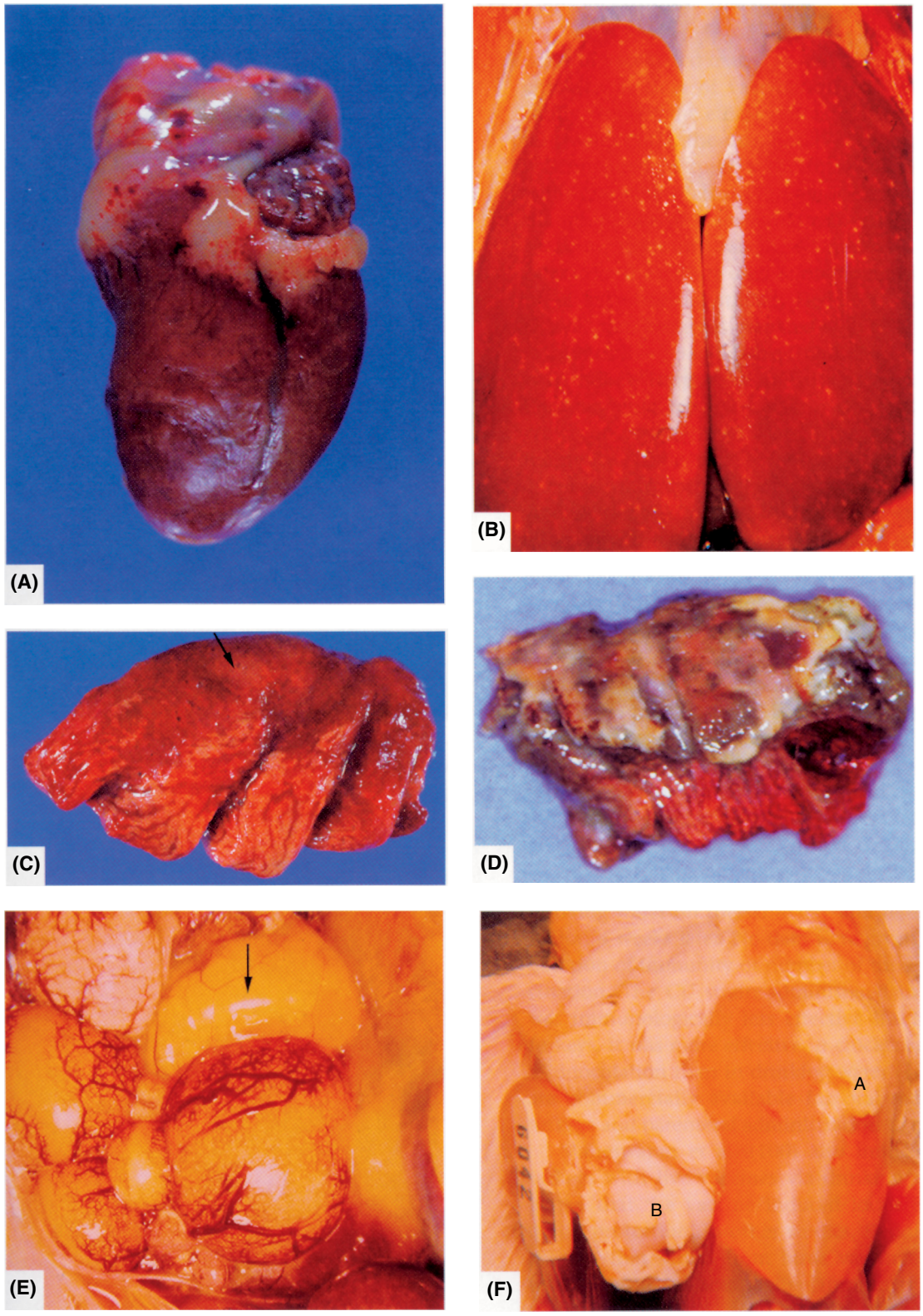

Figure 19.10. (A) Acute FC. Subepicardial hemorrhages in a turkey. (B) Acute FC. Multiple necrotic foci in turkey liver. (C) Acute FC. Turkey lung with extensive hemorrhage and patchy areas of necrosis (arrow) and emphysema. (D) Submassive necrosis with fibrous exudate on pleural surface. (E) Acute FC. Flaccid ovarian follicle (arrow) with thecal blood vessels less evident than normal. (F) Chronic FC. Caseous exudate in sternal bursa (A) and hock joint (B) of a turkey.

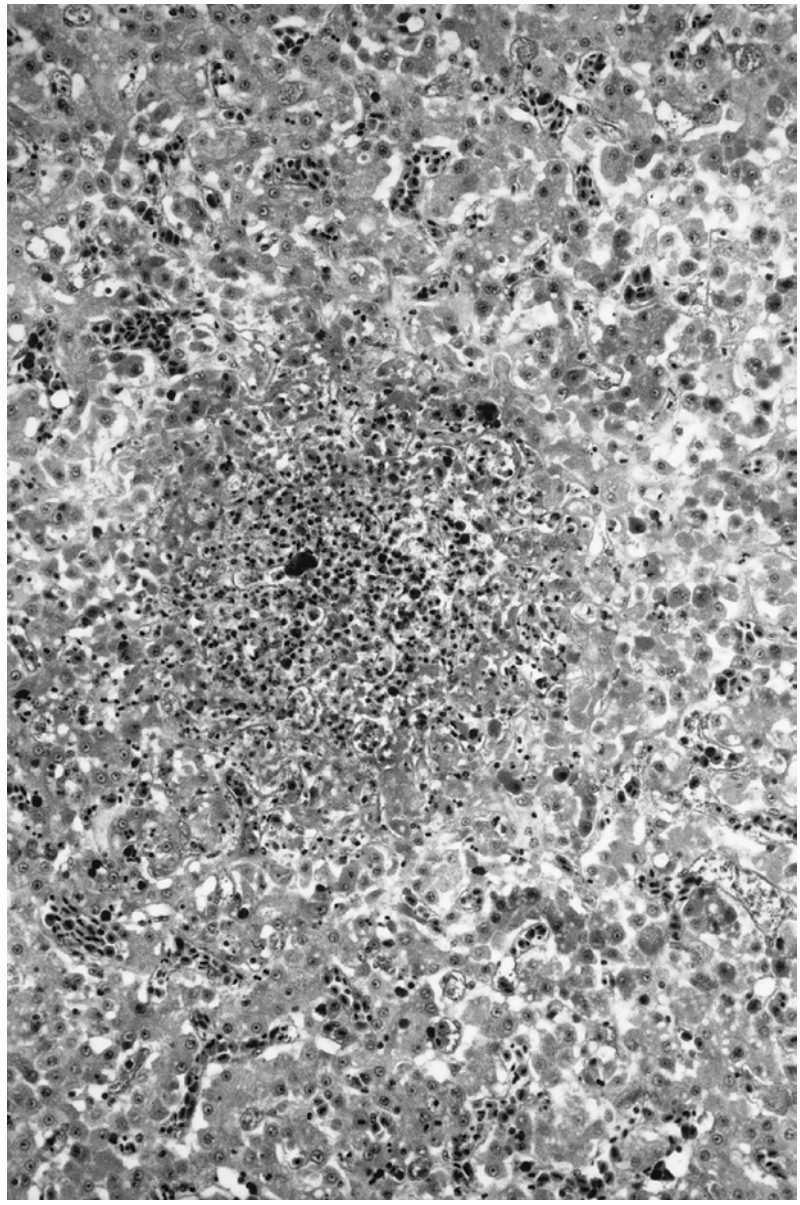

Figure 19.11. Acute FC. Coagulative necrosis and heterophilic infiltration in turkey liver. H&E, ×600.

Immunity

Pasteur (128) used an avirulent culture attenuated by prolonged growth on artificial medium and produced immunity that protected fowl against subsequent exposure. In field use, his method did not prove practical because uniform attenuation could not be obtained, and heavy losses sometimes occurred in vaccinated flocks.

Since Pasteur's classic work, numerous attempts have been made to produce efficient vaccines against FC, but results have not been consistent. There can be little doubt, however, that a substantial, but not absolute, immunity can be induced in fowl by using killed *P. multocida* vaccines under controlled conditions (7, 65). Killed *P. multocida* vaccines usually are prepared by growing selected immunogenic strains on a suitable medium and suspending them in formalinized saline solution. The killed organisms usually are incorporated with an adjuvant and injected subcutaneously.

Under field conditions, losses from FC sometimes occur in vaccinated flocks. This failure may be due to improperly prepared or administered vaccine or immune impaired birds. Heddleston and Reisinger (69) demonstrated that stress caused by changing the social or peck order of vaccinated males, as well as fowlpox infection in chickens at time of vaccination and exposure, significantly reduced the efficacy of vaccination. In experimental studies (130), the manifestation of acquired resistance was impaired in turkeys vaccinated against *P. multocida* while receiving aflatoxin in their feed. It also was observed that an isolate of *P. multocida* recovered from an FC outbreak

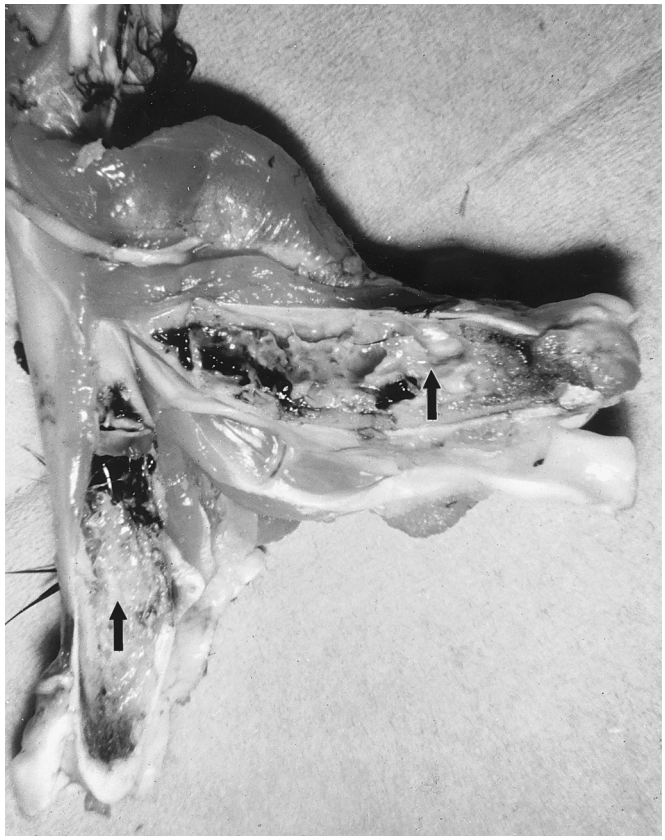

Figure 19.12. Chronic FC. Caseous exudate (arrows) in turkey humerus.

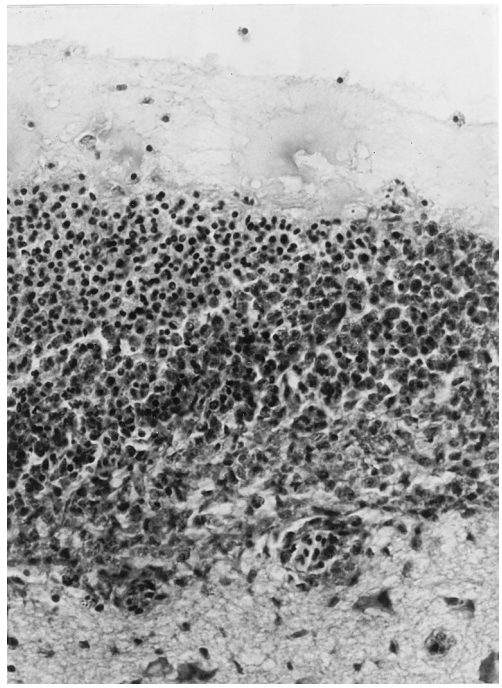

Figure 19.13. Chronic FC. Fibrinoheterophilic meningitis in turkey. H&E, ×400.

in previously vaccinated turkeys differed serologically from the culture used in preparing vaccine (73).

In experimental studies, Heddleston and Rebers (67) showed that bacterins prepared with tissues from infected turkeys or live *P. multocida* administered in drinking water will induce immunity in turkeys against a different immunogenic type. A bacterin prepared with bacteria grown on conventional agar media did not induce cross immunity. These studies indicate that *P. multocida* produces a wider spectrum of immunogens *in vivo* than *in vitro*. Rimler (144) showed that turkeys vaccinated with *in vivo*-grown *P. multocida* and challenged with the homologous strain produced serum that passively immunized poults against 5 different serotypes.

Bierer and others at Clemson University stimulated renewed interest in live FC vaccine administered in drinking water. Bierer and Derieux (11) demonstrated good immunity in 14-week-old turkeys that were given a live culture of *P. multocida* (CU strain, previously CS-148) in drinking water 2 weeks before challenge exposure. The vaccine, however, killed 4.2% of 120 turkeys. The best results were obtained by inoculating 8-week-old turkeys with a killed bacterin and then administering the live vaccine 2 weeks later; the live vaccine killed only 2.5% of 120 turkeys. Derieux and Bierer (30) stated that good immunity may be obtained in 6-week-old turkeys by administering 2 doses of vaccine in drinking water on the same day and repeating the vaccination 4 weeks later. No data were given, however, as to duration of immunity or number of turkeys killed by vaccination. The CU strain administered in drinking water was immunologically less effective in chickens than in turkeys. It was more effective in chickens by wing-web or SC inoculation than in drinking water (29). Live vaccines are commercially available for oral administration to turkeys and parenteral administration to chickens.

Maheswaran et al. (103) also induced immunity in turkeys with live vaccines via drinking water; they suggested that the vaccine induced localized, but not systemic, protection. In other studies, Heddleston et al. (75) showed that serum from birds vaccinated via drinking water would induce passive immunity in chicks and turkeys.

Passive immunity for prevention of FC was studied in 1892 by Kitt, who used immune horse serum. This method was used frequently, but because of the short duration of passive immunity, it is presently used little if at all. Bolin and Eveleth (15) reported that *P. multocida* antiserum prepared in chickens gave maximum protection 16–24 hours after injection; protection began to decline after 48 hours and had disappeared after 192 hrs.

Diagnosis

A presumptive diagnosis of FC may be made from clinical observations, necropsy findings, or isolation of *P. multocida*. A conclusive diagnosis should be based on all 3. Signs and lesions of the disease were described previously.

Isolation and Identification

P. multocida can be isolated readily from viscera of birds that die of acute FC and usually from lesions of chronic

cases; it is less likely to be isolated from dehydrated, emaciated survivors of an acute outbreak. A tentative diagnosis of acute FC can be made by demonstrating bipolar organisms in liver imprints (Figure 19.2) using Wright's stain. Immunofluorescent microscopy can be used to identify *P. multocida* in tissue or exudate (105).

Bone marrow, heart blood, liver, meninges, or localized lesions are preferred for culturing. To isolate *P. multocida*, sear the tissue or exudate with a spatula and obtain a specimen by inserting a sterile cotton swab or wire loop through the seared surface. If birds are living, squeeze mucus from the nostril or insert a cotton swab into the nasal cleft. Transfer the specimen to peptone broth and streak on dextrose starch agar containing 5% chicken serum or other suitable media. Specimens also may be streaked on MacConkey and blood agar media to aid in identification.

Colonies characteristic of *P. multocida* (described under Etiology) are transferred to dextrose starch agar slants incubated 18–24 hours. Tubes of phenol red broth base containing 1% glucose, lactose, sucrose, mannitol, and maltose, respectively, are then inoculated with growth from the slant. Fermentation of glucose, sucrose, and mannitol without gas is characteristic of *P. multocida*. Lactose usually is not fermented, but some avian isolates will ferment it. Inoculate 2% tryptose in 0.85% saline solution, incubate 24 hours at 37°C, and test for indole (Kovac's test). Indole is almost always produced by *P. multocida*. There should be no hemolysis of blood and no growth on MacConkey agar (Table 19.2).

Inoculation of animals may be used as an aid in isolating *P. multocida* from contaminated materials. Rabbits, hamsters, or mice are inoculated subcutaneously or intraperitoneally with 0.2 ml exudate or minced tissue. If *P. multocida* is present, the animal usually dies within 24–48 hours, and the organism can be isolated in pure culture from heart, blood, or liver.

Serologic diagnosis of FC by rapid whole-blood agglutination, serum plate agglutination, agar diffusion tests, or enzyme-linked immunosorbent assay (ELISA) has limited value in chronic cholera and no value with the acute form of the disease.

Differential Diagnosis

Avibacterium gallinarum and *Gallibacterium anatis* biovar *haemolytica* are 2 closely related bacteria that may be isolated from diseased poultry and incorrectly identified as *P. multocida* (66). *Avibacterium gallinarum* was first described by Hall et al. (56), who isolated it along with *P. multocida* from chickens with other maladies characterized by inflammation of the upper respiratory tract. The gel diffusion precipitin test shows a common antigen between *Avibacterium gallinarum* and *P. multocida*. Clark and Godfrey (25) found *Avibacterium gallinarum* associated with a respiratory disease complex of chickens in southern California. Gilchrist (46), in a survey of avian respiratory diseases in New South Wales, reported finding *Avibacterium gallinarum*, *Gallibacterium anatis* biovar *haemolytica*, and *P. multocida*. Harbourne (58) isolated *Gallibacterium anatis* biovar *haemolytica* on 4 occasions from livers of young chickens and turkeys. *Gallibacterium anatis* biovar *haemolytica* was isolated from young chickens with salpingitis, which was often accompanied by nasal catarrh, helminth infection, or leukosis; the organism was also isolated from the lungs of fowl with chronic respiratory disease and infectious bronchitis (117). Matthes et al. (106) isolated *Gallibacterium anatis* biovar *haemolytica* from chickens with a septicemia. Chloramphenicol was effective in treatment. Hacking and Pettit (55) reported on 8 cases of *Gallibacterium anatis* biovar *haemolytica* in pullets and laying hens: 5 cases involved decreased egg production, with some birds showing peritonitis or salpingitis; 3 cases involved increased mortality; some birds had enteritis, enteritis, and hepatitis, or respiratory infection. In most cases, *Gallibacterium anatis* biovar *haemolytica* was thought to be a secondary pathogen.

Differential characteristics of *P. multocida*, *Avibacterium gallinarum*, and *Gallibacterium anatis* biovar *haemolytica* that may be isolated from poultry are listed in Table 19.2.

Treatment

Antibacterial chemotherapy has been used extensively in the treatment of FC with varying success, depending to a large extent on the promptness of treatment and drug used. Sensitivity testing is often advantageous, because strains of *P. multocida* vary in susceptibility to chemotherapeutic agents (34, 166), and resistance to treatment may develop, especially during prolonged use of these agents.

Sulfonamides

Several of the sulfonamides have been employed both experimentally and in naturally occurring outbreaks. The main disadvantages of the sulfonamides are their bacteriostatic instead of bactericidal action, inability to cure localized abscesses, and their toxic effect on birds. The use of sulfonamides for treatment of FC has been reviewed (48).

Antibiotics

Streptomycin given intramuscularly (IM) at a dose of 150,000 mg prevented deaths in adult turkeys when administered before or at the time of inoculation of *P. multocida*. When treatment was delayed for 6–24 hours or dosage was reduced, chronic infection resulted (108). Penicillin, streptomycin, penicillin and streptomycin, and oxytetracycline (administered IM at the time of experimental exposure of chickens) all possessed activity as therapeutic agents (10). Chlortetracycline reduced losses in chicks about 80% when given at the rate of 40 mg/kg body weight IM 30 minutes after parenteral inoculation of the organism (102). Chicks that received mash containing 1 mg/g had 50% fewer losses than untreated controls. In an outbreak of FC in pheasants, however, Alberts and Graham (2) did not observe any beneficial results when 1 mg/g mash was fed. When chlortetracycline was given IM, a slight reduction in mortality was recorded. Novobiocin administered in feed or water reduced death losses in experimentally exposed turkeys (57).

Chloramphenicol (20 mg/kg body weight) in a single IM injection was effective in treating FC, but in flocks in which

FC and fowl typhoid or fowlpox were concurrently present, chloramphenicol treatment was not successful (81). A chloramphenicol-dexamethasone-pyribenzamine combination was used successfully with vaccination in treatment of FC in breeding turkeys. Respiratory problems, which occurred 1 week after the initial outbreak, responded readily to IM administration of this drug combination (51). Water-soluble erythromycin at the rate of 1 lb/50 gallon of drinking water halted mortality in t2wo flocks of Muscovy ducklings infected with *P. multocida* (62). Fluoroquinolones are used successfully to treat FC. *Pasteurella multocida* isolates from poultry are typically highly susceptible to fluoroquinolones (47).

Antibiotics used in rations at very low levels for promotion of growth, according to the experiments of Dorsey and Harshfield (36), did not significantly influence the course of FC infection in inoculated birds. At therapeutic levels, birds that received penicillin and streptomycin in feed died at about the same rate as controls. No deaths occurred in groups that received sulfaquinoxaline or sulfamerazine. These workers also found oxytetracycline and chlortetracycline effective in preventing mortality in experimental FC in a small flock of laying birds; mortality was 80% in an untreated group compared with 12% in a group receiving mash containing oxytetracycline at the level of 500 g/ton. In 6 naturally occurring outbreaks, oxytetracycline at this level in feed checked mortality, but losses returned in 3 flocks after withdrawal of the antibiotic.

Prevention and Control

Management Procedures

Prevention of FC can be effected by eliminating reservoirs of *P. multocida* or by preventing their access to poultry flocks. Good management practices, with emphasis on sanitation, are the best means of preventing FC. Unlike many bacterial diseases, FC is not a disease of the hatchery. Therefore, infection occurs after birds are in the hands of the producer, and consideration must be given to the many ways that infection might be introduced into a flock.

The primary source of infection is usually sick birds or those that have recovered and still carry the causative organism. Only young birds should be introduced as new stock; they should be raised in a clean environment completely isolated from other birds. Isolation should be extended to housing. Unless separate houses can be provided for first- and second-year layer flocks, the older flock should be marketed in its entirety. Different species of birds should not be raised on the same premises. The danger of mixing birds from different flocks cannot be overemphasized. Farm animals (particularly pigs, dogs, and cats) should not have access to the poultry area. Water fountains should be self-cleaning, and feeders should be covered to prevent contamination as much as possible.

P. multocida has been recovered from many species of free-flying birds and warrants consideration as source of bacteria to poultry; wit measures should be taken to prevent their association with the flock. Raising turkeys in areas where FC is a serious problem may warrant their confinement in houses from which free-flying birds, rodents, and other animals can be excluded. If an outbreak of FC occurs, the flock should be quarantined and disposed of as soon as economically feasible. All housing and equipment should be cleaned and disinfected before repopulation.

Vaccination

Vaccination should be considered in areas where FC is prevalent, but it should not be substituted for good sanitary practice. Commercially produced bacterins and live vaccines are available. Bacterins usually contain whole cells of serotypes 1, 3, and 4 emulsified in an oil adjuvant. Because a bacterin will not provide protection against an FC challenge from a serotype not contained in that bacterin, an autogenous whole-cell bacterin containing a locally isolated strain other than serotypes 1, 3, or 4 may be used (63). The choice of adjuvant for an autogenous vaccine can be water-in-oil emulsion or aluminum hydroxide (9). Autogenous bacterins using aluminum hydroxide as the adjuvant are useful for the vaccination of turkey breeder or broiler breeder flocks that are in lay because the water-in-oil emulsion, in combination with the whole bacterial cell, results in a significant tissue response by the bird. This response can result in significant declines in egg production. The negative effect on egg production is less with aluminum hydroxide adjuvant whole-cell FC bacterins. It has been well documented that aluminum hydroxide bacterins do not stimulate the immune response as well as water-in-oil bacterins (69, 107). Therefore, if an aluminum hydroxide bacterin is used, revaccination may be required to afford immunity to a flock for an entire laying cycle.

Three live vaccines available for use in the United States are CU, a strain of low virulence; M-9, a mutant of CU with very low virulence; and PM-1, a mutant of CU intermediate in virulence between CU and M-9. Vaccination of chickens and turkeys with these live *P. multocida* vaccines induces protection against heterologous serotype challenge. The use of live FC vaccines stimulates an effective immune response but has the disadvantage of potentially resulting in mortality in the vaccinated birds (11). If the mortality post vaccination becomes excessive, it can be reduced by the administration of an antibiotic. This should be avoided, if possible, until at least 4 days post vaccination when there will be at least partial immunity induced by the vaccine (123).

When considering the most appropriate vaccination program for FC, the following should be taken into consideration: prevalence of FC in the area, most prevalent serotypes of *P. multocida* in area, age of birds to be vaccinated, and the value of the birds to be vaccinated (i.e., breeder turkeys vs. commercial turkeys or parent chicken breeders vs. grandparent chicken breeders). There have been many successful vaccination protocols for chicken breeders against FC. Bacterins, live vaccines, or both are used, and usually 2 doses are given: the first at 8–10 weeks of age and the second at 18–20 weeks of age. Protection occurs only against serotypes contained in the

bacterin and does not give solid immunity for an entire laying cycle. Some of the more commonly used vaccination programs consist of administering a live vaccine in the wing web at 10–12 weeks of age followed by either another live vaccine in the wing web or a bacterin at 18–20 weeks. Vaccination with live vaccine provides protection against multiple serotypes, but the vaccine can cause chronic FC. The use of a bacterin at 10–12 weeks and a live vaccine at 18–20 weeks, just prior to movement to the laying house, gives protection against multiple serotypes and minimizes live vaccine-induced chronic FC (79).

One of the most successful programs for vaccination of both breeder turkeys and commercial meat turkeys is the use of a live vaccine in the drinking water every 4 weeks beginning at 6–8 weeks of age and continuing for the life of the flock. Bacterins also can be used in breeder turkeys. They are vaccinated 2–5 times before the onset of egg production, with the first vaccination beginning at 6–8 weeks.

Riemerella anatipestifer Infection

Jaime A. Ruiz and Tirath S. Sandhu

Introduction

Definition and Synonyms

Riemerella anatipestifer (RA) infection is a contagious disease of domestic ducks, geese, turkeys, and various other domestic and wild birds. It is also known as new duck disease, duck septicemia, anatipestifer syndrome, anatipestifer septicemia, and infectious serositis. In geese, RA infection has been called goose influenza or septicemia anserum exsudativa (49). It occurs as an acute or chronic septicemia characterized by fibrinous pericarditis, perihepatitis, airsacculitis, caseous salpingitis, and meningitis. *Riemerella columbina* (RC), a similar organism to RA, has been isolated from clinically diseased pigeons (69).

Economic Significance

R. anatipestifer infection is a major disease confronting the duck industry worldwide. It accounts for significant economic losses due to high mortality, weight loss, condemnations, downgrading, and salvage. Prevention and control programs consist of diagnosing the infection, vaccinating at-risk flocks, and treating the disease, which all add to the production cost.

Public Health Significance

The disease has no public health significance.

History

R. anatipestifer infection was first described in 1932 in Pekin ducks from 3 farms on Long Island, New York (33). The report referred to a new disease which became known in the area as the "new duck disease". The disease was first observed in 7- to 10-week-old ducks with about 10% mortality and later spread to younger ducklings of about 3 weeks of age. Six years later, the disease was observed in ducks from a commercial farm in Illinois and was reported as "duck septicemia" (23). Dougherty and colleagues (18) gave the disease the designation "infectious serositis" after a comprehensive pathologic study. Leibovitz (48) recommended the term *R. anatipestifer* infection to identify the disease as being caused specifically by *R. anatipestifer* and to differentiate it from other infections with similar pathology. Riemer (66) described a similar disease, septicemia anserum exsudativa, found in geese. The causative agent, *Pasteurella septicaemiae*, is identical to RA based on reported characteristics (35, 81).

Etiology

Classification

In 1932, Hendrickson and Hilbert (33) isolated and characterized the causative bacterium of RA and called it *Pfeifferella anatipestifer*. Bruner and Fabricant (10) studied and compared its characteristics with those of *Brucella, Pasteurella, Moraxella, Actinobacillus*, and *Haemophilus*, concluding that the organism had more in common with *Moraxella sp*. They subsequently suggested the name *Moraxella anatipestifer*. Thereafter, it was listed in the 7th edition of *Bergey's Manual of Determinative Bacteriology* as *Pasteurella anatipestifer* (8). Based on its uncertain taxonomic status, RA was placed as species *incertae sedis* in the 8th (81) and 9th (52) editions of *Bergey's Manual of Systematic Bacteriology*.

Comparing its DNA-base composition, DNA-DNA homology, and cellular fatty-acid profile indicated it should be excluded from the genus *Moraxella* as well as *Pasteurella* (5, 52). Piechulla et al. (63) suggested that RA be transferred to the *Flavobacterium*/*Cytophaga* group on the basis of its low but significant DNA binding and ability to produce menaquinones and branched-chain fatty acids. Subsequently, Segers et al. (80) reported significant differences between RA and its close genotypic relatives *Flavobacterium* and *Weeksella*. They suggested placing this organism in a separate genus, *Riemerella*, in honor of Riemer (66), who first described the disease "septicemia anserum exsudativa" in geese in 1904. They ultimately named it *Riemerella anatipestifer* on the basis of a DNA-ribosomal RNA hybridization analysis, its protein and fatty acid methylester (FAME) profiles, and its phenotypic characteristics such as lack of pigment production and presence of respiratory quinone, menaquinone 7.

R. anatipestifer-like organisms of taxon 1502 (37) isolated from ducks and geese were assigned to the genus *Coenonia* and named *Coenonia anatina* gen. nov., sp. nov. on the basis of its phenotypic and genotypic characteristics and FAME profiles (86). *C. anatina* differs from RA by the absence of arginine dihydrolase and gelatinase and by the presence of hyaluronidase, chondroitin sulfatase activity, aesculin hydrolysis, and b-glucosaminidase activity. Mavromatis et al. (54), Yuan et al. (91), and Zhou et al. (95) published genome sequences of RA strains ATCC 11845, RA-GD, and RA-YM, respectively.

Morphology and Staining

R. anatipestifer is a Gram-negative, nonmotile, nonspore-forming rod that occurs singly, in pairs, and occasionally in chains. The cells vary from 0.2–0.4 mm in width and 1–5 mm in length. Many cells stain bipolar with Wright's stain, and a capsule can be demonstrated in preparations with India ink.

Growth Requirements

The organism grows well on chocolate agar, blood agar, and trypticase soy agar. Growth of fastidious strains can be enhanced by adding 0.05% yeast extract and 5% newborn calf serum. Growth is more abundant with increased carbon dioxide (23). Hendrickson and Hilbert (33) described the organism as a strict aerobe on the basis of results obtained with the pyrogallic acid and sodium hydroxide procedure for removing oxygen. However, because carbon dioxide also would be depleted by reacting with the sodium hydroxide, neither oxygen nor carbon dioxide was available to the organism. Although some strains of RA grow at an incubation temperature of 45ºC, no growth is observed at 4ºC or 55ºC (4); indeed, maximum growth usually occurs in 48–72 hours when incubated at 37ºC in a candle jar that provides increased carbon dioxide and moisture, both of which favor growth.

Colony Morphology

Colonies on blood agar, when grown for 24–48 hours at 37ºC in a candle jar, are 1–2 mm in diameter, convex, entire, transparent, glistening, and butyrous. Some strains produce slimy growth. Colonies on clear media are iridescent when observed with obliquely transmitted light.

Biochemical Properties

Riemerella anatipestifer does not ferment sugars in routine media, but has been reported to produce acid in dextrin, glucose, maltose, inositol, trehalose, mannose, and fructose by growing it in buffered single substrate medium (2, 4, 36). The organism liquefies gelatin and produces a slight alkaline reaction in litmus milk. Usually, indol and hydrogen sulfide are not produced; however, some strains are indol positive (37). Nitrate is not reduced to nitrite, and starch is not hydrolyzed. No growth occurs on MacConkey's agar and no hemolysis takes place on blood agar. *R. anatipestifer* produces oxidase, catalase, and phosphatase (27). It is negative for aesculin hydrolysis, hyaluronidase, and chondroitin sulfatase (37). Some strains produce urease and arginine dihydrolase.

R. anatipestifer is positive for acid and alkaline phosphatase; ester lipase C8 (APIZYME system); leucine-, valine- and cystine-arylamidases; phosphoamidase; α-glucosidase; and esterase C4, whereas it is negative for the following enzyme activities: α- and β-galactosidases, β-glucuronidase, β-glucosidase, α-mannosidase, β-glucosaminidase, lipase C14, fucosidase, and ornithine and lysine decarboxylases (63, 80).

Susceptibility to Chemical and Physical Agents

Most RA strains do not survive on solid media for more than 3–4 days at 37ºC or room temperature; in contrast, cultures in broth may be viable for 2–3 weeks when stored at 4ºC. Incubation at 55ºC for 12–16 hours resulted in nonviability of the organism (4). *R. anatipestifer* has been reported to survive in tap water and turkey litter for 13 and 27 days, respectively (6). It is sensitive to penicillin, novobiocin, chloramphenicol, lincomycin, enrofloxacin, ceftiofur, streptomycin, erythromycin, ampicillin, bacitracin, neomycin, and tetracycline, but is resistant to kanamycin and polymyxin B (4, 13). *R. anatipestifer* is also relatively resistant to gentamicin.

Strain Classification

R. anatipestifer isolates have been serotyped using agglutination and agar-gel precipitin (AGP) reactions. Both of these tests involve surface antigens that are presumed to be polysaccharides (9). Plate agglutination is rapid and convenient; tube agglutination is favored over AGP because it is quantitative in terms of antibody titers.

To date, 21 serotypes have been reported. Based on agglutination reactions, Harry (26) identified 16 serotypes (A through P), 4 of which (E, F, J, and K) were lost when they were stored. He also found serotypes G and N to be identical to serotypes I and O, respectively (7, 26). Seven serotypes (1 through 7) were differentiated using AGP reaction (9). Subsequently, Bisgaard (7) reported serotypes 1, 2, 3, 4, 5, and 6 to be serologically identical to Harry's types A, I/G, L, H, M, and B, respectively. Bisgaard (7) also suggested designating serotypes numerically to avoid confusion and to standardize serotype nomenclature to recognize new serotypes. He identified 2 new serotypes (12 and 13). Serotype 7 was reported to be identical to serotype O/N, and a new serotype, 8, was isolated (77).

Sandhu and Leister (78) revised the typing scheme that Bisgaard proposed. They redesignated Harry's serotypes C and D as types 9 and 10, excluded serotype 4, which was not RA, and reported 5 new serotypes: 11, 14, 15, 16 and 17. Loh et al. (51) reported serotypes 13 and 17 were identical. They redesignated Harry's type P as serotype 4 and added 3 new serotypes 17, 18 and 19, which were isolated from ducks in Singapore. Two new serotypes 20 and 21, were isolated from ducks in Thailand (61); one of these, serotype 20, was later excluded because it was determined it was not RA (71). A new serotype isolated from ducks in Thailand replaced serotype 20 (71). All serotypes reacted specifically with homologous-type antisera with the exception of serotype 5, which gave minor cross reactions with serotypes 2 and 9 (51, 77).

Higgins et al. (34) demonstrated that cell lysates of various serotypes showed many bands when subjected to polyacrylamide gel electrophoresis. Most of the bands were common to all serotypes, but some were specific to individual serotypes. Subramaniam and colleagues (83) cloned an outer membrane protein gene (*OmpA*) from RA that encoded for a 42-kDa major antigenic outer membrane protein (*OmpA*). All reference strains of RA had the *OmpA* gene, although some minor genetic differences were observed in different strains. Hu et al. (39) demonstrated that *OmpA* is a virulent factor for RA. Tsai et al. (84) reported that all of the RA strains fall into a single cluster based on the phylogenetic analysis of the 16S rRNA gene and that the 16S rRNA gene-based polymerase PCR may be a suitable test for screening RA infections.

Recently, most of the RA strains were shown to contain plasmids (12). A 3.9b plasmid carried protein genes similar to the virulence-associated genes of other bacteria. An insertion sequence element found on a second plasmid may be important in epidemiological studies (87). Yu et al. (90) studied the genomic diversity of pathogenic RA isolates using profiles of plasmid patterns (90). DNA fingerprinting has been useful in investigating disease outbreaks (22).

Pathobiology and Epidemiology

Incidence and Distribution

Riemerella anatipestifer infection occurs worldwide and has been recognized in countries that have intensive duck production (73). Wide variation has been observed in the severity of the disease depending on the strain of the organism, the age of the host, and the route of exposure (31, 79). Often, more than one serotype is responsible for the disease at a single farm or in the same hatch of birds.

Natural and Experimental Hosts

R. anatipestifer infection is a disease that primarily affects domestic ducks and geese. Naturally occurring outbreaks, however, have been reported in turkeys (32, 92). Serious outbreaks in turkeys in the United States and other countries showed that RA is a potential pathogen of domestic turkeys (21, 57, 58, 82). *R. anatipestifer* also has been isolated from pheasants (11), chickens (68), guinea fowl and quail (58), partridge (89), and other waterfowl (19, 46, 56, 64, 88). It has also been isolated from gulls, budgerigars, guillemots, and pigs (37).

Chickens, geese, pigeons, rabbits, and mice were reported to be refractory to infection with RA; guinea pigs succumbed to inoculation of large doses intraperitoneally (23, 33). However, Heddleston (31) observed that 8×10^6 organisms inoculated into the foot pad killed 5 of 7 1-day-old chicks; 4×10^6 organisms in 2-week-old white Chinese goslings produced signs and lesions similar to those seen in Pekin ducklings.

Ducklings 1–8 weeks of age are highly susceptible. Ducklings younger than 5 weeks of age usually die within 1–2 days after clinical signs appear; older birds may survive longer. The disease is rare in breeder ducks.

Transmission, Carriers, Vectors

Infection takes place via the birds' respiratory tract (47) or through skin wounds, particularly on the feet (2). RA and RA-like bacteria have been isolated from pharyngeal mucosa of clinically normal ducklings (70). Cooper (16) suggested that in turkeys the disease may be transmitted by arthropod vectors based on its seasonal occurrence and the apparent affinity of RA for host erythrocytes. The disease can be reproduced most consistently by injecting the organism intravenously, subcutaneously, intraperitoneally, intramuscularly, in the foot pad, or in the infraorbital sinus. Experimental infection by subcutaneous and intravenous routes caused high mortality, whereas no or low mortality was observed in ducklings infected by the oral or nasal route (3, 29, 79).

Incubation Period

The incubation period is usually 2–5 days. Artificial infection of ducklings by the subcutaneous, intravenous, or infraorbital sinus routes resulted in clinical signs and deaths as early as 24 hours post infection.

Clinical Signs

Signs most often observed are listlessness, ocular and nasal discharge, mild coughing and sneezing, greenish diarrhea, ataxia, torticollis (Figure 19.16A), tremor of head and neck, and coma. Affected ducklings lie on their backs paddling with their legs and are unable to move with the rest of the brood. Surviving ducks may be stunted (62). Adverse environmental conditions or concomitant disease often predispose birds to outbreaks of RA infection. Mortality may vary from 5%–75%; morbidity is usually higher.

Pathology

Gross

The most obvious gross lesion in ducks is fibrinous exudate, which involves serosal surfaces in general, but is most evident in the pericardial cavity, over the surface of the liver (Figure 19.14), and in air sacs. Similar lesions have been reported in turkeys and other birds. Fibrinous airsacculitis is common; both abdominal and thoracic air sacs may be involved. The spleen may be enlarged and mottled. Mucopurulent exudate in nasal sinuses and caseous exudate in oviducts also have been observed (18).

Chronic localized infections may occur under the skin and occasionally in the joints. Skin lesions usually take the form of necrotic dermatitis on the lower back or around the vent. Yellowish exudate has been observed between layers of the skin and fat.

Microscopic

Fibrinous exudate on the heart contains a few inflammatory cells, primarily mononuclear cells, and heterophils (Figure 19.15). In acute cases, severe focal necrosis of the heart muscle is

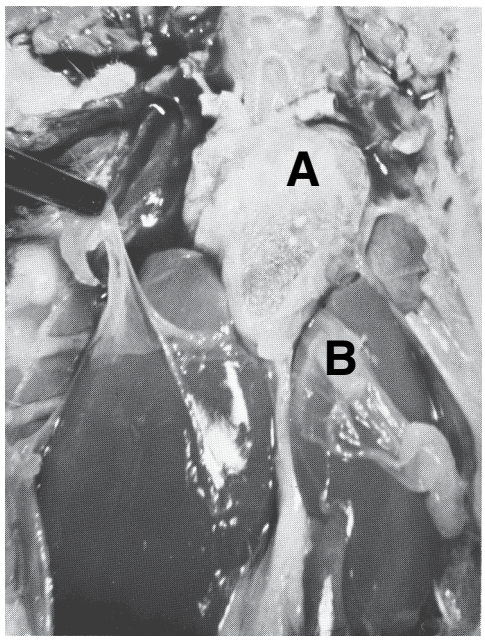

Figure 19.14. *Riemerella anatipestifer* infection. Fibrinous epicarditis (A), pericarditis, and perihepatitis (B). Forceps hold exudate from surface of liver.

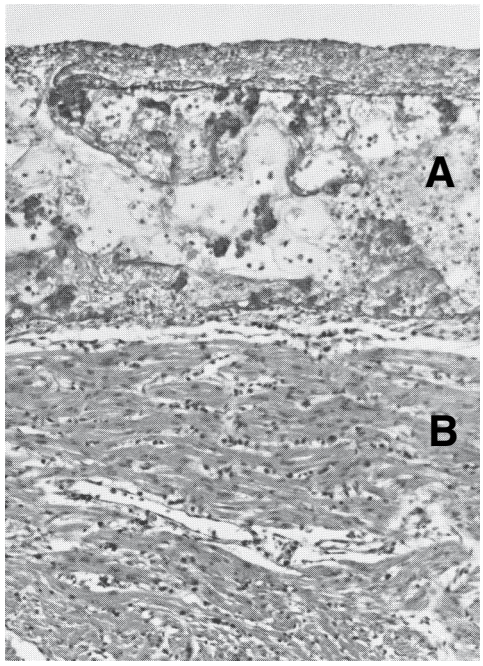

Figure 19.15. *Riemerella anatipestifer* infection. Fibrinous exudate (A) over surface of heart (B). H&E, ×150.

present (Figure 19.16). Liver lesions observed in the acute stage of the disease are mild periportal mononuclear leukocytic infiltration, cloudy swelling, and hydropic degeneration of parenchymal cells (Figure 19.16). In less acute cases, moderate periportal lymphocytic infiltration may be observed (62).

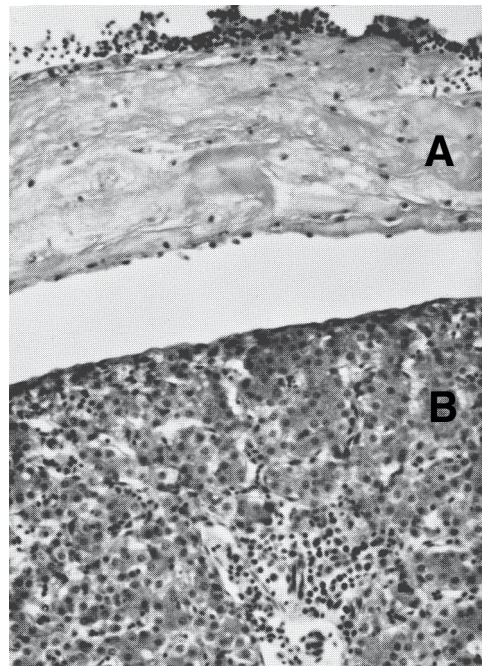

Figure 19.16. *Riemerella anatipestifer* infection. Fibrinous exudate (A) over surface of liver. (B) H&E, ×300.

In air sacs, mononuclear cells are the predominant cell type in the exudate. Multinuclear giant cells and fibroblasts may be observed in chronic cases (18). The respiratory tract also may be infected without showing clinical signs. The lungs of infected ducks may be unaffected; there may be interstitial cellular infiltration and proliferation of lymphoid nodules adjacent to parabronchi (62), or there may be an acute fibrinopurulent pneumonia (23). Infections of the central nervous system can produce fibrinous and lymphocytic meningitis (Figure 19.16B). Jortner and his colleagues (44) studied lesions in the central nervous system of naturally infected ducklings and described diffuse fibrinous meningitis with leukocytic infiltration in and around the walls of meningeal blood vessels. Extensive exudate was observed in the ventricular system. Slight to moderate leukocytic and microglial infiltrates were observed in subpial and periventricular brain tissue. Lymphoid necrosis and depletion of lymphocytes have been observed in the spleen and cloacal bursa (79). Biofilm formation has been described as a contributing factor in persistent RA infections (38).

Immunity

Ducklings that recover from the disease are resistant to subsequent infection (2, 23, 33). Inactivated bacterins have been used in ducks to prevent RA infection. Ducks vaccinated with formalin-inactivated bacterins and subsequently challenged with strains representing serotypes 1, 2, and 5 developed homologous, but not heterologous, protection. A trivalent bacterin containing these strains protected against challenge with each serotype, but the protection lasted only a short time (72). Harry and Deb (28) evaluated the effectiveness of

several types of bacterins and conducted a field trial with a formalin inactivated bacterin. A single dose of oil-emulsion bacterin provided longer lasting immunity in ducklings (20, 72). Cell-free culture filtrate also has been reported to provide significant protection against homologous challenge (60). Outer membrane proteins *OmpA* and *P45* failed to protect against a virulent challenge, but produced RA-specific antibodies (42). One-day-old ducklings exposed to live avirulent strains by aerosol or through the drinking water were resistant when challenged at 3–6 weeks of age with virulent homologous strains (74). Passive protection of progeny can be achieved by immunizing the female breeder ducks; maternal immunity lasts for about 2–3 weeks (75). RA-specific antibodies were detected in the egg yolk and sera of vaccinated breeder ducks (50); maternal antibodies in the progeny lasted up to 10 days of age. Cell-mediated immunity to RA antigens was transient (similar to vaccination with the bacterin), and live vaccine induced longer lasting protection (34, 74).

Han et al. (25) identified and described an immunogenic protein, chaperonin *GroEL* (*GroEL*), from the outer membrane of RA strain WJ4 using an immunoproteomic assay based on matrix-assisted laser desorption/ionization time of flight mass spectrometry. They found that *GroEL* is highly conserved among RA strains; indeed, the DNA sequence identity was more than 97.5% between WJ4 and the 9 additional RA strains.

Diagnosis

Isolation and Identification of the Causative Agent

Although a presumptive diagnosis may be made from clinical signs and necropsy findings, a definite diagnosis should be based on isolating and identifying RA. The bacterium can be isolated most readily when birds are in the acute stage of the disease. Suitable tissues for culture are the brain, blood from the heart, air sacs, bone marrow, lungs, liver, and exudates from lesions. Samples should be taken aseptically, streaked on blood agar or trypticase soy agar containing 0.05% yeast extract, and incubated in a candle jar at 37ºC for 24–72 hours. Adding newborn calf serum (5%) and gentamicin (5 mg/1,000 ml) to plate media is helpful for isolating RA from contaminated specimens. Isolated colonies should be selected for inoculation of the differential media and identified on the basis of characteristics described in "Etiology." Serotype identification can be established by agglutination and/or AGP reactions with specific antisera. Molecular fingerprinting by restriction endonuclease analysis and repetitive sequence PCR are useful to differentiate RA strains and may be helpful in epidemiological studies (15, 43, 45, 67, 90). Using PCR amplifying 16S rDNA has been reviewed by Qu et al. (65). A rapid assay for detecting RA has been developed based on the *GroEL* and *OmpA* genes sequence of RA using loop-mediated isothermal amplification (LAMP) (24, 93). In addition, Hu et al. developed a multiplex polymerase chain reaction (m-PCR) that discriminates RA, *Escherichia coli*, and *Salmonella enterica* in clinical samples from diseased ducks (40).

Serology

Immunofluorescent procedures can be used to identify RA in tissue or exudate from infected birds (53). Agglutination test and ELISA can be used to detect serum antibodies. ELISA is more sensitive than agglutination test but is not serotype-specific (30, 41, 50).

Differential Diagnosis

R. anatipestifer infection should be differentiated from other septicemic diseases caused by *Pasteurella multocida*, *Coenonia anatina*, *Escherichia coli*, *Streptococcus faecium*, and salmonellae. Because these diseases produce gross lesions that cannot be distinguished from those caused by RA, diagnosis must include isolating and identifying the causal organism.

Differential diagnosis also should include chlamydiosis, especially in turkeys and in areas where this disease is a serious problem.

Intervention Strategies

Management Procedures

The most important aspects of preventing RA include biosecurity, management, and sanitation practices. This includes proper ventilation, especially in houses where ducks are raised in total confinement. Predisposing factors such as stress due to overcrowding or being exposed to hot or cold weather should be avoided. Strict measures should be taken to prevent the infection from spreading from diseased to healthy flocks. If ducks are raised on wire, the floors should be washed and sanitized periodically to avoid accumulating manure and to reduce exposing healthy birds to infection

Vaccination

Types of Vaccine

Inactivated Bacterins. Inactivated bacterins prevent or reduce mortality due to RA (28, 47, 72). Because immunity induced by bacterins is serotype-specific, an ideal bacterin should contain cells of the predominant serotypes to provide effective protection. A bacterin containing serotypes 1, 2, and 5 has been used in the United States and Canada. Ducklings are vaccinated at 2 and 3 weeks of age to provide adequate protection up to market age (47). A single inoculation of oil-emulsified bacterin has been reported to produce longer lasting protection, but it may cause unfavorable lesions at the inoculation site (20, 72). Using autogenous bacterins containing virulent field strains provided good protection against homologous virulent challenge.

Live Vaccines. A live RA vaccine developed against serotypes 1, 2, and 5 provided significant protection against experimental or field infections with virulent organisms when administered to 1-day-old ducklings by aerosol or in the drinking water (74). A single vaccination protected ducklings up to at least 42 days of age. The vaccine strains grew in the upper respiratory tract and produced a humoral antibody response. The vaccine was demonstrated to be avirulent to 1-day-old ducklings

when administered by aerosol or injected into the infraorbital sinus. The vaccine strains were safe in ducks up to 10 backpassages using the contact-exposure method.

Breeder ducks can be vaccinated with the bacterin or live vaccine to provide protection in progeny through maternal immunity, which may last up to 2–3 weeks of age. Maternally immune ducklings respond successfully to active immunization with a live or inactivated vaccine (75).

Treatment

Riemerella anatipestifer antibiotic resistance profiles change over time (94). Antibiotics and sulfa drugs have been tested to treat RA with varying degrees of success. Sulfamethazine, 0.2%–0.25%, delivered via drinking water or feed, was reported to prevent the onset of clinical signs in ducks exposed experimentally to RA (2). Sulfaquinoxaline at levels of 0.025% or 0.05% in feed was effective in reducing mortality in both field and experimental infections (17, 76). Medicated feeds containing novobiocin (0.0303%–0.0368%) or lincomycin (0.011%–0.022%) were reported to be highly effective in reducing mortality when started 3 days prior to experimental infection. A combination of sulfadimethoxine and ormetoprim, when administered at 0.02%–0.12% levels in feed, prevented or reduced mortality and gross lesions in experimentally exposed ducks (55, 76).

Chen et al. (14) reported chloramphenicol resistance in RA isolated from ducks and geese in Taiwan. Tetracyclines were of little value for treating RA infection (1, 76). Subcutaneous injection of lincomycin-spectinomycin, penicillin, or a combination of penicillin and dihydrostreptomycin were reported to be effective in reducing mortality in artificially infected ducklings (76). Enrofloxacin has been shown to be highly effective in preventing mortality in ducklings when given in drinking water at levels of 50 ppm for the first day followed by 25 ppm for the next 4 days (85). Ceftiofur, a broad-spectrum cephalosporin, reduced mortality in experimentally infected ducklings given a single dose of 2 mg/kg body weight subcutaneously 5 hours after infection (13). Zhong et al. (94) performed Kirby-Bauer tests to analyze antibiotic resistance of 224 isolates of RA. Higher levels of resistance were found for aztreonam, cefepime, oxacillin, penicillin G, ceftazidime, and trimethoprim/sulfamethoxazole (87.8%, 64.3%, 88.6%, 86.9%, 75.9%, and 79.2% resistance, respectively). The lowest resistance rates were observed for amikacin (9.5%), cefoperazone (7.2%), imipenem (3.2%), and neomycin (9.5%).

Ornithobacterium rhinotracheale Infection

Richard P. Chin, Paul C.M. van Empel, and Hafez M. Hafez

Introduction

Definition and Synonyms

Ornithobacterium rhinotracheale infection is a contagious disease of birds that causes respiratory distress, mortality, and decreased growth. The severity of clinical signs, duration of the disease, and mortality are extremely variable and are influenced by environmental factors such as poor management, inadequate ventilation, high stocking density, poor litter conditions, and poor hygiene.

Economic Significance

O. rhinotracheale can be associated with high economic losses in poultry due to increased mortality and condemnation rates, decreased egg production, or decreased growth.

Public Health Significance

Currently, *O. rhinotracheale* has not been found to be of any public health significance.

History

O. rhinotracheale was first characterized in 1993 by Charlton et al. (16). The following year, Vandamme et al. (105) reported the phylogenetic position and various genotypic, chemotaxonomic, and classical phenotypic characteristics of 21 isolates, and proposed the name *O. rhinotracheale*. In retrospect, the first known isolation of *O. rhinotracheale* was made in 1981 in northern Germany from 5-week-old turkeys with nasal discharge, facial edema, and fibrinopurulent airsacculitis (46). Since its identification by Vandamme et al. in 1994, *O. rhinotracheale* has been isolated from birds in numerous countries throughout the world. Additional history can be found in the previous edition *of Diseases of Poultry* (18).

Etiology

Classification

Name and Synonyms

O. rhinotracheale belongs to the rRNA superfamily V within the Cythophaga-Flavobacterium-Bacteroides phylum, and is closely related to 2 other poultry bacteria, *Riemerella anatipestifer* and *Coenonia anatina* (105, 106).

Morphology and Staining

O. rhinotracheale is a Gram-negative, nonmotile, highly pleomorphic, rod-shaped, nonsporulating bacterium. From agars, it appears as short, plump rods measuring 0.2–0.9 μm in width and 0.6–5 μm in length (Figure 19.17). Very long rods measuring up to 15 μm can be observed from fluid media, .

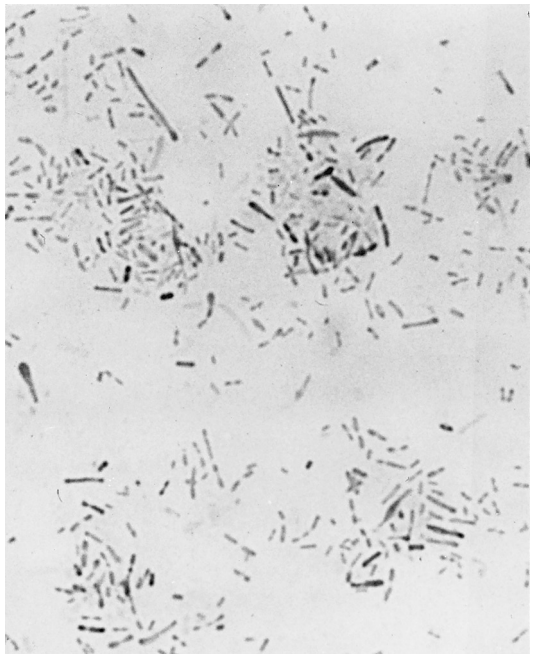

Figure 19.17. *Ornithobacterium rhinotracheale* showing highly pleomorphic nature. Gram stain of bacteria from a 48-hour culture. Gram stain, ×375. (Charlton)

Growth Requirements

O. rhinotracheale grows aerobically, microaerobically, and anaerobically. The optimal growth temperature is 37ºC; however, growth can occur at 30ºC–42ºC. The bacteria grows best on 5%–10% sheep blood agar, but readily grows on tryptose soy agar and chocolate agar. No growth occurs on MacConkey agar, Endo agar, Gassner agar, Drigalski agar, or Simmons citrate media. The growth in fluid media can be strain dependent, and media such as brain heart infusion broth, Pasteurella broth, or Todd Hewitt broth are needed.

Colony Morphology

O. rhinotracheale develop very small, nonhemolytic colonies that are circular, gray to gray-white, sometimes with a reddish glow, and convex with an entire edge. On primary isolation, the colonies of most *O. rhinotracheale* cultures show great differences in size (1–3 mm after 48 hours' incubation) but when subcultured, the colony size becomes more uniform. Prolonged incubation can give hemolytic activity on sheep blood agar (83).

Biochemical Properties

Conventional biochemical tests can be inconsistent. Phenotypic characteristics include the production of oxidase, lack of catalase production, lack of motility, no reaction on triple sugar iron agar, production of beta-galactosidase, the inability to reduce nitrate to nitrite, and the inability to grow on MacConkey agar. There is 1 report of a cytochrome oxidase-negative strain of *O. rhinotracheale* isolated from turkeys in Germany (67). Predominant fatty acids detected are 15:0 iso, 16:0, 15:0 iso 3OH, 17:0 iso, 16:0 3OH, 17:0 iso 3OH, and unknown peaks with equivalent chain lengths of 13.566 and 16.580.

Susceptibility to Chemical and Physical Agents

O. rhinotracheale strains were completely inactivated by a 0.5% solution containing formic and glyoxyl acid, and a 0.5% solution of an aldehyde-based (20% glutaraldehyde) product after 15 minutes of exposure time (41). These preparations were able to inactivate *O. rhinotracheale in vitro* at concentrations of 0.5% within 15 minutes.

Antigenic Structure and Toxins

Currently, no special structures or properties such as pili, fimbriae, plasmids, or specific toxic activities have been reported.

Strain Classification

Antigenicity

Using boiled extract antigens (BEAs) and monovalent antisera in the agar gel precipitation (AGP) and ELISA tests, 18 serotypes (A through R) of *O. rhinotracheale* have been determined (93, 96). Serotype A was the most prevalent serotype among chicken isolates (97%) and turkey isolates (61%) (96). There appears to be a correlation between the geographic origin of the *O. rhinotracheale* isolates and their serotype. Serotype C could be isolated only from chickens and turkeys in South Africa and United States (33, 91, 96). There is no indication of host specificity of the serotypes.

Hafez and Sting (42) compared the efficacy of using different antigen extractions (heat-stable, proteinase K-stable, and sodium dodecyl sulfate) for serotyping *O. rhinotracheale* in the AGP and ELISA tests. Results indicate that the AGP test with heat-stable or proteinase K-stable antigen extractions is a suitable method for serotyping. Numerous cross reactions were seen with the ELISA, making it unreliable for serotyping.

Immunogenicity or Protective Characteristics

Using a novel experimental method of combining immune depletion and passive transfer of immunity within the same host, Schuijffel et al. found that the antibody-mediated immunity in chickens was a key component in the protection against *O. rhinotracheale* infection (72).

Molecular

Amonsin et al. (3), using multilocus enzyme electrophoresis, repetitive sequence based-PCR, and 16S rRNA gene sequencing demonstrated that the majority of 55 *O. rhinotracheale* isolates recovered from domesticated poultry throughout the world had limited heterogeneity and were represented by a small group of closely related clones. They propose that the bacterium was recently introduced to domesticated poultry from wild bird populations.

Twenty-three isolates of *O. rhinotracheale* from France were tested using the random amplified polymorphic DNA (RAPD) analysis (50). Results showed that this method gave reproducible DNA fingerprints and a good level of discrimination, thus appearing to be another method for typing.

Van Empel et al. (90) used amplified fragment length polymorphism (AFLP) to characterize 56 isolates belonging to different serotypes which were isolated from different bird species from various countries. These isolates could be grouped in 3 major clusters with significantly different DNA fingerprints.

Popp and Hafez (62) investigated several *O. rhinotracheale* isolates from turkeys and chickens originated from Germany, Hungary, and Spain by pulsed-field gel electrophoresis (PFGE) of genomic macro-restriction fragments using the enzyme SalI. In general, most isolates showed differences in DNA fingerprints, although the overall profiles were very similar and a correlation between geographic origin, serotype, and DNA fingerprint pattern was observed. In contrast, Koga and Zavaleta (49) recently investigated 25 *O. rhinotracheale* isolates from broilers, breeders, and layers from several geographic zones of Peru using PCR and repetitive extragenic palindromic PCR (rep-PCR) techniques. All 25 isolates tested had a genetic profile similar to that of the *O. rhinotracheale* type strain (American Type Culture Collection 51463) that was isolated from a turkey in the United Kingdom.

Pathogenicity

Pathogenicity differences appear to exist between isolates of O. *rhinotracheale*. Three South African *O. rhinotracheale* field isolates inoculated into the caudal abdominal air sacs of 28-day-old broiler chickens showed significant differences in the production of airsacculitis and arthritis (86). In addition, van Veen et al. (103) found that Dutch and South African isolates were more pathogenic than an American isolate in broiler chickens when aerosol challenged.

The pathogenicity of 119 isolates from turkeys and chickens using the embryo lethality test were studied (40). This study showed that the inoculation of about 500 cfu of *O. rhinotracheale* into the allantoic sac of 11-day-old embryos discriminated between pathogenic and nonpathogenic *O. rhinotracheale* isolates. On the basis of death rate, isolates considered to be nonpathogenic had an embryo death rate 10%–20%, moderately pathogenic had a 21%–60% embryo death rate, and highly pathogenic isolates had a death rate of greater than 60%.

Soriano et al. found *in vitro* adherence of *O. rhinotracheale* isolates to chicken tracheal epithelial cells (76).

Pathobiology and Epidemiology

Incidence and distribution

After being recognized in 1994, numerous isolations of *O. rhinotracheale* have been reported throughout the world (1, 2, 4, 10, 12, 13, 15, 21, 24, 25, 26, 31, 32, 35, 37, 44, 46, 48, 50, 58, 60, 66, 70, 75, 76, 80, 84, 85, 108).

Natural and Experimental Hosts

O. rhinotracheale has been isolated throughout the world from numerous bird species, including chicken, chukar partridge, duck, falcons, goose, guinea fowl, gull, ostrich, partridge, pheasant, pigeon, quail, rook, and turkey (16, 38, 98, 105). In commercial poultry, all ages appear to be susceptible, although pathogenicity appears more significant in older birds.

Many case reports of *O. rhinotracheale* infection report a concomitant infection with other respiratory pathogens, such as *Escherichia coli* (19, 70), *Bordetella avium* (15), Newcastle disease virus (85), infectious bronchitis virus (26, 60, 71), avian metapneumovirus (8, 33, 47, 56), *Mycoplasma synoviae* (108), and *Chlamydophila psittaci* (99). Most experimental studies have concluded that when experimentally inoculated by itself, *O. rhinotracheale* causes minimal pathologic lesions in chickens and turkeys and that the severity of lesions is enhanced when there is a concurrent infection with respiratory viruses or bacteria (5, 19, 22, 28, 95, 97, 103).

However, some studies report production of pathologic lesions similar to those seen in field cases in chickens and turkeys using *O. rhinotracheale* alone (69, 79, 86, 103).

Transmission, Carriers, Vectors

O. rhinotracheale appears to spread horizontally by direct and indirect contact through aerosols or drinking water. *O. rhinotracheale* was found to survive 1 day at 37ºC, 6 days at 22ºC, 40 days at 4ºC, and at least 150 days at –12ºC (54). The survival of *O. rhinotracheale* at lower temperatures may be associated with the higher incidence of reported infections during the winter months. It did not survive 24 hours at 42ºC.

There is circumstantial evidence that vertical transmission occurs (104). In addition, *O. rhinotracheale* has been isolated from the ovaries, oviduct, hatching eggs, infertile eggs, dead embryos, and dead-in-shell chickens and turkeys (5, 23, 59, 84, 90). However, when *O. rhinotracheale* was inoculated into embryonating chicken eggs, the embryos were killed by the ninth day and *O. rhinotracheale* was not isolated from the eggs, suggesting it is not transmitted via eggs during hatching (107).

Incubation Period

Experimental inoculation of 22-week-old turkeys with O. *rhinotracheale* resulted in depression, coughing, and decreased feed intake within 24 hours (79). In 48 hours, turkeys were coughing bloody mucus. Five days PI, the coughing had decreased and the surviving turkeys were less depressed.

In experimental infections in 5-week-old chickens, *O. rhinotracheale* infected the respiratory organs within 2 days PI and clinical signs were seen after 4 days (97).

Clinical Signs

The severity of clinical signs, duration of the disease, and mortality of *O. rhinotracheale* outbreaks are extremely variable. They can be influenced by many environmental factors such as poor management, inadequate ventilation, high stocking density, poor litter conditions, poor hygiene, high ammonia levels, concurrent diseases, and the type of secondary infection.

Clinical signs in broiler chickens generally appear at 3–6 weeks of age, with a mortality rate of 2%–10% showing listlessness, decrease in food intake, reduced weight gains, and transient nasal discharge and sneezing, followed by facial

edema (28, 60, 98). *O. rhinotracheale* also can cause sudden death (up to 20% in a couple of days) in young birds with infections of the brains and skull (29) with or without respiratory symptoms.

In broiler breeders, the disease affects the birds in the laying period, primarily at the peak of production or soon before entering production. There is a slight increase in mortality and a decrease in feed intake, and there are some mild respiratory symptoms. Mortality is variable and relatively low in uncomplicated cases. There can be a drop in egg production, decrease in egg size, and poor eggshell quality. Fertility and hatchability are unaffected in many cases (31).

In commercial laying-type chickens, decreased egg production, increased misshapen eggs, and increased mortality have been associated with *O. rhinotracheale* infection (80).

Roepke (66) found a higher severity of clinical signs and mortality in older turkeys, and the majority of young infected flocks appeared clinically normal. In many cases young poults are affected between 2 and 8 weeks of age (15). Normal mortality ranges between 1% and 15% during the acute phase (8 days), but infections can be accompanied with mortality rates of up to 50% (6, 20). Initial signs are coughing, sneezing, and nasal discharge, followed, in some cases, by severe respiratory distress, dyspnea, prostration, and sinusitis. These symptoms are accompanied by a reduction in feed consumption and water intake. In turkey breeder flocks, there also can be a decrease in egg production and an increase in the number of unsuitable hatching eggs (20, 98).

O. rhinotracheale has been reported to cause neurological signs or paralysis through arthritis, meningitis, osteitis, and osteomyelitis in chickens and turkeys (25, 82, 98).

Pathology

Gross Lesions

In broiler chickens, the common gross lesions include pneumonia, pleuritis, and airsacculitis. At slaughter or postmortem examination, foamy, white, creamy exudate can be seen in the air sacs (predominantly abdominal) (Figure 19.18), most of the time accompanied by unilateral pneumonia (95). Lesions caused by *O. rhinotracheale* can lead to condemnation rates of 50% or more (100). In addition, subcutaneous edema over the cranium with adjacent osteitis, osteomyelitis, and encephalitis has been reported in chickens (29, 30, 78).

In turkeys, there is edema and unilateral or bilateral consolidation of the lungs with fibrinous exudate on the pleura (Figure 19.19). In addition, there could be fibrinosuppurative airsacculitis, pericarditis, peritonitis, and mild tracheitis. In some cases, swelling of the liver and spleen, as well as degeneration of heart muscles, has been observed (37). Infections of the joints and vertebrae can be seen in older birds.

Microscopic Lesions

Most histologic lesions can be seen in the lungs, pleura, and air sacs. In field cases, the lungs (Figure 19.20) are congested and throughout the parenchyma there are large collections of fibrin admixed with macrophages and heterophils lying free within the lumen of air capillaries and parabronchi. There are pronounced and diffuse interstitial infiltrates of macrophages with smaller numbers of heterophils. There are widespread coalescing foci of necrosis, often centered within the lumen of parabronchi with extension of the necrosis into the adjacent parenchyma. These necrotic foci usually are filled with dense aggregates of necrotic heterophilic infiltrate or exudate, and there can be scattered small clusters of bacteria seen within the necrotic foci. Numerous blood capillaries can be distended and filled with fibrin thrombi. The pleura and air sacs can be severely thickened and edematous with interstitial fibrin deposits, diffuse heterophilic infiltrate, scattered small foci of necrotic heterophilic infiltrate, and fibrosis.

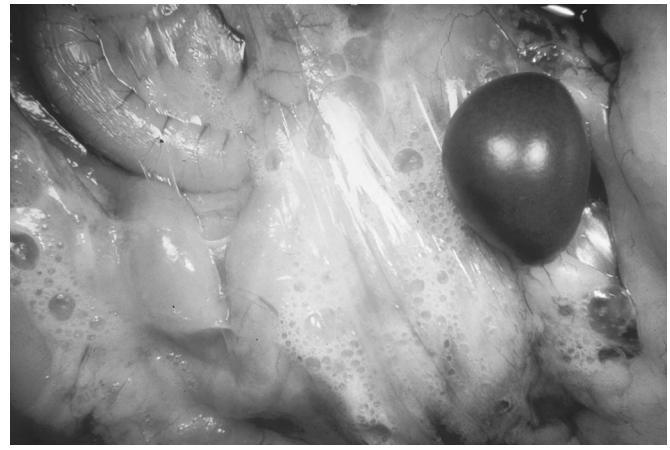

Figure 19.18. Thickened, opaque air sacs with profuse, foamy, white to yellow, "yogurt-like" exudate associated with infection of *Ornithobacterium rhinotracheale* in 36-day-old broiler chickens. Possible concurrent infection with infectious bronchitis virus. (Salem)

Figure 19.19. Pneumonia and pleuritis associated with *Ornithobacterium rhinotracheale* infection in a 31-week-old turkey. (Shivaprasad)

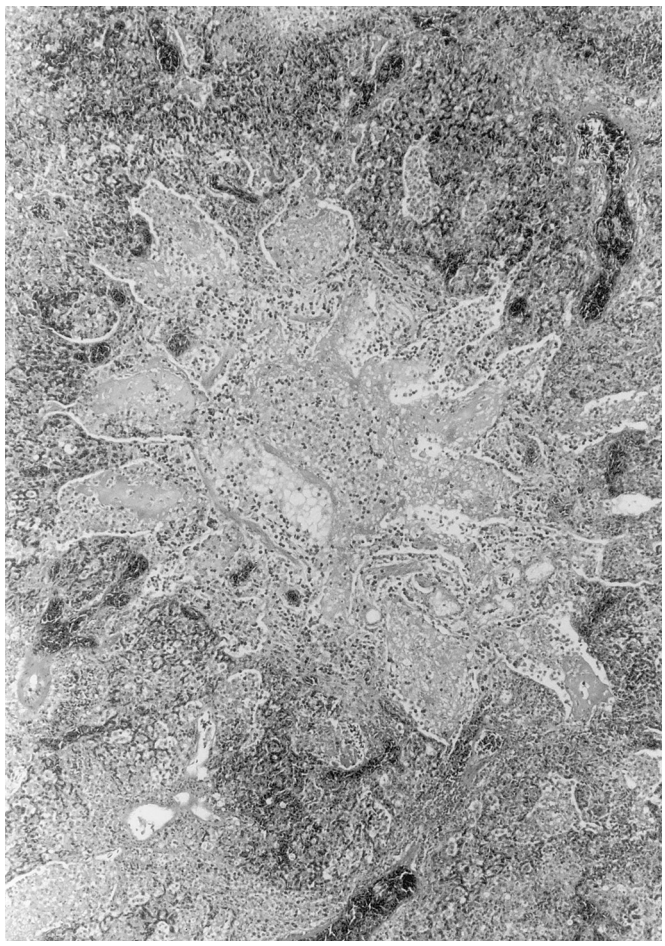

Figure 19.20. Severe fibrinoheterophilic inflammation of lung associated with *Ornithobacterium rhinotracheale* infection in a 31-week-old turkey. H&E. ×15. (De Rosa)

Immunity

Minimal information is available regarding immunity to *O. rhinotracheale*. The active immunity induced by inactivated vaccines was found to be serotype specific, but live vaccination can induce a degree of cross protection between some serotypes (74). Passive immunity can be induced for up to 3–4 weeks by maternally derived antibodies.

Diagnosis

A presumptive diagnosis may be made based on clinical signs and necropsy findings. However, a definitive diagnosis must be based on the isolation and identification of *O. rhinotracheale* and/or detection of antibodies.

Isolation and Identification of Causative Agent

Bacterial Isolation and Identification

The trachea, lungs, and air sacs are the best tissues from which to isolate *O. rhinotracheale*. The infraorbital sinus and nasal cavity are also suitable sites for culture, but *O. rhinotracheale* can be masked easily by the overgrowth of other bacteria. Culturing heart blood and liver tissue under field conditions has revealed negative results (37), although *O. rhinotracheale* has been isolated from those organs, as well as joints, brain, ovary, and oviduct after experimental infections (5, 88).

O. rhinotracheale can be isolated on common, nonselective blood or chocolate agar. Colonies grow in 24 hours, but it is best to hold inoculated plates for 48–72 hours in air enriched with 7.5%–10% CO_2. Colonies will appear pinpoint to small (approximately 1–2 mm diameter), gray to gray-white, circular, and convex with an entire edge. Gram stain will reveal characteristic pleomorphic Gram-negative bacteria. Colonies are catalase-negative and oxidase-positive. Pure *O. rhinotracheale* cultures have a distinct odor, similar to that of butyric acid.

In contaminated samples with fast-growing bacteria, such as *E. coli*, *Proteus* sp., or *Pseudomonas* sp., *O. rhinotracheale* colonies may be overgrown and are difficult to detect in routine investigation. Because it has been shown that most *O. rhinotracheale* isolates are resistant to gentamicin (5), Back recommended the use of 10 μg of gentamicin/ml of blood agar medium in an effort to isolate *O. rhinotracheale* from contaminated samples. Blood agar containing 5 μg/ml of gentamicin and polymyxin B also was effective (89).

The API-20NE system (bioMérieux, France) was found useful for the identification of *O. rhinotracheale* (96). Ninety-nine percent of isolates were found to have biocodes 0-2-2-0-0-0-4 (65%) or 0-0-2-0-0-0-4 (34%). For those isolates that were positive for arginine dihydrolase test, biocodes 0-3-2-0-0-0-4 or 0-1-2-0-0-0-4 were found.

The API-ZYM system can be used to determine the enzymatic activity. In this system, the consistent findings are negative reactions for lipase, β-glucuronidase, β-glucosidase, α-mannosidase, and α-fucosidase (17).

Another rapid commercial Gram-negative bacterial identification system was used to investigate 110 *O. rhinotracheale* strains and found to be a suitable adjunct to classical tests (63). The rapid slide agglutination test has been used for diagnostic purposes (10, 11). In a study of 112 isolates, however, autoagglutinable strains were regularly found (93). The agar-gel precipitation test (AGP), using known positive antisera, can be used to identify and serotype *O. rhinotracheale* isolates (96). Another method used for the identification of suspect isolates is the PCR (34, 46, 90).

Antigen Detection

PCR was used for the detection of *O. rhinotracheale* in tracheal swabs of heavily infected broilers (46). In addition, immunofluorescence antibody test (93) and immunohistochemical staining were used to detect *O. rhinotracheale* in chickens (100). Subsequently, Van Veen et al. (102) found that the immunofluorescence assay and the peroxidase-antiperoxidase test were equally sensitive. Using these tests, they were able to identify a higher percentage of *O. rhinotracheale*-infected chicken broiler flocks at slaughter when compared with conventional diagnostic methods (i.e., serology and/or bacteriology).

Serology

Serology is useful for flock monitoring or as an aid in the diagnosis of *O. rhinotracheale* infection.

The serum plate agglutination test (SPAT) has been used as a rapid test for the detection of antibodies against *O. rhinotracheale* (11, 27, 43). One SPAT was developed using a nonserotyped Minnesota isolate of *O. rhinotracheale* and reported to have good sensitivity and susceptibility (6). However, in another study (53) the SPAT detected only 65% of infected birds during the first 2 weeks of infection and declined significantly thereafter. This suggests that the SPAT detects IgM antibodies, which are efficient in agglutination with specific antigens. In addition, most SPAT reactions are serotype-specific, although cross reactions occur (92).

ELISAs have been developed using different serotypes and extracted antigens of *O. rhinotracheale*. Boiled extract antigens, which are used for serotyping, tend to give the best results for serotype-specific tests (96). Conversely, SDS-antigen extraction (39) and extracted outer membrane proteins of *O. rhinotracheale* (53) will result in more cross reactions, allowing detection of antibodies against different serotypes with 1 test. Field surveys using these ELISAs or commercial ELISA kits have been useful for monitoring flocks and the diagnosis of *O. rhinotracheale* infections (7, 39, 43, 64, 68, 70, 87, 96).

Erganis et al. (27) developed a dot immunobinding assay (DIA) which appeared to be less sensitive than other agglutination tests.

Popp and Hafez (61) investigated the effect of amoxicillin treatment on the antibody kinetics following experimental infection. They found that immediate treatment did not influence the antibody response, whereas treatment that started 7 days PI resulted in a lower antibody response.

Differential Diagnosis

Respiratory lesions associated with *O. rhinotracheale* are similar to those caused by numerous bacteria, such as *E. coli*, *Pasteurella multocida*, *R. anatipestifer*, *Avibacterium paragallinarum*, *Coenonia anatine*, and *Chlamydophila psittaci*.

Intervention Strategies

Management Procedures

O. rhinotracheale appears to be highly contagious and strict biosecurity measures should be followed to prevent its introduction into a flock. However, after a farm is infected, *O. rhinotracheale* becomes endemic, especially in multiple-age farms and in areas with intensive poultry production (41, 66).

Vaccination

Vaccination of broiler chickens with injectable, inactivated vaccines was found effective (94, 104), but is probably impractical in most commercial flocks. Vaccination of broiler breeders with inactivated vaccines stimulated the development of high maternal antibodies (9, 14), which were sufficient to protect progeny against experimental challenge for up to 4 weeks of age (94) and produced lower mortality and condemnation rates in the progeny from vaccinated breeders (14). In addition, using a sprayed, live vaccine at 14 days of age resulted in the lowest percent of airsacculitis and pneumonia in challenged birds.

Schuijffel et al. (73) demonstrated that cross-protective immunity against different *O. rhinotracheale* serotypes can be induced by live vaccination in chickens. The genes encoding 8 cross-reactive antigens were amplified, cloned in an expression vector, and expressed in *E. coli*. Purified recombinant proteins with a molecular mass ranging from 35.9–62.9 kDa were mixed and tested as a subunit vaccine for protection against challenge with homologous and heterologous *O. rhinotracheale* serotypes. Subunit vaccination resulted in the production of antibodies reactive to the recombinant proteins on Western blot, and this 8-valent vaccine provided both homologous and heterologous protection against *O. rhinotracheale* challenge in chickens. In a subsequent study (74), they found that these 8 antigens are highly conserved among different *O. rhinotracheale* serotypes, but the different antigens were not expressed by all serotypes. In addition, their 4-component subunit vaccine was able to protect chickens against challenge with a heterologous *O. rhinotracheale* serotype.

Sprenger et al. (81) vaccinated 6-week-old turkeys either intranasally with a live vaccine or subcutaneously with a killed *O. rhinotracheale* vaccine, and challenged them intratracheally with live *O. rhinotracheale* at 14 or 21 weeks of age. Airsacculitis and pneumonia occurred less frequently in vaccinated birds than in unvaccinated birds after challenge, and *O. rhinotracheale* was recovered from unvaccinated, challenged birds but not from vaccinated, challenged birds or unchallenged birds.

Field trials using monovalent or trivalent bacterins in meat turkey flocks resulted in production of antibodies for a short duration (36). In addition, the mortality and condemnation rates were lower in the vaccinated group compared to the unvaccinated group.

A temperature-sensitive mutant of *O. rhinotracheale* was developed (52) and used as a live vaccine in turkeys (51). Turkeys were vaccinated at 5 days of age via the drinking water, and challenged 7 weeks post vaccination. Vaccinated birds had a significantly lower mean score for gross lesions when compared to unvaccinated birds, as well as a lower rate of reisolation and number of colony-forming units of *O. rhinotracheale*/gram of lung tissue.

Vaccination of young turkeys with autogenous bacterins successfully reduced the number of outbreaks of *O. rhinotracheale* infections in turkeys in Israel (10).

Roepke (65) administered an autogenous live vaccine (oral route) in 6-week-old turkeys that resulted in a decrease in pathologic lesions and mortality when the birds were older. It is interesting to note that the birds were simultaneously spray-vaccinated with a live avian paramyxovirus 1 vaccine without any problems.

Due to the possibility of infection by several serotypes, it may be necessary to use different serotypes in the vaccines.

Treatment

The treatment of *O. rhinotracheale* infections with antibiotics is very difficult because of the variable susceptibility of strains.

O. rhinotracheale can acquire reduced susceptibility or resistance against antibiotics such as amoxicillin, ampicillin, doxycycline, enrofloxacin, flumequine, gentamicin, lincomycin, trimethoprim-sulfonamide, tetracycline, and tylosin (21, 55, 57, 77, 98, 101).

Susceptibility can depend on the regime used by the poultry industry in various geographical locations. For example, in countries were eggs are regularly dipped in an antibiotic such as enrofloxacin almost all isolates will show resistance to that antibiotic (90).

In 1996, Hafez reported that water medication using amoxicillin at a dose of 250 ppm for 3–7 days gave satisfactory results in most cases, and application of chlortetracycline at a dose of 500 ppm in drinking water for 4–5 days appeared to be effective (31). However, recent studies have shown that treatment with amoxicillin is no longer efficacious (57). In some cases, injections with various tetracyclines and penicillins were found to be effective.

Sixty-eight *O. rhinotracheale* isolates from the United States were found susceptible to ampicillin, erythromycin, penicillin, spectinomycin, and tylosin, and 54 of the 68 isolates were susceptible to neomycin, sarafloxacin, and tetracycline (59). It was also found that German isolates had a significantly lower percentage susceptible to erythromycin and sarafloxacin when compared with isolates from the United States.

Bordetellosis (Turkey Coryza)

Mark W. Jackwood and Y.M. Saif

Introduction

Definition and Synonyms

Bordetellosis in poultry is a highly contagious upper respiratory tract disease caused by *Bordetella avium (B. avium)*. The disease is still at times referred to as turkey coryza. Other synonyms that have been largely abandoned are alcaligenes rhinotracheitis (ART), adenovirus-associated respiratory disease, acute respiratory disease syndrome, *B. avium* rhinotracheitis (BART), and turkey rhinotracheitis. The numerous names used for this disease reflect the initial confusion that surrounded its etiology.

Economic Significance

Colonization of ciliated epithelium by *B. avium* results in protracted inflammation and distortion of the respiratory mucosa. In young turkeys, the disease is characterized by sneezing, mouth breathing, altered vocalization, stunted growth, clear oculonasal discharge, submandibular edema, tracheal collapse, and a predisposition to other infectious diseases. In chickens, the disease is similar, but *B. avium* appears to be an opportunistic pathogen. A careful analysis of the economic impact of bordetellosis has not been made; however, impaired growth and mortality resulting from secondary colisepticemia probably cause significant losses to the turkey industry.

Public Health Significance

Members of the Bordetella genus are well known for their capacity to colonize ciliated epithelium and produce respiratory disease in vertebrates. There is some evidence that *B. avium* can be a rare opportunistic human pathogen (48, 132). *Bordetella hinzii*, detected in turkeys and previously designated *B. avium*-like, has been associated with septicemia and bacteremia in older or immune-compromised people (27, 63, 75) and in patients with cystic fibrosis (38, 132).

History

Turkey rhinotracheitis (coryza) attributable to a bacterium of the genus Bordetella was first reported by Filion et al. (37) from Canada in 1967. Nearly a decade later, a similar syndrome was recognized, and in Germany the causative agent was identified as Bordetella bronchiseptica-like (53); whereas in the United States it was associated with a respiratory adenovirus (18, 108), but attempts to reproduce it experimentally often failed (29, 65, 119). Many other agents also were associated with the disease but attempts to experimentally reproduce it failed (2, 84, 101, 118) (for a review see the 12th edition of *Diseases of Poultry*). In 1980, the etiologic agent was reported to be *Alcaligenes faecalis* (109), and 2 types of the bacterium were observed and designated type I and type II. Then, in 1984, following phenotypic, serologic, and nucleic acid characterization, the name *B. avium* was proposed and generally accepted (77). In addition, it was shown that *Alcaligenes faecalis* type I isolates were the same as *B. avium*, and *A. faecalis* type II isolates were designated *B. avium*-like to differentiate them from the etiologic agent of bordetellosis (67, 70). Further characterization of *B. avium*-like isolates led researchers to designate that organism as *Bordetella hinzii* (130). Finally, in 1985, a similar disease of turkeys was recognized in England and Wales (3). The cause of that disease, which also has been called turkey rhinotracheitis, was shown to be a pneumovirus (25) (see Pneumovirus Infection in Chapter 3).

Etiology

Classification

Bordetellosis of turkeys is caused by *B. avium* alone and could be complicated by with environmental stresses and other respiratory pathogens. Experimental transmission (106) of the disease to susceptible poults by Simmons et al. (119) in the United States clearly established the etiologic agent as a small

Gram-negative bacillus. The bacterium, tentatively identified as *Alcaligenes faecalis*, closely resembled *Bordetella bronchiseptica*, except for its failure to split urea.

A systematic study by Kersters et al. (77) compared 28 pathogenic turkey isolates from diverse sources with 50 culture-collection strains of closely related bacteria. Kersters et al. based their conclusions on morphologic, physiologic, nutritional, serologic, electrophoretic, and DNA-RNA hybridization and determined that the bacterial cause of turkey rhinotracheitis represented a new species of *Bordetella*; the name *B. avium* sp. nov. was proposed. Further molecular characterization of *B. avium* has confirmed its unique taxonomic position among species of the *Bordetella* and *Alcaligenes* genera (15, 55, 68, 96, 131, 146). Recently the complete genome of *B. avium* (strain 197N) was elucidated (116). The genome is approximately 3.73 Mb in length and has an overall similarity of 97% (nucleotides) and 75% (proteins) with *B. pertusis*, *B. parapertusis*, and *B. bronchiseptica*. Almost a third of the predicted proteins for *B. avium* do not have an orthologue in *B. bronchiseptica*, verifying that *B. avium* is the most distant member of the *Bordetella* genus.

Morphology and Staining

B. avium is a Gram-negative, nonfermentative, motile, strictly aerobic bacillus (Table 19.4) (67, 77). Filamentous forms have been observed following the growth of *B. avium* in broth media high in nutrients (30).

Growth Requirements

B. avium grows readily on MacConkey, Bordet-Gengou, veal infusion, trypticase soy blood agar, brain heart infusion (BHI), and many other solid media (6) but not on minimal essential medium (67). Trypticase soy and BHI broth support optimal growth when aeration is provided by agitation (5).

Table 19.4. Physical properties of *Bordetella avium*.

Characteristics	References
Gram-negative rod (0.4–0.5 mm 3 1–2 mm)	77, 122a
Strict aerobe	77, 122a
Motile	76, 122a
Capsulated	76, 122a
Fimbriated (2 mm diameter)	69
Colonies, 0.2–1 mm at 24 hours; round, glistening Convex (some strains dissociate to larger colonies)	55, 77
Hemagglutination of guinea pig erythrocytes	44, 67
Erythrocytes of other species	55, 109
Growth temperature, optimal at 35°C, killed at 45°C	5
Generation time, 35–40 minutes at 35°C	5
Strict tropism for ciliated epitehlium	7, 46
Toxins	
Dermonecrotic (heat labile) toxin	39, 110, 112
Heat stable toxin	125
Osteotoxin	42
Tracheal cytotoxin	42
Guanine 1 cytosine composition of DNA, 61.6–62.6 mol%	77

Leyh et al. (82) have developed a defined minimal medium for growth of *B. avium* and detection of auxotrophic mutants.

Colony Morphology

Most strains of *B. avium* produce small, compact, translucent, pearl-like colonies (type I) with entire edges and glistening surfaces (77). Type 1 colonies are typically 0.2–1 mm in diameter after 24 hours of incubation and 1–2 mm in diameter after 48 hours of incubation. Many isolates develop a slightly raised, brown-tinged center when grown 48 hours on MacConkey agar (Figure 19.21). A small percentage of strains dissociate into a rough colony type with a dry appearance and a serrated irregular edge (72). Rough colonies were found to be nonpathogenic (72). A third colony type, characterized by a circular, convex colony with an entire edge, smooth surface, and larger size than type I colonies, also has been reported (55).

Biochemical Properties

B. avium is a nonfermenting bacterium and is generally unreactive in biochemical tests. Biochemical properties of the organism are listed in Table 19.5. It is catalase and oxidase positive but the urease test and nitrate reduction test are negative.

Susceptibility to Chemical and Physical Agents

Most commonly used disinfectants appear to kill *B. avium* when used according to manufacturers' recommendations. Survival of *B. avium* is prolonged by low temperatures, low humidity, and neutral pH (23). On simulated carrier materials, such as dust and feces from turkey houses, the organism survived 25–33 days at 10ºC with a relative humidity 32%–58%, whereas at 40ºC with similar humidity the organism survived less than 2 days (23). Survival of the organism for at least 6 months in undisturbed damp litter has been reported (12). In BHI broth culture, bacteria are killed within 24 hours at 45ºC (5). Survival may be greatly prolonged at 10ºC on smooth surfaces such as glass or aluminum (23). Fumigation of an unclean room with methyl bromide effectively stopped transmission of the disease to day-old susceptible poults (120).

Resistance to streptomycin, sulfonamides, and tetracycline by some strains of *B. avium* is encoded on up to 5 plasmids ranging in size from 16–51.5 kb (28, 86); however, most strains are sensitive *in vitro* to a large number of antibacterials. Treatment of *B. avium*-infected turkeys with oxytetracycline administered parenterally or by aerosol results in either no effect or a transient reduction in bacterial numbers, even though the strain of *B. avium* was sensitive to oxytetracycline *in vitro* (35, 127, 140).

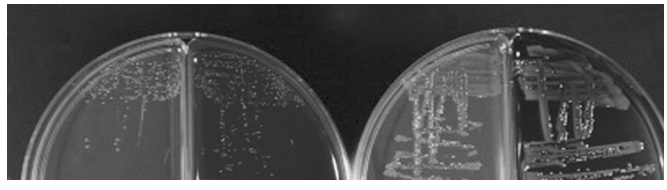

Figure 19.21. Colonies of *Bordetella avium* strain 002 (left) and *B. hinzii* strain 128 (right) grown on MacConkey and blood agar, 48 hours at 37°C.

Table 19.5. Biomechanical properties of *Bordetella avium*.

Biochemical test	Results	References
Oxidase (Kovac's reagent)	Positive	77, 122a, 146
Catalase	Positive	55, 125, 146
Urease	Negative	55a, 77, 122a
Nitrate reduced to nitrite	Negative	54, 75, 109
Growth on MacConkey agar (lactose not fermented)	Positive	77, 122a
Triple sugar iron agar	Alkaline slant, no change in butt	15, 67, 122a
Alkalinize amides and organic salts (Greenwood's low peptone)	Several positive	15, 16, 16a, 55

Antigenic Structure and Toxins

The antigenic structure of *B. avium* and related bacteria has been studied by agar gel precipitation, cross agglutination, and Western immunoblotting (5, 51, 67, 69, 77). All evidence to date suggests that *B. avium* isolates from various sources are closely related antigenically (77). Using antisera produced in rabbits, Kersters et al. (77) identified 6 different surface antigens, 3 of which were cross-reactive among 3 strains of *B. avium*. In addition, they found 2 or 3 precipitation lines in common with *B. bronchiseptica*.

Further antigenic relatedness was demonstrated with *Alcaligenes denitrificans* and *Achromobacter xylosoxidans* (77). Jackwood et al. (67) have demonstrated antigenic cross reactivity between *B. avium* and *B. hinzii* (see later discussion) bacteria. Using convalescent serum and tracheal washings in immunoblotting procedures, Hellwig and Arp (51) have shown that infected turkeys recognize at least 8 outer-membrane proteins of *B. avium*. These proteins range in size from about 14–116 kD. Leyh and Griffith (81) examined the outer-membrane protein profiles of 50 virulent *B. avium* isolates and found 2 major sarkosyl-insoluble proteins of 21 and 37 kD, and at least 13 other lesser proteins, using sodium dodecyl sulfate-polyacrylamide gel electrophoresis (SDS-PAGE). *B. avium* was found to have an electrophoresis profile distinctly different from those of both *B. hinzii* and *B. bronchiseptica*.

Varley and Carter (147) examined 7 *Bordetella* isolates from turkeys in the United Kingdom from the early 1980s using SDS-PAGE and compared those with known strains of *B. avium*, *B. bronchiseptica*, and *A. faecalis*. All electrophoretic profiles were similar to both known *B. avium* and *A. faecalis* strains, indicating the usefulness of the procedure in distinguishing between *Bordetella* sp. but not for *A. faecalis*. Gentry-Weeks et al. (41) identified 5 outer-membrane proteins with molecular masses of 21, 38, 40, 43, and 48 kD being produced in *Escherichia coli* into which genes from *B. avium* had been cloned. Moore and Jackwood (97) produced monoclonal antibodies to a whole-cell *B. avium* preparation that recognized a 41-kD protein. These monoclonal antibodies were used to inhibit *B. avium* guinea pig red blood cell hemagglutination and could also be used to demonstrate the binding of the 41-kD protein to guinea pig erythrocytes. Hemagglutination also was inhibited following treatment of whole-cell *B. avium* with proteinase K, indicating that part of the hemagglutinin is on the outside of the cell and with periodic acid, which cleaves carbohydrates from protein. This strongly suggests that the *B. avium* hemagglutinin is a carbohydrate closely associated with the 41-kD surface protein.

In a related study, Arp et al. (10) demonstrated complete inhibition of guinea pig red blood cell hemagglutination by *B. avium* using the gangliosides GD_{1a} and GT_{1b} and partial inhibition of hemagglutination using N-acetylneuraminic acid. When these same compounds, along with bovine submaxillary mucin and horseshoe crab lectin, were used to treat *B. avium*, adherence to the tracheal mucosa in turkeys was inhibited *in vivo*. The authors speculated that these compounds may be chemically related to the receptors for *B. avium* on the tracheal mucosa.

Five toxins are associated with *B. avium*: a heat-labile toxin (110), a dermonecrotic toxin (39), a tracheal cytotoxin (39), a heat-stable toxin (125), and an osteotoxin (42). Toxins of *B. avium* are considered to be virulence factors, and their activities are described in that section.

Strain Classification

Antigenicity

Studies of *B. avium* from various sources have revealed a great similarity in electrophoretic patterns of outer-membrane proteins (50, 77, 147). Furthermore, antigenic profiles examined by cross agglutination, agar gel precipitation, and Western immunoblotting showed little variation among *B. avium* strains (51, 77). *B. avium* shares several cross-reactive antigens with *B. hinzii* and other Bordetella species (51, 67).

Genetic and Molecular

Despite the apparent genetic and molecular similarity among *B. avium* strains, differences have been noted in toxin production (17, 110, 125), adherence to tracheal mucosa (9), plasmid profiles (71, 126), antibiotic sensitivity (71), pathogenicity (52, 114), and colony morphology (72, 77). Recently, restriction enzyme analysis and ribotyping were used to characterize isolates of *B. avium*, and 12 different fingerprint profiles were observed (113). A HinfI/DdeI restriction enzyme analysis was found to be useful as an epidemiological tool (105). In addition, those profiles were clearly distinguishable from other species of *Bordetella*.

Pathogenicity

Differences in pathogenicity have been reported among *B. avium* strains (109, 114). Differences in pathogenicity,

Table 19.6. Differentiation of *Bordetella avium* and *B. hinzii*.

Characteristics	*B. avium*	*B. hinzii*
Pathogenicity	Positive	Negative
In vivo adhesion[a]	Positive	Negative
Hemagglutination[b]	Positive	Negative
Growth on minimal essential medium agar (64)	Negative	Positive
Growth in 6.5% NaCl broth (64)	Few positive	Most positive
Other distinguishing features:		
Outer membrane profiles on SDS-PAGE[c] (50, 67)		
Cellular fatty acid analyses (68, 96)		
Alkalinization of amides and organic acids (15, 16b)		

[a]Adhesion to turkey tracheal mucosa (6a, 9).
[b]Hemagglutination of guinea pig erythrocytes (67) may be weak or inconsistent with some strains of organisms grown in liquid medium.
[c]SDS-PAGE, sodium dodecyl sulfate-polyacrylamide gel electrophoresis.

associated with colony morphology and hemagglutination, led to categorization of isolates into various groups or types (15, 67, 109). Further studies of the molecular characteristics of *B. avium* and related bacteria have identified several differentiating features of *B. avium* (Table 19.6). Strains previously referred to as group 1 (109) and type 1 (67) should now be called *B. avium*. Strains earlier referred to as *B. avium*-like, (68) were assigned to a new species designated *B. hinzii* (145). In general, *B. hinzii* was considered to be non-pathogenic in turkeys; however, a recent study found that some strains of *B. hinzii* can colonize and induce tracheal lesions in poults (107).

Virulence Factors

Major virulence factors of *B. avium* can be divided into those involved in adhesion, local mucosal injury, or systemic effects. Adhesion to cilia of respiratory epithelium is a consistent trait of *B. avium* and other species of *Bordetella*. The surface structures or molecules of *B. avium* responsible for adhesion have been reported (10, 97), and the fimbriae (pili) and hemagglutinin appear to have roles (9, 70). Although fimbriae have been suggested as possible adhesive factors of *B. avium* (70), morphologically similar fimbriae are also common on adhesion-defective mutants and *B. avium*-like bacteria (50, 70). A fimbrial biogenesis operon (BAV1965-1962) has been identified in *B. avium* and was found to be active at 37ºC but not 22ºC (85). Bacteria grown at the lower nonpermissive temperature had significantly lower levels of adherence to turkey tracheal rings. Hemagglutination (HA) of guinea pig erythrocytes correlates closely with virulence (39, 67) but appears to be unrelated to fimbriae (70). Two genes, hagA and hagB, have been identified in *B. avium* and are apparently involved in HA activity (138). Antibodies against the HagB but not HagA protein blocked hemagglutination.

Transposon-induced mutants selected for loss of HA activity had reduced adherence *in vivo* (9). Temple et al. (137), working with a hemagglutination-negative mutant of *B. avium*, reported that no clinical signs of disease were observed when given to 1-day-old or 1-week-old turkeys. As with other *Bordetella* species, it seems likely that more than 1 surface molecule is responsible for adhesion to cilia. Spears et al. (130), working with lipopolysaccharide (LPS) mutants of *B. avium*, showed that mutations in the wlbA and wlbL genes, 2 of the 12 genes associated with LPS biosynthesis, induced a clumped-growth phenotype and decreased tracheal colonization and serum resistance. In addition, the core region and possibly the O antigen were associated with that phenotype (117). In a recent study the Baa1 autotransporter protein was also shown to be a host cell attachment factor (133).

Several local effects have been attributed to toxins of *B. avium*. An acute cytotoxic and ciliostatic effect of *B. avium* on turkey tracheal organ cultures was reported by Gray et al. (45, 47) and others (87). Rimler (110) described a heat-labile toxin capable of killing mice and young turkeys. The toxin was later shown to produce necrotic and hemorrhagic lesions in the skin of turkeys and guinea pigs after intradermal injection and similar lesions in the liver and pancreas of turkeys following intraperitoneal injection (108, 112).

Recent work has shown that *B. avium* produces a dermonecrotic toxin with physical, antigenic, and biologic properties comparable to those reported for the heat-labile toxin (39). The dermonecrotic toxin is a cell-associated, 155-kD protein with biologic activity comparable to dermonecrotic toxins of B. pertussis and *B. bronchiseptica* (39). The toxin appears not to be responsible for ciliostasis (112) or local epithelial damage (143). Gentry-Weeks et al. (40) produced spontaneous-phase variants of *B. avium* that lacked dermonecrotic toxin and 4 outer-membrane proteins when grown in media containing nicotinic acid and $MgSO_4$. These variants had a different colony morphology but retained the ability to agglutinate guinea pig red blood cells. Passage in susceptible turkeys caused these variants to revert to the wild type. A role for the dermonecrotic toxin has been established in the pathogenesis of bordetellosis in turkeys by Temple et al. (137), who reported that a dermonecrotic toxin-negative mutant was nonpathogenic when given to 1-day-old or 1-week-old turkeys.

Another toxin of *B. avium* implicated in local mucosal injury is the tracheal cytotoxin (TCT) isolated by Gentry-Weeks et al. (39). The TCT of *B. pertussis*, which is chemically identical to that produced by *B. avium*, has been shown to specifically damage ciliated epithelial cells leading to a loss of epithelium and poor clearance of mucus (44). The TCT of *B. avium* is an anhydropeptidoglycan monomer with a mass of 921 kD. Whether TCT is the mediator of cytotoxic activity reported earlier by Gray et al. (45, 47) is unclear.

Simmons et al. (125) have identified a *B. avium* heat-stable toxin capable of causing diarrhea and death in mice inoculated intraperitoneally; however, there is no evidence that the toxin produces adverse effects in poultry. None of 18 *B. avium* strains from Australia had the mouse-lethal toxin that was

found in several reference strains from other turkey-producing areas in the world (17).

An osteotoxin recently was found to be associated with *B. avium*. It has been identified as beta cystathionase and is lethal to MC3T3-E1 osteogenic cells, fetal bovine trabecular cells, UMR106-01 (BSP) rat osteosarcoma cells, and embryonic bovine tracheal cells (42). This toxin might be responsible for the cartilage lesions that lead to tracheal softening and collapse. Examination of several *B. avium* strains for the production of extracytoplasmic adenylate cyclase (39, 112) or pertussis toxin (39) failed to detect either one by immunologic and functional assays. Earlier studies by Simmons et al. (124) suggested that *B. avium* produces a histamine-sensitizing factor similar to that produced by other *Bordetella* species.

Virulence factors in *Bordetella* spp. have been shown to be coordinately regulated at the genetic level by the bvg (bordetella virulence gene) locus. Expression of virulence factors can be modulated by environmental conditions including temperature, sulfate ions, and nicotinic acid. This phenomenon is termed antigenic variation and has been reported in *B. avium* (72). In addition, genetic evidence for a bvg locus in *B. avium* has been reported (40, 116). In a study to detect virulence genes of B. pertussis by Southern hybridization, it was determined that the bvgS gene was present in *B. avium* but the bvgA was not (40). Since that report, the *B. avium* bvg homolog has been cloned and sequenced, which showed a frame shift in the poly (C) tract suggesting a different phase variation mechanism in *B. avium* from other *Bordetella* (24, 116).

Acquisition of iron (Fe) from the host, an essential characteristic for most bacteria, was shown to be important for colonization and proliferation of *B. avium* (99). The *B. avium* Fe utilization locus consists of a putative outer-membrane heme receptor (BhuR) that mediates acquisition of Fe from hemin and hemoproteins, and 6 other accessory genes (rhuIR and bluSTUV). Expression of BhuR is regulated by sigma factor rhuI which is likely expressed in a Fe uptake regulator (Fur) dependent manor in response to environmentally available Fe (78, 79, 80).

A number of systemic pathophysiologic effects have been attributed to *B. avium* infection. These effects include elevation of serum corticosterone (93), enhanced leukocyte migration (92), altered electrocardiograms (149), reduced body temperature (31), reduced levels of monoamines in brain and lymphoid tissues (32, 33), reduced levels of liver tryptophan 2,3-dioxygenase (148), and reduced thyroid hormones in conjunction with fasting (34). Beginning with the original recognition of turkey rhinotracheitis in North Carolina, reports from flock service people have suggested defective immune function in affected poults (122). Vaccination of these poults with live vaccines resulted in unexpected deaths. This background, along with the observation of reduced cloacal bursa size in some poults with rhinotracheitis (118), led to a series of experiments to determine effects of *B. avium* infection on immune function. Initial studies in poults infected with *B. avium* (122) found a decreased lymphocyte blastogenesis response to concanavalin A and a depletion of thymic lymphocytes. Subsequent studies of cell-mediated immunity in *B. avium*-infected poults showed the reverse effect with enhanced graft-versus-host and delayed hypersensitivity responses (90, 91), both measures of cell-mediated immunity. More recent research has shown that *B. avium* can induce apoptosis in tracheal explant cultures and induce nitric oxide production, which is part of the innate immune response and plays a role in nonspecific defense against pathogens (94).

Pathobiology and Epizootiology

Incidence and Distribution

Bordetellosis is an important disease in major turkey-producing regions of the United States, Canada (20), Australia (16), and Germany (53). The etiology of turkey rhinotracheitis in Great Britain, France, Israel, and South Africa, however, frequently may include viruses and other bacteria in addition to *B. avium* (49, 84). Hopkins et al. (61) detected *B. avium* antibodies by ELISA in 42 of 44 wild turkeys being translocated in Arkansas. Thus, *B. avium* may be a significant problem in wild turkeys, or it may be that wild turkeys act as a reservoir for the infection. McBride et al. (89) surveyed 3 backyard turkey flocks located within 1 mile of commercial turkey farms in California and found all turkeys sampled at each location to be seropositive to *B. avium* when tested by microagglutination. A survey between 1998 and 2000 found *B. avium* antibodies in sera from 100 individuals representing 41 different species of wild and domestic birds (104). In addition, Raffel et al. (104) isolated *B. avium* from mallards (*Anas platyrhynchos*), wild turkeys (*Meleagris gallopavo*), and Canada geese (*Branta canadenisis*). Hollamby et al. (59) detected antibodies against *B. avium* in peafowl (*Pavo cristatus*).

Natural and Experimental Hosts

The natural host of *B. avium* is the turkey, although isolations of *B. avium* also have been made from chickens and other avian species (55, 123). Strains of *B. avium* isolated from avian species other than turkeys are pathogenic for day-old turkeys (55). A study of the prevalence of *B. avium* in North Carolina broiler flocks during the winter months revealed a 62% infection rate (14). Furthermore, a higher isolation rate was found from flocks with respiratory disease. Attempts to reproduce rhinotracheitis experimentally in chickens revealed that only 2 of 8 *B. avium* strains colonized the trachea and produced disease (13); however, a later study (15) suggested that the isolations from chickens may have included both *B. avium* and *B. hinzii* bacteria. Finally, it was reported that *B. avium* appears to be an opportunistic pathogen in chickens (73). Prior exposure to an upper-respiratory disease vaccine, such as infectious bronchitis virus or Newcastle disease virus, was necessary to induce clinical signs in leghorn chickens.

Turkey and chicken strains of *B. avium* are similar (77), and cross infection can occur between the species (123). Bordetellosis in chickens tends to be less severe than in turkeys

(95, 123). A strain of *B. avium*, pathogenic for turkeys and Japanese quail, failed to produce clinical disease in guinea pigs, hamsters, and mice (88). Naturally occurring infection with *B. avium* typically is recognized in turkeys 2–6 weeks old (20, 53, 102), although older turkeys and breeder flocks may also develop clinical disease (74, 76). Experimental inoculation of poults more than 1–2 weeks old frequently results in colonization but with only mild disease.

Transmission and Carriers

Bordetellosis is highly contagious. The disease is readily transmitted to susceptible poults through close contact with infected poults or through exposure to litter or water contaminated by infected poults (120). Infection is not transmitted between adjacent cages, thus providing evidence against aerosol transmission (120). Litter contaminated by a flock infected with *B. avium* is likely to remain infective for 1–6 months (12, 23). Although a carrier state has not been demonstrated in turkeys recovered from bordetellosis, the possibility seems likely.

Incubation Period

The incubation period is 7–10 days when susceptible poults are exposed to infected poults by close direct contact (120). Intranasal or intraocular inoculation of day-old poults with 10^5 to 10^7 colony-forming units of *B. avium* results in clinical signs (nasal exudate) of bordetellosis in 4–6 days (4, 46, 114).

Clinical Signs

An abrupt onset of sneezing (snick) in a high percentage of 2– to 6-week-old turkeys over the course of a week is suggestive of bordetellosis. Older turkeys also may develop a dry cough (76). A clear nasal discharge can be expressed by placing gentle pressure over the bridge of the beak between the nostrils. During the first 2 weeks of disease, the nares and feathers of the head and wings become crusted with wet, tenacious, brownish exudate (Figure 19.22), and some birds develop submaxillary edema. Mouth breathing, dyspnea, and altered vocalization in the second week of clinical signs result when the nasal cavity and upper trachea become partially occluded with mucoid exudate. Tracheal softening can be palpated through the skin of the neck in some birds beginning in the second week of disease. Behavioral changes include reduced activity, huddling, and decreased consumption of feed and water. Concurrent infections and poor weight gains contribute to poor flock performance and numerous birds with stunted growth (5). Signs of disease begin to subside after a course of 2–4 weeks (46, 102, 114, 144).

Morbidity and Mortality

Bordetellosis in turkeys is typically characterized by high morbidity and low mortality. In turkeys 2–6 weeks of age, morbidity reaches 80%–100% (114), whereas the mortality rate is less than 10%. Infection of a breeder flock with *B. avium* resulted in only 20% morbidity with no mortality (76). High mortality rates (greater than 40%) in young turkeys frequently are associated with concurrent isolation of *Escherichia coli*

Figure 19.22. Clinical appearance of a poult with bordetellosis: open-mouth breathing, dark stains around eye and nostril, and foamy exudate at the medial canthus of the eye.

(20, 114). Experimental studies of concurrent *B. avium* and *E. coli* infections in 2- to 4-week-old turkeys revealed defective clearance of *E. coli* from tracheas (36, 142) and increased severity of airsacculitis attributable to *E. coli* (141). Adverse environmental temperatures (5), high humidity (128), poor air quality, and concurrent respiratory pathogens may increase mortality rates (114).

Cook et al. (26) studied the interaction of turkey rhinotracheitis virus (TRTV), a pneumovirus, with *B. avium* and a Pasteurella-like organism in turkeys. When the TRTV was administered alone, the virus could be isolated from only the trachea, but when given in combination with the bacteria, it was capable of invasion and could be isolated from the heart, liver, spleen, kidney, and cecal tonsils. Hinz et al. (56) described an outbreak of *B. avium* in combination with *Chlamydia psittaci* in 6 different turkey flocks on a large multiple-age grow-out operation. Mortality in the affected flocks ranged from %–20%, and the high mortality was attributed to secondary infections from *Klebsiella pneumoniae, E. coli*, and *Pseudomonas fluorescens*.

Pathology

Gross Lesions

Gross lesions are confined to the upper respiratory tract and vary with the duration of infection. Nasal and tracheal exudates change in character from serous initially to tenacious and mucoid during the course of disease. Tracheal lesions consisting of generalized softening and distortion of the cartilaginous rings, dorsal-ventral compression, and fibrinomucoid luminal exudate are highly suggestive of bordetellosis (4, 144). In isolated cases, there is severe infolding of the dorsal tracheal wall into the lumen immediately below the larynx (Figure 19.23) (4, 140). In cross-section, tracheal rings appear to have thick walls and a diminished lumen. Distortion of tracheal cartilages persists at least 53 days post infection (4).



Figure 19.23. Cross sections of a collapsed trachea from a poult with bordetellosis. The section on the top left, taken immediately below the larynx, has extreme dorsal-ventral infolding. Other sections were taken at 5-cm intervals along the trachea. (*Am J Vet Res*.)

Accumulation of mucoid exudate in an area of tracheal infolding frequently leads to death by suffocation (4). Hyperemia of the nasal and tracheal mucosae and edema of interstitial tissues of the head and neck are apparent during the first 2 weeks of infection.

Microscopic and Ultrastructural Lesions

Cilia-associated bacterial colonies, progressive loss of ciliated epithelium, and depletion of mucus from goblet cells are distinctive characteristics of bordetellosis (4). Colonization of ciliated epithelium begins on the nasal mucosa, progresses down the trachea, and moves into primary bronchi within 7–10 days. Bacteria adhere specifically to cilia and have not been found attached to other cell types (7). As seen by scanning electron microscopy, surfaces of adherent bacteria are covered with numerous knob-like surface projections (Figure 19.24). Colonized cells having increased eosinophilia of the apical cytoplasm may protrude slightly from the mucosa (140). Bacterial colonies (Figure 19.25) are most apparent on the tracheal mucosa 1–2 weeks after onset of clinical signs, before loss of ciliated cells is extensive (4, 7).

During the first 2 weeks of clinical signs, ciliated tracheal epithelium is gradually lost and replaced by nonciliated cuboidal epithelium (Figure 19.26). These immature hyperplastic cells have basophilic cytoplasm with variable numbers of small mucous granules (4, 140). Late in the disease, squamous metaplasia of tracheal epithelium may occur (Figure 19.27). Linear, eosinophilic inclusions occur in the cytoplasm of tracheal epithelium during the first 3 weeks of disease (4, 7). Ultrastructurally, these inclusions are proteinaceous crystals composed of parallel filaments surrounded by membrane (7). During the third and fourth week of disease, the tracheal mucosa becomes distorted by numerous folds and mounds of dysplastic epithelium. Depending on the severity of the disease, the tracheal epithelium returns to normal 4–6 weeks after the onset of signs (4, 46), when *B. avium* can no longer be isolated.

Discharge of copious mucoid exudates from the upper respiratory tract is accompanied by depletion of mucus from isolated goblet cells and mucous glands along the mucosa (4, 140). Alveolar glands become cystic and lined by immature epithelium with small mucous granules (Figure 19.25). Goblet cells remain largely depleted of mucous granules from the first through the third week of clinical disease.



Figure 19.24. Numerous *Bordetella avium* bacteria (arrows) intimately associated with cilia of tracheal epithelial cells. The bacterial surfaces are covered with irregularly shaped, knob-like projections, which may contribute to adhesion.

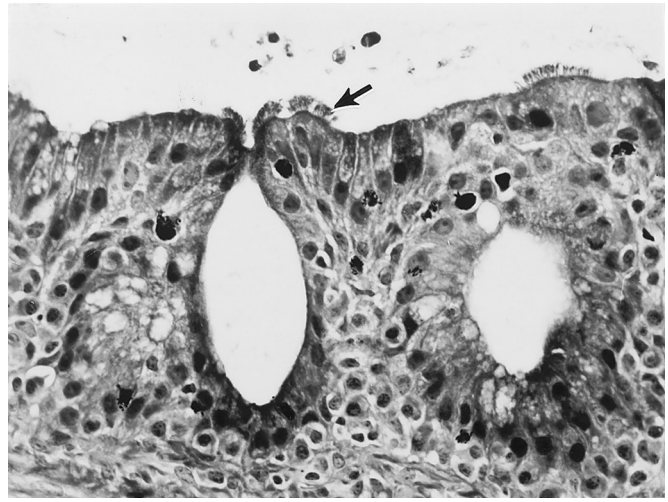

Figure 19.25. Trachea from a poult infected 3 weeks previously with *Bordetella avium*. Characteristic lesions of bordetellosis include cilia-associated bacterial colonies (arrow), loss of ciliated epithelium, dilated mucous glands depleted of mucus, and interstitial infiltration of plasma cells and lymphocytes.

Cellular exudates in the tracheal lamina propria begin with multifocal infiltrates of heterophils and change to predominantly lymphocytes and plasma cells as clinical signs subside (4, 46). In the third through fifth weeks of disease, a diffuse increase in mucosal plasma cells is accompanied by multifocal lymphoid nodules in the submucosa. Mucosal surface exudates change from mucopurulent to fibrinopurulent after the first week of disease (7).

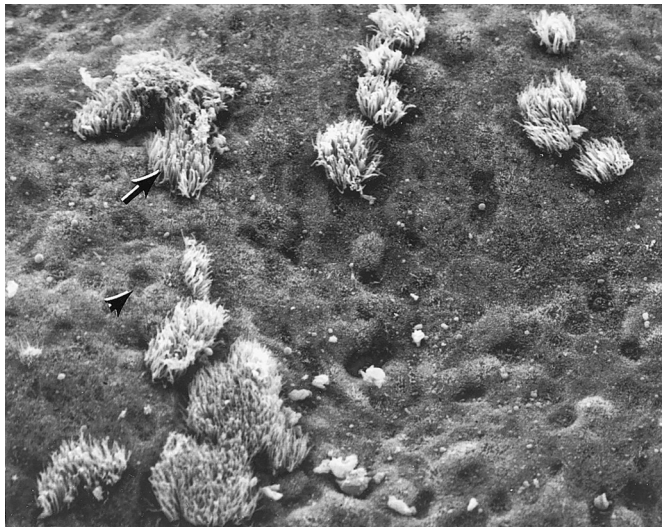

Figure 19.26. Loss of ciliated epithelium from the tracheal mucosal surface. Isolated clumps of ciliated cells (arrow) and dark pits left where ciliated cells have sloughed (arrowhead).

Pulmonary lesions are restricted to primary bronchi and bronchus-associated lymphoid tissue (141, 144). In contrast to the tracheal mucosa, the bronchial mucosa maintains a near normal appearance including ciliated columnar epithelium and goblet cells (144). Mild colonization of isolated ciliated cells by *B. avium* is accompanied by a mild infiltrate of heterophils. Bronchus-associated lymphoid tissue, normally found at the junction of primary and secondary bronchi, becomes grossly apparent, and lymphoid nodules protrude into the bronchial lumen (144). Other changes of lymphoid tissues include the depletion of cortical lymphocytes from the thymus during the early disease (122).

In summary, distinctive microscopic lesions of diagnostic value include cilia-associated bacterial colonies, cytoplasmic inclusions, cystic mucosal glands, and generalized loss of ciliated epithelium.

Pathogenesis of the Infectious Process

Initial adhesion of bacteria to ciliated cells of the oronasal mucosa leads to progressive colonization from the upper trachea to the primary bronchi over the next week. Expansion of the bacterial population along the respiratory mucosa stimulates acute inflammation and the release of mucus from goblet cells, leading to sneezing, coughing, and nasal obstruction. Spread of infection against the flow of mucociliary clearance occurs as motile "swarmer" bacteria break free from microcolonies and move within the layer of mucin to other ciliated cells. Apparently, tracheal mucus does not contain receptor analogs to impede the spread of the bacteria. During the next week, many of the cells colonized by *B. avium* slough into the tracheal lumen, leaving large surfaces devoid of cilia.

How *B. avium* damages the tracheal mucosa and cartilage remains unknown, but the tracheal cytotoxin may be involved. The formation of cytoplasmic protein crystals and delayed

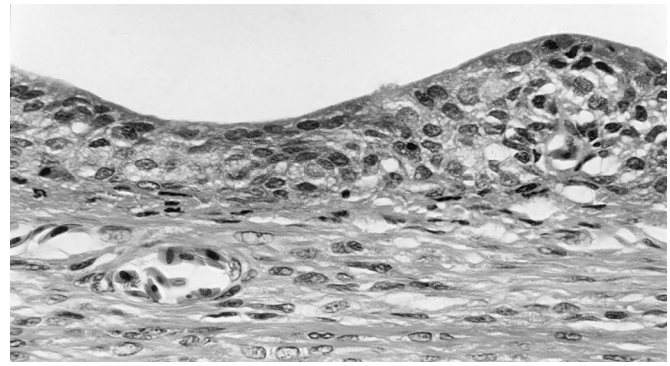

Figure 19.27. Squamous metaplasia of tracheal epithelium occurs in some poults late in the course of bordetellosis.

restitution of normal mucosa are suggestive of a toxin that alters cell growth and differentiation. The molecular basis for softening and the collapse of tracheal rings may result from abnormal connective tissue metabolism leading to qualitative and quantitative changes in collagen and elastin (148).

As ciliated cells are progressively lost, the flow of mucus and exudates becomes sluggish, particularly in the upper trachea and nasal cavity. Obstruction of nasolacrimal ducts causes foamy ocular exudate to accumulate at the medial canthus of the eye. Signs of bordetellosis result from local and systemic products of the inflammatory response, soluble bacterial toxins, and physical obstruction of large air passages.

Within a week of the onset of clinical signs, local and systemic immune responses develop to *B. avium* antigens. Antibody transported from serum and antibody produced by submucosal plasma cells accumulates in respiratory secretions. Local antibody interacts with free "swarmer" *B. avium* cells to inhibit their motility and to prevent adhesion to other ciliated cells. Colonies of bacteria among the cilia are largely protected from host defenses; however, numerous bacteria are shed along with colonized epithelial cells. The bacterial population diminishes over the next several weeks as colonized cells are lost, and newly formed ciliated cells are protected from colonization by antibody.

Some convalescent birds are probably slow to clear all *B. avium* from their respiratory tissues and serve as a source of infection for susceptible flocks. As mucosal immunity wanes over the next 4–8 weeks, any residual population of *B. avium* in the nasal cavity or sinuses can again expand to produce clinical infection or be transmitted to susceptible birds.

Immunity

Active Immunity

An active immune response is generated in most turkeys inoculated with live *B. avium* or various bacterins. The serum antibody response to a temperature-sensitive mutant of *B. avium* is variable, depending on vaccination dosage, turkey age, and environmental factors affecting colonization (5, 22, 52, 58, 62, 66, 74). Studies have suggested that poults less than 3 weeks of age respond poorly to *B. avium* vaccines (58, 66).

Most turkeys develop a humoral immune response to infection with *B. avium* (4, 64, 136). Serum antibodies, detected by microtiter agglutination, appear within 2 weeks after experimental exposure to *B. avium* and reach peak levels by 3–4 weeks post exposure (4, 64). The period of peak antibody titer is followed within 1 week by resolution of clinical disease and a decline in bacterial numbers in the trachea (4). This, combined with evidence for maternal immunity, suggests an important role for humoral immunity in the prevention and recovery from infection (12, 54).

Infection with *B. avium* has been reported as potentially immunosuppressive since Simmons et al. (122) reported thymic lesions and suppression of lymphocyte blastogenesis. Although subsequent tests have revealed no evidence for defects in cellular immunity (90, 91, 92), infection with *B. avium* apparently interferes with immunity to live *Pasteurella multocida* and hemorrhagic enteritis vaccines (111, 122). Reduced monoamine concentrations in brain and lymphoid tissues and elevated serum corticosterone have been recorded in turkeys infected with *B. avium* (32, 33, 93). Such hormonal changes are probably not unique to bordetellosis.

Passive Immunity

Neighbor et al. (100) evaluated maternal antibody in poults from immunized and nonimmunized hens. Resistance to clinical disease and gross lesions was greatest in poults with maternal antibody, as measured by ELISA. Convalescent serum and tracheal secretions from turkeys infected with *B. avium* inhibit adherence of the bacteria to the tracheal mucosa in turkeys (8). Moreover, adherence of *B. avium* is inhibited whether convalescent serum is administered locally or parenterally. The passive administration of convalescent serum is believed to mimic many aspects of maternal immunity. Suresh et al. (136) evaluated antibody levels in serum, tracheal washings, and lacrimal secretions from turkeys experimentally infected with *B. avium*. Turkeys were sacrificed at weekly intervals through 8 weeks post inoculation (PI). Maternal antibody was undetectable by 3 weeks of age, and the appearance of serum and mucosal antibody was associated with clearance of *B. avium* from the trachea. Using serum and tracheal secretions collected from turkeys during a 4-week course of infection, at least 8 *B. avium* surface proteins were identified using Western immunoblots (51).

Diagnosis

The diagnosis of bordetellosis is currently based on clinical signs and lesions, isolation of *B. avium* from the respiratory tract, a positive serologic test, or some combination of these. Additional diagnostic techniques that have been developed include a monoclonal antibody-based latex bead agglutination test (135), an indirect fluorescent antibody staining technique using a monoclonal antibody (134), a capillary gas chromatography assay for cellular carbohydrates using per-acetylated aldonitriles and O-methyloximes (98), and a polymerase chain reaction technique (106, 115).

Isolation and Identification of Causative Agent

Bacterial isolation is accomplished on MacConkey agar inoculated with a swab sample from the tracheal mucosa. Samples collected from the choanal opening and nostril, or by passing a swab into the trachea through the larynx, commonly yield large numbers of nonpathogenic bacteria (121, 129). When turkeys are available for necropsy examination, swab samples should be collected aseptically through an opening in the midcervical trachea. After 24 hours of incubation on MacConkey agar, colonies of *B. avium* are clear and pinpoint in size. Although most contaminating bacteria form large mucoid colonies (often lactose fermenters), which mask *B. avium* in the more concentrated streak pattern, the minute colonies of *B. avium* may be recognized in the more diluted streak pattern. By incubating culture plates up to 48 hours, *B. avium* colonies are more easily recognized and may develop a brownish raised center (Figure 19.21). Early in the course of infection, pure cultures can be obtained from the trachea, but in later stages, *E. coli* and other opportunistic bacteria may be isolated (114). Physical and biochemical characteristics that serve to distinguish *B. avium* from closely related bacteria are presented in Tables 19.4 and 19.5.

Serology

Serologic testing has proven to be useful experimentally and in the natural disease for detection of serum antibodies to *B. avium*. Jackwood and Saif (64) developed a microagglutination test (MAT) using a killed, neotetrazolium-chloride-stained *B. avium* antigen in a microtiter system. The MAT has been shown to correlate well with bacterial isolation. It seems likely that serologic tests remain positive for a period after *B. avium* can no longer be cultured. In a field study by Slavik et al. (129), flocks with a history of respiratory disease were more commonly positive serologically for *B. avium*, even though bacteria were not isolated. In experimentally infected poults, antibody is detectable by the MAT from 2 weeks PI until at least 5–7 weeks PI (4, 5, 64). Peak titers occur at about 3–4 weeks PI. For each of the preceding tests, agglutination occurs at serum dilutions of 1:320 to 1:512 (4, 64). Use of heterologous *B. avium* antigen has little effect on agglutination titers (5).

Hopkins et al. (60) developed an ELISA for detection of serum antibodies to *B. avium* using a whole-bacteria antigen, a 1:200 serum dilution, and a 1:3,200 dilution of commercially available anti-turkey IgG conjugate. Serologic results obtained with ELISA correlate well with those from the MAT, but ELISA is more sensitive for detection of maternal antibody in day-old poults (60). Although *B. avium* has antigens in common with closely related *B. hinzii* bacteria, no evidence indicates that these related bacteria cause a positive serologic reaction to *B. avium* in nature. Several different variations of ELISA procedures have been developed for *B. avium* (11, 19, 100, 136, 139). The variations include a dot-immunobinding assay (139) and a particle concentration fluorescence immunoassay (19). All of these detect maternal antibody and are reproducible and sensitive. Recently a commercially available ELISA kit has become available, and it has proven to be very useful (83).

Differential Diagnosis

Bordetellosis must be differentiated from other primary and secondary causes of rhinotracheitis. Mycoplasmosis, chlamydiosis, and respiratory cryptosporidiosis may mimic or contribute to many of the clinical signs of bordetellosis (2, 57, 76, 84). Of the viral agents, Newcastle disease virus, avian paramyxovirus type 2 (Yucaipa virus), adenovirus, influenza virus, and pneumovirus should be considered (25, 84). Although *B. avium* alone can produce all of the clinical signs and lesions of bordetellosis in the natural disease, *B. avium* is more frequently accompanied by Newcastle disease, Mycoplasma spp., and opportunistic bacteria such as *E. coli*.

Currently, the greatest diagnostic challenge is to differentiate *B. avium* from *B. hinzii* bacteria in primary cultures. Distinguishing characteristics of these closely related bacteria are presented in Table 19.5; however, pathogenicity testing in day-old poults is definitive. Intranasal inoculation of day-old poults with a 24-hour broth culture of *B. avium* is expected to produce clinical disease and nasal discharge in susceptible poults within 3–5 days.

Intervention Strategies

Management Procedures

B. avium is highly contagious by direct contact and through contamination of water, feed, and litter. Strict biosecurity measures are required to prevent infection of clean flocks, and rigorous clean-up procedures are required to eliminate the organism from contaminated premises. A minimal clean-up procedure for contaminated premises should include complete removal of litter, thorough washing of all surfaces, disinfection of watering systems and feeders, and the application of a disinfectant followed by either formaldehyde fumigation or by the application of a dilute formaldehyde solution to all surfaces. *B. avium* is tracked easily from 1 facility to another, so the use of disinfectant foot baths, clean outer clothing, and even a required shower between visits to different houses and locations is essential. Because the severity of bordetellosis is exacerbated by adverse environmental and infectious factors, attempts should be made to optimize temperature, humidity, and air quality while avoiding or delaying the use of live attenuated vaccines.

Vaccination

Vaccines available commercially for the prevention of bordetellosis in turkeys include a live temperature-sensitive (ts) mutant of *B. avium* (Art Vax, Schering-Plough Animal Health, Union, NJ) and a whole-cell bacterin (ADJUVAC-ART, which used to be available from Sanofi Animal Health, Inc., Overland Park, KS). The live ts-mutant vaccine was induced by nitrosoguanidine mutation of a virulent *B. avium* isolate obtained from North Carolina (21). Original studies indicated that the ts mutant colonized the nasal mucosa and induced moderate levels of serum antibodies (21). Although subsequent use of the vaccine in Utah indicated substantial protection (22, 74), other controlled experiments indicated only moderate reduction in lesion severity or delayed the onset of clinical disease (52, 58, 62, 66). The ts mutant has the capacity to adhere to respiratory epithelium, but its slow growth rate may critically limit its ability to colonize and induce protective immunity (5, 9). Use of the ts-mutant vaccine, according to label directions in day-old poults, failed to prevent infection and disease; however, use of the vaccine in poults 3 weeks of age and older prevented disease but not infection (58, 66). There is concern that turkeys less than 3 weeks of age may be unable to respond adequately to *B. avium* antigens or be unable to mount an adequate local immune response. Glunder et al. (43) inoculated killed *B. avium* with adjuvant into 1-, 7-, 10-, 14-, and 21-day-old poults and found that regardless of age at vaccination, serum antibodies were first detected at 28 days of age.

Houghten et al. (62) compared a spray method of vaccination with the method recommended by the manufacturer for the ts-mutant vaccine. Turkeys were immunized at 2 days of age, using a spray cabinet, followed 14 days later with another coarse spray exposure to the ts-mutant vaccine. Another group of turkeys was similarly immunized by eye-drop exposure followed 14 days later by oral exposure. The spray and eye-drop/oral methods of immunization were equally effective in reducing the severity of tracheal lesions, but neither method prevented infection of the trachea by virulent challenge strains.

Several studies have indicated that breeder hen vaccination may be useful for prevention of bordetellosis in progeny poults (12, 54, 100). Vaccination of breeder hens with either heat-killed (54) or formalin-killed (12) adjuvanted bacterins delayed the onset and severity of clinical disease in challenge-exposed poults. Passive immunization of 3-week-old poults with convalescent serum reduces adherence of *B. avium* to the tracheal mucosa in a dose- and time-dependent manner (8). Taken in total, these studies suggest that maternal antibody of the IgG class may confer temporary immunity to newly hatched poults. Additionally, vaccination of poults with purified pilus preparations and adjuvanted bacterins results in significant protection against *B. avium* colonization and clinical disease (1).

Because *B. avium* and *B. hinzii* bacteria are antigenically related, Jackwood and Saif (69) designed experiments to determine whether poults infected with nonpathogenic *B. hinzii* bacteria would develop immunity to *B. avium*. The *B. hinzii* bacteria failed to persist for a significant period in the respiratory tract and failed to induce either a serologic response or protection to *B. avium* challenge. Development of improved vaccines for bordetellosis requires better characterization of protective antigens of *B. avium* and an understanding of the turkey's immune response to them.

Treatment

Treatment of bordetellosis with antibiotics administered in the water, by injection, or by aerosol has produced minimal clinical improvement in most cases. Treatment of an infected breeder flock with 1.8 g tetracycline-HCl and 2×106 IU potassium penicillin-G/gallon of drinking water for 3 days produced

clinical improvement within 24 hours (76). Treatment of bordetellosis in young turkeys with an aerosol of oxytetracycline-HCl reduced mortality associated with subsequent Newcastle disease vaccination compared with untreated flocks (35). Although these clinical testimonials suggest a favorable response to treatment, it remains unclear whether clinical improvement results from antibacterial effects against *B. avium* or to secondary pathogens such as *E. coli*.

In a group of experimentally infected poults, parenteral administration of long-acting oxytetracycline had no apparent effect on *B. avium* infection (127). Treatment of experimental bordetellosis with oxytetracycline-HCl administered by aerosol caused a transient reduction of bacterial numbers in the trachea and a delay in clinical signs and lesion development (140). However, by 4 days after treatment, bacterial numbers and disease severity were similar between treated and nontreated groups (140).

Yersin et al. (150) were able to demonstrate up to a 40% reduction in the loss of cilia following the treatment of *B. avium*-infected turkeys with niacin added to the drinking water at 70 mg/L. Niacin treatment also reduced clinical signs, increased body weight, and reduced adherence of bacteria to the tracheal epithelium when treated turkeys were compared with untreated infected turkeys. The authors speculate that the mechanism for this therapeutic effect may be the result of the inhibition of glucocorticoid-induced DNA strand breakage and subsequent ADP-ribosylation of nuclear DNA. This action would allow for the continued protein synthesis necessary to maintain ATP-mediated functions in the cilia of the trachea. Pardue and Luginbuhl (103) observed that administration of 0.016% oxy-halogen formulation in the drinking water at 4, 7, 10, 14, and 17 days of age reduced many of the signs associated with bordetellosis in turkeys.

References

Introduction

1. Rimler, R.B., T.S. Sandhu, and J.R. Glisson. 1998. Pasteurellosis, Infectious Serositis, and Pseudotuberculosis. In: *Isolation and Identification of Avian Pathogens*, 4th ed. D.E. Swayne, J.R. Glisson, M.W. Jackwood, J.E. Pearson, and W.M. Reed, eds. American Association of Avian Pathologists: Kennett Square, PA. 17–25.

Fowl Cholera

1. Alberts, J.O., and R. Graham. 1948. Fowl cholera in turkeys. *North Am Vet*. 29:24–26.
2. Alberts, J.O., and R. Graham. 1951. An observation on aureomycin therapy of fowl cholera in pheasants. *Vet Med*. 46:505–506.
3. Anderson, L.A.P., M.G. Coombes, and S.M.K. Mallick. 1929. On the dissociation of *Bacillus avisepticus*. *Indian J Med Res*. 29:611–622.
4. Anonymous. 1867. Poultry Diseases, USDA Monthly Rep, 216–217.
5. Arsov, R. 1965. The portal of infection in fowl cholera. *Nauchni Tr Vissh Vet Med Inst*. 14:13–17.
6. Baba, T., and Y. Bito. 1966. Studies on the toxin of *Pasteurella multocida*. *Jpn J Bacteriol*. 21:711–714.
7. Bairey, M.H. 1975. Immune response to fowl cholera antigens. *Ann J Vet Res*. 36:575–578.
8. Berkman, S. 1942. Accessory growth factor requirements of the members of the genus *Pasteurella*. *J Infect Dis*. 71:201–211.
9. Bhasin, J.L., and E.L. Biberstein. 1967. Fowl cholera in turkeys—the efficacy of adjuvant bacterins. *Avian Dis*. 11:159–168.
10. Bierer, B.W. 1962. Treatment of avian pasteurellosis with injectable antibiotics. *J Am Vet Med Assoc*. 141:1344–1346.
11. Bierer, B.W., and W.T. Derieux. 1972. Immunologic response of turkeys to an avirulent *Pasteurella multocida* vaccine in the drinking water. *Poult Sci*. 51:408–416.
12. Bisgaard, M., P. Kuhnert, J.E. Olsen, and H. Christensen. 2005. Investigations on the existence of phenotypic criteria for separation of 16S rRNA clusters A and B of *Pasteurella multocida*. In: *The ASM conference Pasteurellaceae 2005 in collaboration with the International Pasteurellaceae Society Proceedings*. Kohala Coast, Hawaii. 45–46.
13. Blackall, P.J., N. Fegan, G.T.I. Chew, and D.J. Hampton. 1998. Population structure and diversity of avian isolates of *Pasteurella multocida* from Australia. *Microbiol*. 144:279–289.
14. Blackall, P.J., N. Fegan, G.T.I. Chew, and D.J. Hampton. 1999. A study of the use of multilocus enzyme electrophoresis as a typing tool in fowl cholera outbreaks. *Avian Pathol*. 28:195–198.
15. Bolin, F.M., and D.F. Eveleth. 1951. The use of biological products in experimental fowl cholera. *Proc Annu Meet Am Vet Med Assoc*. 88:110–112.
16. Breed, R.S., E.G.D. Murray, and N.R. Smith. 1957. *Bergey's Manual of Determinative Bacteriology*, 7th ed. Williams and Wilkins, Baltimore. 195–402.
17. Brogden, K.A., and R.A. Packer. 1979. Comparison of *Pasteurella multocida* serotyping systems. *Am J Vet Res*. 40:1332–1335.
18. Brogden, K.A., K.R. Rhoades, and K.L. Heddleston. 1978. A new serotype of *Pasteurella multocida* associated with fowl cholera. *Avian Dis*. 22:185–190.
19. Buchanan, R.E., J.G. Holt, and E.F. Lessel. 1966. *Index Bergeyana*. Williams and Wilkins, Baltimore. 786–792.
20. Carpenter, T.E., K.P. Snipes, R.W. Kasten, D.W. Hird, and D.C. Hirsch. 1991. Molecular epidemiology of *Pasteurella multocida* in turkeys. *Amer J Vet Res*. 52:1345–1349.
21. Carter, G.R. 1955. Studies on *Pasteurella multocida*. I. A hemagglutination test for the identification of serological types. *Am J Vet Res*. 16:481–484.
22. Christensen, J.P., H.H. Dietz, and M. Bisgaard. 1998. Phenotypic and genotypic characters of isolates of *Pasteurella multocida* obtained from back-yard poultry and two outbreaks of avian cholera in the avifauna in Denmark. *Avian Pathol*. 27:373–381.
23. Christensen, J.P., and M. Bisgaard. 2000. Fowl cholera. In: *Scientific Technical Review. Off Int Epiz*. 19(2):626–637.
24. Christensen, H., M. Bisgaard, O. Angen, W. Frederiksen, and J.E. Olsen. 2005. Characterization of sucrose negative variants of *Pasteurella multocida* including isolates from large cat bite-wounds. *J Clin Microbiol*. 43:259–270.

25. Clark, D.S., and J.F. Godfrey. 1960. Atypical Pasteurella infections in chickens. *Avian Dis*. 4:280–290.
26. Curtice, C. 1902. Goose septicemia. *Univ RI Agric Exp Stn Bull*. 86:191–203.
27. Das, M.S. 1958. Studies on *Pasteurella septica* (*Pasteurella multocida*). Observations on some biophysical characteristics. *J Comp Pathol Ther*. 68:288–294.
28. de Jong, M.F., and G.H.A. Borst. 1985. Selective media for the isolation of *P. multocida* and *B. bronchiseptica*. *Vet Rec*. 116:167.
29. Derieux, W.T. 1978. Responses of young chickens and turkeys to virulent and avirulent *Pasteurella multocida* administered by various routes. *Avian Dis*. 22:131–139.
30. Derieux, W.T., and B.W. Bierer. 1975. The CU strain of *Pasteurella multocida*. *Proc West Poult Dis Conf*. 24:64–66.
31. DeVolt, H.M., and C.R. Davis. 1932. A cholera-like disease in turkeys. *Cornell Vet*. 22:78–80.
32. Dimov, I. 1964. Survival of avian *Pasteurella multocida* in soils at different acidity, humidity and temperature. *Nauchni Tr Vissh Vet Med Inst Sofia*. 12:339–345.
33. Donahue, J.M., and L.O. Olson. 1972. Biochemic study of *Pasteurella multocida* from turkeys. *Avian Dis*. 16:501–505.
34. Donahue, J.M., and L.O. Olson. 1972. The *in vitro* sensitivity of *Pasteurella multocida* of turkey origin to various chemotherapeutic agents. *Avian Dis*. 16:506–511.
35. Dorsey, T.A. 1963. Studies on fowl cholera. I. A biochemic study of avian *Pasteurella multocida* strains. *Avian Dis*. 7:386–392.
36. Dorsey, T.A., and G.S. Harshfield. 1959. Studies on control of fowl cholera. *South Dakota State Univ Agric Exp Stn Bull*. 23:1–18.
37. Dougherty, E. 1953. Disease problems confronting the duck industry. *Proc Annu Meet Am Vet Med Assoc*. 90:359–365.
38. Eigaard, N.M., Permin, A., Christensen, J.P., Bojesen, A.M., and Bisgaard, M. 2006. Clonal stability of *Pasteurella multocida* in free-range layers affected by fowl cholera. *Avian Pathol*. 35:165–173.
39. Faddoul, G.P., G.W. Fellows, and J. Baird. 1967. Pasteurellosis in wild birds in Massachusetts. *Avian Dis*. 11:413–418.
40. Fegan, N., P.J. Blackall, and J.L. Pahoff. 1995. Phenotypic characterisation of *Pasteurella multocida* isolates from Australian poultry. *Vet Microbiol*. 47:281–286.
41. Fenstermacher, R., and B.S. Pomeroy. 1941. Encephalitis-like symptoms in turkeys associated with a *Pasteurella* sp. *Cornell Vet*. 31:295–301.
42. Flossmann, K.D., Feist, H., Hofer, M., and W. Erler. 1974. Untersuchungen uber chemisch definierte Nahrmedien fur *Pasteurella multocida* und *P. haemolytica*. *Z Allg Mikrobiol*. 14:29–38.
43. Gadberry, J.L., and N.G. Miller. 1977. Use of bacteriophages as an adjunct in the identification of *Pasteurella multocida*. *Am J Vet Res*. 38:129–130.
44. Garlinghouse, L.E., R.F. DiGiacomo, G.L. Van Hoosier, and J. Condon. 1971. Selective media for *Pasteurella multocida* and *Bordetella bronchiseptica*. *J Lab Anim Sci*. 31:39–42.
45. Gershman, M., J.F. Witter, H.E. Spencer, and A. Kalvaitis. 1964. Epizootic of fowl cholera in the common eider duck. *J Wildl Manage*. 28:587–589.
46. Gilchrist, P. 1963. A survey of avian respiratory disease. *Aust Vet J*. 39:140–144.
47. Glisson, J.R. 1995. Fluoroquinolone use in the poultry industry. In: *Drugs and Therapeutics for Poultry*. American Association of Avian Pathologists. Kennett Square, Pennsylvania. 73–75.
48. Glisson, J.R., C.L. Hofacre, and J.P. Christensen. Fowl cholera. In: *Diseases of Poultry*, 12th ed. Y.M. Saif, ed. Blackwell Publishing Professional, Ames, Iowa. 739–758.
49. Glorioso, J.C., G.W. Jones, H.G. Rush, L.J. Pentler, C.A. Darif, and J.E. Coward. 1982. Adhesion of type A *Pasteurella multocida* to rabbit pharyngeal cells and its possible role in rabbit respiratory tract infection. *Infect Immun*. 35:1103–1109.
50. Gooderham, K.R. 1990. Avian pasteurellosis and Pasteurella-like organisms. In: *Poultry Diseases*, 4th ed. F.T.W. Jordan and M. Pattison, eds. W.B. Saunders Company Ltd., London. 42–47.
51. Grant, G., A.M. Russell, and D.M. Fraser. 1968. Treatment of fowl cholera. *Vet Rec*. 83:419.
52. Gray, H. 1913. Some diseases of birds. In: *A System of Veterinary Medicine*, vol. 1. E.W. Hoare, ed. Alexander Eger, Chicago. 420–432.
53. Gregg, D.A., L.O. Olson, and E.L. McCune. 1974. Experimental transmission of *Pasteurella multocida* from raccoons to turkeys via bite wounds. *Avian Dis*. 18:559–564.
54. Gunawardana, G.A., K.M. Townsend, and A.J. Frost. 2000. Molecular characterization of avian *Pasteurella multocida* isolates from Australia and Vietnam by REP-PCR and PFGE. *Vet Microbiol*. 72:97–109.
55. Hacking, W.C., and J.R. Pettit. 1974. *Pasteurella hemolytica* in pullets and laying hens. *Avian Dis*. 18:483–486.
56. Hall, W.J., K.L. Heddleston, D.H. Legenhausen, and R.W. Hughes. 1955. Studies on pasteurellosis: I. A new species of *Pasteurella* encountered in chronic fowl cholera. *Am J Vet Res*. 16:598–604.
57. Hamdy, A.H., and C.J. Blanchard. 1970. Effect of novobiocin on fowl cholera in turkeys. *Avian Dis*. 14:770–778.
58. Harbourne, J.F. 1962. A hemolytic coccobacillus recovered from poultry. *Vet Rec*. 74:566–567.
59. Harper, M., A. Cox, M. John, J. Steen, M. Edmunds, F. St. Michael, B. Adler, and J. Boyce. 2011. Rapid multiplex PCR assay for typing *Pasteurella multocida* isolates. In: *International Pasteurellaceae Conference 2011*. Elsinore, Denmark. Final Programme and Abstracts. 12.
60. Harper, M., A.D. Cox, B. Adler, and J.D. Boyce. 2011. *Pasteurella multocida* lipopolysaccharide: the long and the short of it. *Vet Microbiol*. 153:109–115
61. Harper, M., F. St. Michael, M. John, E. Vinogradov, B. Adler, J.D. Boyce, and A.D. Cox. 2011. *Pasteurella multocida* Heddleston serovars 1 and 14 express different lipopolysaccharide structures but share the same lipopolysaccharide biosynthesis outer core locus. *Vet Microbiol*. 150:289–296.
62. Hart, L. 1963. Treatment of duck cholera with erythromycin. *Aust Vet J*. 39:92–93.
63. Heddleston, K.L. 1962. Studies on pasteurellosis. V. Two immunogenic types of Pasteurella multocida associated with fowl cholera. *Avian Dis*. 6:315–321.
64. Heddleston, K.L. 1970. Personal communication.
65. Heddleston, K.L. 1972. Avian pasteurellosis. In: *Diseases of Poultry*, 6th ed. M.S. Hofstad, B.W. Calnek, C.F. Helmboldt, W.M. Reid, and H.W. Yoder, Jr. eds. Iowa State University Press, Ames, Iowa. 219–241.
66. Heddleston, K.L. 1975. Pasteurellosis. In: *Isolation and Identification of Avian Pathogens*. S.B. Hitchner, C.H. Domermuth, H.G. Purchase, and J.E. Williams, eds. American Association of Avian Pathologists, Kennett Square, Pennslyvania. 38–51.
67. Heddleston, K.L., and P.A. Rebers. 1972. Fowl cholera: Cross-immunity induced in turkeys with formalin-killed in-vivo-propagated *Pasteurella multocida*. *Avian Dis*. 16:578–586.

68. Heddleston, K.L., and P.A. Rebers. 1975. Properties of free endotoxin from *Pasteurella multocida*. *Am J Vet Res*. 36:573–574.
69. Heddleston, K.L., and R.C. Reisinger. 1960. Studies on pasteurellosis. IV. Killed fowl cholera vaccine adsorbed on aluminum hydroxide. *Avian Dis*. 4:429–435.
70. Heddleston, K.L., and L.P. Watko. 1963. Fowl cholera: Susceptibility of various animals and their potential as disseminators of disease. *Proc Annu Meet US Livest Sanit Assoc*. 67:247–251.
71. Heddleston, K.L., and G. Wessman. 1975. Characteristics of *Pasteurella multocida* of human origin. *J Clin Microbiol*. 1:377–383.
72. Heddleston, K.L., L.P. Watko, and P.A. Rebers. 1964. Dissociation of a fowl cholera strain of *Pasteurella multocida*. *Avian Dis*. 8:649–657.
73. Heddleston, K.L., J.E. Gallagher, and P.A. Rebers. 1970. Fowl cholera: immune responses in turkeys. *Avian Dis*. 14:626–635.
74. Heddleston, K.L., J.E. Gallagher, and P.A. Rebers. 1972. Fowl cholera: gel diffusion precipitin test for serotyping *Pasteurella multocida* from avian species. *Avian Dis*. 16:925–936.
75. Heddleston, K.L., P.A. Rebers, and G. Wessman. 1975. Fowl cholera: Immunologic and serologic response in turkeys to live *Pasteurella multocida* vaccine administered in the drinking water. *Poult Sci*. 54:217–221.
76. Hendrickson, J.M., and K.F. Hilbert. 1932. The persistence of *P. avium* in the blood and organs of fowls with spontaneous fowl cholera. *J Infect Dis*. 50:89–97.
77. Henry, B.S. 1933. Dissociation in the genus *Brucella*. *J Infect Dis*. 52:374–402.
78. Hirsh, D.C., D.A. Jessup, K.P. Snipes, T.E. Carpenter, D.W. Hird, and R.H. Mccapes. 1990. Characteristics of *Pasteurella multocida* isolated from waterfowl and associated avian species in California. *J Wildlife Dis*. 26:204–209.
79. Hofacre, C.L., J.R. Glisson, and S.H. Kleven. 1986. Comparison of vaccination protocols of broiler breeder hens for *Pasteurella multocida* utilizing enzyme-linked immunosorbent assay and virulent challenge. *Avian Dis*. 31:260–263.
80. Hopkins, B.A., T.H.M. Huang, and L.D. Olson. 1998. Differentiating turkey postvaccination isolants of *Pasteurella multocida* using arbitrarily primed polymerase chain reaction. *Avian Dis*. 42:265–274.
81. Horvath, Z., M. Padanyi, and Z. Palatka. 1962. Chloramphenicol in the treatment of fowl cholera. *Magy Allatory Lapja*. 17:332–336.
82. Hughes, T.P. 1930. The epidemiology of fowl cholera. II. Biological properties of *P. avicida*. *J Exp Med*. 51:225–238.
83. Hughes, T.P., and I.W. Pritchett. 1930. The epidemiology of fowl cholera. III. Portal of entry of *P. avicida*; reaction of the host. *J Exp Med*. 51:239–248.
84. Hungerford, T.G. 1968. A clinical note on avian cholera. The effect of age on the susceptibility of fowls. *Aust Vet J*. 44:31–32.
85. Hunter, B., and G. Wobeser. 1980. Pathology of experimental avian cholera in mallard ducks. *Avian Dis*. 24:403–414.
86. Iliev, T., R. Arsov, I. Dimov, G. Girginov, and E. Iovcev. 1963. Swine, cattle, and sheep as carriers and latent sources of pasteurella infection for fowl. *Nauchni Tr Vissh Vet Med Inst. Sofia*. 11:281–288.
87. Iliev, T., R. Arsov, E. Iovcev, and G. Girginov. 1963. Role of swine in the epidemiology of fowl cholera. *Nauchni Tr Vissh Vet Med Inst. Sofia*. 11:289–293.
88. Iliev, T., R. Arsov, and V. Lazarov. 1965. Can fowls, carriers of *Pasteurella*, excrete the organism in faeces? *Nauchni Tr Vissh Vet Med Inst*. 14:7–12.
89. Iovcev, E. 1967. The role of *Argas persicus* in the epidemiology of fowl cholera. *Angew Parasitol*. 8:114–117.
90. Jaksic, B.L., M. Dordevic, and B. Markovic. 1964. Fowl cholera in wild birds. *Vet Glas*. 18:725–730.
91. Jensen, W.I., and C.S. Williams. 1964. Botulism and fowl cholera. In: *Waterfowl Tomorrow*. J.P. Linduska, ed. US Government Printing Office, Washington, D.C. 333–341.
92. Jordan, R.M.M. 1952. The nutrition of Pasteurella septica. II. The formation of hydrogen peroxide in a chemically-defined medium. *Br J Exp Pathol*. 33:36–45.
93. Juszkiewicz, T. 1966. Hyperthermia and prednisolone acetate as provocative factors of *Pasteurella multocida* infection in chickens. *Pol Arch Weter*. 10:141–151.
94. Juszkiewicz, T. 1966. Effects of shaking and premedication with methylprednisolone on some biochemical indices associated with *Pasteurella multocida* infection of cockerels. *Pol Arch Weter*. 10:129–140.
95. Karaivanov, L., and O. Mraz. 1973. Use of phagodiagnostics in *Pasteurella multocida*. *Acta Vet (Brno)*. 42:195–200.
96. Kehrenbert, C., Walker, R.D., Wu, C.C., and Schwarz, D. 2006. Antimicrobial resistance in members of the family Pasteurellaceae. In: *Antimicrobial Resistance in Bacteria of Animal Origin*. F.M. Aarestrup, ed. ASM press, Washington, D.C. 167–186.
97. Kim, C.J., and K.V. Nagaraja. 1990. DNA fingerprinting for differentiation of field isolates from reference vaccine strains of *Pasteurella multocida* in turkeys. *Amer J Vet Res*. 51:207–210.
98. Kirchner, C., and A. Eisenstark. 1956. Lysogeny in *Pasteurella multocida*. *Am J Vet Res*. 17:547–548.
99. Knight, D.P., J.E. Paine, and D.C.E. Speller. 1983. A selective medium for *Pasteurella multocida* and its use with animal and human species. *J Clin Pathol*. 36:591–594.
100. Kyaw, M.H. 1944. Pathogenesis of *Pasteurella septica* infection in developing chick embryo. *J Comp Pathol*. 54:200–206.
101. Lewontin, R.C., and J.L. Hubby. 1966. A molecular approach to the study of genic heterozygosity in natural populations: II Amount of variation and degree of heterozygosity in natural populations of *Drosophilia pseudoobscura*. *Genet*. 54:595–609.
102. Little, P.A. 1948. Use of Aureomycin in some experimental infections in animals. *Ann NY Acad Sci*. 51:246–253.
103. Maheswaran, S.K., J.R. McDowell, and B.S. Pomeroy. 1973. Studies on *Pasteurella multocida*. I. Efficacy of an avirulent mutant as a live vaccine in turkeys. *Avian Dis*. 17:396–405.
104. Manninger, R. 1919. Concerning a mutation of the fowl cholera bacillus. *Zentralbl Bakteriol Abt I Orig*. 83:520–528.
105. Marshall, J.D. 1963. *The use of immunofluorescence for the identification of members of the genus Pasteurella in chemically fixed tissues*. PhD Diss., University of Maryland.
106. Matthes, S., H. Loliger, and H.J. Schubert. 1969. Enzootisches Auftreten der *Pasteurella hemolytica* beim Huhn. *Dtsch Tierarztl Wochenschr*. 76:94–95.
107. Matsumoto, M., and D.H. Helfer. 1977. A bacterin against fowl cholera in turkeys: Protective quality of various preparations originated from broth cultures. *Avian Dis*. 21:382–393.
108. McNeil, E., and W.R. Hinshaw. 1948. The effect of streptomycin on *Pasteurella multocida in vitro*, and on fowl cholera in turkeys. *Cornell Vet*. 38:239–246.

109. Morishita, T.Y., L.J. Lowenstine, D.C. Hirsch, and D.L. Brooks. 1996. *Pasteurella multocida* in raptors: prevalence and characterization. *Avian Dis*. 40:908–918.
110. Morishita, T.Y., L.J. Lowenstine, D.C. Hirsch, and D.L. Brooks. 1996. *Pasteurella multocida* in Psittacines: prevalence, pathology, and characterization of isolates. *Avian Dis*. 40:900–907.
111. Morris, E.J. 1958. Selective media for some *Pasteurella* species. *J Gen Microbiol*. 19:305–311.
112. Muhairwa, A.P., J.P. Christensen, and M. Bisgaard. 2000. Investigations on the carrier rate of *Pasteurella multocida* in healthy commercial poultry and flocks affected by fowl cholera. *Avian Pathol*. 29:133–142.
113. Muhairwa, A.P., M.M.A. Mtambo, J.P. Christensen, and M. Bisgaard. 2001. Occurrence of *Pasteurella multocida* and related species in free ranging village poultry and their animal contacts. *Vet Microbiol*. 78:139–153.
114. Murata, M., T. Horiuchi, and S. Namioka. 1964. Studies on the pathogenicity of *Pasteurella multocida* for mice and chickens on the basis of O-groups. *Cornell Vet*. 54:293–307.
115. Mutters, R., P. Ihm, S. Pohl, W. Frederiksen, and W. Mannheim. 1985. Reclassification of the genus *Pasteurella* Trevisan 1887 on the basis of deoxyribonucleic acid homology, with proposals for the new species *Pasteurella dagmatis, Pasteurella canis, Pasteurella stomatis, Pasteurella anatis*, and *Pasteurella langaa*. *Intl J System Bacteriol*. 35:309–322.
116. Namioka, S., and M. Murata. 1961. Serological studies on *Pasteurella multocida*. II. Characteristics of somatic (O) antigen of the organism. *Cornell Vet*. 51:507–521.
117. Nicolet, J., and H. Fey. 1965. Role of *Pasteurella haemolytica* in salpingitis of fowls. *Schweiz Arch Tierheilkd*. 107:329–334.
118. Nielsen, J.P., M. Bisgaard, and K.B. Pedersen. 1986. Production of toxin in strains previously classified as *Pasteurella multocida*. *Acta Pathol Microbiol. Immunol Scand Sect B*. 94:203–204.
119. Nobrega, R., and R.C. Bueno. 1950. The influence of the temperature on the viability and virulence of *Pasteurella avicida*. *Boll Soc Paulista Med Vet*. 8:189–194.
120. Olson, L.D. 1966. Gross and histopathological description of the cranial form of chronic fowl cholera in turkeys. *Avian Dis*. 10:518–529.
121. Olsen, J.E., D.J. Brown, M.N. Skov, and J.P. Christensen. 1993. Bacterial typing methods suitable for epidemiological analysis. Applications in investigations of salmonellosis among livestock. *Vet Quarterly*. 15:125–134.
122. Olson, L.D., and E.L. McCune. 1968. Experimental production of the cranial form of fowl cholera in turkeys. *Am J Vet Res*. 29:1665–1673.
123. Olson, L.D., and G.T. Schlink. 1985. Onset and duration of immunity and minimum dosage with CU cholera vaccine in turkeys via drinking water. *Avian Dis*. 30:87–92.
124. Pabs-Garnon, L.F., and M.A. Soltys. 1971. Methods of transmission of fowl cholera in turkeys. *Am J Vet Res*. 32:1119–1120.
125. Park, P.Y. 1982. Disseminated intravascular coagulation in experimental fowl cholera of chickens. *Korean J Vet Res*. 22:211–219.
126. Pasteur, L. 1880a. Sur les maladies virulents et en particulier sur la maladie appelee vulgairement cholera des poules. *CR Acad Sci*. 90:239–248, 1030–1033.
127. Pasteur, L. 1880b. De l'attenuation du virus du cholera des poules. *CR Acad Sci*. 91:673–680.
128. Pasteur, L. 1881. Sur les virus-vaccins du cholera des poules et du charbon. CR Travaux Congr Int Dir Stn Agron Sess Versailles, 151–162.
129. Petrov, D. 1975. Studies on the gamasid red mite of poultry, *Dermanyssus gallinae*, as a carrier of *Pasteurella multocida*. *Vet Med Nauk (Bulg)*. 12:32–36.
130. Pier, A.C., K.L. Heddleston, S.J. Cysewski, and J.M. Patterson. 1972. Effect of aflatoxin on immunity in turkeys. II. Reversal of impaired resistance to bacterial infection by passive transfer of plasma. *Avian Dis*. 16:381–387.
131. Pirosky, I. 1938. Sur l'antigen glucidolipidique des Pasteurella. *CR Soc Biol*. 127:98–100.
132. Pritchett, I.W., and T.P. Hughes. 1932. The epidemiology of fowl cholera. VI. The spread of epidemic and endemic strains of *Pasteurella avicida* in laboratory populations of normal fowl. *J Exp Med*. 55:71–78.
133. Pritchett, I.W., F.R. Beaudette, and T.P. Hughes. 1930. The epidemiology of fowl cholera. IV. Field observations of the "spontaneous" disease. *J Exp Med*. 51:249–258.
134. Pritchett, I.W., F.R. Beaudette, and T.P. Hughes. 1930. The epidemiology of fowl cholera. V. Further field observations of the spontaneous disease. *J Exp Med*. 51:259–274.
135. Rebers, P.A., A.E. Jensen, and G.A. Laird. 1988. Expression of pili and capsule by the avian strain P-1059 of *Pasteurella multocida*. *Avian Dis*. 32:313–318.
136. Reis, J. 1941. On the presence of *Pasteurella avicida* in feces of infected birds. *Arq Inst Biol (San Paulo)*. 12:307–309.
137. Rhoades, K.R. 1964. The microscopic lesions of acute fowl cholera in mature chickens. *Avian Dis*. 8:658–665.
138. Rhoades, K.R., and R.B. Rimler. 1987. Capsular groups of *Pasteurella multocida* isolated from avian hosts. *Avian Dis*. 31:895–898.
139. Rhoades, K.R., and R.B. Rimler. 1987. Effects of *Pasteurella multocida* endotoxins on turkey poults. *Avian Dis*. 31:523–526.
140. Rhoades, K.R., and R.B. Rimler. 1988. Toxicity and virulence of capsular serogroup D *Pasteurella multocida* strains isolated from turkeys. *J Am Med Assoc*. 192:1790.
141. Rhoades, K.R., and R.B. Rimler. 1988. Unpublished data.
142. Rifkind, D., and M.J. Pickett. 1954. Bacteriophage studies on the hemorrhagic septicemia Pasteurellae. *J Bacteriol*. 67:243–246.
143. Rimler, R.B. 1984. Comparisons of serologic responses of white leghorn and New Hampshire red chickens to purified lipopolysaccharides of *Pasteurella multocida*. *Avian Dis*. 28:984–989.
144. Rimler, R.B. 1987. Cross-protection factor(s) of *Pasteurella multocida*: Passive immunization of turkeys against fowl cholera caused by different serotypes. *Avian Dis*. 31:884–887.
145. Rimler, R.B. 1994. Presumptive identification of *Pasteurella multocida* serogroups A, D, and F by capsule depolymerisation with mucopolysaccharidases. *Vet Rec*. 134:191–192.
146. Rimler, R.B., and M. Phillips. 1986. Fowl cholera: Protection against *Pasteurella multocida* by ribosome-lipopolysaccharide vaccine. *Avian Dis*. 30:409–415.
147. Rimler, R.B., and K.R. Rhoades. 1987. Serogroup F, a new capsule serogroup of *Pasteurella multocida*. *J Clin Microbiol*. 25:615–618.
148. Rimler, R.B., P.A. Rebers, and M. Phillips. 1984. Lipopolysaccharides of the Heddleston serotypes of *Pasteurella multocida*. *Am J Vet Res*. 45:759–763.
149. Rosen, M. 1971. Avian cholera. In: *Infectious and Parasitic Diseases of Wild Birds*. J.W. Davis, L.H. Karstad, D.O. Trainer, and R. Anderson, eds. Iowa State University Press, Ames, Iowa. 59–74.
150. Rosen, M.N., and A.I. Bischoff. 1949. The 1948–49 outbreak of fowl cholera in birds in the San Francisco Bay area and surrounding counties. *Calif Fish Game*. 35:185–192.

151. Rosenbusch, C., and I.A. Merchant. 1939. A study of the hemorrhagic septicemia Pasteurellae. *J Bacteriol*. 37:69–89.
152. Ryu, E. 1961. Studies on *Pasteurella multocida*. VI. The relationship between inhibitory action of blood and susceptibility of animals to Past. multocida. *Jpn J Vet Sci*. 23:357–361.
153. Salmon, D.E. 1880. Investigations of fowl cholera. Rep US Comm Agric. 401–445.
154. Saxena, S.P., and A.B. Hoerlein. 1959. Lysogeny in *Pasteurella*. I. Isolation of bacteriophages from *Pasteurella* strains isolated from shipping fever and those from other infectious processes. *J Vet Anim Husb*. 3:53–66.
155. Selander, R.K., D.A. Caugant, H. Ochman, J.M. Musser, M.N. Gilmour, and T.S. Whittam. 1989. Methods of multilocus enzyme electrophoresis for bacterial population genetics and systematics. *Appl Environ Microbiol*. 51:873–884.
156. Sellyei, B., Varga, Z., Ivanics, E., and Magyar, T. 2008. Characterization and comparison of avian *Pasteurella multocida* strains by conventional and ERIC-PCR assays. *Acta Vet Hung*. 56:429–440.
157. Serdyuk, H.G., and P.F. Tsimokh. 1970. Role of free-living birds and rodents in the distribution of pasteurellosis. *Veterinariia*. 6:53–54.
158. Simms, B.T. 1951. Rep Chief Bureau Anim Indust, USDA. 44–45.
159. Skidmore, L.V. 1932. The transmission of fowl cholera to turkeys by the common house fly (*Musca domestics* Linn) with brief notes on the viability of fowl cholera microorganisms. *Cornell Vet*. 22:281–285.
160. Smith, I.M., and A.J. Baskerville. 1983. A selective medium for isolation of *P. multocida* in nasal specimens from pigs. *Br Vet J*. 139:476–486.
161. Snipes, K.P., D.C. Hirsh, R.W. Kasten, T.E. Carpenter, D.W. Hird, and R.H. Mccapes. 1990. Homogeneity of characteristics of *Pasteurella multocida* isolated from turkeys and wildlife in California. *Avian Dis*. 34:315–320.
162. Subaaharan, S., L.L. Blackall, and P.J. Blackall. 2010. Development of a multi-locus sequence typing scheme for avian isolates of *Pasteurella multocida*. *Vet Microbiol*. 141:354–361.
163. Townsend, K.M., J.D. Boyce, J.Y. Chung, A.J. Frost, and B. Adler. 2001. Genetic organization of *Pasteurella multocida* cap loci and development of a multiplex capsular PCR typing system. *J Microbiol*. 39:924–929.
164. Van Es, L., and J.F. Olney. 1940. An inquiry into the influence of environment on the incidence of poultry diseases. *Univ Neb Agric Exp Stn Res Bull*. 118:17–21.
165. Vaught, R.W., H.C. McDougle, and H.H. Burgess. 1967. Fowl cholera in waterfowl at Squaw Creek National Wildlife Refuge, Missouri. *J Wildl Manage*. 31:248–253.
166. Walser, M.M., and R.B. Davis. 1975. *In vitro* characterization of field isolates of *Pasteurella multocida* from Georgia turkeys. *Avian Dis*. 19:525–532.
167. Watko, L.P. 1966. A chemically defined medium for growth of *Pasteurella multocida*. *Can J Microbiol*. 12:933–937.
168. Watko, L.P., and K.L. Heddleston. 1966. Survival of shell-frozen, freeze-dried, and agar slant cultures of *Pasteurella multocida*. *Cryobiology*. 3:53–55.
169. Wessman, G.E., and G. Wessman. 1970. Chemically defined media for *Pasteurella multocida* and *Pasteurella ureae*, and a comparison of their thiamine requirements with those of *Pasteurella haemolytica*. *Can J Microbiol*. 16:751–757.
170. Wilson, G.S., and A.A. Miles. 1964. *Topley and Wilson's Principles of Bacteriology and Immunity*. Williams and Wilkins, Baltimore. 932–953.
171. Wilson, M.A., R.M. Duncan, G.E. Nordholm, and B.M. Berlowski. 1995. Serotypes and DNA fingerprint profiles of *Pasteurella multocida* isolated from raptors. *Avian Dis*. 39:94–99.
172. Wilson, M.A., R.M. Duncan, G.E. Nordholm, and B.M. Berlowski. 1995b. *Pasteurella multocida* isolated from wild birds of North America: A serotype and DNA fingerprint study of isolates from 1978 to 1993. *Avian Dis*. 39:587–593.
173. Yaw, K.E., and J.C. Kakavas. 1957. A comparison of the protection-inducing factors in chickens and mice of a type 1 strain of *Pasteurella multocida*. *Am J Vet Res*. 18:661–664.

Riemerella anatipestifer Infection

1. Ash, W.J. 1967. Antibiotics and infectious serositis in White Pekin ducklings. *Avian Dis*. 11:38–41.
2. Asplin, F.D. 1955. A septicaemic disease of ducklings. *Vet Rec*. 67:854–858.
3. Asplin, F.D. 1956. Experiments on the transmission of a septicaemic disease of ducklings. *Vet Rec*. 68:588–590.
4. Bangun, A., D.N. Tripathy, and L.E. Hanson. 1981. Studies of *Pasteurella anatipestifer*: An approach to its classification. *Avian Dis*. 25:326–337.
5. Bangun, A., J.L. Johnson, and D.N. Tripathy. 1987. Taxonomy of *Pasteurella anatipestifer*. 1. DNA base composition and DNA-DNA hybridization analysis. *Avian Dis*. 31:43–45.
6. Bendheim, U., and A. Even-Shoshan. 1975. Survival of *Pasteurella multocida* and *Pasteurella anatipestifer* in various natural media. *Refu Vet*. 32:40–46.
7. Bisgaard, M. 1982. Antigenic studies on *Pasteurella anatipestifer*, species incertae sedis, using slide and tube agglutination. *Avian Pathol*. 11:341–350.
8. Breed, R.S., E.F. Lessel, Jr., and E. Heist Clise. 1957. Genus I. *Pasteurella Trevisan*, 1887. In: *Bergey's Manual of Determinative Bacteriology*, 7th ed. R.S. Breed, E.G.D. Murray, and N.R. Smith, eds. Williams and Wilkins, Baltimore, MD. 395–402.
9. Brogden, K.A., K.R. Rhoades, and R.B. Rimler. 1982. Serologic types and physiologic characteristics of 46 avian *Pasteurella anatipestifer* cultures. *Avian Dis*. 26:891–896.
10. Bruner, D.W., and J. Fabricant. 1954. A strain of *Moraxella anatipestifer* (*Pfeifferella anatipestifer*) isolated from ducks. *Cornell Vet*. 44:461–464.
11. Bruner, D.W., C.I. Angstrom, and J.I. Price. 1970. *Pasteurella anatipestifer* infection in pheasants. A case report. *Cornell Vet*. 60:491–494.
12. Chang, C.F., P.E. Hung, and Y.F. Chang. 1998. Molecular characterization of a plasmid isolated from *Riemerella anatipestifer*. *Avian Pathol.* 27:339–345.
13. Chang, C.F., W.H. Lin, T.M. Yeh, T.S. Chiang, and Y.F. Chang. 2003. Antimicrobial susceptibility of *Riemerella anatipestifer* isolated from ducks and the efficacy of ceftiofur treatment. *J Vet Diagn Invest*. 15:26–29.
14. Chen, Y.P., M.Y. Tsao, S.H. Lee, C.H. Chou, and H.J. Tsai. 2010. Prevalence and molecular characterization of chloramphenicol resistance in *Riemerella anatipestifer* isolated from ducks and geese in Taiwan. *Avian Pathol*. 39:333–338.

15. Christensen, H., and M. Bisgaard. 2010. Phylogenetic relationships of *Riemerella anatipestifer* serovars and related taxa and an evaluation of specific PCR tests reported for *R. anatipestifer*. *J Appl Microbiol*. 108:1612–1619.
16. Cooper, G.L. 1989. *Pasteurella anatipestifer* infections in California turkey flocks: Circumstantial evidence of a mosquito vector. *Avian Dis*. 33:809–815.
17. Dean, W.F., J.I. Price, and L. Leibovitz. 1973. Effect of feed medicaments on bacterial infections in ducklings. *Poult Sci*. 52:549–558.
18. Dougherty, E., L.Z. Saunders, and E.H. Parsons. 1955. The pathology of infectious serositis of ducks. *Am J Pathol* 31:475–487.
19. Eleazer, T.H., H.G. Blalock, J.S. Harrell, and W.T. Derieux. 1973. *Pasteurella anatipestifer* as a cause of mortality in semiwild pen-raised mallard ducks in South Carolina. *Avian Dis*. 17:855–857.
20. Floren, U., P.K. Storm, and E.F. Kaleta. 1988. *Pasteurella anatipestifer* sp.i.c. bei Pekingenten: Pathogenitätsprüfungen und Im mu nisierung mit einer inaktivierten, homologen, monovalenten (serotyp 6/B) Ölemulsionsvakzine. *Dtsch Tierärztl Wochenschr*. 95:210–214.
21. Frommer, A., R. Bock, A. Inbar, and S. Zemer. 1990. Muscovy ducks as a source of *Pasteurella anatipestifer* infection in turkey flocks. *Avian Pathol*. 19:161–163.
22. Fulton R.M., and R.B. Rimler. 2010. Epidemiologic investigation of *Riemerella anatipestifer* in a commercial duck company by serotyping and DNA fingerprinting. *Avian Dis*. 54:969–972.
23. Graham, R., C.A. Brandly, and G.L. Dunlap. 1938. Studies on duck septicemia. *Cornell Vet*. 28:1–8.
24. Han, X., C. Ding, L. He, Q. Hu, and S. Yu. 2011. Development of loop-mediated isothermal amplification (LAMP) targeting the GroEL gene for rapid detection of *Riemerella anatipestifer*. *Avian Dis*. 55:379–383.
25. Han, X., Q. Hu, S. Ding, W. Chen, C. Ding, L. He, X. Wang, J. Ding, and S. Yu. 2011. Identification and immunological characteristics of chaperonin GroEL in *Riemerella anatipestifer*. *Appl Microbio Biotechnol*. 93(3):1197–205.
26. Harry, E.G. 1969. *Pasteurella* (*Pfeifferella*) *anatipestifer* serotypes isolated from cases of anatipestifer septicaemia in ducks. *Vet Rec*. 84:673.
27. Harry, E.G. 1981. Personal communication.
28. Harry, E.G., and J.R. Deb. 1979. Laboratory and field trials on a formalin inactivated vaccine for the control of *Pasteurella anatipestifer* septicaemia in ducks. *Res Vet Sci*. 27:329–333.
29. Hatfield, R.M., and B.A. Morris. 1988. Influence of the route of infection of *Pasteurella anatipestifer* on the clinical and immune responses of White Pekin ducks. *Res Vet Sci*. 44:208–214.
30. Hatfield, R.M., B.A. Morris, and R.R. Henry. 1987. Development of an enzyme-linked immunosorbent assay for the detection of humoral antibody to *Pasteurella anatipestifer*. *Avian Pathol*. 16:123–140.
31. Heddleston, K.L. 1972. Infectious serositis. In: *Diseases of Poultry*, 6th ed. M.S. Hofstad, B.W. Calnek, C.F. Helmboldt, W.M. Reid, and H.W. Yoder, Jr., eds. Iowa State University Press, Ames, Iowa. 246–251.
32. Helfer, D.H., and C.F. Helmboldt. 1977. *Pasteurella anatipestifer* infection in turkeys. *Avian Dis*. 21:712–715.
33. Hendrickson, J.M., and K.F. Hilbert. 1932. A new and serious septicemic disease of young ducks with a description of the causative organism, *Pfeifferella anatipestifer*, N.S. *Cornell Vet*. 22:239–252.
34. Higgins, D.A., R.R. Henry, and Z.V. Kounev. 2000. Duck immune response to *Riemerella anatipestifer* vaccines. *Dev Comp Immunol*. 24:153–167.
35. Hinz, K.H., H. Grebe, and M. Knapp. 1976. Moraxella septicaemiae-Infektion bei Gänsen. *Zentralbl Veterinaermed Med B*. 23:341–345.
36. Hinz, K.H., M. Ryll, and B. Köhler. 1998a. Detection of acid production from carbohydrates by *Riemerella anatipestifer* and related organisms using the buffered single substrate test. *Vet Microbiol*. 60:277–284.
37. Hinz, K.H., M. Ryll, B. Köhler, and G. Glünder. 1998b. Phenotypic characteristics of *Riemerella anatipestifer* and similar micro-organisms from various hosts. *Avian Pathol*. 27:33–42.
38. Hu, Q., X. Han, X. Zhou, S. Ding, C. Ding, and S. Yu. 2010. Characterization of biofilm formation by *Riemerella anatipestifer*. *Vet Microbiol*. 144:429–436.
39. Hu, Q., X. Han, X. Zhou, C. Ding, Y. Zhu, and S. Yu. 2011. OmpA is a virulence factor of *Riemerella anatipestifer*. *Vet Microbiol*. 150:278–283.
40. Hu, Q., J. Tu, X. Han, Y. Zhu, C. Ding, and S. Yu. 2011. Development of multiplex PCR assay for rapid detection of *Riemerella anatipestifer*, *Escherichia coli*, and *Salmonella enterica* simultaneously from ducks. *J Microbiol Methods*. 87:64–69.
41. Huang, B., J. Kwang, H. Loh, J. Frey, H.-M. Tan, and K.L. Chua. 2002. Development of an ELISA using a recombinant 41 kDa partial protein (P45N9) for the detection of *Riemerella anatipestifer* infection in ducks. *Vet Microbiol*. 88:339–349.
42. Huang, B., S. Subramaniam, J. Frey, H. Loh, H.M. Tan, C.J. Fernandez, J. Kwang, and K.L. Chua. 2002. Vaccination of ducks with recombinant outer membrane protein (OmpA) and a 41 kDa partial protein (P45N9) of *Riemerella anatipestifer*. *Vet Microbiol*. 84:219–230.
43. Huang, B., S. Subramaniam, K.L. Chua, J. Kwang, H. Loh, J. Frey, and H.M. Tan. 1999. Molecular fingerprinting of *Riemerella anatipestifer* by repetitive sequence PCR. *Vet Microbiol*. 67:213–219.
44. Jortner, B.S., R. Porro, and L. Leibovitz. 1969. Central-nervous-system lesions of spontaneous *Pasteurella anatipestifer* infection in ducklings. *Avian Dis*. 13:27–35.
45. Kardos, G., J. Nagy, M. Antal, A. Bistyák, M. Tenk, and I. Kiss. 2007. Development of a novel PCR assay specific for *Riemerella anatipestifer*. *Lett Appl Microbiol*. 44:145–148.
46. Karstad, L., P. Lusis, and J.R. Long. 1970. *Pasteurella anatipestifer* as a cause of mortality in captive wild waterfowl. *J Wildl Dis*. 6:408–413.
47. Layton, H.W., and T.S. Sandhu. 1984. Protection of ducklings with a broth-grown *Pasteurella anatipestifer* bacterin. *Avian Dis*. 28:718–726.
48. Leibovitz, L. 1972. A survey of the so-called "anatipestifer syndrome." *Avian Dis*. 16:836–851.
49. Levine, N.D. 1965. Goose influenza (septisemia anserum exsudative). In: *Diseases of Poultry*, 5th ed. H.E. Biester and L.H. Schwarte, eds. Iowa State University Press, Ames, Iowa. 469–471.
50. Lobbedey, L., and B. Schlatterer. 2003. Development and application of an ELISA for the detection of duck antibodies against *Riemerella anatipestifer* antigens in egg yolk and in serum of their offspring. *J Vet Med B*. 50:81–85.
51. Loh, H., T.P. Teo, and H. Tan. 1992. Serotypes of *Pasteurella anatipestifer* isolates from ducks in Singapore: A proposal of new serotypes. *Avian Pathol*. 21:453–459.
52. Mannheim, W. 1984. Family III. Pasteurellaceae Pohl 1981a, 382. In: *Bergey's Manual of Systematic Bacteriology*, 9th ed.,

vol. 1. N.R. Krieg and J.G. Holt, eds. Williams and Wilkins, Baltimore, Maryland. 550–557.
53. Marshall, J.D., Jr., P.A. Hansen, and W.C. Eveland. 1961. Histobacteriology of the genus P*asteurella*. 1. *Pasteurella anatipestifer*. *Cornell Vet*. 51:24–34.
54. Mavromatis, K., M. Lu, M. Misra, A. Lapidus, M. Nolan, S. Lucas, N. Hammon, S. Deshpande, J.F. Cheng, R. Tapia, C. Han, L. Goodwin, S. Pitluck, K. Liolios, I. Pagani, N. Ivanova, N. Mikhailova, A. Pati, A. Chen, K. Palaniappan, M. Land, L. Hauser, C.D. Jeffries, J.C. Detter, E.M. Brambilla, M. Rohde, M. Göker, S. Gronow, T. Woyke, J. Bristow, J.A. Eisen, V. Markowitz, P. Hugenholtz, H.P. Klenk, and N.C. Kyrpides. 2011. Complete genome sequence of *Riemerella anatipestifer* type strain (ATCC 11845). *Stand Genomic Sci*. 4:144–153.
55. Mitrovic, M., E.G. Schildknecht, G. Maestrone, and H.G. Luther. 1980. Rofenaid in the control of *Pasteurella anatipestifer* and *Escherichia coli* infections in ducklings. *Avian Dis*. 24:302–308.
56. Munday, B.L., A. Corbould, K.L. Heddleston, and E.G. Harry. 1970. Isolation of *Pasteurella anatipestifer* from black swan (*Cygnus atratus*). *Aust Vet J*. 46:322–325.
57. Nagaraja, K.V. 1988. Personal communication.
58. Pascucci, S., L. Giovannetti, and P. Massi. 1989. *Pasteurella anatipestifer* infection in guinea fowl and Japanese quail (*Coturnix coturnix japonica*). *Proc Int Congr World Vet Poultry Assoc*. 9:47.
59. Pathanasophon, P., P. Phuektes, T. Tanticharoenyos, W. Narongsak, and T. Sawada. 2002. A potential new serotype of *Riemerella anatipestifer* isolated from ducks in Thailand. *Avian Pathol*. 31:267–270.
60. Pathanasophon, P., T. Sawada, T. Pramoolsinsap, and T. Tanti charoenyos. 1996. Immunogenicity of *Riemerella anatipestifer* broth culture bacterin and cell-free culture filtrate in ducks. *Avian Pathol*. 25:705–719.
61. Pathanasophon, P., T. Sawada, and T. Tanticharoenyos. 1995. New serotypes of *Riemerella anatipestifer* isolated from ducks in Thailand. *Avian Pathol*. 24:195–199.
62. Pickrell, J.A. 1966. Pathologic changes associated with experimental *Pasteurella anatipestifer* infection in ducklings. *Avian Dis*. 10:281–288.
63. Piechulla, K., S. Pohl, and W. Mannheim. 1986. Phenotypic and genetic relationships of so-called *Moraxella* (*Pasteurella*) *anatipestifer* to the Flavobacterium/Cytophaga group. *Vet Microbiol*. 11:261–270.
64. Pierce, R.L., and M.W. Vorhies. 1973. *Pasteurella anatipestifer* infection in geese. *Avian Dis*. 17:868–870.
65. Qu, F.F., C. Cai, X.J. Zheng, and D.B. Zhang. 2006. Rapid identification of *Riemerella anatipestifer* on the basis of specific PCR amplifying 16S rDNA. *Wei Sheng Wu Xue Bao* 46:13–17. Article in Chinese.
66. Riemer. 1904. Kurze Mitteilung über eine bei Gänsen beobachtete exsudative Septikämie und deren Erreger. *Zentralbl Bakteriol I Abt I Orig*. 37:641–648.
67. Rimler, R.B., and G.E. Nordholm. 1998. DNA fingerprinting of *Riemerella anatipestifer*. *Avian Dis*. 42:101–105.
68. Rosenfeld, L.E. 1973. *Pasteurella anatipestifer* infection in fowls in Australia. *Aust Vet J*. 49:55–56.
69. Rubbenstroth, D., H. Hotzel, J. Knobloch, L. Teske, S. Rautenschlein, and M. Ryll. 2011. Isolation and characterization of atypical *Riemerella columbina* strains from pigeons and their differentiation from *Riemerella anatipestifer*. *Vet Microbiol*. 147:103–112.
70. Ryll, M., H. Christensen, M. Bisgaard, J.P. Christensen, K.H. Hinz, and B. Köhler. 2001. Studies on the prevalence of *Riemerella anatipestifer* in the upper respiratory tract of clinically healthy ducklings and characterization of untypable strains. *J Vet Med B*. 48:537–546.
71. Ryll, M., and K.H. Hinz. 2000. Exclusion of strain 670/89 as type strain of serovar 20 of *Riemerella anatipestifer*. *Berl Münch Tierärztl Wsch*. 113:65–66.
72. Sandhu, T. 1979. Immunization of White Pekin ducklings against *Pasteurella anatipestifer* infection. *Avian Dis*. 23:662–669.
73. Sandhu, T.S. 1986. Important diseases of ducks. In: *Duck Production Science and World Practice*. D.J. Farrell and P. Stapleton, eds. University of New England, Australia. 111–134.
74. Sandhu, T.S. 1991. Immunogenicity and safety of a live *Pasteurella anatipestifer* vaccine in White Pekin ducklings: Laboratory and field trials. *Avian Pathol*. 20:423–432.
75. Sandhu, T.S. 1992. Unpublished data.
76. Sandhu, T.S., and W.F. Dean. 1980. Effect of chemotherapeutic agents on *Pasteurella anatipestifer* infection in White Pekin ducklings. *Poult Sci*. 59:1027–1030.
77. Sandhu, T., and E.G. Harry. 1981. Serotypes of *Pasteurella anatipestifer* isolated from commercial White Pekin ducks in the United States. *Avian Dis*. 25:497–502.
78. Sandhu, T.S., and M. Leister. 1991. Serotypes of *Pasteurella anatipestifer* isolates from poultry in different countries. *Avian Pathol*. 20:233–239.
79. Sarver, C.F., T.Y. Morishita, and B. Nersessian. 2005. The effect of route of inoculation and challenge dosage on *Riemerella anatipestifer* infection in Pekin ducks. *Avian Dis*. 49:104–107.
80. Segers, P., W. Mannheim, M. Vancanneyt, K. DeBrandt, K.H. Hinz, K. Kersters, and P. Vandamme. 1993. *Riemerella anatipestifer* gen. nov., comb. nov., the causative agent of septicemia anserum exsudativa, and its phylogenetic affiliation within the Flavobacterium-Cytophaga rRNA homology group. *Int J Syst Bacteriol*. 43:768–776.
81. Smith, J.E. 1974. Genus *Pasteurella* Trevisan 1987. In: *Bergey's Manual of Determinative Bacteriology*, 8th ed. R.E. Buchanan and N.E. Gibbons, eds. Williams and Wilkins, Baltimore, Maryland. 370–373.
82. Smith, J.M., D.D. Frame, G. Cooper, A.A. Bickford, G.Y. Ghazikhanian, and B.J. Kelly. 1987. *Pasteurella anatipestifer* infection in commercial meat-type turkeys in California. *Avian Dis*. 31:913–917.
83. Subramaniam, S., B. Huang, H. Loh, J. Kwang, H.M. Tan, K.L. Chua, and J. Frey. 2000. Characterization of a predominant immunogenic outer membrane protein of *Riemerella anatipestifer*. *Clin Diag Lab Immunol*. 7:168–174.
84. Tsai, H.J., Y.T. Liu, C.S. Tseng, and M.J. Pan. 2005. Genetic variation of the ompA and 16S rRNA genes of *Riemerella anatipestifer*. *Avian Pathol*. 34:55–64.
85. Turbahn, A., S.C.D. Jäckel, E. Greuel, A.D. Jong, R. Froyman, and E.F. Kaleta. 1997. Dose response study of enrofloxacin against *Riemerella anatipestifer* septicaemia in Muscovy and Pekin ducklings. *Avian Pathol*. 26:791–802.
86. Vandamme, P., M. Vancanneyt, P. Segers, M. Ryll, B. Köhler, W. Ludwig, and K.H. Hinz. 1999. *Coenonia anatina* gen. nov., sp. nov., a novel bacterium associated with respiratory disease in ducks and geese. *Int J Syst Bacteriol*. 49:867–874.
87. Weng, S.C., W.H. Lin, C.F. Chang, and C.F. Chang. 1999. Identification of a virulence-associated protein homolog gene and ISRa1 in a plasmid of *Riemerella anatipestifer*. *FEMS Microbiol Letters*. 179:11–19.

88. Wobeser, G., and G.E. Ward. 1974. *Pasteurella anatipestifer* infection in migrating whistling swans. *J Wildl Dis*. 10:466–470.
89. Wyffels, R., and J. Hommez. 1990. *Pasteurella anatipestifer* geisoleerd uit ademhalingsletsels bij grijze patrijzen (*Perdix perdix*). *Vlaam Diergeneeskd Tijdschr*. 59:105–106.
90. Yu, C.Y., Y.W. Liu, S.J. Chou, M.R. Chao, B.C. Weng, J.G. Tsay, C.H. Chiu, C. Ching Wu, T. Long Lin, C.C. Chang, and C. Chu. 2008. Genomic diversity and molecular differentiation of *Riemerella anatipestifer* associated with eight outbreaks in five farms. *Avian Pathol*. 37:273–279.
91. Yuan, J., W. Liu, M. Sun, S. Song, J. Cai, and S. Hu. 2011. Complete genome sequence of the pathogenic bacterium *Riemerella anatipestifer* strain RA-GD. *J Bacteriol*. 193:2896–2897.
92. Zehr, W.J., and J. Ostendorf, Jr. 1970. *Pasteurella anatipestifer* in turkeys. *Avian Dis*. 14:557–560.
93. Zheng, F., G. Lin, J. Zhou, G. Wang, X. Cao, X. Gong, and C. Qiu. 2011. Loop-mediated isothermal amplification assay targeting the ompA gene for rapid detection of *Riemerella anatipestifer*. *Mol Cell Probes*. 25:65–67.
94. Zhong C.Y., A.C. Cheng, M.S. Wang, K. Zhu de, Q.H. Luo, C.D. Zhong, L. Li, and Z. Duan. 2009. Antibiotic susceptibility of *Riemerella anatipestifer* field isolates. *Avian Dis*. 53:601–607.
95. Zhou, Z., X. Peng, Y. Xiao, X. Wang, Z. Guo, L. Zhu, M. Liu, H. Jin, D. Bi, Z. Li, and M. Sun. 2011. Genome sequence of poultry pathogen *Riemerella anatipestifer* strain RA-YM. *J Bacteriol*. 193:1284–1285.

Ornithobacterium rhinotracheale Infection

1. Abdul-Aziz, T.A., and L.J. Weber. 1999. *Ornithobacterium rhinotracheale* infection in a turkey flock in Ontario. *Can Vet J*. 40:349–350.
2. Allymehr, M. 2006. Seroprevalence of *Ornithobacterium rhinotracheale* infection in broiler and broiler breeder chickens in West Azerbaijan Province, Iran. *J Vet Med A Physiol Pathol Clin Med*. 53:40–42.
3. Amonsin, A., J.F.X. Wellehan, L.L. Li, P. Vandamme, C. Lindeman, M. Edma, R.A. Robinson, and V. Kapur. 1997. Molecular epidemiology of *Ornithobacterium rhinotracheale*. *J Clin Microbiol*. 35:2894–2898.
4. Arns, C., H.M. Hafez, T. Yano, M. Monteiro, M. Alves, H. Domingues, and L. Coswig. 1998. *Ornithobacterium rhinotracheale*: Detecção sorológica em aves matrzes e Fragos de Corte. Association of broiler procedures, APINCO'98. Campinas, 56.
5. Back, A., R. Gireesh, D. Halvorson, and K. Nagaraja. 1997. Experimental studies of *Ornithobacterium rhinotracheale* (ORT) infection. *Proc West Poult Dis Conf*. 96:7–8.
6. Back, A., D. Halvorson, G. Rajashekara, and K.V. Nagaraja. 1998. Development of a serum plate agglutination test to detect antibodies to *Ornithobacterium rhinotracheale*. *J Vet Diagn Invest*. 10:84–86.
7. Ballagi, A., G. Holmquist, M. Odmark, and V. Leathers. 2000. ELISA test for the detection of *Ornithobacterium rhinotracheale* infection in chickens and turkeys. *Proc West Poult Dis Conf*. 49:50–51.
8. Bano, S., K. Naeem, and S.A. Malik. 2003. Evaluation of pathogenic potential of avian influenza virus serotype H9N2 in chickens. *Avian Dis*. 47:817–822.
9. Bisschop, S.P., M. van Vuuren, and B. Gummow. 2004. The use of a bacterin vaccine in broiler breeders for the control of *Ornithobacterium rhinotracheale* in commercial broilers. *J S Afr Vet Assoc*. 75:125–128.
10. Bock, R., P. Freidlin, M. Manoim, A. Inbar, A. Frommer, P. Vandamme, and P. Wilding. 1997. *Ornithobacterium rhinotracheale* (ORT) associated with a new turkey respiratory tract infectious agent in Israel. *Intl Congr World Vet Poult Assoc*. 11:120.
11. Bock, R., P. Freidlin, S. Tomer, M. Manoim, A. Inbar, A. Frommer, P. Vandamme, P. Wilding, and D. Hickson. 1995. *Ornithobacterium rhinotracheale* (ORT) associated with a new turkey respiratory tract infectious agent. *Proc Annu Conv Israel Branch World Vet Assoc*. 33:43–45.
12. Canal, C.W., J.A. Leao, D.J. Ferreira, M. Macagnan, C.T. Pippi Salle, and A. Back. 2003. Prevalence of antibodies against *Ornithobacterium rhinotracheale* in broilers and breeders in Southern Brazil. *Avian Dis*. 47:731–737.
13. Canal, C.W., J.A. Leao, S.L. Rocha, M. Macagnan, C.A. Lima-Rosa, S.D. Oliveira, and A. Back. 2005. Isolation and characterization of *Ornithobacterium rhinotracheale* from chickens in Brazil. *Res Vet Sci*. 78:225–230.
14. Cauwerts, K., P. De Herdt, F. Haesebrouck, J. Vervloesem, and R. Ducatelle. 2002. The effect of *Ornithobacterium rhinotracheale* vaccination of broiler breeder chickens on the performance of their progeny. *Avian Pathol*. 31:619–624.
15. Charlton, B.R. 1999. *Bordetella avium* and *Ornithobacterium rhinotracheale* from California poultry submissions. *Proc West Poult Dis Conf*. 48:80.
16. Charlton, B.R., S.E. Channing-Santiago, A.A. Bickford, C.J. Cardona, R.P. Chin, G.L. Cooper, R. Droual, J.S. Jeffrey, C.U. Meteyer, H.L. Shivaprasad, and R. Walker. 1993. Preliminary characterization of a pleomorphic gram-negative rod associated with avian respiratory disease. *J Vet Diagn Invest*. 5:47–51.
17. Chin, R.P., and B.R. Charlton. 2008. Ornithobacteriosis. In: *A Laboratory Manual for the Isolation, Identification and Characterization of Avian Pathogens*, 5th ed. L. Dufour-Zavala, D.E. Swayne, J.R. Glisson, J.E. Pearson, W.M. Reed, M.W. Jackwood, and P.R. Woolcock, eds. American Association of Avian Pathologists, Inc., Athens, Georgia. 75–76.
18. Chin, R.P., P.C.M. van Empel, and H.M. Hafez. 2008. *Ornithobacterium rhinotracheale* infection. In: *Diseases of Poultry*, 12th ed., Y.M. Saif, A.M. Fadly, J.R. Glisson, L.R. McDougald, L.K. Nolan, and D.E. Swayne, eds. Blackwell Publishing, Ames, Iowa. 765–774.
19. De Rosa, M., R. Droual, R.P. Chin, and H.L. Shivaprasad. 1997. Interaction of *Ornithobacterium rhinotracheale* and *Bordetella avium* in turkey poults. *Proc West Poult Dis Conf*. 47:52–53.
20. De Rosa, M., R. Droual, R.P. Chin, H.L. Shivaprasad, and R.L. Walker. 1996. *Ornithobacterium rhinotracheale* infection in turkey breeders. *Avian Dis*. 40:865–874.
21. Devriese, L.A., J. Hommez, P. Vandamme, K. Kersters, and F. Haesebrouck. 1995. *In vitro* antibiotic sensitivity of *Ornithobacterium rhinotracheale* strains from poultry and wild birds. *Vet Rec*. 137:435–436.
22. Droual, R., and R. Chin. 1997. Interaction of *Ornithobacterium rhinotracheale* and *Escherichia coli* 78:H9 when inoculated into the air sac in turkey poults. *Proc West Poult Dis Conf*. 46:11.
23. El-Gohary, A. 1998. *Ornithobacterium rhinotracheale* (ORT) associated with hatching problems in chicken and turkey eggs. *Vet Med J Giza*. 46:183–191.

24. El-Gohary, A., and M.H.H. Awaad. 1998. Concomitant *Ornithobacterium rhinotracheale* (ORT) and *E. coli* infection in chicken broilers. *Vet Med J Giza* 46:67–75.
25. El-Sukhon, S.N., A. Musa, and M. Al-Attar. 2002. Studies on the bacterial etiology of airsacculitis of broilers in northern and middle Jordan with special reference to *Escherichia coli*, *Ornithobacterium rhinotracheale*, and *Bordetella avium*. *Avian Dis*. 46:605–612.
26. Erbeck, D.H., and B.L. McMurray. 1998. Isolation of Georgia variant (Georgia isolate 1992) infectious bronchitis virus but not *Ornithobacterium rhinotracheale* from a Kentucky broiler complex. *Avian Dis*. 42:613–617.
27. Erganis, O., H.H. Hadimli, K. Kav, M. Corlu, and D. Ozturk. 2002. A comparative study on detection of *Ornithobacterium rhinotracheale* antibodies in meat-type turkeys by dot immunobinding assay, rapid agglutination test and serum agglutination test. *Avian Pathol*. 31:201–204.
28. Franz, G., R. Hein, J. Bricker, P. Walls, E. Odor, M. Salem, and B. Sample. 1997. Experimental studies in broilers with a Delmarva *Ornithobacterium rhinotracheale* isolate. *Proc West Poult Dis Conf*. 46:46–48.
29. Goovaerts, D., M. Vrijenhoek, and P. van Empel. 1998. Immunohistochemical and bacteriological investigation of the pathogenesis of *Ornithobacterium rhinotracheale* infection in South Africa in chickens with osteitis and encephalitis syndrome. *Proc Meet European Soc Vet Pathol*. 46:81.
30. Goovaerts, D., M. Vrijenhoek, and P. van Empel. 1999. Immuno-histochemical and bacteriological investigation of the pathogenesis of *Ornithobacterium rhinotracheale* infection in chickens with osteitis and encephalitis syndrome. *Proc West Poult Dis Conf*. 48:79.
31. Hafez, H.M. 1996. Current status on the role of *Ornithobacterium rhinotracheale* (ORT) in respiratory disease complexes in poultry. *Archiv fuer Gefluegelkunde* 60:208–211.
32. Hafez, H.M. 1997. Serological surveillance on *Ornithobacterium rhinotracheale* "ORT" in broiler breeder flocks. *Proc Int Congr World Vet Poult Assoc*. 11:331.
33. Hafez, H.M. 1998. Respiratory diseases in turkey: Serological surveillance for antibodies against *Ornithobacterium rhinotracheale* (ORT) and turkey rhinotracheitis (TRT). *Proc Intl Symp Turkey Dis*. 1:138–145.
34. Hafez, H.M., and W. Beyer. 1997. Preliminary investigation on *Ornithobacterium rhinotracheale* (ORT) isolates using PCR-fingerprints. *Proc Intl Congr World Vet Poult Assoc*. 11:51.
35. Hafez, H.M., and S. Friedrich. 1998. Isolierung von *Ornithobacterium rhinotracheale* "ORT" aus Mastputen in Österreich. *Tieraerztliche Umschau*. 53:500–504.
36. Hafez, H.M., S. Jodas, A. Stadler, and P. van Empel. 1999. Efficacy of *Ornithobacterium rhinotracheale* inactivated vaccine in commercial turkey under field condition. *Proc Intl Symp Turkey Dis*. 2:107–117.
37. Hafez, H.M., W. Kruse, J. Emele, and R. Sting. 1993. Eine Atemwegsinfektion bei Mastputen durch Pasteurella-ähnliche Erreger: Klinik, Diagnostik und Therapie. In: *Proc Intl Conf Poult Dis*. Potsdam, Germany, 105–112.
38. Hafez, H.M., and M. Lierz. 2010. *Ornithobacterium rhinotracheale* in nextling falcons. *Avian Dis*. 54:161–163.
39. Hafez, H.M., A. Mazaheri, and R. Sting. 2000. Efficacy of ELISA for detection of antibodies against several *Ornithobacterium rhinotracheale* serotypes. *Deutsche Tierärztliche Wochenschrift*. 107:142–143.
40. Hafez, H.M., and C. Popp. 2003. *Ornithobacterium rhinotracheale*: Bestimmung der Pathogenität an Hühnerembryonen. Proc 64th Schriftreihe der Deutsche Veterinärmedizinische Gesellschaft (DVG), Fachgruppe "Geflügelkrankheiten." Deutsche Veterinär medizinische Gesellschaft, Giessen, Fachgespräch, Hannover, Germany, 79–85.
41. Hafez, H.M., and D. Schulze. 2003. Examination on the efficacy of chemical disinfectants on *Ornithobacterium rhinotracheale in vitro*. *Archiv fuer Gefluegelkunde*. 67:153–156.
42. Hafez, H.M., and R. Sting. 1999. Investigations on different *Ornithobacterium rhinotracheale* "ORT" isolates. *Avian Dis*. 43:1–7.
43. Heeder, C.J., V.C. Lopes, K.V. Nagaraja, D.P. Shaw, and D.A. Halvorson. 2001. Seroprevalence of *Ornithobacterium rhinotracheale* infection in commercial laying hens in the North Central region of the United States. *Avian Dis*. 45:1064–1067.
44. Hinz, K.H., C. Blome, and M. Ryll. 1994. Acute exudative pneumonia and airsacculitis associated with *Ornithobacterium rhinotracheale* in turkeys. *Vet Rec*. 135:233–234.
45. Hinz, K.H., and H.M. Hafez. 1997. The early history of *Ornithobacterium rhinotracheale* (ORT). *Archiv fuer Gefluegel Kunde*. 61:95–96.
46. Hung, A.L., and A. Alvarado. 2001. Phenotypic and molecular characterization of isolates of *Ornithobacterium rhinotracheale* from Peru. *Avian Dis*. 45:999–1005.
47. Jirjis, F.F., S.L. Noll, D.A. Halvorson, K.V. Nagaraja, F. Martin, and D.P. Shaw. 2004. Effects of bacterial coinfection on the pathogenesis of avian pneumovirus infection in turkeys. *Avian Dis*. 48:34–49.
48. Joubert, P., R. Higgins, A. Laperle, I. Mikaelian, D. Venne, and A. Silim. 1999. Isolation of *Ornithobacterium rhinotracheale* from turkeys in Quebec, Canada. *Avian Dis*. 43:622–626.
49. Koga, Y., and A.I. Zavaleta. 2005. Intraspecies genetic variability of *Ornithobacterium rhinotracheale* in commercial birds in Peru. *Avian Dis*. 49:108–111.
50. Leroy-Sétrin, S., G. Flaujac, K. Thénaisy, and E. Chaslus-Dancla. 1998. Genetic diversity of *Ornithobacterium rhinotracheale* strains isolated from poultry in France. *Letters Appl Microbiol*. 26:189–193.
51. Lopes, V., A. Back, D.A. Halvorson, and K.V. Nagaraja. 2002. Minimization of pathologic changes in *Ornithobacterium rhinotracheale* infection in turkeys by temperature-sensitive mutant strain. *Avian Dis*. 46:177–185.
52. Lopes, V., A. Back, H.J. Shin, D.A. Halvorson, and K.V. Nagaraja. 2002. Development, characterization, and preliminary evaluation of a temperature-sensitive mutant of *Ornithobacterium rhinotracheale* for potential use as a live vaccine in turkeys. *Avian Dis*. 46:162–168.
53. Lopes, V., G. Rajashekara, A. Back, D.P. Shaw, D.A. Halvorson, and K.V. Nagaraja. 2000. Outer membrane proteins for serologic detection of *Ornithobacterium rhinotracheale* infection in turkeys. *Avian Dis*. 44:957–962.
54. Lopes, V., B. Velayudhan, D.A. Halvorson, and K.V. Nagaraja. 2002. Survival of *Ornithobacterium rhinotracheale* in sterilized poultry litter. *Avian Dis*. 46:1011–1014.
55. Malik, Y.S., K. Olsen, K. Kumar, and S.M. Goyal. 2003. *In vitro* antibiotic resistance profiles of *Ornithobacterium rhinotracheale* strains from Minnesota turkeys during 1996–2002. *Avian Dis*. 47:588–593.
56. Marien, M., A. Decostere, A. Martel, K. Chiers, R. Froyman, and H. Nauwynck. 2005. Synergy between avian pneumovirus and *Ornithobacterium rhinotracheale* in turkeys. *Avian Pathol*. 34:204–211.

57. Marien, M., H. Nauwynck, L. Duchateau, A. Martel, K. Chiers, L. Devriese, R. Froyman, and A. Decostere. 2006. Comparison of the efficacy of four antimicrobial treatment schemes against experimental *Ornithobacterium rhinotracheale* infection in turkey poults pre-infected with avian pneumovirus. *Avian Pathol*. 35:230–237.
58. Naeem, K., A. Malik, and A. Ullah. 2003. Seroprevalence of *Ornithobacterium rhinotracheale* in chickens in Pakistan. *Vet Rec*. 153:533–534.
59. Nagaraja, K., A. Back, S. Sorenger, G. Rajashekara, and D. Halvorson. 1998. Tissue distribution post-infection and antimicrobial sensitivity of *Ornithobacterium rhinotracheale*. *Proc West Poult Dis Conf*. 47:57–60.
60. Odor, E.M., M. Salem, C.R. Pope, B. Sample, M. Primm, K. Vance, and M. Murphy. 1997. Isolation and identification of *Ornithobacterium rhinotracheale* from commercial broiler flocks on the Delmarva Peninsula. *Avian Dis*. 41:257–260.
61. Popp, C., and H.M. Hafez. 2002. Investigations on *Ornithobacterium rhinotracheale*. *Proc Intl Symp Turkey Dis*. 4:245–252.
62. Popp, C., and H.M. Hafez. 2003. Ornithobacterium Rhinotracheale: Differenzierung Verschiedener Isolate Mittels Serotypisierung und Pulsfeld-Gelelektrophorese. In: *Proc 64th Schriftreihe der Deutsche Veterinärmedizinische Gesellschaft (DVG), Fach gruppe "Geflügelkrankheiten."* Fachgespräch, Hannover, Germany, 70–78.
63. Post, K.W., S.C. Murphy, J.B. Boyette, and P.M. Resseguie. 1999. Evaluation of a commercial system for the identification of *Ornithobacterium rhinotracheale*. *J Vet Diagn Invest*. 11:97–99.
64. Refai, M., A. El-Gohary, S.A. Attia, and R.A. Khalifa. 2005. Diagnosis of *Ornithobacterium rhinotracheale* infection in chickens by ELISA. *Egypt J Immunol*. 12:87–93.
65. Roepke, D.C. 2001. Unpublished data.
66. Roepke, D.C., A. Back, D.P. Shaw, K.V. Nagaraja, S.J. Sprenger, and D.A. Halvorson. 1998. Isolation and identification of *Ornithobacterium rhinotracheale* from commercial turkey flocks in the upper Midwest. *Avian Dis*. 42:219–221.
67. Ryll, M., R. Gunther, H.M. Hafez, and K.H. Hinz. 2002. Isolierung und Differenzierung eines Cytochromoxidase-negativen Ornithobacterium rhinotracheale-Stamms aus Puten. *Berl Munch Tierarztl Wochenschr*. 115:274–277.
68. Ryll, M., K.H. Hinz, U. Neumann, U. Löhren, M. Südbeck, and D. Steinhagen. 1997. Pilotstudie zur Prävalenz der Ornithobacterium rhinotracheale-Infektion bei Masthühnern in Nordwestdeutschland. *Berl Munch Tierarztl Wochenschr*. 110:267–271.
69. Ryll, M., K.H. Hinz, H. Salisch, and W. Kruse. 1996. Pathogenicity of *Ornithobacterium rhinotracheale* for turkey poults under experimental conditions. *Vet Rec*. 139:19.
70. Sakai, E., Y. Tokuyama, F. Nonaka, S. Ohishi, Y. Ishikawa, M. Tanaka, and A. Taneno. 2000. *Ornithobacterium rhinotracheale* infection in Japan: preliminary investigations. *Vet Rec*. 146:502–503.
71. Salem, M., E.M. Odor, B. Sample, M. Murphy, and G. Franz. 1997. *Ornithobacterium rhinotracheale*, update and field survey in the Delmarva Peninsula. *Proc West Poult Dis Conf*. 46:59.
72. Schuijffel, D.F., P.C. van Empel, A.M. Pennings, J.P. Van Putten, and P.J. Nuijten. 2005. Passive immunization of immune-suppressed animals: chicken antibodies protect against *Ornithobacterium rhinotracheale* infection. *Vaccine*. 23:3404–3411.
73. Schuijffel, D.F., P.C. van Empel, A.M. Pennings, J.P. van Putten, and P.J. Nuijten. 2005. Successful selection of cross-protective vaccine candidates for *Ornithobacterium rhinotracheale infection*. *Infect Immun*. 73:12–21.
74. Schuijffel, D.F., P.C. van Empel, R.P. Segers, J.P. Van Putten, and P.J. Nuijten. 2006. Vaccine potential of recombinant *Ornithobacterium rhinotracheale* antigens. *Vaccine*. 24:1858–1867.
75. Soriano Vargas, E., P. Fernandez Rosas, and G. Tellez Isais. 2000. *Ornithobacterium rhinotracheale*: Un agente patogeno emergente en avicultura. *Vet Mex*. 31:245–253.
76. Soriano, V.E., M.G. Longinos, P.G. Navarrete, and R.P. Fernandez. 2002. Identification and characterization of *Ornithobacterium rhinotracheale* isolates from Mexico. *Avian Dis*. 46:686–690.
77. Soriano, V.E., N.A. Vera, C.R. Salado, R.P. Fernandez, and P.J. Blackall. 2003. *In vitro* susceptibility of *Ornithobacterium rhinotracheale* to several antimicrobial drugs. *Avian Dis*. 47:476–480.
78. Soto, E. 1999. Unpublished data.
79. Sprenger, S.J., A. Back, D.P. Shaw, K.V. Nagaraja, D.C. Roepke, and D.A. Halvorson. 1998. *Ornithobacterium rhinotracheale* infection in turkeys: experimental reproduction of the disease. *Avian Dis*. 42:154–161.
80. Sprenger, S.J., D.A. Halvorson, K.V. Nagaraja, R. Spasojevic, R.S. Dutton, and D.P. Shaw. 2000. *Ornithobacterium rhinotracheale* infection in commercial laying-type chickens. *Avian Dis*. 44:725–729.
81. Sprenger, S.J., D.A. Halvorson, D.P. Shaw, and K.V. Nagaraja. 2000. *Ornithobacterium rhinotracheale* infection in turkeys: immunoprophylaxis studies. *Avian Dis*. 44:549–555.
82. Szalay, D., R. Glavits, C. Nemes, A. Kosa, and L. Fodor. 2002. Clinical signs and mortality caused by *Ornithobacterium rhinotracheale* in turkey flocks. *Acta Vet Hung*. 50:297–305.
83. Tabatabai, L.B., M.K. Zimmerli, E.S. Zehr, R.E. Briggs, and F.M. Tatum. 2010. *Ornithobacterium rhinotracheale* North American field isolates express a hemolysin-like protein. *Avian Dis*. 54:994–1001.
84. Tanyi, J., A. Bistyak, E. Kaszanyitzky, F. Vetesi, and M. Dobos-Kovacs. 1995. Isolation of *Ornithobacterium rhinotracheale* from chickens, hens and turkeys showing respiratory symptoms. Preliminary report. *Magyar Allatorvosok Lapja*. 50:328–330.
85. Travers, A.F. 1996. Concomitant *Ornithobacterium rhinotracheale* and Newcastle disease infection in broilers in South Africa. *Avian Dis*. 40:488–490.
86. Travers, A.F., L. Coetzee, and B. Gummow. 1996. Pathogenicity differences between South African isolates of *Ornithobacterium rhinotracheale*. *Onderstepoort J Vet Res*. 63:197–207.
87. Turan, N., and S. Ak. 2002. Investigation of the presence of *Ornithobacterium rhinotracheale* in chickens in Turkey and determination of the seroprevalance of the infection using the enzyme-linked immunosorbent assay. *Avian Dis*. 46:442–446.
88. van Beek, P.N.G.M., P.C.M. van Empel, G. van den Bosch, P.K. Storm, J.H. Bongers, and J.H. Du Preez. 1994. Adem halings problemen, groeivertraging en gewrichtsontsteking bij kalkoenen en vleeskuikens door een Pasteurella-achtige bacterie: *Ornithobacterium rhinotracheale* or "Taxon 28." *Tijdschrift voor Dier genee skunde*. 119:99–101.
89. van Empel, P. 1997. *Ornithobacterium rhinotracheale*: An update. Proc Fachgruppe "Geflügelkrankheiten" der Deutsche Veterinärmedizinische Gesellschaft. Hannover, Germany, 20–25.
90. van Empel, P. 1998. *Ornithobacterium rhinotracheale*. PhD dissertation. Universiteit Utrecht.
91. van Empel, P. 1998. *Ornithobacterium rhinotracheale*: Current status and control. *Proc Intl Symp Turkey Dis*. 1:129–137.
92. van Empel, P. 1998. Unpublished data.
93. van Empel, P. 2000. Unpublished data.

94. van Empel, P., and H. van den Bosch. 1998. Vaccination of chickens against *Ornithobacterium rhinotracheale* infection. *Avian Dis*. 42:572–578.
95. van Empel, P., H. van den Bosch, D. Goovaerts, and P. Storm. 1996. Experimental infection in turkeys and chickens with *Ornithobacterium rhinotracheale*. *Avian Dis*. 40:858–864.
96. van Empel, P., H. van den Bosch, P. Loeffen, and P. Storm. 1997. Identification and serotyping of *Ornithobacterium rhinotracheale*. *J Clin Microbiol*. 35:418–421.
97. van Empel, P., M. Vrijenhoek, D. Goovaerts, and H. van den Bosch. 1999. Immunohistochemical and serological investigation of experimental *Ornithobacterium rhinotracheale* infection in chickens. *Avian Pathol*. 28:187–193.
98. van Empel, P.C.M., and H.M. Hafez. 1999. *Ornithobacterium rhinotracheale*: A review. *Avian Pathol*. 28:217–227.
99. van Loock, M., T. Geens, L. De Smit, H. Nauwynck, P. van Empel, C. Naylor, H.M. Hafez, B.M. Goddeeris, and D. Vanrompay. 2005. Key role of *Chlamydophila psittaci* on Belgian turkey farms in association with other respiratory pathogens. *Vet Microbiol*. 107:91–101.
100. van Veen, L., E. Gruys, K. Frik, and P. van Empel. 2000. Increased condemnation of broilers associated with *Ornithobacterium rhinotracheale*. *Vet Rec*. 147:422–423.
101. van Veen, L., E. Hartman, and T. Fabri. 2001. *In vitro* antibiotic sensitivity of strains of *Ornithobacterium rhinotracheale* isolated in The Netherlands between 1996 and 1999. *Vet Rec*. 149:611–613.
102. van Veen, L., J. Nieuwenhuizen, D. Mekkes, M. Vrijenhoek, and P. van Empel. 2005. Diagnosis and incidence of *Ornithobacterium rhinotracheale* infections in commercial broiler chickens at slaughter. *Vet Rec*. 156:315–317.
103. van Veen, L., P. van Empel, and T. Fabri. 2000. *Ornithobacterium rhinotracheale*, a primary pathogen in broilers. *Avian Dis*. 44:896–900.
104. van Veen, L., M. Vrijenhoek, and P. van Empel. 2004. Studies of the transmission routes of *Ornithobacterium rhinotracheale* and immunoprophylaxis to prevent infection in young meat turkeys. *Avian Dis*. 48:233–237.
105. Vandamme, P., P. Segers, M. Vancanneyt, K. van Hove, R. Mutters, J. Hommez, F. Dewhirst, B. Paster, K. Kersters, E. Falsen, L.A. Devriese, M. Bisgaard, K.H. Hinz, and W. Mannheim. 1994. *Ornithobacterium rhinotracheale* gen. nov., sp. nov., isolated from the avian respiratory tract. *Int J System Bacteriol*. 44:24–37.
106. Vandamme, P., M. Vancaneyt, P. Segers, M. Ryll, B. Köhler, and K.H. Hinz. 1999. *Coenonia anatina* gen. nov. sp. nov. a novel bacterium associated with respiratory disease in ducks and geese. *Int J System Bacteriol*. 49:867–874.
107. Varga, J., L. Fodor, and L. Makrai. 2001. Characterisation of some *Ornithobacterium rhinotracheale* strains and examination of their transmission via eggs. *Acta Vet Hung*. 49:125–130.
108. Zorman-Rojs, O., I. Adovc, D. Bencina, and I. Mrzel. 2000. Infection of turkeys with *Ornithobacterium rhinotracheale* and *Mycoplasma synoviae*. *Avian Dis*. 44:1017–1022.

Bordetellosis (Turkey Coryza)

1. Akeila, M.A., and Y.M. Saif. 1988. Protection of turkey poults from *Bordetella avium* infection and disease by pili and bacterins. *Avian Dis*. 32:641–649.
2. Andral, B., C. Louzis, D. Tarp, J.A. Newman, G. Bennejean, and R. Gaumont. 1985. Respiratory disease (rhinotracheitis) in turkeys in Brittany, France, 1981–1982. I. Field observations and serology. *Avian Dis*. 26–34.
3. Anonymus. 1985. Turkey rhinotracheitis of unknown aetiology in England and Wales: A preliminary report from the British Veterinary Poultry Association. *Vet Rec*. 653–654. 1985.
4. Arp, L.H., and N.F. Cheville. 1984. Tracheal lesions in young turkeys infected with *Bordetella avium*. *Am J Vet Res*. 45:2196–2200.
5. Arp, L.H., and S.M. McDonald. 1985. Influence of temperature on the growth of *Bordetella avium* in turkeys and *in vitro*. *Avian Dis*. 29:1066–1077.
6. Arp, L.H. 1986. Adherence of *Bordetella avium* to turkey tracheal mucosa: effects of culture conditions. *Am J Vet Res*. 47:2618–2620.
6a. Arp, L.H., and E.E. Brooks. 1986. An *in vivo* model for the study of *Bordetella avium* adherence to tracheal mucosa in turkeys. *Am J Vet Res*. 47:2614–2617.
7. Arp, L.H., and J.A. 1987. Fagerland. Ultrastructural pathology of *Bordetella avium* infection in turkeys. *Vet Pathol*. 24:411–418.
8. Arp, L.H., and D.H. Hellwig. 1988. Passive immunization versus adhesion of *Bordetella avium* to the tracheal mucosa of turkeys. *Avian Dis*. 32:494–500.
9. Arp, L.H., R.D. Leyh, and R.W. Griffith. 1988. Adherence of *Bordetella avium* to tracheal mucosa of turkeys: correlation with hemagglutination. *Am J Vet Res*. 49:693–696.
10. Arp, L.H., E.L. Huffman, and D.H. Hellwig. 1993. Glycoconjugates as components of receptors for *Bordetella avium* on the tracheal mucosa of turkeys. *Am J Vet Res*. 54:2027–2030.
11. Barbour, E.K., M.K. Brinton, S.D. Torkelson, J.B. Johnson, and P.E. Poss. 1991. An enzyme-linked immunosorbent assay for detection of *Bordetella avium* infection in turkey flocks: sensitivity, specificity, and reproducibility. *Avian Dis*. 35:308–314.
12. Barnes, H.J., and M.S. Hofstad. 1983. Susceptibility of turkey poults from vaccinated and unvaccinated hens to alcaligenes rhinotracheitis (turkey coryza). *Avian Dis*. 27:378–392.
13. Berkhoff, H.A., F.M. McCorkle, Jr., and T.T. Brown. 1983. Pathogenicity of various isolates of *Alcaligenes faecalis* for broilers. *Avian Dis*. 27:707–713.
14. Berkhoff, H.A., H.J. Barnes, S.I. Ambrus, M.D. Kopp, G.D. Riddle, and D.C. Kradel. 1984. Prevalence of *Alcaligenes faecalis* in North Carolina broiler flocks and its relationship to respiratory disease. *Avian Dis*. 28:912–920.
15. Berkhoff, H.A., and G.D. Riddle. 1984. Differentiation of *Alcaligenes*-like bacteria of avian origin and comparison with *Alcaligenes* spp. reference strains. *J Clin Microbiol*. 19:477–481.
16. Blackall, P.J., and J.G. Farrah. 1985. Isolation of *Bordetella avium* from poultry. *Aust Vet J*. 62:370–372.
16a. Blackall, P.J., and J.G. Farrah. 1986. An evaluation of two methods of substrate alkalinization for the identification of *Bordetella avium* and other similar organisms. *Vet Microbiol*. 11:301–306.
16b. Blackall, P.J., and C.M. Doheny. 1987. Isolation and characterisation of *Bordetella avium* and related species and an evaluation of their role in respiratory disease in poultry. *Aust Vet J*. 64:235–239.
17. Blackall, P.J., and D.G. Rogers. 1991. Absence of mouse-lethal toxins in Australian isolates of *Bordetella avium*. *Vet Microbiol*. 27:393–396.

18. Blalock, H.G., D.G. Simmons, K.E. Muse, J.G. Gray, and W.T. Derieux. 1975. Adenovirus respiratory infection in turkey poults. *Avian Dis*. 19:707–716.
19. Blore, P.J., M.F. Slavik, and N.K. Neighbor. 1991. Detection of antibody to *Bordetella avium* using a particle concentration fluorescence immunoassay (PCFIA). *Avian Dis*. 35:756–760.
20. Boycott, B.R., H.R. Wyman, and F.C. Wong. 1984. *Alcaligenes faecalis* rhinotracheitis in Manitoba turkeys. *Avian Dis*. 28:1110–1114.
21. Burke, D.S., and M.M. Jensen. 1980. Immunization against turkey coryza by colonization with mutants of *Alcaligenes faecalis*. *Avian Dis*. 24:726–733. 1980.
22. Burke, D.S., and M.M. Jensen. 1981. Field vaccination trials against turkey coryza using a temperature-sensitive mutant of *Alcaligenes faecalis*. *Avian Dis*. 25:96–103.
23. Cimiotti, W., G. Glunder, and K.H. Hinz. 1982. Survival of the bacterial turkey coryza agent. *Vet Rec*. 110:304–306.
24. Collins, L.U., A. Fatmi, and F. Schodel. 1996. Gene regulation in *Bordetella avium*. Abstract B-171, 184. 96th General Meeting of the American Society for Microbiology. May 19–23.
25. Collins, M.S., and R.E. Gough. 1988. Characterization of a virus associated with turkey rhinotracheitis. *J Gen Virol*. 69:909–916.
26. Cook, J.K., M.M. Ellis, and M.B. Huggins. 1991. The pathogenesis of turkey rhinotracheitis virus in turkey poults inoculated with the virus alone or together with two strains of bacteria. *Avian Pathol*. 20:155–166.
27. Cookson, B.T., P. Vandamme, L.C. Carlson, A.M. Larson, J.V. Sheffield, K. Kersters, and D.H. Spach. 1994. Bacteremia caused by a novel *Bordetella* species, "*B. hinzii*." *J Clin Microbiol*. 32:2569–2571.
28. Cutter, D.L., and G.H. Luginbuhl. 1991. Characterization of sulfonamide resistance determinants and relatedness of *Bordetella avium* R plasmids. *Plasmid*. 26:136–140.
29. Dillman, R.C., and D.G. Simmons. 1977. Histopathology of a rhinotracheitis of turkey poults associated with adenoviruses. *Avian Dis*. 21:481–491.
30. Domingo, D.T., M.W. Jackwood, and T.P. Brown. 1992. Filamentous forms of *Bordetella avium*: culture conditions and pathogenicity. *Avian Dis*. 36:707–713.
31. Edens, F.W., F.M. McCorkle, and D.G. Simmons. 1984. Body temperature response of turkey poults infected with A*lcaligenes faecalis*. *Avian Pathol*. 13:787–795.
32. Edens, F.W., F.M. McCorkle, D.G. Simmons, and A.G. Yersin. 1987. Brain monoamine concentrations in turkey poults infected with *Bordetella avium*. *Avian Dis*. 31:504–508.
33. Edens, F.W., F.M. McCorkle, D.G. Simmons, and A.G. Yersin. 1987. Effects of *Bordetella avium* on lymphoid tissue monoamine concentrations in turkey poults. *Avian Dis*. 31:746–751.
34. Edens, F.W., J.D. May, A.G. Yersin, and H.M. Brown-Borg. 1991. Effect of fasting on plasma thyroid and adrenal hormone levels in turkey poults infected with *Bordetella avium*. *Avian Dis*. 35:344–347.
35. Ficken, M.D. 1983. Antibiotic aerosolization for treatment of alcaligenes rhinotracheitis. *Avian Dis*. 27:545–548.
36. Ficken, M.D., J.F. Edwards, and J.C. Lay. 1986. Clearance of bacteria in turkeys with *Bordetella avium*-induced tracheitis. *Avian Dis*. 30:352–357.
37. Filion, P.R., S. Cloutier, E.R. Vrancken, and G. Bernier. 1967. Infection respiratoire du dindonneau causee par un microbe apparente au *Bordetella bronchiseptica*. *Can J Comp Med Vet Sci*. 31(5):129–143.
38. Funke, G., T. Hess, A. von Graevenitz, and P. Vandamme. 1996. Characteristics of *Bordetella hinzii* strains isolated from a cystic fibrosis patient over a 3-year period. *J Clin Microbiol*. 34:966–969.
39. Gentry-Weeks, C.R., B.T. Cookson, W.E. Goldman, R.B. Rimler, S.B. Porter, and R. Curtiss, 3rd. 1988. Dermonecrotic toxin and tracheal cytotoxin, putative virulence factors of *Bordetella avium*. *Infect Immun*. 56:1698–1707.
40. Gentry-Weeks, C.R., D.L. Provence, J.M. Keith, and R. Curtiss, 3rd. 1991. Isolation and characterization of *Bordetella avium* phase variants. *Infect Immun*. 59:4026–4033.
41. Gentry-Weeks, C.R., A.L. Hultsch, S.M. Kelly, J.M. Keith, and R. Curtiss, 3rd. 1992. Cloning and sequencing of a gene encoding a 21-kilodalton outer membrane protein from *Bordetella avium* and expression of the gene in *Salmonella typhimurium*. *J Bacteriol*. 174:7729–7742.
42. Gentry-Weeks, C.R., J.M. Keith, and J. Thompson. 1993. Toxicity of *Bordetella avium* beta-cystathionase toward MC3T3-E1 osteogenic cells. *J Biol Chem*. 268:7298–7314.
43. Glunder, G., H. van der Ven, and A. Foulman. 2004. Studies on the efficacy of different adjuvants in live stock specific bacterial vaccines for turkeys against *Bordetella* infection and onset of antibody titers in respect to the age of the turkey poults. *Pol J Vet Sci*. 7:77–81.
44. Goldman, W.E., and L.A. Herwaldt. 1985. *Bordetella pertussis* tracheal cytotoxin. *Dev Biol Stand*. 61:103–111.
45. Gray, J.G., J.F. Roberts, R.C. Dillman, and D.G. Simmons. 1981. Cytotoxic activity of pathogenic *Alcaligenes faecalis* in turkey tracheal organ cultures. *Am J Vet Res*. 42:2184–2186.
46. Gray, J.G., J.F. Roberts, R.C. Dillman, and D.G. Simmons. 1983. Pathogenesis of change in the upper respiratory tracts of turkeys experimentally infected with an *Alcaligenes faecalis* isolate. *Infect Immun*. 42:350–355.
47. Gray, J.G., J.F. Roberts, and D.G. Simmons. 1983. *In vitro* cytotoxicity of an *Alcaligenes faecalis* and its relationship in *in vivo* tracheal pathologic changes in turkeys. *Avian Dis*. 27:1142–1150.
48. Harrington, A.T., J.A. Castellanos, T.M. Ziedalski, J.E. Clarridge, 3rd, and B.T. Cookson. 2009. Isolation of *Bordetella avium* and novel *Bordetella* strain from patients with respiratory disease. *Emerg Infect Dis*. 15:72–74.
49. Heller, E.D., Y. Weisman, and A. Aharonovovitch. 1984. Experimental studies on turkey coryza. *Avian Pathol*. 13:137–143.
50. Hellwig, D.H., L.H. Arp, and J.A. Fagerland. 1988. A comparison of outer membrane proteins and surface characteristics of adhesive and non-adhesive phenotypes of *Bordetella avium*. *Avian Dis*. 32:787–792.
51. Hellwig, D.H., and L.H. Arp. 1990. Identification of *Bordetella avium* antigens recognized after experimental inoculation in turkeys. *Am J Vet Res*. 51:1188–1191.
52. Herzog, M., M.F. Slavik, J.K. Skeeles, and J.N. Beasley. 1986. The efficacy of a temperature-sensitive mutant vaccine against Northwest Arkansas isolates of *Alcaligenes faecalis*. *Avian Dis*. 30:112–116.
53. Hinz, K.H., G. Glunder, and H. Luders. 1978. Acute respiratory disease in turkey poults caused by *Bordetella bronchiseptica*-like bacteria. *Vet Rec*. 103:262–263.
54. Hinz, K.H., G. Korthas, H. Luders, B. Stiburek, G. Glunder, H.E. Brozeit, and T. Redmann. 1981. Passive immunisation of turkey poults against turkey coryza (bordetellosis) by vaccination of parent breeders. *Avian Pathol*. 10:441–447. 1981.

55. Hinz, K.H., G. Gluinder, and K.J. Romer. 1983. A comparative study of avian bordetella-like strains, *Bordetella bronchiseptica, Alcaligenes faecalis* and other related nonfermentable bacteria. *Avian Pathol*. 12:263–276.

55a. Hinz, K.H., and G. Glunder. 1986. Identification of *Bordetella avium* sp. nov. by the API 20 NE system. *Avian Pathol*. 15:611–614.

56. Hinz, K.H., U. Heffels-Redmann, and M. Poppel. 1992. [Multicausal infectious respiratory tract disease of young fattening turkeys]. *Dtsch Tierarztl Wochenschr*. 99:75–78.

57. Hinz, K.H., M. Rull, U. Heffels-Redmann, and M. Poeppel. 1992. Multicausal infectious respiratory disease of turkey poults. *Dtsch Tierarztl Wochenschr*. 75–78.

58. Hofstad, M.S., and E.L. Jeska. 1985. Immune response of poults following intranasal inoculation with Artvax vaccine and a formalin-inactivated *Bordetella avium* bacterin. *Avian Dis*. 29:746–754.

59. Hollamby, S., J.G. Sikarskie, and J. Stuht. 2003. Survey of peafowl (*Pavo cristatus*) for potential pathogens at three Michigan zoos. *J Zoo Wildl Med*. 34:375–379.

60. Hopkins, B.A., J.K. Skeeles, G.E. Houghten, and J.D. Story. 1988. Development of an enzyme-linked immunosorbent assay for *Bordetella avium*. *Avian Dis*. 32:353–361.

61. Hopkins, B.A., J.K. Skeeles, G.E. Houghten, D. Slagle, and K. Gardner. 1990. A survey of infectious diseases in wild turkeys (*Meleagridis gallopavo silvestris*) from Arkansas. *J Wildl Dis*. 26:468–472.

62. Houghten, G.E., J.K. Skeeles, M. Rosenstein, J.N. Beasley, and M.F. Slavik. 1987. Efficacy in turkeys of spray vaccination with a temperature-sensitive mutant of *Bordetella avium* (Art Vax). *Avian Dis*. 31:309–314.

63. Hristov, A.C., P.G. Auwaerter, M. Romagnoli, and K.C. Carroll. 2008. *Bordetella hinzii* septicemia in association with Epstein-Barr virus viremia and an Epstein-Barr virus-associated diffuse large B-cell lymphoma. *Diagn Microbiol Infect Dis*. 61:484–486.

64. Jackwood, D.J., and Y.M. Saif. 1980. Development and use of amicroagglutination test to detect antibodies to *Alcaligenes faecalis* in turkeys. *Avian Dis*. 24:685–701.

65. Jackwood, D.J., Y.M. Saif, P.D. Moorhead, and R.N. Dearth. 1982. Infectious bursal disease virus and *Alcaligenes faecalis* infections in turkeys. *Avian Dis*. 26:365–374.

66. Jackwood, M.W., and Y.M. Saif. 1985. Efficacy of a commercial turkey coryza vaccine (Art-Vax) in turkey poults. *Avian Dis*. 29:1130–1139.

67. Jackwood, M.W., Y.M. Saif, P.D. Moorhead, and R.N. Dearth. 1985. Further characterization of the agent causing coryza in turkeys. *Avian Dis*. 29:690–705.

68. Jackwood, M.W., M. Sasser, and Y.M. Saif. 1986. Contribution to the taxonomy of the turkey coryza agent: cellular fatty acid analysis of the bacterium. *Avian Dis*. 30:172–178.

69. Jackwood, M.W., and Y.M. Saif. 1987. Pili of *Bordetella avium*: expression, characterization, and role in *in vitro* adherence. *Avian Dis*. 31:277–286.

70. Jackwood, M.W., and Y.M. Saif. 1987. Lack of protection against *Bordetella avium* in turkey poults exposed to *B. avium*-like bacteria. *Avian Dis*. 31:597–600.

71. Jackwood, M.W., Y.M. Saif, and D.L. Coplin. 1987. Isolation and characterization of *Bordetella avium* plasmids. *Avian Dis*. 31:782–786.

72. Jackwood, M.W., D.A. Hilt, and P.A. Dunn. 1991. Observations on colonial phenotypic variation in *Bordetella avium*. *Avian Dis*. 35:496–504.

73. Jackwood, M.W., S.M. McCarter, and T.P. Brown. 1995. *Bordetella avium*: an opportunistic pathogen in Leghorn chickens. *Avian Dis*. 39:360–367.

74. Jensen, M.M., and M.S. Marshall. 1981. Control of turkey *Alcaligenes rhinotracheitis* in Utah with a live vaccine. *Avian Dis*. 25:1053–1057.

75. Kattar, M.M., J.F. Chavez, A.P. Limaye, S.L. Rassoulian-Barrett, S.L. Yarfitz, L.C. Carlson, Y. Houze, S. Swanzy, B.L. Wood, and B.T. Cookson. 2000. Application of 16S rRNA gene sequencing to identify *Bordetella hinzii* as the causative agent of fatal septicemia. *J Clin Microbiol*. 38:789–794.

76. Kelly, B.J., G.Y. Ghazikhanian, and B. Mayeda. 1986. Clinical outbreak of *Bordetella avium* infection in two turkey breeder flocks. *Avian Dis*. 30:234–237.

77. Kersters, K., K.H. Hinz, A. Hertle, P. Segers, A. Lievens, O. Siegmann, and J. De Ley. 1984. *Bordetella avium* sp. nov. isolated from the respiratory tracts of turkeys and other birds. *Int J Syst Bacteriol*. 34:56–70.

78. King, N.D., A.E. Kirby, and T.D. Connell. 2005. Transcriptional control of the rhuIR-bhuRSTUV heme acquisition locus in *Bordetella avium*. *Infect Immun*. 73:1613–1624.

79. Kirby, A.E., D.J. Metzger, E.R. Murphy, and T.D. Connell. 2001. Heme utilization in *Bordetella avium* is regulated by RhuI, a heme-responsive extracytoplasmic function sigma factor. *Infect Immun*. 69:6951–6961.

80. Kirby, A.E., N.D. King, and T.D. Connell. 2004. RhuR, an extracytoplasmic function sigma factor activator, is essential for heme-dependent expression of the outer membrane heme and hemoprotein receptor of *Bordetella avium*. *Infect Immun*. 72:896–907.

81. Leyh, R., and R.W. Griffith. 1992. Characterization of the outer membrane proteins of *Bordetella avium*. *Infect Immun*. 60:958–964.

82. Leyh, R.D., R.W. Griffith, and L.H. Arp. 1988. Transposon mutagenesis in *Bordetella avium*. *Am J Vet Res*. 49:687–692.

83. Lindsey, D.G., P.D. Andrews, G.S. Yarborough, J.K. Skeeles, B. Glidewell-Erickson, G. Campbell, and M.B. Blankford. *Evaluation of a commercial ELISA kit for detection and quantitation of antibody against Bordetella avium*. Abstract 31, Proc 75th Ann Meet Conf Res Workers Anim Dis. Chicago, IL. 1994.

84. Lister, S.A., and D.J. Alexander. 1986. Turkey rhinotracheitis: A review. *Vet Bull*. 56:637–663.

85. Loker, S.B., L.M. Temple, and A. Preston. 2011. The *Bordetella avium* BAV1965–1962 fimbrial locus is regulated by temperature and produces fimbriae involved in adherence to turkey tracheal tissue. *Infect Immun*. 79:2423–2429.

86. Luginbuhl, G.H., D.L. Cutter, G. Campodonico, J. Peace, and D.F. Simmons. 1986. Plasmid DNA of virulent *Alcaligenes faecalis*. *Am J Vet Res*. 47(3):619–621.

87. Marshall, D.R., D.G. Simmons, and J.G. Gray. 1984. Evidence for adherence-dependent cytotoxicity of *Alcaligenes faecalis* in turkey tracheal organ cultures. *Avian Dis*. 28:1007–1015.

88. Marshall, D.R., D.G. Simmons, and J.G. Gray. 1985. An *Alcaligenes faecalis* isolate from turkeys: pathogenicity in selected avian and mammalian species. *Am J Vet Res*. 46:1181–1184.

89. McBride, M.D., D.W. Hird, T.E. Carpenter, K.P. Snipes, C. Danaye-Elmi, and W.W. Utterback. 1991. Health survey of backyard poultry and other avian species located within one mile of commercial California meat-turkey flocks. *Avian Dis*. 35:403–407.

90. McCorkle, F.M., D.G. Simmons, and G.H. Luginbuhl. 1982. Delayed hypersensitivity response in *Alcaligenes faecalis*-infected turkey poults. *Avian Dis*. 26:782–786.

91. McCorkle, F.M., D.G. Simmons, and G.H. Luginbuhl. 1983. Graft-vs-host response in *Alcaligenes faecalis*-infected turkey poults. *Am J Vet Res*. 44:1141–1142.
92. McCorkle, F.M., and D.G. Simmons. 1984. *In vitro* cellular migration of leukocytes from turkey poults infected with *Alcaligenes faecalis*. *Avian Dis*. 28:853–857.
93. McCorkle, F.M., F.W. Edens, and D.G. Simmons. 1985. *Alcaligenes faecalis* infection in turkeys: effects on serum corticosterone and serum chemistry. *Avian Dis*. 29:80–89.
94. Miyamoto, D.M., K. Ruff, N.M. Beach, S.B. Stockwell, A. Dorsey-Oresto, I. Masters, and L.M. Temple. 2011. *Bordetella avium* causes induction of apoptosis and nitric oxide synthase in turkey tracheal explant cultures. *Microbes Infect*. 13:871–879.
95. Montgomery, R.D., S.H. Kleven, and P. Villegas. 1983. Observations on the pathogenicity of *Alcaligenes faecalis* in chickens. *Avian Dis*. 27:751–761.
96. Moore, C.J., H. Mawhinney, and P.J. Blackall. 1987. Differentiation of *Bordetella avium* and related species by cellular fatty acid analysis. *J Clin Microbiol*. 25:1059–1062.
97. Moore, K.M., and M.W. Jackwood. 1994. Production of monoclonal antibodies to the *Bordetella avium* 41-kilodalton surface protein and characterization of the hemagglutinin. *Avian Dis*. 38:218–224.
98. Mouahid, M., R. Mutters, and W. Mannheim. 1991. Rapid identification of *Bordetella avium* and related organisms on the basis of their cellular carbohydrate patterns. *Avian Pathol*. 20:627–636.
99. Murphy, E.R., R.E. Sacco, A. Dickenson, D.J. Metzger, Y. Hu, P.E. Orndorff, and T.D. Connell. 2002. BhuR, a virulence-associated outer membrane protein of *Bordetella avium*, is required for the acquisition of iron from heme and hemoproteins. *Infect Immun*. 70:5390–5403.
100. Neighbor, N.K., J.K. Skeeles, J.N. Beasley, and D.L. Kreider. 1991. Use of an enzyme-linked immunosorbent assay to measure antibody levels in turkey breeder hens, eggs, and progeny following natural infection or immunization with a commercial *Bordetella avium* bacterin. *Avian Dis*. 35:315–320.
101. Page, R.K., O.J. Fletcher, P.D. Lukert, and R. Rimler. 1978. Rhinotracheitis in turkey poults. *Avian Dis*. 22:529–534.
102. Panigrahy, B., L.C. Grumbles, R.J. Terry, D.L. Millar, and C.F. Hall. 1981. Bacterial coryza in turkeys in Texas. *Poult Sci*. 60:107–113.
103. Pardue, S.L., and G.H. Luginbuhl. 1998. Improvement of poult performance following *Bordetella avium* challenge by administration of a novel oxy-halogen formulation. *Avian Dis*. 42:140–145.
104. Raffel, T.R., K.B. Register, S.A. Marks, and L. Temple. 2002. Prevalence of *Bordetella avium* infection in selected wild and domesticated birds in the eastern USA. *J Wildl Dis*. 38:40–46.
105. Register, K.B., R.E. Sacco, and G.E. Nordholm. 2003. Comparison of ribotyping and restriction enzyme analysis for inter- and intraspecies discrimination of *Bordetella avium* and Bordetella hinzii. *J Clin Microbiol*. 41:1512–1519.
106. Register, K.B., and A.G. Yersin. 2005. Analytical verification of a PCR assay for identification of *Bordetella avium*. *J Clin Microbiol*. 43:5567–5573.
107. Register, K.B., and R.A. Kunkle. 2009. Strain-specific virulence of *Bordetella hinzii* in poultry. *Avian Dis*. 53:50–54.
108. Rhoades, K.R., and R.B. Rimler. 1987. The effects of heat-labile *Bordetella avium* toxin on turkey poults. *Avian Dis.* 31:345–350.
109. Rimler, R.B., and D.G. Simmons. 1983. Differentiation among bacteria isolated from turkeys with coryza (rhinotracheitis). *Avian Dis*. 27:491–500.
110. Rimler, R.B. 1985. Turkey coryza: toxin production by *Bordetella avium*. *Avian Dis*. 29:1043–1047.
111. Rimler, R.B., and K.R. Rhoades. 1986. Fowl cholera: influence of *Bordetella avium* on vaccinal immunity of turkeys to *Pasteurella multocida*. *Avian Dis*. 30:838–839.
112. Rimler, R.B., and K.R. Rhoades. 1986. Turkey coryza: selected tests for detection and neutralization of *Bordetella avium* heat-labile toxin. *Avian Dis*. 30:808–812.
113. Sacco, R.E., K.B. Register, and G.E. Nordholm. 2000. Restriction enzyme analysis and ribotyping distinguish *Bordetella avium* and *Bordetella hinzii* isolates. *Epidemiol Infect*. 124:83–90.
114. Saif, Y.M., P.D. Moorhead, R.N. Dearth, and D.J. Jackwood. 1980. Observations on *Alcaligenes faecalis* infection in turkeys. *Avian Dis*. 24:665–684.
115. Savelkoul, P.H., L.E. de Groot, C. Boersma, I. Livey, C.J. Duggleby, B.A. van der Zeijst, and W. Gaastra. 1993. Identification of *Bordetella avium* using the polymerase chain reaction. *Microb Pathog*. 15:207–215.
116. Sebaihia, M., A. Preston, D.J. Maskell, H. Kuzmiak, T.D. Connell, N.D. King, P.E. Orndorff, D.M. Miyamoto, N.R. Thomson, D. Harris, A. Goble, A. Lord, L. Murphy, M.A. Quail, S. Rutter, R. Squares, S. Squares, J. Woodward, J. Parkhill, and L.M. Temple. 2006. Comparison of the genome sequence of the poultry pathogen *Bordetella avium* with those of *B. bronchiseptica*, *B. pertussis*, and *B. parapertussis* reveals extensive diversity in surface structures associated with host interaction. *J Bacteriol*. 188:6002–6015.
117. Shelton, C.B., L.M. Temple, and P.E. Orndorff. 2002. Use of bacteriophage Ba1 to identify properties associated with *Bordetella avium* virulence. *Infect Immun*. 70:1219–1224.
118. Simmons, D.F., R.K. Page, P.V. Lukert, O.J. Fletcher, S.E. Miller, and R.C. Dillman. 1977. Bursal changes in turkey poults with acute respiratory disease. *J Am Vet Med Assoc*. 171:1104–1105.
119. Simmons, D.G., S.E. Miller, J.G. Gray, H.G. Blalock, and W.M. Colwell. 1976. Isolation and identification of a turkey respiratory adenovirus. *Avian Dis*. 20:65–74.
120. Simmons, D.G., and J.G. Gray. 1979. Transmission of acute respiratory disease (rhinotracheitis) of turkeys. *Avian Dis*. 23:132–138.
121. Simmons, D.G., J.G. Gray, L.P. Rose, R.C. Dillman, and S.E. Miller. 1979. Isolation of an etiologic agent of acute respiratory disease (rhinotracheitis) of turkey poults. *Avian Dis*. 23:194–203.
122. Simmons, D.G., A.R. Gore, and E.C. Hodgin. 1980. Altered immune function in turkey poults infected with *Alcaligenes faecalis*, the etiologic agent of turkey rhinotracheitis (coryza). *Avian Dis*. 24:702–714.

122a. Simmons, D.G., L.P. Rose, and J.G. Gray. 1980. Some physical, biochemic, and pathologic properties of *Alcaligenes faecalis*, the bacterium causing rhinotracheitis (coryza) in turkey poults. *Avian Dis*. 24:82–90.

123. Simmons, D.G., D.E. Davis, L.P. Rose, J.G. Gray, and G.H. Luginbuhl. 1981. *Alcaligenes faecalis*-associated respiratory disease of chickens. *Avian Dis*. 25:610–613.
124. Simmons, D.G., L.P. Rose, F.M. McCorkle, and G.H. Luginbuhl. 1983. Histamine-sensitizing factor of *Alcaligenes faecalis*. *Avian Dis*. 27:171–177.

125. Simmons, D.G., C. Dees, and L.P. Rose. 1986. A heat-stable toxin isolated from the turkey coryza agent, *Bordetella avium. Avian Dis*. 30:761–765.
126. Simmons, D.G., L.P. Rose, F.J. Fuller, L.C. Maurer, and G.H. Luginbuhl. 1986. Turkey coryza: lack of correlation between plasmids and pathogenicity of *Bordetella avium*. *Avian Dis*. 30:593–597.
127. Skeeles, J.K., W.S. Swafford, D.P. Wages, H.M. Hellwig, M.F. Slavik, J.N. Beasley, G.E. Houghten, P.J. Blore, and D. Crawford. 1983. Studies on the use of a long-acting oxytetracycline in turkeys: Efficacy against experimental infections with *Alcaligenes faecalis* and *Pasteurella multocida*. *Avian Dis*. 27:1126–1130.
128. Slavik, M.F., J.K. Skeeles, J.N. Beasley, G.C. Harris, P. Roblee, and D. Hellwig. 1981. Effect of humidity on infection of turkeys with *Alcaligenes faecalis*. *Avian Dis*. 25:936–942.
129. Slavik, M.F., J.K. Skeeles, C.F. Meinecke, and L. Holloway. 1981. The involvement of *Alcaligenes faecalis* in turkeys submitted for diagnosis as detected by bacterial isolation and microagglutination test. *Avian Dis*. 25:761–763.
130. Spears, P.A., L.M. Temple, and P.E. Orndorff. 2000. A role for lipopolysaccharide in turkey tracheal colonization by *Bordetella avium* as demonstrated *in vivo* and *in vitro*. *Mol Microbiol*. 36:1425–1435.
131. Spears, P.A., L.M. Temple, D.M. Miyamoto, D.J. Maskell, and P.E. Orndorff. 2003. Unexpected similarities between *Bordetella avium* and other pathogenic Bordetellae. *Infect Immun*. 71:2591–2597.
132. Spilker, T., A.A. Liwienski, and J.J. LiPuma. 2008. Identification of *Bordetella* spp. in respiratory specimens from individuals with cystic fibrosis. *Clin Microbiol. Infect*. 14:504–506.
133. Stockwell, S.B., H. Kuzmiak-Ngiam, N.M. Beach, D. Miyamoto, R. Fernandez, and L. Temple. 2011. The autotransporter protein from *Bordetella avium*, Baa1, is involved in host cell attachment. *Microbiol Res*. 167:55–60.
134. Suresh, P. 1993. Detecting *Bordetella avium* in tracheal sections of turkeys by monoclonal antibody-based indirect fluorescence microscopy. *Avian Pathol*. 22:791–795.
135. Suresh, P., and L.H. Arp. 1993. A monoclonal antibody-based latex bead agglutination test for the detection of *Bordetella avium*. *Avian Dis*. 37:767–772.
136. Suresh, P., L.H. Arp, and E.L. Huffman. 1994. Mucosal and systemic humoral immune response to *Bordetella avium* in experimentally infected turkeys. *Avian Dis*. 38:225–230.
137. Temple, L.M., A.A. Weiss, K.E. Walker, H.J. Barnes, V.L. Christensen, D.M. Miyamoto, C.B. Shelton, and P.E. Orndorff. 1998. *Bordetella avium* virulence measured *in vivo* and *in vitro*. *Infect Immun*. 66:5244–5251.
138. Temple, L.M., D.M. Miyamoto, M. Mehta, C.M. Capitini, S. Von Stetina, H.J. Barnes, V.L. Christensen, J.R. Horton, P.A. Spears, and P.E. Orndorff. 2010. Identification and characterization of two *Bordetella avium* gene products required for hemagglutination. *Infect Immun*. 78:2370–2376.
139. Tsai, H.J., and Y.M. Saif. 1991. Detection of antibodies against *Bordetella avium* in turkeys by avidin-biotin enhancement of the enzyme-linked immunosorbent assay and the dot-immunobinding assay. *Avian Dis*. 35:801–808.
140. Van Alstine, W.G., and M.S. Hofstad. 1985. Antibiotic aerosolization: the effect on experimentally induced *Alcaligenes* rhinotracheitis in turkeys. *Avian Dis*. 29:159–176.
141. Van Alstine, W.G., and L.H. Arp. 1987. Effects of *Bordetella avium* infection on the pulmonary clearance of Escherichia coli in turkeys. *Am J Vet Res*. 48:922–926.
142. Van Alstine, W.G., and L.H. Arp. 1987. Influence of *Bordetella avium* infection on association of *Escherichia coli* with turkey trachea. *Am J Vet Res*. 48:1574–1576.
143. Van Alstine, W.G., and L.H. Arp. 1987. Effects of *Bordetella avium* toxin on turkey tracheal organ cultures as measured with a tetrazolium-reduction assay. *Avian Dis*. 31:136–139.
144. Van Alstine, W.G., and L.H. Arp. 1988. Histologic evaluation of lung and bronchus-associated lymphoid tissue in young turkeys infected with *Bordetella avium*. *Am J Vet Res*. 49:835–839.
145. Vandamme, P., J. Hommez, M. Vancanneyt, M. Monsieurs, B. Hoste, B. Cookson, C.H. Wirsing von Konig, K. Kersters, and P.J. Blackall. 1995. *Bordetella hinzii* sp. nov., isolated from poultry and humans. *Int J Syst Bacteriol*. 45:37–45.
146. Varley, J. 1986. The characterisation of *Bordetella*/*Alcaligenes*-like organisms and their effects on turkey poults and chicks. *Avian Pathol*. 15:1–22.
147. Varley, J., and S.D. Carter. 1992. Characterization of the proteins of *Bordetella* isolates from turkeys in the UK by polyacrylamide gel electrophoresis. *Avian Pathol*. 21:137–140.
148. Yersin, A.G., F.W. Edens, and D.G. Simmons. 1990. Tryptophan 2,3-dioxygenase activity in turkey poults infected with *Bordetella avium*. *Comp Biochem Physiol B* 97:755–759.
149. Yersin, A.G., F.W. Edens, and D.G. Simmons. 1991. Effect of *Bordetella avium* infection on electrocardiograms in turkey poults. *Avian Dis*. 35:668–673.
150. Yersin, A.G., F.W. Edens, and D.G. Simmons. 1991. Tracheal cilia response to exogenous niacin in drinking water of turkey poults infected with *Bordetella avium*. *Avian Dis*. 35:674–680.

Chapter 20

Infectious Coryza and Related Bacterial Infections

Pat J. Blackall and Edgardo Soriano-Vargas

Introduction

Definition and Synonyms

Infectious coryza (IC) is an acute respiratory disease of chickens caused by the bacterium known as *Avibacterium paragallinarum*, once known as *Haemophilus paragallinarum* and *Haemophilus gallinarum* (15). The genus *Avibacterium* also contains the species *Av. gallinarum*, once known as *Pasteurella gallinarum* (15) as well as 3 other species—*Av. avium, Av. endocarditidis* and *Av. volantium* (8, 15). Hence, this chapter has integrated our current knowledge on all bacterial species within the genus *Avibacterium*. It is generally accepted that *Av. paragallinarum* is a primary pathogen while the other genus members are either opportunistic pathogens (*Av. endocarditidis, Av. gallinarum*) or not recognized as pathogens (*Av. avium*, *Av. volantium*).

The clinical syndrome of infectious coryza has been described in the early literature as roup, contagious or infectious catarrh, cold, and uncomplicated coryza (151). The disease was named infectious coryza because it was infectious and primarily affected the nasal passages (5). No specific syndrome name has been allocated to the disease conditions associated with *Av. gallinarum* and *Av. endocarditidis*.

Economic Significance

The greatest economic losses associated with infectious coryza result from poor growth performance in growing birds and marked reduction (10%–40%) in egg production in layers. The disease can have a much greater impact than the relatively simple scenario described above. An outbreak of the disease in older layer birds in California, which was not associated with any other pathogen, caused a total mortality of 48% and a drop in egg production from 75%–15.7% over a 3-week period (27).

Infectious coryza can have a significant impact in meat chickens. In California, 2 cases of infectious coryza, one complicated by the presence of *Mycoplasma synoviae*, caused increased condemnations, mainly due to airsacculitis, that varied from 8.0%–15% (54). In Alabama, an infectious coryza outbreak in broilers that was not complicated by any other disease agent caused a condemnation rate of 69.8%, virtually all due to airsacculitis (70).

When infectious coryza occurs in chicken flocks in developing countries, the added presence of other pathogens and stress factors can result in disease outbreaks that are associated with greater economic losses than those reported in high-health flocks in developed countries. In China, outbreaks of infectious coryza have been associated with morbidities of 20%–50% and mortalities of 5%–20% (45). Infectious coryza also has been reported in kampung (village) chickens in Indonesia (107, 135).

Outbreaks of disease associated with *Av. gallinarum* have not been commonly reported. Mortalities in chickens have been reported at 5%–10% (28) and 10%–34% (56). In turkeys, mortalities of 18%–26% have been reported (7). In most cases of disease associated with *Av. gallinarum*, the possibility that other infectious agents such as viruses and mycoplasmas were involved in the overall disease complex remains a possibility.

Av. endocarditidis has been associated with valvular endocarditis in broiler breeders (6, 8).

Public Health Significance

There is no public health significance to *Av. paragallinarum* or *Av. endocarditidis*. There are 3 reports of *Av. gallinarum* as a possible cause of disease in humans (1, 2, 3). However, these reports lack definitive molecular or phylogenetic data and some have been suggested to be misidentifications (62). On the balance of the available evidence, *Av. gallinarum* does not appear to have public health significance.

History

As early as 1920, Beach (4) believed that infectious coryza was a distinct clinical entity. In 1932, De Blieck (52) isolated the causative agent and named it *Bacillus hemoglobinophilus coryzae gallinarum*.

The first report to draw attention to organisms that appear to resemble the organism *Av. gallinarum* was Schneider (127). The description of the species *P. gallinarum* occurred in 1955 (67). *Av. endocarditidis* has only recently been recognized (8).

Diseases of Poultry, Thirteenth Edition. David E. Swayne.
© 2013 John Wiley & Sons, Inc. Published 2013 by John Wiley & Sons, Inc.

Etiology

Classification

A full review of the various early names used for the causative agent of infectious coryza (*Haemophilus gallinarum; Haemophilus paragallinarum*) is provided by Blackall and Soriano (25). Within the genus *Avibacterium, Av. paragallinarum* is the only primary pathogen (15). A recent extensive phylogenetic analysis has shown that while five species are currently recognized with the genus *Avibacterium* (*avium, endocarditidis, gallinarum, paragallinarum*, and *volantium*), there may only be 2 or 3 species (9). For the purpose of this review, where possible, the *Avibacterium* terminology will be used regardless of the names used in original study. The term "avian hemophili" will be used to refer to all members of the genus *Avibacterium*.

There has been a long history of confusion over the requirement for X-(hemin) and V-(nicotinamide adenine dinucleotide; NAD) factors for *in vitro* growth by *Av. paragallinarum* that history is documented by Blackall and Soriano (25). It is now accepted that both V-factor dependent and V-factor independent isolates of *Av. paragallinarum* exist, with the independent form present in South Africa and Mexico (35, 65, 71, 96).

Morphology and Staining

Av. paragallinarum and *Av. gallinarum* are both Gram-negative nonmotile bacteria. In 24-hour cultures, both appear as short rods or coccobacilli 1–3 mm in length and 0.4–0.8 mm in width, with a tendency for filament formation. A capsule may be demonstrated in virulent strains of *Av. paragallinarum* (69, 124). *Av. paragallinarum* undergoes degeneration within 48–60 hours, showing fragments and ill-defined forms. Subcultures to fresh medium at this stage will again yield the typical rod-shaped morphology.

Growth Requirements

The reduced form of NAD (NADH; 1.56–25 μg/mL medium) (104, 113) or its oxidized form (20–100 μg/mL) (118) is necessary for the *in vitro* growth of most isolates of *Av. paragallinarum*. The exceptions are the isolates described in South Africa and Mexico that are NAD independent. Sodium chloride (NaCl) (1.0%–1.5%) (113) is essential for growth of *Av. paragallinarum*. Chicken serum (1%) is required by some strains (69), whereas others merely show improved growth with this supplement (24). Brain heart infusion, tryptose agar, and chicken-meat infusion are some basal media to which supplements are added (69, 86, 118). A medium that is particularly developed for the isolation of *Av. paragallinarum* in the face of contaminating Gram-positive organisms has been described (139). Complex media are often used to obtain dense growth of organisms for characterization studies (109, 110). There is now recognition that some isolates of *Av. paragallinarum* still show satellitic growth even on a medium that is designed to provide all necessary and known growth requirements (16). A number of bacterial species excrete V-factor that will support growth of *Av. paragallinarum* on media that lack V-factor (104).

In contrast, *Av. gallinarum* has no need for NAD for *in vitro* growth and grows on a range of basic media such as dextrose starch agar (67) and blood agar (99). Similarly, *Av. endocarditidis* grows well on blood agar with no need for NAD (8).

The determination of the growth factor requirements of the avian hemophili is not an easy process. Commercial growth factor disks used for this purpose may yield a high percentage of cultures that falsely appear to be both X- and V-factor dependent (19). For well-equipped laboratories, the porphyrin test (81) is recommended for X-factor testing. For classical X- and V-factor testing, the use of purified hemin and NAD as supplements to otherwise complete media also may be considered.

Av. paragallinarum is commonly grown in an atmosphere of 5% carbon dioxide; however, carbon dioxide is not an essential requirement, because the organism is able to grow under reduced oxygen tension or anaerobically (60, 104). *Av. gallinarum* also does not require carbon dioxide but a more uniform colony development does occur if isolates are incubated under an atmosphere of 5%–10% carbon dioxide (15). *Av. endocarditidis* does not need carbon dioxide (8).

For *Av. paragallinarum*, the minimal and maximal temperatures of growth are 25° and 45°C, respectively; the optimal range is 34°C–42°C. *Av. endocarditidis, Av. gallinarum*, and *Av. paragallinarum* are commonly grown at 37°C–38°C.

Colony Morphology

Av. paragallinarum typically gives tiny dewdrop, nonhemolytic colonies up to 0.3 mm in diameter on suitable media. In obliquely transmitted light, mucoid (smooth) colonies are iridescent, whereas rough colonies are noniridescent (68, 110, 119). A range other intermediate colony forms have been observed.

Av. gallinarum colonies on serum or dextrose-starch agar are iridescent, circular, smooth, and entire, and may reach up to 1.5 mm after 24 hours of incubation (particularly if in 5%–10% carbon dioxide) (41). A grayish-yellow pigment is typically produced (15).

Av. endocarditidis colonies on blood agar are nonhemolytic, circular, smooth, and entire, with a grayish tinge, and may reach 1.5 mm after 24 hours of incubation (8).

Biochemical Properties

The ability to reduce nitrate to nitrite and ferment glucose without the formation of gas is common to all members of the genus *Avibacterium*. Oxidase activity and a failure to produce indole or hydrolyse urea or gelatin are also uniform characteristics (15). Table 20.1 presents the properties that allow an identification of all members of the genus *Avibacterium*. The failure of *Av. paragallinarum* to ferment either galactose or trehalose and its lack of catalase clearly separate this organism from the other members of the genus. As noted earlier, there is now doubt that all 5 described species in this genus are true species (9). Indeed, isolates of

Table 20.1. Differential tests for the genus *Avibacterium*.

Taxon	*Avibacterium gallinarum*	*Avibacterium paragallinarum*	*Avibacterium volantium*	*Avibacterium avium*	*Avibacterium sp. A.*
Catalase	+	–	+	+	+
Symbiotic growth	–	V	+	+	+
ONPG	d	–	+	–	V
Acid from					
L-arabinose	–	–	–	–	+
D-galactose	+	–	+	+	+
Maltose	+	+	+	–	V
D-mannitol	–	+	+	–	V
D-sorbitol	–	+	V	–	–
Trehalose	+	–	+	+	+
α-glucosidase	+	–	+	+	+

All species are Gram-negative and nonmotile. All species reduce nitrate, are oxidase positive, and ferment glucose. Most isolates of *Avibacterium paragallinarum* require an enriched carbon dioxide (5%–10%) atmosphere, and most will show an improved growth in the presence of 5%–10% chicken serum. Most isolates of *Avibacterium gallinarum* show an improved growth in an enriched carbon dioxide (5%–10%) atmosphere.

catalase-positive organisms with intermediate properties to the recognized species were reported some time ago (14). Hence, if using phenotypic identification, isolates with properties that do not match those shown in Table 20.1 are best reported as *Avibacterium* sp.

Susceptibility to Chemical and Physical Agents

Av. paragallinarum is a delicate organism that is inactivated rather rapidly outside the host. Infectious exudate suspended in tap water is inactivated in 4 hours at ambient temperature; when suspended in saline, the exudate is infectious for at least 24 hours at 22°C. Exudate or tissue remains infectious when held at 37°C for 24 hours and, on occasion, up to 48 hours; at 4°C, exudate remains infectious for several days. At temperatures of 45°C–55°C, hemophili are killed within 2–10 minutes. Infectious embryonic fluids treated with 0.25% formalin are inactivated within 24 hours at 6°C, but the organism survives for several days under similar conditions when treated with thimerosal, 1:10,000 (152).

Av. paragallinarum may be maintained on blood agar plates by weekly passages. Young cultures maintained in a "candle jar" will remain viable for 2 weeks at 4°C. Chicken embryos 6–7 days old may be inoculated with single colonies or broth cultures via the yolk sac; yolk from embryos dead in 12–48 hours will contain a large number of organisms which may be frozen and stored at –20°C––70°C or lyophilized (151).

There is little specific knowledge on the susceptibility of *Av. gallinarum* or *Av. endocarditidis* to either chemical or physical agents. Cultures of *Av. gallinarum* have been shown to survive well when held at room temperature on Dorset egg slopes (99).

Strain Classification

Antigenicity

Page (104, 105) classified his organisms of *Av. paragallinarum* with a plate agglutination test using whole cells and chicken antisera into serovars A, B, and C. It is now recommended to use a hemagglutination inhibition (HI) test to serotype isolates by the Page scheme (17). This HI test, which uses fixed chicken erythrocytes and rabbit hyperimmune sera, results in fewer nontypable isolates than the original agglutination technology (17).

The distribution of Page serovars differs from country to country. A full review of serovar distribution was provided in the previous edition of *Diseases of Poultry* (25). The additional knowledge gained recently has been the presence of Page serovars A, B, and C in Peru (90), Thailand (47), and Uganda (38).

A recent study has shown the potential for both a multiplex PCR assay and a PCR-restriction fragment length polymorphism assay to recognize the Page serovars (115). This work requires confirmation with a larger collection of isolates.

The suggestion that Page serovar B of *Av. paragallinarum* is not a true serovar, but rather consists of variants of serovar A or C that have lost their type-specific antigen (86, 124), is erroneous—Page serovar B is clearly a true serovar (146).

An alternative serologic classification of *Av. paragallinarum*—the Kume scheme—based on an HI test using potassium thiocyanate-treated and -sonicated cells, rabbit hyperimmune sera, and glutaraldehyde-fixed chicken erythrocytes has been developed (83). The modified Kume scheme consists of serogroups A, B, and C which match the Page serovars of A, B, and C (18). The 9 currently recognized Kume serovars are A-1, A-2, A-3, A-4, B-1, C-1, C-2, C-3, and C-4 (18). Many isolates that were nontypable in the Page scheme by agglutination tests were easily typed using the Kume scheme (59).

The Kume scheme has not been widely applied because it is technically demanding to perform. The previous edition provided a detailed listing of the known Kume serovar distribution. The additional knowledge gained recently has been the presence of Kume serovar C-1 in Mexico (95) and serovar B-1 in Panama (40).

Two serotyping schemes for *Av. gallinarum* have been reported (97, 99) but there appears to have been no adoption of either of these serotyping schemes.

Immunogenicity or Protective Characteristics

Infectious coryza is relatively unusual among common bacterial infections in that a bacterin (inactivated whole cell vaccine) is protective against the disease when the bacterin is adequately prepared. From the early days of bacterin production, it was obvious that protection was limited in terms of strain coverage (87). Later studies confirmed a correlation between Page serovars and immunovar specificity (23, 86, 112). Chickens vaccinated with a bacterin prepared from one Page serovar were protected only against homologous challenge from that Page serovar. There is evidence that the cross-protection within Page serovar B is only partial (145).

A cross-protection study using the reference strains of the 9 Kume serovars of *Av. paragallinarum* has been completed (131). Within Kume serogroup A, serovars A-1, A-2, and A-3 are strongly cross-protective while there is good cross-protection between serovars A-1 and A-4. Within Kume serogroup C, there was a good level of cross-protection for serovars C-1, C-2, and C-3, with some exceptions. Kume serovars C-1, C-2, and C-3 all provided protection against a C-1 challenge. In contrast, with the serovar C-2 and C-3 challenge, the respective homologous group was significantly better protected than the heterologous groups. The only instance of a vaccine being able to provide cross-protection across Kume serogroups that was at the same level as the homologous level was for the serovar C-4 vaccine and the serovar B-1 challenge. Thus, this study broadly confirmed the widely accepted dogma that serogroups A, B, and C represent 3 distinct immunovars.

There are reports of undefined heterogeneity within the B serogroup. Bivalent vaccines containing Page serovars A and C provide protection against Page serovar B strain Spross, but not against 2 South African isolates of Page serovar B (145). Furthermore, there is only partial cross-protection within various strains of Page serovar B (145). Poor vaccine protection against IC due to serovar B strains in Argentina has been suggested to be due to antigenic differences between field isolates and the "standard" serovar B strains in commercial vaccines from North America or Europe (140). These difficulties have resulted in at least 1 commercial vaccine that contains multiple Page serovar B strains to provide better protection (79). Vaccination/challenge exposure studies are needed to study the antigenicity and immunospecificity of recent serovar B isolates.

There have been suggestions that Kume serovar C-3 as well as other serovars of NAD-independent *Av. paragallinarum* are so antigenically different that they are causing vaccine failure (33, 34, 36, 58, 72). However, it has been shown that a commercial vaccine, specified as containing serovars A, B, and C without details of the actual strains, provided acceptable levels of protection against NAD-independent isolates of Page serovar A and Kume serovar C-3 (80). It is possible that differences in challenge models may explain these differing results. Clearly in those regions of the world with NAD-independent forms of *Av. paragallinarum*, there is a need for careful consideration when selecting a vaccine for a prevention and control program.

There is little knowledge about the immunogenicity of *Av. gallinarum*. Autogenous vaccines have been used (99), although there is no literature on the effectiveness of these products or the existence of different immunovars.

Molecular Techniques

DNA fingerprinting by restriction endonuclease analysis has been shown to be a suitable typing technique, providing useful insights in epidemiologic studies of both *Av. paragallinarum* (22) and *Av. gallinarum* (7). Ribotyping is another molecular technique that has proven useful, providing insight into the links between the NAD-independent *Av. paragallinarum* isolates from South Africa (93), the epidemiologic relationships among Chinese isolates of *Av. paragallinarum* (91), and the heterogeneity and epidemiological links among *Av. gallinarum* isolates (7, 46). Enterobacterial repetitive intergenic consensus polymerase chain reaction (ERIC-PCR, a DNA fingerprinting method that uses the polymerase chain reaction technique, has been shown to be capable of typing *Av. paragallinarum* isolates (132). The DNA-based alternative to Page serotyping (115) (mentioned above) requires more validation before it can be recommended as a replacement technology.

These nucleic acid techniques (including the species-specific PCR assays discussed below) are advancing to the stage where they offer a rapid and convenient method for identification and typing. These techniques are likely to replace time-consuming and cumbersome cultural, biochemical, and serological means of identification and typing in the near future.

Pathogenicity

As a general observation, the pathogenicity of *Av. paragallinarum* can vary according to factors such as the growth conditions, passage history of the isolate, and the state of the host. There is now considerable specific evidence of variation in pathogenicity among *Av. paragallinarum* isolates. The reference strains of Kume serovars A-1, A-4, C-1, C-2, and C-3 showed higher virulence than the strains for serovars A-2, A-3, B-1, and C-4 (130). On the basis of field observations in South Africa, it has been suggested that the NAD-independent isolates may cause airsacculitis more commonly than the classic NAD-dependent *Av. paragallinarum* isolates (72). In contrast, experimental infections have shown that South African NAD-dependent isolates are more virulent than NAD-independent isolates (29, 30, 58). The virulence of the NAD-dependent serovar C-3 strains has been suggested as explaining the large number of coryza outbreaks in vaccinated flocks in South Africa (32). Experimental transformation of a serovar C-3 NAD-dependent isolate to NAD-independence markedly reduced the virulence of the transformant (136). Within a serovar, variation in virulence has also been reported: Yamaguchi et al. (146) found that 1 of 4 strains of *Av. paragallinarum* serovar B failed to produce clinical signs. This

variation within a serovar may explain the report that a South African serovar B isolate failed to cause clinical signs in experimentally infected chickens (58).

The early experimental infections of chickens with *Av. gallinarum* resulted in little mortality (67). Field isolates from Israel have caused swollen wattles in 6-week-old chickens (99) while both an American field isolate and the type strain have caused endocarditis in mature leghorn chickens given high intravenous (IV) doses (141). Intramuscular injection of chickens with an Argentinean isolate resulted in severe myositis at the inoculation site (138). An American field isolate, when give by the intramuscular (IM) route, caused severe myostitis at the inoculation site as well as pericarditis, perihepatitis, airsacculitis, and synovitis (57, 128). Because the type strain failed to give similar results, there is evidence of strain variation in pathogenicity (57, 128).

Virulence Factors

A range of factors has been associated with the pathogenicity of *Av. paragallinarum*. Considerable attention has been paid to HA antigens. In both Page serovars A and C, mutants lacking HA activity have been used to demonstrate that the HA antigen plays a key role in colonization (119, 149).

The capsule also has been associated with colonization, and has been suggested to be the key factor in the lesions associated with IC (119, 126). The capsule of *Av. paragallinarum* has been shown to protect the organism against the bactericidal activity of normal chicken serum (121). It has been suggested that a toxin released from capsular organisms during *in vivo* multiplication was responsible for the clinical disease (82).

Av. paragallinarum is capable of acquiring iron from chicken and turkey transferrin, suggesting that iron sequestration may not be an adequate host defense mechanism (103). In contrast, two strains of *Av. avium* were unable to acquire iron from these transferrins despite apparently having the same receptor proteins (103).

Crude polysaccharide extracted from *Av. paragallinarum* is toxic to chickens and may be responsible for the toxic signs that may follow administration of bacterin (75). The role, if any, of this component in the natural occurrence of the disease is unknown.

A range of other putative virulence factors has been reported. A putative RTX-like protein and metalloproteases have been identified by phenotypic methods (114), while a hemocin has been confirmed by both phenotypic and genotypic methods (137). The hemocin of *Av. paragallinarum* is active against *Gallibacterium anatis* biovar *hemolytica* and some isolates of *P. multocida* but not against isolates of *Av. gallinarum* (137). It is possible that hemocin resistance may partly explain the reports of co-infections between *Av. paragallinarum* and *Av. gallinarum* (116, 129). The demonstration that cultures of *Av. paragallinarum* produce *in vitro* membrane vesicles that contain proteases, the putative RTX protein and hemagglutinins, raises the possibility of these vesicles being involved in the development of infectious coryza (108).

There is no specific knowledge on any virulence factors associated with *Av. gallinarum* or *Av. endocarditidis*.

Pathobiology and Epizootiology

Incidence and Distribution

Infectious coryza occurs wherever chickens are raised and is a common problem in the intensive chicken industry. The disease also has been reported in other, less intensive situations. As an example, infectious coryza has been a problem in kampung (village) chickens in Indonesia (107) as well as hobby flocks in Great Britain (143).

While reports are scarce and scattered, *Av. gallinarum* is probably present wherever chickens are raised. Outbreaks of disease associated with *Av. gallinarum* have been reported in chickens in Europe (99), North and South America (56, 138), and Africa (94).

Natural and Experimental Hosts

The chicken is the natural host for *Av. paragallinarum*. There are reports that the village chickens of Africa (39) and Asia (107, 154) are as susceptible to infectious coryza as normal commercial breeds. While there have been reports of IC due to *Av. paragallinarum* in a number of bird species other than chickens, reviewed by Yamamoto (150), these reports need to be interpreted carefully. Because a range of hemophilic organisms, none of which are *Av. paragallinarum*, have been described in birds other than chickens (53, 66, 106), only those studies that involve detailed bacteriology can be regarded as definitive proof of the presence of *Av. paragallinarum* in birds other than chickens. The following species are refractory to experimental infection: turkey, guinea fowl, pigeon, sparrow, duck, crow, rabbit, guinea pig, and mouse (39, 151, 152). The observation that *Av. paragallinarum* isolates are resistant to 6 hours of treatment with chicken serum but not turkey or guinea fowl serum may help explain the host specificity of the organism (39).

Av. gallinarum has been consistently associated with chickens (46). Outbreaks of disease associated with this species also have been reported in guinea fowl in Africa (94) and turkeys in Europe (7). A single isolate has been reported from a healthy duck (98) and a goose of unspecified health status (99).

Age of Host Most Commonly Affected

All ages of chickens are susceptible to *Av. paragallinarum* (150), but the disease is usually less severe in juvenile birds. The incubation period is shortened, and the course of the disease tends to be longer in mature birds, especially hens with active egg production.

Transmission, Carriers, Vectors

Chronic or healthy carrier birds have long been recognized as the main reservoir of IC infection. The application of molecular fingerprinting techniques has confirmed the role of carrier birds in the spread of IC (22). Infectious coryza seems to

occur most frequently in fall and winter, although such seasonal patterns may be coincidental to management practices (e.g., introduction of susceptible replacement pullets onto farms where IC is present). On farms where multiple age groups are brooded and raised, spread of the disease to successive age groups usually occurs within 1–6 weeks after such birds are moved from the brooder house to growing cages near older groups of infected birds (48). Infectious coryza is not an egg-transmitted disease. Epidemiologic studies have suggested that *Av. paragallinarum* may be introduced onto isolated ranches by the airborne route (153).

There is no knowledge on the routes of transmission, carrier status, or vectors for *Av. gallinarum* or *Av. endocarditidis*.

Incubation Period

The characteristic feature of IC is a coryza of short incubation that develops within 24–48 hours after inoculation of chickens with either culture or exudate. The latter more consistently induces disease (110). Susceptible birds exposed by contact to infected cases may show signs of the disease within 24–72 hours. In the absence of a concurrent infection, IC usually runs its course within 2–3 weeks.

Clinical Signs

The most prominent features of IC are an acute inflammation of the upper respiratory tract including involvement of nasal passage and sinuses with a serous to mucoid nasal discharge, facial edema, and conjunctivitis (Figures 20.1A and 20.1B). Figure 20.1B illustrates the typical facial edema. Swollen wattles may be evident, particularly in males. Rales may be heard in birds with infection of the lower respiratory tract.

A swollen head–like syndrome associated with *Av. paragallinarum* has been reported in broilers in the absence of avian pneumovirus, but in the presence or absence of other bacterial pathogens such as *M. synoviae* and *M. gallisepticum* (54, 116). Arthritis and septicemia have been reported in broiler and layer flocks, respectively, in which the presence of other pathogens has contributed to the disease complex (116).

Birds may have diarrhea, and feed and water consumption usually is decreased; in growing birds this means an increased number of culls, and in laying flocks a reduction in egg production (10%–40%). A foul odor may be detected in flocks in which the disease has become chronic and complicated with other bacteria.

The most common signs seen in outbreaks of disease where *Av. gallinarum* has played a potential role have been those of an acute respiratory disease, coughing and sneezing, with some outbreaks involving peri-orbital swelling and keratoconjunctivitis. Swollen wattles have been reported in cases in Israel (99) and Africa (94).

Morbidity and Mortality

IC is usually characterized by low mortality and high morbidity. Variations in age and breed may influence the clinical picture (10). Complicating factors such as poor housing, parasitism, and inadequate nutrition may add to severity and duration of the disease. When complicated with other diseases such as fowlpox, infectious bronchitis, infectious laryngotracheitis, *Mycoplasma gallisepticum* infection, and pasteurellosis, IC is usually more severe and prolonged, with resulting increased mortality (116, 151). Even in the absence of any other pathogen, older birds can suffer a high mortality as shown by an outbreak in California in which the total mortality reached 48% (27).

While not common, high mortalities have been seen associated with *Av. gallinarum* in broilers (up to 34%) (56) and in turkeys (up to 26%) (7).

Pathology

Gross

Av. paragallinarum produces an acute catarrhal inflammation of mucous membranes of nasal passages and sinuses. There is frequently a catarrhal conjunctivitis (Figure 20.1B) and subcutaneous edema of face and wattles (Figure 20.1A). Typically, pneumonia and airsacculitis are rarely present; however, reports of outbreaks in broilers have indicated significant levels of condemnations (up to 69.8%) due to airsacculitis (Figure 20.2), even in the absence of any other recognized viral or bacterial pathogens (54, 70).

The lesions associated with *Av. gallinarum* infections have been diverse and include airsacculitis, conjunctivitis, pericarditis, perihepatitis, and sinusitis (46). The only pathological condition that has been associated with *Av. endocarditidis* has been valvular endocarditis (6).

Microscopic

Fujiwara and Konno (63) studied the histopathologic response of chickens from 12 hours to 3 months after intranasal inoculation with *Av. paragallinarum*. Essential changes in the nasal cavity, infraorbital sinuses, and trachea consisted of sloughing, disintegration, and hyperplasia of mucosal and glandular epithelia, and edema and hyperemia with heterophil infiltration in the tunica propria of the mucous membranes. Pathologic changes first observed at 20 hours reached maximum severity by 7–10 days, with subsequent repair occurring within 14–21 days. In birds with involvement of the lower respiratory tract, acute catarrhal bronchopneumonia was observed, with heterophils and cell debris filling the lumen of secondary and tertiary bronchi; epithelial cells of air capillaries were swollen and showed hyperplasia. Catarrhal inflammation of air sacs was characterized by swelling and hyperplasia of the cells, with abundant heterophil infiltration. In addition, a pronounced infiltration of mast cells has been observed in the lamina propria of the mucous membrane of the nasal cavity (125). The products of mast cells, heterophils, and macrophages may be responsible for the severe vascular changes and cell damage leading to coryza. A dissecting fibrinopurulent cellulitis similar to that seen in chronic fowl cholera has been reported in broiler and layer chickens (54).

Shivaprasad and Droual (128) examined the histopathology caused by experimental infection with the *Av. gallinarum* strain associated with severe mortality in broilers in California. The lesions caused by this field isolate were more severe than those associated with the type strain and included severe

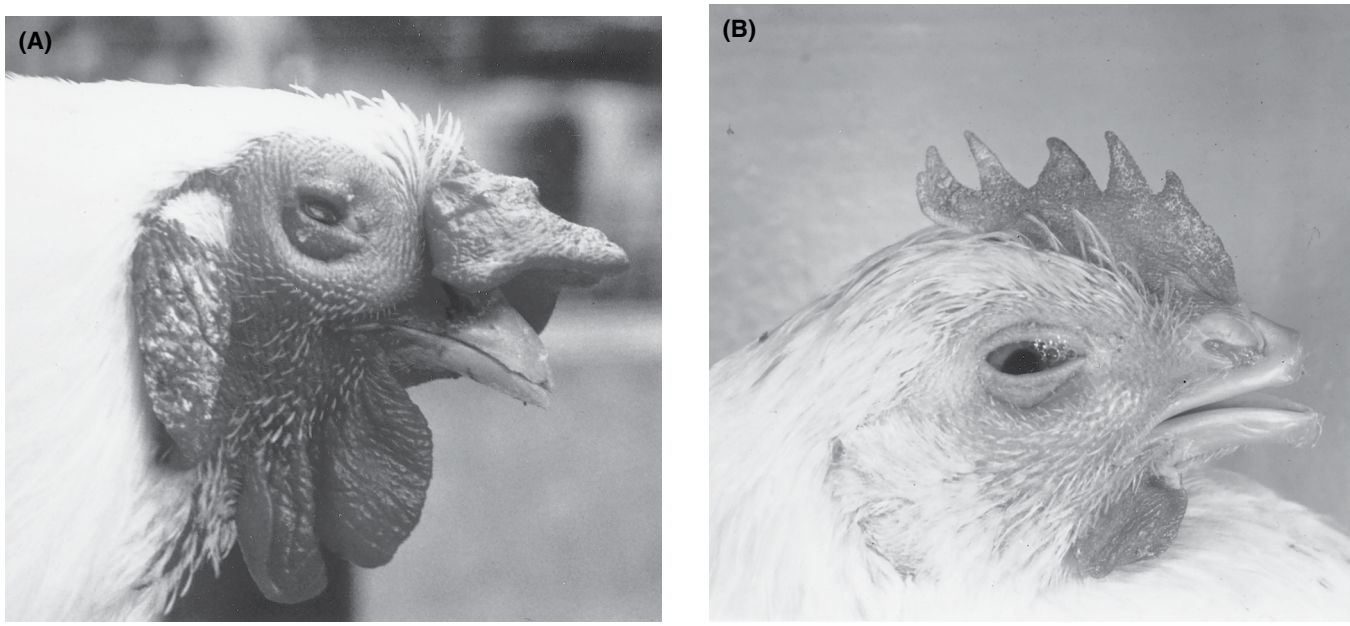

Figure 20.1. Chickens artificially infected with *Avibacterium paragallinarum*. (A) Mature male with coryza and facial edema. (B) Mature female showing conjunctivitis, nasal discharge, and open-mouth breathing.

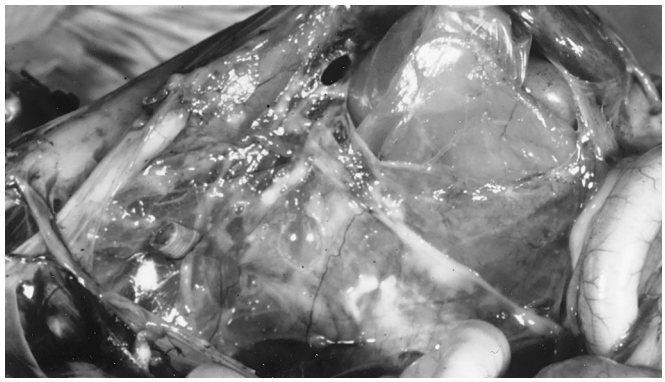

Figure 20.2. Field infection with IC showing caseopurulent air sac lesions.

subacute to chronic pyogranulomatous pneumonia, airsacculitis, pericarditis, perihepatitis, synovitis, and myositis. There was severe lymphoid depletion of the cloacal bursa (128).

Immunity

Chickens that have recovered from active infection with *Av. paragallinarum* possess varying degrees of immunity to re-exposure. Pullets that have experienced IC during their growing period are generally protected against a later drop in egg production. Resistance to re-exposure among individual birds may develop as early as 2 weeks after initial exposure by the intrasinus route (117).

It has been shown that experimentally infected chickens develop a cross-serovar (Page scheme) immunity (111). In contrast, as discussed earlier, bacterins provide only serovar-specific immunity (112). This suggests that cross-protective antigens are expressed *in vivo* that are either not expressed or expressed at very low levels *in vitro*.

The protective antigens of *Av. paragallinarum* have not been definitively identified. It has been suggested that the capsule of *Av. paragallinarum* contains protective antigens (120). Using both Page serovar A and C strains, a crude polysaccharide extract was shown to provide serovar-specific protection (75).

Considerable attention has been paid to the role of HA antigens as protective antigens. It has been long noted that for Page serovar A organisms, there is a close correlation between HI titer and both protection (85) and nasal clearance of the challenge organism (82) in vaccinated chickens. Purified HA antigen from a Page serovar A organism has been shown to be protective (76). Takagi and colleagues have shown that a monoclonal antibody specific for the HA of Page serovar A provides passive protection, and that the HA antigen purified by use of this antibody is also protective (133, 134). Two hemagglutinin epitopes—HPA5.1 and HPC5.5 (serovar A- and C-derived, respectively)—have been shown to provide serovar specific protection, suggesting the possibility of novel infectious coryza vaccines (101, 102, 144). It is worth noting that vaccines that do not stimulate HI titers can still be protective (47, 64, 131), suggesting that other antibodies do have a role in protection.

While autogenous bacterins of *Av. gallinarum* have been used and have been shown to stimulate antibodies (99), there is no detailed understanding of the efficacy of these products or the key antigens for protection.

Diagnosis

Isolation and Identification of Causative Agent

While *Av. paragallinarum* is considered to be a fastidious organism, it is not difficult to isolate, requiring simple media and procedures. Specimens should be taken from 2 or 3

chickens in the acute stage of the disease (1–7 days' incubation). The skin under the eyes is seared with a hot iron spatula and an incision made into the sinus cavity with sterile scissors. A sterile cotton swab is inserted deep into the sinus cavity where the organism is most often found in pure form. Tracheal and air sac exudates also may be taken on sterile swabs. Where transport delays are possible, the swabs should be placed in a commercial transport medium containing supplements to improve viability of the organism (37, 142). The swab is streaked on a blood agar plate, which is then cross-streaked with a *Staphylococcus* culture and incubated at 37°C in a large screw-cap jar in which a candle is allowed to burn out. *Staphylococcus epidermidis* (104) or *S. hyicus* (24), which are commonly used as "feeders," should be pretested because not all strains actively produce the V-factor (Figure 20.3). The characteristic feature of satellitism allows the recognition of the possible presence of *Av. paragallinarum*. Terzolo et al. (139) have reported the successful use of an isolation medium that contains selective agents that inhibit the growth of Gram-positive bacteria. This medium has the advantage of not using either a "feeder" organism or additives such as NADH. The drawback with the use of a complete medium for isolation is that there is no characteristic marker for the presence of *Av. paragallinarum*, forcing the diagnostic bacteriologist to sift among numerous colonies for possible *Av. paragallinarum*.

At the simplest level, IC may be diagnosed on the basis of a history of a rapidly spreading disease in which coryza is the main manifestation, combined with the isolation of a catalase-negative bacterium showing satellitic growth.

Better equipped laboratories should attempt more complete biochemical identification as described earlier. Additional studies of this nature are essential when isolates of NAD-independent *Av. paragallinarum* are suspected. To perform this biochemical testing, the suspect isolates are best grown in pure culture on medium that does not require the addition of a nurse colony. While many different media have been developed to support the growth of *Av. paragallinarum*, the medium called TM/SN (24) has proven very effective. The medium described by Terzolo et al. (139) is particularly suited for those laboratories where the cost of such ingredients as NADH and albumin is too expensive. The carbohydrate fermentation tests shown in Table 20.1 can be done in a phenol red broth base (110), an agar plate format (11), or an agar tube method (139).

Two PCR tests, one a conventional PCR (43) and the other a real-time PCR (50) (both based on the same target), have been developed for *Av. paragallinarum*. Both PCRs are specific for *Av. paragallinarum*, rapid, and able to detect all known variants. The conventional PCR, termed the HP-2 PCR, has been validated for use on colonies on agar or on mucus obtained from squeezing the sinus of live birds (43). When used directly on sinus swabs obtained from artificially-infected chickens in pen trials performed in Australia, the HP-2 PCR has been shown to be the equivalent of culture, but much more rapid (43). When used in China, direct PCR examination of sinus swabs outperformed traditional culture when used on routine diagnostic submissions (42). The problems of poor samples, delayed transport, and poor quality (but expensive) media mean that culture will have a higher failure rate in developing countries than in developed countries, making the PCR an attractive diagnostic option. The real-time PCR has been shown to have an increased analytical sensitivity (10- to 100-fold) over the conventional PCR (50).



Figure 20.3. Satellite phenomenon. Tiny dewdrop colonies of *Avibacterium paragallinarum* growing adjacent to *Staphylococcus* culture (broad streak) on a blood agar plate.

The HP-2 PCR is a robust test: Sinus swabs stored for up to 180 days at 4°C or –20°C were 80% positive in the PCR, whereas culture failed after 3 days of storage at 4°C (44). The HP-2 PCR has proven very useful in South Africa where the diagnosis of infectious coryza is complicated by the presence of NAD-independent *Av. paragallinarum* and *Ornithobacterium rhinotracheale* as well as the traditional form of NAD-dependent *Av. paragallinarum* (92).

A PCR method that uses universal primers that target the 16S rRNA gene followed by restriction enzyme digestion has been suggested as a possible molecular diagnostic tool (89). Further extended validation of this technology is required before it can be recommended for use.

Isolation of *Av. gallinarum* and *Av. endocarditidis* is best done using sheep blood agar plates incubated at 37°C with the plates for *Av. gallinarum* being under a 5%–10% carbon dioxide atmosphere. Phenotypic tests (Table 20.1) should be performed using conventional methodologies. No molecular diagnostic test has been developed for *Av. gallinarum* or *Av. endocarditidis*.

Serology

There is no totally suitable serological test for the diagnosis of infectious coryza. However, despite this absence of a "perfect" test, serological results are often useful for retrospective/epidemiological studies in the local area. A review of the techniques that have been used in the past is presented by Blackall et al. (21).

At this time, the best available test methodology is the HI test. While a range of HI tests has been described, 3 main forms of HI tests have been recognized—simple, extracted, and treated HI tests (26). Full details of how to perform these tests are available elsewhere (26). In the following text, the advantages and disadvantages of the three HI tests are briefly and critically discussed.

The simple HI is based on whole bacterial cells of Page serovar A *Av. paragallinarum* and fresh chicken erythrocytes (78). Although simple to perform, this HI test can only detect antibodies to serovar A. The test has been widely used to both detect infected as well as vaccinated chickens (21). A variation of this test (whole bacterial cells and glutaraldehyde-fixed chicken erythrocytes) has been shown to detect antibodies due to all 9 Kume serovars in vaccinated chickens (131).

The extracted HI test is based on KSCN-extracted and sonicated cells of *Av. paragallinarum* and glutaraldehyde-fixed chicken erythrocytes (122). This extracted HI test has mainly been validated for the detection of antibodies to Page serovar C organisms. The test has been shown to be capable of detecting a serovar-specific antibody response in Page serovar C-vaccinated chickens (122). A major weakness with this assay is that in chickens infected with serovar C, the majority of the birds remain seronegative (147).

The treated HI test is based on hyaluronidase-treated whole bacterial cells of *Av. paragallinarum* and formaldehyde-fixed chicken erythrocytes (148). The extracted HI has not been widely used or evaluated. It has been used to detect antibodies to Page serovars A, B, and C in vaccinated chickens with only serovar A- and C-vaccinated chickens yielding high titers (145). The test has been used to screen chicken sera in Indonesia for antibodies arising from infection with serovars A and C (135).

Vaccinated chickens with titers of 1:5 or greater in the simple or extracted HI tests have been found to be protected against subsequent challenge (122). There is not enough knowledge or experience yet to draw any sound conclusions on whether there is a correlation between titer and protection for the treated HI test.

Overall, the serological test of choice remains either the simple HI test (78) for infections or vaccinations associated with serovar A, the extracted or treated HI tests (122, 148) for vaccinations associated with serovar C, and the treated HI test (148) for infections associated with serovar C. There has been so little work performed on serological assays for infections or vaccinations associated with serovar B that it is not possible to recommend any test.

Both plate agglutination and gel precipitin tests have been described for the detection of antibodies to *Av. gallinarum* (99) but there has been no apparent use of these assays.

Differential Diagnosis

Infectious coryza must be differentiated from other diseases such as chronic respiratory disease, chronic fowl cholera, fowlpox, ornithobacterosis, swollen head syndrome, and avitaminosis A, which can produce similar clinical signs. Because *Av. paragallinarum* infections often occur in mixed infections, one should consider the possibility of other bacteria or viruses as complicating IC, particularly if mortality is high and the disease takes a prolonged course (see Pathogenicity; Morbidity and Mortality).

Because the conditions linked with *Av. gallinarum* are generally linked with upper respiratory disease, a similar range of disease conditions as those listed above needs to be considered. For *Av. endocarditidis*, a range of other bacteria have been associated with endocarditis: *Staphylococcus aureus, Enterococcus faecalis, Streptococcus zooepidemicus*, and *Streptococcus pluranimalium* (6).

Intervention Strategies

Management Procedures

Recovered carrier birds are the main source of infectious coryza; therefore, practices such as buying breeding males or started chicks from unknown sources should be discouraged. Only day-old chicks should be secured for replacement purposes unless the source is known to be free of IC. Isolation rearing and housing away from old stock are desirable practices. To eliminate the agent from a farm, it is necessary to depopulate the infected or recovered flock(s) because birds in such flocks remain reservoirs of infection. After cleaning and disinfection of the equipment and houses, the premises should be allowed to remain vacant for 2–3 weeks before restocking with clean birds.

Suitable disinfectants, given via drinking water and spraying, have been shown to support the efficacy of vaccines but are not a replacement for vaccines (31, 74).

Vaccination

Types of Vaccines

Commercial IC bacterins are widely available. Because the literature of the various factors influencing the efficacy of bacterins has been reviewed (12), only key points are considered here. Bacterins must contain at least 10^8 colony-forming units/mL to be effective (87).

There is disagreement in the literature as to the effect of different inactivating agents on the efficacy of bacterins, with a full review provided by Blackall and Soriano (25). Overall, the published literature suggests that while vaccines containing formalin as the inactivating agent can be protective, it is possible that a similar vaccine containing thimerosal would be even more efficient.

A number of adjuvants have been shown to be effective for IC bacterins, in particular, aluminium hydroxide gel, mineral oil, and saponin (20). As with any bacterin that contains adjuvants, particularly mineral oil, the potential adverse reaction at the site of injection (55) should be considered when using such products.

Inactivated IC bacterins provide, at best, protection only against the Page serovars included in the vaccine; therefore, it is vital that bacterins contain the Page serovars present in the target population. The confirmed existence of Page serovar B

as a true serovar with full pathogenicity, as well as its widespread occurrence, means that this serovar must be included in inactivated bacterins in areas where serovar B is present (61). However, because different strains of serovar B provide only partial cross-protection among themselves (145), it may be necessary to prepare an autogenous bacterin for use in areas where the B serovar is endemic or consider commercial bacterins that contain multiple serovar B strains (79). The finding that some Kume serovars within serogroup C are not fully cross-protective (131) needs to be considered in areas where multiple Kume C serovars are known to exist.

Because dissociation of *Av. paragallinarum* has been reported (123), care should be taken in selecting the proper seed culture, media, and incubation period to obtain the most immunogenic product.

A range of mixed bacterins containing inactivated viruses and *Av. paragallinarum* have been described, as previously reviewed (25). There is one report that a combined *Av. paragallinarum–M. gallisepticum* bacterin suppressed the immune response to the *Av. paragallinarum* component (88).

There appears to have been no widespread use of *Av. gallinarum* vaccines.

Field Vaccination Protocol and Regimes

IC bacterins are generally injected in birds between 10 and 20 weeks of age and yield optimal results when given 3–4 weeks prior to an expected natural outbreak. Two injections given approximately 4 weeks apart before 20 weeks of age seem to result in better performance of layers than a single injection. When administered to growing birds, the bacterin reduces losses from complicated respiratory disease. Both subcutaneous and intramuscular routes have been effective (23, 51, 87). Injection of the bacterin into the leg muscle gave better protection than when injected into the breast muscle (77). The intranasal route was not effective (23). Oral delivery of an IC bacterin was effective, but this route required 100 times as many cells as with the parenteral route (100). Significant immunity has been demonstrated for about 9 months following vaccination (23, 84, 87).

Because infectious coryza has been a problem in broilers in some parts of the world (54, 116), there is an interest in the possibility of day-old vaccination in broilers. A limited level of protection has been achieved in broilers vaccinated at day of age and challenged at day 31 (49).

Treatment

Various sulfonamides and antibiotics are useful in alleviating the severity and course of IC and have been reviewed (21). It should be noted that drug resistance in *Av. paragallinarum* occurs (13). Indeed, a multidrug-resistant plasmid has been reported to be common in isolates of *Av. paragallinarum* from Taiwan, with the plasmid conferring resistance to streptomycin, sulfonamides, kanamycin, and neomycin (73). Relapse often occurs after treatment is discontinued and the carrier state is not eliminated (152). Erythromycin and oxytetracycline are 2 commonly used antibiotics.

Acknowledgement

We would like to acknowledge the contribution of Drs Richard Yamamoto and Masakazu Matsumoto who were a authors for this chapter in previous editions.

References

1. Ahmed, K., P.P. Sein, M. Shahnawaz, and A.A. Hoosen. 2002. *Pasteurella gallinarum* neonatal meningitis. *Clin Microbiol Infect.* 8:55–57.
2. al Fadel Saleh, M., M.S. al-Madan, H.H. Erwa, I. Defonseka, S.Z. Sohel, and S.K. Sanyal. 1995. First case of human infection caused by *Pasteurella gallinarum* causing infective endocarditis in an adolescent 10 years after surgical correction for truncus arteriosus. *Pediatrics*. 95:944–948.
3. Arashima, Y., K. Kato, R. Kakuta, T. Fukui, K. Kumasaka, T. Tsuchiya, and K. Kawano. 1999. First case of *Pasteurella gallinarum* isolation from blood of a patient with symptoms of acute gastroenteritis in Japan. *Clin Inf Dis.* 29:698–699.
4. Beach, J.R. 1920. The diagnosis, therapeutics, and prophylaxis of chicken-pox (contagious epithelioma) of fowls. *J Am Vet Med Assoc.* 58:301–312.
5. Beach, J.R., and O.W. Schalm. 1936. Studies of the clinical manifestations and transmissability of infectious coryza of chickens. *Poult Sci.* 15:466–472.
6. Bisgaard, M., A.M. Bojesen, J.P. Christensen, and H. Christensen. 2010. Observations on the incidence and aetiology of valvular endocarditis in broiler breeders and detection of a newly described taxon of *Pasteurellaceae, Avibacterium endocarditidis*. *Avian Pathol*. 39:177–181.
7. Bisgaard, M., H. Christensen, K.-P. Behr, G. Baron, and J.P. Christensen. 2005. Investigations on the clonality of strains of *Pasteurella gallinarum* isolated from turkeys in Germany. *Avian Pathol.* 34:106–110.
8. Bisgaard, M., J.P. Christensen, A.M. Bojesen, and H. Christensen. 2007. *Avibacterium endocarditidis* sp. nov., isolated from valvular endocarditis in chickens. *Int J Syst Evol Microbiol*. 57:1729–1734.
9. Bisgaard, M., N. Nórskov-Lauritsen, S.J. de Wit, C. Hess, and H. Christensen. 2012. Multilocus sequence phylogenetic analysis of *Avibacterium*. *Microbiol*. doi:10.1099/mic.0.054429–0.
10. Blackall, P.J. 1983. Development of a vaccine against infectious coryza. *Proc Internat Union Immunol Soc.* 66:99–104.
11. Blackall, P.J. 1983. An evaluation of methods for the detection of carbohydrate fermentation patterns in avian *Haemophilus* species. *J Microbiol Methods.* 1:275–281.
12. Blackall, P.J. 1995. Vaccines against infectious coryza. *World's Poult Sci J.* 51:17–26.
13. Blackall, P.J. 1988. Antimicrobial drug resistance and the occurrence of plasmids in *Haemophilus paragallinarum*. *Avian Dis.* 32:742–747.
14. Blackall, P.J. 1988. Biochemical properties of catalase-positive avian haemophili. *J Gen Microbiol.* 134:2801–2805.
15. Blackall, P.J., H. Christensen, T. Beckenham, L.L. Blackall, and M. Bisgaard. 2005. Reclassification of *Pasteurella gallinarum, [Haemophilus] paragallinarum, Pasteurella avium* and *Pasteurella volantium* as *Avibacterium gallinarum* gen. nov., comb. nov., *Avibacterium paragallinarum* comb. nov., *Avibacterium avium* comb. nov. and *Avibacterium volantium* comb. nov. *Int J Syst Evol Microbiol*. 55:353–362.

16. Blackall, P.J., H. Christensen, and M. Bisgaard. 2011. Unusual growth variants of *Avibacterium paragallinarum*. *Aust Vet J.* 89:273–275.
17. Blackall, P.J., L.E. Eaves, and G. Aus. 1990. Serotyping of *Haemophilus paragallinarum* by the Page scheme: comparison of the use of agglutination and hemagglutination-inhibition tests. *Avian Dis.* 34:643–645.
18. Blackall, P.J., L.E. Eaves, and D.G. Rogers. 1990. Proposal of a new serovar and altered nomenclature for *Haemophilus paragallinarum* in the Kume hemagglutinin scheme. *J Clin Microbiol.* 28:1185–1187.
19. Blackall, P.J., and J.G. Farrah. 1985. An evaluation of commercial discs for the determination of the growth factor requirements of the avian haemophili. *Vet Microbiol.* 10:125–131.
20. Blackall, P.J., and M. Matsumoto. 2003. Infectious coryza. In: *Diseases of Poultry*, 11th ed. Y.M. Saif, H.J. Barnes, J.R. Glisson, A.M. Fadly, L.R. McDougald, and D.E. Swayne, eds. Iowa State University Press, Ames, Iowa. 691–703.
21. Blackall, P.J., M. Matsumoto, and R. Yamamoto. 1997. Infectious coryza. In: *Diseases of Poultry*, 10th ed. B.W. Calnek, H.J. Barnes, C.W. Beard, L.R. McDougald, and Y.M. Saif, eds. Iowa State University Press, Ames, Iowa. 179–190.
22. Blackall, P.J., C.J. Morrow, A. McInnes, L.E. Eaves, and D.G. Rogers. 1990. Epidemiologic studies on infectious coryza outbreaks in northern New South Wales, Australia, using serotyping, biotyping, and chromosomal DNA restriction endonuclease analysis. *Avian Dis.* 34:267–276.
23. Blackall, P.J., and G.G. Reid. 1987. Further efficacy studies on inactivated, aluminum-hydroxide-adsorbed vaccines against infectious coryza. *Avian Dis.* 31:527–532.
24. Blackall, P.J., and G.G. Reid. 1982. Further characterization of *Haemophilus paragallinarum* and *Haemophilus avium*. *Vet Microbiol.* 7:359–367.
25. Blackall, P.J., and E.V. Soriano. 2008. Infectious coryza and related bacterial infections. In: *Diseases of Poultry*, 12th ed. Y.M. Saif, A.M. Fadly, J.R. Glisson, L.R. McDougald, L.K. Nolan, and D.E. Swayne, eds. Blackwell Publishing Professional, Ames. 789–803.
26. Blackall, P.J., and R. Yamamoto. 1998. Infectious coryza. In: *A Laboratory Manual for the Isolation and Identification of Avian Pathogens*, 4th ed. D.E. Swayne, J.R. Glisson, M.W. Jackwood, J.E. Pearson, and W.M. Reed, eds. American Association of Avian Pathologists, Philadelphia. 29–34.
27. Bland, M.P., A.A. Bickford, B.R. Charlton, G.C. Cooper, F. Sommer, and G. Cutler. 2002. Case report: A severe infectious coryza infection in a multi-age layer complex in central California. 51st Western Poultry Disease Conference/XXVII Convención Anual ANECA. Puerto Vallarta, Mexico. 56–57.
28. Bock, R.R., Y. Samberg, and R. Mushin. 1977. An outbreak of a disease in poultry associated with *Pasteurella gallinarum*. *Ref Vet.* 34:99–103.
29. Bragg, R.R. 2002. Virulence of South African isolates of *Haemophilus paragallinarum*. Part 2: Naturally occurring NAD-independent field isolates. *Onderstepoort J Vet Res*. 69:171–175.
30. Bragg, R.R. 2002. Virulence of South African isolates of *Haemophilus paragallinarum*. Part 1: NAD-dependent field isolates. *Onderstepoort J Vet Res*. 69:163–169.
31. Bragg, R.R. 2004. Limitation of the spread and impact of infectious coryza through the use of a continuous disinfection programme. *Onderstepoort J Vet Res.* 71:1–8.
32. Bragg, R.R. 2005. Effects of differences in virulence of different serovars of *Haemophilus paragallinarum* on perceived vaccine efficacy. *Onderstepoort J Vet Res.* 72:1–6.
33. Bragg, R.R. 2004. Evidence of possible evasion of protective immunity by NAD-independent isolates of *Haemophilus paragallinarum* in poultry. *Onderstepoort J Vet Res.* 71:53–58.
34. Bragg, R.R., L. Coetzee, and J.A. Verschoor. 1996. Changes in the incidences of the different serovars of *Haemophilus paragallinarum* in South Africa: a possible explanation for vaccination failures. *Onderstepoort J Vet Res.* 63:217–226.
35. Bragg, R.R., L. Coetzee, and J.A. Verschoor. 1993. Plasmid-encoded NAD independence in some South African isolates of *Haemophilus paragallinarum*. *Onderstepoort J Vet Res.* 60:147–152.
36. Bragg, R.R., J.M. Greyling, and J.A. Verschoor. 1997. Isolation and identification of NAD-independent bacteria from chickens with symptoms of infectious coryza. *Avian Pathol.* 26:595–606.
37. Bragg, R.R., P. Jansen Van Rensburg, E. Van Heerden, and J. Albertyn. 2004. The testing and modification of a commercially available transport medium for the transportation of pure cultures of *Haemophilus paragallinarum* for serotyping. *Onderstepoort J Vet Res.* 71:93–98.
38. Byarugaba, D.K., U.M. Minga, P.S. Gwakisa, E. Katunguka-Rwakishaya, M. Bisgaard, and J.E. Olsen. 2007. Investigations of the occurrence of *Avibacterium paragallinarum* infections in Uganda. *Avian Dis.* 51:534–539.
39. Byarugaba, D.K., U.M. Minga, P.S. Gwakisa, E. Katunguka-Rwakishaya, M. Bisgaard, and J.E. Olsen. 2007. Virulence characterization of *Avibacterium paragallinarum* isolates from Uganda. *Avian Pathol.* 36:35–42.
40. Calderón, E.N., K. Thomas, V. Morales-Erasto, C. Salgado-Miranda, and E. Soriano-Vargas. 2010. Identification of *Avibacterium paragallinarum* serovar B-1 from severe infectious coryza outbreaks in Panama. *Avian Dis*. 54:1095–1097.
41. Carter, G.R. 1984. Genus I. *Pasteurella*. In: *Bergey's Manual of Systematic Bacteriology*. N.R. Kreig and J.G. Holt, eds. Williams and Wilkins, Baltimore/London. 552–557.
42. Chen, X., Q. Chen, P. Zhang, W. Feng, and P. J. Blackall. 1998. Evaluation of a PCR test for the detection of *Haemophilus paragallinarum* in China. *Avian Pathol.* 27:296–300.
43. Chen, X., J.K. Miflin, P. Zhang, and P.J. Blackall. 1996. Development and application of DNA probes and PCR tests for *Haemophilus paragallinarum*. *Avian Dis.* 40:398–407.
44. Chen, X., C. Song, Y. Gong, and P.J. Blackall. 1998. Further studies on the use of a polymerase chain reaction test for the diagnosis of infectious coryza. *Avian Pathol.* 27:618–624.
45. Chen, X., P. Zhang, P.J. Blackall, and W. Feng. 1993. Characterization of *Haemophilus paragallinarum* isolates from China. *Avian Dis.* 37:574–576.
46. Christensen, H., F. Dziva, J.E. Elmerdahl, and M. Bisgaard. 2002. Genotypical heterogeneity of *Pasteurella gallinarum* as shown by ribotyping and 16S rRNA sequencing. *Avian Pathol.* 31:603–609.
47. Chukiatsiri, K., J. Saipreeyajan, W. Neramitansuk, and N. Chansiripornchai. 2009. Efficacy of an autogenous killed vaccine of *Avibacterium paragallinarum*. *Avian Dis.* 53:382–386.
48. Clark, D.S., and J.F. Godfrey. 1961. Studies of an inactivated *Hemophilus gallinarum* vaccine for immunization of chickens against infectious coryza. *Avian Dis.* 5:37–47.
49. Conde, M.D., Y.D. Huberman, A.M. Espinoza, R.I. Delgado, and H.R. Terzolo. 2011. Vaccination of one-day-old broiler chicks against infectious coryza. *Avian Dis.* 55:119–122.
50. Corney, B.G., I.S. Diallo, L. Wright, G. Hewitson, A. De Jong, X. Tolosa, P. Burrell, P. Duffy, B. Rodwell, D.B. Boyle, and P.J. Blackall. 2008. Rapid and sensitive detection of *Avibacterium paragallinarum* in the presence of other bacteria using a 5′ *Taq*

nuclease assay: a new tool for diagnosing infectious coryza. *Avian Pathol.* 37:599–604.
51. Davis, R.B., R.B. Rimler, and E.B. Shotts Jr. 1976. Efficacy studies on *Haemophilus gallinarum* bacterin preparations. *Am J Vet Res.* 37:219–222.
52. De Blieck, L. 1932. A haemoglobinophilic bacterium as the cause of contagious cattarh of the fowl (coryza infectiosa gallinarum). *Vet J.* 88:9–13.
53. Devriese, L.A., N. Viaene, E. Uyttebroek, R. Froyman, and J. Hommez. 1988. Three cases of infection by *Haemophilus*-like bacteria in psittacines. *Avian Pathol.* 17:741–744.
54. Droual, R., A.A. Bickford, B.R. Charlton, G.L. Cooper, and S.E. Channing. 1990. Infectious coryza in meat chickens in the San Joaquin Valley of California. *Avian Dis.* 34:1009–10016.
55. Droual, R., A.A. Bickford, B.R. Charlton, and D.R. Kuney. 1990. Investigation of problems associated with intramuscular breast injection of oil-adjuvanted killed vaccines in chickens. *Avian Dis.* 34:473–478.
56. Droual, R., H.L. Shivaprasad, C.U. Meteyer, D.P. Shapiro, and R.L. Walker. 1992. Severe mortality in broiler chickens associated with *Mycoplasma synoviae* and *Pasteurella gallinarum*. *Avian Dis.* 36:803–807.
57. Droual, R., R.L. Walker, H.L. Shivaprasad, J.S. Jeffrey, C.U. Meteyer, R.P. Chin, and D.P. Shapiro. 1992. An atypical strain of *Pasteurella gallinarum*: pathogenic, phenotypic and genotypic characteristics. *Avian Dis.* 36:693–699.
58. Dungu, B., B. Brett, R. MacDonald, S. Deville, L. Dupuis, J. Theron, and R.R. Bragg. 2009. Study on the efficacy and safety of different antigens and oil formulations of infectious coryza vaccines containing an NAD-independent strain of *Avibacterium paragallinarum*. *Onderstepoort J Vet Res.* 76:299–309.
59. Eaves, L.E., D.G. Rogers, and P.J. Blackall. 1989. Comparison of hemagglutinin and agglutinin schemes for the serological classification of *Haemophilus paragallinarum* and proposal of a new hemagglutinin serovar. *J Clin Microbiol.* 27:1510–1513.
60. Eliot, C.P., and M.R. Lewis. 1934. A hemophilic bacterium as the cause of infectious coryza in the fowl. *J Am Vet Med Assoc.* 84:878–888.
61. Fernández, R.P., H.L. Colíndres, Q.E. Velásquez, V.E. Soriano, and P.J. Blackall. 2005. Protection conferred by bivalent and trivalent infectious coryza bacterins against prevalent serovars of *Avibacterium (Haemophilus) paragallinarum* in Mexico. *Avian Dis*. 49:585–587.
62. Frederiksen, W., and B. Tonning. 2001. Possible misidentification of *Haemophilus aphrophilus* as *Pasteurella gallinarum*. *Clin Inf Dis.* 32:987–989.
63. Fujiwara, H., and S. Konno. 1965. Histopathological studies on infectious coryza of chickens. I. Findings in naturally infected cases. *Nat Inst Anim Health Q (Tokyo)*. 5:36–43.
64. Garcia, A., F. Romo, A.M. Ortiz, and P.J. Blackall. 2008. The challenge trial—a gold standard test to test the protective efficacy of infectious coryza vaccines. *Avian Pathol.* 37:183–186.
65. Garcia, A.J., E. Angulo, P.J. Blackall, and A.M. Ortiz. 2004. The presence of nicotinamide adenine dinucleotide-independent *Haemophilus paragallinarum* in Mexico. *Avian Dis.* 48:425–429.
66. Grebe, H.H., and K.-H. Hinz. 1975. Vorkommen von Bakterien der Gattung *Haemophilus* bei verschiedenen Vogelarten. *Zbl Vet Med B.* 22:749–757.
67. Hall, W.J., K.L. Heddleston, D.H. Legenhausen, and R.W. Hughes. 1955. Studies on pasteurellosis. I. A new species of *Pasteurella* encountered in chronic fowl cholera. *Am J Vet Res*. 16:598–604.
68. Hinz, K.-H. 1976. Beitrag zur Differenzierung von *Haemophilus*-Stämmen aus Hühnern. IV. Mitteilung: Untersuchungen Uber die Dissoziation von *Haemophilus paragallinarum*. *Avian Pathol*. 5:51–66.
69. Hinz, K.H. 1973. Beitrag zur differenzierung von *Haemophilus*-stämmen aus hühnern I. Mitteilung: Kulturelle und biochemische untersuchungen. *Avian Pathol*. 2:211–229.
70. Hoerr, F.J., M. Putnam, S. Rowe-Rossmanith, W. Cowart, and J. Martin. 1994. Case report: Infectious coryza in broiler chickens in Alabama. 43rd Western Poultry Disease Conference. 42.
71. Horner, R.F., G.C. Bishop, and C. Haw. 1992. An upper respiratory disease of commercial chickens resembling infectious coryza, but caused by a V-factor independent bacterium. *Avian Pathol.* 21:421–427.
72. Horner, R.F., G.C. Bishop, C.J. Jarvis, and T.H.T. Coetzer. 1995. NAD (V-factor)-independent and typical *Haemophilus paragallinarum* infection in commercial chickens: a five year field study. *Avian Pathol.* 24:453–463.
73. Hsu, Y.-M., H.K. Shieh, W.-H. Chen, T.-Y. Sun, and J.-H. Shiang. 2007. Antimicrobial susceptibility, plasmid profiles and haemocin activities of *Avibacterium paragallinarum* strains. *Vet Microbiol.* 124:209–218.
74. Huberman, Y.D., D.J. Bueno, and H.R. Terzolo. 2005. Evaluation of the protection conferred by a disinfectant against clinical disease caused by *Avibacterium paragallinarum* serovars A, B, and C from Argentina. *Avian Dis.* 49:588–591.
75. Iritani, Y., S. Iwaki, and T. Yamaguchi. 1981. Biological activities of crude polysaccharide extracted from two different immunotype strains of *Hemophilus gallinarum* in chickens. *Avian Dis.* 25:29–37.
76. Iritani, Y., K. Katagiri, and H. Arita. 1980. Purification and properties of *Haemophilus paragallinarum* hemagglutinin. *Am J Vet Res.* 41:2114–2118.
77. Iritani, Y., K. Kunihiro, T. Yamaguchi, T. Tomii, and Y. Hayashi. 1984. Difference of immune efficacy of infectious coryza vaccine by different site of injection in chickens. *J Jap Soc Poult Dis.* 20:182–185.
78. Iritani, Y., G. Sugimori, and K. Katagiri. 1977. Serologic response to *Haemophilus gallinarum* in artifically infected and vaccinated chickens. *Avian Dis.* 21:1–8.
79. Jacobs, A.A., K. van den Berg, and A. Malo. 2003. Efficacy of a new tetravalent coryza vaccine against emerging variant type B strains. *Avian Pathol.* 32:265–269.
80. Jacobs, A.A.C., and J. van der Werf. 2000. Efficacy of a commercially available coryza vaccine against challenge with recent South African NAD-independent isolates of *Haemophilus paragallinarum*. *J S Afr Vet Assoc.* 71:109–110.
81. Kilian, M. 1974. A rapid method for the differentiation of *Haemophilus* strains. The porphyrin test. *Acta Pathol Microbiol Immunol Scand Sect B*. 82:835–842.
82. Kume, K., A. Sawata, and T. Nakai. 1984. Clearance of the challenge organisms from the upper respiratory tract of chickens injected with an inactivated *Haemophilus paragallinarum* vaccine. *Jap J Vet Sci.* 46:843–850.
83. Kume, K., A. Sawata, T. Nakai, and M. Matsumoto. 1983. Serological classification of *Haemophilus paragallinarum* with a hemagglutinin system. *J Clin Microbiol.* 17:958–964.
84. Kume, K., A. Sawata, and Y. Nakase. 1980. *Haemophilus* infections in chickens. 3. Immunogenicity of serotypes 1 and 2 strains of *Haemophilus paragallinarum*. *Jap J Vet Sci*. 42:673–680.

85. Kume, K., A. Sawata, and Y. Nakase. 1980. Relationship between protective activity and antigen structure of *Haemophilus paragallinarum* serotypes 1 and 2. *Am J Vet Res.* 41:97–100.
86. Kume, K., A. Sawata, and Y. Nakase. 1980. Immunological relationship between Page's and Sawata's serotype strains of *Haemophilus paragallinarum*. *Am J Vet Res.* 41:757–760.
87. Matsumoto, M., and R. Yamamoto. 1975. Protective quality of an aluminum hydroxide-absorbed broth bacterin against infectious coryza. *Am J Vet Res.* 36:579–582.
88. Matsuo, K., S. Kuniyasu, S. Yamada, S. Susumi, and S. Yamamoto. 1978. Suppression of immune responses to *Haemophilus gallinarum* with non-viable *Mycoplasma gallisepticum* in chickens. *Avian Dis.* 22:552–561.
89. Mendoza-Espinoza, A., Y. Koga, and A.I. Zavaleta. 2008. Amplified 16S ribosomal DNA restriction analysis for identification of *Avibacterium paragallinarum*. *Avian Dis.* 52:54–58.
90. Mendoza-Espinoza, A., H.R. Terzolo, R.I. Delgado, A.I. Zavaleta, Y. Koga, and Y.D. Huberman. 2009. Serotyping of *Avibacterium paragallinarum* isolates from Peru. *Avian Dis.* 53:462–465.
91. Miflin, J.K., X. Chen, and P.J. Blackall. 1997. Molecular characterisation of isolates of *Haemophilus paragallinarum* from China by ribotyping. *Avian Pathol.* 27:119–127.
92. Miflin, J.K., X. Chen, R.R. Bragg, J.M. Welgemoed, J.M. Greyling, R.F. Horner, and P.J. Blackall. 1999. Confirmation that PCR can be used to identify NAD-dependent and NAD-independent *Haemophilus paragallinarum* isolates. *Onderstepoort J Vet Res.* 66:55–57.
93. Miflin, J.K., R.F. Horner, P.J. Blackall, X. Chen, G.C. Bishop, C.J. Morrow, T. Yamaguchi, and Y. Iritani. 1995. Phenotypic and molecular characterization of V-factor (NAD)-independent *Haemophilus paragallinarum*. *Avian Dis.* 39:304–308.
94. Mohan, K., F. Dziva, and D. Chitauro. 2000. *Pasteurella gallinarum*: Zimbabwean experience of a versatile pathogen. *Onderstepoort J Vet Res.* 67:301–305.
95. Morales-Erasto, V., A. García-Sánchez, C. Salgado-Miranda, M. Talavera-Rojas, F. Robles, P.J. Blackall, and E. Soriano-Vargas. 2011. ERIC-PCR genotyping of emergent serovar C-1 isolates of *Avibacterium paragallinarum* from Mexico. *Avian Dis*. 55:686–688.
96. Mouahid, M., M. Bisgaard, A.J. Morley, R. Mutters, and W. Mannheim. 1992. Occurrence of V-factor (NAD) independent strains of *Haemophilus paragallinarum*. *Vet Microbiol.* 31:363–368.
97. Mráz, O., P. Jelen, and J. Bohácek. 1977. On species characteristics of *Pasteurella gallinarum* Hall *et al*., 1955. *Acta Vet Brno* 46:135–147.
98. Muhairwa, A.P., M.M.A. Mtambo, J.P. Christensen, and M. Bisgaard. 2001. Occurrence of *Pasteurella multocida* and related species in village free ranging chickens and their animal contacts in Tanzania. *Vet Microbiol.* 78:139–153.
99. Mushin, R., R. Bock, and M. Abrams. 1977. Studies on *Pasteurella gallinarum*. *Avian Pathol.* 6:415–423.
100. Nakamura, T., S. Hoshi, Y. Nagasawa, and S. Ueda. 1994. Protective effect of oral administration of killed *Haemophilus paragallinarum* serotype A on chickens. *Avian Dis.* 38:289–292.
101. Noro, T., E. Oishi, T. Kaneshige, K. Yaguchi, K. Amimoto, and M. Shimizu. 2008. Identification and characterization of haemagglutinin epitopes of *Avibacterium paragallinarum* serovar C. *Vet Microbiol.* 131:406–413.
102. Noro, T., K. Yaguchi, K. Amimoto, and E. Oishi. 2007. Identification and expression of a gene encoding an epitope that induces hemagglutination inhibition antibody to *Avibacterium paragallinarum* serovar A. *Avian Dis.* 51:84–89.
103. Ogunnariwo, J.A., and A.B. Schryvers. 1992. Correlation between the ability of *Haemophilus paragallinarum* to acquire ovotransferrin-bound iron and the expression of ovotransferrin-specific receptors. *Avian Dis.* 36:655–663.
104. Page, L.A. 1962. *Haemophilus* infections in chickens. I. Characteristics of 12 *Haemophilus* isolates recovered from diseased chickens. *Am J Vet Res*. 23:85–95.
105. Page, L.A., A.S. Rosenwald, and F.C. Price. 1963. *Haemophilus* infections in chickens. IV. Results of laboratory and field trials of formalinized bacterins for the prevention of disease caused by *Haemophilus gallinarum*. *Avian Dis*. 7:239–256.
106. Piechulla, K., K.-H. Hinz, and W. Mannheim. 1985. Genetic and phenotypic comparison of three new avian *Haemophilus*-like taxa and of *Haemophilus paragallinarum* Biberstein and White 1969 with other members of the family *Pasteurellaceae* Pohl 1981. *Avian Dis.* 29:601–612.
107. Poernomo, S., M.R., Sutarma, and P.J. Blackall. 2000. Characterization of isolates of *Haemophilus paragallinarum* from Indonesia. *Aust Vet J.* 78:759–762.
108. Ramón Rocha, M.O., O. Garcia-González, A. Pérez-Méndez, J. Ibarra-Caballero, V. M. Pérez-Márquez, S. Vaca, and E. Negrete-Abascal. 2006. Membrane vesicles released by *Avibacterium paragallinarum* contain putative virulence factors. *FEMS Microbiol Lett.* 257:63–68.
109. Reid, G.G., and P.J. Blackall. 1984. Pathogenicity of Australian isolates of *Haemophilus paragallinarum* and *Haemophilus avium* in chickens. *Vet Microbiol.* 9:77–82.
110. Rimler, R.B. 1979. Studies of the pathogenic avian haemophili. *Avian Dis.* 23:1006–1018.
111. Rimler, R.B., and R.B. Davis. 1977. Infectious coryza: *In vivo* growth of *Haemophilus gallinarum* as a determinant for cross protection. *Am J Vet Res.* 38:1591–1593.
112. Rimler, R.B., R.B. Davis, and R.K. Page. 1977. Infectious coryza: cross-protection studies, using seven strains of *Haemophilus gallinarum*. *Am J Vet Res.* 38:1587–1589.
113. Rimler, R.B., E.B. Shotts Jr, J. Brown, and R.B. Davis. 1977. The effect of sodium chloride and NADH on the growth of six strains of *Haemophilus* species pathogenic to chickens. *J Gen Microbiol.* 98:349–354.
114. Rivero-García, P.C., C.V. Cruz, P.S. Alonso, S. Vaca, and E. Negrete-Abascal. 2005. *Haemophilus paragallinarum* secretes metalloproteases. *Can J Microbiol.* 51:893–896.
115. Sakamoto, R., Y. Kino, and M. Sakaguchi. 2011. Development of a multiplex PCR and PCR-RFLP method for serotyping of *Avibacterium paragallinarum*. *J Vet Med Sci*. 74:271–273. http://www.jstage.jst.go.jp/browse/jvms/advpub/0/_contents.
116. Sandoval, V.E., H.R. Terzolo, and P.J. Blackall. 1994. Complicated infectious coryza cases in Argentina. *Avian Dis.* 38:672–678.
117. Sato, S., and M. Shifrine. 1964. Serologic response of chickens to experimental infection with *Hemophilus gallinarum*, and their immunity to challenge. *Poult Sci.* 43:1199–1204.
118. Sato, S., and M. Shifrine. 1965. Application of the agar gel precipitation test to serologic studies of chickens inoculated with *Haemophilus gallinarum*. *Avian Dis.* 9:591–598.
119. Sawata, A., and K. Kume. 1983. Relationship between virulence and morphological or serological properties of variants

dissociated from serotype 1 *Haemophilus paragallinarum* strains. *J Clin Microbiol.* 18:49–55.
120. Sawata, A., K. Kume, and T. Nakai. 1984. Relationship between anticapsular antibody and protective activity of a capsular antigen of *Haemophilus paragallinarum*. *Jap J Vet Sci.* 46:475–486.
121. Sawata, A., K. Kume, and T. Nakai. 1984. Susceptibility of *Haemophilus paragallinarum* to bactericidal activity of normal and immune chicken serum. *Jap J Vet Sci.* 46:805–813.
122. Sawata, A., K. Kume, and Y. Nakase. 1982. Hemagglutinin of *Haemophilus paragallinarum* serotype 2 organisms: occurrence and immunologic properties of hemagglutinin. *Am J Vet Res.* 43:1311–1314.
123. Sawata, A., K. Kume, and Y. Nakase. 1979. Antigenic structure and relationship between serotypes 1 and 2 of *Haemophilus paragallinarum*. *Am J Vet Res.* 40:1450–1453.
124. Sawata, A., K. Kume, and Y. Nakase. 1980. Biologic and serologic relationships between Page's and Sawata's serotypes of *Haemophilus paragallinarum*. *Am J Vet Res.* 41:1901–1904.
125. Sawata, A., T. Nakai, K. Kume, H. Yoshikawa, and T. Yoshikawa. 1985. Lesions induced in the respiratory tract of chickens by encapsulated or nonencapsulated variants of *Haemophilus paragallinarum*. *Am J Vet Res.* 46:1185–1191.
126. Sawata, A., T. Nakai, K. Kume, H. Yoshikawa, and T. Yoshikawa. 1985. Intranasal inoculation of chickens with encapsulated or non-encapsulated variants of *Haemophilus paragallinarum*: electron microscopic evaluation of the nasal mucosa. *Am J Vet Res.* 46:2346–2353.
127. Schneider, L. 1948. Additional data to the etiology of pasteurellosis with special reference to different species of hosts. *Acta Vet Hung.* 1:31–42.
128. Shivaprasad, H.L., and R. Droual. 2002. Pathology of an atypical strain of *Pasteurella gallinarum* infection in chickens. *Avian Pathol.* 31:399–406.
129. Soriano, E.V., V.E. Morales, V.H. Vega, A.P. Zepeda, N.R. Reyes, S.A. Ramirez, and S.B. Lagunas. 2006. Natural co-infection of *Avibacterium paragallinarum* and *Av. gallinarum* in *Mycoplasma* spp. seropositive game chickens. AAAP/AVMA Conference. Honolulu. 153.
130. Soriano, V.E., G.M. Longinos, R.P. Fernandez, Q.E. Velasquez, C.A. Ciprian, F. Salazar-Garcia, and P.J. Blackall. 2004. Virulence of the nine serovar reference strains of *Haemophilus paragallinarum*. *Avian Dis.* 48:886–889.
131. Soriano, V.E., G.M. Longinos, G. Téllez, R.P. Fernández, F. Suárez-Güemes, and P.J. Blackall. 2004. Cross-protection study of the nine serovars of *Haemophilus paragallinarum* in the Kume haemagglutinin scheme. *Avian Pathol.* 33:506–511.
132. Soriano, V.E., G. Tellez, B.M. Hargis, L. Newberry, C. Salgado-Miranda, and J.C. Vazquez. 2004. Typing of *Haemophilus paragallinarum* strains by using enterobacterial repetitive intergenic consensus-based polymerase chain reaction. *Avian Dis.* 48:890–895.
133. Takagi, M., N. Hirayama, H. Makie, and S. Ohta. 1991. Production, characterization and protective effect of monoclonal antibodies to *Haemophilus paragallinarum* serotype A. *Vet Microbiol.* 27:327–338.
134. Takagi, M., N. Hirayama, T. Simazaki, K. Taguchi, R. Yamaoka, and S. Ohta. 1993. Purification of hemagglutinin from *Haemophilus paragallinarum* using monoclonal antibody. *Vet Microbiol.* 34:191–197.
135. Takagi, M., T. Takahashi, N. Hirayama, Istiananingsi, S. Mariana, K. Zarkasie, M. Ogata, and S. Ohta. 1991. Survey of infectious coryza of chickens in Indonesia. *J Vet Med Sci.* 53:637–642.
136. Taole, M., J. Albertyn, E. Van Heerden, and R.R. Bragg. 2002. Virulence of South African isolates of *Haemophilus paragallinarum*. Part 3: Experimentally produced NAD-independent isolate. *Onderstepoort J Vet Res*. 69:189–196.
137. Terry, T.D., Y.M. Zalucki, S.L. Walsh, P.J. Blackall, and M.P. Jennings. 2003. Genetic analysis of a plasmid encoding haemocin production in *Haemophilus paragallinarum*. *Microbiol.* 149:3177–3184.
138. Terzolo, H.R., L.M. Gogorza, and A.G. Salamanco. 1980. *Pasteurella gallinarum*: Primer aislamiento en Argentina y prueba de patogenicidad en pollos parrilleros. *Rev Med Vet (Buenos Aires)*. 61:400–409.
139. Terzolo, H.R., F.A. Paolicchi, V.E. Sandoval, P.J. Blackall, T. Yamaguchi, and Y. Iritani. 1993. Characterization of isolates of *Haemophilus paragallinarum* from Argentina. *Avian Dis.* 37:310–314.
140. Terzolo, H.R., V.E. Sandoval, and F. Gonzalez Pondal. 1997. Evaluation of inactivated infectious coryza vaccines in chickens challenged by serovar B strains of *Haemophilus paragallinarum*. *Avian Pathol.* 26:365–376.
141. Tjahjowati, G., J.P. Orr, M. Chirino-Trejo, and J.H.L. Mills. 1995. Experimental reproduction of endocarditis with *Pasteurella gallinarum* in mature leghorn chickens. *Avian Dis.* 39:489–498.
142. Vazquez, M.E. 2011. Evaluation of the viability of *Avibacterium paragallinarum* in two commercial transport media. 16th World Veterinary Poultry Congress, Cancun.
143. Welchman, D.D.B., S.A. King, P. Wragg, A.M. Wood, R.M. Irvine, W.J. Pepper, R. Dijkman, and J.J. de Wit. 2011. Infectious coryza in chickens in Great Britain. *Vet Rec.* 167:912–913.
144. Wu, J.-R., Y.-R. Wu, J.-H. Shien, Y.-M. Hsu, C.-F. Chen, H. K. Shieh, and P.-C. Chang. 2011. Recombinant proteins containing the hypervariable region of the haemagglutinin protect chickens against challenge with *Avibacterium paragallinarum*. *Vaccine.* 29:660–667.
145. Yamaguchi, T., P.J. Blackall, S. Takigami, Y. Iritani, and Y. Hayashi. 1991. Immunogenicity of *Haemophilus paragallinarum* serovar B strains. *Avian Dis.* 35:965–968.
146. Yamaguchi, T., P.J. Blackall, S. Takigami, Y. Iritani, and Y. Hayashi. 1990. Pathogenicity and serovar-specific hemagglutinating antigens of *Haemophilus paragallinarum* serovar B strains. *Avian Dis.* 34:964–968.
147. Yamaguchi, T., Y. Iritani, and Y. Hayashi. 1988. Serological response of chickens either vaccinated or artificially infected with *Haemophilus paragallinarum*. *Avian Dis.* 32:308–312.
148. Yamaguchi, T., Y. Iritani, and Y. Hayashi. 1989. Hemagglutinating activity and immunological properties of *Haemophilus paragallinarum* field isolates in Japan. *Avian Dis.* 33:511–515.
149. Yamaguchi, T., M. Kobayashi, S. Masaki, and Y. Iritani. 1993. Isolation and characterisation of a *Haemophilus paragallinarum* mutant that lacks a hemagglutinating antigen. *Avian Dis.* 37:970–976.
150. Yamamoto, R. 1991. Infectious coryza. In: *Diseases of Poultry*, 9th ed. B.W. Calnek, H.J. Barnes, C.W. Beard, W.M. Reid, and H.W. Yoder, Jr., eds. Iowa State University Press, Ames, Iowa. 186–195.

151. Yamamoto, R. 1972. Infectious coryza. In: *Diseases of Poultry*, 6th ed. M.S. Hofstad, B.W. Calnek, C.F. Helmboldt, W.M. Reid, and H.W. Yoder Jr., eds. Iowa State University Press, Ames, Iowa. 272–281.
152. Yamamoto, R. 1978. Infectious coryza. In: *Diseases of Poultry*, 7th ed. M.S. Hofstad, B.W. Calnek, C.F. Hembolt, W.M. Reid, and H.W. Yoder Jr., eds. Iowa State University Press, Ames, Iowa. 225–232.
153. Yamamoto, R., and G.T. Clark. 1966. Intra- and interflock transmission of *Haemophilus gallinarum*. *Am J Vet Res.* 27:1419–1425.
154. Zaini, M.Z., and M. Kanameda. 1991. Susceptibility of the indigenous domestic fowl (*Gallus gallus domesticus*) to experimental infection with *Haemophilus paragallinarum*. *J Vet Malaysia.* 3:21–24.

Chapter 21

Mycoplasmosis

Introduction

Naola Ferguson-Noel

Mycoplasmas (class Mollicutes) are found in humans, many animal species, plants, and insects. These prokaryotes are characterized by their very small size, small genome, and complete absence of cell walls; they are bound by a plasma membrane only (26). This accounts for the "fried egg" type of colony morphology, resistance to antibiotics that affect cell wall synthesis, and complex nutritional requirements. Mycoplasmas tend to be quite host-specific; some infect only a single species of animal, whereas others may have the ability to infect several different host species. In general, mycoplasmas colonize mucosal surfaces and most species are noninvasive. However, some species, including *Mycoplasma gallisepticum* (33) and *M. synoviae* (11), are known to have the ability to penetrate cells.

Characterization

Mycoplasma species from avian sources generally require a protein-rich medium containing 10%–15% added animal serum. Further supplementation with some yeast-derived component is often beneficial. Growth of *M. synoviae* requires the addition of nicotinamide adenine dinucleotide (NAD) (see *M. synoviae* section). A medium described by Frey (16) or a medium described by Bradbury (2) is commonly used for the cultivation of avian mycoplasmas.

Mycoplasma organisms tend to grow rather slowly, usually prefer 37°C–38°C, and are rather resistant to thallium acetate and penicillin, which are frequently employed in media to retard growth of contaminant bacteria and fungi. Colonies form on agar media after 3–10 days at 37°C; however, nonpathogenic species such as *M. gallinarum* and *M. gallinaceum* may develop colonies within 1 day (*M. gallinarum* and *M. gallinaceum* are frequently isolated as contaminants during attempts to isolate pathogenic avian mycoplasmas). Typical colonies are small (0.1–1 mm), smooth, circular, and somewhat flat with a denser central elevation (Figure 21.1). Variations in colony morphology have been described, but cannot be relied upon to differentiate the various species. Individual cells vary from 0.2–0.5 μm and are basically coccoid to coccobacilliform, but slender rods, filaments, and ring forms have been described.

Fermentation of carbohydrates is variable, but all species may be divided into those that ferment glucose with acid production and those that do not. Glucose is frequently added to broth media to enhance growth of the carbohydrate-fermenting species and to provide an indication of growth when glucose fermentation produces acid in media containing phenol red. Phosphatase activity is often present, as is arginine decarboxylase. Most species that do not ferment glucose use the amino acid arginine as their major source of energy. *M. iowae* and some other species, however, ferment glucose and hydrolyze arginine.

One useful characteristic of *M. gallisepticum, M. meleagridis*, and *M. synoviae* is hemagglutination of erythrocytes from chickens or turkeys. Hemagglutinating antigens are used for hemagglutination-inhibition serologic tests for these 3 pathogenic species.

Direct staining of mycoplasma colonies on agar surfaces or colony imprints with specific fluorescent antibody (9, 31) has been commonly used to determine the species of avian mycoplasma isolates. Additional methods include growth inhibition (8), immunodiffusion (22), and others. More recently, molecular methods such as sequencing of the 16S rRNA gene (17) and polymerase chain reaction (20, 21, 35) have been used with increasing frequency.

Classification

Mycoplasmas are members of the class Mollicutes, order Mycoplasmatales. The genus *Mycoplasma* has more than 120 species, a DNA G + C content of 23%–40%, a genome size of 580–1,350 kb, requires cholesterol for growth, occurs in humans and animals, and has a usual optimum growth temperature of 37°C. The genus *Ureaplasma* is differentiated on the basis of hydrolysis of urea. Acholeplasmas are classified in order Acholeplasmatales, family Acholeplasmataceae, genus

Diseases of Poultry, Thirteenth Edition. David E. Swayne.
© 2013 John Wiley & Sons, Inc. Published 2013 by John Wiley & Sons, Inc.

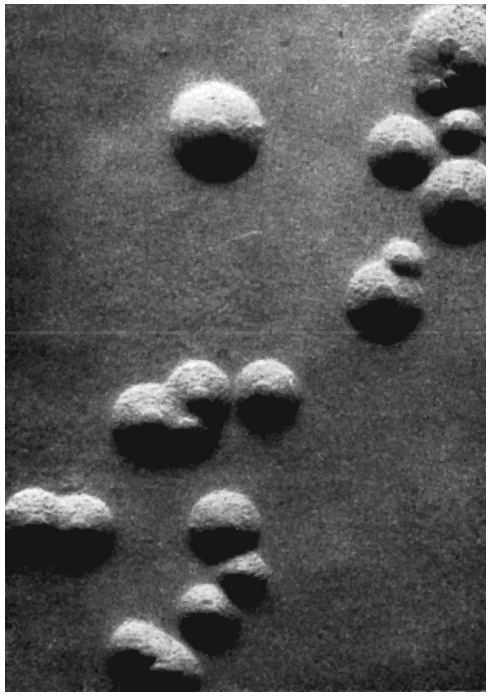

Figure 21.1. Colonies of *Mycoplasma gallisepticum* on agar. ×40. (Hofstad)

Acholeplasma. They are characterized by lack of a growth requirement for cholesterol (26). Phylogenetic analysis of the 16S ribosomal RNA gene has been used to analyze genetic relationships and classify mycoplasmas (7, 32). The complete genome sequences of several mycoplasma species have been reported, and as more mycoplasma genomes become available the analysis and comparison of these genomes allows further characterization and investigation of the genetic basis of mycoplasma biology and evolutionary relationships (1).

Earlier serotype designations for avian mycoplasmas (10) have been replaced by species names. A current listing of avian mycoplasma species is found in Table 21.1. In addition, there are numerous mycoplasma isolates from various species of birds, including strain 1220, a pathogen of domestic geese (30), isolates from various avian species including ratites and penguins, as well as unidentified isolates from domestic poultry.

The most up-to-date listing of *Mycoplasma* species can be found on the web site of the National Center for Biotechnology Information (http://www.ncbi.nlm.nih.gov/). The minimum requirements for the description of new species of mycoplasma are determined by the International Committee on Systematics of Prokaryotes Subcommittee on the Taxonomy of Mollicutes (7).

Acknowledgement

The expertise and effort of Dr. Stanley H. Kleven to previous versions of this subchapter are gratefully acknowledged.

Table 21.1. Characteristics of avian mycoplasmas.

Species	Usual host	Glucose fermentation	Arginine hydrolysis	Reference
A. laidlawii[a]	Various	+	–	(29)
M. anatis	Duck	+	–	(27)
M. anseris	Goose	–	+	(6)
M. buteonis	Buteo hawk	+	–	(25)
M. cloacale	Turkey, goose	–	+	(4)
M. columbinasale	Pigeon	–	+	(18)
M. columbinum	Pigeon	–	+	(28)
M. columborale	Pigeon	+	–	(28)
M. corogypsi	Black vulture	+	–	(24)
M. falconis	Saker falcon	–	+	(25)
M. gallinarum	Chicken	–	+	(15)
M. gallinaceum	Chicken	+	–	(18)
M. gallisepticum	Chicken, turkey, house finch, other	+	–	(12)
M. gallopavonis	Turkey	+	–	(18)
M. glycophilum	Chicken	+	–	(13)
M. gypis	Griffon vulture	–	+	(25)
M. imitans	Duck, goose, partridge	+	–	(3)
M. iners	Chicken	–	+	(12)
M. iowae	Turkey	+	+	(18)
M. lipofaciens	Chicken	+	+	(5)
M. meleagridis	Turkey	–	+	(34)
M. pullorum	Chicken	+	–	(18)
M. sturni	European starling	+	–	(14)
M. synoviae	Chicken, turkey	+	–	(18, 23)
U. gallorale[b]	Chicken	–	–	(19)

[a] Acholeplasma species do not require sterols for growth.
[b] Ureaplasma species are characterized by splitting of urea.

Mycoplasma gallisepticum Infection

Ziv Raviv and David H. Ley

Introduction

Definition and Synonyms

Mycoplasma gallisepticum (MG) infections are commonly known as chronic respiratory disease (CRD) of chickens and infectious sinusitis of turkeys. *M. gallisepticum* disease is characterized by respiratory rales, coughing, nasal discharge, and conjunctivitis, and frequently infraorbital sinusitis in turkeys. Clinical manifestations are usually slow to develop and the infection or disease may have a long course. Air sac disease describes a severe airsacculitis that is the result of MG or *Mycoplasma synoviae* (MS) infection complicated by a respiratory virus infection (e.g., infectious bronchitis or Newcastle disease) and usually *Escherichia coli*.

Economic Significance

M. gallisepticum is the most pathogenic and economically significant mycoplasmal pathogen of poultry. Airsacculitis in chickens or turkeys resulting from MG infections, with or without complicating pathogens, causes increased condemnations at processing. Economic losses from condemnations or downgrading of carcasses, reduced feed and egg production efficiency, and increased medication costs are additional factors that make MG one of the costliest infectious diseases confronting commercial poultry production worldwide. Prevention and control programs, which may include surveillance (isolation and identification, serology, molecular detection and characterization), vaccination, and eradication of infected breeding stock, account for additional costs.

Public Health Significance

M. gallisepticum infects a relatively narrow range of exclusively avian host species and has no public health significance.

History

The first accurate description of the disease in turkeys was probably made in 1905 by Dodd (109) in England, and termed epizootic pneumoenteritis. In 1935, Nelson (342) described coccobacilliform bodies associated with an infectious coryza of chickens. Later he associated the organisms with a coryza of slow onset and long duration, and eventually was able to grow the coccobacilliform bodies in embryonating eggs, tissue culture, and cell-free medium. Dickinson and Hinshaw (107) named the disease infectious sinusitis of turkeys in 1938. In 1943 Delaplane and Stuart (101) cultivated in embryos an agent isolated from chickens with CRD and later from turkeys with sinusitis. In the early 1950s Markham and Wong (304) and Van Roekel and Olesiuk (436) reported the successful cultivation of the organisms from chickens and turkeys, and suggested they were members of the pleuropneumonia group (*Mycoplasma* spp.).

Etiology

Classification

M. gallisepticum is an avian pathogen within the genus *Mycoplasma* (class *Mollicutes*) which includes more than 200 species infecting animals and humans (http://www.ncbi.nlm.nih.gov/Taxonomy/Browser/wwwtax.cgi) (369). Mollicutes are eubacteria without cell walls and the smallest self-replicating (can be grown on artificial cell-free media) prokaryotes (369). *M. gallisepticum* was first classified and differentiated from other avian mycoplasmas by serotyping (460, 461) and was commonly designated serotype A (241, 462). The species designation MG was made in 1960 by Edward and Kanarek (114). In 1993 a mycoplasma with phenotypic and antigenic similarities to MG was differentiated by molecular techniques and designated *M. imitans* (49, 186).

Mycoplasma phylogeny and taxonomy continue to be re-examined by the application of molecular tools (e.g., DNA-DNA hybridization [60], DNA sequence analysis of the 16S rRNA gene [369, 445], 16S rRNA PCR and denaturing gradient gel electrophoresis [315], and tRNA gene PCR [403]). The complete genome sequence has been determined for MG strains R_{low} (361), R_{high}, and F (414), and a database dedicated to the comparative genomics of Mollicutes, including MG, has been established (28).

Morphology and Staining

M. gallisepticum stains well with Giemsa, and by light microscopy organisms generally appear coccoid, approximately 0.25–0.5 μm in size. Based on electron microscopy (EM) studies, Tajima et al. (416) described capsular material associated with MG cells in contact with chicken tracheal epithelium. Also by EM, organisms appear round or may show a filamentous or flask-shaped polarity of the cell body. This polarity appears prior to division (330) and is due to the presence of well-organized attachment organelle (blebs or tip structures) (74) (Figure 21.2). Such structures are involved in motility, chemotaxis, (240, 264, 325), host-pathogen interactions (e.g., cytadherence—hence also termed attachment organelles), and pathogenicity (20).

Growth Requirements

M. gallisepticum replication requires a rather complex medium usually enriched with 10%–15% heat-inactivated swine, horse, or avian serum. Several types of liquid or agar media will support the growth of avian mycoplasmas (250). Frey et al. (145) developed a culture medium that incorporated all essential ingredients including yeast autolysate and glucose. When prepared with 10%–15% swine serum, it is a convenient and very effective medium for cultivation of most mycoplasmas. Extraneous bacterial and fungal contamination usually is

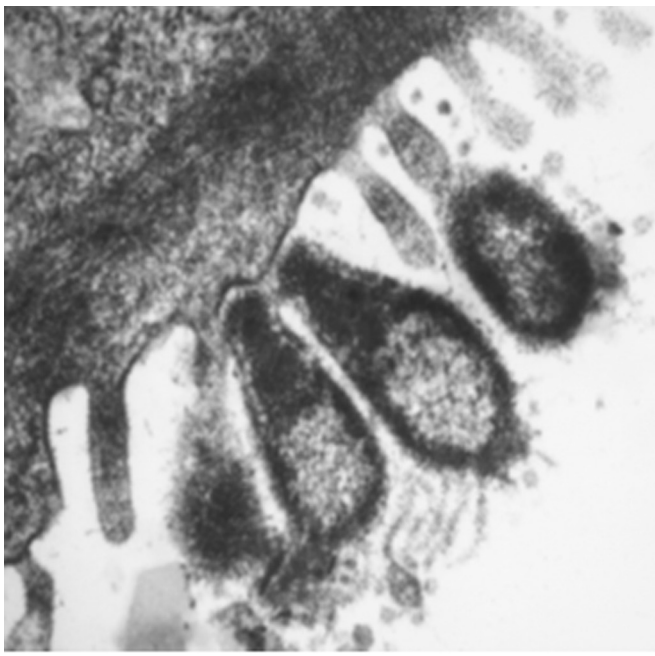

Figure 21.2. Electron micrograph (EM) of MG cells attaching to a tracheal epithelial cell. The MG cells have flask-shaped morphology and lack of cell wall. The dark elongated tips of the flask-shaped organisms are the MG attachment organelles. (Image courtesy of Dr. Stanley H. Kleven)

controlled by the inclusion of thallous acetate (up to 1:2,000) and penicillin (up to 2,000 IU/ml). *M. gallisepticum* is one of the avian *Mycoplasma* spp. that ferments glucose, which lowers the pH causing the incorporated phenol red indicator to change from red to orange/yellow, making it possible to visually detect growth in broth. Optimal growth in broth medium generally occurs at approximately pH 7.8 with aerobic incubation at 37ºC and usually is evident in 3–5 days, but some field isolates may take longer and require multiple passages (278). Growth may not be evident, but 2 or 3 serial passages at 5- to 7-day intervals may increase the number of isolations. Direct plating of exudates or tissue swabs onto mycoplasma agar may result in colonies after 4–5 days of incubation, but initial culture in broth is generally a more sensitive isolation method. Inoculated plates should be covered and incubated at 37ºC in a very moist atmosphere and may require at least 3–7 days of incubation before typical mycoplasmal colonies are sufficiently large to be observed at low magnification (250). *M. gallisepticum* also may be isolated or propagated in embryonating chicken eggs. See Isolation and Identification of Causative Agent.

Colony Morphology

M. gallisepticum colonies form on agar medium inoculated directly or following passage from broth or agar cultures (250). It often is very difficult to obtain colony growth directly from clinical specimens. Evidence of colony growth is best studied at low magnification with the aid of a dissecting microscope and indirect light. Characteristic colonies appear as tiny, smooth, circular, translucent masses that may have a dense central area ("fried egg" appearance). They rarely are more than 0.2–0.3 mm in diameter and frequently occur in ridges along the streak line, because closely adjacent colonies readily coalesce. Variations in colony morphology of isolates representing various species of avian mycoplasmas have been noted, but *Mycoplasma* spp. designations cannot be determined by colony characteristics alone.

Biochemical Properties

Biochemical and related biologic properties of MG have been described (197, 371, 462). More recently MG was identified as the first bacterium in which messenger RNA is not polyadenylated (364). *M. gallisepticum* ferments glucose and maltose with production of acid but not gas. It does not ferment lactose, dulcitol, or salicin. Sucrose is rarely fermented; results with galactose, fructose, trehalose, and mannitol are variable. It does not hydrolyze arginine and is phosphatase-negative. It reduces 2,3,5-triphenyl tetrazolium and neotetrazolium. *M. gallisepticum* causes complete hemolysis of horse erythrocytes incorporated into agar medium and agglutinates turkey and chicken erythrocytes.

Susceptibility to Chemical and Physical Agents

It is assumed that most of the commonly employed chemical disinfectants are effective against MG. Inactivation has been produced by phenol, formalin, β-propiolactone, and thimerosal. Resistance to penicillin and low concentration (1:4,000) of thallous acetate make these valuable additives to mycoplasma culture media as inhibitors of bacterial and fungal contamination, respectively.

Broth cultures of MG remained viable for 2–4 years when stored at –30ºC, and viable organisms were recovered from lyophilized broth culture stored at 4ºC for at least 7 years, and from lyophilized infective chicken turbinates stored at 4ºC for 13–14 years (462). Broth cultures of MG that had been frozen at –60ºC since 1965 were viable upon subculturing more than 20 years later (465). Lyophilized broth cultures including MG, *M. synoviae* (MS), and *M. meleagridis* (MM) were routinely found to be viable when subcultured at 10–15 years. However, loss of MG viability in liquids should be anticipated depending on the strain, medium or diluent, and temperature. *M. gallisepticum* F strain in powdered skim milk, phosphate-buffered saline (PBS), tryptose phosphate broth, and distilled water stored at 4º, 22º, and 37ºC was stable in all diluents for 24 hours when stored at 4º or 22º but not 37ºC (245). An MG inoculum stock culture showed a post-thaw drop of titer (color-changing units) of 10^3 in 24 hours at 4ºC and 10^5 at room temperature (276).

M. gallisepticum was inactivated in infected chicken hatching eggs that reached 45.6ºC during a 12- to 14-hour heating procedure (463).

Antigenic Structure and Toxins

The antigenic characteristics of MG and relatively species-specific polyclonal antibody response to the organism have been used to identify both the organism (growth inhibition

and immunofluorescence tests) and immunologic response (serologic tests) to infection (10, 250). These tests were empirically developed and optimized to enhance their sensitivity and species-specificity with little or no knowledge of the organism's antigenic structure. Proteins constitute more than two-thirds of the mycoplasma membrane mass, with the rest being membrane lipids (371). The plasma membrane of MG contains approximately 200 polypeptides (204) that typically for mycoplasmas are associated with surface antigenic variation, adhesion to host cells, motility, and nutrient transport (325, 452). The preceding information and that from many other reports indicates that the MG genome is highly committed to antigenic variation and variable expression of surface proteins (12, 40, 61, 149, 150, 177, 356).

Considerable effort has been made to identify MG antigens, especially those with adhesin or hemagglutinin properties, which may play key roles in the pathogenesis of and immune response to infection. Adhesins are integral membrane proteins with regions exposed on the cell surface that attach to receptor sites on host epithelial cells, which allow for colonization and infection, and as such are considered important virulence factors and antigens.

M. gallisepticum proteins or lipoproteins with molecular weights ranging from 60–75 kDa have been described as immunodominant adhesins or hemagglutinins (16, 26, 50, 142, 239, 308). Originally, 2 MG genes, pMGA and pvpA, were described, which encode major surface proteins with pathogenic, antigenic, and immune evasion properties (306, 308, 471). The pMGA multigene family was found to encode variant copies of a major cell surface lipoprotein hemagglutinin of 67 kDa (p67) (29, 168, 204, 310). Immunoblotting techniques revealed that the surface antigens p52 and p67 (pMGA) were specific to MG and the closely related species *M. imitans*. No antigenic difference was revealed within these species with anti-p52 serum, while anti-p67 serum confirmed the antigenic variability of p67 (205). The pMGA gene family occupies a minimum of 7.7% of the genome of strain F and 16% of the genome of strain R (29), which are significant genomic commitments to antigenic variability and hypothesized function of immune evasion (306). The pMGA genes undergo phase-variable expression (on-off switching and antigenic variation) both *in vitro* and *in vivo* (169, 170, 309), and they are thought to provide virulence mechanisms by facilitation of immune evasion and establishment of chronic infection.

In 2003 Papazisi et al., sequenced and annotated the genome of MG strain R_{low} and renamed the pMGA gene family and protein *vlhA* and VlhA, respectively (361). The *vlhA* genes encode hemagglutinin in MG and are located in 5 loci around the chromosome, and antigenic variation is generated by alternating transcription of only one of the numerous translationally competent genes (7, 345). Homologues of the *vlhA* gene family have been found in another pathogenic avian mycoplasma, *M. synoviae*. However, MG is phylogenically quite distant from MS and the organization and mechanism used to generate antigenic diversity in *vlhA* genes of these 2 species is also quite distinct. The differences between the *vlhA* loci in MG and those in MS, and the absence of homologues in species more closely related to these 2 organisms than they are to each other, have led to the suggestion that *vlhA* loci in at least one, and possibly both species, may have arisen by horizontal gene transfer (307).

The MG *pvpA* gene, present as a single chromosomal copy, encodes a putative cytadhesin-related protein that is surface exposed and localized in the attachment organelle (45). The *pvpA* gene contains multiple proline codons, tetrapeptide motif repeats, 2 directly repeated sequences, and variable size deletions in its C-terminus, and its protein shows high-frequency phase and size variation, which adds to the complexity of antigenic variation in MG (45, 209, 275, 471). Antigenic variation and expression of PvpA and p67a (VlhA), major immunogenic surface proteins, were correlated with antibody response *in vivo*, suggesting that immune modulation may have a key role in generating surface diversity (275). Other adhesins identified in MG are GapA (or Mgc1) and Mgc2 (175, 195, 224). Like PvpA, the Mgc2 adhesin localizes at the attachment organelle structure of the cell surface (195). GapA is a primary cytadhesin that appears to work in a coordinated way with at least one other cytadherence-related protein, CrmA, undergoing concomitant phase variation in expression (175, 334, 358, 359, 361, 454). Expression of these 2 components has been correlated with binding to erythrocytes (454) and efficient attachment to cultured cells (359). These results demonstrated that both GapA and CrmA are required for MG cytadherence and pathogenesis (359, 360).

Some MG cytadhesin genes and proteins have homologues in other *Mycoplasma* spp., including some that are human pathogens, suggesting that there may be some conservation of cytadhesin genes and proteins among pathogenic mycoplasmas infecting widely divergent hosts (175, 195, 224, 314, 383).

Potent toxins have not been associated with MG. See Virulence Factors.

Strain Classification

Certain isolates of MG are known by their isolate or other designations and sometimes are called strains. Various strains of MG should not be confused with the numerous serotype designations that identified avian mycoplasmas prior to speciation within the genus *Mycoplasma*. Some MG isolates from both chickens and turkeys were described as "variant" or "atypical" because they were often difficult to isolate and were less pathogenic, transmissible, and immunogenic than expected of field isolates (108, 228, 301, 464). Furthermore, because of demonstrated variability in antigenic phenotypes, MG strains, including well-established reference strains, may differ markedly in their antigen profiles and their virulence-related surface properties (382). Therefore, it has become increasingly important to develop methods to characterize and identify MG strains and strain variability. Recognition of intraspecific (strain) genotypic and phenotypic heterogeneity may be by serologic methods or electrophoretic analysis of cell proteins, but has become more discriminatory and reproducible with the application of molecular techniques.

Antigenicity

Antigenic variation of MG strains and isolates has long been recognized empirically with reports of atypical or variant strains (108, 228, 464), and demonstrated by serologic assays (35, 108, 252, 288, 308, 356), immunoblots, and monoclonal antibodies (18, 61, 97, 149, 150, 202, 239, 275, 313, 356, 382, 397).

It is now well known that significant antigenic variability among MG strains can affect the sensitivity and specificity of serological tests, depending on the strain infecting the flock and the strain used to prepare antigen. Kleven et al. (252) tested MG strains with homologous and heterologous hemagglutination-inhibition (HI) assays and found that homologous HI titers were generally higher than heterologous titers. They also reported that MG strain A5969, commonly used as an HI antigen strain in many laboratories, was relatively insensitive for detecting antibodies against all of the strains studied and that none of the antigens tested were efficient in detecting HI antibodies against all other strains studied (252). Similarly, studies on the detection of antibody response to vaccination with MG strain ts-11 suggested that the major membrane antigen of MG had slightly different antigenic profiles in different strains, thereby necessitating the use of autologous (homologous) antigens in serodiagnostic assays to increase sensitivity of the tests for mycoplasma antibodies (346). Antigenic variability among MG strains presents a great challenge to the development and optimization of antigen/antibody-based assays (e.g., serologic, immunofluorescence, and growth inhibition organism identification tests).

The range of MG strain antigenicity, as well as its variability, is based at least in part on the organism's genomic mechanisms of immune evasion and adaptation to changes in the host environment, resulting in the expression of MG antigenic surface proteins that demonstrate high frequency variation, switching, and immune modulation (34, 35, 40, 150, 169, 273, 275, 290, 454). See Antigenic Structure and Toxins, Pathogenesis of the Infectious Process, Immunity, and Vaccination.

Immunogenicity or Protective Characteristics

As discussed previously, antigenic variability among and within MG strains and a range of immune responses to them have been recognized in the field and studied in the laboratory, culminating in current concepts of immune evasion, phenotypic on-and-off switching, phase variation, etc., and the ongoing elucidation of the underlying mechanisms. See Antigenic Structure and Toxins, Pathogenesis of the Infectious Process, and Immunity.

The attenuated virulence, immunogenicity, and protective characteristics of 3 MG strains (F, ts-11, and 6/85) have been applied to their commercial development as live vaccines (see Live *M. gallisepticum* Vaccines). Immunogenic and protective characteristics also have been described for some other MG strains that may be vaccine candidates, including house finch and house finch-like strains (136, 137, 350), the GT5 strain (from the avirulent R_{high} strain with reconstitution of the gene encoding the major cytadhesin GapA) (360), and Mg 7 (MG R_{low} strain with transposon disruption of its dihydrolipoamide dehydrogenase gene) (155). See Pathogenesis of the Infectious Process, Immunity, and Vaccination.

Genetic or Molecular

M. gallisepticum strains have been differentiated from one another by direct comparison of protein banding patterns resulting from sodium dodecyl sulfate-polyacrylamide gel electrophoresis (SDS-PAGE) or restriction fragment length polymorphism (RFLP) of DNA (237, 252, 255, 389). DNA and ribosomal RNA gene probes (236, 336, 470) and physical chromosomal mapping (428) also have been used to characterize MG-intraspecific (strain) differences. These procedures for MG strain identification are costly, complex, and time consuming. DNA fingerprinting methods as arbitrary primed PCR (AP-PCR) or random amplification of polymorphic DNA (RAPD) are MG strain identification methods that have proven efficient and very useful for epidemiological studies and for the identification of vaccine strains and field isolates (24, 78, 79, 81, 128, 132, 138, 161, 256, 279, 432). However, RAPD banding patterns are prone to variability and are difficult to reproduce and standardize, making interpretation challenging and subjective. Amplified fragment length polymorphism (AFLP) has been successfully used to explore the genomic variability of several *Mycoplasma* spp., including MG (81, 132, 198, 257, 392). Molecular differentiation of MG by pulse-field gel electrophoresis (PFGE) was attempted but considered laborious, expensive, and time consuming (311, 322).

Pure culture is a preliminary requirement for the implementation of DNA fingerprinting methods, a requirement that might be very difficult to achieve in field situations (See Diagnosis, Isolation, and Identification of Causative Agent). In an attempt to address this requirement a method to separate rapidly growing nonpathogenic avian mycoplasmas from slower-growing MG field strains was proposed (44). More recently *pvpA, mgc2, gapA, crmA, crmB*, and *crmC* gene PCRs followed by RFLP (PCR-RFLP) of the amplicon has been used for MG strain identification (42, 291, 298). However, targeted sequencing of single or multiple genomic loci—*mgc2*, *pvpA*, *gapA*, *MGA_0319*—and 16S-23S rDNA ISR has become the preferable approach for MG strain differentiation (genotyping) in case studies and outbreak investigations (138, 198, 209, 256, 368, 402).

Pathogenicity

Isolates and strains of MG vary widely in their relative virulence, depending on the genotypic and phenotypic characteristics of the isolates, method of propagation, number of passages through which they have been maintained, and challenge route and dosage. Yolk-passaged organisms from MG-inoculated embryonating chicken eggs were often considered to be more infective than broth-passaged organisms.

The S6 strain of Zander (3, 126, 476) was a pathogenic isolate from the brain of a turkey with infectious sinusitis that was demonstrated to cause encephalitis and be highly neurotropic (90). The A5969 strain was given that designation by

Jungherr et al. (221) for a pathogenic culture supplied by Van Roekel. The R strain was isolated by Dale Richey at the University of Georgia Poultry Diagnostic Research Center in 1963 from a chicken with airsacculitis. The R strain has been used widely for bacterin production and as a virulent strain for MG challenge studies (174, 244, 254, 381, 421, 468). The genotypic and phenotypic properties (including pathogenicity) of low- (R_{low}) and high- (R_{high}) passage R strains have been under intensive study, especially since the complete genome sequencing of R_{low} (361). R_{low} is capable of cytadherence and cell invasion, and is pathogenic, while R_{high} shows diminished capacities in comparison (314, 358, 360, 453). Much et al. (333) reported that after aerosol inoculation of chickens, MG was re-isolated from the organs of birds infected with R_{low} but not recovered from birds infected with R_{high}. They concluded that these 2 mycoplasma populations derived from strain R differed in their capacity to cross the mucosal barrier, and that cell invasion may play a major role in the observed systemic spread of MG (333).

The live F strain MG vaccine has proven relatively more virulent for turkeys than usually noted in chickens (277, 286, 381). The 6/85 and ts-ll vaccine strains are less virulent for chickens and turkeys than the F strain (1, 123, 124, 254, 305, 450, 451).

House finch and house finch-like strains of MG have shown relatively low virulence for chickens and turkeys (136, 137, 350), and vary in their ability to cause disease, induce antibody responses, and persist in their original host (180).

Virulence Factors

Razin et al. (371) observed that the molecular mechanisms of mycoplasmal pathogenicity have remained largely elusive and that the clinical picture of mycoplasmal infections was more suggestive of damage due to host immune and inflammatory responses (immunopathology) rather than direct toxic effects by mycoplasmal cell components. Virulence factors associated with MG include motility and cytadhesion (20, 80, 190, 207, 240, 314, 325, 334), the ability to vary surface components, which may function in immune evasion and/or adaptation to host environments (34, 275, 306, 309, 310), and the ability to invade cells (264, 333, 442, 453). Furthermore, additional MG virulence factors were identified. The MG 'Mycoplasma specific lipoprotein A (MslA) was demonstrated with reduced expression in the attenuated F vaccine strain and with lower *in vivo* virulence in R_{low} *mslA* knockout mutants, suggesting this lipoprotein plays a role in MG virulence (413). The OsmC-like adhesion protein also confers organic hydroperoxide resistance for MG in the extracellular milieu and may be essential for survival and pathogenesis (208). *M. gallisepticum* and MS homologous cysteine proteases (CysP) were demonstrated to digest chicken IgG and provided another possible mechanism for these organisms' prolonged survival despite the antibody response of their host (85).

Papazisi et al. (361) sequenced the complete genome of MG strain R_{low} and identified a number of potential virulence factors involved in cytadherence, binding biomolecules, and heat shock proteins. Signature sequence mutagenesis, which allows for comprehensive screening of the MG genome for the identification of novel virulence-associated determinants from a mixed mutant population, was used to identify a virulence-associated gene encoding dihydrolipoamide dehydrogenase (200). Comparative genomic analyses of virulent R_{low}, attenuated R_{high}, and F MG strains was used to identify determinants involved in pathogenesis and survival in the host (414). This approach revealed mutations in numerous genes and indicated a range of protein functions potentially involved in virulence. While these included putative cytadherence-related functions, which are of primary importance for MG virulence, other novel virulence determinants such as glycerol metabolism linked to H_2O_2 production, subtilases, and haloacid dehalogenase hydrolases were indicated. Comparative genomic hybridization analyses identified few common genes missing or divergent in vaccine strains F, ts-11, and 6/85, indicating that no single gene was likely responsible for their attenuation (414). See Antigenic Structure and Toxins, Pathogenesis of the Infectious Process, and Immunity.

Pathobiology and Epidemiology

Incidence and Distribution

M. gallisepticum infections have resulted in important flock health and decision-making challenges in chickens and turkeys in all areas of commercial production in the United States and are worldwide in distribution (251, 273).

In the United States, the incidence of MG in commercial poultry decreased considerably during the past 50 years as the result of extensive control programs under the National Poultry Improvement Plan (NPIP) (10). The NPIP has been especially effective in controlling infections in primary and multiplier breeder flocks. However, outbreaks continue to occur in meat flocks, and MG infection is endemic in many large multiple-age commercial egg production units (see Intervention Strategies). There is increasing evidence that small backyard or "free-range/village" poultry flocks may be subclinically infected and serve as sources of infection for commercial flocks (125, 225, 316, 425).

Beginning in 1994, MG was identified as the cause of conjunctivitis in free-ranging house finches and some other songbird species in the eastern United States and Canada (278, 279). MG infection and disease in house finches expanded to the bird's western range by 2002–2005 (112, 281).

Natural and Experimental Hosts

M. gallisepticum infections naturally occur primarily in gallinaceous birds, particularly chickens and turkeys. However, MG has also been isolated from naturally occurring infections in pheasants, chukar partridge, grey partridge, peafowl, bobwhite quail, and Japanese quail (39, 89, 335, 373, 441). *M. gallisepticum* also has been isolated from ducks and geese (37, 64, 213), and from a yellow-naped Amazon parrot (46)

and greater flamingos (117). *M. gallisepticum* was not isolated in culture but was detected by polymerase chain reaction (PCR) in 4 mature rooks (*Corvius frugilegus*) with pericarditis and pneumonia in a Scotland survey of wild birds (362).

A report by Davidson et al. (100) of MG isolated from wild turkeys (*Meleagris gallopavo*) noted that the turkeys involved were in confinement rather than free-ranging in their natural habitat. A follow-up survey of the same population 8 years later found no conclusive evidence that MG was present, indicating that MG did not persist or spread in this wild turkey population (293). Other surveys of wild turkeys have found MG sero-negative (199, 294) and sero-positive (87, 146) populations. However, MG has rarely been isolated from wild turkeys, perhaps due in part to the common occurrence of other *Mycoplasma* spp., especially *M. gallopavonis* (87, 146).

Low prevalence (5 and 2.7%) of antibodies to MG were detected by serum plate agglutination (SPA) from lesser prairie chickens sampled from southwestern Kansas in 2000 and 2001, but no confirmatory serologic or organism identification methods were used (183).

Prior to 1994, there were reports of mycoplasma isolations from various other free-ranging birds, but the significance of occasionally reported MG was not clearly established. Similarly, attempts to determine the pathogenicity of MG for various free-ranging birds were not very conclusive. However, in 1994 free-ranging house finches (*Carpodacus mexicanus*) with conjunctivitis and peri-ocular swelling were observed in the mid-Atlantic and eastern United States, and MG was isolated and shown to be the etiology (140, 258, 278, 295, 296, 411, 412). The disease quickly became widespread, affecting house finches throughout their entire eastern range and negatively impacting their population (102, 105, 188, 189, 343, 379). By 2002–2005 the disease in house finches had extended to their western range (112, 281).

M. gallisepticum conjunctivitis has been reported at much lower prevalence for American goldfinches, pine grosbeaks, and evening grosbeaks, with single confirmed isolations reported from a purple finch and blue jay (187, 279, 324). One field survey found tufted titmouse positive by MG PCR but no isolates were made, and individuals from 10 additional songbird species were MG SPA-positive only (297).

In another field survey 358 birds representing 13 different families showed no clinical signs but 13 species from 9 families had positive MG SPA reactions with all birds negative by PCR (130). Experimental infections produced clinical disease in pine siskins and tufted titmouse, but house sparrows were infected without clinical disease (130). Later studies of disease susceptibility and comparative infectiousness of wild bird species after experimental inoculation with MG indicated that house sparrows and pigeons were none to mildly susceptible to clinical disease and were only mildly infectious to naïve house finches, while American goldfinches developed intermediate clinical disease and remained infectious to naive house finches for up to 49 days post inoculation (103, 164).

Random amplified polymorphic DNA (RAPD) analyses of MG isolates spanning temporal, geographic, and songbird species ranges resulted in banding patterns essentially identical to each other but different from other MG strains and isolates tested (279). These results indicated that this outbreak of MG in songbirds was caused by a single field strain (RAPD-type) and not by any vaccine strain (F, ts-11, 6/85) or isolate analyzed from poultry (279). Further analyses (81, 363) showed some genomic variability among songbird MG isolates but supported previous observations that during the initial stages of the MG epidemic in songbirds, isolates from different geographic locations and songbird species had genotypes that appeared to be highly similar, further supporting a single point source of origin. One 2001 isolate from New York was clearly different from the other songbird samples and clustered together with the vaccine and reference strains, indicating that substantial molecular evolution or a separate introduction may have occurred (81), but was not sustained.

Experimental infections using a house finch MG isolate found that infection and disease can result in chickens and turkeys but that biosecurity measures that restrict direct contact between poultry and infected house finches reduce the potential for transmission (350, 404). However, an atypical MG isolate from commercial turkeys was very similar to isolates from house finches by RAPD and DNA sequence analyses, suggesting the possibility that this was an incident of commercial poultry naturally infected by a songbird-like MG strain (137).

Specific pathogen free and/or mycoplasma-free domestic breeds of chickens, turkeys, and their embryonating eggs are the most commonly used experimental hosts for MG (47). Budgerigars, partridges, house finches, and domestic canaries also have been used as experimental hosts (62, 103, 130, 147, 191, 258, 319, 378, 411, 412).

M. gallisepticum can probably infect susceptible birds at any age, although very young birds are seldom submitted with naturally occurring disease. However, young birds generally are considered somewhat more susceptible to experimental infections (47, 158).

Transmission, Carriers, Vectors

Horizontal transmission occurs readily by direct or indirect contact of susceptible birds with clinical or subclinical infected birds resulting in high infection/disease prevalence within flocks. The upper respiratory tract and/or conjunctiva are portals of entry for the organism in aerosols or droplets (47).

Experimental intra-crop inoculation of house finches resulted in infection, disease, and a serological response (106). *M. gallisepticum* seldom survives for more than a few days outside of a host, so clinical or subclinical carrier birds are essential to the epidemiology of MG diseases. However, additional transmission and more widespread disease outbreaks may occur via fomites—contaminated airborne dust and droplets, or feathers, coupled with suboptimal biosecurity and personnel practices. In house finches, experimentally infected birds were demonstrated to indirectly infect naïve birds through contacted bird feeders and support the possible transmission of MG by fomites (104).

Survival time of MG depends on at least conditions of substrate, pH, temperature, and humidity. *M. gallisepticum* remained viable in chicken feces for 1–3 days at 20ºC, on muslin cloth for 3 days at 20ºC or 1 day at 37ºC, and in egg yolk for 18 weeks at 37ºC or 6 weeks at 20ºC (75). *M. gallisepticum* survived in the human nasal passage for 24 hours; on straw, cotton, and rubber for 2 days; on human hair for 3 days; and on feathers for 2–4 days (84). Field isolates of MG did not survive longer than 7 days on paper discs at 30ºC, 37ºC, and outdoor temperatures (337). Of 160 environmental samples tested from infected poultry flocks, 103 were positive using MG specific PCR, but only 6 were positive by culture, indicating that PCR is more sensitive for assessing dissemination of the organism than culture, which unlike PCR requires viable organisms for positive results (312).

Horizontal spread of MG within a chicken flock has been described in 4 phases: a latent phase (12–21 days) before antibody was first detected in inoculated birds, a period (1–21 days) in which infection gradually appeared in 5%–10% of the population, a period (7–32 days) in which 90%–95% of the remaining population developed antibody, and a terminal phase (3–19 days) in which the remainder of the population became positive (318). Increasing the population density increased the rate at which horizontal spread occurred. Feberwee et al. (134) described an experimental model of horizontal transmission in chickens to study transmission dynamics and efficacy of intervention strategies.

Some potential reservoirs of MG (carrier birds) in the United States are backyard flocks (125, 316), multiple-age commercial layer flocks (246, 326), and some free-ranging songbird species (137, 140, 279, 281, 324, 404). Good management and biosecurity practices are necessary to ensure that MG infections are not introduced from these and other sources to MG-free flocks.

Vertical transmission (*in ovo*/transovarian) of MG is known to occur in eggs laid by naturally infected hens (chickens or turkeys) and has been induced following experimental infections of susceptible leghorn chickens (172, 287, 354). The highest rates of transmission were found during the acute phase of the disease when MG levels in the respiratory tract peaked (171, 287). In separate studies, peak egg transmission was detected 4 weeks after MG challenge in approximately 25% of the eggs (172) and at 3–6 weeks post challenge in more than 50% of the eggs (390). On a flock basis, egg transmission rates decline as the post-infection interval lengthens. Transmission rates of approximately 3% at 8–15 weeks post infection (377) and approximately 5% at 20–25 weeks post infection (172) have been reported. During chronic infections under field conditions egg transmission is likely to occur at much lower levels (273). Horizontal transmission of MG from infected progeny that hatch, even very few infected birds resulting from very low transmission rates, is likely to involve entire flocks that receive any infected birds. *M. gallisepticum* control programs (10) must focus on primary and multiplier breeder flocks because of the severe epidemiological consequences of egg transmission. Serologic monitoring of breeder flocks at very short intervals (turkeys every 3 weeks, chickens every 2 weeks) could optimize the ability to detect and prevent the consequences of egg transmission.

Incubation Period

In experimental infections of chickens or turkeys, with uniform and high dosages, the MG incubation period varies from 6–21 days. Sinusitis often develops in experimentally inoculated turkeys within 6–10 days. However, development of clinical signs following a known exposure, even in turkeys that are considered highly susceptible, can be highly variable depending on MG strain virulence, complicating infections (polymicrobial infections) and environmental and other stressors (47, 108). Therefore, under natural conditions it is very difficult to estimate the possible date of exposure based on the appearance of clinical signs. Many variable factors seem to influence the onset and extent of clinical disease so meaningful incubation periods cannot be stated. Chickens and turkeys often develop clinical infections near the onset of egg production, suggesting a low level of subclinical infection (perhaps due to egg transmission) that becomes clinical in response to stressors. This apparent extended incubation period was especially common in offspring of infected chickens or turkeys hatched from eggs dipped in antibiotic solutions for control of MG infection. The possible role of contamination from other (external) sources of infection is not always clear and can rarely be proven beyond reasonable doubt. Many outbreaks of MG appeared to represent this type of infection with delayed onset in which serologic evidence first appeared in older birds, often without clinical signs (301, 431, 464). In other situations, especially in turkeys exposed to virulent MG strains, clinical signs may be apparent before positive serology and are the first indicator of infection (280).

Clinical Signs

Chickens

The most characteristic signs of naturally occurring MG disease in adult flocks are tracheal rales, nasal discharge, and coughing. Feed consumption is reduced, and birds lose weight. In laying flocks, egg production declines but usually is maintained at a lowered level (326). However, flocks may have serologic evidence of infection with no obvious clinical signs, especially if they encountered the infection at a younger age and have partially recovered. Male birds may have the most pronounced signs, and the disease is often more severe during winter. In broiler flocks, most outbreaks occur after 4 weeks of age. Signs are frequently more marked than those observed in mature flocks. Severe outbreaks with high morbidity and mortality observed in broilers are frequently due to concurrent infections and environmental factors (247). See Morbidity and Mortality.

Conjunctivitis developed in chickens following eye-drop inoculation of Australian field strains of MG combined with infectious bronchitis virus (399). Cases of kerato-conjunctivitis caused by MG were reported in commercial layer chickens in Japan, first appearing around 30 days of age (348). Chickens

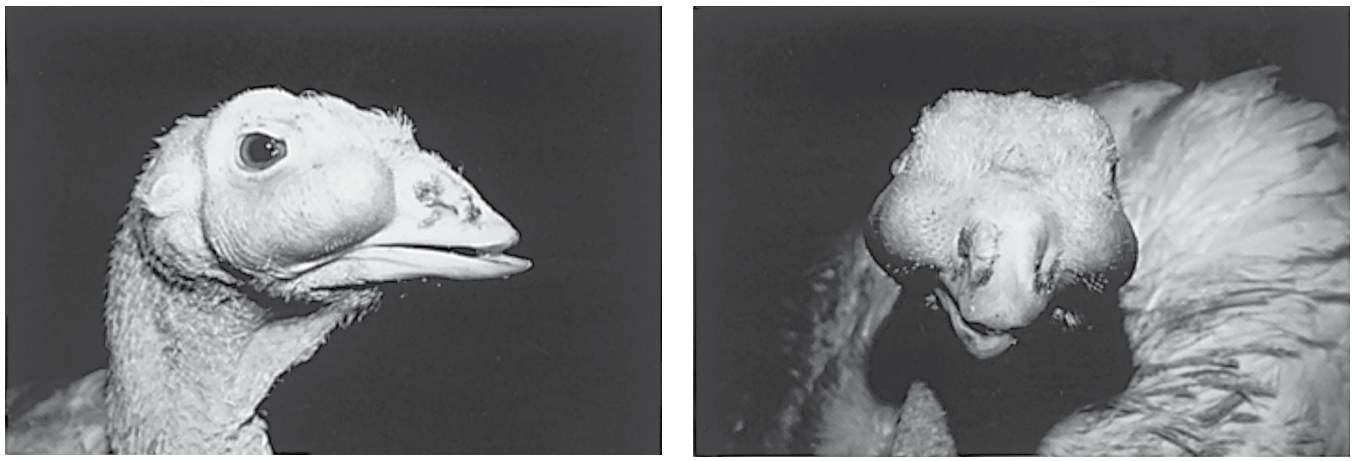

Figure 21.3. Turkey with advanced case of infectious sinusitis showing marked swelling of infraorbital sinuses and nasal exudate.

showed swelling of the facial skin and the eyelids, increased lacrimation, congestion of conjunctival vessels, and respiratory rales.

Turkeys

Turkeys are more susceptible to MG than chickens, commonly developing more severe clinical signs including sinusitis (Figure 21.3), respiratory distress, listlessness, decreased feed intake, and weight loss. Inoculation by the eye-drop, intranasal, or intratracheal routes often results in fewer and milder lesions than intrasinus or intra-air sac inoculation (47). Turkeys sometimes do not develop sinusitis unless organisms are injected directly into the sinus (108). As in chickens, more severe outbreaks with high morbidity and mortality frequently result with the involvement of complicating factors such as colibacillosis or environmental stressors (247). Nasal discharge with foamy eye secretions frequently precedes the more typical swelling of the paranasal (infraorbital) sinuses. Partial to complete closure of the eyes sometimes results from severe swelling of the sinuses. Feed consumption may remain near normal as long as the birds can see to eat. As the disease progresses, affected birds fail to gain weight and body mass may even decrease. Tracheal rales, coughing, and labored breathing may become evident if tracheitis or airsacculitis is present. An encephalitic form of MG has been reported in 12- to 16-week-old commercial meat turkeys displaying torticollis and opisthotonos (83). In breeding flocks, there may be a drop in egg production.

Morbidity and Mortality

Embryos. Inoculation of broth cultures or exudates containing MG into 7-day-old embryonating chicken eggs via the yolk sac route usually results in embryo deaths within 5–7 days. One or more yolk passages may be necessary before typical deaths and lesions are produced. Dwarfing, generalized edema, liver necrosis, and enlarged spleens are most typical. The organism reaches its highest concentration in the yolk sac, yolk, and chorioallantoic membrane (CAM) just prior to embryo death. Studies showed that MG strains varied in their *in ovo* virulence and that there was no correlation between *in ovo* virulence and other *in vivo* or *in vitro* methods for virulence evaluation (274). *M. gallisepticum* embryo mortality was prevented in eggs containing maternal MG antibodies, although MG could be re-isolated from the yolk sac membrane of live embryonating eggs after 17 days of incubation (274). Inoculation of embryonating eggs is rarely employed for the primary isolation of avian mycoplasmas now that adequate culture media are available.

Chickens. *M. gallisepticum* infection usually affects nearly all chickens in a flock but disease is variable in severity and duration. It tends to be more severe and of longer duration in the cold months and affects younger birds more severely than mature birds, although there may be a considerable loss from lowered egg production in laying flocks.

Although MG is considered the primary cause of chronic respiratory disease (CRD), other organisms frequently cause complications. Severe air sac infection, frequently designated as complicated CRD, or air sac disease, is the condition more commonly encountered in the field. Newcastle disease (ND) or infectious bronchitis (IB) may precipitate outbreaks of MG infection. *E. coli* is a frequent complicating organism. The effects of MG, *E. coli*, and IB virus (IBV) infections alone or together in chickens have been reported (127, 181, 182). Severe air sac infection was reproduced when all 3 agents were combined, and *E. coli* did not readily infect the air sacs without previous infection by MG alone or in combination with either IB or ND virus. Investigators have noted increased severity and duration of the disease when both MG and IBV were present (399).

Mortality may be negligible in adult laying flocks, but there can be a reduction in egg production (73, 326). In broilers the mortality may range from low in uncomplicated disease to as much as 30% in complicated outbreaks, especially during the colder months. Retarded growth, downgrading of carcasses, and condemnations constitute further losses.

Figure 21.4. House finch with conjunctivitis. MG infection in house finches (*Carpodacus mexicanus*) with conjunctivitis was first reported in 1994, spread rapidly in the eastern North American range and later to the western range, and is now endemic throughout. (American Association of Avian Pathologists)

Turkeys. *M. gallisepticum* infection of turkeys causes disease in most of a flock, although turkeys may not exhibit sinusitis and the lower respiratory form of infection may be most prominent (108). Infection with MG may last for months in untreated flocks. Clinical signs, morbidity, and mortality associated with MG infection in turkeys may be highly variable. Typically, meat turkeys experience outbreaks between 8 and 15 weeks of age. Initially, mild respiratory signs may progress in 2–7 days to a severe cough in 80%–90% of the flock. Swollen sinuses with nasal discharge may affect 1%–70% of birds in affected flocks. Condemnations primarily result from airsacculitis and related systemic effects.

Pathology

Gross

Gross lesions consist primarily of mucosal congestion and catarrhal exudate in nasal and paranasal passages, trachea, bronchi, and air sacs. Sinusitis with mucoid to caseous exudate accumulation is usually most prominent in turkeys but is also observed in chickens and other affected avian hosts. Air sacs frequently contain caseous exudate that may be focal, multifocal, or diffused. Some degree of pneumonia may be observed. In severe cases of advanced air sac disease in chickens or turkeys, there is the triad of caseous airsacculitis, fibrinous perihepatitis, and pericarditis resulting in high mortality and extensive condemnations at processing. However, these lesions may occur with other disease agents and are not pathognomonic for MG. Commercial layer chickens with MG keratoconjunctivitis had marked edema in the facial subcutis and eyelids, with occasional corneal opacity (348). Conjunctivitis with peri-ocular swelling and inflammation are characteristics of MG in house finches (Figure 21.4) and other songbirds (191, 278, 279, 324) and have been seen in chukar partridges (319). Oviducts distended with exudate (salpingitis) have been associated with decreased egg production in MG-infected flocks (111, 349).

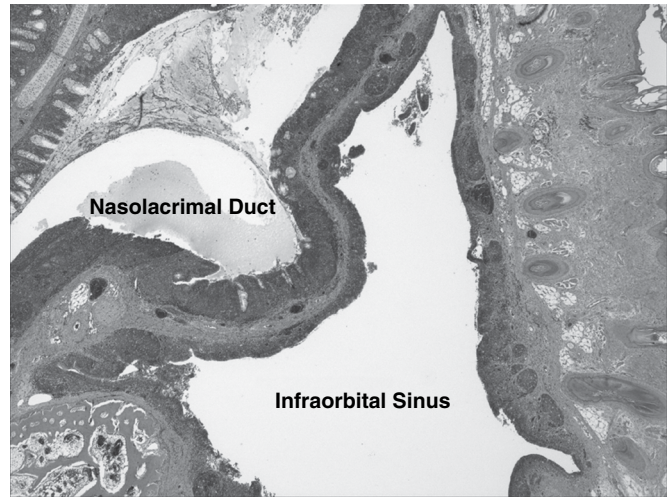

Figure 21.5. This cross section of the nasal cavity shows the infraorbital sinus and nasolacrimal duct. The mucosa of each is increased in thickness due to a nodular and diffuse infiltration of lymphocytes and other lymphoid cells. The increase in number of lymphoid nodules is called the *lymphofollicular reaction*.

Microscopic

Microscopic pathology of MG in chickens and turkeys is characterized by marked thickening of the mucous membranes of affected respiratory tract tissues from infiltration with primarily mononuclear cells and hyperplasia of the mucous glands (77, 194, 437) (Figure 21.5). Focal areas of lymphoid hyperplasia and germinal centers formation are commonly found in the mucosal lamina propria (Figure 21.6). In trachea, MG was adherent to swollen epithelial cells and there was almost complete destruction of cilia (77, 113). Accumulation of primarily lymphocytes and plasma cells, macrophages, and some heterophils in the lamina propria are commonly observed (Figure 21.7). Tracheal gross and microscopic lesions, particularly increased mucosal thickness, have been used as measures of MG infection and disease (347, 449). Following experimental infection of chickens, trachea mucosal thickness increased significantly from 1–2 weeks and then decreased from 2–3 weeks (156). Lungs may have pneumonic areas, lymphofollicular changes, and granulomatous lesions. Detailed examinations of MG-infected chicken air sacs via light microscopy, scanning EM, and histomorphometric evaluation have been reported (430) (Figure 21.8).

Keratoconjunctivitis in layer chickens associated with MG was characterized by epithelial hyperplasia, severe inflammatory cell infiltration, and edema of the subepithelial and central fibrovascular connective tissue stroma, which resulted in marked thickening of the eyelids (348). In the subepithelial lamina propria, proliferation of lymphocytes and plasma cells accompanying germinal centers was marked and resulted in irregular elevations of the overlying hyperplastic epithelial layer (348).

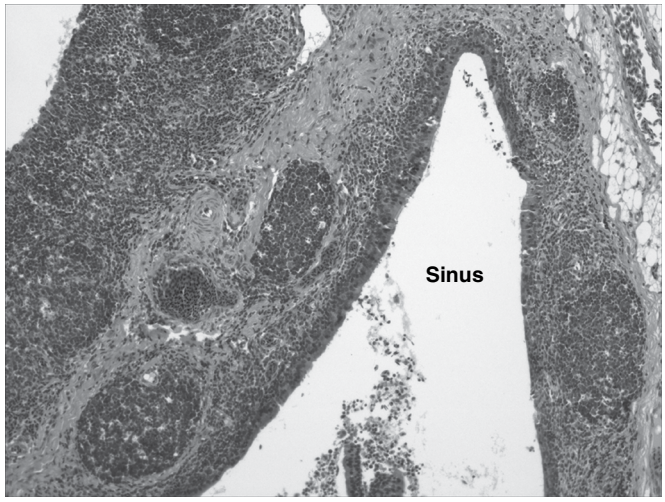

Figure 21.6. The epithelium of the infraorbital sinus (Sinus) is increased in thickness, and there is a nodular proliferation of lymphoid cells in the connective tissue beneath the lining epithelium. The mucosa of the nasolacrimal duct is increased in thickness due to the lymphoid cell infiltration. Exudate is in the sinus.

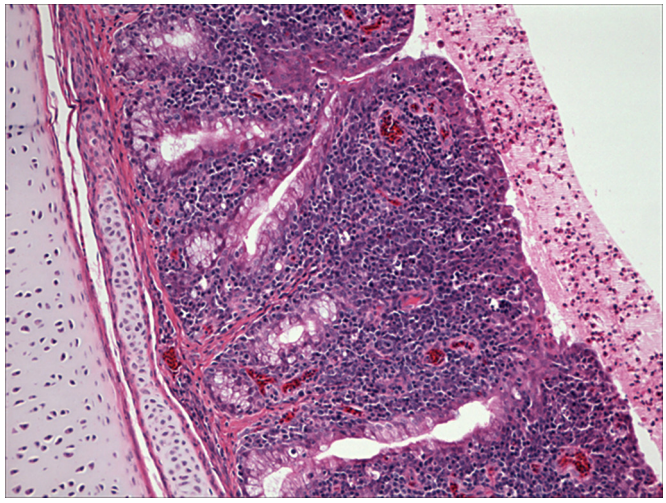

Figure 21.7. Experimentally induced MG lymphocytic tracheitis in a chicken. The tracheal mucosa is increased in thickness due to primarily lymphocytic infiltration in the lamina propria, and the epithelium is deciliated and cuboidal. A layer of mucus with numerous heterophils is observed in the tracheal lumen. (O. Fletcher)

Histologic examination of turkey brains in cases of encephalitic MG revealed moderate to severe encephalitis with lymphocytic cuffing of vessels, fibrinoid vasculitis, focal parenchymal necrosis, and meningitis (83).

Salpingitis associated with reduced egg production in layer chickens was characterized by marked thickening of the oviductal mucosa due to epithelial hyperplasia and marked lymphoplasmacytic infiltration (349).

Ultrastructural

Ultrastructural details of MG interaction with the tracheal epithelium of chickens *in vivo* and *in vitro* have been reported (2, 113, 196, 261, 415). Tracheal lesions occurred in close association with the presence of mycoplasmas and were characterized by degeneration of the epithelial cells and inflammatory cellular infiltration of the mucosa (415). Mycoplasmas were predominantly found extracellularly and only rarely in phagocytic vacuoles of epithelial cells. Mycoplasmas were attached to epithelial cells by their attachment organelles close to the host cell membrane. A release of mucous granules followed by exfoliation of ciliated and nonciliated epithelial cells and infrequent loss of cilia from individual cells was noted (113). Repair of the epithelial surface was affected by basilar epithelial cells differentiating and filling in the spaces formed by exfoliated cells. During infection, there was increasing epithelial thickness due to cellular infiltration and edema (113).

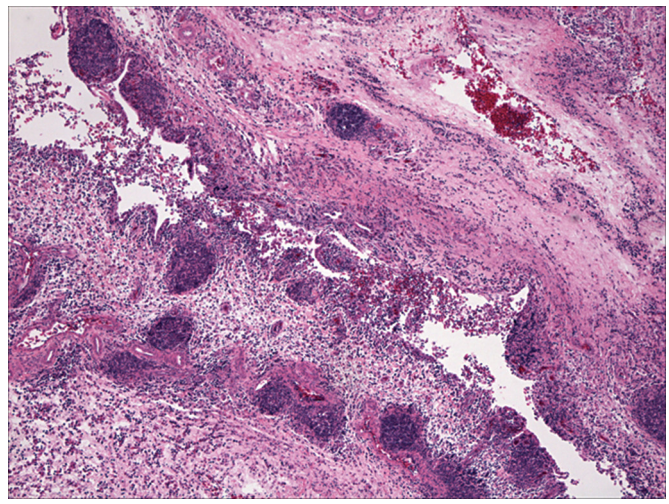

Figure 21.8. Severe, chronic, lymphoplasmacytic airsacculitis in MG-infected chicken. The air sac is markedly increased in thickness by fibrinoheterophilic, lymphoplasmacytic infiltrate, formation of germinal centers, and fibroplasia. The air sac epithelium is hyperplastic, and the lumen contains fibrinoheterophilic exudate and necrotic cell debris. (O. Fletcher)

Incubation of MG with chicken red blood cells resulted in alterations of cell surface morphology and perforations (260, 262), results that may support evidence that MG can penetrate and be present within cells (453).

Pathogenesis of the Infectious Process

Except for infections acquired by egg transmission, the upper respiratory tract and/or conjunctiva generally are accepted to be the portals of entry for naturally acquired MG infections. *M. gallisepticum* is considered to be primarily a surface parasite of the respiratory tract and conjunctiva, although spread to other organs (e.g., brain [83, 426], oviduct [349]) indicates that transient systemic infections occur, resulting in acute and chronic diseases at multiple sites.

Attachment of mycoplasmas to host cells is a prerequisite for successful colonization, infection, and pathogenesis (99, 175, 271, 334, 370) and is considered an important virulence factor (see Virulence Factors and Strain Classification/Antigenicity). *M. gallisepticum* organisms attach to epithelial

cells by their attachment organelle, which also plays a role in gliding motility, another component of pathogenesis (74, 394, 415). Comparative studies using MG strains R_{low} (virulent) and R_{high} (avirulent) identified the cytadhesin protein GapA and accessory protein CrmA and found that both are required for cytadherence and pathogenesis (334, 358, 359), and that phase variation of these proteins correlates with hemadsorption and phenotypic switching (454).

In tissue culture, MG was found capable of entering nonphagocytic host cells, a property that could provide the organism with the opportunity for resisting host defenses and selective antibiotic therapy, establishing chronic infections, and passing through the respiratory mucosal barrier to cause systemic infections (453). Much et al. (333) found that R_{low} and R_{high} strains differed markedly in their ability to invade nonphagocytic eukaryotic cells, and after aerosol inoculation of chickens, MG was re-isolated from the organs of birds infected with R_{low} but not R_{high}. Results showed that these strains differed in their capacity to cross the mucosal barrier, and suggested that cell invasion may play a major role in the systemic spread of MG and avoidance of host defenses allowing for its survival and persistence of infection (333). Furthermore, because adhesion is a prerequisite for cell invasion, the lack of GapA expression in R_{high} may account for its inability to cause systemic infection and air sac lesions (333). Alteration of chicken red blood cell (RBC) surface morphology and perforation suggested that MG RBC penetration may occur (260, 262). More recently MG was demonstrated to invade RBCs *in vitro* and *in vivo* and was detected in the bloodstream as well as inside erythrocytes of infected chickens (442).

Changes in tracheal epithelial surface, induced by MG infection *in vivo* and *in vitro*, include release of mucous granules followed by destruction and exfoliation of ciliated and nonciliated epithelial cells (77, 113). In chicken embryos, MG infection resulted in extensive deciliation, surface erosion, and inflammatory cell infiltration (261). These changes, and ciliostasis as noted in tracheal organ cultures infected with MG (417, 433), likely play both primary and secondary roles in the pathogenesis of MG diseases.

Suppression or stimulation of B and T lymphocytes and cytokine down-regulation or induction (156, 263, 329, 371) may also play roles in pathogenesis. A prominent feature of MG infection is a lymphoproliferative response at the site of infection, and MG-infected cells have been shown to produce chemotactic factors attracting the migration of heterophils and lymphocytes (259, 266). The importance of lymphocyte and macrophage chemotactic factors in the development of tracheal lesions in chickens inoculated with virulent (R_{low}) vs. attenuated (GT5) MG strains was demonstrated (329). Furthermore, in addition to previous assumptions (371), the cumulative indications of severe MG-induced lesions in the presence of robust cell-mediated and humoral immune responses suggest the role of immunopathology in MG pathogenesis.

In the absence of exacerbating environmental stressors or infection with other pathogens, MG infection in the trachea may be self limiting (456) but organisms may persist (carrier state), even in the presence of humoral or local antibody (35, 244, 456). The high frequency phenotypic variation of major surface antigens (150, 169, 454), cell invasion (333), and antibody digestion (85) may be explanations for MG chronic infections, despite a strong immune response (273) (see Immunity).

Complicating bacterial and viral infections, especially colibacillosis, and effects of some live vaccines are known to result in more severe MG diseases (182, 212, 247, 338, 341, 408). Other factors that are likely to contribute to more severe MG diseases include immunosuppression and poor environmental conditions or other stressors (30).

Immunity

Chickens or turkeys that have recovered from clinical signs of MG diseases are known to have some degree of immunity. However, recovered birds may still carry the organism (35) and can transmit infections to susceptible birds by contact or egg transmission. The early literature concerning the immune response to MG was reviewed by Luginbuhl et al. (292). The importance of antibodies and the cloacal bursa (bursa of Fabricius) to the development of MG resistance and serologic response to the organism has been demonstrated (4, 206, 265). However, poor correlation between levels of specific circulating antibody and protection also has been well documented (265, 289, 344, 421, 450).

Increasing antibody titers to MG were found in tracheal washings of infected chickens with a concomitant decrease in organisms and tracheal lesion scores (82, 456). Antibodies persisted in recovered chickens, and upon re-exposure, had a faster rate of MG elimination and less severe tracheal lesions than observed after the first exposure. These results and others indicated that antibodies in respiratory secretions played a role in resistance to MG (15, 119, 206, 456, 458). Respiratory tract antibodies produced in response to MG infection inhibited attachment of the organism to tracheal epithelial cells (15), which may be one important mechanism of immune-mediated protection.

The presence of maternal antibodies to MG in embryonating eggs reduced the *in ovo* virulence of infection and increased the probability of survival of infected embryos (38, 274, 289). Considerable effort has been made to identify MG antigens, especially those with cytadhesion properties, which may play key roles in the pathogenesis of, and immune response to, infection. See Antigenic Structure and Toxins, Virulence Factors, and Vaccination.

Mycoplasmas may affect the cell-mediated immune system by inducing either suppression or stimulation of B and T lymphocytes and inducing expression or down-regulation of cytokines (82, 148, 156, 263, 329, 371, 372).

Lymphoproliferation, interferon, and nitric oxide were detected *in vitro* in antigen-stimulated peripheral blood leukocytes from MG-infected chickens (372). Gaunson et al. (156, 157) examined the numbers and distribution of lymphocytes in the tracheas of chickens exposed to virulent and vaccine strains of MG and found specific stimulation of CD8+ cells (suppressor T cells), particularly in the acute phase of disease.

They observed a primary role for local antibody-mediated responses in controlling MG infection, but also presented evidence for significant natural killer and cytotoxic T cell responses to infection (157).

Studies on variable expression of MG immunodominant surface proteins demonstrating high frequency variation, switching, and immune modulation suggest that this variability may function as a crucial adaptive mechanism enabling the organism to escape from the host immune defenses (immune evasion), adapt to the changing host environment at different stages of a natural infection, and allow for chronic infection despite a strong immune response (35, 40, 150, 169, 273, 275, 454). Additionally, it may be possible for MG to hide from host defenses by entering eukarytotic cells (cell invasion) and spreading systemically, contributing to its survival and persistence of infection (260, 262, 333, 442, 453).

Diagnosis

Isolation and Identification of Causative Agent

The gold standard for MG diagnosis is isolation and identification of the organism. However, MG is a slow-growing and relatively fastidious organism, and might require up to 3 weeks for detectable growth. In some cases the isolation of MG in culture is impaired by the overgrowth of saprophytic mycoplasmas that inhabit the upper respiratory tract of avian species and contaminant bacteria and fungi that may not be successfully inhibited by mycoplasma-selective media. To culture MG, suspensions of tracheal or air sac exudates, turbinates, lungs, or fluid sinus exudate should be inoculated directly to mycoplasma broth and/or agar media (250). Swabs also can be taken from the trachea or choanal cleft (palatine fissure) for MG culture (52, 473, 474). *M. gallisepticum* also may be present in oviducts (111, 349), and has been isolated from the cloaca of turkeys and chickens (9, 300, 439). For culture medium and isolation methods see Growth Requirements and Kleven (250).

During the acute stages of infection (generally in the first 4–8 weeks post infection), the population numbers of MG in the upper respiratory tract and the prevalence of infection in the flock are high (251, 272, 456). Therefore, swabbing tracheas or choanal clefts of 10–20 live birds is usually sufficient to recover the organism, whereas 30–100 cultures may be required at later stages (251). Tracheal or choanal numbers of organisms in chronically infected birds, such as commercial egg layers or backyard poultry, may be so low that MG organism may not be detected by usual sampling and culture methods (273). To optimize the possibility of isolation, flocks should be sampled for MG culture prior to initiation of antimicrobial therapy (323). Ammonium chloride (53) and perhaps other drinking water treatments may hinder the isolation of MG from infected birds.

The following recommendations are for specimens that must be stored and/or shipped to a laboratory for culture (250). Ideally, mycoplasma broth media should be inoculated directly from the bird (swab, exudate, or small tissue sample) and incubated (37ºC) immediately. If short-term storage and/or shipment are necessary, keep inoculated broths at 4ºC or on cold packs (not longer than 24 hours) and use an overnight carrier. Alternatively, tracheas, fluids, or tissues can be collected and frozen on dry ice but must remain on dry ice until arrival at the laboratory. Commercial transport media (Remel M4 or M5, BD/Copan UTM) may be used following the manufacturers' instructions.

Samples of growing broth cultures are transferred to mycoplasma agar medium to allow for colony formation followed by immunofluorescence tests for *Mycoplasma* spp. identification. Direct or indirect immunofluorescence of mycoplasma colonies or colony imprints (154) are commonly used to identify MG field isolates, even with cultures of mixed *Mycoplasm*a spp. (248, 251, 331, 419, 420). Immunoperoxidase procedures, either alone or in combination with immunofluorescence, also may be used for rapid identification of mycoplasma cultures (36). Growth inhibition has been used for *Mycoplasma* spp. identification (86, 248). Mycoplasma species-specific hyperimmune sera, usually produced by research laboratories in rabbits or avian species, are essential reagents for these diagnostic tests (248, 251). Avian mycoplasma pure cultures can be speciated by universal 16S rRNA gene or 16S-23S rRNA intergenic spacer region PCR (211) followed by sequencing of the PCR products. This approach is highly specific but suitable only for pure cultures.

Inoculation of 7-day-old embryonating chicken eggs via the yolk sac with exudates or suspensions from suspect lesions may be used as another means of isolating MG, but the inocula must be free from bacterial and fungal contamination (47, 116, 376). Death of embryos should occur within 5–8 days, but one or more serial passages of harvested yolk material might be required before embryo deaths and typical lesions are noted.

Detection of Causative Agent Genetic Material

Detection of MG using DNA and ribosomal RNA gene probes has been described (110, 139, 153, 160, 203, 235, 388), but for most applications these methods have been superseded by various PCR-based procedures that are relatively less complex and more rapid, sensitive, and specific (129, 151, 186, 232, 339, 386, 387, 396, 398, 444). Multiplex PCR protocols have been described, which allow for the simultaneous detection of different organisms (303, 357, 444). A test based on amplification of the 16S rRNA gene with "Mycoplasma-specific" primers and separation of the PCR product by denaturing gradient gel electrophoresis has been described (315).

Detection of MG-specific DNA by PCR has become the frontline approach at diagnostic and institutional laboratories using commercial conventional PCR kits or established protocols (152, 267). More rapid and highly specific detection by quantitative PCR methods have also been described (71, 72, 179, 320, 366, 401). Detection of MG DNA by PCR compared to isolation of the organism in culture provides a negative or positive result in hours instead of days, does not rely on the presence of viable organisms, and is not susceptible to

saprophytic mycoplasmas and microbial contaminants. However, culture and isolation of MG organisms remains essential for most further studies such as experimental infections, pathogenicity studies, and intra-species (strain) identification (see Strain Classification).

An inoculated mycoplasma broth can be divided and processed for both culture and PCR. When culture and isolation of viable organisms is not necessary or possible, FTA filter paper may be used for the inactivation and storage of MG suspensions or field specimens prior to PCR or other DNA-dependent assays (332).

Serology

Serologic procedures are useful for flock monitoring in MG control programs (10) and to aid in diagnosis when infection is suspected. A positive serologic test together with history and clinical signs typical of MG disease allows a presumptive diagnosis pending isolation and/or identification of the organisms.

The tube agglutination test was a common procedure, especially during the MG control program for turkeys in the 1960s and 1970s but is now rarely used. Serum plate agglutination (SPA) antigen, for the detection of antibodies to MG, is commercially available. Because the SPA test is quick, relatively inexpensive, and sensitive, it has been widely used as an initial screening test for flock monitoring and serodiagnosis (10, 248, 251). However, nonspecific reactors occur in some flocks infected with MS due to cross-reactive antigens (13, 32) or in flocks recently vaccinated with oil-emulsion vaccines and/or vaccines of tissue-culture origin against various agents (5, 173, 384, 466). Certain nonspecific SPA reactions may be reduced by diluting the test serum (384). Some laboratories determine agglutination end points by preparing 2-fold (1:2) dilutions of sera in saline. Sera that react at 1:8 or greater are considered positive, which also may be useful in differentiating between specific and nonspecific reactions (248). The SPA test is highly efficient in detecting IgM antibody, which is the first class of immunoglobulins produced in response to infection (242).

The hemagglutination-inhibition (HI) test has been commonly used to confirm reactors detected by SPA or, more recently, enzyme-linked immunosorbent assays (ELISA). However, the HI test is time consuming, the reagents are not commercially available, and the test may lack sensitivity (108, 248, 251, 252).

ELISAs were developed to increase testing efficiency and improve specificity and sensitivity of results relative to the SPA and HI tests (17, 96, 97, 192, 302, 327, 406, 422). Commercial ELISA test kits are now commonly used for flock monitoring and serodiagnosis. In general, ELISA tests may be slightly less sensitive but more specific than SPA tests and less specific but more sensitive than HI tests (17, 125, 223, 227, 233).

In many diagnostic laboratories, ELISA is the test of choice for MG serology. Efforts continue to improve MG ELISA sensitivity and specificity by identifying, purifying, and expression of genetically recombined specific immunodominant MG proteins for use as ELISA antigens (18, 33, 97, 118, 346, 352, 400). Multiplex ELISA assays for simultaneous serodiagnosis of MG, MS, and *M. meleagridis* were reported (33, 353) and are commercially available. ELISAs also have been used to detect MG local antibodies in respiratory tract washings and lachrymal samples (15, 178, 456) and in egg yolk samples (227, 328). Studies comparing egg yolk and serum for the detection of MG antibodies by ELISA or HI found comparable results, indicating that egg yolk samples could be used instead of serum samples for flock screening (63, 227, 328). VlhA-based colloidal gold immunochromatography assay (GICA), PvpA-based enzymatic rapid immunofiltration assay (ERIFA), and dot immunobinding assays for the detection of MG antibodies have been described (14, 70, 93, 94, 418, 479).

Positive MG serologic test results have been encountered in some chicken breeding flocks with histories of being MG-free. The usually normal-appearing flocks began to have a small percentage of MG SPA test reactors at 28–36 weeks of age. Hemagglutination-inhibition titers rarely exceeded 1:80, and the percent of SPA reactors often did not exceed 20%–40% of the flock during several months of study (301, 464). Low-virulence MG strains, which were difficult to isolate and apparently egg transmitted, were considered responsible (431, 464). Turkeys also have been infected with MG isolates of low virulence, low transmissibility, and poor immunogenicity (108). Antigenic variation of MG isolates demonstrated by immunoblots (18, 19, 397) and agglutination (356) or HI assays (108, 252, 308) is at least partly responsible for "atypical" reactors.

The use of certain antimicrobials, especially early in the course of infection, may affect the development of a detectable antibody response (273, 405). In experimental infection trials, fewer serological responses were found in MG-infected chickens or turkeys treated with antibiotics than in the MG-infected nonmedicated groups (215, 218, 220, 323).

The performance of culture, PCR, plate agglutination, HI, and ELISA tests were compared for the detection of MG infection using samples from SPF layer chickens infected at 66 weeks of age, and the authors concluded that it was not advisable to rely completely on only one test system (131).

Differential Diagnosis

M. gallisepticum infections of poultry must be differentiated from other respiratory diseases and may be clinically obvious only when present in conjunction with complicating respiratory infections such as Newcastle disease or infectious bronchitis and *E. coli* (247, 250).

In chickens, care must be taken to differentiate MG infection from other common respiratory diseases. Newcastle disease and infectious bronchitis or their antibodies may be present as separate entities or as part of the complicated CRD syndrome. Infectious coryza (*Avibacterium paragallinarum*) and fowl cholera (*Pasteurella multocida*) usually can be identified by bacterial culture. *M. synoviae* infection may be present alone or in

addition to MG. Application of both serologic and organism identification test procedures may be necessary in some cases.

In turkeys, respiratory disease, including sinusitis, may be due to avian influenza, aspergillosis, pasteurellosis, chlamydiosis, respiratory cryptosporidiosis, Newcastle disease, MS infection, or vitamin A deficiency as well as MG (250). Avian metapneumoviruses (aMPV), *Bordetella avium* (turkey coryza), and *Ornithobacterium rhinotracheale* (ORT) also should be considered in the differential diagnosis (210, 435). Specific organism identification and/or serologic procedures are needed to differentiate MG from other microbial causes of turkey respiratory disease.

In songbirds with conjunctivitis, *M. sturni* (143, 144, 282, 362, 446) (isolated from European starling, northern mockingbird, blue jay, crows blackbird, magpie, American robin) should be considered as well as MG (140, 187, 189, 279, 324) (isolated from house finch, American goldfinch, purple finch, blue jay, evening grosbeak, and pine grosbeak). Chlamydiosis, other bacterial infections, and avian pox viruses also should be considered.

A mycoplasma strain designated 4229T, isolated in 1984 from the turbinate of a duck in France and similar isolates from geese in France and from a partridge in England, were originally identified as MG by immunofluorescence and growth inhibition tests (49). Subsequent serologic and molecular studies indicated only a partial relationship to MG, and DNA-DNA hybridization studies revealed only approximately 40%–46% genetic homology (49). A new species name, *Mycoplasma imitans*, was proposed for this organism that cross reacts serologically with MG (49, 383) but can be differentiated by molecular techniques (152, 186, 226, 386). *M. imitans* has not been identified in the United States.

Intervention Strategies

Management Procedures

Because MG can be egg transmitted, maintaining commercial flocks free of MG infection is only possible by starting with breeding stocks that are known to be free of the infection and then rearing them with adequate biosecurity to avoid introduction of the organism. Establishing the MG-clean status of breeder flocks and maintaining that status can be accomplished by participation in control programs. In the United States, turkey and chicken primary and multiplier breeders and hatcheries generally have adopted the various MG control programs of the National Poultry Improvement Plan (10) with great success. However, multiple-age production complexes, usually for commercial table egg production, but also for breeders and meat flocks, have become more common worldwide (273). Poultry population densities have increased, sometimes involving multiple companies and different poultry types (breeders, meat birds, layers) in close proximity to each other and backyard flocks. Perhaps because of these risk factors and lapses in biosecurity, maintaining MG-free poultry flocks may be difficult or impossible (273). Therefore, appropriate antimicrobial therapy may be used to reduce morbidity and mortality and production losses. Vaccination may be an option in some situations.

Vaccination

Types of Vaccines

Inactivated Vaccines. Interest in MG vaccines originated in the late 1970s as it became apparent that MG infection was endemic in some multiple-age, egg-laying complexes. *M. gallisepticum* bacterins (killed organisms) with oil-emulsion adjuvant protected young chickens from intra-sinus challenge with virulent MG and commercial egg layers from MG-induced drops in egg production (193). Some investigators found that bacterins could protect broilers from airsacculitis (222, 469) or layers from reductions in egg production (468), but others did not detect much efficacy in commercial egg layers with endemic MG infections (238). Bacterins have been shown to reduce, but usually not eliminate, colonization by MG following challenge (244, 421, 458, 468, 469) and generally are felt to be of minimal value in long-term control of infection on multiple-age production sites (273). A study on the effect of bacterin vaccination on the horizontal transmission of MG in a model system found that there was some reduction in shedding, but concluded that bacterin vaccination would not reduce horizontal transmission of MG between laying hens (133).

Because bacterins are nonliving, they do not engender the safety concerns of live vaccines; however, they are disadvantaged by the need for more than one application (for optimal protection) and the cost of individual bird administration. To enhance the performance of inactivated MG vaccines, various inactivating agents and adjuvants, including formaldehyde and binary ethylenimine, liposomes, iota-carrageenan and saponin, have been investigated (21, 22, 25, 119, 120, 201, 457). *M gallisepticum* bacterins have been produced commercially.

Development of subunit vaccines using MG surface proteins has been investigated (98, 317, 385, 410, 472).

Live Attenuated Vaccines. Live F strain MG vaccine is a relatively mild strain that apparently originated from the Connecticut F strain (434), and has been used in pullet immunization programs (73, 171, 381). However, the original F strain isolate was described as a typical virulent strain (459). That strain was used in Connecticut for live culture vaccination of young broiler breeder replacement flocks to reduce possible egg transmission of MG in subsequent breeder flocks (292). Studies using the Connecticut F strain in young replacement pullets prior to housing in multiple-age egg-laying complexes also have been reported (73, 434). Numerous reports exist on the use of live F strain MG vaccine, which has been produced commercially and used extensively in multiple-age laying complexes to reduce MG-caused egg production losses (1, 51, 54, 73, 91, 95, 171, 172, 243).

In broilers, vaccination with F strain provided some protection from airsacculitis following aerosol challenge with virulent R strain (272, 380, 381). The biologic mechanism

underlying protection by F strain did not involve competition for adherence sites or blockage by prior colonization, and F strain vaccination did not prevent colonization by the challenge strain of MG (272). F strain can be transmitted through the egg (287) and among pen mates (123, 243). However, pullets given F strain by the eye-drop route did not transmit the infection to broilers in pens in the same house when separated by an aisle or empty pen (243).

F strain-vaccinated laying hens produced more eggs than unvaccinated hens in flocks with endemic MG but not as many as MG-clean flocks (73, 326). Vaccination of pullets in isolation facilities at 12 weeks of age resulted in delayed onset of lay and decreased total egg production (65). Moreover, vaccination with F strain before or during the onset of egg production led to an increase in eggshell pimpling (54, 55, 269). A series of trials using this model system followed possible physiological mechanisms involved in the effects of F strain vaccination on reproductive performance (66, 67, 68, 69).

Priming with more attenuated MG live vaccines (6/85 and ts-11) followed by revaccination with F strain was proposed as a method for ameliorating the decrease in production performances associated with F strain vaccination in layers and increasing resistance to MG challenge (269, 438, 440). F strain-vaccinated flocks maintain the organism in the upper respiratory tract for the life of the flock (243).

In laboratory studies, F strain vaccination reduced the population of a challenge strain in the upper respiratory tract (91, 272); in pen trials F strain vaccination effectively displaced infection with a challenge strain (254). MG field strain was displaced from a multiple-age layer complex following 2 years of continuous use of F strain vaccine in replacement pullets (253). Following experimental infection, F strain was found to be pathogenic in turkeys (286), and it has been associated with MG outbreaks in breeder and meat turkeys under field conditions (277). F strain vaccine can be administered by several routes including eye drop, intranasal, and coarse spray (57, 273). This product appeared to be less stable in water solution at room temperature relative to other live MG vaccines (56), and was more stable when resuspended in phosphate buffer saline (PBS) (268). Vaccine generally is administered at 8–14 weeks of age but can be administered as early as 2 weeks of age or less if chicks are at risk of exposure to wild-type infection before 8 weeks (273).

The 6/85 strain of MG originated in the United States, and its development and vaccine characteristics have been described (59, 123, 124). Studies using MG 6/85 vaccine found minimal virulence in chickens and turkeys, little or no transmissibility from bird to bird, and protection from challenge with virulent MG (1, 123, 256, 283, 475). The 6/85 vaccine is administered by spray, results in little or no detectable serologic response, and can be detected in the upper respiratory tract for 4–8 weeks after vaccination (1, 123, 283). In the United Sates, MG 6/85 vaccine has been used primarily for the prevention of egg production losses in commercial table-egg layers. This vaccine is formulated as a freeze-dried pellet and administered as a single dose to pullets 6 weeks of age or older. Similarly to F strain, this product appeared to be more stable when resuspended in phosphate buffer saline (PBS) rather than water (268). To be fully effective, the vaccine must be administered by the aerosol route.

Development and characterization of the ts-11 MG vaccine have been described (450, 451). The ts-11 vaccine originated from an Australian MG field isolate (strain 80083) that was subjected to chemical mutagenesis and selected for temperature-sensitivity (normal growth at 33ºC and reduced growth at 39.5ºC) (451). It was also found that the mutated ts-11 strain lacked expression of the GapA cytadhesin (334). The ts-11 MG vaccine has minimal or no virulence for chickens and turkeys, can be transmitted from bird to bird, stimulates a slow-to-develop response and low levels of detectable circulating antibody, and induces protection to MG experimental and field challenge (1, 23, 43, 88, 158, 283, 344, 448, 450, 451). Detection of antibody response to ts-11 vaccination may be improved by using an ELISA test with autologous antigen (346).

In vaccinated flocks ts-11 persists for the life of the flock in the upper respiratory tract and induces long-lived immunity (396). In experimental studies vaccination of pullets had no impact on egg production, egg and eggshell quality parameters, and egg size distribution (58). Experimental vaccination of broiler breeders showed resistance to infection by field MG in the breeders and their embryos, and better production performance in their broilers (23). A more recent study demonstrated that GapA-positive ts-11 strain induced better protection and SPA response in SPF chickens (393). In the United States, MG ts-11 vaccine has been used primarily for prevention of egg production losses in commercial table egg layers. The vaccine is formulated as a frozen (–40ºC) suspension and administered by the eye-drop route as a single dose to growing pullets 9 weeks of age or older, at least 3 weeks before expected exposure to field challenge. However, Gaunson et al. (158) reported that ts-11 vaccine was safe in birds between 1 and 4 weeks of age and effective in preventing development of severe disease in them after challenge.

Adequate applied concentration of live MG vaccines is crucial for proper colonization and immunization (121, 122, 346, 365, 367, 450). Because of their superior safety characteristics (relative avirulence and low potential for unintended transmission to nontarget, e.g., unvaccinated flocks), both 6/85 and ts-11 vaccines may be considered preferable to F strain when MG vaccination is necessary in situations in which susceptible poultry are nearby (273). Experimentally, MG live vaccines were able to reduce but not prevent challenge strain colonization (135, 320, 367). However, pen and field trials demonstrated the ability of MG live vaccines to induce resistance to infection from wild-type challenge, resulting in displacement of wild-type strains with the vaccine strain on multiple-age production sites (249, 273). This characteristic could be used as a tool for MG eradication from such sites. F strain vaccine had greater ability to displace challenge strains in pen trials than did 6/85 or ts-11, and displaced a field strain of MG on a multiple-age commercial egg

production site (249, 253). However, when vaccination on this farm was stopped, F strain continued to cycle from flock to flock, and eradication of MG was not achieved (253, 273). The ts-11 vaccine was used to vaccinate replacement pullets on a site previously populated with F strain, and displacement of F strain by ts-11 occurred in the vaccinated flocks. After vaccination with ts-11 was discontinued, MG was no longer detected on the farm (273, 432). Similar data for the 6/85 vaccine are not available, but there are reports of complexes that have used 6/85 and became seronegative, suggesting that displacement of wild-type MG strains may have occurred (249, 273). If wild-type MG strains are highly virulent, it may be necessary to vaccinate with F strain for one or more production cycles prior to switching to either 6/85 or ts-11 (249, 273).

Because they are live vaccines, there are concerns for the safety of F, 6/85, and ts-11 strains relative to nontarget flocks that relate mainly to virulence, persistence, transmissibility, and the stability of vaccine properties. The known biological characteristics of F strain vaccine are compatible with examples of "escaped" F strain vaccine associated with MG infection and/or disease in nontarget flocks (166, 249, 277, 286). The 6/85 vaccine has generally been very safe for chickens. However, there have been several instances of 6/85-like isolates (based primarily on RAPD genotyping) made from turkeys showing clinical disease and associated in most cases with a history of chickens vaccinated nearby (249, 256). A genotypically 6/85-like isolate was made from unvaccinated table-egg layers with swollen sinuses (427). The isolate had some phenotypic properties unlike 6/85 vaccine, and the origin and role of the 6/85-like isolate was not established (427). However, it was recommended that live MG vaccines be properly administered so that all birds in the target flock are properly immunized, and that unvaccinated, susceptible flocks should not be allowed to remain in close proximity to vaccinated flocks (427).

Isolates that were ts-11-like have been detected on at least 2 occasions in unvaccinated chicken flocks (249). In both instances, there was a history of possible inadvertent vaccination, and in one there was subsequent spread to neighboring broiler breeders (249). A ts-11-like strain was detected in numerous broiler progeny flocks originated solely from vaccinated broiler breeders (115). Comprehensive genotyping work could not differentiate the ts-11 vaccine from the recovered ts-11-like strain, and *in-vivo* challenge demonstrated similar virulence of the ts-11-like and R strains to broilers. This report implies a reversion to virulence and vertical transmission of the ts-11 vaccine. These experiences suggest that even though live MG vaccines are generally safe, they may have the potential for infecting nontarget flocks and revert to virulence (115, 249). Live MG vaccines should be used only in jurisdictions where they are approved and administered with strict adherence to the manufacturers' instructions and with careful consideration for the safety of nontarget flocks.

Currently available MG vaccines have shown little potential for use in turkeys (6, 78, 249, 273). The F strain vaccine is too pathogenic (277, 286), and the ts-11 vaccine appears to have little or no ability to colonize turkeys (6, 249, 448, 451). A vaccination trial in turkeys using 6/85 vaccine resulted in little or no protection against airsacculitis after heavy aerosol challenge, but there was some protection detected against development of lesions in the upper respiratory tract (249).

Efforts continue to develop new and improved MG vaccines (see Strain Classification, Immunogenicity or Protective Characteristics). An array of strain-differentiating TaqMan real-time PCR assays were proposed for live MG vaccine evaluations (367).

Other Vaccines. A modified live MG vaccine (strain GT5) was constructed by reconstitution of the avirulent high passage R strain (R_{high}) with the gene encoding the major cytadhesin GapA (206, 360). A naturally low virulent MG isolate (K5054) from turkeys, genotypically similar to the house finch strain, has shown potential for use as a vaccine in chickens and turkeys (136, 137). A recombinant fowlpox-MG vaccine has been introduced (41) and its safety assessed (478).

Treatment

M. gallisepticum has shown sensitivity *in vitro* and *in vivo* to several antimicrobials including macrolides, tetracyclines, and fluoroquinolones, but is inherently resistant to penicillins or other antibiotics which act by inhibiting cell wall biosynthesis (48, 216, 219, 234, 270, 285, 405, 429, 443). *M. gallisepticum* may develop resistance and demonstrate cross resistance to commonly used antibiotics (48, 159, 162, 163, 165, 323, 374, 455, 477). The molecular mechanisms of MG resistance to fluoroquinolones, macrolides, pleuromutilins, and other antibiotics were studied (284, 299, 374, 455). Techniques for *in vitro* antimicrobial susceptibility and minimum inhibitory concentration (MIC) testing have been described (48, 185, 423). Antimicrobials have been used to treat MG respiratory diseases (174, 215, 216) and to reduce egg production losses (355) and transmission (340, 354, 391, 405, 467). Antimicrobials may reduce the severity of clinical signs and lesions and significantly reduce populations of MG in the respiratory tract (92, 218).

Attempts to treat CRD with various antimicrobials during the 1960s produced variable results. In many cases, it was doubtful if small increases in weight gain or egg production and moderate reduction of carcass condemnations were sufficient to cover medication costs. However, some more commonly employed treatments that tended to provide favorable results included use of oxytetracycline or chlortetracycline at 200 g/ton feed for at least several days. Tylosin has been injected subcutaneously at 3–5 mg/lb body weight or administered at 2–3 g/gal drinking water for 3–5 days. Administration of very low levels of tylosin in feed to MG-exposed layers in multiple-age complexes was found to lessen egg production losses (355). Tiamulin and tiamulin plus salinomycin were reported to be effective treatments in chickens or turkeys (11, 31, 407).

Attempts to eliminate egg transmission of MG by medication of breeder flocks or their progeny with streptomycin, dihydrostreptomycin, oxytetracycline, chlortetracycline,

erythromycin, or tylosin generally were able to produce considerable reduction in rates of MG infection but generally were not adequate to obtain entirely infection-free flocks. Tylosin and gentamicin injection of chicken breeder eggs and spectinomycin and lincomycin treatment of chicks showed efficacy (340). Efficacy has been shown with spiramycin in layer chickens (11); fluoroquinolones in broilers (27, 215, 217, 230, 231, 323, 424), breeder chickens (405), and layers (354); tilmicosin in chickens (76, 214, 229, 395) and turkeys (220); and tylvalosin in pheasants (141).

Regulations on the use of antimicrobials in poultry are rapidly evolving, vary considerably among jurisdictions (e.g., European Union, United States, etc.), and should be consulted just prior to treatment for verification and currency. In the United States, see the AVMA Judicious Therapeutic Use of Antimicrobials in Poultry, American Association of Avian Pathologists Guidelines to Judicious Therapeutic Use of Antimicrobials in Poultry; AVMA Judicious Use of Antimicrobials for Poultry Veterinarians; Animal Medicinal Drug Use Clarification Act; and the FDA Approved Animal Drug List (Green Book).

Egg injection or dipping with a temperature or pressure differential has been used to introduce antimicrobials into hatching eggs to control MG *in ovo* transmission (8, 167, 184, 340, 351, 409). In general, these methods greatly reduced, but sometimes did not completely eliminate, the possibility of egg transmission. Effects on hatchability were not consistently favorable, and bacterial contamination was troublesome at times. However, the use of antimicrobials for egg injection or dipping made it possible to obtain sufficient MG-free birds to provide the poultry industry with a nucleus for producing clean progeny for large flocks, resulting in MG-free chicken and turkey breeder flocks in the United Sates. An alternative approach for reducing *in ovo* transmission of MG involved heating eggs in a forced-air incubator during a 12- to 14-hour period to reach an internal temperature of 46.1ºC (463). Hatchability was sometimes reduced (2%–3% to 8%–12%), but field studies demonstrated adequate success in many cases (176, 321, 391).

Complete elimination of MG from all birds in an infected flock by mass antimicrobial therapy is an unrealistic expectation, and treatment should be regarded as a method for short-term amelioration of disease and economic effects rather than as a long-term solution to the problem (273, 375, 447).

Acknowledgement

The expertise and effort of Dr. Harry W. Yoder, Jr. to previous versions of this subchapter are gratefully acknowledged.

Mycoplasma meleagridis Infection

Richard P. Chin

Introduction

Definition and Synonyms

Mycoplasma meleagridis (MM) (N strain PPLO, H serotype) is a specific pathogen of turkeys. It is the cause of an egg-transmitted disease in which the primary lesion is an airsacculitis in the progeny. Other manifestations include decreased hatchability, skeletal abnormalities, and poor growth performance.

Economic Significance

Economic losses caused by MM in turkeys have been associated primarily with egg-borne infections. During the early 1980s when the prevalence of MM was very high, the monetary cost to the U.S. turkey industry resulting from MM-related hatchability losses and the cost of egg treatment to control egg-borne infections was estimated at $9.4 million/year (28). Currently, the economic losses due to MM infection in turkeys have been reduced significantly with the availability of MM-free eggs and poults supplied by major turkey breeders.

Public Health Significance

M. meleagridis infections in turkeys have no public health significance.

History

In 1958, Adler et al. (4) were the first investigators to show that airsacculitis in poults hatched from infected eggs could be associated with a mycoplasma other than *M. gallisepticum*. The mycoplasma, later named *M. meleagridis*, was isolated from the air sac lesions of poults originating from 8 breeding flocks from 4 states. The clinical syndrome of airsacculitis and/or associated skeletal abnormalities has been called day-old type airsacculitis (78), airsacculitis deficiency syndrome (109), and turkey syndrome-65 (TS-65) (139).

Etiology

Classification

M. meleagridis (148) was designated as the N strain by Adler et al. (4) and placed in the H serotype by Kleckner (71), Yoder and Hofstad (164), and Dierks et al. (37).

Morphology and Staining

Giemsa-stained smears of broth cultures of MM show coccoid bodies approximately 0.4 μm in diameter, similar to those of *M. gallisepticum* (148, 164). They appear singly, in pairs, or in small clusters. Ultrastructure studies (136) showed that

MM did not possess bleb structures typical of *M. gallisepticum*, but had thicker fibrils in the central nuclear area. In both species, ribosomes were distributed in uniform rings around the cell peripheries. Similar studies by others (58) revealed that the predominant morphotype of MM was a spherical form ranging from 200–700 nm in diameter. Other forms (chains of Streptococcus-like cells) suggested replication by binary fission. Similar forms, including short filaments, have been observed by scanning electron microscopy (66). An acidic mucopolysaccharide capsule was demonstrated. The DNA of type strain 17529 has a guanine and cytosine (GC) base composition of 27.0%–28.1% and a genome size of $4.2 \pm 0.5 \times 10^8$ daltons, with both figures at the lower range exhibited by mycoplasma (5).

Growth Requirements

M. meleagridis is a facultative anaerobe. Growth is optimal at 37ºC–38ºC and slight at 40ºC–42ºC. Most isolates do not adapt readily to broth media (44, 143). Serum or serum fraction (Difco) is an essential ingredient for growth. Swine and horse sera are satisfactory, but chicken and turkey sera are not (143).

A number of media have been described for cultivation of MM (143). A satisfactory broth consists of mycoplasma broth powder (2.1%), yeast autolysate (1%), and heat-inactivated (56ºC for 30 minutes) horse serum (15%) (95, 115, 148). For solid medium, Bacto agar (1.2%) is added to the formulation. The pH of the final medium is 7.5–7.8. Fresh yeast extract (48) may be substituted for the dehydrated product. Another commonly used medium is modified Frey's medium (49, 72). A broth medium designated SP-4, containing cell culture medium components, also supports excellent growth of MM (44).

The fastidious nature of this organism is exemplified in the observation that from time to time, certain batches of media do not support growth of the organism. In such cases, the source of the problem often can be traced to any one of the ingredients, including the water, used in the medium.

Colonial Morphology

Colonies on agar medium after 4–7 days of incubation appear small, flat, and circular (0.04–0.2 mm in diameter), with rough-appearing, dense, elevated centers ("fried-egg" appearance).

Biochemical Properties

The organism does not ferment dextrose or other carbohydrates, nor does it reduce tetrazolium salts (148, 164), but uses arginine (65) and has phosphatase activity (68). Horse erythrocytes incorporated into turkey meat infusion agar are hemolyzed by MM (164).

Susceptibility to Chemical and Physical Agents

Very little is known about susceptibility of MM to chemical and physical agents. It is assumed, however, that most chemical disinfectants would be effective (25).

In broth at pH 8.4–8.7, MM may survive up to 25–30 days at high titers, 10^7 colony-forming units (CFU)/ml (36). Freshly seeded cultures on agar will survive for at least 6 days at room temperature (70, 148). The organism survives for at least 6 hours in the air (9). In *vitro* inactivation of 4 strains of MM at 45ºC varied from 6–24 hours, although at 47ºC inactivation of 2 strains occurred between 40 and 120 minutes (86).

Isolates of MM may be maintained for at least 2 months by mincing colonies on agar in 3% sucrose and freezing at –20 to –70ºC. Yoder and Hofstad (164) found broth-overlaid agar slant cultures to be viable after at least 2 years of storage at –30ºC. Lyophilized cultures remain viable indefinitely (144). The organism does not decline in substantial numbers in turkey semen during cryopreservation and subsequent thawing (46).

Antigenic Structure

M. meleagridis is antigenically unrelated to all other avian mycoplasmas. Use of hyperimmune polyclonal rabbit antiserum as well as monoclonal antibodies produced against MM shows antigen heterogeneity among strains. Moreover, analysis of epitopes with monoclonal antibodies reveals that as for other mycoplasma species, some epitopes are not expressed in all strains (2, 38). The agglutination (4, 164), fluorescent antibody (FA) (33), antiglobulin (3), growth and metabolic inhibition (37, 44, 87, 104), and complement fixation (50, 102) tests have been used to identify MM.

A few isolates possess hemagglutination activity (116, 135, 148). When hemagglutinating and nonhemagglutinating strains of MM were compared by polyacrylamide gel electrophoresis and simple and 2-dimensional immunoelectrophoresis, minor antigenic differences were observed in the latter test only (44). Rhoades (120) showed that the determinant group(s) responsible for hemagglutination differed from that of agglutination.

The organism possesses a heat-stable lipid or polysaccharide toxin that causes an increase in ceruloplasmin activity when injected intravenously into chickens (35). The relationship of this toxin to the capsular material described by Green and Hanson (58) and to hemagglutinating activity is not known. However, hemagglutinating activity is not an essential component for virulence because strains lacking this activity may be highly pathogenic (148, 159).

Strain Classification

Pathogenic and nonpathogenic strains of MM were described by Ghazikhanian and Yamamoto (54, 55). Of 3 strains studied, 1 failed to multiply *in vivo* and another multiplied but failed to produce lesions, although the third multiplied and produced airsacculitis. Zhao et al. (167) showed by sodium dodecyl sulfate-polyacrylamide gel electrophoresis (SDS-PAGE) that these strains differed in their cell protein profiles. Strain variations may account for the variability in clinical manifestations attributed to this organism (42).

Experimental infection of turkey embryos and tracheal explants with MM results in deciliation and sloughing of

epithelial cells (80). When inoculated into the allantoic cavity of 17-day-old turkey embryos, MM induced curved toes, and histological studies including scanning electron microscopy, immunohistochemistry, laser capture microdissection, and PCR revealed fissures in the cartilage, cellular infiltration within the bones, and the presence of MM in tarsometatarsal affected joints (82). MM also was found to cause alterations to the cellular surface topology and necrosis on the surface of the eggshell membranes (81).

Pathobiology and Epidemiology

Incidence and Distribution

Early studies showed that MM was a common pathogen of turkeys with a worldwide distribution (4, 12, 59, 88, 113, 124, 131, 138, 139). These prevalence studies, together with the knowledge that MM was transmitted through the egg, led major primary breeders in the mid 1970s to initiate programs to eradicate the agent from their stocks (56). With the success of these programs, the prevalence of MM has been reduced significantly within the past 30 years in the major turkey-producing areas of the world.

Natural and Experimental Hosts

M. meleagridis is a specific pathogen of turkeys. When injected into turkey embryos by the yolk sac route, the organism produces a high incidence of airsacculitis but causes minimal mortality (145). The high infectivity and low mortality caused by MM in turkey embryos under experimental and natural conditions indicates that it has attained an ideal host-parasite relationship.

When inoculated into the yolk sac of chicken embryos, MM multiplies to high titers without causing high mortality (153, 164), but abnormally shaped toes and severely denuded tracheae may be observed (79). Turkeys of all ages are susceptible to air sac infection with MM when inoculated via the air sac or trachea (77, 95, 147). Chickens are refractory to infection with MM (2, 146). Recently, however, MM was isolated from chicken breeders located near a turkey breeding ranch (10). MM was reported to have been isolated from free-ranging birds of prey in Germany (85) and found to infect peafowl, pigeons, and quails (64). Antibodies were also detected in lesser prairie chickens (60).

Transmission

Vertical Transmission

M. meleagridis is perpetuated primarily through egg transmission. Infection of the female reproductive tract occurs as an endogenous infection during embryonic development (90), as an ascending infection from foci in the cloaca or cloacal bursa after the occluding plate is perforated at sexual maturity (89), or by insemination of hens with MM-containing semen (77, 95, 97, 150, 156). Infection rates of 19%–57% have been found in flocks in which cultures were taken from the vagina of virgin females. Although such hens contribute to the overall egg-transmission rate, particularly when the incidence is high, insemination with mycoplasma-contaminated semen plays a major role in sustaining the egg-transmission rate during the laying season (74, 77, 157). The egg-transmission rate among individual hens may vary from 10%–60% (150). Apparently, however, there is no regular pattern regarding the sequence of infected eggs laid (95).

Transmission starts at a low rate during the first 2–3 weeks of lay, reaches a maximum at midseason, and gradually declines toward the end of the laying season (16, 77). There seems to be some intracyclic fluctuation in the transmission pattern during the laying season (77, 157), but it has not been possible to relate such changes to the insemination schedule.

Egg transmission does not occur in hens in which the organism is found only in the upper respiratory tract (sinus) (77, 95, 142), and is minimal in hens infected via air sac and subsequently inseminated with clean semen (77).

A comparative study of persistence of MM, *M. synoviae*, and *M. gallisepticum* in the genitalia of adult turkeys indicated that MM favored this environment more than the others (142).

Although the exact site in the reproductive system where the organism infects the developing egg is not known, it appears not to be in the ovary; several studies have generally failed to yield the organism from the ova of hens known to be transmitting the organism through their eggs (95, 142, 150). Furthermore, egg transmission occurs at a high rate in the absence of active abdominal airsacculitis.

The organism has been recovered from various sites of the oviduct, with the greatest frequency from the vagina and uterus (97, 150). In hens repeatedly inseminated with MM-contaminated semen, high levels of infection in the uterovaginal region were not sustained, although such hens did transmit the organism through their eggs (144). In hens inseminated with contaminated semen, the organism was found as high as the magnum (77). Although infection rates were low, the organism has been isolated from the shell membrane (2%–4%) and the yolk (including the vitelline membrane) (10%–12%) of preincubated eggs from naturally infected turkeys (56). Mycoplasma counts of 10^3 to 10^5 CFU/vitelline membrane have been obtained (144). Thus, although the organism has the potential to infect the developing egg at various sites in the oviduct, the critical site appears to be in the area of the fimbria or magnum.

As is the case with the female, cloacal infection detected in the male at the time of hatch can persist through sexual maturity; semen taken from such males contains the organism (142, 162). The organism remains localized in the cloaca and phallus and does not ascend the vas deferens or testes (115, 142). Isolation rates of MM from the phallus or semen of naturally infected male flocks have ranged from 13%–32%. Histologic study of the phallus and accessory organs suggests that a possible site of localization is the region of the submucosal gland (52).

Horizontal Transmission

Direct and indirect transmission of MM may occur at any stage of the bird's life. Direct transmission by the airborne route may occur within a hatchery (77) or flock (155), or on occasion between flocks separated by one-quarter mile (56). Airborne transmission in mature turkeys usually results in a high infection rate (up to 100%), which remains localized in the sinus and trachea (77, 95). In young birds during the brooding and growing periods, however, the organism may localize in the genitalia of approximately 5% of the birds infected by the respiratory route (155).

Indirect transmission results from management practices including sexing, vaginal palpation, artificial insemination, and vaccination whereby mycoplasmas are carried manually from infected to noninfected turkeys via contaminated hands, clothing, and equipment (56, 95).

Airborne transmission apparently is of little significance as it pertains to vertical transmission after a bird has reached sexual maturity. Thus, egg transmission does not occur in noninfected females that have been placed in cages adjacent to infected females. Similarly, clean males held in the same room with phallus-infected males produce MM-free semen throughout the production period (142, 144).

Clinical Signs

Despite a high rate of airsacculitis in poults originating from infected dams, respiratory signs are rarely observed. Lateral transmission that may occur by direct or indirect means in adult birds may lead to a high infection rate, but rarely to clinical disease. Thus, *M. meleagridis* commonly occurs as a silent infection in adult birds.

Although not a consistent feature of the disease, the syndrome called TS-65 (also called airsacculitis deficiency syndrome) may be associated with MM egg-borne infection (57). The syndrome, which includes signs of bowing, twisting, and shortening of the tarsometatarsal bone and hock joint swelling, has been reproduced experimentally in MM-free poults (17, 101, 140, 141, 151). Deformation of cervical vertebrae (26, 98), stunting, and abnormal feathering (17) are additional features of the disease.

M. meleagridis acts synergistically in producing severe airsacculitis with *M. iowae* (123) and sinusitis with *M. synoviae* (114). In a flock naturally infected with MM and *M. synoviae*, sinusitis was estimated to be 2.1% in males and 0.13% in females (114). Although it is generally believed that neither agent alone is capable of producing sinusitis, field cases have been encountered in which only MM has been isolated from sinus exudate.

Morbidity and Mortality

Reproductive Performance

M. meleagridis does not adversely affect egg production or fertility and does not cause early incubation mortality (31, 154). It causes late incubation (25–28 days) mortality in artificially (28, 154) and naturally (40) infected turkey embryos. It has been estimated that MM causes a loss in hatchability of 5%–6% of fertile eggs set under commercial conditions (41). Edson (40), using risk analysis, determined the mortality rates of embryos naturally infected with MM and/or an unidentified mycoplasma. The analysis showed that embryos infected with MM, unidentified mycoplasma, and both agents were 5, 7, and 25 times more likely to die than the mycoplasma-free embryos. The unidentified mycoplasma was later identified as *M. iowae* (144), a common mycoplasma of turkeys known to reduce hatchability (122).

Air Sac Lesions and Condemnations

During the mid 1960s, MM-associated airsacculitis was reported to be 1 of the major causes of condemnation of fryer-roaster turkeys in the United States (6, 76). Air sac lesion rates of 10%–25% in first-run poults from MM-infected flocks over a season's production were reported under experimental and commercial conditions (47, 77, 95, 150).

Because air sac lesions caused by uncomplicated MM infection regress within 15–16 weeks (12, 162), it appears that other agents or factors may be involved in the overall picture. Anderson et al. (6) observed a 2-fold or greater increase in incidence of air sac lesions caused by MM in turkeys raised to 12 weeks of age in a high-dust environment.

Brown and Nestor (24) suggested that turkeys selected for low-plasma adrenocorticotropic hormone (ACTH) following cold stress were more resistant to MM infection than those selected for high ACTH levels. Saif et al. (128) reproduced complicated airsacculitis with MM and *Escherichia coli* in poults. Mixed infections of MM and *M. iowae* also accentuate the severity of air sac lesions (123). Therefore, a number of interacting factors may aggravate MM-induced air sac lesions in young turkeys.

Skeletal Abnormalities and Growth Performance

In affected flocks, MM-associated skeletal abnormalities (i.e., TS-65 syndrome) may be observed in poults between 1 and 6 weeks of age (139). Five percent to 10% of the poults may show clinical signs, but on occasion the percentage may reach higher levels. Not all cases progress to an irreversible state (139). Incidence of the disease seems to increase with progression of the laying season. Mortality is due primarily to cannibalism of affected birds. The problem is not associated with a particular strain of bird, but the male seems to be more susceptible.

Peterson (108) found a positive association of skeletal lesions, airsacculitis, and high agglutination titers to MM in poults with the TS-65 syndrome, which supports the view that the syndrome is initiated by a generalized egg-borne infection (141). It was further hypothesized, based on *in vitro* and *in vivo* studies, that the organism may deprive the embryo of biotin, resulting in abnormal bone development (17, 19). Others have postulated that the organism may compete for arginine, an essential amino acid for proper bone development (151). However, *in vitro* studies indicated that MM strains of varying virulence did not differ in their arginine requirement; also, significant differences in plasma arginine concentration between noninfected and infected poults with leg abnormalities were not observed (65).

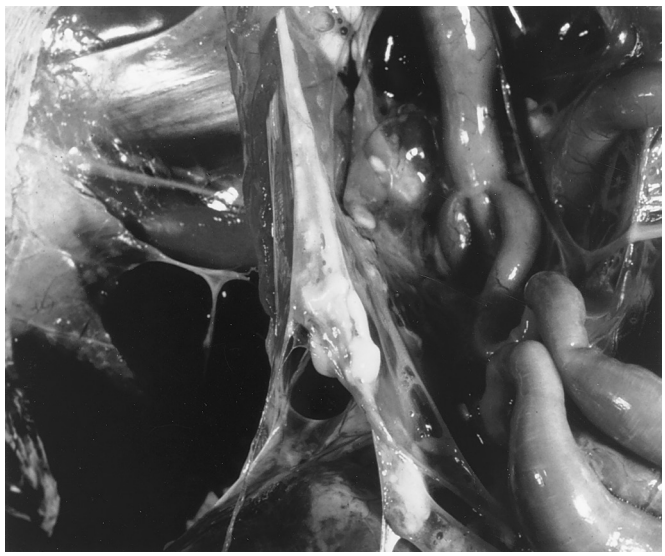

Figure 21.9. Airsacculitis in a 4-week-old turkey caused by egg-borne *Mycoplasma meleagridis* infection. (R. Yamamoto)

Figure 21.10. Bowing of tarsometatarsal bones of a 3-week-old turkey hatched from a *Mycoplasma meleagridis*-infected egg. (Y. Ghazikhanian)

Nelson et al. (101) distributed MM-free and MM-infected eggs in large numbers to 11 cooperators in 8 states to study the leg weakness syndrome under commercial conditions. The results indicated that the total daily mortality, number of cull poults, and skeletal deformity were much lower in poults hatched from MM-free eggs. A significant advantage in weight gain also was observed with MM-free vs. infected poults (15, 103, 139).

Conversely, others (27, 29, 30) were unable to demonstrate any economic advantage of MM-free over MM-infected turkeys. Possible reasons for the divergent results are not clear, but factors such as differences in the genetic makeup of the bird, virulence of MM strains, environmental stresses, and secondary infections may influence the picture.

Pathology

Gross Lesions

Although gross lesions, if any, in poults from infected dams at time of hatch are limited to the air sacs, the organism may be widely distributed in various tissues including feathers, skin, sinus, trachea, lungs, air sacs, cloacal bursa, intestine, cloaca (14, 112, 118), and hock joints (144). The air sac lesions are characterized by thickening of the air sac walls with adherence of a yellow exudate to the tissue and, occasionally, presence of variously sized flecks of caseous material free in the lumen (4). Extension of such lesions to the abdominal air sacs is a common occurrence by 3–4 weeks of age. It is also possible for the organism to be present in air sacs of day-old poults exhibiting no lesions; in such cases, air sac lesions may develop in 3–5 weeks (12). Lesions produced by MM when not mixed with *M. iowae* are not as extensive or fulminating as those described for *M. gallisepticum* (37, 78). Figure 21.9 shows a poult, hatched from an MM-infected egg, with caseopurulent airsacculitis.

Skeletal lesions, when present, usually are associated with severe airsacculitis (108). Sternal bursitis (147), synovitis (128), and ascites (140) are additional lesions observed in experimental infections. The sinusitis produced by MM and *M. synoviae* in mixed infections contains clear mucous to caseous exudate (114). Leg abnormalities in poults hatched from MM-infected eggs are shown in Figure 21.10.

Microscopic Lesions

In embryonic infection with MM, exudative airsacculitis and pneumonia were the only inflammatory lesions seen. Lesions that developed at 25–28 days of age were related to maturation of inflammatory cells. Air sac lesions consisted predominantly of heterophils with some mononuclear cells, including lymphocytes and varying amounts of fibrin and cellular debris. Epithelial necrosis was seen in severely affected air sacs. Mononuclear cells and fibrin were the prominent features of lung lesions (55, 118). Significant or marked microscopic changes in other organs in embryos or poults were not observed despite invasion of the organism into many of these sites (55).

In 7-week-old poults infected with MM by the air sac route, lymphocytic perivascular infiltration and fibrinoheterophilic exudate were observed in 2 days. Some areas of the air sac epithelium became hyperplastic and others underwent necrosis at about 4–8 days. Lymphoid follicles were observed in 16 days. When examined by electron microscopy, the follicles were found to be surrounded by encapsulated collagen bundles and composed of hemocytoblasts of bursal origin presumed to be involved in antibody formation (117). Others observed similar sequential changes in poults infected as embryos or at 1–3 days of age (7, 55, 99).

Wise et al. (139) indicated that gross and microscopic long-bone lesions of TS-65 were similar to those observed in perosis of dietetic origin. The main lesions were seen in proximal ends of the long bones. Cartilage farthest from blood vessels

descending into the proliferative zone from the cartilaginous epiphysis lacked cell density and contained abnormal-appearing chondrocytes. In long-standing cases of 6–8 weeks or longer, growth plates often were normal, suggestive of repair, even though the bones were grossly deformed. These cellular changes in the proliferative zone of the growth plates were seen in all long bones examined, suggesting a generalized response. It was postulated that MM causes a secondary block of nutrients to the growth plates.

A secondary lesion in the medial side of the proximal end of the tarsometatarsal bone of chronic cases with varus deformity was described as a dyschondroplasia or chondrodystrophy resulting from partial failure of the metaphyseal blood supply at the growth plates (139).

Mild mononuclear cell infiltration was observed in the periarticular region of the hock joint in 2-week-old poults inoculated intravenously with MM (111).

The most prominent lesion in hens infected by the vaginal route was focal encapsulated accumulation of lymphocytes present most frequently in the fimbria, uterus, and vagina. Plasma cells and heterophils also were present in significant numbers in the lamina propria of the reproductive tract. The encapsulated follicles were believed to be active in antibody formation (119). Similar lesions in the reproductive tract of turkeys infected with MM were described by Ball et al. (8).

Gerlach et al. (52) examined histologically the phallus and accessory structures of males experimentally infected with MM. The only significant change was an extensive lymphofollicular formation in the region of the mucous-type glands in the submucosa of the lymphfold.

Immunity

Active Immunity

Turkeys inoculated intravenously or by the respiratory route with MM were resistant to reinfection when challenged by the same routes 21 weeks later. There was no correlation, however, between antibody titer and resistance (96). Repeated injections of 20-week-old hens with live organisms failed to induce protective immunity or reduce egg transmission (137).

When hens that had been vaginally infected artificially with MM culture or with contaminated semen were subsequently inseminated with clean semen, the organism was eliminated from the vagina within 4–14 weeks, although hens continuously inseminated with contaminated semen maintained a high incidence of infection (74, 77). However, insemination with clean semen of virgin hens known to be vaginal carriers of MM resulted in a high egg-transmission rate and persistence of oviduct infection (40, 157). In the first-mentioned studies, it appears that an active immune mechanism was functioning to eliminate the organism after removal of the source of infection (i.e., contaminated semen). Persistence of infection in the latter study may be an expression of immune tolerance in hens infected by egg transmission.

Yamamoto et al. (161) found that hens infected with MM via the oviduct during 1 breeding season were free of MM at the start of the second laying season; among 5 adult males infected via the phallus, the organism persisted for 55–344 days. These findings are consistent with the observation that the decline in the egg-transmission rate during the latter part of the laying season may be related to an active immune response. A study by Ortiz et al. (105) suggested that MM infection of the cloacal bursa during embryonic development causes an impairment of the secondary antibody response to innate or inactivated antigens.

Passive Immunity

Maternal antibodies (agglutinins) may be detected in a high percentage of poults from infected dams and persist for approximately 2 weeks post hatching. Such antibodies do not protect against the development of air sac lesions in infected embryos (96, 150). Conversely, purified IgM and IgG antibodies, when injected into the yolk sac of infected embryos, significantly reduced embryo mortality and the incidence of leg deformities in hatched poults, but they did not reduce air sac lesions or isolation rates when compared with the controls (20).

Diagnosis

Isolation and Identification of Causative Agent

Bacterial Isolation and Identification

M. meleagridis may be isolated readily on several commercially available and laboratory-prepared media. For culture media and isolation methods, see Growth Requirements and Kleven (72). Thallium acetate (1:4,000) and penicillin (1,000 units/ml) are inhibitors added to agar plates, slants, and broth. Polymyxin B (100 units/ml) may be added to the broth portion of the overlay to facilitate isolation of MM from highly contaminated sources such as the cloaca and phallus. Mycostatin (50 units/ml) may be added to the agar and broth to inhibit fungi (97). *M. meleagridis* may be selectively isolated from specimens containing mixed cultures by adding to the medium immune serum against the undesired mycoplasma (22).

For large sampling studies in the field (e.g., cultures from the trachea, palatine cleft, vagina, or phallus), placing swab specimens in overlay broth (4) facilitates transport to the laboratory; the broth also serves as an initial enrichment (106). At necropsy, the organism may be isolated from various sites of the respiratory (including sinus) and reproductive systems. The organism may be isolated from the vitelline membrane, air sacs, intestine, and many other sites of infected embryos (see Pathology, Gross). It may also be isolated from the kidneys of poults infected by the air sac route (140).

When growth is apparent in the original broth isolation medium, usually after 4–6 days of incubation, agar plates are streaked and incubated at 37°C in 7%–10% CO_2. Alternatively, plates may be placed in a sealed container with added moisture. Plates are incubated for 5–7 days before being examined for colonies under the dissecting microscope, and are incubated at least 14 days before being discarded as negative.

M. meleagridis may be differentiated from other chicken and turkey mycoplasmas by its inability to utilize glucose and its ability to metabolize arginine and phosphate (65, 68, 131, 164). Definitive identification, however, is based on serologic methods. The direct (33) and indirect (22) FA, growth inhibition (37), and immunoperoxidase (67, 130) tests are commonly used for this purpose. In addition, an antigen-capture ELISA has been developed for detection of mycoplasma antigen directly in broth culture (1).

Antigen Detection

DNA-based tests have recently been developed for the direct detection of the organism in clinical specimens (21, 45, 51, 83, 93, 94, 110, 165, 166). The main advantages of PCR-based methods are their rapidity and their ability to detect MM within a high background flora as in the case of cloacal swabs or from samples collected on antibiotic-treated birds.

Serology

Antibodies are detected in poults hatched from infected eggs in 3 weeks and in turkeys infected by contact in 4–5 weeks. Birds with active air sac lesions may have high agglutinin titers, and those with localized infections in the sinus or phallus may be negative or show low titers (2, 96, 162). The rapid plate (RP) test may be quantified by performing it on serially diluted serums. A reaction at a dilution of 1:5 is significant (159, 162), but for flock diagnosis, some samples should react at 1:10 or higher. Each lot of antigen should be pretested with a standard positive serum for its reactive quality at higher serum dilutions.

The hemagglutination-inhibition (HI) test (116, 135) is another useful test for detecting antibodies to MM infections. Although nonhemagglutinating laboratory strains of MM do not elicit high HI antibody responses in turkeys, the HI test is very effective in detecting such antibodies in naturally infected birds (120). Apparently, field infections with MM occur with strains possessing hemagglutinating activity, but this characteristic is quickly lost for most strains when they are cultivated on laboratory media (120). Furthermore, because the antigenic determinant(s) responsible for hemagglutination differs from that of agglutination (120), it is possible to find individual turkeys in an infected flock whose serum is positive in the HI the tube agglutination (TA) tests; the reverse situation also may occur (159).

Yamamoto et al. (159) adapted the HI test to the microtest system. Using 4 units of antigen, titers of 1:40 were considered suspects and 1:80 or greater as reactors. When used as a confirmatory test to the RP test, a positive HI signifies infection, although a negative HI requires a more conservative interpretation and may involve use of other confirmatory tests or follow-up testing for final diagnosis (160). The micro-HI test has been used to identify false-positive RP reactions (144) in flocks recently vaccinated with *Erysipelothrix* vaccine (18).

Kleven and Pomeroy (73) found that the RP test detected IgM, the TA test detected both IgM and IgG, and the HI test detected IgG most efficiently. However, the early HI antibody response of turkeys to high doses of MM given intravenously was of the IgM class (121).

Other tests developed for mass screening are the microagglutination (152), indirect or blocking ELISA (39, 107), recombinant antigen-based ELISA (11), and avidin-biotin enhanced dot-immunobinding assay (34).

Differential Diagnosis

Air sac lesions caused by MM must be differentiated from those caused by *M. gallisepticum*, other mycoplasma serotypes, and other bacteria. The possibility of a mixed infection of MM with *M. synoviae* or *M. iowae* should be considered if embryo mortality, sinusitis, or airsacculitis is observed. *M. meleagridis*-associated skeletal abnormalities must be differentiated from similar lesions caused by *M. iowae* or of dietetic origin.

Intervention Strategies

Management Procedures

Although early studies placed much emphasis on the control of MM infections in turkeys by use of various antibiotic treatment regimens (see Treatment), the goal of primary breeder organizations was to eradicate the agent from their stocks. Because virtually all breeding stocks were infected, a program of test and slaughter—which had been effective in the control of M. *gallisepticum*—was not a practical approach for eradicating MM (158). Experimental studies demonstrated that the administration of antibiotics into eggs either by dipping or by inoculation into the air cell (63) or the small end (43, 91, 92) were useful methods to reduce the egg-transmission rate. Heat treatment of eggs (163) was not effective in eliminating MM from turkey eggs (59, 69, 139). Tylosin (75) or gentamicin (126) was not effective, but spectinomycin (0.6 mg/ml of diluent) (125) was effective in eliminating MM from turkey semen. These studies laid the foundation for effective eradication programs that followed (32).

Vaccination

Vaccines are not available for prevention of MM infection in turkeys.

Treatment

Antibiotics with *in vitro* activity against MM include gentamicin (127); tylosin and tetracycline (149); spectinomycin-lincomycin (61); tiamulin, spectinomycin, and spiramycin (84); doxycycline and the fluoroquinolones (134); and josamycin (132). In trials conducted with turkey embryos, tylosin was the most active; tetracycline, chlortetracycline, and streptomycin were variable; and erythromycin showed no activity against 2 isolates of MM (149).

A combination of lincomycin and spectinomycin administered at 2 g/gallons of water for 5 days (62) or tiamulin at a concentration of 0.025% in the drinking water for 3 days (133) had therapeutic activity against MM infections. Enrofloxacin was effective in reducing mortality of poults with complicated MM infections (23). Parenteral injections or water medication

with tylosin of turkeys in production did not reduce egg transmission (16, 76). However, dipping hatching eggs in antibiotic solution significantly reduced the incidence of air sac infection (13, 76, 108, 129) concomitant with improved hatchability (76, 129), improved performance (13, 100), reduced incidence of skeletal deformities (100, 108), and reduced condemnation at processing (76, 100).

During the late 1960s to early 1980s, before MM-free eggs and poults were available, it was a common practice for multiplier breeders to dip their eggs in antibiotic solution. Tylosin (3,000 ppm) or gentamicin (500 ppm), along with a disinfectant such as quaternary ammonium compound (250 ppm), was used in dip solutions. However, repeated hatching-egg dipping in antibiotics to reduce the incidence of MM infection could lead to induction of antibiotic-resistant organisms (53). Eradication of MM from major primary breeding companies has reduced the practice of hatching-egg dipping in antibiotics by the commercial industry and currently, most major U.S. multiplier breeder companies dip their eggs only when faced with a potential MM outbreak.

Acknowledgement

The expertise and contributions of Drs. G. Yan Ghazikhanian, R. Yamamoto, and Isabelle Kempf to previous versions of this chapter are gratefully acknowledged.

Mycoplasma synoviae Infection

Naola Ferguson-Noel and Amir H. Noormohammadi

Introduction

Mycoplasma synoviae (MS) infection most frequently occurs as a subclinical upper respiratory infection. It may cause air sac lesions when combined with Newcastle disease (ND), infectious bronchitis (IB), or both. At other times, MS becomes systemic and results in infectious synovitis, an acute to chronic infectious disease of chickens and turkeys primarily involving the synovial membranes of joints and tendon sheaths and producing an exudative synovitis, tenovaginitis, or bursitis.

History

Infectious synovitis was first described and associated with a mycoplasma by Olson et al. (126, 127). A respiratory form of *M. synoviae* infection occurs (129) and air sac infection results with some isolates of MS when combined with ND and IB vaccination (82). See Jordan (70, 71) and Timms (160) for reviews of the historical MS literature.

Etiology

Classification

M. synoviae, of the genus *Mycoplasma*, is a species of the class Mollicutes, order Mycoplasmatales. *Mycoplasma* colonies were observed as satellites adjacent to *Micrococcus* colonies by Chalquest and Fabricant (23), who identified the requirement for nicotinamide adenine dinucleotide (NAD). It was designated as serotype S by Dierks et al. (29). Olson et al. (130) studied several isolates and proposed the name *M. synoviae*, which was subsequently confirmed as a separate species (72). In many reference laboratories, identification of *M. synoviae* is based on typical colony and cell morphology, biochemical characteristics, special requirements for growth, and serologic reactions. Immunofluorescence of mycoplasma colonies is a rapid and reliable method for identification of field isolates. DNA sequence analysis of the 16S rRNA gene has proven to be useful for mycoplasma identification and in phylogenetic studies (168). The complete genome sequence of a strain of *M. synoviae* has been published (2, 165) and the genomes of other strains are likely to become available for comparison in the near future.

Morphology and Staining

In Giemsa-stained preparations, *M. synoviae* cells appear as pleomorphic coccoid bodies approximately 0.2 μm in diameter. Ultrastructural studies of avian synovium reveal MS in endocytotic vesicles. The mycoplasma cells are round or pear-shaped with granular ribosomes. They are 300–500 nm in diameter, lack a cell wall, and are bounded by a triple-layered unit membrane (166). An extracellular surface layer has been demonstrated by electron microscopy by ruthenium red and negative staining (1).

Growth Requirements

NAD is required for growth (23); however, it may be possible to substitute nicotinamide for the more expensive NAD for production of antigens (28). Serum is essential for growth, and swine serum is preferred (24). Growth on agar is accomplished by incubation of plates in a closed container to prevent dehydration of the agar. The optimum temperature is 37°C.

Excellent growth is obtained using a modification of Frey's medium (44) (Table 21.2) or a medium described by Bradbury (14). For agar plates, use of 1% of a purified agar such as ionagar #2, Noble agar, or Difco purified agar is recommended. All components except cysteine, NAD, serum, and penicillin may be sterilized by autoclaving at 121°C for 15 minutes. This should be cooled to 50°C and aseptically added to the above components, which have been sterilized by filtration and

Table 21.2. Modified Frey's medium.

Mycoplasma broth base (BBL)	22.5 g
Glucose	3 g
Swine serum	120 ml
Nicotinamide adenine dinucleotide (NAD)	0.1 g
Cysteine hydrochloride	0.1 g
Phenol red (1%)	2.5 ml
Thallium acetate (10%)*	5 ml
Potassium penicillin G*	1,000,000 units
Distilled H_2O	1000 ml
Adjust pH to 7.8 with 20% NaOH and filter sterilize.	

*For potentially contaminated specimens, an extra 20 ml of 1% thallium acetate and 2,000,000 units of penicillin per liter may be added. Ampicillin (200 mg/l to 1 g/l) may be substituted for penicillin.

warmed to 50°C. Pour plates to a depth of approximately 5 mm. Phenol red may be eliminated from agar plates.

On primary isolation, tissue antigens, toxins, and antibodies may be present; therefore, a small inoculum, transferred within 24 hours, or making dilutions of the inoculum in broth may improve results. Transfers are made with a pipette using a 10% inoculum. Inoculation of broth medium with a cotton swab from the trachea, choanal cleft, or synovial or air sac lesion is satisfactory. Plain or charcoal cotton swabs are more effective than rayon swabs, and retaining the swab in the broth medium was more effective than discarding the swab (175), but leaving the swab in the growth medium may lead to increased bacterial contamination of cultures. Direct plating onto agar plates may result in colonies at 3–5 days of incubation, but isolation in broth is more sensitive. Broth cultures should be incubated until a color change of the phenol red indicator from red to orange or yellow is noted (usually after 3–7 days); the culture should then be transferred to an agar plate and subcultured into another broth culture. *M. synoviae* is sensitive to low pH; therefore, cultures incubated for more than a few hours after the phenol red indicator has changed to yellow (pH less than 6.8) may no longer be viable. Plates are observed for the presence of mycoplasma colonies after 3–5 days using a microscope with indirect or low-intensity lighting at a magnification of approximately 330.

Colony Morphology

Colonies on solid media are best observed with a dissecting microscope at × 30 using indirect lighting; they appear as raised, round, slightly latticed colonies with or without centers. Colonies range from less than 1–3 mm in diameter depending on number of colonies present, suitability of medium, and age of culture. Growth is seen on solid medium in 3–5 days.

Biochemical Properties

Biochemical characteristics of *M. synoviae* have been described (23, 29). *M. synoviae* ferments glucose and maltose with production of acid but not gas in suitably enriched media. It does not ferment lactose, dulcitol, salicin, or trehalose. *M. synoviae* is phosphatase negative and produces film and spots (72). Most isolates are capable of hemagglutinating chicken and turkey erythrocytes. Its ability to reduce tetrazolium salts is very limited.

Susceptibility to Chemical and Physical Agents

Resistance to disinfectants has not been determined but is probably similar to that of other mycoplasmas. Day-old chicks placed in contaminated chicken houses which had been cleaned and disinfected and maintained empty for 1 week did not become infected (45). *M. synoviae* is not stable at pH 6.8 or lower. Growth may be affected at temperatures above 39°C. It will withstand freezing; however, the titer is reduced. End points have not been reached, but in yolk material *M. synoviae* is viable for at least 7 years at –63°C and after 2 years at –20°C. Broth cultures maintained frozen at –70°C or lyophilized cultures maintained at 4°C are viable for several years. Survival occurred up to 3 days at room temperature on feathers and up to 12 hours in the nasal cavity of a volunteer, while survival was less than 1 day on most other materials (26). MS was also detected in environmental samples, including feathers, dust, feed, drinking water, and droppings by culture and by PCR (105). A reverse transcriptase PCR detecting 16S rDNA was correlated with viable MS organisms in the environment of infected birds. Positive RT-PCR and culturable MS organisms were found in the environment of a depopulated isolator unit for 3–5 days after depopulation of MS-infected chickens (107).

Antigenic Structure

M. synoviae has 2 major phase- and size-variable antigens, Mycoplasma synovial protein A (MSPA) and Mycoplasma synovial protein B (MSPB) (117). MSPA has been shown to be a hemagglutinin but MSPB has not been linked with any function thus far. Cultures of the hemagglutinin-negative phenotype expressed truncated versions of MSPB and were less pathogenic than hemagglutination positive cultures (114). MSPA and MSPB are expressed as a prolipoprotein, variable lipoprotein hemagglutinin (VlhA), from a single gene named vlhA (118), but the product is then cleaved to form MSPB and MSPA (8, 118). *M. synoviae vlhA* has a high degree of identity with the *vlhA* 4.10 (pMGA1.7 gene) of *M. gallisepticum* (118), which provides a possible explanation for occasional cross reactivity between these organisms in serological testing. There is only a single complete copy of the *vlhA* gene associated with a promoter region in the *M. synoviae* genome but there are a large number of incomplete copies (pseudogenes) present in a cluster adjacent to the complete *vlhA* copy (120, 165). Variability in expression of *vlhA* is thought to be controlled by homologous recombination events between the complete copy of *vlhA* and pseudogenes (120).

Strain Classification

Available information indicates a single serotype of *M. synoviae* (29, 130). *M. synoviae* strains can be differentiated using restriction endonuclease analysis of DNA (96, 111). A simpler, more rapid procedure for differentiation of MS strains is the random amplified polymorphic DNA (RAPD) technique (35, 36), but results may be inconsistent. Pulsed field gel electrophoresis and amplified polymorphic DNA analysis also have been shown to be valuable tools for discriminating among strains of *M. synoviae* (30, 36, 106). Analysis of the conserved domain (approximately 400 base pair of the 5′ end) of the *vlhA* gene by direct nucleotide sequencing or other techniques has been used frequently for identification of *M. synoviae* strains (9, 56, 58, 61, 65, 125, 169). Analysis of the 16S to 23S rRNA intergenic spacer region also has been examined for identification of *M. synoviae* isolates and results may be particularly useful when combined with other mutation detection techniques (141).

Virulence Factors

There is considerable variation among isolates in their ability to produce disease; many isolates cause little or no clinical disease. Although most recent isolates from the U.S. appear to be of relatively low virulence, clinical infectious synovitis has been reported in broilers (154). There have been numerous field reports of MS strains of high virulence in Mexico, Argentina, the Netherlands, and Eastern Europe. The pathogenicity and virulence of field isolates have been compared experimentally (60, 97, 112). Strains also showed differences in pathogenicity for chick embryos (98), but this did not correlate with virulence for chickens. Differences in virulence in MS could not be explained by potential virulence factors such as hemagglutination and hemadsorption, attachment to cells, or ciliostasis (99). However, the hemagglutination-positive phenotype of MS induces infectious synovitis lesions more frequently than does the hemagglutinin-negative phenotype (114). Sialidase activity (11, 108), nitric oxide production (32, 94), and cell invasion (19, 31) have been linked to *M. synoviae* virulence. It is also believed that antigenic variation of MSPA and MSPB contributes to the virulence of *M. synoviae* by providing a means for the organism to evade the host immune system (123).

Pathobiology and Epidemiology

Incidence and Distribution

Infectious synovitis was observed primarily in growing birds 4–12 weeks of age in broiler-growing regions of the United States during the 1950s and 1960s. Since the 1970s the synovitis form has been less frequently observed in chickens in the United States, but the respiratory form has been seen more frequently. Infection without apparent clinical signs is not unusual. *M. synoviae* infection occurs frequently in multi-age commercial layers (109, 134). Infectious synovitis usually appears in turkeys when they are 10–20 weeks old. Breeding stock from all major commercial breeds of chickens and turkeys is largely free of infection. *M. synoviae* is worldwide in distribution.

Natural and Experimental Hosts

Chickens and turkeys are the natural hosts of *M. synoviae*. Ducks (7, 161), geese (6), guinea fowl (138), pigeons (5, 145), Japanese quail (5), pheasants (16), and red-legged partridges (140) have been found to be naturally infected. Pheasants and geese (16, 155), ducks (171), and budgerigars (12) are susceptible by artificial inoculation. *M. synoviae* was isolated from house sparrows (*Passer domesticus*) in Spain (140); Kleven and Fletcher (84) found that sparrows could be artificially infected, but were quite resistant. Rabbits, rats, guinea pigs, mice, pigs, and lambs are not susceptible to experimental inoculation (127).

Natural infection in chickens has been observed as early as 1 week, but acute infection is generally seen when chickens are 4–16 weeks old and turkeys are 10–24 weeks old. Acute infection occasionally occurs in adult chickens. Chronic infection follows the acute phase and may persist for the life of the flock. The chronic stage may be seen at any age and in some flocks may not be preceded by an acute infection.

Transmission

Lateral transmission occurs readily by direct contact. *M. synoviae* has been demonstrated in the respiratory tract of contact control chickens 1–4 weeks following infection of the principals (129). Spread between batteries in the same room occurs. In many respects, the spread appears to be similar to that of *M. gallisepticum* (132) except that it is more rapid. However, slow-spreading infections have been reported (167). Transmission occurs via the respiratory tract, and usually 100% of the birds become infected, although none or only a few develop joint lesions.

Infection has not been thought to occur as a result of environmental contamination after depopulation of infected premises. However, in one study day-old chicks became infected after placing them in a contaminated environment, but evidence of infection was not seen until 33 to 54 days of age (107). Birds are infected for life and remain carriers.

Vertical transmission occurs in naturally and artificially infected chickens (20); however, many flocks hatched from infected dams remain free of infection. Vertical transmission plays a major role in spread of MS in chickens and turkeys. Thus, all eggs used for live virus vaccine production should be obtained from MS-free flocks. Experimental infection of broiler breeders resulted in MS infection in the trachea of day-old progeny, infertile eggs, and dead-in-shell embryos 6–31 days post inoculation (164). When commercial breeder flocks become infected during egg production, the egg-transmission rate appears to be highest during the first 4–6 weeks after infection; transmission thereafter may cease, but infected flocks may shed at any time.

Incubation Period

Infectious synovitis has been seen in 6-day-old chicks, suggesting that the incubation period can be relatively short in birds infected by egg transmission. The incubation period following contact exposure is generally 11–21 days. Antibodies may be detected before clinical disease becomes evident. In birds experimentally infected at 3–6 weeks of age the incubation period varies from 2–20 days, depending on the route of administration. Intratracheal inoculation results in infection of the trachea and sinus as early as 4 days and readily spreads to contact birds. Air sac lesions are at a maximum 17–21 days after aerosol challenge (82). The incubation period also varies with titer and pathogenicity of the inoculum.

Clinical Signs

Chickens

The first observable signs in a flock affected with infectious synovitis are pale comb, lameness, and retarded growth. As the disease progresses, feathers become ruffled and the comb shrinks. In some cases, the comb is bluish red. Swellings usually occur around joints, and breast blisters are common. Hock joints and foot pads are principally involved, but in some birds most joints are affected; however, birds are occasionally found with a generalized infection but without apparent swelling of the joints. Birds become listless, dehydrated, and emaciated. Although birds are severely affected, many continue to eat and drink if placed near feed and water. A greenish discoloration of droppings, which contain large amounts of uric acid or urates, is frequently seen. Acute signs described above are followed by slow recovery; however, synovitis may persist for the life of the flock. In other instances, the acute phase is absent or not noticed, and only a few chronically infected birds are seen in a flock. Chickens infected via the respiratory tract may show slight rales in 4–6 days or may be asymptomatic.

Chondrodystrophy was noted in the opposite leg of chickens inoculated via the foot pad. This may have been due to increased weight-bearing stress on the leg opposite the affected leg (112). Inoculation of 18-day-old chicken embryos via the yolk sac resulted in synovitis and airsacculitis in the chicks (13).

Outbreaks of MS in brown egg layers in the Netherlands were associated with amyloid arthropathy, which was reproduced experimentally (89, 91, 92).

Air sac infection may occur at any age, but is most often observed as a cause of condemnation in broilers (80). Under field conditions, most air sac lesions resulting from *M. synoviae* infection occur in winter. Progeny of MS-infected breeders may have increased air sac condemnation, reduced weight gain, and reduced feed efficiency.

Experimental aerosol inoculation of hens with MS resulted in a detectable drop in egg production in 1 week post challenge; by 2 weeks production dropped 18%, and by 4 weeks production returned to normal (100). Challenge of commercial layers at 10 weeks of age did not result in egg production losses (18). With naturally occurring infection of adults there is usually little or no effect on egg production or egg quality (52, 110, 134), although instances of egg production losses in commercial layers have been observed. Challenged layer chickens were characterized by transient heterophilia, lymphopenia, monocytosis, eosinopenia, and basopenia (17). MS has been implicated as a contributing factor in the development of *Escherichia coli* peritonitis syndrome and associated mortality in commercial layers (143). Recently, *M. synoviae* has been linked with abnormalities of the apical eggshell in commercial egg layers in the Netherlands (38). Broiler breeder hens appear to be less susceptible to producing eggs with the abnormalities after MS infection (39). Studies have found similar conditions in Italy (21) and Germany (142).

Turkeys

M. synoviae generally causes the same type of signs in turkeys as in chickens. Lameness may be the most prominent sign. Warm flocculent swellings of 1 or more joints of lame birds are usually found. Occasionally, there is enlargement of the sternal bursa. Severely affected birds lose weight, but many less severely affected make satisfactory weight gains when separated from the flock. In experimentally infected turkeys (127), the first noticeable sign is failure to grow.

Respiratory signs are not usually observed in turkeys, but MS has been isolated from sinus exudates obtained from turkey flocks exhibiting a very low incidence of sinusitis, and from tracheas and choanal clefts of turkeys exhibiting increased mortality and pneumonia (137). Airsacculitis may at times occur in day-old and older turkeys in MS-infected flocks. Air sac inoculation of mycoplasma-free turkeys results in airsacculitis (49, 148). Rhoades (147) described a synergistic effect of MS and *M. meleagridis* in producing sinusitis in turkeys. Foot pad inoculation of turkeys may result in total cessation of egg production. Challenge with field isolates of MS indicated that recent strains are capable of reproducing synovitis in turkeys (74).

Morbidity and Mortality

Chickens. Morbidity in flocks with clinical synovitis varies from 2%–75%, with 5%–15% being most usual. Respiratory involvement is generally asymptomatic, but 90%–100% of the birds may be infected. Mortality is usually less than 1%, ranging up to 10%. In experimentally infected chickens, mortality may vary from 0%–100% depending on route of inoculation and dose of inoculum.

Turkeys. Morbidity in infected flocks is usually low (1%–20%) but mortality from trampling and cannibalism may be significant.

Pathology

Gross Pathology

Chickens. In early stages of the infectious synovitis form of the disease, chickens frequently have a viscous creamy to gray exudate involving synovial membranes of the tendon sheaths, joints, and keel bursa, and hepatosplenomegaly (Figure 21.11).

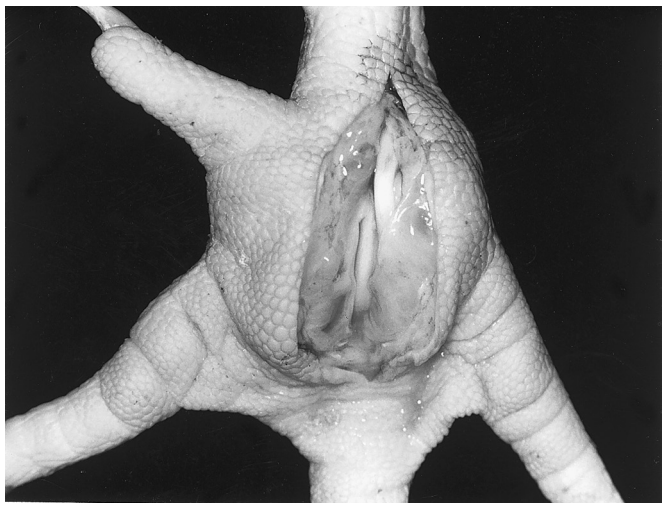

Figure 21.11. Incised swollen foot pad of an 8-week-old turkey with granulation tissue and purulent exudate surrounding digital flexors. Similar lesions can be seen in chickens.

Figure 21.12. Ulceration of articular surface of distal tibiotarsus from a chicken with infectious synovitis.

Kidneys are usually swollen, mottled, and pale. As the disease progresses caseous exudate may be found involving tendon sheaths and joints and extending into muscle and air sacs. Articular surfaces, particularly of the hock and shoulder joints, become variably thinned to pitted over time (Figure 21.12). Generally no gross lesions are seen in the upper respiratory tract. In the respiratory form of the disease, airsacculitis may be present.

Turkeys. Swellings of the joints may not be as prominent as in chickens, but fibrinopurulent exudate is frequently present when the joints are opened. Lesions in the respiratory tract are variable.

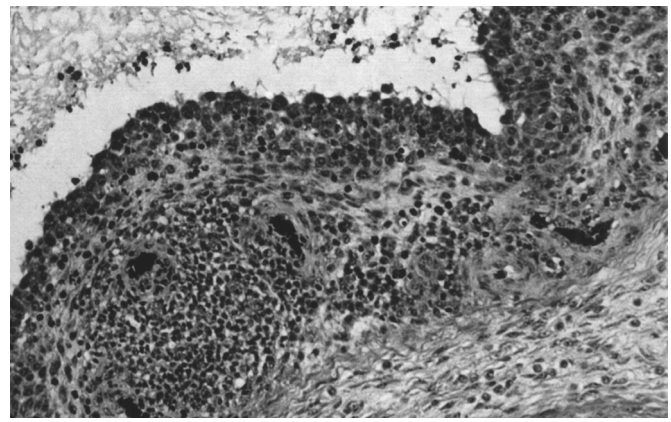

Figure 21.13. Hyperplastic synovial membrane with multiple subsynovial lymphoid aggregates from a 7-week-old turkey with infectious synovitis.

Microscopic Pathology

The histopathology of infectious synovitis (75, 78, 155) in chickens and respiratory disease caused by *M. synoviae* in chickens (43) and turkeys (49, 149) has been described.

The joints, particularly of the foot and hock, have an infiltrate of heterophils and fibrin into joint spaces and along tendon sheaths. The synovial membranes are hyperplastic with villous formation and a diffuse to nodular subsynovial infiltrate of lymphocytes and macrophages (Figure 21.13). Cartilage surfaces, over time, become discolored, thinned, or pitted. Air sacs may have a mild lesion consisting of edema, capillary proliferation, and the accumulation of heterophils and necrotic debris on the surface, to more severe lesions with hyperplasia of epithelial cells, a diffuse infiltrate of mononuclear cells, and necrosis. Other lesions reported to be associated with infectious synovitis are hyperplasia of the macrophage-monocyte system associated with the sheathed arteries of the spleen; lymphoid infiltrates in the heart, liver, and ventriculus (gizzard); and thymic and bursal atrophy. Cardiac pathology has been described in detail (77).

Pathogenesis of the Infectious Process

The route of *M. synoviae* infection may play a significant part in the resulting disease. Natural infection may occur vertically *in ovo* or horizontally by direct contact or airborne spread. Pathogenicity of *M. synoviae* strains generally involves attachment and colonization of the upper respiratory tract plus additional unidentified factors associated with systemic invasion and lesion production.

M. synoviae isolated from air sac lesions are more apt to cause airsacculitis, whereas those isolated from synovia are more apt to produce synovitis (83). Airsacculitis is exacerbated by ND-IB vaccination (82, 156) or any respiratory infection. The severity of the airsacculitis depends on the virulence of the infectious bronchitis virus used in conjunction with MS (62). Air sac lesions are greatly enhanced by cold environmental temperatures (173). Infectious bursal disease causes immunosuppression in chickens, and dual infection with MS results in

more severe air sac lesions (50). However, no synergistic effects were seen with dual infections with avian pneumovirus (79) or with *Ornithobacterium rhinotracheale* (178). Nervous signs with lesions of meningeal vasculitis have been seen in MS-infected turkeys displaying severe synovitis (25).

Immunity

Chickens exposed intranasally to *M. synoviae* were resistant to subsequent foot pad challenge (129). Chickens immunized intranasally with a temperature-sensitive mutant of MS were protected against airsacculitis for at least 21 weeks (116). Prior exposure to MS-H, a temperature-sensitive mutant strain, protected against subsequent challenge with a virulent synovitis-producing field strain (153). Parenteral inoculation of MS frequently overwhelms the bird before adequate resistance can develop. Resistance to lesions induced by MS is cloacal bursa dependent (88, 163), while thymus-dependent lymphocytes may be needed for the development of macroscopic synovial lesions (88).

Diagnosis

Isolation and Identification

Positive diagnosis may be made by isolation and identification of *M. synoviae. M. synoviae* may be isolated from lesions during the acute phase of the disease, but infection of the upper respiratory tract is permanent (82). Isolation from lesions in acutely infected birds is not difficult, but in the chronic stages of infection viable organisms may be no longer present in lesions. Isolation from the upper respiratory tract is more reliable in chronically infected birds. (For medium and isolation methods, see Growth Requirements.) The fluorescent antibody technique using colony imprints (27) or intact colonies (159) may be used for the identification.

Direct detection of MS DNA in tissues or culture medium using DNA probes has been described (4, 40, 63, 76, 176). It is a simple, rapid method of detection, but sensitivity may not be adequate. Polymerase chain reaction is a simple, rapid, and highly sensitive method of detection of MS DNA in tissues or culture medium (46, 93, 152, 177). The PCR procedures are comparable (or in some instances superior) in sensitivity to isolation and identification (41, 151). Several real-time PCR assays also have been described (64, 144, 157).

Serology

Antigen is available commercially for the serum plate agglutination (SPA) test. Antigen should be tested with known positive and negative serums each day. Approximately 2–4 weeks are required for antibodies to develop in infected birds (128). The SPA test may be insensitive in some instances; Ewing et al. (33) reported that the SPA test missed infected commercial layer and breeder flocks that were detected by ELISA.

Nonspecific reactors occur in some flocks when using the SPA test (51, 174), especially in flocks that have been vaccinated with oil emulsion vaccines against various agents. *M. gallisepticum* antigen may be agglutinated on occasion, but reaction is somewhat delayed and usually lower in titer (131). To confirm specificity of the reaction, the HI test is used (162).

ELISA (59, 135, 139) is commonly used as a diagnostic test and for routine testing of flocks, and may replace serum plate agglutination as a primary serologic test. ELISA kits are available commercially. However, it should be noted that performance (specificity and sensitivity) of experimental or commercial ELISA systems is highly dependent on the reagents used, specially the nature and quality of the antigen or antibody used in their preparations. A semi-purified preparation containing antigens in the p46–52 region showed promise as an ELISA antigen (53). A recombinant antigen containing a highly antigenic domain of MSPB (117) has potential as a serodiagnostic reagent (119). The recombinant MSPB antigen from vaccine strain MS-H was more efficient in detecting antibodies in vaccinated chickens than was a similar antigen prepared from strain WVU 1853, suggesting some antigenic variability in that region (121). ELISA also has been used to detect antibodies in the yolk of eggs from commercial layers (54).

In a comparison of diagnostic tests for MS, all serological procedures studied exhibited some false-positive activity (37). Kleven et al. (86) compared the serological response to 2 MS strains in chickens and found that although one of the strains had been reported to be nonreactive on the SPA test, it reacted as expected on that test following experimental infection. However the ELISA responses were weaker than anticipated for both strains. Also, antigenic variability among MS strains results in homologous reactions (using antigen prepared from the same strain used to infect the chickens) that tend to be stronger than heterologous reaction (antigen prepared from a different strain) (86). It is not advisable to rely completely on any single serological procedure. Further confirmation of serologic results may be made by isolation and identification of *M. synoviae* from the upper respiratory tract (150) or by PCR. Under some situations there may be a delayed antibody response in chickens that were proved to be infected by PCR (34).

Specific antibodies of the IgG, IgM, and IgA classes have been detected in the oviduct and albumen of chickens naturally infected by MS, as well is in their developing embryos (10).

Turkeys produce a low level of antibody following respiratory infection; therefore, agglutination may not be effective in determining the *M. synoviae* status of a flock. Significant antibodies develop following foot pad inoculation only (49, 146). Various commercial agglutination antigens vary in their ability to detect agglutinins in turkeys. Individual infected turkeys may not develop detectable antibodies (136). Turkeys that were infected systemically developed a strong antibody response, whereas those birds infected via the upper respiratory tract did not develop circulating antibody, or antibody production was delayed (85). Culture, PCR, ELISA, and HI testing may be required in some cases to detect infection.

Differential Diagnosis

A presumptive diagnosis may be made on the basis of leg weakness, breast blisters, and enlarged foot pads or hock joints. Bacteria as causes of synovitis or arthritis must be eliminated by bacteriologic procedures. *Staphylococcus aureus*, *Escherichia coli*, pasteurellae, and salmonellae also may be present as primary causes of synovitis. *M. gallisepticum* may be a cause of breast blisters and joint lesions (127, 130).

Fibrosis of metatarsal extensor or digital flexor tendons and lymphocytic infiltration of the myocardium associated with the viral arthritis agent help to differentiate it from *M. synoviae* (101). Serum from viral tenosynovitis-infected chickens does not agglutinate MS antigen, but one must bear in mind that MS agglutinins may be present without obvious joint involvement.

In cases with respiratory involvement, *M. gallisepticum* and other causes of respiratory disease should be eliminated.

Intervention Strategies

Management Procedures

M. synoviae is egg transmitted, and the most effective method of control is to select chickens or turkeys from MS-free flocks. Most primary breeding stocks are free of infection, and MS-free sources of replacement breeding stocks should be available. Effective biosecurity measures should be used to prevent introduction of the infection. See Kleven (87) for a review of avian mycoplasma control strategies in commercial poultry.

Outbreaks of MS infection in broilers can often be traced to a specific breeder flock. By the time the infected breeder flock is found, egg transmission may be low or no longer clinically significant. The decision to slaughter infected parent breeder flocks is often made on an economic basis. If such flocks are kept for egg production, progeny should be hatched separately and isolated from MS-free flocks. Antibiotic treatment of breeders is not effective in eliminating MS, although the level of egg transmission may be reduced.

M. synoviae is susceptible *in vitro* to several antibiotics, including chlortetracycline, danofloxacin, enrofloxacin, lincomycin, oxytetracycline, spectinomycin, spiromycin, tetracycline, tiamulin, tilmicosin, aivlosin, and tylosin (15, 22, 48, 57, 69, 73, 81, 90, 170). In contrast to *M. gallisepticum*, MS isolates appear to be resistant to erythromycin (15, 170). High-level resistance to erythromycin and tylosin developed rapidly after low-level exposure *in vitro*, but enrofloxacin resistance developed more gradually. No resistance to tiamulin or oxytetracycline was shown (47). Earlier isolates seem to respond more poorly to chlortetracycline than later isolates (133). Generally, suitable medication is valuable in preventing airsacculitis or synovitis, but treatment of existing lesions is less effective. Antibiotic medication is not thought to eliminate MS infection from the flock, but in a field study a flock naturally infected with MS was medicated with 3 treatments of enrofloxacin and later continuous medication with 600 ppm oxytetracycline in the feed. This flock subsequently became MS negative by PCR, suggesting possible clearance of MS from the flock as a result of medication (42). In another study (158), treatment with enrofloxacin at 10 mg/kg in the drinking water for 14 days did not eliminate detection of MS by PCR. In another study, 2 treatments with enrofloxacin at recommended dose levels did not affect recovery of MS from tracheal swabs, and isolates from the medicated birds exhibited an increased resistance to enrofloxacin as well as substitutions in the topoisomerase IV gene (95).

A summary of data obtained from field and experimental studies indicates that chlortetracycline (50–100 g/ton of feed) given continuously will provide satisfactory control of infectious synovitis in chickens. Higher concentrations (approximately 200 g/ton) are required to control synovitis after infection has occurred. In turkeys, prophylactic levels of 200 g/ton are required. Effectiveness of chlortetracycline may be related to the MS isolate involved (133).

Soluble lincomycin-spectinomycin (2 g/gallon of drinking water) is valuable in preventing airsacculitis in broilers (55). Tiamulin in the drinking water (0.006%–.025%) has been shown to be effective in preventing airsacculitis and synovitis in chickens (3). Other products have been used, but their value in treatment of MS has not been adequately studied.

Treatment of eggs with antibiotics such as tylosin by egg dipping, or egg inoculation with tylosin and gentamycin (115), or heat treatment (172) of hatching eggs have been used in breeding flocks to prevent egg transmission of MS. Exposure of breeders before the onset of egg production with virulent MS reduces egg transmission. This should only be used in flocks in which infection will almost certainly occur.

Vaccination

An inactivated, oil emulsion bacterin has been commercially available, but its role in the control of MS has not been adequately studied. A live temperature-sensitive MS vaccine strain, MS-H, was developed by mutagenesis of a field isolate from Australia (113). Its safety and efficacy have been established under laboratory (102, 103) and field (104) conditions. Vaccine doses of 4.8×10^5 ccu/ml were protective (67); protective immunity was detected after 3–4 weeks post vaccination (68) and persisted for at least 40 weeks (66). The vaccine has been shown to be effective in reducing apical egg shell abnormalities caused by *M. synoviae* infection. Factors other than the temperature-sensitive phenotype appear to be involved in the attenuation of the MS-H vaccine strain (122). This vaccine has received wide use in Australia and several other countries, but it is not licensed in many countries, including the United States. The safety and efficacy of MS-H vaccine also have been assessed in turkeys (124).

Acknowledgement

The expertise and effort of Dr. Stanley H. Kleven to previous versions of this chapter are gratefully acknowledged.

Mycoplasma iowae Infection

Janet M. Bradbury and Ziv Raviv

Introduction

Mycoplasma iowae has been associated with reduced hatchability and late embryo mortality in turkeys. Experimentally it can induce mortality in turkey and chicken embryos and airsacculitis and leg abnormalities in chickens and turkeys. There are occasional field reports of leg problems in young turkeys associated with *M. iowae*.

Economic Significance

Poult hatchability can be reduced by 2%–5%.

History

The type strain, Iowa 695, was characterized and designated avian serotype I (83, 84). Serotypes I, J, K, N, Q, and R (28) were later assigned to one related group (4, 5) and named *Mycoplasma iowae* (44). Type 8 strains from turkeys (11, 78) were also *M. iowae* (1).

Etiology

Classification

M. iowae belongs to the class *Mollicutes*, family *Mycoplasmataceae*, having characteristic colonial morphology, no cell wall, and a growth requirement for sterol. Lack of urease distinguishes it from genus *Ureaplasma* and places it in genus *Mycoplasma*. Identification at the species level is by serologic reaction or specific PCR. Phylogenetic analysis of the 16S rRNA places it in the pneumoniae group with the avian mycoplasmas *M. gallisepticum* and *M. imitans* and the human pathogen *M. pneumoniae* (25), its closest known relative being *M. muris*.

Morphology and Staining

Giemsa staining or dark-field examination reveals coccobacillary organisms with some pleomorphism. Ultrathin sections show cells with a plasma membrane and no cell wall (44). Some studies suggest the presence of an attachment organelle (1) which would be consistent with its phylogenetic placement and with the demonstration of attachment organelle ortholog genes in *M. iowae* strain 695 (81).

Growth Requirements

Like other mycoplasmas, *M. iowae* has complex growth demands including a cholesterol requirement. Incubation is usually at 37°C, although some strains grow best at 41° to 43°C (38) and growth occurs either aerobically or with added CO_2 (44). Recovery from tissues may be more successful by direct plating on agar than via broth (3). Several media formulations have been used and that described by Bradbury (14) works well. The presence and quality of yeast extract are important, and some field isolates may be intolerant of certain media components. Quality control on batches of yeast extract and serum using low-passage field isolates is recommended.

Colony Morphology

Colonies on agar have typical fried egg morphology and a diameter of 0.1–0.3 mm (83).

Biochemical Properties

M. iowae ferments glucose and hydrolyses arginine (44). Glucose metabolism is accompanied by oxygen uptake, distinguishing it from some other avian mycoplasmas (77). Unusually for a mycoplasma, it grows in the presence of 0.5%–1% bile salts (71). Some strains hemagglutinate avian erythrocytes (28, 83, 84), but the property is unstable. Although *M. iowae* hemagglutinins are variably expressed, the relevant proteins and genes have not been characterized (9). Orthologs of *M. penetrans* P35 lipoprotein gene family are present in the *M. iowae* genome (81). Among 6 serovars of *M. iowae* tested for neuraminidase, only strain 695 showed activity (10).

Susceptibility to Chemical and Physical Agents

Resistance of *M. iowae* to disinfectants is unknown, although it may survive better than *M. gallisepticum* or *M. synoviae* in the environment (27). Under experimental conditions *M. iowae* survived 5 days or more on feathers and at least 6 days on human hair and other materials. This may have implications for terminal site disinfection, especially with the oral/fecal mode of transmission. However, the organisms appear to be inactivated by proper cleaning and disinfection.

Antigenic Structure and Toxins

The antigenic structure of *M. iowae* is poorly characterized, and there is significant variation among strains (16, 38, 61, 85). Although SDS-PAGE showed few differences (61, 85), immunoblotting using monoclonal antibodies demonstrated considerable diversity (61). Colony immunoblots probed with a monoclonal antibody revealed phenotypic variation of surface antigen (32, 69). A surface-exposed protein of 41 kD was identified in *M. iowae*, *M. gallisepticum*, and *M. imitans*, providing evidence of an antigenic relationship between them (68). Toxins have not been reported.

Strain Classification

Antigenicity

M. iowae strains were earlier classified into several serovars (28). They give a poor antibody response in chickens and turkeys and little is known about cellular immunity. When raising chicken antibodies to 12 different avian mycoplasmas, the task proved most difficult with *M. iowae* (15). Furthermore, no single antiserum, even from hyperimmunized rabbits, detected all group members by immunofluorescence (24).

Immunogenicity or Protective Characteristics

Little is known about the immunogenicity of *M. iowae*, but it may be slightly immunosuppressive. Experimental infection of day-old turkeys resulted in decreased bursa-to-body-weight ratio and delayed antibody response to sheep erythrocytes (17). A monoclonal antibody reacting with a 65-kD polypeptide in *M. iowae* may be involved in cytadhesion (31).

Genetic or Molecular Characteristics

The *M. iowae* genome is composed of 1,195,147 bp, one of the largest within the genus, and has an average G + C content of 20.00%. It includes 151 tandem repeats, 11 pseudogenes, 2 rRNA loci, and 29 tRNA genes (81). Heterogeneity in the DNA of *M. iowae* strains was reported (24, 85) using restriction enzyme analysis and by restriction fragment length polymorphism using Southern hybridization with 16S rRNA probes (54), but neither provided clear-cut strain differentiation. The 16-23S rRNA intergenic spacer region sequences of 16 *M. iowae* field strains and the 6 serotypes showed 100% similarity (62). Arbitrarily primed PCR was proposed as a molecular tool for differentiation of *M. iowae* field strains (30). Amplified fragment length polymorphism (AFLP) and Roche 454 whole genome sequencing appear useful for intraspecific differentiation of *M. iowae* strains (66).

Pathogenicity

Variability exists in the pathogenicity and virulence of *M. iowae* strains (48, 67, 83). Experimental infection causes dose-related mortality in chicken and turkey embryos (21, 37, 58, 83). Under field conditions, it can cause turkey embryo mortality and reduced hatchability, with some strains appearing more virulent than others. Hatchability losses are widely variable and dependent on the extent of vertical transmission. Losses are not always apparent in eggs from infected turkey breeder flocks, although they can be quite severe and prolonged, possibly due to differences in strain virulence, incubation conditions, and/or breed susceptibility.

Artificial challenge with *M. iowae* can induce mild to moderate airsacculitis in turkeys (28, 67, 83) and leg lesions in chickens and turkeys (18, 19, 20, 23, 83). Severity appears to show strain variation. Such problems are rare in the field but outbreaks associated with *M. iowae* in young turkeys with leg weakness and deformities have been reported (29, 56, 79) and an association with vertebral lesions noted (56).

Virulence Factors

Virulence factors of *M. iowae* are unknown but the availability of the whole genome sequence (81) should stimulate studies on this aspect.

Pathobiology and Epizootiology

Incidence and Distribution

In addition to North America, *M. iowae* has been reported in Western and Eastern Europe (8, 43) and Asia (57, 64, 75) and presumably occurs almost worldwide, although it is not reported in Australia.

Natural and Experimental Hosts

The natural host appears to be the turkey, but isolation from chickens and geese is possible (8, 57, 83). *M. iowae* also has been isolated from parrots (13) and from wild and exotic birds in the United Kingdom (2).

Age of Host Commonly Affected

Turkey embryos in later stages of incubation are most commonly affected, but any age of live turkey may be infected. Little is known about other hosts, although *M. iowae* was isolated from natural infections of adult chickens and geese (21, 57).

Transmission, Carriers, Vectors

Only avian species are known to be infected with *M. iowae*, although isolation from an apple seed in France was reported (38). Egg transmission occurs in turkeys (58, 83) and lateral transmission may occur in the hatchery because the organism is in the meconium; unlike other avian mycoplasmas, *M. iowae* exhibits a predilection for the digestive tract (59).

Horizontal transmission may occur although the organism does not spread rapidly in young flocks. Before achieving reproductive maturity, very few birds may be culture-positive within a flock.

Infection may be spread venereally, and under modern methods of insemination, infected semen can cause dissemination (49, 70). After laying begins, following artificial insemination and for a few weeks thereafter, a high percentage of females may become culture-positive. The organism can be recovered from cloaca and vagina. Although the infected male may play a role in lateral spread, vaginal contamination following hand contact at artificial insemination may be more important (6). Patterns of vertical transmission have been well characterized (37). Within an infected flock there are individuals that lay no infected eggs while others lay only one or a few. The rest lay many infected eggs and are important in determining the extent of vertical transmission.

Incubation Period

Embryos infected via the dam usually die from about 18 days of incubation.

Clinical Signs

Clinical signs are not usually observed in live turkeys, but a few reports (29, 56, 79) have associated *M. iowae* with leg weakness in young poults and low incidences of stunting, lameness, and swollen hocks. Eggs from infected turkey breeders may have reduced hatchability (generally 2%–5%). Affected embryos usually die during the last 10 days of incubation, typically from days 18–24, although sometimes later. Experimentally infected embryos showed a significantly reduced embryo-to-egg-weight ratio (59).

Pathology

Gross Lesions

Embryo lesions are mainly stunting and congestion, with various degrees of hepatitis, edema, and splenomegaly (58, 59, 83) and sometimes swollen down plumule. Chorioallantoic membranes of inoculated turkey embryos are edematous and sometimes hemorrhagic (59). Airsacculitis in inoculated chickens and turkeys is usually mild to moderate (28, 67, 83). Inoculation of day-old poults and chicks resulted in stunting, poor feathering, tenosynovitis, and leg abnormalities including chondrodystrophy, rotated tibia, toe deviations, and sometimes erosion of the articular cartilage of the hock joint and rupture of the digital flexor tendon (19, 22, 23, 83). Inoculated poults also may show cloacal bursal atrophy (17). Some of these lesions have been seen in turkeys in natural infection (56, 79). A low incidence of vertebral lesions, occasionally with wry neck, were reported, as well as splenomegaly (56).

Microscopic Lesions

Chorioallantoic membranes of inoculated turkey embryos showed edema and infiltration with heterophils and mononuclear cells, while parenchymatous organs showed a heterophilic response (59).

After inoculation of day-old poults, splenic lesions consisted of reticular cells with macrophages, plasma cells, and heterophils in the parenchyma. The cloacal bursa had localized congestion with infiltration of plasma cells, heterophils, and reticular cells. Macrophages, lymphocytes, heterophils, and plasma cells were seen in the lamina propria of the duodenum, ileum, and cecal tonsils. Little obvious change was observed in cartilage and tendon except for edema of tendon sheaths (23). Microscopic lesions of vertebral chondrodystrophy in 39- to 65-day-old commercial turkeys have been detailed (56).

Air sac inoculation of poults resulted in thickened air sacs with many inflammatory cells, and exudate on the mucosal surface contained fibrin and inflammatory cells (67). In experimentally infected broiler-breeders, affected joints showed acute tenosynovitis, hemorrhage, and tendon fiber degeneration, later followed by chronic lymphocyte/plasma cell reaction and tendinous and peritendinous fibrosis (19).

Ultrastructural

Adherence of *M. iowae* to embryo intestinal mucosa was demonstrated in artificial infection (59). Most organisms adhered to the microvilli, which often appeared swollen.

The organisms have been demonstrated in cloacal crypts and in the secondary mucosal folds of the vagina of the turkey hen by electron microscopy (74).

Pathogenesis of the Infectious Process

Little is known about the pathogenesis of *M. iowae*. The first step may be attachment to the embryo intestinal epithelial surface (59, 74), in which a 65-kD polypeptide may be involved (31).

In strains that proliferate in the embryo, death probably results from acute nonspecific inflammation of the chorioallantoic membrane and a heterophilic reaction in the parenchymatous organs (59). Western blots of *M. iowae* reacted positively with antibodies to a 48-kD mycoplasma protein, which had immunomodulatory and hematopoietic differentiation activities (39).

Phenotypic variation may play a role in the infectious process by allowing the mycoplasmas to persist despite an immune response, and it is also possible that *M. iowae* is mildly immunosuppressive (17).

Immunity

Active Immunity

Little information exists on active immunity to *M. iowae*, although antibody responses are reported (83). Equally, there is little information on age susceptibility of turkeys. It is difficult or impossible to infect some individuals within a flock of adult breeders (7). Those that become infected and transmit the organism vertically to their eggs usually resolve the infection. This may take a few weeks or 2–3 months. Embryo mortality usually subsides immediately before resolution of the infection. The finding of growth-inhibiting and metabolism-inhibiting antibodies in serum of these turkey hens suggests involvement of an immune response (7).

Passive Immunity

There appears to be no information about passive antibodies, including maternally derived antibodies, in *M. iowae* infection.

Diagnosis

Isolation and Identification of Causative Agent

M. iowae may be present in high numbers in dead embryos (21, 58). After inoculation of poults, it can be isolated from several tissues, especially the gastrointestinal tract and cloaca, but this becomes less frequent with age, and organisms were not recovered after 12 weeks (23, 72). Isolation from oviduct, semen, and phallus of adult chickens and turkeys has been reported (64, 70, 83) and a combined oviduct/cloacal swab was useful during the final stages of an eradication program (82). Samples are streaked onto agar and incubated for 4–5 days or longer at 37°C. Typical *Mycoplasma* colonies can be identified by immunofluorescence, although use of polyclonal antisera to several different serovars may be needed to cover for antigenic variation (24, 53). Although

some monoclonal antibodies might be too specific to detect all isolates, antibodies to a 45-kD antigen reacted with all 22 field isolates tested, with no evidence of phenotypic variation in immunoblots (76).

PCR has been developed for detection of *M. iowae* DNA (12, 26, 34, 35, 48, 51, 52, 60, 63, 65, 80, 86), in some cases with successful use on field samples.

In a further refinement, AFLP was used to differentiate between avian *Mycoplasma* species and confirmed that high genetic homogeneity exists amongst *M. iowae* strains (41).

Serology

Although agglutination, metabolism inhibition, indirect hemagglutination, and ELISA were used in experimental infections (48, 73, 83), the serologic response is weak (22, 23), and nonspecific reactions occurred with ELISA (47). Thus, there is no reliable serologic test for field use.

Differential Diagnosis

M. iowae infection should be considered in cases of low hatchability in turkeys, especially if there is late embryo mortality. However, *M. meleagridis* is also a consideration. None of the embryo lesions are pathognomonic because they can resemble certain nutritional deficiencies, and the down abnormalities may mimic those due to overheating of embryos in the incubator (33). Although not recognized as a significant cause of clinical tenosynovitis, *M. iowae* should be considered in cases in which there is no apparent diagnosis, especially in young turkeys.

Intervention Strategies

Management Procedures

M. iowae was earlier eradicated by certain primary turkey breeders by pre-incubation antibiotic treatment of hatching eggs, backed up by monitoring (1), but this mycoplasma is not currently included in the U.S. National Poultry Improvement Plan or the European Union Council Directive 2009/158/EC.

There is no reliable serologic screening procedure for *M. iowae* and culture can be impractical before birds begin production because of difficulties in isolating the organism and poor horizontal spread. However, it is often possible to detect infection in toms and hens before the onset of reproduction. The well-established *M. iowae* PCR procedures should enhance this possibility and accelerate diagnosis.

M. iowae-free flocks can be maintained by preventing fomite transmission. Special attention should be given when birds reach reproductive age, especially during artificial insemination. Residual site infection is not a known problem with proper terminal cleaning and disinfection procedures.

Vaccination

There is no demand for vaccines against *M. iowae*.

Treatment

Treatment of turkeys has not been an issue because *M. iowae* is not typically associated with clinical disease. The effectiveness of antibiotics in reducing levels of infection were investigated (45, 46) and attempts made to reduce vertical transmission in commercial flocks to alleviate hatchability losses.

M. iowae seems more resistant than other avian mycoplasma pathogens to some antimicrobials (40, 42, 50, 55). The quinolone antibiotics, particularly enrofloxacin (Baytril), have sometimes been effective when administered to laying hens in drinking water early in production. Eggs from medicated turkeys were resistant to *in ovo* challenge with *M. iowae* (46). However, egg treatment with enrofloxacin has been more commonly employed whereby hatching eggs from affected flocks are vacuum-dipped in antibiotic solution. This product is not generally available for food animal use in some countries.

Little is known about development of resistance to antibiotics *in vivo*. *M. iowae* developed resistance rapidly during culture in subinhibitory amounts of erythromycin and tylosin (36). Some resistance was found after culture with enrofloxacin, tiamulin, or oxytetracycline, and resistant mutants occurred more readily and rapidly with *M. iowae* than with *M. gallisepticum* or *M. synoviae*.

Acknowledgement

The expertise and effort of Dr Colin Baxter-Jones and Dr. Stanley H. Kleven to previous versions of this chapter are gratefully acknowledged.

Other Mycoplasmal Infections

Naola Ferguson-Noel

Mycoplasma imitans

Mycoplasma imitans is of interest primarily because of its close relationship to *M. gallisepticum*. It has been isolated from ducks and geese in France and from a partridge in England. *M. imitans* strains share many phenotypic properties with *M. gallisepticum*, including biochemical reactions, hemadsorption, and hemagglutination. The original isolates were initially identified as *M. gallisepticum* on the basis of immunofluorescence and growth-inhibition tests. Further serologic studies indicated only a partial relationship to *M. gallisepticum*, and DNA hybridization studies

with the type strains of *M. gallisepticum* showed a DNA homology of 40%–46% (5, 11). *M. imitans* contains a gene family closely related to the pMGA (now vlhA) family of *M. gallisepticum* (31), and shares epitopes with *M. gallisepticum* hemagglutinin vlhA, pyruvate dehydrogenase pdhA, lactate dehydrogenase, and elongation factor Tu (27).

PCR procedures for *M. gallisepticum* which are based on the 16S rRNA gene (17) do not differentiate between *M. gallisepticum* and *M. imitans*. However, PCR reactions based on other targets such as mgc2, gapA, and MGA_0319 (18) do differentiate between the 2 species.

M. imitans causes ciliostasis in chicken and duck tracheal organ cultures and has an attachment organelle and gliding motility similar to that seen in *M. gallisepticum* (1, 35). It reproduced respiratory disease similar to but somewhat milder than *M. gallisepticum* in red-legged partridges (14). An isolate of *M. imitans* gained virulence on back-passage in turkeys, and reproduced a respiratory disease which was more severe when it was present in a dual infection with rhinotracheitis virus (15). *M. imitans* did not produce signs or lesions when inoculated into chickens, but in a dual infection with infectious bronchitis virus a synergistic effect was seen (16).

Although *M. imitans* has not yet been reported in the United States, and it has not been found in commercial poultry flocks, there is concern about possible misidentification of isolates as *M. gallisepticum* and possible serologic cross-reactions in testing of field flocks.

Mycoplasma gallinarum

M. gallinarum has not been considered to be one of the pathogenic avian mycoplasma species, although there is one report of isolations associated with airsacculitis in a series of broiler flocks and the induction of airsacculitis with concurrent Newcastle disease-infectious bronchitis vaccine administration (24). It also has been suggested that *M. gallinarum* infection delays the onset of fatty liver syndrome in commercial layers (6). *M. gallinarum* and *M. gallinaceum* are often isolated as contaminants during attempts to isolate pathogenic avian mycoplasmas.

M. gallinarum was originally classified as avian serotype B (8) and was named *Mycoplasma gallinarum* (12). It grows well on all commonly used avian mycoplasma media, and has characteristics common to all mycoplasmas, including cell and colony morphology, absence of a cell wall, and a requirement for cholesterol. It does not ferment glucose, but reduces tetrazolium, is positive for arginine decarboxylase, and exhibits film and spots (2). There is genetic heterogeneity among various strains (10) as measured by RFLP analysis of genomic DNA.

M. gallinarum is ordinarily isolated primarily from chickens, but it may also been found in turkeys (3, 20). It has been isolated from jungle fowl (36), ducks (13), pigeons (34), and a Eurasian Griffon (29). It is considered to be worldwide in distribution. *M. gallinarum* is commonly isolated as a contaminant during attempts to isolate *M. gallisepticum* or *M. synoviae*, especially from adult chickens. Isolation of *M. gallinarum* from chicken embryos (3) and demonstration of the organism in oviducts (7, 49) suggest the possibility of egg transmission. It is readily identified by immunofluorescence of colonies on agar (47). No serologic test is available.

Mycoplasma pullorum

M. pullorum was classified as avian serotype C (8) and was later named *Mycoplasma pullorum* (22). It has been isolated from chickens, quail, partridge, pheasants, and turkeys (32). *M. pullorum* has been isolated from turkey embryos from flocks in France which were experiencing low hatchability and was shown to be pathogenic for chicken and turkey embryos (32). Like other mycoplasmas, *M. pullorum* isolates demonstrate genetic heterogeneity (28).

Avian Ureaplasmas

Ureaplasmas differ from mycoplasmas primarily in their ability to hydrolyze urea (26). There are several reports of isolation of avian ureaplasmas (19, 25). These organisms subsequently received the name *Ureaplasma gallorale* (26). There are no reports of avian ureaplasma isolation in North America.

Very little is known about the pathogenicity. Artificial challenge of chickens produced no clinical signs or macroscopic lesions (25). Turkeys and chickens challenged with a turkey ureaplasma isolated in Hungary developed fibrinous airsacculitis and serologic responses (38). Ureaplasmas also were isolated in Eastern Europe from turkeys that were experiencing problems with reduced fertility (39).

Mycoplasma Infections of Geese

Three serologically and biochemically distinct *Mycoplasma* species were isolated from geese in Europe (41). One of these has been further characterized and named *Mycoplasma anseris* (4); it has been associated with airsacculitis, peritonitis, and embryo mortality (45). Another was subsequently identified as *Mycoplasma cloacale* (42), and the third was designated strain 1220. Two other isolates, strains 1223 and 1225, also represent 2 additional species isolated from geese (48).

Clinically, strain 1220 has been associated with reductions in egg production and egg transmission, embryo mortality, infertility, inflammation of the cloaca and phallus, salpingitis, and lack of weight gain in hatched goslings (9, 40, 42, 43), but proof of etiology is unclear because mixed mycoplasma species were isolated. Strain 1220, on experimental inoculation of goose embryos and day-old goslings, resulted in embryo mortality and reduced growth of young goslings (43).

Strain 1220 also has been implicated in a field syndrome of goslings with respiratory and nervous signs (44). Several mycoplasma and acholeplasma species are often associated with mycoplasma disease in ducks and geese (46). More work needs to be done to clarify the role of these mycoplasmas in the field syndromes described.

Mycoplasma Infections of Pigeons

There are 3 species of *Mycoplasma* primarily associated with pigeons: *M. columbinasale* (22), *M. columborale*, and *M. columbinum* (37). One or more of these *Mycoplasma* species have been isolated from normal birds (3, 21, 33), as well as birds showing signs of respiratory disease (23, 30, 34). An isolate of *M. columborale* reproduced airsacculitis in chickens (30). Medication of pigeons infected with *M. columborale* with tylosin elicited a favorable response (30, 34). Even though there has been isolation of these organisms from birds showing respiratory signs, and there have been favorable responses to medication, there is no conclusive proof that pigeon mycoplasmas are etiologically involved in naturally occurring respiratory disease of pigeons.

Acknowledgement

The expertise and effort of Dr. Stanley H. Kleven to previous versions of this chapter are gratefully acknowledged.

References

Introduction

1. Barre, A., A. de Daruvar, and A. Blanchard. 2004. MolliGen, a database dedicated to the comparative genomics of Mollicutes. *Nucleic Acids Res*. 32:D307–310.
2. Bradbury, J.M. 1977. Rapid biochemical tests for characterization of the Mycoplasmatales. *J Clin Microbiol*. 5:531–534.
3. Bradbury, J.M., O.M. Abdul-Wahab, C.A. Yavari, J.P. Dupiellet, and J.M. Bove. 1993. *Mycoplasma imitans* sp. nov. is related to *Mycoplasma gallisepticum* and found in birds. *Int J Syst Bacteriol*. 43:721–728.
4. Bradbury, J.M., and M. Forrest. 1984. *Mycoplasma cloacale*, a new species isolated from a turkey. *Int J Syst Bacteriol*. 34:389–392.
5. Bradbury, J.M., M. Forrest, and A. Williams. 1983. *Mycoplasma lipofaciens*, a new species of avian origin. *Int J Syst Bacteriol*. 33:329–335.
6. Bradbury, J.M., F. Jordan, T. Shimizu, L. Stipkovits, and Z. Varga. 1988. *Mycoplasma anseris* sp. nov found in geese. *Int J Syst Bacteriol*. 38:74–76.
7. Brown, D.R., R.F. Whitcomb, and J.M. Bradbury. 2007. Revised minimal standards for description of new species of the class Mollicutes (division Tenericutes). *Int J Syst Evol Microbiol*. 57:2703–2719.
8. Clyde, W.A. 1964. Mycoplasma species identification based upon growth inhibition by specific antisera. *J Immunol*. 92:958–965.
9. Corstvet, R.E., and W.W. Sadler. 1964. The diagnosis of certain avian diseases with the fluorescent antibody technique. *Poult Sci*. 43:1280–1288.
10. Dierks, R.E., J.A. Newman, and B.S. Pomeroy. 1967. Characterization of avian mycoplasma. *Ann NY Acad Sci*. 143: 170–189.
11. Dusanic, D., R.L. Bercic, I. Cizelj, S. Salmic, M. Narat, and D. Bencina. 2009. *Mycoplasma synoviae* invades non-phagocytic chicken cells *in vitro*. *Vet Microbiol*. 138:114–119.
12. Edward, D.G., and A.D. Kanarek. 1960. Organisms of the pleuropneumonia group of avian origin: their classification into species. *Ann NY Acad Sci*. 79:696–702.
13. Forrest, M., and J.M. Bradbury. 1984. *Mycoplasma glycophilum*, a new species of avian origin. *J Gen Microbiol*. 130:597–603.
14. Forsyth, M.H., J.G. Tully, T.S. Gorton, L. Hinckley, S. Frasca Jr., H.J. Van Kruiningen, and S.J. Geary. 1996. *Mycoplasma sturni* sp. nov., from the conjunctiva of a European starling (*Sturnus vulgaris*). *Int J Syst Bacteriol*. 46:716–719.
15. Freundt, E.A. 1955. The classification of the pleuropneumonia group of organisms (Borrelomycetales). *Int Bull Bacteriol Nomen Taxon*. 5:67–68.
16. Frey, M.L., R.P. Hanson, and D.P. Anderson. 1968. A medium for the isolation of avian Mycoplasmas. *Am J Vet Res*. 29: 2163–2171.
17. Grau, O., F. Laigret, P. Carle, J.G. Tully, D.L. Rose, and J.M. Bove. 1991. Identification of a plant-derived mollicute as a strain of an avian pathogen *Mycoplasma iowae*, and its implications for mollicute taxonomy. *Int J Syst Bacteriol*. 41:473–478.
18. Jordan, F.T.W., H. Erno, G.S. Cottew, K.-H. Hinz, and L. Stipkovits. 1982. Characterization and taxonomic description of five mycoplasma serovars (serotypes) of avian origin and their elevation to species rank and further evaluation of the taxonomic status of *Mycoplasma synoviae*. *Int J Syst Bacteriol*. 32: 108–115.
19. Koshimizu, K., R. Harasawa, I.J. Pan, H. Kotani, M. Ogata, E.B. Stephens, and M.F. Barile. 1987. *Ureaplasma gallorale* sp. nov. from the oropharynx of chickens. *Int J Syst Bacteriol*. 37:333–338.
20. Lauerman, L.H., F.J. Hoerr, A.R. Sharpton, S.M. Shah, and V.L. van Santen. 1993. Development and application of a polymerase chain reaction assay for *Mycoplasma synoviae*. *Avian Dis*. 37: 829–834.
21. Nascimento, E.R., R. Yamamoto, K.R. Herrick, and R.C. Tait. 1991. Polymerase chain reaction for detection of *Mycoplasma gallisepticum*. *Avian Dis*. 35:62–69.
22. Nonomura, I., and H.W. Yoder. 1977. Identification of avian mycoplasma isolates by the agar gel precipitin test. *Avian Dis*. 21:370–381.
23. Olson, N.O., K.M. Kerr, and A. Campbell. 1964. Control of infectious synovitis. 13. The antigen study of three strains. *Avian Dis*. 8:209–214.
24. Panangala, V.S., J.S. Stringfellow, K. Dybvig, A. Woodard, F. Sun, D.L. Rose, and M.M. Gresham. 1993. *Mycoplasma corogypsi* sp. nov., a new species from the footpad abscess of a black vulture, *Coragyps atratus*. *Int J Syst Bacteriol*. 43:585–590.
25. Poveda, J.B., J. Giebel, J. Flossdorf, J. Meier, and H. Kirchhoff. 1994. *Mycoplasma buteonis* sp. nov., *Mycoplasma falconis* sp.

nov., and *Mycoplasma gypis* sp. nov., 3 species from birds of prey. *Int J Syst Bacteriol*. 44:94–98.
26. Razin, S., D. Yogev, and Y. Naot. 1998. Molecular biology and pathogenicity of mycoplasmas. *Microbiol Mol Biol Rev*. 62: 1094–1156.
27. Roberts, D.H. 1964. The isolation of an influenza A virus and a mycoplasma associated with duck sinusitis. *Vet Rec*. 76:470–473.
28. Shimizu, T., H. Erno, and J. Nagatono. 1978. Isolation and characterization of *Mycoplasma columbinum* and *M. columborale* two new species from pigeons. *Int J Syst Bacteriol*. 28:538–546.
29. Skerman, V., V. McGowan, and P.H.A. Sneath. 1980. Approved lists of bacterial names. *Int J Syst Bacteriol*. 30:225–420.
30. Stipkovits, L., R. Glavits, E. Ivanics, and E. Szabo. 1993. Additional data on *Mycoplasma* disease of goslings. *Avian Pathol*. 22:171–176.
31. Talkington, F.D., and S.H. Kleven. 1983. A classification of laboratory strains of avian mycoplasma serotypes by direct immunofluorescence. *Avian Dis*. 27:422–429.
32. Weisburg, W.G., J.G. Tully, D.L. Rose, J.P. Petzel, H. Oyaizu, D. Yang, L. Mandelco, J. Sechrest, T.G. Lawrence, J. Van Etten, and et al. 1989. A phylogenetic analysis of the mycoplasmas: basis for their classification. *J Bacteriol*. 171:6455–6467.
33. Winner, F., R. Rosengarten, and C. Citti. 2000. *In vitro* cell invasion of *Mycoplasma gallisepticum*. *Infect Immun*. 68:4238–4244.
34. Yamamoto, R., C.H. Bigland, and H.B. Ortmayer. 1965. Characteristics of *Mycoplasma meleagridis* sp. n., isolated from turkeys. *J Bacteriol*. 90:47–49.
35. Zhao, S., and R. Yamamoto. 1993. Amplification of *Mycoplasma iowae* using polymerase chain reaction. *Avian Dis*. 37:212–217.

Mycoplasma gallisepticum Infection

1. Abd-el-Motelib, T.Y., and S.H. Kleven. 1993. A comparative study of *Mycoplasma gallisepticum* vaccines in young chickens. *Avian Dis*. 37:981–987.
2. Abu-Zahr, M.N., and M. Butler. 1978. Ultrastructural features of *Mycoplasma gallisepticum* in tracheal explants under transmission and stereoscan electron microscopy. *Res Vet Sci*. 24:248–253.
3. Adler, H.E., Y. Yamamoto, and J. Berg. 1957. Strain differences of pleuropneumonia-like organisms of avian origin. *Avian Dis*. 1:19–27.
4. Adler, H.E., B.J. Bryant, D.R. Cordy, M. Shifrine, and A.J. DaMassa. 1973. Immunity and mortality in chickens infected with *Mycoplasma gallisepticum*: influence of the bursa of Fabricius. *J Infect Dis*. 127:Suppl:S61–66.
5. Ahmad, I., S.H. Kleven, A.P. Avakian, and J.R. Glisson. 1988. Sensitivity and specificity of *Mycoplasma gallisepticum* agglutination antigens prepared from medium with artificial liposomes substituting for serum. *Avian Dis*. 32:519–526.
6. Alessandri, E., P. Massi, F. Paganelli, F. Prandini, and M. Saita. 2005. Field trials with the use of a live attenuated temperature-sensitive vaccine for the control of *Mycoplasma gallisepticum* infection in meat-type turkeys. *Ital J Anim Sci*. 4:282.
7. Allen, J.L., A.H. Noormohammadi, and G.F. Browning. 2005. The vlhA loci of *Mycoplasma synoviae* are confined to a restricted region of the genome. *Microbiol*. 151:935–940.
8. Alls, A.A., W.J. Benton, W.C. Krauss, and M.S. Cover. 1963. The mechanics of treating hatching eggs for disease prevention. *Avian Dis*. 7:89–97.
9. Amin, M.M., and F.T.W. Jordan. 1979. Infection of the chicken with a virulent or avirulent strain of *Mycoplasma gallisepticum* alone and together with Newcastle disease virus or *E. coli* or both. *Vet Microbiol*. 4:35–45.
10. Anonymous. 2011. National Poultry Improvement Plan http://www.aphis.usda.gov/animal_health/animal_dis_spec/poultry/index2.shtml. March 18, 2013.
11. Arzey, G.G., and K.E. Arzey. 1992. Successful treatment of mycoplasmosis in layer chickens with single dose therapy. *Austral Vet J*. 69:126–128.
12. Athamna, A., R. Rosengarten, S. Levisohn, I. Kahane, and D. Yogev. 1997. Adherence of *Mycoplasma gallisepticum* involves variable surface membrane proteins. *Infect Immun*. 65:2468–2471.
13. Avakian, A.P., and S.H. Kleven. 1990. The humoral immune response of chickens to *Mycoplasma gallisepticum* and *Mycoplasma synoviae* studied by immunoblotting. *Vet Microbiol*. 24:155–169.
14. Avakian, A.P., and S.H. Kleven. 1990. Evaluation of sodium dodecyl sulfate-polyacrylamide gel electrophoresis purified proteins of *Mycoplasma gallisepticum* and *M. synoviae* as antigens in a dot-enzyme-linked immunosorbent assay. *Avian Dis*. 34:575–584.
15. Avakian, A.P., and D.H. Ley. 1993. Protective immune response to *Mycoplasma gallisepticum* demonstrated in respiratory-tract washings from *M. gallisepticum*-infected chickens. *Avian Dis*. 37: 697–705.
16. Avakian, A.P., and D.H. Ley. 1993. Inhibition of *Mycoplasma gallisepticum* growth and attachment to chick tracheal rings by antibodies to a 64-kilodalton membrane protein of *M. gallisepticum*. *Avian Dis*. 37:706–714.
17. Avakian, A.P., S.H. Kleven, and J.R. Glisson. 1988. Evaluation of the specificity and sensitivity of two commercial enzyme-linked immunosorbent assay kits, the serum plate agglutination test, and the hemagglutination-inhibition test for antibodies formed in response to *Mycoplasma gallisepticum*. *Avian Dis*. 32:262–272.
18. Avakian, A.P., S.H. Kleven, and D.H. Ley. 1991. Comparison of *Mycoplasma gallisepticum* strains and identification of immunogenic integral membrane proteins with Triton X-114 by immunoblotting. *Vet Microbiol*. 29:319–328.
19. Avakian, A.P., D.H. Ley, J.E. Berkhoff, and M.D. Ficken. 1992. Breeder turkey hens seropositive and culture-negative for *Mycoplasma synoviae*. *Avian Dis*. 36:782–787.
20. Balish, M.F., and D.C. Krause. 2005. Mycoplasma attachment organelle and cell division. In: *Gliding Motility of Mycoplasmas: The Mechanism Cannot be Explained by Current Biololgy*. A. Blanchard and G. Browning, eds. Horizon Bioscience, Wymondham, UK. 189–237.
21. Barbour, E.K., and J.A. Newman. 1989. Comparison of *Mycoplasma gallisepticum* subunit and whole organism vaccines containing different adjuvants by western immunoblotting. *Vet Immunol Immunopathol*. 22:135–144.
22. Barbour, E.K., and J.A. Newman. 1990. Preliminary data on efficacy of *Mycoplasma gallisepticum* vaccines containing different adjuvants in laying hens. *Vet Immunol Immunopathol*. 26: 115–123.
23. Barbour, E.K., S.K. Hamadeh, and A. Eidt. 2000. Infection and immunity in broiler chicken breeders vaccinated with a temperature-sensitive mutant of *Mycoplasma gallisepticum* and impact on performance of offspring. *Poult Sci*. 79:1730–1735.

24. Barbour, E.K., H.A. Shaib, L.S. Jaber, and S.N. Talhouk. 2005. Standardization and evaluation of random application of polymorphic DNA-polymerase chain reaction in subspecies typing of *Mycoplasma gallisepticum*. *Int J Appl Res Vet Med*. 3:138.
25. Barbour, E.K., J.A. Newman, V. Sivanandan, D.A. Halvorson, and J. Sasipreeyajan. 1987. Protection and immunity in commercial chicken layers administered *Mycoplasma gallisepticum* liposomal bacterins. *Avian Dis*. 31:723–729.
26. Barbour, E.K., J.A. Newman, J. Sasipreeyajan, A.C. Caputa, and M.A. Muneer. 1989. Identification of the antigenic components of the virulent *Mycoplasma gallisepticum* (R) in chickens: their role in differentiation from the vaccine strain (F). *Vet Immunol Immunopathol*. 21:197–206.
27. Barbour, E.K., S. Hamadeh, R. Talhouk, W. Sakr, and R. Darwish. 1998. Evaluation of an enrofloxacin-treatment program against *Mycoplasma gallisepticum* infection in broilers. *Prev Vet Med*. 35:91–99.
28. Barre, A., A. de Daruvar, and A. Blanchard. 2004. MolliGen, a database dedicated to the comparative genomics of Mollicutes. *Nucleic Acids Res*. 32:D307–310.
29. Baseggio, N., M.D. Glew, P.F. Markham, K.G. Whithear, and G.F. Browning. 1996. Size and genomic location of the pMGA multigene family of *Mycoplasma gallisepticum*. *Microbiol*. 142: 1429–1435.
30. Baseman, J.B., and J.G. Tully. 1997. Mycoplasmas: sophisticated, reemerging, and burdened by their notoriety. *Emerg Infect Dis*. 3:21–32.
31. Baughn, C.O., W.C. Alpaugh, W.H. Linkenheimer, and D.C. Maplesden. 1978. Effect of tiamulin in chickens and turkeys infected experimentally with avian Mycoplasma. *Avian Dis*. 22: 620–626.
32. Ben Abdelmoumen, B., and R.S. Roy. 1995. Antigenic relatedness between seven avian mycoplasma species as revealed by western blot analysis. *Avian Dis*. 39:250–262.
33. Ben Abdelmoumen Mardassi, B., A.A. Bejaoui, L. Oussaeif, B. Mlik, and F. Amouna. 2008. A recombinant antigen-based ELISA for the simultaneous differential serodiagnosis of *Mycoplasma gallisepticum, Mycoplasma synoviae*, and *Mycoplasma meleagridis* infections. *Avian Dis*. 52:214–221.
34. Bencina, D. 2002. Haemagglutinins of pathogenic avian mycoplasmas. *Avian Pathol*. 31:535–547.
35. Bencina, D., and D. Dorrer. 1984. Demonstration of *Mycoplasma gallisepticum* in tracheas of healthy carrier chickens by fluorescent-antibody procedure and the significance of certain serologic tests in estimating antibody response. *Avian Dis*. 28:574–578.
36. Bencina, D., and J.M. Bradbury. 1992. Combination of immunofluorescence and immunoperoxidase techniques for serotyping mixtures of *Mycoplasma* species. *J Clin Microbiol*. 30:407–410.
37. Bencina, D., T. Tadina, and D. Dorrer. 1988. Natural infection of ducks with *Mycoplasma synoviae* and *Mycoplasma gallisepticum* and mycoplasma egg transmission. *Avian Pathol*. 17:441–449.
38. Bencina, D., M. Narat, A. Bidovec, and O. Zorman-Rojs. 2005. Transfer of maternal immunoglobulins and antibodies to *Mycoplasma gallisepticum* and *Mycoplasma synoviae* to the allantoic and amniotic fluid of chicken embryos. *Avian Pathol*. 34: 463–472.
39. Bencina, D., I. Mrzel, O.Z. RoJs, A. Bidovec, and A. Dovc. 2003. Characterisation of *Mycoplasma gallisepticum* strains involved in respiratory disease in pheasants and peafowl. *Vet Rec*. 152:230–234.
40. Bencina, D., S.H. Kleven, M.G. Elfaki, A. Snoj, P. Dovc, D. Dorrer, and I. Russ. 1994. Variable expression of epitopes on the surface of *Mycoplasma gallisepticum* demonstrated with monoclonal antibodies. *Avian Pathol*. 23:19–36.
41. Biomune-CEVA. 2013. VECTORMUNE® FP-MG http://www.ceva.us/Products/Product-List/VECTORMUNE-R-FP-MG. March 27, 2013.
42. Biro, J., N. Erdei, I. Szekely, and L. Stipkovits. 2006. Differentiation of *Mycoplasma gallisepticum* strains using molecular methods. *Acta Vet Hung*. 54:437–448.
43. Biro, J., J. Povazsan, L. Korosi, R. Glavits, L. Hufnagel, and L. Stipkovits. 2005. Safety and efficacy of *Mycoplasma gallisepticum* TS-11 vaccine for the protection of layer pullets against challenge with virulent *M. gallisepticum* R-strain. *Avian Pathol*. 34:341–347.
44. Boettger, C.M., and J.E. Dohms. 2006. Separating *Mycoplasma gallisepticum* field strains from nonpathogenic avian mycoplasmas. *Avian Dis*. 50:605–607.
45. Boguslavsky, S., D. Menaker, I. Lysnyansky, T. Liu, S. Levisohn, R. Rosengarten, M. Garcia, and D. Yogev. 2000. Molecular characterization of the *Mycoplasma gallisepticum* pvpA gene which encodes a putative variable cytadhesin protein. *Infect Immun*. 68:3956–3964.
46. Bozeman, L.H., S.H. Kleven, and R.B. Davis. 1984. Mycoplasma challenge studies in budgerigars (*Melopsittacus undulatus*) and chickens. *Avian Dis*. 28:426–434.
47. Bradbury, J.M., and S. Levisohn. 1996. Experimental infections in poultry. In: *Molecular and Diagnostic Procedures in Mycoplasmology, Volume II – Diagnostic Procedures, Vol. II*. J.G. Tully, ed. Academic Press, San Diego, California. 361–370.
48. Bradbury, J.M., C.A. Yavari, and C.J. Giles. 1994. *In vitro* evaluation of various antimicrobials against *Mycoplasma gallisepticum* and *Mycoplasma synoviae* by the micro-broth method, and comparison with a commercially-prepared test system. *Avian Pathol*. 23:105–115.
49. Bradbury, J.M., O.M. Abdul-Wahab, C.A. Yavari, J.P. Dupiellet, and J.M. Bove. 1993. *Mycoplasma imitans* sp. nov. is related to *Mycoplasma gallisepticum* and found in birds. *Int J Syst Bacteriol*. 43:721–728.
50. Bradley, L.D., D.B. Snyder, and R.A. Van Deusen. 1988. Identification of species-specific and interspecies-specific polypeptides of *Mycoplasma gallisepticum* and *Mycoplasma synoviae*. *Amer J Vet Res*. 49:511–515.
51. Branton, S.L., and J.W. Deaton. 1985. Egg production, egg weight, eggshell strength, and mortality in three strains of commercial layers vaccinated with F strain *Mycoplasma gallisepticum*. *Avian Dis*. 29:832–837.
52. Branton, S.L., J.D. May, and S.H. Kleven. 1985. Swab absorbability—effect on *Mycoplasma gallisepticum* isolation. *Poult Sci*. 64:2087–2089.
53. Branton, S.L., B.D. Lott, F.W. Austin, and G.T. Pharr. 1997. Effect of drinking water containing ammonium chloride or sodium bicarbonate on *Mycoplasma gallisepticum* isolation in experimentally infected broiler chickens. *Avian Dis*. 41:930–934.
54. Branton, S.L., B.D. Lott, J.W. Deaton, J.M. Hardin, and W.R. Maslin. 1988. F strain *Mycoplasma gallisepticum* vaccination of post-production-peak commercial Leghorns and its effect on egg and eggshell quality. *Avian Dis*. 32:304–307.
55. Branton, S.L., B.D. Lott, J.D. May, W.R. Maslin, C.R. Boyle, and G.T. Pharr. 1997. The effects of F strain *Mycoplasma gallisepticum, Mycoplasma synoviae*, and the dual infection in

commercial layer hens over a 44-week laying cycle when challenged before beginning of lay. I. Egg production and selected egg quality parameters. *Avian Dis*. 41:832–837.
56. Branton, S.L., S.A. Leigh, W.B. Roush, J.L. Purswell, H.A. Olanrewaju, and S.D. Collier. 2008. Effect of selected water temperatures used in *Mycoplasma gallisepticum* vaccine reconstitution on titer at selected time intervals. *Avian Dis*. 52:291–296.
57. Branton, S.L., S.A. Leigh, J.L. Purswell, J.D. Evans, S.D. Collier, H.A. Olanrewaju, and G.T. Pharr. 2010. A chronicle of serologic response in commercial layer chickens to vaccination with commercial F strain *Mycoplasma gallisepticum* vaccine. *Avian Dis*. 54:1108–1111.
58. Branton, S.L., B.D. Lott, J.D. May, W.R. Maslin, G.T. Pharr, S.D. Bearson, S.D. Collier, and D.L. Boykin. 2000. The effects of ts-11 strain *Mycoplasma gallisepticum* vaccination in commercial layers on egg production and selected egg quality parameters. *Avian Dis*. 44:618–623.
59. Branton, S.L., S.M. Bearson, B. Bearson, B.D. Lott, W.R. Maslin, S.D. Collier, G.T. Pharr, and D.L. Boykin. 2002. The effects of 6/85 live *Mycoplasma gallisepticum* vaccine in commercial layer hens over a 43-week laying cycle on egg production, selected egg quality parameters, and egg size distribution when challenged before beginning of lay. *Avian Dis*. 46:423–428.
60. Brown, D.R., R.F. Whitcomb, and J.M. Bradbury. 2007. Revised minimal standards for description of new species of the class Mollicutes (division Tenericutes). *Int J Syst Evol Microbiol*. 57: 2703–2719.
61. Brown, J.E., S.L. Branton, and J.D. May. 1997. Epitope diversity of F strain *Mycoplasma gallisepticum* detected by flow cytometry. *Avian Dis*. 41:289–295.
62. Brown, M.B., and G.D. Butcher. 1991. *Mycoplasma gallisepticum* as a model to assess efficacy of inhalant therapy in budgerigars (*Melopsittacus undulatus*). *Avian Dis*. 35:834–839.
63. Brown, M.B., M.L. Stoll, A.E. Scasserra, and G.D. Butcher. 1991. Detection of antibodies to *Mycoplasma gallisepticum* in egg yolk versus serum samples. *J Clin Microbiol*. 29:2901–2903.
64. Buntz, B., J.M. Bradbury, A. Vuillaume, and D. Rousselot-Paillet. 1986. Isolation of *Mycoplasma gallisepticum* from geese. *Avian Pathol*. 15:615–617.
65. Burnham, M.R., S.L. Branton, E.D. Peebles, B.D. Lott, and P.D. Gerard. 2002. Effects of F-strain *Mycoplasma gallisepticum* inoculation at twelve weeks of age on performance and egg characteristics of commercial egg-laying hens. *Poult Sci*. 81:1478–1485.
66. Burnham, M.R., E.D. Peebles, S.L. Branton, R.L. Walzem, and P.D. Gerard. 2003. Effects of F-strain *Mycoplasma gallisepticum* inoculation on serum very low density lipoprotein diameter and fractionation of cholesterol among lipoproteins in commercial egg-laying hens. *Poult Sci*. 82:1630–1636.
67. Burnham, M.R., E.D. Peebles, S.L. Branton, M.S. Jones, and P.D. Gerard. 2003. Effects of F-strain *Mycoplasma gallisepticum* inoculation at twelve weeks of age on the blood characteristics of commercial egg laying hens. *Poult Sci*. 82:1397–1402.
68. Burnham, M.R., E.D. Peebles, S.L. Branton, D.V. Maurice, and P.D. Gerard. 2003. Effects of F-strain *Mycoplasma gallisepticum* inoculation at twelve weeks of age on egg yolk composition in commercial egg laying hens. *Poult Sci*. 82:577–584.
69. Burnham, M.R., E.D. Peebles, S.L. Branton, M.S. Jones, P.D. Gerard, and W.R. Maslin. 2002. Effects of F-strain *Mycoplasma gallisepticu*m inoculation at twelve weeks of age on digestive and reproductive organ characteristics of commercial egg laying hens. *Poult Sci*. 81:1884–1891.
70. Buyuktanir, O., T. Yildirim, C. Yakicier, O. Genc, and N. Yurdusev. 2008. A recombinant PvpA protein-based diagnostic prototype for rapid screening of chicken *Mycoplasma gallisepticum* infections. *Vet Microbiol*. 129:139–149.
71. Callison, S.A., S.M. Riblet, S. Sun, N. Ikuta, D. Hilt, V. Leiting, S.H. Kleven, D.L. Suarez, and M. Garcia. 2006. Development and validation of a real-time Taqman polymerase chain reaction assay for the detection of *Mycoplasma gallisepticum* in naturally infected birds. *Avian Dis*. 50:537–544.
72. Carli, K.T., and A. Eyigor. 2003. Real-time polymerase chain reaction for *Mycoplasma gallisepticum* in chicken trachea. *Avian Dis*. 47:712–717.
73. Carpenter, T.E., E.T. Mallinson, K.F. Miller, R.F. Gentry, and L.D. Schwartz. 1981. Vaccination with F-strain *Mycoplasma gallisepticum* to reduce production losses in layer chickens. *Avian Dis*. 25:404–409.
74. Carson, J.L., P.C. Hu, and A.M. Collier. 1992. 4. Cell structural and functional elements. In: *Mycoplsamas: Molecular Biology and Pathogenesis*. J. Maniloff, R.N. McElhaney, L.R. Finch, and J. Baseman, eds. American Society for Microbiology, Washington, D.C. 63–72.
75. Chandiramani, N.K., H. Van Roekel, and O.M. Olesiuk. 1966. Viability studies with *Mycoplasma gallisepticum* under different environmental conditions. *Poult Sci*. 45:1029–1044.
76. Charleston, B., J.J. Gate, I.A. Aitken, and L. Reeve Johnson. 1998. Assessment of the efficacy of tilmicosin as a treatment for *Mycoplasma gallisepticum* infections in chickens. *Avian Pathol*. 27:190–195.
77. Charlier, G., G. Meulemans, and P. Halen. 1981. [Microscopic and ultramicroscopic lesions from experimental mycoplasma infection in respiratory tract of chickens. Possible difference between pathogenic and non pathogenic strains (author's translation)]. *Ann Rech Vet*. 12:183–191.
78. Charlton, B.R., A.A. Bickford, R.P. Chin, and R.L. Walker. 1999. Randomly amplified polymorphic DNA (RAPD) analysis of *Mycoplasma gallisepticum* isolates from turkeys from the central valley of California. *J Vet Diagn Invest*. 11:408–415.
79. Charlton, B.R., A.A. Bickford, R.L. Walker, and R. Yamamoto. 1999. Complementary randomly amplified polymorphic DNA (RAPD) analysis patterns and primer sets to differentiate *Mycoplasma gallisepticum* strains. *J Vet Diagn Invest*. 11: 158–161.
80. Chen, H., S. Yu, X. Shen, D. Chen, X. Qiu, C. Song, and C. Ding. 2011. The *Mycoplasma gallisepticum* alpha-enolase is cell surface-exposed and mediates adherence by binding to chicken plasminogen. *Microb Pathog*. 51:285–290.
81. Cherry, J.J., D.H. Ley, and S. Altizer. 2006. Genotypic analyses of *Mycoplasma gallisepticum* isolates from songbirds by random amplification of polymorphic DNA andamplified-fragment length polymorphism. *J Wildl Dis*. 42:421–428.
82. Chhabra, P.C., and M.C. Goel. 1981. Immunological response of chickens to *Mycoplasma gallisepticum* infection. *Avian Dis*. 25: 279–293.
83. Chin, R.P., B.M. Daft, C.U. Meteyer, and R. Yamamoto. 1991. Meningoencephalitis in commercial meat turkeys associated with *Mycoplasma gallisepticum*. *Avian Dis*. 35:986–993.
84. Christensen, N.H., C.A. Yavari, A.J. McBain, and J.M. Bradbury. 1994. Investigations into the survival of *Mycoplasma gallisepticum*, *Mycoplasma synoviae* and *Mycoplasma iowae* on materials found in the poultry house environment. *Avian Pathol*. 23: 127–143.

85. Cizelj, I., R.L. Bercic, D. Dusanic, M. Narat, J. Kos, P. Dovc, and D. Bencina. 2011. *Mycoplasma gallisepticum* and *Mycoplasma synoviae* express a cysteine protease CysP, which can cleave chicken IgG into Fab and Fc. *Microbiol*. 157: 362–372.
86. Clyde, W.A., Jr. 1983. Growth inhibition tests. In: *Methods in Mycoplasmology*, vol. 1. S. Razin and J.G. Tully, eds. Academic Press, New York. 405–410.
87. Cobb, D.T., D.H. Ley, and P.D. Doerr. 1992. Isolation of *Mycoplasma gallopavonis* from free-ranging wild turkeys in coastal North Carolina seropositive and culture-negative for *Mycoplasma gallisepticum*. *J Wildl Dis* 28:105–109.
88. Collett, S.R., D.K. Thomson, D. York, and S.P. Bisschop. 2005. Floor pen study to evaluate the serological response of broiler breeders after vaccination with ts-11 strain *Mycoplasma gallisepticum* vaccine. *Avian Dis*. 49:133–137.
89. Cookson, K.C., and H.L. Shivaprasad. 1994. *Mycoplasma gallisepticum* infection in chukar partridges, pheasants, and peafowl. *Avian Dis*. 38:914–921.
90. Cordy, D.R., and H.E. Adler. 1957. The pathogenesis of the encephalitis in turkey poults produced by a neurotropic pleuropneumonia-like organism. *Avian Dis*. 1:235–245.
91. Cummings, T.S., and S.H. Kleven. 1986. Evaluation of protection against *Mycoplasma gallisepticum* infection in chickens vaccinated with the F strain of *M. gallisepticum*. *Avian Dis*. 30:169–171.
92. Cummings, T.S., S.H. Kleven, and J. Brown. 1986. Effect of medicated feed on tracheal infection and population of *Mycoplasma gallisepticum* in chickens. *Avian Dis*. 30: 580–584.
93. Cummins, D.R., and D.L. Reynolds. 1990. Use of an avidin-biotin enhanced dot-immunobinding assay to detect antibodies for avian mycoplasma in sera from Iowa market turkeys. *Avian Dis*. 34:321–328.
94. Cummins, D.R., D.L. Reynolds, and K.R. Rhoades. 1990. An avidin-biotin enhanced dot-immunobinding assay for the detection of *Mycoplasma gallisepticum* and *M. synoviae* serum antibodies in chickens. *Avian Dis*. 34:36–43.
95. Cunningham, D.L., and N.O. Olson. 1978. *Mycoplasma gallisepticum* vaccination of birds in a multiple age laying flock. *Poult Sci*. 15:1131–1132.
96. Czifra, G., B. Sundquist, T. Tuboly, and L. Stipkovits. 1993. Evaluation of a monoclonal blocking enzyme-linked immunosorbent assay for the detection of *Mycoplasma gallisepticum*-specific antibodies. *Avian Dis*. 37:680–688.
97. Czifra, G., S.H. Kleven, B. Engstrom, and L. Stipkovits. 1995. Detection of specific antibodies directed against a consistently expressed surface antigen of *Mycoplasma gallisepticum* using a monoclonal blocking enzyme-linked immunosorbent assay. *Avian Dis*. 39:28–31.
98. Czifra, G., B.G. Sundquist, U. Hellman, and L. Stipkovits. 2000. Protective effect of two *Mycoplasma gallisepticum* protein fractions affinity purified with monoclonal antibodies. *Avian Pathol*. 29:343–351.
99. Dallo, S.F., and J.B. Baseman. 1990. Cross-hybridization between the cytadhesin genes of *Mycoplasma pneumoniae* and *Mycoplasma genitalium* and genomic DNA of *Mycoplasma gallisepticum*. *Microbial Pathog*. 8:371–375.
100. Davidson, W.R., V.F. Nettles, C.E. Couvillion, and H.W. Yoder, Jr. 1982. Infectious sinusitis in wild turkeys. *Avian Dis*. 26: 402–405.
101. Delaplane, J.P., and H.O. Stuart. 1943. The propagation of a virus in embryonated chicken eggs causing a chronic respiratory disease of chickens. *Amer J Vet Res*. 4:325–332.
102. Dhondt, A.A., D.L. Tessaglia, and R.L. Slothower. 1998. Epidemic mycoplasmal conjunctivitis in house finches from eastern North America. *J Wildl Dis*. 34:265–280.
103. Dhondt, A.A., K.V. Dhondt, and B.V. McCleery. 2008. Comparative infectiousness of three passerine bird species after experimental inoculation with *Mycoplasma gallisepticum*. *Avian Pathol*. 37:635–640.
104. Dhondt, A.A., K.V. Dhondt, D.M. Hawley, and C.S. Jennelle. 2007. Experimental evidence for transmission of *Mycoplasma gallisepticum* in house finches by fomites. *Avian Pathol*. 36: 205–208.
105. Dhondt, A.A., S. Altizer, E.G. Cooch, A.K. Davis, A. Dobson, M.J. Driscoll, B.K. Hartup, D.M. Hawley, W.M. Hochachka, P.R. Hosseini, C.S. Jennelle, G.V. Kollias, D.H. Ley, E.C. Swarthout, and K.V. Sydenstricker. 2005. Dynamics of a novel pathogen in an avian host: Mycoplasmal conjunctivitis in house finches. *Acta Trop*. 94:77–93.
106. Dhondt, K.V., A.A. Dhondt, and D.H. Ley. 2007. Effects of route of inoculation on *Mycoplasma gallisepticum* infection in captive house finches. *Avian Pathol*. 36:475–479.
107. Dickinson, E.M., and W.R. Hinshaw. 1938. Treatment of infectious sinusitis of turkeys with argyrol and silver nitrate. *J Am Vet Med Assoc*. 93:151–156.
108. Dingfelder, R.S., D.H. Ley, J.M. McLaren, and C. Brownie. 1991. Experimental infection of turkeys with *Mycoplasma gallisepticum* of low virulence, transmissibility, and immunogenicity. *Avian Dis*. 35:910–919.
109. Dodd, S. 1905. Epizootic pneumo-enteritis of the turkey. *J Comp Pathol Ther*. 18:239–245.
110. Dohms, J.E., L.L. Hnatow, P. Whetzel, R. Morgan, and C.L. Keeler, Jr. 1993. Identification of the putative cytadhesin gene of *Mycoplasma gallisepticum* and its use as a DNA probe. *Avian Dis*. 37:380–388.
111. Domermuth, C.H., W.B. Gross, and R.T. Dubose. 1967. Mycoplasmal salpingitis of chickens and turkeys. *Avian Dis*. 11:393–398.
112. Duckworth, R.A., A.V. Badyaev, K.L. Farmer, G.E. Hill, and S.R. Roberts. 2003. First case of mycoplasmosis in the native range of the house finch (*Carpodacus mexicanus*). *Auk*. 120:528–530.
113. Dykstra, M.J., S. Levisohn, O.J. Fletcher, and S.H. Kleven. 1985. Evaluation of cytopathologic changes induced in chicken tracheal epithelium by *Mycoplasma gallisepticum in vivo* and *in vitro*. *Amer J Vet Res*. 46:116–122.
114. Edward, D.G., and A.D. Kanarek. 1960. Organisms of the pleuropneumonia group of avian origin: their classification into specie. *Ann NY Acad Sci*. 79:696–702.
115. El Gazzar, M., V.A. Laibinis, and N. Ferguson-Noel. 2011. Characterization of a ts-11–like *Mycoplasma gallisepticum* isolate from commercial broiler chickens. *Avian Dis*. 55: 569–574.
116. El Sayed, S.A., N.K. Chandiramani, and D.N. Garg. 1981. Isolation and characterization of Mycoplasma and Acholeplasma from apparently healthy and diseased (infectious sinusitis) turkeys. *Microbiol Immunol*. 25:639–646.
117. El Shater, S.A.A. 1996. Mycoplasma infection in greater flamingo, grey Chinese goose and white pelican. *Vet Med J Giza*. 44:31–36.

118. Elfaki, M.G., G.O. Ware, S.H. Kleven, and W.L. Ragland. 1992. An enzyme-linked immunosorbent assay for the detection of specific IgG antibody to *Mycoplasma gallisepticum* in sera and tracheobronchial washes. *J Immunoassay*. 13:97–126.
119. Elfaki, M.G., S.H. Kleven, L.H. Jin, and W.L. Ragland. 1992. Sequential intracoelomic and intrabursal immunization of chickens with inactivated *Mycoplasma gallisepticum* bacterin and iota carrageenan adjuvant. *Vaccine*. 10:655–662.
120. Elfaki, M.G., S.H. Kleven, L.H. Jin, and W.L. Ragland. 1993. Protection against airsacculitis with sequential systemic and local immunization of chickens using killed *Mycoplasma gallisepticum* bacterin with iota carrageenan adjuvant. *Vaccine*. 11:311–317.
121. Evans, J.D., S.L. Branton, and S.A. Leigh. 2009. Effect of dosage and vaccination route on transmission of a live attenuated *Mycoplasma gallisepticum* vaccine: a broiler model. *Avian Dis*. 53:416–420.
122. Evans, J.D., S.A. Leigh, S.L. Branton, and S.D. Collier. 2007. Effects of increased dosages of the *Mycoplasma gallisepticum* vaccine MYCOVAC-L in layer chickens subsequently challenged with virulent *M. gallisepticum*: egg production and serologic response. *Avian Dis*. 51:912–917.
123. Evans, R.D., and Y.S. Hafez. 1992. Evaluation of a *Mycoplasma gallisepticum* strain exhibiting reduced virulence for prevention and control of poultry mycoplasmosis. *Avian Dis*. 36:197–201.
124. Evans, R.D., Y.S. Hafez, and C.S. Schreurs. 1992. Demonstration of the genetic stability of a *Mycoplasma gallisepticum* strain following in vivo passage. *Avian Dis*. 36:554–560.
125. Ewing, M.L., S.H. Kleven, and M.B. Brown. 1996. Comparison of enzyme-linked immunosorbent assay and hemagglutination-inhibition for detection of antibody to *Mycoplasma gallisepticum* in commercial broiler, fair and exhibition, and experimentally infected birds. *Avian Dis*. 40:13–22.
126. Fabricant, J. 1958. A re-evaluation of the use of media for the isolation of pleuropneumonia-like organisms of avian origin. *Avian Dis*. 2:409–417.
127. Fabricant, J., and P.P. Levine. 1962. Experimental production of complicated chronic respiratory disease infection ("air sac" disease). *Avian Dis*. 6:13–23.
128. Fan, H.H., S.H. Kleven, and M.W. Jackwood. 1995. Application of polymerase chain reaction with arbitrary primers to strain identification of *Mycoplasma gallisepticum*. *Avian Dis*. 39: 729–735.
129. Fan, H.H., S.H. Kleven, M.W. Jackwood, K.E. Johansson, B. Pettersson, and S. Levisohn. 1995. Species identification of avian mycoplasmas by polymerase chain reaction and restriction fragment length polymorphism analysis. *Avian Dis*. 39: 398–407.
130. Farmer, K.L., G.E. Hill, and S.R. Roberts. 2005. Susceptibility of wild songbirds to the house finch strain of *Mycoplasma gallisepticum*. *J Wildl Dis*. 41:317–325.
131. Feberwee, A., D.R. Mekkes, J.J. de Wit, E.G. Hartman, and A. Pijpers. 2005. Comparison of culture, PCR, and different serologic tests for detection of *Mycoplasma gallisepticum* and *Mycoplasma synoviae* infections. *Avian Dis*. 49:260–268.
132. Feberwee, A., J.R. Dijkstra, T.E. von Banniseht-Wysmuller, A.L. Gielkens, and J.A. Wagenaar. 2005. Genotyping of *Mycoplasma gallisepticum* and *M. synoviae* by Amplified Fragment Length Polymorphism (AFLP) analysis and digitalized Random Amplified Polymorphic DNA (RAPD) analysis. *Vet Microbiol*. 111:125–131.
133. Feberwee, A., T. von Banniseht-Wysmuller, J.C. Vernooij, A.L. Gielkens, and J.A. Stegeman. 2006. The effect of vaccination with a bacterin on the horizontal transmission of *Mycoplasma gallisepticum*. *Avian Pathol*. 35:35–37.
134. Feberwee, A., D.R. Mekkes, D. Klinkenberg, J.C. Vernooij, A.L. Gielkens, and J.A. Stegeman. 2005. An experimental model to quantify horizontal transmission of *Mycoplasma gallisepticum*. *Avian Pathol*. 34:355–361.
135. Feberwee, A., W.J. Landman, T. von Banniseht-Wysmuller, D. Klinkenberg, J.C. Vernooij, A.L. Gielkens, and J.A. Stegeman. 2006. The effect of a live vaccine on the horizontal transmission of *Mycoplasma gallisepticum*. *Avian Pathol*. 35:359–366.
136. Ferguson, N.M., V.A. Leiting, and S.H. Klevena. 2004. Safety and efficacy of the avirulent *Mycoplasma gallisepticum* strain K5054 as a live vaccine in poultry. *Avian Dis*. 48:91–99.
137. Ferguson, N.M., D. Hermes, V.A. Leiting, and S.H. Kleven. 2003. Characterization of a naturally occurring infection of a *Mycoplasma gallisepticum* house finch-like strain in turkey breeders. *Avian Dis*. 47:523–530.
138. Ferguson, N.M., D. Hepp, S. Sun, N. Ikuta, S. Levisohn, S.H. Kleven, and M. Garcia. 2005. Use of molecular diversity of *Mycoplasma gallisepticum* by gene-targeted sequencing (GTS) and random amplified polymorphic DNA (RAPD) analysis for epidemiological studies. *Microbiol*. 151:1883–1893.
139. Fernandez, C., J.G. Mattsson, G. Bolske, S. Levisohn, and K.E. Johansson. 1993. Species-specific oligonucleotide probes complementary to 16SrRNA of *Mycoplasma gallisepticum* and *Mycoplasma synoviae*. *Res Vet Sci*. 55:130–136.
140. Fischer, J.R., D.E. Stallknecht, P. Luttrell, A.A. Dhondt, and K.A. Converse. 1997. Mycoplasmal conjunctivitis in wild songbirds: the spread of a new contagious disease in a mobile host population. *Emerg Infect Dis*. 3:69–72.
141. Forrester, C.A., J.M. Bradbury, C.M. Dare, R.J. Domangue, H. Windsor, J.B. Tasker, and A.P. Mockett. 2011. *Mycoplasma gallisepticum* in pheasants and the efficacy of tylvalosin to treat the disease. *Avian Pathol*. 40:581–586.
142. Forsyth, M.H., M.E. Tourtellotte, and S.J. Geary. 1992. Localization of an immunodominant 64 kDa lipoprotein (LP 64) in the membrane of *Mycoplasma gallisepticum* and its role in cytadherence. *Mol Microbiol*. 6:2099–2106.
143. Forsyth, M.H., J.G. Tully, T.S. Gorton, L. Hinckley, S. Frasca, Jr., H.J. van Kruiningen, and S.J. Geary. 1996. *Mycoplasma sturni* sp. nov., from the conjunctiva of a European starling (*Sturnus vulgaris*). *Int J Syst Bacteriol*. 46:716–719.
144. Frasca, S., Jr., L. Hinckley, M.H. Forsyth, T.S. Gorton, S.J. Geary, and H.J. Van Kruiningen. 1997. Mycoplasmal conjunctivitis in a European starling. *J Wildl Dis*. 33:336–339.
145. Frey, M.C., R.P. Hanson, and D.P. Anderson. 1968. A medium for the isolation of avian Mycoplasma. *Amer J Vet Res*. 29:2163–2171.
146. Fritz, B.A., C.B. Thomas, and T.M. Yuill. 1992. Serological and microbial survey of *Mycoplasma gallisepticum* in wild turkeys (*Meleagris gallopavo*) from six western states. *J Wildl Dis*. 28: 10–20.
147. Ganapathy, K., and J.M. Bradbury. 1998. Pathogenicity of *Mycoplasma gallisepticum* and *Mycoplasma imitans* in red-legged partridges (*Alectoris rufa*). *Avian Pathol*. 27:455–463.
148. Ganapathy, K., and J.M. Bradbury. 2003. Effects of cyclosporin A on the immune responses and pathogenesis of a virulent strain of *Mycoplasma gallisepticum* in chickens. *Avian Pathol*. 32:495–502.

149. Garcia, M., and S.H. Kleven. 1994. Expression of *Mycoplasma gallisepticum* F-strain surface epitope. *Avian Dis*. 38:494–500.
150. Garcia, M., M.G. Elfaki, and S.H. Kleven. 1994. Analysis of the variability in expression of *Mycoplasma gallisepticum* surface antigens. *Vet Microbiol*. 42:147–158.
151. Garcia, M., M.W. Jackwood, S. Levisohn, and S.H. Kleven. 1995. Detection of *Mycoplasma gallisepticum, M. synoviae*, and *M. iowae* by multi-species polymerase chain reaction and restriction fragment length polymorphism. *Avian Dis*. 39: 606–616.
152. Garcia, M., N. Ikuta, S. Levisohn, and S.H. Kleven. 2005. Evaluation and comparison of various PCR methods for detection of *Mycoplasma gallisepticum* infection in chickens. *Avian Dis*. 49:125–132.
153. Garcia, M., M.W. Jackwood, M. Head, S. Levisohn, and S.H. Kleven. 1996. Use of species-specific oligonucleotide probes to detect *Mycoplasma gallisepticum, M. synoviae*, and *M. iowae* PCR amplification products. *J Vet Diagn Invest*. 8:56–63.
154. Gardella, R.S., R.A. Del Giudice, and J.G. Tully. 1983. Immunofluorescence. In: *Methods in Mycoplasmology*, Vol. I. S. Razin and J.G. Tully, eds. Academic Press, New York. 431–439.
155. Gates, A.E., S. Frasca, A. Nyaoke, T.S. Gorton, L.K. Silbart, and S.J. Geary. 2008. Comparative assessment of a metabolically attenuated *Mycoplasma gallisepticum* mutant as a live vaccine for the prevention of avian respiratory mycoplasmosis. *Vaccine*. 26:2010–2019.
156. Gaunson, J.E., C.J. Philip, K.G. Whithear, and G.F. Browning. 2000. Lymphocytic infiltration in the chicken trachea in response to *Mycoplasma gallisepticum* infection. *Microbiology Reading*. 146:1223–1229.
157. Gaunson, J.E., C.J. Philip, K.G. Whithear, and G.F. Browning. 2006. The cellular immune response in the tracheal mucosa to *Mycoplasma gallisepticum* in vaccinated and unvaccinated chickens in the acute and chronic stages of disease. *Vaccine*. 24:2627–2633.
158. Gaunson, J.E., C.J. Philip, K.G. Whithear, and G.F. Browning. 2006. Age related differences in the immune response to vaccination and infection with *Mycoplasma gallisepticum*. *Vaccine*. 24:1687–1692.
159. Gautier-Bouchardon, A.V., A.K. Reinhardt, M. Kobisch, and I. Kempf. 2002. *In vitro* development of resistance to enrofloxacin, erythromycin, tylosin, tiamulin and oxytetracycline in *Mycoplasma gallisepticum*, *Mycoplasma iowae and Mycoplasma synoviae. Vet Microbiol*. 88:47–58.
160. Geary, S.J. 1987. Development of a biotinylated probe for the rapid detection of *Mycoplasma gallisepticum*. *Isr J Med Sci*. 23:747–751.
161. Geary, S.J., M.H. Forsyth, S. Aboul Saoud, G. Wang, D.E. Berg, and C.M. Berg. 1994. *Mycoplasma gallisepticum* strain differentiation by arbitrary primer PCR (RAPD) fingerprinting. *Mol Cell Probes*. 8:311–316.
162. Gerchman, I., I. Lysnyansky, S. Perk, and S. Levisohn. 2008. *In vitro* susceptibilities to fluoroquinolones in current and archived *Mycoplasma gallisepticum* and *Mycoplasma synoviae* isolates from meat-type turkeys. *Vet Microbiol*. 131:266–276.
163. Gerchman, I., S. Levisohn, I. Mikula, L. Manso-Silvan, and I. Lysnyansky. 2011. Characterization of *in vivo*-acquired resistance to macrolides of *Mycoplasma gallisepticum* strains isolated from poultry. *Vet Res*. 42:90.
164. Gharaibeh, S., and A. Hailat. 2011. *Mycoplasma gallisepticum* experimental infection and tissue distribution in chickens, sparrows and pigeons. *Avian Pathol*. 40:349–354.
165. Gharaibeh, S., and M. Al-Rashdan. 2011. Change in antimicrobial susceptibility of *Mycoplasma gallisepticum* field isolates. *Vet Microbiol*. 150:379–383.
166. Gharaibeh, S., V. Laibinis, R. Wooten, L. Stabler, and N. Ferguson-Noel. 2011. Molecular characterization of *Mycoplasma gallisepticum* isolates from Jordan. *Avian Dis*. 55: 212–216.
167. Ghazikhanian, G.Y., R. Yamamoto, R.H. McCapes, W.M. Dungan, and H.B. Ortmayer. 1980. Combination dip and injection of turkey eggs with antibiotics to eliminate *Mycoplasma meleagridis* infection from a primary breeding stock. *Avian Dis*. 24:57–70.
168. Glew, M.D., P.F. Markham, G.F. Browning, and I.D. Walker. 1995. Expression studies on four members of the pMGA multigene family in *Mycoplasma gallisepticum* S6. *Microbiol*. 141:3005–3014.
169. Glew, M.D., G.F. Browning, P.F. Markham, and I.D. Walker. 2000. pMGA phenotypic variation in *Mycoplasma gallisepticum* occurs *in vivo* and is mediated by trinucleotide repeat length variation. *Infect Immun*. 68:6027–6033.
170. Glew, M.D., N. Baseggio, P.F. Markham, G.F. Browning, and I.D. Walker. 1998. Expression of the pMGA genes of *Mycoplasma gallisepticum* is controlled by variation in the GAA trinucleotide repeat lengths within the 5′ noncoding regions. *Infect Immun*. 66:5833–5841.
171. Glisson, J.R., and S.H. Kleven. 1984. *Mycoplasma gallisepticum* vaccination: effects on egg transmission and egg production. *Avian Dis*. 28:406–415.
172. Glisson, J.R., and S.H. Kleven. 1985. *Mycoplasma gallisepticum* vaccination: further studies on egg transmission and egg production. *Avian Dis*. 29:408–415.
173. Glisson, J.R., J.F. Dawe, and S.H. Kleven. 1984. The effect of oil-emulsion vaccines on the occurrence of nonspecific plate agglutination reactions for *Mycoplasma gallisepticum* and *M. synoviae*. *Avian Dis*. 28:397–405.
174. Glisson, J.R., I.H. Cheng, J. Brown, and R.G. Stewart. 1989. The effect of oxytetracycline on the severity of airsacculitis in chickens infected with *Mycoplasma gallisepticum*. *Avian Dis*. 33:750–752.
175. Goh, M.S., T.S. Gorton, M.H. Forsyth, K.E. Troy, and S.J. Geary. 1998. Molecular and biochemical analysis of a 105 kDa *Mycoplasma gallisepticum* cytadhesin (GapA). *Microbiol*. 144: 2971–2978.
176. Goren, E. 1978. [Mycoplasma synoviae control. I. Studies on the thermal sensitivity of pathogenic avian mycoplasmas (*Mycoplasma synoviae, Mycoplasma gallisepicum* and *Mycoplasma meleagridis*)]. *Tijdschrift voor Diergeneeskunde*. 103:1217–1230.
177. Gorton, T.S., and S.J. Geary. 1997. Antibody-mediated selection of a *Mycoplasma gallisepticum* phenotype expressing variable proteins. *FEMS Microbiol Lett*. 155:31–38.
178. Grodio, J.L., E.L. Buckles, and K.A. Schat. 2009. Production of house finch (*Carpodacus mexicanus*) IgA specific anti-sera and its application in immunohistochemistry and in ELISA for detection of *Mycoplasma gallisepticum*-specific IgA. *Vet Immunol Immunopathol*. 132:288–294.
179. Grodio, J.L., K.V. Dhondt, P.H. O'Connell, and K.A. Schat. 2008. Detection and quantification of *Mycoplasma gallisepticum* genome load in conjunctival samples of experimentally

infected house finches (*Carpodacus mexicanus*) using real-time polymerase chain reaction. *Avian Pathol*. 37:385–391.
180. Grodio, J.L., D.M. Hawley, E.E. Osnas, D.H. Ley, K.V. Dhondt, A.A. Dhondt, and K.A. Schat. 2012. Pathogenicity and immunogenicity of three *Mycoplasma gallisepticum* isolates in house finches (*Carpodacus mexicanus*). *Vet Microbiol*. 155(1):53–61.
181. Gross, W.B. 1961. The development of "air sac disease." *Avian Dis*. 5:431–439.
182. Gross, W.B. 1990. Factors affecting the development of respiratory disease complex in chickens. *Avian Dis*. 34:607–610.
183. Hagen, C.A., S.S. Crupper, R.D. Applegate, and R.J. Robel. 2002. Prevalence of mycoplasma antibodies in lesser prairie-chicken sera. *Avian Dis*. 46:708–712.
184. Hall, C.F., A.I. Flowers, and L.C. Grumbles. 1963. Dipping of hatching eggs for control of *Mycoplasma gallisepticum*. *Avian Dis*. 7:178–183.
185. Hannan, P.C. 2000. Guidelines and recommendations for antimicrobial minimum inhibitory concentration (MIC) testing against veterinary mycoplasma species. *International Research Programme on Comparative Mycoplasmology. Vet Res*. 31:373–395.
186. Harasawa, R., D.G. Pitcher, A.S. Ramirez, and J.M. Bradbury. 2004. A putative transposase gene in the 16S-23S rRNA intergenic spacer region of *Mycoplasma imitans*. *Microbiol*. 150:1023–1029.
187. Hartup, B.K., G.V. Kollias, and D.H. Ley. 2000. Mycoplasmal conjunctivitis in songbirds from New York. *J Wildl Dis*. 36: 257–264.
188. Hartup, B.K., J.M. Bickal, A.A. Dhondt, D.H. Ley, and G.V. Kollias. 2001. Dynamics of conjunctivitis and *Mycoplasma gallisepticum* infections in House Finches. *Auk*. 118:327.
189. Hartup, B.K., A.A. Dhondt, K.V. Sydenstricker, W.M. Hochachka, and G.V. Kollias. 2001. Host range and dynamics of mycoplasmal conjunctivitis among birds in North America. *J Wildl Dis*. 37:72–81.
190. Hatchel, J.M., R.S. Balish, M.L. Duley, and M.F. Balish. 2006. Ultrastructure and gliding motility of *Mycoplasma amphoriforme*, a possible human respiratory pathogen. *Microbiol*. 152:2181–2189.
191. Hawley, D.M., J. Grodio, S. Frasca, L. Kirkpatrick, and D.H. Ley. 2011. Experimental infection of domestic canaries (*Serinus canaria domestica*) with *Mycoplasma gallisepticum*: a new model system for a wildlife disease. *Avian Pathol*. 40:321–327.
192. Higgins, P.A., and K.G. Whithear. 1986. Detection and differentiation of *Mycoplasma gallisepticum* and *M. synoviae* antibodies in chicken serum using enzyme-linked immunosorbent assay. *Avian Dis*. 30:160–168.
193. Hildebrand, D.G., D.E. Page, and J.R. Berg. 1983. *Mycoplasma gallisepticum* (MG)—laboratory and field studies evaluating the safety and efficacy of an inactivated MG bacterin. *Avian Dis*. 27:792–802.
194. Hitchner, S.B. 1949. The pathology of infectious sinusitis of turkeys. *Poult Sci*. 28:106–118.
195. Hnatow, L.L., C.L. Keeler, Jr., L.L. Tessmer, K. Czymmek, and J.E. Dohms. 1998. Characterization of MGC2, a *Mycoplasma gallisepticum* cytadhesin with homology to the *Mycoplasma pneumoniae* 30-kilodalton protein P30 and *Mycoplasma genitalium* P32. *Infect Immun*. 66:3436–3442.
196. Hod, I., Y. Yegana, A. Herz, and S. Levinsohn. 1982. Early detection of tracheal damage in chickens by scanning electron microscopy. *Avian Dis*. 26:450–457.
197. Holt, J.G., N.R. Kreig, P.H.A. Sneath, J.T. Staley, and S.T. Williams. 1994. The Mycoplasmas (or Mollicutes): Cell wall-less bacteria. In: *Bergey's Manual of Determinative Bacteriology*, 9th ed., W.R. Hensyl, ed. Williams and Wilkins, Baltimore. 705–717.
198. Hong, Y., M. Garcia, S. Levisohn, P. Savelkoul, V. Leiting, I. Lysnyansky, D.H. Ley, and S.H. Kleven. 2005. Differentiation of *Mycoplasma gallisepticum* strains using amplified fragment length polymorphism and other DNA-based typing methods. *Avian Dis*. 49:43–49.
199. Hopkins, B.A., J.K. Skeeles, G.E. Houghten, D. Slagle, and K. Gardner. 1990. A survey of infectious diseases in wild turkeys (*Meleagridis gallopavo silvestris*) from Arkansas. *J Wildl Dis*. 26:468–472.
200. Hudson, P., T.S. Gorton, L. Papazisi, K. Cecchini, S. Frasca, Jr., and S.J. Geary. 2006. Identification of a virulence-associated determinant, dihydrolipoamide dehydrogenase (lpd), in *Mycoplasma gallisepticum* through *in vivo* screening of transposon mutants. *Infect Immun*. 74:931–939.
201. Hussein Ael, D., T.M. El-Shaib, S.M. Saoud, N.A. Shalaby, H. Sultan, and A.M. Ragab. 2007. Protective immune response of *Mycoplasma gallisepticum* vaccines in poultry. *Egypt J Immunol*. 14:93–99.
202. Hwang, Y.S., V.S. Panangala, C.R. Rossi, J.J. Giambrone, and L.H. Lauerman. 1989. Monoclonal antibodies that recognize specific antigens of *Mycoplasma gallisepticum* and *M. synoviae*. *Avian Dis*. 33:42–52.
203. Hyman, H.C., S. Levisohn, D. Yogev, and S. Razin. 1989. DNA probes for *Mycoplasma gallisepticum* and *Mycoplasma synoviae*: application in experimentally infected chickens. *Vet Microbiol*. 20:323–337.
204. Jan, G., C. Brenner, and H. Wroblewski. 1996. Purification of *Mycoplasma gallisepticum* membrane proteins p52, p67 (pMGA), and p77 by high-performance liquid chromatography. *Protein Expr Purif*. 7:160–166.
205. Jan, G., M. Le Henaff, C. Fontenelle, and H. Wroblewski. 2001. Biochemical and antigenic characterisation of *Mycoplasma gallisepticum* membrane proteins P52 and P67 (pMGA). *Arch Microbiol*. 177:81–90.
206. Javed, M.A., S. Frasca, Jr., D. Rood, K. Cecchini, M. Gladd, S.J. Geary, and L.K. Silbart. 2005. Correlates of immune protection in chickens vaccinated with *Mycoplasma gallisepticum* strain GT5 following challenge with pathogenic *M. gallisepticum* strain R(low). *Infect Immun*. 73:5410–5419.
207. Jenkins, C., S.J. Geary, M. Gladd, and S.P. Djordjevic. 2007. The *Mycoplasma gallisepticum* OsmC-like protein MG1142 resides on the cell surface and binds heparin. *Microbiol*. 153: 1455–1463.
208. Jenkins, C., R. Samudrala, S.J. Geary, and S.P. Djordjevic. 2008. Structural and functional characterization of an organic hydroperoxide resistance protein from *Mycoplasma gallisepticum*. *J Bacteriol*. 190:2206–2216.
209. Jiang, H.X., J.R. Chen, H.L. Yan, X.N. Li, Z.L. Chen, and Z.L. Zeng. 2009. Molecular variability of DR-1 and DR-2 within the pvpA gene in *Mycoplasma gallisepticum* isolates. *Avian Dis*. 53:124–128.
210. Jirjis, F.F., S.L. Noll, D.A. Halvorson, K.V. Nagaraja, and D.P. Shaw. 2002. Pathogenesis of avian pneumovirus infection in turkeys. *Vet Pathol*. 39:300–310.
211. Johansson, K.E., M. Heldtander, and B. Pettersson. 1998. Characterization of mycoplasmas by PCR and sequence analysis with universal 16S rDNA primers. In: *Methods in Molecular Biology: Mycoplasma Protocols*, Vol. 104. R.J. Miles and

A.J. Nicholas, eds. Humana Press Inc., Totowa, New Jersey. 145–165.
212. Jordan, F.T. 1972. The epidemiology of disease of multiple aetiology: the avian respiratory disease complex. *Vet Rec*. 90: 556–562.
213. Jordan, F.T., and M.M. Amin. 1980. A survey of Mycoplasma infections in domestic poultry. *Res Vet Sci*. 28:96–100.
214. Jordan, F.T., and B.K. Horrocks. 1996. The minimum inhibitory concentration of tilmicosin and tylosin for *Mycoplasma gallisepticum* and *Mycoplasma synoviae* and a comparison of their efficacy in the control of *Mycoplasma gallisepticum* infection in broiler chicks. *Avian Dis*. 40:326–334.
215. Jordan, F.T., C.A. Forrester, P.H. Ripley, and D.G. Burch. 1998. *In vitro* and *in vivo* comparisons of valnemulin, tiamulin, tylosin, enrofloxacin, and lincomycin/spectinomycin against *Mycoplasma gallisepticum*. *Avian Dis*. 42:738–745.
216. Jordan, F.T., C.A. Forrester, A. Hodge, and L.G. Reeve-Johnson. 1999. The comparison of an aqueous preparation of tilmicosin with tylosin in the treatment of *Mycoplasma gallisepticum* infection of turkey poults. *Avian Dis*. 43:521–525.
217. Jordan, F.T., B.K. Horrocks, S.K. Jones, A.C. Cooper, and C.J. Giles. 1993. A comparison of the efficacy of danofloxacin and tylosin in the control of *Mycoplasma gallisepticum* infection in broiler chicks. *J Vet Pharmacol Ther*. 16:79–86.
218. Jordan, F.T.W., S. Gilbert, D.L. Knight, and C.A. Yavari. 1989. Effects of baytril, tylosin, and tiamulin on avian mycoplasmas. *Avian Pathol*. 18:659–673.
219. Jordan, F.T.W., C.A. Forrester, P.H. Ripley, and D.G.S. Burch. 1998. *In vitro* and *in vivo* comparisons of valnemulin, tiamulin, tylosin, enrofloxacin, and lincomycin/spectinomycin against *Mycoplasma gallisepticum*. *Avian Dis*. 42: 738–745.
220. Jordan, F.T.W., C.A. Forrester, A. Hodge, and L.G. Reeve Johnson. 1999. The comparison of an aqueous preparation of tilmicosin with tylosin in the treatment of *Mycoplasma gallisepticum* infection of turkey poults. *Avian Dis*. 43:521–525.
221. Jungherr, E.L., R.E. Luginbuhl, M.E. Tourtellotte, and B.W.E. 1955. Significance of serological testing for chronic respiratory disease. *Proc Ann Meeting Am Vet Med Assoc*. 92:315.
222. Karaca, K., and K.M. Lam. 1987. Efficacy of commercial *Mycoplasma gallisepticum* bacterin (MG-Bac) in preventing air-sac lesions in chickens. *Avian Dis*. 31:202–203.
223. Kaszanyitzky, E., G. Czifra, and L. Stipkovits. 1994. Detection of *Mycoplasma gallisepticum* antibodies in turkey blood samples by ELISA and by the slide agglutination and haemagglutination inhibition tests. *Acta Vet Hung*. 42:69–78.
224. Keeler, C.L., Jr., L.L. Hnatow, P.L. Whetzel, and J.E. Dohms. 1996. Cloning and characterization of a putative cytadhesin gene (mgc1) from *Mycoplasma gallisepticu*m. *Infect Immun*. 64:1541–1547.
225. Kelly, P.J., D. Chitauro, C. Rohde, J. Rukwava, A. Majok, F. Davelaar, and P.R. Mason. 1994. Diseases and management of backyard chicken flocks in Chitungwiza, Zimbabwe. *Avian Dis*. 38:626–629.
226. Kempf, I. 1997. DNA amplification methods for diagnosis and epidemiological investigations of avian mycoplasmosis. *Acta Vet Hung*. 45:373–386.
227. Kempf, I., and F. Gesbert. 1998. Comparison of serological tests for detection of *Mycoplasma gallisepticum* antibodies in eggs and chicks hatched from experimentally infected hens. *Vet Microbiol*. 60:207–213.
228. Kempf, I., F. Gesbert, and M. Guittet. 1997. Experimental infection of chickens with an atypical *Mycoplasma gallisepticum* strain: comparison of diagnostic methods. *Res Vet Sci*. 63:211–213.
229. Kempf, I., L. Reeve-Johnson, F. Gesbert, and M. Guittet. 1997. Efficacy of tilmicosin in the control of experimental *Mycoplasma gallisepticum* infection in chickens. *Avian Dis*. 41: 802–807.
230. Kempf, I., R. van den Hoven, F. Gesbert, and M. Guittet. 1998. Efficacy of difloxacin in growing broiler chickens for the control of infection due to pathogenic *Mycoplasma gallisepticum*. *Zentralbl Veterinarmed [B]*. 45:305–310.
231. Kempf, I., F. Gesbert, M. Guittet, G. Bennejean, and A.C. Cooper. 1992. Efficacy of danofloxacin in the therapy of experimental mycoplasmosis in chicks. *Res Vet Sci*. 53:257–259.
232. Kempf, I., A. Blanchard, F. Gesbert, M. Guittet, and G. Bennejean. 1993. The polymerase chain reaction for M*ycoplasma gallisepticum* detection. *Avian Pathol*. 22:739–750.
233. Kempf, I., F. Gesbert, M. Guittet, G. Bennejean, and L. Stipkovits. 1994. Evaluation of two commercial enzyme-linked immunosorbent assay kits for the detection of *Mycoplasma gallisepticum* antibodies. *Avian Pathol*. 23:329–338.
234. Khan, M.A., M.S. Khan, M. Younus, T. Abbas, I. Khan, and N.A. Khan. 2006. Comparative therapeutic efficacy of tiamulin, tylosin and oxytetracyline in broilers experimentally infected with *Mycoplasma gallisepticum*. *Int J Agri Biol*. 8:298.
235. Khan, M.I., and S.H. Kleven. 1993. Detection of *Mycoplasma gallisepticum* infection in field samples using a species-specific DNA probe. *Avian Dis*. 37:880–883.
236. Khan, M.I., B.C. Kirkpatrick, and R. Yamamoto. 1987. A *Mycoplasma gallisepticum* strain-specific DNA probe. *Avian Dis*. 31:907–909.
237. Khan, M.I., K.M. Lam, and R. Yamamoto. 1987. *Mycoplasma gallisepticum* strain variations detected by sodium dodecyl sulfate-polyacrylamide gel electrophoresis. *Avian Dis*. 31:315–320.
238. Khan, M.I., D.A. McMartin, R. Yamamoto, and H.B. Ortmayer. 1986. Observations on commercial layers vaccinated with *Mycoplasma gallisepticum* (MG) bacterin on a multiple-age site endemically infected with MG. *Avian Dis*. 30:309–312.
239. Kheyar, A., S.K. Reddy, and A. Silim. 1995. The 64 kDa lipoprotein of *Mycoplasma gallisepticum* has two distinct epitopes responsible for haemagglutination and growth inhibition. *Avian Pathol*. 24:55–68.
240. Kirchhoff, H. 1992. Motility. In: *Mycoplasmas: Molecular Biology and Pathogenicity*. J. Maniloff, R.N. McElhaney, L.R. Finch, and J.B. Baseman, eds. ASM, Washington. 289–306.
241. Kleckner, A.L. 1960. Serotypes of avian pleuropneumonia-like organisms. *Amer J Vet Res*. 21:274–280.
242. Kleven, S.H. 1975. Antibody response to avian mycoplasmas. *Amer J Vet Res*. 36:563–565.
243. Kleven, S.H. 1981. Transmissibility of the F strain of *Mycoplasma gallisepticum* in leghorn chickens. *Avian Dis*. 25:1005–1018.
244. Kleven, S.H. 1985. Tracheal populations of *Mycoplasma gallisepticum* after challenge of bacterin-vaccinated chickens. *Avian Dis*. 29:1012–1017.
245. Kleven, S.H. 1985. Stability of the F strain of *Mycoplasma gallisepticum* in various diluents at 4, 22, and 37 C. *Avian Dis*. 29:1266–1268.
246. Kleven, S.H. 1996. Mycoplasma in caged layers. *Zootecnica Inter*. 19:34–37.

247. Kleven, S.H. 1998. Mycoplasmas in the etiology of multifactorial respiratory disease. *Poult Sci*. 77:1146–1149.
248. Kleven, S.H. 1998. Mycoplasmosis. In: *A Laboratory Manual for the Isolation and Identification of Avian Pathogens*, 4th ed. D.E. Swayne, J.R. Glisson, M.W. Jackwood, J.E. Pearson, and W.M. Reed, eds. American Association of Avian Pathologists, Kennett Square, Pennsylvania. 74–80.
249. Kleven, S.H. 2000. *Proc New Engl Poult Heal Conf*. 49:3–6.
250. Kleven, S.H. 2008. Mycoplasmosis. In: *A Laboratory Manual for the Isolation, Identification and Characterization of Avian Pathogens*, 5th ed., L. Dufour-Zavala, D.E. Swayne, J.R. Glisson, J.E. Pearson, W.M. Reed, M.W. Jackwood, and P.R. Woolcock, eds. The American Association of Avian Pathologists, Jacksonville, Florida. 59–64.
251. Kleven, S.H., and S. Levisohn. 1996. Mycoplasma infections of poultry. In: *Molecular and Diagnostic Procedures in Mycoplasmology*, Vol. II. J.G. Tully, ed. Academic Press, Inc., New York. 283–292.
252. Kleven, S.H., C.J. Morrow, and K.G. Whithear. 1988. Comparison of *Mycoplasma gallisepticum* strains by hemagglutination-inhibition and restriction endonuclease analysis. *Avian Dis*. 32:731–741.
253. Kleven, S.H., M.I. Khan, and R. Yamamoto. 1990. Fingerprinting of *Mycoplasma gallisepticum* strains isolated from multiple-age layers vaccinated with live F strain. *Avian Dis*. 34:984–990.
254. Kleven, S.H., H.H. Fan, and K.S. Turner. 1998. Pen trial studies on the use of live vaccines to displace virulent *Mycoplasma gallisepticum* in chickens. *Avian Dis*. 42:300–306.
255. Kleven, S.H., G.F. Browning, D.M. Bulach, E. Ghiocas, C.J. Morrow, and K.G. Whithear. 1988. Examination of *Mycoplasma gallisepticum* strains using restriction endonuclease DNA analysis and DNA-DNA hybridization. *Avian Pathol*. 17:559–570.
256. Kleven, S.H., R.M. Fulton, M. Garcia, V.N. Ikuta, V.A. Leiting, T. Liu, D.H. Ley, K.N. Opengart, G.N. Rowland, and E. Wallner-Pendleton. 2004. Molecular characterization of *Mycoplasma gallisepticum* isolates from turkeys. *Avian Dis*. 48:562–569.
257. Kokotovic, B., N.F. Friis, J.S. Jensen, and P. Ahrens. 1999. Amplified-fragment length polymorphism fingerprinting of *Mycoplasma* species. *J Clin Microbiol*. 37:3300–3307.
258. Kollias, G.V., K.V. Sydenstricker, H.W. Kollias, D.H. Ley, P.R. Hosseini, V. Connolly, and A.A. Dhondt. 2004. Experimental infection of house finches with *Mycoplasma gallisepticum*. *J Wildl Dis*. 40:79–86.
259. Lam, K.M. 2002. The macrophage inflammatory protein-1beta in the supernatants of *Mycoplasma gallisepticum*-infected chicken leukocytes attracts the migration of chicken heterophils and lymphocytes. *Dev Comp Immunol*. 26:85–93.
260. Lam, K.M. 2003. *Mycoplasma gallisepticum*-induced alterations in chicken red blood cells. *Avian Dis*. 47:485–488.
261. Lam, K.M. 2003. Scanning electron microscopic studies of *Mycoplasma gallisepticum* infection in embryonic tracheae. *Avian Dis*. 47:193-196.
262. Lam, K.M. 2004. Morphologic changes in chicken cells after *in vitro* exposure to *Mycoplasma gallisepticum*. *Avian Dis*. 48: 488–493.
263. Lam, K.M. 2004. *Mycoplasma gallisepticum*—induced alterations in cytokine genes in chicken cells and embryos. *Avian Dis*. 48:215–219.
264. Lam, K.M. 2005. Chemotaxis in *Mycoplasma gallisepticum*. *Avian Dis*. 49:152–154.
265. Lam, K.M., and W. Lin. 1984. Resistance of chickens immunized against *Mycoplasma gallisepticum* is mediated by bursal dependent lymphoid cells. *Vet Microbiol*. 9:509–514.
266. Lam, K.M., and A.J. DaMassa. 2003. Chemotactic response of lymphocytes in chicken embryos infected with *Mycoplasma gallisepticum*. *J Comp Pathol*. 128:33–39.
267. Lauerman, L.H. 1998. Mycoplasma PCR assays. In: *Nucleic Acid Amplification Assays for Diagnosis of Animal Diseases*. L.H. Lauerman, ed. American Association of Veterinary Laboratory Diagnosticians, Turkock, California. 41–42.
268. Leigh, S.A., J.D. Evans, S.L. Branton, and S.D. Collier. 2008. The effects of increasing sodium chloride concentration on *Mycoplasma gallisepticum* vaccine survival in solution. *Avian Dis*. 52:136–138.
269. Leigh, S.A., S.L. Branton, J.D. Evans, S.D. Collier, and E.D. Peebles. 2010. Effects of vaccination with F-strain *Mycoplasma gallisepticum* on egg production and quality parameters of commercial layer hens previously vaccinated with 6/85-strain *Mycoplasma gallisepticum*. *Poult Sci*. 89:501–504.
270. Levisohn, S. 1981. Antibiotic sensitivity patterns in field isolates of *Mycoplasma gallisepticum* as a guide to chemotherapy. *Isr J Med Sci*. 17:661–666.
271. Levisohn, S. 1984. Early stages in the interaction between *Mycoplasma gallisepticum* and the chick trachea, as related to pathogenicity and immunogenicity. *Isr J Med Sci*. 20: 982–984.
272. Levisohn, S., and M.J. Dykstra. 1987. A quantitative study of single and mixed infection of the chicken trachea by *Mycoplasma gallisepticum*. *Avian Dis*. 31:1–12.
273. Levisohn, S., and S.H. Kleven. 2000. Avian mycoplasmosis (*Mycoplasma gallisepticum*). *Rev Sci Tech*. 19:425–442.
274. Levisohn, S., J.R. Glisson, and S.H. Kleven. 1985. *In ovo* pathogenicity of *Mycoplasma gallisepticum* strains in the presence and absence of maternal antibody. *Avian Dis*. 29:188–197.
275. Levisohn, S., R. Rosengarten, and D. Yogev. 1995. *In vivo* variation of *Mycoplasma gallisepticum* antigen expression in experimentally infected chickens. *Vet Microbiol*. 45:219–231.
276. Ley, D.H. 2006. Unpublished data.
277. Ley, D.H., A.P. Avakian, and J.E. Berkhoff. 1993. Clinical *Mycoplasma gallisepticum* infection in multiplier breeder and meat turkeys caused by F strain: identification by sodium dodecyl sulfate-polyacrylamide gel electrophoresis, restriction endonuclease analysis, and the polymerase chain reaction. *Avian Dis*. 37:854–862.
278. Ley, D.H., J.E. Berkhoff, and J.M. McLaren. 1996. *Mycoplasma gallisepticum* isolated from house finches (*Carpodacus mexicanus*) with conjunctivitis. *Avian Dis*. 40:480–483.
279. Ley, D.H., J.E. Berkhoff, and S. Levisohn. 1997. Molecular epidemiologic investigations of *Mycoplasma gallisepticum* conjunctivitis in songbirds by random amplified polymorphic DNA analyses. *Emerg Infect Dis*. 3:375–380.
280. Davison, S., and F.J. Hoerr (ed.) 2001. AAAP Symposium: Respiratory Diseases of Poultry, Boston, MA. July 15, 2001. American Association of Avian Pathologists.
281. Ley, D.H., D.S. Sheaffer, and A.A. Dhondt. 2006. Further western spread of *Mycoplasma gallisepticum* infection of house finches. *J Wildl* . 42:429–431.
282. Ley, D.H., S.J. Geary, J.E. Berkhoff, J.M. McLaren, and S. Levisohn. 1998. *Mycoplasma sturni* from blue jays and

northern mockingbirds with conjunctivitis in Florida. *J Wildl Dis*. 34:403–406.
283. Ley, D.H., J.M. McLaren, A.M. Miles, H.J. Barnes, S.H. Miller, and G. Franz. 1997. Transmissibility of live *Mycoplasma gallisepticum* vaccine strains ts-11 and 6/85 from vaccinated layer pullets to sentinel poultry. *Avian Dis*. 41:187–194.
284. Li, B.B., J.Z. Shen, X.Y. Cao, Y. Wang, L. Dai, S.Y. Huang, and C.M. Wu. 2010. Mutations in 23S rRNA gene associated with decreased susceptibility to tiamulin and valnemulin in *Mycoplasma gallisepticum*. *FEMS Microbiol Lett*. 308:144–149.
285. Lin, M.Y. 1987. *In vitro* comparison of the activity of various antibiotics and drugs against new Taiwan isolates and standard strains of avian mycoplasma. *Avian Dis*. 31:705–712.
286. Lin, M.Y., and S.H. Kleven. 1982. Pathogenicity of two strains of *Mycoplasma gallisepticum* in turkeys. *Avian Dis*. 26:360–364.
287. Lin, M.Y., and S.H. Kleven. 1982. Egg transmission of two strains of *Mycoplasma gallisepticum* in chickens. *Avian Dis*. 26:487–495.
288. Lin, M.Y., and S.H. Kleven. 1982. Cross-immunity and antigenic relationships among five strains of *Mycoplasma gallisepticum* in young Leghorn chickens. *Avian Dis*. 26:496–507.
289. Lin, M.Y., and S.H. Kleven. 1984. Transferred humoral immunity in chickens to *Mycoplasma gallisepticum*. *Avian Dis*. 28: 79–87.
290. Liu, L., V.S. Panangala, and K. Dybvig. 2002. Trinucleotide GAA repeats dictate pMGA gene expression in *Mycoplasma gallisepticum* by affecting spacing between flanking regions. *J Bacteriol*. 184:1335–1339.
291. Liu, T., M. Garcia, S. Levisohn, D. Yogev, and S.H. Kleven. 2001. Molecular variability of the adhesin-encoding gene pvpA among *Mycoplasma gallisepticum* strains and its application in diagnosis. *J Clin Microbiol*. 39:1882–1888.
292. Luginbuhl, R.E., M.E. Tourtellotte, and M.N. Frazier. 1967. *Mycoplasma gallisepticum*—control by immunization. *Ann N Y Acad Sci*. 143:234–238.
293. Luttrell, M.P., S.H. Kleven, and W.R. Davidson. 1991. An investigation of the persistence of *Mycoplasma gallisepticum* in an Eastern population of wild turkeys. *J Wildl Dis*. 27:74–80.
294. Luttrell, M.P., T.H. Eleazer, and S.H. Kleven. 1992. *Mycoplasma gallopavonis* in eastern wild turkeys. *J Wildl Dis*. 28:288–291.
295. Luttrell, M.P., J.R. Fischer, D.E. Stallknecht, and S.H. Kleven. 1996. Field investigation of *Mycoplasma gallisepticum* infections in house finches (*Carpodacus mexicanus*) from Maryland and Georgia. *Avian Dis*. 40:335–341.
296. Luttrell, M.P., D.E. Stallknecht, J.R. Fischer, C.T. Sewell, and S.H. Kleven. 1998. Natural *Mycoplasma gallisepticum* infection in a captive flock of house finches. *J Wildl Dis*. 34:289–296.
297. Luttrell, M.P., D.E. Stallknecht, S.H. Kleven, D.M. Kavanaugh, J.L. Corn, and J.R. Fischer. 2001. *Mycoplasma gallisepticum* in house finches (*Carpodacus mexicanus*) and other wild birds associated with poultry production facilities. *Avian Dis*. 45: 321–329.
298. Lysnyansky, I., M. Garcia, and S. Levisohn. 2005. Use of mgc2-polymerase chain reaction-restriction fragment length polymorphism for rapid differentiation between field isolates and vaccine strains of *Mycoplasma gallisepticum* in Israel. *Avian Dis*. 49:238–245.
299. Lysnyansky, I., I. Gerchman, S. Perk, and S. Levisohn. 2008. Molecular characterization and typing of enrofloxacin-resistant clinical isolates of *Mycoplasma gallisepticum*. *Avian Dis*. 52: 685–689.
300. MacOwan, K.J., C.J. Randall, and T.F. Brand. 1983. Cloacal infection with *Mycoplasma gallisepticum* and the effect of inoculation with H120 Infectious Bronchitis vaccine virus. *Avian Pathol*. 12:497–503.
301. Mallinson, E.T., and M. Rosenstein. 1976. Clinical, cultural, and serologic observations of avian mycoplasmosis in two chicken breeder flocks. *Avian Dis*. 20:211–215.
302. Mallinson, E.T., D.B. Snyder, W.W. Marquardt, E. Russek-Cohen, P.K. Savage, D.C. Allen, and F.S. Yancey. 1985. Presumptive diagnosis of subclinical infections utilizing computer-assisted analysis of sequential enzyme-linked immunosorbent assays against multiple antigens. *Poult Sci*. 64: 1661–1669.
303. Mardassi, B.B., R.B. Mohamed, I. Gueriri, S. Boughattas, and B. Mlik. 2005. Duplex PCR to differentiate between *Mycoplasma synoviae* and *Mycoplasma gallisepticum* on the basis of conserved species-specific sequences of their hemagglutinin genes. *J Clin Microbiol*. 43:948–958.
304. Markham, F.S., and S.C. Wong. 1952. Pleuropneumonia-like organisms in the etiology of turkey sinusitis and chronic respiratory disease of chickens. *Poult Sci*. 31:902–904.
305. Markham, J.F., C.J. Morrow, P.C. Scott, and K.G. Whithear. 1998. Safety of a temperature-sensitive clone of *Mycoplasma synoviae* as a live vaccine. *Avian Dis*. 42:677–681.
306. Markham, P.F., M.D. Glew, K.G. Whithear, and I.D. Walker. 1993. Molecular cloning of a member of the gene family that encodes pMGA, a hemagglutinin of *Mycoplasma gallisepticum*. *Infect Immun*. 61:903–909.
307. Markham, P.F., M.F. Duffy, M.D. Glew, and G.F. Browning. 1999. A gene family in *Mycoplasma imitans* closely related to the pMGA family of *Mycoplasma gallisepticum*. *Microbiol*. 145:2095–2103.
308. Markham, P.F., M.D. Glew, M.R. Brandon, I.D. Walker, and K.G. Whithear. 1992. Characterization of a major hemagglutinin protein from *Mycoplasma gallisepticum*. *Infect Immun*. 60:3885–3891.
309. Markham, P.F., M.D. Glew, G.F. Browning, K.G. Whithear, and I.D. Walker. 1998. Expression of two members of the pMGA gene family of *Mycoplasma gallisepticum* oscillates and is influenced by pMGA-specific antibodies. *Infect Immun*. 66:2845–2853.
310. Markham, P.F., M.D. Glew, J.E. Sykes, T.R. Bowden, T.D. Pollocks, G.F. Browning, K.G. Whithear, and I.D. Walker. 1994. The organisation of the multigene family which encodes the major cell surface protein, pMGA, of *Mycoplasma gallisepticum*. *FEBS Lett*. 352:347–352.
311. Marois, C., F. Dufour-Gesbert, and I. Kempf. 2001. Molecular differentiation of *Mycoplasma gallisepticum* and *Mycoplasma imitans* strains by pulsed-field gel electrophoresis and random amplified polymorphic DNA. *J Vet Med B Infect Dis Vet Public Health*. 48:695–703.
312. Marois, C., F. Dufour-Gesbert, and I. Kempf. 2002. Polymerase chain reaction for detection of *Mycoplasma gallisepticum* in environmental samples. *Avian Pathol*. 31:163–168.
313. May, J.D., S.L. Branton, S.B. Pruett, and A.J. Ainsworth. 1994. Differentiation of two strains of *Mycoplasma gallisepticum* with monoclonal antibodies and flow cytometry. *Avian Dis*. 38:542–547.
314. May, M., L. Papazisi, T.S. Gorton, and S.J. Geary. 2006. Identification of fibronectin-binding proteins in *Mycoplasma gallisepticum* strain R. *Infect Immun*. 74:1777–1785.

315. McAuliffe, L., R.J. Ellis, J.R. Lawes, R.D. Ayling, and R.A. Nicholas. 2005. 16S rDNA PCR and denaturing gradient gel electrophoresis: a single generic test for detecting and differentiating *Mycoplasma* species. *J Med Microbiol*. 54:731–739.
316. McBride, M.D., D.W. Hird, T.E. Carpenter, K.P. Snipes, C. Danaye-Elmi, and W. W. Utterback. 1991. Health survey of backyard poultry and other avian species located within one mile of commercial California meat-turkey flocks. *Avian Dis*. 35:403–407.
317. McLaren, J.M., D.H. Ley, J.E. Berkhoff, and A.P. Avakian. 1996. Antibody responses of chickens to inoculation with *Mycoplasma gallisepticum* membrane proteins in immunostimulating complexes. *Avian Dis*. 40:813–822.
318. McMartin, D.A., M.I. Khan, T.B. Farver, and G. Christie. 1987. Delineation of the lateral spread of *Mycoplasma gallisepticum* infection in chickens. *Avian Dis*. 31:814–819.
319. McMartin, D.A., A.J. DaMassa, W.D. McKeen, D. Read, B. Daft, and K.M. Lam. 1996. Experimental reproduction of *Mycoplasma gallisepticum* disease in chukar partridges (*Alectoris graeca*). *Avian Dis*. 40:408–416.
320. Mekkes, D.R., and A. Feberwee. 2005. Real-time polymerase chain reaction for the qualitative and quantitative detection of *Mycoplasma gallisepticum*. *Avian Pathol*. 34:348–354.
321. Meroz, M., D. Hadash, and Y. Samberg. 1973. Elimination of avian Mycoplasma organisms by heat treatment of eggs prior to incubation-some technical aspects. *Refu Vet*. 30:101–109.
322. Mettifogo, E., M. Buzinhani, M.R. Buim, A.J. Piantino Ferreira, S.H. Kleven, and J. Timenetsky. 2006. Molecular characterization of MG isolates using RAPD and PFGE isolated from chickens in Brazil. *J Vet Med B Infect Dis Vet Public Health*. 53:445–450.
323. Migaki, T.T., A.P. Avakian, H.J. Barnes, D.H. Ley, A.C. Tanner, and R.A. Magonigle. 1993. Efficacy of danofloxacin and tylosin in the control of mycoplasmosis in chicks infected with tylosin-susceptible or tylosin-resistant field isolates of *Mycoplasma gallisepticum*. *Avian Dis*. 37:508–514.
324. Mikaelian, I., D.H. Ley, R. Claveau, M. Lemieux, and J.P. Berube. 2001. Mycoplasmosis in evening and pine grosbeaks with conjunctivitis in Quebec. *J Wildl Dis*. 37:826–830.
325. Miyata, M. 2005. Gliding motility of mycoplasmas: The mechanism cannot be explained by current biololgy. In: *Mycoplasmas Molecular Biology Pathogeniciy and Strategies for Control*, A. Blanchard and G. Browning, eds. Horizon Bioscience, Wymondham, United Kingdom. 137–163.
326. Mohammed, H.O., T.E. Carpenter, and R. Yamamoto. 1987. Economic impact of *Mycoplasma gallisepticum* and *M. synoviae* in commercial layer flocks. *Avian Dis*. 31:477–482.
327. Mohammed, H.O., R. Yamamoto, T.E. Carpenter, and H.B. Ortmayer. 1986. A statistical model to optimize enzyme-linked immunosorbent assay parameters for detection of *Mycoplasma gallisepticum* and *M. synoviae* antibodies in egg yolk. *Avian Dis*. 30:389–397.
328. Mohammed, H.O., R. Yamamoto, T.E. Carpenter, and H.B. Ortmayer. 1986. Comparison of egg yolk and serum for the detection of *Mycoplasma gallisepticum* and *M. synoviae* antibodies by enzyme-linked immunosorbent assay. *Avian Dis*. 30:398–408.
329. Mohammed, J., S. Frasca, Jr., K. Cecchini, D. Rood, A.C. Nyaoke, S.J. Geary, and L.K. Silbart. 2007. Chemokine and cytokine gene expression profiles in chickens inoculated with *Mycoplasma gallisepticum* strains Rlow or GT5. *Vaccine*. 25:8611–8621.
330. Morowitz, H.J., and J. Maniloff. 1966. Analysis of the life cycle of *Mycoplasma gallisepticum*. *J Bacteriol*. 91:1638–1644.
331. Morse, J.W., J.T. Boothby, and R. Yamamoto. 1986. Detection of *Mycoplasma gallisepticum* by direct immunofluorescence using a species-specific monoclonal antibody. *Avian Dis*. 30: 204–206.
332. Moscoso, H., S.G. Thayer, C.L. Hofacre, and S.H. Kleven. 2004. Inactivation, storage, and PCR detection of Mycoplasma on FTA filter paper. *Avian Dis*. 48:841–850.
333. Much, P., F. Winner, L. Stipkovits, R. Rosengarten, and C. Citti. 2002. *Mycoplasma gallisepticum*: Influence of cell invasiveness on the outcome of experimental infection in chickens. *FEMS Immunol Med Microbiol*. 34:181–186.
334. Mudahi-Orenstein, S., S. Levisohn, S.J. Geary, and D. Yogev. 2003. Cytadherence-deficient mutants of *Mycoplasma gallisepticum* generated by transposon mutagenesis. *Infect Immun*. 71:3812–3820.
335. Murakami, S., M. Miyama, A. Ogawa, J. Shimada, and T. Nakane. 2002. Occurrence of conjunctivitis, sinusitis and upper region tracheitis in Japanese quail (*Coturnix coturnix japonica*), possibly caused by *Mycoplasma gallisepticum* accompanied by *Cryptosporidium* sp. infection. *Avian Pathol*. 31:363–370.
336. Nagai, S., S. Kazama, and T. Yagihashi. 1995. Ribotyping of *Mycoplasma gallisepticum* strains with a 16S ribosomal RNA gene probe. *Avian Pathol*. 24:633–642.
337. Nagatomo, H., Y. Takegahara, T. Sonoda, A. Yamaguchi, R. Uemura, S. Hagiwara, and M. Sueyoshi. 2001. Comparative studies of the persistence of animal mycoplasmas under different environmental conditions. *Vet Microbiol*. 82:223–232.
338. Nakamura, K., H. Ueda, T. Tanimura, and K. Noguchi. 1994. Effect of mixed live vaccine (Newcastle disease and infectious bronchitis) and *Mycoplasma gallisepticum* on the chicken respiratory tract and on *Escherichia coli* infection. *J Comp Pathol*. 111:33–42.
339. Nascimento, E.R., R. Yamamoto, K.R. Herrick, and R.C. Tait. 1991. Polymerase chain reaction for detection of *Mycoplasma gallisepticum*. *Avian Dis*. 35:62–69.
340. Nascimento, E.R. d., M.d.G.F. d. Nascimento, M.W. d. Santos, P.G. d. Oliveirs. Dias, O. d. Almeida Resende, and R. d. Cáia Figuera Silva. 2005. Eradication of *Mycoplasma gallisepticum* and *M. synoviae* from a chicken flock by antimicrobial injections in eggs and chicks. *Acta Scient Vet*. 33:119.
341. Naylor, C.J., A.R. Al Ankari, A.I. Al Afaleq, J.M. Bradbury, and R.C. Jones. 1992. Exacerbation of *Mycoplasma gallisepticum* infection in turkeys by rhinotracheitis virus. *Avian Pathol*. 21:295–305.
342. Nelson, J.B. 1935. Cocco-bacilliform bodies associated with an infectious fowl coryza. *Science*. 82:43–44.
343. Nolan, P.M., S.R. Roberts, and G.E. Hill. 2004. Effects of *Mycoplasma gallisepticum* on reproductive success in house finches. *Avian Dis*. 48:879–885.
344. Noormohammadi, A.H., J.E. Jones, G. Underwood, and K.G. Whithear. 2002. Poor systemic antibody response after vaccination of commercial broiler breeders with *Mycoplasma gallisepticum* vaccine ts-11 not associated with susceptibility to challenge. *Avian Dis*. 46:623–628.
345. Noormohammadi, A.H., P.F. Markham, A. Kanci, K.G. Whithear, and G.F. Browning. 2000. A novel mechanism for control of antigenic variation in the haemagglutinin gene family of *M. synoviae*. *Mol Microbiol*. 35:911–923.

346. Noormohammadi, A.H., G.F. Browning, P.J. Cowling, D. O'Rourke, K.G. Whithear, and P.F. Markham. 2002. Detection of antibodies to *Mycoplasma gallisepticum* vaccine ts-11 by an autologous pMGA enzyme-linked immunosorbent assay. *Avian Dis*. 46:405–411.
347. Nunoya, T., M. Tajima, T. Yagihashi, and S. Sannai. 1987. Evaluation of respiratory lesions in chickens induced by *Mycoplasma gallisepticum*. *Japan J Vet Sci*. 49:621–629.
348. Nunoya, T., T. Yagihashi, M. Tajima, and Y. Nagasawa. 1995. Occurrence of keratoconjunctivitis apparently caused by *Mycoplasma gallisepticum* in layer chickens. *Vet Pathol* 32: 11–18.
349. Nunoya, T., K. Kanai, T. Yagihashi, S. Hoshi, K. Shibuya, and M. Tajima. 1997. Natural case of salpingitis apparently caused by *Mycoplasma gallisepticum* in chickens. *Avian Pathol*. 26: 391–398.
350. O'Connor, R.J., K.S. Turner, J.E. Sander, S.H. Kleven, T. P. Brown, L. Gomez, Jr., and J.L. Cline. 1999. Pathogenic effects on domestic poultry of a *Mycoplasma gallisepticum* strain isolated from a wild house finch. *Avian Dis*. 43: 640–648.
351. Olson, N.O., J.O. Heishman, and A. Cambell. 1962. Dipping of hatching eggs in erythromycin for the control of mycoplasma. *Avian Dis*. 6:191–194.
352. Opitz, H.M., and M.J. Cyr. 1986. Triton X-100-solubilized *Mycoplasma gallisepticum* and *M. synoviae* ELISA antigens. *Avian Dis*. 30:213–215.
353. Opitz, H.M., J.B. Duplessis, and M.J. Cyr. 1983. Indirect micro-enzyme-linked immunosorbent assay for the detection of antibodies to *Mycoplasma synoviae* and *M. gallisepticum*. *Avian Dis*. 27:773–786.
354. Ortiz, A., R. Froyman, and S.H. Kleven. 1995. Evaluation of enrofloxacin against egg transmission of *Mycoplasma gallisepticum*. *Avian Dis*. 39:830–836.
355. Ose, E.E., R.H. Wellenreiter, and L.V. Tonkinson. 1979. Effects of feeding tylosin to layers exposed to *Mycoplasma gallisepitcum*. *Poult Sci*. 58:42–49.
356. Panangala, V.S., M.A. Morsy, M.M. Gresham, and M. Toivio Kinnucan. 1992. Antigenic variation of *Mycoplasma gallisepticum*, as detected by use of monoclonal antibodies. *Amer J Vet Res*. 53:1139–1144.
357. Pang, Y., H. Wang, T. Girshick, Z. Xie, and M.I. Khan. 2002. Development and application of a multiplex polymerase chain reaction for avian respiratory agents. *Avian Dis*. 46:691–699.
358. Papazisi, L., K.E. Troy, T.S. Gorton, X. Liao, and S.J. Geary. 2000. Analysis of cytadherence-deficient, GapA-negative *Mycoplasma gallisepticum* strain R. *Infect Immun*. 68: 6643–6649.
359. Papazisi, L., S. Frasca, Jr., M. Gladd, X. Liao, D. Yogev, and S.J. Geary. 2002. GapA and CrmA coexpression is essential for *Mycoplasma gallisepticum* cytadherence and virulence. *Infect Immun*. 70:6839–6845.
360. Papazisi, L., L.K. Silbart, S. Frasca, D. Rood, X. Liao, M. Gladd, M.A. Javed, and S.J. Geary. 2002. A modified live *Mycoplasma gallisepticum* vaccine to protect chickens from respiratory disease. *Vaccine*. 20:3709–3719.
361. Papazisi, L., T.S. Gorton, G. Kutish, P.F. Markham, G.F. Browning, D.K. Nguyen, S. Swartzell, A. Madan, G. Mahairas, and S.J. Geary. 2003. The complete genome sequence of the avian pathogen *Mycoplasma gallisepticum* strain R(low). *Microbiol*. 149:2307–2316.
362. Pennycott, T.W., C.M. Dare, C.A. Yavari, and J.M. Bradbury. 2005. *Mycoplasma sturni* and *Mycoplasma gallisepticum* in wild birds in Scotland. *Vet Rec*. 156:513–515.
363. Pillai, S.R., H.L. Mays, Jr., D.H. Ley, P. Luttrell, V.S. Panangala, K.L. Farmer, and S.R. Roberts. 2003. Molecular variability of house finch *Mycoplasma gallisepticum* isolates as revealed by sequencing and restriction fragment length polymorphism analysis of the pvpA gene. *Avian Dis*. 47:640–648.
364. Portnoy, V., and G. Schuster. 2008. Mycoplasma gallisepticum as the first analyzed bacterium in which RNA is not polyadenylated. *FEMS Microbiol Lett*. 283:97–103.
365. Purswell, J.L., J.D. Evans, and S.L. Branton. 2011. Serologic response of roosters to gradient dosage levels of a commercially available live F strain-derived *Mycoplasma gallisepticum* vaccine over time. *Avian Dis*. 55:490–494.
366. Raviv, Z., and S.H. Kleven. 2009. The development of diagnostic real-time TaqMan PCRs for the four pathogenic avian mycoplasmas. *Avian Dis*. 53:103–107.
367. Raviv, Z., S.A. Callison, N. Ferguson-Noel, and S.H. Kleven. 2008. Strain differentiating real–time PCR for *Mycoplasma gallisepticum* live vaccine evaluation studies. *Vet Microbiol*. 129:179–187.
368. Raviv, Z., S. Callison, N. Ferguson-Noel, V. Laibinis, R. Wooten, and S.H. Kleven. 2007. The *Mycoplasma gallisepticum* 16S-23S rRNA intergenic spacer region sequence as a novel tool for epizootiological studies. *Avian Dis*. 51:555–560.
369. Razin, S. 1992. Mycoplasma taxonomy and ecology. In: *Mycoplasmas: Molecular Biology and Pathogenesis*. J. Maniloff, R.N. McElhaney, L.R. Finch, and J. Baseman, eds. American Society for Microbiology, Washington, DC. 3–22.
370. Razin, S., and E. Jacobs. 1992. Mycoplasma adhesion. *J Gen Microbiol*. 138:407–422.
371. Razin, S., D. Yogev, and Y. Naot. 1998. Molecular biology and pathogenicity of mycoplasmas. *Microbiol Mol Biol Rev*. 62:1094–1156.
372. Reddy, S.K., S. Pratik, S. Amer, J.A. Newman, P. Singh, and A. Silim. 1998. Lymphoproliferative responses of specific-pathogen-free chickens to *Mycoplasma gallisepticum* strain PG31. *Avian Pathol*. 27:277–283.
373. Reece, R.L., L. Ireland, and D.A. Barr. 1986. Infectious sinusitis associated with *Mycoplasma gallisepticum* in game-birds. *Austral Vet J*. 63:167–168.
374. Reinhardt, A.K., I. Kempf, M. Kobisch, and A.V. Gautier-Bouchardon. 2002. Fluoroquinolone resistance in *Mycoplasma gallisepticum*: DNA gyrase as primary target of enrofloxacin and impact of mutations in topoisomerases on resistance level. *J Antimicrob Chemother*. 50:589–592.
375. Reinhardt, A.K., A.V. Gautier-Bouchardon, M. Gicquel-Bruneau, M. Kobisch, and I. Kempf. 2005. Persistence of *Mycoplasma gallisepticum* in chickens after treatment with enrofloxacin without development of resistance. *Vet Microbiol*. 106:129–137.
376. Rhoades, K.R. 1981. Pathogenicity of strains of the IJKNQR group of avian mycoplasmas for turkey embryos and poults. *Avian Dis*. 25:104–111.
377. Roberts, D.H., and J.W. McDanial. 1967. Mechanism of egg transmission of *Mycoplasma gallispeticum*. *J Comp Pathol*. 77:439–442.
378. Roberts, S.R., P.M. Nolan, and G.E. Hill. 2001. Characterization of *Mycoplasma gallisepticum* infection in captive house finches (*Carpodacus mexicanus*) in 1998. *Avian Dis*. 45:70–75.

379. Roberts, S.R., P.M. Nolan, L.H. Lauerman, L.Q. Li, and G.E. Hill. 2001. Characterization of the mycoplasmal conjunctivitis epizootic in a house finch population in the southeastern USA. *J Wildl Dis*. 37:82–88.
380. Rodriguez, R., and S.H. Kleven. 1980. Evaluation of a vaccine against *Mycoplasma gallisepticum* in commercial broilers. *Avian Dis*. 24:879–889.
381. Rodriguez, R., and S.H. Kleven. 1980. Pathogenicity of two strains of *Mycoplasma gallisepticum* in broilers. *Avian Dis*. 24:800–807.
382. Rosengarten, R., and D. Yogev. 1996. Variant colony surface antigenic phenotypes within mycoplasma strain populations: implications for species identification and strain standardization. *J Clin Microbiol*. 34:149–158.
383. Rosengarten, R., S. Levisohn, and D. Yogev. 1995. A 41-kDa variable surface protein of *Mycoplasma gallisepticum* has a counterpart in *Mycoplasma imitans* and *Mycoplasma iowae*. *FEMS Microbiol Lett*. 132:115–123.
384. Ross, T., M. Slavik, G. Bayyari, and J. Skeeles. 1990. Elimination of mycoplasmal plate agglutination cross-reactions in sera from chickens inoculated with infectious bursal disease viruses. *Avian Dis*. 34:663–667.
385. Saito, S., A. Fujisawa, S. Ohkawa, N. Nishimura, T. Abe, K. Kodama, K. Kamogawa, S. Aoyama, Y. Iritani, and Y. Hayashi. 1993. Cloning and DNA sequence of a 29 kilodalton polypeptide gene of *Mycoplasma gallisepticum* as a possible protective antigen. *Vaccine*. 11:1061–1066.
386. Salisch, H., K.H. Hinz, H.D. Graack, and M. Ryll. 1998. A comparison of a commercial PCR-based test to culture methods for detection of *Mycoplasma gallisepticum* and *Mycoplasma synoviae* in concurrently infected chickens. *Avian Pathol*. 27: 142–147.
387. Salisch, H., M. Ryll, K.H. Hinz, and U. Neumann. 1999. Experiences with multispecies polymerase chain reaction and specific oligonucleotide probes for the detection of *Mycoplasma gallisepticum* and *Mycoplasma synoviae*. *Avian Pathol*. 28: 337–344.
388. Santha, M., K. Burg, I. Rasko, and L. Stipkovits. 1987. A species-specific DNA probe for the detection of *Mycoplasma gallisepticum*. *Inf Immun*. 55:2857–2859.
389. Santha, M., K. Lukacs, K. Burg, S. Bernath, I. Rasko, and L. Stipkovits. 1988. Intraspecies genotypic heterogeneity among *Mycoplasma gallisepticum* strains. *Appl Environ Microbiol*. 54: 607–609.
390. Sasipreeyajan, J., D.A. Halvorson, and J.A. Newman. 1987. Effect of *Mycoplasma gallisepticum* bacterin on egg-transmission and egg production. *Avian Dis*. 31:776–781.
391. Sato, S. 1996. Avian mycoplasmosis in Asia. *Rev Sci Tech*. 15:1555–1567.
392. Savelkoul, P.H., H.J. Aarts, J. de Haas, L. Dijkshoorn, B. Duim, M. Otsen, J.L. Rademaker, L. Schouls, and J.A. Lenstra. 1999. Amplified-fragment length polymorphism analysis: the state of an art. *J Clin Microbiol*. 37:3083–3091.
393. Shil, P.K., A. Kanci, G.F. Browning, M.S. Marenda, A.H. Noormohammadi, and P.F. Markham. 2011. GapA + *Mycoplasma gallisepticum* ts-11 has improved vaccine characteristics. *Microbiol*. 157:1740–1749.
394. Shimizu, T., and M. Miyata. 2002. Electron microscopic studies of three gliding Mycoplasmas, *Mycoplasma mobile*, *M. pneumoniae*, and *M. gallisepticum*, by using the freeze-substitution technique. *Curr Microbiol*. 44:431–434.
395. Shryock, T.R., P.R. Klink, R.S. Readnour, and L.V. Tonkinson. 1994. Effect of bentonite incorporated in a feed ration with tilmicosin in the prevention of induced *Mycoplasma gallisepticum* airsacculitis in broiler chickens. *Avian Dis*. 38:501–505.
396. Silveira, R.M., L. Fiorentin, and E.K. Marques. 1996. Polymerase chain reaction optimization for *Mycoplasma gallisepticum* and *M. synoviae* diagnosis. *Avian Dis*. 40:218–222.
397. Silveira, R.M., E.K. Marques, N.B. Nardi, and L. Fiorentin. 1993. Monoclonal antibodies species-specific to *Mycoplasma gallisepticum* and *M. synoviae*. *Avian Dis*. 37:888–890.
398. Slavik, M.F., R.F. Wang, and W.W. Cao. 1993. Development and evaluation of the polymerase chain reaction method for diagnosis of *Mycoplasma gallisepticum* infection in chickens. *Mol Cell Probes*. 7:459–463.
399. Soeripto, K.G. Whithear, G.S. Cottew, and K.E. Harrigan. 1989. Virulence and transmissibility of *Mycoplasma gallisepticum*. *Austral Vet J*. 66:65–72.
400. Spencer, D.L., K.T. Kurth, S.A. Menon, T. VanDyk, and F.C. Minion. 2002. Cloning and analysis of the gene for a major surface antigen of *Mycoplasma gallisepticum*. *Avian Dis*. 46: 816–825.
401. Sprygin, A.V., D.B. Andreychuk, A.N. Kolotilov, M.S. Volkov, I.A. Runina, N.S. Mudrak, A.V. Borisov, V.N. Irza, V.V. Drygin, and N.A. Perevozchikova. 2010. Development of a duplex real-time TaqMan PCR assay with an internal control for the detection of *Mycoplasma gallisepticum* and *Mycoplasma synoviae* in clinical samples from commercial and backyard poultry. *Avian Pathol*. 39:99–109.
402. Sprygin, A.V., D.B. Andreychuk, N.P. Elatkin, N.G. Zinyakov, S.N. Kolosov, N.S. Mudrak, V.N. Irza, V.V. Drygin, A.V. Borisov, and N.A. Perevozchikova. 2010. Genetic diversity of *Mycoplasma gallisepticum* field isolates using partial sequencing of the pvpA gene fragment in Russia. *Avian Dis*. 54:899–904.
403. Stakenborg, T., J. Vicca, R. Verhelst, P. Butaye, D. Maes, A. Naessens, G. Claeys, C. De Ganck, F. Haesebrouck, and M. Vaneechoutte. 2005. Evaluation of tRNA gene PCR for identification of mollicutes. *J Clin Microbiol*. 43:4558–4566.
404. Stallknecht, D.E., M.P. Luttrell, J.R. Fischer, and S.H. Kleven. 1998. Potential for transmission of the finch strain of *Mycoplasma gallisepticum* between house finches and chickens. *Avian Dis*. 42:352–358.
405. Stanley, W.A., C.L. Hofacre, G. Speksnijder, S.H. Kleven, and S.E. Aggrey. 2001. Monitoring *Mycoplasma gallisepticum* and *Mycoplasma synoviae* infection in breeder chickens after treatment with enrofloxacin. *Avian Dis*. 45:534–539.
406. Stipkovits, L., G. Czifra, and B. Sundquist. 1993. Indirect ELISA for the detection of a specific antibody response against *Mycoplasma gallisepticum*. *Avian Pathol*. 22:481–494.
407. Stipkovits, L., E. Csiba, G. Laber, and D.G. Burch. 1992. Simultaneous treatment of chickens with salinomycin and tiamulin in feed. *Avian Dis*. 36:11–16.
408. Stipkovits, L., R. Glavits, V. Palfi, A. Beres, L. Egyed, B. Denes, M. Somogyi, and S. Szathmary. 2011. Pathologic lesions caused by coinfection of *Mycoplasma gallisepticum* and H3N8 low pathogenic avian influenza virus in chickens. *Vet Pathol*. 49*(2)*:273–83
409. Stuart, E.E., and H.W. Bruins. 1963. Preincubation immersion of eggs in erythromycin to control chronic respiratory disease. *Avian Dis*. 7:287–293.
410. Sundquist, B.G., G. Czifra, and L. Stipkovits. 1996. Protective immunity induced in chicken by a single immunization with

Mycoplasma gallisepticum immunostimulating complexes (ISCOMS). *Vaccine*. 14:892–897.
411. Sydenstricker, K.V., A.A. Dhondt, D.H. Ley, and G.V. Kollias. 2005. Re-exposure of captive house finches that recovered from *Mycoplasma gallisepticum* infection. *J Wildl Dis*. 41:326–333.
412. Sydenstricker, K.V., A.A. Dhondt, D.M. Hawley, C.S. Jennelle, H.W. Kollias, and G.V. Kollias. 2006. Characterization of experimental *Mycoplasma gallisepticum* infection in captive house finch flocks. *Avian Dis*. 50:39–44.
413. Szczepanek, S.M., S. Frasca, Jr., V.L. Schumacher, X. Liao, M. Padula, S.P. Djordjevic, and S.J. Geary. 2010. Identification of lipoprotein MslA as a neoteric virulence factor of *Mycoplasma gallisepticum*. *Infect Immun*. 78:3475–3483.
414. Szczepanek, S.M., E.R. Tulman, T.S. Gorton, X. Liao, Z. Lu, J. Zinski, F. Aziz, S. Frasca, Jr., G.F. Kutish, and S.J. Geary. 2010. Comparative genomic analyses of attenuated strains of *Mycoplasma gallisepticum*. *Infect Immun*. 78:1760–1771.
415. Tajima, M., T. Nunoya, and T. Yagihashi. 1979. An ultrastructural study on the interaction of *Mycoplasma gallisepticum* with the chicken tracheal epithelium. *Amer J Vet Res*. 40: 1009–1014.
416. Tajima, M., T. Yagihashi, and Y. Miki. 1982. Capsular material of *Mycoplasma gallisepticum* and its possible relevance to the pathogenic process. *Infect Immun*. 36:830–833.
417. Takagi, H., and A. Arakawa. 1980. The growth and cilia-stopping effect of *Mycoplasma gallisepticum* 1RF in chicken tracheal organ cultures. *Res Vet Sci*. 28:80–86.
418. Takahata, T., M. Takei, M. Kato, and T. Shimizu. 1996. Responses of dot-immunobinding and agglutinating antibodies in chickens infected with mycoplasmas. *J Japan Vet Med Assoc*. 49:533–535.
419. Talkington, F.D., and S.H. Kleven. 1983. A classification of laboratory strains of avian mycoplasma serotypes by direct immunoflorescence. *Avian Dis*. 27:422–429.
420. Talkington, F.D., and S.H. Kleven. 1984. Additional information on the classification of avian Mycoplasma serotypes. *Avian Dis*. 28:278–280.
421. Talkington, F.D., and S.H. Kleven. 1985. Evaluation of protection against colonization of the chicken trachea following administration of *Mycoplasma gallisepticum* bacterin. *Avian Dis*. 29:998–1003.
422. Talkington, F.D., S.H. Kleven, and J. Brown. 1985. An enzyme-linked immunosorbent assay for the detection of antibodies to *Mycoplasma gallisepticum* in experimentally infected chickens. *Avian Dis*. 29:53–70.
423. Tanner, A.C., B.Z. Erickson, and R.F. Ross. 1993. Adaptation of the Sensititre broth microdilution technique to antimicrobial susceptibility testing of *Mycoplasma hyopneumoniae*. *Vet Microbiol*. 36:301–306.
424. Tanner, A.C., A.P. Avakian, H.J. Barnes, D.H. Ley, T.T. Migaki, and R.A. Magonigle. 1993. A comparison of danofloxacin and tylosin in the control of induced *Mycoplasma gallisepticum* infection in broiler chicks. *Avian Dis*. 37:515–522.
425. Thekisoe, M.M., P.A. Mbati, and S.P. Bisschop. 2003. Diseases of free-ranging chickens in the Qwa-Qwa District of the north-eastern Free State province of South Africa. *J S Afr Vet Assoc*. 74:14–16.
426. Thomas, L., M. Davidson, and R.T. McClusky. 1966. The production of cerbral polyarteritis by *Mycoplasma gallisepticum* in turkeys: the neurotoxic property of the mycoplasma. *J Experim Med*. 123:897–912.
427. Throne Steinlage, S.J., N. Ferguson, J.E. Sander, M. Garcia, S. Subramanian, V.A. Leiting, and S.H. Kleven. 2003. Isolation and characterization of a 6/85-like *Mycoplasma gallisepticum* from commercial laying hens. *Avian Dis*. 47:499–505.
428. Tigges, E., and F.C. Minion. 1994. Physical map of *Mycoplasma gallisepticum*. *J Bacteriol*. 176:4157–4159.
429. Timms, L.M., R.N. Marshall, and M.F. Breslin. 1989. Evaluation of the efficacy of chlortetracycline for the control of chronic respiratory disease caused by *Escherichia coli* and *Mycoplasma gallisepticum*. *Res Vet Sc*. 47:377–382.
430. Trampel, D.W., and O.J. Fletcher. 1981. Light microscopic, scanning electron microscopic, and histomorphometric evaluation of *Mycoplasma gallisepticum*-induced airsacculitis in chickens. *Am J Vet Res*. 42:1281–1289.
431. Truscott, R.B., A.E. Ferguson, H.L. Ruhnke, J.R. Pettit, A. Robertson, and G. Speckmann. 1974. An infection in chickens with a strain of *Mycoplasma gallisepticum* of low virulence. *Can J Comp Med*. 38:341–343.
432. Turner, K.S., and S.H. Kleven. 1998. Eradication of live F strain *Mycoplasma gallisepticum* vaccine using live ts-11 on a multiage commercial layer farm. *Avian Dis*. 42:404–407.
433. Ulgen, M., A. Sen, and T. Carli. 1998. Investigation of pathogenicity of Mycoplasma isolates from chickens in tracheal organ cultures. *Veterinarium*. 9:52–55.
434. van der Heide, L. 1977. Vaccination can control costly chronic respiratory disease in poultry. *Research Report, Conn Storrs Agric Exp Stn*. 47:26.
435. Van Loock, M., T. Geens, L. De Smit, H. Nauwynck, P. Van Empel, C. Naylor, H.M. Hafez, B.M. Goddeeris, and D. Vanrompay. 2005. Key role of *Chlamydophila psittaci* on Belgian turkey farms in association with other respiratory pathogens. *Vet Microbiol*. 107:91–101.
436. Van Roekel, H., and O.M. Olesiuk. 1953. *Proc Annu Meet Am Vet Med Assoc*. 90:289–303.
437. Van Roekel, H., J.E. Gray, N.L. Shipkowitz, M.K. Clarke, and R.M. Luchini. 1957. Etiology and pathology of the chronic respiratory disease complex in chickens. *Univ Mass Agric Exp Stn Bull*. 486.
438. Vance, A.M., S.L. Branton, S.D. Collier, P.D. Gerard, and E.D. Peebles. 2008. Effects of time-specific F-strain *Mycoplasma gallisepticum* inoculation overlays on prelay ts11-strain *Mycoplasma gallisepticum* inoculation on performance characteristics of commercial laying hens. *Poult Sci*. 87:655–660.
439. Varley, J., and F.T.W. Jordan. 1978. The response of turkey poults to experimental infection with strains of *M. gallisepticum* of different virulence and with *M. gallinarum*. *Avian Pathol*. 7:383–395.
440. Viscione, K.A., S.L. Branton, A.M. Vance, P.D. Gerard, S.K. Whitmarsh, and E.D. Peebles. 2008. Effects of 6/85-strain *Mycoplasma gallisepticum* inoculation alone at ten weeks of age or in conjunction with F-strain *Mycoplasma gallisepticum* inoculation overlays at twenty-two or forty-five weeks of age on the performance of commercial egg-laying hens. *Poult Sci*. 87: 588–593.
441. Vitula, F., L. Peckova, H. Bandouchova, M. Pohanka, L. Novotny, D. Jira, J. Kral, K. Ondracek, J. Osickova, D. Zendulkova, K. Rosenbergova, F. Treml, and J. Pikula. 2011. *Mycoplasma gallisepticum* infection in the grey partridge *Perdix perdix*: outbreak description, histopathology, biochemistry and antioxidant parameters. *BMC Vet Res*. 7:34.

442. Vogl, G., A. Plaickner, S. Szathmary, L. Stipkovits, R. Rosengarten, and M.P. Szostak. 2008. *Mycoplasma gallisepticum* invades chicken erythrocytes during infection. *Infect Immun*. 76:71–77.
443. Wang, C., M. Ewing, and S.Y. Aarabi. 2001. *In vitro* susceptibility of avian mycoplasmas to enrofloxacin, sarafloxacin, tylosin, and oxytetracycline. *Avian Dis*. 45:456–460.
444. Wang, H., A.A. Fadl, and M.I. Khan. 1997. Multiplex PCR for avian pathogenic mycoplasmas. *Mol Cell Probes*. 11:211–216.
445. Weisburg, W.G., J.G. Tully, D.L. Rose, J.P. Petzel, H. Oyaizu, D. Yang, L. Mandelco, J. Sechrest, T.G. Lawrence, J. Van Etten, L. James, J. Maniloff, and C.R. Woese. 1989. A phylogenetic analysis of the mycoplasmas: basis for their classification. *J Bacteriol*. 171:6455–6467.
446. Wellehan, J.F., M. Calsamiglia, D.H. Ley, M.S. Zens, A. Amonsin, and V. Kapur. 2001. Mycoplasmosis in captive crows and robins from Minnesota. *J Wildl Dis*. 37:547–555.
447. Wellehan, J.F., M.S. Zens, M. Calsamiglia, P.J. Fusco, A. Amonsin, and V. Kapur. 2001. Diagnosis and treatment of conjunctivitis in house finches associated with mycoplasmosis in Minnesota. *J Wildl Dis*. 37:245–251.
448. Whithear, K.G. 1996. Control of avian mycoplasmoses by vaccination. *Rev Sci Tech*. 15:1527–1553.
449. Whithear, K.G., K.E. Harrigan, and S.H. Kleven. 1996. Standardized method of aerosol challenge for testing the efficacy of *Mycoplasma gallisepticum* vaccines. *Avian Dis*. 40: 654–660.
450. Whithear, K.G., Soeripto, K.E. Harrigan, and E. Ghiocas. 1990. Immunogenicity of a temperature sensitive mutant *Mycoplasma gallisepticum* vaccine. *Austral Vet J*. 67: 168–174.
451. Whithear, K.G., Soeripto, K.E. Harringan, and E. Ghiocas. 1990. Safety of temperature sensitive mutant *Mycoplasma gallisepticum* vaccine. *Austral Vet J*. 67:159–165.
452. Wieslander, A., M.J. Boyer, and H. Wroblewski. 1992. Membrane protein structure. In: *Mycoplasmas: Molecular Biology and Pathogenesis*. J. Maniloff, R.N. McElhaney, L.R. Finch, and J. Baseman, eds. American Society for Microbiology, Washington, D.C. 93–112.
453. Winner, F., R. Rosengarten, and C. Citti. 2000. *In vitro* cell invasion of *Mycoplasma gallisepticum*. *Infect Immun*. 68: 4238–4244.
454. Winner, F., I. Markova, P. Much, A. Lugmair, K. Siebert-Gulle, G. Vogl, R. Rosengarten, and C. Citti. 2003. Phenotypic switching in *Mycoplasma gallisepticum* hemadsorption is governed by a high-frequency, reversible point mutation. *Infect Immun*. 71:1265–1273.
455. Wu, C.M., H. Wu, Y. Ning, J. Wang, X. Du, and J. Shen. 2005. Induction of macrolide resistance in *Mycoplasma gallisepticum in vitro* and its resistance-related mutations within domain V of 23S rRNA. *FEMS Microbiol Lett*. 247:199–205.
456. Yagihashi, T., and M. Tajima. 1986. Antibody responses in sera and respiratory secretions from chickens infected with *Mycoplasma gallisepticum*. *Avian Dis*. 30:543–550.
457. Yagihashi, T., T. Nunoya, and M. Tajima. 1987. Immunity induced with an aluminum hydroxide-adsorbed *Mycoplasma gallisepticum* bacterin in chickens. *Avian Dis*. 31:149–155.
458. Yagihashi, T., T. Nunoya, S. Sannai, and M. Tajima. 1992. Comparison of immunity induced with a *Mycoplasma gallisepticum* bacterin between high- and low-responder lines of chickens. *Avian Dis*. 36:125–133.
459. Yamamoto, R., and H.E. Adler. 1956. The effect of certain antibiotics and chemical agents on pleuropheumonia-like agents of avian origin. *Amer J Vet Res*. 17:538–542.
460. Yamamoto, Y., and H.E. Adler. 1958. Characteristics of pleuropneumonia-like organisms of avian origin. II. Cultural, biochemical, morphological and further serological studies. *J Infect Dis*. 102:243–250.
461. Yamamoto, Y., and H.E. Adler. 1958. Characterization of pleuropneumonia-like organisms of avian origin. 1. Antigenic analysis of seven strains and their comparative pathogenicity for birds. *J Infect Dis*. 102:143–152.
462. Yoder, H.W., Jr. 1964. Characterization of avian Mycoplasma. *Avian Dis*. 8:481–512.
463. Yoder, H.W., Jr. 1970. Preincubation heat treatment of chicken hatching eggs to inactivate mycoplasma. *Avian Dis*. 14:75–86.
464. Yoder, H.W., Jr. 1986. A historical account of the diagnosis and characterization of strains of *Mycoplasma gallisepticum* of low virulence. *Avian Dis*. 30:510–518.
465. Yoder, H.W., Jr. 1988. Unpublished data.
466. Yoder, H.W., Jr. 1989. Nonspecific reactions to Mycoplasma serum plate antigens induced by inactivated poultry disease vaccines. *Avian Dis*. 33:60–68.
467. Yoder, H.W., Jr., and M.S. Hofstad. 1965. Evaluation of tylosin in preventing egg transmission of *Mycoplasma gallisepticum* in chickens. *Avian Dis*. 9:291–301.
468. Yoder, H.W., Jr., and S.R. Hopkins. 1985. Efficacy of experimental inactivated *Mycoplasma gallisepticum* oil-emulsion bacterin in egg-layer chickens. *Avian Dis*. 29:322–334.
469. Yoder, H.W., Jr., S.R. Hopkins, and B.W. Mitchell. 1984. Evaluation of inactivated *Mycoplasma gallisepticum* oil-emulsion bacterins for protection against airsacculitis in broilers. *Avian Dis*. 28:224–234.
470. Yogev, D., S. Levisohn, S.H. Kleven, D. Halachmi, and S. Razin. 1988. Ribosomal RNA gene probes to detect intraspecies heterogeneity in *Mycoplasma gallisepticum* and *M. synoviae*. *Avian Dis*. 32:220–231.
471. Yogev, D., D. Menaker, K. Strutzberg, S. Levisohn, H. Kirchhoff, K.H. Hinz, and R. Rosengarten. 1994. A surface epitope undergoing high-frequency phase variation is shared by *Mycoplasma gallisepticum* and *Mycoplasma bovis*. *Infect Immun*. 62:4962–4968.
472. Yoshida, S., A. Fujisawa, Y. Tsuzaki, and S. Saitoh. 2000. Identification and expression of a *Mycoplasma gallisepticum* surface antigen recognized by a monoclonal antibody capable of inhibiting both growth and metabolism. *Infect Immun*. 68:3186–3192.
473. Zain, Z.M., and J.M. Bradbury. 1995. The influence of type of swab and laboratory method on the recovery of *Mycoplasma gallisepticum* and *Mycoplasma synoviae* in broth medium. *Avian Pathol*. 24:707–716.
474. Zain, Z.M., and J.M. Bradbury. 1996. Optimising the conditions for isolation of *Mycoplasma gallisepticum* collected on applicator swabs. *Vet Microbiol*. 49:45–57.
475. Zaki, M.M., N. Ferguson, V. Leiting, and S.H. Kleven. 2004. Safety of *Mycoplasma gallisepticum* vaccine strain 6/85 after backpassage in turkeys. *Avian Dis*. 48:642–646.
476. Zander, D.V. 1961. Origin of S6 strain Mycoplasma. *Avian Dis*. 5:154–156.
477. Zanella, A., P.A. Martino, A. Pratelli, and M. Stonfer. 1998. Development of antibiotic resistance in *Mycoplasma gallisepticum in vitro*. *Avian Pathol*. 27:591–596.

478. Zhang, G.Z., R. Zhang, H.L. Zhao, X.T. Wang, S.P. Zhang, X. J. Li, C.Z. Qin, C.M. Lv, J.X. Zhao, and J.F. Zhou. 2010. A safety assessment of a fowlpox-vectored *Mycoplasma gallisepticum* vaccine in chickens. *Poult Sci*. 89:1301–1306.
479. Zhang, J., Y. Guo, S. Hu, D. Bi, X. Wang, Y. Xiao, X. Gao, Z. Li, M. Liu, F. Peng, and Q. Xu. 2011. An adhesion molecule-based colloidal gold immunochromatography assay strip for rapidly and specifically detecting chicken antibodies against *Mycoplasma gallisepticum*. *Res Vet Sci*. 90:379–384.

Mycoplasma meleagridis Infection

1. Abdelmoumen, B.B., and R.S. Roy. 1995. An enzyme-linked immunosorbent assay for detection of avian mycoplasma in culture. *Avian Dis*. 39:85–93.
2. Adler, H. 1958. A PPLO slide agglutination test for the detection of infectious sinusitis of turkeys. *Poult Sci*. 37:1116–1123.
3. Adler, H.E., and A.J. DaMassa. 1964. Enhancement of *Mycoplasma* agglutination titers by use of anti-globulin. *Proc Soc Exp Biol Med*. 116:608–610.
4. Adler, H.E., J. Fabricant, R. Yamamoto, and J. Berg. 1958. Symposium on chronic respiratory diseases of poultry. I. Isolation and identification of pleuropneumonia-like organisms of avian origin. *Am J Vet Res*. 19:440–447.
5. Allen, T.C. 1971. Base composition and genome size of *Mycoplasma meleagridis* deoxyribonucleic acid. *J Gen Microbiol*. 69:285–286.
6. Anderson, D.P., R.R. Wolfe, F.L. Cherms, and W.E. Roper. 1968. Influence of dust and ammonia on the development of air sac lesions in turkeys. *Am J Vet Res*. 29:1049–1058.
7. Arya, P.L., J.H. Sautter, and B.S. Pomeroy. 1971. Pathogenesis and histopathology of airsacculitis in turkeys produced by experimental inoculation of day-old poults with *Mycoplasma meleagridis*. *Avian Dis*. 15:163–176.
8. Ball, R.A., V.B. Singh, and B.S. Pomeroy. 1969. The morphologic response of the turkey oviduct to certain pathogenic agents. *Avian Dis*. 13:119–133.
9. Beard, C.W., and D.P. Anderson. 1967. Aerosol studies with avian *Mycoplasma*. I. Survival in the air. *Avian Dis*. 11:54–59.
10. Béjaoui Khiari, A., A. Landoulsi, H. Aissa, B. Mlik, F. Amouna, A. Ejlassi, and B. Ben Abdelmoumen Mardassi. 2011. Isolation of *Mycoplasma meleagridis* from chickens. *Avian Dis*. 55:8–12.
11. Ben Abdelmoumen Mardassi, B., A. Béjaoui, L. Oussaeif, B. Mlik, and F. Amouna. 2008. A recombinant antigen-based ELISA for the simultaneous differential serodiagnosis of *Mycoplasma gallisepticum, Mycoplasma synoviae*, and *Mycoplasma meleagridis* infections. *Avian Dis*. 52:214–221.
12. Bigland, C.H. 1969. Natural resolution of air sac lesions caused by *Mycoplasma meleagridis* in turkeys. *Can J Comp Med*. 33: 169–172.
13. Bigland, C.H. 1970. Experimental control of *Mycoplasma meleagridis* in turkeys by the dipping of eggs in tylosin and spiramycin. *Can J Comp Med*. 34:26–30.
14. Bigland, C.H. 1972. The tissue localization of *Mycoplasma meleagridis* in turkey embryos. *Can J Comp Med*. 36:99–102.
15. Bigland, C.H., and M.L. Benson. 1968. *Mycoplasma meleagridis* ("N"-strain mycoplasma-PPLO): Relationship of airsac lesions and isolations in day-old turkeys (*Meleagridis gallopavo*). *Can Vet J*. 9:138–141.
16. Bigland, C.H., W. Dungan, R. Yamamoto, and J.C. Voris. 1964. Airsacculitis in poults from different strains of turkeys. *Avian Dis*. 8:85–92.
17. Bigland, C.H., and F.T.W. Jordan. 1974. Experimental relationship of biotin and *Mycoplasma meleagridis* in the etiology of turkey syndrome 1965. *Proc Western Poult Dis Conf*. 23:55–61.
18. Bigland, C.H., and J.J. Matsumoto. 1975. Nonspecific reaction to Mycoplasma antigens caused in turkey sera by *Erysipelothrix insidiosa* bacterins. *Avian Dis*. 19:617–621.
19. Bigland, C.H., and M.W. Warenycia. 1978. Effects of biotin, folic acid and pantothenic acid on the growth of *Mycoplasma meleagridis*, a turkey pathogen. *Poult Sci*. 57:611–618.
20. Bigland, C.H., M.W. Warenycia, and M. Denson. 1979. Specific immune gammaglobulin in the control of *Mycoplasma meleagridis*. *Poult Sci*. 58:319–328.
21. Boyle, J.S., R.T. Good, and C.J. Morrow. 1995. Detection of the turkey pathogens *Mycoplasma meleagridis* and *M. iowae* by amplification of genes coding for rRNA. *J Clin Microbiol*. 33:1335–1338.
22. Bradbury, J.M., and M. McClenaghan. 1982. Detection of mixed *Mycoplasma* species. *J Clin Microbiol*. 16:314–318.
23. Braunius, W.W. 1987. Effect of Baytril (Bay Vp 2674) on young turkeys with respiratory infection. *Tijdschr Diergeneeskd*. 12: 531–533.
24. Brown, K.I., and K.E. Nestor. 1974. Interrelationships of cellular physiology and endocrinology with genetics. 2. Implications of selection for high and low adrenal response to stress. *Poult Sci*. 53:1297–1306.
25. Brunner, H., and G. Laber. 1985. Chemotherapy of Mycoplasma infections. In: The *Mycoplasma IV. Mycoplasma Pathogenicity*. S. Razin and M.F. Barile, eds. Academic Press, Orlando, Florida. 403–450.
26. Cardona, C.J., and A.A. Bickford. 1993. Wry necks associated with *Mycoplasma meleagridis* infection in a backyard flock of turkeys. *Avian Dis*. 37:240–243.
27. Carpenter, T.E. 1983. A microeconomic evaluation of the impact of *Mycoplasma meleagridis* infection in turkey production. *Prev Vet Med*. 1:289–301.
28. Carpenter, T.E., R.K. Edson, and R. Yamamoto. 1981. Decreased hatchability of turkey eggs caused by experimental infection with *Mycoplasma meleagridis*. *Avian Dis*. 25:151–156.
29. Carpenter, T.E., H.P. Riemann, and C.E. Franti. 1982. The effect of *Mycoplasma meleagridis* infection and egg dipping on the weight-gain performance of turkey poults. *Avian Dis*. 26:272–278.
30. Carpenter, T.E., H.P. Riemann, and R.H. McCapes. 1982. The effect of experimental turkey embryo infection with *Mycoplasma meleagridis* on weight, weight gain, feed consumption, and conversion. *Avian Dis*. 26:689–695.
31. Cherms, F.L., and M.L. Frey. 1967. *Mycoplasma meleagridis* and fertility in turkey breeder hens. *Avian Dis*. 11:268–274.
32. Chin, R.P., G.Y. Ghazikhanian, and I. Kempf. 2008. *Mycoplasma meleagridis* infection. In: *Diseases of Poultry*, 12th ed. Y.M. Saif, A.M. Fadly, J.R. Glisson, L.R. McDougald, L.K. Nolan and D.E. Swayne, eds. Blackwell Publishing, Ames, Iowa. 834–845.
33. Corstvet, R.E., and W.W. Sadler. 1964. The diagnosis of certain avian diseases with the fluorescent antibody technique. *Poult Sci*. 43:1280–1288.
34. Cummins, D.R., and D.L. Reynolds. 1990. Use of an avidin-biotin enhanced dot-immunobinding assay to detect antibodies for avian mycoplasma in sera from Iowa market turkeys. *Avian Dis*. 34:321–328.

35. Curtis, M.J., and G.A. Thornton. 1973. The effect of heat killed *Mycoplasma gallisepticum* and *M. meleagridis* on plasma caeruloplasmin activity in the fowl. *Res Vet Sci*. 15:399–401.
36. DaMassa, A.J., and H.E. Adler. 1969. Effect of pH on growth and survival of three avian and one saprophytic *Mycoplasma* species. *Appl Microbiol*. 17:310–316.
37. Dierks, R.E., J.A. Newman, and B.S. Pomeroy. 1967. Characterization of avian *Mycoplasma*. *Ann NY Acad Sci*. 143:170–189.
38. Dufour-Gesbert, F., I. Kempf, F. De Simone, and M. Kobisch. 2001. Antigen heterogeneity and epitope variable expression in *Mycoplasma meleagridis* isolates. *Vet Microbiol*. 78:261–273.
39. Dufour-Gesbert, F., I. Kempf, and M. Kobisch. 2001. Development of a blocking enzyme-linked immunosorbent assay for detection of turkey antibodies to *Mycoplasma meleagridis*. *Vet Microbiol*. 78:275–284.
40. Edson, R.K. 1980. *Mycoplasma meleagridis* infection of turkeys: Motivation, methods, and predictive tools for eradication. PhD dissertation, University of California, Davis, CA.
41. Edson, R.K., R. Yamamoto, H.B. Ortmayer, and D.E. Massey. 1979. The effect of *Mycoplasma meleagridis* on hatchability of turkey eggs. *Proceedings of the 28th Western Poultry Disease Conference and 13th Poultry Health Symposium*. Davis, California. 24–29.
42. El-Ebeedy, A.A., M.E.S. Easa, M.Z. Sabey, M.A. Hafez, A.M. Ammar, and A. Rashwan. 1982. Pathological changes in air sacs and lungs of turkey poults after experimental inoculation with different isolates of *Mycoplasma meleagridis*. *J Egypt Vet Med Assoc*. 42:91–100.
43. Elmahi, M.M., and M.S. Hofstad. 1979. Prevention of egg transmission of *Mycoplasma meleagridis* by antibiotic treatment of naturally and experimentally infected turkey eggs. *Avian Dis*. 23:88–94.
44. Elmahi, M.M., R.F. Ross, and M.S. Hofstad. 1982. Comparison of seven isolates of *Mycoplasma meleagridis*. *Vet Microbiol*. 7:61–76.
45. Fan, H.H., S.H. Kleven, M.W. Jackwood, K.E. Johansson, B. Pettersson, and S. Levisohn. 1995. Species identification of avian mycoplasmas by polymerase chain reaction and restriction fragment length polymorphism analysis. *Avian Dis*. 39: 398–407.
46. Ferrier, W.T., H.B. Ortmayer, F.X. Ogasawara, and R. Yamamoto. 1982. The survivability of *Mycoplasma meleagridis* in frozen-thawed turkey semen. *Poult Sci*. 61:379–381.
47. Fox, M.L., and C.H. Bigland. 1970. Differences between cull and normal turkeys in natural infection with *Mycoplasma meleagridis* at one day of age. *Can J Comp Med*. 34:285–288.
48. Freundt, E.A. 1983. Culture media for classic mycoplasmas. In: *Methods in Mycoplasmology*, vol. I. *Mycoplasma Characterization*. S. Razin and J.G. Tully, eds. Academic Press, New York. 127–135.
49. Frey, M.L., R.P. Hanson, and D.P. Anderson. 1968. A medium for the isolation of avian *Mycoplasmas*. *Am J Vet Res*. 29: 2163–2171.
50. Frey, M.L., S.T. Hawk, and P.A. Hale. 1972. A division by microcomplement fixation tests of previously reported avian mycoplasma serotypes into identification groups. *Avian Dis*. 16:780–792.
51. Garcia, M., I. Gerchman, R. Meir, M.W. Jackwood, S.H. Kleven, and S. Levisohn. 1997. Detection of *Mycoplasma meleagridis* and *M. iowae* from dead-in-shell turkey embryos by polymerase chain reaction and culture. *Avian Pathol*. 26: 765–778.
52. Gerlach, H., R. Yamamoto, and H.B. Ortmayer. 1968. Zur Pathologie der Phallus-Infektion der Puten mit Mycoplasma meleagridis. *Arch Gefluegelkd*. 32:396–399.
53. Ghazikhanian, G., and R. Yamamoto. 1969. Tylosin resistant strains of *Mycoplasma meleagridis*. *Proc West Poult Dis Conf*. 18:36–37.
54. Ghazikhanian, G., and R. Yamamoto. 1974. Characterization of pathogenic and nonpathogenic strains of *Mycoplasma meleagridis*: *In ovo* and *in vitro* studies. *Am J Vet Res*. 35:425–430.
55. Ghazikhanian, G., and R. Yamamoto. 1974. Characterization of pathogenic and nonpathogenic strains of *Mycoplasma meleagridis*: Manifestations of disease in turkey embryos and poults. *Am J Vet Res*. 35:417–424.
56. Ghazikhanian, G., R. Yamamoto, R.H. McCapes, W.M. Dungan, and H.B. Ortmayer. 1980. Combination dip and injection of turkey eggs with antibiotics to eliminate *Mycoplasma meleagridis* infection from a primary breeding stock. *Avian Dis*. 24:57–70.
57. Gordon, R.F. (Chairman). 1965. Report of Working Party. A new syndrome in turkey poults. *Vet Rec*. 77:1292.
58. Green, F.I., and R.P. Hanson. 1973. Ultrastructure and capsule of *Mycoplasma meleagridis*. *J Bacteriol*. 116:1011–1018.
59. Grimes, T.M. 1972. Means of obtaining *Mycoplasma*-free turkeys in Australia. *Aust Vet*. 48:124.
60. Hagen, C.A., S.S. Crupper, R.D. Applegate, and R.J. Robel. 2002. Prevalence of mycoplasma antibodies in lesser prairie-chicken sera. *Avian Dis*. 46:708–712.
61. Hamdy, A.H., C.J. Farho, C.J. Blanchard, and M.W. Glenn. 1969. Effect of lincomycin and spectinomycin on airsacculitis of turkey poults. *Avian Dis*. 13:721–728.
62. Hamdy, A.H., Y.M. Saif, and C.W. Kasson. 1982. Efficacy of lincomycin-spectinomycin water medication on *Mycoplasma meleagridis* airsacculitis in commercially reared turkey poults. *Avian Dis*. 26:227–233.
63. Hofstad, M.S. 1974. The injection of turkey hatching eggs with tylosin to eliminate *Mycoplasma meleagridis* infection. *Avian Dis*. 18:134–138.
64. Hollamby, S., J.G. Sikarskie, and J. Stuht. 2003. Survey of peafowl (*Pavo cristatus*) for potential pathogens at three Michigan zoos. *J Zoo Wildl Med*. 34:375–379.
65. Ibrahim, A.A., and R. Yamamoto. 1977. Arginine catabolism by *Mycoplasma meleagridis* and its role in pathogenesis. *Infect Immun*. 18:226–229.
66. Ibrahim, A.A., and R. Yamamoto. 1977. Morphology and growth cycle of *Mycoplasma meleagridis* viewed by scanning-electron microscopy. *Avian Dis*. 21:415–421.
67. Imada, Y., I. Uchida, and K. Hashimoto. 1987. Rapid identification of mycoplasma by indirect immunoperoxidase test using small square filter paper. *J Clin Microbiol*. 25:17–21.
68. Jordan, F.T.W. 1983. Recovery and identification of avian mycoplasmas. In: *Methods in Mycoplasmology*, vol. 2., *Diagnostic Mycoplasmology*. J.G. Tully and S. Razin, eds. Academic Press, New York. 69–79.
69. Jordan, F.T.W., and M.M. Amin. 1978. The influence of preincubation heating of turkey eggs on *Mycoplasma* infection. *Avian Pathol*. 7:349–355.
70. Jordan, F.T.W., B.L. Nutor, and S. Bozkur. 1982. The survival and recognition of *Mycoplasma meleagridis* grown at 37°C and then maintained at room temperature. *Avian Pathol*. 11: 123–129.

71. Kleckner, A.L. 1960. Serotypes of avian pleuropneumonia-like organisms. *Am J Vet Res*. 21:274–280.
72. Kleven, S.H. 2008. Mycoplasmosis. In: *A Laboratory Manual for the Isolation, Identification and Characterization of Avian Pathogens*, 5th ed. L. Dufour-Zavala, D.E. Swayne, J.R. Glisson, J.E. Pearson, W.M. Reed, M.W. Jackwood, and P.R. Woolcock, eds. American Association of Avian Pathologists, Jacksonville, Florida. 59–64.
73. Kleven, S.H., and B.S. Pomeroy. 1971. Characterization of the antibody response of turkeys to *Mycoplasma meleagridis*. *Avian Dis*. 15:291–298.
74. Kleven, S.H., and B.S. Pomeroy. 1971. Role of the female in egg transmission of *Mycoplasma meleagridis* in turkeys. *Avian Dis*. 15:299–304.
75. Kleven, S.H., B.S. Pomeroy, and R.C. Nelson. 1971. Ineffectiveness of antibiotic treatment of semen in the prevention of egg transmission of *Mycoplasma meleagridis* in turkeys. *Poult Sci*. 50:1522–1526.
76. Kumar, M.C., S. Kumar, R.E. Dierks, J.A. Newman, and B.S. Pomeroy. 1966. Airsacculitis in turkeys. II. Use of tylosin in the control of the egg transmission of *Mycoplasma* spp. other than *Mycoplasma gallisepticum* in turkeys. *Avian Dis*. 10:194–198.
77. Kumar, M.C., and B.S. Pomeroy. 1969. Transmission of *Mycoplasma meleagridis* in turkeys. *Am J Vet Res*. 30: 1423–1436.
78. Kumar, S., R.E. Dierks, J.A. Newman, C.I. Pfow, and B.S. Pomeroy. 1963. Airsacculitis in turkeys. I. A study of airsacculitis in day-old poults. *Avian Dis*. 7:376–385.
79. Lam, K.M. 2004. Pathogenicity of *Mycoplasma meleagridis* for chicken cells. *Avian Dis*. 48:916–920.
80. Lam, K.M., A.J. DaMassa, and G.Y. Ghazikhanian. 2003. Infection of the turkey embryonic trachea with *Mycoplasma meleagridis*. *Avian Pathol*. 32:289–293.
81. Lam, K.M., A.J. DaMassa, and G.Y. Ghazikhanian. 2003. Interactions between the membranes of turkey cells and *Mycoplasma meleagridis*. *Avian Dis*. 47:611–617.
82. Lam, K.M., A.J. DaMassa, and G.Y. Ghazikhanian. 2004. *Mycoplasma meleagridis*-induced lesions in the tarsometatarsal joints of turkey embryos. *Avian Dis*. 48:505–511.
83. Lauerman, L.H., A.R. Chilina, J.A. Closser, and D. Johansen. 1995. Avian mycoplasma identification using polymerase chain reaction amplicon and restriction fragment length polymorphism analysis. *Avian Dis*. 39:804–811.
84. Levisohn, S. 1981. Antibiotic sensitivity patterns in field isolates of *Mycoplasma gallisepticum* as a guide to chemotherapy. *Isr J Med Sci*. 17:661–666.
85. Lierz, M., R. Schmidt, L. Brunnberg, and M. Runge. 2000. Isolation of *Mycoplasma meleagridis* from free-ranging birds of prey in Germany. *J Vet Med, Series B*. 47:63–67.
86. Matsumoto, M., and R. Yamamoto. 1971. Inactivation of *Mycoplasma meleagridis* by immune serum or heat treatment. *Proc West Poult Dis Conf*. 20:70–74.
87. Matsumoto, M., and R. Yamamoto. 1973. Demonstration of complement-dependent and independent systems in immune inactivation of *Mycoplasma meleagridis*. *J Inf Dis*. 127: S43–S51.
88. Matzer, N. 1972. *Mycoplasma meleagridis* in Guatemalan turkeys. *Avian Dis*. 16:945–948.
89. Matzer, N., and R. Yamamoto. 1970. Genital pathogenesis of *Mycoplasma meleagridis* in virgin turkey hens. *Avian Dis*. 14:321–329.
90. Matzer, N., and R. Yamamoto. 1974. Further studies on the genital pathogenesis of *Mycoplasma meleagridis*. *J Comp Pathol*. 84:271–278.
91. McCapes, R.H., R. Yamamoto, G. Ghazikhanian, W.M. Dungan, and H.B. Ortmayer. 1977. Antibiotic egg injection to eliminate disease. I. Effect of injection methods on turkey hatchability and *Mycoplasma meleagridis* infection. *Avian Dis*. 21:57–68.
92. McCapes, R.H., R. Yamamoto, H.B. Ortmayer, and W.F. Scott. 1975. Injecting antibiotics into turkey hatching eggs to eliminate *Mycoplasma meleagridis* infection. *Avian Dis*. 19:506–514.
93. Moalic, P.Y., F. Gesbert, and I. Kempf. 1998. Utility of an internal control for evaluation of a *Mycoplasma meleagridis* PCR test. *Vet Microbiol*. 15:41–49.
94. Moalic, P.Y., F. Gesbert, F. Laigret, and I. Kempf. 1997. Evaluation of polymerase chain reaction for detection of *Mycoplasma meleagridis* infection in turkeys. *Vet Microbiol*. 58:187–193.
95. Mohamed, Y.S., and E.H. Bohl. 1967. Studies on the transmission of *Mycoplasma meleagridis*. *Avian Dis*. 11:634–641.
96. Mohamed, Y.S., and E.H. Bohl. 1968. Serologic studies on *Mycoplasma meleagridis* in turkeys. *Avian Dis*. 12:554–566.
97. Mohamed, Y.S., S. Chema, and E.H. Bohl. 1966. Studies on *Mycoplasma* of the "H" serotype (*Mycoplasma meleagridis*) in the reproductive and respiratory tracts of turkeys. *Avian Dis*. 10:347–352.
98. Moorhead, P.D., and Y.S. Mohamed. 1968. Case report: Pathologic and microbiologic studies of crooked-neck in a turkey flock. *Avian Dis*. 12:476–482.
99. Moorhead, P.D., and Y.M. Saif. 1970. *Mycoplasma meleagridis* and *Escherichia* coli infections in germ-free and specific pathogen free turkey poults: Pathologic manifestations. *Am J Vet Res*. 31:1645–1653.
100. Nelson, R.C. 1971. Evaluation of egg dipping (1967–70). *Symp on Leg Weakness in Turkeys*. Iowa State University Press. 13–21.
101. Nelson, R.C., W.M. Dungan, and C.T. Larsen. 1974. Comparison of the performance of *Mycoplasma meleagridis*-free and infected poults. *Proc Western Poult Dis Conf*. 23: 66–69.
102. Newman, J.A. 1967. The detection and control of *Mycoplasma meleagridis*. PhD dissertation, University of Minnesota, St. Paul, MN.
103. O'Brien, J.D.P. 1979. Effect of *Mycoplasma meleagridis* on hatchability. *Proc Western Poult Dis Conf*. 28:29–31.
104. Ogra, M.S., and E.H. Bohl. 1970. Growth-inhibition test for identifying *Mycoplasma meleagridis* and its antibody. *Avian Dis*. 14:364–373.
105. Ortiz, A.M., R. Yamamoto, A.A. Benedict, and A.P. Mateos. 1981. The immunosuppressive effect of *Mycoplasma meleagridis* on nonreplicating antigens. *Avian Dis*. 25:954–963.
106. Ortmayer, H.B. 1970. A cultural field screening procedure for detection of *Mycoplasma meleagridis* in the reproductive tract of turkeys. MS thesis, University of California, Davis, CA.
107. Ortmayer, H.B., and R. Yamamoto. 1981. *Mycoplasma meleagridis* antibody detection by enzyme-linked immunosorbent assay (ELISA). *Proc Western Poult Dis Conf*. 30:63–66.
108. Peterson, I.L. 1968. Field significance of *Mycoplasma meleagridis* infection. *Poult Sci*. 47:1708–1709.
109. Pohl, R. 1969. Airsacculitis and pantothenic acid-biotin deficiency in turkeys in New Zealand. *NZ Vet J*. 7:183.

110. Raviv, Z., and S.H. Kleven. The development of diagnostic real-time TaqMan PCRs for the four pathogenic avian mycoplasmas. 2009. *Avian Dis*. 53:103–107.
111. Reis, R., J.M.L. DaSilva, and R. Yamamoto. 1970. Pathologic changes in the joint and other organs of turkey poults after intravenous inoculation of *Mycoplasma meleagridis*. *Avian Dis*. 14:117–125.
112. Reis, R., and R. Yamamoto. 1971. Pathogenesis of single and mixed infections caused by *Mycoplasma meleagridis* and *Mycoplasma gallisepticum* in turkey embryos. *Am J Vet Res*. 32:63–74.
113. Resende, M., R. Reis, and P.P. Ornellas-Santos. 1969. *Mycoplasma* of poultry origin. III. Identification of *Mycoplasma meleagridis*. *Arq Esc Vet*. 21:157–161.
114. Rhoades, K. 1977. Turkey sinusitis: Synergism between *Mycoplasma synoviae* and *Mycoplasma meleagridis*. *Avian Dis*. 21:670–674.
115. Rhoades, K.R. 1969. Experimentally induced *Mycoplasma meleagridis* infection of turkey reproductive tracts. *Avian Dis*. 13:508–519.
116. Rhoades, K.R. 1969. A hemagglutination-inhibition test for *Mycoplasma meleagridis* antibodies. *Avian Dis*. 13:22–26.
117. Rhoades, K.R. 1971. *Mycoplasma meleagridis* infection: Development of air sac lesions in turkey poults. *Avian Dis*. 15:910–922.
118. Rhoades, K.R. 1971. *Mycoplasma meleagridis* infection: Development of lesions and distribution of infection in turkey embryos. *Avian Dis*. 15:762–774.
119. Rhoades, K.R. 1971. *Mycoplasma meleagridis* infection: Reproductive tract lesions in mature turkeys. *Avian Dis*. 15:722–729.
120. Rhoades, K.R. 1978. Comparison of *Mycoplasma meleagridis* antibodies demonstrated by tube agglutination and hemagglutination-inhibition test. *Avian Dis*. 22:633–638.
121. Rhoades, K.R. 1978. Inhibition of avian mycoplasmal hemagglutination by IgM type antibody. *Poult Sci*. 57:608–610.
122. Rhoades, K.R. 1981. Pathogenicity of strains of the I J K N Q R group of avian mycoplasmas for turkey embryos and poults. *Avian Dis*. 25:104–111.
123. Rhoades, K.R. 1981. Turkey airsacculitis: Effect of mixed mycoplasmal infections. *Avian Dis*. 25:131–135.
124. Rosenfeld, L.E., and T.M. Grimes. 1972. Natural and experimental cases of airsacculitis associated with *Mycoplasma meleagridis* infections in turkeys. *Aust Vet J*. 48:240–243.
125. Rott, M., H. Pfutzner, H. Gigas, and B. Mach. 1989. Die Nachweishaufigkeit von Mycoplasma meleagridis bei Repro duktionsputen in Abhangigkeit vom Legealter. *Arch Exper Vet Med Leipzig*. 43:737–741.
126. Saif, Y.M., and K.I. Brown. 1972. Treatment of turkey semen to eliminate *Mycoplasma meleagridis*. *Turkey Res, Ohio Agric Res Cent*. Wooster, Ohio. 49–50.
127. Saif, Y.M., L.C. Ferguson, and K.E. Nestor. 1971. Treatment of turkey hatching eggs for control of *Arizona* infection. *Avian Dis*. 15:448–461.
128. Saif, Y.M., P.D. Moorhead, and E.H. Bohl. 1970. *Mycoplasma meleagridis* and *Escherichia coli* infections in germfree and specific pathogen free turkey poults: Production of complicated airsacculitis. *Am J Vet Res*. 31:1637–1643.
129. Saif, Y.M., K.E. Nestor, and K.E. McCracken. 1970. Tylosin tartrate absorption of turkey and chicken eggs dipped using pressure and temperature differentials. *Poult Sci*. 49:1641–1649.
130. Sharp, P., P. Van Ess, B. Ji, and C.B. Thomas. 1991. Immunobinding assay for the speciation of avian mycoplasmas adapted for use with a 96-well filtration manifold. *Avian Dis*. 35:332–336.
131. Shimizu, T., and T. Yagihashi. 1980. Isolation of *Mycoplasma meleagridis* from turkeys in Japan. *Jpn J Vet Sci*. 42:41–47.
132. Sokkar, I.M., A.M. Soliman, S. Mousa, and M.Z. El-Demerdash. 1986. *In-vitro* sensitivity of mycoplasma and associated bacteria isolated from chickens and turkeys and ducks at the area of Upper Egypt. *Assiut Vet Med J*. 15:243–250.
133. Stipkovits, L., G. Laber, and E. Schultze. 1977. Prophylactical and therapeutical efficacy of tiamuline in mycoplasmosis of chickens and turkeys. *Poult Sci*. 56:1209–1215.
134. Takahata, T., R. Yamamoto, and H.B. Ortmayer. 1994. Unpublished data.
135. Thornton, G.A., D.R. Wise, and M.K. Fuller. 1975. A *Mycoplasma meleagridis* haemagglutination-inhibition test. *Vet Rec*. 96:113–114.
136. Uppal, P.K., D.R. Wise, and M.K. Boldero. 1972. Ultrastructural characteristics of *Mycoplasma gallisepticum*, *M. gallinarum and M. meleagridis. Res Vet Sci*. 13:200–201.
137. Vlaovic, M.S., and C.H. Bigland. 1971. The attempted immunization of turkey hens with viable *Mycoplasma meleagridis*. *Can J Comp Med*. 35:338–341.
138. Vlaovic, M.S., and C.H. Bigland. 1971. A review of mycoplasma infections relative to *Mycoplasma meleagridis*. *Can Vet J*. 12:103–109.
139. Wise, D.R., M.K. Boldero, and G.A. Thornton. 1973. The pathology and aetiology of turkey syndrome ’65 (T.S.65). *Res Vet Sci*. 14:194–200.
140. Wise, D.R., and M.K. Fuller. 1975. Experimental reproduction of turkey syndrome ’65 with *Mycoplasma meleagridis* and *Mycoplasma gallisepticum* and associated changes in serum protein characteristics. *Res Vet Sci*. 19:201–203.
141. Wise, D.R., M.K. Fuller, and G.A. Thornton. 1974. Experimental reproduction of turkey syndrome ’65 with *Mycoplasma meleagridis*. *Res Vet Sci*. 17:236–241.
142. Yamamoto, R. 1967. Localization and egg transmission of *Mycoplasma meleagridis* in turkeys exposed by various routes. *Ann NY Acad Sci*. 143:225–233.
143. Yamamoto, R. 1978. Mycoplasma meleagridis infection. In: *Diseases of Poultry*, 7th ed. M.S. Hofstad, B.W. Calnek, C.F. Helmboldt, W.M. Reid, and H.W. Yoder, Jr., eds. Iowa State University Press, Ames, Iowa. 250–260.
144. Yamamoto, R. 1991. Mycoplasma meleagridis infection. In: *Diseases of Poultry*, 9th ed. H.J. Barnes, B.W. Calnek, C.W. Beard, W.M. Reid, and H.W. Yoder, Jr., eds. Iowa State University Press, Ames, Iowa. 212–223.
145. Yamamoto, R., and C.H. Bigland. 1966. Infectivity of *Mycoplasma meleagridis* for turkey embryos. *Am J Vet Res*. 27:326–330.
146. Yamamoto, R., and C.H. Bigland. 1964. Pathogenicity to chicks of *Mycoplasma* associated with turkey airsacculitis. *Avian Dis*. 8:523–531.
147. Yamamoto, R., and C.H. Bigland. 1965. Experimental production of airsacculitis in turkey poults by inoculation with “N”-type *Mycoplasma*. *Avian Dis*. 9:108–118.
148. Yamamoto, R., C.H. Bigland, and H.B. Ortmayer. 1965. Characteristics of *Mycoplasma meleagridis* sp. n., isolated from turkeys. *J Bacteriol*. 90:47–49.

149. Yamamoto, R., C.H. Bigland, and H.B. Ortmayer. 1966. Sensitivity of *Mycoplasma meleagridis* to various antibiotics. *Poult Sci*. 45:1139.
150. Yamamoto, R., C.H. Bigland, and I.L. Peterson. 1966. Egg transmission of *Mycoplasma meleagridis*. *Poult Sci*. 45:1245–1257.
151. Yamamoto, R., F.H. Kratzer, and H.B. Ortmayer. 1974. Recent research on *Mycoplasma meleagridis*. *Proc Western Poult Dis Conf*. 23:53–54.
152. Yamamoto, R., and A. Ortiz. 1974. Microtiter agglutination test for *Mycoplasma meleagridis*. *Proc World's Poult Congr*. 15:171–172.
153. Yamamoto, R., and H.B. Ortmayer. 1966. Pathogenicity of *Mycoplasma meleagridis* for turkey and chicken embryos. *Avian Dis*. 10:268–272.
154. Yamamoto, R., and H.B. Ortmayer. 1967. Effect of *Mycoplasma meleagridis* on reproductive performance. *Poult Sci*. 46:1340.
155. Yamamoto, R., and H.B. Ortmayer. 1967. Hatcher and intraflock transmission of *Mycoplasma meleagridis*. *Avian Dis*. 11:288–295.
156. Yamamoto, R., and H.B. Ortmayer. 1967. Localization and persistence of avian mycoplasma in the genital system of the mature turkey. *J Am Vet Med Assoc*. 150:1371.
157. Yamamoto, R., and H.B. Ortmayer. 1969. Egg transmission of *Mycoplasma meleagridis* in naturally infected turkeys under different mating systems. *Poult Sci*. 48:1893.
158. Yamamoto, R., and H.B. Ortmayer. 1971. Control of *Mycoplasma meleagridis* (N-strain). *Proc World Vet Congr*. 19:498–501.
159. Yamamoto, R., H.B. Ortmayer, and R.K. Edson. 1978. Microhemagglutination-inhibition test for *Mycoplasma meleagridis*. *Proc World's Poult Congr*. 16:1417–1427.
160. Yamamoto, R., H.B. Ortmayer, and R.K. Edson. 1979. Serology of *Mycoplasma meleagridis*. *Proc Western Poult Dis Conf*. 28:23.
161. Yamamoto, R., H.B. Ortmayer, and C.S. Joshi. 1968. Persistence of *Mycoplasma meleagridis* in the genitalia of experimentally infected turkeys. *Poult Sci*. 47:1734.
162. Yamamoto, R., H.B. Ortmayer, and M. Matsumoto. 1970. Standardization and application of *Mycoplasma meleagridis* agglutination test. *Proc World's Poult Congr Sci Comm*. 14:139–148.
163. Yoder, H.W., Jr. 1970. Preincubation heat treatment of chicken hatching eggs to inactivate mycoplasma. *Avian Dis*. 14:75–86.
164. Yoder, H.W., Jr., and M.S. Hofstad. 1964. Characterization of avian mycoplasma. *Avian Dis*. 8:481–512.
165. Zhao, S., and R. Yamamoto. 1993. Detection of *Mycoplasma meleagridis* by polymerase chain reaction. *Vet Microbiol*. 36: 91–97.
166. Zhao, S., and R. Yamamoto. 1993. Species-specific recombinant DNA probes for *Mycoplasma meleagridis*. *Vet Microbiol*. 35:179–185.
167. Zhao, S., R. Yamamoto, G.Y. Ghazikhanian, and M.I. Khan. 1988. Antigenic analysis of three strains of *Mycoplasma meleagridis* of varying pathogenicity. *Vet Microbiol*. 18:373–377.

Mycoplasma synoviae Infection

1. Ajufo, J.C., and K.G. Whithear. 1980. The surface layer of *Mycoplasma synoviae* as demonstrated by the negative staining technique. *Res Vet Sci*. 29:268–270.
2. Barre, A., A. de Daruvar, and A. Blanchard. 2004. MolliGen, a database dedicated to the comparative genomics of Mollicutes. *Nucleic Acids Res*. 32:D307–310.
3. Baughn, C.O., W.C. Alpaugh, W.H. Linkenheimer, and D.C. Maplesden. 1978. Effect of tiamulin in chickens and turkeys infected experimentally with avian *Mycoplasma*. *Avian Dis*. 22:620–626.
4. Ben Abdelmoumen, B., R.S. Roy, and R. Brousseau. 1999. Cloning of *Mycoplasma synoviae* genes encoding specific antigens and their use as species-specific DNA probes. *J Vet Diagn Invest*. 11:162–169.
5. Bencina, D., D. Dorrer, and T. Tadina. 1987. *Mycoplasma* species isolated from six avian species. *Avian Pathol*. 16:653–664.
6. Bencina, D., T. Tadina, and D. Dorrer. 1988. Natural infection of geese with *Mycoplasma gallisepticum* and *Mycoplasma synoviae* and egg transmission of the mycoplasmas. *Avian Pathol*. 17:925–928.
7. Bencina, D., T. Tadina, and D. Dorrer. 1988. Natural infection of ducks with *Mycoplasma synoviae* and *Mycoplasma gallisepticum* and mycoplasma egg transmission. *Avian Pathol*. 17:441–449.
8. Bencina, D., M. Narat, P. Dovc, M. Drobnic-Valic, F. Habe, and S.H. Kleven. 1999. The characterization of *Mycoplasma synoviae* EF-Tu protein and proteins involved in hemadherence and their N-terminal amino acid sequences. *FEMS Microbiol Lett*. 173:85–94.
9. Bencina, D., M. Drobnic-Valic, S. Horvat, M. Narat, S.H. Kleven, and P. Dovc. 2001. Molecular basis of the length variation in the N-terminal part of *Mycoplasma synoviae* hemagglutinin. *FEMS Microbiol Lett*. 203:115–123.
10. Bencina, D., M. Narat, A. Bidovec, and O. Zorman-Rojs. 2005. Transfer of maternal immunoglobulins and antibodies to *Mycoplasma gallisepticum* and *Mycoplasma synoviae* to the allantoic and amniotic fluid of chicken embryos. *Avian Pathol*. 34:463–472.
11. Bercic, R.L., B. Slavec, M. Lavric, M. Narat, O. Zorman-Rojs, P. Dovc, and D. Bencina. 2008. A survey of avian *Mycoplasma* species for neuraminidase enzymatic activity. *Vet Microbiol*. 130:391–397.
12. Bozeman, L.H., S.H. Kleven, and R.B. Davis. 1984. *Mycoplasma* challenge studies in budgerigars (*Melopsittacus undulatus*) and chickens. *Avian Dis*. 28:426–434.
13. Bradbury, J.M., and L.J. Howell. 1975. The response of chickens to experimental infection '*in ovo*' with *Mycoplasma synoviae*. *Avian Pathol*. 4:277–286.
14. Bradbury, J.M. 1977. Rapid biochemical tests for characterization of the Mycoplasmatales. *J Clin Microbiol*. 5:531–534.
15. Bradbury, J.M., C.A. Yavari, and C.J. Giles. 1994. *In vitro* evaluation of various antimicrobials against *Mycoplasma gallisepticum* and *Mycoplasma synoviae* by the micro-broth method, and comparison with a commercially-prepared test system. *Avian Pathol*. 23:105–115.
16. Bradbury, J.M., C.A. Yavari, and C.M. Dare. 2001. Detection of *Mycoplasma synoviae* in clinically normal pheasants. *Vet Rec*. 148:72–74.
17. Branton, S.L., J.D. May, B.D. Lott, and W.R. Maslin. 1997. Various blood parameters in commercial hens acutely and chronically infected with *Mycoplasma gallisepticum* and *Mycoplasma synoviae*. *Avian Dis*. 41:540–547.
18. Branton, S.L., B.D. Lott, J.D. May, W.R. Maslin, G.T. Pharr, J.E. Brown, and D.L. Boykin. 1999. The effects of F strain *Mycoplasma gallisepticum*, *Mycoplasma synoviae*, and the dual infection in commercial layer hens over a 44-week laying cycle when challenged before beginning of lay. II. Egg size distribution. *Avian Dis*. 43:326–330.

19. Buim, M.R., M. Buzinhani, M. Yamaguti, R.C. Oliveira, E. Mettifogo, P.M. Ueno, J. Timenetsky, G.M. Santelli, and A.J. Ferreira. 2011. *Mycoplasma synoviae* cell invasion: elucidation of the *Mycoplasma* pathogenesis in chicken. *Comp Immunol Microbiol Infect Dis*. 34:41–47.
20. Carnaghan, R.B.A. 1961. Egg transmission of infectious synovitis. *J Comp Pathol*. 71:279–285.
21. Catania, S., D. Bilato, F. Gobbo, A. Granato, C. Terregino, L. Iob, and R.A. Nicholas. 2010. Treatment of eggshell abnormalities and reduced egg production caused by *Mycoplasma synoviae* infection. *Avian Dis*. 54:961–964.
22. Cerda, R.O., G.I. Giacoboni, J.A. Xavier, P.L. Sansalone, and M.F. Landoni. 2002. *In vitro* antibiotic susceptibility of field isolates of *Mycoplasma synoviae* in Argentina. *Avian Dis*. 46: 215–218.
23. Chalquest, R.R., and J. Fabricant. 1960. Pleuropneumonia-like organisms associated with synovitis in fowls. *Avian Dis*. 4: 515–539.
24. Chalquest, R.R. 1962. Cultivation of the infectious-synovitis-type pleuropneumonia-like organisms. *Avian Dis*. 6:36–43.
25. Chin, R.P., C.U. Meteyer, R. Yamamoto, H.L. Shivaprasad, and P.N. Klein. 1991. Isolation of *Mycoplasma synoviae* from the brains of commercial meat turkeys with meningeal vasculitis. *Avian Dis*. 35:631–637.
26. Christensen, N.H., C.A. Yavari, A.J. McBain, and J.M. Bradbury. 1994. Investigations into the survival of *Mycoplasma gallisepticum*, *Mycoplasma synoviae* and *Mycoplasma iowae* on materials found in the poultry house environment. *Avian Pathol*. 23: 127–143.
27. Corstvet, R.E., and W.W. Sadler. 1964. The diagnosis of certain avian diseases with the fluorescent antibody technique. *Poult Sci*. 43:1280–1288.
28. DaMassa, A.J., and H.E. Adler. 1975. Growth of *Mycoplasma synoviae* in a medium supplemented with nicotinamide instead of B-nicotinamide adenine dinucleotide. *Avian Dis*. 19:544–555.
29. Dierks, R.E., J.A. Newman, and B.S. Pomeroy. 1967. Characterization of avian mycoplasma. *Ann N Y Acad Sci*. 143:170–189.
30. Dufour-Gesbert, F., A. Dheilly, C. Marois, and I. Kempf. 2006. Epidemiological study on *Mycoplasma synoviae* infection in layers. *Vet Microbiol*. 114:148–154.
31. Dusanic, D., R.L. Bercic, I. Cizelj, S. Salmic, M. Narat, and D. Bencina. 2009. *Mycoplasma synoviae* invades non-phagocytic chicken cells *in vitro*. *Vet Microbiol*. 138:114–119.
32. Dusanic, D., D. Bencina, I. Oven, I. Cizelj, M. Bencina, and M. Narat. 2012. *Mycoplasma synoviae* induces upregulation of apoptotic genes, secretion of nitric oxide and appearance of an apoptotic phenotype in infected chicken chondrocytes. *Vet Res*. 43:7.
33. Ewing, M.L., L.H. Lauerman, S.H. Kleven, and M.B. Brown. 1996. Evaluation of diagnostic procedures to detect *Mycoplasma synoviae* in commercial multiplier-breeder farms and commercial hatcheries in Florida. *Avian Dis*. 40:798–806.
34. Ewing, M.L., K.C. Cookson, R.A. Phillips, K.R. Turner, and S.H. Kleven. 1998. Experimental infection and transmissibility of *Mycoplasma synoviae* with delayed serologic response in chickens. *Avian Dis*. 42:230–238.
35. Fan, H.H., S.H. Kleven, and M.W. Jackwood. 1995. Studies of intraspecies heterogeneity of *Mycoplasma synoviae, M. meleagridis*, and *M. iowae* with arbitrarily primed polymerase chain reaction. *Avian Dis*. 39:766–777.
36. Feberwee, A., J.R. Dijkstra, T.E. von Banniseht-Wysmuller, A.L. Gielkens, and J.A. Wagenaar. 2005. Genotyping of *Mycoplasma gallisepticum* and *M. synoviae* by Amplified Fragment Length Polymorphism (AFLP) analysis and digitalized Random Amplified Polymorphic DNA (RAPD) analysis. *Vet Microbiol*. 111:125–131.
37. Feberwee, A., D.R. Mekkes, J.J. de Wit, E.G. Hartman, and A. Pijpers. 2005. Comparison of culture, PCR, and different serologic tests for detection of *Mycoplasma gallisepticum* and *Mycoplasma synoviae* infections. *Avian Dis*. 49:260–268.
38. Feberwee, A., J.J. de Wit, and W.J. Landman. 2009. Induction of eggshell apex abnormalities by *Mycoplasma synoviae*: field and experimental studies. *Avian Pathol*. 38:77–85.
39. Feberwee, A., and W.J. Landman. 2010. Induction of eggshell apex abnormalities in broiler breeder hens. *Avian Pathol*. 39:133–137.
40. Fernandez, C., J.G. Mattsson, G. Bölske, and K.-E. Johansson. 1993. Species-specific oligonucleotide probes complementary to 16S rRNA of *Mycoplasma gallisepticum* and *Mycoplasma synoviae*. *Res Vet Sci*. 55:130–136.
41. Fiorentin, L., M.A.Z. Mores, I.M. Trevisol, S.C. Antunes, J.L.A. Costa, R.A. Soncini, and N.A. Vieira. 2003. Test profiles of broiler breeder flocks housed in farms with endemic *Mycoplasma synoviae* infection. *Brazil J Poult Sci*. 5:37–43.
42. Fiorentin, L., R.A. Soncini, J.L. da Costa, M.A. Mores, I.M. Trevisol, M. Toda, and N.D. Vieira. 2003. Apparent eradication of *Mycoplasma synoviae* in broiler breeders subjected to intensive antibiotic treatment directed to control *Escherichia coli*. *Avian Pathol*. 32:213–216.
43. Fletcher, O.J., D.P. Anderson, and S.H. Kleven. 1976. Histology of air sac lesions induced in chickens by contact exposure to *Mycoplasma synoviae*. *Vet Pathol*. 13:303–314.
44. Frey, M.L., R.P. Hanson, and D.P. Anderson. 1968. A medium for the isolation of avian Mycoplasmas. *Am J Vet Res*. 29: 2163–2171.
45. Furuta, K., Y. Makino, K. Komi, Y. Nakamura, and S. Oda. 1985. Sanitization of a chicken house contaminated with mycoplasmas. *Jpn Poult Sci*. 22:126–133.
46. Garcia, M., M.W. Jackwood, S. Levisohn, and S.H. Kleven. 1995. Detection of *Mycoplasma gallisepticum, M. synoviae*, and *M. iowae* by multi-species polymerase chain reaction and restriction fragment length polymorphism. *Avian Dis*. 39: 606–616.
47. Gautier-Bouchardon, A.V., A.K. Reinhardt, M. Kobisch, and I. Kempf. 2002. *In vitro* development of resistance to enrofloxacin, erythromycin, tylosin, tiamulin and oxytetracycline in *Mycoplasma gallisepticum, Mycoplasma iowae and Mycoplasma synoviae*. *Vet Microbiol*. 88:47–58.
48. Gerchman, I., I. Lysnyansky, S. Perk, and S. Levisohn. 2008. *In vitro* susceptibilities to fluoroquinolones in current and archived *Mycoplasma gallisepticum* and *Mycoplasma synoviae* isolates from meat-type turkeys. *Vet Microbiol*. 131:266–276.
49. Ghazikhanian, G., R. Yamamoto, and D.R. Cordy. 1973. Response of turkeys to experimental infection with *Mycoplasma synoviae*. *Avian Dis*. 17:122–136.
50. Giambrone, J.J., C.S. Eidson, and S.H. Kleven. 1977. Effect of infectious bursal disease on the response of chickens to *Mycoplasma synoviae*, Newcastle disease virus, and infectious bronchitis virus. *Am J Vet Res*. 38:251–253.
51. Glisson, J.R., J.F. Dawe, and S.H. Kleven. 1984. The effect of oil-emulsion vaccines on the occurrence of nonspecific plate agglutination reactions for *Mycoplasma gallisepticum* and *M. synoviae*. *Avian Dis*. 28:397–405.

52. Gole, V.C., K.K. Chousalkar, and J.R. Roberts. 2012. Prevalence of antibodies to *Mycoplasma synoviae* in laying hens and possible effects on egg shell quality. *Prev Vet Med*. 106:75–78.
53. Gurevich, V.A., D.H. Ley, J.F. Markham, K.G. Whithear, and I.D. Walker. 1995. Identification of *Mycoplasma synoviae* immunogenic surface proteins and their potential use as antigens in the enzyme-linked immunosorbent assay. *Avian Dis*. 39:465–474.
54. Hagan, J.C., N.J. Ashton, J.M. Bradbury, and K.L. Morgan. 2004. Evaluation of an egg yolk enzyme-linked immunosorbent assay antibody test and its use to assess the prevalence of *Mycoplasma synoviae* in UK laying hens. *Avian Pathol*. 33:91–95.
55. Hamdy, A.H., S.H. Kleven, and E.L. McCune. 1976. Efficacy of Linco-Spectin water medication on *Mycoplasma synoviae* airsacculitis in broilers. *Avian Dis*. 20:118–125.
56. Hammond, P.P., A.S. Ramirez, C.J. Morrow, and J.M. Bradbury. 2009. Development and evaluation of an improved diagnostic PCR for *Mycoplasma synoviae* using primers located in the haemagglutinin encoding gene *vlhA* and its value for strain typing. *Vet Microbiol*. 136:61–68.
57. Hannan, P.C.T., G.D. Windsor, A. deJong, N. Schmeer, and M. Stegemann. 1997. Comparative susceptibilities of various animal-pathogenic mycoplasmas to fluoroquinolones. *Antimicrob Agents Chemother*. 41:2037–2040.
58. Harada, K., M. Kijima-Tanaka, M. Uchiyama, T. Yamamoto, K. Oishi, M. Arao, and T. Takahashi. 2009. Molecular typing of Japanese field isolates and live commercial vaccine strain of *Mycoplasma synoviae* using improved pulsed-field gel electrophoresis and *vlhA* gene sequencing. *Avian Dis*. 53:538–543.
59. Higgins, P.A., and K.G. Whithear. 1986. Detection and differentiation of *Mycoplasma gallisepticum* and *M. synoviae* antibodies in chicken serum using enzyme-linked immunosorbent assay. *Avian Dis*. 30:160–168.
60. Hinz, K.H., C. Blome, and M. Ryll. 2003. Virulence of *Mycoplasma synoviae* strains in experimentally infected broiler chickens. *Berl Munch Tierarztl Wochenschr*. 116:59–66.
61. Hong, Y., M. Garcia, V. Leiting, D. Bencina, L. Dufour-Zavala, G. Zavala, and S.H. Kleven. 2004. Specific detection and typing of *Mycoplasma synoviae* strains in poultry with PCR and DNA sequence analysis targeting the hemagglutinin encoding gene vlhA. *Avian Dis*. 48:606–616.
62. Hopkins, S.R., and H.W. Yoder, Jr. 1982. Influence of infectious bronchitis strains and vaccines on the incidence of *Mycoplasma synoviae* airsacculitis. *Avian Dis*. 26:741–752.
63. Hyman, H.C., S. Levisohn, D. Yogev, and S. Razin. 1989. DNA probes for *Mycoplasma gallisepticum* and *Mycoplasma synoviae*: Application in experimentally infected chickens. *Vet Microbiol*. 20:323–338.
64. Jarquin, R., J. Schultz, I. Hanning, and S.C. Ricke. 2009. Development of a real-time polymerase chain reaction assay for the simultaneous detection of *Mycoplasma gallisepticum* and *Mycoplasma synoviae* under industry conditions. *Avian Dis*. 53:73–77.
65. Jeffery, N., R.B. Gasser, P.A. Steer, and A.H. Noormohammadi. 2007. Classification of *Mycoplasma synoviae* strains using single-strand conformation polymorphism and high-resolution melting-curve analysis of the *vlhA* gene single-copy region. *Microbiology*. 153:2679–2688.
66. Jones, J.F., K.G. Whithear, P.C. Scott, and A.H. Noormohammadi. 2006. Duration of immunity with *Mycoplasma synoviae*: comparison of the live attenuated vaccine MS-H (Vaxsafe MS) with its wild-type parent strain, 86079/7NS. *Avian Dis*. 50:228–231.
67. Jones, J.F., K.G. Whithear, P.C. Scott, and A.H. Noormohammadi. 2006. Determination of the effective dose of the live *Mycoplasma synoviae* vaccine, Vaxsafe MS (strain MS-H) by protection against experimental challenge. *Avian Dis*. 50:88–91.
68. Jones, J.F., K.G. Whithear, P.C. Scott, and A.H. Noormohammadi. 2006. Onset of immunity with *Mycoplasma synoviae*: comparison of the live attenuated vaccine MS-H (Vaxsafe MS) with its wild-type parent strain (86079/7NS). *Avian Dis*. 50:82–87.
69. Jordan, F.T., C.A. Forrester, A. Hodge, and L.G. Reeve-Johnson. 1999. The comparison of an aqueous preparation of tilmicosin with tylosin in the treatment of *Mycoplasma gallisepticum* infection of turkey poults. *Avian Dis*. 43:521–525.
70. Jordan, F.T.W. 1975. Avian Mycoplasma and pathogenicity—A review. *Avian Pathol*. 4:165–174.
71. Jordan, F.T.W. 1981. Mycoplasma-induced arthritis in poultry. *Israel J Med Sci*. 17:622–625.
72. Jordan, F.T.W., H. Erno, G.S. Cottew, K.-H. Hinz, and L. Stipkovits. 1982. Characterization and taxonomic description of five mycoplasma serovars (serotypes) of avian origin and their elevation to species rank and further evaluation of the taxonomic status of Mycoplasma synoviae. *Int J Syst Bacteriol*. 32:108–115.
73. Jordan, F.T.W., S. Gilbert, D.L. Knight, and C.A. Yavari. 1989. Effects of Baytril, Tylosin, and Tiamulin on avian mycoplasmas. *Avian Pathol*. 18:659–673.
74. Kang, M.S., P. Gazdzinski, and S.H. Kleven. 2002. Virulence of recent isolates of mycoplasma synoviae in turkeys. *Avian Dis*. 46:102–110.
75. Kawakubo, Y., K. Kume, M. Yoshioka, and Y. Nishiyama. 1980. Histopathological and immunopathological studies on experimental *Mycoplasma synoviae* infection of the chicken. *J Comp Pathol*. 90:457–468.
76. Kempf, I., F. Gesbert, M. Guittet, J.P. Le Pennec, and G. Bennejean. 1991. Sondes nucléiques spécifiques de Mycoplasma gallisepticum et *Mycoplasma synoviae*: préparation et intérêt. *Rev Med Vet (Toulouse)*. 142:887–892.
77. Kerr, K.M., and N.O. Olson. 1967. Cardiac pathology associated with viral and mycoplasmal arthritis in chickens. *Ann. N Y Acad Sci*. 143:204–217.
78. Kerr, K.M., and N.O. Olson. 1970. Pathology of chickens inoculated experimentally or contact-infected with *Mycoplasma synoviae*. *Avian Dis*. 14:291–320.
79. Khehra, R.S., R.C. Jones, and J.M. Bradbury. 1999. Dual infection of turkey poults with avian pneumovirus and *Mycoplasma synoviae*. *Avian Pathol*. 28:401–404.
80. King, D.D., S.H. Kleven, D.M. Wenger, and D.P. Anderson. 1973. Field studies with *Mycoplasma synoviae*. *Avian Dis*. 17: 722–726.
81. Kleven, S.H., and D.P. Anderson. 1971. *In vitro* activity of various antibiotics against *Mycoplasma synoviae*. *Avian Dis*. 15: 551–557.
82. Kleven, S.H., D.D. King, and D.P. Anderson. 1972. Airsacculitis in broilers from *Mycoplasma synoviae*: effect on air-sac lesions of vaccinating with infectious bronchitis and Newcastle virus. *Avian Dis*. 16:915–924.
83. Kleven, S.H., O.J. Fletcher, and R.B. Davis. 1975. Influence of strain of *Mycoplasma synoviae* and route of infection on development of synovitis or airsacculitis in broilers. *Avian Dis*. 19:126–135.
84. Kleven, S.H., and W.O. Fletcher. 1983. Laboratory infection of house sparrows (*Passer domesticus*) with *Mycoplasma gallisepticum* and *Mycoplasma synoviae*. *Avian Dis*. 27:308–311.

85. Kleven, S.H., G.N. Rowland, and M.C. Kumar. 2001. Poor serological response to upper respiratory infection with *Mycoplasma synoviae* in turkeys. *Avian Dis*. 45:719–723.
86. Kleven, S.H., N. Ferguson-Noel, Z. Raviv, R. Wooten, and V. Laibinis. 2007. Serological responses of chickens to low challenge doses of *Mycoplasma synoviae*. *Avian Dis*. 51:738–743.
87. Kleven, S.H. 2008. Control of avian mycoplasma infections in commercial poultry. *Avian Dis*. 52:367–374.
88. Kume, K., Y. Kawakubo, C. Morita, E. Hayatsu, and M. Yoshioka. 1977. Experimentally induced synovitis of chickens with *Mycoplasma synoviae*. Effects of bursectomy and thymectomy on course of the infection for the first four weeks. *Am J Vet Res*. 38:1595–1600.
89. Landman, W.J., and R.G. Bronneberg. 2003. [*Mycoplasma synoviae*-associated amyloid arthropathy in white leghorns: case report]. *Tijdschr Diergeneeskd*. 128:36–40.
90. Landman, W.J., D.J. Mevius, K.T. Veldman, and A. Feberwee. 2008. *In vitro* antibiotic susceptibility of Dutch *Mycoplasma synoviae* field isolates originating from joint lesions and the respiratory tract of commercial poultry. *Avian Pathol*. 37:415–420.
91. Landman, W.J.M., and A. Feberwee. 2001. Field studies on the association between amyloid arthropathy and *Mycoplasma synoviae* infection, and experimental reproduction of the condition in brown layers. *Avian Pathol*. 30:629–639.
92. Landman, W.J.M., and A. Feberwee. 2004. Aerosol-induced Mycoplasma synoviae arthritis: the synergistic effect of infectious bronchitis virus infection. *Avian Pathol*. 33:591–598.
93. Lauerman, L.H., F.J. Hoerr, A.R. Sharpton, S.M. Shah, and V.L. van Santen. 1993. Development and application of a polymerase chain reaction assay for *Mycoplasma synoviae*. *Avian Dis*. 37:829–834.
94. Lavric, M., D. Bencina, S. Kothlow, B. Kaspers, and M. Narat. 2007. *Mycoplasma synoviae* lipoprotein MSPB, the N-terminal part of VlhA haemagglutinin, induces secretion of nitric oxide, IL-6 and IL-1beta in chicken macrophages. *Vet Microbiol*. 121:278–287.
95. Le Carrou, J., A.K. Reinhardt, I. Kempf, and A.V. Gautier-Bouchardon. 2006. Persistence of *Mycoplasma synoviae* in hens after two enrofloxacin treatments and detection of mutations in the parC gene. *Vet Res*. 37:145–154.
96. Ley, D.H., and A.P. Avakian. 1992. An outbreak of *Mycoplasma synoviae* infection in North Carolina turkeys: comparison of isolates by sodium dodecyl sulfate-polyacrylamide gel electrophoresis and restriction endonuclease analysis. *Avian Dis*. 36: 672–678.
97. Lockaby, S.B., F.J. Hoerr, L.H. Lauerman, and S.H. Kleven. 1998. Pathogenicity of *Mycoplasma synoviae* in broiler chickens. *Vet Pathol*. 35:178–190.
98. Lockaby, S.B., F.J. Hoerr, S.H. Kleven, and L.H. Lauerman. 1999. Pathogenicity of *Mycoplasma synoviae* in chicken embryos. *Avian Dis*. 43:331–337.
99. Lockaby, S.B., F.J. Hoerr, L.H. Lauerman, B.F. Smith, A.M. Samoylov, M.A. Toivio-Kinnucan, and S.H. Kleven. 1999. Factors associated with virulence of *Mycoplasma synoviae*. *Avian Dis*. 43:251–261.
100. Lott, B.D., J.H. Drott, T.H. Vardaman, and F.N. Reece. 1978. Effect of *Mycoplasma synoviae* on egg quality and egg production of broiler breeders. *Poult Sci*. 57:309–311.
101. Macdonald, J.W., C.J. Randall, M.D. Dagless, and D.A. McMartin. 1978. Observations on viral tenosynovitis (viral arthritis) in Scotland. *Avian Pathol*. 7:471–482.
102. Markham, J.F., C.J. Morrow, P.C. Scott, and K.G. Whithear. 1998. Safety of a temperature-sensitive clone of *Mycoplasma synoviae* as a live vaccine. *Avian Dis*. 42:677–681.
103. Markham, J.F., C.J. Morrow, and K.G. Whithear. 1998. Efficacy of a temperature-sensitive *Mycoplasma synoviae* live vaccine. *Avian Dis*. 42:671–676.
104. Markham, J.F., P.C. Scott, and K.G. Whithear. 1998. Field evaluation of the safety and efficacy of a temperature-sensitive *Mycoplasma synoviae* live vaccine. *Avian Dis*. 42:682–689.
105. Marois, C., F. Oufour-Gesbert, and I. Kempf. 2000. Detection of *Mycoplasma synoviae* in poultry environment samples by culture and polymerase chain reaction. *Vet Microbiol*. 73:311–318.
106. Marois, C., F. Dufour-Gesbert, and I.I. Kempf. 2001. Comparison of pulsed-field gel electrophoresis with random amplified polymorphic DNA for typing of *Mycoplasma synoviae*. *Vet Microbiol*. 79:1–9.
107. Marois, C., J.P. Picault, M. Kobisch, and I. Kempf. 2005. Experimental evidence of indirect transmission of *Mycoplasma synoviae*. *Vet Res*. 36:759–769.
108. May, M., S.H. Kleven, and D.R. Brown. 2007. Sialidase activity in *Mycoplasma synoviae*. *Avian Dis*. 51:829–833.
109. Mohammed, H.O., T.E. Carpenter, R. Yamamoto, and D.A. McMartin. 1986. Prevalence of *Mycoplasma gallisepticum* and *M. synoviae* in commercial layers in southern and central California. *Avian Dis*. 30:519–526.
110. Mohammed, H.O., T.E. Carpenter, and R. Yamamoto. 1987. Economic impact of *Mycoplasma gallisepticum* and *Mycoplasma synoviae* in commercial layer flocks. *Avian Dis*. 31:477–482.
111. Morrow, C.J., K.G. Whithear, and S.H. Kleven. 1990. Restriction endonuclease analysis of *Mycoplasma synoviae* strains. *Avian Dis*. 34:611–616.
112. Morrow, C.J., J.M. Bradbury, M.J. Gentle, and B.H. Thorp. 1997. The development of lameness and bone deformity in the broiler following experimental infection with *Mycoplasma gallisepticum* or *Mycoplasma synoviae*. *Avian Pathol*. 26: 169–187.
113. Morrow, C.J., J.F. Markham, and K.G. Whithear. 1998. Production of temperature-sensitive clones of *Mycoplasma synoviae* for evaluation as live vaccines. *Avian Dis*. 42:667–670.
114. Narat, M., D. Bencina, S.H. Kleven, and F. Habe. 1998. The hemagglutination-positive phenotype of *Mycoplasma synoviae* induces experimental infectious synovitis in chickens more frequently than does the hemagglutination-negative phenotype. *Infect Immun*. 66:6004–6009.
115. Nascimento, E.R., and M.G.F. Nascimento. 1994. Eradication of *Mycoplasma gallisepticum* and *M. synoviae* from a chicken flock in Brazil. *Proc West Poult Dis Conf*. 43:58–59.
116. Nonomura, I., and Y. Imada. 1982. Temperature sensitive mutant of *Mycoplasma synoviae* 1. Production and selection of a nonpathogenic but immunogenic clone. *Avian Dis*. 26: 763–775.
117. Noormohammadi, A.H., P.F. Markham, K.G. Whithear, I.D. Walker, V.A. Gurevich, D.H. Ley, and G.F. Browning. 1997. *Mycoplasma synoviae* has two distinct phase-variable major membrane antigens, one of which is a putative hemagglutinin. *Infect Immun*. 65:2542–2547.
118. Noormohammadi, A.H., P.F. Markham, M.F. Duffy, K.G. Whithear, and G.F. Browning. 1998. Multigene families encoding the major hemagglutinins in phylogenetically distinct mycoplasmas. *Infect Immun*. 66:3470–3475.

119. Noormohammadi, A.H., P.F. Markham, J.F. Markham, K.G. Whithear, and G.F. Browning. 1999. *Mycoplasma synoviae* surface protein MSPB as a recombinant antigen in an indirect ELISA. *Microbiology*. 145:2087–2094.
120. Noormohammadi, A.H., P.F. Markham, A. Kanci, K.G. Whithear, and G.F. Browning. 2000. A novel mechanism for control of antigenic variation in the haemagglutinin gene family of *Mycoplasma synoviae*. *Mol Microbiol*. 35:911–923.
121. Noormohammadi, A.H., G.F. Browning, P.J. Cowling, D. O'Rourke, K.G. Whithear, and P.F. Markham. 2002. Detection of antibodies to *Mycoplasma gallisepticum* vaccine ts-11 by an autologous pMGA enzyme-linked immunosorbent assay. *Avian Dis*. 46:405–411.
122. Noormohammadi, A.H., J.F. Jones, K.E. Harrigan, and K.G. Whithear. 2003. Evaluation of the non-temperature-sensitive field clonal isolates of the *Mycoplasma synoviae* vaccine strain MS-H. *Avian Dis*. 47:355–360.
123. Noormohammadi, A.H. 2007. Role of phenotypic diversity in pathogenesis of avian mycoplasmosis. *Avian Pathol*. 36:439–444.
124. Noormohammadi, A.H., F. Hemmatzadeh, and K.G. Whithear. 2007. Safety and efficacy of the *Mycoplasma synoviae* MS-H vaccine in turkeys. *Avian Dis*. 51:550–554.
125. Ogino, S., Y. Munakata, S. Ohashi, M. Fukui, H. Sakamoto, Y. Sekiya, A.H. Noormohammadi, and C.J. Morrow. 2011. Genotyping of Japanese field isolates of *Mycoplasma synoviae* and rapid molecular differentiation from the MS-H vaccine strain. *Avian Dis*. 55:187–194.
126. Olson, N.O., J.K. Bletner, D.C. Shelton, D.A. Munro, and G.C. Anderson. 1954. Enlarged joint condition in poultry caused by an infectious agent. *Poult Sci*. 33:1075.
127. Olson, N.O., D.C. Shelton, J.K. Bletner, D.A. Munro, and G.C. Anderson. 1956. Studies of infectious synovitis in chickens. *Am J Vet Res*. 17:747–754.
128. Olson, N.O., K.M. Kerr, and A. Campbell. 1963. Control of infectious synovitis. 12. Preparation of an agglutination test antigen. *Avian Dis*. 7:310–317.
129. Olson, N.O., H.E. Adler, A.J. DaMassa, and R.E. Corstvet. 1964. The effect of intranasal exposure to *Mycoplasma synoviae* and infectious bronchitis on development of lesions and agglutinins. *Avian Dis*. 8:623–631.
130. Olson, N.O., K.M. Kerr, and A. Campbell. 1964. Control of infectious synovitis. 13. The antigen study of three strains. *Avian Dis*. 8:209–214.
131. Olson, N.O., R. Yamamoto, and H.B. Ortmayer. 1965. Antigenic relationship between Mycoplasma synoviae and *Mycoplasma gallisepticum*. *Am J Vet Res*. 26:195–198.
132. Olson, N.O., and K.M. Kerr. 1967. The duration and distribution of synovitis-producing agents in chickens. *Avian Dis*. 11: 578–585.
133. Olson, N.O., and S.P. Sahu. 1976. Efficacy of chlortetracycline against *Mycoplasma synoviae* isolated in two periods. *Avian Dis*. 20:221–229.
134. Opitz, H.M. 1983. *Mycoplasma synoviae* infection in Maine's egg farms. *Avian Dis*. 27:324–326.
135. Opitz, H.M., J.B. Duplessis, and M.J. Cyr. 1983. Indirect micro enzyme linked immunosorbent assay ELISA for the detection of antibodies to *Mycoplasma synoviae* and *Mycoplasma gallisepticum*. *Avian Dis*. 27:773–786.
136. Ortiz, A., and S.H. Kleven. 1992. Serological detection of *Mycoplasma synoviae* infection in turkeys. *Avian Dis*. 36: 749–752.
137. Osorio, C., O.J. Fletcher, T. Abdul-Aziz, E. Gonder, B. Tilley, and D.H. Ley. 2007. Pneumonia of turkey breeder hens associated with *Mycoplasma synoviae*. *Avian Dis*. 51:791–796.
138. Pascucci, S., N. Maestrini, S. Govoni, and A. Prati. 1976. *Mycoplasma synoviae* in the guinea fowl. *Avian Pathol*. 5: 291–297.
139. Patten, B.E., P.A. Higgins, and K.G. Whithear. 1984. A urease-ELISA for the detection of mycoplasma infections in poultry. *Aust Vet J*. 61:151–155.
140. Poveda, J.B., J. Carranza, A. Miranda, A. Garrido, M. Hermoso, A. Fernandez, and J. Domenech. 1990. An epizootiological study of avian Mycoplasmas in Southern Spain. *Avian Pathol*. 19:627–633.
141. Ramirez, A.S., C.J. Naylor, C.A. Yavari, C.M. Dare, and J.M. Bradbury. 2011. Analysis of the 16S to 23S rRNA intergenic spacer region of *Mycoplasma synoviae* field strains. *Avian Pathol*. 40:79–86.
142. Ranck, M.F., V. Schmidt, H.C. Philipp, M. Voss, J. Kacza, A. Richter, K. Fehlhaber, and M.E. Krautwald-Junghanns. 2010. [*Mycoplasma synoviae*-associated egg-pole shell defects in laying hens]. *Berl Munch Tierarztl Wochenschr*. 123:111–118.
143. Raviv, Z., N. Ferguson-Noel, V. Laibinis, R. Wooten, and S.H. Kleven. 2007. Role of *Mycoplasma synoviae* in commercial layer *Escherichia coli* peritonitis syndrome. *Avian Dis*. 51:685–690.
144. Raviv, Z., and S.H. Kleven. 2009. The development of diagnostic real-time TaqMan PCRs for the four pathogenic avian mycoplasmas. *Avian Dis*. 53:103–107.
145. Reece, R.L., L. Ireland, and P.C. Scott. 1986. Mycoplasmosis in racing pigeons. *Aust Vet J*. 63:166–167.
146. Rhoades, K.R. 1975. Antibody responses of turkeys experimentally exposed to *Mycoplasma synoviae*. *Avian Dis*. 19: 437–442.
147. Rhoades, K.R. 1977. Turkey sinusitis: synergism between *Mycoplasma synoviae* and *Mycoplasma meleagridis*. *Avian Dis*. 21:670–674.
148. Rhoades, K.R. 1981. Turkey airsaccultis: effect of mixed mycoplasmal infections. *Avian Dis*. 25:131–135.
149. Rhoades, K.R. 1987. Airsacculitis in turkeys exposed to *Mycoplasma synoviae* membranes. *Avian Dis*. 31:855–860.
150. Sahu, S.P., and N.O. Olson. 1976. Evaluation of broiler breeder flocks for nonspecific *Mycoplasma synviae* reaction. *Avian Dis*. 20:49–64.
151. Salisch, H., K.-H. Hinz, H.-D. Graack, and M. Ryll. 1998. A comparison of a commercial PCR-based test to culture methods for detection of *Mycoplasma gallisepticum* and *Mycoplasma synoviae* in concurrently infected chickens. *Avian Pathol*. 27: 142–147.
152. Salisch, H., M. Ryll, K.-H. Hinz, and U. Neumann. 1999. Experiences with multispecies polymerase chain reaction and specific oligonucleotide probes for the detection of *Mycoplasma gallisepticum* and *Mycoplasma synoviae*. *Avian Pathol*. 28: 337–344.
153. Scott, P.C., J. Jones, C.J. Morrow, D.H. Ley, and K.G. Whithear. 1994. Experiences with a live attenuated *Mycoplasma synoviae* vaccine. *Proc West Poult Dis Conf*. 43:97–98.
154. Senties-Cué, H.L. Shivaprasad, and R.P. Chin. 2005. Systemic *Mycoplasma synoviae* infection in broiler chickens. *Avian Pathol*. 34:137–142.
155. Sevoian, M., G.H. Snoeyenbos, H.I. Basch, and I.M. Reynolds. 1958. Infectious synovitis I. Clinical and pathological manifestations. *Avian Dis*. 2:499–513.

156. Springer, W.T., C. Luskus, and S.S. Pourciau. 1974. Infectious bronchitis and mixed infections of *Mycoplasma synoviae* and *Escherichia coli* in gnotobiotic chickens. I. Synergistic role in the airsacculitis syndrome. *Infect Immun*. 10:578–589.
157. Sprygin, A.V., D.B. Andreychuk, A.N. Kolotilov, M.S. Volkov, I.A. Runina, N.S. Mudrak, A.V. Borisov, V.N. Irza, V.V. Drygin, and N.A. Perevozchikova. 2010. Development of a duplex real-time TaqMan PCR assay with an internal control for the detection of *Mycoplasma gallisepticum* and *Mycoplasma synoviae* in clinical samples from commercial and backyard poultry. *Avian Pathol*. 39:99–109.
158. Stanley, W.A., C.L. Hofacre, G. Speksnijder, S.H. Kleven, and S.E. Aggrey. 2001. Monitoring *Mycoplasma gallisepticum* and *Mycoplasma synoviae* infection in breeder chickens after treatment with enrofloxacin. *Avian Dis*. 45:534–539.
159. Talkington, F.D., and S.H. Kleven. 1983. A classification of laboratory strains of avian mycoplasma serotypes by direct immunofluorescence. *Avian Dis*. 27:422–429.
160. Timms, L.M. 1978. *Mycoplasma synoviae*: A review. *Vet Bull*. 48:187–198.
161. Tiong, S.K. 1990. Mycoplasmas and acholeplasmas isolated from ducks and their possible association with pasteurellas. *Vet Rec*. 127:64–66.
162. Vardaman, T.H., and H.W. Yoder, Jr. 1969. Preparation of *Mycoplasma synoviae* hemagglutinating antigen and its use in the hemagglutination-inhibition test. *Avian Dis*. 13: 654–661.
163. Vardaman, T.H., K. Landreth, S. Whatley, L.J. Dreesen, and B. Glick. 1973. Resistance to *Mycoplasma synoviae* is bursal dependent. *Infect Immun*. 8:674–676.
164. Vardaman, T.H. 1976. The resistance and carrier status of meat-type hens exposed to *Mycoplasma synoviae*. *Poult Sci*. 55:268–273.
165. Vasconcelos, A.T., H.B. Ferreira, C.V. Bizarro, S.L. Bonatto, M.O. Carvalho, P.M. Pinto, D.F. Almeida, L.G. Almeida, R. Almeida, L. Alves-Filho, E.N. Assuncao, V.A. Azevedo, M.R. Bogo, M.M. Brigido, M. Brocchi, H.A. Burity, A.A. Camargo, S.S. Camargo, M.S. Carepo, D.M. Carraro, J.C. de Mattos Cascardo, L.A. Castro, G. Cavalcanti, G. Chemale, R.G. Collevatti, C.W. Cunha, B. Dallagiovanna, B.P. Dambros, O.A. Dellagostin, C. Falcao, F. Fantinatti-Garboggini, M.S. Felipe, L. Fiorentin, G.R. Franco, N.S. Freitas, D. Frias, T.B. Grangeiro, E.C. Grisard, C.T. Guimaraes, M. Hungria, S.N. Jardim, M.A. Krieger, J.P. Laurino, L.F. Lima, M.I. Lopes, E.L. Loreto, H.M. Madeira, G.P. Manfio, A.Q. Maranhao, C.T. Martinkovics, S.R. Medeiros, M.A. Moreira, M. Neiva, C.E. Ramalho-Neto, M.F. Nicolas, S.C. Oliveira, R.F. Paixao, F.O. Pedrosa, S.D. Pena, M. Pereira, L. Pereira-Ferrari, I. Piffer, L.S. Pinto, D.P. Potrich, A.C. Salim, F.R. Santos, R. Schmitt, M.P. Schneider, A. Schrank, I.S. Schrank, A.F. Schuck, H.N. Seuanez, D.W. Silva, R. Silva, S.C. Silva, C.M. Soares, K.R. Souza, R.C. Souza, C.C. Staats, M.B. Steffens, S.M. Teixeira, T.P. Urmenyi, M.H. Vainstein, L.W. Zuccherato, A.J. Simpson, and A. Zaha. 2005. Swine and poultry pathogens: the complete genome sequences of two strains of *Mycoplasma hyopneumoniae* and a strain of *Mycoplasma synoviae*. *J Bacteriol*. 187: 5568–5577.
166. Walker, E.R., M.H. Friedman, N.O. Olson, S.P. Sahu, and H.F. Mengoli. 1978. An ultrastructural study of avian synovium infected with an arthrotropic *Mycoplasma*, *Mycoplasma synoviae*. *Vet Pathol*. 15:407–416.
167. Weinack, O.M., G.H. Snoeyenbos, and S.H. Kleven. 1983. Strain of *Mycoplasma synoviae* of low transmissibility. *Avian Dis*. 27:1151–1156.
168. Weisburg, W.G., J.G. Tully, D.L. Rose, J.P. Petzel, H. Oyaizu, D. Yang, L. Mandelco, J. Sechrest, T.G. Lawrence, J. Van Etten, and et al. 1989. A phylogenetic analysis of the mycoplasmas: basis for their classification. *J Bacteriol*. 171: 6455–6467.
169. Wetzel, A.N., K.M. Lefevre, and Z. Raviv. 2010. Revised *Mycoplasma synoviae vlhA* PCRs. *Avian Dis*. 54:1292–1297.
170. Whithear, K.G., D.D. Bowtell, E. Ghiocas, and K.L. Hughes. 1983. Evaluation and use of a micro-broth dilution procedure for testing sensitivity of fermentative avian mycoplasmas to antibiotics. *Avian Dis*. 27:937–949.
171. Yamada, S., and K. Matsuo. 1983. Experimental infection of ducks with *Mycoplasma synoviae*. *Avian Dis*. 27:762–765.
172. Yoder, H.W., Jr. 1970. Preincubation heat treatment of chicken hatching eggs to inactivate mycoplasma. *Avian Dis*. 14:75–86.
173. Yoder, H.W., Jr., L.N. Drury, and S.R. Hopkins. 1977. Influence of environment on airsacculitis: effects of relative humidity and air temperature on broilers infected with *Mycoplasma synoviae* and infectious bronchitis. *Avian Dis*. 21:195–208.
174. Yoder, H.W., Jr. 1989. Nonspecific reactions to *Mycoplasma* serum plate antigens induced by inactivated poultry disease vaccines. *Avian Dis*. 33:60–68.
175. Zain, Z.M., and J.M. Bradbury. 1995. The influence of type of swab and laboratory method on the recovery of *Mycoplasma gallisepticum* and *Mycoplasma synoviae* in broth medium. *Avian Pathol*. 24:707–716.
176. Zhao, S., and R. Yamamoto. 1990. Recombinant DNA probes for *Mycoplasma synoviae*. *Avian Dis*. 34:709–716.
177. Zhao, S., and R. Yamamoto. 1993. Detection of *Mycoplasma synoviae* by polymerase chain reaction. *Avian Pathol*. 22: 533–542.
178. Zorman-Rojs, O., I. Zdovc, D. Bencina, and I. Mrzel. 2000. Infection of turkeys with *Ornithobacterium rhinotracheale* and *Mycoplasma synoviae*. *Avian Dis*. 44:1017–1022.

Mycoplasma iowae Infection

1. Al-Ankari, A.S., and J.M. Bradbury. 1996. *Mycoplasma iowae*: a review. *Avian Pathol*. 25:205–229.
2. Amin, M.M. 1977. Avian mycoplasma: studies on isolation, infection and control. PhD Thesis, University of Liverpool.
3. Amin, M.M., and F.T.W. Jordan. 1978. A comparative study of some cultural methods in the isolation of avian mycoplasma from field material. *Avian Pathol*. 7:455–470.
4. Aycardi, E.R., D.P. Anderson, and R.P. Hanson. 1971. Classification of avian mycoplasmas by gel diffusion and growth inhibition tests. *Avian Dis*. 15:434–447.
5. Barber, T.L., and J. Fabricant. 1971. A suggested reclassification of avian mycoplasma serotypes. *Avian Dis*. 15:125–138.
6. Baxter-Jones, C. 1993. An introduction to *Mycoplasma iowae*. In: *Newly Emerging and Re-emerging Avian Diseases: Applied Research and Practical Applications for Diagnosis and Control*. AAAP, Minneapolis, Minnesota. 9–11.
7. Baxter-Jones, C. 1995. Unpublished data.
8. Benčina, D., I. Mrzel, T. Tadina, and D. Dorrer. 1987. *Mycoplasma* spp. in chicken flocks with different management systems. *Avian Pathol*. 16:599–608.

9. Benčina, D. 2002. Haemagglutinins of pathogenic avian mycoplasmas. *Avian Pathol*. 31:535–547.
10. Berčič, R.L., B. Slavec, M. Lavrič, M. Narat, O. Zorman-Rojs, P. Dovč, and D. Benčina. 2008. A survey of avian *Mycoplasma* species for neuraminidase enzymatic activity. *Vet Microbiol*. 130: 391–397.
11. Bigland, C.H., and R. Yamamoto. 1964. Study of natural and experimental infection of mycoplasma associated with turkey airsacculitis. *Avian Dis*. 8:531–538.
12. Boyle, J.S., R.T. Good, and C.J. Morrow. 1995. Detection of the turkey pathogens *Mycoplasma meleagridis* and *M. iowae* by amplification of genes coding for rRNA. *J Clin Microbiol*. 33:1335–1338.
13. Bozeman, L.H., S.H. Kleven, and R.B. Davis. 1984. *Mycoplasma* challenge studies in budgerigars (*Melopsittacus undulatus*) and chickens. *Avian Dis*. 28:426–434.
14. Bradbury, J.M. 1977. Rapid biochemical tests for characterization of the Mycoplasmatales. *J Clin Microbiol*. 5:531–534.
15. Bradbury, J.M. 1982. The use of chicken antiserum for the identification of avian mycoplasmas by immunofluorescence. *Avian Pathol*. 11:113–121.
16. Bradbury, J.M. 1983. *Mycoplasma iowae*—an avian mycoplasma with unusual properties. *Yale J Biol Med*. 56:912.
17. Bradbury, J.M. 1984. Effect of *Mycoplasma iowae* infection on the immune system of the young turkey. *Isr J Med Sci*. 20: 985–988.
18. Bradbury, J.M., and A. Ideris. 1982. Abnormalities in turkey poults following infection with *Mycoplasma iowae*. *Vet Rec*. 110:559–560.
19. Bradbury, J.M., and D.F. Kelly. 1991. *Mycoplasma iowae* infection in broiler breeders. *Avian Pathol*. 20:67–78.
20. Bradbury, J.M., and J.D. McCarthy. 1981. Rupture of the digital flexor tendons of chickens after infection with *Mycoplasma iowae*. *Vet Rec*. 109:428–429.
21. Bradbury, J.M., and J.D. McCarthy. 1983. Pathogenicity of *Mycoplasma iowae* for chick embryos. *Avian Pathol*. 12: 483–496.
22. Bradbury, J.M., and J.D. McCarthy. 1984. *Mycoplasma iowae* infection in chicks. *Avian Pathol*. 13:529–543.
23. Bradbury, J.M., A. Ideris, and T.T. Oo. 1988. *Mycoplasma iowae* infection in young turkeys. *Avian Pathol*. 17:149–171.
24. Bradbury, J.M., A. Al-Ankari, C.A. Yavari, C. Baxter-Jones, and G.P. Wilding. 1992. Comparison of *Mycoplasma iowae* field strains by restriction enzyme analysis. *IOM Letters* 2:154.
25. Brown, D.R., M. May, J.M. Bradbury, M.F. Balish, M.J. Calcutt, J.I. Glass, S. Tasker, J.B. Messick, K.E. Johansson, and H. Neimark. 2011. Genus I. Mycoplasma Nowak 1929, 1349 nom. cons. Jud. Comm. Opin. 22, 1958, 166AL. In: *Bergey's Manual of Systematic Bacteriology*, 2nd ed., vol. 4. N.R. Krieg, J.T. Staley, D.R. Brown, B.P. Hedlund, B.J. Paster, N.L. Ward, W. Ludwig, and W.B. Whitman, eds. 575–613.
26. Cai, H., P. Bell-Rogers, L. Parker, A. Ferencz, and P. Pozder. 2008. Development and field validation of a *Mycoplasma iowae* real-time polymerase chain reaction assay. *J Vet Diagn Invest*. 20: 230–235.
27. Christensen, N.H., C.A. Yavari, A.J. McBain, and J.M. Bradbury. 1994. Investigations into the survival of Mycoplasma gallisepticum, Mycoplasma synoviae and Mycoplasma iowae on materials found in the poultry house environment. *Avian Pathol*. 23: 127–143.
28. Dierks, R.E., J.A. Newman, and B.S. Pomeroy. 1967. Characterization of avian mycoplasma. *Ann NY Acad Sci*. 143:170–189.
29. Dunn, P., E. Wallner-Pendleton, and B. Love. 2005. Case report: *Mycoplasma iowae* infection in commercial turkeys. Paper presented at the 77th Northeastern Conference on Avian Diseases, Ithaca, NY (cited by Ley et al. 2010, (56)).
30. Fan, H.H., S.H. Kleven, and M.W. Jackwood. 1995. Studies of intraspecies heterogeneity of *Mycoplasma synoviae, Mycoplasma meleagridis*, and *Mycoplasma iowae* with arbitrarily primed polymerase chain reaction. *Avian Dis*. 39:766–777.
31. Fiorentin, L., V.S. Panangala, Y.J. Zhang, and M. Toivio-Kinnucan. 1998. Adhesion inhibition of *Mycoplasma iowae* to chicken lymphoma DT40 cells by monoclonal antibodies reacting with a 65-kD polypeptide. *Avian Dis*. 42:721–731.
32. Fiorentin, L., Y. Zhang, and V.S. Panangala. 2000. Phenotypic variation of *Mycoplasma iowae* surface antigen. *Avian Dis*. 44:434–438.
33. French, N.A. 1994. Effect of incubation-temperature on the gross pathology of turkey embryos. *Br Poult Sci*. 35:363–371.
34. Garcia, M., M.W. Jackwood, M. Head, S. Levisohn, and S.H. Kleven. 1996. Use of species-specific oligonucleotide probes to detect *Mycoplasma gallisepticum, Mycoplasma synoviae*, and *M. iowae* PCR amplification products. *J Vet Diagn Invest*. 8: 56–63.
35. Garcia, M., I. Gerchman, R. Meir, M.W. Jackwood, S.H. Kleven, and S. Levisohn. 1997. Detection of *Mycoplasma meleagridis* and *Mycoplasma iowae* from dead-in-shell turkey embryos by polymerase chain reaction and culture. *Avian Pathol*. 26:765–778.
36. Gautier-Bouchardon, A.V., A.K. Reinhardt, M. Kobisch, and I. Kempf. 2002. *In vitro* emergence of resistance to enrofloxacin, erythromycin, tylosin, tiamulin and oxytetracycline in *Mycoplasma gallisepticum*, *Mycoplasma iowae and Mycoplasma synoviae. Vet Microbiol*. 88:47–58.
37. Grant, M. 1987. Significance, epidemiology and control methods of *Mycoplasma iowae* in turkeys. Ph.D. thesis. Council for National Academic Awards.
38. Grau, O., F. Laigret, P. Carle, J.G. Tully, D.L. Rose, and J.M. Bové. 1991. Identification of a plant-derived mollicute as a strain of an avian pathogen *Mycoplasma iowae*, and its implications for mollicute taxonomy. *Int J Syst Bacteriol*. 41:473–478.
39. Hall, R.E., D.P. Kestler, S. Agarwal, and K.M. Goldstein. 1999. Expression of the monocytic differentiation/activation factor P48 in Mycoplasma species. *Microbial Pathogenesis*. 27:145–153.
40. Hannan, P.C.T., G.D. Windsor, A. de Jong, N. Schmeer, and M. Stegemann. 1997. Comparative susceptibilities of various animal-pathogenic mycoplasmas to fluoroquinolones. *Antimicrob Agents Chemother*. 41:2037–2040.
41. Hong, Y., M. Garcia, S. Levisohn, I. Lysnyansky, V. Leiting, P.H.M. Savelkoul, and S.H. Kleven. 2005. Evaluation of amplified fragment length polymorphism for differentiation of avian mycoplasma species. *J Clin Microbiol*. 43:909–912.
42. Islam, K.M.S., U. Klein, and D.G.S. Burch. 2009. The activity and compatibility of the antibiotic tiamulin with other drugs in poultry medicine—A review. *Poult Sci*. 88:2353–2359.
43. Jordan, F.T.W., and M.M. Amin. 1980. A survey of mycoplasma infections in domestic poultry. *Res Vet Sci*. 28:96–100.
44. Jordan, F.T.W., H. Ernø, G.S. Cottew, K.H. Hinz, and L. Stipkovits. 1982. Characterization and taxonomic description of 5 mycoplasma serovars (serotypes) of avian origin and their elevation to species rank and further evaluation of the taxonomic status of *Mycoplasma synoviae*. *Int J Syst Bacteriol*. 32:108–115.

45. Jordan, F.T.W., B.K. Horrocks, and S.K. Jones. 1991. A comparison of Baytril, Tylosin, and Tiamulin in the control of *Mycoplasma iowae* infection of turkey poults. *Avian Pathol*. 20:283–289.
46. Jordan, F.T.W., B.K. Horrocks, and R. Froyman. 1993. A model for testing the efficacy of enrofloxacin (Baytril) administered to turkey hens in the control of *Mycoplasma iowae* infection in eggs and embryos. *Avian Dis*. 37:1057–1061.
47. Jordan, F.T. W., C. Yavari, and D.L. Knight. 1987. Some observations on the indirect ELISA for antibodies to *Mycoplasma iowae* serovar I in sera from turkeys considered to be free from mycoplasma infections. *Avian Pathol*. 16:307–318.
48. Kempf, I., A. Blanchard, F. Gesbert, M. Guittet, and G. Bennejean. 1994. Comparison of antigenic and pathogenic properties of *Mycoplasma iowae* strains and development of a PCR-based detection assay. *Res Vet Sci*. 56:179–185.
49. Kempf, I., M. Guittet, F.X. Le Gros, D. Toquin, and G. Bennejean. 1989. *Mycoplasma iowae*: field and laboratory studies to evaluate egg transmission in turkeys. *Avian Pathol*. 18:299–305.
50. Kempf, I., C. Ollivier, R. L'Hospitalier, M. Guittet, and G. Bennejean. 1989. Concentrations minimales inhibitrices de 13 antibiotiques vis-à-vis de 21 souches de mycoplasmes des vollailles. *Point Vet* 20:935–940.
51. Kiss, I., K. Matiz, E. Kaszanyitzky, Y. Chavez, and K.E. Johansson. 1997. Detection and identification of avian mycoplasmas by polymerase chain reaction and restriction fragment length polymorphism assay. *Vet Microbiol*. 58:23–30.
52. Laigret, F., J. Deaville, J.M. Bové, and J.M. Bradbury. 1996. Specific detection of *Mycoplasma iowae* using polymerase chain reaction. *Mol Cell Probe*. 10:23–29.
53. Leiting, V.A., and S.H. Kleven. 2000. Preparation of a heterogeneous conjugate to detect *Mycoplasma iowae* by immunofluorescence. *Avian Dis*. 44:697–700.
54. Levisohn, S., E. Eliasian, H. Fan, and S.H. Kleven. 1994. Molecular typing of *Mycoplasma iowae* strains. *IOM Letters*. 3:437–438.
55. Levisohn, S., I. Gerchmann, and Y. Weisman. 1996. Antibiotic resistance in *M. iowae*: selective pressure by field treatment. *IOM Letters*. 4:404–405.
56. Ley, D.H., R.A. Marusak, E.J. Vivas, H.J. Barnes, and O.J. Fletcher. 2010. *Mycoplasma iowae* associated with chondrodystrophy in commercial turkeys. *Avian Pathol*. 39:87–93.
57. Lin, M.Y., S.S. Lin, W.S. Su, Y.C. Lan, and I.C. Chung. 1995. Isolation and identification of avian mycoplasmas from geese in Taiwan. *J Chinese Soc Vet Sci*. 21:347–353.
58. McClenaghan, M., J.M. Bradbury, and J.N. Howse. 1981. Embryo mortality associated with avian Mycoplasma serotype I. *Vet Rec*. 108:459–460.
59. Mirsalimi, S.M., S. Rosendal, and R.J. Julian. 1989. Colonization of the intestine of turkey embryos exposed to *Mycoplasma iowae*. *Avian Dis*. 33:310–315.
60. Ongor, H., R. Kalin, M. Karahan, B. Çetinkaya, and M. Akan. 2009. Detection of mycoplasma species in turkeys by culture and polymerase chain reaction. *Rev sci tech Off int Epiz*. 28:1103–1109.
61. Panangala, V.S., M.M. Gresham, and M.A. Morsy. 1992. Antigenic heterogeneity in *Mycoplasma iowae* demonstrated with monoclonal antibodies. *Avian Dis*. 36:108–113.
62. Ramírez, A.S., C.J. Naylor, D.G. Pitcher, and J.M. Bradbury. 2008. High inter-species and low intra-species variation in 16S-23S rDNA spacer sequences of pathogenic avian mycoplasmas offers potential use as a diagnostic tool. *Vet Microbiol*. 128:279–87.63.
63. Ramírez, A.S., C.M. Dare, C.A. Yavari, and J.M. Bradbury. 2012. A diagnostic PCR for *Mycoplasma iowae* using primers located in the intergenic spacer region and the 23S rRNA gene. *Avian Pathol*. 41(3):317–22.
64. Rathore, B.S., G.C. Mohanty, and B.S. Rajya. 1979. Isolation of mycoplasma from oviducts of chickens and their pathogenicity. *Indian J Microbiol*. 19:192–197.
65. Raviv, Z., and S.H. Kleven. 2009. The development of diagnostic real-time Taqman PCRs for the four pathogenic avian mycoplasmas. *Avian Dis*. 53:103–107.
66. Raviv, Z. 2012. Unpublished data.
67. Rhoades, K.R. 1981. Turkey airsacculitis: effect of mixed mycoplasmal infections. *Avian Dis*. 25:131–135.
68. Rosengarten, R., S. Levisohn, and D.A. Yogev. 1995. A 41-kDa variable surface protein of *Mycoplasma gallisepticum* has a counterpart in *Mycoplasma imitans* and *Mycoplasma iowae*. *FEMS Microbiol Lett*. 132:115–123.
69. Rosengarten, R., and D. Yogev. 1996. Variant colony surface antigenic phenotypes within mycoplasma strain populations: implications for species identification and strain standardization. *J Clin Microbiol*. 34:149–158.
70. Shah-Majid, M., and S. Rosendal. 1986. *Mycoplasma iowae* from turkey phallus and semen. *Vet Rec*. 118:435.
71. Shah-Majid, M., and S. Rosendal. 1987. Evaluation of growth of avian mycoplasmas on bile salt agar and in bile broth. *Res Vet Sci*. 43:188–190.
72. Shah-Majid, M., and S. Rosendal. 1987. Oral challenge of turkey poults with *Mycoplasma iowae*. *Avian Dis*. 31:365–369.
73. Shah-Majid, M., and S. Rosendal. 1992. Serological response of turkeys to the intravaginal inoculation of *Mycoplasma iowae*. *Vet Rec*. 131:420.
74. Shareef, J., J. Wilcox, and P. Kumar. 1990. Adherence of *Mycoplasma iowae* to epithelial mucosa of the cloaca. *Zentralblatt für Bakt*. 20:872–874.
75. Shimizu, T., K. Numano, and K. Ichida. 1979. Isolation and identification of mycoplasmas from various birds: an ecological study. *Jap J Vet Sci*. 41:273–282.
76. Singh, P., C.A. Yavari, J.A. Newman, and J.M. Bradbury. 1997. Identification of *Mycoplasma iowae* by colony immunoblotting utilizing monoclonal antibodies. *J Vet Diagn Invest*. 9:357–362.
77. Taylor, R.R., K. Mohan, and R.J. Miles. 1996. Diversity of energy-yielding substrates and metabolism in avian mycoplasmas. *Vet Microbiol*. 51:291–304.
78. Timms, L. 1967. Isolation and identification of avian mycoplasma. *J Med Lab Technol*. 24:79–89.
79. Trampel, D.W., and F. Goll, Jr. 1994. Outbreak of *Mycoplasma iowae* infection in commercial turkey poults. *Avian Dis*. 38: 905–909.
80. Wang, H., A.A. Fadl, and M.I. Khan. 1997. Multiplex PCR for avian pathogenic mycoplasmas. *Mol Cell Probe*. 11:211–216.
81. Wei, S., Z. Guo, T. Li, T. Zhang, X. Li, Z. Zhou, Z. Li, M. Liu, R. Luo, D. Bi, H. Chen, R. Zhou, and H. Jin. 2012. Genome sequence of *Mycoplasma iowae* strain 695, an unusual pathogen causing deaths in turkeys. *J Bacteriol*. 194:547–548.
82. Wilding, G.P. 1995. Unpublished data.
83. Yoder, H.W., Jr., and M.S. Hofstad. 1962. A previously unreported serotype of avian mycoplasma. *Avian Dis*. 6:147–160.
84. Yoder, H.W., Jr., and M.S. Hofstad. 1964. Characterization of avian mycoplasma. *Avian Dis*. 8:481–512.

85. Zhao, S., and R. Yamamoto. 1989. Heterogeneity of *Mycoplasma iowae* determined by restriction enzyme analysis. *J Vet Diagn Invest*. 1:165–169.
86. Zhao, S., and R. Yamamoto. 1993. Amplification of *Mycoplasma iowae* using polymerase chain reaction. *Avian Dis*. 37:212–217.

Other Mycoplasmal Infections

1. Abdul-Wahab, O.M., G. Ross, and J.M. Bradbury. 1996. Pathogenicity and cytadherence of *Mycoplasma imitans* in chicken and duck embryo tracheal organ cultures. *Infect Immun*. 64:563–568.
2. Barber, T.L., and J. Fabricant. 1971. A suggested reclassification of avian mycoplasma serotypes. *Avian Dis*. 15:125–138.
3. Bencina, D., D. Dorrer, and T. Tadina. 1987. *Mycoplasma* species isolated from six avian species. *Avian Pathol*. 16:653–664.
4. Bradbury, J.M., F. Jordan, T. Shimizu, L. Stipkovits, and Z. Varga. 1988. *Mycoplasma anseris* sp. nov found in geese. *Int J Systc Bacteriol*. 38:74–76.
5. Bradbury, J.M., O.M. Abdul-Wahab, C.A. Yavari, J.P. Dupiellet, and J.M. Bove. 1993. *Mycoplasma imitans* sp. nov. is related to *Mycoplasma gallisepticum* and found in birds. *Int J Syst Bacteriol*. 43:721–728.
6. Branton, S.L., S.M. Bearson, B.L. Bearson, W.R. Maslin, S.D. Collier, J.D. Evans, D.M. Miles, and G.T. Pharr. 2003. *Mycoplasma gallinarum* infection in commercial layers and onset of fatty liver hemorrhagic syndrome. *Avian Dis*. 47:458–462.
7. De Las Mulas, J.M., A. Fernandez, M.A. Sierra, J.B. Poveda, and J. Carranza. 1990. Immunohistochemical demonstration of *Mycoplasma gallinarum* and *Mycoplasma gallinaceum* in naturally infected hen oviducts. *Res Vet Sci*. 49:339–345.
8. Dierks, R.E., J.A. Newman, and B.S. Pomeroy. 1967. Characterization of avian mycoplasma. *Ann N Y Acad Sci*. 143:170–189.
9. Dobos-Kovacs, M., Z. Varga, G. Czifra, and L. Stipkovits. 2009. Salpingitis in geese associated with *Mycoplasma* sp. strain 1220. *Avian Pathol*. 38:239–243.
10. Dovc, P., D. Bencina, and I. Zajc. 1991. Genotypic heterogeneity among strains of *Mycoplasma gallinarum*. *Avian Pathol*. 20: 705–711.
11. Dupiellet, J.P., A. Vuillaume, D. Rousselot, J.M. Bové, and J.M. Bradbury. 1990. Serological and molecular studies on *Mycoplasma gallisepticum* strains. *Zentralbl Bakteriol Mikrobiol Hyg Suppl*. 20:859–864.
12. Edward, D.G., and E.A. Freundt. 1956. The classification and nomenclature of organisms of the Pleuropneumonia group. *J Gen Microbiol*. 14:197–207.
13. El Ebeedy, A.A., I. Sokkar, A. Soliman, A. Rashwan, and A. Ammar. 1987. *Mycoplasma* infection of ducks. I. Incidence of mycoplasmas, acholeplasmas and associated *E. coli* and fungi at Upper Egypt. *Israel J Med Sci*. 23:529.
14. Ganapathy, K., and J.M. Bradbury. 1998. Pathogenicity of *Mycoplasma gallisepticum* and *Mycoplasma imitans* in red-legged partridges (*Alectoris rufa*). *Avian Pathol*. 27:455–463.
15. Ganapathy, K., R.C. Jones, and J.M. Bradbury. 1998. Pathogenicity of *in vivo*-passaged *Mycoplasma imitans* in turkey poults in single infection and in dual infection with rhinotracheitis virus. *Avian Pathol*. 27:80–89.
16. Ganapathy, K., and J.M. Bradbury. 1999. Pathogenicity of *Mycoplasma imitans* in mixed infection with infectious bronchitis virus in chickens. *Avian Pathol*. 28:229–237.
17. Garcia, M., M.W. Jackwood, S. Levisohn, and S.H. Kleven. 1995. Detection of *Mycoplasma gallisepticum, M. synoviae*, and *M. iowae* by multi-species polymerase chain reaction and restriction fragment length polymorphism. *Avian Dis*. 39: 606–616.
18. Garcia, M., N. Ikuta, S. Levisohn, and S.H. Kleven. 2005. Evaluation and comparison of various PCR methods for detection of *Mycoplasma gallisepticum* infection in chickens. *Avian Dis*. 49:125–132.
19. Harasawa, R., K. Koshimizu, I.J. Pan, and M.F. Barile. 1985. Genomic and phenotypic analyses of avian ureaplasma strains. *Japan J Vet Sci*. 47:901–909.
20. Jordan, F.T.W., and M.M. Amin. 1980. A survey of mycoplasma infections in domestic poultry. *Res Vet Sci*. 28:96–100.
21. Jordan, F.T.W., J.N. Howse, M.P. Adams, and O.O. Fatunmbi. 1981. The isolation of *Mycoplasma columbinum* and *M. columborale* from feral pigeons. *Vet Rec*. 109:450.
22. Jordan, F.T.W., H. Erno, G.S. Cottew, K.-H. Hinz, and L. Stipkovits. 1982. Characterization and taxonomic description of five mycoplasma serovars (serotypes) of avian origin and their elevation to species rank and further evaluation of the taxonomic status of *Mycoplasma synoviae*. *Int J Syst Bacteriol*. 32: 108–115.
23. Keymer, I.F., R.H. Leach, R.A. Clarke, M.E. Bardsley, and R.R. McIntyre. 1984. Isolation of *Mycoplasma* spp. from racing pigeons (*Columba livia*). *Avian Pathol*. 13:65–74.
24. Kleven, S.H., C.S. Eidson, and O.J. Fletcher. 1978. Airsacculitis induced in broilers with a combination of *Mycoplasma gallinarum* and respiratory viruses. *Avian Dis*. 22:707–716.
25. Koshimizu, K., H. Kotani, T. Magaribuchi, T. Yagihashi, K. Shibata, and M. Ogata. 1982. Isolation of ureaplasmas from poultry and experimental infection in chickens. *Vet Rec*. 110:426–429.
26. Koshimizu, K., R. Harasawa, I.J. Pan, H. Kotani, M. Ogata, E.B. Stephens, and M.F. Barile. 1987. *Ureaplasma gallorale* sp. nov. from the oropharynx of chickens. *Int J Syst Bacteriol*. 37:333–338.
27. Lavric, M., D. Bencina, and M. Narat. 2005. *Mycoplasma gallsepticum* hemagglutinin vlhA, pyruvate dehydrogenase pdhA, lactate dehydrogenase, and elongation factor Tu share epitopes with Mycoplasma imitans homologues. *Avian Dis*. 49:507–513.
28. Lobo, E., M.C. Garcia, H. Moscoso, S. Martinez, and S.H. Kleven. 2004. Strain heterogeneity in *Mycoplasma pullorum* isolates identified by random amplified polymorphic DNA techniques. *Span J Agri Res*. 2:500–503.
29. Loria, G.R., E. Ferrantelli, G. Giardina, L. Li Vecchi, L. Sparacino, F. Oliveri, L. McAuliffe, and R.A. Nicholas. 2008. Isolation and characterization of unusual *Mycoplasma* spp. from captive Eurasian Griffon (*Gyps fulvus*) in Sicily. *J Wildl Dis*. 44:159–163.
30. MacOwan, K.J., H.G.R. Jones, C.J. Randall, and F.T.W. Jordan. 1981. *Mycoplasma columborale* in a respiratory condition of pigeons and experimental airsacculitis of chickens. *Vet Rec*. 109:562.
31. Markham, P.F., M.F. Duffy, M.D. Glew, and G.F. Browning. 1999. A gene family in *Mycoplasma imitans* closely related to the pMGA family of *Mycoplasma gallisepticum*. *Microbiology*. 145:2095–2103.
32. Moalic, P.Y., I. Kempf, F. Gesbert, and F. Laigret. 1997. Identification of two pathogenic mycoplasmas as strains of *Mycoplasma pullorum*. *Int J Syst Bacteriol*. 47:171–174.

33. Nagatomo, H., H. Kato, T. Shimizu, and B. Katayama. 1997. Isolation of Mycoplasmas from fantail pigeons. *J Vet Med Sci*. 59:461–462.
34. Reece, R.L., L. Ireland, and P.C. Scott. 1986. Mycoplasmosis in racing pigeons. *Aust Vet J*. 63:166–167.
35. Samuel, M.D., D.R. Goldberg, C.B. Thomas, and P. Sharp. 1995. Effects of *Mycoplasma anatis* and cold stress on hatching success and growth of mallard ducklings. *J Wildl Dis*. 31:172–178.
36. Shah-Majid, M. 1987. A case-control study of *Mycoplasma gallinarum* in the male and female reproductive tract of indigenous fowl. *Isr J Med Sci*. 23:530.
37. Shimizu, T., H. Erno, and J. Nagatono. 1978. Isolation and characterization of *Mycoplasma columbinum* and *M. columborale*: two new species from pigeons. *Int J Syst Bacteriol*. 28:538–546.
38. Stipkovits, L., A. Rashwan, and M.Z. Sabry. 1978. Studies of pathogenicity of turkey Ureaplasma. *Avian Pathol*. 7:577–582.
39. Stipkovits, L., P.A. Brown, R. Glavits, and R.J. Julian. 1983. The possible role of ureaplasma in a continuous infertility problem in turkeys. *Avian Dis*. 27:513–523.
40. Stipkovits, L., J.M. Bove, M. Rousselot, P. Larrue, M. Labat, and A. Vuillaume. 1984. Studies on mycoplasma infection of laying geese. *Avian Pathol*. 14:57–68.
41. Stipkovits, L., Z. Varga, K.M. Dobos, and M. Santha. 1984. Biochemical and serological examination of some mycoplasma strains of goose origin. *Acta Vet Acad Sci Hung*. 32:117–125.
42. Stipkovits, L., Z. Varga, G. Czifra, and K.M. Dubos. 1986. Occurrence of Mycoplasmas in geese affected with inflammation of the cloaca and phallus. *Avian Pathol*. 15: 289–299.
43. Stipkovits, L., Z. Varga, R. Glavits, F. Ratz, and E. Molnar. 1987. Pathological and immunological studies on goose embryos and one-day-old goslings experimentally infected with a *Mycoplasma* strain of goose origin. *Avian Pathol*. 16:453–468.
44. Stipkovits, L., R. Glavits, E. Ivanics, and E. Szabo. 1993. Additional data on *Mycoplasma* disease of goslings. *Avian Pathol*. 22:171–176.
45. Stipkovits, L., and I. Kempf. 1996. Mycoplasmoses in poultry. *Rev Sci Tech Off Int Epiz*. 15:1495–1525.
46. Stipkovits, L., and S. Szathmary. 2012. *Mycoplasma* infection of ducks and geese. *Poult Sci*. 91:2812–2819.
47. Talkington, F.D., and S.H. Kleven. 1983. A classification of laboratory strains of avian mycoplasma serotypes by direct immunofluorescence. *Avian Dis*. 27:422–429.
48. Varga, Z., L. Stipkovits, M. Dobos-Kovacs, and G. Czifra. 1989. Biochemical and serological study of two mycoplasma strains isolated from geese. *Arch Exp Veterinarmed*. 43: 733–736.
49. Wang, Y., K.G. Whithear, and E. Ghiocas. 1990. Isolation of *Mycoplasma gallinarum* and *M. gallinaceum* from the reproductive tract of hens. *Aust Vet J*. 67:31–32.

Chapter 22

Clostridial Diseases

Introduction

Catherine M. Logue

This chapter focuses on four of the primary recognized clostridial associated diseases of poultry. Ulcerative enteritis (UE), which is caused by *Clostridium colinum*, necrotic enteritis (NE), caused by *C. perfringens*, botulism, caused by *C. botulinum*, and gangrenous dermatitis (GD), caused by *C. perfringens* or *C. septicum*.

Ulcerative enteritis (UE) was first recognized as a disease of quail (26) and has been found to occur worldwide in production birds as well as wild and exotic hosts including quail, grouse, turkeys, chickens, and partridge (3, 32, 37, 41). UE is typically recognized as a disease of young birds (3, 19, 29). The causative agent *C. colinum* is a close relative of *C. piliforme*, the agent of Tyzzer's disease (4). Transmission of the disease appears to be through fecal spread and ingestion of contaminated feed, water, or litter (47). As a spore-former, *C. colinum* can persist in environments long after an outbreak ends and recovered birds can remain as carriers. Infection of humans with *C. colinum* has not been reported. Outbreaks of disease in chickens often accompany periods of stress, coccidiosis, chicken infectious anemia (CIA), or infectious bursal disease (IBD).

Originally, ulcerative enteritis (UE) and necrotic enteritis (NE) were considered the same disease but gross histopathologic analysis shows distinctions (6, 15). Control of UE can be difficult because of the potential for persistence of spores.

Necrotic enteritis (NE) is primarily a disease of young chicks and is associated with the pathogen *C. perfingens*. The disease is both an infection and intoxication in birds (28). Economic consequences of NE in poultry are estimated to be $2 billion worldwide (25). Strains of *C. perfingens* that cause disease in birds also have been linked with enterotoxin production and foodborne illness in humans (46). Diet and feeding conditions have a significant impact on the development of NE in a flock. Feeds high in fishmeal, or wheat- and barley based-diets, and sources of fermentable carbohydrates appear to exacerbate the development of NE (5, 34, 45). Studies have demonstrated an increase in NE in regions where the use of in-feed antimicrobials has been reduced in an effort to produce a more "organic like" product. Control and prevention of NE is best through reducing the exposure via dietary control, with coccidiostatic drugs the method of choice (9, 48).

Botulism in poultry and other birds is caused by an intoxication resulting in neurotoxigenic damage as a result of *C. botulinium*. The organism has caused disease in a wide range of bird hosts including ducks, geese, poultry, and wild birds (2, 21, 27, 43, 49). Outbreaks in production flocks appear to be seasonally related, and they are common in the warmer months (8, 23). Mortality as high as 40% has been recognized in broiler flocks (7, 38).

Control of botulism in a flock may be difficult because of the ability of the organism to produce spores which have the potential to persist.

Treatment of botulism in flocks has shown promise with commonly used antibiotics and recombinant vaccines (1, 44) but their use for large numbers has yet to be evaluated. Acidification of water, which also lowers the gut pH, may have the effect of enhancing normal flora growth and inhibiting *C. botulinum* (13).

Gangrenous dermatitis (GD) is a disease of chickens and turkeys usually caused by one of three agents: *C. perfingens* types A and C, *C. septicum*, or *Staphylococcus aureus* (see Chapter 23). Disease appears to be caused by each of these organisms either singly or in combination (11, 16, 20, 39). Disease in birds is primarily associated with lesions of the skin and subcutaneous tissue often referred to as necrotic dermatitis, gangrenous cellulitis, gangrenous dermatomyositis, wing rot, avian malignant edema, gas edema disease, and blue wing disease. Bird species affected include chickens, broilers, broiler breeders, layers, turkeys, and turkey breeders. The spores of these clostridial species are typically found in the soil, dust, feces, etc., which can make control of the pathogen difficult. Control can be enhanced by total clean-out of the facility; use of vaccines and antimicrobials also has been shown to reduce

Diseases of Poultry, Thirteenth Edition. David E. Swayne.
© 2013 John Wiley & Sons, Inc. Published 2013 by John Wiley & Sons, Inc.

losses. Failure to control with antimicrobials may occur if underlying viral infections are occurring simultaneously.

Some unusual clostridial species associated with diseases in birds include *C. chauvoei* causing lesions on the combs and liver of birds (35), and infection of the intestine and livers of ostriches (24) resulting in neuroparalysis. *C. difficile* and *C. sordelli* associated disease has been reported in ostriches (12, 33, 42). *C. novyi* and *C. sporogenes* have caused disease in chickens (30, 31), Tyzzer's disease in a lorikeet associated with *C. piliforme*, (36) and enterotoxemia associated with *C. tertium* (10) in a lorkeet. *C. perfingens* has been linked with hepatitis in birds (18, 22, 40) and *C. difficile* has caused mortality in ostriches; it is also associated with poultry and may pose a health risk to humans through contaminated meat and poultry products (14, 17).

Acknowledgement

With acknowledgement to Dr John Barnes who wrote the introduction for the 12th edition.

Ulcerative Enteritis

J. Glenn Songer and Francisco Uzal

Introduction

Ulcerative enteritis (UE) was first seen in epidemics in quail, leading to a popular name, quail disease. It is an acute bacterial infection, also occurring in young chickens, turkeys, and other upland game birds. A single case has been described in a lory (43). UE is characterized by sudden onset and rapidly increasing mortality in a flock.

UE occurs worldwide, including in the US (47), England (23), Japan (31), Canada (38), Germany (46), and India (26, 48, 49). It is important in some concentrated poultry-raising areas (10) and is a threat to game birds in confinement and in the wild. Infection of humans has not been reported, so there are no apparent public health issues.

History and Etiology

Quail disease was first reported in the US in 1907 (37). Scattered outbreaks in quail and grouse (1, 20, 32, 33, 34, 42) occurred during the next 2 decades. Subsequently, infection was discovered in wild and domestic turkeys (11, 47), and other species were found susceptible, including pigeons (21), chickens (22, 47), robins (50), pheasants, blue grouse, partridges (44), California quail (12), and lorikeets (43). Japanese quail may have genetic differences in susceptibility (15). The chronology of events leading to isolation and identification of the etiologic agent have been described (2, 3, 7, 39, 40).

Classification

Early on, quail inoculated with a Gram-positive, pleomorphic, aerobic, nonmotile bacterium from the liver of a diseased quail developed UE. The organism, classified as *Corynebacterium perdicum*, grew poorly on solid media and in fluid media. Virulence was rapidly lost on subculture (35). Subsequently, a Gram-negative, anaerobic bacillus isolated from the intestine and liver of infected quail was cultivated in thioglycollate broth cultures and fed to quail, which developed the typical clinical syndrome (3).

Peckham (39, 40) reported recovery of a Gram-positive, anaerobic, spore-forming rod when clinical material was inoculated into the yolk sacs of chick embryos. UE was reproduced with this organism, and it was re-isolated from inoculated quail, fulfilling Koch's postulates. Similar anaerobes were isolated from chickens and turkeys with UE, and it was established that the disease was caused by the same organism in chickens, turkeys, and quail (40).

This anaerobe, the demonstrated cause of UE, is *Clostridium colinum* (5, 8). 16S rRNA sequence analysis places *C. colinum* in subcluster XIV-b with six other *Clostridium* spp. It is most closely related to *C. piliforme*, the agent of Tyzzer's disease (14).

Morphology and Staining

As noted, *Clostridium colinum* is a Gram-positive bacillus, occurring singly as straight or slightly-curved rods with rounded ends. Sporulation is rare on artificial media, but if present, spores are oval and subterminal. Sporogenic cells are much longer and thicker than nonsporing cells (Figure 22.1).

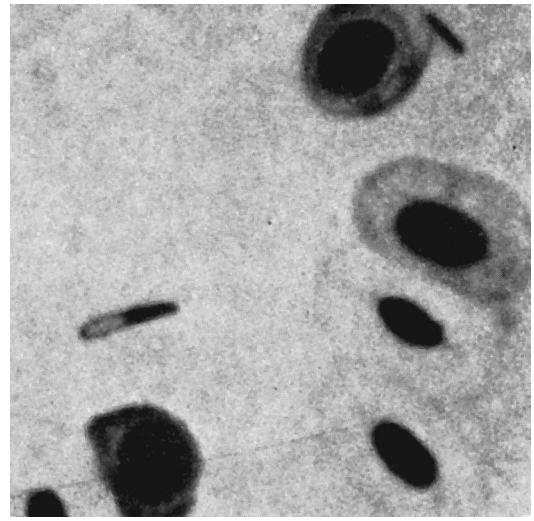

Figure 22.1. Blood smear from quail with UE. Note two bacteria, one of which has a subterminal spore. (M.C. Peckham)

Growth Requirements

Clostridium colinum is fastidious in its growth requirements. It needs an enriched medium and anaerobic environment. The best isolation medium is tryptose-phosphate agar (Difco) with 0.2% glucose, 0.5% yeast extract, and 8% horse plasma. Pre-reduced plates are inoculated with material from liver lesions and incubated anaerobically for 24–48 hours at 35°C–42°C (19). The resulting colonies are 1–2 mm in diameter, white, circular, convex, and semi-translucent, with filamentous margins. Growth in liquid medium (solid medium without the agar) can be detected as early as 12–16 hours post-inoculation (PI). Actively growing cultures produce gas, but for no longer than 6–8 hours, after which growth settles to the bottom of the tube (5). Subcultures should be made from actively growing broth cultures still producing gas.

Biochemical Characteristics

Glucose, mannose, raffinose, sucrose, trehalose, fructose, and maltose are fermented, although the latter two are fermented only weakly. Mannitol is fermented by some strains, one of which is the type strain, ATCC 27770. Arabinose, cellobiose, erythritol, glycogen, inositol, lactose, melezitose, melibiose, rhamnose, sorbitol, and xylose are not fermented. Fermentation products are acetic and formic acids (5, 8).

Esculin hydrolysis is common, but most strains, including the type strain, do not hydrolyze starch. Nitrate is not reduced and no indole is produced. Milk remains unchanged, and casein is not digested. The organism grows well in chopped meat carbohydrate broth. Pyruvate and lactate are not utilized and gelatin is not liquefied. Catalase, urease, lipase, and lecithinase are not produced.

Clostridium colinum resembles *C. difficile* in culture, but they can be differentiated biochemically; *C. difficile* hydrolyzes gelatin and does not ferment raffinose (19).

Susceptibility to Chemical and Physical Agents

Clostridium colinum is, by virtue of its production of spores, highly-resistant to chemical agents and physical insults. Spores of *C. colinum* are resistant to organic solvents (8). Yolk cultures may remain viable for at least 16 years at −20°C, and they survive heating at 70°C for 3 hours, 80°C for 1 hour, and 100°C for 3 minutes (40).

Pathogenesis and Epidemiology

Incidence and Distribution

UE is commonly recognized in quail, but chickens, turkeys, and many other avian species are affected worldwide.

Natural and Experimental Hosts

As noted, UE is found in a wide range of avian hosts, butc quail are among the most susceptible species. Natural infections have been found in bobwhite quail (*Colinus virginianus*), California quail (*Lophortyx california*), Gambel's quail (*L. gambelii*), mountain quail (*Oreortyx picta*), scaled quail (*Callipepla squamata*), and sharp-tailed grouse (*Pedioecetes phasianellus*) (37). Ruffed grouse (*Bonasa umbellus*) (32, 33), domestic turkeys (*Meleagris gallopavo*) and chickens (*Gallus gallus*) (18, 47), European partridge (*Perdix perdix*), wild turkeys (*M. gallopavo*) (18), chukar partridge (*Alectoris graeca*) (44), pigeons (*Columba livia*) (21), pheasants (*Phasianus colchicus*), blue grouse (*Dendragapus obscurus*) (12); and crested quail (*L.c. californicus*) (23) are also affected. An outbreak of UE in robins (*Turdus migratorius*), confirmed by isolation of *C. colinum* from the liver, provided the first evidence that UE could affect passerine birds (50). UE also has been confirmed in lories (*Trichoglossus* spp.) and red lories (*Eos* spp.) (43). Outbreaks in chickens often accompany or follow coccidiosis, chicken infectious anemia, infectious bursal disease, or stress conditions.

Experimental infections are difficult and can be reliably produced only in quail (9). UE is more frequently seen in young birds. Chickens 4–12 weeks (40), turkeys 3–8 weeks (11), and quail 4–12 weeks of age are most commonly affected. However, disease has been reported in adult quail (27). The potential importance of coccidiosis in outbreaks of UE in chickens was confirmed by producing UE in 5-week-old chickens previously infected with *Eimeria brunetti* and *E. necatrix* but not with either one alone (16). Oral administration of at least 10^7 viable cells of *C. colinum* is required to experimentally reproduce UE in quail (8).

Transmission

UE is transmitted via the fecal:oral route under natural conditions. Birds become infected by ingesting contaminated feed, water, or litter. The organism produces spores, resulting in permanent contamination of premises after an outbreak.

The carrier status of recovered birds or survivors in a flock has not been studied critically. Chronic carriers, however, are considered important in perpetuation of UE. A complement-fixation (CF) test has been used to detect carriers (36).

Incubation Period

After experimental inoculation, the acute disease develops, accompanied by death of quail, in 1–3 days. The course of the disease in a flock is generally about 3 weeks, with peak mortality occurring 5–14 days after the initial case.

Clinical Signs

Birds may die from acute disease with no premonitory signs. They are usually well muscled and fat and have feed in the crop. Quail often exhibit watery, white droppings. As UE progresses, infected birds become listless and humped up, with eyes partly closed and feathers dull and ruffled. Notable

emaciation, with atrophy of pectoral muscles, is seen in birds affected for a week or longer. Young quail may be subject to 100% mortality in a few days. The mortality rate in chickens typically ranges from 2%–10%.

Pathology

Gross Pathology

Acute lesions in quail are characterized by marked duodenal hemorrhagic enteritis. Small punctate mucosal ulcers surrounded by a hemorrhagic halo may be visible from the serosal side of the intestine. Ulcerations may be extensive enough to erode the whole thickness of the intestinal wall, causing perforation and subsequent peritonitis (16).

Subacute or chronic lesions can be observed in birds surviving for several days. They consist of multiple large, roundish yellow ulcers surrounded by hemorrhages in any part of the small or large intestine and ceca. These ulcers later coalesce to form larger lesions and may be covered by diphtheritic membranes. Blood is commonly found in the gut (Figure 22.2A, B). As ulcers increase in size, the hemorrhagic border disappears. Ulcers may be deep in the mucosa, but in older lesions, they are often superficial with raised edges. Ulcers in ceca may have a central depression filled with strongly attached, dark-staining material. Perforation of ulcers frequently occurs, resulting in peritonitis and intestinal adhesions (16).

Peckham (40) described a presentation of UE in turkeys characterized by the presence of necrotic, diphtheritic membrane occupying the middle third of the intestine. This combination of necrosis and sloughing of intestinal mucosa appeared similar to lesions produced by *E. brunetti* infection in chickens.

Liver lesions are not always evident. When present, they vary from light yellow mottling to multiple large, irregular, gray or yellow circumscribed foci, sometimes surrounded by a pale yellow halo (Figure 22.2F). The spleen may be congested, enlarged, and hemorrhagic. Gross lesions are usually absent from other organs, although peritonitis or polyserositis can be observed when intestinal perforation occurs (16).

Microscopic Pathology

A clear description of the histopathology of UE in quail can be found elsewhere (16).

Acute cases reveal erosion of intestinal mucosal epithelium, edema of intestinal wall, vascular congestion, and heterophilic infiltration of the lamina propria and, occasionally, the submucosa. The lumen of the intestine contains desquamated epithelium, blood cells, cell debris, fibrin, and Gram-positive bacteria.

As the lesions progress, mucosal ulcers involving villi and extending into the submucosa develop. Most ulcers are covered by thick pseudomembranes composed of desquamated epithelial cells, fibrin, cell debris, mixed inflammatory infiltrate, and bacilli. Epithelial cells adjacent to these ulcers exhibit coagulation necrosis with karyolysis and karyorrhexis. Lymphocytic and granulocytic infiltration occurs adjacent to the ulcers. Small clumps of Gram-positive bacteria are often present in necrotic tissue and in the lumen (Figure 22.2 C, D, E). At later stages, transmural necrosis and inflammation can be observed.

Vascular fibrin and bacterial thrombosis in the mucosa is an almost constant finding in both the acute and chronic lesions.

Liver lesions, when present, are poorly demarcated foci of coagulative necrosis, with minimal inflammatory reaction and occasional intralesional, Gram-positive bacterial colonies, randomly scattered throughout the parenchyma (23) (Figure 22.2 F, G, H).

Pathogenesis

UE has been reproduced by administration of large numbers of viable *C. colinum* cells orally (8). After oral infection, the bacterium adheres to the intestinal villi, producing inflammation and ulcers in the small and upper large intestine. If the birds survive the initial intestinal phase, the organism then migrates to the liver via portal circulation, producing the hepatic lesions described above. The role of an *in situ*-produced toxin in the pathogenesis of UE has been suggested but not demonstrated. Birds that have recovered from the disease remain carriers, and as with birds suffering an active infection, shed the bacterium in their droppings. Infection also can be introduced by flies feeding on contaminated fecal material.

Active Immunity

Active immunity develops in birds recovering from naturally-occurring infections. When survivors of a UE outbreak are subsequently challenged, no noticeable effect is seen (28), whereas 85% of similarly challenged susceptible controls die. It has been observed, however, that those surviving due to antimicrobial therapy remain highly susceptible to infection (30, 41).

Diagnosis

A presumptive diagnosis of UE can be made on the basis of gross and/or microscopic lesions. The presence of typical intestinal ulcerations sometimes accompanied by necrosis of the liver and an enlarged, hemorrhagic spleen suffices for a presumptive diagnosis. As an aid in diagnosis, necrotic liver tissue can be crushed between 2 slides, fixed by heat, and stained by Gram's method. Large, Gram-positive rods, subterminal spores, and free spores can be seen. Isolation of *C. colinum* from liver or spleen provides final confirmation of the diagnosis. Because the organism is often present in the liver in pure culture, isolation from liver rather than from ulcerative, intestinal lesions is recommended. *C. perfringens* may be present as a secondary invader but is easy to recognize (7, 19).

A fluorescent antibody (FA) is highly specific for diagnosis of UE; correlation between a presumptive diagnosis based

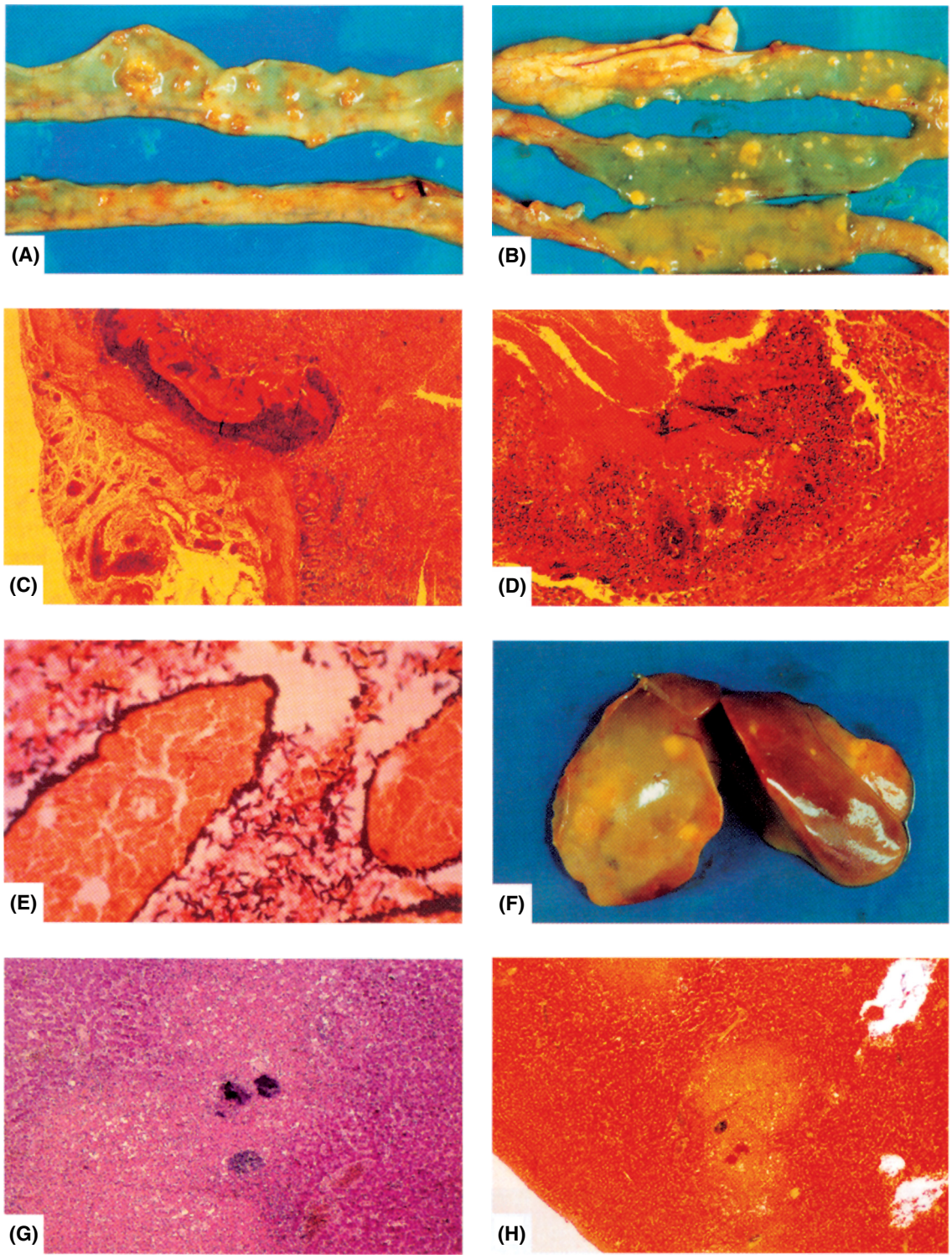

Figure 22.2. Ulcerative enteritis lesions in quail. (A) Early intestinal ulceration visible from both mucosal and serosal surfaces. Note the hyperemia around some lesions and occasional ulcers with marginal hemorrhage. (B) More advanced ulcers filled with diphtheritic, necrotic membranes. (C) Transmural ulcer containing necrotic tissue and inflammatory exudates with adjacent focal peritonitis. (D) Higher magnification of (C). Note the sharp demarcation between viable and necrotic tissue by a zone of inflammation, inflammatory exudates, and bacterial colonies. (E) Gram-stained, high magnification of inflammatory zone showing numerous large, Gram-positive bacilli typical of *Clostridium colinum*. (F) Areas of necrosis in chicken liver. (G) Microscopic appearance of liver lesion. Note the spreading areas of necrosis without distinct separation for normal tissue, minimal inflammatory response, and bacterial colonies. (H) Gram stain of liver lesion. Note Gram-positive staining colonies in necrotic foci.

on gross lesions and the FA test is 100% (6). An agar gel immunodiffusion test also has been used for diagnosis of UE (4). Soluble bacterial antigens that reacted with antisera against *C. colinum* were found in high concentration in intestinal contents. These antigens were identical to antigens present in culture filtrates of *C. colinum*. Antigens were not, however, species specific, as some strains of *C. perfringens* types A and C have cross-reacting antigens. Cross-reactivity among clostridial species makes this test unreliable for diagnostic purposes.

Differential Diagnosis

Similar diseases that must be differentiated from UE include coccidiosis, necrotic enteritis by *C. perfringens*, and histomoniasis. Frequently, coccidiosis in chickens, turkeys, and pheasants precedes or occurs concurrently with UE (Figure 22.3). Both diseases may be present in the same or different specimens submitted for diagnosis (11, 12, 16, 39). It is imperative that a differential diagnosis between coccidiosis and UE be made because medication for each disease is distinct. Furthermore, these diseases may occur simultaneously, necessitating use of two different medications.

A condition initially described as necrotic enteritis frequently occurs in broilers in densely populated areas. At one time, UE and necrotic enteritis were thought to be the same disease, but it has been conclusively demonstrated (17) that they are distinct. Gross and histopathologic differentiation of necrotic enteritis and UE has been described (24), although sometimes the differences in the lesions between UE and necrotic enteritis are minimal.

Histomoniasis produces caseous cores in ceca and necrotic areas of varying size in the liver. This combination of cecal and liver lesions, seen in chickens, turkeys, and other gallinaceous birds, makes it imperative that cecal ulcerations and liver necrosis of UE be distinguished from histomoniasis. An enlarged hemorrhagic spleen and intestinal ulcerations are characteristic of UE. Histologic examination of the liver or ceca of birds with histomoniasis will reveal histomonads.

Coccidiosis may affect different parts of the intestine, from the duodenum to the ceca, depending on the coccidian species involved. Fecal examination and histopathology will reveal the presence of coccidia in the affected tissues.

Intervention Strategies

Management Procedures

The infectious organism is in the feces and remains viable indefinitely in litter. Thus, on problem farms, contaminated litter should be removed and clean litter introduced for each brood. In chickens, it is essential to avoid stresses caused by overcrowding to keep coccidiosis under control and to use preventive measures against viral diseases, which may act as stressors and/or cause immunosuppression.

Game farm managers should exercise caution to avoid overgrazing ranges and overcrowding birds. Placing birds on 0.5-inch wire mesh is recommended on farms where UE is a problem. Survivors of an outbreak may be carriers and should not be mixed with unexposed birds.

Treatment

UE can be prevented and/or controlled through medication of either drinking water or feed. Early use of sulfonamides for treatment of UE was unsuccessful (13, 44), but streptomycin administered by injection or in feed or water has prophylactic and therapeutic value against the disease in quail. Streptomycin at a level of 60 g/ton of feed or 1 g/gal of water gives complete protection when administered prophylactically (27, 28, 29, 30, 41). Addition of 100 g bacitracin/ton of feed provides protection (41). Bacitracin methylene disalicylate can be used at

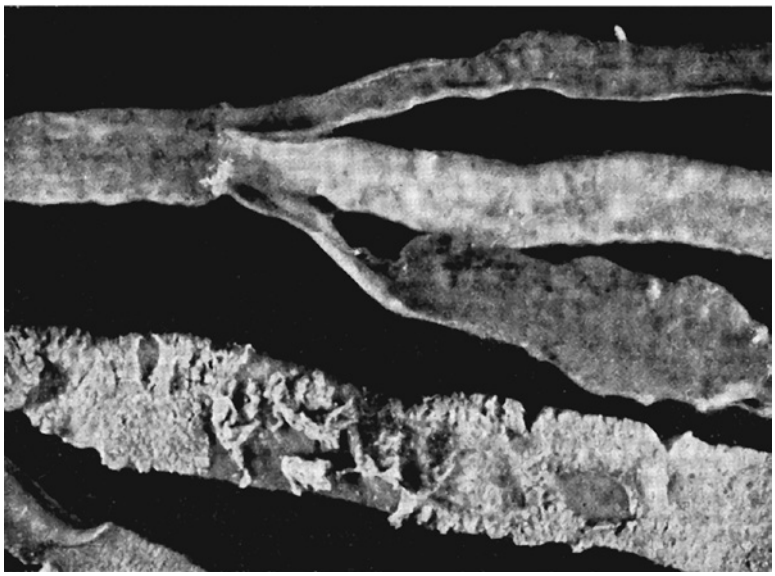

Figure 22.3. Combined UE and *Eimeria brunetti* coccidial infection in the intestine of a chicken. Note small ulcers in ceca and rectum. Diphtheritic membrane is due to coccidial infection. (M.C. Peckham)

200 g/ton for control of UE in quail. Other chemotherapeutics reported to have efficacy for control of UE in quail include furazolidone, chlortetracycline (41), penicillin, ampicillin (31), and tylosin (25, 31).

Acknowledgement

The authors acknowledge contributions by Herman Berkhoff, Martin Ficken, and Dennis Wages to previous editions of this chapter.

Necrotic Enteritis

Kenneth Opengart and J. Glenn Songer

Introduction

Commercial poultry production has become an increasingly specialized industry, based upon large economic investments (24). Genetic selection has resulted in faster growth rates and improved feed efficiency, offsetting, in part, the 65%–70% of producers' total costs that are in feed. Factors which improve production efficiency also increase production pressure. A concurrent result to added production pressure can be that the incidence of some economically important diseases, such as necrotic enteritis (NE), also increase.

Definition and Synonyms

Clinical NE can be defined as a disease of primarily young chickens, caused by infection with, and toxin production by, *Clostridium perfringens* type A and type C. The clinical infection is characterized by sudden onset, high mortality, and necrosis of the mucous membrane of the small intestine. The disease is also known as clostridial enteritis, enterotoxemia, and rot gut.

Economic Significance

Loss of growth efficiency and mortality negatively impact profitability (87). In fact, the difference between profit and loss is often determined by the incidence of infectious diseases, one of which is necrotic enteritis (NE). Losses due to NE are estimated to cost the poultry industry $2 billion annually worldwide (79).

Public Health Significance

Clostridium perfringens type A and type C, in addition to producing toxins which can induce NE in poultry, also produce enterotoxins at the moment of sporulation which can produce foodborne illness in humans. Two distinct diseases are induced by these subtypes; type A *C. perfringens* produces diarrhea and type C *C. perfringens* produces necrotic enteritis in humans (104). High percentages of *C. perfringens*-positive carcasses have been reported following processing (30, 80) and outbreaks of type A food poisoning traced to consumption of chicken have been reported (52, 91).

History

Bennetts isolated *C. perfringens* from intestinal lesions in a Black Orpington pullet in 1930 and attributed the bird's death to this infection (13, 71, 82). "Six-day disease," characterized by *C. perfringens* invasion of chick intestinal mucosa (54, 74, 75), was reproduced in day-old chicks by intragastric (IG) administration of *C. perfringens* (54, 77, 78, 109). "Necrotic enteritis" was the term applied to an intestinal disorder in young cockerels (67, 68, 69, 82, 85); disease was reproduced by administration of *C. perfringens per os* (15, 67, 86).

Etiology

NE is common, and some consider it the most clinically dramatic bacterial enteric disease of poultry (68). *Clostridium perfringens* is a Gram-positive, anaerobic, spore-forming rod (87, 96), motile via type IV pili (105). A commensal in the intestinal tract of vertebrates, it is frequently isolated from environments contaminated by feces (87, 96). It also causes avian malignant disease, gizzard erosions, and gangrenous dermatitis (20, 45, 72, 102) in birds as well many other diseases of humans and other animals, (51, 96, 110). Conventional morphologic description and biochemical characteristics of *C. perfringens* can be found in earlier editions of *Diseases of Poultry*.

Strain Classification and Toxins

Clostridium perfringens lacks much of the genetic machinery required to produce essential amino acids (81, 94) so it obtains them *in vivo* via the action of its armada of exotoxins and exoenzymes on host tissues (22). The organism produces 17 or more toxic exoproteins (22, 96) and is classified into toxigenic types A–E based on production of 4 distinct toxins (51, 96, 110) (Table 22.1). NE is commonly caused by *C. perfringens* types A and C (39, 56, 71, 87, 89, 102).

The mechanism through which *C. perfringens* expresses its virulence for birds is not yet clearly understood. If the strains of *C. perfringens* which produce NE follow the paradigm of other toxinotypes of the organism, pathogenesis is likely toxin-mediated. *Clostridium perfringens* alpha (CPA) toxin is a zinc-dependent phospholipase/sphingomyelinase

Table 22.1. Toxinotypes of *Clostridium perfringens*.

	Major toxins			
Type	**Alpha (CPA)**	**Beta (CPB)**	**Epsilon (ETX)**	**Iota (ITX)**
A	X			
B	X	X	X	
C	X	X		
D	X		X	
E	X			X

Table 22.2. Virulence of selected *C. perfringens* strains in a necrotic enteritis model.

Strain	Toxinotype	Source	Virulence for chicks
JGS4143	A	Poultry NE	+++
JGS5252	A	Poultry NE	++++
JGS1235	A	Poultry ulcerative enteritis, hepatitis	+
JGS1882	A	Porcine neonatal enteritis	–
JGS4142	A	Bovine neonatal hemorrhagic enteritis	–
JGS1473	A	Chicken normal flora	–

C (40). It has been detected in large amounts in the feces of poultry (44, 73, 96, 104), and data suggest a role for it in the pathogenesis of NE (7, 44, 51, 98). High titer anti-CPA antibodies have been reported in birds recovered from NE (72, 73) but not in normal birds; in NE flocks, approximately 15%–20% of birds are seropositive at 5 weeks post-hatching, and nearly 80% are positive by 8 weeks. Newly hatched chicks have anti-CPA antibodies, and higher titers are found in those produced by older hens (73). Birds also develop anti-CPA antibody titers after experimental inoculation (26, 72, 73).

The role of CPA in the development of NE, however, is also somewhat in doubt (60, 102). A CPA mutant, constructed from a virulent chicken isolate, retained full virulence *in vivo*. Others (26, 63), however, suggest that CPA may serve as a protective antigen. More recent work has shown that CPA is produced in the intestines of conventional chicks challenged with the CPA mutant, possibly by members of the normal flora (27).

A novel toxin (NetB) with an amino acid sequence (*netB*) similar to that of CPB (38% identity) and *Staphylococcus aureus* alpha toxin (31% identity) has been identified in NE strains of *C. perfringens*. NetB, in native and recombinant forms, caused rounding and lysis of chicken hepatoma cells, while a *netB* mutant failed to produce disease (59). The authors found that approximately 25% of chick-virulent strains were polymerase chain reaction- (PCR) and Western blot-negative for *netB* and NetB, respectively, suggesting that NetB might not always be an essential virulence factor (59).

Virulence Factors

The key factor for development of natural disease and for experimental reproduction of NE is the creation of an intestinal environment that favors anarchic growth of *C. perfringens* (4, 5, 8, 26, 35, 56). Virulence varies by strain and NE has been reproduced with isolates from field cases of NE and cholangiohepatitis (4, 69). Not all strains of *C. perfringens* type A are equally virulent (Table 22.2).

Pathobiology and Epizootiology

The pathobiology and epizootiology of NE in poultry has been well described in detail in earlier editions of *Diseases of Poultry*.

Transmission, Carriers, Vectors

The source of NE-producing strains of *C. perfringens* is, ultimately, the chickens themselves. Small numbers of NE strains may be resident, permanently or transiently, in the gut of normal chickens. Chicks may acquire these strains from hatching and growing environments (29, 30, 104). Additional birds may then become colonized, with contamination of the litter increasing exponentially. Given proper conditions in the intestines of other birds, outbreaks of NE could occur, further increasing the availability of NE strains.

NE outbreaks may have been associated with contamination of poultry feed (34, 49, 82). Vectors (flies) (32) and even vertical (93) transmission have been suggested. Patterns of NE occurrence are also affected by management-related stress (28, 92), bedding on high-fiber litter (16, 39, 103), dietary restriction or fasting (84), and season (58).

Litter management practices also may increase the risk of NE infection. Litter is typically completely replaced after use in 8–10 broiler flocks. However, some producers recycle or "decake" the litter (by removing the upper 5–10 cm of manure, bedding material, and spilled feed), increasing subsequent exposure of chicks to *Eimeria* oocysts, coliforms, and *C. perfringens* (43, 95, 97).

Clinical Signs

Birds with NE are depressed (39, 87, 104), reluctant to move (39, 48), and have ruffled feathers (39, 104). They are usually diarrheic (104) and may be inappetant, anorexic (20, 39), and dehydrated (68). The course is often peracute, with death in 1–2 hours (19, 20). Mortality rates may be as high as 50% (19, 31, 67).

Pathology

Gross lesions are usually jejunal and ileal (14, 39, 67, 68, 87, 104) but can also be duodenal and cecal (104). The small intestine is distended (39, 87, 104) and friable (55, 104). The mucosa may have a "Turkish towel" appearance. (Figure 22.4). More specifically, the mucosa has a focal-to-confluent pseudomembrane, and petechial hemorrhage is common (39) (Figure 22.5A,C).

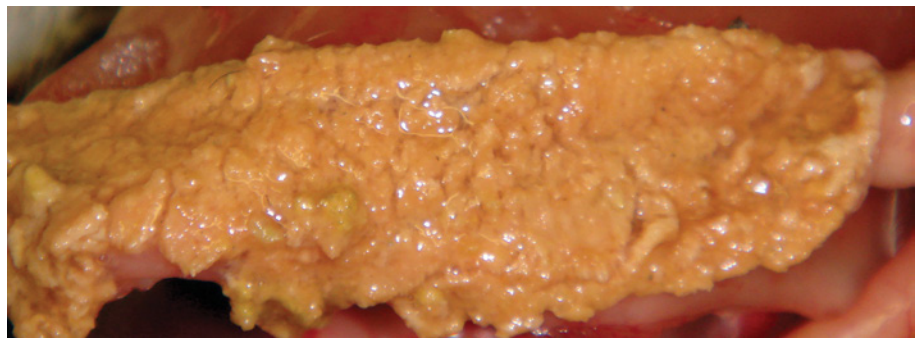

Figure 22.4. Characteristic Turkish towel appearance of the mucosa of the small intestine of a chicken with necrotic enteritis. (D. Ritter)

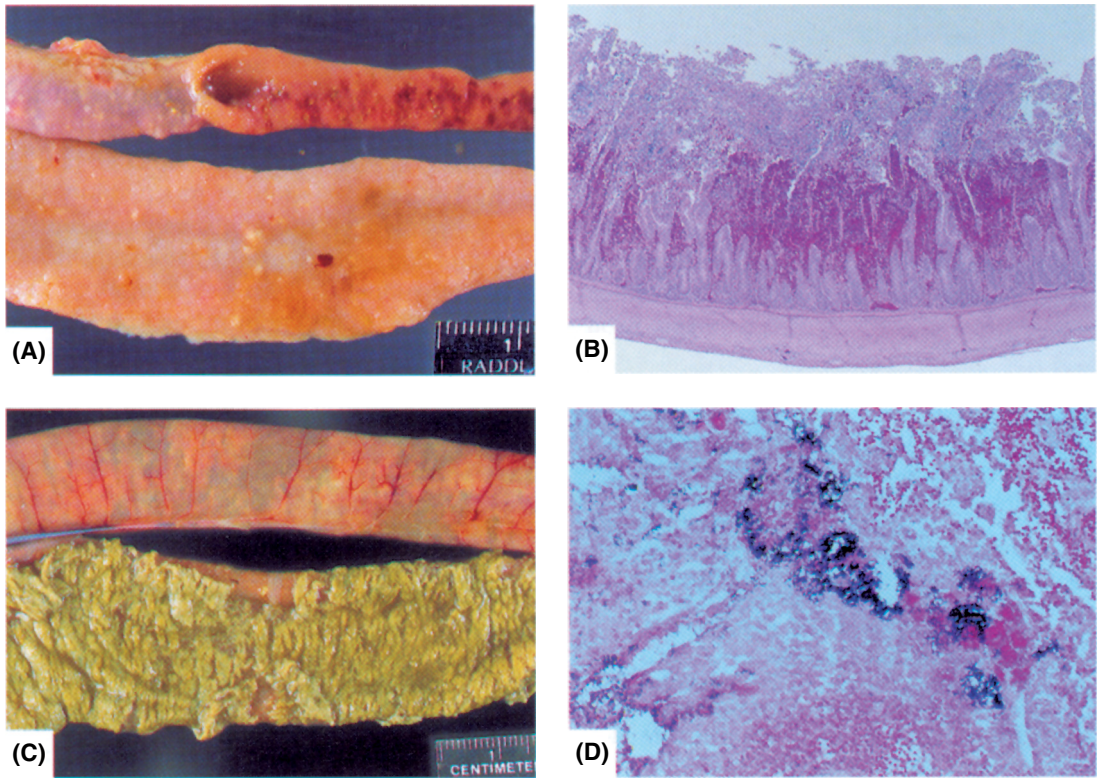

Figure 22.5. (A) Mild to moderate necrotic enteritis in a 7-week-old broiler breeder chicken with concurrent coccidiosis. Note the hyperemia and diffuse necrosis of the mucosa with multifocal ulcerations. (L. Munger) (B) Intestine of a turkey showing uniform diffuse coagulation necrosis of mucosa. Deeper viable mucosal tissue is demarcated from necrotic luminal mucosal tissue by a zone of intense hyperemia, hemorrhage, and inflammation. (H.J. Barnes) (C) Severe necrotic enteritis in a commercial broiler. Note the "Turkish towel" appearance to the necrotic pseudomembrane covering the intestinal mucosa. (C. Hofacre) (D) Necrotic enteritis in a 6-week-old ostrich caused by *C. difficile*. Note the severe diffuse coagulation necrosis with separation from the underlying viable tissue by an intense zone of inflammation with numerous large Gram-positive bacilli located at the interface of the necrotic and viable tissue. (L. Munger and H.J. Barnes)

Microscopically, there is extensive villous necrosis (21, 68), and cellular degeneration may reach the submucosa (39) or even the muscularis mucosa (82) (Figure 22.5B,D). Coagulation necrosis is common at villous apices (39) and the demarcation between necrotic and normal tissue is defined by accumulation of mononuclear cells at the junction (3, 67, 68). Large, Gram-positive rods compatible with *C. perfringens* are associated with areas of necrosis (39) but apparently do not invade viable cells (87).

Clostridium perfringens may gain access to portal circulation and then the biliary ducts, leading to the development of cholangiohepatitis (70). Pale, focal liver lesions (39, 71, 104) examined microscopically reveal extensive multifocal coagulative necrosis in the liver (82) and bile ducts (57). Gall bladder and hepatic ducts are distended with inspissated material (90), and Gram-positive bacilli are found in necrotic areas (57). Hepatitis alone also has been reported (71, 72).

Pathogenesis of the Infectious Process

NE is sometimes exacerbated by co-infection with coccidia. Early reports specifically named *Eimeria brunetti* and *Eimeria maxima* in mixed infections (48, 82). Mucosal damage by

sporozoites and merozoites (54), reduction in intestinal pH (3, 9), and increased transit time (48) allow establishment and proliferation of *C. perfringens* (9, 10, 11, 108). *Clostridium perfringens* numbers are several logs higher in birds with acute coccidiosis than in normal birds. The organism adheres more readily to cecal mucosa in gnotobiotic, *Eimeria*-infected chicks than in non-infected birds (10). Mortality in conventional birds infected with *C. perfringens* and *Eimeria* spp. may be 25% or more higher than in *Eimeria*-free birds (33).

Dietary factors which have been shown to experimentally create an environment favorable for the development of NE include wheat- or barley-based feeds, diets high in fishmeal (usually approximately 50% [103]), and diets which provide rapidly fermentable carbohydrates or proteins into the small intestine (26, 88). Dietary zinc also increases the attack rate in birds challenged with *Eimeria* and *C. perfringens* (8).

Exposure to *C. perfringens* can be by gavage (less effective)(28, 31, 39), exposure to litter from infected flocks (moderately effective) (8, 45 46), or by offering feed mixed with broth cultures of *C. perfringens* (highly effective) (3, 4, 26, 45, 69, 103).

Chickens without *C. perfringens* among the normal microbiota are uncommon (31, 61, 93, 99, 100, 104). Normal chicken flora strains or strains from enteric disease in other species are not virulent for chickens (K.K. Cooper and J.G. Songer, unpublished). Intestines of NE-affected birds, however, do contain large numbers of *C. perfringens* (often 10^6–10^8 CFU/gram of mucosa [9, 68]), although high numbers of intestinal *C. perfringens* alone are not sufficient to induce NE; clonal expansion of specific pathogenic toxin types is necessary.

Genetic characterization has revealed that healthy birds may carry as few as two pulsed-field (PFGE) types of type A organisms (38) to as many as 5 or more (12, 44, 83). Birds with NE, on the other hand, are typically colonized by a single PFGE type, which is different from those types found in healthy birds (38, 83). After natural recovery or treatment, birds again yield multiple PFGE types, usually including one or more from pre-disease populations, but without the NE-producing strain (12, 83). This dominance established by NE strains may be the result of bacteriocin production, because NE strains inhibit growth of non-NE strains *in vitro* (12).

Decreased intestinal motility, intestinal mucosal damage, and intestinal obstruction, in addition to the dietary factors noted above, favor the growth of *C. perfringens* and the subsequent development of NE (4, 28, 70, 104).

As noted, dietary composition is perhaps the most important nonbacterial factor contributing to the growth of virulent strains and development of disease. Increased dietary animal protein leads to increased numbers of *C. perfringens* in ceca; source and amino acid content of the protein also may be important (33, 44, 67, 84, 104). The incidence of NE in birds on wheat- or barley-based diets is 6–10 times greater than that in birds on maize-based diets (16, 58, 106) and mortality is 2–3 times higher (104). This may be due, at least in part, to nutrient availability to *C. perfringens*; the organism proliferates at a higher rate *in vitro* in digested wheat or barley than in digested corn (6, 104). The form of feed components also influences incidence of NE (104). Pelleted feeds yield higher rates of gain (36). However, while smaller particles are more digestible by birds, they are also more rapidly and more easily metabolized by *C. perfringens* (42), leading in many cases to higher mortality due to NE (17, 104).

Immunity

Passive Immunity

Chicks mature immunologically at about 3–4 weeks of age (65), while maternal anti-CPA antibodies persist for approximately 3 weeks (47). These factors suggest a possible explanation for the fact that most NE outbreaks in broiler chickens occur later than 2–3 weeks of age (38, 67, 72). NE also has been reported in older birds (3- to 6-month-old layers and 12-16-week-old replacement pullets) (39, 87).

Active Immunity

Vaccination of broiler breeder hens with type A and type C toxoids yielded a strong serum antibody response to CPA (5). Antibodies also have been shown to be passively transferred to progeny. Protection against subclinical NE and hepatitis was greater in chicks vaccinated with the type C toxoid despite the fact that the anti-CPA response was higher in type A vaccinates (72).

Chicks inoculated with a fully virulent NE strain of *C. perfringens* (daily for 5 days) and then treated with bacitracin were protected upon re-challenge. Immunization of birds with recombinant CPA toxoids provides partial (26) or complete (63) protection against challenge. The incidence of NE in vaccinated birds was significantly less than in nonvaccinates; lesion scores in nonvaccinated birds averaged 2.37, while those in vaccinated birds were 1.35. Inoculation with a CPA-deficient mutant also has been shown to protect birds (102).

Five immunogenic proteins (CPA, glyceraldehyde-3-phosphate dehydrogenase, pyruvate:ferredoxin oxidoreductase [PFOR], fructose 1,6-biphosphate aldolase [FBA], and a hypothetical protein [HP]) were produced as recombinants and used to immunize broiler chicks (62). Immunity to each protein provided significant protection against a relatively mild NE challenge. However, responses to CPA, HP, and PFOR offered substantial protection against a severe challenge. Primary immunization with CPA toxoid and boosting with active toxin yielded the greatest degree of protection against severe challenge (63).

Oral immunization with an avirulent *Salmonella enterica* serovar Typhimurium vaccine vector carrying genes encoding FBA or HP also was significantly protective against challenge (64, 111). The cloned C-terminus of *cpa* (111) into a recombinant attenuated *Salmonella enterica* serovar Typhimurium (RASV) offered protection to broiler chicks orally immunized at 3 days of age.

Diagnosis

Diagnosis of NE is relatively straightforward. Birds with compatible clinical signs and gross lesions on necropsy should be further examined for microscopic lesions (see above) and for

appropriate bacteriological findings. In the latter case, recovery of large numbers of *C. perfringens* (large, Gram-positive rods, some with spores, producing a double zone of hemolysis on blood agar) from the small intestine are suggestive of NE. When examined by PFGE, these isolates are likely to be identical. PCR assays for *netB* will likely be positive.

Intervention Strategies

NE can be controlled or prevented by reducing exposure to risk factors (18). Alterations to feed composition, such as removing fishmeal from the diet, have been effective in reducing incidence of NE (39).

Coccidiostatic drugs have been the method of choice for the prevention of coccidiosis in broiler chickens for the past 50 years (37, 107). Ionophores have been most popular, and these drugs are serendipitously anti-clostridial (2). Anticoccidial poultry vaccines use wild-type and attenuated strains of *Eimeria* spp. and live, multivalent anti-coccidial vaccines are now registered around the world (107). Ionophores have been used in combination with coccidial vaccines to both promote the development of coccidial immunity and limit the potential for controlled coccidial exposure to induce NE (66, 107). The live parasites in these coccidial vaccines cause intestinal damage (76, 104, 107) allowing *C. perfringens* to proliferate extensively in recently immunized birds (108). Thus, anticoccidial vaccination increases the risk of developing NE (107) and untimely withdrawal of ionophores from feed may contribute to the problem.

The incidence of NE and the subsequent use of therapeutic antibiotics to treat the disease have increased in areas of the world where the use of in-feed antibiotics for the purpose of growth promotion has been curtailed (23, 25, 104). NE has been treated with lincomycin, bacitracin, oxytetracycline, penicillin, and tylosin in water, or bacitracin, lincomycin, virginiamycin, penicillin, avoparcin, and nitrovin in feed (11, 31, 39, 45).

Results of competitive exclusion (CE) studies suggest clear but limited value in the establishment of normal microbiota (41, 50). On the other hand, a Swedish CE product decreased the incidence of NE and reduced mortality in experimental challenge (31, 35). *Bacillus subtilis* spores competitively exclude *C. perfringens* from broiler chicks (65) and *Bacillus*-colonized chicks have increased body weight and feed efficiency compared to controls (101). The use of probiotics such as *L. acidophilus* and *S. faecium* may reduce the severity of NE (39, 104). The use of prebiotics, which stimulate growth of beneficial intestinal flora (1, 53, 104), has produced mainly negative results.

The Future

The past decade has brought progress in understanding NE and its pathogenesis. Recombinant proteins have provided insights into means for protection of birds against natural or experimentally induced disease. Traditional and contemporary methods yield results that may make the minimization of NE's impact on the poultry industry a realizable goal.

Botulism

Hanna Skarin, Gunilla Blomqvist and Viveca Båverud

Introduction

Botulism is a paralytic disease caused by intoxication with neurotoxins produced by *Clostridium botulinum*. Synonyms are "limberneck" and "Western duck sickness." Free-ranging and confinement-reared poultry and feral birds can be affected. Most avian cases are caused by *C. botulinum* type C or mosaic type C/D, although outbreaks due to other toxin types have been described (7, 14, 29, 72, 84, 92).

The public health significance of avian type C outbreaks is considered minimal because only a few human type C botulism intoxications have been reported but are not well documented (34, 44). Nonhuman primates, however, have succumbed to type C botulism (88, 93).

History

Botulism was first reported in chickens in 1917 (15). Western duck sickness, first recognized in the United States in the early 1900s, was later found to be caused by *C. botulinum* type C toxin (25). The first *C. botulinum* type C strains were isolated from *Lucilia caeser* larvae, which had caused botulism in chickens (6). For additional historic information, see (12, 16, 49, 74).

Etiology

C. botulinum is an anaerobic and spore-forming bacterium. The species consists of 4 genetically diverse groups (I–IV) producing antigenically different types of botulinum neurotoxins (A, B, C, D, E, F, and G) (33). Human disease has primarily been associated with groups I and II (types A, B, E, and F), whereas animal botulism is usually caused by strains belonging to group III (types C and D). Cases of avian botulism in natural or commercial settings have primarily been caused by *C. botulinum* type C, although type A has also caused disease in poultry, and type E has caused disease in fish-eating birds (7, 14, 18, 29, 87). Diagnostic analyses of samples from avian botulism outbreaks often report neutralization by both C and D antitoxins (31, 50, 92). This correlates with genetic studies

on strains isolated from avian species, which have demonstrated a chimeric neurotoxin gene coding for 2 parts type C toxin and 1 part type D toxin (56, 84, 92).

Morphology and Staining

The Gram-positive rod-shaped cells of *C. botulinum* measure 1–1.2 μm in width and 4–7 μm in length (81). They are motile, often occurring singly or in short chains (63). Subterminal or occasional terminal endospores are present in aging cultures (18).

Growth Requirements

C. botulinum group III strains are nonproteolytic or weakly proteolytic and show varying lecithinase and lipase activity (63, 81). The lowest pH that permits growth of the organism is between 4.7 and 5.6 depending on strain and serotype (82). Type C spores are more easily heat inactivated than type A and B spores but are more resistant to heat than type E spores (80).

Colony Morphology

Colonies have an irregular morphology. They can be flat or raised, with round or irregular edges. Lipase- and lecithinase-positive colonies can be distinguished by an iridiscent sheen and an opaque precipitation formed on agar containing egg yolk (84).

Susceptibility to Chemical and Physical Agents

Hydrogen peroxide vapor is effective at deactivating spores of *C. botulinum* (45). Sodium hypochlorite (0.1%) inactivates spores within 5 minutes (67).

Pathogenicity

Different strains of *C. botulinum* group III have different pathogenic capabilities, depending on whether or not they harbor the phage carrying the neurotoxin gene. It has also been proposed that strains can be transformed into various pathogenic variants by exchanging plasmids containing other toxin genes (85).

Virulence Factors

The virulence factors so far investigated from group III strains are the botulinum neurotoxin, BoNT (referred to as C1 and D1), and two ribosylating toxins (C2 and C3), all located on extrachromosomal elements (85). The completed genome of a type C/D strain also revealed genes coding for other plasmid-encoded toxins (83). The function of these is yet to be defined.

Botulinum neurotoxins are among the most potent toxins known (78). They are released by the bacteria as progenitor toxins, which are complexes of the neurotoxins associated with nontoxic proteins (NAPs). The NAPs are believed to increase resistance to acid and protease degradation (23). However, at the mildly alkaline pH of the small intestine, the progenitor toxin is cleaved by proteases into the active neurotoxin consisting of a 100-kD heavy chain and a 50-kD light chain (13, 55). The C-terminal domain of the heavy chain binds to receptors on the presynaptic neuron, whereas the N-terminal domain is responsible for internalization of the light chain into the cytosol (57). The light chain is a zinc-dependent metalloprotease that becomes activated inside the cytosol. There it performs serotype-specific cleavage of soluble N-ethylmaleimide-sensitive factor attachment protein receptor (SNARE) proteins involved in docking and fusion of acetylcholine vesicles with the presynaptic membrane (55). The outcome is a persistent block of acetylcholine release, which results in muscle paralysis.

The type C and D neurotoxin genes are located on large bacteriophages that propagate like large plasmids (39, 75). These bacteriophages can be lost during cultivation, which results in BoNT-negative strains. However, nontoxigenic strains can also be reconverted into BoNT-positive strains by taking up either type C or D phages (62).

Chickens, turkeys, pheasants, and peafowl are susceptible to toxin types A, B, C, and E, but not to D or F toxin (26). Chickens are most sensitive to types A given intravenously but more susceptible to type C toxin if given orally (26, 54). Furthermore, type C/D toxin has been demonstrated to be more toxic to avian species than pure type C toxin (54, 92).

Trypsin-activated C2 toxin causes increased membrane permeability in a variety of cultured tissues (66). Increased permeability is caused by changes in the actin cytoskeleton, depolymerization of actin filaments, and cell rounding. The active toxin contains 2 proteins, an actin-ADP-ribosylating enzyme (C2I) and a binding and translocation protein (C2II) (1, 40, 65). Toxicity requires C2II attachment to receptors, which enables translocation of the C2I protein into the cell (8). Experiments in mice showed that the C2 toxin exhibits enterotoxic properties (64). Ducks inoculated intravenously with C2 toxin showed cardiopulmonary symptoms (43). However, the role of C2 toxin in natural botulism outbreaks is presently unclear.

The C3 toxin is another actin filament disaggregating exotoxin that inactivates GTP-binding proteins of the Rho subfamily (2). The role of the C3 toxin in botulism is not known.

Pathobiology and Epizootology

Incidence and Distribution

The disease has affected waterfowl and poultry worldwide (44). Many severe cases have been reported from confined broiler flocks and in wild birds (7, 16, 30, 44, 60, 69). Botulism in ducks, broiler chickens, and pheasants occur more frequently and with greater severity during warmer months. However, outbreaks in broiler chickens also have been reported during winter (18, 52).

Natural and Experimental Hosts

Type C botulism has occurred in many species of birds including chickens, turkeys, ducks, gulls, pheasants, and ostriches (3, 7, 48, 60, 86, 97). Other animal species affected by type C toxin include mink, ferrets, rodents, cattle, pigs, dogs, horses, fish, and a variety of zoo mammals (53, 89).

Transmission, Carriers, Vectors

C. botulinum type C is distributed worldwide and is considered as a normal bacterium of marshland, soils, and sediments, although with limited prevalence (76, 95). Type C spores are commonly found in and around poultry and pheasant farms where botulism has occurred (18, 47, 87). In the case of *C. botulinum* type C contamination in poultry units, the feed has been suggested as the most likely source (87). Large amounts of *C. botulinum* and toxin are produced and spread to healthy birds during outbreaks. In confined poultry flocks, the spread is mainly via cecal droppings and carcasses containing *C. botulinum* and toxin (18). In wild waterfowl, maggots and other invertebrates feeding on carcasses of intoxicated birds also play a major role for secondary poisoning (20, 35, 94).

Incubation Period

The time to onset of paralytic symptoms varies and depends on the amount of ingested type C spores and intestinal toxin production, or preformed toxin. Chickens orally administered with 10^2 or more of type C spores developed illness in 6–13 days (54). In another experiment symptoms and death occurred on day 3 when 10^7 viable spores were administered (37). With high levels of neurotoxin, disease appears within hours. With low toxin doses, onset of paralysis occurs within 1–2 days (19, 26, 27, 42).

Clinical Signs

Clinical signs of botulism in chickens, turkeys, pheasants, and ducks are similar (12, 16, 42, 74). In chickens, flaccid paralysis of legs, wings, neck, and eyelids are predominant features of the disease (Figure 22.6). Paralytic signs progress cranially from the legs to include wings, neck, and eyelids. Initially, affected birds are found sitting and are reluctant to move. If coaxed to walk, they appear lame. Wings droop when paralyzed. Limberneck, the original and common name for botulism, precisely describes the paralysis of the neck. Because of eyelid paralysis, birds appear comatose and may seem dead. Gasping has been reported when birds are handled. Death results from cardiac and respiratory failure (89). Affected chickens have ruffled feathers, which may fall out with handling. Quivering of certain feather tracts has been observed. Broiler chickens showing signs of botulism may have diarrhea with excess urates in the loose droppings.

Morbidity and Mortality

Morbidity and mortality are related to the levels of intoxication. In severe cases, up to 40% mortality has been observed in broiler flocks (16, 71). Millions of wild waterfowl have died from type C botulism throughout the world (76). On separate occasions the mortality has been reported to be greater than 100,000 birds (12, 44). In other cases, outbreaks in small lakes have been limited to the relatively few waterfowl in these habitats (5, 87).

Figure 22.6. Botulism in chickens showing paralysis of wing and lower eyelid, difficulty breathing caused by partial paralysis of respiratory muscles, and ruffled hackle feathers.

Pathology

Birds with type C botulism lack characteristic gross or microscopic lesions.

Pathogenesis of the Infectious Process

Avian type C botulism can be caused by ingestion of preformed toxin or by toxico-infection. More than 2,000 minimum lethal doses (MLD) of type C toxin/gram of carcass tissue of intoxicated birds have been found (7). Birds scavenging such carcasses can readily obtain enough toxin to become affected. Fly-blown carcasses may have maggots containing 10^4–10^5 MLD of neurotoxin (87). In aquatic environments, small crustaceans and insect larvae may contain *C. botulinum* in their gut. If large numbers die due to oxygen depletion, toxin can be produced within these invertebrates. Ingestion of toxin-laden invertebrates has been proposed as the cause of type C botulism in ducks (74, 96).

In 2 cases of type C botulism in broiler chickens, carcasses were implicated as the source of preformed toxin (7, 30). In the majority of reported broiler chicken outbreaks, however, no toxin sources were identified. Thus, it was suggested that spores of *C. botulinum* type C can multiply and produce toxin within the intestines of the chicken (18, 28, 69, 79). The term toxico-infection has been adapted to describe the form of botulism caused by intraintestinally produced toxin in broiler chickens (89). The toxico-infectious form of type C botulism has been

shown experimentally in leghorn chickens and pheasants fed botulinum spores. When the birds were ceco-ligated and orally administered spores, no symptoms developed. This suggests that the cecum is the site of toxin production (47, 54). Although the toxin production principally takes place in the cecum, the quantity of the toxin produced is not sufficient to kill the host (47). It has been shown that type C toxin bound to *C. botulinum* cells via a heat-stable cell component is orally more toxic than the toxin on its own (36). By the ingestion of cecal droppings where cell-bound toxin is available, blood levels of toxin could increase to reach the threshold for botulism to occur (37).

Experimental treatment of chickens with the immunosuppressive drug cyclophosphamide indicate that stress and concurrent infections can predispose chickens to the disease (68).

Diagnosis

Isolation and Identification of Causative Agent

Isolation of *C. botulinum* is of little help in diagnosis (41). However, detection and isolation of the organism in clinical samples from animals or feed or environmental samples may prove useful in epidemiologic studies. The organism can be cultivated anaerobically at 30°C–42°C in cooked-meat medium or trypticase-peptone-glucose-yeast (TPGY) medium (58, 84). After 2 days of incubation, the sample can be analyzed for the presence of the neurotoxin or the neurotoxin gene. Real-time PCR assays have been developed for detection of the BoNT gene of types A–F (21, 46, 50).

Obtaining *C. botulinum* type C strains in pure culture is very difficult, partly because of the obligatory anaerobic growth, but also because there are no known traits suitable to use for selective cultivation and due to its poor growth on agar plates (22, 84). At present, the organism is isolated through repeated culturing in broth and on agar plates. Another problem isolating toxigenic strains is the unstable lysogeny of the phage carrying the neurotoxin gene (75).

Fingerprinting methods such as pulsed-field gel electrophoresis (PFGE) and randomly amplified polymorphic DNA analysis (RAPD) have been applied to group I–III strains (32, 38, 59, 61, 84).

Toxin Detection

Diagnosis of botulism requires detection of toxin in serum, crop, or gastrointestinal content from morbid birds (16, 89). Detection of toxin in tissues of dead birds does not confirm botulism because *C. botulinum* can grow and produce toxin in decaying body tissues.

The mouse bioassay is a sensitive and reliable method for confirming heat-labile toxin in serum (16). Groups of mice are inoculated with suspect serum samples. Other mice receive samples inoculated with suspect serum samples treated with type-specific antiserum. If toxin is present in the sample, signs and deaths of mice given untreated samples usually occur within 48 hours. Mice inoculated with antitoxin will be protected (51). In case of low levels of toxin in diseased animals, repeated inoculation of mice with suspect serum may be required (27). However, the mouse bioassay is a time-consuming and expensive method requiring use of laboratory animals. Endopep mass spectrometry has been used to detect active toxin and is anticipated to be an attractive alternative to the mouse bioassay (31). Other immunoassays for types C and D toxin also have been developed (11, 24, 73).

Differential Diagnosis

The differential diagnosis of botulism is based on clinical signs and lack of gross or microscopic lesions. In advanced stages of the disease, clinical signs of flaccid paralysis are obvious; during mild intoxications, only leg paralysis may be observed. The mild form of the disease must be differentiated from transient paralysis syndrome of Marek's disease, fowl cholera, drug and chemical toxicity and appendicular skeletal problems. Lead poisoning of waterfowl is commonly confused with botulism (74, 89).

Intervention Strategies

Management Procedures

Management practices should emphasize removal of potential sources of the organism and its toxin from the environment. Prompt disposal of dead birds and culling of sick birds is very important in prevention and control. In problem areas, removal of contaminated litter and thorough disinfection using calcium hypochlorite or formalin may help reduce spore numbers in the environment. Disinfection of areas around poultry houses has been recommended because spores may be located in the soil outside of the poultry facility and can be transported back into houses. Fly control may be another means of reducing the risk of toxic maggots in the environment (77). Two cases of type C botulism were reported in commercial broilers and were associated with elevated intake of iron from water and feed sources. However, the relationship between iron and toxicoinfectious type C botulism needs to be experimentally confirmed (70).

Vaccination

Active immunization with inactivated toxin has been successfully used in pheasant operations and to protect chickens and ducks from experimental botulism (10, 17, 48, 91). During the last decades recombinant subunit vaccines have been developed to prevent botulism (4, 90). However, the practical usefulness of vaccination of large numbers of birds has so far not been evaluated.

Treatment

Many sick birds, if isolated and provided with water and feed, will recover. Treatment of large numbers of morbid birds is difficult, and various protocols have been used but not verified experimentally. The patterns of disease in untreated broiler houses can rise and fall during a given outbreak and therefore it is difficult to know whether a particular treatment is effective (18). However, several treatments have been reported to be of benefit.

Commercial broiler chickens in outbreaks of botulism have been successfully treated with several antibiotics including bacitracin, streptomycin, tylosin, amoxicillin, penicillin, and chlorotetracycline (9, 71, 74). Inoculation with specific antitoxin neutralizes only free and extracellular bound toxin and might be considered for treating valuable birds in zoologic collections. This is impractical in commercial poultry, duck, or pheasant outbreaks.

Acknowledgement
With acknowledgement to John E. Dohms, who wrote this chapter in the 12th edition of *Diseases of Poultry*.

Gangrenous Dermatitis

Kenneth Opengart

Introduction

Definition
Gangrenous dermatitis (GD) is a disease of chickens and turkeys caused by *Clostridium septicum, C. perfringens* type A, and *Staphylococcus aureus*. Characterized by a sudden onset of acute mortality, the primary lesion in affected birds is necrosis of the skin and subcutaneous tissue, usually involving the breast, abdomen, wing, or thigh.

Economic Significance
The economic impact on a flock of birds can be relatively straightforward to estimate because it is primarily related to the degree of GD-associated mortality that occurs within the flock. Because the mortality associated with the disease occurs quickly and the disease generally appears in close-to-market-age broilers and turkeys, economic losses are associated with any lost investment in production costs (chick/poult cost and feed consumed) and the loss of income related to the reduction in marketable pounds.

Public Health Significance
The public health significance of GD is thought to be minimal because nearly all affected birds succumb quickly to infection and do not make it to processing age.

History

Gangrenous dermatitis was first reported in the early 1930s as severe necrosis of muscle and subcutaneous tissue following intramuscular inoculation of *Clostridium welchii* (*C. perfringens*) (43) and a diagnostic case in which *C. perfringens*, *C. septicum*, and *C. novyi* were isolated from chickens (5). Gangrenous dermatitis has been reported in many areas of the world since its initial description (2, 4, 6, 8, 9, 10, 11, 17, 18, 19, 25, 27, 28, 33, 38, 49, 51).

Etiology

Classification
Gangrenous dermatitis may be caused by *C. septicum* (17, 18, 25, 27, 33, 50), *C. perfringens* type A (4, 11, 56), and *S. aureus* (6, 9, 19, 33), either singly or in combination (18, 28, 33, 49), with combined infections generally being more severe. The severity of the disease and its resulting mortality depend upon the bacterial strains involved in the infection and their ability to produce toxins (57).

Names and Synonyms
Gangrenous dermatitis is also referred to as necrotic dermatitis, clostridial dermatitis, gangrenous cellulitis, gangrenous dermatomyositis, avian malignant edema, gas edema disease, wing rot, and, in some instances, blue wing disease—a component of chicken infectious anemia virus (CIAV) infection (7, 46, 55).

Morphology and Staining
Clostridia are short, thick, Gram-positive spore forming bacillus. Clostridial spores are oval and located subterminally.

Growth Requirements
Culture for *C. septicum* and *C. perfringens* should be carried out anaerobically on blood agar plates containing 2.5% agar, which will reduce the swarming over the plate surface (16). Incubation is for 1–2 days at 37°C.

Colony Morphology
On pre-reduced blood agar plates, *C. septicum* colonies appear glossy, gray, and β-hemolytic, and are circular (1–5 mm) with slightly raised irregular margins. *C. perfringens* colonies appear smooth and circular (2–4 mm) and are surrounded by an inner β-hemolytic and an outer α-hemolytic zone (39).

Biochemical Properties
C. septicum ferments glucose, maltose, lactose, and salicin but not sucrose or mannitol. Principal products of fermentation are acetic and butyric acids. Gelatin is hydrolyzed, milk is not digested, and indole is not produced. Growth on McClung-Toabe egg yolk agar demonstrates an absence of lecithinase and lipase production. The use of the same agar with *C. perfringens* cultures, however, can be used to detect lecithinase and lipase production (39).

Antigenic Structure and Toxins
C. septicum produces four toxins (alpha, beta, delta and gamma) which have distinct functions that collectively lead to the pathogenicity of the organism (42).

Strain Classification

Positive identification of the organism is made by inoculation of differential media (1). Presumptive identification of *C. septicum* can be made using fluorescent antibody (39).

Genetic or Molecular

A quantitative real-time PCR test has been reported which targets the *C. septicum*-specific gene *csa*, thus providing a mechanism for accurately quantifying the levels of *C. septicum* within the avian intestine (41). Multilocus sequence typing (MLST) has been used to determine the degree of relatedness among populations of both *C. perfringens* (26) and *C. septicum* (42) recovered from GD.

Pathogenicity

The prevalence of *C. septicum* and *C. perfringens* toxin genes has been investigated using MLST (26, 42) and suggests that, as has been reported in more recent field cases (35, 41, 42, 52), *C. septicum* is the more prominent etiologic agent of GD.

Pathobiology and Epizootiology

Incidence and Distribution

Gangrenous dermatitis occurs sporadically in chickens and turkeys throughout the world.

Natural and Experimental Hosts

Natural outbreaks of GD have been described in broilers (4, 6, 9, 17, 18, 25, 27, 28, 33, 49), commercial layers (18, 49), broiler breeders (19), and turkeys (8, 12, 15, 53) in many parts of the world including the United States (18, 49), the United Kingdom (17), Germany (27, 33), Belgium (19), Argentina (4), New Zealand (38), Egypt (2), and India (10, 11, 51).

Experimental reproduction of GD in chickens (18, 25, 27, 33, 49) and turkeys (49) following intramuscular or subcutaneous inoculation of *C. septicum*, *C. perfringens* type A, or *S. aureus* has been reported to cause mortality and lesions similar to those that occur in naturally occurring outbreaks.

Transmission, Carriers, and Vectors

Clostridia are ubiquitous in the poultry house environment and can be isolated from soil, feces, dust, contaminated litter or feed, and intestinal contents (1, 32). Staphylococci are also ubiquitous and common inhabitants of skin and mucous membranes of poultry and areas where poultry are hatched, reared, and processed. Despite the ubiquitous nature of Clostridia and Staphylococci, the presence of these organisms does not necessarily indicate a disease challenge. Other contributing factors described below are thought to play a major role in the development of clinical disease within a flock.

Incubation Period

The incubation period of GD is relatively short (12–24 hours) with mortality often occurring in well-fleshed birds that may still have feed in their crop, an indication of the peracute onset of the disease.

Clinical Signs

Clinical signs in naturally occurring outbreaks of GD are general in nature and include depression, incoordination, inappetence, leg weakness, ataxia, and high fever (17, 18, 25, 27, 49).

Morbidity and Mortality

Because the onset of illness is acute, morbidity may appear low. The best indicator of infection can be a greatly elevated rate of mortality. Mortality can range from 1%–60% of a flock (17).

Pathology

Gross Pathology

Gross lesions of GD in chickens and turkeys consist of dark reddish-purple to green, weepy areas of the skin, usually devoid of feathers. Affected areas usually include wings, breast, abdomen, or legs (11, 12, 17, 18, 25, 27, 49). Extensive blood-tinged edema, with or without gas (emphysema), is present beneath the affected skin (Figures 22.7 and 22.8A-C). Underlying musculature is discolored gray or tan and may contain edema and gas between muscle bundles. In some cases, emphysema and serosanguineous fluid are present in subcutaneous tissue, but there is no loss of integrity to the overlying skin (28). Lesions associated with clostridial dermatitis in turkeys also may occur around the tail head (Figure 22.8D). Vesicle-like lesions and tissue edema are present laterally and ventrally around the tail. Tail feather shafts may be soft, blood-filled, and broken (8, 12).

Figure 22.7. Characteristic subcutaneous congestion and emphysema associated with gangrenous dermatitis in a chicken. (D. Ritter)

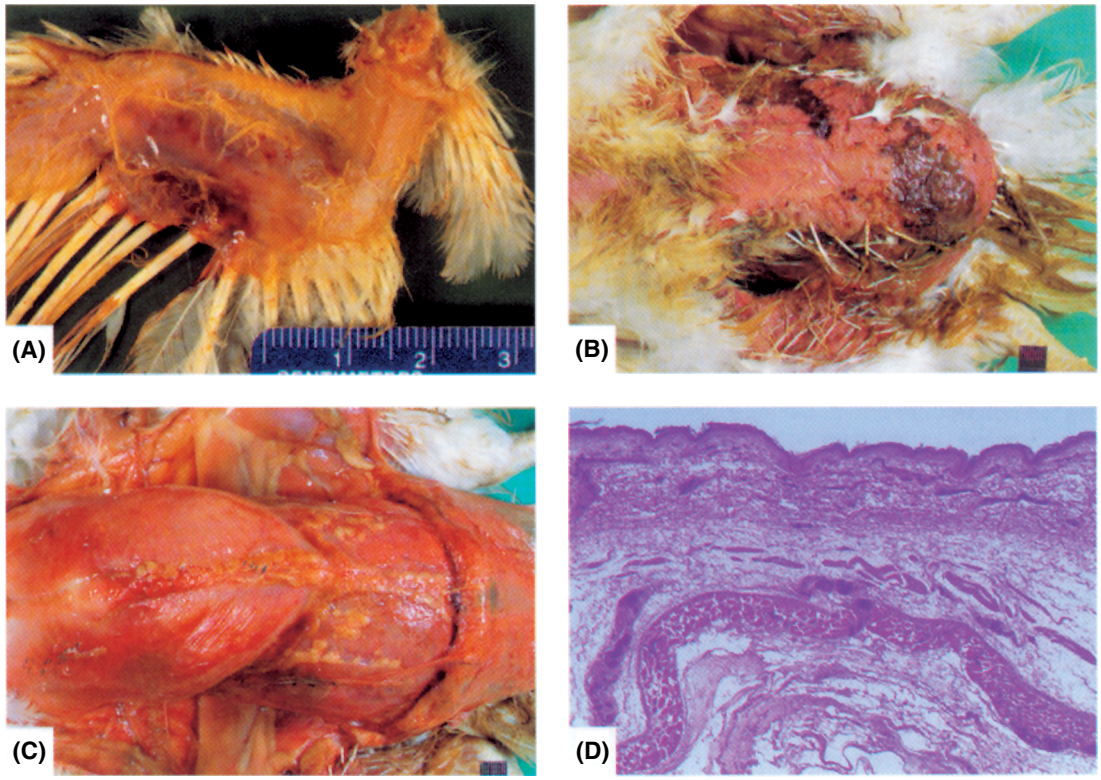

Figure 22.8. (A) Gangrenous dermatitis affecting the wing of a 12-day-old broiler. Spontaneous separation of epidermis revealing edematous, hyperemia acutely inflamed dermis. (L. Munger and H.J. Barnes) (B) Broiler, 6-week-old, with gangrenous dermatitis. Extensive discolored patches of necrotic skin are present on the abdomen. (H.J. Barnes) (C) Same bird as in (A). Skin is reflected to show discolored muscle and serosanguinous fluid expanding underlying dermis. (H.J. Barnes) (D) Skin from a turkey with gangrenous dermatitis. Dermis beneath a normal epidermis is markedly expanded by fluid and gas. Cutaneous muscle is undergoing rhadomyolysis. Cellular changes are minimal to absent. (H.J. Barnes)

Microscopic Pathology

Microscopic changes are characterized by edema and emphysema (Figure 22.8D) with numerous large, basophilic bacilli or small cocci within subcutaneous tissues (9, 49). Severe congestion, hemorrhage, and necrosis of underlying skeletal muscle are often present. Liver, if affected, contains small, randomly scattered, discrete areas of coagulation necrosis with intralesional bacteria. Bursal changes, in cases suspected to have concurrent infectious bursal disease (IBD), are characterized by extensive follicular necrosis and atrophy (9, 28).

Pathogenesis of the Infectious Process

Contributing Factors

There is great genetic diversity among strains of Clostridia and their ability to produce toxins, which partially accounts for the varied degree of pathogenicity, especially among strains of *C. perfringens* (26).

Additionally, in many instances, GD is believed to occur as a sequela to other diseases which produce immunosuppressive effects such as IBD virus, CIAV (7, 22, 46, 55), reticuloendotheliosis virus (30), reovirus (7, 13, 14), and avian adenovirus infections, including inclusion body hepatitis virus (9, 17, 28, 36, 40, 48). In addition, some outbreaks of GD have been reported to be breeder flock-associated (i.e., progeny from specific breeder flocks consistently develop GD) (20, 48).

Environmental factors (high litter moisture due to poor litter quality, poor drinker management or poor ventilation) may predispose flocks to GD, especially when present in conjunction with challenges from immunosuppressive viruses. Poor husbandry practices, especially failing to remove dead birds from an area in a timely manner, also may predispose a flock to GD. Other management practices which can induce skin damage due to scratching, such as overcrowding, feed outages, meal time feeding, and bird migration in tunnel-ventilated houses, can increase GD incidence (58). The incidence of GD also has been observed to be related to the season of the year with peak occurrence in the spring. In the absence of other predisposing factors such as immunosuppressive infectious agents and management factors, GD tends to be associated with certain strains or breeds, males more often than females, and flocks that perform above production standards. Affected farms tend to have repeat outbreaks.

Diagnosis

A presumptive diagnosis of GD can be made in a flock with an acute onset of high mortality with very low morbidity and characteristic skin lesions. Confirmation of a diagnosis of GD

requires the presence of typical gross and microscopic lesions and the isolation of the causative agent(s). In field cases of GD, staphylococci and clostridia can be isolated from exudates of skin and subcutaneous tissue or underlying muscle (9, 11, 18, 27, 49). As mentioned previously, the occurrence of GD often can be preceded by other infectious agents affecting the immune function of the bird. Diagnosis of an underlying etiology is often necessary to fully understand the complexity of the GD infection.

Isolation and Identification of Causative Agent

Swabs or samples of tissues or exudates from gross lesions should be submitted for bacterial culture as soon as possible after collection. If clostridial infection is suspected, anaerobic transport media is helpful and will improve the success of isolation.

Differential Diagnosis

A variety of skin conditions must be differentiated from GD including contact or ulcerative dermatitis ("breast burn") (23) and , scabby hip dermatitis of broiler chickens (24, 47), and plantar pododermatitis of turkeys (37). Infectious or inflammatory process (IP), a condition usually caused by *Escherichia coli* in market age broilers involving the subcutaneous tissues of the abdomen, thigh, and leg, also can cause the dermis to appear reddened and edematous (21). However, this condition never has emphysematous lesions or mortality associated with it and is generally only a problem observed at the processing plant.

Dermatitis caused by mycotic agents (3, 34, 44) can be differentiated from GD by the demonstration of fungal elements in impression smears or tissue sections and by isolating and identifying the agent. Vesicular lesions involving the wattles, comb, shanks, and feet have been described in chickens (29, 45, 54) and have been suspected of or proven to be due to the ingestion of the fungus *Cladosporium herbarum*, producing an ergot-like disease, or *Ammi visnaga* seeds, which lead to photosensitization. These lesions invariably occur only on unfeathered areas of the skin and should be differentiated easily.

Intervention Strategies

Management Procedures

When possible, risk of GD infection has been mitigated with the placement of less susceptible strains or breeds on at-risk farms. Additionally, total clean out of farms, followed by thorough cleaning and disinfection of the house and floor, has reduced or eliminated GD infection on farms with historical problems. In these cases, large amounts of water mixed with a phenolic disinfectant (1,500 gallons/20,000 feet^2) have been used to achieve a saturation depth of 3–4 inches of the dirt floor pad. Treating the floor with salt at 60–100 pounds/1,000 feet^2 prior to placement of bedding material also has decreased the incidence of GD on problem farms. Generally, management procedures to improve litter condition, reduce litter moisture, acidify litter pH, reduce bacterial levels in the environment, and minimize trauma are useful adjuncts to other prevention and control methods.

Vaccination

Administration of a mixed clostridial bacterin at 1 day of age has been shown to reduce losses in flocks due to GD (20). Similar results have been reported in 5-week-old chickens vaccinated with a mixed *E. coli*, *S. aureus*, and *C. perfringens* bacterin following bacterial challenge with live cultures of the same organisms (31). There are currently no commercial vaccines available for the control of GD.

Treatment

Gangrenous dermatitis has historically been treated effectively with the administration of many antibiotics including chlortetracycline (25), oxytetracycline (49), erythromycin (49), penicillin (9, 11, 28) in the water, and chlortetracycline (27, 49) or furoxone (27) in the feed. In many cases and more recently, however, antibiotics used for control have proven to be of limited use (17, 19, 20, 33).

In the face of underlying and predisposing immunosuppressive viral infection, antibiotic treatment is ineffective because birds are unable to completely clear the bacterial infection even in the presence of a therapeutic antibiotic. In these cases, modification of vaccine programs directed at immunosuppressive agents such as IBD and CIAV may sometimes be used to combat widespread GD problems.

Water treatment with copper sulfate (2) or drinking water acidification with citric or propionic acid have been used to reduce, but not eliminate, mortality in flocks where the rate of mortality does not justify the use of an antibiotic or where antibiotics are no longer effective.

References

Introduction

1. Arimitsu, H., J.C. Lee, Y. Sakaguchi, Y. Hayakawa, M. Hayashi, M. Nakaura, H. Takai, S.N. Lin, M. Mukamoto, T. Murphy, and K. Oguma K. 2004. Vaccination with recombinant whole heavy chain fragments of *Clostridium botulinum* Type C and D neurotoxins. *Clin Diagn Lab Immunol.* 11:496–502.
2. Blandford, T.B., and T.A. Roberts. 1970. An outbreak of botulism in broiler chickens. *Vet Rec.* 87:258–61.
3. Bullis, K.L., and H. Van Roekel. 1944. Uncommon pathological conditions in chickens and turkeys. *Cornell Vet.* 34: 312–319.
4. Collins, M.D., P.A. Lawson, A. Willems, J.J. Cordoba, J. Fernandez-Garayzabal, P. Garcia, J. Cai, H. Hippe, and J.A. Farrow. 1994. The phylogeny of the genus *Clostridium*: Proposal of five new genera and eleven new species combinations. *Int J Syst Bacteriol.* 44:812–826.

5. Cooper, K.K., H.T. Trinh, and J.G. Songer. 2009. Immunization with recombinant alpha toxin partially protects broiler chicks against experimental challenge with *Clostridium perfringens*. *Vet Microbiol.* 133:92–97.
6. Davis, R.B., J. Brown, and D.L. Dawe. 1971. Quail—biological indicators in the differentiation of ulcerative and necrotic enteritis of chickens. *Poult Sci.* 50:737–740.
7. Dohms, J.E. 1987. Laboratory investigation of botulism in poultry. In: *Avian Botulism: An International Perspective*, M.W. Eklund and V.R. Dowell, eds. Charles C. Thomas, Springfield, IL. 295–314.
8. Dohms, J.E., P.H. Allen, and J.K. Rosenberger, 1982. Cases of type C botulism in broiler chickens. *Avian Dis.* 26:204–10.
9. Engberg, R.M., M.S. Hedemann, T.D. Leser, and B.B. Jensen. 2000. Effect of zinc bacitracin and salinomycin on intestinal microflora and performance of broilers. *Poult Sci.* 79:1311–1319.
10. Ferrell, S.T., and L. Tell. 2001. *Clostridium tertium* infection in a rainbow lorikeet (*Trichoglossus haematodus haematodus*) with enteritis. *J Avian Med Surg.* 15:204–208.
11. Frazier, M.N., W.J. Parizek, and E. Garner. 1964. Gangrenous dermatitis of chickens. *Avian Dis.* 8:269–273.
12. Frazier, K.S., A.J. Herron, M.E. Hines II, J.M. Gaskin, and N.H. Altman. 1993. Diagnosis and enterotroxemia due to *Clostridium difficile* in captive ostriches (*Struthio camelus*). *J Vet Diag Invest.* 5:623–625.
13. Graham, A.F., and B.M. Lund. 1986. The effect of citric acid on growth of proteolytic strains of *Clostridium botulinum*. *J Appl Bacteriol.* 61:39–49.
14. Harvey, R.B., K.N. Norman, K. Andrews, M.E. Hume, C.M. Scanlan, T.R. Callaway, R.C. Anderson, and D.J. Nisbet. 2011. *Clostridium difficile* in poultry and poultry meat. *Foodborne Path Dis.* 8:1321–1323.
15. Helmboldt, C.F., and E.S. Bryant. 1971. The pathology of necrotic enteritis in domestic fowl. *Avian Dis.* 15:775–780.
16. Hofacre, C.L., J.D. French, R.K. Page, and O.J. Fletcher. 1986. Subcutaneous clostridial infection in broilers. *Avian Dis.* 30:620–622.
17. Indra, A., H. Lassnig, N. Baliko, P. Much, A. Fieder, S. Huhulescu, and F. Allerberger. 2009. *Clostridium difficile*: a new zoonotic agent? *Wien Klin Wochenschr.* 12:91–95.
18. Kaldhusdal, M., C. Schneitz, M. Hofshagen, and E. Skjerve. 2001. Reduced incidence of Clostridium perfringens- associated lesions and improved performance in broiler chickens treated with normal intestinal bacteria from adult fowl. *Avian Dis.* 45:149–156.
19. Kirkpatrick, C.M., and H.E. Moses. 1953. The effects of streptomycin against spontaneous quail disease in bobwhites. *J Wildl Manage.* 17:24–28.
20. Kohler, B., V. Bergmann, W. Witte, R. Heiss, and K. Vogel. 1978. Dermatitis bei broilern durch *Staphylococcus aureus*. *Monatsh Veterinaermed.* 33:22–28.
21. Kurazono, H., K. Shimozawa, G. Sakaguchi, M. Takahashi, T. Shimizu, and H. Kondo. 1985. Botulism among penned pheasants and protection by vaccination with C1 toxoid. *Res Vet Sci.* 38:104–8.
22. Lovland, A., and M. Kaldhudadl. 2001. Severely impaired production performance in broiler flocks with high incidence of *Clostridium perfringens*-associated hepatitis. *Avian Pathol.* 30:73–81.
23. Lloyd, C.S., G.J. Thomas, J.W. MacDonald, E.D. Borland, K. Standring, and J.L. Smith. 1976. Wild bird mortality caused by botulism in Britain, 1975. *Biol Conserv.* 10:119–129.
24. Lublin, A., S. Mechani, I. Horowitz, Y., Weisman. 1993. A paralytic like disease of the ostrich (*Struthio camelus masaicus*) associated with *Clostridium chauvoei* infection. *Vet Rec.* 132:273–275.
25. McReynolds, J.L., J.A. Byrd, R.C. Anderson, R.W. Moore, T.S. Edrington, and K.J. Genovese. 2004. Evaluation of immunosuppressants and dietary mechanisms in an experimental disease model for necrotic enteritis. *Poult Sci.* 83:1948–1952.
26. Morse, G.B. 1907. Quail disease in the United States. United States Department of Agriculture, BAI Circ 109.
27. Neimanis, A., D. Gavier-Widén, F. Leighton, T. Bollinger, T. Rocke, and T. Mörner. 2007. An outbreak of type C botulism in herring gulls (*Larus argentatus*) in southeastern Sweden. *J Wildl Dis.* 43:327–36.
28. Opengart, K. 2008. Necrotic enteritis. In: *Diseases of Poultry*, 12th ed. Saif, Y.M., A.M. Fadly, J.R. Glisson, L.R. McDougald, L.K. Nolan, and D.E. Swayne, eds. Blackwell Publishing, Ames, IA. 872–879.
29. Peckham, M.C. 1960. Further studies on the causative organism of ulcerative enteritis. *Avian Dis.* 4:449–456.
30. Peterson, E.H. 1964. Clostridium novyi isolated from chickens. *Poult Sci.* 43:1062–1063
31. Peterson, E.H. 1967. The isolation of Clostridium sporogenes from the viscera of day old chicks. *Poult Sci.* 46:527–529.
32. Pizzaro, M., U. Hofle, A. Rodriquez-Bertos, M. Gonzalez-Huecas, and M. Castano. 2005. Ulcerative enteritis (quail disease) in lories. *Avian Dis.* 49:606–608.
33. Poonacha, K.B., Donahue, J.M. 1997. Acute clostridial hepatitis in an ostrich. *J Vet Diag Invest.* 9:203–210.
34. Prescott J.F. 1979. The prevention of experimentally induced necrotic enteritis in chickens by avoparcin. *Avian Dis.* 23:1072–1074.
35. Prukner-Radovcic, E., L. Milakovic Novac, S. Ivesa Petricevic, and N. Grgic. 1995. *Clostridium chauvoei* in hens. *Avian Pathol.* 24:201–206.
36. Raymond, J.T., K. Topham, K. Shirota, T. Ikeda, and M.M. Garner. 2001. Tyzzer's disease in a neonatal rainbow lorikeet (*Trichoglossus haematodus haematodus*). *Vet Pathol.* 38:326–327.
37. Richards, S.M., and B.W. Hunt. 1973. Ulcerative enteritis in partridges. *Vet Rec.* 111:591–592.
38. Roberts, T.A., and I.D. Aitken. 1974. Botulism in birds and mammals in Great Britain and an assessment of the toxicity of *Clostridium botulinum* type C toxin in domestic fowl. In: *Spore Research*. A.N. Barker, G.W. Gould, and J. Wolf, eds. Academic Press, London. 1–9.
39. Saunders, J.R., and A.A. Bickford. 1965. Clostridial infections of growing chickens. *Avian Dis.* 9:317–326.
40. Sasaki, J., M. Goryo, H. Okoshi, H. Furukawa, K. Honda, and K. Okada. 2000. Cholangiohepatitis in broiler chickens in Japan: histopathological, immunohistochemical and microbiological studies of spontaneous disease. *Acta Vet Hung.* 48:59–67.
41. Shillinger, J.E., and L.C. Morley. 1934. Studies on ulcerative enteritis in quail. *J Am Vet Med Assoc.* 84:25–35.
42. Shrivaprasad, H.L. 2003. Hepatitis associated with *Clostridium difficile* in an ostrich chick. *Avian Pathol.* 32:57–62.

43. Smart, J.L., P.W. Laing, and C.E. Winkler, 1983. Type C botulism in intensively farmed turkeys. *Vet Rec.* 113:198–200.
44. Smith, L.A., and J.M. Rusnak, 2007. Botulism neurotoxin vaccines: past, present, and future. *Crit Rev Immunol.* 27:303–318.
45. Truscott, R.B., and F. Al-Sheikhly. 1977. Reproduction and treatment of necrotic enteritis in broilers. *Am J Vet Res.* 38:857–861.
46. Van Immerseel, F., J. De Buck, F. Pasmans, G. Huyghebaert, F. Haesebrouck, and R. Ducatelle. 2004. *Clostridium perfringens* in poultry: an emerging threat for animal and public health. *Avian Pathol.* 33:537–549.
47. Wages, D.P. 2008. Ulcerative enteritis. In: *Diseases of Poultry*, 12th ed. Saif, Y.M., A.M. Fadly, J.R. Glisson, L.R. McDougald, L.K. Nolan, and D.E. Swayne, eds. Blackwell Publishing, Ames, IA. 867–871.
48. Williams, R.B. 2002. Anticoccidial vaccines for broiler chickens: pathways to success. *Avian Pathol.* 31:317–353.
49. Woo, G.H., H.Y. Kim, Y.C. Bae, Y.H. Jean, S.S. Yoon, E.J. Bak, E.K. Hwang, and Y.S. Joo., 2010. Outbreak of botulism (*Clostridium botulinum* type C) in wild waterfowl: Seoul, Korea. *J Wildl Dis*. 46:951–5.

Ulcerative Enteritis

1. Barger, E.H., S.E. Park, and R. Graham. 1934. A note on so-called quail disease. *J Am Vet Med Assoc.* 84:776–783.
2. Bass, C.C. 1939. Observations on the specific cause and the nature of "quail disease" or ulcerative enteritis in quail. *Proc Soc Exp Biol Med.* 42:375–380.
3. Bass, C.C. 1941. Specific cause and nature of ulcerative enteritis of quail. *Proc Soc Exp Biol Med.* 46:250–52.
4. Berkhoff, G.A. 1975. Ulcerative enteritis-clostridial antigens. *Am J Vet Res.* 36:583–585.
5. Berkhoff, H.A. 1985. *Clostridium colinum* sp. *nov*., nom. rev., the causative agent of ulcerative enteritis (quail disease) in quail, chickens, and pheasants. *Int J Syst Bacteriol*. 35:155–159.
6. Berkhoff, G.A., and C.L. Kanitz. 1976. Fluorescent antibody test in diagnosis of ulcerative enteritis. *Avian Dis.* 20:525–533.
7. Berkhoff, G.A., S.G. Campbell, and H.B. Naylor. 1974. Etiology and pathogenesis of ulcerative enteritis ("quail disease"). Isolation of the causative anaerobe. *Avian Dis*. 18:186–194.
8. Berkhoff, G.A., S.G. Campbell, H.B. Naylor, and L.D.S. Smith. 1974. Etiology and pathogenesis of ulcerative enteritis ("quail disease"): Characterization of the causative anaerobe. *Avian Dis.* 18:195–204.
9. Berkhoff, G.A., and S.G. Campbell. 1974. Etiology and pathogenesis of ulcerative enteritis ("quail disease"). The experimental disease. *Avian Dis*. 18:205–212.
10. Bryant, E.S., W. Gerencer, E.T. Mallinson, and G. Stein. 1973. Report of the committee on nomenclature and reporting of disease, Northeastern Conference on Avian Disease. *Avian Dis*. 17:904–911.
11. Bullis, K.L., and H. Van Roekel. 1944. Uncommon pathological conditions in chickens and turkeys. *Cornell Vet.* 34:312–319.
12. Buss, I.O., R.D. Conrad, and J.R. Reilly. 1958. Ulcerative enteritis in the pheasant, blue grouse and California quail. *J Wildl Manage.* 22:446–449.
13. Churchill, H.M., and D.R. Coburn. 1945. Sulfonamide drugs in the treatment of ulcerative enteritis of quail. *Vet Med.* 40:309–311.
14. Collins, M.D., P.A. Lawson, A. Willems, J.J. Cordoba, J. Fernandez-Garayzabal, P. Garcia, J. Cai, H. Hippe, and J.A. Farrow. 1994. The phylogeny of the genus *Clostridium*: Proposal of five new genera and eleven new species combinations. *Int J Syst Bacteriol.* 44:812–826.
15. Collins, W.M., J.W. Hardiman, W.E. Urban Jr., and A.C. Corbett. 1975. Genetic differences in susceptibility to ulcerative enteritis in Japanese quail. *Poult Sci.* 54:2051–2054.
16. Davis, R.B. 1973. Ulcerative enteritis in chickens: Coccidiosis and stress as predisposing factors. *Poult Sci.* 52:1283–1287.
17. Davis, R.B., J. Brown, and D.L. Dawe. 1971. Quail—biological indicators in the differentiation of ulcerative and necrotic enteritis of chickens. *Poult Sci.* 50:737–740.
18. Durant, A.J., and E.R. Doll. 1941. Ulcerative enteritis in quail. *Missouri Agr Exp Stn Res Bull.* 325:3–27.
19. Ficken, M.D., and H.A. Berkhoff. 1989. Clostridial infections. In: *Isolation and Identification of Avian Pathogens*. H.G. Purchase, L.H. Arp, C.H. Domermuth, and J.E. Pearson eds. American Association of Avian Pathologists, Kennett Square, PA, 47–51.
20. Gallagher, B.A. 1924. Ulcerative enteritis in quail. *Am Game Prot Assoc Bull*. (Apr):14–15.
21. Glover, J.S. 1951. Ulcerative enteritis in pigeons. *Can J Comp Med Vet Sci.* 15:295–297.
22. Graubmann, H.D., and G. Grafner. 1971. Ulcerative enteritis in the chicken (quail disease). Occurrence and pathology. *Monatsh Veterinarmed*. 26:903–907.
23. Harris, A.H. 1961. An outbreak of ulcerative enteritis amongst bobwhite quail (*Colinus virginianus*). *Vet Rec.* 73:11–13.
24. Helmboldt, C.F., and E.S. Bryant. 1971. The pathology of necrotic enteritis in domestic fowl. *Avian Dis.* 15:775–780.
25. Jones, J.E., B.L. Hughes, and W.E. Mulliken. 1976. Use of tylosin to prevent early mortality in bobwhite quail. *Poult Sci.* 55:1122–1123.
26. Katiyar, A.K., A.G.R. Pillai, R.P. Awadhiya, and J.L. Vegad. 1986. An outbreak of ulcerative enteritis in chickens. *Indian J Anim Sci.* 56:859–862.
27. Kirkpatrick, C.M., and H.E. Moses. 1953. The effects of streptomycin against spontaneous quail disease in bobwhites. *J Wildl Manage.* 17:24–28.
28. Kirkpatrick, C.M., H.E. Moses, and J.T. Baldini. 1950. Streptomycin studies in ulcerative enteritis in bobwhite quail. I. Results of oral administration of the drug to manually exposed birds in the fall. *Poult Sci*. 29:561–569.
29. Kirkpatrick, C.M., H.E. Moses, and J.T. Baldini. 1952. The effects of several antibiotic products in feed on experimental ulcerative enteritis in quail. *Am J Vet Res.* 13:99–100.
30. Kirkpatrick, C.M., H.E. Moses, and J.T. Baldini. 1952. Streptomycin studies in ulcerative enteritis in bobwhite quail. II. Concentrations of streptomycin in drinking water suppressing the experimental disease. *Am J Vet Res*. 13:102–104.
31. Kondo, F., J. Tottori, and K. Soki.1988. Ulcerative enteritis in broiler chickens caused by *Clostridium colinum* and *in vitro* activity of 19 antimicrobial agents in tests on isolates. *Poult Sci.* 67:1424–1430.
32. LeDune, E.K. 1935. Ulcerative enteritis in ruffed grouse. *Vet Med.* 30:394–395.
33. Levine, P.P. 1932. A report on an epidemic disease in ruffed grouse. *Trans 19th Am Game Conf*. 437–441.
34. Levine, P.P., and F.C. Goble. 1947. Diseases of grouse. In: *The Ruffed Grouse*. G. Bump, R.W. Darrow, F.C. Edminster, and W.F. Crissey, eds. New York State Conservation Department, Albany, NY. 401–442.

35. Morley, L.C., and P.W. Wetmore. 1936. Discovery of the organism of ulcerative enteritis. Proc N Am Wildl Conf, 74th Congr, 2nd sess. Senate Comm Print: Washington, DC, 471–473.
36. Morris, J.A. 1948. The use of the complement fixation test in the detection of ulcerative enteritis in quail. *Am J Vet Res.* 9:102–103.
37. Morse, G.B. 1907. Quail disease in the United States. United States Department of Agriculture, BAI Circ 109.
38. Ononiwu, J.C., J.F. Prescott, H.C. Carlson, and R. Julian. 1978. Ulcerative enteritis caused by *Clostridium colinum* in chickens. *Can Vet J.* 19:226–229.
39. Peckham, M.C. 1959. An anaerobe, the cause of ulcerative enteritis ("quail disease"). *Avian Dis.* 3:471–478.
40. Peckham, M.C. 1960. Further studies on the causative organism of ulcerative enteritis. *Avian Dis.* 4:449–456.
41. Peckham, M.C., and R. Reynolds. 1962. The efficacy of chemotherapeutic drugs in the control of experimental ulcerative enteritis in quail. *Avian Dis.* 6:111–118.
42. Pickens, E.N., H.M. DeVolt, and J.E. Shillinger. 1932. An outbreak of quail disease in bobwhite quail. *Maryland Conservationist.* 9:18–19.
43. Pizzaro, M., U. Hofle, A. Rodriquez-Bertos, M. Gonzalez-Huecas, and M. Castano. 2005. Ulcerative enteritis (quail disease) in lories. *Avian Dis.* 49:606–608.
44. Richards, S.M., and B.W. Hunt. 1973. Ulcerative enteritis in partridges. *Vet Rec.* 111:591–592.
45. Rosen, M.N., and A.I. Bischoff. 1949. Field trials of sulfamethazine and sulfaquinoxaline in the treatment of quail ulcerative enteritis. *Cornell Vet.* 39:195–197.
46. Schneider, J., and K. Haass. 1968. Beobachtungen zur ulceroesen enteritis (quail disease) bei huehnerkueken. *Berl Munch Tieraerztl Wochenschr.* 81:466–468.
47. Shillinger, J.E., and L.C. Morley. 1934. Studies on ulcerative enteritis in quail. *J Am Vet Med Assoc.* 84:25–35.
48. Shukla, P.K., and B.S. Rajya. 1968. Affections of the lower alimentary tract of domestic fowl. I. On the occurrence and morphology of ulcerated enteritis simulating "quail disease." *Indian Vet J.* 45:10–13.
49. Sing, N., M.S. Kwatra, and M.S. Oberoi. 1984. An outbreak of ulcerative enteritis ("quail's disease") in broilers in Punjab. *Indian J Poult Sci.* 19:277–279.
50. Winterfield, R.W., and G.A. Berkhoff. 1977. Ulcerative enteritis in robins. *Avian Dis.* 21:328–330.

Necrotic Enteritis

1. Adams, C. 2004. Nutricines in poultry production: focus on bioactive feed ingredients. *Nutr Abst Rev Ser B.* 74:1–12.
2. Allen, P.C., and R.H. Fetterer. 2002. Recent advances in biology and immunobiology of *Eimeria* species and in diagnosis and control of infection with these coccidian parasites of poultry. *Clin Microbiol Rev.* 15:58–65.
3. Al-Sheikhly, F., and A. Al-Saieg. 1980. Role of coccidia in the occurrence of necrotic enteritis of chickens. *Avian Dis.* 24:324–333.
4. Al-Sheikhly, F., and R.B. Truscott. 1977. The interaction of *Clostridium perfringens* and its toxins in the production of necrotic enteritis of chickens. *Avian Dis.* 21:256–263.
5. Al-Sheikhly, F., and R.B. Truscott. 1977. The pathology of necrotic enteritis of chickens following infusion of broth cultures of *Clostridium perfringens* into the duodenum. *Avian Dis.* 21:230–240.
6. Annett, C.B., J.R. Viste, M. Chirino-Trejo, H.L. Classen, D.M. Middleton, and E. Simko. 2002. Necrotic enteritis: effect of barley, wheat and corn diets on proliferation of *Clostridium perfringens* type A. *Avian Pathol.* 31:598–601.
7. Awad, M.M., A.E. Bryant, D.L. Stevens, and J.I. Rood. 1995. Virulence studies on chromosomal alpha-toxin and theta-toxin mutants constructed by allelic exchange provide genetic evidence for the essential role of alpha-toxin in *Clostridium perfringens*-mediated gas gangrene. *Mol Microbiol.* 15:191–202.
8. Baba, E., A.L. Fuller, J.M. Gilbert, S.G. Thayer, and L.R. McDougald. 1992. Effects of *Eimeria brunetti* infection and dietary zinc on experimental induction of necrotic enteritis in broiler chickens. *Avian Dis.* 36:59–62.
9. Baba, E., T. Ikemoto, T. Fukata, K. Sasai, A. Arakawa, and L.R. McDougald. 1997. Clostridial population and the intestinal lesions in chickens infected with *Clostridium perfringens* and *Eimeria necatrix*. *Vet Microbiol.* 54:301–308.
10. Baba, E., H. Wakeshima, K. Fukui, T. Fukata, and A. Arakawa. 1992. Adhesion of bacteria to the cecal mucosal surface of conventional and germ-free chickens infected with *Eimeria tenella*. *Am J Vet Res.* 53:194–197.
11. Baba E., N. Yasuda, T. Fukata, and A. Arakawa. 1988. Effect of *Eimeria tenella* infection on the caecal population of lincomycin-resistant *Clostridium perfringens* introduced into chickens. *Res Vet Sci.* 45:219–221.
12. Barbara, A.J., H.T. Trinh, R.D. Glock, and J. Glenn Songer. 2008. Necrotic enteritis-producing strains of *Clostridium perfringens* displace non-necrotic enteritis strains from the gut of chicks. *Vet Microbiol.* 126:377–382.
13. Bennetts, H.W. 1930. *Bacillus welchii* and bowel lesions. *Aust Vet J.* 4:153–154.
14. Bernier, G., J.B. Phaneuf, and R. Filion. 1974. Necrotic enteritis in broilers. I. Clinoco-pathological aspect. *Can J Comp Med.* 38:280–285.
15. Bernier, G., J.B. Phaneuf, and R. Filion. 1977. Necrotic enteritis in broiler chickens. III. Study of the factors favoring the multiplication of *Clostridium perfringens* and the experimental transmission of the disease. *Can J Comp Med.* 41:112–116.
16. Branton, S.L., B.D. Lott, J.W. Deaton, W.R. Maslin, F.W. Austin, and L.M. Pote. 1997. The effect of added complex carbohydrates or added dietary fiber on necrotic enteritis lesions in broiler chickens. *Poult Sci.* 76:24–28.
17. Branton, S.L., F.N. Reece, and W.M. Hagler, Jr. 1987. Influence of a wheat diet on mortality of broiler chickens associated with necrotic enteritis. *Poult Sci.* 66:1326–1330.
18. Brennan, J., R. Bagg, D. Barnum, J. Wilson, and P. Dick. 2001. Efficacy of narasin in the prevention of necrotic enteritis in broiler chickens. *Avian Dis.* 45:210–214.
19. Brennan, J., G. Moore, S.E. Poe, A. Zimmermann, G. Vessie, and D.A. Barnum. 2001. Efficacy of in-feed tylosin phosphate for the treatment of necrotic enteritis in broiler chickens. *Poult Sci.* 80:1451–1454.
20. Brennan, J., J. Skinner, D.A. Barnum, and J. Wilson. 2003. The efficacy of bacitracin methylene disalicylate when fed in combination with narasin in the management of necrotic enteritis in broiler chickens. *Poult Sci.* 82:360–363.
21. Broussard, C.T., C.L. Hofacre, R.K. Page, and O.J. Fletcher. 1986. Necrotic enteritis in cage-reared commercial layer pullets. *Avian Dis.* 30:617–619.
22. Brynestad, S., and P.E. Granum. 2002. *Clostridium perfringens* and foodborne infections. *Int J Food Microbiol.* 74:195–202.

23. Casewell, M., C. Friis, E. Marco, P. McMullin, and I. Phillips. 2003. The European ban on growth-promoting antibiotics and emerging consequences for human and animal health. *J Antimicrob Chemother.* 52:159–161.
24. Chapman, H.D., Z.B. Johnson, and J.L. McFarland. 2003. Improvements in the performance of commercial broilers in the USA: analysis for the years 1997 to 2001. *Poult Sci.* 82:50–53.
25. Collier, C.T., J.D. van der Klis, B. Deplancke, D.B. Anderson, and H.R. Gaskins. 2003. Effects of tylosin on bacterial mucolysis, *Clostridium perfringens* colonization, and intestinal barrier function in a chick model of necrotic enteritis. *Antimicrob Agents Chemother* 47:3311–3317.
26. Cooper, K.K., H.T. Trinh, and J.G. Songer. 2009 Immunization with recombinant alpha toxin partially protects broiler chicks against experimental challenge with *Clostridium perfringens*. *Vet Microbiol.* 133:92–97.
27. Coursodon C.F., H.T. Trinh, M. Mallozzi, G. Vedantam, R.D. Glock, and J.G. Songer. 2010. *Clostridium perfringens* alpha toxin is produced in the intestines of broiler chicks inoculated with an alpha toxin mutant. *Anaerobe.* 16:614–617.
28. Craven S.E. 2000. Colonization of the intestinal tract by *Clostridium perfringens* and fecal shedding in diet-stressed and unstressed broiler chickens. *Poult Sci.* 79:843–849.
29. Craven, S.E., N.A. Cox, J.S. Bailey, and D.E. Cosby. 2003. Incidence and tracking of *Clostridium perfringens* through an integrated broiler chicken operation. *Avian Dis.* 47:707–711.
30. Craven, S.E., N.A. Cox, N.J. Stern, and J.M. Mauldin. 2001. Prevalence of *Clostridium perfringens* in commercial broiler hatcheries. *Avian Dis.* 45:1050–1053.
31. Craven, S.E., N.J. Stern, N.A. Cox, J.S. Bailey, and M. Berrang. 1999. Cecal carriage of *Clostridium perfringens* in broiler chickens given mucosal starter culture. *Avian Dis.* 43:484–490.
32. Dhillon, A.S., P. Roy, L. Lauerman, D. Schaberg, S. Weber, and D. Bandli. 2004. High mortality in egg layers as a result of necrotic enteritis. *Avian Dis.* 48:675–680.
33. Drew, M.D., N.A. Syed, B.G. Goldade, B. Laarveld, and A.G. Van Kessel. 2004. Effects of dietary protein source and level on intestinal populations of *Clostridium perfringens* in broiler chickens. *Poult Sci.* 83:414–420.
34. Eleazer, T.H., and J.S. Harrell. 1976. *Clostridium perfringens* infection in turkey poults. *Avian Dis.* 20:774–776.
35. Elwinger, K., C. Schneitz, E. Berndtson, O. Fossum, B. Teglof, and B. Engstom. 1992. Factors affecting the incidence of necrotic enteritis, caecal carriage of *Clostridium perfringens* and bird performance in broiler chicks. *Acta Vet Scand.* 33:369–378.
36. Engberg, R.M., M.S. Hedemann, and B.B. Jensen. 2002. The influence of grinding and pelleting of feed on the microbial composition and activity in the digestive tract of broiler chickens. *Br Poult Sci.* 43:569–579.
37. Engberg, R.M., M.S. Hedemann, T.D. Leser, and B.B. Jensen. 2000. Effect of zinc bacitracin and salinomycin on intestinal microflora and performance of broilers. *Poult Sci.* 79:1311–1319.
38. Engstrom, B.E., C. Fermer, A. Lindberg, E. Saarinen, V. Baverud, and A. Gunnarsson. 2003. Molecular typing of isolates of *Clostridium perfringens* from healthy and diseased poultry. *Vet Microbiol.* 94:225–235.
39. Ficken, M.D., and D. Wages. 1997. Necrotic enteritis. In: *Diseases of Poultry*, 10th ed. Y.M. Saif, H.J. Barnes, C.W. Beard, and L.R. McDonald, eds. Iowa State University Press, Ames, IA. 261–264.
40. Flores-Diaz, M., and A. Alape-Giron. 2003. Role of *Clostridium perfringens* phospholipase C in the pathogenesis of gas gangrene. *Toxicon.* 42:979–986.
41. Fukata, T., Y. Hadate, E. Baba, T. Uemura, and A. Arakawa. 1988. Influence of *Clostridium perfringens* and its toxin in germfree chickens. *Res Vet Sci.* 44:68–70.
42. Gabriel, I., S. Mallet, and M. Leconte. 2003. Differences in the digestive tract characteristics of broiler chickens fed on complete pelleted diet or on whole wheat added to pelleted protein concentrate. *Br Poult Sci.* 44:283–290.
43. Gazdzinski, P., and R.J. Julian. 1992. Necrotic enteritis in turkeys. *Avian Dis.* 36:792–798.
44. Gholamiandekhordi, A.R., R. Ducatelle, M. Heyndrickx, F. Haesebrouck, and F. Van Immerseel. 2006. Molecular and phenotypical characterization of *Clostridium perfringens* isolates from poultry flocks with different disease status. *Vet Microbiol.* 113:143–152.
45. Hamdy, A.H., R.W. Thomas, D.D. Kratzer, and R.B. Davis. 1983. Lincomycin dose response for treatment of necrotic enteritis in broilers. *Poult Sci.* 62:585–588.
46. Hamdy, A.H. R.W. Thomas, R.J. Yancey, and R.B. Davis. 1983. Therapeutic effect of optimal lincomycin concentration in drinking water on necrotic enteritis in broilers. *Poult Sci.* 62:589–591.
47. Heier, B.T., A. Lovland, K.B. Soleim, M. Kaldhusdal, and J. Jarp. 2001. A field study of naturally occurring specific antibodies against *Clostridium perfringens* alpha toxin in Norwegian broiler flocks. *Avian Dis.* 45:724–732.
48. Helmboldt, C.F., and E.S. Bryant. 1971. The pathology of necrotic enteritis in domestic fowl. *Avian Dis.* 15:775–780.
49. Hofacre, C.L., J.D. French, R.K. Page, and O.J. Fletcher. 1986. Subcutaneous clostridial infection in broilers. *Avian Dis.* 30:620–622.
50. Hofacre, C.L., R. Froyman, B. Gautrias, B. George, M.A. Goodwin, and J. Brown. 1998. Use of Aviguard and other intestinal bioproducts in experimental *Clostridium perfringens*-associated necrotizing enteritis in broiler chickens. *Avian Dis.* 42:579–584.
51. Hofshagen, M., and H. Stenwig. 1992. Toxin production by *Clostridium perfringens* isolated from broiler chickens and capercaillies (*Tetraourogallus*) with and without necrotizing enteritis. *Avian Dis.* 36:837–843.
52. Hook, D., B. Jalaludin, and G. Fitzsimmons. 1996. Clostridium perfinrgens food-borne-outbreak: an epidemiological investigation. *New Zeal J Pub Health.* 20:119–122.
53. Jackson, M.E., D.M. Anderson, H.Y. Hsiao, G.F. Mathis, and D.W. Fodge. 2003. Beneficial effect of beta-mannanase feed enzyme on performance of chicks challenged with *Eimeria* sp., and *Clostridium perfringens*. *Avian Dis*. 47:759–763.
54. Johansson, K.R., and W.B. Sarles. 1948. Bacterial population changes in the ceca of young chickens infected with *Eimeria tenella*. *J Bacteriol.* 56:635–647.
55. Kaldhusdal, M., and M. Hofshagen. 1992. Barley inclusion and avoparcin supplementation in broiler diets. II. Clinical, pathological, and bacteriological findings in a mild form of necrotic enteritis. *Poult Sci*. 71:1145–1153.
56. Kaldhusdal, M., M. Hofshagen, A. Lovland, H. Langstrand, and K. Redhead. 1999. Necrotic enteritis challenge models with broiler chickens raised on litter: evaluation of preconditions, *Clostridium perfringens* strains and outcome variables. *FEMS Immunol Med Microbiol*. 24:337–343.
57. Kaldhusdal, M., C. Schneitz, M. Hofshagen, and E. Skjerve. 2001. Reduced incidence of *Clostridium perfringens*-associated

lesions and improved performance in broiler chickens treated with normal intestinal bacteria from adult fowl. *Avian Dis.* 45:149–156.
58. Kaldhusdal, M., and E. Skjerve. 1996. Association between cereal contents in the diet and incidence of necrotic enteritis in broiler chickens in Norway. *Prev Vet Med.* 28:1–16.
59. Keyburn, A.L., J.D. Boyce, P. Vaz, T.L. Bannam, M.E. Ford, and D. Parker. 2008. NetB, a new toxin that is associated with avian necrotic enteritis caused by *Clostridium perfringens*. *PLoS Pathog.* 4:e26.
60. Keyburn, A.L., S.A. Sheedy, M.E. Ford, M.M. Williamson, M.M. Awad, and J.I. Rood. 2006. Alpha-toxin of *Clostridium perfringens* is not an essential virulence factor in necrotic enteritis in chickens. *Infect Immun.* 74:6496–6500.
61. Knarreborg, A., M.A. Simon, R.M. Engberg, B.B. Jensen, and G.W. Tannock. 2002. Effects of dietary fat source and subtherapeutic levels of antibiotic on the bacterial community in the ileum of broiler chickens at various ages. *Appl Environ Microbiol.* 68:5918–5924.
62. Kulkarni, R.R., V.R. Parreira, S. Sharif, and J.F. Prescott. 2006. *Clostridium perfringens* antigens recognized by broiler chickens immune to necrotic enteritis. *Clin Vaccine Immunol.* 13:1358–1362.
63. Kulkarni, R.R., V.R. Parreira, S. Sharif, and J.F. Prescott. 2007. Immunization of broiler chickens against *Clostridium perfringens*-induced necrotic enteritis. *Clin Vaccine Immunol.* 14:1070–1077.
64. Kulkarni, R.R., V.R. Parreira, S. Sharif, J.F. Prescott. 2008. Oral immunization of broiler chickens against necrotic enteritis with an attenuated *Salmonella* vaccine vector expressing *Clostridium perfringens* antigens. *Vaccine.* 26:4194–4203.
65. La Ragione, R.M., and M.J. Woodward. 2003. Competitive exclusion by *Bacillus subtilis* spores of *Salmonella enterica* serotype Enteritidis and *Clostridium perfringens* in young chickens. *Vet Microbiol.* 94:245–256.
66. Li, G.Q., S. Kanu, F.Y. Xiang, S.M. Xiao, L. Zhang, and H.W. Chen. 2004. Isolation and selection of ionophore-tolerant *Eimeria* precocious lines: *E. tenella*, *E. maxima* and *E. acervulina*. *Vet Parasitol*. 119:261–276.
67. Long, J.R. 1973. Necrotic enteritis in broiler chickens. I. A review of the literature and the prevalence of the disease in Ontario. *Can J Comp Med*. 37:302–308.
68. Long, J.R., J.R. Pettit, and D.A. Barnum. 1974. Necrotic enteritis in broiler chickens. II. Pathology and proposed pathogenesis. *Can J Comp Med*. 38:467–474.
69. Long, J.R., and R.B. Truscott. 1976. Necrotic enteritis in broiler chickens. III. Reproduction of the disease. *Can J Comp Med*. 40:53–59.
70. Lovland, A., and M. Kaldhusdal. 1999. Liver lesions seen at slaughter as an indicator of necrotic enteritis in broiler flocks. *FEMS Immunol Med Microbiol* 24:345–351.
71. Lovland, A., and M. Kaldhusdal. 2001. Severely impaired production performance in broiler flocks with high incidence of *Clostridium perfringens*-associated hepatitis. *Avian Pathol.* 30:73–81.
72. Lovland, A., M. Kaldhusdal, K. Redhead, E. Skjerve, and A. Lillehaug. 2004. Maternal vaccination against subclinical necrotic enteritis in broilers. *Avian Pathol.* 33:83–92.
73. Lovland, A., M. Kaldhusdal, and L.J. Reitan. 2003. Diagnosing *Clostridium perfringens*-associated necrotic enteritis in broiler flocks by an immunoglobulin G anti-alpha-toxin enzyme-linked immunosorbent assay. *Avian Pathol.* 32:527–534.
74. Mann, T.B. 1945. Chick rearing. II. The bacterial syndrome arising from a diet which is conducive to six-day disease. *J Agr Sci*. 35:98–100.
75. Mann, T.B. 1945. Chick rearing. IV. The mechanism of infection to six-day disease with special reference to intestinal putrefaction. *J Agr Sci*. 35:108–115.
76. Martel, A., L.A. Devriese, K. Cauwerts, K. De Gussem, A. Decostere, and F. Haesebrouck. 2004. Susceptibility of *Clostridium perfringens* strains from broiler chickens to antibiotics and anticoccidials. *Avian Pathol.* 33:3–7.
77. McGaughey, C.A. 1944. Six-day chick disease. *Vet Record.* 56:508.
78. McGaughey, C.A. 1959. "Six day disease" of chicks. *Ceylon Vet J.* 7:41–46.
79. McReynolds, J.L., J.A. Byrd, R.C. Anderson, R.W. Moore, T.S. Edrington, and K.J. Genovese. 2004. Evaluation of immunosuppressants and dietary mechanisms in an experimental disease model for necrotic enteritis. *Poult Sci.* 83:1948–1952.
80. Miwa, N., T. Nishina, S. Kubo, and H. Honda. 1998. Amount of enterotoxigenic *Clostridium perfringens* in meat detected by nested PCR. *Int J Food Micro.* 42:195–200.
81. Myers, G.S., D.A. Rasko, J.K. Cheung, J. Ravel, R. Seshadri, and R.T. DeBoy. 2006. Skewed genomic variability in strains of the toxigenic bacterial pathogen, *Clostridium perfringens. Genome Res.* 16:1031–1040.
82. Nairn, M.E., and V.W. Bamford. 1967. Necrotic enteritis of broiler chickens in Western Australia. *Aust Vet J.* 43:49–54.
83. Nauerby, B., K. Pedersen, and M. Madsen. 2003. Analysis by pulsed-field gel electrophoresis of the genetic diversity among *Clostridium perfringens* isolates from chickens. *Vet Microbiol.* 94:257–266.
84. Olkowski, A.A., C. Wojnarowicz, M. Chirino-Trejo, and M.D. Drew. 2006. Responses of broiler chickens orally challenged with *Clostridium perfringens* isolated from field cases of necrotic enteritis. *Res Vet Sci.* 81:99–108.
85. Parish, W.E. 1961. Necrotic enteritis in the fowl *Gallus gallus domesticus*. I. Histopathology of the disease and isolation of a strain of *Clostridium welchii*. *J Comp Pathol*. 71:377–393.
86. Parish, W.E. 1961. Necrotic enteritis in the fowl. III. The experimental disease. *J Comp Pathol*. 71:405–413.
87. Porter, R.E. 1998. Bacterial enteritides of poultry. *Poult Sci.* 77:1159–1165.
88. Prescott J.F. 1979. The prevention of experimentally induced necrotic enteritis in chickens by avoparcin. *Avian Dis.* 23:1072–1074.
89. Prescott, J.F., R. Sivendra, and D.A. Barnum. 1978. The use of bacitracin in the prevention and treatment of experimentally-induced necrotic enteritis in the chicken. *Can Vet J.* 19:181–183.
90. Sasaki, J.M.G., and K. Okada. 2000. Cholangiohepatitis in chickens induced by bile duct ligations and inoculation of *Clostridium perfringens*. *Avian Pathol.* 29:405–410.
91. Schiemann, D.A. 1977. Laboratory confirmation of an outbreak of *Clostridium perfringens* food poisoning. *Health Lab Sci.* 14:35–38.
92. Shane, S.M., J.E. Gyimah, K.S. Harrington, and T.G. Snider III. 1985. Etiology and pathogenesis of necrotic enteritis. *Vet Res Commun.* 9:269–287.
93. Shane S.M., D.G. Koetting, and K.S. Harrington. 1984. The occurrence of *Clostridium perfringens* in the intestine of chicks. *Avian Dis.* 28:1120–1124.

94. Shimizu, T., K. Ohtani, H. Hirakawa, K. Ohshima, A. Yamashita, and T. Shiba. 2002. Complete genome sequence of *Clostridium perfringens*, an anaerobic flesh-eater. *Proc Natl Acad Sci USA*. 99:996–1001.
95. Sistani, K.R., G.E. Brink, S.L. McGowen, D.E. Rowe, and J.L. Oldham. 2003. Characterization of broiler cake and broiler litter, the by-products of two management practices. *Bioresour Technol.* 90:27–32.
96. Songer, J.G. 1996. Clostridial enteric diseases of domestic animals. *Clin Microbiol Rev.* 9:216–234.
97. Stanley, V.G., C. Gray, M. Daley, W.F. Krueger, and A.E. Sefton. 2004. An alternative to antibiotic-based drugs in feed for enhancing performance of broilers grown on *Eimeria spp*.-infected litter. *Poult Sci*. 83:39–44.
98. Stevens, D.L., R.W. Titball, M. Jepson, C.R. Bayer, S.M. Hayes-Schroer, and A.E. Bryant. 2004. Immunization with the C-Domain of alpha-toxin prevents lethal infection, localizes tissue injury, and promotes host response to challenge with *Clostridium perfringens*. *J Infect Dis.* 190:767–773.
99. Stutz, M.W., and G.C. Lawton. 1984. Effects of diet and antimicrobials on growth, feed efficiency, intestinal *Clostridium perfringens*, and ileal weight of broiler chicks. *Poult Sci.* 63:2036–2042.
100. Stutz, M.W., and G.C. Lawton. 1984. The iron milk most probable number method for enumeration of *Clostridium perfringens* in the diet and the intestine of the chick. *Poult Sci.* 63:2241–2246.
101. Teo, A.Y., and H.M. Tan. 2005. Inhibition of *Clostridium perfringens* by a novel strain of *Bacillus subtilis* isolated from the gastrointestinal tracts of healthy chickens. *Appl Environ Microbiol.* 71:4185–4190.
102. Thompson, D.R., V.R. Parreira, R.R. Kulkarni, and J.F. Prescott. 2006. Live attenuated vaccine-based control of necrotic enteritis of broiler chickens. *Vet Microbiol.* 113:25–34.
103. Truscott, R.B., and F. Al-Sheikhly. 1977. Reproduction and treatment of necrotic enteritis in broilers. *Am J Vet Res.* 38:857–861.
104. Van Immerseel, F., J. De Buck, F. Pasmans, G. Huyghebaert, F. Haesebrouck, and R. Ducatelle. 2004. *Clostridium perfringens* in poultry: an emerging threat for animal and public health. *Avian Pathol.* 33:537–549.
105. Varga, J.J., V. Nguyen, D.K. O'Brien, K. Rodgers, R.A. Walker, and S.B. Melville. 2006. Type IV pili-dependent gliding motility in the Gram-positive pathogen *Clostridium perfringens* and other clostridia. *Mol Microbiol.* 62:680–694.
106. Watkins, K.L., T.R. Shryock, R.N. Dearth, and Y.M. Saif. 1997. *In-vitro* antimicrobial susceptibility of *Clostridium perfringens* from commercial turkey and broiler chicken origin. *Vet Microbiol.* 54:195–200.
107. Williams, R.B. 2002. Anticoccidial vaccines for broiler chickens: pathways to success. *Avian Pathol.* 31:317–353.
108. Williams, R.B., R.N. Marshall, R.M. La Ragione, and J. Catchpole. 2003. A new method for the experimental production of necrotic enteritis and its use for studies on the relationships between necrotic enteritis, coccidiosis and anticoccidial vaccination of chickens. *Parasitol Res.* 90:19–26.
109. Wijewanta, E.A., and P. Senevirtna. 1971. Bacteriological studies of fatal *Clostridium perfringens* type-A infection in chickens. *Avian Dis.* 15:654–661.
110. Yoo, H.S., S.U. Lee, K.Y. Park, and Y.H. Park. 1997. Molecular typing and epidemiological survey of prevalence of *Clostridium perfringens* types by multiplex PCR. *J Clin Microbiol.* 35:228–232.
111. Zekarias, B., H. Mo, and R. Curtiss III. 2008. Recombinant attenuated *Salmonella enterica* serovar Typhimurium expressing the carboxy-terminal domain of alpha toxin from *Clostridium perfringens* induces protective responses against necrotic enteritis in chickens. *Clin Vaccine Immunol.* 15:805–816.

Botulism

1. Aktories, K., M. Bärmann, I. Ohishi, S. Tsuyama, K.H. Jakobs, and E. Habermann. 1986. Botulinum C2 toxin ADP-ribosylates actin. *Nature.* 322:390–2.
2. Aktories, K., C. Mohr, and G. Koch. 1992. *Clostridium botulinum* C3 ADP-ribosyltransferase. *Curr Top Microbiol Immunol.* 175:115–31.
3. Allwright, D.M., M. Wilson, and W.J. Vanrensburg. 1994. Botulism in ostriches (*Struthio camelus*). *Avian Pathol.* 23:183–6.
4. Arimitsu, H., J.C. Lee, Y. Sakaguchi, Y. Hayakawa, M. Hayashi, M. Nakaura, H. Takai, S.N. Lin, M. Mukamoto, T. Murphy, and K. Oguma. 2004. Vaccination with recombinant whole heavy chain fragments of *Clostridium botulinum* Type C and D neurotoxins. *Clin Diagn Lab Immunol.* 11:496–502.
5. Azuma, R., and T. Itoh. 1987. Botulism in waterfowl and idstribution of *C. botulinum* type C in Japan. In: *Avian Botulism: An International Perspective*. M.W. Eklund and V.R. Dowell, eds. Charles C. Thomas, Sprinfield, IL. 167–187.
6. Bengtson, I.A. 1922. Preliminary note on a toxin producing anaerobe isolated from the larvae of *Lucilia caesar*. *Public Health Rep.* 37:164–170.
7. Blandford, T.B., and T.A. Roberts. 1970. An outbreak of botulism in broiler chickens. *Vet Rec.* 87:258–61.
8. Blocker, D., H. Barth, E. Maier, R. Benz, J.T. Barbieri, and K. Aktories. 2000. The C terminus of component C2II of *Clostridium botulinum* C2 toxin is essential for receptor binding. *Infect Immun.* 68:4566–73.
9. Blomqvist, G., E. Berndtson, D.S. Jansson, V. Baverud, and B. Engstrom. 2007. Botulism on a broiler breeder farm in Sweden. *Proceedings of the 15th Congress of the World Veterinary Poultry Association*. Beijing. 553.
10. Boroff, D.A., and J.R. Reilly. 1959. Studies of the toxin of *Clostridium botulinum*. V. Prophylactic immunization of pheasants and ducks against avian botulism. *J Bacteriol*. 77:142–6.
11. Brooks, C.E., H.J. Clarke, D.A. Graham, and H.J. Ball. 2011. Diagnosis of botulism types C and D in cattle by a monoclonal antibody-based sandwich ELISA. *Vet Rec.* 168:455.
12. Clark, W.E. 1987. Avian botulism. In: *Avian Botulism: An International Perspective*. M.W. Eklund and V.R. Dowell, eds. Charles C. Thomas, Springfield, IL. 167–187.
13. DasGupta, B.R., and H. Sugiyama. 1972. A common subunit structure in *Clostridium botulinum* type A, B and E toxins. *Biochem Biophys Res Commun*. 48:108–12.
14. De Fagonde, A.P., and H.F. DSardi. 1967. Botulismo aviar primer caso comprobado en la Republica Argentina. *Bull Off Int Epiz.* 67:1479–1491.
15. Dickson, E.C., 1917. Botulism, a case of limberneck in chickens. *J Am Vet Med Assoc.* 50:612–613.
16. Dohms, J.E. 1987. Laboratory investigation of botulism in poultry. In: *Avian Botulism: An International Perspective*. M.W. Eklund and V.R. Dowell, eds. Charles C. Thomas, Springfield, IL. 295–314.

17. Dohms, J.E., P.H. Allen, and S.S. Cloud. 1982. The immunization of broiler chickens against type C botulism. *Avian Dis.* 26:340–5.
18. Dohms, J.E., P.H. Allen, and J.K. Rosenberger. 1982. Cases of type C botulism in broiler chickens. *Avian Dis.* 26:204–10.
19. Dohms, J.E., and S.S. Cloud. 1982. Susceptibility of broiler chickens to *Clostridium botulinum* type C toxin. *Avian Dis.* 26:89–96.
20. Duncan, R.M., and W.I. Jensen. 1976. A relationship between avian carcasses and living invertebrates in the epizootiology of avian botulism. *J Wildl Dis.* 12:116–126.
21. Fach, P., P. Micheau, C. Mazuet, S. Perelle, and M. Popoff. 2009. Development of real-time PCR tests for detecting botulinum neurotoxins A, B, E, F producing *Clostridium botulinum*, *Clostridium baratii* and *Clostridium butyricum*. *J Appl Microbiol*. 107:465–73.
22. Franciosa, G., L. Fenicia, C. Caldiani, and P. Aureli. 1996. PCR for detection of *Clostridium botulinum* type C in avian and environmental samples. *J Clin Microbiol.* 34:882–5.
23. Fujinaga, Y., K. Inoue, S. Watanabe, K. Yokota, Y. Hirai, E. Nagamachi, and K. Oguma. 1997. The haemagglutinin of *Clostridium botulinum* type C progenitor toxin plays an essential role in binding of toxin to the epithelial cells of guinea pig small intestine, leading to the efficient absorption of the toxin. *Microbiology.* 143:3841–7.
24. Gessler, F., K. Hampe, and H. Bohnel. 2005. Sensitive detection of botulinum neurotoxin types C and D with an immunoaffinity chromatographic column test. *Appl Environ Microbiol.* 71:7897–903.
25. Giltner, L.T., and J.F. Couch. 1930. Western duck sickness and botulism. *Science.* 72:660.
26. Gross, W.B., and L.D. Smith. 1971. Experimental botulism in gallinaceous birds. *Avian Dis.* 15:716–22.
27. Haagsma, J. 1987. Laboratory investigation of botulism in wild birds. In: *Avian Botulism: An International Perspective*. M.W. Eklund and V.R. Dowell, eds. Charles C. Thomas, Springfield, IL. 191–222.
28. Haagsma, J., 1974. [An outbreak of botulism in broiler chickens (author's transl)]. *Tijdschr Diergeneeskd*. 99:979–90.
29. Hannett, G.E., W.B. Stone, S.W. Davis, and D. Wroblewski. 2011. Biodiversity of *Clostridium botulinum* type E associated with a large outbreak of botulism in wildlife from Lake Erie and Lake Ontario. *Appl Environ Microbiol.* 77:1061–8.
30. Harrigan, K.E. 1980. Botulism in broiler chickens. *Aust Vet J.* 565:603–605.
31. Hedeland, M., H. Moura, V. Båverud, A.R. Woolfitt, U. Bondesson, and J.R. Barr.. 2011. Confirmation of botulism in birds and cattle by the mouse bioassay and Endopep-MS. *J Med Microbiol.* 60:1299–305.
32. Hielm, S., J. Björkroth, E. Hyytiä, and H. Korkeala. 1998. Genomic analysis of *Clostridium botulinum* group II by pulsed-field gel electrophoresis. *Appl Environ Microbiol.* 64:703–8.
33. Hill, K.K., T.J. Smith, C.H. Helma, L.O. Ticknor, B.T. Foley, R.T. Svensson, J.L. Brown, E.A. Johnson, L.A. Smith, R.T. Okinaka, P.J. Jackson, and J.D. Marks. 2007. Genetic diversity among Botulinum Neurotoxin-producing clostridial strains. *J Bacteriol.* 189:818–32.
34. Holdeman, L.V. 1970. The ecology and natural history of *Clostridium botulinum*. *J Wildl Dis.* 6:205–10.
35. Hubalek, Z., and J. Halouzka. 1991. Persistence of *Clostridium botulinum* type C toxin in blow fly (*Calliphoridae*) larvae as a possible cause of avian botulism in spring. *J Wildl Dis.* 27:81–5.
36. Hyun, S.H., and G. Sakaguchi. 1988. Cell-bound toxin of *Clostridium botulinum* type C and its pathogenic significance. *Nihon Juigaku Zasshi.* 50:495–501.
37. Hyun, S.H., and G. Sakaguchi. 1989. Implication of coprophagy in pathogenesis of chicken botulism. *Nihon Juigaku Zasshi.* 51:582–6.
38. Hyytia, E., J. Björkroth, S. Hielm, and H. Korkeala. 1999. Characterisation of *Clostridium botulinum* groups I and II by randomly amplified polymorphic DNA analysis and repetitive element sequence-based PCR. *Int J Food Microbiol.* 48:179–89.
39. Inoue, K., and H. Iida. 1970. Conversion of toxigenicity in *Clostridium botulinum* type C. *Jpn J Microbiol.* 14:87–89.
40. Iwasaki, M., I. Ohishi, and G. Sakaguchi. 1980. Evidence that botulinum C2 toxin has two dissimilar components. *Infect Immun.* 29:390–4.
41. Jansen, B.C. 1987. *Clostridium botulinum* type C, its isolation, identification and taxonomic position. In: *Avian Botulism: An International Perspective*. M.W. Eklund and V.R. Dowell, eds. Charles C. Thomas, Springfield, IL. 123–132.
42. Jeffrey, J.S., F.D. Galey, C.U. Meteyer, H. Kinde, and M. Rezvani. 1994. Type C botulism in turkeys: determination of the median toxic dose. *J Vet Diagn Invest.* 6:93–5.
43. Jensen, W.I., and R.M. Duncan. 1980. The susceptibility of the mallard duck (*Anas platyrhynchos*) to *Clostridium botulinum* C2 toxin. *Jpn J Med Sci Biol.* 33:81–6.
44. Jensen, W.I., and J.I. Price. 1987. The global importance of type C botulism in wild birds. In: *Avian Botulism: An International Perspective*. M.W. Eklund and V.R. Dowell, eds. Charles C. Thomas, Springfield, IL. 33–54.
45. Johnston, M.D., S. Lawson, and J.A. Otter. 2005. Evaluation of hydrogen peroxide vapour as a method for the decontamination of surfaces contaminated with *Clostridium botulinum* spores. *J Microbiol Methods.* 60:403–11.
46. Kouguchi, H., T. Suzuki, K. Hasegawa, S. Mutoh, T. Watanabe, K. Niwa, T. Yoneyama, Y. Katoh, and T. Ohyama. 2006. Quantitative detection of gene expression and toxin complex produced by *Clostridium botulinum* serotype D strain 4947. *J Microbiol Methods.* 67:416–23.
47. Kurazono, H., K. Shimozawa, and G. Sakaguchi. 1987. Experimental botulism in pheasants. In: *Avian Boutlism: An International Perspective*. M.W. Eklund and V.R. Dowell, eds. Charles C. Thomas, Springfield, IL. 267–281.
48. Kurazono, H., K. Shimozawa, G. Sakaguchi, M. Takahashi, T. Shimizu, and H. Kondo. 1985. Botulism among penned pheasants and protection by vaccination with C1 toxoid. *Res Vet Sci.* 38:104–8.
49. Levine, N.D. 1965. Botulism. In: *Diseases of Poultry*, 5th ed, H.E. Biester and L.H. Schwaarte, eds. Iowa State University Press, Ames, Iowa. 456–461.
50. Lindberg, A., H. Skarin, R. Knutsson, G. Blomqvist, and V. Båverud. 2010. Real-time PCR for *Clostridium botulinum* type C neurotoxin (BoNTC) gene, also covering a chimeric C/D sequence—application on outbreaks of botulism in poultry. *Vet Microbiol.* 146:118–23.
51. Lindstrom, M., and H. Korkeala, 2006. Laboratory diagnostics of botulism. *Clin Micr Rev.* 19:298–314.
52. Lloyd, C.S., G.J. Thomas, J.W. MacDonald, E.D. Borland, K. Standring, and J.L. Smith. 1976. Wild bird mortality caused by botulism in Britain, 1975. *Biol Conserv.* 10:119–129.
53. Mitchell, W.R., and S. Rosendal. 1987. Type C botulism: The agent, host susceptibility, and predisposing factors. In: *Avian*

Botulism: An International Perspective, M.W. Eklund and V.R. Dowell, eds. Charles C. Thomas, Springfield, IL. 55–71.
54. Miyazaki, S., and G. Sakaguchi. 1978. Experimental botulism in chickens: the cecum as the site of production and absorption of botulinum toxin. *Jpn J Med Sci Biol.* 31:1–15.
55. Montecucco, C., G. Schiavo, and V. Tugnoli. 1996. Botulism neurotoxins: mechanisms of action and therapeutic applications. *Mol Med Today.* 2:418–424.
56. Moriishi, K., M. Koura, N. Fujii, Y. Fujinaga, K. Inoue, B. Syuto, and K. Oguma. 1996. Molecular cloning of the gene encoding the mosaic neurotoxin, composed of parts of botulinum neurotoxin types C1 and D, and PCR detection of this gene from *Clostridium botulinum* type C organisms. *Appl Environ Microbiol.* 62:662–7.
57. Muraro, L., S. Tosatto, L. Motterlini, O. Rossetto, and C. Montecucco. 2009. The N-terminal half of the receptor domain of botulinum neurotoxin A binds to microdomains of the plasma membrane. *Biochem Biophys Res Commun.* 380:76–80.
58. Myllykoski, J., M. Lindström, R. Keto-Timonen, H. Söderholm, J. Jakala, H. Kallio, A. Sukura, and H. Korkeala. 2009. Type C bovine botulism outbreak due to carcass contaminated non-acidified silage. *Epidemiol Infect.* 137:284–93.
59. Nakamura, K., T. Kohda, K. Umeda, H. Yamamoto, M. Mukamoto, and S. Kozaki.. 2010. Characterization of the D/C mosaic neurotoxin produced by *Clostridium botulinum* associated with bovine botulism in Japan. *Vet Microbiol.* 140:147–54.
60. Neimanis, A., D. Gavier-Widén, F. Leighton, T. Bollinger, T. Rocke, and T. Mörner. 2007. An outbreak of type C botulism in herring gulls (*Larus argentatus*) in southeastern Sweden. *J Wildl Dis.* 43:327–36.
61. Nevas, M., D. Gavier-Widén, F. Leighton, T. Bollinger, T. Rocke, and T. Mörner. 2005. Diversity of proteolytic *Clostridium botulinum* strains, determined by a pulsed-field gel electrophoresis approach. *Appl Environ Microbiol.* 71:1311–7.
62. Oguma, K. 1976. The stability of toxigenicity in *Clostridium botulinum* types C and D. *J Gen Microbiol.* 92:67–75.
63. Oguma, K., T. Yamaguchi, K. Sudou, N. Yokosawa, and Y. Fujikawa. 1986. Biochemical classification of *Clostridium botulinum* type C and D strains and their nontoxigenic derivatives. *Appl Environ Microbiol.* 51:256–60.
64. Ohishi, I. 1983. Response of mouse intestinal loop to botulinum C2 toxin: enterotoxic activity induced by cooperation of non-linked protein components. *Infect Immun.* 40:691–5.
65. Ohishi, I., M. Iwasaki, and G. Sakaguchi. 1980. Purification and characterization of two components of botulinum C2 toxin. *Infect Immun.* 30:668–73.
66. Ohishi, I., M. Iwasaki, and G. Sakaguchi. 1981. Vascular permeability activity of botulinum C2 toxin elicited by cooperation of two dissimilar protein components. *Infect Immun.* 31:890–5.
67. Oie, S., A. Obayashi, H. Yamasaki, H. Furukawa, T. Kenri, M. Takahashi, K. Kawamoto, and S. Makino. 2011. Disinfection methods for spores of *Bacillus atrophaeus, B. anthracis, Clostridium tetani, C. botulinum* and *C. difficile*. *Biol Pharm Bull*. 34:1325–9.
68. Okamoto, K., K. Sato, M. Adachi, and T. Chuma. 1999. Some factors involved in the pathogenesis of chicken botulism. *J Jpn Vet Med Assoc.* 52:159–163.
69. Page, R.K., and O.J. Fletcher. 1975. An outbreak of type C botulism in three-week-old broilers. *Avian Dis.* 19:192–195.
70. Pecelunas, K.S., D.P. Wages, and J.D. Helm. 1999. Botulism in chickens associated with elevated iron levels. *Avian Dis.* 43:783–7.
71. Roberts, T.A., and I.D. Aitken. 1974. Botulism in birds and mammals in Great Britain and an assessment of the toxicity of *Clostridium botulinum* type C toxin in domestic fowl. In: *Spore Research*. A.N. Barker, G.W. Gould, and J. Wolf, eds. Academic Press, London. 1–9.
72. Roberts, T.A., A.I. Thomas, and R.J. Gilbert. 1973. A third outbreak of type C botulism in broiler chickens. *Vet Rec.* 92:107–9.
73. Rocke, T.E., S.R. Smith, and S.W. Nashold, 1998. Preliminary evaluation of a simple *in vitro* test for the diagnosis of type C botulism in wild birds. *J Wildl Dis.* 34:744–51.
74. Rosen, M.N. 1971. Botulism. In: *Infectious and Parasitic Diseases of Wild Birds*. J.W. Davis, R.C. Anderson, L. Karstad, and D.O. Trainer eds. Iowa State University Press, Ames, Iowa. 100–117.
75. Sakaguchi, Y., et al. 2005. The genome sequence of *Clostridium botulinum* type C neurotoxin-converting phage and the molecular mechanisms of unstable lysogeny. *Proc Natl Acad Sci USA*. 102:17472–7.
76. Sandler, R.J., T.E. Rocke, M.D. Samuel, and T.M. Yuill. 1993. Seasonal prevalence of *Clostridium botulinum* type C in sediments of a northern California wetland. *J Wildl Dis.* 29:533–9.
77. Sato, S. 1987. Control of botulism in poultry flocks. In: *Avian Botulism: An International Perspective*. M.W. Eklund and V.R. Dowell, eds. Charles C. Thomas, Springfield, IL. 349–356.
78. Schiavo, G., M. Matteoli, and C. Montecucco, 2000. Neurotoxins affecting neuroexocytosis. *Physiol Rev.* 80:717–66.
79. Schletter, C.H. 1979. *Clostridium botulinum* type C toxin infection in broiler farms in North West Germany. *Berl Munch Tierarztl Wochenschr.* 92:50–57.
80. Segner, W.P., and C.F. Schmidt. 1971. Heat resistance of spores of marine and terrestrial strains of *Clostridium botulinum* type C. *Appl Microbiol.* 22:1030–3.
81. Segner, W.P., C.F. Schmidt, and J.K. Boltz. 1971. Enrichment, isolation, and cultural characteristics of marine strains of *Clostridium botulinum* type C. *Appl Microbiol.* 22:1017–24.
82. Segner, W.P., C.F. Schmidt, and J.K. Boltz. 1971. Minimal growth temperature, sodium chloride tolerance, pH sensitivity, and toxin production of marine and terrestrial strains of *Clostridium botulinum* type C. *Appl Microbiol.* 22:1025–9.
83. Skarin, H., T. Håfström, J. Westerberg, and B. Segerman. 2011. *Clostridium botulinum* group III: a group with dual identity shaped by plasmids, phages and mobile elements. *BMC Genomics.* 12:185.
84. Skarin, H., A. Lindberg, G. Blomqvist, A. Aspán, and V. Båverud. 2010. *Molecular characterisation and comparison of Clostridium botulinum type C avian strains Avian Pathol.* 39:511–518.
85. Skarin, H., and B. Segerman, 2011. Horizontal gene transfer of toxin genes in *Clostridium botulinum*: involvement of mobile elements and plasmids. *Mobile Genetic Elements.* 1:1–3.
86. Smart, J.L., P.W. Laing, and C.E. Winkler, 1983. Type C botulism in intensively farmed turkeys. *Vet Rec.* 113:198–200.
87. Smart, J.L., T. A. Roberts, and L. Underwood. 1987. Avian botulism in the British Isles. In: *Avian Botulism: An International Perspective*. M.W. Eklund and V.R. Dowell, eds. Charles C. Thomas, Springfield, IL. 111–122.
88. Smart, J.L., T.A. Roberts, K.G. McCullagh, V.M. Lucke, and H. Pearson. 1980. An outbreak of type C botulism in captive monkeys. *Vet Rec.* 107:445–6.

89. Smith, G.R. 1987. Botulism in water birds and its relation to comparative medicine. In: *Avian Botulism: An International Perspective*. M.W. Eklund and V.R. Dowell, eds. Charles C. Thomas, Springfield, IL. 73–86.
90. Smith, L.A., and J.M. Rusnak. 2007. Botulism neurotoxin vaccines: past, present, and future. *Crit Rev Immunol.* 27:303–318.
91. Takeda, M., H. Kasai, Y. Torii, M. Mukamoto, T. Kohda, K. Tsukamoto, and S. Kozaki. 2006. Protective effect of botulinum C/D mosaic toxoid against avian botulism. *J Vet Med. Sci.* 68:325–30.
92. Takeda, M., K. Tsukamoto, T. Kohda, M. Matsui, M. Mukamoto, and S. Kozaki. 2005. Characterization of the neurotoxin produced by isolates associated with avian botulism. *Avian Dis.* 49:376–81.
93. Wagenaar, R.O., G.M. Dack, and D.P. Mayer. 1953. Studies on mink food experimentally inoculated with toxin-free spores of *Clostridium botulinum* type-B, type-C, and type-E. *Am J Vet Res.* 14:479–483.
94. Wobeser, G. 1997. Avian botulism—another perspective. *J Wildl Dis.* 33:181–6.
95. Wobeser, G.A. 1997. Botulism. In: *Diseases of Wild Waterfowl*, 2nd ed. Plenum Publishing Corp, New York. 149–162.
96. Wobeser, G.A. 1987. Control of botulism in wild birds. In: *Avian Botulism: An International Perspective*. M.W. Eklund and V.R. Dowell, eds. Charles C. Thomas, Springfield, IL. 339–348.
97. Woo, G.H., H.Y. Kim, Y.C. Bae, Y.H. Jean, S.S. Yoon, E.J. Bak, E.K. Hwang, and Y.S. Joo. 2010. Outbreak of botulism (*Clostridium botulinum* type C) in wild waterfowl: Seoul, *Korea. J Wildl Dis.* 46:951–5.

Gangrenous Dermatitis

1. Allen, S.D. 1985. Clostridium. In: *Manual of Clinical Microbiology*, 4th ed. E.H. Lennette, A. Balows, W.J. Hausler, Jr., and H.J. Shadomy, eds. American Society of Microbiologists: Washington, DC, 434–444.
2. Awaad, M.H.H. 1986. A research note on the treatment of naturally induced gangrenous dermatitis in chickens by copper sulfate. *Vet Med J Giza Egypt.* 34:121–124.
3. Beemer, A.M., S. Schneerson-Porat, and E.S. Kuttin. 1970. *Rhodo torula mucilaginosa* dermatitis on feathered parts of chickens: An epizootic on a poultry farm. *Avian Dis.* 14:234–239.
4. Bianco, O., J. Quinones, J. Bergesio, M. Demo, and C. Pajaro. 1985. Dermatitis gangrenosa en pollos parrilleros: Dos brotes en Rio Cuarto. *Vet Arg.* 19:879–883.
5. Bliek, L. de and J. Jansen. 1931. Gasoedeem bij kippen na bloedtappen. *Tijdschr Diergeneeskd.* 58:513–518.
6. Bootes, B.W., and G. Slennet. 1964. Staphylococcosis in chickens. *Aust Vet J.* 40:238–239.
7. Bülow, V. von. 1991. Avian infectious anemia and related syndromes caused by chicken anemia virus. *Crit Rev Poult Biol.* 3:1–17.
8. Carr, D., D. Shaw, D.A. Halvorson, B. Rings, D. Roepke. 1996. Excessive mortality in market-age turkeys associated with cellulitis. *Avian Dis.* 40:736–741.
9. Cervantes, H.M., L.L. Munger, D.H. Ley, and M.D. Ficken. 1988. Staphylococcus-induced gangrenous dermatitis in broilers. *Avian Dis.* 32:140–142.
10. Chakrabarti, A., S.K. Das, C. Lodh, S. Mukhopadhyay, and D.K. Basak. 1993. An outbreak of gangrenous dermatitis in broiler chickens in West Bengal. *Indian Vet J.* 70:271–272.
11. Char, N.L., D.I. Khan, M.R.K. Rao, V. Gopal, and G. Narayana. 1986. A rare occurrence of clostridial infection in poultry. *Poult Advis.* 19:59–62.
12. Clark, S., R. Poter, B. McComb, R. Lippert, S. Olson, S. Nohner, and H.L. Shivaprasad. 2010. Clostridial dermatitis and cellulitis: an emerging disease of turkeys. *Avian Dis.* 54:788–794.
13. Engström, B.E., and M. Luthman. 1984. Blue wing disease of chickens: Signs, pathology and natural transmission. *Avian Pathol.* 13:1–12.
14. Engström, B.E., O. Fossum, and M. Luthman. 1988. Blue wing disease of chickens: Experimental infection with a Swedish isolate of chicken anaemia agent and an avian reovirus. *Avian Pathol.* 17:33–50.
15. Fenstermacher, R., and B.S. Pomeroy. 1939. Clostridium infection in turkeys. *Cornell Vet.* 29:25–28.
16. Ficken, M.D., and H.A. Berkhoff. 1989. Clostridial infections. In: *Isolation and Identification of Avian Pathogens*. H.G. Purchase, L.H. Arp, C.H. Domermuth, and J.E. Pearson, eds. American Association of Avian Pathologists, Kennett Square, PA, 47–51.
17. Fowler, N.G., and S.N. Hussaini. 1975. *Clostridium septicum* infection and antibiotic treatment in broiler chickens. *Vet Rec.* 96:14–15.
18. Frazier, M.N., W.J. Parizek, and E. Garner. 1964. Gangrenous dermatitis of chickens. *Avian Dis.* 8:269–273.
19. Froyman, R., L. Deruyttere, and L.A. Devriese. 1982. The effect of antimicrobial agents on an outbreak of staphylococcal dermatitis in adult broiler breeders. *Avian Pathol.* 11:521–525.
20. Gerdon, D. 1973. Effects of a mixed clostridial bacterin on incidence of gangrenous dermatitis. *Avian Dis.* 17:205–206.
21. Glunder, G. 1990. Dermatitis in broilers caused by *Escherichia coli*: Isolation of *Escherichia coli* from field cases, reproduction of the disease with *Escherichia coli* 078:K80 and conclusions under consideration of predisposing factors. *J Vet Med. B* 37:383–391.
22. Goodwin, M.A., J. Brown, S.I. Miller, M.A. Smeltzer, and W. D. Waltman. 1989. Infectious anemia caused by a parvovirus-like virus in Georgia broilers. *Avian Dis.* 33:438–445.
23. Greene, J.A., S.I. McCracken, and R.T. Evans. 1985. A contact dermatitis of broilers—clinical and pathological findings. *Avian Pathol.* 14:23–38.
24. Harris, G.C., Jr., M. Musbah, J.N. Beasley, and G.S. Nelson. 1978. The development of dermatitis (scabby-hip) on the hip and thigh of broiler chickens. *Avian Dis.* 22:122–130.
25. Helfer, D.H., E.M. Dickinson, and D.H. Smith. 1969. *Clostridium septicum* infection in a broiler flock. *Avian Dis.* 13:231–233.
26. Hibberd, M.C., A.P. Neumann, T.G. Rehberger, and G.R. Siragusa. 2011. Multilocus sequence typing subtypes of poultry clostridium perfringens isolates demonstrate disease niche partitioning. *J Clin Microbiol.* 49:1556–1567.
27. Hinz, K.H., M. Knapp, U. Lohren, and J. Batke. 1975. Gaso de merkrankung bei broilern. *Dtsch Tierarztl Wochenschr.* 82:307–310.
28. Hofacre, C.L., J.D. French, R.K. Page, and O.J. Fletcher. 1986. Subcutaneous clostridial infection in broilers. *Avian Dis.* 30:620–622.
29. Hoffman, H.A. 1939. Vesicular dermatitis in chickens. *J Am Vet Med Assoc.* 95:329–332.
30. Howell, L.J., R. Hunter, and T.J. Bagust. 1982. Necrotic dermatitis in chickens. *New Zealand Vet J.* 30:87–88.
31. Kaul, M.K., S.K. Tanwani, and R. Sharda. 2001. Preliminary studies on bacterin against gangrenous dermatitis. *Indian Vet J.* 78:282–285.

32. Kohler, B., S. Kolbach, and J. Meine. 1974. Untersuchungen zur nekrotischen enteritis der huhner 2. Mitt.: Microbiologische aspekte. *Monatsh Veterinaermed*. 29:385–391.
33. Kohler, B., V. Bergmann, W. Witte, R. Heiss, and K. Vogel. 1978. Dermatitis bei broilern durch *Staphylococcus aureus*. *Monatsh Veterinaermed.* 33:22–28.
34. Kuttin, E.S., A.M. Beemer, and M. Meroz. 1976. Chicken dermatitis and loss of feathers from *Candida albicans*. *Avian Dis.* 20:216–218.
35. Li, G., H.S. Lillehoj, K.W. Lee, S.I. Jang, P. Marc, C.G. Gay, G.D. Ritter, D.A. Bautista, K. Phillips, A.P. Neumann, T.G. Rehberger, and G.R. Siragusa. 2010. An outbreak of gangrenous dermatitis in commercial broiler chickens. *Avian Pathol.* 39:247–253.
36. Long, R.V. 1973. Necrotic dermatitis. *Poult Dig*. 32:20–22.
37. Martland, M.F. 1984. Wet litter as a cause of plantar pododermatitis, leading to foot ulceration and lameness in fattening turkeys. *Avian Pathol.* 13:241–252.
38. Martland, M.F. 1985. Ulcerative dermatitis in broiler chickens: The effects of wet litter. *Avian Pathol.* 14:353–364.
39. Miller, D.A. 1998. Clostridial diseases. In: *A Laboratory Manual for the Isolation and Identification of Avian Pathogens*, 4th ed. D.E. Swayne, J.R. Glisson, M.W. Jackwood, J.E. Pearson, and W.M. Reed, eds. AAAP, Kennett Square, PA. 61–68.
40. Monreal, G. 1984. Nachweis von neutralisierenden antikorpern gegen 11 serotypen der aviaren adenoviren. *Arch Gefluegelkd.* 48:245–250.
41. Neumann, A.P., S.M. Dunham, T.G. Rehberger, and G.R. Siragusa. 2010. Quantitative real-time PCR assay for *Clostridium septicum* in poultry gangrenous dermatitis associated samples. *Mol Cell Probes.* 24:211–218.
42. Neumann, A.P., and T.G. Rehberger. 2009. MLST analysis reveals a highly conserved core genome among poultry isolates of *Clostridium septicum*. *Anaerobe.* 15:99–106.
43. Niemann, K.W. 1930. *Clostridium welchii* infection in the domesticated fowl. *J Am Vet Med Assoc.* 77:604–606.
44. Page, R.K., O.J. Fletcher, C.S. Eidson, and G.E. Michaels. 1976. Dermatitis produced by *Rhodotorula glutins* in broiler-age chickens. *Avian Dis.* 20:416–421.
45. Perek, M. 1958. Ergot and ergot-like fungi as the cause of vesicular dermatitis (sod disease) in chickens. *J Am Vet Med Assoc.* 132:529–533.
46. Pope, C.R. 1991. Chicken anemia agent. *Vet Immun Immunopathol.* 30:51–65.
47. Proudfoot, F.G., and H.W. Hulan. 1985. Effects of stocking density on the incidence of scabby hip syndrome among broiler chickens. *Poult Sci.* 64:2001–2003.
48. Rosenberger, J.K., S. Klopp, R.J. Eckroade, and W.C. Krauss. 1975. The role of the infectious bursal agent and several avian adenoviruses in the hemorrhagic-aplastic-anemia syndrome and gangrenous dermatitis. *Avian Dis.* 19:717–729.
49. Saunders, J.R., and A.A. Bickford. 1965. Clostridial infections of growing chickens. *Avian Dis.* 9:317–326.
50. Shirasaka, S., and Y. Benno. 1982. Isolation of *Clostridium septicum* from diseased chickens in broiler farms. *Jpn J Vet Sci.* 44:807–809.
51. Shukla, R.P., B.P. Joshi, D.J. Ghadasara, and K.S. Prajapati. 1992. Pathological studies on outbreaks of gangrenous dermatitis in chickens. *Indian Vet J.* 69:690–692.
52. Tellez, G., N. Pumford, M. Morgan, A. Wolfenden, and B. Hargis. 2009. Evidence of *Clostridium septicum* as a primary cause of cellulitis in commercial turkeys. *J Vet Diagn Invest.* 21:374–377.
53. Thachil, A.J., B. McComb, M.A. Anderson, D.P. Shaw, D.A. Halvorson, and K.V. Nagaraja. 2010. Role of *Clostridium perfringens* and *Clostridium septicum* in causing turkey cellulitis. *Avian Dis.* 54:795–801.
54. Trenchi, H. 1960. Ingestion of *Ammi visnaga* seeds and photosensitization—the cause of vesicular dermatitis in fowls. *Avian Dis.* 4:275–280.
55. Vielitz, E., and H. Landgraf. 1988. Anaemia-dermatitis of broilers: Field observations on its occurrence, transmission and prevention. *Avian Pathol.* 17:113–120.
56. Weymouth, D.K., M. Gershman, and H.L. Chute. 1963. Report of Clostridium in capons. *Avian Dis.* 7:342–343.
57. Wilder, T.D., J.M. Barbaree, K.S. Macklin, and R.A. Norton. 2001. Differences in the pathogenicity of various bacterial isolates in an induction model for gangrenous dermatitis in broiler chickens. *Avian Dis.* 45:659–662.
58. Willouhby, D.H., A.A. Bickford, G.L. Cooper, and B.R. Charlton. 1996. Periodic recurrence of gangrenous dermatitis associated with *Clostridium septicum* in broiler operations. *J Vet Diagn Invest.* 8:259–261.

Chapter 23

Other Bacterial Diseases

Introduction

Catherine M. Logue

Bacterial diseases of poultry cause significant losses to the poultry industry annually. This chapter focuses on the diseases of poultry that are not covered in specific chapters but are usually sporadic in nature and their overall impact on poultry production is limited but can still result in loss. The less common pathogens implicated in poultry loss included here are *Staphylococcus*, *Streptococcus*, *Erysipelas*, spirochetes, and tuberculosis. The section on enterococci and its association with disease is included in the section on streptococci. These organisms have an increased influence in disease production due to their ability to cause local and systemic disease (10, 13) and the limited use of growth promoters in poultry production (1, 2, 5, 14).

This chapter includes a section devoted to a collection of miscellaneous organisms that have caused disease in poultry or are a public health concern. In most cases the disease strain has caused an unusual outbreak in production or exotic birds. In some instances, reproduction of the disease using bird models was not possible. Earlier editions of *Diseases of Poultry* have specific chapters for organisms such as *Bacillus anthracis*, *Brucella*, *Coxiella*, and *Franciscella* (Tularemia).

New taxonomic classification using genomic based approaches has reclassified some bacteria from one genus into another (e.g., *Pasteurella anatis* is now classified in the genus *Gallibacterium*) (3), or created new genera or species for previously unnamed organisms (e.g., *Coenonia*, *Pelistega*, and *Suttonella*) (7, 15, 16).

Public health concerns from pathogens such as *Campylobacter* (Chapter 17), *Arcobacter*, *Helicobacter* (12), *Listeria* (4, 8), methicillin-resistant *Staphylococcus aureus* (MRSA) (6, 9), and mycobacteria (11) are gaining increased attention because of the risk of poultry as a source of these pathogens for human illness. In each case, their potential for causing illness in humans appears to be greater than the risk for disease in birds where the organism has a commensal relationship with its host.

Disease syndromes also included in the final section of this chapter include beak necrosis, venereal disease of geese, and liver granulomas, but are not identified to a specific organism responsible because of the multifactorial nature of the disease.

Unusual pathogens identified in disease include *Neisseria, Candida,* micro, yeasts, eubacterium, and *Enterococcus*.

Often, bacteria are identified as the primary pathogen or cause of disease in birds but this outcome occurs in significantly fewer situations where the organism is an opportunist or is a co-pathogen with another agent. The use of Koch's postulates to reproduce the disease often fails because all of the conditions of the disease may not be reproducible or there are too many factors to reproduce these conditions.

Acknowledgement

With acknowledgement to Dr John Barnes who wrote the introduction for the 12th edition.

Staphylococcosis

Claire B. Andreasen

Introduction

Staphylococcus infections are common in poultry. These infections are primarily caused by *Staphylococcus aureus*, although other species are occasionally involved (8, 21, 22, 117, 127). The clinical signs vary with the site of entry. The most frequent sites are the bones, tendon sheaths, and joints, especially the tibiotarsal and stifle joints (Table 23.1). Staphylococcal infections occur less frequently in other locations including skin (21, 49, 64, 114, 117, 142), sternal bursa (136), yolk sac

Diseases of Poultry, Thirteenth Edition. David E. Swayne.

© 2013 John Wiley & Sons, Inc. Published 2013 by John Wiley & Sons, Inc.

Table 23.1. Staphylococcal-related infections in poultry.

Location	Age	Lesion	Usual outcome
Bone	Any, usually older	Osteomyelitis	Lameness
Joint	Any, usually older	Arthritis/Synovitis	Lameness
Yolk sac	Chicks, poults	Omphalitis	Death
Blood	Any	Generalized necrosis	Death
Skin	Young	Gangrenous dermatitis	Death
Feet	Mature	Bumblefoot	Lameness

(146), heart (12), vertebrae (18), eyelid (22), and testis (95), and as granulomas in the liver and lungs (7, 86, 99). Infections are usually characterized by increased heterophil counts and marked heterophilic infiltration of tendons, synovial membranes, and other affected organs (4). Staphylococcal septicemia, causing acute deaths in laying birds (13), seems to be most prevalent in hot weather and resembles fowl cholera. The route of entry, pathogenesis, and host response are not completely defined. Staphylococcal disease is usually chronic and responds poorly to antimicrobial therapy or immunization.

Economic Significance

Staphylococcal infections are a worldwide problem in chickens and turkeys and cause economic losses due to decreased weight gain, decreased egg production, lameness and bird losses from osteomyelitis and septicemia, and condemnation of carcasses at slaughter (89, 100). During the processing of turkeys, a high correlation between green-discolored livers and *S. aureus* has been made and termed "green-liver osteomyelitis complex" (11, 23). Although *S. aureus* is the most commonly isolated pathogen in this condition, *Escherichia coli* and numerous opportunistic bacteria also have been isolated from affected turkeys (11).

Public Health Significance

In addition to being a major disease-producing organism for poultry, approximately 50% of typical and atypical *S. aureus* strains produce enterotoxins that can cause food poisoning in human beings (45, 51, 60, 113, 129). Poultry-associated food poisoning can occur due to the contamination of carcasses with these strains at processing. *S. aureus* strains from processed poultry are thought to be endemic to the processing plant or transmitted from the hands of workers in the plant (1, 80, 109, 131). The literature varies as to the origin of processing plant strains, with biotyping indicating the passage of human staphylococcal strains to poultry in processing plants; plasmid profiling indicates that endemic strains in the processing plant are primarily introduced by incoming birds (39).

Methicillin-resistant *Staphylococcus aureus* (MRSA), which has emerged as an important human pathogen, also may be a concern in chicken meat (27, 41, 46, 74, 82, 85, 98, 104, 110, 140, 141). Methicillin-resistant strains of *S. aureus* are resistant to beta-lactam antibiotics including the semi-synthetic penicillins (140). Many isolates are also resistant to numerous other antibiotics including the fluoroquinolones. MRSA has been detected in poultry in several countries, but its prevalence and significance for human health are incompletely understood at present (19, 98, 104, 110, 135). In studies from Belgium, the Netherlands, and Korea, 0%–100% of the poultry on farms or entering abattoirs were colonized with MRSA (82, 98, 104, 110). MRSA has been isolated from raw poultry meat or meat products in a number of countries, with prevalence rates of 0.3%–37% (46, 74, 85, 141). Many MRSA detected in poultry belong to the livestock-associated clonal complex CC398 (98, 104, 110), although some organisms are reported to be of a genetic (spa) type not usually associated with MRSA CC398 in other livestock (110). MRSA ST9 also has been detected in poultry (98). Colonization by MRSA CC398 has been documented in poultry farmers (135) and poultry slaughterhouse workers, with higher rates of carriage among people who handle live birds than dead birds (98).

It is theoretically possible for the *mecA* gene, which is responsible for methicillin resistance, to be transmitted between species of staphylococci found in animals and staphylococci found in humans (41). For this reason, poultry-associated methicillin-resistant species other than *S. aureus* also can be a concern for human health. Methicillin-resistant coagulase-negative staphylococci that have been detected in chickens include *S. lentus*, *S. sciuri, S. epidermidis*, and *S. saprophyticus* (66, 70), with a prevalence of nearly 50% reported in chicken carcasses at slaughter in Switzerland (70).

History

Staphylococcosis in poultry and other avian species has been recognized for more than 100 years; most early reports describe arthritis and synovitis (58, 65, 69, 88).

Etiology

Classification

The genus *Staphylococcus* contains approximately 45 species and 24 subspecies (44). It is the most important genus in the family Staphylococcaceae. The term staphylococcus refers to the morphology of these microorganisms; in stained smears, they often resemble clusters of grapes. Other genera in the family include *Gemella*, *Macrococcus*, and *Salinicoccus* (44). *Macrococcus* and *Salinicoccus* are considered to be nonpathogenic. In rare cases, *Gemella* spp. have been involved in human disease (84, 134).

A number of *Staphylococcus* species have been isolated from the skin and nares of healthy poultry, including *S. aureus*,

S. epidermidis, S. xylosus, *S. cohnii*, *S. lentus*, *S. saprophyticus*, *S. sciuri*, and *S. gallinarum* (34, 35, 36, 72, 102, 117, 124). *S. aureus* is the most common species isolated from poultry that are ill (12, 13, 18, 22, 64, 86, 99, 136, 146). Other species are also found occasionally and in some cases may be opportunists. In one outbreak of systemic illness, the major staphylococcal species isolated from the liver, blood, and hock of sick 6-week old chickens included *S. lentus*, *S. simulans*, *S. cohnii*, *S. gallinarum*, and *S. capitis* (8). In this study, *S. aureus* was uncommon. *S. hyicus* has been associated with fibrinoheterophilic blepharitis in chickens and turkeys (22) and was isolated from 5 of 9 tibiotarsal growth plates of turkeys with stifle joint osteoarthritis (127). This species also was linked to chronic folliculitis and epidermitis with acantholysis in layer hens of the leghorn breed (21). *S. sciuri*, *S. simulans*, *S. epidermidis*, *S. lentus*, *S. warneri*, *S. cohnii*, and *S. intermedius* have been reported from scabby hip lesions in broiler chickens (117). Other staphylococci found in humans and domestic animals are not known to be important pathogens in poultry.

Morphology and Staining

Typical staphylococci are Gram-positive, coccoid in shape, and found in clusters when grown on solid media. In liquid media, they may occur in short chains. Older cultures (older than 24 hours) may stain Gram-negative.

Growth Requirements

Staphylococci are readily isolated on 5% blood agar with growth evident in 18–24 hours.

Colony Morphology

S. aureus is considered to be the most pathogenic staphylococcal species in poultry and is isolated from the majority of clinical infections. Within 24 hours, aerobic growth of *S. aureus* results in circular, smooth, β-hemolytic colonies, 1–3 mm in diameter, which are often pigmented white to orange (145). Colonies of coagulase-negative staphylococci are similar but are often gray to cream or white, and non-hemolytic.

Biochemical Properties

S. aureus is aerobic, facultatively anaerobic, β-hemolytic, usually coagulase positive, catalase positive, fermentative for glucose and mannitol, and gelatinase positive. *S. hyicus* is similar biochemically to *S. aureus* but some strains have a delayed positive coagulase reaction. Most other staphylococci found in poultry are coagulase negative. Coagulase-negative staphylococci can be identified to the species level using panels of biochemical tests (26, 37, 77), automated systems (26, 75), or genetic testing (26, 30, 40, 50, 91, 125). However, this is infrequently done in clinical laboratories.

Susceptibility to Chemical and Physical Agents

Staphylococci are extremely hardy and remain viable for long periods on solid media or in exudates. Some strains are heat and disinfectant resistant (90). A resistance feature used to isolate *S. aureus* from heavily contaminated clinical material is its tolerance to high (7.5%) concentrations of NaCl (76, 111).

Antigenic Structure and Toxins

The antigenic nature of *S. aureus* is often complex. Strains may have a capsule consisting of glucosaminouronic acid, manosaminouronic acid, lysine, glutamic acid, glycine, alanine, or glucosamine; polysaccharide A consisting of linear ribitol teichoic acid, *N*-acetylglucosamine, and D-alanine; and protein-A, a cell-wall component that interacts nonspecifically with the Fc portion of immunoglobulin and may be a virulence factor. A variety of enzymes and toxins including hyaluronidase (spreading factor), deoxyribonuclease, fibrinolysin, lipase, protease, hemolysins, leukocidin, dermonecrotic toxin, hemolysins, exfoliative toxins, and enterotoxins also can contribute to a strain's pathogenicity and virulence (2, 6, 96, 145). Toxic shock syndrome toxin 1 (TSST-1) also has been found in *S. aureus* isolated from chickens, but there is currently no evidence that this toxin is directly linked to disease in poultry (74).

Strain Classification

Phenotyping techniques, such as biotyping and phage typing, as well as genetic techniques have been used to classify poultry *S. aureus*. Biotyping can determine the origin and epidemiological connections of *S. aureus* isolates as host-specific (human or domestic animal) ecovars (33, 59) or nonhost-specific biotypes (122). Phage typing has been used for poultry and historically for human *S. aureus* strains (52, 119, 120, 121, 122). In poultry, phage typing has been used to determine the association between country or region of origin (Europe, Australia, Argentina, Japan) and pathogenic and nonpathogenic strains (52, 73, 119, 122, 132), but 2.2%–25.8% of chicken *S. aureus* remain nontypable by this method (122). Phages tend to be specific for *S. aureus* of poultry origin and cannot be used to type strains from other species (121).

Genomic fingerprinting by pulsed-field gel electrophoresis (PFGE) is also a useful method for discriminating poultry *S. aureus* strains and for subtyping strains of avian phage groups or poultry-specific ecovars (16, 63, 122). This technique was able to type all chicken *S. aureus* strains, including those that were not phage typable (122). *S. aureus* also can be genetically typed by multilocus sequence typing (MLST) and spa (staphylococcal surface protein A) typing (19, 128). MLST can be used to group MRSA into clonal complexes (e.g., CC398), which contain genetically related sequence types (19, 128). Spa typing can distinguish strains that cannot be typed by PFGE or MLST (19). The MLST type ST5 (CC5) is reported to be particularly common among poultry-associated *S. aureus*, although other isolates including CC398 have also been found (17, 61, 87).

Strains also have been classified using antibiotic susceptibility patterns, plasmid profiles (76), and serotyping based on capsular polysaccharides (29). Chicken capsular types were type 5 (91%) and type 8 (9%), and turkey capsule types were type 5 (33%), type 8 (38%), and nontypable (29%) (29).

Virulence Factors

Coagulase-positive isolates of *S. aureus* are considered to be pathogenic for poultry. Coagulase-negative strains are often nonpathogenic in poultry, but can be pathogenic in some species.

Pathobiology and Epizootiology

Incidence and Distribution

Staphylococcus spp. are ubiquitous, normal inhabitants of skin and mucous membranes and are common environmental organisms where poultry are hatched, reared, or processed. Most staphylococcal species are considered to be normal flora, which suppress other potential pathogens through interference or competitive exclusion. Some have the potential to be pathogenic and produce disease if allowed entry through the skin or mucous membranes.

Staphylococcus spp. and staphylococcosis have been associated with poultry throughout the world (9, 20, 31, 32, 53, 56, 67, 73, 79, 80, 94, 97, 100, 109, 112, 122, 130, 132, 133, 137, 144, 148). According to one recent genetic study, many *S. aureus* in broiler chickens may have descended from a single MLST clone (ST5) that was acquired from humans approximately 30–60 years ago, became adapted to chickens, and disseminated widely (87).

Natural and Experimental Hosts

All avian species are susceptible to staphylococcal infections.

Transmission, Carriers, and Vectors

The pathogenesis of *S. aureus* infections is not completely defined, but for infection to occur, a breakdown in the natural defense mechanisms of the host must occur (2, 6). In most cases, this would involve damage to an environmental barrier, such as a skin wound or inflamed mucous membrane, and hematogenous dissemination where a locus of infection (e.g., osteomyelitis) is established, usually in the metaphyseal joint (9, 12, 28, 103). The open navel of newly hatched chicks leading to omphalitis, minor surgical procedures (e.g., trimming of toes, beak, or comb; removal of the snood), and parenteral vaccinations may offer additional means of entry for staphylococci.

Another type of host defense impairment occurs following infectious bursal disease (115), chicken infectious anemia, or possibly Marek's disease, in which the cloacal bursa (bursa of Fabricius) or thymus is damaged and the immune system is compromised. Under these conditions, septicemic staphylococcal infections can occur and cause acute death. Gangrenous dermatitis caused by *S. aureus*, either with or without *Clostridium septicum*, (142) can be seen following early infectious bursal disease virus infection (49, 114).

Escherichia coli was discovered to be the predominant bacterial organism in the livers of turkeys immediately following challenge with virulent hemorrhagic enteritis virus (HEV). However, when livers of survivors were cultured 2 weeks post exposure, *Staphylococcus* spp. were the predominant bacteria (105). This suggests that HEV, and possibly other similar viral intestinal infections, may create portals of entry and provide the underlying basis for subsequent staphylococcal problems associated with older, commercial turkeys.

Susceptibility to staphylococcal infections also may be genetically influenced. Two related lines of New Hampshire chickens had significant differences in mortality following experimental infection (25). A syndrome of acantholytic folliculitis and epidermitis associated with *S. hyicus* also appears to be genetically influenced, and was restricted to hens in one line of leghorn chickens (21). The avian major histocompatibility complex influences the susceptibility to staphylococcal skeletal disease in chickens (68).

Incubation Period

The incubation period is short. In experimental infections of chickens, clinical signs were evident 48–72 hours following intravenous inoculation, but the severity of lesions was dose dependent (4). Experimentally, chickens can be readily infected by the intravenous route, but not as well by the intratracheal or aerosol routes (67). The ability to consistently produce experimental disease is dependent on the number of intravenously administered bacteria (4). At least 10^5 organisms/kg body weight are necessary (100, 101).

Clinical Signs

Early clinical signs include ruffled feathers, lameness in one or both legs, drooping of one or both wings, reluctance to walk, and fever (100). This can be followed by severe depression and death. Birds surviving the acute disease have swollen joints, sit on their hocks and keel bone, and are reluctant or unable to stand (43, 100). Clinical signs of septicemic staphylococcal infection and gangrenous dermatitis occur in birds in good condition and may be evident only because of increased mortality in the flock (13, 49, 114).

Morbidity and Mortality

Morbidity and mortality due to staphylococcosis is usually low, even in the face of septicemia, unless chicks have been massively contaminated from exposure to unusually high numbers of bacteria. This may occur in the hatchery environment or through vaccination or service procedures. Reluctance to walk to feeders and waterers can lead to debilitation and death. Several reports from diagnostic laboratories have indicated that *S. aureus* is the most common bacterial agent isolated from infected legs and joints (71, 78). The number of chickens that develop gangrenous dermatitis is low, but usually all chickens that develop lesions succumb to the infection (14, 49, 78).

Pathology

Gross Pathology

Gross lesions of osteomyelitis in bone consist of focal yellow areas of caseous exudate or lytic areas (Figure 23.1A), which cause affected bones to be fragile. Bones and sites most frequently involved are the proximal tibiotarsus and proximal femur. Less commonly, the proximal tarsometatarsus, distal femur, distal tibiotarsus, proximal humerus, ribs, or vertebrae may be involved. In affected birds, the femoral head often separates from the shaft by a fracture through the neck when

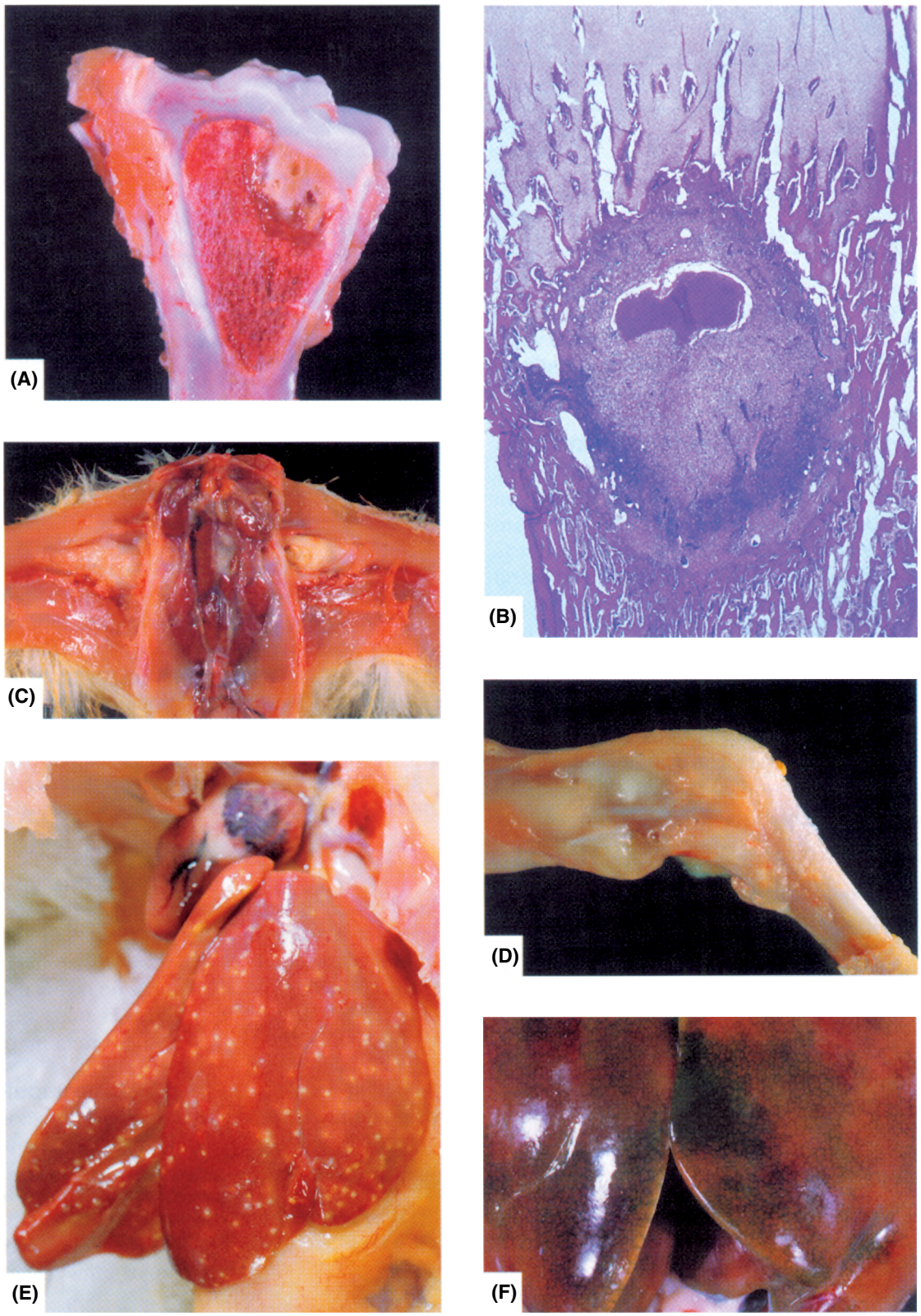

Figure 23.1. Lesions of staphylococcosis. (A) Osteomyelitis of proximal tibiotarsus (×5). (H.J. Barnes) (B) Focal osteomyelitis subjacent of physis of proximal tibiotarus (×5). (H.J. Barnes) (C) Bilateral osteomyelitis of femoral head due to *Staphylococcus aureus* infection in a 2-week-old turkey. Note the extension through the joint into the body cavity. (D) Three-week-old turkey. Swollen hock joint with extension of inflammatory exudates along tendon sheaths. (L. Munger) (E) Leghorn, 20 weeks old. Multiple foci of necrosis in liver following septicemic staph infection. (L. Munger) (F) Green liver discoloration seen in turkeys with osteomyelitis. (H.J. Barnes)

the coxofemoral joint is disarticulated (femoral head necrosis) (Figure 23.1C) (100, 103).

Arthritis, periarthritis, and synovitis are common. Affected joints are swollen and filled with inflammatory exudate as the infection (osteomyelitis) extends from nearby metaphyseal areas (Figure 23.1D) (93, 103). Spondylitis involving articulating thoracolumbar vertebrae may cause lameness indirectly because of the impingement on the spinal cord (18, 103).

Gross lesions of septicemic staphylococcal infection consist of necrosis and vascular congestion in many internal organs including the liver (Figure 23.1E), spleen, kidneys, and lungs (13). Dark, moist areas under the skin with crepitation are seen in gangrenous dermatitis (13, 49). Following mild trauma, gangrenous dermatitis lesions develop on the wing tips of birds infected with chicken infectious anemia virus. This condition has been referred to as "blue-wing disease."

Staphylococcal-related hatchery infections are common and can cause increased mortality within the first few days after hatching. Chicks have wet navel areas and deteriorate rapidly. Internally, the yolk sacs are enlarged with abnormal color and consistency.

Plantar abscess ("bumblefoot") is a common infection seen in mature chickens that leads to massive swelling of the foot and lameness. Partially, or less commonly, entirely green-discolored livers (Figure 23.1F) have been associated with osteomyelitis and/or associated soft tissue lesions (e.g., arthritis, periarthritis, tenosynovitis) in commercial turkeys at processing; this condition is called green-liver osteomyelitis complex. Carcasses with lesions from which staphylococci or other bacteria are isolated also have liver discoloration, but frequently turkeys with liver discoloration do not have demonstrable osteomyelitis or associated lesions, or bacteria cannot be isolated from the lesions (11, 23).

Liver spots are another common cause of condemnation in commercial turkeys, but most affected livers yield no aerobic or facultatively anaerobic bacteria. In one study, *S. cohnii* and other staphylococci were isolated most frequently from the few culture-positive livers in 2 flocks with histories of high liver condemnation (108). Ascarid larval migration appeared to be the most likely cause of the liver lesions (108).

Microscopic Pathology

Histologically, staphylococcal lesions consist of necrosis; bacterial colonies are composed of large numbers of Gram-positive, coccoid bacteria and heterophils (Figure 23.1B) (6, 42, 54, 100). Supernatants from pathogenic *S. aureus* resulted in increased chemotaxis of heterophils compared to supernatants from nonpathogenic *S. xylosus*; this appears to correlate with the heterophilic infiltrate seen in staphylococcal lesions (5). Long-standing lesions are primarily granulomatous.

Immunity

Neither active nor passive immunity appears to be effective in preventing *S. aureus* infections in poultry. It has been implied that specific antibody to *S. aureus* may promote the development of *S. aureus*-related infections in chickens (47, 55). Additionally, anti-staphylococcal antibodies may not significantly increase the opsonization and phagocytosis of *S. aureus* compared to the naturally exposed complement-activating cell wall materials during infection (3). However, egg yolk antibodies from immunized hens can inhibit *in vitro* growth of *S. aureus* (57, 149). Toxoids have not proven to be effective in other species (2, 6). Vaccines incorporating various *S. aureus* virulence factors and surface antigens including cell wall components (e.g., peptidoglycan and teichoic acid), capsular polysaccarides, and cell wall-anchored proteins (e.g., the hemoglobin receptor IsdB) have been used in other species with variable results (3, 15, 118, 123). Some approaches appear to show promise, but some promising human vaccines have failed efficacy testing in clinical trials (15, 118).

Diagnosis

Isolation and Identification of Causative Agent

Staphylococcosis is diagnosed by culturing suspected clinical material including exudate from joints, yolk material, and stab swabs of internal organs. The basic medium for growing staphylococci is blood agar (preferably sheep or bovine). Organisms grow well with colonies 1–3 mm in diameter within 18–24 hours. Most *S. aureus* strains are β-hemolytic; other staphylococci are usually nonhemolytic. Heavily contaminated material should be streaked onto a selective medium inhibitory for Gram-negative bacteria, such as mannitol-salt or phenylethyl-alcohol agar (76, 111, 145).

Most *S. aureus* colonies will be pigmented, whereas most other staphylococcal colonies are gray to white. Colonies should be selected and Gram stained. Staphylococci are Gram-positive cocci. Biochemical tests such as the catalase test can differentiate staphylococci from other Gram-positive organisms such as *Streptococcus*. Coagulase and mannitol fermentation tests are useful in the presumptive identification of *S. aureus*. The coagulase test is commonly used to differentiate *S. aureus* from coagulase-negative staphylococci such as *S. epidermidis* (Table 23.2). A few other staphylococcal species including *S. pseudintermedius, S. intermedius*, *S. hyicus*, *S. lutrae*, *S. lugdunensis*, *S. schleiferi subsp. coagulans*, and *S. delphini* also may be coagulase positive (10, 38, 48, 116) but none of these species are commonly associated with clinical disease in chickens. Unlike most other staphylococci, *S. aureus* also ferments mannitol. Panels of biochemical tests (26, 37, 77) and genetic testing (26, 30, 40, 50, 91, 125) can be used for the definitive identification of staphylococci to the species level;

Table 23.2. Differentiation of *Staphylococcus aureus* and *S. epidermidis*.

Characteristic	*S. aureus*	*S. epidermidis*
Colony pigment	+	–
Hemolysis	+	–
Coagulase	+/–	
D. mannitol fermentation	+	–

however, this is rarely done in clinical laboratories. Commercially available systems also can be used (26, 75), but these systems may have difficulty identifying some species from veterinary specimens (139).

Serology

Serology is generally not used for the diagnosis of staphylococcosis, but a microtiter plate agglutination assay (3, 47) and an indirect immunofluorescent antibody titer assay have been described (3). Both have primarily been used in research.

Differential Diagnosis

Staphylococcosis can resemble infection with *E. coli, Pasteurella multocida, Salmonella gallinarum, Mycoplasma synoviae*, reoviruses, or any other infection of bones or joints that is hatchery-related, associated with mechanical trauma, or causes septicemia.

Intervention Strategies

Management Procedures

Any management procedure reducing damage to host defense mechanisms will help prevent staphylococcosis. Because wounds are a portal of entry for *S. aureus* into the body, interventions that decrease the risk of injury also help prevent infection. Sharp objects such as splinters, jagged rocks, or metal edges that can cut or puncture the feet should be eliminated from areas where poultry are reared. Maintenance of good litter quality reduces foot pad ulceration. Particular attention should be given to hatchery management and sanitation. *S. aureus* is ubiquitous, and conditions in incubators and hatchers are ideal for bacterial growth. Recently hatched and hatching chicks with open navels and immature immune systems can be infected easily, leading to mortality and chronic infections shortly after hatching. Prevention of early infections with infectious bursal disease virus and chicken infectious anemia virus also help prevent staphylococcosis (115).

Poultry under mild stress are more resistant to experimental staphylococcosis than those not stressed (24, 62, 81, 100). Resistance is attributed to an increase in heterophil numbers, which occurs in birds under stress. The heterophil is thought to be the most important cell in controlling bacterial infections, particularly *S. aureus* (4, 101).

Vaccination

Staphylococcal bacterins have been ineffective in preventing infections in poultry (2, 6), but the use of live, avirulent vaccines based on the principle of bacterial interference have shown some promise. Using the principle of bacterial interference, a live, avirulent vaccine for the prevention of staphylococcosis in turkeys has been developed. A naturally occurring, coagulase-negative, avirulent *S. epidermidis* isolate, designated strain 115, that colonizes cells and tissues in the respiratory tract and prevents adherence of virulent strains of *S. aureus* is used (92). In addition to interfering with the colonization of virulent *S. aureus, S. epidermidis* 115 secretes a stable, antibiotic-like bacteriocin capable of inhibiting and killing virulent *S. aureus*. The vaccine is administered by aerosol at 1–10 days and again at 4–6 weeks of age. Use of strain 115 in commercial flocks has reduced the number of turkeys with staphylococcosis and improved overall health and survival. Similar results were found when strain 115 was used in chickens (67, 83, 92, 106, 107, 143).

Competitive gut exclusion using *Lactobacillus acidophilus* was attempted to exclude *S. aureus* from experimentally infected, germ-free chickens. The treatment was effective in reducing *S. aureus* counts in crop contents, but counts in the ceca and rectum were unaffected (138).

Treatment

S. aureus infection sometimes can be treated successfully, but sensitivity tests should always be performed because antibiotic resistance is common (32, 34, 126, 147). Drugs used successfully for treatment include penicillin, streptomycin, tetracyclines, erythromycin, novobiocin, sulfonamides, lincomycin, and spectinomycin.

Acknowledgement

The contributions of J. Kirk Skeeles to previous editions are acknowledged.

Streptococcus and Enterococcus

Stephan G. Thayer and W. Douglas Waltman

Streptococcus

Introduction

Streptococcosis in avian species is worldwide in distribution, occurring as both acute septicemic and chronic infections with mortality ranging from 0.5%–50%. Streptococci are part of the normal intestinal and mucosal flora of most avian species, including wild birds (8). Streptococci are ubiquitous in nature and commonly found in various poultry environments.

Lancefield group D *Streptococcus* spp. are commonly referred to as "fecal strep." Application of new bacteriologic techniques, especially DNA-DNA and DNA-rRNA hybridization, has led to the reclassification of most of the Lancefield group D streptococci to the *Enterococcus* spp. (36, 72).

History

Acute streptococcal infections of poultry were first described in chickens in 1902 (66) and 1908 (57) as apoplectiform septicemia. Chronic streptococcosis caused 50% mortality in a flock over a 4-month period (43) and was identified as the cause of mortality due to salpingitis and peritonitis in chickens (33). Streptococcosis in turkeys was reported as early as 1932 (83). Bacterial or vegetative endocarditis associated with streptococci was first reported in 1927 (71) and again in 1947 (52). A more extensive historical review of streptococcosis can be found in other references (37, 59, 68, 76).

Etiology

The genus Streptococcus is composed of Gram-positive, spherical bacteria occurring in singles, pairs, and short chains, which are nonmotile, nonspore-forming, facultative anaerobes. They are catalase negative and ferment a variety of sugars. *Streptococcus* spp., isolated from avian species and associated with disease, includes *S. zooepidemicus* (also referred to as *S. gallinarum*) from Lancefield antigenic serogroup type C, *S. bovis*, and *S. dysgalactiae*. Another species, *S. pleomorphus*, an obligate anaerobe in normal cecal contents of chickens, turkeys, and ducks, also has been described (1). *S. mutans*, a common bacterium in the human oral cavity, has been associated with septicemia and mortality in geese. Contaminated drinking water and poor-quality litter were possible predisposing factors (46).

Both experimental and naturally occurring infections of *S. bovis* causing acute septicemia and joint infections have been found in racing pigeons (24, 26). *S. dysgalactiae* has been cultured from broilers with cellulitis, a condition observed on the skin and subcutaneous tissue at processing (82). *Streptococcus* spp. has been isolated from lesions of osteomyelitis in turkeys, along with *E. coli* and *Staphylococcus* spp. (21).

Naturally occurring and experimental poultry infections resulting in bacterial endocarditis are commonly associated with streptococci and other bacteria. These include *S. zooepidemicus* (58), *S. gallinaceous* (15), *E. faecalis* (18, 33, 47), *E. faecium* (33, 73), *E. durans* (18, 33), *Staphylococcus aureus*, and *Pasteurella multocida* (41).

Pathobiology and Epidemiology

S. zooepidemicus occurs almost exclusively in mature chickens but has been documented as a cause of mortality in wild birds (47). Experimentally, rabbits, mice, turkeys, pigeons, ducks, and geese are susceptible.

Transmission of streptococci occurs most commonly via oral and aerosol routes. Transmission can occur, however, through skin lesions, especially in caged layers. Aerosol transmission of *S. zooepidemicus* results in acute septicemia in chickens. Incubation periods range from 1 day to several weeks, with 5–21 days being most common. Endocarditis occurs when septicemic streptococcal infection progresses to a subacute or chronic stage (48).

Clinical Signs

With *S. zooepidemicus* infections, clinical signs are typical of an acute septicemic infection and include lassitude, blood-stained tissue and feathers around the head, yellow droppings, emaciation, and pale combs and wattles. Cyanosis in the terminal stages also has been described (68). Mortality can range from low to 50%. Breeders or layers may have an egg production drop of as much as 15%.

Streptococcus spp. and *Staphylococcus aureus* have been isolated in cases of acute fibronopurulent conjunctivitis (14). In pigeons, *S. bovis* infection produced the acute onset of mortality with occasional lameness, inappetence, diarrhea, and the inability to fly (24).

Pathology

Gross Pathology

Gross lesions of *S. zooepidemicus* in acute disease are characterized by splenomegaly, hepatomegaly (with or without miliary to 1-cm red, tan, or white foci), enlarged kidneys, congestion of subcutaneous tissue, and peritonitis. Subcutaneous and pericardial fluid may appear serosanguineous. Blood-stained feathers around the mouth and head with blood coming from the mouth have been described (57, 68). In pigeons, congestion of the spleen and liver with accumulations of fluid around the pectoral muscles has been observed (24). In broilers, cellulitis involving the skin and subcutaneous tissues observed at processing have been associated with both *Escherichia coli* and *S. dysgalactiae* (82).

Microscopic Pathology

Microscopically, the liver has dilated sinusoids congested with red blood cells and increased heterophils. If foci are present grossly, there are multiple areas of necrosis and/or infarction with heterophil accumulation and thrombosis.

In experimental inoculations of pigeons with *S. bovis*, leptomeningitis and encephalitis with diffuse heterophil infiltration and perivascular cuffing are common (24).

Lesions of chronic streptococcal infections include fibrinous arthritis and/or tenosynovitis, osteomyelitis, salpingitis, fibrinous pericarditis and perihepatitis, necrotic myocarditis, and valvular endocarditis (Figure 23.2). Vegetative valvular lesions are usually yellow, white, or tan; are small; and have raised rough areas on the valvular surface (Figure 23.3). Valve lesions are found most consistently on the mitral valve, and less frequently are found on the aortic or right atrioventricular valve. Additional gross lesions associated with valvular endocarditis include enlarged, pale, flaccid heart; pale to hemorrhagic areas in the myocardium, especially at the base of the valves, below the affected valve, or apex of the heart; infarcts in the liver, spleen, or heart and, less commonly, infarcts in the lung, kidney, and brain. Infarcts can be light colored or hemorrhagic with sharp margins. In the liver, infarcts usually are located near the ventral and posterior margins and are well demarcated, extending beneath the capsule into the parenchyma (39) (Figure 23.4). Lesions of longer duration tend to have a sharp, narrow, lighter colored band just inside the infarct margin (48).

Microscopically, valvular lesions consist primarily of fibrin with bacteria, heterophils, macrophages, and fibroblasts. There is interstitial edema and infiltrative valvular distortion, with focal deposition of platelets and fibrin and subsequent microbial growth (42, 48). Cardiac histiocytes (Anichkov's

Figure 23.2. Streptococcus zooepidemicus infection showing perihepatitis and peritonitis. (M.C. Peckham)

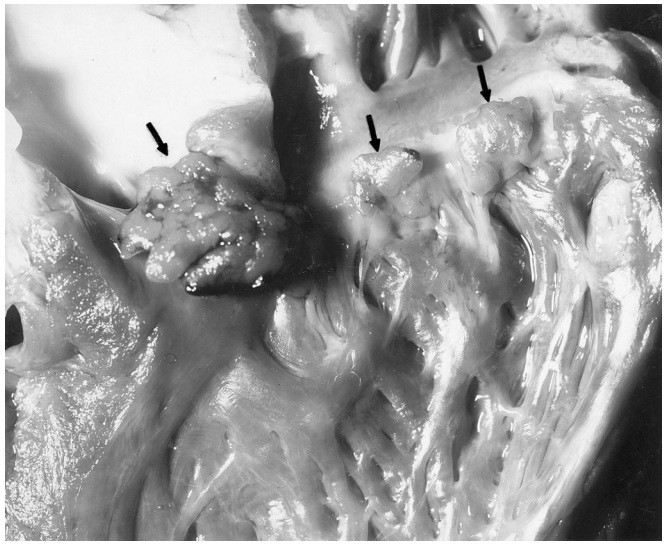

Figure 23.3. Bacterial endocarditis showing vegetations of mitral valve (arrows).

Figure 23.4. Bacterial endocarditis, showing infarcts of liver and myocardium.

myocytes) are numerous in the fibrous portion of the valve. Events leading to the vegetative valve lesion are (1) edema that loosens the valve surface epithelium, (2) fibrin deposition, and (3) bacterial attachment to the fibrin and colony formation. Other microscopic lesions related to endocarditis include cerebral vasculitis and infarcts, leptomeningitis, glomerulonephritis, and thrombosed pulmonary vessels (48). Cerebral lesions usually are confined to the corpus striatum. Focal granulomas can be found in virtually any tissue as a result of septic emboli. Liver infarcts are characterized by portal venous thrombosis followed by necrosis. Aggregates of bacteria are present throughout necrotic areas with a zone of heterophils just within the necrotic border, a characteristic feature of the lesion (Figure 23.5). Gram-positive bacterial colonies are observed readily in thrombosed vessels and within necrotic foci with tissue Gram stains.

Diagnosis

Isolation and Identification of Causative Agent

Demonstration of bacteria typical of streptococci in blood films (Figure 23.6) or impression smears of affected heart valves or lesions from birds with typical signs and lesions provide a presumptive diagnosis of streptococcosis.

Isolation of *S. zooepidemicus*, or any other Lancefield serogroup C streptococci from typical lesions in poultry with appropriate clinical signs, will confirm streptococcosis. Streptococci are readily isolated on blood agar. The lack of growth on

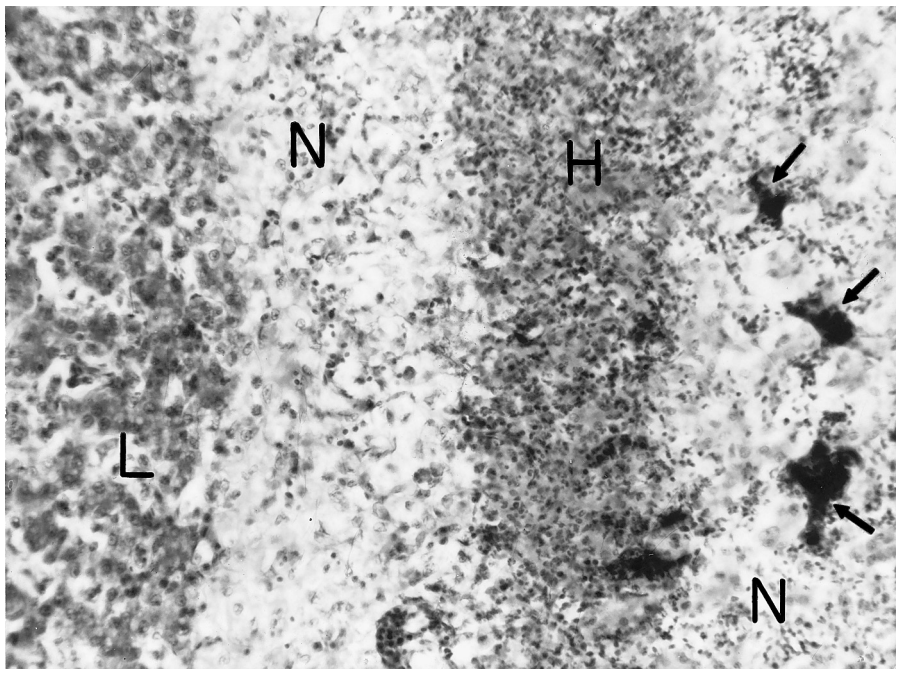

Figure 23.5. Margin of liver infarct associated with bacterial endocarditis, showing clumps of bacteria (arrows), necrotic area (N), zone of necrotic heterophils (H), and relatively normal liver tissue (L). H&E, ×400.

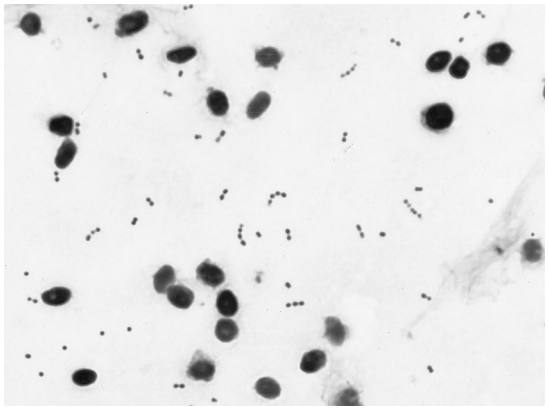

Figure 23.6. *Streptococcus zooepidemicus* in blood of naturally infected chicken. Gram, ×800. (L.A. Devriese)

MacConkey agar, different types of hemolysis, variable pyrrolidonylarylamidase (PYR) reaction, and variable reactivity on bile esculin agar help to differentiate the avian streptococci. The fermentation of mannitol, sorbitol, arabinose, sucrose, and raffinose are useful in the speciation of Lancefield serogroup D streptococci. *S. zooepidemicus* and other Lancefield serogroup C streptococci can be further differentiated using additional conventional tests or automated systems (44, 68, 84). Preferred tissues for culture include liver, spleen, blood, yolk, embryo fluids, or any suspected lesion area. Diagnosis of bacterial endocarditis can be made based on valvular vegetations with secondary infarcts of myocardium, liver, and/or spleen. In suspected cases, it is important to culture lesions to establish a definitive diagnosis and rule out other bacteria.

Serology

A rapid detection test by latex agglutination has been described for the identification of antigenic serogroup C streptococci in animals (44).

Differential Diagnosis

Differential diagnosis includes other bacterial septicemic diseases (e.g., staphylococcosis, colibacillosis, pasteurellosis, and erysipelas).

Treatment

Treatment includes the use of antibiotics such as penicillin, erythromycin, novobiocin, oxytetracycline, chlortetracycline, and tetracycline in acute and subacute infections. Clinically affected birds respond well early in the course of the disease. As the disease progresses within a flock, treatment efficacy decreases. Antibacterial susceptibility should be performed on bacterial isolates in any clinical cases of streptococcosis. There is no treatment for poultry with bacterial endocarditis.

In vitro susceptibility of *S. bovis* from pigeons has been demonstrated to the penicillins, macrolides, lincomycin, tetracyclines, chloramphenicol, and nitrofurans (25).

Prevention and control require reducing stress and preventing immunodepressive diseases and conditions. Proper cleaning and disinfection can reduce environmental streptococcal resident flora to minimize external exposure. The use of formaldehyde reduces the total count of *Streptococcus* spp. in hatchers by as much as 85.7%. Reduction of 7 log-10 bacterial counts also has been demonstrated compared with ozone use, which produced bacterial-count reduction of 4 log-10 (85).

Enterococcus

Introduction

The previous chapter on streptococcosis included streptococci in both Lancefield antigenic serogroups C and D. With the application of new bacteriologic techniques, especially DNA-DNA and DNA-rRNA hybridization, most of the Lancefield group D streptococci have been reclassified as *Enterococcus* spp. (36, 72).

Enterococci are ubiquitous in nature and commonly found in various poultry environments. *Enterococcus* spp. are considered normal microflora of the intestinal tract of poultry (27). Although they are found in the intestinal tract of chickens, comparatively few enterococci can be found in litter (54).

History

The history of *Enterococcus* spp. infections is minimal due to the inclusion of the Lancefield antigenic serogroup D in the Streptococcus genus. Early reports of "fecal strep" infections in poultry were reported as early as 1947 (68), 1956 (3), 1962 (41), and 1971 (48). Most of these reports included the enterococci in the Streptococcus species, which makes the confirmation of earlier reports difficult. Most of the earlier reported cases involved bacterial endocarditis, hepatic granulomas, and occasionally acute septicemia.

Figure 23.7. Enterococcus faecalis on a blood agar/MacConkey agar bi-plate demonstrating growth on blood agar and no growth on MacConkey agar containing crystal violet.

Etiology

The genus Enterococcus is composed of Gram-positive, spherical bacteria occurring in singles, pairs, and short chains. They are catalase negative and ferment sugars with a significant acid pH shift. Common avian isolates can be separated by their differential ability to ferment mannitol, sorbitol, L-arabinose, sucrose, and raffinose and by their lack of growth on MacConkey agar containing crystal violet (Figure 23.7, Table 23.3). *Enterococcus* spp. isolated from avian species and associated with disease includes *E. faecalis, E. faecium, E. durans, E. avium, E. hirae, and E. cecorum* from Lancefield antigenic serogroup D streptococci. In this chapter, *E. faecalis subsp. faecalis, E. faecalis subsp. liquefaciens*, and *E. faecalis subsp. zymogenes* will all be considered as *E. faecalis*. Other enterococci species also have been isolated from poultry (19, 22).

Bacterial endocarditis, commonly associated with both streptococci and enterococci, can be caused by many different bacteria in naturally occurring and experimental poultry infections. These include *E. faecalis* (27, 38, 45), *E. faecium* (75), *E. durans* (23), *E. hirae* (19), *Streptococcus zooepidemicus*, *Staphylococcus aureus*, and *Pasteurella multocida* (41). Of the enterococci isolated from naturally occurring infections, *E. faecalis* has been the most common isolate and the one most consistent in producing bacterial endocarditis in experimental infections via the intravenous route.

Table 23.3. Enterococcus differential fermentation characteristics and alkaline phosphatase activity (Alk Phos). *Enterococcus* does not grow on MacConkey agar containing crystal violet.

	Fermentation[1] of					
Species	**Mannitol**	**Sorbitol**	**L-arabinose**	**Sucrose**	**Raffinose**	**Alk Phos**
E. avium	+	+	+	+	-	–
E. cecorum[2]	d[3]	d	–	+	+	+
E. durans	–	–	–	–	–	–
E. faecalis	+	+	–	+	–	d
E. faecium	+	–	+	+	d	–
E. hirae	–	–	–	+	+	–

[1] + = ferments specific sugar, – = no fermentation of specific sugar

[2] *E. cecorum* - API 20 strep = 5672472, API rapid 32 strep = 2717 670 7110

[3] d = delayed

Pathobiology and Epidemiology

E. faecalis affects species of all ages; it is a serious disease occurring in embryos and young chicks from fecally contaminated eggs (3, 4). *E. faecium* has been identified as a cause of mortality in ducklings (75).

Transmission of enterococci occurs most commonly via oral and aerosol routes. However, transmission can occur through skin injuries, especially in caged layers. Most enterococci are pathogenic when administered intravenously. Aerosol transmission of *E. faecalis* results in acute septicemia in chickens (3). High mortality from acute septicemia and liver granulomas occur after experimental oral inoculation with *E. faecalis* (42). *E. faecalis* has been incriminated as the cause of loss of intestinal epithelium integrity allowing bacteria such as *Bacteroides* spp., *Catena bacterium* spp., *Eubacterium* spp., and *Streptococcus* spp. to produce liver granulomas in turkeys (65). These bacteria and *Proprionibacterium* spp., *Corynebacterium* spp., *Staphylococcus* spp., and *Lactobacillus* spp. have been isolated from turkey liver granulomas. Concurrent enteric infections, or any condition compromising the intestinal villous epithelium and allowing penetration of resident enterococci, can result in septicemia and/or bacterial endocarditis. Incubation periods range from 1 day to several weeks, with 5–21 days being most common.

Experimental bacterial endocarditis results from intravenous exposure. *E. faecalis* isolates and other species of enterococci from intestines of apparently normal birds can produce endocarditis (40, 63, 69, 70). Endocarditis can occur when a septicemic enterococcal infection progresses to a subacute or chronic stage (48).

Chicks experimentally inoculated with *E. faecalis* had higher retained yolk weights, higher total plasma protein levels, and decreased Newcastle disease antibody passive transfer (absorption) through infected yolk sacs (57).

Enterococcus spp. has been associated with brain necrosis and encephalomalacia in young chickens (2, 15, 20, 28). Some enterococci, however, have been demonstrated to have a beneficial effect on growth and feed efficiency (67) and are the subject of research as potential probiotics. *E. faecalis* has been reported to be a bacterial component of amyloid arthropathy in chickens (55, 56).

Clinical Signs

Enterococcus spp. in poultry can result in 2 distinct clinical forms of disease, acute and subacute/chronic. In the acute form, clinical signs are related to septicemia and include depression, lethargy, lassitude, pale combs and wattles, ruffled feathers, diarrhea, fine head tremors, and decrease or cessation of egg production. Often, only dead birds are found.

In the subacute/chronic form, depression, loss of body weight, lameness, and head tremors may be observed. Chickens experimentally inoculated intravenously with *E. faecalis* develop leukocytosis 2–3 days post inoculation; the highest values occur in birds that develop endocarditis (41). Heterophils predominate, along with a slight monocytosis. Body temperatures are elevated in birds with persistent bacteremia. Numbers of bacteria present in peripheral blood vary considerably. Clinically affected birds eventually die if not treated.

Egg transmission or fecal contamination of hatching eggs with enterococci may result in late embryo mortality and an increased number of chicks or poults unable to "pip" or penetrate through the shell at hatch (4). Overall bacterial contamination, including *Enterococci* spp., at the time of hatching can contribute to mortality of chicks early in life (73).

Pathology

Gross Pathology

Gross lesions of enterococci in acute disease are characterized by splenomegaly, hepatomegaly, enlarged kidneys, and congestion of subcutaneous tissue. Omphalitis and/or enlarged yolk sacs are observed in chicks or poults infected at hatching (4, 46, 74). Hepatomegaly, splenic necrosis, fibrinous pericarditis, perihepatitis, and airsacculitis were observed in ducks infected with *E. faecium* (63).

Lesions of chronic enterococcal infections include fibrinous arthritis and/or tenosynovitis, osteomyelitis, fibrinous pericarditis and perihepatitis, necrotic myocarditis, and valvular endocarditis. Vegetative valvular lesions are usually yellow, white, or tan; are small; and have raised rough areas on the valvular surface. Valve lesions are found most consistently on the mitral valve, and less frequently on the aortic or right atrioventricular valves. The changes are similar to those observed with *S. zooepidemicus* infection.

Additional gross lesions associated with valvular endocarditis include enlarged, pale, flaccid heart; pale to hemorrhagic areas in the myocardium, especially at the base of the valve, below the affected valve, or at the apex of the heart (48); infarcts in the liver, spleen, or heart; and, less commonly, infarcts in the lung, kidney, and brain. Infarcts can be light colored or hemorrhagic with sharp margins. In the liver, infarcts usually are located near the ventral and posterior margins and are well demarcated, extending beneath the capsule into the parenchyma (30). Lesions of longer duration tend to have a sharp, narrow, lighter colored band just inside the infarct margin (48).

Microscopic Pathology

Microscopically, the liver has dilated sinusoids congested with red blood cells and increased heterophils. If foci are present grossly, there are multiple areas of necrosis and/or infarction with heterophil accumulation and thrombosis. Splenomegaly is characterized by congestion and hyperplasia of cells in the mononuclear phagocytic system (42).

Microscopically, valvular lesions consist primarily of fibrin with bacteria, heterophils, macrophages, and fibroblasts. There is interstitial edema and infiltrative valvular distortion, with focal deposition of platelets and fibrin and subsequent microbial growth (41, 48). Cardiac histiocytes (Anichkov's myocytes) are numerous in the fibrous portion of the valve. Other microscopic lesions related to endocarditis include cerebral vasculitis and infarcts, leptomeningitis, glomerulonephritis,

and thrombosed pulmonary vessels (45). Cerebral lesions usually are confined to the corpus striatum. Focal granulomas can be found in virtually any tissue as a result of septic emboli. Liver infarcts are characterized by portal venous thrombosis followed by necrosis. Aggregates of bacteria are present throughout necrotic areas with a zone of heterophils just within the necrotic border; a characteristic feature of the lesion, Gram-positive bacterial colonies, are readily observed in thrombosed vessels and within necrotic foci with tissue Gram stains.

Diagnosis

Demonstration of bacteria typical of enterococci in blood films or impression smears of affected heart valves or lesions from birds with typical signs and lesions will provide a presumptive diagnosis of enterococcosis.

Isolation of *Enterococcus spp*. (without fecal contamination) from typical lesions in poultry with appropriate clinical signs will confirm enterococcosis. Enterococci are easily isolated using blood agar and MacConkey agar as primary isolation media (34, 84). There is a distinct lack of growth of the enterococci on MacConkey agar due to the presence of crystal violet in current formulations (Figure 23.7).

For contaminated specimens the addition of phenylethanol agar (PEA) to the standard battery of media provides selectivity for Gram-positive organisms. Presumptive identification of enterococci can be accomplished noting gamma (no) hemolysis on blood agar, black precipitate on bile esculin agar and a positive reaction on pyrrolidonyl-beta-naphthalamide (PYR) agar (58) (Figure 23.8).

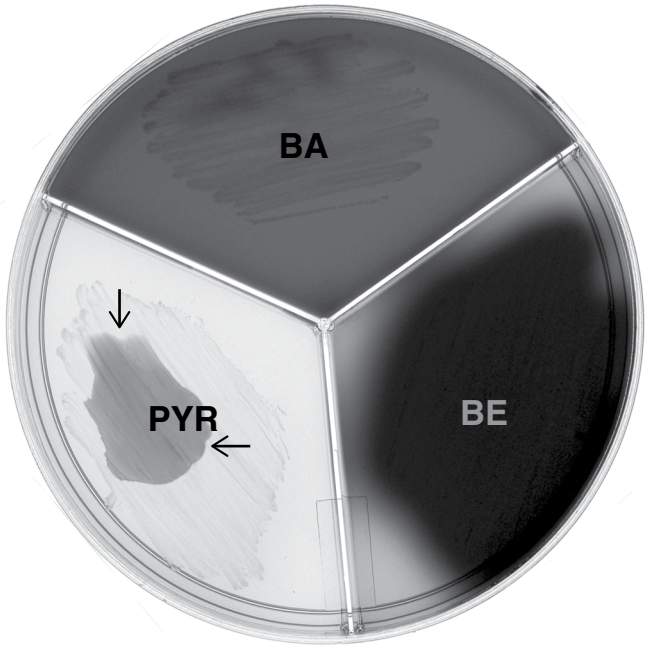

Figure 23.8. *Enterococcus faecalis* on a tri-plate with blood agar, bile esculin agar, and PYR agar. Note gamma (none) hemolysis on blood agar, black precipitate on bile esculin agar, and magenta color (arrows) which developed after addition of PYR reagent to 18- to 24-hour culture. This combination of reactions is indicative of group D *Enterococcus*. Speciation requires carbohydrate testing. See Table 23.3.

Further speciation can then be accomplished using differential fermentation of mannitol, sorbitol, arabinose, sucrose, or raffinose (Table 23.3). Numerous commercial systems are available for bacterial identification but care should be used in interpretation or acceptance of identifications. Suspected inaccuracies should always be backed up with secondary methods, often including conventional biochemical tests (45, 79, 81). Preferred tissues for culture include liver, spleen, blood, yolk, embryo fluids, or any suspected lesion area. Diagnosis of bacterial endocarditis can be made based on valvular vegetations with secondary infarcts of myocardium, liver, and/or spleen. In suspected cases, it is important to culture lesions to establish a definitive diagnosis and rule out other bacteria. Differential diagnosis includes other bacterial septicemic diseases (e.g., staphylococcosis, colibacillosis, pasteurellosis, and erysipelas).

Intervention Strategies

Prevention and control require reducing stress and preventing immunosuppressive diseases and conditions. Proper cleaning and disinfection can reduce environmental enterococcal resident flora to minimize external exposure.

Treatment

Treatment can include the use of antibiotics such as penicillin, erythromycin, novobiocin, oxytetracycline, chlortetracycline, or tetracycline in acute and subacute infections. Clinically affected birds respond well early in the course of the disease. As the disease progresses within a flock, treatment efficacy decreases.

Novobiocin has been found to be efficacious in ducks with *E. faecium* infection (74). Bacitracin in feed decreases the incidence of some strains of enterococci in young chickens (10). Certain enterococcus strains can develop resistance after exposure to antibiotics such as tylosin, but treatment with such antibiotics may not shift the overall number of resistant organisms (24).

Chickens fed certain growth-promoting antibiotics may develop greater numbers of *E. faecium* and *E. faecalis* populations in comparison to other enterococci (50, 51). Antimicrobial susceptibility should be performed on bacterial isolates in clinical cases of enterococcosis prior to the initiation of treatment.

Enterococci vary in their resistance and susceptibility to growth-promoting agents (35). Chickens fed 50 g of chlortetracycline compared to nonmedicated controls had diversity in antimicrobial resistance patterns suggesting that other factors are involved in antibiotic resistance acquisition besides feeding low-level antibiotics (16, 62, 64).

Environmental forces, feeding schedules, stress, and interactions between different genotypes and housing influence the response of chickens to enterococcal infections (49, 78). There is no treatment for poultry with bacterial endocarditis.

Species of Emerging Importance

Three species of enterococcus have emerged as pathogens isolated with increasing frequencies, so these have been addressed separately.

Enterococcus hirae

An enterococcus associated with growth depression in chickens was examined by Farrow and Collins in 1985 (38). They showed that the isolated organism, *Enterococcus faecium*, contained atypical strains. DNA-DNA hybridization studies showed that *Streptococcus durans* (now *E. durans*) and *E. faecium* are distinct species and that many strains previously classified as atypical *E. faecium* should be reclassified under a new species name of *Enterococcus hirae* sp nov. The proposed species showed biochemical characteristics which were between *E. faecium* and *E. durans* (38). *E. hirae* and *E. durans* have been reported to be in the small intestine until the chickens are 3–4 weeks old, whereas *E. faecalis* is more commonly associated with the gut flora of 1-day-old chicks (27).

DeVriese et al. found age differences in the ability *S. zooepidemicus* and *E. durans* to cause septicemia and endocarditis: Those infections were more limited to mature birds, where*as E. hirae* appeared to infect young chickens in which the most episodes of endocarditis were associated with the right side of the heart (27).

Chadfield et al. characterized several outbreaks of *E. hirae* in broiler flocks that demonstrated increased mortality due to septicemia and endocarditis (19). In subsequent work Chadfield et al. also were able to experimentally reproduce sepsis and endocarditis infections in 4-week-old chickens with both *S. gallinaceus* and *E. hirae* (17).

E. hirae infections can be difficult to detect. Typical post mortem lesions include septicemia and endocarditis. However, early infection and low mortality often accompany breaks caused by *E. hirae*. Several outbreaks were investigated using pulsed-field gel electrophoresis (PFGE) profiling. Clonality varied from those separated by only 2 bands to nonclonality. However, use of the combination of phenotypic and genotypic characterization confirmed the identity of *E. hirae* in all outbreaks (19).

A recent report documented osteomyelitis in the proximal femur of 3-week-old broilers that also suffered from valvular endocarditis and liver necrosis (53). Devriese et al. reported focal necrosis of the brain caused by *E. hirae* in young chicks (28).

Enterococcus durans

Streptococcus durans was originally documented in 1937. It was found in milk and dairy products in addition to the intestines of humans and other warm-blooded animals (12). DNA-DNA hybridization studies showed *S. durans* (now *Enterococcus durans*) and *Enterococcus faecium* as distinct species and that many strains previously classified as atypical *E. faecium* should be reclassified under a new species name of *Enterococcus hirae* sp nov. The proposed species show biochemical characteristics which are between *E. faecium* and *E. durans*, thus supporting all three as distinct and separate species from *E. faecium* (38).

A case report by Cardona et al. reported *E. durans* associated with bacteremia and *E. durans* was isolated from multiple organs and brains from the birds showing neural signs along with elevated mortality. Histological lesions included liver necrosis and brain stem and cerebellar malacia (15).

Abe et al. reported *Enterococcus durans* was isolated from the brain, liver, kidney, lungs, and spleen of 7- to 12-day old chicks that showed neurological signs or mortality. Histologically, malacic lesions were seen in the parenchyma of the brain stem and the cerebral hemisphere. Congestion and hemorrhage with capillary thrombosis were observed. Observation and isolation of *E. durans* from the malacic lesions in the brain stem and cerebral hemisphere suggest pathogenicity of the organism (2).

These enterococci can be identified by conventional biochemical testing but molecular methodology including several different PCRs has provided significant improvement in ease of identification and specificity (5, 32, 52). The application of DNA microarrays has led to the ability to distinguish not only species identifiers but also those for virulence and antibiotic resistance (13).

Enterococcus cecorum

Streptococcus cecorum, now called *Enterococcus cecorum*, was first isolated from chickens in 1983. Since then a few subsequent reports of this organism have been made, mostly as results of fecal surveys (27, 29, 30, 31, 77). However, reports of this organism as a disease agent in avian and chicken species began to surface around 2002. Bone lesions were referenced in this 2002 work with vertebral abscesses and osteomyelitis reported in the years since. Reports of *E. cecorum* in broilers and broiler breeders came out of Europe, Canada, and the United States. Weakness and lameness were observed along with mortality, which typically resulted from culling. Poor feed conversion and condemnations at processing were also observed (4).

Another report documented disease involving *Enterococcus cecorum* which was referred to as enterococcal vertebral osteoarthritis. Observations of male broiler breeder and broiler flocks made in North Carolina showed significant morbidity and mortality. In almost all cases *E. cecorum* was isolated in pure culture from spinal abscesses in flocks seen in North Carolina (61).

A case report by Armour et al. (6) documented similar lesions in several broiler and broiler breeder flocks in Georgia. Lameness with femoral osteomyelitis and septic arthritis of the hocks was observed. Posturing was commonly seen in these birds (Figure 23.9). Vertebral osteomyelitis of the thoracic vertebra was seen in the broiler breeders

Figure 23.9. A 49-day-old male broiler breeder displaying a characteristic posture associated with compression of the spinal cord. (N. Amour)

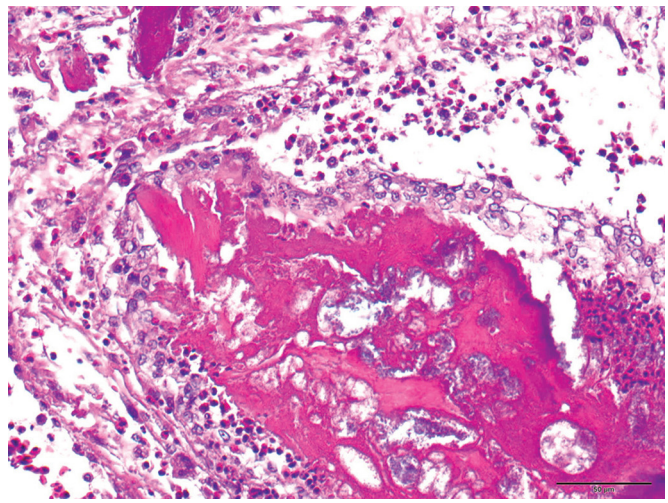

Figure 23.11. Granulomatous inflammation involving necrotic bone with intralesional bacteria, surrounded by multinucleated giant cells, osteoclasts and trans-migrating heterophils. (N. Amour)

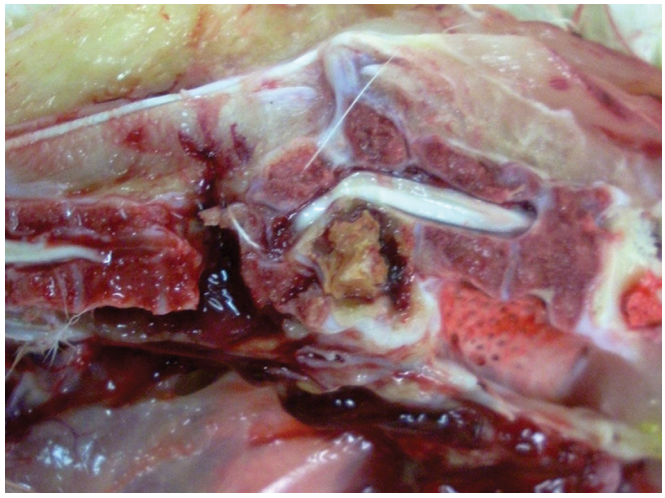

Figure 23.10. Vertebral osteomyelitis, with dorsal collapse of the vertebral column and spinal cord compression. (N. Amour)

(Figures 23.10 and 23.11). Males were affected more than females (6). Enterococcus cecorum was isolated from hock, femoral, and vertebral lesions. Other bacteria such as *Escherichia coli* and *Staphylococcus aureus* can cause similar lesions but none with the frequency and consistency of *E. cecorum*. The fecal-oral route appeared to be the primary means of exposure (9).

Onset of observable disease involving *E. cecorum* has been observed as early as 2 weeks of age with mortality of up to 7% beginning by 3–4 weeks of age. Males seem to be affected more than females. Compression of the spinal cord by narrowing of the caudal thoracic vertebrae and arthritis of the hock joints were also seen. Bacterial culture consistently yielded *E. cecorum* from almost all lesions.

The disease frequently occurs on subsequent placements. Prophylactic antibiotics initiated during the first week have been shown to be the only effective intervention. *E. cecorum* always increased mortality rates (23). *E. cecorum* also has presented as bacterial arthritis as evidenced by inflammation in hock, stifle, and coxofemoral joints with osteomyelitis in the femur and vertebral column (80, 86). Makrai et al. (60) reported that *Enterococcus cecorum* was isolated from multiple flocks of broiler breeder males between 5 and 13 weeks of age showing vertebral osteomyelitis and spondylolisthesis. The incidence of disease was reported to be between 8% and 30% with birds sitting with feet slightly raised (Figure 23.9).

Narrowing of the vertebral bodies was a frequent observation and histological evidence included sclerosis, infiltration with heterophils, tissue fibrosis, and increased osteoclast activity. Twenty-four samples were collected and *Enterococcus cecorum* was isolated from all. Biochemical and 16S rRNA gene sequencing confirmed the agent as *E. cecorum* (60).

Enterococcus cecorum isolates from control birds in Canada and Belgium in addition to case birds from Canada were tested by biochemical methods and partial 16S rRNA sequencing. The cecal isolates from the control birds appeared to have a diverse composition, whereas those arising from case studies appeared to be of a single major clonal line. Antimicrobial testing showed isolates from those cases showed lower susceptibilities than did the control isolates (19). The prevalence of reports from different areas indicates distribution is becoming worldwide (6, 7, 11, 20, 60, 80).

Erysipelas

Joseph M. Bricker and Y.M. Saif

Introduction

Definition and Synonyms

Erysipelas is a septicemic disease which generally occurs sporadically in various avian populations. It is worldwide in distribution and the infection and disease have been described in a wide variety of avian species, usually as an acute, fulminating infection of individuals. Erysipelas also affects a wide variety of mammalian species and has been reported in reptiles and amphibians. The etiologic agent of erysipelas is a small Gram-positive bacterium, *Erysipelothrix rhusiopathiae*, which also causes swine erysipelas and erysipeloid in humans. Although the disease is sporadic in poultry, endemic areas exist.

Economic Significance

Historically in birds, erysipelas has been primarily of economic importance as a disease of turkeys. Erysipelas not only causes death but frequently affects the fertility of the male. Further marketing losses may result from lack of finish, condemnation, or downgrading, resulting from postmortem evidence of septicemia. With the widespread artificial insemination of turkey hens, prevention of erysipelas has become a problem facing producers of turkey hatching eggs. With more confinement growing of turkeys, it has become a less important problem, except in endemic areas.

Though infrequent, economically significant outbreaks have occurred in other species including chickens and ducklings. Affected chicken flocks may suffer depression of egg production. Erysipelas has been reported in meat-type chickens including both breeders and broiler-type chickens. Additionally, *E. rhusiopathiae* has caused outbreaks of erysipelas in pheasants, ducks, geese, guinea fowl, chukars, grebes, and emus.

Public Health Significance

Erysipeloid in humans is considered an occupational disease particularly affecting fish handlers, butchers, kitchen workers, veterinarians, and animal caretakers, and may be a local or septicemic, and occasionally fatal, infection.

History

Knowledge of the organism and disease has been known in Europe since the late 19th century, although primarily as a disease of swine. Sporadic cases of infection were reported in various avian species prior to 1936 but Beaudette and Hudson (3) were the first to call attention to the economic significance of the disease in North American turkeys; other outbreaks were reported shortly thereafter. The disease is worldwide in distribution and of economic concern to turkey growers, particularly those located in endemic areas. The infection has been reported from time to time in 1 or small groups of other species of birds, including those housed in zoos.

Following the introduction of bacterins in the early 1950s and the availability of penicillin as a treatment, various programs of preventive vaccination and/or treatment were developed.

Etiology

Classification

Name and Synonyms

E. rhusiopathiae belongs to the family Lactobacillaceae. A second genomic species, *E. tonsillarum*, was described based on DNA homology studies with type strains of *E. rhusiopathiae* (64). Some investigators have provided evidence that there may be an additional distinct genomic species other than *E. rhusiopathiae* and *E. tonsillarum* (43, 65) or perhaps 2 additional distinct new species (69). Verbarg et al. (72) identified a new third genomic species with a proposed species name of *Erysipelothrix inopinata*. Only *E. rhusiopathiae* is considered the causative agent of erysipelas in avian species.

Morphology and Staining

The organism stains Gram-positive but tends to decolorize, a trait particularly noticeable in older cultures. *E. rhusiopathiae* is nonmotile, does not form spores, and does not stain acid-fast. The cellular morphology of the organism is variable. Cells taken from smooth colonies or isolated from the tissues of acutely infected birds are slender, straight, or slightly curved rods measuring 0.2–0.4 by 0.8–2.5 μm and may occur singly or in short chains. Organisms from older cultures or rough colonies are filamentous rods and may form masses that resemble mycelia. These filamentous rods usually appear somewhat thickened and may appear beaded following staining. The filamentous form begins to appear after several passages on artificial media. Both short rods and short filaments may be observed from a single colony (intermediate colony type). *E. tonsillarum* is morphologically indistinguishable from *E. rhusiopathiae*.

Growth Requirements

E. rhusiopathiae is facultatively anaerobic and grows readily, although sparsely, on ordinary culture media and moderately well in thioglycollate broth and various other broths containing serum and serum components. The addition of serum to broth media supports heavier growth with a powdery sediment forming after 24 hours. Protein hydrolysates, glucose, and certain detergents, such as Tween 80, also enhance growth. The organism grows especially well in deep stabs of semisolid medium prepared by adding 0.5% agar to tryptose phosphate broth. Feist et al. (20) described a medium that supported

high bacterial yields but was devoid of serum. Groschup and Timoney (24) indicated that higher cell densities were obtained with Feist medium than with horse serum-supplemented brain heart infusion broth. However, Sato et al. (50) reported higher bacterial yields with tryptic soy broth supplemented with 0.3% Tris and 0.1% Tween 80 than with Feist medium or 2 different supplemented heart infusion broths. Reduced oxygen or increased carbon dioxide (5%–10%) enhances growth, but neither is necessary to support growth.

E. rhusiopathiae grows in a temperature range from 4°C (slow growth) to 42°C, with an optimal range of 35°C–37°C. The optimal pH for growth is mildly alkaline, pH 7.4–7.8. Oleic acid and riboflavin have been reported as essential for growth. The organism does not form a pellicle.

Colony Morphology

Three different colony types have been described for *E. rhusiopathiae*. Smooth colonies are dewy, colorless to bluish gray, and of pinpoint size (0.5–0.8 mm) with smooth edges. Most strains of *E. rhusiopathiae* and organisms isolated directly from infected tissues form this colony type. Some strains, however, form rough colonies that consist of long, thickened filamentous rods. Rough colonies are opaque, flat, dry, and of pinhead size (1–2 mm) with irregular or lobed edges. The dissociation from smooth to rough colony type is described as intermediate colony type in which both short rods and short filaments may be identified. Most strains produce a narrow zone of alpha hemolysis in a medium containing 5%–10% horse or bovine blood after 2–3 days' incubation at 37°C in an atmosphere of 5%–10% carbon dioxide. A test tube brush type of growth (lateral radiating projections) occurs 48 hours post inoculation in gelatin stab culture incubated at 21°C.

Biochemical Properties

E. rhusiopathiae ferments galactose, dextrose, fructose, maltose, lactose, and levulose without gas production. *E. tonsillarum* differs in its ability to ferment sucrose (65); however, investigators have indicated that this property may not be unique to *E. tonsillarum* (43). Lead acetate agar or triple-sugar iron (TSI) agar is usually blackened, indicating hydrogen sulfide (H_2S) production, and xylose is occasionally fermented. Strains that do not produce H_2S have been isolated. Litmus milk occasionally is acidified slightly without coagulation. The organism is catalase negative, does not produce indole, does not reduce nitrites, is Voges-Proskauer and methyl red negative, does not hydrolyze esculin, and does not reduce 0.1% methylene blue. Of 3 methods used to measure acid production (chemical indicator, change in pH, and production of titratable acidity), the chemical indicator gives the most valid reproducible results.

Susceptibility to Chemical and Physical Agents

Disinfectants containing quarternary ammonium compounds, chlorine, phenolic compounds, or sodium hydroxide are effective against *E. rhusiopathiae*. However, it is important to note that these disinfectants are only effective when surfaces are thoroughly clean and devoid of any debris or particulate material. The organism is resistant to 0.001% crystal violet and 0.5% potassium tellurite and can grow in the presence of 0.1% sodium azide, characteristics which are useful for isolating the organism. *E. rhusiopathiae* is inactivated with 0.5% formalin.

E. rhusiopathiae is very resistant to desiccation and may survive the smoking and pickling processes used for processing meat and remain viable in frozen or chilled meat, dried blood, decaying carcasses, or fish meal. Apart from tissues, it is killed at 70°C in 5–10 minutes.

Although it has been suggested that the organism remained viable in soil and multiplied in alkaline soils during warm weather, Wood (77) reported that under experimental conditions, *E. rhusiopathiae* was inactivated at different rates in soil when parameters of temperature, pH, and organic matter content were tested. Temperature exerted the greatest effect on viability. Populations of the pathogen survived 35 days at 3°C and 2 days at 30°C. Organisms did not survive longer than 11–18 days under various conditions of organic matter content and pH.

Antigenic Structure and Toxins

Essentially all strains of *E. rhusiopathiae* possess at least one or more common antigen (22, 52, 63). These antigens are heat labile and consist of protein or a complex of protein, carbohydrate, and lipid (75). The cellular fatty acid profiles of several strains of *E. rhusiopathiae* and *E. tonsillarum* were determined, which demonstrated no differences between the two species (67). Schubert and Fiedler (53) investigated the murein component of the cell wall and determined that the murein belonged to the B1delta type. *E. rhusiopathiae* resembles mycobacteria in that it has a high lipid content in its cell wall (almost 30%). Similar to some Gram-negative bacteria, *E. rhusiopathiae* has a rather low hexosamine content but differs from them in having a limited complement of amino acids. *E. rhusiopathiae* produces no known toxins.

Strain Classification

Antigenicity

A serotype-based scheme using a heat-stable antigen (cell wall peptidoglycan) has been in use for many years to differentiate *E. rhusiopathiae* into serotypes. These antigens are extracted easily from the organism using acid or by autoclaving a washed whole-cell inactivated culture for 1 hour at 121°C. Determination of serotype is accomplished with a double-diffusion gel system using specific hyperimmune rabbit sera. The preferred system for serotyping *E. rhusiopathiae* isolates is a numerical system described by Kuscera (32). Using the numerical system, strains previously designated as types A or B now become types 1 and 2, respectively. Subtypes of some serotypes have been described (e.g., serotypes 1 and 2) and are designated by a number followed by a lowercase letter. Although 26 serotypes of *E. rhusiopathiae* have been described (2, 18), the identification of *E. tonsillarum* and possibly 2 other

strains as distinct species has led to a re-evaluation of the serotyping scheme. Lack of assay standardization among laboratories also has led to discrepancies with the interpretation of results. In one instance, a serotype 25 reference strain designated KS20A was originally named serotype 23. The majority of *E. rhusiopathiae* strains isolated from poultry fall into 3 major serotypes: types 1 (both subtypes 1a and 1b) and 2 and 5 (16, 17, 19, 78).

With the development of molecular typing methods, the practical use of the serological-based method is primarily confined to research because serology is laborious and requires a sufficient supply of serotype-specific antisera.

Immunogenicity or Protective Characteristics

Galan and Timoney (22) described a 64,000- to 66,000-MW protein gene, which was cloned and expressed as a fusion protein in a heterologous vector. Groschup et al. (23) demonstrated that a 64,000- to 66,000-MW protein was protective for mice. Makino et al. (35) also cloned this gene and designated the expressed protein as surface protein A (SpaA). SpaA consists of a 160-residue C-terminal repeat containing 8 repeats of 20 and 19 amino acids. Each repeat begins with the dipeptide GW, which appears to bind the protein to the cell surface (37). The N-terminal half of the protein is highly variable and is involved in immunoprotection. Nagai et al. (39) developed a new strain-typing method that targets the hypervariable region of SpaA. Shimoji et al. (61) described a protein designated SpaA.1 whose sequence was different from SpaA at the C-terminal region and at residues 426 and 435. Monoclonal antibodies reactive to the protective antigen have been described (30, 35, 51).

Recently, To and Nagai (71) described 2 additional Spa antigens, SpaB and SpaC, which they noted were specific for certain somatic serotypes of *E. rhusiopathiae*. Additionally, Ingebritson et al. (28) described the association of several Spa types with serotype and their role in protection following challenge. Some strains evaluated contained more than one Spa type. These studies were conducted in mice with *Erysipelothrix* isolates obtained from non-avian species. Additional studies will be needed to provide clarity of the role of the Spa types and protective immunity in avian erysipelas.

Additionally, Shimoji et al. (56) identified 2 adhesive surface proteins designated RspA and RspB. Both proteins were present in surface extracts of *E. rhusiopathiae* and in culture supernatants. Recombinant RspA, expressed in *E. coli* as a fusion protein, induced partial protection in mice following challenge.

Genetic or Molecular

Methodologies including molecular and genetic techniques are replacing the current serotype-based classification scheme of *Erysipelothrix* spp., but the comparison between the 2 approaches is not clear cut. Using DNA-DNA hybridization Takahashi et al. (65) reported that strains of serotypes 3, 7, 10, 14, 20, 22, and 23 are *E. tonsillarum* and that strains of *E. rhusiopathiae* belong to serotypes 1, 2, 4, 5, 6, 8, 9, 11, 12, 15, 16, 17, 19, and 21 and type N. Strains not possessing a type-specific antigen are designated type N. Strains belonging to serotypes 13 and 18 exhibited low levels of DNA homology with *E. rhusiopathiae* and *E. tonsillarum*, and the investigators suggested that each of these 2 serotypes possibly constitute a distinct genomic species. The classification of strains belonging to serotypes 24, 25, and 26 were not reported in this study. More recently, Takahashi et al. (68), using DNA-DNA hybridization experiments, identified *Erysipelothrix* strains of the same serotype, particularly seroypes 3, 15, and 16, that could be classified as *E. rhusiopathiae* or *E. tonsillarum*. They also proposed a reorganization of the taxonomic classification within *Erysipelothrix* species referring to *E. rhusiopathiae*, *E. tonsillarum*, Other sp.-1, Other sp.-2, and Other sp.-3.

Based on use of a multiplex real-time PCR assay, Pal et al. (45) reported a classification for their serotype 23 reference strain as *E. rhusiopathiae* and for their serotype 24 and serotype 26 reference strains as *E. tonsillarum*. These investigators also refer to serotype 13 as *Erysipelothrix* sp. Strain 1 and serotype 18 as *Erysipelothrix* sp. Strain 2. Using randomly amplified polymorphic DNA (RAPD) analysis, Okatani et al. (42) determined that 2 strains belonging to serotypes 15 and 16 had the RAPD pattern of *E. tonsillarum*. Furthermore, a serotype 10 strain had the RAPD profile of *E. rhusiopathiae*. Ribotyping of the 16S rRNA genes of *Erysipelothrix* strains revealed that several strains with the same serotype could belong to either genomic species (2). Kiuchi et al. (31) reported that the nucleotide sequences of 16S rRNA from *E. rhusiopathiae* and *E. tonsillarum* had 99.8% homology. A rapid typing method using automated ribotyping has been described (43).

Chooromoney et al. (12) analyzed strains of *Erysipelothrix* spp. by multilocus enzyme electrophoresis and indicated that serotyping was unreliable for epidemiologic studies, although serotype analysis was useful when 1 electrophoretic type contained multiple serotypes or subtypes or for strains isolated from different species and of varying virulence. Bernath et al. (4) evaluated the protein profiles of 12 strains of *E. rhusiopathiae* using polyacrylamide electrophoresis (SDS-PAGE) and autoradiography and found no significant correlation between serotype and percentages of common proteins of identical molecular weight.

Further clarity is needed to ascertain the relationships between molecular characterization, serotype, genomic species, immunogenicity, and the ability to cause disease in avian species.

Pathogenicity

There is no reported correlation between serologic grouping and the biochemical pattern of strains of *E. rhusiopathiae* isolated from birds and production of the septicemic, urticarial, or endocardial form of erysipelas or of the carrier state (6).

Virulence Factors

Enzymes

The enzyme hyaluronidase initially was thought to be involved in the virulence of *E. rhusiopathiae*, but studies in mice

revealed no association with hyaluronidase production and the pathogenicity of a particular strain (55). Neuraminidase, however, appears to correlate better with the virulence of *E. rhusiopathiae* isolates. This enzyme is produced during logarithmic growth, and the amount of enzyme activity is lower in strains of lower virulence or avirulent strains compared with highly virulent isolates. No apparent relationship exists, however, between the amount of neuraminidase activity and serotype. Abrashev and Orozova (1) identified that large glycoproteins were better inducers of neuraminidase production in cultures of *E. rhusiopathiae*. Using a peanut lectin hemagglutination assay, Wang et al. (74) evaluated neuraminidase production by a variety of *E. rhusiopathiae* isolates. Media, incubation conditions, and pH were evaluated on enzyme production, with medium and pH exhibiting the main influences. Neuraminidase was not produced by *E. tonsillarum* strains. Tesh and Wood (70) reported that the enzyme coagulase also was produced by strains of *E. rhusiopathiae*.

Other Factors

Lachmann and Deicher (33) inferred the presence of a capsule following their discovery of a 14,000– to 22,000-MW surface polysaccharide. Shimoji et al. (57) demonstrated a capsule using transmission electron microscopy, which showed polar thickening on some *E. rhusiopathiae* strains. Other investigators have demonstrated, at least in part, that the virulence of *E. rhusiopathiae* for mice was associated with the presence of a capsule (57). Shimoji et al. (58) discovered that murine macrophages were able to phagocytose 3- to 4-fold more avirulent acapsular bacteria than virulent bacteria in the presence of normal serum.

Partridge et al. (46) cloned and characterized a bacterial stress protein designated DnaK, which was highly expressed in *E. rhusiopathiae*. A heat shock gene homolog designated *dnaJ*, located immediately 3' to the *dnaK* gene, was also cloned (47).

Makino et al. (36) reported cloning a gene from *E. rhusiopathiae*, which encoded a 16,000-MW hemolysin. A review of virulence factors of *E. rhusiopathiae* has been compiled (62).

Pathobiology and Epidemiology

Incidence and Distribution

E. rhusiopathiae is worldwide in distribution and its adaptiveness is indicated by its ability to infect a wide variety of vertebrate species. It has been isolated from the tissues of birds, mammals, reptiles, and amphibians, as well as the surface slime of fish (21, 29, 40, 41).

Outbreaks of erysipelas in poultry occur sporadically, although locations exist in the world where the disease is endemic. Although the disease in turkeys has been reported more frequently among males than females, there is no evidence of differing susceptibility between sexes. Based on field observations it is suggested that the portal of entry (skin) is breached more frequently in the male, but the incidence in hens may increase due to artificial insemination and frequent handling of females.

Natural and Experimental Hosts

The organism has been isolated in nature from a wide variety of both birds and mammals. In avian species, it appears that the susceptibilities of various populations differ. Genetic resistance may play a role in susceptibility to disease based on findings of an outbreak in turkeys with different genetic backgrounds (48). Though several species have been used as experimental hosts (pigeon, turkey, chicken, budgerigar, mouse, and rat), turkeys, chickens, and mice are the hosts most commonly used with avian erysipelas. For more information on additional species affected by erysipelas, please refer to the 12th edition of *Diseases of Poultry*.

Age of Host Commonly Affected

Under field conditions, the disease is most commonly reported in older birds, though *E. rhusiopathiae* is pathogenic for turkeys of any age or sex. Hollifield et al. (26) reported erysipelas in 2- to 4-day-old turkey poults following toe trimming at a hatchery. In addition to turkeys, other avian species are susceptible to infection with *E. rhusiopathiae*, both experimentally and under field conditions, and serious losses have been reported in chickens, ducks, and geese following naturally occurring outbreaks of the disease. In older chickens, however, septicemia could be produced only by intrapalpebral or subconjunctival installation of the pathogen along with injury to that tissue. Administration of hydrocortisone not only increased susceptibility to *E. rhusiopathiae* but shortened the course of infection and increased mortality, thus appearing to increase pathogenicity. Shibatani et al. (54) were able to induce septicemia in 3-week-old chickens using an *E. rhusiopathiae* strain previously isolated from an outbreak of erysipelas in chicken layers.

Transmission, Carriers, and Vectors

The actual portal of entry and pathogenesis of *E. rhusiopathiae* infection in birds have not been definitely established, although contaminated material as the source of infection and entry through breaks in the mucous membranes or skin are the most frequent precursors. Fishmeal and fish in general have been identified as probable sources of infection for avian species. Cousquer (15) reported an outbreak of erysipelas in racing pigeons after ingestion of composted waste. Cannibalism and fighting among birds apparently result in increased losses. Permitting the carcasses of infected dead birds to remain on the premises to be picked at or eaten by penmates also increases the spread and increases losses at unpredictable rates. Although it has been reported that the organism can survive in soil and that soil may serve as a source of the organism, current evidence indicates that soil serves only as a temporary reservoir for the organism. There is no evidence of vertical or egg transmission of *E. rhusiopathiae* (38).

Infection and disease can be produced in turkeys inoculated orally with chicken embryo yolk-propagated organisms or

when allowed to feed on viscera of turkeys that died from erysipelas. Broth cultures instilled orally, intranasally, or into the conjunctival sac (without damaging the membrane) have not been shown to be infectious. Corstvet (14) and Bricker and Saif (9) found that subcutaneous (SC) inoculation of virulent cultures resulted in local multiplication followed by septicemia, with 80%–100% mortality in susceptible turkeys. Parenteral injection of most avian strains of the organism regularly kills mice (*Mus musculus*), pigeons, and turkeys, but guinea pigs and chickens usually survive. Takahashi et al. (66) reported that none of 14 *E. tonsillarum* strains tested induced any signs of disease or lesions when inoculated intramuscularly (IM) into white leghorn chickens and suggested that *E. tonsillarum* should not be considered to be a potential pathogen for chickens.

It is of interest to note that difficulties have been encountered with reproducing consistent mortality experimentally with *E. rhusiopathiae* isolates of avian origin. Reducing the number of passages on artificial media to an absolute minimum appears essential to maintaining virulence of the organism. Boyer and Brown (7) maintained virulence of an *E. rhusiopathiae* strain by storing infected liver at 4°C, which served as a source of the organism for further bird passage.

A small proportion of turkeys exposed to *E. rhusiopathiae* naturally or experimentally may become asymptomatic carriers. The number of organisms used to challenge turkeys, route of inoculation (oral or parenteral), administration of antibiotics, time after vaccination and challenge, and age of the turkey apparently do not influence this carrier state. Isolations of *E. rhusiopathiae* from carriers are most frequent from cecal tonsils, liver, large intestine, heart, and blood. Xu et al. (78) reported a total of 95 isolates obtained from the pharynx of healthy chickens, ducks, and geese.

The role of vectors in transmission of erysipelas is still unclear. Although the stable fly, horsefly, mosquito, and other biting flies have been implicated in mechanical transmission of *E. rhusiopathiae*, Chirico et al. (11) indicated that the poultry red mite, *Dermanyssus gallinae*, can act as a reservoir for *E. rhusiopathiae* and isolated *E. rhusiopathiae* from the integument as well as the interior of the mite. Recent research has supported this concept (19). However, under experimental conditions, Brännström et al. (8) were unable to establish transmission of *E. rhusiopathiae* with *D. gallinae*.

Incubation Period

In naturally occurring outbreaks, the incubation period cannot be readily ascertained. Experimental SC inoculation of turkeys with 10^4–10^6 organisms usually kills most of the birds in 44–70 hours; a few may die after 96–120 hours. With oral exposure, signs of disease generally occur 2–3 days later than with SC inoculation, and with a lower death rate. Occasionally, a turkey dies 2–3 weeks after oral exposure. A SC inoculum of 10^2, instead of 10^4 or 10^6, organisms delays clinical signs by about 24 hours. The incubation period does not seem to vary among turkeys 7, 12, 16, and 20 weeks of age or between sexes.

Clinical Signs

In turkey flocks, outbreaks usually start suddenly, with losses of 1 to several birds; owners may suspect that deaths are from poisoning, stampede injuries, or predators. A few droopy birds (especially toms) may be noticed, but these individuals are usually easily aroused. Just prior to death, some birds may be very droopy, with unsteady gait. Some may have cutaneous lesions; affected males may have swollen purplish, turgid snoods (fleshy tubular appendage on dorsal surface of head). Some turkeys are now "desnooded" shortly after hatching; as a result, such lesions are infrequently seen. Gradual emaciation, weakness, and signs of anemia occur in some cases of which endocarditis is the cause of death; other turkeys with vegetations (especially vaccinated birds) may die suddenly without signs, probably as a result of emboli. Sudden losses of hens with peritonitis, perineal congestion, and skin discoloration 4–5 days after artificial insemination have been reported.

The main clinical signs in chickens are general weakness, depression, diarrhea, and sudden death. In laying chickens, egg production may be decreased. Affected ducks, geese, pheasant, and quail generally are depressed, have diarrhea, and die suddenly.

Morbidity and Mortality

Mortality rates vary among different avian species. Morbidity and mortality are frequently about the same in unvaccinated flocks of turkeys and other species of poultry because most sick birds die. These parameters also depend on whether prior immunization or early treatment was administered. In immunized flocks some birds may be depressed and recover. The pattern of morbidity and mortality may range from sickness or death of occasional birds in good condition to sudden loss of several within 24 hours. Mortality can range from much less than 1% to as high as 25%–50% of a given group, although adjacent groups may not be affected.

Pathology

Gross Pathology

In naturally occurring outbreaks, the lesions are suggestive of a generalized septicemia, and the following lesions have been observed in different outbreaks in turkeys. There is generalized congestion; degeneration of fat on the anterior edge of the thigh; degeneration and hemorrhage in pericardial fat; petechial hemorrhage in abdominal fat; hemorrhage in heart muscle; and a friable, enlarged, and possibly mottled liver, spleen, and usually kidney. Other gross lesions may be fibrinopurulent exudate in joints and pericardial sac, fibrin plaques on heart muscle, thickening of the proventriculus and gizzard wall with ulceration, small yellow nodules in ceca, catarrhal or sanguinocatarrhal enteritis, vegetative endocarditis, dark crusty skin lesions, a turgid irregular reddish purple snood in toms, hydropericardium, and distended visceral blood vessels. Other lesions noted with varying frequency in field outbreaks are diffuse skin reddening and a dirty brick-red muscle color. Some birds that die have no lesions other than slight catarrhal enteritis and petechiae in the heart fat.

In experimental infections, some of the lesions observed in naturally occurring outbreaks are not uncommon. Endocarditis, except in vaccinated birds, is rare in experimentally infected birds. In some field cases, and in birds vaccinated twice or more with bacterin and intravenously challenged, congestive heart failure with vegetations of the atrioventricular valves (sometimes extending as much as 7 cm into the aorta) have been found. Asymptomatic carrier turkeys are usually free of gross lesions.

In ducks, geese, and pheasants, lesions are similar to those observed in other avian species, with the addition of dark congested areas in the foot webs of ducks.

Microscopic Pathology

Generally, the histopathologic features of acute erysipelas in turkeys reflect rather closely the observed gross findings, and specific cellular alterations are those expected in septicemic infections (5). Vascular changes dominate the histopathologic picture, with generalized engorgement of blood vessels and sinusoidal channels in virtually all organs. Although there may be a strong central (cardiac or vasomotor) basis for vascular congestion, there is also evidence of direct vascular damage. Intravascular aggregations of bacteria accompanied by fibrin thrombi are frequent in capillaries, sinusoids, and venules. Overt hyalinization of walls of affected vessels is not uncommon. Edema and hemorrhage, especially prominent in lung and heart (Figure 23.12), are further evidence of severe vascular damage. In addition, rounding up of vascular endothelial cells or mononuclear phagocytic system (MPS) cells of sinusoids is a consistent histologic finding, and engulfed bacteria are demonstrated readily in MPS cells in the liver and spleen.

Damage to parenchymal cells is generalized in acute erysipelas and is especially obvious in liver, spleen, and kidney. Degenerative changes in hepatic cells vary from cloudy swelling with cellular dissociation to overt coagulative necrosis. Focal or massive necrosis apparently related to thrombosis of major portal vessels is seen occasionally, but diffuse degenerative changes are much more common (Figure 23.13). In spleen, the earliest observable change is necrosis and lysis of lymphoid elements. This progresses to nearly total loss of lymphocytes, with the hyalinization of sheathed arteries of white pulp and surrounding reticular elements (Figure 23.14). The epithelium of proximal tubules undergoes early degenerative change in affected turkeys. Swelling, dissociation, and separation from the basement membrane are frequent and prominent changes that are seen in renal epithelial cells; overt coagulative necrosis is rare. It is not unusual to find degenerative changes or necrosis in a variety of other organs such as

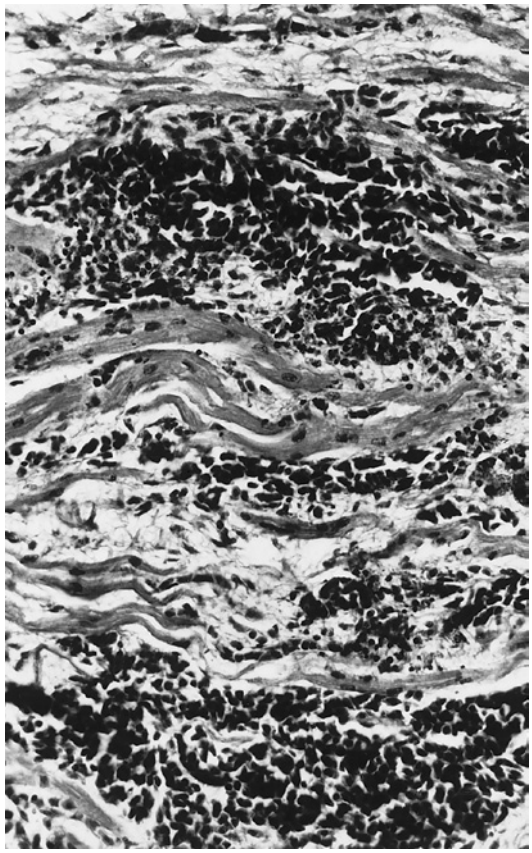

Figure 23.12. Acute erysipelas, turkey heart. Interstitial hemorrhages and separation of myocardial fibers (edema). H&E, ×100.

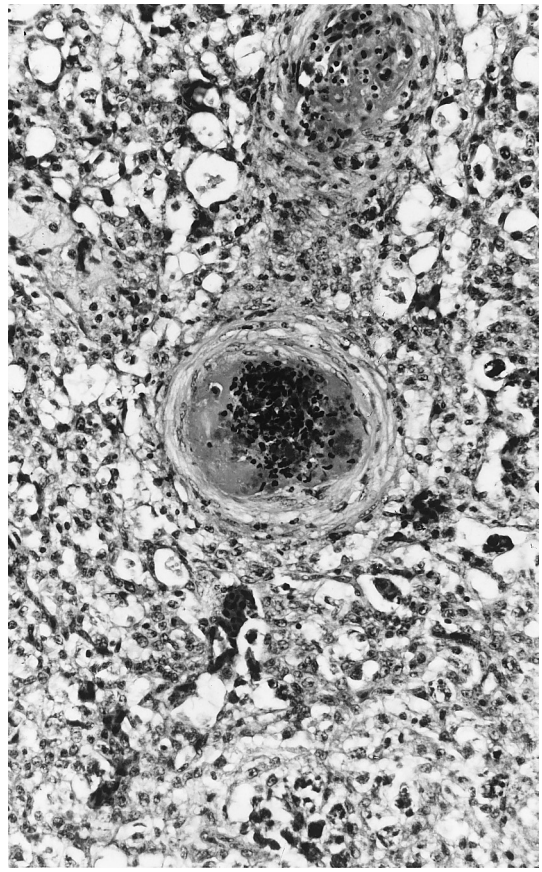

Figure 23.13. Acute erysipelas, turkey liver. Fibrin thrombus containing bacterial aggregates in the central portal blood vessel. Severe vacuolar degeneration of surrounding hepatocytes and several large basophilic sinusoidal, reticuloendothelial (Kupffer) cells are evident. H&E, ×100.

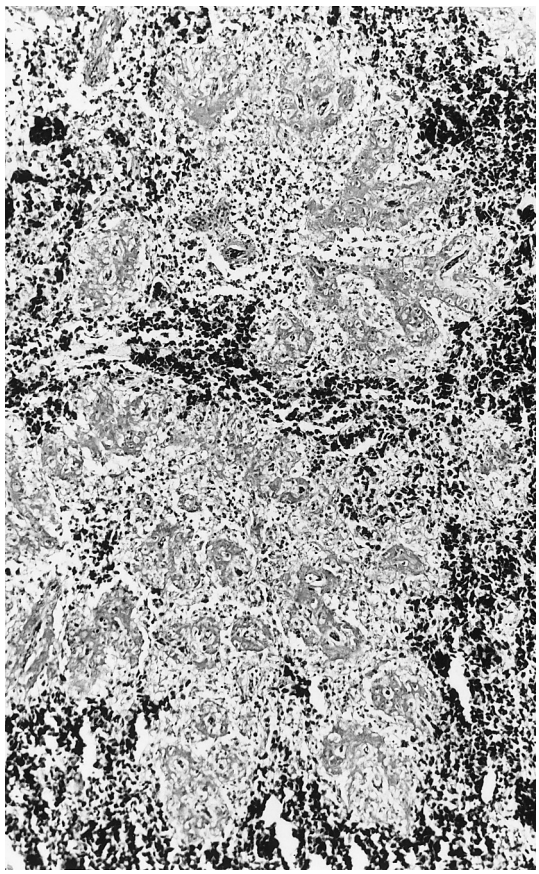

Figure 23.14. Acute erysipelas, turkey spleen. Hyalonized sheathed arterioles within 2 malpighian corpuscles and nearly tortal depletion of lymphocytes are evident. Surrounding sinusoids are engorged with erythrocytes. H&E. ×100.

lung, heart, pancreas, gastrointestinal tract, skeletal muscle, and skin. However, these changes are seldom as remarkable in frequency or magnitude as parenchymatous changes in liver, spleen, and kidney. Regardless of the site of involvement, hemorrhage and fibrin deposition frequently accompany parenchymatous necrosis.

The cellular inflammatory component of peracute or acute erysipelas lesions is minimal. In scarified skin of turkeys infected by this route, there may be extensive heterophil infiltration, congestion, edema, and necrosis. Cellular inflammatory response as judged from examination of field cases is more prominent in turkeys with subacute or chronic disease. Heterophil and mononuclear leukocytic infiltration as well as proliferation of MPS cells can be found around necrotizing lesions in liver and spleen as well as in heart valves and synovial membranes of joints. The pathology of experimentally induced subacute or chronic erysipelas in turkeys has not been reported.

The histopathologic alterations in acute erysipelas outbreaks in chickens are very similar to those described in turkeys. Shibatani et al. (54) described disseminated intravascular coagulation in chickens inoculated experimentally. These investigators also observed depletion of lymphocytes in the cloacal bursa (bursa of Fabricius) and thymus and suggested that thromboplastin released from these tissues following depletion played a role in disseminated intravascular coagulation.

Pathogenesis of the Infectious Process

The precise mechanism(s) by which the organism causes disease is still not very well understood. *E. rhusiopathiae* appears to be able to gain access to the body by the oral route or by entry through breaks in the skin. In swine, *E. rhusiopathiae* can induce disease by gaining access through the palatine tonsils or other pharyngeal lymphoid tissue. This mode of pathogenesis is probable for turkeys based on experimental evidence with orally administered challenge cultures and live vaccines (9).

Although not completely clear, the pathogenicity of different isolates of *E. rhusiopathiae* may be related to their ability to produce various virulence factors to help them to resist or survive phagocytosis and to avoid host defenses. These factors include specific attachment factors (capsule or adhesins), enzymes such as neuraminidase and coagulase, and stress proteins. The expression of high levels of a stress protein could allow the organism to resist oxidation and survive the low pH environment of the phagolysosome following phagocytosis. More studies are needed to fully elucidate the pathogenesis of *E. rhusiopathiae* in avian species.

Immunity

Active Immunity

Birds recovered from acute infections have a high degree of resistance to re-infection and death. The use of bacterins prevents disease under both experimental and field conditions. Bacterin in conjunction with penicillin at the beginning of an outbreak usually controls losses. Long-lasting immunity is not produced by only 1 bacterin injection in turkeys. The immune response is more effective from 2 or more doses at intervals of at least 2–4 weeks. Experiments with 4– to 7-week-old turkeys have shown that protective immunity begins to decline between 4 and 5 weeks post vaccination.

Administration of a live erysipelas vaccine, either subcutaneous (SC) or through the drinking water, also has been shown to induce some protection following challenge. Bricker and Saif (9) reported an effective level of protection in turkeys vaccinated through the drinking water with a live serotype 1a strain of *E. rhusiopathiae*, followed by challenge with the homologous serotype. Two vaccine doses administered 2–3 weeks apart were necessary to induce a sufficient protective response that lasted at least 3 weeks following administration of the second vaccine dose. Administration of this live vaccine directly into the esophagus of turkeys did not induce a protective immune response. It is speculated that lymphoid tissue in the pharyngeal region plays a role in the induction of an immune response to organisms introduced by the drinking water route.

Passive Immunity

Treatment with swine erysipelas antiserum (horse origin) alone is said to be of some value if administered very early, but it is not practical because of the expense and the lack of uniform efficacy. A combination of both antiserum and penicillin has been used successfully in ducks.

Diagnosis

Isolation and Identification of Causative Agent

Because gross lesions of dead birds indicate septicemia, diagnosis depends on the demonstration and identification of *E. rhusiopathiae*. Rapid presumptive diagnosis is provided by the presence in liver, spleen, heart blood, or bone marrow smears of clumps and segregated Gram-positive, beaded, slender, and pleomorphic rods. Particularly helpful with decomposed specimens are bone marrow culture and smear. Viemmas et al. (73) described the use of immunoperoxidase staining to detect *E. rhusiopathiae* from the tissues of experimentally infected turkeys.

Isolation of *E. rhusiopathiae* from sick birds that are killed and then cultured is neither as easy nor as frequently positive as culturing from birds dead of the disease. Detecting the organism from a carrier requires multiple samples from various tissues. Isolation from endocardial tissues is facilitated by finely mincing before inoculating enrichment broth. With birds dead from the infection, however, liver, spleen, or bone marrow will suffice. Useful inhibitory media are the sodium azide-crystal violet medium described by Packer (44) and the tryptose phosphate broth medium with 5% horse serum plus kanamycin, neomycin, vancomycin, and novobiocin described by Wood (76). These media are the most satisfactory, although they do not completely prevent growth of other organisms (particularly with samples of intestinal contents) and may inhibit growth of some strains of *E. rhusiopathiae*. Shimoji et al. (59) described a selective media containing tryptic soy broth, ethidium bromide, and sodium azide. For primary isolation, recovery is favored by inoculating biplates containing 5% blood agar and Packer's medium followed by incubation in an atmosphere of 5%–10% CO_2 or reduced oxygen. Ordinary atmosphere is suitable after a few passages on artificial media. Typical colonies composed of Gram-positive rods are selected and placed in TSI medium or Kligler's lead acetate medium and incubated for 24 hours at 37°C. An excellent presumptive test for *E. rhusiopathiae* is a blackening of the medium (due to H_2S production) before there is a very noticeable change in the medium color.

Makino et al. (34) described a direct, rapid, sensitive test for detection of both *E. rhusiopathiae* and *E. tonsillarum* using the polymerase chain reaction methodology. Using primers to amplify a 937-bp DNA region from *E. rhusiopathiae*, Shimoji et al. (59) designed a broth cultivation-PCR technique for rapid diagnosis of erysipelas. In a report comparing detection methods, Fidalgo et al. (21) indicated that a combination of cultural and PCR methodologies was optimal. Takeshi et al. (69) performed a PCR test using 4 specific primer sets for the identification of *E. rhusiopathiae*, *E. tonsillarum*, and strains representing serotypes 13 and 18. Hennig et al. (25) used DNA obtained from histochemically processed liver tissue to diagnose erysipelas in ring-necked pheasants by the PCR technique.

In the past, mice were used for protection tests and diagnostics but currently such procedures are not recommended. *E. rhusiopathiae* may be detected in tissues using specific fluorescein-labeled antibody if the reagent is available.

Sudden losses of adolescent turkeys in good flesh but with septicemic lesions and intramuscular (IM) and subpleural ecchymotic and suffusion hemorrhages, suggest erysipelas. Also significant is a marked hemorrhagic condition of the skin, facial tissues, and muscular tissues of the breast. In many cases, predominant losses will be in males, but in breeding flocks, sudden losses in hens with peritonitis, SC and cutaneous discoloration, and a history of insemination just prior to this suggest *E. rhusiopathiae* infection. Diagnosis is further validated by procedures described previously and in more detail by Cooper and Bickford (13).

Serology

Plate, tube, and microagglutination tests, in addition to passive hemagglutination, hemagglutination-inhibition, complement-fixation, growth agglutination, and growth-inhibition tests, have been used in erysipelas research, but their usefulness for the diagnosis of avian erysipelas have not been evaluated fully. Actual information regarding the nature of immunity induced in turkeys following natural exposure to *E. rhusiopathiae* or to erysipelas vaccines is scarce. Infected birds that recover appear to be solidly immune. It is not known whether one particular serotype or strain of the organism is effective in detecting antibodies to other serologic types or strains of *E. rhusiopathiae*. Sato et al. (49) described latex agglutination and ELISA tests using the 64,000-MW protective antigen of *E. rhusiopathiae*. At present, these tests are mainly useful for research studies.

Differential Diagnosis

Fowl cholera, colibacillosis, salmonellosis, staphylococcosis, streptococcosis, listeriosis (septicemic form), highly virulent avian influenza, and peracute Newcastle disease might be confused with the acute septicemic form of the disease. The less common forms of the disease (urticaria and endocarditis) may be caused by other miscellaneous bacterial agents or possibly fungal pathogens. All of these agents are differentiated easily from *E. rhusiopathiae* by Gram staining or biochemical activity. *Lactobacillus* sp., which occasionally may be isolated from intestinal tracts or livers of poultry and is biochemically similar to *Erysipelothrix*, may be differentiated using the highly selective Packer's medium containing sodium azide and crystal violet. Gram staining, growth on Packer's medium, and the typical reaction pattern in TSI medium or Kligler's lead acetate medium are excellent presumptive tests. Confirmatory diagnosis is by molecular methodologies such as PCR, fluorescent antibody test, or animal pathogenicity tests.

Intervention Strategies

Management Procedures

It has been suggested, though not established, that various environmental factors may make avian species more susceptible to *E. rhusiopathiae* infection. Early field observations indicated that the beginning of rainy, cold weather, which frequently coincided with sexual maturity, was related to outbreaks of erysipelas in turkeys on the range. This may apply to flocks of other avian species. The source of the organism may be contaminated feed, soil, or decaying matter; infected carrier birds in the flock; or infected rodents. Apparently, the relationship between environmental factors and disease does not apply to cases involving individually confined birds, as in a zoo. It is not possible to make clear-cut and specific recommendations for preventive or control management. A general suggestion is to use clean disinfected equipment and to rotate turkey ranges away from previously contaminated areas. Beneficial management practices in handling an outbreak of erysipelas in turkeys include thorough decontamination of equipment with disinfectants, prompt removal of dead birds and other carrion from premises, encouraging adequate feed and water intake, and handling birds as little and as gently as possible or practical. If unlimited range is available, it might be desirable to move the flock to clean ground, but such a practice may contaminate the new range.

With no specific and effective recommendations for management control of this disease in turkeys, it is suggested that birds be properly vaccinated in areas where erysipelas is known to be a problem.

Vaccination

Types of Vaccine

The most widely used products for the immunization of turkeys against erysipelas are the formalin-inactivated, aluminum hydroxide-adsorbed *E. rhusiopathiae* bacterins which may contain either whole or lysed bacterial cells. These bacterins initially were developed for use in swine and were shown to be effective in preventing erysipelas in turkeys. For the potency testing of inactivated erysipelas vaccines, both serology and ELISA assays are available and have been approved by regulatory authorities in many countries.

Although live erysipelas vaccines for swine have been in use for approximately 50 years, only recently has a live vaccine become available for use in turkeys.

Other approaches to vaccine development have focused on acapsular mutants, truncated protective antigen, and the use of bacterial vectors for expressing *E. rhusiopathiae* protective antigen (10, 27, 60).

Field Vaccination Protocols and Regimes

A regimen of immunization can be suggested for meat turkeys as well as those kept for hatching egg production. Because the disease in other avian species is so sporadic, immunization other than in turkeys is not generally recommended. It is also important to remember that effective immunization of mice or swine is not an adequate demonstration of the ability of a bacterin to protect turkeys. Cultures avirulent for turkeys and without immunogenicity for them may kill mice or provide protection. At this time, the immunizing capacity for turkeys can be assessed properly only with challenge of vaccinated turkeys.

Suggested for meat turkeys in areas of high risk is a single dose of the bacterin inoculated SC at the dorsal surface of the neck behind the atlas. For turkeys kept as breeders, at least 2 doses of bacterin should be administered at a 4-week interval prior to onset of egg production. The first dose may be given at 16–20 weeks of age (at selection time) and an additional dose given just prior to beginning of lay.

Improved vaccines properly used, adequate testing of the biologicals, planned immunization programs based on flock and premise history, and proper diagnosis of disease outbreaks as a basis for prompt treatment must be combined for effective prevention of erysipelas.

Treatment

The antibiotic of choice for an outbreak in market or breeder turkeys is a rapid-acting form of penicillin. Any antibiotic should be used under veterinary supervision according to current treatment procedure. Label directions should be followed carefully. As soon as diagnosis is definitely established, potassium or sodium penicillin should be administered IM at the rate of about 10,000 U/lb body weight simultaneously with a full dose of erysipelas bacterin. Control usually has been attained by giving penicillin (1 million U/gal) in drinking water for 4 or 5 days to all birds in the flock when a presumptive diagnosis is made. All birds in the affected flock should be treated. Some recommendations suggest the use of procaine penicillin or other longer-acting derivatives; under certain circumstances, these may be used successfully, but in outbreaks, rapid-acting formulations are almost mandatory. A combination of longer-acting and rapid-acting antibiotic formulations may provide the best control if individual SC or IM injection is feasible and cost effective. Especially in meat-bird flocks, however, catching and handling each bird may be impractical or even harmful. Sterile abscesses and downgrading may follow IM injections. Care should be taken to observe the required withdrawal periods for the antibiotic used. Turkeys and possibly other birds with advanced signs of the disease at treatment time often will not recover. Experimental use of certain antibiotics including penicillin will control the infection but will not eliminate carriers. Antibiotics other than penicillin may increase the carrier rate in a flock of turkeys.

Comparative studies are lacking on efficacy of various antibiotics for controlling *E. rhusiopathiae* infection in avian populations. Erythromycin and broad-spectrum antibiotics have been found effective. Sulfonamides and oral oxytetracycline are not effective treatments.

Avian Intestinal Spirochetosis

David J. Hampson

Introduction

Definitions and Synonyms

Avian intestinal spirochetosis (AIS) is a condition characterized by extensive colonization of the avian cecum and/or rectum with anaerobic intestinal spirochetes of the genus *Brachyspira*. The main species involved in the condition are *Brachyspira intermedia* and *Brachyspira pilosicoli*, with *Brachyspira alvinipulli* and *Brachyspira hyodysenteriae* being less frequently reported. Avian intestinal spirochetosis occurs in adult chickens and other birds, in which it is most commonly associated with delayed and/or reduced egg production and wet feces.

Economic Significance

Colonization with *Brachyspira* species is widespread among flocks of layer and breeder hens (116). A study in the United Kingdom published in 2006 suggested that AIS resulted in a potential annual loss to the laying hen industry of around £14 million (US$22 million) (18). Losses to the meat chicken industry associated with infection of breeder flocks also may be high (75, 115). In 1998 it was calculated that a commercial broiler flock hatched from eggs from a breeder flock with clinical AIS lost approximately £9,900 (US$15,500) annually from reduced growth rates and poor feed digestion (106). Additional losses associated with reduced egg production and increased feed consumption was estimated at £10,600 (US$16,600)/flock annually. Besides delayed and/or reduced egg production in laying hen flocks, AIS can reduce profitability due to mortalities, downgrading of fecally stained eggs, and increased labor costs associated with cleaning of cages and houses. There also may be local adverse environmental effects through increased odor from wet feces and attraction of flies. Due to its nonspecific signs AIS often goes undiagnosed, and its full economic significance is not appreciated.

Public Health Significance

Some avian strains of *B. pilosicoli* are closely related to strains from humans and other animals, and there probably is no barrier to cross-species transmission of this spirochete (43). Strains of *B. pilosicoli* isolated from humans have been used experimentally to colonize 1-day-old chicks (26, 80, 133, 134), and adult laying hens (50), and there seems to be no reason why avian strains could not colonize humans. *B. pilosicoli* has been isolated from lake and dam water frequented by ducks colonized by *B. pilosicoli*, emphasizing the potential for some avian intestinal spirochetes to be transmitted by ingestion of contaminated water (90). However, the likelihood of healthy poultry industry workers becoming infected with *B. pilosicoli* from contact with chickens is low. The other *Brachyspira* species associated with AIS are not known to infect human beings.

History

There are several early accounts of intestinal spirochetes in birds, which are recorded in the AIS chapter in the 12th edition of this book. Interest in intestinal spirochetes was rekindled following the discovery in the early 1970s that *Treponema hyodysenteriae* (later called *Serpulina hyodysenteriae* and now *Brachyspira hyodysenteriae*) was the etiologic agent of swine dysentery, an important mucohemorrhagic diarrheal disease of pigs (38). In the 1980s studies showed that intestinal spirochete infections were common in flocks of laying hens and in broiler breeder hens in the Netherlands (22, 24, 25, 26, 27, 28, 29), and also occurred in the UK (36). Colonization was associated with various syndromes including delayed and/or reduced egg production and wet feces. At that time the species of spirochetes involved were unknown. Subsequent work in the USA (81, 111, 125, 131), Australia (75, 97, 115), and Europe (11, 17, 18, 30, 55) confirmed and extended these results, including the identification and naming of the main pathogenic *Brachyspira* species causing disease in poultry (76). Necrotizing typhlitis and high mortality associated with spirochetes was reported in common rheas in 1992 (104), and since then forms of AIS have been reported in a number of other species of poultry including farmed geese and ducks (34, 52, 86).

Etiology

Classification and Host Specificity

Spirochetes are bacteria classified in the order Spirochaetales, in the families Spirochaetaceae, Brachyspiraceae, and Leptospiraceae. The intestinal spirochetes associated with AIS belong to the family Brachyspiraceae, genus *Brachyspira* (92).

The genus *Brachyspira* currently contains 7 officially named species (*B. hyodysenteriae*, *B. intermedia*, *B. innocens*, *B. murdochii*, *B. alvinipulli*, *B. pilosicoli* and *B. aalborgi*), and several proposed species including "*B. canis*," "*B. pulli*," "*B. suanatina*," and "*B. corvi*" (23, 47, 54, 100, 110, 115, 135, 137, 138). All official species except *B. aalborgi* previously belonged to the genus *Serpulina* (39, 89). All of the species colonize the large intestine, but only *B. pilosicoli* and *B. aalborgi* are known to attach by 1 cell end to cecal or colonic enterocytes (77). The *Brachyspira* species have close similarities in their 16S rRNA gene sequences, indicating that they have evolved into different species relatively recently (91). A wide range of *Brachyspira* species has been found in birds, and this suggests that they may have been the original hosts

Table 23.4. Morphologic, biochemical, and other characteristics of the four main pathogenic *Brachyspira* species reported in birds.

	Species			
Characteristic	***B. intermedia***	***B. pilosicoli***	***B. alvinipulli***	***B. hyodysenteriae***
Pathogenicity	Moderate to mild	Moderate to mild	Moderate to mild (severe in geese)	Severe
Colonization of cecal epithelial surface	Random in lumen and crypts—not attached to epithelium	May be attached by 1 cell end to cecal enterocytes	Random in lumen and crypts—not attached to epithelium	Random in lumen and crypts – not attached to epithelium
β-Hemolysis pattern	Weak (occasionally intermediate or strong)	Weak	Weak	Strong
Indole production	+	– (occasionally positive)	–	+ (occasionally negative)
Hippurate hydrolysis	–	+ (occasionally negative)	+	–
Type strain	PWS/A^T – ATCC 51140	P43/6/78^T – ATCC 51139	C1^T – ATTC 51933	B78^T – ATCC 274164

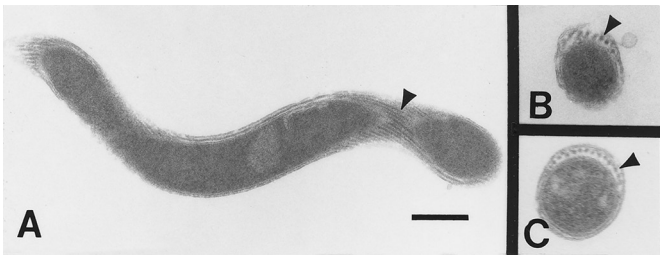

Figure 23.15. (A) *Brachyspira alvinipulli*. The spirochete cell is helically shaped on longitudinal orientation. On transverse sections, an end (B) and the middle (C) of spirochete cells have 8 and 16 periplasmic flagella (arrows), respectively. (D.E. Swayne)

of an ancestral *Brachyspira*-like anaerobic spirochete when it first colonized the intestinal tract.

Pathotypes

Based on experimental studies and naturally occurring colonization, *B. intermedia*, *B. pilosicoli*, *B. alvinipulli*, and *B. hyodysenteriae* are considered to be potential pathogens in birds. Of these, *B. intermedia* is the most frequently encountered pathogenic species in birds, and *B. hyodysenteriae* is the least commonly reported. Their features are summarized in Table 23.4. Where the other species and proposed species occur in birds, these are generally thought of as being commensals (76), however considerably more work is required to investigate this assumption.

Morphology and Staining

Brachyspira species are Gram-negative, helical shaped bacteria with diameters ranging from 0.25–0.6 μm, lengths from 3–19 μm, amplitudes from 0.45–0.79 μm, and wavelengths from 2.7–3.7 μm. They are readily identified in wet mounts by darkfield or phase contrast microscopy. Each spirochete cell contains a central protoplasmic cylinder, multiple periplasmic flagella, and an outer envelope (Figure 23.15). The periplasmic flagella are endocellular and divided into 2 equal sets, with each set originating from opposite poles of the protoplasmic cylinder and overlapping with the other set in the middle of the cell. The number of periplasmic flagella has been used for spirochete classification; however, this has limited value because the numbers can vary between and within species. *B. pilosicoli* and *B. aalborgi* typically have 4 flagella at each cell end, while the other *Brachyspira* species have 8 or more at each end. The rotation of periplasmic flagella between the outer membrane and protoplasmic cylinder confers a corkscrew-like movement to spirochete cells. These morphologic features and motility permit spirochetes to traverse highly viscous liquids, such as mucus, which immobilize externally flagellated bacteria (82).

Growth Requirements

Brachyspira species are anaerobic, but will tolerate transient exposure to air (108). Due to their slow growth rates and tendency to become overgrown by other more rapidly growing species, it is necessary to use selective solid media systems for primary isolation, most of which were developed to isolate swine intestinal spirochetes (1, 56, 61). Typically, these systems consist of trypticase soy agar with 5%–10% defibrinated ovine or bovine blood, and 1–5 selective antibiotics (including spectinomycin, rifampin, spiramycin, vancomycin, polymixin, and/or colistin). Because the different *Brachyspira* species vary in their tolerance to these antimicrobials, a recommended "general" brachyspira plate contains 400 μg/ml spectinomycin and 25 μg/ml each of colistin and vancomycin (56). Incubation is at 37°C–42°C for up to 10 days; however, for most avian isolates visible growth is usually present in 2–5 days. Typical gaseous environments are 94% H_2 and 6% CO_2, generated using anaerobic gas packs in an anaerobic jar, or 80% N_2, 10% H_2, and 10% CO_2 in an anaerobic chamber. The spirochetes can be further propagated in anaerobic brain heart infusion broth containing 10% fetal bovine serum, with 1% oxygen to enhance growth (108), or in a prereduced anaerobic trypticase soy broth medium ("Kunkle's medium") (62). Growth of 10^8–10^9 cells/mL can be achieved in these broths within 2–3 days.

Colony Morphology and Hemolysis on Blood Agar

Brachyspira species grow as a dull flat sheen on the surface of agar plates, forming confluent areas of growth with sharply defined edges, sometimes penetrating into the agar. Most *Brachyspira* species are weakly hemolytic, although *B. hyodysenteriae* and "*B. suanatina*" are strongly hemolytic, and occasional avian strains of *B. intermedia* and other unidentified species can cause intermediate to strong hemolysis (52, 53, 76). Growth can be confirmed by the characteristic morphology and motility of the bacteria on wet mounts using dark-field or phase contrast microscopy. Because individual birds may be colonized with mixed *Brachyspira* strains and species, this may complicate the final identification process.

Biochemical Properties

Brachyspira species typically contain alkaline and acid phosphatase, esterase, esterase lipase, β-galactosidase, and phosphorylase activities. Differences in hemolysis patterns, production of indole, hippurate hydrolysis, and the presence or absence of β-galactosidase and β-glucosidase activities have been used to categorize isolates (31). A commercial API-ZYM system and numerical 5-digit coding system for enzyme activities has been used in differentiating avian and mammalian isolates (48). Because these phenotypic properties can vary, more specific molecular based techniques now have largely replaced biochemical testing for species identification.

Susceptibility to Chemical and Physical Agents

Strains of *B. pilosicoli* can survive for extended periods in water, particularly at colder temperatures (4 days at 25°C; 66 days at 4°C)(90). Similarly, strains of *B. hyodysenteriae* and *B. pilosicoli* can survive for prolonged periods in porcine feces and in soil mixed with porcine feces (78–210 days at 10°C) (15). On the other hand, strains of *B. intermedia* and *B. pilosicoli* are relatively short lived in chicken feces (approximately 3 days at 4°C, at 10^9/g feces), and do not persist in the environment of chicken houses (94). The reduced viability in chicken feces is likely due to its typically dry and acidic nature. Most common disinfectants are efficacious against *Brachyspira* species (94), although it is best to remove organic matter first (20). Cleaning, disinfection, and resting of empty houses between batches of hens has the potential to break cycles of AIS on infected farms (94).

Virulence Factors

The mechanisms by which *Brachyspira* species cause disease in avian and mammalian species are still incompletely understood. Since the last edition of this book, and at the time of this writing (2011), the complete genome sequences of single strains of *B. hyodysenteriae* (13), *B. piloscoli* (141), *B. murdochii* (93), and *B. intermedia* (37) have been published, and other strains and *Brachyspira* species are being sequenced (79). These data have provided the opportunity for new lines of investigation into disease mechanisms and identification of virulence factors, for example by comparing gene content and expression in pathogenic and nonpathogenic species. Nevertheless, research is still impeded by a lack of easy methods for genetic manipulation of these bacteria, and without this it is still difficult to assess the functional significance of individual genes or groups of genes. Moreover, in the case of AIS, generally it is not even clear whether and to what extent the underlying pathologic mechanisms are common to the different pathogenic species. Indeed, the development of AIS likely requires the activity of multiple virulence factors that may vary between the pathogenic species involved.

Virulence attributes of pathogenic *Brachyspira* species can be considered to consist of a set of "lifestyle" virulence factors involved in initial colonization and fitness for survival and proliferation in the microenvironment adjacent to the mucosa of the large intestine, and other "essential" virulence factors that are required for lesion production and/or disease. To some extent the lifestyle factors, including such things as ability to survive in an anaerobic environment, to use available substrates, to be motile, and to undergo chemotaxis are shared by commensal and pathogenic *Brachyspira* species, since all *Brachyspira* species are able to colonize the large intestine. Subtle differences in such lifestyle factors presumably cause differences in behavior. For example, some *Brachyspira* species show a limited host range (e.g., *B. aalborgi* is largely restricted to humans), while others have a much broader host range (e.g., *B. pilosicoli* colonizes many species of birds and animals).

To date, only *B. hyodysenteriae* and *B. pilosicoli* have received much study in relation to their potential virulence factors, mainly because these are important enteric pathogens of pigs. Even so, the host range and virulence trait determination of *B. hyodysenteriae* remains poorly understood. For example *B. hyodysenteriae* strains isolated from rheas caused severe necrotizing typhlitis and high mortality rates in rheas, but were apathogenic and failed to produce significant intestinal colonization in swine (113). Similarly, strains of *B. hyodysenteriae* recovered from swine vary in their virulence in experimentally inoculated swine (2).

As part of the colonization process *Brachyspira* spp. cells penetrate and move through the mucus overlying the epithelium of the large intestine. All *Brachyspira* spp. cells are motile, but they vary in their attraction to colonic mucin. Comparison of the genome sequences of *B. hyodysenteriae* and *B. pilosicoli* has shown that *B. pilosicoli* has fewer methyl-accepting chemotaxis genes than *B. hyodysenteriae*, with no *mcpC* genes, and hence these species are likely to have different chemotactic responses that may help to explain their different host range and colonization sites (141). Experimentally, strains of *B. intermedia* and *B. innocens* have been shown to be less attracted to mucin than virulent strains of *B. hyodysenteriae* (78). On the other hand, while cells of both *B. hyodysenteriae* and *B. pilosicoli* were shown to be attracted to and entered mucin solutions, this attraction was reduced at mucin concentrations above 6% for *B. hyodysenteriae* but not *B. pilosicoli* (83). Even within a species it is evident that there are substantial

strain differences; for example, *B. pilosicoli* strains varied in their motility and chemotactic responses to mucin (83), while 2 avirulent strains of *B. hyodysenteriae* were less attracted to mucin than were virulent strains tested under the same conditions (78).

Besides chemotaxis, the role of motility in colonization has been confirmed by experiments in which *B. hyodysenteriae* strains with disruptions introduced to their flagella genes (*flaA* and *flaB*) had reduced motility and a reduced ability to colonize (59, 103). Similar experiments have not been conducted with the other pathogenic *Brachyspira* species, but it can be assumed that motility is important for their colonization. For example, *B. pilosicoli* shows increased motility under viscous conditions, including increased mucus concentrations equivalent to those found in the colon (82, 83).

Another lifestyle virulence factor of *Brachyspira* species is their NADH oxidase activity, which is believed to enhance their ability to colonize the colonic mucosa by protecting them from oxygen toxicity. Consistent with this, *B. hyodysenteriae* strains with an inactivated *nox* gene showed a reduced ability both to colonize swine and to cause disease (112).

A characteristic feature of *B. pilosicoli* is the ability of individual cells to attach by one of their pointed cell ends to the luminal surface of enterocytes in the large intestine, creating a "false brush border" on the surface (Figure 23.16). *B. pilosicoli* surface lipoproteins may be involved in facilitating this attachment by interactions with specific receptors on the cell surface (138, 141). Where this layer of attached spirochetes is dense it may form a physical barrier that prevents the reabsorption of water and electrolytes, resulting in watery diarrhea.

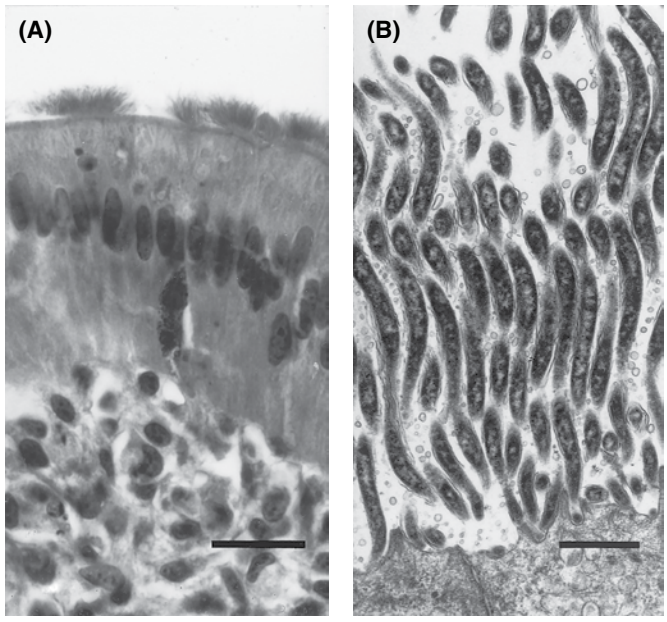

Figure 23.16. (A) Tight association of *Brachyspira pilosicoli* with the luminal surface of cecal epithelium. (B) The orientation is at right angles to the epithelial cells. (D.E. Swayne)

In vitro studies using Caco-2 cell monolayers have indicated that the cell junctions are the initial targets of attachment by *B. pilosicoli* (85). Colonized monolayers demonstrated a time-dependent series of changes, including accumulation of actin at the cell junctions, loss of tight junction integrity, and condensation and fragmentation of nuclear material consistent with apoptosis. Using quantitative reverse transcription PCR, the colonized monolayers demonstrated a significant up-regulation of interleukin-1β (IL-1β) and IL-8 expression. These cytokines/chemokines are likely to be responsible for attracting inflammatory cells to the colonization site. Candidates for inducing such cellular damage include the biological activity of lipooligosaccharides (see below) and/or the action of membrane proteases, including a subtilisin-like serine protease similar to that of other Gram-negative bacteria (21, 141).

The lipooligosaccharides (LOS) in the cell envelope of *Brachyspira* species have some of the same biological properties as lipopolysaccharides from other Gram-negative bacteria, and are likely to contribute to lesion production. Studies with LOS extracted from *B. hyodysenteriae* has shown that they have a variety of effects, including being toxic for mouse peritoneal macrophages, increasing uptake of red blood cells by murine peritoneal cells via Fc and C3 receptors, acting as a mitogen for murine splenocytes, generating chemotactic factors in fresh swine serum (88), inducing interleukin-1 (IL-1) and tumor necrosis factor (TNF) from murine peritoneal cells, augmenting natural killer cell activity (35), and inducing production of pro-inflammatory cytokines such as interleukin-6 (87). The LOS of other pathogenic *Brachyspira* species have not been studied, other than to show that they are antigenically heterogenous among *B. pilosicoli* strains (70). *B. pilosicoli* sonicates (likely containing LOS) did cause significant up-regulation of IL-1β, TNF-α, and IL-6, while culture supernatants and sonicates of nonpathogenic *B. innocens* did not alter cytokine expression (85).

Sequencing of the genome of *B. hyodysenteriae* strain WA1 identified a previously unrecognized plasmid containing 31 genes, including 6 *rfbA-D* genes that were predicted to be involved with rhamnose biosynthesis, and hence LOS structure, as well as others associated with glycosylation (13). In a recent study, a set of PCRs were developed to amplify portions of 9 of the plasmid genes (67). PCR products were generated when used with DNA extracted from virulent strain B204, but not with DNA from avirulent strain A1. Analysis of the DNA using PFGE confirmed the presence of a plasmid band in strains WA1 and B204, but not in strain A1. These results suggested that the lack of the plasmid might explain why strain A1 is avirulent. Subsequently, 264 Australian field isolates of *B. hyodysenteriae* were tested, and only one was found to lack the plasmid; when this strain was used experimentally to infect pigs, significantly fewer became colonized and developed swine disease (SD) compared to the pigs infected with the control strain containing the plasmid. The results support the likelihood that plasmid-encoded genes of *B. hyodysenteriae*, possibly the *rfbA-D* gene cluster, are involved in colonization and/or disease expression. These

genes were not identified in the sequenced strains of *B. pilosicoli* or *B. murdochii* (141), but were identified in the genome of *B. intermedia* PWS/A^T (37), implying that this species also may be able to incorporate rhamnose into its LOS.

A final potential "essential" virulence determinant in *B. hyodysenteriae* is the spirochete's strong hemolytic activity (38). A number of studies on *B. hyodysenteriae* molecules with hemolytic activity have been conducted over the years. Currently, 8 genes encoding proteins with predicted hemolytic activity have been described in *B. hyodysenteriae*, and all but one of these appears to be present in *B. pilosicoli* (13, 141). Further work is required to investigate the latter gene for its potential contribution to virulence. In addition, the genetic basis of the strong hemolysis produced by "*B. suanatina*" and some other of the non-*B. hyodysenteriae* isolates from ducks and game birds requires investigation (52, 53).

Pathobiology and Epizootiology

Host Range

Besides chickens, spirochetes have been recorded colonizing the ceca and recta of a variety of domesticated avian species, including common rheas (16, 104), pheasants (141), partridges (52), turkeys (105), geese (86), ducks (34), and captive or free-living wild birds, especially aquatic birds of the orders Anseriformes and Ciconiiformes (52, 53, 90, 120), but also in Corvid species (54).

Incidence and Distribution

Cases of AIS in poultry have been reported in European and Scandinavian countries, North America, and Australia (11, 22, 30, 36, 55, 75, 81, 115, 125); they almost certainly occur elsewhere but go unrecorded. Besides caged or housed flocks, outdoor free-range flocks and organic flocks with access to outside areas are commonly affected (17, 55, 140). Necrotizing typhlitis in rheas has been reported in the US and Europe (16, 63, 104).

There have been relatively few detailed epidemiologic surveys of AIS, and in these, the incidence of colonization and disease has varied with the avian species examined and the methods used for demonstrating spirochetes. Surveys have shown the condition to be remarkably common in flocks of laying hens and broiler breeder hens. For example, in a survey conducted in the 1980s in chicken flocks mainly from the Netherlands, using a direct fluorescent antibody test (FAT) on feces, 27.6% of flocks with intestinal disorders were positive for intestinal spirochetes, whereas only 4.4% of flocks without enteric signs were positive (24). A study in Western Australia used selective culture on feces collected from 37 randomly selected laying hen flocks and 30 broiler breeder flocks (75). Overall, 53% of the breeder hen flocks and 35% of the layer hen flocks yielded samples containing intestinal spirochetes. Moreover, 64% of the flocks with diarrhea or poor production were colonized, compared to only 24% of flocks with normal feces. Within-flock prevalence varied from 10%–95% of the samples tested. More recent surveys have supplemented or even replaced selective culture with PCR assays to identify the spirochete species present. Using these modifications, even higher overall prevalence rates were found in the eastern states of Australia, where spirochetes were recovered from 43% of 28 randomly selected broiler breeder farms and from 68% of 22 laying hen farms (115). Within these farms, most of which contained multi-aged flocks, infection was detected in 26% of 112 broiler breeder flocks (each in individual houses) and in 54% of 68 laying hen flocks. Within-flock prevalence varied from 10%–100% of samples examined, with a mean of 47%. In this study there was a highly significant correlation between colonization and wet litter, with infected flocks on average having 14% greater fecal water content than flocks that were not colonized. Spirochetes were not detected in 45 broiler flocks on 19 farms that were surveyed. In a study in Northern Italy, 72.4% of 29 laying hen farms and 71.1% of 42 sheds contained chickens infected with intestinal spirochetes (11). There was a significant association between the presence of spirochetes and using deep pits rather than conveyor belts to remove feces. Sheds housing birds older than 40 weeks were significantly more likely to contain pathogenic spirochetes than younger flocks. Colonization was significantly associated with reduced egg production, but not with increased fecal water content. In a survey of laying hen flocks more than 40 weeks of age in Pennsylvania, 76% of 21 flocks contained chickens that were colonized by pathogenic *Brachyspira* species (81).

In surveys of various bird species held in zoological collections, colonization with intestinal spirochetes has been commonly detected in waterfowl of the order Anseriformes, but not in other species (90, 120).

Prevalence of Pathogenic Species

In the above surveys around 70% of laying flocks and 50% of breeding flocks contained birds colonized by intestinal spirochetes. Isolates from about 67% of these colonized flocks typically belonged to pathogenic species, of which *B. intermedia* accounts for around two-thirds of the isolates and *B. pilosicoli* for most of the remainder (11, 81, 115, 119). *B. alvinipulli* and *B. hyodysenteriae* occasionally have been detected in chickens (30, 55), as well as in flocks of geese in Hungary (86). Infection of rheas with *B. hyodysenteriae* is widespread in the US (16, 57), and has been recorded in some feral and farmed ducks (52, 53, 34). Individual flocks and hens may be colonized by more than one pathogenic species (55, 97, 115, 119).

Strains Present

In one study, multilocus enzyme electrophoresis (MLEE) was used to examine multiple *Brachyspira* isolates from 4 chicken farms (119). On 1 farm 16 *B. murdochii* isolates were detected with 14 different electrophoretic types (ETs), while 5 isolates of *B. pilosicoli* all belonged to the same ET. On the second farm, 5 of 6 *B. pilosicoli* isolates belonged to the same ET, and the sixth was distinct, while 2 *B. intermedia* isolates were

different from each other. On the third farm, 3 isolates of *B. intermedia* all belonged to the same ET. On the fourth farm, the 4 *B. intermedia* isolates all belonged to different but related ETs. Hence, some infected farms may have a dominant strain of a species present, but other strains of the same or other *Brachyspira* species also may be present. This heterogeneity also was found in a study on a western Australian laying hen farm, where 20 *B. intermedia* isolates examined using PFGE were divided into 4 different PFGE types (97). The existence of strain heterogeneity among isolates from a farm is important, because different strains may have different biologic properties that may affect the clinical outcome, including virulence traits and antimicrobial susceptibilities.

Where there are different strains on a farm they may have been independently introduced or they may have arisen from "microevolution" of original strains that were present (7). Some of the pathogenic *Brachyspira* species appear to have a recombinant population structure, and the various species may undergo extensive genetic rearrangements and sequence drift that generates genetic diversity (137, 144). Novel genetic information may be acquired from other species/strains through the activity of a prophage-like gene transfer agent observed in different *Brachyspira* species (74, 79, 114) and/or from horizontal gene transfer via bacteriophages with broad trophism, that themselves may have undergone extensive gene remodeling (37).

Anatomic Location

Intestinal spirochetes colonize the ceca and rectum, but not the small intestine. Spirochetes primarily are found in crypt lumina and to a lesser extent in the cecal contents adjacent to enterocytes. *B. pilosicoli* cells may be found in groups attached by 1 cell end to the surface epithelium (Figure 23.16), although they can colonize the ceca without attachment being seen.

Spirochetemia with *B. pilosicoli* has been reported in humans (9, 136). It is not known whether *B. pilosicoli* spirochetemia occurs in birds and other animal species, but goes unrecognized because of difficulties in isolating the spirochete.

Spirochete Persistence in the Ceca

Spirochetes can persistently colonize ceca (22, 25, 28). In one study spirochetes were detected in cecal droppings from the time of experimental infection at 14 weeks of age until the termination of the experiment 23 weeks later (29). In another experiment the same spirochete strain 1380, later identified as *B. intermedia* (76), was still present in the feces of experimentally infected laying hens after 9 months (25).

Transmission, Carriers, and Vectors

Intestinal spirochetes are transmitted between birds by the fecal-oral route, either directly or indirectly. Aerosol transmission of feces between birds that are held in close proximity in confined conditions is likely to occur. Transmission of spirochetes between flocks of birds in different houses on a farm is most likely to occur through the movement of personnel who have clothing or boots contaminated with chicken feces. Wild birds and animals such as rats and mice also potentially can introduce and/or spread infection. Insects such as flies or species such as dogs or feral animals might serve as mechanical carriers. A major potential source of transmission is through the water supply. Wild ducks have been shown to shed strains of *B. pilosicoli*, *B. hyodysenteriae*, and *B. intermedia* in their feces (52, 53, 90), and these may survive in effluent ponds or dams supplying drinking water (90).

Incubation Period

The incubation period of AIS is variable. Both the dose of the organism and secondary environmental factors can profoundly influence the incubation time. Disease signs can occur in chickens as early as 5 days after experimental inoculation (126), although often it may take several weeks for significant levels of colonization to occur and clinical signs to develop (41, 42).

Influence of Age on Spirochete Colonization

Experimentally, the pathogenicity of avian intestinal spirochetes is greatest when they are given to 1-day-old birds via crop gavage (126), although natural infection of such young birds does not seem to occur. In commercial laying hens it is unusual to detect colonization much before 15 weeks of age, and more colonized hens are found as the flocks become older (11, 115). This age-related distribution likely reflects increasing levels of exposure rather than differences in age susceptibility.

Influence of Diet and Microbiota on Spirochete Colonization

For *Brachyspira* species to colonize they must reach the large intestine, then establish and interact successfully within the local microenvironment. It is assumed that the spirochetes survive passage through the upper intestinal tract inside boluses of food or feces. Studies in swine have shown that once in the large intestine the spirochetes interact with various anaerobic bacterial species forming part of the normal microbiota of the cecum and colon, including species such as *Clostridium perfringens*. These species act synergistically with *B. hyodysenteriae* to facilitate spirochete colonization and augment inflammation and lesion production (45, 143).

Dietary influences on colonization with *B. intermedia* have been shown in experimentally infected laying hens. In particular, diets based on wheat seem to promote colonization with *B. intermedia* compared to diets based on barley or barley and sorghum (95). Furthermore, different wheat varieties have been shown to vary in their influence on promoting colonization by *B. intermedia* (96). In one study of laying hens fed wheat-based diets the addition of exogenous enzymes designed to hydrolyse the nonstarch polysaccharides in the wheat reduced *B. intermedia* colonization following experimental infection (42). In the same study and in a subsequent study, the addition of zinc bacitracin (ZnB) to the diet reduced colonization with *B. intermedia* (41, 42), but dietary ZnB enhanced colonization with *B. pilosicoli* (49, 117). Because

ZnB mainly acts on Gram-positive bacteria rather than on the spirochetes themselves, these conflicting results indicate that there are likely to be complex positive and negative interactions between different components of the cecal microbiota and different *Brachyspira* species in chickens.

Taken together, these studies suggest that different clinical outcomes may occur in infected hens depending on their diet, intestinal microenvironment and microbiota, as well as the particular *Brachyspira* species involved in the colonization. These findings may help explain some of the heterogeneity in clinical signs and pathology seen in different commercial flocks with AIS.

Clinical Signs and Pathology

Information about clinical signs and pathology of AIS is limited, and available data have come from 3 main sources. The first is from experimental infection of 1-day-old chicks. These data provide a guide to the pathogenic potential of certain isolates, but the results must be viewed with caution because the associated colonization and disease may not be representative of natural infections in adult birds. The second source comes from experimental infection of adult chickens using defined isolates. This system is more representative of natural disease, but also has limitations. The experimental hens are usually individually caged, appropriately fed, and relatively free of stress, and these conditions do not reflect the situation in many commercial flocks where AIS occurs. Disease is often quite mild or absent under these experimental conditions; for example, only slight reductions in egg production and/or increased fecal water content have been observed in the absence of obvious histologic changes in the ceca of some experimentally colonized birds (40, 117). Furthermore, because these experiments are time consuming, testing tends to be done with only 1 or a few spirochete strains under a restricted set of standard dietary and other conditions. The birds are not co-infected with other species or strains of spirochetes, or with other enteric pathogens, as may occur in commercial flocks. The third source of information comes from observations of natural cases of AIS. These are important data of direct industry relevance in terms of observing changes in production, but are limited by the fact that often there may be co-infections that are unrecognized or which make the attribution of production losses or pathology associated with AIS difficult to allocate. Another problem with some of the earlier descriptions of AIS in the field is that it was not known what species of spirochete were involved (22, 36).

Besides the *Brachyspira* species and perhaps even strains involved in the colonization, the initiation and severity of clinical disease is likely influenced by the host species, husbandry, nutrition, environment, and genetics. Some specific predisposing factors for AIS that have been observed in the field include molting, recent onset of egg production, poor or inappropriate feed quality, floor housing, and light-laying breeds of hens (18, 36, 125, 131). Crowding of birds induces stress and increases the opportunity for spirochete transmission between individuals held in close proximity. In addition, exposure to the stress hormone norepinephrine has been shown to increase the potential virulence of *B. pilosicoli* by enhancing its growth, attraction to mucin, and attachment to Caco-2 cells (84). Because norepinephrine may be present in the intestinal tract, it is likely that this effect also occurs *in vivo*, and possibly with other pathogenic *Brachyspira* species under stressful conditions.

Naturally occurring or experimental colonization of birds with intestinal spirochetes broadly may result in: (1) subclinical colonization, (2) mild to moderate clinical disease, or (3) severe clinical disease.

Subclinical Colonization

Colonization by spirochetes without disease has been reported in chickens (75, 81, 115), mostly associated with apparently commensal *Brachyspira* species such as *B. innocens, B. murdochii* and/or "*B. pulli*" (76). In wild birds, especially waterfowl, most spirochetes are not associated with enteric disease, and are considered to be commensals forming part of the normal microbiota. From an epidemiologic perspective it is also important to note that wild birds may carry pathogenic species without showing obvious clinical signs (52, 53, 90).

Mild to Moderate Clinical Disease

The "mild to moderate" disease spectrum is seen particularly in association with strains of *B. intermedia, B. pilosicoli*, and *B. alvinipulli*, mainly in layer hens and broiler breeder hens. These infections tend to be associated with diarrhea and/or reduced egg production, but cecal changes are mild or inapparent.

Infections with B. intermedia. In early studies *B. intermedia* strain 1380 was used to experimentally infect broiler chicks (27), laying hens (28), and 14-week-old broiler hens and cocks, where the eggs were collected and hatched (29). Infected chicks showed variable reductions in growth rate; wet droppings with increased fat content; and increased serum content of protein, lipid, carotenoids, and biliruben (27). Laying hens showed increased fecal fat content (28); developed slimy, wet, frothy feces (25); or had wet droppings and produced significantly fewer eggs (29). Spirochetes were found penetrating the cecal mucosal lining between undamaged columnar cells, in "gap-like" lesions running through the epithelium, and accumulated just under the epithelium. There was some erosion of the superficial mucosa but there were no clear signs of inflammation in the connective or lymphatic tissues. The eggs from infected hens were significantly lighter, had paler yolks, and had a lower carotenoid content. Broiler chicks hatched from eggs from the infected hens had pale, mucoid, and wet feces, and the chicks were significantly lighter than control chicks at 2 and 3 weeks of age. They tended to develop rickets and had low blood plasma concentrations of carotenoids and alkaline phosphatase activity. They were not themselves colonized by spirochetes.

Experimental infection of laying hens with *B. intermedia* strain HB60 caused reduced growth rates, increased fecal water content, and decreased egg production and egg weight,

but did not induce any characteristic pathological changes in the ceca (40, 42, 96).

Infections with B. pilosicoli. Newly hatched broiler chicks have been infected with human, porcine, and/or canine isolates of *B. pilosicoli* (26, 80, 133, 134). Clinical signs either were not observed (26), or the chicks developed watery diarrhea (133, 134), sometimes with a depressed growth rate (134). Gross cecal lesions were not seen, but there were variable histologic changes, including the characteristic presence of a dense mat of spirochetes attached by 1 cell end to cecal enterocytes (80, 133, 134), sometimes with a diffuse thickening of the cecal epithelial brush border (80). There was variable crypt elongation, crypt lumina were dilated, and there was mild focal infiltration of the lamina propria with heterophils. Sometimes spirochetes were found between enterocytes or producing gap-like lesions; subepithelial accumulation of spirochetes and focal erosion without an inflammatory reaction also were recorded (26). Vacuolation and protein deposition were observed in the apical cytoplasm of some luminal enterocytes. Sometimes microvilli were obscured, damaged, or obliterated by large numbers of attached spirochetes, and there was disruption to the terminal web microfilaments. Individual spirochetes invaginated into the cellular membrane and indented into the terminal web cytoplasm, but did not penetrate it.

Experimental infection of broiler breeder hens with avian *B. pilosicoli* strain CPSp1 resulted in a transient increase in fecal water content, fecal staining of eggshells, and/or a significant reduction in egg production (117, 118). The ceca of infected birds were gassy and the contents were frothy, fluid, and pale, but no gross or histologic lesions were observed. Spirochetes were isolated but they were not found attached to the cecal epithelium. Infection of laying hens with strain CPSp1 resulted in no disease signs (49), whereas infection with a human isolate of *B. pilosicoli* resulted in a persistent and significant increase in fecal water content (50). Again, neither attachment of spirochetes nor gross pathologic changes were observed.

Natural infection of 2 layer flocks with *B. pilosicoli* was associated with a 5% reduction in egg production, diarrhea in up to 25% of chickens, wet droppings, feces smeared on feathers around the vent ("pasty vents"), lethargy, and depression (131). The apical surfaces of cecal enterocytes were covered by a dense layer of spirochetes aligned parallel to each other and perpendicular to the mucosal surface (Figure 23.16). Four turkey flocks that had increased mortalities were shown to be infected with *B. pilosicoli* (105). Large numbers of spirochetes were attached along the surface epithelium of the ceca, extending into the middle of the crypts. Focal mucosal erosions occurred in some ceca, with spirochetes attaching directly to the exposed basement membrane or invading the lamina propria. This was accompanied by an increase in the number of subepithelial mononuclear inflammatory cells.

Infections with B. alvinipulli. Experimental infection of 1-day-old chicks and 14-month-old hens with *B. alvinipulli* strain 91-1207/C1 resulted in yellow, golden, or orange cecal droppings (126). The ceca were dilated and contained pale-green to yellow fluid to frothy contents. Infected birds had moderately severe lymphoplastic typhlitis and proctitis with lymphocyte and/or heterophil exocytosis, mild cecal villus epithelial cell hyperplasia, edema in the lamina propria of villus tips, and submucosal lymphocytic follicles (Figure 23.17). Some chicks had mildly dilated cecal crypts. Mats of spirochetes were present over the villus surface and in the crypts, with spirochete cells oriented randomly on the cecal epithelial luminal surface or in the crypt lumina. Spirochetes rarely invaded between and below the cecal epithelial cells (Figure 23.18).

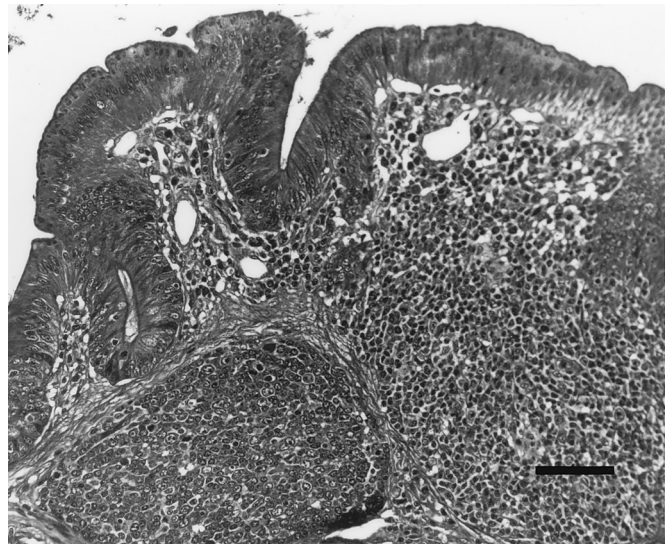

Figure 23.17. Mild lymphocytic typhlitis and mild epithelial hyperplasia in a chicken colonized with *Brachyspira alvinipulli*. Bar = 50 µm. (D.E. Swayne)

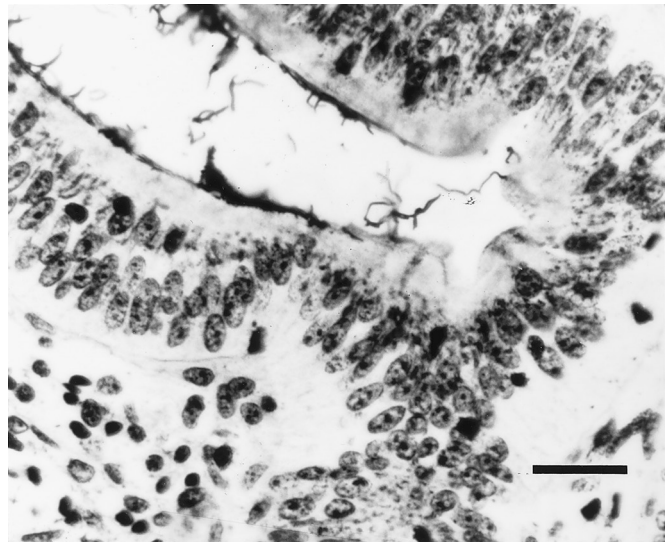

Figure 23.18. Randomly oriented *Brachyspira alvinipulli* spirochetes on the villous surface epithelium in the cecum. Warthin-Starry silver stain. Bar = 20 µm. (D.E. Swayne)

B. alvinipulli strain 91-1207/C1 was originally identified in 2 flocks of laying hens in which 5% of the chickens had wet feces, clinical diarrhea, and pasty vents, and produced dirty, fecal-stained eggshells (125). Spirochetes were present within the crypts and/or in the lumina of the ceca, and chickens with pasty vents had mild lymphocytic typhlitis.

Cases of AIS in Which the Spirochetes Were Not Identified. In an early study in the Netherlands, an unidentified weakly hemolytic spirochete designated "strain K1" was isolated from a hen on a laying hen farm where there was prolonged intermittent diarrhea and an early decrease in egg production (22). Naturally infected birds had a mild typhlitis. There was a slight increase in numbers of goblet cells, focal "gap-like" lesions in the cecal epithelium that were filled with spirochetes, and mild degeneration and mononuclear cell infiltration beneath the gaps. Ten-week-old hens experimentally infected with mucosal homogenates or strain K1 showed a transient increase in fecal water content, and this recurred after 8–9 weeks.

A study in the UK reported retarded growth rate and delayed onset of egg production in 22-week old pullets (36). The mucosal crypts of the ceca were distended with sloughed epithelial cells and inflammatory debris, and there was marked mononuclear leukocytic infiltration of the lamina. Spirochete cells were randomly oriented on the cecal epithelial luminal surface or in crypt lumina.

In the Netherlands, observations were made on 8 broiler breeder flocks with a history of AIS caused by uncharacterized spirochetes (106). Flocks with clinical signs had decreased egg production and increased feed consumption. Three percent of eggs produced were too light for successful hatching. Commercial broiler flocks hatched from eggs laid in periods when clinical signs of AIS were present in the breeder flocks showed increased feed conversion and consumption. Weak chicks, retarded growth, and poor feed digestion occurred in the broiler flocks. Antibiotic treatment of the breeder hens before the onset of lay resulted in offspring that performed normally.

Severe Disease

Descriptions of severe disease associated with AIS include the typhlitis seen in rheas naturally infected with *B. hyodysenteriae* (17, 104), where mortality rates can range from 25%–80%; a similar syndrome in geese infected with *B. alvinipulli*, where 18%–28% mortality was recorded over a period of 2–3 months (86); and in duck flocks infected with *B. hyodysenteriae* or *B. pilosicoli*, where there was hemorrhagic to fibrinonecrotic typhlocolitis and 17%–18% mortality (34). Ducks also had renal degeneration with fibrosis and mineralization, hepatic and splenic amyloidosis, and swelling of some metatarsal and phalangeal joints.

Most clinically affected rheas that become colonized with *B. hyodysenteriae* are more than 6 months old (17). Adult birds can be affected, but these cases usually involve concurrent stress such as recent shipping. Clinically, 1–2 days prior to death a few birds may show depression, have reduced bodyweight, and pass watery feces with caseous cores; however, rheas often die suddenly without clinical signs (104). Ceca are dilated and have thickened walls with ulcerations and lumina containing thick pseudomembranes (Figure 23.19) (104, 124). Cecal walls have severe mucosal necrosis, crypt elongation, and hyperplasia of glandular epithelial and goblet cells, and the cecal lumina contain mucus, colonies of spirochetes, bacilli, and fibrinonecrotic debris (Figure 23.20). Experimental

Figure 23.19. *Brachyspira hyodysenteriae*. Thick necrotic pseudomembrane attached to the cecal mucosa of a juvenile common rhea with necrotizing typhlitis. (D.E. Swayne)

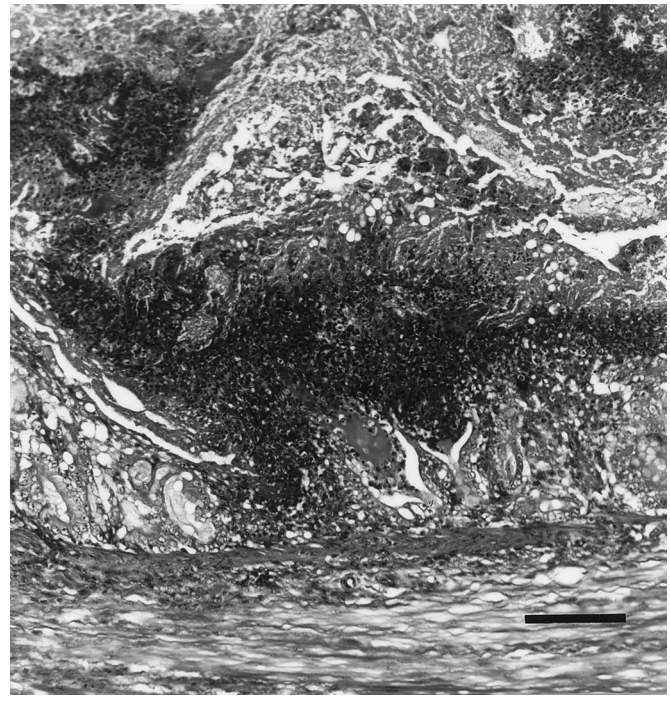

Figure 23.20. *Brachyspira hyodysenteriae*, juvenile rhea. Thickened cecal mucosa contains dilated crypts filled with mucus. Lumen has a necrotic pseudomembrane composed of necrotic heterophils and sloughed epithelium, bacteria, and mucus. H&E. Bar = 50 µm. (D.E. Swayne)

inoculation of 1-day-old chickens and turkeys with intestinal spirochetes from rheas produced similar although less severe lesions (57).

In the original rhea cases, a strongly β-hemolytic spirochete identified as *B. hyodysenteriae* was isolated (57). Inoculation of 1-day-old common rhea chicks reproduced the gross and histologic lesions within 5–9 days (124). In other cases in rheas, unclassified weakly β-hemolytic spirochetes have been isolated (104).

Experimental infections of 1-day-old chicks with porcine strains of *B. hyodysenteriae* have resulted in severe changes. These include reduced weight gain, atrophic and thickened ceca with mucus in the cecal lumina, necrosis of the epithelium at the tips of plicae, abundant spirochetes in crypts, an edematous lamina propria with accompanying heterophilic inflammation, epithelial and goblet cell hyperplasia, and crypt elongation (3, 121, 122, 133).

Severe disease associated with *B. alvinipulli* infection has been recorded in 2 goose flocks in Hungary (86). Following molting at the end of the first egg laying season, 28% of the 1,500 laying birds in flock A died during an 8-week period and 18% of the 4,500 laying birds in flock B died during a 12-week period. Affected geese had hemorrhagic to necrotic inflammation of the colon/rectum and fibrinonecrotic typhlitis accompanied by severe degeneration. Spirochetes were present in the mucous membrane of the large intestine. The kidneys were swollen, and some geese had visceral gout. The large intestine had a necrotic epithelial layer and the lamina propria contained hemorrhage as well as infiltration with lymphocytes, histiocytes, and heterophilic granulocytes. Sometimes necrosis extended into the upper third of the lamina. Kidneys had degeneration of the tubular epithelial cells, focal or diffuse intertubular fibroblast cell proliferation with atrophy of the glomeruli and tubules, and mineral deposition. Lymphohistiocytic inflammation of the liver was observed. Nine isolates were identified as *B. alvinipulli* while another (from flock A) was strongly beta-hemolytic but indole negative, and was tentatively identified as *B. hyodysenteriae*.

Immunity

Little is known about immunity to intestinal spirochetes in birds, and prolonged colonizations of individual experimentally infected birds have been observed (25). Humoral antibodies to *Brachyspira* spp. preparations may or may not be produced following naturally occurring colonization. Antibodies can be detected in birds from which spirochetes cannot be isolated, and other birds may yield spirochetes on culture but be serologically negative (120, 124).

Diagnosis

Introduction

Gross pathologic and histologic examinations are rarely sufficient to allow an unequivocal diagnosis of AIS. Hence, the diagnosis of AIS is usually confirmed using microbiological techniques to identify the associated spirochetes in birds with clinical, pathologic, and/or production data consistent with AIS.

Demonstration of spirochetes

Visualization of helical-shaped bacteria in feces or cecal droppings by dark-field or phase contrast microscopy can be followed up by electron microscopy to look for periplasmic flagella, which are characteristic of spirochetes. Demonstration of spirochete antigens by direct or indirect fluorescent antibody tests (IFAT) or immunohistochemical (IHC) methods using polyclonal antisera also is possible; for example, IFAT using antiserum raised against *B. hyodysenteriae* was used in the early epidemiologic surveys for AIS (22, 24). However, neither ultrastructural morphology nor identification of antigens by IFAT or IHC using polyclonal antisera will reliably distinguish between spirochete groups or species. Monoclonal antibodies to cell envelope proteins of *B. pilosicoli* have been described (69, 127), and these could increase the specificity of IFAT for identifying this species in chickens. Similar species-specific reagents are needed for the other avian pathogenic spirochetes.

Isolation of Causative Spirochetes

Culturing and further characterization of isolates is important to help identify the spirochete species, and to allow strain typing and determination of antimicrobial sensitivity. The level of detection of culture is dependent on the number of organisms and type and condition of the sample, with fresh cecal droppings or cecal mucosa being optimal material to culture.

Identification of Causative Spirochetes

Phenotypic Properties

Isolated bacteria can be confirmed as spirochetes by their characteristic morphology and motility under dark field or phase contrast microscopy, by the presence of periplasmic flagella observed under transmission electron microscopy, and/or by their reactivity in immunofluorescent microscopy using specific antisera (see above). As discussed under Etiology, the observation of hemolytic patterns on blood agar and the patterns of biochemical reactivity can allow a presumptive identification of some *Brachyspira* species (Table 23.4).

Genotypic Properties

The use of molecular methodology has greatly improved spirochete identification (and detection). In the past MLEE has been extremely useful in defining the current *Brachyspira* species (68, 71, 76), but it is too slow and cumbersome for routine use, and has now been replaced by multilocus sequence typing (MLST) (66, 101). For example, using MLST, recently it has been shown that strains currently identified as *B. intermedia* on phenotypic grounds may in fact represent several different species (99).

PCR assays have been used on isolated spirochetes or on the growth on primary isolation plates to identify and differentiate *Brachyspira* species (6, 8, 123). They have even been used on spirochetes recovered by laser capture from fixed cecal mucosa of turkeys (105). To date the most reliable PCR

assays for amplification of DNA from *B. pilosicoli* have been based on the 16S rRNA gene, which contains a signature sequence for this species. PCR assays for *B. intermedia* have been less reliable, but, in retrospect, this may be due to the diversity among strains currently identified as *B. intermedia* (99). Problems of sensitivity and specificity have arisen using PCR systems for *B. intermedia* based on the 23S rRNA gene sequence and or the NADH-oxidase (*nox*) gene (33, 123), although an improved PCR based on modified *nox* primers appears to work well for this species (30, 81, 97, 98). Whether or not it will prove necessary to develop other PCR systems to identify the different sub-groups identified among strains currently designated as *B. intermedia* will depend on what is discovered about their biological properties and pathogenic significance (99). Both *nox* and *tly* gene PCRs are regularly used for *B. hyodysenteriae* (32, 64), but to date no reliable direct PCR assays have been described for *B. alvinipulli*.

A number of other schemes have been developed to detect and/or identify *Brachyspira* species without the need for culture and biochemical analysis. These involve PCR amplification of specific gene sequences, followed by restriction enzyme digestion of the products to give species-specific banding patterns after gel electrophoresis (restriction fragment polymorphism analysis: RFLP). Genes that have been used in RFLP analysis for identifying different (mainly swine) *Brachyspira* species include the 16S rRNA gene (110), the 23S rRNA gene (12, 72, 129), and the *nox* gene (102, 130). In addition, several studies have used PCR to amplify *Brachyspira*-specific portions of the 16S rRNA or *nox* genes, and then sequenced these products to help identify the species from which they originated (11, 30, 81).

Another adjunct to diagnosis is the use of a fluorescent *in situ* hybridization technique that uses fluorescent oligonucleotide probes specific for sequences present in the 16S or 23S rRNA of different *Brachyspira* species to visualize spirochetes associated with the mucosa in formalin-fixed tissues (14, 58). This technique has been further modified so that visualized spirochetes are isolated by laser capture microdissection, subjected to direct 16S rRNA gene PCR, and the subsequent DNA sequence analyzed (60). The advantage of these techniques is that they provide simultaneous identification and localization of the spirochetes associated with the intestinal mucosa. They should prove particularly useful in investigating aspects of the pathogenesis of AIS.

Strain Typing

Typing of individual *Brachyspira* species strains can provide important epidemiologic information to help devise control measures. Early studies used MLEE to differentiate intestinal spirochete isolates into species and strains (71, 76, 109), but this technique is not particularly good for discriminating all strains, and is time-consuming. Pulsed-field gel electrophoresis is a commonly used strain typing technique for *B. pilosicoli, B. intermedia*, and *B. hyodysenteriae*, and gives better strain discrimination than MLEE (5, 6, 97, 123, 137). Other methods such as random amplified polymorphic DNA (RAPD) analysis (10, 33), MLST (66, 101), and multiple-locus variable-number tandem repeats analysis (46) also are becoming more widely available for strain typing of the various *Brachyspira* species.

PCR on Feces

A two-step nested duplex PCR has been described for the detection of *B. intermedia* and *B. pilosicoli* in DNA extracted directly from washed chicken feces (98). The first round of PCR amplified genus-specific portions of the 16S rRNA and *nox* genes, while the second round used a nested *B. pilosicoli*-specific 16S rRNA gene PCR and a *B. intermedia* specific *nox* PCR. Washing removed potential PCR inhibitors, and a two-step amplification procedure compensated for any loss of sensitivity associated with the washing step. This assay was rapid and should enhance diagnostic capacity for AIS, especially if it could incorporate a *B. alvinipulli*-specific PCR in the second round of amplifications.

A further advance was the development of a multiplex-quantitative polymerase chain reaction (M-qPCR) assay for detecting and quantifying *B. hyodysenteriae*, *B. pilosicoli*, and *B. intermedia* in chicken and pig feces (107). The method was based on amplification and detection of a 198 base pair portion of the *nox* gene, using TaqMan probes. The assay could detect 10^2 to 10^3 cells/0.2 g of feces, giving an improved detection threshold compared to standard PCRs. M-qPCR assays of this type should become valuable tools for detecting and quantifying low numbers of pathogenic intestinal spirochetes in chicken feces; however, this specific assay has been criticized for failing to detect all strains of *B. pilosicoli* from pig feces due to allelic variation in the *nox* region where the probe bound (19).

Serology

Several serologic tests have been developed to determine exposure of swine to *B. hyodysenteriae*, including an ELISA using a recombinant surface protein (65). Similar assays have not yet been developed for the other *Brachyspira* species that infect birds.

Differential Diagnosis

Spirochetes identified in fecal specimens from poultry should be distinguished from other helical bacteria including *Campylobacter*, *Arcobacter*, *Helicobacter*, and *Spirillum*. Wet droppings have a number of causes, and these may interact in a multifactorial way to result in severe problems. In cases of chronic diarrhea or pasty vents, nutritional problems such as excess dietary salt, fats, or raw soybean meal should be investigated. Increased urinary output due to excessive drinking, kidney damage, and incorrect amounts of calcium and electrolytes in the diet can result in wet litter, as can water spillage. Other infectious causes of chronic diarrhea include enteric salmonellosis, colibacillosis, coccidiosis, and histomoniasis.

In the case of necrotizing typhlitis other potential causes include *Salmonella*, especially group B serotypes, *Clostridium difficile*, *C. perfringens*, *C. sordelli*, and *Histomonas meleagridis*.

Intervention Strategies

Biosecurity

In farms that do not have AIS, strict biosecurity measures should be put in place to prevent entry. There should be good physical containment (security fencing) around the farm, and bird-proof netting around openings in the houses. Entry of personnel should be restricted, preferably with shower-in and shower-out facilities. Replacement hens should only be obtained from sources known to be free of AIS. The food and water supply should be free of contamination. In particular, the water supply should be protected from fecal contamination from feral waterfowl.

Management Procedures in Flocks with AIS

Farms with AIS should practice the same precautions as outlined above, but they also should decrease contact with potentially infectious feces by raising hens off floors, frequently changing litter and removing manure, implementing good rodent and insect control programs, minimizing dietary and molting stress, and providing high-quality feed ingredients while avoiding ingredients that enhance spirochete colonization (e.g., wheat). To prevent transmission between flocks on a site, and particularly from older to younger flocks, clean coveralls and boots as well as disinfectant boot dips should be provided at the entrance to each house.

In the case of rheas, it is best to avoid raising them on swine farms, and visiting other rhea farms should be discouraged. Proper cleaning and disinfection of clothing, shoes, and equipment should be done before returning to the home flock following visits to rhea shows, rhea farms, or swine operations. All introductions of new rhea stocks should follow a minimum of 60 days of quarantine and take place after 2–3 negative cloacal cultures for *B. hyodysenteriae*. Birds should be segregated into age groups, and strict biosecurity measures should be implemented to minimize potential transmission of *B. hyodysenteriae* from asymptomatic adolescent or adult birds to susceptible rhea chicks.

Vaccination

No commercial vaccines are available to prevent AIS. Vaccination with an autogenous *B. intermedia* bacterin failed to prevent colonization of experimental laying hens following challenge with this strain (4).

Probiotics

To date there has been no clear evidence for the beneficial effects of using probiotic bacteria to help prevent or control AIS *in vivo*; however, cell-free extracts of 2 *Lactobacillus* strains have been shown to suppress the growth and motility of *B. pilosicoli in vitro*, and to significantly reduce adherence and invasion of the spirochete in a three-dimensional avian cecal organ culture model (73).

Antimicrobial Treatment

Introduction

No chemotherapeutic compounds appear to have been approved and registered for the treatment or prevention of AIS. Nevertheless, compounds used to treat or prevent swine dysentery and/or porcine colonic spirochetosis should have similar efficacy for treatment of AIS (38).

In Vitro *Testing of Antimicrobials*

Antimicrobial sensitivity testing should be conducted using either an approved agar dilution or broth dilution method to establish a minimum inhibitory concentration (MIC). There are only a few publications on *in vitro* antimicrobial susceptibility testing of intestinal spirochetes from birds. A U.S. study examined 2 isolates of *B. pilosicoli* and 2 of *B. alvinipulli* from chickens, and 3 isolates of *B. hyodysenteriae* and 1 of uncertain identity from rheas (132). All 8 isolates were susceptible to tiamulin, lincomycin, and carbadox; resistant to streptomycin; and gave strain-dependent results for chlortetracycline, oxytetracycline, tylosin, bacitracin, erythromycin, neomycin, and penicillin. A larger study investigated susceptibilities of predominantly Australian isolates of *B. intermedia* (n = 25) and *B. pilosicoli* (n = 17) from chickens (44). Isolates of both species generally were susceptible to tiamulin, lincomycin, metronidazole and tetracycline. The *B. intermedia* isolates tended to be less susceptible to tiamulin and more susceptible to lincomycin, tylosin, and ampicillin than the *B. pilosicoli* isolates. Although not classed as resistant, 4 isolates of *B. intermedia* had an elevated MIC range for tiamulin (1–4 mg/L), 11 isolates of *B. intermedia* and 5 of *B. pilosicoli* had an elevated MIC range for lincomycin (10–50 mg/L), 1 isolate of *B. pilosicoli* had an elevated MIC range for tetracycline (10–20 mg/L), and 1 isolate of *B. intermedia* and 5 of *B. pilosicoli* had an elevated MIC range for ampicillin (10–50 mg/L). A clear lack of susceptibility to tylosin (MIC greater than 4 mg/L) was seen in 11 isolates each of *B. intermedia* and *B. pilosicoli*, and to ampicillin (MIC greater than 32 mg/L) in 2 isolates of *B. pilosicoli*.

Twenty *B. intermedia* isolates that were recovered from layer flocks in Belgium and the Netherlands between 2008 and 2010 were tested using a broth microdilution method (139). The MIC distribution patterns for tylosin, tilmicosin, lincomycin, and doxycycline were found to be bimodal, with acquired resistance against doxycycline in 3 strains, against the macrolides in 2 strains, and against lincomycin in 1 strain. The MICs of tiamulin and valnemulin showed a monomodal distribution, but with tailing toward the higher MIC values, suggesting low-level acquired resistance in 6 isolates.

A Swedish study investigated antimicrobial susceptibility of 30 *Brachyspira* spp. isolates from commercial laying hens

and 18 from free-living wild mallards (*Anas platyrhynchos*) (51). Presumed pathogens (*B. alvinipulli*, *B. intermedia*, *B. pilosicoli*), commensals (*B. murdochii*, *B. innocens*, "*B. pulli*"), and isolates of undetermined species affiliation were included. The laying hens had not been exposed to therapeutic levels of antimicrobials for at least 50 weeks before sampling, and low levels of environmental antimicrobial exposure were presumed in mallards. No isolates with decreased susceptibility to tylosin, valnemulin, tiamulin, or doxycycline were found. Decreased susceptibility to lincomycin (MIC 16 μg/ml) was detected in 2 isolates (*Brachyspira* sp.) from laying hens. Five isolates showed decreased susceptibility to ampicillin (MIC 16 to greater than 32 μg/ml), including 2 "*B. pulli*" and 1 *B. alvinipulli* from laying hens, and isolates of *B. pilosicoli* and "*B. pulli*" from mallards. Decreased susceptibility to ampicillin was associated with β-lactamase activity in 4 isolates. Isolates with decreased susceptibility to ampicillin were present in flocks where fully susceptible isolates of the same species or other genotypes occurred.

Overall these *in vitro* data from different regions suggest that drugs such as tiamulin, lincomycin, and metronidazole should prove useful in the treatment of AIS, regardless of the *Brachyspira* species involved. Nevertheless it is recommended that *in vitro* susceptibility testing be undertaken on several representative isolates before antimicrobial therapy is contemplated. To avoid possible toxicity, tiamulin should not be used in combination with ionophores (e.g., monensin, salinomycin, and narasin).

In Vivo *Treatment with Antimicrobials*

Treatment of laying hens with some antimicrobials is problematic because of the withdrawal times needed to avoid residues being present in the eggs. In addition, drugs such as the nitroimidazoles are not available for use in food-producing animals in many countries. There have been several reports on the outcome of antimicrobial treatment of flocks with AIS, as well as of treatment of individual experimentally infected hens.

In a study on a UK laying hen unit with AIS, treatment of immature hens with 125 ppm dimetridazole in-feed for 10 days resulted in improved condition and egg production, and spirochetes were not isolated at postmortem (36). Similarly, in the Netherlands, in-water treatment of infected broiler breeder flocks with 120 ppm Ridzol S (a 5-nitroimidazole) for 6 days resulted in a temporary increase in egg production (106). Lasting effects required early treatment, whereas late treatment did not improve production. Re-infection of birds in some flocks may have resulted from contact with infected litter or from ineffective treatment of parts of a flock. Longer intervals between medications were suggested to increase the numbers of spirochetes shed in the feces.

In an Australian study, 2 houses each of 8,000 40-week-old broiler breeder hens with AIS were treated with antimicrobials in the water (115). The first house received lincospectin at 50 mg/bird/day for 7 days, while the second house received tiamulin at 25 mg/kg bodyweight for 5 days. Treatment with lincospectin resulted in slimy feces persisting for several weeks. Hens in the lincospectin-treated house remained negative for spirochetes for 3 months, after which time 30% of fecal samples were spirochete positive. Three weeks after tiamulin treatment ceased approximately 30% of fecal samples from the house again became spirochete positive, increasing to 80% after another 3 months. Both houses were then water medicated with oxytetracycline at 60 mg/kg for 4 days. This removed the low level of infection from the first house, but only reduced the prevalence from 80%–60% in the second house. Subsequently, the prevalence in the second house built up to 70% after 4 weeks. It was assumed that re-infection occurred either from the environment of the houses or from birds that had not received adequate medication to remove the infection.

In a UK study, 3 flocks of approximately 12,000 laying hens on a multi-age site were found infected with *B. pilosicoli* (18). In-water treatment with tiamulin at 12.5 mg/kg bodyweight for 3 days resulted in increased egg production and reduced mortality.

In laying hens experimentally infected with *B. intermedia*, both zinc bacitracin (ZnB) at 50 ppm in the food and 256 pp of a dietary enzyme designed to hydrolyse the non-starch polysaccharides in wheat (Avizyme 1302) resulted in less colonization (42). In a subsequent experiment, 100 ppm ZnB inhibited colonization with *B. intermedia*, whereas hens treated with tiamulin at 25 mg/kg bodyweight for 5 days became spirochete negative and maintained egg production, although they later became re-infected (41). The use of ZnB is not necessarily recommended for the control of AIS, because 50 ppm in the food resulted in an increased susceptibility of laying hens to infection with *B. pilosicoli* (49, 117). Treatment of broiler breeder hens with either tiamulin at 25 mg/kg bodyweight for 5 days or with lincomycin at 20 mg/kg for 5 days removed experimental infection with *B. pilosicoli* (118).

Taken together, these studies suggest that treatment with tiamulin, lincomycin/lincospectin, dimetronidazole, or even chlortetracycline should assist with control of AIS in adult hens. Regular treatments with courses of antimicrobials, for example, given at 1- to 2-month intervals, together with thorough house cleaning and implementation of strict biosecurity measures to prevent spread of infection between houses may be required for effective long-term control.

For rheas with severe AIS, treatment with dimetridazole (25–50 mg/kg bodyweight once or twice daily), lincomycin (25 mg/kg twice daily), or erythromycin (15–25 mg/kg once daily) for 5–7 days has been successful in reducing illness and deaths (124).

Acknowledgement

The author wishes to acknowledge Dr. David E. Swayne for his excellent contributions to this chapter in the 11th and 12th editions.

Tuberculosis

Richard M. Fulton and Susan Sanchez

Introduction

Tuberculosis of poultry, often termed avian mycobacteriosis, avian tuberculosis, avian TB, or TB, is a contagious disease caused by *Mycobacterium avium*. Avian tuberculosis is a chronic infection. Persistence in a flock, once established, induces unthriftiness, decreased egg production, and finally causes death. Although tuberculosis in commercial poultry in the United States is rarely diagnosed, tuberculosis still occurs sporadically in backyard poultry and game birds, and it remains an important problem in captive exotic birds.

Public Health Significance

The literature contains a number of instances in which it was claimed that *M. avium* was responsible for a tuberculous infection in humans. In the United States, the first case of avian tuberculosis in humans (with adequate proof) was published in 1930 (35).

With a decline in the incidence of tuberculosis due to *M. tuberculosis* in humans, increasing interest has been directed toward other mycobacteria, i.e., *M. avium* (32, 129, 145). Moreover, *M. avium* infections have been common in patients with acquired immune deficiency syndrome (AIDS) (25, 33, 64, 142). In the United States, *M. avium* serovars 1, 4, and 8 are isolated most frequently from AIDS patients, and serovars 4, 8, 9, 16, and 19 are isolated most frequently from non-AIDS patients (33). *M. avium* serovar 1 commonly is isolated from wild birds as well as AIDS patients (44, 55). Based on pulsed-field gel electrophoresis (PFGE), *M. avium* isolates recovered from humans and animals have some relatedness, but the human isolates are more closely related to pig isolates rather than those from birds (10, 36). *M. avium* serovar 2, the organism most frequently isolated from chickens, is rarely isolated from humans. However, these findings were reported before the advent of molecular typing which makes the interpretation of infection based upon serotype alone more difficult. Classic avian strains are clearly moleculary distinct from human, other mammal, and environmental isolates (80, 139). Thus, it would appear that most human *M. avium* infections would more likely be due to human-to-human or human-to-environment contact rather than bird-to-human contact.

History

Tuberculosis in chickens was first described in 1884 (23). Initially, Koch (66) maintained that tubercle bacilli were a single species irrespective of host. However, Rivolta and later Maffucci (73) showed that the microorganism of tuberculosis in chickens was dissimilar to that of bovine tuberculosis. Eventually, Koch (67) declared that tuberculosis of poultry was unlike tuberculosis of humans and that the disease in humans was dissimilar to that of cattle.

Cases of avian tuberculosis in domestic poultry have declined with the development of integrated commercial poultry farming. Cases in chickens and turkeys are predominantly in hobby flocks. The occurrence of avian tuberculosis in birds in zoo aviaries has become an important disease with increasing economic consequences. Certain species of exotic birds have increased in value as they near extinction, thereby increasing the significance of mortalities from avian tuberculosis. Management and control of the disease is difficult because exotic species are often maintained for years. The ability of the *M. avium* to survive in the soil and the lack of adequate procedures for cleaning and disinfecting contaminated premises have become a major obstacle to the elimination of avian tuberculosis from zoologic collections. This is made more complex by the lack of efficacious vaccines or suitable drug-treatment regimens.

Etiology

The most common cause of avian tuberculosis in chickens in the United States is *M. avium* serovars 1 and 2 (122). In Europe, *M. avium* serovar 3 has been isolated from wild birds (81, 84) and in Japan serotype 9 (*M. avium* subspecies *hominissuis*) also has been isolated from painted quail (82, 111); however, neither of these organisms has been isolated from domestic birds in the United States (101), with the exception of a single imported white-headed tree duck (*Dendrocygna viduata*) from which serotype 3 was isolated (131). The subspecies (sbsps) classification of bacteria belonging to *M. avium* in recent years has further been clarified with the advent of molecular techniques. This classification has further elucidated correlation of certain characteristics such as host predilection and pathogenicity to particular subspecies. Historically the determination of the etiological agent involved isolation, biochemical typing, and determination of polar glycolipid surface antigen type by agglutination. Newer methods of classification have allowed *M. avium* serovars 1, 2, and 3 to be reclassified as *M. avium* sbsps *avium*. *M. avium* sbsps *avium* may further be identified as *M. avium* positive for IS1245 and IS901 or *M. avium* IS1245 RFLP "bird type," or a combination of these (4, 28, 80, 86, 88, 111). Two subspecies have been proposed – *M. avium* sbsps *avium* and *M. avium* sbsps *hominissuis* depending on their molecular classification (28, 86, 108, 148). *M. avium* sbsps *avium* is known to be virulent for chickens (4, 28, 78, 86, 134). IS901 was found in 97.8% of strains from birds and its presence is thought to be related to pathogenicity (28, 86, 109, 116). For the purposes of this text, the agent of avian tuberculosis in poultry will be referred to as *M. avium*.

Growth Requirements and Colony Morphology

In contrast to *M. tuberculosis* and *M. bovis* (114), *M. avium* grows at temperatures ranging from 25°C–45°C, although the most favorable temperature range is 39°C–45°C. *M. avium* is aerobic. However, for primary isolation, growth is enhanced by an atmosphere of 5%–10% carbon dioxide (125).

Special media (113) designed for culturing tubercle bacilli is desirable for isolation from field materials. Colonies are larger if the medium contains glycerin. Some subspecies of *M. avium* such as *paratuberculosis* and *sylvaticum* require mycobactin as a growth factor for initial and subsequent growth (76). On media containing whole egg or egg yolk and incubated at 37.5°C–40°C, small, slightly raised, discrete, grayish white colonies form in 10 days to 3 weeks. If the inoculum has abundant bacteria, colonies will be numerous and coalesce. Colonies are hemispheric and do not penetrate the medium. They gradually change from grayish white to light ocher and become darker as the age of the culture increases. In one instance, bright yellow colonies have been described (62).

Subcultures on solid media result in growth within 6–8 days and reach maximal development in 3–4 weeks. Such cultures usually appear moist and unctuous; the surface eventually becomes roughened. The colonies are creamy or sticky and are readily removable from the underlying medium. In liquid media, growth occurs at the bottom of the tube as well as at the liquid surface. Recently, 3 culture media were evaluated to determine the best media to use when culturing tissue and fecal samples from *M. avium*-infected Japanese quail. Modified Herrold egg yolk with mycobactin; Lowenstein-Jensen; and Lowenstein-Jensen with cycloheximide, nalidixic acid, and lincomycin were evaluated. Lowenstein-Jensen media (without additives) provided more positive cultures, had greater numbers of colonies on positive tubes, and had shorter incubation times than the other media (118). Liquid media MGIT was shown to detect more positive samples faster than conventional media; however, a combination of traditional media and MGIT was necessary to isolate *M. avium* from all positive samples (110).

A definite relationship appears to exist between the type of colony and virulence (6). *M. avium* with smooth transparent (SMT) colonies were virulent for chickens; in contrast, variants with smooth-domed (SMD) or smooth-opaque (SMO) or rough colonies (RG) were avirulent regardless of source (6, 120). Colony morphology is transient and variable and other colony morphologies have been observed, although with lesser frequency (94). These different colony morphologies also vary in their ability to stimulate oxygen radicals, to multiply within the cells, and their capacity to up- or down-regulate cytokines/chemokines (8, 59, 94, 106). Differences in colony morphology are mostly due to the presence in SMT or the absence in RG of glycopeptidolipids. Glycopeptidolipids seem to limit macrophage response and may be key virulence factors (8).

The most characteristic morphologic feature of *M. avium* is its acid-fastness. The organisms are bacillary in morphology, but club-like, curved, and crooked forms are also seen in some preparations. Cords are not formed. Branching infrequently occurs. Most of the bacteria have rounded ends and vary in length from 1–3 mm. Spores are not produced, and the organisms are nonmotile. Spherical or conical granules occur anywhere within the cytoplasm.

Biochemical Properties

There appear to be no significant biochemical differences between *M. avium* and *M. intracellulare*. The *M. avium* and *M. intracellulare* group (MAIG), however, do have features that separate them from other species or groups of mycobacteria (31). MAIG does not produce niacin, does not hydrolyze Tween-80, is peroxidase-negative, produces catalase, does not have urease or arylsulfatase, and does not reduce nitrate; there are variations in these features, particularly in the results of tests for arylsulfatase. MAIG lack most amidases except for pyrazinamidase and nicotinamidase. Detailed listings of the biochemical features of MAIG and related microorganisms are available (99, 113).

Further identification of mycobacterial cultures may be performed using high-performance liquid chromatography (HPLC) for the identification of mycolic acids (24) or through the use of molecular tests such as 16S rRNA, *hsp65* and *groEL2* sequencing, as well as polymerase chain reaction (PCR) detection of IS elements (71, 138).

Disease in poultry is mostly attributed to one subspecies, namely *M. avium* sbps *avium*. However, in pet and wild birds, speciation of mycobacterium isolates is warranted because infection has been reported with several subspecies of *M. avium* and other species of *Mycobacterium* including *M. tuberculosis*, *M. bovis*, *M. fortuitum*, and *M. genavense* (6, 9, 10, 14, 33, 39, 51, 52, 53, 61, 62, 63, 76, 92, 113).

Sensitivity to Antituberculosis Drugs

Generally, *M. avium* is more resistant to the commonly used antituberculosis drugs as compared to *M. tuberculosis* and *M. bovis* (31). However, synergistic effects of antimycobacterial drug combinations (i.e., ethambutol and rifampicin) on *M. avium* complex have been reported (51). This generalized increase in resistance is attributed to its lipid-rich cell wall (69, 87). This is further proven by the correlation between colony phenotype and the extent of antimicrobial resistance. Transparent colonies are always more resistant than their opaque counterparts (57, 93). The ability to bind the lipoprotein Congo red further demonstrates the association of resistance in *M. avium* and its cell wall: white colonies, which do not bind lipoprotein, are more resistant than red colonies (16, 87).

In approximately 50 strains of *M. avium* from chickens and swine and 11 from humans, in egg yolk agar, most strains will grow in the presence of 10 mg, but not in 50 mg, of streptomycin/mL, in more than 10 mg of p-aminosalicylic acid/mL, and in more than 40 mg isoniazid/mL medium. On the same kind of medium, *M. avium* is relatively resistant to ethambutol, thionamide, viomycin, and pyrazinamide. The inhibitory concentration is variable, depending on the medium and procedure (40).

Strain Classification

M. avium belongs to the slow growing nontuberculous bacteria group and together with *M. intracellulare* form the *Mycobacterium avium* complex (MAC). MAC organisms' reservoir is the environment. All members of the MAC have been isolated from animals. Strains of *M. avium* have traditionally been identified by serologic procedures (100). A numbering scheme was developed on the basis of the production of similar polar glycolipid surface antigens for reporting MAC serotypes or serovars (147). Serological typing allows for the recognition of at least 28 serovars of *M. avium* (serotypes 1–6) and *M. intracellulare* serotypes 7, 12–20, and 22–28) (143). *M. avium* can be further subdivided into *M. avium* sbsps *paratuberculosis* isolated from ruminants and free-ranging birds (2, 11), *M. avium* sbsps *silvaticum* isolated from wood pigeons and other exotic birds, and *M. avium* sbsps *avium* isolated from birds and other domestic animals (29, 74). While *Mycobacterium avium* sbsps *paratuberculosis* has been recovered by culture from wild birds, it has only been shown to cause lesions in one crow in spite of testing more than 250 birds (5, 22). In 2002 Mijs (80) and collaborators suggested the *M. avium* sbsps *avium* can be further subdivided based on phenotypic and genotypic grounds into *M. avium* sbsps *avium* for isolates originating from birds (serovars 1, 2, and 3) and *M. avium* sbsps *hominissuis* (serovars 4, 6, 8–11, and 21) for isolates recovered from humans and animals (1, 29, 42, 74, 119). Serovars 1 and 2 occur mainly in animals, whereas 4–20 are commonly found in humans (123). Some serovars of *M. avium* found in swine (serovars 4 and 8) also have been isolated from humans (146). Serovars 1 and 2 are most commonly isolated from chickens, and serovar 3 is recovered sporadically from wild birds (77, 81).

Distinguishing serovars provides a means for studying origin and distribution of specific strains. This typing method is simple and can be conducted in microtiter plates (130). However, not all isolates can be reliably serotyped using this method because some are untypable (13, 18); furthermore, interlaboratory reproducibility is low and antigen failure is common (137). In the past few years it has been demonstrated that a combination of molecular techniques is by far a more accurate method of classifying *M. avium* isolates. Strains have been identified based on the presence or absence of insertion elements (IS) and are further subdivided by restriction fragment length polymorphisms (RFLP). All *M. avium* sbsps *avium* are of the genotype IS1245^{+}, IS901^{+}, IS1311^{+}, and have the IS1245 RFLP unique 3-band pattern called "bird type" for those isolates from birds which correspond to serovars 1, 2, and 3. *M. avium* sbsps *sylvaticum* has the same genotype except that the IS1245 RFLP differs in band sizes (27, 28, 86, 88, 111). The presence of IS901 in isolates has been associated with virulence for birds (86). Nevertheless, these insertion elements are by nature mobile, and there is the possibility that they can be found in unrelated bacteria. Therefore, they should only be used for further typing isolates already known to be part of the MAC. Molecular techniques with more accurate strain classification allow better epidemiologic study of these organisms (28, 29, 54, 68, 86, 98, 117). Chief among them are sequence-based classifications (80, 138) of the ribosomal operon and housekeeping genes (139). Sequencing of the *hsp65* housekeeping gene is preferred for mycobacteria species identification but will not achieve subspecies separation within *M. avium* unless the 3' end sequence of *hsp65* is used and then it has only been shown to distinguish among *M. avium* subsps *avium*, *M. avium* subsps *paratuberculosis*, and *M. avium* subsps *hominissuis* (138). With future progress of molecular tools, newer and more discriminatory typing methods for this dynamic group of organisms will emerge (91, 139).

Pathobiology and Epidemiology

Incidence and Distribution

Avian tuberculosis in chickens is caused by *M. avium* subsps *avium* (serovars 1, 2, and 3) and is worldwide in distribution, but occurs most frequently in the North Temperate Zone (133). As stated previously, avian tuberculosis is diagnosed rarely in commercial poultry. It has been diagnosed in 21 hens in the Czech Republic (109), in small flocks of 30–400 chickens in Canada (83), in relatively small free-range commercial flocks of 2,000 chickens in Australia (42), and in a commercial egg laying flock in Spain (43). Historical evidence has shown that the highest incidence of infection in the United States was found in flocks of the north central states: North Dakota, South Dakota, Kansas, Nebraska, Minnesota, Iowa, Missouri, Wisconsin, Illinois, Michigan, Indiana, and Ohio. The incidence of the disease in western and southern states is low. The explanation for this is not entirely obvious, although there are several possible contributing factors such as climate, flock management, and duration of infection. The necessity of keeping birds closely confined during winter provides favorable conditions for the spread of the disease.

The difficulty of tuberculin testing all chickens in the United States, or even a majority of the flocks, makes it impossible to obtain exact data on the incidence of *M. avium* infection of chickens. Slaughter data maintained in the United States by the National Agricultural Statistics Service for the years 1995 through 2005 revealed that avian tuberculosis was the cause for the condemnation of young chickens only in 1997 and 1998, at a rate of 7.5 and 6.2 birds/10 million birds slaughtered, respectively. In mature chickens during the same period, avian tuberculosis was diagnosed during 1996, 1999, 2000, 2001, 2002, 2003, 2004, and 2005 at a rate of 2.1, 1,870, 1,630, 14.6, 0.59, 2.4, 18.4, and no birds/10 million slaughtered, respectively. The same agency reported that there were no condemnations at slaughter due to tuberculosis during from 2006 through September 2011. Avian tuberculosis was diagnosed in mature turkeys only in 2003 at a rate of 0.04/10

million turkeys (70, 90). Because visual inspection alone is used to derive these numbers, this figure may represent an under- or overestimation of the true incidence. The diagnosis at inspection was most likely based only on emaciation and the presence of granulomas (11).

From 1985 to 2001, a Midwestern animal diagnostic laboratory (Fulton, unpublished data) received 6,059 avian submissions involving 15,097 birds. Only 27 cases (0.45%) involving 36 animals (0.24%) were diagnosed with tuberculosis. Of these cases, only 3 cases (0.05%) (4 animals) were chickens from hobby flocks; 2 cases were in peafowl; and 1 case each in pigeons, doves, quail, and partridges. By far, the largest group represented was exotic captive birds (parrots, toucans, budgerigars, and finches). Three different zoos had diagnoses of avian tuberculosis in such species as penguins, a crane, a duck, an ostrich, and toucans. No cases were seen in commercial chickens or turkeys.

Avian tuberculosis also occurs in some Latin American countries such as Brazil, Uruguay, Venezuela, and Argentina.

Overall, there has been significant reduction in the prevalence of avian tuberculosis due in part to the changes in poultry husbandry. Increasing emphasis has been placed on the desirability of maintaining all-pullet flocks, rather than older hens.

Historical information from the 1960s reports infection of animals by *M. avium* in certain European countries. It is said to be rare in Finland (141), but not uncommon in Norway (38) and Denmark (2); *M. avium* infection occurs in Germany (78, 103) and Great Britain (72). In Australia, avian tuberculosis is unknown in Queensland and West Australia but occurs in other states. In South Africa, the incidence in poultry is low (65). Infections probably occur in domestic and wild fowl in other countries, but the incidence and distribution cannot be determined because bacteriologic studies are not universally done. In Kenya, avian tuberculosis has been reported in lesser flamingoes (21). Historical prevalence of tuberculosis in animals may be found in Thoen et al. (122) and Thorel et al. (135).

Natural and Experimental Hosts

Birds

All species of birds can be infected with *M. avium*. Generally speaking, domesticated fowl or captive wild birds are affected more frequently than those living in a wild state. Avian tuberculosis has been reported in domesticated or captive-raised ducks, geese, swans, peafowl, pheasants, quail, partridge, pigeons, doves, turkeys, birds of prey, and other captive and/or wild birds. Pet birds including parrots, cockatoos, budgerigars, finches, flycatchers, and canaries have been infected (35, 39, 85, 97, 104, 107).

Although uncommon, infections and disease may be expected to develop in wild birds in contact with farm premises where avian tuberculosis is prevalent in chickens. Pheasants seem to be unusually susceptible to infection by *M. avium* (107). The disease also has been observed in sparrows, crows, barn owls, cowbirds, blackbirds, eastern sparrow hawks, starlings, wood pigeons, Canada geese, wild turkeys (41), American bald eagles (50), painted quail (75), and sandhill and whooping cranes.

Avian tuberculosis has been reported in ostriches, emus, and rheas housed in zoologic parks and in a 3-year-old female emu in a commercial flock (105).

Avian tuberculosis, although reported (49), is not common in turkeys and usually is contracted from infected chickens. Avian tuberculosis has been reported in wild birds and is reviewed elsewhere (9, 35, 39, 56, 60, 77, 101). The susceptibility of studied species suggests that domestic chickens, sparrows, ring-necked pheasants, grey partridges, and laughing gulls are highly susceptible; guinea fowl and domestic turkeys are less susceptible; domestic geese and domestic ducks are moderately resistant; while domestic pigeons, collared turtle doves, and the rook are highly resistant to infection (30).

Avian tuberculosis is more common among birds in many zoologic gardens than in domestic fowl (81). Infections usually result from *M. avium* serovar 1 or serovar 2 (128) as was recently reported in a zoologic collection of waterbirds (30). Tuberculosis in psittacine birds also may be due to *M. tuberculosis* or *M. bovis* (1, 53, 78). During a 9-year period of identification of *Mycobacterium* spp.-infected pet birds in Switzerland it was found that *M. genavense* (71.8%) was the predominant species followed by *M. avium* complex (16.7%), *M. fortuitum* (4.2%), *M. tuberculosis* (4.2%), *M. gordonae* (2.2%), and *M. nonchromogenicum* (2.2%) (52). In other studies (89), *M. genavense* is a common isolate of zoological collections. Luckily, *M. genavense* may be differentiated from *M. avium* by PCR with restriction enzyme digestion (79).

Mammals

M. avium can infect and cause disease in some domesticated mammals, but lesions usually are localized (38, 39, 45, 72, 124). Microorganisms may multiply in tissue for a considerable period and induce sensitivity to tuberculin. Disseminated tuberculosis caused by *M. avium* has been reported in rabbits and swine (123).

Although spontaneous infection of mammals may not be of comparable severity to that developed in fowl, it is possible to produce extensive changes in many species of mammals by introducing the infective agent artificially. The relative pathogenicity of *M. avium* for many of the domesticated mammals is summarized in Table 23.5.

In the United States and Europe, *M. avium* serovar 2 is the most common cause of tuberculous lesions in swine (58, 121, 144). Tuberculosis will remain an unnecessary economic burden on the swine industry until it is eliminated from chickens and other barnyard fowl. There has been a gradual but definite decrease of tuberculosis in swine in the United States (126). Reasons for the decrease may be the lower incidence of avian tuberculosis in poultry as a result of the increasing practice of maintaining one-age flocks and a change to confinement rearing of swine. In the past when

Table 23.5. Comparative pathogenicity of *Mycobacterium avium* for certain mammals.

Animal	Susceptibility
Cat	Highly resistant
Cattle	Infection occurs; usually localized
Deer	Infection reported
Dog	Highly resistant
Goat	Assumed to be relatively resistant
Guinea pig	Relatively resistant
Hamster	Susceptible (intratesticular)
Horse	Infection reported
Llamas	Susceptible
Marsupial	Infection reported
Mink	Readily infected
Monkey	Susceptible
Mouse	Relatively resistant
Rabbit	Readily infected
Rat	Relatively resistant
Sheep	Moderately susceptible
Swine	Readily infected

pork prices were high, pork production would expand by using vacant farm buildings (outdated chicken houses). With the advent of contract pork production, a market no longer exists for swine raised in this fashion.

Age of Host Commonly Affected

Avian tuberculosis appears to be less prevalent in young fowl not because the younger birds are more resistant to infection, but because in older birds the disease has had a greater opportunity to become established through a longer period of exposure. Although tuberculosis lesions are usually less severe in young chickens than adult birds, extensive or generalized avian tuberculosis in young chickens has been observed. Such birds are an important source of dissemination of virulent tubercle bacilli and must be considered a source to other fowl and susceptible mammals.

Tuberculosis causes important death losses in captive wild birds of zoo aviaries (81). The significance of these findings is emphasized by reports of disease in valuable endangered species. Numerous reports also are available on tuberculosis in pet birds (1, 12, 52, 78, 105, 112, 140).

Transmission

The tremendous number of tubercle bacilli exuded from ulcerated tuberculous lesions of the intestine in poultry creates a constant source of virulent bacteria. Although other sources of infection exist, none equals infective fecal material in the importance for dissemination of avian tuberculosis. Fecal discharges also may contain tubercle bacilli from lesions of the liver and mucosa of the gallbladder expelled through the common bile duct. The respiratory tract is also a potential source of infection, especially if lesions occur in tracheal and bronchial mucosa.

The contaminated environment, especially soil and litter, is the most important source for the transmission of the bacilli to uninfected animals. The longer the premises have been occupied by infected birds and the more concentrated the poultry population, the more prevalent the infection is likely to be.

M. avium may persist in soil for up to 4 years (102). *M. avium* bacilli remained viable in carcasses buried 3 feet deep for 27 months. Virulent strains of *M. avium* have been found to survive in sawdust for 168 days at 20°C and 244 days at 37°C (103).

M. avium has been isolated from eggs of naturally infected chickens, but hatched chicks failed to develop avian tuberculosis (35, 37, 39, 102). *M. avium* does not survive in eggs after 6 minutes of boiling, and in preparation of scrambled eggs, 2 minutes of frying was sufficient to kill the bacteria.

M. avium can be disseminated in carcasses of tuberculous fowl and offal from chickens dressed for food. Cannibalism might play a part in transmission.

Dissemination of *M. avium* on shoes, equipment, and materials (crates and feed sacks) used in the care and maintenance of infected poultry can be involved in transfer from diseased to healthy flocks.

Wild birds such as sparrows, starlings, and pigeons may be infected with *M. avium* and may spread *M. avium* to poultry flocks. Although not very likely, swine may have ulcerative intestinal lesions from *M. avium* and, thus, constitute a source of infection for other animals and birds.

Clinical Signs

Clinical signs are not pathognomonic. In advanced infections, the bird is less lively than its pen mates, fatigues easily, and may have a depressed appearance. Although appetite usually remains good, progressive and striking loss of weight commonly occurs, evident as atrophy of breast muscles with a prominent keel. In extreme cases, the body fat eventually disappears, and the face of the affected bird appears smaller than normal.

Feathers assume a dull and ruffled appearance. Comb, wattle, and earlobes often appear pale and thinner than normal and have a dry epidermis. Occasionally, the comb and wattles have a bluish discoloration. Icterus, indicative of advanced hepatic damage, may be noted.

Even when the disease is severe, the temperature of the affected bird remains within the normal range. In many instances, the bird reveals a unilateral lameness and walks with a peculiar jerky, hopping gait and even paralysis. In those cases, investigation of bone and joints for tuberculous lesions is warranted (26). Lesions may rupture and discharge fluid with caseous material.

With advanced emaciation, nodular masses can be palpated along the intestine. However, the hepatomegaly that many tuberculous birds possess may make this procedure difficult or impossible. Intestinal nodules may be ulcerative, resulting in severe diarrhea.

Affected birds may die within a few months or live for many, depending on severity or extent of the disease. A bird may die suddenly as a consequence of hemorrhage from the rupture of the affected liver or spleen.

In a flock situation, clinical signs may vary between infected birds. Two clinical syndromes were described in an infected commercial flock of laying hens. One group had good body condition and continued to lay eggs but had nodular masses in the infraorbital sinuses, liver, and intestines. Another group within the same flock was emaciated, did not lay eggs, lacked sinus lesions, and had numerous nodular masses in internal organs (43).

Pathology

Gross Pathology

Lesions are seen most frequently in liver, spleen, intestines, and bone marrow. Some organs, such as heart, ovaries, testes, and skin, are affected infrequently and cannot be considered organs of predilection. For turkeys, ducks, and pigeons, lesions predominate in the liver and spleen but also occur in many other organs (39).

Lesions of avian tuberculosis in chickens are characterized by pinpoint to several centimeter, irregular grayish yellow or grayish white nodules in spleen, liver, and intestine (Figure 23.21A, B, D). Involvement of liver and spleen results in enlargement, which can result in fatal hemorrhage from rupture. Large nodules have an irregular knobby contour, with smaller nodules present over the capsular surface of affected organs. Lesions near the surface in such organs as liver and spleen are easily enucleated from adjacent tissues. Nodules are firm but can be incised easily. Mineralization is rare. On cross-section, a nodule may contain a variable number of small yellowish foci or a single soft yellowish caseous center surrounded by a fibrous capsule. The capsule continuity may be interrupted by small circumscribed necrotic foci. The fibrous capsule is of variable thickness and consistency, depending on the size and duration of the lesion. It is barely discernible or apparently absent in small lesions and measures 1–2 mm in thickness in larger nodules. Intestines may have white, firm nodules that bulge from the serosal surface. Involvement of lungs is usually less severe than that of liver or spleen.

Granuloma formation is frequent within bone marrow (Figures 23.21C and 23.22). Infection of bone marrow probably occurs very early in the course of the disease and results from the bacteremia.

Microscopic Pathology

The basic lesion of *M. avium* infection consists of multiple granulomas with central caseous necrosis. Granulomas consist of the accumulation of large numbers of macrophages with abundant cytoplasm (epithelioid macrophages). Epithelioid macrophage populations expand within the granuloma and fuse near the periphery to form multinucleate giant cells. In larger nodules, the central area of the granuloma may have coagulative or caseous necrosis. In large nodules, only the multinucleate giant cells may persist as a mantle around the necrotic core. Immediately peripheral to the multinucleate giant cells is a collection of both epithelioid and histiocytic macrophages (Figure 23.23). A fibrous capsule consisting of fibrocytes and minute blood vessels also occurs near the outer portion of the peripheral area. Acid-fast bacilli are numerous in the central or necrotic zone of the tubercle but can be found in large numbers in the epithelioid zone adjacent and distal to multinucleate giant cells (Figure 23.24).

The outermost region of the granulomas is encapsulated by fibrous connective tissue, macrophages, some lymphocytes, and an occasional granulocyte. Calcification of the tubercle rarely occurs in fowl. Amyloid deposition in the surrounding parenchymal elements has been reported in liver, spleen, and kidney.

Microscopically, lesions of avian tuberculosis in turkeys vary considerably but are similar to avian tuberculosis of chickens. In other instances, lesions are diffuse, with extensive destruction of surrounding parenchyma. Cytoplasmic masses or large giant cells may be numerous, and large numbers of granulocytes are commonly present. Some lesions become circumscribed by a broad, dense zone of fibrous connective tissue.

Pathogenesis of the Infectious Process

Ingestion of the bacillus results in intestinal infection and eventual bacillemia. Bacillemia allows for the transfer of bacilli from the intestine directly to the liver. The bacillemia, which probably occurs intermittently and perhaps early in most instances, also provides for a generalized distribution of lesions. No tissue, with the possible exception of the central nervous system, appears to be exempt from infection.

Cheville et al. (19) studied experimental *M. avium* infection in chickens. The disease course in young chicks lasted for 30 days after intravenous challenge. Single acid fast bacilli were first found 5 days post infection in cells of periarterial lymphoid sheaths of the spleen without other histologic evidence of infection. Many bacilli were found within aggregated histiocytic macrophages of the sheath 10 days post challenge. By day 14, miliary tubercles were found within lymphoid sheaths. Delayed type hypersensitivity (DTH), as judged by wattle thickness, first occurred 2 days post infection and increased in intensity as the disease progressed (Figure 23.21E). This response decreased as the disease became more severe. The disease process was divided into 3 periods: a latency period, a lesion development period, and a cachexia period.

The latency period occurred for the first 7 days of the infection. During this period, there were no microscopic lesions, but DTH reactions appeared and increased in intensity with time. The lesion development period occurred from days 8–17 post infection. Bacilli multiplied in lymphoid sheaths during this time. Serum antibody titers developed, the thymus atrophied, and small tubercles with few bacilli developed.

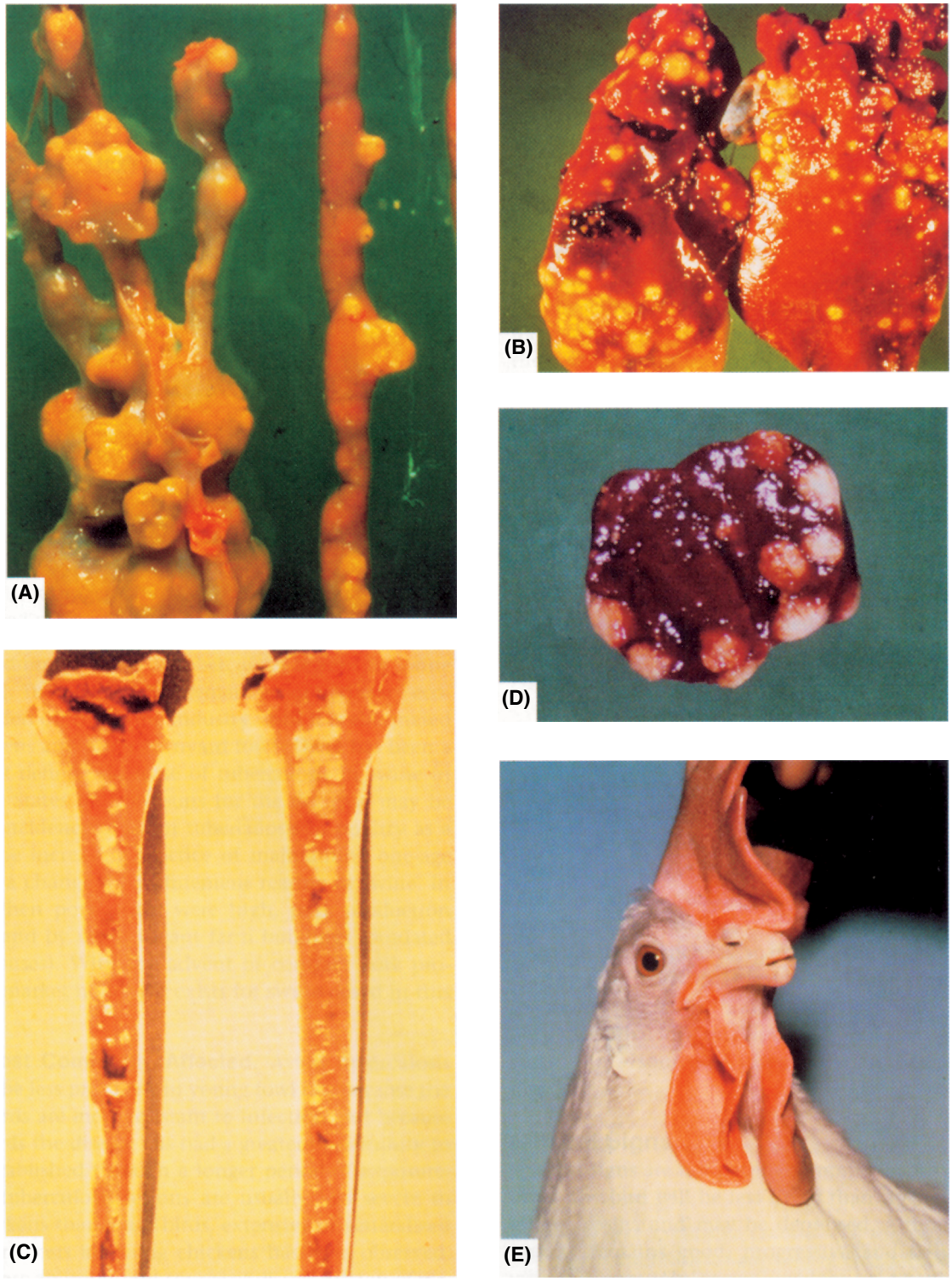

Figure 23.21. Tuberculous lesions in intestine (A), liver (B), bone marrow (C); and spleen (D) of naturally infected chickens. Note the variation in size of granulomas in the liver and spleen. (E) Positive reaction in the left wattle of tuberculous chicken 48 hours after intradermal infection of avian tuberculin. (M.C. Peckham)

Cachexia lasted from day 18 until death. During this period, massive tubercles with large numbers of bacilli developed, there was lymphoid atrophy, DTH disappeared, and amyloid was deposited at the periphery of tubercles. In addition to lymphocyte-intact chickens, these studies also used both bursectomized and thymectomized chicks. There was very little difference in the pathogenesis between lymphocyte-intact and -depleted chicks.

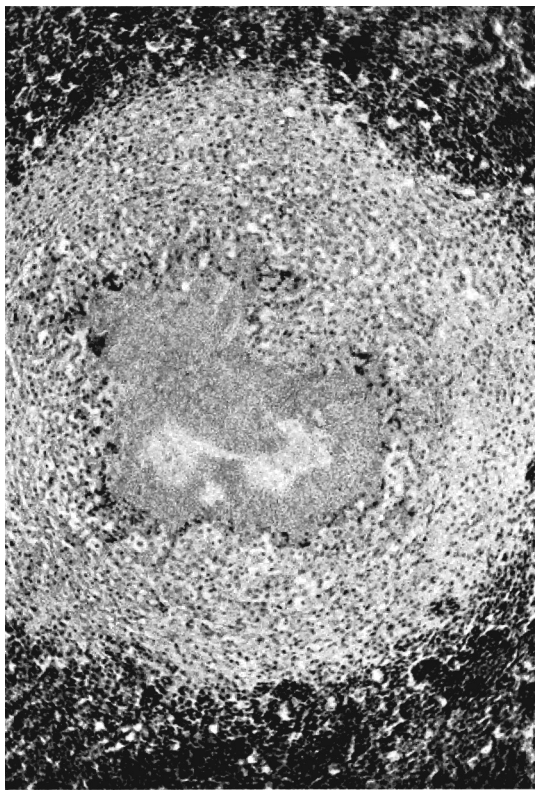

Figure 23.22. Small tuberculous granuloma in bone marrow of a naturally infected chicken. The central necrotic region is surrounded by a zone of dense connective tissue. ×100.

Figure 23.23. Developing tubercle in lung of chicken. ×100.

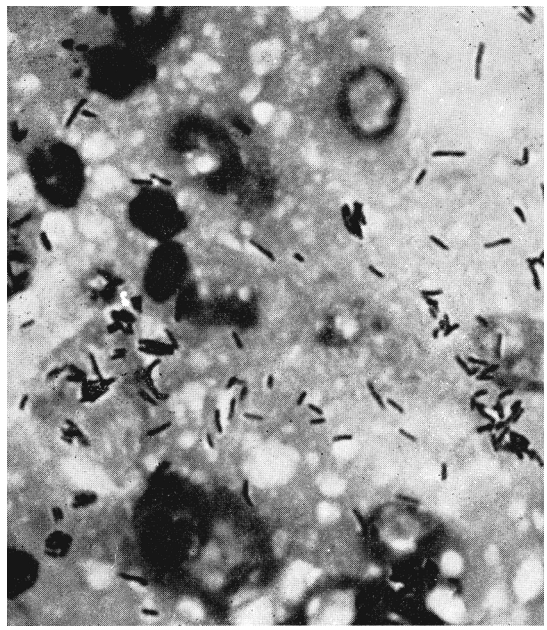

Figure 23.24. Numerous tubercle bacilli in smear preparation from a small lesion of lung of a naturally infected chicken. Ziehl-Neelsen stain, ×1600.

The capacity of *M. avium* to produce progressive disease may be related to cell wall constituents and certain complex lipids present in the cell wall, such as cord factor, sulfur-containing glycolipids (sulfatides), or strongly acidic lipids (96, 127). Although not yet proven in the avian species, lipoarabinomannan, an outer cell wall component of all mycobacteria including *M. avium*, also may play a role in the pathogenesis through its oxygen radical scavenging, inhibition of protein kinase C, and blocking activation of γ interferon (17, 20, 26, 47). *M. tuberculosis* and *M. avium* prevent fusion of phagosomes (the vacuole where they reside intracellularly) with lysosome and maturation of the resulting phagolysosome (115). It appears, however, that the effect of the aforementioned components alone or together on phagosome-lysosome fusion cannot account for virulence.

DTH develops following exposure to mycobacteria; once activated, macrophages demonstrate an increased capacity to kill intracellular *M. avium*. The DTH responses are mediated by lymphocytes, which release lymphokines that act to attract, immobilize, and activate blood-borne mononuclear cells at the site where virulent bacilli or their products exist. Tumor necrosis factor, alone or in combination with interleukin-2, but not γ interferon, has been associated with macrophage killing of *M. avium* serovar 1 (7).

The DTH contributes to accelerated tubercle formation and is, in part, responsible for cell-mediated immunity in tuberculosis. Activated macrophages that lack sufficient subcellular microbiocidal components to kill virulent tubercle bacilli are destroyed by the intracellular growth of the organism, and a lesion develops. A combination of toxic lipids and factors released by virulent *M. avium* may (1) cause disruption of the phagosome, (2) inhibit phagolysosome formation, (3) interfere with the release of hydrolytic

enzymes from the attached lysosomes, and/or (4) inactivate lysosomal enzymes released into the cytoplasmic vacuole. Toxic oxygen metabolites are not responsible for killing activated macrophages. However, the significance of hydrogen peroxide, activated oxygen radical(s), and nitric oxide in resistant macrophages of birds exposed to virulent *M. avium* remains to be elucidated (115). *M. avium* has been shown to induce caspase-1 activity in macrophages and may serve as a mechanism for its pathogenicity (96).

Diagnosis

A presumptive diagnosis of avian tuberculosis in fowl usually can be made based on gross lesions (15). Demonstration of acid-fast bacilli in smears or histologic sections of liver, spleen, or other organs strengthens the diagnosis and is sufficient for most diagnostic cases. Inoculation of suitable media to isolate and identify the causative agent confirms the diagnosis of avian tuberculosis and allows speciation of the causative agent (63). In live, suspected infected birds, fecal smears for culture, staining, and/or PCR may be attempted but these tests are not reliable due to intermittent or no fecal shedding of bacilli (136). Fecal positivity increases as the disease course progresses (118). PCR has been used to detect mycobacteria including *M. avium* and *M. genavense* in formalin-fixed tissue which may further aid diagnostic considerations (46). PCR also may be used to detect mycobacteria in organ samples as well as further differentiate isolates (75, 105).

Tuberculin Test

When administered properly, the tuberculin test provides a satisfactory procedure for determining the presence of avian tuberculosis in a flock. The technique involves intradermal injection of the wattle with 0.03–0.05 mL of a U.S. Department of Agriculture (USDA) supplied purified protein derivative tuberculin prepared from *M. avium* in a manner previously described (3). The injection site then is monitored for a reaction (Figure 23.21E). A more complete methodology and interpretation has been reported elsewhere (112). Tuberculin testing in poultry may reveal a false-negative result twice during the course of infection: once during early infection and again during late infection, when there is immune system exhaustion or anergy. This test is also unreliable in some bird species (116).

Serology

Enzyme-linked Immunosorbent Assay

Enzyme-linked immunosorbent assay (ELISA) has detected mycobacterial antibodies in sera of chickens experimentally inoculated with *M. avium* serovar 2, but false-positives may be common (132). ELISA is less specific than the tuberculin test.

Rapid Agglutination Test

A whole-blood agglutination test has been described for diagnosis of avian tuberculosis in fowl and is a better test than tuberculin for waterfowl (61, 98). The agglutination test has been more useful for detecting infected birds in a diseased flock; however, occurrence of false-positive agglutination reactions in healthy birds is a drawback (48).

Differential Diagnosis

The most expedient way to diagnose the disease is by necropsy. Granulomas are rather characteristic, but other conditions must be differentiated. These include coligranulomas (Hjarre's disease), pullorum disease, other *Salmonella* infections, *Staphylococcus* infection, fowl cholera, aspergillosis, and neoplasia. Presence of numerous acid-fast bacilli in lesions is significant. When available, culture and identification of *M. avium* is helpful but not essential for a diagnosis.

Intervention Strategies

Management Procedures

In backyard poultry and captive birds, the tuberculin test should be used to detect avian tuberculosis. Removal of chickens that react reduces environmental contamination and subsequent infections. The whole-blood agglutination test also may serve to detect infected birds and may be more reliable. However, if the residual flock is permitted to occupy the same contaminated premises, contaminated soil may be a continuing source for infection. Furthermore, neither the tuberculin nor the agglutination tests can be depended upon for detection of every tuberculous fowl. As long as one infected bird remains in a flock, dissemination of the disease to healthy fowl is possible. Consequently, termination of the entire flock and repopulation on noninfected soil may be the best approach to control avian tuberculosis.

Procedures for establishing and maintaining avian tuberculosis-free backyard flocks should include the following: (1) Abandon old equipment and establish other facilities on new soil. Ordinarily, it has been impractical to render an infected environment satisfactorily safe by disinfection. (2) Provide proper fencing or other measures to prevent unrestricted movement of chickens, thus preventing exposure from previously infected premises. (3) Eliminate the old flock, burning carcasses of birds that show lesions of tuberculosis. (4) Establish a new flock in the new environment from avian tuberculosis-free stock. If chickens in a clean flock are prevented access to an infected environment and are protected against accidental exposure to an infected environment and accidental exposure to *M. avium*, it is reasonable to believe that they will remain free from avian tuberculosis.

Recommendations for control of avian tuberculosis in exotic birds include the following: (1) Prevent contact with tuberculous birds; premises and housing previously used by them are to be avoided. (2) Quarantine additions to the aviary for 60 days and retest with avian tuberculin.

Vaccination

Use of experimental vaccines containing inactivated and/or live mycobacteria for protecting chickens against tuberculosis has been evaluated (95). The best results were obtained

in chickens vaccinated with live *M. intracellulare* serovar 6 (*M. avium* serovar 6) given orally. These fowl showed 70% protection after intramuscular (IM) challenge with *M. avium*. Encouraging results were also reported in chickens after combined IM vaccination with inactivated plus live *M. intracellulare* serovar 7 and serovar Darden (*M. avium* serovars 7 and 19). Recently, vaccination of chickens using various fractions of a homologous strain of *M. avium* for vaccine production and challenge revealed that the number of lesions and bacilli/gram of liver were decreased; it did not, however, prevent infection (34).

Treatment

Treatment with antituberculosis drugs is impractical and is rarely done to treat domestic backyard poultry. However, combinations of antituberculosis drugs have been used to treat certain exotic birds maintained in captivity (126). Clinical remission was observed in 3 birds that received a combination of isoniazid (30 mg/kg), ethambutol (30 mg/kg), and rifampicin (45 mg/kg). The recommended duration of therapy was 18 months, provided that there were no adverse side effects. More information concerning treatment may be found in Dhama et al. (26).

Miscellaneous and Sporadic Bacterial Infections

Tahseen Abdul-Aziz and H. John Barnes

Surveys of bacteria isolated from poultry often include a variety of unusual bacteria of low incidence. Similarly, microbial surveys of eggs, dead embryos, chicks with omphalitis and yolk sacculitis, and chick mortality frequently reveal a diversity of bacteria, generally in low incidence that typically are found in the environment and are not normally associated with disease. Because the importance of isolates recovered infrequently in surveys is unknown, or not considered significant, they are not covered in detail in this review. Additionally, interest in achieving and maintaining intestinal homeostasis in meat-producing birds has led to methods to quantify microbial populations by molecular methods. Organisms identified in these studies also are not discussed, nor are organisms considered to be normal flora.

Acinetobacter

The genus *Acinetobacter* belongs to the family Moraxellaceae. *Acinetobacter* spp. are nonfermentative, nonmotile, oxidase-negative, strictly aerobic, small, Gram-negative coccobacilli (224). The organism is occasionally recovered from dead-in-shell embryos and weak chicks (107, 129). *A. lwoffi* and *A. calcoaceticus* were isolated from outbreaks of septicemia in hens. Mortality was approximately 15%, and there was multifocal necrosis and green discoloration of the liver (69, 109). Turkeys also are affected as *Acinetobacter* has occasionally been isolated from dead-in-shell embryos and weak poults, respiratory disease, septicemia, and inflamed joints (70). Other clinical presentations include pigeons with arthritis (66) and ducks with arthritis, septicemia, or airsacculitis (19, 229).

Aegyptianella

Aegyptianella pullorum is an obligate intracellular organism in the family *Anaplasmataceae*, order Rickettsiales, which is most closely related to *Anaplasma* spp. (178). It causes the tick-borne disease aegyptianellosis (84). The disease occurs in tropical and subtropical areas and has been identified in a variety of birds including chickens, turkeys, and guinea fowl. With the exception of wild turkeys in the Rio Grande area of Texas (36) and an Amazon parrot imported into England from South America (168), the organism has only been identified in Europe, Asia, and Africa.

Affected birds experience increased mortality and develop severe anemia, which can predispose them to ascites and right ventricular heart failure (100). Aegyptianellosis occurs mainly in free-ranging poultry and wild birds that are infested with fowl ticks in the genus *Argas*. Diagnosis depends on identifying the typical organism in erythrocytes of infected birds (84). In stained blood smears the organism appears as purple, 0.3- to 4-μm diameter intracytoplasmic inclusions (178). Treatment with tetracyclines and supportive care are generally effective (84). Prevention is the same as that for spirochetosis (see *Borrelia*, below).

Aeromonas

Aeromonas is a small Gram-negative rod that is commonly found in aquatic environments. It frequently colonizes the intestines of animals and can contaminate poultry carcasses during processing. *Aeromonas* has public health significance because it can cause intestinal and extraintestinal diseases in people including gastroenteritis, septicemia, necrotizing fasciitis, and myonecrosis (102).

Aeromonas hydrophila, either alone or in combination with other organisms, causes localized and systemic infections in avian species including poultry (78, 192). *Aeromonas* was recovered from turkeys experiencing severe diarrhea. Inflammation and hemorrhage of the intestinal mucosa were characteristic findings in affected poults. Experimental inoculation of chicks with the turkey isolate caused significant mortality (76). *Aeromonas* was among the organisms identified from cellulitis lesions in turkey

carcasses at processing (163). *A. hydrophila* has been isolated from ducks with salpingitis (20), septicemia (128), airsacculitis (229), and granulomatous inflammation of salt glands (114). A bacterin prepared from 3 strains that caused high mortality in experimentally inoculated ducklings successfully controlled losses in commercial duck flocks (128). *A. formicans* has been isolated infrequently from arthritic lesions in ducks at processing (22). *Aeromonas* and *E. coli* were the most frequently isolated bacteria from geese with necrotic inflammation of the phallus (see Goose Venereal Disease, below) (137). *Aeromonas* caused severe necrotizing enteritis and septicemia in a 10-year-old ostrich. Pure cultures were isolated from the intestine, liver, lung, and trachea of the bird (72).

Aeromonas is among environmental bacteria that can be recovered from dead-in-shell embryos and weak chicks (129). Microbial contamination of ostrich eggs by *Aeromonas* is associated with reduced hatchability (61).

Arcanobacterium (*Actinomyces*)

The genus *Arcanobacterium* belongs to the family Actinomycetaceae. Organisms are pleomorphic, Gram-positive, facultative anaerobes that do not form spores. Colonies are small, hemolytic, and grow slowly under microaerophilic conditions. They colonize the skin and mucous membranes (224). *A. pyogenes* was formerly classified as a species in the genus *Corynebacterium* and later *Actinomyces*.

A chronic, disseminated granulomatous disease of turkeys suspected to be actinomycosis has been observed sporadically (189). Serious outbreaks of osteomyelitis involving the proximal tibiotarsi and/or thoracic vertebra caused by *A. pyogenes* in commercial male turkey flocks resulted in considerable economic loss (28). Lame birds in 20 affected flocks averaged 20% (range, 5%–50%), age averaged 16 weeks (range, 12–20 weeks), and weekly mortality averaged 2.8% (range, 0.5%–10.5%). Hen flocks were not affected (11). Club-shaped, pleomorphic, Gram-positive bacilli in smears of lesions provided a rapid diagnosis (28). Osteomyelitis was reproduced in 15-week-old male turkeys inoculated intravenously with a representative isolate.

Septicemia, visceral lesions, cutaneous abscesses, mortality of nearly 14%, and a decrease in egg production of more than 27% occurred in caged layers infected with *A. pyogenes*. Portal of entry was through skin lesions caused by poor caging (54).

Bacillus

Bacillus spp. occasionally have been associated with embryo mortality and yolk sac infections in chickens (41, 60, 61, 222), turkeys (29), ducks (13), and ostriches (60, 61). *Bacillus* spp. and *E. coli* were the most commonly cultured bacteria from reproductive disorders of hens (83). *Bacillus cereus*, an organism that can cause foodborne illness in people, infected turkey hens following artificial insemination and was found in 25% of their unhatched eggs. The prevalence fell to 4% after the infection was controlled (29).

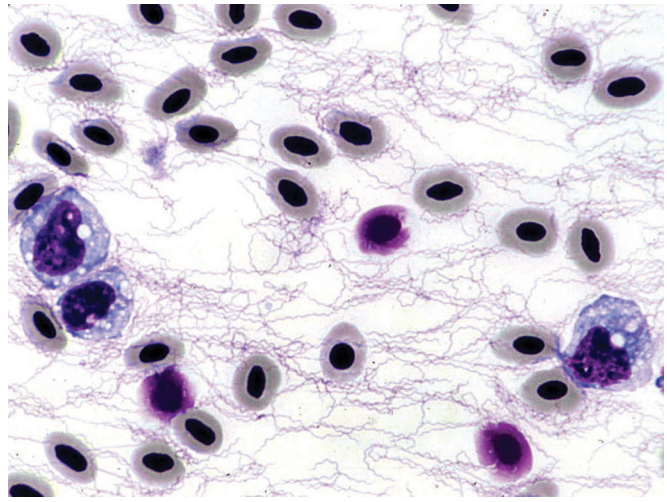

Figure 23.25. *Borrelia anserina* in blood film during the acute stage of infection. Giemsa, ×1200.

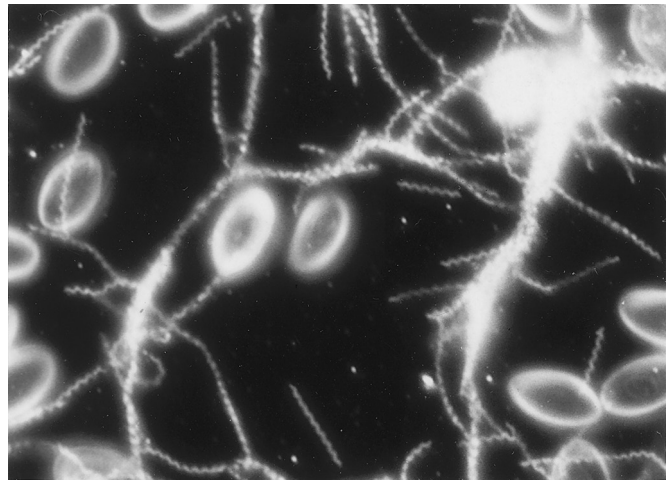

Figure 23.26. *Borrelia anserina* in plasma from infected chicken during terminal stages of spirochetosis. Note agglomeration of organisms. Dark-field, ×480.

Borrelia

Borrelia are highly motile, helical spirochetes that stain well with aniline dyes, hematologic stains, and silver impregnation (Figure 23.25). Spirochetes can be readily identified in wet smears of blood or tissues by dark-field or phase microscopy (44) (Figure 23.26).

Borrelia anserina causes nonrelapsing, tick-borne spirochetosis in avian species including chickens, turkeys, pheasants, geese, and ducks in tropical and subtropical areas. Occasional outbreaks have been identified in the southwestern United States in chickens, turkeys, and pheasants (53). Extensively

reared free-range flocks are more likely to be affected than confined flocks, and indigenous breeds of chickens are generally more resistant than exotic breeds (174). The disease is usually an acute septicemia characterized by high morbidity and mortality, but may be mild if birds are infected with low-virulent strains (12).

Birds also can develop asymptomatic infections with *B. burgdorferi*, the cause of Lyme disease in people, and serve as hosts for ticks capable of spreading the spirochete to mammals (47, 110, 113, 135, 186). Wild turkeys also are hosts for *B. lonestari* and *B. miyamotoi* (104, 187). No clinical disease has been recognized in birds infected with *Borrelia* species other than *B. anserina*.

Occurrence of spirochetosis corresponds with the distribution of fowl ticks in the genus *Argas*, which serve as both the reservoir and primary vector. Attempts to transmit *B. anserina* with the tick *Amblyomma cajennense* were unsuccessful (120). In addition to ticks and other biting arthropods (mosquitoes, mites), infection can result from cannibalism; scavenging on carcasses; multiple use of syringes and needles; or ingestion of infective blood, droppings, or infected ticks. Virulent strains are capable of penetrating unbroken skin. *B. anserina* is not resistant outside of the host. Recovered birds are not carriers; organisms disappear from tissues at or shortly after they disappear from the circulation (12).

Birds infected with virulent strains of *B. anserina* are visibly sick, with cyanosis or pallor of the comb and wattles, ruffled feathers, dehydration, inactivity, and anorexia. A marked elevation in body temperature begins shortly after infection accompanied by rapid weight loss. Affected birds pass fluid green droppings containing excess bile and urates, and have increased water consumption. Late in the disease, birds develop paresis or paralysis, become anemic, and are somnolent to comatose. Body temperatures are subnormal just prior to death. Birds recovering from the disease are often emaciated and have temporary residual weakness or paralysis (12). Infection with low-virulent strains may be mild or inapparent (53).

Marked enlargement and mottling of the spleen is typical of spirochetosis (Figure 23.27) but may not be evident when birds are infected with low-virulent strains (53) or early in the disease. Livers often are enlarged and contain small hemorrhages, pale foci, or marginal infarcts. Kidneys are swollen and pale with excess urates distending the ureters. Green, mucoid intestinal contents are usually present, and often there are variable amounts of hemorrhage, especially at the proventriculus-ventriculus junction. Fibrinous pericarditis occurs infrequently. Extensive hemorrhage and muscle necrosis occur in naturally infected pheasants (12).

Splenic lesions result from macrophage and lymphoid hyperplasia, erythrophagocytosis, and hemosiderin deposition. Multifocal necrosis and hyalinization of white pulp and/or extensive hemorrhage may be present in some birds. The liver is congested with increased periportal infiltrates of mixed lymphocytes, hemocytoblasts, and phagocytic cells with vacuolated cytoplasm. Erythrophagocytosis and hemosiderin are seen in Kupffer cells. Extramedullary hematopoiesis may be present. Lymphoplasmacytic infiltrates occur in kidneys and intestinal lamina propria of some birds. Occasionally, there is mild to moderate lymphocytic meningoencephalitis (9, 12).

Figure 23.27. An enlarged, mottled spleen is characteristic of spirochetosis caused by highly virulent strains of *Borrelia anserina* in chickens. Low-virulence strains may not produce splenic lesions. Spleens may appear differently in other avian species depending on the amount of necrosis and hemorrhage. A few serosal hemorrhages on the proventriculus also can be seen in this bird.

Spirochetosis can be tentatively diagnosed by finding characteristic lesions in birds with signs consistent with the disease. Larval ticks on the birds, evidence of tick bites, or presence of ticks in the bird's environment increases the likelihood of spirochetosis. Diagnosis is confirmed by demonstrating *B. anserina* in blood or tissue sections. In chickens exposed to ticks (*Argus miniatus*) infected with *B. anserina*, spirochetes were found in blood smears prepared from the exposed birds between day 5 and day 12 post exposure, with the peak number of spirochetemic birds occurring between days 7 and 9. Spirochetes were not found in blood smears from any of the exposed birds after day 13 (131).

Borrelia cannot be cultured on routine bacteriologic media but will grow in chick embryos following yolk sac inoculation or in susceptible young chicks or poults (44). It can be grown in liquid medium but loses virulence (126). Bursectomy or dexamethasone treatment of chicks may be necessary to detect low-virulent strains (58). Isolates are usually maintained in ticks, day-old chicks, chicken or turkey embryos, or by cryopreservation (-70°C or in liquid nitrogen) in 5% glycerol or dimethylsulfoxide added to infective blood (44, 119). Several serologic methods have been used to detect antibodies in immune birds. Spirochetal antibodies occur in yolk of eggs from immune hens (44).

Arsenicals and most antibiotics, including penicillin, chloramphenicol, kanamycin, streptomycin, tylosin, and tetracyclines, are effective in treating infected birds. Intramuscular injections of penicillin at 20,000 IU/bird given 3 times in 24 hours or 20 mg oxytetracycline given daily for 2 days represent current treatment regimens (12).

Active immunity follows recovery or immunization. Immunity is serotype-specific; infection with other *B. anserina* serotypes can occur in recovered or vaccinated birds. An autogenous or polyvalent vaccine containing multiple serotypes may be necessary to provide full protection (223). Controlled infection followed by antibiotic treatment 3 days later also has been used to induce active immunity. Passive maternal immunity provides protection for 5–6 weeks (12). Preventing fowl tick infestation is the best method to control spirochetosis in endemic areas. Young chickens in dense poultry areas during the summer are more likely to be infested with fowl ticks (191). Adult ticks can remain alive without feeding and carry the spirochete for as long as 3 years (12).

Citrobacter

Citrobacter is a genus in the *Enterobacteriaceae* family. The organism commonly colonizes mucous membranes of the respiratory and digestive tracts of normal birds, but can be an opportunistic pathogen. *Citrobacter* is one of many environmental bacteria that are occasionally isolated from unhatched eggs, weak chicks, and yolk sac infections (129, 222). It has been isolated from the liver of 2-week-old turkey poults with respiratory disease (70) and was isolated from 10% of airsacculitis lesions in processed broilers (195). *C. freundii* infrequently has been isolated from young ducks with salpingitis (20). *C. murliniae* was isolated from visceral organs of clinically sick and dead ducks, quail, and chickens (90).

Coenonia

Coenonia is a genus in the family Flavobacteriaceae that contains a single species, *C. anatina*, which was previously identified as *Riemerella anatipestifer*-like taxon 1502. It causes an exudative septicemia in ducks and geese (219).

Coryneform Bacteria

A Gram-positive, pleomorphic, coryneform bacterium with certain characteristics of *Erysipelothrix*, *Lactobacillus*, and *Listeria* was isolated from an outbreak of polyarthritis in chickens (147). *Corynebacterium* sp. accounted for 18% of 132 isolates from blood samples, livers, and hock joints of clinically ill commercial broilers within 2 weeks of processing (7).

Coxiella

Coxiella brunetti is an obligate intracellular, Gram-negative bacterium that causes Q fever in humans. It can also infect different animal species including mammals, reptiles, fish, and ticks. Phylogenetically, it is related to the genus *Legionella*. The bacterium resides within cytoplasmic parasitophorous vacuoles in the infected cell (56, 221, 235).

Infection with *Coxiella*-like organisms has been described in psittacine birds, a toucan, and lorikeets. Affected birds were either asymptomatic or weak and lethargic. Emaciation, hepatomegaly, and splenomegaly were seen in affected birds. Histologic lesions included hepatitis, hepatic necrosis, epicarditis, myocarditis, cardiomyopathy, enteritis, splenic granulomas, nephritis, pneumonitis, and lymphohistiocytic encephalitis. A consistent lesion in parakeets was histiocytic vasculitis and perivasculitis with formation of small microgranulomas adjacent to affected vessels. Infiltrating macrophages had cytoplasmic, lightly basophilic, granular inclusions that represented the organisms. There are variations in the reported results of the staining properties of the inclusions in tissue sections with different histochemical stains (194, 221, 235). Infection of poultry has not been reported, but there is serologic evidence that it occurs (153).

Enterobacter

Enterobacter is a normal inhabitant of the avian digestive tract (18). Similar to other Gram-negative bacteria in the *Enterobacteriaceae* family, it can infect eggs and young birds causing embryo loss, omphalitis, yolk sac infections, and mortality in young birds (70, 129, 183, 222, 230). *Enterobacter* has been isolated infrequently from turkeys with cellulitis (163).

Flavobacterium

Flavobacterium is a dominant proteolytic bacterium in the upper respiratory tract of chickens and turkeys (33) that is rarely associated with clinical disease. It has been recovered from ducks with arthritis (19), an adult goose with salpingitis (20), chickens, a pigeon, a finch with septicemia and/or arthritis (218), and unhatched eggs and weak chicks (129). Heavy, pure cultures of *F. meningosepticum* were obtained from a 5-week-old ostrich chick that failed to grow and thrive and had airsacculitis, pneumonia, and thymic atrophy/hypoplasia (124).

Gallibacterium

The genus *Gallibacterium* is a member of the family *Pasteurellaceae*. Bacterial isolates of avian origin formerly identified as taxons 2 and 3 were classified within the genus *Gallibacterium*. These isolates were from salpingitis in ducks, salpingitis and septicemia in geese, septicemia and pneumonia in pigeons, septicemia in turkeys, pneumonia in pheasants, and septicemia in parakeets and budgerigars. Four species (*G. anatis, G. salpingitidis, G. melopsittaci*, and *G. trehalosifermentans*), 3 new genomespecies (*Gallibacterium* genomespecies 1, 2, 3), and an unnamed taxon (Group V) were proposed. *G. salpingitidis* includes isolates from salpingitis in ducks and geese (24, 42).

Gallibacterium anatis was formerly classified as *Pasteurella hemolytica*-like, *Actinobacillus salpingitidis*, or *Pasteurella anatis* (42). The organism is known to be a normal inhabitant of the upper respiratory tract and lower reproductive tract of chickens, but is also considered a cause of salpingitis and peritonitis in laying hens (103). Chickens, ducks, geese, and

ostriches have been affected. In a study involving 31 flocks of table egg layers, *G. anatis* was isolated from the heart, liver, spleen, intestine, and reproductive tract of hens in several flocks (157). Field isolates from septic laying hens and a well-characterized strain of *G. anatis* were pathogenic for pullets and layers following inoculation (26, 204, 205). Mortality was higher in birds inoculated intravenously compared to those inoculated intraperitoneally, and lesions were more severe in experimentally immunosuppressed birds (26). Twelve-week old specific-pathogen-free leghorn chickens inoculated intranasally with 1 of 3 strains of *G. anatis* developed histologic lesions of varying severity in the trachea, lung, air sacs, and liver, with no clinical signs or mortality (239).

Bacteria originally reported as atypical *Actinobacillus lignieresii*, which were later classified as taxon 2 and taxon 3 (currently classified as *Gallibacterium*) (24), were isolated from lesions of salpingitis in egg-laying ducks and geese. Isolation from the cloaca and penis of normal geese suggests that salpingitis probably results from an ascending infection (20). A similar conclusion was reached about the role of *Actinobacillus* in goose venereal disease (see above) (136).

Hafnia

Hafnia is a Gram-negative rod-shaped bacterium in the family *Enterobacteriaceae. Hafnia alvei* infrequently has been identified as a cause of septicemia in pullets and laying hens (34, 175). Infections were characterized by loss of appetite, diarrhea, opisthotonus, decreased egg production, and increased mortality. Scattered pale foci in the liver, hepatomegaly, splenomegaly, and catarrhal to hemorrhagic enteritis were seen on necropsy. Microscopically, degeneration, multifocal necrosis, and inflammation of the liver; lymphocytic depletion and necrosis of the spleen; and intestinal hyperemia, hemorrhage, and catarrhal enteritis were identified. Gram-negative bacteria were numerous within lesions, occurring frequently as intravascular emboli.

Helicobacter

A distinct group of bacteria, previously identified as *Campylobacter*-like organisms, has been placed into the genus *Helicobacter* based on their phenotypic characteristics and 16S rRNA sequences (164). *Helicobacter* species are Gram-negative, curved or spiral shaped bacteria. Species in this genus are separated into two groups: gastric helicobacters and enterohepatic helicobacters (134).

Helicobacter pullorum, a species in the enterohepatic group, has been identified in intestinal contents of broiler chickens, laying hens, guinea fowl, and turkeys (134, 238), and livers and intestines of layers with lesions characteristic of "vibrionic hepatitis" (31). The organism has been found infecting chickens in Europe and Australia (38, 141). *Helicobacter pullorum* may have public health significance, because there are reports of its association with gastroenteritis, bacteremia, and liver and gall bladder diseases in humans (32, 108, 197, 199, 210).

Helicobacters can be cultured using procedures for isolating campylobacters; however, they are inhibited by polymyxin B, which was used in some older media formulations. A PCR to detect the organism has been developed (32, 77, 197). A multiplex PCR is useful for identifying and differentiating *Arcobacter*, *Campylobacter*, and *Helicobacter* (81, 156). Specific identification requires a combination of phenotypic and genotypic analyses (77, 140, 164, 198).

Helicobacter canadensis, a species closely related to *H. pullorum*, has been found in geese, guinea fowl, and pheasants. It also has been identified from people with diarrhea (155, 179, 226).

Two additional *Helicobacter* species, *H. anseris* and *H. brantae*, infect Canada geese. Although these two *Helicobacter* species are suspected to be possible human pathogens, they have not been implicated in human disease. Environmental contamination of parks by feces from geese infected with these organisms is considered a potential public health concern. Another avian species (*H. pametensis*) has been described from a tern (64) and other unnamed, distinct strains have been isolated from avian species (190).

Klebsiella

Klebsiella is an environmental contaminant that occasionally causes embryo mortality, yolk sac infections, and mortality in young chickens, turkeys, and ostriches (107, 129, 165, 170, 183, 184, 222, 230).

The organism has been associated with cutaneous, respiratory, ocular, systemic, and reproductive diseases of poultry. *Klebsiella* was among aerobic bacteria isolated from turkeys with cellulitis (80). *Klebsiella* was isolated from turkey flocks with adenoviral inclusion body tracheitis that experienced respiratory disease and increased mortality. An outbreak of ocular disease caused by *Klebsiella* affected a flock of 4-week-old chickens (132). *Klebsiella* and *Staphylococcus aureus* were isolated from a septicemic disease in 20-week-old layers experiencing increased mortality. Mortality and clinical disease followed oral inoculation of young chicks with 3 *Klebsiella* biotypes. Chicks inoculated with *K. pneumoniae* had the highest mortality (62). *Klebsiella* has been infrequently isolated from reproductive diseases including salpingitis and oophoritis in hens (15, 193). Localized and systemic infections with *Klebsiella* occur in young ostriches causing "ostrich fading chick syndrome," an often-fatal disease of birds less than 3 weeks of age (211). Hydroponically grown alfalfa sprouts being fed to the birds were heavily contaminated with the organism and believed to be the source of infection (230).

Lawsonia

Lawsonia intracellularis is an obligate, intracellular, *Campylobacter*-like organism that causes proliferative enteropathy in a variety of animals, especially pigs, horses, and hamsters (123). Among avian species the disease has been reported in young ostriches and emus (48, 125). Infection of

ratites was associated with increased mortality, poor growth, diarrheal disease, tenesmus, and rectal prolapse. Affected intestinal mucosa was thickened and rugose. Enterocyte proliferation, crypt changes, and infiltration of the mucosa with mixed inflammatory cells were seen microscopically. Intraepithelial, comma-shaped bacteria were visible with Warthin-Starry silver staining in the apices of enterocytes, which were identified as *L. intracellularis* by specific immunofluoresence. Affected birds responded to treatment with chlortetracycline (125). Chickens were not susceptible to experimental *Lawsonia* exposure (45). Furthermore, the organism was not found in normal chickens or those with malabsorption syndrome in the southeastern U.S. (139). Genomic analysis of organisms from several animal species including ostriches showed they are closely related (49).

Listeria

Outbreaks of listeriosis caused by *Listeria monocytogenes* occur sporadically in chickens, turkeys, waterfowl, pigeons, and other avian species (85, 86, 116, 127). Young birds are most susceptible (14). The organism is important because of its ability to cause human infections following contact with infected birds (85) or consumption of contaminated poultry or poultry products, especially those that are precooked and "ready to eat" (55). Intestinal colonization of poultry and presence of *L. monocytogenes* in feces represent potential sources of the organism for listeriosis in ruminants (65).

Septicemic and encephalitic forms of listeriosis are recognized in birds. Emaciation and diarrhea characterize birds with septicemia. Neurological signs including depression, incoordination, ataxia, torticollis, and opisthotonos are seen in the encephalitic form (51, 52). Torticollis is especially common in affected birds. In the septicemic form, there is splenomegaly, multifocal hepatic necrosis, myocardial necrosis, and pericarditis. Myocardial degeneration, necrosis, and inflammation are often extensive (127, 171). Ascites and petechial hemorrhages in liver, heart, spleen, kidneys, and brain were seen in affected broilers (225). Salpingitis developed in hens following the acute systemic phase of the infection (112).

Birds with the encephalitic form may have visible inflammatory foci in the brain stem but usually lack gross lesions (51, 52, 85, 116, 225). Microscopically, gliosis and satellitosis in the cerebellum and hemorrhages, fibrin thrombi, and abscesses containing Gram-positive bacteria are present in the midbrain, cerebellum, and medulla oblongata of birds with encephalitic listeriosis. Lesions tend to be most severe in the medulla oblongata (51, 116).

The organism is commonly found in feces and soil in temperate areas of the world. Infection can follow inhalation, ingestion, or wound contamination. An outbreak of listeriosis occurred in broilers shortly after beak trimming (225). Cold, wet conditions causing excessively moist litter were associated with an outbreak of encephalitic listeriosis and the organism was isolated from litter, water, and soil samples (51). In another outbreak, the poultry house had been flooded 10 days before onset of the disease, and conditions were hot and humid (116).

Listeria can be readily isolated and does not require special procedures (50) except it may be difficult to recover from birds with the encephalitic form of the disease. However, direct culture of brain stem was positive in 4 of 5 samples collected in an outbreak of encephalitic listeriosis (52). Chicken embryos are readily infected and can be used for isolation. *Listeria monocytogenes* is the only species that has been implicated in poultry disease and it needs to be differentiated from other species of *Listeria* (50). There are 13 serotypes; the majority of human and animal infections are caused by serotypes 4B, 1/2a, and 1/2b (50). Demonstrating antigen in fixed tissues that have lesions of a septicemic disease is useful for confirming a diagnosis of listeriosis when culture is not possible (171). A comprehensive review of diagnostic methods for identifying *Listeria* has been published (73).

Prevention of listeriosis depends on identifying and eliminating sources of infection. Based on the history of published outbreaks, avoiding wet conditions would seem prudent even though the risk for developing listeriosis has not been proven. The organism is often resistant to most commonly used antibiotics.

Moraxella

Moraxella has been isolated occasionally from turkeys with respiratory disease (70). *Moraxella osloensis* caused a fowl cholera-like disease in commercial turkeys. Affected birds had at least one consolidated, pneumonic lung, multiple hemorrhages and inflammation of serous membranes, and abnormal spleens and livers. The organism could be distinguished from *Pasteurella multocida* by its growth on eosin-methylene blue and MacConkey's agar. The disease was reproduced in experimentally inoculated turkeys (68). *Moraxella* sp. also has been recovered from salpingitis in layers (22) and from dead-in-shell embryos or weak chicks (129). An ostrich developed granulomatous conjunctivitis from which *M. phenylpyruvica* was isolated (87).

Mycobacterium avium subsp. *paratuberculosis*

Natural infections of poultry with *Mycobacterium avium* subsp. *paratuberculosis* have not been reported, but chickens are susceptible to experimental infection (215, 217) and develop an immune response following exposure to the organism (43). A related mycobacterial strain that causes chronic intestinal disease of wood pigeons (*Columba palumbus*) in Europe (212, 216) produces lesions consistent with paratuberculosis in experimentally inoculated calves (46, 213). Both the wood pigeon strain and *M. avium* subsp. *paratuberculosis* may have significant public health importance, because they have been associated with Crohn's disease and sarcoidosis in people (138). Granulomatous liver lesions with intralesional acid-fast

bacteria identified by PCR as *M. avium* subsp. *paratuberculosis* have been reported in a sparrow (143).

Neisseria

Neisseria are nonfermentative, rod-shaped diplococci that do not grow on MacConkey's agar and are nonhemolytic, oxidase-positive, and catalase-positive. *Neisseria weaveri* has been isolated from tracheas and lungs of chickens and turkeys in flocks with respiratory disease. Lesions in affected birds included tracheitis and pneumonia. Turkeys were more frequently affected than chickens. Ages of infected birds ranged from 5 weeks to 3 years. Usually other bacteria or viruses were identified in affected flocks. Its role in respiratory disease is unknown (40). *Neisseria* are also commonly identified in goose venereal disease (see below) and it can cause pneumonia in young ostriches (98).

Nocardia

Nocardia is an aerobic actinomycete. It is Gram-positive, very long, thin, obviously branched, finely beaded, and weakly acid-fast (224). The organisms are widely distributed in the soil as saprophytes. *Nocardia* typically causes granulomatous lesions, especially in the respiratory system. The organism has rarely been isolated from poultry although chickens are susceptible to experimental infection following oral or intraperitoneal inoculation (162). A 26.8% mortality rate due to systemic nocardiosis has been reported in pigeons (59).

Oerskovia

Oerskovia is a Gram-positive bacterium that morphologically resembles *Nocardia*. It is widely distributed in the environment. On agar, colonies are yellow and the organism forms branching vegetative hyphae that penetrate into agar, without aerial hyphae (224). Infection of animals and humans with *Oerskovia* is rare. The organism was isolated, along with α-hemolytic *Staphylococcus*, from a clinically ill pigeon that had a large granulomatous mass at the base of the heart adjacent to the esophagus and trachea. Colonies of Gram-positive bacilli were present within granulomas (231).

Pelistega

Bacterial isolates associated with respiratory disease in pigeons have been placed into a novel genus, *Pelistega*, as a single species, *P. europea*. It is a Gram-negative, non-motile, rod-shaped bacterium taxonomically related to *Taylorella equigenitalis*, the cause of contagious equine metritis (220).

Planococcus

Planococcus is a halophilic, motile, Gram-positive coccus that is unrelated to other cocci and normally associated with marine environments. Pure cultures of *P. halophilus* were obtained from livers of 43-week-old layers with multifocal hepatic necrosis. Mortality approaching 6% occurred in the flock during the month after onset of the disease. High ambient temperatures (up to 46°C) during the outbreak were thought to be a contributing factor (1).

Plesiomonas

Plesiomonas shigelloides, the one species in the genus, is closely related to species in the genus *Aeromonas*. It is commonly found in freshwater environments and has been infrequently isolated from avian species, mainly aquatic birds (101). Concurrent infections with *P. shigelloides* and *Edwardsiella tarda* caused fatal septicemia in young penguins (158).

Proteus

Proteus is a genus in the family *Enterobacteriaceae* that inhabits the lower intestinal tract. The organism is capable of penetrating the eggshell following fecal contamination. Experimental inoculation of fertile eggs resulted in 100% embryonic mortality (30). Temperature influences egg penetration and survival time within the egg (2).

Proteus occasionally causes embryonic death, yolk sac infections, and mortality in young chickens, turkeys, and ducks (13, 107, 129, 165, 170, 181, 183, 184, 222). However, experimental inoculation with an isolate from ducklings failed to cause disease (181).

Septicemia due to *Proteus* has occurred in quail (145, 182), pheasants infected with low pathogenic avian influenza virus (209), and broilers suspected of having immune deficiency (172). *Proteus* has been recovered occasionally from a low percentage of salpingitis and oophoritis lesions in layers (15, 22, 193), and has been associated with respiratory disease in chickens (130, 207, 237). An isolate from chickens with respiratory disease caused 50% mortality in experimentally inoculated 4-week-old chickens (130). *Proteus mirabilis* was isolated from the lung, trachea, and kidney of chickens experiencing respiratory signs, diarrhea, paralysis, and high mortality. The disease was reproduced with isolates of the organism (237). *Proteus* was isolated infrequently from turkeys with cellulitis (80, 163) and white leghorn pullets with necrotic dermatitis that seroconverted to reticuloendotheliosis virus (97). In waterfowl, *Proteus* can occasionally produce arthritis, salpingitis, airsacculitis, septicemia (19, 20, 229), and granulomatous inflammation of salt glands (114).

Pseudomonas

Pseudomonas causes localized or systemic disease in young and growing poultry, invades fertile eggs causing death of embryos and newly hatched birds, and reduces shelf life of contaminated meat. Pseudomonads are capable of digesting eggshell cuticle if the humidity is high (25).

They are ubiquitous, often associated with soil, water, and humid environments. *Pseudomonas* is generally considered

to be an opportunist that produces respiratory infections, including airsacculitis (195), sinusitis (70), keratitis and keratoconjunctivitis (115), or septicemia and its sequelae when introduced into tissues of susceptible birds. Above normal mortality in young birds due to omphalitis and yolk sac infections acquired in the hatchery have been described (228). Chickens (10, 63, 117, 144, 176, 228), turkeys (8, 80, 88), ducks (19, 114, 181, 229), pheasants (96), ostriches (99, 148, 166, 230), geese (201), and a variety of pet and captive birds have been affected. Although birds of any age may be infected, young birds are most susceptible, as are severely stressed or immunodeficient birds. Concurrent infections with viruses and other bacteria, especially mycoplasmas, are common and may enhance susceptibility to *Pseudomonas* (169, 172, 201). Morbidity and mortality are usually 2%–10% but can be much higher, approaching 100%.

Pseudomonas aeruginosa is the most common species causing infections, especially yolk sac infections and septicemia in young chicks. Virulence varies among isolates. Mortality following yolk sac inoculation of chicks ranged from 0%–90% (228). Isolates examined in another study were highly virulent, causing 50%–100% mortality in experimentally inoculated 4-week-old chickens (130).

Pseudomonas fluorescens caused death of turkey embryos following dipping of eggs in contaminated antibiotic solution, and it has been associated with multi-causal respiratory disease of chickens (130) and turkeys (93). *Pseudomonas stutzeri* was isolated from chickens with respiratory disease but produced only low mortality in experimentally inoculated chickens (130). A *P. putida*-like organism has been isolated from osteomyelitis lesions in processed tom turkeys (H.J. Barnes, unpublished data).

Mortality characterizes most *Pseudomonas* infections. Death usually occurs rapidly, often within 24–72 hours after infection. Clinical signs vary depending on whether infections are localized or systemic, but may include anorexia; stunting; lassitude; lameness; neurologic signs; swelling of head, wattles, and sinuses; swelling of hock joints or foot pads; respiratory distress; diarrhea; or conjunctivitis (63, 88, 115, 117, 152). Infections of the nasal glands in ducks resulted in granulomatous adenitis (114).

Lesions are consistent with clinical findings and include subcutaneous edema and fibrin, occasionally with hemorrhage; exudate in affected joints; inflammation of serous membranes mimicking lesions of colisepticemia (airsacculitis, pericarditis, hepatic serositis); pneumonia; swelling and necrotic foci in liver, spleen, kidney, and brain; conjunctivitis; sinusitis; and occasionally keratitis (63, 88, 115, 130, 152). Chicks that survived yolk sac inoculation had retained, inflamed yolk sacs when examined 14 days post inoculation (228). Unilateral panophthalmitis characterized by corneal perforation and phacolysis occurred in young turkeys with ocular *Pseudomonas* infection (Figure 23.28). The rapidly progressive destruction of the eye may be related to proteases produced by the organism (8). Large numbers of bacteria, often in and around affected blood vessels within most tissues, including brain (Figure 23.29), are typically seen microscopically in acute lesions. Heterophilic exudate in the pharynx and pulmonary foci were present in respiratory infections of pheasants (96). A similar case characterized by pseudodiphtheritic membranes and granulomatous lesions in the respiratory and upper digestive tract occurred in a group of young ostriches experiencing high mortality. Intralesional bacteria were identified as *P. aeruginosa* by immunohistochemistry and confirmed by culture (148). *Pseudomonas* was isolated infrequently from adult hens with salpingitis and oophoritis (15, 193), from turkeys with cellulitis (80, 163), and from geese with venereal disease (see below), and was the

Figure 23.28. Panophthalmitis with corneal perforation in an 18-day-old turkey poult. A heavy pure growth of *Pseudomonas aeruginosa* was obtained on culture, and intralesional bacteria were present in tissues on histopathology.

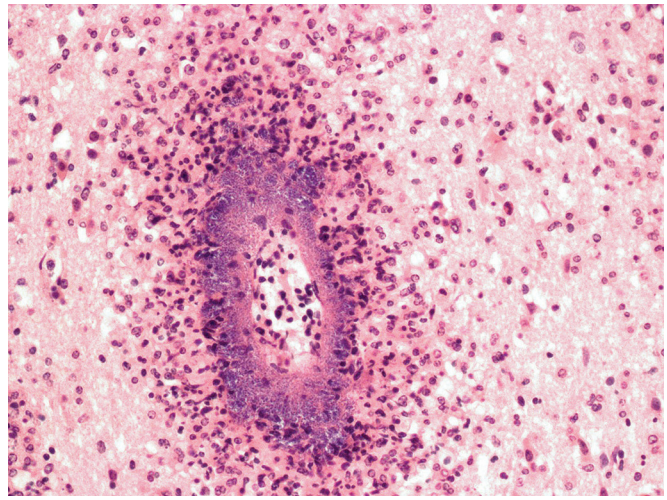

Figure 23.29. A blood vessel in the brain of a 3-day-old chick with marked neurologic signs is disrupted by numerous bacteria. A perivascular zone of necrotic debris is present. A heavy pure growth of *Pseudomonas aeruginosa* was isolated from the brain.

Figure 23.30. Subcutaneous lesions in the upper neck area of chicks following the use of a Marek's disease vaccine contaminated by *Pseudomonas*. (L. Munger)

most common bacterium recovered from abnormal joints of broiler chickens in a study of leg weakness (27).

Pseudomonas is among a variety of bacteria often recovered from dead embryos and sick newly hatched chickens, turkeys, pheasants, ducks, and ostriches (30, 61, 107, 129, 165, 181, 222). With the exception of a respiratory outbreak in pheasants attributed to exploding contaminated eggs in the incubator, presence of *P. aeruginosa* in embryos is not considered a source of infection for other birds. Severe outbreaks have followed injection of large numbers of birds with contaminated vaccines (Figure 23.30) (144, 214) and antibiotic solutions (37, 232). In these cases, contamination resulted from poor hygiene during mixing and handling, not from the products themselves. Contact with infected birds (152) and intense, continuous broiler production with different ages being raised at the same facility (63) can result in spread of *Pseudomonas* infection. In some outbreaks, the source of the organism and how it spread could not be determined.

Diagnosis requires isolation and identification of the organism. Various methods including serologic, phage, and aeruginocine typing methods, and molecular testing (180) may be useful in epidemiologic studies.

Prevention and control are based on identifying and eliminating the source of the organism. Measures to prevent yolk sacculitis and omphalitis by different bacteria are applied to the prevention of infection of newly hatched chicks with *Pseudomonas*. Good hygiene, especially in hatcheries and when birds are injected, is fundamental to preventing the infection. Cleaning and disinfection of equipment and use of sterile techniques in preparing vaccines and injectables will prevent *Pseudomonas* infections resulting from inoculation (37).

Sensitivity of isolates to hatchery disinfectants needs to be determined (234). *Pseudomonas aeruginosa* is known for its resistance to disinfectants; it has been isolated from the stock solution of most commonly used biocides (133). A commercial quaternary ammonium disinfectant was ineffective at completely inactivating high concentrations (10^9) of *P. aeruginosa* that had been isolated from chicks with omphalitis. It was generally effective when numbers of organisms were low (10^3) and had a variable effect on intermediate concentrations (10^6). Potentiation of the disinfectant with Ethylenediaminetetraacetic acid (EDTA) substantially improved its efficacy when tested *in vitro* (227). *Pseudomonas* spp. were found to adapt to growth in increasing concentrations of disinfectants following serial passage (133).

Antibiotics can be useful in reducing losses if initiated early in the disease, but because the organism has high antibiotic resistance, antimicrobial susceptibility testing is essential. Resistance to antibiotics is due to low permeability of the outer membrane to chemicals, as well as to efflux mechanisms that remove many antimicrobial agents (133).

Rothia

The genus *Rothia* belongs to the family *Micrococcaceae*. *Rothia* spp. are Gram-positive, aerobic, rod-shaped or coccus-shaped bacteria that are included within a group of bacteria called "coryeneforms" (224). *Rothia* was the only bacterium isolated from osteomyelitis and joint lesions in lame or recumbent tom turkeys in an affected flock. Intravenous inoculation of unaffected turkeys reproduced the clinical signs and lesions and the organism was reisolated from the birds (H.J. Barnes, unpublished data).

Segmented filamentous bacteria

Segmented filamentous bacteria (SFB) are Gram-positive, anaerobic, endospore-forming bacteria that appear microscopically as filamentous, septate organisms with peculiar morphological characteristics. Because they have not been cultured *in vitro*, this group of organisms does not have an official taxonomic name, although they have been given the provisional name *Arthromatus candidatus* (196).

They are commensals in the intestinal tracts of mammals (including humans), birds, fish, and insects (35). Histologically, they can be seen embedded in the apical cytoplasm of enterocytes, displacing microvilli (236). In turkeys, SFB are 0.6–1.1 μm wide and up to 13.5 μm long (4). Challenge and gene sequencing studies suggest there are different host-specific types or species. Chickens are refractory to infection with SFB from mice even following corticosteroid treatment (3), and the intestinal tract of mice are not colonized by SFB from rats, and vice versa (208). Additionally, SFB from rats, mice, and chickens show differences in 16S rRNA sequences that are sufficient to suggest the existence of different, but closely related, species (196).

Often SFB are markedly increased in young chickens, turkeys, and quail with gastrointestinal diseases, especially during cold periods (82). While most frequently found in ill birds, SFB may not be pathogens, but rather they overgrow

when conditions are altered because of enteric disease. High numbers of SFB were present in the jejunum of poults with experimental stunting syndrome (4), but subsequent studies using filtered inocula showed they were not the cause of the disease (188). However, depressed growth (11%–14%) occurred when poults were inoculated with 2 isolates of similar filamentous bacteria (151).

Among intestinal microflora, SFB are the only ones known to play a role in postnatal maturation and development of intestinal mucosal immunity, specifically inducing and regulating T-cell responses (35).

Streptobacillus

Streptobacillus moniliformis, a Gram-negative, often beaded, non-branching, filamentous bacterium, can infect turkeys, usually following rat bites or exposure to infected rats. Polyarthritis and synovitis occur in infected birds; other tissues are usually normal. The disease can be reproduced in turkeys following experimental inoculation of the organism by intravenous, subcutaneous, or footpad routes, but not by oral administration. Chickens are not susceptible. Diagnosis requires isolation and identification of the organism. Infection can be prevented through rodent control (79, 146).

Suttonella

A unique Gram-negative, rod-shaped bacterium isolated from the lungs of passerine birds (tits) experiencing episodes of mortality in Great Britain was described as a new species, *Suttonella ornithocola* (71, 111). The association between *Suttonella ornithocola* and mortality was uncertain until recently when the organism was isolated from pneumonic lungs of passerines (122). The organism has not been associated with disease in poultry.

Vibrio

Vibrio spp. are Gram-negative, comma-shaped bacteria that are widespread in coastal and estuarine environments. *Vibrio cholerae*, the cause of cholera in humans, results from infection with serogroup O1 or O39 strains that produce cholera toxin (toxigenic strains). Other non-O1 isolates of *V. cholerae* may also pose a potential risk of gastroenteritis in humans (6).

Non-O1 *V. cholerae* has been isolated from geese that died following weight loss and lassitude of 2–3 days' duration (185), from nasal cavities of apparently healthy ducks (23), and from tissues of ducks with airsacculitis or septicemia (229). Individuals working with ill birds that have contact with coastal waters and shellfish need to be aware that birds can be a source of human infection (185). Conjunctivitis caused by *V. cholerae* NAG, a potential human pathogen, occurred in ducklings (21). The organism also was isolated from the intestines and water where the ducks were being kept. Exposure of domesticated ducks was believed to have come from free-living birds. Both O1 and non-O1 *V. cholerae* have been frequently isolated from feces of aquatic birds and their environments (161).

Vibrionic hepatitis is probably a misnomer, because the disease is suspected to be caused by *Campylobacter* spp., although the etiology has not been definitively identified (240). *Vibrio metschnikovii* (*metschnicovii*) is occasionally isolated from waterfowl (92) and there are a few reports of *V. metschnikovii* isolated from humans with bacteremia, neonatal sepsis, postoperative wound infection, pneumonia, diarrhea, or foot and leg ulcers (167).

Vibrio alginolyticus, a dominant proteolytic bacterium in the upper respiratory tract of chickens and turkeys, does not cause disease but may enhance pathogenicity of avian influenza viruses by providing a mechanism for cleavage of the virus hemagglutinin (33).

Diseases Caused by or Associated with Bacteria

Beak Necrosis

A Gram-positive bacterium with affinity for keratin was associated with beak necrosis that affected nearly half of the birds in a flock of 1-year-old broiler breeder hens and caused approximately 10% mortality (39). Feeding fine feed (mash) predisposes birds to oral and beak lesions although the exact mechanism of how lesions develop is unknown. Oral lesions resolve rapidly after birds are put on pelleted feed (74). Injury to the epidermis occurs initially and is followed by necrosis, ulceration, and bacterial growth. Affected birds have decreased leukocytes and anemia (75). Beak deformity, loss of the distal end of the mandible, and osteomyelitis occur in severely affected birds. Weight loss and mortality result from impaired feeding (67). Males are more often affected than females (67). Use of 40-mm grids over feeders to restrict male access to feed resulted in a higher occurrence of oral and beak lesions (94). Visibly affected birds need to be culled for welfare reasons. In one study, beak lesions were the major cause for culling male broiler breeders (95).

Goose Venereal Disease

An infectious venereal disease of uncertain etiology characterized by inflammation of the phallus and cloaca of ganders in breeding flocks was first described in Hungary (206). Subsequently, flocks have been affected in other European countries, Russia, and the Middle East. Initially, the base of the phallus becomes swollen and inflamed, with the process extending to the cloaca. Later, there is necrosis, ulceration, and eventually considerable scarring of the mucosa, often making reproduction impossible. Similar lesions may develop in the cloaca of hens following breeding. Morbidity ranges from 20%–100%, and newly introduced birds readily contract the disease. Increased infertility and gander mortality of approximately 5% are flock problems resulting from the disease (202).

A variety of bacteria, especially *Neisseria*, *Mycoplasma* spp., and *Candida albicans* affecting the phallus of ganders

and cloaca of hens, has been associated with the disease (17, 136, 200, 202). Normal phallus microflora of unaffected ganders has been established (159) and is similar, with the exception of mycoplasmas and *Candida albicans*, to that of affected ganders (17). Use of antimicrobials effective against mycoplasmas substantially reduces disease severity (57). A similar disease attributed to *Candida albicans* spread through goose flocks in Israel (16). Dramatic improvement followed treatment with mycostatin and antibiotics. Vaccination with ethanol-inactivated fungus provided good control of the disease (118). A zygomycete, *Mucor janssenii*, found in one flock of affected ganders reproduced a similar disease in experimentally inoculated birds (137). Exposure of SPF Muscovy ducks and geese to isolates alone and in various combinations produced only mild clinical signs and lesions except in a female contaminated by an affected gander and inoculated with *C. albicans*. Trauma is considered to be a likely initiating factor followed by infection with opportunistic bacteria and fungi (136).

It is recommended that ganders be examined at each breeding season and affected birds removed from the flock. Artificial insemination can be used in affected flocks to improve fertility (17).

Intracellular Infection in Ducks

Mortality in Muscovy ducks (*Cairina moschata*) caused by an intracellular organism primarily affecting endothelial cells in the lungs was initially attributed to *Haemoproteus* infection (105). However, subsequent examination of additional cases revealed that the organism was not a protozoan, but probably a bacterium capable of forming spores or an unidentified microorganism. Recently the organism has been identified as a yeast in the family Saccharomycetales (142). Muscovy ducks are most susceptible and can contract the infection from asymptomatic infected Pekin ducks. Experimental transmission is possible using blood from infected ducks.

At necropsy, lungs are dark red-purple, slightly edematous, and firm. Microscopically, air capillaries are obliterated because of marked swelling of endothelial cells, which are often packed with intracellular organisms, and interlobular septa are widened and contain inflammatory cells and edema. Organisms stain poorly with hematoxylin and eosin but are readily demonstrated with periodic-acid-Schiff or silver stains (106, 173).

Liver Granulomas and Related Granulomatous Disorders

Granulomas are occasionally seen in livers of turkeys and, less frequently, chickens at processing. Affected livers and carcasses are condemned. The incidence in individual flocks may reach 50%.

Granulomas are focal or multifocal, single to coalescing lesions that are grossly visible as firm, lobulated, roughly spherical, pale yellow to white masses ranging in size from a few millimeters to several centimeters. Advanced lesions have a rough appearance and may be "gritty" when cut. Bile stasis of adjacent normal hepatic tissue is often marked. Liver granulomas are caused by a variety of infectious and parasitic agents. *E. coli*, *Eubacterium*, and other bacteria are among the more common etiologic agents (203). Similar granulomas are occasionally seen in the spleen and rarely in other tissues.

Microscopically, lesions are typical heterophilic granulomas (149) that contain a central caseous mass covered by a layer of multinucleated giant cells, which is confluent except in areas where the process is still active. A more diffuse zone of heterophils, macrophages, fibroblasts, and lymphocytes surrounds the caseated center. Heterophils can be seen migrating through the layer of giant cells and are especially numerous in areas where giant cells are absent or discontinuous. Diffuse and focal lymphocytes form the outermost layer of the lesion. Fibrosis may be extensive in chronic lesions. Bacteria generally are not visible unless special stains are used. Tangles of filamentous organisms usually can be seen with silver stains such as Warthin-Starry or Dieterle, and Gram-positive filamentous or coccoid organisms may be seen with Gram's stain (5, 121, 150).

A variety of bacteria have been isolated from the lesions including *Actinomyces* (189), *Catenabacterium*, *Corynebacterium*, *Eubacterium*, *Propionibacterium*, *Enterococcus* (*Streptococcus*), and *Staphylococcus* (121, 150). Liver granulomas occurred after intravenous inoculation of turkeys with *Catenabacterium* spp. isolated from a naturally infected turkey. Chickens, peafowl, guinea pigs, rabbits, hamsters, and mice did not develop lesions (150). Granulomatous lesions were reproduced experimentally in the liver and spleen of turkeys and in the spleen of chickens by intravenous inoculation of *Eubacterium tortuosum* (5, 89), even though the organism is part of the normal cecal flora (89). Often, mucosal ulcers in the lower intestinal tract can be found in affected birds, suggesting that liver lesions develop from bacteria carried to the liver from the intestine via the bloodstream (5, 89, 121, 150).

Liver granulomas also occur in chickens and other poultry species but much less frequently. Gram-positive, filamentous bacteria morphologically and tinctorially distinct from *Eubacterium*, segmented filamentous organisms, *Actinomyces*, and *Nocardia* were present in sporadic cases of visceral granulomas in broiler chickens at processing in the United States (91). Lesions also occurred in the spleen, cecum, and mesentery of some birds. Numerous Gram-positive filamentous bacteria morphologically compatible with *Eubacterium tortuosum* were found within granulomatous lesion in the liver of a 7-week-old quail (233).

Larvae of *Ascaridia dissimilis* also can cause hepatic foci ("white-spotted livers") in turkeys that need to be differentiated from bacterial granulomas. Only a low percentage of these hepatic foci in turkey livers at processing yielded bacteria; *E. coli* and *Salmonella* spp. were occasionally isolated (160). Exposing turkey poults to *Ascaridia dissimilis* ova reproduced the lesions (159). No causative organism initially was identified in granulomatous lesions in ceca and livers of older chickens from small flocks in Canada (154), but subsequently, larvae of the cecal worm, *Heterakis gallinarum*, were found to be associated with the lesions (177).

References

Introduction

1. Casewell, M., C. Friis, E. Marco, P. McMullin, and I. Phillips 2003. The European ban on growth-promoting antibiotics and emerging consequences for human and animal health. *J Antimicrob Chem.* 52:159–161.
2. Castanon, J.I.R. 2007. History of the use of antibiotic as growth promoters in European Poultry feeds. *Poult Sci.* 86:2466–2471.
3. Christensen H., M. Bisgaard, A.M. Bojesen, R. Mutters, and J. E. Olsen 2003. Genetic relationships among avian isolates classified as *Pasteurella haemolytica*, '*Actinobacillus salpingitidis*' or *Pasteurella anatis* with proposal of *Gallibacterium anatis* gen. nov., comb. nov., and description of additional genomospecies within *Gallibacterium* gen. nov. *Int J Sys Evol Microbiol*. 53:275–287.
4. Cox, N.A., J.S. Bailey, E.T. Ryser, and E.H. Marth 1999. Incidence and behavior of *Listeria monocytogenes* in poultry and egg products. In: *Listeria, Listeriosis and Food Safety*, 2nd ed. Ryser, E.T., and E.H. Marth, eds. Marcel Dekker, Inc., New York. 565–600.
5. Dibner, J.J., and Richards, J.D. 2005. Antibiotic growth promoters in Agriculture: History and mode of action. *Poult Sci.* 84: 634–643.
6. Fessler A.T., K. Kadlec, M. Hassel, T. Hauschild, C. Eidam, R. Ehricht, S. Monecke, and S. Schwarz. 2011. Characterization of methicillin-resistant *Staphylococcus aureus* isolates from food and food products of poultry origin in Germany. *Appl Environ Microbiol.* 77:7151–7157.
7. Foster, G., H. Malnick, P.A. Lawson, J. Kirkwood, S.K. MacGrego, and M.D. Collins 2005. *Suttonella ornithocola* sp. nov., from birds of the tit families, and emended description of the genus *Suttonella*. *Int J Syst and Evol Microbiol*. 55:2269–2272.
8. Gray, M.L. 1958. Listeriosis in fowls—A review. *Avian Dis.* 2:296–314.
9. Lee, J.H. 2003. Methicillin (oxacillin)-resistant *Staphylococcus aureus* strains isolated from major food animals and their potential transmission to humans. *Appl Environ Microbiol.* 69:6489–94.
10. McNamee, P.T., and D.C. King 1996. Endocarditis in broiler breeder rearers due to *Enterococcus hirae*. *Vet Rec.* 138:240.
11. McFadden, J.J., and H.M. Fidler. 1996. Mycobacteria as possible causes of sarcoidosis and Crohn's disease. *Soc Appl Bacteriol Symp Ser.* 25:47S–52S.
12. On, S.L. 2001. Taxonomy of *Campylobacter*, *Arcobacter*, *Helicobacter* and related bacteria: current status, future prospects and immediate concerns. *Symp Ser Soc Appl Microbiol*. 30:1S–15S.
13. Randall, C.J., and D.B. Pearson. 1991. Enterococcal endocarditis causing heart failure in broilers. *Vet Rec.* 129:535.
14. Singer, R.S., and C.L. Hofacre. 2006. Potential impacts of antibiotic use in poultry production. *Avian Dis.* 50:161–172.
15. Vandamme, P., M. Vancanneyt, P. Segers, M. Ryll, B. Kohler, W. Ludwig, and K-H. Hinsz. 1999. *Coenonia anatina* gen.nov., sp. Nov., a novel bacterium associated with respiratory disease in ducks and geese. *Int J Syst Bacteriol*. 48:867–874.
16. Vandamme, P., P. Segers, M. Ryll, J. Hommez, M. Vancanneyt, R. Coopman, R. De Baere, Y. Van De Peer, K. Kersters, R. De Wachter, and K.H. Hinz 1999. *Pelistega europaea* gen. nov., sp. nov., a bacterium associated with respiratory disease in pigeons: taxonomic structure and phylogenetic allocation. *Int J Syst and Evol Microbiol*. 48:431–440.

Staphylococcosis

1. Adams, B.W., and G.C. Mead. 1983. Incidence and properties of *Staphylococcus aureus* associated with turkeys during processing and further-processing operations. *J Hyg.* 91:479–490.
2. Anderson, J.C. 1986. *Staphylococcus*. In: *Pathogenesis of Bacterial Infections in Animals*, 1st ed. C.L. Gyles and C.O. Thoen, eds. Iowa State University Press, Ames, IA, 14–20.
3. Andreasen, C.B., J.R. Andreasen, A.E. Sonn, and J.A. Oughton. 1996. Comparison of the effect of different opsonins on the phagocytosis of fluorescein-labeled staphylococcal bacteria by chicken heterophils. *Avian Dis.* 40:778–782.
4. Andreasen, C.B., K.S. Latimer, B.G. Harmon, J.R. Glisson, J.M. Golden, and J. Brown. 1991. Heterophil function in healthy chickens and in chickens with experimentally induced staphylococcal tenosynovitis. *Vet Pathol.* 28:419–427.
5. Andreasen, J.R., C.B. Andreasen, M. Anwer, and A.E. Sonn. 1993. Chicken heterophil chemotaxis using staphylococcal-generated chemoattractants. *Avian Dis.* 37:835–838.
6. Andreasen, J.R., C.B. Andreasen, M. Anwer, and A.E. Sonn. 1993. Heterophil chemotaxis in chickens with natural staphylococcal infections. *Avian Dis.* 37:284–289.
7. Arp, L.H., I.M. Robinson, and A.E. Jensen. 1983. Pathology of liver granulomas in turkeys. *Vet Pathol.* 20:80–89.
8. Awan, M.A., M. Matsumoto. 1998. Heterogeneity of staphylococci and other bacteria isolated from six-week-old broiler chickens. *Poult Sci.* 77:944–9.
9. Bajljosov, D., Z. Sachariev, and L. Georgiev. 1974. Characteristics of staphylococci isolated from slaughter fowl. *Monatsh Veterinaermed.* 29:692–694.
10. Bascomb, S., and M. Manafi. 1998. Use of enzyme tests in characterization and identification of aerobic and facultatively anaerobic Gram-positive cocci. *Clin Microbiol Rev.* 11:318–40.
11. Bayyari, G.R., W.E. Huff, R.A. Norton, J.K. Skeeles, J N. Beasley, N.C. Rath, and J.M. Balog. 1994. A longitudinal study of green-liver osteomyelitis complex in commercial turkeys. *Avian Dis.* 38:744–754.
12. Bergmann, V., B. Köhler, and K. Vogel. 1980. *Staphylococcus aureus* infection of fowls on industrialized poultry units. I. Types of infection. *Arch Exp Vet.* 34:891–903.
13. Bickford, A.A., and A.S. Rosenwald. 1975. Staphylococcal infections in chickens. *Poult Dig*. July:285–287.
14. Bitay, Z., L. Quarini, R. Glavits, and R. Fischer. 1984. *Staphylococcus* infection in fowls. *Magy Allatorv Lapja.* 39:86–91.
15. Broughan J., R. Anderson, and A.S. Anderson. 2011. Strategies for and advances in the development of *Staphylococcus aureus* prophylactic vaccines. *Expert Rev Vaccines.* 10:695–708.
16. Butterworth, A., N.A. Reeves, D. Harbour, G. Werrett, and S. C. Kestin. 2001. Molecular typing of strains of *Staphylococcus aureus* isolated from bone and joint lesions in lame broilers by random amplification of polymorphic DNA. *Poult Sci.* 80:1339–43.
17. Bystroń J., M. Podkowik, T. Piasecki, A. Wieliczko, J. Molenda, and J. Bania. 2010. Genotypes and enterotoxin gene content of *S. aureus* isolates from poultry. *Vet Microbiol*. 144:498–501.
18. Carnaghan, R.B.A. 1966. Spinal cord compression in fowls due to spondylitis caused by *Staphylococcus pyogenes*. *J Comp Pathol.* 76:9–14.
19. Catry B., E. Van Duijkeren, M.C. Pomba, C. Greko, M.A. Moreno, S. Pyörälä, M. Ruzauskas, P. Sanders, E.J. Threlfall, F. Ungemach, K. Törneke, C. Munoz-Madero, and J. Torren-Edo;

Scientific Advisory Group on Antimicrobials (SAGAM). 2010. Reflection paper on MRSA in food-producing and companion animals: epidemiology and control options for human and animal health. *Epidemiol Infect*. 138:626–44.
20. Chen, D.W., M.H. Gan, and R.P. Liu. 1984. Studies on staphylococcosis in chickens. III. Properties and pathogenicity of *Staphylococcus aureus*. *Chinese J Vet Med.* 10:6–8.
21. Chénier S., and L. Lallier. 2012. Acantholytic folliculitis and epidermitis associated with *Staphylococcus hyicus* in a line of White Leghorn laying chickens. *Vet Pathol.* 49:284–287.
22. Cheville, N.F., J. Tappe, M. Ackermann, and A. Jensen. 1988. Acute fibrinopurulent blepharitis and conjunctivitis associated with *Staphylococcus hyicus*, *Escherichia coli*, and *Streptococcus* sp. in chickens and turkeys. *Vet Pathol*. 25:369–375.
23. Clark, R.S., H.J. Barnes, A.A. Bickford, R.P. Chin, and R. Droual. 1991. Relationship of osteomyelitis and associated soft-tissue lesions with green liver discoloration in turkeys. *Avian Dis.* 35:139–146.
24. Coates, S.R., D.K. Buckner, and M.M. Jensen. 1977. The inhibitory effect of *Corynebacterium parvum* and *Pasteurella multocida* pretreatment on staphylococcal synovitis in turkeys. *Avian Dis.* 21:319–322.
25. Cotter, P.F., and R.L. Taylor, Jr. 1991. Differential resistance to *Staphylococcus aureus* challenge in two related lines of chickens. *Poult Sci.* 70:1357–1361.
26. Cunha, Mde. L., Y.K. Sinzato, and L.V. Silveira. 2004. Comparison of methods for the identification of coagulase-negative staphylococci. *Mem Inst Oswaldo Cruz*. 99:855–60.
27. Cuny C., A. Friedrich, S. Kozytska, F. Layer, U. Nübel, K. Ohlsen, B. Strommenger, B. Walther, L. Wieler, and W. Witte. 2010. Emergence of methicillin-resistant *Staphylococcus aureus* (MRSA) in different animal species. *Int J Med Microbiol.* 300:109–17.
28. Daum, R.S., H. Davis, S. Shane, D. Mulvihill, R. Campeau, and B. Farris. 1990. Bacteremia and osteomyelitis in an avian model of *Staphylococcus aureu*s infection. *J Orthop Res.* 8:804–813.
29. Daum, R.S., A. Fattom, S. Freese, and W. Karakawa. 1994. Capsular polysaccharide serotypes of coagulase-positive staphylococci associated with tenosynovitis, osteomyelitis, and other invasive infections in chickens and turkeys: Evidence for new capsular types. *Avian Dis.* 38:762–771.
30. De Buyser, M.-L., A. Morvan, S. Aubert, F. Dilasser, and N. el Solh. 1992. Evaluation of a ribosomal RNA gene probe for the identification of species and subspecies within the genus *Staphylococcus*. *J Gen Microbiol.* 138:889–899.
31. Devriese, L.A. 1980. Pathogenic staphylococci in poultry. *World Poult Sci.* 36:227–236.
32. Devriese, L.A. 1980. Sensitivity of staphylococci from farm animals to antibacterial agents used for growth promotion and therapy: A ten year study. *Ann Rech Vet.* 11:399–408.
33. Devriese, L.A. 1984. A simplified system for biotyping *Staphylococcus aureus* strains isolated from different animal species. *J Appl Bacteriol.* 56:215–220.
34. Devriese, L.A., A.H. Devos, J. Beumer, and R. Moes. 1972. Characterization of staphylococci isolated from poultry. *Poult Sci.* 51:389–397.
35. Devriese, L.A., A.H. Devos, and L.R. van Damme. 1975. Quantitative aspects of the *Staphylococcus aureus* flora of poultry. *Poult Sci.* 54:95–101.
36. Devriese, L.A., B. Poutrel, R. Kilpper-Balz, and K.H. Schleifer. 1983. *Staphylococcus gallinarium* and *Staphylococcus caprae*, two new species from animals. *Int J Syst Bacteriol.* 33:480–486.
37. Devriese, L.A., K.H. Schleifer, and G.O. Adegoke. 1985. Identification of coagulase-negative staphylococci from farm animals. *J Appl Bacteriol.* 58:45–55.
38. Devriese L.A., M. Vancanneyt, M. Baele, M. Vaneechoutte, E. De Graef, C. Snauwaert, I. Cleenwerck, P. Dawyndt, J. Swings, A. Decostere, and F. Haesebrouck. 2005. *Staphylococcus pseudintermedius* sp. nov., a coagulase-positive species from animals. *Int J Syst Evol Microbiol*. 55:1569–73.
39. Dodd, C.E., B.J. Chaffey, W.M. Waites. 1987. Plasmid profiles as indicators of the source of contamination of *Staphylococcus aureus* endemic within poultry processing plants. *J Appl Bacteriol.* 63:417–425.
40. Drancourt, M., and D. Raoult.2002. *rpoB* gene sequence-based identification of *Staphylococcus* species. *J Clin Microbiol*. 40:1333–8.
41. Duquette, R.A., and Nuttall T.J. 2004. Methicillin-resistant *Staphylococcus aureus* in dogs and cats: an emerging problem? *J Small Anim Pract.* 45:591–7.
42. Emslie, K.R., and S. Nade. 1985. Acute hematogenous staphylococcal osteomyelitis. *Comp Pathol Bull.* 17:2–3.
43. Emslie, K.R., N.R. Ozanne, and S.M.L. Nade. 1983. Acute haemotogenous osteomyelitis: An experimental model. *Pathology.* 141:157–167.
44. Euzeby, J.P. 2011 [cited 7 Nov 2011]. List of prokaryotic names with standing in nomenclature: a folder available on the Internet [database online]. Available at http://www.bacterio.cict.fr/.
45. Evans, J.B., G.A. Ananaba, C.A. Pate, and M.S. Bergdoll. 1983. Enterotoxin production by atypical *Staphylococcus aureus* from poultry. *J Appl Bacteriol.* 54:257–261.
46. Fessler A.T., K. Kadlec, M. Hassel, T. Hauschild, C. Eidam, R. Ehricht, S. Monecke, and S. Schwarz. 2011. Characterization of methicillin-resistant *Staphylococcus aureus* isolates from food and food products of poultry origin in Germany. *Appl Environ Microbiol.* 77:7151–7157.
47. Forget, A., L. Meunier, and A.G. Borduas. 1974. Enhancement activity of homologous anti-staphylococcal sera in experimental staphylococcal synovitis of chicks: A possible role of immune adherence antibodies. *Infect Immun.* 9:641–644.
48. Foster G., H.M. Ross, R.A. Hutson, and M.D. Collins. 1997. *Staphylococcus lutrae* sp. nov., a new coagulase-positive species isolated from otters. *Int J Syst Bacteriol*. 47:724–6.
49. Frazier, M.N., W.J. Parizek, and E. Garner. 1964. Gangrenous dermatitis of chickens. *Avian Dis.* 8:269–273.
50. Freney, J., W.E. Kloos, V. Hajek, J.A. Webster, M. Bes, Y. Brun, and C. Vernozy-Rozand C. 1999. Recommended minimal standards for description of new staphylococcal species. Subcommittee on the taxonomy of staphylococci and streptococci of the International Committee on Systematic Bacteriology. *Int J Syst Bacteriol.* 49:489–502.
51. Gibbs, P.A., J.T. Patterson, and J. Harvey. 1978. Biochemical characteristics and enterotoxigenicity of *Staphylococcus aureus* strains isolated from poultry. *J Appl Bacteriol.* 44:57–74.
52. Gibbs, P.A., J.T. Patterson, and J.K. Thompson. 1978. Characterization of poultry isolates of *Staphylococcus aureus* by a new set of poultry phages. *J Appl Bacteriol.* 44:387–400.
53. Glavits, R., F. Ratz, T. Fehervari, and J. Povazsan. 1984. Pathological studies in chicken embryos and day-old chicks experimentally infected with *Salmonella typhimurium* and *Staphylococcus aureus*. *Acta Vet Hung.* 32:39–49.

54. Griffiths, G.L., W.I. Hopkinson, and J. Lloyd. 1984. Staphylococcal necrosis of the head of the femur in broiler chickens. *Aust Vet J.* 61:293.
55. Gross, W.G., P.B. Siegel, R.W. Hall, C.H. Domermuth, and R.T. Duboise. 1980. Production and persistence of antibodies in chickens to sheep erythrocytes. 2. Resistance to infectious diseases. *Poult Sci*. 59:205–210.
56. Guarda, F., G. Cortellezzi, C. Cucco, and O. Massimino. 1979. Blindness due to *Staphylococcus aureus* in pullets. *Clin Vet.* 102:315–324.
57. Guimaraes M.C., L.G. Amaral, L.B. Rangel, I.V. Silva, C.G. Matta, and M.F. Matta. 2009. Growth inhibition of *Staphylococcus aureus* by chicken egg yolk antibodies. 57:377–82.
58. Gwatkin, R. 1940. An outbreak of staphylococcal infection in barred Plymouth rock males. *Can J Comp Med.* 4:294–296.
59. Hajek, V., and E. Marsalek. 1971. The differentiation of pathogenic staphylococci and a suggestion for their taxonomic classification. *Zentralbl Bakteriol [A].* 217:176–182.
60. Harvey, J., J.T. Patterson, and P.A. Gibbs. 1982. Enterotoxigenicity of *Staphylococcus aureus* strains isolated from poultry: Raw poultry carcasses as a potential food-poisoning hazard. *J Appl Bacteriol.* 52:2514–258.
61. Hasman H., A. Moodley, L. Guardabassi, M. Stegger, R.L. Skov, and F.M. Aarestrup. 2010. Spa type distribution in *Staphylococcus aureus* originating from pigs, cattle and poultry. *Vet Microbiol.* 141:326–31.
62. Heller, E.D., D.B. Nathan, and M. Perek. 1979. Short heat stress as an immunostimulant in chicks. *Avian Pathol.* 8:195–203.
63. Hennekinne, J.A., A. Kerouanton, A. Brisabois, and M.L. De Buyser. 2003. Discrimination of *Staphylococcus aureus* biotypes by pulsed-field gel electrophoresis of DNA macro-restriction fragments. *J Appl Microbiol.* 94:321–9.
64. Hoffman, H.A. 1939. Vesicular dermatitis in chickens. *J Am Vet Med Assoc.* 48:329–332.
65. Hole, N., and H.S. Purchase. 1931. Arthritis and periostitis in pheasants caused by *Staphylococcus pyogenes aureus*. *J Comp Pathol Ther.* 44:252–257.
66. Huber H., D. Ziegler, V. Pflüger, G. Vogel, C. Zweifel, and R. Stephan. 2011. Prevalence and characteristics of methicillin-resistant coagulase-negative staphylococci from livestock, chicken carcasses, bulk tank milk, minced meat, and contact persons. *BMC Vet Res*. 7:6.
67. Jensen, M.M., W.C. Downs, J.D. Morrey, T.R. Nicoll, S.D. LeFevre, and C.M. Meyers. 1987. Staphylococcosis of turkeys. 1. Portal of entry and tissue colonization. *Avian Dis*. 31:64–69.
68. Joiner, K.S., F.J. Hoerr, E. van Santen, and S. Ewald. 2005. The avian major histocompatibility complex influences bacterial skeletal disease in broiler breeder chickens. *Vet Pathol.* 42:275–81.
69. Jungherr, E. 1933. Staphylococcal arthritis in turkeys. *J Am Vet Med Assoc.* 35:243–249.
70. Kawano, J., A. Shimizu, Y. Saitoh, M. Yagi, T. Saito, and R. Okamoto. 1996. Isolation of methicillin-resistant coagulase-negative staphylococci from chickens. *J Clin Microbiol.* 34:2072–7.
71. Kibenge, F.S.B., M.D. Robertson, G.E. Wilcox, and D.A. Pass. 1982. Bacterial and viral agents associated with tenosynovitis in broiler breeders in Western Australia. *Avian Pathol.* 11:351–359.
72. Kibenge, F.S., J.I. Rood, and G.E. Wilcox. 1983. Lysogeny and other characteristics of *Staphylococcus hyicus* isolated from chickens. *Vet Microbiol.* 8:411–5.
73. Kibenge, F.S.B., G.E. Wilcox, and D. Perret. 1982. *Staphylococcus aureus* isolated from poultry in Australia. I. Phage typing and cultural characteristics. *Vet Microbiol.* 7:471–483.
74. Kitai S., A. Shimizu, J. Kawano, E. Sato, C. Nakano, T. Uji, and H. Kitagawa. 2005. Characterization of methicillin-resistant *Staphylococcus aureus* isolated from retail raw chicken meat in Japan. *J Vet Med Sci.* 67:107–10.
75. Kloos, W.E., and C.G. George. 1991. Identification of *Staphylococcus* species and subspecies with the Microscan Pos ID and rapid Pos ID panel systems. *J Clin Microbiol.* 29:738–744.
76. Kloos, W.E., and J.H. Jorgensen. 1985. Staphylococci. In: *Manual of Clinical Microbiology*, 4th ed. E.H. Lenette, A. Balows, W.J. Hausler, Jr., and H.J. Shadomy, eds. American Society of Microbiologists, Washington, DC. 143–153.
77. Kloos, W.E., and K. Schleifer. 1975. Simplified scheme for routine identification of human *Staphylococcus* species. *J Clin Microbiol.* 1:82–8.
78. Köhler, B., V. Bergmann, W. Witte, R. Heiss, and K. Vogel. 1978. Dermatitis bei broilen durch *Staphylococcus aureus*. *Monatsch Veterinaermed.* 33:22–28.
79. Köhler, B., H. Nattermann, W. Witte, F. Friedrichs, and E. Kunter. 1980. *Staphylococcus aureus* infection of fowls on industrialized poultry units. II. Microbiological tests for S. aureus and other pathogens. *Arch Exp Veterinaermed.* 34:905–923.
80. Kusch, D. 1977. Biochemical characteristics and phage-typing of staphylococci isolated from poultry. *Zentralbl Bakteriol Parasit Infekt Hyg [IB].* 164:360–367.
81. Larson, C.T., W.B. Gross, and J.W. Davis. 1985. Social stress and resistance of chicken and swine to *Staphylococcus aureus* challenge infections. *Can J Comp Med.* 49:208–210.
82. Lee, J.H. 2003. Methicillin (Oxacillin)-resistant *Staphylococcus aureus* strains isolated from major food animals and their potential transmission to humans. *Appl Environ Microbiol.* 69:6489–94.
83. LeFevre, S.D., and M.M. Jensen. 1987. Staphylococcosis of turkeys. 2. Assay of protein A levels of staphylococci isolated from turkeys. *Avian Dis*. 31:70–73.
84. Liberto, M.C., G. Matera, R. Puccio, V. Barbieri, A. Quirino, R. Capicotto, V. Guadagnino, K. Pardatscher, and A. Foca. 2006. An unusual case of brain abscess by *Gemella morbillorum*. *Jpn J Infect Dis.* 59:126–8.
85. Lim S.K., H.M. Nam, H.J. Park, H.S. Lee, M.J. Choi, S.C. Jung, J.Y. Lee, Y.C. Kim, S.W. Song, and S.H. Wee. 2010. Prevalence and characterization of methicillin-resistant *Staphylococcus aureus* in raw meat in Korea. *J Microbiol Biotechnol.* 20:775–8.
86. Linares, J.A., and W.L. Wigle. 2001. *Staphylococcus aureus* pneumonia in turkey poults with gross lesions resembling aspergillosis. *Avian Dis.* 45:1068–72.
87. Lowder B.V., C.M. Guinane, N.L. Ben Zakour, L.A. Weinert, A. Conway-Morris, R.A. Cartwright, A.J. Simpson, A. Rambaut, U. Nübel, and J.R. Fitzgerald. 2009. Recent human-to-poultry host jump, adaptation, and pandemic spread of *Staphylococcus aureus*. *Proc Natl Acad Sci USA*. 106: 19545–50.
88. Lucet, A. 1892. De l'ostèo-arthrite aigue infectieuse des jeunes oies. *Ann Inst Pasteur (Paris)*. 6:841–850.
89. McNamee P.T., and J.A. Smyth. 2000. Bacterial chondronecrosis with osteomyelitis ('femoral head necrosis') of broiler chickens: a review. *Avian Pathol.* 29:253–70.
90. Mead, G.C., and B.W. Adams. 1986. Chlorine resistance of *Staphylococcus aureus* isolated from turkeys and turkey products. *Appl Microbiol.* 3:131–133.

91. Mellmann, A., K. Becker, C. von Eiff, U. Keckevoet, P. Schumann, and D. Harmsen D. 2006. Sequencing and staphylococci identification. *Emerg Infect Dis.* 12:333–6.
92. Meyers, C.M., and M.M. Jensen. 1987. Staphylococcosis of turkeys. 3. Bacterial interference as a possible means of control. *Avian Dis*. 31:744–79.
93. Miner, M.L., R.A. Smart, and A.E. Olson. 1968. Pathogenesis of staphylococcal synovitis in turkeys: Pathologic changes. *Avian Dis.* 12:46–60.
94. Minzat, R.M., V. Volintir, S. Panaitescu, I. Javanescu, B. Kelciov, and E. Cretu. 1977. A peculiar form of staphylococcal infection in chickens. *Lucr Stiint Inst Agron Timisoara, Ser Med Vet.* 14:141–144.
95. Monleon R., M.P. Martin, and H. John Barnes. 2008. Bacterial orchitis and epididymo-orchitis in broiler breeders. *Avian Pathol.* 37:613–7.
96. Morse, S.I. 1980. Staphylococci. In: *Microbiology*, 3rd ed. B.D. Davis, R. Dulbecco, H.N. Eisen, and H.S. Ginsberg, eds. Harper and Row Publishers, Philadelphia. 623–633.
97. Moya, S.F. 1986. *Staphylococcus aureus* as a potential contaminant of animal feeds. *Ciencias Vet, Costa Rica.* 8:77–80.
98. Mulders M.N., A.P. Haenen, P.L. Geenen, P.C. Vesseur, E.S. Poldervaart, T. Bosch, X.W. Huijsdens, P.D. Hengeveld, W.D. Dam-Deisz, E.A. Graat, D. Mevius, A. Voss, and A.W. Van De Giessen. 2010. Prevalence of livestock-associated MRSA in broiler flocks and risk factors for slaughterhouse personnel in The Netherlands. *Epidemiol Infect*. 138:743–55.
99. Munger, L.L., and B.L. Kelly. 1973. Staphylococcal granulomas in a leghorn hen. *Avian Dis.* 17:858–860.
100. Mutalib, A., C. Riddell, and A.D. Osborne. 1983. Studies on the pathogenesis of staphylococcal osteomyelitis in chickens. I. Effect of stress on experimentally induced osteomyelitis. *Avian Dis.* 27:141–156.
101. Mutalib, A., C. Riddell, and A.D. Osborne. 1983. Studies on the pathogenesis of staphylococcal osteomyelitis in chickens. II. Role of the respiratory tract as a route of infection. *Avian Dis.* 27:157–160.
102. Nagase, N., A. Sasaki, K. Yamashita, A. Shimizu, Y. Wakita, S. Kitai, and J. Kawano. 2002. Isolation and species distribution of staphylococci from animal and human skin. *J Vet Med Sci.* 64:245–50.
103. Nairn, M.E. 1973. Bacterial osteomyelitis and synovitis of the turkey. *Avian Dis.* 17:504–517.
104. Nemati M., K. Hermans, U. Lipinska, O. Denis, A. Deplano, M. Struelens, L.A. Devriese, F. Pasmans, and F. Haesebrouck. 2008. Antimicrobial resistance of old and recent *Staphylococcus aureus* isolates from poultry: first detection of livestock-associated methicillin-resistant strain ST398. *Antimicrob Agents Chemother.* 52:3817–9.
105. Newberry, L.A., D.G. Lindsey, J.N. Beasley, R.W. McNew, and J.K. Skeeles. 1994. A summary of data collected from turkeys following acute hemorrhagic enteritis virus infection at different ages. Proc 45th NC Avian Dis Conf., Oct 9-11. Des Moines, IA, 63.
106. Nicoll, T.R., and M.M. Jensen. 1987. Preliminary studies on bacterial interference of staphylococcosis of chickens. *Avian Dis.* 31:140–144.
107. Nicoll, T.R., and M.M. Jensen. 1987. Staphylococcosis of turkeys. 5. Large-scale control programs using bacterial interference. *Avian Dis*. 31:85–88.
108. Norton, R.A., G.R. Bayyari, J.K. Skeeles, W.E. Huff, and J.N. Beasley. 1994. A survey of two commercial turkey farms experiencing high levels of liver foci. *Avian Dis.* 38:887–894.
109. Notermans, S., J. Dufrenne, and W.J. van Leeuwen. 1982. Contamination of broiler chickens by *Staphylococcus aureus* during processing; incidence and origin. *J Appl Bacteriol.* 52:275–280.
110. Persoons D., S. Van Hoorebeke, K. Hermans, P. Butaye, A. de Kruif, F. Haesebrouck, and J. Dewulf. 2009. Methicillin-resistant *Staphylococcus aureus* in poultry. *Emerg Infect Dis.* 15:452–3.
111. Pezzlo, M. 1992. Identification of commonly isolated aerobic Gram-positive bacteria. In: *Clinical Microbiology Procedures Handbook*, vol 1. H.D. Isenberg, chief ed. American Society for Microbiology, Washington, DC. 1.20.1–1.20.12.
112. Rao, M.V.S., S.B. Kulshrestha, and S. Kumar. 1977. Biological properties and drug sensitivity reactions of intestinal staphylococci of poultry. *Indian J Anim Sci.* 46:648–651.
113. Raska, K., V. Matejovska, D. Matejovska, M.S. Bergdoll, and P. Petrus. 1981. To the origin of contamination of foodstuffs by enterotoxigenic staphylococci. In: *Staphylococci and Staphylococcal Infections*. J. Jeljaszewicz, ed. Gustav Fischer Verlag, Stuttgart. 381–385.
114. Rosenberger, J.K., S. Klopp, R.J. Eckroade, and W.C. Krauss. 1975. The role of the infectious bursal agent and several avian adenoviruses in the hemorrhagic-aplastic-anemia syndrome and gangrenous dermatitis. *Avian Dis.* 19:717–729.
115. Santivatr, D., S.K. Maheswaran, J.A. Newman, and B.S. Pomeroy. 1981. Effect of infectious bursal disease virus infection on the phagocytosis of *Staphylococcus aureus* by mononuclear phagocytic cells of susceptible and resistant strains of chickens. *Avian Dis.* 25:303–311.
116. Sasaki T., K. Kikuchi, Y. Tanaka, N. Takahashi, S. Kamata, and K. Hiramatsu. 2007. Reclassification of phenotypically identified *Staphylococcus intermedius* strains. *J Clin Microbiol.* 45:2770–78.
117. Scanlan, C.M., and B.M. Hargis. 1989. A bacteriologic study of scabby-hip lesions from broiler chickens in Texas. *J Vet Diagn Invest.* 1:170–3.
118. Schaffer A.C., and J.C. Lee. 2008. Vaccination and passive immunisation against *Staphylococcus aureus*. *Int J Antimicrob Agents.* 32 Suppl 1:S71–8.
119. Shimizu, A. 1977. Establishment of a new bacteriophage set for typing avian staphylococci. *Am J Vet Res.* 38:1601–1605.
120. Shimizu, A. 1977. Isolation and characteristics of bacteriophages from staphylococci of chicken origin. *Am J Vet Res.* 38:1389–1392.
121. Shimizu, A. 1977. Bacteriophage typing of chicken staphylococci by adapted phages. *Jpn J Vet Sci.* 39:7–13.
122. Shimizu, A., J. Kawano, C. Yamamoto, O. Kakutani, and M. Fujita. 1997. Comparison of pulsed-field gel electrophoresis and phage typing for discriminating poultry strains of *Staphylococcus aureus*. *Am J Vet Res.* 58:1412–1416.
123. Shinefield, H.R., and S. Black. 2005. Prevention of *Staphylococcus aureus* infections: advances in vaccine development. *Expert Rev Vaccines.* 4:669–76.
124. Skalka, B. 1991. Occurrence of staphylococcal species in clinically healthy domestic animals. *Vet Med (Praha).* 36:9–19.
125. Skow, A., K.A. Mangold, M. Tajuddin, A. Huntington, B. Fritz, R.B. Thomson Jr., and K.L. Kaul. 2005. Species-level identification of staphylococcal isolates by real-time PCR and melt curve analysis. *J Clin Microbiol.* 43:2876–80.

126. Takahashi, I., T. Yokoyama, T. Uehara, and T. Yoshida. 1986. Susceptibility of *S. aureus* and *Streptococcus* isolates from diseased animals to commonly used antibacterial agents and nosiheptide. I. Susceptibility of *S. aureus*. *Bull Nippon Vet Zootech*. 35:43–49.
127. Tate, C.R., W.C. Mitchell, and R.G. Miller. 1993. *Staphylococcus hyicus* associated with turkey stifle joint osteomyelitis. *Avian Dis.* 37:905–907.
128. Tenover F.C., and R.V. Goering. 2009. Methicillin-resistant *Staphylococcus aureus* strain USA300: origin and epidemiology. *J Antimicrob Chemother.* 64:441–6.
129. Terayama, T., H. Ushioda, M. Shingaki, M. Inaba, A. Kai, and S. Sakai. 1977. Coagulase types of *Staphylococcus aureus* from food poisoning outbreaks and types of incriminated foods. *Ann Rpt Tokyo Metrop Res Lab Public Health.* 28:1–4.
130. Terzolo, H.R., J.A. Villar, A.S. Zamora, and A. Zoratti De Verona. 1978. *Staphylococcus* infection of fowls. *Gaceta Vet.* 40:388–402.
131. Thompson, J.K., and J.T. Patterson. 1983. *Staphylococcus aureus* from a site of contamination in a broiler processing plant. *Rec Agr Res.* 31:45–53.
132. Thompson, J.K., J.T. Patterson, and P.A. Gibbs. 1980. The use of a new phage set for typing poultry strains of *Staphylococcus aureus* obtained from seven countries. *Br Poult Sci.* 21:95–102.
133. Vaid, M.Y., M.A. Muneer, M. Naeem, and H.A. Hashmi. 1979. A study on the incidence of *Staphylococcus* infections in poultry. *Pak J Sci.* 31:155–158.
134. Valipour, A., H. Koller, U. Setinek, and O.C. Burghuber. 2005. Pleural empyema associated with *Gemella morbillorum*: report of a case and review of the literature. *Scand J Infect Dis.* 37:378–81.
135. Vanderhaeghen W., K. Hermans, F. Haesebrouck, and P. Butaye. 2010. Methicillin-resistant *Staphylococcus aureus* (MRSA) in food production animals. *Epidemiol Infect.* 138:606–25.
136. Van Ness, G. 1946. *Staphylococcus citreus* in the fowl. *Poult Sci.* 25:647–648.
137. Wang, C.T., Y.C. Lee, and T.H. Fuh. 1977. Artificial infection of chicks with *Staphylococcus aureus*. *J Chin Soc Vet Sci.* 3:1–6.
138. Watkins, B.A., and B.F. Miller. 1983. Competitive gut exclusion of avian pathogens by *Lactobacillus acidophilus* in gnotobiotic chicks. *Poult Sci.* 62:1772–1779.
139. Watts, J.L., and R.J. Yancey. 1994. Identification of veterinary pathogens by use of commercial identification systems and new trends in antimicrobial susceptibility testing of veterinary pathogens. *Clin Microbiol Rev.* 7:346–356.
140. Weese, J.S., M. Archambault, B.M. Willey, P. Hearn, B.N. Kreiswirth, B. Said-Salim, A. McGeer, Y. Likhoshvay, J.F. Prescott, and D.E. Low. 2005. Methicillin-resistant *Staphylococcus aureus* in horses and horse personnel, 2000-2002. *Emerg Infect Dis.* 11:430–5.
141. Weese J.S., B.P. Avery, and R.J. Reid-Smith. 2010. Detection and quantification of methicillin-resistant *Staphylococcus aureus* (MRSA) clones in retail meat products. *Lett Appl Microbiol.* 51:338–42.
142. Wilder, T.D., J.M. Barbaree, K.S. Macklin, and R.A. Norton. Differences in the pathogenicity of various bacterial isolates used in an induction model for gangrenous dermatitis in broiler chickens. *Avian Dis*. 45:659–62.
143. Wilkinson, D.M., and M.M. Jensen. 1987. Staphylococcosis of turkeys. 4. Characterization of a bacteriocin produced by an interfering staphylococcus. *Avian Dis*. 31:80–84.
144. Willemart, J.P. 1980. Staphylococcal synovitis in poultry and its treatment with tiamulin. *Bull Acad Vet Fr.* 53:209–213.
145. Willett, H.P. 1992. *Staphylococcus*. In: *Zinsser Microbiology*, 20th ed. W.K. Joklik, H.P. Willett, D.B. Amos, and C.M. Wilfert, eds. Appleton and Lange, Norwalk, CT. 401–416.
146. Williams, R.B., and L.L. Daines. 1942. The relationship of infectious omphalitis of poults and impetigo staphylogenes in man. *J Am Vet Med Assoc.* 101:26–28.
147. Witte, W., and H. Kühn. 1978. Macrolide (antibiotic) resistance of *Staphylococcus aureus* strains from outbreaks of synovitis and dermatitis among chickens in large production units. *Arch Exp Veterinaermed* 32:105–114.
148. Wos, Z., and H. Jagodzinska. 1978. Characteristics of staphylococci found in chicken carcasses. *Przem Spozyw.* 32:186–187.
149. Zhen Y.H., L.J. Jin, J. Guo, X.Y. Li, Z. Li, R. Fang, and Y.P. Xu. 2008. Characterization of specific egg yolk immunoglobulin (IgY) against mastitis-causing *Staphylococcus aureus*. *J Appl Microbiol.* 105:1529–35.

Streptococcosis and Enterococcis

1. Abdul-Aziz, T.A. 1994. Pathogenicity of *Enterococcus hirae* for chicken embryos and betamethazone-treated chicks. *Res Vet Sci.* 56:397–398.
2. Abe, Y., K. Nakamura, M. Yamada, and Y. Yamamoto. 2005. Encepalomalacia with *Enterococcus durans* infection in the brain stem and cerebral hemisphere in chick in Japan. *Avian Dis.* 50:139–141.
3. Agrimi, P. 1956. Studio sperimentale su alcuni focolai di streptococcosi nel pollo. *Zooprofilassi.* 11:491–501.
4. Alaboudi, A.R., D.A. Hammed, H.A. Basher, and M.G. Hassen. 1992. Potential pathogenic bacteria from dead-in-shell chicken embryos. *Iraqi J Vet Sci.* 5:109–114.
5. Arias, C., B. Robredo, K.V. Singh, C. Torres, D. Panesso, and B.E. Murray. 2006. Rapid identification of *Enterococcus hirae* and *Enterococcus durans* by PCR and detection of a homologue of the *E. hirae* mur-2 gene in *E. durans*. *J Clin Microbiol*. 44:1567–1570.
6. Armour, N.K., S.R. Collett, and S.M. Williams. 2011. *Enterococcus cecorum*-related arthritis and osteomyelitis in broilers and broiler breeders. *The Poultry Informed Professional.* 117:1–7.
7. Aziz, T., and H.J. Barnes. 2007. Is spondylitis an emerging disease in broiler breeders? *World Poultry.* 23:44–45.
8. Baele, M., L.A. Devriese, P. Butaye, and F. Haesebrouck. 2002. Composition of enterococcal and streptococcal flora from pigeon intestines. *J Appl Microbiol.* 92:348–351.
9. Bager, F., M. Madsen, J. Christensen, and F.M. Aarestrup. 1997. Avoparcin used as a growth promoter is associated with the occurrence of vancomycin-resistant *Enterococcus faecium* on Danish poultry and pig farms. *Prev Vet Med.* 31:95–112.
10. Barnes, E.M., G.C. Mead, C.S. Impey, and B.W. Adams. 1978. The effect of dietary bacitracin on the incidence of *Streptococcus faecalis* subspecies *liquefaciens* and related streptococci in the intestines of young chicks. *Poult Sci.* 19:713–723.
11. Barnes, E.M., C.S. Impey, B.J.H. Stevens, and J.L. Peel. 1977. *Streptococcus pleomorphus* sp.nov.: An anaerobic streptococcus isolated mainly from the caeca of birds. *J Gen Microbiol*. 102:45–53.
12. Breed, R.S., E.G.D. Murray, and N.R. Smith. 1957. *Bergey's Manual of Determinative Bacteriology*, 7th ed. Williams and Wilkins, Baltimore.

13. Champagne, J., M.S. Diarra, H. Rempel, E. Topp, C.W. Greer, J. Harel, and L. Masson. 2011. Development of a DNA microarray for enterococcal species, virulence, and antibiotic resistance gene determinations among isolates from poultry. *Appl Environ Microbiol.* 77:2625–2633.
14. Cheville, N.F., J. Tappe, M. Ackermann, and A. Jensen. 1988. Acute fibrinopurulent blepharitis and conjunctivitis associated with *Staphylococcus hyicus*, *Escherichia coli*, and *Streptococcus spp*. in chickens and turkeys. *Vet Pathol*. 25:369–375.
15. Cardona, C.J., A.A. Bickford, B.R. Charlton, and G.I. Cooper. 1993. *Enterococcus durans* infection in young chickens associated with bacteremia and encephalomalacia. *Avian Dis.* 37:234–239.
16. Cervantes, H. 2006. Should antibiotic feed additives be banned? Poultry USA. Watt Publishing Company.
17. Chadfield, M.S., A.M. Bojesen, J.P. Christensen, J. Juul-Hansen, S. Saxmose Nielsen, and M. Bisgaard. 2005. Reproduction of sepsis and endocarditis by experimental infection of chickens with *Streptococcus gallinaceus* and *Enterococcus hirae*. *Avian Pathol.* 34:238–247.
18. Chadfield, M.S., J.P. Christensen, H. Christensen, and M. Bisgaard. 2004. Characterization of streptococci and enterococci associated with septicemia in broiler parents with high prevalence of endocarditis. *Avian Pathol.* 33:610–617.
19. Chadfield, M.S., J.P. Christensen, J. Juhl-Hansen, H. Christensen, and M. Bisgaard. 2005. Characterization of *Enterococcus hirae* outbreaks in broiler flocks demonstrating increased mortality because of septicemia and endocarditis and/or altered production parameters. *Avian Dis.* 49:16–23.
20. Chamanza, R.T., T.H. Fabri, L. van Veen, and R.M. Dwars. 1998. Enterococcus-associated encephalomalacia in one-week-old chicks. *Vet Rec.* 143:450–451.
21. Clark, S.R., H.J. Barnes, A.A. Bickford, R.P. Chin, and R. Droual. 1991. Relationship of osteomyelitis and associated soft-tissue lesions with green liver discoloration in tom turkeys. *Avian Dis.* 35:139–146.
22. Collins, M.D., D. Jones, J.A.E. Farrow, R. Kilpper-Balz, and K.H. Schleifer. 1984. *Enterococcus avium* nom. rev., comb. nov.; *E. casseliflavus* nom. rev., comb. nov.; *E. durans* nom. rev., comb. nov.; *E. gallinarum* comb. nov.; and *E. malodoratus* sp. nov. *Int J System Bacteriol*. 34:220–223.
23. De Hert, P., P. De Foort, J. Van Steelant, H. Swam, L. Tanghe, S. Van Goethem, and M. Vanrobaeys. 2008. Enterococcus cecorum osteomyelitis and arthritis in broiler chickens. *Vlaams Diergeneekundig Tijdschrift*. 78:44–48.
24. De Herdt, P., M. Desmidt, F. Haesebrouck, R. Ducatelle, and L.A. Devriese. 1992. Experimental *Streptococcus bovis* infections in pigeons. *Avian Dis.* 36:916–925.
25. De Herdt, P., L.A. Devriese, B. De Groote, R. Ducatelle, and F. Haesebrouck. 1993. Antibiotic treatment of *Streptococcus bovis* infections in pigeons. *Avian Pathol.* 22:605–615.
26. De Herdt, P., R. Ducatelle, F. Haesebrouck, L.A. Devriese, B. De Groote, and S. Roels. 1994. An unusual outbreak of *Streptococcus bovis* septicemia in racing pigeons (*Columba livia*). *Vet Rec.* 134:42–43.
27. Devriese, L.A., J. Hommes, R. Wijfels, and F. Haesebrouck. 1991. Composition of the enterococcal and streptococcal intestinal flora of poultry. *J Appl Bacteriol.* 71:46–50.
28. Devriese, L.A., R. Ducatelle, E. Uyttebroek, and F. Haesebrouck. 1991. *Enterococcus hirae* infection and focal necrosis of the brain of chicks. *Vet Rec.* 129:316.
29. DeVriese, L.A., G.N. Dutta, J.A.E. Farrow, A. van de Kerckhove, and B.A. Phillips. 1983. *Streptococcus cecorum*, a new species isolated from chickens. *Int J Syst Bacteriol.* 33:772–776.
30. DeVriese, L.A., J. Hommez, B. Pot, and F. Haesebrouck. 1994. Identification and composition of the streptococcal and enterococcal flora of tonsils, intestines, and faeces of pigs. *J Appl Bacteriol.* 77:31–36.
31. Devriese, L.A., L. Laurier, P. De Herdt, and F. Haesebrouck. 1992. Enterococcal and streptococcal species isolated from faeces of calves, young cattle, and dairy cows. *J Appl Bacteriol.* 72:29–31.
32. DeVriese, L.A., M. Vancanneyt, P. Deschermaeker, M. Baele, H.W. Van Landuyt, B. Gordts, P. Butaye, J. Swings, and F. Haesebrouck. 2002. Differentiation and identification of *Enterococcus durans*, *E. hirae*, and *E. villorum*. *J Appl Microbiol*. 92:821–827.
33. Devriese, L.A., P. Vandamme, B. Pot, M. Vanrobaeys, K. Kersters, and F. Haesebrouck. 1998. Differentiation between *Streptococcus gallolyticus* strains of human clinical and veterinary origins and *Streptococcus bovis* strains from the intestinal tracts of ruminants. *J Clin Microbiol.* 36:3520– 3523.
34. Domermuth, C.H., and W.B. Gross. 1969. A medium for isolation and tentative identification of fecal streptococci, and their role as avian pathogens. *Avian Dis.* 13:394–399.
35. Dutta, G.N., and L.A. Devriese. 1982. Susceptibility of fecal streptococci of poultry origin to nine growth- promoting agents. *Appl Environ Microbiol.* 44:832–837.
36. Facklam, R.F., and D.F. Sahm. 1995 Enterococcus. In: *Manual of Clinical Microbiology*, 6th ed. P.M. Murray, E.J. Baron, M.A. Pfaller, F.C. Tenover, and R.H. Yolken, eds. American Society of Microbiology Press, Washington, DC. 308–314.
37. Facklam, R.A. 2002. What happened to the Streptococci: Overview of taxonomic and nomenclature changes. *Clin Microbiol Rev.* 15:613–630.
38. Farrow, J.A., and M.D. Collins. 1985. *Enterococcus hirae*, a new species that includes amino acid assay strain NCDO 1258 and strains causing growth depression in young chickens. *Int J Syst Bacteriol.* 35:73–75.
39. Farrow, J.A., E.D. Jones, B.A. Phillips, and M.D. Collins. 1983. Taxonomic studies on some group streptococci. *J Gen Microbiol.* 129:1423–1432.
40. Gross, W.B. 1991. Use of corticosterone and ampicillin for treatment of *Streptococcus faecalis* infection in chickens. *Am J Vet Res.* 52:1288–1291.
41. Gross, W.B., and C.H. Domermuth. 1962. Bacterial endocarditis of poultry. *Am J Vet Res.* 23:320–329.
42. Hernandez, D.J., E.D. Roberts, L.G. Adams, and T. Vera. 1972. Pathogenesis of hepatic granulomas in turkeys infected with *Streptococcus faecalis* var. *liquefaciens*. *Avian Dis*. 15:201–216.
43. Hudson, C.B. 1933. A specific infectious disease of chickens due to a hemolytic streptococcus. *J Am Vet Med Assoc.* 82:218–231.
44. Inzana, T.C., and B. Irtani. 1989. Rapid detection of group C streptococci from animals by latex agglutination. *J Clin Microbiol.* 27:309–312.
45. Inzani, T.J., D.S. Lindsey, X.J. Meng, and K.W. Post. 2002. Gram-positive Bacteria, In: Manual of Commercial Methods in Clinical Microbiology. Truant, A.L., ed. . ASM Press, Washington, DC. 348.
46. Ivanics, E., Z. Bitay, and R. Glavits. 1984. *Streptococcus mutans* infection in geese. *Magy Allatorv Lapja.* 39:92–95.
47. Jensen, W.I. 1979. An outbreak of streptococcosis in eared grebes (*Podiceps nigricollis*). *Avian Dis.* 23:543–546.

48. Jortner, B.S., and C.F. Helmboldt. 1971. Streptococcal bacterial endocarditis in chickens. *Vet Pathol.* 8:54–62.
49. Katanbaf, M.N., P.B. Siegel, and W.B. Gross. 1987. Prior experience and response of chickens to a streptococcal infection. *Poult Sci.* 66:2053–2055.
50. Kaukas, A.M., M. Hinton, and A.H. Linton. 1987. The effect of ampicillin and tylosin on the faecal enterococci of healthy young chickens. *c* 62:441–447.
51. Kaukas, A.M., M. Hinton, and A.H. Linton. 1988. The effect of growth-promoting antibiotics on the faecal enterococci of healthy young chickens. *J Appl Bacteriol.* 64:57–64.
52. Knijff, E., F. Dellaglio, A. Lombardi, C. Andrighetto, and S. Torriani. 2001. Rapid identification of *Enterococcus durans* and *Enterococcus hirae* by PCR with primers targeted to *ddl* genes. *J Microbiol Methods.* 47:35–40.
53. Kolbjornsen, O., B. David, and M. Gilhuus. 2011. Bacterial osteomyelitis in a 3-week-old broiler chicken associated with *Enterococcus hirae*. *Vet Pathol.* 48:1134–1137.
54. Kuntz, R.L., P.G. Hartel, K. Rodgers, and W.I. Segars. 2004. Presence of *Enterococcus faecalis* in broiler litter and wild bird feces for bacterial tracking. *Water Res.* 38:3551–3557.
55. Landman, W.J. 1999. Amyloid arthropathy in chickens. *Vet Q.* 21:78–82.
56. Landman, W.J., A.E. vd Bogaard, P. Doornenbal, P.C. Tooten, A.R. Elbers, and E. Gruys. 1998. The role of various agents in chicken amyloid arthropathy. *Amyloid.* 5:266–278.
57. Mack, W.B. 1908. Apoplectiform septicemia in chickens. *Am Vet Rev.* 33:330–332.
58. MacFaddin, J.F. 2000. *Biochemical Tests for the Identification of Medical Bacteria*, 3rd ed. Lippincott Williams and Wilkins, Baltimore, MD.
59. Manero, A., and A.R. Blanch. 1999. Identification of *Enterococcus spp*. with a biochemical key. *Appl Environ Microbiol*. 65:4425–4430.
60. Makrai, L., C. Nemes, A. Simon, E. Ivanics, Z. Dudor, and R. Glavitis. 2011. Association of *Enterococcus cecorum* with vertebral osteomyelitis and spondylolisthesis in broiler parent chickens. *Acta Vet Hung.* 59:11–21.
61. Martin, M., L. Martin, and H.J. Barnes. April 2010. Pathogenesis of Vertebral Osteoarthritis in Male Broiler Breeders caused by *Enterococcus cecorum*. Completed Research Report, Project # F026. U.S. Poultry and Egg.
62. Mazurkiewicz, M., A. Latala, A. Wieliczko, A. Zalesinski, and M. Tomaszewski. 1990. Efficacy of Baytril in the control of bacterial diseases of poultry. *Med Eterynaryjnego.* 46:286–289.
63. McNamee, P.T., and D.C. King. 1996. Endocarditis in broiler breeder rearers due to *Enterococcus hirae*. *Vet Rec.* 138:240.
64. Molitoris, E., M.I. Krichevsky, D.J. Fagerberg, and C.L. Quarles. 1986. Effects of dietary chlortetracycline on the antimicrobial resistance of broiler faecal streptococcaceae. *J Appl Bacteriol.* 60:185–193.
65. Moore, W.E.C., and W.B. Gross. 1968. Liver granulomas of turkeys—causative agents and mechanism of infection. *Avian Dis.* 12:417–422.
66. Nogaard, V.A., and J.R. Mohler. 1902. Apoplectiform septicemia in chickens. US Dep Agric BAI Bull 36.
67. Owings, W.J., D.L. Reynolds, R.J. Hasiak, and P.R. Ferkett. 1990. Influence of dietary supplementation with *Streptococcus faecium* M-74 on broiler body weight, feed conversion carcass characteristics, and intestinal microbial colonization. *Poult Sci.* 69:1257–1264.
68. Peckham, M.C. 1966. An outbreak of streptococcosis (*apoplectiform septicemia*) in white rock chickens. *Avian Dis.* 10:413–421.
69. Povar, M.L., and B. Brownstein. 1947. Valvular endocarditis in the fowl. *Cornell Vet.* 37:49–54.
70. Randall, C.J., and D.B. Pearson. 1991. Enterococcal endocarditis causing heart failure in broilers. *Vet Rec.* 129:535.
71. Rouff, K.L., R.A. Whiley, and D. Beighton. 2003. Streptococcus. In: *Manual of Clinical Microbiology*, 8th ed. P.R. Murray, E.J. Baron, J.H. Jorgensen, M.A. Pfaller, and R.H. Yolken., eds. American Society for Microbiology, Press, Washington, DC. 405–421.
72. Rouff, K.L. 1995. Streptococcus. In: *Manual of Clinical Microbiology*, 6th ed. P.R. Murray, E.J. Baron, M.A. Pfaller, F.C. Tenover, and R.H. Yolken, eds. American Society of Microbiology Press, Washington, DC. 299–307.
73. Rudy, A. 1991. The effects of microbial contamination of incubators on the health of broiler chicks in the first days of life. *Zesz Nauk Akad Rolniczej we Wroclawin Weter.* 49:19–26.
74. Sander, J.E., E.M. Willingham, J.L. Wilson, and S.G. Thayer. 1998. The effect of inoculating *Enterococcus faecalis* into the yolk sac on chick quality and maternal antibody absorption. *Avian Dis.* 42:359–363.
75. Sandhu, T.S. 1988. Fecal streptococcal infection of commercial white pekin ducklings. *Avian Dis.* 32:570–573.
76. Schlegel, L.A., F. Grimont, E. Ageron, P.A.D. Grimont, and A. Bouvet. 2003. Reappraisal of the taxonomy of the *Streptococcus bovis*/*Streptococcus equinus* complex and related species: description of *Streptococcus gallolyticus* subsp. *Gallolyticus* subsp. nov., *S. gallolyticus* subsp. *Macedonicus* subsp. nov., and *S. gallolyticus* subsp. *Pasteurianus* subsp. nov. *Int J Syst Evol Microbiol*. 53:631–645.
77. Scupham, A., T. Patton, E. Bent, and D. Bayles. 2008. Comparison of the cecal microbiota of domestic and wild turkeys. *Microb Ecol.* 56:322–331.
78. Siegel, P.B., M.N. Katanbaf, N.B. Anthony, D.E. Jones, A. Martin, W.B. Gross, and E.A. Dunnington. 1987. Responses of chickens to *Streptococcus faecalis*: Genotype-housing interactions. *Avian Dis.* 31:804–808.
79. Singer, D.A., E.M. Jochimson, P. Gielerak, and W.R. Jarvis. 1996. Pseudo-outbreak of *Enterococcus durans* infections and colonization associated with introduction of an automated identification system software update. *J Clin Microbiol.* 34:2685–2687.
80. Stalker, M.J., M.L. Brash, A. Weisz, R.M. Ouckama, and D. Slavic 2010. Arthritis and osteomyelitis associated with *Enterococcus cecorum* infection in broiler and broiler breeder chickens in Ontario, Canada. *J Vet Diag Invest.* 22:643–645.
81. Tsakris, A., N. Woodford, S. Pournaras, M. Kaufman, and J. Douboyas 1998. Apparent increased prevalence of high-level aminoglycoside-resistant *Enterococcus durans* resulting from false identification by a semi-automated software system. *J Clin Microbiol.* 36:1419–1421.
82. Vaillancourt, J.P., A. Elfadil, and J.R. Bisaillon. 1992. Cellulitis in the broiler fowl. *Med Vet Quebec.* 22:168–172.
83. Volkmar, F. 1932. Apoplectiform septicemia in turkeys. *Poult Sci.* 11:297–300.
84. Wages, D.P. 1998. Streptococcosis. In: *Isolation and Identification of Avian Pathogens*, 4th ed. D.E. Swayne, J.R. Glisson, M.W. Jackwood, J.E. Pearson, W.M. Reed, eds. American Association of Avian Pathologists, Kennett Square, PA. 58–60.

85. Whistler, P.E., and B.W. Sheldon. 1989. Biocidal activity of ozone versus formaldehyde against poultry pathogens inoculated in a prototype setter. *J Poult Sci.* 68:1068–1073.
86. Wood, A., G. McKenzie, N.C. McGillveray, L. Brown, A. DeVriese, and M. Baele. 2002. Isolation of *Enterococcus cecorum* from bone lesions in broiler chickens. *Vet Record* 150:27.

Erysipelas

1. Abrashev, I., and P. Orozova. 2006. Erysipelothrix rhusiopathiae neuraminidase and its role in pathogenicity. *Z Naturforsch*. 61c:434–438.
2. Ahrne, S., I.M. Stenstrom, N.E. Jensen, B. Pettersson, M. Uhlen, and G. Molin. 1995. Classification of *Erysipelothrix* strains on the basis of restriction fragment length polymorphisms. *Int J Syst Bacteriol*. 45:382–385.
3. Beaudette, F.R., and C.B. Hudson. 1936. An outbreak of acute swine erysipelas infection in turkeys. *J Am Vet Med Assoc*. 88:475–488.
4. Bernath, S., G. Kuscera, I. Kadar, G. Horvath, and G. Morovjan. 1997. Comparison of the protein patterns of *Erysipelothrix rhusiopathiae* strains by SDS-PAGE and autoradiography. *Acta Vet Hung*. 45:417–422.
5. Bickford, A.A., R.E. Corstvet, and A.S. Rosenwald. 1978. Pathology of experimental erysipelas in turkeys. *Avian Dis*. 22:503–518.
6. Bisgaard, M., V. Nørrung, and N. Tornoe. 1980. Erysipelas in poultry. Prevalence of serotypes and epidemiological investigations. *Avian Pathol*. 9:355–362.
7. Boyer, C.I., and J.A. Brown. 1957. Studies on erysipelas in turkeys. *Avian Dis*. 1:42–52.
8. Brännström, S., I. Hansson, and J. Chirico. 2010. Experimental study on possible transmission of the bacterium *Erysipelothrix rhusiopathiae* to chickens by the poultry red mite, *Dermanyssus gallinae. Exp Appl Acarol*. 50: 299–307.
9. Bricker, J.M., and Y.M. Saif. 1988. Use of a live oral vaccine to immunize turkeys against erysipelas. *Avian Dis*. 32:668–673.
10. Cheun, H.I., K. Kawamoto, M. Hiramatsu, H. Tamaoki, T. Shirahata, S. Igimi, and S.I. Makino. 2004. Protective immunity of SpaA-antigen producing *Lactococcus lactis* against *Erysipelothrix rhusiopathiae* infection. *J Appl Microbiol*. 96:1347–1353.
11. Chirico, J., H. Eriksson, O. Fossum, and D. Jansson. 2003. The poultry red mite, *Dermanyssus gallinae*, a potential vector of *Erysipelothrix rhusiopathiae* causing erysipelas in hens. *Med Vet Entomol*. 17:232–234.
12. Chooromoney, K.N., D.J. Hampson, G.J. Eamens, and M.J. Turner. 1994. Analysis of *Erysipelothrix rhusiopathiae* and *Erysipelothrix tonsillarum* by multilocus enzyme electrophoresis. *J Clin Microbiol*. 32:371–376.
13. Cooper, G.L., and A.A. Bickford. 2008. Erysipelas. In: *A Laboratory Manual for The Isolation and Identification of Avian Pathogens*, 5th ed. L. Dufour-Zavala, D.E. Swayne, J.R. Glisson, J.E. Pearson, W.M. Reed, M.W. Jackwood, and P.R. Woolcock, eds. American Association of Avian Pathologists, Jacksonville, FL. 36–38.
14. Corstvet, R.E. 1967. Pathogenesis of *Erysipelothrix insidiosa* in the turkey. *Poult Sci*. 46:1247.
15. Cousquer, G. 2005. Erysipelas outbreak in racing pigeons following ingestion of compost. *Vet Rec*. 156:656.
16. Cross, G.M.J., and P.D. Claxton. 1979. Serological classification of Australian strains of *Erysipelothrix rhusiopathiae* isolated from pigs, sheep, turkeys and man. *Aust Vet J*. 55:77–81.
17. Eamens, G.J., M.J. Turner, and R.E. Catt. 1988. Serotypes of *Erysipelothrix rhusiopathiae* in Australian pigs, small ruminants, poultry, and captive wild birds and animals. *Aust Vet J*. 65:249–252.
18. Enoe, C., and V. Nørrung. 1992. Experimental infection of pigs with serotypes of *Erysipelothrix rhusiopathiae*. *Proc Int Pig Vet Soc Conf*. 345.
19. Eriksson, H., D.S. Jansson, K.-E. Johansson, V. Båverud, J. Chirico, and A. Aspán. 2009. Characterization of *Erysipelothrix rhusiopathiae* isolates from poultry, pigs, emus, the poultry red mite and other animals. *Vet Microbiol*. 137: 98–104.
20. Feist, H., K.D. Flossmann, and W. Erler. 1976. Einige Unter suchungen zum Nahrstoffbedarf der Rotlaufbakterien. *Arch Exp Veterinarmed*. 30:49–57.
21. Fidalgo, S.G., Q. Wang, and T.V. Riley. 2000. Comparison of methods for detection of *Erysipelothrix spp*., and their distribution in some australasian seafoods. *Appl Environ Microbiol*. 66:2066–2070.
22. Galan, J.E., and J.F. Timoney. 1990. Cloning and expression in *Escherichia coli* of a protective antigen of *Erysipelothrix rhusiopathiae*. *Infect Immun*. 58:3116–3121.
23. Groschup, M.H., K. Cussler, R. Weiss, and J.F. Timoney. 1991. Characterization of a protective protein antigen of *Erysipelothrix rhusiopathiae*. *Epidemiol Infect*. 107:637–649.
24. Groschup, M.H., and J.F. Timoney. 1990. Modified Feist broth as a serum-free alternative for enhanced production of protective antigen of *Erysipelothrix rhusiopathiae*. *J Clin Microbiol*. 28:2573–2575.
25. Hennig, G.E., H.D. Goebel, J.J. Fabis, and M.I. Khan. 2002. Diagnosis by polymerase chain reaction of erysipelas septicemia in a flock of ring-necked pheasants. *Avian Dis*. 46:509–514.
26. Hollifield, J.L., G.L. Cooper, and B.R. Charlton. 2000. An outbreak of erysipelas in 2-day-old poults. *Avian Dis*. 44:721–724.
27. Imada, Y., N. Goji, H. Ishikawa, M. Kishima, and T. Sekizaki. 1999. Truncated surface protective antigen (SpaA) of *Erysipelothrix rhusiopathiae* serotype 1a elicits protection against challenge with serotypes 1a and 2b in pigs. *Infect Immun*. 67:4376–4382.
28. Ingebritson, A.L., J.A. Roth, and P.J. Hauer. 2010. *Erysipelothrix rhusiopathiae*: Association of Spa-type with serotype and role in protective immunity. *Vaccine*. 28: 2490–2496.
29. Kanai, Y., H. Hayashidani, K.I. Kaneko, M. Ogawa, T. Takahashi, and M. Nakamura. 1997. Occurrence of zoonotic bacteria in retail game meat in Japan with special reference to Erysipelothrix. *J Food Protect*. 60:328–331.
30. Kitajima, T., E. Oishi, K. Amimoto, S. Ui, H. Nakamura, K. Oda, S. Katayama, A. Izumida, and Y. Shimizu. 2000. Quantitative diversity of 67 kDa protective antigen among serovar 2 strains of *Erysipelothrix rhusiopathiae* and its implication in protective immune response. *J Vet Med Sci*. 62:1073–1077.
31. Kiuchi, A., M. Hara, H.S. Pham, K. Takikawa, and K. Tabuchi. 2000. Phylogenetic analysis of the *Erysipelothrix rhusiopathiae* and *Erysipelothrix tonsillarum* based upon 16S rRNA. *DNA Seq*. 11:257–260.
32. Kuscera, G. 1973. Proposal for standardization of the designations used for serotypes of *Erysipelothrix rhusiopathiae* (Migula) Buchanan. *Int J Syst Bacteriol*. 23:184–188.

33. Lachmann, P.G., and H. Deicher. 1986. Solubilization and characterization of surface antigenic components of *Erysipelothrix rhusiopathiae* T28. *Infect Immun*. 52:818–822.
34. Makino, S., Y. Okada, T. Maruyama, K. Ishikawa, T. Takahashi, M. Nakamura, T. Ezaki, and H. Morita. 1994. Direct and rapid detection of *Erysipelothrix rhusiopathiae* DNA in animals by PCR. *J Clin Microbiol*. 32:1526–1531.
35. Makino, S., K. Yamamoto, S. Murakami, T. Shirahata, K. Uemura, T. Sawada, H. Wakamoto, and H. Morita. 1998. Properties of repeat domain found in a novel protective antigen, SpaA, of *Erysipelothrix rhusiopathiae*. *Microb Pathog*. 25:101–109.
36. Makino, S., K. Katsuta, and T. Shirahata. 1999. A novel protein of *Erysipelothrix rhusiopathiae* that confers haemolytic activity on *Escherichia coli*. *Microbiology* 145:1369–1374.
37. Makino, S., K. Yamamoto, H. Asakura, and T. Shirahata. 2000. Surface antigen, SpaA, of *Erysipelothrix rhusiopathiae* binds to Gram-positive bacterial cell surfaces. *FEMS Microbiol Lett*. 186:313–317.
38. Mazaheri, A., H.C. Philipp, H. Bonsack, and M. Voss. 2006. Investigations of the vertical transmission of *Erysipelothrix rhusiopathiae* in laying hens. *Avian Dis*. 50:306–308.
39. Nagai, S., H. To, and A. Kanda. 2008. Differentiation of *Erysipelothrix rhusiopathiae* strains by nucleotide sequence analysis of a hypervariable region in the *spA* gene: discrimination of a live vaccine strain from field isolates. *J Vet Diagn Invest*. 20: 336–342.
40. Nakazawa, H., H. Hayashidani, J. Higashi, K.I. Kaneko, T. Takahashi, and M. Ogawa. 1998. Occurrence of *Erysipelothrix spp*. in chicken meat parts from a processing plant. *J Food Protect*. 61:1207–1209.
41. Nakazawa, H., H. Hayashidani, J. Higashi, K.I. Kaneko, T. Takahashi, and M. Ogawa. 1998. Occurrence of *Erysipelothrix spp*. in broiler chickens at an abbatoir. *J Food Protect*. 61:907–909.
42. Okatani, A.T., H. Hayashidani, T. Takahashi, T. Taniguchi, M. Ogawa, and K.I. Kaneko. 2000. Randomly amplified polymorphic DNA analysis of *Erysipelothrix spp*. *J Clin Microbiol*. 38:4332–4336.
43. Okatani, A.T., M. Ishikawa, S. Yoshida, M. Sekiguchi, K. Tanno, M. Ogawa, T. Horikita, T. Horisaka, T. Tanaguchi, Y. Kato, and H. Hayashidani. 2004. Automated ribotyping, a rapid typing method for analysis of *Erysipelothrix spp*. strains. *J Vet Med Sci*. 66:729–733.
44. Packer, R.A. 1943. The use of sodium azide (NaN_3) and crystal violet in a selective medium for streptococci and *Erysipelothrix rhusiopathiae*. *J Bacteriol*. 46:343–349.
45. Pal, N., J.S. Bender, and T. Opriessnig. 2010. Rapid detection and differentiation of *Erysipelothrix spp*. by a novel multiplex real-time PCR assay. *J Appl Microbiol*. 108:1083–1093.
46. Partridge, J., J. King, J. Krska, D. Rockabrand, and P. Blum. 1993. Cloning, heterologous expression, and characterization of the *Erysipelothrix rhusiopathiae* DnaK protein. *Infect Immun*. 61:411–417.
47. Rockabrand, D., J. Partridge, J. Krska, and P. Blum. 1993. Nucleotide sequence analysis and heterologous expression of the *Erysipelothrix rhusiopathiae dnaJ* gene. *FEMS Microbiol Lett*. 111:79–86.
48. Saif, Y.M., K.E. Nestor, R.N. Dearth, and P.A. Renner. 1984. Possible genetic variation in resistance of turkeys to erysipelas and fowl cholera. *Avian Dis*. 28:770–773.
49. Sato, H., Y. Yamazaki, K. Tsuchiya, T. Aoyama, N. Akaba, T. Suzuki, A. Yokoyama, H. Saito, and N. Maehara. 1998. Use of the protective antigen of *Erysipelothrix rhusiopathiae* in the enzyme-linked immunosorbent assay and latex agglutination. *Zbl Vet Med B*. 45:407–420.
50. Sato, H., H. Miyazaki, H. Sakakura, T. Suzuki, H. Saito, and N. Maehara. 1999. Isolation and purification of a protective protein antigen of *Erysipelothrix rhusiopathiae*. *Zbl Vet Med B*. 46:73–84.
51. Sato, H., Y. Yamazaki, A. Kodairo, H. Saito, and N. Maehara. 1999. Preparation and partial characterization of monoclonal antibodies against the protective protein antigen of *Erysipelothrix rhusiopathiae*. *Zbl Vet Med B*. 46:85–92.
52. Sawada, T., and T. Takahashi. 1987. Cross protection of mice and swine inoculated with culture filtrate of attenuated *Erysipelothrix rhusiopathiae* and challenge exposed to strains of various serovars. *Am J Vet Res*. 48:239–242.
53. Schubert, K., and F. Fiedler. 2001. Structural investigations on the cell surface of *Erysipelothrix rhusiopathiae*. *Syst Appl Microbiol*. 24:26–30.
54. Shibatani, M., T. Suzuki, M. Chujo, and K. Nakamura. 1997. Disseminated intravascular coagulation in chickens inoculated with *Erysipelothrix rhusiopathiae*. *J Comp Pathol*. 117:147–156.
55. Shimoji, Y., H. Asato, T. Sekizaki, Y. Mori, and Y. Yokomizo. 2002. Hyaluronidase is not essential for the lethality of *Erysipelothrix rhusiopathiae* infection in mice. *J Vet Med Sci*. 64:173–176.
56. Shimoji, Y., Y. Ogawa, M. Osaki, H. Kabeya, S. Maruyama, T. Mikami, and T. Sekizaki. 2003. Adhesive surface proteins of *Erysipelothrix rhusiopathiae* bind to polystyrene, fibronectin, and type 1 and IV collagens. *J Bacteriol*. 185:2739–2748.
57. Shimoji, Y., Y. Yokomizo, T. Sekizaki, Y. Mori, and M. Kubo. 1994. Presence of a capsule in *Erysipelothrix rhusiopathiae* and its relationship to virulence for mice. *Infect Immun*. 62:2806–2810.
58. Shimoji, Y., Y. Yokomizo, and Y. Mori. 1996. Intracellular survival and replication of *Erysipelothrix rhusiopathiae* within murine macrophages: Failure of induction of the oxidative burst of macrophages. *Infect Immun*. 64:1789–1793.
59. Shimoji, Y., Y. Mori, K. Hyakutake, T. Sekizaki, and Y. Yokomizo. 1998. Use of an enrichment broth cultivation-PCR combination assay for rapid diagnosis of swine erysipelas. *J Clin Microbiol*. 36:86–89.
60. Shimoji, Y., Y. Mori, T. Sidizaki, T. Shibahara, and Y. Yokomizo. 1998. Construction and vaccine potential of acapsular mutants of *Erysipelothrix rhusiopathiae*: use of excision of Tn916 to inactivate a target gene. *Infect Immun*. 66:3250–3254.
61. Shimoji, Y., Y. Mori, and V.A. Fischetti. 1999. Immunological characterization of a protective antigen of *Erysipelothrix rhusiopathiae*: identification of the region responsible for protective immunity. *Infect Immun*. 67:1646–1651.
62. Shimoji, Y. 2000. Pathogenicity of *Erysipelothrix rhusiopathiae*: virulence factors and protective immunity. *Microbes Infect* 2:965–972.
63. Takahashi, T., M. Takagi, and T. Sawada. 1984. Cross protection in mice and swine immunized with live erysipelas vaccine to challenge exposure with strains of *Erysipelothrix rhusiopathiae* of various sero types. *Am J Vet Res*. 45:2115–2118.
64. Takahashi, T., T. Fujisawa, Y. Benno, Y. Tamura, T. Sawada, S. Suzuki, M. Muramatsu, and T. Mitsuoka. 1987. *Erysipelothrix tonsillarum* sp. nov. isolated from tonsils of apparently healthy pigs. *Int J Syst Bacteriol*. 37:166–168.

65. Takahashi, T., T. Fujisawa, Y. Tamura, S. Suzuki, M. Muramatsu, T. Sawada, Y. Benno, and T. Mitsuoka. 1992. DNA relatedness among *Erysipelothrix rhusiopathiae* strains representing all twenty-three serovars and *Erysipelothrix tonsillarum*. *Int J Syst Bacteriol*. 42:469–473.
66. Takahashi, T., M. Takagi, R. Yamaoka, K. Ohishi, M. Norimatsu, Y. Tamura, and M. Nakamura. 1994. Comparison of the pathogenicity for chickens of *Erysipelothrix rhusiopathiae* and *Erysipelothrix tonsillarum*. *Avian Pathol*. 23:237–245.
67. Takahashi, T., Y. Tamura, Y.S. Endoh, and N. Hara. 1994. Cellular fatty acid composition of *Erysipelothrix rhusiopathiae* and *Erysipelothrix tonsillarum*. *J Vet Med Sci*. 56:385–387.
68. Takahashi, T., T. Fujisawa, A. Umeno, T. Kozasa, K. Yamamoto, and T. Sawada. 2008. A taxonomic study on *Erysipelotherix* by DNA-DNA hybridization experiments with numerous strains isolated from extensive origins. *Microbiol Immunol*. 52:469–478.
69. Takeshi, K., S. Makino, T. Ikeda, N. Takada, A. Nakashiro, K. Nakanishi, K. Oguma, Y. Katoh, H. Sunagawa, and T. Ohyama. 1999. Direct and rapid detection by PCR of *Erysipelothrix sp*. DNAs prepared from bacterial strains and animal tissues. *J Clin Microbiol*. 37:4093–4098.
70. Tesh, M.J., and R.L. Wood. 1988. Detection of coagulase activity in *Erysipelothrix rhusiopathiae*. *J Clin Microbiol*. 26:1058–1060.
71. To, H., and S. Nagai. 2007. Genetic and antigenic diversity of the surface protective antigen proteins of *Erysipelothrix rhusiopathiae*. *Clin Vaccine Immunol*. 14:813–820.
72. Verbarg, S., H. Rheims, S. Emus, A. Fruhling, R. Kroppenstedt, E. Stackebrandt, and P. Schumann. 2004. *Erysipelothrix inopinata* sp. Nov., isolated in the course of sterile filtration of vegetable peptone broth, and description of Erysipelotrichaceae fam. nov. *Int J Syst Evol Micr*. 54:221–225.
73. Viemmas, I., N. Papaopannou, S. Frydas, and T. Tsangaris. 1995. The use of immunoperoxidase in the detection of the *Erysipelothrix insidiosa* antigen in experimentally infected turkeys. *Int J Immunopath Ph*. 8:87–92.
74. Wang, Q., B.J. Chang, B.J. Mee and T.V. Riley. 2005. Neuraminidase production by *Erysipleothrix rhusiopathiae*. *Vet Microbiol*. 107:265–272.
75. White, R.R., and W.F. Verwey. 1970. Isolation and characterization of a protective antigen-containing particle from culture supernatant fluids of *Erysipelothrix rhusiopathiae*. *Infect Immun*. 1:380–386.
76. Wood, R.L. 1965. A selective liquid medium utilizing antibiotics for isolation of *Erysipelothrix insidiosa*. *Am J Vet Res*. 26:1303–1308.
77. Wood, R.L. 1973. Survival of *Erysipelothrix rhusiopathiae* in soil under various environmental conditions. *Cornell Vet*. 63:390–410.
78. Xu, K.Q., X.F. Hu, C.H. Gao, Q.Y. Lu, and J.H. Wu. 1984. Studies on the serotypes and pathogenicity of *Erysipelothrix rhusiopathiae* isolated from swine and poultry. *Chinese J Vet Med*. 10:9–11.

Avian Intestinal Spirochetosis

1. Achacha, M., and S. Messier. 1992. Comparison of six different culture media for isolation of *Treponema hyodysenteriae*. *J Clin Microbiol.* 30:249–251.
2. Achacha M., S. Messier, and K.R. Mittal. 1996. Development of an experimental model allowing discrimination between virulent and avirulent isolates of *Serpulina* (*Treponema*) *hyodysenteriae*. *Can J Vet Res.* 60:45–49.
3. Adachi, Y., M. Sueyoshi, E. Miyagawa, H. Minato, and S. Shoya. 1985. Experimental infection of young broiler chicks with *Treponema hyodysenteriae*. *Microbiol Immunol.* 29:683–688.
4. Amin, M.M., N.D. Phillips, T. La, and D.J. Hampson 2009. Vaccination with an autogenous bacterin fails to prevent colonization by *Brachyspira intermedia* in experimentally infected laying chickens. *Vet Microbiol.* 133:372–376.
5. Atyeo, R.F., S.L. Oxberry, and D.J. Hampson. 1996. Pulsed-field gel electrophoresis for sub-specific differentiation of *Serpulina pilosicoli* (formerly "*Anguillina coli*"). *FEMS Microbiol Lett.* 141:77–81.
6. Atyeo, R.F., S.L. Oxberry, B.G. Combs, and D.J. Hampson. 1998. Development and evaluation of polymerase chain reaction tests as an aid to diagnosis of swine dysentery and intestinal spirochaetosis. *Lett Appl Microbiol.* 26:126–130.
7. Atyeo, R.F., S.L. Oxberry, and D.J. Hampson. 1999. Analysis of *Serpulina hyodysenteriae* strain variation and its molecular epidemiology using pulsed-field gel electrophoresis. *Epidemiol Infect.* 123:133–138.
8. Atyeo, R.F., T.B. Stanton, N.S. Jensen, D.S. Suriyaarachichi, and D.J. Hampson. 1999. Differentiation of *Serpulina* species by NADH oxidase gene (*nox*) sequence comparisons and nox-based polymerase chain reaction tests. *Vet Microbiol.* 67:47–60.
9. Bait-Merabet, L., A. Thille, P. Legrand, C. Brun-Buisson, and V. Cattoir. 2008. *Brachyspira pilosicoli* bloodstream infections: case report and review of the literature. *Ann Clin Microbiol Antimicrob.* 7:19.
10. Backhans, A., D.S. Jansson, A. Aspán, and C. Fellström. 2011. Typing of *Brachyspira* spp. from rodents, pigs and chickens on Swedish farms. *Vet Microbiol*. 153:156–162.
11. Bano, L., G. Merialdi, P. Bonilauri, G. Dall'Anese, K. Capello, D. Comin, G. Cattoli, V. Sanguinetti, D.J. Hampson, and F. Agnoletti. 2008. Prevalence, disease associations and risk factors for colonization with intestinal spirochaetes (*Brachyspira* spp.) in flocks of laying hens in north-eastern Italy. *Avian Pathol*. 37:281–286.
12. Barcellos, D.E., M. de Uzeda, N. Ikuta, V.R. Lunge, A.S. Fonseca, I.I. Kader, and G.E. Duhamel. 2000. Identification of porcine intestinal spirochetes by PCR-restriction fragment length polymorphism analysis of ribosomal DNA encoding 23S rRNA. *Vet Microbiol.* 75:189–198.
13. Bellgard, M.I., P. Wanchanthuek, T. La, K. Ryan, P. Moolhuijzen, Z. Albertyn, B. Shaban, Y. Motro, D.S. Dunn, D. Schibeci, A. Hunter, R. Barrero, N.D. Phillips, and D.J. Hampson. 2009. Genome sequence of the pathogenic intestinal spirochete *Brachyspira hyodysenteriae* reveals adaptations to its lifestyle in the porcine large intestine. *PLoS ONE.* 4(3): e4641.
14. Boye, M., T.K. Jensen, K. Møller, T.D. Leser, and S.E. Jorsal. 1998. Specific detection of the genus *Serpulina, S. hyodysenteriae* and *S. pilosicoli* in porcine intestines by fluorescent rRNA *in situ* hybridization. *Mol Cell Probes.* 12:323–330.
15. Boye, M., S.B. Baloda, T.D. Leser, and K. Møller. 2001. Survival of *Brachyspira hyodysenteriae* and *B. pilosicoli* in terrestrial microcosms. *Vet Microbiol*. 81:33–40.
16. Buckles, E.L., K.A. Eaton, and D.E. Swayne. 1997. Cases of spirochete-associated necrotizing typhlitis in captive common rheas (*Rhea americana*). *Avian Dis.* 41:144–148.
17. Burch, D.G.S., and A.H. Beynon. 2006. Poor production—spirochaetosis? *Ranger*. June edition, 37–38.
18. Burch, D.G.S., C. Harding, R. Alvarez, and M. Valks. 2006. Treatment of a field case of avian intestinal spirochaetosis

caused by *Brachyspira pilosicoli* with tiamulin. *Avian Pathol.* 35:211–216.
19. Bürki, S., E.M. Vilei, J. Frey, and M.M. Wittenbrink. 2011. Allelic variations of the nox gene of *Brachyspira pilosicoli* impair its detection by qPCR. *Vet Microbiol.* 149:291–292.
20. Corona-Barrera, E., D.G. Smith, B. Murray, and J.R. Thomson. 2004. Efficacy of seven disinfectant sanitisers on field isolates of *Brachyspira pilosicoli*. *Vet Rec.* 154:473–474.
21. Dassanayake, R.P., N.E. Caceres, G. Sarath, and G.E. Duhamel. 2004. Biochemical properties of membrane-associated proteases of *Brachyspira pilosicoli* isolated from humans with intestinal disorders. *J Med Microbiol.* 53:319–23.
22. Davelaar, F.G., H.F. Smit, K. Hovind-Hougen, R.M. Dwars, and P.C. van der Valk. 1986. Infectious typhlitis in chickens caused by spirochetes. *Avian Pathol.* 15:247–258.
23. Duhamel, G.E., D.J. Trott, N. Muniappa, M.R. Mathiesen, K. Tarasiuk, J.I. Lee, and D.J. Hampson. 1998. Canine intestinal spirochetes consist of *Serpulina pilosicoli* and a newly identified group provisionally designated "*Serpulina canis*" sp. nov. *J Clin Microbiol*. 36:2264–2270.
24. Dwars, R.M., H.F. Smit, F.G. Davelaar, and W. van T Veer. 1989. Incidence of spirochaetal infections in cases of intestinal disorder in chickens. *Avian Pathol.* 18:591–595.
25. Dwars, R.M., H.F. Smit, and F.G. Davelaar. 1990. Observations on avian intestinal spirochaetosis. *Vet Quart.* 12:51–55.
26. Dwars, R.M., F.G. Davelaar, and H.F. Smit. 1992. Infection of broiler chicks (*Gallus domesticus*) with human intestinal spirochaetes. *Avian Pathol.* 21:559–568.
27. Dwars, R.M., F.G. Davelaar, and H.F. Smit. 1992. Spirochaetosis in broilers. *Avian Pathol.* 21:261–273.
28. Dwars, R.M., H.F. Smit, and F.G. Davelaar. 1992. Influence of infection with avian intestinal spirochetes on the faeces of laying hens. *Avian Pathol.* 21:513–515.
29. Dwars, R.M., F.G. Davelaar, and H.F. Smit. 1993. Infection of broiler parent hens with avian intestinal spirochaetes: effects on egg production and chick quality. *Avian Pathol.* 22:693–701.
30. Feberwee, A., D.J. Hampson, N.D. Phillips, T. La, H.M.J. F. van der Heijen, G.J. Wellenberg, R.M. Dwars, and W.J.M. Landman. 2008. Identification of *Brachyspira hyodysenteriae* and other pathogenic *Brachyspira* species in chickens from laying flocks with diarrhea or reduced production or both. *J Clin Microbiol.* 46:593–600.
31. Fellström, C., B. Pettersson, M. Uhlen, A. Gunnarsson, and K.E. Johansson. 1995. Phylogeny of *Serpulina* based on sequence analyses of the 16S rRNA gene and comparison with a scheme involving biochemical classification. *Res Vet Sci.* 59:5–9.
32. Fellström. C., U. Zimmerman, A. Aspan, and A. Gunnarsson. 2001. The use of culture, pooled samples and PCR for identification of herds infected with *Brachyspira hyodysenteriae*. *Anim Health Res Rev.* 2:37–43.
33. Fellström, C., T. Råsbäck, K.-E. Johansson, T. Olofsson, and A. Aspán. 2008. Identification and genetic fingerprinting of *Brachyspira* species. *J Microbiol Meth.* 72:133–140.
34. Glávits, R., E. Ivanics, A. Thuma, E. Kaszanyitzky, P. Samu, K. Ursu, L. Dencso, and A. Dán. 2011. Typhlocolitis associated with spirochaetes in duck flocks. *Avian Pathol.* 40:23–31.
35. Greer, J.M., and M.J. Wannemuehler. 1989. Pathogenesis of *Treponema hyodysenteriae*: Induction of interleukin-1 and tumour necrosis factor by a treponema butanol/water extract (endotoxin). *Microbiol Pathogen.* 7:279–288.
36. Griffiths, I.B., B.W. Hunt, S.A. Lister, and M.H. Lamont. 1987. Retarded growth rate and delayed onset of egg production associated with spirochaete infection in pullets. *Vet Rec.* 121:35–37.
37. Håfström T., D.S. Jansson, and B. Segerman. 2011. Complete genome sequence of *Brachyspira intermedia* reveals unique genomic features in *Brachyspira* species and phage-mediated horizontal gene transfer. *BMC Genomics.* 12:395.
38. Hampson, D.J. 2012. *Brachyspiral colitis*. In: *Diseases of Swine*, 10th ed. J.J. Zimmerman, L.A. Karriker, A. Ramirez, K.J. Schwartz, and G.W. Stevenson, eds. Wiley-Blackwell, Ames, Iowa. 680–696.
39. Hampson, D.J., and T. La. 2006. Reclassification of *Serpulina intermedia* and *Serpulina murdochii* in the genus *Brachyspira* as *Brachyspira intermedia* comb. nov., and *Brachyspira murdochii* comb. nov. *Int J Syst Evol Microbiol*. 56:1009–1012.
40. Hampson, D.J., and A.J. Mclaren. 1999. Experimental infection of laying hens with *Serpulina intermedia* causes reduced egg production and increased faecal water content. *Avian Pathol.* 28:113–117.
41. Hampson, D.J., S.L. Oxberry, and C.P. Stephens. 2002. Influence of in-feed zinc bacitracin and tiamulin treatment on experimental avian intestinal spirochaetosis caused by *Brachyspira intermedia*. *Avian Pathol.* 31:285–291.
42. Hampson, D.J., N.D. Phillips, and J.R. Pluske. 2002. Dietary enzyme and zinc bacitracin inhibit colonisation of layer hens by the intestinal spirochaete *Brachyspira intermedia*. *Vet Microbiol.* 86:351–360.
43. Hampson, D.J., S.L. Oxberry, and T. La. 2006. Potential for zoonotic transmission of *Brachyspira pilosicoli*. *Emerg Infect Dis.* 12:869–870.
44. Hampson, D.J., C.P. Stephens, and S.L. Oxberry. 2006. Antimicrobial susceptibility testing of *Brachyspira intermedia* and *Brachyspira pilosicoli* isolates from Australian chickens. *Avian Pathol.* 35:12–16.
45. Harris, D.L., T.J.L. Alexander, S.C. Whipp, I.M. Robinson, R.D. Glock, and P.J. Matthews. 1978. Swine dysentery: Studies of gnotobiotic pigs inoculated with *Treponema hyodysenteriae*, *Bacteroides vulgatus*, and *Fusobacterium necrophorum*. *J Am Vet Med Assoc.* 172:468–471.
46. Hidalgo, Á., A. Carvajal, T. La, G. Naharro, P. Rubio, N.D. Phillips, and D.J. Hampson. 2010. A multiple-locus variable-number tandem repeats analysis of the swine dysentery pathogen, *Brachyspira hyodysenteriae*. *J Clin Microbiol.* 48:2859–2865.
47. Hovind-Hougen, K., A. Birch-Andersen, R. Henrik-Nielsen, M. Orholm, J.O. Pedersen, P.S. Teglbjaerg, and E.H. Thaysen. 1982. Intestinal spirochetosis: morphological characterization and cultivation of the spirochete *Brachyspira aalborgi* gen. nov., sp. nov. *J Clin Microbiol*. 16:1127–1136.
48. Hunter, D., and T. Wood. 1979. An evaluation of the API ZYM system as a means of classifying spirochaetes associated with swine dysentery. *Vet Rec.* 104:383–384.
49. Jamshidi, A., and D.J. Hampson. 2002. Zinc bacitracin enhances colonisation by the intestinal spirochaete *Brachyspira pilosicoli* in experimentally infected layer hens. *Avian Pathol.* 31:293–298.
50. Jamshidi, A., and D.J. Hampson. 2003. Experimental infection of layer hens with a human isolate of *Brachyspira pilosicoli*. *J Med Microbiol.* 52:361–364.
51. Jansson D.S., and M. Pringle. 2011. Antimicrobial susceptibility of *Brachyspira* spp. isolated from commercial laying hens and free-living wild mallards (*Anas platyrhynchos*). *Avian Pathol*. 40:387–393.

52. Jansson, D.S., C. Brojer, D. Gavier-Widen, A. Gunnarsson, and C. Fellström. 2001. *Brachyspira* spp. (*Serpulina* spp.) in birds: a review and results from a study of Swedish game birds. *Anim Health Res Rev*. 2:93–100.
53. Jansson, D.S., K.E. Johansson, T. Olofsson, T. Råsbäck, I. Vagsholm, B. Pettersson, A. Gunnarsson, and C. Fellström. 2004. *Brachyspira hyodysenteriae* and other strongly beta-haemolytic and indole-positive spirochaetes isolated from mallards (*Anas platyrhynchos*). *J Med Microbiol.* 53:293–300.
54. Jansson, D.S., C. Fellström, and K.E. Johansson. 2008. Intestinal spirochetes isolated from wild-living jackdaws, hooded crows and rooks (genus *Corvus*): provisionally designated "*Brachyspira corvi*" sp. nov. *Anaerobe* 14:287–295.
55. Jansson, D.S., C. Fellström, T. Råsbäck, I. Vågsholm, A. Gunnarsson, F. Ingermaa, and K.E. Johansson. 2008. Phenotypic and molecular characterization of *Brachyspira* spp. isolated from laying hens in different housing systems. *Vet Microbiol*. 130:348–362.
56. Jenkinson, S.R., and C.R. Wingar. 1981. Selective medium for the isolation of *Treponema hyodysenteriae*. *Vet Rec.* 109:384–385.
57. Jensen, N.S., T.B. Stanton, and D.E. Swayne. 1996. Identification of the swine pathogen *Serpulina hyodysenteriae* in rheas (*Rhea americana*). *Vet Microbiol.* 52:259–269.
58. Jensen, T.K., K. Møller, M. Boye, T.D. Leser, and S.E. Jorsal. 2000. Scanning electron microscopy and fluorescent *in situ* hybridization of experimental *Brachyspira* (*Serpulina*) *pilosicoli* infection in growing pigs. *Vet Pathol.* 37:22–32.
59. Kennedy, M.J., E.L. Rosey, and R.J. Yancey Jr. 1997. Characterization of *fla*A- and *fla*B- mutants of *Serpulina hyodysenteriae*: both flagellin subunits, FlaA and FlaB, are necessary for full motility and intestinal colonization. *FEMS Microbiol Lett*. 153:119–128.
60. Klitgaard, K., L. Molbak, T.K. Jensen, C.F. Lindboe, and M. Boye. 2005. Laser capture microdissection of bacterial cells targeted by fluorescence in situ hybridization. *Biotechniques.* 39:864–868.
61. Kunkle, R.A., and J.M. Kinyon. 1988. Improved selective medium for the isolation of *Treponema hyodysenteriae*. *J Clin Microbiol.* 26:2357–2360.
62. Kunkle, R.A., D.L. Harris, and J.M. Kinyon. 1986. Autoclaved liquid medium for propagation of *Treponema hyodysenteriae*. *J Clin Microbiol.* 24:669–671.
63. Kutzer, P., C. Schulze, and G. Neumann. 2007. *Brachyspira hyodysenteriae*-associated typhlocolitis in rheas (*Rhea Americana*) in Germany. Proc 4th Int Conf Colonic Spirochaetal Infect in Animals and Humans, Prague, Czech Republic, Abstract 44.
64. La, T., N.D. Phillips, and D.J. Hampson. 2003. Development of a duplex PCR assay for the detection of *Brachyspira hyodysenteriae* and *Brachyspira pilosicoli* in pig feces. *J Clin Microbiol.* 41:3372–3375.
65. La, T., N.D. Phillips, and D.J. Hampson. 2009. Evaluation of recombinant Bhlp29.7 as an ELISA antigen for detecting pig herds with swine dysentery. *Vet Microbiol*. 133:98–104.
66. La, T., N.D. Phillips, B.L. Harland, P. Wanchanthuek, M.I. Bellgard, and D.J. Hampson. 2009. Multilocus sequence typing as a tool for studying the molecular epidemiology and population structure of *Brachyspira hyodysenteriae*. *Vet Microbiol.* 138:330–338.
67. La, T., N.D. Phillips, P. Wanchanthuek, M.I. Bellgard, A.J. O'Hara, and D.J. Hampson. 2011. Evidence that the 36 kb plasmid of *Brachyspira hyodysenteriae* contributes to virulence. *Vet Microbiol.* 153:150–155.
68. Lee, J.I., and D.J. Hampson. 1994. Genetic characterisation of intestinal spirochetes and their association with disease. *J Med Microbiol.* 40:365–371.
69. Lee, B.J., and D.J. Hampson. 1995. A monoclonal antibody reacting with the cell envelope of spirochaetes isolated from cases of intestinal spirochaetosis in pigs and humans. *FEMS Microbiol Lett.* 131:179–184.
70. Lee, B.J., and D.J. Hampson. 1999. Lipooligosaccharide profiles of *Serpulina pilosicoli* strains, and their serological cross-reactivities. *J Med Microbiol.* 48:411–415.
71. Lee, J.I., D.J. Hampson, A.J. Lymbery, and S.J. Harders. 1993. The porcine intestinal spirochaetes: Identification of new genetic groups. *Vet Microbiol.* 34:273–285.
72. Leser, T.D., K. Møller, T.K. Jensen, and S.E. Jorsal. 1997. Specific detection of *Serpulina hyodysenteriae* and potentially pathogenic weakly haemolytic porcine intestinal spirochaetes by polymerase chain reaction targeting 23S rDNA. *Mol Cell Probes* 11:363–372.
73. Mappley, L.J., M.A. Tchórzewska, W.A. Cooley, M.J. Woodward, and R.M. La Ragione. 2011. Lactobacilli antagonize the growth, motility, and adherence of *Brachyspira pilosicoli*: a potential intervention against avian intestinal spirochetosis. *Appl Environ Microbiol.* 77:5402–5411.
74. Matson, E.G., M.G. Thompson, S.B. Humphrey, R.L. Zuerner, and T.B. Stanton. 2005. Identification of genes of VSH-1, a prophage-like gene transfer agent of *Brachyspira hyodysenteriae*. *J Bacteriol.* 187:5885–5892.
75. McLaren, A.J., D.J. Hampson, and S.J. Plant. 1996. The prevalence of intestinal spirochaetes in commercial poultry flocks in Western Australia. *Aust Vet J.* 74:31–33.
76. McLaren, A.J., D.J. Trott, D.E. Swayne, S.L. Oxberry, and D.J. Hampson. 1997. Genetic and phenotypic characterization of intestinal spirochetes colonizing chickens, and allocation of known pathogenic isolates to three distinct genetic groups. *J Clin Microbiol.* 35:412–417.
77. Mikosza, A.S.J., and D.J. Hampson. 2001. Human intestinal spirochetosis: *Brachyspira aalborgi* and/or *Brachyspira pilosicoli*? *Anim Health Res Rev.* 2:83–91.
78. Milner, J.A., and R. Sellwood. 1994. Chemotactic response to mucin by *Serpulina hyodysenteriae* and other porcine spirochetes: Potential role in intestinal colonization. *Infect Immun.* 62:4095–4099.
79. Motro, Y., T. La, M.I. Bellgard, D.S. Dunn, N.D. Phillips, and D.J. Hampson. 2009. Identification of genes associated with prophage-like gene transfer agents in the pathogenic intestinal spirochaetes *Brachyspira hyodysenteriae, Brachyspira pilosicoli* and *Brachyspira intermedia*. *Vet Microbiol.* 134: 340–345.
80. Muniappa, N., G.E. Duhamel, M.R. Mathiesen, and T.W. Bargar. 1996. Light microscopic and ultrastructural changes in the ceca of chicks inoculated with human and canine *Serpulina pilosicoli*. *Vet Pathol.* 33:542–550.
81. Myers, S.E., P.A. Dunn, N.D. Phillips, T. La, and D.J. Hampson. 2009. *Brachyspira intermedia* and *Brachyspira pilosicoli* are commonly found in older laying flocks in Pennsylvania. *Avian Dis.* 53:533–537.
82. Nakamura, S., Y. Adachi, T. Goto, and Y. Magariyama. 2006. Improvement in motion efficiency of the spirochete *Brachyspira pilosicoli* in viscous environments. *Biophys J* 90:3019–3026.
83. Naresh, R., and D.J. Hampson. 2010. Attraction of *Brachyspira pilosicoli* to mucin. *Microbiology.* 156:191–197.

84. Naresh, R., and D.J. Hampson. 2011. Exposure to norepinephrine enhances *Brachyspira pilosicoli* growth, attraction to mucin and attachment to Caco-2 cells. *Microbiology.* 157:543–547.
85. Naresh, R., Y. Song, and D.J. Hampson. 2009. The intestinal spirochete *Brachyspira pilosicoli* attaches to cultured Caco-2 cells and induces pathological changes. *PLoS ONE.* 4: e8352.
86. Nemes, C.S., R. Glavits, M. Dobos-Kovacs, E. Ivanics, E. Kaszanyitzky, A. Beregszaszi, L. Szeredi, and L. Dencso. 2006. Typhlocolitis associated with spirochaetes in goose flocks. *Avian Pathol.* 35:4–11.
87. Nibbelink, S.K., R.E. Sacco, and M.J. Wannemuehler. 1997. Pathogenicity of *Serpulina hyodysenteriae*: *in vivo* induction of tumor necrosis factor and interleukin-6 by a serpulinal butanol/water extract (endotoxin). *Microb Pathogen.* 23:181–187.
88. Nuessen, M.E., L.A. Jones, and R.D. Glock. 1983. Involvement of lipopolysaccharide in the pathogenicity of *Treponema hyodysenteriae*. *J Immunol.* 131:997–999.
89. Ochiai, S., Y. Adachi, and K. Mori. 1997. Unification of the genera S*erpulina* and *Brachyspira*, and proposals of *Brachyspira hyodysenteriae* Comb. Nov., *Brachyspira innocens* comb. nov., and *Brachyspira pilosicoli* comb. nov. *Microbiol Immunol*. 41:445–452.
90. Oxberry, S.L., D.J. Trott, and D.J. Hampson. 1998. *Serpulina pilosicoli*, waterbirds and water: Potential sources of infection for humans and other animals. *Epidemiol Infect.* 121:219–225.
91. Paster, B.J., and F.E. Dewhirst. 1997. Taxonomy and phylogeny of intestinal spirochaetes. In: *Intestinal Spirochaetes in Domestic Animals and Humans*. D.J. Hampson and T.B. Stanton, eds. CABI, Wallingford, UK 47–61.
92. Paster, B.J., and F.E. Dewhirst. 2000. Phylogenetic foundation of spirochetes. *J Mol Microbiol Biotechnol.* 2:341–344.
93. Pati, A., J. Sikorski, S. Gronow, C. Munk, A. Lapidus, A. Copeland, T. Glavina Del Tio, M. Nolan, S. Lucas, F. Chen, H. Tice, J.F. Cheng, C. Han, J.C. Detter, D. Bruce, R. Tapia, L. Goodwin, S. Pitluck, K. Liolios, N. Ivanova, K. Mavromatis, N. Mikhailova, A. Chen, K. Palaniappan, M. Land, L. Hauser, Y.J. Chang, C.D. Jeffries, S. Spring, M. Rohde, M. Göker, J. Bristow, J.A. Eisen, V. Markowitz, P. Hugenholtz, N.C. Kyrpides, and H.P. Klenk. 2010. Complete genome sequence of *Brachyspira murdochii* type strain (56–150). *Stand Genomic Sci.* 2:260–269.
94. Phillips, N.D., T. La, and D.J. Hampson. 2003. Survival of intestinal spirochaete strains from chickens in the presence of disinfectants and in faeces held at different temperatures. *Avian Pathol.* 32:639–643.
95. Phillips, N.D., T. La, J.R. Pluske, and D.J. Hampson. 2004. A wheat-based diet enhances colonisation with the intestinal spirochaete *Brachyspira intermedia* in experimentally-infected laying hens. *Avian Pathol.* 33:451–457.
96. Phillips, N.D., T. La, J.R. Pluske, and D.J. Hampson. 2004. The wheat variety used in the diet of laying hens influences colonisation with the intestinal spirochaete *Brachyspira intermedia*. *Avian Pathol.* 33:586–590.
97. Phillips, N.D., T. La, and D.J. Hampson. 2005. A cross-sectional study to investigate the occurrence and distribution of intestinal spirochaetes (*Brachyspira* spp.) in three flocks of laying hens. *Vet Microbiol*. 105:189–198.
98. Phillips, N.D., T. La, and D.J. Hampson. 2006. Development of a two-step nested duplex PCR assay for the rapid detection of *Brachyspira pilosicoli* and *Brachyspira intermedia* in chicken faeces. *Vet Microbiol.* 116:239–245.
99. Phillips, N.D., T. La, M.A. Amin, and D.J. Hampson. 2010. *Brachyspira intermedia* strain diversity and relationships to other indole-positive *Brachyspira* species. *Vet Microbiol.* 143: 246–254.
100. Råsbäck, T., D.S. Jansson, K.E. Johansson, and C. Fellström. 2007. A novel enteropathogenic, strongly haemolytic spirochaete isolated from pig and mallard, provisionally designated '*Brachyspira suanatina*' sp. nov. *Environ Microbiol*. 9:983–991.
101. Råsbäck, T., K.-E. Johansson, D.S. Jansson, C. Fellström, Y. Alikhani, T. La, D.S. Dunn, and D.J. Hampson. 2007. Development of a multilocus sequence typing scheme for intestinal spirochaetes of the genus *Brachyspira*. *Microbiology.* 153:4074–4087.
102. Rohde, J., A. Rothkamp, and G.F. Gerlach. 2002. Differentiation of porcine *Brachyspira* species by a novel nox PCR-based restriction fragment length polymorphism analysis. *J Clin Microbiol.* 40:2598–2600.
103. Rosey, E.L., M.J. Kennedy, and R.J. Yancey. 1996. Dual *fla*A1 *fla*B1 mutant of *Serpulina hyodysenteriae* expressing periplasmic flagella is severely attenuated in a murine model of swine dysentery. *Infect Immun.* 64:4154–4162.
104. Sagartz, J.E., D.E. Swayne, K.A. Eaton, J.R. Hayes, K.D. Amass, R. Wack, and L. Kramer. 1992. Necrotizing typhlocolitis associated with a spirochete in rheas (*Rhea americana*). *Avian Dis.* 36:282–289.
105. Shivaprasad, H.L., and G.E. Duhamel. 2005. Cecal spirochetosis caused by *Brachyspira pilosicoli* in commercial turkeys. *Avian Dis.* 49:609–613.
106. Smit, H.F., R.M. Dwars, F.G. Davelaar, and G.A.W. Wijtten. 1998. Observations on the influence of intestinal spirochaetosis in broiler breeders on the performance of their progeny and egg production. *Avian Pathol.* 27:133–141.
107. Song, Y., and D.J. Hampson. 2009. Development of a multiplex qPCR for detection and quantitation of pathogenic intestinal spirochaetes in the faeces of pigs and chickens. *Vet Microbiol.* 137:129–136.
108. Stanton, T.B., and D.F. Lebo. 1988. *Treponema hyodysenteriae* growth under various culture conditions. *Vet Microbiol.* 18: 177–190.
109. Stanton, T.B., D.J. Trott, J.I. Lee, A.J. McLaren, D.J. Hampson, B.J. Paster, and N.S. Jensen. 1996. Differentiation of intestinal spirochaetes by multilocus enzyme electrophoresis and 16S rRNA sequence comparisons. *FEMS Microbiol Lett.* 136:181–186.
110. Stanton, T.B., E. Fournie-Amazouz, D. Postic, D.J. Trott, P.A. Grimont, G. Baranton, D.J. Hampson, and I. Saint Girons. 1997. Recognition of two new species of intestinal spirochetes: *Serpulina intermedia* sp. nov., and *Serpulina murdochii* sp. nov. *Int J Syst Bacteriol*. 47:1007–1012.
111. Stanton, T.B., D. Postic, and N.S. Jensen. 1998. *Serpulina alvinipulli* sp. nov., a new *Serpulina* species that is enteropathogenic for chickens. *Int J Syst Bacteriol*. 48:669–676.
112. Stanton, T.B., E.L. Rosey, M.J. Kennedy, N.S. Jensen, and B.T. Bosworth. 1999. Isolation, oxygen sensitivity, and virulence of NADH oxidase mutants of the anaerobic spirochete *Brachyspira* (*Serpulina*) *hyodysenteriae*, etiologic agent of swine dysentery. *Appl Environ Microbiol.* 65:5028–5034.
113. Stanton, T.B., N.S. Jensen, B.T. Bosworth, and R.A. Kunkle. 2001. Evaluation of the virulence of rheas *S. hyodystenteriae* strains for swine. First International Virtual Conference of Infectious Diseases of Animals http://www.ars.usda.gov/sp2UserFiles/ad_hoc/36253000VirtualConference/Posters/I00006.pdf.
114. Stanton, T.B., M.G. Thompson, S.B. Humphrey, and R.L. Zuerner. 2003. Detection of bacteriophage VSH-1 svp38 gene in *Brachyspira* spirochetes. *FEMS Microbiol Lett.* 224:225–229.

115. Stephens, C.P., and D.J. Hampson. 1999. Prevalence and disease association of intestinal spirochaetes in chickens in eastern Australia. *Avian Pathol.* 28:447–454.
116. Stephens, C.P., and D.J. Hampson. 2001. Intestinal spirochaete infections in chickens: a review of disease associations, epidemiology and control. *Anim Health Res Rev.* 2:101–110.
117. Stephens, C.P., and D.J. Hampson. 2002. Experimental infection of broiler breeder hens with the intestinal spirochaete *Brachyspira* (*Serpulina*) *pilosicoli* causes reduced egg production. *Avian Pathol.* 31:169–175.
118. Stephens, C.P., and D.J. Hampson. 2002. Evaluation of tiamulin and lincomycin for the treatment of broiler breeders experimentally infected with the intestinal spirochaete *Brachyspira pilosicoli*. *Avian Pathol.* 31:299–304.
119. Stephens, C.P., S.L. Oxberry, N.D. Phillips, T. La, and D.J. Hampson. 2005. The use of multilocus enzyme electrophoresis to characterise intestinal spirochaetes (*Brachyspira* spp.) colonising hens in commercial flocks. *Vet Microbiol*. 107:149–157.
120. Stoutenburg, J.W., D.E. Swayne, T.M. Hoepf, R. Wack, and L. Kramer. 1995. Frequency of intestinal spirochetes in avian species from a zoologic collection and private rhea farms in Ohio. *J Zoo Wildl Med.* 26:272–278.
121. Sueyoshi, M., Y. Adachi, S. Shoya, E. Miyagawa, and H. Minato. 1986. Investigations into location of *Treponema hyodysenteriae* in the cecum of experimentally infected young broiler chicks by light- and electron microscopy. *Zbl Bakt Hyg. A* 261:447–453.
122. Sueyoshi, M., Y. Adachi, and S. Shoya. 1987. Enteropathogenicity of *Treponema hyodysenteriae* in young chicks. *Zbl Bakt Hyg. A* 266:469–477.
123. Suriyaarachchi, D.S., A.S.J. Mikosza, R.F. Atyeo, and D.J. Hampson. 2000. Evaluation of a 23S rDNA polymerase chain reaction assay for identification of *Serpulina intermedia*, and strain typing using pulsed-field gel electrophoresis. *Vet Microbiol.* 71:139–148.
124. Swayne, D.E., and A.J. McLaren. 1997. Avian intestinal spirochaetes and avian intestinal spirochaetosis. In: *Intestinal Spirochaetes in Domestic Animals and Humans*. D.J. Hampson and T.B. Stanton, eds. CABI, Wallingford, UK. 267–300.
125. Swayne, D.E., A.J. Bermudez, J.E. Sagartz, K.A. Eaton, J.D. Monfort, J.W. Stoutenburg, and J.R. Hayes. 1992. Association of cecal spirochetes with pasty vents and dirty eggshells in layers. *Avian Dis.* 36:776–781.
126. Swayne, D.E., K.A. Eaton, J. Stoutenburg, D.J. Trott, D.J. Hampson, and N.S. Jensen. 1995. Identification of a new intestinal spirochete with pathogenicity for chickens. *Infect Immun.* 63:430–436.
127. Tenaya, I.W.M., J.P. Penhale, and D.J. Hampson. 1998. Preparation of diagnostic polyclonal and monoclonal antibodies against outer envelope proteins of *Serpulina pilosicoli*. *J Med Microbiol.* 47:317–324.
128. Thuma, A., A. Dán, E. Kaszanyitzky, B. Fazekas, A. Tóth, and R. Glávits. 2011. Experimental inoculation of day-old ducks with *Brachyspira pilosicoli* and *B. alvinipulli*. *Acta Vet Hung*. 59:165–174
129. Thomson, J.R., W.J. Smith, B.P. Murray, D. Murray, J.E. Dick, and K.J. Sumption. 2001. Porcine enteric spirochete infections in the UK: surveillance data and preliminary investigation of atypical isolates. *Anim Health Res Rev.* 2:31–36.
130. Townsend, K.M., V.N. Giang, C.P. Stephens, P.T. Scott, and D.J. Trott. 2005. Application of *nox*-restriction fragment length polymorphism for the differentiation of *Brachyspira* intestinal spirochetes isolated from pigs and poultry in Australia. *J Vet Diagn Invest*. 17:103–109.
131. Trampel, D.W., N.S. Jensen, and L.J. Hoffman. 1994. Cecal spirochetosis in commercial laying hens. *Avian Dis.* 38:895–898.
132. Trampel, D.W., J.M. Kinyon, and N.S. Jensen. 1999. Minimum inhibitory concentration of selected antimicrobial agents for *Serpulina* isolated from chickens and rheas. *J Vet Diagn Invest.* 11:379–382.
133. Trott, D.J., and D.J. Hampson. 1998. Evaluation of day-old specific-pathogen-free chicks as an experimental model for pathogenicity testing of intestinal spirochaete species. *J Comp Pathol.* 118:365–381.
134. Trott, D.J., A.J. McLaren, and D.J. Hampson. 1995. Pathogenicity of human and porcine intestinal spirochetes in one-day-old specific-pathogen-free chicks: an animal model of intestinal spirochetosis. *Infect Immun.* 63:3705–3710.
135. Trott, D.J., T.B. Stanton, N.S. Jensen, G.E. Duhamel, J.L. Johnson, and D.J. Hampson. 1996. *Serpulina pilosicoli* sp. nov., the agent of porcine intestinal spirochetosis. *Int J System Bacteriol*. 46:206–215.
136. Trott, D.J., N.S. Jensen, I. Saint Girons, S.L. Oxberry, T.B. Stanton, D. Lindquist, and D.J. Hampson. 1997. Identification and characterization of *Serpulina pilosicoli* isolates recovered from the blood of critically ill patients. *J Clin Microbiol.* 35:482–485.
137. Trott, D.J., A.S.J. Mikosza, B.G. Combs, S.L. Oxberry, and D.J. Hampson. 1998. Population genetic analysis of *Serpulina pilosicoli* and its molecular epidemiology in villages in the Eastern Highlands of Papua New Guinea. *Int J System Bacteriol.* 48:659–668.
138. Trott, D.J., D.P. Alt, R.L. Zuerner, M. . Wannemuehler, and T.B. Stanton. 2001. The search for *Brachyspira* outer membrane proteins that interact with the host. *Anim Health Res Rev.* 2:19–30.
139. Verlinden, M., F. Boyen, F. Pasmans, A. Garmyn, F. Haesebrouck, and A. Martel. 2011. Antimicrobial susceptibility pattern of *Brachyspira intermedia* isolates from European layers. *Microb Drug Resist* 17:485–488.
140. Wagenaar J., M. van Bergen, L. van der Graaf, and W. Landman 2003. Free-range chickens show a higher incidence of *Brachyspira* infections in the Netherlands. *Proc 2nd Int Conf Colon Spiro Infect Anim and Humans*. Eddleston, Scotland 16.
141. Wanchanthuek, P., M.I. Bellgard, T. La, K. Ryan, P. Moolhuijzen, B. Chapman, M. Black, D. Schibeci, A. Hunter, R. Barrero, N.D. Phillips, and D.J. Hampson. 2010. The complete genome sequence of the pathogenic intestinal spirochete *Brachyspira pilosicoli* and comparison with other *Brachyspira* genomes. *PLoS ONE.* 5:e11455.
142. Webb, D.M., G.E. Duhamel, M.R. Mathiesen, N. Muniappa, and A.K. White. 1997. Cecal spirochetosis associated with *Serpulina pilosicoli* in captive juvenile ring-necked pheasants. *Avian Dis.* 41:997–1002.
143. Whipp, S.C., I.M. Robinson, D.L. Harris, R.D. Glock, P. J. Matthews, and T.J.L. Alexander. 1979. Pathogenic synergism between *Treponema hyodysenteriae* and other selected anaerobes in gnotobiotic pigs. *Infect Immun.* 26:1042–1047.
144. Zuerner, R.L., T.B. Stanton, F.C. Minion, C. Li, N.W. Charon, D.J. Trott, and D.J. Hampson. 2004. Genetic variation in *Brachyspira*: chromosomal rearrangements and sequence drift distinguish *B. pilosicoli* from *B. hyodysenteriae*. *Anaerobe.* 10:229–237.

Tuberculosis

1. Ackerman, L.J., S.C. Benbrook, and B.C. Walton. 1974. *Mycobacterium tuberculosis* infection in a parrot (*Amazona farinosa*). *Annu Rev Respir Dis.* 109:388–390.
2. Andersen, S. 1965. The distribution of avian tuberculosis in Denmark. *Medlemsbl Dan Dyrlaegeforen.* 2:54–59.
3. Angus, R.D. 1978. Production of reference PPD tuberculins for veterinary use in the United States. *J Biol Stand.* 6:221–228.
4. Bartos, M., P. Hlozek, P. Svastova, L. Dvorska, T. Bull, L. Matlova, I. Parmova, I. Kuhn, J. Subbs, M. Moravkova, J. Kintr, V. Beran, I. Melicharek, M. Ocepek, and I. Pavlik. 2005. Identification of members of *Mycobacterium avium* species by ACCU-Probes, serotyping, and single IS900, IS901, IS1245 and IS901-flanking region PCR with internal standards. *J Microbiol Meth.* 64:333–345.
5. Beard, P.M., M.J. Daniels, D. Henderson, A. Pirie, K. Rudge, D. Buxton, S. Rhind, A. Creig, M.R. Hutchings, I. McKendrik, K. Stevenson, and J.M. Sharp. 2001. Paratuberculosis infection of non-ruminant wildlife in Scotland. *J Clin Microbiol.* 39:1517–1521.
6. Belisle, J.T., and P.J. Brennan. 1994. Molecular basis of colony morphology in *Mycobacterium avium*. *Res Microbiol.* 145:237–242.
7. Bermudez, L., and L. Young. 1988. Tumor necrosis factor, alone or in combination with IL-2, but not IFN-gamma, is associated with macrophage killing of *Mycobacterium avium* complex. *J Immunol.* 140:3006–3013.
8. Bhatnagar, S., and J.S. Schorey. 2006. Elevated mitogen-activated protein kinase signaling and increased macrophage activation in cells infected with a glycopeptidolipid-deficient *Mycobacterium avium*. *Cell Microbiol.* 8:85–96.
9. Bickford, A.A., G.H. Ellis, and H.E. Moses. 1966. Epizootiology of tuberculosis in starlings. *J Am Vet Med Assoc.* 149:312–318.
10. Bono, M., T. Jemmi, C. Bernasconi, D. Burki, A. Telenti, and T. Bodmer. 1995. Genotypic characterization of *Mycobacterium avium* strains recovered from animals and their comparison to human strains. *Appl Environ Microbiol.* 61:371–373.
11. Bremner, A.S. 1996. *Poultry Meat Hygiene and Inspection*. Saunders, London.
12. Britt, J.O., E.B. Howard and W.J. Rosskopf. 1980. Psittacine tuberculosis. *Cornell Vet.* 70:218–225.
13. Boddinghaus, M.L., J. Wolters, W. Heikens, and E.C. Botter. 1990. Phylogenetic analysis and identification of different serovars of *Mycobacterium intracellulare* at the molecular level. *FEMS Microbiol Lett.* 70:197–203.
14. Buogo, C.H., L. Bacciarinini, N. Robert, T. Bodmer, and J. Nocolet. 1997. Presence of *Mycobacterium genavense* in birds. *Schweiz Arch Tierheilkd.* 139:397–402.
15. Bush, M.A., R.J. Montali, C.O. Thoen, E.E. Smith, W. Peritino, and D.W. Johnson. 1978. Avian tuberculosis: Status of antemortem diagnostic procedures. *Proc 1st Int Birds Captivity Symp*. 185–195.
16. Cangelosi G.A., C.O. Palermo, and L.E. Bermudez. 2001 Phenotypic consequences of red-white colony type variation in *Mycobacterium avium*. *Microbiol.* 147:527–533.
17. Chan, J., X. Fan, S.W. Hunter, P.J. Brennan, and B.R. Bloom. 1991. Lipoarabinomannan, a possible virulence factor involved in persistence of *Mycobacterium tuberculosis* within macrophages. *Infect Immun.* 59:1755–1761.
18. Chatterjee, D., and K.H. Khoo. 2001. The surface glycopeptidolipids of mycobacteria: structures and biological properties. *Cell Mol Life Sci.* 58:2018–2042.
19. Cheville, N.F., and W.D. Richards. 1971. The influence of thymic and bursal lymphoid systems in avian tuberculosis. *Am J Pathol* 64:97–122.
20. Colavecchia, S., A. Jolly, A. Stempler, E. Fernández, and S. Mundo. 2009. Lipoarabinomannans from *Mycobacterium avium* subsp. *Avium* affect bovine immune responses to different antigens. *Vet Immunol Immunopath*. 128:317.
21. Cooper, J.E., L. Karstad, and E. Boughton. 1975. Tuberculosis in lesser flamingos in Kenya. *J Wild Dis.* 11:32–36.
22. Corn J.L., E.J.B. Manning, S. Sreevatsan, and J.R. Fisher. 2005. Isolation of *Mycobacterium avium* subsps. *paratuberculosis* from free-ranging birds and mammals on livestock premises. *Appl Environ Microbiol*. 71:6963–6967.
23. Cornil, V., and P. Megnin. 1884. Tuberculose et diphtherie des gallinaces. *CR Soc Biol.* 36:617–621.
24. Crawford, J.T. 1994. Development of rapid techniques for identification of *M. avium* infections. *Res Microbiol*. 145: 177–180.
25. Denis, M. 1994. Immunomodulatory events in *Mycobacterium avium* infections. *Res Microbiol.* 145:225–229.
26. Dhama, K., M. Mahendran, R. Tiwari, S.D. Singh, D. Kumar, S. Singh, and P.M. Sawani. 2011. Tuberculosis in birds: insights into the *Mycobacterium avium* infections. *Vet Med Int.* 2011:1–14
27. Dvorska, L., M. Bartos, O. Ostandal, J. Kaustova, L. Maltova, and I. Pavlik. 2002. IS1311 and IS1245 restriction fragment length polymorphism analyses, serotypes, and drug susceptibilities of *Mycobacterium avium* complex isolates obtained from a human immunodeficiency virus-negative patient. *J Clin Microbiol.* 40:3712–3719.
28. Dvorska, L., T.J. Bull, M. Bartos, L. Maltova, P. Svastova, R.T. Weston, J. Kintr, I. Parmova, D.V. Soolingen, and I. Pavlik. 2003. A standardized restriction fragment length polymorphism (RFLP) method for typing *Mycobacterium avium* isolates links IS901 with virulence for birds. *J Micobiol Meths.* 55:11–27.
29. Dvorska L., L. Maltova, M. Bartos, I Parmova, T.J. Bull, and I. Pavlik. 2004. Study of *Mycobacterium avium* complex strains isolated from cattle in the Czech Republic between 1996 and 2000. *Vet Microbiol.* 99:239–250.
30. Dvorska, L., L. Maltova, W.Y. Ayele, O.A. Fischer, T. Amemori, R.T. Weston, J. Alvarez, V. Beran, M. Moravkova, and I. Pavlik. 2007. Avian tuberculosis in naturally infected captive water birds of the Areideae and Threskiornithidae families studied by serotyping, IS 901 RFLP typing, and virulence for poultry. *Vet Microbiol.* 119:366–374.
31. Engbaek, H.C., E.H. Runyon, and A.G. Karlson. 1971. *Mycobacterium avium Chester*: Designation of neotype strain. *Int J Syst Bacteriol.* 21:192–196.
32. Falk, G.A., S.J. Hadley, F.E. Sharkey, M. Liss, and C. Muschenheim. 1973. *Mycobacterium avium* infections in man. *Am J Med.* 54:801–810.
33. Falkingham III, J.O. 1994. Epidemiology of *Mycobacterium avium* infections in the pre- and post-HIV era. *Res Microbiol.* 145:169–172.
34. Falkingham III, J.O., W.B. Gross, and F.W. Pierson. 2004. Effect of different cell fractions of *Mycobacterium avium* and vaccination regimens of *Mycobacterium avium* infection. *Scand J Immunol.* 59:478–484.
35. Feldman, W.H. 1938. *Avian Tuberculosis Infections*. Williams and Williams: Baltimore.

36. Feizabadi, M.M., I.D. Robertson, D.V. Cousins, D. Dawson, W. Chew, G.L. Gilbert, and D.J. Hampson. 1996. Genetic characterization of *Mycobacterium avium* isolates recovered from humans and animals in Australia. *Epidemiol Infect.* 116:41–49.
37. Fitch, C.P., and R.E. Lubbenhusen. 1928. Completed experiments to determine whether avian tuberculosis can be transmitted through eggs of tuberculous fowls. *J Am Vet Med Assoc.* 72:636–649.
38. Fodstad, F.H. 1967. A survey of mycobacterial infections detected in animals in Norway in 1966. *Medlemsbl Nor Veterinaerforen.* 19:314–327.
39. Francis, J. 1958. *Tuberculosis in Animals and Man: A Study in Comparative Pathology*. Cassell, London.
40. Fulton, R.M., and C.O. Thoen. 2003. Tuberculosis. In: *Diseases of Poultry*, 11th ed. Y.M. Saif, H.J. Barnes, J.R. Glisson, A.M. Fadly, L.R. McDougald, and D.E. Swayne eds. Iowa State University Press, Ames, Iowa. 836–844.
41. Gerhold, R.W., and J.R. Fischer. 2005. Avian tuberculosis in a wild turkey. *Avian Dis.* 49:164–166.
42. Gill, I.J., and M.L. Blandy. 1986. Control of avian tuberculosis in a commercial poultry flock. *Aus Vet J.* 63:422–423.
43. Gonzalez, M., A. Rodriguez-Bertos, I. Gimeno, J.M. Flores and M. Pizarro. 2002. Outbreak of avian tuberculosis in 48-week-old commercial laying hen flock. *Avian Dis.* 46:1055–1061.
44. Good, R.C. 1985. Opportunistic pathogens in the genus *Mycobacterium*. *Annu Rev Microbiol.* 39:347–369.
45. Gunnes, G., K. Nord, S. Vatn, and F. Saxegaard. 1995. A case of generalized avian tuberculosis in a horse. *Vet Rec.* 136:565–566.
46. Gyimesi, Z.S., I.H. Stalis, J.M. Miller, and C.O. Thoen. 1999. Detection of *Mycobacterium avium* in formalin-fixed tissues of captive birds using polymerase chain reaction. *J Zoo Wildl Med.* 30:348–353.
47. Hamasur, B., G. Källenius, and S.B. Svenson. 1999. A new rapid and simple method for large-scale purification of mycobacterial lipoarabinomannan. *FEMS Immunol Med Microbiol.* 24:11–17.
48. Hiller, K., T. Schliesser, G. Fink, and P. Dorn. 1967. Zur serologischen Diagnose der Huhnertuberkulose. *Berl Munch Tierarztl Wochenschr.* 80:212–216.
49. Hinshaw, W.R., K.W. Niemann, and W.H. Busic. 1932. Studies of tuberculosis of turkeys. *J Am Vet Med Assoc.* 80:765–777.
50. Hoenerhoff, M., M. Kiupel, J. Sikarskie, C. Bolin, H. Simmons, and S. Fitzgerald. 2004. Mycobacteriosis in an American bald eagle (*Haliaeetus leucocephalus*). *Avian Dis.* 48:437–441.
51. Hoffner, S.E., S.B. Svenson, and G. Kallenius. 1987. Synergistic effects of antimycobacterial drug combinations on *Mycobacterium avium* complex determined radiometrically in liquid medium. *Eur J Clin Microbiol.* 6:530–535.
52. Hoop, R.K., E.C. Böttger, and G.E. Pfyffer. 1996. Etiological agents of mycobacterioses in pet birds between 1986 and 1995. *J Clin Microbiol.* 34:991–992.
53. Hoop, R.K. 2002. Mycobacterium tuberculosis in a canary (*Serinus canaria L.*) and a blue-fronted amazon parrot (*Amazona amazona aestiva*). *Avian Dis*. 46:502–504.
54. Horan K.L., R. Freeman, K. Weigel, M. Semret, S. Pfaller, T.C. Covert, D.V. Soolingen, S.C. Leao, M.A. Behr, and G.A. Cangelosi. 2006. Isolation of the genome sequence strain *Mycobacterium avium* 104 from multiple patients over a 17-year period. *J Clin Microbiol.* 44:783–789.
55. Horsburgh, C. ., Jr., U.G. Mason, D.C. Farhi, and M.D. Iseman. 1985. Disseminated infection with *Mycobacterium avium intracellulare*. *Medicine.* 64:36–48.
56. Hoybraten, P. 1959. Tuberkulose tiefeller nos fuglen. *Nord Vet Med.* 11:780–786.
57. Jarlier, V., and H. Nikaido. 1994. Mycobacterial cell wall: structure and role in natural resistance to antibiotics. *FEMS Microbiol Lett.* 123:11–18.
58. Jorgensen, J.B. 1978. Serological investigation of strains of *Mycobacterium avium* and *Mycobacterium intracellulare* isolated from animals and nonanimal sources. *Nord Vet Med.* 30: 155–162.
59. Kansal, R.G., R. Gomez-Flores, and R.T. Mehta. 1998. Change in colony morphology influences the virulence as well as the biochemical properties of the *Mycobacterium avium* complex. *Microbial Path.* 25:203–214.
60. Karlson, A.G. 1978. Avian tuberculosis. In: *Mycobacterial Infections of Zoo Animals*. R.J. Montali, ed. Smithsonian Institution Press, Washington, DC. 21–24.
61. Karlson, A.G., M.R. Zinober, and W.H. Feldman. 1950. A whole blood rapid agglutination test for avian tuberculosis. *Am J Vet Res.* 11:137–141.
62. Karlson, A.G., C.L. Davis, and M.L. Cohn. 1962. Scotochromogenic *Mycobacterium avium* from a trumpeter swan. *Am J Vet Res.* 23:5754–579.
63. Karlson, A.G., C.O. Thoen, and R. Harrington. 1970. Japanese quail: Susceptibility to avian tuberculosis. *Avian Dis.* 14:39–44.
64. Kiehn, T., F. Edwards, P. Brannon, A. Tsang, M. Maio, J. Gold, E. Whimbey, B. Wong, K. McClatchy, and D. Armstrong. 1985. Infections caused by *Mycobacterium avium* complex in immunocompromised patients: Diagnosis by blood culture and fecal examination, antimicrobial susceptibility tests, and morphological and seroagglutination characteristics. *J Clin Microbiol.* 21:168–173.
65. Kleeberg, H.H. 1975. Tuberculosis and other Mycobacterioses. In: *Diseases Transmitted from Animals to Man*, 6th ed. W.T. Hubbert, W.F. McCulloch, and P.R. Schnurrenberger, eds. Charles C. Thomas, Springfield, IL. 303–360.
66. Koch, R. 1890. Ueber bakteriologische Forschung. *Wien Med Bl.* 13:531–535.
67. Koch, R. 1902. Address before the second general meeting. *Trans Br Congr Tuberc.* 1:235.
68. Kumar S., M. Bose, and M. Isa. 2006. Genotype analysis of human *Mycobacterium avium* isolates from India. *Indian J Med Res.* 123:139–144.
69. Lambert, P.A. 2002. Cellular impermeability and uptake of biocides and antibiotics in Gram-positive bacteria and mycobacteria. *J Appl Microbiol.* Symp Sppl 92:46S–54S.
70. Lange, J. Personal communication with R.M. Fulton.
71. Leclerc M.C., N. Haddad, R. Moreau, and M.F. Thorel. 2000. Molecular characterization of environmental *Mycobacterium* strains by PCR-restriction fragment length polymorphism of *hsp65* and by sequencing of *hsp65*, and 16S and ITS1 rDNA. *Res Microbiol.* 151:629–638.
72. Lesslie, I.W., and K.J. Birn. 1967. Tuberculosis in cattle caused by the avian type tubercle bacillus. *Vet Rec.* 80:559–564.
73. Maffucci, A. 1890. Beitrag zur Aetiologie der Tuberkulose (Huhnertuberculose). *Zentralbl Allg Pathol Pathol Anat.* 1:409–416.
74. Maltova L., L. Dvorska, W.Y. Ayele, M. Bartos, T. Amemori, and I. Pavlik. 2005. Distribution of *Mycobacterium avium* complex isolates in tissue samples from pig fed peat naturally contaminated with mycobacteria as a supplement. *J Clin Microbiol.* 43:1261–1268.

75. *Manual of Diagnostic Tests and Vaccines for Terrestrial Animals 2011*. Avian tuberculosis. Chapter 2.3.6. 497–506. http://www.oie.int/fileadmin/Home/eng/Health_standards/tahm/2.03.06_AVIAN_TB.pdf.
76. Matthews, P.R.J., J.A. McDiarmid, P. Collins, and A. Brown. 1977. The dependence of some strains of *Mycobacterium avium* of mycobactin for initial and subsequent growth. *J Med Microbiol*. 2:53–57.
77. McDiarmid, A. 1948. The occurrence of tuberculosis in the wild wood-pigeon. *J Comp Pathol Ther.* 58:128–133.
78. Meissner, G., K.H. Schroder, G.E. Amadio, W. Anz, S. Chaparas, H.W.B. Engel, P.A. Jenkins, W. Kappler, H.H. Kleeberg, E. Kubala, M. Kubin, D. Lauterbach, A. Lind, M. Magnusson, Z.D. Mikova, S.R. Pattyn, W.B. Schaefer, J.L. Stanford, M. Tsukamura, L.G. Wayne, I. Willers, and E. Wolinsky. 1974. A cooperative numerical analysis of nonscoto- and nonphoto-chromogenic slowly growing mycobacteria. *J Gen Microbiol.* 83:207–235.
79. Mendenhall, M.K., S.L. Ford, C.L. Emerson, R.A. Wells, L.G. Gines, and I.S. Eriks. 2000. Detection and differentiation of *Mycobacterium avium* and *Mycobacterium genavense* by polymerase chain reaction and restriction enzyme digestion analysis. *J Vet Diagn Invest.* 12:57–60.
80. Mijs, W., P. de Haas, R. Rossau, T. Van Der Laan, L. Rigouts, F. Portaels, and D. van Soolingen. 2002. Molecular evidence to support a proposal to reserve the designation *Mycobacterium avium* subsp. *avium* for bird-type isolates and "*M. avium* subsps. *hominissuis*" for the human/porcine type of *M. avium*. *Int J Syst Evol Microbiol*. 52:1505–1518.
81. Montali, R.J., M. Bush, C.O. Thoen, and E. Smith. 1976. Tuberculosis in captive exotic birds. *J Am Vet Med Assoc.* 169:920–927.
82. Morita, Y., Murayama, S., Iiasiiizaki, F., and Y. Katsube 1999. Pathogenicity of *Mycobacterium avium* Complex serovar 9 isolated from painted quail (*Excalfatoria chinensis*) *J Vet Med Sci*. 61:1309–1312.
83. Mutalib, A.A., and C. Riddell. 1988. Epizootiology and pathology of avian tuberculosis in chickens in Saskatchewan. *Can Vet J.* 29:840–842.
84. Painter, K.S. 1997. Avian tuberculosis caused by *Mycobacterium avium* serotype 3 in captive wildfowl. *Vet Record.* 140:457–458.
85. Peavy, G.M., S. Silverman, E.B. Howard, R.S. Cooper, L.J. Rich and G.N. Thomas. 1976. Pulmonary tuberculosis in a sulfur-crested cockatoo. *J Am Vet Med Assoc.* 915–919.
86. Pavlik I., P. Svastova, J. Bartl, L. Dvorska, and I Rychlik. 2000. Relationship between IS901 in the *Mycobacterium avium* complex isolated from birds, animals, humans, and the environment and virulence for poultry. *Clin Diag Lab Immunol.* 7:212–217.
87. Philalay J.S., C.O. Palermo, K.A. Hauge, T.R. Rustand, and G.A. Cangelosi. 2004. Genes required for intrinsic multidrug resistance in *Mycobacterium avium*. *Antimicrob Agents Chemother.* 48: 3412–3418.
88. Picardeau M., and V. Vincent. 1996. Typing of *Mycobacterium avium* isolates by PCR. *J Clin Microbiol.* 34:389–392.
89. Portaels F., L. Realini, L. Bauwens, B. Hirschel, W.M. Meyers, and W. De Meurichy. 1996. Mycobacteriosis caused by Mycobacterium genavense in birds kept in a zoo: 11-year survey. *J Clin Microbiol.* 34:319–323.
90. Poultry Slaughter. Annual Summary. 2002, 2003, 2004, 2005, 2006. National Agricultural Statistics Service. United States Department of Agriculture.
91. Radomski, N., V.C. Thibault, C. Karoui, K. deCruz, T. Chochard, C. Gutierrez, P. Supply, F. Biet, and M.L. Boschiroli. 2010. Determination of genotypic diversity of *Mycobacterium avium* subspecies from human and animal origins by mycobacterial interspersed repetitive-unit-variable-number tandem-repeat and IS*1311* restriction fragment length polymorphism typing methods. *J Clin Microbiol.* 48:1026–1034.
92. Ramis, A., L. Ferrer, A. Aranaz, E. Liebana, A. Mateos, L. Dominguez, C. Pascual, J. Fdez-Garayazabal, and M.D. Collins. 1996. *Mycobacterium genavense* infection in canaries. *Avian Dis.* 40:246–251.
93. Rastogi N., K.S. Goh, and S. Chavel-Seres. 1997. Stazyme, a mycobacteriolytic preparation from a Staphylococcus strain, is able to break the permeability barrier in multiple drug resistant *Mycobacterium avium*. *FEMS Immunol Microbiol.* 19: 297–305.
94. Reddy, V.M. Mechanisms of *Mycobabterium avium* complex pathogenesis. 1998. *Front Biosci.* 8:d525–531.
95. Rossi, L. 1974. Immunizing potency of inactivated and living *Mycobacterium avium* and *Mycobacterium intracellulare* vaccines against tuberculosis of domestic fowls. *Acta Vet Brno.* 43:133–138.
96. Rostagi, N., and W.W. Barrow. 1994. Cell envelope constituents and the multifaceted nature of *Mycobacterium avium* pathogenicity and drug resistance. *Res Microbiol.* 145:243–252.
97. Saggese, M.D., G. Riggs, I. Tizard, G. Bratton, R. Taylor and D.N. Phalen. 2007. Gross and microscopic findings and investigation of the aetiopathogenesis of mycobacteriosis in a captive population of white-winged ducks (*Carina scutulata*). *Av Pathol.* 36:415–422.
98. Rozanska, M. 1965. Preparation of antigen for whole blood rapid agglutination test and its specificity for diagnosis of avian tuberculosis. *Bull Vet Inst Pulaway.* 9:20–25.0
99. Sanchez S., and R.M. Fulton. 2008. Tuberculosis. In: *A Laboratory Manual for the Isolation, Identification and Characterization of Avian Pathogens*, 5th ed. L. Dufour-Zavala, D.E. Swayne, J.R. Glisson, M.W. Jackwood, J.E. Pearson, W.M. Reed, P. Wakenell, and P. Woolcock eds. American Association of Avian Pathologists, Kennett Square, PA. 53–58.
100. Schaefer, W.B. 1965. Serologic identification and classification of the atypical mycobacteria by their agglutination. *Am Rev Respir Dis.* 92:85–93.
101. Schaefer, W.B., J.V. Beer, N.A. Wood, E. Boughton, P.A. Jenkins, and J. Marks. 1973. A bacteriological study of endemic tuberculosis in birds. *J Hyg (Camb).* 71:549–557.
102. Schalk, A.F., L.M. Roderick, H.L. Fousr, and G.S. Harshfield. 1935. Avian tuberculosis: Collected studies. North Dakota Agric Exp Stn Tech Bull. 279.
103. Schliesser, T., and A. Weber. 1973. Untersuchungen uber die Tenazitat von Mykobakterien der Gruppe III nach Runyon in Sagemehleinstreu. *Zentralbl Veterinaermed [B].* 20:710–714.
104. Scrivner, L.H., and C. Elder. 1931. Cutaneous and subcutaneous tuberculosis in turkeys. *J Am Vet Med Assoc.* 79:244–247.
105. Shane, S.M., A. Camus, M. G. Strain, C.O. Thoen, and T.N. Tully. 1993. Tuberculosis in commercial emus (*Dromaius novaehollandiae*). *Avian Dis.* 37:1172–1176.
106. Shiratsuch, H., and M.D. Basson. 2003. Caspase activation may be associated with *Mycobacterium avium* pathogenicity. *American J Surg.* 186:547–551.
107. Singbeil, B.A., A.A. Bickford, and J.H. Stolz. 1993. Isolation of *Mycobacterium avium* from ringneck pheasants (*Phasianus colchicus*). *Avian Dis.* 37:612–615.

108. Semret, M., C.Y. Turenne, P. de Haas, D.M. Collins, and M.A. Behr. 2006. Differentiating host-associated variants of *M. avium* by PCR for detection of large sequence polymorphisms. *J Clin Microbiol*. 44:881–887.
109. Shitaye, J.E., L. Matlova, A. Horvathova, M. Moravkova, L. Dvorska-Bartosova, F. Treml, J. Lamka and I. Pavlík. 2008. *Mycobacterium avium* subsp. *avium* distribution studied in a naturally infected hen flock and in the environment by culture, serotyping and IS901 RFLP methods. *Vet Microbiol*. 127:155–164.
110. Shitaye, E.J., V. Beran, J. Svobodová, M. Morávková, V. Babák, and I. Pavlík. 2009. Comparison of conventional culture, the manual fluorescent MGIT system and the automated fluorescent MGIT 960 culture system for the detection of *Mycobacterium avium* ssp. *Avium* in tissues of naturally infected hens. *Folia Microbiol.* 54:137–141.
111. Soolingen D.V., J. Bauer, V. Ritacco, S.C. Leao, I. Pavlik, V. Vincent, N. Rastogi, A. Gori, T. Bodmer, C. Garzelli, and M.J. Garcia. 1998. IS1245 restriction length polymorphism typing of *Mycobacterium avium* isolates: proposal for standardization. *J Clin Microbiol.* 36:3051–3054.
112. Stanz, K.M., P.E. Miller, A.J. Cooley, J.A. Langenberg, and C.J. Murphy. 1995. Mycobacterial keratitis in a parrot. *J Am Vet Med Assoc.* 206:1177–1180.
113. Steinmetz, H.W., C. Rutz, R.K. Koop, P. Grest, C. Rohrer Bley, and J.M. Hatt. 2006. Possible *Mycobacterium tuberculosis* in a green-winged macaw (*Ara chloroptera*). *Avian Dis.* 50:641–645.
114. Stenburg, H., and A. Turunen. 1968. Differentiation of *Mycobacteria* isolated from domestic animals. *Zentralbl Veterinaermed [B].* 15:494–503.
115. Sturgill-Koszycki, S., P.L. Haddix, and D.G. Russell. 1997. The interaction between *Mycobacterium* and the macrophage analyzed by two-dimensional polyacrylamide gel electrophoresis. *Electrophoresis.* 18:2558–2565.
116. Tell, L.A., L. Woods, and R.L. Cromie. 2001. Mycobacteriosis in birds. *Rev Sci Tech Off Int Epiz.* 20:180–203.
117. Tell, L.A., C.M. Leutenegger, R.S. Larsen, D.W. Agnew, L. Keener, M.L. Needham, and B.A. Rideout. 2003. Real-time polymerase chain reaction testing for the detection of *Mycobacterium genavense* and *Mycobacterium avium* complex species in avian samples. *Avian Dis.* 47:1406–1415.
118. Tell, L.A., A.L. Woods, J. Foley, M.L. Needham, and R.L. Walker. 2003. Diagnosis of mycobacteriosis: comparison of culture, acid-fast stains, and polymerase chain reaction for the identification of *Mycobacterium avium* in experimentally inoculated Japanese quail (*Coturnix japonica*). *Avian Dis.* 47:444–452.
119. Thegerstrom J., B.I. Marklund, S. Hoffner, D. Alexon-Olsson, J. Kauppinen, and B. Olsen. 2005. Mycobacterium avium with the bird type IS1245 RFLP profile is commonly found in wild and domestic animals, but rarely in humans. *Scand J Infect Dis.* 37:15–20.
120. Thoen, C.O. 1979. Factors associated with pathogenicity of mycobacteria. In: *Microbiology*. R. Schlessinger, ed. American Society of Microbiologists, Washington, DC. 162–167.
121. Thoen, C.O. 1992. Tuberculosis. In: *Diseases of Swine*, 7th ed. A.D. Leman, B. Straw, W.L. Mengeling, S. D'Allaire, and D.J. Taylor, eds. Iowa State University Press, Ames, IA. 617–626.
122. Thoen, C.O. 1994. *Mycobacterium avium* infections in animals. *Res Microbiol.* 145:173–177.
123. Thoen, C.O. 1994. Tuberculosis in wild and domestic mammals. In: *Tuberculosis: Pathogenesis, Prevention and Control*. B.R. Bloom, ed. American Society of Microbiologists, Washington, DC. 157–162.
124. Thoen, C.O. 1997. Tuberculosis. In: *Diseases of Poultry*, 10th ed. B.W. Calnek, H.J. Barnes, C.W. Beard, L.R. McDougald, and Y.M. Saif, eds. Iowa State University Press, Ames, IA. 167–178.
125. Thoen, C.O. 1998. Tuberculosis. In: *A Laboratory Manual for the Isolation and Identification of Avian Pathogens*, 4th ed. D.E. Swayne, J.R. Glisson, M.W. Jackwood, J.E. Pearson, and W.M. Reed, eds. American Association of Avian Pathologists, Kennett Square, PA. 69–73.
126. Thoen, C.O. 1999. Tuberculosis. In: *Diseases of Swine*. 8th ed. B.E. Straw, S. D'Allaire, W.L. Mengeling, and D.J. Taylor, eds. Iowa State University Press, Ames, IA. 601–611.
127. Thoen, C.O., and R. Chiodini. 1993. *Mycobacterium*. In: *Pathogenesis of Bacterial Infections in Animals*. C.L. Gyles and C.O. Thoen, eds. Iowa State University Press, Ames, IA. 44–56.
128. Thoen, C.O., and E.M. Himes. 1981. Tuberculosis. In: *Infectious Diseases of Wild Mammals*, 2nd ed. J.W. Davis, L.H. Karstad, and D.O. Trainer, eds. Iowa State University Press, Ames, IA. 263–274.
129. Thoen, C.O., and D.E. Williams. 1994. Tuberculosis, tuberculoidosis and other mycobacterial infections. In: *Handbook of Zoonoses*, Section A, 2nd ed. G.W. Beran, ed. CRC Press: Boca Raton, FL. 41–60.
130. Thoen, C.O., J.L. Jarnagin, and M.L. Champion. 1975. Micromethod for serotyping strains of Mycobacterium avium. *J Clin Microbiol.* 1:469–471.
131. Thoen, C.O., E.M. Himes, and J.H. Campbell. 1976. Isolation of *Mycobacterium avium* serotype 3 from a white-headed tree duck. *Avian Dis.* 20:587–592.
132. Thoen, C.O., W.G. Eacret, and E.M. Himes. 1978. An enzyme-labeled antibody test for detecting antibodies in chickens infected with *Mycobacterium avium* serotype 2. *Avian Dis.* 22:162–168.
133. Thoen, C.O., A.G. Karlson, and E.M. Himes. 1981. Mycobacterial infections in animals. *Rev Infect Dis.* 3:960–972.
134. Thoen, C.O., E.M. Himes, and A.G. Karlson. 1984. *Mycobacterium avium* complex. In: *The Mycobacteria: A Sourcebook*. G.P. Kubica and L.G. Wayne, eds. Marcel Dekker, New York. 1251–1275.
135. Thorel, M.F., H. Huchzermeyer, R. Weis, and J.J. Fontaine. 1997. *Mycobacterium avium* infections in animals. Literature Review. *Vet Res.* 28:439–447.
136. Thornton C.G., M.R. Cranfield, K.M. MacLellan, T.L. Brink, Jr., J.D. Strandberg, E.A. Carlin, J.B. Torrelles, J.N. Maslow, J.L.B. Hasson, D.M. Heyl, S.J. Sarro, D. Chatterjee, and S. Passen. 1999. Processing postmortem specimens with C18-caboxypropylbetaine and analysis by PCR to develop an antemortem test for *Mycobacterium avium* infections in ducks. *J Zoo Wildl Med.* 30:11–24.
137. Tsang, A.Y., J.C. Denner, P.J. Brennan, and J.K. McClatchy. 1992. Clinical and epidemiological importance of typing of *Mycobacterium avium* complex isolates. *J Clin Microbiol.* 30:479–484
138. Turenne C.Y., M. Semret, D.V. Cousins, D.M. Collins, and M.A. Behr. 2006. Sequencing of *hps65* distinguishes among

subsets of the subsets of the *Mycobacterium avium* complex. *J Clin Microbiol.* 44:433–440.
139. Turenne, C.Y., R. Wallace Jr., and M.A Behr. 2007. *Mycobacterium avium* in the postgenomic era. *Clin Microbiol Rev.* 20:205–229.
140. Vanderheyden, N. 1986. Avian tuberculosis: Diagnosis and attempted treatment. *Proc 1986 Annu Meet Assoc Avian Vet*. 203–211.
141. Vasenius, H. 1965. Tuberculosislike lesions in slaughter swine in Finland. *Nord Vet Med.* 17:17–21.
142. Wallace, J.M., and J.B. Hannah. 1988. *Mycobacterium avium* complex infections in patients with the acquired immunodeficiency syndrome. *Chest.* 93:926–932.
143. Wayne, L.G., R.C. Good, A. Tsang, R. Butler, D. Dawson, D. Groothus, W. Gross, J. Hawkins, J. Kilburn, M. Kubin, K.H. Schröder, V.A. Silcox, C. Smith, M.F. Thorel, C. Woodley, and M.A. Yarkus. 1993. Serovar determination and molecular taxonomic correlation in *Mycobacterium avium*, *Mycobacterium intracellulare*, and *Mycobacterium scrofulaceum*: A cooperative study of the international working group on mycobacterial taxonomy. *Int J Syst Bacteriol.* 43:482–489.
144. Weber. A., T. Schliesser, J.M. Schultze, and U. Bertelsmann. 1976. Serologische Typendifferenzierung aviarer Mykobacterienstamme isoliert von Schlachtrindern. *Zentralbl Bakterial [orig A].* 235:202–206.
145. Wiesenthal, A.M., K.E. Powell, J. Kopp, and J.W. Spindler. 1982. Increase in *Mycobacterium avium* complex isolation among patients admitted to a general hospital. *Public Health Rep.* 97:61–65.
146. Wolinsky, E. 1979. Nontuberculous mycobacteria and associated diseases. *Am Rev Respir Dis.* 119:107–159.
147. Wolinsky, E., and W.B. Schaefer. 1973. Proposed numbering scheme for mycobacterial serotypes by agglutination. *Int J Syst Bacteriol.* 23:182–183.
148. Wouter, M., P. de Haas, R. Rossau, T. Van Der Laan, L. Rigouts, F. Portaels, and D. van Soolingen. 2002. Molecular evidence to support a proposal to reserve the designation *Mycobacterium avium* subsp. *avium* for bird-type isolates and *M. avium* subsp. *hominissuis* for the human/porcine type of *M. avium*. *Int J Syst Bacteriol*. 52:1505–1518.

Miscellaneous and Sporadic Bacterial Infections

1. Abdel Gabbar, K.M., P. Dewani, and B.M. Junejo. 1995. Possible involvement of *Planococcus halophilus* in an outbreak of necrotic hepatitis in chickens. *Vet Rec.* 136:74.
2. Al Aboudi, A.R., I.M.S. Shnawa, A.A. Hassen, and R.B. Al Sanjary. 1988. Penetration rate of *Proteus* organism through egg shell membranes at different temperatures. *Iraqi J Vet Sci.* 1:1–8.
3. Allen, P.C. 1992. Comparative study of long, segmented, filamentous organisms in chickens and mice. *Lab An Sci.* 42:542–547.
4. Angel, C.R., J.L. Sell, J.A. Fagerland, D.L. Reynolds, and D.W. Trampel. 1990. Long-segmented filamentous organisms observed in poults experimentally infected with stunting syndrome agent. *Avian Dis.* 34:994–1001.
5. Arp, L.H., I.M. Robinson, and A.E. Jensen. 1983. Pathology of liver granulomas in turkeys. *Vet Pathol.* 20:80–89.
6. Austin, B. 2010. Vibrios as causal agents of zoonoses. *Vet Microbiol.* 140:310–317.
7. Awan, M.A., and M. Matsumoto. 1998. Heterogeneity of staphylococci and other bacteria isolated from six-week-old broiler chickens. *Poult Sci.* 77:944–949.
8. Aziz, T.A., and H.J. Barnes. 2001. Panophthalmitis with perforation of the cornea in poults associated with *Pseudomonas aeruginosa*. *Proc. 52nd North-Central Avian Dis Conf*. 61.
9. Bandopadhyay, A.C., J.L. Vegad, and M.A. Quadri. 1994. Pathobiochemical changes in liver and brain in experimental avian spirochaetosis. *Indian J An Sci.* 64:340–345.
10. Bapat, J.A., V.B. Kulkarni, and D.V. Nimje. 1985. Mortality in chicks due to *Pseudomonas aeruginosa*. *Indian J An Sci.* 55:538–539.
11. Barbour, E.K., M.K. Brinton, A. Caputa, J.B. Johnson, and P.E. Poss. 1991. Characteristics of *Actinomyces pyogenes* involved in lameness of male turkeys in north-central United States. *Avian Dis.* 35:192–196.
12. Barnes, H.J. 1997. Spirochetosis (Borreliosis). In: *Diseases of Poultry*, 10th ed. B.W. Calnek, H.J. Barnes, C.W. Beard, L.M. McDougald, and Y.M. Saif, eds. Iowa State University Press, Ames, IA. 318–324.
13. Baruah, K.K., P.K. Sharma, and N.N. Bora. 2001. Fertility, hatchability and embryonic mortality in ducks. *Indian Vet J.* 78:529–530.
14. Basher, H.A., D.R. Fowler, F.G. Rodgers, A. Seaman, and M. Woodbine. 1984. Pathogenicity of natural and experimental listeriosis in newly hatched chicks. *Res Vet Sci.* 36:76–80.
15. Batra, G.L., S. Balwant, G.S. Grewal, and S.S. Sodhi. 1982. Aetiopathology of oophoritis and salpingitis in domestic fowl. *Indian J An Sci.* 52:172–176.
16. Beemer, A.M., E.S. Kuttin, and Z. Katz. 1973. Epidemic venereal disease due to *Candida albicans* in geese in Israel. *Avian Dis.* 17:639–649.
17. Behr, K.P., K.H. Hinz, and S. Rottmann. 1990. Phallus-inflammation of ganders: clinical observations and comparative bacteriological examinations of healthy and altered organs. *Zentralbl Veterinarmed. [B]* 37:774–776.
18. Binek, M., W. Borzemska, R. Pisarski, B. Blaszczak, G. Kosowska, H. Malec, and E. Karpinska. 2000. Evaluation of the efficacy of feed providing on development of gastrointestinal microflora of newly hatched broiler chickens. *Archiv Geflugelkunde.* 64:147–151.
19. Bisgaard, M. 1981. Arthritis in ducks. I. Aetiology and public health aspects. *Avian Pathol.* 10:11–21.
20. Bisgaard, M. 1995. Salpingitis in web-footed birds: prevalence, aetiology and significance. *Avian Pathol.* 24:443–452.
21. Bisgaard, M., and K.K. Kristensen. 1975. Isolation, characterization and public health aspects of *Vibrio cholerae* NAG isolated from a Danish duck farm. *Avian Pathol.* 4:271–276.
22. Bisgaard, M., and A. Dam. 1981. Salpingitis in poultry. II. Prevalence, bacteriology, and possible pathogenesis in egg-laying chickens. *Nord Vet*. 33:81–89.
23. Bisgaard, M., R. Sakazaki, and T. Shimada. 1978. Prevalence of non-cholera vibrios in *cavum nasi* and pharynx of ducks. *Acta Pathol Microbiol Scand. [B]* 86:261–266.
24. Bisgaard, M., B.M. Korczak, H.J. Busse, P. Kuhnert, A.M. Bojesen, and H. Christensen. 2009. Classification of the taxon 2 and taxon 3 complex of Bisgaard within *Gallibacterium* and description of *Gallibacterium melopsittaci* sp. nov., *Gallibacterium trehalosifermentans* sp. nov., and *Gallibacterium salpingitidis* sp. nov. *Int J Syst Evol Microbiol*. 59:735–744.
25. Board, R.G., S. Loseby, and V.R. Miles. 1979. A note on microbial growth on hen egg-shells. *Brit Poult Sci.* 20:413–420.

26. Bojesen, A.M., O.L. Nielsen, J.P. Christensen, and M. Bisgaard. 2004. *In vivo* studies of *Gallibacterium anatis* infection in chickens. *Avian Pathol.* 33:145–152.
27. Bracewell, C.D., D.C. Scott, J.A. Binstead, E.D. Borland, A.E. Buckle, P. Cooper, J.D. Corkish, A.B. Davies, P.C. Jones, J. Kemp, A.R.M. Kidd, and T.W.A. Little. 1986. A field investigation of leg weakness in broilers, Booklet No. 2520. Ministry of Agriculture Fisheries and Food, London, UK. 133.
28. Brinton, M.K., L.C. Schellberg, J.B. Johnson, R.K. Frank, D.A. Halvorson, and J.A. Newman. 1993. Description of osteomyelitis lesions associated with *Actinomyces pyogenes* infection in the proximal tibia of adult male turkeys. *Avian Dis.* 37:259–262.
29. Bruce, J., and E.M. Drysdale. 1983. The bacterial flora of candling-reject and dead-in-shell turkey eggs. *Brit Poult. Sci.* 24:391–395.
30. Bruce, J., and E.M. Drysdale. 1994. Trans-shell transmission. In: *Microbiology of the Avian Egg*, R.G. Board and R. Fuller, eds. Chapman and Hall, London. 63–91.
31. Burnens, A.P., J. Stanley, and J. Nicolet. 1996. Possible association of *Helicobacter pullorum* with lesions of vibrionic hepatitis in poultry. In: *Campylobacters, Helicobacters, and Related Organisms*. D.G. Newell, J.M. Ketley, and R.A. Feldman, eds. Plenum Press, New York and London. 291–293.
32. Burnens, A.P., J. Stanley, R. Morgenstern, and J. Nicolet. 1994. Gastroenteritis associated with *Helicobacter pullorum*. *Lancet.* 344:1569–1570.
33. Byrum, B.R., and R.D. Slemons. 1995. Detection of proteolytic bacteria in the upper respiratory tract flora of poultry. *Avian Dis.* 39:622–626.
34. Casagrande Proietti, P., F. Passamonti, M. Pia Franciosini, and G. Asdrubali. 2004. *Hafnia alvei* infection in pullets in Italy. *Avian Pathol.* 33:200–204.
35. Caselli, M., J. Holton, P. Boldrini, D. Vaira, and G. Calo. 2010. Morphology of segmented filamentous bacteria and their patterns of contact with the follicle-associated epithelium of the mouse terminal ileum: implications for the relationship with the immune system. *Gut Microbes.* 1:367–372.
36. Castle, M.D., and B.M. Christensen. 1985. Isolation and identification of *Aegyptianella pullorum* (Rickettsiales, Anaplasmataceae) in wild turkeys from North America. *Avian Dis.* 29:437–445.
37. Castro, A.G.M.d., A.M.d. Carvalho, M. Hipolito, A. Paludetti, Jr., A.G.M. De Castro, and A.M. De Carvolho. 1989. Mortality in chickens caused by *Pseudomonas aeruginosa*. *Arq Instit Biol Sao Paulo.* 56:62.
38. Ceelen, L.M., A. Decostere, K. Van den Bulck, S.L. On, M. Baele, R. Ducatelle, and F. Haesebrouck. 2006. *Helicobacter pullorum* in chickens, Belgium. *Emerg Infect Dis.* 12:263–267.
39. Cheng, K.J., E.E. Gardiner, and J.W. Costerton. 1976. Bacteria associated with beak necrosis in broiler breeder hens. *Vet Rec.* 99:503–505.
40. Chin, R.P. 2002. Isolation of an unidentified, nonfermentative, gram-negative bacterium from turkeys and chickens: 38 cases (1995-2001). *Avian Dis.* 46:447–452.
41. Choudhury, B., A. Chanda, P. Dasgupta, R.K. Dutta, S. Lila, B. Sanatan, L. Saha, and S. Bhuin. 1993. Studies on yolk sac infection in poultry, antibiogram of isolates and correlation between *in-vitro* and *in-vivo* drug action. *Indian J An Hlth.* 32:21–23.
42. Christensen, H., M. Bisgaard, A.M. Bojesen, R. Mutters, and J.E. Olsen. 2003. Genetic relationships among avian isolates classified as *Pasteurella haemolytica*, '*Actinobacillus salpingitidis*' or *Pasteurella anatis* with proposal of *Gallibacterium anatis* gen. nov., comb. nov., and description of additional genomospecies within *Gallibacterium* gen. nov. *Int J Syst Evol Microbiol.* 53:275–287.
43. Chui, L.W., R. King, E.Y. Chow, and J. Sim. 2004. Immunological response to *Mycobacterium avium* subsp. *paratuberculosis* in chickens. *Can J Vet Res*. 68:302–308.
44. Collett, R.S. 2008. Spirochetosis. In: *A Laboratory Manual for the Isolation, Identification, and Characterization of Avian Pathogens*, 5th ed. L. Dufour-Zavala, D.E. Swayne, J.R. Glisson, J.E. Pearson, W.M. Reed, M.W. Jackwood, and P.R. Woolcock, eds. Am Assoc Avian Pathologists, Athens, GA. 31–35.
45. Collins, A.M., R.J. Love, S. Jasni, and S. McOrist. 1999. Attempted infection of mice, rats and chickens by porcine strains of *Lawsonia intracellularis*. *Aust Vet J.* 77:120–122.
46. Collins, P., A. McDiarmid, L.H. Thomas, and P.R. Matthews. 1985. Comparison of the pathogenicity of *Mycobacterium paratuberculosis* and *Mycobacterium* spp isolated from the wood pigeon (*Columba palumbus*-L). *J Comp Pathol.* 95:591–597.
47. Comstedt, P., S. Bergstrom, B. Olsen, U. Garpmo, L. Marjavaara, H. Mejlon, A.G. Barbour, and J. Bunikis. 2006. Migratory passerine birds as reservoirs of Lyme borreliosis in Europe. *Emerg Infect Dis.* 12:1087–1095.
48. Cooper, D.M., D.L. Swanson, and C.J. Gebhart. 1997. Diagnosis of proliferative enteritis in frozen and formalin-fixed, paraffin-embedded tissues from a hamster, horse, deer and ostrich using a *Lawsonia intracellularis*-specific multiplex PCR assay. *Vet Microbiol.* 54:47–62.
49. Cooper, D.M., D.L. Swanson, S.M. Barnes, and C.J. Gebhart. 1997. Comparison of the 16S ribosomal DNA sequences from the intracellular agents of proliferative enteritis in a hamster, deer, and ostrich with the sequence of a porcine isolate of *Lawsonia intracellularis*. *Int J Syst Bacteriol.* 47:635–639.
50. Cooper, G., and A. Bickford. 2008. Listeriosis. In: *A Laboratory Manual for the Isolation, Identification, and Characterization of Avian Pathogens*, 5th ed. L. Dufour-Zavala, D.E. Swayne, J.R. Glisson, J.E. Pearson, W.M. Reed, M.W. Jackwood, and P.R. Woolcock, eds. Am Assoc Avian Pathologists, Athens, GA. 39–41.
51. Cooper, G., B. Charlton, A. Bickford, C. Cardona, J. Barton, S. Channing Santiago, and R. Walker. 1992. Listeriosis in California broiler chickens. *J Vet Diag Invest.* 4:343–345.
52. Cooper, G.L. 1989. An encephalitic form of listeriosis in broiler chickens. *Avian Dis.* 33:182–185.
53. Cooper, G.L., and A.A. Bickford. 1993. Spirochetosis in California game chickens. *Avian Dis.* 37:1167–1171.
54. Corrales, W., L.M. Vivo, and E. Gutierrez. 1988. Cutaneous abscesses in a flock of caged layers. Report of an outbreak. *Revista Avicultura.* 32:15–27.
55. Cox, N.A., J.S. Bailey, E.T. Ryser, and E.H. Marth. 1999. Incidence and behavior of *Listeria monocytogenes* in poultry and egg products. In: *Listeria, Listeriosis and Food Safety*, 2nd ed. Ryser, E.T., and E.H. Marth, eds. Marcel Dekker, Inc., New York. 565–600.
56. Cutler, S.J., M. Bouzid, and R.R. Cutler. 2007. Q fever. *J Infect.* 54:313–318.
57. Czifra, G., Z. Varga, M. Dobos Kovacs, and L. Stipkovits. 1986. Medication of inflammation of the phallus in geese. *Acta Vet Hung.* 34:211–223.
58. DaMassa, A.J., and H.E. Adler. 1979. Avian spirochaetosis: enhanced recognition of mild strains of *Borrelia anserina* with bursectomized and dexamethasone-treated chickens. *J Comp Pathol.* 89:413–420.

59. Darzi, M.M., M.S. Mir, N. Nashiruddullah, and S.A. Kamil. 2006. Nocardiosis in domestic pigeons (*Columba livia*). *Vet Rec.* 158:834–836.
60. Deeming, D.C. 1995. Possible effect of microbial infection on yolk utilisation in ostrich chicks. *Vet Rec.* 136:270–271.
61. Deeming, D.C. 1996. Microbial spoilage of ostrich (*Struthio camelus*) eggs. *Brit Poult Sci.* 37:689–693.
62. Dessouky, M.I., A. Moursy, Z.M. Niazi, and O.A. Abd Alla. 1982. Experimental *Klebsiella* infection in baby chicks. *Archiv Geflugelkunde.* 46:145–150.
63. Devriese, L.A., N.J. Viaene, and G.D. Medts. 1975. *Pseudomonas aeruginosa* infection on a broiler farm. *Avian Pathol.* 4:233–237.
64. Dewhirst, F.E., C. Seymour, G.J. Fraser, B.J. Paster, and J.G. Fox. 1994. Phylogeny of *Helicobacter* isolates from bird and swine feces and description of *Helicobacter pametensis* sp. nov. *Int J Syst Bacteriol*. 44:553–560.
65. Dijkstra, R.G., and I. Ivanov. 1979. *Listeria monocytogenes* in intestinal contents and faeces from healthy broilers of different ages in the litter and its potential danger for other animals, i.e. cattle. In: *Problems of Listeriosis, Proc 7th Int Symp*. 1977. 289–294.
66. Duchatel, J.P., D. Janssens, F. Vandersanden, and H. Vindevogel. 2000. Arthritis in a racing pigeon (*Columba livia)*, associated with *Acinetobacter lwoffii*. *Ann Med Vet.* 144:153–154.
67. Duff, S.R.I., P.M. Hocking, and C.J. Randall. 1990. Beak and oral lesions in broiler breeding fowl. *Avian Pathol.* 19:451–466.
68. Emerson, F.G., G.E. Kolb, and F.A. VanNatta. 1983. Chronic cholera-like lesions caused by *Moraxella osloensis*. *Avian Dis.* 27:836–838.
69. Erganis, O., M. Corlu, O. Kaya, and M. Ates. 1988. Isolation of *Acinetobacter calcoaceticus* from septicaemic hens. *Vet Rec.* 123:374.
70. Fales, W.H., E.L. McCune, and J.N. Berg. 1978. The isolation of Gram negative nonfermentative bacteria from turkeys with respiratory distress. *Proc Am Assoc Vet Lab Diag.* 21:227–242.
71. Foster, G., H. Malnick, P.A. Lawson, J. Kirkwood, S.K. Macgregor, and M.D. Collins. 2005. *Suttonella ornithocola* sp. nov., from birds of the tit families, and emended description of the genus *Suttonella*. *Int J Syst Evol Microbiol*. 55:2269–2272.
72. Franca, M., R.L. Walker, R. Kokka, and H.L. Shivaprasad. 2009. *Aeromonas* species associated with necrotizing enteritis and septicemia in an adult male ostrich (*Struthio camelus*). *Avian Dis.* 53:310–316.
73. Gasanov, U., D. Hughes, and P.M. Hansbro. 2005. Methods for the isolation and identification of *Listeria* spp., and *Listeria monocytogenes*: a review. *FEMS Microbiol Rev*. 29:851–875.
74. Gentle, M.J. 1986. Aetiology of food-related oral lesions in chickens. *Res Vet Sci.* 40:219–224.
75. Gentle, M.J., M.H. Maxwell, L.N. Hunter, and E. Seawright. 1989. Haematological changes associated with food-related oral lesions in Brown Leghorn hens. *Avian Pathol.* 18:725–733.
76. Gerlach, H., and K. Bitzer. 1971. *Aeromonas hydrophila* infection in young turkeys. *Dtsch Tierarztl Wochenschr.* 78:606–608.
77. Gibson, J.R., M.A. Ferrus, D. Woodward, J. Xerry, and R.J. Owen. 1999. Genetic diversity in *Helicobacter pullorum* from human and poultry sources identified by an amplified fragment length polymorphism technique and pulsed-field gel electrophoresis. *J Appl Microbiol.* 87:602–610.
78. Glunder, G., and O. Siegmann. 1989. Occurrence of *Aeromonas hydrophila* in wild birds. *Avian Pathol.* 18:685–695.
79. Glunder, G., K.H. Hinz, and B. Stiburek. 1982. Arthritis due to *Streptobacillus moniliformis* in turkeys in German Federal Republic. *Dtsch Tierarztl Wochenschr.* 89:367–370.
80. Gomis, S., A.K. Amoako, A.M. Ngeleka, L. Belanger, B. Althouse, L. Kumor, E. Waters, S. Stephens, C. Riddell, A. Potter, and B. Allan. 2002. Histopathologic and bacteriologic evaluations of cellulitis detected in legs and caudal abdominal regions of turkeys. *Avian Dis.* 46:192–197.
81. Gonzalez, A., P. Piqueres, Y. Moreno, I. Canigral, R.J. Owen, J. Hernandez, and M.A. Ferrus. 2008. A novel real-time PCR assay for the detection of *Helicobacter pullorum*-like organisms in chicken products. *Int Microbiol.* 11:203–208.
82. Goodwin, M.A., G.L. Cooper, J. Brown, A.A. Bickford, W.D. Waltman, and T.G. Dickson. 1991. Clinical, pathological, and epizootiological features of long-segmented filamentous organisms (bacteria, LSFOs) in the small intestines of chickens, turkeys, and quails. *Avian Dis.* 35:872–876.
83. Goswami, S., B. Chaudhury, and A. Mukit. 1988. Reproductive disorders of domestic hen. *Indian Vet J.* 65:747–749.
84. Gothe, R. 1992. *Aegyptianella*: an appraisal of species, systematics, avian hosts, distribution, and developmental biology in vertebrates and vectors and epidemiology. *Adv. Dis Vector Res.* 9:67–100.
85. Gray, M.L. 1958. Listeriosis in fowls—A review. *Avian Dis.* 2:296–314.
86. Gray, M.L., and A.H. Killinger. 1966. *Listeria monocytogenes* and listeric infections. *Bacteriol Rev.* 30:309–382.
87. Gurel, A., A. Gulc Ubuk, and N. Turan. 2004. A granulomatous conjunctivitis associated with *Morexella phenylpyruvica* in an ostrich (*Struthio camelus*). *Avian Pathol.* 33:196–199.
88. Hafez, H.M., H. Woernle, and G. Heil. 1987. *Pseudomonas aeruginosa* infections in turkey poults and treatment trials with apramycin. *Berl Munch Tierarztl Wochenschr.* 100:48–51.
89. Hafner, S., B.G. Harmon, S.G. Thayer, and S.M. Hall. 1994. Splenic granulomas in broiler chickens produced experimentally by inoculation with *Eubacterium tortuosum*. *Avian Dis.* 38:605–609.
90. Haruna, E.S., M. Usman, S. Ahmed, J.S. Shaibu, A.A. Makinde, L.H. Lombin, and M.M. Henton. 2004. Isolation of *Citrobacter murliniae* from clinically ill and dead quail, ducks and chickens. *Vet Rec.* 154:119–120.
91. Hill, J.E., L.C. Kelley, and K.A. Langheinrich. 1992. Visceral granulomas in chickens infected with a filamentous bacteria. *Avian Dis.* 36:172–176.
92. Hinz, K.H., M. Ryll, and G. Glunder. 1999. Isolation and identification of *Vibrio metschnicovii* from domestic ducks and geese. *Zentralbl Veterinarmed. [B]* 46:331–339.
93. Hinz, K.H., M. Ryll, U. Heffels Redmann, and M. Poppel. 1992. Multicausal infectious respiratory disease of turkey poults. *Dtsch Tierarztl Wochenschr.* 99:75–78.
94. Hocking, P.M. 1990. Assessment of the effects of separate sex feeding on the welfare and productivity of broiler breeder females. *Brit Poult Sci.* 31:457–463.
95. Hocking, P.M., and R. Bernard. 1997. Effects of male body weight, strain and dietary protein content on fertility and musculo-skeletal disease in naturally mated broiler breeder males. *Brit Poult Sci.* 38:29–37.
96. Honich, M. 1972. Outbreak of *Pseudomonas aeruginosa* infection among pheasant chicks. *Magyar Allatorvosok Lapja.* 27:329–335.
97. Howell, L.J., R. Hunter, and T.J. Bagust. 1982. Necrotic dermatitis in chickens. *NZ Vet J.* 30:87–88.

98. Huchzermeyer, F.W. 1994. *Ostrich Diseases*. Agricultural Research Council, Onderstepoort Veterinary Institute, Pretoria, South Africa.
99. Huchzermeyer, F.W. 1999. Veterinary problems. In: *The Ostrich—Biology, Production and Health*. D.C. Deeming, ed. CAB International, Wallingford, Oxon, UK. 293–320.
100. Huchzermeyer, F.W., J.A. Cilliers, C.D. Diaz Lavigne, and R.A. Bartkowiak. 1987. Broiler pulmonary hypertension syndrome. I. Increased right ventricular mass in broilers experimentally infected with *Aegyptianella pullorum. Onderstepoort J Vet Res.* 54:113–4.
101. Jagger, T.D. 2000. *Plesiomonas shigelloides*—a veterinary perspective. *Infect Dis Rev.* 2:199–210.
102. Janda, J.M., and S.L. Abbott. 2010. The genus *Aeromonas*: taxonomy, pathogenicity, and infection. *Clin Microbiol Rev.* 23:35–73.
103. Johnson, T.J., C. Fernandez-Alarcon, A.M. Bojesen, L.K. Nolan, D.W. Trampel, and T. Seemann. 2011. Complete genome sequence of *Gallibacterium anatis* strain UMN179 isolated from a laying hen with peritonitis. *J Bacteriol.* 193:3676–3677.
104. Jordan, B.E., K.R. Onks, S.W. Hamilton, S.E. Hayslette, and S.M. Wright. 2009. Detection of *Borrelia burgdorferi* and *Borrelia lonestari* in birds in Tennessee. *J Med Entomol.* 46:131–138.
105. Julian, R.J., and D.E. Galt. 1980. Mortality in muscovy ducks (*Cairina moschata*) caused by *Haemoproteus* infection. *J Wildl Dis.* 16:39–44.
106. Julian, R.J., T.J. Beveridge, and D.E. Galt. 1985. Muscovy duck mortality not caused by *Haemoproteus*. *J Wildl Dis.* 21:335–337.
107. Kabilika, H.S., M.M. Musonda, and R.N. Sharma. 1999. Bacterial flora from dead-in-shell chicken embryos in Zambia. *Indian J Vet Res.* 8:1–6.
108. Karagin, P.H., U. Stenram, T. Wadstrom, and A. Ljungh. 2010. *Helicobacter* species and common gut bacterial DNA in gallbladder with cholecystitis. *World J Gastroenterol.* 16:4817–4822.
109. Kaya, O., M. Ates, O. Erganis, M. Corlu, and S. Sanlioglu. 1989. Isolation of *Acinetobacter lwoffi* from hens with septicemia. *J Vet Med. [B]* 36:157–158.
110. Kipp, S., A. Goedecke, W. Dorn, B. Wilske, and V. Fingerle. 2006. Role of birds in Thuringia, Germany, in the natural cycle of *Borrelia burgdorferi sensu lato*, the Lyme disease spirochaete. *Int J Med Microbiol.* 296 Suppl 40:125–128.
111. Kirkwood, J.K., S.K. Macgregor, H. Malnick, and G. Foster. 2006. Unusual mortality incidents in tit species (family Paridae) associated with the novel bacterium *Suttonella ornithocola*. *Vet Rec.* 158:203–205.
112. Kiupel, H. 1972. Listeriosis in the fowl with special reference to diagnosis and epidemiology. *Monatshefte fur Veterinarmedizin* 27:812–815.
113. Kjelland, V., S. Stuen, T. Skarpaas, and A. Slettan. 2010. *Borrelia burgdorferi sensu lato* in *Ixodes ricinus* ticks collected from migratory birds in Southern Norway. *Acta Vet Scand.* 52:59–64.
114. Klopfleisch, R., C. Muller, U. Polster, J.P. Hildebrandt, and J.P. Teifke. 2005. Granulomatous inflammation of salt glands in ducklings (*Anas platyrhynchos*) associated with intralesional Gram-negative bacteria. *Avian Pathol.* 34:233–237.
115. Krishnamohan Reddy, Y., B. Mohan, and Y.K. Reddy. 1993. An outbreak of purulent conjunctivitis in chicks. *J Assam Vet Council.* 3:62.
116. Kurazono, M., K. Nakamura, M. Yamada, T. Yonemaru, and T. Sakoda. 2003. Pathology of listerial encephalitis in chickens in Japan. *Avian Dis.* 47:1496–1502.
117. Kurkure, N.V., D.R. Kalorey, W. Shubhangi, P.S. Sakhare, and A.G. Bhandarkar. 2001. Mortality in young broilers due to *Pseudomonas aeruginosa*. *Indian J Vet Res.* 10:55–57.
118. Kuttin, E.S., A.M. Beemer, M. Pinto, E.S. Kuttin, and G.L. Baum. 1980. Vaccination of geese suffering from candidosis. In: *Human and animal mycology, Proc 7th ISHAM Congress 1979*. 64–67.
119. Labruna, M.B., J.S. Resende, N.R.S. Martins, and M.A. Jorge. 1999. Cryopreservation of an avian spirochete strain in liquid nitrogen. *Arq Brasil Med Vet Zootecnia.* 51:551–553.
120. Labruna, M.B., R.C. Leite, J.S. Resende, A.A. Fernandes, and N.R.S. Martins. 1997. Failure of transmission of *Borrelia anserina* by *Amblyomma cajennense* (Acari:Ixodidae). *Arq Brasil Med Vet Zootecnia.* 49:499–503.
121. Langheinrich, K.A., and B. Schwab. 1972. Isolation of bacteria and histomorphology of turkey liver granulomas. *Avian Dis.* 16:806–816.
122. Lawson, B., H. Malnick, T.W. Pennycott, S.K. Macgregor, S.K. John, G. Duncan, L.A. Hughes, J. Chantrey, and A.A. Cunningham. 2011. Acute necrotising pneumonitis associated with *Suttonella ornithocola* infection in tits (Paridae). *Vet J.* 188:96–100.
123. Lawson, G.H., and C.J. Gebhart. 2000. Proliferative enteropathy. *J Comp Pathol.* 122:77–100.
124. Leard, T., and W. Maslin. 1993. *Flavobacterium meningosepticum* septicemia associated with thymic atrophy/hypoplasia in an ostrich chick. *Vet Pathol.* 30:454.
125. Lemarchand, T.X., T.N. Tully, Jr., S.M. Shane, and D.E. Duncan. 1997. Intracellular *Campylobacter*-like organisms associated with rectal prolapse and proliferative enteroproctitis in emus (*Dromaius novaehollandiae*). *Vet Pathol.* 34: 152–156.
126. Levine, J.F., M.J. Dykstra, W.L. Nicholson, R.L. Walker, G. Massey, and H.J. Barnes. 1990. Attenuation of *Borrelia anserina* by serial passage in liquid medium. *Res Vet Sci.* 48:64–69.
127. Levine, N.D. 1965. Listeriosis, botulism, erysipelas, and goose influenza. In: *Diseases of Poultry*, 5th ed. H.E. Beister and L.H. Schwarte, eds. Iowa State University Press, Ames, IA. 451–471.
128. Li, K., W. Huang, J. Yuan, W. Yu, K.M. Li, W.X. Huang, J.H. Yuan, and W.R. Yu. 1998. Pathogen identification and immunization experiments of *Aeromonas hydrophila* disease in ducks. *Chinese J Vet Med.* 24:13–14.
129. Lin, J.A., C. Shyu, and C.L. Shyu. 1996. Detection of Gram-negative bacterial flora from dead-in-shell chicken embryo, non-hatched eggs, and newly hatched chicks. *J Chinese Soc Vet Sci.* 22:361–366.
130. Lin, M.Y., M.C. Cheng, K.J. Huang, and W.C. Tsai. 1993. Classification, pathogenicity, and drug susceptibility of hemolytic Gram-negative bacteria isolated from sick or dead chickens. *Avian Dis.* 37:6–9.
131. Lisboa, R.S., R.C. Teixeira, C.P. Rangel, H.A. Santos, C.L. Massard, and A.H. Fonseca. 2009. Avian spirochetosis in chickens following experimental transmission of *Borrelia anserina* by *Argas* (*Persicargas*) *miniatus*. *Avian Dis.* 53:166–168.
132. Liu, S.G., M.H. Gan, and Z.M. Zhao. 1988. Studies on *Klebsiella* infection in chickens. I. Diagnosis and control of ophthalmia caused by *Klebsiella*. *Chinese J Vet Med.* 14:7–9.
133. Loughlin, M.F., M.V. Jones, and P.A. Lambert. 2002. *Pseudomonas aeruginosa* cells adapted to benzalkonium

chloride show resistance to other membrane-active agents but not to clinically relevant antibiotics. *J Antimicrob Chemother.* 49:631–639.

134. Manfreda, G., A. Parisi, A. Lucchi, R.G. Zanoni, and A. De Cesare. 2011. Prevalence of *Helicobacter pullorum* in conventional, organic, and free-range broilers and typing of isolates. *Appl Environ Microbiol.* 77:479–484.
135. Marie-Angele, P., E. Lommano, P.F. Humair, V. Douet, O. Rais, M. Schaad, L. Jenni, and L. Gern. 2006. Prevalence of *Borrelia burgdorferi sensu lato* in ticks collected from migratory birds in Switzerland. *Appl Environ Microbiol.* 72:976–979.
136. Marius Jestin, V., M.L. Menec, E. Thibault, J.C. Moisan, and R. L'Hospitalier. 1987. Normal phallus flora of the gander. *J Vet Med. B* 34:67–78.
137. Marjankova, K., K. Krivanec, and J. Zajicek. 1978. Mass occurrence of necrotic inflammation of the penis in ganders caused by phycomycetes. *Mycopathologia.* 66:21–26.
138. McFadden, J.J., and H.M. Fidler. 1996. Mycobacteria as possible causes of sarcoidosis and Crohn's disease. *Soc Appl Bacteriol Symp Ser.* 25:47S–52S.
139. McOrist, S., L. Keller, and A.L. McOrist. 2003. Search for *Lawsonia intracellularis* and *Bilophila wadsworthia* in malabsorption-diseased chickens. *Can J Vet Res.* 67:232–234.
140. Melito, P.L., D.L. Woodward, K.A. Bernard, L. Price, R. Khakhria, W.M. Johnson, and F.G. Rodgers. 2000. Differentiation of clinical *Helicobacter pullorum* isolates from related *Helicobacter* and *Campylobacter* species. *Helicobacter.* 5:142–147.
141. Miller, K.A., L.L. Blackall, J.K. Miflin, J.M. Templeton, and P.J. Blackall. 2006. Detection of *Helicobacter pullorum* in meat chickens in Australia. *Aust Vet J.* 84:95–97.
142. Millins, C., J.E. Hill, and G. Wobeser. 2010. Intracellular yeasts in endothelial cells of a great blue heron (*Ardea herodias*). *J Vet Diag Invest.* 22:131–134.
143. Miranda, A., M.A. Pires, M.L. Pinto, L. Sousa, R. Sargo, J. Rodrigues, A.C. Coelho, M. Matos, and A.M. Coelho. 2009. *Mycobacterium avium* subspecies *paratuberculosis* in a diamant sparrow. *Vet Rec.* 165:184.
144. Mireles, V., C. Alvarez, and S.A. Salsbury. 1979. *Pseudomonas aeruginosa* infection due to contaminated vaccination equipment. *Proc 28th Western Poult Dis Conf*. 55–57.
145. Mohamed, H.A.A.E. 2004. *Proteus* spp. infection in quails in Assiut governorate. *Assiut Vet Med J*. 50:196–204.
146. Mohamed, Y.S., P.D. Moorhead, and E.H. Bohl. 1969. Natural *Streptobacillus moniliformis* infection of turkeys, and attempts to infect turkeys, sheep, and pigs. *Avian Dis.* 13:379–385.
147. Mohan, K., L.C. Shroeder-Tucker, D. Karenga, F. Dziva, A. Harrison, and P. Muvavarirwa. 2002. Unidentified coryneform bacterial strain from cases of polyarthritis in chickens: phenotype and fatty acid profile. *Avian Dis.* 46:1051–1054.
148. Momotani, E., M. Kiryu, M. Ohshiro, M. Murakami, Y. Ashida, S. Watanabe, and Y. Matsubara. 1995. Granulomatous lesions caused by *Pseudomonas aeruginosa* in the ostrich (*Struthio camelus*). *J Comp Pathol.* 112:273–282.
149. Montali, R.J. 1988. Comparative pathology of inflammation in the higher vertebrates (reptiles, birds and mammals). *J Comp Pathol.* 99:1–26.
150. Moore, W.E.C., and W.B. Gross. 1968. Liver granulomas of turkeys—causative agents and mechanism of infection. *Avian Dis.* 12:417–422.
151. Morishita, T.Y., K.M. Lam, and R.H. McCapes. 1992. Isolation of two filamentous bacteria associated with enteritis in turkey poults. *Poult Sci.* 71:203–207.
152. Mosqueda, T.A., N.G. Moedano, and G.J. Moreno. 1976. *Pseudomonas aeruginosa* as a source of nervous signs and lesions in young chicks. Proc 25th Western Poult Dis Conf. 68–69.
153. Muramatsu, Y., K. Hukuta, S. Satoh, M. Muramatsu, M. Nishimura, H. Nagahata, H. Ueno, C. Morita, and Y. Tamura. 2006. Seroepidemiologic survey of *Coxiella burnetii* and attempt to detect coxiella DNA in aged non-laying chickens in a prefecture of Japan where poultry farming prospers. *J Vet Med Sci.* 68:1007–1008.
154. Mutalib, A.A., and C. Riddell. 1982. Cecal and hepatic granulomas of unknown etiology in chickens. *Avian Dis.* 26:732–740.
155. Nebbia, P., C. Tramuta, M. Ortoffi, E. Bert, S. Cerruti Sola, and P. Robino. 2007. Identification of enteric *Helicobacter* in avian species. *Schweiz Arch Tierheilkd.* 149:403–407.
156. Neubauer, C., and M. Hess. 2006. Detection and identification of food-borne pathogens of the genera *Campylobacter*, *Arcobacter* and *Helicobacter* by multiplex PCR in poultry and poultry products. *J Vet Med. [B]* 53:376–381.
157. Neubauer, C., M. De Souza-Pilz, A.M. Bojesen, M. Bisgaard, and M. Hess. 2009. Tissue distribution of haemolytic *Gallibacterium anatis* isolates in laying birds with reproductive disorders. *Avian Pathol.* 38:1–7.
158. Nimmervoll, H., C. Wenker, N. Robert, and S. Albini. 2011. Septicaemia caused by *Edwardsiella tarda* and *Plesiomonas shigelloides* in captive penguin chicks. *Schweiz Arch Tierheilkd.* 153:117–121.
159. Norton, R.A., F.J. Hoerr, F.D. Clark, and S.C. Ricke. 1999. Ascarid-associated hepatic foci in turkeys. *Avian Dis.* 43:29–38.
160. Norton, R.A., S.C. Ricke, J.N. Beasley, J.K. Skeeles, and F.D. Clark. 1996. A survey of sixty turkey flocks exhibiting hepatic foci taken at time of processing. *Avian Dis.* 40:466–472.
161. Ogg, J.E., R.A. Ryder, and H.L. Smith, Jr. 1989. Isolation of *Vibrio cholerae* from aquatic birds in Colorado and Utah. *Appl Environ Microbiol.* 55:95–99.
162. Okoye, J.O.A., H.C. Gugnani, and C.N. Okeke. 1991. Experimental infection of chickens with *Nocardia asteroides* and *Nocardia transvalensis*. *Avian Pathol.* 20:17–24.
163. Olkowski, A.A., L. Kumor, D. Johnson, M. Bielby, M. Chirino Trejo, and H.L. Classen. 1999. Cellulitis lesions in commercial turkeys identified during processing. *Vet Rec.* 145:228–229.
164. On, S.L. 2001. Taxonomy of *Campylobacter*, *Arcobacter*, *Helicobacter* and related bacteria: current status, future prospects and immediate concerns. *Symp Ser Soc Appl Microbiol.* 30:1S–15S.
165. Orajaka, L.J.E., and K. Mohan. 1985. Aerobic bacterial flora from dead-in-shell chicken embryos from Nigeria. *Avian Dis.* 29:583–589.
166. Pandey, G.S., U. Zieger, A. Nambota, Y. Nomura, K. Kobayashi, and A. Mweene. 2001. Pneumonitis due to *Pseudomonas aeruginosa* in an adult ostrich in Zambia. *Indian Vet J.* 78:39–42.
167. Pariente Martin, M., E. Escribano Garaizabal, P.J. Liria Sanchez, and M.D. Crespo Sanchez. 2008. *Vibrio metschnikovii* from a human infected leg ulcer. *Rev Inst Med Trop Sao Paulo.* 50:311–312.
168. Peirce, M.A., G.C. Backhurst, and D.E.G. Backhurst. 1977. Haematozoa of East African birds. III. Three years' observations

on the blood parasites of birds from Ngulia. *E Afr Wildl J.* 15:71–79.
169. Peterson, B.H. 1975. Concurrent infection of chicks with *M. synoviae* and *Pseudomonas* species. *Poult Sci*. 54:1804–1805.
170. Plesser, O., A. Even Shoshan, and U. Bendheim. 1975. The isolation of *Klebsiella pneumoniae* from poultry and hatcheries. *Refu Vet.* 32:99–105.
171. Ramos, J.A., M. Domingo, L. Dominguez, L. Ferrer, and A. Marco. 1988. Immunohistologic diagnosis of avian listeriosis. *Avian Pathol.* 17:227–233.
172. Randall, C.J., W.G. Siller, A.S. Wallis, and K.S. Kirkpatrick. 1984. Multiple infections in young broilers. *Vet Rec.* 114:270–271.
173. Randall, C.J., S. Lees, G.A. Pepin, and H.M. Ross. 1987. An unusual intracellular infection in ducks. *Avian Pathol.* 16:479–491.
174. Rashid, J., and A. Ali. 1991. Comparative study of pathogenicity of experimentally produced *Borrelia anserina* infection in commercial broiler and Desi chicks. *Pakistan J Zool.* 23:361–362.
175. Real, F., A. Fernandez, F. Acosta, B. Acosta, P. Castro, S. Deniz, and J. Oros. 1997. Septicemia associated with *Hafnia alvei* in laying hens. *Avian Dis.* 41:741–7.
176. Reddy, M.V., S.M. Mohiuddin, A.S. Rao, and H. Vikram Reddy. 1986. *Pseudomonas aeruginosa* infection in chicken. *Indian J An Sci.* 56:221–223.
177. Riddell, C., and A. Gajadhar. 1988. Cecal and hepatic granulomas in chickens associated with *Heterakis gallinarum* infection. *Avian Dis.* 32:836–838.
178. Rikihisa, Y., C.B. Zhang, and B.M. Christensen. 2003. Molecular characterization of *Aegyptianella pullorum* (Rickettsiales, Anaplasmataceae). *J Clin Microbiol.* 41:5294–5297.
179. Robino, P., L. Tomassone, C. Tramuta, M. Rodo, M. Giammarino, G. Vaschetti, and P. Nebbia. 2010. Prevalence of *Campylobacter jejuni, Campylobacter coli* and enteric *Helicobacter* in domestic and free living birds in North-Western Italy. *Schweiz Arch Tierheilkd.* 152:425–431.
180. Sadasivan, P.R., V.A. Srinivasan, A.T. Venugopalan, and R.A. Balaprakasam. 1977. Aeruginocine typing and antibiotic sensitivity of *Pseudomonas aeruginosa* of poultry origin. *Avian Dis.* 21:136–138.
181. Safwat, E.E.A., M.H. Awaad, A.M. Ammer, and A.A. El Kinawy. 1986. Studies on *Pseudomonas aeruginosa*, *Proteus vulgaris* and *S. typhi-murium* infection in ducklings. *Egyptian J An Prod.* 24:287–294.
182. Sah, R.L., M.P. Mall, and G.C. Mohanty. 1983. Septicemic *Proteus* infection in Japanese quail chicks (*Coturnix coturnix japonica*). *Avian Dis.* 27:296–300.
183. Salmon, S.A., and J.L. Watts. 2000. Minimum inhibitory concentration determinations for various antimicrobial agents against 1570 bacterial isolates from turkey poults. *Avian Dis.* 44:85–98.
184. Sarakbi, T. 1989. *Klebsiella*—a killer in the hatchery. *Int Hatchery Pract.* 3:19, 21.
185. Schlater, L.K., B.O. Blackburn, R. Harrington, Jr., D.J. Draper, J.V. Wagner, B.R. Davis, and J. Van Wagner. 1981. A non-O1 *Vibrio cholerae* isolated from a goose. *Avian Dis.* 25:199–201.
186. Scott, J.D., J.F. Anderson, and L.A. Durden. 2012. Widespread dispersal of *Borrelia burgdorferi*-infected ticks collected from songbirds across Canada. *J Parasitol.* 98:49–59.
187. Scott, M.C., M.E. Rosen, S.A. Hamer, E. Baker, H. Edwards, C. Crowder, J.I. Tsao, and G.J. Hickling. 2010. High-prevalence *Borrelia miyamotoi* infection among wild turkeys (*Meleagris gallopavo*) in Tennessee. *J Med Entomol.* 47:1238–1242.
188. Sell, J.L., D.L. Reynolds, and M. Jeffrey. 1992. Evidence that bacteria are not causative agents of stunting syndrome in poults. *Poult Sci.* 71:1480–1485.
189. Senior, V.E., R. Lake, and C. Pratt. 1962. Suspected actinomycosis of turkeys. *Can Vet J.* 3:120–125.
190. Seymour, C., R.G. Lewis, M. Kim, D.F. Gagnon, J.G. Fox, F.E. Dewhirst, and B.J. Paster. 1994. Isolation of *Helicobacter* strains from wild bird and swine feces. *Appl Environ Microbiol.* 60:1025–1028.
191. Shah, A.H., M.N. Khan, Z. Iqbal, M.S. Sajid, and M.S. Akhtar. 2006. Some epidemiological aspects and vector role of tick infestation on layers in the Faisalabad district (Pakistan). *World's Poult Sci J.* 62:145–157.
192. Shane, S.M., and D.H. Gifford. 1985. Prevalence and pathogenicity of *Aeromonas hydrophila*. *Avian Dis.* 29:681–689.
193. Sharma, J.K., D.V. Joshi, and K.K. Baxi. 1980. Studies on the bacteriological etiology of reproductive disorders of poultry. *Indian J Poult Sci.* 15:78–82.
194. Shivaprasad, H.L., M.B. Cadenas, S.S. Diab, R. Nordhausen, D. Bradway, R. Crespo, and E.B. Breitschwerdt. 2008. *Coxiella*-like infection in psittacines and a toucan. *Avian Dis.* 52: 426–432.
195. Silva, M.C.A., D.B. Melo, W.L.R. Costa, L.M.B. Fernandes, M.H. Pinna, and J. Vieira Neto. 2011. Macroscopic and microscopic aspects of airsacculitis in slaughtered broilers in Brazil. In: *Animal hygiene and sustainable livestock production. Proceedings of the XVth International Congress of the International Society for Animal Hygiene*, Vienna, Austria, 3-7 July 2011, Volume 2, J. Kofer, and H. Schobesberger, eds. Tribun EU, Brno; Czech Republic. 603–605.
196. Snel, J., P.P. Heinen, H.J. Blok, R.J. Carman, A.J. Duncan, P.C. Allen, and M.D. Collins. 1995. Comparison of 16S rRNA sequences of segmented filamentous bacteria isolated from mice, rats, and chickens and proposal of "*Candidatus Arthromitus*." *Int J Syst Bacteriol.* 45:780–782.
197. Stanley, J., D. Linton, A.P. Burnens, F.E. Dewhirst, S.L. On, A. Porter, R.J. Owen, and M. Costas. 1994. *Helicobacter pullorum* sp. nov.-genotype and phenotype of a new species isolated from poultry and from human patients with gastroenteritis. *Microbiol.* 140:3441–3449.
198. Steinbrueckner, B., G. Haerter, K. Pelz, A. Burnens, and M. Kist. 1998. Discrimination of *Helicobacter pullorum* and *Campylobacter lari* by analysis of whole cell fatty acid extracts. *FEMS Microbiol Lett.* 168:209–212.
199. Steinbrueckner, B., G. Haerter, K. Pelz, S. Weiner, J.A. Rump, W. Deissler, S. Bereswill, and M. Kist. 1997. Isolation of *Helicobacter pullorum* from patients with enteritis. *Scand J Infect Dis.* 29:315–318.
200. Stipkovits, L., Z. Varga, G. Czifra, and M. Dobos Kovacs. 1986. Occurrence of mycoplasmas in geese affected with inflammation of the cloaca and phallus. *Avian Pathol.* 15: 289–299.
201. Stipkovits, L., R. Glavits, E. Ivanics, and E. Szabo. 1993. Additional data on mycoplasma disease of goslings. *Avian Pathol.* 22:171–176.
202. Stipkovits, L., Z. Varga, J. Meszaros, G. Czifra, and M. Dobos Kovacs. 1986. Mycoplasma infection of geese associated with disorders of reproductive tract. *Israel J Vet Med.* 42:84–88.

203. Supartika, I.K., M.J. Toussaint, and E. Gruys. 2006. Avian hepatic granuloma. A review. *Vet Q.* 28:82–9.
204. Suzuki, T., A. Ikeda, T. Taniguchi, M. Nakazawa, and T. Sawada. 1997. Pathogenicity of an "*Actinobacillus salpingitidis*"/avian *Pasteurella haemolytica*-like organism for laying hens. *J Japan Vet Med Assoc.* 50:381–385.
205. Suzuki, T., A. Ikeda, J. Shimada, T. Sawada, and M. Nakazawa. 1997. Pathogenicity of an *Actinobacillus salpingitidis*/avian *Pasteurella haemolytica*-like isolate from layer hens that died suddenly. *J Japan Vet Med Assoc.* 50:85–88.
206. Szep, I., M. Pataky, and G. Nagy. 1973. [Infectious inflammation of cloaca and penis of geese. I. Epidemiology and control]. *Magyar Allatorvosok Lapja*. 28:539–542.
207. Tanaka, M., H. Takuma, N. Kokumai, E. Oishi, T. Obi, K. Hiramatsu, and Y. Shimizu. 1995. Turkey rhinotracheitis virus isolated from broiler chicken with swollen head syndrome in Japan. *J Vet Med Sci.* 57:939–941.
208. Tannock, G.W., J.R. Miller, and D.C. Savage. 1984. Host specificity of filamentous, segmented microorganisms adherent to the small bowel epithelium in mice and rats. *Appl Environ Microbiol.* 47:441–442.
209. Tantaswasdi, U., A. Malayaman, and K.F. Shortridge. 1986. Influenza A virus infection of a pheasant. *Vet Rec.* 119:375–376.
210. Tee, W., J. Montgomery, and M. Dyall-Smith. 2001. Bacteremia caused by a *Helicobacter pullorum*-like organism. *Clin Infect Dis.* 33:1789–1791.
211. Terzich, M., and S. Vanhooser. 1993. Postmortem findings of ostriches submitted to the Oklahoma Animal Disease Diagnostic Laboratory. *Avian Dis.* 37:1136–1141.
212. Thorel, M.F., M.C. Blom-Potar, and N. Rastogi. 1990. Characterization of *Mycobacterium paratuberculosis* and "wood-pigeon" mycobacteria by isoenzyme profile and selective staining of immunoprecipitates. *Res Microbiol.* 141:551–561.
213. Thorel, M.F., P. Pardon, K. Irgens, J. Marly, and P. Lechopier. 1984. Experimental paratuberculosis: pathogenicity of mycobactin-dependent mycobacteria strains to calves. *Ann Rech Vet.* 15:365–374.
214. Trenchi, H., M.T. Bellizzi, C.G.d. Souza, and C.G. De Souza. 1981. Contamination of Marek's disease vaccine with *Pseudomonas* (achromogenic variety). *Gaceta Vet.* 43:982–989.
215. Valente, C., V. Cuteri, R. Quondam Giandomenico, L. Gialletti, and M.P. Franciosini. 1997. Use of an experimental chick model for paratuberculosis enteritis (Johne's disease). *Vet Res.* 28:239–246.
216. Van der Schaaf, A., J.L. Hopmans, and J. Van Beek. 1976. Mycobacterial intestinal disease in woodpigeons (*Columba palumbus*). *Tijdschr Diergeneeskd.* 101:1084–1092.
217. Van Kruiningen, H.J., B. Ruiz, and L. Gumprecht. 1991. Experimental disease in young chickens induced by a *Mycobacterium paratuberculosis* isolate from a patient with Crohn's disease. *Can J Vet Res.* 55:199–202.
218. Vancanneyt, M., P. Segers, L. Hauben, J. Hommez, L.A. Devriese, B. Hoste, P. Vandamme, and K. Kersters. 1994. *Flavobacterium meningosepticum*, a pathogen in birds. *J Clin Microbiol.* 32:2398–2403.
219. Vandamme, P., M. Vancanneyt, P. Segers, M. Ryll, B. Kohler, W. Ludwig, and K.H. Hinz. 1999. *Coenonia anatina* gen. nov., sp. nov., a novel bacterium associated with respiratory disease in ducks and geese. *Int J Syst Bacteriol*. 49:867–874.
220. Vandamme, P., P. Segers, M. Ryll, J. Hommez, M. Vancanneyt, R. Coopman, R. De Baere, Y. Van de Peer, K. Kersters, R. De Wachter, and K.H. Hinz. 1998. *Pelistega europaea* gen. nov., sp. nov., a bacterium associated with respiratory disease in pigeons: taxonomic structure and phylogenetic allocation. *Int J Syst Bacteriol*. 48:431–440.
221. Vapniarsky, N., B.C. Barr, and B. Murphy. 2011. Systemic *Coxiella*-like infection with myocarditis and hepatitis in an Eclectus parrot (*Eclectus roratus*). *Vet Pathol.* 49(4):717–22.
222. Venkanagouda, G. Krishnappa, and A.S. Upadhye. 1996. Bacterial etiology of early chick mortality. *Indian Vet J.* 73:253–256.
223. Verma, R.K., A.R. Muley, and K.N.P. Rao. 1991. Some observations on the strainic variation of *Borrelia anserina*. *Indian Vet J.* 68:818–821.
224. Versalovic, J., K.C. Carroll, G. Funke, J.H. Jorgensen, M.L. Landry, and D.W. Warnock, (eds.) 2011. *Manual of Clinical Microbiology*, 10th ed. ASM Press, Washington, DC. 2314.
225. Vijayakrishna, S., T.V. Reddy, K. Varalakshmi, and K.V. Subramanyam. 2000. Listeriosis in broiler chicken. *Indian Vet J.* 77:285–286.
226. Waldenstrom, J., S.L. On, R. Ottvall, D. Hasselquist, C.S. Harrington, and B. Olsen. 2003. Avian reservoirs and zoonotic potential of the emerging human pathogen *Helicobacter canadensis*. *Appl Environ Microbiol.* 69:7523–7526.
227. Walker, S.E., J.E. Sander, I.H. Cheng, and R.E. Wooley. 2002. The *in vitro* efficacy of a quaternary ammonia disinfectant and/or ethylenediaminetetraacetic acid-tris against commercial broiler hatchery isolates of *Pseudomonas aeruginosa*. *Avian Dis.* 46:826–830.
228. Walker, S.E., J.E. Sander, J.L. Cline, and J.S. Helton. 2002. Characterization of *Pseudomonas aeruginosa* isolates associated with mortality in broiler chicks. *Avian Dis.* 46:1045–1050.
229. Watts, J.L., S.A. Salmon, R.J. Yancey, Jr., B. Nersessian, and Z.V. Kounev. 1993. Minimum inhibitory concentrations of bacteria isolated from septicemia and airsacculitis in ducks. *J Vet Diag Invest.* 5:625–628.
230. Welsh, R.D., R.W. Nieman, S.L. Vanhooser, and L.B. Dye. 1997. Bacterial infections in ratites. *Vet Med.* 92:992–998.
231. Wibbelt, G., and J.S. McKay. 2001. *Oerskovia* spp. infection in a pigeon—case report and review. *Eur J Vet Pathol*. 7:79–82.
232. Williams, B.J., and H.L. Newkirk. 1966. *Pseudomonas* infection of one-day-old chicks resulting from contaminated antibiotic solutions. *Avian Dis.* 10:353–356.
233. Williams, S.M., S. Hafner, and Y. Sundram. 2007. Liver granulomas due to *Eubacterium tortuosum* in a seven-week-old Bobwhite quail. *Avian Dis.* 51:797–799.
234. Willinghan, E.M., J.E. Sander, S.G. Thayer, and J.L. Wilson. 1996. Investigation of bacterial resistance to hatchery disinfectants. *Avian Dis.* 40:510–515.
235. Woc-Colburn, A.M., M.M. Garner, D. Bradway, G. West, J. D'Agostino, J. Trupkiewicz, B. Barr, S.E. Anderson, F.R. Rurangirwa, and R.W. Nordhausen. 2008. Fatal coxiellosis in Swainson's Blue Mountain Rainbow Lorikeets (*Trichoglossus haematodus moluccanus*). *Vet Pathol.* 45:247–254.
236. Yamauchi, K.E., and J. Snel. 2000. Transmission electron microscopic demonstration of phagocytosis and intracellular processing of segmented filamentous bacteria by intestinal epithelial cells of the chick ileum. *Infect Immun.* 68:6496–6504.
237. Ye, S., S. Xu, Y. Huang, L. Zhang, Z. Wong, W. Jiang, S.Z. Ye, S.L. Xu, Y.J. Huang, L.M. Zhang, Z.J. Wong, and W.M. Jiang.

1995. Investigation of *Proteus* infections in chickens. *Chinese J Vet Sci Tech.* 25:14–15.

238. Zanoni, R.G., S. Piva, M. Rossi, F. Pasquali, A. Lucchi, A. De Cesare, and G. Manfreda. 2011. Occurrence of *Helicobacter pullorum* in turkeys. *Vet Microbiol.* 149:492–496.
239. Zepeda, V.A., N.L. Calderon-Apodaca, M.L. Paasch, P.G. Martin, D.A. Paredes, S. Ramirez-Apolinar, and E. Soriano-Vargas. 2010. Histopathologic findings in chickens experimentally infected with *Gallibacterium anatis* by nasal instillation. *Avian Dis.* 54:1306–1309.
240. Zhang, Q. 2008. Campylobacteriosis. In: *Diseases of Poultry*, 12th ed. Y.M. Saif, A.M. Fadly, J.R. Glisson, L.R. McDougald, L.K. Nolan, and D.E. Swayne, eds. Blackwell Publishing, Ames, IA. 675–689.

Chapter 24

Avian Chlamydiosis

Daisy Vanrompay

Introduction

Definition and Synonyms

Avian chlamydiosis is caused by the bacterium *Chlamydia psittaci*. Avian chlamydiosis is a respiratory disease, usually systemic and occasionally fatal. Today, *C. psittaci* has been demonstrated in about 465 bird species spanning 30 bird orders (61). This chapter primarily covers avian chlamydiosis as it occurs in birds raised commercially for meat and egg production. It should be noted that the disease in pet birds is quite similar, and the disease characteristics, transmission, and diagnosis are essentially the same. An update of the disease and control procedures for chlamydiosis in companion birds was published (104) and is on the American Veterinary Medical Association (AVMA) and Centers for Disease Control and Prevention (CDC) Web sites.

Chlamydia psittaci can be transmitted to humans. The disease in birds and humans originally was called psittacosis or parrot fever (80) because it was first recognized in psittacine birds and in humans associated with psittacine birds. Ornithosis was a term introduced in 1941 by Meyer (76, 77) to differentiate the disease in or contracted from domestic and wild fowl from the disease in or contracted from psittacine birds. However, the two syndromes are actually the same (84). Today we speak of chlamydiosis in birds and psittacosis in humans.

Public Health Significance

Chlamydia psittaci can infect humans and precautions should be taken when handling infected birds or contaminated materials. Most infections are through inhalation of infectious aerosols; thus, poultry processing plant employees are especially at risk, as are farm workers, veterinarians, poultry inspectors, and taxidermists (26, 27, 28, 35, 42, 64, 120, 138).

In humans, the incubation period is usually 5–14 days; however, longer periods are known (104). Infections vary from inapparent infections to severe systemic disease with pneumonia (14). Secondary spread among humans rarely occurs. Because the disease is rarely fatal in properly treated patients, awareness of the danger and early diagnosis are important.

History

The first description of a psittacosis outbreak dates from 1879 and was described by Jacob Ritter, linking the disease to pet parrots and finches (94). Historical aspects of chlamydia-related diseases in animals and humans are reviewed by Andersen and Vanrompay (1) and more recently by Pospischil (92).

Etiology

Classification

The members of the family *Chlamydiaceae*, order *Chlamydiales* are obligate, intracellular Gram-negative bacteria. In 1999, Everett et al. (33) proposed a reassignment from the single genus *Chlamydia* into 2 genera, *Chlamydia* and *Chlamydophila*, based on clustering analyses of the 16S rRNA and 23S rRNA genes (Table 24.1). However, recent comparative genome analyses are consistent with the conclusion that host-divergent strains of chlamydia are biologically and ecologically closely related. The previous taxonomic separation of the genus based on ribosomal sequences is neither consistent with the natural history of the organism revealed by genome comparisons, nor widely used by the chlamydia research community 11 years after its introduction. Consequently, it was proposed to reunite the *Chlamydiaceae* into a single genus, *Chlamydia* (63) (Table 24.1). Accordingly, the chlamydia nomenclature is used in this chapter.

Morphology and Staining

The 3 morphologically distinct forms of *Chlamydia* are termed elementary body (EB), reticulate body (RB), and intermediate body (IB). The EB (Figure 24.1) is a small, electron-dense, spherical body, about 0.2–0.3 mm in diameter. The EB is the infectious form of the organism, which attaches to the target epithelial cell and gains entry. The EBs have a highly electron-dense nucleoid located at the periphery of the EB and clearly separated from an electron-dense cytoplasm. Following entry into the host cell, the EB expands in size to form the RB, which is the intracellular, metabolically active form. The RB measures approximately 0.5–2.0 mm in diameter (Figure 24.2). The

Diseases of Poultry, Thirteenth Edition. David E. Swayne.
© 2013 John Wiley & Sons, Inc. Published 2013 by John Wiley & Sons, Inc.

Table 24.1. Chlamydiaceae taxonomy.

	Chlamydial taxonomy in the late 1990s		**Chlamydial taxonomy used in the 21st century (Everett et al., 1999) (33)**				**Chlamydial taxonomy used in the 21st century (Stephens et al., 2009) (106)**	
Order	*Chlamydiales*		*Chlamydiales*				*Chlamydiales*	
Family	*Chlamydiaceae*		*Chlamydiaceae*, *Simkaniaceae, Parachlamydiaceae*, *Waddliaceae*				*Chlamydiaceae*, *Simkaniaceae, Parachlamydiaceae, Waddliaceae*	
Genus	*Chlamydia*		*Chlamydia*		*Chlamydophila*		*Chlamydia*	
Species	*C. trachomatis*	Trachoma biovar LGV biovar Murine biovar Porcine biovar	*C. trachomatis* *C. muridarum* ***C. suis***	Trachoma biovar LGV biovar			*C. trachomatis* *C. muridarum* ***C. suis***	Trachoma biovar LGV biovar
	C. pneumoniae	Human biovar Koala biovar Equine biovar			***C. pneumoniae***	TWAR biovar Koala biovar Equine biovar	***C. pneumoniae***	TWAR biovar Koala biovar Equine biovar
	C. psittaci	Avian subtype Abortion subtype Feline subtype Guinea-pig subtype			***C. psittaci*** ***C. abortus*** *C. felis* *C. caviae*		***C. psittaci*** ***C. abortus*** *C. felis* *C. caviae*	
	C. pecorum				***C. pecorum***		***C. pecorum***	

(Adapted from Schautteet and Vanrompay, 201)

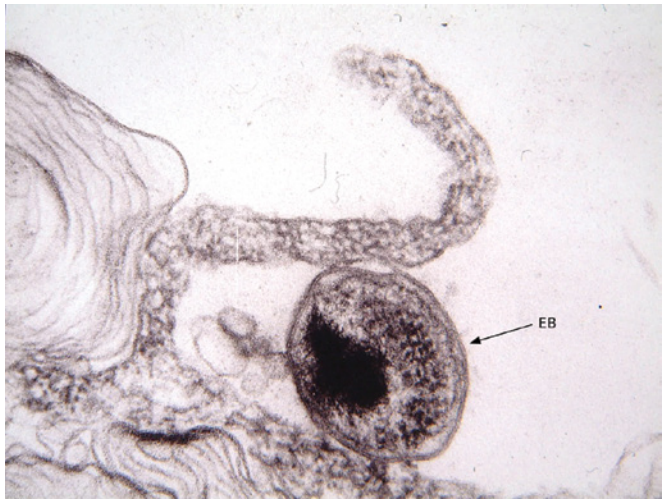

Figure 24.1. Buffalo green monkey (BGM) cell culture, 1 hour after inoculation with the *C. psittaci* Texas Turkey genotype D strain showing an elementary body (EB) attached to the side of a host cell microvillus.

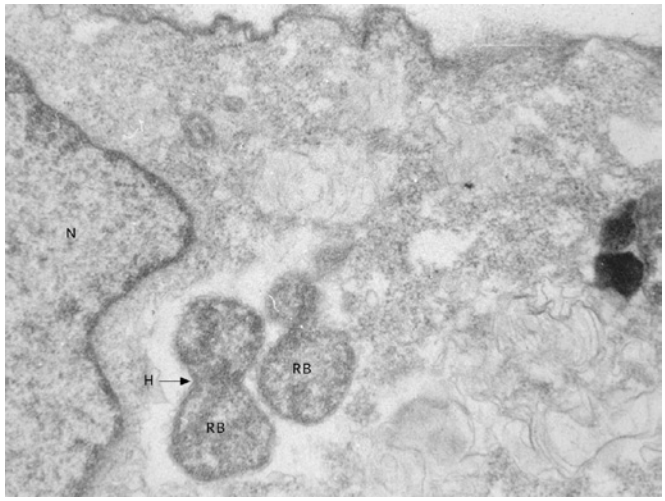

Figure 24.2. Buffalo green monkey (BGM) cell culture, 18 hours after inoculation with a *C. psittaci* genotype B strain (89/1326). Note the vacuole near the nucleus (N) with an early and late stage of division of a reticulate body (R). Note the "hour-glass" profile (arrow H).

RB divides by binary fission and thereafter matures into new EBs. During this maturation, morphologically intermediate forms (IB), measuring about 0.3–1.0 mm in diameter, can be observed. The IB has a central electron-dense core with radially arranged individual nucleoid fibers surrounding the core. Cytoplasmic granules are tightly packed at the periphery of the IB and are separated from the core by a translucent zone.

The Gram stain is of no practical value in identifying chlamydiae because the presence of peptidoglycan in the chlamydial cell envelope has yet to be established, although the genes encoding the enzymes for peptidoglycan biosynthesis are present (108). Chlamydiae are large enough to be seen with a light microscope using special optics or selective stains. Chlamydiae can be observed in swab smears or touch impressions of infected tissues by staining them with Castaneda, Giemsa, Giménez (40), modified Giménez, Machiavello, or Stamp methods (2). Chlamydiae appear dark purple with Giemsa; blue with Castaneda; and red with Machiavello, Giménez, modified Giménez, and Stamp stains against contrasting backgrounds. The modified Giménez method (136) is most often used.

Biochemical Properties

The RB is the intracellular, metabolically active form. Although DNA and RNA are both found in the EB and the RB, the ratio of RNA to DNA is greater in the RB. The RBs synthesize their own DNA, RNA, and protein, but some of their metabolic capabilities are limited when compared with free-living, colonizing bacteria. For example, they cannot complete the pentose cycle and do not use pyruvate by way of the tricarboxylic acid cycle. They can, however, catabolize pyruvic, aspartic, and glutamic acids, generating CO_2 and 2- and 4-carbon residues.

Susceptibility to Chemical and Physical Agents

The survival of microorganisms in aerosols depends on 5 different factors: relative humidity (RH), temperature, level of oxygen, presence of UV radiation, and constituents of the aerosol and of air (116). The degree to which these factors influence the survival of microorganisms in aerosols depends strongly on the type of microorganism and the time it has to spend in the aerosol. In general, the following rule applies: Gram-negative bacteria survive the best at low temperatures and RH. Thus, *C. psittaci* remains viable at low temperatures and is resistant to desiccation. The bacterium is highly susceptible to repeated freeze-thawing cycles and is destroyed within 3 minutes when exposed to UV-light.

Chlamydiae are highly susceptible to chemicals that affect their lipid content or the integrity of their cell walls. Even in a milieu of tissue debris they are inactivated rapidly by surface-active compounds, such as quaternary ammonium compounds and lipid solvents (104). Infectivity is destroyed within minutes by exposure to common disinfectants such as benzalkonium chloride, alcoholic iodine solution, 70% ethanol, 3% hydrogen peroxide, and silver nitrate, but they are resistant to cresol compounds and lime. Dilute suspensions (20%) of infectious tissue homogenates are inactivated by incubation for 5 minutes at 56ºC, 48 hours at 37ºC, 12 days at 22ºC, and 50 days at 4ºC (88).

Antigenic Structure and Toxins

The cysteine-rich major outer membrane protein (MOMP) is well studied. It has a molecular weight of 40 kDa and represents approximately 60% of the weight of the outer membrane. The MOMP of *C. psittaci* is an immunodominant protein, and there is considerable evidence that antibodies to surface-accessible epitopes of MOMP have a protective role in immunity to chlamydial infection (23). The outer membrane

protein A (*ompA*) gene (formerly referred to as *omp1* gene) encodes the MOMP. The *ompA* gene contains 5 conserved- and four variable-sequence regions, VS1–VS4, which encode for the variable-protein domains VDI–VDIV. VDI, VDII, and VDIV especially protrude from the *C. psittaci* membrane. Epitope mapping has shown the presence of genus- and species-specific antigenic determinants within the conserved regions. However, species-specific antigenic determinants also have been found in the most conserved parts of VDIV. Serovar-specific antigenic determinants are located within VDI and VDII. Monoclonal antibodies to the highly immunoaccessible serovar-specific epitopes on the MOMP can passively neutralize chlamydial pathogenicity and infectivity. Monoclonal antibodies to genus-, species-, or serovar-specific epitopes on the MOMP are excellent tools for specific chlamydial diagnosis.

A chlamydial cysteine-rich heat shock protein 60 (hsp60 or GroEL) has been described that is cross-reactive with other Gram-negative bacteria such as *Escherichia coli*, *Neisseria gonorrhoeae*, and *Coxiella burnetii* (144). Thus, the presence of cross-reactive epitopes on the chlamydial outer membrane should be kept in mind when choosing or interpreting a specific diagnostic test.

Other chlamydia proteins under study are OmcA (EnvA or Omp3), OmcB (EnvB or Omp2), Hc1, RpoB', RpoB, polymorphic outer membrane proteins (pmps), PorB (OmpB), Omp85, elongation factor Tu (EF-Tu/TufA), DnaK (hsp70), and OprB (19, 62, 79, 81, 107, 114).

The chlamydial lipopolysaccharide (LPS) also is an essential constituent of the outer membrane and, like the MOMP, represents one of the major surface-exposed antigens of chlamydiae in both the EB and the RB. It has a molecular weight of 10 kDa and is chemically and serologically related to the LPS of Gram-negative *Enterobacteriaceae*. In fact, the chlamydial LPS contains several antigenic determinants cross-reacting with the LPS of enterobacterial Re mutants of *Salmonella* species and *Acinetobacter calcoaceticus* (20, 83). However, the chlamydial LPS contains in its saccharide moiety a trisaccharide of 3-deoxy-D-manno-2-octulosonic acid (Kdo) of the sequence αKdo(2→8)-αKdo-(2→4)-αKdo. This antigenic epitope is shared only by all members of the genus *Chlamydia* and, thus, represents a *Chlamydiaceae*-specific antigen useful for specific diagnosis (21).

A putative chlamydial cytotoxin has been described (16, 22) in all chlamydia genomes studied so far (103, 106), including the *C. psittaci* 6BC and Cal10 strains (48). So far, extensive comparisons among *C. psittaci* clinical isolates have not been made, nor has the actual function of the *C. psittaci* putative cytotoxin or its cellular localization been established with certainty.

Strain Classification

Antigenicity

All *Chlamydiaceae* are recognized by monoclonal antibodies (MAbs) that detect the LPS αKdo(2→8)-αKdo-(2→4)-αKdo. *Chlamydia* species have a common antigenic epitope in variable segment 4 of the MOMP: NPTI, TLNPTI, LNPTIA, or LNPTI. *C. psittaci* strains are recognized by serovar-specific monoclonal antibodies. The 8 known *C. psittaci* serovars (A–F, M56, and WC) can be distinguished by use of a panel of serovar-specific monoclonal antibodies in a micro-immunofluorescence test (3, 6, 134). However, serotyping is currently rarely performed because the serovar-specific MAbs are not provided by a commercial supplier and because serotyping appears less discriminatory compared to the newly developed molecular characterization methods (66, 89, 125).

Genetic, Molecular

Chlamydia species are mostly distinguished by analysis of: (1) full-length 16S and 23S rDNAs, (2) the 16S-23S intergenic spacer (*rrn* spacer), (3) signature sequences in the 16S and 23S ribosomal genes (33, 34), (4) the *Chlamydiaceae* RNase P RNA gene (*rnpB*) encoding a ribonucleoprotein complex that removes 5' leader sequences from tRNA precursors during tRNA biosynthesis (54), or (5) the outer membrane protein A (*ompA*) gene encoding the *Chlamydia* major outer membrane protein (MOMP). Polymerase chain reaction (PCR)-restriction fragment length polymorphism (RFLP), nested (multiplex) PCR, TaqMan-based real-time PCR, micro arrays, PCR followed by high resolution melt (HRM) curve analysis of the amplified 16S rRNA gene, as well as gene sequencing has been described for identifying *Chlamydia* species in livestock (34, 36, 74, 96, 99).

Genotyping of *C. psittaci* by *AluI* (RFLP analysis of the *ompA* gene) was introduced in 1995 as a more sensitive, more reliable subtyping method compared to *C. psittaci* serotyping (102). RFLP analysis of the *ompA* gene of all known *C. psittaci* serovars revealed corresponding restriction patterns or genotypes (5, 127). More recently, *ompA* genotyping by real-time PCR using genotype-specific probes has been described, allowing the detection of an additional variant described as the avian *C. psittaci* genotype E/B (36, 37). A few years ago, a genotyping micro array was introduced, allowing the identification of all currently known avian and mammalian *C. psittaci* genotypes (98). Genotyping is very convenient because it is a rapid, powerful technique that can be used directly on clinical samples in any veterinary clinical laboratory.

Some avian *ompA* genotypes appear to occur more often in a specific order of birds. Genotype A, for instance, is endemic among psittacine birds (*Psittacidae*) but it also has been found in turkeys, ducks, pigeons, and *Passeriformes*. Genotype B is endemic in pigeons (*Columbiformes*) but also can infect chickens, turkeys, ducks, *Psittacidae*, and *Passeriformes* (6). Waterfowl (*Anseriformes*), such as ducks and geese, most frequently seem to be infected with genotype C. Genotype C also has been detected in chickens and pigeons (29, 145). Genotype D strains are most often associated with turkeys, but they can also infect pigeons. More recently, genotype D has been detected in chickens (28). Genotype E, also known as Cal-10, MP, or MN, was first isolated during an outbreak of pneumonia in humans during the early 1930s. Later on, genotype E isolates were obtained from a variety of bird species including turkeys, pigeons, ducks, ostriches, and rheas. Genotype F is

represented by the psittacine isolates VS225, Prk Daruma, 84/2334 (125), and 10433-MA, but has also been isolated on a Belgian turkey farm (123). Genotype E/B is often found in ducks, but it has also been detected in parrots (52), turkeys (118), and pigeons (38). The mammalian M56 and WC genotypes were isolated during an outbreak in muskrats and hares and during an outbreak of enteritis in cattle, respectively. All genotypes should be considered to be readily transmissible to humans.

Occasional detections of *C. abortus* (68, 109) and so far nonclassified chlamydial agents (65), as well as genetic evidence on intermediate strains between *C. psittaci* and *C. abortus* (125), suggest that the spectrum of *Chlamydiaceae spp*. encountered in birds is not confined to a single species.

Recently, Pannekoek et al. (98) used multi-locus sequence typing (MLST) for studying the population structure of *C. psittaci* and *C. abortus* because Van Loock et al. (125) showed that *ompA* sequencing and even sequencing of the *rrn* spacer (33, 34) cannot always distinguish *C. psittaci* from *C. abortus*. The obtained MLST scheme was based on the partial sequences of 7 housekeeping genes, *enoA*, *fumC*, *gatA*, *gidA*, *hemN*, *hflX* and *oppA*, representative for the whole genome sequence. MLST of *C. psittaci* strains resulted in 11 unique sequence types (STs). MLST was extremely useful for distinguishing the phylogenetic highly related species *C. psittaci* and *C. abortus*. Interestingly, according to MLST, the *ompA* genotype F strain 84/2334 appears to be a *C. abortus* strain instead of a *C. psittaci* strain (89).

According to Wang et al. (140), high-resolution genotyping within 1 chlamydia species can be achieved by multi-locus variable-number tandem-repeat (VNTR) analysis (MLVA) in combination with *ompA* sequencing (MLVA-*ompA*). This method is highly accurate for distinguishing closely related strains within 1 *Chlamydia* species. VNTR analysis was used for exploring the diversity of *C. psittaci*. For *C. psittaci*, 20 selected genetic loci were initially tested on 9 avian reference strains including representatives of all major *ompA* genotypes (A to F and E/B). Thereafter, 8 loci were retained for a more complete study performed on more than 150 *C. psittaci* isolates from different bird species and geographical origins. The MLVA system provides an additional level of discrimination within the *C. psittaci* species, with 20 distinct patterns identified to date (66). MLVA could provide the high resolution needed for local epidemiology and accurate contact tracing in cases in which zoonosis is contracted from poultry. However, current MLVA (and MLST) methods are still easier to perform on culturable samples or clinical samples of *C. psittaci*-infected poultry with a high bacterial DNA load.

Pathogenicity

Chlamydia psittaci strains isolated from birds fall into 2 general categories: (1) Highly virulent strains that cause acute epidemics in which 5%–30% of affected birds die and (2) less virulent strains that cause slowly progressive epidemics. Strains of both high and low virulence appear to have equal ability to spread rapidly through a flock, as evidenced by serologic test results. Highly virulent strains are isolated most often from turkeys and occasionally from ducks, chickens, pigeons, and clinically normal wild birds.

The isolates serotyped from some of the earlier outbreaks with high mortality have been of serotype D (6, 135). More recently, highly virulent strains have been characterized in European turkeys, ducks, and chickens. A highly virulent Genotype D strain was isolated on a French chicken farm (Vanrompay et al., 2012, unpublished results) as well as a highly virulent, not yet characterized strain on another French chicken farm (65). Highly virulent strains cause rapidly fatal disease in natural and experimental hosts with lesions characterized by extensive vascular congestion and inflammation of vital organs. Highly virulent strains have a broad spectrum of pathogenicity for laboratory animals and can cause serious human infections (some fatal) in poultry handlers and laboratory research workers. Strains of low virulence cause slowly progressive epidemics with a mortality rate of less than 5% when uncomplicated by secondary bacterial or parasitic infection. Strains of this category are routinely isolated from pigeons and ducks and occasionally from turkeys, sparrows, and other wild birds. The turkey isolates from outbreaks with low mortality have been of genotype B or E. Birds infected with these strains usually do not develop the severe vascular damage typical in birds infected with the virulent strains, nor do they have the severe clinical signs (115).

Virulence Factors

The initial event in the infectious process begins with attachment of *C. psittaci* EBs to microvilli at the apical surface of a susceptible columnar epithelial cell (58) (Figure 24.1). The EB travels down the microvillus and locates in indentions of the eukaryotic plasma membrane, some of which resemble coated pits. The bases of micropilli represent areas of active transport of extracellular materials into the cells and, therefore, might assist rapid and efficient entry of EBs. After 1–3 hours, the EBs are internalized in invaginations of the plasma membrane. Uptake of *C. psittaci* is an endocytic mechanism, involving microfilament-dependent and/or independent processes. The *C. psittaci* containing endocytic vesicles or vacuoles escape interaction with lysosomes and proceed in about 8–12 hours to the nuclear area, where EBs are converted to RBs. Conversion to RBs primarily involves reduction of disulfide bond cross-linking among the outer membrane proteins altering the EB cell wall. Synthesis of DNA, RNA, and proteins is initiated, permitting growth and binary fission of the RBs. Binary fission is characterized by the appearance of typical "hourglass" profiles inside the vacuole (Figure 24.2). The enlarging vacuole also is termed an "inclusion."

C. psittaci microorganisms do not always remain within the inclusion throughout their intracellular development. In some cases and in apparent correlation with high virulence of strains, the inclusion membrane seems to degrade during the active multiplication, liberating the bacteria into the cytoplasm of the host cell (128). About 30 hours after internalization of the EB, the first RBs are reorganized into newly

formed EBs. At about 48–50 hours, the developing chlamydial inclusion may contain anywhere from 100–500 progeny, depending on the characteristics of the *C. psittaci* strain (Figure 24.3). With most *C. psittaci* strains, the host cell has undergone severe degenerative changes, and microorganisms are released by lysis (Figure 24.4). Exocytosis of the inclusion, followed by a "healing" or closing of the open-cavern structures where the inclusion had existed, has been reported (128). Persistent infections may occur with aberrant nonreplicating RBs remaining inside the host cell cytoplasm.

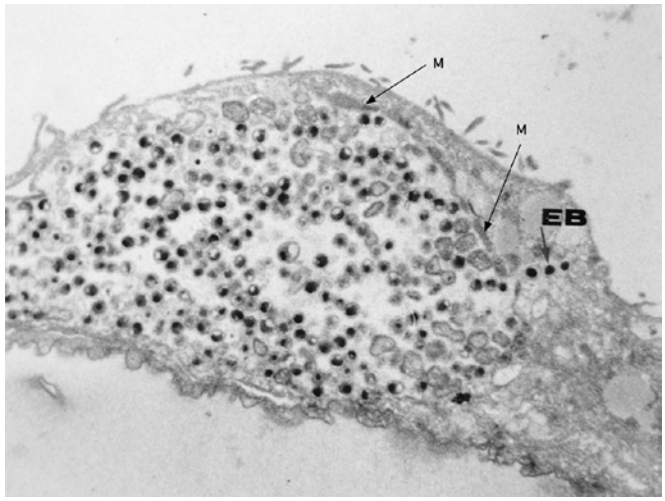

Figure 24.3. BGM cell culture, 52 hours after inoculation with a *C. psittaci* genotype D strain (92/1293), isolated from diseased turkeys. Note the large inclusion and the elementary bodies (EB) apparently "escaping" from the inclusion. Also notice the mitochondria (M) lining the inclusion.

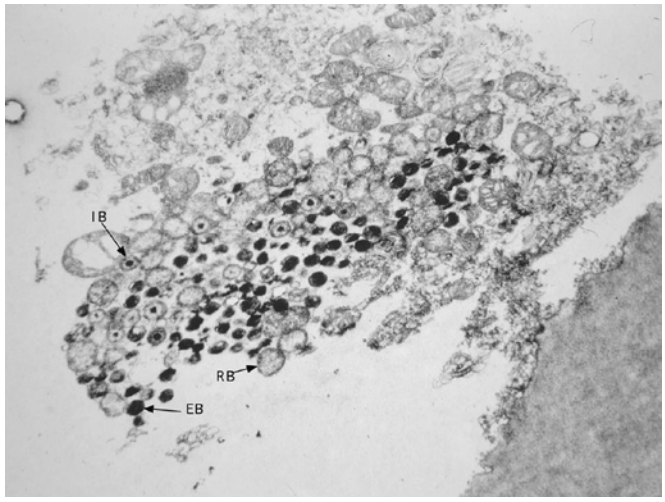

Figure 24.4. BGM microcarrier culture, 50 hours post inoculation with the *C. psittaci* Texas Turkey genotype D strain showing lysis of an infected BGM cell. The cell is sloughing off the microcarrier (MC). Note the presence of elementary bodies (E), reticulate bodies (R), and intermediate bodies (I).

Long, unique, rosette-like structures and projections have been observed on the surface of both EBs and RBs of *C. psittaci* strain Mn (73). Shortly after the first description of a type III secretion system (T3SS) in *C. caviae* (GPIC strain) (59), Bavoil and Hsia speculated that Matsumoto's projections are in fact functional T3SSs, injecting chlamydial virulence proteins into the host cell cytoplasm (10). A detailed description of the *C. psittaci* T3SS and the role of the chlamydial T3SS in virulence can be found in recent papers (13, 15, 18, 91).

Outer virulence factors under study are the polymorphic membrane proteins (pmps) (114). The pmps belong to the family of autotransporters. Although specific roles in pathogenesis have been described for some pmps, including adhesion, their role in the growth and development of *Chlamydiaceae* is still unclear (78, 113).

Chlamydiaceae also can engage in a long-term relationship with the host cell, a phenomenon known as persistence, in which no visible growth of the chlamydial organisms can be observed. The normal developmental cycle can be interrupted by a number of conditions and agents, such as antibiotics, nutrient deprivation, or immune factors, interferon-gamma (IFN-γ) in particular (41). This is generally accompanied by the development of relatively small inclusions, enlarged pleiotrophic aberrant RBs, and inhomogeneity of the inclusions. Aberrant RBs accumulate chromosomes, but genes for cell division are no longer expressed. Once the stress-inducing factor is removed, aberrant RBs revert to normal RBs, complete the developmental cycle, and generate infectious EBs.

Pathobiology and Epidemiology

Incidence and Distribution

Avian chlamydiosis occurs worldwide, with the incidence and distribution varying greatly with the species of bird and the genotype of the chlamydial organism. The economic losses in poultry and the human infections usually follow a sporadic pattern. Antibiotics have been used extensively to control the spread of the disease in birds and to reduce the risk to humans.

The disease pattern in turkeys has changed. Historically, most outbreaks were explosive and occurred in free-ranging birds (45, 51). These severe respiratory disease outbreaks were attributed to genotype D. Chlamydia was thought to have been introduced from the outside. Today, genotype D and sometimes genotype A are found in confinement turkeys when death losses are high; genotype B is less virulent (6, 97). Introduction through vertical transmission (70, 141) or through infected hatchlings (27) may occur. Recent studies on turkeys in Belgium and France showed that strains (genotypes A, B, D, E, E/B, and F) of high and low virulence are widely distributed in commercial turkeys and may be endemic. Chlamydia is part of the turkey respiratory disease complex (123). Infection of turkeys with *C. psittaci* also seems to predispose animals to more severe clinical outcomes of a simultaneous or subsequent infection with *Escherichia coli*, APV, and/or ORT (121–123).

Information on the incidence and epidemiology of chlamydia in domestic ducks is more limited. In the United States, it has not been a significant problem although infections occur. *Chlamydia psittaci* infections in ducks seem to occur more often in Australia, China, and Europe (9, 24, 49, 57, 69, 143). In Europe, the number of outbreaks in ducks seems to be increasing (64). Former European isolates have been characterized as genotype C (134). More recently, outbreaks in French ducks were associated with human disease. Human samples and duck isolates exhibited the same PCR-RFLP restriction pattern, which appeared to be intermediate between genotypes A and B. Analysis of *ompA* gene sequences and comparison to those of the type strains showed that the isolates could not be strictly assigned to any of the generally accepted *C. psittaci* genotypes. Further analysis by MLVA of the PCR-positive human samples revealed 2 distinct patterns, which were related to previously isolated *C. psittaci* duck strains (64).

Reports on *C. psittaci* outbreaks on chicken farms or of zoonotic transmissions linked to contact with *C. psittaci*-infected chickens are extremely rare. It could be that chickens rarely become infected and/or that the strains infecting chickens are less virulent, presenting a minor risk for humans. Recently, the author investigated the occurrence of *C. psittaci* by performing a retrospective study with 300 serum samples collected in 2005 from 10 randomly selected chicken breeder, broiler, and layer farms in Belgium. Sera were examined using a recombinant MOMP-based enzyme-linked immunosorbent assay (ELISA) (139). We obtained 98%, 95%, and 95% seropositive results for layers, broilers, and breeders, respectively (28), and seropositive birds were found on all farms. Therefore, the statement that *C. psittaci* infections occur less frequently in chickens is not true. Recently, highly virulent genotype D strains (Vanrompay et al., 2012, unpublished results), as well as less virulent genotypes B, C, and E/B strain have been found in chickens in Belgium, China, France, and Germany (35, 65, 146; Vanrompay et al., 2012, unpublished results).

In 2008, 3 cases of atypical pneumonia in individuals working at a French slaughterhouse processing guinea fowl, ducks, and especially chickens prompted an epidemiologic survey of the 10 farms that had supplied the birds. Using a *Chlamydiaceae*-specific real-time PCR assay, chlamydial agents were detected in 14 of the 25 investigated flocks. In 1 duck flock studied, 20% of the tested animals were positive. Additionally, 12 of 18 (67%) and 1 of 6 (17%) of the chicken and guinea fowl flocks examined were PCR positive, respectively. Positivity for the chicken flocks ranged from 10%–100%. For the positive guinea fowl flock, 12.5% of the tested animals were positive. Rather unexpectedly, *Chlamydia psittaci* was identified only in the positive duck flock, whereas ArrayTube DNA microarray testing indicated the presence of a new chlamydia agent in of all the other French poultry flocks that were examined. Further studies are needed to define the exact taxonomic status of the agent found in chickens and guinea fowl (65).

Strains occurring naturally in birds are distinct from those in mammals (5, 6, 86). Attempts to infect birds with mammalian strains usually resulted in aborted or asymptomatic infections (60, 115).

Natural and Experimental Hosts

Chlamydiae or chlamydial antibodies have been found in at least 465 bird species (61). Common reservoirs of chlamydiae include wild and feral birds such as sea gulls, ducks, Canada geese, herons, egrets, pigeons, blackbirds, grackles, house sparrows, and killdeer, all of which freely intermingle with domestic birds. Highly virulent strains of *C. psittaci* can be carried by and excreted in large numbers without any apparent effect on these hosts.

Experimental hosts of avian chlamydiae can include virtually any species of bird. Mammalian laboratory hosts used for avian chlamydiae are principally mice and occasionally guinea pigs. Mice and guinea pigs are the natural hosts for *C. muridarum* and *C. caviae*, respectively. Investigators using these animals should determine the chlamydial status of the breeding stock. Rabbits are refractory to clinical disease caused by avian chlamydiae, but they may be used to produce polyclonal antibodies.

Younger domestic birds generally are more susceptible than older birds to infection, clinical disease, and mortality. However, maternal antibodies might protect against respiratory disease outbreaks on the farm. Infection in old turkeys, such as spent breeder hens, can go unnoticed unless birds are subjected to stressful conditions such as shipment to market on crowded trucks. Turkey toms may have a higher mortality rate than turkey hens (117).

Transmission, Carriers, and Vectors

Transmission of *C. psittaci* primarily occurs from one infected bird to another susceptible bird in close proximity. The agent is excreted in feces and nasal discharges. Fecal shedding occurs intermittently and can be activated through stress caused by nutritional deficiencies, prolonged transport, overcrowding, chilling, breeding, egg laying, treatment, or handling. Bacterial excretion periods during natural infection can vary depending on virulence of the strain, infection dose, and host immune status. However, shedding may occur for several months. Transmission of chlamydiae occurs mainly through inhalation of contaminated material and, sometimes, ingestion.

Large numbers of *C. psittaci* cells can be found in respiratory tract exudate and fecal material of infected birds. The importance of the respiratory exudate in transmission has become more apparent. In turkeys, the lateral nasal glands become infected early and remain infected for more than 60 days. Choanal/oropharyngeal swabs are more consistent for isolation of the agent than fecal swabs, especially during early stages of infection. Direct aerosol transmission through aerosolization of respiratory exudate must be considered as the primary method of transmission

Avian species, including domestic poultry sharing aquatic or moist soil habitats with wild infected aquatic birds, may become infected via contaminated water. Granivorous birds, like pigeons, doves, pheasants, and house sparrows, may

become infected by dust inhalation in barnyards and grain storage sites contaminated by feces. The consumption of infected carcasses may transmit *C. psittaci* to host species that are predators or scavengers of other birds.

Transmission of *C. psittaci* in the nest is possible. In many species, such as *Columbiformes*, cormorants, egrets, and herons, transmission from parent to young may occur through feeding by regurgitation, while contamination of the nesting site with infective exudates or feces may be important in other species, such as snow geese, gulls, and shorebirds. Furthermore, *C. psittaci* can be transmitted from bird to bird by blood-sucking ectoparasites such as lice, mites, and flies or, less commonly, through bites or wounds. Transmission of *C. psittaci* by arthropod vectors may be facilitated in the nest. Mites from turkey nests can contain chlamydiae (30), and during an epidemic in turkeys in South Carolina, simulid flies were suspected as a possible method of transfer (85).

Vertical transmission has been demonstrated in turkeys, chickens, ducks, parakeets, seagulls, and snow geese, although the frequency appears to be fairly low (70, 141). However, it could serve as a route to introduce chlamydiae into a poultry flock.

Chlamydia psittaci can be introduced into poultry through the wild bird population. Contaminated feed or equipment also can be a source of infection, and feed should therefore be protected from wild birds. Careful cleaning of equipment being used in several barns during one and the same production round is extremely important because *C. psittaci* can survive in feces and bedding for up to 30 days (52).

Incubation Period, Clinical Signs, Morbidity and Mortality, Pathology, and Pathogenesis

Turkeys

In 1959, Page, (87) was the first to examine the pathogenesis of a *C. psittaci* infection in commercial turkeys after inoculation by aerosol or by the oral route with a genotype D strain. In 1995, Vanrompay et al. (129) used immunodetection to study the pathogenesis of *C. psittaci* genotype A, B, and D strains in specific pathogen free turkeys kept in negative pressure isolation units. Use of immunodetection allowed precise determination of tissue and cell tropism. In this study, turkeys were aerosol infected, because this most likely represents the natural route of infection (87). From these studies, the following pathogenic sequence of events can be deduced for all 3 genotypes investigated. In turkeys infected by aerosol, the primary site of replication is the upper respiratory tract, where epithelial cells become infected. Subsequently, epithelial cells of the lower respiratory tract and macrophages throughout the respiratory tract become infected. Then, intense replication occurs in the respiratory tract. At the same time, chlamydiae can be demonstrated in plasma and monocytes, indicating septicemia, and chlamydiae appear in epithelial cells and macrophages of various tissues throughout the body.

In turkeys, an experimental infection with a genotype B strain induced much milder clinical signs and lesions than infection with genotype A or D strains (132). The genotype B strain had a longer incubation period, took longer to reach maximum titers in the tissues, and had shorter periods during which the organism was found in the tissues.

The incubation period of chlamydiosis in naturally infected birds varies, depending upon the number of chlamydiae inhaled, the virulence or pathogenicity of the infecting strain for that host species, and host immunogenetics. Experimentally, definitive disease signs in young turkeys receiving a virulent strain may be evident in 5–10 days. In birds naturally exposed to smaller doses or in older birds, the period may be longer. Strains of lower virulence, which cause less severe signs, may have longer incubation periods. Clinical signs may not be noticeable until 2–8 weeks after exposure.

Signs of chlamydiosis in turkeys infected with virulent strains are cachexia, anorexia, elevated body temperature, conjunctivitis, and respiratory distress. Diseased birds excrete yellow-green, gelatinous droppings. Egg production of severely affected hens declines rapidly to 10%–20% and may temporarily cease or remain at a very low rate until complete recovery. Disease signs in a flock infected with strains of low virulence are usually anorexia and loose, green droppings in some birds, with less effect on egg production.

At the peak of disease outbreak in a flock infected with a virulent strain, 50%–80% of the birds will show clinical signs, whereas morbidity from less virulent strains is only 5%–20%. Mortality caused by virulent chlamydia ranges from 10%–30% and is only 1%–4% with less virulent strains.

The less virulent strains cause gross lesions, which are similar to those caused by virulent strains, only less severe and extensive. In overwhelming infections with virulent strains, lungs show diffuse congestion, and the pleural cavity may contain fibrinous exudate. In fatal cases, a dark transudate may fill the thoracic cavity. The pericardial membrane is thickened, congested, and coated with fibrinous exudate. The heart may be enlarged, and its surface may be covered with thick fibrin plaques or encrusted with yellowish, flaky exudate (Figure 24.5). The liver is enlarged and discolored and may be coated with thick fibrin. Air sacs are thickened and heavily coated with fibrinous exudate (Figure 24.6). The spleen is enlarged, dark, and soft and may be covered with gray-white spots representing areas of focal cellular proliferation. The peritoneal serosa and mesentery show vascular congestion and may be coated with foamy, white fibrinous exudate. All of these exudates contain large numbers of mononuclear cells in which numerous microcolonies of chlamydial RBs may be seen. Fibrinous exudates, found on all organs and tissues of the thoracic and peritoneal cavities, reflect vascular damage as well as increasing inflammatory response caused by the continued multiplication of the organisms. In birds that survive infection with a strain of low virulence, the lungs may not be seriously affected. However, multiplication of organisms on the epicardium may result in the formation of 1 or more fibrin plaques.

Vanrompay et al. (130) examined histopathologic changes in 4 groups of 20 specific pathogen free (SPF) turkeys kept in isolation units and inoculated by the natural route of

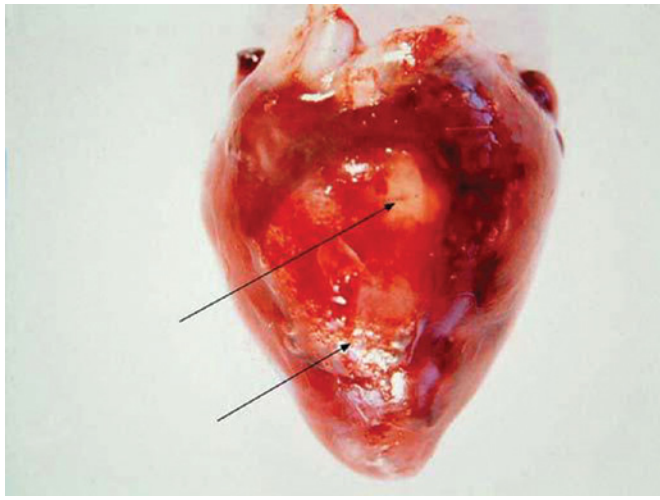

Figure 24.5. Turkey experimentally infected (aerosol) with a *C. psittaci* genotype A strain (84/55) isolated from the lungs of a budgerigar. Note the presence of serous fluid together with fibrin in the pericardial sac.

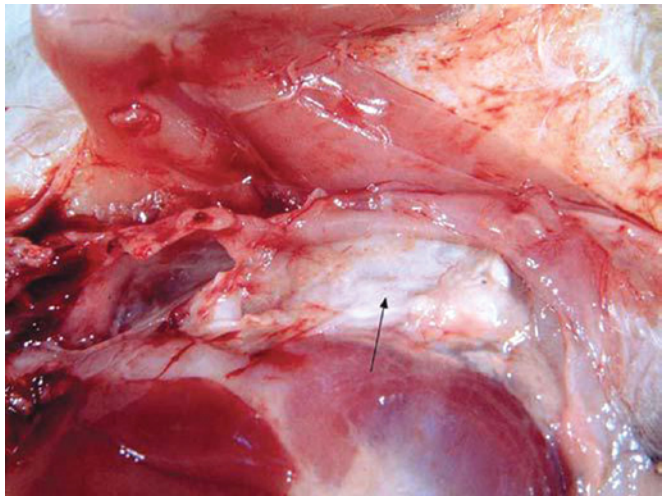

Figure 24.6. Turkey experimentally infected (aerosol) with a *C. psittaci* genotype A strain (84/55). Note the thickened abdominal airsac totally covered with fibrin cloths (arrow).

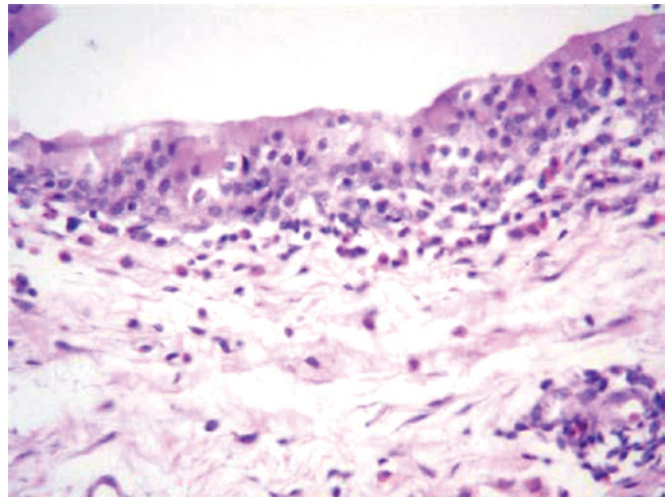

Figure 24.7. Hematoxylin and eosin staining of experimentally infected turkeys. Conjunctiva with infiltration of lymphocytes and heterophils together with epithelial vacuolization and hyperplasia. ×172.

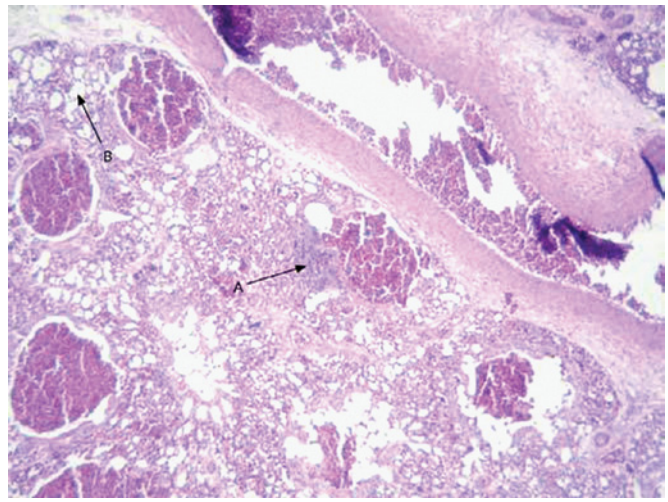

Figure 24.8. Hematoxylin and eosin staining of experimentally infected turkeys. Congested lung with infiltration of lymphocytes (arrow A) and dilated bronchi and parabronchi (arrow B). ×69.

infection (aerosol). Turkeys were experimentally infected with strain 84/55 (*C. psittaci* genotype A), isolated from a parakeet, strain 92.1293 from a turkey (*C. psittaci* genotype D), the Texas Turkey strain (*C. psittaci* genotype D), or strain 89/1326 (*C. psittaci* genotype B) from a pigeon. All 4 strains proved to be pathogenic for SPF turkeys. Turkeys showed conjunctivitis, sinusitis, rhinitis, keratitis, pericarditis (Figure 24.5), pneumonia, airsacculitis (Figure 24.6), hepatosplenomegaly, enteritis, congestion of the kidneys, and congestion of the ovaries or testes. There were epithelial erosions and fibrin deposit in the conjunctivae (Figure 24.7), corneal ulceration, bronchopneumonia (Figure 24.8), fibrinous necrotizing airsacculitis (Figure 24.9), fibrinous pericarditis, interstitial nephritis, peritonitis, and catarrhal enteritis. The type and distribution of the lesions was similar for genotypes A and D. However, the lesions produced after genotype A infection appeared more severe. For genotype B, in comparison with both other genotypes, no lesions were observed in the small intestine, pancreas, ovary, and testis.

Controlled dual infections in SPF turkeys demonstrated the pathogenic interplay between *C. psittaci*, avian metapneumovirus, and *E. coli*. *Escherichia coli* is a predisposing factor for the outcome of a *C. psittaci* infection. It can increase the severity of a *C. psittaci* infection and can reactivate a latent *C. psittaci* infection (121). An aMPV infection during the acute phase of a *C. psittaci* infection aggravates the severity of clinical signs, macroscopic lesions, pharyngeal aMPV excretion, and histological tracheal lesions. However, no clear

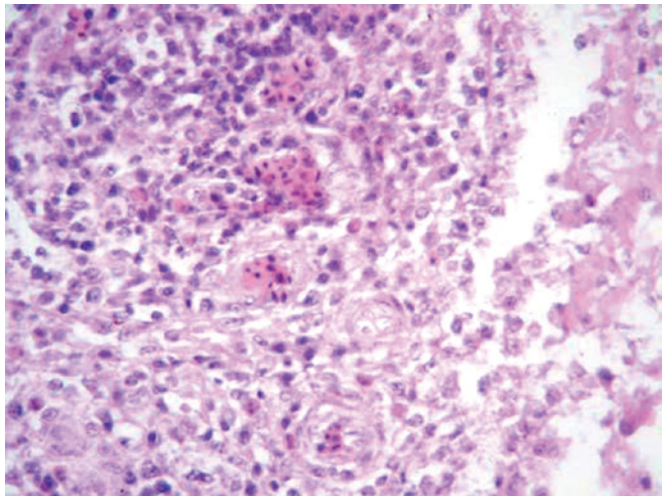

Figure 24.9. Hematoxylin and eosin staining of experimentally infected turkeys. Fibrinous necrotizing airsacculitis. ×172.

interaction was established after aMPV infection in latently *C. psittaci*-infected turkeys (122).

Chickens

Epidemiologic evidence formerly indicated that chickens are relatively resistant to disease caused by *C. psittaci*. Acute infection progressing to disease and mortality only occurred in young birds, and the incidence of actual epidemics was very low. Most natural infections in chickens were believed to be inapparent and transient. However, *C. psittaci* strains isolated from turkeys caused similar pathology and mortality in chickens as in turkeys (111, 112).

Recently, highly virulent *C. psittaci* strains have been isolated from the lungs of diseased chickens raised in Belgium, France, Germany, and China (35, 65, 146; Vanrompay et al., 2012, unpublished results). The strains obtained from Belgian and French farms were genotype D and could successfully be used to reproduce the disease in experimentally infected SPF chickens (Vanrompay et al., 2012, unpublished results). Chickens showed conjunctivitis, rhinitis, pneumonia, fibrinous airsacculitis, fibrinous pericarditis, and hepatosplenomegaly. Mortality was observed.

Ducks and Geese

Chlamydiosis in domestic ducks is important both economically and as a public health hazard, especially in Australia, China, and Europe (8, 9, 17, 24, 49, 50, 57, 64, 67, 69, 72, 82, 142). Chlamydiosis in ducks is usually a severe, debilitating, often fatal disease in which young ducks develop trembling, imbalanced gait, and cachexia. They become anorexic with green, watery intestinal contents and develop a serous to purulent discharge from the eyes and nostrils causing the feathers on the head to become encrusted with exudate. As the disease progresses, the ducks become emaciated and die in convulsions. Morbidity ranges from 10%–80%, and mortality varies from 0–30% depending on age and the presence of concurrent infections. Recently, severe outbreaks associated with human disease were reported in France (65).

Incidental to studies of chlamydiosis in ducks, several investigators have observed *C. psittaci* antibodies or the disease in geese and have isolated *C. psittaci* from diseased tissues (1). Clinical disease and necropsy findings were similar to those in ducks.

Pigeons

The incubation period for chlamydiosis in pigeons is not known. Infection is endemic and is believed to be perpetuated primarily by a parent-to-nestling transmission cycle (39, 101).

Signs of uncomplicated chlamydiosis in pigeons are variable, but those that develop acute disease are anorexic, unthrifty, and diarrhetic (71). Some develop conjunctivitis, swollen eyelids, and rhinitis. Respiratory difficulty is accompanied by rattling sounds. As disease progresses, birds become weak and emaciated. Recovered birds become asymptomatic carriers. Some birds progress through an infection showing no signs or, at the most, transient diarrhea before becoming carriers. Salmonellosis or trichomoniasis exacerbates the illness in chlamydia-infected carrier birds, inducing signs and lesions of acute disease. Serologic surveys indicate that infection rates in pigeons of 30%–90% and active infection rates, as measured by isolation, of 20% are common (90, 101). Gross lesions of uncomplicated chlamydiosis in pigeons are fibrinous exudates on thickened air sacs, the peritoneal serosa, and occasionally the epicardium. The liver is usually swollen, soft, and discolored. The spleen may be enlarged, soft, and dark. Greater than normal amounts of urates are seen in cloacal contents if catarrhal enteritis occurs. In less severe infections, only the liver or air sacs are involved. Some heavily infected shedders have no lesions (87, 90).

Pheasants, Quail, Guinea Fowl, Peacocks and Partridges

Chlamydiosis has been reported in farm-raised pheasants, quail, peacocks, guinea fowl and partridges from all over the world (32). The clinical signs and lesions are similar to those seen in other birds. Morbidity and mortality can be very high, especially in young birds. Human infections have been reported (31, 45, 65, 75, 110, 142).

Immunity

Natural immunity to chlamydia is generally poor and short-lived. As birds become older, however, they become more resistant to clinical disease, even though infection may occur. Indeed, some birds, notably pigeons, are refractory to disease-producing infection, even with highly virulent strains.

The immune response to *Chlamydia* is a coordinated event in which innate immune cells, B cells and T cells, act in concert and each of these immune effectors have roles in recognizing different stages of the infection. To date, chlamydial vaccine studies suggest that the ideal, efficacious vaccine should induce systemic CD4+ T helper (Th) 1 responses, but also a humoral response because B cells are important antigen-presenting cells in the activation of antigen-specific memory Th2 cells (95).

Less is known about innate immune detection of *Chlamydia* (93). Beeckman et al. (12) determined the cytokine responses following *C. psittaci* infection of avian monocytes/macrophages. High IL-10 and no TGF-β responses were observed at 4 hours post inoculation. This could induce macrophage deactivation and NF-κB suppression, and thereby could dampen innate immunity and promote *C. psittaci* survival in macrophages.

Diagnosis

Specimen Collection and Storage of Samples

Laboratory diagnosis of avian chlamydiosis usually includes isolation and/or identification of the organism from the host. Isolation requires inoculation of cell cultures, embryonating SPF chicken eggs or mice with living *C. psittaci*. Specimens should be collected aseptically, because contaminating bacteria may interfere with the isolation of chlamydiae.

Proper handling of clinical samples is necessary to prevent loss of infectivity. If specimens are used to inoculate animals or cell cultures immediately, most diluents will be adequate; however, if the specimen is to be shipped or stored, a special diluent should be used. A diluent consisting of sucrose–phosphate–glutamate (SPG) was developed for *Rickettsiae* and has proven satisfactory for transport of chlamydial field samples (105). The recommended medium for chlamydiae consists of SPG buffer (sucrose, 74.6 g/liter; KH_2PO_4, 0.512 g/liter; K_2HPO_4, 1.237 g/liter; and L-glutamic acid, 0.721 g/liter), which can be sterilized by autoclaving. To this is added fetal calf serum (10%), vancomycin and streptomycin (100 mg/ml), and nystatin and gentamicin (50 mg/ml). The antibiotics reduce the effect of contamination even when samples are shipped at ambient temperatures. This medium also serves as a laboratory diluent and a medium for freezing of chlamydiae.

For isolation, the following samples should be preferably collected: pharyngeal/choanal slit swabs in live birds (4, 129). Cloacal swabs or fresh feces are less optimal because chlamydial shedding is intermittent. In dead birds, lungs, spleen, liver, thickened exudate-coated air sacs and free exudates can be sampled. Samples should not be frozen if they can be processed in 2κ3 days; otherwise, they should be stored at –80ºC.

The same tissues can be collected for antigen detection, PCR, and other molecular tests. If the DNA extraction will not be done immediately, it may be beneficial to collect the specimen in a DNA stabilization buffer (25).

The stability of chlamydiae during storage depends upon the material in which it is contained. Chlamydiae in tissue specimens or yolk-sac suspension can be preserved indefinitely by storage at –80º C (1). Note that chlamydiae harvested from cell culture require special media during freezing. A satisfactory method for freezing them is to replace the cell culture medium with SPG buffer before freezing, because the organism is highly susceptible to the presence of sodium ions in the medium (105).

Microscopic Examination of Specimens

Cytological and Immunohistochemical Staining

Chlamydiae can be detected in smears of exudates and feces and in impression smears of tissues by cytological staining as mentioned formerly. However, none of the stains specifically detects chlamydia. They are all less sensitive than antibody-based antigen detection methods or specific nucleic acid amplification techniques (NAATs) (7, 136). Therefore, use of a cytological staining is losing popularity.

Today, immunohistochemistry (115) is not often used for routine diagnosis. It is more in use for research or retrospective examination of samples for chlamydiae.

Antigen Enzyme-Linked Immunosorbent Assays

A number of manufacturers produce enzyme-linked immunosorbent assay (ELISA) kits for detection of *Chlamydia trachomatis* in humans. These test kits detect *C. psittaci* as they react to the lipopolysaccharide (LPS) or family (*Chlamydiales*) antigen. ELISA is rapid, does not require a high level of expertise, and is safe for the technician because the sample can be inactivated. A number of test kits have been evaluated for use in avian samples (133), although none of the kits are licensed for *C. psittaci*. These kits detect the lipopolysaccharide antigen, which gives false positives, because the chlamydial LPS shares epitopes with the LPS of other Gram-negative bacteria. The more recently developed ELISAs use more specific monoclonal antibodies. However, these kits still lack sensitivity: a few hundred organisms are needed for a positive reaction. The general rule with these tests is that a diagnosis of chlamydiosis can be made when a strong positive reaction is seen along with clinical signs of chlamydiosis.

Isolation

Preparation of Inoculum

Tissue specimens, fecal samples, and swabs are routinely used as samples for the isolation of *Chlamydia*. Prior to inoculation, samples must be treated properly. The processing of samples is similar for inoculation of cell cultures or embryonating eggs. A number of laboratories use SPG buffer or transport medium (105) as diluent. These diluents have the advantage of stabilizing the agent during refrigeration or freezing. Penicillin and tetracyclines should be avoided because they inhibit the growth of *C. psittaci*.

A standard procedure is to prepare 20% tissue suspensions in diluent. The suspensions are centrifuged (2,790 × g, 4ºC) for 10 minutes. The supernatants are collected and 10 µl/ml streptomycin sulfate (streptomycin sulfate 1% w/v) and 20 µl/ml vancomycin (vancomycin 0.5 w/v) are added. If needed, 0.1% amphotericin B can be added. After 1 hour of incubation at room temperature, the suspensions are centrifuged for 30 minutes (2,790 × g, 4ºC) and supernatants are immediately used for inoculation or stored at –80ºC until use. Swabs are shaken for 1 hour at 4ºC on a rocking platform, centrifuged (2,790 × g, 4ºC), and the supernatant immediately used or stored at –80ºC until use.

Fecal samples, although not preferably used for diagnosis because of the intermittent chlamydia shedding and the risk for false negatives, are processed as follows. A 20% suspension is made in diluent, and the suspension is shaken for 1 hour (4ºC) on a rocking platform. Afterward, the suspension is sonicated for 10 minutes using an ultrasonic water bath. The supernatant is collected, and 10 µl/ml streptomycin sulfate (streptomycin sulfate 1% w/v), 20 µl/ml vancomycin (vancomycin 0.5 w/v), and 0.1% amphotericin B are added. The suspension is incubated at room temperature (1 hour) and subsequently centrifuged (2,790 × g, 4ºC) for 30 minutes. The supernatant is collected and thereafter ultracentrifuged (45,000 × g, 4ºC, 45 minutes). The supernatant is discarded, and the remaining chlamydia pellet is re-suspended in diluent and immediately used for inoculation or stored at –80ºC until use.

Cell cultures and SPF embryonating chicken eggs

Cell cultures are the most common and convenient method for the isolation of *C. psittaci*. The most commonly used cell lines are BGM, Vero, McCoy, HeLa, and L-929, although a number of other cell cultures, such as chicken embryo fibroblasts, can be used. A study showed BGM to be the most sensitive, with Vero and L-929 listed as satisfactory (136). Standard cell culture medium is used, containing 5%–10% fetal calf serum and antibiotics like vancomycin, streptomycin, and amphotericin B because they do not inhibit the growth of *C. psittaci*.

The culture equipment must be suitable for the following procedures: (1) identification by fluorescent antibody (FA) or another appropriate technique of staining of the infected monolayer, (2) centrifugation (500–1,500 × g for 60 to 90 minutes) of the inoculum onto the monolayer at 37ºC to enhance infectivity (eventually in the presence of DEAE), (3) possible blind passages at 3 or 6 days post inoculation to increase sensitivity of isolation, (4) examination of the sample 2–3 times during passage, and (v) protection of humans against possible infection. Small, flat-bottomed vials (1-dram shell vials) or bottles with 12-mm diameter glass coverslips meet these requirements and are often used because the cell culture monolayer can be grown directly on the coverslip. Several vials are inoculated with each sample to permit fixing and staining at various times and to permit passages of negative samples after 6 days of incubation.

Chlamydiae can be isolated from cells that are replicating normally. Most diagnosticians, however, prefer to use nonreplicating host cells for two reasons: (1) to provide increased nutrients for the replication of chlamydiae and (2) because nonreplicating cells can be maintained for longer periods for observation. Host-cell replication is suppressed most commonly using cycloheximide (0.5–2.0 mg/ml). Incubation is usually at 37ºC–39ºC, depending on the cell culture used. Disruption of the monolayer by freeze-thawing should be avoided because it can destroy *C. psittaci*.

Some laboratories still use chicken embryos for primary isolation of chlamydiae. The standard procedure is to inject up to 0.3 ml of inoculum into the yolk sacs of 6-day-old embryos (136). Replication of chlamydia usually will cause the death of the embryo within 5–12 days after inoculation. If no deaths occur, 2 additional blind passages are usually made before calling the sample negative. Chlamydia infection typically causes vascular congestion of the yolk-sac membranes, which are harvested and homogenized as a 20% yolk-sac suspension. This suspension can be frozen (–80ºC) to preserve the strain or inoculated into other eggs if needed or into cell culture monolayers. *C. psittaci* is usually identified by immunofluorescence staining of yolk-sac impression smears.

Staining Cell Monolayers or Yolk-Sac Impression Smears

The preferred method for fixing of the monolayer is to remove the medium, wash once with PBS, and fix with cold acetone for 10 minutes (–20ºC). If the cell culture vessel is plastic, the monolayer can be fixed with a mixture of 50% acetone and 50% methyl alcohol or with 100% methyl alcohol. The preferred method for staining is the fluorescence method. With the fluorescence method, the fluorescein-conjugated anti-chlamydia serum is applied to the glass slide and incubated for minimum of 30 minutes at 37ºC. The slides are then washed with PBS and deionized water, air dried, and mounted to be monitored by use of a fluorescence microscope. Commercially fluorescently labeled monoclonal antibodies are available. Conjugates also can be prepared from polyclonal sera from rabbits, guinea pigs, sheep, or goats. The fluorescein-labeled conjugate is then prepared using standard conjugation techniques.

Nucleic Acid Amplification Techniques

The possibilities of diagnostic detection of *Chlamydia psittaci* are considerably improved with the introduction of molecular methods which permit direct identification from clinical specimens and accelerate diagnosis from several days to a single working day. Tests published in the literature mainly use 2 different genomic target regions for amplification, namely the ribosomal RNA gene region (34, 53, 55, 56, 74).

The sensitivity of the PCR largely depends on the amount and quality of the extracted DNA. Optimal extraction of nucleic acids from a wide range of clinical samples is one of the most underappreciated but nevertheless challenging and important steps. Proper extraction must efficiently release nucleic acids from samples, remove PCR inhibitors, avoid the degradation of nucleic acids, and ensure adequate concentration of the nucleic acids after extraction. This is relatively easily achievable for viral and mammalian amplification targets, but much more difficult for nucleic acid targets of bacteria. Several in-house and commercial DNA extraction methods have been described (25, 100). The use of commercial kits can be recommended, especially when dealing with PCR inhibitors. They contain a special buffer reagent for lysis of the bacterial and eukaryotic host cells, mostly based on a guanidine-detergent lysing solution. Simultaneous disruption of cells and inactivation of nucleases is achieved by lysis in strong denaturing reagents, for instance 4 M guanidinium isothiocyanate or 4 M guanidinium-hydrochloride.

Tissue sample homogenization in cell culture medium, PBS, or Tris buffered saline and/or freeze-thaw cycles of samples lead to rapid loss of chlamydial target DNA. Specimens that contain low target numbers before freezing often become negative after cryostorage. Preservation of DNA from degradation is critically important. DeGraves et al. (25) advise collecting all specimens for PCR analysis in a DNA stabilization reagent. Such reagents are commercially available, e.g., the RNA/DNA Stabilization Reagent for Blood/Bone Marrow from Roche Applied Science.

Nested PCR procedures are more sensitive than traditional PCR and in most cases are also more sensitive than real-time PCR. However, they are more time consuming. False positives can more easily occur due to post-PCR carryover. Two highly sensitive nested PCR assays have been developed to detect *C. psittaci* (100, 124). Recently, an SYBR green-based real-time PCR was developed targeting the rDNA ribosomal spacer of *C. psittaci* (37).

Sachse et al. (99) developed a DNA microarray-based detection and identification method for *Chlamydia spp*. The test uses the ArrayTube platform technology (CLONDIAG chip technologies). The company also has developed an *ompA*-based *C. psittaci* genotyping microarray (31).

Serology

Serology alone is not particularly useful in diagnosing a current chlamydial infection in birds because of the high prevalence of this infection in birds and the long-term (up to several months) persistence of antichlamydial antibodies. In most bird species, there is a high background rate of antichlamydial antibodies, and until we have more information on the disease pattern in certain bird species in relation to direct identification of the bacteria and serology, we are unable to comment on the real significance of antibody titers obtained. Thus, to determine if a single bird is infected, serology should always be used in conjunction with antigen or gene detection, or paired sera should be examined. However, obligatory examination of paired sera removes serology from immediate clinical relevance. A positive test is evidence that the bird was infected by the bacterium but does not necessarily indicate an active infection. False negative results can occur in birds with acute infections that are sampled before seroconversion. Treatment with antibiotics also may delay and/or diminish the antibody response. The main serological methods that are being used for detecting chlamydial antibodies are: (1) various methods of elementary body agglutination (EBA) (47), (2) the complement fixation test (CF) (47), (3) an indirect (micro) immunofluorescence (MIF) test, and (4) several commercial ELISAs.

The EBA detects primarily IgM antibodies and thus can detect early infections (43, 44, 45). A negative result does not guarantee that a bird is free of infection because the sensitivity of the test is rather low. The direct complement fixation (DCF) test detects avian IgG but not IgM. Its disadvantages are that: (1) the test antigens are not commercially available, (2) the test cannot be used for testing sera from avian species whose immunoglobulins do not fix complement, (3) it is only relatively sensitive, (4) it cannot be used to differentiate between IgG and IgM antibodies, and (5) it is fairly laborious when there is a large number of samples to be tested. The modified DCF test is more sensitive but has the same disadvantages as the DCF test (45, 46).

The indirect IF test detects all immunoglobulin isotypes and is, as is the MIF test, widely used to detect *C. trachomatis*, *C. pneumoniae*, and *C. psittaci* antibodies in human sera. The MIF test appears to be more sensitive than the complement fixation tests. Some years ago a large number of commercially available ELISAs were evaluated for demonstrating *C. psittaci* antibodies in birds. All of these ELISAs were highly sensitive but showed low specificity because they were mainly based on the use of whole chlamydial organisms, LPS, or chlamydial outer membrane fractions of LPS and lipoglycoprotein nature (1). More recently, peptide-based ELISA systems or ELISAs using recombinant LPS have become commercially available for the specific detection of *C. trachomatis*, *C. pneumoniae*, and *C. abortus* antibodies (1). These tests performed as well as the MIF assay but were less time consuming, less expensive, and easier to perform. In the future this principle also might be useful in the serodiagnosis of *C. psittaci* infections. At present, an ELISA using recombinant MOMP of *C. psittaci* already has been described (139) for testing avian sera. The test detects antibodies against all *Chlamydia* species.

Differential Diagnosis

Suspected chlamydiosis may have to be differentiated from pasteurellosis, particularly in turkeys, in which some signs and lesions may be similar. Pasteurellosis can be ruled out by appropriate culture procedures. Because of some similar signs and lesions, *Ornithobacterium rhinotracheale* infections and mycoplasmosis may need to be ruled out in turkeys and chickens suspected of having chlamydiosis. This can be accomplished by culturing and serologic testing. Colibacillosis may mimic chlamydiosis to some extent, but it can be excluded by the use of appropriate coliform culturing procedures. Avian influenza or aMPV may have to be ruled out in suspected chlamydiosis by virus isolation and serologic testing.

Intervention Strategies

Management Procedures

Ideally birds should be reared in confinement without contact with contaminated equipment or premises. Contact with potential reservoirs or vectors such as pet birds, rodents, arthropods, and wild and feral birds also should be prevented. General sanitation must be practiced diligently. Movement of people should be restricted so that visitors do not have free access to premises holding birds. This is easier to accomplish if birds are confined in houses and if the "all-in-all-out" principle is used on the farm.

Recently, *C. psittaci* bioaerosol monitoring became available, which could be used for monitoring infection pressure in the poultry industries (117, 119).

Vaccination

Commercial chlamydia vaccines for poultry are not available.

Protective immunity to *Chlamydiaceae* is believed to be effected primarily through the action of CD4+ T helper type 1 (Th1) lymphocytes, CD8+ T lymphocytes, mononuclear phagocytes, and cytokines secreted by these cells. In addition, the role of local antibodies in mucosal secretions is not to be underestimated. The only protective chlamydial antigen that has been unambiguously identified is the major outer membrane protein (MOMP). However, attempts at chlamydial vaccine development based on a subunit design using MOMP have generally failed, probably because the immunogens did not induce the protective cellular and humoral immune responses elicited by native bacterial epitopes. In light of current knowledge on protective chlamydial immunity, plasmid DNA expressing the MOMP of *C. psittaci* has been tested for its ability to raise a protective immune response in SPF turkeys against challenge with *C. psittaci* strains (126, 137). Effective priming of T cell memory and significant reduction in clinical signs, lesions, bacterial excretion, and *C. psittaci* replication in tissues was observed.

Prevention by Means of Ovotransferrin

Recently, ovotransferrin (natural anti-microbial protein) was successfully used to reduce clinical signs, lesions, excretion, and chlamydia replication in experimentally infected SPF turkeys (120). Also, *C. psittaci* infection pressure on a turkey broiler farm was significantly reduced by administering ovotransferrin aerosols. Ovotransferrin significantly reduced respiratory disease, mortality, and antibiotic use on the farm (117).

Treatment

Chlamydiosis treatment for poultry has not changed over the years (1, 104, 131). The drug of choice varies from country to country. Among tetracylines, which are the drugs of choice, chlortetracycline and doxycycline are most often used. Enrofloxacin (fluoroquinolone antibiotic) also can be used. Turkeys can be treated with chlortetracycline (CTC) at a concentration of 400 g/ton of pelleted feed. Care must be taken so that heat generated during pelleting does not destroy CTC and lower the active concentration below an effective level. The CTC-medicated feed must be given for 2 weeks and then replaced by nonmedicated feed for 2 days prior to the birds being slaughtered for human consumption. Calcium supplements should not be added to CTC-medicated pellets because calcium ions chelate CTC and diminish its effectiveness. Turkeys also can be treated with doxycycline hyclate formulations for drinking water (doxycycline hyclate 500 mg/g, dose of 20 mg/kg bodyweight/day) for 5 days or enrofloxacin (100 mg/ml) at a daily dose of 10 mg of enrofloxacin/kg of bodyweight, in water, for 3–5 days and in case of mixed or chronic infections for 5–10 days. Medicated drinking water should be replaced every 24 hours. It is recommended that all turkeys on an infected premises be treated.

Essentially the same treatment methods are used to treat other fowl infected with *C. psittaci*. In other birds, salmonellosis may often be a complicating factor so it may be necessary to use a combination of antibiotics. Treatment may not be effective in eliminating the carrier state. Additional periods of treatment may be needed, especially when birds are kept for several weeks.

State Regulations

Because regulations may vary from country to country, the appropriate public health and/or animal health agencies should be consulted as necessary. In many countries, psittacosis (humans) and even chlamydiosis in poultry are notifiable diseases and must be reported within 48 hours.

According to USDA regulations, movement of poultry, carcasses, or offal from any premise is prohibited where the existence of chlamydiosis has been proved by isolation of a chlamydial agent. The Animal and Plant Health Inspection Service of the USDA and the U.S. Department of Health and Human Services forbid interstate movement of birds from infected flocks, but there is no restriction on movement of eggs from such flocks.

Acknowledgement

A.A. Andersen is acknowledged as senior author of this chapter for the 12th and earlier editions of *Diseases of Poultry*.

References

1. Andersen, A.A., and D. Vanrompay. 2008. Avian chlamydiosis (psittacosis, ornithosis). In: *Diseases of Poultry*, 12th ed. Y.M. Saif, A.M. Fadly, J.R.. Glisson, L.R. McDougald, L.K. Nolan, and D.E. Swayne, eds. Wiley-Blackwell, Ames, Iowa.
2. Andersen, A.A. 2004. Avian chlamydiosis. In: *Manual of Diagnostic Tests and Vaccines for Terrestrial Animals* (mammals, birds and bees), Office International des Epizooties (OIE), 5th Ed. OIE, Paris. 856–867.
3. Andersen, A.A. 1997. Two new serovars of *Chlamydia psittaci* from North America birds. *J Vet Diagn Invest*. 9(2):159–164.
4. Andersen, A.A. 1996. Comparison of pharyngeal, fecal, and cloacal samples for the isolation of *Chlamydia psittaci* from experimentally infected cockatiels and turkeys. *J Vet Diagn Invest*. 8:448–450.
5. Andersen, A.A. 1991. Comparison of avian *Chlamydia psittaci* isolates by restriction endonuclease analysis and serovar-specific monoclonal antibodies. *J Clin Microbiol*. 29:244–249.
6. Andersen, A. A. 1991. Serotyping of *Chlamydia psittaci* isolates using serovar-specific monoclonal antibodies with the microimmunofluorescence test. *J Clin Microbiol*. 29:707–711.
7. Arizmendi, F., and J.E. Grimes. 1995. Comparison of the Gimenez staining method and antigen detection ELISA with culture for detecting chlamydiae in birds. *J Diagn Invest*. 7: 400–401.
8. Arzey, G.G., and K.E. Arzey. 1990. Chlamydiosis in layer chickens. *Aust Vet J*. 67:461.

9. Arzey, K.E., G.G. Arzey, and R.L. Reece. 1990. Chlamydiosis in commercial ducks. *Aust Vet J*. 67:333–334.
10. Bavoil P.M., and Hsia R.C. 1998. Type III secretion in *Chlamydia*: a case of déjà vu? *Mol Microbiol*. 28:860–2.
11. Beasley, J.N., R.W. Moore, and J.R. Watkins. 1961. The histopathologic characteristics of disease producing inflammation of the air sacs in turkeys: A comparative study of pleuropneumonia-like organisms and ornithosis in pure and mixed infections. *Am J Vet Res*. 22:85–92.
12. Beeckman, D.S.A, L. Rothwell, P. Kaiser, and D. Vanrompay. 2010. Differential cytokine expression in *Chlamydophila psittaci* genotype A-, B- or D-infected chicken macrophages after exposure to *Escherichia coli* O2:K1 LPS. *Dev Comp Immunol*. 34: 812–20.
13. Beeckman, D.S.A, and D. Vanrompay. 2010. Bacterial secretion systems with emphasis on the Chlamydial type III secretion system. *Curr Iss Mol Biol*. 12:17–42.
14. Beeckman, D.S.A., and D. Vanrompay. 2009. Zoonotic *Chlamydophila psittaci* infections from a clinical perspective. *Clin Microbiol Infect*. 15:11–17.
15. Beeckman, D.S., T. Geens, J.P. Timmermans, P. Van Oostveldt, and D.C. Vanrompay. 2008. Identification and characterization of a type III secretion system in *Chlamydophila psittaci*. *Vet Res*. 39:27.
16. Belland, R.J., M.A. Scidmore, D.D. Crane, D.M. Hogan, W. Whitmire, G. McClarty, and H.D. Caldwell. 2001. *Chlamydia trachomatis* cytotoxicity associated with complete and partial cytotoxin genes. *Proc Nat Acad Sc USA*. 98:13984–9.
17. Bennedsen, M., and A. Filskov. 2000. An outbreak of psittacosis among employees at a poultry abattoir. Proceedings of the Fourth Meeting of the European Society for *Chlamydia* Research: Helsinki, Finland, 315.
18. Betts-Hampikian, H.J., and K.A. Fields. 2010. The chlamydial type III secretion mechanism: revealing cracks in a tough nut. *Front Microbiol*. 1:114.
19. Birkelund, S., M. Morgan-Fisher, E. Timmerman, K. Gevaert, A.C. Shaw, and G. Christiansen. 2009. Analysis of proteins in *Chlamydia trachomatis* L2 outer membrane complex, COMC. *FEMS Immunol Med Microbiol*. 55:187–95.
20. Brade, H., L. Brade, and F.E. Nano. 1987. Chemical and serological investigations on the genus-specific lipopolysaccharide epitope of *Chlamydia*. *Proc Nat Acad Sc USA*. 84:2508–2512.
21. Brade, L., M. Nurminen, P.H. Makela, and H. Brade. 1985. Antigenic properties of *Chlamydia trachomatis* lipopolysaccharide. *Infect Immun*. 48:569–572.
22. Byrne, G.I. 2010. *Chlamydia trachomatis* strains and virulence: rethinking links to infection prevalence and disease severity. *J Infect Dis*. 201:Suppl 2:S126–33.
23. Caldwell, H.D., and L.J. Perry. 1982. Neutralization of *Chlamydia trachomatis* infectivity with antibodies to the major outer membrane protein. *Infect Immun*. 38:745–754.
24. Cao, J., Q. Yang, L. Yang, Z. Liu, and C. He. 2006. Epidemic investigation of avian *Chlamydia psittaci* in Beijing and other provinces around. *Vet Sc China*. 36:931–934.
25. DeGraves, F.J., D. Gao, and B. Kaltenboeck. 2003. High-sensitivity quantitative PCR platform. *Biotechniques*. 34:106–10, 112–5.
26. Deschuyffeleer, T., L. Tyberghien, V. Dickx, T. Geens, J. Saelen, D. Vanrompay, and L. Brackman. 2012. Risk assessment and management of *Chlamydia psittaci* in poultry processing plants. *Ann Occup Hyg*. 56:340–349.
27. Dickx, V., and D. Vanrompay. 2011. Zoonotic transmission of *Chlamydia psittaci* in a chicken and turkey hatchery. *J Med Microbiol*. 60:775–779.
28. Dickx, V., T. Geens, T. Deschuyffeleer, L. Tyberghien, T. Harkinezhad, D.S.A. Beeckman, L. Braeckman, and D. Vanrompay. 2010. *Chlamydophila psittaci* zoonotic risk assessment in a chicken and turkey slaughterhouse. *J Clin Microbiol*. 48:3244–3250.
29. Dickx, V., D.S.A. Beeckman, L. Dossche, P. Tavernier, and D. Vanrompay. 2010. *Chlamydophila psittaci* in homing and feral pigeons and zoonotic transmission. *J Clin Microbiol*. 59: 1348–1353.
30. Eddie, B., K.F. Meyer, F.L. Lambrecht, and D.P. Furman. 1962. Isolation of *ornithosis bedsoniae* from mites collected in turkey quarters and from chicken lice. *J Infect Dis*. 110:231–237.
31. Ehricht, R., P. Slickers, S. Goellner, H. Hotzel, and K. Sachse. 2006. Optimized DNA microarray assay allows detection and genotyping of single PCR-amplifiable target copies. *Mol Cell Probes*. 20:60–63
32. Erbeck, D.H., and S.A. Nunn. 1999. Chlamydiosis in pen-raised bobwhite quail (*Colinus virginianus*) and chukar partridge (*Alectoris chukar*) with high mortality. *Avian Dis*. 43:798–803.
33. Everett, K.D.E., R.M. Bush, and A.A. Andersen. 1999. Emended description of the order *Chlamydiales*, proposal of *Parachlamydiaceae* fam. nov., and *Simkaniaceae* fam. nov., each containing one monotypic genus, revised taxonomy of the family *Chlamydiaceae*, including a new genus and five new species, and standards for the identification of organisms. *Int J of Syst Bacteriol*. 49:415–440.
34. Everett, K.D.E., L.J. Hornung, and A.A. Andersen. 1999. Rapid detection of the *Chlamydiaceae* and other families in the order *Chlamydiales*: Three PCR tests. *J Clin Microbiol*. 37:575–580.
35. Gaede, W., K.F. Reckling, B. Dresenakmp, S., Kenklies, E. Scubert, U. Noack, H.M. Irmscher, C. Ludwig, H. Hotzel, and K. Sachse. 2008. *Chlamydophila psittaci* infections in humans during an outbreak of psittacosis from poultry in Germany. *Zoo Pub H*. 55:184–188.
36. Geens T., A. Desplanques, M. Van Loock, B.M. Bönner, E. F. Kaleta, S. Magnino, A.A. Andersen, K.D.E. Everett, and D. Vanrompay. 2005. Sequencing of the *Chlamydia psittaci ompA* reveals a new genotype, E/B, and the need for a rapid discriminatory genotyping method. 2005a. *J Clin Microbiol*. 43: 2456–2461.
37. Geens T., Dewitte A., Boon N., and Vanrompay D. 2005. Development of a *Chlamydophila psittaci* species-specific and genotype-specific real-time PCR. *Vet Res*. 36:787–797.
38. Geigenfeind, I., D. Vanrompay, and D. Haag-Wackernagel. 2012. Prevalence of *Chlamydia psittaci* in the feral pigeon population of Basel, Switzerland. *J Med Microbiol*. 61:261–265.
39. Geigenfeind, I., and D. Wackernagel. 2010. Detection of *Chlamydophila psittaci* from feral pigeons in environmental samples: problems with currently available techniques. *Integrative Zoology* 5:63–9.
40. Gimenez, D.F. 1964. Staining *Rickettsiae* in yolk sac cultures. *Stain Technology*. 39:135–140.
41. Goellner, S., E. Schubert, E. Liebler-Tenorio, H. Hotzel, H.P. Saluz, and K. Sachse. 2006. Transcriptional response patterns of *Chlamydophila psittaci* in different *in vitro* models of persistent infection. *Infect Immun*. 74:4801–8.
42. Goupil, F., D. Pelle-Duporte, S. Kouyoumdjian, B. Carbonnelle, and E. Tuchais. 1998. Severe pneumonia with a pneumococcal

aspect during an ornithosis outbreak. *Presse Médicale*. 27: 1084–1088.
43. Grimes, J.E., T.N. Tully, Jr., F. Arizmendi, and D.N. Phalen. 1994. Elementary body agglutination for rapidly demonstrating chlamydial agglutins in avian serum with emphasis on testing cockatiels. *Avian Dis*. 38:822–831.
44. Grimes, J.E., and F. Arizmendi. 1993. Elementary body agglutination: A rapid clinical diagnostic aid for avian chlamydiosis. Proceedings of the 1993 Annual Conference of the Association of Avian Veterinarians. 30–40.
45. Grimes, J.E., and P.B. Wyrick. 1991. Chlamydiosis (Ornithosis). In: *Diseases of Poultry*, 9th ed. B.W. Calnek, H.J. Barnes, C.W. Beard, W.M. Reid, and H.W. Yoder, Jr., eds. Iowa State University Press, Ames, IA. 311–325.
46. Grimes, J.E. 1989. Serodiagnosis of avian chlamydia infection. *J Am Vet Med Assn*. 195:1561–1564.
47. Grimes, J.E., and L.A. Page. 1978. Comparison of direct and modified direct complement-fixation and agar-gel precipitin methods in detecting chlamydial antibody in wild birds. *Avian Dis*. 22:422–430.
48. Grinblat-Huse, V., E.F. Drabek, H.H. Creasy, S.C. Daugherty, K.M. Jones, I. Santana-Cruz, L.J. Tallon, T.D. Read, T.P. Hatch, P. Bavoil, and G.S. Myers. 2011. Genome sequences of the zoonotic pathogens *Chlamydia psittaci* 6BC and Cal10. *J Bacteriol*. 193:4039–40.
49. Guérin, J.L., A. Ballot, B. Sraka, and O. Léon. 2006. Portage de *Chlamydophila psittaci* dans la filiére canard mulard: évaluation du portage chez les reproducteurs et incidence sur le statut du caneton. In: *Proceedings des 7èmes Jourées de la recherche sur les palmipèdes à foie gras*. 18–19 Octobre 2006, Arcachon, France p. 37–40.
50. Haas W.H., C.M. Swaan, A. Meijer, G. Neve, U. Buchholz, M. Beer, J.E. van Steenbergen, and G. Krause. 2007. A Dutch case of atypical pneumonia after culling of H5N1 positive ducks in Bavaria was found infected with *Chlamydophila psittaci*. *Euro Surveill*. 12:E071129.3.
51. Hall, C.F., S.E. Glass, J.E. Grimes, and R.W. Moore. 1975. An epidemic of ornithosis in Texas turkeys in 1974. *Southwestern Veterinarian* 28:19–21.
52. Harkinezhad, T., T. Geens, and D. Vanrompay. 2009. *Chlamydophila psittaci* infections in birds: a review with emphasis on zoonotic consequences. *Vet Microbiol*. 135:68–77.
53. Herring, A.J., M. McClenaghan, and I.D. Aitken. 1986. Nucleic acid techniques for strain differentiations and detection of *Chlamydia psittaci*. In: *Chlamydial Infections*. D. Oriel, G. Ridgeway, J. Schachter, D. Taylor-Robinson, and M. Ward, eds. Cambridge University Press: Cambridge, England, 578–580.
54. Herrmann, B., B. Pettersson, K.D. Everett, N.E. Mikkelsen, and L.A. Kirsebom. 2000. Characterization of the *rnpB* gene and RNase P RNA in the order *Chlamydiales*. *Int J Syst Evol Microbiol*. 1:149–58.
55. Hewinson, R.G., P.C. Griffiths, B.J. Bevan, S.E.S. Kirwan, M.E. Field, M.J. Woodward, and M. Dawson. 1997. Detection of *Chlamydia psittaci* DNA in avian clinical samples by polymerase chain reaction. *Vet Microbiol*. 54:155–166.
56. Hewinson, R.G., S.E.S. Rankin, B.J. Bevan, M. Field, and M.J. Woodward. 1991. Detection of *Chlamydia psittaci* from avian field samples using the PCR. *Vet Rec*. 128:129–130.
57. Hinton, D.G., A. Shipley, J.W. Galvin, J.T. Harkin, and R.A. Brunton. 1993. Chlamydiosis in workers at a duck farm and processing plant. *Austr Vet J*. 70:174–176.
58. Hodinka, R.L., and P.B. Wyrick. 1986. Ultrastructural study of mode of entry of *C. psittaci* into 929 cells. *Infect Immun*. 54: 855–863.
59. Hsia, R.C., Y. Pannekoek, E. Ingerowski, and P.M. Bavoil. 1997. Type III secretion genes identify a putative virulence locus of *Chlamydia*. *Mol Microbiol*. 25:351–9.
60. Johnson, M.C., and J.E. Grimes. 1983. Resistance of wild birds to infection by *Chlamydia psittaci* of mammalian origin. *J Infect Dis*. 147:162.
61. Kaleta, E.F., and E.M. Taday. 2003. Avian host range of *Chlamydia spp*. based on isolation, antigen detection and serology. *Avian Pathol*. 32:435–461.
62. Kubo A., and R.S. Stephens. 2000. Characterization and functional analysis of PorB, a *Chlamydia* porin and neutralizing target. *Mol Microbiol*. 38:772–80.
63. Kuo, C., and R. Stephens. 2011. Family I. *Chlamydiacaea*. In: *Bergey's Manual of Systematic Bacteriology*, 2nd ed. W.B. Whitman, ed. Springer Science and Business Media, New York. 845.
64. Laroucau, K., B. de Barbeyrac, F. Vorimore, M. Clerc, C. Bertin, T. Harkinezhad, K. Verminnen, F. Obeniche, I. Capek, C. Bébéar, B. Durand, G. Zanella, D. Vanrompay, B. Garin-Bastuji, and K. Sachse. 2009. Chlamydial infection in duck farms associated with human cases of psittacosis in France. *Vet Microbiol*. 135:82–89.
65. Laroucau, K., F. Vorimore, R. Aaziz, A. Berndt, E. Schubert, and K. Sachse. 2009. Isolation of a new chlamydia agent from infected domestic poultry coincided with cases of atypical pneumonia among slaughterhouse workers in France. *Infect Genet Evol*. 9:1240–1247.
66. Laroucau, K.S., F. Thierry K. Vorimore, E. Blanco, R. Kaleta, S. Hoop, D. Magnino, K. Vanrompay, G. Sachse, S.A. Myers, P.M. Bavoil, G. Vergnaud, and C. Pourcel. 2008. High resolution typing of *Chlamydophila psittaci* by multilocus VNTR analysis (MLVA). *Infect Genet Evol*. 8:171–181.
67. Lederer, P., and R. Muller. 1999. Ornithosis—studies in correlation with an outbreak. *Gesundheitswesen* 61:614–619.
68. Lemus, J.A., J.A. Fargallo, P. Vergara, D. Parejo, and E. Banda. 2010. Natural cross chlamydial infection between livestock and free-living bird species. *PLoS One*. 5:e13512.
69. Léon, O., B. Sraka, A. Ballot, C. Armand, and J.L. Guérin, 2004. Evaluation du portage de *Chlamydophila psittaci* au sein de la filière canards gras: implications pour la santé publique. In: *Proceedings des 6èmes Journées de la recherche sur les palmipèdes à foie gras*, 7–8 Octobre 2004, Arcachon, France.
70. Lublin, A., G. Shudari, S. Mechani, and Y. Weisman. 1996. Egg transmission of *Chlamydia psittaci* in turkeys. *Vet Rec*. 139:300.
71. Magnino, S., D. Haag-Wackernagel, I. Geigenfeind, S. Helmecke, A. Dovc, E. Prukner-Radovcić, E. Residbegović, V. Ilieski, K. Laroucau, M. Donati, S. Martinov, and E.F. Kaleta. 2009. Chlamydial infections in feral pigeons in Europe: Review of data and focus on public health implications. *Vet Microbiol*. 135: 54–67.
72. Martinov, S.P., and G.V. Popov. 1992. Recent outbreaks of ornithosis in ducks and humans in Bulgaria. In: *Proceedings of the European Society for Chlamydia Research*. P.A. Mardh, M. La Placa, and M. Ward, eds. *Uppsala University Centre for STD Research, Uppsala, Sweden*. 203.
73. Matsumoto, A. 1973. Fine structures of cell envelopes of *Chlamydia* organisms as revealed by freeze-etching and negative staining techniques. *J Bacteriol*. 116:1355–1365.

74. Messmer, T.O., S.K. Skelton, J.F. Moroney, H. Daugharty, and B.S. Fields. 1997. Application of a nested, multiplex PCR to psittacosis outbreaks. *J Clin Microbiol*. 35:2043–2046.
75. Meyer, K.F. 1965. Ornithosis. In: *Diseases of Poultry*, 5th ed. H.E. Biester and L.H. Schwarte, eds. Iowa State University Press, Ames, IA. 675–770.
76. Meyer, K.F., B. Eddie, and H.Y. Yanamura. 1942. Ornithosis (psittacosis) in pigeons and its relation to human pneumonitis. In: *Proceedings of the Society for Experimental Biology and Medicine*. 49:609–615.
77. Meyer, K.F. 1941. Phagocytosis and immunity in psittacosis. *Schweizerische Medizinische Wochenschrift*. 71:436–438.
78. Mölleken, K., E. Schmidt, and J.H. Hegemann. 2010. Members of the Pmp protein family of *Chlamydia pneumoniae* mediate adhesion to human cells via short repetitive peptide motifs. *Mol Microbiol*. 78:1004–17.
79. Mölleken, K., and J.H. Hegemann. 2008. The *Chlamydia* outer membrane protein OmcB is required for adhesion and exhibits biovar-specific differences in glycosaminoglycan binding. *Mol Microbiol*. 67: 403–419.
80. Morange, A. 1895. De la psittacose, ou infection spéciale déterminée par des perruches. These, Academie de Paris.
81. Mygind P., Christiansen G., Persson K., and S. Birkelund. Analysis of the humoral immune response to Chlamydia outer membrane protein 2. 1998. *Clin Diagn Lab Immunol*. 5:313–8.
82. Newman, C.P., S.R. Palmer, F.D. Kirby, and E.O. Caul. 1992. A prolonged outbreak of ornithosis in duck processors. *Epidemiol Infect*. 108:203–210.
83. Nurminen, M., E. Wahlstrom, M. Kleemola, M. Leinonen, P. Saikku, and P.H. Make. 1984. Immunologically relatedketodeoxyoctonate-containing structures in *Chlamydia trachomatis* Re mutants of *Salmonella* species, and *Acinetobacter calcoaceticus* var. *anitratus. Infect Immun*. 44:609–13.
84. Page, L.A., and J.E. Grimes. 1984. Avian Chlamydiosis (Ornithosis). In: *Diseases of Poultry*, 8th ed. M.S. Hofstad, H.J. Barnes, B.W. Calnek, W.M. Reid, and H.W. Yoder, Jr., eds. Iowa State University Press, Ames, IA. 283–308.
85. Page, L.S., W.T. Derieux, and R.C. Cutlip. 1975. An epornitic of fatal chlamydiosis (ornithosis) in South Carolina turkeys. *J Am Vet Med Assn*. 166:175–178.
86. Page, L.A. 1967. Comparison of "pathotypes" among chlamydial (psittacosis) strains recovered from diseased birds and mammals. *Bull Wildlife Dis Assn*. 3:166v175.
87. Page, L.A. 1959. Experimental ornithosis in turkeys. *Avian Dis*. 3:51–66.
88. Page, L.A. 1959. Thermal inactivation studies on a turkey ornithosis virus. *Avian Dis*. 3:67–79.
89. Pannekoek, Y, V. Dickx, D.S. Beeckman, K.A. Jolley, W.C. Keijzers, E. Vretou, M.C. Maiden, D. Vanrompay, and A. van der Ende. 2010. Multilocus sequence typing of *Chlamydia* reveals an association between *Chlamydia psittaci* genotypes and host species. *PLoS One*. 5:e14179.
90. Pavlak, M., K. Vlahovic, J. Greguric, Z. Zupanicic, J. Jercic, and J. Bozikov. 2000. An epidemiologic study of *Chlamydia sp*. in feral pigeons. *Zeitschrift fur Jagdwissenschaft*. 46:84–95.
91. Petersen, J., D.P. Wilson, G. Myers, P. Timms, and P.M. Bavoil. 2007. Type III secretion à la *Chlamydia*. *Trends Microbiol*. 15:241–251.
92. Pospischil A. 2009. From disease to etiology: historical aspects of *Chlamydia*-related diseases in animals and humans. *Drugs Today (Barc)*. 45(Suppl B):141–146.
93. Puolakkainen M. 2009. Innate immunity and vaccines in chlamydial infection with special emphasis on *Chlamydia pneumoniae*. *FEMS Immunol Med Microbiol*. 55:167–77.
94. Ritter, J. 1980. Beitrag zur Frage des Pneumotyphus [Eine Hausepidemie in Uster (Schweiz) betreffend]. *Deutsches Archiv für Klinische Medizin*. 25:53–96.
95. Roan, N.R., and M.N. Starnbach. 2008. Immune-mediated control of *Chlamydia* infection. *Cell Microbiol*. 10:9–19.
96. Robertson, T., S. Bibby, D. O'Rourke, T. Belfiore, H. Lambie, and A.H. Noormohammadi. 2009. Characterization of Chlamydiaceae species using PCR and high resolution melt curve analysis of the 16S rRNA gene. *J Appl Microbiol*. 107:2017–28.
97. Ryll, M., K.H. Hinz, U. Neumann, and K.P. Behr. 1994. Pilotstudie uber das Vorkommen von *Chlamydia psittaci*-infectionen in kommerzillen putenherden Niedersachsens. *Dtsch Tierärztl Wochenschr*. 101:163–165.
98. Sachse, K., K. Laroucau, H. Hotzel, E. Schubert, R. Ehricht, and P. Slickers. 2008. Genotyping of *Chlamydophila psittaci* using a new DNA microarray assay based on sequence analysis of *omp*A genes. *BMC Microbiology*. 8:63.
99. Sachse, K., H. Hotzel, P. Slickers, and R. Ehricht. 2005. DNA microarray-based detection and identification of *Chlamydia* and *Chlamydophila spp*. *Mol Cell Probes*. 19:41–50.
100. Sachse, K., and H. Hotzel. 2003. Detection and differentiation of Chlamydiae by nested PCR. *Methods Mol Biol*. 216:123–36.
101. Salinas, J., M.R. Caro, and F. Cuello. 1993. Antibody prevalence and isolation of *Chlamydia psittaci* from pigeons. *Avian Dis*. 37:523–527.
102. Sayada, C.H., A.A. Andersen, C.H. Storey, A. Milon, F. Eb, N. Hashimoto, N. Hirai, J. Elion, and E. Denamur. 1995. Usefulness of omp1 restriction mapping for avian *Chlamydia psittaci* isolate differentiation. *Res Microbiol*. 146:155–165.
103. Schöfl, G., A. Voigt, K. Litsche, K. Sachse, and H.P. Saluz. 2011. Complete genome sequences of four mammalian isolates of *Chlamydophila psittaci*. *J Bacteriol*. 193:4258.
104. Smith, K.A., C.T. Campbell, J. Murphy, M.G. Stobierski, and L.A. Tengelsen. 2010. Compendium of measures to control *Chlamydophila psittaci* infection among humans (psittacosis) and pet birds (Avian Chlamydiosis). *J. Exotic Pet Med*. 20:32–45.
105. Spencer, W.N., and F.W. Johnson. 1983. Simple transport medium for the isolation of *Chlamydia psittaci* from clinical material. *Vet Rec*. 113:535–6.
106. Stephens, R.S., G. Myers, M. Eppinger, and P.M. Bavoil. 2009. Divergence without difference: phylogenetics and taxonomy of *Chlamydia* resolved. *FEMS Immunol Med Microbiol*. 55:115–9.
107. Stephens, R.S., K. Koshiyama, E. Lewis, and A. Kubo. 2001. Heparin-binding outer membrane protein of chlamydiae. *Mol Microbiol*. 40:691–699.
108. Stephens R.S., S. Kalman, C. Lammel, J. Fan, R. Marathe, L. Aravind, W. Mitchell, L. Olinger, R.L. Tatusov, Q. Zhao, E.V. Koonin, and R.W. Davis. 1998. Genome sequence of an obligate intracellular pathogen of humans: *Chlamydia trachomatis*. *Science*. 282:754–759.
109. Sting, R., E. Lerke, H. Hotzel, S. Jodas, C. Popp, and H.M. Hafez. 2006. Comparative studies on detection of *Chlamydophila psittaci* and *Chlamydophila abortus* in meat turkey flocks using cell culture, ELISA, and PCR. *Dtsch Tierärztl Wochenschr*. 113: 50–4.
110. Strauss, J. 1967. Microbiologic and epidemiologic aspects of duck ornithosis in Czechoslovakia. *Am J Ophthalmol*. 63: 1246–1259.

111. Suwa, T., S. Ando, N. Hashimoto, and C. Itakura. 1990. Pathology of experimental chlamydiosis in chickens. *Nihon Juigaku Zasshi*. 52: 275–283.
112. Takahashi, T., I. Takashima, and N. Hashimoto. 1988. Shedding and transmission of *Chlamydia psittaci* in experimentally infected chickens. *Avian Dis*. 32:650–8.
113. Tan, C., R.C. Hsia, H. Shou, J.A. Carrasco, R.G. Rank, and P.M. Bavoil. 2010. Variable expression of surface-exposed polymorphic membrane proteins in *in vitro*-grown *Chlamydia trachomatis*. *Cell Microbiol*. 12:174–87.
114. Tanzer, R.J., D. Longbottom, and T.P. Hatch. 2001. Identification of polymorphic outer membrane proteins of *Chlamydia psittaci* 6BC. *Infect Immun*. 69:2428–2434.
115. Tappe, J.P., A.A. Andersen, and N.F. Cheville. 1989. Respiratory and pericardial lesions in turkeys infected with avian or mammalian strains of *Chlamydia psittaci*. *Vet Pathol*. 26:386–395.
116. Theunissen, H.J., N.A. Lemmens-den Toom, A. Bruggraaf, E. Stolz, and M.F. Michel. 1993. Influence of temperature and relative humidity on the survival of *Chlamydia pneumoniae* in aerosols. *App Environ Microbiol*. 59:2589–2593.
117. Van Droogenbroeck, C., L. Dossche, T. Wauman, S. Van Lent, T.T.T. Phan, D.S.A. Beeckman, and D. Vanrompay. 2011. Ovotransferrin as an antimicrobial in turkeys naturally infected with *Chlamydia psittaci*, avian metapneumovirus and *Ornithobacterium rhinotracheale*. *Vet Microbiol*. 153:257–263.
118. Van Droogenbroeck, C., D.S.A. Beeckman, K. Verminnen, M. Marien, H. Nauwynck, L. de Thibault de Boesinghe, and D. Vanrompay. 2009. Simultaneous zoonotic transmission of *Chlamydophila psittaci* genotypes D, F and E/B to a veterinary scientist. *Vet Microbiol*. 135:78–81.
119. Van Droogenbroeck, C., M. Van Risseghem, L. Braeckman, and D. Vanrompay. 2009. Evaluation of bioaerosol sampling techniques for the detection of *Chlamydophila psittaci* in contaminated air. *Vet Microbiol*. 135:31–7.
120. Van Droogenbroeck, C., D.S.A. Beeckman, E. Cox, and D. Vanrompay. 2008. Prophylactic use of ovotransferrin against chlamydiosis in SPF turkeys. *Vet Microbiol*. 132:372–378.
121. Van Loock, M., K. Loots, M. Van Heerden, D. Vanrompay, and B.M. Goddeeris. 2006. Exacerbation of *Chlamydia psittaci* pathogenicity in turkeys superinfected by *Escherichia coli*. *Vet Res*. 37:745–755.
122. Van Loock, M., K. Loots, S. Van de Zande, M. Van Heerden, H. Nauwynck, B.M. Goddeeris and D. Vanrompay. 2006. Pathogenic interactions between *Chlamydia psittaci* and avian pneumovirus infections in turkeys. *Vet Microbiol*. 112:53–63.
123. Van Loock, M., T. Geens, L. De Smit, H. Nauwynck, P. Van Empel, C. Naylor, H.M. Hafez, B.M. Goddeeris and D. Vanrompay. 2005. Key role of *Chlamydia psittaci* on Belgian turkey farms in association with other respiratory pathogens. *Vet Microbiol*. 107:91–101.
124. Van Loock, M., K. Verminnen, T.O. Messmer, G. Volckaert, B.M. Goddeeris, and D. Vanrompay. 2005. Use of a nested PCR-enzyme immunoassay with an internal control to detect *Chlamydophila psittaci* in turkeys. *BMC Infect Dis*. 5:76.
125. Van Loock, M., D. Vanrompay, B. Herrmann, J. Vander Stappen, G. Volckaert, B.M. Goddeeris, and K.D.E. Everett. 2003. Missing links in the divergence of *Chlamydophila abortus* from *Chlamydophila psittaci*. *Int J Syst Evol Microbiol*. 53: 761–770.
126. Vanrompay, D., E. Cox, G. Volckaert, and B. Goddeeris. 1999. Turkeys are protected from infection with *Chlamydia psittaci* by plasmid DNA vaccination against the major outer membrane protein. *Clin Exp Immunol*. 118:49–55.
127. Vanrompay, D., P. Butaye, C. Sayada, R. Ducatelle, and F. Haesebrouck. 1997. Characterization of avian *Chlamydia psittaci* strains using *omp1* restriction mapping and serovar-specific monoclonal antibodies. *Res Microbiol*. 148:327–333.
128. Vanrompay, D., G. Charlier, R. Ducatelle, and F. Haesebrouck. 1996. Ultrastructural changes in avian *Chlamydia psittaci* serovar A-, B-, and D- in Buffalo Green Monkey cells. *Infect Immun*. 64:1265–1271.
129. Vanrompay, D., J. Mast, R. Ducatelle, F. Haesebrouck, and B. Goddeeris. 1995. *Chlamydia psittaci* in turkeys: pathogenesis of infections in avian serovars A, B, and D. *Vet Microbiol*. 47:245.
130. Vanrompay, D., R. Ducatelle, and F. Haesebrouck. 1995. Pathology of experimental chlamydiosis in turkeys. *Vlaams Diergeneeskundig Tijdschr*. 60:19–24.
131. Vanrompay, D., R. Ducatelle, and F. Haesebrouck. 1995. *Chlamydia psittaci* infections: a review with emphasis on avian chlamydiosis. *Vet Microbiol*. 45:93–119.
132. Vanrompay, D., R. Ducatelle, and F. Haesebrouck. 1994. Pathogenicity for turkeys of *Chlamydia psittaci* strains belonging to the avian serovars A, B, and D. *Avian Pathol*. 23:247–262.
133. Vanrompay, D, A. Van Nerom, R. Ducatelle, and F. Haesebrouck. 1994. Evaluation of five immunoassays for detection of *Chlamydia psittaci* in cloacal and conjunctival specimens from turkeys. *J Clin Microbiol*. 32:1470–4.
134. Vanrompay, D., A.A. Andersen, R. Ducatelle, and F. Haesebrouck. 1993. Serotyping of European isolates of *Chlamydia psittaci* from poultry and other birds. *J Clin Microbiol*. 31:134–137.
135. Vanrompay, D., R. Ducatelle, F. Haesebrouck, and W. Hendrickx. 1993. Primary pathogenicity of an European isolate of *Chlamydia psittaci* from turkey poults. *Vet Microbiol*. 38:103–113.
136. Vanrompay D., R. Ducatelle, and F. Haesebrouck. 1992. Diagnosis of avian chlamydiosis: specificity of the modified Giménez staining on smears and comparison of the isolation in eggs and three different cell cultures. *J Vet Med B*. 39:105–112.
137. Verminnen, K., D.S.A. Beeckman, S. De Smedt, N. Sanders, and D. Vanrompay. 2010. Vaccination of turkeys against *Chlamydophila psittaci* through optimised DNA formulation and administration. *Vaccine*. 28:3095–3105.
138. Verminnen, K., B. Duquenne, D. De Keukeleire, B. Duim, Y. Pannekoek, L. Braeckman, and D. Vanrompay. 2008. Evaluation of a *Chlamydophila psittaci* diagnostic platform for zoonotic risk assessment. *J Clin Microbiol*. 46:281–285.
139. Verminnen, K., M. Van Loock, H.M. Hafez, R. Ducatelle, F. Haesebrouck, and D. Vanrompay. 2006. Evaluation of a recombinant enzyme-linked immunosorbent assay for detecting *Chlamydophila psittaci* antibodies in turkeys. *Vet Res*. 37: 623–632.
140. Wang, Y., R.J. Skilton, L.T. Cutcliffe, E. Andrews, I.N. Clarke, and P. Marsh. 2011. Evaluation of a high resolution genotyping method for *Chlamydia trachomatis* using routine clinical samples. *PLoS One*. 6:e16971.
141. Wittenbrink, M.M., M. Mrozek, and W. Bisping. 1993. Isolation of *Chlamydia psittaci* from a chicken egg: Evidence of egg transmission. *J Vet Med, Series B*. 40:451–452.
142. Yang, J., Y. Ling, J. Yuan, W. Pang, and C. He. 2011. Isolation and characterization of peacock *Chlamydophila psittaci* infection in China. *Avian Dis*. 55:76–81.

143. Yang, L., C. He, Q. Yang, M. Lei, W. Liu, and C. Zhang. 2007. Survey on *Chlamydia* infection in poultry. *Chinese J Vet Med*. 43:41–42.
144. Yuan, Y., K. Lyng, Y.X. Zhang, D.D. Rockey, and R.P. Morrison. 1992. Monoclonal antibodies define genus-specific, species-specific, and cross-reactive epitopes of the chlamydial 60-kilodalton heat shock protein (hsp60): specific immunodetection and purification of chlamydial hsp60. *Infect Immun*. 60:2288–2296.
145. Zhang, F., S. Li, J. Yang, W. Pang, L. Yang, and C. He. 2008. Isolation and characterization of *Chlamydophila psittaci* isolated from laying hens with cystic oviducts. *Avian Dis*. 52: 74–78.
146. Zhou, J., G. Lin, F. Zheng, X. Gong, and G. Wang. 2010. Isolation of *Chlamydophila psittaci* from laying hens in China. *Vet Res*. 3:43–45.

IV Fungal Diseases

Chapter 25 Fungal Infections 1077

Chapter 25

Fungal Infections

Michael J. Dykstra, Bruce R. Charlton, Richard P. Chin, and H. John Barnes

Introduction

Few fungi are common pathogens in avian species, and they are opportunistic rather than obligate parasites. All are members of the kingdom Fungi. A recent report of pythiosis in an ibis has brought a member of the Oomycota in the kingdom Stramenopila to the discussion of fungal infections, although these organisms are not true fungi (5). Fungi are unicellular or multicellular heterotrophic eukaryotes that derive nutrition by absorption, reproduce by asexual or sexual means or both, and possess cell walls. Fungi are divided into 4 phyla based on their sexual structures (Ascomycota, Basidiomycota, Chytridiomycota, and Zygomycota). Fungi without a known sexual phase ("fungi imperfecti") are included in a fifth artificial taxonomic group, Deuteromycota (1, 3, 4, 6).

Historically, fungi have been classified according to the morphologic characteristics of their sexual (teleomorph) and asexual forms (anamorph), with the teleomorph form having precedence in nomenclature, under the umbrella of Kingdom Plantae. This nomenclatural practice has continued despite removal of fungi from the Kingdom Plantae in the 1970s. The result is at times confusing, or even crosswise to common sense.

For instance, note the nomenclature applied to aspergilli. The genus *Aspergillus* belongs to the phylum Deuteromycota, which is composed entirely of anamorphs; however, some aspergilli also have teleomorphs, so by definition they belong to a separate phylum (Ascomycota) and are assigned to a different genus as well. For example, *Aspergillus fischerianus*, the asexual anamorph, becomes *Neosartorya fischeri*, the sexual teleomorph, on the basis of meiotic production of ascospores. Additionally, reproductive patterns aside, synonyms have been applied lavishly to certain fungal species and diseases over time. An attempt is made in this chapter to present taxonomy that conforms to the International Code of Botanical Nomenclature (Tokyo Code).

Mycotic diseases are relatively uncommon diseases but are often devastating to the infected host. Most fungi are decomposers subsisting primarily on plant materials and other organic debris but can attack living hosts under certain conditions. Most clinically important fungi, other than yeasts, produce airborne spores for dissemination. Except for the dermatophytoses, which affect the integument, animals are dead-end hosts for fungal infections, because they are not contagious.

This chapter is similar to previous editions. The first focus is aspergillosis, followed by other fungal infections representing the less common mycoses. Aspergillosis is by far the most prevalent mycosis of birds and is an economically important respiratory disease of poultry. Candidiasis is the principal fungal infection of the digestive tract of poultry. Zygomycosis has similar signs and gross lesions to aspergillosis. Ochroconosis is uncommon in modern poultry production but is regionally significant. Macrorhabdosis is a recently described mycotic infection of the proventriculus/ventriculus of unknown significance in poultry.

Histoplasmosis and cryptococcosis are rare fungal infections of poultry but are notable as public health hazards. Information on these can be found in previous editions of this book. For additional earlier references on fungal diseases, see (2).

Acknowledgement

The authors gratefully acknowledge the contributions of H.L. Chute, J.L. Richard, and R.A. Kunkle to this chapter. Much of the text has been provided by them through previous editions. Their research on mycotic infections in poultry provides the basis for our understanding of these diseases today. For the sake of brevity, early references have been deleted but can be found in this chapter in the 11th edition of *Diseases of Poultry* authored by R.A. Kunkle.

Diseases of Poultry, Thirteenth Edition. David E. Swayne.
© 2013 John Wiley & Sons, Inc. Published 2013 by John Wiley & Sons, Inc.

Aspergillosis

Introduction

Definition and Synonyms

Aspergillosis is a disease caused by infection with the genus *Aspergillus*, which is composed of approximately 180 species (28). Manifestations of aspergillosis depend on which organs or systems are involved and whether the infection is localized or disseminated. Aspergillosis in birds usually affects the lower pulmonary system with florid lesions in air sacs and lungs. In young poultry, the disease is referred to as brooder pneumonia. Other synonyms for avian aspergillosis include fungal or mycotic pneumonia, pneumomycosis, bronchomycosis, and colloquialisms such as "asper" and "air sac." Less common manifestations relate to infections of the eye, brain, skin, joints, and viscera. Two recent reviews on aspergillosis have been published. One primarily covers *Aspergillus* infections of wild and captive exotic birds (7), while the other concentrates primarily on *Aspergillus fumigatus* infections in poultry (2).

Economic Significance

The financial cost of aspergillosis is most readily apparent in turkey production where the disease primarily affects grow-out flocks. In Iowa, between 1985 and 1994, aspergillosis was reported in a yearly average of 8.3% of flocks ranging in age from 13–18 weeks (47). Mortality attributed to aspergillosis averaged 4.5%, placing it as the second most costly disease with an estimated yearly loss of $5,260/affected flock in Iowa—$338,000 annually statewide. In 2000, Iowa ranked ninth in turkey production in the United States with roughly a 3% share of national production (5). Assuming an even distribution of aspergillosis nationwide, mortality due to aspergillosis amounted to financial losses of more than $11 million yearly. However, losses from carcass condemnations typically far outstrip mortality losses.

Public Health Significance

Aspergillosis is not a zoonotic or contagious disease. Allergic pneumonitis can develop in people with frequent exposure to moldy hay, compost, or other forms of decaying organic matter in which *Aspergillus* and other allergenic organisms thrive. Humans who have uncontrolled diabetes, are pregnant, or are immunocompromised are at risk for developing fungal infections (34). Immunocompromised birds also are believed to be more susceptible to *Aspergillus* infections (7, 40).

History

Molds, likely belonging to the genus *Aspergillus*, were described in ducks, jays, and swans in the early 1800s. The first description of *Aspergillus* in a lesion was in 1842 when Rayer and Montagne identified *A. candidus* from the air sac of a bullfinch. *Aspergillus fumigatus* was first reported in the lungs of a bustard (*Otis tardaga*) by Fresenius in 1863. He named the species and used the term aspergillosis for the disease. Early investigators believed that fungi found in lesions of birds were growing saprophytically on "morbid products" within the body. Aspergillosis subsequently was found to be most common in turkeys. The disease was described in poults in 1898 and adult turkeys in 1937. Experimental pulmonary aspergillosis was easily produced by intra-thoracic injection of fungal conidia as early as 1884. In 1935, aspergillosis was produced in poults by feeding mash contaminated with *A. fumigatus* (29).

Etiology

Classification

Aspergillus fumigatus is the principal agent causing aspergillosis in poultry. Isolation of *A. flavus* is less common (40). Other rarely isolated species include *A. terreus, A. glaucus, A. nidulans, A. niger, A. nigrescens*, and *Eurotium amstelodami* (also known as *A. amstelodami*, though the name is taxonomically invalid). Both *A. fumigatus* and *A. flavus* lack a sexual stage so placing them in a taxonomic group is not based on typical phylogenetic classification criteria. Most treatments deal with orders, families, genera, and species (27, 28). Thus, a key to aspergilli will list: order Moniliales, family Moniliaceae, genus *Aspergillus*. Alternate classification schemes for the genus appear to be equally valid.

Aspergillus fumigatus *Fresenius 1863*

Colony Morphology

Aspergillus fumigatus grows rapidly on Sabouraud dextrose agar (SDA), Czapek yeast agar (CYA), or potato dextrose agar (PDA) at 25ºC–37ºC. Colonies develop a diameter of approximately 3–4 cm in 7 days. The flat colonies are initially white and turn blue-green as conidia begin to mature, especially near the center of the colony. As the colony matures, conidial masses become gray-green, but the colony edge remains white. The colony surface varies slightly among isolates; it is smooth and velvety to slightly floccose or folded. The colony reverse is usually colorless. This description represents typical characteristics of clinical isolates, but variations occur in colony color, morphology, and growth rate (27, 28, 36).

Microscopic Morphology and Staining

Hyphae measure 3–5 µm in diameter, have parallel sides, are frequently septate, and branch dichotomously. Spore-bearing branches (conidiophores) of *A. fumigatus* are smooth, colorless

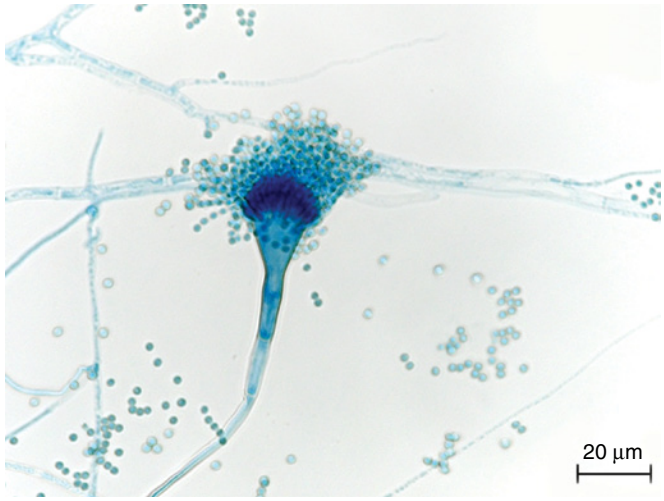

Figure 25.1. *Aspergillus fumigatus*. Conidiophore with flask-shaped vesicle, phialides, and chains of conidia. Lactophenol cotton blue, ×450. (M.J. Dykstra)

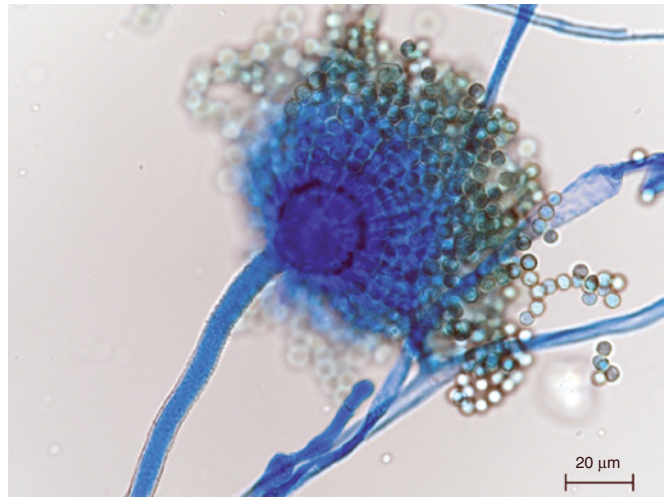

Figure 25.2. *Aspergillus flavus*. Conidiophore with globose vesicle, phialides, and radiate chains of conidia. Lactophenol cotton blue, ×410. (M.J. Dykstra)

to light green near the vesicle, up to 200–400 µm in length, and 5–11 µm in diameter. The conidiophore gradually enlarges distally to form a flask-shaped vesicle. The vesicle is 15–30 µm in diameter with a single (uniseriate) layer of conidiogenous cells called phialides over the distal half. Phialides are 5–9 µm in length. Conidial heads are predominantly columnar with parallel chains of conidia grouped tightly together, but this feature is frequently disturbed when slide mounts are made (Figure 25.1). Conidial chains may attain a length of up to 400 µm. Conidia, green in mass, are smooth to finely roughened, globose to subglobose, with a diameter of 2–3 µm.

Visualization of wet-mount specimens is improved using methylene blue or lactophenol cotton blue stains. Fungal elements in embedded tissue sections are best seen with periodic acid-Schiff (PAS) or Gomori's methenamine silver (GMS) staining.

Aspergillus flavus *Link 1809*

Colony Morphology

Aspergillus flavus grows rapidly, obtaining a colony diameter of 6–7 cm in 10 days at 25ºC on SDA, CYA, or PDA; some isolates may grow slower. Colonies are initially white but turn yellow to yellow-green with a white colony edge as conidia develop. Mature colonies may become somewhat olive-green. The colony may be furrowed radially or flat. Brown to black-brown sclerotia (densely tangled mats of mycelia), which begin as white tufts of mycelium, may be present. Isolates vary considerably in color and numbers of sclerotia, if any are present. The colony reverse varies from colorless to pinkish drab to brown in sclerotial strains. Conidial heads of *A. flavus* are radiate with the chains of conidia splitting to form loose columns, though this feature is frequently not evident in slide mounts (Figure 25.2).

Microscopic Morphology

Conidiophores (400–800 µm long and 8–17 µm in diameter) of *A. flavus* are thick-walled, rough, and colorless. Vesicles, although more elongated when young, are globose to subglobose (20–45 µm in diameter) with a row of cells (metulae) bearing phialides (biseriate) over the entire surface of the vesicle. Phialides bear chains of globose to subglobose, smooth to finely echinulate conidia with a diameter of 3–6 µm. Some isolates are uniseriate, bearing a single layer of phialides directly on the vesicles.

Growth Requirements

The causative agents of aspergillosis are ubiquitous, due in part to their broad nutritional capabilities. They commonly occur in soil, grains, and decaying plant matter. Growth is supported in virtually all laboratory media but is inhibited by cycloheximide. *Aspergillus fumigatus* grows well with chicken feather keratin as its sole carbon and nitrogen source (68) and can utilize the binding resins in fiberglass for nutrition (16).

The optimum temperature for rapid culture of *A. fumigatus* is 38ºC. The organism is thermotolerant, with growth occurring at temperatures as high as 55ºC and survival at temperatures up to 70ºC (35). Growth also occurs at temperatures as low as 9ºC and at relative humidity levels ranging from 11%–96% (48). An oxygen tension as low as 0.5% will support growth and conidiation (21).

Biochemical Properties

Identification of fungi, including aspergilli, is based primarily on colony and microscopic morphology, and growth characteristics. Biochemical criteria are infrequently used as adjuncts for species identification. Analysis of isoenzyme patterns has been examined as a taxonomic tool. The only enzyme pattern common to all strains of *A. fumigatus* is glutamate dehydrogenase (35).

Susceptibility to Chemical and Physical Agents

Some species of *Aspergillus* are quite resistant to chemical agents and can grow in sanitizing fluids, sulfuric acid, copper sulfate plating baths, and formalinized tissues in museum

specimens (67). Phenolic disinfectants are commonly used fungicidal agents. Commercial preparations of enilconazole have been used to control aspergilli in the poultry house environment (55). Certain oils derived from spices, such as cinnamaldehyde, inhibit *Aspergillus* growth (38).

Toxins

Aspergillus is among the most common mycotoxigenic genera. Aflatoxins, along with other mycotoxins, are discussed in detail in Chapter 31.

Numerous experimental studies have demonstrated that mycotoxins consumed by poultry can interfere with resistance to various infections. Additionally, toxins produced by pathogenic species of *Aspergillus*, particularly *A. flavus* and *A. fumigatus*, may be involved in the pathogenesis of *Aspergillus* infections in poultry, but no enhanced pathogenicity of aflatoxigenic strains of *A. flavus* for turkey poults was found experimentally. *Aspergillus flavus* conidia caused neither mortality nor antibody production, whereas *A. fumigatus* conidia caused approximately 50% mortality and induced antibodies in turkey poults after aerosol exposure (63). Previously, a toxin had been considered to be potentially involved in avian aspergillosis caused by *A. fumigatus* (29). Clinical signs and torticollis in turkey poults without CNS lesions (63, 64) indicated the possibility of toxin involvement in aspergillosis caused by *A. fumigatus* (66).

Gliotoxin is among several toxins produced by *A. fumigatus* (2). Most isolates obtained in an outbreak of aspergillosis in turkeys produced the toxin (57, 62). Turkeys are quite sensitive to oral doses of the toxin. It is immunosuppressive, cytotoxic, and inhibits blastogenesis of turkey peripheral blood lymphocytes (61). Gliotoxin in excess of 6 ppm occurred in tissues of experimentally infected turkey poults (59). Higher concentrations of the toxin have been found in the lungs of naturally infected turkeys (62). In a murine model of disseminated aspergillosis, animals infected with a nongliotoxin-producing strain of *A. fumigatus* survived significantly longer than mice infected with a gliotoxin-producing strain (70). It is likely that gliotoxin production is a virulence factor that contributes to the pathologic changes in aspergillosis.

Virulence Factors

Metabolites necessary for the pathogenicity of *A. fumigatus* have not been identified. A discussion of the organism's virulence factors requires consideration of its success as a saprobe, in addition to its role as an opportunistic, noncontagious pathogen. The ability to use a variety of substrates, copious production of airborne conidia, and hydrophobicity of the conidia contribute to its success as a ubiquitous saprobe. Widespread distribution of the organism ensures inhalation of conidia by susceptible hosts. Conidia are small enough (2–3 μm) to bypass physical barriers in the upper respiratory tract and become deposited deep within the respiratory system. The accelerated growth rate of the fungus at temperatures found within piles of rotting vegetation coincides with homeotherm body temperatures. *In vitro* growth of *A. fumigatus* is enhanced by hydrocortisone, the pharmaceutical equivalent of the endogenous stress-induced hormone corticosterone (44). Aspergillosis likely results more from the dose of inhaled conidia and susceptibility of the host than virulence of specific isolates.

Aspergillus fumigatus produces a number of proteolytic enzymes capable of degrading host tissues, especially the extracellular matrix. Elastinolytic and collagenolytic enzymes are of particular interest. However, studies using knock-out mutants have not identified which proteases play essential roles in the pathogenesis of pulmonary aspergillosis (35).

Recent studies have used embryonating eggs to assess virulence of various *A. fumigatus* strains (24).

Pathobiology and Epidemiology

Incidence and Distribution

Two primary forms of aspergillosis, acute and chronic, occur in poultry. Acute aspergillosis usually affects young birds and is characterized by high morbidity and mortality. Chronic aspergillosis occurs in adult birds, especially turkey breeders, or occasionally in captive birds in aviaries. While chronic aspergillosis is less common, significant economic losses can accrue in commercial poultry flocks when adult birds die due to their high value. Aspergillosis is a greater problem in confined flocks where stress factors and poor air quality may be involved, or where moldy litter or grain is present.

Contaminated poultry litter is often the source of *Aspergillus* conidia (15). Seventy-three species of fungi were isolated from air, litter, and tissues in a confinement turkey house. *Aspergillus* was among the 4 most frequently isolated fungal genera (29). Aspergilli also have been among the most common fungi found in other studies of air or litter flora of poultry houses (29). Air flora density of the major fungal genera within the poultry house decreased when the windows were opened during the spring (65). Reducing dust in poultry houses and improving ventilation resulted in a 75% decrease in the incidence of fungal disease (56). Elimination of moldy feed from the diet and environment, along with proper management of sawdust litter, prevented reoccurrence of fungal ophthalmitis in flocks in poultry houses in which there had been previously affected flocks (6).

Despite the widespread assumption that high concentrations of *Aspergillus* conidia are needed for most avian infections, a 3-year study of a puffin aviary demonstrated no outbreak of aspergillosis, even when extremely large numbers of *A. flavus* conidia were recovered from the air, following importation of birds into the facility from the wild (18). Because conidia of *Aspergillus* spp. are frequently found by air sampling in a wide variety of environments, including poultry houses (2) whether birds are infected or not, it appears that other factors such as environmental stresses, immunosuppressive compounds, inadequate nutrition, or other infectious diseases are critical for aspergillosis to develop.

Aspergillus fumigatus is found frequently, but it is not always pathogenic for young broiler chicks (12). When 16 isolates of *A. fumigatus* were compared for pathogenicity by air sac inoculation of turkey poults, mortality was not influenced by the number of conidia given or source of the isolates; a single environmental isolate produced no mortality (48). In addition to *Aspergillus*, the following genera also were found within lungs and air sacs: *Penicillium*, *Paecilomyces*, *Cephalosporium*, *Trichoderma*, *Scopulariopsis*, and *Mucor* (29).

Natural and Experimental Hosts

Aspergillosis occurs in most domesticated and several wild animals. Aspergillosis in humans has increased dramatically during recent years as a complication of therapeutic immunosuppression (3, 34). Poultry and exotic and wild avian species appear to be particularly susceptible to pulmonary aspergillosis. Unlike birds, immunocompetent mammals are naturally resistant to pulmonary aspergillosis unless exposed to overwhelming doses of conidia. Rodents used as models for studying invasive pulmonary aspergillosis must be pretreated with cortisone or other immunosuppressive agents for the disease to develop (43). In contrast, experimental aspergillosis in turkeys requires no pretreatment (30).

Age of Host Commonly Affected

Pulmonary aspergillosis is the most common form of the disease in avian species and is seen most frequently in young broiler chickens, turkey poults, young and mature breeder turkeys, captive raptors, and penguins (51). The disease is known to occur in a wide variety of avian species, and all birds, captive or free, domesticated or wild, should be considered potentially susceptible to *Aspergillus* infections.

Pulmonary Aspergillosis

Differences in susceptibility to pulmonary aspergillosis caused by *A. fumigatus* were found among Japanese quail, turkeys, and 3 strains of chickens (29). Inbred strains were more susceptible than crossbred or outbred strains during an outbreak of aspergillosis in hatchery chicks (29).

Systemic Aspergillosis

Systemic aspergillosis in poults and caponized 5-week-old cockerels has been reported. The latter resulted from a caponizing infection (29). Systemic aspergillosis in turkey poults caused by *A. flavus* involved the sternum (20). Intravenous inoculation of *A. fumigatus* conidia causes acute miliary hepatitis (33).

Dermatitis

Cutaneous lesions as a manifestation of aspergillosis are rare in avian species. However, necrotic granulomatous dermatitis from which *A. fumigatus* was isolated has been described in chickens (29).

Omphalitis

Simultaneous *A. fumigatus* infection of the yolk sac and lungs of young turkey poults has been reported. Increased morbidity and mortality were observed in birds 3–9 days of age. Culture of the organism and demonstration of mycelial invasion of the tissues by histopathology confirmed the diagnosis (10).

Figure 25.3. Broiler chicken, 7 days, ocular aspergillosis. This form is characterized by extensive keratoconjunctivitis. Panophthalmitis is another form of ocular aspergillosis in which internal structures, especially those in the posterior segment of the eye, are affected. The latter is considered to result from hematogenous spread. (T. Abdul-Aziz)

Mycotic osteomyelitis

A. fumigatus infection in bone caused deformed vertebrae resulting in partial paralysis of young chickens. Presumably, infections were sequela to lung disease with hematogenous dissemination of the organism (8).

Ophthalmitis

Ocular aspergillosis in birds due to *Aspergillus* (Figure 25.3) has been reported since 1940. Similar lesions have been described in young chicks and turkey poults (29). Infections were typically unilateral and two forms of ocular aspergillosis were apparent among these early cases. One form involved primarily the conjunctiva and external surfaces of the eye with development of caseous exudate or plaques beneath the nictitating membrane. Fungus was readily isolated from cultured plaque material. The other form did not involve the cornea and occurred in turkey poults with concurrent

respiratory aspergillosis. Most pathologic changes occurred in the posterior eye involving the vitreous humor with extension into adjacent tissues. Pathogenesis of the two conditions was apparently quite different. Keratitis and superficial infections probably resulted from exposure of conjunctival surfaces to fungal elements from environmental sources. Mycotic ophthalmitis involving the posterior eye most likely resulted from hematogenous dissemination of the organism from a primary respiratory infection. Although not frequent, the latter type of eye infection usually is apparent in birds with respiratory involvement. The superficial eye infection was reproduced in chickens by introducing conidia of *A. fumigatus* into the eye. The yellow caseous plaque can become adherent to the cornea in the superficial type of infection. After injecting conidia of *A. fumigatus* into the abdominal air sacs of chickens, one bird developed a plaque on the surface of one eye. The route of infection to the eye in this bird was not determined (29).

Ocular swelling in *Aspergillus* infections may resemble infectious coryza or vitamin A deficiency in chicks (29).

Recently, Beckman and coworkers (6) described a somewhat different fungal ophthalmitis in a group of chicks from a breeder farm that had recurring problems with similar eye infections. The causative agent was *A. fumigatus*, but in addition to exudate within the conjunctival sac, there was histopathologic evidence of fungal invasion of the anterior chamber and cornea. Although the chicks had respiratory lesions, the authors did not consider the route of infection to be hematogenous from the respiratory lesions, because there was no involvement of intraocular structures.

Turkeys experimentally exposed to aerosols of conidia occasionally developed a cloudy eye with retinitis, iridocyclitis, and secondary involvement of the remainder of the eye (65). There was a cellular infiltration of heterophils and macrophages, and cellular debris and fungal elements were present in the chambers and retina. The pecten was severely involved with edema, heterophils, mononuclear cells, and fungal elements present. In some turkeys, the pecten contained granulomas.

Following oculonasal vaccination against Newcastle disease, mortalities increased rapidly in chickens that had contracted superficial ocular aspergillosis in the hatchery. This type of ocular involvement occurred in 5 widely separated flocks of young poults and 3 breeding flocks (29).

Encephalitis

Numerous reports describe encephalitic or meningoencephalitic aspergillosis in a variety of avian species. In turkeys, necrotic foci in the cerebrum or cerebellum were found in naturally occurring aspergillosis (29) and in turkey poults experimentally exposed to aerosols of *A. fumigatus* conidia (64). Besides turkeys, meningoencephalitis also has occurred in Eider ducklings and chickens (73). Others have described encephalitic aspergillosis in turkey poults and chickens occurring as caseous necrotic lesions of the cerebrum and cerebellum or as granulomatous encephalitis (29).

Fungal hyphae occurred in the cerebellum of a poult that exhibited nervous signs. In an outbreak of pneumomycosis and nervous manifestations, *A. fumigatus*, *A. niger*, and *Penicillium variotii* were recovered from internal organs. *Aspergillus fumigatus*, and later *Diplococcium* spp., were recovered from the brains of poults that showed incoordination. In most cases, concurrent infection of the lungs and air sacs occurred, along with the kidney and liver (29).

Transmission, Carriers, and Vectors

Aspergillosis is not transmissible. Infections are acquired from environmental exposure. Disturbances of soil or movement of hay, compost, or litter can produce aerosols that provide for respiratory exposure to conidia. Fresh litter, especially if it has been wet previously and contaminated with *A. fumigatus*, is associated with outbreaks of aspergillosis (15).

Aspergillosis can be acquired *in ovo*. Egg embryos are quite susceptible to infection by *A. fumigatus* during incubation. Embryo contamination occurred when a petroleum jelly suspension of *A. fumigatus* conidia was applied to the surface of incubating eggs, and infections increased when the incubating eggs were dusted with *A. fumigatus* conidia. Within eight days after the dusting application, the organism had penetrated the eggshell (29).

Outbreaks of aspergillosis in chicks often originate in hatcheries. A mortality rate of 1%–10% was observed among 21 ranches where 210,000 chicks were involved. Infection could not be traced to hatching eggs but was readily found in incubators, hatchers, incubator rooms, and intake ducts. Signs and lesions were noted in some day-old chicks, but generally, classic lesions were observed in chicks at 5 days of age. Chicks up to 2 days old were infected easily with *A. fumigatus* spores by contaminating the forced-draft incubator with wheat seeded with *A. fumigatus*. Chicks older than 3 days were resistant to infection (29).

Incubation Period

In an outbreak in captive wild poults, mortality totaling 75% began at 5 days, reached a peak at 15 days, and subsided at 3 weeks of age (29). Some affected poults died with convulsions within 24 hours. Onset of signs did not occur before 48 hours in turkey poults experimentally infected with high doses of *A. fumigatus* or *A. flavus* (65). Airsacculitis can be evident within 24 hours after intra-air sac inoculation of *A. fumigatus* (30).

Signs

Signs can be subtle, even in cases in which postmortem examination reveals severe airsacculitis. Dyspnea, gasping, and accelerated breathing may be present. When these signs are associated with other respiratory diseases, such as infectious bronchitis or infectious laryngotracheitis, they often are accompanied by gurgling and rattling noises, whereas in aspergillosis there usually is no sound. Somnolence, inappetence, emaciation, increased thirst, and pyrexia were attributed to aspergillosis. The birds rapidly became emaciated and developed diarrhea in the later stages. Dysphagia occurred in

cases when the esophageal mucosa was involved. Mortality was as high as 50% in confined birds on some farms, whereas birds running outdoors were more resistant or escaped infection entirely. Serous secretions from nasal and ocular mucosa also have been described. About 10% of a flock of adult chickens with aspergillosis had signs resembling laryngotracheitis but mortality was not increased. However, egg production temporarily declined (29).

Because torticollis and/or a lack of equilibrium occur in both experimental (64) and naturally occurring *Aspergillus* infections (29), this should be considered a characteristic sign of avian aspergillosis. However, other infectious agents, including other genera of fungi, can cause similar signs.

Broiler breeder pullets naturally infected with *A. flavus* exhibited increased mortality and decreased growth rate, but no respiratory distress. This presentation differed from typical *A. fumigatus* infections, which are characterized by clinical respiratory signs (40).

Morbidity and Mortality

Aspergillosis is characterized by high morbidity and mortality in chicks and poults and low morbidity and mortality in mature poultry. Morbidity can be underestimated in finishing flocks until slaughter inspection reveals pulmonary lesions. Condemnation of turkey carcasses due to airsacculitis is the second leading cause of postmortem condemnations in the United States (1).

An outbreak of aspergillosis associated with contaminated litter resulted in loss of approximately one-third of a flock of turkey poults (15). The litter may have supported fungal growth during the outbreak. Mortality of 96% in a flock of turkey poults was recorded in another outbreak. The possible connection of the addition of glucose to drinking water of this flock and the source of infection was not addressed by the authors (46). A change of feed and litter may have helped quell an outbreak in chickens, which resulted in 26% mortality (52).

Approximately 50% of turkey poults died following a 10-minute aerosol exposure to conidia of *A. fumigatus*, resulting in 5×10^5 colony-forming units/g of lung tissue (63). No deaths occurred in turkey poults similarly exposed to *A. flavus*, perhaps because of the greater size of *A. flavus* conidia (3–6 µm) compared to *A. fumigatus* conidia (2–3 µm) as they might not reach as deeply into the respiratory tract. All turkey poults aerosol-exposed to 2.2×10^6 viable units of *A. fumigatus*/g of lung tissue died by day 5. Lower doses (5.2×10^5 viable units) delayed and reduced mortality. Deaths began at 3–4 days post exposure.

Pathology

Gross Lesions

Lesions of uncomplicated pulmonary aspergillosis evolve over several days and diminish in a few weeks. Acute lesions of experimental aspergillosis in turkeys rapidly progressed in severity. At 24 hours, white miliary foci were present on air sac membranes, and lung lesions consisted of straw-colored gelatinous subpleural edema. Air sacs became progressively thicker and opaque with focal granulomas that increased in size and changed shape from raised domes (1 mm) to flat or umbilicated plaques (2–5 mm) that tended to coalesce. Extensive white discoloration of lungs and granulomatous pneumonia were evident by 72 hours after intra-air sac infection with *A. fumigatus* (30).

Lung lesions in experimental aerosol infection of turkey poults consisted of small white caseous nodules (approximately 1 mm in diameter) scattered throughout lung tissue (Figure 25.4), usually accompanied by similar sized caseous plaques on thickened air sac membranes (65) (Figure 25.5). Occasionally, red-tinged ascites was present. Yellow-white nodules up to 5 × 8 mm were found in the lungs of wild poults reared in captivity (29). In an outbreak of aspergillosis in

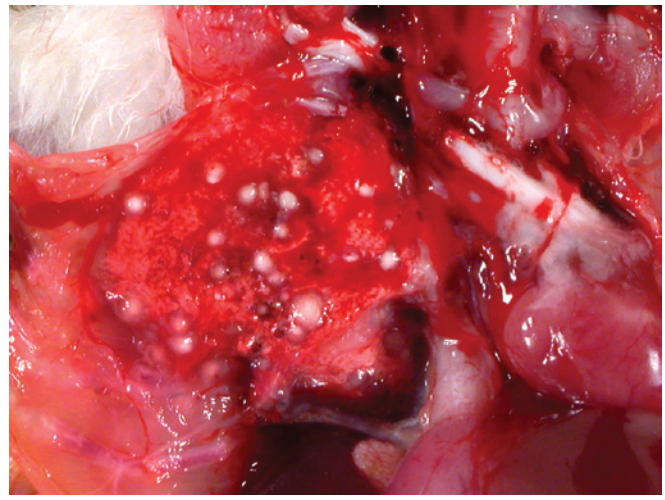

Figure 25.4. Turkey poult, 2 weeks. Numerous caseous nodules in the lung are characteristic of respiratory aspergillosis ("brooder pneumonia"). (H.J. Barnes)

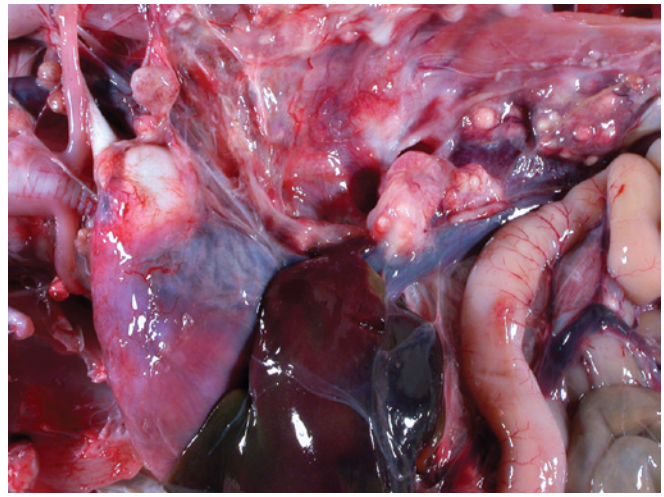

Figure 25.5. Turkey, 8 weeks. Air sacs containing numerous spherical nodules are granulomas caused by *Aspergillus flavus*. (H.J. Barnes)

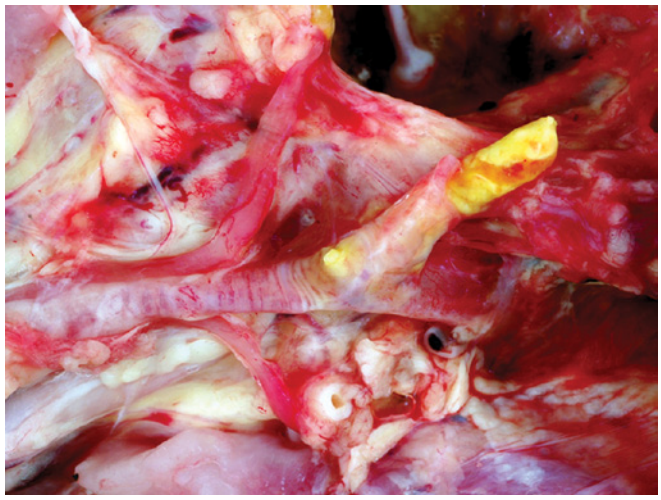

Figure 25.6. Broiler breeder, 61 weeks. Caseous exudate in the syrinx was caused by aspergillosis. (H.J. Barnes)

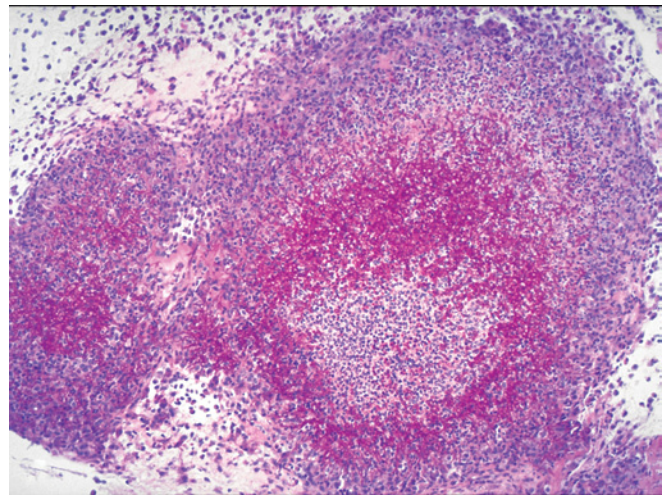

Figure 25.7. Experimentally induced granulomatous lesion in the air sac due to aspergillosis. A central caseous core is bordered by a narrow, uniform palisade of macrophages and small giant cells surrounded by a less distinct broad zone of predominantly macrophages and scattered heterophils. PAS stain, ×90. (R.A. Kunkle and H.J. Barnes)

chicks, yellow foci were not found but lungs were a diffuse gray-yellow (29).

In advanced cases of aspergillosis, when the organism is exposed to air, it can sporulate on the surface of caseous lesions and on the walls of thickened air sacs, producing visible green-gray mold growth (65).

Caseous, gelatinous, or less commonly mucoheterophilic exudate may be present in the syrinx of infected birds (Figure 25.6). Localized tracheal aspergillosis caused by *A. flavus* was characterized by grossly visible yellow caseous plaques that adhered to the mucosal surface, occasionally occluding the trachea and reddened tracheal walls (4).

Lesions in the brain have been described as white to yellow circumscribed areas that are usually visible on the surface. They may be in the cerebellum or cerebrum or, less frequently, both (65).

Ascites in chickens was a frequent sequela to pulmonary aspergillosis caused by *A. fumigatus*. Acute *cor pulmonale* was the suspected cause of vascular failure (25).

Histopathology

In a study of acute pulmonary aspergillosis in turkey poults, granulomatous airsacculitis and pleuritis were seen as early as 24 hours after intra-air sac inoculation with *A. fumigatus* (30). Air sac membranes were thickened up to 100-fold by massive infiltrates of heterophils, multinucleate giant cells, and other leukocytes. Germinating conidia were seen in the membrane interstitium, and lymphohistiocytic perivasculitis was discernible in less severely affected areas. Granulomas had centers composed of necrotic cellular debris and heterophils with a peripheral palisade of epithelioid macrophages and aggregates of lymphocytes (Figure 25.7). Examination of heterophilic granulomas stained with Gomori's methenamine silver stain revealed large numbers of germinating conidia centrally and hyphae extending peripherally through the layer of macrophages (Figure 25.8). Lung lesions consisted of heterophilic

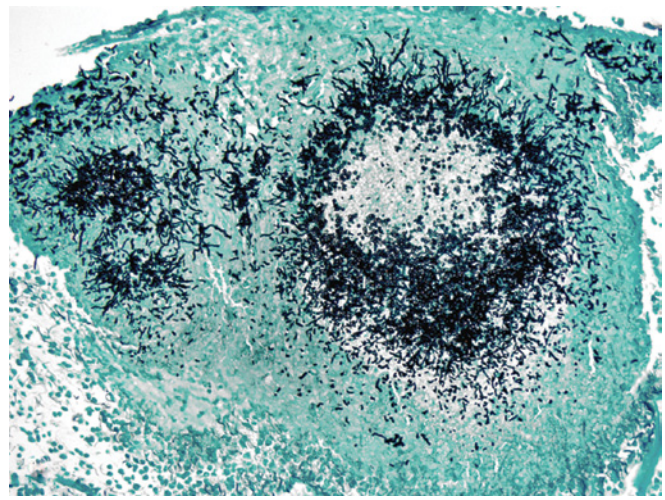

Figure 25.8. Organisms stain well with Gomori's methenamine silver stain ×90. (R.A. Kunkle and H.J. Barnes)

and lymphohistiocytic or granulomatous pleuritis and pneumonia with edema and hemorrhage in the initial 48 hours, but had progressed to extensive effacement of parenchymal architecture because of necrosis, hemorrhage, and massive infiltrates of leukocytes by 72 hours. Epithelioid macrophages admixed with multinucleate giant cells were arranged in sheets. Intact and degenerate heterophils predominated in areas of necrosis. Septate hyphae were mostly localized to areas of necrosis and aggregates of multinucleate giant cells. Vascular invasion with thrombosis is often seen in severe cases.

Nonviable *A. fumigatus* conidia produced a transient airsacculitis and pneumonia characterized by edema and infiltrates of heterophils and macrophages (32). Multinucleate giant cells were not present in these lesions, in contrast to

active infections with *Aspergillus*, in which both epithelioid macrophages and multinucleate giant cells were prominent features.

In a study of subacute and chronic phases of aspergillosis, examination of lung tissues from turkey poults revealed no differences in histopathologic lesions caused by *A. fumigatus* or *A. flavus* (58). Lesions seen in the first 2 weeks of the study were characterized by focal accumulations of lymphocytes, some macrophages, and a few giant cells. Later, lesions consisted of granulomas with a central area of necrosis containing heterophils surrounded by macrophages, giant cells, lymphocytes, and some fibrous tissue. By 8 weeks postexposure, surviving poults had mature fibrous granulomatous lesions consisting of necrotic centers surrounded by giant cells and a thick layer of fibrocytes and collagen containing a few scattered heterophils. Using Gridley's fungal stain, the organisms could be seen within the necrotic areas of the lesions. Areas of conidial production were seen in tissue sections of the well-oxygenated bronchi, bronchioles, and air sacs.

Brain lesions consisted of solitary abscesses with necrotic centers infiltrated with heterophils and surrounded by giant cells. Hyphae were seen in the central area of some lesions.

Eye lesions were characterized by edema of the pecten, which was infiltrated heavily with heterophils and mononuclear cells. Granulomas were found in the pecten. Fungal hyphae, heterophils, macrophages, and cellular debris were found in the chambers and retina of the eye. Edema and some heterophils were found in the sclera and surrounding tissues. In cases of ophthalmitis in turkeys, primary involvement was in the vitreous humor and adjoining tissues. In one turkey, hyphae were seen in the center of the lens (29).

In the trachea, occlusions consisted of fungal hyphae and heterophilic granulomatous exudate, the mucosa was necrotic and infiltrated with macrophages, and fibroplasia was evident in the subadjacent tracheal wall (4).

Pathogenesis

Conidia of *A. fumigatus* are 2–3 μm in diameter. Once inhaled, they are deposited deep within the respiratory tract. In a study of infected chick lung tissue, conidia adhered to epithelial surfaces and smooth muscle cells lining the apices of interatrial septa of parabronchi shortly after their inhalation (29). Conidia swelled slightly prior to producing germ tubes, which by 25 hours had developed into septate hyphae. Presumably, this transformation occurred in both intra- and extracellular locations as conidia were found on and in host cells. Hyphae were frequently seen within the cytoplasm of giant cells with little evidence of detriment to either. Examination of infected air sacs revealed conidia attached to the membrane surface within 1 hour. They were translocated from the luminal surface to the interior of the membrane, where conidial germination was evident within 24 hours (30, 32). Necrosis of tissue occurred concurrently with the fulminant inflammatory response, which, by 24 hours, included massive numbers of heterophils admixed with cellular debris. Proteases expressed during the vegetative growth of *A. fumigatus*, in addition to heterophil-mediated lysis, may contribute significantly to the destruction of pulmonary parenchyma (23).

Conidia of *A. fumigatus* may be disseminated by the hematogenous route in poultry as has been described in humans (29). *Aspergillus fumigatus* was isolated from the blood of turkeys immediately after a 15-minute aerosol exposure of conidia. At this time, macrophages harvested by lung lavage contained numerous ingested conidia (58). This may be the route of dissemination that results in eye and brain lesions (65). Some experimentally exposed turkeys had torticollis, and brain lesions were found at necropsy. Torticollis also occurs in naturally occurring infections of *A. fumigatus* in turkeys, geese, and chickens (29). The organism usually was cleared from the bloodstream by 24 hours post exposure.

Immunity

Evidence for immunity against aspergillosis in poultry is lacking; however, the majority of turkeys experimentally infected with *A. fumigatus* recover from pulmonary aspergillosis within 4–5 weeks if they are not re-exposed to the agent (32, 33). Likewise, resolution of pulmonary aspergillosis has been described in Japanese quail surviving experimental infection (9). The mechanisms involved in convalescence from aspergillosis in avian species have not been described. It has been proposed that macrophages and neutrophils alone, independent of lymphocyte responses, clear *Aspergillus* from pulmonary tissues in immunocompetent mammals (69). However, immunologic memory is assumed to have a role in protecting mice against lethal challenge subsequent to low-dose challenge (29).

Experimental vaccination of turkeys against aspergillosis has yielded only limited protection by decreasing mortality (64) or lessening early histopathologic lesions (60). Vaccination did not protect against pulmonary lesions and may have increased the likelihood of chronic *A. fumigatus* infection. Some vaccinates remained culture-positive and nonvaccinated controls were culture-negative at 8 weeks post challenge.

Natural recovery from aspergillosis does not appear to confer protection in turkeys. Convalescent turkeys remained susceptible to pulmonary aspergillosis in which recovery from unilateral *A. fumigatus*-induced airsacculitis did not protect against contralateral air sac challenge (31). Likewise, passive cellular immunization failed to protect turkeys against *A. fumigatus* challenge and splenic lymphocytes did not respond to conidial antigen preparations, regardless of the previous exposure status of the donor turkey (33).

Diagnosis

Isolation and Identification of Causative Agent

Aspergillosis usually is diagnosed at postmortem examination, often based on identifying characteristic caseous nodules in the lungs or plaques in the air sacs of affected birds. Bronchoscopy was useful for observing plaques in the bronchi and trachea of an ostrich, and biopsy specimens of infected material were obtained for histologic evaluation, bacterial

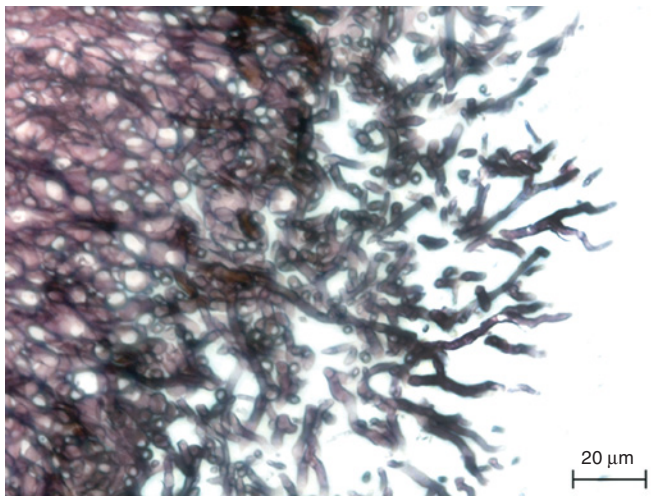

Figure 25.9. Hyphae consistent with *Aspergillus* sp. in air sac wall of a chicken. Note the dichotomous branching toward the right side of the image. Gomori methenamine silver, ×405. (M.J. Dykstra)

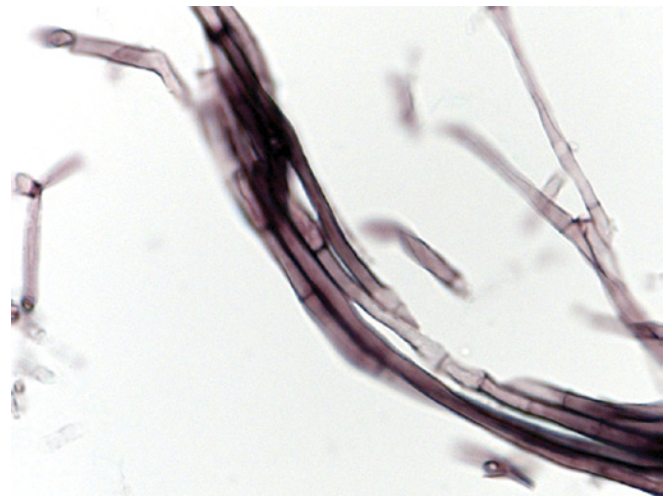

Figure 25.10. Hyphae consistent with *Aspergillus* sp. in air sac wall of a chicken. Note the numerous cross walls (septa). Gomori methenamine silver, ×800. (M.J. Dykstra)

and fungal examination, and culture (39). Although it is sometimes possible to observe fungal growth and sporulation on the caseous nodules or plaques, especially in the air sacs, confirmation should be made by isolation and identification of the causative fungus. Although *A. fumigatus* is the most likely agent of avian aspergillosis, other species of *Aspergillus* and other fungal genera can cause the disease. Therefore, isolates should be identified.

Because most agents causing the mycoses are ubiquitous saprophytes, diagnostic samples need to be collected carefully using aseptic technique. These samples can be examined microscopically by placing a small portion of the nodule in 20% potassium hydroxide (KOH) on a microscope slide, teasing the material apart, and covering it with a glass coverslip. Following gentle heating of the slide over a flame, the specimen can be examined for hyphae within the exudate. If the preparation is too thick, the slide will need to be incubated 12–24 hours in a moist chamber and re-examined. To aid in elucidating the fungus, KOH can be mixed with ink dye (Ink blue, Parker Pen Co., Janesville, WI). Hyphae of *Aspergillus* stained with the ink dye appear as blue-stained, septate, dichotomously branched structures 2–8 µm in diameter with hyphal walls that are generally parallel (Figures 25.9, 25.10).

Aseptically obtained specimens can be plated directly onto appropriate mycologic media. Alternatively, specimens can be placed into saline, minced briefly in a tissue grinder, and then streaked onto mycologic media. Replicate plates should be incubated at both 27º and 37ºC. Collected fluids can be centrifuged, and the sediment examined microscopically or cultured as above.

Satisfactory media for isolating and identifying most isolates from cases of aspergillosis include SDA, CYA, and PDA. All cultures should be examined daily, and peripheral portions of fungal colonies transferred to fresh media to lessen the chance of bacterial overgrowth, which can suppress fungal growth.

For light microscopic examination, a small portion of the colony containing reproductive structures can be placed into a drop of suitable mounting medium (e.g., lactophenol cotton blue) on a clear glass slide, teased apart, covered with a coverslip, and examined.

Serological Tests

Serologic tests are of limited value due to the nonspecific nature of the fungal antigens. Agar gel precipitin was used in comparisons of *A. fumigatus* and *A. flavus* infections in turkey poults. Although most of the *A. fumigatus*-infected poults were positive for precipitating antibodies, poults infected with *A. flavus* were not (63). Antibody response, as measured by enzyme-linked immunosorbent assay (ELISA) and agar gel immunodiffusion, was erratic, although most poults with high antibody scores had marked lesions and low weight (49). Additionally, a direct ELISA technique has been used in turkeys with a correlation occurring between exposure level and ELISA titer (53). Perhaps use of serologic methods to identify poults with aspergillosis for culling would be advantageous because there is no legal or effective therapy for treating positive birds.

Aspergilli produce a range of antigenic molecules. Antigenic and allergenic properties of *A. fumigatus* extracts have long been recognized in mammalian aspergillosis, but few reports have been made of the serologic responses of birds infected with *Aspergillus*. The qualitative and quantitative variability of the composition of the antigenic extracts, even between batches prepared in the same laboratory, and the multitude of antigens produced increase the difficulty in preparing standardized reagents (22, 35).

A multiyear study using an ELISA test to identify *Aspergillus* antibodies in 1,314 plasma samples from a number of avian orders showed equivocal relationships between the presence of antibody and aspergillosis in the birds (11).

Detection of galactomannan, a major cell wall component of *Aspergillus* spp., in sera or bronchoalveolar lavage (BAL) fluid with an immunoenzymatic test (Platelia, Bio-Rad, Hercules CA) or a latex agglutination test (LA Pastorex *Aspergillus*, Bio-Rad, Hercules CA) has proven useful in aiding early diagnosis of invasive pulmonary aspergillosis in humans (26).

A recent study using one of the commercial galactomannan assay kits to test plasma samples from 56 confirmed avian aspergillosis cases demonstrated a diagnostic accuracy of 70% (12), suggesting that this procedure could be a useful diagnostic test for potentially infected breeder populations, along with classical histologic examination and fungal identification following culture. In cases in which invasive techniques are contraindicated or fungi could not be isolated from lesions or tissue or body fluid samples did not reveal fungal elements, this test could help determine proper therapeutic approaches.

Recent use of a modified limulus assay to detect endotoxin (FungitellBeacon Diagnostics Laboratory, East Falmouth MA) for testing human patient serum for the presence of 1-β–D-glucan residues found in the cell walls of many fungi has successfully demonstrated the presence of fungi such as *Aspergillus* spp. and *Candida* spp., though some known cases of cryptococcosis showed equivocal results and a zygomycosis case yielded a negative test (26, 41, 45).

Despite the fact that polymerase chain reaction (PCR) techniques have been in use for almost 20 years by various investigators to help diagnose invasive aspergillosis in humans, the lack of standardized methodologies has hampered the interpretation and reliability of PCR results (72). In addition to recent attempts to standardize PCR techniques for aspergillosis (72), some workers have reported increased reliability when combining PCR with galactomannan assays to help identify invasive aspergillosis (42).

The use of serological assays in the poultry industry would be potentially helpful when dealing with high-value breeder populations.

Differential Diagnosis

Clinical signs of avian aspergillosis are nonspecific and depend on the organ systems involved. Pulmonary aspergillosis is usually differentiated from other avian respiratory diseases by the granulomatous lesions observed at necropsy; however, *Staphylococcus aureus* pneumonia in newly placed poults can appear similar (37). Exudative fibrinous or fibrinoheterophilic airsacculitis and pneumonia are also frequently seen in cases of mycoplasmosis, colibacillosis, fowl cholera, and chlamydophilosis. Mycobacteriosis and other mycoses also need to be considered when granulomas predominate.

Intervention Strategies

Management Procedures

Aspergillus fumigatus infection in young chicks and poults has been moderately controlled by hatchery sanitation. Sophisticated sampling equipment and media are available to monitor air in hatcheries. Moldy litter or feed and access to musty, moldy straw stacks should be avoided. Examination of premises or materials used for feed or litter usually will reveal the source of infection.

Areas around feed hoppers and watering places are fertile areas for growth of molds. Unless a permanent yard system is used, frequent moving of feed troughs and watering places is advisable. Placing feed containers and watering fountains on screened, elevated platforms helps prevent turkeys from picking up molds that develop in such places. Drainage is advisable for areas where water is likely to stand after it rains.

Daily cleaning and disinfection of feed and water utensils aids in eliminating infection. Spraying the ground around containers with chemical solutions may be advisable if it is impossible to change feeding areas frequently. In outbreaks, a 1:2,000 aqueous solution of copper sulfate for all drinking water may be used to aid in preventing the spread, although it should not be relied on as a permanent method of control. The mold count of contaminated litter and the mortalities of turkeys due to aspergillosis was reduced by treating the litter with nystatin and copper sulfate (15). A thiabendazole solution sprayed on green oak wood shaving litter was efficacious in reducing mold spore counts in the litter, and decreasing pulmonary lesions of aspergillosis in turkeys raised on that litter (17). Mortality due to aspergillosis in a broiler flock was reduced within 2 days of treatment of litter with an enilconazole solution (54).

Prevention is currently the preferred means of control. This usually involves eliminating the source of the organism, such as moldy feed and litter, and treating the poultry houses and litter with antifungal compounds. In spite of precautions and preventive measures, outbreaks of aspergillosis frequently occur in some houses and at certain times of the year, particularly during the winter in closed rearing houses. Evidently, increased ventilation within poultry rearing houses reduces the airborne mycoflora (65), suggesting that this could be used as a preventive measure in controlling aspergillosis. Natural ventilation appeared to be better than forced-air ventilation. A significant effect of the type of natural ventilation design (curtain or sliding door), however, was not evident in studies evaluating turkey performance using mortality, average daily gain, feed conversion, condemnations at slaughter, or average individual bird weight as measures of production (13).

Generally, an effective means of therapy for avian aspergillosis is not available. Although certain drugs have been used for the treatment of mammalian aspergillosis, they are usually not cost-effective for poultry. The most active fungistats *in vitro* against 64 strains of *Aspergillus*, 26 strains of *Rhizopus*, and 2 strains of *Mucor* from 56 lung tissue samples of poultry with aspergillosis were nystatin, amphotericin B, crystal violet, and brilliant green (29). Infections in chick embryos have been controlled by amphotericin B (29) and phenylmercuric dinaphthylmethane disulfonate (29).

Dimethyldithiocarbamate, injected subcutaneously, was effective against *A. fumigatus* infection in 5- and 10-week-old

chickens. The drug significantly reduced the lesion size and isolation of the organism from tissues in comparisons between treated and untreated infected birds (14). Exposure of chicks to enilconazole fumigation at the time of experimental infection with *A. fumigatus* reduced morbidity and mortality (71). In another experimental aspergillosis study comparing the efficacy of azole compounds, treatment of poults by crop gavage with itraconazole was the most effective in reducing lesion scores and weight loss (50). Miconazole has been used successfully for treating raptors with clinical aspergillosis (19).

Vaccines are not a practical alternative, and none are commercially available. Experimental vaccine preparations have generally not been efficacious with the possible exception of a germling (germinated conidia) vaccine prepared from *A. fumigatus*. Mortality was reduced by 50% in turkey poults vaccinated with the germling vaccine and subsequently challenged with aerosols of *A. fumigatus* conidia (65).

Candidiasis (Crop Mycosis)

Definition and Synonyms

Candidiasis is a mycosis caused by infection with the mycelial yeasts of the genus *Candida*, principally *C. albicans*. Birds are particularly susceptible to oral and crop candidiasis, which resembles thrush in humans. The term thrush is often used for *Candida* infections of the upper digestive tract in people and other animals, but crop mycosis is the most commonly used term for infection in birds. Stomatitis oidica, muguet (French), soor (German), moniliasis, oidiomycosis, and sour crop are other terms for the disease.

Significance

Candidiasis affects chickens, turkeys, geese, pigeons, guinea fowl, pheasants, quail, and several nonpoultry avian species (1, 3, 5, 8, 9). Occurrence of avian candidiasis is sporadic, but outbreaks can be costly. The first major reported outbreak resulted in mortality up to 20% in young turkeys, and another report the following year described the loss of 10,000 chicks because of candidiasis (1). Forty percent mortality occurred in a relatively recent outbreak in a flock of 6-week-old turkeys. The causative agent in that case was predominantly *C. rugosa* instead of *C. albicans* (3).

History

The significance of yeast cells in infections of the digestive tract of humans was recognized by Langenbeck in 1859. Historical synonyms for the disease and etiologic agent can be confusing. Moniliasis denotes infection with the genus *Monilia*, which is an outdated and invalid taxon that has been replaced by *Candida* (Third International Microbiological Congress, 1939). The term moniliasis is rarely used today.

Jungherr stated that *Monilia albicans* colonization is common in gallinaceous birds, pathogenic to birds and rabbits following intravenous (IV) inoculation, and indistinguishable from strains isolated from people. He associated *M. albicans*, *M. krusei*, and *Oidium pullorum* with cases of candidiasis but considered *M. krusei* insignificant. *Mucor* spp. and aspergilli also were associated with some cases. Hinshaw reported candidiasis in 12 flocks of turkeys, with lesions similar to those in chickens. Gierke documented an outbreak of a candidiasis-like disease in turkeys in California. The disease in turkeys and other fowl in New South Wales was reported by Hart. The disease in turkeys and chickens in California has been reviewed by Mayeda. Blaxland and Fincham studied 5 serious outbreaks in young turkeys. Investigators agreed that the mycotic infections were usually associated with poor hygiene conditions or other debilitating infections, and indicated the complexity of the etiology.

In 1939, Stovall presented a specific set of environmental conditions, which improved identification of yeasts from birds because this allowed the biologic characteristics of an isolate to remain constant (1).

Etiology

The primary agent of candidiasis is *C. albicans*, although other *Candida* species have been isolated from both healthy and diseased birds. In a mycological survey of crops from broilers, *C. albicans* comprised 95% of isolates. Other species included *C. ravautii*, *C. salmonicola*, *C. guilliermondii*, *C. parapsilosis*, *C. catenulata*, and *C. brumptii* (11). Only *C. albicans* and *C. parapsilosis* were associated with crop mycosis. An outbreak of candidiasis in turkeys yielded isolates of *C. albicans*, *C. rugosa*, *C. famata*, *C. tropicalis*, and *C. guilliermondii. C. rugosa* was the sole isolate from several affected crops (3).

Candidiasis is an opportunistic endogenous mycosis that results from a disturbance of the microflora or other debilitation of the host, rather than exposure to an external source. Extremes of age and concurrent disease are often implicated when immunosuppression is suspected to be the underlying problem. Prolonged or otherwise inappropriate antimicrobial therapy that upsets microflora ecology is the most likely initiator of candidiasis.

Pathogenesis and Epidemiology

Incidence and Distribution

Candida species have a worldwide distribution. They constitute part of the normal microflora of the digestive system and can be readily isolated from the intestines and mucocutaneous surfaces of clinically normal birds, humans, and other animals.

Mycosis of the digestive tract may occur more frequently than limited reports suggest. Perhaps the disease is not considered very significant. However, serious outbreaks have been reported in many species of birds (see History) and candidiasis is potentially zoonotic.

Clinical Signs

Signs are not specific for candidiasis. Affected chicks show poor growth, stunting, listlessness, and roughness of feathers. When it is a secondary infection, signs of the primary disease may predominate.

Young birds are more susceptible than older birds to mycosis of the digestive tract. As infected birds grow older, they tend to recover from the infection. In one outbreak, losses amounted to 10,000 of 50,000 chicks less than 60 days of age. Also, turkeys younger than 4 weeks of age succumbed rapidly to infection. In contrast, a high percentage of recoveries occurred when birds were older than 3 months of age (1).

Gross Lesions

Lesions occur most frequently in the crop and consist of thickening of the mucosa with white to off-white, raised circular or rugose lesions (Figure 25.11). Often, curd-like pseudomembranous patches that are peeled easily from the eroded mucosal surface are seen. The mouth and esophagus may be diphtheritic and eroded.

When the proventriculus is involved, it is swollen, serosa has a glossy appearance, and mucosa is hemorrhagic and often covered with catarrhal or necrotic exudate. The frequent association of candidiasis with other debilitating conditions, such as ventricular (gizzard) erosions and intestinal coccidiosis, needs to be considered. It is unlikely that gizzard erosions are directly related to candidiasis. Likewise, thickened intestines with watery contents that are frequently noted in cases of candidiasis are probably caused by coccidia or other protozoa.

Systemic candidiasis resulted when 14-day-old broiler chickens were inoculated intravenously with a suspension of *C. albicans* cells. Growth of the birds was severely retarded, neural disturbances were noted, and there was marked hepatic, renal, and pancreatic congestion.

Cutaneous candidiasis resulted in feather loss and superficial dermatitis in 70% of a flock of 18-month-old laying chickens. Comb candidiasis in roosters in a broiler breeder flock produced up to 10% morbidity without increased mortality or reduced fertility (4).

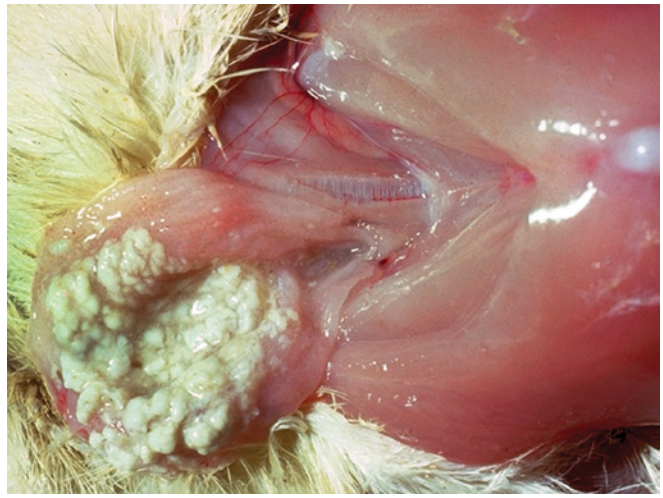

Figure 25.11. Candidiasis (crop mycosis). Crop is markedly thickened by a soft, yellow-white pseudomembrane that has a curd-like appearance. (H.J. Barnes)

Microscopic Lesions

Colonization of the keratinized stratified squamous epithelium of oral, crop, and esophageal mucosa is typically limited to the stratum corneum, which may spread into the superficial stratum spinosum. The mucosal surface is covered by exudate composed of necrotic debris, sloughed epithelial cells, leukocytes, bacterial colonies, and the yeast and pseudohyphal forms of *Candida*. Epithelial edema and parakeratotic hyperkeratosis may be evident. Epithelial inflammation is characterized by mixed infiltrates of macrophages, lymphocytes, plasmacytes, and heterophils. Superficial epithelial microabscesses, submucosal edema, and interface inflammation may be present. Bacteria are often numerous in the exudate. Submucosal colonization with attendant inflammation is less frequent.

In typical *Candida* infections, there are both mycelial and yeast forms within the lesions. Yeast cells are oval and 3–6 μm in diameter. Mycelia consist of both hyphae and pseudohyphae. Pseudohyphae are composed of elongated yeast-like cells arranged in chains that appear similar to hyphae but have prominent constrictions between adjoining cells. Hyphae have parallel sides, are septate, and measure 3–5 μm in width. Fungal morphology in tissue sections is best seen with either periodic acid Schiff or Gomori's methenamine silver stains (Figure 25.12).

Focal periportal necrosis in the liver of some birds suggests the action of a toxin. A soluble endotoxin, toxic for mice, has been isolated from *C. albicans*. Vascular damage in infected turkeys may be associated with *Candida* endotoxin (1). Atheromatous lesions were present on the intimal surface of the abdominal aorta in more than 50% of turkeys exposed to *C. albicans*, whereas only 12.5% of uninfected turkeys had similar lesions. *Candida* isolated from infected humans produces a metabolite similar to gliotoxin produced by *Aspergillus*. Gliotoxin, an epipolythiodioxopiperzine,

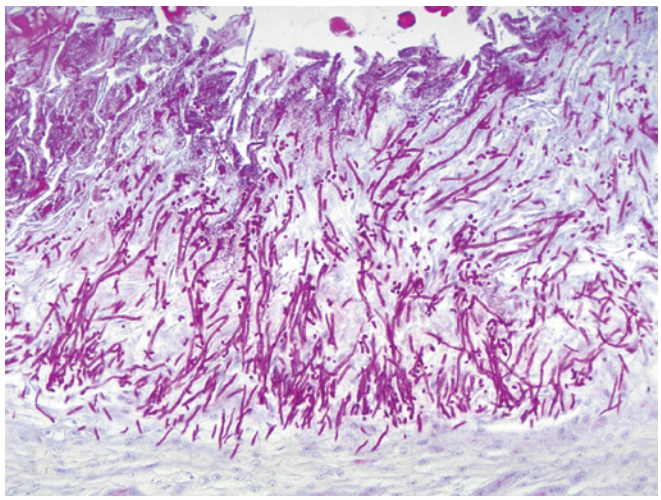

Figure 25.12. In this section of affected crop, the perpendicular arrangement of hyphae, minimal inflammation, and lack of invasion of deeper tissues are characteristic microscopic changes in crop mycosis caused by *Candida*. PAS, ×70. (H.J. Barnes)

possesses immunomodulating and antiphagocytic properties (7).

Diagnosis

A clinical picture including poor hygiene or history of long-term antimicrobial therapy is supportive when candidiasis is suspected. Observation of characteristic proliferative white curd-like lesions and heavy growth, predominantly of yeast colonies on primary culture, serves to diagnose candidiasis. Because it is possible to cultivate *C. albicans* from normal tissues, an original heavy growth of the organism is required for diagnosis. Direct microscopic examination of fresh tissue samples is useful for demonstrating pseudohyphae and budding yeast. *Candida* stains Gram positive.

Aseptically collected scrapings of mucosal lesions can be streaked onto SDA with 50 µg/ml chloramphenicol and 0.5 mg/ml cycloheximide for inhibiting bacterial and mold growth, respectively. Additional media containing only chloramphenicol also should be used, because some *Candida* isolates are sensitive to cycloheximide. Incubation of duplicate plates at both 27ºC and 37ºC is recommended. Plates should be examined daily for 5 days, but not discarded until after 1 month. On SDA, *Candida* produces a white to cream-colored, high-convex colony after incubation for 24–48 hours at 37ºC.

Microscopic morphology of young cultures consists of oval budding yeast cells about 5.5 × 3.5 µm. Hyphae and occasionally chlamydospores, which are spherical, swollen cells with a thickened cell wall, are seen in older cultures. Formation of chlamydospores is facilitated by growth on Cornmeal-Tween 80 agar. Clusters of blastoconidia on the sides of pseudohyphae are a distinguishing feature, as is germ-tube production in appropriate media (11).

Candida species can be identified by their utilization of carbohydrates. Commercial carbohydrate assimilation panels (API20C Yeast system [BioMerieux Vitek, Inc., Hazelwood, MO] and RapID Yeast Plus System [Innovative Diagnostic Systems, L.P., Norcross, GA]) are available (6, 10).

Treatment and Control

Because candidiasis is likely to be related to unhygienic, unsanitary, overcrowded conditions, these conditions need to be corrected. Affected birds need to be segregated for protection against cannibalism.

Denatured alcohol and coal-tar derivatives were ineffective as disinfectants, but iodine disinfects were effective. For treatment, one level teaspoon of powdered copper sulfate ("bluestone," $CuSO_4$) can be added to 2 gallons of drinking water in nonmetal containers every other day for 1 week. An Epsom salt flush after treatment is recommended. Using a 1:2,000 solution of $CuSO_4$ for turkeys as the sole source of drinking water during the course of the outbreak is usually effective. However, $CuSO_4$ was found to be ineffective for treating or preventing candidiasis in experimentally infected chicks and poults (1). Lesions in the mouth can be treated by local application of a suitable antiseptic. Appearance of the disease in very young chicks suggests that the egg shell surface could be a source of infection. Dipping eggs in an iodine solution prior to incubation would prevent this possibility.

C. albicans mixed with poultry droppings and applied to wooden boards was killed after exposure to 2% formaldehyde or 1% sodium hydroxide solution for 1 hour. Treatment with 5% aqueous iodine monochloride in hydrochloric acid for 3 hours also was effective for disinfection (1).

Nystatin is useful for treating candidiasis in chickens and turkeys. A 220-mg nystatin/kg diet was effective in eliminating candidiasis in a flock of turkeys. The highest level of nystatin (110 mg/kg) showed significant protection against mycotic infection. In experimental candidiasis in both chickens and turkeys, the severity of crop lesions was significantly reduced in the group fed the lowest level of nystatin (11 mg/kg). Turkeys fed nystatin (100 g/ton) had higher average weights and milder crop lesions than untreated controls. Dispersing nystatin in drinking water at 62.5–250 mg/L with sodium lauryl sulfate (7.8–25 mg/L) for 5 days successfully treated crop mycosis in chickens. Candidiasis in chickens was successfully prevented by adding nystatin at a minimum level of 142 mg/kg ration for 4 weeks (1). *In vitro* drug susceptibility testing of clinical isolates of *Candida* resulted in the recommendation that nystatin be administered by water because poultry with candidiasis tend to show decreased feed consumption but increased water consumption (2).

Adding chlortetracycline (500 g/ton) to a vitamin A-deficient ration had no effect on the incidence or severity of candidiasis (1).

Sporadic Fungal Infections

Dermatophytosis (Favus)

Dermatophytosis, dermatomycosis, ringworm, and favus are terms applied to fungal infections of skin. Favus usually is used to denote the disease in poultry. Favus has a worldwide distribution but its occurrence is sporadic. The infection is contagious and transmissible to humans, similar to dermatophytoses of other animals.

The primary etiologic agent of favus, *Microsporum gallinae*, was first described in 1881 as *Epidermophyton gallinae*, later as *Achorion gallinae*, then *Trichophyton gallinae*, and eventually accepted as *Microsporum gallinae*. Favus caused by *M. gallinae* has been reported in chickens, turkeys, ducks, quail, and canaries (4). Favus is rarely encountered in commercial flocks. It occurs most commonly in backyard, hobby, or other small chicken flocks (1, 2, 3).

Microsporum gallinae is a primary pathogen. Other than skin lesions, affected birds are typically healthy. However, if the disease is left unchecked, it will spread gradually through a flock and can produce ringworm lesions in people in contact with the chickens. The infection typically produces white scaly or crusty lesions on the comb and skin of the head and neck with loss of feathers.

Microscopically, fungal colonization is limited to the epidermis. The skin surface is thickened by orthokeratotic hyperkeratosis and serocellular crusts with heterophils admixed with hyphae. Acanthosis and acantholysis with hydropic degeneration may be present. Lymphohistiocytic and heterophilic epidermitis and dermatitis are seen. Examination of feather follicles reveals fungal colonization of the keratinized shaft. In tissues stained with periodic acid-Schiff or Gomori's methenamine silver stains, fungal morphology consists of branching, septate hyphae with parallel sides, 2–5 μm in diameter. Skin scrapings placed into a drop of 10% KOH on a glass slide, which is then coverslipped and gently heated over a flame, can be used to visualize intact and fragmented intralesional hyphae.

Scrapings can be cultured on SDA with 50 μg/ml chloramphenicol and 0.5 mg/ml cycloheximide and incubated at or around 27°C. Colonies of *M. gallinae* usually develop within 1–2 weeks at 27°C, or about 4 weeks at 20°C. Colonies are initially white and velvety, but become tinged with pink as the culture ages. The colony reverse is initially yellow, which gradually changes to red. Microscopically, cultures are composed of slender (2–5 μm) branching, septate hyphae bearing abundant microconidia and fewer macroconidia. Microconidia are pyriform (pear-shaped) and measure 2 × 4 μm. Macroconidia (6–8 × 15–50 μm) have thin smooth or echinulate walls, contain 4–10 cells, are blunt tipped, and have a curved and tapering base (5).

Introduction of birds with lesions of favus into existing flocks should be avoided. Birds with favus need to be segregated to prevent transmission of the agent. Other reservoirs, such as contaminated soil, may exist, but *M. gallinae* has been isolated only from infections. There is no label-approved treatment for poultry, but topical application of miconazole ointment on affected areas is apparently efficacious (2). Use of examining gloves with proper disposal is encouraged to prevent transmission to people.

Ochroconosis (Dactylariosis)

Ochroconosis is a sporadic fungal encephalitis of birds caused by the dematiaceous, thermophilic fungus *Ochroconis gallopava* (formerly *Dactylaria gallopava*) (1), first described in 1964 as *Diplorhinotrichum gallopavum* (1). Young chickens, turkey poults, and quail chicks have been affected with the disease (1, 2). Rare infections occur in people, especially immunosuppressed transplant patients (3).

Although ochroconosis occurs infrequently, it can be serious in an affected flock causing moderate mortality approximating the morbidity rate. An outbreak in a flock of young chickens resulted in fatal encephalitis in 200 birds from a flock of 65,000. The disease was reproduced experimentally by injecting a spore suspension into the left posterior thoracic air sac, left maxillary sinus, and cerebrum. A mortality rate of 3%–5% occurred in an outbreak of 60,000 broilers due to ohroconosis. Ochroconosis in turkey poults caused 20% mortality (1) and mortality ranged from 15%–20% in an outbreak involving Japanese quail chicks (2).

Clinical signs are consistent with central nervous system disease and include incoordination, loss of equilibrium, tremors, torticollis, paralysis, and death. Gross lesions may be confined to the brain with involvement of both cerebellum and cerebrum. Lesions have been described as focally extensive, circumscribed, firm, and gray or red (1, 2). Pulmonary granulomas are seen in some cases (1).

Histologically, lesions are characterized by multifocal to coalescing areas of necrosis infiltrated with numerous heterophils, macrophages, and multinucleated giant cells. Dematiaceous (pigmented) hyphae of *Ochroconis* are readily apparent in H&E-stained tissue sections. Hyphae typically are scattered throughout the lesion in a random arrangement and are yellow to light brown, septate, irregularly branched, and 1.2–2.4 μm in diameter. Fungal elements are frequently located within multinucleated giant cells.

Small pieces of lesions can be ground and inoculated onto slants of SDA and incubated at both 24°C and 37°C.

Ochroconis gallopava grows well at both room temperature and 37ºC; however, maximum growth of this thermophilic fungus is achieved at 45ºC. Chloramphenicol (0.05 g/liter) added to the media retards bacterial growth. Growth is inhibited on media containing cycloheximide (1). After 2–5 days on SDA agar at 24ºC or 37ºC, colonies are velvety, gray-brown with a flat or wrinkled surface. The reverse side of the colony is a deep purple-red. Red pigment diffuses into the surrounding medium, forming a halo around the colony. Microscopic examination shows light tan to brown septate hyphae with numerous oval, 2-celled, brown conidia ($3.2 \times 9.0\,\mu m$) borne on short unbranched conidiophores.

Ochroconosis has been associated with contaminated litter and egg incubators. Introduction of contaminated wood chips and sawdust litter was implicated in an outbreak in chickens (1). The organism apparently prefers acidic environments with moderately high temperatures. *Ochroconis gallopava* occurs and grows in effluents of acid hot springs, thermal soils, and coal waste piles (1, 3). Removal of contaminated litter and decontamination of incubators by fumigation is recommended when the disease occurs.

Zygomycosis (Mucormycosis)

Zygomycosis is caused primarily by fungi belonging to the genera *Mucor*, *Rhizopus*, *Absidia*, *Rhizomucor*, and *Mortierella*. Historically, the term phycomycosis has been used for this group, but it is not the name of a recognized taxon. Mucormycosis is a commonly used term for these infections because most zygomycosis cases are caused by members of the Order Mucorales, but this is a problematic usage because *Mortierella* is in the order Mortierellales.

Clinical syndromes associated with zygomycosis depend on the organ or system infected. Zygomycoses are acquired from environmental sources; are not contagious; and occur in birds, mammals, and humans. Infection of mammals is associated with immunosuppression or diabetes.

Zygomycoses are uncommon in avian species. Both localized and systemic infections in birds have been reported (2). Multifocal white nodules in the lungs were the only lesion in a chicken with pulmonary zygomycosis. Diagnosis of zygomycosis was confirmed by histopathology (4). Disseminated zygomycosis with concurrent pulmonary aspergillosis affected a flock of layer cockerels, but not pullets, although they were housed together. Mortality was increased and granulomas were found in lung, air sac, peritoneum, liver, spleen, and kidney. *Rhizopus* was isolated from granulomas in various tissues, but only *Aspergillus* was isolated from lung lesions (5). *Absidia corymbifera* caused zygomycosis in broiler chicks. High levels of the fungus in soil and litter were considered the source of the infection (6). Zygomycotic airsacculitis, with involvement of intercostal muscles, in a duck yielded growth of *Mucor* (3). Zygomycotic ventriculitis and proventriculitis resulting from *Rhizopus* (7) or *Mucor* infection (2) have been described in ostriches. Impaction predisposes to the disease (1).

Zygomycoses can be diagnosed with relative assurance by histopathology. Lesions are characterized by heterophilic granulomatous or granulomatous inflammation, usually with numerous multinucleated giant cells. Necrosis and angioinvasion occur frequently. Granulomas typically have a necrotic center. Zygomycetes are more easily visualized with periodic acid-Schiff or Gomori's methenamine silver stains. Hyphae are relatively wide (7–20 μm) with nonparallel sides and irregular distensions, and have few or no septa and infrequent random branching.

Specific etiologic diagnosis is based on growth and colony characteristics and microscopic morphology. Samples can be streaked on SDA with chloramphenicol. Cycloheximide inhibits growth. Growth is relatively rapid at 27ºC; in most cases mature colonies are obtained within 4 days. Methods to differentiate genera can be found in medical mycology texts.

Macrorhabdosis (Megabacteriosis)

Macrorhabdosis results from heavy infections with *Macrorhabdus ornithogaster*, an opportunistic yeast that colonizes the isthmus between the proventriculus and ventriculus. Previously the organisms were considered large bacteria and called megabacteria (8). Macrorhabdosis is widespread and affects a variety of birds including poultry. Infection in pet and aviary birds ranges from serious disease with high mortality to asymptomatic carriers (1, 2, 5). Among domesticated birds, *Macrorhabdus* infection has been identified in chickens, turkeys, guinea fowl, quail, partridge, ducks, geese, pigeons, and ostriches. Affected chickens have been in noncommercial flocks and often had other concurrent diseases (1, 3, 5, 6). Possible occurrence of the organism in commercial poultry has not been studied. Day-old chicks are readily infected experimentally, the organism multiplies in the proventriculus and isthmus, and food utilization is impaired (2, 7). Japanese quail have been infected with proventricular mucosal scrapings from an infected chicken (5).

Macrorhabdosis is a chronic progressively debilitating, gastrointestinal disease characterized by emaciation, prostration, anorexia, cachexia, and death. Proventriculi are enlarged because of thickening of the walls. Moderate to marked lymphoplasmacytic and heterophilic inflammation of the proventriculus and ventriculus are seen microscopically. Numerous organisms, especially in areas of heterophilic inflammation, are present in the mucus, proventricular crypts, koilin, and, less frequently, the epithelium. Diagnosis is confirmed by finding characteristic large, Gram-variable, PAS + organisms in fecal smears, gastric mucus, or in the isthmus and adjacent proventriculus

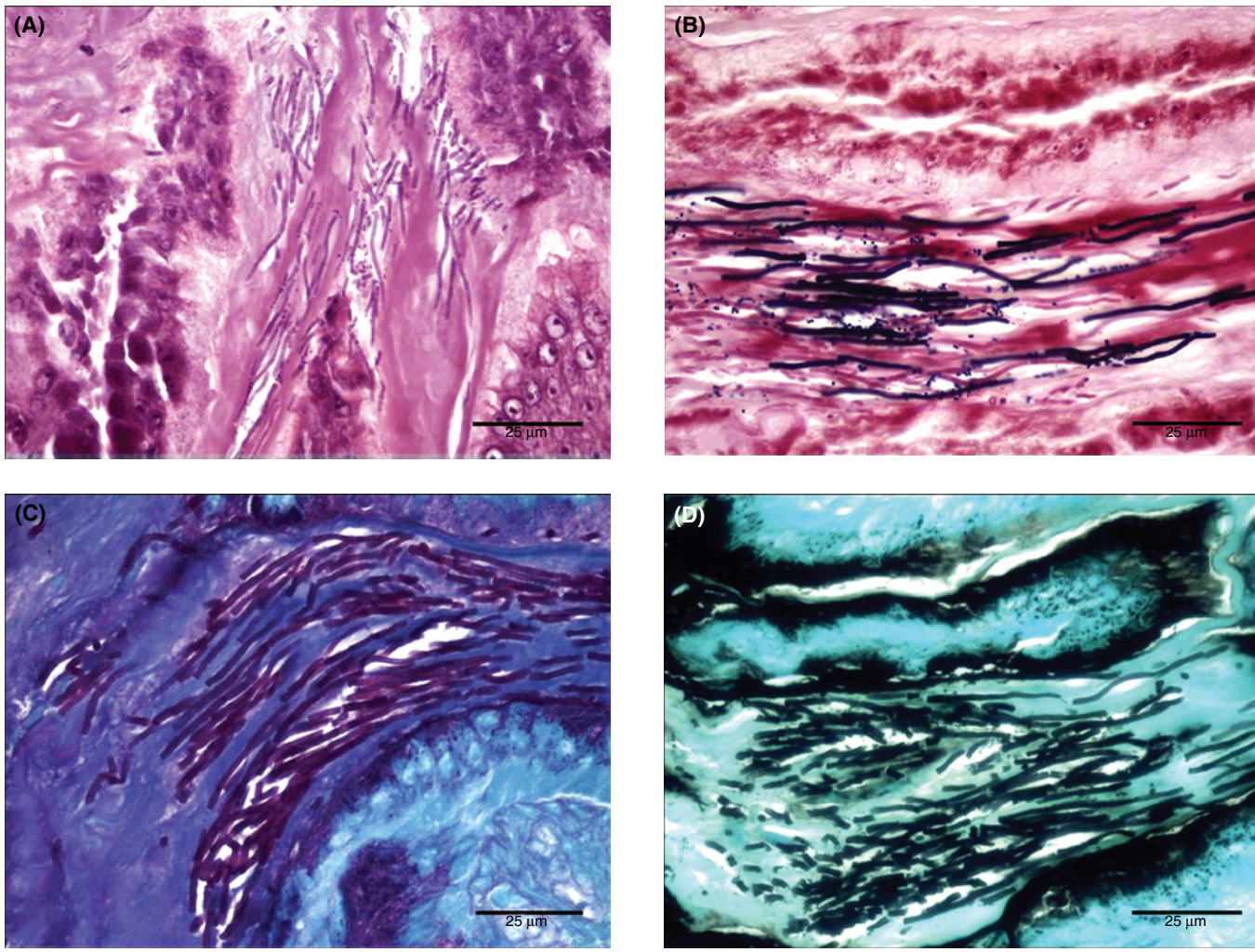

Figure 25.13 Hobby chicken, adult, gastric isthmus, *Macrorhabdus ornithogaster*. (A) Organisms are large, elongated, and arranged in parallel bundles H&E stain. They stain variably with Gram stain (B), but are strongly PAS (C) and GMS (D) positive. Bar = 25 mm (O.J. Fletcher [1]).

and ventriculus (1, 4, 5). Often they are arranged in parallel bundles (Figure 25.13). *Macrorhabdus* needs to be differentiated from *Candida*, which is similar in size and morphology. Treatment with a combination of antifungal and gastric acidifiers has reduced losses. Depopulation, thorough cleaning and disinfection, and leaving the premises vacant for at least 6 weeks are necessary to control the disease.

References

Introduction

1. Hungerford, L.L., C.L. Campbell, and A.R. Smith. 1998. *Veterinary Mycology Laboratory Manual*. Iowa State University Press, Ames, IA. 1–75.
2. Kunkle, R.A. Fungal diseases. In: *Diseases of Poultry*, 11th ed. Y.M. Saif, H.J. Barnes, J.R. Glisson, A.M. Fadly, L.R. McDougald, and D.E. Swayne, eds. Iowa State Press, Ames, IA. 883–902.
3. Kwon-Chung, K.J., and J.E. Bennett. 1992. *Medical Mycology*. Lea and Febiger, Philadelphia, PA. 1–866.
4. Pal, M. 2007. *Veterinary and Medical Mycology*. Indian Council of Agricultural Research, Krishi Anusandhan Bhawan, Pusa, New Delhi 110 012. 1–401.
5. Pesavento P.A., B. Barr, and S.M. Riggs. 2008. Cutaneous pythiosis in a nestling white-faced ibis. *Vet Pathol*. 45:538–541.
6. Sutton, D.A., A.W. Fothergill, and M.G. Rinaldi. 1998. *Guide to Clinically Significant Fungi*. Williams & Wilkins Co., Baltimore. 1–471.

Aspergillosis

See (29) for references prior to 1980.

1. Anon. 2001. *Poultry Slaughter, 1995–2000*. National Agricultural Statistics Service, United States Department of Agriculture, Washington, D.C.
2. Arne, P., S. Thierry, D. Wang, M. Deville, G. Le Loc'h, A. Desoutter, F. Femenia, A. Nieguitsila, W. Huang, R. Chermette, and J. Guillot. 2011. *Aspergillus fumigatus* in poultry. *Int J Microbiol*. 2011:1–14.

3. Barnes, A.J., and D.W. Denning. 1993. Aspergilli—significance as pathogens. *Rev Med Microbiol*. 4:176–180.
4. Barton, J.T., B.M. Daft, D.H. Read, H. Kinde, and A.A. Bickford. 1992. Tracheal aspergillosis in 6 1/2-week-old chickens caused by *Aspergillus flavus*. *Avian Dis*. 36:1081–1085.
5. Baumel, C.P., M. Imerman, J. Lawrence, J. Sell, and D. Trampel. 2000. Iowa's turkey industry—an economic review. In: *Iowa State University Agriculture and Home Economics Experiment Station*. S. Thompson, ed. University Extension, Ames, IA.
6. Beckman, B.J., C.W. Howe, D.W. Trampel, M.C. DeBey, J.L. Richard, and Y. Niyo. 1994. *Aspergillus fumigatus* keratitis with intraocular invasion in 15-day-old chicks. *Avian Dis*. 38:660–665.
7. Beernaert, L.A., F. Pasmans, L. Van Waeyenberghe, F. Haesebrouck, and A. Martel. 2010. *Aspergillus* infections in birds: a review. *Avian Pathol*. 39:325–331.
8. Bergmann, V., G. Heider, and K. Vogel. 1980. Mykotische spondylitis als ursache von bewegungsstorungen bei broilern. *Monatsh Veterinarmed*. 35:349–351.
9. Chaudhary, S.K., J.R. Sadana, and A.K. Pruthi. 1988. Sequential pathological studies in Japanese quails infected experimentally with *Aspergillus fumigatus*. *Mycopathologia* 103:157–166.
10. Cortes, P.L., H.L. Shivaprasad, M. Kiupel, and G. Senties-Cue. 2005. Omphalitis associated with *Aspergillus fumigatus* in poults. *Avian Dis*. 49:304–308.
11. Cray, C., T. Watson, and K.L. Arheart. 2009. Serosurvey and diagnostic application of antibody titers to *Aspergillus* in avian species. *Avian Dis*. 53:491–494.
12. Cray, C., T. Watson, M. Rodriguez, and K.L. Arheart. 2009. Application of galactomannan analysis and protein electrophoresis in the diagnosis of aspergillosis in avian species. *J Zoo Wildl Med*. 40:64–70.
13. DeBey, M.C., D.W. Trampel, J.L. Richard, D.S. Bundy, L.J. Hoffman, V.M. Meyer, and D.F. Cox. 1994. Effect of building ventilation design on environment and performance of turkeys. *Am J Vet Res*. 55:216–220.
14. Delap, S.K., J.K. Skeeles, J.N. Beasley, D.L. Kreider, C.E. Whitfill, G.E. Houghten, E.M. Walker, Jr., D.J. Cannon, and P.L. Earls. 1989. *In vivo* studies with dimethyldithiocarbamate, a possible new antimicrobial for use against *Aspergillus fumigatus* in poultry. *Avian Dis*. 33:497–501.
15. Dyar, P.M., O.J. Fletcher, and R.K. Page. 1984. Aspergillosis in turkeys associated with use of contaminated litter. *Avian Dis*. 28:250–255.
16. Ezeonu, I.M., D.L. Price, S.A. Crow, and D.G. Ahearn. 1995. Effects of extracts of fiberglass insulations on the growth of *Aspergillus fumigatus* and *A. versicolor*. *Mycopathologia*. 132:65–69.
17. Fate, M.A., J.K. Skeeles, J.N. Beasley, M.F. Slavik, N.A. Lapp, and J.W. Shriver. 1987. Efficacy of thiabendazole (Mertect 340-F) in controlling mould in turkey confinement housing. *Avian Dis*. 31:145–148.
18. Faucette, T.G., M. Loomis, K. Reininger, D. Zombeck, H. Stout, C. Porter, and M.J. Dykstra. 1999. A three-year study of viable airborne fungi in the North Carolina Zoological Park R.J.R. Nabisco Rocky Coast Alcid Exhibit. *J Zoo Wildl Med*. 30:44–53.
19. Furley, C.W., and A.G. Greenwood. 1982. Treatment of aspergillosis in raptors (order falconiformes) with miconazole. *Vet Rec*. 111:584–585.
20. Ghazikhanian, G.Y. 1989. An outbreak of systemic aspergillosis caused by *Aspergillus flavus* in turkey poults. *J Am Vet Med Assoc*. 194:1798.
21. Hall, L.A., and D.W. Denning. 1994. Oxygen requirements of *Aspergillus* species. *J Med Microbiol*. 41:311–315.
22. Hearn, V.M. 1992. Antigenicity of *Aspergillus* species. *J Med Vet Mycol*. 30:11–25.
23. Iadarola, P., G. Lungarella, P.A. Martorana, S. Viglio, M. Guglielminetti, E. Korzus, M. Gorrini, E. Cavarra, A. Rossi, J. Travis, and M. Luisetti. 1998. Lung injury and degradation of extracellular matrix components by *Aspergillus fumigatus* serine proteinase. *Exp Lung Res*. 24:233–251.
24. Jacobsen, I.D., K. Grosse, S. Slesiona, B. Hube, A. Berndt, and M. Brock. 2010. Embryonated eggs as an alternative infection model to investigate *Aspergillus fumigatus* virulence. *Infect Immun*. 78:2995–3006.
25. Julian, R.J., and M. Goryo. 1990. Pulmonary aspergillosis causing right ventricular failure and ascites in meat-type chickens. *Avian Pathol*. 19:643–654.
26. Kedzierska, A., P. Kochan, A. Pietrzyk, and J. Kedzierska. 2007. Current status of fungal cell wall components in the immunodiagnostics of invasive fungal infections in humans: galactomannan, mannan and (1→3)-beta-D-glucan antigens. *Eur J Clin Microbiol Infect Dis*. 26:755–766.
27. Klich, M.A. 2002. *Identification of common Aspergillus species*. Centraalbureau voor Schimmelcultures, Utrecht, Netherlands. 1–116.
28. Klich, M.A., and J.I. Pitt. 1988. *A Laboratory Guide to the Common Aspergillus Species and their Telemorphs*. CSIRO, Division of Food Processing, North Ryde, NSW, Australia. 1–116.
29. Kunkle, R.A. 2003. Aspergillosis. In: *Diseases of Poultry*, 11th ed. Y.M. Saif, H.J. Barnes, J.R. Glisson, A.M. Fadly, L.R. McDougald, and D.E. Swayne, eds., Iowa State Press, Ames, IA. 883–895.
30. Kunkle, R.A., and R.B. Rimler. 1996. Pathology of acute aspergillosis in turkeys. *Avian Dis*. 40:875–886.
31. Kunkle, R.A., and R.E. Sacco. 1998. Susceptibility of convalescent turkeys to pulmonary aspergillosis. *Avian Dis*. 42:787–790.
32. Kunkle, R.A., and R.B. Rimler. 1998. Early pulmonary lesions in turkeys produced by nonviable *Aspergillus fumigatus* and/or *Pasteurella multocida* lipopolysaccharide. *Avian Dis*. 42: 770–780.
33. Kunkle, R.A., R.B. Rimler, and E.M. Steadham. 1999. Absence of protection against challenge with *Aspergillus fumigatus* by adoptive transfer of splenocytes from convalescent turkeys. *Avian Dis*. 43:678–684.
34. Kwon-Chung, K.J., and J.E. Bennett. 1992. *Medical Mycology*. Lea and Febiger, Philadelphia, PA. 1–866.
35. Latge, J.P. 1999. *Aspergillus fumigatus* and aspergillosis. *Clin Microbiol Rev*. 12:310–350.
36. Leslie, C.E., B. Flannigan, and L.J. Milne. 1988. Morphological studies on clinical isolates of *Aspergillus fumigatus*. *J Med Vet Mycol*. 26:335–341.
37. Linares, J.A., and W.L. Wigle. 2001. *Staphylococcus aureus* pneumonia in turkey poults with gross lesions resembling aspergillosis. *Avian Dis*. 45:1068–1072.
38. Mahmoud, A.L. 1994. Antifungal action and antiaflatoxigenic properties of some essential oil constituents. *Lett Appl Microbiol*. 19:110–113.

39. Marks, S.L., E.H. Stauber, and S.B. Ernstrom. 1994. Aspergillosis in an ostrich. *J Am Vet Med Assoc*. 204:784–785.
40. Martin, M.P., K.P. Bouck, J. Helm, M.J. Dykstra, D.P. Wages, and H.J. Barnes. 2007. Disseminated *Aspergillus flavus* infection in broiler breeder pullets. *Avian Dis*. 51:626–631.
41. Mokaddas, E., M.H. Burhamah, S. Ahmad, and Z.U. Khan. 2010. Invasive pulmonary aspergillosis due to *Aspergillus terreus*: value of DNA, galactomannan and (1→3)-beta-D-glucan detection in serum samples as an adjunct to diagnosis. *J Med Microbiol*. 59:1519–1523.
42. Musher, B., D. Fredricks, W. Leisenring, S.A. Balajee, C. Smith, and K.A. Marr. 2004. *Aspergillus* galactomannan enzyme immunoassay and quantitative PCR for diagnosis of invasive aspergillosis with bronchoalveolar lavage fluid. *J Clin Microbiol*. 42:5517–5522.
43. Nawada, R., R. Amitani, E. Tanaka, A. Niimi, K. Suzuki, T. Murayama, and F. Kuze. 1996. Murine model of invasive pulmonary aspergillosis following an earlier stage, noninvasive *Aspergillus* infection. *J Clin Microbiol*. 34:1433–1439.
44. Ng, T.T., G.D. Robson, and D.W. Denning. 1994. Hydrocortisone-enhanced growth of *Aspergillus* spp.: implications for pathogenesis. *Microbiology*. 140:2475–2479.
45. Obayashi, T., K. Negishi, T. Suzuki, and N. Funata. 2008. Reappraisal of the serum (1→3)-beta-D-glucan assay for the diagnosis of invasive fungal infections—a study based on autopsy cases from 6 years. *Clin Infect. Dis*. 46:1864–1870.
46. Ononiwu, J.C., and M.A. Momoh. 1983. An outbreak of aspergillosis in turkey poults. *Bull An Hlth Prod Afr*. 31:75–77.
47. Owings, W.J. 1995. *Turkey Health Problems: A Summary of 12 Years of Iowa Grower Surveys*. Iowa State University Extension Publication PS-257. Ames, IA.
48. Pasanen, A.L., P. Kalliokoski, P. Pasanen, M.J. Jantunen, and A. Nevalainen. 1991. Laboratory studies on the relationship between fungal growth and atmospheric temperature and humidity. *Environ Int*. 17:225–228.
49. Peden, W.M., and K.R. Rhoades. 1992. Pathogenicity differences of multiple isolates of *Aspergillus fumigatus* in turkeys. *Avian Dis*. 36:537–542.
50. Perelman, B., B. Smith, D. Bronstein, A. Gur-Lavie, and E.S. Kuttin. 1992. Use of azole compounds for the treatment of experimental aspergillosis in turkeys. *Avian Pathol*. 21:591–599.
51. Pier, A.C., and J.L. Richard. 1992. Mycoses and mycotoxicoses of animals caused by aspergilli. *Biotechnology*. 23:233–248.
52. Rao, M.R.K.M., C. Choudary, and D.I. Khan. 1982. An outbreak of acute aspergillosis in chicks. *Indian Vet J*. 59:341–342.
53. Redig, P.T. 1993. Avian aspergillosis. In: *Zoo and Wild Animal Medicine*. M.E. Fowler, ed. W.B. Saunders Company, Philadelphia. 178–181.
54. Redmann, T., and B. Schildger. 1989. Therapeutischer einsatz von enilconazol bei broiler-kuken mit aspergillose. *Dtsch Tierarztl Wochenschr*. 96:15–17.
55. Redmann, T., and B. Schildger. 1989. Therapeutischer Einsatz von Enilconazol bei Broiler-Kuken mit Aspergillose. *Dtsch Tierarztl Wochenschr*. 96:15–17.
56. Reece, R.L., T.K. Taylor, D.B. Dickson, and P.J. Kerr. 1986. Mycosis of commercial Japanese quail, ducks and turkeys. *Aust Vet J*. 63:196–197.
57. Richard, J.L. 1990. Additional mycotoxins of potential importance to human and animal health. *Vet Hum Toxicol*. 32 Suppl:63–69.
58. Richard, J.L., and J.R. Thurston. 1983. Rapid hematogenous dissemination of *Aspergillus fumigatus* and *A. flavus* spores in turkey poults following aerosol exposure. *Avian Dis*. 27:1025–1033.
59. Richard, J.L., and M.C. DeBey. 1995. Production of gliotoxin during the pathogenic state in turkey poults by *Aspergillus fumigatus* Fresenius. *Mycopathologia* 129:111–115.
60. Richard, J.L., W.M. Peden, and J.M. Sacks. 1991. Effects of adjuvant-augmented germling vaccines in turkey poults challenged with *Aspergillus fumigatus*. *Avian Dis*. 35:93–99.
61. Richard, J.L., W.M. Peden, and P.P. Williams. 1994. Gliotoxin inhibits transformation and its cytotoxic to turkey peripheral blood lymphocytes. *Mycopathologia*. 126:109–114.
62. Richard, J.L., T.J. Dvorak, and P.F. Ross. 1996. Natural occurrence of gliotoxin in turkeys infected with *Aspergillus fumigatus*, Fresenius. *Mycopathologia*. 134:167–170.
63. Richard, J.L., R.C. Cutlip, J.R. Thurston, and J. Songer. 1981. Response of turkey poults to aerosolized spores of *Aspergillus fumigatus* and aflatoxigenic and nonaflatoxigenic strains of *Aspergillus flavus*. *Avian Dis*. 25:53–67.
64. Richard, J.L., J.R. Thurston, R.C. Cutlip, and A.C. Pier. 1982. Vaccination studies of aspergillosis in turkeys: subcutaneous inoculation with several vaccine preparations followed by aerosol challenge exposure. *Am J Vet Res*. 43:488–492.
65. Richard, J.L., J.R. Thurston, W.M. Peden, and C. Pinello. 1984. Recent studies on aspergillosis in turkey poults. *Mycopathologia*. 87:3–11.
66. Richard, J.L., M.C. Debey, R. Chermette, A.C. Pier, A. Hasegawa, A. Lund, A.M. Bratberg, A.A. Padhye, and M.D. Connole. 1994. Advances in veterinary mycology. *J Med Vet Mycol*. 32 Suppl 1:169–187.
67. Rippon, J.W. 1988. *Medical Mycology: The Pathogenic Fungi and the Pathogenic Actinomycetes*, 3rd ed. W.B. Saunders Co., Philadelphia. 1–797.
68. Santos, R., A.A. Firmino, C.M. de Sa, and C.R. Felix. 1996. Keratinolytic activity of *Aspergillus fumigatus* Fresenius. *Curr Microbiol*. 33:364–370.
69. Schaffner, A., H. Douglas, and A. Braude. 1982. Selective protection against conidia by mononuclear and against mycelia by polymorphonuclear phagocytes in resistance to *Aspergillus*. Observations on these two lines of defense *in vivo* and *in vitro* with human and mouse phagocytes. *J Clin. Invest*. 69:617–631.
70. Sutton, P., P. Waring, and A. Mullbacher. 1996. Exacerbation of invasive aspergillosis by the immunosuppressive fungal metabolite, gliotoxin. *Immunol Cell Biol*. 74:318–322.
71. Van Cutsem, J. 1983. Antifungal activity of enilconazole on experimental Aspergillosis in chickens. *Avian Dis* 27:36–42.
72. White, P.L., S. Bretagne, L. Klingspor, W.J. Melchers, E. McCulloch, B. Schulz, N. Finnstrom, C. Mengoli, R.A. Barnes, J.P. Donnelly, and J. Loeffler. 2010. *Aspergillus* PCR: one step closer to standardization. *J Clin Microbiol*. 48:1231–1240.
73. Zook, B.C., and G. Migaki. 1985. Aspergillosis in animals. In: *Aspergillosis*. Y. Al-Doory and G.E. Wagner, eds. Charles C. Thomas, Springfield, IL. 207–256.

Candidiasis (Crop Mycosis)

1. Kunkle, R.A. 2003. Candidiasis (Thrush). In: *Diseases of Poultry*, 11th ed. Y.M. Saif, H.J. Barnes, J.R. Glisson, A.M. Fadly, L.R. McDougald, and D.E. Swayne, eds. Iowa State Press, Ames, IA. 896–899.

2. Lin, M.Y., K.J. Huang, and S.H. Kleven. 1989. *In vitro* comparison of the activity of various antifungal drugs against new yeast isolates causing thrush in poultry. *Avian Dis*. 33:416–421.
3. Moretti, A., D. Piergili Fioretti, L. Boncio, P. Pasquali, and E. Del Rossi. 2000. Isolation of *Candida rugosa* from turkeys. *J Vet Med. [B]* 47:433–439.
4. Osorio, C., O. Fletcher, M.J. Dykstra, K. Post, and H.J. Barnes. 2007. Comb candidiasis affecting roosters in a broiler breeder flock. *Avian Dis*. 51:618–622.
5. Pollock, C. 2003. Fungal diseases of columbiformes and anseriformes. *Vet Clin Exot Anim*. 6:351–361.
6. Ramani, R., S. Gromadzki, D.H. Pincus, I.F. Salkin, and V. Chaturvedi. 1998. Efficacy of API 20C and ID 32C systems for identification of common and rare clinical yeast isolates. *J Clin Microbiol*. 36:3396–3398.
7. Shah, D.T., and B. Larsen. 1991. Clinical isolates of yeast produce a gliotoxin-like substance. *Mycopathol*. 116:203–208.
8. Tsai, S.S., J.H. Park, K. Hirai, and C. Itakura. 1992. Aspergillosis and candidiasis in psittacine and passeriforme birds with particular reference to nasal lesions. *Avian Pathol*. 21:699–709.
9. Velasco, M.C. 2000. Candidiasis and cryptococcosis in birds. *Sem Avian Exotic Pet Med*. 9:75–81
10. Wadlin, J.K., G. Hanko, R. Stewart, J. Pape, and I. Nachamkin. 1999. Comparison of three commercial systems for identification of yeasts commonly isolated in the clinical microbiology laboratory. *J Clin Microbiol*. 37:1967–1970.
11. Wyatt, R.D. 2008. Candidiasis. In: *A Laboratory Manual for the Isolation, Identification, and Characterization of Avian Pathogens*, 5th ed. L.Dufour-Zavala, D.E. Swayne, J.R. Glisson, J.E. Pearson, W.M. Reed, M.W. Jackwood, and P.R. Woolcock, eds. Am Assoc Avian Pathologists, Athens, GA. 78–79.

Sporadic Fungal Infections

Dermatophytosis (Favus)

1. Bradley, F.A., A.A. Bickford, and R.L. Walker. 1993. Diagnosis of favus (avian dermatophytosis) in oriental breed chickens. *Avian Dis*. 37:1147–1150.
2. Droual, R., A.A. Bickford, R.L. Walker, S.E. Channing, and C. McFadden. 1991. Favus in a backyard flock of game chickens. *Avian Dis*. 35:625–630.
3. Fonseca, E., and L. Mendoza. 1984. Favus in a fighting cock caused by *Microsporum gallinae*. *Avian Dis*. 28:737–741.
4. Kunkle, R.A. 2003. Favus. In: *Diseases of Poultry*, 11th ed. Y.M. Saif, H.J. Barnes, J.R. Glisson, A.M. Fadly, L.R. McDougald, and D.E. Swayne, eds. Iowa State Press, Ames, IA. 899–900.
5. Wyatt, R.D. 2008. Ringworm (Favus). In: *A Laboratory Manual for the Isolation, Identification, and Characterization of Avian Pathogens*, 5th ed. L.Dufour-Zavala, D.E. Swayne, J.R. Glisson, J.E. Pearson, W.M. Reed, M.W. Jackwood, and P.R. Woolcock, eds. Am Assoc Avian Pathologists, Athens, GA. 79–80.

Ochroconosis (Formerly Dactylariosis)

1. Kunkle, R.A. 2003. Dactylariosis. In: *Diseases of Poultry*, 11th ed. Y.M. Saif, H.J. Barnes, J.R. Glisson, A.M. Fadly, L.R. McDougald, and D.E. Swayne, eds. Iowa State Press, Ames, IA. 900–901.
2. Shane, S.M., J. Marovits, T.G. Snider III, and K.S. Harrington. 1985. Encephalitis attributed to dactylariosis in Japanese quail chicks (*Coturnix coturnix japonica*). *Avian Dis*. 29:822–828.
3. Wong, J.S.J., M.I. Schousboe, S.S.L. Metcalf, Z.H. Endre, J.M. Hegarty, M.J. Maze, E.R. Keith, L.M. Seaward, and R.G. Podmore. 2010. *Ochroconis gallopava* peritonitis in a cardiac transplant patient on continuous ambulatory peritoneal dialysis. *Transplant Infect Dis*. 12:455–458.

Zygomycosis (Mucormycosis)

1. Gulbahar, M.Y., Agaoglu, Z., Biyik, H., and Yuksek, N. 2000. Zygomycotic proventriculitis and ventriculitis in ostriches (*Struthio camelus*) with impaction. *Aust Vet J*. 78:247–249
2. Jeffrey, J.S., R.P. Chin, H.L. Shivaprasad, C.U. Meteyer, and R. Droual. 1994. Proventriculitis and ventriculitis associated with zygomycosis in ostrich chicks. *Avian Dis*. 38:630–634.
3. McCaskey, P.C., and K.A. Langheinrich. 1984. Zygomycosis in the duck. *Avian Dis*. 28:791–798.
4. Migaki, G., K.A. Langheinrich, and F.M. Garner. 1970. Pulmonary mucormycosis (phycomycosis) in a chicken. *Avian Dis*. 14:179–185.
5. Mukaratirwa, S. 2006. Outbreak of disseminated zygomycosis and concomitant pulmonary aspergillosis in breeder layer cockerels. *J Vet Med. [B]* 53:51–53.
6. Pal, M., and C.W. Lee. 1994. Pulmonary zygomycosis in chicks due to *Absidia corymbifera*. *Korean J Vet Clin Med*. 11:1–3.
7. Perelman, B., and E. Kuttin. 1992. Zygomycosis in ostriches. *Avian Pathol*. 21:675–680.

Macrorhabdosis (Megabacteriosis)

1. Behnke, E.L., and O.J. Fletcher. 2011. *Macrorhabdus ornithogaster* (Megabacterium) infection in adult hobby chickens in North America. *Avian Dis*. 55:331–334.
2. Hannafusa, Y., A. Bradley, E.E. Tomaszewski, M.C. Libal, and D.N. Phalen. 2007. Growth and metabolic characterization of *Macrorhabdus ornithogaster*. *J Vet Diagn Invest*. 19:256–265.
3. Jansson, D.S., C. Brojer, R. Mattsson, R. Feinstein, T. Morner, and C. Hard af Segerstad. 2008. Mycotic proventriculitis in gray partridges (*Perdix perdix*) on two game bird farms. *J Zoo Wildl Med*. 39:428–437.
4. Kheirandish, R., and M. Salehi. 2011. Megabacteriosis in budgerigars: diagnosis and treatment. *Comp Clin Pathol*. 20:501–505.
5. Martins, N.R.S., A.C. Horta, A.M. Siqueira, S.Q. Lopes, J.S. Resende, M.A. Jorge, R.A. Assis, N.E. Martins, A.A. Fernandes, P.R. Barrios, T.J.R. Costa, and L.M.C. Guimaraes. 2006. *Macrorhabdus ornithogaster* in ostrich, rhea, canary, zebra finch, free range chicken, turkey, guinea-fowl, columbina pigeon, toucan, chuckar partridge and experimental infection in chicken, Japanese quail and mice. *Arq Bras Med Vet Zootec*. 58:291–298.
6. Pennycott, T.W., G. Duncan, and K. Venugopal. 2003. Marek's disease, candidiasis and megabacteriosis in a flock of chickens (*Gallus gallus domesticus*) and Japanese quail (*Coturnix japonica*). *Vet Rec*. 153:293–297.
7. Phalen, D.N., and R.P. Moore. 2003. Experimental infection of white-leghorn cockerels with *Macrorhabdus ornithogaster* (Megabacterium). *Avian Dis*. 47:254–260.
8. Tomaszewski, E.K., K.S. Logan, K.F. Snowden, C.P. Kurtzman, and D.N. Phalen. 2003. Phylogenetic analysis identifies the 'megabacterium' of birds as a novel anamorphic ascomycetous yeast, *Macrorhabdus ornithogaster* gen. nov., sp. nov. *Int J Syst Evol Microbiol*. 53:1201–1205.

V Parasitic Diseases

Chapter 26 External Parasites and Poultry Pests 1099
Chapter 27 Internal Parasites 1117
Chapter 28 Protozoal Infections 1147

Chapter 26

External Parasites and Poultry Pests

Nancy C. Hinkle and Robert M. Corrigan

Introduction

Poultry producers must contend with pest arthropods on their flocks as well as environmental pests that affect the animals, workers, facilities, and the surrounding area. Effective pest management requires an understanding of the organism's biology and behavior as well as strategies adapted for specific housing and production systems. This chapter addresses the biology, behavior and management of the external parasites that attack poultry (mites, lice, fleas, ticks), as well as the pest arthropods (e.g. flies, beetles) and rodents (mice and rats) that create infestation problems in and around poultry facilities.

Ectoparasites and Arthropod Pests

The dermal environment of birds provides an ideal habitat for numerous species of fleas, ticks, lice and mites. Ectoparasites are external parasites, those that live on the skin or feathers, as opposed to endoparasites, which are internal parasites such as tapeworms and flukes. Some of these groups are very closely tied to their hosts, with all life stages occurring on the bird. Typically these are spread by bird-to-bird contact. Others, e.g. fleas, feed on the host and spend some life stages on the host while other stages develop in the off-host environment.

Poultry production methods and animal housing influence degree and type of infestation. For instance, in modern high-density layer units, the northern fowl mite (*Ornithonyssus sylviarum*) thrives and rapidly spreads through the flocks. By comparison, the red mite (*Dermanyssus gallinae*) fares poorly because suspended wire caging provides little off-host habitat. Because breeder facilities provide a long-term stable habitat, insects such as bed bugs that live off-host but move to the host to feed can establish and flourish. Detection is important and easier for parasites that live on the bird (lice, northern fowl mites, hard ticks, sticktight fleas) than for those that move onto the bird only to feed (bedbugs, chicken mites, soft ticks).

Economically, the most prevalent and significant pests of the various segments of the poultry industry are northern fowl mites for caged layers and breeder flocks, lesser mealworms for broilers, and flies for caged layers (16). Backyard flocks and other poultry are particularly susceptible to these and other pests.

Mites

Northern Fowl Mites

Ornithonyssus sylviarum, the northern fowl mite, is the most significant poultry ectoparasite, prevalent particularly in caged layer and breeder flocks (Figure 26.1). These hematophagous mites tend to congregate around the vent where their feeding results in skin inflammation, irritation, scabbing, and anemia (Figure 26.2). Mite numbers may reach tens of thousands/animal, resulting in feather discoloration around the vent due to concentrations of living and dead mites, mite eggs, and mite feces. All life stages occur on the host, allowing this mite to thrive even in suspended cage production situations. The mites quickly disperse through poultry houses, often reaching almost 100% prevalence in untreated flocks. Northern fowl mites are also common on wild birds, having been found on more than 72 bird species, providing a natural reservoir and source of reinfestation. In warmer regions of the world the tropical fowl mite (*Ornithonyssus bursa*) replaces the northern fowl mite, producing the same severe pathology.

While dislodged mites cannot survive on mammalian hosts, they will move to workers in egg-processing lines and attempt to feed, producing pruritus and irritation. Personnel issues may arise with egg handlers refusing to work until mites are eliminated.

Because these mites develop rapidly, from egg to adult in 4 or 5 days, they can complete their life cycle in a week, allowing mite populations to explode dramatically. The protonymph feeds a couple of times, then molts to the adult, which feeds several times during its 3- to 7-day adulthood (18). Northern fowl mites can develop extremely high numbers (tens of thousands/bird), especially upon initial infestation of caged laying hens just coming into production. In pullets the immature immune system does not suppress mites, so numbers rapidly increase and the flock becomes heavily infested. At this stage, mites are numerous on birds, moving onto eggs and producing maximum damage to birds. Mite feeding causes blood loss, scabbing, and pruritus. As the bird's immune

Diseases of Poultry, Thirteenth Edition. David E. Swayne.
© 2013 John Wiley & Sons, Inc. Published 2013 by John Wiley & Sons, Inc.

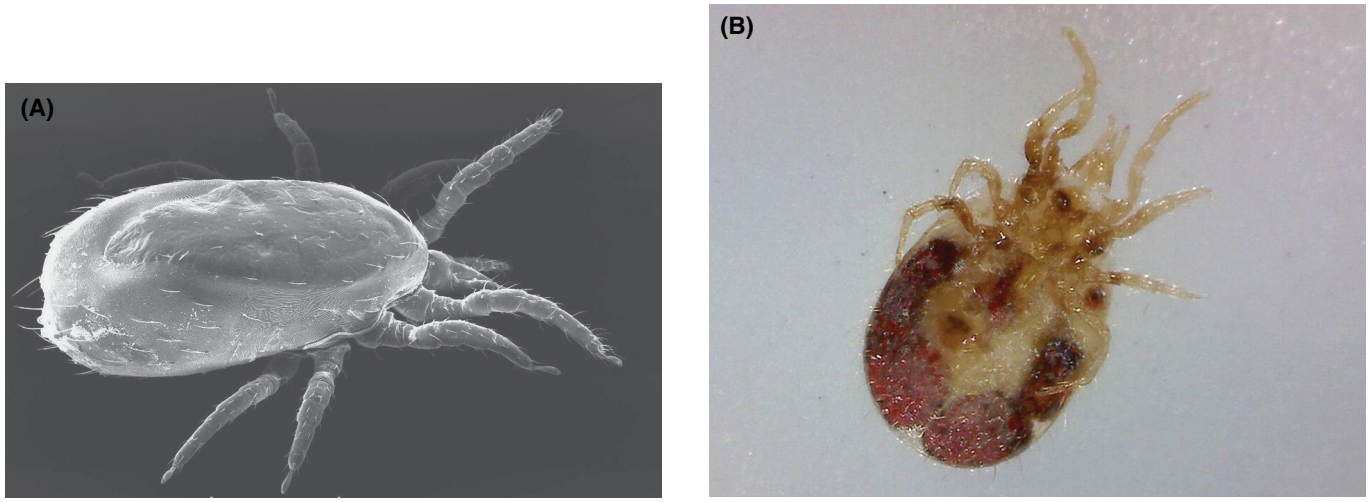

Figure 26.1. Northern fowl mite (*Ornithonyssus sylviarum*) is the most common ectoparasite found on chickens. (A) Scanning electron micrograph. (J.P. Owen). (B) Photograph. (J. Nixon)

system matures, the mite population declines, but without treatment mites never completely disappear from the house. While only a few birds may be infested, they continue to serve as inapparent foci for reinfestation of the rest of the flock.

Because of their small size (less than 0.5 mm length), northern fowl mites can hide in cracks and crevices. Even on depopulated farms, mites can survive without hosts for several weeks, depending on weather conditions, and infest subsequent flocks. Mite control is based on exclusion and acaricides. Biosecurity is critical, because mites are capable of moving within and among facilities on equipment and personnel.

Bird mites are not host specific in that they can survive and reproduce on any avian species (though typically they are more successful on their preferred host), but they are limited to birds and cannot perpetuate their populations on mammals or other vertebrates. They have been recorded moving among poultry houses by hitchhiking on house mice and other peridomestic rodents.

Mite infestation affects birds adversely, requiring redirection of energy and nutrients from body growth and egg production to enhancing the immune system. Feed conversion efficiency and weight gain are reduced as the immune system expends energy to suppress mites, diverting resources from body maintenance and egg production to stimulating the immune system. In breeder flocks, pruritus and irritation to the vent region reduce rooster libido, interfering with mating and significantly lowering egg fertility.

Economic impacts of northern fowl mite infestations in caged layer operations were documented and showed that at periods of peak mite infestation, profits can be reduced by $0.50/hen/year (23). This justifies investments in monitoring for mites and timely acaricide treatments to suppress infestations before they spread throughout the house.

Acaricide treatments are not 100% effective due to several factors. Birds are missed in applications. Sprayer pressure does not allow complete coverage and product penetration

Figure 26.2. Northern fowl mite (*Ornithonyssus sylviarum*) feeding produces inflammation and scabbing around the vent. (B. Mullens)

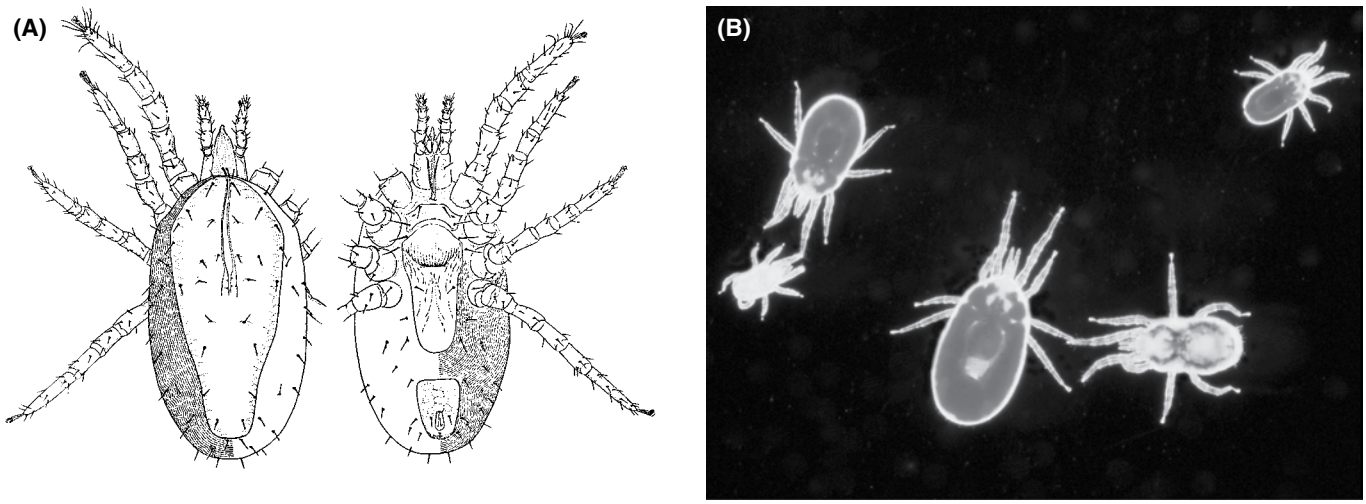

Figure 26.3. Chicken or red mite (*Dermanyssus gallinae*) hides in the roost, moving onto birds at night to feed. (A) Illustration. (E.W. Baker). (B) Photograph. (O. Kilpinen)

to the skin where mites are located. Mite populations are resistant to most available acaricides, so are not eliminated by chemical treatments.

Because northern fowl mites are found primarily around the vent region, it is critical to deliver an acaricide to the site of infestation, penetrating thick plumage on the bird's underside. This requires considerable pressure in spray applications, ensuring that the material reaches the skin, producing sufficient pressure that birds are lifted off the cage bottom. In treating breeders, which are floor birds that run around loose, the challenges include getting sufficient spray delivered to each bird, ensuring it penetrates the feathers and adequately covers the vent region, and confirming that each bird is treated (18).

Nontraditional treatments have been tested for mite suppression, but results show only temporary alleviation of mite numbers. Sulfur at high rates eliminated mites from birds for 3 months, but neem, kaolin clay, diatomaceous earth, and *Beauveria bassiana* reduced mites for less than 2 weeks (24). Thorough application continues to be the challenge because even the most potent acaricides are effective only if they reach sites where mites are found. Future research will include investigation of vaccines for mite control because it has been demonstrated that birds are capable of developing immune responses to modulate mite numbers (23). It also may be possible to select for host animal resistance, developing bird strains with characteristics that permit them to tolerate or avoid mite infestation (16).

Poultry Red Mite

The poultry red mite (chicken mite or roost mite), *Dermanyssus gallinae*, is another haematophagous mite, but it is not a permanent ectoparasite (Figure 26.3). Bloodfeeding stages (adult and nymphal mites) move to the host to feed at night while the host is roosting, but otherwise hide themselves in cracks and crevices nearby in the environment, where eggs are deposited as well. Within 2 months a female chicken mite and her descendants can amount to over 2,000 mites, so mite populations can escalate rapidly (22). Adult chicken mites can live for several weeks in protected environmental areas even in the absence of hosts.

Dermanyssus mites are rare in U.S. caged layer operations, but are occasionally found on breeder farms, where mite irritation may force setting hens to leave their nests. They are very common in many European caged layer operations, constituting the primary pest of laying hens in Europe, and may increase in prevalence in North America as production practices are altered (e.g., free range and cage-free). Loss of product registrations and development of acaricide resistance in mite populations are also making mite suppression more challenging.

Not only are egg production and fertility reduced by mites, but feed conversion efficiency can be significantly impacted. In severe infestations, mite feeding can produce anemia and result in increased mortality, especially in younger birds.

Scaly Leg Mites

Scaly leg mites (*Knemidocoptes mutans*) (Figure 26.4) are small mites that burrow into the skin of the birds' shanks and feet, producing tissue swelling, enlargement of scales so they stick out, and leakage of lymphatic fluid (Figure 26.5). This mite infests wild birds as well as domesticated fowl. All stages of this mite live on the bird and transmission occurs through direct contact. If left untreated, scaly leg mite infestation can produce leg and claw deformity. Typical treatments for scaly leg mites include spraying with insecticides or dipping the affected limbs in mixtures of linseed oil and kerosene weekly until the condition resolves. Veterinarians sometimes prescribe off-label ivermectin to treat scaly leg mites.

Depluming Mites

The depluming mite (*Knemidocoptes laevis*) burrows into the skin at the base of feathers, producing severe irritation and resulting in feather-pulling. These mites are very small and may be difficult to see without magnification. When they

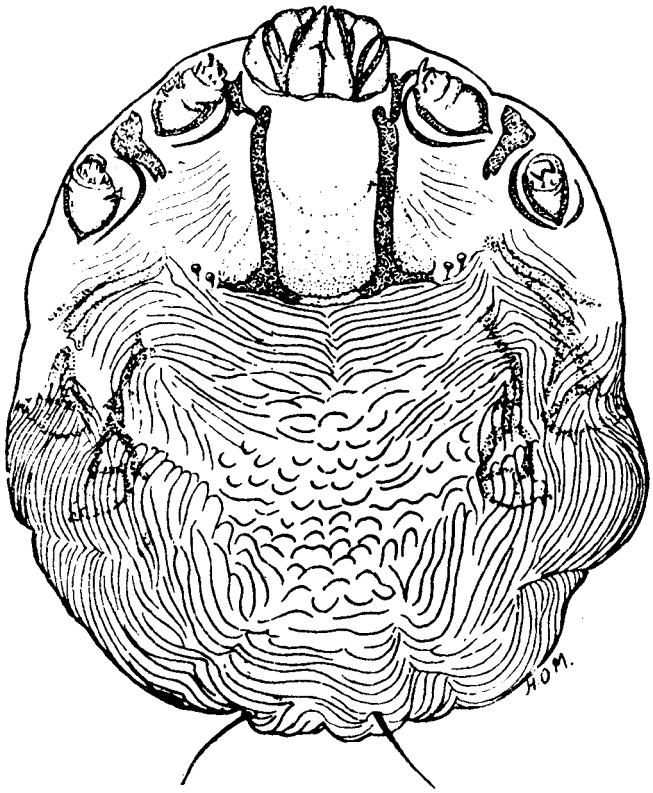

Figure 26.4. Scaly leg mite (*Knemidocoptes mutans*) (E.J.L. Soulsby).

Figure 26.5. Scaly leg mites (*Knemidocoptes mutans*) burrow under the skin, distorting the legs and feet and causing the scales to stick out. (University of California)

crawl around on the bird, they may be dislodged and spread to other members of the flock.

Chiggers

Larval chiggers, *Neoschoengastia americana*, are problems on turkeys allowed to range outdoors in the USA (Figure 26.6). These gregarious mites tend to attach to a bird in large numbers (approximately 100/animal), and such clustered feeding activity produces skin inflammation and lesion formation. Such damaged areas must be removed at slaughter, resulting in carcass downgrading and financial loss. After the larvae have fed (typically for 4–6 days), they drop off the turkey, and subsequent life stages are nonparasitic. These free-living stages must be eliminated from the environment to prevent bird infestation.

Figure 26.6. Larva of turkey chigger (*Neoschoengastia americana*) (N. Hinkle)

Other Pest Mites

The species described above are the most significant mite pests of poultry, but there are other mite species found on or in the quills, in the respiratory system, in air sacs, and within subcutaneous tissues. Poultry mites can cause retarded growth, reduced egg production, lowered vitality, damaged plumage, and even death. Typically the main effects, constant irritation and blood loss, are not apparent without careful examination.

Mite Control

The most challenging aspect of treating birds for mites, lice, and other ectoparasites is getting the product through the feathers to the target pest. Because feathers are designed to repel water, aqueous pesticide sprays have difficulty penetrating plumage, resulting in inadequate treatment and wastage as the material drips off the animal. Similarly, dusting is time consuming and laborious, because each animal must be handled individually and the acaricidal dust directed to the site of infestation. This stresses the birds and may cause injury as well. The most critical component of poultry mite integrated pest management (IPM) is prevention; all animals should be quarantined and inspected before they are allowed on the property. When infestations occur, they should be addressed quickly and attacked using all integrated pest management options.

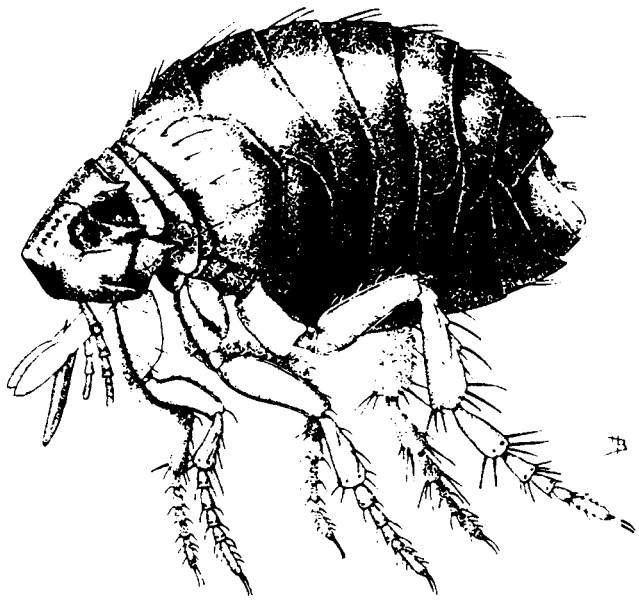

Figure 26.7. Sticktight flea (*Echidnophaga gallinacea*). (USDA)

Figure 26.8. Sticktight fleas *(Echidnophaga gallinacea)* attach on fleshy areas. (P. Kaufman)

Fleas

The main flea pest of poultry is the sticktight flea (*Echidnophaga gallinacea*) (Figure 26.7). Sticktight fleas are occasionally pests on backyard flocks, but not on commercial poultry. Mammals having contact with sticktight flea-infested backyard flocks (such as dogs, cats, swine, etc.) occasionally acquire sticktight fleas, as well. These fleas are small, less than 2 mm long before feeding.

The sticktight flea can be found on a wide variety of birds. Adult females are usually attached to the skin on the host's head in clusters of dozens or hundreds (Figure 26.8). This flea is unique among poultry fleas because the females embed their mouthparts deep in the skin, making the adult females sessile; the male remains mobile on the host's body and may mate with numerous females. Other adult fleas of birds and mammals are intermittent feeders on poultry. Numerous sticktight fleas embedded around the eyes can produce swelling and interfere with vision.

Eggs are laid by the immobile females and fall off the host's body into the environment. Larvae develop in the litter, feeding on organic debris, and pupate in the same area. Adults may emerge within a week or, if hosts are not present, remain quiescent within the cocoon for several weeks or months. This emphasizes the need for bedding removal to eliminate subsequent population resurgence.

Small numbers of sticktight fleas can be removed by hand using tweezers to pull them off individually. To prevent reinfestation, birds should be treated with a pyrethroid insecticide registered for on-bird application and flea larval habitat modified to break the life cycle. Because flea larvae thrive in shavings, litter, straw, and other floor covering material, the coop should be cleaned out, all contaminated materials removed (off the property to prevent their returning) or burned, and replaced with fresh shavings. The new shavings should be sprayed with an insect growth regulator (such as methoprene or pyriproxyfen). Birds should be monitored to catch any subsequent infestation and arrest it prior to establishment of the population.

Lice

Only chewing lice (Order Mallophaga) infest birds. These lice feed on feathers, feather debris, skin scales, and other dermal scurf (15). Because they can chew through feather shafts, fresh blood may be found in their gastrointestinal tracts, but they are not bloodsuckers. More than 40 species have been reported from domestic birds, although most of these are rare on commercial flocks. Chickens have 7 typical louse species, and 3 are commonly found on turkeys. While the economic impact has not been determined, louse infestation can be very damaging to young birds, resulting in stunted growth, reduced food conversion efficiency, and other adverse effects.

Each louse species is relatively host-specific, although they may transfer to atypical hosts when in close association. Poultry louse species have similar life cycles and habits. They live continuously on their feathered hosts and are strongly host-dependent, soon dying if dislodged. Eggs are attached to the feathers. A single female may produce from 50 to 300 eggs during her lifespan. Young lice go through 3 instars which are similar in appearance to adults, varying in color and size. Typically the louse egg incubation period is about 4 to 7 days, and nymphs take about 3 weeks to mature. Lice mate on the host, and egg laying begins a few days after they reach adulthood. Lice differ in their predilection sites and these preferences have given rise to the common names applied to louse species.

Chicken Body Louse

The chicken body louse (*Menacanthus stramineus*) is the most common species on adult birds (Figure 26.9). It tends to stay on the skin rather than on the feathers and frequently locates on less densely feathered areas such as around the vent, although in heavy infestations it may be distributed over the

entire body (Figure 26.10A and B). Parting of the feathers reveals straw-colored body lice rapidly running on the skin, searching for cover. Clusters of eggs are glued to bases of feather quills; the eggs hatch in about a week, and lice reach maturity in 3 weeks. These lice feed on skin debris and at the base of feathers, producing skin irritation and injury which may result in scabbing. Weight gain may be reduced as a result of the constant irritation.



Figure 26.9. Chicken body louse (*Menacanthus stramineus*). (N. Hinkle)

Shaft Louse

The shaft louse or small body louse (*Menopon gallinae*) is similar in appearance to the body louse, but smaller (Figure 26.11). It is found primarily on the feathers of the breast and thighs. This louse rests on the feather shaft and rapidly descends the shaft, scurrying for cover, when feathers are parted. It feeds on feathers and typically does not infest young birds until they are fully feathered. Heavily infested birds will display restlessness.

Chicken Head Louse

The chicken head louse, *Cuclotogaster heterographa*, is an oblong (approximately 1 mm long), grayish louse found mainly around the head and neck areas of birds. It orients itself near the host's skin in the down or at the base of feathers, particularly on the top and back of the head and under the beak. Female lice attach individual pearly-white

Figure 26.10. (A) Chicken body louse (*Menacanthus stramineus*). (N. Hinkle). (B) Clusters of lice eggs are glued to feathers. (N. Hinkle)

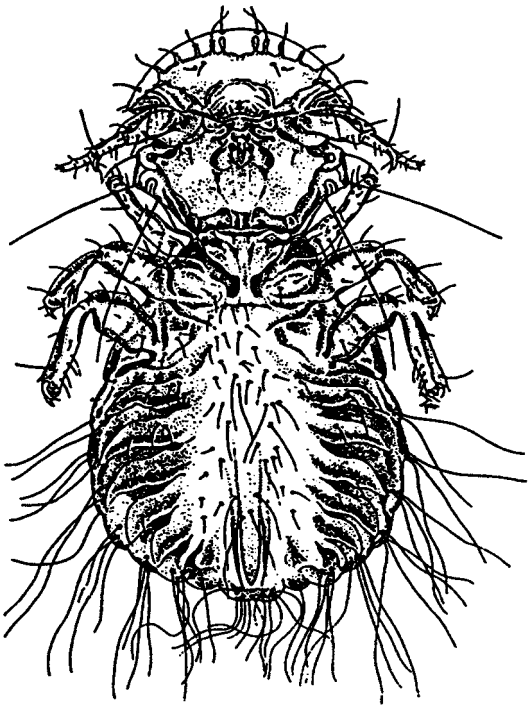

Figure 26.11. Shaft louse (*Menopon gallinae*). (R. Kriner)

eggs to the base of small head feathers and the eggs hatch within five days. Head lice do not feed on blood but can be very irritating to young chickens and turkeys. Heavily infested individuals may decline and die before they are a month old.

Ticks

Ticks are eight-legged bloodsucking arthropods, not insects. The two major groups of ticks are hard ticks (Ixodidae) and soft ticks (Argasidae). The most significant avian ticks are argasids, long-lived ticks that feed repeatedly as adults. Because these ticks live off the host and move onto the birds to feed only at night, they may be easily overlooked and large numbers can be present, exsanguinating birds before they are noticed.

Fowl Tick

The most important tick in poultry is the soft-bodied tick *Argas persicus*, known as the fowl tick (sometimes called the "blue bug"), although many species of hard ticks will feed intermittently on poultry (Figure 26.12). Soft ticks spend most of their lives in cracks and other hiding places off the bird, moving to fowl at night to take a blood meal. Mating takes place off the host in these hiding places. A few days after each feeding, the female tick lays a batch of eggs (up to 500) in these hidden crevices. Depending on temperature, the eggs may hatch in a couple of weeks or several months. Larvae emerging from the eggs crawl to a host fowl and take their first blood meal, then detach and hide off the host while molting to the nymphal stage. Soft ticks have many nymphal instars,



Figure 26.12. Fowl tick (*Argas persicus*). Dorsal view on left, ventral on right. (USDA)

each of which must blood feed, so repeated feeding by large soft tick populations may result in blood loss, emaciation, and fatal anemia. In addition, the fowl tick has been shown to transmit a number of significant spirochete, piroplasmosis, rickettsial, and bacterial diseases of importance in many parts of the world. Because these ticks are nocturnally active, they may not be noticed unless the flock is checked at night. Soft ticks may be common in backyard flocks but typical commercial production facilities rarely provide environmental conditions conducive to their populations. Adult argasids are highly resistant to starvation, allowing them to survive without feeding for more than a year in the absence of a host, confounding eradication from infested premises. All cracks and crevices that may harbor ticks must be thoroughly treated with an appropriate acaricide to successfully eliminate a fowl tick infestation, and treatment may need to be repeated to suppress tick larvae that hatch from the remaining eggs.

Lesser Mealworms (Adults Known as Darkling Beetles)

Alphitobius diaperinus, commonly known as the darkling beetle, is the most significant pest in broiler houses worldwide (Figure 26.13). Both larval and adult stages of these omnivorous beetles feed on dead and dying birds, spilled feed, and excreta, picking up and perpetuating pathogens (Figure. 26.14). Notable among these are various avian disease agents including the viruses that cause infectious bursal disease and leucosis virus, as well as tapeworm eggs and *Eimeria* (12). Bacterial pathogens involved in human foodborne disease outbreaks that are maintained and transmitted by darkling beetles include *Campylobacter* and *Salmonella* (10). Of particular concern is the darkling beetle's capability to maintain *Salmonella* internally during pupation, so that newly-emerged adult beetles coming out of the clay floor or foam insulation can recontaminate a broiler house and subsequent flocks (25).

Figure 26.13. Darkling beetle (*Alphitobius diaperinus*). (A. Roche)

Figure 26.14. Lesser mealworm (*Alphitobius diaperinus*). (A. Roche)

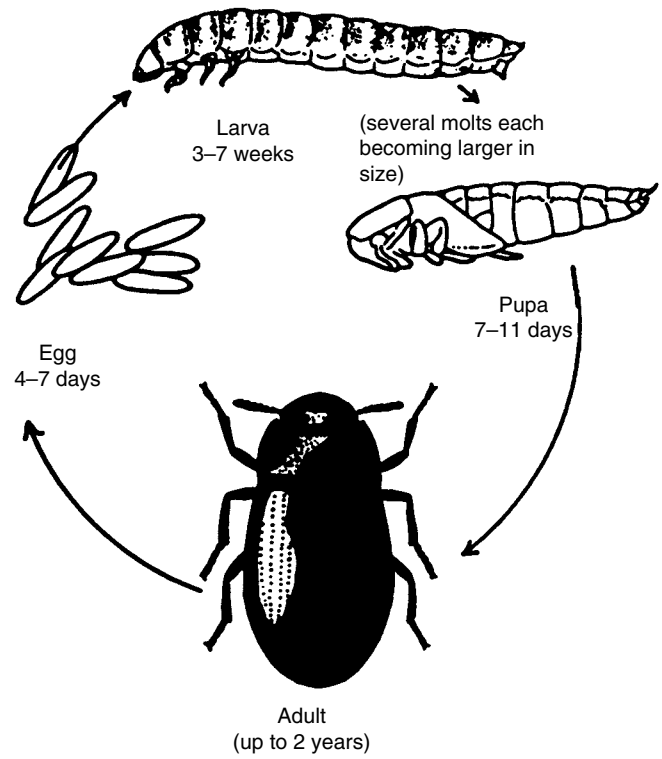

Figure 26.15. Life cycle of the darkling beetle.

Darkling beetles reduce feed conversion efficiency, damage housing structures, and can adversely affect community relations when adult beetles migrate from field-applied litter to nearby neighborhoods. The broiler house environment is ideal for darkling beetles, resulting in high populations. Birds consume both adult and larval beetles, resulting in reduced feed consumption and interfering with weight gain (Figure 26.15). Larval beetles seek protected niches in which to pupate, often burrowing into insulation to create pupal chambers and thus destroying the insulative capacity of the polyurethane (32). Pupae are highly desirable food to mice, which rip into the insulation to extract them, further damaging the material. This increases heating and cooling costs, requires frequent replacement of damaged insulation, and decreases flock productivity. When litter is removed between flocks and applied to pastures or agricultural lands as a soil amendment, adult beetles in the litter frequently fly to nearby structures (attracted to lights at night) and may enter homes through spaces around doors and windows or plumbing, electrical, or cable penetrations.

Darkling beetle control is complicated by the broiler house environment, especially the litter-covered floors, food availability, and stable habitat. Pesticides applied to shavings or litter are rapidly degraded by high pH and moisture conditions, as well as litter microbes. Very few pesticides are registered for application in the presence of birds, so most products are limited to being applied prior to flock placement, leaving weeks for the chemical to lose efficacy and for beetle populations to increase without effective intervention.

Several studies are investigating control alternatives, such as nematodes, fungi, and other entomopathogens, but they are not available commercially. Another line of research is the use of lower-toxicity natural products such as diatomaceous earth, an inert powder made from siliceous remains of prehistoric freshwater unicellular organisms.

Updated lists of pesticides available for darkling beetle suppression in poultry houses can be found on Cooperative Extension Service websites. Effective use of these products involves taking advantage of the pest's behavior such as the

fact that larvae and adult beetles tend to concentrate under feeders and around the periphery, so insecticide applications should focus on these locations. Application should closely follow label instructions for best results.

Flies

Biting Flies

Although many Diptera will feed on poultry (mosquitoes, midges, gnats, stable flies), only a few are of veterinary importance, generally because they serve as intermediate hosts for other parasites. Haemosporidians are vector-borne parasites (Phylum Apicomplexa) that are commonly found in birds. Avian haemosporidian parasites have a cosmopolitan distribution and are divided into 4 genera: *Plasmodium*, *Haemoproteus*, *Fallisia*, and *Leucocytozoon*.

Black flies (family Simuliidae) are important as vectors for transmission of *Leucocytozoon* spp. (an apicomplexan blood parasite) to poultry such as turkeys and ducks. Infection with this protozoan causes intravascular hemolytic anemia in birds, frequently resulting in significant mortality. Black flies seldom enter buildings, so restriction of birds indoors during seasons and times of day when black flies are host-seeking (generally around dawn and dusk) offers some protection. Larval black flies develop only in flowing water, but adults may fly several miles to find hosts. If larval development sites can be located, successful control can be obtained by treating the streams with formulations of *Bacillus thuringiensis* var. *israelensis.*

Biting midges, *Culicoides* spp., serve as intermediate hosts for *Haemoproteus nettionis* which can infect domestic ducks, exacting reproductive costs and affecting survival. Similarly, *Haemoproteus meleagridis* infection produces muscle inflammation and significantly interferes with weight gain and growth in turkeys. Biting midge larvae can develop in virtually any standing water (puddles, ponds, tree holes, etc.) so vector suppression is unlikely to be achieved. However, biting midges are disinclined to enter structures, so keeping birds indoors during midge activity periods (typically around dawn and dusk) can reduce exposure.

Several genera of mosquitoes can transmit avian *Plasmodium* spp. (avian malaria). Mosquitoes also transmit the viruses causing Eastern Equine Encephalitis (EEE), Western Equine Encephalitis (WEE), and other encephalitides. Epiornitics of EEE occasionally occur in pheasants and partridges, while other wild birds serve as amplifying hosts for the virus. In contrast, WEE rarely produces clinical disease in avian species, although it has been reported to cause encephalitis and paralysis in turkeys. Mosquito control should focus on larval suppression to prevent emergence of blood-sucking adults. There are many reliable mosquito larvicides, including *Bacillus thuringiensis* var. *israelensis*.

The pigeonfly (hippoboscid fly, lousefly), *Pseudolynchia canariensis*, is especially harmful to nestling pigeons and also transmits *Haemoproteus columbae*, a malaria-like disease of pigeons. This fly is unusual in that the larva matures inside the female and pupates immediately following deposition.

Figure 26.16. Mating house flies (*Musca domestica*). (N. Hinkle)



Figure 26.17. House fly (*Musca domestica*) puparium and larva. (N. Hinkle)

Nonbiting Flies

Around poultry facilities, especially layer houses, house flies (*Musca domestica*) are the most common pest (Figures 26.16 and 26.17). House flies serve as intermediate hosts for some poultry parasites (e.g., tapeworms) and as mechanical vectors of several significant pathogens. Large numbers of flies can be distracting and annoying to workers, and fly specks on eggshells render the product less attractive to consumers. House fly larvae (maggots) thrive in moist hen feces, so the continually renewed habitat under battery cages is ideal for producing abundant larvae. Similarly, the area under the slats in breeder houses provides moist, undisturbed bird feces for house fly oviposition and larval development. Late-instar larvae migrate to drier portions of the house (such as along walls) to pupate, and emerging adult flies move upstairs, or sometimes exit the house and migrate through the community. For this reason, they can be serious problems in neighbor relations, with potential conflict resulting in litigation.

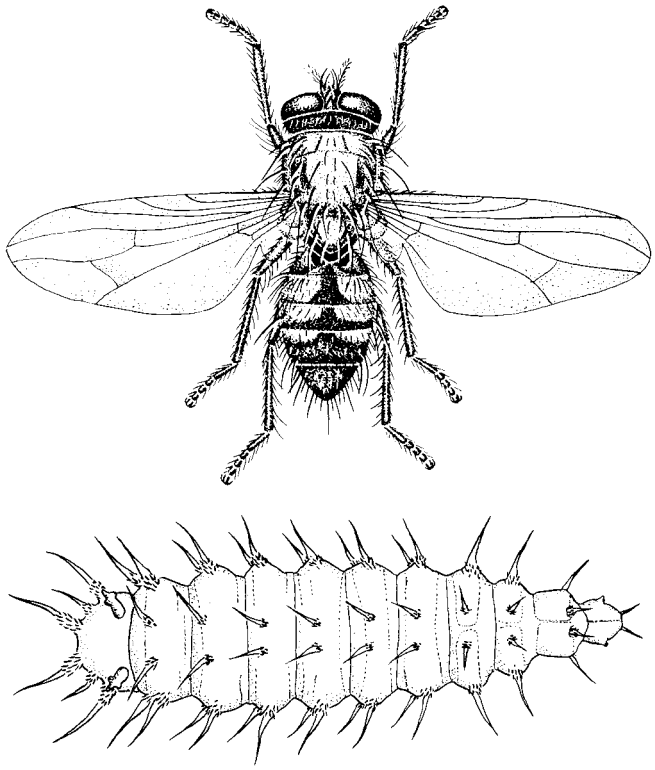

Figure 26.18. *Fannia* spp. Adult and spinose larva. (Cooperative Extension Service, University of California)

In some portions of the country, especially with open-sided California-style laying houses, other filth-breeding flies in the genus *Fannia* can become a severe problem in cooler months. *Fannia canicularis* (the little house fly) is commonly found during winter months in southern California layer houses (Figure 26.18). Adult males have a lekking behavior in which they circle continuously about 5 feet off the ground, putting them in front of workers' faces and producing annoyance. *Fannia* tend not to enter homes, but they frequently hover on walkways and patios. Because they seldom land, they are less likely than house flies to transmit pathogens, but they are inclined to move away from the poultry facility to nearby homes and aggravate neighbors, resulting in poor community relations.

Blow flies and flesh flies (Calliphoridae and Sarcophagidae, respectively) oviposit and feed on decaying carcasses, illustrating the necessity of promptly and properly disposing of dead birds. If mortality is to be composted, the carrion must be adequately covered with material to prevent fly access, otherwise adult flies will crawl through the overlaying litter and oviposit, resulting in maggot production from the compost.

Because flies are highly mobile and frequent materials containing potential human pathogens (*E. coli*, *Salmonella*, etc.), they play a significant role in maintenance and transmission of these threats to human health (13). Fly suppression is important both from a nuisance perspective and because they serve as mechanical vectors of potential public health concern (1).

Bed Bugs

The poultry bug (*Haematosiphon inodorus*) and the common human bed bug (*Cimex lectularius*) (Figures 26.19A and B) are associated with chickens and other poultry. These hematophagous bugs hide during the day in cracks and crevices around the poultry roost, moving to the birds to feed at night. Their nocturnal habit means they are seldom observed until populations have reached tremendous numbers, at which point they can have severe effects on production. Both the poultry bug and the bed bug are widespread around the world, and the bed bug, in particular, is currently experiencing a re-emergence as a public health pest. Concerns are that bed bugs may migrate from poultry facilities, or be carried on clothing or belongings of personnel, to infest homes. Some bed bug populations demonstrate high levels of resistance to many of the insecticides available for their suppression, frustrating control efforts (28).

Control Recommendations

Pest suppression strategies include pesticides as well as mechanical, cultural, and biological control options (2, 18). Water and substrate (manure and litter) management are crucial in fly suppression. Litter management is the foundation for darkling beetle suppression. Prevention through use of mite-free stock and restricted movement of personnel and equipment on mite-infested farms is the only reliable method for northern fowl mite control.

Restrictions on equipment and personnel movement not only limit distribution of ectoparasites, but also help to reduce pathogen transmission. Before equipment is moved between farms it should be thoroughly cleaned and disinfected. When darkling beetle-containing litter is removed from houses, it should be rapidly hauled away from the premises to prevent beetles from migrating back into the facilities. Likewise, when manure is cleaned out of layer houses, it should be immediately composted or dried to kill maggots already developing in it and prevent subsequent fly oviposition.

Different aged flocks should not be raised in close proximity because older birds can serve as a reservoir for infestation of young birds. All in/all out practices, maintaining uniform flock age, helps to minimize contamination of incoming flocks.

Advances in ventilation and nipple watering systems have improved litter conditions to where they are no longer favorable for fly larval development in broiler houses. Inattention to equipment service and maintenance, however, can result in leakage and soaked litter, producing maggots and fly outbreaks. Identifying problems and instituting timely corrective actions can prevent an incipient problem from turning into a disaster.



Figure 26.19. Common bedbugs (*Cimex lectularius*) hide in cracks and crevices during the day, moving onto birds at night to feed. (A) Illustration. (USDA) (B) Photograph (Centers for Disease Control)

Integrated pest management incorporates a range of options for arthropod suppression based on pest biology and behavior, production conditions, and host attributes. Pest identification is the first step in developing successful control strategies (2). Chemical insecticides play a critical role in poultry pest management, protecting bird health and profitability. Wise pesticide use requires understanding modes of action so that insecticide classes can be appropriately rotated to forestall resistance. All label requirements and warnings must be followed to ensure human, animal, and environmental safety. Excellent information on poultry pests and their suppression are available (2, 18). Current registrations and recommendations are available through the Cooperative Extension Service (or at sites such as www.ent.uga.edu/pmh/), along with assistance in identifying pest arthropods.

Rodent Integrated Pest Management for Poultry Operations

Introduction

Commensal (or domestic) rodents are important economic and health-related pests in poultry facilities. On a global scale, 3 species are of most significance (Figure 26.20): (1) the house mouse (*Mus musculus/domesticus*), (2) the Norway (brown) rat (*Rattus norvegicus*), and (3) the roof (black) rat (*Rattus rattus*). The black rat occurs mostly in tropical and subtropical regions. Depending on the country and/or specific locale, other rodent species may occur and be important, but the commensal species comprise the majority of rodent pest issues to poultry and other livestock. Additional information on other rodent pest species is available (33).

Maintaining rodent-free poultry facilities can be significantly challenging. In fact, for many commercial operations it may be nearly impossible on a practical level. All 3 species can gain entry to buildings through relatively small openings. Furthermore, rodents (mice in particular) are among nature's best-equipped stowaways and can be delivered directly into a poultry facility hidden in delivery boxes, trucks, trailers, pallets, or voids of processing equipment.

Once inside and left unchecked for even relatively short periods of time, rodents can multiply to serious pest levels quickly due to the uniquely abundant and easily accessible resources of poultry structures. Nutritious food (grains, eggs, birds, insects) is essentially available *ad lib*. Rodent harborages may be limited only by the size of the structure itself.

For example, in layer facilities that contain shallow or deep pits to collect poultry manure, the conical mounds of dried manure provide excellent rodent harborages. Additional harborage resources are available in the soil below slab walkways and within the structural void elements (walls, ceilings) of the house. Because poultry facilities are typically uniform in their construction and distribution of food and water, rodents can use an entire layer facility, which might measure 1,500 m^2 or more. Finally, using the ubiquitous feathers found in poultry facilities, rodents can build protected, dry, and

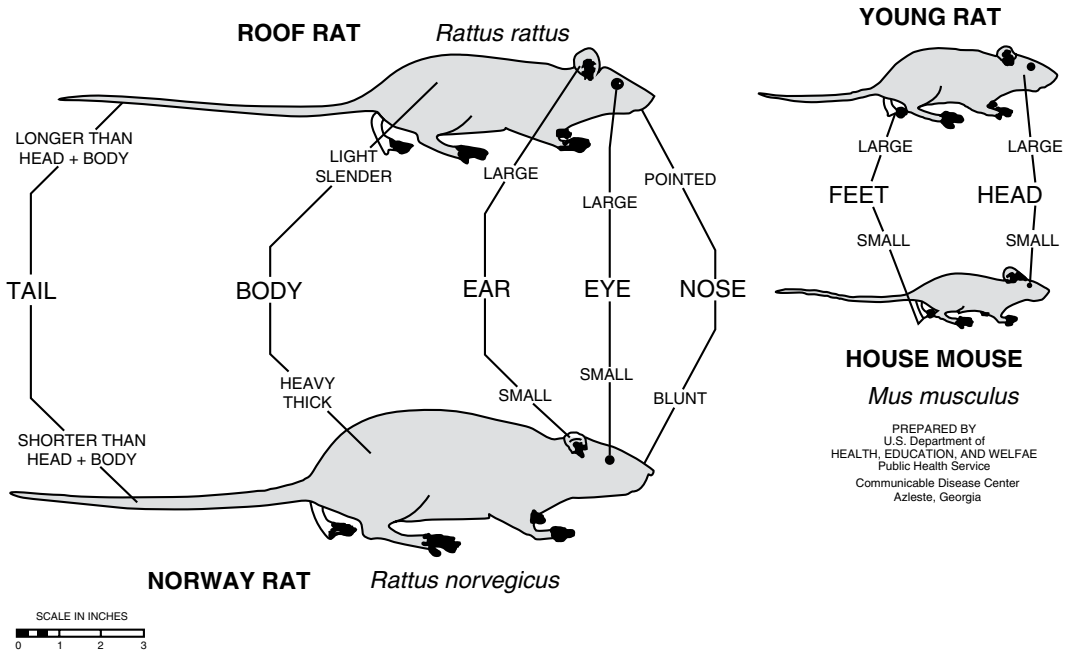

Figure 26.20. Field identification of domestic rodents.

well-insulated nests, which in turn contribute to unusually high survival rates of rodent litters. Consequently, poultry facilities have produced some of the largest densities of mouse populations ever recorded (3). Mouse densities of 3,000 mice/414 m^2 (70,000 mice/hectare) have been reported in Texas chicken barns (26).

Economic Impact

Rodents pose significant economic threats to poultry and other livestock operations along several fronts (19). Rodents consume and contaminate feed meant for the poultry on a daily basis. They constantly gnaw on structural, mechanical, electrical, and other utility components of buildings. Rodents undermine concrete slabs and walkways via their burrowing activities, causing collapse and walkway deterioration, which in turn affects operations and production. Because of their tunneling and burrowing activities, rodents are particularly destructive to building insulation, which in turn can affect energy usage and poultry production (31). Finally, the costs associated with the customized IPM programs necessary to control and prevent rodents in poultry operations can be substantial.

Public Health Significance

When rodents exist in and around any type of poultry facility, biosecurity of the operation is compromised. Similar to the threat of other wild animals being active around livestock facilities, rats and mice can serve as vectors for disease organisms (33), including several poultry diseases (20) (Table 26.1).

Table 26.1. A selection of poultry diseases in which rodents have been implicated or directly involved in transmission.

Disease	Agent	Rodents Implicated
Bordetellosis	Bacteria	Rats
Campylobacteriosis	Bacteria	Rats, mice
Erysipelas	Bacteria	Rats
Fowl cholera	Virus	Rats, mice
Fowl pox	Virus	Rats
Leptospirosis	Bacteria	Rats, mice
Salmonellosis	Bacteria	Rats, mice

Concern exists for food safety regarding *Salmonella*, *Campylobacter*, and other microbial pathogens potentially associated with rodent pests and foodborne illnesses (20). Several serotypes of *Salmonella* have been associated with rodents (14) including *S. enteriditis*, *S. typhimurium*, and *S. dublin*. Because rodents are capable of both mechanical and physiological transmission of pathogenic microbes, there may be others in the future.

Rodents can spread or accelerate the spread of established diseases from contaminated areas to uncontaminated areas via their droppings, feet, fur, urine, saliva, or blood. They can introduce a disease to nearby uninfected poultry buildings on the same or different farms within a company operation. With rats, the contamination threat can extend to farms and properties separated by a few miles (29). More research is sorely needed on the precise role wild rodents play as disease threats in poultry production from the field to the market.

Table 26.2. Reproductive capabilities of the 3 commensal rodents, assuming 1 year of life (11).

	Sexual maturity in females (days)	Gestation period (days)	Number of litters: Range (avg.)	Pups per litter: Range (avg.)	Total production/ female	Age at weaning; begin to forage outside of nest (days)	Cycle of days in heat
Norway. rat	75–90	21–25	2–7 (4)	6–14	36–39	28	4
Roof rat	68–90	20–23	3–9 (5)	5–8	31–34	28	4
House mouse	35–60	18–21	6–8	2–13 (5)	43–45	21–28	4

Rodent Biology and Behavior in Poultry Environments

Commensal rodents adapt well to specific habitats whether they are city streets, residential homes, strip malls, livestock operations, warehouses, crop fields, and so on. In fact, differences can exist in the biology (e.g., reproductive rates and success) (4) and behavior (territories, foraging, nesting, etc.) among rodents within different habitats. The following discussion addresses each of the 3 commensal rodent species in poultry environments. Table 26.2 provides their generalized comparative life histories.

House Mouse

The house mouse is the poultry industry's number one pest in most parts of the world and is probably familiar to most everyone. It has been described as a mammalian weed (3) and the second most successful mammal on Earth (5).

The house mouse is typically a brown to grayish rodent with relatively large ears and small eyes, and weighs from 0.5–1 oz. (15–30 g). Most adults measure from 5.5–7.5 inches (14 to 19 cm) in length including the 3- to 4-inch (7 to 10 cm) tail (Figure 26.20).

Poultry operations are ideal breeding environments for rodents for the reasons listed earlier, and this is particularly true of the small house mouse that can find harborages in virtually any component of a poultry operation. A house mouse litter typically contains 4–7 pups; the dam can produce upwards of 8 litters in a year's lifetime (Table 26.2). Inside warm, protected livestock facilities with abundant food resources, mice can produce litters at 24- to 28-day intervals and the young can achieve sexual maturity in 35–40 days. This is among the fastest rate for the house mouse of any environment (4). Most wild mice live for less than 1 year, but some individuals may live as long as 2 years.

In and around poultry operations, mice feed on the most abundant food, various grain feeds. Their grain diet is supplemented with any broken poultry eggs, opportunistic killing and eating of chicks, dead poultry carcasses, insect larvae, and any other natural foods that exist near the facility (weed seeds, berries, acorns, soil invertebrates, etc.).

Mouse territories in poultry houses are among the smallest recorded, ranging from 3–30 feet (1–10 m) from the nests (17). However, mice will disperse several hundred feet and farther, should disruptions occur (e.g., when houses undergo cleanouts, construction, etc.). In some locales, mice may move from fields to enclosures and back again with seasonal change.

Norway Rats

Norway (brown) rats are large, robust rodents with most adults weighing from 12–16 oz. (340–453 g). Larger rats approaching 27 oz. (770 g) or more occur, but are uncommon. The brown rat's fur ranges from reddish to grayish brown on the back and sides, with gray to yellow-white bellies underneath. Brown rats are about 13–18 inches (33 to 46 cm) long including the 6- to 8.5-inch (15 to 22 cm) tail (Figure 26.20).

The average brown rat litter contains 8–12 pups, and an adult female, depending on her longevity, can produce from 4 to 7 litters over the course of 1 year. Rat pups can attain sexual maturity within 8 weeks in good environments (i.e., poultry houses), but more typically about 12 weeks are necessary. Females can enter estrus every 4–5 days and may mate within 24–48 hours following the birthing of a litter (Table 26.2). Wild rats live 5 to 12 months, but some may survive for upwards of 2 years.

The brown rat is mostly a burrowing animal. Rat burrows are usually 6 feet (2m) long and 6–12 inches (15–30 cm) deep, containing a main entrance and 2 escape holes. Burrows tend to be established along wall foundations, beneath heavy objects, or within dense vegetation, but may occur anywhere if food is nearby. The brown rat also will occupy elevated areas and enclosed ceilings around poultry buildings in a similar manner as the roof rat.

Like the house mouse, rats are opportunists around poultry facilities. Each rat consumes from 0.5–2.5 ounces (14–70 g) of food/day. Thus, a large infestation of rats can consume considerable amounts of poultry feed in a short period of time. Because each rat requires upwards of 1 ounce (29 ml) of water daily, they are constantly gnawing into water lines and causing leaks in poultry operations.

Rats forage at distances of 50–450 feet (15–137 m) from their nests, depending on various factors. For severe infestations in and around poultry operations where there are many rats and abundant food and shelter, the territories are at the lower end of the range. Should disruptions occur to the rat's nesting areas (house cleanouts, construction, etc.), the rats will disperse, with the strongest rats sometimes covering large distances (e.g., 5 miles/8 km over a few days) to establish new colonies at neighboring farms.

Roof Rats

The roof (black) rat is a medium-sized rat with a sleeker appearance than the Norway rat (Figure 26.20). Adults weigh 5–9 ounces (150–255 g) and are grayish-black to solid black in color with a buff-white to gray belly.

Roof rats measure about 16 inches (41 cm) in total length from the nose to the end of the tail. This is about the same total length as the Norway rat, but the black rat's tail is longer than the body and is one of its key identifying characteristics. The tail reaches the snout when pulled back over the top of the body. The snout is pointed; the ears are large and reach the eyes when pulled down. As its name implies, the roof rat tends to occupy elevated areas such as ceilings, soffits, trees and bush canopies, the head spaces of grain elevators, and so forth. The reproductive rates of Norway and roof rats are similar, although the roof rat is slightly less prolific (4–8 pups/litter) (Table 26.2).

The roof rat also is an opportunistic forager and will eat nearly anything that is nutritional and available around the poultry operation as well as berries, nuts, seeds, fruits, slugs, snails, birds, and a wide range of insects found in the natural environs away from buildings. Roof rats have foraging ranges similar in length to Norway rats' and occasionally may be even greater.

Rodent IPM For Poultry Operations

As discussed earlier, poultry houses intrinsically provide a "perfect storm" for commensal rodent infestations once rodents achieve a foothold. Unless rodent management programs are proactive, well-designed and comprehensive (i.e., integrated pest management), rodent populations in poultry operations will rebound explosively following inadequate control efforts (8). Designing, implementing, and sustaining effective and efficient IPM programs for poultry operations is challenging, even for the best pest management professionals (6). Rodents may infest the entire length of a facility from the manure pit and ground floors to the attic, as well as along the immediate exterior walls of each building. Secondary and tertiary rodent populations may exist around the peripheral areas of poultry farms, causing "waves" of new rodent immigrations as the established infestations are eliminated or reduced. Moreover, when rodent baiting programs are employed, the baits must compete with the copious amounts of food already available to the rodents.

Therefore, effective poultry rodent IPM programs must be comprised of 4 elements: (1) ongoing inspections and monitoring, (2) pest exclusion, (3) sanitation and cultural practices, and (4) population reduction efforts using rodenticide baits and/or traps. Unfortunately, rodent control efforts around livestock environments are all too frequently woefully underestimated in their complexity, scope, and costs necessary to attain control and to sustain the program over the long term.

Conducting Rodent Inspections

The most important step in poultry rodent IPM programs is to establish routine and ongoing inspections of the premises and the immediate surrounding areas. Proactive inspections to prevent infestations from ever occurring (or from ever accelerating to a serious level) can save poultry producers headaches and, in some cases, the actual survival of the business itself. Should an infestation occur, inspections provide insight into both the severity and the scope of the infestation. Moreover, once a control program is completed, an inspection should assess the program's effectiveness.

Rodent sightings, droppings, tracks, burrows, pathways, and fresh gnawings, as well as dead rodents, all can indicate where rodents are active as well as pinpoint suspected nesting zones. The most revealing rodent inspections are done using bright flashlights within the first 2 hours after sunset or the hour before sunrise. If rodents are present, such inspections will reveal the location, distribution, and severity of the infestation, which will aid in determining control procedures, such as the most important areas to eliminate harborages, where to concentrate baits and/or traps, and possible overlooked food and water spillages.

Because mice produce 40–100 droppings in a single evening and rats about 20–50, droppings are one of the more common signs seen by poultry personnel when the rodents themselves are not noticed.

Rodent burrows are another of the more common signs seen during inspections. Insulated walls and ceilings are common nesting locations for rodents, and burrow entrances are easily spotted. Rodents (especially mice) will readily burrow into dry poultry manure of just a few inches in diameter and height. The earth below slab walkways will be tunneled out by all 3 species. Rat burrows around poultry buildings are conspicuous due to their large openings of 1–2 inches (2.5–5 cm) in diameter. When rodents are seen repeatedly during the day, it indicates an established and probably severe infestation level.

Pest Exclusion

Although the cost to render a commercial poultry facility 100% rodent-proof can be prohibitive, rodents should be excluded in all areas wherever possible. Sometimes, poultry producers dismiss conducting *any* rodent proofing under the assumption that since rodents cannot be kept out of farm structures completely it is not worth doing at all, which is an unfortunate assumption. Pest exclusion programs should play a major part in poultry rodent IPM. But, similar to a facility's ongoing plumbing and electrical maintenance programs, rodent exclusion efforts also must be done correctly. Stuffing steel wool into rodent holes is not effective rodent proofing, nor is attaching "weather strips" to door bases.

Performing effective elementary pest exclusion can make the difference between poultry rodent infestations being minor and easily corrected or being severe and requiring a significant amount of time and effort, while the operation remains at serious economic and disease related risks.

For example, all grain storage bins and containers can and must be made rodent proof. Delivery doors, building foundations, roof areas, and cooler boxes can all be modified to deny rodents entry and harborage without major expenses

Figure 26.21. A mouse nest built out of a collection of feathers. These simple nests can house mouse families and should be disrupted via weekly sanitation programs. Note the mouse scurrying along the wall once the nest was touched with the inspector's shoe.

or time commitments. Gaps around augers, pipes, and wires (where these enter structures) can be easily sealed using Portland cement mortar, masonry, or metal collars.

More details on rodent exclusion materials and methods are available (7, 11, 27, 30).

Sanitation and Cultural Practices

Once rodents become established inside poultry houses, eliminating their food source is obviously not feasible. Because the rodents use the walls, ceilings, ground, and poultry manure for nest sites, it is also impossible to eliminate all indoor rodent harborages.

An important exception to this, however, is the management of dry manure in deep and shallow pit egg layer facilities for controlling mice. In these facilities, mice can build up to extremely high densities because they commonly construct their nests within the accumulating manure mounds in the pit and on the various shields and support trusses. The conical mounds of manure below the cages can essentially serve as thousands of high-rise condominiums for mouse families from one end of a layer house to the other. Mice also can harbor within the smaller manure piles that accumulate on the litter shields directly below the cages in stacked cage arrangements.

Many egg layer facilities conduct their pit manure cleanouts on a yearly schedule. However, should mice get a foothold in these facilities, the manure may need to be removed several times in the course of the year until the mouse population is brought back under control. At a minimum, any manure build-up on the litter shields or the support trusses must be removed as frequently as is feasible (14–30 days). One family of mice (8–15 mice), for example, can nest within 1 pile of dried manure measuring only several cubic inches.

Even loose feathers will be gathered by mice and used to construct conical feather nests along the floors of houses in which the manure has been removed (Figure 26.21). These nests can be identified, the mice destroyed, and the nests easily removed using a broom.

Consistent maintenance and repair of all interior feed and watering systems is essential to effective rodent IPM. Quick repair of any leaking feed and water lines is required, otherwise large mouse infestations develop near the malfunctioning systems. Sanitation efforts along exterior areas also can make the difference between minor and serious infestations and the frequency with which new rodents recolonize a poultry facility following successful extermination campaigns.

Weeds and rodents, for example, have always gone hand-in-hand. Weeds provide rodents with food, water, nesting material, and cover from predators. Thus, weed control outdoors is a critical element of controlling rodents indoors. Maintaining an uncluttered 3-foot weed-free perimeter around all buildings is the standard practice for rodent prevention.

Rats are discouraged from burrowing near building foundations when a perimeter strip of heavy gravel is present. Gravel should be at least 1 inch (2.54 cm) in diameter and laid in a band at least 2–3 feet (0.75–1 m) wide and 6 inches (15 cm) deep.

Exterior feed bins must be kept in good repair and all spillage from leaks should be cleaned daily (preferably before dusk). All exterior debris (e.g., old equipment, boards, pallets, etc.) that rodents can use for burrowing beneath must be eliminated.

Population Reduction

When rodent infestations develop in and around poultry operations, population reduction to supplement the other steps of IPM is usually necessary. This is achieved by using traps and poison (rodenticide) baits (where allowed).

Traps

Various rodent traps can help check new incoming rodents and supplement baiting programs for existing infestations. In areas or cases where poison baits are not allowed, trapping programs may comprise the largest part of the population reduction program beyond sanitation and pest exclusion efforts. Skillful installation of traps in strategic locations can capture significant numbers of rodents and prevent infestations from escalating.

Multiple-capture live mouse traps (also called "curiosity traps") are commonly used inside poultry operations. As their name suggests, these traps can capture multiples of mice. Several models and trade names are available to the poultry producer (e.g., Ketch-All, Repeater Tin Cat, Kwik-Katch Pro-Catch, etc.), and are effective and useful as a supplemental method for controlling mice (Figure 26.22).

The ordinary rat snap trap can be effective for minor rat infestations or to capture the single elusive rat. However, it must be stressed that beyond merely capturing a rodent here and there (which even the homeowner can do), skill and experience are necessary for any meaningful impact on a rodent infestation using these traps.

Figure 26.22. One brand of a multiple catch trap used for capturing mice inside commercial livestock facilities. Several different models exist on the market and information is easily gathered by searching the Internet.

The drawback of trapping programs is that they involve daily servicing by personnel, and for their use in moderate to severe infestations this can amount to several hours every day. Discussion on curiosity traps, snap traps, glue traps, and the various models and the techniques for using traps at the scale necessary for poultry IPM efforts are available (7, 9).

Rodenticide Baits and Bait Containers

If used carefully and correctly, rodenticide baiting programs can provide high levels of control in relatively short periods of time (i.e., a cost-effective approach). However, for some cases, and for some locales, poison baits are either not appropriate due to pesticide contamination risks, or they are not permitted due to company or governmental restrictions on the use of pesticide baits in food production facilities. In these cases, traps, sanitation, cultural practices, and exclusion comprise the program profile.

When rodenticide baiting programs are allowed, their use is not a job for the do-it-yourselfer unless the infestation is of a minor level. And although many poultry producers and operation managers may be "certified" to apply various chemicals and pesticides, rarely, if ever, are producers trained adequately to address the complexity of baiting and trapping efforts in poultry facilities when infestations are beyond a minor level.

Poultry rodent IPM programs require cost-effective and sustainable results. However, they also demand high levels of safety to both the poultry product and the various nontargets that may live on or visit the facility grounds. Nontarget animals such as dogs, cats, hawks, owls, coyotes, foxes, and others can be harmed if rodenticide baits are not applied with experience and if caution is not exercised at all times. The safety issues associated with use of poison baits around poultry environments goes beyond simply reading the label and following product directions.

When rodenticide campaigns are being considered, a pest management professional is needed for the majority of cases. Moreover, the professionals themselves should have expertise specifically in poultry rodent IPM. Installing bait and traps at prescribed spacing around the building perimeter and then simply servicing the baits on a weekly or monthly basis thereafter will not achieve success and may merely result in a "harvesting" program that can go on for long periods of time (Collins 2012, personal communication).

A variety of rodenticide baits are available that are labeled for use around poultry operations. Rodenticides are of two broad chemical groups: anticoagulants and nonanticoagulants (Table 26.3).

For safety reasons, rodenticide baits are usually installed inside protective bait containers (also called bait boxes or bait stations). However, Norway rat burrows can be safely baited without bait stations via direct treatment of the burrows (although specific techniques must be adhered to in order to avoid bait translocation (7)).

As with the baits themselves, there are also several different types of bait stations. Some are more effective or appropriate for use in one type of poultry operation, or for specific locations within particular poultry houses, than others (7, 9). For example contemporary bait stations include models designed as PVC T-tube stations (and variations) to facilitate bait installments onto narrow ledges or for baiting in elevated areas for reaching roof rats. Information on all of the rodenticide baits and bait stations is accessible via the Internet.

Baiting Strategies

It is emphasized here that there is no one-size-fits-all baiting strategy for commercial poultry facilities. Pest control workers not experienced in poultry rodent IPM programs sometimes try to implement the same conventional baiting schemes as for other buildings they service (e.g., warehouses, factories, etc.). However the different types of poultry facilities and the specific operation (layer, broiler, turkey, hatchery, etc.) demand that each operation and its particular infestation *be* analyzed *prior* to proceeding with any type of baiting program.

Examples and detailed discussions of baiting strategies for poultry facilities are available (8, 9).

Summary

Commensal rodents find commercial poultry facilities near-perfect habitats for reproducing and expanding their populations. Infestations can become severe, threatening economic damage to an operation and quickly escalating potential for disease transmission.

Consequently, rodent IPM programs for poultry operations require tailored programs employing site-specific inspections, sanitation, exclusion, traps, and skilled bait station installation. Poultry rodent IPM programs are unlike other urban rodent control operations that even professionals in the exterminating industry encounter. Both the poultry producer and the pest professional must recognize this prior to initiating control efforts.

Table 26.3. Examples of rodenticide baits used for poultry rodent IPM programs.

Active ingredient	Examples of trade name*	Formulations available	Dose required to kill/comments
Anticoagulants			
Brodifacoum	Jaguar, D-Con, Final, Ropax Bar-Bait, Havoc, others	Pellets, blocks, packs	Single dose; kills warfarin-resistant rodents
Bromadiolone	Contrac, Boothill, Hawk, Trax-one, Just One Bite, Maki, Brigand, Resolv	Pellets, blocks, packs, soft sachets	Single dose; kills warfarin-resistant rodents in USA; resistance has developed in some countries
Diphacinone	Ramik Green, Contrax-D, Ditrac, others	Pellets, blocks, packs	Death may occur in rats after 1 feeding, but multiple feedings usually necessary
Difenacoum	Multi-Kill	Pellets, blocks, packs	Single dose, genetic resistance has developed in some countries
Difethialone	Generation, First Strike	Pellets, bait packs, sachets	Single dose; kills warfarin-resistant rodents
Flocoumafen	Storm	Blocks, pellets	
Warfarin	Ferret, Contrax	Bulk pails, place packs, 50-lb. bulk	Best results are achieved when warfarin is ingested in repeated doses over 4–10 days for rats, sometimes longer for mice; genetic resistance in some locations
Nonanticoagulants			
Bromethalin	Assault, Fastrac, Trounce, Vengeance, Others	Pellets, blocks, packs	Single dose; stop-feed action; not as widely used as anticoagulants
Cholecalciferol	Rampage, Quintox	Place packs (meal, pellets, and canary seed)	1–3 feedings are lethal; not as widely used as anticoagulants
Zinc phosphide	Many brands	Pellets and mixed grains	Single dose (acute) bait; quick kill results; some rodents may become bait-shy to zinc phosphide

* Many bait products exist under several trade names depending on the country. No endorsement of named products is intended, nor is criticism implied to similar products not mentioned.

References

1. Axtell, R.C. 1986. Fly management in poultry production: cultural, biological, and chemical. *Poult Sci.* 65:657–667.
2. Axtell, R.C. 1999. Poultry integrated pest management: Status and future. *Integr Pest Man Rev.* 4:53–73.
3. Berry, R.J., ed. 1981. Biology of the House Mouse. Zoological Society of London Symposium No. 47. Academic Press, New York. 964 pp.
4. Bronson, F.H. 1979. The reproductive ecology of the house mouse. *Quart Rev Biol.* 54:265–299.
5. Bronson, F.H. 1984. The adaptability of the house mouse. *Scient Amer.* 250(3):116–125.
6. Collins, D. 2012. Contemporary rodent IPM for poultry facilities. Personal Communication. Collins Pest Management/Poultry IPM Specialists. Evansville, IN.
7. Corrigan, R.M. 2001. *Rodent Control. A Practical Guide for Pest Management Professionals*. GIE Media Cleveland, OH. 353 pp.
8. Corrigan, R.M., and R.E. Williams. 1986. The house mouse in poultry operations: pest significance and a novel baiting strategy for its control. In: *Proceedings of the Twelfth Vertebrate Pest Conference (1986)*. Davis, CA. Paper 15. http://digitalcommons.unl.edu/vpc12/15.
9. Corrigan, R.M., and R.M. Timm. 1993. *Controlling Rodents in Commercial Poultry Facilities*. Purdue University Cooperative Extension Service, West Lafayette, IN. 16 pp.
10. Crippen, T.L., C.L. Sheffield, S.V. Esquivel, R.E. Droleskey, and J.F. Esquivel. 2009. The acquisition and internalization of *Salmonella* by the lesser mealworm, *Alphitobius diaperinus* (Coleoptera: Tenebrionidae). *Vector Borne Zoonotic Dis.* 9:65–72.
11. Frantz, S.C., and D.E. Davis. 1991. Bionomics and integrated pest management of commensal rodents. In: *Ecology and Management of Food Industry Pests*. J.R. Gorham, ed. Assoc. Off. Anal. Chem, Arlington, VA. 243–313.
12. Goodwin, M.A., and W.D. Waltman. 1996. Transmission of *Eimeria*, viruses, and bacteria to chicks: darkling beetles (*Alphitobius diaperinus*) as vectors of pathogens. *J Appl Poult Res.* 5:51–55.
13. Graczyk, T.K., R. Knight, R.H. Gilman, and M.R. Cranfield. 2001. The role of non-biting flies in the epidemiology of human infectious diseases. *Microbes Infect.* 3:231–235.
14. Henzler, D.J., and H.M. Opitz. 1992. The role of mice in the epizootiology of *Salmonella enteritidis* infection on chicken layer farms. *Avian Dis.* 36:625–631.
15. Hinkle, N.C. 2002. Poultry Pest Management (Arthropods). In: *Encyclopedia of Pest Management*. D. Pimentel, ed. Marcel Dekker, New York. 657–660.
16. Hinkle, N.C., and L.A. Hickle. 1999. California caged layer pest management evaluation. *J Appl Poult Res.* 8:327–338.
17. Hurst, J.L., and J. Berreen. 1985. Observations on the trap-response of wild house mice, *Mus domesticus* Rutty, in poultry houses. *J Zool London.* 210:619–622.

18. Kaufman, P.E., D.A. Rutz, and C.W. Pitts. 2000. *Pest Management Recommendations for Poultry*. The Pennsylvania State University, 18 pp.
19. Meerburg, B.G. 2006. Zoonotic Risks of Rodents in Livestock Production. Ph.D. Dissertation, University of Amsterdam. 167 pp.
20. Meerburg, B.G., and A. Kijlstra. 2007. Role of rodents in the transmission of *Salmonella* and *Campylobacter*. *J Sci Food Agri.* 87:2774–2781.
21. Meerburg, B.G., G.R. Singleton, and A. Kijlstra. 2009. Rodent-borne diseases and their risks for public health. *Crit Rev Microbiol.* 35:221–270.
22. Mul, M.F. and C.J.M. Koenraadt. 2009. Preventing introduction and spread of *Dermanyssus gallinae* in poultry facilities using the HACCP method. *Exp Appl Acarol.* 48:167–181.
23. Mullens, B.A., J.P. Owen, D.R. Kuney, C.E. Szijj, and K.A. Klinger. 2009. Temporal changes in distribution, prevalence and intensity of northern fowl mite (*Ornithonyssus sylviarum*) parasitism in commercial caged laying hens, with a comprehensive economic analysis of parasite impact. *Vet Parasit.* 160:116–133.
24. Mullens, B.A., D. Soto, C.D. Martin, B.L. Callahan, and A.C. Gerry. 2012. Northern fowl mite (*Ornithonyssus sylviarum*) control evaluations using liquid formulations of diatomaceous earth, kaolin, sulfur, azadirachtin, and *Beauveria bassiana* on caged laying hens. *J Appl Poult Res.* 21:111–116.
25. Roche, A.J., N.A. Cox, L.J. Richardson, R.J. Buhr, J.A. Cason, B.D. Fairchild and N.C. Hinkle. 2009. Transmission of *Salmonella* to broilers by contaminated larval and adult lesser mealworms, *Alphitobius diaperinus* (Coleoptera: Tenebrionidae). *Poult Sci.* 88:44–48.
26. Selander, R.K. 1970. Behavior and genetic variation in natural populations. *Integr Comp Biol.* 10: 53–66.
27. Scott, H.G. 1991. Design and Construction. Building Out Pests. In: *Ecology and Management of Food-Industry Pests*. J. Gorham, ed. Association of Official Analytical Chemists, Arlington, Va. 331–343.
28. Steelman, C.D., A.L. Szalanski, R. Trout, J.A. McKern, C. Solorzano, and J.W. Austin. 2008. Susceptibility of the bed bug *Cimex lectularius* L. (Heteroptera: Cimicidae) collected in poultry production facilities to selected insecticides. *J Agri Urban Ent*. 25:41–51.
29. Taylor, K.D. and R.J. Quy. 1978. Long distance movements of a common rat (*Rattus norvegicus*) revealed by radio-tracking. *Mammalia.* 42(1):63–71.
30. Timm, R.M., and G.R. Bodman. 1983. Rodent-proof construction: drains and feeding equipment. Cooperative Extension Service, IANR, UNL, NebGuide G83–657. 4 pp.
31. Timm, R.M. and D.D. Fisher.1986. An economic threshold model for house mouse damage to insulation. In: *Proceedings of the Twelfth Vertebrate Pest Conference*. T. P. Salmon, ed. University of California, Davis. 237–241.
32. Vaughan, J.A., E.C. Turner, Jr., and P.L. Ruszler. 1984. Infestation and damage of poultry house insulation by the lesser mealworm, *Alphitobius diaperinus* (Panzer). *Poult Sci.* 63:1094–1100.
33. World Health Organization. 2008. Public Health Significance of Urban Pests. X. Bonnefoy, H. Kampen, and K. Sweeney, eds. Copenhagen. 569 pp.

Chapter 27

Internal Parasites

Larry R. McDougald

Introduction

The worm parasites of poultry (trematodes, acanthocephalans, cestodes, and nematodes) are represented by numerous species and are often serious limitations to productivity of poultry, well-being of pet or zoo birds, or threats to survival of wildlife. In highly developed poultry industries, the threat of damage from these parasites has been limited by technology; the practice of keeping poultry indoors may effectively eliminate access to arthropods and lower animals known to serve as essential intermediate hosts for the parasites. Today, only a handful of parasites are important in commercial poultry, although many are found in small flocks reared in natural environments. A rich fauna of internal parasites can be found by examination of birds from backyard flocks and feral or free-range poultry. Wild birds of nonpoultry species have an abundant fauna of worms of all types. Many are important in the commercial production of game birds. The important parasites of poultry normally have a short, direct life cycle, and are fecund enough to prosper in the poultry house environment. This is particularly true in cases in which management does not require frequent cleanout between flocks. Even though all cestodes have intermediate hosts, they may be important because the intermediate host is well suited to the poultry house environment.

The difficulty in control of internal parasites is underscored by the fact that there have been no new products registered specifically for control of worms in chickens in many years. Excellent products are approved for use in other animals which can be used off-label by veterinary prescription. Even though mild infections of most worms cause little damage, some bring in other diseases, such as the well-known relationship between *Heterakis gallinarum* and blackhead disease (*Histomonas meleagridis*). Recent widespread clinical outbreaks of blackhead disease underscore the need for advances in this area. Among anthelmintics, few have been approved for use in poultry, and there is currently no product approved for treatment of cestode infections. Recent changes in the FDA's regulation of off-label use of products by veterinarians has provided some relief by allowing the use of some modern products, but there are still major parasites in many bird species for which there is no treatment.

Nematodes and Acanthocephalans

Introduction

Birds in general are hosts to a great number of worm parasites, particularly the nematodes (roundworms). However, most commercial poultry are reared indoors, restricting the opportunity for exposure to worms requiring intermediate hosts mainly to those with direct life cycles. The shortened growing period for broilers further reduces the exposure to worms, because many of the nematodes require 4 weeks or more to reach sexual maturity and produce infective ova. Worm burdens are more likely to reach damaging populations in warm weather and in birds that are kept for 7 weeks or more such as broiler-breeders or layers, turkeys, and heavy broiler/roasters.

The nematodes reported from chickens in North America are listed in Table 27.1. One can see that host specificity is not as strict with nematodes as with some other classes of parasites.

Diseases of Poultry, Thirteenth Edition. David E. Swayne.
© 2013 John Wiley & Sons, Inc. Published 2013 by John Wiley & Sons, Inc.

Table 27.1. Nematodes reported from chickens in the United States.

Nematode	Location	Intermediate Host	Other Definitive Host
Baylisascaris procyonis	Brain		Raccoons (accidental parasite in chicken, turkey, partridge, quail)
Oxyspirura mansoni	Eye	Cockroach	Turkey, duck, grouse, guinea fowl, peafowl, pigeon, quail
Syngamus trachea	Trachea	None	Turkey, goose, guinea fowl, pheasant, peafowl, quail
Capillaria contorta	Mouth, esophagus, crop	None or earthworm	Turkey, duck, guinea fowl, partridge, pheasant, quail
C. annulata	Esophagus, crop	Earthworm	Turkey, goose, grouse, guinea fowl, partridge, pheasant, quail
Gongylonema ingluvicola	Crop, esophagus, proventriculus	Beetle, cockroach	Turkey, partridge, pheasant, quail
Dispharynx nasuta	Proventriculus	Sowbug	Turkey, grouse, guinea fowl, partridge, pheasant, pigeon, quail
Tetrameres americana	Proventriculus	Grasshopper, cockroach	Turkey, duck, grouse, pigeon, quail
T. fissispina	Proventriculus	Amphipod, grasshopper, cockroach, earthworm	Turkey, duck, goose, guinea fowl, pigeon, quail
Cheilospirua hamulosa	Gizzard	Grasshopper, beetle	Turkey, grouse, guinea fowl, pheasant, quail
Ascaridia galli	Small intestine	None	Turkey, duck, goose, quail
Capillaria anatis	Small intestine, cecum, cloaca	None	Turkey, duck, goose, partridge, pheasant
C. bursata	Small intestine	Earthworm	Turkey, goose, pheasant
C. caudinflata	Small intestine	Earthworm	Turkey, duck, goose, grouse, guinea fowl, partridge, pheasant, pigeon, quail
Capillaria obsignata	Small intestine	None	Turkey, goose, guinea fowl, cecum pigeon, quail
Heterakis gallinarum	Cecum	None	Turkey, duck, goose, grouse, guinea fowl, partridge, pheasant, quail
Subulura brumpti	Cecum	Earwig, grasshopper, beetle, cockroach	Turkey, dove, duck, grouse, guinea fowl, partridge, pheasant, quail
S. strongylina	Cecum	Beetle, cockroach, grasshopper	Guinea fowl, quail
Strongyloides avium	Cecum	None	Turkey, goose, grouse, quail
Trichostrongylus tenuis	Cecum	None	Turkey, duck, goose, guinea fowl, pigeon, quail

Table 27.2. Nematodes reported from poultry or commercially raised game birds other than chickens.

Nematode	Location	Intermediate Host	Other Definitive Host
Cyathostoma bronchialis	Trachea	None or earthworm	Turkey, duck, goose, (chicken)
Cymea colini	Proventriculus	Cockroach	Turkey, grouse, prairie chicken, quail, (chicken)[a]
Tetrameres crami	Proventriculus	Amphipod	Duck
Microtetrameres helix	Proventriculus	Grasshopper	Pigeon
Amidostomum anseris	Gizzard	None	Duck, goose, pigeon
A. skrjabini	Gizzard	None	Duck, pigeon, (chicken)
Ascaridia columbae	Small intestine	None	Pigeon, dove
A. dissimilis	Small intestine	None	Turkey
A. numidae	Small intestine	None	Guinea fowl
Omithostrongylus quadriradiatus	Small intestine	None	Pigeon, dove
Heterakis dispar	Cecum	None	Duck, goose
H. isolonche	Cecum	None	Duck, grouse, pheasant, prairie chicken, quail
Capillaria columbae	Large intestine	None	Pigeon, dove

[a]Experimental

Table 27.3. Nematodes reported from wild birds in the United States that pose a potential problem for poultry or commercially raised game birds.

Nematode	Location	Intermediate Host	Definitive Host
Oxyspirura petrowi	Eye	Unknown	Grouse, quail, pheasant, prairie chicken
Splendidofilaria californiensis	Heart	Unknown	Quail
Singhfilaria hayesi	Subcutaneous	Unknown	Turkey, quail
Splendidofilaria pectoralis	Subcutaneous	Unknown	Grouse
Chandlerella chitwoodae	Connective tissues	Unknown	Grouse
Aproctella stoddardi	Body cavity	Unknown	Turkey, dove, quail
Cardiofilaria nilesi	Body cavity	Mosquito	Chicken
Echinura uncinata	Esophagus, gizzard, proventriculus, small intestine	Water flea	Duck, goose
E. parva	Proventriculus, gizzard	Unknown	Duck, goose
Tetrameres pattersoni	Proventriculus	Grasshopper, cockroach	Quail
T. ryjikovi	Proventriculus	Unknown	Duck
Cymea neeli	Proventriculus, gizzard	Unknown	Turkey
C. pileata	Proventriculus	Unknown	Quail
Physaloptera acuticauda	Proventriculus	Unknown	Chicken, pheasant
Amidostomum acutum	Gizzard	None	Duck
A. raillieti	Gizzard	None	Duck, dove
Cheilospirura spinosa	Gizzard	Grasshopper	Grouse, partridge, pheasant, quail, turkey
Cymea eurycerea	Gizzard	Unknown	Pheasant, quail, turkey
Epomidiostomum uncinatum	Gizzard	None	Chicken, duck, goose, pigeon
Streptocara crassicauda	Gizzard	Amphipod	Chicken, duck
Ascaridia bonasae	Small intestine	None	Grouse
A. compar	Small intestine	None	Grouse, partridge, pheasant, quail
Porrocaecum ensicaudatum	Small intestine	Earthworm	Chicken, duck
Capillaria phasianina	Small intestine, cecum	Unknown	Partridge, pheasant, guinea fowl
C. tridens	Small intestine	Unknown	Turkey
Aulonocephalus lindquisti	Cecum, large intestine	Unknown	Quail
A. pennula	Cecum	Unknown	Turkey
A. quaricensis	Cecum	Unknown	Quail

Note: Some of these have been reported from domestic poultry outside of the United States.

Most of the nematodes infect the turkey and a variety of game birds, although a sharing of these parasites is not important except where more than 1 species of bird is mixed with others in common rearing pens. Also, some of the parasites are accidental, such as *Baylisascaris procyonis*, a parasite of the raccoon. Nematodes not found in chickens but reported from game birds or other poultry are listed in Table 27.2. In many cases experiments have not been done to determine whether the chicken is a suitable host for these worms. Wild birds are host to numerous nematode species but most are not known to infect commercial poultry. Some of these are highly pathogenic to their hosts and even cause mortality. Table 27.3 lists nematodes from wild birds that are also known to infect poultry or game birds. It cannot be expected that commercial chickens or turkeys could become infected with these worms because many require intermediate hosts not found indoors. However, birds reared outdoors in pens, or free-range birds, could become exposed, because many of these parasites exist in reservoirs of backyard poultry and game birds. The life cycles of these parasites are largely unknown.

Worm parasites of poultry have received little research attention for many years, so that much of the literature involves case reports or superficial surveys. The scientific names are those of Yamaguti (49), except where modified by modern authorities on nomenclature. The classification of families follows that used in a series on nematode parasites of vertebrates edited by Anderson and Bain (2). This edition of *Diseases of Poultry* has been streamlined by the elimination of detailed morphological descriptions, the basis of classical parasite taxonomy. The detailed information is of course available in most previous editions of this reference, especially the 12th edition. The figures illustrating the key taxonomic characters are retained for use of those wishing to make detailed examination of worms.

Nematodes

Morphology of Nematodes Used in Identification

Nematodes are usually spindle-shaped with the anterior and posterior ends attenuated. The body covering or cuticle is often marked by microscopic transverse grooves. Longitudinal folds (alae) may be present at the anterior or posterior ends.

The posterior alae are sometimes modified to form a bursa (Figure 27.21B, below), which functions in copulation. Cuticular ornamentations occasionally found on the anterior extremities are spines, cordons, or shields (Figure 27.19A, below).

The mouth opening on the anterior end of the worm is usually surrounded by lips bearing sensory organs (Figure 27.16A, below). The mouth may lead directly into a cavity immediately anterior to the esophagus (Figure 27.18, below), or this may be reduced or absent. The esophagus may be simple (consisting of 1 undivided part) or more complex (consisting of a short, anterior, muscular part and a long, posterior, glandular part). A bulb may or may not be present at the posterior end (Figure 27.8, below). The intestine follows the esophagus and leads to a short rectum connecting to the anal or cloacal opening near the posterior end.

Nematodes usually have separate sexes. These may be fairly similar in appearance, such as in *Ascaridia galli*, or may be remarkably different, as in *Tetrameres americana* (Figure 27.28, below), in which the elongate male is much smaller than the globular female. The male worm usually can be identified by the presence of 2 (rarely 1) chitinous structures known as spicules, located near the posterior end of the body (Figure 27.8, below). Spicules are considered as organs for use during copulation, keeping the vulva and vagina open and possibly guiding the amoeboid sperm into the female reproductive tract. Eggs (ova) or larvae are discharged through the vulva, the location of which varies between genera of nematodes.

Development and Life Cycles

About half of the species of nematodes in poultry have a direct life cycle (depending only on the bird host), while others depend on such intermediate hosts as insects, crustaceans, snails, and slugs. Several use paratenic hosts, in which no development takes place, but which facilitate parasite survival and dispersal between hosts.

Nematodes normally pass through 4 developmental stages and 4 successive molting events (shedding of the cuticle) before maturing and producing eggs. Eggs laid by the female are excreted in the droppings, regardless of the site of infection of the adult worm. Some eggs are embryonating before leaving the host, but most require suitable conditions outside the host for the development of infective larvae. Most hatch only when consumed by a new host, but a few hatch in the environment and release larvae. Eggs require several days to weeks to embryonate (develop larvae inside). Nematodes with direct life cycles infect birds when the egg or larva is consumed. Worms with indirect life cycles infect the bird when the intermediate host or vector is consumed. Blood-feeding arthropods serving as intermediate hosts may inject larvae in saliva during feeding. For reasons discussed above, nematodes with direct life cycles predominate in commercial poultry.

After infection takes place, the worm requires several weeks to mature and produce eggs (the prepatent period). Some larval development takes place, followed by a final molt, allowing the worm to become an adult.

Nematodes Important to Commercial Poultry Production

Genus Ascaridia

The worms of the genus *Ascaridia* invade the small intestine where they cause light-to-moderate damage. These all have a direct life cycle and resemble each other except for size, contributing to possible confusion. Microscopically, the tails of male worms are used for identification (Figure 27.1). It is doubtful that the reported host range for these worms is accurate. Eggs embryonate in 14–30 days in the environment. Eggs hatch after ingestion by a bird host, releasing second-stage larvae. These invade the mucous layer of the small intestine for a few days before molting to the third stage. It is common to find numerous third-stage larvae in a bird, with low numbers

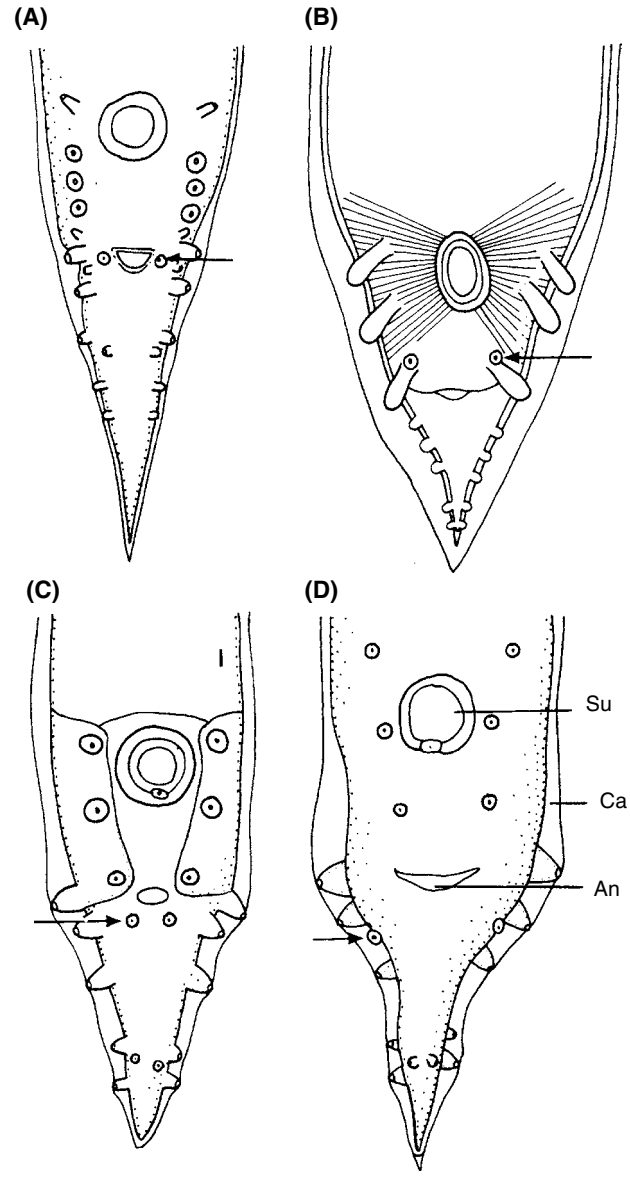

Figure 27.1. Male tails. (A) *Ascaridia columbae*. (After Wehr and Hwang). (B) *Ascaridia compar*. (After Linstow) (C) *Ascaridia dissimilis*. (D) *Ascaridia galli*. (After Wehr)

of adults. After 18–30 days, there is a final molt, and the adults begin producing eggs.

Ascaridia bonasae. The host of *Ascaridia bonasae* is the grouse and Bobwhite quail. The worm is normally much smaller than *A. galli*.

Ascaridia columbae. The hosts of *Ascaridia columbae* are pigeons and doves, usually found in the lumen of the small intestine, but also in other parts of the digestive tract. They are of low pathogenicity.

Ascaridia compar. The hosts of *Ascaridia compar* are grouse, partridge, pheasant, and Bobwhite quail.

Ascaridia dissimilis. The host of *Ascaridia dissimilis* is the turkey. *Ascaridia dissimilis* is very common in commercial turkey flocks with numbers of worms in natural infections reaching 2,000/bird (30). Mortality and low productivity are associated with this worm (18, 29). Aberrant migration of larvae may cause hepatic foci and granulomas (31). Infections cause anorexia, intestinal inflammation, diarrhea, and possible depression of immune competence.

Ascaridia galli. Chickens are the host of *Ascaridia galli*, but this worm also has been reported from turkeys, doves, ducks, and geese; it is not known whether all these reports are accurate. These are large worms, sometimes reaching 116 mm in length (approximately 4.5 inches). The eggs are very similar in appearance and size to those of *Heterakis gallinarum* (Figure 27.2), and may survive outdoor conditions for more than a year (14). These worms are common in poultry, even cage layers, where worm eggs are mechanically carried by flies. Pathogenicity is generally low, although in heavy infections there is decreased weight gain (35). It is not uncommon to find worm burdens so high that the intestine is blocked. Birds commonly develop age resistance after 3 months, resulting in significantly lower worm burdens (27, 45). An important nuisance factor with this worm is the occasional finding of adult worms in table eggs (36). This is apparently associated with the use of older dewormers such as piperazine, which narcotize the worm rather than killing it. As the worm passes out through the cloaca, it may recover and begin migrating up the oviduct to the shell gland where it may be included in the egg. Worms inside eggs can be detected by candling, although this is more difficult with brown-shelled eggs. This nuisance has been greatly reduced by the use of modern anthelminthics to effectively kill both larvae and adult worms.

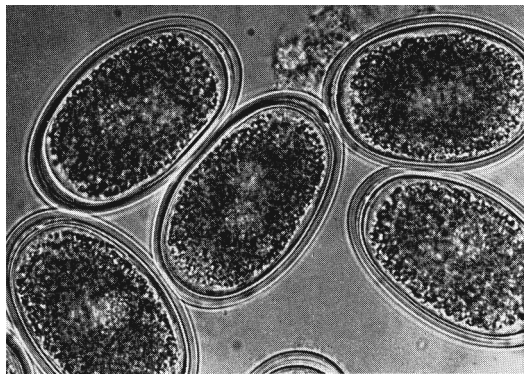

Figure 27.2. *Ascaridia galli* eggs freshly voided from a chicken. ×400 (Benbrook)

Ascaridia numidae. *Ascaridia numidae* is a parasite of the guinea fowl. It is found in the small intestine or occasionally the ceca.

Genus Capillaria

Several species in the genus *Capillaria* may infect the crop or upper digestive system, while others are intestinal. They are usually thin and threadlike. The eggs are easily recognized by the prominent opercula at both ends. Some use intermediate hosts, whereas others have a direct life cycle. The structures of the male bursa and female vulva are used to identify species of this genus (Figure 27.3 and Table 27.4).

Capillaria annulata. *Capillaria annulata* (Figure 27.4) is a parasite has been reported in turkeys, pheasants, quail, chickens, and other game birds. It invades the mucosa of the crop. It may result in morbidity and mortality, and uses earthworms (*Eisenia foetidus* and *Allobophora caliginosus*) as intermediate hosts.

Capillaria contorta. *Capillaria contorta* (Figure 27.5) infects all gallinaceous birds and invades the mucosa of the crop and esophagus. It may result in morbidity and mortality. The life cycle is direct.

Capillaria obsignata. *Capillaria obsignata* (Figure 27.6), one of the most important worms in commercial chickens, is also reported in the turkey, guinea fowl, pigeon, and Bobwhite quail. It is found in the small intestinal mucosa where it induces a catarrhal exudate and thickening of the wall. Morbidity and mortality are possible in heavy infections.

Capillaria caudinflata. *Capillaria caudinflata* infects the small intestine of all gallinaceous birds. It uses earthworms (*Eisenia foetidus* and *Allobophora caliginosus*) as intermediate hosts.

Capillaria bursata. *Capillaria bursata* infects the small intestine of gallinaceous birds, and uses earthworms as the intermediate host.

Capillaria anatis. *Capillaria anatis* is reported from the chicken, turkey, duck, goose, partridge, and pheasant. This worm is found in the cecum or sometimes in the small intestine. The life cycle is not known.

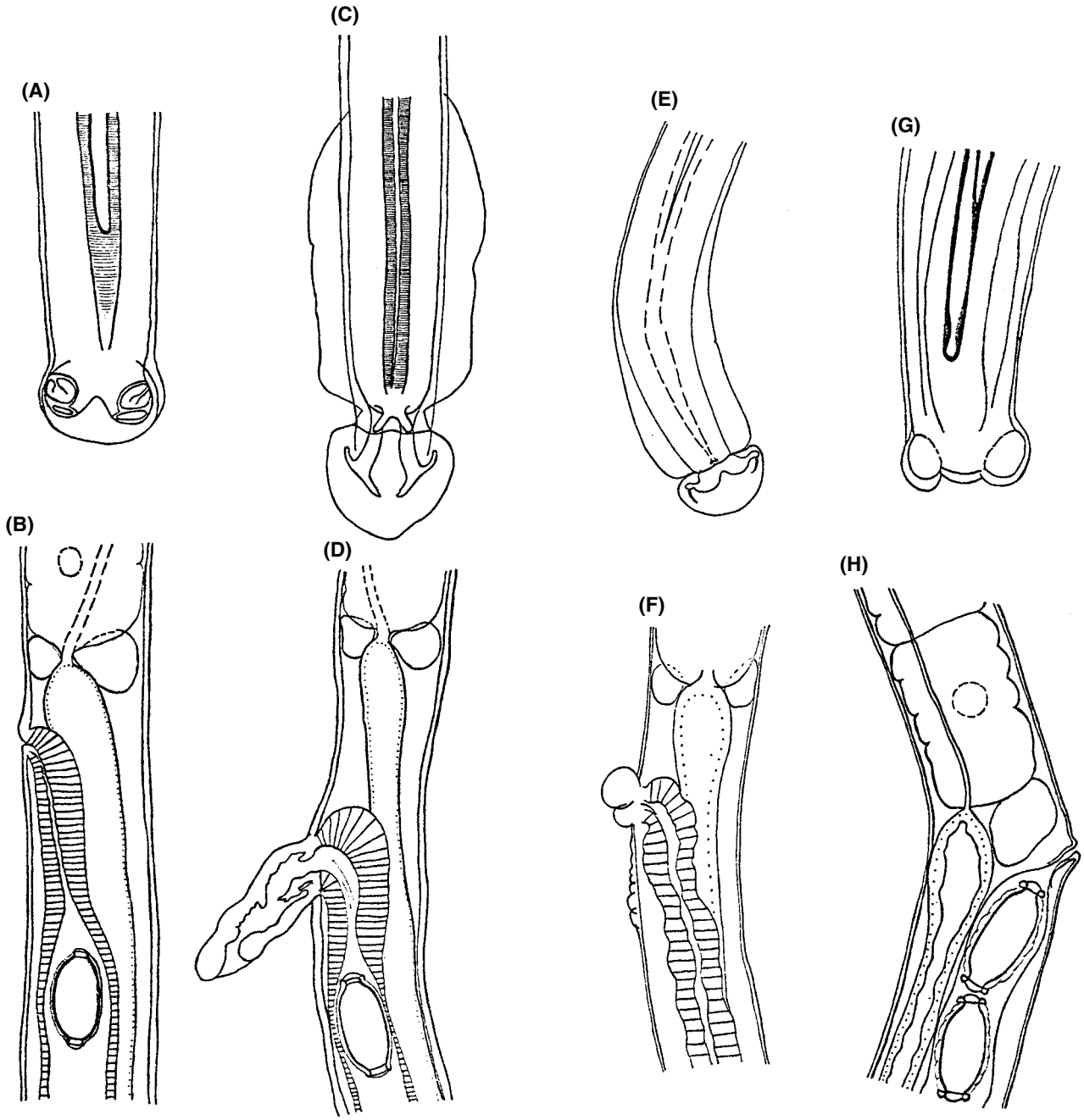

Figure 27.3. Male bursa (A, C, E, G) and female vulva (B, D, F, H) of *Capillaria obsignata* (A, B), *Capillaria caudinflata* (C, D), *Capillaria bursata* (E, F), and *Capillaria anatis* (G, H). (After Wakelin)

Table 27.4. Characteristics of *Capillaria* from chickens in the United States.

Characteristic	*C. anatis*	*C. bursata*	*C. caudinflata*	*C. obsignata*
Male				
Lateral caudalae	–	+	+	–
Spicule sheath	Spines	No spines	Minute spines	No spine
Female				
Vulvar appendage	None	Semicircular	Pronounced	None

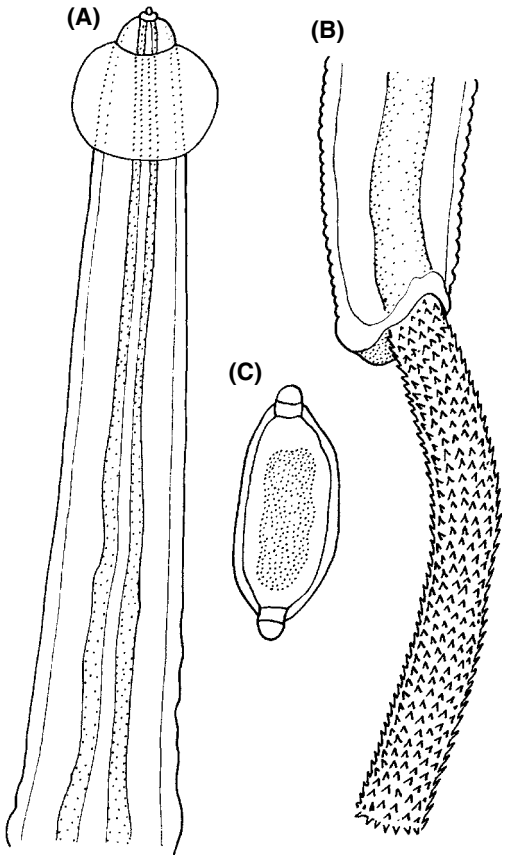

Figure 27.4. Capillaria annulata. (A) Head end. (B) Male tail. (After Ciurea) (C) Egg.

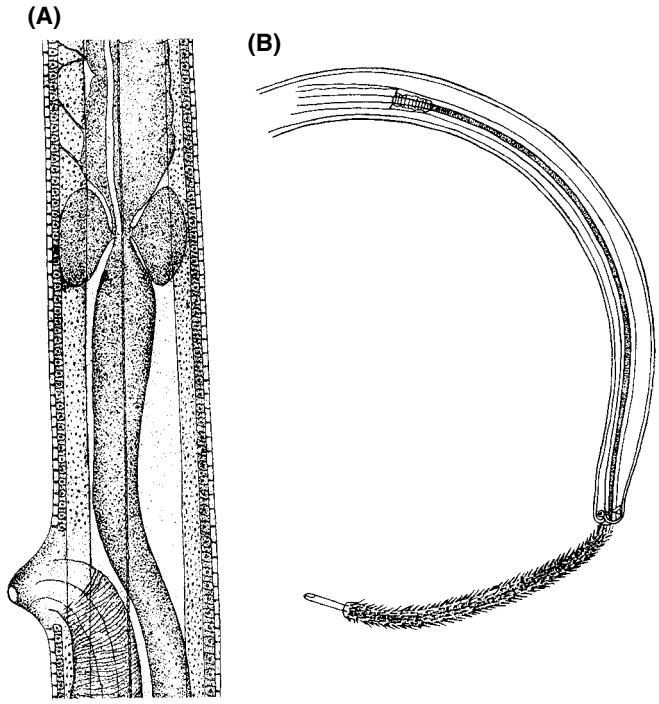

Figure 27.5. Capillaria contorta. (A) Region of vulva. (After Eberth) (B) Male tail. (After Travassos)

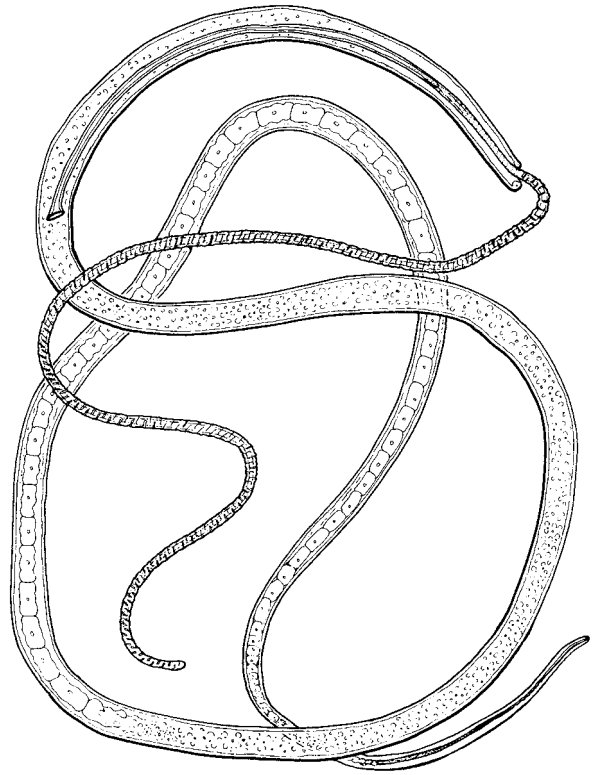

Figure 27.6. *Capillaria obsignata*. (After Gagarin)

Genus Heterakis

Worms of the genus *Heterakis* are small and thin and are found primarily in the ceca of birds. Several species of these worms are common in commercial poultry and game birds.

Heterakis bonasae. *Heterakis bonasae* infects the ceca of the ruffed grouse and Bobwhite quail. Prevalence and worm burdens are sometimes high (17, 23). In contrast to results with *H. gallinarum*, *H. bonasae* could not serve as a vector for blackhead disease (Histomoniasis) in Bobwhite quail (10).

Heterakis dispar. *Heterakis dispar* infect the ceca of ducks and geese, but are relatively nonpathogenic (Figure 27.7A).

Heterakis gallinarum. The hosts of *Heterakis gallinarum* are the chicken, turkey, duck, goose, grouse, guinea fowl, partridge, pheasant, and quail. This nematode is an abundant parasite of replacement layers and all chickens that are maintained on soil or litter. Worms are small and white, generally thin. Microscopic identification is based on the head and esophagus (Figure 27.8A), but eggs are similar to those of *A. galli*. Without doubt, this is the most important nematode in poultry because it serves as a transport host for *Histomonas meleagridis*, the causative agent of blackhead disease (47). Although there are other species of cecal worms, *H. gallinarum* is the only one known to carry blackhead disease. Blackhead disease can be produced by dosing birds orally with embryonating eggs, larvae, or male worms (38, 43). The life cycle of the

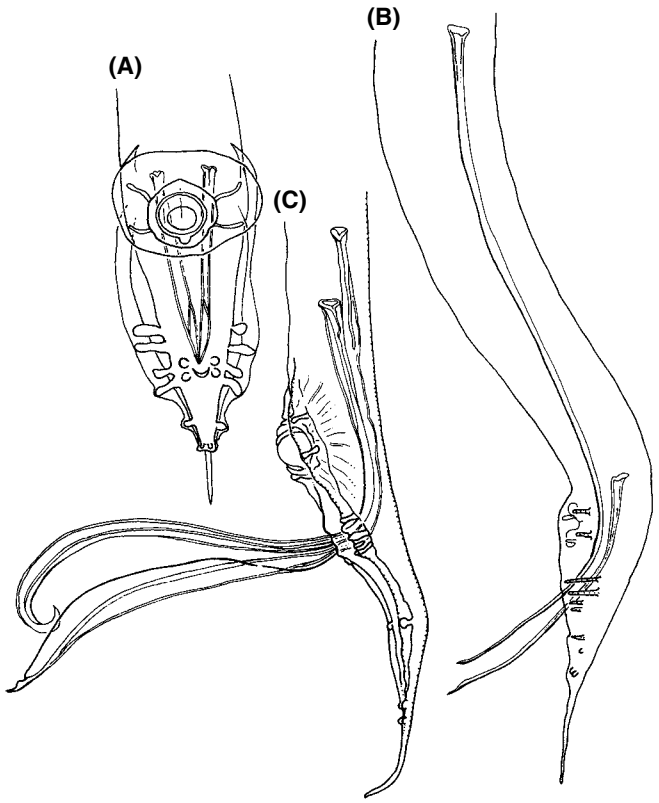

Figure 27.7. Male tails. (A) *Heterakis dispar*. (After Madsen) (B) *Heterakis gallinarum*. (After Lane) (C) *Heterakis isolonche*. (After Cram et al.)

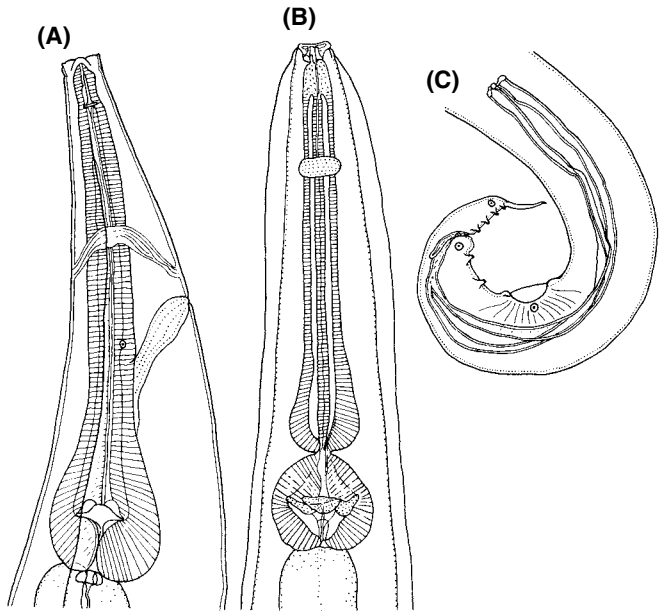

Figure 27.8. (A) *Heterakis gallinarum*, head. (B) *Subulura suctoria*, head. (After Skrjabin and Shikhobalova) (C) *Subulura strongylina*, male tail. (After Barreto)

worm is direct, although worm eggs may be ingested by earthworms, where they hatch and live for months before being ingested by a bird. The ring-necked pheasant is the best host for *H. gallinarum*, followed by guinea fowl and chickens (27). Turkeys rarely develop patent infections, but larval parasitism is sufficient to allow initiation of histomoniasis. The worm itself is of low pathogenicity, although inflammation and thickening of the cecal wall and nodule formation on the mucosa and submucosa are seen in heavy infections (24). Larvae may migrate to the liver, causing hepatic granulomas (37).

Heterakis isolonche. *Heterakis isolonche* is reported from the duck, grouse, pheasant, prairie chicken, and Bobwhite quail. It is very similar to *H. gallinarum*, but differentiated by the size and appearance of the spicules (Figure 27.7C). It is somewhat more pathogenic than other species, reportedly causing high mortality in pen-reared pheasants, but is less pathogenic in quail and grouse.

Nematodes Important in Game Birds, Waterfowl, or Poultry Reared Outdoors

Aproctella stoddardi

Aproctella stoddardi is found in Bobwhite quail, doves, grouse, and turkeys, in the body cavity. Morphology is illustrated in Figure 27.9. A biting arthropod is thought to be the intermediate host. Heavy infections may result in mortality in doves.

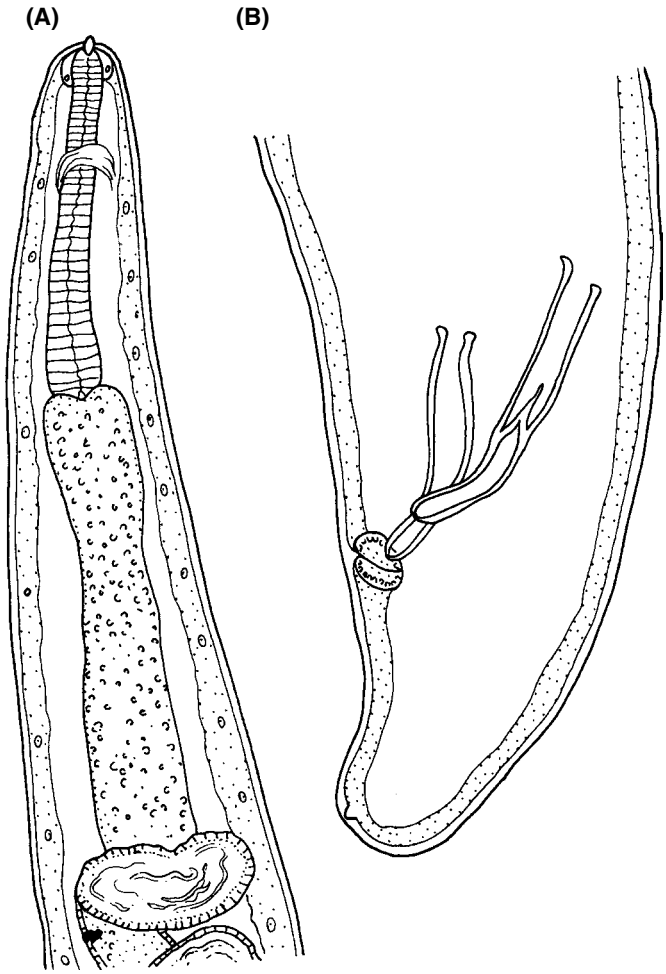

Figure 27.9. *Aproctella stoddardi*. (A) Head. (B) Male tail. (After Anderson)

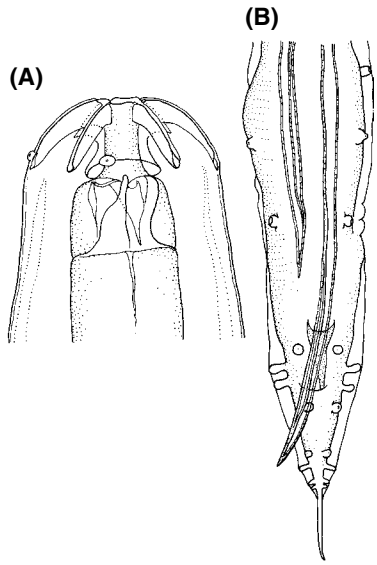

Figure 27.10. *Aulonocephalus lindquisti*. (A) Head. (B) Male tail. (After Chandler)

The eggs apparently hatch *in utero*, as unsheathed larvae are present in the uterus.

Aulonocephalus lindquisti

The hosts of *Aulonocephalus lindquisti* are Bobwhite quail and blue or scaled quail, mostly in western Texas. These are bright pink worms, mostly in the ceca, but sometimes in the large intestine (Figure 27.10). The pathogenicity and life cycle are unknown.

Baylisascaris procynois, Baylisascaris columnaris

Baylisascaris procynois, Baylisascaris columnaris are parasites of raccoons and skunks, respectively, occasionally infecting birds through consumption of infected feces. Birds are not a suitable host for the worm, but the larvae migrate to the brain, causing severe neurological signs. This condition has been reported from partridges, emu, quail, and other birds, and has been produced experimentally in chickens (25).

Genus Cheilospirura *and Relatives*

Genus *Cheilospirura* and their relatives are worms that are found under the horny lining of the gizzard (ventriculus).

Amidostomum anseris. The *Amidostomum anseris* (Figure 27.11) infects the gizzard of ducks, geese, and pigeons. A slender and reddish worm, 10–24 mm long, is found under the horny lining of the gizzard and occasionally in the proventriculus. Eggs are thin-shelled, 85–110 × 50–82 μm. Heavy losses among geese have been attributed to this nematode. The lining of the gizzard may be necrotic and detached, with loss of blood. The life cycle is direct, and eggs are passed in the partly developed stage. Eggs may hatch and invade the birds through the skin or orally.

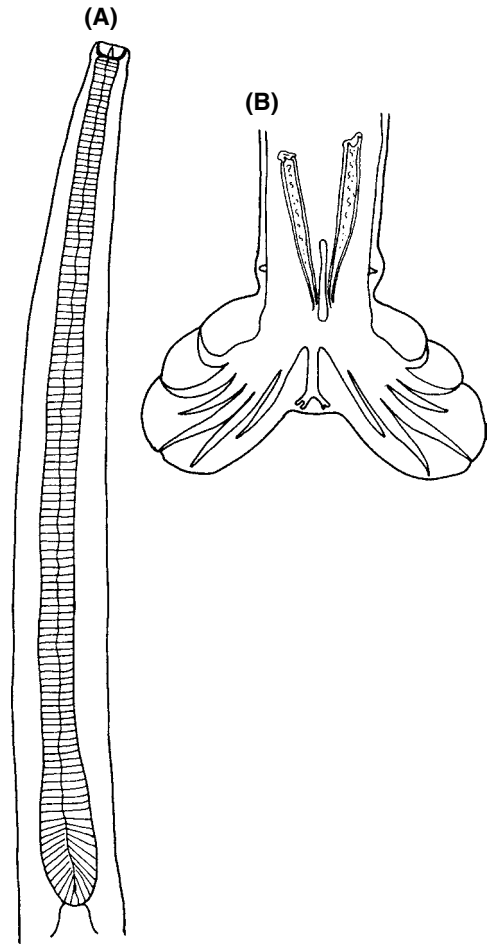

Figure 27.11. *Amidostomum anseris*. (A) Anterior. (After Boulenger) (B) Male bursa. (After Railliet)

Amidostomum skrjabini. Amidostomum skrjabini infects ducks, geese, and pigeons. It is Smaller and distinguished microscopically from *A. anseris* and *A. raillieta* (Figure 27.12) Eggs are laid partly developed.

Cheilospirura hamulosa. Cheilospirura hamulosa (Figure 27.13) infects most gallinaceous birds. It uses grasshoppers, beetles, weevils, and sandhoppers as intermediate hosts. In heavy infections the wall of the gizzard may show small local lesions in the lining and muscular tissue, with soft nodules enclosing parasites in the muscular portion and sometimes causing severe damage.

Cheilospirura spinosa. The hosts of *Cheilospirura spinosa* (Figure 27.14) are grouse, partridge, pheasant, quail, and wild turkey. Grasshoppers serve as the intermediate host. Heavy infections in quail are known to cause the gizzard lining to be hemorrhagic and necrotic, with marked proliferative changes in the gizzard wall.

Cyrnea colini. Cyrnea colini (Figure 27.15) is a proventicular worm of the turkey, grouse, prairie chicken, and quail in the United States which is similar in appearance to

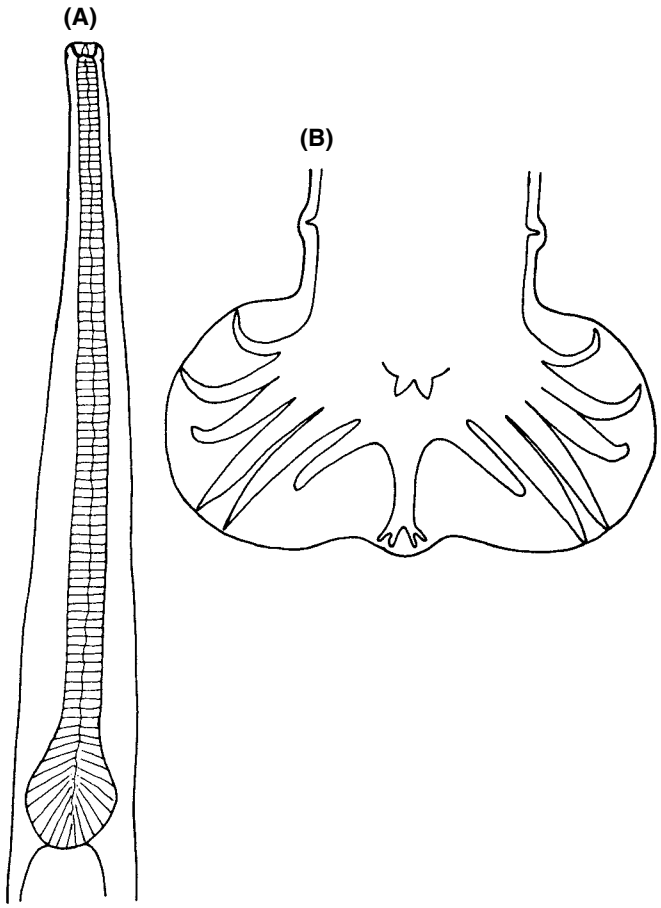

Figure 27.12. (A) Head, *Amidostomum raillieti*. (B) Male bursa, *Amidostomum skrjabini*. (After Boulenger)

Cheilospirura hamulosa but smaller and lacking cuticular adornments on the anterior of the body. The cockroach (*Blattella germanica*) serves as an intermediate host. No pathology has been reported.

Epomidiostomum uncinatum. Epomidiostomum uncinatum (Figure 27.16) is reported in ducks, geese, and pigeons (42).

Hadjelia truncate. Hadjelia truncate is similar in appearance to other gizzard worms; this parasite was recently reported as a clinical problem in meat pigeons in California (41). Infections were characterized by severe ventriculitis and emaciation.

Codiostomum struthonis

Codiostomum struthonis parasitizes the ceca and colon of the ostrich. The life cycle is unknown but is likely direct. Pathogenesis is not determined.

Cyathostoma bronchialis

Cyathostoma bronchialis is reported in ducks, geese, and turkeys in the United States. Chickens have been experimentally infected. A closely related species (*C. variegatum*) has been reported from the emu in the United States. The worm is found in the larynx, trachea,

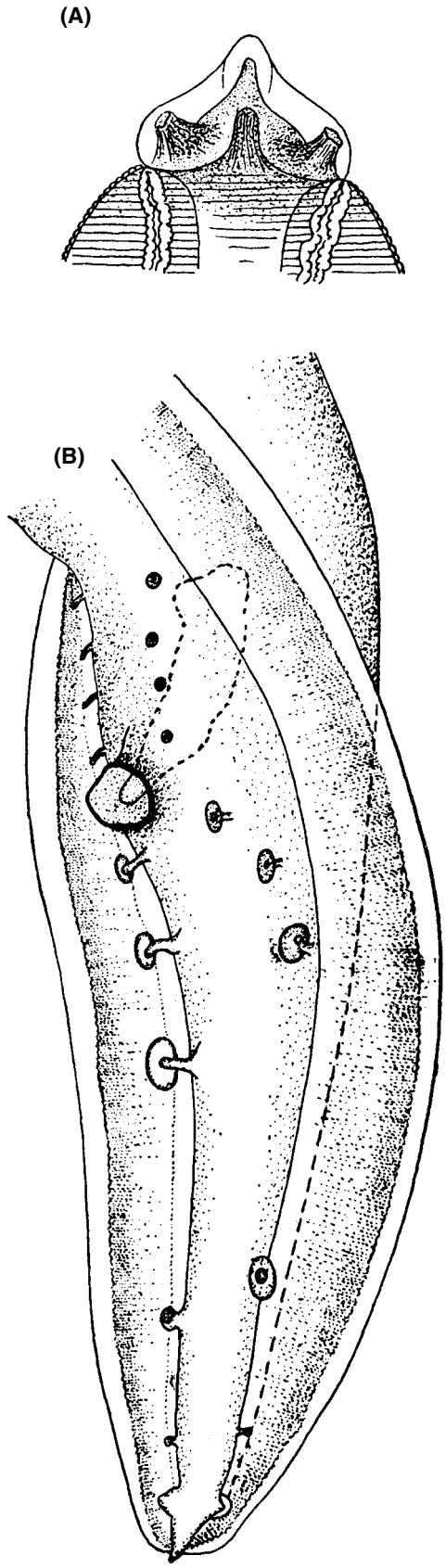

Figure 27.13. *Cheilospirura hamulosa*. (A) Head. (After Drasche) (B) Male tail. (After Cram)

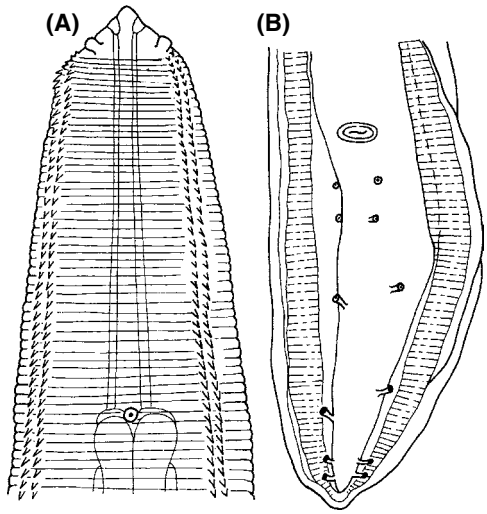

Figure 27.14. *Cheilospirura spinosa*. (A) Head. (B) Male tail. (After Cram)

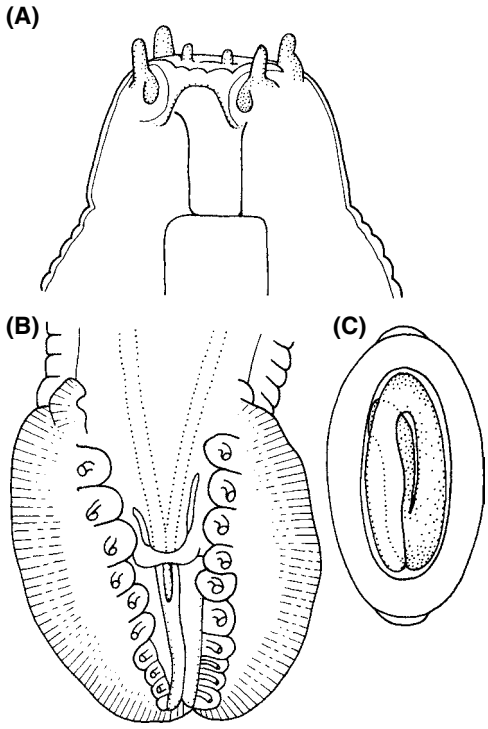

Figure 27.15. *Cyrnea colini*. (A) Head. (B) Male tail. (After Cram) C. Egg.

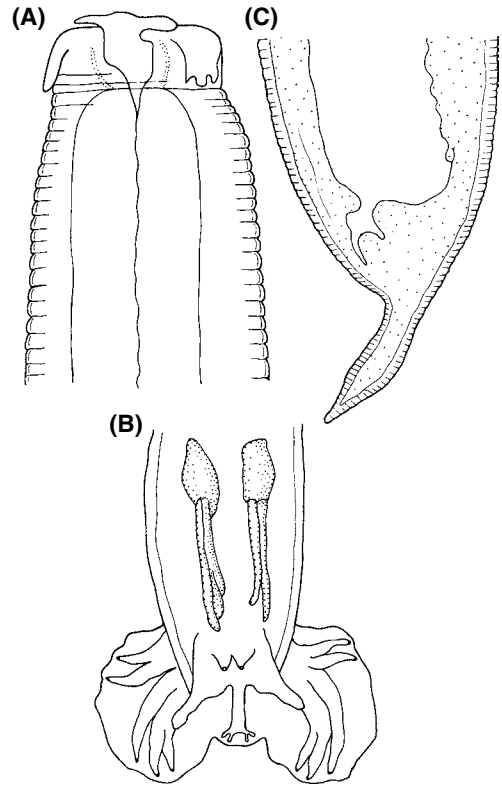

Figure 27.16. *Epomidiostomum uncinatum*. (A) Head. (B) Male tail. (C) Female tail. (After Skrjabin)

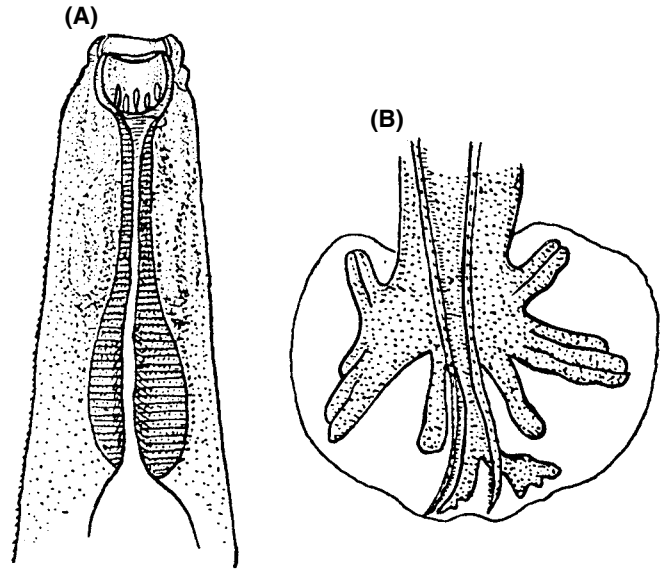

Figure 27.17. *Cyathostoma bronchialis*. (A) Head. (B) Male tail.

bronchi, and sometimes the abdominal air sacs, causing "gaping." This species is very similar to *Syngamus*, but is larger and less firmly united *in copula* (Figure 27.17). The life cycle may be direct, or the worm may use an earthworm as a paratenic host. Infective larvae migrate to the lungs through the peritoneal cavity and air sacs (15). Mortality as high as 20% with high morbidity has been reported in domestic geese. The disease may last several months, with birds showing signs of respiratory distress. Morbidity and mortality also have been reported from Mandarin ducks (53). Recovering birds may be stunted.

Deletrocephalus dimidiatus

Deletrocephalus dimidiatus parasitizes the small and large intestines of the rhea. The life cycle is probably direct, and causes anemia from consuming blood.

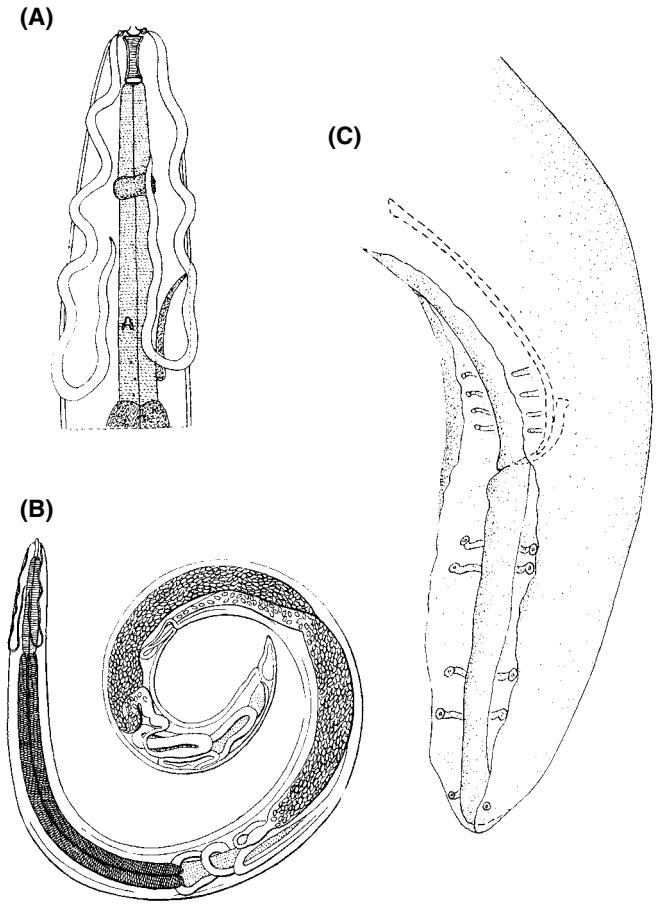

Figure 27.18. *Dispharynx nasuta*. (A) Head. (After Seurat) (B) Female (After Piana) (C) Male tail. (After Cram)

Dicheilonema rhea

Dicheilonema rhea is a filariid worm infecting the rhea. It is found in the abdominal and appendage fascia, but causes no remarkable pathology. The life cycle is unknown.

Dispharynx nasuta. The nematode *Dispharynx nasuta* (Figure 27.18) parasitizes most galliform and passerine birds in the United States. It is found in the wall of the proventriculus, sometimes the esophagus, and occasionally the small intestine. It uses the pillbug (*Armadillidium vulgarae*) and the sowbug (*Porcellio scaber*) as intermediate hosts. Heavy infections are known as grouse disease in the northeastern United States, and may kill pigeons. Ulcers in the proventriculus and destruction of tissues are common in heavy infections.

Echinura uncinata

Echinura uncinata is reported from wild and domestic ducks and geese in Canada. This worm (Figure 27.19) invades the mucosa of the esophagus, proventriculus, gizzard, small intestine, and possibly the air sacs and can cause morbidity and mortality. It uses water fleas of the genus *Daphnia* as intermediate hosts.

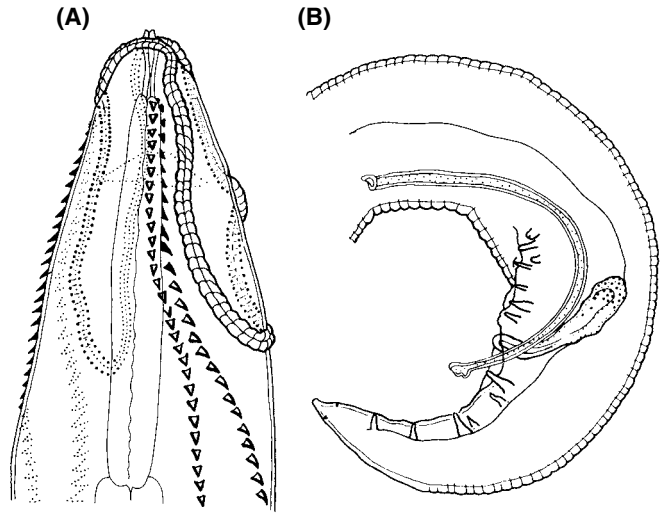

Figure 27.19. *Echinura uncinata*. (A) Head. (B) Male tail. (After Romanova)

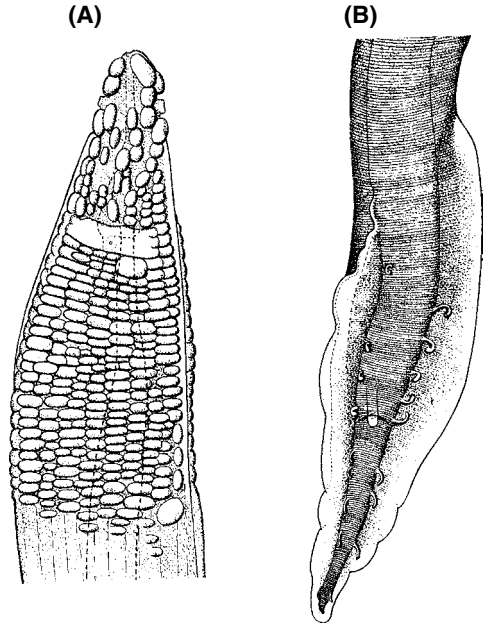

Figure 27.20. *Gongylonema ingluvicola*. (A) Head. (B) Male tail. (After Ransom)

Gongylonema ingluvicola

Gongylonema ingluvicola is reported in the chicken, turkey, partridge, pheasant, and Bobwhite quail. Adults (Figure 27.20A) are found in the mucosa of the crop, and sometimes in the esophagus and proventriculus. The beetle *Copris minutus* and cockroaches serve as intermediate hosts. This worm is of low pathogenicity, but burrows into the crop mucosa, causing white convoluted tracks.

Libyostrongylus douglassii

Libyostrongylus douglassii is found in ostriches, where it parasitizes the wall of the proventriculus and causes up to 50% mortality. The life cycle is direct, and the eggs hatch

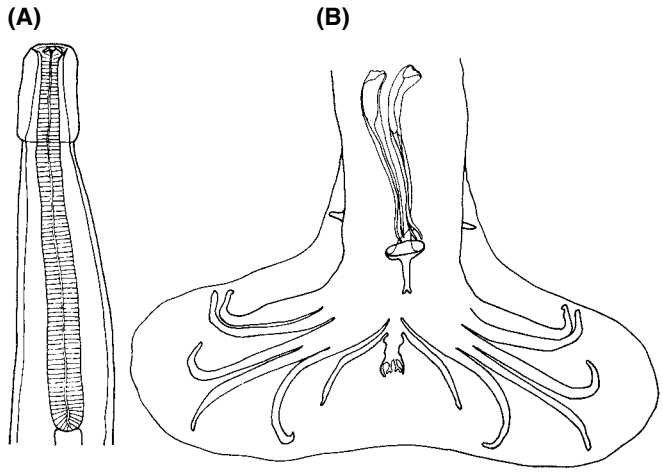

Figure 27.21. *Ornithostrongylus quadriradiatus*. (A) Head. (B) Bursa of male. (After Stevenson)

on the ground where they remain infective for as long as 30 months.

Ornithostrongylus quadriadiatus

Ornithostrongylus quadriadiatus is found in the small intestine of pigeons and doves (Figure 27.21). These worms are delicate, slender worms, and red when freshly collected, apparently from ingested blood. The life cycle is direct; eggs hatch within 25 hours after voiding. Infective larvae are swallowed by a host and mature in the small intestine. The worm matures in 5–6 days. Pigeons may suffer catarrhal enteritis and blood loss. Birds may become moribund and anorexic and have pronounced greenish diarrhea. Intestines are markedly hemorrhagic and have a greenish mucoid content with masses of sloughed epithelium.

Oxyspirura mansoni

Oxyspirura mansoni, the eye worm, is reported from the chicken, turkey, duck, grouse, guinea fowl, peafowl, pigeon, quail, and a wide variety of passeriform birds (1) (Figure 27.22). It is located beneath the nictitating membrane and in the conjunctival sacs and nasolacrimal ducts. Eggs are swallowed and passed in the droppings where they are eaten by a cockroach (*Pycnoscelus surinamensis*). Upon ingestion of cockroaches, the infective larva migrates from the crop, up the esophagus to the mouth, and through the nasolacrimal duct to the eye. Severe opthalmia may develop, with white cheesy material collecting beneath the eyelids (40). Many wild birds also are host to this parasite.

Oxyspirura petrowi

Oxyspirura petrowi is reported from the grouse, pheasant, and prairie chicken. The life cycle and pathogenicity are similar to that of *O. mansoni*.

Sicarius uncinipenis

Sicarius uncinipenis parasitizes the gizzard of the rhea.

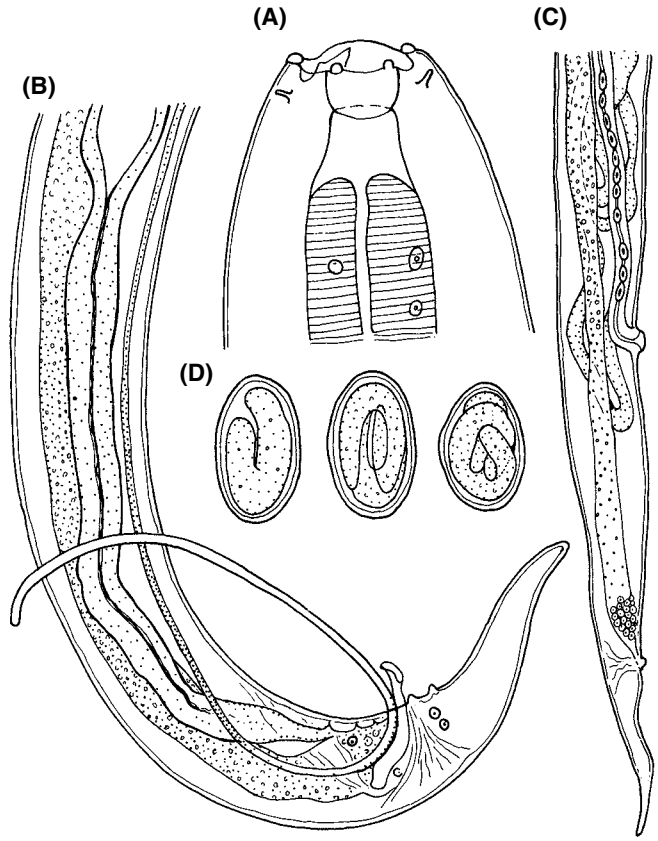

Figure 27.22. *Oxyspirura mansoni*. (A) Head. (B) Male tail. (C) Female tail. (D) Eggs. (B–D after Ransom)

Sicarius waltoni

Sicarius waltoni parasitizes the gizzard of the rhea.

Singhfilaria hayesi. The hosts of *Singhfilaria hayesi* are turkeys and quail, where it infects the subcutaneous tissues around the esophagus, crop, and trachea (Figure 27.23). It is of low pathogenicity, and the life cycle is unknown.

Strongloides avium

Strongloides avium infects quail, grouse, turkeys, chickens, and geese (Figure 27.24). It also has been reported from the junco and the coot and in chickens in Puerto Rico (6, 29). It is found in the ceca, or sometimes in the intestine. In the intestine of the avian host, the population consists of only parthenogenetic females. Eggs hatch in the soil soon after being passed. Larvae may develop into free-living males and females or into infective larvae. Infection takes place when larvae are swallowed by a host or if the larvae penetrate the skin of the host. Larvae of this genus are known to penetrate the skin of humans, resulting in cutaneous eruptions, which is of some medical concern. In heavy infections the walls of the ceca are thickened and bloody. It may cause mortality.

Genus Subulura

The genus *Subulura* is known to parasitize a wide variety of galliform birds and even ducks. These are largely cecal worms

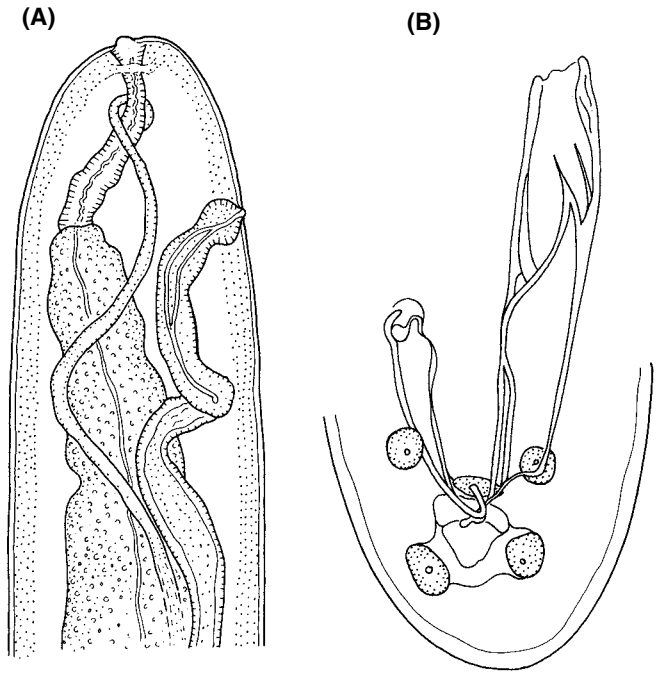

Figure 27.23. *Singhfilaria hayesi*. (A) Head. (B) Male tail. (After Anderson and Prestwood)

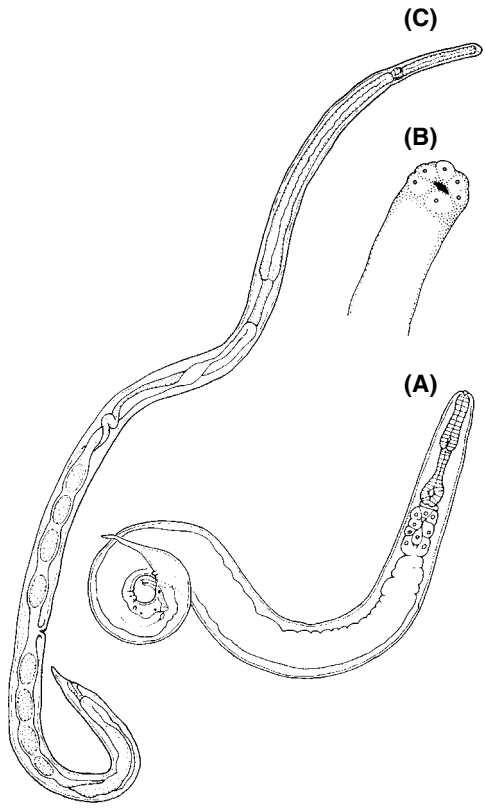

Figure 27.24. *Strongyloides avium*. (A) Free-living male. (After Cram) (B) Head, parasitic female. (C) Parasitic (parthenogenetic) female. (B and C after Sakamoto and Sarashina)

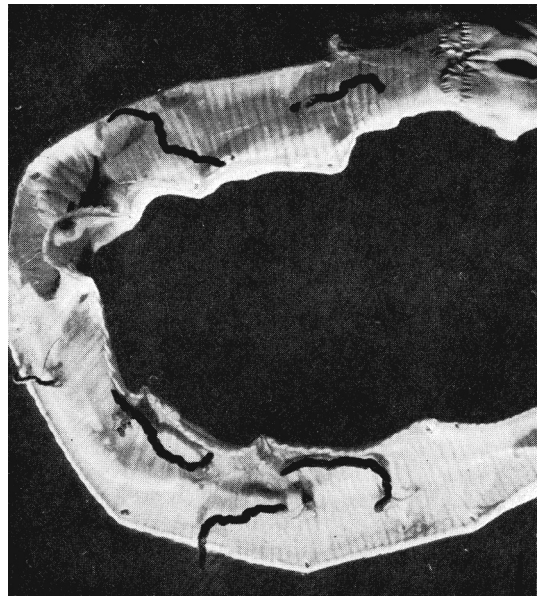

Figure 27.25. *Syngamus trachea*. Trachea showing attached gapeworms. (After Wehr)

and they use an intermediate host, beetles or cockroaches (3, 9). Little or no pathogenicity is reported for these worms.

Subulura brumpti. Subulura brumpti parasitizes most gallinaceous birds and ducks. They are small worms which can be separated from *H. gallinarum* by microscopy. The eggs are almost spherical (82–86 × 66–76 μm), and fully embryonated when laid.

Subulura strongylina. Subulura strongylina is reported from chickens, guinea fowl and quail, and is identified microscopically by tail morphology (Figure 27.8C).

Subulura suctoria. Subulura suctoria is reported from several gallinaceous birds (Figure 27.8B). They are larger than *S. brumpti, with* eggs measuring 51–70 × 45–64 μm.

Syngamus trachea

Syngamus trachea is reported from the chicken, turkey, goose, guinea fowl, pheasant, peafowl, emu, and quail. Known commonly as gapeworms, these worms are found in the trachea and cause labored breathing (Figure 27.25). They are also called redworms because of their prominent color and forked worms because the male and female are always locked in copulation to form a "Y" (Figure 27.26). Lesions or nodules result from inflammatory reactions at the site of attachment of male worms. This parasite is common in poultry or game birds reared in outdoor pens where birds have access to the intermediate hosts. Females apparently attach and reattach. The life cycle may be direct, by ingestion of embryonating eggs or infective larvae, or may involve an intermediate host. The earthworms *Eisenia foetidus* and *Allolobophora caliginosus* are known to become infected, with the larvae encysting in the body musculature.

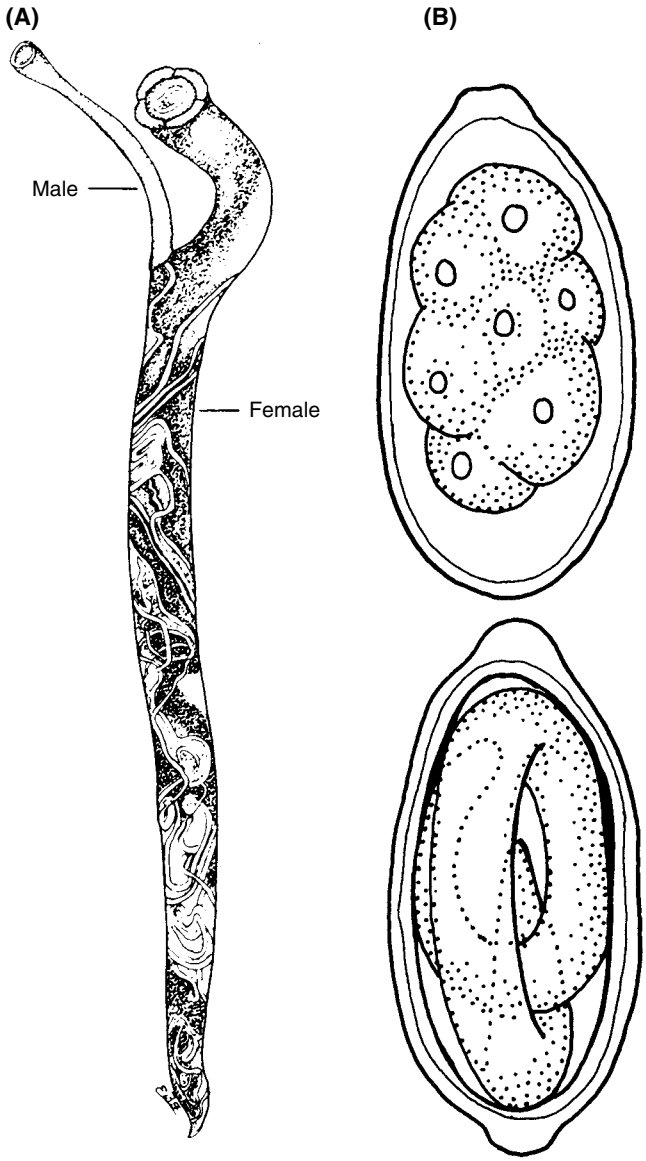

Figure 27.26. *Syngamus trachea*. (A) Male and female worms. (After Wehr) (B) Egg.

Encysted larvae are known to remain infective for up to 4 years. Slugs and snails also may serve as a transfer host. When ingested, infective larvae penetrate the wall of the crop and esophagus and migrate to the lungs, or penetrate the duodenum to be carried to the lungs by the portal bloodstream. Young turkey poults, chicks, and pheasant chicks are most susceptible and may suffocate from the inflammation and obstruction by worms. Some birds also may suffer marked changes in the blood (22).

Genus Tetrameres

Worms of the genus *Tetrameres* are parasites of the upper digestive tract, mostly the proventriculus. These relatively pathogenic nematodes use an intermediate host and are not seen in poultry reared indoors. They are easily recognized by the bright red color and distinctive globular shape of the female. The host range includes gallinaceous birds and waterfowl.

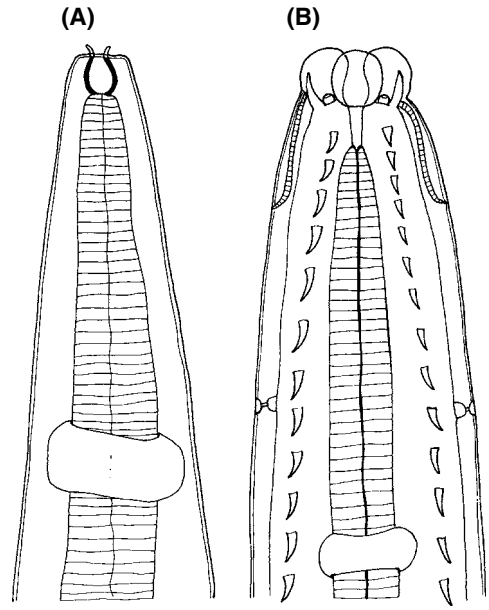

Figure 27.27. (A) *Tetrameres americana*, head. (Courtesy Graybill) (B) *Tetrameres fissispina*, head. (Travassos)

Tetrameres Americana. *Tetrameres Americana* (Figure 27.27) is reported from the chicken, turkey, duck, grouse, pigeon, and Bobwhite quail. At necropsy these bright red worms can be seen through the wall of the unopened proventriculus. Grasshoppers (*Melanoplus femurrubrum* and *M. differentialis*) or cockroaches (*Blatella germanica*) serve as intermediate hosts. These worms are easily recognized because of the extreme sexual dimorphism and the red color (Figure 27.28); the female is globular (Figure 27.28B), while the male (Figure 27.28A) is elongate like other nematodes. Eggs are $42–50 \times 24$ μm, and embryonating when laid. Chickens become emaciated and anemic, although quail are affected less (8). In chickens, the wall of the proventriculus may be thickened to the point of blocking the lumen. *T. Americana* has been reported from wild (13) and laboratory-raised pigeons (16).

Tetrameres crami. The hosts of *Tetrameres crami* are wild and domestic ducks, where they are found in the proventriculus. Intermediate hosts include the amphipods *Gammarus fasciatus* and *Hyalella knickerbocki* (44). This worm is smaller than *T. Americana*.

Tetrameres fissispina. *Tetrameres fissispina* is reported from the chicken, turkey, duck, guinea fowl, goose, pigeon, and quail. It is common in ducks and geese and rare in other poultry. Intermediate hosts include amphipods, grasshoppers, earthworms, and cockroaches. Fish may serve as a transport host. Considerable tissue reaction occurs, with degeneration of the glandular tissue, edema, and extensive leukocyte infiltration (46).

Tetrameres pattersoni. *Tetrameres pattersoni* is found in the proventriculus of the Bobwhite quail and uses grasshoppers (*Melanoplus femurrubrum* or *Chortophaga viridifasciata*) or

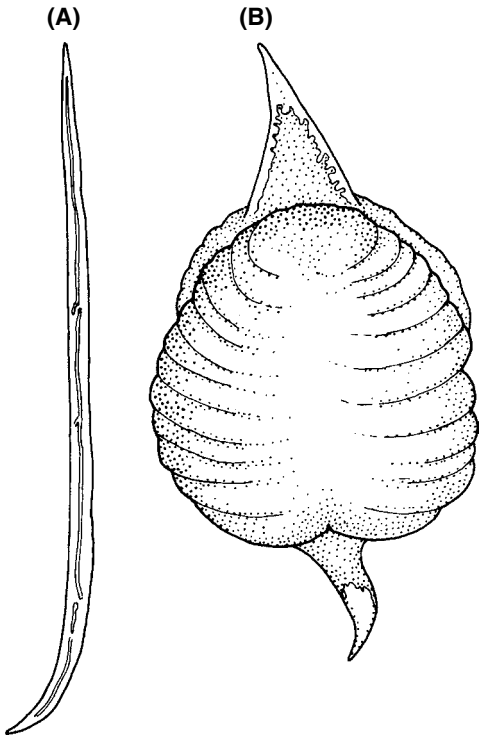

Figure 27.28. *Tetrameres americana*. (A) Male. (B) Female. (After Cram)

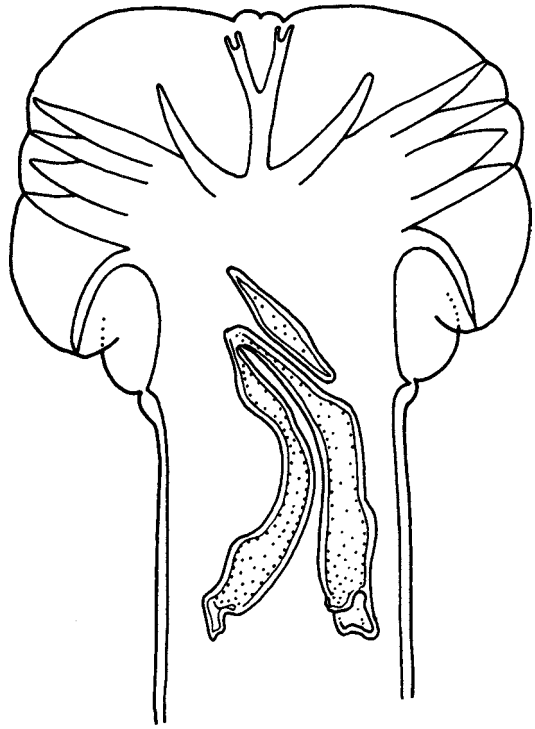

Figure 27.29. *Trichostrongylus tenuis*. Bursa of male. (After Railliet)

cockroaches (*Blatella germanica*) as intermediate hosts. Worms can be so numerous that the wall of the proventriculus is destroyed and death may result.

Trichostrongylus tenuis

Trichostrongylus tenuis is a parasite reported from most galliform birds, waterfowl, pigeons, and emu. These small, slender worms are found in the ceca and occasionally the intestine (Figure 27.29). These worms are highly pathogenic and were associated with the decline of the red grouse population in Scotland. Administration of as few as 500 larvae can cause mortality. The ceca become distended and congested, the mucosa inflamed and thickened. Heavy mortality occurs mainly in the fall in young birds from that year's hatch, and again in the spring. With emus, a bloody, mucoid diarrhea may be extensive. The life cycle is direct.

Vaznema zschokkei

Vaznema zschokkei parasitizes the proventriculus of the rhea. These are 16–23 mm in length.

Treatment and Control of Nematodes

Nematode control measures include sanitation, interruption of the life cycle, and use of anthelminthic products. Modern poultry practices such as confinement rearing of broilers and pullets and caging of laying hens have significantly decreased the variety of nematodes and generally the levels of infection. An increasing trend toward free-range rearing may lead to greater variety of worm species and increased risk, especially because these operations often dispense with the use of parasiticides and other drugs. This trend already has been recognized in the European Union (EU) (12, 33). Poultry such as broiler breeder replacements, which are often raised in earthen floored houses with restricted feeding, are likely to harbor the direct-life cycle intestinal worms *Ascaridia galli, Capillaria obsignata*, and *Heterakis gallinarum*. It is commonly thought that all broiler breeder farms are contaminated with these worms. Pen rearing of game birds allows parasitic worms to flourish, requiring a regular program of chemical treatment.

The life cycle of parasites is interrupted by confining the birds to keep them from contacting and consuming the intermediate host. Treating the soil with disinfectants is thought to be beneficial, but there is a dearth of published scientific evaluations of such programs. For small flocks, it is worthwhile to keep the birds off the ground with wire screen floors to reduce contact with worm eggs in the droppings.

Raising different species or ages of birds together in the same pens or in close proximity creates more opportunity for some parasites to prosper. For instance, turkeys should not be raised with chickens or any other birds likely to harbor the cecal worm (*H. gallinarum*) because they are likely to carry *Histomonas meleagridis*, the agent of blackhead disease. Similarly, the chukar partridge is more susceptible to blackhead disease than the ring-necked pheasant, which also is a good host for cecal worms.

Chemotherapy

Only a few compounds have been tested for efficacy against roundworms in poultry, and only against the common worms *A. galli, H. gallinarum*, and *C. obsignata*. Some of the older

drugs are not recommended because there is lack of sufficient efficacy or other problems associated with their use. For instance, piperazine, the only product approved for use in chickens, was tested at a wide range of dosages and found to be largely ineffective (19, 48). Haloxon, an organic phosphate, has toxicity issues in sheep and goats and is not commonly available in the United States. Other older drugs that are not commonly used include phenothiazine and santonin (extract of wormwood gall still available at natural remedy stores).

The benzimidazoles, represented by several products, are highly effective. Fenbendazole, approved for use in growing turkeys, is highly effective when given in the feed at 16 ppm for 6 days (5–10 mg/kg body weight). Fenbendazole was more than 98% effective in removal of adult and larval turkey ascarids (28, 51). Albendazole, cambendazole, levamisole (L-tramisole), and other compounds in this family are also highly effective (4, 5, 11, 32, 34). Some are available in a water-soluble formulation. Pyrantel pamoate was not effective in the treatment of *A. galli* in chickens (48).

Regular programs of worming are recommended for poultry that are to be kept for more than a few weeks. Turkeys, broiler breeder replacements, layer replacements, heavy broilers (roasters), and most game birds are reared for 8 to 20 weeks on litter, providing ample opportunity for worms to mature and contaminate the premises with more worm eggs. Of the worms found in poultry, *Capillaria obsignata* is the most pathogenic. Aside from the potential damage caused by the worm itself, the main concern is that *Heterakis gallinarum* carries the protozoan responsible for blackhead disease (*Histomonas meleagridis*). Outbreaks are common in many types of poultry. For many years blackhead disease was considered a minor nuisance in chickens. However, it is not uncommon for blackhead to cause 10% mortality, increased culling, and nonuniformity in breeder or layer flocks. Outbreaks may be seen at 8–10 weeks, but producers report problem farms where outbreaks occur earlier–4 weeks of age. Because there is no treatment for blackhead disease, it is important to remove the carriers by early and frequent deworming with a bendimidazole type dewormer, capable of killing the larvae. Deworming of turkeys is usually practiced on a regular basis, but is of little value in preventing outbreaks of blackhead disease because of its easy lateral transmission in turkey flocks after introduction of infection from outside (20, 21).

Acanthocephalans in Poultry

The acanthocephalans (thorny-headed worms) resemble nematodes or other worms but many differences are apparent. They are named for the spiny proboscis at the anterior end, which bears a number of recurved hooks arranged in rows. The number, form, and arrangement of the hooks are used in species identification. Like tapeworms, this group of worms has no digestive tract, and absorbs nutrients directly through the body wall. The sexes are separate; the male is smaller than the female and often distinguished externally by a bell-shaped bursa surrounding the genital pore. Various arthropods, snakes, lizards, and amphibians serve as hosts of the larval stages (42).

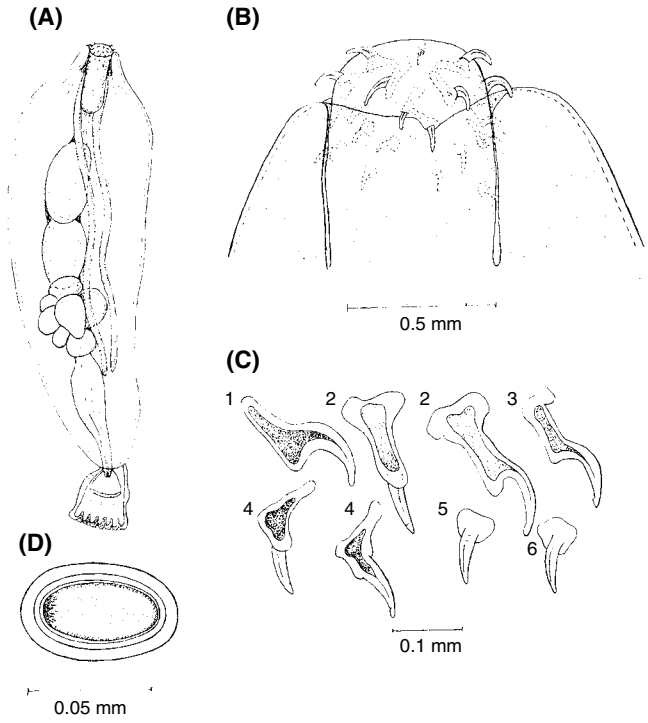

Figure 27.30. *Oncicola canis*. (A) Male showing reproductive organs. (B) Proboscis. (C) Hooks from proboscis (numerals indicate row). (D) Egg. (Price)

These worms are known from a wide variety of vertebrates, but are uncommon in poultry. All known species of Acanthocephala require 1 or more intermediate hosts, a fact that limits the importance of this group in poultry reared indoors where the variety of invertebrates is limited. Only 4 species of Acanthocephala have been reported as parasites of domestic poultry in North America. Three of these were reported from immature forms, and could have resulted from accidental infections.

Onicola canis

The *Onicola canis* (Figure 27.30) is reported from turkeys in Texas. Larval worms were found encysted under the epithelial lining of the esophagus, in some birds more than 100/bird, and were considered as possibly causing death. The adults normally occur in the dog and coyote.

Prosthoryhnchus formosus

Immature specimens of *Prosthoryhnchus formosus* (Figure 27.31) were reported from chickens at necropsy in New Jersey. Other bird hosts include the flicker and the robin (39).

Polymorphus boschadis

The *Polymorphus boschadis* (Figure 27.32) has been reported from ducks in Canada. It causes morbidity and mortality in domestic waterfowl, especially in young birds. It causes inflammation of the intestine, anemia, and cachexia (general ill health). Affected birds develop staggering gait and drooping head and wings.

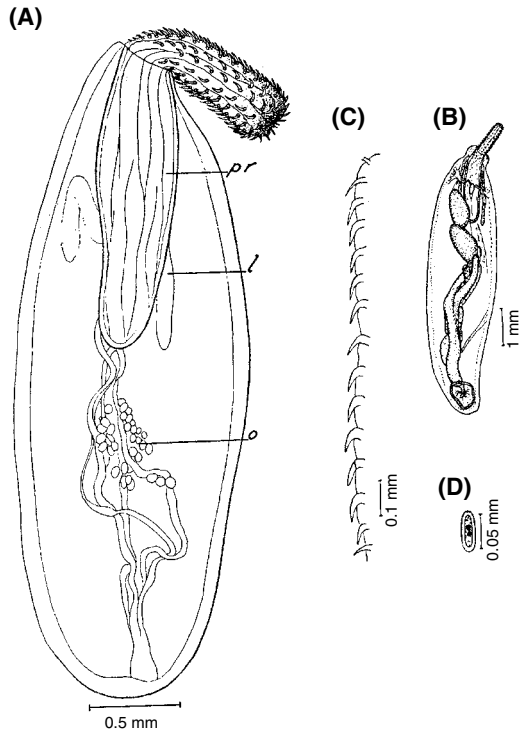

Figure 27.31. *Prosthorhynchus formosus*. (A) Young female (l, lemniscus; o, ovary; pr, proboscis receptacle). (Jones) (B) Male. (C) Hooks from proboscis. (D) Egg. (VanCleave)

Other Acanthocephalans From Poultry

Several other spiny-headed worms reported in other regions include *Leiperacanthus gallinarum, Mediorhynchus gallinarum*, and *Neoschongastia gallinarum* in Asia; *Macracanthorhynchus hirudinaceus* in chickens in Brazil; *Prosthorhynchus rhea* in South America; and *Prosthorhynchus transversus* in passerine birds, partridge, and pheasant in Europe.

Public Health Significance

None of the helminths discussed in this section pose a threat to public health. It is reportedly possible for larvae of *Strongyloides avium* to cause a creeping cutaneous eruption in accidental infections (larva currens), but the lesions are minor and leave no lasting pathology. There is no recent literature on this subject.

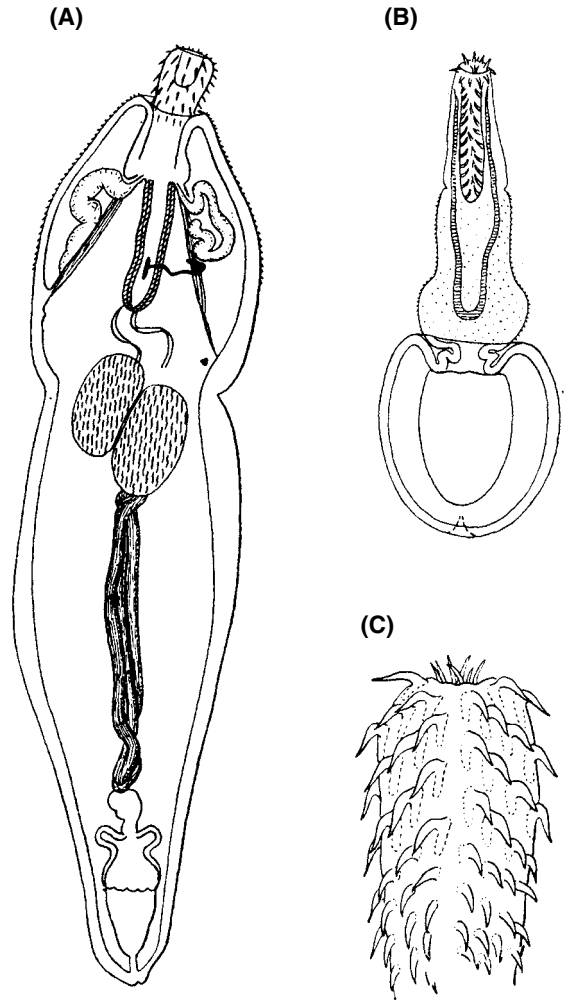

Figure 27.32. *Polymorphus boschadis*. (A) Male. (B) Larva from *Gamarus pulex*. (C) Proboscis of larva. (Luhe)

Acknowledgement

I acknowledge the contribution of previous authors of this chapter, particularly Thomas Yazwinski and Christopher Tucker, for their contributions to earlier versions of this work.

Cestodes and Trematodes

Introduction

Many species of worm parasites are seen during necropsy examination of the digestive tract or other internal organs of poultry. Some of these are large enough to cause intestinal blockage in severe cases. Others are so small that a hand lens may be required to distinguish them from intestinal contents. If flattened in shape, they are probably flatworms belonging to the phylum Platyhelminthes. Tapeworms are in the class Cestoda, and flukes are in the class Trematoda. Accurate

identification is essential for effective control. Species identification may give direction to control measures aimed at eliminating the intermediate host, thus breaking the life cycle. Others may require treatment with anthelmintics.

Cestodes

Most birds are hosts to some species of cestodes or tapeworms (phylum Platyhelminthes/class Cestoda). A high percentage of chickens or turkeys may be infected with tapeworms if they are reared on a range or in backyard flocks. These parasites are found more frequently in warmer seasons, when intermediate hosts are abundant. Many species of tapeworms are now considered rare in intensive poultry-rearing regions because the birds do not come in contact with intermediate hosts. Beetles and houseflies inhabiting poultry houses still act as intermediate hosts for the 2 large chicken tapeworms known only by the scientific names *Raillietina cesticillus* and *Choanotaenia infundibulum*.

Some infections of the larger tapeworms may appear to block completely the intestine of an infected bird, but mortality from cestodiasis or long-term effects are rare. Different species vary considerably in pathogenicity, so species identification is worthwhile.

Diagnosticians are often satisfied with a diagnosis of cestodiasis or taeniasis without making further attempts at identification. However, prevention and control strategies may vary with each species of tapeworm. Only after the species has been determined can an assessment of flock damage and possible control measures be considered (Table 27.5). For identification of the less common species, specialized textbooks may be needed to supplement the keys and illustrations included in this text (8, 11, 15, 16).

Tapeworms or cestodes are flattened, ribbon-shaped, usually segmented worms. The term proglottid is used to describe these individual segments because the latter term is defined otherwise by classic zoologists (Figure 27.33). One to several gravid proglottids are shed daily from the posterior end of the worm. Each proglottid contains 1 or more sets of reproductive organs which may become crowded with a mass of eggs as the maturing proglottid becomes a gravid proglottid.

Tapeworms are characterized by complete absence of a digestive tract and obtain their nourishment by absorption from the gut contents of the host. Although the duodenum, jejunum, or ileum is the usual site for attachment, 1 species (*Hymenolepis megalops*) from ducks is found in the cloaca or cloacal bursa. Birds become infected by eating an intermediate host, thus allowing the larval stage of the tapeworm access

Table 27.5. Tapeworms and hosts from poultry in the United States.

Tapeworm	Definitive Hosts (occasional hosts)	Intermediate Hosts	Degree of Pathogenicity
Amoebotaenia cuneata	Chicken (turkey)	Earthworm	Mild
Choanotaenia infundibulum	Chicken (turkey)	Housefly, beetle	Moderate
Davainea proglottina	Chicken	Slug, snail	Severe
Hymenolepis carioca	Chicken (turkey, bobwhite quail)	Stable fly, dung beetle	Unknown
H. cantaniana	Chicken (turkey, peafowl, bobwhite quail)	Beetle	Mild or harmless
Raillietina cesticillus	Chicken (turkey, guinea fowl, bobwhite quail)	Beetle	Mild or harmless
R. tetragona	Chicken (guinea fowl, peafowl, bobwhite quail, turkey)	Ant	Moderate to severe
R. echinobothrida	Chicken (turkey)	Ant	Moderate to severe
R. magninumida	Guinea fowl (chicken, turkey)	Beetle	Unknown
Davainea meleagridis	Turkey	Unknown	Unknown
Drepanidotaenia watsoni	Wild turkey	Unknown	Unknown
Imparmargo baileyi	Wild turkey	Unknown	Unknown
Raillietina georgiensis	Wild turkey (domestic turkey)	Ant	Unknown
R. ransomi	Wild turkey	Unknown	Unknown
R. williamsi	Wild turkey	Unknown	Unknown
Metroliasthes lucida	Turkey (guinea fowl, chicken)	Grasshopper	Unknown
Diorchis nyrocae	Wild and domestic duck	Copepod crustacean	Unknown
Fimbriaria fasciolaris	Duck (chicken)	Copepod crustacean	Unknown
Hymenolepis anatina	Wild and domestic duck	Freshwater crustacean	Severe
H. compressa	Duck, goose	Unknown	Unknown
H. collaris	Wild and domestic duck (chicken)	Freshwater crustacean (snail = auxiliary)	Unknown
H. coronula	Duck	Crustacean, snail	Unknown
H. lanceolata	Goose, duck	Crustacean	Severe
H. megalops	Duck	Unknown	Unknown
H. parvula	Wild and domestic duck	Leech	Unknown

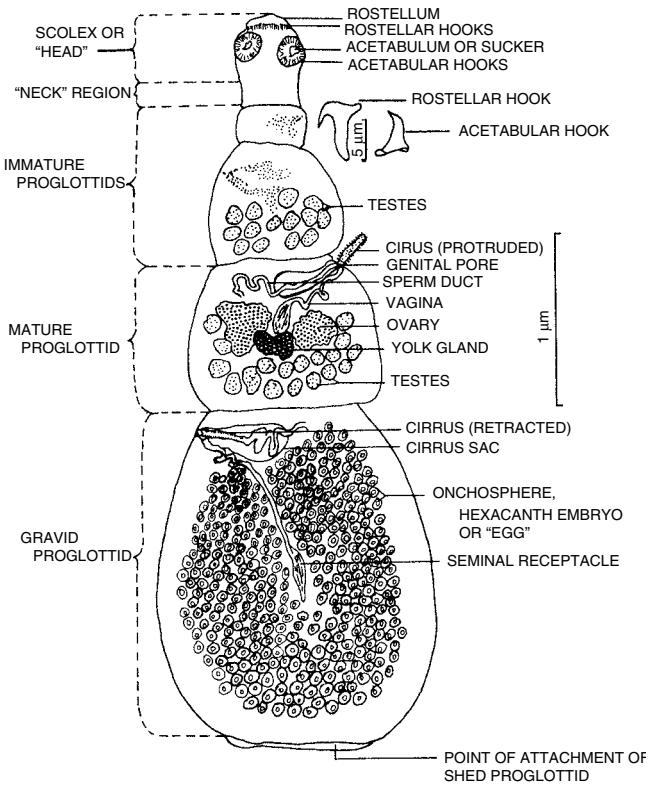

Figure 27.33. Adult tapeworm (*Davainea proglottina*). Although readily seen with the naked eye, this species has been called a microscopic tapeworm because it is small and often overlooked.

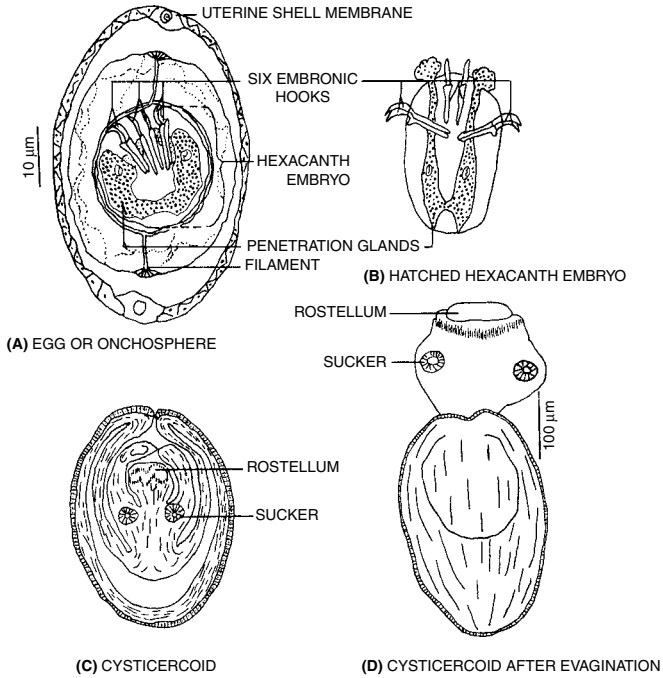

Figure 27.34. Larval stages of the chicken tapeworm (*Raillietina cesticillus*). (A) The egg is encapsulated by a membrane derived from the uterus wall. Eggs are occasionally found free in feces, but more often enclosed within a gravid proglottid. (B) Hexacanth embryos escape from shell membranes; active hooks and enzymes from secretory glands assist in penetration of gut wall of the beetle intermediate host. (C) Cysticercoid that has developed in the hemocoele of a beetle. (D) Scolex in the cysticercoid has evaginated after exposure to bile and enzymes in gut of the fowl.

to the intestine. This larval tapeworm is known as a cysticercoid (Figure 27.34C). The intermediate host may be an insect, crustacean, earthworm, slug, snail, or leech depending upon the species of tapeworm.

Most cestodes are host specific for a single or a few closely related birds. Identification of the parasite to genus and species helps pinpoint the intermediate host. The diagnostician then may be able to suggest practical control measures. Completion of a 2-host life cycle depends upon a unique set of ecologic conditions which juxtapose the host and the intermediate host. Thus, minor changes in flock management may cause a break in the life cycle and comprise an effective control measure.

History, Incidence, and Distribution

More than 4,000 species of tapeworms have been described from animals (14), with many of the earlier species bearing the genus name *Taenia*. Because no poultry tapeworms are currently listed in this genus, the term taeniasis is no longer appropriate, and the term cestodiasis would be a better substitute for infection with poultry tapeworms. Slender threadlike forms (*Hymenolepis carioca*) may require some magnification to distinguish individual proglottids, thus indicating that they are tapeworms. Some small forms (e.g., *Davainea proglottina*) are almost microscopic.

Classification

More than 1,400 species of tapeworms have been described from wild and domestic birds. Because most of them have no common name, they are best recognized by their genus and species names.

Three families (Davainidae, Dilepididae, and Hymenolepidae) and 10 genera (*Amoebotaenia, Choanotaenia, Davainea, Diorchis, Drepanidotaenia, Imparmargo, Metroliasthes, Raillietina, Hymenolepis, Fimbriaria*) are recognized here because they may appear in birds brought to diagnostic laboratories in the United States.

Morphology and Life Cycles

Adults

The anatomic features needed to identify poultry tapeworms are illustrated by describing *Davainea proglottina* (Figure 27.33). This species differs from most other tapeworms in possessing only 1 or 2 each of immature, mature, and gravid proglottids compared with dozens or hundreds in other species. The entire connected chain of proglottids is called a strobila. Besides the strobila, 2 other regions, the scolex and the neck, are recognized. Anchorage is accomplished by the

scolex with the assistance of 4 pairs of suckers or acetabula, which may possess 1 or 2 rows of acetabular hooks. If hooks are present, the species is described as armed; if absent, it is unarmed. A plunger-shaped organ known as the rostellum is frequently present at the anterior end. The rostellum may assist in anchorage by means of 1 or 2 rows of rostellar hooks and by the suction created by partial withdrawal of the rostellum into the scolex. The neck is an undifferentiated area between the scolex and the strobila from which new proglottids proliferate.

A set of both male and female reproductive organs are found in each proglottid. Morphologic differences in size and location of these organs are used in taxonomic descriptions of different species. Older gravid proglottids containing numerous eggs are shed individually or in short chains late in the day after the worm has absorbed and stored nutrients from the gut contents of the host. *D. proglottina* generally sheds 1 gravid proglottid/day, and *Raillietina cesticillus* may produce as many as 10–12.

Onchosphere

Within the uterus, the fertilized egg develops into a multicellular embryo called an onchosphere or hexacanth embryo. The onchosphere is a multicellular larva containing penetration glands and numerous muscular attachments to activate the hooks. Each gravid proglottid may contain several hundred of these multicellular embryos or eggs. Distinctive membranes (Figure 27.34A) surrounding the eggs may be useful in identifying the species.

Cysticercoid

Intermediate hosts such as beetles, houseflies, slugs, or snails become infected by swallowing individual eggs from the feces, or they devour the entire proglottid after being attracted by odor or movement. The 6-hooked embryo hatches from the egg in the gut of the intermediate host and penetrates the gut wall. The larva reorganizes and changes in polarity to become a cysticercoid in about 2 weeks (Figure 27.34C and D). The cysticercoid remains within the body cavity of the intermediate host until the latter is eaten by the bird host. In the digestive tract the cysticercoid is activated by bile and attaches to the intestine to begin the formation of a strobila. The first gravid proglottids appear in the feces 2–3 weeks after the cysticercoid is swallowed.

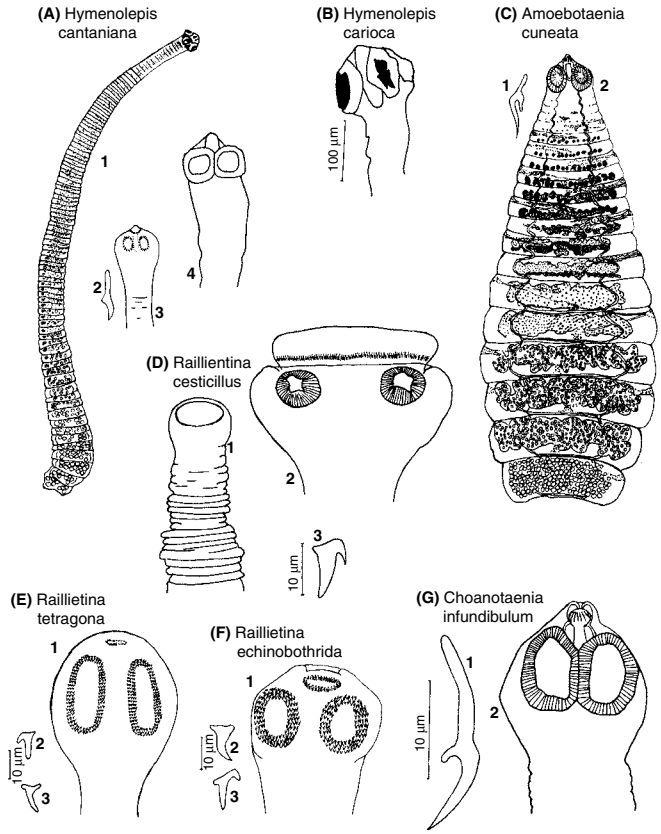

Figure 27.35. Tapeworms of chickens. Scolex characteristics: (A) *Hymenolepis cantaniana*. (1) Scolex and strobilia (Ransom); (2) Hook (Yamaguti); (3) Scolex (Neveu-Lemaire); (4) Scolex (Wehr). (B) *H. carioca* scolex. (C) *Amoebotaenia cuneata* (Monnig). (1) Rostellar hook; (2) Entire worm. (D) *Raillietina cesticillus*. (1) Scolex (Ackert); (2) Scolex (Monnig); (3) Rostellar hook (Ransom). (E) *R. tetragona*. (1) Scolex (Monnig); (2, 3) Rostellar and acetabular hooks (Ransom). (F) *R. echinobothrida*. (1) Scolex (Monnig); (2, 3) Rostellar and acetabular hooks (Ransom). (G) *Choanotaenia* infundibulum. (1) Hook (Ransom); (2) Scolex (Monnig).

Diagnosis and Identification

Distinctive characteristics of tapeworms may best be demonstrated by examining (1) the scolex (Figures 27.33 and 27.35), (2) the eggs (Figures 27.34 and 27.37), or (3) individual proglottids of recently shed and whole live specimens (Figures 27.33 and 27.36) (11). Although differential staining can be used to show the internal organs of mature proglottids, this procedure is too slow for most diagnostic laboratories. Preservation in alcohol or formalin, although required before staining, often obscures useful characteristics needed for rapid identification. The intestine is best opened with scissors under water, thus permitting the strobila to float free, revealing the area to which the scolex is attached. Recovery of the scolex is worth considerable effort because its characteristics alone may indicate the species. Freeing the scolex may be accomplished by (1) teasing apart the mucosa with 2 dissecting needles, (2) cutting a deep gouge into the mucosa under the attachment point with a sharp scalpel, or (3) leaving the intestine submerged in saline for a few hours in the refrigerator. Wet-mount preparations of the scolex examined under a coverglass with 3,100 or higher magnification may reveal sufficient characteristics to make a species identification. Hook characteristics may require measurement with an ocular micrometer under higher magnification. Semipermanent cleared preparations of scolices may be made by using a drop of Hoyer's solution (prepared by

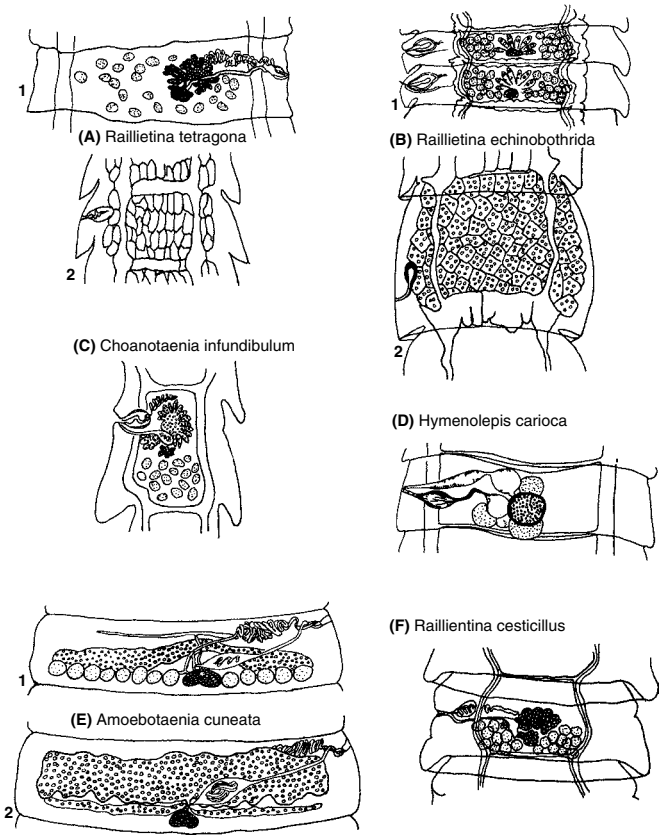

Figure 27.36. Mature and gravid proglottids of chicken tapeworms. (A) *Raillietina tetragona*. (1) Mature proglottid (Ransom); (2) Gravid proglottid showing egg capsules (Neveu-Lemaire). (B) *R. echinobothrida*. (1) Mature proglottid (Fuhrmann); (2) Gravid proglottid (Lang). (C) *Choanotaenia infundibulum* (Fuhrmann). (D) *Hymenolepis carioca* (Sawada). (E) *Amoebotaenia cuneata*. (1) Mature proglottid; (2) Gravid proglottid filled with eggs (Fuhrmann). (F) *Raillietina cesticillus*: mature proglottid (Monnig).

adding to 50 mL of distilled water the following ingredients in this order: 30 g gum arabic flakes, 200 g chloral hydrate, and 20 g glycerin). Distinctive egg characteristics may be demonstrated by teasing apart a gravid proglottid under a coverglass (Figure 27.37). Wet preparations of mature or gravid proglottids under low magnification may reveal diagnostic characteristics such as the location, size, and shape of the cirrus pouch and the location of the genital pore and the gonads. If further details of the internal structure of the proglottid are required for identification, it may be necessary to kill, fix, stain, destain, dehydrate, and permanently mount the specimen (1).

Tapeworms of Chickens

A dichotomous key is given to the 8 species of tapeworms commonly found in chickens from the continental United States. In such keys, successive selections must be made between 1a and 1b, 2a and 2b, etc., until a species name is designated. After viewing a portion of the worm under the microscope, make a comparison of the appropriate figures organized under scolices (Figure 27.35), eggs (Figure 27.37), or proglottids (Figure 27.36). With rare species, additional descriptions from other texts may be required (16).

Key to Species

1a. Minute forms, less than 1 cm long. A very limited number of proglottids with the terminal proglottid being gravid with egg..... 2
1b. Longer than 1 cm..... 3
2a. Wedge-shaped worm. Contains about 20 proglottids. Posterior proglottids wide, short (Figures 27.35C, 27.36E, and 27.37) ..... *Amoebotaenia cuneata*
2b. Contains only 2–5 proglottids, rarely 9. Posterior proglottids as long as wide (Figure 27.33)..... *Davainea proglottina*
3a. Threadlike, never more than 1.5 mm wide; fragile scolex is usually lost; often more than 100 worms in a single bird; proglottids short and wide, genus *Hymenolepis*.....4
3b. Robust worms, gravid proglottids wider than 2 mm 5
4a. Mature worms with gravid proglottids present, less than 12 mm long (Figure 27.35A)..... *H. cantaniana*
4b. Mature specimens with a total length including gravid proglottids of more than 12 mm (Figures 27.35B and 27.36D) ..... *H. carioca*
5a. 5–12 embryos enclosed in single capsule; verify by opening terminal proglottid; view under a coverglass (Figure 27.37 F).....6
5b. Embryos in single egg capsules enclosed in distinct membranes (examine under high power).....7
6a. Cirrus sac small (75–100 mm long). Suckers markedly oval in shape (Figures 27.35E and 27.36A) ..... *R. tetragona*
6b. Cirrus sac large (130–180 mm). Suckers round (Figures 27.35 F and 27.36B) ..... *R. echinobothrida*
7a. Outer membrane prolonged in 2 elongated filaments (Figures 27.37B) ..... Choanotaenia *infundibulum*
7b. Outer membrane smooth and round, 2 elongated filaments (Figures 27.34A and 27.37D)..... *R. cesticillus*

Species descriptions are given for these 8 chicken tapeworms to assist in verifying tentative identifications.

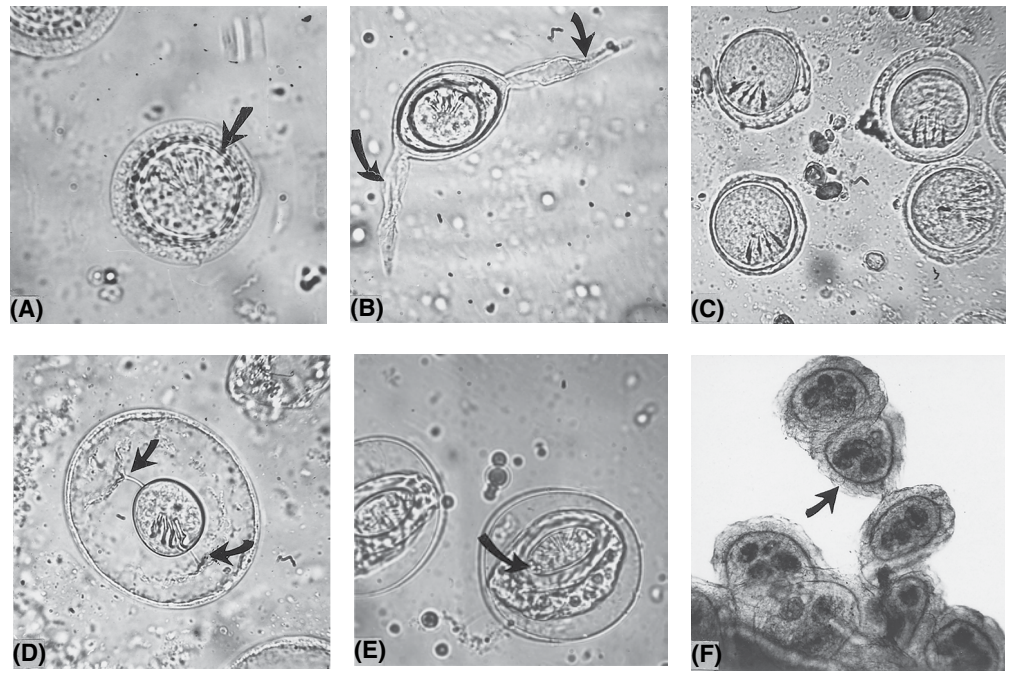

Figure 27.37. Eggs of chicken tapeworms (high power). (A) *Amoebotaenia sphenoides* showing distinctive granular layer. (B) *Choanotaenia infundibulum* with elongated filaments. (C) *Davainea proglottina*. (D) *Raillietina cesticillus*: Gravid proglottid showing distinctive funnel-shaped structures between membranes. (E) *Hymenolepis carioca* or *H. cantaniana* showing football-shaped embryophore with granular accumulations at the poles. (F) Capsules containing 6–12 eggs. Found in the chicken (*Raillietina tetragona*, *R. echinobothrida*) and 2 turkey tapeworms (*R. georgiensis, R. williamsi*).

Amoebotaenia cuneata (Linstow 1872)

Diagnostic Characteristics

This short (less than 4 mm, 25–30 proglottids) tapeworm may be recognized as whitish projections among the villi of the duodenum (Figure 27.35C); a triangular anterior end with a pointed scolex gives the entire worm a wedge-shaped anterior. Suckers unarmed, rostellum armed with a single row of 12–14 distinctive hooks 25–32 mm long, 12–15 testes located transversely in a single row across the posterior end of the proglottid (Figure 27.37E), genital pores usually alternate regularly, located at extreme anterior point of proglottid margin; 6-hooked single embryos, surrounded by a distinctive granular layer (Figure 27.37A); embryonal hooks, 6 mm.

Life History

Several species of earthworms belonging to the genera *Allotophora, Pheritima, Ocnerodrilus*, and *Lumbricus* act as intermediate hosts for this tapeworm. Literature descriptions of pathogenicity range from "comparatively slight" to "cause of death." No controlled experiments have been reported.

Choanotaenia infundibulum (Bloch 1779)

Diagnostic Characteristics

This large robust tapeworm, *Choanotaenia infundibulum*, is extremely white and is readily seen attached to the upper half of the intestine: Mature worms up to 23 cm long; large rostellum armed with a single row of 16–22 large (25–30 mm) hooks, suckers unarmed (Figure 27.35G); genital pores irregularly alternate; 25–60 testes are grouped in posterior portion of proglottid (Figure 27.36C); eggs are with distinctive elongated filaments (Figure 27.37B); and embryonal hooks are 18 mm long.

Life History and Pathogenicity

Houseflies and several species of beetles are proven natural hosts. Other insects including 9 families of beetles, grasshoppers, and termites are proven experimental hosts. Gravid proglottids are released 13 days after swallowing an infected fly. No controlled experiments testing pathogenicity have been reported.

Davainea proglottina (Davaine 1860)

Diagnostic Characteristics

This microscopic *Davainea proglottina* tapeworm may be recognized in the duodenal mucosa by protrusion of the gravid proglottids above the villi if the open intestine is floated in water. Eggs are without distinctive membranes, but embryonal hooks are distinctive, 10–11 mm long (Figure 27.37C). Mature worms measure up to 4 mm long; never with more than 9 proglottids; suckers are armed with 3–6 rows of hooks (Figure 27.33); the rostellum is armed; genital pores regularly alternate and are located near the anterior margin; and the cirrus is disproportionately large.

Life History

Several species of slugs and snails host larval stages of this tapeworm. More than 1,500 cysticercoids have developed along the digestive tract of susceptible slugs, where they have remained infective for more than 11 months. Tapeworms may live as long as 3 years; more than 3,000 worms have been recovered from a single bird.

Pathogenicity

This parasite is one of the more harmful species in young birds. In controlled experiments, a 12% reduction in growth

rate has been reported (5). Uncontrolled reports include emaciation, dull plumage, slow movements, breathing difficulties, thickened mucosal membranes that produce hemorrhage and fetid mucus, leg weakness, paralysis, and death.

Hymenolepis cantaniana (Polonio 1860)

Diagnostic Characteristics

Hymenolepis cantaniana is a short, hymenolepid tapeworm (maximum length 2 cm) that superficially resembles the longer *H. carioca*. It is usually listed as unarmed, but rostellar hooks have been described by European investigators (Figure 27.35A); the fragile rostellum is frequently lost; genital pores are unilateral, anterior to middle of proglottid; eggs are similar to those of H. carioca; embryonal hooks measure 13–14 mm.

Life History

Dung beetles (Scarabeidae) are intermediate hosts; each beetle may carry 100 or more cysticercoids. A unique larval development involves budding, which produces many cysticercoids from a single onchosphere. This tapeworm is considered relatively nonpathogenic, although no controlled experiments have been reported.

Hymenolepis carioca (Magalhaes 1898)

Diagnostic Characteristics

Several thousand specimens of this extremely slender species have been found in the duodenum of a single chicken or turkey. The worm is so slender (about 1 mm in diameter) that the hundreds of inconspicuous proglottids look more like a thread than a worm. Suckers are unarmed; rostellar sacs are present; rostellum is rudimentary (Figure 27.35B); there are 3 testes, usually in a straight row; genital pores are unilateral, located anterior to middle of proglottid margin (Figure 27.36D); an inner membrane enveloping the onchosphere is elongated into a football shape with granular deposits at poles (Figure 27.37E); embryonal hooks measure 10–12 mm.

Life History

Twenty-six species belonging to 9 families of beetles and 1 species of termite are experimental or natural intermediate hosts; dung and ground beetles are the most common source of infection. Reports incriminating the housefly are probably erroneous.

Pathogenicity

Experimental infections establishing several hundred worms/bird had no effect on weight gains. These results indicate that this species is relatively nonpathogenic.

Raillietina cesticillus (Molin 1858)

Diagnostic Characteristics

Scolex of this large robust tapeworm (up to 15 cm long) embeds deeply in the mucosa of the duodenum or jejunum. The distinctive, wide, flat, rostellum bears a double row of 300–500 hammer-shaped hooks. The flattened rostellum acts as a retractable piston drawing into an outer sleeve of the scolex, thus providing a firm grip on the mucosa (Figures 27.35D1 and D2); there are 4 unarmed weak suckers; genital pores alternate irregularly (Figure 27.36F); there are 20–30 testes posteriad in proglottid; single eggs are encapsulated in uterine membranes; and mature eggs have 2 distinctive funnel-shaped filaments between the middle and inner membranes (Figure 27.37D).

Life History

More than 100 species of beetles belonging to 10 families are proven natural or experimental intermediate hosts. A minute histerid beetle (*Carcinops pumilio*) is the natural intermediate host in broiler houses. The darkling beetle (*Alphitobius diaperinus*), grasshoppers, ants, and lepidopterous larvae have proved negative as experimental hosts. As many as 930 cysticercoids have been found in a single ground beetle.

Pathogenicity

Early reports attribute this parasite with causing emaciation, degeneration, and inflammation of villi, reduction of blood sugar and hemoglobin, and reduced growth rate. None of these early reports could be confirmed in extensive controlled experiments with broilers and layers maintained on optimum nutritional diets (2). Experimental infections (135 worms/bird) produced by feeding 300 cysticercoids caused no reduction in weight gain in broilers or reduced egg production in layers when compared with uninfected controls.

Raillietina tetragona (Molin 1858)

Diagnostic Characteristics

Raillietina tetragona are moderately large tapeworms measuring up to 25 cm long × 3 mm wide. Scolex (Figure 27.35E1) anchors in the posterior half of the intestine; the rostellum is armed with 90–100 hooks, 6–8 mm long, arranged in a single or double row (Figure 27.35E2); suckers are oval-shaped, armed with 8–12 rows of minute hooks, 3–8 mm long (Figure 27.35E); genital pores are usually unilateral (Figure 27.36A); the uterus breaks up into capsules containing 6–12 eggs (Figures 27.36A2 and 27.37F), similar to *R. echinobothrida* from chickens and *R. williamsi* and *R. georgiensis* from turkeys; and the cirrus sac is small (75–100 mm long), more anterior in proglottid margin than with *R. echinobothrida*.

Life History

Several species of small ants that nest under rocks or boards act as intermediate hosts. The minimum prepatent period after feeding cysticercoids to chickens is 13 days.

Pathogenicity

Weight loss was demonstrated in controlled experiments (9) with white leghorns and hybrids infected with an average of 12–16 worms/bird. Decreases in egg production in 4 breeds of hens occurred after administering 50 cysticercoids/bird, causing reduced glycogen levels in livers and the intestinal mucosa of infected chickens.

Raillietina echinobothrida (Megnin 1881)

Diagnostic Characteristics

The *Raillietina echinobothrida* species resembles *R. tetragona* but differs in the following characteristics: The strobila is larger (34 cm long × 4 mm wide); the scolex has rounded suckers containing 200–250 hooks, 10–13 mm long (Figure 27.35 F) with 8–15 rows of hooks 5–15 mm long (Figures 27.35 F2 and 3); genital pores are in the posterior half of the proglottid (Figure 27.36B2); the cirrus sac is large (130–180 mm long); and gravid proglottids frequently loosen from each other in the center, making a window-like arrangement not found in *R. tetragona*.

Life History

As with *R. tetragona*, numerous species of ants have been found naturally infected with cysticercoids. Concurrent infections with both *R. echinobothrida* and *R. tetragona* cysticercoids have been found in ants.

Pathogenicity

R. echinobothrida is usually listed as one of the most pathogenic tapeworms because its presence has often been associated with nodular disease of chickens. Nadakal et al. (10) reported parasitic granulomas approximately 1–6 mm in diameter at the sites of worm attachment 6 months after experimental infection with 200 cysticercoids. The condition was associated with catarrhal hyperplastic enteritis as well as lymphocytic, polymorphonuclear, and eosinophilic infiltration.

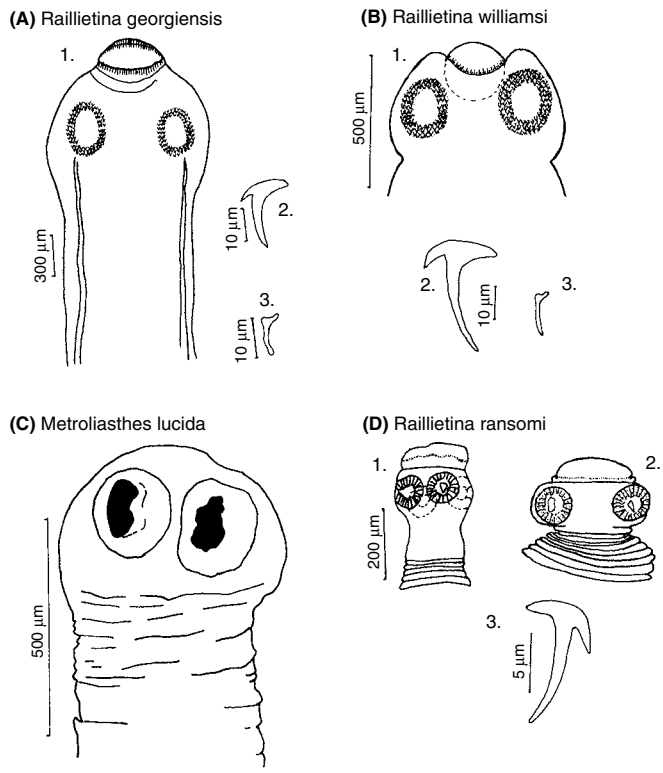

Figure 27.38. Scolices of turkey tapeworms. (A) *Raillietina georgiensis*. (1) Scolex; (2) Rostellar hook; (3) Acetabular hook (Reid and Nugara). (B) *R. williamsi*. (1) Scolex; (2) Rostellar hook; (3) Acetabular hook (Williams). (C) *Metroliasthes lucida* scolex (Ransom). (D) *R. ransomi*. (1, 2) Scolex; (3) Rostellar hook (Williams).

Tapeworms of Turkeys

Six species of tapeworms from domestic and/or wild turkeys have been reported from the United States (12). Because these tapeworms are readily transferred between wild and domestic turkeys, wild turkeys provide a reservoir for these parasites of domestic birds. No controlled experiments on pathogenicity have been reported for any species. Descriptions included here are limited to the 2 species with known life cycles. Scolex (Figure 27.38) and proglottid characteristics (Figure 27.39) of different species are organized in separate figures to facilitate comparisons if complete specimens are unavailable.

Raillietina georgiensis (Reid and Nugara 1961)

Description and Diagnostic Characteristics

Rhw *Raillietina georgiensis* species is a large (15–38 cm long × 3.5 mm wide) robust tapeworm from domestic and wild turkeys. Scolex (Figure 27.38A) is armed with a double row of 230 moderate length (12–23 mm) rostellar hooks and 8–10 circles of acetabular hooks, 8–13 mm long (Figures 27.38A2 and A3); genital pores are unilateral, located in the middle of the proglottid (Figure 27.39A); eggs are in uterine capsules, similar to *R. tetragona* and *R. echinobothrida*.

Life History

A small brownish ant (*Pheidole vinelandica*) that frequents turkey ranges has been found naturally infected; gravid proglottids appear in droppings within 3 weeks after turkeys have fed on infected ants. This tapeworm was introduced to a domestic farm by wild turkeys.

Pathogenicity

Enteritis is present if parasites are found in large numbers. Some host damage is assumed on the basis of a close relationship to *R. echinobothrida* from chickens.

Metroliasthes lucida (Ransom 1900)

Description and Diagnostic Characteristics

Metroliasthes lucida is a long tapeworm (20 cm) from turkeys and guinea fowl, rarely in chickens. There are unarmed scolex and suckers, 200–250 mm in diameter (Figure 27.38C); genital pores irregularly alternate, near middle of the margin in mature proglottids but posterior in gravid proglottids; the uterus consists of 2 sacs side by side, visible to the naked eye in gravid proglottids, and is known as the parauterine organ (Figures 27.39C2 and C3); eggs have 3 membranes, 75 × 50 mm.

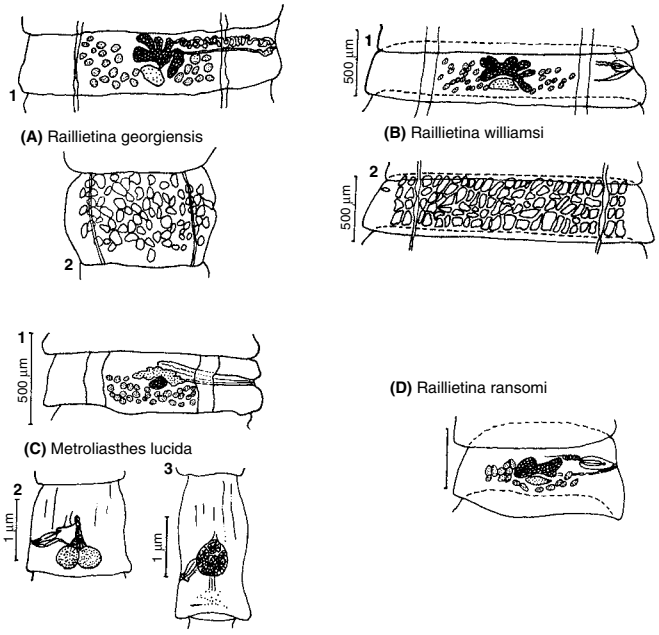

Figure 27.39. Mature and gravid proglottids of domestic and wild turkey tapeworms. (A) *Raillietina georgiensis* (Reid and Nugara). (B) *R. williamsi*. (1) Mature proglottid; (2) Gravid proglottid showing position of egg capsules, each containing several eggs (Williams). (C) *Metroliasthes lucida*. (1) Mature proglottid; (2) Proglottid showing 2-part uterus and developing parauterine organ; (3) Gravid proglottid (Ransom). (D) *R. ransomi* mature proglottid (Williams).

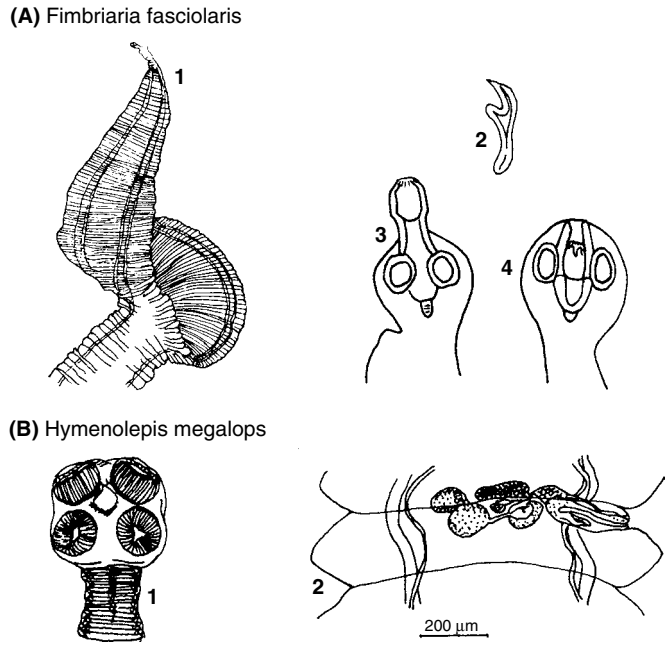

Figure 27.40. Tapeworms of ducks and geese. (A) *Fimbriaria fasciolaris*. (1) Pseudoscolex showing irregular distension of the anterior end and the minute scolex (Todd); (2) Rostellar hook (Fuhrmann); (3) Scolex with rostellum extended; (4) Scolex with rostellum withdrawn (Neveu-Lemaire). (B) *H. megalops*. (1) Scolex; (2) Mature proglottid (Yamaguti).

Life History
Several species of grasshoppers serve as intermediate hosts; cysticercoid development requires 15–42 days depending on temperature. The pathogenicity is unknown.

Tapeworms of Ducks and Geese

Domestic ducks and geese frequently become infected with numerous species of tapeworms introduced by wild ducks and geese. Some of these species have occasionally been reported in chickens. Two of the more common species are described in this section. Life cycles usually involve crustaceans or other aquatic invertebrates. No controlled pathogenicity studies have been made on any of these species.

Fimbriaria fasciolaris (Pallas 1781)

Description and Diagnostic Characteristics
This large (5–43 cm long × 1–5 mm wide) twisted tapeworm of ducks also occurs in chickens and 31 species of wild birds. This distinctive flaring anterior neck region is known as the pseudoscolex; strobila is unsegmented, but cross striations give the impression of segmentation (Figure 27.40A1); there are minute scolex (Figures 27.40A3 and A4) attached to pseudoscolex, 100–130 mm wide; suckers are unarmed; the retractile rostellum has 10–12 hooks 17–22 mm long (Figure 27.40A2); genital pores are unilateral and closely crowded together; onchospheres are 35–45 mm in diameter; hooks are 16 mm long.

Life History
Cysticercoids develop in copepod crustaceans (*Diaptomus* sp., *Cyclops* sp.); intermediate hosts are ingested with drinking water to infect the definitive host. The pathogenicity is unknown.

Hymenolepis megalops (Nitzsch, in Creplin 1829)

Description and Diagnostic Characteristics
Hymenolepis megalops, a cosmopolitan tapeworm of waterfowl (Figure 27.40B), is 3–6 mm long and readily recognized by the large scolex (1–2 mm wide) attached to the cloaca or the cloacal bursa. Suckers and rostellum are unarmed, the latter containing a rudimentary central pit; eggs are not in capsules.

Life History
Onchospheres develop into cysticercoids after 18 days in ostracod crustacea. The definitive host is infected by eating ostracods.

Pathogenicity
Reports range from severe damage to mortality if other cestodes (*H. coronula, H. furcigera*) are also present.

Prevention and Control

The change in production methods in commercial poultry, from backyard or range management to confinement rearing in large houses, has brought on marked reductions in tapeworm infections in chickens and turkeys. These birds no longer have easy access to the required insect or other invertebrate hosts for most cestode and trematode parasites. *Davainea proglottina*, 1 of the most pathogenic species, was reported from 23% of the chickens submitted to the diagnostic laboratory in New York in 1932. No cases have been found in recent years, probably because poultry no longer have easy access to garden slugs. We can expect a more diverse fauna of cestodes in birds reared under free range conditions.

Prevention of contact with the intermediate host is the first step to consider in tapeworm control. Elimination of intermediate hosts may provide additional benefits besides tapeworm control. If *Choanotaenia infundibulum* appears in a cage layer facility, housefly control will benefit the producer by preventing nuisance and public health complaints (Chapter 32). If *Raillietina cesticillus* tapeworms appear in broiler houses, beetle control measures for the darkling beetle (*Alphitobius diaperinus*) also may reduce populations of the true intermediate host, *Carcinops pumilio*, a minute histerid beetle. Identification of worm species will help to suggest control measures, where the control of the intermediate host is to be recommended.

Treatment

In the United States, there are no products for use in feed for treatment of tapeworms in poultry. Historically, butynorate (dibutyltin dilaurate) was used for treatment of 6 species of chicken tapeworms (*Raillietina cesticillus, R. tetragona*, *Choanotaenia infundibulum, D. proglottina, Hymenolepis carioca*, and *Amoebotaenia sphenoides*) (3). Thus, all efforts toward control must be directed toward prevention by reducing populations of the intermediate hosts.

Trematodes

Trematodes (flukes) are flat, leaflike, parasitic organisms belonging to the phylum Platyhelminthes, class Trematoda. They differ from the cestodes (class Cestoda) in having a digestive system, and they do not form proglottids. The life cycle of all trematodes parasitizing birds requires a molluscan as an intermediate host; some species also use a second intermediate host. Because adult trematodes and larval metacercariae invade almost every cavity and tissue of birds, they may show up unexpectedly at necropsy.

More than 500 species belonging to some 125 genera and 27 families are known to occur in the 4 orders of birds most likely to be submitted to diagnostic laboratories as domestic or pet birds (4). Twenty of these flukes are considered potentially dangerous to poultry in the Western Hemisphere. These flukes belong to 4 orders: Anseriformes (ducks and geese), Galliformes (chickens and turkeys), Columbiformes (pigeons and allies), and Passeriformes (perching birds). Flukes are less host specific than tapeworms, so wild birds often introduce infection in areas where domestic poultry is reared. Because many snails live in ponds and streams, ducks and geese are the most frequently parasitized. The oviduct fluke (*Prosthogonimus* sp.), which is a frequent parasite of many species of wild birds, sometimes causes problems with ducks and chickens (6). This species will be used to illustrate fluke morphology and life history. *P. macrorchis* is the species name recognized in the United States, and this fluke is known as *P. ovatus* or by other specific names in other countries.

Morphology and Life History

The body of the adult fluke (Figure 27.41) is a flattened oval, and it bears 2 suckers. The digestive system consists of the mouth (within the oral sucker), the pharynx, a short esophagus, and 2 intestinal ceca. An anus is lacking in the trematodes. Two testes and 1 ovary are present in the same individual. After fertilization, the zygote is enclosed along with yolk cells from the vitellaria by an eggshell. Large numbers of eggs are stored in a prominent convoluted uterus. The excretory system, which originates in a series of flame cells bearing a tuft of cilia, drains with a series of collecting tubules that empty through an excretory pore near the posterior end of the parasite. The arrangement pattern of these collecting tubules is used as a family characteristic in the classification of flukes.

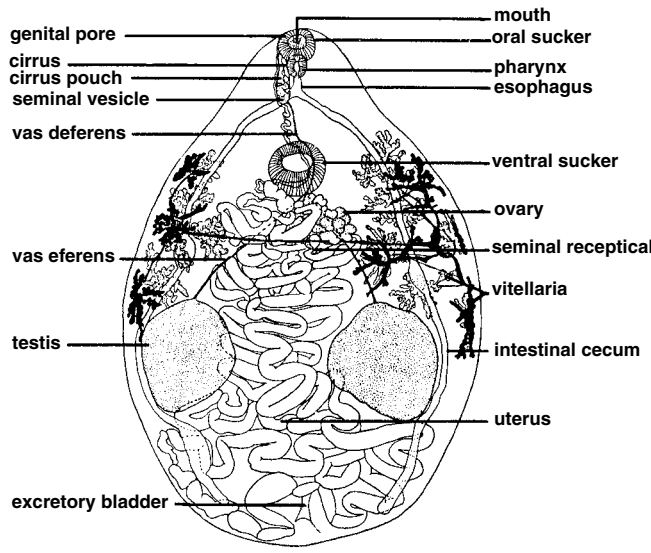

Figure 27.41. Morphology of an adult trematode (*Prosthogonimus macrorchis*). (Macy)

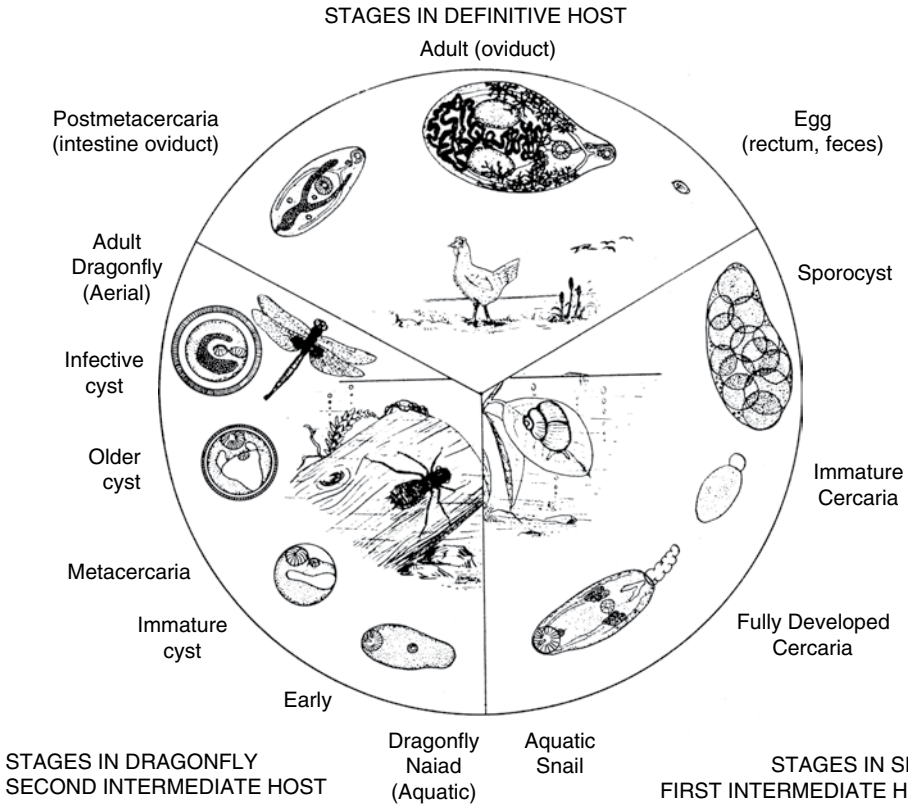

Figure 27.42. Life cycle of a typical digenetic trematode (*P. macrorchis*). (Macy)

Life Cycle

Adult flukes continually shed eggs, which pass out with the feces of the host. These eggs contain an embryo that develops into a larval stage known as a miracidium. In this group of trematodes, the miracidium hatches after the egg is swallowed by a susceptible snail. Larval development continues within the snail through a succession of stages known as sporocysts and cercariae. The cercariae emerge from the snail and swim about in a lake or pond. Some are drawn into the brachial basket of a dragonfly naiad. The cercaria encysts (metacercaria) and remains in the insect until either the naiad or an infected adult dragonfly is eaten by a bird (Figure 27.42).

Identification

Twenty-four trematodes that are occasionally seen in birds at diagnostic laboratories have been described with keys by Kingston (4). More extensive listings of species are provided by Yamaguti (17), McDonald (7), and Schell (13). The latter text also describes methods of identifying, collecting, preserving, and staining trematodes with emphasis on North American families and genera.

Pathogenicity

Prosthogonimus sp., popularly known as the oviduct fluke, has caused economic losses to poultry producers by (1) drastically reducing egg production after a recent infection and (2) occasionally being enveloped within a hen's egg and later discovered by a complaining customer. Other organs of the bird invaded by flukes include (1) metacercarial cysts in the skin of chickens and turkeys (*Collyriclum faba*); (2) small adult flukes in the conjunctival sac of the eye (*Philophthalmus gralli*); (3) adults in the liver, pancreas, and bile duct of ducks and turkeys (*Amphimerus elongatus*); (4) adults in the collecting tubules of the excretory system of chickens, turkeys, and pigeons (*Tanaisia bragai*); (5) adults and eggs in the circulatory system of ducks by 3 species of blood fluke; and (6) 14 species of flukes that invade various areas of the digestive tract.

Control

If the life cycle is known and evidence of pathogenicity or economic loss is clear, changes in management are indicated. Efforts should be directed toward fencing poultry off from access to lakes or streams where dragonfly naiads, snails, and other aquatic intermediate hosts are abundant (6).

No chemotherapeutic products are available for use in poultry for control or prevention of trematode infections.

References

Nematodes and Acanthocephalans

1. Addison, E.M., and R.C. Anderson. 1969. A review of the eye worms of the genus *Oxyspirura* (Nematode: Spiruroidea). *J Wildl Dis*. 55:1–58.
2. Anderson, R.C., and O. Bain. 1976. CIH keys to the nematode parasites of vertebrates. No. 3. Keys to genera of the order Spirurida. Part 3. Diplotriaenoiden, Aprocloidea and Filarioidea. Commonwealth Agricultural Bureau, Farnham Royal, Bucks England. 59–116.
3. Barus, V. 1970. Studies on the nematode *Subulura sactoria*. *Folia Parasitol (Prague)*. 17:191–199.
4. Bruynooghe, D., D. Thienpont, and O.F.J. van Parijs. 1968. Use of tetramisole as an anthelmintic in poultry. *Vet Rec*. 82:701–706.
5. Clarkson, M.J., and M.K. Beg. 1970. The anthelmintic activity of *L*-tetramisole against Ascaridia and Capillaria obsignata in the fowl. *Vet Rec*. 86:652–654.
6. Cram, E.B. 1929. A new roundworm parasite, Strongyloides avium of the chicken with observations of its life history and pathogenicity. *North Am Vet*. 10:27–30.
7. Cram, E.B. 1933. Observations on the life history of *Tetrameres patterson*. *J Parasitol*. 10:97–98.
8. Cram, E.B., M.F. Jones, and E.A. Allen. 1931. *The Bobwhite Quail: Its Habits, Preservation, and Increase*. H.L. Stoddard, ed. Charles Scribner's Sons, New York. 240–296.
9. Cuckler, A.C., and J.E. Alicata. 1944. The life history of *Subulura brumpti*, a cecal nematode of poultry in Hawaii. *Trans Am Microbiol Soc*. 63:345–357.
10. Davidson, W.R., G.L. Doster, and M.B. McGhee. 1978. Failure of *Heterakis bonasae* to transmit *Histomonas meleagridis*. *Avian Dis*. 22:627–632.
11. Enigk, K., and A. Dey-Harza. 1970. Zur Behandlung der haufigsten nematodeninfectionen des hausgeflugels. *Dtch Tieraerztl Wochenschr*. 78:178–181.
12. Esquenet, C., P. DeHerdt, H. De Bosschere, S. Ronsman, R. Ducatelle, and J. Van Erum. 2003. An outbreak of Histomoniasis in free-range layer hens. *Avian Pathol*. 2:67–74.
13. Ewing, S.A., J.L. West, and A.L. Malle. 1967. *Tetrameres* sp. (Nematoda: Spiruridae) found in pigeons (*Columba livia*) in Kansas and Oklahoma. *Avian Dis*. 11:407–412.
14. Farr, M.M. 1956. Survival of the protozoan parasite *Histomonas meleagridis* in feces of infected birds. *Cornell Vet*. 46:178–187.
15. Fernando, M.A., I.J. Hoover, and S.G. Ogungbade. 1973. The migration and development of *Cyatostoma bronchialis* in geese. *J Parasitol*. 59:759–764.
16. Flatt, R.E., and L.R. Nelson. 1969. *Tetrameres americana* in laboratory pigeons (*Columba livia*). *Lab Anim Care*. 19:853–856.
17. Forrester, D.J., J.A. Conti, A.O. Bush, L.D. Campbell, and R.K. Frohlich. 1984. Ecology of helminth parasitism of bobwhites in Florida. *Proc Helm Soc Wash*. 51:255–260.
18. Hemsley, R.V. 1971. Fourth stage *Ascaridia* spp. Larvae associated with high mortality in turkeys. *Can Vet J*. 12:147–149.
19. Holtzen, H., and T. Yazwinski. 1988. Efficacies of piperazine salts and coumaphos in poultry artificially infected with *A. galli*. In: *Proc Anim Dis Res Work Southern States*. Atlanta, GA.
20. Hu, J., A.L. Fuller, and L.R. McDougald. 2005. Blackhead disease in turkeys: Direct transmission of *Histomonas meleagridis* from bird to bird in a laboratory model. *Avian Dis*. 49:328–331.
21. Hu, J., and L.R. McDougald. 2003. Direct lateral transmission of *Histomonas meleagridis* in turkeys. *Avian Dis*. 47:489–492.
22. Hwang, J.C. 1964. Hemogram of turkey poults experimentally infected with Syngamus trachea. *Avian Dis*. 8:380–390.
23. Kala, P.I., R.W. Dimmick, and S. Patton. 1997. Helminths in ruffed grouse at the host's southeastern range boundary. *J Wildlife Dis*. 33:503–510.
24. Kaushik, R.K., and V.P.S. Deorani. 1969. Studies on tissue responses in primary and subsequent infections with H*eterakis gallinae* in chickens and on the process of formation of cecal nodules. *J Helminthol*. 43:69–78.
25. Kazacos, K.R., and W.L. Wirtz. 1983. Experimental cerebrospinal nematodiasis due to *Baylisascaris procyonis* in chickens. *Avian Dis*. 27:55–65.
26. Levine, P.P. 1938. Infection of the chicken with *Capillaria columbae* (RUD). *J Parasitol*. 24:45–52.
27. Lund, E.E., and A.M. Chute. 1972. Reciprocal responses of eight species of galliform birds and three parasites: *Heterakis gallinarum, Histomonas meleagridis*, and *Parahistomonas wenrichi*. *J Parasitol*. 58:940–945.
28. Norton, R.A., T.A. Yazwinski, and Z. Johnson. 1991. Research note: Use of fenbendazole for the treatment of turkeys with experimentally induced nematode infections. *Poult Sci*. 70:1835–1837.
29. Norton, R.A., B.A. Hopkins, J.K. Skeeles, J.N. Beasley, and J.M. Kreeger. 1992. High mortality of domestic turkeys associated with *Ascaridia dissimilis*. *Avian Dis*. 36:469–473.
30. Norton, R.A., G.R. Bayyari, J.K. Skeeles, W.E. Huff, and J.N. Beasley. 1994. A survey of two commercial turkey farms experiencing high levels of liver foci. *Avian Dis*. 36:469–473.
31. Norton, R.A., F.J. Hoerr, F.D. Clark, and S.C. Ricke. 1999. Ascarid associated hepatic foci in turkeys. *Avian Dis*. 43: 29–38.
32. Pankavich, J.A., G.P. Poeschel, A.L. Shor, and A. Gallo. 1973. Evaluation of levamisole against experimental infections of *Ascaridia*, *Heterakis* and *Capillaria* spp. in chickens. *Am J Vet Res*. 34:501–505.
33. Permin, A., M. Bisgaard, F. Frandsen, M. Perman, J. Kold, and P. Nansen. 1999. Prevalence of gastrointestinal helminths in different poultry production systems. *Br Poult Sci*. 40:439–443.
34. Pote, L.M., and T.wA. Yazwinski. 1985. Efficay of fenbendazole in chickens. *Arkansas Farm Res*. 34:2.
35. Reid, W.M., and J.L. Carmon. 1958. Effects of numbers of *Ascaridia galli* in depressing weight gains in chicks. *J Parasitol*. 44:183–186.
36. Reid, W.M., J.L. Mabon, and W.C. Harshburger. 1973. Detection of worm parasites in chicken eggs by candling. *Poult Sci*. 52:2316–2324.
37. Riddell, C., and A. Gajadhar. 1988. Cecal and hepatic granulomas in chickens associated with *Heterakis gallinarum* infection. *Avian Dis*. 32:836–838.
38. Ruff, M.D., L.R. McDougald, and M.F. Hansen. 1970. Isolation of *Histomonas meleagridis* from embryonated eggs of *Heterakis gallinarum*. *J Protozool*. 17:10–11.
39. Schmidt, G.D., and O.W. Olsen. 1964. Life cycle and development of *Proshynohus formosus* (Van Cleave, 1918) Travassos, 1926, an acanthocephalan parasite of birds. *J Parasitol*. 50: 721–730.
40. Schwabe, C.W. 1951. Studies on *Oxyspirura mansoni*: The tropical eyeworm of poultry II. Life history. *Pac Sci*. 5:18–35.

41. Senties-Cue, B.R. Charlton, L. Anthenill, S. Naem, L. McDougald, and M. Bland. 2011. Parasitic ventriculitis caused by *Hadjelia truncata* in California rock pigeons (*Columba livia*). *J Vet Diagn Invest*. 23:1243–1246.
42. Spakulova, M., V. Birova, and J.K. Macko. 1991. Seasonal changes in the species composition of nematodes and acanthocephalans of ducks in East Slovakia. *Biologia*. 46:119–128.
43. Springer, W.T., J. Johnson, and W.M. Reid. 1969. Transmission of Histomoniasis with male *Heterakis gallinarum* (Nematoda). *Parasitology*. 59:401–405.
44. Swales, W.E. 1933. *Tetrameres crami* Sp. Nov., a nematode parasitizing the proventriculus of a domestic duck in Canada. *Can J Res*. 8:334–336.
45. Tongson, M.S., and B.M. McGraw. 1967. Experimental ascaridiasis: Influence of chicken age and infective dose on structure of *Ascaridia galli* populations. *Exp Parasitol*. 21:160–172.
46. Tsvetaeva, N.P. 1960. Pathomorphological changes in the proventriculus of the duck infected by experimental tetrameriasis. *Helminthologia*. 2:143–150.
47. Tyzzer, E.E. 1926. *Heterakis vesicularis* Froelich 1791: A vector of an infectious disease. *Proc Soc Exp Med*. 23:708–709.
48. Verma, N.P., K. Bhatmager, and D.P. Bannerjee. 1991. Comparative efficacy of three broad spectrum anthelmintics against *Ascaridia galli* in poultry. *Indian J Anim Sci*. 61:834–835.
49. Yamaguti, S. 1961. The nematodes of vertebrates. In: *Parts I and II: Systema Helminthum*, *Vol 3*. *Nematodes*. Interscience, New York. 1–1261.
50. Yazwinski, T.A. 1999. Turkey worms (*A. dissimilis*) and fenbendazole. *Turkey World*. July-Aug:22–23.
51. Yazwinski, T.A., P. Andrews, H. Holtzen, B. Presson, N. Wood, and Z. Johnson. 1986. Dose-titration of fenbendazole in the treatment of poultry nematodiasis. *Avian Dis*. 30:716–718.
52. Yazwinski, T.A., M. Rosenstein, R.D. Schwartz, K. Wilson, and Z. Johnson. 1993. The use of fenbendazole in the treatment of commercial turkeys infected with *Ascaridia dissimilis*. *Avian Pathol*. 22:177–181.
53. Zieris, H., and P. Betke. 1991. *Cyathostoma bronchialis* (Muhling (1884). Ordnung Strogylida, Familie Syngamidae bei Mandarinenten (*Aix galericulata*) als Todesursache. *Monatschefte fur Vet*. 46:146–149.

Cestodes and Trematodes

1. Ash, L.R., and T.C. Orihel. 1987. *Parasites: A Guide to Laboratory Procedures and Identification*. American Society of Clinical Pathologists, Chicago, IL.
2. Botero, H., and W.M. Reid. 1969. The effects of the tapeworm *Raillietina cesticillus* upon body weight gains of broilers, poults and on egg production. *Poult Sci*. 48:536–542.
3. Kerr, K.B. 1952. Butynorate, an effective and safe substance for the removal of *R. cesticillus* from chickens. *Poult Sci*. 31: 328–336.
4. Kingston, N. 1984. Trematodes. In: *Diseases of Poultry*, 8th ed. M.S. Hofstad, H.J. Barnes, B.W. Calnek, W.M. Reid, and H.W. Yoder, Jr., eds. Iowa State University Press, Ames, Iowa, 668–690.
5. Levine, P.P. 1938. The effect of infection with Davainea proglottina on the weights of growing chickens. *J Parasitol*. 24:550–551.
6. Macy, R.W. 1934. Studies on the taxonomy, morphology and biology of *Prosthogonimus macrorchis* Macy, a common oviduct fluke of domestic fowls in North America. *Minn Agric Exp Tech Bull*. 98:1–64.
7. McDonald, M.E. 1981. Key to trematodes reported in waterfowl. *US Dept Int Fish Wildl Serv Resource Pub 142*. Washington, DC.
8. Monnig, H.O. 1934. *Veterinary Helminthology and Entomology*. Baillerie, Tindall and Cox, London.
9. Nadakal, A.M., and K.V. Nair. 1979. Studies on the metabolic disturbances caused by *Raillietina tetragona* (Cestoda) infection in domestic fowl. *Indian J Exp Biol*. 17:310–311.
10. Nadakal, A.M., K. Mohandas, K.O. John, and K. Muraleedharan. 1973. Contribution to the biology of the fowl cestode *Raillietina echinobothrida* with a note on its pathogenicity. *Trans Am Microsc Soc*. 92:273–276.
11. Reid, W.M. 1962. *Chicken and Turkey Tapeworms*. Handbook. University of Georgia Poultry Department, Athens, GA.
12. Reid, W.M. 1984. Cestodes. In: *Diseases of Poultry*, 8th ed. M.S. Hofstad, H.J. Barnes, B.W. Calnek, W.M. Reid, and H.W. Yoder, Jr., eds. Iowa State University Press, Ames, Iowa. 649–667.
13. Schell, S.C., 1985. *Handbook of Trematodes of North America North of Mexico*. University Press, Moscow, Idaho.
14. Schmidt, G.D. 1986. *Handbook of Tapeworm Identification*. CRC Press, Boca Raton, Florida.
15. Wardle, R.A., and J.A. McLeod. 1952. *The Zoology of Tapeworms*. University of Minnesota Press, Minneapolis, Minneapolis.
16. Yamaguti, S. 1959. Systema Helminthum, vol. 2: *The Cestodes of Vertebrates*. Interstate, New York.
17. Yamaguti, S. 1971. *Synopsis of Digenetic Trematodes of Vertebrates*, vols. 1 and 2. Keigaku, Tokyo.

Chapter 28

Protozoal Infections

Introduction

Larry R. McDougald

Protozoa found in poultry are categorized within several taxonomic groups. Many are found in the phylum Apicomplexa (1). These are intracellular parasites characterized by the presence of an apical complex in the sporozoite. Genera include *Eimeria, Isospora, Hemoproteus, Leucocytozoon, Plasmodium, Toxoplasma, Sarcocystis, Wenyonella, Tyzzeria*, and *Cryptosporidium*. A second phylum, Sarcomastigophora, includes the flagellates and amebas. These include *Histomonas, Trypanosoma, Chilomastic, Entamoeba, Endolimax*, and *Spironucleus*, and *Cochlosoma*. Some of these, such as *Cochlosoma* (2, 3), are poorly understood or uncommon. A third group, the Microspora, is represented by *Encephalitozoon cuniculi*. This parasite may be egg-transmitted, and is associated with embryo mortality, but little is known of its importance (5, 6). Modern practices of poultry rearing minimize the impact of many parasites while increasing the risk from others. Occasionally, previously unknown protozoans are discovered by the use of modern diagnostic methods such as polymerase chain reaction (PCR), where it was not possible to discern different species by conventional methods (4).

Many protozoans are known from chickens, turkeys, and game birds, but only a few flourish under these conditions. Parasites with short, direct life cycles, such as coccidiosis, are favored, while others involving intermediate hosts are normally not a problem in poultry. An exception to the latter is blackhead disease (histomoniasis), which has a complicated life cycle involving intermediate hosts, but takes advantage of reservoir hosts (chickens) and is able to spread easily from bird to bird within a flock of turkeys. The importance of some of these parasites may change or increase with more emphasis placed on production in other systems, such as free range.

Control of protozoan parasites is becoming difficult with the limitation in the use of chemotherapeutic agents and the lack of vaccines for some diseases. Only with coccidiosis has a good measure of success been achieved by vaccination. Historically, producers have depended on anticoccidial drugs for control of coccidiosis in broiler chickens. However, there have been no new products in this area for several years, and it is unlikely that new products will be developed. With the emergence of drug resistance or tolerance to these drugs, more importance has been placed on vaccination with live vaccines. The use of such vaccines not only gives control of disease, but at the same time repopulates the production facilities with coccidia that are more sensitive to drugs and sometimes less pathogenic. With the introduction of attenuated coccidia in vaccines, this approach has become more important in disease control programs. Emphasis toward biological control and away from chemotherapy in production of "all-natural" poultry favors this type of program. The growth of the game bird industry has also created more need for tools for disease control. This industry has long been ignored in making modern drugs and vaccines available for disease control.

Blackhead disease remains a serious and enigmatic limit to production of poultry and game birds. In recent years turkey companies have experienced massive losses over an entire growing season, sometimes with loss of an entire flock of 10,000–30,000 birds. At one time, highly effective drugs (nitroimidazoles) were available for treatment of outbreaks, but these were deregistered in the early 1990s, leaving us without effective means of control. There are no products approved for treatment of outbreaks of blackhead, and no vaccines. Experimental work shows that turkeys can be successfully vaccinated against histomoniasis with live cultures of attenuated *H. meleagridis*, but no commercial vaccine is under development. One product, nitarsone, is available for prevention of blackhead, but is not effective in all cases. Combination approvals for use with other products in feed are limited. It is not approved for use in game birds.

Diagnostic tools for protozoan diseases in poultry have been developed, particularly with coccidia and *Histomonas*. PCR-based tests are sometimes used to confirm diagnoses, particularly with blackhead disease. enzyme-linked immunosorbent assay (ELISA), Western blot, and other tests are routinely used in research.

Diseases of Poultry, Thirteenth Edition. David E. Swayne.
© 2013 John Wiley & Sons, Inc. Published 2013 by John Wiley & Sons, Inc.

Coccidiosis

Larry R. McDougald and Steve H. Fitz-Coy

Introduction

Coccidiosis is a disease of universal importance in poultry production. The protozoan parasites of the genus *Eimeria* multiply in the intestinal tract and cause tissue damage, with resulting interruption of feeding and digestive processes or nutrient absorption, dehydration, blood loss, loss of skin pigmentation and increased susceptibility to other disease agents. Historically, the spectacular onset of coccidiosis with bloody diarrhea and high mortality inspired awe and dread on the part of poultry growers and bird fanciers. Like many parasitic diseases, coccidiosis is largely a disease of young animals because immunity quickly develops after exposure and gives protection against later disease outbreaks. Unfortunately, no cross immunity exists between species of *Eimeria* in birds, and later outbreaks may be the result of different species. The short, direct life cycle and high reproductive potential of coccidia in poultry often lead to severe outbreaks of disease in small backyard flocks or in the modern poultry house, where 15,000–30,000 chickens may be reared on litter.

Coccidiosis may strike any type of poultry in any type of facility. The disease may be mild, resulting from the ingestion of a few oocysts, and may escape notice, or it may be severe as a result of ingestion of millions of oocysts. Most infections are relatively mild, but because of the potential for the disastrous outbreak and the resulting financial loss, almost all young poultry are given continuous medication with low levels of anticoccidial drugs, which prevent the infection or reduce infections to a low, immunizing level. In the past, vaccines against coccidiosis have been used mostly in breeder pullets and in turkeys. Vaccination of broilers has rarely been practiced because even light infections with some species of coccidia can affect weight gain, feed conversion, and pigmentation of the skin. However, new vaccines with improved administration techniques are targeting this larger market with encouraging results.

Classification and Taxonomic Relationships

The biology and taxonomy of coccidia were reviewed by Long (24) and Pellerdy (37). Coccidia are members of the phylum Apicomplexa, which is characterized by the presence of an apical complex in sporozoites. All apicomplexans are intracellular parasites. The genera *Eimeria, Isospora, Haemoproteus*, *Leucocytozoon, Plasmodium, Toxoplasma, Sarcocystis, Wenyonella, Tyzzeria*, and *Cryptosporidium* are found in poultry.

The most common apicomplexans in poultry belong to the genus *Eimeria*, described in this section, or the genus *Cryptosporidium*, discussed in a later section of this chapter. The oocyst, a thick-walled zygote shed in fecal matter by the infected host, is fairly distinctive and is often used in diagnosis and identification of species. Oocysts are enclosed in a thick outer shell and consist of a single cell that begins the process of sporulation to yield the infective stage in 48–72 hours. Infective oocysts contain 4 sporocysts, which in turn contain 2 sporozoites (Figure 28.1).

The closely related parasites, *Sarcocystis, Toxoplasma, Cryptosporidia*, and avian malaria, are discussed in the sections Miscellaneous and Sporadic protozoal Infections and Cryptosporidiosis.

When oocysts are ingested, the oocyst wall is crushed in the ventriculus (gizzard), and the sporozoites are released from sporocysts by the action of chymotrypsin and bile salts in the small intestine. Sporozoites enter epithelial cells or are taken into intraepithelial lymphocytes, where development begins. Species of coccidia are identified on the basis of (1) oocyst morphology, (2) host specificity, (3) immune specificity, (4) appearance and location of gross lesions within the natural host, and (5) length of the prepatent period. The host specificity of *Eimeria* in birds and mammals is very strict, so that parasites from different species of birds or animals can be considered different species, even though they may have similar-appearing oocysts.

Biological characteristics useful in the identification of species are (1) location of lesions in the intestine; (2) appearance of gross lesions; (3) oocyst size, shape, and color; (4) size of endogenous tissue stages (schizonts, merozoites, meronts, gametocytes); (5) location of the parasites within tissues; (6) minimum prepatent period in experimental infections; and

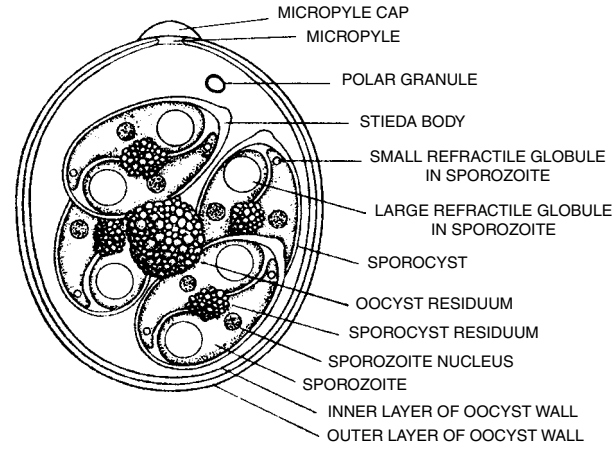

Figure 28.1. Diagram of sporulated oocyst of genus *Eimeria*. The oocysts of all *Eimeria* contain 4 sporocysts, each with 2 sporozoites, after sporulation.

(7) immunogenicity in comparison with reference strains. In recent years biochemical and molecular tools also have been used for identification of coccidia. Techniques of value include the electrophoretic pattern of metabolic enzymes (40) and PCR (42). Monoclonal antibodies are useful in experimental work but have not been developed to be specific for species identification. Digital image analysis (6) is useful for analysis of photographic imagery. For diagnostic purposes, the traditional biological characteristics are usually adequate. However, taxonomic difficulties are encountered in identification of species with morphologically similar oocysts which are found with overlapping tissue specificity. Species can identified by comparison of isolates with several criteria listed in Tables 28.1 or 28.3, below.

Life Cycle

Coccidiosis differs from bacterial and viral diseases in the self-limiting nature of its development. The life cycle of *E. tenella* (Figure 28.2) is typical of all *Eimeria*, although some species vary in the number of asexual generations and the time required for each developmental stage. After the oocyst wall is crushed in the ventriculus (gizzard) and the sporozoites are released, the sporozoites enter cells in the mucosa of the intestine and begin the cell cycle leading to reproduction. At least 2 generations of asexual development (sometimes as many as 4) called schizogony or merogony give rise to a sexual phase, where small, motile microgametes seek out and unite with macrogametes. The resulting zygote matures into an oocyst, which is released from the intestinal mucosa and is shed in the feces. With each species, the reproductive potential from a single ingested oocyst is fairly constant. The entire process takes 4–6 days, depending on species, although oocysts may be shed for several days after patency is reached. In some species (*E. tenella, E. necatrix*), the maximum tissue damage may occur when second-generation schizonts rupture to release merozoites. Other species may have small scattered schizonts, which cause little damage, but the gametocytes may elicit a strong reaction with cellular infiltration and thickened, inflamed tissues.

Relationship between Coccidiosis and Other Poultry Diseases

The tissue damage and changes in intestinal tract function may allow colonization by various harmful bacteria, such as *Clostridium perfringens*, leading to necrotic enteritis (17, 26) or *Salmonella typhimurium* (2, 3). Cecal coccidiosis (*E. tenella*) may contribute to increased severity of the blackhead organism (*Histomonas meleagridis*) in chickens. Experimental infections with the 2 organisms were characterized by a higher incidence of hepatic disease, as compared with mono-infection with *Histomonas* (28).

Immunosuppressive diseases may act in concert with coccidiosis to produce a more severe disease. Marek's disease may interfere with development of immunity to coccidiosis (4), and infectious bursal disease (IBD) may exacerbate coccidiosis, placing a heavier burden on anticoccidial drugs (29).

Coccidiosis in Chickens

Coccidiosis remains one of the most expensive and common diseases of poultry production in spite of advances in chemotherapy, management, nutrition, and genetics. The disease is often diagnosed in birds brought to diagnostic laboratories (1), but the vast majority of cases are diagnosed in the field and handled by poultry service personnel. The current expense for preventive medication exceeds $90 million in the United States and more than $300 million worldwide.

Incidence and Distribution

Coccidia are found wherever chickens are raised. Their strict host specificity eliminates wild birds as sources of infection. The most common means of spread of coccidia is mechanical, by personnel who move between pens, houses, or farms. Coccidial infections are self limiting and depend largely on the number of oocysts ingested and on the immune status of the bird. Surveys in North and South America revealed coccidia present in almost all broiler farms (25, 30, 32). Very high percentages of positive flocks were also reported from Europe (5, 23, 43). Oocysts in the litter or droppings of broiler chickens are usually most numerous between 3 and 5 weeks of age and often decline thereafter. Few oocysts are found after birds are removed from a farm, because the parasites are killed by ammonia or composting heat in poultry litter or droppings. The ubiquitous nature of poultry coccidia precludes the possibility of elimination or prevention of coccidia by quarantine, disinfection, or sanitation.

Etiology and Diagnosis

Nine species of *Eimeria* have been described from chickens (Table 28.1). New evidence suggests that all should be considered valid. Concurrent infection with 2 or more species of coccidia is common (31). Each species causes separate and distinct, recognizable diseases, independent of the other species.

Characteristics useful in the identification of *Eimeria* species are listed previously under Classification and Taxonomic Relationships. However, for diagnostic purposes, the traditional characteristics are adequate, and a satisfactory diagnosis can be made from Table 28.1. Cross immunity and biochemical studies require pure species isolates propagated from single oocysts. The severity of infection based on gross lesions is often graded on a scale of 0–4 as described by Johnson and Reid (22), where 0 is normal and 4 is the maximum lesion. Microscopic examination of lesions or droppings is also used to grade infections, by counting the number of parasite forms in a field. In this technique, at least 5 fields should be examined. A typical scoring system used by some diagnosticians is based on the species, number, and type of parasites. For E. maxima a typical score system is: 0 = no parasites, 1 = 1–10 parasites/field, 2 = 11–20, 3 = 21–49, and 4 = 50 or more/field. With other species, 1 = 1–25/field, 2 = 26–50, 3 = 51–75, and 4 = greater than 75.

Table 28.1. Diagnostic table of coccidia.

	CHARACTERISTICS	E. acervulina	E. brunetti	E. maxima	E. mitis †	E. mivati ‡	E. necatrix	E. praecox	E. tenella	SPECIES OF DOUBTFUL VALIDITY E. hagani
MACROSCOPIC LESIONS	ZONE PARASITIZED		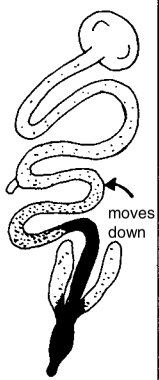			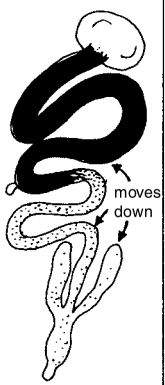				
	MACROSCOPIC LESIONS	light infection: whitish round lesions sometimes in ladder-like streaks heavy infection: plaques coalescing, thickened intestinal wall	coagulation necrosis mucoid, bloody enteritis in lower intestine	thickened walls, mucoid, blood - tinged exudate, petechiae	no discrete lesions in intestine, mucoid exudate	light infection: rounded plaques of oocysts heavy infection: thickened walls coalescing plaques	ballooning, white spots (schizonts), petechiae, mucoid blood - filled exudate	no lesions, mucoid exudate	onset: hemorrhage into lumen later: thickening, whitish mucosa, cores clotted blood	pinhead hemorrhages petechiae
MICROSCOPIC CHARACTERISTICS	MILLIMICRONS OOCYSTS REDRAWN FROM ORIGINALS	10 20 30	10 20 30 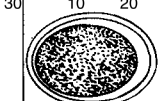	10 20 30 	10 20 30	10 20 30	10 20 30 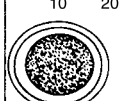	10 20 30 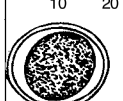	10 20 30 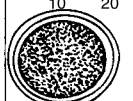	non available
	LENGTH×WIDTH μ LENGTH= WIDTH=	AV=18.3×14.6 17.7–20.2 13.7–16.3	24.6×18.8 20.7–30.3 18.1–24.2	30.5×20.7 21.5–42.5 16.5–29.8	15.6×14.2 11.7–18.7 11.0–18.0	15.6×13.4 11.1–19.9 10.5–16.2	20.4×17.2 13.2–22.7 11.3–18.3	21.3×17.1 19.8–24.7 15.7–19.8	22.0×19.0 19.5–26.0 16.5–22.8	19.1×17.6 15.8–20.9 14.3–19.5
	OOCYST SHAPE AND INDEX-LENGTH/WIDTH	ovoid 1.25	ovoid 1.31	ovoid 1.47	subspherical 1.09	ellipsoid to broadly ovoid 1.16	oblong ovoid 1.19	ovoidal 1.24	ovoid 1.16	broadly ovoid 1.08
	SCHIZONT, MAX IN MICRONS	10.3	30.0	9.4	15.1	17.3	65.9	20	54.0	
	PARASITE LOCATION IN TISSUE SECTIONS	epithelial	2nd generation schizonts subepithelial	gametocytes subepithelial	epithelial	epithelial	2nd generation schizonts subepithelial	epithelial	2nd generation schizonts subepithelial	epithelial
LIFE HISTORY CHARACTERISTICS	MINIMUM PREPATENT PERIOD-HR	97	120	121	93	93	138	83	115	99
	SPORULATION TIME MINIMUM (HR)	17	18	30	15	12	18	12	18	18

†= From Norton and Joyner (1980)
‡= As described by Edgar and Siebold (1964)
◉= Complied from various sources (1982)

Peter L. Long and W.Malcolm Reid
Department of Poultry Science
The University of Georgia, Athens

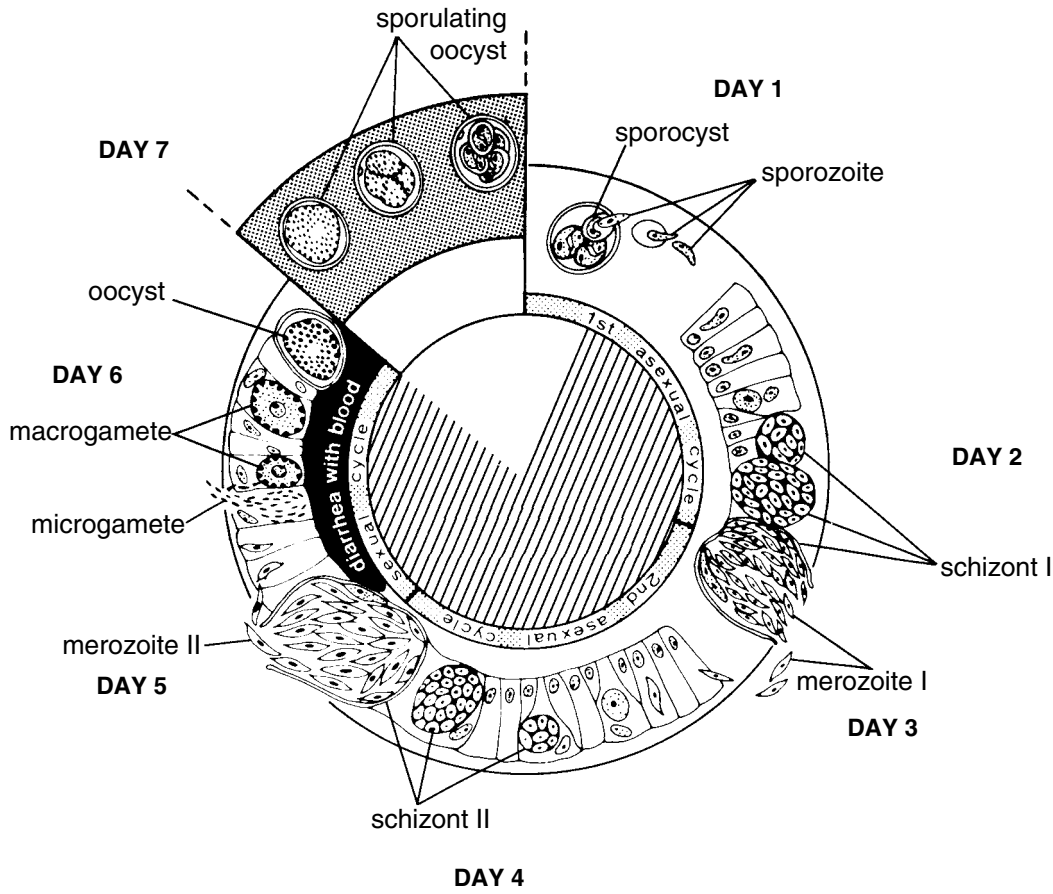

Figure 28.2. The 7-day life cycle of *E. tenella* includes 2 or more asexual cycles and 1 sexual cycle during the 6 days after an oocyst has been swallowed by the host. The new generation of oocysts becomes infective to the next host after sporulation.

Eimeria acervulina Tyzzer 1929

Eimeria acervulina Tyzzer 1929 is the most frequently encountered species in commercial poultry in North and South America (30, 31, 32) and is commonly reported on other continents. Oocysts are ovoid and often show thinning of the shell at the small end. The average size of oocysts is 18.3 × 14.6 μm, but the range is 17.7–20.2 × 13.7–16.3 μm.

Pathogenicity

Severity of infection may vary with the isolate, the number of oocysts ingested, and the immune state of the bird. Ingestion of 10^3, 10^4, 10^5, or 10^6 oocysts by young white rock chicks resulted in mild to severe coccidiosis, with lesion scores ranging from 1.1 (10^3 oocysts) to 4.0 (10^6 oocysts) (38). Reduction in rate of weight gain was also proportional to the infective dose. Watery and mucoid droppings may be seen as early as 4 days post exposure. Heavy infections often cause lesions to coalesce, and sometimes mortality may result. Light to moderate infections may produce little effect on weight gain and feed conversion but may cause loss of carotenoid and xanthophyll pigments from the blood and skin because of reduced absorption in the small intestine. The intestinal mucosa may be thickened, resulting in poor feed conversion (Figure 28.3B, C, D, and E). Egg production may be depressed in laying birds.

Gross White Plaques, Arranged Transversely

The intestine may be pale and contain watery and mucoid fluid. The gross lesion in light infections is limited to the duodenal loop, with only a few plaques/cm. In heavy infections, lesions may extend some distance through the small intestine, and plaques may overlap or coalesce. The plaques are generally smaller in heavy infections due to crowding. The lesions may be composed of schizonts, gametocytes, and developing oocysts. Microscopy of smears from intestinal lesions usually reveals numerous oocysts and gametocytes of varying stage of development.

Histopathology of the small intestine reveals the ovoid gametocytes in the mucosal cells lining the villi. In moderate to heavy infections, the tips of villi are broken off, leading to truncation and fusion of villi and thickening of the mucosa. Some epithelial cells may contain more than 1 parasite. Capillaries may be engorged with red blood cells and there is infiltration of granulocytes in the area parasitized. Schiff's reagent will stain the macrogametes and developing oocysts a brilliant red, because of the polysaccharide used in oocyst wall formation.

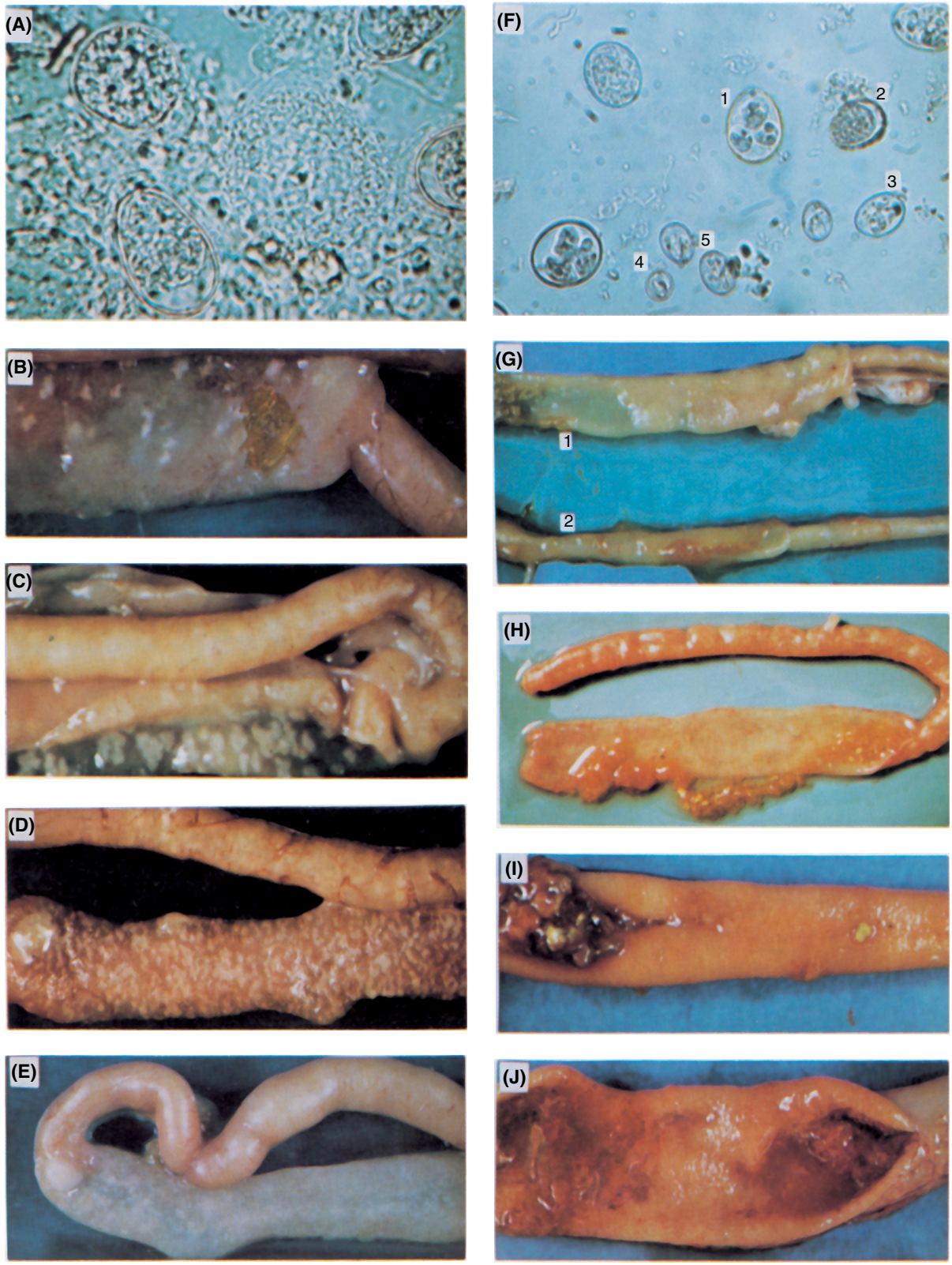

Figure 28.3. (A) Oocysts and a microgametocyte (center) of *Eimeria maxima* (Long, P.L., L.P. Joyner, B.J. Millard, and C.C. Norton. 1976. A guide to laboratory techniques used in the study and diagnosis of avian coccidiosis. *Folia Vet Lat*. 6(3):201-17). (B) *E. acervulina* (+2). (C) *E acervulina* (+2). (D) *E. acervulina* (+3). (E) *E. acervulina* (+4). (F) 1. Sporulated *E. maxima* with distinctive brownish walls; 2. unsporulated *E. maxima* showing roughened outer wall; 3. probably *E. tenella*; 4. end view, probably *E. mitis*; 5. side view, probably 2 *E. mitis*. (G) 1. Normal midgut; 2. *E. maxima* midgut (+1). (H) *E. maxima* midgut (+2 or +3) (Long et al., 1976). (I) *E. maxima* (+3). (J) *E. maxima* close-up view (+4).

Eimeria brunetti Levine 1942

About 10%–20% of field isolates in surveys in the United States and South America contained *E. brunetti* (25, 30, 31). The oocysts of *E. brunetti* average 24.6 × 18.8 μm and are easily confused with *E. tenella*. This species is found primarily in the lower small intestine, usually from the yolk sac diverticulum to near the cecal juncture. In severe cases, the lesion may extend from the gizzard to the cloaca and extend into the ceca (Figure 28.4E, F, G, and H). Most field infections are difficult to recognize based on gross lesions but can be confirmed by observation of typically sized oocysts by microscopy. The average oocyst size is 24.6 × 18.8 μm, with a range of 20.7–30.3 by 18.1–24.2 μm. Oocysts are ovoid, with a length/width index of 1.31.

Pathogenicity

Although less serious than *E. tenella* or *E. necatrix*, *E. brunetti* can produce moderate mortality, loss of weight gain, poor feed conversion, and other complications. Inoculation with $1–2 \times 10^5$ oocysts frequently will cause 10%–30% mortality and reduced gain in survivors. Light infections of *E. brunetti* are overlooked easily unless careful attention is paid to the lower small intestine. Such light infections can cause reduced weight gain and poor feed conversion, even though gross lesions are not clearly apparent.

Gross Lesions and Histopathology

At early stages of infection, the mucosa of the lower small intestine may be covered with tiny petechiae and have some thickening, loss of color, and watery contents. In heavy infections, the mucosa is badly damaged, with coagulation necrosis appearing on days 5–7 post infection (PI) and with a caseous eroded surface over the entire mucosa. Coagulated blood and mucosal casts are apparent in the droppings. Thickening of the mucosa and edematous swelling occurs in severe infections, especially on the sixth day PI.

The asexual stages of first- and second-generation schizogony generally occur in the upper small intestine. Histopathology on the fourth day of infection reveals schizonts, cellular infiltration, and some damage to the mucosa. By the fifth day, many of the tips of villi are broken off. Merozoites invade the epithelium and develop into sexual stages in the lower small intestine and ceca. In severe cases, the villi may be completely denuded, leaving only the basement membranes intact.

Eimeria hagani Levine 1938

The taxonomic status of *E. hagani* was considered by some to be in doubt because the original description was incomplete. However, a strain of *E. hagani* was studied in depth by Oluleye (36). The oocysts average 18.0 × 14.7 μm (sporulated 19.6 × 14.7 μm). Sporocysts are 11.3 × 6.9 mm, and sporozoites are 12.9 × 2.1 μm. The prepatent period is 98 hours. Sporulation requires 17–44 hours at 23.5°C. The gross lesions consist of petechiae and white opacities in the upper small intestine. There is not blood, although the mucosa can appear reddish. The intestinal contents may be creamy or watery. In histopathology, the parasites are seen in the tips of villi, some as far as two-thirds down the length. Maturation of first generation schizonts is 36–48 hours, second generation at 60 hours, and third generation by 96 hours. The schizonts average 14.4 × 13.2, 6.2 × 5.8, or 8.9 × 3.1 μm for first, second- or third-generation schizonts, respectively. Merozoites were 8.8 × 1.1 mm. Immunity is species specific, separating it from *E. acervulina, E. mitis, E. mivati*, and other species. This species is described as producing hemorrhagic spots, catarrhal inflammation, engorged capillary beds, and watery intestinal contents between 96 and 120 hours PI, and is moderately pathogenic.

Eimeria maxima Tyzzer 1929

The mid-small intestine is often parasitized with *E. maxima*, from below the duodenal loop past the yolk sac diverticulum, but in heavy infections, the lesions may extend throughout the small intestine. *E. maxima* is an easy species to recognize because of the characteristic large oocysts, 30.5 × 20.7 mm (21.5–42.5 × 16.5–29.8), which usually have a distinctive yellowish color (Figure 28.3A, F, G, H, I, and J). Oocysts have a shape index of 1.473. An abundance of yellow-orange mucus and fluid often is in the midgut. This species can be differentiated from *E. necatrix* by the lack of large schizonts associated with the lesions and from *E. brunetti* by the larger oocysts and the appearance and location of the lesions.

Pathogenicity

E maxima is moderately to highly pathogenic. Infection with $50–200 \times 10^3$ oocysts causes poor weight gain, morbidity, diarrhea, and sometimes mortality. Some isolates are capable of 30% mortality in 5-week-old chickens with 100,000 oocysts. There is often extreme emaciation, pallor, roughening of feathers, and anorexia. Producers interested in maintaining good skin color in chickens must be concerned with subclinical infections because of the effect of this species on absorption of xanthophyll and carotenoid pigments in the small intestine.

Gross Lesions and Histopathology

Minimal tissue damage occurs with the first 2 asexual cycles, which develop superficially in the epithelial cells of the mucosa. When the sexual stages develop in deeper tissues on days 5–8 PI, lesions develop because of congestion and edema, cellular infiltration, and thickening of the mucosa. Infected host cells become enlarged, pushing into the subepithelial zone. Microscopic hemorrhages occur near the tips of the villi, and foci of infection can be seen from the serosal surface. The intestine may be flaccid and filled with fluid, and the lumen often contains yellow or orange mucus and blood. This condition has been described as "ballooning." Microscopic pathology is characterized by edema and cellular infiltration, developing schizonts through day 4, and sexual stages (macrogametes and microgametes) in deeper tissues on days 5–8. In severe infections, considerable disruption of the mucosa occurs.

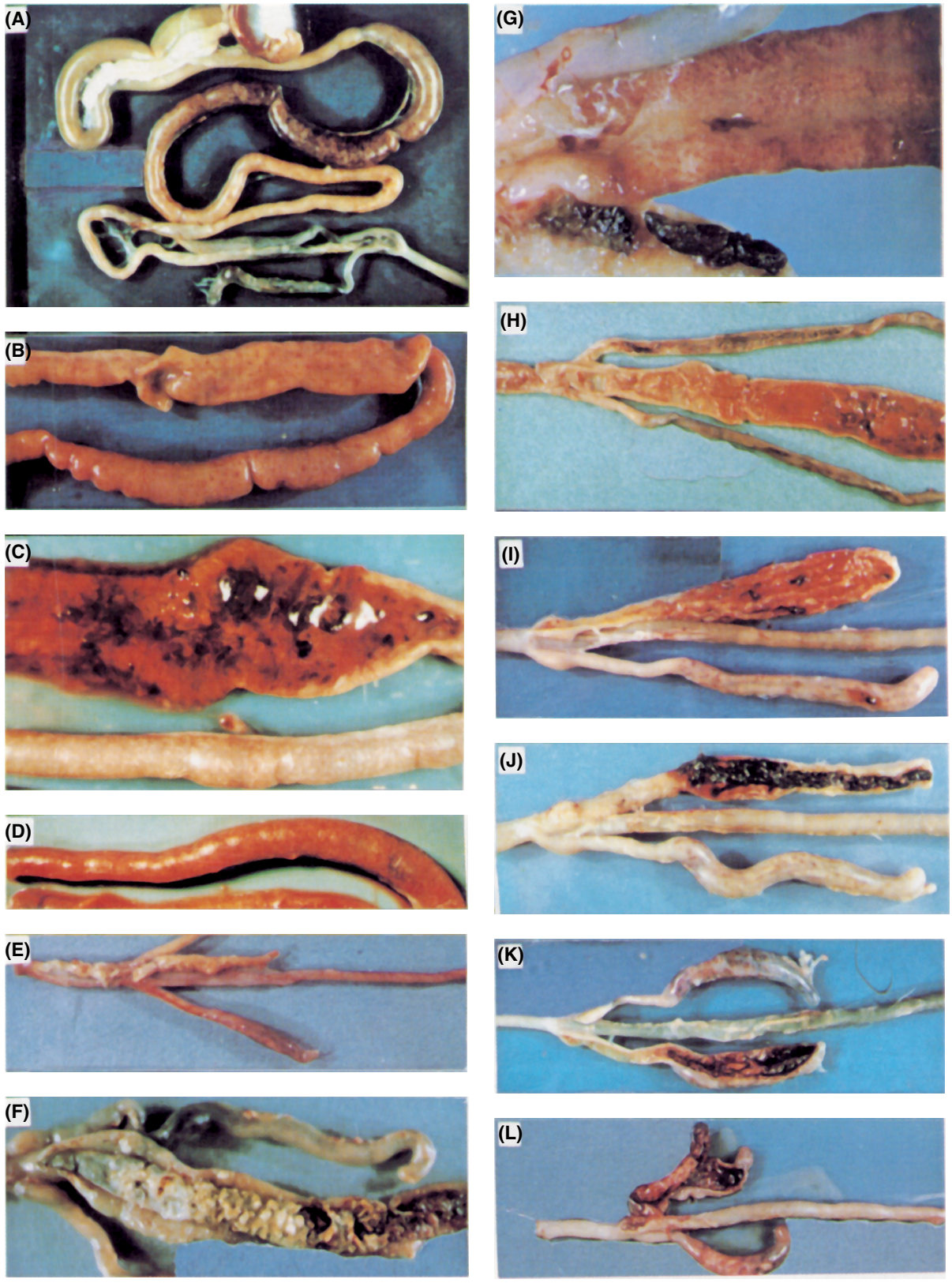

Figure 28.4. (A) *Eimeria necatrix* showing ballooning in midgut. (B) *E. necatrix* (+2). (C) *E. necatrix* (Long et al., 1976). (D) *E. necatrix* (4+). (E) *E. brunette* (+4). (F) *E. brunette* (+4). (G) *E. brunetti* (+3). (H) *E. brunette* (+4) (Long et al., 1976). (I) *E. tenella* (+2). (J) *E. tenella* (+3). (K) *E. tenella* (+4). (L) *E. tenella* (+4) with cecal core.

Eimeria mitis Tyzzer 1929

The lower small intestine is the normal site of this parasite, from the yolk sac diverticulum to the cecal necks. The lesions are normally indistinct with this species, but the potential for pathogenic effects on weight gain and morbidity is well documented (13). Oocysts average 16.2 × 16.0 (shape index 1.01), giving them a subspherical appearance.

Pathogenicity

Infection with 5×10^5–5×10^6 oocysts will weight gain and cause morbidity and loss of pigmentation in broiler chickens. In layers, this species may affect egg production and induce a molt. The lack of distinct gross lesions causes this species to be overlooked or misdiagnosed in subclinical infections.

Gross Lesions and Histopathology

Clinically, the gross lesion is very slight and can be easily overlooked. The lower small intestine appears pale and flaccid, and microscopic examination of smears from the mucosal surface may reveal numerous tiny oocysts (15.6 × 14.2 mm). The infection is distinguished easily from *E. brunetti* by the smaller, round oocysts. In light infections, the appearance of the gross lesion may be similar to *E. brunetti*. The gross lesions of this species are unremarkable because the developing parasites do not tend to localize in colonies as do other species, and the schizonts and gametocytes are superficial in the mucosa.

Eimeria mivati Edgar and Siebold 1964

Eimeria mivati Edgar and Siebold 1964 was first identified in 1959 as a small strain of *E. acervulina* and later named as a separate species (11). The zone of infection extends from the duodenal loop to the ceca and cloaca in heavy infections. Oocysts are broadly ovoid, averaging 15.6 × 13.4, and the shape index is 1.16.

There is considerable controversy regarding the validity of *E. mivati* as a species, dating from the work of Shirley with isoenzymes and later work with species-specific primers for PCR. However, recent evaluation of field samples have produced isolates that fit the morphologic description of Edgar and Seibold, and do not react with primers for other known species. Results using the ITS1 and ITS2 region primers indicate that these organisms are different from the other 7 known species for which specific primers have been developed. Further work is needed to settle the taxonomic status of this species.

Pathogenicity

Infection with 5×10^5–1×10^6 oocysts of *E. mivati* causes reduced weight gain and morbidity. Mortality as high as 40% has been seen in experimental infections (S. Fitz-Coy, personal observations).

Gross Lesions and Histopathology

Early lesions appear in the duodenum and later in the midgut and lower small intestine. In light infections, isolated lesions resemble those of *E. acervulina* but are more circular in shape. These lesions, representing colonies of gametocytes and developing oocysts, may be seen from the serosal surface of the gut. Gross lesions sometimes include red petechiae and round white spots for 72–240 hours PI. Histopathology reveals parasitism of the mucosal cells of the villi of the small intestine. In contrast to *E. acervulina*, this species may be found from the tip to the base of villi, sometimes causing severe denuding of the mucosa.

Eimeria necatrix Johnson 1930

Because of the spectacular lesions in the small intestine, this species was one of the best known by early poultry producers. The lesion is found in the small intestine in approximately the same location as *E. maxima* (Figure 28.4A, B, C, and D). Probably because of the low reproductive capability of *E. necatrix*, it is not able to compete with other coccidia and is diagnosed mostly in older birds such as brooder pullets or layer pullets 9–14 weeks old. The intestine often is dilated to twice its normal size (ballooning), and the lumen may be filled with blood and fluid laden with merozoites and clusters of large, mature schizonts. The oocysts are ovoid and average 20.4 × 17.2 mm, which is near in size to those of *E. tenella*. Curiously, the oocysts are found only in the ceca, rather than in the intestine, where lesions are found. The sexual stages (gametocytes) develop ceca, and are scattered rather than clustered. *E. necatrix* is a poor producer of oocysts.

Pathogenicity, Gross Lesions, and Histopathology

E. necatrix along with *E. tenella* are the most pathogenic of the chicken coccidia. Infection with 10^4–10^5 oocysts is sufficient to cause severe weight loss, morbidity, and mortality. Survivors may be emaciated, suffer secondary infections, and lose pigmentation. Droppings of infected birds often contain blood, fluid, and mucus. Naturally occurring infections have caused mortality in excess of 25% in commercial flocks. In experimental infections, 100% mortality is possible. Layer pullets suffering outbreaks at 7–20 weeks of age may suffer mortality, morbidity, loss of uniformity, and decreased egg-laying potential. Gross lesions may be seen as early as 2–3 days PI, associated with first-generation schizogony, but the severe lesions at 4–6 days PI are caused by second-generation schizogony. The intestine may be ballooned; the mucosa thickened; and the lumen filled with fluid, blood, and tissue debris. From the serosal surface, the foci of infection can be seen as small white plaques or red petechiae. In dead birds, these lesions appear white and black, giving rise to the expression "salt and pepper" appearance. Smears examined microscopically on days 4–5 PI may contain numerous clusters of large (66 mm) schizonts, each containing hundreds of merozoites. The clusters of schizonts deep in the mucosa often penetrate the submucosa and damage the layers of smooth muscle and destroy blood vessels. In these instances, the foci are large enough to be seen from the serosal surface. Later, scar tissue may be seen where epithelial regeneration is incomplete. Few pathogenic effects are seen with the invasion of the cecal mucosa by the third-generation schizonts and gametocytes because of the nonclustering nature of these stages. The third-generation schizonts produce only 6–16 merozoites.

Lesions may extend from the ventriculus-gizzard junction to the ileo-cecal junction in severe infections, causing dilation (ballooning) and thickening of the mucosa. The lumen may be filled with blood and pieces of mucosal tissue. Microscopic examination of smears from the mucosal surface reveals numerous clusters of large schizonts, which are characteristic for this species and distinguish it from others that overlap in habitat. Also, oocysts are never associated with lesions of this species.

Histopathology of midgut from affected birds reveals a submucosa and lamina propria crowded with large clusters of schizonts. Often, large areas of the mucosa are sloughed off, and the lesion may extend through the muscle layers to near the serosal membranes.

Eimeria praecox Johnson 1930

Eimeria praecox Johnson 1930 is named from the short prepatent period (about 83 hours); hence a "precocious" parasite. Even though *E. praecox* is often overlooked because no prominent lesions exist, it is easily detected by timed infections of experimental birds. The oocysts are recognized easily because they are generally larger than those of other species found in the duodenum. At 21.3 × 17.1 mm, they are larger than *E. acervulina, E. mivati*, and *E. mitis*, and smaller than *E. maxima*. The shape index is 1.25.

Pathogenicity, Gross Lesions, and Histopathology

Heavy infections cause reduced weight gain, loss of pigmentation, dehydration, and poor feed conversion. The gross lesions consist of watery intestinal contents and sometimes mucus and mucoid casts. Most of the infection is confined to the duodenal loop. Small pinpoint hemorrhages may be seen on the mucosal surface on days 4–5 of infection. Recent studies suggest that this species may cause morbidity and reduced weight gain (15). Severe infections may cause dehydration. The epithelial cells of the sides of the villi (but not the tips) are most often infected. There may be several parasites in each cell. Three to four asexual generations are normal, followed by gametogony. Infections with this species cause little tissue reaction.

Eimeria tenella (Railliet and Lucet 1891) Fantham 1909

E. tenella is the best known of poultry coccidia because of the easily recognizable lesions and often spectacular losses it causes in commercial broilers or layer pullets. This species inhabits the ceca (rarely adjacent intestinal tissues), causing a severe disease characterized by bleeding, high morbidity and mortality, lost weight gain, emaciation, loss of skin pigmentation, and other signs. Oocysts are ovoid, averaging 22 × 19 mm (shape index 1.16). Diagnosis is dependent upon finding cecal lesions with prominent blood and often firm bloody cores and accompanying clusters of large schizonts and oocysts (Figure 28.4I, J, K, and L).

Pathogenicity, Pathogenesis, and Epidemiology

Experimental inoculation with 10^4 or more sporulated oocysts can cause morbidity, mortality, and greatly reduced weight gain, making this one of the most pathogenic species in chickens. Inoculation with 10^3 oocysts is sufficient to cause bloody droppings and other signs of infection. The most pathogenic stage is the second-generation schizont, which matures at 4 days PI. Like *E. necatrix*, this species produces clusters of large schizonts, which may contain hundreds of merozoites. The schizonts develop deep in the lamina propria, so that the mucosa and associated blood vessels are disrupted when the schizonts mature and merozoites are released. Onset of mortality in a flock is rapid. Most of the mortality occurs between days 5 and 6 PI, and in acute infections, it may follow the first signs of infection by only a few hours. Blood loss may reduce the erythrocyte count and hematocrit value as much as 50%. The maximum effect on weight gain is seen at 7 days PI. Some of the weight lost from dehydration may be regained quickly, but growth will always lag behind that of uninfected birds. The exact cause of death is not known, but toxic factors are suspected. Blood loss alone does not account for mortality. In a few cases, death may result from gangrenous or ruptured cecal pouches. Extracts of infected cecal pouches produce acute blood coagulation and death when injected intravenously into other chicks. The possible role of bacterial products in mortality from coccidiosis is suggested by the lack of mortality from *E. tenella* in germ-free chicks.

Gross Lesions and Histopathology

Even during maturation of the first generation of schizonts, small foci of denuded epithelium may be seen. By day 4 PI, the second-generation schizonts are maturing, and hemorrhages are apparent. The cecal pouch may become greatly enlarged and distended with clotted blood and pieces of cecal mucosa in the lumen. On days 6 and 7, the cecal core becomes hardened and drier; eventually it is passed in the feces. Regeneration of the epithelium is rapid and may be complete by day 10. The infection usually can be seen from the serosal surface of the ceca as dark petechiae and foci, which become coalesced in severe infections. The cecal wall is often greatly thickened because of edema and infiltration and later scar tissue.

Microscopically, the first-generation schizonts are widely scattered and mature at 2–3 days PI. Small focal areas of hemorrhage and necrosis may appear near blood vessels of the inner circular muscles of the muscularis layer. Heterophil infiltration of the submucosa proceeds rapidly as the large second-generation schizonts develop in the lamina propria. These are found in clusters or colonies that generally are progeny of a single first-generation schizont. Maturation of the second-generation schizonts is accompanied by excessive tissue damage, bleeding, disruption of the cecal glands, and destruction of the mucosa and muscularis layer. Microgametes and macrogametes are seen in the tissues on days 6 and 7, and mature oocysts are released into the lumen in large numbers. Regeneration of the epithelium and glands may be complete by day 10 in light infections, but the epithelium may never completely recover in severe infections. Lost muscularis mucosa is not replaced, and the submucosa becomes densely fibrosed.

Epidemiology of Coccidiosis

Natural and Experimental Hosts

The chicken is the only natural host of these 8 species of *Eimeria* (*E. acervulina, E. brunetti, E. maxima, E. mitis, E. mivati, E. necatrix, E. praecox, E. tenella*) (Table 28.1). Reports of these species of *Eimeria* infecting other birds can be considered spurious. Cross-transmission of *Eimeria* spp. from chickens to other host species has been unsuccessful except for a few instances in which severely immunocompromised birds were used.

Naïve chickens of all ages and breeds are susceptible to infection. However, immunity develops after mild infections, limiting further infection. Newly hatched chicks often have high levels of maternal antibodies but it does not appear that this limits susceptibility. Outbreaks are common at 3–6 weeks of age and are seldom seen in poultry flocks at less than 3 weeks. In special situations, infections may be seen as early as 1 week of age. Data from routine necropsy of chickens over several years in the United States (personal observations of S. Fitz-Coy, based on gross and microscopic evidence) showed that the prominent species were *E. acervulina* (97%), *E. maxima* (64%), and *E. tenella* (64%). Less common species were *E. mivati, E. brunetti, E. mitis*, and *E. praecox*. Surveys of coccidia in broiler houses in Georgia demonstrated that oocysts of coccidia build up during the growth of a flock and then decline as the birds become immune to further infection (39). This self-limiting nature of coccidial infections is widely known in chickens and other poultry. There is no stimulation of cross-protective immunity between species of coccidia. Thus, several outbreaks of coccidiosis are possible in the same flock, with different species involved in each. Breeder pullets and layer pullets are at greatest risk because they are kept on litter for 20 weeks or more. Normally, the infections with *E. acervulina, E. tenella, E. mitis, E. mivati, E. praecox*, and *E. maxima* are seen at 3–6 weeks of age and then *E. necatrix* at 8–18 weeks of age. *E. brunetti* is seen both early and late.

Coccidiosis rarely occurs in layers and breeders during the laying cycle because of prior exposure to coccidia and resulting immunity. If a flock is not exposed to a particular species early in life or if immunity is depressed because of other diseases, outbreaks may occur after layers are moved to production houses. Outbreaks of any species in layers can reduce or eliminate egg production for several weeks.

Transmission and Vectors

Ingestion of viable sporulated oocysts is the only natural method of transmission. Infected chickens may shed oocysts in the feces for several days or weeks. The oocysts in feces become infective through the process of sporulation in about 2 days. Susceptible birds in the same flock may ingest the oocysts through litter-pecking or the contamination of food or water.

Although no natural intermediate hosts exist for the *Eimeria* spp., oocysts can be spread mechanically by many different animals, insects, contaminated equipment, wild birds, and dust. Oocysts generally are considered resistant to environmental extremes and to disinfectants, although survival time varies with conditions. Oocysts may survive for many weeks in soil, but survival in poultry litter is limited to a few days because of the heat and ammonia released by composting and the action of molds and bacteria. Viable oocysts have been reported from the dust inside and outside broiler houses, as well as from insects in poultry litter (39). The darkling beetle, common in broiler litter, is a mechanical carrier of oocysts. Transmission from 1 farm to another is facilitated by movement of personnel and equipment between farms and by the migration of wild birds, which may mechanically spread the oocysts. New farms may remain free of coccidia for most of the first growout of chickens until the introduction of coccidia to a completely susceptible flock. Such outbreaks, often more severe than those experienced on older farms, are often called "the new-house syndrome."

Oocysts may survive for many weeks under optimal conditions but will be quickly killed by exposure to extreme temperatures or drying. Exposure to 55°C or freezing kills oocysts very quickly. Even 37°C kills oocysts when continued for 2–3 days. Sporozoites and sporocysts can be frozen in liquid nitrogen with appropriate cryopreservation technique, but oocysts cannot be adequately infiltrated with cryoprotectants to effect survival. The threat of coccidiosis is less during hot, dry weather and greater in cooler, damp weather.

Diagnosis of Coccidiosis

Coccidiosis can best be diagnosed from birds killed for immediate necropsy. Attempts to identify characteristic lesions in birds that have been dead for 1 hour or longer are frustrated by the postmortem changes in the intestinal mucosa. The entire intestinal tract should be examined. A microscope should be available for viewing endogenous forms on questionable lesions. The finding of a few oocysts by microscopic examination of smears from the intestine indicates the presence of infection, but not a diagnosis of clinical coccidiosis. Coccidia and mild lesions are present in the intestines of birds 3–6 weeks old in most flocks. Coccidiosis should be diagnosed if the gross lesions are serious or if other economic parameters are threatened. Diagnosis should be based on finding lesions and confirming microscopic stages on necropsy of typical birds from the flock, rather than from culls. Cryptosporidia may be found in chickens or turkeys but are distinguished easily from Eimeria by their small size and location in the brush border of the mucosal cells (14, 19).

Microscopic Examination

Developing schizonts, gametocytes, and oocysts of coccidia may be seen in smears taken from the suspected lesion. A small amount of mucosal scraping should be diluted with saline on a slide and then covered with a coverslip. Oocysts or macrogametes are most easily seen, but in many cases, the lesion is caused by maturing schizonts. Diagnostic characteristics that are of value include the clusters of the large schizonts of *E. necatrix* and *E. tenella*, the small round oocysts of *E. mitis*, or the large gametocytes of *E. maxima*. Presence of

clusters of large schizonts in the midgut area is pathognomonic for *E. necatrix*, and a similar finding in the ceca indicates *E. tenella*. Oocysts associated with lesions in the duodenum are *E. acervulina, E. mivati*, or *E. praecox*, and oocysts associated with lesions in the lower gut are *E. mitis, E. mivati*, or *E. brunetti*.

Oocyst size and shape are less useful as diagnostic characteristics in chickens than once thought, because of the extensive overlapping in size of the species. However, the combination of oocyst size, location in the gut, and appearance of the lesions gives considerable confidence in diagnosis. Measurement of 20–30 oocysts of the predominant type of oocyst usually gives a good indication of the size of the unknown species. This information is useful in conjunction with other observations in the identification of species in field cases.

Lesion Scoring

The severity of lesions is roughly proportional to the number of oocysts ingested by the bird and correlates with other parameters such as reduced weight gain, loss of skin pigmentation, and diarrhea. The most commonly used practice is based on the system devised by Johnson and Reid (22). In this technique, a score of 0–4 is assigned to a bird, where 0=normal and 4=the most severe case. This technique is most useful in experimental infections, where the dose of oocysts and medicaments are controlled, and the species are known. In the field, lesion scoring is generally useful in gauging the severity of infections but may not correlate with microscopic scoring. Even though several species of coccidia may be present at some time, only 4 separate sections of the intestine are usually scored: (1) the duodenum (upper), with lesions of *E. acervulina and E. mivati*; (2) the midgut from the duodenum past the yolk sac diverticulum, with lesions of *E. maxima, E. praecox, E. necatrix*, and *E. mitis*; (3) the lower small intestine from the yolk sac diverticulum to the cecal junctures, with lesions of *E. mitis, E. necatrix, E. maxima*, and *E. brunetti*; and (4) the ceca, where only *E. tenella* is found.

Microscopic Scoring

As with lesion scores, the severity of coccidiosis can be judged by the number and appearance of parasite forms seen upon microscopic examination of smears from the mucosa, lumen, or feces. Microscopic scoring is particularly useful for detecting and rating species that do not produce easily seen gross lesions, such as *E. mitis, E. hagani*, and *E. praecox*.

Droppings Score

In laboratory infections, the droppings score may be used in the same manner as lesion score for a rapid and fairly reliable rating of the infection (31). The extent of abnormal droppings is rated on a scale of 0–4, where 4=maximum diarrhea, with mucus, fluid, and/or blood. This technique has obvious complications where birds are infected with more than 1 species of *Eimeria*.

Histopathology Methods

Ordinary methods in histopathology are satisfactory for routine examination of tissues infected with coccidia. Staining of sections with H&E or other common histologic stains will demonstrate developing stages. Specialized techniques will identify specific stages: Staining with Schiff's reagent gives a brilliant red color with the polysaccharide associated with the refractile body and with wall-forming bodies in the macrogamete. Monoclonal antibodies conjugated with fluorescent markers such as fluorescein are very useful in research because specific stages of parts of cells can be readily identified.

Procedures Used in Species Identification

Most of the species of coccidia are easily identified by attention to well-established biological characteristics (Table 28.1, 28.3) (25, 30, 32, 43). The largest oocysts belong to E. maxima, making it easily distinguished from other species. Some species are identified easily by the location and appearance of gross lesions in concert with the size of oocysts or schizonts (*E. acervulina, E. maxima, E. necatrix*, and *E. tenella*). The lesions produced by other species are not reliably distinct, and oocyst sizes overlap with those of other species. For *E. praecox*, the best method is determination of prepatent period by timed inoculation of birds in laboratory cages. Oocysts produced in less than 90 hours can only be *E. praecox. E. brunetti* oocysts are indistinguishable from those of *E. praecox, E. tenella*, and *E. necatrix* on size alone, but the location in the lower gut and appearance of the lesions are reliable indicators. *E. mitis* is located in the mid-lower gut, has small subspherical oocysts, and has a prepatent period of 99 hours, separating it from *E. brunetti*.

Because of the overlapping size, area parasitized, and lack of distinct lesions, it has been difficult to separate *E. hagani* from other species of the duodenum with small oocysts. In this case, immunization tests were very useful (36). Poultry develop immunity to reinfection after inoculation with *Eimeria*, but there is no cross protection between species. This strict specificity of immunity has been exploited as a technique for distinguishing species of coccidia for taxonomic purposes. This test requires pure cultures of the test species and test animals reared in isolation for mono-immunization and challenge. When *E. hagani* oocysts were used to immunize chickens, the resulting immunity protected against reinfection by the same culture but not against other species. Conversely, birds immunized with other species were not protected against infection with the culture of *E. hagani*. Overall, the technique is time consuming and requires extensive laboratory isolation facilities and access to pure cultures of known species of coccidia, but may be useful as a research tool when used in concert with other tests or observations.

Preservation of Coccidia for Experimental Work

Droppings or litter collected in the field, or intestinal contents in the diagnostic lab, can be saved for isolation of coccidia in a solution of 2%–4% potassium dichromate. Aeration of oocyst suspensions is necessary to allow sporulation. A

Table 28.2. Preventive anticoccidials approved by FDA for use in feed formulation. (Historical and scientific interest only. Not all products are available.) (9)

Trade or Empirical Name, Approval Label (Manufacturer)	Trade Name	First Approval by FDA	Drug Withdrawal (Days before Slaughter)
Sulfaquinoxaline, 0.015–0.025% (Merck)	SQ, Sulquin	1948	10
Nitrofurazone, 0.0055% (Hess & Clark; Smith-Kline)	nfz, Amifur	1948	5
Arsanilic acid or sodium arsanilate, 0.04% for 8 days (Abbott)	Pro-Gen	1949	5
Butynorate, 0.0375% for turkeys (Solvay)	Tinostat	1954	28
Nicarbazin, 0.0125% (Merck)	Nicarb	1955	4
Furazolidone, 0.0055–0.011% (Hess & Clark)	nf-180	1957	5
Nitromide, 0.025% + sulfanitran, 0.03% + roxarasone, 0.005% (Solvay)	Unistat-3	1958	5
Oxytetracycline, 0.022% (Pfizer)	Terramycin	1959	3
Amprolium, 0.0125–0.025% (MSD-AGVET)	Amprol	1960	0
Chlortetracycline, 0.022%	(American Aureomycin Cyanamid)	1960	(See feeding restrictions)
Zoalene, 0.004–0.0125% (Solvay)	Zoamix	1960	(higher levels, 5 days)
Amprolium, 0.0125% + ethopabate, 0.0004/0.004% (Merck)	Amprol Plus, Amprol Hi-E	1963	0
Buquinolate, 0.00825% (Norwich-Eaton)	Bonaid	1967	0
Clopidol or meticlorpindol, 0.0125–0.025% (A. L. Laboratories)	Coyden	1968	0 days at 0.0125%; 5 days at 0.025%
Decoquinate 0.003% (Rhone-Poulenc)	Deccox	1970	0
Sulfadimethoxine, 0.0125% + ormetoprim, 0.0075% (Hoffmann-La Roche)	Rofenaid	1970	5
Monensin, 0.01–0.0121 % (Elanco)	Coban	1971	0
Robenidine, 0.0033% (American Cyanamid)	Robenz, Cycostat	1972	5
Lasalocid, 0.0075–0.0125% (Hoffmann-La Roche)	Avatec	1976	3
Salinomycin, 0.004–0.0066% (Agri-Bio)	Bio-Cox	1983	0
Halofuginone, 3 ppm (Hoechst-Roussell Agri-Vet)	Stenorol	1987	5
Narasin, 54–72g/T (Elanco)	Monteban	1988	0
Madurimicin, 5–6 ppm (American Cyanamid)	Cygro	1989	5
Narasin + nicarbazin,54–90 g/T (Elanco)	Maxiban	1989	5
Semduramycin, 25ppm (Pfizer)	Aviax	1995	0
Diclazuril, 1 ppm (Schering-Plough)	Clinicox	1999	0

good-quality aquarium pump is highly effective and can be regulated with valves and tubes to service several bottles at one time. For short-term storage, suspensions of oocysts may be refrigerated at temperatures above 4°C. Freezing temperatures quickly kill coccidial oocysts, as do elevated temperatures. Oocysts are quickly killed by storage at 37°C or higher.

Prevention and Control

Control of Coccidiosis by Chemotherapy

Early emphasis in chemotherapy was centered on the treatment of outbreaks with sulfonamides or other compounds as soon as signs of infection were apparent. The concept of preventive medication emerged with the realization that most of the damage is done by the time signs of coccidiosis are widespread in a flock. Today, almost all broiler flocks receive preventive medication (Table 28.2). Treatment is used as a last resort or when other programs have failed. The historical aspects of chemotherapy have been reviewed extensively by McDougald (27). Consult a current Feed Additives Compendium for up-to-date information on approved products (12).

Characteristics of Anticoccidial Drugs

All types of drugs used for coccidiosis control are unique in the mode of action, the way in which parasites are killed or arrested, and the effects of the drug on the growth and performance of the bird. Following are the most important characteristics.

Spectrum of Activity. There are several important species of coccidia in chickens, several more in turkeys, and many others in other hosts. A drug may be efficacious against 1 or several of these parasites; very few drugs are equally efficacious against all.

Mode of Action. Each class of chemical compound is unique in the type of action exerted on the parasite, and even in the developmental stage of the parasite most affected. The chemical mode of action of some drugs is known to be a highly detailed event, and the action of other drugs remains a mystery. The sulfonamides and related drugs compete for the incorporation of para-aminobenzoic acid and metabolism of folic acid. Amprolium competes for absorption of thiamine by the

parasite. The quinoline coccidiostats and clopidol inhibit energy metabolism in the cytochrome system of the coccidia. The polyether ionophores upset the osmotic balance of the protozoan cell by altering the permeability of cell membranes for alkaline metal cations.

Endogenous Stage Affected. The coccidia are prone to attack by drugs at various stages in the development in the host. Totally unrelated drugs may attack the same stage of parasite. The quinolones and ionophores arrest or kill the sporozoite or early trophozoite. Nicarbazin, robenidine, and zoalene destroy the first- or second-generation schizonts, and the sulfonamides act on the developing schizonts and on the sexual stages. Diclazuril acts in early schizogony with *E. tenella* but is delayed to later schizogony with *E. acervulina* and to the maturing macrogamete with *E. maxima*. The time of action in the life cycle has been construed as having significance in the use of drugs in certain types of programs in which immunity is desired, but there is no good evidence that this is true under practical conditions.

Coccidiocidal vs. Coccidiostatic Medications.. Some drugs kill the parasite, but others only arrest development. When coccidiostatic medication is withdrawn, arrested parasites may continue to develop and contaminate the environment with oocysts. In such cases, a relapse of coccidiosis is possible. In general, the coccidiocidal drugs have been more effective than those that are coccidiostatic.

Effects of Drugs on the Target Animal. Most compounds used in animal feeds have good selective toxicity, providing toxicity for the parasite but being nontoxic to vertebrates. Unfortunately, toxicity and side effects of drugs on the host are possible where formulation errors lead to overdose. Sometimes, a drug may exhibit side effects at the recommended use level. Some of the toxicity may be the result of management, genetics, nutrition, or other interaction, and in other cases, the margin of safety is just too narrow. Environmental interaction is possible with nicarbazin, which interacts with high temperatures and high humidity to produce excess mortality. Nicarbazin also is highly toxic to layers, causing a bleaching of brown-shelled eggs, mottling of yolks, reduced hatchability, and reduced production. The ionophores are highly toxic at elevated doses, causing a transient paralysis in mild overdoses or a permanent paralysis and mortality in more severe cases. Monensin was once thought to interact with methionine to reduce feather growth, but this relationship is not clear. Under some conditions, lasalocid will stimulate water consumption and excretion, resulting in a wet litter. With slight overdoses, most of the ionophores depress weight gain under laboratory conditions. A withdrawal period of 5–7 days is often practiced to allow compensatory growth to make up for the lost gain. The ionophores are known for their toxicity to other animals. For example, monensin and salinomycin are highly toxic to horses. The lethal dose—50% (LD_{50}) for monensin in horses—is about 2 mg/kg body weight. Salinomycin is highly toxic to turkeys at levels greater than 15 g/ton and causes excessive mortality at the level recommended for use in chickens (60 g/ton), while monensin and lasalocid are well tolerated in turkeys at the level used for chickens.

Programs for Use of Anticoccidial Drugs in Broilers

In broilers, the objective is usually to produce the maximum growth and feed efficiency with minimum of disease, and in layers or breeders, the objective may be immunization. The choice of a product or program may depend on the season of the year or other factors which affect exposure. The following several types of programs are practiced.

Continuous Use of a Single Drug. Often, a single product will be used from day 1 to slaughter, or with a withdrawal period of 3–7 days. Most products are approved for use until slaughter, but producers withdraw medication for economic or other reasons.

Shuttle or Dual Programs. The use of 1 product in the starter feed and another in the grower feed is called a shuttle program in the United States and a dual program in other countries. Some programs might contain as many as 3 drugs, with 1 drug in the starter, another in grower, and yet another in the finisher. The shuttle program usually is intended to improve coccidiosis control. Intensive use of the polyether ionophore drugs for many years produced strains of coccidia in the field that have reduced sensitivity to the ionophores. It is a common practice to use another drug such as nicarbazin, diclazuril, or clopidol in either the starter or grower feed to bolster the anticoccidial control and take some pressure off of the ionophore. In other cases, the order of these drugs is reversed. The use of shuttle programs is thought to reduce buildup of drug resistance. Historically, a high percentage of producers use some type of shuttle program.

Rotation of Products. It is considered sound management to make periodic changes in anticoccidial drug use. Most producers in the United States consider changes in the spring and fall. Rotation of drugs may improve productivity because of the build-up of isolates or species of coccidia that have reduced sensitivity after products have been used for a long time. Producers often notice a boost in productivity for a few months after a change of anticoccidial drugs. The seasonal rotation of products is intended to correspond with the intrinsic properties of the drugs. In the United States, nicarbazin must be used principally in the cooler months of the year, which also corresponds with maximum coccidiosis challenge. In the summer months, coccidiosis challenge tends to be milder, so weaker anticoccidials are used.

Drug Resistance

The development of tolerance to drugs by coccidia after exposure to medication is the most serious limitation to the effectiveness of these products. Surveys reveal widespread

drug resistance in coccidia in the United States, South America, and Europe (16, 20, 23, 25, 31, 32). Even though coccidia develop less resistance to some drugs than others, long-term exposure to any drug will produce a loss in sensitivity and, eventually, resistance. Drug resistance is a genetic phenomenon, and when established in a line of coccidia, will remain for many years or until selection pressure and genetic drift force return to sensitivity in the population. Drugs such as the quinolones and clopidol have a well-defined mode of action, and resistance develops quickly as coccidia are selected with cytochromes, which do not bind as readily to the drug. The polyether ionophores, in contrast, have a more complicated mode of action involving the mechanisms of active transport of alkaline metal cations across cell membranes, and it has taken many years for coccidia to become tolerant, and in some cases, completely resistant. Many other drugs appear to be intermediate in selecting resistance in coccidia. The primary defense against drug resistance is the use of less intensive programs, shuttle programs, and frequent rotation of drugs. Rotation of programs, used alone, will not prevent the development of resistance. In some instances coccidia are able to become resistant to drugs after only a few months of use, and once developed, drug resistance is slow to dissipate. In recent years it has become a common practice to incorporate live coccidiosis vaccines in the rotation program, reasoning that the drug-sensitive vaccine strains tend to replace the drug resistant wild types. This approach has had demonstrable effects on the drug sensitivity profile on farms where it has been practiced.

Anticoccidial Drugs Used for Broilers in the United States

The products currently approved for use in chickens in the United States are listed in Table 28.2. Not all are still available commercially, but the approvals remain. Those used at present include monensin, narasin, salinomycin, semduramicin, lasalocid (polyether ionophores), diclazuril, nicarbazin, amprolium/ethopabate, decoquinate, clopidol, sulfadimethoxine/ormetoprim, and sulfaquinoxaline. A product combining narasin with nicarbazin is also used to take advantage of synergism between these molecules. Other products listed with approvals but lacking in significant activity include chlortetracycline and oxytetracycline. These products may prevent mortality from coccidiosis when given at high levels because of antibacterial activity but are not of much value in general use. The polyether ionophores became the drugs of choice for prevention of coccidiosis in 1972 and remain the most extensively used today. Other drugs, such as clopidol, diclazuril, halofuginone, nicarbazin, and robenidine, are used mostly in shuttle programs as an adjunct to the ionophores.

Immunization During Medication Programs in Broilers

Chickens develop immunity to coccidiosis after natural exposure and may even develop substantial immunity while receiving anticoccidial drugs (7, 18). The poultry industry has learned to take advantage of this phenomenon, practicing longer withdrawal programs of 2–3 weeks in some instances.

Coccidiosis Vaccines

Considerable research on coccidiosis vaccines in recent years has produced new live products. Increasingly, these products are finding use in the broiler industry. When live oocysts of coccidia are given to chickens at an early age, protection against the species contained in the inoculum is stimulated. The virulence of coccidia in these vaccines is attenuated largely by the size of the dose and by the means of administration. Some vaccines sold internationally or under development in the United States contain modified live coccidia with attenuation by genetic selection for short life cycle development. The use of coccidiosis vaccines in broilers has been limited by the possibility of adverse reactions, particularly a negative effect on feed efficiency. More recent advances in administration methods have overcome much of this limitation. The Coccivac products pioneered in this growing family now includes several other live vaccines in various countries (Coccivac, Immucox, Paracox, Livacox, BioVet, Advent, Nobilis, In-OvoCox, and others). Some new live vaccines have been prepared from attenuated lines of oocysts (e.g., Paracox7 and Livacox7). These vaccines normally contain 3 or more species of Eimeria, which are thought to be the most important. The Eimeria infecting poultry immunize only against themselves, so that the vaccine will only protect against the included species. As is well known, several species not normally included in the vaccines are capable of causing depressed gain, poor feed conversion, and loss of skin color, and are sometimes the cause of apparent vaccine failure. The success of some vaccines may depend more on a novel administration technique rather than attenuation. One experimental product was encapsulated in alginate beads and then mixed into the starter feed for "trickle administration." Other methods presently used are spray cabinet administration, direct eye-spray, *in ovo* inoculation, or spraying the oocysts directly into feed or water in the poultry house. One product is mixed into gels, which are placed into the chick boxes for the chicks to eat (8). Other experimental approaches include inoculation of parasites or antigens *in ovo* and inoculation via the yolk sac diverticulum.

Monoclonal antibody technology has led to the identification of coccidial proteins, which offer some protection from infection when inoculated into young chicks. These proteins can be made in quantity if the gene that encodes the protein is cloned into a bacterial cell. Research is making progress in identifying broad-spectrum antigens and appropriate routes of administration. One product based on this approach is CoxAbic, which is composed of an antigen developed from a monoclonal protein produced in the gametocyte of *E. maxima*. CoxAbic is given to hens in 2 doses to confer maternal protection during the first 3 weeks of brooding.

Table 28.3. Diagnostic characteristics of *Eimeria* in turkeys.

SPECIES → CHARACTERISTICS ↓	*E. adenoeides*	*E. dispersa*	*E. gallopavonis*	*E. innocua*	*E. meleagridis*	*E. meleagrimitis*	*E. subrotunda*
Lesions *Occasional lesions* *Parasites no lesions* *Species distinctive*							
Macroscopic lesions	*liquid feces with mucus and flecks of blood,* **loose whitish cecal cores**	*cream–colored serosal surface, dilation of intestine, yellowish mucoid feces*	*edema, ulceration of mucosal ileum, yellow exudate, flecks of blood in feces*	*none*	*cream–colored ceca, formation of caseous plug, a few petechial hemorrhages*	*spotty congestion and petechiae from duodenum to ileum, dilation of jejunum, casts*	*none*
Length× Width (in μm) *Length=* *Width=*	*AV=25.6× 16.6* *18.9–31.3* *12.6–20.9*	*AV=26.1×21.0* *21.8–31.1* *17.7–23.9*	*AV=27.1×17.2* *22.7–32.7* *15.2–19.4*	*AV=22.4×20.9* *18.57–25.86* *17.34–24.54*	*AV=24.4× 18.1* *20.3–30.8* *15.4–20.6*	**AV=19.2×16.3** **15.8–26.9** **13.1–21.9**	*AV=21.8× 19.8* *16.48–26.42* *14.21–24.44*
Oocyst shape and index length/ width	*ellipsoidal* **1.54**	*broadly oval* **1.24**	*ellipsoidal* **1.52**	*subspherical* **1.07**	*ellipsoidal* **1.34**	*ovoid* **1.17**	*subspherical* **1.10**
Minimum sporulation	*24 hr*	*35 hr*	**15 hr**	**under 45 hr**	*24 hr*	**18 hr**	**48 hr**
Prepatent period (minumum)	*103 hr*	**120 hr**	**105 hr**	**114 hr**	*110 hr*	*103 hr*	**95 hr**
Refractile body	*yes*	*no*	*yes*	*no*	*yes*	*yes*	*no*
Pathogenicity	**++++**	+	**++++**	*none*	**none**	**++++**	*none*

Control Programs Used in Breeders and Layers

Pullets started on the floor and later reared as caged layers are not as dependent on immunity to coccidiosis as are floor layers. They are often protected against coccidiosis with preventive medication, as are broilers, until they are moved to cages. Breeder pullets that will be kept on the floor during lay should have immunity to coccidiosis. Controlled exposure vaccination can be given by means of commercially produced live products (described above). Natural or accidental exposure assumes the presence of oocysts of important species. A broad-spectrum anticoccidial drug is sometimes given at the lowest approved level to provide protection for 6–12 weeks. Some producers reduce the level of the drug during the final 4 weeks in a step-down program, although as mentioned previously, chickens tend to develop immunizing infections despite the presence of the drug. This approach allows moderate numbers of coccidia to develop in the birds, stimulating the host immune system to protect against serious outbreaks. Such exposure usually is sufficient to protect against all species, because not all species are present throughout the growing period. Outbreaks of *E. necatrix* have sometimes occurred at 8–16 weeks, after all medication has been stopped. Climatic and seasonal conditions may add to the inherent uncertainties of this method.

Disinfection and Sanitation

Older recommendations for coccidiosis control often suggest directions for sanitation and disinfection to prevent outbreaks. Most of these are no longer considered valid because (1) there have been too many failures in such programs, (2) oocysts are extremely resistant to common disinfectants, (3) complete house sterilization is never complete, and (4) an oocyst-sterile environment for floor-maintained birds could prevent early establishment of immunity and allow late outbreaks. In addition to disinfectants normally used in poultry houses, specific products have been used to target the oocyst for destruction. A product available in some countries contains an ammonium salt and sodium hydroxide (OO-cide).

Chickens reared in cages rarely suffer outbreaks of coccidiosis. The exceptions are usually in single rows of cages in which there has been accidental fecal contamination of feed or water.

Coccidiosis in Turkeys

Coccidiosis in turkeys is common but is often unrecognized because the lesions in turkeys are less spectacular than those in chickens. Several species infect turkeys, but only about 4 are economically important. Typical signs of coccidiosis in turkeys are watery or mucoid diarrhea, blood-streaked feces, ruffled feathers, anorexia, and general signs of illness. Recovery is quick, so lesions could go undetected at necropsy. Several species have been found in commercial turkey farms throughout the United States (8). Coccidia infecting domestic turkeys also infect wild turkeys. The common species of *Eimeria* found in commercial turkey operations are *E. meleagrimitis, E. adenoeides, E. meleagridis*, and *E. dispersa*. *E. gallopavonis* is seen in a low percentage of flocks. Range-rearing of turkeys can add significantly to the exposure of wildlife to coccidiosis and other diseases.

Turkeys of all ages are susceptible to primary infection, but birds older than 6–8 weeks are considered more resistant to the disease. They can suffer weight loss and morbidity but are not killed as easily as are younger birds. Reductions in the rate of weight gain are often unrecognized until adequate coccidiosis control measures have been instituted.

Etiology

Seven species of *Eimeria* have been described in turkeys in the United States. Identifying characteristics of each species are listed in Table 28.3. *E. innocua* and *E. subrotunda* have been so rarely recovered that further work will be required to re-establish the validity of these species.

Besides the *Eimeria*, species reported from the turkey include *Isospora* and *Cryptosporidium* (see the next section). The *Eimeria* spp. are strictly intestinal, contrasting with *Cryptosporidium*, which may cause both respiratory and intestinal infection (17). The most pathogenic species of *Eimeria* are *E. adenoeides, E. meleagrimitis, E. gallopavonis*, and *E. dispersa*. Differentiation of oocysts of the pathogenic species from those of milder species is difficult because some of the species are poorly described. For instance, differentiation of *E. adenoeides* and *E. meleagridis* is difficult because they inhabit the ceca and have oocysts that are fairly similar.

Eimeria adenoeides Moore and Brown 1951

Gross lesions appear primarily in the ceca but extend to the lower small intestine and cloaca. Cecal contents are often hardened into a core consisting of mucosal debris. The cecal and/or intestinal wall is often swollen and edematous. Oocysts are ellipsoidal and have a high shape index length/width (5/1.54). The oocysts average 25.6×16.6 mm. Typical oocysts of E. adenoeides are more pointed at 1 end than other species, aiding in recognition.

Pathogenesis

E. adenoeides is one of the most pathogenic of the turkey coccidia. Experimental infections of 25,000–100,000 oocysts in young poults may produce mortality up to 100% on days 5 or 6 PI. Turkeys several months old may lose considerable weight after infection. Outward signs of infection are apparent after 4 days PI. Feces are frequently fluid, may be blood-tinged, and may contain mucous casts. White or gray caseous cores may be produced in the ceca. In mild to moderate infections the cecal contents may be viscous and filled with oocysts. The lesions heal quickly, so no evidence of infection may be seen soon after the acute phase unless the cecal core remains.

Gross Lesions and Histopathology

By day 4 PI, the intestine may suffer congestion, edema, petechial hemorrhage, and mucous secretion. Five days PI, the ceca contain white caseous material, which condenses into

a core. The serosal surface of the intestine appears pale and may be edematous and dilated.

Invasion of the submucosa by heterophils occurs throughout the intestine, especially in the lower small intestine, ceca, and rectum. Epithelial cells at the tips of villi are most often invaded, but deep glands may also be parasitized. Edema is common deep in the muscular layers as the infection progresses. After day 5, regeneration of lost mucosa is rapid.

Eimeria dispersa Tyzzer 1929

The small intestine, principally the midgut region, is commonly parasitized, but some infection may occur in the cecal necks. Oocysts are large (average, 26.1 × 21.0 mm) and broadly ovoid (index = 1.24). Sporozoites lack a refractile body, and the oocyst wall is distinctively contoured and lacks the double wall common to other species. The prepatent period is 120 hours, longer than for other species.

Pathogenesis

Compared with some of the other species, the pathogenicity is low, but infection with 10^6–2×10^6 oocysts can cause reduction in rate of weight gain and diarrhea in young poults.

Natural and Experimental Hosts

The natural host of *Eimeria dispersa* Tyzzer 1929 is apparently the Bobwhite quail, in which the parasite is more pathogenic than in turkeys. This is the only *Eimeria* in chickens or turkeys known to infect more than one species. Experimental inoculation has produced patent infections in domestic and wild turkeys, Hungarian partridge (*Perdix perdix*), ruffed grouse (*Bonasa umbellus*), sharp-tailed grouse (*Pediocetes phasianellus campestris*), Japanese and Bobwhite quail, and other pheasants. Infection in chickens often requires immunosuppression.

Gross Lesions and Histopathology

Three days PI, the duodenum appears cream-colored on the serosal surface. Later, the entire intestine may become dilated with thickening of the wall. Dilation continues on the fifth and sixth days, along with secretion of a cream-colored mucoid material containing denuded epithelium from the duodenum. Individual villi may become so dilated as to be visible to the naked eye.

The duodenum shows edema and progressively increasing congestion of capillaries. Separation of the epithelium and basement membranes may result in the lamina propria being exposed to a fibrin network or an open fluid-filled space. Necrosis is common on distal tips of villi. Parasites do not invade the glands.

Eimeria gallopavonis Hawkins 1952

Lesions from *Eimeria gallopavonis* Hawkins 1952 are restricted to the area posterior to the yolk sac diverticulum and tend to be most severe in the lower small intestine and large intestine. Some foci of infection may be seen in the ceca. Oocysts are elongate, averaging 27.1 × 17.2 mm (index = 1.52). Differentiation of this species from *E. adenoeides* is often difficult. One difference is that *E. gallopavonis* has more rounded oocysts.

Pathogenesis

Experimental infection with 5×10^4–2×10^5 oocysts causes mortality of 10%–100% in 2– to 6-week-old poults. Mortality occurs 5–6 days PI.

Gross Lesions and Histopathology

On days 4 and 5 post exposure, second- and third-generation schizonts are numerous in the ileum, necks of the ceca, and rectum. By day 6 the rectum is parasitized mostly with gamonts. Marked inflammatory and edematous changes on days 5–6 are followed by the sloughing of soft white caseous necrotic material containing numerous oocysts and flecks of blood on days 7 and 8.

Eimeria meleagridis Tyzzer 1929

Oocysts of *Eimeria meleagridis* Tyzzer 1929 are ellipsoidal, averaging 24.4 × 18.12 mm (index 1.34). Visible lesions may be seen in the ceca with yellow-white caseous cores, but this species is considered virtually nonpathogenic. Oocysts resemble those of other pathogenic species in the ceca, and differentiation is difficult.

Pathogenesis

Most studies have characterized this species as almost nonpathogenic. Up to 5×10^6 oocysts produce little effect on the growth of 4– to 8-week-old poults. Earlier reports indicating greater pathogenicity may have come from mixed infections with *E. adenoeides*.

Gross Lesions and Histopathology

Nonadherent cream-colored caseous cecal cores are characteristics of infection in young poults. The core may be passed intact. The mucosa is somewhat thickened and may contain petechial hemorrhages in dilated portions of the ceca. The plugs disappear 5.5–6 days PI, and many oocysts may be found in cecal contents.

Edema and lymphocytic infiltration may be seen histologically, but less extensively than with *E. adenoeides* and *E. gallopavonis*. First-generation schizonts develop in the surface epithelium of the small intestine, but later stages occur in the cecal epithelium.

Eimeria meleagrimitis Tyzzer 1929

Infection with *E. meleagrimitis* is primarily upper intestinal but may spread throughout the small intestine in heavy infections. This is the most pathogenic of the upper-intestinal coccidia in turkeys. The oocysts are small (average, 19.2 × 16.3 mm) and ovoid (index = 1.17).

Pathogenesis
Experimental infection of young poults produces morbidity and mortality, lost weight gain, dehydration, and general unthriftiness. Inoculation of 2×10^5 oocysts produces some mortality and morbidity, but this species is not as pathogenic as *E. adenoeides*.

Gross Lesions and Histopathology
Infected birds show signs of dehydration. In the duodenum, enlargement and congestion are marked on days 5 and 6 of infection. Large amounts of mucus and fluid may be found in the lumen. Feces may contain occasional flecks of blood and mucous casts 5–7 days PI.

The tips of villi are most commonly parasitized, and the epithelium may be completely denuded, although hemorrhage is rare. Capillaries of the villi are markedly dilated and the tips edematous. Eosinophilic infiltration may begin as early as 2 hours PI and is extensive at the height of the infection.

Eimeria subrotunda Moore, Brown, and Carter, 1954
Poults inoculated with *Eimeria subrotunda* Moore, Brown, and Carter, 1954 produced no gross lesions and it was considered nonpathogenic (34). Parasites develop primarily in the upper small intestine anterior to the yolk stalk diverticulum and are located in the epitehelial cells in the tips of the villi. Oocysts are subspherical (index = 1.099) and average 21.77 × 19.81 mm. Oocysts have no refractile granule.

Eimeria innocua Moore and Brown 1952
Eimeria innocua Moore and Brown 1952 is said to produce no gross lesions and is considered nonpathogenic. The area parasitized is the small intestine, in the epithelial cells at the tips of villi. Oocysts are sub-spherical (index = 1.072), and average 22.4 × 20.9 mm. Oocysts have no polar granule. The prepatent period for oocyst production is 114 hours.

Undescribed Species
Several species of coccidia that do not fit descriptions of established species have been isolated from wild or domestic turkeys but have not been adequately described or named. Thus, some difficulty may be expected in identifying coccidia found in field cases unless the pathology and appearance are distinctive.

Prevention and Control of Turkey Coccidiosis
Drugs effective in chickens are generally effective in turkeys, but the optimal level of application may vary, and the toxicity of some drugs is significantly higher in turkeys than in chickens.

Treatment
As in chickens, treatment of outbreaks in turkeys is less desirable than the prevention by chemotherapy or immunization. When treatment is necessary, application of amprolium (0.012%–0.025% in water) or a sulfonamide (dosage depending on drug, often given 2 days on drug, 3 days off, and 2 days on, sometimes repeated a second week) is recommended. The toxicity of sulfonamides limits their usefulness for turkeys.

Control by Chemotherapy
Most producers use anticoccidial drugs continuously in the feed for at least 8 weeks. Generally, poults are confined to a brooding facility at that time. Later, the birds may be moved to range or to other facilities. Drugs approved historically for use in feed include amprolium (0.0125%–0.25%), butynorate (0.0275%), sulfaquinoxaline (0.0175%), sulfadimethoxine (0.006%–0.25%) + ormetoprim (0.00375%), monensin (54–90 g/ton), halofuginone (1.5–3.0 ppm); diclazuril (1.0 ppm), and lasalocid (75–125 ppm). Not all are available.

Prevention with Planned Immunization
The principle of immunization by exposure to a small number of pathogenic oocysts of the important species of *Eimeria* was developed with chickens and is represented by a single product for turkeys in the United States (Coccivac-T®, Schering-Plough, Millsboro, Delaware) and in Canada (Immucox® for turkeys, Vetech, Guelph, Ontario). The inoculum is sprayed on the feed during the first 1–7 days or sprayed on the poults at 1 day of age at the hatchery, and causes a mild infection. There are inherent risks in use of virulent strains of coccidia, and occasional treatment at 3–4 weeks of age is necessary if 1 of the species multiplies too rapidly, but the program has been used with moderate success.

Coccidiosis in Geese
Numerous species of coccidia have been described from domestic and wild geese. The most prevalent and damaging in commercial flocks are *E. truncata*, which causes renal coccidiosis, and *E. anseris*, which causes intestinal coccidiosis. Renal coccidiosis may produce high mortality from the blockage of kidney function in young goslings. Coccidia may be introduced into domestic flocks by migrating and resident wild geese.

Eimeria truncata Raillet and Lucet 1891
Flock losses due to renal coccidiosis have been reported as high as 87% in Iowa. Geese aged 3–12 weeks are affected, although the disease is most acute in goslings. Signs of infection include depression, weakness, diarrhea with whitish feces, and anorexia. Eyes become dull and sunken, and wings are drooped. Survivors may show vertigo and torticollis. Birds quickly develop immunity to reinfection.

Oocysts and endogenous stages of *E. truncata* are found only in the kidneys or cloaca near the junction of the ureters. Diagnosis of *E. truncata* is ensured by finding the distinctive oocysts in the kidneys and ureters. Oocysts average 21.3 × 16.7 mm and have truncated ends.

Natural and Experimental Hosts
Although thorough cross-infection experiments have not been done in most cases, *E. truncata* has been reported from domestic and wild geese, ducks, and swans.

Gross Lesions and Histopathology
The kidneys may be enlarged and protrude from the sacral bed. The normal reddish brown is altered to light grayish yellow or grayish red. Pinhead-sized grayish white foci or hemorrhagic petechiae may be seen; they contain numerous oocysts and accumulations of urates. Invading and growing parasites may distort the kidney tubules to many times the normal size. Eosinophils and signs of necrosis are present in focal areas.

Eimeria anseris Kotlan 1933
The oocysts average 19.2 × 16.6 mm. Differentiation from the 14 species listed by Pellerdy (37) may be difficult.

Pathogenesis
E. anseris may produce anorexia, tottering gait, debility, diarrhea and morbidity, and sometimes mortality. The small intestine becomes enlarged and filled with thin, reddish-brown fluid. Catarrhal inflammatory lesions are most intense in middle and lower portions of the small intestine. There may be large whitish nodules or a fibrinous diphtheroid necrotic enteritis. Under dry pseudomembranous flakes, the oocysts and endogenous stages of the parasite are found in large numbers. Parasite stages invade epithelial cells of the posterior half of the intestine in closely packed rows. Developing gametocytes penetrate deeply into subepithelial tissues of the villi.

Treatment
Various sulfonamide drugs have been used in treatment of renal and intestinal coccidiosis of geese. Some studies indicated a favorable response, but unfortunately, there have been no controlled experiments.

Coccidiosis in Ducks

Coccidiosis in ducks is sporadic but is sufficiently frequent to warrant more attention from researchers. Cases involving moderate to heavy mortality have been reported on domestic duck farms in New York, New Jersey, Hungary, and Japan. Coccidia were recovered from every farm sampled on Long Island, New York. Clinical and subclinical coccidiosis appears to be common and can produce morbidity and mortality as well as poor performance.

Species of Coccidia and Descriptions
Although 13 species of coccidia have been reported from domestic and wild ducks, the descriptions are often insufficient to use in diagnosis (32). Many species will remain in doubt until further work is completed. Coccidia in ducks may be of *Eimeria, Wenyonella*, or *Tyzzeria*. The genus can be determined readily from the sporulated oocyst. The oocysts of Eimeria have 4 sporocysts, each containing 2 sporozoites; *Wenyonella* have 4 sporocysts, each with 4 sporozoites; and *Tyzzeria* have 8 naked sporozoites not contained within sporocysts.

Tyzzeria perniciosa Allen 1936, from domestic ducks in the United States, have thin-walled oocysts measuring 10–12.3 × 9–10.8 mm and sporulate to produce 8 free sporozoites.

Wenyonella philiplevinei Leibovitz 1968 is the best described of the coccidia from ducks. It is found in the lower intestine from the posterior jejunal annular band to the cloaca. The prepatent period is 93 hours. The oocysts have 3-layered walls, measure 15.5–21 × 12.5–16 mm (average, 18.7 × 14.4), and have a micropyle at 1 end, 1–2 polar granules, and no oocyst residuum. Sporulation results in 4 sporocysts/oocyst, each containing 4 sporozoites.

Pathogenesis of Duck Coccidiosis
Signs of infection with *T. perniciosa* usually include anorexia, weight loss, weakness, distress, morbidity, and up to 70% mortality. Hemorrhagic areas are common in the anterior portion of the intestine but may be found throughout. Bloody or cheesy exudate is common. The epithelial lining may be sloughed in long sheets. Parasite invasion may extend through the mucosal and submucosal layers as deep as the muscular layers. Acute hemorrhage as early as day 4 may be followed by death on days 5–6.

With *W. philiplevinei*, the effects are limited to 72–96 hours PI. Occasional petechial hemorrhages appear in the posterior ileal mucosa. Diffuse congestion is found in lower intestinal mucosa. In severe infections, mortality may occur on day 4.

Coccidiosis in Pigeons

Coccidiosis in pigeons is similar to, but less severe than, that caused in chickens by *E. necatrix*. Young pigeons suffer the greatest losses, but mortality may occur in birds as old as 3–4 months.

The most frequently occurring species of coccidia in pigeons is *E. labbeana* (Labbe 1896) Pinto 1928. Oocysts are spherical or subspherical, averaging 19.1 × 17.4 mm.

Pathogenesis
Mortality of 15%–70% has been reported in young pigeons in various parts of the world. Subclinical infections may persist in older birds for long periods. Immunity does not appear to be as self-limiting as reported for other species. Common signs of infection are anorexia, greenish diarrhea, marked dehydration, and emaciation. Droppings may be blood tinged, and the entire digestive tract may be inflamed. The common condition of going light is frequently attributed to coccidiosis.

Treatment
Favorable response has been reported after the use of sulfonamides in drinking water at the same level or half the level recommended for chickens. A product was introduced in 1987 in France and Belgium for specific use in pigeons. The active ingredient is clazuril, a close relative of the diclazuril under development for use in chickens. This product is highly effective in treating coccidiosis in pigeons.

Cryptosporidiosis

Larry R. McDougald

Introduction

Cryptosporidiosis is caused by small coccidian parasites of the genus *Cryptosporidium*, which live within the microvillous region of epithelial cells of the respiratory and gastrointestinal tracts of vertebrates. Naturally occurring infections have been reported from at least 9 different avian hosts. In chickens, turkeys, and quail, these parasites are primary pathogens that can produce respiratory and/or intestinal disease, resulting in morbidity and mortality. Species of *Cryptosporidium* infecting mammals have received considerable attention in recent years because of the widespread increase in immunocompromised hosts (5). Several reviews of the biology of Cryptosporidium are available (11, 12, 30, 42).

Human Health Importance

Whereas cryptosporidiosis is important in humans and other animals, there is no evidence that *C. baileyi*, the avian species, causes any infection in other animals. Similarly, *C. parvum*, which is the predominant human pathogen, is not commonly seen in poultry. There is good evidence that *C. meleagridis*, an occasional but highly pathogenic species in turkeys, may actually be synonymous with *C. parvum*. Species reported from poultry are summarized in Table 28.4.

History and Taxonomy

The type species *C. muris* was described from laboratory mice by Tyzzer (39), who later also described many of the life cycle stages and named a second species, *C. parvum* (40, 41). Many other species were named from a variety of vertebrate hosts because researchers assumed an unwarranted degree of host specificity. Only a few are now considered valid. Two species (*C. baileyi* and *C. meleagridis*) infect chickens, turkeys, and quail (29). In chickens and turkeys, *C. baileyi* causes both intestinal (cloaca and cloacal bursa) and respiratory infections, and small intestinal infections of *C. meleagridis* infections are associated with diarrheal disease in turkeys and quail. An isolate that causes high mortality in quail, once thought distinct from *C. baileyi* and *C. meleagridis*, is now considered similar to *C. meleagridis* (29). However, as mentioned above, *C. meleagridis* may be a synonym of *C. parvum*.

Life Cycle and Morphology

Taxonomy of the coccidia is based on the differences in oocyst structure, sequence similarities in the 18 s RNA gene, the heat shock gene (HSP-70), host specificity, and site of infection (4, 29, 41). In contrast to other coccidia found in poultry, *Cryptosporidium* spp. oocysts do not have sporocysts surrounding the sporozoites, 4 of which lie naked within the oocyst wall (Figure 28.5). *C. baileyi* shows little host specificity among birds.

The life cycle of *Cryptosporidium*, like other true coccidia belonging to the suborder Eimeriorina, can be divided into 6 major developmental events (Figure 28.6): excystation (release of infective sporozoites), merogony (asexual multiplication within epithelial cells), gametogony (formation of male and female gametes), fertilization (union of gametes), oocyst wall formation (to produce an environmentally resistant form), and sporogony (the formation of infective sporozoites within the oocyst wall).

The life cycle differs in several respects from that of *Eimeria* spp. infecting poultry (8). The intracellular stages of Cryptosporidium spp. are confined to the microvillous region of the host cell. Oocysts sporulate within the host cell and are infective when released in the feces. Oocysts are of 2 types: thin walled or thick walled. Thin-walled oocysts are not environmentally resistant and contain sporozoites surrounded by a single unit membrane. Upon release from the host cell, the sporozoites invade adjacent host cells. Thick-walled oocysts have a multilayered wall and are passed through the feces to infect other hosts. The majority of oocysts are the thick-walled form. In mammals, the thin-walled, autoinfective oocysts and type I meronts (asexual stages) cause reinfection within the same host, allowing severe infections to build up

Table 28.4. Distinguishing features of *Cryptosporidium* spp. infecting poultry.

Species	Host(s)	Site of Infection	Measurements of Oocysts (mm)
C. baileyi	Chicken, turkey, duck	Bursa of Fabricius, cloaca, respiratory epithelium	6.2 × 4.6 (mean), 6.3 – 5.6 × 4.8 – 4.5 (range)
C. meleagridis	Turkey, chicken	Small intestine	5.2 × 4.6 (mean), 6.0 – 5.6 × 4.8 – 4.5 (range)
Cryptosporidium spp.	Quail	Small intestine	Approximately 5

Source: See references 4, 22, 26.

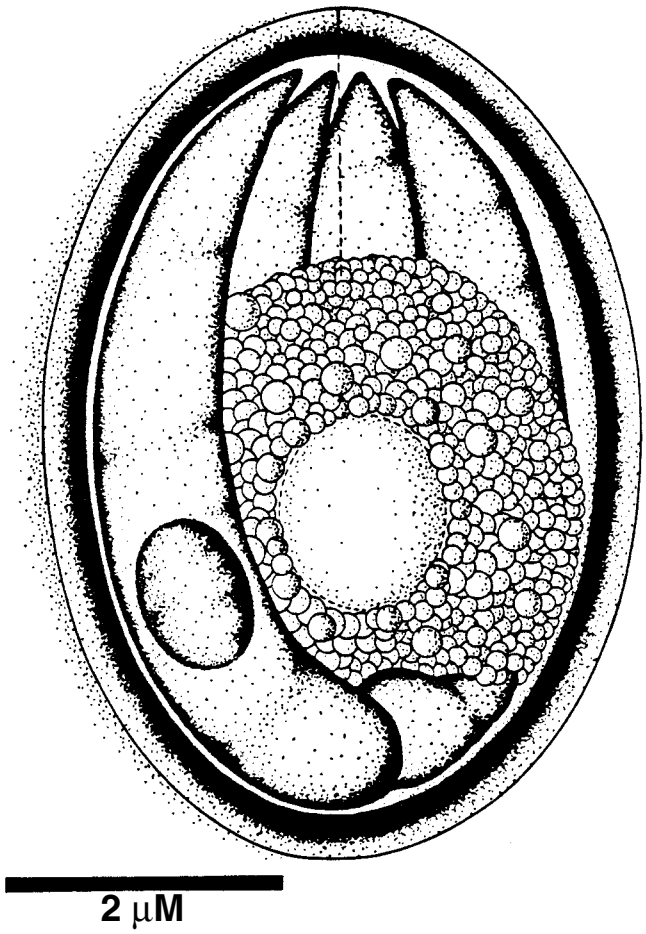

Figure 28.5. Composite line drawing of an oocyst of *Cryptosporidium baileyi*. Note the 4 sporozoites surrounding the oocyst residuum and the suture in the 2-layered oocyst wall.(8)

after ingestion of a small number of ingested oocysts. This is particularly important in immune-deficient hosts and may lead to a chronic life-threatening disease. Another feature of *Cryptosporidium* spp., which differs from Eimeria spp. in mammalian and avian hosts, is the frequent establishment of infections in the mucosal epithelium of a wide variety of organs. *C. baileyi* can infect the cloaca, the cloacal bursa, the upper and lower respiratory tracts, and the eyelids.

Diagnosis of cryptosporidiosis is difficult because of its diminutive size and its location at the brush border of the epithelial cell. The tiny oocysts are difficult to see with light microscopy because they are only a fraction of the size of other coccidian oocysts and have no features to make them stand out against a light background. For the same reason, they can be missed even in histopathology. Phase contrast and interference contrast microscopy are useful in wet preparations. Oocyst morphology may be useful for species identification (Table 28.4). Only *C. baileyi* can be identified on the basis of morphology alone because it is larger and more ovoid than *C. meleagridis* from turkeys or quail. *Cryptosporidium* isolated from quail will not infect chickens or turkeys. Thus, the species infecting quail can only be distinguished from *C. meleagridis* on the basis of host specificity. Oocyst walls of all forms are about 0.5 mm thick, colorless, and have no micropyle (Figure 28.5).

Incidence and Distribution

Cryptosporidium spp. are prevalent in domesticated, caged, and wild birds, reported from 30 bird species. The reported worldwide distribution of *Cryptosporidium* spp. in avian hosts corresponds to the regions in which poultry health specialists and biologists have used appropriate diagnostic tools and

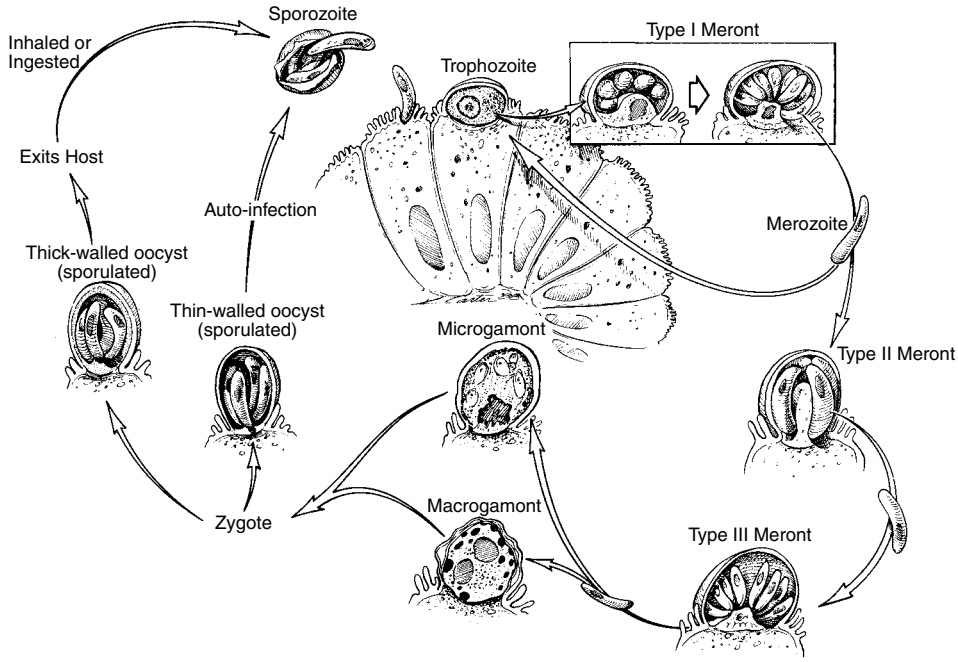

Figure 28.6. Life cycle of *Cryptosporidium baileyi* as it occurs in the mucosal epithelium of the intestine (cloacal bursa and cloaca) and the respiratory tract of broiler chickens.

will continue to expand as awareness of their importance as primary pathogens increases.

Cryptosporidiosis in Chickens

Cryptosporidium (probably *C. baileyi*) was diagnosed in 6.8% of 1,000 consecutive histology cases of chickens in Georgia (16). In North Carolina, *Cryptosporidium* spp. oocysts were found in the feces of 9 (27.3%) of 33 broilers, 3 (10%) of 30 broiler breeders, and 1 (5.9%) of 17 layers (25). Using an ELISA, 22% of 454 broiler flocks in the Delmarva region were found to have birds that were seropositive for *Cryptosporidium* spp. when they were processed (6, 35). The number of positives among different companies sampled ranged from 2.8%–40%. These investigations did not distinguish between intestinal and respiratory infections. Goodwin found respiratory cryptosporidiosis widespread in farms under contract to a broiler complex in North Georgia (16). The factors responsible for clinical expression of respiratory cryptosporidiosis are not understood but may cause high mortality and morbidity, with subsequent lower weight gains and higher feed/gain ratios (10). Experimentally induced respiratory and intestinal infections in broiler chickens have established the pathogenic potential of *C. baileyi* (2, 28). These and other data indicate that *Cryptosporidium* spp. are common in broiler chickens, and could have a significant impact on productivity and performance.

Pathogenesis and Epidemiology

Oocysts are picked up from heavy fecal contamination of the litter or cages. *C. baileyi* generally invades the epithelium of the cloaca and cloacal bursa. Respiratory infections apparently result from the inhalation or aspiration of oocysts that are present in the environment. As few as 100 oocysts can result in intestinal infections when given orally, or in respiratory infections when inoculated intratracheally. Oocysts of *C. baileyi* are infective at the time they are passed in the feces, and no vectors have been identified. Because *C. baileyi* can infect a variety of avian hosts, it is possible that wild birds may serve as carriers. Although *C. baileyi* is not infective for mammals, it is possible that rodents (mice and rats) and insects can serve as mechanical carriers (18).

Mild to heavy intestinal and respiratory signs can be seen as early as 3 days after inoculation of oocysts. Intestinal disease is usually mild. No overt signs of gastrointestinal disease occur in chickens receiving oocysts by gavage into the crop.

Signs of respiratory disease may appear within the first week after intratracheal (IT) inoculation of *C. baileyi* oocysts into 7- or 9-day-old broiler chickens, sometimes with severe morbidity and mortality (2, 9, 26). Oral inoculation of broilers with 4×10^5 oocysts produced only asymptomatic intestinal infections.

Respiratory signs of sneezing and coughing occur in most IT-inoculated chickens by 6 days PI. By 12 days PI, respiratory signs are more severe, and many of the birds extend their heads to facilitate breathing. Severe respiratory signs are present for about 3–4 weeks PI, after which there may be gradual improvement. Weight gains were depressed with respiratory infection but not with intestinal infections (9). Chickens were more resistant to intratracheal inoculation at 28 than at 7 or 14 days of age (28).

Airsacculitis and pneumonia can occur as early as 6 days but are more common 12–28 days following IT inoculation of *C. baileyi* oocysts. Early in the disease process, posterior thoracic air sacs are slightly thickened and contain foamy, clear to white or gray fluid. By day 12, air sacs may become very thick and contain white caseous exudate. The lungs of birds with severe airsacculitis are almost always affected and exhibit focal consolidation (10%–80%), particularly in the ventral region. Abdominal air sacs may also be affected.

Histopathology of IT-inoculated chicks shows large numbers of parasites throughout the microvillous region

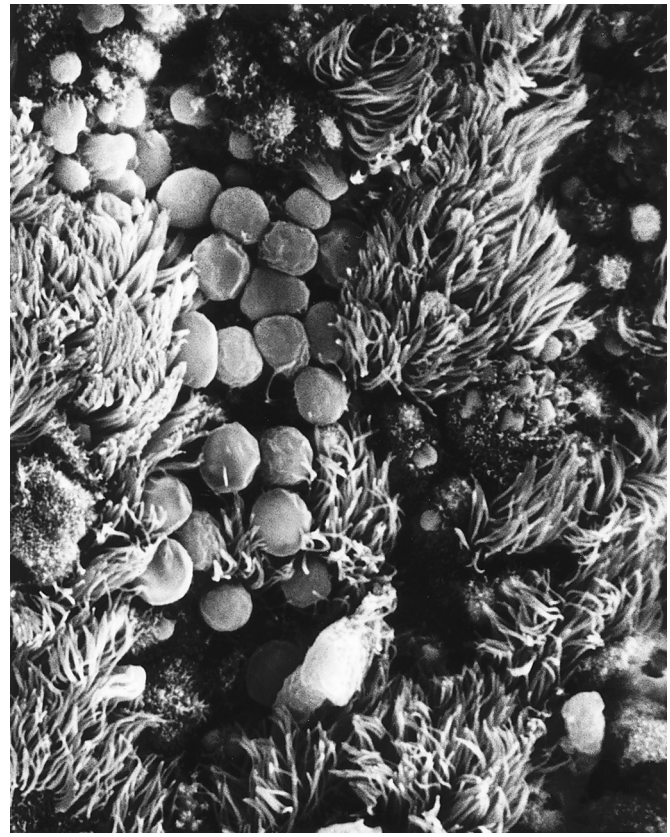

Figure 28.7. The mucosal surface of the primary bronchi obtained from a broiler chicken 4 days after intratracheal inoculation of *Cryptosporidium baileyi*, as shown by scanning electron microscopy. Some developmental stages of the parasite can be seen among the cilia of the respiratory surface. At this stage of infection, the mucociliary elevator is probably still functional, and the bird would not have overt signs of respiratory distress. On days 10–18 after intratracheal inoculation, developmental stages of the parasite form a virtual monolayer on the respiratory surface. Few or no cilia can be found. (S.L. White)

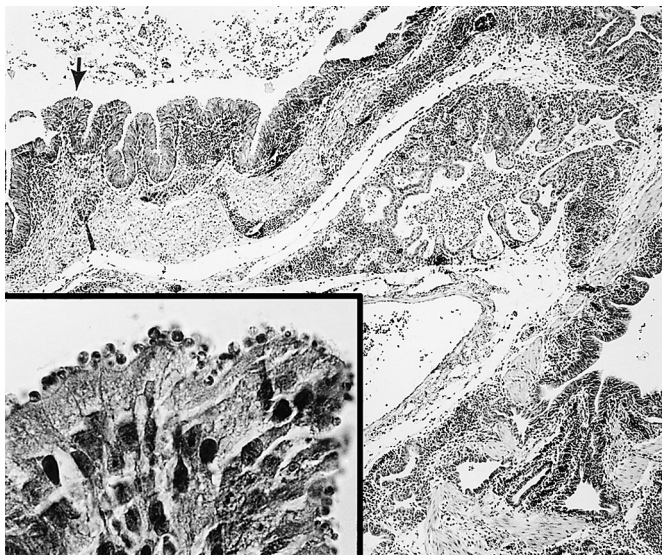

Figure 28.8. *Cryptosporidium baileyi* in the lungs of a broiler chicken. Accumulation of lymphoid cells around bronchi 6 days after intratracheal inoculation of *C. baileyi* oocysts. H&E-stained histologic section. Inset: A higher magnification of the villus (arrow) showing the numerous developmental stages of the parasite on the epithelial surface.

of the epithelium lining the trachea and bronchi (15). Cilia are lost by replacement with developing parasites by 4 days PI (Figure 28.7). By 12 days, almost all cilia may be replaced by developing parasites, and the mucociliary elevator function ceases in affected trachea and bronchi. Histologic lesions include epithelial cell hyperplasia, thickening of the mucosa by mononuclear cell infiltrates with some heterophils, loss of cilia, and discharge of mucocellular exudate into the airways. There is accumulation of mucus, sloughed epithelial cells, lymphocytes, macrophages, and parasites in the tertiary bronchi and atria of the lungs. Affected lobules are expanded by accumulation of exudate and infiltration of mononuclear cells (Figure 28.8). Affected air sacs lined with respiratory epithelium also contain large numbers of parasites and suffer similar changes.

Intestinal (cloaca and cloacal bursa) cryptosporidiosis in chickens (produced by *C. baileyi*) may result in histologic lesions but does not usually result in gross lesions or overt signs of disease. Several reports suggest, however, that performance of broilers can be adversely affected. An unusually high mortality was associated with *C. baileyi* infection in the cloacal bursa, and there were lower pigmentation scores when inoculated birds were compared with noninfected controls (2, 19).

Interaction of *C. baileyi* and other respiratory pathogens predisposes birds to secondary invasion by *Escherichia coli* because of the disruption of the mucociliary elevator (9). Infectious bronchitis virus and *E. coli* also enhance the severity of *C. baileyi*-induced respiratory disease in chickens.

Cryptosporidiosis in Turkeys

Two species of *Cryptosporidium* found in turkeys are *C. meleagridis* (35) and *C. baileyi*. However, the description of *C. meleagridis* is indistinguishable from that of *C. parvum*. The intestinal (cloacal bursa and cloaca) and respiratory infections produced by *C. baileyi* are similar to those described previously for chickens (8, 9, 27).

Slavin reported small intestinal cryptosporidiosis (34) due to *C. meleagridis* in a flock of 10– to 14-day-old turkey poults. Illness was associated with diarrhea, unthriftiness, and moderate mortality. More than 30 years later, several outbreaks of this disease were reported (17, 43), although the number of reported cases is low.

Turkey poults infected with *C. meleagridis* may develop severe diarrhea. Numerous parasites are seen lining the brush border of the mucosa of the middle and lower small intestine. The gut becomes pale and distended with cloudy mucoid fluid and gas bubbles. Villi in the affected regions become atrophic; crypts become hypertrophic; and large numbers of lymphocytes, heterophils, and some macrophages and plasma cells accumulate within the lamina propria (17).

There are several case reports of severe respiratory cryptosporidiosis in commercial turkeys caused by *Cryptosporidium* spp. (probably *C. baileyi*) (14, 22, 32, 37). The disease may have upper or lower respiratory involvement. Upper respiratory infections may cause acute bilateral swelling of infraorbital sinuses, similar to that reported for birds infected with *Mycoplasma* spp., and serous conjunctivitis (14, 22). Case reports of lower respiratory tract infections reported signs including rattling, coughing, sneezing, and gasping (32, 37). The trachea and bronchi were colonized, with concomitant airsacculitis and pneumonia. Microscopic lesions of the infected tissues included deciliation of the epithelium and inflammation.

Intratrachael (IT) inoculation with *C. baileyi* from the intestinal tract of broiler chickens into the trachea of turkeys produced respiratory signs similar to those observed in natural outbreaks (27).

Although there are reports of clinical outbreaks, the importance of *Cryptosporidium* spp. in commercially reared turkeys is not clear.

Cryptosporidiosis in Quail

Both respiratory and intestinal cryptosporidiosis have been reported in commercially grown quail, but the species involved has not been adequately described. Field reports suggest similar respiratory disease and low mortality similar to that seen with cryptosporidiosis in chickens (38). Histologic examination revealed parasites in the microvillous region of epithelial cells lining the nasal cavity, trachea, bronchi, salivary glands of the roof of the mouth, esophageal glands, and cloacal bursa. Pathologic changes in the respiratory mucosa were similar to those described previously for chickens

infected experimentally with *C. baileyi*. In another spectacular case of cryptosporidiosis, 5 successive hatches of 25,000 young quail (*Colinus virginianus*) developed severe, fatal intestinal cryptosporidiosis (23). Diarrhea developed 4–6 days after hatching, and mortality soon exceeded 90%. At necropsy, numerous developmental stages of the parasite were observed in the microvillous border of the small intestine. No parasites were observed in the cecum, colon, cloacal bursa, respiratory tract, or other tissues. Oocysts, obtained from the intestines of these infected quail, were not infective to day-old broilers. Based on recent work, this isolate was probably *E. meleagridis* (29).

A similar outbreak was reported from young quail due to a combination of *Cryptosporidium* sp. and a reovirus isolated from intestinal contents (33). Subsequent laboratory studies (20) suggested that the *Cryptosporidium* and not the reovirus was responsible for the intestinal disease.

Prevention and Control

There are no effective anti-cryptosporidial drugs or vaccines, and other approaches to the control are still experimental. Sanitation or disinfection may provide some help, but no proven programs can be recommended.

Sanitation

The oocysts of *Cryptosporidium* spp. infecting poultry are remarkably resistant to chemical agents that readily kill most viral, bacterial, and fungal pathogens. Destruction of oocysts in commercial production facilities is not considered practical. In the laboratory, oocysts remain viable for months when stored at 4°C in a solution of 2.5% potassium dichromate. Oocyst viability is also maintained after a 10– to 15-minute incubation in 25% commercial bleach (sodium hypochlorite). Incubation of *C. baileyi* oocysts for 30 minutes at room temperature in each of 9 commonly used disinfectants mixed with water at the highest concentration recommended by the manufacturers had little or no effect on viability (36). Incubation in 50% ammonia resulted in the greatest reduction in excystation, and 50% commercial bleach destroyed many of the oocysts. Steam cleaning is a safe and effective means of disinfecting contaminated laboratory cages because oocysts are destroyed by temperatures greater than 65°C.

Immunity

A single intestinal and/or respiratory infection with *C. baileyi* can stimulate an immune response in broiler chickens of sufficient magnitude to clear the parasite from the infected mucosae and to protect the host against reinfection of the same species (6, 9). Experience with cryptosporidiosis in other animals suggests that immune protection may be short-lived. Oral or IT inoculation of oocysts into 8– to 14-day-old broilers results in heavy infections of the exposed mucosae for 14–16 days and then a rapid clearance of the parasite. High titers of circulating antibodies specific to *C. baileyi* can be detected after primary infections, and the birds exhibit a delayed hypersensitivity reaction to *C. baileyi* oocyst antigens. Data from laboratory studies and from a serologic survey suggest that acquired immunity may be important in the protection of broilers from cryptosporidiosis during the last several weeks of growout. Studies are needed to identify antigens of *Cryptosporidium* spp. that may be candidates for use as vaccines.

Diagnosis and Culture

Active infections in poultry, both respiratory and intestinal, can be diagnosed by identifying oocysts from fluids obtained from the respiratory tract or from the feces. Identification of *Cryptosporidium* spp. oocysts differs somewhat from techniques used for the oocysts of *Eimeria* spp. For viewing, oocysts are concentrated and observed by standard brightfield or phase contrast microscopy (7), acid-fast staining (13, 31), negative staining (4, 21), and staining with auramine-O for examination by fluorescence microscopy (25). These techniques allow one to readily distinguish *Cryptosporidium* spp. oocysts from yeast cells or Blastocystis that are often present in specimens.

Fecal or respiratory specimens can be collected and submitted fresh, in 10% formalin or in an aqueous solution of 2.5% potassium dichromate. A highly effective method of obtaining specimens in the field and in the laboratory is with moist cotton-tipped swabs. Vigorous swabbing of the tracheal or cloacal epithelium will remove oocysts from the microvillous border. The swabs are placed in a tube containing 1 mL of water or fixative for transportation to the laboratory.

Cryptosporidium infection also can be detected by demonstrating other stages of the life cycle from fresh or stained mucosal scrapings from the mucosa (24). Abbassi (1) described a semiquantitative microscopic slide flotation method that was reliable for *C. baileyi* in feces and organs of chickens. These parasites also appear in histologic sections stained with hematoxylin and eosin as 2– to 6-mm basophilic bodies within the brush border of the epithelial cells. Because of the small size of these parasites, transmission electron microscopy (TEM) is useful to reveal developmental stages and oocysts within the host cells. Inoculation of chicken embryos (10 days) with oocysts of *C. baileyi* is a good method for propagation of this species in the laboratory, providing about 50% of the number of oocysts obtained from chickens (44).

Previous exposure to the parasite can be demonstrated by testing for serum antibodies specific to *Cryptosporidium* sp. by ELISA or other immunologic tests (6, 35).

Amplification of DNA sequences with PCR is a useful tool for identifying some species of *Cryptosporidium* (29), but studies with 8 DNA loci revealed homologies between *C. meleagridis* and the human pathogen *C. parvum*, which could not be resolved by PCR (3).

Histomoniasis (Blackhead) and Other Protozoan Diseases of the Intestinal Tract

Michael Hess and Larry R. McDougald

Histomoniasis

Introduction

Histomoniasis affects mainly the ceca and liver of many gallinaceous birds, although it may be found in the cloacal bursa, kidney, spleen, and other tissues (36). Morbidity and death occur as a result of liver damage. Caused by the protozoan *Histomonas meleagridis*, the disease is characterized by ulceration and inflammation of the cecal walls, engorgement of the ceca with large caseous casts, inflammation of the mesenteries, and severe necrosis of the liver. It has been called infectious enterohepatitis or blackhead. The signs leading to the use of the term blackhead are neither pathognomonic nor distinctive because many other diseases may produce a similar appearance (Figure 28.9A). The role of the cecal worm (*Heterakis gallinarum*) as an intermediate host and the earthworm as an accessory host and the ability of the organism to colonize new hosts by cloacal contact comprise one of the most intriguing relationships in parasitology. Research on histomoniasis became neglected after the discovery of highly effective control measures in the late 1960s, leaving considerable basic biological and biochemical work undone.

Economic Significance

Annual losses from mortality in turkeys has been estimated to exceed $2 million. Other types of poultry also suffer losses. Decreased production from morbidity, loss of flock uniformity, and chemotherapy expense increase the cost of production of broiler breeder hens. Although histomoniasis is usually less severe in chickens, losses from morbidity and mortality are estimated to be greater in chickens than in turkeys because of the frequency of occurrence and the numbers of birds involved (1). Clinical blackhead disease in broiler breeder pullet flocks reached epidemic proportions in the mid to late 1990s and continues as a severe threat to production of breeder hens. Outbreaks of histomoniasis in leghorn pullets in Georgia and Florida caused up to 20% mortality and high morbidity. Chicken houses may become badly contaminated by *Heterakis* worm eggs, causing outbreaks in flock after flock. In many instances, poultry companies have discontinued the use of individual farms because of intractable contamination with *Heterakis* and *Histomonas*. The nitroimidazole antihistomonals were disallowed by the Food and Drug Administration in the 1990s, leaving no products available for treatment of blackhead disease. Histomoniasis remains an important limit to productivity in chickens, turkeys, and other fowl. This disease has no public health significance because it affects only birds.

History

Histomoniasis in turkeys was first described in 1895. The literature has been reviewed in depth (23, 28, 34). The discovery that chickens suffered a milder form of the blackhead, and often remained carriers, resulted in the first useful recommendation for control: Turkeys should not be reared with chickens or on a range where chickens have been produced during the previous several years. The role of cecal worms (*Heterakis*) and earthworms as intermediate hosts for Histomonas explains this long period of infectivity on uninhabited range.

Tyzzer described the parasite as a simple cell with flagella as well as pseudopodia and published extensive observations on its biology (38, 39). The complicated nature of the pathogenesis of histomoniasis was described in detail between 1964 and 1974 by studies showing that certain bacteria are necessary in addition to the histomonads to produce disease. This interesting *Histomonas*-bacteria connection was discovered using germ-free techniques at the universities of Georgia and Notre Dame. More recently, it was found that *Eimeria tenella*, the cecal coccidium, contributes significantly to the development of liver lesions in the chicken (27), and that histomoniasis is able to spread from bird to bird by means of cloacal contact with fresh droppings.

Etiology and Classification

The causative agent is *H. meleagridis*, a flagellated ameboid protozoan of about 10 μm. A larger (17 μm), nonpathogenic, 4-flagellated histomonad found in the cecum was named as a separate species, *H. wenrichi*.

The disease is commonly called blackhead, after the mistaken impression that birds commonly developed a blackened head sooner after death than with other diseases. Other common names include histomoniasis and enterohepatitis.

Other agents, such as trichomonads and fungi (*Candida albicans*), have been advanced as etiologic agents of blackhead (34). However, these organisms cause separate, unrelated diseases. The term pseudo-blackhead has been sometimes used to describe cases that did not respond to antihistomonals, but this term has little diagnostic value. Differential diagnosis used to resolve questionable infections includes microscopic observation, histopathology, and culture of responsible organisms.

Morphology

H. meleagridis in its nonamoeboid state is nearly spherical, about 10 μm (3–16 μm) in diameter. The amoeboid phase is highly pleomorphic. Pseudopodia may be observed if the slide

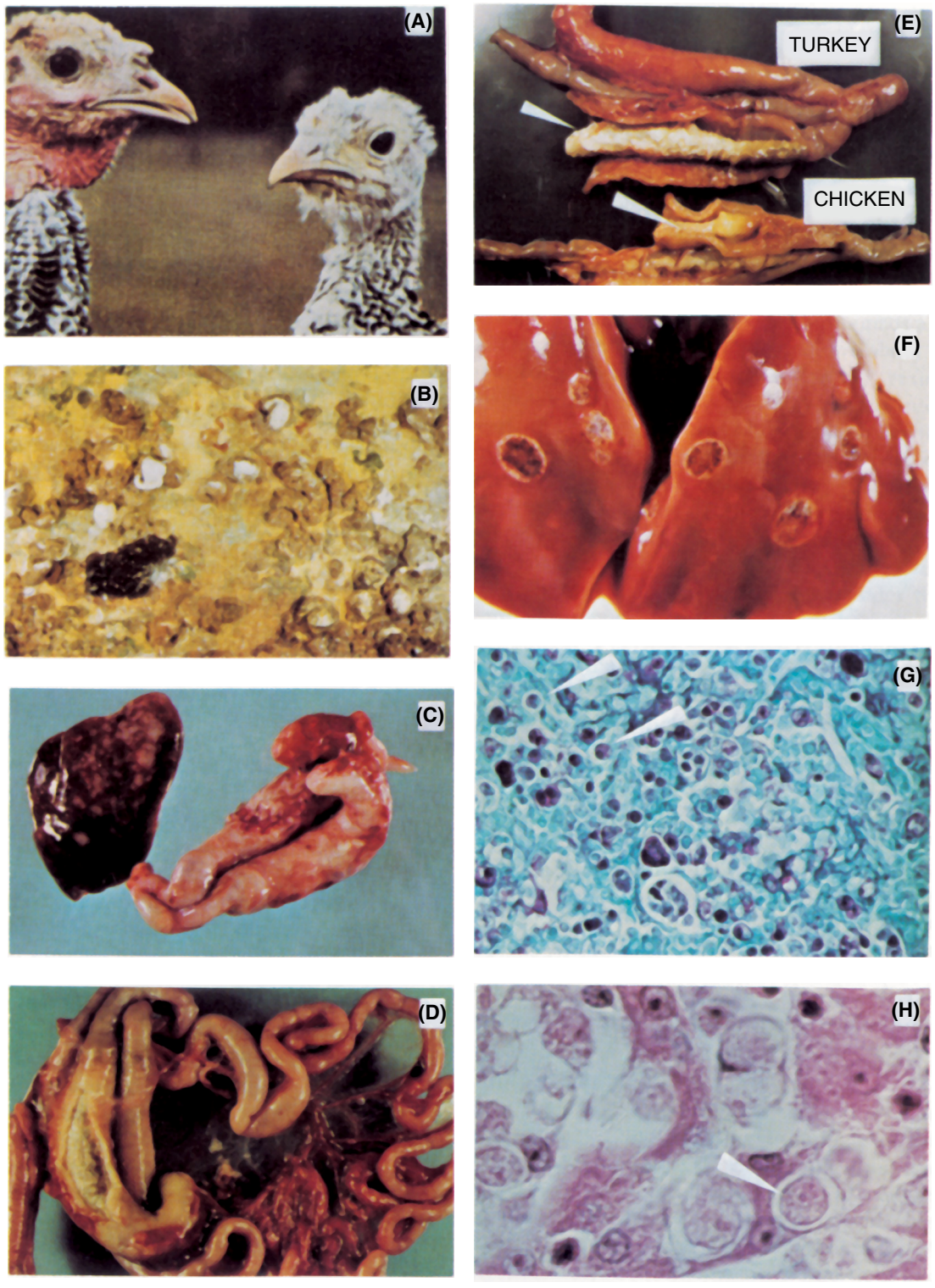

Figure 28.9. (A) Normal uninfected poult (left); histomoniasis-infected poult of the same age (right). Sickly appearance occurs later in the course of infection and is not distinctive to histomoniasis. (P. Hilbrich) (B) Brilliant yellow material in feces often constitutes the first sign of histomoniasis outbreaks in turkeys. (L.R. McDougald) (C) Liver and cecum from poult 14 days after feeding on *Heterakis gallinarum ova*. Note engorgement of ceca and diffuse nature of liver lesions. (L.R. McDougald) (D) Intestinal tract from experimentally infected turkey showing engorged cecum, core, and inflamed mesenteries. (E) Chicken and turkey ceca 10 days PI with *Histomonas meleagridis*. Note cecal cores (arrows). (L.R. McDougald) (F) Discrete pathognomonic lesions with raised surface from a turkey infected with histomoniasis. (R.L. Kemp) (G) Liver section showing histomonad PAS stain (arrows). (R.K. Page) (H) Liver sections showing histomonads (arrow). H&E × 1,000. (R.L. Kemp)

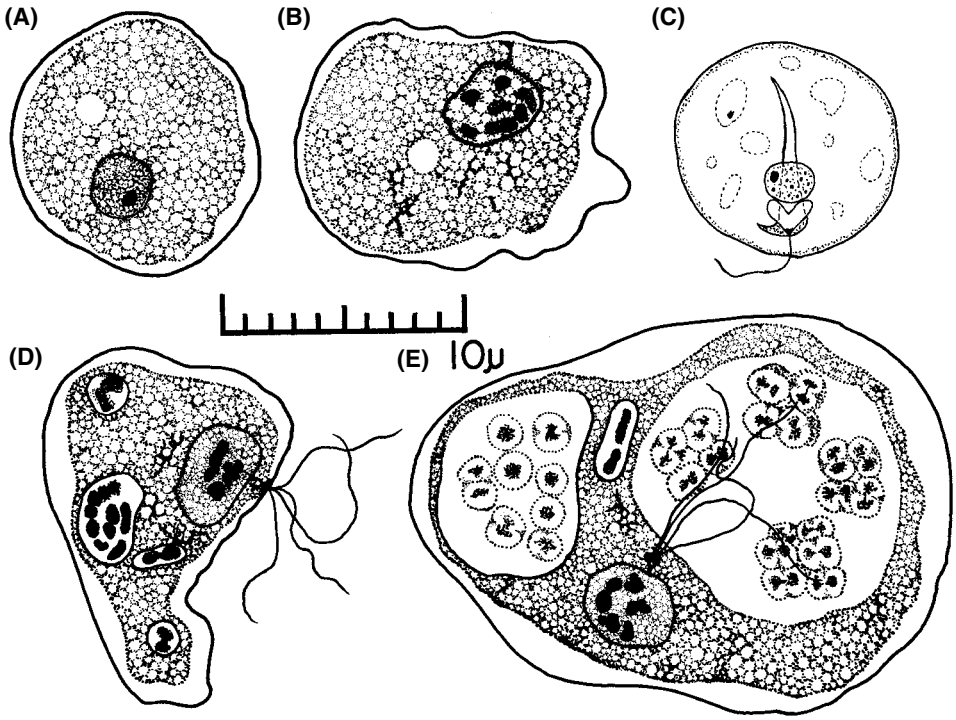

Figure 28.10. Examples of *H. meleagridis* (A, B, C) compared with *H. wenrichi* (D, E) showing variations for each species. (A) Tissue type *H. meleagridis* in fresh preparation from liver lesion, viewed with phase-contrast microscopy. (B) *H. meleagridis*. Transitional stage with pseudopodia but no flagellum, in lumen of the cecum. Distribution of chromatin suggests the beginnings of binary fission. (C) An organism from culture, with free flagellum typical of lumen-dwelling forms. (B.M. Honigberg and G.F. Bennett) (D) Small *H. wenrichi*, structurally distinguishable from *H. meleagridis* by its larger size and by presence of 4 flagella. (E) *H. wenrichi* as viewed in stained smear from cecum in which packets of Sarcina were abundant. Drawn from living specimens (A, B, D, and E) or tissue sections.

is warmed during microscopy (Figure 28.10). Cecal lumen forms have a single flagellum 6–11 μm in length. A pelta and an axostyle are wholly contained within the cell. The parabasal body is V-shaped and anterior to the nucleus. The nucleus is spheroid to ellipsoid or ovoid and averages 2.2 × 1.7 μm. These organisms lack mitochondria, instead relying on other organelles (hydrogenosomes) for energy metabolism. Hydrogenosomes are only observed by means of electron microcrospy.

The tissue forms usually lack flagella and reportedly exist in several different forms: (1) Parasites in the invasive stage at the peripheral areas of the lesions are 8–17 μm in size, amoeboid, and appear to form pseudopods. (2) A vegetative stage is larger (12–21 μm) and more numerous and is clustered in vacuoles in degenerating tissue. (3) A third stage present in older lesions is eosinophilic and smaller and may represent a degenerating form.

Life Cycle

The Role of Heterakis gallinarum. The survival and transmission of *Heterakis gallinarum* is intimately associated with the cecal nematode *H. gallinarum* (38). It is doubtful that any other organism or mechanism is responsible for survival of histomoniasis from 1 flock to the next. Early attempts to find the histomonad in cecal worm eggs were inconclusive until Gibbs (10) demonstrated small bodies seen with the light microscope. Lee (19) observed a small form (3 μm) by electron microscopy, and histomonads have been cultured *in vitro* from heterakid eggs (35).

Histomonads are found in intestinal epithelial cells of very young worms or newly hatched larvae. The mechanism of egg infection by histomonads has not been determined. Springer et al. (36) found that triturated male worms recently removed from chickens carry viable histomonads. Female worms are less likely to transmit viable histomonads until the eggs within them mature. Unembryonated eggs are unlikely to transmit the infection. The female worms probably become infected with the histomonads during copulation and incorporate the protozoan into eggs before shell formation.

In the ceca of its host, the histomonad leaves the worm larva and multiples in the lumen and mucosa. Within 2–3 days the tissue forms enter the bloodstream and are carried to the liver by the hepatic-portal system. In the cecal tissues and in the liver the cells divide and grow, forming necrotic areas that are visible on gross inspection. Infection of other organs sometimes occurs, including the cloacal bursa, the kidney, the pancreas, and the spleen. The DNA of histomonads is also found in other tissues where lesions are not seen.

The Role of Earthworms. Earthworms can serve as transport hosts in which heterakid eggs hatch and survive. The larvae persist indefinitely in tissues in an infective state (21). The earthworm, thus, serves as a means for collection and concentration of heterakid eggs from the poultry yard environment.

Earthworm transmission of *Histomonas* to the ring-necked pheasant (*Phasianus colchicus torquatus*) has been of documented importance in a partridge-pheasant histomoniasis outbreak at a game-rearing station in central Iowa (18). On range or pastures, where climate and soil types favor survival of heterakids and earthworms, the latter must be considered in attempts to control a recurrent histomoniasis problem.

Transmission by Direct Contact. Transmission of blackhead within a turkey flock occurs readily by direct contact between susceptible birds and infected birds or fresh droppings and does not require an intermediate host (12, 13, 15). These findings illustrate how an outbreak can spread through a flock of turkeys in a week or 2, killing most of the birds. In chickens, there is little evidence that infections spread in this way, placing more emphasis on contamination of the soil with cecal worm eggs (11).

Although direct infection of turkeys by oral ingestion of viable histomonads in fresh droppings or diseased tissues is possible, their extremely delicate nature makes this route rather unlikely. Histomonads cannot survive long outside the host unless protected by the heterakid egg or earthworm. Several studies showed that oral ingestion of organisms in feces or from cultures did not produce infections in turkeys unless the acidity of the crop was neutralized.

Pathogenicity

Characteristics of the definitive host influence clinical manifestations of infection by *Histomonas meleagridis* more than variations of pathogenicity of the parasite. These characteristics include species, breed, and intestinal flora.

Although naturally occurring infections occur in several species, the turkey is considered the most susceptible host because most infected turkeys suffer morbidity and death. Chickens are easily infected but often have a milder form of the disease. Outbreaks lead to an increase in mortality, culling, and loss of flock uniformity. Some other birds (peacocks, pheasants, etc.) are also severely affected. Variation in susceptibility has been found among different breeds and strains of chickens. Chickens 4–6 weeks old are most susceptible to infection, although turkeys of any age are highly susceptible. The 1990s rash of clinical outbreaks in broiler breeder pullets was unexplained, but it was suspected that concurrent outbreaks of immunosuppressive viral infections contributed by depressing T-cell responses.

Bacterial flora are also important in the development of blackhead disease. Lesions of histomoniasis were not produced in germ-free turkeys or chickens unless bacteria were introduced (37). Disease was produced when *Clostridium perfringens*, *Escherichia coli*, *B. subtilis*, or mixed cultures were present. Isolates of *Histomonas* grown *in vitro* frequently lose pathogenicity in successive passages (6, 7). This fact discouraged early workers from attempting vaccine development using attenuated cultures because there was no way to stabilize the degree of attenuation (39). Although field strains with variable pathogenicity have been found, none has been characterized, with the exception of *H. wenrichi*, now listed as a separate species.

Susceptibility to Physical and Chemical Agents

The naked protozoan is not resistant to environmental conditions outside the bird. Thus, it is not important to practice extensive decontamination, even after an outbreak. Much attention is given to control of the intermediate host, the cecal worm. This is more important in chickens than in turkeys because chicken farms are often contaminated with cecal worms. Turkey farms are rarely contaminated with histomonad-bearing worms; otherwise, every flock would suffer blackhead outbreaks. Instead, outbreaks occur from the fresh introduction of worm eggs into a facility, usually on the shoes of the workers.

Control of worms depends on frequent application of benzamidazole-type wormers. Longer treatment is necessary (2–3 days) for a high degree of worm control. Some veterinarians recommend litter or soil treatment to reduce contamination by worm eggs, but there is no experimental evidence that this is effective.

Incidence and Distribution

There have been no surveys to describe the prevalence of histomoniasis. However, the disease probably occurs wherever suitable avian hosts exist. In general, it is more prevalent in areas favoring the coexistence of the cecal worm *Heterakis gallinarum*, but it is regularly reported by diagnostic laboratories in the United States, Canada, and Mexico (1). Recent outbreaks in Europe emphasize the international prevalence of this disease. The scientific literature includes many reports from Asia. Outbreaks in turkeys tend to be sporadic, whereas exposure in chickens may be chronic. Most of the commercial breeder pullet facilities in North America are thought to be contaminated with *Heterakis*, which are potent reservoirs for histomoniasis. Game birds reared in captivity and some wild birds also serve as reservoirs.

Pathogenesis and Epidemiology

Natural and Experimental Hosts

Numerous gallinaceous birds are reported as hosts for *H. meleagridis*. The turkey, chicken, chukar partridge, peacock, pheasant, and ruffed grouse may be severely affected, while guinea fowl, Bobwhite quail, and ostrich have a milder form of the disease. Ducks may become asymptomatic carriers. The coturnix quail can be infected experimentally, but it is a poor host.

Vectors

The common cecal worm, *Heterakis gallinarum*, is the only worm known to serve as an intermediate host for blackhead (38). Even closely related nematodes are unable to serve as hosts. Worm ova are resistant to environmental conditions and may remain infective for 2–3 years. Most gallinaceous birds are host to the cecal worm, and wild populations may serve as reservoirs. The common earthworm has been shown to consume and harbor infective larvae of the cecal worm, thus serving as a vector. While poorly documented, arthropods such as flies, grasshoppers, sowbugs, and crickets may serve as mechanical vectors. Diagnosticians are sometimes confused by the inability to find cecal worms in birds with histomoniasis. Some of the reasons for this are that the cecal worm remains in larval form for 2–3 weeks and is very small (2–3 mm). Also, the development of histomoniasis

destroys the environment for the worm, so that many are killed or expelled.

Incubation Period

Disease is caused when histomonads penetrate the cecal wall, multiply, enter the bloodstream, and eventually parasitize the liver. Overt signs of histomoniasis are apparent from 7–12 days and occur most commonly 11 days PI. The infection begins with reddening and thickening of the cecal mucosa within 3 days. The incubation period varies with the size of the infective dose. Infections from worm eggs require longer than those beginning from cloacal exposure within an outbreak. Experimentally, cecal and liver lesions in turkeys develop about 3 days earlier with cloacal inoculation compared with infection via heterakid eggs. Once an infection is established in a turkey facility from introduction of cecal worm ova, the outbreak may spread rapidly by direct contact. Turkeys become infective to others within 2–3 days after becoming infected.

Clinical Signs

Signs of histomoniasis in turkeys (Figure 28.9A and B, below) include yellow feces, drowsiness, dropping of the wings, walking with a stilted gait, closed eyes, head down close to the body or tucked under a wing, and anorexia. Sick birds tend to huddle together. The head may or may not be cyanotic, a sign observed by those who gave the disease the name blackhead. About 6–12 days PI, turkeys become emaciated. Infections in chickens may be mild and go unnoticed or may be severe and cause high mortality. Sulfur-colored droppings are seen in the later stages of disease when liver function is severely damaged and bile pigments are excreted through the kidneys. In chickens, the main signs are drooping feathers, morbidity, and closed eyes. Cecal discharges may contain blood, and caseous cecal cores are common. Sometimes gross pathology of blackhead in chickens may resemble cecal coccidiosis.

Clinical Pathology

In chickens, total leukocytes are increased, composed mainly of heterophils, lymphocytes, and basophils. Hemoconcentration occurs with severe dehydration.

In turkeys there is a decline in serum nitrogen, uric acid, and hemoglobin levels during the incubation period, but these return to normal prior to death. Blood sugar levels rise during the cecal phase, decrease during liver lesion development, and drop below normal prior to death. Serum albumin falls very low, but the globulins increase significantly during the acute infection in turkeys (25).

Plasma levels of glutamic oxaloacetic transaminase (GOT) and lactic dehydrogenase (LDH) increase as liver lesions develop in turkeys (26), but glutamic pyruvic transaminase (GPT) remains essentially unchanged. There is very little GPT activity in avian liver or other tissues, suggesting that it is not an important enzyme in birds. Appearance of a brilliant yellow urine pigment coincides with depressed liver function and elevated enzymes resulting from tissue damage. In acutely ill turkeys, the proportion of hemoglobins in the methemoglobin state in the blood is greatly elevated, possibly contributing to cyanosis and the purported blackhead appearance.

Morbidity and Mortality

The degree of illness is variable, especially in chickens and other birds. Turkeys are more uniformly affected, with flock mortality commonly 80%–100%. The time of onset in chickens varies. Blackhead may be diagnosed at 6–7 weeks of age in a flock, then at earlier ages in successive flocks as the disease reservoir becomes established in a facility. Outbreaks are seen as early as 3 weeks. Farmer and Stephenson (8) reported that turkeys confined to areas contaminated by chickens suffered 89% morbidity and 70% mortality. Although losses from histomoniasis in chickens are generally low, mortality has exceeded 30% in some naturally occurring infections. Mortality may occur as early as 6 days PI in experimental infections, but is most common at 9–12 days PI. Occasionally, a strain of *Histomonas* with apparent high virulence for chickens is found. There are no reference strains of *Histomonas*, precluding easy study of this phenomenon.

Gross Lesions

The primary lesions of histomoniasis develop in the ceca and liver (Figure 28.9C, D, E, F). In recent years, lesions are also reported from other organs, such as the spleen, cloacal bursa, pancreas, and kidneys (36). Lesions are observed initially in the ceca. After tissue invasion by histomonads, cecal walls become thickened and hyperemic. Serous and hemorrhagic exudate from the mucosa fills the lumen of ceca and distends the walls with a caseous or cheesy core, and ulceration of the cecal wall may lead to perforation of the organ and cause generalized peritonitis.

Liver lesions in turkeys are often apparent a few days after infection and are highly variable in appearance. Often, the lesion is described as a circular depressed area of necrosis up to 1 cm in diameter and is circumscribed by a raised ring. Although these lesions are often seen (Figure 28.9C,F), they may take on other appearances. In heavy infections, lesions may be small, numerous, and mostly subsurface, and they may involve a large part of the liver. In rare cases of recovery, lesions leave purulent scars on the surface of the liver. The liver may be enlarged and discolored green or tan. Lesions in lung, kidney, spleen, and mesenteries are sometimes recognized as white rounded areas of necrosis.

Histopathology

Initial invasion of the cecal wall results in hyperemia and heterophil leukocyte infiltration, probably a combined response to bacteria, histomonads, and heterakid juveniles (2). Within 5–6 days, numerous histomonads are visible as pale, lightly stained, ovoid bodies (Figure 28.9G, H) within lacunae in the lamina propria and muscularis mucosa. Large numbers of lymphocytes and macrophages have infiltrated tissues by this time, and the heterophil population has also increased. Cecal cores are composed of sloughed epithelium, fibrin, erythrocytes, and leukocytes along with trapped cecal ingesta. The core initially may be amorphous and red tinged, but by

about 12 days, it appears laminated, dry, and yellowish from buildup of successive layers of exudate. By 12–16 days, giant cells appear in the tissues of the cecum. Coagulation necrosis and histomonad invasion extend well into the muscular tunic, extending nearly to the serosa. In survivors, histomonads are scarce within the tissues by 17–21 days and are mostly concentrated near the serosal layers. Large numbers of giant cells form and may appear grossly as granulomata bulging upon the serosal aspect of the cecum. Old lesions, after recovery, are characterized by lymphoid centers scattered throughout the cecal tissue. Expulsion of cores and the regeneration of epithelium may occur, particularly in chickens, but the cecum may suffer permanent damage.

The liver has microscopic lesions visible by 6–7 days PI and consisting of small clusters of heterophils, lymphocytes, and monocytes near portal vessels. Histomonads are difficult to visualize in these areas. After 10–14 days, the lesions are enlarged, becoming confluent in some areas. There is extensive lymphocytic and macrophage infiltration, and heterophils are present in moderate numbers. Hepatocytes in centers of the lesions necrose and disintegrate. Many individual or clustered histomonads are visible in lacunae near the periphery of lesions. From 14–21 days PI, necrosis becomes increasingly severe, resulting in large areas consisting of little more than reticulum and cellular debris. Histomonads at this stage are present mostly as small bodies in macrophages. If recovery occurs, foci of lymphoid cells remain, along with areas of fibrosis and regenerating hepatocytes.

Immunity

Immunity to blackhead has not received much study, and most of the reports on this topic are more than 50 years old. Early work suggested that a partial immunity developed after infections, which might or might not be adequate to protect against reinfection (3, 39). Most work with immunity in turkeys has relied on drug treatment to terminate infections, because turkeys usually die from the disease.

Attempts to immunize chickens and turkeys with histomonads attenuated *in vitro* have been only partially successful. Some protection was demonstrated against cloacal inoculation of pathogenic or attenuated strains of histomonads, but very little against histomonad-containing heterakid eggs (22). Although reports are not in agreement, some protective immunity is obtained while drug therapy is being administered. Research on the use of attenuated strains for immunization was abandoned because it was considered impossible to stabilize the degree of attenuation *in vitro* and impractical to inoculate birds with the live cultures.

Chickens and turkey produce antibodies against *H. meleagridis* antigens prepared from infected livers and ceca, and after natural or experimental infections. In some reports, antibodies in turkeys and chickens did not confer resistance to reinfection. Such antibodies persisted for a considerable time (3). Birds recovering from histomoniasis may harbor parasites in the ceca without signs or lesions of the disease (5).

Recent experimental work suggests that infected birds develop precipitins and lysins in the serum, and that birds given injections of *H. meleagridis* antigen may develop good protection against reinfection.

Passive Immunity. Attempts to transfer immunity from resistant to susceptible chickens and turkeys by repeated intraperitoneal injections of serum from immune birds have been unsuccessful. When birds receiving immune serum were challenged by cloacal inoculation of infected liver homogenates, turkeys died from histomoniasis, and all chickens developed typical cecal lesions (4, 5).

Diagnosis

Most experienced poultry workers make a field diagnosis in turkeys on the basis of gross appearance of lesions. Laboratory confirmation is sometimes necessary to rule out concurrent infections with other agents that affect the cecum or liver (coccidiosis, salmonellosis, aspergillosis, and upper digestive tract trichomoniasis). Chickens are more likely to have lesions in the ceca that can be confused with other diseases, particularly cecal coccidiosis.

The presence of characteristic lesions in turkeys is sufficient for presumptive diagnosis. Identification of histomonads by microscopy adds confidence to the diagnosis. The organisms are most easily observed with phase-contrast microscopy with fresh specimens. Histomonads remain active and are more easily identified if the microscope stage is warmed, either with a special stage incubator or small incandescent light bulb. Tissue forms are not easily identified by microscopy.

For routine diagnostic histopathology, any of several stains, including hematoxylin and eosin or periodic acid-Schiff (Figure 29.9G), may be used (18). Excellent cytologic preparations have been made from fresh cultures using Hollande's cupric picroformol and a protein-silver stain.

Where freshly killed birds are available, it is a simple matter to cultivate histomonads *in vitro* as a diagnostic aid, using Dwyer's medium (6, 24). If samples are taken from freshly killed birds the test is more than 75% accurate. The medium consists of 85% Medium 199 in Hank's balanced salt solution, 5% chicken embryo extract (CEE50), and 10% horse or sheep serum, adjusted to pH 7.2. A small amount (10–20 mg) of rice powder (organically produced rice flour from a health food store) is added, and then the tubes are sealed, incubated at 4°C overnight, and observed with an inverted microscope. Cultures obtained in this way can be maintained by subculturing every 2–3 days, and can be used to infect birds experimentally, but they tend to become nonpathogenic within 6–8 weeks.

While it is not usually necessary for diagnosis, PCR tests are highly accurate in identification of *H. meleagridis*. Recent tests rely on primers based on the small-subunit RNA fraction (21).

Prevention and Control

Because there are no chemotherapeutic products available for treatment of infections, and there is no commercial vaccine for histomoniasis, control measures focus on prevention.

The primary reservoir of infection is the cecal worm ova. Thus, prevention is largely a matter of avoidance of contact of susceptible birds with sources of egg contamination and prevention of exposure to carriers.

For the protection of turkeys, exclusion of chickens from any contact is essential because chickens may often harbor large numbers of egg-laying cecal worms. Outdoor turkey ranges can become contaminated with heterakid eggs, creating a situation in which histomoniasis recurs in turkey flocks for many years. Because of the longevity of infectious eggs, range rotation is not practical as a solution.

Rearing turkeys indoors tends to reduce outbreaks of blackhead, but exacerbates the extent and severity of outbreaks. It is most likely that outbreaks arise by the introduction of a small number of cecal worm ova into the growing facility. After introduction, the infection spreads throughout the flock by direct contact. The recent observation that histomoniasis cannot spread within a flock without direct contact between birds offers a potential method for containing outbreaks. If the growing facility is divided into subunits, even by netting or other barriers, the outbreak will be limited to the contaminated units.

Leghorn pullets and broiler breeder pullets often become infected in problem houses where worm eggs have built up in number for several years. In some areas histomoniasis is reportedly common in broilers. In some instances, disinfection may have value in killing worm eggs, but there is no experimental work to support this conclusion.

The discovery that cecal coccidiosis (*E. tenella*) interacts with histomoniasis in chickens is important because coccidia are often present in growing facilities. In experimental tests, the number of birds showing liver lesions, as well as the severity of lesions, was increased when both parasites were present, even when low infections of coccidia were used (27). These results suggest that better prevention of coccidiosis in breeder and layer pullets is important in avoiding problems with blackhead.

Chemotherapy

Management practices alone are rarely adequate to keep the disease at a low level in commercial flocks; therefore, preventive chemotherapy is sometimes practiced during the high-risk part of the growout. Presently, the only product available for the prevention of histomoniasis in poultry is nitarsone (Histostat®, Alpharma, Clifton, NJ).

Five drugs were at one time registered for treatment of outbreaks in the United States (9), including 2 arsenicals, 2 nitroimidazoles, and 1 nitrofuran (Table 28.5). However, regulatory action has removed the most useful drugs (nitroimidazoles) from the market. These products are also unavailable in other countries. Preventive use of nitarsone is usually effective in keeping blackhead at a low level, but its use in breeder stock presents additional problems. Breeder pullets and males are commonly reared on skip-a- day feeding programs, which lead to exacerbated toxicity of the arsenic. The arsenicals are not strong enough to be effective as treatment drugs and are not approved for this use. For a historical review of older literature on antihistomonal drugs, see Joyner et al. (17) and Joyner (16).

Because of the close association of *H. meleagridis* with bacteria, it has become common practice to treat outbreaks with antibiotics. While it is generally beneficial to administer antibiotics to combat secondary infections, there is no evidence that such treatments have a direct effect on histomoniasis (14).

Worm control is considered a central part of blackhead control programs for chickens. Frequent worming with benzamidazole-type anthelmintics is known to reduce exposure to both worms and histomonads. It is important to administer wormers at least 1 week prior to the usual expected time of outbreaks, based on the history for each farm.

Table 28.5. Feed additives or water treatments at one time registered in the United States for the prevention or treatment of blackhead disease in turkeys.[a]

			Conditions of Use		
Drug	**Trade Name**	**Supplier**	**Use Level**	**Withdrawal**	**Approval for Chickens**
Carbarsone[b]	Carb-O-Sep	N/A	0.025–0.037%	5	No
Dimentridazole[b]	Emtrymix	N/A	0.015–0.02%[c] or 0.16–0.08%[d]	5	No
Furazolidone[b]	nf-180	N/A	0.011%[c]	5	Yes
	Furox	N/A	0.022%[d]	5	Yes
Ipronidazole[b]	Ipropran	N/A	0.00625%[c]	4	No
			0.0625%[c]	4	No
Nitarsone	Histostat-50	Alpharma	0.01875%	5	Yes

[a]Some products were also available for water treatment.

[b]Only nitarsone remains available in the USA.

[c]Preventive level.

[d]Treatment level.

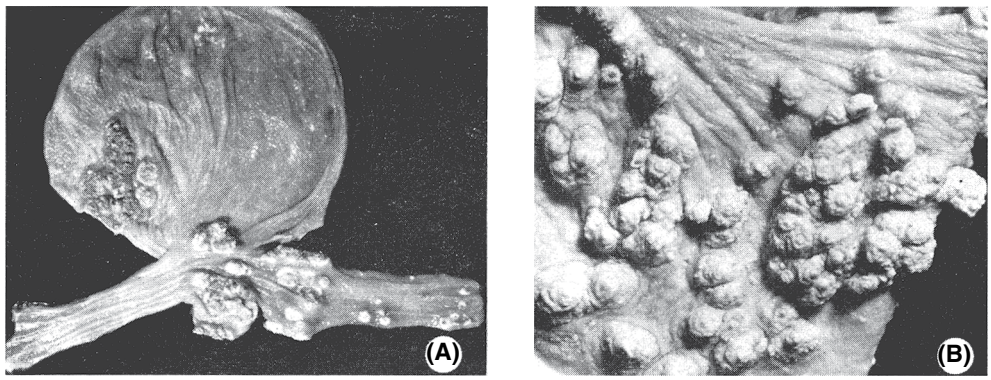

Figure 28.11. (A) Necrotic ulceration of the esophagus and crop seen in trichomoniasis. (B) Necrotic ulcers characteristic of trichomoniasis of upper digestive tract. Note pyramidal shape of tissue (W.R. Hinshaw and A.S. Rosenwald)

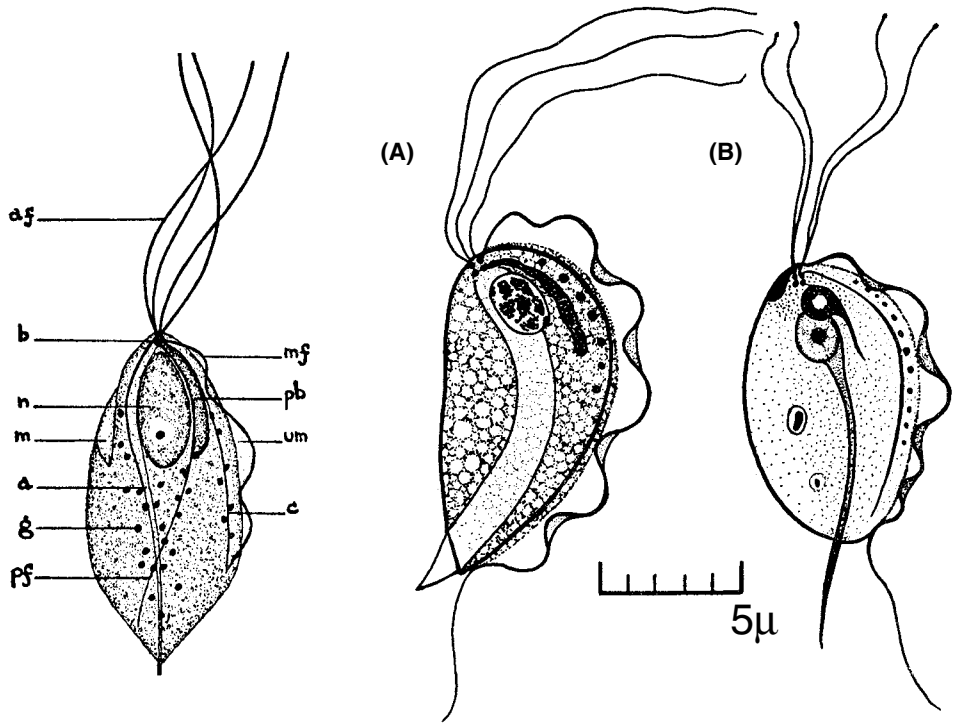

Figure 28.12. *Trichomonas gallinae*, semidiagrammatic (left): (a) axostyle, (af) anterior flagellum, (b) blepharoplast, (c) costa, (g) cytoplasmic granules, (m) mouth, (mf) marginal filament, (n) nucleus, (pb) parabasal body, (pf) parabasal fibril, (um) undulating membrane. (STabler) Two common trichomonads of the lower digestive tract of domestic birds (right), as specimens fixed in Schaudinn's fluid and stained with Heidenhain's hematoxylin may appear. (A) *Tritrichomonas eberthi*. (B) *Trichomonas gallinarum*. (E.E. Lund)

Trichomoniasis

Introduction

Trichomoniasis in birds, affecting the upper digestive tract, is caused by the flagellated protozoan *Trichomonas gallinae* (Figure 28.11A, B). In pigeons, it causes a condition known as canker. Turkeys, chickens, and a wide variety of wild birds are parasitized with varying degrees of pathogenicity (20).

Description

These intestinal flagellates are rapidly moving, pear-shaped protozoa that range in size from 5–9 μm in length and from 2–9 μm in width (Figure 28.12). There are typically 4 free flagella arising from a basal granule at the anterior pole of the organism. A slender axostyle usually extends well beyond the posterior end of the body. An undulating membrane originates at the anterior pole of the body and ends short of the posterior pole, with the enclosed flagellum not trailing free at the posterior end. The flagella and internal structures can be seen only with the aid of phase-contrast microscopy or special stains.

Incidence and Distribution

Squabs usually become infected with their first taste of "pigeon milk" from the crop of adults and usually remain carriers throughout life. With virulent strains, mortality may be as high as 50% before sufficient protective immunity develops. Pigeons are often blamed for transmission of trichomoniasis

to turkeys and chickens. The economic impact of the disease in turkeys and chickens is difficult to assess, although infections are occasionally reported. When captive birds of prey such as falcons are allowed to feed on pigeons, infection may result in a condition known as frounce among falconers.

Life Cycle

T. gallinae reproduces by longitudinal binary fission. Cysts, sexual stages, or vectors are not known. The organism is transferred to squabs by infection of "pigeon milk" from adults. In chicken and turkey flocks, infection is spread by contamination of drinking water and perhaps feed.

Pathogenesis and Pathology

Nearly all pigeons are carriers of this organism. The virulence of *Trichomonas* varies widely, with some strains capable of causing mortality. At one time investigators considered trichomoniasis to be synonymous with blackhead disease. However, these investigators failed to consider that more than 1 parasite might produce lesions of similar appearance. Affected birds may cease to feed and become listless, ruffled in appearance, and emaciated before death. A greenish to yellowish fluid may be seen in the oral cavity and may drip from the beaks of infected birds.

Gross Lesions

T. gallinae invade the mucosal surface of the buccal cavity, sinuses, pharynx, esophagus, and crop and occasionally the conjunctiva and proventriculus (Figure 28.11A, B). The liver is frequently invaded, and occasionally other organs—but not the digestive tract below the proventriculus—are involved.

Lesions appear initially as small, circumscribed caseous areas on the surface of the oral mucosa, which may be surrounded by a thin zone of hyperemia. These may enlarge and become confluent. The build-up of caseous material may be sufficient to occlude the lumen of the esophagus partially or completely. These lesions eventually may penetrate tissue and extensively involve other regions of the head and neck, including the nasopharynx, orbits, and cervical soft tissues. In the liver, lesions appear on the surface and extend into the parenchyma as solid, white to yellow circular or spherical masses.

Histopathology

Pigeons infected with a virulent strain of *T. gallinae* had purulent inflammation with caseous necrosis as the predominant lesion (33). Trichomonads multiply in secretions and on the mucosal surface of the oropharynx. Ulceration of the mucosa with a massive inflammatory response, primarily heterophils, is well established by the fourth day of experimental infections. In the liver, focal necrotic abscesses occurred in all zones of lobules, with an inflammatory reaction characterized by mononuclear cells and heterophils. As liver lesions progressed, no intact hepatocytes remained in the center of foci; trichomonads were most numerous at the periphery.

Immunity

The relatively high incidence of infections in otherwise normal pigeons can be attributed to strain variations, acquired immunity, or both. Pigeons are immune to disease from virulent strains of trichomonads after recovery from sublethal trichomoniasis. Plasma from pigeons harboring any of 3 strains of *T. gallinae* could protect other pigeons against disease but not infection from a virulent strain.

Antigens of *T. gallinae* have been studied in regard to taxonomy with the conclusion that virulence and antigenic composition were related (7).

Diagnosis

Clinical signs and gross lesions are highly suggestive and may be confirmed by microscopic observation of organisms in direct wet smears from the mouth or crop. Histopathologic examination or cultivation of organisms in artificial media may help in cases in which the parasites are absent in fresh smears. Trichomoniasis must be differentiated from candidiasis and hypovitaminosis-A, which can produce somewhat similar lesions. History, cultivation for fungi, and histopathologic examination may prove useful in resolving problem diagnoses.

Several other species of flagellates that inhabit the avian gastrointestinal tract are frequently misidentified as *T. gallinae*. These other species of trichomonads and more distantly related flagellates have never been unequivocally demonstrated to be pathogenic for the avian host. Their recognition as harmless commensals will prevent unnecessary expenditures for therapeutic measures.

One trichomonad, *Tetratrichomonas gallinarum*, is a common inhabitant of the cecum of chickens and other gallinaceous birds. This trichomonad or a closely related species occasionally has been isolated from liver and blood. Although lesions have been ascribed to this organism, no confirmation of pathogenicity has come from experimental infection.

Other lower intestinal protozoa such as *Chilomastix gallinarum* (Figure 28.13), a cyst-forming flagellate with a large cytostomal cleft but no undulating membrane, and *Cochlosoma anatis*, with a ventral sucker covering half the surface of the body, are apparently nonpathogenic. Although additional controlled experiments with flagellates found in the lower intestine are needed, for the present, they should not be considered important.

Prevention and Control

Because *T. gallinae* is transmitted from parent to squab in pigeons and by contamination of feed and water by oral fluids in the case of domestic fowl, sick birds should be removed from a flock. Drugs with activity against other related protozoa (*H. melelagridis*, *Entamoeba histolytica*, and *Giardia lamblia*) are active against trichomoniasis in pigeons or turkeys; however, none is approved for use in domestic birds. McLoughlin (31) found dimetridazole useful at a level of 0.05% in drinking water for pigeons. This

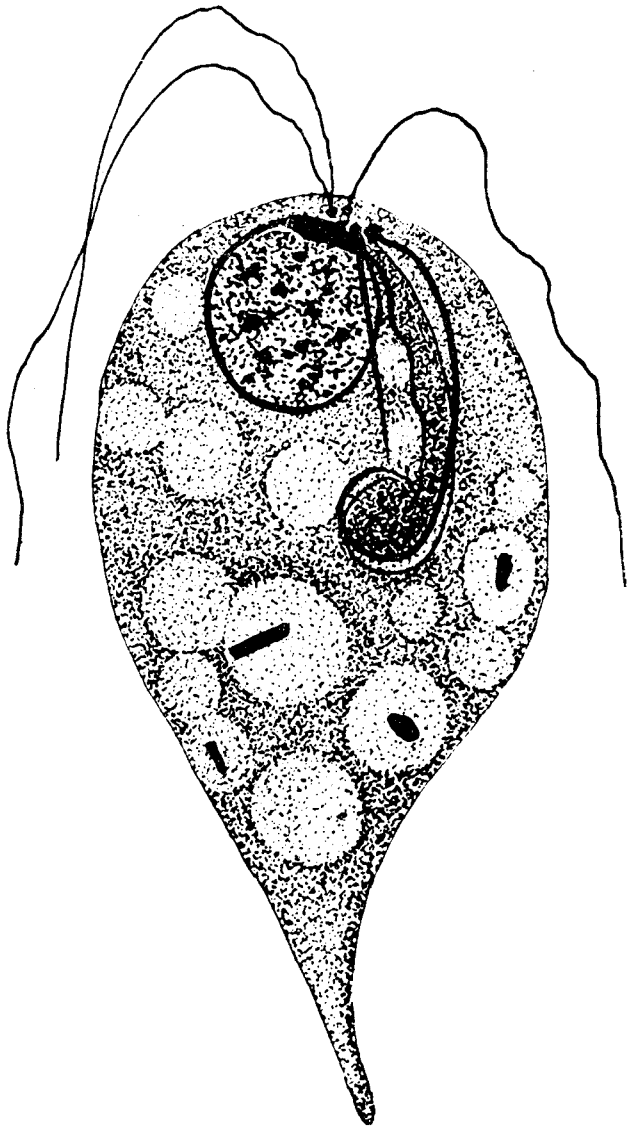

Figure 28.13. *Chilomastix gallinarum*, semidiagrammatic, illustrating details of morphology. (W.C. Boeck and M. Tanabe)

drug is no longer available in the United States. There is no vaccine for this parasite.

Hexamitiasis

Etiology and Distribution

Hexamitiasis, or infectious catarrhal enteritis, of poults is caused by the protozoan *Spironucleus meleagridis*. There is apparently no well-known common name for this parasite other than the original generic name *Hexamita*. There is no good measure of economic losses from this parasite. However, the USDA estimated that an annual loss of $667,000 occurred from hexamitiasis in turkeys from 1942–1951 (40). Cases of hexamitiasis are encountered sporadically in diagnostic laboratories in the United States. The disease has been reported from several areas of the United States, Canada, Scotland, England, and Germany. The organism has also been found in pheasants, quail, chukar partridges, and peafowl, which may be a source of infection for range-reared turkeys. The 8 prominent flagella include 4 anterior, 2 anterolateral, and 2 posterior. The 4 anterior flagella are recurved along the body (Figure 28.14). McNeil et al. (32), who named the species, described it as being 6–12.4 × 2–5 μm in size with binucleate large endosomes.

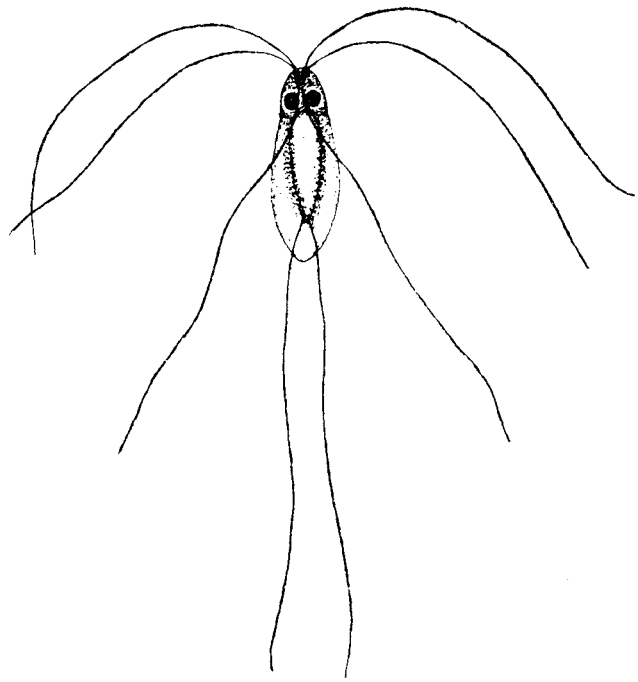

Figure 28.14. *Spironucleus meleagridis* from the intestine of a turkey.(25)

Pathology

Affected poults do not show specific signs, but a watery diarrhea occurs that may become yellowish later in the course of the disease. The poults at first are nervous and active but later tend to become listless and huddled. Convulsions and coma may occur as the terminal stage is approached.

Lesions include catarrhal inflammation and atony resulting in distention, especially in the upper small intestine. Intestinal contents are watery, and large numbers of *S. meleagridis* may be seen in the crypts upon microscopic examination. A yellowish discoloration of the liver surface was described in an outbreak in Germany.

Diagnosis

The presence of watery diarrhea and the microscopic demonstration of flagellated *S. meleagridis* in fresh smears of duodenal contents are sufficient to establish the diagnosis. Survivors may become carriers; thus, the parasites may be seen without any signs of infection. These parasites are easily distinguished from other protozoa by their rapid,

darting movement. They are small in comparison with other flagellates.

Control and Treatment

There is no effective treatment, although butynorate (0.0375%) and chlortetracycline (0.0055%) were approved for use at 1 time. There is no vaccine for this parasite. The removal of carrier birds, the separation of older stock from poults, and the exclusion of other avian host species from the area of the poult flock are thought to minimize transmission. Attention to principles of good management is considered important in reducing losses to this and other parasitic diseases.

Sporadic Protozoa in the Digestive Tract

Several species of the genera *Entamoeba* and *Endolimax* occur naturally in the ceca or feces of various domestic fowl or can be established experimentally. Apparently, none of these are pathogenic; they exist by feeding on intestinal contents.

The amebas have irregularly shaped trophozoites with a single nucleus with a more or less prominent endosome. They produce cysts containing 1, 4, or 8 nuclei. Phase-contrast microscopy or stained preparations is recommended for observing these organisms. A number of species have been reported (20, 30).

Miscellaneous and Sporadic Protozoal Infections

Alex J. Bermudez

Cochlosoma anatis

The genus *Cochlosoma* was created by Kotlan in 1923 to include a peculiar flagellate, *C. anatis*, found in the intestines of the European domestic duck (128). The most striking feature of these flagellated protozoa is a distinct ventral adhesive disk. The significance of these enteric protozoa has been uncertain for many years. Previous editions of *Diseases of Poultry* suggest that *C. anatis* is either a parasite of unknown significance (89) or apparently nonpathogenic (95). More recent case reports and research suggest *C. anatis* is a significant pathogen in both turkeys and ducks (13, 16, 27, 125). The parasite appears to cause limited pathology to the intestinal tract but causes diarrhea and stunting of both turkey poults and ducklings. This parasite cannot be cultured *in vitro* (88). Material for experimentation must be collected from the feces or intestines of infected birds.

Etiology and Classification

Cochlosoma was described in 1923 from the duck (128). Tyzzer, in 1930, described 2 similar genera from the intestines of the ruffed grouse. He erected a new family, Cochlosomidae, to include the type genus *Cochlosoma* Kotlan (128). *C. anatis* is the type species for this family (110). Numerous authors have noted similarities between *Cochlosoma* and close relatives *Giardia* and *Trichomonas* (27, 76, 98, 109). The resulting question is whether *Cochlosoma* should be assigned to the order Retortamonadida or Trichomonadida. The adhesive disc is the primary similarity between *Cochlosoma* and *Giardia* (81). *Cochlosoma* has a parabasal apparatus, tubular axostyle, and crescent shaped pelta, all of which are similar to trichomonads (81). Pecka et al. conducted an extensive ultrastructural study of *Cochlosoma* in an attempt to more accurately classify these protozoa (110). In this report, a close relationship between *Cochlosoma* and Retortamonadida was rejected and the ultrastructural homology of *C. anatis* with *Trichomonas* was demonstrated, justifying the classification of this genus within the order Trichomonadida Kirby, 1947 and family Cochlosomatidae Tyzzer, 1930, emend. (83, 110). These taxanomic relationships have been confirmed by the phylogenetic analysis of the small-subunit rRNA gene (55).

Morphology

By light microscopy, *C. anatis* is general pyriform to ovoid in shape, 6–12 μm long and 4–7 μm wide. The anterior end is wide and tapering to a narrowly rounded posterior end. A characteristic adhesive disc on the anteroventral surface is the predominate morphologic feature on light microscopy (Figure 28.15). The parasite has a single nucleus and can be distinguished readily on Giemsa- or trichrome-stained impression smears (27). The trophozoites are distinguished easily from other protozoan flagellates in wet mount preparations by their characteristic motion. Flagella produce a whipping motion, which causes a stiff jumping or jerking motion and results in the parasite rotating around its long axis as it moves forward. This motion contrasts with the jerking motion of *Trichomonas* and the rapid darting motion of *Spironucleus* (Hexamita) (98). Although *C. anatis* has an undulating membrane, this feature is not distinct on wet mount preparations of the parasite examined under standard light microscopy.

The morphology of *C. anatis* with scanning electron microscopy is illustrated by Figure 28.16 (27, 88, 110, 125). On scanning electron microscopy, the trophozoite has a conical shape. The prominent ventral adhesive disc forms the base of the cone, and the body tapers toward the proximal end (27). The parasite has a prominent lateral groove, an undulating membrane, 6 flagella, and an axostyle (88). On the left side, the disc is interrupted by a lateral groove, which extends along

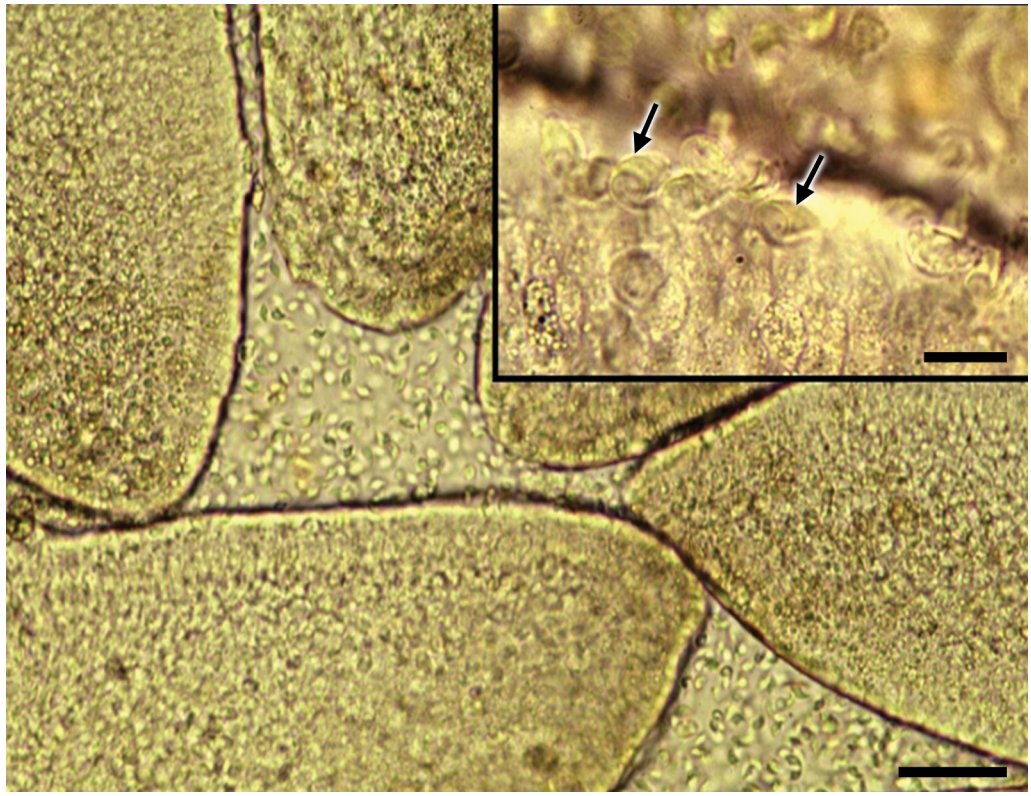

Figure 28.15. *Cochlosoma anatis* as viewed by light microscopy in a wet mount preparation of mucosa of the jejunum of a turkey. Numerous protozoan cells are evident between the intestinal villi. Bar = 80 mm. Inset: Higher magnification; distinct ventral disc indicated by arrows. Bar = 10 mm.

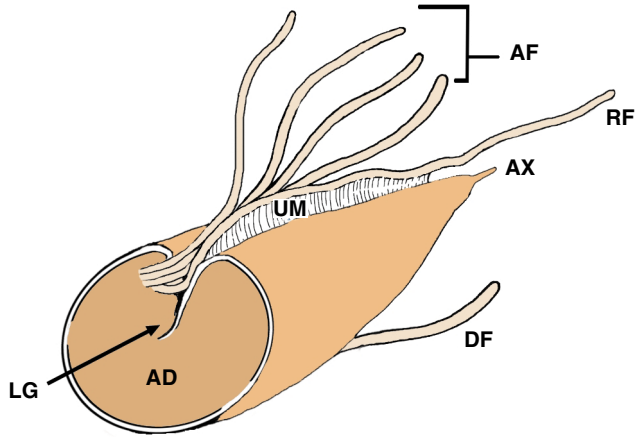

Figure 28.16. *Cochlosoma anatis*: Prominent external features, ventral view. Ventral adhesive disc (AD), recurrent flagellum (RF), undulating membrane (UM), anterior flagella (AF), axostyle (AX), and anterior opening to the lateral groove (LG). The lateral groove runs the full length of the trophozoite adjacent to the undulating membrane. Not visible is the origin of the single dorsal flagellum (DF).

the length of the body (110). Four anterior flagella emerge as 2 pairs, just above the lateral groove, on the left wall of the ventral disc (110, 125). The recurrent flagellum arises with the 4 anterior flagella and is associated with the undulating membrane and trails beyond. The sixth flagellum arises to the left of the body midline on the dorsal surface. The axostyle extends from the posterior end of the trophozoite as a thin projection (110). The organelle structure of *C. anatis* has been extensively characterized by transmission electron microscopy (110).

Transmission, Incubation Period, and Life Cycle

Oral or cloacal inoculation of fecal material containing *C. anatis* has been used to reproduce the disease in ducklings (13). Ducks shed trophozoites by 7 days post inoculation (PI) (13). Oral transmission was also demonstrated experimentally in turkeys (88). Some turkeys had positive intestinal mucosal scrapings by 4 days PI, and all poults were infected by 6 days PI (88). Transmission was also successful when naïve turkeys were placed with infected turkeys. House flies have been implicated as a potential means of transmission from the environment to a susceptible host (96).

Reproduction in this species was recorded briefly by Kotlan. He observed longitudinal division and cysts with 4 or more nuclei but published no drawings of divisional stages or of the cysts and gave no dimensions for the cysts (110). Division of *C. anatis* by longitudinal fission has also been described in subsequent studies, but no cysts have been reported (76, 128). Studies by Evans et al. (39) document both the longitudinal binary fission of *C. anatis* as well as pseudocyst formation. Pseudocysts also produced active *C. anatis* infection in turkeys (39).

Pathogenesis and Epidemiology

Natural and Experimental Hosts

Naturally occurring *C. anatis* infections have been described in the turkey, duck, goose, and coot (13, 27, 109, 128). Experimental *C. anatis* infections have been produced in bobwhite quail and chickens (88). *Cochlosoma spp*. infections have been reported in a wide variety of wild birds including the Eastern robin, American magpie, woodcock, waxbill, and a variety of finches (109, 111, 128). These reports suggest wild birds, particularly waterfowl, may serve as a reservoir for *C. anatis*.

Site of Infection

Cochlosoma is found in the cecum of the European domestic duck, and mainly in the colon or lower ileum of ducks (76). Travis found these protozoa to be common in the cloaca of ducks, frequently present in the colon, and occasionally present in the cecum (128). Similarly, Watkins et al. found *C. anatis* only in the last 10 cm of the colon and in the cloaca of ducks (131). One-day-old ducklings experimentally inoculated with *C. anatis* were infected in both the jejunum and colon 25 days PI (13). In a goose, C. anatis was found primarily in the colon and also in the cecum (109).

In a study of infectious catarrhal enteritis (hexamitiasis) in turkeys, numerous poults were concurrently infected with *Cochlosoma* throughout the intestinal tract, and in adults, infection was noted in the region of the cecal tonsil (98). In a natural outbreak of enteritis in turkeys, large numbers of *C. anatis* were found in the small intestines with isolated protozoa found in the ileum and none in the cecum or colon (27). In an experimental infection of turkeys, trophozoites were present in the duodenum, jejunum, and ileum of all birds and also the cecum and colon of some birds (88). *C. anatis* was present in the ileum of bobwhite quail and the cecum of 1 experimentally inoculated chicken (88).

Clinical Signs and Pathogenicity

Kotlan noted in his first description of *C. anatis* infection in ducks that the intestinal wall was swollen and catarrhal at the point where a mass of the flagellates were attached and the intestinal contents were mixed with blood. Kimura was unable to attach any pathogenic significance to this organism in ducks but noted inflamed intestinal tracts that were ascribed to a bacterial infection rather than to *C. anatis* (76). Travis did not observe pathogenic changes in the birds he studied (128). Severe runting and mortality were reported in ducklings infected with *C. anatis* (13). Numerous *C. anatis* with low numbers of *Trichomonas* and *Spironucleus* (Hexamita) were observed, but no other microscopic lesions were noted. *C. anatis* was highly suspected as the cause of the runting, and the pathogenicity of *C. anatis* was then studied experimentally in ducks. Although the inoculum contained low numbers of Hexamita spp. and trichomonads and *Campylobacter jejuni* was isolated, it was concluded that *C. anatis* was at least implicated in the severe runting (reduced body weight and delayed feather growth) of ducklings. Many infected ducklings also died of secondary Gram-negative bacterial septicemia (13). The same authors in a separate experiment found *C. anatis* infection increased intestinal villus length and altered mucosal enzyme concentrations in ducklings (14).

McNeil and Hinshaw found that *C. anatis* was often present in the intestines of turkeys in cases of hexamitiasis (98). They questioned the significance of this parasite in turkey poults because in their experience *C. anatis* was always found in association with *Spironucleus* (Hexamita) or in combinations with *Spironucleus* and *Salmonella*. Campbell reported a case of *C. anatis* infection in turkeys in which affected turkeys, 2–10 weeks of age, had severe catarrhal enteritis (23). Although the clinical signs in these cases were attributed to *C. anatis* because it was the predominate organism, *Trichomonas* and *Spironucleus* were also usually present. Cooper et al. identified *C. anatis* as the likely etiologic agent in a series of cases of diarrhea and enteritis in turkeys 7–12 weeks of age, with body weight gains depressed an average of 16% at processing (27). However, recent experimental *C. anatis* infections in turkeys would suggest that this protozoan causes little or no microscopic change in the intestinal tract (15, 17). A combination of *C. anatis* and turkey coronavirus was more pathogenic than either agent alone (125). However, both the *C. anatis*- and coronavirus-infected poults gained less than the negative controls. These findings are interesting in that *C. anatis* infections in turkeys often occur in combination with a variety of enteric viruses or other enteric pathogens. All these experimental findings with *C. anatis* are in general agreement with the case report by Cooper et al. in which a 16% decrease in body weight was noted in *C. anatis*-infected flocks (27).

Finch aviaries have reported significant mortality at 6–12 weeks of age as the result of *Cochlosoma* infections (91, 111). Clinical signs included debility, dehydration, and the passing of whole seeds in the droppings.

The exact role of the ventral adhesive disc in the pathogenicity of *Cochlosoma* is still unknown. In multiple scanning and transmission electron microscopy images, a clear indentation in the mucosal brush border of the hosts with the same size and shape as the ventral adhesive disk suggests that the ventral disc serves as the attachment to the intestinal mucosa (27, 110, 131). It appears likely that this attachment to the microvillous border plays some role in pathogenicity of *C. anatis* in turkeys and ducklings. Whether this attachment causes a direct pathologic effect or a mechanical blockage of nutrient absorption or in some other way interferes with nutrient utilization has not been fully characterized.

Prevention and Control

Treatment

Multiple reports have shown that natural or experimental *Cochlosoma* infections can be treated successfully with members of the nitroimidazole family. However, these products are no longer available for use in poultry. Experimental infection of ducklings treated orally at 12 days PI with 7.5 mg

of metronidazole/100 g of body weight for 5 days resulted in complete compensatory weight gain (13). In waxbills, an outbreak was successfully treated with 250 mg/L of metronidazole in the drinking water for 3 days. (111). During a survey for *Cochlosoma* infection in finches, the evaluation of the efficacy of metronidazole and ronidazole showed that at all dosages and duration of treatments investigated resulted in the clearance of the infection (47). Metronidazole and dimetridazole given at either 30 or 60 mg/L successfully eliminated the organism (99), but not when either drug was given at 15 mg/L. Metronidazole administered at 100 mg/L in the drinking water completely eliminated the negative production effects of *C. anatis* infection in turkeys (17).

Roxarsone at 0.002% in the drinking water did not reduce the number of *C. anatis* trophozoites in infected birds (99). The use of roxarsone in the drinking water at the recommended concentration (0.002%) improved the production performance compared with a *C. anatis*-infected group but did not cure the infection (15). Finally, roxarsone in the drinking water given at 2 times the label-recommended dose (0.004%) for 2 days followed by 3 days at 0.002% prevented the negative production effects of a *C. anatis* infection and significantly decreased the parasitic burden (15). Because this product is no longer available in the United States, such treatment can no longer be recommended.

Prevention

As with most poultry diseases, the prevention of *C. anatis* infection can best be accomplished by not introducing the organism onto the poultry farm. Introduction by both human traffic and wild birds, particularly waterfowl, appear to be the greatest risk factors for the introduction of this parasite onto the farm. *C. anatis* is killed in droppings that are allowed to dry at room temperature for 24 hours (15). Phenolic or quaternary ammonium disinfectants and 10% formalin all kill the protozoa with a 10-minute contact time (17). Given these parameters, eradication of this parasite can be accomplished readily from a depopulated farm.

Nitarsone, a feed additive, has been used to prevent *C. anatis* infection in turkeys in the United States. The efficacy of this prevention program is uncertain. Feeding nitarsone prior to the inoculation of turkeys with *C. anatis* did not prevent infection, and no differences were observed in trophozoite numbers in treated and control poults (130). Other experimental studies suggest that nitarsone can significantly decrease the parasitic burden of infected poults during a 2-week experimental period (15). In this study, production losses were only slightly ameliorated using this feed additive.

Leucocytozoonosis

Leucocytozoonosis affects blood and tissue cells of the internal organs of birds. Reviews of this and other parasitic diseases have been summarized by Lund (90), Levine (84), and Fallis et al. (41).

Leucocytozoon was assigned to the order Haemospororina of the phylum Apicomplexa (83, 87). Similarities in life cycle and ultrastructure of some life stages of *Leucocytozoon*, *Haemoproteus*, and *Plasmodium* warrant inclusion of all 3 genera in a single family, Plasmodiidae (83, 84). Approximately 60 valid *Leucocytozoon* species have been described, all in birds, except a single *Leucocytozoan* species observed in the teiid lizard in Brazil (58, 83).

The life cycle requires 2 hosts; sporogony is in insects, although schizogony (merogony) and gametogony are in tissues or blood cells, respectively, of the vertebrate host. *Leucocytozoon* is prevalent in areas with a suitable ecology and ethology for dipterous invertebrate hosts, simuliid flies and culicoid midges. At least 3 species of *Leucocytozoon* reported in domestic fowl are known to cause outbreaks in North America resulting in economic losses in ducks, geese, turkeys, and chickens. Outbreaks of leucocytozoonosis are sporadic in North America (2), but the disease is relatively common in the open chicken houses of southern and eastern Asia (135), the Philippines, Indonesia, and eastern Africa (30).

Leucocytozoon simondi Mathis and Leger 1910

Infection with *L. simondi* has been reported from 27 species of ducks and geese in United States, Canada, Europe, and Vietnam by Hsu et al. (58). *L. anatis* from ducks and *L. anseris* from geese are considered synonyms of *L. simondi*. Approximately 14%–20% of ducks and geese along the northeastern seaboard of North America carry *Leucocytozoon* infections (8, 10). Eighty percent of geese at Seney Wildlife Refuge in Michigan had some parasitemia in 1963 just prior to the egg-laying season, and each year all goslings become infected (57).

Ducks and geese are suitable hosts for *L. simondi*, but chickens, turkeys, pheasants, and ruffed grouse are not.

Bloodsucking flies known to serve as the vector for *Leucocytozoon* in ducks include *Simulium venustum*, *S. croxtoni*, *S. euradminiculum*, and *S. rugglesi*.

Etiology

Sporogony occurs in the insect vector and may be completed in 3–4 days. Ookinetes develop following fertilization of the macrogametocyte and may be found in the stomach of the insect within 12 hours after a blood meal. Oocysts form from the ookinetes within the stomach of the invertebrate host and produce sporozoites, which migrate to the salivary glands after emerging from the oocyst. Viable sporozoites have been found in vectors up to 18 days after the last blood meal.

Schizogony takes place in internal organs of the vertebrate host, such as liver, brain, spleen, and lungs. Hepatic schizonts in liver cells measure up to 45 μm when mature. Merozoites and syncytia are released from hepatic schizonts (syncytium refers to cytoplasm bounded by a plasma membrane and containing 2 or more nuclei). Some merozoites enter parenchymal cells of the liver and initiate another schizogonic cycle, and others enter erythrocytes or erythroblasts to develop into

gametocytes. Syncytia are phagocytized by macrophages or reticuloendothelial cells throughout the body, where they develop into megaloschizonts up to 400 μm in size. Merozoites released from the megaloschizont enter lymphocytes and other leukocytes to form gametocytes.

The gametocytes of *L. simondi* found in the blood average 14.5 × 5.5 μm and usually inhabit elongate spindle-shaped host cells averaging about 48 μm in length. The parasite lies beside the nucleus of the host cell. Elongate gametocytes probably develop exclusively in leukocytes, predominantly lymphocytes and monocytes, and mature round gametocytes are found in erythrocytes. According to Allan and Mahrt (4), each *Leucocytozoon* species enters gametogony in only 1 type of host cell; therefore, the presence of 2 morphologic types in the same bird suggests a concurrent host infection with 2 species. Desser et al. (29) observed infections in some areas of northern Michigan that were characterized by presence of both hepatic schizonts and round gametocytes, which he attributed to different strains of *L. simondi*.

Gamonts may be differentiated with a Romanowsky stain based on the dark blue staining cytoplasm of the macrogamete with its red nucleus, and the very pale blue staining cytoplasm of the microgamont with its pale pink nucleus. The microgamonts are more delicate and subject to distortion (84).

Pathogenesis and Epidemiology

The pathogenicity of *L. simondi* in ducks and geese is well documented. An outbreak of *L. simondi* among ducks in Michigan resulted in 35% mortality. Extensive losses of young goslings, attributed to infections of *L. simondi*, are observed annually at Seney Wildlife Refuge, with mortality greater than 70% occurring every 4 years (57). However, not all infections cause such severe disease. An experimental infection in anatid ducklings caused no mortality and no difference in growth rate (115).

Clinical signs vary with age and the condition of the host. Young ducklings manifest inappetence, weakness, listlessness, dyspnea, and sometimes death within 24 hours. Signs in adults appear less abruptly and consist of listlessness and low mortality. About 60% of fatalities occur 11–19 days post exposure. Some pathologic effects of the disease are anemia, leukocytosis, splenomegaly, and liver degeneration and hypertrophy. Extensive tissue damage was noted in the spleen and heart of ducks carrying megaloschizonts.

Kocan (80) described an anti-erythrocyte factor in sera from acutely infected ducks, which agglutinated and hemolyzed normal untreated erythrocytes as well as infected cells. This factor was believed to be a product of the parasite, and its action may account for the osmotic fragility of erythrocytes and anemia associated with *L. simondi* infections (92).

The greatest number of infections in northern Michigan occurred in July. Gametocytes decreased in number in the blood until midwinter, when they disappeared or become scarce and then reappeared in the spring.

Leucocytozoon smithi Laveran and Lucet 1905

L. smithi was first seen in turkeys in the eastern United States by T. Smith, after whom it is named, and has since been reported in turkeys in North Dakota, Minnesota, Nebraska, California, Texas, Missouri, France, Germany, the Crimea, and Canada.

In the United States, it can be widespread in adult turkeys (123): 289 of 357 turkeys were found infected in Georgia, 60 of 67 in Florida, 4 of 12 in Alabama, and 7 of 9 in South Carolina. The incidence of infection in pen-raised and free-ranging mature wild turkeys in the Cumberland State Forest in Virginia was 100%. The incidence of infection in wild turkeys in South Carolina, Mississippi, and the Midwestern states was 100%, 33%, and 3%, respectively (24, 44, 124). Economically significant outbreaks of *L. smithi* infection in turkeys are infrequent in North America (2), probably because of a transition to confinement rearing of commercial turkeys and the general shift away from raising turkeys in regions where blackflies and midges are abundant.

Etiology

L. smithi may be observed in the blood as rounded gametocytes that later become elongate, averaging 20–22 μm in length. They inhabit elongate cells averaging 45× 14 μm, with pale cytoplasmic "horns" extending out beyond the enclosed parasite. The host cell forms a long, thin, dark band along each side of the parasite. Gamonts are found only in leukocytes. The staining characteristics of the gamonts with a Romanowsky stain are similar to those of *L. simondi* (84) (Figure 28.17). Intracellular schizogonous forms are found in the liver. Both schizonts and megaloschizonts were observed and illustrated by Siccardi et al. (116).

Several aspects of the life cycle were described in detail in citations within previous editions of *Diseases of Poultry* (114).

Pathogenesis and Epidemiology

L. smithi generally resembles *L. simondi* of Anseriformes, but turkeys are probably not susceptible to the latter. *L. smithi* is not transmissible experimentally to chickens or ducks.

Simulium occidentale, *S. aureum*, *S. meridionale*, *S. nigroparvum*, and *S. slossonae* have been listed as vectors for *L. smithi* (41, 79).

The progress of leucocytozoonosis in susceptible young turkeys may be rapid and fatal. Clinical signs include anorexia, excessive thirst, depression, somnolence, and sometimes muscular incoordination. Death may occur suddenly during the acute stage of the disease.

Heavy infections of *L. smithi* do not seem to occur in mature wild turkeys. Few signs of infection are observed in wild turkeys, possibly because of local factors such as time at which suitable vectors are prevalent and the age of birds at first exposure.

Domestic hens infected with *Leucocytozoon* had decreased egg production, egg weight, and hatchability and higher mortality than uninfected hens (72). Recovered birds may harbor the parasite in their blood for more than 1 year (30). There is

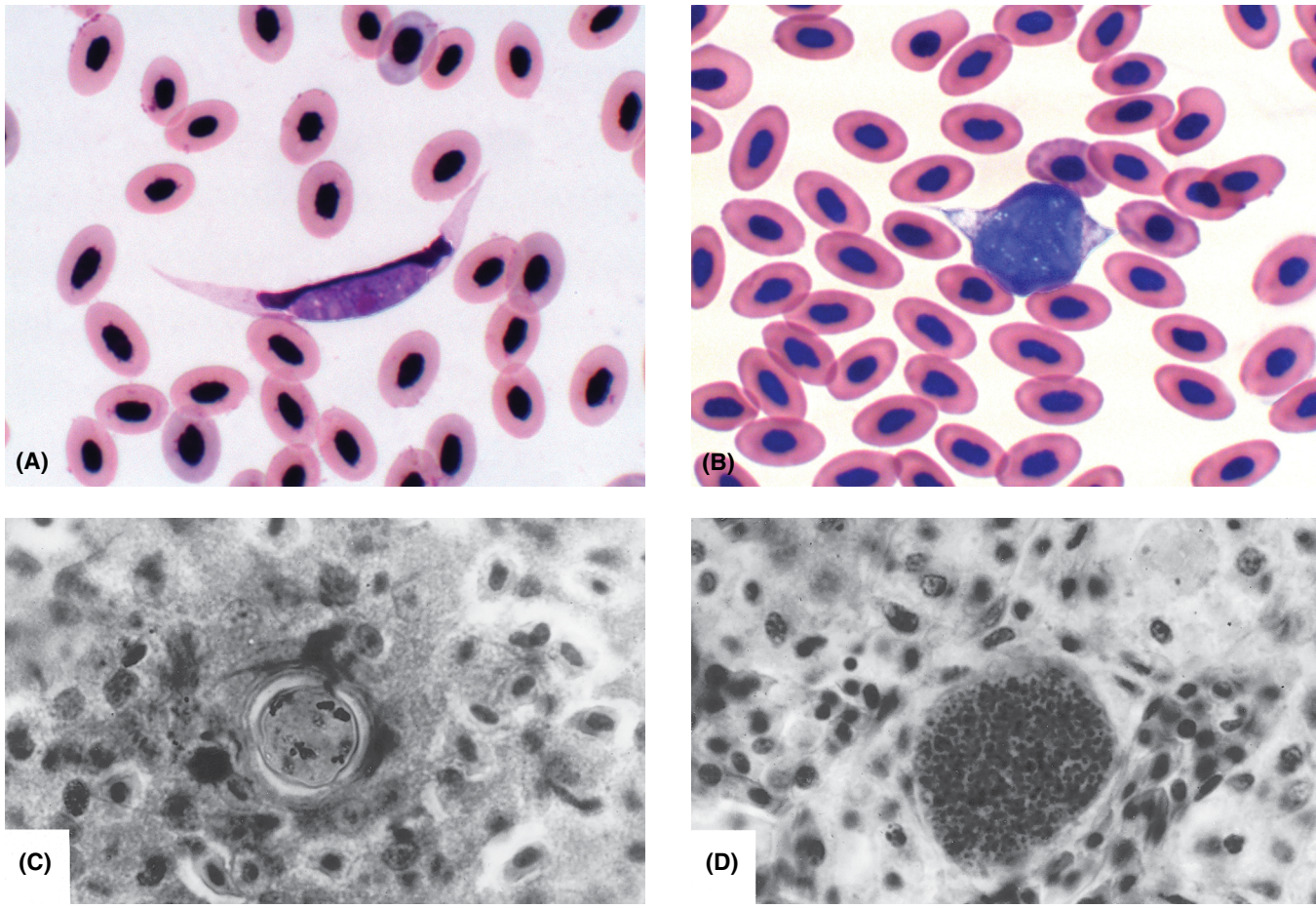

Figure 28.17. (A) *Leucocytozoon simondi*. Duck blood, Giemsa stain. (B) *Leukocytozoon smithi*. Turkey blood, Wright-Giemsa. (C) *Leukocytozoon smithi*. Megaloschizont in turkey liver, x1000. (D) *Leukocytozoon smithi*. Megaloschizont in turkey liver, day 10. (26)

often loss of vigor, and birds may suffer moist tracheal rales and coughing. Some birds die when subjected to stress. Males showed reduced mating activity (84).

Johnson et al. (70) reported that death results from obstruction of the circulatory system by large numbers of parasites. The lungs, small intestine, liver, and spleen may be congested, and the liver and spleen enlarged, in affected turkeys. Lund (90) cites extensive description of pathogenesis.

Leucocytozoon caulleryi Mathis and Leger 1909

L. caulleryi frequently is found in chickens in southern and eastern Asia. Infections occur frequently in Japan (101). Reports of leucocytozoonosis in South Carolina probably caused by *L. caulleryi* are the only known cases of this disease in chickens in North America. In 1 survey, 13.6% of domestic back yard chickens in South Carolina were infected (106). *L. andrewsi and L. schueffneri* are considered by some protozoologists to be synonymous with *L. caulleryi* (84).

Etiology

The domestic chicken is the only reported host for *L. caulleryi*. Insect vectors are *Culicoides arakawa*, *C. circumscriptus*, and *C. odibilis*. Akiba's discovery that the vector was a species of *Culicoides* and not *Simulium* prompted some to place *L. caulleryi* in a new genus called *Akiba* (41). Leucocytozoonosis epizootics, widespread during summer months in Japan, are serious enough to cause deaths in growing chicks and reduced egg production in hens (101).

Pathogenesis

Early schizonts occur in the lung, spleen, and thymus (58). Megaloschizonts, often readily visible on gross examination, are found in numerous tissues including the liver, spleen, kidneys, pancreas, heart, lungs, proventriculus, ventriculus, intestines, and brain (51).

Mature gamonts are round and occupy round host cells, erythrocytes, and leukocytes about 20 μm in diameter. The nucleus of the host cell reportedly disappears after infection, a characteristic that differs from other species with round gametocytes. Macrogametes (12–15 μm) stain more darkly with Romanowsky stain than microgamonts (10–15 μm), according to Levine (84).

Serious outbreaks of *L. caulleryi* in chickens are characterized by hemorrhage in the peritoneal cavity, perirenal hemorrhage, and subdural hemorrhage (51).

Extensive hemorrhage in the kidneys and other tissues occurs when merozoites are released from megaloschizonts. In infected laying hens, the uterus is edematous on gross examination with schizont development, granuloma formation, and inflammation of the uterus noted on histopathology (105).

Leucocytozoon sabrazesi Mathis and Leger 1910

L. sabrazesi has been found in domestic chickens in Southeast Asia, causing anemia, thickened oral discharge, and paralysis of the legs. Megaloschizont formation has not been reported for this parasite. Merozoites enter both erythroblasts and leukocytes to form elongate gametocytes within spindle-shaped host cells (6–7 × 4–6 μm), whose nuclei appear as thin bands beside the parasite (30). Macrogametes (22 × 6.5 μm) have a more compact nucleus and stain more darkly with a Romanowsky stain than the microgamonts (20 × 6 μm) (63). The insect vector is unknown.

Leucocytozoon schoutedeni Rodham, Pons, Vandenbranden, and Bequaert 1913

L. schoutedeni, which was found in 50% of chickens in East Africa (30), is unknown elsewhere. Gametocytes are round (11–13 μm) and found in round host cells (18 μm) whose nuclei surround the parasite about one-half of its length. Staining characteristics of the gametocytes have not been reported. The Simulium fly serves as the invertebrate host for *L. schoutedeni*.

Diagnosis

Leucocytozoon infections are diagnosed by direct microscopic observation and identification of gametocytes in stained blood or schizonts in tissue sections. Solis (120) described the high staining contrast of *Leucocytozoon* in peripheral blood films stained with brilliant cresyl blue. A variety of serologic tests including the agar gel precipitation test, indirect indirect fluorescent antibody (IFA), ELISA, and latex agglutination test have been developed for detecting antibodies to *L. caulleryi* (64, 67).

Treatment and Control

Drug treatment of leucocytozoonosis has had limited success. No effective treatment has been found for *L. simondi*. Pyrimethamine (1 ppm) and sulfadimethoxine (10 ppm) administered simultaneously reportedly will prevent but not cure infections of *L. caulleryi*. Halofuginone has been used for treatment in Asia. Clopidol in feed effectively controlled *L. smithi* according to Siccardi et al. (116).

Control requires elimination of the insect vector from the environment of the vertebrate host. A large-scale aerial treatment program using an organophosphate insecticide (2% temephos granules) for control of larval Simulium substantially reduced adult and larval blackfly populations and reduced the level of *L. smithi* blood parasitemia in turkeys in 1 study (78).

Repellents sprayed within houses to discourage entrance of the insect vector lowered mortality and incidence of disease but did not completely prevent infection in the flock (41).

The control of *L. caulleryi* by vaccination using an oil-adjuvanted rR7 vaccine has shown promising results in both laboratory and field trials (65, 66). This vaccine uses a recombinant R7 protein (rR7) from second-generation *L. caulleryi* schizonts.

Avian Malaria

Parasites of the genus *Plasmodium* (phylum Apicomplexa) cause the presence of pigment in infected erythrocytes of the host. Schizogony occurs in blood, and gametocytes are found in mature erythrocytes. All species of *Plasmodium* are transmitted by mosquitoes. These characteristics distinguish them from Haemoproteus and Leucocytozoon species and other members of the family Plasmodiidae.

About 65 species of *Plasmodium* from more than 1,000 different birds have been described, but only 35 are considered valid (9, 83). Species pathogenic for domestic fowl are found mostly in Asia, Africa, and South America. Malaria outbreaks have been recorded in North American birds of the orders Anseriformes, Passeriformes, and Columbiformes.

Etiology

Although many species of *Plasmodium* can be introduced into various domestic fowl, only a few appear to be natural parasites of these birds. *P. gallinaceum* occurs in jungle fowl and domestic hens, *P. juxtanucleare* parasitizes domestic hens and turkeys, *P. durae* and *P. griffithsi* occur in turkeys, *P. lophurae* of the fire-backed pheasant can also parasitize chickens and has been host-adapted to other domestic fowl and ducks, *P. fallax* of guinea fowl has been adapted to various domestic fowl, and *P. hermani* will infect domestic and wild turkeys and bobwhite quail (38, 48).

Other species found primarily in passerine birds that can infect domestic fowl or have been experimentally transmitted to them include *P. relictum*, *P. elongatum*, *P. cathemerium*, and *P. circumflexum* (75).

Life Cycle

Only a general outline of the malarian life cycle can be given here. Consult Garnham (49) for information on the life cycles of various species. Greiner et al. (54) presented color plates of 24 species.

Avian plasmodia develop in culicine mosquitoes of the genera *Culex* and *Aedes*, and rarely in *Anopheles*. Gametocytes from an avian blood meal are taken up by the mosquito, after which gamete formation, oocyst development, and sporogony occur. Infective sporozoites entering the avian host from the bite of a mosquito invade cells of the reticuloendothelial system and typically progress through 2 generations of primary exoerythrocytic schizonts: cryptozoites and metacryptozoites. Merozoites produced by the second generation are released into the bloodstream and invade

erythrocytes. An interchange of parasites between blood and reticuloendothelial tissues may occur, resulting in secondary exoerythrocytic schizonts (phanerozoites) in many tissues, especially spleen, kidney, and liver endothelial cells. These may be responsible for subsequent heavy parasitemias.

The trophozoite inside an erythrocyte is known as the ring form because of its appearance. Romanowsky staining shows a band of blue cytoplasm surrounding a vacuole and a peripheral red-stained nucleus. The characteristic malarial pigment, visible in stained smears, is formed as the parasite consumes and metabolizes the host cell hemoglobin. Nuclear division (schizogony) leads to formation of multiple nuclei, which bud off to form merozoites. The host cell ruptures to release merozoites for infection of other erythrocytes. After several asexual cycles, some merozoites differentiate into gametocytes and await ingestion by a suitable mosquito. The species of avian plasmodia vary in numbers of merozoites formed in exoerythrocytic and erythrocytic stages, in timing of the life cycle, and in morphology of various stages.

Pathology and Pathogenesis

The pathologic effects in avian hosts range from no apparent signs to severe anemia and death. *P. gallinaceum*, *P. juxtanucleare*, *and P. durae* are the most pathogenic for domestic fowl and may cause 90% mortality. Intense and severe anemia and generalized hypoxia may occur in acute *P. gallinaceum* malaria (75). A similar situation occurs in ducks affected with *P. lophurae*. Severe anemia may also occur in *P. juxtanucleare* infections.

Other pathologic changes occur in avian malaria. The exoerythrocytic stages of *P. gallinaceum* may block capillaries in the brain, resulting in death due to central nervous system dysfunction. Also, *P. durae* produces exoerythrocytic schizonts in the capillaries of the brain, sometimes producing high mortality (59).

Zoonotic Disease

Human malaria is an extremely important worldwide public health concern; however, no avian *Plasmodium* species has been reported to be capable of causing infection in humans (28).

Immunity

Immunologic factors such as antigen-antibody complex and hemagglutinins and such conditions as splenomegaly, anemia, and nephritis have been studied extensively in *P. gallinaceum* infections (97, 121).

Treatment and Control

The life cycle of the malaria parasite must be broken by the eradication of mosquitoes or by isolation of the flock from the vector by suitable housing. Although avian models have been used extensively in chemotherapeutic studies, information on potential preventative medications or treatments is limited. Studies with *P. durae* suggest that halofuginone is a possible preventive, and a combination of sulfachloropyrazine and sulfamonomethoxine could be used in treatment (59). Penguins are extremely susceptible to *Plasmodium* infection and have been treated successfully with a combined treatment of chloroquine and primaquine phosphate (52).

Haemoproteus Infections

Haemoproteus infections are characterized by schizogony (merogony) in visceral endothelial cells, gametocyte development in circulating erythrocytes, and the presence of pigment in granules in infected erythrocytes. Transmission is by various biting dipterans of the families Hippoboscidae and Ceratopogonidae (83). Characteristics of *Haemoproteus* are similar enough to *Plasmodium* and *Leucocytozoon* that the genera are placed in the same family, Plasmodiidae. Infections occur throughout tropical and temperate areas of the New and Old Worlds wherever vector species and avian hosts coexist.

There are about 128 species of *Haemoproteus* that have been reported from birds, mostly in wild waterfowl, raptors, passerines, and some other families of birds (83, 86). In surveys of wild birds, *Haemoproteus* species are the most commonly identified blood parasite. Many of the reported species become synonymous as life cycles are defined and cross-transmission studies are conducted, as shown by Bennett and coworkers (8, 132).

Species found in domestic poultry and pet birds include *Haemoproteus meleagridis* in domestic and wild turkeys (53), *H. columbae and H. saccharovi* in pigeons and doves, and *H. nettionis* in waterfowl (90).

Etiology

H. columbae of pigeons and doves is the most extensively studied of these parasites. Sporogony occurs in 2 families of flies. Sporogony is completed in 6–7 days in the ceratopogonids or in 7–14 days in the hippoboscids. Schizonts (meronts) of various sizes and numbers of merozoites occur in the pulmonary vascular endothelium in alveolar septa of pigeons. The merozoites invade erythrocytes and mature into gametocytes (3). Further development requires ingestion by a suitable vector (arthropod) in a blood meal.

Vectors include the hippoboscid *Pseudolynchia canariensis* for *H. columbae* and the ceratopogonid *Culicoides* for *H. nettionis* (80). Vectors for *H. meleagridis include C. edeni*, *C. hinmani*, *C. arboricoli*, *C. knowltoni*, and *C. haemoproteus* (5).

Atkinson (5) studied experimental infections of *H. meleagridis* in turkeys and partially defined the life cycle. He observed ookinetes, oocysts, sporozoites, and megaloschizonts, with at least 2 generations of schizogony. First-generation schizonts matured 5 and 8 days post infection and produced elongate merozoites. Second-generation megaloschizonts developed after 8 and 17 days in cardiac and skeletal muscles

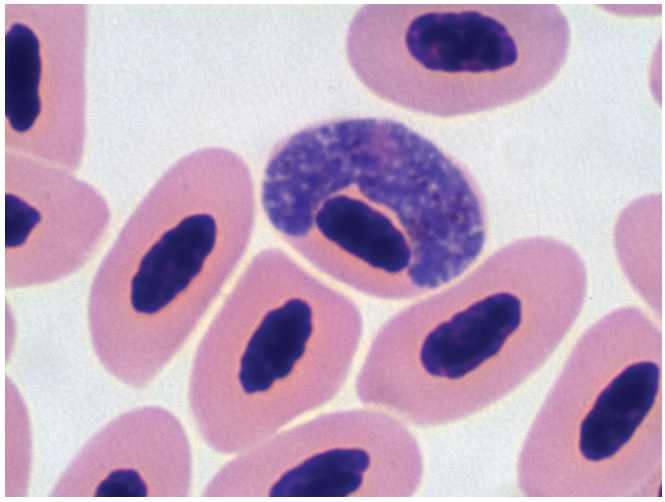

Figure 28.18. *Haemoproteus columbae*. Pigeon blood, Giemsa stain.

and yielded spherical merozoites that developed into erythrocytic gametocytes (Figure 28.18).

Pathogenesis and Pathology

Signs from experimental infections with *H. meleagridis* in turkeys include severe lameness, diarrhea, severe depression, emaciation, and anorexia (5). Anemia and enlarged livers occasionally are attributed to infections. Necropsy of wild turkeys revealed myopathy associated with megaloschizonts. Skeletal muscles contained numerous fusiform cysts oriented in parallel order with muscle fibers (6). Pigeons infected with *H. saccharovi* had enlarged gizzards. Muscovy ducks (*Carina moschata*) infected with *H. nettionis* suffered lameness, dyspnea, and sudden death with hemorrhage on the heart as well as edematous lungs and swollen firm livers, spleens, and kidneys, although this species was nonpathogenic for other species of ducks (73). *Haemoproteus* infections in most avian species are asymptomatic; however, when exotic species are exposed to Hemoproteus species from outside of their biogeographical range fatal infections with hepatic hemorrhage and large protozoal hepatic cysts have been observed (46).

Diagnosis

The diagnosis of *Haemoproteus* infection requires microscopic examination of stained blood smears. Both restriction enzyme based-methods and PCR assays have been developed which can distinguish between *Haemoproteus spp*., *Plasmodium spp*., and *Leucocytozoon spp*. (7, 56).

Treatment and Control

Control of insect vectors may be useful in local situations (75). However, complete life cycles are not known for most species, precluding specific control recommendations. No drugs are approved for commercial use, although atebrin and plasmochin have marginal effects against *H. columbae* in experimental treatment

Trypanosomiasis

Although trypanosomes have been reported from many species of wild and domestic birds, their pathologic significance appears to be minimal or nil. Even the taxonomic grouping of these organisms is unclear.

Several species have been named, including *Trypanosoma avium*, *T. numidae*, *T. calmetti*, and *T. gallinarum*. The possibility that the latter 3 are synonyms of *T. avium* cannot be ruled out in absence of a rigorous taxonomic study (40). The American Type Culture Collection (ATCC) lists 2 trypanosomes from avian species, *T. avium and T. bennetti* (83).

T. avium and its life cycle were described by Molyneaux (102), who summarized vector relationships for all avian trypanosomes and listed culicine mosquitoes and simuliids as known vectors.

Sarcocystosis

Sarcocystosis, previously called sarcosporidiosis, is caused by apicomplexan protozoa of the genus *Sarcocystis* Lankester 1882. The disease is recognized by the presence of elongated cysts (sarcocysts) located in muscles. The nature of the causative organism was unclear until discovery that coccidian oocysts are shed by the final host after eating flesh from another animal containing sarcocysts. These parasites are closely related to the *Toxoplasma*, *Eimeria*, and other apicomplexans. Numerous reviews of the taxonomy of Sarcocystis species have been published (114).

Sarcocystosis is not economically important to the poultry industry, but it occurs extensively in wild ducks and other birds. Many infected game birds are discarded by hunters for aesthetic reasons. Sarcocystosis from birds does not appear to be a public health hazard. The parasites are killed by cooking and storage at subfreezing temperatures.

Distribution

Avian sarcocystosis is found throughout the world in individual birds but is rare in domestic chickens. A study in northwest Ethiopia found that 6.6% of the chickens examined had sarcocysts within skeletal muscle specimens (134) but this high incidence of infection does not occur in modern poultry production systems. Two isolated cases of sarcocystosis in wild turkeys were reported in the southeastern United States (36, 126). The incidence is as high as 40% in ducks and 93% in grackles (42), and is influenced by species, age, and geographic location of the host. Sarcocystosis occurs more often in puddling than in diving ducks.

Etiology

Sarcocystis horvathi (*S. gallinarum*, *S. horvathi)* is the etiologic agent in chickens (85) and *S. rileyi* (*Balbiani rileyi*, *S. anatina*) in ducks. *S. falcatula* has been described in numerous passerine, psittacine, and columbid species (85). Based on microscopic differences in the wall substance of microcysts, however, at least 5 different species of Sarcocystis are present in birds (31). These are 2-host parasites, with a mammalian host serving as the definitive host.

Sarcocystis is classified in the phylum Apicomplexa, suborder Eimeriorina (85) and the family Sarcocystidae (83), and is characterized as multiplying by endodyogeny. Cysts or pseudocysts containing zoites are formed in parenteral cells of the host. It appears to have strong host specificity (84). The classification of *Sarcocystis* is based on discovery of its coccidial nature with a disporocystid (a tetrazoic isosporanlike oocyst), an obligatory 2-host life cycle (often carnivore-herbivore), reproduction by endodyogeny, and characteristic ultrastructure (93, 118). The morphology of *Sarcocystis* has been fully characterized (114).

Life Cycle

Obligatory two-host life cycles have been described from 86 species of *Sarcocystis* (107). Two vertebrate hosts are required in the life cycle of all of these species, usually a carnivorous predator or scavenger and the prey or food animal. Sexual reproduction occurs in the predator (definitive host) and asexual reproduction in the prey (intermediate host). The intermediate host becomes infected by fecal contamination from an infected definitive host.

Sarcocystis from shoveler ducks (*Anas dypeata*) were transmitted to the striped skunk (*Mephitis mephitis*) (25, 133). When muscle containing sarcocysts was eaten by skunks, sporocysts (1.4 × 12.4 μm) were shed sporadically from 19–63 days PI. Shoveler ducks orally administered sporocysts developed microcysts (80 × 16 μm) in skeletal muscle 85 days later and macrocysts (1–3 × less than 1 mm) 154 days PI (25). The opossum was susceptible to infection with tissue cysts from ducks (38). In another study (119), the transmission of *S. falcatula* was demonstrated with the opossum (*Didelphis virginiana*) serving as the definitive host. Although asexual parasites were not found in ducks (*Anas platyrhynchos*) given fecal sporocysts from opossums, the intermediate host spectrum of some avian species of *Sarcocystis* is apparently quite broad (20). Sarcocysts from grackles and cowbirds are also infective to the opossum.

Levine (85) lists the chicken as the intermediate host and the dog as the definitive host for *S. horvathi*. The life cycle for *S. horvathi* is not completely defined.

The life cycle of *Sarcocystis* spp. is summarized as follows: Cardiac, smooth, or skeletal muscle tissues are eaten by a definitive host, releasing cystozoites that penetrate the intestinal wall and develop into macrogametocytes and microgametocytes in subepithelial tissues. Oocysts (containing 2 sporocysts, each with 4 sporozoites) are produced and are shed in feces as fully sporulated sporocysts. Sporozoites are released when sporocysts are ingested by the intermediate host, and invade the mucosa of the intestine. Schizogony (merogony) occurs in endothelial cells of various organs. After several asexual generations, the merozoites develop into young cyst stages, containing metrocytes and later cystozoites, and mature into the third-generation meronts (sarcocysts) in myocardial, skeletal, and smooth muscle tissues (93, 119).

Pathogenicity

The pathogenicity of sarcocystosis in birds is variable. The presence of sarcocysts in the skeletal muscle and heart of waterfowl is often an incidental finding, with no clinical disease being evident. In contrast, some avian species develop serious or fatal sarcocystosis as the protozoa undergo schizogeny in the endothelium of the infected intermediate avian host (108). Isolated cases of sarcocystosis reportedly cause severe debility and death in wild turkeys and backyard chickens (36, 104, 126). Similar fatal disease has commonly been reported in psittacine birds where pulmonary hemorrhage and edema are the cause of death (108). Box and Duszynski (18) attributed death of 4 of 12 sparrows and morbidity of 3 of 6 canaries to experimental sarcocystosis.

Transmission, Carriers, Vectors and Incubation Period

Attempts at direct transmission of *S. rileyi* to young ducks by oral, intramuscular (IM), and intravenous (IV) administration of cystozoites and cohabitation with infected ducks were unsuccessful, emphasizing the requirement of a second host (123).

Sporocyst-contaminated food is the common source of infection for the intermediate host (birds); infection in the carnivorous definitive host (mammal) results from ingestion of sarcocyst-infected tissues of the intermediate hosts. Cystozoites from sarcocysts in confined migratory ducks were found to be viable for 3 years. Thus, intermediate hosts may serve as an available source of infection for prolonged periods over a widespread area. *Sarcocystosis* appears to be most prevalent in hosts that frequently drink from shallow or stagnant water (puddling ducks, cattle, sheep, or swine) (122). Infections are seldom found in juvenile grackles (42) or in juvenile ducks, suggesting a long incubation period. Microcysts and macrocysts were found in ducks 85 and 154 days PI, respectively (25), and macrocysts were observed in sparrows and canaries 70 days PI (19).

Clinical Signs

Sarcocysts usually are found in the skeletal muscles of birds. Spindler (122) reported that heavy infections may cause signs of disease, and ducks may fly low and slowly. Adverse signs were not observed in experimentally infected ducks (25). Box and Duszynski (18) noted labored breathing and morbidity in canaries and sudden death in sparrows given oocysts. Psittacine birds with acute sarcocystosis likewise develop marked respiratory signs prior to death (108). Chickens with *Sarcocystis*-associated encephalitis exhibit distinct neurologic signs (104).

Gross Lesions

Sarcocysts running lengthwise in the musculature of the breast, thigh, neck, or esophagus are the usual lesions associated with avian sarcocystosis (Figure 28.19). Lung consolidation and splenomegaly were observed in infected canaries (18), and pulmonary edema and hemorrhage, hepatomegaly, and splenomegaly have been described in psittacine birds (104, 108). Lesions have not been seen in definitive hosts with experimental infections.

Figure 28.19. Sarcocytosis in wild mallard; a severe, naturally occurring infection. Photo by J. Runningen, *Field Guide to Wildlife Diseases*, US Department of Interior Fish and Wildlife Service, 1987.

Histopathology

Fatty degeneration of muscles, enlargement and rupture of parasitized muscle fibers, and inflammatory responses around sarcocysts in muscles were reported (122). *Sarcocystis*-associated encephalitis has been described in chickens, turkeys, and other nondomesticated avian species (36, 104, 126). Systemic sarcocystosis has been described in a wild turkey with inflammatory changes associated with protozoal schizonts and merozoites in the heart, lung, and liver (36).

Immunity

Active and passive immunity have not been demonstrated. Animals have been immunized against sarcocystosis by repeated injections of untreated or formalin-treated toxin. Serum from immunized animals gives protection to other animals against the toxin (122).

Zoonotic Disease

While human cases of sarcocystosis occur, they are typically asymptomatic and have been exclusively associated with the consumption of raw or undercooked beef or pork (1).

Diagnosis

Diagnosis is based on the identification of sarcocysts or cystozoites in tissues. Large sarcocysts are seen easily in gross specimens; smaller cysts and cystozoites can be identified by histologic examination of muscle tissue. *Sarcocystis* schizonts and merozoites can be differentiated from other systemic protozoal infections (*Toxoplasma* and *Neospora*) by immunohistochemistry (94, 104). Molecular techniques using PCR amplification and restriction endonuclease digestion are also be used in the identification of *Sarcocystis* species (35). Infections of *Sarcocystis* may be diagnosed in the definitive host by identification of sporocysts in feces.

Prevention and Control

Chemotherapy of avian sarcocystosis is not practical, placing the burden of control on prevention by breaking the infection cycle. Modern production systems prevent infections by preventing contact of poultry with oocyst-contaminated excreta of the definitive mammal host.

Toxoplasmosis

Toxoplasmosis is a parasitic disorder of mammals, birds, and reptiles affecting primarily the central nervous system but sometimes also the reproductive system, skeletal muscles, and visceral organs. The majority of infections are inapparent or latent, with overt toxoplasmosis resulting at times of stress or immunosuppression.

Only sporadic cases of toxoplasmosis in chickens and turkeys have been reported (33, 50, 112, 117). Studies of avian tissues using the mouse inoculation test and histologic examination indicates that a somewhat higher incidence of infection exists than is apparent based on the observation of clinical disease. Nevertheless, the disorder is uncommon in chickens and is of little significance to the health of commercial poultry.

Toxoplasmosis is a significant zoonotic disease and a human health problem of increasing importance due to a growing immunodeficient population (122). Humans are typically exposed to the disease by the ingestion of oocysts shed by felids, congenital infection, or the consumption of raw or undercooked meat products (127). Serologic prevalence of *Toxoplasma* infection in humans typically ranges between 10% and 80% and varies markedly based on environmental conditions and cultural dietary habits (127). An average seroprevalence of 14% was reported in the United States (45). A multi-country case-control study of the source of Toxoplasma infection in pregnant women revealed that the greatest risk factors were ingestion of undercooked meats, soil contact, and travel outside of Europe and North America (26). Poultry products were not implicated as a significant risk factor in this study although the consumption of any raw meat product, including uncooked poultry or eggs, is a potential source of human infection (32).

The true nature of Toxoplasma as close relatives of *Eimeria* was not known until 1969. The literature presents extensive overviews of history and current knowledge of toxoplasmosis (32, 33, 45, 71, 84, 127).

Etiology

A single species, *Toxoplasma gondii*, is the cause of toxoplasmosis in all hosts. Synonyms for the agent in avian hosts are *T. avium and T. paddae*.

T. gondii is a coccidian with sexual stages similar to *Isospora* (60). Endodyogeny, however, is unique to *T. gondii*. *Toxoplasma* is classified in the family Sarcocystidae, along with *Sarcocystis*, in the suborder Eimeriorina and phylum Apicomplexa (83).

Numerous Toxoplasma isolates have been designated strains based on differing pathogenicity in different hosts rather than on immunologic variation, although the latter may occur with some strains.

Free *T. gondii* zoites are crescent shaped (4–6 × 2–3 μm), with one extremity more rounded than the other and a nucleus near the rounded end. No pseudopods, cilia, or flagella are present. Ultrastructure of developmental stages has been described (84, 114).

Life Cycle

Both schizogonic and gametogenic developmental cycles are known to occur in the intestinal epithelium of some members of the cat family (Felidae). Both an enteroepithelial cycle and an extraintestinal cycle have been described.

The enteroepithelial cycle occurs only in cats, resulting from infection by encysted organisms (bradyzoites), free or intracellular individual organisms (tachyzoites), or oocysts (43). The prepatent period is 24 days or longer if oocysts are ingested, 5 days after ingestion of tachyzoites, and only 3–5 days if bradyzoites are the source of infection. Asexual development (schizogony) occurs in the intestinal epithelium.

The sexual phase also occurs only in intestinal epithelial cells of Felidae. Gametocytes develop throughout the small intestine but more commonly in the ileum. Microgametocytes (7–10 × 5–8 μm) give rise to 12–32 microgametes (2–5 μm). Following fertilization of the macrogamete (13 μm), oocysts develop and detach unsporulated from the intestinal epithelium. Oocysts are shed for 7–20 days. Sporulation is complete in 1–5 days, depending on the environmental temperature and oxygen, and results in the development of 2 sporocysts (6–8 × 5–7 μm), each containing 4 sporozoites.

In birds and other nonfelines, only the extraintestinal (tissue) cycle of *T. gondii* is known. After ingestion, *T. gondii* tachyzoites reproduce by endodyogeny within parasitophorous vacuoles of many cell types. Tachyzoites may spread to the brain, eye, heart, liver, lungs, and nucleated red blood cells of birds. Eight or more tachyzoites are produced in a host cell. A final generation of tachyzoites develops into tissue cysts, in which bradyzoites multiply by endodyogeny (113). Encysted bradyzoites develop intracellularly in the brain, heart, eyes, and skeletal muscles but are walled off as immunity develops. Cysts may persist for the life of the host or, if immunity wanes, bradyzoites may be released and a proliferation of tachyzoites renewed. The tissue cycle may reverse again and cysts form from tachyzoites (68, 71, 127).

Pathogenesis and Epidemiology

Infective oocyts of *T. gondii* are produced only by members of the Felidae (domestic cats, ocelots, pumas, jaguarundi, bobcats, and Asian leopards) (71). More than 63 species of birds and 27 species of other animals become infected from ingestion of oocysts and develop cysts in tissues without passing oocysts in the feces (117). Naturally occurring infections have been diagnosed in chickens, turkeys, ducks, and many wild birds (21, 50, 90, 112). Ruiz and Frenkel (113) isolated *T. gondii* from 54% of chickens that were reared in small backyard poultry flocks in Costa Rica. In contrast, Kuticic (82) found that only 0.4% of commercial chickens cultured positive for *T. gondii* in Croatia. In the United States, 2,094 samples of retail chicken meat were assayed in a nationwide survey and *T. gondii* was not found in any samples (32). Presumably, commercial chickens have little exposure to *T. gondii* oocysts, in contrast with free-range birds.

Transmission, Carriers, and Vectors

T. gondii has been reisolated from Japanese quail, bluejays, crows, turkeys, and chickens after experimental infections (34, 100). Tachyzoites and bradyzoites may be spread to birds by carnivorous ingestion, and sporulated oocysts are spread by cat feces.

The question of congenital infection occurring in chicks from naturally infected parents remains unresolved. Jacobs and Melton (69) found that 12 of 62 pools of reproductive tract tissues from chickens were infected with *T. gondii*, but the parasite could not be isolated from any of 108 eggs from these hens. In another study, 1 of 327 eggs from hens with chronic toxoplasmosis was positive. Iannuzzi and Renieri (62) concluded that toxoplasmas did not survive in unembryonating eggs and was not a factor in transmission. However, Caballero-Servin (22) reported successful transovarian transmission of the parasite by experimentally infecting hens, which resulted in embryonic mortality and congenital malformation of 18% of the surviving chicks.

Coprophagous arthropods such as flies and cockroaches can serve as transport hosts for the *Toxoplasma* (129). Earthworms ingest *Toxoplasma* oocysts and are a source of infection for chickens (113).

Course of the Disease

During the 1950s, several cases were reported that involved 12%–50% of the chickens within a flock (12, 33). Clinical signs in affected chickens included anorexia, weight loss, pale combs, spasms, paralysis, and a loss of eyesight (33). In a recent case report, chickens affected with *T. gondii*-induced peripheral neuritis were emaciated and had difficulty standing (50). A wild turkey with systemic toxoplasmosis was emaciated, weak, and readily captured (112).

Susceptibility of chickens to *T. gondii* may vary with age of host, strain of infective agent, and route of infection. Oral inoculation with 10^3 or 10^5 *Toxoplasma* oocysts (37, 74) produced no clinical signs in 4-week-old chickens. Furthermore, chickens inoculated with tachyzoites by intravenous or oral route showed no clinical disease or adverse production effects (74). Turkeys also were resistant to the oral inoculation of *Toxoplasma* oocysts (34).

Inoculation of chicks with tissue cysts by abnormal routes such as intracerebral (IC) (12) or intraperitoneal (IP) routes (77) produced clinical signs. Inoculation with tissue cysts intravenously (IV), intraperitoneally (IP), IM, and subcutaneously (SC) also produced parasitemia and chronic infections in older birds. Clinical signs in experimentally inoculated chickens include anorexia, emaciation, paleness and shrinking of the comb, drop in egg production, whitish feces, diarrhea, incoordination, ataxia, trembling, opisthotonos, torticollis, blindness, and high mortality (11, 12, 77, 90).

Gross Lesions

Gross lesions include enlargement of liver and spleen, necrotic hepatitis, pericarditis, myocarditis, ulcerative enteritis, lung congestion, and encephalitis (12, 90).

Histopathology

In chickens inoculated by IC and IM routes, *Toxoplasma* tissue cysts were found in the cerebrum, brain stem, optic chiasma, and most frequently, around ventricles and in molecular and Purkinje layers of the cerebellum. Free trophozoites were seldom found, and then only in the brain. Toxoplasma cysts were found in the myocardium, pancreas, and testes of chickens infected IM (12).

Coagulation necrosis and diffuse sinusoidal congestion were observed in the liver. The myocardium, pancreas, and testes were diffusely infiltrated with lymphocytes, plasma cells, and heterophils. In the brain, infection caused lymphocytic lesions and plasma cell-cuffing of blood vessels; lymphocytic infiltration of choroid villi; ependymal proliferation of the lateral ventricle; thickening of leptomeninges; and gliosis of the lateral ventricle and around vessels of the cerebrum, brain stem, and cerebellum (12).

Oral inoculation of chickens with *Toxoplasma* oocysts produced focal necrosis in the spleen, liver, and intestine, and a mixed leukocyte infiltration (37). Lymphocytic foci were also noted in the myocardium, skeletal muscle, and liver. Of the 12 chickens inoculated, only 1 developed lesions in the brain with perivascular leukocyte infiltration, gliosis, and 1 tissue cyst noted in the cerebrum (37).

Zoonotic Disease

Toxoplasmosis can affect numerous mammalian hosts, including humans, following the consumption of oocytes shed by infected felids or uncooked meat containing infective *T. gondii* bradyzoites (1). Prevention of infection is by the sanitary disposal of cat feces and the thorough cooking of meat. Most postnatal infections are inapparent, whereas congenitally acquired toxoplasmosis causes both severe disease and sequelae (1).

Diagnosis

T. gondii may be isolated and identified by injecting suspensions of infected tissues into various species of laboratory animals, chicken embryos, or cell cultures. Inoculation of mice IP or IC with suspensions of brain and heart are preferred methods of isolation (33). Mice inoculated with virulent strains die within a few days. Less virulent isolates may not produce mortality, and can only be detected serologically or by examination for cysts 8–10 weeks after inoculation.

Impression smears of peritoneal fluids or tissues stained with Giemsa or tissue sections of brain, liver, spleen, lung, lymph node, and eye often suffice for direct microscopic observation of Toxoplasma.

Toxoplasma can be grown in the chorioallantoic cavity of 6– to 12-day-old embryonating chicken eggs. Embryos succumb 7–10 days PI with hemorrhage and nodular lesions in skin and viscera. Numerous yellow-white plaques 0.5–3 mm in diameter develop on the chorioallantoic and amniotic membranes. Smears of the chorioallantoic membrane and yolk sac stained with Wright's stain reveal numerous free and intracellular toxoplasmas.

Toxoplasma must be differentiated from other protozoa such as *Sarcocystis* and *Neospora*. Immunohistochemical stains capable of distinguishing between these species are available in several laboratories (36, 94, 104). A reliable PCR technique has been developed to detect *T. gondii* in formalin-fixed, paraffin-embedded tissue (61). The use of PCR testing in diagnosis of toxoplasmosis in fresh tissues was reviewed by Morgan (103).

Serology

Historically, avian toxoplasmosis serology testing was considered impractical because most avian species do not seroconvert using the human dye test. However, the modified agglutination test and ELISA test detected antibodies within 2 weeks of inoculation of chickens, and at 68 days PI (37). The latex agglutination test was judged insensitive in detecting *T. gondii* antibodies, and no antibodies were detected by the dye test or the indirect hemagglutination test. Other workers have used an ELISA test to demonstrate seroconversion in chickens and pigeons within 2 or 3 weeks of inoculation, respectively (11).

Treatment, Prevention, and Control

Chemotherapy has not been used to control avian toxoplasmosis. Prevention of avian toxoplasmosis requires management practices that eliminate the source of infective tachyzoites and oocysts by preventing exposure to rodents, coprophagous arthropods, and especially cats. Oocysts disseminated throughout the premises are resistant to common laboratory detergents, acids, and alkalis, and are, therefore, difficult to destroy. However, they may be destroyed by ammonia, drying, and a temperature of 55°C (84).

References

Introduction

1. Levine, N.D. 1985. *Veterinary Protozoology*. Iowa State University Press, Ames, IA, 414.
2. Bollinger, T.K., and Barker, I.K. 1996. Runting of ducklings associated with *Cochlosoma anatis* infection. *Avian Dis*. 40:181–185.
3. Cooper, G.L. 1995. Enteritis in turkeys associated with an unusual flagellated protozoan (*Cochlosoma anatis*). *Avian Dis*. 39:183–190.
4. Lollis, L., R.W. Gerhold, L.R. McDougald, and R. Beckstead. 2011. Molecular characterization of *Histomonas meleagridis* in the United States using the ITS-1, 5. 8 s, and ITS-2 rRNA regions to identify genetic variation. *J Parasitol*. 97: 610–615.
5. Reetz, J. 1993. Naturlich Mikrosporidien (*Encephalitozoon cuniculi*)Infectionen bei Huhnern. *Terarztlich Praxix*. 21: 429–435.

6. Reetz, J. 1994. Naturlich Ubertragung von Mikrosporidien (*Encephalitozoon cuniculi*) uber das Nuhnerei. *Tierarztlich Praxix*. 22:147–150.

Coccidiosis

1. AAAP Committee on Disease Reporting. 1987. Summary of commercial poultry disease reports. *Avian Dis*. 31:926–982.
2. Arakawa, A., E. Baba, and T. Fukata. 1981. *Eimeria tenella* infection enhances *Salmonella typhimurium* infections in chickens. *Poult Sci*. 60:2203–2209.
3. Baba, E., T. Fukata, and A. Arakawa. 1982. Establishment and persistence of *Salmonella typhimurium* infection stimulated by *Eimeria tenella* in chickens. *Poult Sci*. 61:1410.
4. Biggs, P.M., P.L. Long, S.G. Kenzy, and D.G. Rootes. 1969. Investigations into the association between Marek's disease and coccidiosis. *Acta Vet*. 38:65–75.
5. Braunius, W.W. 1986. Incidence of *Eimeria* species in broilers in relation to the use of anticoccidial drugs. In: *Proceedings of the Georgia Coccidiosis Conference*. University of Georgia: Athens, GA, 409–414.
6. Castanon, C.A.B., J.S. Fraga, S. Fernandez, L.F. Costa, and A. Gruber. 2005. Digital image analysis in the diagnosis of chicken coccidiosis. *Proc Inter Coccidiosis Conf*. 9:162.
7. Chapman, H.D. 1999. The development of immunity to *Eimeria* species in broilers given anticoccidial drugs. *Avian Pathol*. 28:155–162.
8. Dasgupta, T., and E.H. Lee. 2000. A gel delivery system for coccidiosis vaccine: Uniformity of distribution of oocysts. *Can Vet J*. 41:613–616.
9. Davies, S.F.M., L.P. Joyner, and S.B. Kendall. 1963. *Coccidiosis*. Oliver and Boyd, Edinburgh and London.
10. Edgar, S.A. 1986. Coccidiosis in turkeys: Biology and incidence. In: *Proceedings of the Georgia Coccidiosis Conference*. University of Georgia: Athens, GA. 116–123.
11. Edgar, S.A., and C.T. Siebold. 1964. A new coccidium of chickens, *Eimeria mivati* sp. n. (Protozoa: Eimeriidae), with details of its life history. *J Parasitol*. 50:193–204.
12. Feed Additive Compendium. 2001. *Miller Publishing Co*., Minneapolis, MN.
13. Fitz-Coy, S.H., and S.A. Edgar. 1992. Pathogenicity and control of *Eimeria mitis* infections in broiler chickens. *Avian Dis*. 36:44–48.
14. Fletcher, O.J., J.F. Munnell, and R.K. Page. 1975. Cryptosporidiosis of the bursa of Fabricius in chickens. *Avian Dis*. 19:630–639.
15. Gore, T.C., and P.L. Long. 1982. The biology and pathogenicity of a recent field isolate of *Eimeria praecox*, Johnson 1930. *J Protozool*. 29:82–85.
16. Hamet, N. 1986. Resistance to anticoccidial drugs in poultry farms in France from 1975 to 1984. In: *Proceedings of the Georgia Coccidiosis Conference*. University of Georgia: Athens, GA, 415–421.
17. Helmbolt, C.F., and E.S. Bryant. 1971. The pathology of necrotic enteritis in domestic fowl. *Avian Dis*. 15:775–780.
18. Hu, J., L. Fuller, and L.R. McDougald. 2000. Do anticoccidials interfere with development of protective immunity against coccidiosis in broilers? *J Appl Poultry Res*. 9:352–358.
19. Hoerr, J.F., F.M. Ranck, and T.F. Hastings. 1978. Respiratory cryptosporidiosis in turkeys. *J Am Vet Med Assoc*. 173: 1591–1593.
20. Jeffers, T.K. 1974. *Eimeria tenella*: Incidence, distribution and anticoccidial drug resistance of isolants in major broiler producing areas. *Avian Dis*. 18:74–84.
21. Jeffers, T.K. 1974. *Eimeria acervulina* and *Eimeria maxima*: Incidence and anticoccidial drug resistance of isolants in major broiler producing areas. *Avian Dis*. 18:331–342.
22. Johnson, J., and W.M. Reid. 1970. Anticoccidial drugs: Lesion scoring techniques in battery and floor-pen experiments with chickens. *Exp Parasitol*. 28:30–36.
23. Litjens, J.B. 1986. The relationship between coccidiosis and the use of anticoccidials in broilers in the southern part of the Netherlands. In: *Proceedings of the Georgia Coccidiosis Conference*. University of Georgia: Athens, GA, 442–448.
24. Long, P.L. 1982. The Biology of the Coccidia. Dissertation, University of Georgia. University Park Press. Baltimore, MD.
25. Mattiello, R., J.D. Boviez, and L.R. McDougald. 2000. *Eimeria brunetti* and *E. necatrix* in chickens of Argentina and confirmation of seven species of Eimeria. *Avian Di*. 44:711–714.
26. Maxey, B.W., and R.K. Page. 1977. Efficacy of lincomycin feed medication for the control of necrotic enteritis in broiler-type chickens. *Poult Sci*. 56:1909–1913.
27. McDougald, L.R. 1982. Chemotherapy of coccidiosis (Chapter 9). In: *The Biology of the Coccidia*. P.L. Long, ed. University Park Press, Baltimore, Md. 373–427.
28. McDougald, L.R., and J. Hu. 2001. Blackhead disease (*Histomonas meleagridis*) aggravated in broiler chickens by concurrent infection with cecal coccidiosis (*Eimeria tenella*). *Avian Dis*. 45:307–312.
29. McDougald, L.R., T. Karlsson, and W.M. Reid. 1979. Interaction of infectious bursal disease and coccidiosis in layer replacement chickens. *Avian Dis*. 23:999–1005.
30. McDougald, L.R., L. Fuller, and R. Mattiello. 1997. A survey of coccidia on 43 poultry farms in Argentina. *Avian Dis*. 41:923–929.
31. McDougald, L.R., A.L. Fuller, and J. Solis. 1986. Drug sensitivity of 99 isolates of coccidia from broiler farms. *Avian Dis*. 30:690–694.
32. McDougald, L.R., J.M.L. Da Silva, J. Solis, and M. Braga. 1987. A survey of sensitivity to anticoccidial drugs in 60 isolates of coccidia from broiler chickens in Brazil and Argentina. *Avian Dis*. 31:287–292.
33. Morehouse, N.F., and R.R. Barron. 1970. Coccidiosis: Evaluation of coccidiostats by mortality, weight gains, and fecal scores. *Exp Parasitol*. 28:25–29.
34. Moore, E.N. and J.A. Brown. 1952. A new coccidian of turkeys, *Eimeria innocua* n. sp. (Protozoa: Eimeriidae). *Cornell Vet*. 42:395–402.
35. Moore, E.N., J.A. Brown, and R.D. Carter. 1954. A new coccidian of turkeys, *Eimeria subrotunda* n. sp. (Protozoa: Eimeriidae). *Poultry Sci*. 33:925–929.
36. Oluleye, O.B. 1982. The life history and pathogenicity of a chicken coccidium *Eimeria hagani, Levine, 1938*. Ph.D. Dissertation, Auburn University, Alabama USA. 66.
37. Pellerdy, L.P. 1974. *Coccidia and Coccidiosis*, 2nd ed. Akademine Kiado, Budapest.
38. Reid, W.M., and J. Johnson. 1970. Pathogenicity of *Eimeria acervulina* in light and heavy coccidial infections. *Avian Dis*. 14:166–177.
39. Reyna, P.S., G.F. Mathis, and L.R. McDougald. 1982. Survival of coccidia in poultry litter and reservoirs of infection. *Avian Dis*. 27:464–473.

40. Shirley, M.W. 1986. Studies on the immunogenicity of the seven attenuated lines of *Eimeria* given as a mixture to chickens. *Avian Pathol*. 15:629–638.
41. Shirley, M.W. 1979. A reappraisal of the taxonomic status of *Eimeria mivati*, Edgar and Seibold 1964, by enzyme electrophoresis and cross-immunity tests. *Parasitol*. 78:221–237.
42. Tsuji, N., S. Kawazu, and M. Ohta. 1997. Discrimination of eight chicken *Eimeria* species using the two step polymerase chain reaction. *J Parasitol*. 83:966–970.
43. Williams, R.B., A.C. Bushell, J.M. Reperant, T.G. Doy, J.H. Morgan, M.W. Shirley, P. Yvore, M.M. Carr, and Y. Fremont. 1996. A survey of *Eimeria* species in commercially-reared chickens in France during 1994. *Avian Pathol*. 25:113–130.

Cryptosporidiosis

1. Abbassi, H., M. Wyers, J. Cabaret, and M. Naciri. 2000. Rapid detection and quantification of *Cryptosporidium baileyi* oocysts in feces and organs of chickens using a microscopic slide flotation method. *Parasitol Res*. 86:179–187.
2. Blagburn, B.L., D.S. Lindsay, J.J. Giambrone, C.A. Sundermann, and F.J. Hoerr. 1987. Experimental cryptosporidiosis in broiler chickens. *Poult Sci*. 66:442–449.
3. Champliaud, D., P. Gobet, M. Naciri, O. Vagner, J. Lopez, J.C. Buisson, I. Varga, G. Harly, R. Mancassola, and A. Bonnin. 1998. Failure to differentiate *Cryptosporidium parvum* from C. meleagridis based on PCR amplification of eight DNA sequences. *Appl Environ Microbiol*. 64:1454–1458.
4. Current, W.L. 1983. Human cryptosporidiosis. *N Engl J Med*. 309:1326–1327.
5. Current, W.L. 1989. Cryptosporidium spp. In: *Parasitic Infections in the Compromised Host*. P.D. Walzer and R.M. Genta, eds. Marcel Dekker, Inc., New York. 281–341.
6. Current, W.L., and D.B. Snyder. 1988. Development of and serologic evaluation of acquired immunity to *Cryptosporidium baileyi* by broiler chickens. *Poult Sci*. 67:720–729.
7. Current, W.L., N.C. Reese, J.V. Ernst, W.S. Bailey, M.B. Heyman, and W.M. Weinstein. 1983. Human cryptosporidiosis in immunocompetent and immunodeficient persons. Studies of an outbreak and experimental transmission. *N Engl J Med*. 308:1252–1257.
8. Current, W.L., S.J. Upton, and T.B. Haynes. 1986. The life cycle of *Cryptosporidium baileyi* n. sp. (Apicomplexa, Cryptosporidiidae) infecting chickens. *J Protozool*. 33:289–296.
9. Current, W.L., M.N. Novilla, and D.B. Snyder. 1987. Cryptosporidiosis in poultry: An update (Are *Cryptosporidium* spp. primary pathogens?). *Proc Nat Meet Poult Health Condem*. 22:17–29.
10. Dhillon, A.S., H.L. Thacker, A.V. Dietzel, and R.W. Winterfield. 1981. Respiratory cryptosporidiosis in broiler chickens. *Avian Dis*. 25:747–751.
11. Dubey, J.P., C.A. Speer, and R. Fayer. 1990. *Cryptosporidiosis of Man and Animals*. CRC Press: Boca Raton, FL.
12. Fayer, R., and B.L.P. Ungar. 1986. *Cryptosporidium* spp. and cryptosporidiosis. *Microbiol Rev*. 50:458–483.
13. Garcia, L.S., D.A. Bruckner, T.C. Brewer, and R.Y. Shimizu. 1983. Techniques for the recovery and identification of *Cryptosporidium* oocysts from stool specimens. *J Clin Microbiol*. 18:185–190.
14. Glisson, J.R., T.P. Brown, M. Brugh, R.K. Page, S.H. Kleven, and R.B. Davis. 1984. Sinusitis in turkeys associated with respiratory cryptosporidiosis. *Avian Dis*. 28:783–790.
15. Goodwin, M.A. and J. Brown. 1987. Histologic incidence and distribution of *Cryptosporidium* sp. infection in chickens. *J Am Vet Med Assoc*. 190:1623.
16. Goodwin, M.A., J. Brown, R.S. Resurreccion, and J.A. Smith. 1996. Respiratory coccidiosis (*Cryptosporidium baileyi*) among northern Georgia broilers in one company. *Avian Dis*. 40:572–575.
17. Goodwin, M.A., W.L. Steffens, I.D. Russell, and J. Brown. 1988. Diarrhea associated with intestinal cryptosporidiosis in turkeys. *Avian Dis*. 32:63–67.
18. Goodwin, M.A., and W.D. Waltman. 1996. Transmission of *Eimeria*, viruses, and bacteria to chicks: Darkling beetles (*Alphitobius diaperius*) as vectors of pathogens. *J Appl Poultry Res*. 5:51–55.
19. Gorham, S.L., E.T. Mallinson, D.B. Snyder, and E.M. Odor. 1987. Cryptosporidiosis in the bursa of Fabricius: A correlation with mortality rates in broiler chickens. *Avian Pathol*. 16:205–211.
20. Guy, J.S., M.G. Levy, D.H. Ley, H.J. Barnes, and T.M. Craig. 1987. Experimental reproduction of enteritis in Bobwhite quail (*Colinus virginianus*) with *Cryptosporidium* and Reovirus. *Avian Dis*. 31:713–722.
21. Heine, J. 1982. Ein einfache Nachweismethode fur Kryptosporidien im Kot. *Zentralbl Veterinaermed Reihe*. *B* 29: 324–327.
22. Hoerr, F.J., F.M. Ranck, Jr., and T.F. Hastings. 1978. Respiratory cryptosporidiosis in turkeys. *J Am Vet Med Assoc*. 173:1591–1593.
23. Hoerr, F.J., W.L. Current, and T.B. Haynes. 1986. Fatal cryptosporidiosis in quail. *Avian Dis*. 30:421–425.
24. Latimer, K.S., M.A. Goodwin, and M.K. Davis. 1988. Rapid cytologic diagnosis of respiratory cryptosporidiosis in chickens. *Avian Dis*. 32:826–830.
25. Ley, D.H., M.G. Levy, L. Hunter, W. Corbett, and H.J. Barnes. 1988. Cryptosporidia-positive rates of avian necropsy accessions determined by examination of auramine o-stained fecal smears. *Avian Dis*. 32:108–113.
26. Lindsay, D.S., and B.L. Blagburn. 1990. Cryptosporidiosis in birds. In: *Cryptosporidiosis of Man and Animals*. J.P. Dubey, C.A. Speer, and R. Fayer, eds. CRC Press, Boca Raton, Fla. 125–148.
27. Lindsay, D.S., B.L. Blagburn, and F.J. Hoerr. 1987. Experimentally induced infection in turkeys with *Cryptosporidium baileyi* isolated from chickens. *Am J Vet Res*. 48:104–108.
28. Lindsay, D.S., B.L. Blagburn, C.A. Sundermann, and J.J. Giambrone. 1988. Effect of broiler chicken age on susceptibility to experimentally induced *Cryptosporidium baileyi* infection. *Am J Vet Res*. 49:1412–1414.
29. Morgan, U.M., P.T. Monis, L. Xiao, J. Limor, I. Sulaiman, S. Raidal, P. O'Donoghue, R. Gasser, A. Murray, R. Fayer, B.L. Blagburn, A.A. Lal, and R.C.A. Thompson. 2001. Molecular and phylogenetic characterisation of *Cryptosporidium* from birds. *Int J Parasitol*. 31:289–296.
30. O'Donoghue, P.J. 1995. *Cryptosporidium* and cryptosporidiosis in man and animals. *Int J Parasit*. 25:139–195.
31. Payne, P., L.A. Lancaster, M. Heinzman, and J.A. McCutchan. 1983. Identification of *Cryptosporidium* in patients with the acquired immunologic syndrome. *N Engl J Med*. 309:613–614.
32. Ranck, F.M., Jr., and F.J. Hoerr. 1986. Cryptosporidia in the respiratory tract of turkeys. *Avian Dis*. 31:389–391.
33. Ritter, G.D., D.H. Ley, M. Levy, J. Guy, and H.J. Barnes. 1986. Intestinal cryptosporidiosis and Reovirus isolated from Bobwhite quail (*Colinus virginianus*) with enteritis. *Avian Dis*. 30:603–608.

34. Slavin, D. 1955. *Cryptosporidium meleagridis* (sp. nov.). *J Comp Pathol*. 65:262–266.
35. Snyder, D.B., W.L. Current, E. Russek-Cohen, S. Gorham, E.T. Mallison, W.W. Marquardt, and P.K. Savage. 1988. Serologic incidence of *Cryptosporidium* in Delmarva broiler flocks. *Poult Sci*. 67:730–735.
36. Sundermann, C.A., D.S. Lindsay, and B.L. Blagburn. 1987. Evaluation of disinfectants for ability to kill avian *Cryptosporidium* oocysts. *Compan Anim Pract*. 2:36–39.
37. Tarwid, J.N., R.J. Cawthorn, and C. Riddell. 1985. Cryptosporidiosis in the respiratory tract of turkeys in Saskatchewan. *Avian Dis*. 29:528–532.
38. Tham, V.L., S. Kniesberg, and B.R. Dixon. 1982. Cryptosporidiosis in quails. *Avian Pathol*. 11:619–626.
39. Tyzzer, E.E. 1907. A sporozoan found in the peptic glands of the common mouse. *Proc Soc Exp Biol Med*. 5:12–13.
40. Tyzzer, E.E. 1910. An extracellular coccidium, *Cryptosporidium muris* (gen et sp. nov.) of the gastric glands of the common mouse. *J Med Res*. 23:487–509.
41. Tyzzer, E.E. 1912. *Cryptosporidium parvum* (sp. nov.), a coccidium found in the small intestine of the common mouse. *Arch Protistenkd*. 26:394–412.
42. Tzipori, S., and J.K. Griffiths. 1998. Natural history and biology of *Cryptosporidium parvum*. *Adv Parasitol*. 40:6–36.
43. Wages, D.P. 1987. Cryptosporidiosis and turkey viral hepatitis in turkey poult. *J Am Vet Med Assoc*. 190:1623.
44. Wunderlin, E., P. Wild, and J. Eckert. 1997. Comparative reproduction of *Cryptosporidium baileyi* in embryonated eggs and in chickens. *Parasitol Res*. 83:712–715.

Histomoniasis (Blackhead) and Other Protozoan Diseases of the Intestinal Tract

1. AAAP Committee on Disease Reporting. 1986. Summary of commercial poultry disease reports. *Avian Dis*. 31:926–987.
2. Clarkson, M.J. 1962. Studies on the immunity to *Histomonas meleagridis* in the turkey and the fowl. *Res Vet Sci*. 3:443–448.
3. Clarkson, M.J. 1963. Immunity to histomoniasis (blackhead). *Immunology*. 6:156–168.
4. Clarkson, M.J. 1966. Progressive serum protein changes in turkeys infected with *Histomonas meleagridis*. *J Comp Pathol*. 76:387–397.
5. Cuckler, A.C. 1970. Coccidiosis and histomoniasis in avian hosts. In: *Immunity to Parasitic Animals*. G.J. Jackson, R. Herman, and I. Singer, eds. Appleton-Century-Crofts, New York. 371–397.
6. Dwyer, D.M. 1970. An improved method for cultivating *Histomonas meleagridis*. *J Parasitol*. 56:191–192.
7. Dwyer, D.M. 1974. Analysis of the antigenic relationships among *Trichomonas, Histomonas, Dientamoeba*, and *Entamoeba*. *J Protozool*. 21:139–145.
8. Farmer, R.K., and J. Stephenson. 1949. Infectious eneterohepatitis (blackhead) in turkeys: A comparative study of methods of infection. *J Comp Pathol*. 59:119–126.
9. Feed Additive Compendium. 2006. Miller Publishing Company, Minneapolis, MN.
10. Gibbs, B.J. 1962. The occurrence of the protozoan parasite *Histomonas meleagridis* in the adult and eggs of the cecal worm *Heterakis gallinae*. *J Protozool*. 59:877–884.
11. Hu, J., L. Fuller, P.L. Armstrong, and L.R. McDougald. 2006. Histomoniasis in chickens: Attempted transmission in absence of vectors. *Avian Dis*. 50:277–279.
12. Hu, J., L. Fuller, and L.R. McDougald. 2004. Infection of turkeys with *Histomonas meleagridis* by the cloacal drop method. *Avian Dis*. 48: 746–750.
13. Hu, J., L. Fuller, and L.R. McDougald. 2005. Blackhead disease in turkeys: Direct transmission of *Histomonas meleagridis* from bird to bird in a laboratory model. *Avian Dis*. 49:328–331.
14. Hu, J., and L.R. McDougald. 2002. Effect of anticoccidials and antibiotics on the control of blackhead disease in broiler breeder pullets. *J Appl Poult Res*. 11:351–357.
15. Hu, J., and L.R. McDougald. 2003. Direct lateral transmission of *Histomonas meleagridis* in turkeys. *Avian Dis*. 47:489–492.
16. Joyner, L.P. 1966. In: *Experimental Chemotherapy*, vol. 4. R.J. Schnitzer and F. Hawking, eds. Academic Press, New York. 425–428.
17. Joyner, L.P., S.F.M. Davies, and S.D. Kendall. 1963. Chemotherapy of Histomoniasis. In: *Experimental Chemotherapy*, vol. 1. R.J. Schnitzer and F. Hawking, eds. Academic Press, New York. 333–349.
18. Kemp, R.L., and W.M. Reid. 1966. Staining techniques for differential diagnosis of Histomoniasis and mycosis in domestic poultry. *Avian Dis*. 10:357–363.
19. Lee, D.L. 1969. The structure and development of *Histomonas meleagridis* (Masticamoebidae: Protozoa) in the female reproductive tract of its host, *Heterakis gallinae* (Nematoda). *Parasitology*. 59:877–884.
20. Levine, N.D. 1973. *Protozoan Parasites of Domestic Animals and of Man*, 2nd ed. Burgess, Minneapolis.
21. Hafez, H.M., R. Hauck, D. Luschow, and L. McDougald. 2005. Comparison of the specificity and sensitivity of PCR, nested PCR and real-time PCR for the diagnosis of histomoniasis. *Avian Dis*. 49:366–370.
22. Lund, E.E., P.C. Augustine, and D.J. Ellis. 1966. Earthworm transmission of *Heterakis* and *Histomonas* to turkeys and chickens. *Exp Parasitol*. 18:403–407.
23. McDougald, L. 2005. Blackhead disease (histomoniasis) in poultry: A critical review. *Avian Dis*. 49:462–476.
24. McDougald, L., and R.B. Galloway. 1973. Blackhead disease *in vitro* isolation of *Histomonas meleagridis* as a potentially useful diagnostic aid. *Avian Dis*. 17:847–450.
25. McDougald, L.R., and M.F. Hansen. 1969. Serum protein changes in chickens subsequent to infection with *Histomonas meleagridis*. *Avian Dis*. 13:673–677.
26. McDougald, L.R. and M.F. Hansen. 1970. *Histomonas meleagridis*: Effect on plasma enzymes in chickens and turkeys. *Exp Parasitol*. 27:229–235.
27. McDougald, L.R., and J. Hu. 2001. Blackhead disease (*Histomonas meleagridis*) aggravated in broiler chickens by concurrent infection with cecal coccidiosis (*Eimeria tenella*). *Avian Dis*. 45:307–312.
28. McDougald, L.R., and W.M. Reid. 1976. *Protozoa of Medical and Veterinary Interest*, vol. 1. Academic Press: New York. 140–161.
29. McDougald, L.R. 2005. Blackhead disease (histomoniasis) in poultry: A critical review. *Avian Dis*. 49:462–476.
30. McDowell, S., Jr. 1953. A morphological and taxonomic study of the caecal protozoa of the common fowl, *Gallus gallus* L. *J Morphol*. 92:337–399.
31. McLoughlin, D.K. 1966. Observations on the treatment of *Trichomonas gallinae* in pigeons. *Avian Dis*. 10:288–290.

32. McNeil, E., W.R. Hinshaw, and C.A. Kofoid. 1941. *Hexamita meleagridis* sp. nov. from the turkey. *Am J Hyg*. 34:71–82.
Perez Mesa, C., R.M. STabler, and M. Berthrong. 1961. Histopathological changes in the domestic pigeon infected with *Trichomonas gallinae* (Jones' Barn Strain). *Avian Dis*. 5:48–60.
33. Reid, W.M. 1967. Etiology and dissemination of the blackhead disease syndrome in turkeys and chickens. *Exp Parasitol*. 21:249–275.
34. Ruff, M.D., L.R. McDougald, and M.F. Hansen. 1970. Isolation of *Histomonas meleagridis* from embryonated eggs of the *Heterakis gallinarum*. *J Protozool*. 17:10–11.
35. Springer, W.T., J. Johnson, and W.M. Reid. 1969. Transmission of Histomoniasis with male *Heterakis gallinarum* (Nematoda). *Parasitology*. 59:401–405.
37. Shivaprasad, H.L., R.P. Senties-Cue, R.P. Chin, R. Crespo, B. Charlton, and G. Cooper. 2002. Blackhead in turkeys, a re-emerging disease? In: *Proceedings of the 4th International Symposium on Turkey Diseases*. Berlin. H.M. Hafez (ed.), Berlin Free University, Berlin. 143–144.
38. Tyzzer, E.E. 1920. The flagellate character of the parasite producing "blackhead" in turkeys *Histomonas meleagridis*. *J Parasitol*. 6:124–130.
39. Tyzzer, E.E. 1934. Studies on histomoniasis, or "blackhead" infection, in the chicken and turkey. *Proc Am Acad Arts Sci*. 69:189–264.
40. USDA. 1954. Losses in Agriculture. United States Department Agriculture, ARS: Washington, DC.

Miscellaneous and Sporadic Protozoal Infections

1. Acha, P.N., and B. Szyfres. 2003. *Zoonoses and Communicable Diseases Common to Man and Animals*, vol. 3, 3rd ed. Pan American Health Organization, Washington, D.C.
2. Adams, W.W., R.C. Hargreaves, E. Hughes, J.A. Newman, E.M. Odor, I.L. Peterson, and W.T. Springer. 1987. American Association of Avian Pathologists 1986 summary of commercial poultry disease reports and 1986 pet, zoo, and wild bird disease report. *Avian Dis*. 31:926–982.
3. Ahmed, F.E., and A.H.H. Mohammed. 1978. Studies of growth and development of gametocytes in *Haemoproteus columbae* Kruse. *J Protozool*. 25:174–177.
4. Allan, R.A., and J.L. Mahrt. 1987. Populations of Leucocytozoon gametocytes in blue grouse (*Dendragapus obscurus*) from Hardwicke Island, *British Columbia. J Protozool*. 34:363–366.
5. Atkinson, C.T. 1985. *Epidemiology and pathogenicity of Haemoproteus meleagridis Levine 1961 from Florida turkeys*. PhD Dissertation, University of Florida, Gainesville, Florida.
6. Atkinson, C.T., and D.J. Forrester. 1987. Myopathy associated with megaloschizonts of *Haemoproteus meleagridis* in a wild turkey from Florida. *J Wildl Dis*. 23:495–498.
7. Beadell, J.S., and R.C. Fleischer. 2005. A restriction enzyme-based assay to distinguish between avian hemosporidians. *J Parasitol*. 91:683–685.
8. Bennett, G.F., and M. Cameron. 1974. Seasonal prevalance of avian hematozoa in passerine birds of Atlantic Canada. *Can J Zool*. 52:1259–1284.
9. Bennett, G.F., and M. Laird. 1973. Collaborative investigation into avian malaria: An international research programme. *J Wildl Dis*. 9:26–28.
10. Bennett, G.F., A.D. Smith, W. Whitman, and M. Cameron. 1975. Hematozoa of the Anatidae of the Atlantic Flyway. II. The maritime provinces of Canada. *J Wildlife Dis*. 11:280–9.
11. Biancifiori, F., C. Rondini, V. Grelloni, and T. Frescura. 1986. Avian toxoplasmosis: Experimental infection of chicken and pigeon. *Comp Immunol Microbiol Infect Dis*. 9:337–346.
12. Bickford, A.A., and J.R. Saunders. 1966. Experimental toxoplasmosis in chickens. *Am J Vet Rev*. 27:308–318. 000
13. Bollinger, T.K., and I.K. Barker. 1996. Runting of ducklings associated with *Cochlosoma anatis* infection. *Avian Dis*. 40:181–185.
14. Bollinger, T.K., I.K. Barker, and M.A. Fernando. 1996. Effects of the intestinal flagellate, *Cochlosoma anatis*, on intestinal mucosal morphology and disaccharidase activity in Muscovy ducklings. *Int J Parasitol*. 26:533–542.
15. Boucher, M. 2001. *Cochlosoma anatis infection in turkeys*. M.S. thesis, University of Missouri, Columbia, Missouri.
16. Boucher, M., and A.J. Bermudez. 1999. Effects of *Cochlosoma anatis* infection in turkeys. *Proc North Central Avian Dis. Conf*. 50:98–99.
17. Boucher, M., and A.J. Bermudez. 2000. Control of *Cochlosoma anatis* infection in turkeys. *Convention Notes Amer Vet Med Assoc*. 137:730.
18. Box, E.D., and D.W. Duszynski. 1978. Experimental transmission of *Sarcocystis* from icterid birds to sparrows and canaries by sporocysts from the opossum. *J Parasitol*. 64:682–688.
19. Box, E.D. and D.W. Duszynski. 1980. *Sarcocystis* of passerine birds: Sexual stages in the opossum (*Didelphis virginiana*). *J Wildl Dis*. 16:209–215.
20. Box, E.D., and J.H. Smith. 1982. The intermediate host spectrum in a *Sarcocystis* species of birds. *J Parasitol*. 68:668–673.
21. Burridge, M.J., W.J. Bigler, D.J. Forrester, and J.M. Henneman. 1979. Serologic survey for *Toxoplasma gondii* in wild animals in Florida. *J Am Vet Med Assoc*. 175:964–967.
22. Caballero-Servin, A. 1974. Congenital malformations in *Gallus gallus* induced by *Toxoplasma gondii*. *Rev Invest Salud Publica (Mexico)*. 34:87–94.
23. Campbell, J.G. 1945. An infectious enteritis in young turkeys associated with *Cochlosoma* sp. *Vet J*. 101:255–259.
24. Castle, M.D., and B.M. Christensen. 1990. Hematozoa of wild turkeys from the Midwestern United States: translocation of wild turkeys and its potential role in the introduction of Plasmodium kempi. *J Wildlife Dis*. 26:180–185.
25. Cawthorn, R.J., D. Rainnie, and G. Wobeser. 1981. Experimental transmission of *Sarcocystis* sp. (protozoa: Sarcocystidae) between the shoveler (*Anas clypeata*) duck and the striped skunk (*Mephitis mephitis*). *J Wildl Dis*. 17:389–394.
26. Cook, A.J.C., R.E. Gilbert, W. Buffolano, J. Zufferey, E. Petersen, P.A. Jenum, W. Foulon, A.E. Semprini, and D.T. Dunn. 2000. Sources of *Toxoplasma* infection in pregnant women: European multicentre case-control study. *British Med J*. 321:142–147.
27. Cooper, G.L., H.L. Shivaprasad, A.A. Bickford, R. Nordhausen, R.J. Munn, and J.S. Jeffrey. 1995. Enteritis in turkeys associated with an unusual flagellated protozoan (*Cochlosoma anatis*). *Avian Dis*. 39:183–190.
28. Cox, F.E.G. 1998. Babesiosis and Malaria. In: *Zoonoses*, S.R. Palmer, E.J.L. Soulsby, and D.I.H. Simpson, eds. Oxford University Press, New York. 599–607.
29. Desser, S.S., J. Stuht, and A.M. Fallis. 1978. Leucocytozoonosis in Canada geese in upper Michigan. 1. Strain differences among geese from different localities. *J Wildl Dis*. 14:124–131.

30. Dick, J. 1978. *Leucocytozoon smithi*: Persistence of gametocytes in peripheral turkey blood. *Avian Dis*. 22:82–85.
31. Drouin, T.E., and J.L. Mahrt. 1980. The morphology of cysts of *Sarcocystis* infecting birds in western Canada. *Can J Zool*. 58:1477–1482.
32. Dubey, J.P. 2010. *Toxoplama gondii* infections in chickens (*Gallus domesticus*): Prevalence, clinical disease, diagnosis, and public health significance. *Zoonoses Public Health*. 57:60–73.
33. Dubey, J.P., and C.P. Beattie. 1988. *Toxoplasmosis of Animals and Man*. CRC Press, Inc., Boca Raton, FL.
34. Dubey, J.P., M.E. Camargo, M.D. Ruff, G.C. Wilkins, S.K. Shen, O.C.H. Kwok, and P. Thulliez. 1993a. Experimental toxoplasmosis in turkeys. *J Parasitol*. 79:949–952.
35. Dubey, J.P., D.S. Linsay, B.M. Rosenthal, C.E. Kerber, N. Kasai, H.F.J. Pena, O.C.H. Kwok, S.K. Shen and S.M. Gennari. 2001. Isolates of *Sarcocystis falcatula*-like organisms from South American opossums *Didelphis marsupialis* and *Dedelphis albiventris* from Sao Paulo, *Brazil. J Parasitol*. 87:1449–1453.
36. Dubey, J.P., C.F. Quist, and D.L. Fritz. 2000. Systemic sarcocystosis in a wild turkey from Georgia. *J Wildlife Dis*. 36:755–760.
37. Dubey, J.P., M.D. Ruff, M.E. Camargo, S.K. Shen, G.L. Wilkins, O.C.H. Kwok, and P. Thulliez. 1993b. Serologic and parasitologic responses of domestic chickens after oral inoculation with *Toxoplasma gondii* oocysts. *Am J Vet Res*. 54:1668–1672.
38. Duszynski, D.W., and E.D. Box. 1978. The opossum (*Didelphis virginiana*) as a host for *Sarcocystis debonei* from cowbirds (*Molothrus ater*) and grackles (*Cassidiz mexicanus, Quiscalus quiscula*). *J Parasitol*. 64:326–329.
39. Evans, N.P., R.D. Evans, S. Fitz-Coy, F.W. Pearson, J.L. Robertson, and D.S. Lindsay. 2006. Identification of new morphological and life-cycle stages of *Cochlosoma anatis* and experimental transmission using pseudocysts. *Avian Dis*. 50:22–27.
40. Fallis, A.M., R.L. Jacobson, and J.N. Raybould. 1973. Haematozoa in domestic chickens and guinea fowl in Tanzania and transmission of *Leucocytozoon neavet* and *Leucocytozoon schoutedent*. *J Protozool*. 20:438–442.
41. Fallis, A.M., S.S. Desser, and R.A. Khan. 1974. On species of *Leucocytozoon*. *Adv Parasitol*. 12:1–67.
42. Fayer, R. and R.M. Kocan. 1971. Prevalence of Sarcocystis in grackles in Maryland. *J Protozool*. 18:547–548.
43. Fayer, R., A.J. Johnson, and P.K. Hildebrandt. 1976. Oral infection of mammals with *Sarcocystis fusiformis* bradyzoites from cattle and sporocysts from dogs and coyotes. *J Parasitol*. 62:10–14.
44. Fedynich, A.M., and O.E. Rhodes, Jr. 1995. Hemosporid (Apicomplexa, Hematozoea, Hemosporida) community structure and pattern in wintering wild turkeys. *J Wildlife Dis*. 31:404–409.
45. Feldman, H.A. 1974. Toxoplasmosis: An overview. *Bull N Y Acad Med*. 50:110–127.
46. Ferrell, S.T., K. Snowden, A.B. Marlar, M. Garner, and N.P. Lung. 2007. Fatal hemoprotozoal infections in multiple avian species in a zoological park. *J Zoo Wildl Med*. 38:309–316.
47. Filippich, L.J., and P.J. O'Donoghue. 1997. *Cochlosoma* infections in finches. *Aust Vet J*. 75:561–563.
48. Forrester, D.J., J.K. Nayar, and M.D. Young. 1987. Natural infection of *Plasmodium hermani* in the northern bobwhite, *Colinus virginianus*, in Florida. *J Parasitol*. 73:865–866.
49. Garnham, P.C.C. 1966. *Malaria Parasites and Other Haemosporidia*. Blackwell: Oxford, England.
50. Goodwin, M.A., J.P. Dubey, and J. Hatkin. 1994. *Toxoplasma gondii* peripheral neuritis in chickens. *J Vet Diagn Invest*. 6:382–385.
51. Goto, M., H. Fujihara, and M. Morita. 1966. Pathological studies of leucocytozoonosis in chickens. *Jap J Vet Sci*. 28:183–190.
52. Graczyk, T.K., M.L. Shaw, M.R. Cranfield, and F.B. Beall. 1994. Hematologic characteristics of avian malaria cases in African black-footed penguins (*Spheniscus demersus*) during the first outdoor exposure season. *J Parasitol*. 80:302–308.
53. Greiner, E.C., and D.J. Forrester. 1980. *Haemoproteus meleagridis* Levine 1961: Redescription and developmental morphology of the gametocytes in turkeys. *J Parasitol*. 66:652–658.
54. Greiner, E.D., G.F. Bennett, M. Laird, and C.M. Herman. 1975. Avian hematozoa. I. A color pictorial guide to some species of Haemoproteus, Leucocytozoon, and Trypanosoma. *Wildl Dis*. 68 (WD75-3). [Color fiche].
55. Hampl, V., M. Vrlik, I. Cepicka, Z. Pecka, J. Kulda, and J. Tachezy. 2006. Affiliation of *Cochlosoma* to trichomonads by phylogenic analysis of the small-subunit rRNA gene and a new family concept of the order Trichomonadida. *Int J Syst Evol Microbiol*. 56:305–312.
56. Hellgren, O., J. Waldenstrom, and S. Bensch. 2004. A new PCR assay for simultaneous studies of *Leucocytozoon*, *Plasmodium* and *Haemoproteus* from avian blood. *J Parasitol*. 90:797–802.
57. Herman C.M., J.H. Barrows, Jr., and I.B. Tarshis. 1975. Leucocytozoonosis in Canada geese at the Seney National Wildlife Refuge. *J Wildl Dis*. 11:404–411.
58. Hsu, C.K., G.R. Campbell, and N.D. Levine. 1973. A checklist of the species of the genus *Leucocytozoon*. *J Protozool*. 20:195–203.
59. Huchzermeyer, F.W. 1993. Pathogenicity and chemotherapy of *Plasmodium durae* in experimentally infected domestic turkeys. *Onderstepoort J Vet Res*. 60:103–110.
60. Hutchinson, W.M., J.F. Dunachie, K. Work, and J.C. Siim. 1971. The life cycle of the coccidian parasite, *Toxoplasma gondii*, in the domestic cat. *Trans R Soc Trop Med Hyg*. 65:380–399.
61. Hyman, J.A., L.K. Johnson, M.M. Tsai, and T.J. O'Leary. 1995. Specificity of polymerase chain reaction identification of *Toxoplasma gondii* infection in paraffin-embedded animal tissues. *J Vet Diagn*. 7:275–278.
62. Iannuzzi, L. and G. Renieri. 1971. The egg in the epidemiology of Toxoplasmosis. Tests of experimental infections by injection through the shell. *Acta Med Vet*. 17:311–317.
63. Isobe, T. and K. Akiba. 1990. Early schizonts of *Leucocytozoon caulleryi*. *J Parasitol*. 76:587–589.
64. Isobe, T., S. Shimizu, S. Yoshihara, and Y. Yokomizo. 2000. Cyclosporin A, but not bursectomy, abolishes the protective immunity of chickens against *Leucocytozoon caulleryi*. *Dev Comp Immunol*. 24:433–441.
65. Ito, A., and T. Gotanda. 2002. The correlation of protective effects and antibody production in immunized chickens with recombinant R7 vaccine against *Leucocytozoon caullweyi*. *J Vet Med Sci*. 64:405–411.
66. Ito, A., and T Gotanda. 2004. Field efficacy of recombinant R7 vaccine against chicken leucocytozoonosis. *J Vet Med Sci*. 66:483–487.
67. Ito, A., and T Gotanda. 2005. A rapid assay for detecting antibodies against leukocytozoonosis in chickens with a latex agglutination test using R7 antigen. *Avian Pathol*. 34:15–19.
68. Jacobs, L. 1974. *Toxoplasma gondii*: Parasitology and transmission. *Bull N Y Acad Med*. 50:128–145.

69. Jacobs, L., and M.L. Melton. 1966. Toxoplasmosis in chickens. *J Parasitol*. 52:1158–1162.
70. Johnson, E.P., G.W. Underhill, J.A. Cox, and W.L. Threlkeld. 1938. A blood protozoon of turkeys transmitted by *Simulium nigroparvum* (Twinn). *Am J Hyg*. 27:649–665.
71. Jones, S.R. 1973. Toxoplasmosis: A review. *J Am Vet Med Assoc*. 163:1038–1042.
72. Jones, J.E., B.D. Barnett, and J. Solis. 1972. The effect of *Leucocytozoon smithi* infection on production, fertility, and hatchability of broad breasted white turkey hens. *Poult Sci*. 51:543–545.
73. Julian, R.J., and D.E. Galt. 1980. Mortality in Muscovy ducks (*Cairina moschata*) caused by *Haemoproteus* infection. *J Wildl Dis*. 16:39–44.
74. Kaneto, C.N., A.J. Costa, A.C. Paulillo, F.R. Moraes, T.O. Murakami, and M.V. Meireles. 1997. Experimental toxoplasmosis in broiler chicks. *Vet Parasitol*. 60:203–210.
75. Kemp, R.L. 1978. Haemoproteus. In: *Diseases of Poultry*, 7th ed. M.S. Hofstad, B.W. Calnek, C.F. Helmbodt, W.M. Reid, and H.W. Yoder, Jr., eds. Iowa State University Press, Ames, Iowa. 824–825.
76. Kimura, G.G. 1934. *Cochlosoma rostratum* sp. nov., an intestinal flagellate of domesticated ducks. *Trans Am Microsc Soc*. 53:102–115.
77. Kinjo, T. 1972. Experimental toxoplasmosis in fowls. III. Reactions of chicks at 30–40 days old and one day old. IV. Susceptibility of chick embryos. *Sci Bull Coll Agric (Okinawa)*. 19:407–420.
78. Kissam, J.B., R. Noblet, and G.I. Garris. 1975. Large scale aerial treatment of an endemic area with abate granular larvicide to control black flies (*Diptera simuliidae*) and suppress *Leucocytozoon smithi* of turkeys. *J Med Entomol*. 12:359–362.
79. Kiszewski, A.E., and E.W. Cupp. 1986. Transmission of *Leucocytozoon smithi* (Sporozoa: Leucocytozoidae) by black flies (*Diptera simuliidae*) in New York, USA. *J Med Entomol*. 23:256–262.
80. Kocan, R.M. 1968. Anemia and mechanism of erythrocyte destruction in ducks with acute *Leucocytozoon* infections. *J Protozool*. 15:455–462.
81. Kulda, J., and E. Nohynkova. 1978. Flagellates of the human intestine and intestines of other species. In: *Parasitic Protozoa*, vol. 2. J.P. Kreier, ed. Academic Press, New York. 1–138.
82. Kuticic, V., and T. Wikerhauser. 2000. A survey of chickens for viable toxoplasms in Croatia. *Acta Vet Hung*. 48:183–185.
83. Lee, J.J., G.F. Leedale, and P. Bradbury. 2000. *An Illustrated Guide to the Protozoa,* vol. 1, 2nd ed. Allen Press Inc., Lawrence, KS.
84. Levine, N.D. 1973. *Protozoan Parasites of Domestic Animals and of Man*, 2nd ed. Burgess: Minneapolis, MN.
85. Levine, N.D. 1986. The taxonomy of *Sarcocystis* (Protozoa: Apicomplexa) species. *J Parasitol*. 72:372–382.
86. Levine, N.D., and G.R. Campbell. 1971. A checklist of the species of the genus *Haemoproteus* (Apicomplexa, Plasmodiidae). *J Protozool*. 18:475–484.
87. Levine, N.D., J.O. Corliss, F.E.G. Cox, G. Deroux, J. Grain, B.M. Honigberg, G.F. Leedale, A.R. Loeblich III, J. Lom, D. Lynn, E.G. Merinfeld, F.C. Page, G. Poljansky, V. Sprague, J. Vavra, and F.G. Wallace. 1980. A newly revised classification of the protozoa. *J Parasitol*. 27:37–58.
88. Lindsay, D.S., C.T. Larsen, A.M. Zajac, and F.W. Pierson. 1999. Experimental *Cochlosoma anatis* infections in poultry. *Vet Parasitology*. 81:21–27.
89. Lund, E.E., and M.M. Farr. 1965. Protozoa. In: *Diseases of Poultry*, 5th ed. H.E. Biester and L.H. Schwarte, eds. Iowa State University Press, Ames, Iowa. 1056–1148.
90. Lund, E.E. 1972. Other protozoan diseases. In: *Diseases of Poultry*, 6th ed., M.S. Hofstad, B.W. Calnek, C.F. Helmboldt, W.M. Reid, and H.W. Yoder, Jr., eds. Iowa State University Press, Ames, Iowa. 990–1046.
91. Macwhirter, P. 1994. Passeriformes. In: *Avian Medicine: Principles and Application*. B.R. Ritchie, G.J. Harrison, and L.R. Harrison, eds. Wingers Publishing, Inc., Lake Worth, Florida. 1172–1199.
92. Maley, G.J.M., and S.S. Desser. 1977. Anemia in *Leucocytozoon simondi* infections. I. Quantification of anemia, gametocytemia, and osmotic fragility of erythrocytes in naturally infected Pekin ducklings. *Can J Zool*. 55:355–358.
93. Markus, M.B., R. Killick-Kendrick, and P.C.C. Garnham. 1974. The coccidial nature and life-cycle of *Sarcocystis*. *J Trop Med Hyg*. 77:248–259.
94. Marsh, A.E., B.C. Barr, L. Tell, M. Koski, E. Greiner, J. Dame, and P.A. Conrad. 1997. *In vitro* cultivation and experimental inoculation of *Sarcocystis falcatula* and *Sarcocystis neurona* merozoites into budgerigars (*Melopsittacus undulates*). *J Parasitol*. 83:1189–1192.
95. McDougald, L.R. 1997. Other protozoan diseases of the intestinal tract. In: *Diseases of Poultry*, 10th ed. B.W. Calnek, H.J. Barnes, C.W. Beard, L.R. McDougald, and Y.M. Saif, eds. Iowa State University Press, Ames, Iowa. 890–899.
96. McElroy, S.M., A.L. Szalanski, T. Mckay, A.J. Bermudez, C.B. Owens, and C.D. Steelman. 2005. Molecular assay for the detection of *Cochlosoma anatis* in house flies and turkey specimens by polymerase chain reaction. *Vet Parasitol*. 127:165–168.
97. McGhee, R.B. 1970. Avian malaria. In: *Immunity to Parasitic Animals*, vol. 2. D.J. Jackson, R. Herman, and I. Singer, eds. Appleton-Century-Crofts, New York. 295–329.
98. McNeil, E., and W.R. Hinshaw. 1942. *Cochlosoma rostratum* from the turkey. *J Parasitol*. 28:349–350.
99. Meade, S.M., C.T. Larsen, F.W. Pierson, and D.S. Lindsay. 2000. The effectiveness of fenbendazole, roxarsone, and nitroimidazole derivatives in the treatment of Cochlosoma anatis infection of turkeys. *Proc Northeastern Conf Avian Dis*. 72:22.
100. Miller, N.L., J.K. Frenkel, and J.P. Dubey. 1972. Oral infections with *Toxoplasma* cysts and oocysts in felines, other mammals, and in birds. *J Parasitol*. 58:928–937.
101. Miura, S., K. Ohshima, C. Itakura, and S. Yamogiwa. 1973. A histopathological study on Leucocytozoonosis in young hens. *Japan J Vet Sci*. 35:175–181.
102. Molyneux, D.H. 1977. Vector relationships in the trypanosomatidae. *Adv Parasitol*. 15:1–82.
103. Morgan, U.M. 2000. Detection and characterization of parasites causing emerging zoonoses. *Int J Parasitol*. 30:1407–1421.
104. Mutalib, A., R. Keirs, W. Maslin, M. Topper, and J.P. Dubey. 1995. *Sarcocystis*-associated encephalitis in chickens. *Avian Dis*. 39:436–440.
105. Nakamura, K., Y. Mitarai, N. Tanimura, H. Hara, A. Ikeda, J. Shimada, and T. Isobe. 1997. Pathogenesis of reduced egg production and soft-shelled eggs in laying hens associated with *Leucocytozoon caulleryi* infection. *J Parasitol*. 83:325–327.
106. Noblet, R., H.S. Moore, IV, and G.P. Noblet. 1976. Survey of *Leucocytozoon* in South Carolina. *Poult Sci*. 55:447–449.

107. Odening, K. 1998. The present state of species-systematics in *Sarcocystis Lankester*, 1882 (Protista, Sporozoa, Coccidia). *Syst Parasitol*. 41:209–233.
108. Page, C.D., R.E. Schmidt, J.H. English, C.H. Gardiner, G.B. Hubbard, and G.C. Smith. 1992. Antemortem diagnosis and treatment of sarcocystosis in two species of psittacines. *J Zoo Wildl Med*. 23:77–85.
109. Pecka, Z. 1991. Domestic geese (*Anser anser* L.) as a new host of *Cochlosoma anatis* Kotlan, 1923. *Folia Parasitol*. 38:91–92.
110. Pecka, Z., E. Nohynkova, and J. Kulda. 1996. Ultrastructure of *Cochlosoma anatis* Kotlan, 1923 and taxonomic position of the family Cochlosomatidae (Parabasala: Trichomonadida). *Europ J Protistol*. 32:190–201.
111. Poelma, F.G., P. Zwart, G.M. Dorrestein, and C.M. Iordens. 1978. Cochlosomose, een probleem bij de opfok van prachtvinken in volieres. *Tijdschr Diergeneesk*. 103:589–593.
112. Quist, C.F., J.P Dubey, M.P. Luttrell, and W.R. Davidson. 1995. Toxoplasmosis in wild turkeys: A case report and serologic survey. *J Wildlife Dis*. 31:255–258.
113. Ruiz, A., and J.K. Frenkel. 1980. Intermediate and transport hosts of *Toxoplasma gondii* in Costa Rica. *Am J Trop Med Hyg*. 29:1161–1166.
114. Saif, Y.M., A.M. Fadly, J.R. Glisson, L.R. McDougald, L.K. Noland, and D.E. Swayne. 2008. *Diseases of Poultry*, 12th ed. Blackwell Publishing, Ames, Iowa.
115. Shutler, D., C.D. Ankney, and A. Mullie. 1999. Effects of the blood parasite *Leucocytozoon simondi* on growth rates of anatid ducklings. *Can J Zool*. 77:1573–1578.
116. Siccardi, F.J., H.O. Rutherford, and W.T. Derieux. 1974. Pathology and prevention of *Leucocytozoon smithi* infection in turkeys. *Avian Dis*. 18:21–32.
117. Siim, J.C., U. Biering-Sorenson, and T. Moller. 1963. Toxoplasmosis in domestic animals. *Adv Vet Sci*. 8:335–429.
118. Simpson, C.R., and D.J. Forrester. 1973. Electron microscopy of Sarcosystis sp: Cyst wall, micropore, rhoptries, and an unidentified body. *Int J Parasitol*. 3:467–470.
119. Smith, J.H., J.L. Meier, P.J.G. Neill, and E.D. Box. 1987. Pathogenesis of *Sarcocystis falcatula* in the budgerigar. II. Pulmonary pathology. *Lab Invest*. 56:72–84.
120. Solis, J. 1973. Nonsusceptibility of some avian species to turkey *Leucocytozoon* infection. *Poult Sci*. 52:498–500.
121. Soni, J.L., and H.W. Cox. 1975. Pathogenesis of acute avian malaria. II. Anemia mediated by a cold-active autohemagglutinin from the blood of chickens with acute *Plasmodium gallinaceum* infection. *Am J Trop Med Hyg*. 24:206–213.
122. Spindler, L.A. 1972. Sarcosporidiosis. In: *Diseases of Poultry*, 6th ed. M.S. Hofstad, B.W. Calnek, C.F. Helmboldt, W.M. Reid, and H.W. Yoder, Jr., eds. Iowa State University Press, Ames, Iowa. 1046–1054.
123. Springer, W.T. 1984. Other blood and tissue protozoa. In: *Diseases of Poultry*, 8th ed. M.S. Hofstad, H.J. Barnes, B.W. Calnek, W.M. Reid, and H.W. Yoder, Jr., eds. Iowa State University Press, Ames, Iowa. 727–740.
124. Stacey, L.M., C.E. Couvillion, C. Siefker, and G.A. Hurst. 1990. Occurrence and seasonal transmission of hematozoa in wild turkeys. *J Wildlife Dis*. 26:442–446.
125. Straight, M.M., C.T. Larsen, R.B. Duncan, C. Tirawattanawanich, F.W. Pierson, and D.S. Lindsay. 1999. *Cochlosoma anatis*: Co-infection with turkey corona virus. *Proc Northeastern Conf Avian Dis*. 71:58.
126. Teglas, M.B., S.E. Little, K.S. Latimer, and J.P. Dubey. 1998. *Sarcocystis*-associated encephalitis and myocarditis in a wild turkey (*Meleagridis gallopavo*). *J Parasitol*. 84:661–663.
127. Tenter, A.M., A.R. Heckeroth, L.M. Weiss. 2000. *Toxoplasma gondii*: from animals to humans. *Int J Parasitol*. 30:1217–1258.
128. Travis, B.V. 1938. A synopsis of the flagellate genus *Cochlosoma* Kotlan, with the description of two new species. *J Parasitol*. 24:343–351.
129. Wallace G.D. 1973. Intermediate and transport hosts in the natural history of *Toxoplasma gondii*. *Am J Trop Med Hyg*. 22:456–464.
130. Walsh, C.P., C.T. Larsen, A.M. Zajac, and D.S. Lindsay. 1999. Attempted *in vitro* culture and *in vivo* treatment of *Cochlosoma anatis*. *Proc Ann Meet Amer Ass Vet Parasitogist*.. 44:69.
131. Watkins, R.A., W.D. O'Dell, and A.J. Pinter. 1989. Redescription of the flagellar arrangement in the duck intestinal flagellate, *Cochlosoma anatis* and description of a new species, *Cochlosoma soricis N. sp. from shrews. J Protozool*. 36:527–531.
132. White, E.M., and G.F. Bennett. 1979. Avian Haemoproteidae, 12. *The hemoproteids of the grouse family Tetraonidae. Can J Zool*. 57:1465–1472.
133. Wicht, R.J. 1981. Transmission of *Sarcocystis rileyi* to the striped skunk (*Mephitis mephitis*). *J Wildl Dis*. 17:387–388.
134. Woldemeskel, M., and F. Gebreab. 1996. Prevalance of sarcocysts in livestock in northwest Ethiopia. *Zentralbl Veterinarmed [B]*. 43:55–58.
135. Yu, C.Y., J.S. Wang, and C.C. Yeh. 2000. *Culicoides arakawae* (diptera: Ceratopogonidae) population succession in relation to leucocytozoonosis prevalence on a chicken farm in Taiwan. *Vet Parasitol*. 93:113–120.

VI Noninfectious Diseases

Chapter 29	Nutritional Diseases	1205
Chapter 30	Developmental, Metabolic and Other Noninfectious Disorders	1233
Chapter 31	Mycotoxicoses	1271
Chapter 32	Toxins and Poisons	1287

Chapter 29

Nutritional Diseases

Kirk C. Klasing

Introduction

Poultry require at least 36 dietary nutrients at appropriate concentrations and balance (Table 29.1). Worldwide, the majority of poultry diets are based on soymeal as the primary protein source, and grains such as corn, sorghum, or wheat, as the primary energy source. To prevent nutrient deficiencies, grain-soy based diets are typically supplemented with concentrated sources of methionine, sodium chloride, calcium, phosphorus, zinc, manganese, copper, iron, selenium, and all of the essential vitamins. Nutrient deficiencies or toxicities most often result from errors in diet formulation or milling and these supplemented nutrients are the most probable causes of nutritional problems. Severely deficient or toxic levels often are expressed as characteristic pathologies to organs and tissues. Marginal deficiencies or toxicities often result in suboptimal growth, impaired resistance to infectious diseases, decreased egg production, or lowered hatchability, but rarely result in clear deficiency symptoms.

Quantitative nutrient requirements of the young chicks and poults and of single comb white leghorn hens are quite well established (Table 29.1); however, the requirements of growing chicks and poults after the first few weeks of age and the requirements for many nutrients of breeding age broilers and turkeys have not been determined experimentally and are rough estimates (97).

Some developmental and metabolic diseases are exacerbated by high rates of growth and can be minimized by limiting the consumption of a diet that maximizes production rates. In particular, feed restriction markedly reduces ascites (14), sudden death syndrome (49), and skeletal disorders (43). Chapter 30 should be consulted for information on these diseases. The following sections examine the effects of individual nutrient deficiencies or toxicities on poultry health.

Water

Poultry can survive much longer without food than without water. Unlike larger farm animals, chickens and turkeys are most productive with access to a continuous water supply because they drink only small amounts at a time. An insufficient amount results in decreased growth, egg production, and resistance to heat stress. More specific signs include hemoconcentration, increased erythrocyte osmotic fragility, visceral urates and renal disease indicated by increased spaces between membrane infoldings of the distal convoluted tubular epithelium, increased number of cytoplasmic vacuoles in proximal convoluted tubules, and increased mucin production and dilation of collecting ducts (101, 159).

The quantity of water consumed by chicks is correlated directly with the salt (NaCl) and protein content of their diet (1, 2, 9, 121). Sodium or potassium bicarbonates cause similar increases in water intake of broiler chicks. Chlorine and phosphorus also increase water intake, but not as much as sodium or potassium, and calcium has little effect (9, 121). The effect of protein is presumably due to increased excretion of nitrogen and minerals such as phosphorus and sulfur that are constituents of protein. Excess water excretion often results in wet litter, which predisposes birds to foot pad dermatitis (1, 117).

Proteins and Amino Acids

Commercial diets usually are formulated using a "least cost" approach, and meeting the essential amino acid requirements greatly impacts the cost of the diet. For this reason, the limiting amino acids in the diet are typically supplied with very little margin of safety. The protein requirement represents the collective need for 10 absolutely essential amino acids (arginine, histidine, isoleucine, leucine, lysine, methionine, phenylalanine, threonine, tryptophan, and valine), 2 amino acids (cysteine and tyrosine) that can be synthesized from essential amino acids, 2 amino acids that are essential for the young chick (glycine or serine and proline), plus additional amino acids to satisfy the nitrogen requirement for synthesis of nonessential amino acids, purines, pyrimidines, and other nitrogenous compounds.

Practical ingredients usually are limiting in 1 or more amino acids. Grains such as corn, milo, and wheat are most deficient in lysine, whereas soybean meal is most deficient in methionine. It is often cost effective to supply these limiting amino acids in the form of pure amino acids, especially lysine and

Diseases of Poultry, Thirteenth Edition. David E. Swayne.
© 2013 John Wiley & Sons, Inc. Published 2013 by John Wiley & Sons, Inc.

Table 29.1. Nutrient requirements of poultry.[1]

		Required Level			
Nutrient	**Unit**	**Egg-laying strain from 0–6 wk**	**White-egg layers at 100 % production**	**Broiler from 0–3 wk**	**Turkey from 0–4 wk**
Crude protein	%	18.00	15.00	23.00	28.00
Arginine	%	1.00	0.70	1.25	1.60
Glycine + serine	%	0.70	–	1.25	1.00
Histidine	%	0.26	0.17	0.35	0.58
Isoleucine	%	0.60	0.65	0.80	1.10
Leucine	%	1.10	0.82	1.20	1.90
Lysine	%	0.85	0.69	1.10	1.60
Methionine	%	0.30	0.30	0.50	0.55
Methionine + cystine	%	0.62	0.58	0.90	1.05
Phenylalanine	%	0.54	0.47	0.72	1.00
Phenylalanine + tyrosine	%	1.00	0.83	1.34	1.80
Threonine	%	0.68	0.47	0.80	1.00
Trytophan	%	0.17	0.16	0.20	0.26
Valine	%	0.62	0.70	0.90	1.20
Linoleic acid	%	1.00	1.00	1.00	1.00
Calcium	%	0.90	3.25	1.00	1.20
Nonphytate phosphorus	%	0.4	0.25	0.45	0.60
Potassium	%	0.25	0.15	0.30	0.70
Sodium	%	0.15	0.15	0.20	0.17
Chlorine	%	0.15	0.13	0.20	0.15
Magnesium	mg/kg	600	500	600	500
Manganese	mg/kg	60.00	20.00	60	60.00
Zinc	mg/kg	40.00	35.00	40.00	70.00
Iron	mg/kg	80.00	45.00	80.00	80.00
Copper	mg/kg	5.00	?	8.00	8.00
Iodine	mg/kg	0.35	0.035	0.35	0.40
Selenium	mg/kg	0.15	0.06	0.15	0.20
A	IU/kg	1500	3000	1500	5000
D	IU/kg	200	300.00	200.0	1100
E	IU/kg	10.00	5.00	10.00	12.00
K	mg/kg	0.50	0.50	0.50	1.75
Riboflavin	mg/kg	3.60	2.50	3.60	4.00
Pantothenic acid	mg/kg	10.00	2.00	10.00	10.00
Niacin	mg/kg	27.00	10.00	35.00	60.00
B_{12}	mg/kg	0.009	0.004	0.01	0.003
C	mg/kg	0	0	0	0
Choline	mg/kg	1300	1050	1300	1600
Biotin	mg/kg	0.15	0.10	0.15	0.25
Folic acid	mg/kg	0.55	0.25	0.55	1.00
Thiamin	mg/kg	1.00	0.70	1.80	2.00
Pyridoxine	mg/kg	3.00	2.50	3.50	4.50

[1]Requirements are taken from NRC (1994) and are based on diets with standard energy contents and a dry matter of 90%.

methionine. Threonine, tryptophan, arginine, and isoleucine also may be supplied as pure amino acids when economically advantageous.

Amino Acid Deficiency

Clinical Signs and Signalment

In contrast to the specific signs that may occur as a result of vitamin or mineral deficiencies, the effects of essential amino acid deficiencies are nonspecific: reduced growth, reduced feed consumption, lower meat yield, decreased egg production and egg size, and loss of body weight in adults. The decrease in feed intake due to a severe deficiency occurs within hours of consumption of a deficient diet and is due to a distortion in plasma and tissue amino acid levels. Unlike severe deficiencies, marginal amino acid deficiencies often result in increased food intake with concomitant reduction of body weight gain and lean tissue growth resulting in increased body fat. Some amino acids have additional effects. Methionine

Figure 29.1. Lysine deficiency. Stunting and retarded development are apparent in this chick (right) fed a diet without sufficient lysine when compared with the normal control chick (left) fed adequate lysine. (D.E. Swayne)

deficiency may exacerbate choline or vitamin B_{12} deficiencies owing to its role in methyl group metabolism. Lysine deficiency causes impaired pigmentation of bronze turkey poults (51) and can result in stunting and retarded development in chicks (Figure 29.1). Arginine deficiency tends to cause the wing feathers to curl upward, giving the chick a distinct ruffled appearance. Several other amino acids have been reported to affect feather growth and structure (51).

When animals are provided with dietary protein in excess of their requirements, the surplus protein is catabolized, and the nitrogen released is converted to uric acid. An excess of protein may cause hyperuricemia and exacerbate articular gout in genetically susceptible birds (11). Excess protein together with excess calcium has been shown to cause visceral gout in growing chickens (55). The oxidation of excess methionine, lysine, arginine, and phosphorylated amino acids contribute to metabolic acidosis, which impairs bone mineralization, eggshell thickness, and growth.

Toxicity

High levels of well-balanced protein are well tolerated, but excesses of individual amino acids due to feed mixing errors are especially toxic. Acute toxicity of individual amino acids manifests as a severe decrease in food intake and growth rate. Methionine is the most toxic of the amino acids and also the amino acid most likely to be supplemented to a poultry diet. Methionine toxicity causes splenic hemosiderosis leading to the accumulation of heme Fe and darkening of the spleen (38). The margin of safety for supplemented DL-methionine is very narrow with toxicity occurring at about 2–3 times the requirement in growing chicks. Methionine is often supplemented as DL-2-hydroxy-4-methylthiobutanoic acid (HMB), which is less toxic than L- or DL-methionine (15, 158). The relative order of toxicity of amino acids for growing chickens is methionine → phenylalanine → tryptophan → histidine → lysine → tyrosine → threonine → isoleucine → arginine → valine → leucine. Amino acid toxicity usually can be diagnosed by high levels of the toxic amino acid in the blood or the diet.

Carbohydrates

Starch is the primary source of metabolizable energy in practical poultry diets. Nonstarch polysaccharides (NSP) are not digested by the endogenous enzymes and may have either positive or negative effects on intestinal health depending on their chemical and physical properties. Some grains (e.g., wheat, barley, and rye), legumes, and distillers dried grains have NSP that increase the susceptibility of poultry to several important bacterial and parasitic pathogens. Grain NSP have been implicated in susceptibility to dysbacteriosis, *Clostridium perfringens*, and *Salmonella enteriditis* (130, 131, 162). This effect of NSP is thought to be due to increased viscosity of the digesta in the ileum and ceca, inducing epithelial inflammation and providing nutritional substrates that facilitate microbial overgrowth. In recent years, the diminishing use of antibiotics in the feed of poultry has exacerbated this problem (162) unless exogenous enzymes are added to break down the NSP.

Intestinal lactase activity is low in chickens; this limits the amount of lactose that can be tolerated. Milk byproducts, such as whey, are excellent sources of protein and some vitamins but excessive levels in the diet cause growth depression and severe diarrhea.

Fats

Fats are important in the diet of poultry as concentrated sources of energy and sources of the essential nutrients linoleic acid and linolenic acid. Linoleic acid deficiency in young chicks results in suboptimal growth and enlarged fatty livers, and in laying hens results in lowered egg production, egg size, and hatchability (143). Reduced concentrations of arachidonic acid and increased concentrations of eicosatrienoic acid in tissue and egg lipids are a characteristic sign of essential fatty acid deficiency (143).

Unsaturated fatty acids may undergo oxidative rancidity, with multiple effects: Essential fatty acids are destroyed; aldehydes that are formed may react with free amino groups in proteins, reducing amino acid availability; and reactive oxygen intermediates generated during rancidification may destroy activities of vitamins A, D, and E and water-soluble vitamins such as biotin. The addition of synthetic antioxidants or plethoric levels of tocopherols to poultry feeds provides protection to essential fatty acids and other essential nutrients.

Vitamins

The amounts of various vitamins needed in poultry diets are very low, ranging from about 0.001% for pantothenic acid to about 0.000,000,3% for vitamin B_{12}, yet moderate

deficiencies are often more debilitating than those of protein, energy, or fat (74). The vitamins function as cofactors for enzymes, hormones (e.g., vitamins A, D), or antioxidants (previtamin A and vitamin E). Choline does not meet the definition of a vitamin, but is commonly referred to as one. Although the specific functions of the water-soluble vitamins in metabolism are biochemically distinct, the deficiency symptoms are often similar. Usually the overall growth rate of young birds is impaired and tissues that turn over rapidly are most affected, including the growth plate of bones, feather follicles, the epithelia surfaces of skin, and hematopoietic tissues. Common symptoms that arise from defects in these tissues are dyschondroplasia, chondrodystrophy, dermatitis, poor feathering, anemia, and increased susceptibility to infectious diseases. For example, chondrodystrophy ("perosis") occurs in young birds when the diet is deficient in choline, nicotinic acid, pyridoxine, biotin, folic acid, zinc, or manganese. Chondrodystrophy is an anatomic deformity of leg bones of young birds that is characterized by decreased linear bone growth, enlargement of the tibiometatarsal joint, and twisting or bending of the distal end of the tibia and proximal end of the metatarsus, with secondary varus or valgus deformation of the legs. When severe, the gastrocnemius tendon slips from its condyles and mobility is greatly affected. It appears that chondrodystrophy occurs because the growth plate is an avascular tissue and chondrocyte growth and maturation depends on nutrient diffusion into the connective tissue matrix, which makes this region very susceptible to deficiencies of a variety of nutrients that have unrelated biochemical functions. Analysis of the diet may be the only way to determine whether a specific nutritional deficiency is responsible for the condition.

Modern poultry diets using grain and soymeal are deficient in most of the vitamins if they are not supplemented. In practice, poultry diets should be formulated to contain a large margin of safety for all of the vitamins to compensate for possible losses during feed processing, transportation, and storage, and for variations in feed composition and environmental conditions.

The fat-soluble vitamins A, D, and E are stored relatively well and birds can withstand long periods of depletion before deficiency symptoms manifest. Birds with adequate stores of most of the vitamins also can withstand feed restriction without deficiency symptoms because tissue catabolism liberates vitamins from muscle, fat, and other tissues. Thus, vitamin deficiencies are not usually important determinants of the clinical signs of feed restriction or starvation. The level of deposition of the vitamins into the egg directly reflects the amount in the diet. Marginal deficiencies of vitamins may not decrease egg production but are likely to influence embryonic development (74, 157).

Excretion rates of vitamins A and D are limited and toxicity of these vitamins is a frequent problem. Water-soluble vitamins are not stored to a large extent, excesses are excreted mostly in urine, and they are relatively nontoxic.

Vitamin A

From a nutritional perspective, vitamin A is the most challenging of the vitamins because it is deficient in most feedstuffs and is among the most likely to become toxic upon over-supplementation. Corn has moderately high levels of beta carotene, which is converted to retinol, so diets that are high in corn are less likely to cause severe deficiencies compared to diets based on wheat or sorghum. Nevertheless, corn-based diets still require supplementation with additional vitamin A when fed to chicks or laying hens.

With the exception of its role in vision, retinol and retinal must be converted to retinoic acid for its required function. Retinoic acid binds to specific nuclear receptors and induces the expression or repression of more than 500 genes that regulate cell replication, differentiation, and death. Retinoic acid is among the most important signaling molecules in ontogenesis. It regulates the expression of *Hox* genes along the axis of the early-stage embryo, the induction of digit formation, and the connection of the extra-embryonic blood supply to the forming heart (165). Retinoic acid also regulates the commitment of differentiating stem cells along specific paths important in epithelial differentiation, bone modeling, spermatogenesis, and leukopoesis. For example, retinoic acid induces the differentiation of epithelial basal cells into the cubodial, columnar, and goblet cells characteristic of the soft, moist epithelia. When vitamin A is deficient, the basal cells differentiate into squamous cells (squamous metaplasia), which may become stratified and keratinized to form a hard, dry epithelia characteristic of the skin. Vitamin A deficiency can affect the epithelia of the esophagus, intestines, cloaca, respiratory tract, conjunctiva of the eye, ureters, cloacal bursa (bursa of Fabricius), and vaginal region of the oviduct.

Retinal, the aldehyde form of retinol, covalently binds to opsins in sensory cells of the retina and plays an essential role in the detection of light, especially in dim lighting (137).

Vitamin A Deficiency

Clinical Signs and Signalment. Vitamin A deficiency in the embryo results in a grossly abnormal cardiovascular system, characterized by an absence of vascular networks and by a ballooned, noncompartmentalized, randomly positioned heart without an inflow tract at the posterior site of the heart (136, 165). Embryos often die during the first week of incubation. Those embryos that survive to term may be too weak to hatch or die shortly thereafter (148).

In growing chicks and poults, severely deficient birds display decreased growth, depression, inappetence, unthriftiness, increased mortality due to infections, unsteady gait, and postural imbalance (13, 31, 75). In the absence of accompanying infectious diseases, deficiencies of vitamin A may cause epithelial damage in the oropharynx and esophagus without marked growth depression (13). Periorbital edema may occur (Figure 29.2A). In broilers, severe deficiencies result in hyperproliferation and decreased maturation of enterocytes, a decrease in the number of goblet cells, and blunting of villi with decreased expression of brush-border

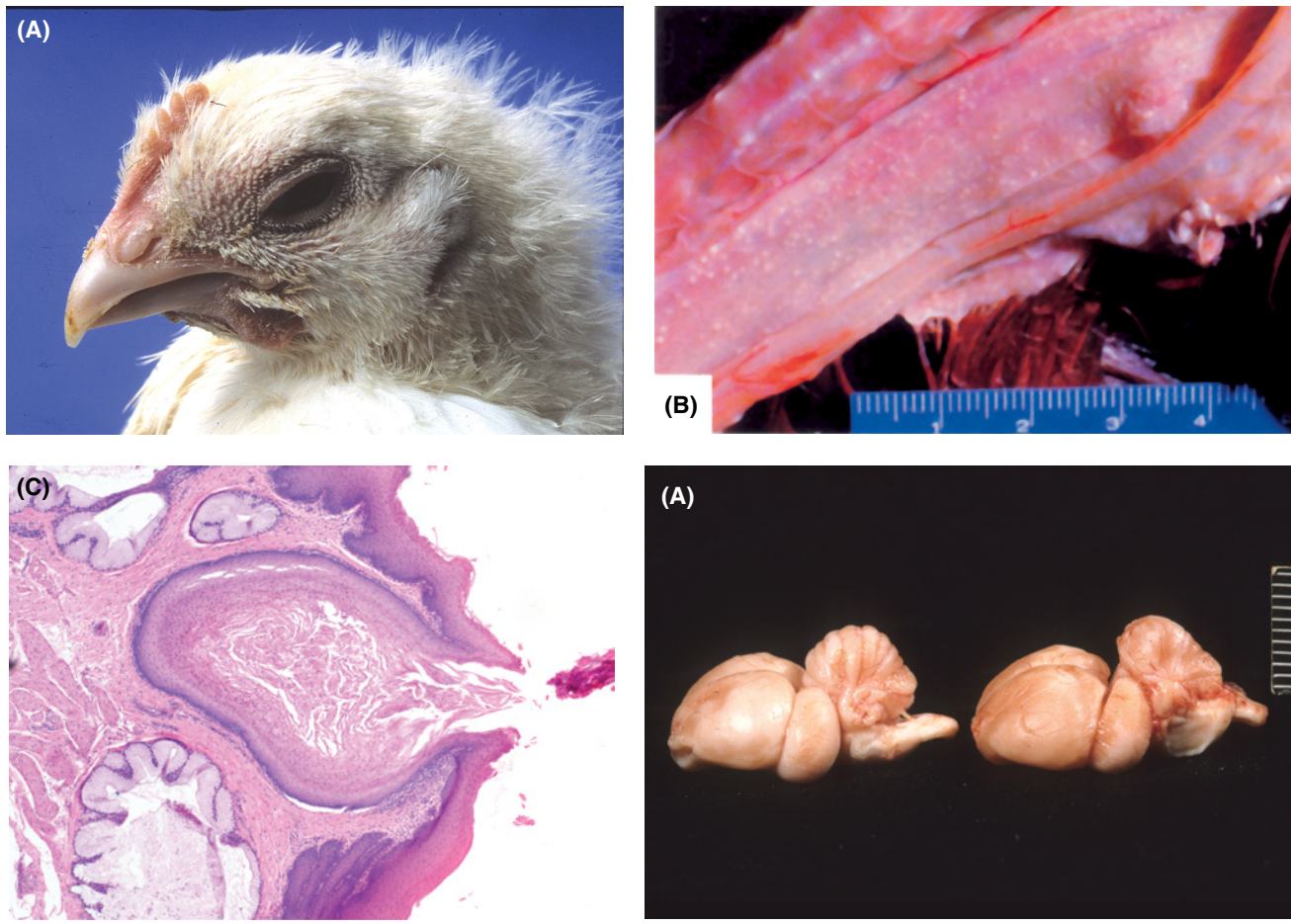

Figure 29.2. Vitamin A deficiency. (A) Periorbital edema and lack of pigmentation. (D.E. Swayne) (B) Distended, impacted mucosal glands resembling pustules in the esophagus. (H.J. Barnes) (C) Squamous metaplasia has replaced all but a few focal areas of normal mucosa in the base of this esophageal gland. Distention has resulted from occlusion of opening and accumulation of keratin and cellular debris in the lumen. Inflammation resulting in formation of a pustule will occur if contents contact surrounding tissues. (D) Normal brain with prominent cerebellar folia (left) and vitamin A-deficient brain with flattened cerebellar folia (right). (D.E. Swayne)

enzymes (135). Impaired growth rate of deficient broiler chicks appears to be secondary to diminished digestive function. In acute vitamin A deficiency, lacrimation usually occurs, and a caseous material may be seen under the eyelids. Deficiencies of vitamin A are deleterious for development of the cloacal bursa and thymus. Infectious diseases may occur secondary to immunodeficiency (31, 120, 147) including Newcastle disease, *Mycobacterium tuberculosis par avium*, *Escherichia coli*, *Candida sp*., and *Salmonella typhimurium*. Death from infection may occur before other clinical signs of vitamin A are evident.

Vitamin A can be stored in relatively large amounts as retinyl-fatty acid esters in the liver. Depending on storage levels, it usually takes 2–5 months for deficiency signs to develop in adult chickens or turkeys. The plasma vitamin A level tends to be maintained until storage pools are depleted and is not a reliable indicator of status until the deficiency is severe. Hepatic levels are a better indicator prior to the onset of deficiency symptoms. Deficient hens display weakness, weight loss, ruffled feathers, a sharp drop in egg production, increased incidence of blood spots in eggs, and increased susceptibility to infections, followed by swelling of the nictitating membrane and a watery discharge from the nostrils and eyes (75). As the deficiency continues, milky white, caseous material accumulates in the eyes, displacing the nictitating membrane, and eyelids may become stuck together. When chronic, infection of the eye results in necrosis and irreversible blindness that is unrelated to vision loss due to depletion of retinal in the opsin pigments of the eye. An increased frequency of atretic ovarian follicles containing hemorrhages either throughout the follicle or between the theca interna and granulosa cell layer has been observed in hens exposed to vitamin A deficiency over a period of 5–8 months (19).

Pathology. Vitamin A-deficiency lesions first appear in the esophagus and pharynx and are confined largely to mucous glands and their ducts. The original epithelium is replaced by a keratinizing epithelium (i.e., squamous metaplasia;) that blocks ducts of the mucous glands, causing them to become distended with secretions and necrotic materials. Small, white

nodules may be found in the nasal passages, mouth, esophagus, and pharynx and may extend into the crop. Nodules range in size from microscopic lesions to 2 mm in diameter (Figure 29.2B). As the deficiency progresses, lesions enlarge, are raised above the surface of the mucous membrane, and have a depression in the center. Small ulcers surrounded by inflammatory products may appear at the site of these lesions. This condition resembles certain stages of fowlpox, and the 2 conditions can be differentiated only by microscopic examination. Bacterial and viral infections often occur because of breakdown of the mucous membrane.

Clinical signs and lesions of vitamin A deficiency of the respiratory tract are variable; it is difficult to differentiate this condition from infectious coryza, fowlpox, or infectious bronchitis. In vitamin A deficiency, thin diphtheritic membranes and nasal plugs usually are limited to the cleft palate and its adjacent epithelium. They may be removed easily without bleeding. Atrophy and degeneration of the respiratory mucous membrane and its glands occur. Later, the original epithelium is replaced by a stratified squamous keratinizing epithelium. In early stages of vitamin A deficiency in chickens, turbinates are filled with seromucoid water-clear masses that may be forced out of the nodules and cleft palate by application of slight pressure. The vestibule becomes plugged and overflows into paranasal sinuses. Exudate also may fill sinuses and other nasal cavities, causing swelling of one or both sides of the face. Mucous membranes, cleared of inflammatory products, appear thin, rough, and dry.

Similar lesions frequently may be found in the trachea and bronchi. In early stages, these may be difficult to see. As the condition progresses, the mucous membrane is covered with a dry, dull, fine film that is slightly uneven, whereas a normal membrane is even and moist. In some cases, small nodule-like particles may be found in or beneath the mucous membrane in the upper part of the trachea.

Chronic vitamin A deficiency causes damage to the kidney tubules, which leads to azotemia and visceral urate deposits (e.g., "visceral gout") in severe cases (119).

Histopathology. An early histologic lesion of vitamin A deficiency is atrophy and deciliation of columnar-ciliated epithelium of the respiratory tract. Nuclei often present with marked karyorrhexis. A pseudomembrane formed by the atrophying and degenerating ciliated cells may hang as tufts on the basement membrane; later these are sloughed. During this process, new cylindric or polygonal cells may be formed singly or in pairs and appear as islands beneath the epithelium. These new cells proliferate, and their nuclei enlarge, containing less chromatin as they develop. Cell boundaries are less clearly defined; finally, the columnar ciliated epithelial lining of nasal cavities and communicating sinuses, trachea, bronchi, and submucous glands are transformed into a stratified squamous keratinizing epithelium. Lesions in glands of tongue, palate, and esophagus (Figure 29.2C) are similar to those of the respiratory tract (75, 115).

Vitamin A deficiency in young chicks and ducks causes marked retardation and suppression of endochondral bone growth (75). The proliferating zone is reduced. Hypertrophied cells accumulate, surrounded by uncalcified matrix. Vascular invasion of the epiphyseal cartilage is reduced and exhibits irregular patterns such as branching. The number of endosteal and periosteal osteoblasts is decreased, leading to impaired bone growth and thinning of bone cortex. Bone remodeling is inhibited. Disproportionate growth of brain and spinal cord relative to that of the axial skeleton appears to cause compression of brain tissue (Figure 29.2D). Increased cerebrospinal fluid pressure is one of the earliest signs of vitamin A deficiency.

Treatment of Deficiency. Poultry found to be severely deficient in vitamin A should be given a stabilized vitamin A preparation at a level of approximately 10,000 IU vitamin A/kg of ration. It also may be provided in the water or via injection. Absorption of vitamin A is rapid; therefore, chickens or turkeys not in advanced stages of deficiency should respond promptly, except for blindness due to xerophthalmia, which is often permanent.

Hypervitaminosis A

Vitamin A is usually supplemented to poultry diets as retinyl-esters of acetate or palmitate at a level of 3,000 to 10,000 IU/kg. Mistakes in formulation of vitamin premixes can result in toxicity at levels between 35,000 and 60,000 IU/kg. In broilers signs of toxicity include slow growth, an unsteady gait, reluctance to walk, and a higher incidence of tibial dyschondroplasia as indicated by widened epiphyseal growth plates with irregular tunneling by blood vessels. Severe toxicity results in anorexia, conjunctivitis, adhesions of the eyelids, encrustations around the mouth, and thinning of the frontal bones of the skull with thickened osteoid seams (82, 128).

Signs of hypervitaminosis A in leghorn chicks differ from those of broiler chicks administered similar levels of vitamin A (128). The epiphyseal growth plates in tibiae of leghorn chicks are normal in width but contain a narrower proliferative or maturation zone and a wider hypertrophic zone. Leghorns have normal osteoid seams in the skull and parathyroid morphology, whereas parathyroid hyperplasia occurs in broiler chicks.

Vitamin D

Vitamin D acts as a hormone to regulate calcium and phosphorus metabolism in poultry and is critical for the formation and maintenance of a normal skeleton and for strong eggshells (34, 43). Vitamin D_3 (cholecalciferol) can be synthesized from 7-dehydrocholesterol in the skin under the influence of ultraviolet light. Although this synthesis can reduce the dietary requirement for vitamin D (40, 84), it is not sufficient to satisfy requirements of poultry raised in conventional confinement housing. Poultry diets commonly are supplemented with vitamin D_3; however, 25-(OH)D_3 also is sometimes used because it has a higher bioavailability (7). The

plant source of vitamin D activity, ergocalciferol (vitamin D_2), is not efficiently used by poultry (35) and should not be used as a supplement.

The metabolically active form of vitamin D is 1,25-dihydroxycholecalciferol ($1,25(OH)_2D_3$). The first hydroxylation occurs in the liver to give $25\text{-}(OH)D_3$, which is the primary storage and circulating form of vitamin D (3, 95, 116). The second hydroxylation occurs in the kidneys and is tightly regulated by calcium status, being activated by parathyroid hormone or low blood calcium or phosphate. Many other hydroxylation products of $25(OH)D_3$ have been identified but their functions have not been fully characterized. $1,25(OH)_2D_3$ functions in the regulation of calcium metabolism by stimulating the intestinal absorption of calcium, influencing osteoblast and osteoclast activity, and increasing renal tubular reabsorption of calcium in response to metabolic demands for calcium. $1,25(OH)_2D_3$ also influences cellular differentiation in the immune system, skin, and growth plate of the bone (42, 72, 95). $1,25(OH)_2D_3$ traverses the cellular membranes and binds to receptors in the nucleus. Receptors are present in almost all tissues of the body and more than 100 genes are known to be regulated by $1,25(OH)_2D_3$, including calbindin, which is important in calcium absorption and egg shell mineralization, and osteocalcin, which is important in bone mineralization. The opening of calcium channels in the cell membrane is an important non-genomic action of $1,25(OH)_2D_3$, which initiates a variety of immediate, nongenomic regulatory actions in cells (96).

Vitamin D Deficiency

Clinical Signs and Signalment. Hatchability is reduced markedly by vitamin D deficiency. Embryonic mortality is greatest late during incubation. Chicks and poults that do not hatch have a high incidence of chondrodystrophy in which the upper or lower mandible is shortened or deformed (124, 157).

The first signs of vitamin D deficiency in growing chicks or poults are slower growth and an awkward gait. As the deficiency advances rickets become evident as severe fragility and bending of long bones due to poor mineralization (114). Beaks and claws become soft and pliable, feathering is poor, and birds walk with obvious effort and take a few unsteady steps before squatting on their hocks, which they rest upon while swaying slightly from side to side. A moderate deficiency of vitamin D results in an increased incidence of tibial dyschondroplasia (6, 72, 152), especially when calcium or phosphorus levels are not optimal. Many of the signs of a vitamin D deficiency may be similar to calcium deficiency, and analysis of levels of these two nutrients in the diet, or $25\text{-}(OH)D_3$ in blood plasma, will confirm the cause (48).

In confined laying hens, signs of deficiency begin to occur as soon as 2 weeks after they are deprived of vitamin D. The first sign is a marked increase in the number of thin-shelled and soft-shelled eggs, followed soon after by marked decrease in egg production. Biochemical indicators include a rapid decrease in the concentrations of $25(OH)D_3$ in the blood, followed by a decrease in blood calcium concentration (75, 134). Egg production and eggshell strength may vary in a cyclic manner. Several cycles of decreased egg production and shell strength may each be followed by periods of relatively normal production and eggshell strength. Individual hens may show temporary loss of the use of the legs, with recovery after laying an egg that is usually shell-less. During periods of extreme leg weakness, hens show a characteristic posture that has been described as a "penguin-type squat." Later, beak, claws, and keel become very soft and pliable. The sternum usually is bent, and ribs lose their normal rigidity and turn inward at the junction of the sternal and vertebral portions, producing a characteristic inward curve of the ribs along the sides of the thorax.

Pathology

In laying and breeding chicken and turkey hens receiving deficient vitamin D, characteristic changes observed on necropsy are confined to bones and parathyroid glands. The latter become enlarged from hypertrophy and hyperplasia. Bones are soft and break easily. Well-defined knobs are present on the inner surface of the ribs at the costochondral junction (rachitic rosary) (Figure 29.3A). Many ribs show evidence of pathologic fracture in this region. In chronic vitamin D deficiency, marked skeletal distortions become apparent. The spinal column may bend downward in the sacral and coccygeal region; the sternum usually shows a lateral bend and an acute dent near the middle of the breast. These changes reduce the size of the thorax with consequent crowding of vital organs. The beak may be soft and pliable (Figure 29.3B).

The most characteristic internal signs of vitamin D deficiency in chicks and poults are a bending of the ribs at their juncture with the spinal column and a bending of the ribs downward and posteriorly (Figure 29.3A). Poor calcification can be observed at the epiphysis of the tibia or femur (Figure 29.4). Bones of vitamin D-deficient chicks have reduced calcium content with an increased proportion of osteoid, and a greater proportion of bone mineral is present as a low-density amorphous form of calcium phosphate (36). The epiphyseal plate of long bones becomes wide and degenerative due to the failure of cartilage-producing cells to hypertrophy and mature, leading to their accumulation rather than replacement by osteoblasts (77, 88). As the deficiency progresses, the columns of chondrocytes in the degenerating hypertrophic zone of the epiphyseal plate become shortened and thickened, and exhibit an irregular pattern of invasion by metaphyseal blood vessels. Irregular patterns of cartilage and bone development occur in the primary and secondary spongiosa (88). Porosity of cortical bone increases due to resorption of bone in haversion canals. Decrease in trabecular bone volume due to increased osteoclast resorbing activity contributes to diminished mechanical strength of long bones (69). When severe, the loss of strength leads to fractures (Figure 29.4).

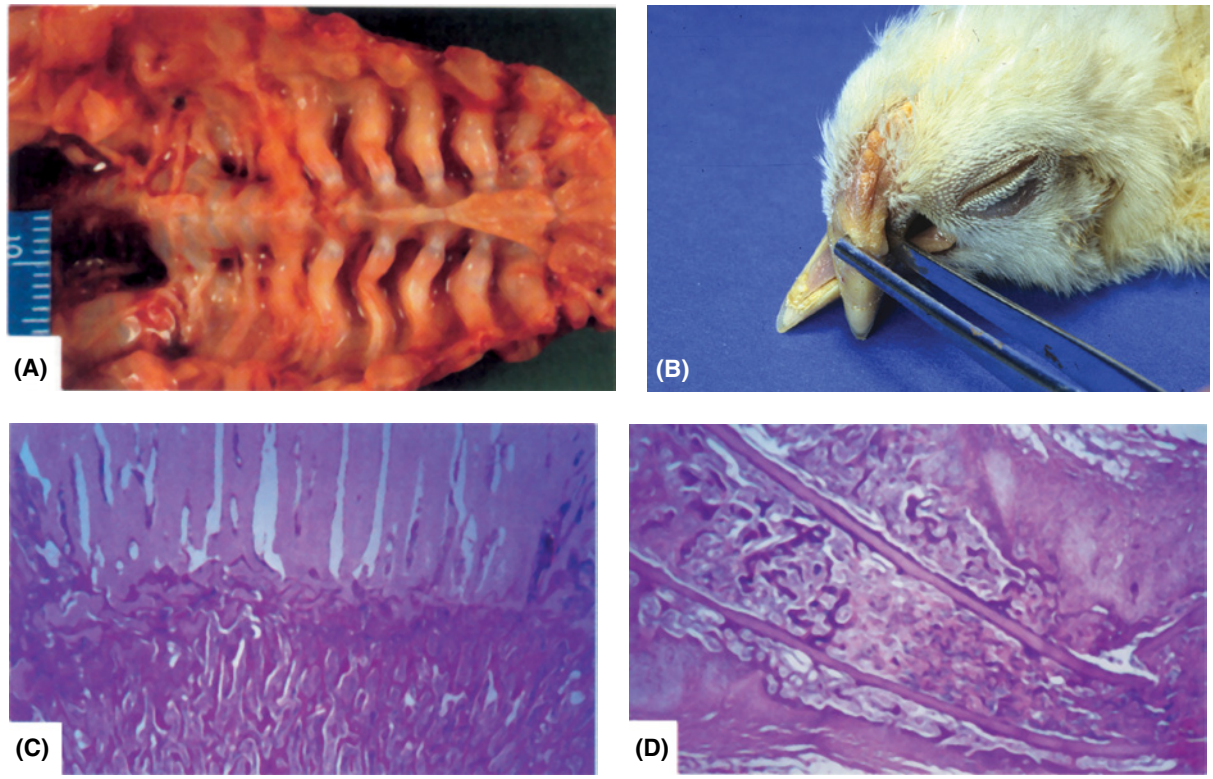

Figure 29.3. Rickets. (A) Soft, thick ribs form a flattened thorax in this severely affected 8-day-old broiler chicken. Vertebrae are also short and thick. In less affected birds, enlargement at junctions of ribs with vertebrae and sternum, folding of sterna portions of caudal ribs resulting in a flat, broad thorax, and occasionally pathologic rib fractures may be seen. (L. Munger) (B) Beak of affected chicken is soft and easily bent. (D.E. Swayne) (C) Field or infectious rickets in turkeys occurs secondarily to intestinal disease. In this affected poult, there is excess, hypertrophic cartilage that is poorly vascularized because of a compression-induced fold fracture involving trabeculae at the physical-metaphyseal junction. (H.J. Barnes) (D) Osteopenia ("cage layer fatigue"). Pathologic fracture of rib with imperfect callous formation. There is minimal mineral being deposited at the fracture site. (H.J. Barnes)

The histopathology of rickets differs significantly depending on the cause of the disease (46, 77, 88). Refer to the section on calcium and phosphorus for further information on this topic.

Treatment of Deficiency. Feeding a single massive dose of 15,000 IU vitamin D_3 cured rachitic chicks more promptly than when generous levels of the vitamin were added to feed (61). In giving massive doses to rachitic chicks, it should be remembered that excess vitamin D can be toxic. The dose should be scaled to the degree of deficiency, and excessive amounts of vitamin D should not be added to feed.

Hypervitaminosis D

The relative toxicity of vitamin D and its metabolites follows the same pattern as their bioactivity: D_2 is less than D_3, which is less than $25(OH)D_3$, which is less than $1,25(OH)_2D_3$ (122). Although vitamin D_3 and $25(OH)D_3$ have little metabolic activity themselves, their affinity for the vitamin D transport protein causes the displacement of vitamin $1,25(OH)_2D_3$, which is then free to activate calcium mobilization. Elevated rates of calcium absorption and mobilization from the bone cause elevated levels of calcium in body fluids, resulting in soft-tissue calcification, cellular degeneration, and inflammation. Vitamin D toxicity is exacerbated by high levels of dietary calcium or phosphorus, especially in the growing chick. In broiler chicks, pathology can be detected at 30,000 IU/kg of vitamin D_3 when fed throughout the growth period. Lesions include atrophy of parathyroid gland associated with the proliferation of connective tissues, calcium deposits in basal areas of the aortic valve and renal tubular lumina, and epithelial calcification in blood vessel walls that in the brain caused vacuolization and necrosis (27). High levels of vitamin D_3 (80,000 IU /kg diet) cause cardiac arrhythmia and a 2.5-fold increase in the incidence of sudden death syndrome that is associated with changes in cardiomyocytes and apoptotis in the His–Purkinje conductive system (94).

Hens are generally more resistant to vitamin D toxicity than growing chicks, but toxic levels can be transferred to the egg, causing excessive mobilization of eggshell calcium and late embryonic death. Very high levels of vitamin D_3 (4 million IU/kg diet) rapidly induce renal damage from dystrophic calcification of kidney tubules. Calcification may be less often observed in the aorta and other arteries. A moderate excess of vitamin D has been reported to increase the incidence of

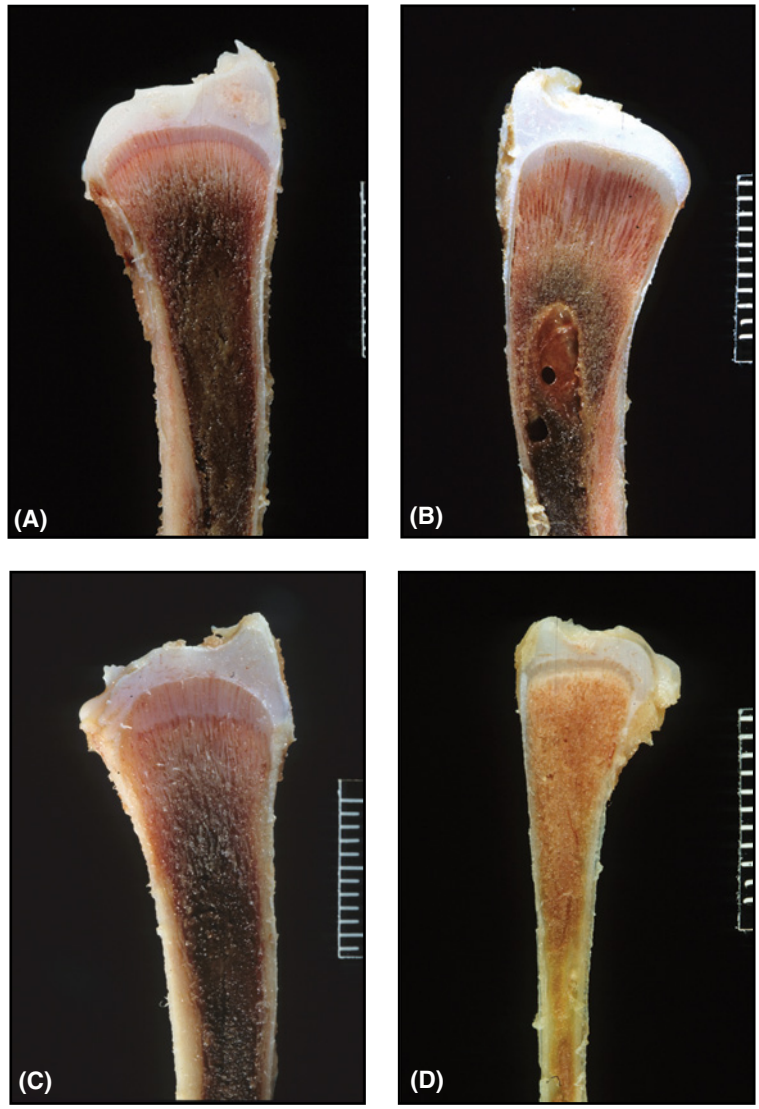

Figure 29.4. Effects of nutrient deficiencies on tibiotarsal bones of broiler chickens. (D.E. Swayne) (A) Control fed an adequate diet. (B) Phosphorus deficiency; prominent wide zone of hypertrophy. (C) Calcium/phosphorus deficiency; widened zone of proliferation. (D) Lysine deficiency; hypoplasia.

eggshell pimpling (50) due to excessive localized calcareous deposits on and within the eggshell. Scraping off the pimples exposes the underlying eggshell membranes. In laying hens, $25(OH)D_3$ becomes toxic at around 825 μg/kg feed (132).

Vitamin E

The term vitamin E refers to 2 groups of compounds that have antioxidant activity in cellular membranes: the tocopherols and the tocotrienols (64). Vitamin E is usually supplemented to poultry diets as α-tocopherol. In the feed, vitamin E is a very effective antioxidant; it protects unsaturated fatty acids, including the essential fatty acids, as well as many vitamins and xanthophylls (138). Diets that contain high levels of unstabilized polyunsaturated fatty acids become depleted of vitamin E and are most likely to cause deficiencies.

Vitamin E integrates into cellular membranes and protects against oxidative damage that lead to cell death (12, 99). Cell membranes also are defended against oxidative damage by the selenium-dependent enzyme glutathione peroxidase. Thus, vitamin E and selenium have interactive effects on cell viability.

Vitamin E has a low level of toxicity for poultry, and problems with excess levels are often due to interference with vitamin A absorption and metabolism (164).

Deficiency of Vitamin E

During vitamin E deficiency, oxidative damage may cause encephalomalacia, exudative diathesis, and nutritional myopathy (muscular dystrophy) in chicks; enlarged hocks and dystrophy of the ventricular musculature in turkeys; and nutritional myopathy in ducks. Vitamin E deficiency is exacerbated by low levels of dietary selenium, and vice versa (63, 93). Exudative diathesis in chicks and myopathies of ventriculus and heart in young poults may not occur during vitamin E deficiency when dietary selenium is adequate (113). Meat and eggs from vitamin E-deficient birds have increased susceptibility to oxidative rancidity during processing and storage.

No outward signs occur in mature chickens or turkeys receiving low levels of vitamin E over prolonged periods. However, hatchability of eggs from vitamin E-deficient hens is reduced markedly with embryonic mortality occurring as early as the fourth day of incubation, depending on the severity of the deficiency (75, 157). Symptoms in the vitamin E-deficient embryo include cloudy spots in the eyes, blindness, abnormal vascular system, hemorrhages, and stunting. Turkey embryos may have bilateral cataracts that can cause blindness. Testicular degeneration occurs in males deprived of vitamin E for prolonged periods.

Because of the similarities of vitamin E and selenium deficiency syndromes, measurement of their concentrations in blood plasma will reveal if either or both are deficient (63). Measuring vitamin E levels in feed may not be indicative of levels consumed by birds due to the rapid loss during storage.

Clinical Signs, Signalment, and Pathology. **Encephalomalacia in Chicks**. Encephalomalacia is a nervous syndrome characterized by ataxia or paresis (Figure 29.5A), backward or downward retractions of the head (sometimes with lateral twisting), forced movements, decreasing coordination, rapid contraction and relaxation of the legs, and finally complete prostration and death. Low levels of dietary selenium or high levels of dietary long-chain polyunsaturated fatty acids, especially linoleic acid, increase the severity of encephalomalacia (45, 113).

The cerebellum, striatal hemispheres, medulla oblongata, and mesencephalon are affected most commonly. In chicks killed soon after the appearance of signs of encephalomalacia, the cerebellum is softened and swollen, and the meninges are edematous (Figure 29.5B). Minute hemorrhages are often visible on the surface of the cerebellum. The convolutions are flattened. As much as four-fifths of the cerebellum may be affected, or lesions may be so small they cannot be recognized grossly. A day or 2 after signs of encephalomalacia appear, necrotic areas present a green-yellow opaque appearance. One or 2 days later, the cerebellum may become pale and shrunken (Figure 29.5C). In the corpus striatum, necrotic tissue is frequently pale, swollen, and wet, and in early stages becomes sharply delineated from remaining normal tissue. The greater portion of both hemispheres may be destroyed. In other cases, lesions are apparent only on microscopic examination. Medullary lesions are not so readily noted in a macroscopic examination.

Histologically, lesions include circulatory disturbances (ischemic necrosis), demyelination, and neuronal degeneration (Figure 29.5D, E). Meningeal, cerebellar, and cerebral vessels are markedly hyperemic, and a severe edema usually develops. Capillary thrombosis often results in necrosis of varying extent. In the normal chick cerebellum, myelinated tracts exhibit a strongly positive reaction with Luxol fast blue, whereas in affected chicks, the staining reaction is markedly diminished, diffusely or locally accentuated. Degenerative neuronal changes occur everywhere but are most prominent in Purkinje cells and in large motor nuclei. Ischemic cell change is most frequently encountered. Cells are shrunken and intensely hyperchromatic, and the nucleus is typically triangular. Peripheral chromatolysis with the Nissl substance packed along the periphery of the cell nucleus also is common.

Signs of encephalomalacia in turkey poults are similar to those observed in chicks (67). Poults with paresis usually do not have brain lesions but have poliomyelomalacia (Figure 29.5 F).

Exudative Diathesis. Exudative diathesis is an edema of subcutaneous tissues (Figure 29.6) associated with abnormal permeability of capillary walls. In severe cases, chicks stand with their legs far apart as a result of accumulation of fluid under the ventral skin. This green-blue viscous fluid is seen easily through the skin and usually contains some blood components from slight hemorrhages that appear throughout the breast and leg musculature and in the intestinal walls. Edematous subcutaneous tissue contains hyaline vascular lesions and hemorrhages. In laying hens, the thigh muscles are more susceptible to deficiency lesions than the breast muscles and show degenerative muscle fibers including calcium deposits, vascular lesions, and hemorrhages (58). Distention of the pericardium and sudden death have been noted.

Vitamin E deficiency in the presence of adequate dietary selenium does not result in severe signs of exudative diathesis. The combined deficiency appears to be due to their complementary antioxidant functions and their interactions on the expression of selenoprotein genes (63, 113).

Nutritional Myopathy (Muscular Dystrophy). When vitamin E deficiency is accompanied by a sulfur amino acid deficiency, chicks show signs of nutritional myopathy, particularly of the breast muscle, at about 4 weeks-of-age. The condition is characterized by light-colored streaks of easily distinguished affected bundles of muscle fibers in the breast (Figure 29.7A). A similar dystrophy occurs throughout all skeletal muscles of the body in vitamin E-deficient ducks.

The initial histologic change is hyaline degeneration. Mitochondria undergo swelling, coalesce, and form intracytoplasmic globules. Later, muscle fibers are disrupted transversely. Extravasation separates groups of muscle fibers and individual fibers. The transuded plasma usually contains erythrocytes and heterophilic leukocytes. In more chronic conditions, reparative processes dominate the picture. There is a pronounced proliferation of cell nuclei and also fibroplasia, leaving a scar in the degenerate muscle.

Vitamin E and selenium deficiency in chickens and especially in turkeys may result in an extreme myopathy of the ventriculus (Figure 29.7B) and heart muscles (113).

Treatment of Deficiency. If not too far advanced, exudative diathesis and nutritional myopathy in chicks are readily reversed by the administration of vitamin E and selenium by injection, by oral dosing, or in feed. Encephalomalacia may or may not respond to treatment with vitamin E, depending on the extent of damage to the cerebellum.

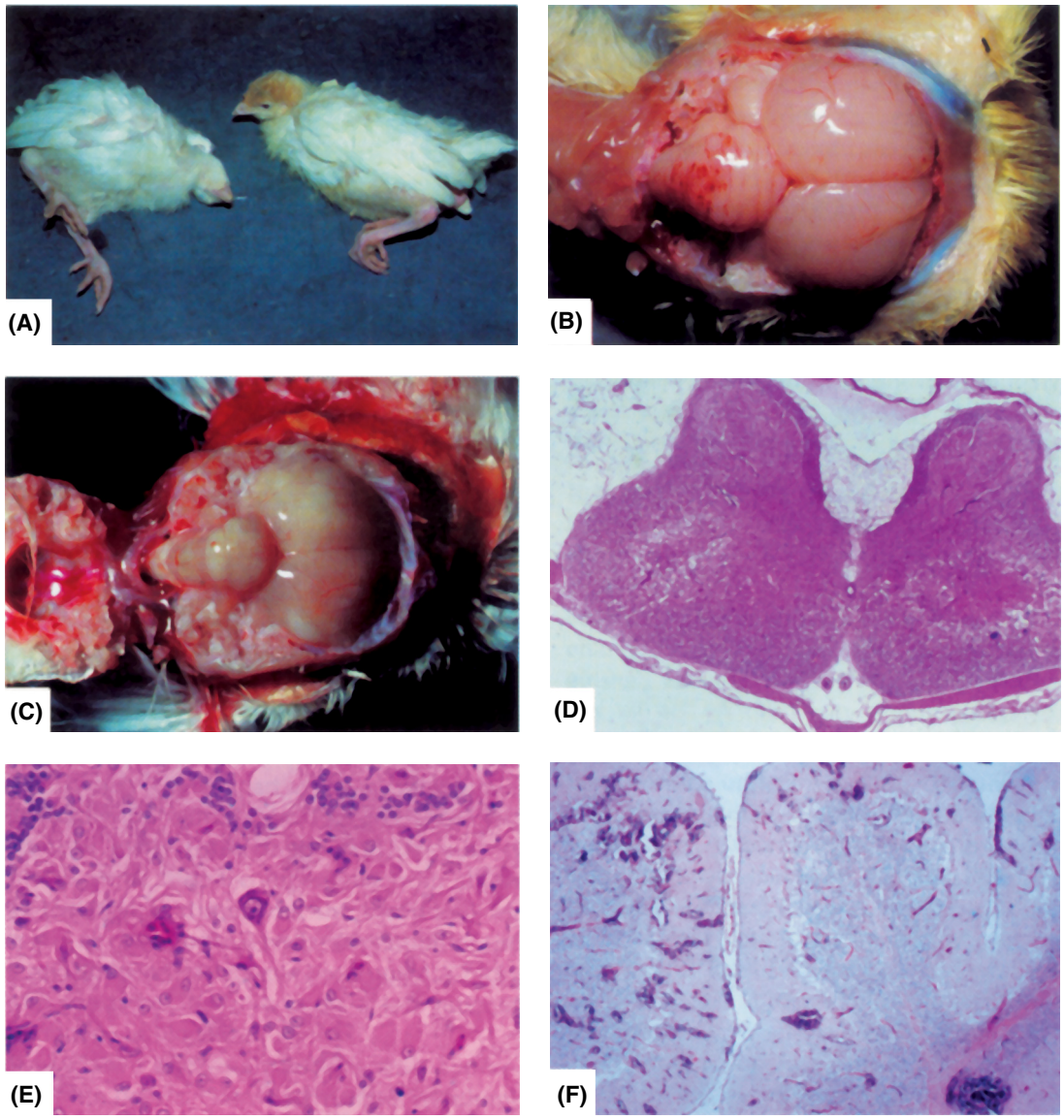

Figure 29.5. Nutritional encephalomalacia (vitamin E deficiency). (A) Paresis in 1 poult and another with pronounced neurologic signs. While either clinical manifestation can be seen in turkeys, the latter is seen in chickens ("crazy chick disease"). (H.J. Barnes) (B) Birds with neurologic signs have cerebellar swelling, edema, hemorrhage, and attenuation of folia. Coning of the swollen cerebellum into the foramen magnum is often seen. Lesions in the cerebrum also may occur but are not common. (H.J. Barnes) (C) This bird with chronic nutritional encephalomalacia survived 3 days after onset of signs. Affected areas are now pale and shrunken. (H.J. Barnes) (D) Severe malacia of cerebellum. Variable portions of affected outer folia are sharply separated from inner normal tissue. There is congestion and hemorrhage. At higher magnification characteristic fibrin thrombi in small vessels would be seen. Inflammatory cells are minimal to absent. (H.J. Barnes) (E) Increased swollen astrocytes replace much of the normal cerebellar architecture in this bird with chronic encephalomalacia. Only isolated parts of the granular layer and individual Purkinje cells remain. (H.J. Barnes) (F) Poults with paresis usually do not have brain lesions but have bilateral poliomyelomalacia, as seen here. (H.J. Barnes)

Vitamin K

Vitamin K is required is a cofactor in the post-translational carboxylation of glutamic acid in prothrombin, osteocalcin, and several other calcium binding proteins. In the absence of vitamin K, an abnormal prothrombin lacking γ-carboxyglutamic acid is secreted into the blood by the liver. Because prothrombin is an important part of the blood-clotting mechanism, deficiency of vitamin K results in markedly prolonged blood-clotting time (65). An affected chick or poult may bleed to death from a slight bruise or other injury. Vitamin K deficiency is relatively rare and is most likely to occur following the administration of antibiotics, such as sulfaquinoxaline, or by consumption of warfarin-related rodenticides (142).

Clinical Signs, Signalment, and Pathology of Deficiency

In growing chicks, signs of vitamin K deficiency occur as early as 2–3 weeks; hemorrhages appear externally at areas that receive abrasions such as the feet and wings. Internally,

petechial hemorrhages in the liver and erosion of the kaolin lining of the gizzard may occur. Chicks show an anemia that may result partly from loss of blood but also from development of a hypoplastic bone marrow. Although blood-clotting time is a fairly good measure of vitamin K deficiency, a more accurate one is obtained by determining prothrombin time.

Inadequate vitamin K in breeder diets causes increased embryo mortality late in incubation (79, 157). Dead embryos appear hemorrhagic.

Treatment of Deficiency

Within 4–6 hours after vitamin K is administered to deficient chicks, blood clots normally, but recovery from anemia or disappearance of hemorrhages cannot be expected to take place promptly.

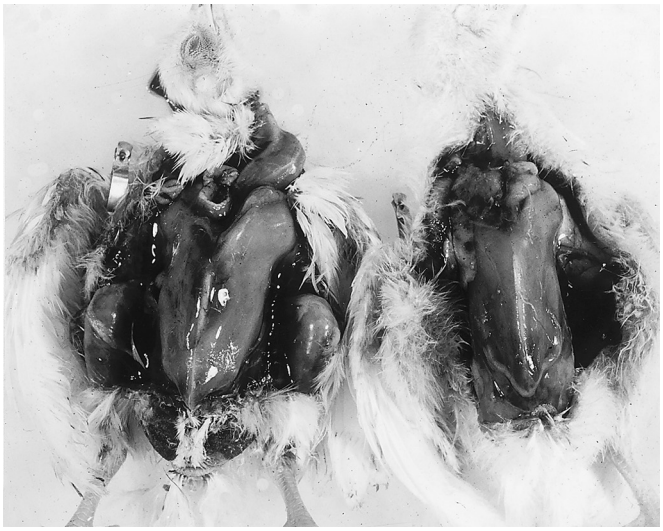

Figure 29.6. Exudative diathesis in chicks. (M.L. Scott)

Thiamin (Vitamin B_1)

The active form of thiamin is thiamin pyrophosphate, which is an important cofactor in decarboxylation, dehydrogenase, and transketolase reactions. These enzymes are critical in the metabolism of carbohydrates, lipids, and branched-chain amino acids. Deficiency of thiamin leads to extreme anorexia, polyneuritis, and death. Adequacy can be tested by the erythrocyte transketolase activation coefficient assay or thiamin concentrations in blood (47).

Excess thiamin that is not needed by tissues is excreted in the urine and no appreciable storage pools are known. Excess thiamin is well tolerated, even at very high levels, but may have an analgesic effect.

Clinical Signs, Signalment, and Pathology of Deficiency

Anorexia is usually the first sign of deficiency and can quickly become severe, resulting in weight loss and leg weakness. Polyneuritis is observed in mature chickens approximately 3 weeks after they are placed on a thiamin-deficient diet. In young chicks, it may appear before 2 weeks of age. Onset is sudden in young chicks but more gradual in mature birds. Adult chickens often show a blue comb. As the deficiency progresses paralysis of muscles occurs, beginning with the flexors of the toes and progressing upward, affecting the extensor muscles of legs, wings, and neck. The chicken characteristically sits on its flexed legs and draws back the head in a "star-gazing" position (Figure 29.8). Retraction of the head is due to paralysis of the anterior muscles of the neck. The chicken soon loses the ability to stand or sit upright, and it topples to the floor, where it may lie with the head still retracted.

The body temperature may drop to as low as 35.6°C. A progressive decrease in respiration rate occurs. Adrenal glands hypertrophy more markedly in females than males. Apparently, the degree of hypertrophy determines the degree of edema, which occurs chiefly in the skin. The epinephrine content of the adrenal gland increases as the organ hypertrophies. Atrophy of genital organs is more pronounced in males than

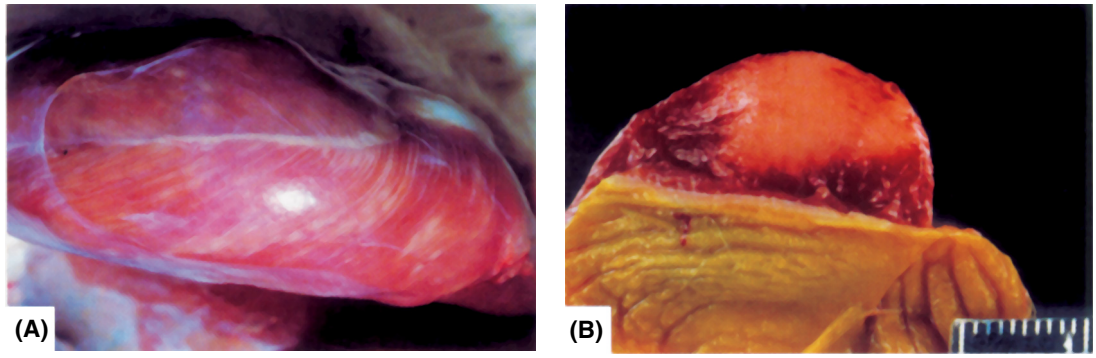

Figure 29.7. Nutritional myopathy. (A) Degeneration of muscle fibers can result from inadequate vitamin E and/or selenium. These are seen as pale, often fusisform, linear streaks in skeletal muscle. Fibrosis, intramuscular fat deposition, and other myopathies can produce similar changes. (H.J. Barnes) (B) Ventricular myopathy. Deficiency of vitamin E and/or selenium can produce myopathic changes in smooth muscle as well as cardiac and skeletal muscle. Lesions are seen as extensive, pale areas in ventriculus musculature. Turkeys are commonly affected. (L. Munger)

females. The heart shows a slight degree of atrophy; the right side may be dilated, with the auricle more frequently affected than the ventricle. Atrophy of the stomach and intestinal walls may be sufficiently severe to be easily noted.

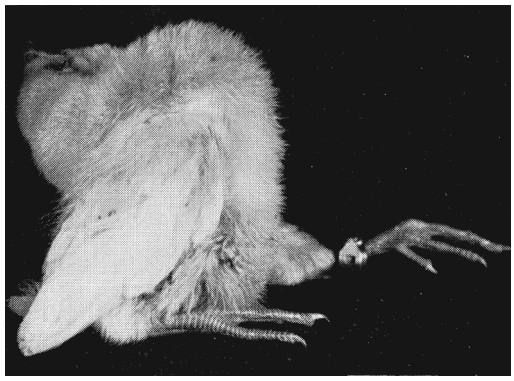

Figure 29.8. Typical stargazing pose displayed by chick suffering from thiamin deficiency. (M.L. Scott)

Crypts of Lieberkühn in the duodenum of deficient chicks become dilated (Figure 29.9) (53). Mitosis of epithelial cells in the crypts decreases markedly. In advanced stages of deficiency the mucosal lining disappears, leaving a connective tissue framework. Necrotic cells and cell debris accumulate in the enlarged crypts. Exocrine cells of the pancreas show cytoplasmic vacuolation with the formation of hyaline bodies.

Treatment of Deficiency

Chickens suffering from thiamin deficiency respond in a matter of a few hours to oral administration of the vitamin. Because thiamin deficiency causes extreme anorexia, supplementing feed with the vitamin is not a reliable treatment until after chickens have mostly recovered.

Riboflavin (Vitamin B_2)

Riboflavin is a cofactor in more than 50 enzymes, many of which are vitally associated with oxidation-reduction reactions involved in cell respiration.

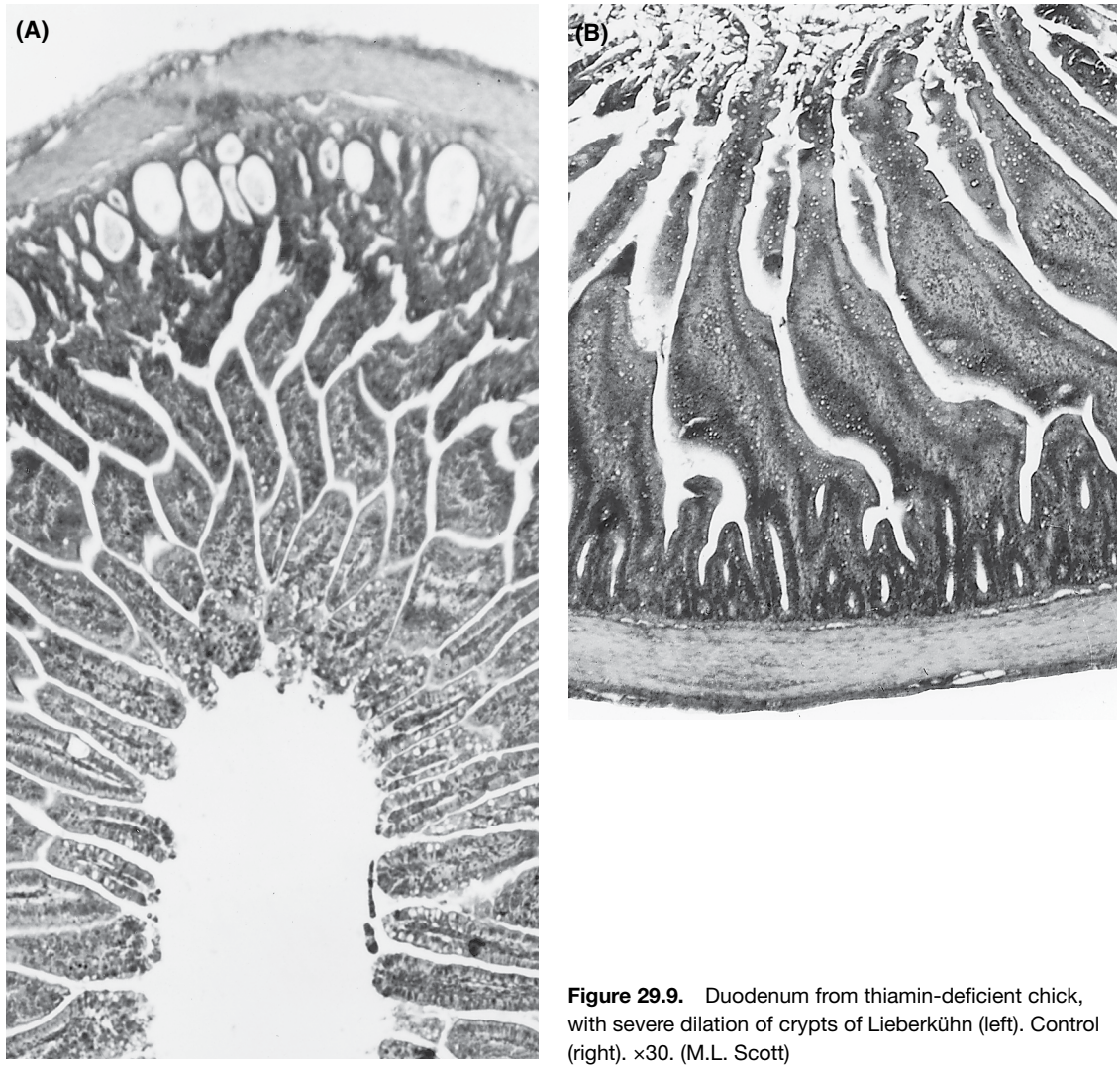

Figure 29.9. Duodenum from thiamin-deficient chick, with severe dilation of crypts of Lieberkühn (left). Control (right). ×30. (M.L. Scott)

Figure 29.10. Curled-toe paralysis (riboflavin deficiency). Typical signs include poor growth, reluctance to stand or walk, sitting on hocks, and toes curled inward. (D.E. Swayne)

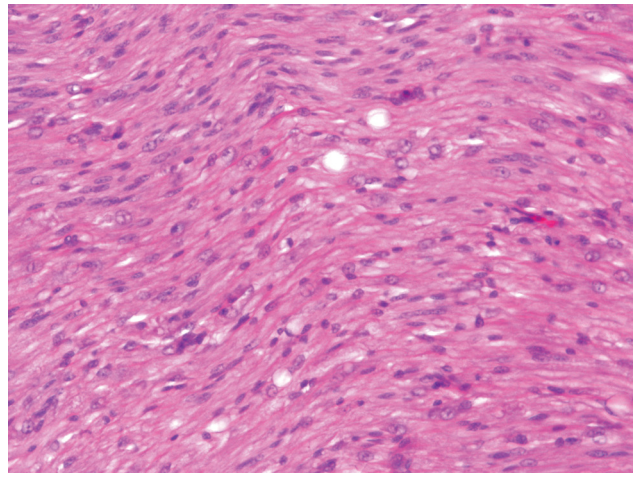

Figure 29.11. Curled-toe paralysis. Peripheral neuropathy characterized by axonal swelling and degeneration, Schwann cell activation and proliferation, and myelin degeneration. ×70. (D.E. Swayne)

Clinical Signs, Signalment, and Pathology of Deficiency

When chicks are fed a diet deficient in riboflavin, they grow very slowly and become weak and emaciated, and diarrhea develops between the first and second weeks. Appetite is not affected as much as with a thiamin deficiency. Chicks may not walk except when forced to, and then they frequently walk on their hocks with the aid of their wings. Leg paralysis may be more prevalent than curled-toe paralysis (29). Toes curl inward when both walking and resting (Figure 29.10). Chicks are usually found in a resting position with drooping wings. Leg muscles are atrophied and flabby, and the skin is dry and harsh. Young chicks in advanced stages of deficiency do not move around but lie with their legs sprawled out.

Riboflavin deficiency in young turkeys (110) is characterized by poor growth, poor feathering, leg paralysis, and encrustations in the corners of the mouth and on the eyelids. Severe dermatitis and edematous swelling may occur on the feet and shanks.

In severe cases of riboflavin deficiency, chicks show marked swelling and softening of sciatic, cervical, and lumbar spinal nerves (21, 22, 23). Sciatic nerves usually undergo the most pronounced changes, sometimes reaching a diameter 4–5 times normal size. Histologically, affected nerves show degenerative changes in myelin sheaths of the main peripheral nerve trunks (Figure 29.11). This may be accompanied by axis cylinder swelling and fragmentation. Schwann cell proliferation, myelin changes, gliosis, and chromatolysis occur in the spinal cord. Fine structural examination of the sciatic nerve reveals that redundant folds and loops of myelin form symmetric or asymmetric expansions of the sheath resulting in segmental demyelination. In broiler chicks with riboflavin deficiency, ventral and dorsal spinal nerve roots, distal intramuscular nerves, and subcutaneous nerves are much less affected (23). In cases of curled-toe paralysis, degeneration of the neuromuscular end plate and muscle tissues is often found. Riboflavin is probably also essential for myelin metabolism of the main peripheral nerve trunks. No gross dystrophy develops, although muscle fibers are in some cases completely degenerated. The sciatic nerve exhibits myelin degeneration in 1 or more branches. Similar changes are apparent in the brachial nerve trunks. Chicks fed riboflavin-deficient diets develop pancreatic and duodenal lesions as described for thiamin deficiency in addition to the more classic nervous signs (53).

A deficiency of riboflavin in the diet of hens results in decreased egg production, increased embryonic mortality, and an increase in size and fat content of the liver. Hatchability of eggs decreases within 2 weeks after hens are fed a riboflavin-deficient diet but improves to near normal levels within 7 days after adequate amounts of riboflavin are added to the diet. Embryos that fail to hatch from eggs of hens fed diets low in this vitamin are dwarfed with a high incidence of edema, degeneration of Wolffian bodies, and defective down (123). The down is referred to as "clubbed" and results from failure of the down feathers to rupture the sheaths, causing feathers to coil in a characteristic way. The major metabolic consequence of embryonic riboflavin deficiency appears to be a severe impairment of fatty acid oxidation (149).

Treatment of Deficiency

Two 100-µg doses of riboflavin should be sufficient for treatment of riboflavin-deficient chicks or poults, followed by incorporation of an adequate level in the ration. When the curled-toe deformity is of long standing, however, irreparable damage has occurred and administration of riboflavin no longer cures the condition.

Pantothenic Acid

Pantothenic acid is a component of coenzyme A, which is involved in the formation of citric acid in the Krebs cycle, synthesis and oxidation of fatty acids, oxidation of keto acids resulting from deamination of amino acids, acetylation of choline, and many other reactions.

Clinical Signs, Signalment, and Pathology of Deficiency
Signs of pantothenic acid deficiency in chicks are difficult to differentiate from those of a biotin deficiency; deficiencies of either result in dermatosis, ruffled and broken feathers, chondrodystrophy, poor growth, and mortality. Chicks are emaciated and crusty, scab-like lesions appear in corners of the mouth (53). Eyelid margins are granular, and small scabs develop on them. Eyelids frequently are stuck together by a viscous exudate and vision is restricted. There is slow sloughing of the keratinizing epithelium of the skin. Outer layers of skin between the toes and on bottoms of the feet sometimes peel off; small cracks and fissures appear at these points. These cracks and fissures enlarge and deepen, so chicks move about very little. In some cases, skin layers of the feet of deficient chicks cornify, and wart-like protuberances develop on the balls of the feet.

Necropsy shows the presence of a pasty substance in the mouth and an opaque gray-white exudate in the proventriculus. The liver is hypertrophied and may vary in color from a faint to dirty yellow. The spleen is atrophied slightly. Kidneys are somewhat enlarged. Nerves and myelinated fibers of the spinal cord show myelin degeneration. These degenerating fibers occur in all segments of the cord down to the lumbar region.

Embryos from pantothenic acid-deficient hens have high mortality and show hemorrhages and severe edema. The peak day of embryonic mortality depends on the degree of pantothenic acid deficiency and borderline deficiencies produce extremely weak chicks that fail to survive (157).

Dietary pantothenic acid deficiency in chicks produces duodenal and pancreatic lesions as described under thiamin deficiency (but of lesser extent), dermatosis, and severe ataxia progressing to inability to stand. In addition, there is pronounced lymphocytic necrosis and lymphoid depletion in the cloacal bursa (bursa of Fabricius), thymus, and spleen (53).

Treatment of Deficiency
Pantothenic acid deficiency appears to be completely reversible, if not too far advanced, by oral treatment or injection with the vitamin followed by restoration of an adequate level in the diet.

Nicotinic Acid (Niacin)

Nicotinic acid is the vitamin component in 2 important coenzymes, nicotinamide adenine dinucleotide (NAD) and nicotinamide adenine dinucleotide phosphate (NADP), that are required for more than 200 reactions involved in the metabolism fatty acids, carbohydrates, amino acids, and nucleic acids. Niacin can be synthesized from tryptophan, though this conversion is not efficient, especially in turkeys and ducks (26, 74). Modern diets rarely have sufficiently excess tryptophan to provide adequate tryptophan and must be supplemented. Excessive supplementation should be avoided because levels above 0.75% dietary niacin cause decreased bone thickness dimensions and bone strength (66).

Clinical Signs, Signalment, and Pathology of Deficiency
Severely deficient chicks show anorexia, slow growth, inflammation of the oral cavity, dermatitis, poor feathering, and an enlargement of the hock joints (chondrodystrophy) and bowing of the legs (perosis) (25, 26, 114). The perosis caused by a niacin deficiency is not as severe as that due to a manganese deficiency and the Achilles tendon rarely slips from its condyles. The tongue of deficient chicks may turn black due to necrosis. Poults and ducklings may develop diarrhea in addition to the above symptoms. Niacin deficiency in chicks produces duodenal and pancreatic lesions comparable to those of thiamin deficiency (53). Chicken and turkey hens do not develop the above signs of niacin deficiency; however, niacin is needed to optimize egg weight and hatchability (57).

Treatment of Deficiency
Supplementing a deficient ration with required amounts of nicotinic acid has little or no effect on cases that have progressed to the extent that the tendon has slipped from its condyles (chondrodystrophy) or on advanced cases of enlarged hock disorder in adult tom turkeys.

Pyridoxine (Vitamin B_6)

Pyridoxal phosphate and pyridoxamine phosphate are cofactors involved in transamination and decarboxylation of amino acids as well as glycogen mobilization.

Clinical Signs, Signalment, and Pathology of Deficiency
Pyridoxine deficiency is relatively rare and most likely to occur with diets containing high levels of protein and especially methionine (112). Severely pyridoxine-deficient chicks show depressed appetite, poor growth, chondrodystrophy resulting in bone curvature, and characteristic nervous signs (54). Chicks show jerky, nervous movements of the legs when walking and often undergo extreme spasmodic convulsions that usually terminate in death. During these convulsions, chicks may run aimlessly about, flapping their wings and falling to their sides or rolling completely over on their backs where they perform rapid jerking motions with their feet and heads. These signs may be distinguished from those of encephalomalacia (vitamin E deficiency) by the relatively greater intensity of activity of the chicks during a seizure, which results in complete exhaustion and often death. Clinical signs of pyridoxine deficiency in ducklings include poor growth and food consumption, hyperexcitability, weakness, microcytic hypochromic anemia, convulsions, and death (161).

A pyridoxine deficiency causes a defect in collagen fibers in cortical bone and articular cartilage matrix and increased solubility of proteoglycans and collagen (89). These structural defects apparently cause chondrodystrophy and osteoarthritis in deficient chicks.

In adult birds, pyridoxine deficiency causes marked reduction of egg production and hatchability, as well as anorexia and weight loss.

Figure 29.12. Dermatosis at the corners of the beak. Biotin deficiency. (D.E. Swayne).

Biotin

Biotin is a cofactor in carboxylation and decarboxylation reactions involved in the metabolism of lipids, glucose, and some amino acids. Biotin bioavailability for chickens and turkeys varies greatly among practical feed ingredients (90), making diet formulation based on the content of ingredients difficult.

Clinical Signs, Signalment, and Pathology of Deficiency

The signs of a biotin deficiency are variable due to the marked influence of other dietary factors, especially the amount and type of fat. In chicks and poults, a deficiency causes slow growth, ruffled feathers, chondrodystrophy, and dermatosis of the feet and skin around the beak and eyes (Figure 29.12). Many of these signs are similar to those of a pantothenic acid deficiency and a differential diagnosis requires the analysis of vitamin levels in the diet. Dermatitis of the footpads without involvement of the head (footpad dermatitis) has become an economically important disease of broilers and poults. Footpad dermatitis can be exacerbated by a biotin deficiency but is most often caused by environmental factors, such as wet litter, and is not usually prevented by extra dietary biotin (117).

Defects in bone growth due to biotin deficiency include shortened tibiae, higher bone density and bone ash, and an abnormal pattern of bone modeling characterized by the mid-diaphyseal cortex being thicker than the lateral side. These bone defects appear to be the result of altered eicosanoid metabolism due to impaired elongation of dietary linoleic acid to arachidonic acid (145).

In broiler chicks and poults, a biotin deficiency may lead to sudden death without external lesions. Chicks become lethargic and develop hepatic and renal steatosis, decreased plasma glucose, increased plasma-free fatty acids, and increased ratio of C16:1–C18:0 fatty acids in liver and adipose tissue (20, 104, 151, 153). This condition is known as fatty liver and kidney syndrome (FLKS) and can occur with a marginal deficiency, especially when dietary fat is low, triggering lipogenesis from carbohydrates. Apparently the diversion of biotin to lipogenic enzymes diminishes the amount available for the biotin-dependent enzyme pyruvate carboxylase, causing impaired gluconeogenesis, hypoglycemia, and death. Stresses that deplete glycogen, such as fasting, exacerbate the situation. Chicks with FLKS frequently do not have the characteristic signs of biotin deficiency. This may be a temporal phenomenon wherein the changes in tissue metabolism leading to FLKS occur rapidly in biotin-depleted chicks, but the classic signs of biotin deficiency require a longer period of time to develop (20).

Biotin has been suspected of having a role in "acute death syndrome" (or "sudden death syndrome") in broiler chickens (76). Biotin deficiency alters the unsaturated fatty acid profile in tissue lipids in a manner suggestive of impaired conversion of linoleic acid to arachidonic acid (144). The latter is a precursor of the prostaglandins, prostocyclin I2 and thromboxane A2, which have marked effects on the vascular system.

Mortality of embryos from biotin-deficient eggs is increased during the first and third weeks of incubation (108, 129, 157). Many embryos that fail to hatch are chondrodystrophic, characterized by reduced size, a parrot beak, severely crooked tibia, shortened or twisted tarsometatarsus, shortened bones of the wing and skull, and shortening and bending of the scapula. Embryos may develop syndactylia, an extensive webbing between the third and fourth toes. If chicks hatch they are usually ataxic as well as deformed.

Treatment of Deficiency

Injection or oral administration of a few micrograms of biotin prevents biotin deficiency signs in deficient chicks and turkey poults, but reversal of existing signs has not been explored.

Folic Acid (Folacin)

Folic acid is a cofactor of the enzyme system involved in the transfer of methyl groups of such important metabolites as choline, methionine, purines, and uric acid. Folic acid is required for normal nucleic acid metabolism and formation of the nucleoproteins required for cell replication. There are more biologically active forms of folate than any other vitamin, making their quantification in foods difficult.

Clinical Signs, Signalment, and Pathology of Deficiency

Folic acid deficiency in chicks is characterized by poor growth, very poor feathering, macrocytic anemia, leukopenia, and chondrodystrophy. Asynchronous cell division causes red blood cells to have large, multilobular nuclei. Poorly developed feathers with weak and brittle shafts give deficient birds a very unthrifty appearance. Folic acid is required for pigmentation in feathers of Rhode Island red and black leghorn chicks. Thus, folic acid, lysine, copper, and iron appear to be required for prevention of achroma of feathers. Turkey poults display a cervical paralysis that is quickly fatal. Folate deficiency is exacerbated by low levels of other methyl donors, especially choline and methionine (106).

Embryos from deficient hens die soon after pipping the air cell and display a deformed upper mandible and bending of the tibiotarsus (157).

Treatment of Deficiency

A single intramuscular (IM) injection of folic acid returns hemoglobin values and growth rates to normal within 1 week. Addition of 5 mg folic acid/kg feed gives similar results. Folate absorption is relatively well regulated (127) and high dietary levels are well tolerated.

Vitamin B_{12} (Cobalamin)

Vitamin B_{12} is involved in nucleic acid, carbohydrate, and fat metabolism. One of its main enzyme functions involves isomerization of methylmalonyl coenzyme A to form succinyl CoA.

Clinical Signs, Signalment, and Pathology of Deficiency

Vitamin B_{12} deficiency results in slow growth, decreased efficiency of feed utilization, mortality, and reduced egg size and hatchability (141). Signs of a folate deficiency also may occur due to trapping of folate (74). Vitamin B_{12} deficiency has been reported to cause myelin degeneration in chicks. Chondrodystrophy may occur in vitamin B_{12}-deficient chicks or poults when their diets lack choline, methionine, or betaine as sources of methyl groups.

Vitamin B_{12}-deficient embryos have a peak in mortality at day 17 of incubation and show reduced size, myoatrophy of the legs, diffuse hemorrhages, chondrodystrophy, edema, and fatty liver (157).

Treatment of Deficiency

IM injection of 2 µg vitamin B_{12}/hen increases hatchability of eggs from hens with a deficiency of vitamin B_{12}. Oral dosing also is effective (141). Similarly, B_{12} injections of young chicks followed by supplementation of the diet reverses the deficiency signs.

Choline

Choline has 3 primary functions in birds: structural as part of phospholipids; neurotransmitter as part of acetylcholine; and methyl donor, via betaine, in the synthesis of methionine, creatine, carnitine, and N-methylnicotinamide. Choline can be synthesized by chickens but the rate is insufficient for growth or egg production (37, 56).

Clinical Signs, Signalment, and Pathology of Deficiency

In addition to poor growth, the most consistent lesion of choline deficiency in chicks and poults is chondrodystrophy (Figures 29.13 and 29.14). Young turkeys have a high requirement for choline and, therefore, will show a high incidence of severe chondrodystrophy. Chondrodystrophy is first characterized by pinpoint hemorrhages and a slight puffiness about the hock joint, followed by an apparent flattening of the tibiometatarsal joint caused by rotation of the metatarsus. The metatarsus continues to twist and may become bent or bowed until it is out of alignment with the tibia. When this condition exists, the leg cannot adequately support the weight of the bird.

Figure 29.13. Choline deficiency. Stunting; poor feathering; and short, thick, bowed legs typical of chondrodystrophy are seen in a bird that had been fed a choline-deficient diet. (D.E. Swayne)

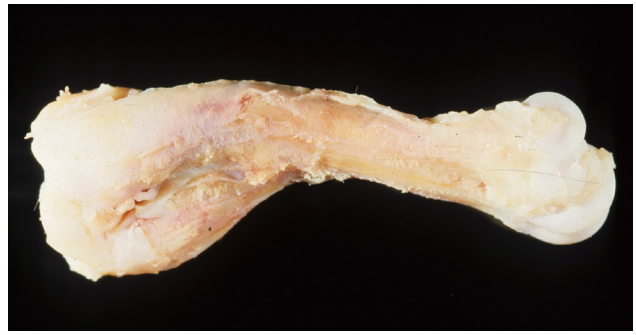

Figure 29.14. Choline deficiency. Chondrodystrophy and deformity of tibiotarsus from broiler chicken given a diet lacking adequate choline. (D.E. Swayne)

The articular cartilage is deformed and the Achilles tendon (tendo calcaneous) may slip from its condyles. Choline deficiency also may result in hepatic steatosis, especially in females.

Treatment of Deficiency

If choline deficiency is noted in chicks or poults before severe signs of chondrodystrophy have developed, the deficiency can be cured by supplementing the ration with sufficient choline to meet the requirements. After the tendon has slipped in chicks or poults suffering from choline deficiency, the damage is irreparable.

Essential Inorganic Elements

The essential minerals needed in macro amounts in the diet are calcium, phosphorus, sulfur, magnesium, potassium, sodium, and chlorine. The essential trace elements are manganese,

iron, copper, zinc, iodine, molybdenum, chromium, and selenium. Arsenic, boron, fluoride, nickel, rubidium, vanadium, and some rare earth minerals also may have essential functions, but mechanistic information is lacking. Analyses of individual mineral constituents in the body of chickens show that major portions of calcium, phosphorus, magnesium, and zinc are present in bones. Other essential elements are distributed largely in muscles, other soft tissues, and body fluids. Minerals function structurally, as catalysts in enzymes, and as regulators of osmotic pressure, acid-base balance, and cell signaling. Deficiencies of a mineral may be reflected in 1 or more of these functions. Excessive levels are also of great concern for many minerals. The maximum tolerable dietary levels set by regulatory agencies are often based on potentially toxic levels in meat and egg products, which may be lower than levels that cause pathology to poultry (98).

The properties of different mineral sources used to fortify poultry diets greatly influence their bioavailability, and consequently the amount needed to prevent deficiency or toxicity. These differences can be an order of magnitude or greater. Important properties include metallic versus salt, ionic versus covalent bonded, type of salt, organic versus inorganic, and hydration. A discussion of these important characteristics can be found elsewhere (4, 98) and the dietary concentrations provided below are for highly available mineral sources.

Calcium and Phosphorus

Calcium (Ca) and phosphorus (P) are closely associated in metabolism, particularly in bone formation. The major portion of dietary calcium is used for bone formation in growing chicks or poults and for eggshell formation in mature hens. Calcium also is essential for clotting of blood and it is required along with sodium and potassium for normal contraction of cardiac muscle. Calcium is an integral constituent of cell signaling and regulatory pathways.

In addition to its role in bone formation, phosphorus is an essential component of phospholipids, purine nucleotides, and many other macromolecules, and is involved in the regulation of many cellular and metabolic processes including acid-base balance. The phosphorus in plant-based feedstuffs is poorly available because much of it is present in phytic acid and is not released by digestive enzymes. The availability of phosphorus can be increased by dietary phytase of microbial origin. Efficient utilization of calcium and phosphorus depends on the presence of an adequate amount of vitamin D in the diet. An excess of calcium induces a phosphorus deficiency. Likewise, an excess of phosphorus induces a calcium deficiency.

Calcium and Phosphorus Deficiency

Deficiencies of calcium and phosphorus in the diet of growing broiler chicks cause rickets. Differentiating rickets from a calcium deficiency from rickets due to vitamin D deficiency or tibial dyschondroplasia requires histopathological examination (46, 133). Tibiae from chicks fed a calcium-deficient diet for 2 weeks show widening of the proliferating prehypertrophic zone of epiphyseal cartilage and irregular contours in the boundary between the zones of proliferating and hypertrophic cartilage (86). Irregular cartilage columns and elongated epiphyseal vessels occur. By 4 weeks, the epiphyseal growth plate is widened, and in some cases, extended as a cartilaginous plug into the metaphysis. Histologically, the proliferating and hypertrophic zones become irregular and often contain areas of nonviable cells. The hypertrophied zone is markedly widened in some chicks by 4 weeks. Metaphyseal blood vessels invade along the lateral, but not the apical, region of the cartilaginous plug; cartilage columns of the metaphysis become thickened and irregular. A phosphorus deficiency results in similar histopathology but with a marked lengthening of the columns of degenerating hypertrophied epiphyseal cartilage and metaphyseal primary spongiosa (87). In severe cases of rickets, chicks display a spraddle-legged posture, folding fractures, and bowing or rotation of the tibiotarsus. In a study of field rickets in broilers, calcium deficiency typically causes accumulation of proliferating chondrocytes, whereas a phosphorus deficiency causes accumulation of hypertrophic chondrocytes in the metaphyseal zone (39). Fluoride appears to interact with dietary P to induce rickets (118). Blood calcium levels are defended relatively well by the vitamin D-PTH endocrine system but calcium deficiency progressively alters electro- and echocardiographic parameters in broilers, suggesting decreased cardiac function (163). Severely phosphorus-deficient chicks have increased respiratory rates, polycythemia, ascites, and decreased CO_2 and O_2 levels, presumably due to poor rib strength and infolding, which interfere with respiratory movements of the rib cage (68).

In laying hens, calcium deficiency results in reduced egg production and thin-shelled eggs as well as calcium mobilization from bones, first by complete removal of the medullary bone, followed by a gradual removal of the cortical bone (43). Finally, bones become so thin that spontaneous fractures may occur, especially in vertebrae, tibia, and femur. This condition may be associated with a syndrome commonly termed "cage layer fatigue." Although a marginal calcium deficiency has often been found to be a triggering agent in cage layer fatigue, the syndrome is not due to a simple deficiency of calcium but also involves other etiologic factors (150).

Excess Calcium or Phosphorus

Excess calcium causes a phosphorus deficiency and the development of rickets in broilers (87). In leghorn pullets, excess calcium causes urolithiasis, nephrosis, and visceral urate deposition. An excess of calcium interferes with the digestibility of other minerals in addition to phosphorus, including magnesium, manganese, and zinc; this may result in secondary deficiencies. High dietary levels of these minerals decrease the toxicity of calcium. Excess phosphorus causes a thinning of the egg shell independent of calcium status.

Magnesium

Magnesium (Mg) acts as a cofactor or an activator of many critical enzymes including the reactions involving ATP that energize all major metabolic pathways. Magnesium levels in

many feedstuffs are adequate, so magnesium is not heavily supplemented to poultry diets and deficiencies are rare.

Deficiency

Acute magnesium deficiencies are severe, beginning with lethargy, slow growth, and hypomagnesemia, followed by hyperexcitability if disturbed. Tibiae have decreased magnesium and increased calcium content (146) and exhibit abnormalities including thickening of trabeculae, increased retention of cartilage cores, and the occurrence of elongated and inactive osteocytes in the metaphysis. Deficient chicks have thickening of the cortex, the presence of elongated inactive osteocytes, and enlargement of Haversion canals within the diaphysis. The epiphyseal plate, however, appears normal. The parathyroid appears hyperactive, perhaps in response to the hypocalcemia that is characteristic of magnesium deficiency.

Excess Magnesium

Under certain conditions rations may contain excess magnesium, producing detrimental effects including reduced growth rate and bone ash in chicks and decreased egg size, eggshell thinning, and diarrhea in hens. The maximum tolerable level of magnesium in the diets of poultry is about 0.5% for growing birds and 0.75% for laying hens (98). Diets with marginal levels of phosphorus enhance the sensitivity of hens to toxicosis (59).

Sodium and Chlorine (Salt)

Sodium (Na) is found chiefly in extracellular fluids. Sodium is connected intimately with maintenance of membrane potentials, cellular transport processes, and the regulation of the hydrogen ion concentration of blood. Chloride, the major mineral anion in extracellular fluids, plays a role in fluid, ionic, and acid-base balance. Many feedstuffs are deficient in sodium and chloride so salt is supplemented to most poultry diets.

Clinical Signs and Signalment of Deficiency

Chicks receiving diets deficient in sodium not only fail to grow but also develop softened bones, corneal keratinization, adrenal hypertrophy, and decrease in both plasma and special fluid volumes. Cardiac output drops, mean arterial pressure falls, the hematocrit increases, elasticity of subcutaneous tissue decreases, adrenal function is impaired, and a state of shock results, which if uncorrected, terminates in death.

Lack of salt in the diet of laying hens results in an abrupt decrease in egg production, reduced egg size, loss of weight, and cannibalism. In turkeys, low dietary salt impairs egg production and hatchability. A chloride deficiency in chicks causes extremely poor growth rate, high mortality, hemoconcentration, dehydration, reduced blood chloride, and nervous signs characteristic of Cl deficiency. When startled, chicks fall forward with their legs outstretched behind them and lay paralyzed for several minutes, then appear quite normal until frightened again (Figure 29.15).

Figure 29.15. Characteristic sign of chloride deficiency. (R.M. Leach)

Excess Salt

Large amounts of salt in the ration are toxic to chickens and turkeys. The lethal dose is approximately 4 g/kg bodyweight. Young chicks appear to be more susceptible to toxic effects of salt than are older chickens. Poultry are much less tolerant to salt supplied via the water than by the diet. Signs of salt intoxication include intense thirst, pronounced muscular weakness, inability to stand, and convulsive movements preceding death. Hemorrhages and severe congestion occur in the gastrointestinal tract, muscles, liver, and lungs. Excess sodium results in ascites, right ventricular hypertrophy, and right ventricular failure in broiler chickens (Figure 29.16) and turkeys (139), and contributes to spontaneous cardiomyopathy in turkeys (44). Matterson et al. (129) fed day-old poults graded quantities of salt for 23 days and observed edema and mortality at 4% salt but none at 2%. Young turkey poults have signs of salt toxicity at 1.85% salt, including respiratory distress, ascites, hydropericardium, hydrothorax, and sudden death (126). High levels of salt also cause the excretion of dilute urine and wet litter.

Potassium

Potassium (K) is found primarily in the intracellular compartment of the body. The soft tissues of the chicken contain more than 3 times as much potassium as sodium. Potassium has an essential role in the maintenance of membrane potential and cellular fluid balance. Potassium participates directly in numerous biochemical reactions and is necessary for normal heart activity, reducing contractility of the heart muscle and favoring relaxation. Many feedstuffs contain adequate levels of potassium so deficiencies are relatively rare.

Clinical Signs and Signalment of Deficiency

The main effect of potassium deficiency is overall muscle weakness characterized by weak extremities, poor intestinal tone with distention, cardiac weakness, and weakness of the respiratory muscles and their ultimate failure. Severely affected individuals may exhibit tetanic seizures followed by death. Low levels of potassium in laying diets cause decreased egg production and eggshell thinning.

Figure 29.16. Sodium excess. Cardiomegaly, especially involving the right ventricle, ascites, and fibrin masses in the body cavity and on the liver capsule, occurred in this chicken given excess sodium. (D.E. Swayne)

In one experiment, a diet low in potassium produced low plasma potassium concentrations simultaneous with a high incidence of sudden death syndrome at the onset of egg production in restricted fed broiler breeder pullets (62). The hypothesis that low dietary potassium leads to this syndrome, however, requires additional testing.

Dietary Balance of Macrominerals

The balance among dietary minerals has a profound effect on acid-base balance and certain developmental, metabolic, and physiologic functions in poultry (10, 100, 102). Diets rich in mineral anions, particularly Cl, tend to cause metabolic acidosis and result in disturbances of Ca metabolism, increased incidence and severity of tibial dyschondroplasia in immature fowl, and reduced eggshell calcification in laying hens. Diets rich in mineral cations, particularly calcium or sodium, result in the excretion of alkaline urine and the precipitation of divalent mineral salts. Growing chicks given high levels of sodium bicarbonate develop visceral urate deposition (i.e., "visceral gout") that is especially pronounced in the kidney, which displays urate granulomas (tophi) in renal interstitium and tubular necrosis (92).

High levels of dietary electrolytes also increase fecal moisture and can cause problems with wet litter. Increasing dietary concentrations of sodium, potassium, or phosphorus causes linear increases in the water intake of the laying hens and linear increases in the moisture content of their excreta. Each 1 g/kg increase in dietary mineral increases the moisture content of the excreta by 9, 12 and 5.6 g/kg for sodium, potassium, and phosphorus, respectively (121). Various sodium salts ameliorate heat stress in chickens, at least in part by increasing water intake (2).

Manganese

Manganese (Mn) is an important activator of many enzymes and is also a component of arginase, pyruvate carboxylase, and Mn-superoxide dismutase. Functions such as superoxide dismutase activity and activation of glycosyltransferases are very sensitive to a deficiency of manganese. Glycosyltransferase enzymes are important for the synthesis of glycosaminoglycans, mucopolysaccharides, and glycoproteins in bone and cartilage. Manganese deficiencies are relatively common in poultry because the manganese in many feedstuffs is poorly absorbed.

Clinical Signs and Signalment of Deficiency

In laying chickens, manganese deficiency causes decreases in growth, egg production, egg weight, shell thickness, and sperm quality (8). Shells have translucent areas and abnormalities of the mammillary layer. In growing chicks, manganese deficiency impairs endochondral bone growth. Cells of the epiphyseal growth plate are arranged irregularly and the extracellular matrix is greatly reduced (80). Deficiency also decreases Mn-superoxide dismutase activity in tissues such as the heart (83) and causes the ultrastructure of cone photoreceptor cells of the eye to be disorganized (41). In broiler chicks, growth rate and efficiency are not as sensitive to a marginal deficiency as other signs (83).

Manganese deficiency results in decreased hatchability of fertile eggs and chondrodystrophy in embryos. Chicks hatched from manganese-deficient eggs exhibit ataxia, particularly when excited.

Manganese is generally considered to be one of the least toxic minerals and poultry tolerate diets with up to 2,000 mg/kg without physical signs of toxicosis (98), although immunosuppression occurs at lower levels (85). Manganese at toxic levels can be diagnosed by high plasma manganese concentrations (30).

Iodine

Iodine (I) is an integral part of the thyroid hormones triiodothyronine and thyroxin, which regulate metabolism, especially energetics. No other metabolic functions for iodine have been described in poultry. When the intake of iodine is suboptimal, the thyroid tissue enlarges and goiter results. Some feedstuffs have goitrogens, which impair iodine utilization and cause deficiencies in the presence of normal dietary iodine levels.

Iodine deficiency decreases hatchability, with mortality occurring late in incubation. Hatching time is delayed, embryo size is reduced, and yolk sac absorption is retarded. Severe deficiencies cause laying hens to stop laying and become obese (114).

Some egg producers feed high levels of iodine to enrich eggs and add economic value. High levels of dietary iodine decrease egg weight, albumen index, and Haugh units (81, 160). Iodine reduces the growth rate of chicks at 900 mg/kg and this effect is mitigated by dietary bromine (16). High levels of iodine also reduce male fertility. Iodine toxicosis is normalized within about 7 days of returning birds to a diet with normal iodine levels (81).

Copper

Copper (Cu) is a component of a variety of intracellular and extracellular enzymes engaged in redox reactions including cytochrome oxidase, catalase, ceruloplasmin, lysyl oxidase, superoxide dismutase, and tyrosinase. In the absence of copper, dietary iron is absorbed and deposited in the liver and elsewhere, but hemoglobin synthesis is impaired resulting in anemia, characterized by reduced numbers of circulating erythrocytes. Lysyl oxidase catalyzes oxidation of lysine residues in formation of the cross-linking in elastin and collagen. Weakened connective tissue due to copper deficiency causes dissecting aneurysms, particularly of the aorta, and bone fragility (109). In broilers, a copper deficiency also causes hypertriglyceridemia, hypercholesterolemia, and prolonged prothrombin time (70). A deficiency of copper in laying hens causes reduced egg production, increased egg size, and abnormal eggshell calcification. Eggshell abnormalities include shell-less eggs, misshapen eggs, wrinkled eggshells, and reduced eggshell thickness. The palisade layer of the eggshell appears normal; however, the mammillary layer has enlarged mammillary knobs and increased spacing between knobs. This may be related to an abnormal structure of eggshell membranes caused by a decrease in lysine cross-linking (18).

Relatively high levels of copper (100–200 mg/kg diet) often are fed to poultry because of an antibiotic-like effect that improves indices of intestinal health, growth, and efficiency (5).

Excess Copper

Excessive copper causes abnormalities of the ventriculus. In broiler chicks, the ventricular lining becomes rough, thickened, and warty in appearance at very high levels. Histologically the koilin layer becomes thickened with sloughing of epithelial cells into the area under the koilin layer and the inclusion of clusters of sloughed cells within the koilin layer. Ventricular erosions and fissures in the ventricular lining may be accompanied by hemorrhages under the koilin layer. Liver pathology, including proliferation of bile ducts and infiltration of lymphocytes, and the elevation serum creatine kinase, aspartate amino transferase, and lactate dehydrogenase occurs in laying hens (28). In the liver of broilers, excess copper causes mitochondria to swell, increase H_2O_2 production, and undergo oxidative injury (125). Ducks are more sensitive than chickens to copper toxicosis (98).

Iron

Iron (Fe) is an essential component of heme, the porphyrin nucleus of hemoglobin and the cytochromes, and is a component of several enzymes. Iron deficiency results in a hypochromic, microcytic anemia, reduced concentration of non-heme iron in plasma, and abnormal feather pigmentation in breeds having colored plumage. Iron-deficient chicks develop vacuolated aortic and lung smooth muscle cells that are surrounded by disorganized elastic lamellae with diffuse and fragmented networks of elastic fibers and microfibrils (60). A deficiency in laying hens also causes anemia in the developing chick embryo and reduced hatchability (91). Chicks that survive incubation are weak and listless; however, they recover when given supplemental iron.

High dietary iron is well tolerated in poultry, but not many other avian species. Characteristic signs of chronic iron toxicosis include decreased growth and efficiency of gain (24). The liver, heart, and pancreatic beta cells are most affected by iron overload (98). The primary diagnostic indication is hemochromatosis, which is the deposition of microscopically visible brownish-yellow granules of hemosiderin in lysosomes of hepatic cells. As storage increases, the lysosomes become damaged and ionic iron is released, causing oxidative damage to cell membranes and proteins. In advanced stages, the liver becomes cirrhotic.

Zinc

Zinc (Zn) is an activator or a cofactor of more than 250 enzymes. Zinc also stabilizes "zinc finger" structural motifs, which are involved in protein-DNA interactions that regulate gene expression. Zinc plays a critical role in cell proliferation, differentiation, and survival. Zinc is deficient in many feedstuffs and must be supplemented in most practical poultry diets. A marginal deficiency of zinc has a larger impact on growth and egg production than a marginal deficiency of any of the other trace minerals. Zinc also is supplemented in plethoric amounts to poults and chicks as a growth promoter, and to hens to induce molt.

Clinical Signs and Signalment of Deficiency

Deficiency of zinc results in decreased food intake, slow growth, poor feathering, dehydration, enlarged hocks (Figure 29.17), short, thickened long bones (chondrodystrophy), an awkward arthritic gait, scaling of the skin, and dermatosis of the feet (143, 228). Histologic lesions include hyperkeratinization of skin of the shank and feet and parakeratosis of the esophagus. Nucleoli of the crop epithelium are enlarged and contain increased amounts of RNA. Severe epiphyseal growth plate lesions are characterized by reduced cellularity and abnormally shaped chondrocytes in areas remote from blood vessels. These changes are due to decreased chondrocyte proliferation and increased cell apoptosis. Cells closer to blood vessels are normal, apparently because they

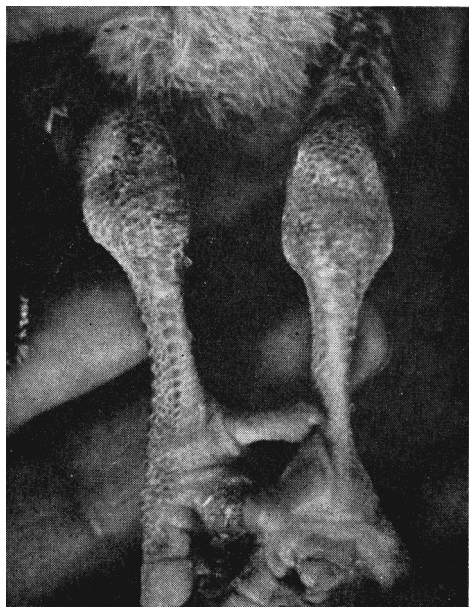

Figure 29.17. Enlarged hocks in poult caused by zinc deficiency. (R.J. Young)

are able to obtain sufficient zinc (140). Lymphoid organs become depleted of lymphocytes and reticular cells of the thymus become necrotic (33). The effect of deficiency is greatest on the cloacal bursa, followed by thymus, and then spleen. The zinc requirement of poults is higher than for chicks. Thus, at the same dietary zinc level, poults are more likely to show enlarged hocks and poor feathering.

Ducks exhibit poor growth and epidermal lesions of the feet, particularly interdigital webs (154). Pathology of the epidermis is evident in the interdigital web, mucous membrane of the tongue, and epithelium in other parts of the gastrointestinal tract. Hyperkeratosis and acanthosis characterize the tongue and interdigital web lesions. Intercellular spacing between prickle cells and basal cells is increased and number of desmosomes is diminished. Prickle cells have an abnormal structure, enlarged nuclei and nucleoli, and decreased content of free ribosomes, tonofilaments, and other structures. Lymphoid organs are affected similarly to those of chickens (32).

One of the most dramatic embryonic abnormalities resulting from a nutritional deficiency occurs when the breeding diet is deficient in zinc and also contains excess calcium and phosphorus. Zinc-deficient embryos may have only a head and complete viscera but no spinal column beyond a few vertebrae, and no wings, body wall, or legs (73).

Excess Zinc

In zinc toxicity, pathologic changes occur first in the pancreas and then in the ventriculus and thyroid. In hens, zinc (200 ppm as zinc oxide) results in pancreatic edema, dilated acinar lumina, vacuolated cytoplasm, and reduced zymogen granule density in the peripheral exocrine cells and occasional periacinar fibrotic infiltration (71). Thyroid follicles, especially those located centrally, are decreased in size and display cell hyperplasia and hypertrophy with hyperplastic cells filling the lumen. Excessive dietary levels of zinc (e.g., 20,000 ppm as zinc oxide) are sometimes fed to induce molt in laying hens (103). Zinc results in weight loss followed by an abrupt decline in egg production and onset of molt followed by rapid resumption of egg laying after dietary zinc concentrations are returned to normal.

In growing chicks, high levels of zinc result in a rough, pale ventricular lining, which may show evidence of fissures and, less frequently, ulceration (155). Inflammatory cells infiltrate the epithelium. Pancreases and thyroid lesions are similar to those of laying hens.

Selenium

Selenium is a constituent of many proteins, including glutathione peroxidase, which serve to protect tissues against oxidative damage and iodothyronine deiodinase, which is needed for the conversion of thyroxine to its active form. Severe selenium deficiencies are rare and limited to regions where feedstuffs are grown on very selenium deficient soils, but marginal deficiencies occur in many geographical areas. Selenium supplementation has a very low margin for error because of its high potential for toxicity and teratogenicity. Furthermore, the levels of selenium in the soils, feedstuffs, and water in some geographical regions are high and further supplementation is unwarranted.

Clinical Signs and Signalment of Deficiency

Classical Se deficiency diseases in chickens include poor growth and feathering, impaired fat digestion, exudative diathesis, pancreatic atrophy, and nutritional muscular dystrophy (52). Myopathy of ventriculus and heart occur in deficient poults and ducklings. Pancreatic lesions begin as vacuolation and hyaline body formation in the exocrine pancreas, followed by cytoplasm degenerated until acini are represented by rings of cells with a central lumen embedded in fibrous tissue (Figure 29.18). Vitamin E and selenium have a mutual sparing effect in prevention of these diseases (see Vitamin E), though selenium is especially important for preventing exudative diathesis.

Treatment

Feeding or injecting selenium results in marked clinical recovery of pancreatic atrophy and exudative diathesis (17, 107). High dietary levels of vitamin E (15–20 times the amount needed for prevention of other vitamin E-deficiency diseases) protect against the pancreatic degeneration caused by selenium deficiency.

Excess

Excess inorganic selenium interferes with sulfur metabolism due to the formation of sulfur-selenium complexes and the substitution of selenium for sulfur in cysteine. Excess organic selenium, usually as selenomethionine, is incorporated readily

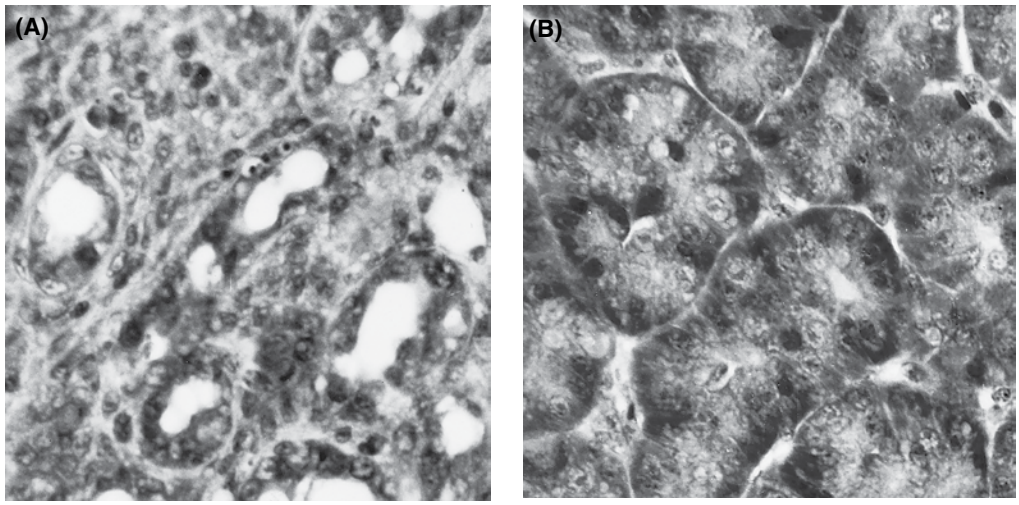

Figure 29.18. Pancreas from selenium-deficient chick. Acini consist of degenerating cells forming central lumen with extensive interstitial fibrosis (left). Control (right). x250. (M.L. Scott)

into proteins because $tRNA_{met}$ does not distinguish selenomethionine from methionine, and selenomethionine is readily incorporated into proteins in place of methionine. These aberrations result in impaired protein synthesis, impaired function of proteins, and mutagenesis. A decrease in growth rate occurs with 5 mg/kg selenium in broiler chicks (98). Acute selenium toxicity in broiler chicks causes watery diarrhea, weakness, somnolence, and cerebellar edema (111). Pectoral muscle atrophy and claw and feather loss also have been noted. Hepatic lesions include vacuolic degeneration, pyknosis of cells of the mononuclear phagocytic system, hemorrhagic dystrophy, and parenchymal atrophy. Kidneys show diffuse tubulonephrosis followed by the necrosis of tubular epithelium. Myocardial and skeletal myodegeneration and damage of the spleen, thymus, and cloacal bursa also occur (105).

The developing embryo is particularly affected by high selenium (78, 156). Hatchability is typically poor and those that hatch are often deformed. Legs, toes, wings, beaks, or eyes may be rudimentary or completely lacking. Down is often wiry and sparse.

Public Health Significance

Poultry products are an important part of the human diet and supply highly bioavailable forms of nutrients. Levels of vitamins and minerals in meat and eggs are highly dependent on the levels in the diet. Birds fed diets that are deficient in vitamins or minerals do not supply intended levels of nutrition to human consumers. In fact, the vitamin and trace mineral qualities of poultry products are often optimized at levels that are above the requirement for the animal. Animals deficient in nutrients are often immunocompromised, resulting in increased incidence of infectious diseases and, in some cases, evolution of more pathogenic disease organisms.

Often animals can serve as buffers for high levels of minerals or other nutrients found in plants and other foodstuffs, thereby reducing human exposure to potentially toxic nutrients including some heavy metals (98). However, levels of some nutrients (e.g., selenium, iodine, copper, fluoride, and vitamin A) may accumulate in meat or eggs to levels that might adversely affect human health. Prompt diagnosis and correction of toxicities is important for safeguarding the human food supply.

References

1. Abd El-Wahab, A., C.F. Visscher, A. Beineke, M. Beyerbach, and J. Kamphues. 2012. Effects of high electrolyte contents in the diet and using floor heating on development and severity of foot pad dermatitis in young turkeys. *J Anim Physiol Anim Nutr.* 2011 Oct 13. doi: 10.1111/j.1439-0396.2011.01240.x.
2. Ahmad, T., T. Mushtaq, N. Mahr Un, M. Sarwar, D.M. Hooge, and M.A. Mirza. 2006. Effect of different non-chloride sodium sources on the performance of heat-stressed broiler chickens. *Br Poult Sci.* 47:249–256.
3. Ameenuddin, S., M.L. Sunde, and M.E. Cook. 1985. Essentiality of vitamin D3 and its metabolites in poultry nutrition: a review. *World Poult Sci J.* 41:52–63.
4. Ammerman, C.B., D.H. Baker, and A.J. Lewis. 1995. *Bioavailability of Nutrients for Animals*. Academic Press, San Diego.
5. Arias, V.J., and E.A. Koutsos. 2006. Effects of copper source and level on intestinal physiology and growth of broiler chickens. *Poult Sci.* 85:999–1007.
6. Atencio, A., H.M. Edwards, Jr., and G.M. Pesti. 2005. Effect of the level of cholecalciferol supplementation of broiler breeder hen diets on the performance and bone abnormalities of the progeny fed diets containing various levels of calcium or 25-hydroxycholecalciferol. *Poult Sci.* 84:1593–1603.
7. Atencio, A., G.M. Pesti, and H.M. Edwards, Jr. 2005. Twenty-five hydroxycholecalciferol as a cholecalciferol substitute in broiler breeder hen diets and its effect on the performance and general health of the progeny. *Poult Sci.* 84:1277–1285.
8. Attia, Y.A., E.M. Qota, F. Bovera, A.E. Tag El-Din, and S.A. Mansour. 2010. Effect of amount and source of manganese and/or phytase supplementation on productive and reproductive performance and some physiological traits of dual

purpose cross-bred hens in the tropics. *British Poult Sci.* 51:235–245.
9. Austic, R.E. 1979. Nutritional influences on water intake in poultry. *Proc Cornell Nutr Conf*. Syracuse, NY. pp. 37–41.
10. Austic, R.E., and J.F. Patience. 1988. Undetermined anion in poultry diets: influence on acid-base balance, metabolism and physiological performance. *Crit Rev Poult Biol.* 1:315–345.
11. Austic, R.E., and R.K. Cole. 1972. Impaired renal clearance of uric acid in chickens having hyperuricemia and articular gout. *Am J Physiol.* 223:525–530.
12. Avanzo, J.L., C.X. de Mendonca, Jr., S.M. Pugine, and M. de Cerqueira Cesar. 2001. Effect of vitamin E and selenium on resistance to oxidative stress in chicken superficial pectoralis muscle. *Comp Biochem Physiol Toxicology and Pharmacology. CBP* 129:163–173.
13. Aye, P.P., T.Y. Morishita, Y.M. Saif, J.D. Latshaw, B.S. Harr, and F.B. Cihla. 2000. Induction of vitamin A deficiency in Turkeys. *Avian Dis.* 44:809–817.
14. Baghbanzadeh, A., and E. Decuypere. 2008. Ascites syndrome in broilers: physiological and nutritional perspectives. *Avian Pathol.* 37:117–126.
15. Baker, D.H., and K.P. Boebel. 1980. Utilization of the D- and L-isomers of methionine and methionine hydroxy analogue as determined by chick bioassay. *J Nutr.* 110:959–964.
16. Baker, D.H., T.M. Parr, and N.R. Augspurger. 2003. Oral iodine toxicity in chicks can be reversed by supplemental bromine. *J Nutr.* 133:2309–2312.
17. Bartholomew, A., D. Latshaw, and D.E. Swayne. 1998. Changes in blood chemistry, hematology, and histology caused by a selenium/vitamin E deficiency and recovery in chicks. *Biol Trace Elem Res.* 62:7–16.
18. Baumgartner, S., D.J. Brown, J.E. Salevsky, and J.R.M. Leach. 1978. Copper deficiency in the laying hen. *J Nutr.* 108:804–811.
19. Bermudez, A.J., D.E. Swayne, M.W. Squires, and M.J. Radin. 1993. Effects of vitamin A deficiency on the reproductive system of mature White Leghorn hens. *Avian Dis.* 37–183.
20. Bryden, W.L. 1991. Tissue depletion of biotin in chickens and the development of deficiency lesions and the fatty liver and kidney syndrome. *Avian Pathol.* 20:259–269.
21. Cai, Z., J.W. Finnie, and P.C. Blumbergs. 2006. Avian riboflavin deficiency: an acquired tomaculous neuropathy. *Vet Pathol.* 43:780–781.
22. Cai, Z., J.W. Finnie, and P.C. Blumbergs. 2006. Avian riboflavin deficiency: an acquired tomaculous neuropathy. *Vet Pathol.* 43:780–781.
23. Cai, Z., P.C. Blumbergs, J.W. Finnie, J. Manavis, and P.D. Thompson. 2009. Selective vulnerability of peripheral nerves in avian riboflavin deficiency demyelinating polyneuropathy. *Vet Pathol.* 46:88–96.
24. Cao, J., X.G. Luo, P.R. Henry, C.B. Ammerman, R.C. Littell, and R.D. Miles. 1996. Effect of dietary iron concentration, age, and length of iron feeding on feed intake and tissue iron concentration of broiler chicks for use as a bioassay of supplemental iron sources. *Poult Sci.* 75:495–504.
25. Chen, B.-J. 1989. *Studies on the conversion of tryptophan to niacin in chickens and ducks*. Ph.D. Thesis. Cornell University, Ithaca, NY.
26. Chen, B.-J., T.-F. Shen, and R.E. Austic. 1996. Efficiency of tryptophan-niacin conversion in chickens and ducks. *Nutr Res.* 16:91–104.
27. Chiang, Y.H., J.D. Kim, C.S. Lee, and M.F. Holick. 1997. Biological, biochemical and histopathological observations of broiler chicks fed different levels of vitamin D-3. III: Histopathological observation. *Korean J An Nutr Feedstuffs.* 21:245–250.
28. Chiou, P.W.-S., K.-L. Chen, and B. Yu. 1997. Toxicity, tissue accumulation and residue in egg and excreta of copper in laying hens. *An Feed Sci Tech.* 67:49–60.
29. Chung, T.K., and D.H. Baker. 1990. Riboflavin requirement of chicks fed purified amino acid and conventional corn-soybean meal diets. *Poult Sci.* 69:1357–1363.
30. Conly, A.K., R. Poureslami, E.A. Koutsos, A.B. Batal, B. Jung, R. Beckstead, and D.G. Peterson. 2012. Tolerance and efficacy of tribasic manganese chloride in growing broiler chickens. *Poult Sci.* 91:1633–1640.
31. Cortes, P.L., A.K. Tiwary, B. Puschner, R.M. Crespo, R.P. Chin, M. Bland, and H.L. Shivaprasad. 2006. Vitamin A deficiency in turkey poults. *J Vet Diagn Invest.* 18:489–494.
32. Cui, H., F. Jing, and P. Xi. 2003. Pathology of the thymus, spleen and bursa of Fabricius in zinc-deficient ducklings. *Avian Pathol.* 32:259–264.
33. Cui, H., P. Xi, D. Junliang, L. Debing, and Y. Guang. 2004. Pathology of lymphoid organs in chickens fed a diet deficient in zinc. *Avian Pathol.* 33:519–524.
34. de Matos, R. 2008. Calcium metabolism in birds. *Vet Clin North Am Exotic An Pract*. 11:59–82, vi.
35. DeLuca, H.F., M. Nakada, Y. Tanaka, R. Sicinski, and M. Phelps. 1988. The plasma binding protein for vitamin D is a site of discrimination against vitamin D-2 compounds by the chick. *Biochim Biophys Acta.* 965:16–21.
36. Dickson, I.R., and E. Kodicek. 1979. Effect of vitamin D deficiency on bone formation in the chick. *Biochem J.* 182:429–435.
37. Dilger, R.N., T.A. Garrow, and D.H. Baker. 2007. Betaine can partially spare choline in chicks but only when added to diets containing a minimal level of choline. *J Nutr.* 137:2224–2228.
38. Dilger, R.N., C. Kobler, C. Weckbecker, D. Hoehler, and D.H. Baker. 2007. 2-keto-4-(methylthio)butyric acid (keto analog of methionine) is a safe and efficacious precursor of L-methionine in chicks. *J Nutr.* 137:1868–1873.
39. Dinev, I. 2012. Clinical and morphological investigations on the incidence of forms of rickets and their association with other pathological states in broiler chickens. *Res Vet Sci.* 92:273–277.
40. Edwards, H.M., Jr., M.A. Elliot, S. Sooncharernying, and W.M. Britton. 1994. Quantitative requirement for cholecalciferol in the absence of ultraviolet light. *Poult Sci.* 73:288–294.
41. Endo, K., N. Itoh, S. Maehara, A. Shinozaki, T. Imagawa, M. Uehara, N. Mizuno, S. Sasaki, T. Hiraga, and H. Teraoka. 2008. Functional disorder of the retina in manganese-deficient Japanese quail revealed by electroretinography using a contact lens electrode with built-in light source. *J Vet Med Sci.* 70:139–144.
42. Farquharson, C., J.S. Rennie, N. Loveridge, and C.C. Whitehead. 1996. *In vivo* and *in vitro* effect of 1,25-dihydroxyvitamin D3 and 1,25-dihydroxy-16-ene-23-yne-vitamin D3 on the proliferation and differentiation of avian chondrocytes: their role in tibial dyschondroplasia. *J Endocrin.* 148:465–474.
43. Fleming, R.H. 2008. Nutritional factors affecting poultry bone health. *Proc Nutr Soc.* 67:177–183.
44. Frame, D.D., D.M. Hooge, and R. Cutler. 2001. Interactive effects of dietary sodium and chloride on the incidence of spontaneous cardiomyopathy (round heart) in turkeys. *Poult Sci.* 80:1572–1577.
45. Fuhrmann, H., and H.P. Sallmann. 2000. Brain, liver and plasma unsaturated aldehydes in nutritional encephalomalacia of chicks. *J Vet Med.* 47:149–155.

46. Gay, C.V., V.R. Gilman, and R.M. Leach, Jr. 2007. Immunolocalization of vascularization factors in normal, tibial dyschondroplasia and rachitic cartilage. *Avian Pathol.* 36:445–451.
47. Geyer, J., M. Netzel, I. Bitsch, T. Frank, R. Bitsch, K. Kramer, and P.P. Hoppe. 2000. Bioavailability of water- and lipid-soluble thiamin compounds in broiler chickens. *Int J Vit Nutr Res.* 70:311–316.
48. Goff, J.P., and R.L. Horst. 1995. Assessing adequacy of cholecalciferol supplementation in chicks using plasma cholecalciferol metabolite concentrations as an indicator. *J Nutr.* 125:1351–1357.
49. Gonzales, E., J. Buyse, M.M. Loddi, T.S. Takita, N. Buys, and E. Decuypere. 1998. Performance, incidence of metabolic disturbances and endocrine variables of food-restricted male broiler chickens. *Br Poult Sci.* 39:671–678.
50. Goodson-Williams, D.A.R.R., Sr., and J.A. McGuire. 1986. Effects of feeding graded levels of vitamin D3 on egg shell pimpling in aged hens. *Poult Sci.* 65:1556–1560.
51. Grau, C.R., T.E. Roudybush, P. Vohra, F.H. Kratzer, M. Yang, and D. Nearenberg. 1989. Obscure relations of feather melanization and avian nutrition. *Worlds Poult Sci J.* 45:241–246.
52. Gries, C.L., and M.L. Scott. 1972. Pathology of selenium deficiency in the chick. *J Nutr.* 102:1287–1296.
53. Gries, C.L., and M.L. Scott. 1972. The pathology of thiamin, riboflavin, pantothenic acid and niacin deficiencies in the chick. *J Nutr.* 102:1269–1285.
54. Gries, C.L., and M.L. Scott. 1972. The pathology of pyridoxine deficiency in chicks. *J Nutr.* 102:1259–1267.
55. Guo, X., K. Huang, and J. Tang. 2005. Clinicopathology of gout in growing layers induced by high calcium and high protein diets. *Br Poult Sci.* 46:641–646.
56. Harms, R.H., and G.B. Russell. 2002. Betaine does not improve performance of laying hens when the diet contains adequate choline. *Poult Sci.* 81:99–101.
57. Harms, R.H., N. Ruiz, R.E. Buresh, and H.R. Wilson. 1988. Effect of niacin supplementation of a corn-soybean meal diet on performance of turkey breeder hens. *Poult Sci.* 67:336–338.
58. Hassan, S., J. Hakkarainen, L. Jonsson, and J. Tyopponen. 1990. Histopathological and biochemical changes associated with selenium and vitamin E deficiency in chicks. *Zentralb Veterinar.* 37:708–720.
59. Hess, J.B., and W.M. Britton. 1997. Effects of dietary magnesium excess in White Leghorn hens. *Poult Sci.* 76:703–710.
60. Hill, C.H., C.M. Ashwell, S.J. Nolin, F. Keeley, C. Billingham, A. Hinek, and B. Starcher. 2007. Dietary iron deficiency compromises normal development of elastic fibers in the aorta and lungs of chicks. *J Nutr.* 137:1895–1900.
61. Hooper, J.H., J.L. Halpin, and J.C. Fritz. 1942. The feeding of single massive doses of vitamin D to birds [abst]. *Poult Sci.* 21:472.
62. Hopkinson, W.I. 1991. Reproduction of the sudden death syndrome of broiler breeders. *Avian Pathol.* 20:403–408.
63. Huang, J.Q., D.L. Li, H. Zhao, L.H. Sun, X.J. Xia, K.N. Wang, X. Luo, and X.G. Lei. 2011. The selenium deficiency disease exudative diathesis in chicks is associated with downregulation of seven common selenoprotein genes in liver and muscle. *J Nutr.* 141:1605–1610.
64. Jensen, S.K., and C. Lauridsen. 2007. Alpha-tocopherol stereoisomers. *Vitam Horm.* 76:281–308.
65. Jin, S., and J.L. Sell. 2001. Dietary vitamin K1 requirement and comparison of biopotency of different vitamin K sources for young turkeys. *Poult Sci.* 80:615–620.
66. Johnson, N.E., X.L. Qiu, L.D. Gautz, and E. Ross. 1995. Changes in dimensions and mechanical properties of bone in chicks fed high levels of niacin. *Food Chem Tox.* 33:265–271.
67. Jortner, B.S., J.B. Meldrum, C.H. Domermuth, and L.M. Potter. 1985. Encephalomalacia associated with hypovitaminosis E in turkey poults. *Avian Dis.* 29:488–498.
68. Julian, R.J., J. Summers, and J.B. Wilson. 1986. Right ventricular failure and ascites in broiler chicks caused by phosphorus-deficient diets. *Avian Dis.* 30:453–459.
69. Kannan, Y., H. Harayama, and S. Kato. 1997. Effects of dietary calcium levels on the histomorphology of proximal tibia in vitamin D-deficient chicks. *Jap Poult Sci.* 34:124–131.
70. Kaya, A., A. Altiner, and A. Ozpinar. 2006. Effect of copper deficiency on blood lipid profile and haematological parameters in broilers. *J Vet Med A Physiol Pathol Clin Med.* 53:399–404.
71. Kaya, S., M. Ortatatli, and S. Haliloglu. 2002. Feeding diets supplemented with zinc and vitamin A in laying hens: effects on histopathological findings and tissue mineral contents. *Res Vet Sci.* 73:251–257.
72. Khan, S.H., R. Shahid, A.A. Mian, R. Sardar, and M.A. Anjum. 2010. Effect of the level of cholecalciferol supplementation of broiler diets on the performance and tibial dyschondroplasia. *J Anim Physiol Anim Nutr.* 94:584–593.
73. Kienholz, E.W., D.E. Turk, M.L. Sunde, and W.G. Hoekstra. 1961. Effects of zinc deficiency in the diets of hens. *J Nutr.* 75:211–221.
74. Klasing, K. 1998. *Comparative Avian Nutrition*. CAB International, Wallingford, United Kingdom. 1–350.
75. Klasing, K.C. 2008. Nutritional diseases. In: Y.M. Saif, ed. *Diseases of Poultry*, 12th ed. Blackwell Publishing, Ames, Iowa. 1121–1148.
76. Kratzer, F.H., J.L. Buenrostro, and B.A. Watkins. 1985. Biotin related abnormal fat metabolism in chickens and its consequences. *Ann N Y Acad Sci.* 447:401–402.
77. Lacy, D.L., and W.E. Huffer. 1982. Studies on the pathogenesis of avian rickets. I. Changes in epiphyseal and metaphyseal vessels in hypocalcemic and hypophosphatemic rickets. *Am J Pathol.* 109:288–301.
78. Latshaw, J.D., T.Y. Morishita, C.F. Sarver, and J. Thilsted. 2004. Selenium toxicity in breeding ring-necked pheasants (*Phasianus colchicus*). *Avian Dis.* 48:935–939.
79. Lavelle, P.A., Q.P. Lloyd, C.V. Gay, and R.M. Leach, Jr. 1994. Vitamin K deficiency does not functionally impair skeletal metabolism of laying hens and their progeny. *J Nutr.* 124:371–377.
80. Leach, R.M., and C.V. Gay. 1987. Role of epiphyseal cartilage in endochonral bone formation. *J Nutr.* 117:784–790.
81. Lewis, P.D. 2004. Responses of domestic fowl to excess iodine: a review. *Br J Nutr.* 91:29–39.
82. Li, J., D. Bi, S. Pan, Y. Zhang, and D. Zhou. 2008. Effects of high dietary vitamin A supplementation on tibial dyschondroplasia, skin pigmentation and growth performance in avian broilers. *Res Vet Sci.* 84:409–412.
83. Li, S., Y. Lin, L. Lu, L. Xi, Z. Wang, S. Hao, L. Zhang, K. Li, and X. Luo. 2011. An estimation of the manganese requirement for broilers from 1 to 21 days of age. *Res Trace Elem Res.* 143:939–948.
84. Lietzow, J., H. Kluge, C. Brandsch, N. Seeburg, F. Hirche, M. Glomb, and G.I. Stangl. 2012. Effect of short-term UVB exposure on vitamin D concentration of eggs and vitamin D status of laying hens. *J Ag Food Chem.* 60:799–804.

85. Liu, X., Z. Li, C. Han, Z. Zhang, and S. Xu. 2012. Effects of dietary manganese on Cu, Fe, Zn, Ca, Se, IL-1beta, and IL-2 changes of immune organs in cocks. *Res Trace Elem Res.* 148:336–344.
86. Long, P.H., S.R. Lee, G.N. Rowland, and W.M. Britton. 1984. Experimental rickets in broilers: gross, microscopic, and radiographic lesions. II. Calcium deficiency. *Avian Dis.* 28: 921–932.
87. Long, P.H., S.R. Lee, G.N. Rowland, and W.M. Britton. 1984. Experimental rickets in broilers: gross, microscopic, and radiographic lesions. I. Phosphorus deficiency and calcium excess. *Avian Dis.* 28:460–474.
88. Long, P.H., S.R. Lee, G.N. Rowland, and W.M. Britton. 1984. Experimental rickets in broilers: gross, microscopic, and radiographic lesions. III. Vitamin D deficiency. *Avian Dis.* 28:933–943.
89. Masse, P.G., I. Ziv, D.E.C. Cole, J.D. Mahuren, S. Donovan, M. Yamauchi, and D.S. Howell. 1998. A cartilage matrix deficiency experimentally induced by vitamin B6 deficiency. *Proc Soc Exp Biol Med.* 217:97–103.
90. Misir, R., and R. Blair. 1988. Biotin bioavailability of protein supplements and cereal grains for starting turkey poults. *Poult Sci.* 67:1274–1280.
91. Morck, T.A., and R.E. Austic. 1981. Iron requirements of white leghorn hens. *Poult Sci.* 60:1497–1503.
92. Mubarak, M., and A.A. Sharkawy. 1999. Toxopathology of gout induced in laying pullets by sodium bicarbonate toxicity. *Environ Tox Pharm.* 7:227–236.
93. Mueller, A.S., J. Fischer, E. Most, and J. Pallauf. 2009. Investigation into selenium requirement of growing turkeys offered a diet supplemented with two levels of vitamin E. *J Anim Physiol Anim Nutr.* 93:313–324.
94. Nain, S., B. Laarveld, C. Wojnarowicz, and A.A. Olkowski. 2007. Excessive dietary vitamin D supplementation as a risk factor for sudden death syndrome in fast growing commercial broilers. *Comp Biochem Physiol A Mol Integr Physiol.* 148:828–833.
95. Norman, A.W., and S. Hurwitz. 1993. The role of the vitamin D endocrine system in avian bone biology. *J Nutr.* 123:310–316.
96. Norman, A.W., and S. Hurwitz. 1993. The role of the vitamin D endocrine system in avian bone biology. *J Nutr.* 123:310–316.
97. NRC. 1994. *Nutrient Requirements of Poultry*, 9th ed. National Academies, Washington, D.C. 1–157.
98. NRC. 2005. *Mineral Tolerances of Animals*. 2nd ed. The National Academies, Washington, D.C. 1–510.
99. Nunes, V.A., A.J. Gozzo, I. Cruz-Silva, M.A. Juliano, T.A. Viel, R.O. Godinho, F.V. Meirelles, M.U. Sampaio, C.A. Sampaio, and M.S. Araujo. 2005. Vitamin E prevents cell death induced by mild oxidative stress in chicken skeletal muscle cells. *Comp Biochem Physiol C Toxicol Pharmacol.* 141:225–240.
100. Olanrewaju, H.A., J.P. Thaxton, W.A. Dozier, 3rd, and S.L. Branton. 2007. Electrolyte diets, stress, and acid-base balance in broiler chickens. *Poult Sci.* 86:1363–1371.
101. Onderka, D.K., J.A. Hanson, F.L. Leggett, and L.D. Armstrong. 1987. Renal pathology in chicks following water deprivation. *Avian Dis.* 31:735–739.
102. Oviedo-Rondon, E.O., A.E. Murakami, A.C. Furlan, I. Moreira, and M. Macari. 2001. Sodium and chloride requirements of young broiler chickens fed corn-soybean diets (one to twenty-one days of age). *Poult Sci.* 80:592–598.
103. Park, S.Y., S.G. Birkhold, L.F. Kubena, D.J. Nisbet, and S.C. Ricke. 2004. Review on the role of dietary zinc in poultry nutrition, immunity, and reproduction. *Res Trace Elem Res.* 101:147–163.
104. Pearce, J., and D. Balnave. 1978. A review of biotin deficiency and the fatty liver and kidney syndrome in poultry. *Br Vet J.* 134:598–609.
105. Peng, X., H. Cui, J. Deng, Z. Zuo, and W. Lai. 2011. Histological lesion of spleen and inhibition of splenocyte proliferation in broilers fed on diets excess in selenium. *Biol Trace Elem Res.* 140:66–72.
106. Pesti, G.M., G.N. Rowland, and K.-S. Ryu. 1991. Folate deficiency in chicks fed diets containing practical ingredients. *Poult Sci.* 70:600–604.
107. Reddish, J.M., J.D. Latshaw, N.R. St.-Pierre, C. Pretzman, and M. Wick. 2005. Myosin heavy chain isoform expression is not altered in the pectoralis major muscle in selenium-deficient chickens recovering from exudative diathetic myopathy. *Poult Sci.* 84:462–466.
108. Robel, E.J., and V.L. Christensen. 1987. Increasing hatchability of turkey eggs with biotin egg injections. *Poult Sci.* 66:1429–1430.
109. Rucker, R.B., B.R. Rucker, A.E. Mitchell, C.T. Cui, M. Clegg, T. Kosonen, J.Y. Uriu-Adams, E.H. Tchaparian, M. Fishman, and C.L. Keen. 1999. Activation of chick tendon lysyl oxidase in response to dietary copper. *J Nutr.* 129:2143–2146.
110. Ruiz, N., and R.H. Harms. 1989. Riboflavin requirement of turkey poults fed a corn-soybean meal diet from 1 to 21 days of age. *Poult Sci.* 68:715–718.
111. Salyi, G., G. Banhidi, E. Szabo, G. Sandor, and F. Ratz. 1993. Acute selenium poisoning in broilers. *Magyar Allatorvosok Lapja.* 48:22–26.
112. Scherer, C.S., and D.H. Baker. 2000. Excess dietary methionine markedly increases the vitamin B-6 requirement of young chicks. *J Nutr.* 130:3055–3058.
113. Scott, M.L. 1980. Advances in our understanding of vitamin E *Fed Proc*. 39:2736–2739.
114. Scott, M.L., M.C. Nesheim, and R.J. Young. 1982. *Nutrition of the Chicken*, 3rd ed. M.L. Scott and Associates, Ithaca, New York. 1–591.
115. Seifried, O. 1930. Studies on A-avitaminosis in chickens. I. Lesions of the respiratory tract and their relation to some infectious diseases. *J Exp Med*. 52:5.
116. Shanmugasundaram, R., and R.K. Selvaraj. 2012. Vitamin D-1alpha-hydroxylase and vitamin D-24-hydroxylase mRNA studies in chickens. *Poult Sci.* 91:1819–1824.
117. Shepherd, E.M., and B.D. Fairchild. 2010. Footpad dermatitis in poultry. *Poult Sci.* 89:2043–2051.
118. Shim, M.Y., C. Parr, and G.M. Pesti. 2011. The effects of dietary fluoride on growth and bone mineralization in broiler chicks. *Poult Sci.* 90:1967–1974.
119. Siller, W.G. 1981. Renal pathology of the fowl—A review. *Avian Pathol.* 10:187–262.
120. Sklan, D., D. Melamed, and A. Friedman. 1994. The effect of varying levels of dietary vitamin-A on immune response in the chick. *Poult Sci.* 73:843–847.
121. Smith, A., S.P. Rose, R.G. Wells, and V. Pirgozliev. 2000. Effect of excess dietary sodium, potassium, calcium and phosphorus on excreta moisture of laying hens. *Br Poult Sci.* 41:598–607.
122. Soares, J.H. 1995. Calcium bioavailability. In: *Bioavailability of Nutrients for Animals*. C.B. Ammerman, D.H. Baker, and A.J. Lewis, eds. Academic Press, San Diego. 95–118.

123. Squires, M.W., and E.C. Naber. 1993. Vitamin profiles of eggs as indicators of nutritional status in the laying hen—Riboflavin study. *Poult Sci.* 72:483–494.
124. Stevens, V.I., R. Blair, R.E. Salmon, and J.P. Stevens. 1984. Effect of varying levels of dietary vitamin D3 on turkey hen egg production, fertility and hatchability, embryo mortality and incidence of embryo beak malformations. *Poult Sci.* 63:760–764.
125. Su, R., R. Wang, H. Cao, J. Pan, L. Chen, C. Li, D. Shi, and Z. Tang. 2011. High copper levels promotes broiler hepatocyte mitochondrial permeability transition *in vivo* and *in vitro*. *Res Trace Elem Res.* 144:636–646.
126. Swayne, D.E., A. Shlosberg, and R.B. Davis. 1986. Salt poisoning in turkey poults. *Avian Dis.* 30:847–852.
127. Tactacan, G.B., J.C. Rodriguez-Lecompte, K. O, and J.D. House. 2012. The adaptive transport of folic acid in the intestine of laying hens with increased supplementation of dietary folic acid. *Poult Sci.* 91:121–128.
128. Tang, K.-N., G.N. Rowland, and J.R. Veltmann, Jr. 1985. Vitamin A toxicity: comparative changes in bone of the broiler and leghorn chicks. *Avian Dis.* 29:416–429.
129. Taniguchi, A., and T. Watanabe. 2007. Roles of biotin in growing ovarian follicles and embryonic development in domestic fowl. *J Nutr Sci Vitamin.* 53:457–463.
130. Teirlynck, E., F. Haesebrouck, F. Pasmans, J. Dewulf, R. Ducatelle, and F. Van Immerseel. 2009. The cereal type in feed influences Salmonella Enteritidis colonization in broilers. *Poult Sci.* 88:2108–2112.
131. Teirlynck, E., M.D. Gussem, J. Dewulf, F. Haesebrouck, R. Ducatelle, and F. Van Immerseel. 2011. Morphometric evaluation of "dysbacteriosis" in broilers. *Avian Pathol.* 40:139–144.
132. Terry, M., M. Lanenga, J.L. McNaughton, and L.E. Stark. 1999. Safety of 25-hydroxyvitamin D3 as a source of vitamin D3 in layer poultry feed. *Vet Human Tox.* 41:312–316.
133. Thorp, B.H., C.C. Whitehead, and J.S. Rennie. 1991. Avian tibial dyschondroplasia: a comparison of the incidence and severity as assessed by gross examination and histopathology. *Res Vet Sci.* 51:48–54.
134. Tsang, C.P.W., and A.A. Grunder. 1993. Effect of dietary contents of cholecalciferol, 1,25-dihydroxycholecalciferol and 24,25-dihydroxycholecalciferol on blood concentrations of 25-hydroxycholecalciferol, 1,25-dihydroxycholecalciferol, total calcium and eggshell quality. *Br Poult Sci.* 34:1021–1027.
135. Uni, Z., G. Zaiger, O. Gal-Garber, M. Pines, I. Rozenboim, and R. Reifen. 2000. Vitamin A deficiency interferes with proliferation and maturation of cells in the chicken small intestine. *Br Poult Sci.* 41:410–415.
136. Vermot, J., and O. Pourquie. 2005. Retinoic acid coordinates somitogenesis and left-right patterning in vertebrate embryos. *Nature.* 435:215–220.
137. Villazana-Espinoza, E.T., A.L. Hatch, and A.T. Tsin. 2006. Effect of light exposure on the accumulation and depletion of retinyl ester in the chicken retina. *Exp Eye Res.* 83:871–876.
138. Voljc, M., T. Frankic, A. Levart, M. Nemec, and J. Salobir. 2011. Evaluation of different vitamin E recommendations and bioactivity of alpha-tocopherol isomers in broiler nutrition by measuring oxidative stress *in vivo* and the oxidative stability of meat. *Poult Sci.* 90:1478–1488.
139. Wages, D.P., M.D. Ficken, M.E. Cook, and J. Mitchell. 1995. Salt toxicosis in commercial turkeys. *Avian Dis.* 39:158–161.
140. Wang, X., G.J. Fosmire, C.V. Gay, and R.M. Leach, Jr. 2002. Short-term zinc deficiency inhibits chondrocyte proliferation and induces cell apoptosis in the epiphyseal growth plate of young chickens. *J Nutr.* 132:665–673.
141. Ward, N.E., J.E. Jones, and D.V. Maurice. 1986. Vitamin B_{12} nutriture of chickens fed raw soybean meal. *Poult Sci.* 65:106–113.
142. Watanabe, K.P., A. Saengtienchai, K.D. Tanaka, Y. Ikenaka, and M. Ishizuka. 2010. Comparison of warfarin sensitivity between rat and bird species. *Comp Biochem Physiol C Toxicol Pharmacol.* 152:114–119.
143. Watkins, B.A. 1991. Importance of essential fatty acids and their derivatives in poultry. *J Nutr.* 121:1475–1485.
144. Watkins, B.A., and F.H. Kratzer. 1987. Dietary biotin effects on polyunsaturated fatty acids in chick tissue lipids and prostaglandin E2 levels in freeze-clamped hearts. *Poult Sci.* 66:1818–1828.
145. Watkins, B.A., S.D. Bain, and J.W. Newhrey. 1989. Eicosanoic fatty acid reduction in the tibiotarsus of biotin-deficient chicks. *Calcif Tissue Int.* 45:41–46.
146. Weaver, V.M., and J. Welsh. 1993. 1,25-dihydroxycholecalciferol supplementation prevents hypocalcemia in magnesium-deficient chicks. *J Nutr.* 123:764–771.
147. West, C.E., J.H. Rombout, A.J. van der Zijpp, and S.R. Sijtsma. 1991. Vitamin A and immune function. *Proc Nutr Soc.* 50:251–262.
148. West, C.E., S.R. Sijtsma, H.P. Peters, J.H. Rombout, and A.J. van der Zijpp. 1992. Production of chickens with marginal vitamin A deficiency. *Br J Nutr.* 68:283–291.
149. White, H.B.I. 1996. Sudden death of chicken embryos with hereditary riboflavin deficiency. *J Nutr.* 126:1303S-1307S.
150. Whitehead, C.C. 2004. Overview of bone biology in the egg-laying hen. *Poult Sci.* 83:193–199.
151. Whitehead, C.C., and W.G. Siller. 1983. Experimentally induced fatty liver and kidney syndrome in the young turkey. *Res Vet Sci.* 34:73–80.
152. Whitehead, C.C., H.A. McCormack, L. McTeir, and R.H. Fleming. 2004. High vitamin D3 requirements in broilers for bone quality and prevention of tibial dyschondroplasia and interactions with dietary calcium, available phosphorus and vitamin A. *Br Poult Sci.* 45:425–436.
153. Whitehead, C.C., D.W. Bannister, A.J. Evans, W.G. Siller, and P.A.L. Wight. 1976. Biotin deficiency and fatty liver and kidney syndrome in chicks given purified diets containing different fat and protein levels. *Br J Nutr.* 35:115–125.
154. Wight, P.A.L., and W.A. Dewar. 1976. The histopathology of zinc deficiency in ducks. *J Pathol*. 120:183-.
155. Wight, P.A.L., W.A. Dewar, and C.L. Saunderson. 1986. Zinc toxicity in the fowl: ultrastructural pathology and relationship to selenium, lead and copper. *Avian Pathol.* 15: 23–38.
156. Willhite, C.C. 1993. Selenium teratogenesis: Species-dependent response and influence on reproduction. *Ann N Y Acad Sci.* 678:169–77
157. Wilson, H.R. 1997. Effects of maternal nutrition on hatchability. *Poult Sci.* 76:134–143.
158. Xie, M., S.S. Hou, W. Huang, and H.P. Fan. 2007. Effect of excess methionine and methionine hydroxy analogue on growth performance and plasma homocysteine of growing Pekin ducks. *Poult Sci.* 86:1995–1999.

159. Yagil, R., C. Luchtenstein, and N. Meyerstein. 1976. Hemoconcentration and erythrocyte fragility in chickens exposed to heat and dehydration. *Am J Vet Res.* 37:103–106.
160. Yalcin, S., Z. Kahraman, S.S. Yalcin, and H.E. Dedeoglu. 2004. Effects of supplementary iodine on the performance and egg traits of laying hens. *Br Poult Sci.* 45:499–503.
161. Yang, C.-P., and S.-L. Jenq. 1989. Pyridoxine deficiency and requirement in mule ducklings. *J Chin Agric Chem Soc.* 27:450–459.
162. Yegani, M., and D.R. Korver. 2008. Factors affecting intestinal health in poultry. *Poult Sci.* 87:2052–2063.
163. Zamani Moghaddam, A.K., H. Hassanpour, S. Soroori, M. Yadegari, and G. Tajeri. 2010. Effect of dietary calcium deficiency on the cardiac function of broiler chickens based on electro- and echocardiography. *Acta Vet Hung.* 58:167–176.
164. Zhou, X.D., X.F. Dong, J.M. Tong, P. Xu, and Z.M. Wang. 2012. High levels of vitamin E affect retinol binding protein but not CYP26A1 in liver and hepatocytes from laying hens. *Poult Sci.* 91:1135–1141.
165. Zile, M.H. 2010. Vitamin A—not for your eyes only: requirement for heart formation begins early in embryogenesis. *Nutrients.* 2:532–550.

Chapter 30

Developmental, Metabolic, and Other Noninfectious Disorders

Rocio Crespo and H.L. Shivaprasad

Introduction

The diseases and conditions discussed in this chapter represent a heterogeneous group; in some cases the etiology is quite clear, whereas in others it is questionable or unknown. They vary in economic importance and frequency of occurrence. Emphasis has been placed on metabolic diseases of economic importance to the modern poultry industries. Diseases described in this chapter have been classified by body system primarily affected; however, the initial part of this chapter covers disorders induced by the environment or management conditions and diseases that are not associated with a specific body system—conditions such as cannibalism or amyloidosis.

Poultry developmental, metabolic, and other disorders that are rarely seen today or that are of historical importance only have been removed from this chapter. These conditions include crooked toes, wry neck, embryonic cartilage of ratites, rupture of the right auricle in chickens, emphysema, cartilaginous and osseous lung nodules, atherosclerosis, endocardiosis, dilation of the proventriculus in chickens, hepatic lipidosis in turkeys, chorioretinitis, buphthalmos, ophthalmopathy, blepharoconjunctivitis, endophthalmitis, and xanthomatosis. Detailed information of these ailments is covered in the 12th edition of *Diseases of Poultry* (62).

Feather Pecking and Cannibalism

Feather pecking is a major welfare problem. It is a behavior expressed by dominant birds on subordinates. Pecking may vary from pecking without removal of feathers to plucking of the feathers. Birds with damaged feathers have poor thermoregulation and greater energy demands than unaffected birds (305). The egg production in affected laying hens usually drops.

Vent pecking is a separate form of pecking that also can be observed in well-feathered birds (350). It generally occurs soon after birds have come into lay. It is more common when birds in floor systems lay their eggs on the floor in crowded areas. It occurs immediately after oviposition, and exposure of the mucous membrane stimulates pecking by other birds. Vent pecking is responsible for at least 80% of all prolapses (134). It is also possible that vent pecking may trigger the onset of salpingitis in the oviduct and perhaps egg peritonitis (300).

If the feathers or tissue are severely damaged, hemorrhage may occur. Appearance of blood on the exposed skin may induce more pecking and lead to the death of the bird or the bird has to be culled. Cannibalism is the most severe outcome of both feather and vent pecking (396).

Etiology

Individual and strain difference in the incidence of feather pecking suggest a genetic component. Light breeds of the Mediterranean class (e.g., white leghorns) have been much more prone to feather pecking than the heavier breeds of the American and Asiatic classes (406). Studies in feather pecking behavior have demonstrated a genetic heritability of this trait (224). Some researchers have found links between feather pecking and feather pigmentation (206). Cannibalism is reportedly more common in the modern brown hybrids than in the white layer lines (350), but no estimates of heritability of cannibalism have been developed (224).

There is an ongoing debate regarding the causes of feather pecking. Feather pecking may be redirected foraging behavior (food searching and food consumption) as well as dust bathing (343, 350). Other possible causes of feather pecking may be fearfulness (36, 177) or stress (112). Some conditions reported to stimulate feather pecking are bright light, pelleted or compressed feed, absence of foraging materials, high-density rearing systems, nutritional and mineral deficiencies, and irritation from external parasites (112). Feather pecking also may be related to accelerated sexual maturity and increased egg production (56, 187). Feather pecking is more common in females than males (187), and the presence of males is an important factor in reducing the problem (134).

Although feather pecking and feather damage are more severe in hens housed in cages than in floor systems, cannibalism is less likely to occur in hens housed in cages than it is in hens housed in pens (23, 352). Because feather pecking and cannibalism tend to reoccur within the same group or in adjacent cages, it may be a learned behavior (384).

Diseases of Poultry, Thirteenth Edition. David E. Swayne.
© 2013 John Wiley & Sons, Inc. Published 2013 by John Wiley & Sons, Inc.

Intervention Strategies

Outbreaks of feather pecking and cannibalism occur unpredictably in birds, despite the measures taken to reduce their risk. Feather pecking and cannibalism can best be prevented by providing adequate diet, replacing mash diets with pelleted feed, rearing the birds on floor litter rather than slats, reducing light intensity, providing perches as a refuge for pecked birds, and avoiding overcrowding (12, 193, 350). Environmental enrichment with substitute pecking devices allows the birds to exercise their natural behavior and reduce pecking among birds (191). Substitute pecking devices that can increase social pecking, such as plastic rods or shoelaces, and systems that may be ignored by birds, such as beads or motorized devices, should be avoided. Simple devices such as hanging white or yellow strings are particularly attractive stimuli to chickens (192). Inclusion of oat hulls and other insoluble dietary fiber in diets decreases the incidence and severity of feather pecking (160).

Beak trimming is performed as a means to minimize injury due to feather pecking and cannibalism. Yet there is an increasing public concern that break trimming is associated with pain. It has been banned in some countries and bans are under consideration in others (224). Plastic devices have been used in preventing feather pecking in game bird rearing (12, 119), but these devices are not satisfactory for use in chickens (351).

Environment-Induced Disorders

Heat Stress

All classes of poultry experience heat distress when high temperature and humidity are above their comfort level. Birds, unlike mammals, do not have sweat glands. When the environmental temperatures are between 28°C and 35°C (82°F and 95°F), birds use nonevaporative cooling (radiation, conduction, and convection) to dissipate heat. Birds manipulate nonevaporative cooling in two ways: (1) by increasing the surface area by hanging wings loosely at their sides, and (2) by increasing the peripheral blood flow (428). As the environmental temperature approaches the body temperature of the bird (41°C or 106°F), the rate of respiration increases and the bird open-mouth breathes to increase evaporative cooling or water evaporation. If panting (open-mouth breathing) fails to prevent body temperature from rising, birds become listless, then comatose, and soon die due to respiratory, circulatory, or electrolyte imbalances (383).

An increased respiration rate alters the acid-base balance because the CO_2 concentration in the blood decreases (26). Consequently, laying flocks experience an increase in the number of thin-shell eggs caused by a reduction in ionized calcium in the blood with the higher pH. Panting or open-mouth breathing in heat-stressed birds may increase the incidence of respiratory infections because the natural filters of the nasal passages are bypassed. Feed intake also is reduced in heat stress, which tends to decrease growth rate. In laying flocks this results in reduced egg size, lower egg production, and poor egg quality.

The extent of the losses from heat stress are determined by the age, environmental history, maximum temperature to which the bird is exposed, duration of the high temperatures, rate of temperature change, and relative humidity of the air (142).

To prevent or alleviate heat stress, air circulation in the house should be increased by running ventilation equipment at full capacity. Inside air can be cooled by using sprinklers or spraying down the floor, walls, ceiling, and outside roof with cool water. Adequate drinking water should be available, and lowering water temperature will aid in heat dissipation.

Nutritional modifications usually involve optimizing the diet to meet the altered needs of stressed birds for energy and protein and providing certain additional nutrients which have specific beneficial effects. The energy content of the feed should be decreased (22 kcal/kg for each 2.5°C) with the possible inclusion of or an increase in the content of fat in the diet (347). Nonenergy nutrient content (proteins, amino acids, vitamins, minerals) also should be high. Egg production is improved by increasing the intake of protein relative to energy (10). Electrolyte solutions (sodium, chloride, potassium, and bicarbonate) in the drinking water help replenish the electrolytes and correct the acid/base imbalance (347). Addition of vitamins (A, C, and E) and electrolyte supplements may help in preventing heat stress (376), possibly by replenishing the minerals and correcting the acid-base imbalance. Fresh, cool drinking water also should be available to help reduce heat stress (385). Some drugs, such as nicarbazin or monensin (348, 385), have deleterious interactions when administered to heat-stressed birds, whereas others, such as virginiamycin (385), may alleviate heat distress.

Preventive measures consist of installation of fans and foggers, proper construction of ventilation ducts, insulation of buildings and water pipes, use of roof overhangs to prevent the sunlight from shining into the house, and use of white or aluminum paint on the outside to reflect heat. In southern climates where low production and mortality from heat are constant problems, installation of foggers and sprinklers or evaporative coolers is essential. Enhancement of adaptability of birds to heat stress conditions, such as early thermal conditioning, also should be considered (71).

Asphyxiation

Crowding or piling of birds in a corner generally causes asphyxiation. This typically occurs when birds are moved to new quarters, when they are frightened, or when young birds are chilled. Asphyxiation also may occur when electric power fails or a ventilation system is faulty in controlled-environment houses that have no windows. Mortality sometimes occurs at night in generally healthy flocks. Asphyxiation of baby chicks can occur in chick boxes that are piled too high without an air space between each box, in boxes that do not have sufficient ventilation holes, or in boxes placed in a closed compartment such as the trunk of a car. Necropsy of birds that have asphyxiated usually does not reveal specific gross or histologic lesions, but a thorough examination will eliminate other possible causes of death. In some birds, there are nonspecific

changes such as congestion of the trachea and lungs, and in older birds feathers will be worn off where birds have been trampled.

Asphyxiation of chicks in the brooder house can be controlled by putting a circle of corrugated cardboard around the brooder area for the first week of life and gradually widening the diameter as chicks get older. This prevents piling in a corner during the night. When birds are moved to new quarters, the use of a dim light or lantern the first few nights will decrease the possibility of piling-up and asphyxiation. Birds transferred to new quarters should be checked late in the evening for signs of piling. Frequent observation of the flock is very important the first few days after acquiring a group of new chicks or grown birds.

Incubation and Hatchery-Related Problems

Poor incubation causes major losses to the industry, not only due to low hatchability or increased early mortality (128), but also due to growth depression, unevenness of the flock, increased susceptibility to infectious agents, and increased incidence of leg problems (295). It is important to identify the problem to minimize the losses in a flock. Temperature, humidity, ventilation, and egg turning are critical factors for hatching good-quality birds. Embryos or recently hatched birds are more susceptible to chilling or overheating than older birds. A typical effect of high incubation temperature, and sometimes low humidity, is "unhealed navels." Unhealed navel is a broad term that includes black buttons, strings, and ectopic viscera. Temperatures that are 3° higher than normal during the last week of incubation are associated with increased numbers of late dead embryos, unevenness in the flock, skin necrosis, and high incidence of leg problems including slipped tendons. Effects of low incubation temperature are more pronounced during the first week of incubation. These include high incidence of late dead embryos, pipped alive chicks, increased residual albumen, unsteady gait, and high incidence of spraddle leg deformities. Low temperature while in the hatcher increases navel abnormalities such as improper closure of the navel, bloody navels, and urates attached to the yolk sac. Starvation and dehydration may occur when birds are accidentally held in hatching machines for long periods.

Early chick mortality also is associated with rupture of the yolk sac. Late-hatching chicks may have a higher incidence of ruptured yolk sac. Because of the dry conditions in the hatcher the yolk sac may adhere to the wall of the abdomen, reducing its mobility and increasing its susceptibility to injury. However, if the humidity during incubation is higher than normal, the hatchlings may have large yolk sacs. During hatchery manipulations the birds may be squeezed too firmly, increasing the incidence of ruptured yolk sacs (359).

Prevention of hatchery-caused injuries and conditions depends on firm standards for operation and maintenance of equipment, especially ventilation systems. Environmental temperature, humidity, and pressures must be monitored daily and variations minimized. Unhatched eggs left in the hatching trays should be examined to establish specific causes of mortality or hatching abnormalities, and to aid in later analysis of poor flock performance.

Starve-Out

Mortality in young birds between 1 and 10 days of age that is not caused by infectious diseases is commonly referred to as starve-out, because it is generally associated with lack of water or nutrient intake. Temperature, light, and water and feed quality may contribute to early mortality. In commercial hatcheries, birds may be 24–48 hours old before they are removed, and additional time is spent in processing and transportation to the farm. As a result, most birds are delivered when they are 50 hours old or older, but will do well if they are placed in a suitable brooding environment and given adequate feed and water. However, mortality up to 6.14% has been reported in birds if placement is delayed to 72 hours after hatching, and up to 35.14% if they were not placed until 120 hours (116). There are no specific gross lesions associated with starve-out. In general, the starve-out birds are smaller, dehydrated, and have dark shanks. The crop, proventriculus, and gizzard may contain litter material, but not feed. Infectious diseases should be ruled out before making a diagnosis of starve-out.

The optimal temperature in the house at placement and during the first week is crucial for encouraging birds to seek water and feed. The birds must have adequate light to easily find the feeders and drinkers. Drinkers and feeders should be adequately spaced and easily accessible. The feed should be palatable. If the crumbles or pellets are too large, the birds will not be able to eat them. If the feed is too fine, it will stick to the beaks of the birds. If the feed or water is too warm the chicks will not eat or drink. Subcutaneous injection with a glucose solution has been tried for prevention of starve-outs. However, no differences were found in the total mortality between fasted and glucose-treated poults at 2 weeks of age (266).

Dehydration

Dehydration is generally caused by failure of birds to find water, inability to reach the water, failure to provide adequate amount of water, or in some cases by a deterring factor in the water. Faulty electrical heating devices used to prevent freezing may cause an electrical charge in the water, and birds will not drink. A chick's inability to "peep" during the later stages of incubation may be caused by dehydration. Chicks can survive several days without water but will die beginning on the fourth or fifth day; however, mortality normally stops abruptly if water is provided. Laying birds need a constant water supply or production will drop. Birds will die if the water restriction is severe. Signs of dehydration include insufficient weight (or even weight loss) for size and age, dry and wrinkled skin

on the shanks, blue discoloration of the beak, dry and dark breast musculature, dark kidneys, accumulation of urates in the ureters, visceral urate deposition ("visceral gout"), and darkening of the blood. To prevent dehydration in chicks, water fountains should be placed directly on the litter without any platform, and surrounding, but not underneath the brooder heater. When large type or automatic drinkers replace a small drinker, the old type should be kept for a few days and gradually moved toward the new source of water supply to accustom birds to the change.

Problems Related to Vaccination

Killed vaccines and bacterins usually employ an oil adjuvant to stimulate a localized inflammatory reaction and improve the immune response. When oil-emulsion bacterins are administered subcutaneously into the neck, the adjuvant may infiltrate into the adjacent tissues causing dermatitis, neuritis, and myositis (1, 61). Neurological and/or musculoskeletal problems, which impair the birds' ability to eat, have been documented when a killed vaccine is delivered into the neck musculature and/or subcutaneously too close to the skull. Killed vaccines administered intramuscularly into the breast or leg muscles may produce severe granulomatous myositis near the site of injection (Figure 30.1) (81). The birds may be reluctant to move, lose weight, and have reduced production; the meat may be downgraded at the processing plant due to trimming of affected areas. Live or attenuated vaccines and bacterins also have been reported to cause pathologic changes in the birds. Young chickens given vaccines *in ovo* subcutaneously at the hatchery have sometimes shown neurologic signs, pyogranulomatous myositis, neuritis, and meningomyelitis (Figure 30.2). Because these vaccines do not have irritant substances, the tissue reaction is thought to be a misdirected vaccine (147). Improper sanitation or cleaning of vaccine equipment may result in bacterial contamination, and has caused nervous signs and increased mortality in young birds (262). Adequate training of vaccinating crews helps to minimize the inflammatory reaction in the tissues from incorrect injection of bacterins and vaccines.

Figure 30.1. Layer chickens with severe myositis and muscle atrophy secondary to vaccination. Bar = 1 cm.

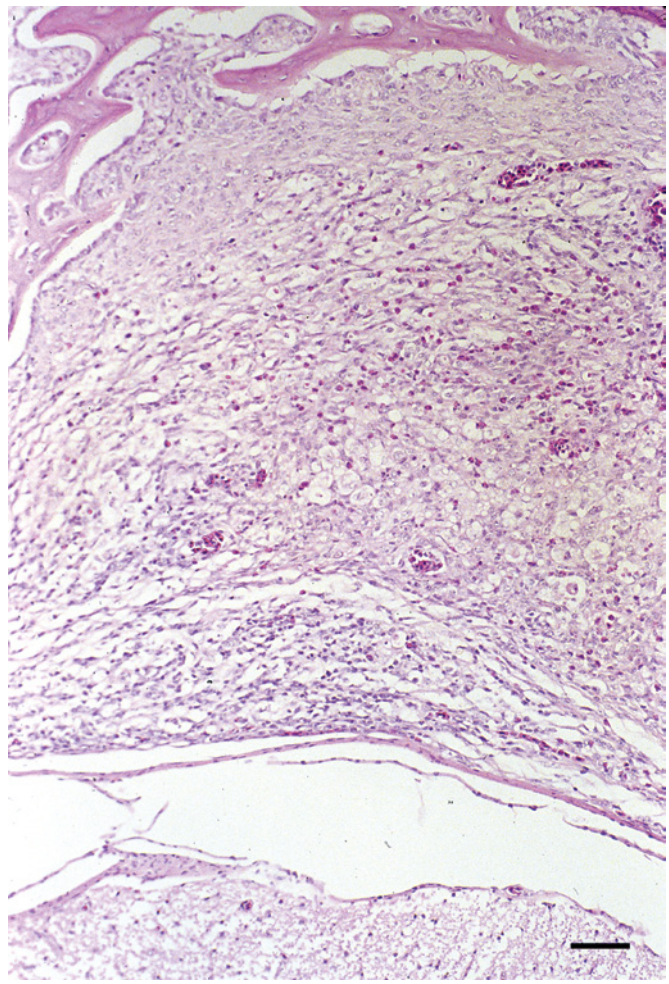

Figure 30.2. Histologic section of meninges around the spinal cord (bottom) of a 2-day-old broiler chicken that was vaccinated in the neck. Note the nonsuppurative meningitis, most likely associated with misdirected vaccination. H & E, bar = 10 µm.

Amyloidosis

Amyloidosis is a well-recognized pathological disorder in birds, characterized by deposition of proteinaceous material between cells in various tissues and organs of the body. Once the deposition of amyloid has started the disease is irreversible, because these proteins have low solubility and are resistant to proteolytic digestion (209). Amyloidosis is generally divided into primary amyloidosis and secondary amyloidosis (207). The former occurs as a consequence of various plasma cell dyscrasias, such as multiple myeloma, and other monoclonal proliferations of B lymphocytes. The latter occurs in association with chronic inflammatory diseases, such as tuberculosis and long-standing suppurative processes. More than

15 biochemical types of amyloid protein are recognized in mammals (215); however, only amyloid A (AA) has been detected in birds (219, 271). Amyloidosis caused by AA is frequently associated with an underlying infectious or inflammatory condition (208). Landman et al. have published an excellent review of amyloidosis in birds (219) . Among the domestic avian species, waterfowl are most susceptible to amyloidosis. Ducks as young as 4 weeks of age may be affected (363), although it is most common in adults.

Clinical Signs and Pathology

No specific clinical signs or gross lesions are associated with systemic amyloidosis. Clinical signs in ducks may include anorexia, lethargy, loss of weight, decreased egg production in layers, swollen abdomen, and increased mortality. In brown egg-laying type chickens, locomotor problems due to swollen joints and weight loss can be encountered, but often the birds with amyloidosis are found dead with no prior clinical signs.

Brown egg-laying type chickens are particularly susceptible to amyloid arthropathy associated with *Enterococcus faecalis* (220, 221) and *Mycoplasma synoviae* (MS) infections (222). Amyloid arthropathy associated with MS has been reported in turkeys (362), but has not been reproduced experimentally. Other bacteria such as *E. coli*, *Salmonella enteritidis*, and *Staphylococcus aureus* also have been implicated in chickens (218). The authors of this chapter also have observed amyloidosis associated with *M. gallisepticum*. Amyloidosis also has been found in layer hens with mixed infection of fowlpox and *S. hyicus* (273). The authors hypothesize that although amyloidosis might have existed prior to these infections, the presence of these pathogens might have been synergistic in increasing the severity.

Another condition in which amyloidosis is frequently encountered in mature chickens is hepatitis-splenomegaly syndrome, which results from infection by hepatitis E virus (see Hepatitis E Infections in Chapter 14). Amyloidosis associated with mycobacteriosis is a common finding in waterfowl and other birds in zoological collections (143, 265). Management and genetic factors also may be important in the incidence of amyloidosis, especially in ducks raised commercially.

Amyloid deposition may be found in any tissue. The most commonly affected organs are liver, spleen, intestine, and kidney. Gross lesions may be lacking or minimal when amyloid deposits are present in small amounts. However, with large deposits, gross lesions can be present including severe ascites ("water belly"), which is most common in ducks, and diffusely enlarged heavy liver with firm to rubbery consistency and pale or brown or gray smooth surfaces (Figure 30.3). Cut surfaces of the liver may have a smooth, waxy appearance and the capsule may be thickened due to fibrosis. Occasionally the livers of some affected birds may have multiple hyperplastic nodules of various sizes that may have the normal color of the liver. Spleen can be severely enlarged and mottled white. Kidneys and adrenals may be enlarged and pale. Brown egg-laying type chickens with amyloid arthropathy may have enlarged joints with presence of orange-yellowish material in the joints (Figure 30.4).

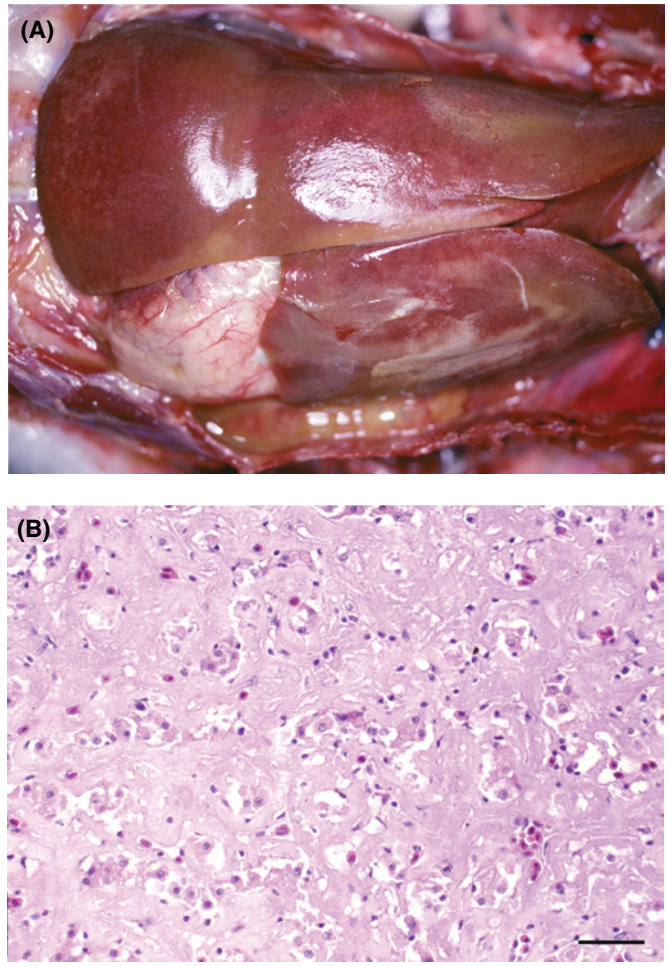

Figure 30.3. Hepatic amyloidosis in a 57-week-old duck. The liver is severely enlarged and pale. Note the impression of the rib cage on the right lobe. B. Histologic section of the liver. Note that the amyloid appears as homogeneous eosinophilic material deposited extracellularly. Most hepatocytes have disappeared. H & E, bar = 65 µm.

Figure 30.4. Amyloid arthropathy in 32-week-old brown chicken layers caused by Enterococcus feacalis. From left to right, normal control to most severely affected. There is accumulation of amyloid in the lumen of the tibiotarsal joint. Note that the articular cartilage is partially destroyed. (Barbara Daft)

During gross examination, application of Lugol's iodine to a suspected organ stains amyloid a distinctly brown color. Application of dilute sulfuric acid changes amyloid from brown to blue. Microscopically, amyloid appears as homogenous eosinophilic material deposited extracellularly in many organs. Stains such as Congo red or the Shtasrburg method (369) can be used to detect AA in formalin-fixed tissues.

Intervention Strategies

There is no treatment for amyloidosis, but prevention of chronic infections or stress in birds reduces its incidence. Treatment of the underlying inflammatory disease or eliminating the stress factor should be started as soon as possible to prevent or stop the progressive deposit of amyloid in the tissues. Feeding a high dose of vitamin A enhanced deposition of AA in the joints of chickens, while methylprednisolone (an anti-inflammatory drug) and pentoxifylline had an inhibitory effect (356).

Diseases of the Skeleton

Dyschondroplasia

Dyschondroplasia is a skeletal disease of birds in which there is impairment of normal endochondral bone formation. Dyschondroplasia is characterized by an avascular plug of abnormal cartilage in the growth plate of long bones that extends into the metaphysis. It is most commonly recognized in the proximal tibiotarsus; hence, the condition is often described as tibial dyschondroplasia (TD). Dyschondroplasia also occurs in the proximal and distal femur, the distal tibia, the proximal tarsometatarsus, and the proximal humerus, but is less severe (311). Reviews on the condition have been written by Farquharson and Jefferies (117), Leach and Mnsonego-Ornan (227), Orth and Cook (294), Thorp (391), and Whitehead (411).

Clinical Signs

In many broiler chicken flocks up to 30% of birds may have lesions of TD. In turkey flocks the incidence has been reported as high as 79% (405). Most birds show no clinical signs. If masses of cartilage are large, birds may exhibit reluctance to move, stilted gait, and bilateral swelling of the femoral-tibial joints that is often associated with bowing of the legs. The severity of the TD lesions has been correlated with the degree of anterior bowing of the tibiotarsus and lameness in broiler chickens (244). The concave surfaces of such bones have hypertrophied cortices. This is considered an adaptive change (93). A high association between leg deformities and TD also has been described in turkeys (405). Fractured fibulae and bowing of the tibia have been associated with TD (311). These fractures occur at the iliofibularus, but are not always associated with abnormal tibiotarsal curvature (89). Dyschondroplasia in the femoral head in broiler chickens has been associated with a widened and shortened femoral neck and, in some cases, with fractures of the femoral head (85, 86, 87).

In a survey of leg weakness in broiler chicken flocks processed at 7 week of age or earlier, few birds were culled because of TD (335). However, dyschondroplastic lesions can be recognized on radiographs and with a hand-held, low-intensity X-ray imaging scope (lixiscope) from 2 week of age (391). Downgrading of carcasses and trimming of deformed legs at processing have been attributed to TD (37, 335). If broiler chickens are kept to roaster weights, lesions may be much more severe. In such birds, fractures below the abnormal cartilage in the tibia may cause severe crippling. Resolution of the abnormal cartilage may start as early as 48 days of age, but sequestra of abnormal cartilage separated from the growth plate and bowing of the tibia may persist to as late as 30 weeks of age, even though the proximal growth plate of the tibiotarsus in a chicken closes at 16–17 weeks of age.

In turkeys, TD is recognized as early as 5 weeks (311), peaking between 12 and 14 weeks of age (170). The incidence rate decreases after 15 weeks of age, until the age of closure of the proximal tibial physis at 22 to 24 weeks, but 5% or more of the toms may still retain some abnormal cartilage (405). Whereas there is no correlation between the bodyweight of turkeys and TD in early ages, the severity of TD is directly correlated with bodyweight between 14 and 15 week of age (318).

Pathology

Gross lesions of TD are characterized by abnormal masses of cartilage, usually cone shaped, below the growth plate, primarily in the proximal tibiotarsus (Figure 30.5), but also at

Figure 30.5. Medial view of sagittal sections of two proximal tibiotarsal bones from broiler chickens with tibial dyschondroplasia. The abnormal cartilage is only present in the posterior part of the metaphysis (right). Abnormal cartilage fills the whole metaphysis, and the proximal end of the bone is enlarged (left). (Craig Riddell)

other sites. In mild cases, these cones of abnormal cartilage mainly develop below the posterior medial part of the growth plate. In severe cases, masses of cartilage develop from the whole growth plate and fill the whole metaphysis. Interestingly, dyschondroplasia within the proximal tibiotarsus appears to be bilateral, and the incidence and severity of the TD is similar in both legs (117).

Microscopically, TD is characterized by persistence and accumulation of prehypertrophic cartilage. The separation of the prehypertrophic cartilage from the proliferating cartilage is not sharply demarcated and few vessels penetrate the abnormal cartilage from the metaphysis. Normal growth plates or those with small dyschondroplastic lesions have few or no apoptotic chondrocytes, while in severe lesions numerous apoptotic cells with shrunken nuclei and little cytoplasm are present (319), suggesting that apoptosis is secondary to the formation of the cartilaginous plug. Other studies have shown quite the opposite, that TD lesions are associated with lack of apoptosis, which may be responsible for the retention of chondrocytes (283).

Ultrastructural and biochemical studies have demonstrated that the lesion begins in the prehypertrophic zone. The chondrocytes in the abnormal cartilage do not differentiate into fully hypertrophic chondrocytes (151, 310, 408), which are needed for cartilage vascularization, mineralization, and resorption. The abnormal chondrocyte mitochondria retain less calcium and phosphorus as compared to normal chondrocytes.

Pathogenesis and Etiology

The occurrence of TD is influenced by genetic selection (329, 388, 439). However, the pathogenesis of TD is not well understood. In the past it was thought that TD was associated with defects of metaphyseal vasculature. The current data indicates TD is a consequence of an inability of the prehypertrophic chondrocytes to undergo terminal differentiation. It is essential to recognize the mechanisms involved in the maturation of chondrocytes to prevent TD; unfortunately, these processes are not fully understood.

Changes in extracellular matrix composition between the abnormal cartilage and normal hypertrophic cartilage have been reported. Alkaline phosphatase and type X collagen, markers of chondrocyte differentiation, as well as c-myc protein, an inducer of apoptosis, are reduced in the extracellular matrix of dyschondroplastic lesions (117, 408). On the other hand, the chondrocytes still retain the ability to express alkaline phosphatase and type X collagen (323, 408). One theory suggests that an increase in nonreducible collagen cross-links observed in the matrix of abnormal cartilage in chickens (294) may be associated with the lack of release of collagen type X from the chondrocytes (408). Also, proteins such as α-enolase, G protein, caleumein, type II collagen precursor, and others, which are proteins associated with signal transduction, energy metabolism, and secretory functions that are integral to cell viability, are downregulated in the dyschondroplastic tissue (317).

Some studies have shown that locally produced peptide growth factors play important autocrine and paracrine roles in development of the growth plate (229). TGF-β has been found in the prehypertrophic and hypertrophic chondrocytes of the growth plate, and it regulates chondrocyte differentiation (392). TGF-β expression was reduced in transitional chondrocytes in TD, but its expression was increased where the lesion was being repaired (242). Fibroblast growth factor-β, a potent angiogenic factor, also is reduced in TD (416). Additionally, insulin-like growth factor-I (IGF-I), basic fibroblast growth factor, and transforming growth factor-α, which are normally found in more mature chondrocytes of the growth plate, are reduced in dyschondroplastic chondrocytes (392).

A recent study suggests that the dyschondroplastic cartilage is a hypoxic environment possibly caused by decreased proteolysis due to the failure in expression or lack of activation of some extracellular matrix metalloproteinases (e.g., MMP-2 and MMP-13) and not due to an increased production of the extracellular matrix macromolecules (402) . This study also proposes that some growth factors cannot exert their functions because they may be arrested in extracellular matrix storage sites.

Rapeseed meal, sorghum, and some types of soybean have been suggested as increasing the occurrence of TD (403). Some dietary supplements that are linked to increased incidence of TD include rations containing added cysteine or homocysteine (294), high level of vitamin A (65,512 IU/kg) (188), copper-deficient diets (228), rations contaminated with the fungus *Fusarium* sp. or its product fusarochromanone (59, 338), and rations containing dithiocarbamate fungicides (294, 319, 322). Some antibiotics, such as zinc bacitracin and salinomycin, also may increase the incidence of TD (404).

Intervention Strategies

Rapid growth impacts incidence of TD because restricting feeding reduces the incidence of this disorder (341). The presence of the most severe lesions of TD in the proximal tibiotarsus may be due to the growth plate at the site with the most rapid growth. Daily fasting can reduce incidence of TD without causing growth depression (109). It has been suggested that diurnal rhythms may be important in reducing TD (113). An interrupted- and increasing-light program had no effect on clinical and subclinical tibial dyschondroplasia in roaster chickens (338). An intermittent light program helped reduce the incidence of TD in some cases (438, 442). Although reducing the growth rate of experimental birds decreased the incidence of TD, there was no direct correlation between growth of individual birds and the incidence of TD (214, 332).

The incidence and severity of TD also can be influenced by nutrition. Feeding high levels of phosphorus relative to the level of calcium (107, 108, 336, 341) can increase the incidence and severity of TD in broiler chickens. Feeding turkey poults similar levels of phosphorus and calcium did not result in a high incidence of TD (349). TD in broiler chickens was not eliminated by feeding a ration containing 1.5% calcium and 0.5% available phosphorus (336).

Numerous studies have shown that addition of high vitamin D or its metabolites, such as 1,25-dihydroxicholecalciferol, are

effective in the prevention of TD (117, 326, 414). However, some of these metabolites at high concentration have a toxic potential (325). On the other hand, no correlation between the plasma level of 1,25-hydroxycholecalciferol and the incidence of TD was found in one series of experiments, and it was suggested that the ability to utilize the vitamin D metabolite at the receptor level might affect the incidence of TD (113). The incidence of TD was prevented when chicks received ultraviolet radiation even without vitamin D_3 supplementation (110).

Osteoporosis

Osteoporosis is an age-related disease of laying hens characterized by a decrease of normal mineralization of structural bone, resulting in increased fragility and susceptibility to fracture. It was first described in caged laying hens that had brittle bones and were unable to stand, but could eat and drink (53). The condition was then called "cage layer fatigue." Osteoporosis in today's commercial egg-laying hens is usually a consequence of osteomalacia caused by inadequate diet or lack of absorption of calcium, phosphorus, or metabolites of vitamin D (412). During the life of the flock, bone fragility is responsible for up to 30% of fractures in commercial caged birds (140, 412), while in non-cage systems the mean prevalence of bone breakages may be as high as 80% (433). On the other hand, the incidence of new breaks during catching, transporting, and processing is higher within layers in conventional cage systems than in other systems.

Clinical Signs and Pathology

Osteoporosis consists of loss in bone quality, which predisposes the birds to fractures in a range of bones of the body. Keel bone, followed by tibia and humerus, have the highest incidence of fractures in layers with non-cage systems (433). Ischium, humerus, and keel bones show the highest incidence of fractures, followed by fractures of pubis, ulna, coracoid, and femur in caged birds (139). Osteoporosis can cause paralysis due to the collapse of the vertebra (13), but in many cases in which the vertebra are not fractured, the loss of structural bone has been linked to exposure and pressure of the spinal cord and nerves (412). Osteoporosis is more severe between 25 and 50 weeks of age (121).

Sterna are often deformed, and there is characteristic infolding of the ribs at the junction of the sternal and vertebral components. The bone cortex is thin, but there are no changes in the external dimensions of the bone because cortical bone resorption is restricted to the endosteal surface (9). Parathyroid glands are enlarged. Many birds have regressive ovaries and are dehydrated, while some dead birds have an egg in the oviduct and have died acutely.

Histologically, the cortices of bones are thin, with enlarged absorption spaces. Medullary bone is reduced in quantity, and largely consists of unmineralized osteoid. The ribs may be deformed by small fractures. Damage to the spinal cord is often associated with pressure on the nerves, which may cause paralysis.

Pathogenesis and Etiology

With the onset of sexual maturity there is a rise in estrogen resulting in a switch from structural bone formation to accumulation of medullary bone (412). The resorption of structural bone starts at sexual maturity and continues during the production life so that osteoporosis is more severe at the end of lay. Increased bone fragility is associated with loss of mineral and with modifications in the collagen structure (210, 377).

Type of housing may affect the incidence of osteoporosis. Confinement of laying hens in cages significantly reduces bone strength (211, 281). Structural bone loss and decreased bone strength are directly associated with reduced exercise. Numerous publications discuss the relationship between type of housing and bone strength (120, 235, 407, 413). Bones from laying hens kept in perchery systems are stronger than those from hens kept in enriched cages, litter, or wire systems, while hens kept in conventional cages had the weakest bones. In one experiment, bones from egg layers became stronger after just 20 days of transferring the birds from cages to floor pens (278). Hens from cages had a greater incidence of freshly broken bones after handling at processing than hens from other housing systems (140). The incidence of bone fractures also is influenced by the method of handling (141).

Genetic selection to maximize egg production might have contributed to the osteoporosis by producing strains of birds with poor bone quality. Bishop et al. (19) reduced the incidence of bone fractures and increased bone strength after 5 generations of selection in a commercial line of white leghorns. They found that cancellous and medullary bone volumes were poorly heritable parameters, but keel radiography density, humeral and tibial strength, and an index calculated from these 3 traits were promising predictors of bone characteristics and resistance to osteoporosis.

Intervention Strategies

Nutritional approaches may alleviate and even prevent this condition. Adequate inclusion rates of calcium, phosphorus, and vitamin D are particularly important. Feeding 2% calcium 2 weeks prior the start of lay followed by transfer to a higher calcium level during lay may reduce structural bone loss (123, 257). Feeding calcium in particulates, either as oyster shell or limestone granules, may extend the period of calcium absorption during the night, which reduces the depletion of medullary bone and benefits the eggshell quality (121, 122); however, it does not have much impact on the loss of structural bone. A combination of limestone with fluoride and/or vitamin K_3 during the laying period had no greater benefits than limestone alone (122).

It has been hypothesized that formation of strong cortical bone and adequate medullary bone prior to egg production may be helpful in reducing osteoporosis during lay. Increased calcium in the ration prior to egg production may be necessary, but it has been suggested that if increased calcium is fed for too long before egg production, the parathyroid gland may be suppressed. Manipulation of lighting programs to delay

sexual maturity has proven to have little effect on bone strength at the end of lay (172).

Treatment of pullets with alendronate just prior to the onset of lay decreased the loss of cancellous bone (390), but did not stop the loss of structural bone at the time of lay (435). In a recent paper, dietary supplementation with gallium prevented osteoporosis in hybrid laying hens (236).

Valgus and Varus Deformation

Deformation of the long bones of the broiler chicken and turkey is a significant cause of economic loss due to culling and death of affected birds. Such deformation includes many different types of twisting or bending of the bones and has been described by terms such as long bone distortion, twisted legs, or crooked legs. The general topic of deformation of the long bones in domestic poultry was reviewed by Riddell (332, 337) and Thorp (387, 391). The most common type of long bone deformation in the broiler chicken is valgus or varus deformation (VVD) of the intertarsal joint (195, 316, 335). In the turkey, similar deformation is also common but is often associated with varus deformation of the femoral-tibial joint (330). In broiler chickens, the incidence of birds affected with valgus deformation varies from 30%–40%, while varus deformation of the tarsal joint affects 1%–3% of the birds (232).

Clinical Signs and Pathology

Valgus or "knock-kneed" results from the outward deviation of the tarsometatarsus when aligned with the tibiotarsus (316). Varus deviation or "bow-legged" is the consequence of inward deviation of the tarsometatarsus when aligned with the tibiotarsus (316). The major deformity is in the distal tibiotarsus, with similar but less severe angulation in the proximal tarsometatarsus (Figures 30.6 and 30.7). The valgus deviation is more common, but varus deviation may result in more restricted walking ability in poultry (51, 232). The defect may affect both legs but is often unilateral, with the right leg more commonly affected than the left leg (92, 335). In contrast, other studies (232) often described valgus angulation to be bilateral, whereas varus deviation was unilateral in most cases. Approximately 70% of affected birds are males (335). Most birds have either valgus or varus deformation, but the occasional bird will have valgus deformation of one leg and varus deformation of the other leg. These birds have been described as "windswept" (97).

Valgus angulation appears progressively between 2 and 7 weeks of age; on the other hand, varus deviation appears suddenly between 5 and 15 days of age (195, 232, 333). As the severity of the valgus angulation increases, the gastrocnemius tendon may become displaced and the distal tibial condyles become flattened. In the varus deviation, the gastrocnemius tendon is always displaced medially (232). In some cases, the angulation progresses to displacement and separation of the tarsal bones from the shaft of the tibia. With severe angulation, birds are forced to walk on the posterior surface of the hock, which becomes bruised and swollen. In some instances, the distal shaft of the tibia will penetrate the skin.

Pathogenesis and Etiology

The pathogenesis of the deformation has not been defined; however, an increase in growth rate has been associated with an increased incidence of VVD. Slowing growth rate can reduce the incidence of VVD (167, 178, 333). However, reducing energy in the diet does not improve the quality of the cortical bone and reduced limb angulation might be due to

Figure 30.6. Broiler chicken with unilateral valgus deformation of the intertarsal joint. (333)

Figure 30.7. Tibiotarsal and tarsometatarsal bones from a broiler chicken with unilateral valgus deformation. (333)

lower bodyweight placing less stress on the skeleton (233). A higher incidence of VVD occurs in broiler chickens raised in cages compared with broiler chickens raised in floor pens (167, 324, 333). This may be explained by a lack of exercise in cages (167). Cortical bone in chickens is stronger with exercise (344). Different photoperiods affect the incidence of VVD (46, 338). It is unknown whether this is due to a change in growth rate, amount of exercise, or a hormonal factor. Angular limb deformities are reportedly higher in turkeys subsequent to malabsorption syndrome (307).

Young, normal broiler chickens have slight valgus deformation. This small inclination of the growth plate in a rapidly growing chicken may promote deviant growth (316, 333). In the rapidly growing modern broiler chicken, the vascular morphology of the growth plate is irregular, and this may predispose the chicken to VVD (386). Some workers have noted a delay in cortical bone differentiation, which precedes the angulation (69, 184, 185).

Valgus and varus deformities may each have a different etiologic pathogenesis (232) and these deformities may have genetic predispositions (225). In addition, genetic selection may influence the incidence of leg deviations. Le Bihan-Duval et al. (226) estimated that the susceptibility to valgus deformity was genetically independent of meat conformation, whereas varus deformation increased with body weight.

VVD should not be mistaken for leg deformities caused by several nutritional deficiencies, such as manganese deficiency (see Manganese in Chapter 29). An association between VVD and dyschondroplasia has been noted (311, 316, 333). Although TD may weaken bones and predispose to deformation, it may be secondary to the deformation (436). In a breeding study, it was observed that VVD was unrelated to TD (329).

Degenerative Joint Disease

Degenerative changes in joints have been recognized primarily in coxofemoral joints of mature male turkeys (82, 88) and mature meat-type chickens (88, 102), and in the spine of laying hens (440). Degenerative joint changes are more common in males than females (4). They also have been reported in the femoral-tibial and intertarsal joints of turkeys (83, 103) and male broiler breeding fowls (99, 102). Duff (82) reviewed early reports of degenerative hip disease in poultry.

Clinical Signs and Pathology

Degeneration of the articular cartilage causes pain and lameness (106) by exposing the subchondral bone and impairing the ability of the cartilage to provide a smooth articulating surface to the joint (49). Turkeys with degenerative hip disease assume a stance with abducted pelvic limbs and constantly shift weight from one leg to another and are reluctant to move. In turkeys, the initial gross lesions are found in the articular surface of the antitrochanteric region of the acetabulum (82). As the degeneration progresses both the femoral and acetabular components of the coxofemoral joint become involved as well as the femoral-tibial and intertarsal joints (Figure 30.8). Erosions, fissures, and thinning are characteristic lesions of the articular cartilage. Flaps of cartilage and/or osteophytes that may break free, seen as bone fragments within the joint, may form within the degenerative articular cartilage. The articular cartilage of birds with degenerative joint disease is more hydrated with a higher uronic acid content than that from normal joints (5). Periarticular fibrosis accompanies severe lesions (82).

Figure 30.8. Anterior and lateral views of distal femora from breeding turkeys with degenerative joint disease. Note the erosions and thinning of the articular cartilage.

Microscopic changes in the cartilage include loss of normal structure, areas of necrosis, fissures, and massive chondrocyte clusters (84). Surface fibrillation occurs in the articular cartilage (5). In some cases there is evidence of disturbed endochondral ossification. It was proposed that the lesion in such cases could be described as osteochondrosis dissecans (83). There also is mild hyperplasia and hypertrophy of the synovium (5).

Pathogenesis and Etiology

The pathogenesis of many of the joint lesions described above is not clear; however, morphologic and biochemical changes of the articular cartilage are similar to those in mammals. Some may result from primary damage to the articular cartilage, whereas others may be sequelae to osteochondrosis (88, 102). Because heavy chicken breeds, white-broad breasted turkeys, and broiler chickens are more affected by this disease, genetic factors may play a role in modifying cartilage development (5).

Spontaneous Bone Fractures

Bone fractures are one cause of downgrading and trimming of poultry carcasses. Fractures may occur spontaneously on the farm or during catching or transportation. In meat-type poultry, spontaneous fractures occur more frequently during the last part of the grow-out. In turkey breeders, complete fractures have been associated with pre-existing stress or partial fractures in males (57). In laying hens, osteoporosis is the most common predisposing factor to bone fracture (see Osteoporosis).

Clinical Signs and Pathology

Fractures of leg bones cause lameness in affected birds. Birds may die if they do not reach feed or water or are killed by other birds in the flock. Femoral fractures were associated with increased mortality of up to 1%/week in flocks of heavy tom turkeys (57, 309). At necropsy birds had complete closed

oblique fracture of the femur. In breeding turkeys the fracture line was associated with a site of callus formation (57). Lower ash, calcium, and phosphorus were found in the bone cortex of broilers with fractures, as opposed to those bones of birds from the same flock that did not have fractures (393). Similar findings have been reported in turkey breeder flocks (58).

Pathogenesis and Etiology

Poor bone quality increases the risk of bone breakage (60, 321). Growth rate is considered an important determinant of bone strength. Selection for increased bodyweight associated with increased breast muscle, with no appreciable changes in the skeleton (51, 239), puts higher stress on the cortical bone. This increases the probability of fractures. Heavy birds with large breast muscle are less active than light birds (169, 239); lack of exercise may be responsible for decrease of bone density (280). Growing male birds may be more susceptible to fractures than females because males have a more porous cortex and are less adapted to physical stress than females (345). In turkeys, leg fractures occur more frequently in the femur of growing birds (239). There is indication that maturation, including mineralization rates, occurs slower in the femur than is observed in the tibia (239). Bone strength also is related to the organic matrix composition, and especially to the collagen cross-links of the cortex (320). Nutrition also is an important factor to bone strength. Imbalances in inorganic and/or organic nutrients may decrease bone strength and increase the risk of fracture (321).

Handling of birds during catching and transport may create unnatural tensile and bending stresses on the bone, which may alter the cortex composition, predisposing the bones to complete fractures (57). Chickens that are held by both legs have fewer incidences of broken bones than those that are held by 1 leg only (141).

Other Abnormalities of the Skeleton

Abnormalities of the Spine

Spondylolisthesis or "kinky back" is the most common abnormality of the spine. It occurs when the anterior end of the articulating fourth thoracic vertebra dislocates, triggering the posterior end to override the fifth vertebra, causing compression of the spinal cord and posterior paralysis. This rotation causes a kyphotic angulation of the floor of the spinal canal and spinal cord compression (Figure 30.9). Another form of spondylolisthesis is characterized by step-like defects between adjacent thoracic vertebrae, producing stenosis of the vertebral canal (105).

By palpating the ventral surface of the spinal column during necropsy, one can readily detect the deformation of the spinal column. A diagnosis of spondylolisthesis is best confirmed by removing, decalcifying, and splitting the spinal column along a midline longitudinal plane to allow visualization of the spinal cord compression. A few birds affected with spondylolisthesis are found in most broiler flocks. In some flocks, the incidence of affected birds has reached 2%. The peak incidence occurs at 3–6 weeks of age. Affected birds are alert, remain

Figure 30.9. Midline longitudinal section through the thoracic-lumbar region of the spinal column of a broiler chicken with spondylolisthesis, cervical end to right. Note the rotation of the body of vertebra T4, deformation of T5, and spinal cord compression. (C. Riddell and J. Howell. *Avian Dis*. 16(2):444–452.)

Figure 30.10. Broiler chicken with spondylolisthesis. (C. Riddell and J. Howell. *Avian Dis*. 16(2):444–452.)

sitting on their hocks with their feet slightly raised off the ground (Figure 30.10), and use their wings in an attempt to escape when approached. Severely affected birds often become laterally recumbent and often die from dehydration. Wise (437) and Riddell (332) have written reviews on the condition.

Lordosis and subclinical spondylolisthesis are common in broiler chickens. The lordosis develops after hatching. It can be decreased by slowing the growth rate. The incidence of spondylolisthesis can be increased by genetic selection. It is postulated that spondylolisthesis is a development disorder influenced by conformation and growth rate.

Several other spinal deformities occur sporadically at a low incidence in commercial poultry. These deformities include scoliosis and rumplessness and have been reviewed by Riddell (328).

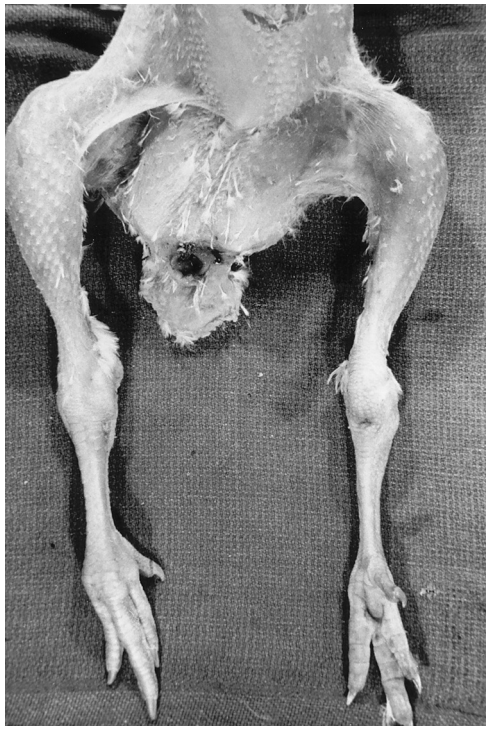

Figure 30.11. Turkey with rotated tibia of left leg. Rotation is nearly 180° and the footpads face in opposite directions. (Craig Riddell)

Osteochondrosis

Osteochondrosis is a focal degenerative lesion of the growth plate, articular cartilage, or bone that is associated with ischemic and necrotic lesions of the growth plate, articular cartilage, or bone. It is rare in poultry, and when it occurs, its causes are usually related to focal bacterial infection (234, 389) or mechanical forces acting on rapidly growing cartilage (104, 259). A variety of microscopic degenerate lesions including eosinophilic streaks or scars, occlusion and thrombosis of vascular canals, and necrosis in the growth plate and epiphysis have been described in growing meat-type birds (259, 333). These lesions may be associated with and in some cases may cause TD (86). Osteochondrosis has primarily been described in cervical and thoracic vertebrae of broiler chickens (180, 246), and in the femoral head (86, 87, 104, 201, 334) and the antitrochanter (88) of broiler chickens and turkeys.

Rotated Tibia

Rotated tibia has been reported in turkeys, broilers, guinea fowl, and ratites (332, 335, 382). Rotated tibia is very common in ratites, especially in ostriches and emus. Affected birds often have the affected leg extended laterally. Either or both legs may be affected. The defect is restricted to the shaft of the tibia, which is rotated externally, often to 90° or greater. There is no angulation of bones, and the hock joint is normal, with no displacement of the gastrocnemius tendon. In some extreme cases, the rotation reaches 180°. In such cases, if both legs are extended ventrally, the 2 footpads face in opposite directions (Figure 30.11). Rotation or torsion of the femur, tibiotarsus, and tarsometatarsus is normal during early development of the chicken. Femurs and tibiotarsi rotate externally, whereas the tarsometatarsi rotate medially when the axis of the distal articular surface is compared with that of the proximal articular surface (93). Rotated tibia represents excessive and abnormal rotation during development. Rotated tibia differs from VVD in that no angulation of bones is present. In broiler flocks, the peak incidence occurs at 3 weeks of age, no sex predisposition is apparent, and the number of birds with either the right leg or left leg affected is approximately equal (335).

The exact etiology of tibial rotation is not known, but genetics and nutritional and management factors may be involved (382). Genetic selection of broilers appeared to be responsible for changes in the size, shape and quality of tibiotarsi in commercial broilers compared to traditional and commercial layer lines may explain why rotation is seen in broilers and no other chicken lines (174). Early rickets has been suggested as a predisposing factor in guinea fowl (14). An increased incidence of rotated tibia has been reported in turkeys subsequent to malabsorption syndrome at an early age (307).

Figure 30.12. Two-day-old turkey poults with splayed legs.

Spraddle Legs

Birds with spraddle legs have one or both legs splayed laterally from the coxofemoral joint (Figure 30.12). It is usually associated with high humidity during incubation or newly hatched chicks being placed on slippery floors. The birds have their legs directed laterally and are unable to stand. Affected birds are culled, but this condition may not be manifested until birds are 2–3 weeks of age as the leg deformity becomes obvious.

Diseases of Muscles and Tendons

Deep Pectoral Myopathy

Deep pectoral myopathy also has been called green muscle disease. The condition was first described in Oregon in breeder turkey hens older than 10 months of age, with up to 9% of

some flocks being affected (79). Since then it has also been described in meat-type breeding chicken, meat turkeys, and broilers (144, 155, 189, 190, 327). Both sexes have the defect (154), but males have a higher incidence of this condition. Condemnation of affected muscles can be higher than 3% in some meat-type poultry flocks (16).

Clinical Signs and Pathology

The lesion does not affect the general health of birds and is generally only found at processing. The lesion can be unilateral or bilateral. Chronic lesions result in dimpling or flattening of the breast muscles. These lesions can be detected by palpation (157). Comprehensive descriptions of the pathology have been provided in turkeys (370) and in broiler breeder chickens (432). Lesions in both types of birds are similar. In early lesions, the whole deep pectoral muscle is swollen, pale, and edematous with necrosis in the middle third to three-fifths of the muscle. The overlying fascia is often opaque with edema between the deep and superficial muscles. In older lesions, the edema disappears and the necrotic muscle becomes more prominent and drier with greenish areas. In chronic lesions, the necrotic muscle has shrunk and is uniformly green, dry, and friable and enclosed by a fibrous capsule. It may shrink to a fibrous scar. The muscle posterior to the necrotic muscle becomes atrophied, pale, and sometimes fibrosed. The sternum adjacent to the necrotic muscle is roughened and irregular.

When examined microscopically, the fibers in the green necrotic muscle are swollen and uniformly eosinophilic with discoid necrosis. Nuclei are absent or faint. Blood vessels within the necrotic tissue often contain only nuclei of lysed red blood cells. Surrounding the necrotic tissue, there is an inflammatory reaction with heterophils, macrophages, and giant cells, and in chronic cases, a fibrous capsule. Viable, degenerate, and regenerating muscle fibers are often enveloped by the capsule. Brown pigment and cyst-like structures containing yellow material are also found within the capsule. In the muscle posterior to the necrotic tissue, fibers may be atrophied and replaced by fat, and in some instances, fibrosis is present. Vascular lesions consisting of thromboses, intimal proliferation, and aneurysm formation are found in and around the necrotic tissue. Ultrastructural studies on affected muscles have been conducted (190, 432).

Pathogenesis and Etiology

In a series of experiments, Wight (431), Siller (372, 373), and Martindale (246) demonstrated that deep pectoral myopathy is the result of ischemia secondary to the swelling in a tight fascia of a vigorously exercised muscle. In prior studies, surgical occlusion of arteries to the pectoral muscles in both turkeys and chickens resulted in infarcts similar in appearance to the lesions of deep pectoral myopathy (293, 371). In subsequent studies, temporary occlusion of the subclavian artery combined with electrically induced contractions of the deep pectoral muscle induced necrosis of the muscle in both lightweight and broiler strains of chicken. Similar electrically induced contractions alone produced necrosis of the muscle in the broiler strains, but not in the lightweight chickens (431). Subsequently, it was demonstrated that the necrosis could be produced by voluntary wing movements (373). Surgical incision of the fascia around the deep pectoral muscle prior to exercise, however, would prevent development of the lesion (372). Angiography demonstrated complete ischemia in the deep pectoral muscle associated with an increase in subfascial pressure following electrical stimulation of the muscle. After 24 hours, the ischemia only persisted in the middle of the muscle (246).

Modification of handling procedures may reduce the incidence (375, 430). Some evidence has been produced for a hereditary predisposition (157). This predisposition may be related to inadequate vasculature in muscles of meat-type birds (431), but not to body weight or breast width (158). No specific nutritional factors are known to influence the condition (144, 156). Slowing the rate of growth of turkeys does not reduce the incidence of the deep pectoral myopathy (409).

Rupture of the Gastrocnemius Tendon

Lameness due to rupture of the gastrocnemius tendon has been recognized commonly in meat-type chickens and rarely in turkeys. It can cause considerable economic loss in broiler breeder flocks and in broiler chickens raised to roaster weights. The early literature was reviewed by Peckham (303).

Clinical Signs and Pathology

Up to 20% of a flock may be affected. Most outbreaks are in broiler breeder chickens older than 12 weeks of age, but may be seen in broiler chickens as early as 7 weeks of age. The rupture can be unilateral or bilateral. Onset of lameness is acute. Birds with bilateral rupture have a characteristic posture in which the bird sits on its hocks with its toes flexed (Figure 30.13). In affected birds, a swelling can be palpated on the posterior surface of the leg just above the hock. With acute lesions, hemorrhage can be seen through the skin. With older lesions, there is green discoloration. With chronic



Figure 30.13. Roaster chicken with bilateral rupture of the gastrocnemius tendon. The hock-sitting posture with toes directed ventrally is characteristic. (Craig Riddell)

lesions, no discoloration may be apparent, but a firm mass of abnormal subcutaneous tissue can be palpated. Dissection of acute lesions reveals a blood-filled swelling under the skin on the posterior surface of the leg, within which the free end of the ruptured tendon can be found. The rupture generally occurs as an irregular transverse break just above the hock joint. In older and chronic lesions, the blood is partially or completely reabsorbed and fibrous tissue encloses the end of the ruptured tendon and surrounding tissue. Microscopic lesions are variable. In many acute lesions, there is hemorrhage only. In older lesions, there is fibrous tissue surrounding resolving hematomas and the ruptured tendon. Synovial hyperplasia and infiltration of heterophils and macrophages vary from very little to massive. The infiltration of inflammatory cells occurs within the tendon and in the synovial membranes and cavities, and may be associated with masses of heterophil debris and some bacterial colonies.

Pathogenesis and Etiology

Historically, rupture of the gastrocnemius tendon was associated with tenosynovitis, in particular that due to reoviruses (100). However, in many cases the rupture appears to have a noninfectious origin (63, 80). In cases associated with tenosynovitis, there was a marked inflammatory response, whereas in spontaneous rupture there was a minimal inflammatory response.

The tensile strength of the flexor digitus perforatus and perforans tendon to the third digit is less in meat-type chickens than in egg-type chickens, suggesting that this could predispose meat-type birds to tenosynovitis (398). This could also predispose to spontaneous rupture of tendons. Tissue of the gastrocnemius tendon in meat-type birds has a less organized appearance than that in egg-type birds (399). In addition, many meat-type birds have a hypovascular area in the gastrocnemius tendon just above the hock joint. This hypovascular area is associated with thickened chondrocyte plaques, chondrocyte death, and excessive lipid accumulation in the tendon. These changes may predispose to noninfectious tendon rupture (98). Little research has been conducted on the effect of nutrition on tendon strength. In one study, administration of glycine, vitamin C or E, or copper had no effect on tensile strength of tendons (400). In another study, restricted feeding had no effect on tensile strength of tendons, but the ratio of tensile strength to body weight was less in chickens fed *ad libitum* than in those on feed restriction (334). Prolonged sitting by broilers does not predispose the tendons to ischemia and subsequent necrosis (66). In a recent study, rupture of tendons was linked to male aggression and not bodyweight or exercise of the hens (63).

Ligament Failure and Avulsion

Lesions of ligaments of the intertarsal joint were a significant cause of lameness in meat-type poultry (55). Lesions have been reported in the capital femoral ligament in young adult broiler chickens (91), in the posterior cruciate and other ligaments of the femoral-tibial joint in young adult broiler chickens (90, 95, 96, 99) and turkeys (82, 103), and in the intercondylar and collateral ligaments of the intertarsal joint of turkeys (103, 200) and broiler chickens (94, 99). Avulsion of the retinaculum on the distal tibia of turkeys also has been seen (59).

Clinical Signs and Pathology

Lameness has been attributed to lesions in the capital femoral ligament. Lesions found include stretching, partial or total rupture, and avulsion, sometimes with a piece of cartilage or bone from the femoral head insertion. Stretched ligaments sometimes contain hematomas or are infiltrated with fat. Microscopic lesions include fraying of collagen bundles and acellularity and hyalinization of the collagen in the tendon, along with necrosis, fissures, and hemorrhage in cartilage adjacent to the site of insertion (91). Lameness is also associated with lesions in ligaments of the femoral-tibial joint. The posterior cruciate ligament has been the most commonly affected, but the cranial cruciate, collateral, and caudal meniscofemoral ligaments also have been affected. In the cruciate ligament, total or partial rupture near the tibial insertion or avulsion from the tibial insertion occurs. Microscopic lesions are similar to those described for affected femoral capital ligaments. In addition, multicellular clusters and mucoid degeneration in the tendons and disorganization of subchondral bone with cysts and granulation at the avulsion site have been found (90). Some abnormalities of the menisci of the knee joint have been associated with ligament disruption (101). Lameness also has been associated with partial or total rupture of intercondylar ligament and with rupture or avulsion of collateral ligaments. Most microscopic changes in affected ligaments have been similar to those described for other affected ligaments (94, 200). In contrast to clinical signs associated with avulsion of other ligaments, avulsion of the retinaculum was not reported; however, there were increased condemnations of legs due to hematomas and muscle discoloration at slaughter (59).

Pathogenesis and Etiology

Ligament rupture is often due to trauma. Microscopic lesions similar to those described in ruptured ligaments have been described in intact ligaments of broiler-type chickens, indicating that these changes precede the rupture (96). In individual male broiler breeding chickens, tendon or ligament failure is often found at more than one site, suggesting a predisposition to ligament and tendon failure in these birds (95). Ligament failure may in part be age related, because the incidence appears to increase with age (99). Ligament lesions were less severe in turkeys fed a restricted amount of feed when compared with turkeys fed *ad libitum* (103). Rupture of ligaments may be secondary to stress induced by limb angulation (94, 200, 332).

Diseases of the Circulatory System

Pulmonary Hypertension Syndrome in Broiler Chickens

Pulmonary hypertension syndrome (PHS), also known as ascites syndrome, occurs worldwide in growing broiler chickens, with estimates that PHS accounts for 25% of the overall

mortality in the broiler industry and 5%–7% of the condemnations (73). PHS was first reported in flocks of broiler chickens reared at high altitudes (and low oxygen tensions) in Bolivia (150). It has since been described worldwide in flocks reared at high and low altitudes. Interactions between management, environment, and genetic factors play a significant role in developing this disease (76, 146). Recent reviews have been written by Baghbanzadeh and Decuypere (8), Gupta (146), and Hassanzadeh (166).

Clinical Signs

The peak incidence of ascites occurs in the fifth or sixth weeks of the growing period. Affected birds usually are smaller than normal and listless with ruffled feathers and a pale, shrunken comb. Severely affected birds have abdominal distension caused by accumulation of ascitic fluid with or without fibrin clots (150, 251, 434) (Figure 30.14). Birds may be reluctant to move and are dyspneic and cyanotic (251). Some birds may die suddenly before ascites develops (199, 202). Electrocardiogram of affected chickens shows an increased voltage of ventricular depolarization complex, consistent with dilation and hypertrophy of the right ventricle (282, 420). These changes in the echocardiogram are preceded by modifications in the left ventricle consistent with enlargement and progressive left failure and compensatory right ventricular hypertrophy (287, 290).

Pathology

Gross lesions include ascites, right-side cardiac enlargement, often left-side ventricular dilation, and variable liver changes. The cardiac enlargement includes dilation of the right atrium, sinus venosus, and vena cava as well as the right ventricle (Figure 30.15) and hypertrophy of both the right ventricle and right muscular atrioventricular valve. The ratio of the weight of the right ventricle to the weight of the total ventricles is greatly increased (175), and there is nodular thickening of the atrioventricular valves (150, 289). Endocardiosis is more common in the left atrioventricular valve (289). Hydropericardium may be present. The arteries from ascitic broilers appeared flaccid and lacked elasticity (270). The livers in affected birds vary from congested or mottled to shrunken with a grayish capsule and irregular surface. Lungs are congested and edematous (150, 251, 434). Blood from affected birds has increased packed cell volume, hemoglobin, and red and white blood cell counts. Heterophils and monocytes are increased at the expense of lymphocytes (251). A similar condition has been reported in meat-type ducklings (197).

Microscopic lesions have been described in the heart, major blood vessels, liver, lung, and kidney (150, 251, 270, 272, 434). The myocardial fibers are mildly disorganized, with occasional

Figure 30.14. Broiler chicken with abdomen distended with fluid secondary to right ventricular heart failure. (Craig Riddell)

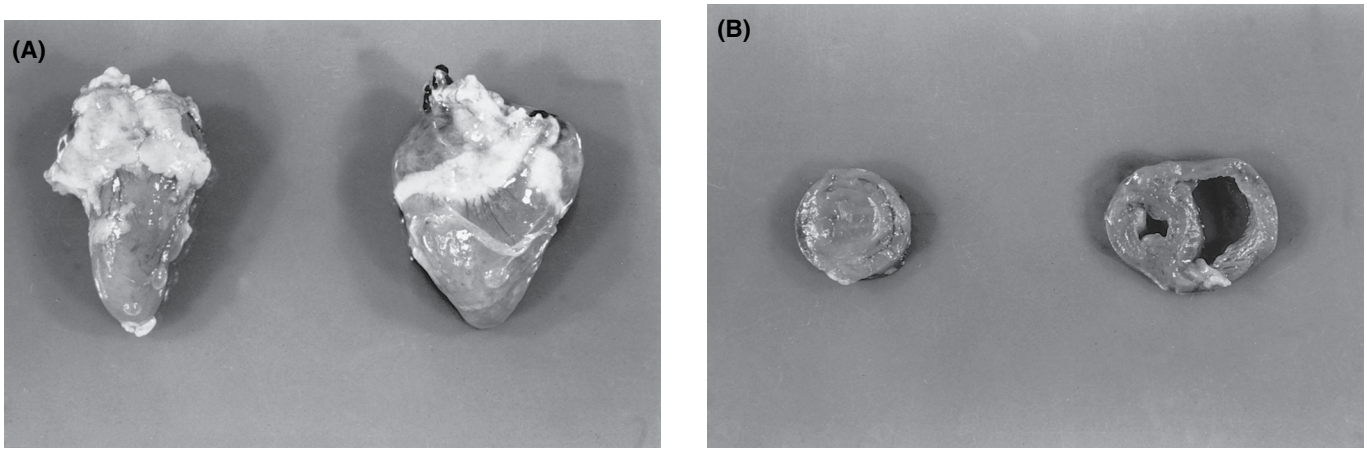

Figure 30.15. Right ventricular heart failure in a broiler chicken. (A) Enlarged heart (right) compared with a normal heart (left). (B) Transverse section through the enlarged heart showing dilation and hypertrophy of the right ventricle compared with a transverse section through the normal heart. (Craig Riddell)

myocardial degeneration and calcification; edema; and some proliferation of loose connective tissue between fibers, focal hemorrhages, and infiltrations of heterophils. The arterial wall is thinner than in normal birds, or occasionally there is total loss of elastic elements. There is also reduced network density of the structural matrix of the vascular wall, as well as increased thickness of fibers in vena cava. The liver has hepatocytic necrosis, dilation of hepatic sinusoids, and often fibrosis of the capsule. Foci of lymphocytes and heterophils in the liver are common. The lungs are often hyperemic with visible evidence of hemorrhage, edema, and hypertrophy of smooth muscle around the parabronchi, and collapse of the atria and air capillaries. Cartilaginous and osseous nodules may be found in the lungs (62).

Ultrastructural changes in PHS include myofibril disorganization, mitochondrial abnormalities and hyperplasia in the heart, thickening of alveolar and capillary walls in the lung, and thickened basement membranes and tubular degeneration in the kidney (252, 253, 255). There is also disruption of elastic elements in the wall of vena cava (270). Abnormal calcium deposits have been demonstrated in the mitochondria of cardiac myocytes of birds with PHS (255). Increased serum troponin T found in live birds with PHS was another indicator of myocardial damage associated with PHS (256).

Pathogenesis and Etiology

Despite the intensive investigation of the syndrome, the primary cause of ascites is unclear. Pulmonary hypertension causing right ventricular hypertrophy and failure has been considered the main cause of ascites (199). In recent years, it has become apparent that pathogenesis is multifactorial, with the interaction of genetic and environmental factors being the most likely causes (76, 204). Because there is a complex interrelationship between the cardiovascular, respiratory, circulatory, and other systems in the body, some of the observed changes in ascites syndrome may represent secondary compensatory responses. It is also possible that multiple genetic factors may play a role in this complex disease (314).

PHS can be induced by environmental and experimental conditions that predispose to tissue hypoxia, such as high altitude, cold temperature, respiratory hypoxia, or increased metabolic rate (204, 297, 299). Hypoxemia results in increased cardiac output, polycythemia, increased hemoglobin, and increased hematocrit. These changes in the blood produce an increased blood viscosity and larger and more rigid red blood cells, which may have difficulty passing through the capillary bed of the lung (237, 254, 263).

Chickens susceptible to ascites have low thyroid hormone activity, predisposing them to a low capacity for oxygen consumption (75, 353) and possibly tissue hypoxemia. Additionally, thyroid hormone has been suggested as a modulator of the beta-adrenergic system, which is an important regulator of cardiovascular performance. Ascites-sensitive birds have a higher density of the beta-adrenergic receptors than ascites-resistant birds and the characteristics of these receptors are different from normal birds (161, 163, 164).

Although the highest incidence of PHS occurs at the end of the growth period, it is now thought that the incubation conditions may influence the postnatal characteristics of PHS. Several studies have demonstrated that low oxygen levels during incubation influence the occurrence of ascites later in life. Embryos exposed to high carbon dioxide concentrations during the third week (40) and/or during the first 10 days (74) of incubation had lower incidence of ascites during the growth period than those incubated under normal concentrations. Similarly, (165) birds incubated at high altitude (low oxygen) showed less right ventricular hypertrophy and ascites mortality than those incubated at low altitude. In all of these studies, chickens exposed to less oxygen during incubation hatched earlier than those exposed to normal amounts, and the embryos might have experienced hypoxia for a shorter time. They also had higher plasma triiodothyronine and thyroxine (40, 165). Furthermore, embryos incubated at high altitude had higher plasma corticosteroid and lactic acid levels (165) and reduced binding capacity of myocardial beta-adrenergic receptors (164), suggesting an adaptation of the heart to hypoxia.

Wideman and French showed that animals that survived an ascites challenge produce offspring with reduced ascites syndrome (423). Body weight had a negative genetic correlation at cold temperatures (72, 298). On the other hand, there was a weak but positive correlation to bodyweight under normal conditions. Lubritz et al. demonstrated correlations between clinical ascites and coronary arterial pressure index (243). A recent study revealed that PHS-susceptible broilers have an elevated pulmonary arterial pressure, associated with increased precapillary (arteriole) resistance, when compared to PHS-resistant broilers (424). Cisar et al. found that the concentration of 2 mitochondrial matrix proteins involved in the aerobic metabolism was elevated in an ascites-resistant line broilers with ascites (45). Alternative selection systems that look into parameters other than just body weight should be considered to reduce PHS (297, 445).

Accumulation of reactive oxygen may damage the cell membranes of different systems in the body. A direct correlation between low concentration of antioxidant in the lung and enlarged right ventricular weight has been found in broiler chickens (27). Lower levels of antioxidants also have been reported in the lung and liver (114). This suggests a deficiency in the control of oxidative stress. Dietary supplementation with coenzyme Q_{10} reduced PHS in broilers (130), probably by reducing free radicals.

Increased resistance to blood flow through the lung can cause pulmonary hypertension, and consequently right ventricular failure and ascites. Pulmonary hypertension in broiler chickens has been induced experimentally by clamping of a single pulmonary artery (418). Clamping of the arteries induces pulmonary hypertension more successfully than occluding the left extra-pulmonary bronchus (421), probably because chickens have an effective gas exchange system but poor blood perfusion through the lung. Inflammatory reaction causes thickening of the gas exchange barrier and may persist even after the causative agent is removed (115). Right

ventricular hypertrophy and subsequent ascites has been associated with lung damage induced by infectious agents such as aspergillus (198, 444), *Escherichia coli*, or infectious bronchitis virus (394); however, pulmonary hypertensive response secondary to exposure to endotoxins or other microparticles in the lung (44) is linked to genetic factors rather than the source or dosage. Hypervolemia also produces resistance to the blood flow through the lung. Sodium toxicosis resulting in ascites secondary to the increase of blood volume and decrease of erythrocyte deformability should not be mistaken for PHS (see Sodium in Chapter 32).

Intervention Strategies

There is no single treatment or preventive system for the control of PHS. Management to reduce early growth rate offers the best solution in birds at risk. Manipulation of the photoperiod and feed restriction are common techniques for the control of ascites. Intermittent lighting programs during the early stages of life significantly reduce PHS (39, 162). The beneficial effect of intermittent lighting was more pronounced when applied from days 3–14 and/or from days 10–21 of age. Initial growth depression was followed by a compensatory growth, so that the final weight was the same.

Feed restrictions may be used for early growth management (11). However, there are conflicting results in compensatory growth and carcass yield (204). Limiting the *ad libitum* food intake or skip-one-day programs may reduce PHS without compromising body weight (11, 204). The incidence of PHS is lower in broiler chickens fed mash diets as compared with those given pelleted diets (216, 368), without reducing body weight, weight gain, feed consumption, or feed conversion rate (24).

Several strategies have been used to prevent the accumulation of reactive oxygen and reduce the incidence of ascites. While vitamin E was able to reduce ascites when implanted in the liver (25), no benefits were observed when the feed was supplemented with vitamin E alone (118). Supplemental L-arginine reduced the incidence of PHS mortality in experimental broilers, suggesting that L-arginine might be required as a substrate for nitric oxide, a powerful endogenous pulmonary vasodilator (419). Alternatively, nitric oxide may induce pulmonary hypertension by releasing reactive oxygen (6, 52). The manipulation of other important antioxidants, such as uric acid, flavonoids, or carotenoids, has not been investigated (8).

During the development of ascites, chickens develop systemic hypotension, which triggers retention of fluid and electrolytes (124). Furosemide, a diuretic that acts as a vasodilator, reduced PHS mortality in experimental broiler chickens, probably by reducing fluid and electrolyte retention, and pulmonary vascular resistance (417).

Systemic acid-base balance also influences the ventilation and perfusion through the lung. Intravenous infusions of 1.2 M HCl led to pulmonary vascular resistance and bradycardia, and could trigger pulmonary hypertension (422). Alternatively, the addition of 1% sodium bicarbonate to a broiler ration to cause alkalosis reduced the incidence of PHS in experimental birds in a hypobaric chamber (296).

Dilated Cardiomyopathy in Turkeys

Dilated cardiomyopathy (DCM) has commonly been called round heart disease and less commonly the cardiohepatic syndrome. The term round heart disease should be discontinued, because it is used for a different disease that occurs in chickens (340). In addition, it only describes a gross change but does not indicate the pathology accurately. The early literature on the syndrome has been reviewed by Czarnecki (68) and the reader is referred to this review for more detail and specific citations.

Clinical Signs and Pathology

The highest rate of mortality due to spontaneous DCM occurs in young poults, commonly peaking at 2 weeks of age and disappearing at 3 weeks of age. The authors of this chapter have occasionally seen spontaneous CDM in turkeys up to 10–12 weeks of age. Mortality in flocks averages 0.5%–3% (126). Affected young turkeys may die suddenly or may have ruffled feathers, drooping wings, and labored breathing prior to death. On the electrocardiogram, affected turkeys have increased end-diastolic volume and decreased ejection fraction and systolic blood pressure (129). On postmortem examination, affected young turkeys have greatly enlarged hearts due to dilation of both ventricles. Often, the right ventricle is more dilated. Hydropericardium and ascites may or may not be present. Lungs are generally congested and edematous. Livers may be slightly swollen with rounded edges. In older turkeys from affected flocks the most prominent lesion is enlargement of the heart and hypertrophy of the left ventricle.

Microscopic changes in abnormal hearts are nonspecific and include congestion, degeneration of myofibers, focal infiltration of lymphocytes, and in older turkeys, increased fibroelastic tissue under the endocardium of the left ventricle. Vacuolization of hepatic cells, focal necrosis, bile duct hyperplasia, and intracytoplasmic PAS-positive globules in hepatocytes have been described in the swollen livers.

Pathogenesis and Etiology

DCM in turkeys has been reproduced with similar environmental and management factors as PHS in chickens, such as hypoxic conditions in incubation (65), high altitude, and hypobaric chamber with cold weather (125, 203). The incidence of DCM also can be reduced by slowing the growth rate (31, 203), using an intermittent light program early in the turkeys' lives (48), and providing a diet containing low sodium (0.10%–0.12%) and 0.38%–0.40% chloride (126). In addition, the drug furazolidone has been shown to induce DCM. However, furazolidone-induced DCM is significantly different from the naturally occurring disease, suggesting a different etiology (223).

Turkeys with DCM have a decrease in some enzymes involved in the energy supply, such as creatinine kinase, lactate dehydrogenase, the Ca^{2+} transport system, β-receptor-stimulated adenylyl cyclase (129), diminished concentration of Adenosine-5'-triphosphate (ATP) (238), and reduced concentration of fatty acids, the main substrate for cardiac metabolism (223). Genetic studies have identified 2 possible

genes, troponin T and phospholamban, which may be involved in DCM (241). Troponin T is an essential protein in the Ca^{2+} regulation of striated muscle during contraction, while phospholamban protein regulates the Ca of muscle during diastole. In turkeys with DCM induced by furazolidone, the troponin T protein is reduced by 61% and phospholamban is only reduced by 18% (240). Troponin T has an abnormal structure in domestic turkeys (17, 18), which may predispose them to DCM.

Sudden Death Syndrome in Broiler Chickens

Sudden death syndrome (SDS) describes a condition in which healthy broiler chickens die suddenly for no discernible cause. The syndrome has been also called heart attack and flip-over. The latter term has been used because birds dead from the syndrome are commonly found on their backs. The condition was first described as "edema of lungs" in England (168) and subsequently as "died in good condition" in Australia (186). Today, birds dead from SDS are found in most broiler flocks throughout the world. The incidence varies from 0.5%–4% (32, 41, 176, 335, 380). Reviews on SDS have been written by Olkowski and Classen (285) and Riddell (339).

Clinical Signs

Sudden death syndrome has been reported to occur from 1–8 weeks of age, with the greatest losses occurring from 2–4 week of age (32, 335, 380). It is more common in males than females (288, 292). In some broiler flocks, the weekly incidence increases throughout the growing period, suggesting an error in diagnosis or a different syndrome (335). It is possible that birds dying from PHS may have been misdiagnosed as dying from SDS (339).

Affected chickens show no clinical signs or unusual behavior until less than a minute before death (276). Birds may squawk during the attack, with loss of balance, convulsions, and violent flapping (276). Most birds die on their backs with one or both legs extended or raised (331, 380). Comparison of blood from birds just after death from SDS with blood from killed healthy birds revealed no consistent differences in serum levels of sodium, potassium, chloride, calcium, phosphorus, magnesium, or glucose (331). Serum lactate dehydrogenase, glutamic oxaloacetic transaminase (182), and creatinine phosphokinase (313) were increased in SDS chickens compared to healthy chickens.

Pathology

Birds that die from SDS are well fleshed with a full gastrointestinal tract. Livers are enlarged, pale, and friable, and the gallbladder generally is empty. Kidneys may be pale and the lungs are often congested and edematous (292, 380). The congestion and edema of the lungs may be a postmortem artifact, because it is not found in freshly dead birds (331). The ventricles of the heart are generally contracted, and the thyroid, thymus, and spleen may be congested; there may be hemorrhages in the kidney (292). In a study of organ weights, relative liver weights of broilers dead from SDS were significantly greater than the liver weights of control birds, but no significant differences were noted between SDS and control birds in relative weights of lungs, hearts, and intestines (30).

Microscopic lesions reported are nonspecific. Degeneration and infiltration of lymphoid cells and heterophils have been described in the heart (292). However, the cellular infiltrations have been considered to be normal lymphoid foci and foci of ectopic hemopoiesis (331). Use of an allochrome stain and a hematoxylin-basic fuchsin-picric acid stain did not demonstrate any degenerative changes in hearts of birds dying from SDS (331). In contradiction to these previous studies of the heart in SDS, a more recent study described arteriosclerotic changes and myocardial necrosis, mostly in the left ventricle of broiler chickens that had died suddenly without clinical signs (205, 291).

Pathogenesis and Etiology

Sudden death syndrome has been described in most modern broiler-type chickens (32, 335), but is not well understood. It has been suggested that SDS is a metabolic disease and that genetic, nutritional, and environmental factors may affect the incidence (331). SDS was associated with acute cardiac dysrhythmia, consistent with ventricular fibrillation (286). Birds that later died of SDS had a higher heart rate than the rest of the flock (287). Furthermore, a higher percentage of chickens that died with SDS had cardiac arrhythmias (288). Serum lactate dehydrogenase and creatine kinase activities of male broilers were significantly higher than those of females, but there was no difference in serum aspartate aminotransferase or serum electrolyte levels of potassium, sodium, and chloride between males and females (446). Similar susceptibility to SDS was found between six strains of commercial broiler chickens, including Arbor Acres, Avian Farms, Cobb-500, Hubbard-Peterson, ISA, and Ross (136). The heritability of SDS is low (43).

In a nutritional study SDS was higher in birds fed crumble-pelleted feed vs. mash (312). Incidence was not affected by feed restriction or growth rate (335, 342). In a field survey, flocks on wheat-based rations had higher SDS those on corn-based rations (335). This difference also was noted in some experimental trials (20), but not in other studies (179, 264). Protein type and concentration in the diet influence the incidence of SDS. Chickens fed meat meal protein had a lower incidence of SDS than those on soybean meal (20). Also, higher protein in the finisher diet reduced the incidence of SDS (264). Addition of vitamins did not affect the incidence of SDS (179, 264, 381, 410), but it has been suggested that thiamine may influence the incidence (47). The concentration of calcium, phosphorus, and magnesium (196) or potassium (179) in rations had no effect on the incidence of SDS.

A lighting program with a short photoperiod at an early age decreased early growth rate and decreased the incidence of SDS (46, 338). Extended dark periods (more than 8 hours) reduced SDS, but had a negative effect on body weight (355). Decrease in SDS may be associated with lower heart rates during dark periods (21), but in another study, light intensity did not affect the incidence of SDS (275).

High stocking density (183) and the use of ionophores, especially monensin (335), are other factors proposed to influence SDS.

Aortic Rupture

Aortic rupture (AR) or dissecting aneurysm is characterized by sudden death in growing turkeys due to internal hemorrhage. The condition is seen worldwide. Mortality in the past has been reported to reach 50%, but losses in affected flocks at present usually reach 1%–5%. AR also has been described in ostriches and emus (382).

In the previous edition of this book (62), sudden death in turkeys associated with perirenal hemorrhage (SDPH) was described as a distinct condition. It is believed that SDPH may be associated with rupture of aorta or a small blood vessel in and around the kidneys. This is based on the observations that many birds that died during an episode of AR also had perirenal hemorrhages. Therefore, these two conditions are described as one in this chapter.

Clinical Signs and Pathology

AR occurs in turkeys between 7 and 24 weeks of age, with peak mortality between 12 and 16 weeks of age. The incidence is primary in male turkeys. Affected birds die suddenly. The dead turkeys are in good body condition. At necropsy, the head, skin, and musculature may be pale. Upon internal examination, gross lesions consist of clotted blood in the abdominal cavity surrounding a portion of kidneys or whole kidneys. Clotted blood may be present in the oral cavity, trachea, lungs, and pericardial sac. Careful dissection of the posterior abdominal aorta and its branches in the vicinity of the kidneys reveals tears or ruptures in the aorta, between the celiac and ischiatic arteries (Figure 30.16), but is most common around the celiac artery. In some cases, at the site of the rupture the aorta was dilated, and the wall was thin and had lost its elasticity. Aneurysm and rupture of the coronary artery also have been described (366).

Histologically, the tunica intima and media may be thrown into deep folds and partially separated from the tunica

Figure 30.16. Aortic rupture. Left: Abdominal bleeding, around the kidneys, secondary to ruptured artery in a 16-week-old meat turkey. Right: Tear of the aorta wall (arrow) at the level of the ischiatic artery.

adventitia. Fibers of the tunica media may show mild to severe degenerative changes and may be infiltrated with heterophils and macrophages. The media may be thickened due to an increase in collagen and fibroblastic proliferation. Dissolution or disappearance of the elastic fibers of the media occurs at the site of rupture. Degenerative changes and areas of erosion and cellular infiltration may be present in the adventitia. There is often displacement of the internal elastic lamina. A marked intimal thickening or a large fibrous intimal plaque often occurs in the region of rupture. Sudan II or Oil Red O stains may reveal lipid accumulations in the affected intima and media.

Pathogenesis and Etiology

Copper deficiency, hypertension, hormonal influences, diet, lathyrism, zinc deficiency, pharmaceuticals, management practices, and parasites have been suggested as predisposing factors for AR (397). Low copper levels were found in the livers of turkeys and ostriches from field outbreaks of aortic rupture (137, 366, 401). Copper is important in collagen synthesis and it has been suggested that copper deficiency may play a role in AR. Because AR occurs primarily in male turkeys and copper deficiency has not been consistently found in birds with AR and/or perirenal hemorrhage, other factors also may be implicated. High blood pressure in young male turkeys also may be a predisposing factor, but paradoxically, the administration of diethylstilbestrol decreased blood pressure and increased the incidence (212, 213). Several reports have emphasized the possible role of intimal plaques in the pathogenesis of aortic rupture in turkeys. It has been suggested that these plaques and the absence of an intramural vasa vasorum around the abdominal aorta result in impaired nutrition to, and degeneration of, the media (274). Male turkeys have greater relative left and total ventricular weights than do females of the same age. This might explain the greater susceptibility of male turkeys (29). Beta-aminopropionitrile, a toxic product that occurs in the sweet pea (*Lathyrus odoratus*), will produce AR in turkeys (303). Dietary aspirin had no effect on the incidence of aortic rupture or perirenal hemorrhage (28, 127). Fast weight gain, continuous lighting programs, crowding, and hyperactivity increased the incidence (269), whereas increased room temperature, toe clipping, step up/step down lighting, and dietary reserpine reduced the incidence (127).

Diseases of the Digestive System and Liver

Fatty Liver-Hemorrhagic Syndrome

Fatty liver-hemorrhagic syndrome (FLHS) affects chickens worldwide, including commercial layers and broiler breeders. FLHS is associated with high-energy diets along with restricted exercise, and is most common during hot weather.

Clinical Signs and Pathology

The first sign of FLHS is an increase in mortality (38), with birds in full production found dead with pale heads. Mortality usually does not reach 5%. There is often a sudden drop in egg production. Dead birds have large blood clots in the abdomen, arising from the liver and often partially enveloping the liver (Figure 30.17). The liver is generally enlarged, pale, and friable, with smaller hematomas within the parenchyma. These hematomas may be recent and dark red, or older and green to brown. Similar hematomas may be seen in clinically healthy birds in the same flock if such are examined during or after an outbreak. Large amounts of fat are present in the abdominal cavity and around the viscera. Most of the birds have active ovaries and often have an egg in the oviduct.

Microscopic examination of the liver shows hepatocytes distended with fat vacuoles, hemorrhages of various sizes and organizing hematomas, and often small irregular masses of uniform eosinophilic material, likely derivative of plasma protein (429). The fat content of livers generally exceeds 40% dry weight and may reach 70%. Increased lipid accumulation in the liver was observed in commercial layer hens stimulated with estradiol; however, there were no significant differences in free cholesterol

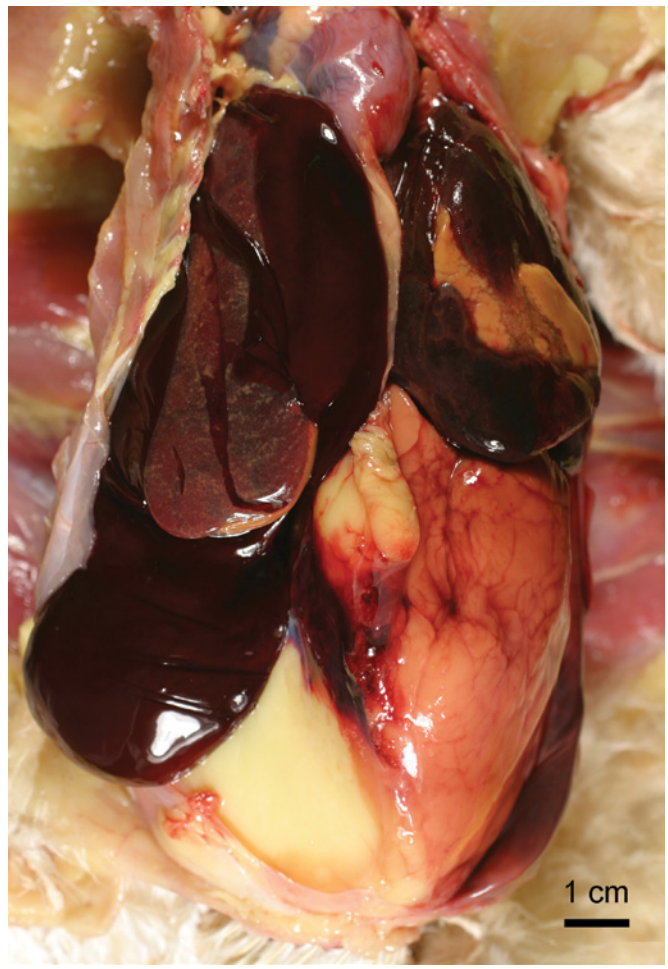

Figure 30.17. Fatty liver-hemorrhagic syndrome. A large blood clot is molded over the left lobe of the liver. Note the excess abdominal fat.

or phospholipids (230). These results suggest that estradiol stimulated the synthesis of fatty acids and triacyglycerols in the liver.

Common indicators of hepatic disease such as aspartate aminotransferase and other plasma enzymes were increased in birds from an FLHS-susceptible strain or commercial birds fed diets that induced FLHS (78, 443). Birds affected with FLHS had higher concentrations of estradiol (148), calcium, and phosphorus (153) in the plasma than unaffected ones. No changes have been found in concentrations of progesterone (148), major plasma proteins, or glucose.

Pathogenesis and Etiology

The fat content in the liver normally rises with the initiation of egg production and is influenced by estrogen. Injection of immature chickens with estradiol has been shown to result in hepatic steatosis and hemorrhage (301). Similar injection of laying hens caused liver enlargement, death from liver hemorrhage, and neurologic disorders (379). In one experiment, treatment with synthetic estrogens was more damaging at 34 °C than at 21 °C (2), which agrees well with the field observations that FLHS is more frequent during the hot weather. Additionally, birds exposed to high temperatures are more likely to be in a positive energy balance.

Excessive consumption of high-energy diets, regardless of the source, in birds whose exercise is restricted results in excessive fat deposition. Excessive fat may disrupt architecture of the liver and result in weakening of the reticular framework and blood vessels in the liver. A pathogenic relationship between hepatic steatosis and hemorrhage has been suggested (302). Lysis of the reticulin framework of the liver has been reported in FLHS. A strong association of reticulolysis with severity of liver hemorrhage has been described in experimental birds (248). Focal necrosis of hepatocytes leading to vascular injury has been described as another mechanism to explain the hemorrhage (181, 441). It has been postulated that excessive lipid peroxidation of unsaturated fatty acids in the liver may overwhelm cell repair mechanisms and result in tissue damage (378). However, chickens susceptible to FLHS were supplemented with ascorbic acid, tocopherol, or L-cysteine, and there was no improvement in FLHS (77).

Because energy balance is a factor in FLHS, many studies have focused on the influence of diet FLHS increases as the total energy in the diet increases, regardless of the source. However, when isocaloric diets were compared, a diet that provided the energy in fat rather than in carbohydrates reduced the incidence (149). It was hypothesized that diets richer in fat might have reduced the hepatic metabolism by reducing *de novo* fatty acid synthesis in the liver. Furthermore, size of the liver, rather than lipid content in the liver or high-fat diets, was directly related to FLHS (354).

The possibility of toxins causing FLHS should not be ignored. Aflatoxin has been considered as a possible cause but produces different liver lesions. FLHS in chickens also must be differentiated from rupture of the liver associated with hepatitis E virus (see Hepatitis E Infections in Chapter 14). Livers are generally not fatty in ruptured livers of chickens associated with hepatitis E virus.

Figure 30.18. White, broad-breasted, meat turkey with pendulous crop.

Pendulous Crop

Pendulous crop occurs at a low incidence in many chicken and turkey flocks. In severely affected birds, the crop is greatly distended and full of feed, particles of bedding, and fluid, which often has a foul smell (Figure 30.18). The lining of the crop may be ulcerated. Birds continue to eat, but digestion is impaired and birds become emaciated and die. Carcasses of affected birds are generally condemned at processing. The possibility that diet may influence the incidence of pendulous crop is supported by the experimental production of pendulous crops with rations containing cerelose as a substitute for starch. It was suggested that increased liquid intake in hot weather may be responsible. Additionally, hereditary predisposition has been proposed in turkeys. Neither of these factors appears to be important. For further discussion on the possible etiologies of pendulous crop review the 8th edition of this *Diseases of Poultry* (303).

Impaction

Impaction of the crop, proventriculus, or ventriculus (gizzard) has occasionally been reported in poultry, waterfowl, and ratites, but rarely in chickens. Gizzard impaction can cause high mortality during the first 3 weeks of life in turkeys. Proventricular and gizzard impaction are common in ostrich and other ratite chicks. Affected birds are emaciated, with empty intestinal tracts, but affected crops, proventriculi, and/or gizzards are full of a solid mass of interwoven fibrous material. This fibrous mass often extends into the upper duodenum, and in some birds, masses of fibrous material are found lower in the intestine. Impaction results from the birds eating litter or fibrous material that cannot be processed in the crop, proventriculus, or gizzard. In ratites impaction due to foreign bodies such as rocks, metallic objects, pebbles, etc. is common. Crop impaction due to feather eating was associated with improper management (267). Prevention is aimed at discouraging the eating of litter or fibrous materials by young poults and ratite chicks.

Intussusception and Volvulus

Intussusception and volvulus are occasionally seen in poultry. Intussusception occurs most frequently in the intestine, but sometimes in the proventriculus (358). Volvulus occurs when there is torsion of the intestine around itself or the root of the mesentery. In young birds, volvulus of the small intestine may be caused by twisting around the yolk sac. Intussusception and volvulus have been reported in chickens secondary to enteritis or abnormal peristalsis caused by nematode or coccidial infection. Intestinal torsion also may be associated with pedunculated neoplastic stalks. The clinical signs are anorexia and progressive weight loss, and death occurs over a few days. The affected and distal portions of the intestine are severely congested due to circulatory compromise and the intestinal epithelium rapidly becomes necrotic. If an early diagnosis is made, resection of the affected intestine can be performed in a valuable bird.

Cloacal Prolapse

Cloacal prolapse may involve the intestines, reproductive tract (oviduct or phallus), and ureter(s). The prolapsed tissue has a smooth surface and is shiny and congested. Cloacal prolapse may be associated with diarrhea, impaction, or nutritional imbalances. It occurs commonly in young ostriches and it has been associated with *Cryptosporidium* sp. infection (15). In laying hens, cloacal prolapse may result from egg laying. In poultry, picking of the prolapsed tissue may result in cloacal rupture and evisceration.

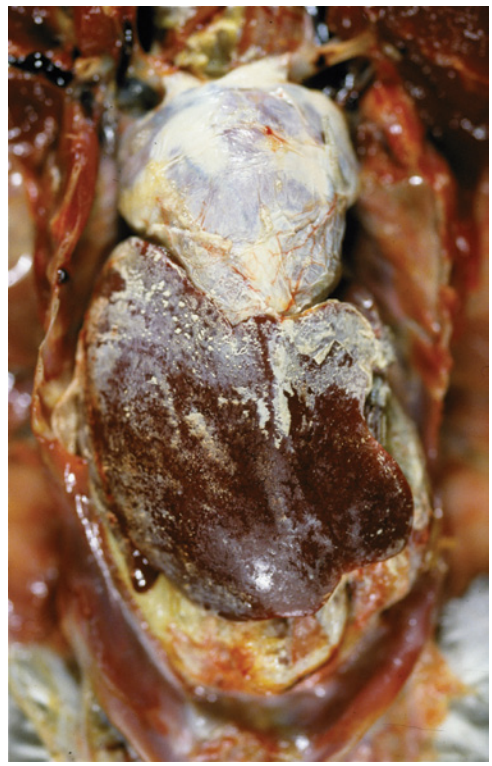

Figure 30.19. Visceral urate deposition over the heart and liver of an adult pigeon.

Diseases of the Urinary System

An excellent review of renal pathology of the fowl was written by Siller (374). This discussion covers only metabolic conditions of major importance commonly seen in commercial poultry. It does not cover descriptions of miscellaneous conditions such as congenital malformations and baby chick nephropathy.

An increased substrate load on the kidney that leads to dysfunction of this organ with precipitation of insoluble products within the kidney itself or other organs can cause urolithiasis or urate deposition. Urolithiasis and urate deposition together are responsible for significant losses in poultry. Historically, urate deposition has been described as 2 distinct syndromes, known as visceral urate deposition ("visceral gout") and articular urate deposition ("articular gout"). These two syndromes are different from the point of etiology, morphology, and pathogenesis. Visceral urate deposition (VUD) is described under urolithiasis because they are related conditions in commercial poultry. VUD also can be seen in individual birds of any species as a sequelae to acute renal failure (Figure 30.19).

Urolithiasis and Visceral Urate Deposition

Urolithiasis is characterized by severe atrophy of one or both kidneys, distended ureters often containing uroliths, and varying degrees of renal and visceral urates deposits. Visceral urate deposition (visceral gout) occurs when there is a failure of urinary excretion. Urolithiasis is primarily seen in laying flocks and has been associated with increased mortality and decreased egg production (245, 425).

Clinical Signs and Pathology

Overall mortality in affected flocks may exceed 2% for several months, and mortality in excess of 50% may be due to urolithiasis (22, 245). Renal lesions have been recognized in clinically normal birds in flocks undergoing an outbreak, and 3.2%–6.3% of hens in some affected flocks had renal lesions at processing (245). Affected chickens die suddenly and may be in good condition and in full lay (22) or they may have a reduced muscle mass, small pale combs, and white pasting on pericloacal feathers (35).

Focal mineralization of the kidneys, progressive obstruction of the ureters by uroliths, causes kidney atrophy "upstream" of the site of uretral obstruction and compensatory hypertrophy by the undamaged portions of the kidney. The ureters arising from the atrophied lobes are dilated and full of clear mucus and often contain white irregular concretions or uroliths (35). These uroliths are composed of compact masses of microcrystalline to fine pleomorphic crystals of calcium sodium urate, with random substitution of magnesium and potassium for the calcium and sodium, respectively (284). The kidney atrophy is often more severe in anterior lobes and is unilateral, but it may be bilateral. The surviving ipsilateral or contralateral lobes may be enlarged. Atrophied kidneys and dilated ureters are often accompanied by diffuse visceral urate deposits (22, 35, 245) (Figure 30.20). Visceral

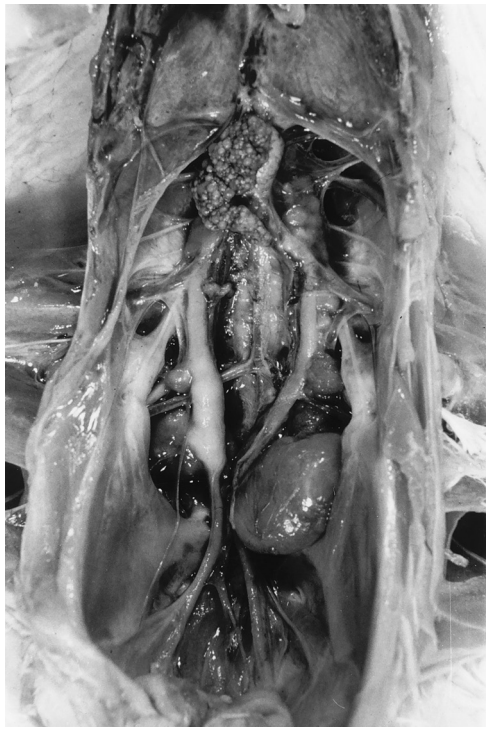

Figure 30.20. Urolithiasis in a chicken. There is severe atrophy of the right kidney and anterior lobes of the left kidney. The right ureter is distended with white material. (Craig Riddell)

urate deposition is characterized by precipitation of urates in the kidneys and on serous surfaces of the heart, liver, mesenteries, air sacs, and/or peritoneum (Figure 30.19). In severe cases, surfaces of muscles and synovial sheaths of tendons and joints may be involved, and precipitation may occur within the liver, spleen, and other organs. The deposits on serosal surfaces appear grossly as a white chalky coating, while those within viscera may be microscopic.

Microscopic lesions in affected kidneys consist of dilation of ureter branches and tubules, tubular degeneration and loss of tubules, cellular casts, urate crystals, and varying degrees of fibrosis (22, 35). Much of the urate deposits are lost when tissues are processed for histology, but evidence of its presence is often seen as blue or pink amorphous material under the microscope. Feathery crystals or basophilic spherical masses may be seen within tissues under the microscope in some cases. Fixing and processing tissues in 90% or absolute alcohol will preserve urates.

Urolithiasis has been primarily recognized as a disease of laying birds, but reports indicate that lesions (Figure 30.20) and mortality may start during the rearing period (35, 54). In a sequential study of one outbreak, minor focal cortical tubular necrosis was found by microscopic study in grossly normal kidneys of 4-week-old pullets. In 7-week-old pullets, the kidneys were grossly swollen with tubular necrosis and casts, eosinophilic globules in glomeruli, and interstitial infiltration of heterophils and lymphocytes. Typical lesions of urolithiasis were found in 14-week-old birds (35).

Pathogenesis and Etiology

Wideman et al. (426) conducted renal function studies on chickens during outbreaks of urolithiasis and concluded that the physiologic impact of the kidney damage was the result of reduced renal mass, rather than of inappropriate renal handling of minerals or electrolytes. A significant reduction in number of glomeruli also has been reported in birds affected by urolithiasis (279). The uroliths may cause sudden death by blockage of ureters but probably occur secondary to kidney damage (245).

A marked difference in susceptibility to urolithiasis caused by high-calcium diets has been described between 2 strains of leghorn chickens (231). The more susceptible strain produced more alkaline urine and had a higher proportion of juxtamedullary nephrons (426). Excess dietary calcium induced urolithiasis in growing pullets and male breeders (132, 145, 268, 357, 415). Formation of uroliths may be due to high levels of urinary calcium and decreased hydrogen ions in the urine (133). Dietary acidification with ammonium chloride, ammonium sulfate, or methionine has been shown to decrease the incidence of uroliths and gross kidney lesions in urolithiasis induced experimentally with high-calcium diets (131, 231, 416, 427). Ammonium chloride was not considered a practical treatment for use in the field because it caused increased water consumption, urine flow, and manure moisture (131), but other compounds did not have this disadvantage (231, 427). Ammonium sulfate was more effective than 2 forms of methionine in a single trial (231).

Outbreaks of urolithiasis and visceral urate deposition in poultry also have been attributed to infectious causes, such as nephrotropic strains of infectious bronchitis virus (3, 35, 54, 64) and renal cryptosporidiosis (395). Exposure of pullets to the Gray strain of infectious bronchitis virus subsequent to feeding a high-calcium laying ration increased the incidence of urolithiasis and gross kidney damage (133). Noninfectious factors, such as vitamin A deficiency (374), treatment with sodium bicarbonate (70), and mycotoxins, such as oosporein (304), induced urolithiasis and visceral urate deposition. Water deprivation has been suggested as a cause on the basis of field observations (194).

Articular Urate Deposition

Articular urate deposition ("articular gout"), unlike the visceral type, is a sporadic problem of little economic importance in poultry. Clinically this condition is characterized by leg shifting, lameness, and inability to bend the toes. It is characterized by tophi, deposits of urates around joints, particularly those of the feet, hence confusion with bumble foot. The joints are enlarged and the feet appear deformed (Figure 30.21). When these joints are opened, the periarticular tissue is white due to urate deposition, and white semi-fluid deposits of urates may be found. In chronic cases urate precipitates also can be observed in the comb, wattles, trachea, etc. Unlike visceral urate deposition, the kidneys are usually grossly normal. Histologically there is granulomatous inflammation in the synovium. Therapy is palliative only. Removal of the deposits is not recommended due to the difficulty and profuse bleeding.

Figure 30.21. Articular urate deposition ("articular gout") in a mature chicken causing enlargement and deformity of toes and feet. (M.C. Peckham)

As it has been reproduced by feeding high-protein diets, the etiology is suggested as excess production of uric acid. Studies in a line of chickens bred for high incidence of articular urate deposition, however, indicate that they may have a defect in tubular secretion of uric acid (7, 50).

Diseases of the Reproductive System

Cystic Right Oviduct

In the female chicken embryo, 2 Müllerian ducts start to develop into oviducts. The left duct develops into a functional oviduct, while the right duct regresses. If this regression is not complete, partial development will result in a cystic right oviduct. Cystic right oviducts are common incidental findings in postmortem examination of chickens. They vary in size from small, 2-cm diameter, elongated cysts to large, fluid-filled sacs up to 10 cm or more in diameter (Figure 30.22). Small cysts are of little consequence, but large cysts compress the abdominal viscera. The large sacs can result in a bird with a pendulous abdomen and should be differentiated from ascites.

False Layer

The term false layer has been used to describe a bird that has the characteristics of a bird in production, visiting the nest regularly but not laying eggs (180). This bird has a normal-appearing ovary and oviduct, but the infundibulum fails to engulf the ovum after it has been ovulated. At necropsy, these birds show excessive amounts of orange-colored fat and have liquid yolk or coagulated yolk in the body cavity. This defect may result as a sequel to infectious bronchitis at an early age (33, 34).

Internal Layer

In some birds, soft-shelled eggs or fully formed eggs may be found in the peritoneal cavity. This indicates that the yolk progressed normally through the oviduct to a certain point and then reverse peristalsis discharged the egg into the body cavity. A bird with a large accumulation of eggs in the peritoneal cavity may assume a penguin-like posture.

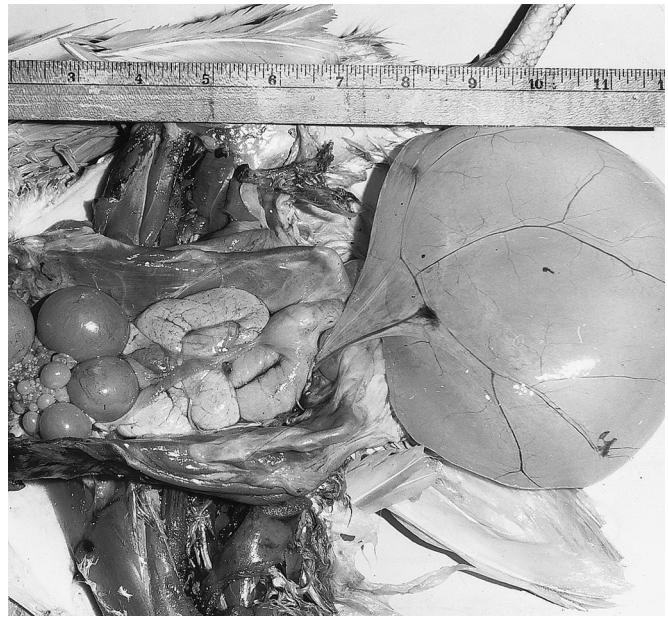

Figure 30.22. Cystic right oviduct in a chicken. (M.C. Peckham)

Impacted Oviduct

Occasionally, an oviduct is occluded by masses of yolk, coagulated albumen, shell membranes, and in some instances, fully formed eggs. Large masses of yolk-like material also may be found in the oviduct, and upon transection, these masses have the appearance of concentric rings.

Egg-Bound

Egg-bound is a condition in which an egg is lodged in the cloaca but cannot be laid. It may result from inflammation of the oviduct, partial paralysis of the muscles of the oviduct, or production of an egg so large that it is physically impossible for it to be laid. Young pullets laying an unusually large egg are more prone to the problem. Prolapse of the oviduct, usually along with the cloaca, may be seen as a sequela of dystocia.

Phallus Prolapse

Phallus prolapse is occasionally seen in anseriformes and ratites associated with infection or immunodepression. The exact cause of prolapse is unknown. In geese, phallus erosions and prolapse have been associated with *Neisseria* spp. infection (see Miscellaneous and Sporadic Bacterial Infections in Chapter 23). In ratites, phallus prolapse usually occurs at the end of the breeding season and after sudden weather changes (42, 173). One report associates *Cryptosporidium* spp. infection with cloacal and phallus prolapse in ostriches (306). Frostbite and bacterial infection may occur as a sequela of phallus prolapse.

Abnormal Eggs and Depressed Production

Poor egg quality and depressed egg production are common problems that cause great economic loss to the poultry industry. They can be due to a multitude of factors involving nutrition, management, environment, and disease.

Sex Reversal

An abnormal increase of testosterone or a hormonal imbalance may cause the development of male secondary sexual characteristics, such as larger comb and wattles, in affected females. Possible causes include damage of the left ovary by infection with the development of the vestigial right organ as a testicle, or neoplasia in the adrenal glands or ovary that results in the production of testosterone.

Diseases of the Integumentary System

Contact Dermatitis

Erosive lesions affecting the skin on the plantar surface of the feet and the posterior surface of the hocks, thigh, or breast overlying the sternum have been recognized in turkeys and broiler chickens. Breast, thigh, hock, and even footpad conditions have been an important cause of downgrading of chicken and turkey carcasses (135, 260, 360). Depending on the location, these skin lesions have been called by different names. Lesions in the footpads are known as pododermatitis or footpad dermatitis (360), while lesions on the breast are known as breast burn in chickens (138) and breast buttons in turkeys (135). Ulcers and erosions of the skin covering the thigh and hip of broiler chickens have been described as scabby hip (159, 308). A common feature of all of these skin lesions is that they appear to be due to contact irritation and are associated with poor litter conditions. In recent years, improvements in the litter management and the use of nipple drinkers in the poultry houses have contributed to reducing the incidence of this condition (261).

Clinical Signs and Pathology

Dermatitis on the foot and hock appear as dark black scabs filling ulcers on the plantar footpad (Figure 30.23), digits, and caudal tibiotarsus-tarsometatarsus joint (138, 247). In turkeys, early changes of pododermatitis occur during the first week of life and become more severe over a short period of time; by 6 weeks of age the changes typical of pododermatitis are fully developed (258). Early changes include enlargement of foot scales, cracks, abrasions, and a superficial scab. These changes proceed to a deep ulcer. Histologic lesions include defective keratin in the stratum intermedium, particularly adjacent to the ulcer, and infiltration of heterophils in adjacent epidermis. The center of the lesion is occupied by a necrotic mass of cellular debris, which may enclose plant material and bacteria. The base of the mass is underlain by heterophils and often macrophages and a line of giant cells.



Figure 30.23. Severe pododermatitis in a 16-week-old turkey. Bar = 1 cm.

Many birds also have similar ulcers filled with black scabs on the posterior of the hock and on the breast.

The breast lesions in turkeys were characterized by a granulomatous response with no giant cells noted, but connective tissue proliferation occurred below the ulcers (135), probably related to the chronicity of the lesion. Scabby hip syndrome is characterized by ulcers and erosions covered by scabs on the skin of the thigh of broiler chickens associated with femoral head degeneration (308) and in chicken flocks kept in high density (159).

Pathogenesis and Etiology

Field outbreaks of contact dermatitis have been associated with poor litter conditions (138), wet litter (152, 247, 249), and coarse bedding materials (171, 277). Cool temperatures prior to 12 weeks of age increased the incidence of breast buttons, while no association was found with the feathering condition (277). An epidemiologic study by McIlroy et al. (260) found that dermatitis lesions were more frequent with increased stocking density, increased age, particular feeds, male birds, and winter. A study has shown that the decrease in

the prevalence of dermatitis in the 1990s is associated with improved management of litter and improvements in house designs, particularly the use of nipple drinkers (261) even when stock density and age of slaughter are kept the same as in the 1980s. Also, new systems of floor drainage allow for higher stocking densities without increasing the incidence pododermatitis (250). Supplementation with biotin, riboflavin, pantothenic acid, and sulfur amino acids that have been shown to affect the structural components of the skin did not significantly reduce pododermatitis (360).

Diseases of the Eye and Ear

There are many conditions and diseases that affect the eye, which have been reviewed by Shivaprasad (364). Diseases involving the ear in birds in general have not been well studied, but they occur. Common conditions that affect the ear of poultry have been reviewed recently by Shivaprasad (367).

Ammonia Burn

Ammonia burn describes a keratoconjunctivitis in poultry caused by exposure to ammonia fumes resulting from unsanitary conditions. Ammonia in the poultry house results primarily from the decomposition of nitrogenous compounds in the litter and fecal matter. Clinical signs include photophobia, excess lacrimation, and respiratory congestion. Affected birds keep their eyelids closed and are reluctant to move. They may rub their heads and eyelids against their wings. The cornea has a gray, cloudy appearance and may be ulcerated. Edema and hyperemia may be present in the conjunctiva but often may not be very obvious. The condition is generally bilateral, and affected birds do not eat and become emaciated. Microscopically, the lesions are characterized by necrosis of the epithelium of the cornea, ulceration, and infiltration of heterophils into the epithelium and substantia propria. The opacification of the cornea is a result of ulceration, cellular infiltration, and edema of the cornea (364). Inflammation of the conjunctiva can be severe. Many birds recover if exposure to ammonia fumes is eliminated. Time of recovery depends on the severity of damage to the cornea and may take 1 month or longer if lesions are severe. Prevention of the condition is based on proper ventilation and litter management. The ammonia fumes are formed in wet litter.

Eye-Notch Syndrome

Eye-notch syndrome refers to a widespread lesion in the eyelid of caged layers (364). The condition appears to start as a small scab or erosion on the lower lid, which develops into a fissure with a tag of flesh attached to one side. Microscopically, it is characterized as blepharoconjunctivitis. The significance and cause of the condition are unknown.

Cataracts

The opacification of the lens is referred as cataracts. It is uncommon among most domestic poultry. The condition has been described in chickens, turkeys, and quail. Cataracts might be caused by noninfectious etiologies such as suboptimal incubation conditions, hereditary, old age, and nutritional deficiencies (e.g., vitamin E), as well as infectious conditions such as viral diseases such as avian encephalomyelitis. Lens opacity is normally bilateral, resulting in blindness. Microscopically the lesion is characterized by degeneration of lens fibers, epithelial hyperplasia, formation of bladder cells, and liquefaction in advance stages (364).

Retinal Dysplasia

Abnormal development of the retina, most probably inherited as an autosomal recessive trait, has been described both in layer and broiler commercial chickens (364, 365). The disease is present in chicks when they are a few days old and becomes apparent when they are 5 or 7 days old. Clinically the chicks with retinal dysplasia are smaller than their counterparts, wander aimlessly, and are unable to find feed and water. Ophthalmoscopic examination of the eyes in these chicks showed lack of papillary reflexes and normal posterior and anterior segments. The incidence of blindness was generally less than 1%, and postmortem examination did not reveal any gross lesions in the eyes. Microscopic examination of the eyes revealed degeneration of photoreceptors (rods and cones) in the earlier stages followed by rosette formation, disorganization of retinal layers, synechiae of the retina, reactive and proliferative retinal pigmented epithelial cells, and inflammation of the choroid in later stages. If the birds survived for several weeks, progressive changes such as retinal detachment, cataract formation, fibrosis, and metaplastic changes to cartilage were seen (364).

Partial retinal dysplasia and degeneration leading to blindness in 2%–5% of chickens was reported in chickens that were a cross between barred Plymouth Rock and Rhode Island red breeds (315). Clinical signs of blindness were first evident at 5–6 weeks of age, and by 6 months most of the chicks did not respond to visual stimuli. Retinopathy characterized by loss of photoreceptors resulting in blindness in 0.2% of the chicks was also reported in a commercial layer breeder flock (67). This condition was recognized in chicks as early as 3 weeks of age but it was more evident at 8 weeks of age.

Other Developmental Anomalies of the Eye

Several anomalies are described in young chicks and turkey poults. These include albinism (346), keratoglobus or corneal ectasia (217), microphthalmia (111), cyclopia, triple eyes, buphthalmia, anophthalmia, corneal edema, and optic nerve hypoplasia (361, 364). These defects can have genetic origins, but most are the result of suboptimal incubation conditions.

Diseases of the Ear

External ear is the continuation of the skin. Therefore, it is prone to infections by virus (e.g., pox viruses), bacteria, fungus, parasites (mites), nutrition (vitamin A deficiency), trauma, and occasionally neoplasia. Middle ear infections originating from the oropharynx through the Eustachian tube resulting in neurological signs are common. One common cause of otitis media is *Pasteurella multocida* in turkeys and chickens. However, other bacteria can cause similar lesions.

Diseases of the inner ear are rare but both bacteria and viruses can cause otitis interna. One of the common sequelae of meningitis of the brain is otitis interna, probably as an extension through the vestibulocochlear (VIII cranial) nerve.

Acknowledgement

Grateful acknowledgement is made to Dr. C. Riddell, previous author of this chapter, for much of the material on reviews of several conditions and many of the figures.

References

1. Ahmed, O.A.R., L.D. Olson, and E.L. McCune. 1974. Tissue irritation induced in turkeys by fowl cholera bacterins. *Avian Dis*. 18:590–601.
2. Akiba, Y., K. Takahasi, M. Kimura, S.I. Hirama, and T. Matsumoto. 1983. The influence of environmental temperature, thyroid status and a synthetic oestrogen on the induction of fatty livers in chicks. *Brit Poult Sci*. 24:71–80.
3. Alexander, D.J., and R.E. Gough. 1978. A long-term study of the pathogenesis of infection of fowls with three strains of avian infectious bronchitis virus. *Res Vet Sci*. 24:228–233.
4. Almeida Paz, I.C.L., A.A. Mendes, A. Balog, L.C. Vulcano, A.W. Ballarin, I.C.L. Almeida, S.E. Takahashi, C.M. Komiyama, M.C. Silva, and K.F.G. Cardoso. 2008. Study on the bone mineral density of broiler suffering femoral joint degenerative lesions. *Brazil J Poult Sci*. 10:103–108.
5. Anderson-Mackenzie, J.M., D.J.S. Hulmes, and B.H. Thorp. 1997. Degenerative joint disease in poultry—differences in composition and morphology of articular cartilage are associated with strain susceptibility. *Res Vet Sci*. 63:29–33.
6. Arab, H.A., R. Jamshidi, A. Rassouli, G. Shams, and M.H. Hassanzadeh. 2006. Generation of hydroxyl radicals during ascites experimentally induced in broilers. *Brit Poult Sci*. 47: 216–222.
7. Austic, R.E., and R.K. Cole. 1972. Impaired renal clearance of uric acid in chickens having hyperuricemia and articular gout. *Am J Physiol*. 223:525–530.
8. Baghbanzadeh, A., and E. Decuypere. 2008. Ascites syndrome in broilers: physiological and nutritional perspectives. *Avian Pathol*. 37:117–126.
9. Bain, S.D., and B.A. Watkins. 1993. Local modulation of skeletal growth and bone modeling in poultry. *J Nutr*. 123 (Suppl. 2): 317–322.
10. Balnave, D., and J. Brake. 2005. Nutrition and management of heat-stressed pullets and laying hens. *World Poult Sci J*. 61: 399–406, 516, 520, 525, 530, 536.
11. Balog, J.M. 2003. Ascites syndrome (Pulmonary Hypertension Syndrome) in broiler chickens: Are we seeing the light at the end of the tunnel? *Avian and Poult Biol Rev*. 14:99–126.
12. Bass, C.C. 1939. Control of "nose-picking" form of cannibalism in young closely confined quail fed raw meat. *Proc Soc Exp Biol Med*. 40:488–489.
13. Bell, D.J., and W. Siller. 1962. Cage layer fatigue in brown leghorns. *Res Vet Sci*. 3:219–230.
14. Bergmann, V., and M. Pietsch. 1976. Bieträge zur differntialdagnose der bewegungsstörungen beim junghuhn. 4. Mitt.: Tibiotorsion beim perlhuhn-eine perosisähnliche erkrankung in einem perhuhnmastbetrieb. *Monatsh Veterinaermed*. 31:581–585.
15. Bezuidenhout, A.J., M.-L. Penrith, and W.P. Burger. 1993. Prolapse of the phallus and cloaca in the ostrich (*Struthio camelus*). *J South Afr Vet Assoc*. 64:156–158.
16. Bianchi, M., M. Petracci, A. Franchini, and C. Cavani. 2006. The occurrence of deep pectoral myopathy in roaster chickens. *Poult Sci*. 85:1843–1846.
17. Biesiadecki, B.J., and J.P. Jin. 2002. Exon skipping in cardiac troponin T of turkeys with inherited dilated cardiomyopathy. *J Biol Chem*. 277:18459–18468.
18. Biesiadecki, B.J., K.L. Schneider, Z.B. Yu, S.M. Chong, and J.P. Jin. 2004. An R111C polymorphism in wild turkey cardiac troponin I accompanying the dilated cardiomyopathy-related abnormal splicing variant of cardiac troponin T with potentially compensatory effects. *J Biol Chem*. 279: 13825–13832.
19. Bishop, S.C., R.H. Fleming, H.A. McCormack, D.K. Flock, and C.C. Whitehead. 2000. Inheritance of bone characteristics affecting osteoporosis in laying hens. *Brit Poult Sci*. 41:33–40.
20. Blair, R., J.P. Jacob, and E.E. Gardiner. 1990. Effect of dietary protein source and cereal type on the incidence of sudden death syndrome in broiler chickens. *Poult Sci*. 69:1331–1338.
21. Blanchard, S.M., L.A. Degernes, D.K. DeWolf, Jr., and J.D. Garlich. 2002. Intermittent biotelemetric monitoring of electrocardiograms and temperature in male broilers at risk for sudden death syndrome. *Poult Sci*. 81:887–891.
22. Blaxland, J.D., E.D. Borland, W.G. Siller, and L. Martindale. 1980. An investigation of urolithiasis in two flocks of laying fowls. *Avian Pathol*. 9:5–19.
23. Blokhuis, H.J., and P.R. Wiepkema. 1998. Studies of feather pecking in poultry. *Vet Quart*. 20:6–9.
24. Bölükbasi, S.C., M.S. Aktas, and M. Güzel. 2005. The effect of feed regimen on ascites induced by cold temperatures and growth performance in male broilers. *Int J Poult Sci*. 4:326–329.
25. Bottje, W., S. Wang, K. Beers, and D. Cawthon. 1998. Age-related changes in lung-epithelial lining fluid (ELF) antixoidants in broilers under cold temperature conditions. *Poult Sci*. 77 (Suppl. 1):127.
26. Bottje, W.G., and P.C. Harrison. 1985. The effect of tap water, carbonated water, sodium bicarbonate and calcium chloride on blood acid-base balance in cockerels subjected to heat stress. *Poult Sci*. 64:107–113.
27. Bottje, W.G., G.F. Erf, T.K. Bersi, S. Wang, D. Barnes, and K.W. Beers. 1997. Effect of dietary DL-alpha-tocopherol on tissue alpha- and gamma-tocopherol and pulmonary hypertension syndrome (ascites) in broilers. *Poult Sci*. 76:1506–1512.
28. Boulianne, M., and D.B. Hunter. 1990. Aspirin: A treatment for sudden death syndrome in turkeys? Proceedings of the 39th Western Disease Conference. Sacramento. 89–90.
29. Boulianne, M., D.B. Hunter, R.J. Julian, M.R. O'Grady, and P.W. Physick-Sheard. 1992. Cardiac muscle mass distribution in the domestic turkey and relationship to electrocardiogram. *Avian Dis*. 36:582–589.
30. Bowes, V.A., R.J. Julian, S. Leeson, and T. Stirtzinger. 1988. Effect of feed restriction on feed efficiency and incidence of sudden death syndrome in broiler chickens. *Poult Sci*. 67: 1102–1104.
31. Breeding, S.W., W.A. McRee, M.D. Ficken, and P.R. Ferket. 1994. Effect of protein restriction during brooding on spontaneous turkey cardiomyopathy. *Avian Dis*. 38:366–370.
32. Brigden, J.L., and C. Riddell. 1975. A survey of mortality in four broiler flocks in western Canada. *Can Vet J*. 16:194–200.

33. Broadfoot, D.I., B.S. Pomeroy, and W.M. Smith Jr. 1954. Effects of infectious bronchitis on egg production. *J Am Vet Med Assoc*. 124:128–130.
34. Broadfoot, D.I., B.S. Pomeroy, and W.M. Smith Jr. 1956. Effects of infectious bronchitis in baby chicks. *Poult Sci*. 35: 757–762.
35. Brown, T.P., J.R. Glisson, G. Rosales, P. Villegas, and R.B. Davis. 1987. Studies of avian urolithiasis associated with an infectious bronchitis virus. *Avian Dis*. 31:629–636.
36. Bubier, N.E., and R.H. Bradshaw. 1996. Fear as a mechanism underlying aggressive pecking in aviary-housed laying hens. *Brit Poult Sci*. 37:S12-S13.
37. Burton, R.W., A.K. Sheridan, and C.R. Howlett. 1981. The incidence and importance of tibial dyschondroplasia to the commercial broiler industry in Australia. *Brit Poult Sci*. 22:153–160.
38. Butler, E.J. 1976. Fatty liver diseases in the domestic fowl: A review. *Avian Pathol*. 5:1–14.
39. Buys, N., J. Buyse, M. Hassanzadeh, and E. Decuypere. 1998. Intermittent lighting reduces the incidence of ascites in broilers: an interaction with protein content of feed on performance and the endocrine system. *Poult Sci*. 77:54–61.
40. Buys, N., E. Dewil, E. Gonzales, and E. Decuypere. 1998. Different CO_2 levels during incubation interact with hatching time and acites susceptibility in two broiler lines selected for different growth rate. *Avian Pathol*. 27:605–612.
41. Cassidy, D.M., M.A. Gibson, and F.G. Proudfoot. 1975. The histology of cardiac blood clots in chicks exhibiting the "flip-over" syndrome. *Poult Sci*. 54:1882–1886.
42. Castello Llobet, J.A. 1997. Patología gastrointestinal. In: Cría de Avestruces, Emúes y Ñandúes, 2nd ed. Real Escuela de Avicultura, ed. Grinver—Arts Gràfiques, S. A., Sant Joan Despí, Barcelona (Spain). 243–274.
43. Chambers, J.R. 1986. Heritability of crippling and acute death syndrome in sire and dam strains of broiler chickens. *Poult Sci*. 65 (Suppl. 1):23.
44. Chapman, M.E., W. Wang, G.F. Erf, and R.F. Wideman Jr. 2005. Pulmonary hypertensive responses of broilers to bacterial lipopolysaccharide (LPS): evaluation of LPS source and dose, and impact of pre-existing pulmonary hypertension and cellulose micro-particle selection. *Poult Sci*. 84:432–441.
45. Cisar, C.R., J.M. Balog, N.B. Anthony, and A.M. Donoghue. 2005. Differential expression of cardiac muscle mitochondrial matrix proteins in broilers from ascites-resistant and susceptible lines. *Poult Sci*. 84:704–708.
46. Classen, H.L., and C. Riddell. 1989. Photoperiodic effects on performance and leg abnormalities in broiler chickens. *Poult Sci*. 68:873–879.
47. Classen, H.L., M.R. Bedford, and A.A. Olkowski Thiamine nutrition and sudden death syndrome in broiler chickens. Proceedings of the XIXth World's Poultry Congress. Amsterdam. pp 572–574. 1992.
48. Classen, H.L., C. Riddell, F.E. Robinson, P.J. Shand, and A.R. McCurdy. 1994. Effect of lighting treatment on the productivity, health, behavior and sexual maturity of heavy male turkeys. *Brit Poult Sci*. 35:215–225.
49. Clyne, M.J. 1987. Pathogenesis of degenerative joint disease. *Equine Vet J*. 19:15–18.
50. Cole, R.K., and R.E. Austic. 1980. Hereditary uricemia and articular gout in chickens. *Poult Sci*. 59:951–975.
51. Cook, M.E. 2000. Skeletal deformities and their causes: introduction. *Poult Sci*. 78:982–984.
52. Cotran, R.S., V. Kumar, and T. Collins, eds. 1999. *Diseases of Immunity*, 6th ed. W.B. Saunders Co., Philadelphia. 189–195.
53. Couch, J.R. 1955. Cage layer fatigue. *Feed Age*. 5:55–57.
54. Cowen, B.S., R.F. Wideman, H. Rothenbacher, and M.O. Braune. 1987. An outbreak of avian urolithiasis on a large commercial egg farm. *Avian Dis*. 31:392–397.
55. Craig, F. Traumatic hock disorder in poultry. Proceedings 16th Western Poultry Disease Conference. Sacramento. 11–12. 1967.
56. Craig, J.V., M.L. Jan, C.R. Polley, A.L. Bhagwat, and A.D. Dayton. 1975. Changes in relative aggressiveness and social dominance associated with selection for early egg production in chickens. *Poult Sci*. 54:1647–1658.
57. Crespo, R., S.M. Stover, R. Droual, R.P. Chin, and H.L. Shivaprasad. 1999. Femoral fractures in a young male turkey breeder flock. *Avian Dis*. 43:150–154.
58. Crespo, R., S.M. Stover, K.T. Taylor, R.P. Chin, and H.L. Shivaprasad. 2000. Morphometric and mechanical properties of femora in young adult male turkeys with femoral fractures. *Poult Sci*. 79:602–608.
59. Crespo, R., C. Hall, and G.Y. Ghazikhanian. 2002. Avulsion of the common retinaculum in meat turkeys. *Avian Dis*. 46: 245–248.
60. Crespo, R., S.M. Stover, H.L. Shivaprasad, and R.P. Chin. 2002. Microstructure and mineral content of femora in male turkeys with and without fractures. *Poult Sci*. 81:1184–1190.
61. Crespo, R., and R. McMillan. 2008. Facial cellulitis induced in chickens by Mycoplasma gallisepticum bacterin and its treatment. *Avian Dis*. 52:698–701.
62. Crespo, R., and H.L. Shivaprasad. 2008. Developmental, metabolic, and other noninfectious disorders. In: *Diseases of Poultry*, 12th ed. Y.M. Saif, A.M. Fadly, J.R. Glisson, L.R. McDougald, L.K. Nolan, and D.E. Swayne, eds. Blackwell Publishing Professional, Ames, Iowa. 1149–1195.
63. Crespo, R., and H.L. Shivaprasad. 2011. Rupture of gastrocnemius tendon in broiler breeder hens. *Avian Dis*. 55:495–598.
64. Cumming, R.B. 1963. Infectious avian nephrosis (uremia) in Australia. *Aust Vet J*. 39:145–147.
65. Cummings, T.S. 1988. Hatchery-associated round heart disease in poultry. In: Proceedings of the 125th Annual AVMA Meeting. Portland, Oregon. 132.
66. Cummings, T.S., S.L. Branton, P.A. Stayer, and D.L. Magee. 2006. Wind speed effects on "green leg" condemnations in broiler. In: 143rd AVMA/AAAP Annual Convention. Honolulu, Hawaii.
67. Curtis, R., J.R. Baker, P.E. Curtis, and A. Johnston. 1988. An inherited retinopathy in commercial breeding chickens. *Avian Pathol*. 17:87–99.
68. Czarnecki, C.M. 1984. Cardiomyopathy in turkeys. *Comp Biochem Physiol A*. 77:591–598.
69. Dämmrich, K., and G. Rodenhoff. 1970. Skelettveränderungen bei Mastküken. *Zbl Vet Med. B* 17:131–146.
70. Davison, S., and R.F. Wideman. 1992. Excess sodium bicarbonate in the diet and its effect on Leghorn chickens. *Brit Poult Sci*. 33:859–870.
71. De Basilio, V., M. Valariño, S. Yahav, and M. Picard. 2000. Early age thermal conditioning and a dual feeding program for male broilers challenged by heat stress. *Poult Sci*. 80:29–36.
72. De Greef, K.H., L.L.G. Janss, A.L.J. Vereijken, R. Pit, and C.L.M. Gerritsen. 2001. Disease-induced variability of genetic correlations: Ascites in broilers as a case study. *J Anim Sci*. 79:1723–1733.

73. De Smit, L., K. Tona, V. Bruggeman, O. Onagbesan, M. Hassanzadeh, L. Arckens, and E. Decuypere. 2005. Comparison of three lines of broilers differing in ascites susceptibility or growth rate. 2. Egg weight loss, gas pressures, embryonic heat production and physiological hormone levels. *Poult Sci*. 84:1446–1452.
74. De Smit, L., V. Bruggeman, K. Tona, M. Debonne, O. Onagbesan, and L. Arckens. 2006. Embryonic development plasticity: increase CO_2 in the incubator during the early stages of incubation changes the developmental trajectories of the chick during prenatal and postnatal growth. *Comp Biochem Physiol*. 145: 166–175.
75. Decuypere, E., J. Buyse, and N. Buys. 2000. Ascites in broiler chickens: exogenous and endogenous structural and functional causal factors. *World Poult Sci J*. 56:367–377.
76. Decuypere, E., J. Buyse, M. Hassanzadeh, and N. Buys. 2005. Further insights into the susceptibility of broilers to ascites. *Vet J*. 169:319–320.
77. Diaz, G.J., E.J. Squires, and R.J. Julian. 1994. Effect of selected dietary antioxidants on fatty liver-haemorrhagic syndrome in laying hens. *Brit Poult Sci*. 35:621–629.
78. Diaz, G.J., E.J. Squires, and R.J. Julian. 1999. The use of selected plasma enzyme activities for the diagnosis of fatty liver-hemorrhagic syndrome in laying hens. *Avian Dis*. 43:768–773.
79. Dickinson, E.M., J.O. Stevens, and D.H. Helfer. 1968. A degenerative myopathy in turkeys. Proceedings 17th Western Poultry Disease Conference. 7.
80. Dinev, I. 2008. Clinical and morphological studies on spontaneous rupture of the gastrocnemius tendon in broiler breeders. *Brit Poult Sci*. 49:7–11.
81. Droual, R., A.A. Bickford, B.R. Charlton, and D.R. Kuney. 1990. Investigation of problems associated with intramuscular breast injection of oil-adjuvanted killed vaccines in chickens. *Avian Dis*. 34:473–478.
82. Duff, S.R. 1984. The morphology of degenerative hip disease in male breeding turkeys. *J Comp Path*. 94:127–139.
83. Duff, S.R. 1984. Osteochondrosis dissecans in turkeys. *J Comp Path*. 94:467–476.
84. Duff, S.R. 1984. The histopathology of degenerative hip disease in male breeding turkeys. *J Comp Path*. 94:115–125.
85. Duff, S.R. 1984. Consequences of capital femoral dyschondroplasia in young adult and skeletally mature broilers. *Res Vet Sci*. 37:310–319.
86. Duff, S.R. 1984. Dyschondroplasia of the caput femoris in skeletally immature broilers. *Res Vet Sci*. 37:293–302.
87. Duff, S.R. 1984. Capital femoral epiphyseal infarction in skeletally immature broilers. *Res Vet Sci*. 37:303–309.
88. Duff, S.R. 1985. Further studies of degenerative hip disease; antitrochanteric degeneration in turkeys and broiler type chickens. *J Comp Path*. 95:113–122.
89. Duff, S.R. 1985. Fractured fibulae in broiler fowls. *J Comp Path*. 95:525–536.
90. Duff, S.R. 1985. Cruciate ligament rupture in young adult broiler knee joints. *J Comp Path*. 95:537–548.
91. Duff, S.R. 1985. Hip instability in young adult, broiler fowls. *J Comp Path*. 95:373–382.
92. Duff, S.R., and B.H. Thorp. 1985. Abnormal angulation/torsion of the pelvic appendicular skeleton in broiler fowl: morphological and radiological findings. *Res Vet Sci*. 39:313–319.
93. Duff, S.R., and B.H. Thorp. 1985. Patterns of physiological bone torsion in the pelvic appendicular skeletons of domestic fowl. *Res Vet Sci*. 39:307–312.
94. Duff, S.R. 1986. Rupture of the intercondylar ligament in intertarsal joints of broiler fowls. *J Comp Path*. 96:159–169.
95. Duff, S.R. 1986. Further studies on knee ligament failure in broiler breeding fowls. *J Comp Path*. 96:485–495.
96. Duff, S.R. 1986. Further studies on cruciate and collateral knee ligaments in adult broiler fowls. *Avian Pathol*. 15:407–420.
97. Duff, S.R. 1986. Windswept deformities in poultry. *J Comp Path*. 96:147–158.
98. Duff, S.R., and I.A. Anderson. 1986. The gastrocnemius tendon of domestic fowl: histological findings in different strains. *Res Vet Sci*. 41:402–409.
99. Duff, S.R., and P.M. Hocking. 1986. Chronic orthopaedic disease in adult male broiler breeding fowls. *Res Vet Sci*. 41: 340–348.
100. Duff, S.R., and C.J. Randall. 1986. Tendon lesions in broiler fowls. *Res Vet Sci*. 40:333–338.
101. Duff, S.R. 1987. Meniscal lesions in knee joints of broiler fowls. *J Comp Path*. 97:451–462.
102. Duff, S.R. 1987. Destructive cartilage loss in the joints of adult male broiler breeding fowls. *J Comp Path*. 97:237–246.
103. Duff, S.R., P.M. Hocking, and R.K. Field. 1987. The gross morphology of skeletal disease in adult male breeding turkeys. *Avian Pathol*. 16:635–651.
104. Duff, S.R., and C.J. Randall. 1987. Observations on femoral head abnormalities in broilers. *Res Vet Sci*. 42:17–23.
105. Duff, S.R. 1990. Do different forms of spondylolisthesis occur in broiler fowls? *Avian Pathol*. 19:279–294.
106. Duncan, I.J., E.R. Beatty, P.M. Hocking, and S.R. Duff. 1991. Assessment of pain associated with degenerative hip disorders in adult male turkeys. *Res Vet Sci*. 50:200–203.
107. Edwards, H.M., Jr., and J.R. Veltmann, Jr. 1983. The role of calcium and phosphorus in the etiology of tibial dyschondroplasia in young chicks. *J Nutr*. 113:1568–1575.
108. Edwards, H.M., Jr. 1984. Studies on the etiology of tibial dyschondroplasia in chickens. *J Nutr*. 114:1001–1013.
109. Edwards, H.M., Jr., and P. Sorensen. 1987. Effect of short fasts on the development of tibial dyschondroplasia in chickens. *J Nutr*. 117:194–200.
110. Edwards, H.M., Jr., M.A. Elliot, and S. Sooncharernying. 1992. Effect of dietary calcium on tibial dyschondroplasia. Interaction with light, cholecalciferol, 1,25-dihydroxycholecalciferol, protein, and synthetic zeolite. *Poult Sci*. 71:2041–2055.
111. Ehrlich, D., J. Stuchbery, and J. Zappia. 1989. Morphology of congenital microphthalmia in chicks (*Gallus gallus*). *J Morphol*. 199:1–13.
112. El-Lethey, H., V. Aerni, T.W. Jungi, and B. Wechsler. 2000. Stress and feather pecking in laying hens in relation to housing conditions. *Brit Poult Sci*. 41:22–28.
113. Elliot, M.A., and H.M. Edwards, Jr. 1994. Effect of genetic strain, calcium and feed withdrawal on growth, tibial dyschondroplasia, plasma 1,25-dihydroxycholecalciferol, plasma 25-hydroxycholecalciferol in sixteen-day-old chickens. *Poult Sci*. 73:509–519.
114. Enkvetchakul, B., W. Bottje, N. Anthony, R. Moore, and W. Huff. 1993. Compromised antioxidant status associated with ascites in broilers. *Poult Sci*. 72:2272–2280.
115. Enkvetchakul, B., J. Beasley, and W. Bottje. 1995. Pulmonary arteriole hypertrophy in broilers with pulmonary hypertension syndrome (Ascites). *Poult Sci*. 74:1677–1682.
116. Fanquey, R.C., L.K. Misra, R.J. Terry, and W.F. Kreger. 1977. Effect of sex and time of hatch relative to time of placement on early mortality. *Poult Sci*. 56:1713.

117. Farquharson, C., and D. Jefferies. 2000. Chondrocytes and longitudinal bone growth: the development of tibial dyschondroplasia. *Poult Sci*. 78:994–1004.
118. Fathi, M., K.N. Adl, Y.E. Nezhad, H.A. Shahryar, M. Daneshyar, and T. Tanha. 2012. The effects of vitamin E and L-Arginine supplementation on antioxidant status and biochemical indices of broiler chickens with pulmonary hypertension syndrome. *J Anim Vet Adv*. 11:158–164.
119. Faure, J.M., J.M. Melin, and C. Mantovani. 1993. Welfare of guinea fowl and game birds. Proceedings of the 4th European Symposium on Poultry Welfare, C.J. Savory and B.O. Hughes, eds. Potters Bar. Universities Federation for Animal Welfare. 148–157.
120. Fleming, R.H., C.C. Whitehead, D. Alvey, N.G. Gregory, and L.J. Wilkins. 1994. Bone structure and breaking strength in laying hens housed in different husbandry systems. *Brit Poult Sci*. 35:651–662.
121. Fleming, R.H., H.A. McCormack, and C.C. Whitehead. 1998. Bone structure and strength at different ages in laying hens and effects of dietary particulate limestone, vitamin K and ascorbic acid. *Brit Poult Sci*. 39:434–440.
122. Fleming, R.H., H.A. McCormack, L. McTeir, and C.C. Whitehead. 2003. Effects of dietary particulate limestone, vitamin K3 and fluoride and photostimulation on skeletal morphology and osteoporosis in laying hens. *Brit Poult Sci*. 44: 683–689.
123. Fleming, R.H. 2008. Nutrirional factors affecting poultry bone health. *Proc Nutr Soc*. 67:177–183.
124. Forman, M.F., and R.F. Wideman. 1999. Renal responses of normal and preascitic broilers to systemic hypotension induced by unilateral pulmonary artery occlusion. *Poult Sci*. 78: 1773–1785.
125. Frame, D.D. Roundheart disease in Utah turkey flocks. 1991. Proceedings of the 40th Western Poultry Disease Conference. Sacramento. 95–96.
126. Frame, D.D., D.M. Hooge, and R. Cutler. 2001. Interactive effects of dietary sodium and chloride on the incidence of spontaneous cardiomyopathy (round heart) in turkeys. *Poult Sci*. 80:1572–1577.
127. Frank, R.K., S.L. Noll, M. el Halawani, J.A. Newman, D.A. Halvorson, and G.R. Ruth. 1990. Perirenal hemorrhage syndrome in market turkey toms: effect of management factors. *Avian Dis*. 34:833–842.
128. French, N.A. 2000. Effect of short periods of high incubation temperature on hatchability and incidence of embryo pathology of turkey eggs. *Brit Poult Sci*. 41:377–382.
129. Genao, A., K. Seth, U. Schmidt, M. Carles, and J.K. Gwathmey. 1996. Dilated cardiomyopathy in turkeys: An animal model for the study of human heart failure. *Lab An Sci*. 46:399–404.
130. Geng, A.L., and Y.M. Guo. 2005. Effects of dietary coenzyme Q10 supplementation on hepatic mitochondrial function and the activities of respiratory chain-related enzymes in ascitic broiler chickens. *Brit Poult Sci*. 46:626–634.
131. Glahn, R.P., R.F. Wideman Jr., and B.S. Cowen. 1988. Effect of dietary acidification and alkalinization on urolith formation and renal function in Single Comb White Leghorn laying hens. *Poult Sci*. 67:1694–1701.
132. Glahn, R.P., R.F. Wideman Jr., and B.S. Cowen. 1988. Effect of Gray strain infectious bronchitis virus and high dietary calcium on renal function of Single Comb White Leghorn pullets at 6, 10, and 18 weeks of age. *Poult Sci*. 67:1250–1263.
133. Glahn, R.P., R.F. Wideman Jr., and B.S. Cowen. 1989. Order of exposure to high dietary calcium and Gray strain infectious bronchitis virus alters renal function and the incidence of urolithiasis. *Poult Sci*. 68:1193–1204.
134. Glatz, P.C. 2005. What is beak-trimming and why are birds trimmed? In: *Beak Trimming*. P.C. Glatz, ed. Nottingham University Press, Nottingham, England. 1–18.
135. Gonder, E., and H.J. Barnes. 1987. Focal ulcerative dermatitis ("breast buttons") in marketed turkeys. *Avian Dis*. 31:52–58.
136. Gonzalez, E., J. Buyse, T.S. Takita, J.R. Satori, and E. Decuypere. 1998. Metabolic disturbances in male broilers of different strains. 1. Performance, mortality, and right ventricular hypertrophy. *Poult Sci*. 77:1646–1653.
137. Graham, C.L. 1977. Copper levels in livers of turkeys with naturally occurring aortic rupture. *Avian Dis*. 21:113–116.
138. Greene, J.A., R.M. McCracken, and R.T. Evans. 1985. A contact dermatitis of broilers—clinical and pathological findings. *Avian Pathol*. 14:23–38.
139. Gregory, N.G., and L.J. Wilkins. 1989. Broken bones in domestic fowl: Handling and processing damage in end-of-lay battery hens. *Brit Poult Sci*. 31:555–562.
140. Gregory, N.G., L.J. Wilkins, S.D. Eleperuma, A.J. Ballantyne, and N.D. Overfield. 1990. Broken bones in domestic fowls: Effect of husbandry system and stunning method in end-of-lay hens. *Brit Poult Sci*. 31:59–69.
141. Gregory, N.G., L.J. Wilkins, D.M. Alvey, and S.A. Tucker. 1993. Effect of catching method and lighting intensity on the prevalence of broken bones and on the ease of handling of end-of-lay hens. *Vet Rec*. 132:127–129.
142. Grieve, D.B. 2000. Environmental considerations for commercial egg-type layers and breeders. Influence of Environmental Factors on Poultry Health—ACPV Workshop. American College of Poultry Veterinarians, ed., Sacramento, CA. 103–109.
143. Griner, L.A., ed. 1983. Birds, order Anseriformes. Zoological Society of San Diego, San Diego, California. 158–168.
144. Grunder, A.A., K.G. Hollands, and J.S. Gavora. 1979. Incidence of degenerative myopathy among turkeys fed corn or wheat based rations. *Poult Sci*. 58:1321–1324.
145. Guo, X., K. Huang, and J. Tang. 2005. Clinicopathology of gout in growing layers induced by high calcium and high protein diets. *Brit Poult Sci*. 46:641–646.
146. Gupta, A.R. 2011. Ascites syndrome in poultry: a review. *World Poult Sci Assoc*. 67:457–468.
147. Gustafson, C.R., G.L. Cooper, B.R. Charlton, and A.A. Bickford. 2003. Postural and neurologic deficits in broiler chicks after cervical vaccination with live vaccine. *J Vet Diagn Invest*. 15:361–364.
148. Haghighi-Rad, F., and D. Polin. 1981. The relationship of plasma estradiol and progesterone levels to the fatty liver hemorrhagic syndrome in laying hens. *Poult Sci*. 60:2278–2283.
149. Haghighi-Rad, F., and D. Polin. 1982. Lipid alleviates fatty liver hemorrhagic syndrome. *Poult Sci*. 61:2465–2472.
150. Hall, S.A., and N. Machicao. 1968. Myocarditis in broiler chickens reared at high altitude. *Avian Dis*. 12:75–84.
151. Hargest, T.E., R.M. Leach, and C.V. Gay. 1985. Avian dyschondroplasia. I. Ultrastructure. *Am J Path*. 119:175–190.
152. Harms, R.H., B.L. Damron, and C.F. Simpson. 1977. Effect of wet litter and supplemental biotin and/or whey on the production of foot pad dermatitis in broilers. *Poult Sci*. 56:291–296.
153. Harms, R.H., O.M. Junqueira, and R.D. Miles. 1985. Plasma calcium, phosphorus, 25-dihydroxyvitamin D3, and

1–25-dihydroxyvitamin D3 of hens with fatty liver syndrome. *Poult Sci*. 64:768–770.
154. Harper, J.A., P.E. Bernier, J.O. Stevens, and E.M. Dickinson. 1969. Degenerative myopathy in the domestic turkey. *Poult Sci*. 48:1816.
155. Harper, J.A., D.H. Helfer, and E.M. Dickinson. 1971. Hereditary myopathy in turkeys. Proceedings of the 20th Western Disease Conference. Sacramento, CA. p 76.
156. Harper, J.A., and D.H. Helfer. 1972. The effect of vitamin E, methionine and selenium on degenerative myopathy in turkeys. *Poult Sci*. 51:1757–1759.
157. Harper, J.A., P.E. Bernier, D.H. Helfer, and J.A. Schmitz. 1975. Degenerative myopathy of the deep pectoral muscle in the turkey. *J Her*. 66:362–366.
158. Harper, J.A., P.E. Bernier, and L.L. Thompson-Cowley. 1983. Early expression of hereditary deep pectoral myopathy in turkeys due to forced wing excercise. *Poult Sci*. 62:2303–2308.
159. Harris, G.C., Jr., M. Musbah, J.N. Beasley, and G.S. Nelson. 1978. The development of dermatitis (scabby-hip) on the hip and thigh of broiler chickens. *Avian Dis*. 22:122–130.
160. Hartini, S., M. Choct, G. Hinch, A. Kocher, and J.V. Nolan. 2002. Effects of light intensity during rearing and beak trimming and dietary fiber sources on mortality, egg production, and performance of ISA brown laying hens. *J Appl Poult Res*. 11:104–110.
161. Hassanzadeh, M., N. Buys, A. Vanderpooten, and E. Decuypere. 1997. Myocardial-adrenergic receptor characteristics in T3-induced ascies and in broiler lines differing in ascites susceptibility. *Avian Pathol*. 26:293–303.
162. Hassanzadeh, M., M.H. Bozorgmerifard, A.R. Akabari, J. Buyse, and E. Decuypere. 2000. Effect of itermittent lighting schedules during the natural scotoperios on T3-induced ascites in broiler chickens. *Avian Pathol*. 29:433–439.
163. Hassanzadeh, M., J. Buyse, and E. Decuypere. 2001. Relatonship between myocardial-adregenic receptor characterisitics with the incidence of ascites in broiler chickens. *Avian Pathol*. 30: 169–174.
164. Hassanzadeh, M., J. Buyse, and E. Decuypere. 2002. Further evidence for the involvement of cardiac beta-adrenergic receptors in right ventricle hypertrophy and ascites in broiler chickens. *Avian Pathol*. 31:177–181.
165. Hassanzadeh, M., M.H. Bozorgmerifard, J. Buyse, V. Bruggeman, and E. Decuypere. 2004. Effect of chronic hypoxia during embryonic development on physiological functioning and on hatching and post-hatching parameters related to ascites syndrome in broiler chickens. *Avian Pathol*. 33 558–564.
166. Hassanzadeh, M. 2010. Endogenous and environmental factors interactions that contribute to the development of ascites in broiler chickens: a review. *Int J Vet Res*. 4:117–126, 134.
167. Haye, U., and P.C. Simons. 1978. Twisted legs in broilers. *Brit Poult Sci*. 19:549–557.
168. Hemsley, L.A. 1965. The causes of mortality in fourteen flocks of broiler chickens. *Vet Rec*. 77:467–472.
169. Hester, P.Y. 1994. The role of environment and management on leg abnormalities in meat-type fowl. *Poult Sci*. 73:904–915.
170. Hester, P.Y., and P.R. Ferket. 1994. Relationship between tibial dyschondroplasia and long bone distortion in male turkeys. *Poult Sci*. 73 (Suppl. 1):4.
171. Hester, P.Y., D.L. Cassens, and T.A. Bryan. 1997. The applicability of particle board residue as a litter material for male turkeys. *Poult Sci*. 76:248–255.
172. Hester, P.Y., D.A. Wilson, P. Settar, J.A. Arango, and N.P. O'Sullivan. 2011. Effect of lighting programs during the pullet phase on skeletal integrity of egg-laying strains of chickens. *Poult Sci*. 90:1645–1651.
173. Hicks-Alldredge, K.D. 1996. Reproduction. In: *Ratite Management, Medicine, and Surgery*. T.N. Tully, Jr., and S. Shane, eds. Krieger Publishing Co., Malabar, FL. 47–57.
174. Hocking, P.M., D.A. Sandercock, S. Wilson, and R.H. Fleming. 2009. Quantifying genetic (co)variation and effects of genetic selection on tibial bone morphology and quality in 37 lines of broiler, layer and traditional chickens. *Brit Poult Sci*. 50:443–450.
175. Huchzermeyer, F.W., and A.M. De Ruyck. 1986. Pulmonary hypertension syndrome associated with ascites in broilers. *Vet Rec*. 119:94.
176. Huchzermeyer, F.W., J.A. Cilliers, C.D. Diaz Lavigne, and R.A. Bartkowiak. 1987. Broiler pulmonary hypertension syndrome. I. Increased right ventricular mass in broilers experimentally infected with Aegyptianella pullorum. *Onderstepoort J Vet*. 54: 113–114.
177. Hughes, B.O., and I.J.H. Duncan. 1972. The influence of strain and environmental factors upon feather pecking and cannibalism in fowls. *Brit Poult Sci*. 13:525–547.
178. Hulan, H.W., F.G. Proudfoot, D. Ramey, and K.B. McRae. 1980. Influence of genotype and diet on general performance and incidence of leg abnormalities of commercial broilers reared to roaster weight. *Poult Sci*. 59:748–757.
179. Hunt, J.R., and E.E. Gardiner. 1982. Effect of various diets on the incidence of acute death syndrome ("flip-over") of chickens. *Poult Sci*. 61:1481.
180. Hutt, F.B., K. Goodwin, and W.D. Urban. 1956. Investigations of nonlaying hens. *Cornell Vet*. 46:257–273.
181. Ibrahim, I.K., R.D. Hodges, and R. Hill. 1980. Haemorrhagic liver syndrome in laying fowl fed diets containing rapeseed meal. *Res Vet Sci*. 29:68–76.
182. Imaeda, N. 1999. Characterization of serum enzyme activities and electrolyte levels in broiler chickens after death from sudden death syndrome. *Poult Sci*. 78:66–69.
183. Imaeda, N. 2000. Influence of the stocking density and rearing season on incidence of sudden death syndrome in broiler chickens. *Poult Sci*. 79:201–204.
184. Itakura, C., and S. Yamagiwa. 1970. Histopathological studies on bone dysplasia of chickens. I. Histopathology of the bone. *Nippon Juigaku Zasshi*. 32:105–117.
185. Itakura, C., and S. Yamagiwa. 1971. Histopathological studies on bone dysplasia of chickens. 3. A collective occurrence of bowleg (genu varum) among broiler chicks. *Jap J Vet Sci*. 33:11–16.
186. Jackson, C.A., D.J. Kingston, and L.A. Hemsley. 1972. A total mortality survey of nine batches of broiler chickens. *Aust Vet J*. 48:481–487.
187. Jensen, P., L. Keeling, K. Schutz, L. Andersson, P. Mormede, H. Brandstrom, B. Forkman, S. Kerje, R. Fredriksson, C. Ohlsson, S. Larsson, H. Mallmin, and A. Kindmark. 2005. Feather pecking in chickens is genetically related to behavioural and developmental traits. *Physiol Behav*. 86:52–60.
188. Jiakui, L., B. Dingren, P. Siyi, Z. Yanhong, and Z. Donghai. 2008. Effects of high dietary vitamin A supplementation on tibial dyschondroplasia, skin pigmentation and growth performance in avian broilers. *Res Vet Sci*. 84:409–412.
189. Jones, H.G.R., C.J. Randall, and C.P.J. Mills. 1978. A survey of mortality in three adult broiler breeder flocks. *Avian Pathol*. 7:619–628.

190. Jones, J.M., N.R. King, and M.M. Mulliner. 1974. Degenerative myopathy in turkey breeder hens: a comparative study of normal and affected muscle. *Brit Poult Sci*. 15:191–196.
191. Jones, R.B., and N.L. Carmichael. 1999. Responses of domestic chicks to selected pecking devices presented for varying durations. *Appl Anim Behav Sci*. 64:125–140.
192. Jones, R.B., N.L. Carmichael, and E. Rayner. 2000. Pecking preferences and pre-dispositions in domestic chicks: Implications for the development of environmental enrichment devices. *Appl Anim Behav Sci*. 69:291–312.
193. Jones, R.B. 2005. Environmental enrichment can reduce feather pecking. In: *Beak Trimming*. P.C. Glatz, ed. Nottingham University Press, Nottingham, England. 97–100.
194. Julian, J.R. 1982. Water deprivation as a cause of renal disease in chickens. *Avian Pathol*. 11:615–617.
195. Julian, J.R. 1984. Valgus-varus deformity of the intertarsal joint in broiler chickens. *Can Vet J*. 25:254–258.
196. Julian, J.R. 1986. The effect of increased mineral levels in the feed of leg weakness and sudden death syndrome in broiler chickens. *Can Vet J*. 27:157–160.
197. Julian, J.R. 1988. Ascites in meat-type ducklings. *Avian Pathol*. 17:11–21.
198. Julian, J.R., and M. Goryo. 1990. Pulmonary aspergillosis causing right ventricular failure and ascites in meat-type chickens. *Avian Pathol*. 19:643–654.
199. Julian, J.R. 1993. Ascites in poultry. *Avian Pathol*. 22:419–454.
200. Julian, R.J. 1984. Tendon avulsion as a cause of lameness in turkeys. *Avian Dis*. 28:244–249.
201. Julian, R.J. 1985. Osteochondrosis, dyschondroplasia, and osteomyelitis causing femoral head necrosis in turkeys. *Avian Dis*. 29:854–866.
202. Julian, R.J., J. Summers, and J.B. Wilson. 1986. Right ventricular failure and ascites in broiler chickens caused by phosphorus-deficient diets. *Avian Dis*. 30:453–459.
203. Julian, R.J., S.M. Mirsalimi, L.G. Bagley, and E.J. Squires. 1992. Effect of hypoxia and diet on spontaneous turkey cardiomyopathy (round-heart disease). *Avian Dis*. 36: 1043–1047.
204. Julian, R.J. 2005. Production and growth related disorders and other metabolic diseases of poultry—a review. *Vet J*. 169: 350–369.
205. Kawada, M., R. Hirosawa, T. Yanai, T. Masegi, and K. Ueda. 1994. Cardiac lesions in broilers which died without clinical signs. *Avian Pathol*. 23:503–511.
206. Keeling, L., L. Andersson, K.E. Schütz, S. Kerje, R. Fredriksson, Ö. Carlborg, C.K. Cornwallis, T. Pizzari, and P. Jensen. 2004. Chicken genomics: feather-pecking and victim pigmentation. *Nature*. 431:645–646.
207. King, N.W., and J. Alroy. 1996. Amyloidosis. In: *Veterinary Pathology*, 6th ed. T.C. Jones, R.D. Hunt, and N.W. King, eds. Williams and Wilkins, Baltimore. 50–55.
208. Kisilevsky, R. 1983. Amyloidosis: a familiar problem in the light of current pathogenetic developments. *Lab Invest*. 49: 381–389.
209. Klunk, W.E., J.W. Pettegrew, and D.J. Abraham. 1989. Quantitative evaluation of Congo red binding to amyloid-like proteins with a beta-pleated sheet conformation. *J Histochem Cytochem*. 37:1273–1281.
210. Knott, L., C.C. Whitehead, R.H. Fleming, and A.J. Bailey. 1995. Biochemical changes in the collagenous matrix of osteoporotic avian bone. *Biochem J*. 310:1045–1051.
211. Knowles, T.G., D.M. Broom, N.G. Gregory, and L.J. Wilkins. 1993. Effect of bone strength on the frequency of broken bones in hens. *Res Vet Sci*. 54:15–19.
212. Krista, L.M., P.E. Waibel, and R.E. Burger. 1965. The influence of dietary alterations, hormones, and blood pressure on the incidence of dissecting aneurysm in turkeys. *Poult Sci*. 44: 15–22.
213. Krista, L.M., P.E. Waibel, R.N. Shoffner, and J.H. Sautter. 1965. Natural dissecting aneurysm (aortic rupture) and blood pressure in the turkey. *Nature*. 214:1162–1163.
214. Kuhlers, D.L., and G.R. McDaniel. 1996. Estimates of heritabilities and genetic correlations between tibial dyschondroplasia expression and body weight at two ages in broilers. *Poult Sci*. 75:959–961.
215. Kumar, V., A.K. Abbas, N. Fausto, and J. Aster, eds. 2010. *Disease of the Immune System*. Saunders, Elsevier Inc., Philadelphia.
216. Lamas da Silva, J.M., N. Dale, and J.B. Luchesi. 1988. Effect of pelleted feed on the incidence of ascites in broilers reared at low altitudes. *Avian Dis*. 32:376–378.
217. Landman, W.J.M., M.H. Boeve, R.M. Dwars, and E. Gruys. 1998. Keratoglobus lesion in the eyes of rearing broiler breeders. *Avian Pathol*. 27:256–262.
218. Landman, W.J.M., A.E.J.M. Bogaard, P. Doornenbal, P.C.J. Tooten, A.R.W. Elbers, and E. Gruys. 1998. The role of various agents in chicken amyloid arthropathy. *Int J Exp Clin Inv*. 5:266–278.
219. Landman, W.J.M., E. Gruys, and A.L.J. Gielkens. 1998. Avian amyloidosis. *Avian Pathol*. 27:437–449.
220. Landman, W.J.M., D.R. Mekkes, R. Chamanza, P. Doornenbal, and E. Gruys. 1999. Arthropathic and amyloidogenic *Enterococcus faecalis* infections in brown layers: A study on infection routes. *Avian Pathol*. 28:545–557.
221. Landman, W.J.M., B. Zekarias, and E. Gruys. 2000. *Enterococcus faecalis*-induced avian AA amyloid arthropathy: An animal model for studying amyloidogenesis. *J Rheumat*. 27 (Suppl. 59):30.
222. Landman, W.J.M., and A. Feberwee. 2001. Field studies on the association between amyloid arthropathy and Mycoplasma synoviae infection, and experimental reproduction of the condition in brown layers. *Avian Pathol*. 31:629–639.
223. Lax, D., R.T. Holman, S.B. Johnson, S.-L. Zhang, Y. Li, G.R. Noren, N.A. Staley, and S. Einzig. 1994. Myocardial lipid composition in turkeys with dilated cardiomyopathy. *Cardio Res*. 28:407–413.
224. Lay Jr., D.C., R.M. Fulton, P.Y. Hester, D.M. Karcher, J.B. Kjaer, J.A. Mench, B.A. Mullens, R.C. Newberry, C.J. Nicol, N.P. O'Sullivan, and R.E. Porter. 2011. Hen welfare in different housing systems. *Poult Sci*. 90:278–294.
225. Le Bihan-Duval, E., C. Beaumont, and J.J. Colleau. 1996. Genetic parameters of the twisted legs syndrome in broiler chickens. *Gen Selec Evol*. 28:177–195.
226. Le Bihan-Duval, E., C. Beaumont, and J.J. Colleau. 1997. Estimation of the genetic correlations between twisted legs and growth or conformation traits in broiler chickens. *J An Breed Gen*. 114:239–259.
227. Leach Jr., R.M., and E. Monsonego-Ornan. 2007. Tibial dyschondroplasia 40 years later. *Poult Sci*. 86:2053–2058.
228. Leach, R.M., and M.S. Lilburn. 1992. Current knowledge on the etiology of tibial dyschondroplasia in the avian species. *Poult Sci Rev*. 4:57–65.

229. Leach, R.M., and W.O. Twal. 1994. Autocrine, paracrine, and hormonal signals involved in growth plate chondrocyte differentiation. *Poult Sci*. 73:883–888.
230. Lee, B.K., J.S. Kim, H.J. Ahn, J.H. Hwang, J.M. Kim, H.T. Lee, B.K. An, and C.W. Kang. 2010. Changes in hepatic lipid parameters and hepatic messenger ribonucleic acid expression following estradiol administration in laying hens (*Gallus domesticus*). *Poult Sci*. 89:2600–2667.
231. Lent, A.J., and R.F. Wideman. 1993. Susceptibility of two commercial single comb White Leghorn strains to calcium-induced urolithiasis: efficacy of dietary supplementation with DL-methionine and ammonium sulphate. *Brit Poult Sci*. 34:577–587.
232. Leterrier, C., and Y. Nys. 1992. Clinical and anatomical differences in varus and valgus deformities of chick limbs suggest different aetio-pathogenesis. *Avian Pathol*. 21:429–442.
233. Leterrier, C., N. Rose, P. Costantin, and Y. Nys. 1998. Reducing growth rate of broiler chickens with a low energy diet does not improve cortical bone quality. *Brit Poult Sci*. 39:24–30.
234. Ley, D.H., R.A. Marusak, E.J. Vivas, H.J. Barnes, and O.J. Fletcher. 2010. Mycoplasma iowae associated with chondrodystrophy in commercial turkeys. *Avian Pathol*. 39:87–93.
235. Leyendecker, M., H. Hamann, J. Hartung, J. Kamphues, U. Neumann, C. Surie, and O. Distl. 2005. Keeping laying hens in furnished cages and an aviary housing system enhances their bone stability. *Brit Poult Sci*. 46:536–544.
236. Li, C., Z. Jiang, and X. Liu. 2009. Biochemical mechanism of gallium on prevention of fatal cage-layer osteoporosis. *Biol Trace Elem Res*. 134:195–202.
237. Li, K., L. Zhao, G. Geng, L. Ma, S. Dong, T. Xu, J. Wang, H. Wang, Y. Tian, and J. Qiao. 2011. Increased calcium deposits and decreased Ca2+-ATPase in erythrocytes of ascitic broiler chickens. *Res Vet Sci*. 90:468–473.
238. Liao, R., L. Nascimben, J. Friedrich, J.K. Gwathmey, and J.S. Ingwall. 1996. Decreased energy reserve in an animal model of dilated cardiomyopathy. Relationship to contractile performance. *Circ Res*. 78:893–902.
239. Lilburn, M.S. 1994. Skeletal growth of commercial poultry species. *Poult Sci*. 73:897–903.
240. Lin, K.-C., K. Gyenai, R.L. Pyle, T. Geng, J. Xu, and E.J. Smith. 2006. Candidate gene expression analysis of toxin-induced dilated cardiomyopathy in the turkey (*Meleagris gallopavo*). *Poult Sci*. 85:2216–2221.
241. Lin, K.-C., J. Xu, D. Kamara, T. Geng, K. Gyenai, K.M. Reed, and E.J. Smith. 2007. DNA sequence and haplotype variation in two candidate genes for dilated cardiomyopathy in the turkey *Meleagris gallopavo*. *Genome*. 50:463–469.
242. Loveridge, N., C. Farquharson, J.E. Hesketh, S.B. Jakowlew, C.C. Whitehead, and B.H. Thorp. 1993. The control of chondrocyte differentiation during endochondral bone growth *in vivo*: changes in TGF-beta and the proto-oncogene c-myc. *J Cell Sci*. 105:949–956.
243. Lubritz, D.L., J.L. Smith, and B.N. McPherson. 1995. Heritability of ascites and the ratio of right to total ventricle weight in broiler breeder male lines. *Poult Sci*. 74:1237–1241.
244. Lynch, M., B.H. Thorp, and C.C. Whitehead. 1992. Avian tibial dyschondroplasia as a cause of bone deformity. *Avian Pathol*. 21:275–285.
245. Mallinson, E.T., H. Rothenbacher, R.F. Wideman, D.B. Snyder, E. Russek, A.I. Zuckerman, and J.P. Davidson. 1984. Epizootiology, pathology, and microbiology of an outbreak of urolithiasis in chickens. *Avian Dis*. 28:25–43.
246. Martindale, L., W.G. Siller, and P.A. Wight. 1979. Effects of subfascial pressure in experimental deep pectoral myopathy of the fowl: An angiographic study. *Avian Pathol*. 8:425–436.
247. Martland, M.F. 1984. Wet litter as a cause of plantar pododermatitis leading to foot ulceration and lameness in fattening turkeys. *Avian Pathol*. 13:241–252.
248. Martland, M.F., E.J. Butler, and G.R. Fenwick. 1984. Rapeseed induced liver haemorrhage, reticulolysis and biochemical changes in laying hens: the effects of feeding high and low glucosinolate meals. *Res Vet Sci*. 36:298–309.
249. Martland, M.F. 1985. Ulterative dermatitis in broiler chickens: The effect of wet litter. *Avian Pathol*. 14:353–364.
250. Martrenchar, A., B. Broilletot, D. Huonnic, and F. Pol. 2002. Risk factors for foot-pad dermatitis in chickens and turkey broilers in France. *Prev Vet Med*. 52:213–226.
251. Maxwell, M.H., G.W. Robertson, and S. Spence. 1986. Studies on an ascitic syndrome in young broilers. 1. Haematology and pathology. *Avian Pathol*. 15:511–524.
252. Maxwell, M.H., G.W. Robertson, and S. Spence. 1986. Studies on an ascitic syndrome in young broilers. 2. Ultrastructure. *Avian Pathol*. 15:525–538.
253. Maxwell, M.H., T.T. Dolan, and C.W. Mbugua. 1989. An ultrastructural study of an ascitic syndrome in young broilers reared at high altitude. *Avian Pathol*. 18:481–494.
254. Maxwell, M.H., G.W. Robertson, and C.C. McCorquodale. 1992. Whole blood and plasma viscosity values in normal and ascitic broiler chickens. *Brit Poult Sci*. 33:871–877.
255. Maxwell, M.H., G.W. Robertson, and M.A. Mitchell. 1993. Ultrastructural demonstration of mitochondrial calcium overload in myocardial cells from broiler chickens with ascites and induced hypoxia. *Res Vet Sci*. 54:267–277.
256. Maxwell, M.H., G.W. Robertson, and D. Moseley. 1994. Potential role of serum troponin T in cardiomyocyte injury in the broiler ascites syndrome. *Brit Poult Sci*. 35:663–667.
257. Mayeda, B., and R.A. Ernst. 2008. Prevention of fatal cage-layer osteoporosis. *Avian Dis*. 52:544–545.
258. Mayne, R.K., P.M. Hocking, and R.W. Else. 2006. Foot pad dermatitis develops at an early age in commercial turkeys. *Brit Poult Sci*. 47:36–42.
259. McCaskey, P.C., G.N. Rowland, R.K. Page, and L.R. Minear. 1982. Focal failures of endochondral ossification in the broiler. *Avian Dis*. 26:701–717.
260. McIlroy, S.G., E.A. Goodall, and C.H. McMurray. 1987. A contact dermatitis of broliers: epidemiological findings. *Avian Pathol*. 16:93–105.
261. Menzies, F.D., E.A. Goodall, D.A. McConaghy, and M.J. Alcorn. 1998. An update on the epidemiology of contact dermatitis in commercial broilers. *Avian Pathol*. 27:174–180.
262. Mireles, V., and C. Alvarez. 1979. *Pseudomonas aeruginosa* infection due to contaminated vaccination equipment. Proceedings of the 28th Western Poultry Disease Conference. Davis, CA. 55–57.
263. Mirsalimi, S.M., and R.J. Julian. 1991. Reduced erythrocyte deformability as a possible contributing factor to pulmonary hypertension and ascites in broiler chickens. *Avian Dis*. 35: 374–379.
264. Mollison, B., W. Guenter, and B.R. Boycott. 1984. Abdominal fat deposition and sudden death syndrome in broilers: the effects of restricted intake, early life caloric (fat) restriction, and calorie: protein ratio. *Poult Sci*. 63:1190–1200.
265. Montali, R.J., M. Bush, and E.E. Smith. 1978. Pathology of tuberculosis in captive exotic birds. In: *Mycobacterial Infections*

of Zoo Animals. R.J. Montali, ed. Smithsonian Institution Press, Washington, D.C. 209–215.
266. Moran, E.T., Jr. 1990. Effects of egg weight, glucose administration at hatch, and delayed access to feed and water on the poult at 2 weeks of age. *Poult Sci*. 69:1718–1723.
267. Morishita, T.Y. 1999. Crop impaction resulting from feather ball formation in cage layers. *Avian Dis*. 43:160–163.
268. Moyle, J.R., R.F. Wideman, S.M. Whipple, D.E. Yoho, and R.K. Bramwell. 2011. Urolithiasis in male boiler breeders. *Int J Poult Sci*. 10:839–841.
269. Mutalib, A.A., and J.A. Hanson. 1990. Sudden death in turkeys with perirenal hemorrhage: Field and laboratory findings. *Can Vet J*. 31:637–642.
270. Nain, S., C. Wojnarowicz, B. Laarveld, and A.A. Olkowski. 2009. Vascular remodeling and its role in the pathogenesis of ascites in fast growing commercial broilers. *Res Vet Sci*. 86: 479–484.
271. Nakamura, K., H. Tanaka, Y. Kodama, M. Kubo, and T. Shibahara. 1998. Systemic amyloidosis in laying Japanese quail. *Avian Dis*. 42:209–214.
272. Nakamura, K., Y. Ibaraki, Z. Mitarai, and T. Shibahara. 1999. Comparative pathology of heart and liver lesions of broiler chickens that died of ascites, heart failure, and others. *Avian Dis*. 43:526–532.
273. Nakamura, K., A. Waseda, Y. Yamamoto, M. Yamada, M. Nakazawa, E. Hata, T. Terazaki, A. Enya, T. Imada, and K. Imai. 2006. Pathology of cutaneous fowlpox with amyloidosis in layer hens inoculated with fowlpox vaccine. *Avian Dis*. 50: 152–156.
274. Neumann, F., and H. Ungar. 1973. Spontaneous aortic rupture in turkeys and the vascularization of the aortic wall. *Can Vet J*. 14:136–138.
275. Newberry, R.C., J.R. Hunt, and E.E. Gardiner. 1986. Light intensity effects on performance, activity, leg disorders, and sudden death syndrome of roaster chickens. *Poult Sci*. 65: 2232–2238.
276. Newberry, R.C., E.E. Gardiner, and J.R. Hunt. 1987. Behavior of chickens prior to death from sudden death syndrome. *Poult Sci*. 66:1446–1450.
277. Newberry, R.C. 1993. The role of temperature and litter type in the development of breast buttons in turkeys. *Poult Sci*. 72: 467–474.
278. Newman, S., and S. Leeson. 1998. Effect of housing birds in cages or an aviary system on bone characteristics. *Poult Sci*. 77:1492–1496.
279. Niznik, R.A., R.F. Wideman, B.S. Cowen, and R.E. Kissell. 1985. Induction of urolithiasis in single comb white Leghorn pullets: effect on glomerular number. *Poult Sci*. 64:1430–1437.
280. Nordin, M., and V.H. Frankel. 1989. Biomechanics of bone. In: *Basic Biomechanics of the Musculoskeletal System*, 2nd ed. M. Nordin and V.H. Frankel, eds. Lea and Febiger, Malvern, PA. 3–29.
281. Norgaard-Nielsen, G. 1990. Bone strength of laying hens kept in an alternative system, compared with hens in cages and on deep-litter. *Brit Poult Sci*. 31:81–89.
282. Odom, T.W., B.M. Hargis, C.C. Lopez, M.J. Arce, Y. Ono, and G.E. Avila. 1991. Use of electrocardiographic analysis for investigation of ascites syndrome in broiler chickens. *Avian Dis*. 35:738–744.
283. Ohyama, K.C., C. Farquharson, C. Whitehead, and I.M. Shapiro. 1997. Further observations on programmed cell death in the epiphyseal growth plate: Comparison of normal and dyschondroplastic epiphyses. *J Bone Miner Res*. 12:1647–1656.
284. Oldroyd, N.O., and R.F. Wideman Jr. 1986. Characterization and composition of uroliths from domestic fowl. *Poult Sci*. 65:1090–1094.
285. Olkowski, A.A., and H.L. Classen. 1995. Sudden death syndrome in broiler chickens: A review. *Poult Avian Biol Rev*. 6:95–105.
286. Olkowski, A.A., and H.L. Classen. 1997. Malignant ventricular dysrhythmia in broiler chickens dying of sudden death syndrome. *Vet Rec*. 140:177–179.
287. Olkowski, A.A., H.L. Classen, C. Riddell, and C.D. Bennett. 1997. A study of electrocardiographic patterns in a population of commercial broiler chickens. *Vet Res Commun*. 21:51–62.
288. Olkowski, A.A., and H.L. Classen. 1998. High incidence of cardiac arrhythmias in broiler chickens. *J Vet Med. A* 45:83–91.
289. Olkowski, A.A., H.L. Classen, and L. Kumor. 1998. Left atrioventricular valve degeneration, left ventricular dilation and right ventricular failure: A possible association with pulmonary hypertension and aetiology of ascites in broiler chickens. *Avian Pathol*. 27:51–59.
290. Olkowski, A.A., J.A. Abbott, and H.L. Classen. 2005. Pathogenesis of ascites in broilers raised at low altitude: aetiological considerations based on echocardiographic findings. *J Vet Med. A* 52:166–171.
291. Olkowski, A.A., C. Wojnarowicz, S. Nain, B. Ling, J.M. Alcorn, and B. Laarveld. 2008. A study on pathogenesis of sudden death syndrome in broiler chickens. *Res Vet Sci*. 85:131–140.
292. Ononiwu, J.C., R.G. Thomson, H.C. Carlson, and R.J. Julian. 1979. Pathological studies of "sudden death syndrome" in broiler chickens. *Can Vet J*. 20:70–73.
293. Orr, J.P., and C. Riddell. 1977. Investigation of the vascular supply of the pectoral muscles of the domestic turkey and comparison of experimentally produced infarcts with naturally occurring deep pectoral myopathy. *Am J Vet Res*. 38:1237–1242.
294. Orth, M.W., and M.E. Cook. 1994. Avian tibial dyschondroplasia: a morphological and biochemical review of the growth plate lesion and its causes. *Vet Path*. 31:403–414.
295. Oviedo-Rondón, E.O., M.J. Wineland, S. Funderburk, J. Small, H. Cutchin, and M. Mann. 2009. Incubation conditions affect leg health in large, high-yield broilers. *J Appl Poult Res*. 18:640–646.
296. Owen, R.L., R.F. Wideman, R.M. Leach, and B.S. Cowen. 1993. Effect of age at exposure to hypobaric hypoxia and dietary changes on mortality due to ascites. Proceedings of the 42nd Western Poultry Disease Conference. Sacramento, CA. 16–18.
297. Pakdel, A., P. Bijma, B.J. Ducro, and H. Bovenhuis. 2005. Selection strategies for body weight and reduced ascites susceptibility in broilers. *Poult Sci*. 84:528–535.
298. Pakdel, A., J.A.M. van Arendonk, A.L.J. Vereijken, and H. Bovenhuis. 2005. Genetic parameters of ascites-related traits in broilers: effect of cold and normal temperature conditions. *Brit Poult Sci*. 46:35–42.
299. Pakdel, A., J.A.M. Van Arendonk, A.L.J. Vereijken, and H. Bovenhuis. 2005. Genetic parameters of ascites-related traits in broilers: correlations with feed efficiency and carcase traits. *Brit Poult Sci*. 46:43–53.
300. Parkinson, G.B. 2005. Management of body weight. In: *Poultry Welfare Issues*. P.C. Glatz, ed. Nottingham Unversity Press, Nottingham, England. 123–125.

301. Pearson, A.W., and E.J. Butler. 1978. The oestrogenised chick as an experimental model for fatty liver-haemorrhagic syndrome in the fowl. *Res Vet Sci*. 24:82–86.
302. Pearson, A.W., and E.J. Butler. 1978. Pathological and biochemical observations on subclinical cases of fatty liver-haemorrhagic syndrome in the fowl. *Res Vet Sci*. 24:65–71.
303. Peckham, M.C. 1984. Vices and miscellaneous diseases and conditions. In: *Diseases of Poultry*, 8th ed. M.S. Hofstad, H.J. Barnes, B.W. Calnek, W.M. Reid, and H.W. Yoder Jr., eds. Iowa Sated University Press, Ames, IA. 741–782.
304. Pegram, R.A., and R.D. Wyatt. 1981. Avian gout caused by oosporein, a mycotoxin produced by Caetomium trilaterale. *Poult Sci*. 60:2429–2440.
305. Peguri, A., and C. Coon. 1993. Effect of feather coverage and temperature on layer performance. *Poult Sci*. 72:1318–1329.
306. Penrith, M.-L., A.J. Bezuidenhout, W.P. Burger, and J.F. Putterill. 1994. Evidence for cryptosporidial infection as a cause of prolapse of the phallus and cloaca in ostrich chicks (*Struthio camelus*). *Onderstepoort J Vet*. 61:283–289.
307. Perry, R.W., G.N. Rowland, T.L. Foutz, and J.R. Glisson. 1991. Poult malabsorption syndrome. III. Skeletal lesions in market-age turkeys. *Avian Dis*. 35:707–713.
308. Peterson, E.H. 1974. Case report: a condition of bone degeneration in chickens and its possible relationship to so-called "scabby" hip. *Poult Sci*. 53:822–824.
309. Philippe, C., J.-P. Vaillancourt, L.K. Ivy, J. Barnes, D. Wages, and L. Baucom. 1999. Causes of mortality in male turkeys during the last part of grow-out. Proceedings of the 48th Western Poultry Disease Conference. Vancouver, Canada. 87–88.
310. Poulos, P.W., Jr. 1978. Tibial dyschondroplasia (osteochondrosis) in the turkey. A morphologic investigation. *Acta Radiol*. 358 (Suppl.):197–227.
311. Poulos, P.W., Jr., S. Reiland, K. Elwinger, and S.E. Olsson. 1978. Skeletal lesions in the broiler, with special reference to dyschondroplasia (osteochondrosis). Pathology, frequency and clinical significance in two strains of birds on high and low energy feed. *Acta Radiol*. 358 (Suppl.):229–275.
312. Proudfoot, F.G., and H.W. Hulan. 1982. Effect of reduced feeding time using all mash or crumble-pellet dietary regimens on chicken broiler performance, including the incidence of acute death syndrome. *Poult Sci*. 61:750–754.
313. Qujeq, D., and H.R. Aliakbarpour. 2005. Serum activities of enzymes in broiler chickens that died from sudden death syndrome. *Pakistan J Biol Sci*. 8:1078–1080.
314. Rabie, T.S.K.M., R.P.M.A. Crooijmans, H. Bovenhuis, A.L.J. Vereijken, T. Veenendaal, J.J. van der Poel, J.A.M. Van Arendonk, A. Pakdel, and M.A.M. Groenen. 2005. Genetic mapping of quantitative trait loci affecting susceptibility in chicken to develop pulmonary hypertension syndrome. *An Gen*. 36:468–476.
315. Randall, C.J., and I. McLachlan. 1979. Retinopathy in commercial layers. *Vet Rec*. 105:41–42.
316. Randall, C.J., and C.P.J. Mills. 1981. Observations on leg deformity in broilers with particular reference to the intertarsal joint. *Avian Pathol*. 10:407–431.
317. Rasaputra, K.S., B.R. Liyanage, J.O.L. Jr., F.M. McCarthy, and N.C. Rath. 2010. Tibial dyschondroplasia-associated proteomic changes in chicken growth plate cartilage. *Avian Dis*. 54:1166–1171.
318. Rath, N.C., G.R. Bayyari, J.N. Beasley, W.E. Huff, and J.M. Balog. 1994. Age-related changes in the incidence of tibial dyschondroplasia in turkeys. *Poult Sci*. 73:1254–1259.
319. Rath, N.C., W.E. Huff, G.R. Bayyari, and J.M. Balog. 1998. Cell death in avian tibial dyschondroplasia. *Avian Dis*. 42: 72–79.
320. Rath, N.C., J.M. Balog, W.E. Huff, G.R. Huff, G.B. Kulkarni, and J.F. Tierce. 1999. Comparative differences in the composition and biomechanical properties of tibiae of seven- and seventy-two-week-old male and female broiler breeder chickens. *Poult Sci*. 78:1232–1239.
321. Rath, N.C., G.R. Huff, W. Huff, and J.M. Balog. 2000. Factors regulating bone maturity and strength in poultry. *Poult Sci*. 79:1024–1032.
322. Rath, N.C., W.E. Huff, J.M. Balog, and G.R. Huff. 2004. Comparative efficacy of different dithiocarbamates to induce tibial dyschondroplasia in poultry. *Poult Sci*. 83:266–274.
323. Rath, N.C., M.P. Richards, W.E. Huff, G.R. Huff, and J.M. Balog. 2005. Changes in the tibial growth plates of chickens with thiram-induced dyschondroplasia. *J Comp Path*. 133: 41–52.
324. Reece, F.N., J.W. Deaton, J.D. May, and K.N. May. 1971. Cage versus floor rearing of broiler chickens. *Poult Sci*. 50: 1786–1790.
325. Rennie, J.S., H.A. McCormack, C. Farquharson, J.L. Berry, E.B. Mawer, and C.C. Whitehead. 1995. Interaction between dietary 1,25-dihydroxycholecalciferol and calcium and effects of management on the occurrence of tibial dyschondroplasia, leg abnormalities and performance in broiler chickens. *Brit Poult Sci*. 36:465–477.
326. Rennie, J.S., and C.C. Whitehead. 1996. Effectiveness of dietary 25- and 1-hydroxycholecalciferol in combating tibial dyschondroplasia in broiler chickens. *Brit Poult Sci*. 37:413–421.
327. Richardson, J.A., J. Burgener, R.W. Winterfield, and A.S. Dhillon. 1980. Deep pectoral myopathy in seven-week-old broiler chickens. *Avian Dis*. 24:1054–1059.
328. Riddell, C. 1975. Pathology of developmental and metabolic disorders of the skeleton of domestic chickens and turkeys. I. Abnormalities of genetic or unknown aetiology. *Vet. Bull*. 45: 629–640.
329. Riddell, C. 1976. Selection of broiler chickens for a high and low incidence of tibial dyschondroplasia with observation on spondylolisthesis and twisted legs (perosis). *Poult Sci*. 55:145–151.
330. Riddell, C. 1980. A survey of skeletal disorders in five turkey flocks in Saskatchewan. *Can J Comp Med*. 44:275–279.
331. Riddell, C., and J.P. Orr. 1980. Chemical studies of the blood, and histological studies of the heart of broiler chickens dying from acute death syndrome. *Avian Dis*. 24:751–757.
332. Riddell, C. 1981. Skeletal deformities in poultry. *Adv Vet Sci Comp*. 25:277–310.
333. Riddell, C. 1983. Pathology of the skeleton and tendons of broiler chickens reared to roaster weights. I. Crippled chickens. *Avian Dis*. 27:950–962.
334. Riddell, C., M.W. King, and K.R. Gunasekera. 1983. Pathology of the skeleton and tendons of broiler chickens reared to roaster weights. II. Normal chickens. *Avian Dis*. 27:980–991.
335. Riddell, C., and R. Springer. 1985. An epizootiological study of acute death syndrome and leg weakness in broiler chickens in western Canada. *Avian Dis*. 29:90–102.
336. Riddell, C., and D.A. Pass. 1987. The influence of dietary calcium and phosphorus on tibial dyschondroplasia in broiler chickens. *Avian Dis*. 31:771–775.
337. Riddell, C. 1992. Non-infectious skeletal disorders of poultry: An overview. In: *Bone Biology and Skeletal Disorders in Poultry*.

C.C. Whitehead, ed. Carfax Publishing Company, Abingdon, England. 119–141.
338. Riddell, C., and H.L. Classen. 1992. Effects of increasing photoperiod length and anticoccidials on performance and health of roaster chickens. *Avian Dis*. 36:491–498.
339. Riddell, C. 1993. Developmental and metabolic disease of meat-type poultry. Proceedings of the Xth World Veterinary Poultry Association Congress. Sydney, Australia. 79–89.
340. Riddell, C. 1997. Developmental, metabolic, and other noninfectious disorders. In: *Diseases of Poultry*, 10th ed. B.W. Calnek, H.J. Barnes, C.W. Beard, L.R. McDougald, and Y.M. Saif, eds. Iowa State University Press, Ames, Iowa. 913–950.
341. Roberson, K.D., C.H. Hill, and P.R. Ferket. 1993. Additive amelioration of tibial dyschondroplasia in broilers by supplemental calcium or feed deprivation. *Poult Sci*. 72:798–805.
342. Robinson, F.E., H.L. Classen, J.A. Hanson, and D.K. Onderka. 1992. Growth performance, feed efficiency and the incidence of skeletal and metabolic disease in full-fed and feed restricted broiler and roaster chickens. *J Appl. Poult Res*. 1:33–44.
343. Rodenburg, T.B., H. Komen, E.D. Ellen, K.A. Uitdehaag, and J.A.M. van Arendonk. 2008. Selection method and early-life history affect behavioural development, feather pecking and cannibalism in laying hens: a review. *Appl Anim Behav Sci*. 110:217–228.
344. Rodenhoff, G., and K. Dämmrich. 1973. Untersuchungen zur Beeinflussung der Röhrenknochenstruktur durch verschiedene Haltungssysteme bei Masthähnchen. *Berl Munch Tierarztl Wochenschr*. 86:230–233, 241–244.
345. Rose, N., P. Constantin, and C. Leterrier. 1996. Sex differences in bone growth of broiler chickens. *Growth* 60:49–59.
346. Rymer, J., V. Choh, S. Bharadwaj, V. Pamanabhan, L. Modilevsky, E. Jovanovich, B. Yeh, Z. Zhang, H. Guan, W. Payne, and C.F. Wildsoet. 2007. The albino chick as a model for studying ocular development anomalies, including refractive errors, associated with albinism. *Exp Eye Res*. 85:431–432.
347. Sahin, K., and O. Kucuk. 2003. Heat stress and dietary vitamin supplementation of poultry diets. *Nutr Abs Rev*. *Series B* 73: 41R-50R.
348. Sandercock, D.A., and M.A. Mitchell. 1996. Dose dependent myopathy in monensin supplemented broiler chickens: Effects of acute heat stress. *Brit Poult Sci*. 37:S92-S94.
349. Sanders, A.M., and H.M. Edwards, Jr. 1991. The effects of 1,25-dihydroxycholecalciferol on performance and bone development in the turkey poult. *Poult Sci*. 70:853–866.
350. Savory, C.J. 1995. Feather pecking and cannibalism. *World Poult Sci J*. 51:215–219.
351. Savory, C.J., and J.D. Hetherington. 1997. Effects of plastic anti-pecking devices on food intake and behaviour of laying hens fed on pellets or mash. *Brit Poult Sci*. 38:125–131.
352. Savory, C.J., and J.S. Mann. 1997. Behavioural development in groups of pen-housed pullets in relation to genetic strain, age and food form. *Brit Poult Sci*. 38:38–47.
353. Scheele, C.W., E. Decuypere, P.F. Vereijken, and F.J. Schreurs. 1992. Ascites in broilers. 2. Disturbances in the hormonal regulation of metabolic rate and fat metabolism. *Poult Sci*. 71:1971–1984.
354. Schumann, B.E., E.J. Squires, S. Leeson, and B. Hunter. 2003. Effect of hens fed dietary flaxseed with and without a fatty liver supplement on hepatic, plasma and production characteristics relevant to fatty liver haemorrhagic syndrome in laying hens. *Brit Poult Sci*. 44:234–244.
355. Scott, T.A. 2002. Evaluation of lighting programmes, diet density, and short-term use of mash as compared to crumbled starter to reduce incidence of sudden death syndrome in broiler chicks to 35 days of age. *Can. J. An. Sci*. 82:375–383.
356. Sevimli, A., D. Misirlioğlu, Ü. Polat, M. Yalçin, A. Akkoç, and C. Uğuz. 2005. The effects of vitamin A, pentoxyfylline and methylprednisolone on experimentally induced amyloid arthropathy in brown layer chicks. *Avian Pathol*. 34:143–149.
357. Shane, S.M., R.J. Young, and L. Krook. 1969. Renal and parathyroid changes produced by high calcium intake in growing pullets. *Avian Dis*. 13:558–567.
358. Sharma, U.K. 1972. Intussusception of the proventriculus of chickens. *Avian Dis*. 16:453–457.
359. Shaw, D.P., and D.A. Halvorson. 1993. Early chick mortality associated with rupture of the yolk sac. *Avian Dis*. 37:720–723.
360. Shepherd, E.M., and B.D. Fairchild. 2010. Footpad dermatitis in poultry. *Poult Sci*. 89:2043–2051.
361. Shibuya, K., H. Ymazaki, M. Mitzutani, T. Nunoya, M. Tajima, and T. Satou. 2002. Hereditary visual impairment in a new mutant strain of chicken, GSN/1. *Acta Neuropath*. 103:137–144.
362. Shivaprasad, H.L., C.U. Meteyer, and J.S. Jeffrey. 1991. Amyloidosis in turkeys. 34th Annual Meeting of the American Association of Veterinary Laboratory Diagnosticians. San Diego, CA. 57.
363. Shivaprasad, H.L. 1992. Amyloidosis in commercial Pekin ducks. 35th Annual Meeting of the American Association of Veterinary Laboratory Diagnosticians. Louisville, KY. 63.
364. Shivaprasad, H.L. 1999. Poultry ophthalmology. In: *Veterinary Ophthalmology*, 3rd ed. K.N. Gelatt, ed. Lippincott Williams and Wilkins, Media, PA. 1177–1207.
365. Shivaprasad, H.L., and R. Korbel. 2003. Blindness due to retinal dysplasia in broiler chicks. *Avian Dis*. 47:769–773.
366. Shivaprasad, H.L., R. Crespo, and B. Puschner. 2004. Coronary artery rupture in male commercial turkeys. *Avian Pathol*. 33:226–232.
367. Shivaprasad, H.L. 2008. Eye and ear. In: *Avian Histopathology*, 3rd ed. O. Fletcher, ed. American Association of Avian Pathologists, Athens, GA. 292–323.
368. Shlosberg, A., I. Zadikov, U. Bendheim, V. Handji, and E. Berman. 1992. The effects of poor ventilation, low temperatures, type of feed and sex of bird on the development of acites in broilers. Pyhysiopathological factors. *Avian Pathol*. 21:369–382.
369. Shtrasburg, S., R. Gal, E. Gruys, S. Perl, B.M. Martin, B. Kaplan, R. Koren, A. Nyska, M. Pras, and A. Livneh. 2005. An ancillary tool for the diagnosis of amyloid A amyloidosis in a variety of domestic and wild animals. *Vet Path*. 42:132–139.
370. Siller, W.G., and P.A. Wight. 1978. The pathology of deep pectoral myopathy of turkeys. *Avian Pathol*. 7:583–617.
371. Siller, W.G., P.A. Wight, L. Martindale, and D.W. Bannister. 1978. Deep pectoral myopathy: an experimental simulation in the fowl. *Res Vet Sci*. 24:267–268.
372. Siller, W.G., L. Martindale, and P.A. Wight. 1979. The prevention of experimental deep pectoral myopathy of the fowl by fasciotomy. *Avian Pathol*. 8:301–307.
373. Siller, W.G., P.A. Wight, and L. Martindale. 1979. Exercise-induced deep pectoral myopathy in broiler fowls and turkeys. *Vet Sci Comm*. 2:331–336.
374. Siller, W.G. 1981. Renal pathology of the fowl—a review. *Avian Pathol*. 10:187–262.

375. Siller, W.G. 1985. Deep pectoral myopathy: A penalty of successful selection for muslce growth. *Poult Sci*. 64:1591–1595.
376. Smith, A. 2005. Vitamin nutrition for optimal productivity. *Internat Poult Prod*. 13:7–9.
377. Sparke, A.J., T.J. Sims, N.C. Avery, A.J. Bailey, R.H. Fleming, and C.C. Whitehead. 2002. Differences in composition of avian bone collagen following genetic selection for resistance to osteoporosis. *Brit Poult Sci*. 43:127–134.
378. Squires, E.J., and S. Leeson. 1988. Aetiology of fatty liver syndrome in laying hens. *Br Vet J*. 144:602–609.
379. Stake, P.E., T.N. Fredrickson, and C.A. Bourdeau. 1981. Induction of fatty liver-hemorrhagic syndrome in laying hens by exogenous beta-estradiol. *Avian Dis*. 25:410–422.
380. Steele, P., and J. Edgar. 1982. Importance of acute death syndrome in mortalities in broiler chicken flocks. *Aust Vet J*. 58:63–66.
381. Steele, P., J. Edgar, and G. Doncon. 1982. Effect of biotin supplementation on incidence of acute death syndrome in broiler chickens. *Poult Sci*. 61:909–913.
382. Stewart, J. 1994. Ratites. In: *Avian Medicine: Principles and Applications*. B.W. Ritchie, G.J. Harrison, and L.R. Harrison, eds. Wingers Publishing, Lake Worth, FL. 1285–1326.
383. Swain, S., and D.J. Farrell. 1975. Effects of different temperature regimens on body composition and carry-over effects on energy metabolism of growing chickens. *Poult Sci*. 54:513–520.
384. Tablante, N.L., J.-P. Vaillancourt, S.W. Martin, M. Shoukri, and I. Estevez. 2000. Spatial distribution of cannibalism mortalities in commercial laying hens. *Poult Sci*. 79:705–708.
385. Teeter, R.G., and T. Belay. 1996. Broiler management during acute heat stress. *An Feed Sci Tech*. 58:127–142.
386. Thorp, B.H. 1988. Pattern of vascular canals in the bone extremities of the pelvic appendicular skeleton in broiler type fowl. *Res Vet Sci*. 44:112–124.
387. Thorp, B.H. 1992. Abnormalities in the growth of leg bones. In: *Bone Biology and Skeletal disorders in Poultry*. C.C. Whitehead, ed. Carfax Publishing Company, Abingdon, England. 147–166.
388. Thorp, B.H., B. Ducro, C.C. Whitehead, C. Farquharson, and P. Sorensen. 1993. Avian tibial dyschondroplasia: The interaction of genetic selection and dietary 1,25-dihydroxycholecalciferol. *Avian Pathol*. 22:311–324.
389. Thorp, B.H., C.C. Whitehead, L.A. Dick, J.M. Bradbury, R.C. Jones, and A. Wood. 1993. Proximal femoral degeneration in growing broiler fowl. *Avian Pathol*. 22:325–342.
390. Thorp, B.H., S. Wilson, S. Rennie, and S.E. Solomon. 1993. The effect of a biphosphonate on bone volume and eggshell structure in the hen. *Avian Pathol*. 22:671–682.
391. Thorp, B.H. 1994. Skeletal disorders in the fowl: A review. *Avian Pathol*. 23:203–236.
392. Thorp, B.H., S.B. Jakowlew, and C. Goddard. 1995. Avian dyschondroplasia: Local deficiencies in growth factors are integral to the aetiopathogenesis. *Avian Pathol*. 24:135–148.
393. Thorp, B.H., and D. Waddington. 1997. Relationships between the bone pathologies, ash and mineral content of long bones in 35-day-old broiler chickens. *Res Vet Sci*. 62:67–73.
394. Tottori, J., R. Yamaguchi, Y. Murakawa, M. Sato, K. Uchida, and S. Tateyama. 1997. Experimental production of ascites in broiler chickens using infectious bronchitis virus and Escherichia coli. *Avian Dis*. 41:214–220.
395. Trampel, D.W., T.M. Pepper, and B.L. Blagburn. 2000. Urinary tract cryptosporidiosis in commercial laying hens. *Avian Dis*. 44:479–484.
396. Turner, S.P. 2011. Breeding against harmful social behaviours in pigs and chickens: State of the art and the way forward. *Appl Anim Behav Sci*. 134:1–9.
397. van Veen, L. 1999. Aortic rupture in poultry: a review. *Tijdschr Diergeneeskd*. 124:244–247.
398. van Walsum, J. 1975. Contribution to the aetiology of synovitis in chickens, with special reference to non-infective factors. II. *Tijdschr Diergeneeskd*. 100:76–83.
399. van Walsum, J. 1977. Contribution to the aetiology of synovitis in chickens, with special reference to non-infective factors. III. *Tijdschr Diergeneeskd*. 102:793–800.
400. van Walsum, J. 1979. Contribution to the aetiology of synovitis in chickens, with special reference to non-infective factors. IV. *Tijdschr Diergeneeskd*. 104 (Suppl.):90–96.
401. Vanhooser, S.L., E. Stair, W.C. Edwards, M.R. Labor, and D. Carter. 1994. Aortic rupture in ostrich associated with copper deficiency. *Vet Hum Tox*. 36:226–227.
402. Velada, I., F. Capela-Silva, F. Reis, E. Pires, C. Egask, P. Rodrigues-Santos, and M.T. Barros. 2011. Expression of genes encoding extracellular matrix macromolecules and metalloproteinases in avian tibial dyschondroplasia. *J Comp Path*. 145:174–186.
403. Vidyadaran, M.K., A.S. King, and H. Kassim. 1990. Quantitative comparisons of lung structure of adult domestic fowl and red jungle fowl with reference to broiler ascites. *Avian Pathol*. 19:51–58.
404. Waldenstedt, L. 2006. Nutritional factors of importance for optimal leg health in broilers: a review. *An Feed Sci Tech*. 126:291–307.
405. Walser, M.M., F.L. Cherms, and H.E. Dziuk. 1982. Osseous development and tibial dyschondroplasia in five lines of turkeys. *Avian Dis*. 26:265–271.
406. Weaver, C.H., and S. Bird. 1934. The nature of cannibalism occurring among adult domestic fowls. *J Am Vet Med Assoc*. 85:623–637.
407. Webster, A.B. 2004. Welfare implications of avian osteoporosis. *Poult Sci*. 83:184–192.
408. Webster, S.V., C. Farquharson, D. Jefferies, and A.P. Kwan. 2003. Expression of type X collagen, Indian hedgehog and parathyroid hormone related-protein in normal and tibial dyschondroplastic chick growth plates. *Avian Pathol*. 32:69–80.
409. Werner, C., J. Riegel, and M. Wicke. 2008. Slaughter performance of four different turkey strains, with special focus on the muscle fiber structure and the meat quality of the breast muscle. *Poult Sci*. 87:1849–1859.
410. Whitehead, C.C., and C.J. Randall. 1982. Interrelationships between biotin, choline and other B-vitamins and the occurrence of fatty liver and kidney syndrome and sudden death syndrome in broiler chickens. *Br J Nut*. 48:177–184.
411. Whitehead, C.C. 1997. Dyschondroplasia in poultry. *Proc Nutr Soc*. 56:957–966.
412. Whitehead, C.C., and R.H. Fleming. 2000. Osteoporosis in cage layers. *Poult Sci*. 78:1033–1041.
413. Whitehead, C.C. 2004. Skeletal disorders in laying hens: the problem of osteoporosis and bone fractures In: *Welfare of the Laying Hen*. Papers from the 27th Poultry Science Symposium of the World' s Poultry Science Association UK Branch, July 2003. G.C. Perry, ed. Wallingford, UK: CABI Publishing, Bristol, UK. 259–278.
414. Whitehead, C.C., H.A. McCormack, L. McTeir, and R.H. Fleming. 2004. High vitamin D3 requirements in broilers for

bone quality and prevention of tibial dyschondroplasia and interactions with dietary calcium, available phosphorus and vitamin A. *Brit Poult Sci*. 45:425–436.
415. Wideman Jr., R.F., J.A. Closser, W.B. Roush, and B.S. Cowen. 1985. Urolithiasis in pullets and laying hens: role of dietary calcium and phosphorus. *Poult Sci*. 64:2300–2307.
416. Wideman Jr., R.F., W.B. Roush, J.L. Satnick, R.P. Glahn, and N.O. Oldroyd. 1989. Methionine hydroxy analog (free acid) reduces avian kidney damage and urolithiasis induced by excess dietary calcium. *J Nutr*. 119:818–228.
417. Wideman Jr., R.F., M. Ismail, Y.K. Kirby, W.G. Bottje, R.W. Moore, and R.C. Vardeman. 1995. Furosemide reduces the incidence of pulmonary hypertension syndrome (ascites) in broilers exposed to cool environmental temperatures. *Poult Sci*. 74: 314–322.
418. Wideman Jr., R.F., and Y.K. Kirby. 1995. A pulmonary artery clamp model for inducing pulmonary hypertension syndrome (ascites) in broilers. *Poult Sci*. 74:805–812.
419. Wideman Jr., R.F., Y.K. Kirby, M. Ismail, W.G. Bottje, R.W. Moore, and R.C. Vardeman. 1995. Supplemental L-arginine attenuates pulmonary hypertension syndrome (ascites) in broilers. *Poult Sci*. 74:323–330.
420. Wideman Jr., R.F., and Y.K. Kirby. 1996. Electroradiographic evaluation of broilers during onset of pulmonary hypertension initiated by unilateral pulmonary artery occlusion. *Poult Sci*. 75:407–416.
421. Wideman Jr., R.F., Y.K. Kirby, R.L. Owen, and H. French. 1997. Chronic unilateral occlusion of an extrapulmonary primary bronchus induces pulmonary hypertension syndrome (ascites) in male and female broilers. *Poult Sci*. 76:400–404.
422. Wideman Jr., R.F., Y.K. Kirby, M.F. Forman, N. Marson, R.W. McNew, and R.L. Owen. 1998. The infusion rate dependent influence of acute metabolic acidosis on pulmonary vascular resistance in broilers. *Poult Sci*. 77:309–321.
423. Wideman Jr., R.F., and H. French. 1999. Broiler breeder survivors of chronic unilateral pulmonary artery occlusion produce progeny resistant to pulmonary hypertension syndrome (ascites) induced by cool temperatures. *Poult Sci*. 78:404–411.
424. Wideman Jr., R.F., M.L. Eanes, K.R. Hamal, and N.B. Anthony. 2010. Pulmonary vascular pressure profiles in broilers selected for susceptibility to pulmonary hypertension syndrome: Age and sex comparisons. *Poult Sci*. 89:1815–1924.
425. Wideman, R.F., E.T. Mallinson, and H. Rothenbacher. 1983. Kidney function of pullets and laying hens during outbreaks of urolithiasis. *Poult Sci*. 62:1954–1970.
426. Wideman, R.F., and A.C. Nissley. 1992. Kidney structure and responses of two commercial single comb White Leghorn strains to saline in the drinking water. *Brit Poult Sci*. 33: 489–504.
427. Wideman, R.F., B.C. Ford, R.M. Leach, D.F. Wise, and W.W. Robey. 1993. Liquid methionine hydroxy analog (free acid) and DL-methionine attenuate calcium-induced kidney damage in domestic fowl. *Poult Sci*. 72:1245–1258.
428. Wiernusz, C.J., and R.G. Teeter. 1993. Feeding effects on broiler thermobalance during thermoneutral and high ambient temperature expossure. *Poult Sci*. 72:1917–1924.
429. Wight, P.A.L., and D.W.F. Shannon. 1977. Plasma protein derivative (amyloid-like substance) in livers of rapeseed-fed fowls. *Avian Pathol*. 6:293–305.
430. Wight, P.A.L., L. Martindale, and W.G. Siller. 1979. Oregon disease and husbandry. *Vet Rec*. 105:470–471.
431. Wight, P.A.L., W.G. Siller, L. Martindale, and J.H. Filshie. 1979. The induction by muscle stimulation of a deep pectoral myopathy in the fowl. *Avian Pathol*. 8:115–121.
432. Wight, P.A.L., and W.G. Siller. 1980. Pathology of deep pectoral myopathy of broilers. *Vet Path*. 17:29–39.
433. Wilkins, L.J., J.L. McKinstry, N.C. Avery, T.G. Knowles, S.N. Brown, J. Tarlton, and C.J. Nicol. 2011. Influence of housing system and design on bone strength and keel bone fractures in laying hens. *Vet Rec*. 169:414.
434. Wilson, J.B., R.J. Julian, and I.K. Barker. 1988. Lesions of right heart failure and ascites in broiler chickens. *Avian Dis*. 32: 246–261.
435. Wilson, S., and S.E. Solomon. 1998. Bisphosphonates: A potential role in the prevention of osteoporosis in laying hens. *Res Vet Sci*. 64:37–40.
436. Wise, D.R., and A.R. Jennings. 1972. Dyschondroplasia in domestic poultry. *Vet Rec*. 91:285–286.
437. Wise, D.R. 1975. Skeletal abnormalities in table poultry—a review. *Avian Pathol*. 4:1–10.
438. Wong-Valle, J., G.R. McDaniel, D.L. Kuhlers, and J.E. Bartels. 1993. Effect of lighting program and broiler line on the incidence of tibial dyschondroplasia at four and seven weeks of age. *Poult Sci*. 72:1855–1860.
439. Wong-Valle, J., G.R. McDaniel, D.L. Kuhlers, and J.E. Bartels. 1993. Correlated responses to selection for high or low incidence of tibial dyschondroplasia in broilers. *Poult Sci*. 72: 1621–1629.
440. Yamasaki, K., and C. Itakura. 1983. Pathology of degenerative osteoarthritis in laying hens. *Nippon Juigaku Zasshi*. 45:1–8.
441. Yamashiro, S., M.K. Bhatnagar, J.R. Scott, and S.J. Slinger. 1975. Fatty haemorrhagic liver syndrome in laying hens on diets supplemented with rapeseed products. *Res Vet Sci*. 19:312–321.
442. Yildiz, H.S., M. Petek, G.R. Sönmez, I.l. Arican, and B. Yilmaz. 2009. Effects of lighting schedule and ascorbic acid on performance and tibiotarsus bone characteristics in broilers. *Turk J Vet An Sci*. 33:469–476.
443. Yousefi, M., M. Shivazad, and I. Sohrabi-Haghdoost. 2005. Effect of dietary factors on induction of fatty liver-hemorrhagic syndrome and its diagnosis methods with use of serum and liver parameters in laying hens. *Int J Poult Sci*. 4:568–572.
444. Zafra, R., J. Pérez, R.A. Pérez-Écija, C. Borge, R. Bustamante, and A.T. Carbonero, C. 2008. Concurrent aspergillosis and ascites with high mortality in a farm of growing broiler chickens. *Avian Dis*. 52:711–713.
445. Zerehdaran, S., E.M.v. Grevehof, E.H.v.-d. Waaij, and H. Bovenhuis. 2006. A bivariate mixture model analysis of body weight and ascites traits in broilers. *Poult Sci*. 85:32–38.
446. Zhang, W., C. He, J. Qiao, S.S. Dong, S.W. Li, and W.M. Zhang. 2008. Differences in ventricular vulnerability, serum enzyme activities, and electrolyte levels between male and female broilers. *Poult Sci*. 87:1402–1406.

Chapter 31

Mycotoxicoses

Frederic J. Hoerr

Introduction

Definition and Synonyms

A mycotoxicosis is a disease caused by a toxic metabolite of a fungus (mycotoxin). Hundreds of mycotoxins are now recognized and characterized chemically and biologically. The historical importance of mycotoxins in poultry health and the foundational clinical reports and research were detailed and referenced in previous editions of this text (20, 21). This edition summarizes previous information and references only new information.

The mycotoxins usually associated with poultry health problems are the ergot alkaloids, aflatoxins, trichothecenes, and other mycotoxins produced by *Fusarium*, ochratoxins, oosporein, citrinin, and fumonisins.

Economic Significance.

Although analytical surveys of grains used for poultry feed commonly detect low to moderate levels of mycotoxins, overt intoxication is difficult to document, but subclinical toxicosis is considered common. The success of mycotoxin prevention and amelioration programs reinforces the conventional wisdom that mycotoxins adversely impact poultry health and well-being.

Public Health Significance

Most grains used directly or as ingredients for human food are also used as feedstuffs for poultry and livestock, and carry the same risks for fungal growth and mycotoxin contamination. Airborne mycotoxin exposure is now documented in poultry houses as posing possible risks for poultry and farm workers (50).

Poultry products present a low risk for human toxin exposure because mycotoxins generally have low distribution to skeletal muscle, which is the major product consumed. Mycotoxin distributions to liver, kidney, and eggs are of greater concern. Metabolism and residue studies show that mycotoxins are generally rapidly metabolized and excreted in urine or feces. Residues in liver and kidney are generally transient and in low concentrations relative to the exposure dose. Chronic exposure to mycotoxins causes changes in color and size of liver and kidney, a visible indicator of rejection from the food chain at slaughter. In modern production, mycotoxin exposure of poultry is somewhat self-limiting because the deleterious effects must be addressed because of production economics. Of concern, however, is that aflatoxin residues in poultry tissues may build up to higher levels in regions with no regulatory limits on aflatoxin levels for poultry feed and may therefore pose a risk to consumers' health (22).

Ergotism

Etiology and Toxicology

Ergotism is characterized by vascular, neurologic, and endocrine disorders and is caused by toxic alkaloids produced by *Claviceps* spp., which attack cereal grains. Rye is especially affected, but wheat and other leading cereal grains also are affected, with regional differences. *Claviceps purpurea* is frequently implicated because of its wide host range among cereals. The mycotoxins form in the sclerotium, a visible, hard, dark mass of mycelium that displaces grain tissue. In the normal cycle, the sclerotium falls to the ground, germinates, and produces spores that infect the flower of the new crop, and the cycle repeats. The sclerotium is channeled into the food chain during harvest.

Ergot is detected in wheat, barley, oats, rye, rice, and other cereals in cooler grain-rearing climates worldwide. Sorghum ergot alkaloid produced by *Claviceps africana* spread globally from Africa in the 1990s. Tolerances for ergot in international trade vary, but grain can be declared "ergoty" with sclerotium concentrations as low as 0.1%–0.33%. Weed seed contaminants of grain also can be a source of ergot.

Lysergic acid is the chemical building block of the 40 or more alkaloids produced by *Claviceps* spp. In general, the alkaloids produce convulsive and sensory neurologic disorders, vasoconstriction and gangrene of extremities, and altered neuroendocrine control of the anterior pituitary gland. The toxicity is mostly in the alkaloid fraction of the ergot extract, but the value of total alkaloid content is not entirely predictive, which creates difficulty in defining critical concentrations of toxins (32). Pelleting feeds can increase the toxicity of ergot, possibly through increased liberation of toxins.

Diseases of Poultry, Thirteenth Edition. David E. Swayne.
© 2013 John Wiley & Sons, Inc. Published 2013 by John Wiley & Sons, Inc.

Natural Disease

Ergotism in poultry occurs as decreases in spontaneous activity, feed intake, growth, and egg production, as well as onset of diarrhea. Necrosis, vesicles, and ulcers develop on the beak, comb, wattles, and toes, and the combs and wattles can became permanently atrophied and disfigured. At necropsy, visceral congestion is observed. Young poultry are generally more sensitive.

Experimental Disease

In chickens, ergotism causes reductions in appetite and growth, as well as mortality, with more variable poor feathering, nervousness, loss of coordination, and inability to stand. At necropsy, cardiac enlargement can occur. Broilers are generally more sensitive to ergot than leghorns.

Metabolism and Residues

Ergotamine tartrate accumulates in trace amounts in broiler tissues when fed at relatively high concentrations. About 5% of the alkaloid is excreted unchanged, and the remainder is excreted as a mixture of metabolites.

Fusarium Mycotoxins

Incidence and Distribution

The genus *Fusarium* produces many mycotoxins injurious to poultry through chemical and radiomimetic injury; cardiac toxicity; and skeletal, digestive, and reproductive disorders. *Fusarium* toxins that are commonly detected in grain and feed production channels include trichothecenes, fumonisins, zearalenone, and moniliformin, alone or in combinations. Mycotoxins produced by *Fusarium* also occur in combination with aflatoxin or ochratoxin.

Trichothecenes

Etiology and Toxicology

Trichothecene mycotoxins are produced by common soil and plant fungi found worldwide, including *Fusarium* and its perithecial stages, Calonectria and Gibberella, and various other genera. *Fusarium* produces about one-half of the more than 100 trichothecenes, with greatest toxin production at high humidity and temperatures of 6°C–24°C.

Trichothecenes have a tetracyclic sesquiterpene nucleus with a characteristic epoxide ring. Poultry are usually exposed to nonmacrocyclic trichothecenes, which includes type A trichothecenes (T-2 toxin, neosolanial, diacetoxyscirpenol [DAS], and others) and type B (nivalenol, deoxynivalenol [DON, vomitoxin], fusarenone-X, and others). Toxicity resides in the epoxide ring, which is stable during prolonged storage or normal cooking temperatures. In general, trichothecenes damage structural lipids and inhibit the synthesis of protein and DNA, and many are chemical irritants.

T-2 toxin, DAS, DON, and nivalenol occur in feedstuffs worldwide, including corn, wheat, barley, oats, rice, rye, sorghum, safflower seed, mixed feed, and brewer's grains (44). Deoxynivalenol is the most prevalent and occurs naturally with zearalenone, aflatoxin, and other mycotoxins. Grains contaminated with DON may be diverted to poultry feeds because DON has relatively low toxicity for poultry in comparison to swine, which experience feed refusal and emesis.

Natural Disease

Both historical and recent accounts of trichothecene mycotoxicosis reflect chemical burn and radiomimetic effects expressed as feed refusal, extensive necrosis of oral mucosa and skin in contact with the mold toxins, acute digestive tract disease, and depressed bone marrow and immune functions. Decreases in egg production and shell quality, neurological signs, malformed feathers, rickets, gout, and generalized hemorrhages can develop. Recovery generally occurs when an unadulterated diet is provided.

Experimental Disease

Experimental trichothecene mycotoxicosis in poultry has required several approaches to reproduce the disease spectrum observed naturally, including purified toxins administered alone or in combinations, and toxigenic fungal cultures. Purified trichothecenes are generally less toxic than more complex toxigenic fungal cultures.

Collectively, these toxins cause feed refusal and impaired growth and reproductive capability; and whole-body pathology including chemical injury to skin and alimentary mucosa; radiomimetic injury to bone marrow, lymphoid tissues, gastrointestinal tract, and feathers; hepatosis; and thyroid alterations. Neurotoxicity is inconsistently observed. Quail are more resistant than chickens, and ducks are more sensitive, but all develop similar signs and lesions. Many trichothecenes caused erosive and exudative injury to the oral mucosa. Focal yellow oral plaques form and progress to confluent yellow-gray, raised accumulations of exudate with underlying ulcers located near major salivary duct openings on the palate, tongue, and floor of the mouth. Thick crusts accumulate along the interior margin of the beak (Figures 31.1 A, B). Histopathology reveals mucosal necrosis and ulceration; superficial crusts of exudate, bacterial colonies, and feed components; and submucosal inflammation.

The systemic histopathology caused by T-2 toxin or DAS occurs as rapid necrosis and depletion of lymphoid and hematopoietic tissues and then a relatively rapid recovery. The liver and gallbladder develop necrosis and hemorrhage, followed by mild proliferation of bile ductules. Necrosis of mucosal epithelium occurs in the proventriculus, gizzard, and intestine. The feather epithelium may undergo necrosis with the sequela of feather malformation.

Extended exposure to T-2 toxin and DAS adversely affects body weight, skin pigmentation, and feathers (Figure 31.2), bone marrow (with anemia and leukopenia), lymphoid organs, liver, and thyroid gland (Figures 31.2 and 31.3 A, B). Coagulation can be impaired and serum vitamin E concentration is decreased. Egg production and hatchability are generally decreased relative to the toxicity of the different

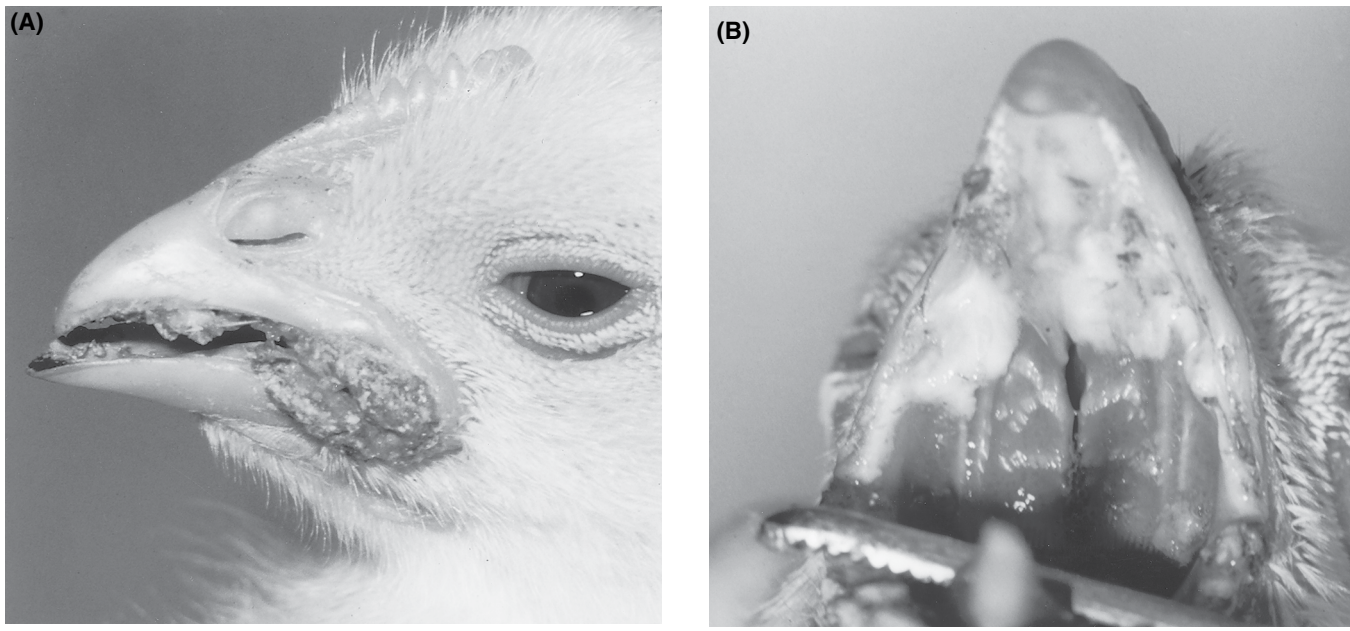

Figure 31.1. Fusariotoxicosis. Trichothecene mycotoxins cause chemical irritation of the upper digestive tract mucosa. (A) Crusts at the beak commissure of a broiler chicken fed diacetoxyscirpenol for 8 days. (B) Beak and palate ulceration and crusting in a broiler chicken following 14 days' consumption of diacetoxyscirpenol (4 mg/kg diet).

Figure 31.2. Feathers from a chicken fed T-2 toxin for 24 days (right) are narrow because of radiomimetic injury to the developing barbs; control (left).

trichothecenes. Immune responses are generally depressed and associated with increased severity of concurrent infectious diseases (6, 14, 55).

DON and nivalenol are relatively nontoxic to poultry, affecting digestive and lymphoid tissues, but at doses higher than those that cause feed refusal and emesis in swine. In broilers, DON decreases the villus height, decreases the absorptive surface area, and alters transport function in the lower small intestine and reduces weight gain in the starter period (4, 57, 58). Diets with DON and zearalenone cause digestive immunodepression and delay recovery from coccidiosis (15, 16). Gout has occurred in leghorn hens. In ducks, DON and zearalenone cause lymphoid atrophy.

T-2 toxin reduces the anticoccidial activity of lasalocid. T-2 toxin and other studied trichothecenes are metabolized in the liver and excreted mostly in the bile and feces within 48 hours along with various metabolites. A relatively small amount of T-2 toxin is excreted into the egg and is detectable in yolk and albumen. Deoxynivalenol is rapidly eliminated in feces and transmitted to eggs at trace to undetectable concentrations; however, it was detected as a natural adulterant in home-produced eggs (46). DON is not detectable in skeletal muscle.

Moniliformin

Etiology and Toxicology

Moniliformin is produced by *Fusarium verticillioides* (formerly *F. moniliforme*) and other *Fusarium subglutinans*, as well as other *Fusarium* spp., and is cardiotoxic and nephrotoxic in poultry. *F. verticillioides* causes ear rot, kernel rot, and stalk rot of unharvested corn, and occurs in stored high-moisture shelled corn and on oats, soybeans, sorghum, barley, wheat, and corn that are visually sound. *F. verticillioides* also produces fumonisins, zearalenone, fusariocin A, and other toxic fractions. Purified moniliformin is less toxic than more complex fungal cultures.

Natural Disease

Field reports indicate that *F. verticillioides* (*F. moniliforme*) and moniliformin mycotoxicosis is problematic, but verification is lacking. Moniliformin was detected in 26 of 50 (52%) of poultry feed samples from central Europe, nearly all of which also contained fumonisin B1 (26), indicating the potential for intoxication of poultry.

Broiler breeders and leghorns experience reduced rate of lay and delayed peaks in production. Uneven feed consumption

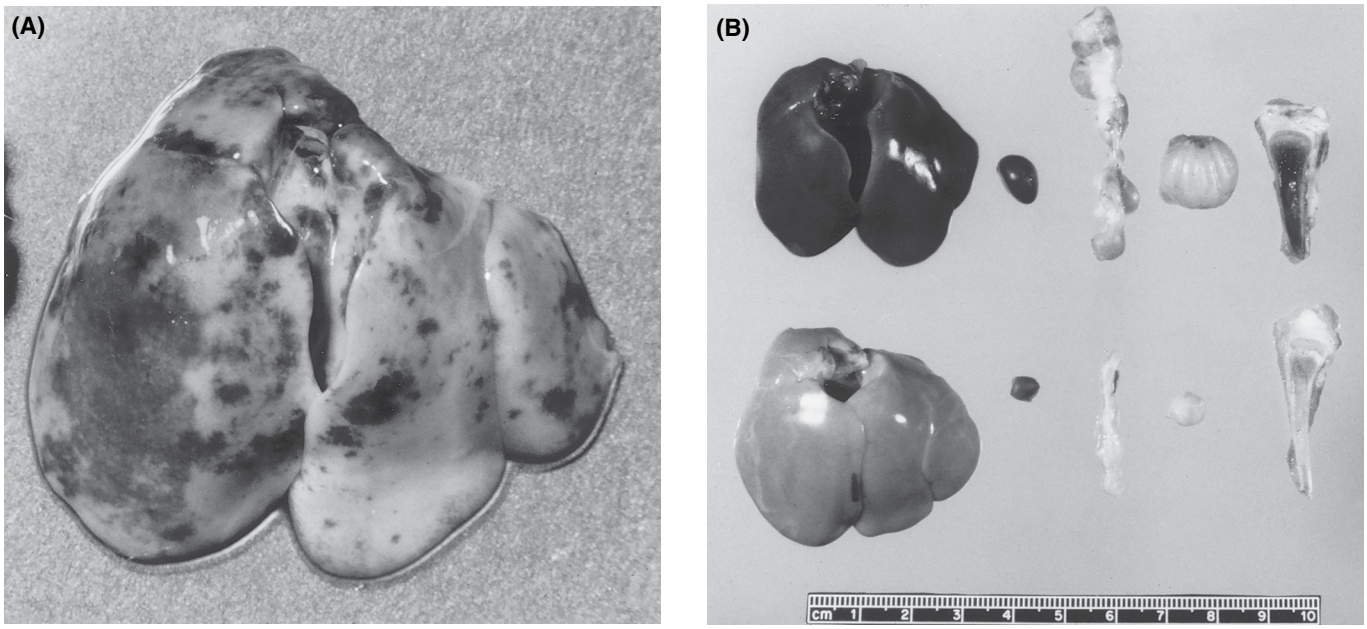

Figure 31.3. Experimental trichothecene mycotoxicosis in broiler chickens. (A) Hemorrhage in the liver occurring 20 hours after consumption of feed mixed with a culture of *Fusarium sporotrichiella* that produced T-2 toxin and neosolaniol. (B) Daily oral doses of T-2 toxin caused fatty degeneration of the liver (bottom row) compared with control (top row). The radiomimetic effects are evidenced by atrophy of the spleen, thymus, and bursa of Fabricius and pallor of the bone marrow.

can occur along with diarrhea, feed passage, fecal-stained egg shells, and blood smears on egg shells. Contaminated corn can be high in moisture, low in protein, and high in crushing strength, which contributes to larger particle size in the feed and maldigestion.

Experimental Disease

Experimental moniliformin toxicity occurs as cardiac toxicity, ascites, and nephrosis, with decreases in feed intake and weight gain, slowing of the heart rate, dyspnea, and cyanosis. A combination of fumonisin and moniliformin causes sudden death that resembles spiking mortality of broilers, with decreased blood glucose and immunodepression. Younger chickens are more sensitive than hens.

Lesions at necropsy comprise enlargement of the heart, ascites, and digestive and cutaneous hemorrhages and edema. Muscle fibers can develop degeneration and necrosis, which is partially alleviated by selenium supplementation. Kidney develops nephrosis with mineralized casts. Liver develops vacuolar degeneration and focal necrosis of hepatocytes; bile duct proliferation and fibrosis occur with ongoing intoxication.

Fumonisins

Etiology and Toxicology

F. verticillioides (*F. moniliforme*) also produces the fumonisins, which are the cause of equine leukoencephalomalacia (moldy corn poisoning) and porcine pulmonary edema syndrome. Several fumonisins are produced (B1, B2, B3), but fumonisin B1 is the most common. Fumonisins are also produced by other species of *Fusarium*. The toxicity of fumonisin B1 is related to disrupted sphingolipid synthesis.

Natural Disease

Fumonisin and aflatoxin were detected in the feed of laying hens that developed black adhesive diarrhea; reductions in feed intake, egg production, and body weight; lameness; and increased mortality. The diarrhea was reproducible in chicks and in laying hens with the suspect feed and with diets spiked with fumonisin.

Experimental Disease

Fumonisin B1 toxicosis occurs as diarrhea, catarrhal enteritis (Figures 31.4 A, B), impaired weight gain and feed conversion, and transient decreases in egg production. Poults are more sensitive than chicks, but poultry in general are quite resistant to fumonisins in comparison to horses and swine. Although concentrations that are toxic to poultry are higher than those likely to occur in grain, *F. moniliforme* produces other toxins that could be problematic.

At necropsy, lesions include enlargement of the liver and variable enlargement of the kidney, proventriculus, and gizzard; atrophy of lymphoid organs; and rickets. Histologically, the liver can have multifocal necrosis, bile ductule hyperplasia, and hypertrophy of Kupffer cells. The intestine has villous atrophy and goblet cell hyperplasia. Rickets can develop and involve the zones of proliferating and hypertrophied cartilage. Fumonisin B1 in combination with moniliformin causes lesions reflective of both toxins, including ascites and enlargement of the heart, and lymphoid depletion and

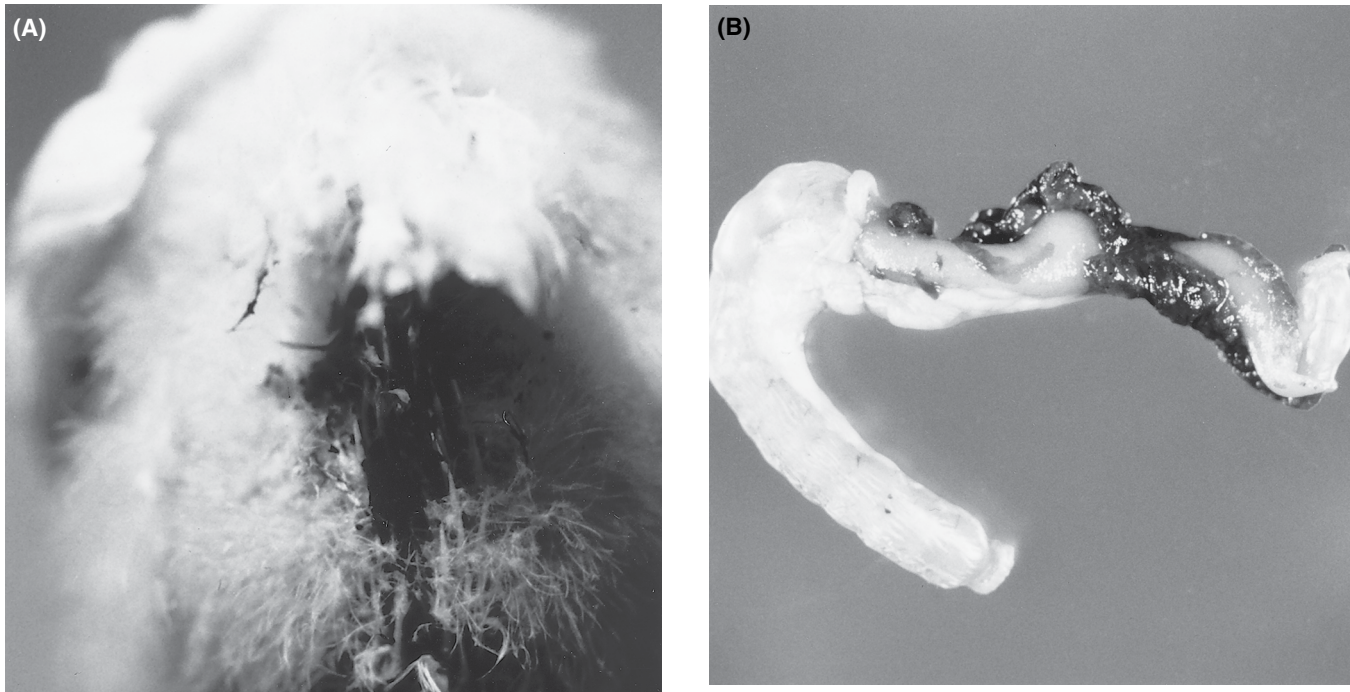

Figure 31.4. (A) Diarrhea and (B) catarrhal enteritis in broiler chickens fed cultures of *Fusarium moniliforme* that produced fumonisin B1.

immunodepression. Fumonisin B1 is metabolized by the liver and excreted in feces.

Fusarochromanone

Etiology and Toxicology

Fusarochromanone is produced by *Fusarium* spp. and causes tibial dyschondroplasia (TD) in chickens. Long bone deformities in broiler chickens have been induced by cultures of *F. moniliforme, F. roseum*, *and F. equiseti*, as well as *Aspergillus niger* and *A. flavus*. *F. roseum* that was isolated from overwintered barley caused tibial dyschondroplasia in broilers, due to the toxic fraction TDP-1 (fusarochromanone).

Experimental Disease

Chicks fed fusarochromanone as cultures of *Fusarium* develop dyschondroplasia in the tibial growth plate in 4 days. Although the cellular and biochemical site of fusarochromanone action is not known, increased dietary levels of copper and zinc have a partial sparing effect. *Fusarium* strains that produced fusarochromanone also can be immunodepressive.

Zearalenone

Etiology and Toxicology

Grains infected with the fungus *Gibberella zeae* (*Fusarium graminearum*, *F. roseum* "Graminearum") are a source of zearalenone, a mycotoxin with estrogenic activity. Zearalenone and zearalenol occur naturally, with zearalenone being the most prevalent and most closely examined in poultry, although zearalenol is more active estrogenically. Zearalenone occurs in corn, sorghum, wheat, barley, oats, milo, rye, and other grains. Toxicity occurs chiefly in swine as reproductive failure. Chickens tolerate zearalenone better than turkeys or swine and provide an outlet for grains unfit for swine. Zearalenone is relatively nontoxic for chickens, but it has potential adverse effects and may be an indicator of other toxins present.

Natural Disease

Broiler breeders exposed to zearalenone experienced a decrease in egg production; however, fertility, hatchability, and broiler performance remained normal. The hens had lowered serum progesterone, ascites, and cystic inflammation of the oviduct.

Experimental Disease

Poultry are relatively resistant to zearalenone in comparison to swine. Turkeys are the most sensitive, with reproductive and sex hormone-sensitive tissues targeted. Leghorn hens are generally tolerant of zearalenone, but egg production and egg quality can decrease. Lesions include swelling of the cloaca, oviduct enlargement, and reproductive tract cysts. Males experience decreases in comb and testicle weight and fertility. Male turkey poults can display precocious strutting behavior and develop caruncles, dewlaps, and soft tissue swelling of the vent. Lymphocyte cytokine expression is impaired (51)

Metabolism and Residues

Zearalenone distributes chiefly to liver and gallbladder and is excreted in feces as zearalenone and zearalenol. Egg residues are minimal or undetectable, and are restricted to yolk.

Other Fusarium Toxins

Strains of *F. moniliforme* (now *F. verticillioides*) that produce other or unknown toxins were variably associated with immunodepression, reduced egg production, and suspected thiamine deficiency.

Aflatoxins

Etiology and Toxicology

Aflatoxins are highly toxic and carcinogenic mycotoxins produced by *Aspergillus flavus*, *A. parasiticus*, and *Penicillium puberulum*. Poultry feeds and ingredients are vulnerable to fungal growth and aflatoxin formation. Aflatoxin-producing fungi and aflatoxin-contaminated animal feedstuffs are recognized worldwide with adverse implications for poultry health and well-being.

The aflatoxins have two fused dihydrofuran rings with various moieties, and members are designated by their blue (B) or green (G) color reaction to fluorescent light and by their chromatographic values. Aflatoxin B1 is the most toxic and primarily affects the liver. Chronic aflatoxicosis results in neoplasia in many species, usually in the liver, but other organs may be involved. Aflatoxin B1 is the most potent carcinogen but several aflatoxin metabolites are also carcinogenic. Aflatoxins are relatively stable in feed but are sensitive to oxidizing agents such as hypochlorite (commercial bleach).

Poultry are considered highly susceptible to aflatoxins; however, there is wide variability in species sensitivity. In general, ducklings and turkey poults are the most sensitive to aflatoxins and quail show intermediate sensitivity, whereas chickens are the most resistant (9).

Natural Disease

Aflatoxicosis occurs in poultry worldwide. The direct and indirect effects of aflatoxicosis include increased mortality from heat stress (broiler breeders); loss of egg production (leghorns); anemia, hemorrhages, liver condemnations, paralysis, lameness, and impaired performance (broilers); nervous signs and mortality (ducks); impaired ambulation and paralysis (quail); impaired immunity (turkeys); and increased susceptibility to infectious disease in many species. Cases of concurrent aspergillosis and aflatoxicosis have occurred and confirm that *Aspergillus* spp, are a threat to poultry production in the feed, litter, and environment.

Detailed descriptions of the first cases of aflatoxicosis were reviewed in the previous editions of *Diseases of Poultry*. Early accounts of spontaneous aflatoxicosis in literature are now recognized to have significant contributions from cyclopiazonic acid and possibly sterigmatocystin and other toxins. Lethal aflatoxicosis in ducklings occurs as inappetance, reduced growth, abnormal vocalizations, feather picking, purple discoloration of legs and feet, and lameness. Ataxia, convulsions, and opisthotonus precede death. At necropsy, liver and kidneys are enlarged and pale. Chronic cases have hydropericardium and ascites; shrunken, firm, nodular liver; bile-distended gallbladder; and hemorrhages. Microscopic lesions in the liver are fatty change in hepatocytes, proliferation of bile ductules, and fibrosis, accompanied by vascular and degenerative lesions in pancreas and kidney.

Turkeys develop inappetance, reduced spontaneous activity, unsteady gait, recumbency, anemia, and death. At necropsy, there is generalized visceral congestion and edema. The liver and kidney are congested, enlarged, and firm; the gallbladder is full; and the duodenum has mucoid content. Lethal aflatoxicosis causes either dark red or yellow discoloration of the liver (Figure 31.5). Microscopic lesions are vacuolar (fatty) degeneration of hepatocytes, karyomegaly, and necrosis of centrilobular hepatocytes. Chronic toxicity occurs as hepatocyte regeneration, proliferation of bile ductules, and reticuloendothelial cell hyperplasia, along with and degenerative lesions in the heart, kidney, and intestine.

Aflatoxicosis in chickens closely resembles that in ducks and turkeys.

Experimental Disease

Aflatoxicosis impairs all important production parameters including weight gain, feed intake, feed conversion efficiency, pigmentation, processing yield, egg production, and male and female reproductive performance. Some influences are direct effects of intoxication, and others are indirect from reduced feed intake and stress.

Susceptibility of poultry to aflatoxins varies among species, breeds, and genetic lines, with age and sex also being important. In general, ducklings, turkeys, and pheasants are susceptible; whereas chickens, bobwhite and Japanese quail, chukar partridge, and guinea fowl are relatively resistant. The sensitivity of turkeys and other poultry to aflatoxin B1 is associated with efficient hepatic cytochrome P450-mediated bioactivation and deficient detoxification by glutathione S-transferases (41).

The pathology of experimental aflatoxicosis is similar to that of the naturally occurring disease. Acute intoxication in ducks causes pale, yellow-green discoloration, and atrophy of the liver, with the left lobe being more affected. Microscopic lesions chiefly involve hepatocytes as fatty degeneration, potentially massive necrosis, and hemorrhage. Proliferation of bile ductules develops by the second day and progresses rapidly. Subacute or nonlethal intoxication of ducks produces similar lesions in liver. The kidney develops membranous glomerulopathy and interstitial fibrosis. Histologic lesions in liver and kidney are illustrated in Figures 31.6 A, B, and C.

Aflatoxicosis in chickens causes yellow to ocher discoloration of the liver, with multifocal hemorrhage and a reticulated pattern on the capsular surface. In time, the livers develop white foci as hepatic lipid content increases. Histologic lesions occur as fatty degeneration of hepatocytes, karyomegaly and

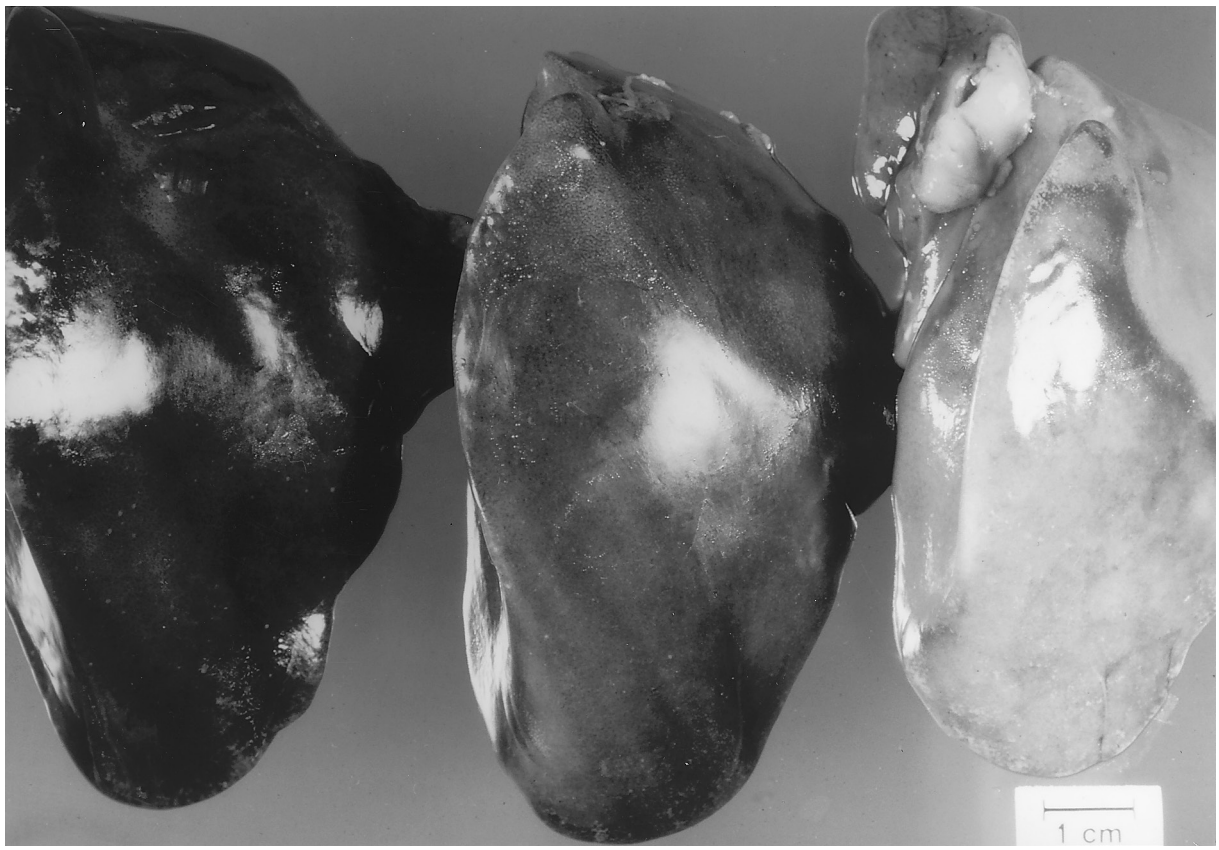

Figure 31.5. Lethal aflatoxicosis in turkeys caused liver discoloration from congestion and necrosis (left), to fatty degeneration (right). Aflatoxin B1 (200 ppb) was detected in the feed.

prominent nucleoli in hepatocytes, proliferation of bile ducts, and fibrosis. Basophilic, vacuolated, regenerative hepatocytes and inflammation by heterophils and mononuclear cells occur in the portal zones. Turkeys develop less severe fatty change, but bile duct proliferation and nodular regeneration of densely eosinophilic hepatocytes are found.

Aflatoxin causes microcytic hypochromic anemia associated with a decrease in the iron absorption and retention. Young poultry are more susceptible to anemia. Total leukocytes are increased but with concurrent lymphopenia. Aflatoxin decreases total serum protein, lipoprotein, carotenoid pigment, cholesterol, triglycerides, uric acid, calcium, phosphorus, iron, copper, zinc, and lactate dehydrogenase. Serum sorbital dehydrogenase, glutamic dehydrogenase, and potassium are increased. In Japanese quail, the degree of decrease in total protein and albumin and the increase in β-glucuronidase are correlated with resistance to aflatoxin. Blood clotting time and ratio of aspartate aminotransferase to alanine aminotransferase are indicators of resistance in ducks.

In laying hens, chronic aflatoxicosis affects renal functions and induces calcium phosphate and sodium losses through the urine (34).

Bruising is an economically important problem during transport and processing of poultry. Aflatoxin promotes bruising by increased capillary fragility and by interfering with prothrombin and other coagulation components.

Skin pigmentation is a desirable and economically significant for broilers in some markets. Aflatoxin impairs pigmentation in broilers by inhibiting intestinal absorption of carotenoid pigments and causing sequestration of pigments in the liver.

Aflatoxin interacts with nutritional components. The severity of aflatoxicosis is enhanced by diets low in fat, protein, and riboflavin and vitamin D_3; and high in tannic acid. Aflatoxin influences calcium and phosphorus metabolism by altering the metabolism of vitamin D and parathyroid hormone. In broilers, steatorrhea can develop from a deficiency of pancreatic amylase and lipase. Hens experience impaired digestion in association with small intestinal crypt hyperplasia (2). Vitamins A, C, and E and alpha-lipoic acid have an ameliorating role in aflatoxicosis through the reduction of oxidative stress (1, 24).

Aflatoxin adversely affects reproduction and hatchability. Mature leghorn males experience decreased semen volume, testis weight, and spermatocrits, as well as testosterone values, caused indirectly by reduced feed intake during aflatoxicosis. Microscopic examination of sperm reveals abnormal spermatozoa and histologically, a cessation of spermatogenesis in seminiferous tubules. Plasma testosterone concentration and responsiveness are lowered in maturing Leghorn males.

Loss of hatchability due to embryonic death is a sensitive indicator of aflatoxicosis, and is more sensitive than decreased

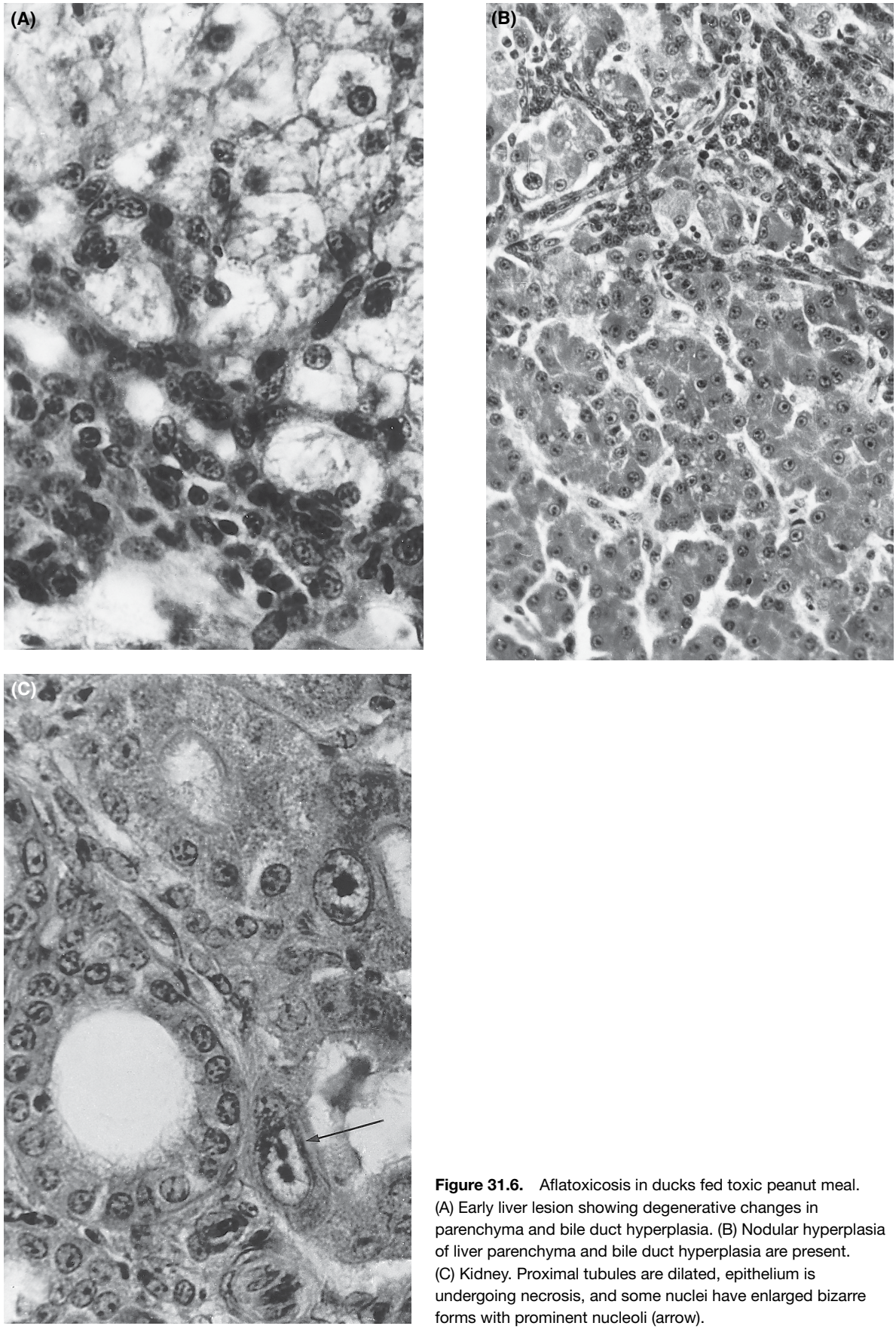

Figure 31.6. Aflatoxicosis in ducks fed toxic peanut meal. (A) Early liver lesion showing degenerative changes in parenchyma and bile duct hyperplasia. (B) Nodular hyperplasia of liver parenchyma and bile duct hyperplasia are present. (C) Kidney. Proximal tubules are dilated, epithelium is undergoing necrosis, and some nuclei have enlarged bizarre forms with prominent nucleoli (arrow).

egg production. Once decreased, egg production may require several weeks to return. Aflatoxin impairs egg production by reducing synthesis and transport of yolk precursors in the liver, resulting in decreases in egg size and yolk parameters. In Japanese quail, aflatoxin hepatotoxicity adversely effects feed conversion, maturation, egg production, and egg quality.

Spontaneous aflatoxicosis is strongly associated with increased susceptibility to infectious disease. In chickens, aflatoxin exacerbates cecal coccidiosis (13), Marek's disease, salmonellosis, inclusion body hepatitis, and infectious bursal disease virus. Impaired response to vaccination is documented for Newcastle disease, infectious bronchitis, infectious bursal disease, and fowl cholera. Vaccination failure to fowl cholera and increased susceptibility to coccidiosis is documented for turkeys.

Aflatoxin-induced immunodepression with reduced mitogenic responses of B and T lymphocytes accompanies atrophy of the cloacal bursa (bursa of Fabricius), thymus, and spleen. Aflatoxin is toxic for B lymphocytes in the late-stage embryo, and immune dysfunction occurs in progeny of broiler breeders exposed to aflatoxin. Other affected parameters include cell-mediated immune response, clearance functions of macrophages, and serum complement activity. Despite these examples of aflatoxin-induced immunodepression, other data show no measurable immunodepression at aflatoxin concentrations higher than commonly encountered in feedstuffs.

Pharmacological Interactions

Aflatoxicosis can influence drug effectiveness by decreasing the plasma half-life of ceftiofur and chlortetracycline, and increasing tissue residues of enrofloxacin and ciprofloxacin (23).

Metabolism and Residues

Poultry reared on diets contaminated with aflatoxin constitute a minimal aflatoxin threat to the human food supply. Aflatoxins distribute to edible tissues in low concentrations and clear rapidly after nontoxic diets are provided. With sustained ingestion, higher toxin residues occur to a greater degree in liver and muscle of younger birds generally, and in older birds, in dose-related pattern (22).

In broilers and turkeys, metabolites of aflatoxins concentrate in the ventriculus (gizzard), liver, and kidney, and are excreted in bile, urine, and feces in 4 days. Aflatoxin B1 metabolizes into conjugated aflatoxins B2a and M1 in the liver, and is further reduced to aflatoxicol. The dominant enzyme responsible for bioactivation and metabolism of aflatoxin B1 is the hepatic cytochrome P450 enzyme group (11, 12, 40, 42). Selenium supplementation increases the percentage of conjugated aflatoxin and partially protects turkeys from toxicosis.

The half-life of aflatoxin B1 in laying hens is about 67 hours, and the feed:egg transmission ratio is about 5,000:1. Most aflatoxin is excreted through the bile and intestine, but aflatoxin B1 and aflatoxicol can be detectable in ova and eggs for 7 days or longer (27). Aflatoxin B1 can accumulate in reproductive organs with transfer to egg yolk and albumen, resulting in residues in the yolk sac and liver of hatched progeny.

Ochratoxins

Etiology and Toxicology

Ochratoxins are among the most toxic mycotoxins to poultry. These nephrotoxic metabolites are produced chiefly by *Penicillium viridicatum* and *Aspergillus ochraceus* on grains and feedstuffs throughout North America, Europe, and Asia. Ochratoxins are isocoumarin compounds linked to L-b-phenylalanine and are designated A, B, C, and D. Ochratoxin A (OA) is the most common and most toxic, and is relatively stable. Some ochratoxin-producing fungi produce other mycotoxins toxic to poultry, including citrinin. Ochratoxin is the major determinant in porcine endemic nephropathy, a chronic wasting disease of swine in Denmark and Ireland. Ochratoxin in combination with fumonisin B1 and penicillic acid is a risk factor in Balkan nephropathy of swine and poultry in Bulgaria (45).

Ochratoxin A (OA) occurs in corn, most small grains, and animal feeds. Ochratoxin A has been documented in contaminated moldy grain for game birds, and in ingredients for chicken feed, including sorghum, peanuts, sunflower, rice bran, and millet, some samples of which were also contaminated with aflatoxin. Ochratoxin A readily forms in poultry feed under conditions of high temperature and moisture.

Natural Disease

Ochratoxicosis has occurred as clinical diseases and processing plant problems, affecting chickens, turkeys, and geese. Problems are associated with contaminated feed ingredients including corn gluten meal, corn, bakery products, as well as pelleted feed. The clinical signs include reductions in weight gain and pigmentation, enteritis and diarrhea, and processing problems associated with intestinal fragility. At necropsy, lesions include pale discoloration of kidney and liver, visceral urate deposition (i.e., visceral gout), and enteritis. Histologic lesions in the kidney include edema, degeneration of proximal and distal tubules, and interstitial fibrosis.

Experimental Disease

The clinical signs of experimental ochratoxicosis include feed refusal and reductions in growth and feed utilization, and pigmentation. Combined exposure to OA and aflatoxin causes synergistic reduction of growth and feed performance of broilers. In breeders and laying hens, OA toxicosis can result in delayed sexual maturity and reductions in egg production, egg quality, fertility, and hatchability. Embryos can develop renal lesions, and hatched progeny have reductions in growth and are immunodepressed (60, 61). Ochratoxin A mycotoxicosis causes primarily renal disease

but also influences hepatic, immunologic, and hematopoietic functions. Poultry are sensitive to ochratoxin and Ringneck pheasants and Japanese quail are most sensitive among the game birds.

The pathology of acute lethal OA mycotoxicosis occurs as swelling and discoloration of the kidney and liver, with urate accumulation in the ureters, and variable gout. Histologic lesions include acute tubular nephrosis with cast formation and interstitial heterophilic inflammation. Vacuolar change and necrosis occurs in hepatocytes. The bone marrow has suppression of hematopoiesis, and lymphocyte depletion occurs in lymphoid organs.

In subacute OA mycotoxicosis, liver and kidney weight increase. In the kidney, enlargement is associated with hyperplasia of tubular epithelium, membranous glomerulopathy, and interstitial inflammation. Lymphocytic depletion from primary lymphoid organs may be severe, with reductions in cellular and humoral immune functions, including macrophage functions (19, 59). Accompanying the lesions of immunosuppression are impaired response to vaccination, and increased susceptibility to coccidiosis, salmonellosis, and colibacillosis. Defective cortical bone formation due to osteopenia has been described.

The spectrum of histologic lesions in the kidney and liver, as well as skeletal muscle, pancreas, and bone, are reflected in serum biochemical changes. Renal function tests are generally decreased. Additional effects on blood include myelocytic anemia and leukopenia. Ochratoxin A can prolong coagulation due to a reduction in clotting factors.

Metabolism and Residues

Ingested OA distributes chiefly to the kidney and to a lesser degree to liver and muscle. Ochratoxin A is rapidly eliminated from chickens with a half-life of about 4 hours. Liver and kidney are the tissues of choice to monitor for residues, and residues occur in the absence of renal lesions. Residues persist for 4 days or less when toxic diets are replaced. Ochratoxin A distributes to egg yolk and albumin, although OA residues in eggs have low correlation to dose and may be undetectable in eggs.

Citrinin

Etiology and Toxicology

Citrinin is a natural contaminant of corn, rice, and other cereal grains and is produced by many species of *Penicillium* and *Aspergillus*. *A. citrinin* occurs mainly in Canada and northern Europe. First purified as a yellow crystalline compound from *P. citrinum* in 1931, its antibiotic properties against staphylococci and other bacteria were recognized before the nephrotoxicity was discovered. Citrinin is one of the causes of yellow rice mycotoxicosis described in Japan, and is implicated in porcine endemic nephropathy, which also involves ochratoxin. Citrinin is heat sensitive.

Natural Disease

Citrinin mycotoxicosis occurs as wet litter associated with diuresis and reductions in weight gain resulting in small, uneven chickens at processing age. The kidneys may be swollen and show degenerative changes in the tubules.

Experimental Disease

Citrinin is nephrotoxic and causes diuresis in poultry, with turkeys being the most sensitive. Removal of the toxin allows a return to normal renal function. Citrinin acts directly on the kidney to increase urine flow rates and free water clearance with increases in sodium, potassium, and inorganic phosphate excretion. Citrinin is physiologically active at the level of the renal tubule, but gross and microscopic lesions may be absent or relatively mild. When present, lesions include epithelial degeneration and necrosis in proximal and distal tubules. The liver may have focal necrosis and hemorrhage. Lymphocyte necrosis and depletion occur in lymphoid tissues. With ongoing exposure to citrinin, dose-related nephropathy occurs with loss of tubular parenchyma and fibrosis. Anemia and leukopenia have been described. Systemic biochemical effects include hyperkalemia, metabolic acidosis, reduced blood pH, and base excess.

In broilers, citrinin residues are detectable only in blood and liver. In laying hens with prolonged exposure, citrinin is detectable in muscle, trachea, and egg albumin.

Oosporein

Etiology and Toxicology

Oosporein is a red, toxic, dibenzoquinone metabolite of *Chaetomium* spp. originally extracted from *Oospora coloran*. In poultry, oosporein causes high mortality from gout. *Chaetomium* spp. are isolated from numerous feeds and grains, including peanuts, rice, and corn, and toxigenic cultures affect both plant and animal bioassays.

Natural Disease

Oosporein mycotoxicosis has occurred in poultry in both North and South America and is characterized by mortality associated with nephrotoxicity and gout.

Experimental Disease

Experimental oosporein mycotoxicosis causes visceral and periarticular urate deposition (gout) related to impaired renal function and elevated plasma uric acid. The proximal tubular epithelial cells are targeted (Figure 31.7). Water consumption increases with fluid and fecal droppings. Feed consumption and egg production decreased at doses capable of inducing nephrotoxicity and gout.

Lesions observed at necropsy include dehydration, swollen pale kidneys, and extensive visceral gout. This may be accompanied by focal necrosis in the liver, distention of the gallbladder with bile, increased diameter of the proventriculus associated with mucosal exudate, and bile staining of the

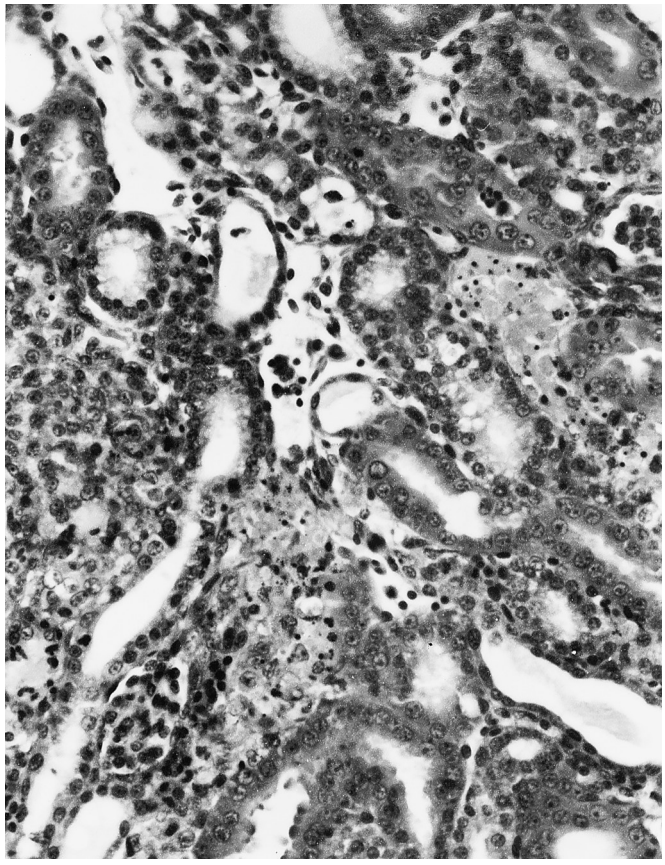

Figure 31.7. Kidney from a chicken fed oosporein for 3 days. The renal cortex has necrosis of proximal tubules.

ventriculus (gizzard) and intestinal contents. Periarticular gout develops with ongoing toxicity. The plasma uric acid concentrations are increased and serum chemistry changes are generally reflective of renal toxicity.

Other Mycotoxins

Cyclopiazonic Acid

Cyclopiazonic acid (CPA) is an indole-tetramic acid neurotoxin produced by some of the same strains of *Aspergillus flavus* that produce aflatoxins and by some *Aspergillus oryzae* strains (5). Some features of turkey "X" disease in the United Kingdom in 1959, notably enteritis and opisthotonus, were not fully accountable to aflatoxin and are explained by the presence of CPA, which was identified in stored samples from the original episodes. Ten of 45 strains of *Aspergillus flavus* isolated from feed produced both CPA and aflatoxin in culture. The toxin is also produced by *Penicillium* spp. and is a contaminant of meats, outer portions of cheeses, peanuts, corn, and millet.

Cyclopiazonic acid affects weight gain, feed conversion, and male reproductive parameters, and causes mortality. It has additive toxicity with aflatoxin and T-2 toxin. Lesions occur in the proventriculus, ventriculus (gizzard), liver, and spleen. Mucosal necrosis also occurs in the ventriculus (gizzard), with dilation of the proventriculus lumen, and the mucosae are thickened by hyperplasia and ulceration. Yellow foci of necrosis may occur in the liver and there is generalized lymphoid depletion. At CPA exposures too low to affect bodyweight, oxidative stress is measurable in liver and kidney through increased organ-specific enzymes (33).

Cyclopiazonic acid residues occur in chicken muscles as 14% of an oral dose, 48 hours after dosing, and in eggs, with higher concentrations in albumen.

Sterigmatocystin

Sterigmatocystin, a biogenic precursor to aflatoxin B1, is hepatotoxic and hepatocarcinogenic. It occurs less commonly than aflatoxin and is associated with visibly moldy products. Sterigmatocystin is produced on small grains, coffee beans, animal feeds and silage, and on cheese by many species of Aspergillus and other cereal fungi (49). It has been detected in North America, Europe, and Japan. Sterigmatocystin is less toxic than aflatoxin but is produced in higher concentrations.

In hens, sterigmatocystin mycotoxicosis occurs as decreases in feed intake and egg production and as loss of pigmentation in brown-shelled eggs. At necropsy, the liver is pale and fatty with hemorrhages.

Experimental sterigmatocystin mycotoxicosis affects liver, pancreas, lymphoid organs, and kidney. Histologically, the liver has congestion and hemorrhage, and necrosis of periacinar hepatocytes accompanied by heterophils. The pancreas displays cytoplasmic vacuolation from zymogen-granule loading in exocrine cells. Lymphocyte necrosis and depletion occur in lymphoid organs. The kidney has mild degeneration and necrosis of tubular epithelium. Serum chemistries reflect these target organ lesions, and there is leukopenia.

Sterigmatocystin reduces embryonic weight, and causes malformations and mortality in chicken embryos.

Rubratoxins

Rubratoxins A and B are hepatotoxic mycotoxins produced by *Penicillium rubrum* and *P. purpurogenum* and were recognized before aflatoxicosis was defined. In 1958, an investigation of poultry hemorrhagic syndrome yielded these toxigenic fungi from feed and litter of affected chickens. It is noteworthy that *A. flavus* and *P. citrinum*, producers of aflatoxins and citrinin, respectively, also were studied. Chicks fed toxigenic cultures of *P. rubrum* and *P. purpurogenum* develop bloody diarrhea. At necropsy, hemorrhages occur in muscles and viscera, and erosions and free blood occur in the proventriculus and gizzard.

Purified rubratoxin (20% A, 80% B), however, shows relatively low toxicity for chickens. Acute lethal intoxication produces congestion and hemorrhages. Dietary rubratoxin causes decreased growth, and at necropsy, liver enlargement and atrophy of lymphoid organs.

Penicillic Acid

Penicillic acid, discovered in 1913, is a metabolite of numerous species of *Penicillium* and *Aspergillus* and is potentially important to poultry because of high concentrations in corn

and poultry feed. Penicillic acid has low toxicity for broilers, and purified toxin has a minimal effect when fed solely at concentrations likely to occur naturally. Growth and feed conversion are affected, however, when fed with low doses of aflatoxin.

Tenuazonic Acid and Alternaria Toxins

Tenuazonic acid is a metabolite of *Alternaria* spp. and has a spectrum of biological effects. Investigations of poultry hemorrhagic syndrome revealed marked toxicity by a toxigenic culture of *Alternaria. Alternaria* spp. are common in corn and agricultural commodities and can produce multiple toxins. Tenuazonic acid has moderate toxicity for broilers and leghorns, causing hemorrhage in multiple tissues and hemorrhage and erosions in the proventriculus and gizzard.

Patulin

Patulin is a mycotoxin produced by several species of *Aspergillus*, *Penicillium*, and *Byssochlamys*. Patulin-producing *Penicillium* were isolated from chick starter feed. Patulin has relatively low toxicity and produces watery crop content, acute ascites, and hemorrhage in the lumen of the proventriculus, ventriculus (gizzard), and intestine. Growth is suppressed when fed in combination with low doses of aflatoxin. Patulin is associated with misshapen eggs with reduced calcium content in the shell.

Other Mycotoxins and Toxigenic Fungi

Kojic acid is mildly toxic to liver and kidney, and may cause anemia at high exposure levels. Tremorigens, slaframine, and other toxigenic fungi examined for toxicity in poultry, including *Diplodia maydis*, *Phomopsis leptostromiformis*, *Helminthosporium maydis* Race T, and uncharacterized metabolites of *Penicillium citrinum*, were reviewed in previous editions of this book (20, 21).

Diagnosis

Diagnosis of a mycotoxicosis begins with the assessment of the clinical history and signs. The onset of a problem may coincide with the delivery of new feed. The source of exposure may be contaminated equipment used for transportation, milling, and feeding. Clinical signs and lesions caused by mycotoxins are not pathognomonic. For example, oral lesions are often taken as evidence of trichothecene mycotoxins (T2-toxin), but similar lesions are caused by high concentrations of fines in the feed, copper sulfate, quaternary ammonia disinfectants, candidiasis, and hypovitaminosis A.

A definitive diagnosis of mycotoxicosis involves identification and quantification of specific toxins. This is difficult in poultry production because of the rapid and high volume use of feed and ingredients. The variable but often limited analytic capability of diagnostic laboratories and the biochemical complexity of finished feeds are additional factors that make confirmation difficult. Analyses for aflatoxin, fumonisins, DON, and zearalenone are readily available for feeds, but analyses for ochratoxins, zearalenol, T-2 toxin, DAS, ergot alkaloids, and citrinin are less so. Confirmation of a mycotoxicosis caused by other trichothecenes, cyclopiazonic acid, sterigmatocystin, rubratoxin, or less common mycotoxins, especially in feeds, is possible in relatively fewer laboratories.

Analytic techniques for mycotoxins require complex pretreatment extraction and detection methods that include chromatography (thin-layer, gas, and liquid), mass spectrometry, capillary electrophoresis, and monoclonal antibody-based technology that use enzyme-linked immunosorbant assay (ELISA) technology (48). A current trend is toward the use of multimycotoxin methods for the simultaneous analysis of several of the important Fusarium mycotoxins, which is best achieved by liquid chromatography with tandem mass spectrometry (25).

ELISA test kits should be used for validated applications because interfering substances in ingredients and feeds may give inaccurate results. Some assays are standardized and validated for grain and certain other ingredients but not for finished feeds, which can be a variable substrate for extraction and analysis. The black light evaluation of grains for *A. flavus* growth is an acceptable presumptive test for aflatoxin but does not confirm actual toxin. Numerous bioassays are defined for mycotoxin screening tests, but positive test results are presumptive.

Laboratory personnel should be consulted before sending samples, because laboratories differ in the capabilities to conduct screening and confirmation tests for mycotoxins. Identification of mycotoxin residues in blood or tissues is possible but not routinely available. An ELISA test for confirmation of aflatoxin in liver showed high sensitivity and specificity and would complement diagnostic investigation.

If a mycotoxicosis is suspected, a complete diagnostic evaluation is desirable in addition to feed analysis. A flock rarely experiences a single disease stress, and other diseases may be occurring in concert with mycotoxins to affect production adversely. A mycotoxicosis may be suspected but not confirmed by feed analysis; however, a complete laboratory evaluation can exclude other significant diseases. Birds that recently died and those obviously sick should be selected for submission. When any toxicity is suspected, the following tissues should be collected in clean containers and stored frozen until tested: crop content, proventriculus and ventriculus (gizzard) content, liver, kidney, fat, and bile. Analysis of selected mycotoxins in body fluid and tissue is progressing and may be available in certain laboratories (7).

Moldy feed appears unwholesome and indicates the potential for mycotoxin formation. It can be unpalatable and have reduced nutritive value, with decreases in vitamins, amino acids, and the energy level of fats. *Aspergillus*, *Penicillium*, and *Fusarium* are mycotoxin-producing fungal genera that occur in most poultry feeds, so the potential for toxin formation is evident.

Feed and ingredient samples should be properly collected and promptly submitted to a feed testing laboratory for

analysis. Mycotoxin formation may occur unevenly in a batch of feed or grain, and multiple samples from different sites, including areas with caked or moldy feed, increase the likelihood of confirming a mycotoxin formation zone (hot spot). Sampling is usually the largest source of variability associated with a mycotoxin test procedure. Samples should be collected all along the chain of ingredient storage, feed manufacture and transport, feed bins, and feeders within poultry houses. Fungal activity increases as feed moves from the feed mill to feeders and is associated with an increase in fines (small particles of feed) and higher zinc concentrations.

Samples of 500 g (1 lb) should be collected and submitted in separate containers. Clean paper bags, properly labeled, are adequate. Sealed plastic or glass containers are appropriate only for short-term storage and transport because grain rapidly deteriorates in airtight containers. A written record of sample collection and the application of labels directly to specimen containers (not the lids) help to ensure sample integrity.

Rapid on-site screening tests for several mycotoxins (aflatoxin, T-2 toxin, DON, fumonisin, ochratoxin, and zearalenone) are available in monoclonal antibody-based detection kits. Grain can be screened for potential aflatoxin contamination by examination for green fluorescence under a black (ultraviolet) light to estimate the degree of *A. flavus* contamination. The presence of aflatoxin, however, must be confirmed by a chromatographic analysis.

Treatment

Toxic feed should be removed and replaced with unadulterated feed. Poultry generally recover from most mycotoxicoses soon after an uncontaminated diet is available. Substandard management and concurrent infectious disease are especially detrimental to poultry stressed by mycotoxins and should be corrected. Vitamins, trace minerals (especially selenium), protein, and lipid requirements are increased by some mycotoxins and can be compensated by feed formulation and water-based treatment. Increasing the crude protein, dietary energy, and vitamin supplementation can counteract the effects of aflatoxin; for example amendment with either sunflower or soybean oil alleviated some effects of aflatoxin. Vitamins E and C partially counteract the toxicity of T-2 toxin and ochratoxin A in chicks.

Another strategy for treatment of mycotoxicoses in the presence of contaminated feeds involves specific nutrients that metabolize to form detoxicants. Supplemental methionine and N-acetylcysteine counteracted aflatoxin, likely through the enhancement of glutathione formation.

Prevention

While overt intoxication by mycotoxins is relatively uncommon, contamination of feedstuffs by fungi capable of producing mycotoxins is quite common. A survey of 100 poultry feed samples detected 22 genera of fungi from which a total of 10 different mycotoxins were detected in toxigenic cultures (27). Many mycotoxins described in this chapter have subclinical effects on hatchability, shell quality, immunosuppression, and processing parameters, at toxin concentrations too low to register as diagnostically significant. Preventing the insidious effects of mycotoxins by an integrated program to prevent mycotoxin formation and inhibit the effects of mycotoxins already formed can substantially benefit poultry health and production.

Feed Manufacturing and Management

Prevention of mycotoxicoses centers on using mycotoxin-free feedstuffs and feed manufacturing and management practices that prevent mold growth and mycotoxin formation. This ideally involves access to analytical capability to confirm the purchase of ingredients free of mycotoxins, or at least the type and degree of contamination so that risk can be assessed and addressed. Proper storage of ingredients and feed processing, shipping, and handling procedures are necessary to minimize mycotoxin formation. A quality control program can monitor success of these practices.

Distillers dried grain solubles (DDGS) are a byproduct of the ethanol fuel industry and are a global feed commodity, with 90% of DDGS fed to poultry and livestock in the United States. DDGS vary in quality and nutritional value. The fermentation process removes starch from the grain substrate, but mycotoxins generally remain with approximately a 3-fold concentration. DDGS have formulation limits in poultry rations and the toxins are generally diluted in finished feed; however, the potential exists for substantial mycotoxin exposure (28, 52).

Manufacturing and maintaining feed of low moisture (less than 12%), keeping the feed fresh, and maintaining clean feed handling equipment are key control points in preventing mold growth. Mycotoxins form in decayed, crusted, built-up feed in feeders, feed mills, and storage bins. Regular inspection of feed bins identifies flow problems such as feed separation, central feed-down, and feed bridging, which enhance fungal activity and mycotoxin formation. Temperature extremes cause moisture condensation and migration in bins and create high-risk situations for mycotoxin formation. Bin inspection and cleaning between flocks to certify absence of feed residue is a practical control point. Tandem feed bins on farms allow cleaning between successive feed deliveries. Minimizing feed residence time on the farm is important, even under cool, dry conditions. Adequate ventilation of poultry housing to reduce relative humidity removes moisture available for fungal growth and toxin formation in feeders. Selection of feeder equipment that minimizes surface-area contact with feed decreases the potential for mycotoxin formation.

Pelleting feed destroys some fungal spores and generally decreases the fungal burden. Pelleting is made further effective by the addition of an antifungal agent.

Antifungal Agents

Antifungal agents added to feeds to prevent fungal growth have no effect on toxin already formed but may be effective with other feed management practices. Regulatory approval of these various compounds in feeds differs among countries. Organic acids are effective against *Fusarium*, *Aspergillus*, and *Penicillium*, in order of declining susceptibility. The effectiveness of organic acids may be reduced by particle size of feed ingredients and buffering by certain ingredients. Organic acids are generally corrosive and irritating to skin, but some have been modified to counteract this. Other agents showing efficacy in reducing fungal growth or mycotoxin formation include phosphates (tetrasodium pyrophosphate and alkaline sodium polyphosphate), spice oils and extracts, and ammonium hydroxide. Gentian violet and thiabendazole are effective but no longer approved for use in the United States for animal feeds. Copper sulfate is a poor mold inhibitor for poultry feeds. Other antifungal strategies include controlled storage atmospheres, irradiation, and fumigation.

Detoxification with Binding Agents

Detoxification using mycotoxin-binding agents is effective for decreasing or preventing intoxication for feed at risk for mycotoxin contamination (29). Inorganic mineral adsorbents or binders including various clays, soils, and zeolites can be part of an integrated approach. Zeolites are silica-containing compounds that are practical and economical feed additives that can reduce the effects of aflatoxin and cyclopiazonic acid but not T-2 toxin, DAS, or ochratoxin A (62). The adsorbent activity is shown by a number of zeolitic ores and Bentonite clay. Further processing of silicate-type binders may increase their efficacy for protection. Adsorbents can counteract mycotoxins, but vary in efficacy and in the correlation of *in vitro* and *in vivo* testing. Sodium bentonite also binds the ionophore drug monensin, which competes with aflatoxin for binding sites on the clay (30, 31). Polyvinylpolypyrrolidone, a synthetic binder, diminishes the toxicity of aflatoxin for chickens. Cholestyramine is a bile acid sequestrant that binds fumonisins and is a potential detoxicant (43).

Progress continues in the development and application of organic detoxification compounds. Esterified glucomannan, a cell wall derivative of *Saccharomyces cerevisiae*, a yeast used in beer fermentation, is protective against aflatoxin and ochratoxin and shows moderate binding activity for fumonisins, zearalenone, and T-2 toxin (35, 36). Esterified glucomannan is generally protective against naturally contaminated feed containing multiple toxins. Fermentation products may show ameliorating effects through mechanisms other than absorption (38). Products containing algae and plant extracts demonstrate binding and ameliorate toxicity (14). Some products are combinations of enzyme detoxicants, various binders, nutrient supplements, or traditional spices including turmeric, thyme, and oregano (8, 10, 17, 18, 39, 54). One proposed mechanism of action of natural compounds to reduce toxicity is through the reduction of oxidative stress (37).

Other methods of prevention include ozone treatment of grain, which reduces aflatoxin contamination. Ammoniation is effective in decontaminating feeds and grains for aflatoxin, and composting contaminated corn with poultry litter is effective in detoxifying aflatoxin.

Microbial feed additives show potential as an alternative detoxification method through the metabolism or degradation of mycotoxins (3, 53). Certain cultures of *Lactobaccillus* prevent aflatoxin absorption from the small intestine while *Eubacterium*, from the rumen, can degrade and counteract the toxicity of DON. Multiple bacterial strains selected from the lower small intestine are capable of degrading DON (56). *Nocardia corynebacteroides* shows potential in ameliorating aflatoxin (47).

Long-term efforts to prevent mycotoxin exposure involve developing grain-producing plants that resist fungal infection, reduce the toxic effects of the mycotoxins, and interrupt mycotoxin biosynthesis.

References

1. Alpsoy, L., and M.E. Yalvac. 2011. Key roles of vitamins A, C, and E in aflatoxin B1-induced oxidative stress. *Vitam Horm*. 86:287–305.
2. Applegate, T.J., G. Schatzmayr, K. Prickel, C. Troche, and Z. Jiang. 2009. Effect of aflatoxin culture on intestinal function and nutrient loss in laying hens. *Poult Sci*. 88:1235–1241.
3. Awad, W.A., K. Ghareeb, J. Bohm, and J. Zentek. 2010. Decontamination and detoxification strategies for the Fusarium mycotoxin deoxynivalenol in animal feed and the effectiveness of microbial biodegradation. *Food Addit Contam Part A Chem Anal Control Expo Risk Assess*. 27:510–520.
4. Awad, W.A., M. Hess, M. Twaruzek, J. Grajewski, R. Kosicki, J. Bohm, and J. Zentek. 2011. The impact of the fusarium mycotoxin deoxynivalenol on the health and performance of broiler chickens. *Int J Mol Sci*. 12:7996–8012.
5. Chang, P.K., K.C. Ehrlich, and I. Fujii. 2009. Cyclopiazonic acid biosynthesis of Aspergillus flavus and Aspergillus oryzae. *Toxins*. 1:74–99.
6. Danicke, S., J. Pappritz, T. Goyarts, B. Xu, and S. Rautenschlein. 2011. Effects of feeding a Fusarium toxin-contaminated diet to infectious bursal disease virus-infected broilers on the protein turnover of the bursa of Fabricius and spleen. *Arch An Nut*. 65:1–20.
7. De Baere, S., J. Goossens, A. Osselaere, M. Devreese, V. Vandenbroucke, P. De Backer and S. Croubels. 2011. Quantitative determination of T-2 toxin, HT-2 toxin, deoxynivalenol and deepoxy-deoxynivalenol in animal body fluids using LC-MS/MS detection. *J Chromatogr B*. 879:2403–2415.
8. Denli, M., J.C. Blandon, M.E. Guynot, S. Salado and J.F. Perez. 2009. Effects of dietary AflaDetox on performance, serum biochemistry, histopathological changes, and aflatoxin residues in broilers exposed to aflatoxin B(1). *Poult Sci*. 88:1444–1451.
9. Diaz, G.J., E. Calabrese and R. Blain. 2008. Aflatoxicosis in chickens (Gallus gallus): an example of hormesis? *Poult Sci*. 87:727–732.
10. Diaz, G.J., A. Cortes and L. Botero. 2009. Evaluation of the ability of a feed additive to ameliorate the adverse effects of aflatoxins in turkey poults. *Br Poult Sci*. 50:240–250.

11. Diaz, G.J., H.W. Murcia and S.M. Cepeda. 2010. Bioactivation of aflatoxin B1 by turkey liver microsomes: responsible cytochrome P450 enzymes. *Br Poult Sci*. 51:828–837.
12. Diaz, G.J., H.W. Murcia, and S.M. Cepeda. 2010. Cytochrome P450 enzymes involved in the metabolism of aflatoxin B1 in chickens and quail. *Poult Sci*. 89:2461–2469.
13. Ellakany, H.F., S.S. Abuakkada, S.S. Oda, and Y.S. El-Sayed. 2011. Influence of low levels of dietary aflatoxins on Eimeria tenella infections in broilers. *Tr An Health Prod*. 43:249–257.
14. Ghareeb, K., W.A. Awad, and J. Bohm. 2012. Ameliorative effect of a microbial feed additive on infectious bronchitis virus antibody titer and stress index in broiler chicks fed deoxynivalenol. *Poult Sci*. 91:800–807.
15. Girgis, G.N., J.R. Barta, M. Brash, and T.K. Smith. 2010. Morphologic changes in the intestine of broiler breeder pullets fed diets naturally contaminated with Fusarium mycotoxins with or without coccidial challenge. *Avian Dis*. 54:67–73.
16. Girish, C.K., T.K. Smith, H.J. Boermans, P. Anil Kumar, and G.N. Girgis. 2010. Effects of dietary Fusarium mycotoxins on intestinal lymphocyte subset populations, cell proliferation and histological changes in avian lymphoid organs. *Food Chem Tox*. 48:3000–3007.
17. Gowda, N.K., D.R. Ledoux, G.E. Rottinghaus, A.J. Bermudez, and Y.C. Chen. 2009. Antioxidant efficacy of curcuminoids from turmeric (*Curcuma longa L*.) powder in broiler chickens fed diets containing aflatoxin B1. *Br J Nutr*. 102:1629–1634.
18. Gowda, N.K., D.R. Ledoux, G.E. Rottinghaus, A.J. Bermudez, and Y.C. Chen. 2008. Efficacy of turmeric (*Curcuma longa*), containing a known level of curcumin, and a hydrated sodium calcium aluminosilicate to ameliorate the adverse effects of aflatoxin in broiler chicks. *Poult Sci*. 87:1125–1130.
19. Hassan, Z.U., M.Z. Khan, M.K. Saleemi, A. Khan, I. Javed, and M. Noreen. 2012. Immunological responses of male White Leghorn chicks kept on ochratoxin A (OTA)-contaminated feed. *J Immunotox*. 9:56–63.
20. Hoerr, F.J. 2008. Mycotoxicoses. In: *Diseases of Poultry*, 12th ed. Y.M. Saif, ed. Blackwell Publishing, Ames, IA. 1197–1230.
21. Hoerr, F.J. 2003. Mycotoxicoses. In: *Diseases of Poultry*, 11th ed. Y.M. Saif, ed. Iowa State Press, Ames, IA. 1103–1132.
22. Hussain, Z., M.Z. Khan, A. Khan, I. Javed, M.K. Saleemi, S. Mahmood, and M.R. Asi. 2010. Residues of aflatoxin B1 in broiler meat: effect of age and dietary aflatoxin B1 levels. *Food Chem Tox*. 48:3304–3307.
23. Kalpana, S., M. Aggarwal, G. Srinivasa Rao, and J.K. Malik. 2012. Effects of aflatoxin B1 on tissue residues of enrofloxacin and its metabolite ciprofloxacin in broiler chickens. *Env Tox Pharm*. 33:121–126.
24. Karaman, M., H. Ozen, M. Tuzcu, Y. Cigremis, F. Onder, and K. Ozcan. 2010. Pathological, biochemical and haematological investigations on the protective effect of alpha-lipoic acid in experimental aflatoxin toxicosis in chicks. *Br Poult Sci*. 51:132–141.
25. Krska, R., P. Schubert-Ullrich, A. Molinelli, M. Sulyok, S. MacDonald, and C. Crews. 2008. Mycotoxin analysis: an update. *Food Add Contam A*. 25:152–163.
26. Labuda, R., A. Parich, E. Vekiru, and D. Tancinova. 2005. Incidence of fumonisins, moniliformin and Fusarium species in poultry feed mixtures from Slovakia. *Ann Agric Environ Med* 12:81–86.
27. Labuda, R., and D. Tancinova. 2006. Fungi recovered from Slovakian poultry feed mixtures and their toxinogenity. *Ann Agric Environ Med*. 13:193–200.
28. Liu, K. 2011. Chemical composition of distillers grains, a review. *J Agr Food Chem*. 59:1508–1526.
29. Liu, Y.L., G.Q. Meng, H.R. Wang, H.L. Zhu, Y.Q. Hou, W.J. Wang, and B.Y. Ding. 2011. Effect of three mycotoxin adsorbents on growth performance, nutrient retention and meat quality in broilers fed on mould-contaminated feed. *Br Poult Sci*. 52:255–263.
30. Magnoli, A.P., M.P. Monge, R.D. Miazzo, L.R. Cavaglieri, C.E. Magnoli, C.I. Merkis, A.L. Cristofolini, A.M. Dalcero, and S.M. Chiacchiera. 2011. Effect of low levels of aflatoxin B(1) on performance, biochemical parameters, and aflatoxin B(1) in broiler liver tissues in the presence of monensin and sodium bentonite. *Poult Sci*. 90:48–58.
31. Magnoli, A.P., M. Texeira, C.A. Rosa, R.D. Miazzo, L.R. Cavaglieri, C.E. Magnoli, A.M. Dalcero, and S.M. Chiacchiera. 2011. Sodium bentonite and monensin under chronic aflatoxicosis in broiler chickens. *Poult Sci*. 90:352–357.
32. Mainka, S., S. Danicke, H. Bohme, J. Wolff, S. Matthes, and G. Flachowsky. 2005. Comparative studies on the effect of ergot contaminated feed on performance and health of piglets and chickens. *Arch An Nutr*. 59:81–98.
33. Malekinejad, H., P. Akbari, M. Allymehr, R. Hobbenaghi, and A. Rezaie. 2011. Cyclopiazonic acid augments the hepatic and renal oxidative stress in broiler chicks. *Human Exp Toxicol*. 30: 910–919.
34. Martinez-de-Anda, A., A.G. Valdivia, F. Jaramillo-Juarez, J.L. Reyes, R. Ortiz, T. Quezada, M.C. de Luna, and M.L. Rodriguez. 2010. Effects of aflatoxin chronic intoxication in renal function of laying hens. *Poult Sci*. 89:1622–1628.
35. Matur, E., E. Ergul, I. Akyazi, E. Eraslan, and Z.T. Cirakli. 2010. The effects of *Saccharomyces cerevisiae* extract on the weight of some organs, liver, and pancreatic digestive enzyme activity in breeder hens fed diets contaminated with aflatoxins. *Poult Sci*. 89:2213–2220.
36. Matur, E., E. Ergul, I. Akyazi, E. Eraslan, G. Inal, S. Bilgic, and H. Demircan. 2011. Effects of *Saccharomyces cerevisiae* extract on haematological parameters, immune function and the antioxidant defence system in breeder hens fed aflatoxin contaminated diets. *Br Poult Sci*. 52:541–550.
37. Mueller, K., N.M. Blum, H. Kluge, and A.S. Mueller. 2011. Influence of broccoli extract and various essential oils on performance and expression of xenobiotic- and antioxidant enzymes in broiler chickens. *Br J Nutr*. 1–15.
38. Osweiler, G.D., S. Jagannatha, D.W. Trampel, P.M. Imerman, S.M. Ensley, I. Yoon, and D.T. Moore. 2010. Evaluation of XPC and prototypes on aflatoxin-challenged broilers. *Poult Sci*. 89: 1887–1893.
39. Rangsaz, N., and M.G. Ahangaran. 2011. Evaluation of turmeric extract on performance indices impressed by induced aflatoxicosis in broiler chickens. *Tox Ind Health*. 27:956–960.
40. Rawal, S., and R.A. Coulombe, Jr. 2011. Metabolism of aflatoxin B1 in turkey liver microsomes: the relative roles of cytochromes P450 1A5 and 3A37. *Toxicol Appl Pharmacol*. 254: 349–354.
41. Rawal, S., J.E. Kim, and R. Coulombe, Jr. 2010. Aflatoxin B1 in poultry: toxicology, metabolism and prevention. *Res Vet Sci*. 89:325–331.
42. Rawal, S., S.S. Yip, and R.A. Coulombe, Jr. 2010. Cloning, expression and functional characterization of cytochrome P450 3A37 from turkey liver with high aflatoxin B1 epoxidation activity. *Chem Res Toxicol*. 23:1322–1329.

43. Scott, P.M. 2012. Recent research on fumonisins: a review. *Food Add Cont A*. 29:242–248.
44. Sobrova, P., V. Adam, A. Vasatkova, M. Beklova, L. Zeman, and R. Kizek. 2010. Deoxynivalenol and its toxicity. *Interdiscip Toxicol*. 3:94–99.
45. Stoev, S.D., M.F. Dutton, P.B. Njobeh, J.S. Mosonik, and P.A. Steenkamp. 2010. Mycotoxic nephropathy in Bulgarian pigs and chickens: complex aetiology and similarity to Balkan endemic nephropathy. *Food Add Cont A*. 27:72–88.
46. Tangni, E.K., N. Waegeneers, I. Van Overmeire, L. Goeyens, and L. Pussemier. 2009. Mycotoxin analyses in some home produced eggs in Belgium reveal small contribution to the total daily intake. *Sci Total Environ*. 407:4411–4418.
47. Tejada-Castaneda, Z.I., E. Avila-Gonzalez, M.T. Casaubon-Huguenin, R.A. Cervantes-Olivares, C. Vasquez-Pelaez, E.M. Hernandez-Baumgarten, and E. Moreno-Martinez. 2008. Biodetoxification of aflatoxin-contaminated chick feed. *Poult Sci*. 87:1569–1576.
48. Turner, N.W., S. Subrahmanyam, and S.A. Piletsky. 2009. Analytical methods for determination of mycotoxins: a review. *Anal Chim Acta*. 632:168–180.
49. Versilovskis, A., and S. De Saeger. 2010. Sterigmatocystin: occurrence in foodstuffs and analytical methods—an overview. *Mol Nut Food Res*. 54:136–147.
50. Wang, Y., T. Chai, G. Lu, C. Quan, H. Duan, M. Yao, B.A. Zucker, and G. Schlenker. 2008. Simultaneous detection of airborne aflatoxin, ochratoxin and zearalenone in a poultry house by immunoaffinity clean-up and high-performance liquid chromatography. *Env Res*. 107:139–144.
51. Wang, Y.C., J.L. Deng, S.W. Xu, X. Peng, Z.C. Zuo, H.M. Cui, Y. Wang, and Z.H. Ren. 2012. Effects of zearalenone on IL-2, IL-6, and IFN-gamma mRNA levels in the splenic lymphocytes of chickens. *Sci World J*. 2012:567327.
52. Wu, F., and G.P. Munkvold. 2008. Mycotoxins in ethanol co-products: modeling economic impacts on the livestock industry and management strategies. *J Ag Food Chem*. 56:3900–3911.
53. Wu, Q., A. Jezkova, Z. Yuan, L. Pavlikova, V. Dohnal, and K. Kuca. 2009. Biological degradation of aflatoxins. *Drug Metabol Rev*. 41:1–7.
54. Yarru, L.P., R.S. Settivari, N.K. Gowda, E. Antoniou, D.R. Ledoux, and G.E. Rottinghaus. 2009. Effects of turmeric (*Curcuma longa*) on the expression of hepatic genes associated with biotransformation, antioxidant, and immune systems in broiler chicks fed aflatoxin. *Poult Sci*. 88:2620–2627.
55. Yohannes, T., A.K. Sharma, S.D. Singh, and T.K. Goswami. 2012. Immunopathological effects of experimental T-2 mycotoxocosis in broiler chicken co-infected with infectious bronchitis virus (IBV). *Vet Immunol Immunopath*. 146:245–253.
56. Yu, H., T. Zhou, J. Gong, C. Young, X. Su, X.Z. Li, H. Zhu, R. Tsao, and R. Yang. 2010. Isolation of deoxynivalenol-transforming bacteria from the chicken intestines using the approach of PCR-DGGE guided microbial selection. *BMC Microbiol*. 10:182.
57. Yunus, A.W., A. Blajet-Kosicka, R. Kosicki, M.Z. Khan, H. Rehman, and J. Bohm. 2012. Deoxynivalenol as a contaminant of broiler feed: intestinal development, absorptive functionality, and metabolism of the mycotoxin. *Poult Sci*. 91:852–861.
58. Yunus, A.W., K. Ghareeb, M. Twaruzek, J. Grajewski, and J. Bohm. 2012. Deoxynivalenol as a contaminant of broiler feed: effects on bird performance and response to common vaccines. *Poult Sci*. 91:844–851.
59. Zahoor ul, H., M.Z. Khan, A. Khan, I. Javed, and M. Noreen. 2012. *In vivo* and *ex vivo* phagocytic potential of macrophages from progeny of breeder hens kept on ochratoxin A (OTA)-contaminated diet. *J Immunotoxicol*. 9:64–71.
60. Zahoor ul, H., M.Z. Khan, A. Khan, I. Javed, and M.K. Saleemi. 2011. Immunological status of the progeny of breeder hens kept on ochratoxin A (OTA)-contaminated feed. *J Immunotoxicol*. 8:122–130.
61. Zahoor ul, H., M.Z. Khan, M.K. Saleemi, A. Khan, I. Javed, and A. Hussain. 2011. Immunological status of White Leghorn chicks hatched from eggs inoculated with ochratoxin A (OTA). *J Immunotoxicol*. 8:204–209.
62. Zhao, J., R.B. Shirley, J.D. Dibner, F. Uraizee, M. Officer, M. Kitchell, M. Vazquez-Anon, and C.D. Knight. 2010. Comparison of hydrated sodium calcium aluminosilicate and yeast cell wall on counteracting aflatoxicosis in broiler chicks. *Poult Sci*. 89:2147–2156.

Chapter 32

Toxins and Poisons

Richard M. Fulton

Introduction

Paracelsus recognized more than 400 years ago that it is "the dose that makes the poison." Although that may be obvious with known toxic materials, it is also true for more benign products such as growth promotants and chemotherapeutics usually considered safe. Deliberate or inadvertent overdosages may cause illness, and a misplaced decimal in water or feed medication frequently results in toxicity. A general feature of modern complex poultry rations, feed mill equipment, and feed delivery to poultry farms is that any component included in a ration may at some time be mistakenly included at a higher than desired rate. This may occur through human or mechanical error. Furthermore, when toxicoses do occur, they are added to the pre-existing background of complicating infectious agents, vaccine administrations, and environmental exposures. This usually leads to multi-factoral mixed clinical presentations of toxic, infectious, environmental, and management diseases, rather than "pure" toxicoses. Additionally, some highly pathogenic infectious or environmental diseases of poultry present such rapidly elevating mortalities that acute toxicoses may be suspected incorrectly.

For example, sulfaquinoxaline poisoning occurs in meat-type chickens, even at recommended doses, because of high water intake in warm buildings, particularly in hot weather, or because of poor feed mixing. Disease may also be caused by toxic levels of some nutrients (e.g., excess dietary sodium causes significant losses in chickens and turkeys around the world). High levels of vitamins A and D are toxic. Some compounds have differential species or age toxicities, and others have increased toxicity in naïve animals with no previous adaptive exposure. Ionophore anticoccidials commonly exhibit such differential adaptive resistance to toxicity. Furthermore, waterfowl are sensitive to some drugs at a dose safe for chickens and turkeys. The immune system seems to be affected by many toxic agents. In addition to disease caused by poisons, the problem of residues in eggs and meat must also be considered. For information on drugs approved in the United States, withdrawal times, and drug and chemical residues, see Booth (33), the Green Book On-line (www.fda.gov/AnimalVeterinary/Products/ApprovedAnimalDrugProducts/ucm042847.htm), naccvp.com, or the current Feed Additive Compendium. In rationalizing withdrawal times in egg-laying chickens, it must be remembered that compounds begin to be deposited in chicken egg yolk 10 days before that egg is laid.

Poisonous substances are widely distributed in nature. Mycotoxins, covered previously, are important to the poultry industries, but toxins are also produced by bacteria (botulinum toxin, methylmercury, toxic amines) or occur naturally (selenium, phytotoxins). Pesticides, herbicides and other synthetic chemicals, metals such as lead, and industrial contaminants add to the list of toxic materials. Many chemicals and human drugs have been given to birds in feed and water to study their toxic effects. These experimental toxicities generally have not been included in this chapter, except as they may relate to potential naturally occurring or iatrogenic poisonings in poultry.

Poisons and toxins are not major causes of production loss or disease in poultry in most countries, although some, such as lead, pesticides, and botulism, are significant in wild birds. However, in 1985, Terzic and Curcic (327) reported that 40% of 2,065 poisoning cases seen at the Belgrade Veterinary Facility during a 17-year period were in poultry. In 2005, Sharpe and Livesey (297) reported that 1.4% of 876 poisoning cases of food safety concern that were seen at the Veterinary Laboratories Agency in England and Wales were in poultry, most of which were lead poisoning in waterfowl. Poisoning occurs more frequently in free-range and backyard flocks and in village poultry where birds forage in neighboring gardens and fields or receive household waste and weeds cut from roadsides and fields. Some of these poisonings are malicious. Contaminated litter on the floor and in nest boxes is an added source of toxins in chickens not raised on wire. Because suspected toxicity cases are more likely to be submitted to a diagnostic laboratory than are other sick birds, statistics collected from that source may not be an accurate indication of the incidence of poisoning compared with other disease.

Toxicants covered in this chapter are presented by primary use. Levels of toxic substances that may cause depressed growth in broilers and turkeys or decreased egg production in layers are summarized in Table 32.1.

Diseases of Poultry, Thirteenth Edition. David E. Swayne.
© 2013 John Wiley & Sons, Inc. Published 2013 by John Wiley & Sons, Inc.

Table 32.1. Levels in feed (unless otherwise noted) of selected toxins documented to decrease growth rate in broilers and turkeys and reduce egg production in layers.

Toxin	Broilers	Turkeys	Layers
Antimicrobials and Growth Promotants			
Sulfadimethoxine (% in water)	NA[a]	NA	0.05
Sulfaquinoxaline (%)	NA	NA	0.10
Nicabazine (mg/kg)	NA	NA	70
Arsanilic acid (mg/kg)	1000	400	NA
Nitarsone (mg/kg)	300	600	NA
Roxarsone (mg/kg)	90	550	NA
Nutrients and Other Feed- and Water-Related Toxicants			
Aluminum (%)	0.30	0.30	0.15
Arsenic (inorganic pentoxide) (mg/kg)	40	40	40
Boron (mg/kg)	435	435	870
Boric acid (mg/kg)	2500	2500	5000
Cadmium (mg/kg)	400	400	8–60
Copper (mg/kg)	500–1000	500–1000	1000
Fluoride (mg/kg)	1300	1300	1300
Iodine (mg/kg)	500	500	300
Iron (mg/kg)	200–2000	200–2000	NA
Lead (acetate) (mg/kg)	630	630	630
Mercury (mg/kg)	50	50	5
Molybdenum (mg/kg)	200	200	200
Potassium (%)	0.90	0.90	NA
Selenium (mg/kg)	5	5	80
Sodium (%)	0.80	0.80	0.80
Sodium chloride (%)	2.0	2.0	2.0
Tungsten (mg/kg)	1000	1000	1000
Vanadium (mg/kg)	6	6	20–30
Zinc (mg/kg)	NA	NA	20,000
Other			
Ammonia (ppm)	**50**	**25**	**75**

[a]NA—not available.
Source: 268,269

Antimicrobials, Anticoccidials, and Growth Promotants

Most reports of poisoning with chemotherapeutic agents involve inappropriate use or overdose of ionophore anticoccidials or growth promotants. Toxicity of a variety of chemotherapeutic agents in poultry and pigeons has been reviewed (275, 276).

Sulfonamides

Sulfonamides were used as the primary form of prevention and treatment for coccidiosis in poultry between the early 1940s and late 1950s. Sulfaquinoxaline and sulfamethazine were most widely used. The toxic level of sulfonamides is close to the therapeutic level in poultry, and even the therapeutic level has a detrimental effect on hemopoietic and immune systems. Previous low-level or continuous-preventive medication has a protective effect against subsequent higher doses (100).

Sulfonamides are difficult to mix evenly in feed, and they have low solubility in acidic water. These characteristics may cause some birds to receive a toxic dose even when appropriate treatment levels are added to bulk rations or water supplies. This is less likely at lower preventive levels. Both feed and water medication require accurate estimates of daily consumption if each chicken is to receive a therapeutic and nontoxic daily dose. Sulfa poisoning has occurred when no allowance was made for increased water and feed consumption of the modern broiler that eats to its physical capacity rather than to its metabolic need, or, more frequently, for the effect of increased water consumption at high environmental temperatures or in hot broiler houses. For broilers, previous authors of this chapter recommended one-half of the therapeutic dose, and at temperatures greater than 27°C (81°F), one-third of the therapeutic dose for water medication. Repeat treatment is hazardous and should not be recommended without a postmortem examination of a subset of individuals to make sure that there is no evidence of sulfa toxicity. Even the newer so-called safe sulfas need to be used with care (65, 276).

Under no circumstances should sulfas be given simultaneously in both the feed and water. Decreased solubility in acidic water may lead to delayed clearance of sulfas from water lines and result in detectable drug levels in meat and eggs beyond published withdrawal times.

Hemorrhagic syndrome, which occurred frequently when sulfas were in widespread use, is a manifestation of sulfa toxicity and occurs at and above therapeutic dose levels. In addition to blood dyscrasia, bone marrow depression, and thrombocytopenia, sulfonamides depress the lymphoid system and immune function in birds. Similar but more dramatic hematologic manifestations and diatheses are seen in domestic mammals given sulfa-containing poultry rations or water medications. Focal bacterial granulomas are often found in tissues and organs of chickens dying from sulfa poisoning. Epithelial necrosis and degeneration in the liver, kidney, and other organs may be caused by the direct effects of the drug, or hypoxia secondary to drug-induced anemia. When determining withdrawal times in chickens whose eggs reach the human food chain, deposition in the yolk 10 days prior to the production of an egg must be considered (31).

Signs

Chickens and turkeys with sulfa toxicity are depressed, pale, and frequently underweight. In adults, there is a marked decrease in egg production and shell quality; brown eggs may be depigmented (72, 251). Secondary bacterial infections including septicemia and gangrenous dermatitis may follow sulfonamide toxicity (65).

Pathology

For descriptions of gross and microscopic pathology, see (65, 72, 101).

Hemorrhage in skin, muscles, and internal organs is the most consistent and extensive gross lesion of sulfonamide intoxication. Hemorrhage may be present in comb, eyelids, face, wattles, anterior chamber of the eye, and musculature of breast and thighs. Normal dark-red bone marrow in growing birds changes to pink in mild cases and yellow in severe cases. The entire length of the intestinal tract may be spotted with petechial and ecchymotic hemorrhages, and the cecal lumen may contain blood. Hemorrhage may be present in the proventriculus and beneath the ventriculus (gizzard) lining. There may be ulcers at the proventricular-ventricular junction. The liver is swollen, pale red, or icteric, and may be studded with petechiae or foci of necrosis. The spleen is commonly enlarged, has hemorrhagic infarcts, and contains gray nodular areas. "Paintbrush" ecchymotic hemorrhages occur in the myocardium. Thymus and bursa of Fabricius are small.

Microscopically, areas of caseous necrosis surrounded by a mantle of giant cells occur in liver, spleen, lungs, and kidneys. Lymphocyte and heterophil infiltrates are present at the periphery of necrotic foci. Lymphoid hypoplasia around splenic sheaths, edema and fibroplasia of the capsule, and macrophages containing hemosiderin are common. Early changes in the liver are periportal mononuclear infiltration associated with bile duct hyperplasia. Hemosiderin deposits are present in necrotic areas, and thrombosis of portal vessels is present. An early change in kidneys is interstitial lymphocytic infiltrate, but this may be associated with concomitant infections. Degeneration and necrosis of tubular epithelium are associated with hyaline casts. Glomeruli are enlarged, and Bowman's capsule is dilated with hyaline material. Lungs are congested with interlobular and interstitial edema. Interstitial tissues contain mononuclear foci. There is degeneration and necrosis of lymphocytes and depletion of bursal follicles.

In femoral bone marrow, there is decreased intrasinusoidal erythropoiesis with thrombocytopenia and agranulocytosis, focal increase in extrasinusoidal lymphopoiesis, and, in some instances, myelopoiesis. There are also focal areas of hyalinization, necrosis, and fibroplasia. Hemosiderin deposits and extrasinusoidal edema are present.

Nitrofurans

Nitrofuran use is no longer permitted in some countries. Prominent signs of nitrofurazone (NFZ) toxicity in chicks include depression, incoordination, ruffled feathers, and growth retardation (251). Poor growth may be partially related to feed aversion, because feed consumption drops as the level of NFZ increases. Ducklings on toxic levels of NFZ die suddenly without clinical signs. Nervous signs and hyperexcitability have been described in acute toxicity in chicks and poults. Loud vocalization, opisthotonos, aimless running and flying, and convulsions may be seen. Acute nervous signs of NFZ toxicosis disappear within hours after supplying unmedicated feed and water. Chronic exposure to furazolidone also may reversibly delay sexual maturity in male broiler breeder chickens (12, 308).

Furazolidone (FZ) toxicity mainly affects the heart in turkeys, ducks, and chickens (62, 219). Marked individual and age susceptibility to FZ occurs. Some poults, chicks, and ducklings grow well without cardiac damage when fed 400–700 mg FZ/kg feed, whereas others fail to grow and develop ascites and signs associated with heart failure. Frequency and severity of clinical signs are dose related. Recovery occurred in affected ducklings (343). There also is clinical evidence that FZ may cause nervous signs in chicks and poults and infertility in male breeders (275).

FZ causes dose-related biventricular cardiomyopathy with prominent dilation of ventricles and thinning of either the right or left ventricular wall. Secondary heart failure results in passive congestion with lung edema or marked congestion of liver and other organs, and ascites depending on whether heart failure is mainly left- or right-sided. Right-sided heart failure with marked cardiac enlargement is usually more common up to 3 weeks of age (171).

In turkeys, FZ-induced cardiomyopathy cannot be distinguished from spontaneous turkey cardiomyopathy (STC). The cause of STC is not known, but clinically it is associated with rapid growth, low serum protein, and stressors such as low incubator oxygen, poor ventilation, and fumes from brooders, which might induce ischemic cardiomyopathy. The mechanism of how high doses of FZ cause dilatory cardiomyopathy is not known (131).

Most microscopic lesions result from heart failure. Cardiac lesions include edema, thinning of myocardial muscle fibers, and multifocal myocytolysis with increased connective tissue. Epicardial fibrosis and endocardial fibroelastosis may also occur. Ultrastructural changes include myofibrillar lysis, clumps of Z-band material, and increased glycogen in myocardial fibers. Changes in heart muscle enzyme levels accompany tissue alterations.

Aminoglycoside Antibiotics

After subcutaneous injection, gentamicin (an aminogylcoside) causes depression in turkey poults; edema and hemorrhages at the injection site; and large, pale, and nephrotic kidneys (25, 285). Aminoglycosides and various other antibiotics used for egg inoculation have caused embryo mortality. Streptomycin and dihydrostreptomycin sulfate injected intramuscularly for sinusitis in turkey poults causes respiratory distress, paresis, and mild convulsions (275, 276).

Ionophore Antibiotics

Ionophores (ion carriers) facilitate movement of some monovalent cations, such as sodium and potassium, and divalent cations, such as calcium and magnesium, across cell membranes. They can have both anticoccidial and antibacterial activity, and the group is used extensively in poultry and ruminant feeds. Ionophores are coccidiocidal because of their ability to preferentially move ions, usually Na+, into various stages of the parasite.

Toxic levels of ionophores cause potassium to leave and calcium to enter cells, particularly myocytes, resulting in cell death. Signs of toxicity are related to high extracellular potassium and high intracellular (intramitochondrial) calcium. For more specific information on metabolism and toxicity of monensin, see (33, 53, 85, 243). Ionophore toxicity varies with species and age; equidae are very susceptible, and adult poultry, particularly turkeys, are more susceptible than broilers (134, 155, 297). There is a synergistic effect with antibiotics in the same family of drugs (332) and increased toxicity with nonrelated antibiotics, other drugs (36, 42, 84, 190, 255, 261, 275), and low-protein rations (276). Dehydration because of diarrhea or periods of water and/or feed deprivation can precipitate toxic events (49, 128). Monensin, lasalocid, salinomycin, and narasin have been associated with toxicity in poultry, guinea fowl, quail, and other species (68, 128, 136, 210, 264, 292, 297, 345). Lethal toxicoses have been described in equidae and other mammals accidentally exposed to ionophore-containing poultry rations. Poultry have an adaptative resistance to dietary ionophores and an inverse age sensitivity, with adult naïve poultry being more susceptible than young previously exposed birds.

Signs

Signs vary from anorexia with depression, weakness, and reluctance to move to complete paralysis in which birds lie in sternal recumbency with neck and legs extended. Less severely affected birds may show posterior paralysis with legs extended. Dyspnea has occurred in affected adult turkeys (Figure 32.1). Signs are associated with muscle damage. Death may follow respiratory failure or be secondary to dehydration. Mortality is variable but may exceed 70% (106). In some cases of suspected ionophore toxicity in turkeys, morbidity may be low with only a few poults paralyzed. The term knockdown syndrome has been used for this condition (49). Poults with botulism may show similar signs. Reduced egg production (345) and fertility with weak chicks also have occurred (256).

Figure 32.1. Acute ionophore toxicity. Dyspnea and drooping wings suggest heat stress. (H.J. Barnes)

Pathology

Subchronic monensin toxicity (338) resulted in opaque fibrin plaques on the epicardium, hemorrhage in coronary fat, and decreased liver weight. In acutely affected turkeys, pallor and atrophy of mainly type I fibers of leg and back muscles have been observed associated with monensin use (26, 259, 337). However, clinical signs and gross lesions are often absent in breeders ingesting high levels of monensin (106).

Microscopic changes in heart and skeletal muscle consist of scattered areas of hyalinization with muscle necrosis and myofiber degeneration and necrosis. Birds with respiratory signs often have lesions in tracheal muscles. Type I fibers appear to be selectively affected (136). Heterophils, macrophages, and occasionally lymphocytes may be present. Frequently, when exposed to low doses or interaction with other drugs occurs, affected areas are very cellular with large numbers of satellite or sarcolemmal nuclei, indicating regeneration is occurring (Figure 32.2). Ultrastructural changes have been described (332). Peripheral neuropathy characterized by edema, demyelination, and axonal degeneration accompanied by marked hypertrophy and hyperplasia of neurilemmal cells may be seen with lasalocid toxicity (128).

Differential Diagnosis

Because there is a marked individual, age, and species variation in susceptibility and the toxic effect may be potentiated

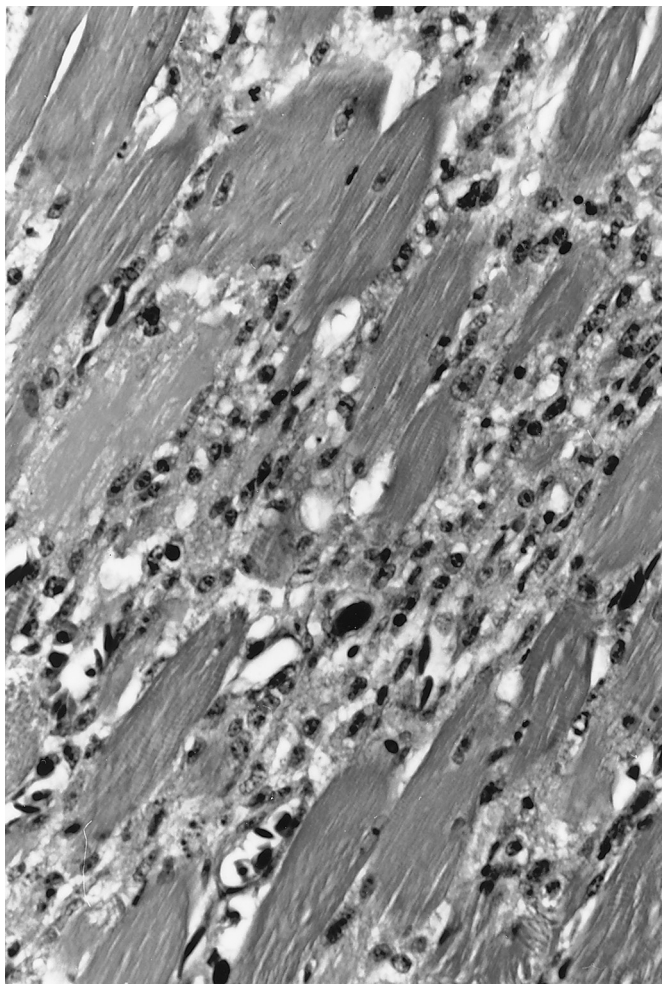

Figure 32.2. Muscle from a young turkey with knockdown. Minimal muscle necrosis and inflammation along with increased sarcolemmal or satellite cell nuclei indicate regeneration.

by other drugs, normal levels of ionophore should not be dismissed if clinical signs and histologic changes indicate ionophore toxicity. High serum or plasma levels of muscle enzymes may be useful in differentiating ionophore toxicity from botulism (230). Ionophore toxicity also must be distinguished from vitamin E/selenium deficiency and Cassia (Senna) ingestion, which may produce similar signs and lesions.

Other Anticoccidials

3,5-dinitro-o-toluamide (dinitrotolumide, dinitolmide, DNOT, Zoalene, Zoamix) can cause ataxia, torticollis, incoordination, and reduced growth (169, 251, 275). Nicarbazin (Nicarb) can make broiler chicks listless, dull, and ataxic; in older birds, there can be reduced egg production, shell depigmentation, yolk mottling, and reduced hatchability (20, 168, 196). Nicarbazin depresses growth rate at 150 mg/kg feed. Even when used at recommended levels, nicarbazin increases metabolic rate and heat production (22, 275, 351). This makes older broilers more susceptible to heat stress and pulmonary hypertension syndrome. Generally, there are no gross lesions, but there may be hepatic and renal epithelial degeneration (251, 276). Nitrophenide (Megasul) has caused nervous signs but with rapid recovery (251). Ducks, geese, and chukar partridges may have depressed growth and mortality from halofuginone (Stenorol) (23, 100), and reduced skin strength has been found in chickens (126, 214). Use of t-butylaminoethanol may result in reduced growth due to choline deficiency.

Antiprotozoals

Organic arsenicals and imidazoles such as dimetridazole (Nitrazol, Emtryl), used for histomoniasis, have caused growth depression; drops in egg production; nervous signs (ataxia, incoordination, tremors); convulsions; and death in geese, ducks, pigeons, and turkeys (275, 276, 279). Waterfowl may be poisoned by doses safe for other poultry. Quinacrine HCl (Atabrine), used for Haemoproteus infections in pigeons, was fatal at a dose of approximately 50 mg/kg.

Organic Arsenical and Imidazole Feed Additives

Phenylarsonic acids such as arsanilic acid (p-amino-benzene arsanilate) and sodium arsanate, roxarsone (3-nitro-4-hydroxyphenylarsonic acid), and nitarsone (4-nitrophenylarsonic acid, Histostat-50) are used to improve feed efficiency in livestock. p-Ureidobenzenearsonic acid (Carb-o-sep, Carbarsone) and dimetridazole (1,2-dimethyl-5-nitroimidazole, Nitrazol, Emtryl) are used for prevention and control of histomoniasis. Toxicity occurs with accidental or deliberate overdose or in dehydrated animals or birds (243). Peripheral neuropathy causing lameness in turkeys developed after they were given twice the recommended level of 3-nitro-4-hydroxyphenylarsonic acid (358). Toxicity, with liver lesions suggestive of inorganic trivalent arsenite, occurred in broilers receiving 10 times the recommended dose of this same growth promotant. Lesions may have resulted from degradation and reduction of the organic product to the trivalent state, or, more likely, from biliary excretion of inorganic arsenic present as a contaminant (296). Cysteine exacerbates toxicity, perhaps by reducing the arsenical to the more toxic trivalent state. The manufacturer of 3-Nitro (roxarsone) voluntarily stopped its production and sale based upon an FDA study (179) that found a higher level of inorganic arsenic in the livers of treated chickens in contrast to nontreated chickens.

Signs

Ataxia and incoordination usually are seen, but stunting and depression also may be prominent signs. Lameness may be evident in turkey poults.

Pathology

Gross changes may be absent, although affected birds are usually small with an empty digestive tract. Microscopically, peripheral nerves may show loss of myelin, fragmentation of

axons, and proliferation of neurilemmal cells (276, 280). Ulcerative cholecystitis occurred in turkey poults (41).

Anthelmintics

All anthelmintics are probably toxic if a sufficient overdose is given, but generally birds are more resistant than mammals to anthelmintics.

Benzimidazoles

Cambendazole, mebendazole, and fenbendazole are well tolerated by birds (282).

Imidazothiazoles

Levamisole and tetramisole are not quite as safe as benzimidazoles. The lethal dose—50% (LD_{50}) of tetramisole for chickens—is 2.75 g/kg. Geese and captive birds are more susceptible (282), with a fatal dose for captive kiwis between 25 and 43 mg/kg (120); 300 mg/kg is toxic for geese and as little as 66 mg/kg of levamisole is toxic for some wild birds. Anthelmintic activity of *dl*-tetramisole resides in the l-isomer (levamisole), so the effective dose of levamisole is half that of tetramisole. This doubles the safety margin. Tetramisole is no longer available in most countries. Levamisole poisoning has occurred in geese being treated for Amidostomum infection (365). Levamisole was toxic for ducks parenterally at 40 and 80 mg/kg (133). Microscopic lesions in kiwis killed by levamisole were similar to those of mammals consisting of pulmonary congestion, edema, and bronchopneumonia and severe periacinar cytoplasmic vacuolation of hepatocytes (120).

Organophosphates

Organophosphorus compounds have caused poisoning in birds eating treated feed intended for horses (159, 207). The resin pellet form of dichlorvos (DDVP) is toxic because it is retained in the ventriculus. Colored breeds of chickens are more susceptible than white breeds to coumaphos, and naphthaphos has a narrow safety range for chickens, with 50 mg/kg being fatal (282).

Ivermectin

Ivermectin has a wide safety margin in birds. An oral or injectable dose of 0.1 mg/kg has been suggested (282). Ivermectin is effective against a wide range of parasites. Zeman (366) tried 1.8 mg/kg for *Dermanyssus gallinae*. This dose was more effective in chickens weighing more than 450 g. The toxic dose for chickens is 5.4 mg/kg, which causes 4-hour somnolence, 16.2 mg/kg, which causes 24-hour listlessness and ataxia, and 48.6 mg/kg, which results in death 5 hours post injection. Canaries given 20–60 mg/bird IM showed temporary immobility.

Other Anthelmintics

Phenothiazine is relatively nontoxic for birds, and hygromycin B is safe at 8 g/900 kg feed (282).

Nutrients and Other Feed- and Water-Related Toxicants

Amino Acids

Interaction among some amino acids relates to growth, but only methionine is toxic to poultry. Methionine toxicity affects chickens and quail (178, 295) and has caused depressed growth and cervical paralysis in turkey poults (132). Mortality can occur at levels of 1.8% in feed. Methionine attenuates calcium-induced kidney damage (350). Ethinone (a methionine antagonist) toxicity in chicks can be relieved by methionine.

Antinutrients

A variety of feedstuffs and potential feed stuffs are poorly digestible, contain factors that inhibit digestion (protein inhibitors), depress growth, cause pasting of feces, or increase the incidence of skeletal disorders. Antinutritional factors in some of these products (e.g., soybean and some other beans) can be destroyed by heat. The nutritional value of some feedstuffs (e.g., wheat, barley, and rye) can be improved by enzymes (37, 118, 157, 167). Antinutrients that can be found in plants include proteases, tannins, saponins, antivitamins, lectins, b-glucans, pentosans, polysaccharides, concanavalin A, hemagglutinins, vicine, convicine, alkaloids, and sinapines. Feedstuffs known to contain antinutrient factors are alfalfa (170, 331); amaranth (4); jackbeans (81, 199, 239); fababeans (242, 286); lima beans (238); narbon beans (91); soybeans (170, 201); jojoba (15); lupins (38, 257, 284); peas (39); vetch (285); barley, rye, and wheat (21, 37, 215); and sorghum (325).

Protein Supplements

Fish and Meat Meals

Gizzerosine, histamine, histidine, and other biogenic amines cause digestive disturbances, stunting, and osteoporosis (156, 322). Biogenic amines result from heating or bacterial spoilage of fish and animal byproducts. Toxic products get into poultry feed through fish or meat meal. Excess acid secretion in the proventriculus is stimulated by gizzerosine, causing gizzard erosion and hemorrhage (152, 222, 293). Broiler chickens may die from hypovolemic shock. Black ingesta and blood may run from the mouth (vomito negro), and the contents of the digestive tract are often melanic. Other biogenic amines reduce broiler feed efficiency (182).

Minerals

For information on trace mineral deficiency and toxicity (tissue levels, signs, etc.), see (268 and 269). Information on poultry in these references is included for the following minerals: aluminum, arsenic, cadmium, calcium, chloride, chromium, cobalt, copper, fluoride, iodine, iron, lead, magnesium, manganese, mercury, molybdenum, nickel, phosphorus, potassium, selenium, sodium, tungsten, vanadium, and zinc. More detailed information on macro and trace mineral deficiencies and excesses are reported in Chapter 29, Nutritional Diseases.

Aluminum
Aluminum depressed growth rate in chicks due to decreased feed intake and decreased egg production in adults when 0.3% was added to the feed (32, 360). Aluminum also may interfere with phosphorus retention (89, 96, 161) and iron absorption resulting in anemia (135). Aluminum absorption after ingestion may be affected by the acidity of the ration (48).

Calcium
Excess absorbed calcium is excreted through kidneys; high levels cause ureter and kidney impaction, resulting in nephrosis. Very young birds are most susceptible. This condition may be produced in pullets by feed delivery mistakes in which layer ration is accidentally fed to pullets. High mortality from hyperuricemia with visceral urate deposits may result from kidney damage because of high dietary calcium. Lung pathology with damage to parenchyma from calcium deposits also may occur in young chicks. It is possible that nephrosis and visceral urate deposits in young and dead-in-shell chicks may result from kidney obstruction by calcium. Excess unabsorbed calcium remaining in the intestine increases fecal water content of pullets and hens on high-calcium rations. If the source of calcium is dicalcium phosphate, the alkaline solution formed in the upper digestive tract may result in epithelial necrosis (248, 251, 341), particularly if the mineral has been "top-dressed" on feed and birds eat undiluted material.

Urolithiasis in pullet and layer flocks may be caused by high calcium and low phosphorus in pullet rations. The incidence also may be increased by infectious bronchitis virus infection (124).

Cobalt
Moderate levels (125 ppm) stimulate polycythemia and induce pulmonary hypertension. Higher levels (500 ppm) cause marked tibial dyschondroplasia as well as necrosis and fibrosis in the pancreas; liver; and skeletal, smooth, and cardiac muscles. All levels reduce feed intake and growth (77).

Copper
Copper sulfate is added to water for treatment of enteritis or yeast infection or to clean algae or scum from water lines and drinkers. Addition to feed is another method for treating enteritis and candidiasis. It also may be sprayed on litter to control Aspergillus or used as an antifungal preparation on wood. Birds occasionally are poisoned by eating copper sulfate crystals. Diets low in calcium may increase susceptibility to copper toxicity (194). Mortality in turkeys offered water containing copper sulfate may have resulted from dehydration caused by water refusal rather than from copper poisoning. Toxicity signs are depression and weakness with convulsions and coma terminally (251) or anemia (144, 243, 280). Gross lesions include necrosis of proventriculus and ventriculus (gizzard) epithelium with sloughing of koilin lining (121, 148).

Fluoride
Growth, production, and egg quality were reduced by 700 and 1,000 mg sodium fluoride/kg feed (129). Leg deformity has also been described. Laying birds can tolerate ingesting 4.453 mg fluoride/day for up to 74 weeks (57).

Iodine
Reduced egg production and weight and increased embryonic mortality in the first week and at pipping occurred when 350 ppm of iodine was added to the ration of turkey breeder hens (55). With experimentally induced iodine toxicity in chickens, researchers found that clinical signs were poor growth and a bizarre syndrome of chicks falling over, lying motionless, getting up, and then repeating falling over (18).

Magnesium
Excess magnesium causes bone abnormalities by replacing calcium and affecting phosphorus utilization (195).

Phosphorus
Excess phosphorus affects growth plate development of bones and increases tibial dyschondroplasia and leg deformities. Phosphate may also be caustic to moist oral and epithelial surfaces. White phosphorus induces mortality and hematologic abnormalities after oral ingestion (315, 316).

Potassium
Potassium in the form of fertilizer or potassium permanganate is toxic. The latter caused epithelial necrosis of the digestive tract (251).

Sodium (Sodium Chloride, Sodium Bicarbonate)
Excess ionic sodium, usually from sodium chloride in feed or water, causes significant economic losses in poultry in many countries. Most toxicity results from consuming saline water, not water deprivation. Sodium in feed can be toxic for young chicks and poults with or without water deprivation. In some cases of toxicity at apparently low salt levels, analysis may have been for chloride, with salt level calculated from chloride level. When Na+ toxicity is suspected, both feed and water should be analyzed for Na+, not estimated from chloride content. There may be sources of Na+ in feed or water other than sodium chloride. Levels of Na+ in feed and water are additive. Sources of sodium also may be naturally occurring in soil or water (216).

Young birds are much more sensitive to Na+ toxicity than are adults, probably because their kidneys are not yet fully developed (217). Water with Na+ greater than 0.4% (4,000 ppm) is quite toxic and will cause high mortality within a few days. Lower levels may be toxic as well, depending on the amount of Na+ in feed. Levels of Na+ greater than 0.12% (1,200 ppm) are toxic for some chicks and poults and produce heart failure with edema and ascites. Feed with Na+ greater than 0.85% is toxic for some chicks and poults. Much lower levels will cause heart failure and ascites even when water is available freely. Because steroids increase Na+ and water retention (294), resulting in hypervolemia, hypertension, right ventricular failure, and ascites, stress may also contribute to Na+ susceptibility. Birds have poor renal concentrating ability

and difficulty reducing plasma osmolality by excretion of salt in excess of water. Some waterfowl have nasal salt glands, which allow them to excrete Na+ if an excess is ingested.

Three forms of disease result from Na+ toxicity in young birds. At high levels, birds develop acute, severe diarrhea and dehydration, lose weight, and die. There is often acute kidney damage, particularly with sodium bicarbonate (218), which may be ischemic because of increased red blood cell rigidity. Potassium may have a protective effect (310). At lower levels, loose droppings also occur, but birds gain weight, at least for 1–2 days, because of associated water retention. Depending on the Na+ level, they may subsequently eat less and grow poorly, or continue to eat and grow well. Water retention, with hypervolemia and reduced red blood cell deformability (220), can lead to functional cardiac overload, causing marked right ventricular hypertrophy and dilation, valvular insufficiency, edema, and ascites in chicks (172, 173, 221). At intermediate levels of excess sodium, a variety of clinical signs and pathologic changes are seen, depending partly on how long birds survive with hypertension before heart failure occurs and how long they survive afterward. Many lesions described for Na+can be attributed to heart failure. The severity of ascites may be affected by other dietary, environmental, and water constituents (288, 306).

Signs At low levels of excess Na+, only watery droppings are seen until ascites occurs. At this stage, chicks and poults are dyspneic, depressed, and have a swollen abdomen. At high Na+ levels, birds are obviously sick and depressed within a few hours, with thirst and diarrhea. They may have rough, dirty, wet feathers or down. Nervous signs may be present, and some birds may be prostrate. At intermediate levels, stunting of some birds may be prominent. Excess Na+may cause reduced egg production and increased mortality in adults (69).

Pathology Chicks with ascites and edema frequently have excess fluid in lungs and hydropericardium. Young males may have cystic dilation of seminiferous tubules (280). There is cardiac hypertrophy, which in chickens is mainly right-sided. Poults have biventricular hypertrophy with dilatory cardiomyopathy. At levels of Na+ causing dehydration, the following also may be seen: cyanosis, myocardial hemorrhage, nephrosis, and enteritis.

Microscopic lesions are frequently secondary to heart failure or dehydration. For a detailed description of histologic lesions, see (224). Glomerulosclerosis (294, 310) may be ischemic in origin. Ultrastructural changes in heart muscle (241) include glycogen accumulation, myofibrillar disarray, Z-band streaming, and disruption of intercalated discs.

Sulfate

The toxic concentration of sulfate is affected by age of the birds, source (water or feed), other salts, etc., and is not clearly defined. Magnesium sulfate may be more toxic than sodium sulfate (334). Diarrhea, reduced growth, and depressed egg production can occur.

Selenium

Some plants accumulate selenium (356), and the addition of acceptable treatment levels of selenium to rations already containing high normal selenium levels may produce toxicosis. This often manifests itself as embryo deformities of the eye, head, or beak in the progeny from such breeder flocks (236). Decreased growth and feed intake resulted when there was 4–8 ppm selenium in drinking water (47), but the toxicity of selenium varies with the form present (153). Selenium can accumulate in the food chain of aquatic birds causing emaciation, hepatitis, and ascites (127). Selenium often causes problems for aquatic birds in certain regions of the United States where selenium concentrations in aquatic plants, invertebrates, and fish increase. Chronic selenium toxicosis in mallards, in addition to weight loss, causes gross lesions of patches of liver necrosis (6). Mallard ducks have hepatocellular vacuolar degeneration progressing to centrolobular and panlobular necrosis. Nephrosis and apoptosis of exocrine pancreas cells were noted (127).

Zinc

Toxic levels of zinc (greater than 500 ppm) cause anorexia, depressed growth, reduced egg production, ventriculus (gizzard) and pancreatic lesions, and hematologic abnormalities (70, 74, 180, 203, 208, 309, 352). Individual birds may be poisoned by ingesting metallic zinc, such as coins or other objects, or galvanized wire from caging in the case of pet birds (277) and in wild waterfowl via contaminated mining areas (309).

Metals and Metalloids

Arsenic

Inorganic, aliphatic, and trivalent organic arsenicals are used as pesticides, weed and brush killers, and defoliants. Toxic effects include diarrhea, nervous signs, and cyanosis. There is inflammation of the digestive tract including crop, proventriculus, and ventriculus (gizzard); hepatosis; and nephrosis (243, 296). Most reports of arsenic toxicity in birds are experimental, except those associated with grasshopper bait (251). For information on organic arsenicals, see Antimicrobials, Anticoccidials, and Growth Promotants.

Cadmium

Toxic levels of cadmium found in industrial waste and sewage sludge cause decreased feed intake and decreased growth, induced kidney lesions, and reduced gonadal mass and function (158, 266, 268, 269, 349). Experimental cadmium toxicity in chicks, poults, and ducklings and free radical-induced lesions by cadmium, silver, and other minerals have been reported (27, 64, 333).

Chromium and Potassium Dichromate

Chromium from industrial waste or coated metal objects may cause depression, anorexia, and paralysis (158, 268, 269).

Lead

All species of birds are susceptible to lead poisoning. Lead is the only metallic poison causing significant disease in birds, and most toxicity occurs in wild species, especially waterfowl. Chickens are more resistant than waterfowl (268, 269). Birds as a group are at risk from metallic lead because the material is retained in the ventriculus (gizzard), ground down, and absorbed slowly. Experimental poisoning trials with chickens show an interaction with some nutrients (92, 192), production of immunotoxic effects with differential gender sensitivity (43), inhibition of avian bone healing (202), and immunosuppression (363).

Lead is widespread in the environment, and there are many possible sources for ingested lead when toxicity occurs. Wild water birds are at greatest risk from ingesting lead shot or contaminated sediments (154), which is the main hazard in North America (291) and elsewhere (143, 235). Lead weights from fishing lines are the most important source in England. Pigeons may also ingest lead shot (73). Birds that eat carrion may be poisoned by lead shot ingested with tissues. Backyard and free-range poultry may pick up lead from paint chips, lead batteries, or other lead objects. Chicks have been poisoned by eating contaminated grit (251). Cage birds may be poisoned from the same environmental sources as children and dogs, mainly paint chips, leaded windows, toys, and lead objects (362).

Signs Most lead poisoning in birds is chronic. Clinical disease usually is seen as wasting, ataxia, lameness or paralysis, and anemia. In acute cases, anorexia, weakness, prostration, and anemia may be prominent. Green diarrhea may result from anorexia, or it may be a direct effect of lead on digestive and nervous systems.

Hematology Basophilic stippling and abnormal erythrocytes may occur in lead-poisoned birds but are not present in all affected birds (Figure 32.3) (251). Finding anemia with mitosis of erythrocytes and large numbers of immature cells may be more significant.

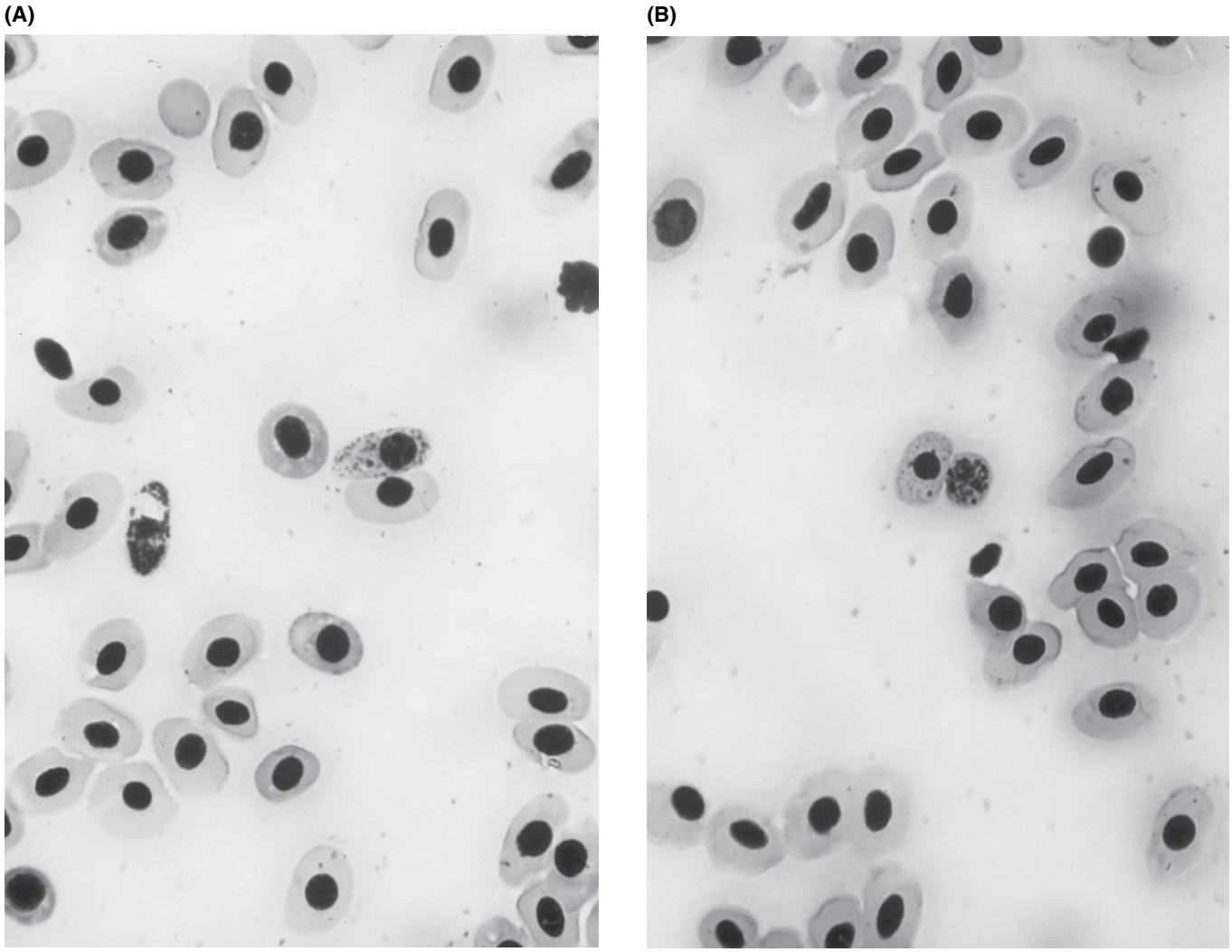

Figure 32.3. Duck with lead poisoning. (A) Immature erythrocytes and 2 cells showing basophilic stippling. (H.J. Barnes) (B) Basophilic stippling in an erythrocyte adjacent to an immature erythrocyte undergoing mitosis. (H.J. Barnes)

Figure 32.4. Ventriculus (gizzard) from duck with lead poisoning. Severe erosion, ulceration, and bile staining of koilin lining. Note 2 lead pellets retrieved from the gizzard. (H.J. Barnes)

Figure 32.5. Lead poisoning, showing distended proventriculus (arrow); there were 15 lead shots in the gizzard.

Pathology Most lesions probably result from anorexia and debility. Emaciation may be prominent, but many ducks and geese that die from lead poisoning are in good body condition. The carcass may be pale with watery blood. Erosion and ulceration of the ventriculus (gizzard) lining can be extensive (Figure 32.4). Impaction of proventriculus frequently is seen and is likely secondary to vagus nerve damage (Figure 32.5).

Microscopically, the most diagnostic lesions are demyelination of peripheral nerves and focal areas of vascular damage in the cerebellum (160), and acid-fast, intranuclear inclusion bodies in the kidney (Figure 32.6), liver, and spleen (204, 251, 280). Inclusions are composed of protein-bound lead and can be demonstrated by special staining or electron microscopy

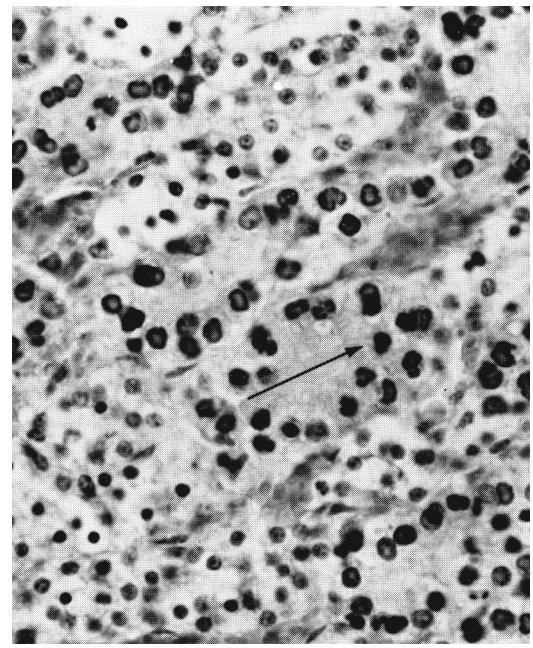

Figure 32.6. Lead poisoning. Acid-fast intranuclear inclusion bodies (arrow) in kidney of mallard duck. ×480. (L.N. Locke)

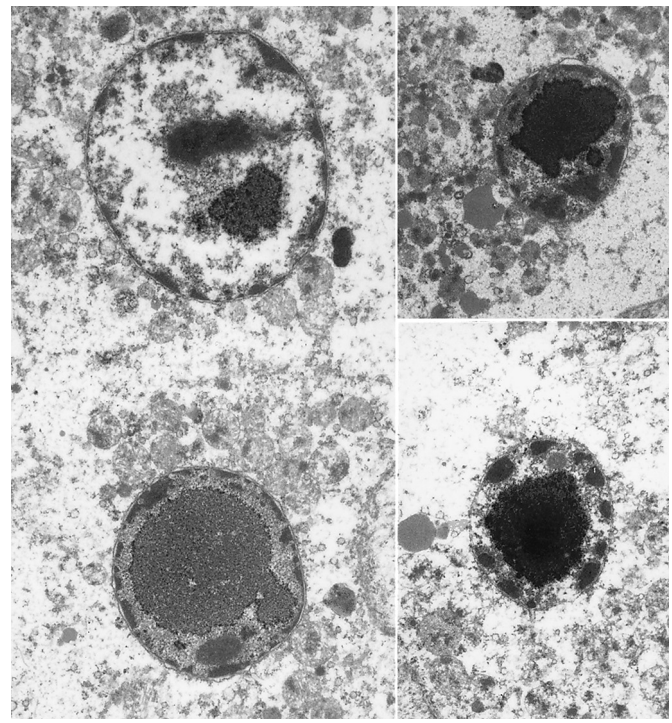

Figure 32.7. Proximal renal epithelium from a bird with lead poisoning. Nuclei contain irregular, variable electron-dense inclusion bodies typical of lead accumulation in kidney. Similar inclusions may be present in the liver. (H.L. Shivaprasad)

(Figure 32.7) (234). Nephrosis with degeneration and necrosis of tubular epithelial cells containing brown pigment has been described. Hemosiderosis is prominent in the spleen and other

organs. Scattered myocardial necrosis associated with hyaline or fibrinoid necrosis of blood vessels (176), arrested mitotic activity in proventricular epithelial cells, and degenerative changes in testes also may be found (212).

Diagnosis The final diagnosis of lead poisoning is based on blood and tissue levels. In chickens, a blood lead level greater than 4 ppm, a liver lead level greater than 18 ppm wet weight, or a 20 ppm wet weight in kidney is considered diagnostic (268, 269). Lead levels in bone also can be determined. Acid-fast inclusions in kidney epithelial cells suggest lead poisoning but may be found in birds that could have ingested lead but died from some other cause. Peripheral nerve lesions, in conjunction with fibrinoid necrosis of blood vessels, which may be found throughout the body and not just in brain and heart, are useful in diagnosis, but similar changes are seen in methylmercury poisoning (280). In lead poisoning, however, lesions in the central nervous system are related only to vascular damage.

Mercury

Organic mercury, used previously as a seed protectant, is discussed later in this chapter along with fungicides. Most organic mercury in the environment today results from methylation by aquatic organisms and action of methogenic bacterial enzymes on elemental mercury from nature (decaying trees) or industry. Tons of mercury as bivalent inorganic mercury, elemental mercury, and phenyl mercury have been discharged into waterways around the world.

Methylmercury, a direct product of biotransformation, gets into small water organisms and enters the food chain when fish eat contaminated plants, insects, or animals (bioconcentration). Fish-eating birds, particularly ducks, may become poisoned from mercury in the food they eat (243). Mercury contamination of pheasants also has occurred. Experimental feeding of low levels of methylmercury resulted in decreased egg production, increased shell-less eggs, and reduced hatchability (243).

Residues in chickens given subclinical amounts of methylmercury were highest in liver, least in muscle, and intermediate in kidney. Eggs had 4 times as much mercury in albumin compared with yolk (243).

Inorganic mercury of medicinal or industrial waste origin may induce anorexia, enteritis, and nephrosis (243, 268, 269).

Tin

Tin from medicinal sources can cause depression, hunching up, and yellow diarrhea (304).

Uranium (Uranyl Nitrate)

Industrial uranium causes depression, anorexia, and nephrosis with severe lesions in collecting tubules, followed by hyperuricemia and visceral urate deposits in birds that survive (189).

Vanadium

Vanadium can contaminate phosphorus sources and cause reduced egg quality, growth, and hatchability (188, 268, 269). Also, there are many reports in the literature of experimental vanadium toxicity.

Vitamins

Vitamin A

Excess vitamin A reduces egg production (185) and growth rate and causes osteodystrophy and osteoporosis (324, 335).

Vitamin D_3 (Cholecalciferol)

Four percent mortality due to kidney failure occurred in chicks when feed was top-dressed with vitamin D_3 powder. Nephrosis with focal mineralization was present throughout the kidneys. Mineralization was also present in the walls of arteries, particularly arteries in the proventriculus. Excess vitamin D_3 has resulted in increased incidence of leg abnormalities in broilers (61). Experimentally induced toxicity indicated that 25-hydroxycholecalciferol was 100 times as toxic as cholecalciferol (274). A variety of lesions were seen, but renal damage was most significant (226). Poultry, pigeons, and wild birds also may be poisoned by rodenticides in which the toxic agent is 25-hydroxycholecalciferol.

Vitamin B_6 (Pyridoxine)

Pyridoxine is toxic for pigeons at levels safe for poultry (90–100 mg/bird, i.e., approximately 200 mg/kg body weight given by injection) (253).

Other

Ethoxyquin

Ethoxyquin (1,2-dihydro-6-ethoxy-2,2,4-trimethylquinolone) is a commonly used antioxidant that may be toxic at high levels (6,500–12,500 mg/kg feed). Mortality is increased. Affected birds have pale, swollen kidneys; dark-brown, enlarged livers; and urates in joints. Proximal tubular necrosis in the kidney and accumulations of dark-brown pigment, interpreted to be ethoxyquin, in hepatocytes, bile ducts, and pulmonary blood capillaries are seen microscopically (200).

Lignosol

Calcium lignosulfonate, a pellet binder, may produce black, sticky cecal contents that adhere to the skin of processed broilers, causing increased condemnation from contamination. It has no effect on body weight or feed conversion (267).

Nitrate and Nitrite

Nitrate is converted to nitrite by bacteria in the digestive tract and is much less toxic than nitrite. High levels of nitrate cause diarrhea, dyspnea, and death. Lower levels affect growth and egg production. Blood hemoglobin is changed to methemoglobin. The effect is greater in young birds, as it is in young mammals, with fetal hemoglobin (78). Most reports of toxicity are experimental, although there are some reports of toxic nitrate levels in leaves and stems of plants (354).

Pen- and Litter-Related Toxicants

Pen and litter-related toxicants include products accidentally or intentionally incorporated into litter or applied to the pen that result in illness. Some are disinfectants and fumigants discussed later in this chapter. Except for boric acid, insecticides mixed into the litter (e.g., fire ant control products) or applied to walls, floor, or ceiling are covered later in this chapter. Copper sulfate, often used as a fungicide in litter, has been discussed with feed- and water-related toxicants above. Toxic mixtures, such as copper-chrome-arsenic formulations, are used as preservatives in the timber industry (232). Occasionally, part of the building structure is toxic; geese have been poisoned from eating urea-formaldehyde foam insulation picked from the wall.

Boric and Orthoboric Acid

Boric acid is used in litter to control darkling beetles and may be consumed by broilers, which results in reduced growth and abnormal feathering (86, 283).

Iron

Ferrous sulfate heptahydrate added to litter to reduce ammonia formation was toxic to broilers (340). Affected chicks were depressed and lethargic. Those that died had severe ventriculus (gizzard) ulceration and liver degeneration. The LD_{50} of ferrous sulfate is 7,010 mg/kg body weight for a single dose. When added to the diet, 3% caused reduced growth and feed intake, and 1.5% had no effect (258).

Pentachlorophenol

Pentachlorophenol has been used as a pesticide in industry and agriculture, but its primary use is as a wood preservative. Logs may be treated before they leave the forest, or wood may be treated after cutting. Sawdust and shavings from treated wood frequently have been used as poultry litter; chickens can become contaminated from contact with these shavings. Because the product is used for many other purposes, pentachlorophenol may also contaminate broilers or table eggs in other ways.

Illness associated with pentachlorophenol has been caused by toxic impurities such as dioxins (see later discussion). Pure pentachlorophenol can reduce growth, cause kidney hypertrophy, and decrease humoral immune responses (265, 318). It has also been associated with musty taste in eggs and broiler meat. Chlorophenols in litter are metabolized by bacteria and fungi to chloroanisoles. Anisoles have a musty or earthy odor even at very low concentrations, and they are responsible for the taste in eggs and meat from chickens in contact with contaminated litter (116). Reduced hatchability has also been associated with pentachlorophenol contamination (119).

Sulfur

Elemental sulfur may be sprinkled on dirt floors and vaporized by adding water and heating the building before litter is put down. High mortality, ulcerative dermatitis mainly affecting moist areas of the body, irritation of respiratory mucous membranes, and conjunctivitis occurred in chicks placed in treated buildings (260). Lesions probably resulted from sulfur dioxide (from residual sulfur that had not vaporized) dissolving in moisture on the chick's body to form sulfurous acid (H_2SO_3).

Disinfectants and Fumigants

Fumigants are products producing toxic gases used to control rodents, insects, fungi, and bacteria. They can cause toxicity when inhaled or ingested. Phenolic disinfectants can be toxic when inhaled or absorbed through skin.

Phenolic Compounds and Coal-Tar Derivatives

Phenol, cresol, creolin, carbolineum, and creosote products cause damage to vascular endothelium, epithelia of respiratory and digestive tracts, and parenchymal organs, such as liver and kidney (251). Thymus and cloacal bursa are small, but this may result from stunting rather than being a direct effect on the immune system. Hydropericardium is prominent, but ascites and subcutaneous edema are also frequently present if contact is severe. Mortality may be high. Diagnosis is based on a history of contact and by elimination of other causes of ascites and edema. Odor also may provide a useful clue. Cases of creolin toxicity still appear in the literature (198). Coal tar poisoning has been induced in ducks by feeding clay pigeons used in shooting sports (51).

Quaternary Ammonium (Cationic Detergents)

Use of sanitizers to clean poultry drinkers or treat water has resulted in reduced growth or production and, occasionally, severe lesions and death in young chicks (162). High levels of quaternary ammonia cause epithelial irritation of the mouth, pharynx, and upper respiratory tract, resulting in oral, ocular, and nasal discharges. Necrosis of epithelium leads to pseudomembranes in the mouth and epithelial thickening in the esophagus, crop, and proventriculus, with ulcers at the gizzard-proventricular junction (76, 251). Similar lesions have been reported in poults (211).

Chlorine

Low levels (37.5–150 mg/kg) may have a beneficial effect, but high levels (300–1,200 mg/kg) result in reduced growth and increased mortality (67).

Formaldehyde

Formaldehyde gas and formalin (a 37% solution of the gas in water, which is then 100% formalin) have been widely used for many years as antibacterial and antiviral agents in the poultry industry. Photophobia and respiratory signs from contact with high levels of formaldehyde are seen occasionally in newly hatched or recently delivered baby chicks and poults.

Prolonged exposure to high levels of formaldehyde, which dissolves in liquids on mucous membranes to produce formalin, in the hatcher impairs cilial function and causes tracheal epithelial degeneration and sloughing (290). Air quality during subsequent growout, however, has a greater effect on productivity than does early formaldehyde exposure (289). Epithelial necrosis of eyes, mouth, and trachea with pseudomembranous plaques in the mouth and trachea also may be found. Edematous swellings under the lower beak (122), subcutaneous edema (29) during the acute phase, and ascites or edema occurred later in exposed poults.

Other Fumigants

It must be assumed that most or all chemicals used as fumigants are toxic to poultry (243). A few reports of deliberate or accidental poisoning of poultry by other fumigants appear in the literature (303, 348).

Fungicides

Fungicides are used as seed dressings (protectants); as wood preservatives; in paint and plastic; and on cereal crops, fruits, vegetables, and flowers. Previously, poisoning in poultry usually has resulted from the incorporation of treated seed into poultry feed.

Organic Mercurials

Mercurial fungicides, frequently ethyl or methyl mercuric chloride, that cause poisoning with central and peripheral nervous lesions in poultry, wild birds, animals, and humans consuming treated seed are no longer in use (146, 147, 280, 314). Signs of organic mercury poisoning may be nonspecific, or affected birds may show progressive paralysis or other neurologic signs. Specific gross lesions may be lacking, but microscopically, Wallerian degeneration of peripheral nerves and spinal cord and neuronal damage in the brain may be present. Vasculitis also may be obvious in some vessels, particularly in the brain.

Thiram

Arasan (active ingredient thiram, a dithiocarbamate) has caused poisoning in poultry, producing lameness and leg deformity in chicks and poults and soft-shelled eggs in layers (130, 251). It is also teratogenic (245). Thiram increases the incidence and severity of tibial dyschondroplasia (93). The LD_{50} is 485–932 mg/kg body weight in pheasants and 2,800 mg/kg body weight in mallard ducks (66).

Captan

Captan is an organic seed protectant. It is less toxic than Arasan. It depresses feed consumption, slows growth, and reduces egg production (251).

For descriptions of other organic synthetic fungicides, see (243). Pentachlorophenol, a widely used wood preservative, and copper sulfate, a litter treatment, were covered previously in this chapter.

Herbicides

Chlorates

Sodium and potassium chlorates used as herbicides and defoliants are moderately toxic for poultry. They act by converting hemoglobin to methemoglobin. The lethal dose for chickens is 5 g/kg (243).

Organic Synthetic Herbicides

Amitrate (3-amino 1,2,4-triazole) causes hypothyroidism and reduces weight gain in chickens (359). Phenoxyherbicides, such as 2,4-D, cause kidney enlargement. Some herbicides are toxic for embryos (88). See (243) for additional information.

Dipyridyl Herbicides (Diquat and Paraquat)

Paraquat toxicity results from free radical induced membrane damage caused by the inhibition of the glutathione peroxidase system. Selenium is protective. Experimental oral paraquat poisoning in turkeys produced diarrhea, listlessness, and anorexia with terminal convulsions. Gastroenteritis was present at necropsy (313). Turkeys are more resistant than are mammals (144, 243), but exposure of mallard duck eggs produces cranial and pelvic deformities at hatch (287).

Insecticides

Insecticides may be referred to by either their common or registered name. The common name is not capitalized (e.g., carbaryl), but the trade name is (e.g., Sevin) (243). Organic insecticides (organophosphates, organochlorides, and carbamates) have been widely used, some on animals and birds as systemic larvicides and anthelmintics, as well as on buildings and pens. Wild birds have been poisoned by feeding on treated animals (35, 138). Many insecticides are quite toxic for animals as well as insects, arthropods, and helminths. Some more toxic products are used on crops, wood, and trees as soil insecticides, and as seed dressings. Extensive tables presenting general information on insecticides can be found in (243).

Organochloride Insecticides

The mode of action of organochloride (chlorinated hydrocarbon) insecticide toxicity is unknown. Generally, it acts to diffusely stimulate or depress the nervous system. Organochloride insecticides often remain longer in the environment than other insecticides. Some more persistent ones have been taken off the market or have restricted use. Because they are fat soluble, organochlorides tend to build up in the food chain and be present in yolks of eggs. There is considerable literature available on insecticide toxicity in wild birds, with emphasis on organochlorides (225).

Signs Nervous signs varying from excitement with vocalization to tremors, ataxia, and convulsions are prominent. Prostration and death may occur without other signs. Other signs include salivation, vomiting, diarrhea, and depression. Lameness and leg deformity may also occur. There may be

decreased egg production, a drop in hatchability, embryo mortality, loss of pigment on pigmented eggs, a change in shell texture (chalky), and eggshell thinning. Administration of atropine to acutely affected birds will not alleviate or modify signs of toxicity.

Pathology Specific lesions do not occur in organochloride toxicity. Nonspecific changes such as congestion and hemorrhage may be present. Excess cerebrospinal fluid may be noted when the brains of affected birds are examined.

Chlordane

Chlordane causes chicks to develop ataxia and hyperexcitability. Hens have reduced body weight, decreased egg production, atrophy and cyanosis of the comb and wattles, and hydropericardium (251).

Dichlorodiphenyltrichloroethane (DDT) and Dichlorodiphenyltrichloroethane (DDE)

Dichlorodiphenyltrichloroethane (DDT) and dichlorodiphenyltrichloroethane (DDE) cause hens to develop tremors, decrease production, and lose weight, and there is eggshell thinning (251).

Dieldrin

Pigeons, gulls, and other birds exposed to dieldrin may show nervous signs (11, 251).

Heptachlor

Heptachlor may cause ataxia, salivation, prostration, and death (250, 339).

Lindane

Diarrhea, vomiting, anorexia, depression, convulsions, and sudden death have been associated with lindane poisoning (30, 251).

Mirex

Mirex has caused embryo mortality (3).

Toxaphene

Toxaphene may cause lameness, thin shells, and osteomalacia (247, 251).

Organophosphorus and Carbamate Insecticides

Organophosphorus and carbamate insecticidesinhibit acetylcholinesterase, causing acetylcholine to accumulate, which results in the overstimulation of parasympathetic nerves and muscles (102). Atropine given to effect will often dramatically reverse clinical signs, but efficacy depends on the type of organophosphorus compound and the duration of the intoxication and amount of time lapsed between exposure and treatment. Repeated treatments may be necessary. Some organophosphates and carbamates have delayed neurotoxic effects (see the following discussion). Chickens and other birds are more susceptible than mammals to this type of toxicity.

Signs Chicks and poults may die quickly, showing few signs except dyspnea and paralysis, or they may exhibit lacrimation, salivation, diarrhea, tremors, depression, dullness, lethargy, cyanosis, ataxia, incoordination, and convulsions prior to death. Because of respiratory signs and salivation in early stages, respiratory infection may be suspected initially.

Pathology Few gross lesions occur. There may be congestion with dark blood, and hemorrhages may be present in heart muscle, on serosal surfaces, and on mucosa of intestines. No specific microscopic changes have been identified.

Chlorpyrifos

Signs of chlorpyrifos toxicosis include salivation, lacrimation, gasping, frequent defecation, tremors, convulsions, and recumbency followed by death. The lethal dose, 50% (LD50) for broiler chickens has been cited as 10.79, 18.40, and 25–35 mg/kg (5, 223).

Diazinon

Diazinon is used to control fire ants and darkling beetles, but in birds, diazinon can cause incoordination, paralysis, respiratory signs, and death (151). It is also used to control pests in soil and grass, causing death in Canada geese (117, 317). The LD50 for diazinon in broiler chicks is 6.32 mg/kg (223).

Dichlorvos (DDVP)

Dichlorvos induces staggering, frothing from the mouth, paralysis, and convulsions (94) The LD50 in broiler chicks is 6.30 mg/kg (223).

Dimethoate

Toxic effects of dimethoate include reduced growth and egg production (299, 300).

Famphur

Mortality in raptors has resulted from famphur toxicity (149).

Fenthion

Laying hens exposed experimentally to fenthion had neurologic deficits followed by decreased egg production and reduced body weight (330).

Malathion

Malathion causes dullness, salivation, loose droppings, cyanosis, paralysis, and death. Lesions produced include injected subcutaneous vessels and dark, congested heart (40, 251). In geese, there may be flaccid paralysis.

Monocrotophos

Monocrotophos toxicity has been associated with salivation, mortality in quail, and weight loss and embryo abnormalities in chickens (305).

Parathion
Parathion induces lacrimation, salivation, dyspnea, tremors, and convulsions (251).

Carbamates
Various carbamates such as carbaryl, carbofuran, and others are toxic for pheasants, pigeons, turkey poults, chickens, and ducks (16, 95, 272). Signs include reduced growth, lameness, weakness, ataxia, and death. There may be tibial dyschondroplasia, retarded testicular development because of degeneration of seminiferous epithelium, nerve fiber degeneration, and congestion of organs and tissues.

Delayed Organophosphorus Neurotoxicity

Delayed neurotoxicity occurs several days to weeks after exposure, causing progressive degeneration of the peripheral nerves and spinal cord, which leads to weakness and paralysis. Acetyl cholinesterase is not affected. Delayed neurotoxicity may result from ingestion or absorption of a variety of triaryl phosphates; chemicals found in phenylphosphorothioate insecticides such as leptophos, cyanofenphos, and their analogues; as well as a variety of industrial chemicals, including fire retardants and lubricants. Malathion and dimethoate also may cause delayed neurotoxicity. Mature chickens, pheasants, and mallard ducklings are highly susceptible (243). Chicks hatched after *in ovo* exposure also show clinical signs (103). There are many reports of delayed neurotoxicity in chickens from these products. Most describe experimentally induced lesions (1, 2, 90, 191, 206, 344). A previous author of this chapter saw turkeys in Ontario, Canada, with typical clinical signs of ataxia and paralysis and histologic lesions of delayed organophosphorus neurotoxicity in spinal cord and peripheral nerves. Clinical cases occurred in Europe after chickens ate scraps of synthetic leather containing tri-ortho-cresyl-phosphate (TOCP) (251).

Signs Ataxia, falling sideways, inability to rise, lack of leg reflexes, and prostration may be evident. Birds appear bright and eat and drink if given access to food and water for several days.

Pathology There are no gross lesions. Degeneration of axons and myelin in peripheral nerves and long tracts of the spinal cord are diagnostic. Axons may be swollen, and spheroids may be present in axon spaces. Digestion chambers containing macrophages and debris may be present in subacute cases.

Other Insecticides

Pyrethrum and Synthetic Pyrethroids
Pyrethrum and synthetic pyrethroids are not very toxic to animals or birds, and there are no reports of illness (56).

Rotenone
Rotenone (derris powder) is prepared from roots of *Derris* spp. Mature chickens are relatively resistant (lethal dose 1,000–3,000 mg/kg); young birds are more susceptible (243). Fish are very susceptible to rotenone.

Nicotine
Nicotine sulfate (Black Leaf 40) has been used to paint chicken roosts to control insects and arthropods, particularly northern fowl mite. It also has been used for internal parasites. In low doses, nicotine stimulates the nervous system through an acetylcholine-like activity. At toxic levels, neural transmission is blocked, causing death from respiratory paralysis (243).

Signs Sudden death, occasionally preceded by depression and coma, is seen in affected birds.

Pathology Because death is from respiratory failure, cyanosis and congestion may be marked. Hemorrhages may be present on the heart and in other tissues.

Rodenticides, Avicides, and Molluscacides

Rodenticides

Information on cholecalciferol and arsenic is presented in Nutrients and Other Feed- and Water-Related Toxicants.

Alpha-naphthyl Thiourea (ANTU)
ANTU causes depression, anorexia, weakness, prostration, and death. Lesions include pulmonary edema, hydropericardium, fatty change in liver, and myocardial degeneration.

Sodium Monofluoroacetate (Compound 1080)
Signs of sodium monofluoroacetate (Compound 1080) are reluctance to move, edema of wattles, dyspnea, cyanosis, and nervous signs. Lesions include dark, unclotted blood, pulmonary hemorrhage and edema, clotted blood in the trachea and air sacs, petechiation, enteritis, and hydropericardium (144, 243).

Strychnine
Toxic effects of strychnine are tonic spasms, respiratory failure, reproductive failure, and increased mortality of progeny from exposed hens (243, 251, 252, 361).

Warfarin, Brodifacoum, and Diphacinone
Warfarin, brodifacoum, and diphacinone are anticoagulant rodenticides sold under a variety of trade names and may be combined with sulfaquinoxaline to interfere with vitamin K synthesis. They inhibit epoxide reductase, which converts vitamin K to its active form. Toxicity causes anemia with fluttering, gasping, and hemorrhages in eyes, mouth, and other tissues (17, 144, 243, 301). Onset may be rapid, and death occurs within 72 hours of ingestion (228). With the long-acting anticoagulants, there is a cumulative effect, and if a small amount of anticoagulant is consumed repeatedly, there may be little or no product found in the digestive tract.

Phosphorus
Elemental yellow, red, and white phosphorus can induce depression, anorexia, diarrhea, ataxia, gastroenteritis, and death (243, 251, 315, 316).

Zinc Phosphide

Weakness, diarrhea, opisthotonos, and convulsions occur with zinc phosphide. There is enteritis, ascites, and hydropericardium (139, 301). In an accidental poisoning of broiler breeder chickens, birds were found dead following ingestion of zinc phosphide-treated oats used as rodent bait. No clinical signs were observed. Gross lesions consisted of hydropericardium and ascites. A petroleum-like odor, a common feature with this poison, of crop contents was detected. Histologic lesions were those of congestion of many internal organs, along with severe pulmonary edema and congestion (329). Wild birds may also succumb to this poison if they are allowed access to zinc phosphide-treated grain (263).

For birds, the toxic doses of several rodenticides (a-chloralase, crimidine, pyriminil, phosphorus, a-chlorohydrim) are given in *Clinical and Diagnostic Veterinary Toxicology* (243).

Avicides

Avitrol (4-aminopyridine or 4-AP)

Avitrol causes disorientation and vocalization (distress calls). Affected pigeons may be molested by normal pigeons. Generalized congestion is present at necropsy, and the characteristic small pellets usually can be found in the ventriculus (115, 229).

2-chloro-4-acetotoluidine (CAT) and 3-chloro-P-toluidine (CPT)

No clinical signs have been described from 2-chloro-4-acetotoluidine (CAT) and 3-chloro-P-toluidine (CPT), but kidney necrosis (from CAT) and liver and kidney necrosis (from CPT) occur (123).

Molluscacides

Metaldehyde

Nervous signs were prominent in ducklings following ingestion of metaldehyde (13).

Toxic Gases

Ammonia

Ammonia levels should be less than 25 ppm, but in poorly ventilated litter-type houses, ammonia may exceed 100 ppm (175). High levels of ammonia (50–75 ppm) reduce food consumption and growth rate (71). Egg production is also reduced. Ammonia dissolves in the liquid on mucous membranes and eyes to produce ammonium hydroxide, an irritating alkali causing keratoconjunctivitis. If levels greater than 100 ppm persist, corneal ulceration and blindness can occur. The condition is painful, and photophobia and stunting are marked. At levels of 75–100 ppm, changes in respiratory epithelium include loss of cilia (244) and increased numbers of mucus-secreting cells (10). Heart rate and breathing may be affected, and there may be hemorrhages in trachea and bronchi. For a review, see (50).

Carbon Monoxide

Carbon monoxide (CO) poisoning may occur in buildings in which defective or unventilated gas-catalytic or open-flame brooders or furnaces are in use, or where poultry are exposed to internal combustion-engine exhaust fumes. Affected chicks or poults show drowsiness, labored breathing, and incoordination. Spasms and convulsions may occur prior to death. At postmortem, blood is bright red. Sublethal levels cause stunting (251, 319). In suspected cases, CO should be measured at several locations in the pen with the ventilation system shut off. Carboxyhemoglobin can be measured in the blood of affected birds. A previous author of this chapter found levels of 70 ppm CO in pens where a repeated high incidence of ascites due to pulmonary hypertension and right ventricular failure occurred. Toxic levels of CO for chickens are as follows: 600 ppm for 30 minutes causes distress; 2,000–3,600 ppm is lethal in 1.5–2 hours (243).

Aerial Endotoxin

Breakdown of bacteria in the litter and environment results in endotoxin in the air in broiler pens. Endotoxin from inhaled air can be found in the blood of people who work in broiler pens (83). Pulmonary hypertension develops in broiler chickens given intratracheal endotoxin and could be a contributing factor in ascites syndrome development (205).

Polytetrafluoroethylene (PTFE)

Fluorinated gases are released when polytetrafluoroethylene (PTFE), used as a nonstick coating (Teflon) on light bulbs, cookware, and ovens, is overheated. Pet birds that inhale the fumes die from lung edema and hemorrhage. Histologic examination reveals epithelial necrosis in tertiary bronchi or parabronchi and vascular damage in blood capillaries (320, 346). PTFE-coated heat lamp bulbs can cause mortality in exposed poultry (34).

Other Toxic Gases

Levels of methane, carbon dioxide, hydrogen sulfide, methyl mercaptan, and dimethyl disulfide were found to be low in poultry and other livestock buildings in Finland (175), but toxic fumes from liquid manure pits in pig barns have killed humans and pigs in North America, and nitrogen dioxide formed in freshly filled silos has killed humans and animals in Canada and the United States. Toxic gases associated with livestock production, including poultry, have been reviewed (243). The effect of sulfur dioxide in chickens has been described (104).

Household and Commercial Products

Alcohol

Ethyl alcohol may be used to dissolve experimental chemicals or drugs given to poultry in feed or water. Clinical signs of intoxication include ataxia and reduced feed consumption. Fatty change in the liver and heart lesions may occur (9, 63). Wild birds frequently are intoxicated from ingesting fermented

fruit (107). Pet birds may obtain alcohol inadvertently, or it may be given by the owner.

Antifreeze (Ethylene Glycol)

Ethylene glycol is toxic when ingested because it breaks down to oxalic acid, which combines with calcium to form calcium oxalate. Calcium oxalate crystals block renal tubules and cause tubular epithelial necrosis leading to hyperuricemia and urate nephrosis with visceral urate deposits. Diagnosis usually is based on finding typical crystals and tubular changes on microscopic examination of kidney (270, 280, 281, 321). Liver necrosis is found in pigeons. Other forms of toxicity may occur in other species (243). Coccidia oocysts treated with ethylene oxide were toxic to chicks and caused kidney lesions similar to ethylene glycol (347). Clinical signs of accidental ingestion in a leghorn chicken consisted of sudden onset of depression, ataxia, convulsions, and death; pale kidneys were present at necropsy (364).

Carbon Tetrachloride

Carbon tetrachloride has been used previously as a household solvent and cleaner. It also has been used to treat tapeworms in chickens (282). It is toxic to animals and birds, interfering with fat metabolism and causing liver and kidney damage. Chickens are more resistant than rats, but low levels cause decreased growth.

Fertilizer

Lawn, garden, and farm fertilizers contain nitrogen, phosphorus, and potassium. The contents of the latter three, in that order, usually are given by numbers representing each element as a percentage of the total. These elements have been discussed previously. Fertilizer may be attractive to birds because it is frequently in the form of small, hard pellets. Some phosphate fertilizers contain very low levels of radioactive material.

Naphthalene

Mothballs frequently are recommended to keep pets and other animals away from gardens or out of attics. They also have been used in chicken nests for ectoparasite control. Mothballs are toxic and can cause poisoning in poultry and pet birds (186).

Urea

Urea is relatively nontoxic for birds. Because it is used in feed preparations for ruminants, the pellets occasionally are found in poultry feed.

Industry-Related Toxicants

Toxic Fat Syndrome, Chick Edema Disease, and Dioxin Toxicity

More than 30 years ago, the most toxic dioxin, 2,3,7,8-tetrachl orodibenzodioxin (TCDD), and other dioxins in the same polychlorinated dibenzodioxin group were found as contaminants in industrial fat (tallow from cattle hides) added to poultry feed. This material, which could be distilled from fat, was called chick edema factor until it was identified. It caused widespread disease in the broiler industry and in other poultry for several years. Occasional cases of dioxin toxicity (chick edema disease) occurred until about 1970. More recently, TCDD toxicity followed environmental contamination in Italy, where adult fowl died with lesions of chick edema disease (262). Dioxin was probably the material causing lesions in toxicosis caused by paint containing chlorinated hydrocarbon (213).

Chickens are more susceptible than some mammals to the toxic effects of TCDD (243). In chickens, dioxin damages vascular endothelium, causing vascular leakage and extensive movement of fluid into body cavities and subcutaneous tissue. The epithelium of some parenchymal organs is damaged, and there is degeneration of heart and skeletal muscle.

Because right ventricular hypertrophy and dilation have been described (8), and many lesions in dioxin toxicity are similar to right-sided heart failure from other causes, the possibility of dioxin contributing to right ventricular failure should be considered.

Depending on the level of TCDD in feed, variable numbers of broilers in a flock will show severe signs of stunting, respiratory distress, weakness, ataxia, and edema. Mortality occasionally can be very high. For a description and review of the syndrome, see (251).

TCDD may be present as a contaminant in herbicides. It and other dioxins are produced by incineration (243) and by industry (97). Contaminated poultry carcasses potentially could serve as a route for human exposure because dioxins are retained in body fat after exposure.

Polybrominated Biphenyl (PBB) and Polychlorinated Biphenyl (PCB)

PBBs or PCBs accidentally may be added to feed, get into feed as contaminants (as in oil or grease from equipment), or be present in the environment from industrial contamination and deliberate dumping. Both PBBs and PCBs are toxic to birds. At low levels, they reduce production, reproduction, hatchability, offspring viability, and thyroid hormone levels (113). Hepatocyte damage and lymphocytes depletion in the cloacal bursa also occur with low-level PBB toxicity (75). Exposure of young embryos magnifies these effects (111). Residues may be found in eggs and meat from birds without clinical signs. PBBs are concentrated in eggs at 1.5 times the dietary level (97). At high levels, lesions of PCB toxicity are similar to dioxin toxicity. It is likely that in some cases, PCBs were contaminated with TCDD.

Crude Petroleum and Oils

Most information on toxicity of oil to birds deals with environmental contamination and the effect of oil spills on waterfowl. Ingested oil causes anorexia, weight loss, incoordination, tremors, and Heinz body anemia. Lesions include lipid pneumonia, enteritis, hepatosis with fatty infiltration, and nephrosis and degeneration of pancreas, spleen, and bursa (233).

Immune responses are impaired. In herring gulls and puffins, lesions suggested a primary toxic hemolytic disease (197) with lymphoid depletion being secondary and stress related. Oil applied to chicken eggs caused embryo mortality and lesions in organs (59). Oils and oil products on the feathers and skin can be removed with detergents.

Biotoxins

Biotoxins are poisonous substances produced by living organisms including bacterial toxins such as botulinum toxin, which in birds is frequently associated with toxin-contaminated maggots, bacterial food poisoning, diseases such as necrotic and ulcerative enteritis, gangrenous dermatitis, and mycotoxins. It is possible that even methylmercury produced by bacteria should be classed as a biotoxin. Insect and snake venoms (193) are also biotoxins. Most of these conditions are of little importance or are discussed in other parts of the text. Botulism is increasing in frequency in housed turkeys and broilers. Birds are very susceptible to botulinum toxin and may show clinical signs following ingestion of very small amounts. The toxin apparently develops in dead birds left in the litter. Birds may pick up toxin from eating decaying tissue or contaminated fly larvae, darkling beetles, or litter. An enzyme-linked immunosorbent assay (ELISA), which may be as sensitive as the mouse-inoculation test, has been developed to identify botulinum toxin (see Chapter 22). Only algae poisoning and rose chafer toxicity are mentioned here.

Algae

Several species of blue-green algae produce a toxin that, when concentrated by rapid algal growth (bloom) in warm bodies of fresh water and a constant light wind blowing the toxic material to the side of the lake, may poison animals and birds consuming it. Toxicity varies directly with concentration (163). Affected chickens may show nervous signs and paralysis before death. Ducks and turkeys also have been poisoned (158). Cyanosis, congestion, and a dilated, distended heart may be seen at necropsy (251). The liver is swollen with necrosis of hepatocytes. Diagnosis is based on identifying toxin in the water (243).

Rose Chafers

Rose chafers (*Macrodactylus subspinosus*) are insects appearing in spring and early summer in eastern and central North America. Young chicks may be poisoned by 15–30 insects (251). Clinical signs include drowsiness, weakness, prostration, and convulsions (251).

Phytotoxins

All or parts of some plants are toxic, or if fed at low levels may only reduce growth rate. Antinutrients are discussed in the section Nutrients and Other Feed- and Water-Related Toxicants. For additional information on plants that are toxic to poultry and pet birds, see (14, 80, 82, 87, 112, 181, 307, 356).

Avocado (Persea americana)

The fruit contains a toxin causing muscle degeneration, hydropericardium, and subcutaneous edema (44, 140).

Black Locust (Robinia pseudoacacia)

The leaf of black locust contains a toxin causing listlessness, paralysis, and hemorrhagic enteritis.

Bladder Pod (Sesbania [Glottidium] vesicaria)

The bladder pod seed contains a toxin and consumption causes diarrhea, cyanosis, prostration, necrotic enteritis, and gizzard ulceration (99).

Cacao (Theobroma cacao, *Theobromine Toxicity*)

The bean waste from processing of cacao is toxic. In acute cases, nervous signs appear and are followed by convulsions and death, cyanosis, cloacal prolapse, and mottled kidneys. In chronic cases, anorexia and diarrhea occur (251).

Cassava (Manihot spp., *Cyanide*, *Polyphenols*)

The cassava root (tuber) is toxic with consumption causing sudden death and depressed growth (98, 249).

Carolina Jessamine (Gelsemium sempervirens)

The entire Carolina Jessamine plant is toxic. Ingestion causes progressive muscle weakness, seizure activity, and death. Lesions reported include reduced muscle mass and presence of identifiable leaves in the proventriculus. Histologically, there was neuronal degeneration and Purkinje cell loss and perimysial fibrosis (328).

Castor Bean (Ricinus communis)

The castor bean is toxic and consumption produces progressive paralysis with prostration (as with botulism), diarrhea, emaciation, swollen pale mottled liver, hemorrhagic catarrhal enteritis, petechiae, degeneration of lymphoid tissue and parenchymal cells of liver and kidney, and bile duct proliferation (166, 237, 251).

Coffee Senna, Sickle Pod (Cassia occidentalis, C. obtusifolia, Senna occidentalis)

The seeds of coffee senna are toxic. Consumption produces weakness, ataxia, paralysis, decreased egg production, diarrhea, and toxic myopathy in pectoralis and semitendinous muscles evident as pale coloration. Histologically, the lesions are edema, muscle degeneration, and necrosis (109, 246, 251, 311, 336). There is also primary axonal damage producing a neuropathy that adds to the paresis (45, 141). Lymphoid populations in the spleen and cloacal bursa also may be decreased (312).

Corn Cockle (Agrostemma githago, *Githagenin Toxicity)*

The corn cockle seed is toxic with consumption causing listlessness, rough feathers, decreased respiratory and heart rate; diarrhea; depressed growth; hydropericardium; and caseous necrosis of crop, pharyngeal mucosa, and mouth (150, 251).

Cotton Seed Meal (Gossypol Toxicity)
Toxicity from cotton seed meal results in cyanosis, inappetence, emaciation, reduced egg production and quality, enteritis, degeneration of liver and kidney, and reduced growth (251).

Coyotillo (Karwinskia humboldtiana)
The coyotillo fruit and seed are toxic, with consumption causing depressed growth, cyanosis, and paralysis.

Crotalaria spp. (Pyrrolizidine Alkaloids, Monocrotaline Toxicity)
The seed, leaf, and stem of Crotalaria are toxic with consumption causing dullness, inactivity, reduced feed consumption, stunting, bright yellow-green urates, subcutaneous edema, ascites, hydropericardium, lung edema, hepatitis, and bile duct hyperplasia (7, 52, 79, 251, 355).

Daubentonia (Daubentonia longifolia, Sesbania drummondii, S. macrocarpa)
The daubentonia seed is toxic with consumption causing weakness, listlessness, stunting, diarrhea, emaciation, proventriculitis with ulceration, enteritis, and liver and kidney degeneration (108, 110, 209, 298).

Death Camas (Zygadenus spp.)
The leaf, stem, and root of death camas are toxic with consumption causing weakness, salivation, diarrhea, and prostration (231).

Eucalyptus cladocalyx *(Cyanide or Prussic Acid)*
The *Eucalyptus cladocalyx* leaf is toxic with consumption causing acute death without premonitory signs.

Hemlock (Conium maculatum, *Conine Toxicity*)
The hemlock seed is toxic with consumption resulting in salivation, weakness, nervous signs, paralysis, diarrhea, reduced growth, hepatic congestion, and enteritis (114).

Jimsonweed (Datura stramonium, D. ferox, *Scopolamine, Hyoscyamine*)
The jimsonweed seed is toxic and consumption causes reduced growth (187).

Leucaena leucocephala (Mimosine Toxicity)
Mimosine is the toxin and is contained in the leaves. Consumption results in depressed growth and osteopathy (145, 174).

Lily of the Valley (Convallaria majalis)
Flowers, leaves, and stems of lily of the valley are toxic to geese, ducks, and chickens (251).

*Milkweed (*Asclepias *spp. Asclepidin Toxicity)*
Consumption of milkweed results in weakness and incoordination, convulsions, and prostration, which may lead to death or recovery (251).

*Nightshade (*Solanum nigrum*, Belladonna Toxicity)*
The immature nightshade fruit is toxic and consumption can cause dilated pupils, incoordination, and prostration (137).

Nitrate (Numerous Plant Species)
See the previous discussion on nitrates and nitrites.

*Oak (*Quercus *spp., Tannin Toxicity)*
The oak leaf is toxic. With consumption, there is severe diarrhea, anorexia, increased water consumption, enteritis, swollen kidneys, visceral gout, and diffuse necrosis of proximal renal tubules (184).

*Oleander (*Nerium oleander*, Glycosides)*
The entire oleander plant is toxic and consumption can result in listlessness, weakness, diarrhea, gastroenteritis, liver degeneration, and death (251, 323). Experimental toxicosis causes hypersalivation, vomiting, diarrhea, depression, and death. Gross lesions consisted of congestion and hemorrhage, while histologic lesions were those of myocardial necrosis, necrotizing hepatitis, and renal tubular necrosis with hemorrhage (240).

*Onions, Green (*Allium ascalonicum*)*
All parts of the green onion plant can be toxic. Excess consumption can cause sudden death with epicardial hemorrhage and pallor, hydropericardium, and hepatosplenomegaly. Microscopic lesions seen include hemosiderin in heptocytes, Kupffer cells, and renal tubules. Onions are known to produce a Heinz body anemia in animals but were not found in geese (60).

Oxalate (Numerous Plant Species, Oxalic Acid)
The leaf and stem of many plants are toxic with consumption causing oxalate nephrosis (354). Also see the previous discussion on ethylene glycol.

Parsley, Ammi majus*, Other Types of Plants (Photosensitization)*
All parts of parsley can be toxic with production of dermatitis (unfeathered areas) and hepatitis (254, 302).

*Pokeberry (*Phytolacca americana*)*
The pokeberry fruit is toxic and can produce ataxia, leg deformity, and ascites (19).

*Potato (*Solanum tuberosum*, Solanine Toxicity)*
Green or spoiled potatoes, peelings, and sprouts can be toxic with production of incoordination and prostration (teratogenic) (137, 326).

*Ragwort (*Senecio jacobea*, Pyrrolizidine Alkaloid)*
All parts of the ragwort plant can be toxic with toxicity producing focal hepatic necrosis and portal fibrosis (52).

Rapeseed Meal (Erucic Acid/Glucosinolate Toxicity; Antinutrients Sinapine, Tannin, Phytic Acid); Canola at Low Glucosinolate Levels

The rapeseed seed can be toxic with production of abnormal odor and taste in eggs, hypothyroidism, depressed growth, anemia, sudden death, ruptured liver, hepatitis, ascites, hydropericardium, periacinar hepatic necrosis, and fatty change in skeletal and heart muscle (24, 28, 46, 58, 105, 125, 177, 273, 353).

*Sweet Pea (*Lathyrus odoratus*, Lathyrism) and Related Species (*Lathyrus *spp.)*

The sweet pea seed (pea) can be toxic, causing skeletal deformity, osteolathyrism (*L. odoratus*), or neurologic disease, neurolathyrism (*L. sativus*, Indian pea) (54, 227, 271).

Tannins (Numerous Plant Species)

Tannins are antinutrients that occur in a variety of plants. It may be important to determine tannin levels in some feedstuffs such as sorghum (165, 325, 342).

*Tobacco (*Nicotiana tabacum*; Nicotine Sulfate Toxicity)*

The tobacco leaf and stem can be toxic, producing stunting and reduced production (teratogenic) (251).

Velvetweed (Malvaceae Family, Cyclopenoid Fatty Acids)

The velvetweed seed can be toxic with consumption causing pasty and rubbery yolk in eggs (183).

*Vetch (*Vicia *spp., Cyanogenic Glycoside)*

The vetch seed (pea) can be toxic, producing excitability, respiratory distress and convulsions (142, 278).

*Yellow Jessamine (*Gelsemium sempervirens*)*

The whole yellow jessamine plant can be toxic with consumption depressing growth (251, 357).

*Yew (*Taxus *spp., Taxine Toxicity)*

All parts of the yew are toxic with consumption producing labored breathing, incoordination, collapse and cyanosis (170).

References

1. Abou-Donia, M.B., and A.A. Komeil. 1979. Delayed neurotoxicity of o-ethyl o-4-cyanophenyl phenylphosphonothioate (cyanofenphos) in hens. *Toxicol Lett*. 4:455–459.
2. Abou-Donia, M.B., D.G. Graham, M.A. Ashry, and P.R. Timmons. 1980. Delayed neurotoxicity of leptophos and related compounds: Differential effects of subchronic oral administration of pure technical grade and degradation products on the hen. *Toxicol App Pharmacol*. 53:150–163.
3. Abuelgasim, A., R. Ringer, and V. Sanger. 1982. Toxicosis of mirex for chick embryos and chickens hatched from eggs inoculated with mirex. *Avian Dis*. 26:34–39.
4. Acar, N., P. Vohra, R. Becker, G.D. Hanners, and R.M. Saunders. 1988. Nutritional evaluation of grain amaranth for growing chickens. *Poult Sci*. 67:1166–1173.
5. Al-Badrany, Y.M.A., and F.K. Mohammad. 2007. Effects of acute and repeated oral exposure to the organophosphate insecticide chlorpyrifos on open-field activity in chicks. *Toxicol Lett*. 174:110-116.
6. Albers, P.H., D.E. Green, and C.J. Sanderson. 1996. Diagnostic criteria for selenium toxicosis in aquatic birds: Dietary exposure, tissue concentrations, and macroscopic effects. *J Wildlife Dis*. 32:468-485.
7. Alfonso, H.A., L.M. Sanchez, M. de los Angeles-Figeurdo, and B.C. Gomez. 1993. Intoxication due to *Crotalaria retusa* and *C. spectabilis* in chickens and geese. *Vet Human Toxicol*. 35:539.
8. Allen, J.R. 1964. The role of "toxic fat" in the production of hydropericardium and ascites in chickens. *Am J Vet Res*. 25:1210–1219.
9. Allen, N.K., S.R. Aakhus-Allen, and M.M. Walser. 1981. Toxic effects of repeated ethanol intubations to chicks. *Poult Sci*. 60:941–943.
10. Al-Mashhadani, E.H., and M.M. Beck. 1985. Effect of atmospheric ammonia on the surface ultrastructure of the lung and trachea of broiler chicks. *Poult Sci*. 64:2056–2061.
11. Amure, J., and J.C. Stuart. 1978. Dieldrin toxicity in poultry associated with wood shavings. *Vet Rec*. 102:387.
12. Andrabi, S.M., M.M. Ahmad, and M. Shahab. 1998. Furazolidone treatment suppresses pubertal testosterone secretion in male broiler breeder birds (*Gallus domesticus*). *Vet Hum Toxicol*. 40(6):321–325.
13. Andreasen, J.R., Jr. 1993. Metaldehyde toxicosis in ducklings. *J Vet Diagn Invest*. 5:500–501.
14. Arai, M., E. Stauber, and C.M. Shropshire. 1992. Evaluation of selected plants for their toxic effects in canaries. *J Am Vet Med Assoc*. 200:1329–1331.
15. Arnouts, S., J. Buyse, M.M. Cokelaere, and E. Decuypere. 1993. Jojoba meal (*Simmondsia chinensis*) in the diet of broiler breeder pullets: Physiological and endocrinological effects. *Poult Sci*. 72:1714–1721.
16. Bahl, A.K., and B.S. Pomeroy. 1978. Acute toxicity in poults associated with carbaryl insecticide. *Avian Dis*. 22:526–528.
17. Bai, K.M., and M.K. Krishnakumari. 1986. Acute oral toxicity of warfarin to poultry, *Gallus domesticus*: A non-target species. *Bull Environ Contam Toxicol*. 37:544–549.
18. Baker, D.H., T.M. Parr, and N.R. Augspurger. 2003. Oral iodine toxicity in chicks can be reversed by supplemental bromine. *J Nutr*. 133:2309–2312.
19. Barnett, B.D. 1975. Toxicity of pokeberries (fruit of *Phytolacca americana* Large) for turkey poults. *Poult Sci*. 54:1215–1217.
20. Bartov, L. 1989. Lack of effect of dietary factors on nicarbazin toxicity in broiler chicks. *Poult Sci*. 68:145–152.
21. Bedford, M.R., and H.L. Classen. 1993. An *in vitro* assay for prediction of broiler intestinal viscosity and growth when fed rye-based diets in the presence of exogenous enzymes. *Poult Sci*. 72:137–143.
22. Beers, K.W., T.J. Raup, W.G. Bottje, and T.W. Odom. 1989. Physiological responses of heat-stressed broilers fed nicarbazin. *Poult Sci*. 68:428–434.
23. Behr, K.P., H. Lüders, and C. Plate. 1986. Safety of halofuginone (Stenorol7) in geese (*Anser anser* f. *dom*.), Muscovy ducks

(*Cairina moschata* f. *dom*.) and Pekin ducks (*Anas platyrhynchos* f. *dom*.). *Dtsch Tieraerztl Wochenschr*. 93:4–8.
24. Bell, J.M. 1993. Factors affecting the nutritional value of canola meal: A review. *Can J Anim Sci*. 73:679–697.
25. Bennett, W.M. 1989. Mechanism of aminoglycoside nephrotoxicity. *Clin Exp Pharm Physiol*. 16:1–6.
26. Bergmann, V., G. Baumann, and B. Kahle. 1989. Zur Pathologie der akuten Monensin-Vergiftung bei Broilern und Lämmern. *Monatsh Vet*. 44:460–463.
27. Bennett, D.C., M.R. Hughes, J.E. Elliott, A.M. Scheuhammer, and J.E. Smits. 2000. Effect of cadmium on Pekin duck total body water, water flux, renal filtration, and salt gland function. *J Toxicol Environ Health A*. 59(1):43–56.
28. Bhatnagar, M.K., S. Yamashiro, and L.L. David. 1980. Ultrastructural study of liver fibrosis in turkeys fed diets containing rapeseed meal. *Res Vet Sci*. 29:260–265.
29. Bierer, B.W. 1958. The ill effects of excessive formaldehyde fumigation on turkey poults. *J Am Vet Med Assoc*. 132:174–176.
30. Blakley, B.R. 1982. Lindane toxicity in pigeons. *Can Vet J*. 23:267–268.
31. Blom, L. 1975. Residues of drugs in eggs after medication of laying hens for eight days. *Acta Vet Scand*. 16:396–404.
32. Bokori, J., S. Fekete, I. Kádar, F. Vetési, and M. Albert. 1993. Complex study of the physiological role of aluminum. II. Aluminum tolerance test in broiler chickens. *Acta Vet Hung*. 41:235–264.
33. Booth, N.H. 1988. Drugs and chemical residues in the edible tissue of animals. In: *Veterinary Pharmacology and Therapeutics*, 6th ed. N.H. Booth and L.E. McDonald eds. Iowa State University Press, Ames, Iowa. 1149–1205.
34. Boucher, M., T.J. Ehmler, and A.J. Bermudez. 1999. Polytetrafluoroethylene gas intoxication in broiler chickens. *Avian Dis*. 44:449-453
35. Bowes, V., and R. Puls. 1992. Fenthion toxicity in bald eagles. *Can Vet J*. 33:678.
36. Braunius, W.W. 1986. Monensin/sulfachloropyrazine intoxicatie bij kalkoenen. *Tijdschr Diergeneeskd*. 111:676–678.
37. Brenes, A., M. Smith, W. Guenter, and R.R. Marquardt. 1993. Effect of enzyme supplementation on the performance and digestive tract size of broiler chickens fed wheat- and barley-based diets. *Poult Sci*. 72:1731–1739.
38. Brenes, A., R.R. Marquardt, W. Guenter, and B.A. Rotter. 1993. Effect of enzyme supplementation on the nutritional value of raw, autoclaved, and dehulled lupins (*Lupinus albus*) in chicken diets. *Poult Sci*. 72:2281–2293.
39. Brenes, A., B.A. Rotter, R.R. Marquardt, and W. Guenter. 1993. The nutritional value of raw, autoclaved, and dehulled peas (*Pisum satirum* L.) in chicken diets as affected by enzyme supplementation. *Can J Anim Sci*. 73:605–614.
40. Brown, C., W.B. Gross, and M. Ehrich. 1986. Effects of social stress on the toxicity of malathion in young chickens. *Avian Dis*. 30:679–682.
41. Brown, T.P., C.T. Larsen, D.L. Boyd, and B.M. Allen. 1991. Ulcerative cholecystitis produced by 3-nitro-4-hydroxyphenylarsonic acid toxicosis in turkey poults. *Avian Dis*. 35:241–243.
42. Broz, J., and M. Frigg. 1987. Incompatibility between lasalocid and chloramphenicol in broiler chicks after a long-term simultaneous administration. *Vet Res Commun*. 11:159–172.
43. Bunn, T.L., J.A. Marsh, and R.R. Dietert. 2000. Gender differences in developmental immunotoxicity to lead in the chicken: Analysis following a single early low-level exposure *in ovo*. *J Toxicol Environ Health A*. 61(8):677–693.
44. Burger, W.P., T.W. Naude, I.B.J. Van Rensburg, C.J. Botha, and A.C.E. Pienaar. 1994. Cardiomyopathy in ostriches (*Struthio camelus*) due to avocado (*Persea americana* var. *guatemalensis*) intoxication. *J S Afr Vet Assoc*. 65:113–118.
45. Calore, E.E., M.J. Cavaliere, M. Haraguchi, S.L. Gorniak, M.L. Dagli, P.C. Raspantini, N.M. Calore, and R. Weg. 1998. Toxic peripheral neuropathy of chicks fed *Senna occidentalis* seeds. *Ecotoxicol Environ Saf*. 39(1):27–30.
46. Campbell, L.D. 1987. Effects of different intact glucosinolates on liver hemorrhage in laying hens and the influence of vitamin K. *Nutr Rep Int*. 35:1221–1227.
47. Cantor, A.H., D.M. Nash, and T.H. Johnson. 1984. Toxicity of selenium in drinking water of poultry. *Nutr Rep Int*. 29:683–688.
48. Capdevielle, M.C., L.E. Hart, J. Goff, and C.G. Scanes. 1998. Aluminum and acid effects on calcium and phosphorus metabolism in young growing chickens (*Gallus gallus domesticus*) and mallard ducks (*Anas platyrhynchos*). *Arch Environ Contam Toxicol*. 35(1):82–88.
49. Cardona, C.J., F.D. Galey, A.A. Bickford, B.R. Charlton, and G.L. Cooper. 1993. Skeletal myopathy produced with experimental dosing of turkeys with monensin. *Avian Dis*. 37:107–117.
50. Carlile, F.S. 1984. Ammonia in poultry houses: A literature review. *World's Poult Sci J*. 40:99–113.
51. Carlton, W.W. 1966. Experimental coal tar poisoning in the White Pekin duck. *Avian Dis*. 10:484–502.
52. Cheeke, P.R. 1988. Toxicity and metabolism of pyrrolizidine alkaloids. *J Anim Sci*. 66:2343–2350.
53. Chapman, H.D., T.K. Jeffers, and R.B. Williams. 2010. Forty years of monensin for the control of coccidiosis in poultry. *Poult Sci*. 89:1788-1801.
54. Chowdhury, S.D. 1988. Lathyrism in poultry: A review. *World's Poult Sci J*. 44:7–16.
55. Christensen, V.L., and J.F. Ort. 1991. Iodine toxicity in large white turkey breeder hens. *Poult Sci*. 70:2402–2410.
56. Coats, J.R. 1990. Mechanisms of toxic action and structure-activity relationships for organochlorine and synthetic pyrethroid insecticides. *Environ Health Perspect*. 87:255–262.
57. Coetzee, C.B., N.H. Casey, and J.A. Meyer. 1997. Fluoride tolerance of laying hens. *Br Poult Sci*. 38(5):597–602.
58. Corner, A.H., H.W. Hulan, D.M. Nash, and F.G. Proudfoot. 1985. Pathological changes associated with the feeding of soybean oil or oil extracted from different rapeseed cultivars to single comb white leghorn cockerels. *Poult Sci*. 64:1438–1450.
59. Couillard, C.M., and F.A. Leighton. 1990. The toxicopathology of Prudhoe Bay crude oil in chicken embryos. *Fund Appl Toxicol*. 14:30–39.
60. Crespo, R., and R.P. Chin. 2004. Effect of feeding green onions (*Allium ascalonicum*) to White Chinese geese (*Threskiornis spinicollis*). *J Vet Diagn Invest*. 16:321–325.
61. Cruickshank, J.J., and J.S. Sim. 1987. Effects of excess vitamin D_3 and cage density on the incidence of leg abnormalities in broiler chickens. *Avian Dis*. 31:332–338.
62. Czarnecki, C.M. 1986. Quantitative morphological alterations during the development of furazolidone-induced cardiomyopathy in turkeys. *J Comp Pathol*. 96:63–75.
63. Czarnecki, C.M., and H.A. Badreldin. 1987. Graded ethanol consumption in young turkey poults: effect on body weight, feed intake and development of cardiomegaly. *Res Commun Subst Abuse*. 8:93–96.

64. Czarnecki, G.L., and D.H. Baker. 1982. Tolerance of the chick to excess dietary cadmium as influenced by dietary cysteine and by experimental infection with *Eimeria acervulina*. *J Anim Sci*. 54:983–988.
65. Daft, B.M., A.A. Bickford, and M.A. Hammarlund. 1989. Experimental and field sulfaquinoxaline toxicosis in leghorn chickens. *Avian Dis*. 33:30–34.
66. Dalvi, R.R. 1988. Toxicology of thiram: A review. *Vet Hum Toxicol*. 30:480–484.
67. Damron, B.L., and L.K. Flunker. 1993. Broiler chick and laying hen tolerance to sodium hypochlorite in drinking water. *Poult Sci*. 72:1650–1655.
68. Davis, C. 1983. Narasin toxicity in turkeys. *Vet Rec*. 113:627.
69. Davison, S., and R.F. Wideman. 1992. Excess sodium bicarbonate in the diet and its effect on leghorn chickens. *Br Poult Sci*. 33:859–870.
70. Dean, C.E., B.M. Hargis, and P.S. Hargis. 1991. Effects of zinc toxicity on thyroid function and histology in broiler chicks. *Toxicol Lett*. 57:309–318.
71. Deaton, J.W., F.N. Reece, and F.D. Thornberry. 1986. Atmospheric ammonia and incidence of blood spots in eggs. *Poult Sci*. 65:1427–1428.
72. Delaplane, J.P., and J.H. Milliff. 1948. The gross and micropathology of sulfaquinoxaline poisoning in chickens. *Am J Vet Res*. 9:92–96.
73. De Ment, S.H., J.J. Chisolm, M.A. Eckhaus, and J.D. Strandberg. 1987. Toxic lead exposure in the urban rock dove. *J Wildl Dis*. 3:273–278.
74. Dewar, W.A., P.A.L. Wight, R.A. Pearson, and M.J. Gentle. 1983. Toxic effects of high concentrations of zinc oxide in the diet of the chick and laying hen. *Br Poult Sci*. 24:397–404.
75. Dharma, D.N., S.D. Sleight, R.K. Ringer, and S.D. Aust. 1982. Pathologic effects of 2,2,4,4,5,5- and 2,3,4,4,5,5-hexabromobiphenyl in white leghorn cockerels. *Avian Dis*. 26:542–552.
76. Dhillon, A.S., R.W. Winterfield, and H.L. Thacker. 1982. Quaternary ammonium compound toxicity in chickens. *Avian Dis*. 26:928–931.
77. Diaz, G.J., R.J. Julian, and E.J. Squires. 1994. Lesions in broiler chickens following experimental intoxication with cobalt. *Avian Dis*. 38:308–316.
78. Diaz, G.J., R.J. Julian, and E.J. Squires. 1995. Effect of graded levels of dietary nitrite on pulmonary hypertension in broiler chickens and dilatory cardiomyopathy in turkey poults. *Avian Pathol*. 24:109–120.
79. Dickinson, J.O., and R.C. Braun. 1987. Effect of 2(3)-tertbutyl-4-hydroxyanisole (BHA) and 2-chloroethanol against pyrole production and chronic toxicity of monocrotaline in chickens. *Vet Hum Toxicol*. 29:11–15.
80. DiTomaso, J.M. 1994. Plants reported to be poisonous to animals in the United States. *Vet Hum Toxicol*. 36:49–52.
81. D'Mello, J.P.F., and A.G. Walker. 1991. Detoxification of jackbeans (*Canavalia ensiformis*): Studies with young chicks. *Anim Fed Sci Tech*. 33:117–127.
82. D'Mello, J.P.F., C.M. Duffus, and J.H. Duffus (eds.). 1991. *Toxic Substances in Crop Plants*. Royal Society of Chemists, Cambridge, United Kingdom. 155-166.
83. Donham, K.J. 1991. Air quality relationships to occupational health in the poultry industry. *Proc North Central Avian Dis Conf*. 42:43–47.
84. Dorn, P., R. Weber, J. Weikel, and E. Wessling. 1983. Intoxikation durch gleichzeitige verabreichung von chloramphenicol und monensin bei puten. *Prakt Tierarzt* 64:240–243.
85. Dowling, L. 1992. Ionophore toxicity in chickens: A review of pathology and diagnosis. *Avian Pathol*. 21:355–268.
86. Dufour, L., J.E. Sander, R.D. Wyatt, G.N. Rowland, and R.K. Page. 1992. Experimental exposure of broiler chickens to boric acid to assess clinical signs and lesions of toxicosis. *Avian Dis*. 36:1007–1011.
87. Dumonceaux, G., and G.J. Harrison. 1994. Toxins. In: *Avian Medicine: Principles and Application*. B.W. Ritchie, G.J. Harrison, and L.R. Harrison, eds. Wingers Publishing, Inc., Lake Worth, Florida. 1030–1049.
88. Dunachie, J.F., and W.W. Fletcher. 1970. The toxicity of certain herbicides to hens' eggs assessed by the egg injection technique. *Ann Appl Biol*. 66:515–520.
89. Dunn, M.A., N.E. Johnson, M.Y.B. Liew, and E. Ross. 1993. Dietary aluminum chloride reduces the amount of intestinal calbindin D-28K in chicks fed low calcium or low phosphorus diets. *J Nutr*. 123:1786–1793.
90. Durham, H.D., and D.J. Ecobichon. 1986. An assessment of the neurotoxic potential of fenitrothion in the hen. *Toxicology*. 41:319–332.
91. Eason, P.J., R.J. Johnson, and G.H. Castleman. 1990. The effects of dietary inclusion of narbon beans (*Vicia narbonensis*) on the growth of broiler chickens. *Aust J Agric Res*. 41: 565–571.
92. Edelstein, S., C.S. Fullmer, and R.H. Wasserman. 1984. Gastrointestinal absorption of lead in chicks: involvement of the cholecalciferol endocrine system. *J Nutr*. 114:692–700.
93. Edwards, H.M., Jr. 1987. Effects of thiuram disulfiram and a trace element mixture on the incidence of tibial dyschondroplasia in chickens. *J Nutr*. 117:964–969.
94. Egyed, M.N., and U. Bendheim. 1977. Mass poisoning in chickens caused by consumption of organo-phosphorus (dichlorvos) contaminated drinking water. *Refu Vet*. 34:107–110.
95. Ehrich, M., L. Correll, J. Strait, W. McCain, and J. Wilcke. 1992. Toxicity and toxicokinetics of carbaryl in chickens and rats: A comparative study. *J Toxicol Environ Health*. 36: 411–423.
96. Elliot, M.A., and H.M. Edwards, Jr. 1991. Some effects of dietary aluminum and silicon on broiler chickens. *Poult Sci*. 70:1390–1402.
97. Elliott, J.E., R.W. Butler, R.J. Norstrom, and P.E. Whitehead. 1988. Levels of Polychlorinated Dibenzodioxins and Polychlorinated Dibenzofurans in Eggs of Great Blue Herons (Ardea herodias) in British Columbia, 1983–1987: Possible Impact on Reproductive Success. Progress Notes No. 176. Canadian Wildlife Service, Ottawa.
98. Elzubeir, E.A., and R.H. Davis. 1988. Sodium nitroprusside, a convenient source of dietary cyanide for the study of chronic cyanide toxicity. *Br Poult Sci*. 29:779–783.
99. Emmel, M.W. 1935. The toxicity of *Glottidium vesicarium* (Jacq) Harper seeds for the fowl. *J Am Vet Med Assoc*. 87:13–21.
100. Ernst, R.A., P. Vohra, F. H. Kratzer, and H.J. Kuhl. 1996. Effect of halofuginone (Stenorol) on Chukar partridge (*Alectoris chukar*). *Poult Sci*. 75(12):1493–1495.
101. Faddoul, G.P., S.V. Amato, M. Sevoian, and G.W. Fellows. 1967. Studies on intolerance to sulfaquinoxaline in chickens. *Avian Dis*. 11:226–240.
102. Farage-Elawar, M. 1989. Enzyme and behavioral changes in young chickens as a result of carbaryl treatment. *J Toxicol Environ Health*. 26:119–131.
103. Farage-Elawar, M., and M. Francis. 1988. Effects of fenthion, fenitrothion and desbromoleptophos on gait, acetylcholine and

neurotoxic esterase in young chicks after *in ovo* exposure. *Toxicology*. 49:253–261.
104. Fedde, M.R., and W.D. Kuhlmann. 1979. Cardiopulmonary responses to inhaled sulfur dioxide in the chicken. *Poult Sci*. 58:1584–1591.
105. Fenwick, G.R., C.L. Curl, E.J. Butler, N.M. Greenwood, and A.W. Pearson. 1984. Rapeseed meal and egg taint: Effects of low glucosinolate Brassica napus meal, dehulled meal and hulls, and of neomycin. *J Sci Food Agric*. 35:749–756.
106. Ficken, M.D., D.P. Wages, and E. Gonder. 1989. Monensin toxicity in turkey breeder hens. *Avian Dis*. 33:186–190.
107. Fitzgerald, S.D., J.M. Sullivan, and R.J. Everson. 1990. Suspected ethanol toxicosis in two wild cedar waxwings. *Avian Dis*. 34:488–490.
108. Flory, W., and C.D. Hebert. 1984. Determination of the oral toxicity of *Sesbania drummondii* seeds in chickens. *Am J Vet Res*. 45:955–958.
109. Flunker, L.K., B.L. Damron, and S.F. Sundlof. 1989. Response of White Leghorn hens to various dietary levels of *Cassia obtusifolia* and nutrient fortification as a means of alleviating depressed performance. *Poult Sci*. 68:909–913.
110. Flunker, L.K., B.L. Damron, and S.F. Sundlof. 1990. Tolerance to ground *Sesbania macrocarpa* seed by broiler chicks and White Leghorn hens. *Poult Sci*. 69:669–672.
111. Fox, L.L., and K.A. Grasman. 1999. Effects of PCB 126 on primary immune organ development in chicken embryos. *J Toxicol Environ Health A*. 58(4):233–244.
112. Fowler, M.E. 1986. Plant poisoning in pet birds and reptiles. In: *Current Veterinary Therapy*. IX. R.W. Kirk, ed. W.B. Saunders Co., Philadelphia. 737–743.
113. Fowles, J.R., A. Fairbrother, K.A. Trust, and N.I. Kerkvliet. 1997. Effects of Aroclor 1254 on the thyroid gland, immune function, and hepatic cytochrome P450 activity in mallards. *Environ Res*. 75(2):119–129.
114. Frank, A.A., and W.M. Reed. 1990. Comparative toxicity of coniine, an alkaloid of *Conium maculatum* (poison hemlock), in chickens, quails, and turkeys. *Avian Dis*. 34:433–437.
115. Frank, R., G.J. Sirons, and D. Wilson. 1981. Residues of 4-aminopyridine in poisoned birds. *Bull Environ Contam Toxicol*. 26:389–392.
116. Frank, R., N. Fish, G.J. Sirons, J. Walker, H.L. Orr, and S. Leeson. 1983. Residues of polychlorinated phenols and anisoles in broilers raised on contaminated wood shaving litter. *Poult Sci*. 62:1559–1565.
117. Frank, R., P. Mineau, H.E. Braun, I.K. Barker, S.W. Kennedy, and S. Trudeau. 1991. Deaths of Canada geese following spraying of turf with diazinon. *Bull Environ Contam Tox*. 46:852–858.
118. Friesen, O.D., W. Guenter, R.R. Marquardt, and B.A. Rotter. 1992. The effect of enzyme supplementation on the apparent metabolizable energy and nutrient digestibilities of wheat, barley, oats, and rye for the young broiler chick. *Poult Sci*. 71: 1710–1721.
119. Galt, D.E. 1988. Reduced hatchability of eggs associated with pentachlorophenol contaminated shavings. *Can Vet J*. 29: 65–67.
120. Gartell, B.D., M.R. Alley, and A.H. Mitchell. 2004. Fatal levamisole toxicosis of captive kiwi (*Apteryx mantelli*). *N Z Vet J*. 53:84–86.
121. Gilbert, R.W., J.E. Sander, and T.P. Brown. 1996. Copper sulfate toxicosis in commercial laying hens. *Avian Dis*. 40(1): 236–239.
122. Gilead, M., and U. Bendheim. 1986. Formalin poisoning in turkeys. *Israel J Vet Med*. 42:193–194.
123. Giri, S.N., A.A. Bickford, and A.E. Barger. 1979. Effects of 2-chloro-4-acetotoluidine (CAT) toxicity on biochemical and morphological alterations in quail. *Avian Dis*. 23:794–811.
124. Glahn, R.P., R.F. Wideman, Jr., and B.S. Cowen. 1989. Order of exposure to high dietary calcium and Gray strain infections bronchitis virus alters renal function and the incidence of urolithiasis. *Poult Sci*. 68:1193–1204.
125. Gough, A.W., and L.J. Weber. 1978. Massive liver hemorrhage in Ontario broiler chickens. *Avian Dis*. 22:205–210.
126. Granot, I., I. Bartov, I. Plavnik, E. Wax, S. Hurwitz, and M. Pines. 1991. Increased skin tearing in broilers and reduced collagen synthesis in skin *in vivo* and *in vitro* in response to the coccidiostat halofuginone. *Poult Sci*. 70:1559–1563.
127. Green, D.E., and P.H. Albers. 1997. Diagnostic criteria for selenium toxicosis in aquatic birds: histologic lesions. *J Wildl Dis*. 33(3):385–404.
128. Gregory, D.G., S.L. Vanhooser, and E.L. Stair. 1995. Light and electron microscopic lesions in peripheral nerves of broiler chickens due to roxarsone and lasalocid toxicoses. *Avian Dis*. 39:408–416.
129. Guenter, W., and P.H.B. Hahn. 1986. Fluorine toxicity and laying hen performance. *Poult Sci*. 65:769–778.
130. Guitart, R., R. Mateo, J.M. Gutierrez, and J. To-Figueras. 1996. An outbreak of thiram poisoning on Spanish poultry farms. *Vet Hum Toxicol*. 38(4):287–288.
131. Gwathmey, J.K. 1991. Morphological changes associated with furazolidone-induced cardiomyopathy: Effects of digoxin and propranolol. *J Comp Pathol*. 104:33–45.
132. Hafez, Y.S.M., E. Chavez, P. Vohra, and F.H. Kratzer. 1978. Methionine toxicity in chicks and poults. *Poult Sci*. 57: 699–703.
133. Haigh, J.C. 1979. Levamisole in waterfowl: Trials on effect and toxicity. *J Zoo Anim Med*. 10:103–105.
134. Halvorson, D.A., C. Van Dijk, and P. Brown. 1982. Ionophore toxicity in turkey breeders. *Avian Dis*. 26:634–639.
135. Han, J., J. Han, and M.A. Dunn. 2000. Effect of dietary aluminum on tissue nonheme iron and ferritin levels in the chick. *Toxicology*. 142(2):97–109.
136. Hanrahan, L.A., D.E. Corrier, and S.A. Naqi. 1981. Monensin toxicosis in broiler chickens. *Vet Pathol*. 18:665–671.
137. Hansen, A.A. 1927. Stock poisoning by plants in the nightshade family. *J Am Vet Med Assoc*. 71:221–227.
138. Hanson, J. and J. Howell. 1981. Possible fenthion toxicity in magpies (*Pica pica*). *Can Vet J*. 22:18–19.
139. Hare, T., and A.B. Orr. 1945. Poultry poisoned by zinc phosphide. *Vet Rec*. 57:17.
140. Hargis, A.M., E. Stauber, S. Casteel, and D. Eitner. 1989. Avocado (*Persea americana*) intoxication in caged birds. *J Am Vet Med Assoc*. 194:64–66.
141. Haraguchi, M., E.E. Calore, M.L. Dagli, M.J. Cavaliere, N.M. Calore, R. Weg, P.C. Raspantini, and S.L. Gorniak. 1998. Muscle atrophy induced in broiler chicks by parts of *Senna occidentalis* seeds. *Vet Res Commun*. 22(4):265–271.
142. Harper, J.A., and G.H. Arscott. 1962. Toxicity of common and hairy vetch seed for poults and chicks. *Poult Sci*. 41: 1968–1974.
143. Harper, M.J., and M. Hindmarsh. 1990. Lead poisoning in magpie geese *Anseranas semipalmata* from ingested lead pellet at Bool Lagoon Game Reserve (South Australia). *Aust Wildl Res*. 17:141–145.

144. Hatch, R.C. 1988. Veterinary Toxicology. In: *Veterinary Pharmacology and Therapeutics*, 6th ed. N.H. Booth and L.E. McDonald, eds. Iowa State University Press, Ames, Iowa. 1001–1148.
145. Hathcock, J.N., M.M. Labadan, and J.P. Mateo. 1975. Effects of dietary protein level on toxicity of *Leucaena leucocephala* to chicks. *Nutr Rep Int*. 11:55–62.
146. Heinz, G.H. 1979. Methylmercury: reproductive and behavioral effects on three generations of mallard ducks. *J Wildl Manage*. 43:394–401.
147. Heinz, G.H., and L.N. Locke. 1976. Brain lesions in mallard ducklings from parents fed methylmercury. *Avian Dis*. 20:9–17.
148. Henderson, B.M., and R.W. Winterfield. 1975. Acute copper toxicosis in the Canada goose. *Avian Dis*. 19:385–387.
149. Henny, C.J., E.J. Kolbe, E.F. Hill, and L.J. Blus. 1987. Case histories of bald eagles and other raptors killed by organophosphorus insecticides topically applied to livestock. *J Wildl Dis*. 23:292–295.
150. Heuser, G.F., and A.E. Schumacher. 1942. The feeding of corn cockle to chickens. *Poult Sci*. 2:86–93.
151. Hill, D.L., C.I. Hall, J.E. Sander, O.J. Fletcher, R.K. Page, and S.W. Davis. 1994. Diazinon toxicity in broilers. *Avian Dis*. 38:393–396.
152. Hino, T., T. Noguchi, and H. Naito. 1987. Effect of gizzerosine on acid secretion by isolated mucosal cells of chicken proventriculus. *Poult Sci*. 66:548–551.
153. Hoffman, D.J., G.H. Heinz, L.J. LeCaptain, J.D. Eisemann, and G.W. Pendleton. 1996. Toxicity and oxidative stress of different forms of organic selenium and dietary protein in mallard ducklings. *Arch Environ Contam Toxicol*. 31(1):120–127.
154. Hoffman, D.J., G.H. Heinz, L. Sileo, D.J. Audet, J.K. Campbell, and L.J. LeCaptain. 2000. Developmental toxicity of lead-contaminated sediment to mallard ducklings. *Arch Environ Contam Toxicol*. 39(2):221–232.
155. Hoop, R.K. 1998. Salinomycin toxicity in layer breeders. *Vet Rec*. 142(20):550.
156. Horikawa, H., T. Masumura, S. Hirano, E. Watanabe, and T. Ishibashi. 1992. Optimum dietary level of gizzerosine for maximum calcium content in the femur of chicks. *Jpn Poult Sci*. 29:361–367.
157. Huisman, J. 1991. Antinutritional factors in poultry feeds and their management. *Proc Eur Symp Poult Nutr*. 8:42–61.
158. Humphreys, D.J. 1979. Poisoning in poultry. *World's Poult Sci J*. 35:161–176.
159. Humphreys, D.J., J.B. Stodulski, R.R. Fysh, and N.M. Howie. 1980. Haloxon poisoning in geese. *Vet Rec*. 107:541.
160. Hunter, B., and G. Wobeser. 1980. Encephalopathy and peripheral neuropathy in lead-poisoned mallard ducks. *Avian Dis*. 24:169–178.
161. Hussein, A.S., A.H. Cantor, A.J. Pescatore, and T.H. Johnson. 1993. Effect of dietary aluminum and vitamin D interaction on growth and calcium and phosphorus metabolism of broiler chicks. *Poult Sci*. 72:306–309.
162. Hutchison, T.W., and W.F. De Witt. 1996. Quaternary ammonium compound toxicity in broiler chickens. *Can Vet J*. 37(8):482.
163. Jackson, A.R.B., M.T.C. Runnegar, R.B. Cumming, and J.F. Brunner. 1986. Experimental acute intoxication of young layer and broiler chickens with the cyanobacterium (blue-green alga) *Microcystis aeruginosa*. *Avian Pathol*. 15:741–748.
164. Jan Baars, A. 2000. The dioxin in chicken incident in Belgium in 1999: trouble or trifle? *Arh Hig Rada Toksikol*. 51(3):311–320.
165. Jansman, A.J.M. 1993. Tannins in feedstuffs for simple-stomached animals. *Nutr Res Rev*. 6:209–236.
166. Jensen, W.I., and J.P. Allen. 1981. Naturally occurring and experimentally induced castor bean (*Ricinus communis*) poisoning in ducks. *Avian Dis*. 25:184–194.
167. Jeroch, H., E. Helander, H.J. Schlöffel, K.H. Engerer, H. Pingel, and G. Gebhardt. 1991. Investigation of effectiveness of beta-glucanase containing enzyme preparation "Avizyme" supplemented to broiler fattening diet based on barley. *Arch Geflügelk* 55:22–25.
168. Jones, J.E., J. Solis, B.L. Hughes, D.J. Castaldo, and J.E. Toler. 1990. Reproduction responses of broiler-breeders to anticoccidial agents. *Poult Sci*. 69:27–36.
169. Jordan, F.T.W., J.M. Howell, J. Howorth, and J.K. Rayton. 1976. Clinical and pathological observations on field and experimental zoalene poisoning in broiler chicks and the effect of the drug on laying hens. *Avian Pathol*. 5:175–185.
170. Julian, R.J. 1991. Poisons and toxins. In: *Diseases of Poultry*, 9th ed. B.W. Calnek, H.J. Barnes, C.W. Beard, W.M. Reed, and H.W. Yoder, eds. Iowa State University Press, Ames, Iowa. 863–884.
171. Julian, R.J. 1993. Ascites in poultry. *Avian Pathol*. 22:419–454.
172. Julian, R.J., G.W. Friars, H. French, and M. Quinton. 1987. The relationship of right ventricular hypertrophy, right ventricular failure, and ascites to weight gain in broiler and roaster chickens. *Avian Dis*. 31:130–135.
173. Julian, R.J., L.J. Caston, and S. Leeson. 1992. The effect of dietary sodium on right ventricular failure-induced ascites, gain and fat deposition in meat-type chickens. *Can J Vet Res*. 56: 214–219.
174. Kamada, Y., N. Oshiro, M. Miyagi, H. Oku, F. Hongo, and I. Chinen. 1998. Osteopathy in broiler chicks fed toxic mimosine in *Leucaena leucocephala*. *Biosci Biotechnol Biochem*. 62(1):34–38.
175. Kangas, J., K. Louhelainen, and K. Husman. 1987. Gaseous health hazards in livestock confinement building. *J Agric Sci (Finl)*. 59:57–62.
176. Karstad, L. 1971. Angiopathy and cardiopathy in wild waterfowl from ingestion of lead shot. *Connecticut Med*. 35:355–360.
177. Karunajeewa, H., E.G. Ijagbuji, and R.L. Reece. 1990. Effect of dietary levels of rapeseed meal and polyethylene glycol on the performance of male broiler chickens. *Br Poult Sci*. 31:545–555.
178. Katz, R.S. and D.H. Baker. 1975. Methionine toxicity in the chick: Nutritional and metabolic implications. *J Nutr*. 105: 1168–1175.
179. Kawalek, J.C. 2011. Provide data on various arsenic species present in broilers treated with roxarsone: Comparison with untreated birds. Study 275.30. Food and Drug Administration, Washington DC.
180. Kazacos, E.A., and J.F. Van Vleet. 1989. Sequential ultrastructural changes of the pancreas in zinc toxicosis in ducklings. *Am J Pathol*. 134:581–595.
181. Keeler, R.F. 1991. *Toxicology of Plant and Fungal Compounds. Handbook of Natural Toxins*, vol. 6. Marcel Dekker, New York.
182. Keirs, R.W., and L. Bennett. 1993. Broiler performance loss associated with biogenic amines. *Proc Md Nutr Conf for Feed Manufacturers*. Baltimore, Maryland. 31–34.
183. Keshavarz, K. 1993. Effect of corn contaminated with velvetweed seeds on eggs. *J Appl Poult Res*. 2:232–238.

184. Kinde, H. 1988. A fatal case of oak poisoning in double-wattled cassowary (*Casuarius casuarius*). *Avian Dis*. 32:849–851.
185. Kinde, H., H.L. Shivaprasad, F.D. Galey, G. Cutler, and D. Hamar. 1992. Sudden drop in egg production associated with vitamin A toxicity in chickens. *Proc West Poult Dis Conf*. 41:5.
186. Klein, P.N. 1989. The effects of naphthalene and p-dichlorobenzene (mothball chemicals) in canaries and finches fed cumulative amounts in contaminated feed. *Proc West Poult Dis Conf*. 38: 164.
187. Kovatsis, A., V.P. Kotsaki-Kovatsi, E. Nikolaidis, J. Flaskos, S. Tzika, and G. Tzotzas. 1994. The influence of *Datura ferox* alkaloids on egg-laying hens. *Vet Hum Toxicol*. 36:89–91.
188. Kubena, L.F., and T.D. Phillips. 1983. Toxicity of vanadium in female leghorn chickens. *Poult Sci*. 62:47–50.
189. Kupsh, C.C., R.J. Julian, V.E.O. Valli, and G.A. Robinson. 1991. Renal damage induced by uranyl nitrate and oestradiol-17b in Japanese quail and Wistar rats. *Avian Pathol*. 20:25–34.
190. Laczay, P., F. Simon, Z. Mora, and J. Lehel. 1990. Comparative studies on the toxic interactions of the ionophore anticoccidials with tiamulin in broiler chicks. *Arch Gefluegelkd*. 54:129–132.
191. Larsen, C., B.S. Jortner, and M. Ehrich. 1986. Effect of neurotoxic organophosphorus compounds in turkeys. *J Toxicol Environ Health*. 17:365–374.
192. Latta, D.M., and W.E. Donaldson. 1986. Lead toxicity in chicks: Interactions with dietary methionine and choline. *J Nutr*. 116:1561–1568.
193. Lawal, S., P.A. Abdu, G.B.D. Jonathan, and O.J. Hambolu. 1992. Snakebites in poultry. *Vet Hum Toxicol*. 34:528–530.
194. Leach, R.M., Jr., C.I. Rosenblum, M.J. Amman, and J. Burdette. 1990. Broiler chicks fed low-calcium diets. 2. Increased sensitivity to copper toxicity. *Poult Sci*. 69:1905–1910.
195. Lee, S.R., W.M. Britton, and G.N. Rowland. 1980. Magnesium toxicity: Bone lesions. *Poult Sci*. 59:2403–2411.
196. Leeson, S., L.J. Caston, and J.D. Summers. 1989. The effect of graded levels of nicarbazin on reproductive performance of laying hens. *Can J Anim Sci*. 69:757–764.
197. Leighton, F.A. 1986. Clinical, gross and histological findings in herring gulls and Atlantic puffins that ingested Prudhoe Bay crude oil. *Vet Pathol*. 23:254–263.
198. Lekkas, S., P. Iordanidis, and E. Artopios. 1986. Intoxication by creolin in broilers. *Israel J Vet Med*. 42:114–119.
199. Leon, A.M., J.P. Caffin, M. Plassart, and M.L. Picard. 1991. Effect of concanavalin A from jackbean seeds on short-term food intake regulation in chicks and laying hens. *Anim Feed Sci Tech*. 32:297–311.
200. Leong, V.Y.M. and T. Brown. 1992. Toxicosis in broiler chicks due to excess dietary ethoxyquin. *Avian Dis*. 36:1102–1106.
201. Leske, K.L., C.J. Jevne, and C.N. Coon. 1993. Extraction methods for removing soybean alpha-galactosides and improving true metabolizable energy for poultry. *Anim Feed Sci Tech*. 41:73–78.
202. Lessler, M.A., and D.A. Ray. 1986. Dietary lead inhibits avian bone fracture healing. *J Physiol*. 371:223P.
203. Levengood, J.M., G.C. Sanderson, W.L. Anderson, G.L. Foley, P.W. Brown, and J.W. Seets. 2000. Influence of diet on the hematology and serum biochemistry of zinc-intoxicated mallards. *J Wildl Dis*. 36(1):111–123.
204. Locke, L.N., G.E. Bagley, and H.D. Irby. 1966. Acid-fast intranuclear inclusion bodies in the kidneys of mallards fed lead shot. *Bull Wildl Dis Assoc*. 2:127–131.
205. Lorenzoni, A.G., and R.F. Wideman. 2008 Intratracheal administration of bacterial lipopolysaccharide elicits pulmonary hypertension in broilers with primed airways. *Poult Sci*. 87:645-654.
206. Lotti, M. 1992. The pathogenesis of organophosphate polyneuropathy. *Crit Rev Toxicol*. 21:465–487.
207. Ludke, J.L., and L.N. Locke. 1976. Duck deaths from accidental ingestion of anthelmintic. *Avian Dis*. 20:607–608.
208. Lu, J., G.F. Coombs, Jr., and J.C. Fleet. 1990. Time-course studies of pancreatic exocrine damage induced by excess dietary zinc in the chick. *J Nutr*. 120:389–397.
209. Marceau-Day, M.L. 1989. A study on the toxicity of *Sesbania drummondii* in chickens and rats. *Diss Abstr Int B*. 49:3045.
210. Mathis, G.F. 1993. Toxicity and acquisition of immunity to coccidia in turkeys medicated with anticoccidials. *J Appl Poult Res*. 2:239–244.
211. Mayeda, B. 1968. The toxic effects in turkey poults of a quaternary ammonium compound in drinking water at 150 and 200 ppm. *Avian Dis*. 12:67–71.
212. Mazliah, J., S. Barron, E. Bental, and I. Reznik. 1989. The effect of chronic lead intoxication in mature chickens. *Avian Dis*. 33: 566–570.
213. McCune, E.L., J.E. Savage, and B.L. O'Dell. 1962. Hydropericardium and ascites in chicks fed a chlorinated hydrocarbon. *Poult Sci*. 41:295–299.
214. McDougald, L.R. 1990. Coccidiostat toxicities. Proc *Natl Meet Poult Health Condemn*. 25:88–93.
215. McNab, J.M., and R.R. Smithard. 1992. Barley β-glucan: An antinutritional factor in poultry feeding. *Nutr Res Rev*. 5:45–60.
216. Meteyer, C.U., R.R. Dubielzig, F.J. Dein, L.A. Baeten, M.K. Moore, J.R. Jehl, and K. Wesenberg. 1997. Sodium toxicity and pathology associated with exposure of waterfowl to hypersaline playa lakes of southeast New Mexico. *J Vet Diagn Invest*. 9(3):269–280.
217. Mirsalimi, S.M., and R.J. Julian. 1993. Saline drinking water in broiler and Leghorn chicks and the effect in broilers of increasing levels and age at time of exposure. *Can Vet J*. 34:413–417.
218. Mirsalimi, S.M., and R.J. Julian. 1993. Effect of excess sodium bicarbonate on the blood volume and erythrocyte deformability of broiler chickens. *Avian Pathol*. 22:495–507.
219. Mirsalimi, S.M., F.S. Qureshi, R.J. Julian, and P.J. O'Brien. 1990. Myocardial biochemical changes in furazolidone-induced cardiomyopathy of turkeys. *J Comp Pathol*. 102:139–147.
220. Mirsalimi, S.M., P.J. O'Brien, and R.J. Julian. 1992. Changes in erythrocyte deformability in NaCl-induced right-sided cardiac failure in broiler chickens. *Am J Vet Res*. 53:2359–2363.
221. Mirsalimi, S.M., P.J. O'Brien, and R.J. Julian. 1993. Blood volume increase in salt-induced pulmonary hypertension, heart failure and ascites in broiler and White Leghorn chickens. *Can J Vet Res*. 57:110–113.
222. Miyazaki, S., and Y. Umemura. 1987. Effects of histamine antagonists, an anticholinergic agent and antacid, on gizzard erosions in broiler chicks. *Br Poult Sci*. 28:39–45.
223. Mohammed, F.K., Y.M. Al-Badrany, and M.M. Al-Jobory. 2008. Acute toxicity and cholinesterase inhibition in chicks dosed orally with organophosphate insecticides. *Arh Hig Toksikol*. 59:145-151.
224. Mohanty, G.C., and J.L. West. 1969. Pathologic features of experimental sodium chloride poisoning in chicks. *Avian Dis*. 13:762–773.
225. Mora, M.A., D.W. Anderson, and M.E. Mount. 1987. Seasonal variation of body condition and organochlorines in wild ducks from California and Mexico. *J Wildl Manage*. 51:132–141.

226. Morrissey, R.L., R.M. Cohn, R.N. Empson, H.L. Greene, O.D. Taunton, and Z.Z. Ziporin. 1977. Relative toxicity and metabolic effects of cholecalciferol and 25-hydroxycholecalciferol in chicks. *J Nutr*. 107:1027–1034.
227. Moslehuddin, A.B.M., Y.D. Hang, and G.S. Stoewsand. 1987. Evaluation of the toxicity of processed *Lathyrus sativus* seeds in chicks. *Nutr Rep Int*. 36:851–855.
228. Munger, L.L., J.J. Su, and H.J. Barnes. 1993. Coumafuryl (Fumarin) toxicity in chicks. *Avian Dis*. 37:622–624.
229. Nelson, H.A., R.A. Decker, and D.L. Osheim. 1976. Poisoning in zoo animals with 4-aminopyridine. *Vet Toxicol*. 18:125–126.
230. Neufeld, J. 1992. Salinomycin toxicosis of turkeys: Serum chemistry as an aid to early diagnosis. *Can Vet J*. 33:677.
231. Niemann, K.W. 1928. Report of an outbreak of poisoning in the domesticated fowl, due to death camas. *J Am Vet Med Assoc*. 73:627–630.
232. Norton, J., M. Evans, and J. Connor. 1987. Timber treatment and poultry litter. *Queensl Agric J*. 113:105–107.
233. Nwokolo, E., and L.O.C. Ohale. 1986. Growth and anatomical characteristics of pullet chicks fed diets contaminated with crude petroleum. *Bull Environ Contam Toxicol*. 37:441–447.
234. Ochiai, K., K. Jin, C. Itakura, M. Goryo, K. Yamashita, N. Mizuno, T. Fujinaga, and T. Tsuzuki. 1992. Pathological study of lead poisoning in whooper swans (*Cygnus cygnus*) in Japan. *Avian Dis*. 36:313–323.
235. Ochiai, K., T. Kimura, K. Uematsu, T. Umemura, and C. Itakura. 1999. Lead poisoining in wild waterfowl in Japan. *J Wildl Dis*. 35(4):766-769.
236. Ohlendorf, H.M., A.W. Kilness, J.L. Simmons, R.K. Stroud, D.J. Hoffman, and J.F. Moore. 1988. Selenium toxicosis in wild aquatic birds. *J Toxicol Environ Health*. 24:67–92.
237. Okoye, J.O.A., C.A. Enunwaonye, A.U. Okorie, and F.O.I. Anugwa. 1987. Pathological effects of feeding roasted castor bean meal (*Ricinus communis*) to chicks. *Avian Pathol*. 16: 283–290.
238. Ologhobo, A.D., D.F. Apata, A. Oyejide, and O. Akinpelu. 1993. Toxicity of raw lima beans (*Phaseolus lunatus* L.) and lima bean fractions for growing chicks. *Br Poult Sci*. 34: 505–522.
239. Ologhobo, A.D., D.F. Apata, and A. Oyejide. 1993. Utilization of raw jackbean (*Canavalia ensiformis*) and jackbean fractions in diets for broiler chicks. *Br Poult Sci*. 34:323–337.
240. Omidi, A., A.T. Razavizadeh, A.R. Movassaghi, and M.R. Aslani. 2011. Experimental oleander (*Nerium oleander*) intoxication in broiler chickens (*Gallus gallus*). *Hum Exp Toxicol*. 31(8):853-8.
241. Onderka, D.K., and R. Bhatnagar. 1982. Ultrastructural changes of sodium chloride-induced cardiomyopathy in turkey poults. *Avian Dis*. 26:835–841.
242. Ortiz, L.T., C. Centeno, and J. Trevino. 1993. Tannins in fababean seeds: Effects on the digestion of protein and amino acids in growing chicks. *Anim Feed Sci Tech*. 41:271–278.
243. Osweiler, G.D., T.L. Carson, W.B. Buck, and G.A. Van Gelder 1985. *Clinical and Diagnostic Veterinary Toxicology*. Kendall/ Hunt Publishing Co., Dubuque, Iowa.
244. Oyetunde, O.O.F., R.G. Thomson, and H.C. Carlson. 1978. Aerosol exposure of ammonia, dust and *Escherichia coli* in broiler chickens. *Can Vet J*. 19:187–193.
245. Page, R.K. 1975. Teratogenic activity of arasan fed to broiler breeder hens. *Avian Dis*. 19:463–72.
246. Page, R.K., S. Vezey, O.W. Charles, and T. Hollifield. 1977. Effects on feed consumption and egg production of coffee bean seed (*Cassia obtusifolia*) fed to White Leghorn hens. *Avian Dis*. 21:90–96.
247. Page, R.K., O.J. Fletcher, S. Vezey, P. Bush, and N. Booth. 1978. Effects of continuous feeding of toxaphene to white leghorn layers. *Avian Pathol*. 7:289–294.
248. Page, R.K., O.J. Fletcher, and P. Bush. 1979. Calcium toxicosis in broiler chicks. *Avian Dis*. 23:1055–1059.
249. Panigrahi, S., J. Rickard, G.M. O'Brien, and C. Gay. 1992. Effects of different rates of drying cassava root on its toxicity to broiler chicks. *Br Poult Sci*. 33:1025–1042.
250. Panigrahy, B., L.C. Grumbles, and C.F. Hall. 1979. Insecticide poisoning in peafowls and lead poisoning in a cockatoo. *Avian Dis*. 23:760–762.
251. Peckham, M.C. 1982. Poisons and toxins. In: *Diseases of Poultry*, 8th ed. M.S. Hofstad, H.J. Barnes, B.W. Calnek, W.M. Reid, and H.W. Yoder, Jr. eds. Iowa State University Press, Ames, Iowa. 783–818.
252. Pedersen, C.A., R.T. Sterner, and M.J. Goodall. 2000. Strychnine alkaloid and avian reproduction: effects occur at lower dietary concentrations with mallard ducks than with bobwhite quail. *Arch Environ Contam Toxicol*. 38(4):530–539.
253. Peeters, N., N. Viaene, and L. Devriese. 1977. Poisoning in pigeons after administration of vitamin B6 (pyridoxine) [abst no. 700). *Poult Abstr*. 4:108.
254. Perelman, B., and E.S. Kuttin. 1988. Parsley-induced photosensitivity in ostriches and ducks. *Avian Pathol*. 17:183–192.
255. Perelman, B., J.M. Abarbanel, A. Gur-Lavie, Y. Meller, and T. Elad. 1986. Clinical and pathological changes caused by the interaction of lasalocid and chloramphenicol in broiler chickens. *Avian Pathol*. 15:279–288.
256. Perelman, B., M. Pirak, and B. Smith. 1993. Effects of the accidental feeding of lasalocid sodium to broiler-breeder chickens. *Vet Rec*. 132:271–273.
257. Perez, L., I. Fernandez-Figares, R. Nieto, J.F. Aguilera, and C. Prieto. 1993. Amino acid ileal digestibility of some grain legume seeds in growing chickens. *Anim Prod* 56:261–267.
258. Pescatore, A.J., and J.M. Harter-Dennis. 1989. Effects of ferrous sulfate consumption on the performance of broiler chicks. *Poult Sci*. 68:1063–1067.
259. Philbey, A.W. 1991. Skeletal myopathy induced by monensin in adult turkeys. *Aust Vet J*. 68:250–251.
260. Phillips, R.A., F.S. Van Sambeek, and R.K. Page. 1995. Acute sulfur toxicity in broiler chicks. *Proc West Poult Dis Conf*. 44:1.
261. Pietsch, W., and E. Ruffle. 1986. Zur toxizität des monensins und zu problemen seines einsatzes im broilerfutter. *Monatsh Vet*. 41:851–854.
262. Poli, A., and G. Renzoni. 1983. Chick oedema disease in fowls naturally contaminated with 2,3,7,8-tetrachlorodibenzyl-p-dioxin (TCDD) [abst no. 2234). *Poult Abstr*. 10:273.
263. Poppenga, R.H., A.F. Zeigler, P.L. Habecker, D.L. Singletary, M.K. Walter, and P.G. Miller. Zinc phosphide intoxication of wild turkeys (*Meleagris gallopavo*). *J Wildl Dis*. 41:218–223.
264. Potter, L.M., J.P. Blake, M.E. Blair, B.A. Bliss, and D.M. Denbow. 1986. Salinomycin toxicity in turkeys. *Poult Sci*. 65: 1955–1959.
265. Prescott, C.A., B.N. Wilkie, B. Hunter, and R.J. Julian. 1982. Influence of a purified grade of pentachlorophenol on the immune response of chickens. *Am J Vet Res*. 43:481–487.

266. Pritzl, M.C., Y.H. Lie, E.W. Kienholz, and C.E. Whiteman. 1974. The effect of dietary cadmium on development of young chickens. *Poult Sci*. 53:2026–2029.
267. Proudfoot, F.G., and W.F. DeWitt. 1976. The effect of the pellet binder "Lignosol FG" on the chickens digestive system and general performance. *Poult Sci*. 55:629–631.
268. Puls, R. 1994. *Mineral Levels in Animal Health: Diagnostic Data*, 2nd ed. Sherpa International, Clearbrook, British Columbia. 354.
269. Puls, R. 1994. *Mineral Levels in Animal Health: Bibliographies*, 2nd ed. Sherpa International: Clearbrook, British Columbia. 26–196.
270. Radi, Z.A, D.L. Miller, and L.J. Thompson. 2003. Ethylene glycol toxicosis in chickens. *Vet Hum Toxicol*. 45:36–37.
271. Raharjo, Y.C., P.R. Checke, and G.H. Arscott. 1988. Effects of dietary butylated hydroxyanisole and cysteine on toxicity of *Lathyrus odoratus* to broiler and Japanese quail chicks. *Poult Sci*. 67:153–155.
272. Rasul, A.R., and J. Howell. 1974. The toxicity of some dithiocarbamate compounds in young and adult domestic fowl. *Toxicol Appl Pharmicol*. 30:63–78.
273. Ratanasethkul, C., C. Riddell, R.E. Salmon, and J.B. O'Niel. 1976. Pathological changes in chickens, ducks and turkeys fed high levels of rapeseed oil. *Can J Comp Med*. 40:360–369.
274. Ratzkowski, C., N. Fine, and S. Edelstein. 1982. Metabolism of cholecalciferol in vitamin D intoxicated chicks. *Isr J Med Sci*. 18:695–700.
275. Reece, R.L. 1988. Review of adverse effects of chemotherapeutic agents in poultry. *World Poult Sci J*. 44:193–216.
276. Reece, R.L., D.A. Barr, W.M. Forsyth, and P.C. Scott. 1985. Investigations of toxicity episodes involving chemotherapeutic agents in Victorian poultry and pigeons. *Avian Dis*. 29:1239–1251.
277. Reece, R.L., D.B. Dickson, and P.J. Burrowes. 1986. Zinc toxicity (new wire disease) in aviary birds. *Aust Vet J*. 63:199.
278. Ressler, C. 1962. Isolation and identification from common vetch of the neurotoxin B-cyano-l-alanine, a possible factor in neurolathyrism. *J Biol Chem*. 237:733–735.
279. Riddell, C. 1984. Toxicity of dimetridazole in waterfowl. *Avian Dis*. 28:974–977.
280. Riddell, C. 1987. *Avian Histopathology*. American Association of Avian Pathologists, Kennett Square, Pennsylvania.
281. Riddell, C., S.W. Nielsen, and E.J. Kersting. 1967. Ethylene glycol poisoning in poultry. *J Am Vet Med Assoc*. 150:1531–1535.
282. Roberson, E.L. 1988. Antinematodal Drugs, Chapter. 55. Anticestodal and Antitrematodal Drugs, Chapter. 56. In: *Veterinary Pharmacology and Therapeutics*, 6th ed., N.H. Booth and L.E. McDonald, eds. Iowa State University Press, Ames, Iowa. 882–999.
283. Rossi, A.F., R.D. Miles, B.L. Damron, and L.K. Flunker. 1993. Effects of dietary boron supplementation on broilers. *Poult Sci*. 72:2124–2130.
284. Rothmaier, D.A., and M. Kirchgessner. 1994. White lupins (*Lupinus albus*, L.) as a replacement for soybean meal in diets for fattening chickens. *Arch Gefluegelkd*. 58:111–114.
285. Rotter, R.G., R.R. Marquardt, and C.G. Campbell. 1991. The nutritional value of low lathyrogenic lathyrus (*Lathyrus sativus*) for growing chicks. *Br Poult Sci*. 32:1055–1067.
286. Rubio, L.A., A. Brenes, and M. Castano. 1990. The utilization of raw and autoclaved fababeans (*Vicia faba* L., var. *minor*) and fababean fractions in diets for growing broiler chickens. *Br J Nutr*. 63:419–430.
287. Sewalk, C.J., G.L. Brewer, and D.J. Hoffman. 2001. Effects of diquat, an aquatic herbicide, on the development of mallard embryos. *J Toxicol Environ Health A*. 62(1):33–45.
288. Sander, J.E., S.I. Savage, and G.N. Rowland. 1998. Sodium sesquicarbonate toxicity in broiler chickens. *Avian Dis*. 42(1):215–218.
289. Sander, J.E., J.L. Wilson, and G.L. Van Wicklen. 1995. Effect of formaldehyde exposure in the hatcher and of ventilation in confinement facilities on broiler performance. *Avian Dis*. 39:420–424.
290. Sander, J.E., J.L. Wilson, G.N. Rowland, and P.J. Middendorf. 1995. Formaldehyde vaporization in the hatcher and the effect on tracheal epithelium of the chick. *Avian Dis*. 39:152–157.
291. Sanderson, G.C., and F.C. Bellrose. 1986. A Review of the Problem of Lead Poisoning in Waterfowl. *Illinois Natural History Survey*, *2nd ed*. Champaign, Illinois.
292. Sawant, S.G., P.S. Terse, and R.R. Dalvi. 1990. Toxicity of dietary monensin in quail. *Avian Dis*. 34:571–574.
293. Scott, M.L. 1985. Gizzard erosion. *Anim Health Nutr Large Anim Vet*. September:22–29.
294. Selye, H., and H. Stone. 1943. Role of sodium chloride in production of nephrosclerosis by steroids. *Proc Soc Exp Biol Med*. 52:190–193.
295. Serafin, J.A. 1981. Factors influencing methionine toxicity in young bobwhite quail. *Poult Sci*. 60:204–214.
296. Shapiro, J.L., R.J. Julian, R.J. Hampson, R.G. Trenton, and I.H. Yo. 1988. An unusual necrotizing cholangiohepatitis in broiler chickens. *Can Vet J*. 29:636–639.
297. Sharpe, R.T., and C.T. Livesey. 2005. Surveillance of suspect animal toxicoses with potential for food safety implications in England and Wales between 1990 and 2002. *Vet Rec*. 157:465–469.
298. Shealy, A.L., and E.F. Thomas. 1928. Daubentonia seed poisoning of poultry. *Univ Fla Agr Exp Stn Bull*. 196.
299. Sherman, M., E. Ross, F.F. Sanchez, and M.T.Y. Chang. 1963. Chronic toxicity of dimethoate to hens. *J Econ Entomol*. 56:10–15.
300. Sherman, M., E. Ross, and M.T.Y. Chang. 1964. Acute and subacute toxicity of several organophosphorus insecticides to chicks. *Toxicol Appl Pharmacol*. 6:147–153.
301. Shivaprasad, H.L., and F. Galey. 1995. Diphacinone and zinc phosphide toxicity in a flock of peafowl. *Proc West Poult Dis Conf*. 44:116–117.
302. Shlosberg, A., M.N. Egyed, and A. Eilat. 1974. The comparative photosensitizing properties of *Ammi majus* and *Ammi visnaga* in goslings. *Avian Dis*. 18:544–550.
303. Shlosberg, A., D. Hadash, S. Tromperl, and M. Meroz. 1976. Poisoning in a flock of chickens after exposure to vapours of methyl bromide and chloropicrin. *Refu Vet*. 33:135–137.
304. Shlosberg, A., S. Held, and R. Bircz. 1978. Poisoning of palm doves with dibutyltin dilaurate. *J Am Vet Med Assoc*. 173:1183–1184.
305. Shlosberg, A., M.N. Egyed, and V. Hanji. 1980. Monocrotophos poisoning in geese caused by drift from crop spraying. *Refu Vet*. 37:42–44.
306. Shlosberg, A., M. Bellaiche, E. Berman, A. Ben David, N. Deeb, A. Cahaner. 1998. Comparative effects of added sodium chloride, ammonium chloride, or potassium bicarbonate in the

drinking water of broilers, and feed restriction, on the development of the ascites syndrome. *Poult Sci*. 77(9):1287–1296.
307. Shropshire, C.M., E. Stauber, and M. Arai. 1992. Evaluation of selected plants for acute toxicosis in budgerigars. *J Am Vet Med Assoc*. 200:936–939.
308. Siddique, M., M.Z. Khan, G. Muhammad, and N. Islam. 1996. Reversibility of furazolidone-induced changes in testes and secondary sex characters of White Leghorn cockerels. *Vet Hum Toxicol*. 38(6):413–417.
309. Sileo, L., W.N. Beyer, and R. Mateo. 2004. Pancreatitis in wild zinc-poisoned waterfowl. *Avian Pathol*. 32:655–660.
310. Siller, W.G. 1981. Renal pathology of the fowl: A review. *Avian Pathol*. 10:187–262.
311. Simpson, C.F., B.L. Damron, and R.H. Harms. 1971. Toxic myopathy of chicks fed *Cassia occidentalis* seeds. *Avian Dis*. 15:284–290.
312. Silva, T.C., S.L. Gorniak, S.C.S. Oloris, P.C. Raspantini, M. Haraguchi, and M.L.Z. Dagli. 2003. Effects of *Senna occidentalis* on chick bursa of Fabricius. *Avian Pathol*. 32:633–637.
313. Smalley, H.E. 1973. Toxicity and hazard of the herbicide, paraquat, in turkeys. *Poult Sci*. 52:1625–1628.
314. Snelgrove-Hobson, S.M., P.V. Rao, and M.K. Bhatnagar. 1988. Ultrastructural alterations in the kidneys of Pekin ducks fed methylmercury. *Can J Vet Res*. 52:89–98.
315. Sparling, D.W., D. Day, and P. Klein. 1999. Acute toxicity and sublethal effects of white phosphorus in mute swans, *Cygnus olor*. *Arch Environ Contam Toxicol*. 36(3):316–322.
316. Sparling, D.W., M. Gustafson, P. Klein, and N. Karouna-Renier. 1997. Toxicity of white phosphorus to waterfowl: acute exposure in mallards. *J Wildl Dis*. 33(2):187–197.
317. Spinato, M.T. 1991. Diazinon toxicity in Canada geese. *Can Vet J*. 32:627.
318. Stedman, T.M., N.H. Booth, P.B. Bush, R.K. Page, and D.D. Goetsch. 1980. Toxicity and bioaccumulation of pentachlorophenol in broiler chickens. *Poult Sci*. 59:1018–1026.
319. Stiles, G.W. 1940. Carbon monoxide poisoning of chicks and poults in poorly ventilated brooders. *Poult Sci*. 19:111–115.
320. Stoltz, J.H., F. Galey, and B. Johnson. 1992. Sudden death in ten psittacine birds associated with the operation of a self-cleaning oven. *Vet Hum Toxicol*. 34:420–421.
321. Stowe, C.M., D.M. Barnes, and T.D. Arendt. 1981. Ethylene glycol intoxication in ducks. *Avian Dis*. 25:538–541.
322. Sugahara, M., T. Hattori, and T. Nakajima. 1992. Effect of dietary gizzerosine from fish meal on mortality and growth of broiler chicks. *Anim Sci Tech (Jpn)*. 63:1234–1239.
323. Tacal, J.V., Jr., B. Daft, and J. McClaine. 1989. Case report: Oleander (*Nerium oleander*) poisoning in two geese. *Proc West Poult Dis Conf*. 38:167–168.
324. Tang, K.N., G.N. Rowland, and J.R. Veltmann. 1985. Vitamin A toxicity: Comparative changes in bone of the broiler and Leghorn chicks. *Avian Dis*. 29:416–429.
325. Teeter, R.G., S. Sarani, M.O. Smith, and C.A. Hibberd. 1986. Detoxification of high tannin sorghum grains. *Poult Sci*. 65:67–71.
326. Temperton, H. 1944. Effect of green and sprouted potatoes on laying pullets. *Vet Med*. 39:13–14.
327. Terzic, L., and M. Curcic. 1985. Toxic chemicals and poisoning of farm animals: Survey of cases examined toxicologically and chemically. *Vet Glasnik*. 39:965–973.
328. Thompson, L.J., K. Frazier, S. Stiver, and E. Styler. 2002. Multiple animal intoxications associated with Carolina Jessamine (*Gelsemium sempervirens*) ingestions. *Vet Hum Toxicol*. 44:272–273
329. Tiwary, A.K., B. Puschner, B.R. Charlton, and M.S. Filigenzi. 2005. Diagnosis of zinc phosphide poisoning in chickens using a new analytical approach. *Avian Dis*. 49:288–291.
330. Tuler, S.M., and J.M. Bowen. 1999. Chronic fenthion toxicity in laying hens. *Vet Hum Toxicol*. 41(5):302–307.
331. Ueda, H., and M. Ohshima. 1987. Effects of alfalfa saponin on chick performance and plasma cholesterol level. *Jpn J Zool Sci*. 58:583–590.
332. Umemura, T., H. Nakamura, M. Goryo, and C. Itakura. 1984. Ultrastructural changes of monensin-oleandomycin myopathy in broiler chicks. *Avian Pathol*. 13:743–751.
333. Van Vleet, J.F., G.D. Boon, and V.J. Ferrans. 1981. Induction of lesions of selenium-vitamin E deficiency in ducklings fed silver, copper, cobalt, tellurium, cadmium or zinc: Protection by selenium or vitamin E supplements. *Am J Vet Res*. 42:1206–1217.
334. Veenhuizen, M.F., and G.C. Shurson. 1992. Effects of sulfate in drinking water for livestock. *J Am Vet Med Assoc*. 201:487–492.
335. Veltmann, J.R., Jr., and L.S. Jensen. 1986. Vitamin A toxicosis in the chick and turkey poults. *Poult Sci*. 65:538–545.
336. Venugopalan, C.S., W. Flory, C.D. Hebert, and T. Tucker. 1984. Assessment of smooth muscle toxicity in *Cassia occidentalis* toxicosis. *Vet Hum Toxicol*. 26:300–302.
337. Wages, D.P., and M.D. Ficken. 1988. Skeletal muscle lesions in turkeys associated with the feeding of monensin. *Avian Dis*. 32:583–586.
338. Wagner, D.D., R.D. Furrow, and B.D. Bradley. 1983. Subchronic toxicity of monensin in broiler chickens. *Vet Pathol*. 20:353–359.
339. Wagstaff, D.J., J.R. McDowell, and H.J. Paulin. 1980. Heptachlor residue accumulation and depletion in broiler chickens. *Am J Vet Res*. 41:765–768.
340. Wallner-Pendleton, E., D.P. Froman, and O. Hedstrom. 1986. Identification of ferrous sulfate toxicity in a commercial broiler flock. *Avian Dis*. 30:430–432.
341. Wallner-Pendleton, E.A., O. Hedstrom, T. Savage, and H. Nakaue. 1989. Toxicity of dicalcium phosphate in the diet of turkey poults. *Avian Dis*. 33:375–376.
342. Waniska, R.D., L.F. Hugo, and L.W. Rooney. 1992. Practical methods to determine the presence of tannins in sorghum. *J Appl Poult Res*. 1:122–128.
343. Webb, D.M., and J.F. Van Vleet. 1991. Early clinical and morphologic alterations in the pathogenesis of furazolidone-induced toxicosis in ducklings. *Am J Vet Res*. 52:1531–1536.
344. Weiner, M.L., and B.S. Jortner. 1999. Organophosphate-induced delayed neurotoxicity of triarylphosphates. *Neurotoxicology*. 20(4):653–673.
345. Weisman, Y., E. Wax, and I. Bartov. 1994. Monensin toxicity in two breeds of laying hens. *Avian Pathol*. 23:575–578.
346. Wells, R.E., and R.F. Slocombe. 1982. Acute toxicosis of budgerigars (*Melopsittacus undulatus*) caused by pyrolysis products from heated polytetrafluoroethylene: Microscopic study. *Am J Vet Res*. 43:1243–1248.
347. Wescott, R.B., and H.C. McDougle. 1967. Ethylene oxide toxicosis in chickens. *J Am Vet Med Assoc*. 151:935–938.
348. Westlake, G.E., P.J. Bunyan, P.I. Stanley, and C.H. Walker. 1981. A study on the toxicity and the biochemical effects of ethylene dibromide in the Japanese quail. *Br Poult Sci*. 22:355–364.

349. Whitehead, C.J., D.N. Prashad, and R.O. Blackburn. 1988. Cadmium-induced changes in avian renal morphology. *Experientia*. 44:193–198.
350. Wideman, R.F., B.C. Ford, R.M. Leach, D.F. Wise, and W. Robey. 1993. Liquid methionine hydroxy analog (free acid) and DL methionine attenuate calcium-induced kidney damage in domestic fowl. *Poult Sci*. 72:1245–1258.
351. Wiernusz, C.J., and R.G. Teeter. 1991. Research note: Maxiban effects on heat-distressed broiler growth rate and feed efficiency. *Poult Sci*. 70:2207–2209.
352. Wight, P.A.L., W.A. Dewar, and C.L. Saunderson. 1986. Zinc toxicity in the fowl: Ultrastructural pathology and relationship to selenium, lead and copper. *Avian Pathol*. 15:23–38.
353. Wight, P.A.L., R.K. Scougall, D.W.F. Shannon, and J.W. Wells. 1987. Role of glucosinolates in the causation of liver haemorrhages in laying hens fed water-extracted or heat-treated rapeseed cakes. *Res Vet Sci*. 43:313–319.
354. Williams, M.C. 1979. Toxicological investigations on *Galenia pubescens*. *Weed Sci*. 27:506–508.
355. Williams, M.C., and R.J. Molyneux. 1987. Occurrence, concentration and toxicity of pyrrolizidine alkaloids in Crotalaria seeds. *Weed Sci*. 35:476–481.
356. Williams, M.C., and J.D. Olsen. 1992. Toxicity to chicks of combinations of miserotoxin, nitrate, selenium, and soluble oxalate. *Poisonous Plants: Proceedings of the Third International Symposium*, L.F. James, R.F. Keeler, E.M. Bailey, P.R. Cheeke, and M.P.J. Hegarty, eds. Iowa State University Press, Ames, Iowa. 143–147.
357. Williamson, J.H., F.R. Craig, C.W. Barber, and F.W. Cook. 1964. Some effects of feeding *Gelsemium sempervirens* (yellow jessamine) to young chickens and turkeys. *Avian Dis*. 8:183–190.
358. Wise, D.R., W.J. Hartley, and N.G. Fowler. 1974. The pathology of 3-nitro-4-hydroxy-phenylarsonic acid toxicity in turkeys. *Res Vet Sci*. 16:336–340.
359. Wishe, H.I. 1976. The effect of aminotriazole on the thyroid gland and development of the white leghorn chick. *Dis Abstr Int*. 37B:1066–1067.
360. Wisser, L.A., B.S. Heinrichs, and R.M. Leach. 1990. Effect of aluminum on performance and mineral metabolism in young chicks and laying hens. *J Nutr*. 120:493–498.
361. Wobeser, G., and B.R. Blakley. 1987. Strychnine poisoning of aquatic birds. *J Wildl Dis*. 23:341–343.
362. Woerpel, R.W., and W.J. Rosskopf. 1982. Heavy-metal intoxication in caged birds. *Compend Cont Ed* . 4(part 1):729–740 and 4(part 2):801–808.
363. Youssef, S.A., A.A. El-Sanousi, N.A. Afifi, and A.M. El Brawy. 1996. Effect of subclinical lead toxicity on the immune response of chickens to Newcastle disease virus vaccine. *Res Vet Sci*. 60(1):13–16.
364. Zaher, A.R., D.L. Miller, and L.J. Thompson. 2003. Ethylene glycol toxicosis in chickens. *Vet Human Toxicol*. 45:36–37.
365. Zajicek, J., O. Kypetova, and P. Matejka. 1985. Levamisole toxicity in breeding geese [abst no. 298). *Poult Abstr*. 1986 12:35.
366. Zeman, P. 1987. Systemic efficacy of ivermectin against *Dermanyssus gallinae* (De Geer, 1778) in fowls. *Vet Parasitol*. 23:141–146.

VII Other Diseases

Chapter 33 Emerging Diseases and Diseases of Complex or Unknown Etiology 1319

Chapter 33

Emerging Diseases and Diseases of Complex or Unknown Etiology

Introduction

Y.M. Saif

The emergence of new diseases and the re-emergence of recognized diseases are familiar events in the annals of poultry medicine. Some of these emerging diseases could have been present earlier but were not recognized because of low prevalence, mild signs and lesions, lack of diagnostic techniques, or misdiagnosis. In other situations, genetic changes in infectious agents could have rendered them more virulent or pathogenic. Similarly, genetic changes in the bird could have altered its susceptibility and resistance to disease. In addition, changes in environmental conditions or management could result in conditions that are favorable for an infectious agent to express pathogenic properties. Because of the global activities of the poultry industry, resulting in the continual movement of personnel, live birds, eggs, and poultry products across political borders, it is difficult to contain an emerging or re-emerging disease to a country or a continent. Hence, it is necessary to maintain a vigilant attitude toward poultry health and to sustain capable diagnostic facilities.

There are disease conditions that have multifactorial etiologies including combinations of infectious agents and, at times, infectious agents plus nutritional or environmental factors. Examples abound of seemingly harmless microbes that do not cause disease in healthy individuals but can express pathogenic potential following an insult, although it might be mild, to the host. *Escherichia coli* is a prime example of such a microbe, earning it a designation of a universal secondary infection in poultry. In the commercial poultry environment, viruses and bacteria, including some that have the potential of causing disease, are common. Live vaccine viruses, some of which are very mild pathogens, may also be present.

In addition, flocks that are immunocompromised because of infectious or noninfectious agents could present unusual disease syndromes, increased susceptibility to disease, or lack of responsiveness to vaccination. The combinations of etiologies of disease could result in additive or synergistic effects. The pathogenesis of the multiple etiologies is not completely understood, but some mechanisms have been suggested or shown to occur.

The upper respiratory tract and the gastrointestinal tract are bombarded continually by a variety of microbes; yet, disease is not necessarily a common event. Natural and acquired defense mechanisms function efficiently to eliminate infections, inhibit replication, or prevent colonization of tissues by microbes. The mucociliary apparatus of the respiratory tract is a highly efficient system for the elimination of microbes and particulate matter. Some viral infections result in the deciliation of parts of the respiratory tract and lysis of infected cells, resulting in accumulation of cellular products and debris. This creates an environment favorable for bacterial multiplication and attachment to cells, which are important events in the pathogenesis of bacterial infections. In the gastrointestinal tract, similar events initiated by viruses have been described, including villous atrophy and consequent increased bacterial replication and adherence to cells. It is common in respiratory and enteric diseases of poultry to encounter a variety of infectious agents. Because of the possible complex etiology of respiratory and enteric disease, it is important to understand the role of the different agents in the disease process. Such understanding should be helpful in designing logical control or prevention strategies.

This chapter was first introduced in the 10th edition of *Diseases of Poultry* with the realization that there will be continuous change in its content. Some of the diseases recognized as emerging at a point in time become either established entities or fail to have a sustained impact. In either case, the outcome will be the removal of these diseases from this chapter.

In this chapter, information is presented on the complexity of respiratory and enteric diseases. In addition, information is presented on two conditions: hypoglycemia-spiking mortality syndrome and proventriculitis/proventricular dilatation. The etiology of these conditions has not been definitely established, although possible infectious causes are speculated.

Diseases of Poultry, Thirteenth Edition. David E. Swayne.
© 2013 John Wiley & Sons, Inc. Published 2013 by John Wiley & Sons, Inc.

Multicausal Respiratory Diseases

John R. Glisson

Although much is known about the individual agents responsible for respiratory diseases in poultry, uncomplicated infections with single agents are the exception. Under commercial conditions, complicated infections involving multiple etiologies with viruses, mycoplasmas and other bacteria, immunosuppressive agents, and unfavorable environmental conditions are more commonly observed than simple infections. In addition, respiratory reactions induced by routine vaccination programs may themselves play a major role in the development of respiratory disease.

Interactions Among Respiratory Pathogens

Perhaps the best understood examples of multiple respiratory infections are those involving mycoplasmas; this subject has been reviewed previously (10, 32). Although uncomplicated *Mycoplasma gallisepticum* infections in turkeys ordinarily result in respiratory signs, sinusitis, and airsacculitis, simple infection with *M. gallisepticum* or *M. synoviae* in chickens often results in mild or even subclinical disease. Interactions with Newcastle disease (ND) virus or infectious bronchitis virus (IBV) are known to increase the severity of *M. gallisepticum* infection (3, 13, 16, 51, 60, 67, 74). Similar interactions also occur with *M. synoviae* (28, 29, 34, 37, 65, 71).

The virulence of respiratory viruses may influence the severity of mycoplasma infections. With *M. synoviae*, concurrent challenge with high-passage field and vaccine strains of IBV resulted in milder respiratory disease than did exposure to field strains (28), and chicken-passaged vaccine virus resulted in more severe airsacculitis than did the original vaccine when birds were concurrently challenged with *M. synoviae* (29).

The timing of exposure to infectious agents is important in the pathogenesis of complicated infections. Generally, respiratory virus and mycoplasma infection must occur concurrently or within a short period of time for synergism to occur (29, 37), but mycoplasma-free chickens had a milder clinical response to IBV challenge than did chickens that were chronically infected with *M. gallisepticum* (67).

Other infectious agents are also known to interact with *M. gallisepticum*. Synergistic effects between *Avibacterium paragallinarum* and *M. gallisepticum* are well known (4, 33, 39, 48); control of *M. gallisepticum* results in milder respiratory disease due to infectious coryza. Interactions are also known between *M. gallisepticum* and adenovirus (5), reovirus (31), and laryngotracheitis (9).

Three-way interactions between vaccine virus (Newcastle disease virus [NDV] and/or IBV), mycoplasma (*M. gallisepticum* or *M. synoviae*), and *Escherichia coli* resulted in more severe respiratory disease than any 2 alone. Combinations of any 2 of the agents resulted in milder disease than the 3-way combination, and challenge with only 1 of the individual agents resulted in very mild or no disease (46, 65). Chickens exposed to IBV and *M. gallisepticum* did not become susceptible to *E. coli* until 8 days post challenge (24).

Interactions with various agents have also been described for *M. meleagridis* in turkeys. Enhanced airsacculitis was observed when germ-free poults were challenged with *M. meleagridis* and *E. coli* (61). An interaction between *M. meleagridis* and *M. synoviae* has been noted for turkey sinusitis (56) but not for airsacculitis (57). Combination infections with *M. meleagridis* and *M. iowae* caused more severe airsacculitis than either agent alone (57). *M. gallinarum*, ordinarily considered to be nonpathogenic, induced airsacculitis in broilers when given in combination with ND/infectious bronchitis vaccine virus (36).

Pathogenicity is increased when infectious bronchitis is combined with *M. imitans* (20); *M. imitans* also shows a similar effect when combined with avian pneumovirus in turkeys (21).

Interactions between *E. coli* and other respiratory agents often occur in the absence of mycoplasma infection. Exposure to *E. coli* or IBV alone resulted in little or no clinical signs or mortality, but challenge with various strains of IBV along with *E. coli* resulted in significantly increased clinical signs and mortality (52, 63, 77). Such a combination challenge with *E. coli* provided a means of evaluating the protection induced by infectious bronchitis vaccine strains against various challenge strains (12, 52). However, Newcastle disease vaccination nonspecifically stimulated resistance against *E. coli* at 2–8 days post vaccination, as measured by the number of *E. coli* recovered from the spleen (30). Turkeys exposed to the LaSota strain of NDV had a decreased tracheal mucus transport rate and reduced tracheal clearance of *E. coli* (19). A highly significant positive correlation between the number of infectious agents encountered during primary exposure and the incidence of colibacillosis after *E. coli* challenge was demonstrated (54). Studies on interactions between *E. coli* and *Bordetella avium* in turkeys have shown that *B. avium*-infected turkeys had higher numbers of *E. coli* in their tracheas and less ability to clear *E. coli* from the tracheas and lungs than did birds free of *B. avium* (69, 70). *B. avium* also adversely affected vaccinal immunity of turkeys to *Pasteurella multocida* (59).

Other respiratory agents may also interact; for example, the pathogenicity of Newcastle disease was enhanced when occurring in combination with *Ornithobacterium rhinotracheale* (68).

Effects of Immunosuppressive Agents

Immunosuppressive agents, especially infectious bursal disease in chickens and hemorrhagic enteritis virus in turkeys, are well known to adversely affect susceptibility to respiratory infections. Challenge of chickens with infectious bursal disease

virus has been shown to adversely affect antibody response and resistance to ND (18, 22, 23, 27), infectious bronchitis (22, 53, 75), *M. synoviae*, (22), and *Aspergillus flavus* (50). "Intermediate" vaccine strains of infectious bursal disease virus were highly variable in their interference with development of ND antibodies following ND vaccination (42).

Specific pathogen free chickens infected with infectious bursal disease virus and *E. coli* and then challenged with various adenovirus strains developed respiratory signs and lesions, and those infected with infectious bursal disease virus and *E. coli* without adenovirus did not (14). Infectious bronchitis virus exacerbated the infectious bursal disease virus-induced suppression of opsonization by *E. coli* antibody in chickens (47). Control of infectious bursal disease in the field is an essential factor in controlling respiratory disease in broilers.

The association between signs and mortality of colibacillosis in turkeys and the presence of hemorrhagic enteritis lesions and viruses in the spleen led to the hypothesis that hemorrhagic enteritis infection often exacerbates colibacillosis (64). This association was subsequently proved in laboratory challenge studies (40). Inclusion of hemorrhagic enteritis virus along with *E. coli* challenge has been useful for the induction of colibacillosis in laboratory studies (49). Control of hemorrhagic enteritis is considered to be an essential factor in controlling colibacillosis in turkeys.

Although Marek's disease herpesvirus is well known as an immunosuppressive agent, its role in respiratory disease has not been extensively studied. However, chickens infected with Marek's disease virus did not respond as well serologically to *M. synoviae* as chickens that were not challenged (35). Marek's disease virus infection may also enhance the virulence of *Cryptosporidium baileyi* (1, 2).

Chicken infectious anemia virus is also recognized as an immunosuppressive agent that may be a risk factor in respiratory and other diseases (26) and may be involved with interfering with vaccinal Newcastle disease antibody production in the field (55).

Role of Environmental Factors

It is evident that environmental factors play a significant role in interacting with infectious agents in the production of respiratory disease in poultry, but there are relatively few published studies of such interactions. Environmental factors that have been studied include atmospheric ammonia, dust, and temperature. Chickens and turkeys continuously exposed to 20 ppm of ammonia showed gross or histologic signs of damage after 6 weeks of exposure, and exposed chickens were more sensitive to infection with NDV (7). Turkeys exposed to 10 or 40 ppm of ammonia had deterioration of their normal mucociliary apparatus, excessive mucus production, matted cilia, and deciliation in tracheal tissue (44), and exhibited impaired clearance of *E. coli* from air sac, liver, and lung (45). Chickens exposed to 70 or 100 ppm of ammonia for 4 days exhibited increased thickness of atrial walls and shrinking air capillaries in their lungs (6). Ammonia levels of 25 or 50 ppm resulted in reduced body weight, feed efficiency, larger lung size, and increased airsacculitis in chickens challenged with IBV (38).

Atmospheric dust also has been shown to have a detrimental effect on the response to respiratory infections. Atmospheric dust significantly increased the severity and incidence of air sac lesions in turkeys with high or low rates of infection with *M. meleagridis* (8). In a broiler house study, losses from colisepticemia generally peaked 1 week after coliform numbers peaked in dust samplings (11). More microscopic lesions in the bronchi were observed when chickens were kept at 27°C than at 16°C. It was postulated that this may have been due to mouth breathing rather than the higher dust levels in the air of the warmer rooms (58).

Hatchery fumigation of day-old chicks may damage the tracheal epithelium (15, 62), possibly increasing susceptibility to early respiratory disease.

Respiratory disease and airsacculitis condemnations are well known to increase during the winter months, but there have been few studies on the effects of temperature on susceptibility to respiratory disease. Chickens challenged with *M. synoviae* and IBV had more extensive air sac lesions when housed at temperatures of 7°C–10°C than when housed at 29°C–24°C or 31°C–32°C (76).

A common observation is that increasing down time between broiler flocks has a beneficial effect on reducing respiratory and other diseases. In a recent field study on the Delmarva Peninsula in the United States, larger flock sizes were associated with increased early respiratory disease, and increased down time decreased early respiratory disease (66).

Vaccination Reactions

Protection of chickens and turkeys against viral respiratory diseases depends upon the widespread use of live respiratory virus vaccines. The live respiratory virus vaccines that have been most widely used are ND vaccines and infectious bronchitis vaccines. Among the live ND vaccines, there are naturally occurring apathogenic strains such as VG/GA, Ulster, and QV4; naturally occurring mild respirotropic lentogenic strains such as B_1 and LaSota; and very limited use of mesogenic strains. Live IBV vaccines are typically chicken embryo-passaged field IBV isolates. Chicken-embryo passage is used to attenuate the virulence of virulent field IBV isolates. A single IBV isolate, for example, Massachusetts 41, may be available as a live vaccine at several different embryo passage levels (virulence attenuation levels).

All of the live respiratory viral vaccines replicate in the bird and cause some degree of cell damage. The clinical manifestation of this viral replication, and its resultant pathology, is called the vaccination reaction. The live respiratory virus vaccines are intended to induce an immune response while inducing only minimal pathology or a minimal vaccination reaction in a healthy bird in a good environment. A normal vaccination reaction for IBV or NDV should become clinically

apparent 3–5 days after vaccination and should persist for an additional 3–5 days. If the vaccination reaction appears clinically to be unusually severe or prolonged, it is often referred to as a rolling vaccination reaction, or, more simply, as a severe vaccination reaction.

Severe or prolonged vaccination reactions following the use of live ND or infectious bronchitis vaccines are a very common occurrence in the commercial poultry industry. Most typically, flocks that undergo a severe vaccination reaction develop respiratory colibacillosis. The pathogenesis of this complex disease interaction follows the same pattern described for the interaction of virulent wild respiratory viruses with *E. coli* (63, 77). Most poultry health specialists agree that respiratory disease that results from the interaction of viral respiratory vaccine viruses with *E. coli* is the most common respiratory disease of commercial poultry.

Several different sets of circumstances can culminate in a severe respiratory vaccination reaction, although regardless of the inciting factors, severe respiratory reactions typically culminate in the development of respiratory colibacillosis. Immunosuppression has been demonstrated to enhance the ability of pathogens to induce disease (18, 22). Likewise, immunosuppression can impede a bird's ability to limit replication of a respiratory virus vaccine, allowing a severe vaccination reaction. Several modified live virus vaccines containing infectious bronchitis virus interfere with the ability of the gland of Harder and head-associated lymphoid tissues to respond to antigenic stimulation (43). Short-term nonspecific immunity against *E. coli* induced by intravenous inoculation of inactivated bacteria or silver nitrate is suppressed by cold stress or by treating with corticosterone (41).

Vaccinating birds with respiratory virus vaccines whose respiratory tracts are contaminated with other pathogens can produce a severe vaccination reaction. The most noted examples are *M. gallisepticum* and *M. synoviae* (10). Birds contaminated with *B. avium* or *E. coli*, however, fit a similar pattern. Newly hatched chicks that have hatched in an environment heavily contaminated with *E. coli* may develop severe respiratory reactions when vaccinated at a young age with live ND or infectious bronchitis vaccines.

Some live ND, infectious bronchitis, and infectious laryngotracheitis vaccines may become more virulent if allowed to spread from bird to bird (17, 25, 29). This vaccine "back-passage" can occur in commercial poultry houses if only a portion of the birds are provided with an immunizing dose of the vaccine and the remaining birds in the house become infected by spread of vaccine virus. This type of vaccine reaction appears to be both prolonged in duration and increased in intensity.

Environmental factors can influence the intensity of a vaccination reaction. As discussed previously, ammonia and dust can interact with respiratory pathogens to enhance the severity of disease (38). This interaction is similar with respiratory vaccine viruses. Improper application of viral respiratory vaccines can enhance the severity of vaccination reactions. Spray application with a very fine spray can allow access of vaccine virus to the deep respiratory tissues and result in excessive viral replication in lungs and air sacs in addition to eliciting a stronger immune response (72). Aerosol vaccination also resulted in more severe airsacculitis after challenge with *M. synoviae* (73). Improper application of vaccines in the drinking water can prevent all birds in a house from receiving an immunizing dose of vaccine, thus providing an opportunity for spread of vaccine virus with a concomitant increase in virulence of the virus.

Because respiratory vaccine viruses of various virulence levels are available, it is important to use the proper vaccine for specific conditions. Typically, very young birds are vaccinated with highly attenuated vaccine viruses, and less attenuated vaccine viruses are used in older birds and in birds that have been previously immunized. Severe vaccination reactions can occur, for example, if chicks are vaccinated at the hatchery with a live ND or infectious bronchitis vaccine intended for use in older birds.

Acknowledgement

The author wishes to acknowledge Stanley H. Kleven, who authored this subchapter in the previous edition of *Diseases of Poultry*, for his substantial contribution to this subchapter.

Multicausal Enteric Diseases

Mary J. Pantin-Jackwood

Introduction

The intestinal tract is a highly complex system that has numerous functions and integrates with other body systems and their functions. The intestinal tract is one of the most important body organs because it provides the mechanism(s) by which the body can derive nutrition from its environment while simultaneously safeguarding the host.

The pathogenesis of enteric diseases is very complex. Combinations of, and interactions between, different viruses, bacteria, and other infectious agents and noninfectious factors may be necessary to elicit an enteric disease. Due to the complex nature of the microbial populations in the intestine it is very difficult to sort out the role of specific pathogens causing enteric disease (121). In addition, interactions between the intestinal tract and other body systems can affect the severity of the disease

and modulate the disease process. The observation that more than one infectious agent, noninfectious factor, and/or host factors may be involved in eliciting an enteric condition has prompted the use of the term multicausal or multifactorial disease.

Enteric diseases cause great economic losses to the poultry industry, mostly from depressed weight gains, impaired feed efficiency, and decreased flock uniformity. Enteric syndromes have been described both in young turkeys and chickens and have been attributed to a variety of causes. These diseases likely result from infection by a mixture of pathogenic agents coupled with or exacerbated by nutritional imbalances, poor management, environmental conditions, and stress (24, 31, 83). In addition, the age and immune status of the birds, and their genetic background, can also affect the clinical presentation of the disease. Consequently the spectrum and intensity of lesions associated with enteric diseases can vary from case to case. In turkeys, a multifactorial enteric disease of young poults, poult enteritis mortality syndrome (PEMS), has been thoroughly described in a previous edition of this textbook (8). Poult enteritis complex (PEC) (7) is a term commonly used that encompasses not only PEMS but several other infectious intestinal diseases of young turkeys including syndromes such as infectious enteritis of turkeys (22, 116), malabsorption syndrome (74, 75, 76, 77), stunting syndrome (2, 4), runting and stunting syndrome of turkeys (17, 54), poult enteritis syndrome (41, 42), and others (7). The most important clinical features associated with PEC include enteritis, growth depression (stunting), impaired feed utilization, and secondary nutritional deficiencies (7). Many other clinical signs might be present in turkey flocks affected by PEC and are well described by Barnes et al. (7). In the more severe forms of PEC, retarded development (runting), immune dysfunction, and mortality have been reported (7, 81). Gross and microscopic lesions of enteritis are present in all forms but tend to be nonspecific.

Similar enteric syndromes have also been described in young broilers since the late 1970s and given several names including malabsorption syndrome (MAS) (48, 67, 101, 103, 113), runting and stunting syndrome (RSS) (6, 28, 56, 60, 65, 91, 96), infectious stunting syndrome (1, 13, 26, 56, 83, 92, 114), pale bird syndrome (16, 30, 49, 62, 112), and others. Among the most common clinical signs reported are poor growth (runting and stunting), diarrhea, abnormal feathering ("helicopter" wing feathers), pigment loss, proventriculitis, bone abnormalities, lymphoid atrophy, and increased mortality (13, 47, 121). Characteristic microscopic lesions of the stunted chickens include villous atrophy of the small intestine and a distention of crypts of Lieberkühn (cystic enteropathy/enteritis) (28, 44, 64, 65, 83, 91, 96, 101, 103, 121, 123).

Etiology

Rarely is a single agent the cause of an enteric disease. Although an agent may be identified as the primary cause, other agents and factors usually contribute to the pathogenic process of the diseased intestine. Similarly, when an agent is isolated and introduced into a susceptible host under experimental conditions, the resulting disease may not be representative of the same infection caused under field conditions. Several enteric viruses have been identified and are individually reviewed in Chapter 12 of this textbook. Nonviral causes of enteric disease, including bacterial and protozoal infections, toxins, parasites, and others, are also discussed in other chapters of this textbook.

Enteric viruses are commonly the cause of most primary insults to the intestinal tract of young birds, providing other agents, especially bacteria, the means to replicate and cause further damage to the intestine (121). Many of these enteric viruses have also been detected in the gut of clinically healthy chickens and turkeys (12, 23, 70, 73, 99, 111), underlining the complexity of enteric diseases. The role that each of the enteric viruses play in enteritis and stunting remains unclear, and the prevalence and distribution of enteric viruses in commercial turkeys and chickens is not well known, because suitable detection methods are not available for all viruses.

In determining the etiology of enteric diseases, intestinal samples or contents have been examined for the presence of viruses by several methods including culturing, electron microscopy, and molecular techniques. Many viruses, alone or in combination, have been associated with poult enteritis in turkeys including turkey coronavirus (TCoV) (7, 20, 32, 39, 53, 78), turkey astrovirus (TAstV-1 and 2) (14, 23, 33, 40, 42, 46, 58, 70, 72, 73, 84, 89), avian nephritis virus (ANV) (14, 40, 70, 72, 73), reovirus (35, 40, 70, 72), rotaviruses (5, 40, 42, 55, 57, 66, 70, 86, 89, 108, 115, 119), adenoviruses (36, 94, 106, 115), parvoviruses (11, 68, 124), picornavirus (12, 18), torovirus (1, 87), and unidentified small round viruses (SRVs) (89, 115, 120). Astroviruses with rotaviruses or rotavirus-like viruses (RVLV) have been the most frequently identified combination in both diseased and healthy turkey flocks (14, 40, 72, 85, 86, 88, 119). More recently, viral metagenomics, a nonbiased, comprehensive approach to virus discovery that does not require virus cultivation, was used to characterize RNA viruses present in the gut of turkeys experiencing enteric disease, and helped identify several new viruses including members of the Picornavirales, Caliciviridae, and Picobirnavirales (18).

In chickens, several enteric viruses, alone or in combination, also have been detected in cases of enteric disease. They include ANV (14, 19, 37, 38, 52, 70, 73), chicken astrovirus (CAstV) (9, 14, 44, 70, 91, 98, 99, 110), enterovirus (28), infectious bronchitis virus (IBV) (60), reovirus (6, 21, 29, 60, 70), rotavirus (55, 65, 66, 70), parvovirus (11, 69, 124), and unidentified entero-like viruses (ELVs) (56). As expected, not only viruses have been found in samples from cases of enteric diseases. In one survey, several pathogens including rotavirus, SRVs, reovirus, adenovirus, *Salmonella, Escherichia coli, Enterococcus, and Eimeria spp*. were detected, either alone or in different combinations, in samples from cases of poult enteritis (40).

Enteritis is readily reproduced by inoculating young birds with fecal material or intestinal homogenates, or by placing them in contact with litter from affected flocks (41, 83, 91, 93, 96, 101, 121, 123). Filtrates from intestinal homogenates can induce significant reductions in weight, signifying a viral etiology, but not to the extent induced by unfiltered homogenates (41). This suggests that the presence of infectious agents other than viruses also play a role in the severity of the disease. Experimental attempts to reproduce enteric disease with agents isolated from cases of enteritis have produced mixed results. Most of these agents by themselves produce transient growth depression, but not clinical disease consistent with that seen in the field. For example, in a study attempting to reproduce PEMS, infections with a turkey coronavirus and an enteropathogenic *E. coli* resulted in high mortality as well as poor weight gain in doubly infected poults, but neither the *E. coli* nor the turkey coronavirus alone produced mortality that differed from the uninfected control poults (34). However, other experimental infections in young turkeys have shown that at least some strains of turkey coronavirus are capable of producing significant depression in weight gain with severe clinical disease, including mortality, in the apparent absence of other infections (27). In a study trying to reproduce RSS by inoculating chickens with several viruses and bacteria isolated from RSS cases in broilers, and given alone or in combination, the disease was only partially reproduced (60).

Several other studies have been conducted attempting to reproduce enteric disease in turkeys and chickens with isolated viral agents. Young turkeys inoculated with ToCV, astroviruses, rotaviruses, reoviruses, enterovirus, turkey torovirus, and SRVs, alone or in combinations, have shown reduced weight gain and enteritis, but not all of the clinical signs or the severity seen in field cases (19, 39, 45, 71, 80, 87, 89, 104, 105, 107, 117, 119). Similarly, reoviruses, rotaviruses, astroviruses, and ELVs, either alone or in combination, partially induced the clinical signs found in MAS and RSS cases in chickens (19, 21, 44, 48, 56, 59, 60, 95, 97, 101, 102, 105, 118).

Pathogenesis

The principal mechanisms by which infectious agents cause enteric disease have been reviewed by Moon (61). Agents that produce diarrhea are not restricted to only one mechanism, but often a combination of mechanisms. The first mechanism is hypermotility and is defined as the increase in intensity, frequency, or rate of intestinal peristalsis that leads to the accelerated transit of ingesta or intestinal contents through the intestines. An alteration in intestinal permeability is another mechanism of diarrhea. When alterations occur in intestinal permeability that allows the net secretion to exceed absorption, the result is increased fluid within the lumen of the intestinal tract, resulting in diarrhea. Hypersecretion is a third mechanism defined as the net intestinal efflux of fluid and electrolytes into the intestinal lumen that occurs despite changes in permeability, absorptive capacity, or osmotic gradients. The mature intestinal epithelial cells, which line the distal portion of the villi, are responsible for the absorptive capacity of the intestine, whereas the immature crypt cells are responsible for secretion. Therefore, alterations in the balance of these cells can contribute to diarrhea. For example, loss of mature cells alters the absorptive capacity and often stimulates the formation of new immature cells to replace the lost cells, thereby altering the ratio of mature to immature cells in favor of the secreting immature cells. The net result is secretory diarrhea. Certain bacterial toxins stimulate secretion of the crypt cells beyond the absorptive capacity of the mature intestinal epithelial cells that result in diarrhea. The mechanism by which bacterial toxins produce secretory diarrhea has also been observed with some enteric viruses (25). Malabsorption is the fourth mechanism identified to cause enteric disease (61). Malabsorption is the process by which the absorptive capacity of the intestines is altered. This may be due to impaired absorptive capacity such as loss of mature epithelial cells. However, malabsorption is often a sequela of maldigestion because the undigested feedstuffs cannot be absorbed (even though the absorptive capacity of the intestines is not impaired). In cases of malabsorption/maldigestion, nutrients within the intestinal lumen may contribute to the diarrhea by creating an osmotic effect.

The involvement of immune cells, and/or their products, in inducing diarrhea and enteric disease is well established. It has been reported that cytokines such as interleukins IL-1 and IL-3 contribute to hypersecretion in chickens (15). Various other cytokines and biochemical mediators have been implicated in inflammatory processes leading to enteric disease and diarrhea (90). A neuroimmunophysiologic model has been suggested for all forms of infectious diarrhea (79). In this model, cytokines liberated from intestinal epithelial cells affect various other cells including immune cells, nerve cells, intestinal mesenchymal cells, etc. The end results include crypt hyperplasia, hypersecretion, malabsorption, and alterations in permeability, with the final sequela being diarrhea. It was also pointed out that this is a host defense mechanism, and although there may be points to intervene and counter the process, one must be careful not to further jeopardize the host by overzealous intervention strategies. There has been increased evidence supporting the role of the enteric nervous system (ENS) in inducing diarrhea during bacterial and viral infections (43, 50, 51).

Several studies have demonstrated the role of the immune response in eliciting enteric disease in broiler chickens and poults (3, 82, 100, 113, 123). There is evidence to indicate that a variety of immune cells, including numerous types of T cells and heterophils, are involved (100, 123). Additionally, the ability to genetically select broiler chickens that are less susceptible to MAS may be closely linked to the genetic expression of immune cells and their products (100, 122).

Barnes and Guy (8) have described the basic pathogenesis involved in PEC in turkeys as follows: alteration of the intestinal mucosa, generally by one or more viruses infecting

enterocytes, inflammation, and proliferation of secondary agents, usually bacteria. Diarrhea is believed to be primarily osmotic because of maldigestion and malabsorption, but may also have a secretory component. Similar mechanisms have been suggested for MAS in chickens (101). Specific mechanisms by which enteric viruses cause diarrhea are discussed in Chapter 12. For example, it appears that astrovirus infection induces changes in expression of constituent enzymes of the brush border, specifically maltase, with a significant decrease in intestinal D-xylose absorption, resulting in disaccharide maldigestion, malabsorption, and subsequently osmotic diarrhea, even though viral infection causes only mild microscopic lesions (10, 45, 84, 109). Recent studies suggest astrovirus infection induces a malabsorption, osmotic diarrhea, through redistribution of specific brush border enzymes and transporters resulting from dysregulation of the actin cytoskeleton (63).

Intervention Strategies

Continued efforts in characterizing the various factors will be needed to identify strategies for the control of enteric diseases in poultry. Control of enteric diseases requires an integrated approach, incorporating both drug and management components (7). Good management practices can help reduce or eliminate exposure of young birds to enteric viruses, but the ubiquity and genetic variability of the many enteric viruses make it difficult or impractical to keep commercial flocks free of infection. Other factors including nutrition, stress reduction, and control of other enteric pathogens (bacteria, protozoa, parasites) are also important in preventing or mitigating disease. Future strategies may rely on drugs and biologics that modulate the immune and neurologic component of the disease in addition to those treatment regimens directed toward specific pathogens. Currently, there are no effective commercial vaccines available for control of most enteric diseases.

Acknowledgement

The author wishes to acknowledge Donald L. Reynolds, who authored this subchapter in the previous edition of *Diseases of Poultry*, for his substantial contribution to this subchapter.

Hypoglycemia-Spiking Mortality Syndrome of Broiler Chickens

James F. Davis

Introduction and History

Hypoglycemia-spiking mortality syndrome (HSMS) is a disease of uncertain, but probable, infectious etiology, characterized by low morbidity and abrupt onset of high mortality (greater than 0.5%) for at least 3 consecutive days with concurrent hypoglycemia in clinically affected birds. Seven-day-old to 14-day-old broiler chicks are usually affected (1); however, it is also frequently diagnosed in 14- to 21-day-old chicks, and the disease has been identified in commercial broilers as old as 42 days (4). Clinical signs include fine head tremors, apparent blindness, ataxia, and coma. Recovery often occurs spontaneously, but rickets and runting-stunting frequently develop in survivors.

Hypoglycemia-spiking mortality syndrome was first recognized in broiler flocks on the Delmarva Peninsula in the United States, in 1986 (3). The disease was subsequently described in 1991 (1) from 41 flocks with naturally occurring disease and 3 flocks with experimental disease. Occurrence of the disease has declined in the Delmarva area but subsequently has increased in the southeastern United States and other areas of the world.

Because the etiology is unknown and there is no specific identifying characteristic of the disease other than severe hypoglycemia, which makes only a clinical definition possible, and because young broilers experience infections with a variety of agents, the relationships among various outbreaks of HSMS remain uncertain. Two clinical forms of the disease have been identified. Type A, which was initially described, is more severe but of shorter duration than type B, a milder form occurring over a longer period, which was identified later (3). This suggests that either HSMS is 1 disease caused by a specific etiologic agent that occurs in different forms (possibly because of additional modifying factors) or that similar clinical diseases result from different causative agents.

Incidence and Distribution

Hypoglycemia-spiking mortality syndrome has been reported in Canada, Colombia, Europe, Great Britain, Guyana, Jamaica, Malaysia, Puerto Rico, South Africa, Thailand, Trinidad, and the United States. Although broiler chicks are most commonly affected, broiler breeder replacements and leghorns are also susceptible.

Etiology

The etiologic agent(s) of HSMS has not been identified conclusively. A serotype-12 avian adenovirus isolated from affected

flocks was pathogenic for embryos and chicks but did not cause HSMS (15). Inclusion body hepatitis caused by an adenovirus was identified in a broiler flock with excess mortality and hypoglycemia (12). However, evidence for adenovirus infection in other flocks with HSMS has not been found (1, 4, 7, 8, 9).

Oral inoculations of unprocessed fecal-intestinal-saline homogenates, fecal-saline homogenates passed through 0.45-microns filters, or crude brain-phosphate-buffered saline homogenates from affected chicks have been used to reproduce the disease in susceptible chicks (6, 7, 9). Hypoglycemia-spiking mortality syndrome has also been reproduced using (1) virus-like particles extracted from intestines of affected chicks and banded in a discontinuous Renograffin gradient, or (2) filtered (0.22-microns porosity filter), homogenized, dead specific pathogen free (SPF) embryos, which had been inoculated via the yolk sac route with the Renograffin-banded particles 72 hours earlier (8). Recently, crude pancreas homogenates have also been used to reproduce HSMS (4).

These findings indicate that at least 1 type of HSMS appears to be caused by an infectious, filterable agent, which may be replicated in SPF chicken embryos via the yolk sac route of inoculation (8). Attempts to replicate the agent in cell cultures have been unsuccessful (4). The agent has yet to be identified, but there is no known public health significance. The Arkansas strain of infectious bronchitis virus (IBV) and avian encephalomyelitis virus have been identified in some of the inocula used to reproduce HSMS experimentally (4, 8). The significance of these 2 common viral agents of chickens in the disease is currently unknown. Because particles similar to arenaviruses have been found by direct EM in droppings from affected chicks, immunohistochemistry (IHC), using polyclonal antibodies against New World and Old World arenaviruses, has been used to examine formalin-fixed tissues from naturally and experimentally infected chicks. Positive staining was found in the cytoplasm of pancreatic islets (Figure 33.1) and acinar cells, Purkinje cells, neurons, hepatocytes, Kupffer cells, macrophages, histiocytes, and fibroblasts of infected birds, but not in these cells of uninfected, matched controls (6, 7, 8). SPF embryos, inoculated via the yolk sac with Renograffin-banded virus-like particles 72 hours previously, were also IHC-positive (8). Specificity of the IHC reaction in these HSMS-infected embryos and chicks still needs to be determined. It is possible that the antibodies are cross-reacting to an epitope that is present on both arenaviruses and another unidentified agent(s). IHC (on the tissues positive with arenavirus antibodies) was negative using 2 monoclonal anti-IBV antibodies and a polyclonal antibody produced against turkey coronavirus (4).

To reproduce HSMS, 1-day-old–2.5-day-old chicks are inoculated orally. Approximately 2 weeks later, chicks are fasted for 2–6 hours and, in some cases, sprayed with a cool (25°C) water mist to cause mild stress. Clinical signs of HSMS begin 1.5–4 hours after fasting and stressing. Plasma glucose levels are severely depressed in affected chicks, occasionally as low as 17 mg/dL. Unexposed controls remain unaffected by fasting and stressing, and plasma glucose levels remain greater than 150 mg/dL (7, 8, 9).

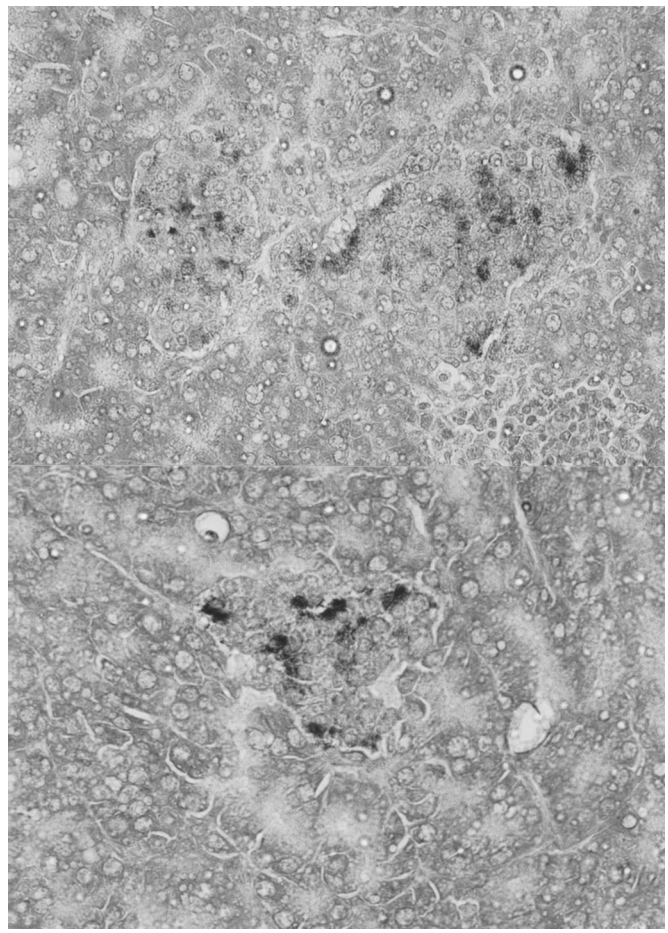

Figure 33.1. Sections of formalin-fixed pancreas from experimentally-infected 14-day-old broiler chicks with severe HSMS, processed for immunohistochemistry (IHC). Antibody was Mouse Ascites Fluid, anti-Tacaribe (ATCC, Rockville, MD, 20852). Counterstain was Nuclear Fast Red (Sigma). Positive staining was enhanced with nickel chloride. Note the IHC positive staining (black) in pancreatic islets. The same tissues were IHC negative using negative control Mouse Ascites Fluid, and sections of pancreas from uninfected control chicks were also IHC negative.

Hypoglycemia-spiking mortality syndrome also resulted when birds were fed darkling beetles (*Alphitobius diaperinus*) collected from built-up litter on farms where the disease had occurred repeatedly (8). Whether beetles or other similar insects may serve as mechanical or true vectors of the agent(s) causing HSMS is still unknown.

Other factors, which some have suggested contribute to HSMS, are certain diets, especially those with high amounts of animal byproducts labile to oxidation. In the initial publication on HSMS, an all-vegetable diet was described which resulted in the highest mortality and a marked increase in susceptibility to *Escherichia coli* septicemia (3). Management errors that would lead to birds being without feed or cause them to experience other stressful events will precipitate

HSMS in infected birds. Although mycotoxins or other toxic substances might be suspected in the disease because of its abrupt onset and high mortality, these substances have not been identified in affected chicks (3). Feeding cockleburs (*Xanthium* spp.) to chicks did not cause clinical disease or hypoglycemia (11).

Pathogenesis and Epidemiology

Clinical signs include huddling, trembling, blindness, loud chirping, litter eating, ataxia, prostration with outstretched legs, and coma. Rapidly growing males in good condition are often most affected (3). Chicks may or may not have diarrhea, but orange mucoid droppings are commonly found.

Gross lesions are nonspecific. Rarely, hemorrhage and necrosis are evident in the liver. There are changes consistent with mild enteritis, especially excess fluid accumulation in the lower intestines and orange mucoid enteritis in the jejunum. Similarly, microscopic changes are nonspecific and consistent with those expected from the gross lesions. Chicks with gross liver lesions have necrotic hepatocytes secondary to fibrinoid necrosis of hepatic arteries (1, 6, 8). Rarely, similar vascular changes also can be seen in the intestines and gut-associated lymphoid tissue. Rickets and severe lymphoid depletion/necrosis of the cloacal bursa also have been observed in affected chicks (1), although these lesions have been rare in more recent cases (4, 6, 7, 8, 9).

Experimentally, the disease seems to have a 10– to 12-day incubation period. At this time, chicks begin passing wet droppings containing undigested feed and they huddle together. If chicks are not fasted or stressed, this digestive disorder and the runting-stunting sequelae associated with it may be the only clinical signs seen. Surviving chicks often remain permanently stunted (7). Plasma from stunted or hypoglycemic chicks is often colorless or pale yellow compared with the deep yellow color of plasma from unaffected controls (8). Insulin-like growth factor-1 (IGF-1), a growth-related hormone (18, 20), is significantly depressed in affected chicks (7).

Acutely hypoglycemic chicks, both from the field (5) and from experimental trials (4), have significantly depressed pancreatic glucagon levels. Pancreata from these chicks are histologically normal with no evidence of cell necrosis. It has been theorized that the apparent viral infection of pancreatic islets in HSMS-affected chickens is responsible for blocking the production of pancreatic glucagon without histologically damaging the glucagon-producing islet cells (5, 7). This effect has been reported with certain arenavirus infections in other species that involve different hormone-producing cells (2, 10, 16, 17, 19). Pancreatic vacuolar degeneration and atrophy, associated with runting-stunting syndrome, can also cause hypoglycemia in affected chicks (4). However, this appears to be unrelated to HSMS.

Stress and acute fasting trigger the glucagon-glycogen pathway (glycogenolysis) to maintain adequate blood glucose levels (13, 14). If chicks are deficient in glucagon and/or glycogen, they can rapidly become hypoglycemic. Chicks with HSMS are deficient in both glucagon (5) and glycogen (4, 8), which makes them extremely susceptible to development of hypoglycemia when acutely fasted and/or stressed.

Diagnosis

A high spike in a mortality curve at 7–21 days of age is suggestive of but not diagnostic for HSMS. Varying numbers of chicks may be affected, or a high mortality spike may be caused by some other condition. Diagnosis of HSMS is based on the typical clinical findings and demonstrating hypoglycemia (blood glucose lower than 150 mg/dL) in affected chicks. Plasma and/or whole blood can be used for glucose determinations; plasma levels determined with a chemical analyzer are considered to be most accurate. However, glucose test strips can be used in association with a hand-held monitor (FreeStyle Blood Glucose Monitoring System, TheraSense, Inc.—Abbott Diabetes Care, Inc., Alameda, CA, 94502) as a fairly accurate screening method for determining blood glucose levels in the field or the laboratory (4). Severely affected chicks typically have blood or plasma glucose levels between 20 and 80 mg/dL. Fasting alone will not result in hypoglycemia in uninfected chicks.

Treatment, Prevention, and Control

There is no specific treatment for the disease. Supportive care based on minimizing stress due to excessive heat, cold, ammonia, poor ventilation, noise, or feed and/or water deprivation is the most important factor (4). Affected chicks should be left alone and allowed to rest as much as possible in good environmental conditions with continuous availability of feed and water. Multiple vitamins, electrolytes, and liquid vitamin E have been used successfully to reduce mortality (3, 4).

Controlled light-dark exposure programs prevent HSMS, both in the field and experimentally (8). Light-dark programs have been used successfully in the prevention of HSMS worldwide in broilers fed a wide variety of diets (4). The physiologic basis for this is attributed to melatonin release and a shift from glycogenolysis to gluconeogenesis by the birds exposed to darkness. Control of darkling beetles is important in preventing carryover of HSMS from 1 flock to the next. Vaccination of broiler breeder hens with an experimental formalin-inactivated autogenous vaccine produced from SPF embryos inoculated with the fourth egg passage of Renograffin-banded virus-like particles (designated The Oakwood Agent) failed to provide protection against experimental challenge of progeny from the hens (4, 7, 8). Experimental trials with live vaccines have not yet been attempted.

Proventriculitis and Proventricular Dilatation of Broiler Chickens

Scott Hafner and James S. Guy

Introduction

Definition and Synonyms

Proventriculitis is a microscopic diagnosis characterized by the presence of inflammation in the proventriculus. Transmissible viral proventriculitis (TVP) is an infectious, transmissible viral disease of chickens that results in enlarged, fragile proventriculi. TVP is characterized by specific microscopic changes that include glandular epithelial (oxynticopeptic) cell necrosis, ductal epithelial cell hyperplasia, and inflammation where lymphocytes predominate (2, 3, 11, 14, 23, 34, 37). Experiments show that TVP can be experimentally reproduced in broiler and specific pathogen free Leghorn chickens by inoculation with a recently identified birnavirus referred to as chicken proventricular necrosis virus (CPNV) (16). Differential diagnoses for TVP include proventriculitis caused by the ingestion of toxins such as biogenic amines, copper sulfate, or mycotoxins (4, 6, 21, 36, 40, 41) or proventriculitis associated with the finding of infectious agents that include bacteria, fungi, cryptosporidia, and viruses (1, 5, 8, 10, 19, 20, 26, 29, 32, 44, 46, 47). In contrast, proventricular dilatation is characterized by an enlarged but thin-walled proventriculus with no microscopic evidence of inflammation. The dilated proventriculus generally is accompanied by a small ventriculus (gizzard) and these changes are physiologic responses to diets low in fiber (30, 38, 42).

Economic Significance

Chickens affected by TVP may cost more to produce due to poor food digestion, poor feed conversion, and stunted growth (7, 11, 19, 23, 28, 37). Rupture of the proventriculus or gastric isthmus during carcass evisceration results in carcass contamination and significant economic loss (14, 19, 27, 32, 33, 35).

Public Health Significance

When chickens with either proventriculitis or proventricular dilatation are slaughtered and processed there may be contamination of the carcass and processing equipment with ingesta or intestinal contents (2, 14, 19, 35). Increased reprocessing and condemnation costs are incurred in an effort to remove potential human pathogens (27, 43).

History

Proventricular dilatation (enlargement of the proventriculus without inflammation) was first described in chicks that were fed a purified ration (30), and later described in commercially raised broiler chickens that were fed a ration low in fiber. In these chickens the proventriculi were dilated and thin-walled (38). Later, it was discovered that proventricular enlargement, with inflammation, could also be induced in chickens that were fed toxins such as biogenic amines (40), copper sulfate (36), and mycotoxins (6). A transmissible proventriculitis that produced a runting syndrome affecting broilers was first identified in the Netherlands (23, 24, 25). A similar syndrome associated with stunted growth and proventriculitis was then described in the United States (31) and later recognized in Australia (37). Other features of this illness included whole-body pallor, fragile proventriculi, a dilated and weakened gastric isthmus, poor feed conversion ratios, and the passage of undigested or poorly digested feed in the feces (7, 9, 11, 14, 19, 28, 35, 37). In an examination of field cases of proventriculitis in the United States, Goodwin et al. (11) identified 60- to 70-nm adenovirus-like viruses in the nuclei of degenerating glandular epithelial cells, leading to the designation of this condition as transmissible viral proventriculitis (12).

Incidence and Distribution

Definitive prevalence data regarding the global incidence and distribution of proventriculitis and proventricular dilatation are not available. However, with regard to TVP, a single study in the United States identified the typical microscopic lesions of this disease in nearly half of the broiler chicken proventriculi examined microscopically (11).

Etiology

Classification

Experimental studies indicate that the cause of TVP is a birnavirus referred to as chicken proventricular necrosis virus (CPNV) (14, 15, 16, 17). CPNV was first identified as a cause of TVP based on isolation from proventriculi of TVP-affected chickens (14). Subsequently, the etiologic role of CPNV in TVP was demonstrated based on experimental challenge studies and detection of the virus in naturally-occurring cases using reverse transcriptase polymerase chain reaction (15, 17).

CPNV was identified as a birnavirus based on a genome comprised of bisegmented, double-stranded RNA, and nucleotide sequence homologies with other birnaviruses (16). The CPNV VP1 protein, the viral RNA-dependent RNA polymerase (RdRp), was shown to possess the unique permuted RdRp sequence motif arrangement characteristic of birnaviruses; however, phylogenetic analyses based on VP1 demonstrated that CPNV is deeply divergent from other birnaviruses (13, 16).

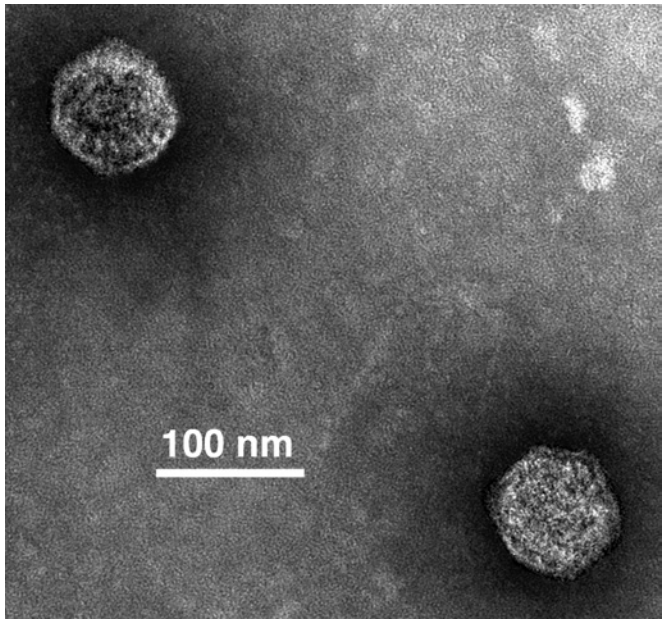

Figure 33.2. Negatively stained viral particles from an experimentally infected chick are icosahedral and are approximately 70 nm in diameter. (14).

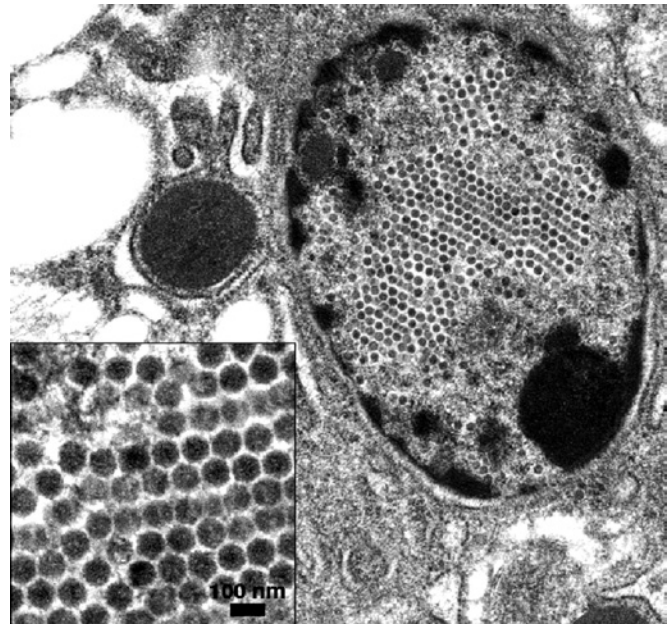

Figure 33.3. There are intranuclear, crystalline arrays of adenovirus-like viruses in the nucleus of a proventricular epithelial cell from an experimentally infected chick. Icosahedral, approximately 70-nm virions are present in crystalline arrays (inset). (14).

Morphology

Negative stain electron microscopy of partially purified preparations of CPNV revealed icosahedral virions, approximately 75 nm in diameter (Figure 33.2) (14, 16). Virions appear to be single-shelled and lack discernable surface structure. Additionally, CPNV is nonenveloped based on insensitivity to chloroform treatment (16). The negative stain appearance of CPNV is supported by examinations of fixed tissues using transmission electron microscopy (Figure 33.3). In these ultrastructural examinations of TVP-affected proventriculi, distinctly hexagonal (icosahedral), 65- to 70-nm virions have been identified in the nuclei of glandular epithelial cells (11, 14). Virions of a similar size and shape also have been detected in proventricular glandular epithelial cells of some Australian TVP-affected chickens (37), and similar but larger (100 nm) virions have been noted in experimentally infected chickens (19). Viral particles in intact nuclei tend to be larger than those found in the cytoplasm of cells with fragmented nuclei (11).

Laboratory Host Systems

Transmissible viral proventriculitis has been experimentally reproduced by inoculation of SPF and commercial broiler chickens with filtered or nonfiltered homogenates of proventriculi collected from TVP-affected chickens (2, 15, 19, 33, 34, 35, 37). Recently, TVP was experimentally reproduced with laboratory-propagated CPNV in SPF and commercial broiler chickens (15).

Chicken proventricular necrosis virus can be propagated in embryonating chicken eggs (15 days of embryonation) by inoculation of the amniotic cavity (14). In inoculated embryos/hatchlings, virus is recovered only from proventriculi or intestinal contents (14, 17).

Pathogenesis and Epizootiology

Natural and Experimental Hosts

Naturally occurring TVP has only been reported in commercially raised broilers; however, the disease is transmissible to both broilers and SPF leghorns (2, 15, 19, 33, 34, 35, 37).

Age of Host Commonly Affected

TVP is primarily a disease of young (3- to 8-week-old) broiler chickens. The disease has been reported to occur most commonly in 4- to 5-week old chickens (2).

Transmission

Routes of natural infection of TVP are not known; however, chickens can be infected experimentally by oral gavage or oculonasal instillation of either crude or filtered (0.2 μm) proventricular homogenates (2, 3, 14, 19, 23, 33, 34, 35, 37). Transmissible viral proventriculitis also has been experimentally reproduced in chickens with CPNV administered by eye drop (15, 17).

Incubation Period

The incubation period for TVP, as determined by detection of characteristic gross and microscopic lesions following CPNV exposure, was determined to be 5–7 days (15, 17). Chickens experimentally inoculated with CPNV developed gross lesions

consisting of enlargement and pallor of the proventriculus by 7 days PI; microscopic lesions were detected by 3–5 days PI (15, 17).

Clinical Signs

The predominant signs in chicks with naturally-occurring TVP include stunted growth, pallor, unthriftiness, and passage of undigested or poorly digested feed in their feces (11). Naturally occurring cases are associated with poor flock production performance data (9, 37). No clinical signs and no mortality were observed in chickens with TVP experimentally induced by CPNV infection (15). No clinical signs are apparent in chickens with proventricular dilatation (42).

Morbidity and Mortality

There is no increased mortality in TVP-affected flocks (37), but an estimated 1% may require reprocessing due to carcass contamination at slaughter (43).

Pathology

Gross Lesions

Chicks with naturally-occurring or experimentally-induced TVP may be significantly smaller than their uninfected counterparts (7, 19, 37). At necropsy, the isthmus between the proventriculus and ventriculus is widened and the proventriculus is enlarged with thickened walls that are mottled gray-white-yellow (Figure 33.4). The lobular pattern is often pronounced with each pale polygonal focus representing an individual gland (11, 35, 37). Some glands are distended and a viscous white material can be expressed by gentle digital pressure. The luminal mucosa may appear thickened and rugose and papillary orifices may be indistinct (Figure 33.5).

In chickens fed excessive levels of copper, proventriculi are enlarged, walls are thick, and the mucosal lining is flattened and stippled brown-black (21). Histamine produces enlarged, flaccid proventriculi with mucosal erosions (40). Similar mucosal erosions are present in chickens exposed to some mycotoxins (6). Proventriculi from chickens that have been fed low-fiber diets are dilated and thin-walled and gizzard musculature is poorly developed (38, 42).

Microscopic Lesions

Light Microscopy. Microscopic lesions in TVP-affected chickens change during the course of infection. At 5–7 days post infection (DPI) experimentally infected chicks exhibit acute necrosis of the glandular epithelial cells that produce pepsinogen and hydrochloric acid. The cytoplasm of these cells is amorphous, granular, or vacuolated, and there are pyknotic or fragmented nuclei. In the nuclei of a few attached or sloughed glandular epithelial cells, nuclear chromatin is marginated and central areas are pale staining, but there are no distinct hyaline or basophilic inclusion bodies. This necrosis is accompanied by accumulations of lymphocytes, macrophages, and fewer plasma cells in the adjacent connective tissue stroma (tunica propria). Collecting ducts (secondary ducts) are dilated and filled with necrotic cells (Figure 33.6) and there may be hyperplasia of the gut-associated lymphoid tissue (GALT) that normally occurs in the proventricular glands. During the transitional stage of infection (14 DPI) there is regeneration of the glandular epithelium by a cuboidal to low columnar duct-like epithelium. In later stages, glandular

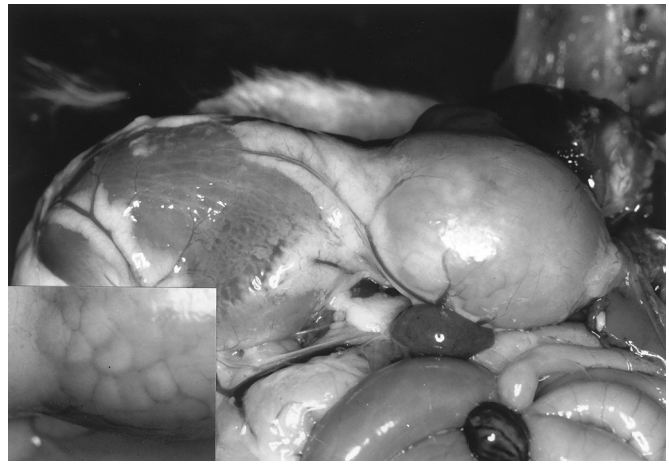

Figure 33.4. Proventriculus from a virus-infected broiler chick is enlarged and mottled gray-white-yellow. Close examination of the serosal surface reveals numerous polygonal pale foci that represent enlarged individual glands (inset).

Figure 33.5. The proventricular mucosa of a virus-infected chick appears thickened and rugose. Papillary orifices are not distinct.

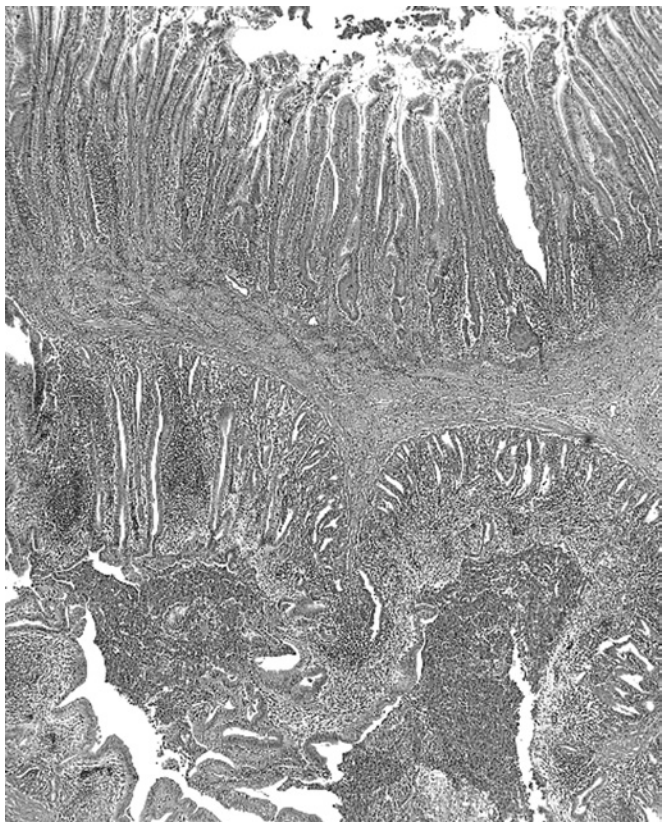

Figure 33.6. In acute naturally occurring proventriculitis, collecting ducts (secondary ducts) are widely dilated by accumulations of necrotic alveolar epithelial cells. H&E, ×40.

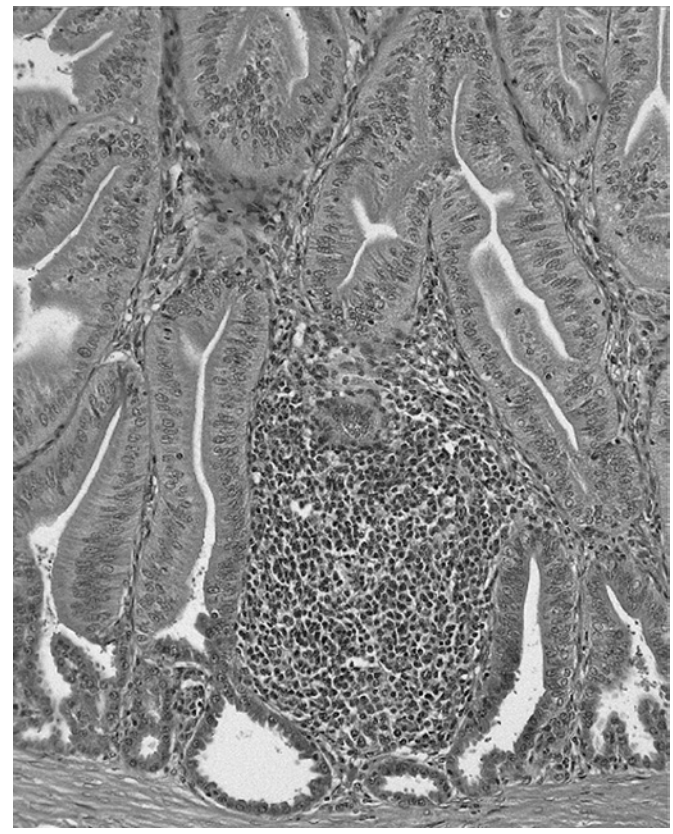

Figure 33.7. In chronic lesions, there is marked hyperplasia of duct-like epithelium that extensively replaces alveolar epithelial cells with accompanying interstitial aggregates of lymphocytes and plasma cells. H&E, ×200.

epithelial cells are partially replaced by hyperplastic ductal epithelium (Figure 33.7) and there is an accompanying lymphocytic proventriculitis with GALT hyperplasia and occasional B cell aggregates that form germinal centers (14, 15, 34, 35). In naturally occurring and experimentally induced disease, there may be destruction of up to 80% of the glandular epithelial cells.

Proventriculitis in chickens can occur secondary to ingestion of excessive levels of histamine with lesions consisting predominantly of mucosal erosion and edema (40). Dilated proventriculi with erosion or ulceration of the luminal mucosa coupled with submucosal inflammation are seen in chickens with experimental cyclopiazonic acid intoxication (6).

There are no light microscopic lesions in physiologic proventricular dilatation.

Electron Microscopy. Intranuclear, icosahedral particles ranging in size from 60–70 nm have been reported in chickens with naturally or experimentally produced TVP (Figure 33.2). Viral particles in intact nuclei tend to be larger than those found in the cytoplasm of cells with fragmented nuclei (11).

Immunity

Nothing is known about immunity to TVP.

Diagnosis

Isolation and Identification of Agent

Isolation of CPNV may be accomplished by inoculation of embryonating chicken eggs with suspensions of proventricular tissues from suspect TVP-affected chickens (14). Proventriculi are homogenized in an appropriate diluent such as minimal essential medium, clarified by centrifugation, and filtered through a 0.45μm filter. Embryonating chicken eggs (15 days of embryonation) are inoculated by the amniotic route and returned to the incubator, and eggs are allowed to hatch. The presence of CPNV in proventriculi of hatchlings is determined by immunohistochemical staining procedures. Immunohistochemistry requires a virus-specific antiserum.

An indirect FA procedure for detection of CPNV antigens has been described for detection of CPNV antigens in proventriculi of infected chickens (14). Indirect FA detected CPNV antigens in proventriculi of experimentally infected chickens from days 3–10 post exposure (PE) (17).

A reverse transcriptase polymerase chain reaction (RT-PCR) procedure has been developed for detection of CPNV RNA (16). The RT-PCR procedure was shown to be highly specific and sensitive compared with detection by

indirect fluorescent antibody (IFA). The RT-PCR procedure detected CPNV in experimentally infected chickens on days 3–14 PI in freshly collected proventriculi and days 1–14 PI in formalin-fixed, paraffin-embedded tissues (17).

Chickens experimentally infected with CPNV exhibited microscopic lesions characteristic of TVP from days 5–35 PI, but the virus was detectable by indirect FA only on days 3–10 PI and by RT-PCR only on days 1–14 PI (17). These findings indicate that timing of sample collection is an important consideration for detection of CPNV in TVP cases using either indirect FA or RT-PCR.

Serology

There is no serologic test for TVP.

Differential Diagnosis

A tentative diagnosis of TVP is made on the basis of the typical microscopic lesions in the proventriculus. TVP must be differentiated from a broad spectrum of offending agents reported to cause proventriculitis or proventricular enlargement in chickens. These include copper sulfate ingestion (3, 36), dietary biogenic amines and mycotoxins (4, 6, 10, 40, 41), bacteria (10, 19), fungi (10, 39, 44), reovirus (22, 26, 31), adenovirus (23, 26), infectious bronchitis virus (47), tumor-inducing viruses (1, 20, 29, 45, 46), Cryptosporidium sp. (8), and idiopathic proliferations of cells interpreted to represent histiocytes (18). A diagnosis of proventricular dilatation relies on observing a dilated, thin-walled proventriculus without microscopic evidence of inflammation (38, 42).

Treatment

There are no specific treatments for proventricular dilatation or TVP.

Prevention and Control

There are no specific prevention or control measures for TVP.

Proventricular dilatation may be prevented by ensuring proper ration formulation, specifically by providing adequate dietary fiber.

Acknowledgement

The authors wish to acknowledge the contributions of Mark A. Goodwin and Mary Pantin-Jackwood, previous co-authors of this subchapter.

References

Multicausal Respiratory Diseases

1. Abbassi, H., F. Coudert, G. Dambrine, Y. Chérel, and M. Naciri. 2000. Effect of *Cryptosporidium baileyi* in specific-pathogen-free chickens vaccinated (CVI988/Rispens) and challenged with HPRS-16 strain of Marek's disease virus. *Avian Pathol*. 29:623–634.
2. Abbassi, H., G. Dambrine, Y. Chérel, F. Coudert, and M. Naciri. 2000. Interaction of Marek's disease virus and *Cryptosporidium baileyi* in experimentally infected chickens. *Avian Dis*. 44:776–789.
3. Adler, H.E. 1960. Mycoplasma, the cause of chronic respiratory disease. *Ann NY Acad Sci.* 79:703–712.
4. Adler, H.E., and R. Yamamoto. 1956. Studies on chronic coryza (Nelson) in the domestic fowl. *Cornell Vet*. 46:337–343.
5. Aghakhan, S.M., M. Pattison, and M. Butler. 1976. Infection of the chicken with an avian adenovirus and *Mycoplasma gallisepticum*. *J Comp Pathol*. 86:1–9.
6. Al-Mashhadani, E.H., and M.M. Beck. 1985. Effect of atmospheric ammonia on the surface ultrastructure of the lung and trachea of broiler chickens. *Poult Sci*. 64:2056–2061.
7. Anderson, D.P., C.W. Beard, and R.P. Hanson. 1964. The adverse effects of ammonia on chickens including resistance to infection with Newcastle disease virus. *Avian Dis*. 8:369–379.
8. Anderson, D.P., R.R. Wolfe, F.L. Cherms, and W.E. Roper. 1968. Influence of dust and ammonia on the development of air sac lesions in turkeys. *Am J Vet Res*. 29:1049–1058.
9. Besrukava, I.Y. 1965. Influence of infectious laryngotracheitis virus on the course of mycoplasmosis in fowls. *Veterinariya (Kiev)*. 5:109–114.
10. Bradbury, J.M. 1984. Avian mycoplasma infections: prototype of mixed infections with mycoplasmas, bacteria and viruses. *Ann Microbiol (Inst Pasteur)*. 135 A:83–89.
11. Carlson, H.C., and G.R. Whenhan. 1968. Coliform bacteria in chicken broiler house dust and their possible relationship to coli-septicemia. *Avian Dis*. 12:297–302.
12. Cook, J.K.A., H.W. Smith, and M.B. Huggins. 1986. Infectious bronchitis immunity: Its study in chickens experimentally infected with mixtures of infectious bronchitis virus and *Escherichia coli*. *J Gen Virol*. 67:1427–1434.
13. Corstvet, R.E., and W.W. Sadler. 1966. A comparative study of single and multiple respiratory infections in the chicken: Multiple infections (with *Mycoplasma gallisepticum*, Newcastle disease virus, and infectious bronchitis virus). *Am J Vet Res*. 27:1703–1720.
14. Dhillon, A. 1986. Pathology of avian adenovirus serotypes in the presence of *Escherichia coli* in infectious-bursal-disease-virus infected specific pathogen-free chickens. *Avian Dis*. 30:81–86.
15. Di Matteo, A.M., M.C. Sonez, C.M. Plano, and I. von Law zewitsch. 2000. Morphologic observations on respiratory tracts of chickens after hatchery infectious bronchitis vaccination and formaldehyde fumigation. *Avian Dis*. 44:507–518.
16. Dunlop, W.R., G. Parke, R.G. Strout, and S.C. Smith. 1964. The effect of sequence of infection on complex respiratory disease. *Avian Dis*. 8:321–327.
17. Eidson, C.S., J.J. Giambrone, B.O. Barger, and S.H. Kleven. 1977. Comparison of the efficacy and transmissibility of conventional NDV vaccines and vaccines prepared after back-passage through chickens. *Poult Sci*. 56:19–25.
18. Farrager, J.T., W.H. Allan, and P.J. Wyeth. 1974. Immunosuppressive effect of infectious bursal agent on vaccination against Newcastle disease. *Vet Rec*. 95:385–388.
19. Ficken, M.D., J.F. Edwards, J.C. Lay, and D.E. Tveter. 1987. Tracheal mucus transport rate and bacterial clearance in turkeys exposed by aerosol to LaSota strain of Newcastle disease virus. *Avian Dis*. 31:241–248.

20. Ganapathy, K., and J.M. Bradbury. 1999. Pathogenicity of *Mycoplasma imitans* in mixed infection with infectious bronchitis virus in chickens. *Avian Pathol*. 28:229–237.
21. Ganapathy, K., R.C. Jones, and J.M. Bradbury. 1998. Pathogenicity of *in vivo*-passaged *Mycoplasma imitans* in turkey poults in single infection and in dual infection with rhinotracheitis virus. *Avian Pathol*. 27:80–89.
22. Giambrone, J.J., C.S. Eidson, and S.H. Kleven. 1977. Effect of infectious bursal disease on the response of chickens to *Mycoplasma synoviae*, Newcastle disease virus, and infectious bronchitis virus. *Am J Vet Res*. 38:251–253.
23. Giambrone, J.J., C.S. Eidson, R.K. Page, O.J. Fletcher, B.O. Barger, and S.H. Kleven. 1976. Effect of infectious bursal agent on the response of chickens to Newcastle disease and Marek's disease vaccination. *Avian Dis*. 20:534–44.
24. Gross, W.B. 1990. Factors affecting the development of respiratory disease complex in chickens. *Avian Dis*. 34:607–610.
25. Guy, J.S., H.J. Barnes, and L. Smith. 1991. Increased virulence of modified-live infectious laryngotracheitis vaccine virus following bird-to-bird passage. *Avian Dis*. 35:348–355.
26. Hagood, L.T., T.F. Kelly, J.C. Wright, and F.J. Hoerr. 2000. Evaluation of chicken infectious anemia virus and associated risk factors with disease and production losses in broilers. *Avian Dis*. 44:803–808.
27. Hirai, K., S. Shimakura, E. Kawamoto, F. Taguchi, S.T. Kim, and C.N. Chang. 1974. The immunodepressive effect of infectious bursal disease virus in chickens. *Avian Dis*. 18:50–57.
28. Hopkins, S.R., and H.W. Yoder. 1982. Influence of infectious bronchitis strains and vaccines on the incidence of *Mycoplasma synoviae* airsacculitis. *Avian Dis*. 26:741–752.
29. Hopkins, S.R., and H.W. Yoder. 1984. Increased incidence of airsacculitis in broilers infected with *Mycoplasma synoviae* and chicken passaged infectious bronchitis vaccine virus. *Avian Dis*. 28:386–396.
30. Huang, H.J., and M. Matsumoto. 2000. Nonspecific innate immunity against *Escherichia coli* infection in chickens induced by vaccine strains of Newcastle disease virus. *Avian Dis*. 44:790–796.
31. Johnson, E.P., and C.H. Domermuth. 1956. Some factors in the etiology and control of so-called avian air-sac disease. *Cornell Vet*. 46:409–418.
32. Jordan, F.T.W. 1975. Avian mycoplasma and pathogenicity—A review. *Avian Pathol*. 4:165–174.
33. Kato, K. 1965. Infectious coryza of chickens. V. Influence of *Mycoplasma gallisepticum* infection on chickens infected with *H. gallinarum. Natl Inst Anim Health Q*. 5:183–189.
34. King, D.D., S.H. Kleven, D.M. Wenger, and D.P. Anderson. 1973. Field studies with *Mycoplasma synoviae*. *Avian Dis*. 17:722–726.
35. Kleven, S.H., C.S. Eidson, D.P. Anderson, and O.J. Fletcher. 1972. Decrease of antibody response to *Mycoplasma synoviae* in chickens infected with Marek's disease herpesvirus. *Am J Vet Res*. 33:2037–2037.
36. Kleven, S.H., C.S. Eidson, and O.J. Fletcher. 1978. Airsacculitis induced in broilers with a combination of *Mycoplasma gallinarum* and respiratory viruses. *Avian Dis*. 22:707–716.
37. Kleven, S.H., D.D. King, and D.P. Anderson. 1972. Airsacculitis in broilers from *Mycoplasma synoviae*: effect on air-sac lesions of vaccinating with infectious bronchitis and Newcastle virus. *Avian Dis*. 16:915–924.
38. Kling, H.F., and C.L. Quarles. 1974. Effect of atmospheric ammonia and the stress of infectious bronchitis vaccination on Leghorn males. *Poult Sci*. 53:1161–1167.
39. Kuniyasu, C., K. Matsui, S. Sato, and K. Ando. 1967. Serological and bacteriological observation of chickens intranasally inoculated with *Mycoplasma gallisepticum*. *Natl Inst Anim Health Q*. 7:202–207.
40. Larsen, C.T., C.H. Domermuth, D.P. Sponenberg, and W.B. Gross. 1985. Colibacillosis of turkeys exacerbated by hemorrhagic enteritis virus: Laboratory studies. *Avian Dis*. 29:729–732.
41. Matsumoto, M., and H.J. Huang. 2000. Induction of short-term, nonspecific immunity against *Escherichia coli* infection in chickens is suppressed by cold stress or corticosterone treatment. *Avian Pathol*. 29:227–232.
42. Mazariegos, L.A., P.D. Lukert, and J. Brown. 1990. Pathogenicity and immunosuppressive properties of infectious bursal disease "intermediate" strains. *Avian Dis*. 34:203–208.
43. Montgomery, R.D., W.R. Maslin, and C.R. Boyle. 1997. Effects of Newcastle disease vaccines and Newcastle disease/infectious bronchitis combination vaccines on the head-associated lymphoid tissues of the chicken. *Avian Dis*. 41:399–406.
44. Nagaraja, K.V., D.A. Emery, K.A. Jordan, J.A. Newman, and B.S. Pomeroy. 1983. Scanning electron microscopic studies of adverse effects of ammonia on tracheal tissues of turkeys. *Am J Vet Res*. 44:1530–1536.
45. Nagaraja, K.V., D.A. Emery, K.A. Jordan, V. Sivanandan, J.A. Newman, and B.S. Pomeroy. 1984. Effect of ammonia on the quantitative clearance of *Escherichia coli* from lungs, air sacs, and livers of turkeys aerosol vaccinated against *Escherichia coli*. *Am J Vet Res*. 45:392–395.
46. Nakamura, K., H. Ueda, T. Tanimura, and K. Noguchi. 1994. Effect of mixed live vaccine (Newcastle disease and infectious bronchitis) and *Mycoplasma gallisepticum* on the chicken respiratory tract and on *Escherichia coli* infection. *J Comp Pathol*. 111:33–42.
47. Naqi, S., G. Thompson, B. Bauman, and H. Mohammed. 2001. The exacerbating effect of infectious bronchitis virus infection on the infectious bursal disease virus-induced suppression of opsonization by *Escherichia coli* antibody in chickens. *Avian Dis*. 45:52–60.
48. Nelson, J.B. 1938. Studies on an uncomplicated coryza of the domestic fowl. IX. The cooperative action of *Haemophilus gallinarum* and the coccobacilliform bodies in the coryza of rapid onset and long duration. *J Exp Med*. 6:847–855.
49. Newberry, L.A., J.K. Skeeles, D.L. Kreider, J.N. Beasley, J.D. Story, R.W. McNew, and B.R. Berridge. 1993. Use of virulent hemorrhagic enteritis virus for the induction of colibacillosis in turkeys. *Avian Dis*. 37:1–5.
50. Okoye, J.O.A., C.N. Okeke, and F.K.O. Ezeobele. 1991. Effect of infectious bursal disease virus infections on the severity of *Aspergillus flavus* aspergillosis of chickens. *Avian Pathol*. 20:167–171.
51. Omuro, M., K. Suzuki, H. Kawamura, and K. Munakata. 1971. Interaction of *Mycoplasma gallisepticum*, mild strains of Newcastle disease virus and infectious bronchitis virus of chickens. *Natl Inst Anim Health Q*. 11:83–93.
52. Peighambari, S.M., R.J. Julian, and C.L. Gyles. 2000. Experimental *Escherichia coli* respiratory infection in broilers. *Avian Dis*. 44:759–769.
53. Pejkovski, C., F.G. Develaar, and B. Kouwenhoven. 1979. Immunosuppressive effect of infectious bursal disease virus on vaccination against infectious bronchitis. *Avian Pathol*. 8:95–106.
54. Pierson, F.W., C.T. Larsen, and C.H. Domermuth. 1996. The production of colibacillosis in turkeys following sequential

exposure to Newcastle disease virus or *Bordetella avium*, avirulent hemorrhagic enteritis virus, and *Escherchia coli*. *Avian Dis*. 40:837–840.
55. Ragland, W.L., H. Mazija, V. Cvelic-Cabrilo, V. Savic, R. Novak, and M. Pogacnik. 1998. Immune suppression of commercial broilers in Croatia, Slovenia, and Bosnia and Herzegovina. *Avian Pathol*. 27:200–204.
56. Rhoades, K.R. 1977. Turkey sinusitis: synergism between *Mycoplasma synoviae* and *Mycoplasma meleagridis*. *Avian Dis*. 21:670–674.
57. Rhoades, K.R. 1981. Turkey airsacculitis: effect of mixed mycoplasmal infections. *Avian Dis*. 25:131–135.
58. Riddell, C., K. Schwean, and H.L. Classen. 1998. Inflammation of the bronchi in broiler chickens, associated with barn dust and the influence of barn temperature. *Avian Dis*. 42:225–229.
59. Rimler, R., and K.R. Rhoades. 1986. Fowl cholera: influence of *Bordetella avium* on vaccinal immunity of turkeys to *Pasteurella multocida*. *Avian Dis*. 30:838–839.
60. Rodriguez, R., and S.H. Kleven. 1980. Pathogenicity of two strains of *Mycoplasma gallisepticum* in broiler chickens. *Avian Dis*. 24:800–807.
61. Saif, Y.M., P.D. Moorhead, and E.H. Bohl. 1970. *Mycoplasma meleagridis* and *E. coli* infections in germ free and specific pathogen free turkey poults: production of complicated airsacculitis. *Am J Vet Res*. 31:1637–1643.
62. Sander, J.E., and W.L. Steffens. 1997. Transmission electron microscopic demonstration of abnormalities on the tracheal cilia of chicks exposed to formaldehyde during hatching. *Avian Dis*. 41:977–980.
63. Smith, H., J. Cook, and Z. Parsell. 1985. The experimental infection of chickens with mixtures of infectious bronchitis virus and *Escherichia coli*. *J Gen Virol*. 66:777–786.
64. Sponenberg, D., C. Domermuth, and C. Larsen. 1985. Field outbreaks of colibacillosis of turkeys associated with hemorrhagic enteritis virus. *Avian Dis*. 29:838–842.
65. Springer, W.T., C. Luskus, and S.S. Pourciau. 1974. Infectious bronchitis and mixed infections of *Mycoplasma synoviae* and *Escherichia coli* in gnotobiotic chickens. I. Synergistic role in the airsacculitis syndrome. *Infect Immun*. 10:578–589.
66. Tablante, N.L., P.Y. Brunet, E.M. Odor, M. Salem, J.M. Harter-Dennis, and W.D. Hueston. 1999. Risk factors associated with early respiratory disease complex in broiler chickens. *Avian Dis*. 43:424–428.
67. Timms, L.M. 1972. The effects of infectious bronchitis superimposed on latent *Mycoplasma gallisepticum* infection in adult chickens. *Vet Rec*. 91:185–185.
68. Travers, A.F. 1996. Concomitant *Ornithobacterium rhinotracheale* and Newcastle disease infection in broilers in South Africa. *Avian Dis*. 40:488–490.
69. Van Alstine, W., and L. Arp. 1987. Effects of *Bordetella avium* infection on the pulmonary clearance of *Escherichia coli* in turkeys. *Am J Vet Res*. 48:922–926.
70. Van Alstine, W., and L. Arp. 1987. Influence of *Bordetella avium* infection on association of Escherichia coli with turkey trachea. *Am J Vet Res*. 48:1574–1576.
71. Vardaman, T.H., F.N. Reece, and J.W. Deaton. 1973. Effect of *Mycoplasma synoviae* on broiler performance. *Poult Sci*. 52:1909–1912.
72. Villegas, P., and S.H. Kleven. 1976. Aerosol vaccination against Newcastle disease. I. Studies on particle size. *Avian Dis*. 20:179–190.
73. Villegas, P., S.H. Kleven, and D.P. Anderson. 1976. Effect of route of Newcastle disease vaccination on the incidence of airsacculitis in chickens infected with *Mycoplasma synoviae*. *Avian Dis*. 20:395–400.
74. Weinack, O.M., G.H. Snoeyenbos, C.F. Smyser, and L.A.S. Soerjadi. 1984. Influence of *Mycoplasma gallisepticum*, infectious bronchitis, and cyclophosphamide on chickens protected by native intestinal microflora against *Salmonella typhimurium* or *Escherichia coli*. *Avian Dis*. 28:416–425.
75. Winterfield, R.W., F.J. Hoerr, and A.M. Fadly. 1978. Vaccination against infectious bronchitis and the immunosuppressive effects of infectious bursal disease. *Poult Sci*. 57:386–391.
76. Yoder, H.W., L.N. Drury, and S.R. Hopkins. 1977. Influence of environment on airsacculitis: Effects of relative humidity and air temperature on broilers infected with *Mycoplasma synoviae* and infectious bronchitis. *Avian Dis*. 21:195–208.
77. Yoder, H.W., C.W. Beard, and B.W. Mitchell. 1989. Pathogenicity of *Escherichia coli* in aerosols for young chickens. *Avian Dis*. 33:676–683.

Multicausal Enteric Diseases

1. Ali, A., and D.L. Reynolds. 1997. Stunting syndrome in turkey poults: isolation and identification of the etiologic agent. *Avian Dis*. 41:870–881.
2. Ali, A., and D.L. Reynolds. 2000. Characterization of the stunting syndrome agent: relatedness to known viruses. *Avian Dis*. 44:45–50.
3. Ali, A., and D.L. Reynolds. 2000. The pathophysiology of stunting syndrome disease of turkeys: Pro-inflammatory cytokines and intestinal apithelium. *Proc Western Poult Dis Conf* 49:104.
4. Angel, C.R., J.L. Sell, and D.W. Trampel. 1990. Stunting syndrome in turkeys. Development of an experimental model. *Avian Dis*. 34:447–453.
5. Asano, K.M., F. Gregori, S.P. Souza, D. Rotava, R.N. Oliveira, L.Y. Villarreal, L.J. Richtzenhain, and P.E. Brandao. 2011. Bovine rotavirus in turkeys with enteritis. *Avian Dis*. 55:697–700.
6. Banyai, K., E. Dandar, K.M. Dorsey, T. Mato, and V. Palya. 2011. The genomic constellation of a novel avian orthoreovirus strain associated with runting-stunting syndrome in broilers. *Virus Genes*. 42:82–89.
7. Barnes, G.L., J.S. Guy, and J.P. Vaillancourt. 2000. Poult enteritis complex. *Rev Sci Tech*. 19:565–588.
8. Barnes, G.L., and J.S. Guy. 2003. Poult enteritis-mortality syndrome. In: *Diseases of Poultry*, 11th ed. Y.M. Saif, H.J Barnes, J.R Glisson, A.M. Fadly, L.R. McDougald, and D.E. Swayne, eds. Blackwell, Ames, Iowa. 1171–1180.
9. Baxendale, W., and T. Mebatsion. 2004. The isolation and characterisation of astroviruses from chickens. *Avian Pathol*. 33:364–370.
10. Behling-Kelly, E., S. Schultz-Cherry, M. Koci, L. Kelley, D. Larsen, and C. Brown. 2002. Localization of astrovirus in experimentally infected turkeys as determined by *in situ* hybridization. *Vet Pathol*. 39:595–598.
11. Bidin, M., I. Lojkic, Z. Bidin, M. Tiljar, and D. Majnaric. 2011. Identification and phylogenetic diversity of parvovirus circulating in commercial chicken and turkey flocks in Croatia. *Avian Dis*. 55:693–696.
12. Boros, A., C. Nemes, P. Pankovics, B. Kapusinszky, E. Delwart, and G. Reuter. 2012. Identification and complete genome characterization of a novel picornavirus in turkey (*Meleagris gallopavo*). *J Gen Virol*. 93:2171–82.

13. Bracewell, C.D., and P. Wyeth. 1981. Infectious stunting of chickens. *Vet Rec*. 109:64.
14. Canelli E., C.P. Cordioli, I. Barbieri, A. Catella, D. Pennelli, R. Ceruti, A. Moreno, and A. Lavazza. 2012. Astroviruses as causative agents of poultry enteritis: genetic characterization and longitudinal studies on field conditions. *Avian Dis*. 56:173–182.
15. Chang, E.B., M.W. Musch, and L. Mayer. 1990. Interleukins 1 and 3 stimulate anion secretion in chicken intestine. *Gastroenterology*. 98:1518–1524.
16. Colnago, G.L., T. Gore, L.S. Jensen, and P.L. Long. 1983. Amelioration of pale bird syndrome in chicks by vitamin E and selenium. *Avian Dis*. 27:312–316.
17. Cullen, G.A. 1988. Runting and stunting syndrome in turkeys. *Vet Rec*. 122:48.
18. Day, J.M., L.L. Ballard, M.V. Duke, B.E. Scheffler, and L. Zsak. 2011. Metagenomic analysis of the turkey gut RNA virus community. *Virol J*. 7:313.
19. de Wit, J.J., G.B. Dam, J.M. de Laar, Y. Biermann, I. Verstegen, F. Edens, and C.C. Schrier. 2011. Detection and characterization of a new astrovirus in chicken and turkeys with enteric and locomotion disorders. *Avian Pathol*. 40:453–461.
20. Dea, S., G. Marsolais, J. Beaubien, and R. Ruppanner. 1986. Coronaviruses associated with outbreaks of transmissible enteritis of turkeys in Quebec: hemagglutination properties and cell cultivation. *Avian Dis*. 30:319–326.
21. Decaesstecker, M., G. Charlier, J. Peeters, and G. Meulemans. 1989. Pathogenicity of fowl enteroviruses. *Avian Pathol*. 18:697–713.
22. Dees, T.A., R.E. Wooley, and J.B. Gratzek. 1972. Infectious enteritis of turkeys: pathogenicity of bacteria-free filtrates and a viral agent isolated from turkeys with infectious enteritis. *Am J Vet Res*. 33:165–170.
23. Domanska-Blicharz, K., A. Seroka, and Z. Minta. 2011. One-year molecular survey of astrovirus infection in turkeys in Poland. *Arch Virol*. 156:1065–1072.
24. Edens, F.W., K.A. Joyce, C.R. Parkhurst, G.B. Havenstein, and M.A. Qureshi. 1998. Effect of litter moisture and brooding temperature on body weights of turkey poults experiencing poult enteritis and mortality syndrome. *Poult Sci*. 77:411–415.
25. Einerhand, A.W. 1998. Rotavirus NSP4 acts as a viral enterotoxin to induce diarrhea and is a potential target for rotavirus vaccines. *J Pediatr Gastroenterol Nutr*. 27:123–124.
26. Frazier, J.A., and R.L. Reece. 1990. Infectious stunting syndrome of chickens in Great Britain: intestinal ultrastructural pathology. *Avian Pathol*. 19:759–777.
27. Gomaa, M.H., D. Yoo, D. Ojkic, and J.R. Barta. 2009. Infection with a pathogenic turkey coronavirus isolate negatively affects growth performance and intestinal morphology of young turkey poults in Canada. *Avian Pathol*. 38:279–286.
28. Goodwin, M.A., J.F. Davis, M.S. McNulty, J. Brown, and E.C. Player. 1993. Enteritis (so-called runting stunting syndrome) in Georgia broiler chicks. *Avian Dis*. 37:451–458.
29. Goodwin, M.A., J.F. Davis, and E.C. Player. 1993. Reovirus-associated enteritis in Georgia broiler chicks. *Avian Dis*. 37:229–233.
30. Goodwin, M.A., M.A. Dekich, K.S. Latimer, and O.J. Fletcher. 1985. Quantitation of intestinal D-xylose absorption in normal broilers and in broilers with pale-bird syndrome. *Avian Dis*. 29:630–639.
31. Guy, J.S. 1998. Virus infections of the gastrointestinal tract of poultry. *Poult Sci*. 77:1166–1175.
32. Guy, J.S., H.J. Barnes, L.G. Smith, and J. Breslin. 1997. Antigenic characterization of a turkey coronavirus identified in poult enteritis- and mortality syndrome-affected turkeys. *Avian Dis*. 41:583–590.
33. Guy, J.S., A.M. Miles, L. Smith, F.J. Fuller, and S. Schultz-Cherry. 2004. Antigenic and genomic characterization of turkey enterovirus-like virus (North Carolina, 1988 isolate): identification of the virus as turkey astrovirus 2. *Avian Dis*. 48:206–211.
34. Guy, J.S., L.G. Smith, J.J. Breslin, J.P. Vaillancourt, and H.J. Barnes. 2000. High mortality and growth depression experimentally produced in young turkeys by dual infection with enteropathogenic *Escherichia coli* and turkey coronavirus. *Avian Dis*. 44:105–113.
35. Heggen-Peay, C.L., M.A. Qureshi, F.W. Edens, B. Sherry, P.S. Wakenell, P.H. O'Connell, and K.A. Schat. 2002. Isolation of a reovirus from poult enteritis and mortality syndrome and its pathogenicity in turkey poults. *Avian Dis*. 46:32–47.
36. Hess, M., R. Raue, and H.M. Hafez. 1999. PCR for specific detection of haemorrhagic enteritis virus of turkeys, an avian adenovirus. *J Virol Methods*. 81:199–203.
37. Hewson, K.A., D. O'Rourke, and A.H. Noormohammadi. 2010. Detection of avian nephritis virus in Australian chicken flocks. *Avian Dis*. 54:990–993.
38. Imada, T. 2008. Avian nephritis. In: *Diseases of Poultry*, 12th ed. Y.M. Saif, A.M. Faddly, J.R. Glisson, L.R. MacDougald, L.K. Nolan, and D.E. Swayne, eds. Blackwell Publishing, Ames, Iowa. 409–413.
39. Ismail, M.M., A.Y. Tang, and Y.M. Saif. 2003. Pathogenicity of turkey coronavirus in turkeys and chickens. *Avian Dis*. 47:515–522.
40. Jindal, N., D.P. Patnayak, Y. Chander, A.F. Ziegler, and S.M. Goyal. 2010. Detection and molecular characterization of enteric viruses from poult enteritis syndrome in turkeys. *Poult Sci*. 89:217–226.
41. Jindal, N., D.P. Patnayak, A.F. Ziegler, A. Lago, and S.M. Goyal. 2009. Experimental reproduction of poult enteritis syndrome: clinical findings, growth response, and microbiology. *Poult Sci*. 88:949–958.
42. Jindal, N., D.P. Patnayak, A.F. Ziegler, A. Lago, and S.M. Goyal. 2009. A retrospective study on poult enteritis syndrome in Minnesota. *Avian Dis*. 53:268–275.
43. Jonsdottir, I.H., A. Sjoqvist, O. Lundgren, and P. Thoren. 1999. Somatic nerve stimulation and cholera-induced net fluid secretion in the small intestine of the rat: evidence for an opioid effect. *J Auton Nerv Syst*. 78:18–23.
44. Kang, K.I., M. El-Gazzar, H.S. Sellers, F. Dorea, S.M. Williams, T. Kim, S. Collett, and E. Mundt. 2012. Investigation into the aetiology of runting and stunting syndrome in chickens. *Avian Pathol*. 41:41–50.
45. Koci, M.D., L.A. Moser, L.A. Kelley, D. Larsen, C.C. Brown, and S. Schultz-Cherry. 2003. Astrovirus induces diarrhea in the absence of inflammation and cell death. *J Virol*. 77:11798–11808.
46. Koci, M.D., and S. Schultz-Cherry. 2002. Avian astroviruses. *Avian Pathol*. 31:213–227.
47. Kouwenhoven, B., F.G. Davelaar, and J. Van Walsum. 1978. Infectious proventriculitis causing runting in broilers. *Avian Pathol*. 7:183–187.
48. Kouwenhoven, B., M. Vertommen, and E. Goren. 1988. Investigations into the role of reovirus in the malabsorption syndrome. *Avian Pathol*. 17:879–892.

49. Lilburn, M.S., H.M. Edwards, Jr., and L.S. Jensen. 1982. Impaired nutrient utilization associated with pale bird syndrome in broiler chicks. *Poult Sci*. 61:608–609.
50. Lundgren, O., and M. Jodal. 1997. The enteric nervous system and cholera toxin-induced secretion. *Comp Biochem Physiol A Physiol*. 118:319–327.
51. Lundgren, O., A.T. Peregrin, K. Persson, S. Kordasti, I. Uhnoo, and L. Svensson. 2000. Role of the enteric nervous system in the fluid and electrolyte secretion of rotavirus diarrhea. *Science*. 287:491–495.
52. Mandoki, M., T. Bakonyi, E. Ivanics, C. Nemes, M. Dobos-Kovacs, and M. Rusvai. 2006. Phylogenetic diversity of avian nephritis virus in Hungarian chicken flocks. *Avian Pathol*. 35:224–229.
53. Maurel, S., D. Toquin, F.X. Briand, M. Queguiner, C. Allee, J. Bertin, L. Ravillion, C. Retaux, V. Turblin, H. Morvan, and N. Eterradossi. 2011. First full-length sequences of the S gene of European isolates reveal further diversity among turkey coronaviruses. *Avian Pathol*. 40:179–189.
54. McLoughlin, M.F., D.A. McLoone, and T.J. Connor. 1987. Runting and stunting syndrome in turkeys. *Vet Rec*. 121:583–586.
55. McNulty, M.S., and D.L. Reynolds. 2008. Rotavirus infections. In: *Diseases of Poultry*, 12th ed. Y.M. Saif, A.M. Faddly, J.R. Glisson, L.R. MacDougald, L.K. Nolan, and D.E. Swayne, eds. Blackwell Publishing, Ames Iowa. 338–350.
56. McNulty, M.S., G.M. Allan, T.J. Connor, J.B. McFerran, and R.M. McCracken. 1984. An entero-like virus associated with the runting syndrome in broiler chickens. *Avian Pathol*. 13:429–439.
57. McNulty, M.S., G.M. Allan, D. Todd, and J.B. McFerran. 1979. Isolation and cell culture propagation of rotaviruses from turkeys and chickens. *Arch Virol* 61:13–21.
58. McNulty, M.S., W.L. Curran, and J.B. McFerran. 1980. Detection of astroviruses in turkey faeces by direct electron microscopy. *Vet Rec*. 106:561.
59. McNulty, M.S., T.J. Connor, F. McNeilly, and J.B. McFerran. 1990. Biological Characterization of avian enteroviruses and enterovirus-like viruses. *Avian Pathol*. 19:75–87.
60. Montgomery, R.D., C.R. Boyle, W.R. Maslin, and D.L. Magee. 1997. Attempts to reproduce a runting/stunting-type syndrome using infectious agents isolated from affected Mississippi broilers. *Avian Dis*. 41:80–92.
61. Moon, H.W. 1978. Mechanisms in the pathogenesis of diarrhea: a review. *J Am Vet Med Assoc*. 172:443–448.
62. Nelson, T.S., L.K. Kirby, Z.B. Johnson, J.T. Halley, and J.N. Beasley. 1982. Digestion of feed by chicks with pale bird syndrome. *Avian Dis* 26:696–700.
63. Nighot, P.K., A. Moeser, R.A. Ali, A.T. Blikslager, and M.D. Koci. 2011. Astrovirus infection induces sodium malabsorption and redistributes sodium hydrogen exchanger expression. *Virology*. 401:146–154.
64. Nili, H., M. Jahantigh, and S. Nazifi. 2007. Clinical observation, pathology, and serum biochemical changes in infectious stunting syndrome of broiler chickens. *Comp Clin Pathol* 16:161–163.
65. Otto, P., E.M. Liebler-Tenorio, M. Elschner, J. Reetz, U. Lohren, and R. Diller. 2006. Detection of rotaviruses and intestinal lesions in broiler chicks from flocks with runting and stunting syndrome (RSS). *Avian Dis*. 50:411–418.
66. Otto, P.H., M.U. Ahmed, H. Hotzel, P. Machnowska, J. Reetz, B. Roth, E. Trojnar, and R. Johne. 2012. Detection of avian rotaviruses of groups A, D, F and G in diseased chickens and turkeys from Europe and Bangladesh. *Vet Microbiol*. 156:8–15.
67. Page, R.K., O.J. Fletcher, G.N. Rowland, D. Gaudry, and P. Villegas. 1982. Malabsorption syndrome in broiler chickens. *Avian Dis*. 26:618–624.
68. Palade, E.A., Z. Demeter, A. Hornyak, C. Nemes, J. Kisary, and M. Rusvai. 2011. High prevalence of turkey parvovirus in turkey flocks from Hungary experiencing enteric disease syndromes. *Avian Dis*. 55:468–475.
69. Palade, E.A., J. Kisary, Z. Benyeda, M. Mandoki, G. Balka, C. Jakab, B. Vegh, Z. Demeter, and M. Rusvai. 2011 Naturally occurring parvoviral infection in Hungarian broiler flocks. *Avian Pathol*. 40:191–197.
70. Pantin-Jackwood, M.J., J.M. Day, M.W. Jackwood, and E. Spackman. 2008. Enteric viruses detected by molecular methods in commercial chicken and turkey flocks in the United States between 2005 and 2006. *Avian Dis*. 52:235–244.
71. Pantin-Jackwood, M.J., E. Spackman, and J.M. Day. 2008. Pathogenesis of type 2 turkey astroviruses with variant capsid genes in 2-day-old specific pathogen free poults. *Avian Pathol*. 37:193–201.
72. Pantin-Jackwood, M.J., E. Spackman, J.M. Day, and D. Rives. 2007. Periodic monitoring of commercial turkeys for enteric viruses indicates continuous presence of astrovirus and rotavirus on the farms. *Avian Dis*. 51:674–680.
73. Pantin-Jackwood, M.J., E. Spackman, and P.R. Woolcock. 2006. Molecular characterization and typing of chicken and turkey astroviruses circulating in the United States: implications for diagnostics. *Avian Dis*. 50:397–404.
74. Perry, R.W., G.N. Rowland, T.L. Foutz, and J.R. Glisson. 1991. Poult malabsorption syndrome. III. Skeletal lesions in market-age turkeys. *Avian Dis*. 35:707–713.
75. Perry, R.W., G.N. Rowland, and J.R. Glisson. 1991. Poult malabsorption syndrome. I. Malabsorption in poult enteritis. *Avian Dis*. 35:685–693.
76. Perry, R.W., G.N. Rowland, and J.R. Glisson. 1991. Poult malabsorption syndrome. II. Pathogenesis of skeletal lesions. *Avian Dis*. 35:694–706.
77. Perry, R.W., G.N. Rowland, J.R. Glisson, W.L. Steffens, and J.A. Quinn. 1991. Skeletal lesions associated with a naturally occurring poult enteritis. *Avian Dis*. 35:158–164.
78. Pomeroy, K.A., B.L. Patel, C.T. Larsen, and B.S. Pomeroy. 1978. Combined immunofluorescence and transmission electron microscopic studies of sequential intestinal samples from turkey embryos and poults infected with turkey enteritis coronavirus. *Am J Vet Res*. 39:1348–1354.
79. Powell, D.W. 1994. New paradigms for the pathophysiology of infectious diarrhea. *Gastroenterology*. 106:1705–1707.
80. Qureshi, M.A., M. Yu, and Y.M. Saif. 1999. A novel "small round virus" inducing poult enteritis and mortality syndrome and associated with immune alterations. *Avian Dis*. 44:275–283.
81. Qureshi, M.A., Y.M. Saif, C.L. Heggen-Peay, F.W. Edens, and G.B. Havenstein. 2001. Induction of functional defects in macrophages by a poult enteritis and mortality syndrome-associated turkey astrovirus. *Avian Dis*. 45:853–861.
82. Rebel, J.M., F.R. Balk, and W.J. Boersma. 2005. Cytokine responses in broiler lines that differ in susceptibility to malabsorption syndrome. *Br Poult Sci*. 46:679–686.
83. Reece, R.L., and J.A. Frazier. 1990. Infectious stunting syndrome of chickens in Great Britain: field and experimental studies. *Avian Pathol*. 19:723–758.
84. Reynolds, D.L., and Y.M. Saif. 1986. Astrovirus: a cause of an enteric disease in turkey poults. *Avian Dis*. 30:728–735.

85. Reynolds, D.L., Y.M. Saif, and K.W. Theil. 1987. Enteric viral infections of turkey poults: incidence of infection. *Avian Dis*. 31:272–276.
86. Reynolds, D.L., Y.M. Saif, and K.W. Theil. 1986. A survey of enteric viruses of turkey poults. *Avian Dis*. 31:89–98.
87. Reynolds, D.L., and A. Ali. 2008. Turkey torovirus infection. In: *Diseases of Poultry*, 12th ed. A.M. Fadly, Y.M. Saif, J.R. Glisson, L.R. McDougald, L.K. Nolan, and D.E. Swayne, eds. Blackwell Publishing, Ames, Iowa. 361–365.
88. Saif, L.J., Y.M. Saif, and K.W. Theil. 1985. Enteric viruses in diarrheic turkey poults. *Avian Dis*. 29:798–811.
89. Saif, Y.M., L.J. Saif, C.L. Hofacre, C. Hayhow, D.E. Swayne, and R.N. Dearth. 1990. A small round virus associated with enteritis in turkey poults. *Avian Dis*. 34:762–764.
90. Sartor, R.B. 1994. Cytokines in intestinal inflammation: pathophysiological and clinical considerations. *Gastroenterology*. 106:533–539.
91. Sellers, H., E. Linneman, A.H. Icard, and E. Mundt. 2010. A purified recombinant baculovirus expressed capsid protein of a new astrovirus provides partial protection to runting-stunting syndrome in chickens. *Vaccine*. 28:1253–1263.
92. Shapiro, F., and I. Nir. 1995. Stunting syndrome in broilers: physical, physiological, and behavioral aspects. *Poult Sci*. 74:33–44.
93. Shapiro, F., I. Nir, and D. Heller. 1998. Stunting syndrome in broilers: effect of stunting syndrome inoculum obtained from stunting syndrome affected broilers, on broilers, leghorns and turkey poults. *Poult Sci*. 77:230–236.
94. Sharma, J.M. 1991. Hemorrhagic enteritis of turkeys. *Vet Immunol Immunopathol*. 30:67–71.
95. Shirai, J., H. Obata, K. Nakamura, K. Furuta, H. Hihara, and H. Kawamura. 1990. Experimental infection in specific-pathogen-free chicks with avian reovirus and avian nephritis virus isolated from broiler chicks showing runting syndrome. *Avian Dis*. 34:295–303.
96. Smart, I.J., D.A. Barr, R.L. Reece, W.M. Forsyth, and I. Ewing. 1988. Experimental reproduction of the runting-stunting syndrome of broiler chickens. *Avian Pathol*. 17:617–627.
97. Smyth, J.A., T.J. Connor, F. McNeilly, D.A. Moffet, V.M. Calvert, and M.S. McNulty. 2007. Studies on the pathogenicity of enterovirus-like viruses in chickens. *Avian Pathol*. 36:119–126.
98. Smyth, V.J., H.L. Jewhurst, B.M. Adair, and D. Todd. 2009. Detection of chicken astrovirus by reverse transcriptase-polymerase chain reaction. *Avian Pathol*. 38:293–299.
99. Smyth, V.J., H.L. Jewhurst, D.S. Wilkinson, B.M. Adair, A.W. Gordon, and D. Todd. 2010. Development and evaluation of real-time TaqMan(R) RT-PCR assays for the detection of avian nephritis virus and chicken astrovirus in chickens. *Avian Pathol*. 39:467–474.
100. Songserm, T., B. Engel, D.J. van Roozelaar, G.L. Kok, A. Pijpers, J.M. Pol, and A.A. ter Huurne. 2002. Cellular immune response in the small intestine of two broiler chicken lines orally inoculated with malabsorption syndrome homogenates. *Vet Immunol Immunopathol*. 85:51–62.
101. Songserm, T., J.M. Pol, D. van Roozelaar, G.L. Kok, F. Wagenaar, and A.A. ter Huurne. 2000. A comparative study of the pathogenesis of malabsorption syndrome in broilers. *Avian Dis*. 44:556–567.
102. Songserm, T., D. van Roozelaar, A. Kant, J. Pol, A. Pijpers, and A. ter Huurne. 2003. Enteropathogenicity of Dutch and German avian reoviruses in SPF white leghorn chickens and broilers. *Vet Res*. 34:285–295.
103. Songserm, T., B. Zekarias, D.J. van Roozelaar, R.S. Kok, J.M. Pol, A.A. Pijpers, and A.A. ter Huurne. 2003. Experimental reproduction of malabsorption syndrome with different combinations of reovirus, *Escherichia coli*, and treated homogenates obtained from broilers. *Avian Dis*. 46:87–94. 2002.
104. Spackman, E., J.M. Day, and M.J. Pantin-Jackwood. 2010. Astrovirus, reovirus, and rotavirus concomitant infection causes decreased weight gain in broad-breasted white poults. *Avian Dis*. 54:16–21.
105. Spackman, E., M. Pantin-Jackwood, J.M. Day, and H. Sellers. 2005. The pathogenesis of turkey origin reoviruses in turkeys and chickens. *Avian Pathol*. 34:291–296.
106. Suresh, M., and J.M. Sharma. 1996. Pathogenesis of type II avian adenovirus infection in turkeys: *in vivo* immune cell tropism and tissue distribution of the virus. *J Virol*. 70:30–36.
107. Swayne, D.E., M.J. Radin, and Y.M. Saif. 1990. Enteric disease in specific-pathogen-free turkey poults inoculated with a small round turkey-origin enteric virus. *Avian Dis*. 34:683–692.
108. Theil, K.W., and Y.M. Saif. 1987. Age-related infections with rotavirus, rotaviruslike virus, and atypical rotavirus in turkey flocks. *J Clin Microbiol*. 25:333–337.
109. Thouvenelle, M.L., J.S. Haynes, and D.L. Reynolds. 1995. Astrovirus infection in hatchling turkeys: histologic, morphometric, and ultrastructural findings. *Avian Dis*. 39:328–336.
110. Todd, D., V.J. Smyth, N.W. Ball, B.M. Donnelly, M. Wylie, N.J. Knowles, and B.M. Adair. 2009. Identification of chicken enterovirus-like viruses, duck hepatitis virus type 2 and duck hepatitis virus type 3 as astroviruses. *Avian Pathol*. 38:21–30.
111. Todd, D., J. Trudgett, F. McNeilly, N. McBride, B. Donnelly, V.J. Smyth, H.L. Jewhurst, and B.M. Adair. 2010. Development and application of an RT-PCR test for detecting avian nephritis virus. *Avian Pathol*. 39:207–213.
112. Tyczkowski, J.K., P.B. Hamilton, and M.D. Ruff. 1991. Altered metabolism of carotenoids during pale-bird syndrome in chickens infected with Eimeria acervulina. *Poult Sci*. 70: 2074–2081.
113. van Hemert, S., A.J. Hoekman, M.A. Smits, and J.M. Rebel. 2004. Differences in intestinal gene expression profiles in broiler lines varying in susceptibility to malabsorption syndrome. *Poult Sci*. 83:1675–1682.
114. Vertommen, M., A. Van Der Laan, and H.M. Veenendaal-Hesselman. 1980. Infectious stunting and leg weakness in broilers. II. Studies on alkaline phosphatase isoenzymes in blood plasma. *Avian Pathol*. 9:143–153.
115. Woolcock, P.R., and H.L. Shivaprasad. 2008. Electron microscopic identification of viruses associated with poult enteritis in turkeys grown in California 1993–2003. *Avian Dis*. 52:209–213.
116. Wooley, R.E. 1986. Serological comparison of the Georgia and Minnesota strains of infectious enteritis in turkeys. *Avian Dis*. 17:150–154. 1973.
117. Yason, C.V., and K.A. Schat. 1986. Pathogenesis of rotavirus infection in turkey poults. *Avian Pathol*. 15:421–435.
118. Yason, C.V., and K.A. Schat. 1987. Pathogenesis of rotavirus infection in various age groups of chickens and turkeys: clinical signs and virology. *Am J Vet Res*. 48:977–983.
119. Yu, M., M.M. Ismail, M.A. Qureshi, R.N. Dearth, H.J. Barnes, and Y.M. Saif. 2000. Viral agents associated with poult enteritis and mortality syndrome: the role of a small round virus and a turkey coronavirus. *Avian Dis*. 44:297–304.

120. Yu, M., Y. Tang, M. Guo, Q. Zhang, and Y.M. Saif. 2000. Characterization of a small round virus associated with the poult enteritis and mortality syndrome. *Avian Dis*. 44:600–610.
121. Zavala, G., and H. Sellers. 2005. Runting-stunting syndrome. *Poult Informed Professional*. 85:1–10.
122. Zekarias, B., T. Songserm, J. Post, G.L. Kok, J.M. Pol, B. Engel, and A. ter Huurne. 2002. Development of organs and intestinal mucosa leukocytes in four broiler lines that differ in susceptibility to malabsorption syndrome. *Poult Sci*. 81:1283–1288.
123. Zekarias, B., N. Stockhofe-Zurwieden, J. Post, F. Balk, C. van Reenen, E. Gruys, and J.M. Rebel. 2005. The pathogenesis of and susceptibility to malabsorption syndrome in broilers is associated with heterophil influx into the intestinal mucosa and epithelial apoptosis. *Avian Pathol*. 34:402–407.
124. Zsak, L., K.O. Strother, and J.M. Day. 2009. Development of a polymerase chain reaction procedure for detection of chicken and turkey parvoviruses. *Avian Dis*. 53:83–88.

Hypoglycemia-Spiking Mortality Syndrome of Broiler Chickens

1. Brown, T.P., P.Y. Brunet, E.M. Odor, D.W. Murphy, and E.T. Mallinson. 1991. Microscopic lesions of naturally occurring and experimental "spiking mortality" in young broiler chickens. *Avian Dis*. 35:481–486.
2. Connolly, B.M., A.B. Jenson, C.J. Peters, S.J. Geyer, J.F. Barth, and R.A. McPherson. 1993. Pathogenesis of Pichinde virus infection in stain 13 guinea pigs: An immunocytochemical, virologic, and clinical chemistry study. *Am J Trop Med Hyg*. 49:10–24.
3. Craig, F.R. 1991. Delmarva Mortality Task Force summary. *Proc Natl Meet Poult Health Condemn*. 26:12–28.
4. Davis, J.F. 2006. Unpublished observations.
5. Davis, J.F., and R. Vasilatos-Younken. 1995. Markedly reduced pancreatic glucagon levels in broiler chickens with spiking mortality syndrome. *Avian Dis*. 39:417–419.
6. Davis, J.F., J.C. de la Torre, M. Teng, A.E. Castro, J.T. Doman, T.L. Noble, and S. Yuen. 1995. Spiking mortality syndrome in chickens. *Vet Rec*. 136:204.
7. Davis, J.F., A.E. Castro, J.C. de la Torre, C.G. Scanes, R. Vasilatos-Younken, J.T. Doman, S.V. Radecki, and M. Teng. 1995. Hypoglycemia and spiking mortality in Georgia chickens: experimental reproduction in broiler breeder chicks. *Avian Dis*. 39:162–174.
8. Davis, J.F., A.E. Castro, J.C. de la Torre, H.J. Barnes, J.T. Doman, M. Metz, H. Lu, S. Yuen, and P.A. Dunn. 1996. Experimental reproduction of severe hypoglycemia and spiking mortality syndrome using embryo-passaged and field-derived preparations. *Avian Dis*. 40:158–172.
9. Davis, J.F., J.C. de la Torre, A.E. Castro, B.M. Connolly, J.T. Doman, and P.A. Dunn. 1997. Experimental reproduction of hypoglycemia-spiking mortality syndrome in broiler chickens with the use of homogenized brains containing arenavirus-like particles. *Avian Dis*. 41: 442–446.
10. De la Torre, J.C., and M.B.A. Oldstone. 1992. Selective disruption of growth hormone transcription machinery by viral infection. *Proc Natl Acad Sci USA*. 89:9939–9943.
11. Goodwin, M.A., E.T. Mallinson, J. Brown, E.C. Player, K.S. Latimer, N. Dale, W.V. Shaff, and T.G. Dickson. 1992. Toxicological pathology of cockleburs (*Xanthium* spp.) for broiler chickens. *Avian Dis*. 36:444–446.
12. Goodwin, M.A., D.L. Hill, M.A. Dekich, and M.R. Putnam. 1993. Multisystemic adenovirus infection in broiler chicks with hypoglycemia and spiking mortality. *Avian Dis*. 37:625–627.
13. Guyton, A.C. 1976. Insulin, glucagon, and diabetes mellitus. In: *Textbook of Medical Physiology*, 5th ed. A.C. Guyton, ed. W.B. Saunders Co., Philadelphia. 1044–1045.
14. Hazelwood, R.L. 1976. Carbohydrate metabolism. In: *Avian Physiology*. P.D. Sturkie, ed. Springer-Verlag, New York. 210–232.
15. Mendelson, C., H.B. Nothelfer, and G. Monreal. 1995. Identification and characterization of an avian adenovirus isolated from a "spiking mortality syndrome" field outbreak in broilers on the Delmarva Peninsula, USA. *Avian Pathol*. 24:693–706.
16. Oldstone, M.B.A., R. Ahmed, M.J. Buchmeier, P. Blount, and A. Tishon. 1985. Pertubation of differentiated functions during viral infection *in vivo*: 1. Relationship of lymphocytic choriomenigitis virus and host strains to growth hormone deficiency. *Virology*. 142:158–174.
17. Rodriguez, M., R.J. von Wedel, R.S. Garrett, P.W. Lampert, and M.B.A. Oldstone. 1983. Pituitary dwarfism in mice persistently infected with lyphocytic choriomeningitis virus. *Lab Invest*. 49:48–53.
18. Scanes, C.G., E.A. Dunnington, F.C. Buonomo, D.J. Donoghue, and P.B. Siegel. 1989. Plasma concentrations of insulin like growth factors IGF-I and IGF-II in dwarf and normal chickens of high and low weight selected lines. *Growth Dev Aging*. 53:151–157.
19. Tishon, A., and M.B.A. Oldstone. 1990. Pertubation of differentiated functions during viral infection *in vivo*. *Am J Pathol*. 137:965–969.
20. Vasilatos-Younken, R., and C.G. Scanes. 1991. Growth hormone and insulin-like growth factors in poultry growth: required, optimal, or ineffective. *Poult Sci*. 70:1764–1780.

Proventriculitis and Proventricular Dilatation of Broiler Chickens

1. Bagust, T.J., T.M. Grimes, and D.P. Dennett. 1979. Infection studies on a reticuloendotheliosis virus contaminant of a commercial Marek's disease vaccine. *Aust Vet J*. 55:153–157.
2. Bayyari, G.R., W.E. Huff, J.M. Balog, N.C. Rath, and J.N. Beasley. 1995. Experimental reproduction of proventriculitis using homogenates of proventricular tissues. *Poult Sci*. 74: 1799–1809.
3. Bayyari, G.R., W.E. Huff, J.N. Beasley, J.M. Balog, and N.C. Rath. 1996. Effect of dietary copper on infectious proventriculitis. *Poult Sci*. 75:1961–1969.
4. Brugh, M., and R.L. Wilson. 1986. Effect of dietary histamine on broiler chickens infected with avian reovirus S1133. *Avian Dis*. 30:199–203.
5. Dormitorio, T.V., J.J. Giambrone, and F.J. Hoerr. 2003. Pathogenicity of proventricular homogenates containing IBDV. *Poult Sci*. 82:42.
6. Dorner, J.W., R.J. Cole, L.G. Lomax, H.S. Gosser, and U.L. Diener. 1983. Cyclopiazonic acid production by *Aspergillus flavus* and its effects on broiler chickens. *Appl Environ Microbiol*. 46:698–703.

7. Goodwin, M.A. 1993. Runting, stunting, enteritis, and failure to thrive. *Proceedings of the Symposium on Newly-Emerging and Re-emerging Avian Diseases: Applied Research and Practical Applications for Diagnosis and Control*. American Association of Avian Pathologists, Minneapolis, Minnesota. 18–29.
8. Goodwin, M.A. 1995. Esophageal and proventricular cryptosporidiosis in a chicken. *Avian Dis*. 39:643–645.
9. Goodwin, M.A., K.S. Latimer, E.C. Player, F.D. Niagro, and R.P. Campagnoli. 1995. Viral proventriculitis in chickens. *Proceedings of the 132nd Annual Meeting of the American Veterinary Medical Association*, Pittsburgh. 140.
10. Goodwin, M.A. 1996. Alimentary system. In: *Avian Histopathology*, 2nd ed. C. Riddell, ed. American Association of Avian Pathologists, Kennett Square, Pennsylvania. 116–118.
11. Goodwin, M.A., S. Hafner, D.I. Bounous, K.S. Latimer, E.C. Player, F.D. Niagro, R.P. Campagnoli, and J. Brown. 1996. Viral proventriculitis in chickens. *Avian Pathol*. 25:369–379.
12. Goodwin, M.A., and S. Hafner. 1997. Transmissible viral proventriculitis. In: *Diseases of Poultry*, 10th ed. B.W. Calnek, H.J. Barnes, C.W. Beard, L.R. McDougald, and Y.M. Saif, eds. Iowa State University Press, Ames, Iowa. 1034–1038.
13. Gorbalenya, A.E., F.M. Pringle, J. Zeddam, B.T. Luke, C.E. Cameron, J. Kalmakoff, T.N. Hanzlik, K.H.J. Gordon, and V.K. Ward. 2002. The palm subdomain-based active site is internally permuted in viral RNA-dependent RNA polymerases of an ancient lineage. *J Mol Biol*. 324:47–62.
14. Guy, J.S., H.J. Barnes, L. Smith, R. Owen, and F.J. Fuller. 2005. Partial characterization of an adenovirus-like virus isolated from broiler chickens with transmissible viral proventriculitis. *Avian Dis*. 49:344–351.
15. Guy, J.S., L.G. Smith, M.E. Evans, and H.J. Barnes. 2007. Experimental reproduction of transmissible viral proventriculitis by infection of chickens with a novel adenovirus-like virus (isolate R11/3). *Avian Dis*. 51:58–65.
16. Guy, J.S., M.A. West, and F.J. Fuller. 2011. Physical and genomic characteristics identify chicken proventricular necrosis virus (R11/3 virus) as a novel birnavirus. *Avian Dis*. 55:2–7.
17. Guy, J.S., M.A. West, F.J. Fuller, R.A. Marusak, H.L. Shivaprasad, J.L. Davis, and O.J. Fletcher. 2011. Detection of R11/3 virus in experimental and naturally occurring cases of transmissible viral proventriculitis with the use of a reverse transcriptase PCR procedure. *Avian Dis*. 55:70–75.
18. Hafner, S., M.A. Goodwin, E.J. Smith, D.I. Bounous, M. Puette, L.C. Kelley, and K.A. Langheinrich. 1996. Multicentric histiocytosis in young chickens. Gross and light microscopic pathology. *Avian Dis*. 40:202–209.
19. Huff, G.R., Q. Zheng, L.A. Newberry, W.E. Huff, J.M. Balog, N.C. Rath, K.S. Kim, E.M. Martin, S.C. Goeke, and J.K. Skeeles. 2001. Viral and bacterial agents associated with experimental transmission of infectious proventriculitis of broiler chickens. *Avian Dis*. 45:828–843.
20. Jackson, C.A.W., S.E. Dunn, D.I. Smith, P.T. Gilchrist, and P.A. MacQueen. 1977. Proventriculitis, "Nakanuke," and reticuloendotheliosis in chickens following vaccination with herpesvirus of turkeys (HVT). *Aust Vet J*. 53:457–458.
21. Jensen, L.S., P.A. Dunn, and K.N. Dobson. 1991. Induction of oral lesions in broiler chicks by supplementing the diet with copper. *Avian Dis*. 35:969–973.
22. Jones, R.C. 2003. Other reovirus infections. In: *Diseases of Poultry*, 11th ed. Y.M. Saif, H.J. Barnes, J.R. Glisson, A.M. Fadly, L.R. McDougald, and D.E. Swayne, eds. Iowa State University Press, Ames, Iowa. 293–298.
23. Kouwenhoven, B., E.G. Davelaar, and J. Van Walsum. 1978. Infectious proventriculitis causing runting in broilers. *Avian Pathol*. 7:183–187.
24. Kouwenhoven, B., M.H. Vertommen, and E. Goren. 1986. Runting in broilers. In: *Acute Virus Infections of Poultry*. J.B. McFerran and M.S. McNulty, eds. Martinus Nijhoff, Dordrecht, the Netherlands. 165–178.
25. Kouwenhoven, B., R.M. Dewars, and J.F.M. Smeets. 1992. *Proc World's Poult Sci. Congr*. 19:558–561.
26. Lenz, S.D., and F.J. Hoerr. 1998. Gastrointestinal pathogenicity of adenoviruses and reoviruses isolated from broiler chickens in Alabama. *J Vet Diagn Invest*. 10:145–151.
27. Leonard, J., and S. Schmittle. 1995. Proventriculitis, proventriculosis distinctions are important. *Feedstuffs*. 67(January 2):12.
28. McNulty, M.S. 1991. Runting stunting syndrome in broiler chickens. *Proceedings of the 26th National Meeting on Poultry Health and Condemnations*. University of Maryland, Ocean City, Maryland. 115–124.
29. Mussman, H.C., and M.J. Twiehaus. 1971. Pathogenesis of reticuloendothelial virus disease in chicks—an acute runting syndrome. *Avian Dis*. 15:483–502.
30. Newberne, P.M., M.E. Muhrer, R. Craghead, and B.L. O'Dell. 1956. An abnormality of the proventriculus of the chick. *J Am Vet Med Assoc*. 128:553–555.
31. Page, R.K., O.J. Fletcher, G.N. Rowland, D. Gaudry, and P. Villegas. 1982. Malabsorption syndrome in broiler chickens. *Avian Dis*. 26:618–624.
32. Pantin-Jackwood, M.J., and T.P. Brown. 2003. Infectious bursal disease virus and proventriculitis in broiler chickens. *Avian Dis*. 47:681–690.
33. Pantin-Jackwood, M.J., T.P. Brown, Y. Kim, and G.R. Huff. 2004. Proventriculitis in broiler chickens: effect of immunosuppression. *Avian Dis*. 48:300–316.
34. Pantin-Jackwood, M.J., T.P. Brown, and G.R. Huff. 2004. Proventriculitis in broiler chickens: immunohistochemical characterization of the lymphocytes infiltrating the proventricular glands. *Vet Pathol*. 41:641–648.
35. Pantin-Jackwood, M.J., T.P. Brown, and G.R. Huff. 2005. Reproduction of proventriculitis in commercial and specific-pathogen-free broiler chickens. *Avian Dis*. 49:352–360.
36. Poupoulis, C., and L.S. Jensen. 1976. Effect of high dietary copper on gizzard integrity of the chick. *Poult Sci*. 55:113–121.
37. Reece, R. 2002. Transmissible (infectious?) proventriculitis of Australian broiler chickens. *Proceedings of the Australian Veterinary Poultry Association Conference*. Australian Veterinary Poultry Association, Surfer's Paradise, Australia. 35–38.
38. Riddell, C. 1976. The influence of fiber in the diet on dilation (hypertrophy) of the proventriculus in chickens. *Avian Dis*. 20:442–445.
39. Schulze, C., and R. Heidrich. 2001. Megabacteria-associated proventriculitis in poultry in the state of Brandenburg, Germany. *Dtsch Tieraerztl Wochenschr*. 108:264–266.
40. Shifrine, M., H.E. Adler, and L.E. Ousterhout. 1960. The pathology of chicks fed histamine. *Avian Dis*. 4:12–21.
41. Stuart, B.P., R.J. Cole, E.R. Waller, and V.E. Vesonder. 1986. Proventricular hyperplasia (malabsorption syndrome) in broiler chickens. *J Exp Pathol Toxicol*. 6:369–386.
42. Taylor, R.D., and G.P.D. Jones. 2004. The influence of whole grain inclusion in pelleted broiler diets on proventricular dilatation and ascites mortality. *Brit Poult Sci*. 45:247–254.

43. Thayer, S.G., and J.L. Walsh. 1993. Evaluation of cross-contamination on automatic viscera removal equipment. *Poult Sci*. 72:741–746.
44. Tomaszewski, E.K., K.S. Logan, K.F. Snowden, C.P. Kurtzman, and D.N. Phalen. 2003. Phylogenetic analysis identifies the 'megabacterium' of birds as a novel anamorphic ascomycetous yeast, *Macrorhabdus ornithogaster*, gen. nov., sp. nov. *Int J Syst Evol Microbiol*. 53:1201–1205.
45. Witter, R.L., and A.M. Fadly. 2003. Reticuloendotheliosis. In: *Diseases of Poultry*, 11th ed. Y.M. Saif, H.J. Barnes, J.R. Glisson, A.M. Fadly, L.R. McDougald, and D.E. Swayne, eds. Iowa State University Press, Ames, Iowa. 517–539.
46. Witter, R.L., and K.A. Schat. 2003. Marek's disease. In: *Diseases of Poultry*, 11th ed. Y.M. Saif, H.J. Barnes, J.R. Glisson, A.M. Fadly, L.R. McDougald, and D.E. Swayne, eds. Iowa State University Press, Ames, Iowa. 407–465.
47. Yu, L., Y. Jiang, S. Low, Z. Wang, S.J. Nam, W. Liu, and J. Kwang. 2001. Characterization of three infectious bronchitis virus isolates from China associated with proventriculitis in vaccinated chickens. *Avian Dis*. 45:416–424.

Index

Page references followed by f denote figures.

AAAV (avian adeno-associated virus), 316–317
AAS (avian adenovirus splenomegaly), 309–316
Abscess, necropsy examination of, 32
Acanthocephalans, 1133–1134, 1133f–1134f
Access control
  to complex, 23
  to farm/site, 20–21
  to poultry house, 16–17
Acholeplasma, 876
Acinetobacter, 1017
Acquired immunity, in Marek's disease, 544–545
Actinomyces, 1018
Active immunity
  avian encephalomyelitis, 492
  avian leukosis/sarcoma viruses, 584
  avian metapneumovirus, 116–117
  beak and feather disease, 273
  bordetellosis, 841–842
  Borrelia anserina infection, 1020
  chicken infectious anemia, 259
  circovirus, 273
  duck virus enteritis (duck plague), 438–439
  erysipelas, 992
  hemorrhagic enteritis, 314
  infectious bronchitis, 147, 149
  infectious bursal disease, 230
  infectious laryngotracheitis, 170
  influenza virus, 200–201
  Mycoplasma iowae, 909
  Mycoplasma meleagridis, 898
  necrotic enteritis, 952
  Newcastle disease, 101–102
  parvovirus of chickens and turkeys, 404
  rotavirus, 389–390
  turkey coronavirus enteritis, 380
  ulcerative enteritis, 946
Acute reticulum cell neoplasia, 600, 600f, 601
Adaptive immunity, 66–67
Adenocarcinoma
  alimentary, 611, 612f
  lung, 614, 614f
  ovary, 605, 606f
  oviduct, 609–610, 609f–610f
  pancreatic, 613, 613f
Adenoma
  adrenal gland, 616
  alimentary, 611
  hepatoma, 612, 612f
  infraorbital sinus, 613
  integumentary system, 619
  parathyroid gland, 616
  pituitary gland, 616
Adenovirus infections, 289–320. *See also specific diseases; specific virus*
  atadenovirus, 301–309
  aviadenovirus, 290–300
  classification, 289–290, 289t–290t
  hemorrhagic enteritis, 309–316
  overview, 289–290
  quail bronchitis, 316–320
  in waterfowl, 420–421
Adherence to intestinal epithelial cells, by *Salmonella,* 695
Adhesins
  Escherichia coli, 757, 758t, 759
  Mycoplasma gallisepticum, 879
Adjuvant, 35, 867
Adrenal gland neoplasia, 616
AEEC (attaching and effacing *Escherichia coli*), 759, 773, 773f
Aegyptianella, 1017
Aeromonas, 1017–1018
Aflatoxins, 1276–1279
  etiology and toxicology, 1276
  experimental disease, 1276–1279, 1278f
  metabolism and residues, 1279
  natural disease, 1276, 1277f
  pharmacological interactions, 1279
AFLP. *See* Amplified fragment length polymorphism (AFLP) analysis
Agar gel diffusion precipitin (AGDP) test
  for duck hepatitis virus type 1, 427
  for fowl cholera, 811
Agar gel immunodiffusion (AGID) test
  for Gallid herpesvirus type 1, 171
  for hemorrhagic enteritis virus, 314–315
  for influenza virus, 189, 202
  for quail bronchitis virus, 319
  for ulcerative enteritis, 948
Agar gel precipitation (AGP) test
  for infectious bronchitis virus, 150–151
  for infectious bursal disease, 230, 233
  for Marek's disease, 547
  for *Ornithobacterium rhinotracheale,* 829, 832
  for parvovirus of waterfowl, 449
  for reovirus, 359, 360
  for reticuloendotheliosis, 603
  for *Riemerella anatipestifer,* 824

Diseases of Poultry, Thirteenth Edition. David E. Swayne.

© 2013 John Wiley & Sons, Inc. Published 2013 by John Wiley & Sons, Inc.

AGDP. *See* Agar gel diffusion precipitin (AGDP) test
Agglutination test. *See also specific test types*
for arizonosis, 712
for *Bordetella avium,* 842
for duck virus enteritis, 439
for *Riemerella anatipestifer,* 824, 827
for *Salmonella,* 703–704
for tuberculosis, 1016
AGID. *See* Agar gel immunodiffusion (AGID) test
AGP. *See* Agar gel precipitation (AGP) test
Agreement on the Application of Sanitary and Phytosanitary Measures (SPS Agreement), 10
Agrimetrics, 24
AgriStats, 24
Airsacculitis
Mycoplasma gallisepticum, 885, 886f
Mycoplasma iowae, 909
Mycoplasma meleagridis, 896, 897, 897f
Mycoplasma synoviae, 903, 904–905
Ornithobacterium rhinotracheale, 831, 831f
Albendazole, for nematodes, 1133
Alcohol toxicity, 1302–1303
Alendronate, for osteoporosis, 1241
Algae toxicity, 1304
Alpha-naphthyl thiourea (ANTU) toxicity, 1301
Alphavirus, 473
Alphitobius diaperinus, 1105–1107, 1106f
Alternaria spp., 1282
Aluminum hydroxide, as vaccine adjuvant, 35
Aluminum toxicity, 1293
ALV. *See* Avian leukosis virus
Amantadine, 206
Amdovirus, 400f
American crow, West Nile virus in, 480
American woodcock, reovirus in, 365
Amidostomum anseris, 1125, 1125f
Amidostomum raillieti, 1126f
Amidostomum skrjabini, 1125, 1126f
Amidostomum spp., 1125, 1125f–1126f
Amino acids, deficiency of, 1206–1207, 1213f
Aminoglycoside toxicity, 1290
Amitrate toxicity, 1299
Ammonia burn, 1258
Ammonia toxicity, 1302
Amoebotaenia cuneata, 1137, 1137f–1139f, 1138, 1139
Amoxicillin, for *Ornithobacterium rhinotracheale,* 834
Amphimerus elongatus, 1144
Amplified fragment length polymorphism (AFLP) analysis
for *Campylobacter,* 742
for *E. coli,* 756
for *Mycoplasma gallisepticum,* 880
for *Mycoplasma iowae,* 908, 910
for *Ornithobacterium rhinotracheale,* 830
for *Pasteurella multocida,* 812
Amprolium, for coccidiosis, 1159–1160, 1161, 1165
aMPV. *See* Avian metapneumovirus (aMPV)
AMV (avian myeloblastosis virus), 556, 556f, 559, 561–562, 563t, 564–565, 576, 580
Amyloidosis, 1236–1238, 1237f
Anemia, chicken infectious, 248–264
Aneurysm, dissecting, 1251–1252
Angara disease. *See* Hydropericardium syndrome (HS)
Animals, access to poultry house by, 16–17
Anthelmintic toxicity, 1292
Antibiotics. *See* Antimicrobials
Antibody-dependent cellular cytotoxicity (ADCC), 63
Antibody level, measurement of, 70
Anticoagulant toxicity, 1301
Anticoccidials, 1159–1161
characteristics of, 1159–1160
drug resistance, 1160–1161
programs for use of, 1160
table of preventative, 1159t
toxicity, 1290–1291
in turkeys, 1165
Antifreeze (ethylene glycol) toxicity, 1303
Antifungal agents
for aspergillosis, 1087–1088
for mycotoxicosis prevention, 1284
Antigen-capture ELISA
for eastern equine encephalitis, 477
for infectious bursal disease, 232
Antigenic drift in influenza viruses, 189–190
Antigenic shift in influenza viruses, 190
Antigen-presenting cell (APC), 64–65
Antimicrobials, 40–43
administration of, 41–43
judicious use principles, 41–42
pharmacologic consideration, 41
for arizonosis, 713
for avian intestinal spirochetosis, 1006–1007
for bordetellosis, 834–844
for *Borrelia anserina,* 1019
for chlamydiosis, 1068
for *Clostridium botulinum,* 957
for enterococcosis, 983
for erysipelas, 994
for *Escherichia coli* infection, 784–785
for fowl cholera, 821–822
for infectious coryza, 868
for *Mycoplasma gallisepticum,* 892–893
for *Mycoplasma iowae,* 910
for *Mycoplasma meleagridis,* 899–900
for *Mycoplasma synoviae,* 906
for *Ornithobacterium rhinotracheale,* 833–834
for paratyphoid infections, 706
for *Pseudomonas,* 1025
for pullorum disease and fowl typhoid, 692–693
resistance, 42–43, 43f
for *Riemerella anatipestifer,* 828
routes of medication, 40–41
for staphylococcosis, 977
for streptococcosis, 980
toxicity, 1288–1291
aminoglycosides, 1290
antiprotozoals, 1291
arsenical and imidazole feed additives, 1291
ionophores, 1290–1291
nitrofurans, 1289–1290
sulfonamides, 1288–1289
for tuberculosis, 1017
for ulcerative enteritis, 948–949
Antinutrients, 1292
Antiprotozoals, toxicity of, 1291
ANTU (alpha-naphthyl thiourea) toxicity, 1301
Aortic rupture, 1251–1252, 1251f
APC (antigen-presenting cell), 64–65
APEC (avian pathogenic *Escherichia coli*), 48
Apoptosis
beak and feather disease virus, 273
chicken infectious anemia virus, 257
infectious bursal disease and, 231
influenza virus, 193, 200
Marek's disease, 540
Newcastle disease and, 101

Apramycin, for colibacillosis, 784
Aproctella stoddardi, 1124–1125, 1124f
Aquabirnavirus, 219
Arasan toxicity, 1299
Arbitrary primed PCR (AP-PCR), for *Pasteurella multocida,* 813
Arbovirus
  classification, 473–474
    Flaviviridae, 474
    Togaviridae, 473–474, 474f
  eastern equine encephalitis (EEE), 474–477, 474f, 476f
  etiology, 473–474
  Highlands J virus, 478
  Israel turkey meningoencephalitis, 478–479
  laboratory host system, 474
  public health significance, 44–45, 473
    nature of disease in humans, 44
    occurrence, 44–45
    reservoirs and sources of infection, 45
  western equine encephalitis (WEE), 477–478
  West Nile virus, 479–482
Arcanobacterium, 1018
Argas persicus (fowl tick), 1105, 1105f
Arginine deficiency, 1207
Arizonosis, 706–713
  antigenic structure, 708
  biochemical properties, 707–708, 708t
  classification, 707
  clinical signs, 709, 709f–710f
  colony morphology, 707
  definition and synonyms, 707
  diagnosis, 711
  differential diagnosis, 711
  economic significance, 707
  etiology, 707–708
  growth requirements, 707
  history, 707
  incidence and distribution, 708
  intervention strategies, 711–713
  isolation and identification of causative agent, 711
  management procedures, 711–712
  morphology and staining, 707
  mortality, 709
  natural and experimental hosts, 708
  overviews, 706–707
  pathogenesis, 711
  pathology, 709–711
    gross lesions, 709–710, 710f
    histopathology, 710–711, 710f
  public health significance, 707
  resistance to chemical and physical agents, 708
  serology, 711, 712
  transmission, 709
  treatment, 713
  vaccination, 712–713
  virulence factors, 711
Arrhenoblastoma (arrhenoma), 607–608, 608f
Arsanilic acid toxicity, 1291
Arsenic toxicity, 1291–1292, 1294
ART (avian rhinotracheitis). *See* Avian metapneumovirus (aMPV)
Arthritis
  E. coli osteoarthritis, 777–778
  viral arthritis, 352–361
Arthropathy, amyloid, 1237, 1237f
Arthropod pests, 1105–1109
  Alphitobius diaperinus (lesser mealworm/darkling beetle), 1105–1107, 1106f
  bed bugs, 1108, 1109f
  control recommendations, 1108–1109
  flies, 1107–1108, 1107f–1108f
Articular urate deposition, 1255–1256, 1256f
Ascaridia bonasae, 1121
Ascaridia columbae, 1120f, 1121
Ascaridia compar, 1120f, 1121
Ascaridia dissimillis, 1120f, 1121
Ascaridia galli, 1120f–1121f, 1121
Ascaridia numidae, 1121
Ascaridia spp., 1120–1121, 1121f
Ascarid larvae, necropsy examination and, 32
Ascites, in colibacillosis, 771
Ascites syndrome. *See* Pulmonary hypertension syndrome (PHS)
Asclepidin toxicity, 1305
Aspergillosis, 1078–1088
  biochemical properties, 1079
  classification, 1078
  clinical signs, 1081–1083, 1081f
  colony morphology, 1078, 1079
  definition and synonyms, 1078
  diagnosis, 1085–1087
  differential diagnosis, 1087
  economic significance, 1078
  etiology, 1078–1080
  growth requirements, 1079
  history, 1078
  immunity, 1085
  incidence and distribution, 1080–1081
  incubation period, 1082
  isolation and identification of agent, 1085–1086
  management procedures, 1087–1088
  morbidity and mortality, 1083
  morphology and staining, 1078–1079
  natural and experimental hots, 1081
  pathobiology and epidemiology, 1080–1085
  pathogenesis, 1085
  pathology, 1083–1085
    gross lesions, 1083–1084, 1083f–1084f
    histopathology, 1084–1085, 1084f
  public health significance, 1078
  serology, 1086–1087
  susceptibility to chemical and physical agents, 1079–1080
  toxins, 1080
  transmission, carriers, and vectors, 1082
  virulence factors, 1080
Aspergillus citrinin, 1280
Aspergillus flavus, 1276, 1281
Aspergillus ochraceus, 1279
Aspergillus oryzae, 1281
Aspergillus parasiticus, 1276
Asphyxiation, 1234–1235
Aspirin, for colibacillosis, 785
Association mapping, 74
Astrocytoma, 614–615, 614f
Astrovirus (AstV), 391–395. *See also* Avian nephritis
  avian nephritis virus, 467–473
  classification, 391, 392f, 393
  clinical signs, 393–394
  diagnosis, 394
  etiology, 392–393
  immune response, 394
  incidence and distribution, 391–392
  intervention strategies, 395
  laboratory host systems, 393
  morphology, 392, 393f
  overview, 391
  pathogenesis and epidemiology, 393–394
  pathology, 394
    gross lesions, 394
    histological lesions, 394
  phylogenetic tree of, 469f
  susceptibility to physical and chemical agents, 393

Atadenovirus, 289t, 290, 301–309, 420
chemical composition, 302
classification, 301
clinical signs, 304–305, 304f
definition and synonyms, 301
diagnosis, 306–307
differential diagnosis, 307–308
economic significance, 301
etiology, 301–303
hemagglutination, 302
history, 301
immunity, 305
incidence and distribution, 303
intervention strategies, 308–309
laboratory host systems, 303
management procedures, 308–309
morphology, 301–302, 302f
natural and experimental hosts, 303
pathobiology and epizootiology, 303–305
pathogenesis of the infectious process, 305
pathology, 305
gross lesions, 305
microscopic lesions, 305, 306f–308f
serology, 306–307
strain classification, 302–303
susceptibility to physical and chemical agents, 302
transmission, carriers, and vectors, 303–304
treatment, 309
vaccination, 309
virus isolation, 306
virus replication, 302
Atherosclerosis, 530, 537–538, 538f
Attaching and effacing *Escherichia coli* (AEEC), 759, 773, 773f
Atypisches Geflugelpest. *See* Newcastle disease
Aulonocephalus lindquisti, 1125, 1125f
Avastrovirus, 468
Aviadenovirus, 289, 289t, 290–300, 420
chemical composition, 291–292
classification, 291
clinical signs, 295–298
in chickens, 297
in ducks and geese, 297
egg production decline, 297
gizzard erosions, 297
in guinea fowl, 298
hydropericardium syndrome, 296–297
inclusion body hepatitis, 295–296
in ostriches, 298
in pigeons, 297
poor feed conversion and growth, 297
in turkeys, 297
definitions and synonyms, 290
diagnosis, 299–300
economic significance, 290–291
etiology, 291–294
hemagglutination, 292
history, 291
immunity, 299
immunosuppression, 299
incidence and distribution, 294
incubation period, 295
intervention strategies, 300
laboratory host systems, 294
management procedures, 300
morphology, 291, 291f–293f
natural and experimental hosts, 294
pathobiology and epidemiology, 294–299
pathogenicity, 294
pathology, 298–299
Gizzard erosions, 299, 299f
hydropericardium syndrome, 298–299
inclusion body hepatitis, 296f, 298, 298f
pancreatitis, 299
respiratory disease, 299
public health significance, 291
serology, 300
strain classification, 292–294
antigenicity, 292
immunogenicity and protective characteristics, 292
molecular characteristics, 292, 294
susceptibility to physical and chemical agents, 292
transmission, 295
vaccination, 300
virus isolation, 299–300
virus replication, 292
Avian adeno-associated virus (AAAV), 316–317
Avian adenovirus splenomegaly (AAS), 309–316
Avian arizonosis. *See* Arizonosis
Avian chlamydiosis. *See* Chlamydiosis
Avian distemper. *See* Newcastle disease
Avian encephalomyelitis, 486–493
chemical composition, 486
classification, 486
clinical signs, 488
diagnosis, 492–493
differential diagnosis, 493
etiology, 486–487
history, 486
immunity, 491–492
incidence and distribution, 487
incubation period, 488
intervention strategies, 493
laboratory host systems, 487
cell cultures, 487
chicken embryos, 487
morbidity and mortality, 488
morphology, 486
natural and experimental hosts, 487
overview, 486
pathobiology and epidemiology, 487–492
pathogenesis, 490–491
pathology, 488–490
gross lesions, 487f, 488–489
microscopic lesions, 489–490, 489f–490f
strain classification, 486–487
susceptibility to physical and chemical agents, 486
transmission, 488
vaccination, 493
virus isolation, 492
Avian hepatitis E virus (HEV), 494–500
chemical composition, 495
classification, 494
clinical signs, 496
diagnosis, 500
differential diagnosis, 500
etiology, 494–495
immunity, 497–498
incidence and distribution, 495–496
intervention strategies, 500
laboratory host systems, 495
morbidity and mortality, 496
morphology, 494, 494f
natural and experimental hosts, 496
overview, 494
pathobiology and epizootiology, 495–499
pathogenesis, 497
pathology, 496–497, 497f–499f
strain classification, 495
susceptibility to physical and chemical agents, 495
transmission, 496
virus replication, 495
Avian influenza. *See* Influenza
Avian intestinal spirochetosis, 995–1007
antimicrobials, 1006–1007
biochemical properties, 997
biosecurity, 1006
classification, 995–996

clinical signs and pathology, 1001–1004, 1002f–1003f
colony morphology, 997
definition and synonyms, 995
diagnosis, 1004–1006
demonstration of spirochetes, 1004
differential diagnosis, 1005–1006
identification of spirochetes, 1004–1005
isolation of spirochetes, 1004
PCR on feces, 1005
serology, 1005
economic significance, 995
etiology, 995–999
growth requirements, 996
history, 995
intervention strategies, 1006–1007
management procedures, 1006
morphology and staining, 996, 996f
pathobiology and epizootiology, 999–1004
age influences, 1000
anatomic location, 1000
clinical signs and pathology, 1001–1004, 1002f–1003f
diet and microbiota influences, 1000–1001
host range, 999
immunity, 1004
incidence and distribution, 829–830
incubation period, 1000
prevalence of pathogenic species, 999
spirochetes in ceca, 1000
strains present, 999–1000
transmission, carriers, and vectors, 830
pathotypes, 996, 996t
probiotics, 1006
public health significance, 826
susceptibility to chemical and physical agents, 997
treatment, 833
virulence factors, 997–999
Avian keratoacanthoma, 617–619, 618f–619f
Avian leukosis virus (ALV), 553–592
chemical composition, 556–558
classification, 555, 557t
clinical signs, 570
definition and synonyms, 553–554
diagnosis, 585–591
differential diagnosis, 589–591
economic significance, 554
endogenous leukosis viruses, 559–561
etiology, 555–566
genetic resistance, 75–76, 584–585, 585t, 592
history, 554–555
immunity, 584
incidence and distribution, 566–567
of disease, 566–567
of infection, 567
incubation period, 569–570
isolation and identification of agent, 585–589
laboratory host systems, 564–565
morphology, 555
natural and experimental hosts, 567
pathogenicity, 565–566
pathology, 570–583
connective tissue tumors, 580–582
erythroblastosis, 573–575
hemangioma, 577–578
lymphoid leukosis, 571–573
myeloblastosis, 576
myelocytomatois, 576–577
nephroma and nephroblastoma, 578–580
nonneoplastic conditions, 570–571
osteopetrosis, 582–583
prevention and control, 591–593
eradication, 591–592
selection for genetic resistance, 592
public health significance, 554
serology, 589
strain classification, 561–564
susceptibility to chemical and physical agents, 561
transmission, 567–568, 568f
vaccination, 591
virus replication, 558–559
Avian metapneumovirus (aMPV), 89, 112–119, 417–418
chemical composition, 113
classification, 113
clinical signs, 116
definition and synonyms, 112
diagnosis, 117–118
differential diagnosis, 118
economic significance, 112
epidemiology, 112–113
etiology, 112–115
history, 112
immunity, 116–117
active, 116–117
cell-mediated, 116
humoral, 116–117
passive, 117
intervention strategies, 118–119
laboratory host systems, 114
cell culture, 114
chicken embryos, 114
management procedures, 118–119
morbidity and mortality, 116
morphology, 113, 113f
natural and experimental hosts, 115
pathobiology, 115–117
pathogenesis, 116
pathogenicity, 114–115, 115f
pathology, 116
gross lesions, 116
microscopic lesions, 116
public health significance, 112
serology, 118
strain classification, 114
susceptibility to physical and chemical agents, 114
transmission, 115
vaccination, 119
virus isolation and identification, 117–118
virus replication, 113–114
Avian mite dermatitis, public health significance of, 52
Avian myeloblastosis virus (AMV), 556, 556f, 559, 561–562, 563t, 564–565, 576, 580
Avian nephritis, 467–473
classification, 468
clinical signs, 470
diagnosis, 471–473
differential diagnosis, 472–473
etiology, 468–470, 468f–469f
genome structure, 468, 468f
incidence and distribution, 470
laboratory host systems, 469
cell cultures, 469
chicken embryos, 469
natural and experimental hosts, 470
overview, 467–468
pathogenesis and epidemiology, 470–471
pathogenicity, 469–470
pathology, 470–471, 471f–472f
gross, 470, 471f
histopathology, 470–471, 471f–472f
phylogenetics, 469f
serology, 472
susceptibility to physical and chemical agents, 468
transmission, 470
treatment, prevention, and control, 473
virus antigen demonstration, 472
virus isolation, 471
virus RNA demonstration, 472

Avian nephrosis. *See* Infectious bursal disease
Avian paramyxovirus serotype 1 (APMV-1). *See* Newcastle disease
Avian paramyxovirus serotypes 2-11 (APMV-2-APMV-11), 89, 90t, 107–112, 417
  chemical composition, 108
  classification, 108
  clinical signs, 110
  definition and synonyms, 107
  diagnosis, 111
  differential diagnosis, 111
  economic significance, 107
  etiology, 108–109
  history, 107–108
  immunity, 111
  incidence and distribution, 109–110
  incubation period, 110
  intervention strategies, 111–112
  laboratory host systems, 108
  management procedures, 111
  morbidity and mortality, 110
  morphology, 108
  natural and experimental hosts, 110
  pathogenesis of the infectious process, 111
  pathogenicity, 109
  pathology, 110–111
    gross, 110
    microscopic, 110–111
  public health significance, 107
  serology, 111
  strain classification, 108–109
    antigenicity, 108
    genetic or molecular, 108–109
    immunogenicity or protective characteristics, 108
  susceptibility to physical and chemical agents, 108
  transmission, carriers, and vectors, 110
  treatment, 112
  vaccination, 111–112
  virus isolation and identification, 111
  virus replication, 108
Avian pathogenic *Escherichia coli* (APEC), 48. *See also* Colibacillosis
Avian pest. *See* Newcastle disease
Avian pneumoencephalitis. *See* Newcastle disease
Avian pneumovirus infection of turkeys (APV). *See* Avian metapneumovirus
Avian rhinotracheitis (ART). *See* Avian metapneumovirus
Avibacterium, differential tests for genus, 861t
Avibacterium paragallinarum, 859–868, 1320. *See also* Infectious coryza
Avibirnavirus, 219
Avicide toxicity, 1302
Avitrol toxicity, 1302
Avocado toxicity, 1304
Avulavirus, 89, 107, 108

Bacillary white diarrhea. *See* Pullorum disease
Bacillus spp., 1018
Bacitracin
  for avian intestinal spirochetosis, 1007
  for enterococcosis, 983
  for ulcerative enteritis, 948–949
Bacteremia, necropsy examination and, 32
Bacterial cultures, 30
Bacterial diseases, 971–1027. *See also specific agents; specific diseases*
  public health significance, 46–50
    botulism, 46
    campylobacteriosis, 47
    chlamydiosis (psittacosis), 47–48
    Clostridium perfringens infection, 46–47
    Erysipelothrix rhusiopathiae infection, 48
    Escherichia coli infection, 48–49
    listeriosis, 49
    mycobacteriosis, 49–50
    salmonellosis, 50
    Staphylococcus aureus infection, 50
Bacteriocins, for *Campylobacter,* 743
Bacteriophages, for colibacillosis, 785
Baits, rodenticide, 1114, 1115t
BALT (bronchial-associated lymphoid tissue), 63
Bankruptcy gut. *See* Hemorrhagic enteritis (HE)
Baylisascaris spp., 1125
B cells, 63–65, 67–69
Beak and feather disease (BFD), 264–275
  chemical composition, 266
  classification, 265–266
  clinical signs, 270–271
  definitions and synonyms, 264–265
  diagnosis, 273–275
  differential diagnosis, 275
  economic significance, 265
  etiology, 265–268
  history, 265
  immunity, 273
  incidence and distribution, 269
  incubation period, 270
  intervention strategies, 275
  management procedures, 275
  morbidity and mortality, 270–271
  morphology, 266
  natural and experimental hosts, 269
  pathobiology and epizootiology, 269–275
  pathogenesis, 273
  pathogenicity, 268
  pathology, 271–273
    gross lesions, 271
    microscopic lesions, 271–272, 272f
    ultrastructural observations, 272–273, 272f
  public health significance, 265
  serology, 274
  strain classification, 266–268
    antigenicity, 266–267
    genetic and molecular characteristics, 267–268
    immunogenicity or protective characteristics, 267
  susceptibility to physical and chemical agents, 266
  transmission, carriers, and vectors, 269–270
  treatment, 275
  vaccination, 275
  virus replication, 266
Beak necrosis, 1026
Beak trimming, 19
Bed bugs, 1108, 1109f
Belladonna toxicity, 1305
Benzimidazoles
  for nematodes, 1133
  toxicity, 1291
BFD. *See* Beak and feather disease
BFPyV (Budgerigar Fledgling polyomavirus), 440
Big-liver-and-spleen disease. *See* Avian hepatitis E virus
Binding agents for mycotoxins, 1284
Biocontainment, 33–38
  chemoprophylaxis, 33
  immunization, 34–38
Bioexclusion, 6, 9–23
  company perspective, 10–11
  country perspective, 10
  disease status and, 11
  global perspective, 9–10

hatchery, 17–19
breeder codes, 19
chick sexers, 19
design and location, 18
sanitation, 18–19
storage facilities, 19
surgical procedures, 19
OIE-listed diseases, 10
poultry house, 11–17
built-up litter and unclean buildings, 13
cleanout and disinfection, 12–13
culling, 13–14
decontamination, 12–13
disinfectants, 13
down time, 12
feed and drinking water, 15, 15f
feed and water medication, 15–16
house access
animals, 16–17
insect, mite, and tick control, 17
people, 16
management of house environment, 11–12
mortality, 14
nest and egg hygiene, 14–15
turnaround time, 12
primary control zone (poultry house and hatchery), 11–19
region/state perspective, 10
secondary control zone (farm or site), 19–22, 22f
tertiary control zone (complex), 22–23
Biosecurity, 9–23
APMVs, 112
avian intestinal spirochetosis, 1006
avian metapneumovirus, 112, 119
avian nephritis virus, 473
bioexclusion, 9–23
Campylobacter infection, 742–743
circovirus, 275
classification of diseases and, 11
common practices, 44
company perspective, 10–11
conceptual, 7
country perspective, 10
disease status and, 11
E. coli, 781
global perspective, 9–10
influenza virus and, 203–204
Newcastle disease, 99, 104
OIE-listed diseases, 10
primary control zone (poultry house and hatchery), 11–19
principles of disease prevention and control, 6, 7–8
procedural, 7–8
region/state perspective, 10
secondary control zone (farm or site), 19–22, 22f
structural, 7
tertiary control zone (complex), 22–23
viral arthritis, 360–361
Biotin, 1220, 1220f
Biotoxins, 1304
algae, 1304
rose chafers, 1304
Bird flu. *See* Influenza
Birnaviridae. *See* Infectious bursal disease (IBD)
Birnavirus
chicken proventricular necrosis virus, 1328–1332
Biting midges, 1107
Black flies, 1107
Blackhead. *See* Histomoniasis
Black locust toxicity, 1304
Bladder pod toxicity, 1304
Blindness, in Marek's disease, 530–531
Blood parasites, necropsy examination and, 32
Blood samples, 27–28, 27f
Blosnavirus, 219
Blow flies, 1108
Blue bugs/fowl ticks *(Argas persicus),* 26, 1105
Bluecomb disease. *See* Turkey coronavirus enteritis
Blue-wing disease, 363, 976
B-lymphocytes, in Newcastle disease, 102
Bocavirus, 400f
Bone fractures, spontaneous, 1242–1243
Bone marrow, 63
Bone marrow granuloma, in tuberculosis, 1013, 1014f, 1015f
Bordetella avium, 834–844, 1320
Bordetellosis, 834–844
antigenic structure, 836
biochemical properties, 835, 836t
classification, 834–835
clinical signs, 839, 839f
colony morphology, 835, 835f
definition and synonyms, 834
diagnosis, 842
differential diagnosis, 843
economic significance, 834
etiology, 834–838
growth requirements, 835
history, 834
immunity
active, 841–842
passive, 842
incidence and distribution, 838
incubation period, 839
isolation and identification of agent, 842
management procedures, 843
morbidity and mortality, 839
morphology, 835, 835t
natural and experimental hosts, 838–839
pathobiology and epizootiology, 838
pathogenesis, 841
pathology
gross, 839–840, 840f
microscopic and ultrastructural, 840–841, 840f–841f
public health significance, 834
serology, 842
strain classification, 836–837
susceptibility to chemical and physical agents, 835
toxins, 836, 837–838
transmission and carriers, 839
treatment, 843–844
vaccination, 843
virulence factors, 837–838
Boric acid toxicity, 1298
Borrelia anserina, 1018–1020, 1018f–1019f
Botulism, 953–957
clinical signs, 955, 955f
colony morphology, 954
diagnosis, 956
differential diagnosis, 956
etiology, 953–954
growth requirements, 954
history, 953
incidence and distribution, 954
incubation period, 955
isolation and identification of causative agent, 956
management procedures, 956
morbidity and mortality, 955
morphology and staining, 954
natural and experimental hosts, 954
pathogenesis, 955–956
pathogenicity, 954
public health significance, 46
susceptibility to chemical and physical agents, 954
transmission, 955
treatment, 956–957
vaccination, 956
virulence factors, 954

Brachyspira spp., 995–1007, 996f, 996t, 998f, 1002f–1003f. *See also* Avian intestinal spirochetosis
Brain, exposure and removal of, 30–31, 31f
Breast burn, 1257
Breast buttons, 1257
Breeder code, 19
Brittle bone disease, 363
Brodifacoum toxicity, 1301
Bronchial-associated lymphoid tissue (BALT), 63
Bronchitis. *See* Infectious bronchitis
Budgerigar Fledgling polyomavirus (BFPyV), 440
Budgerigars
  APMVs in, 107, 109–111
  Gallibacterium in, 1020
  pigeon herpesvirus 1 in, 466
  reovirus in, 365
Buildings, uncleaned, 13
Bumblefoot, 976
Bursal disease. *See* Infectious bursal disease
Bursal lymphoma, 599, 599f
Bursa of Fabricius, 61–63, 62f, 571f
Butynorate (dibutyltin dilaurate), for tapeworms, 1143

Cacao toxicity, 1304
CaCV (canary circovirus), 265–267
Cadmium toxicity, 1294
Cage layer fatigue, 1240. *See also* Osteoporosis
Calcium
  deficiency, 1213f, 1222
  excess, 1222
  toxicity, 1293
CALT (conjunctival-associated lymphoid tissue), 63, 64f
Cambendazole, for nematodes, 1133
Campylobacter infection, 737–743
  classification, 737
  clinical signs, 740
  diagnosis, 741–742
    culture-based methods, 741–742
    immunology-based methods, 742
    nucleic acid-based methods, 742
  etiology, 737
  growth requirements, 737
  immunity, 741
  incidence and distribution, 737–738
  incubation period, 739–740
  intervention strategies, 742–743
    bacteriocins, 743
    biosecurity, 742–743
    competitive exclusion, 743
    feed additives, 743
    phage therapy, 743
    vaccination, 743
  necropsy examination hints, 32
  overview, 737
  pathobiology and epizootiology, 737–741
  pathogenesis of infectious process, 740–741
  pathology, 740
  public health significance, 47
    nature of the disease in humans, 47
    occurrence, 47
    preventive measures, 47
    reservoirs and sources of infection, 47
  transmission, 738–739
    horizontal, 738–739
    vertical, 739
  vectors and carriers, 738–739
Canary circovirus (CaCV), 265–267
Canary pox, 334f, 339, 340–341, 345
Candida albicans, 1026–1027
Candidate genes, 73–74
Candidiasis, 1088–1090
  clinical signs, 1089
  definition and synonyms, 1088
  diagnosis, 1090
  etiology, 1088
  history, 1088
  incidence and distribution, 1089
  pathology, 1089–1091
    gross lesions, 1089, 1089f
    microscopic lesions, 1089–1090
  significance, 1088
  treatment and control, 1090
Cannibalism, 1233–1234
Capillaria anatis, 1121, 1122f, 1122t
Capillaria annulata, 1121, 1123f
Capillaria bursata, 1121, 1122f, 1122t
Capillaria caudinflata, 1121, 1122f, 1122t
Capillaria contorta, 1121, 1123f
Capillaria obsignata, 1121, 1122f–1123f, 1122t, 1133
Capillaria spp., 1121, 1122f–1123f, 1122t
Capillarids, necropsy examination and, 32
Captan toxicity, 1299
Carbamate toxicity, 1300–1301
Carbarsone, for histomoniasis, 1178t
Carbohydrates, 1207
Carbon dioxide, euthanasia with, 28
Carbon monoxide toxicity, 1302
Carbon tetrachloride toxicity, 1303
Carolina jessamine, 1304
Carriers, removal of, 20
Case history, 25–26
Cassava toxicity, 1304
Castor bean toxicity, 1304
Cataracts, 1258
Cationic detergents, 1298
Cats, access to poultry house, 17
CD4 cells, 66–67
CD8 cells, 66–67
CEF cells. *See* Chicken embryo fibroblast (CEF) cells
Ceftiofur, for *Riemerella anatipestifer,* 828
CEK cells. *See* Chicken embryo kidney (CEK) cells
CEL cells. *See* Chicken embryo liver (CEL) cells
Cell cultures
  arboviruses, 474
  avian encephalomyelitis, 487
  avian metapneumovirus, 114, 117
  avian nephritis virus, 469
  chicken infectious anemia virus, 252, 253
  Chlamydia, 1066
  duck hepatitis virus type 1, 423–424
  duck virus enteritis, 433
  egg drop syndrome virus, 303
  enterovirus-like viruses, 397
  FAdV, 294
  Gallid herpesvirus type 1, 166
  infectious bursal disease, 223–224
  influenza virus, 191
  inoculation of, 33
  leukosis/sarcoma viruses, 565, 565f
  Marek's disease, 524, 525–526, 525f, 546
  Newcastle disease virus, 96
  pigeon herpesvirus 1, 466
  poxvirus, 339, 342
  reticuloendotheliosis, 595, 596, 596f
  rotavirus, 385
  viral arthritis, 354
Cell fusion, by Newcastle disease virus, 92
Cell-mediated immunity (CMI), 66–67
  avian metapneumovirus, 116
  hemorrhagic enteritis, 314
  infectious bronchitis, 147
  infectious bursal disease effect on, 230–231
  infectious laryngotracheitis, 170
  Marek's disease, 545

Newcastle disease, 101–102
paratyphoid infections, 700–701
pullorum disease and fowl typhoid, 689
reticuloendotheliosis, 602
turkey coronavirus enteritis, 380
viral arthritis, 358–359
Cellulitis, coliform, 768–772, 771f
CELO (chicken embryo lethal orphan) virus, 289, 300, 316, 319
Central chromatolysis, in avian encephalomyelitis, 489–490, 490f
Cephalosporins, for *Riemerella anatipestifer,* 828
Cervical dislocation, 28
Cestodes, 1135–1143
Amoebotaenia cuneata, 1137f–1139f, 1138, 1139
Choanotaenia infundibulum, 1135, 1137f–1139f, 1138, 1139, 1143
classification, 1136
Davainea proglottina, 1136–1137, 1136f, 1138, 1139–1140, 1143
diagnosis and identification, 1137–1138, 1137f–1139f
Fimbriaria fasciolaris, 1142, 1142f
Hymenolepsis cantaniana, 1137f, 1138, 1140
Hymenolepsis carioca, 1136, 1137f–1139f, 1138, 1140
Hymenolepsis megalops, 1135, 1142, 1142f
key to species, 1138
Metroliasthes lucida, 1141–1142, 1141f–1142f
morphology and life cycle, 1136–1137, 1136f–1138f
number of species described, 1136
overview, 1135–1136, 1135t, 1136f
prevention and control, 1143
Raillietina cesticillus, 1135, 1136f, 1137, 1137f–1139f, 1138, 1140, 1143
Raillietina echinobothrida, 137f–1139f, 1138, 1141
Raillietina georgiensis, 1139f, 1141, 1141f–1142f
Raillietina tetragona, 1137f–1139f, 1138, 1140
table of species, 1135t
treatment, 1143
CF test. *See* Complement fixation (CF) test
Chaetomium spp., 1280
Cheilospirura hamulosa, 1125, 1126f
Cheilospirura spinosa, 1125, 1127f
Cheilospirura spp., 1125, 1126f–1127f
Chemoprophylaxis, 33
Chick edema disease, 1303
Chicken anemia agent (CAA). *See* Chicken infectious anemia
Chicken anemia virus (CAV). *See* Chicken infectious anemia
Chicken body louse *(Menacanthus stramineus),* 1103–1104, 1104f
Chicken embryo fibroblast (CEF) cells
Gallid herpesvirus type 1, 166
infectious bursal disease, 221, 223–224
infectious bursal disease and, 231
influenza virus, 191
Israel turkey meningoencephalitis, 479
Newcastle disease virus, 96
viral arthritis, 354
Chicken embryo kidney (CEK) cells
Gallid herpesvirus type 1, 166
infectious bronchitis virus, 143
infectious bursal disease, 221, 223
Newcastle disease virus, 96
Chicken embryo lethal orphan (CELO) virus, 289, 300, 316, 319
Chicken embryo liver (CEL) cells
egg drop syndrome virus, 303
enterovirus-like viruses, 397, 397f
FAdV, 294
Gallid herpesvirus type 1, 166, 170–171
quail bronchitis virus, 317
rotavirus, 385
Chicken embryo lung cells, for Gallid herpesvirus type 1, 166
Chicken embryos
APMVs, 111
arboviruses, 474
avian encephalomyelitis, 486–487, 487
avian hepatitis E virus, 495
avian metapneumovirus, 114, 117
avian nephritis virus, 469
chicken infectious anemia virus, 253
Chlamydia, 1066
duck hepatitis virus type 1, 423
enterovirus-like viruses, 396–397
Gallid herpesvirus type 1, 166
infectious bronchitis virus, 142–143, 143f
infectious bursal disease, 223
influenza virus, 190–191, 202
inoculation for virus isolation, 32–33
leukosis/sarcoma viruses, 564, 564f
Marek's disease, 524–525
Newcastle disease virus, 96
poxvirus, 338, 342
quail bronchitis virus, 317
reticuloendotheliosis, 597
rotavirus, 385
turkey coronavirus enteritis, 378f
viral arthritis, 354
Chicken head louse *(Cuclotogaster heterographa),* 1104–1105
Chicken hepatoma cell line (LMH cells), 294
Chicken infectious anemia (CIA), 248–264
chemical composition, 250
classification, 249
clinical signs, 254–255
as cofactor in other diseases, 260
definition and synonyms, 248
diagnosis, 260–263
antibody-based detection, 262
DNA-based detection, 260–263
serology, 262–263, 262f
virus isolation, 260–261
differential diagnosis, 263
economic significance, 248
etiology, 249–253
hematology, 254
history, 248–249
immunity, 259
active, 259
immunosuppression, 259–260
passive, 259
immunosuppression by, 1321
incidence and distribution, 253
incubation period, 254
intervention strategies, 263–264
laboratory host systems, 252–253
cell culture, 253
chicken embryos, 253
chicks, 253
management procedures, 263
morbidity and mortality, 255
morphology, 249, 249f
natural and experimental hosts, 253
overview, 248
pathobiology and epizootiology, 253–260
pathogenesis, 258–259
age resistance, 258–259
genetic resistance, 259
route of infection, 259
virus dose, 259

Chicken infectious anemia (*cont'd*)
pathology, 255–257
gross lesions, 255–256, 255f–256f
hemorrhagic-aplastic anemia syndrome, 256, 256f–257f
microscopic lesions, 257, 257f–258f
ultrastructural lesions, 257
strain classification, 251–252
antigenicity, 251–252
attenuation, 252
molecular differences, 252
pathogenicity, 252
susceptibility to physical and chemical agents, 251
transmission, 253–254
treatment, 264
vaccination, 263–264
virus replication, 250–251
Chicken kidney (CK) cells
avian nephritis virus, 467, 469
enterovirus-like viruses, 397
FAdV, 293f, 294
Gallid herpesvirus type 1, 166, 170–171
infectious bronchitis virus, 143
influenza virus, 191
quail bronchitis virus, 317
rotavirus, 385
viral arthritis, 354
Chicken liver cells
avian hepatitis E virus in, 495
egg drop syndrome virus in, 303
Chicken proventricular necrosis virus (CPNV), 1328–1332
Chickens
Acinetobacter spp. in, 1017
Aegyptianella in, 1017
Aeromonas spp. in, 1017
APMVs in, 107–111
articular urate deposition in, 1256, 1256f
aspergillosis in, 1081–1083, 1081f, 1084f
astrovirus in, 391, 393–395
aviadenoviruses in, 290–300
avian adenovirus splenomegaly virus in, 309–316
avian encephalomyelitis in, 486–493
avian hepatitis E virus infection in, 494–500
avian intestinal spirochetosis in, 995–1007
avian metapneumovirus in, 112–119
avian nephritis in, 467–473
Bacillus in, 1018
beak necrosis in, 1026
Borrelia anserina in, 1018–1020, 1018f–1019f
botulism in, 953–957
candidiasis in, 1088–1090
chicken infectious anemia in, 248–264
chlamydiosis in, 1061, 1064
Citrobacter in, 1020
coccidiosis in, 1149–1163
colibacillosis in, 751–785
contact dermatitis in, 1257
coryneform bacteria in, 1020
cryptosporidiosis in, 1169–1170, 1169f–1170f
cystic right oviduct in, 1256, 1256f
deep pectoral myopathy in, 1244–1245
degenerative joint disease in, 1242
dermatophytosis in, 1091
eastern equine encephalitis in, 475–477, 476f
enterovirus-like viruses in, 396–399, 397f–398f
erysipelas in, 986, 989
fatty liver-hemorrhagic syndrome in, 1252–1253, 1252f
Flavobacterium in, 1020
fowl cholera in, 807–823
fowl typhoid in, 678–693
gangrenous dermatitis in, 957–960, 958f–959f
gastrocnemius tendon rupture in, 1245–1246, 1245f
Helicobacter in, 1021
histomoniasis in, 1172, 1175, 1177–1178
hypoglycemia-spiking mortality syndrome of broiler chickens in, 1325–1327, 1326f
inclusion body hepatitis in, 295–296, 296f, 298, 298f
infectious bronchitis in, 139–153
infectious bursal disease in, 219–235
infectious coryza in, 859–868
infectious laryngotracheitis in, 161–174
influenza in, 181–206
keratoacanthoma in, 617–619, 618f–619f
Klebsiella spp. in, 1021
leucocytozoonosis in, 1187–1188
leukosis/sarcoma group of neoplastic diseases in, 553–592
Listeria in, 1022
macrorhabdosis in, 1092–1093, 1093f
Marek's disease in, 515–552
multicentric histiocytosis in, 621–622, 622f
multicausal enteric diseases in, 1322–1325
Mycoplasma gallisepticum infection in, 877–893
Mycoplasma iowae infection in, 908, 909
Mycoplasma synoviae infection in, 900–906
necrotic enteritis in, 949–953
Neisseria in, 1023
Newcastle disease in, 89–107
nutritional diseases in, 1205–1227
ochroconosis in, 1091
Ornithobacterium rhinotracheale infection in, 828–834
osteochondrosis in, 1244
osteoporosis in, 1240–1241
oviductal adenocarcinoma in, 609
parvovirus in, 399–405
poxvirus in, 333–346
Proteus spp. in, 1023
proventriculitis and proventricular dilatation of broiler chickens in, 1328–1332
Pseudomonas spp. in, 1024–1025, 1024f–1025f
pullorum disease in, 678–693
pulmonary hypertension syndrome in, 1246–1249
reoviruses in, 362–363
reticuloendotheliosis in, 593–604
Riemerella anatipestifer in, 825
rotated tibia in, 1244
rotavirus in, 382f, 385–390, 388f
sarcocystosis in, 1190–1191
segmented filamentous bacteria in, 1025
seminoma in, 611
splenomegaly virus in, 290
spondylolisthesis in, 1243, 1243f
staphylococcosis in, 971–977
streptococcosis in, 977–980
sudden death syndrome in, 1250–1251
tapeworms of, 1138–1141
tibial dyschondroplasia in, 1238–1240, 1238f
toxoplasmosis in, 1193–1194
transmissible viral proventriculitis in, 1328–1332
trichomoniasis in, 1179–1180
tuberculosis in, 1008–1017

turkey viral hepatitis in, 483
ulcerative enteritis in, 944–949
urolithiasis and visceral urate deposition in, 1254–1255, 1255f
valgus and varus deformation in, 1241–1242, 1241f
Vibrio in, 1026
viral arthritis in, 352–361
West Nile virus in, 480–481
zygomycosis in, 1092
Chick sexers, 19
Chiggers *(Neoschoengastia americana),* 1102, 1102f
Chilomastix gallinarum, 1180, 1181f
Chlamydia psittaci. See Chlamydiosis
Chlamydiosis, 1055–1068
antigenic structure and toxins, 1057–1058
biochemical properties, 1057
in chickens, 1061, 1064
classification, 1055, 1056t
definition and synonyms, 1055
diagnosis, 1065–1067
ELISA, 1065
isolation, 1065–1066
microscopy, 1065
nucleic-acid amplification techniques, 1066–1067
serology, 1067
specimen collection and storage, 1065
differential diagnosis, 1067
in ducks and geese, 1061, 1064
etiology, 1055–1060
history, 1055
immunity, 1064–1065
incidence and distribution, 1060–1061
intervention strategies, 1067–1068
management procedures, 1067
ovotransferrin, 1068
state regulations, 1068
treatment, 1068
vaccination, 1068
morphology and staining, 1055–1057, 1057f
natural and experimental hosts, 1061
pathobiology and epidemiology, 1060–1065
in pheasants, quail, guinea fowl, peacocks and partridges, 1064
in pigeons, 1064
public health significance, 47–48, 1055
nature of disease in humans, 47
occurrence, 47
preventive measures, 47
reservoirs and sources of infection, 47
strain classification, 1058–1060
antigenicity, 1058
genetic, molecular, 1058–1059
pathogenicity, 1059
virulence factors, 1059–1060, 1060f
susceptibility to chemical and physical agents, 1057
transmission, carriers and vectors, 1061–1062
in turkeys, 1060, 1062–1064, 1063f
Chlamydophila psittaci. See Chlamydiosis
Chloramphenicol, for fowl cholera, 821–822
Chlorate toxicity, 1299
Chlordane toxicity, 1300
Chlorine
deficiency, 1223, 1223f
toxicity, 1298
Chlortetracycline
for avian intestinal spirochetosis, 1007
for chlamydiosis, 1068
for enterococcosis, 983
for fowl cholera, 821–822
for *Mycoplasma gallisepticum,* 892
for *Mycoplasma meleagridis,* 899
for *Mycoplasma synoviae,* 906
for *Ornithobacterium rhinotracheale,* 834
Choanotaenia infundibulum, 1135, 1137, 1137f–1139f, 1138, 1139, 1143
Cholangiocellular tumors, 612–613, 612f–613f
Choline deficiency, 1221, 1221f
Chondrodystrophy, 903, 1208, 1219, 1220, 1221
Chondroma and chrondrosarcoma, 580, 582, 621, 621f
Chorioallantoic membrane, inoculation for virus isolation, 32–33
Chromium toxicity, 1294
Chronic respiratory disease (CRD) of chickens, 877, 884
Chukar partridges. *See* Partridges
CIA. *See* Chicken infectious anemia
Cimex lectularius, 1108, 1109f
Circovirus infections, 264–275
chemical composition, 266
chicken infectious anemia, 248–264
classification, 265–266
clinical signs, 270–271
definitions and synonyms, 264–265
diagnosis, 273–275
differential diagnosis, 275
economic significance, 265
etiology, 265–268
history, 265
immunity, 273
active, 273
passive, 273
incidence and distribution, 269
incubation period, 270
intervention strategies, 275
management procedures, 275
morbidity and mortality, 270–271
morphology, 266
natural and experimental hosts, 269
overview, 247
pathobiology and epizootiology, 269–275
pathogenesis, 273
pathogenicity, 268
pathology, 271–273
gross lesions, 271
microscopic lesions, 271–272, 272f
ultrastructural observations, 272–273, 272f
public health significance, 265
serology, 274
strain classification, 266–268
antigenicity, 266–267
genetic and molecular characteristics, 267–268
immunogenicity or protective characteristics, 267
susceptibility to physical and chemical agents, 266
transmission, carriers, and vectors, 269–270
treatment, 275
vaccination, 275
virus replication, 266
Circovirus-like infection of geese, 421
Circulatory system diseases, 1246–1252
aortic rupture, 1251–1252, 1251f
dilated cardiomyopathy, 1249–1250
pulmonary hypertension syndrome (PHS)
clinical signs, 1247, 1247f
intervention strategies, 1249
pathogenesis and etiology, 1248–1249
pathology, 1247–1248, 1247f
sudden death syndrome, 1250–1251

Citrinin, 1280
etiology and toxicology, 1280
experimental disease, 1280
natural disease, 1280
Citrobacter, 708, 1020
CK cells. *See* Chicken kidney (CK) cells
Claviceps spp., 1271
Cleanout and disinfection, 12
Cloacal bursa. *See also* Bursa of Fabricius
quail bronchitis virus, 319
turkey coronavirus enteritis, 377, 378f, 379, 379f
Cloacal prolapse, 1254
Clopidol
for coccidiosis, 1160, 1161
for leucocytozoonosis, 1188
Clostridial disease, 943–960
botulism, 953–957
clinical signs, 955, 955f
colony morphology, 954
diagnosis, 956
differential diagnosis, 956
etiology, 953–954
growth requirements, 954
history, 953
incidence and distribution, 954
incubation period, 955
isolation and identification of causative agent, 956
management procedures, 956
morbidity and mortality, 955
morphology and staining, 954
natural and experimental hosts, 954
pathogenesis, 955–956
pathogenicity, 954
susceptibility to chemical and physical agents, 954
transmission, 955
treatment, 956–957
vaccination, 956
virulence factors, 954
gangrenous dermatitis, 957–960
antigenic structure and toxins, 957
biochemical properties, 957
clinical signs, 958
colony morphology, 957
definition, 957
diagnosis, 959–960
economic significance, 957
etiology, 957–958
growth requirements, 957
history, 957
incidence and distribution, 958
morphology and staining, 957
pathobiology and epizootiology, 958–959
public health significance, 957
treatment and prevention, 961–962
necrotic enteritis, 949–953
clinical signs, 950
definitions and synonyms, 949
diagnosis, 952–953
economic significance, 949
etiology, 949–950
history, 949
intervention strategies, 953
pathobiology and epizootiology, 950–952
pathogenesis, 951–952
pathology, 950–951, 951f
public health significance, 949
strain classification and toxins, 949–950, 950t
transmission, carriers, vectors, 950
overview, 943–944
ulcerative enteritis, 944–949
biochemical characteristics, 945
classification, 944
clinical signs, 945–946
diagnosis, 946–948
differential diagnosis, 948
etiology, 944–945
growth requirements, 945
history, 944
immunity, 946
incidence and distribution, 945
incubation period, 945
management procedures, 948
morphology and staining, 944–945, 944f
mortality rate, 946
natural and experimental hosts, 945
pathology
gross lesions, 946, 947f
histopathology, 946
susceptibility to chemical and physical agents, 945
transmission, 945
treatment, 948–949
Clostridium botulinum, 46, 943, 953–957. *See also* Botulism
Clostridium chauvoei, 944
Clostridium colinum, 943, 944–948
Clostridium difficile, 944
Clostridium novyi, 944
Clostridium perfringens infection
described, 943–944, 949–953, 957–958
public health significance, 46–47
nature of disease in humans, 46
occurrence, 46–47
reservoirs and sources of infection, 47
Clostridium piliforme, 943
Clostridium septicum, 943, 957–958
Clostridium sordelli, 944
Clostridium sporogenes, 944
Clostridium tertium, 944
Clostridium welchii, 957
Clotting, 28
CMI. *See* Cell-mediated immunity
CNS disease
Marek's disease, 535, 535f, 537, 538f
neoplastic diseases, 614–616
Coal-tar derivatives, toxicity of, 1298
Cobalamin (vitamin B_{12}), 1221
Cobalt toxicity, 1293
Coccidiosis, 1148–1166
anticoccidials, table of preventative, 1159t
in chickens, 1149–1163
diagnosis, 1150t, 1157–1159
Eimeria acervulina, 1150t, 1151, 1152f
Eimeria brunetti, 1150t, 1153, 1154f
Eimeria hagani, 1150t, 1153
Eimeria maxima, 1150t, 1152f, 1153
Eimeria mitis, 1150t, 1152f, 1155
Eimeria mivati, 1150t, 1153
Eimeria necatrix, 1150t, 1154f, 1155–1156
Eimeria praecox, 1150t, 1156
Eimeria tenella, 1150t, 1154f, 1156
epidemiology, 1157
etiology, 1149–1156
incidence and distribution, 1149
life cycle, 1151f
natural and experimental hosts, 1157
prevention and control, 1159–1163
transmission and vectors, 1157
vaccination, 1161
classification and taxonomic relationships, 1148–1149
in ducks, 1166
in geese, 1165–1166
Eimeria anseris, 1166
Eimeria truncata, 1165–1166
genetic resistance to, 78

life cycle, 1149
necropsy examination hints, 32
oocyst morphology, 1148, 1148f
overview, 1148
in pigeons, 1166
Salmonella colonization and, 698
in turkeys, 1162t, 1163–1165
Eimeria adeneides, 1162t, 1163–1164
Eimeria dispersa, 1162t, 1164
Eimeria gallopavonis, 1162t, 1164
Eimeria innocua, 1165
Eimeria meleagridis, 1162t, 1164
Eimeria meleagrimitis, 1162t, 1164–1165
Eimeria subrotunda, 1165
etiology, 1163
prevention and control, 1165
Cochlosoma anatis infection, 1180, 1182–1185
clinical signs and pathogenicity, 1184
etiology and classification, 1182–1183
incubation period, 1183
life cycle, 1183
morphology, 1182–1183, 1183f
natural and experimental hosts, 1184
overview, 1182
prevention, 1185
site of infection, 1184
transmission, 1183
treatment, 1184–1185
Codex Alimenatrius Commission, 10
Codiostomum struthonis, 1126
Coenonia, 1020
COFAL test, 586, 587–588, 587t
Coffee senna toxicity, 1304
Co-inheritance of alleles, 72
Colibacillosis, 751–785
antigenic structure, 755
F (pilus) antigen, 755
H (flagellar) antigen, 755
K (capsular) antigen, 755
O (somatic) antigen, 755
biochemical properties, 754
classification, 753, 753t
clinical signs, 765
colisepticemia, 775–777
of ducks, 777
enteric-origin, 776
hemorrhagic, 776
of layers, 776–777
neonatal, 776
respiratory-origin, 775–776
colisepticemia sequelae, 777–779
coligranuloma, 779, 779f
osteoarthritis and synovitis, 777–778
panophthalmitis, 777
turkey osteomyelitis complex, 778–779
colony morphology, 754
definitions and synonyms, 751
diagnosis, 780–781
diagnostic characteristics, 753t
differential diagnosis, 781
economic significance, 751
etiology, 752–762
growth requirements, 754, 754t
history, 752
immunosuppression and, 1321
incidence and distribution, 762
incubation period, 765
intervention strategies, 781–785
isolation and identification of causative agent, 780–781
localized forms, 766–775
coliform cellulitis, 768–772, 771f
coliform omphalitis/yolk sac infection, 766–768, 767f
diarrheal disease, 772–774, 773f
salpingitis/peritonitis, 774
swollen head syndrome, 772
venereal colibacillosis (acute vaginitis), 773–774
management procedures, 781–782
morbidity and mortality, 765
morphology and staining, 754
natural and experimental hosts, 762–764
host susceptibility factors, 763–764, 764t
Ø157:H7 strain, 754
pathobiology and epidemiology, 762–780
pathogenesis, 779–780
pathology, 765–779, 766t
public health significance, 751–752
strain classification, 755–757
antigenicity, 755–756
molecular typing, 756–757
pathogenicity, 757
susceptibility to chemical and physical agents, 754–755
transmission, carriers, and vectors, 764–765
treatment, 784–785
vaccination, 782–784
immunopotentiation, 783–784
inactivated vaccines, 782
live vaccines, 782–783
molecular vaccines, 783
passive immunization, 783
recombinant and mutant vaccines, 783
virulence factors, 757–762
adhesins, 757–759
genomic location of genes, 760–762
invasins, 760
iron acquisition mechanisms, 759
protectins, 759–760
regulation of virulence, 762
table of, 758t
toxins, 755, 759
Colicins, 772
Coligranuloma, 779, 779f
Collyriclum faba, 1144
Compartmentalization, 10
Competitive exclusion
Campylobacter colonization, 743
necrotic enteritis, 952
paratyphoid infections, 704–705
Complement fixation (CF) test
for *Chlamydia,* 1067
for eastern equine encephalitis, 477
for leukosis/sarcoma group of neoplastic diseases, 585–586
Complement system, 63
Complex, disease control and, 22–23
Concanavalin A (ConA), 69
Condorpox, 336
Conjunctival-associated lymphoid tissue (CALT), 63, 64f
Conjunctivitis
in avian metapneumovirus, 115f, 116
in fowl cholera, 816, 817f
in infectious laryngotracheitis, 167–168, 169f
in Marek's disease, 533
in *Mycoplasma gallisepticum* infection, 882, 883–884, 885, 885f
in Newcastle disease, 99, 100f
Connective tissue tumors
differential diagnosis, 591
pathology, 580–582, 581f
gross, 580–582, 581f
microscopic, 581f, 582
pathogenesis, 582
ultrastructural, 582
Contact dermatitis, 1257–1258, 1257f
Copper
deficiency, 1225
excess, 1225
toxicity, 1293
Copper sulfate, for candidiasis, 1090

Cormorants, Newcastle disease virus variants in, 98, 99
Corn cockle toxicity, 1304
Coronavirus
  infectious bronchitis virus, 139–153
  turkey coronavirus enteritis, 376–381
Corynebacterium parvum, immunosuppression by, 698
Coryneform bacteria, 1020
Coryza, infectious. *See* Infectious coryza
Coryza, turkey. *See* Bordetellosis
Cotton seed meal toxicity, 1305
Coxiella burnetii, 1020
Coyotillo toxicity, 1305
CPE. *See* Cytopathic effect
CPNV (chicken proventricular necrosis virus), 1328–1332
CRD (chronic respiratory disease) of chickens, 877, 884
Crop
  impaction, 1253
  lesions in candidiasis, 1089, 1089f, 1090f
  pendulous, 1253, 1253f
Crop fluid, Newcastle disease, 99, 100f
Crop mycosis. *See* Candidiasis
Crotalaria spp. toxicity, 1305
Crows, West Nile infection in, 419
Cryptococcosis
  described, 1096–1097
  public health significance, 50–51
    nature of disease in humans, 51
    occurrence, 51
    reservoirs and sources of infection, 51
Cryptosporidiosis, 1167–1171
  in chickens, 1169–1170, 1169f–1170f
  diagnosis and culture, 1171
  history, 1167
  human health importance, 1167
  incidence and distribution, 1168–1169
  life cycle and morphology, 1167–1168, 1168f
  prevention and control, 1171
  public health significance, 52
    nature of disease in humans, 52
    occurrence, 52
    reservoirs and sources of infection, 52
  in quail, 1170–1171
  taxonomy, 1167, 1167t
  in turkeys, 1170
Cryptosporidium baileyi, 1167–1171, 1167t, 1168f–1170f, 1321
Cryptosporidium meleagridis, 1167–1168, 1167t, 1170
Culling, 13–14
Curled-toe paralysis, 1218, 1218f
Cutaneous disease, poxvirus as, 338f, 340–341, 342
Cyanide, 1304, 1305
Cyathostoma bronchialis, 1126–1127, 1127f
Cyclopiazonic acid, 1281
Cyrnea colini, 1125–1126, 1127f
Cysticercoid, 1136, 1136f, 1137
Cystic right oviduct, 1256, 1256f
Cytokines, 67, 69–70
Cytopathic effect (CPE)
  arboviruses, 474
  astrovirus, 393
  avian nephritis virus, 469
  chicken infectious anemia, 249, 261, 261f
  duck hepatitis virus type 1, 423
  duck virus enteritis, 433
  in eastern equine encephalitis, 477
  goose hemorrhagic polyomavirus, 441
  infectious bronchitis virus, 143
  Newcastle disease virus, 96
  poxvirus, 339, 342
  viral arthritis, 359, 359f
  West Nile virus, 481
Cytotoxic T cells
  in Marek's disease, 545
  in reticuloendotheliosis, 602
Cytotoxic T lymphocytes (CTL), 66, 67
Cytotoxin, chlamydial, 1058

Dactylariosis. *See* Ochroconosis
DAdV-1. *See* Duck adenovirus type 1
DAdV-2. *See* Duck adenovirus type 2
DAEC (diffuse-adherence *Escherichia coli*), 48
Darkling beetle, 1105–1107, 1106f
Daubentonia toxicity, 1305
Davainea proglottina, 1136–1137, 1136f, 1138, 1139–1140, 1143
DDE toxicity, 1300
DDGS (distillers dried grain solubles), 1283
DDT toxicity, 1300
DDVP (dichlorvos), 1300
Dead bird disposal, 22, 22f
Death camas toxicity, 1305
Decalcification solution, 32
Decontaminated, of equipment, 21
Decoquinate, for coccidiosis, 1161
Deep pectoral myopathy, 1244–1245
Degenerative joint disease, 1242
Dehydration, 1235–1236
Delayed type hypersensitivity, in tuberculosis, 1013–1015
Deletrocephalus dimidiatus, 1127
Deoxynivalenol, 1272–1273
Dependovirus, 400f
Depluming mite *(Knemidocoptes laevis),* 1101–1102
Depopulation, for disease control, 20
Dermal squamous cell carcinoma. *See* Keratoacanthoma
Dermanyssus gallinae (poultry red mite), 26, 52, 1101, 1101f. *See also* Avian mite dermatitis
Dermatitis
  aspergillosis, 1081
  biotin deficiency, 1220
  candidiasis, 1089
  contact, 1257–1258, 1257f
  gangrenous, 957–960
Dermatophytosis (flavus)
  described, 1091
  public health significance, 51
    nature of disease in humans, 51
    occurrence, 51
    reservoirs and sources of infection, 51
Detoxification of mycotoxins, 1284
DFA. *See* Direct fluorescent antibody
DIA (dot immunobinding assay), for *Ornithobacterium rhinotracheale,* 833
Diacetoxyscirpenol, 1272, 1273f
Diagnosis, 23–33
  blood samples, 27–28, 27f
  case history, 25–26
  in disease outbreak, 39
  examination of field birds, 24
  external examination, 26–27
  flock profiling, 25, 26f
  laboratory procedures, 30
    bacterial cultures, 30
    respiratory virus isolation, 30
    Salmonella cultures, 30
  monitoring and surveillance, 23–24
  necropsy
    brain exposure and removal, 30–31, 31f
    communication of results, 33
    gross examination, 30
    histopathologic examination, tissues for, 32
    killing birds for, 28

laboratory procedures, 30
precautions, 28
progressive examination hints, 32–33
specimen disposal, 33
techniques, 28–30, 29f
performance parameters, 24
procedures, 25–33
serologic monitoring, 24–25
Diarrhea
in astrovirus infection, 393–394
in avian nephritis virus infection, 470
in cryptosporidiosis, 1170–1171
in *E. coli* infection, 772–773
in enterovirus-like virus infection, 397–398
in hexamitiasis, 1181
in infectious bursal disease, 226
in multicausal enteric diseases, 1324–1325
in parvovirus of chickens and turkeys, 402, 403
in rotavirus infection, 381, 386–389
in turkey coronavirus enteritis, 378, 379
Diazinon toxicity, 1300
Dicheilonema rhea, 1128
Dichlorvos, 1300
Diclazuril, for coccidiosis, 1160, 1161, 1165
DID. *See* Double immunodiffusion (DID) test
Dieldrin toxicity, 1300
Diet
carbohydrates, 1207
essential inorganic elements, 1221–1227
fats, 1207
least-cost formulization, 1205
proteins and amino acids, 1205–1207
vitamins, 1207–1221
water, 1205
Diffuse-adherence *Escherichia coli* (DAEC), 48
Digestive system diseases
neoplasia, 611–613
alimentary tract, 611–612, 611f
liver, 612–613
cholangiocellular tumors, 612–613, 612f–613f
hepatocellular tumors, 612, 612f
pancreas, adenocarcinoma of, 613, 613f
Dihydrostreptomycin
for *Mycoplasma gallisepticum,* 892
for *Riemerella anatipestifer,* 828
Dilated cardiomyopathy, 1249–1250
Dimethoate toxicity, 1300
Dimethyldithiocarbamate, for aspergillosis, 1087–1088
Dimetridazole
for avian intestinal spirochetosis, 1007
for *Cochlosoma anatis* infection, 1185
for histomoniasis, 1178t
toxicity, 1291
Dinitrotolumide toxicity, 1291
Dioxin toxicity, 1303
Diphacinone toxicity, 1301
Diquat toxicity, 1299
Direct fluorescent antibody (DFA)
Gallid herpesvirus type 1, 171
Mycoplasma meleagridis, 899
Disease challenge, 8
Disease outbreaks, handling, 38–40
nursing care, 39–40
drugs, 39–40
flock disposition, 40
quarantine, 38–39
Disease prevention/control
antimicrobial therapy, 40–43
biocontainment, 33–38
bioexclusion, 9–23
company perspective, 10–11
country perspective, 10
disease status and, 11
global perspective, 9–10
OIE-listed diseases, 10
primary control zone (poultry house and hatchery), 11–19
region/state perspective, 10
secondary control zone (farm or site), 19–22, 22f
tertiary control zone (complex), 22–23
challenges in modern poultry production, 5–6
diagnosis, 23–33
flock health, 4–5
population dynamics, 5
resistance and resilience, 4–5
handling disease outbreaks, 38–40
nursing care, 39–40
quarantine of flock, 38–39
principles, 6–9
biosecurity, 7–8
disease challenge, 8
epidemiology, 8–9
host resistance, 8
risk, 8
Disease resistance, genetics of, 70–79
Disinfectants, 13
toxicity, 1298–1299
chlorine, 1298
coal-tar derivatives, 1298
formaldehyde, 1298–1299
phenolics, 1298
quaternary ammonium, 1298
Disinfection, in candidiasis, 1090
Dispharynx nasuta, 1128, 1128f
Disposal
of dead birds, 22, 22f
of necropsy specimen, 33
Dissecting aneurysm, 1251–1252
Distillers dried grain solubles (DDGS), 1283
DNA fingerprinting
Avibacterium paragallinarum, 862
E. coli, 768
Salmonella, 680
DNA microarrays
Campylobacter, 742
described, 75
DNA probes
for chicken infectious anemia virus, 262
for Marek's disease, 547
for *Mycoplasma gallisepticum,* 888
for *Mycoplasma synoviae,* 905
for *Salmonella,* 703
DNA vaccination
described, 36
for infectious bursal disease, 234
Dogs, access to poultry house, 17
Dot immunobinding assay (DIA), for *Ornithobacterium rhinotracheale,* 833
Double immunodiffusion (DID) test
for adenoviruses, 292, 300
egg drop syndrome virus, 305, 306
Doves, APMVs in, 109
Down time, 12
Doxycycline, for *Mycoplasma meleagridis,* 899
Drinkers, 15, 15f
Drugs. *See also specific drugs*
during disease outbreak, 39–40
Duck adenovirus type 1 (DAdV-1), 301. *See also* Egg drop syndrome
Duck adenovirus type 2 (DAdV-2), 290, 294, 297
Duck circovirus (DuCV), 265–269, 274

Duck diseases
adenovirus, 420–421
avian metapneumoviruses, 417–418
botulism, 954, 955
circovirus-like infection, 421
coccidiosis, 1166
Cochlosoma anatis, 1182–1185
erysipelas, 986, 989–991
fowl cholera, 814
fowl typhoid, 687
hepatitis, 422–431
influenza, 181–206
leucocytozoonosis, 1185–1186, 1187f
Mycoplasma imitans, 910–911
myopathy, nutritional, 1213
parvovirus, 444–451
picornavirus, 431
poxvirus, 339
reovirus, 419–420
Riemerella anatipestifer, 823–828
sarcocystosis, 1190–1191, 1192f
West Nile infection, 420
zinc deficiency, 1226
Duck hepatitis B virus infection, 431
Duck hepatitis virus type 1, 422–429
classification, 422
clinical signs, 425, 425f
diagnosis
molecular methods, 427
serology, 427
virus isolation and identification, 427
differential diagnosis, 427–428
epidemiology, 424–425
etiology, 422–424
history and distribution, 422
immunity, 426
intervention strategies, 428–429
laboratory host systems, 423–424
cell culture, 423–424
embryos, 423
management procedures, 428
morbidity and mortality, 425
morphology, 422
natural and experimental hosts, 424
pathobiology and epidemiology, 424–426
pathogenicity, 424
pathology
biochemical effects, 426
gross lesions, 425, 425f
microscopic/ultrastructural lesions, 425–426, 426f
strain classification, 423
susceptibility to chemical and physical agents, 422–423
transmission, carriers, and vectors, 424–425
treatment, 429
vaccination, 428–429
breeders, 428
ducklings, 428–429
Duck hepatitis virus type 2, 429–430
Duck hepatitis virus type 3, 430–431
Ducks
Aeromonas infection in, 1018
APMVs in, 107–108, 109
astrovirus in, 391
aviadenovirus infection in, 297
avian intestinal spirochetosis in, 999
Bacillus in, 1018
Borrelia anserina in, 1018
chlamydiosis in, 1061, 1064
Citrobacter infection in, 1020
Coenonia infection in, 1020
eastern equine encephalitis in, 475
egg drop syndrome virus in, 301, 303, 306
Gallibacterium in, 1020–1021
intracellular infection in, 1027
lead poisoning in, 1295f–1296f
macrorhabdosis in, 1092
Marek's disease virus in, 529
Proteus infection in, 1023
Pseudomonas in, 1024–1025
reoviruses in, 364–365
reticuloendotheliosis virus in, 597
rotavirus in, 383, 386
seminoma in, 611, 611f
tapeworms of, 1142, 1142f
Vibrio infection in, 1026
Duck virus enteritis (duck plague), 431–440
chemical composition, 434
classification, 432
clinical signs, 435
definition and synonyms, 431
diagnosis, 439
differential diagnosis, 439
economic significance, 432
etiology, 432–433
history, 432
immunity
active, 438–439
passive, 439
incidence and distribution, 434
incubation period, 435
intervention strategies, 439–440
laboratory host systems, 433
management procedures, 439
morbidity and mortality, 435
morphology, 432–433, 432f
natural and experimental hosts, 434
pathobiology and epizootiology, 434–439
pathology
gross lesions, 435–437, 436f–437f
microscopic lesions, 437–438, 438f
serology, 439
strain classification, 433
susceptibility to chemical and physical agents, 433
transmission, carriers, and vectors, 435
vaccination, 440
virus isolation and identification, 439
virus replication, 433
DuCV (duck circovirus), 265–269, 274
Dyschondroplasia, 1238–1240
clinical signs, 1238
intervention strategies, 1239–1240
pathogenesis and etiology, 1239
pathology, 1238–1239, 1238f
Dysgerminoma, 608

EAEC (enteroaggregative *Escherichia coli*), 48, 757
Ear diseases, 1258–1259
Earthworms, role in histomoniasis, 1174
Eastern equine encephalitis (EEE), 474–477, 474f, 476f
clinical signs and pathology, 475–477, 476f
chickens, 475–477, 476f
chukar partridges, 475
ducks, 475
pheasants, 475
turkeys, 475, 476f
diagnosis, 477
differential diagnosis, 477
history, 474
incidence and distribution, 474
intervention strategies, 477
natural and experimental hosts, 474
pathobiology and epizootiology, 474
public health significance, 44–45, 473
serology, 477
transmission, carriers, and vectors, 474–475
Echidnophaga gallinacea (sticktight flea), 1103, 1103f
Echinura uncinata, 1128, 1128f
EDS. *See* Egg drop syndrome
EDTA (ethylenediaminetetraacetic acid), 28
EEE. *See* Eastern equine encephalitis

EGF (epidermal growth factor), 337
Egg-bound, 1256
Egg drop syndrome, 301–309
  chemical composition, 302
  classification, 301
  clinical signs, 304–305, 304f
  definition and synonyms, 301
  etiology, 301–303
  history, 301
  immunity, 305
  incidence and distribution, 303
  laboratory host systems, 303
  morphology, 301–302, 302f
  natural and experimental hosts, 303
  pathobiology and epizootiology, 303–305
  pathogenesis of the infectious process, 305
  pathology, 305
    gross lesions, 305
    microscopic lesions, 305, 306f–308f
  strain classification, 302–303
  susceptibility to physical and chemical agents, 302
  transmission, carriers, and vectors, 303–304
  virus replication, 302
Egg production decline, 1257
  with aviadenovirus infection, 297
  with egg drop syndrome, 304–305, 304f
  with infectious bronchitis, 139, 145–146, 146f
  with influenza, 196, 197
  with Newcastle disease, 90, 99, 101
  with poxvirus, 341
Egg room, 21
Eggs
  fumigation, 14
  hygiene, 14–15
  storage, 14, 19
  washing, 14–15
EHEC (enterohemorrhagic *Escherichia coli*), 48–49, 757, 773
EIA. *See* Enzyme immunoassay
EIEC (enteroinvasive *Escherichia coli*), 48, 757, 773
Eimeria acervulina, 1150t, 1151, 1152f
Eimeria adeneides, 1162t, 1163–1164
Eimeria anseris, 1166
Eimeria brunetti, 946, 948f, 1150t, 1153, 1154f
Eimeria dispersa, 1162t, 1164
Eimeria gallopavonis, 1162t, 1164
Eimeria hagani, 1150t, 1153
Eimeria innocua, 1165
Eimeria labbeana, 1166
Eimeria maxima, 1150t, 1152f, 1153
Eimeria meleagridis, 1162t, 1164
Eimeria meleagrimitis, 1162t, 1164–1165
Eimeria mitis, 1150t, 1152f, 1155
Eimeria mivati, 1150t, 1153
Eimeria necatrix, 1150t, 1154f, 1155–1156
Eimeria praecox, 1150t, 1156
Eimeria subrotunda, 1165
Eimeria tenella, 1150t, 1154f, 1156, 1172
Eimeria truncata, 1165–1166
Electron microscopy
  astrovirus, 392, 393f
  avian encephalomyelitis, 486
  avian hepatitis E virus, 494, 494f
  avian leukosis/sarcoma viruses, 555, 556f
  avian metapneumovirus, 113, 113f
  chicken infectious anemia virus, 249, 249f, 262, 262f
  chicken proventricular necrosis virus, 1329, 1329f
  duck hepatitis type I, 426
  duck virus enteritis, 432, 432f, 433
  eastern equine encephalitis virus, 474f
  egg drop syndrome virus, 301–302, 302f
  enterovirus-like viruses, 395–399, 396f
  goose hemorrhagic polyomavirus, 441f
  hemorrhagic enteritis, 310
  infectious bronchitis virus, 140, 140f
  infectious bursal disease, 220f
  infectious laryngotracheitis virus, 161, 162f, 163f
  influenza virus, 187f
  Marek's disease, 517f
  Mycoplasma gallisepticum, 877, 878f
  parvovirus of chickens and turkeys, 399, 401, 401f, 403–404
  Pasteurella multocida, 808f
  poxvirus, 333, 334f, 342
  reovirus, 351f, 364
  reticuloendotheliosis virus, 594, 594f
  rotavirus, 382, 382f, 384f, 387, 390
  turkey coronavirus, 377, 377f
Elementary bodies (Borrel bodies), of fowlpox virus, 333, 341
Elementary body (EB), chlamydial, 1055–1057, 1057f, 1059–1060, 1060f
Elementary body agglutination, for *Chlamydia,* 1067
ELISA. *See* Enzyme-linked immunosorbent assay
ELVs. *See* Enterovirus-like viruses
Emerging diseases, 1319–1332
  enteric diseases, multicausal, 1322–1325
    etiologies, 1323–1324
    intervention strategies, 1325
    pathogenesis, 1324–1325
  hypoglycemia-spiking mortality syndrome of broiler chickens, 1325–1327, 1326f
    diagnosis, 1327
    etiology, 1325–1327
    history, 1325
    incidence and distribution, 1325
    pathogenesis and epidemiology, 1327
    treatment, prevention, and control, 1327
  respiratory diseases, multicausal, 1320–1322
    environmental factors, role of, 1321
    immunosuppressive agents, effects of, 1320–1321
    interactions among pathogens, 1320
    vaccination reactions, 1321–1322
  transmissible viral proventriculitis (TVP), 1328–1332
    classification, 1328
    clinical signs, 1330
    definition and synonyms, 1328
    diagnosis, 1331–1332
    differential diagnosis, 1330
    economic significance, 1328
    etiology, 1328–1329
    history, 1328
    incidence and distribution, 1328
    incubation period, 1329–1330
    isolation and identification of agent, 1331–1332
    laboratory host systems, 1329
    morbidity and mortality, 1330
    morphology, 1329, 1329f
    natural and experimental hosts, 1329
    pathogenesis and epizootiology, 1329–1331
    pathology, 1330–1331, 1330f–1331f
    prevention and control, 1332
    public health significance, 1328
    transmission, 1329

Emus
influenza in, 198
Lawsonia infection in, 1021
tuberculosis in, 1011
Encephalitis
in aspergillosis, 1082
in ochroconosis, 1091–1092
Encephalomalacia, 1213–1214, 1215f
Encephalomyelitis. *See* Avian encephalomyelitis
Endocarditis
enterococcosis, 982
streptococcosis, 978–979, 979f
Endocrine system, neoplastic diseases of, 616–617
adrenal gland, 616
parathyroid gland, 617
pituitary gland, 616
thymus, 617
thyroid gland, 617
Endolimax spp., 1182
Endothelioma, liver, 579f
Endotoxin, 681, 695
aerial toxicosis, 1302
Pasteurella multocida, 813
Enilconazole, for aspergillosis, 1088
Enrofloxacin
for chlamydiosis, 1068
for colibacillosis, 785
for *Mycoplasma iowae,* 910
for *Mycoplasma meleagridis,* 899
for *Mycoplasma synoviae,* 906
for *Riemerella anatipestifer,* 828
Entamoeba spp., 1182
Enteric diseases
hemorrhagic enteritis, 309–316
multicausal, 1322–1325
necrotic enteritis, 949–953
ulcerative enteritis, 944–949
viral, 375–405
astrovirus, 391–395
duck virus enteritis (duck plague), 431–440
enterovirus-like viruses (ELVs), 395–399
hemorrhagic nephritis enteritis of geese (HNEG), 440–443
overview, 375–376
parvovirus of chickens and turkeys, 399–405
reovirus in chickens, 362–363
reovirus in turkeys, 364
rotavirus, 381–391
turkey coronavirus enteritis, 376–381
Enteroaggregative *Escherichia coli* (EAEC), 48, 757
Enterobacter, 1020
Enterobacterial repetitive intergenic consensus (ERIC), 756, 813
Enterococcosis, 981–985
clinical signs, 982
diagnosis, 981f, 983, 983f
etiology, 981, 981f, 981t
history, 981
pathobiology and epidemiology, 982
pathology, 982–983
treatment, 983
Enterococcus avium, 981t
Enterococcus cecorum, 981t, 984–985
Enterococcus durans, 981t, 984
Enterococcus faecalis, 981–983, 981f, 981t, 983f
Enterococcus faecium, 981–983, 981t
Enterococcus hirae, 981t, 984
Enterogenous cysts, 611
Enterohemorrhagic *Escherichia coli* (EHEC), 48–49, 757, 773
Enteroinvasive *Escherichia coli* (EIEC), 48, 757, 773
Enteropathogenic *Escherichia coli* (EPEC), 48, 757, 773
Enterotoxigenic *Escherichia coli* (ETEC), 48, 757
Enterovirus, 395
Enterovirus-like viruses (ELVs), 395–399. *See also* Duck hepatitis virus type 1; Turkey viral hepatitis
chemical composition, 395
classification, 395
clinical signs, 397–398
diagnosis, 398–399
differential diagnosis, 399
etiology, 395–397
immunity, 398
incidence and distribution, 397
intervention strategies, 399
laboratory host systems, 396–397
morphology, 395, 396f
natural and experimental hosts, 397
overview, 395
pathobiology and epizootiology, 397–398
pathogenesis, 398
pathogenicity, 397
pathology, 398
gross lesions, 398
microscopic lesions, 398
serology, 399
strain classification, 396
susceptibility to physical and chemical agents, 396
transmission, carriers, and vectors, 397
virus isolation and identification, 398–399
virus replication, 395–396, 396f
Entomobirnavirus, 219
Environment
disease control and
complex, 23
farm/site, 20
poultry house, 11–12
induced disorders
asphyxiation, 1234–1235
heat stress, 1234
Marek's disease and, 532
multicausal respiratory disease and, 1321
Environmental Protection Agency (EPA), 13
Enzyme immunoassay (EIA)
for *Campylobacter,* 742
for reticuloendotheliosis, 603, 604
for *Salmonella,* 703, 704
Enzyme-linked immunosorbent assay (ELISA)
antibody level measurement with, 70
for arizonosis, 712
for aspergillosis, 1086
for astrovirus, 394
for aviadenovirus, 300
for avian encephalomyelitis virus, 487, 493
for avian hepatitis E virus infection, 500
for avian intestinal spirochetosis, 1005
for avian metapneumovirus, 117, 118, 418
for avian nephritis virus, 472
for *Bordetella avium,* 842
for *Campylobacter,* 742
for chicken infectious anemia, 262–263
for chlamydiosis, 1065
for circovirus, 273, 274
for circovirus-like infection, 421
for duck hepatitis virus type 1, 427
for duck virus enteritis, 439
for *E. coli,* 781
for eastern equine encephalitis, 477
for egg drop syndrome virus, 306
for erysipelas, 993, 994
flock profiling with, 25, 26f
for fowl typhoid, 690, 691

for Gallid herpesvirus type 1, 171
for goose hemorrhagic polyomavirus, 443
for hemorrhagic enteritis virus, 315
for infectious bronchitis virus, 149–151
for infectious bursal disease, 229–230, 232–233
for infectious laryngotracheitis, 170
for influenza virus, 189, 202
for leukosis/sarcoma group of neoplastic diseases, 586, 587–588, 587t, 588–589, 589
for Marek's disease, 547
for *Mycoplasma gallisepticum,* 889
for *Mycoplasma meleagridis,* 899
for *Mycoplasma synoviae,* 905
for mycotoxicosis diagnosis, 1282
for Newcastle disease virus, 102, 103
for *Ornithobacterium rhinotracheale,* 829, 833
for parvovirus of chickens and turkeys, 401, 405
for parvovirus of waterfowl, 449
for poxvirus, 342–343
for pullorum disease, 690, 691
for reovirus, 360
for reticuloendotheliosis, 602
for *Riemerella anatipestifer* infection, 827
for rotavirus, 390–391
for toxoplasmosis, 1194
for tuberculosis, 1016
for turkey coronavirus, 381
for West Nile virus, 481–482
EPA (Environmental Protection Agency), 13
EPEC (enteropathogenic *Escherichia coli*), 48, 757, 773
Epidemiology, disease control and, 8–9
Epidermal growth factor (EGF), 337
Epididymitis, *E. coli,* 774–775
Epithelioma, intracellular keratinizing, 619, 620f
Epomidiostomum uncinatum, 1126, 1127f
Equipment, sanitation of, 21
Eradication
avian metapneumovirus, 112
infectious laryngotracheitis, 174
leukosis/sarcoma group of neoplastic diseases, 591–592
monitoring and surveillance, 23
Mycoplasma meleagridis infection, 899
principles, 6–7
pullorum disease and fowl typhoid, 692
quail bronchitis virus, 319–320
success of program, 11
Ergotism, 1271–1272
etiology and toxicology, 1271
experimental disease, 1272
metabolism and residues, 1272
natural disease, 1272
ERIC (enterobacterial repetitive intergenic consensus), 756, 813
Erysipelas
antigenic structure, 987
biochemical properties, 987
classification, 986
clinical signs, 990
colony morphology, 987
definition and synonyms, 986
diagnosis, 993
differential diagnosis, 993
economic significance, 986
etiology, 986–989
growth requirements, 986–987
history, 986
immunity, 992–993
incidence and distribution, 989
incubation period, 990
isolation and identification of agent, 993
management procedures, 994
morbidity and mortality, 990
morphology and staining, 986
natural and experimental hosts, 989
pathobiology and epidemiology, 989–993
pathogenesis, 992
pathology
gross, 990–991
microscopic, 991–992, 991f–992f
public health significance, 48, 986
nature of disease in humans, 48
occurrence, 48
reservoirs and sources of infection, 48
serology, 993
strain classification, 987
susceptibility to chemical and physical agents, 987
transmission, carriers, and vectors, 989–990
treatment, 994
vaccination, 992, 994
virulence factors, 988–989
Erysipelothrix rhusiopathiae, 48, 986–994. *See also* Erysipelas
Erysipelothrix tonsillarum, 986
Erythroblastosis
clinical signs, 570
differential diagnosis, 590
incubation period, 569
pathology, 573–575
gross, 573–575, 574f
microscopic, 575, 575f
pathogenesis, 575
ultrastructure, 575
Erythromycin
for avian intestinal spirochetosis, 1007
for fowl cholera, 822
for infectious coryza, 868
for *Mycoplasma gallisepticum,* 893
Erythrovirus, 400f
Escherichia albertii, 752–754, 753t
Escherichia coli. See also Colibacillosis
AEEC (attaching and effacing), 759, 773, 773f
APEC (avian pathogenic), 48
DAEC (diffuse-adherence), 48
EAEC (enteroaggressive), 48, 757
EHEC (enterohemorrhagic), 48–49, 757, 773
EIEC (enteroinvasive), 48, 757, 773
EPEC (enteropathogenic), 48, 757, 773
ETEC (enterotoxigenic), 48, 757
ExPEC (extraintestinal pathogenic), 48
genetic resistance to, 77–78
interaction with respiratory pathogens, 1320
NMEC (neonatal meningitis), 757, 762
public health significance, 48–49
nature of disease in humans, 48
occurrence, 48–49
reservoirs and sources of infection, 49
STEC (Shiga toxin), 48
turkey coronavirus and, 379–380
UPEC (uropathogenic), 757
Escherichia fergusonii, 752–754, 753t
Essential oils, for colibacillosis, 785
ETEC (enterotoxigenic *Escherichia coli*), 48, 757
Ethambutol, for tuberculosis, 1017
Ethinone toxicity, 1292
Ethoxyquin toxicity, 1297
Ethylenediaminetetraacetic acid (EDTA), 28
Ethylene glycol toxicity, 1303
Eucalyptus cladocalyx toxicity, 1305

Euthanasia, 28
Exotic Newcastle disease. *See* Newcastle disease
ExPEC (extraintestinal pathogenic *Escherichia coli*), 48
Expression vector, avian poxvirus, 346
External examination, 26–27
External parasites, 1099–1105
  fleas, 1103, 1103f
  lice, 1103–1105
    chicken head louse, 1104–1105
    chickens body louse, 1103–1104, 1104f
    shaft louse, 1104, 1105f
  mites, 1099–1102
    chiggers, 1102, 1102f
    control of, 1102
    depluming mite, 1101–1102
    northern fowl mite, 26, 52, 1099–1101, 1100f
    poultry red mite, 26, 51, 1101, 1101f
    scaly leg mite, 1101, 1102f
  ticks, 1105, 1105f
Extraintestinal pathogenic *Escherichia coli* (ExPEC), 48, 751, 757, 761, 780
Exudate, necropsy examination and, 32
Exudative diathesis, 1213, 1214, 1216f
Eye diseases
  ammonia burn, 1258
  arizonosis, 709, 711f
  aspergillosis, 1081–1082, 1081f, 1085
  cataracts, 1258
  developmental anomalies, 1258
  E. coli panophthalmitis, 777
  eye-notch syndrome, 1258
  Marek's disease, 533, 534f, 536
  neoplastic diseases, 616
  retinal dysplasia, 1258
Eye-notch syndrome, 1258

FA. *See* Fluorescent antibody (FA) test
FAcV (aviadenovirus of chickens)
  chemical composition, 291–292
  classification, 291
  clinical signs, 295–298
  diagnosis, 299–300
  economic significance, 290–291
  etiology, 291–294
  hemagglutination, 292
  history, 291
  hosts, 294
  immunity, 299
  incidence and distribution, 294
  incubation period, 295
  laboratory host systems, 294
  management procedures, 300
  morphology, 291, 292f, 293f
  pathogenicity, 294
  pathology, 296f, 298–299, 298f–299f
  public health significance, 291
  serology, 300
  strain classification, 292, 294
  susceptibility to chemical and physical agents, 292
  transmission, 295
  vaccination, 300
  virus isolation, 299
  virus replication, 292
Fahey-Crawley virus, 352, 362
Falcon herpesvirus, 465
False layer, 1256
Famphur toxicity, 1300
Fannia spp., 1108, 1108f
Farms, disease control and, 19–22, 22f
  access control, 20–21
    equipment, 21
    people, 20–21
    vehicles, 21
  dead bird disposal, 22, 22f
  egg room, 21
  environment of, 20
  fumigation room, 21–22
  functional units, 20
  isolation, 19–20, 20f
  one age of fowl/farm, 20
  placement, transfers and depletions, 21
  spray vaccination, 37
Fats, dietary, 1207
Fatty acids, 1207
Fatty liver-hemorrhagic syndrome (FLHS), 1252–1253, 1253f
FDA (Food and Drug Administration), 39
Feather dystrophy, 271, 273
Feather folliculoma, 619, 619f
Feather pecking, 1233–1234
Federal Insecticide, Fungicide, and Rodenticide Act (FIFRA), 13
Feed
  antimicrobial administration in, 40–41
  disease control and, 15
  manufacturing and management for mycotoxicosis prevention, 1283
  medication in, 15–16
  toxin levels in, 1288t
Feed additives
  for *Campylobacter,* 743
  for *Cochlosoma anatis* infection, 1185
  for histomoniasis, 1178t, 1179
Feeders, 15, 16
Fenbendazole, for nematodes, 1133
Fenthion toxicity, 1300
Fertilizer toxicity, 1303
Fibrosarcoma, 580–582, 581f
Field birds, examination of, 24
FIFRA (Federal Insecticide, Fungicide, and Rodenticide Act), 13
Fimbriae, of *E. coli,* 757, 759
Fimbriaria fasciolaris, 1142, 1142f
Finch circovirus (FiCV), 265–267
Fish meal, 1292
Fixative, 32
Flagellin, 682, 755
Flaviviridae, 419, 474
Flavobacterium, 1021
Flavus. *See* Dermatophytosis
Fleas, 1103, 1103f
Flesh flies, 1108
FLHS (fatty liver-hemorrhagic syndrome), 1252–1253, 1253f
Flies
  biting, 1107
  nonbiting, 1107–1108, 1107f–1108f
Flip-over. *See* Sudden death syndrome
Flock health, 4–5
  disposition during disease outbreak, 40
  population dynamics, 5
  resistance and resilience, 4–5
  tracking, 24
Flock profiling, 25, 26f
Fluorescence staining, for *Chlamydia* detection, 1066
Fluorescent antibody (FA) test
  for infectious bursal disease, 229
  for Marek's disease, 547
  for poxvirus, 343
  for turkey coronavirus, 380
  for ulcerative enteritis, 946, 948
Fluoride toxicity, 1293
Fluoroquinolones
  for fowl cholera, 822
  for *Mycoplasma gallisepticum,* 893
  for *Mycoplasma meleagridis,* 899
  for *Salmonella,* 706
Folic acid, 1220–1221
Food and Drug Administration (FDA), 39
Formaldehyde, 980, 1298–1299
Formalin fixative, 32
Formalin fumigation, 14

Fowl cholera, 807–823
classification, 808
clinical signs
acute, 815, 816f
chronic, 816, 816f–817f
colony morphology, 808–810, 809f
diagnosis, 820–821
differential diagnosis, 821
etiology, 808–814
growth requirements, 808
history, 807–808
immunity, 819–820
incidence and distribution, 814
management procedures, 822
morphology and staining, 808, 808f–809f
natural and experimental hosts, 814–815
pathogenesis and epizootiology, 814–820
pathogenicity, 813
pathology
acute lesions, 816–817, 817f–819f
chronic lesions, 817, 818f, 820f
physiologic properties, 810, 810t
resistance to chemical and physical agents, 811
subgrouping, 811–813, 811t
toxicity, 813–814
transmission, carriers, and vectors, 815
treatment, 821–822
vaccination, 819–820, 822–823
Fowl paralysis, 530–531, 530f–531f, 532, 538f, 548–549
Fowlpox, 333–346
Fowl tick *(Argas persicus),* 1105, 1105f
Fowl typhoid, 678–693
antigenic structure, 680–681
biochemical properties, 680
classification, 679
clinical signs, 684
colony morphology, 679, 690
diagnosis, 689–691
differential diagnosis, 690
economic significance, 678
etiology, 679–682
growth requirements, 679
history, 678–679
identification of cultures, 690, 690t
immunity, 689
incidence and distribution, 682–683
intervention strategies, 690–693
isolation and identification of agent, 689
management procedures, 691–692
area eradication, 692
national control program, 692
non-gallinarum reactors, 691–692
serologic tests, 691
morbidity and mortality, 684
morphology, 679
natural and experimental hosts, 683
pathobiology and epidemiology, 682–689
pathogenesis, 688–689
pathology, 684–688
gross lesions, 684–687
histopathology, 687–688
public health significance, 678
serology, 690, 691
susceptibility to chemical and physical agents, 680
transmission, 683–684
treatment, 692–693
vaccination, 692
virulence factors, 681–682
FreeCalc (program), 24
Frey's medium, modified, 900, 901t
Fumigation
of eggs, 14
fumigant toxicity, 1298–1299
Fumigation room, 21–22
Fumonisins, 1274–1275
Functional genomics, 75
Fungal infections, 1077–1093
aspergillosis, 1078–1088
candidiasis, 1088–1090
dermatophytosis, 1091
macrorhabdosis, 1092–1093, 1093f
ochroconosis, 1091–1092
public health significance, 50–52
cryptococcosis, 50–51
dermatophytosis, 51
histoplasmosis, 51–52
zygomycosis, 1092
Fungi, necropsy examination and, 32
Fungicide toxicity, 1299
captan, 1299
organic mercurials, 1299
thiram, 1299
Furazolidone
for histomoniasis, 1178t
toxicity, 1289
Fusarium mycotoxins, 1272–1276
fumonisins, 1274–1275
fusarochromanone, 1275
incidence and distribution, 1272
moniliformin, 1273–1274, 1275f
trichothecenes, 1272–1273, 1273f–1274f
zearalenone, 1275–1276
Fusarochromanone, 1275
Galactomannan, of *Aspergillus* spp., 1087
Gallibacterium, 1020–1021
Gallid herpesvirus type1 (GaHV-1), 161–174. *See also* Infectious laryngotracheitis (ILT)
Gallus adeno-like (GAL), 289
GALT (gut-associated lymphoid tissue), 63
Gangrenous dermatitis, 957–960
antigenic structure and toxins, 957
biochemical properties, 957
clinical signs, 958
colony morphology, 957
definition, 957
diagnosis, 959–960
economic significance, 957
etiology, 957–958
growth requirements, 957
history, 957
incidence and distribution, 958
morphology and staining, 957
pathobiology and epizootiology, 958–959
public health significance, 957
treatment and prevention, 961–962
Gases, toxic, 1302
Gastrocnemius tendon rupture, 1245–1246, 1245f
Gastrointestinal diseases. *See* Digestive system diseases; Enteric diseases
GE. *See* Gizzard erosion
Geese
Aeromonas infection in, 1018
APMVs in, 108, 109
aviadenovirus infection in, 297
avian intestinal spirochetosis in, 999, 1004
avian metapneumovirus in, 418
Borrelia anserina in, 1018
chlamydiosis in, 1064
circovirus-like infection in, 421
coccidiosis in, 1165–1166
Coenonia infection in, 1020
duck virus enteritis in, 434–435, 437
egg drop syndrome virus in, 303, 306
erysipelas in, 990, 991
fowl cholera in, 808, 814
Gallibacterium in, 1020–1021
goose hemorrhagic polyomavirus in, 440–443
goose herpesvirus in, 420
Helicobacter in, 1021
hemorrhagic nephritis enteritis of geese in, 440–443

Geese (*cont'd*)
influenza in, 190
leucocytozoonosis in, 1185–1186
macrorhabdosis in, 1092
Marek's disease virus in, 529
Mycoplasma infections in, 911–912
Newcastle disease in, 101
parvovirus in, 444–451
poxvirus in, 339
Pseudomonas in, 1024
reovirus in, 365, 420
reticuloendotheliosis virus in, 597
Riemerella anatipestifer in, 823, 825
tapeworms of, 1142, 1142f
venereal disease, 1026–1027
Vibrio infection in, 1026
West Nile virus in, 419, 479–482, 480f–481f
Gene deletion mutant vaccines, 34–35
Genes, candidate, 73–74
Genetics of disease resistance, 70–79
experimental approaches for molecular genetics, 73–74
association, 74
candidate gene, 73–74
linkage analysis, 74
whole genome scans, 74
functional genomics, 74–75
proteomics, 75
transcriptome profiling, 75
future perspectives, 79
overview, 70–73
heritability, 72
linkage, 72–73, 73f
phenotypic distributions, 72
specific diseases, 75–79
avian influenza, 78–79
avian leukosis, 75–76
coccidiosis, 78
Escherichia coli, 77–78
infectious bursal disease, 78
Marek's disease, 76
salmonellosis, 76–77
Genetic typing, of infectious bronchitis virus, 150
Genomic fingerprinting, of *Staphylococcus aureus,* 973
Genomic probes, poxvirus, 343
Genomics, functional, 75
Genotyping, of *Chlamydia,* 1058–1059
Gentamicin
for arizonosis, 713
for fowl typhoid, 693
for *Mycoplasma gallisepticum,* 893
for *Mycoplasma meleagridis,* 899, 900
for *Mycoplasma synoviae,* 906
for *Salmonella,* 706
toxicity, 1290
GHPV (goose hemorrhagic polyomavirus), 440–443
GHV (goose herpesvirus), 420
Githagenin toxicity, 1304
Gizzard erosion (GE), 290
clinical signs, 297
pathology, 299, 299f
Gizzard impaction, 1253
Gland of Harder, 63, 64f
Gliosis, in avian encephalomyelitis, 489, 489f–490f
Gliotoxin, 1080, 1089–1090
Glucomannan, 1284
Glucosinolate toxicity, 1306
Gongylonema inguvicola, 1128, 1128f
Goose circovirus (GoCV), 265–269, 274
Goose hemorrhagic polyomavirus (GHPV), 440–443
Goose herpesvirus (GHV), 420
Goose parvovirus, 444–451. *See also* Parvovirus
Goose venereal disease, 1026–1027
Gout
articular, 1255–1256, 1256f
visceral, 1254–1255, 1254f
Granulomas, 1027
Granulosa-theca cell tumor, 606–607, 607f
Green muscle disease, 1244–1245
GuCV (gull circovirus), 265
Guinea fowl
Aegyptianella in, 1017
aviadenovirus infection in, 298
avian metapneumovirus in, 115
Avibacterium paragallinarum in, 863
chlamydiosis in, 1061, 1064
enterovirus-like viruses in, 397, 398
fowl typhoid in, 683, 687
Helicobacter in, 1021
macrorhabdosis in, 1092
Newcastle disease virus variants in, 107
pullorum disease in, 683
Riemerella anatipestifer in, 825
seminoma in, 611
Gull circovirus (GuCV), 265
Gumboro disease. *See* Infectious bursal disease (IBD)
Gut-associated lymphoid tissue (GALT), 63
Gyrovirus, 247

HA. *See* Hemagglutinin
Hadjelia truncate, 1126
Haematosiphon inodorus, 1108
Haemophilus gallinarum. See Avibacterium paragallinarum
Haemophilus paragallinarum. See Avibacterium paragallinarum
Haemoproteus spp., 1189–1190
Hafnia, 1021
Halofuginone
for coccidiosis, 1165
for leucocytozoonosis, 1188
toxicity, 1291
Harderian gland, infectious bursal disease effect on, 231
Hatchery, 17–19
breeder codes, 19
chick sexers, 19
design and location, 18
problems related to, 1235
sanitation, 18–19
spray vaccination in, 36–37
storage facilities, 19
surgical procedures, 19
Hawaiian forest birds, poxviruses of, 336, 339, 341, 346
HE. *See* Hemorrhagic enteritis
Health surveys, 24
Heart, 27
Heart attack. *See* Sudden death syndrome
Heart disease
dilated cardiomyopathy, 1249–1250
in eastern equine encephalitis, 475–477, 476f
in enterococcosis, 982
in erysipelas, 991f
in hydropericardium syndrome, 296–298
in pullorum disease, 685–688, 685f–686f, 688f
in sodium excess, 1224f
Heat stress, 1234
Helicobacter, 1021
Helicopter disease, 363, 402
Helper T cells, 67
Helper virus, for reticuloendotheliosis virus, 594, 595, 601
Hemagglutinin (HA), 303, 306
Avibacterium paragallinarum, 863, 865
Bordetella avium, 837
circovirus, 273, 274
duck hepatitis virus type 1, 426
duck virus enteritis, 439
egg drop syndrome virus, 302
FAdV-1 and, 292
influenza, 187–192, 188t, 202, 205

Mycoplasma gallisepticum, 879
Newcastle disease, 102–103
Newcastle disease virus, 92
poxvirus, 337, 343
Hemagglutinin inhibition (HI)
for APMVs, 108
for circovirus, 273, 274
for eastern equine encephalitis, 477
for egg drop syndrome virus, 303, 305–307, 309
for infectious bronchitis virus, 140, 142, 149–151
for infectious coryza, 861, 867
for influenza virus, 189, 202–203
for Israel turkey meningoencephalitis, 479
for *Mycoplasma gallisepticum,* 889
for *Mycoplasma meleagridis,* 899
for *Mycoplasma synoviae,* 905
for Newcastle disease virus, 102–103
for West Nile virus, 481
Hemangioma
clinical signs, 570
differential diagnosis, 591
incubation period, 569–570
pathology, 577–578, 578f
Hemangiopericytoma, 617, 617f
Hemlock toxicity, 1305
Hemolysis, by Newcastle disease virus, 92
Hemorrhage
in APMV infections-, 110
in *Borrelia anserina* infection, 1019
in chicken infectious anemia, 255–256, 256f–258f
in duck hepatitis type I infection, 425, 425f
in duck virus enteritis infection, 435–437, 436f
in encephalomalacia, 1214
in erysipelas, 990–992
in fatty liver-hemorrhagic syndrome, 1252–1253, 1252f
in fowl cholera, 818f
in hemangioma, 577
in hemorrhagic enteritis, 309–316
in hydropericardium syndrome, 298
in infectious bursal disease, 227, 227f, 232
in infectious laryngotracheitis, 168, 169f
in influenza virus infection, 197–200, 198f–199f
in Newcastle disease, 99, 100f
in rotavirus, 387
in sulfonamide toxicity, 1289
in ulcerative enteritis, 946, 947f
in vitamin K deficiency, 1215–1216
Hemorrhagic-aplastic anemia syndrome, 256
Hemorrhagic enteritis (HE), 309–316
chemical composition, 310
classification, 310
clinical signs, 312
definitions and synonyms, 309
diagnosis, 314–315
differential diagnosis, 315
economic significance, 309
etiology, 310–311
history, 309–310
immunity, 314
active, 314
passive, 314
immunosuppression by virus, 1320–1321
incidence and distribution, 311
incubation period, 312
intervention strategies, 315–316
laboratory host systems, 311
management procedures, 315
morbidity and mortality, 312
morphology, 310
natural and experimental hosts, 311
pathobiology and epidemiology, 311–314
pathogenesis, 313–314
pathogenicity, 311
pathology, 312–313
gross lesions, 312, 312f
microscopic lesions, 312–313, 312f–313f
public health significance, 309
serology, 314–315
strain classification, 311
susceptibility to physical and chemical agents, 310–311
transmission, carriers, and vectors, 311–312
treatment, 316
vaccination, 315–316
virus isolation, 314
virus replication, 310
Hemorrhagic fatty liver syndrome (HFLS), 500
Hemorrhagic nephritis enteritis of geese (HNEG), 440–443
chemical composition, 440
classification, 440
clinical signs, 442
diagnosis, 443
differential diagnosis, 443
etiology, 440–441
history, 440
immunity, 443
incidence and distribution, 441
incubation period, 442
intervention strategies, 443
laboratory host system, 441
management procedures, 443
morbidity and mortality, 442
morphology, 440
natural and experimental hosts, 441–442
pathobiology and epizootiology, 441–442
pathogenesis of infectious process, 442–443
pathology, 442, 442f
strain classification, 441
susceptibility to chemical and physical agents, 441
transmission, carriers, and vectors, 442
vaccination, 443
virus replication, 441
Hemorrhagic septicemia, 776
Hepacivirus, 474
Hepatitis
hepatitis-splenomegaly syndrome, 494–500
inclusion body hepatitis, 363
turkey viral hepatitis, 482–485, 484f–485f
in young chicks, 363
Hepatitis E virus. *See* Avian hepatitis E virus
Hepatitis-hydropericardium syndrome. *See* Hydropericardium syndrome (HS)
Hepatitis-splenomegaly syndrome, 494–500, 1237. *See also* Avian hepatitis E virus
Hepatocellular tumors, 612, 612f
Hepatoma, 612, 612f
Hepevirus, 494
Heptachlor toxicity, 1300
Herbicide toxicity, 1299
chlorates, 1299
diquat, 1299
paraquat, 1299
Herd immunity, in Newcastle disease vaccination, 106
Heritability, 72
Herpesvirus
duck virus enteritis, 431–440
Gallid herpesvirus type1 (GaHV-1), 161–174
goose, 420

Herpesvirus (*cont'd*)
Marek's disease, 515–552
pigeon herpesvirus (PHV1), 465–467
pseudorabies virus, 467
turkey herpesvirus (HVT), 551–552
Heterakis bonsae, 1123
Heterakis dispar, 1123, 1124f
Heterakis gallinarum, 1123–1124, 1124f, 1133, 1172, 1173f, 1174, 1175–1176
Heterakis isolonche, 1123, 1124f
Heterakis spp., 1123–1124, 1124f
HEV. *See* Avian hepatitis E virus
Hexacanth embryo, 1136f, 1137
Hexamitiasis, 1181–1182, 1181f
HFLS (hemorrhagic fatty liver syndrome), 500
HI. *See* Hemagglutinin inhibition
Highlands J virus, 478
Histiocytic sarcoma, 580, 581f, 582
Histiocytosis, multicentric, 621–622, 622f
Histomonas meleagridis, 1172–1179, 1173f–1174f
Histomonas wenrichi, 1172, 1174f
Histomoniasis, 1147, 1172–1179, 1173f–1174f, 1177f
clinical pathology, 1176
clinical signs, 1176
diagnosis, 1177–1178
economic significance, 1172
etiology and classification, 1172–1175
history, 1172
immunity, 1177
incidence and distribution, 1175
incubation period, 1176
life cycle, 1174–1175
morbidity and mortality, 1176
morphology, 1172, 1174
natural and experimental hosts, 1175
overview, 1172
pathogenicity, 1175
pathology, 1176–117
gross lesions, 1176, 1177f
histopathology, 1176–1177
prevention and control, 1178–1179, 1178t
susceptibility to chemical and physical agents, 1175
vectors, 1175–1176
Histopathologic examination, tissues for, 32
Histoplasmosis, public health significance of, 51–52
nature of disease in humans, 51
occurrence, 51
reservoirs and sources of infection, 52
Hjarre's disease, 751, 752, 779
HNEG. *See* Hemorrhagic nephritis enteritis of geese
Horizontal gene transfer, 42
Host factors for disease resistance, 61–79. *See also* Immunity
Host range, 9
Host resistance, 8
House flies *(Musca domestica),* 1107, 1107f
HS. *See* Hydropericardium syndrome
Humoral immunity, 67–69, 68t
in avian hepatitis E virus infection, 497
in avian metapneumovirus infection, 116–117
in *Campylobacter* infection, 741
in circovirus infection, 273
in infectious bronchitis, 147, 149
in infectious laryngotracheitis, 170
in influenza virus infection, 200–201
in Marek's disease, 544–545
in Newcastle disease, 102
in paratyphoid infections, 700–701
in reticuloendotheliosis, 601–602
in turkey coronavirus enteritis infection, 380
in viral arthritis, 358
HVT (turkey herpesvirus), 551–552
Hyaluronidase, erysipelas, 988–989
Hydropericardium syndrome (HS), 290
clinical signs, 296–297
pathology, 298–299
Hygiene, nest and egg, 14
Hymenolepsis cantaniana, 1137, 1137f, 1138, 1140
Hymenolepsis carioca, 1136, 1137, 1137f–1139f, 1138, 1140
Hymenolepsis megalops, 1135, 1142, 1142f
Hyperkeratinization of skin, 1224–1225
Hypoglycemia-spiking mortality syndrome of broiler chickens, 1325–1327, 1326f
diagnosis, 1327
etiology, 1325–1327
history, 1325
incidence and distribution, 1325
pathogenesis and epidemiology, 1327
treatment, prevention, and control, 1327
IBD. *See* Infectious bursal disease
IBH. *See* Inclusion body hepatitis
Ichtadenovirus, 289t, 290
ICPI (intracerebral pathogenicity index), Newcastle disease and, 90, 91, 105–106
IFA. *See* Indirect fluorescent antibody (IFA) test
IgA. *See* Immunoglobulin A
IgG. *See* Immunoglobulin G
IgM. *See* Immunoglobulin M
IgY, 102
ILT. *See* Infectious laryngotracheitis
Iltovirus, 161
Imidazoles, 1291–1292
Imidazothiazole toxicity, 1292
Immune system
anatomy of, 62–63, 62f, 64f
assays to measure immunity, 69–70
features of, 63–69, 65f
adaptive immunity, 66–67, 66t
humoral immunity, 67–69, 68t
innate immunity, 63–65
maternal transfer of immunity, 69
overview, 61–62
Immunity. *See also* Vaccination
adaptive, 66–67, 66t
aspergillosis, 1085
assays to measure, 69–70
antibody levels, 70
cytokines, 69–70
macrophages, 69
natural killer cells, 69
T cells, 69–70
astrovirus, 394
aviadenovirus, 299
avian encephalomyelitis, 491–492
avian hepatitis E virus, 497–498
avian intestinal spirochetosis, 1004
avian malaria, 1189
avian metapneumovirus, 116–117
Bordetella avium, 841–842
Borrelia anserina infection, 1020
Campylobacter infection, 741
cell-mediated (CMI), 66
chicken infectious anemia, 259
in chlamydiosis, 1064–1065
circovirus, 273
cryptosporidiosis, 1171
cytokines, 67
cytotoxic T cells, 67
duck hepatitis virus type 1, 426
duck virus enteritis, 438–439
egg drop syndrome virus, 305
enterovirus-like viruses, 398
erysipelas, 1004

fowl cholera, 819–820
fowl typhoid, 689
helper T cells, 67
hemorrhagic enteritis, 314
hemorrhagic nephritis enteritis of geese, 443
histomoniasis, 1177
humoral, 67–69, 68t
infectious bronchitis, 147, 149
infectious bursal disease, 229–230
infectious coryza, 865
infectious laryngotracheitis, 170
influenza virus, 200–201
innate, 63–65
leukosis/sarcoma group of neoplastic diseases, 584
Marek's disease, 543–546
maternal transfer, 69
mucosal, 68
Mycoplasma gallisepticum infection, 887–888
Mycoplasma iowae infection, 909
Mycoplasma meleagridis infection, 898
Mycoplasma synoviae infection, 905
necrotic enteritis, 952
Newcastle disease, 101–102
Ornithobacterium rhinotracheale, 832
paratyphoid infections, 700–701
parvovirus of chickens and turkeys, 404
parvovirus of waterfowl, 449
pigeon herpesvirus, 467
pullorum disease, 689
quail bronchitis virus, 319
reticuloendotheliosis, 601–602
Riemerella anatipestifer infection, 826–827
rotavirus, 389–390
sarcocystosis, 1192
staphylococcosis, 976
Trichomonas gallinae, 1180
trichomoniasis, 1180
turkey coronavirus enteritis, 380
turkey viral hepatitis, 484
ulcerative enteritis, 946
viral arthritis, 358–359
West Nile virus, 481
Immunization. *See* Vaccination
Immunoblotting, poxvirus, 343
Immunodepression, in reticuloendotheliosis, 602
Immunodiffusion tests
for avian encephalomyelitis virus, 492
for poxvirus identification, 343
Immunoevasion, 545–546
Immunofluorescence. *See also specific tests*
for aviadenovirus, 299–300
for avian encephalomyelitis, 487
for avian metapneumovirus, 418
for avian nephritis virus, 471–472
for chicken infectious anemia virus, 262
for duck virus enteritis, 439
for enterovirus-like viruses, 396–397, 397f
for parvovirus of waterfowl, 449
for rotavirus, 387, 391
for turkey coronavirus enteritis, 378f
for West Nile virus, 481
Immunoglobulin(s)
classes of, 67–68, 68t
genes, 69
level measurement, 70
structure of, 68, 68f
Immunoglobulin A (IgA)
in infectious bronchitis, 147
maternal transfer of, 69
in Newcastle disease, 102
properties of, 67–68, 68t
Immunoglobulin G (IgG)
in infectious bronchitis, 147
in infectious bursal disease, 231
in influenza, 201
maternal transfer of, 69
in Newcastle disease, 102
in parvovirus of chickens and turkeys, 404
properties of, 67–68, 68t
in rotavirus, 390
structure of, 68f
Immunoglobulin M (IgM)
in infectious bronchitis, 147
in infectious bursal disease, 231
in influenza, 200
in Newcastle disease, 102
in parvovirus of chickens and turkeys, 404
properties of, 67–68, 68t
Immunohistochemistry
for avian intestinal spirochetosis, 1004
for avian nephritis virus, 471
for chicken infectious anemia virus, 262
for chlamydiosis, 1065
for circovirus, 273
for eastern equine encephalitis, 477
for Gallid herpesvirus type 1, 171
for leukosis/sarcoma group of neoplastic diseases, 588
for *Ornithobacterium rhinotracheale,* 832
for parvovirus of chickens and turkeys, 401, 403, 404f
for rotavirus, 387
Immunomagnetic separation (IMS), for *Salmonella,* 703
Immunoperoxidase staining
for enterovirus-like viruses, 396
for infectious bronchitis virus, 150
for *Mycoplasma meleagridis,* 899
for poxvirus, 343
for reticuloendotheliosis, 603
for rotavirus, 388f
for turkey coronavirus, 377f, 380
Immunosuppression
aviadenovirus, 299
beak and feather disease virus, 273
chicken infectious anemia, 259–260
infectious bursal disease, 230–231
Marek's disease, 546
multicausal respiratory disease and, 1320–1321
reovirus in turkeys, 364
reticuloendotheliosis, 602
Immunotherapy, for infectious bursal disease, 235
Impaction, 1253
IMS (immunomagnetic separation), for *Salmonella,* 703
Inactivated vaccines, 35–36
IncA/C plasmids, 43
Inclusion body hepatitis (IBH), 290, 363
clinical signs, 295–296
pathology, 296f, 298, 298f
Inclusions
adenovirus, 289
aviadenovirus, 291, 292f–293f, 295, 296f, 298–299
Chlamydia in, 1059–1060, 1060f
circovirus, 271–272, 272f
duck virus enteritis, 433, 434f
egg drop syndrome virus, 305, 307f
FAdV, 291, 292f–293f, 295, 296f, 298–299
Gallid herpesvirus type 1, 171
hemorrhagic enteritis, 310
parvovirus of chickens and turkeys, 403
parvovirus of waterfowl, 448
poxvirus, 335, 338f, 341–342
quail bronchitis virus, 317, 318f, 319
Incubation-related problems, 1235
Indiana C adenovirus, 316

Indirect fluorescent antibody (IFA) test
for avian encephalomyelitis virus, 492
for avian intestinal spirochetosis, 1004
for avian metapneumovirus, 118
for avian metapneumoviruses, 418
for *Bordetella avium,* 842
for chicken infectious anemia, 262–263
for chicken proventricular necrosis virus (CPNV), 1331–1332
for Gallid herpesvirus type 1, 171
for *Mycoplasma meleagridis,* 899
for parvovirus of chickens and turkeys, 404–405
for reovirus, 360
for turkey coronavirus, 380–381
Infectious bronchitis, 139–153
chemical composition, 140
chicken infectious anemia as cofactor in disease, 261–262
classification, 140
clinical signs, 145, 145f
diagnosis, 149–151
by antibody-based methods, 150
by nucleic acid-based methods, 150
serology, 150–151
virus isolation, 149
etiology, 140–144
genome organization, 140–141, 141f
history, 139–140
immunity, 147, 149
active, 147, 149
innate, 147
maternally-derived, 149
incidence and distribution, 144
incubation period, 145
interaction with *Mycoplasma* spp., 1320
intervention strategies, 151–153
laboratory host systems, 142–143
cell culture, 143
chicken embryos, 142–143, 143f
organ cultures, 143
management procedures, 151
morbidity and mortality, 139, 145
morphology, 140, 140f
natural and experimental hosts, 144
overview, 139
pathogenesis and epizootiology, 144–149
pathogenicity, 143–144
pathology, 145–147
gross lesions, 145–146, 146f
microscopic lesions, 146–147, 148f
strain classification, 141–142
genetic, 142
serotype, 142
viral evolution and, 142
susceptibility to physical and chemical agents, 141
transmission, carriers, and vectors, 144–145
treatment, 153
vaccination, 139, 151–153
application methods, 152–153
future vaccines, 153
reactions, 1321–1322
types of vaccine, 151–152
virus replication, 140–141
Infectious bursal disease (IBD), 219–235
chemical composition, 220–221
chicken infectious anemia as cofactor in disease, 261–262
classification, 219
clinical signs, 226
diagnosis, 231–233
differential diagnosis, 232
etiology, 219–224
genetic resistance to, 78
history, 219
immunity, 229–231
active, 230
immunosuppression, 230–231
passive, 230
immunization, 230, 233–235
immunosuppression by, 1320–1321
incidence and distribution, 225
incubation period, 226
intervention strategies, 233–235
laboratory host systems, 223–224
cell culture, 223–224
chicken embryos, 223
management procedures, 233
morbidity and mortality, 226
morphology, 219, 220f
natural and experimental hosts, 225–226
overview, 219
pathobiology and epidemiology, 225–231
pathogenesis of the infectious process, 229
pathogenicity, 224
pathology, 226–229
gross lesions, 226–227, 227f
microscopic lesions, 227–229, 228f
ultrastructural, 229
serology, 232–233
strain classification, 222–223
susceptibility to physical and chemical agents, 222
transmission, carriers, and vectors, 226
treatment, 235
virus isolation, 231–232
virus replication, 221–222
Infectious coryza, 859–868
biochemical properties, 860–861, 861t
classification, 860
clinical signs, 864
colony morphology, 860
definitions and synonyms, 859
diagnosis, 865–867
differential diagnosis, 867
economic significance, 859
etiology, 860–863
growth requirements, 860
history, 859
immunity, 865
incidence and distribution, 863
incubation period, 864
intervention strategies, 867–868
isolation and identification of agent, 865–866, 866f
management procedures, 867
morbidity and mortality, 864
morphology, 860
natural and experimental hosts, 863
pathobiology and epizootiology, 863–865
pathology, 864–865
gross, 864, 865f
microscopic, 864–865
public health significance, 859
serology, 866–867
strain classification, 861–863
antigenicity, 861–862
immunogenicity or protective characteristics, 862
molecular techniques, 862
pathogenicity, 862–863
susceptibility to chemical and physical agents, 861
transmission, carriers, and vectors, 863–864
treatment, 868
vaccination, 867–868
field protocols and regimes, 868
types of vaccines, 867–868
virulence factors, 863
Infectious laryngotracheitis (ILT), 161–174

chemical composition, 162–165
classification, 161
clinical signs, 167–168
diagnosis, 170–171
differential diagnosis, 171
economic significance, 161
eradication, 174
etiology, 161–167
genome organization, 162–163, 164f
histopathology, 170
history, 161
immunity, 170
active, 170
passive, 170
incidence and distribution, 167
incubation period, 167
intervention strategies, 172–174
laboratory host systems, 166
cell culture, 166
chicken embryos, 166
management procedures, 172
morbidity and mortality, 168
morphology, 161, 162f, 163f
natural and experimental hosts, 167
overview, 161
pathobiology and epidemiology, 167–170
pathogenesis of the infections process, 168
pathogenicity, 166–167
pathology, 168
gross lesions, 168, 169f
microscopic lesions, 168
serology, 171
strain classification, 165–166
susceptibility to physical and chemical agents, 165
transmission, carriers, and vectors, 167
treatment, 174
vaccination, 172–174
experimental vaccines, 173
live attenuated, 172–173
programs, 173–174
recombinant vaccines, 173
virus isolation, 170–171
virus replication, 165
Infectious stunting syndrome, 1323
Influenza, 181–206
chemical composition, 187
classification, 187
clinical signs, 196–197
definitions and synonyms, 181
diagnosis, 201–203
direct detection of viral proteins or RNA, 201
sample selection and storage, 201–202
serology, 202–203
virus identification, 202
virus isolation, 202
differential diagnosis, 203
economic significance, 181–182, 183t
etiology, 187–193
genetic resistance to, 78–79
history, 182, 184–187, 185t–186t
immunity, 200–201
active, 200–201
passive, 201
incidence and distribution, 193–194
incubation period, 196
intervention strategies, 203–206
laboratory host systems, 190–191
cell culture, 191
chicken embryos, 190–191
management procedures, 203–204
biosecurity, 203–204
decreasing host susceptibility, 204
diagnosis and surveillance, 204
education and behavioral change, 203
elimination of infected poultry, 204
morbidity and mortality, 197
morphology, 187, 187f
natural and experimental hosts, 194
overview, 181–182
pathobiology and epizootiology, 193–201
pathogenesis of the infectious process, 200
pathogenicity, 191–193, 192t
pathology, 197–200
gross lesions, 197–199, 198f–199f
microscopic lesions, 199–200
public health significance, 45, 182, 184t
nature of disease in humans, 45
occurrence, 45
preventive measures, 45
reservoirs and sources of infection, 45
strain classification, 189–190
antigenicity, 189
antigenic variation, 189–190
genetic/molecular characteristics, 190
immunogenicity/protective characteristics, 190
pathotype, 190
strain nomenclature, 189
susceptibility to physical and chemical agents, 187–189
transmission and carriers, 194–196
treatment, 206
vaccination, 204–206
virus replication, 187
in waterfowl, 418–419
Innate immunity, 63–65
Campylobacter infection, 741
Chlamydia and, 1065
infectious bronchitis, 147
Marek's disease, 543–544
Newcastle disease, 101
In ovo infection, Marek's disease, 542
In ovo vaccination
for avian metapneumovirus, 119
delivery systems, 36, 36f
description of, 36
for reovirus, 361
Insect control measures, 17
Insecticides, 1109
in poultry house, 17
toxicity, 1299–1301
carbamate, 1300–1301
nicotine, 1301
organochlorides, 1299–1300
organophosphates, 1300–1301
pyrethrum and pyrethroids, 1301
rotenone, 1301
Insertional mutagenesis, reticuloendotheliosis and, 596
In situ hybridization (ISH)
for astrovirus, 394
for aviadenovirus, 300
Integrated pest management (IPM)
for arthropod pests, 1109
for mite control, 1102
for rodents, 1109–1115
Integumentary system diseases
gangrenous dermatitis, 957–960
keratoacanthoma, 617–619, 618f–619f
Marek's disease, 533, 534f, 536
neoplastic, 617–620
adenoma, 619
feather folliculoma, 619, 619f
hemangiopericytoma, 617, 617f
intracutaneous keratinizing epithelioma, 619, 620f
keratoacanthoma, 617–619, 618f–619f
lipoma, 617
liposarcoma, 617
mast cell tumors, 619–620
squamous cell carcinoma, 617
xanthoma, 620

Interferon
in circovirus, 275
in Marek's disease, 544
in Newcastle disease, 101–102
Interleukins (ILs)
described, 67
in Newcastle disease, 101
Intermediate body (IB), chlamydial, 1055, 1057, 1060f
Internal layer, 1256
Internal parasites, 1117–1144
acanthocephalans, 1133–1134, 1133f–1134f
cestodes, 1135–1143
Amoebotaenia cuneata, 1137f–1139f, 1138, 1139
Choanotaenia infundibulum, 1135, 1137f–1139f, 1138, 1139, 1143
classification, 1136
Davainea proglottina, 1136–1137, 1136f, 1138, 1139–1140, 1143
diagnosis and identification, 1137–1138, 1137f–1139f
Fimbriaria fasciolaris, 1142, 1142f
Hymenolepsis cantaniana, 1137f, 1138, 1140
Hymenolepsis carioca, 1136, 1137f–1139f, 1138, 1140
Hymenolepsis megalops, 1135, 1142, 1142f
key to species, 1138
Metroliasthes lucida, 1141–1142, 1141f–1142f
morphology and life cycle, 1136–1137, 1136f–1138f
number of species described, 1136
overview, 1135–1136, 1135t, 1136f
prevention and control, 1143
Raillietina cesticillus, 1135, 1136f, 1137, 1137f–1139f, 1138, 1140, 1143
Raillietina echinobothrida, 137f–1139f, 1138, 1141
Raillietina georgiensis, 1139f, 1141, 1141f–1142f
Raillietina tetragona, 1137f–1139f, 1138, 1140
table of species, 1135t
treatment, 1143
nematodes, 1117–1133
Amidostomum spp., 1125, 1125f–1126f
Aproctella stoddardi, 1124–1125, 1124f
Ascarida spp., 1120–1121, 1121f
Aulonocephalus lindquisti, 1125, 1125f
Baylisascaris spp., 1125
Capillaria spp., 1121, 1122f–1123f, 1122t
Cheilospirura spp., 1125, 1126f–1127f
Codiostomum struthonis, 1126
Cyathostoma bronchialis, 1126–1127, 1127f
Cyrnea colini, 1125–1126, 1127f
Deletrocephalus dimidiatus, 1127
development and life cycles, 1120
Dicheilonema rhea, 1128
Dispharynx nasuta, 1128, 1128f
Echinura uncinata, 1128, 1128f
Epomidiostomum uncinatum, 1126, 1127f
Gongylonema inguvicola, 1128, 1128f
Hadjelia truncate, 1126
Heterakis spp., 1123–1124, 1124f
Libyostrongylus douglassi, 1128–1129
morphology, 1119–1120
Ornithostrongylus quadriadiatus, 1129, 1129f
overview, 1117–1119
Oxyspirura spp., 1129, 1129f
Sicarius spp., 1129
Singhfilaria hayesi, 1129, 1130f
species reported from chickens, 1118t
species reported from non-chicken commercial birds, 1118t
species reported from wild birds, 1119t
Strongloides avium, 1129, 1130f
Subulura spp., 1124f, 1129–1130
Syngamus trachea, 1130–1131, 1131f
Tetrameres spp., 1131–1132, 1131f–1132f
treatment and control, 1132–1133
Trichostrongylus tenuis, 1132, 1132f
Vaznema zschokkei, 1132
trematodes, 1143–1144
control, 1144
identification, 1144
life cycle, 1144, 1144f
morphology, 1143, 1143f
pathogenicity, 1144
Interstitial cell tumors, 611
Intimin, 757, 759
Intracerebral pathogenicity index (ICPI), Newcastle disease and, 90, 91, 95, 97, 105–106
Intracutaneous keratinizing epithelioma, 619, 620f
Intramuscular injection, vaccination by, 36, 37–38
Intraocular vaccination, 37
Intussusception, 1253–1254
Invasins, 760
Iodine
deficiency, 1224–1225
toxicity, 1293
Ionophores
for coccidiosis, 1160, 1161
toxicity, 1290–1291, 1290f–1291f
IPM. *See* Integrated pest management
Ipronidazole, for histomoniasis, 1178t
Iron
acquisition by *E. coli,* 759
deficiency, 1225
toxicity, 1298
ISH. *See in situ* hybridization
Isoniazid, for tuberculosis, 1017
Israel turkey meningoencephalitis, 478–479
clinical signs and pathology, 478–479
control, 479
diagnosis, 479
differential diagnosis, 479
history, 478
incidence and distribution, 478
pathogenesis and epizootiology, 478
transmission, carriers, and vectors, 478
Itraconazole, for aspergillosis, 1088
Ivermectin toxicity, 1292

Jimsonweed toxicity, 1305
Josamycin, for *Mycoplasma meleagridis,* 899

Keratoacanthoma, 617–619, 618f–619f
Ketotifen, for infectious bursal disease, 235
Kidney disease, with infectious bronchitis virus, 144, 146, 146f, 147
Killed vaccines, 35–36
Klebsiella, 1021
Knemidocoptes mutans (scaly leg mite), 1101, 1102f
Knockdown syndrome, 1290, 1291f
Korean fowl plague. *See* Newcastle disease

Laboratory procedures, 30
Lactase, 1207
LAMP. *See* Loop-mediated isothermal amplification
Lasalocid, for coccidiosis, 1161, 1165
Latent infection
  Marek's disease, 522–523, 539f, 540–541
  pigeon herpesvirus 1, 466
Latex agglutination test, for duck virus enteritis, 439
Lathyrism, 1306
Lawsonia intracellularis, 1021–1022
Lead toxicity, 1295–1297, 1296f–1297f
Leiomyoma, 608, 609f, 611, 620, 620f
Leiomyosarcoma, 611, 620
Lesser mealworms, 1105–1107, 1106f
Leucaena leucocephala toxicity, 1305
Leucocytozoonosis, 1185–1188
  diagnosis, 1188
  Leucocytozoon caulleryi, 1187–1188
  Leucocytozoon sabrezi, 1188
  Leucocytozoon schoutedeni, 1188
  Leucocytozoon simondi, 1185–1186, 1187f
  Leucocytozoon smithi, 1186–1187, 1187f
  treatment and control, 1188
Leukemia, in Marek's disease, 536
Leukosis/sarcoma group of neoplastic diseases, 553–592, 553t
  clinical signs, 570
  connective tissue tumors, 580–582, 581f
    gross, 580–582, 581f
    microscopic, 581f, 582
    pathogenesis, 582
    ultrastructural, 582
  definition and synonyms, 553–554
  diagnosis, 585–591
  differential diagnosis, 589–591
    connective tissue tumors, 591
    erythroblastosis, 590
    hemangioma, 591
    lymphoid leukosis, 589–590
    myeloblastosis, 590
    myelocytomatosis, 590–591
    osteopetrosis, 591
    renal tumors, 591
  economic significance, 554
  erythroblastosis, 573–575, 574f–575f
    gross, 573–575, 574f
    microscopic, 575, 575f
    pathogenesis, 575
    ultrastructure, 575
  etiology, 555–566
    chemical composition, 556–558
      lipids, 557
      nucleic acids, 556–557
      proteins, 557–558
    classification, 555, 557t
    endogenous leukosis viruses, 559–561, 560f, 560t
    laboratory host systems, 564–565
      cell culture, 565, 565f
      chick inoculation, 564
      embryos, 564, 564f
    morphology, 555–556, 555f–556f
    pathogenicity, 565–566
    strain classification, 561–564
      antigenicity, 561–562, 562t
      molecular characteristics, 562
      nomenclature, 563–564, 563t
      pathogenicity, 562–563
    susceptibility to chemical and physical agents, 561
    virus replication, 558–559
      defectiveness and phenotypic mixing, 559, 559t
      penetration of host cell, 558
      synthesis and integration of DNA, 558
      transcription, 558–559
  genetic resistance, 584–585, 585t, 592
  hemangioma, 577–578, 578f
  history, 554–555
  immunity, 584
  incidence and distribution, 566–567
    of disease, 566–567
    of infection, 567
  incubation period, 569–570
  isolation and identification of agent, 585–589, 587t
  lymphoid leukosis, 571–573, 572f, 574f
    gross, 571–572, 571f, 574f
    microscopic, 572, 572f
    pathogenesis, 572–573
    ultrastructural, 576
  myeloblastosis, 574f, 575–576, 576f
    gross, 576
    microscopic, 574f, 576, 576f
    pathogenesis, 576
    ultrastructural, 576
  myelocytomatois, 574f, 576–577, 577f
    gross, 576–577
    microscopic, 574f, 577, 577f
    pathogenesis, 577
    ultrastructure, 577
  natural and experimental hosts, 567
  nephroma and nephroblastoma, 578–582, 579f
    gross, 578, 579f
    microscopic, 578, 579f, 580
    pathogenesis, 580
    ultrastructural, 580
  nonneoplastic conditions, 570–571
  osteopetrosis, 582–583, 582f–583f
    gross, 582, 582f, 583f
    microscopic, 582–583, 583f
    pathogenesis, 583
    ultrastructural, 583
  pathobiology and epidemiology, 566–585
  pathology, 570–584, 574f
    connective tissue tumors, 580–582, 581f
    erythroblastosis, 573–575, 574f–575
    hemangioma, 577–578, 578f
    lymphoid leukosis, 571–573, 572f, 574f
    myeloblastosis, 574f, 575–576, 576f
    myelocytomatois, 574f, 576–577, 577f
    nephroma and nephroblastoma, 578–582, 579f
    nonneoplastic conditions, 570–571
    osteopetrosis, 582–583, 582f–583f
  prevention and control, 591–593
    eradication, 591–592
    selection for genetic resistance, 592
  public health significance, 554
  serology, 589
  transmission, 567–569, 568f
  vaccination, 591
Levamisole
  for nematodes, 1133
  toxicity, 1292
Leydig cell tumors, 611
Libyostrongylus douglassi, 1128–1129
Lice, 1103–1105
  Chicken head louse, 1104–1105
  chickens body louse, 1103–1104, 1104f
  external examination for, 26
  shaft louse, 1104, 1105f
Ligament failure and avulsion, 1246
Lignosol toxicity, 1297
Lily of the valley toxicity, 1305
Limberneck. *See* Botulism
Lincomycin
  for avian intestinal spirochetosis, 1007
  for *Mycoplasma meleagridis,* 899
  for *Mycoplasma synoviae,* 906
  for *Riemerella anatipestifer,* 828

Lindane toxicity, 1300
Linkage, 72–73, 73f
Linkage analysis, 74
Linkage disequilibrium, 73, 74
Linoleic acid, 1207, 1220
Lipoma, 617
Lipooligosaccharides, 998
Lipopolysaccharide (LPS)
  chlamydial, 1058, 1065
  E. coli, 755
  Pasteurella multocida, 812
  Salmonella, 695
Liposarcoma, 617
Listeria monocytogenes, 1022
Listeriosis, public health significance of, 49
  nature of disease in humans, 49
  occurrence, 49
  reservoirs and sources of infection, 49
Litter
  built-up, 13
  in feed and water, 15
Litter beetle, 17
Liver
  in amyloidosis, 1237, 1237f
  in APMV infection, 110
  endothelioma, 579f
  in enterococcosis, 983
  in erysipelas, 991, 991f
  fatty liver-hemorrhagic syndrome, 1252–1253
  in fowl cholera, 816, 818f–819f
  granulomas, 1027
  hepatitis-splenomegaly syndrome, 494–500
  in histomoniasis, 1176, 1177
  in lymphoid leukosis, 571, 571f, 574f
  neoplasia, 612–613
    cholangiocellular tumors, 612–613, 612f–613f
    hepatocellular tumors, 612, 612f
  in paratyphoid infections, 700
  in pullorum disease, 685, 685f, 687, 687f
  in staphylococcosis, 975f, 976
  in streptococcosis, 978–979, 979f–980f
  in tuberculosis, 1013, 1014f
  in turkey viral hepatitis, 483–484, 484f–485f
  in ulcerative enteritis, 946, 947f
Live vaccines. *See also specific diseases*
  characteristics of, 35t
  development of, 34–35
  for fowl cholera, 820, 822, 823
  methods of generating candidate, 35t
  for *Mycoplasma gallisepticum,* 890–892
  for *Riemerella anatipestifer,* 827–828
Local immunity, in Newcastle disease, 102
Loop-mediated isothermal amplification (LAMP)
  for avian leukosis viruses, 588
  for infectious bursal disease, 232
  for Marek's disease, 547
  for reticuloendotheliosis, 603
  for *Riemerella anatipestifer,* 827
LPS. *See* Lipopolysaccharide
Lung, adenocarcinoma of, 614, 614f
Lymphodegenerative syndromes, Marek's disease, 526, 527t, 536–537, 537f, 548
Lymphoid leukosis
  clinical signs, 570
  differential diagnosis, 589–590
  incubation period, 569
  pathology, 571–573
    gross, 571–572, 571f, 574f
    microscopic, 572, 572f
    pathogenesis, 572–573
    ultrastructural, 572
Lymphoma
  Marek's disease, 532–533, 534f, 541–542
  reticuloendotheliosis, 599–600, 599f, 600f, 601
Lymphoproliferative syndromes, in Marek's disease, 526, 527t, 532–536, 541–542
Lyophilization, and infectious bronchitis virus, 141
Lysergic acid, 1271
Lysine deficiency, 1207, 1207f, 1213f

Macrodactylus subsoinosus, 1304
Macrophages, 63–64, 67, 69
  in Marek's disease, 544
  in Newcastle disease, 101
Macrorhabdosis, 1092–1093, 1093f
Magnesium
  deficiency, 1223
  excess, 1223
  toxicity, 1293
Major histocompatibility complex (MHC), 61, 64–67, 73–74, 76–79
Malabsorption syndrome, 363, 1323, 1324, 1325
Malaria, avian, 1188–1189
Malathion toxicity, 1300
Mammals, *Mycobacterium avium* in, 1011–1012, 1012t
Manganese deficiency, 1224
Marble spleen disease (MSD), 309–316
Marek's disease, 515–552
  chicken infectious anemia virus dual infection, 260
  classification, 515–516
  clinical signs, 530–531, 530f–531f
  definition and synonyms, 515
  diagnosis, 546–549
    antibody detection, 547
    antigen detection, 547
    differential diagnosis, 548
    DNA probes, 547
    pathotyping, 548
    PCR, 547
    step 1 (clinical data and gross pathology), 547–548
    step 2 (histology, cytology and histochemistry), 548
    step 3 (virologic criteria), 548
    virus isolation, 546–547
  economic significance, 515
  etiology, 515–526
  genetic resistance, 550–551
  genetic resistance to, 76
  history, 515
  immunity, 543–546
    cell-mediated, 545
    humoral, 544–545
    immunoevasion, 545–546
    immunosuppression, 546
    initiation of response, 543
    innate responses, 543–544
    vaccinal, 545
  immunosuppression by, 1321
  incidence and distribution, 526, 528
  incubation period, 530
  laboratory host systems, 524–526
    cell cultures, 524
    chickens, 524
    embryos, 524–525
    lymphoblastoid cell lines, 525–526
  management procedures, 551
  morbidity and mortality, 531–532
  morphology, 516, 517f
  natural and experimental hosts, 528–529
  pathogenesis, 538–543, 539f
    factors influencing, 542
    nontumor diseases, 542–543
    in ovo infection, 542
    phase 1 (early productive-restrictive infection), 539–540, 539t

phase 2 (latent infection), 539f, 540–541
phase 3 (cytolytic infection), 541
phase 4 (lymphoma development), 541–542
pathology, 532–538
gross, 532–533, 532f, 534f
eye, 533, 534f
integument, 533, 534f
nerves, 532
visceral organs, 532–533, 534f
microscopic, 535f–538f, 536–538
blood, 536
brain, 535
eye, 536
integument, 536
local lesions, 538
lymphodegenerative syndromes, 536–537, 537f
nerves, 533, 535
tumor transplants, 538
vascular syndromes, 537–538, 538f
visceral organs, 535, 536f
public health significance, 515
scientific significance, 515
serotype 2, 552
strain classification, 523–524
pathotypes, 523–524
serotypes, 523
susceptibility to chemical and physical agents, 523
syndromes associated with, 526, 527t
transmission, 529–530
vaccinal immunity, 545
vaccination, 549–550
administration, 549
efficacy, factors affecting, 549–550
strategies, 550
types, 549
viral DNA, 516–518
physical properties, 516
structural organization, 516–518
viral genes and proteins, 518–521, 518t
with homologues in alphaherpesviruses, 518–521
immediate early and early genes with homology to HSV, 518–519
1.8 kb gene family, 520–521
late genes, 519
latency associated transcripts (LATs), 519
Meq (Marek's EcoQ), 519–520
miRNAs, 521
pp38/pp24, 520
telomerase RNA, 521
v-IL8, 520
viral lipase, 520
viral vectors, 521
virus replication, 521–523
latent infection, 522–523
productive infection, 522
transforming infection, 523
virus stock production and stability, 523
MAS. *See* Malabsorption syndrome
Mastadenovirus, 289, 289t
Mast cell tumors, 619–620
Maternal antibodies
in avian metapneumovirus infection, 119
in *Borrelia anserina* infection, 1020
in hemorrhagic enteritis, 314
in infectious bronchitis, 149
interference from, 70
in Marek's disease, 531
in *Mycoplasma meleagridis* infection, 898
in Newcastle disease, 102
in parvovirus of chickens and turkeys, 404
in quail bronchitis virus infection, 319
in rotavirus infection, 390
in viral arthritis, 352, 361
in West Nile virus, 481
Maternal transfer of immunity, 69
Mean death times (MDT), 95
Meat meal, 1292
Medication
during disease outbreak, 39–40
feed and water, 15–16
routes of, 40–41
Megabacteriosis, 1092–1093, 1093f
Melanoma, 616, 616f
Memory cells, 63
Meningitis, *E. coli,* 777
Meningoencephalitis, *E. coli,* 777
Menopon gallinae (shaft louse/small body louse), 1104, 1105f
Mercurials, toxicity of, 1299
Mercury toxicity, 1297
Mesosalpinx, neoplasia of, 608, 608f
Mesothelioma, peritoneal, 613, 613f
Metaldehyde toxicity, 1302
Metals and metalloids, toxicity of
arsenic, 1294
cadmium, 1294
chromium, 1294
lead, 1295–1297, 1295f–1296f
mercury, 1297
tin, 1297
uranium, 1297
vanadium, 1297
Metapneumovirus. *See* Avian metapneumovirus
Methionine
deficiency, 1206–1207
toxicity, 1207, 1292
Metrics, 24
Metroliasthes lucida, 1141–1142, 1141f–1142f
Metronidazole, for *Cochlosoma anatis* infection, 1185
MHC (major histocompatibility complex), 61, 64–67, 73–74, 76–79
Miconazole
for aspergillosis, 1088
for dermatophytosis, 1091
Microagglutination test
for arizonosis, 712
for *Bordetella avium,* 842
Microarrays
for *Chlamydia,* 1058
described, 75
Microbial feed additives, 1284
Microimmunofluorescence (MIF), for *Chlamydia,* 1067
MicroRNAs, 521
Microsporum gallinae, 51, 1091. *See also* Dermatophytosis (flavus)
MIF (microimmunofluorescence), for *Chlamydia,* 1067
Milkweed toxicity, 1305
Mimosine toxicity, 1305
Mineral oil, as vaccine adjuvant, 35
Minerals, 1221–1227
aluminum, 1293
calcium, 1222, 1293
chlorine, 1223, 1223f
cobalt, 1293
copper, 1225, 1293
dietary balance of, 1224
fluorine, 1293
iodine, 1224–1225, 1293
iron, 1225
magnesium, 1222–1223, 1293
manganese, 1224
phosphorus, 1222, 1293
potassium, 1223–1224, 1293
selenium, 1226–1227, 1294
sodium, 1223, 1224f, 1293–1294
sulfate, 1294
toxicity, 1292–1297
zinc, 1225–1226, 1294

Mirex toxicity, 1300
Mites, 1099–1102
  chiggers, 1102, 1102f
  control measures, 17
  control of, 1102
  depluming mite, 1101–1102
  external examination for, 26
  northern fowl mite, 26, 52, 1099–1101, 1100f
  poultry red mite, 26, 52, 1101, 1101f
  public health significance, 52
    nature of disease in humans, 52
    occurrence, 52
    reservoirs and sources of infection, 52
  scaly leg mite, 1101, 1102f
MLEE. *See* Multilocus enzyme electrophoresis
MLST. *See* Multilocus sequence typing
MLVA. *See* Multilocus variable number tandem-repeat analysis
Molecular genetics
  experimental approaches for, 73–74
  functional genomics, 74–75
  review of, 71–73, 73f
Molluscacide toxicity, 1302
Monensin
  for coccidiosis, 1160, 1161, 1165
  toxicity, 1290
Moniliformin, 1273–1274, 1275f
Monitoring
  flock profiling, 25, 26f
  program, 23–24
  serologic, 24–25
Monoclonal antibodies
  for avian intestinal spirochetosis, 1004
  for *Bordetella avium,* 842
  for chicken T lymphocyte antigens, 66, 66t
  for *Chlamydia,* 1058
  for infectious bronchitis virus, 142, 150
  for infectious bursal disease, 232
  for influenza virus, 189, 201, 202
  for Marek's disease, 547
  for *Salmonella,* 703
  for West Nile virus, 481
Monocrotophos toxicity, 1300
Mononegavirales, 89
Moraxella, 1022
Morbidity, defined, 9
Mortality
  defined, 9
  in poultry house, 14
Mosquito vectors, 1107
  of eastern equine encephalitis virus, 474–475
  of Israel turkey meningoencephalitis virus, 478
  of western equine encephalitis virus, 478
  of West Nile virus, 480
Mouse, 1110f, 1111, 1111t
MRSA, 972
MSD (marble spleen disease), 309–316
Mucor janssenii, 1027
Mucormycosis. *See* Zygomycosis
Mucosal immunity, 68
Mucosal invasion, by *Salmonella,* 695–696
Multicentric histiocytosis, 621–622, 622f
Multidrug resistance
  described, 43
  in *E. coli,* 752, 761
Multilocus enzyme electrophoresis (MLEE)
  for avian intestinal spirochetosis, 999, 1004, 1005
  for *E. coli,* 756
  for erysipelas, 988
  for *Pasteurella multocida,* 812
  for *Salmonella,* 680
Multilocus sequence typing (MLST)
  for avian intestinal spirochetosis, 1004, 1005
  for *Chlamydia,* 1059
  for *E. coli,* 756
  for *Pasteurella multocida,* 811, 813
  for *Salmonella,* 680
  for *Staphylococcus aureus,* 973
Multilocus variable number tandem-repeat analysis (MLVA)
  for *Chlamydia,* 1059
  for *Salmonella,* 680
Muscovy duck reovirus, 364, 419
Muscovy ducks, avian metapneumovirus in, 113, 115
Muscular dystrophy, 1214
Musculoskeletal system
  myopathy
    deep pectoral, 1244–1245
    nutritional, 1214, 1216f
  neoplastic diseases, 620–621
    chondroma and chrondrosarcoma, 621, 621f
    leiomyoma and leiomyosarcoma, 620, 620f
    osteoma and osteosarcoma, 620, 621f
    rhabdomyoma and rhabdomyosarcoma, 620, 621f
Mycobacterium avium. See Tuberculosis
Mycobacterium avium subsp. *paratuberculosis,* 1010, 1022–1023
Mycobacterium intracellulare, 1009
Mycoplasma anseris, 911
Mycoplasma cloacale, 911
Mycoplasma columbinasale, 912
Mycoplasma columbinum, 912
Mycoplasma columborale, 912
Mycoplasma gallinaceum, 875
Mycoplasma gallinarum, 875, 911
Mycoplasma gallisepticum, 875, 876f, 877–893
  antigenic structure, 878–879
  biochemical properties, 878
  classification, 877
  clinical signs, 883–884, 884f
  colony morphology, 878
  definition and synonyms, 877
  diagnosis, 888–890
  differential diagnosis, 889–890
  economic significance, 877
  etiology, 877–881
  growth requirements, 877–878
  history, 877
  immunity, 887–888
  incidence and distribution, 881
  incubation period, 883
  interaction among respiratory pathogens, 1320
  isolation and identification of agent, 888–889
  management procedures, 890
  morbidity and mortality, 884–885
  morphology and staining, 877, 878f
  natural and experimental hosts, 881–882
  pathogenesis, 886–887
  pathology, 885–886
    gross, 885
    microscopic, 885–886, 886f
    ultrastructural, 886
  serology, 889
  strain classification, 879–881
    antigenicity, 880
    genetic/molecular, 880
    immunogenicity, 880
    pathogenicity, 880–881
  susceptibility to chemical and physical agents, 878
  transmission, carriers, and vectors, 882–883

treatment, 892–893
vaccination, 890–892
virulence factors, 881
Mycoplasma imitans, 910–911, 1320
Mycoplasma iowae, 875, 907–910
antigenic structure, 907
biochemical properties, 907
classification, 907
clinical signs, 909
colony morphology, 907
diagnosis, 909–910
differential diagnosis, 910
economic significance, 907
etiology, 907–908
growth requirements, 907
history, 907
immunity, 909
incidence and distribution, 908
incubation period, 908
isolation and identification of agent, 909–910
management procedures, 910
morphology and staining, 907
natural and experimental hosts, 908
pathogenesis, 909
pathology, 909
gross, 909
microscopic, 909
ultrastructural, 909
serology, 910
strain classification, 908
susceptibility to chemical and physical agents, 907
transmission, 908
treatment, 910
Mycoplasma meleagridis, 875, 893–900
antigenic structure, 894
biochemical properties, 894
classification, 893
clinical signs, 896
colony morphology, 894
definitions and synonyms, 893
diagnosis, 898–899
differential diagnosis, 899
economic significance, 893
eradication, 900
etiology, 893–895
growth requirements, 894
history, 893
immunity, 898
incidence and distribution, 895
interaction among respiratory pathogens, 1320, 1321
isolation and identification of agent, 898–899
management procedures, 899
morbidity and mortality, 896
morphology and staining, 893–894
natural and experimental hosts, 895
pathology, 897–898
gross lesions, 897, 897f
microscopic lesions, 897–898
serology, 899
strain classification, 894–895
susceptibility to chemical and physical agents, 894
transmission, 895–896
horizontal, 896
vertical, 895
treatment, 906
Mycoplasma pullorum, 911
Mycoplasma spp., 875–912
characterization, 875, 876f
classification, 875–876, 876t
Mycoplasma synoviae, 875, 900–906
antigenic structure, 901
biochemical properties, 901
classification, 900
clinical signs, 903
colony morphology, 901
diagnosis, 905–906
differential diagnosis, 906
etiology, 900–902
growth requirements, 900–901, 901t
history, 900
immunity, 905
incidence and distribution, 902
incubation period, 903
interaction among respiratory pathogens, 1320, 1321
isolation and identification of agent, 905
management procedures, 906
morbidity and mortality, 903
morphology and staining, 900
natural and experimental hosts, 902
pathogenesis, 904–905
pathology, 903–904
gross, 903–904, 904f
microscopic, 904, 904f
serology, 905
strain classification, 902
susceptibility to chemical and physical agents, 901
transmission, 902
vaccination, 906
virulence factors, 902
Mycotic disease. *See* Fungal infections
Mycotoxicoses, 1271–1284
aflatoxins, 1276–1279
etiology and toxicology, 1276
experimental disease, 1276–1279, 1278f
metabolism and residues, 1279
natural disease, 1276, 1277f
pharmacological interactions, 1279
citrinin, 1280
etiology and toxicology, 1280
experimental disease, 1280
natural disease, 1280
cyclopiazonic acid, 1281
definition and synonyms, 1271
diagnosis, 1282–1283
economic significance, 1271
ergotism, 1271–1272
etiology and toxicology, 1271
experimental disease, 1272
metabolism and residues, 1272
natural disease, 1272
Fusarium mycotoxins, 1272–1276
fumonisins, 1274–1275
fusarochromanone, 1275
incidence and distribution, 1272
moniliformin, 1273–1274, 1275f
trichothecenes, 1272–1273, 1273f–1274f
zearalenone, 1275–1276
kojic acid, 1282
ochratoxins, 1279–1280
etiology and toxicology, 1279
experimental disease, 1279–1280
metabolism and residues, 1280
natural disease, 1279
oosporein, 1280–1281
etiology and toxicology, 1280
experimental disease, 1280–1281, 1281f
natural disease, 1280
overview, 1271
patulin, 1282
penicillic acid, 1281–1282
prevention, 1283–1284
antifungal agents, 1284
detoxification with binding agents, 1284
feed manufacturing and management, 1283
public health significance, 1271
rubratoxins, 1281
sterigmatocystin, 1281
tenuazonic acid and alternaria toxins, 1282
treatment, 1283
Myeloblastosis
clinical signs, 570
differential diagnosis, 590

Myeloblastosis (*cont'd*)
incubation period, 569
pathology, 574f, 576
gross, 576
microscopic, 574f, 576, 576f
pathogenesis, 576
ultrastructural, 576
Myelocytomatosis
clinical signs, 570
differential diagnosis, 590–591
incubation period, 569
pathology, 574f, 576–577
gross, 576–577
microscopic, 574f, 577, 577f
pathogenesis, 577
ultrastructure, 577
Mynahs, poxvirus of, 334f, 339
Myocarditis, with reovirus in turkeys, 364
Myopathy
deep pectoral, 1244–1245
nutritional, 1214, 1216f
Myxoma and myxosarcoma, 580, 581f

NA. *See* Neuraminidase
NAD (nicotinamide adenine dinucleotide), 860, 862, 1219
Naphthalene toxicity, 1303
Nasal discharge, in avian metapneumovirus, 115f
Nasal drop vaccination, 37
National Agricultural Statistics Service (NASS), 24
National Poultry Improvement Plan (NPIP), 678–679, 692, 881, 910
Natural killer (NK) cells, 63, 69, 544
Necropsy
brain exposure and removal, 30–31, 31f
communication of results, 33
gross examination, 30
histopathologic examination, tissues for, 32
killing birds for, 28
laboratory procedures, 30
precautions, 28
progressive examination hints, 32–33
specimen disposal, 33
techniques, 28–30, 29f
Necrotic enteritis, 949–953
clinical signs, 950
definitions and synonyms, 949
diagnosis, 952–953
economic significance, 949
etiology, 949–950
history, 949
intervention strategies, 953
pathobiology and epizootiology, 950–952
pathogenesis, 951–952
pathology, 950–951, 951f
public health significance, 949
strain classification and toxins, 949–950, 950t
transmission, carriers, vectors, 950
Neisseria, 1023
Nematodes, 1117–1133
Amidostomum spp., 1125, 1125f–1126f
Aproctella stoddardi, 1124–1125, 1124f
Ascaridia spp., 1120–1121, 1121f
Aulonocephalus lindquisti, 1125, 1125f
Baylisascaris spp., 1125
Capillaria spp., 1121, 1122f–1123f, 1122t
Cheilospirura spp., 1125, 1126f–1127f
Codiostomum struthonis, 1126
Cyathostoma bronchialis, 1126–1127, 1127f
Cyrnea colini, 1125–1126, 1127f
Deletrocephalus dimidiatus, 1127
development and life cycles, 1120
Dicheilonema rhea, 1128
Dispharynx nasuta, 1128, 1128f
Echinura uncinata, 1128, 1128f
Epomidiostomum uncinatum, 1126, 1127f
Gongylonema inguvicola, 1128, 1128f
Hadjelia truncate, 1126
Heterakis spp., 1123–1124, 1124f
Libyostrongylus douglassi, 1128–1129
morphology, 1119–1120
Ornithostrongylus quadriadiatus, 1129, 1129f
overview, 1117–1119
Oxyspirura spp., 1129, 1129f
Sicarius spp., 1129
Singhfilaria hayesi, 1129, 1130f
species reported from chickens, 1118t
species reported from non-chicken commercial birds, 1118t
species reported from wild birds, 1119t
Strongloides avium, 1129, 1130f
Subulura spp., 1124f, 1129–1130
Syngamus trachea, 1130–1131, 1131f
Tetrameres spp., 1131–1132, 1131f–1132f
treatment and control, 1132–1133
Trichostrongylus tenuis, 1132, 1132f
Vaznema zschokkei, 1132
Neomycin
for colibacillosis, 784
for pullorum disease, 692
Neonatal meningitis *Escherichia coli* (NMEC), 757, 762
Neoplastic diseases, 513–622
digestive system, 611–613
alimentary tract, 611–612, 611f
liver, 612–613
cholangiocellular tumors, 612–613, 612f–613f
hepatocellular tumors, 612, 612f
pancreas, adenocarcinoma of, 613, 613f
endocrine system, 616–617
adrenal gland, 616
parathyroid gland, 617
pituitary gland, 616
thymus, 617
thyroid gland, 617
eye, 616
integumentary system, 617–620
adenoma, 619
feather folliculoma, 619, 619f
hemangiopericytoma, 617, 617f
intracutaneous keratinizing epithelioma, 619, 620f
keratoacanthoma, 617–619, 618f–619f
lipoma, 617
liposarcoma, 617
mast cell tumors, 619–620
squamous cell carcinoma, 617
xanthoma, 620
leukosis/sarcoma group, 553–592
lung, 614, 614f
Marek's disease, 515–552
mesothelioma, peritoneal, 613, 613f
multicentric histiocytosis, 621–622, 622f
musculoskeletal system, 620–621
chondroma and chrondrosarcoma, 621, 621f
leiomyoma and leiomyosarcoma, 620, 620f
osteoma and osteosarcoma, 620, 621f
rhabdomyosarcoma, 620, 621f
nervous system, 614–616
astrocytoma, 614–615, 614f
melanoma, 616, 616f
neurofibromas, 615, 615f

neuromas, 615, 616f
pineal body tumor, 615, 615f
overview, 513–514, 604–605
prevalence, 605
renal, 611
reticuloendotheliosis, 593–604
teratoma, 621
transmissible neoplasms, table of, 514t
urogenital system, 605–611
mesosalpinx, 608
leiomyoma, 608, 609f
ovary, 605–608
adenocarcinoma, 605, 606f
arrhenoblastoma, 607–608, 608f
dysgerminoma, 608
granulosa-theca cell tumor, 606–607, 607f
ovarian Sertoli cell tumors, 608, 608f
oviduct, 609–610
adenocarcinoma, 609–610, 609f–610f
testis, 610–611
Leydig cell tumors, 611
seminoma, 610, 611f
Sertoli cell tumor, 610, 611f
Neoschoengastia americana (chiggers), 1102, 1102f
Nephritis. *See* Avian nephritis; Hemorrhagic nephritis enteritis of geese (HNEG)
Nephroma and nephroblastoma
differential diagnosis, 591
pathology, 578–582
gross, 578, 579f
microscopic, 578, 579f, 580
pathogenesis, 580
ultrastructural, 580
Nerves, Marek's disease and, 532, 532f, 533, 535, 535f
Nervous system disease
arizonosis, 709, 709f, 710–711, 710f
aspergillosis, 1082
avian encephalomyelitis, 486–493, 489f–490f
E. coli meningitis, 777
encephalomalacia, 1213–1214, 1215f
Listeria, 1022
Marek's disease, 530–531, 530f–531f, 532, 535, 537, 538f, 548–549
neoplasia, 614–616
astrocytoma, 614–615, 614f
melanoma, 616, 616f
neurofibromas, 615, 615f
neuromas, 615, 616f
pineal body tumor, 615, 615f
Newcastle disease, 99
ochroconosis, 1091–1092
Nest and egg hygiene, 14–15
Nest boxes, 14
Nesting materials, 14
Neuraminidase (NA)
erysipelas, 989
influenza, 187–191, 188t, 202, 205
Newcastle disease virus, 92
Neuraminidase inhibition (NI)
APMVs, 108
influenza virus, 189
Neurofibromas, 615, 615f
Neuromas, 615, 616f
Neurotropic velogenic Newcastle disease, 91
Newcastle disease, 89–107
biologic properties, 92
cell fusion and hemolysis, 92
hemagglutination activity, 92
neuraminidase activity, 92
chemical composition, 92
classification, 89–90
clinical signs, 99–101, 100f
definition and synonyms, 91
diagnosis, 102–104
serology, 103
virus isolation and identification, 102–103
differential diagnosis, 103–104
economic significance, 91
emergence of virulent viruses, 97–98
etiology, 91–95
history, 91
immunity, 101–102
active, 101–102
passive, 102
incidence and distribution, 98
incubation period, 99
interaction with *Mycoplasma* spp., 1320
intervention strategies, 104–107
laboratory host systems, 95–96
animals, 95–96
cell culture, 96
chicken embryos, 96
management procedures, 104–105
international control policies, 104
national control policies, 104–105
morphology, 91, 92f
natural and experimental hosts, 98
overview, 89–91
panzootics of, 98
pathobiology and epidemiology, 98–102
pathogenicity, 96–98
pathology, 101
gross lesions, 101
microscopic lesions, 101
ultrastructural lesions, 101
phylogenetic analysis, 94f, 95
public health significance, 45–46, 91
nature of disease in humans, 45
occurrence, 45–46
preventive measures, 46
reservoirs and sources of infection, 46
strain classification, 93–95
antigenicity, 93, 95
genetic or molecular, 95
immunogenicity, 95
pathogenicity tests, 95
susceptibility to physical and chemical agents, 93
transmission, carriers, and vectors, 98–99
treatment, 107
vaccination, 95, 105–107, 105t
field vaccination protocols and regimens, 106–107
reactions, 1321–1322
strains used in, 105t
types of vaccine, 105–106
virulence determinants, 96–97
F gene, 96–97, 96t
HN gene, 97
replication complex (NP/P/L genes), 97
V gene, 97
virus replication, 92–93
NI. *See* Neuraminidase inhibition
Niacin, 844, 1219
Nicarbazin
for coccidiosis, 1160, 1161
toxicity, 1291
Nicotinamide adenine dinucleotide (NAD), 860, 862, 1219
Nicotine toxicity, 1301
Nidovirales, 376
Nightshade toxicity, 1305
Nitarsone
for *Cochlosoma anatis* infection, 1185
for histomoniasis, 1178t
Nitarsone toxicity, 1291
Nitrate toxicity, 1297
Nitric oxide, 544
Nitric oxide inducing factor (NOIF), 70

Nitrite toxicity, 1297
Nitrofuran toxicity, 1289–1290
Nitroimidazole, for *Cochlosoma anatis* infection, 1184–1185
Nitrophenide toxicity, 1291
Nitrous oxide synthase (NOS), 544
Nivalenol, 1272–1273, 1274f
NK (natural killer) cells, 63, 69, 544
Nocardia, 1023
NOIF (nitric oxide inducing factor), 70
Nonstarch polysaccharides (NSP), 1207
Northern fowl mites *(Ornithonyssus sylviarum),* 26, 52, 1099–1101, 1100f
Norway brown rat, 1110f, 1111, 1111t
NOS (nitrous oxide synthase), 544
Novobiocin
  for enterococcosis, 983
  for fowl cholera, 821
  for *Riemerella anatipestifer,* 828
NP cell activation test, 587, 587t
NPIP. *See* National Poultry Improvement Plan
Nucleic acid probes, for infectious bursal disease, 232
Nursing care, in disease outbreaks, 39–40
  drugs, 39–40
  flock disposition, 40
Nutrition, 1205–1227
  carbohydrates, 1207
  fats, 1207
  inorganic elements, essential, 1221–1227
    calcium, 1222
    chlorine, 1223, 1223f
    copper, 1225
    dietary balance of, 1224
    iodine, 1224–1225
    iron, 1225
    magnesium, 1222–1223
    manganese, 1224
    phosphorus, 1222
    potassium, 1223–1224
    selenium, 1226–1227
    sodium, 1223, 1224f
    zinc, 1225–1226
  nutrient requirements of poultry, 1205, 1206t
  proteins and amino acids, 1205–1207
  toxicity and nutrients, 1292–1297
  vitamins, 1207–1221
    biotin, 1220, 1220f
    choline, 1221, 1221f
    cobalamin (vitamin B_{12}), 1221
    folic acid, 1220–1221
    niacin, 1219
    pantothenic acid, 1218–1219
    pyridoxine (vitamin B_6), 1219–1220
    riboflavin (vitamin B_2), 1217–1218, 1218f
    thiamin (vitamin B_1), 1216–1217, 1217f
    vitamin A, 1208–1210
      deficiency, 1208–1210, 1209f
      hypervitaminosis A, 1210
    vitamin D, 1210–1213
      deficiency, 1211–1212
      hypervitaminosis D, 1212–1213
    vitamin E, 1213–1214
      deficiency, 1213–1214, 1215f
    vitamin K deficiency, 1215–1216
  water, 1205
Nystatin, in candidiasis, 1090

Oak toxicity, 1305
Ochratoxins, 1279–1280
  etiology and toxicology, 1279
  experimental disease, 1279–1280
  metabolism and residues, 1280
  natural disease, 1279
Ochroconosis, 1091–1092
Ocular diseases. *See* Eye diseases
Oerskovia, 1023
Office International des Epizooties (OIE), 9–11
OIE Terrestrial Animal Health Code (Terrestrial Code), 9–11
Oil toxicity, 1303–1304
Oleander toxicity, 1305
Omphalitis
  aspergillosis, 1081
  E. coli, 766–768, 767f
Onchosphere, 1136f, 1137
Onicola canis, 1133, 1133f
Onion toxicity, 1305
Oospora coloran, 1280
Oosporein, 1280–1281
  etiology and toxicology, 1280
  experimental disease, 1280–1281, 1281f
  natural disease, 1280
Ophthalmitis, in aspergillosis, 1081–1082, 1081f, 1085
Orchitis, *E. coli,* 774–775
Organ cultures, for infectious bronchitis virus, 143
Organochloride toxicity, 1299–1300
Organophosphate toxicity, 1292, 1300–1301
Ornithobacterium rhinotracheale infection, 828–834
  biochemical properties, 829
  classification, 828
  clinical signs, 830–831
  colony morphology, 829
  definitions and synonyms, 828
  diagnosis, 832–833
  differential diagnosis, 833
  economic significance, 828
  etiology, 828–830
  growth requirements, 829
  history, 828
  immunity, 832
  incubation period, 830
  isolation and identification of agent, 832
  management procedures, 833
  morphology and staining, 828, 829f
  natural and experimental hosts, 830
  pathobiology and epidemiology, 830–832
  pathogenicity, 829
  pathology
    gross lesions, 831, 831f
    microscopic lesions, 831, 832f
  serology, 833
  strain classification, 829–830
  susceptibility to chemical and physical agents, 829
  transmission, 830
  treatment, 833–834
  vaccination, 833
Ornithobacterium rhinotracheale, 1320
Ornithonyssus sylviarum (northern fowl mites), 26, 52, 1099–1101, 1100f
Ornithostrongylus quadriadiatus, 1129, 1129f
Orthoboric acid toxicity, 1298
Orthomyxoviridae
  influenza viruses, 181–206
Oseltamivir, 206
Osteoarthritis, *E. coli,* 777–778
Osteochondrosis, 1244
Osteoma and osteosarcoma, 580, 620, 621f
Osteomyelitis
  Arcanobacterium, 1018
  aspergillosis, 1081
  enterococcosis, 984, 985f
  staphylococcosis, 974, 975f
Osteopetrosis
  clinical signs, 570
  differential diagnosis, 591

incubation period, 570
pathology, 582–583
gross, 582, 582f, 583f
microscopic, 582–583, 583f
pathogenesis, 583
ultrastructural, 583
Osteoporosis, 1240–1241
clinical signs and pathology, 1240
intervention strategies, 1240–1241
pathogenesis and etiology, 1240
Ostrich
Aeromonas infection in, 1018
APMVs in, 107, 109
aviadenovirus infection in, 298
Bacillus anthracis in, 1018
botulism in, 954
enterovirus-like viruses in, 397
fowl typhoid in, 683
Gallibacterium in, 1021
histomoniasis in, 1175
influenza in, 186t, 197, 200
Klebsiella infection in, 1021
Lawsonia infection in, 1021
macrorhabdosis in, 1092
Neisseria infection in, 1023
Newcastle disease in, 101, 107
Pseudomonas in, 1024–1025
reovirus in, 365
tuberculosis in, 1011
zygomycosis in, 1092
Otitis, 1258–1259
arizonosis, 709, 710f, 711
Ovary
lesions in pullorum disease, 686, 687f–688f, 688
neoplasia of, 605–608
adenocarcinoma, 605, 606f
arrhenoblastoma, 607–608, 608f
dysgerminoma, 608
granulosa-theca cell tumor, 606–607, 607f
ovarian Sertoli cell tumors, 608, 608f
Oviduct
adenocarcinoma, 609–610, 609f–610f
cystic right, 1256
impaction, 1256
Ovotransferrin, for chlamydiosis, 1068
Owl herpesvirus, 465
Oxalate toxicity, 1305
Oxyspirura mansoni, 1129, 1129f
Oxyspirura petrowi, 1129
Oxyspirura spp., 1129, 1129f
Oxytetracycline
for avian intestinal spirochetosis, 1007
for bordetellosis, 844
for *Borrelia anserina,* 1019
for fowl cholera, 821–822
for infectious coryza, 868
for *Mycoplasma gallisepticum,* 892
for *Mycoplasma synoviae,* 906

Pacheco's disease, 161
Pale bird syndrome, 363, 1323
PAMP (pathogen-associated molecular patterns), 63
Pancreas
adenocarcinoma of, 613, 613f
adenovirus infection, necrotizing pancreatitis with, 299
APMV infection and, 110
avian encephalomyelitis and, 491f
turkey viral hepatitis and, 483, 484f
Panophthalmitis, *E. coli,* 777
Pantothenic acid deficiency, 1218–1219
Papilloma, 611
Parakeets. *See also* Budgerigars
Coxiella burnetii in, 1020
Gallibacterium in, 1020
Paralysis, in Marek's disease, 530–531, 530f–531f, 548–549
Paramyxovirinae, 89
Paramyxoviruses, 417
Newcastle disease virus (APMV-1), 89–107
serotypes, 89, 90t
Paraquat toxicity, 1299
Parasites. *See also* External parasites; Internal parasites
external examination for, 26
public health significance, 52–53
avian mite dermatitis, 52
cryptosporidiosis, 52
toxoplasmosis, 52–53
Parathion toxicity, 1301
Parathyroid gland neoplasia, 617
Paratyphoid infections, 693–706
antigenic structure, 695
biochemical properties, 694
classification and nomenclature, 693
clinical signs, 700
colony morphology, 694
competitive exclusion, 704–705
diagnosis, 701–704
culture media, 702–703
culture methods, 702
genus and serotype, confirmation of, 703
rapid detection technologies, 703
sample selection, 701–702
serology, 703–704
distribution of *Salmonella* serotypes, 697
economic significance, 693
etiology, 693–696
gastrointestinal colonization control, 704–705
growth requirements, 694
immunity and resistance, 700–701
incidence in poultry and poultry products, 696–697
intervention strategies, 704–706
morphology, 693–694
natural and experimental hosts, 697–699
mature poultry, 698
predisposing factors, 698–699
young poultry, 697
pathobiology and epizootiology, 696–701
pathogenesis, 700
pathogenicity, 697
pathology, 700
public health significance, 693
risk reduction, 704
sources, vectors, and transmission, 699–700
strain classification, 695
susceptibility to chemical and physical agents, 694–695
treatment, 706
vaccination, 705–706
virulence factors, 695–696
Parrots
fowl typhoid in, 683
Newcastle disease virus variants in, 98, 99
pullorum disease in, 683
reovirus in, 365
Parsley toxicity, 1305
Partridges
avian intestinal spirochetosis in, 999
chlamydiosis in, 1064
eastern equine encephalitis in, 475
enterovirus-like viruses in, 397
Highlands J virus in, 476
histomoniasis in, 1175
macrorhabdosis in, 1092
Mycoplasma imitans in, 910–911
Newcastle disease virus variants in, 107
Riemerella anatipestifer in, 825
rotavirus in, 386

Parvovirus of chickens and turkeys, 399–405
chemical composition, 400–401
classification, 399–400, 400f
clinical signs, 402–403
diagnosis, 404–405
etiology, 399–402
immunity, 404
incidence and distribution, 402
intervention strategies, 405
laboratory host systems, 402
management procedures, 405
morphology, 400, 401f
natural and experimental hosts, 402
overview, 399
pathobiology and epizootiology, 402–404
pathogenesis, 403
pathogenicity, 402
pathology, 403, 404f
phylogenetic tree, 400f
strain classification, 401
susceptibility to chemical and physical agents, 401
transmission, carriers, and vectors, 402
vaccination, 405
virus replication, 401
Parvovirus of waterfowl, 444–451
chemical composition, 444
classification, 444, 445f
clinical signs, 447, 447f
diagnosis, 449
antigen detection, 449
electron microscopy, 449
by PCR, 449
serology, 449
virus isolation and identification, 449
differential diagnosis, 450
economic significance, 444
etiology, 444–446
history, 444
immunity, 449
incidence and distribution, 446
incubation period, 447
intervention strategies, 450–451
laboratory host systems, 445–446
management procedures, 450
morbidity and mortality, 447–448
morphology, 444, 446f
natural and experimental hosts, 446
pathogenesis of infectious process, 448–449
pathology
gross lesions, 448, 448f
microscopic lesions, 448, 448f
susceptibility to chemical and physical agents, 445
transmission, carriers, and vectors, 446–447
vaccination, 450–451
virus replication, 444
Passive hemagglutination test, for avian encephalomyelitis virus, 492
Passive immunity
avian encephalomyelitis, 492
avian leukosis/sarcoma viruses and, 584
avian metapneumovirus, 117
beak and feather disease, 273
bordetellosis, 842
Borrelia anserina infection, 1020
chicken infectious anemia, 259
circovirus, 273
duck virus enteritis (duck plague), 439
erysipelas, 993
fowl cholera, 820
hemorrhagic enteritis, 314
histomoniasis, 1177
infectious bursal disease, 230
infectious laryngotracheitis, 170
influenza, 201
Mycoplasma iowae, 909
Mycoplasma meleagridis, 898
necrotic enteritis, 952
Newcastle disease, 102
parvovirus of chickens and turkeys, 404
rotavirus, 390
turkey coronavirus enteritis, 380
Passive immunization, in colibacillosis, 783
Pasteurella multocida, 807–823
Pathogen-associated molecular patterns (PAMP), 63
Pathogenicity, Newcastle disease and, 95
Pathogenicity islands
E. coli, 757, 759–761
Salmonella, 681–682
Patulin, 1282
PBB (polybrominated biphenyl), 1303
PCB (polychlorinated biphenyl), 1303
PCR. *See* Polymerase chain reaction
Peacocks, chlamydiosis in, 1064
PEC (poult enteritis complex), 391, 1323, 1324–1325
Pelistega europaea, 1023
PEMS (poult enteritis mortality syndrome), 364, 391, 399, 402–403, 773, 1323, 1324
Pendulous crop, 1253, 1253f
Penguin, APMVs in, 108, 110
Penicillic acid, 1281–1282
Penicillin
for bordetellosis, 834–844
for *Borrelia anserina,* 1019
for erysipelas, 994
for fowl cholera, 821–822
for *Ornithobacterium rhinotracheale,* 834
for *Riemerella anatipestifer,* 828
Penicillium citrinum, 1280
Penicillium puberulum, 1276
Penicillium purpurogenum, 1281
Penicillium rubrum, 1281
Penicillium viridicatum, 1279
Pentachlorophenol toxicity, 1298
People
access to complex, 23
access to farm by, 20–21
access to poultry house by, 16
Performance parameters, 24
Pericarditis, in colisepticemia, 775
Peritonitis, *E. coli,* 774
Perosis, 1208
PES (poult enteritis syndrome), 385, 390
Pesticide, defined, 17
Pestivirus, 474
Pests
arthropod, 1105–1109
Alphitobius diaperinus (lesser mealworm/darkling beetle), 1105–1107, 1106f
bed bugs, 1108, 1109f
control recommendations, 1108–1109
flies, 1107–1108, 1107f–1108f
rodents, 1109–1115
economic impact, 1110
exclusion of, 1112–1113
field identification, 1110f
house mouse, 1111
inspections for, 1112
integrated pest management, 1112
Norway (brown) rats, 1111
overview, 1109–1110
population reduction, 1113–1114, 1114f, 1115t
public health significance, 1110, 1110t
reproductive capabilities, 1111t
roof (black) rats, 1112

sanitation and cultural practices, 1113, 1113f
PFGE. *See* Pulsed-field gel electrophoresis
PHA (phytohemagglutinin), 69, 70
Phage therapy, for *Campylobacter,* 743
Phage typing
Pasteurella multocida, 812
Salmonella spp., 695
Staphylococcus aureus, 973
Phallus prolapse, 1256
Pheasants
avian encephalomyelitis in, 487
avian intestinal spirochetosis in, 999
avian metapneumovirus in, 113, 115, 116
Borrelia anserina infection in, 1018–1019
botulism in, 954, 955
chlamydiosis in, 1064
eastern equine encephalitis in, 475
enterovirus-like viruses in, 397
erysipelas in, 990, 991
fowl typhoid in, 683
Gallibacterium in, 1020
histomoniasis in, 1174, 1175
marble spleen disease in, 290, 309–316
Marek's disease in, 529
Newcastle disease in, 101
Newcastle disease virus variants in, 107
Pseudomonas in, 1024–1025
pullorum disease in, 683
reovirus in, 365
reticuloendotheliosis virus in, 597
Riemerella anatipestifer in, 825
rotavirus in, 382, 385–388, 390–391
tuberculosis in, 1011
Phenolics, toxicity of, 1298
Phenotypic distributions of unique genotypes, 72
Phenoxyherbicide toxicity, 1299
Phenylarsonic acid toxicity, 1291
Philphthalmus gralli, 1144
Phosphate transport system (Pst) operon, 762
Phosphorus
deficiency, 1213f, 1222
excess, 1222
toxicity, 1293, 1301
Photosensitization, 1305
PHS. *See* Pulmonary hypertension syndrome
PHV. *See* Pigeon herpesvirus
Phylogenetics, of Newcastle disease virus, 94f, 95
Phytohemagglutinin (PHA), 69, 70
Phytotoxins, 1304–1306
avocado, 1304
black locust, 1304
bladder pod, 1304
cacao, 1304
Carolina jessamine, 1304
cassava, 1304
castor bean, 1304
coffee senna, 1304
corn cockle, 1304–1305
cotton seed meal, 1305
coyotillo, 1305
Crotalaria spp., 1305
Daubentonia, 1305
death camas, 1305
Eucalyptus cladocalyx, 1305
hemlock, 1305
jimsonweed, 1305
Leucaena leucocephala, 1305
lily of the valley, 1305
milkweed, 1305
nightshade, 1305
nitrates, 1305
oak, 1305
oleander, 1305
onions, 1305
oxalates, 1305
parsley, 1305
pokeberry, 1305
potato, 1305
ragwort, 1305
rapeseed meal, 1306
sickle pod, 1304
sweet pea, 1306
tannins, 1306
tobacco, 1306
velvetweed, 1306
vetch, 1306
yellow jessamine, 1306
yew, 1306
PiAdV-1 (pigeon adenovirus), 290, 297
Picornavirus
avian encephalomyelitis, 486–493
duck, 431
enterovirus-like viruses (ELVs), 395–399
Pigeon adenovirus (PiAdV-1), 290, 297
Pigeon circovirus (PiCV), 265–267, 269–270, 272, 272f, 274
Pigeonfly (hippoboscid fly/lousefly) *(Pseudolynchia canariensis),* 1107
Pigeon herpesvirus (PHV1), 465–467
clinical signs, 466
diagnosis, 467
differential diagnosis, 467
distribution in the host, 466
etiology, 466
history, 465
immunity, 467
incidence and distribution, 465
incubation period, 466
morbidity and mortality, 466
natural and experimental hosts, 466
overview, 465
pathobiology and epizootiology, 466–467
pathology, 466–467
gross lesions, 467
histopathology, 467
serology, 467
shedding, 466
transmission, 466
treatment, , and control, 467
vaccination, 467
virus isolation, 467
Pigeon paramyxovirus type 1 (PPMV-1), 91, 97–99, 107
Pigeon poxvirus, 339, 341, 343, 344, 345
Pigeons
APMVs in, 109
aviadenovirus infection in, 297
avian encephalomyelitis in, 487
chlamydiosis in, 1064
erysipelas in, 989
Gallibacterium in, 1020
inclusion body hepatitis in, 296
Listeria in, 1022
macrorhabdosis in, 1092
Mycobacterium in, 1022
Mycoplasma infections in, 912
Newcastle disease in, 98, 99, 101, 105, 107
Pasteurella multocida in, 809
Pelistega in, 1023
rotavirus in, 382, 384–386
seminoma in, 611
visceral urate deposition in, 1254f
Pineal body tumor, 615, 615f
Pituitary gland neoplasia, 616
Planococcus, 1023
Plaque formation, poxvirus, 339
Plasma cells, 64f
Plasmids
antimicrobial resistance and, 42–43, 43f
E. coli, 752, 755, 757, 759–762
Pasteurella multocida, 813

Plasmids (*cont'd*)
in *Salmonella* Pullorum and *Salmonella* Gallinarum, 681–682
Salmonella spp., 695, 696
Plesiomonas, 1023
PM test, 587, 587t
Pneumovirinae, 89
Pododermatitis, 1257–1258, 1257f
Poison. *See* Toxicity
Pokeberry toxicity, 1305
Polybrominated biphenyl (PBB), 1303
Polychlorinated biphenyl (PCB), 1303
Polymerase chain reaction (PCR)
for *Aspergillus* spp., 1087
for aviadenovirus, 292, 300
for avian intestinal spirochetosis, 998, 1004–1005
for avian metapneumovirus, 118
for *Avibacterium paragallinarum,* 861, 862, 866
for *Campylobacter,* 742
for chicken infectious anemia, 261–262
for chicken infectious anemia virus, 262
for *Chlamydia,* 1066–1067
for circovirus, 274
for circovirus-like infection, 421
for cryptosporidiosis, 1171
for duck virus enteritis, 439
for *E. coli,* 781
for erysipelas, 986
for Gallid herpesvirus type 1, 171
for goose hemorrhagic polyomavirus, 443
for hemorrhagic enteritis virus, 314–315
for histomoniasis, 1178
for leukosis/sarcoma group of neoplastic diseases, 588, 588t
for Marek's disease, 547
for *Mycoplasma gallisepticum,* 880, 882, 888–889
for *Mycoplasma imitans,* 911
for *Mycoplasma iowae,* 908, 910
for *Mycoplasma meleagridis,* 899
for *Mycoplasma synoviae,* 905, 906
for *Ornithobacterium rhinotracheale,* 829, 832
for parvovirus of chickens and turkeys, 405
for parvovirus of waterfowl, 449
for *Pasteurella multocida,* 811, 813
for poxvirus, 343–344
for reticuloendotheliosis, 603, 603f
for *Riemerella anatipestifer,* 825, 827
for *Salmonella,* 680, 703
for sarcocystosis, 1192
Polymorphus boschadis, 1133, 1134f
Polyomaviruses, 440–443
Polytetrafluoroethylene toxicity, 1302
Population dynamics, 5
Potassium
deficiency, 1223–1224
toxicity, 1293
Potassium dichromate toxicity, 1294
Potato toxicity, 1305
Poult enteritis complex (PEC), 391, 1323, 1324–1325
Poult enteritis mortality syndrome (PEMS), 364, 391, 399, 402–403, 773, 1323, 1324
Poult enteritis syndrome (PES), 385, 390
Poultry house, 11–17
built-up litter and unclean buildings, 13
cleanout and disinfection, 12–13
culling, 13–14
decontamination, 12–13
disinfectants, 13
down time, 12
feed and drinking water, 15, 15f
feed and water medication, 15–16
house access
animals, 16–17
insect, mite, and tick control, 17
people, 16
management of house environment, 11–12
mortality, 14
nest and egg hygiene, 14–15
turnaround time, 12
Poultry red mite (chicken mite or roost mite) *(Dermanyssus gallinae),* 1101, 1101f
Pox, 333–346
chemical composition, 333, 335
clinical signs, 340
definition and synonyms, 333
diagnosis, 342–344
avian embryo inoculation, 342
bird inoculation, 342
cell culture, 342
microscopy, 342
molecular methods, 343–344
genomic fragments as probes, 343
polymerase chain reaction (PCR), 343–344
restriction endonuclease analysis, 343
serology and protection tests, 342–343
ELISA, 343
fluorescent antibody, 343
immunoblotting, 343
immunodiffusion, 343
immunoperoxidase, 343
neutralization, 343
passive hemagglutination, 343
differential diagnosis, 344
economic significance, 333
etiology, 333–337
as expression vectors for genes from mammalian pathogens, 346
genomic differences, 336
history, 333
incidence and distribution, 339–340
incubation period, 340
intervention strategies, 344–345
laboratory host systems, 337–339, 338f
birds, 338, 339
cell culture, 339
cytopathic effects, 339
embryos, 339
plaque formation, 339
management procedures, 344–345
morbidity and mortality, 340–341
morphology, 333, 334f
natural and experimental hosts, 340
nonessential and immunomodulatory genes, 336–337
pathology
gross, 341
microscopic, 341–342
ultrastructural, 342
public health significance, 333
strain classification, 335–336
susceptibility to chemical and physical agents, 335
transmission, 340
vaccination, 344–346
canary pox, 345
fowlpox, 344–345
in-ovo, 345
pigeon pox, 345
prophylactic, 345
quail pox, 345
recombinant fowlpox, 345–346
vaccine takes, 345
virus replication, 335
PPMV-1 (pigeon paramyxovirus type 1), 91, 97–99, 107
A Practical Guide for Managing Risk in Poultry Production, 12

Prairie chickens, reticuloendotheliosis virus in, 594, 595, 601
Prebiotics, for *Salmonella* colonization control, 705
Predisposition, 9
Prevalence of a disease, 9
Primary lymphoid organs, 62–63
Probiotics
  avian intestinal spirochetosis, 1006
  for colibacillosis, 785
Proglottids, 1135, 1136–1137, 1136f, 1142f
Promoter
  chicken infectious anemia virus, 250
  fowlpox virus, 345–346
Prosthogonimus sp., 1143–1144, 1143f, 1144f
Prosthoryhnchus formosus, 1133, 1134f
Protectins, 759–760
Proteins, 1205–1207
Protein supplements, toxicity from, 1292
Proteolytic enzymes, of *Aspergillus* spp., 1080
Proteomics, 75
Proteus, 1023
Protozoal infections, 1147–1194
  avian malaria, 1188–1189
  coccidiosis, 1148–1166
    anticoccidials, table of preventative, 1159t
    in chickens, 1149–1163
      diagnosis, 1150t, 1157–1159
      Eimeria acervulina, 1150t, 1151, 1152f
      Eimeria brunetti, 1150t, 1153, 1154f
      Eimeria hagani, 1150t, 1153
      Eimeria maxima, 1150t, 1152f, 1153
      Eimeria mitis, 1150t, 1152f, 1155
      Eimeria mivati, 1150t, 1153
      Eimeria necatrix, 1150t, 1154f, 1155–1156
      Eimeria praecox, 1150t, 1156
      Eimeria tenella, 1150t, 1154f, 1156
      epidemiology, 1157
      etiology, 1149–1156
      incidence and distribution, 1149
      life cycle, 1151f
      natural and experimental hosts, 1157
      prevention and control, 1159–1163
      transmission and vectors, 1157
      vaccination, 1161
    classification and taxonomic relationships, 1148–1149
    in ducks, 1166
    in geese, 1165–1166
      Eimeria anseris, 1166
      Eimeria truncata, 1165–1166
    life cycle, 1149
    overview, 1148
    in pigeons, 1166
    in turkeys, 1162t, 1163–1165
      Eimeria adeneides, 1162t, 1163–1164
      Eimeria dispersa, 1162t, 1164
      Eimeria gallopavonis, 1162t, 1164
      Eimeria innocua, 1165
      Eimeria meleagridis, 1162t, 1164
      Eimeria meleagrimitis, 1162t, 1164–1165
      Eimeria subrotunda, 1165
      etiology, 1163
      prevention and control, 1165
  Cochlosoma anatis infection, 1180, 1182–1185
    clinical signs and pathogenicity, 1184
    etiology and classification, 1182–1183
    incubation period, 1183
    life cycle, 1183
    morphology, 1182–1183, 1183f
    natural and experimental hosts, 1184
    overview, 1182
    prevention, 1185
    site of infection, 1184
    transmission, 1183
    treatment, 1184–1185
  cryptosporidiosis, 1167–1171
    in chickens, 1169–1170, 1169f–1170f
    diagnosis and culture, 1171
    history, 1167
    human health importance, 1167
    incidence and distribution, 1168–1169
    life cycle and morphology, 1167–1168, 1168f
    prevention and control, 1171
    in quail, 1170–1171
    taxonomy, 1167, 1167t
    in turkeys, 1170
  Haemoproteus, 1189–1190
  hexamitiasis, 1181–1182, 1181f
  histomoniasis, 1147, 1172–1179, 1173f–1174f, 1177f
    clinical pathology, 1176
    clinical signs, 1176
    diagnosis, 1177–1178
    economic significance, 1172
    etiology and classification, 1172–1175
    history, 1172
    immunity, 1177
    incidence and distribution, 1175
    incubation period, 1176
    life cycle, 1174–1175
    morbidity and mortality, 1176
    morphology, 1172, 1174
    natural and experimental hosts, 1175
    overview, 1172
    pathogenicity, 1175
    pathology, 1176–117
      gross lesions, 1176, 1177f
      histopathology, 1176–1177
    prevention and control, 1178–1179, 1178t
    susceptibility to chemical and physical agents, 1175
    vectors, 1175–1176
  leucocytozoonosis, 1185–1188
    diagnosis, 1188
    Leucocytozoon caulleryi, 1187–1188
    Leucocytozoon sabrezi, 1188
    Leucocytozoon schoutedeni, 1188
    Leucocytozoon simondi, 1185–1186, 1187f
    Leucocytozoon smithi, 1186–1187, 1187f
    treatment and control, 1188
  necropsy examination hints, 32
  overview, 1147
  sarcocystosis, 1190–1192
    clinical signs, 1191
    diagnosis, 1192
    etiology, 1190–1191
    immunity, 1192
    incidence and distribution, 1190
    incubation period, 1191
    life cycle, 1191
    pathogenicity, 1191
    pathology, 1191–1192, 1192f
    prevention and control, 1192
    transmission, carriers and vectors, 1191
    zoonosis, 1192
  toxoplasmosis, 1192–1194
    diagnosis, 1194

Protozoal infections (*cont'd*)
disease course, 1193
etiology, 1192–1193
life cycle, 1193
pathology, 1194
prevention, 1194
serology, 1194
transmission, carriers, and vectors, 1193
zoonosis, 1192, 1194
trichomoniasis, 1179–1181
description, 1179, 1179f
diagnosis, 1180
immunity, 1180
incidence and distribution, 1179–1180
life cycle, 1180
pathology, 1180
prevention and control, 1180–1181
trypanosomiasis, 1190
Proventriculitis and proventricular dilatation of broiler chickens, 1328–1332. *See also* Transmissible viral proventriculitis
Proventriculus
candidiasis, 1089
impact of, 1253
transmissible viral proventriculitis (TVP), 1328–1332
Prussic acid, 1305
Pseudo-fowl pest. *See* Newcastle disease
Pseudolynchia canariensis (pigeonfly or hippoboscid fly/lousefly), 1107
Pseudomonas, 1023–1025, 1024f–1025f
Pseudo-poultry plague. *See* Newcastle disease
Pseudorabies virus, 467
Pseudovogelpest. *See* Newcastle disease
Psittacid herpesvirus type 1 (PsHV-1), 161
Psittacine beak and feather disease. *See* Beak and feather disease (BFD)
Psittacine birds
Coxiella burnetii in, 1020
enterovirus-like viruses, 397
quarantine of, 105
Psittacinepox virus, 339, 340, 341
Psittacosis. *See* Chlamydiosis
Public health significance, 44–53
bacterial diseases, 46–50
botulism, 46
campylobacteriosis, 47
chlamydiosis (psittacosis), 47–48
Clostridium perfringens infection, 46–47
Erysipelothrix rhusiopathiae infection, 48
Escherichia coli infection, 48–49
listeriosis, 49
mycobacteriosis, 49–50
salmonellosis, 50
Staphylococcus aureus infection, 50
biosecurity common practices, 44
fungal diseases, 50–52
cryptococcosis, 50–51
dermatophytosis (falvus), 51
histoplasmosis, 51–52
overview, 44
parasitic diseases, 52–53
avian mite dermatitis, 52
cryptosporidiosis, 52
toxoplasmosis, 52–53
viral diseases, 44–46
arboviral encephalitis, 44–45
avian influenza, 45
Newcastle disease, 45–46
Pullorum disease, 678–693
antigenic structure, 680–681
biochemical properties, 680
classification, 679
clinical signs, 684
colony morphology, 679, 690
diagnosis, 689–690
identification of cultures, 690, 690t
isolation and identification of agent, 689
serology, 690, 691
differential diagnosis, 690
economic significance, 678
etiology, 679–682
growth requirements, 679
history, 678–679
immunity, 689
incidence and distribution, 682–683
intervention strategies, 690–693
management procedures, 691–692
area eradication, 692
elimination of carriers, 691
national control program, 692
non-pullorum reactors, 691–692
serologic tests, 691
morbidity and mortality, 684
morphology, 679
natural and experimental hosts, 683
pathobiology and epidemiology, 682–689
pathogenesis, 688–689
pathology, 684–688
gross lesions, 684–687, 685f–687f
histopathology, 687–688, 687f–688f
public health significance, 678
susceptibility to chemical and physical agents, 680
synonyms, 678
transmission, 683–684
treatment, 692–693
vaccination, 692
virulence factors, 681–682
Pulmonary hypertension syndrome (PHS), 1246–1249
clinical signs, 1247, 1247f
intervention strategies, 1249
pathogenesis and etiology, 1248–1249
pathology, 1247–1248, 1247f
Pulsed-field gel electrophoresis (PFGE)
for avian intestinal spirochetosis, 1000
for botulism, 956
for *Campylobacter,* 742
for *E. coli,* 756
for *Mycobacterium avium,* 1008
for necrotic enteritis, 952
for *Ornithobacterium rhinotracheale,* 830
for *Pasteurella multocida,* 812
for *Salmonella,* 680, 695
for *Staphylococcus aureus,* 973
Pulse dosing, of antimicrobials, 41
Pyrethroid toxicity, 1301
Pyrethrum, 1301
Pyridoxine (vitamin B_6), 1219–1220
Pyrimethamine, for leucocytozoonosis, 1188

Q-fever, 1020
QTL (quantitative trait loci), 71, 74, 76–78
Quail
avian encephalomyelitis in, 487
chlamydiosis in, 1064
cryptosporidiosis in, 1170–1171
egg drop syndrome in, 303
fowl typhoid in, 683
histomoniasis in, 1175
leiomyoma in, 608
macrorhabdosis in, 1092
Marek's disease in, 529
ochroconosis in, 1091
pullorum disease in, 683
quail bronchitis in, 316–320

reovirus in, 365
reticuloendotheliosis virus in, 597
Riemerella anatipestifer in, 825
seminoma in, 611
Sertoli cell tumor in, 610, 611f
ulcerative enteritis in, 944–949, 947f
Quail bronchitis, 290, 316–320
clinical signs, 317
diagnosis, 319
etiology, 316
history, 316
hosts, 317
immunity, 319
incidence and distribution, 316
incubation period, 317
laboratory hosts and pathogenicity, 317
morbidity and mortality, 317
overview, 316
pathology, 317–319, 318f
transmission, carriers, and vectors, 317
treatment, prevention, and control, 319–320
Quail pox, 334f, 336, 339, 340, 345
Quarantine
APMV 2-9, 112
handling disease outbreaks, 38–39
diagnosis, 39
special precautions, 39
specimen submission, 39
Newcastle disease virus and, 104–105
Quaternary ammonium products (quats), 1298
Quinacrine toxicity, 1291
Quinolones
for coccidiosis, 1160, 1161
for *Mycoplasma iowae,* 910

Ragwort toxicity, 1305
Raillietina cesticillus, 1135, 1136f, 1137, 1137f–1139f, 1138, 1140, 1143
Raillietina echinobothrida, 137f–1139f, 1137, 1138, 1141
Raillietina georgiensis, 1139f, 1141, 1141f–1142f
Raillietina ransomi, 1141f, 1142f
Raillietina tetragona, 1137, 1137f–1139f, 1138, 1140
Raillietina williamsi, 1139f, 1141f, 1142f
Random amplification of polymorphic DNA (RAPD)
for avian intestinal spirochetosis, 1005
for botulism, 956
for *Campylobacter,* 742
for *E. coli,* 756
for erysipelas, 988
for *Mycoplasma gallisepticum,* 880, 882
for *Mycoplasma synoviae,* 902
for *Ornithobacterium rhinotracheale,* 829
for *Salmonella,* 695
Ranikhet disease. *See* Newcastle disease
Rapeseed meal toxicity, 1306
Rapid agglutination test
Mycoplasma meleagridis, 899
Ornithobacterium rhinotracheale, 832
RDRP. *See* RNA-dependent RNA polymerase
Real-time polymerase chain reaction
for aviadenovirus, 300
for avian hepatitis E virus infection, 500
for chicken infectious anemia virus, 262
for *Chlamydia,* 1058
for infectious bronchitis virus, 150
for infectious bursal disease, 232
up-regulation of induced cytokines, 70
Real-time reverse transcriptase polymerase chain reaction (RRT-PCR)
for astrovirus, 394
for duck hepatitis type I, 427
for influenza virus, 201, 202
for Newcastle disease, 103, 104
for reovirus in turkeys, 364
for turkey coronavirus, 380
Recombinant vaccines
for avian metapneumovirus, 119
for colibacillosis, 783
development of, 34–35
for fowlpox virus, 345–346
for infectious bronchitis, 153
for infectious bursal disease, 234
for Newcastle disease, 106
Recombination, infectious bronchitis virus and, 142
Recovery, 9
Red mites *(Dermanyssus gallinae),* 26, 52, 1101, 1101f
Renal system tumors, 578–582, 611
clinical signs, 570
differential diagnosis, 591
incubation period, 570
pathology, 578–582
gross, 578, 579f
microscopic, 578, 579f, 580
pathogenesis, 580
ultrastructural, 580
Reoviridae, 382, 382f
Reoviruses, 351–366
diseases in chickens, 362–363
enteric disease, 362–363
hydropericardium, 363
inclusion body hepatitis, 363
respiratory disease, 362
runting-stunting/brittlebone disease/malabsorption syndrome in broilers, 363
systemic infections, 363
diseases in turkeys, 363–364
enteric disease, 364
immunosuppression, 364
myocarditis, 364
tenosynovitis, 363–364
in ducks and geese, 364–365
overview, 351–352, 361–362
viral arthritis, 352–361
in waterfowl, 419–420
Repetitive extragenic palindromic sequence PCR (REP-PCR)
for *Pasteurella multocida,* 813
for *Salmonella,* 695
Replication complication complex, of Newcastle disease virus, 97
Reproductive system diseases, 1256–1257
cystic right oviduct, 1256, 1256f
egg-bound, 1256
egg problems, 1257
false layer, 1256
impacted oviduct, 1256
internal layer, 1256
neoplastic, 605–611
mesosalpinx, 608
leiomyoma, 608, 609f
ovary, 605–608
adenocarcinoma, 605, 606f
arrhenoblastoma, 607–608, 608f
dysgerminoma, 608
granulosa-theca cell tumor, 606–607, 607f
ovarian Sertoli cell tumors, 608, 608f
oviduct, 609–610
adenocarcinoma, 609–610, 609f–610f
testis, 610–611
Leydig cell tumors, 611
seminoma, 610, 611f
Sertoli cell tumor, 610, 611f
phallus prolapse, 1256
sex reversal, 1257

Resilience, of animal to disease, 4–5
Resistance-inducing factor (RIF) test, 587–588, 587t
Resistance to disease, animal's, 4
Respiratory system disease
  aspergillosis, 1078–1088
  aviadenoviruses, 297, 299
  avian metapneumovirus, 112, 114–116
  bordetellosis, 834–844
  chlamydiosis, 1055–1068
  chronic respiratory disease (CRD) of chickens, 877, 884
  colibacillosis and, 775–776
  cryptosporidiosis, 1169–1170, 1169f–1170f
  fowl cholera, 816
  infectious bronchitis, 139–153
  infectious coryza, 859–868
  infectious laryngotracheitis, 161–174
  influenza, 197–199
  multicausal diseases, 1320–1322
  Mycoplasma gallisepticum, 877–893
  Mycoplasma synoviae, 903–904
  neoplastic, 614, 614f
  Newcastle disease, 101
  Ornithobacterium rhinotracheale infection, 828–834
  poxvirus, 340–341
  quail bronchitis, 316–320, 318f
  reovirus in chickens, 362
  zygomycosis, 1092
Respiratory virus isolation, 30
Restriction endonuclease analysis
  for aviadenoviruses, 292
  for avian poxvirus DNA, 343
  for *Avibacterium paragallinarum,* 862
  for *Pasteurella multocida,* 812
Restriction fragment-length polymorphism (RFLP) analysis
  for avian intestinal spirochetosis, 1005
  for *Chlamydia,* 1058
  for *E. coli,* 756
  for infectious bronchitis virus, 150
  for infectious bursal disease, 234
  for infectious laryngotracheitis, 165–166
  for *Mycobacterium avium,* 1010
  for *Mycoplasma gallisepticum,* 880
  for *Pasteurella multocida,* 812
  for poxvirus, 336, 343
  for reovirus, 360
Reticulate body (RB), chlamydial, 1055, 1057, 1057f, 1059–1060, 1060f
Reticuloendotheliosis, 336, 345, 593–604
  chemical composition, 594–595
  classification, 594
  clinical signs, 598
  definition, 593
  diagnosis, 602–603
  differential diagnosis, 603–604
  economic significance, 593
  etiology, 593–597
  history, 593
  immunity, 601–602
  incidence and distribution, 597
  incubation period, 598
  laboratory host systems, 596–597
  morphology, 594
  natural and experimental hosts, 597
  pathogenesis, 600–601
    acute reticulum cell neoplasia, 601
    chronic lymphomas, 601
    runting disease syndrome, 601
    virus infection, 600–601
  pathology, 598–600
    acute reticulum cell neoplasia, 600, 600f
    chicken bursal lymphoma, 599, 599f
    chicken nonbursal lymphoma, 599, 600f
    multiple syndromes, 600
    runting disease syndrome, 598–599, 599f
    turkey lymphoma, 599–600
  prevention and control, 604
  public health significance, 593
  scientific significance, 593
  serology, 603
  strain classification, 596
  transmission, 597–598
    contaminated biological materials and, 598
    horizontal, 597–598
    vertical, 598
  vaccination, 604
  virus isolation and identification, 602–603, 603f
  virus replication, 595–596
    cytopathology, 595, 596f
    defective strain, 595
    host range, 595
    insertional mutagenesis, 596
    nondefective strains, 595
    pseudotypes, 595–596
Retinal dysplasia, 1258
Retinoic acid, 1208
Retroviruses. *See* Avian leukosis virus (ALV); Reticuloendotheliosis
Reverse transcriptase polymerase chain reaction (RT-PCR)
  for APMVs, 111
  for astrovirus, 394
  for avian bornavirus, 421
  for avian hepatitis E virus infection, 500
  for avian metapneumovirus, 115, 118, 418
  for avian nephritis virus, 421, 470, 472
  for chicken proventricular necrosis virus (CPNV), 1331–1332
  for duck hepatitis virus type 1, 427
  for eastern equine encephalitis, 477
  for infectious bronchitis virus, 142, 144, 150
  for infectious bursal disease, 232
  for influenza virus, 201, 202
  for Israel turkey meningoencephalitis, 479
  for Newcastle disease, 103, 104
  for reovirus, 359, 360
  for reovirus in turkeys, 364
  for rotavirus, 385–386, 390–391
  for turkey coronavirus, 380
  for West Nile virus, 419, 481
Reverse transcriptase polymerase chain reaction-restriction enzyme fragment length polymorphisms (RT-PCR-RFLP), infectious bursal disease, 223
RFLP. *See* Restriction fragment-length polymorphism (RFLP) analysis
Rhabdomyosarcoma and rhabdomyoma, 620, 621f
Rheas
  avian intestinal spirochetosis in, 999, 1003–1004, 1003f, 1007
  influenza in, 198, 200
  tuberculosis in, 1011
Riboflavin (vitamin B_2), 1217–1218, 1218f
Ribotyping
  Campylobacter, 742
  for *Salmonella,* 680, 695
Rickets, 1211, 1212f
Riemerella anatipestifer, 823–828
  biochemical properties, 824
  classification, 823–824
  clinical signs, 825
  colony morphology, 824

definition and synonyms, 823
diagnosis, 827
differential diagnosis, 827
economic significance, 823
etiology, 823–825
growth requirements, 824
history, 823
immunity, 826–827
incidence and distribution, 825
incubation period, 825
management procedures, 827
morphology and staining, 824
natural and experimental hosts, 825
pathobiology and epidemiology, 825–827
pathology
gross, 825, 826f
microscopic, 825–826, 826f
serology, 827
strain classification, 824–825
susceptibility to chemical and physical agents, 824
transmission, carriers, and vectors, 825
treatment, 828
vaccination, 827–828
Rifampicin, for tuberculosis, 1017
Rif (resistance-inducing factor) test, 587–588, 587t
Rimantadine, 206
Risk
aggregate, 8
defined, 11, 33
disease determinants, 8
risk assessment, 8
Risk analysis, 10
Risk ratio, 8
RNA-dependent RNA polymerase (RDRP)
astrovirus, 392
infectious bronchitis virus, 142
infectious bursal disease, 220, 221
rotavirus, 383
Robenidine, for coccidiosis, 1160
Rodenticide, 1114, 1115t
Rodenticide toxicity, 1301–1302
Rodents, 1109–1115
control of, 17
economic impact, 1110
exclusion of, 1112–1113
field identification, 1110f
house mouse, 1111
inspections for, 1112
integrated pest management, 1112
Norway (brown) rats, 1111
overview, 1109–1110
population reduction, 1113–1114, 1114f, 1115t
public health significance, 1110, 1110t
reproductive capabilities, 1111t
roof (black) rats, 1112
sanitation and cultural practices, 1113, 1113f
Ronidazole, for *Cochlosoma anatis* infection, 1185
Roof (black) rat, 1110f, 1111t, 1112
Roost areas, 15
Rose chafers toxicity, 1304
Rotated tibia, 1244, 1244f
Rotavirus, 381–391
chemical composition, 383
classification, 382
clinical signs, 386–387
diagnosis, 390–391
differential diagnosis, 391
etiology, 382–386
immunity, 389–390
incidence and distribution, 386
incubation period, 386–387
intervention strategies, 391
laboratory host systems, 385
cell culture, 385
chicken embryos, 386
management procedures, 391
morbidity and mortality, 387
morphology, 382–383, 382f
natural and experimental hosts, 386
overview, 381–382
pathobiology and epidemiology, 386–390
pathogenesis, 388–389, 389f
pathogenicity, 385–386
pathology, 387–388
gross lesions, 387
microscopic lesions, 387–388, 388f
serology, 391
strain classification, 384–385
antigenicity, 384
genetic, 384–385, 385f
susceptibility to physical and chemical agents, 383–384
transmission, carriers, and vectors, 386
vaccination, 391
virus isolation and identification, 390–391
virus replication, 383, 384f
Rotavirus-like viruses (RVLVs), 382, 385
Rotenone toxicity, 1301
Rothia, 1025
Roundworms. *See* Nematodes
Rous sarcoma virus (RSV), 555, 559–562, 562t, 564, 564f–565f, 567, 584–587, 589, 591–592
Roxarsone
for *Cochlosoma anatis* infection, 1185
toxicity, 1291
RRT-PCR. *See* Real-time reverse transcriptase polymerase chain reaction
RSV. *See* Rous sarcoma virus
Rubivirus, 473
Rubratoxins, 1281
Runting disease syndrome, 598–599, 599f, 601, 630–631
Runting-stunting syndrome (RSS), 363, 388, 391, 395, 399, 402–403, 1323, 1324
RVLVs (rotavirus-like viruses), 382, 385

Salinomycin
for coccidiosis, 1160, 1161
for *Mycoplasma gallisepticum,* 892
Salmonella cultures, 30
Salmonella enterica subsp. *arizonae,* 706–713
Salmonella enterica subsp. *enterica* serovar Enteritidis, 693–701, 704–706
Salmonella enterica subsp. *enterica* serovar Gallinarum-Pullorum, 678, 679
Salmonella enterica subsp. *enterica* serovar Typhimurium, 693, 696, 698, 701, 705
Salmonella Gallinarum, 678–693, 694
Salmonella Heidelberg, 698
Salmonella Infantis, 698
Salmonella infections, 677–713
arizonosis, 706–713
chicken infectious anemia as cofactor in disease, 261–262
fowl typhoid, 678–693
genetic resistance to, 76–77
paratyphoid infections, 693–709
public health significance, 50
nature of disease in humans, 50
occurrence, 50
reservoirs and sources of infection, 50
pullorum disease, 678–693
Salmonella Pathogenicity Island, 681–682

Salmonella Pullorum, 678–693, 694
Salmonella Senftenberg, 694
Salmonella Sofia, 696
Salmonella Worthington, 698
Salpingitis
  in *Escherichia coli* infection, 767f, 774
  in *Gallibacterium* infection, 1020–1021
  in *Listeria,* 1022
Salt, 1223
Sample frequency, 24
Sample size determination, 24
Sanitation
  eggs, 14–15
  equipment, 21
  hatchery, 18
Sarcocystosis, 1190–1192
  clinical signs, 1191
  diagnosis, 1192
  etiology, 1190–1191
  immunity, 1192
  incidence and distribution, 1190
  incubation period, 1191
  life cycle, 1191
  pathogenicity, 1191
  pathology, 1191–1192, 1192f
  prevention and control, 1192
  transmission, carriers and vectors, 1191
  zoonosis, 1192
Sarcoma. *See* Leukosis/sarcoma group of neoplastic diseases
Scabby hip, 1257
Scaly leg mite *(Knemidocoptes mutans),* 1101, 1102f
Schwannoma, 615, 615f
Scolex, 1136f–1137f, 1137, 1141f
Secondary lymphoid organs, 62–63
Sedoreovirinae, 382
Segmented filamentous bacteria, 1025–1026
Selenium
  deficiency, 1226, 1227f
  excess, 1226–1227
  toxicity, 1294
Semduramicin, for coccidiosis, 1161
Seminoma, 610, 611f
Serologic monitoring, 24–25
Serology
  for APMVs, 111
  for arizonosis, 711, 712
  for aspergillosis, 1086–1087
  for aviadenovirus, 300
  for avian encephalomyelitis virus, 492–493
  for avian intestinal spirochetosis, 1005
  for avian metapneumovirus, 118
  for avian nephritis virus, 472
  for *Avibacterium paragallinarum,* 866–867
  for *Bordetella avium,* 842
  for chicken infectious anemia, 262–263
  for *Chlamydia,* 1067
  for circovirus, 274
  for duck hepatitis virus type 1, 427
  for duck virus enteritis, 439
  for eastern equine encephalitis, 477
  for egg drop syndrome virus, 306–307
  for enterovirus-like viruses, 399
  for erysipelas, 993
  for fowl typhoid, 690, 691
  for hemorrhagic enteritis virus, 314–315
  for infectious bursal disease, 232–233
  for infectious laryngotracheitis, 171
  for influenza, 202–203
  interpretation of serologic data, 24–25
  for Israel turkey meningoencephalitis, 479
  for leukosis/sarcoma group of neoplastic diseases, 589
  for *Mycoplasma gallisepticum,* 889
  for *Mycoplasma iowae,* 910
  for *Mycoplasma meleagridis,* 899
  for *Mycoplasma synoviae,* 905
  for Newcastle disease, 103, 104
  for *Ornithobacterium rhinotracheale,* 833
  for paratyphoid infections, 703–704
  for parvovirus of chickens and turkeys, 405
  for parvovirus of waterfowl, 449
  for pigeon herpesvirus, 467
  for poxvirus, 342–343
  for pullorum disease, 690, 691
  for reticuloendotheliosis, 603
  for *Riemerella anatipestifer* infection, 827
  for rotavirus, 391
  for staphylococcosis, 977
  for toxoplasmosis, 1194
  for tuberculosis, 1016
  for turkey coronavirus, 381
  for viral arthritis, 360
  for West Nile virus, 481–482
Serotyping, of *Pasteurella multocida,* 811–812
Sertoli cell tumor, 608, 608f, 610, 611f
Serum neutralization, for egg drop syndrome virus, 306–307
Serum plate agglutination test
  for *Mycoplasma gallisepticum,* 889
  for *Mycoplasma synoviae,* 905
  for *Ornithobacterium rhinotracheale,* 833
Sex reversal, 1257
Shaft louse/small body louse *(Menopon gallinae),* 1104, 1105f
Siadenovirus, 289t, 290, 310
Sicarius spp., 1129
Sicarius uncinipenis, 1129
Sicarius waltoni, 1129
Sickle pod toxicity, 1304
Singhfilaria hayesi, 1129, 1130f
Single nucleotide polymorphisms (SNPs), 74
Sinusitis, *Mycoplasma gallisepticum* and, 884, 884f, 885
Skeletal diseases, 1238–1244
  degenerative joint disease, 1242
  dyschondroplasia, 1238–1240
    clinical signs, 1238
    intervention strategies, 1239–1240
    pathogenesis and etiology, 1239
    pathology, 1238–1239, 1238f
  osteochondrosis, 1244
  osteoporosis, 1240–1241
    clinical signs and pathology, 1240
    intervention strategies, 1240–1241
    pathogenesis and etiology, 1240
  rotated tibia, 1244, 1244f
  spondylolisthesis, 1243, 1243f
  spontaneous bone fractures, 1242–1243
  spraddle legs, 1244, 1244f
  valgus and varus deformities, 1241–1242, 1241f
Skin disease. *See also* Dermatitis
  contact dermatitis, 1257–1258, 1257f
  dermatophytosis, 1091
  poxvirus as, 338f, 340–341, 342
Snipe *(Gallinago gallinago),* APMV-11 in, 110
SNPs (single nucleotide polymorphisms), 74
Sodium
  deficiency, 1223, 1224f
  toxicity, 1293–1294
Sodium arsonate toxicity, 1291
Sodium citrate solution, 28

Sodium monofluoroacetate (compound 1080) toxicity, 1301
Sodium salicylate, for colibacillosis, 785
Solanine toxicity, 1305
Source of infection, 9
Specific pathogen free (SPF) flocks
  APMVs and, 108–109, 111
  astrovirus, 394
  aviadenovirus, 300
  avian metapneumovirus, 418
  avian nephritis virus, 469–471, 473
  chicken infectious anemia, 263, 264
  chicken infectious anemia virus, 254
  enteric viruses, 375
  infectious bronchitis virus, 142
  infectious laryngotracheitis, 161
  Newcastle disease and, 102
  parvovirus of chickens and turkeys, 402–403
  pox virus, 339, 342
  reticuloendotheliosis and, 593
  rotavirus, 391
Spectinomycin
  for arizonosis, 713
  for *Mycoplasma meleagridis,* 899
  for *Mycoplasma synoviae,* 906
  for *Riemerella anatipestifer,* 828
SPF. *See* Specific pathogen free (SPF) flocks
Spinareovirinae, 382
Spiramycin
  for *Mycoplasma gallisepticum,* 893
  for *Mycoplasma meleagridis,* 899
Spirochetosis
  avian intestinal, 995–1007
  Borrelia anserina, 1018–1020, 1018f–1019f
Spironucleus meleagridis, 1181–1182, 1181f
Spleen
  anatomy, 64f
  in APMV infection, 110
  in avian hepatitis E virus, 497, 497f
  in *Borrelia anserina* infection, 1019, 1019f
  in erysipelas, 991, 992f
  in marble spleen disease, 309–316, 312f–313f
  in Newcastle disease, 100f, 101
  in paratyphoid infections, 700
  in pullorum disease, 685, 685f, 687
  in quail bronchitis virus infection, 319
  in tuberculosis, 1013, 1014f
Spondylitis, 778, 778f
Spondylolisthesis, 1243, 1243f
Spray vaccination, 36–37
Spread of disease, 9
Squamous cell carcinoma
  digestive tract, 611, 612f
  integumentary, 617
Staphylococcosis, 971–977
  antigen structures, 973
  biochemical properties, 973
  classification, 972–973
  clinical signs, 974
  colony morphology, 973
  diagnosis, 976–977
  differential diagnosis, 977
  economic significance, 972
  etiology, 972–973
  growth requirements, 973
  history, 972
  immunity, 976
  incidence and distribution, 974
  incubation period, 974
  location of infections, 971–972, 972t
  management procedures, 977
  morbidity and mortality, 974
  morphology and staining, 973
  MRSA, 972
  pathobiology and epizootiology, 974–976
  pathology
    gross, 974–976, 975f
    microscopic, 975f, 976
  public health significance, 50, 972
    nature of disease in humans, 50
    occurrence, 50
    reservoirs and sources of infection, 50
  serology, 977
  strain classification, 973
  susceptibility to chemical and physical agents, 973
  toxins, 973
  transmission, 974
  treatment, 977
  vaccination, 976, 977
  virulence factors, 973
Staphylococcus aureus, 50, 957, 971–977, 976t
Staphylococcus epidermidis, 973, 976, 976t
Staphylococcus hyicus, 973
Stargazing posture, 1216, 1217f
Starling circovirus (StCV), 265–267
Starve-out, 1235
Sterigmatocystin, 1281
Sticktight flea *(Echidnophaga gallinacea),* 1103, 1103f
Streptobacillus moniliformis, 1026
Streptococcosis, 977–980
  clinical signs, 978
  diagnosis, 979–980
  differential diagnosis, 980
  etiology, 978
  history, 978
  pathobiology and epidemiology, 978
  pathology, 978–979, 979f–980f
  treatment, 980
Streptococcus bovis, 978, 980
Streptococcus dysgalactiae, 978
Streptococcus gallinarum, 978
Streptococcus mutans, 978
Streptococcus pleomorphus, 978
Streptococcus zooepidemicus, 978–980
Streptomycin
  for fowl cholera, 821–822
  for *Mycoplasma gallisepticum,* 892
  for *Mycoplasma meleagridis,* 899
  for ulcerative enteritis, 948
Stress, 12
  heat stress, 1234
  Marek's disease and, 532
Strobila, 1136
Strongyloides avium, 1129, 1130f
Strychnine toxicity, 1301
Subcutaneous injection, vaccination by, 36, 37–38
Subulura brumpti, 1130
Subulura spp., 1124f, 1129–1130
Subulura strongylina, 1124f, 1130
Subulura suctoria, 1124f, 1130
Sudden death syndrome (SDS), 1250–1251
Sulfa drugs, for *Riemerella anatipestifer,* 828
Sulfate toxicity, 1294
Sulfonamides
  for coccidiosis, 1159, 1160, 1161, 1165, 1166
  for fowl cholera, 821–822
  for infectious coryza, 868
  for leucocytozoonosis, 1188
  for pullorum disease, 692
  toxicity of, 1288–1289
  for ulcerative enteritis, 948
Sulfur toxicity, 1298
Surgical procedures, in hatchery, 19
Surveillance, 23–24
Sus herpesvirus 1, 467
Suttonella, 1026
Swan circovirus (SwCV), 265–267
Swans, duck virus enteritis in, 434

Sweet pea toxicity, 1306
Swollen head syndrome, 772. *See also* Avian metapneumovirus
Syncytia, reovirus, 354
Syngamus trachea, 1130–1131, 1131f
Synovitis
  E. coli, 777–778
  Mycoplasma synoviae, 903–904, 904f

Tanaisia bragai, 1144
Tannin toxicity, 1306
Tapeworms. *See* Cestodes
Taxine toxicity, 1306
TCDD (tetrachlorodibenzodioxin), 1303
T cell receptor (TCR), 66
T cells, 63–67, 69–70
TCV. *See* Turkey coronavirus enteritis
TD (tibial dyschondroplasia), 1211, 1238–1240, 1238f
Telomerase gene, 521
Tenosynovitis
  adenoviruses, 297
  turkey reovirus, 363–364
Tenuazonic acid, 1282
Teratoma, 621
Tertiary control zone, 22–23
Testis, neoplasia of, 610–611
  Leydig cell tumors, 611
  seminoma, 610, 611f
  Sertoli cell tumor, 610, 611f
Tetelo disease. *See* Newcastle disease
Tetrachlorodibenzodioxin (TCDD), 1303
Tetracycline
  for bordetellosis, 834–844
  for *Mycoplasma meleagridis,* 899
  for *Ornithobacterium rhinotracheale,* 834
Tetrameres americana, 1131, 1131f–1132f
Tetrameres crami, 1131
Tetrameres fissispina, 1131, 1131f
Tetrameres pattersoni, 1131–1132
Tetrameres spp., 1131–1132, 1131f–1132f
Tetramisole toxicity, 1292
Tetratrichomonas gallinarum, 1180
Theobromine toxicity, 1304
Thermostability
  avian metapneumovirus, 114
  avian retroviruses, 561
  duck hepatitis virus type 1, 423
  duck virus enteritis, 433
  infectious bronchitis virus, 141
  Newcastle disease virus, 93
  reovirus, 353
Thiamin (vitamin B_1), 1216–1217, 1217f
Thimerosal, 867
Thiram toxicity, 1299
Thymic atrophy, in Newcastle disease, 101
Thymidine kinase (TK) gene, pox, 337
Thymus
  atrophy in chicken infectious anemia, 255, 255f, 257
  described, 61–63, 62f
  neoplasia of, 617
Thyroid gland, neoplasia of, 617
Thyroxine, 1224
Tiamulin
  for avian intestinal spirochetosis, 1007
  for *Mycoplasma gallisepticum,* 892
  for *Mycoplasma meleagridis,* 899
  for *Mycoplasma synoviae,* 906
Tibia, rotated, 1244, 1244f
Tibial dyschondroplasia (TD), 1211, 1238–1240, 1238f
Ticks, 1105
  control measures, 17
  external examination for, 26
Tilmicosin, for *Mycoplasma gallisepticum,* 893
Tin toxicity, 1297
T lymphocytes, in Newcastle disease, 101
TNF-α (tumor necrosis factor-α), 67
Tobacco toxicity, 1306
TOC (turkey osteomyelitis complex), 778–779
Togaviridae, 473–474, 474f
Toll-like receptors (TLRs), 63, 77
Torticollis
  in fowl cholera, 817, 817f
  in *Listeria* infection, 1022
Toxaphene toxicity, 1300
Toxic fat syndrome, 1303
Toxicity, 1287–1306
  amino acids, 1292
  anthelmintics, 1292
    benzimidazoles, 1291
    imidazothiazoles, 1292
    ivermectin, 1292
    organophosphates, 1292
  antimicrobials, anticoccidials, and growth promotants, 1288–1292
    aminoglycosides, 1290
    antiprotozoals, 1291
    ionophores, 1290–1291, 1290f–1291f
    nitrofurans, 1289–1290
    sulfonamides, 1288–1289
antimicrobials and growth promotants
  arsenical and imidazole feed additives, 1291–1292
antinutrients, 1292
avicides, 1302
biotoxins, 1304
  algae, 1304
  rose chafers, 1304
boric acid and orthoboric acid, 1298
disinfectants and fumigants, 1298–1299
  chlorine, 1298
  coal-tar derivatives, 1298
  formaldehyde, 1298–1299
  phenolics, 1298
  quaternary ammonium, 1298
ethoxyquin, 1297
feed levels of, 1288t
fungicides, 1299
  captan, 1299
  organic mercurials, 1299
  thiram, 1299
gases
  aerial endotoxin, 1302
  ammonia, 1302
  carbon monoxide, 1302
  polytetrafluoroethylene, 1302
herbicides, 1299
  chlorates, 1299
  diquat, 1299
  paraquat, 1299
household and commercial products
  alcohol, 1302–1303
  antifreeze (ethylene glycol), 1303
  carbon tetrachloride, 1303
  fertilizer, 1303
  naphthalene, 1303
  urea, 1303
industry-related
  crude petroleum and oils, 1303–1304
  dioxin, 1303
  PCB and PBB, 1303
insecticides, 1299–1301
  carbamate, 1300–1301
  nicotine, 1301
  organochlorides, 1299–1300
  organophosphates, 1300–1301
  pyrethrum and pyrethroids, 1301
  rotenone, 1301
iron, 1298
lignosol, 1297
metals and metalloids

arsenic, 1294
cadmium, 1294
chromium, 1294
lead, 1295–1297, 1295f–1296f
mercury, 1297
tin, 1297
uranium, 1297
vanadium, 1297
minerals, 1292–1297
aluminum, 1293
calcium, 1293
cobalt, 1293
copper, 1293
fluorine, 1293
iodine, 1293
magnesium, 1293
phosphorus, 1293
potassium, 1293
selenium, 1294
sodium, 1293–1294
sulfate, 1294
zinc, 1294
molluscacides, 1302
nitrate and nitrite, 1297
pentachlorophenol, 1298
phytotoxins, 1304–1306
avocado, 1304
black locust, 1304
bladder pod, 1304
cacao, 1304
Carolina jessamine, 1304
cassava, 1304
castor bean, 1304
coffee senna, 1304
corn cockle, 1304
cotton seed meal, 1305
coyotillo, 1305
Crotalaria spp., 1305
Daubentonia, 1305
death camas, 1305
Eucalyptus cladocalyx, 1305
hemlock, 1305
jimsonweed, 1305
Leucaena leucocephala, 1305
lily of the valley, 1305
milkweed, 1305
nightshade, 1305
nitrates, 1305
oak, 1305
oleander, 1305
onions, 1305
oxalates, 1305
parsley, 1305
pokeberry, 1305
potato, 1305
ragwort, 1305
rapeseed meal, 1306
sickle pod, 1304
sweet pea, 1306
tannins, 1306
tobacco, 1306
velvetweed, 1306
vetch, 1306
yellow jessamine, 1306
yew, 1306
protein supplements, 1292
rodenticides, 1301–1302
sulfur, 1298
vitamins, 1297
vitamin A, 1297
vitamin B_6 (pyridoxine), 1297
vitamin D_3 (cholecalciferol), 1297
Toxins
Aspergillus spp., 1080
Bordetella avium, 836, 837
Clostridium botulinum, 953–957
Clostridium perfringens, 949–950
Clostridium septicum, 957
Escherichia coli, 755, 759
Pasteurella multocida, 813–814
Salmonella spp., 695
Staphylococcus aureus, 973
Toxoplasmosis, 1192–1194
diagnosis, 1194
disease course, 1193
etiology, 1192–1193
life cycle, 1193
pathology, 1194
prevention, 1194
public health significance, 52–53
nature of disease in humans, 52
occurrence, 52–53
reservoirs and sources of infection, 53
serology, 1194
transmission, carriers, and vectors, 1193
zoonosis, 1192, 1194
Tracheal organ cultures, for avian metapneumovirus, 117
Transcriptome profiling, 75
Transit facility, 23
Transmissible enteritis. *See* Turkey coronavirus enteritis
Transmissible viral proventriculitis (TVP), 1328–1332
classification, 1328
clinical signs, 1330
definition and synonyms, 1328
diagnosis, 1331–1332
differential diagnosis, 1330
economic significance, 1328
etiology, 1328–1329
history, 1328
incidence and distribution, 1328
incubation period, 1329–1330
isolation and identification of agent, 1331–1332
laboratory host systems, 1329
morbidity and mortality, 1330
morphology, 1329, 1329f
natural and experimental hosts, 1329
pathogenesis and epizootiology, 1329–1331
pathology, 1330–1331
gross lesions, 1330, 1330f
microscopic lesions, 1330–1331, 1331f
prevention and control, 1332
public health significance, 1328
transmission, 1329
Transmission, types of, 9
Traps, rodent, 1113–1114, 1114f
Trematodes, 1143–1144
control, 1144
identification, 1144
life cycle, 1144, 1144f
morphology, 1143, 1143f
pathogenicity, 1144
Trichomonas gallinae, 1179–1181
Trichomoniasis, 1179–1181
description, 1179, 1179f
diagnosis, 1180
immunity, 1180
incidence and distribution, 1179–1180
life cycle, 1180
pathology, 1180
prevention and control, 1180–1181
Trichostrongylus tenuis, 1132, 1132f
Trichothecenes, 1272–1273, 1273f–1274f
TRT (turkey rhinotracheitis). *See* Avian metapneumovirus (aMPV)
Trypanosomiasis, 1190
Tryptophan, 1219
T-2 toxin, 1272–1273, 1273f–1274f
Tube agglutination
for arizonosis, 712
for fowl cholera, 811
for *Mycoplasma gallisepticum,* 889
for *Mycoplasma meleagridis,* 899
Tuberculin test, 1016
Tuberculosis, 1008–1017
antibiotic sensitivity, 1009
biochemical properties, 1009
clinical signs, 1012–1013

Tuberculosis (*cont'd*)
colony morphology, 1009
diagnosis, 1016
differential diagnosis, 1016
etiology, 1008–1010
growth requirements, 1009
history, 1008
incidence and distribution, 1010–1011
management procedures, 1016
natural and experimental hosts, 1011–1012, 1012t
pathobiology and epidemiology, 1010–1016
pathogenesis, 1013–1016
pathology, 1013, 1014f–1015f
public health significance, 49–50, 1008
nature of disease in humans, 49
occurrence, 49
reservoirs and sources of infection, 49–50
serology, 1016
strain classification, 1010
transmission, 1012
treatment, 1017
tuberculin test, 1016
vaccination, 1016–1017
Tumor necrosis factor-□ (TNF-□), 67
Turkey coronavirus enteritis (TCV), 376–381
chemical composition, 376–377
classification, 376
clinical signs, 378–379
diagnosis, 380–381
differential diagnosis, 381
etiology, 376–378
history, 376
immunity, 380
active, 380
passive, 380
incidence and distribution, 378
incubation period, 378
intervention strategies, 381
laboratory host systems, 378
management procedures, 381
morphology, 376, 377f
natural and experimental hosts, 378
pathobiology and epizootiology, 378–380
pathogenesis, 379–380
pathology, 379
gross, 379
microscopic, 379, 379f
ultrastructural, 379
serology, 381
strain classification, 378
susceptibility to physical and chemical agents, 377
transmission, carriers, and vectors, 378
treatment, 381
virus isolation, 380
virus replication, 377, 377f–378f
Turkey coryza. *See* Bordetellosis
Turkey herpesvirus (HVT), 551–552
Turkey osteomyelitis complex (TOC), 778–779
Turkeypox virus, 339, 340, 341
Turkey rhinotracheitis (TRT). *See* Avian metapneumovirus (aMPV)
Turkeys
Acinetobacter spp. in, 1017
adenoviruses in, 290, 294, 296, 297
Aegyptianella in, 1017
Aeromonas spp. in, 1017–1018
APMVs in, 107, 109–111
Arcanbacterium pyogenes in, 1018
arizonosis in, 706–713
aspergillosis in, 1078–1088, 1083f–1084f
astrovirus in, 391–394
aviadenovirus infection in, 297
avian encephalomyelitis in, 487
avian intestinal spirochetosis in, 999
avian metapneumovirus in, 112–119, 417–418
Avibacterium paragallinarum in, 863
Bacillus spp. in, 1018
bordetellosis in, 834–844
Borrelia anserina in, 1018–1019
botulism in, 954, 955
candidiasis in, 1088–1090
Chlamydia in, 1060, 1062–1064, 1063f
Citrobacter infection in, 1020
coccidiosis in, 1162t, 1163–1165
Cochlosoma anatis in, 1182–1185
cryptosporidiosis in, 1170
dactylariosis in, 1095
deep pectoral myopathy in, 1244–1245
degenerative joint disease in, 1242, 1242f
dilated cardiomyopathy in, 1249–1250
eastern equine encephalitis in, 475, 476f
Enterobacter spp. in, 1020
enterovirus-like viruses in, 395–399, 396f
erysipelas in, 986–994
Flavobacterium in, 1020
fowl cholera in, 807–823
fowl typhoid in, 678–693
Gallibacterium in, 1020–1021
gangrenous dermatitis in, 957–960
Haemoproteus meleagridis in, 1189–1190
Helicobacter in, 1021
hemorrhagic enteritis in, 309–316
herpesvirus in, 551–552
hexamitiasis in, 1181–1182
Highlands J virus in, 476
histomoniasis in, 1147, 1172–1179
infectious bursal disease in, 222, 224, 225–226
influenza in-, 181–206
Israel turkey meningoencephalitis in, 478–479
Klebsiella spp. in, 1021
leucocytozoonosis in, 1186–1187, 1187f
Listeria in, 1022
liver granulomas in, 1027
macrorhabdosis in, 1092
Marek's disease in, 519
Moraxella spp. in, 1022
multicausal enteric diseases in, 1322–1325
Mycoplasma gallisepticum infection in, 877–893
Mycoplasma iowae infection in, 907–910
Mycoplasma meleagridis infection in, 893–900
Mycoplasma synoviae infection in, 900–906
necrotic enteritis in, 949–953
Neisseria in, 1023
Newcastle disease in, 98, 101, 107
nutritional diseases in, 1205–1227
ochroconosis in, 1091
Ornithobacterium rhinotracheale infection in, 828–834
osteochondrosis in, 1244
oviductal adenocarcinoma in, 609
parvovirus in, 399–405
pododermatitis in, 1257–1258, 1257f
poxvirus in, 333–346
Proteus spp. in, 1023
Pseudomonas in, 1024–1025
pullorum disease in, 678–693
reoviruses in, 363–364
enteric disease, 364
myocarditis, 364
tenosynovitis, 363–364

reticuloendotheliosis in, 593–604
Riemerella anatipestifer in, 823, 825
rotated tibia in, 1244, 1244f
rotavirus in, 382–383, 384f, 385–391, 389f
Rothia spp. in, 1025
segmented filamentous bacteria in, 1025–1026
spraddle legs in, 1244, 1244f
staphylococcosis in, 971–977
Streptobacillus spp. in, 1026
streptococcosis in, 977–980
tapeworms of, 1141–1142
tibial dyschondroplasia in, 1238–1240
toxoplasmosis in, 1193
trichomoniasis in, 1179–1180
tuberculosis in, 1008, 1011
turkey coronavirus enteritis in, 376–381
turkey viral hepatitis in, 482–485, 484f–485f
valgus and varus deformation in, 1241–1242
Vibrio in, 1026
viral arthritis in, 351, 354, 356
western equine encephalitis in, 477–478
West Nile virus in, 481
Turkey viral hepatitis (TVH), 482–485, 484f–485f
chemical composition, 482
classification, 482
clinical signs, 483
diagnosis, 484
etiology, 482
history, 482
immunity, 484
incidence and distribution, 483
incubation period, 483
intervention strategies, 484
laboratory host systems, 482
morbidity and mortality, 483
morphology, 482
natural and experimental hosts, 483
overview, 482
pathogenesis and epizootiology, 483–484
pathology, 483
gross lesions, 483, 484f
microscopic lesions, 483, 485f
susceptibility to physical and chemical agents, 482
transmission, carriers, and vectors, 483
virus isolation, 484
Turnaround time, 12
TVH. *See* Turkey viral hepatitis
TVP. *See* Transmissible viral proventriculitis
Tylosin
for *Mycoplasma gallisepticum,* 892–893
for *Mycoplasma meleagridis,* 899, 900
for *Mycoplasma synoviae,* 906
Tyzzeria perniciosa, 1166

Ulcerative enteritis, 944–949
biochemical characteristics, 945
classification, 944
clinical signs, 945–946
diagnosis, 946–948
differential diagnosis, 948
etiology, 944–945
growth requirements, 945
history, 944
immunity, 946
incidence and distribution, 945
incubation period, 945
management procedures, 948
morphology and staining, 944–945, 944f
mortality rate, 946
natural and experimental hosts, 945
pathology
gross lesions, 946, 947f
histopathology, 946
susceptibility to chemical and physical agents, 945
transmission, 945
treatment, 948–949
UPEC (uropathogenic *Escherichia coli*), 757
Uranium toxicity, 1297
Urate deposition
articular, 1255–1256, 1256f
visceral, 1254–1255, 1254f
Ureaplasma, 875, 911
Urea toxicity, 1303
Ureidobenzenearsonic acid toxicity, 1291
Urinary system disease, 1254–1256, 1254f–1256f
articular urate deposition, 1255–1256, 1256f
neoplastic, 578–582
urolithiasis, 1254–1255, 1255f
visceral urate deposition, 1254–1255, 1254f
Urogenital system, neoplastic diseases of, 605–611
Urolithiasis, 1254–1255, 1255f
Uropathogenic *Escherichia coli* (UPEC), 757

Vaccination, 34–38
adjuvants, 35, 106
APMVs, 111–112
arizonosis, 712–713
aviadenovirus, 300
avian encephalomyelitis, 493
avian metapneumovirus, 119
booster, 63
Bordetella avium, 843
Borrelia anserina, 1020
botulism, 956
Campylobacter, 743
characteristics of live and inactivated vaccines, 35t
chicken infectious anemia, 263–264
Chlamydia, 1068
coccidiosis, 1161
delivery systems, 36–38
drinking water, 37
intraocular, 37
nasal drop, 37
in ovo vaccination, 36, 36f
spray vaccination, 36–37
droplet size estimation, 37t
on farm, 37
in hatchery, 36–37
subcutaneous and intramuscular injections, 37–38
wing web stab, 37
DNA vaccines, 36
duck hepatitis virus type 1
breeders, 428
ducklings, 428–429
duck virus enteritis, 440
egg drop syndrome, 309
erysipelas, 992, 994
Escherichia coli, 782–784
failure of, 38
fowl cholera, 819–820, 822–823
fowl typhoid, 692
hemorrhagic enteritis, 315
hemorrhagic nephritis enteritis of geese, 443
infectious bronchitis, 139, 151–153
application methods, 152–153
future vaccines, 153
types of vaccine, 151–152
infectious bursal disease, 230, 233–235
infectious coryza, 867–868
influenza, 204–206

Vaccination (*cont'd*)
Israel turkey meningoencephalitis, 479
leukosis/sarcoma group of neoplastic diseases, 591
marble spleen disease virus, 315–316
Marek's disease, 545, 549, 550
methods of generating live vaccine candidate, 34, 35t
Mycoplasma gallisepticum, 890–892
Mycoplasma synoviae, 906
Newcastle disease, 95
field vaccination protocols and regimens, 106–107
strains used in, 105t
types of vaccine, 105–106
Ornithobacterium rhinotracheale, 833
paratyphoid infections, 705–706
parvovirus of chickens and turkeys, 405
parvovirus of waterfowl, 450–451
pigeon herpesvirus, 467
pox, 344–346
canary pox, 345
fowlpox, 344–345
in-ovo, 345
pigeon pox, 345
prophylactic, 345
quail pox, 345
recombinant fowlpox, 345–346
vaccine takes, 345
problems related to, 1236, 1236f
pullorum disease, 692
reactions, 34, 1321–1322
recombinant vaccines, 35
reovirus, 361
reticuloendotheliosis, 604
Riemerella anatipestifer infection, 827–828
rotavirus, 391
staphylococcosis, 976, 977
tuberculosis, 1016–1017
types of vaccines, 34–36, 35t
viral arthritis, 361
West Nile virus, 482
Vaccine failure, 38
Vacuolating autotransporter toxin, 759
Vaginitis, *Escherichia coli,* 773–774
Valgus deformation, 771–772, 1241–1242, 1241f
Vanadium toxicity, 1297
Varus deformation, 771–772, 1241–1242
Vaznema zschokkei, 1132
Vehicle access, controlling, 21
Velvetweed toxicity, 1306
Venereal colibacillosis, 773–774
Venipuncture, 27, 27f
Vent pecking, 1233
Ventriculus lesions, in avian encephalomyelitis, 488–490, 491f
Vertebral osteomyelitis, 984, 985f
Vertical transmission
avian leukosis viruses, 567–569, 568f
Chlamydia, 1062
Marek's disease, 529
Mycoplasma gallisepticum, 883
Mycoplasma iowae, 908
Mycoplasma meleagridis, 895
Mycoplasma synoviae, 902
Ornithobacterium rhinotracheale, 830
reticuloendotheliosis, 598
Salmonella, 699
Vetch toxicity, 1306
Veterinarian, calling in a disease outbreak, 39
V-factor testing, 866, 866f
Vibrio, 1026
Viral arthritis, 352–361
age-associated resistance, 355
biophysical factors, 353–354
biosecurity, 360–361
classification, 353
clinical signs, 355–356
diagnosis, 359–360
location of virus in tissues, 360
molecular methods, 360
serology, 360
virus isolation, 359
etiology, 353–354
history, 352–353
immunity, 358–359
cell-mediated, 358–359
humoral, 358
local antibodies, 358
incidence and distribution, 353
incubation period, 355
laboratory host systems, 354
cell cultures, 354
chick embryos, 354
morbidity and mortality, 355, 356
morphology, 353
natural and experimental hosts, 354–355
overview, 352
pathobiology and epidemiology, 354–359
pathogenicity, 354
pathology, 356, 358
gross lesions, 356–357, 356f–357f
histopathology, 357–358
prevention and control, 360–361
strain classification, 354
susceptibility to physical and chemical agents, 353
transmission, 355
vaccination, 361
virus replication, 353
Viral diseases, public health significance of, 44–46
arboviral encephalitis, 44–45
avian influenza, 45
Newcastle disease, 45–46
Virilism, 608
Virulence determinants, of Newcastle disease virus, 96–97, 96t
Virulence factors
arizonosis, 711
aspergillosis, 1080
avian intestinal spirochetosis, 997–999
Avibacterium paragallinarum, 863
Bordetella avium, 837–838
botulism, 954
Chlamydia, 1059
Clostridium perfringens, 950
erysipelas, 988–989
Mycoplasma gallisepticum, 881
Mycoplasma synoviae, 902
paratyphoid infections, 695–696
pullorum disease and fowl typhoid, 681–682
Staphylococcus, 973
Virus identification. *See specific viruses*
Virus isolation
astrovirus, 393
aviadenovirus, 299
avian encephalomyelitis virus, 492
avian metapneumovirus, 117
avian nephritis, 471
duck hepatitis virus type 1, 427
duck virus enteritis, 439
egg drop syndrome virus, 306
embryo inoculation for, 32–33
enterovirus-like viruses, 398–399
Gallid herpesvirus type 1, 170–171
goose hemorrhagic polyomavirus, 443
hemorrhagic enteritis virus, 314
infectious bronchitis virus, 149–150
infectious bursal disease, 231–232
influenza, 202
Marek's disease, 546–547
Newcastle disease virus, 102
parvovirus of waterfowl, 443–449
pigeon herpesvirus, 467
reovirus, 359

reticuloendotheliosis, 602
rotavirus, 390
turkey coronavirus, 380
turkey viral hepatitis, 484
viral arthritis, 359
West Nile virus, 481
Virus neutralization (VN)
for aviadenovirus, 300
for avian encephalomyelitis virus, 492
for avian metapneumovirus, 117, 118
for chicken infectious anemia virus, 263
for duck hepatitis virus type 1, 424, 426–427
for duck virus enteritis, 439
for eastern equine encephalitis, 477
for Gallid herpesvirus type 1, 171
for infectious bronchitis virus, 142, 149–151
for infectious bursal disease, 222, 223, 229–230, 233
for infectious laryngotracheitis, 165, 170
for influenza virus, 189
for Israel turkey meningoencephalitis, 479
for Marek's disease, 548
for Newcastle disease virus, 102
for parvovirus of waterfowl, 449
for poxvirus, 343
for reovirus, 360
for reticuloendotheliosis virus, 603
Visceral urate deposition, 1254–1255, 1254f
Viscerotropic velogenic Newcastle disease (VVND), 90
Vitamins, 1207–1221
biotin, 1220, 1220f
choline, 1221, 1221f
cobalamin (vitamin B_{12}), 1221
folic acid, 1220–1221
niacin, 1219
pantothenic acid, 1218–1219
pyridoxine (vitamin B_6), 1219–1220
riboflavin (vitamin B_2), 1217–1218, 1218f
thiamin (vitamin B_1), 1216–1217, 1217f
toxicity, 1297
vitamin A, 1297
vitamin B_6 (pyridoxine), 1297
vitamin D_3 (cholecalciferol), 1297
vitamin A, 1208–1210
deficiency, 1208–1210, 1209f
hypervitaminosis A, 1210
vitamin D, 1210–1213
deficiency, 1211–1212
hypervitaminosis D, 1212–1213
for tibial dyschondroplasia, 1239–1240
vitamin E, 1213–1214
for colibacillosis, 785
deficiency, 1213–1214, 1215f
vitamin K deficiency, 1215–1216
VN. *See* Virus neutralization
Volvulus, 1253–1254

Warfarin toxicity, 1301
Water
as *Campylobacter* infection source, 738
disease control and, 15, 15f
medication in, 15–16, 40–51
vaccination using, 37
Waterfowl diseases, 417–451
adenoviruses, 420–421
avian influenza virus, 418–419
avian metapneumovirus, 417–418
avian paramyxoviruses, 417
botulism, 953–957
circovirus-like infection of geese, 421
duck hepatitis B virus (DHBV), 431
duck hepatitis type 2, 429–430
duck hepatitis type 3, 430–431
duck hepatitis type I, 422–429
classification, 422
clinical signs, 425, 425f
diagnosis
molecular methods, 427
serology, 427
virus isolation and identification, 427
differential diagnosis, 427–428
epidemiology, 424–425
etiology, 422–424
history and distribution, 422
immunity, 426
laboratory host systems, 423–424
cell culture, 423–424
embryos, 423
management procedures, 428
morbidity and mortality, 425
morphology, 422
natural and experimental hosts, 424
pathogenicity, 424
pathology
biochemical effects, 426
gross lesions, 425, 425f
microscopic/ultrastructural lesions, 425–426, 426f
strain classification, 423
susceptibility to chemical and physical agents, 422–423
transmission, carriers, and vectors, 424–425
treatment, 429
vaccination, 428–429
breeders, 428
ducklings, 428–429
duck virus enteritis (duck plague), 431–440
clinical signs, 435
definition and synonyms, 431
diagnosis, 439
differential diagnosis, 439
economic significance, 432
etiology, 432–433
chemical composition, 434
classification, 432
morphology, 432–433, 432f
strain classification, 433
susceptibility to chemical and physical agents, 433
virus replication, 433
history, 432
immunity
active, 438–439
passive, 439
incidence and distribution, 434
incubation period, 435
laboratory host systems, 433
management procedures, 439
morbidity and mortality, 435
natural and experimental hosts, 434
pathology
gross lesions, 435–437, 436f–437f
microscopic lesions, 437–438, 438f
serology, 439
transmission, carriers, and vectors, 435
vaccination, 440
virus isolation and identification, 439
fowl cholera, 814
goose herpes virus (GHV), 420
hemorrhagic nephritis enteritis of geese (HNEG), 440–443
chemical composition, 440
classification, 440
clinical signs, 442
diagnosis, 443
differential diagnosis, 443
etiology, 440–441

Waterfowl diseases (*cont'd*)
history, 440
immunity, 443
incidence and distribution, 441
incubation period, 442
laboratory host system, 441
management procedures, 443
morbidity and mortality, 442
morphology, 440
natural and experimental hosts, 441–442
pathogenesis of infectious process, 442–443
pathology, 442, 442f
strain classification, 441
susceptibility to chemical and physical agents, 441
transmission, carriers, and vectors, 442
vaccination, 443
virus replication, 441
Listeria in, 1022
Muscovy duck reovirus, 419
overview, 417
parvovirus, 444–451
chemical composition, 444
classification, 444, 445f
clinical signs, 447, 447f
diagnosis
antigen detection, 449
electron microscopy, 449
by PCR, 449
serology, 449
virus isolation and identification, 449
differential diagnosis, 450
economic significance, 444
etiology, 444–446
history, 444
immunity, 449
incidence and distribution, 446
incubation period, 447
laboratory host systems, 445–446
management procedures, 450
morbidity and mortality, 447–448
morphology, 444, 446f
natural and experimental hosts, 446
pathogenesis of infectious process, 448–449
pathology
gross lesions, 448, 448f
microscopic lesions, 448, 448f
susceptibility to chemical and physical agents, 445
transmission, carriers, and vectors, 446–447
vaccination, 450–451
virus replication, 444
Proteus infection, 1023
Riemerella anatipestifer, 825
Vibrio infection, 1026
West Nile virus, 419
Water intake, 1205
WEE (western equine encephalitis), 44–45, 473, 477–478
Wenyonella philiplevinei, 1166
Western duck sickness. *See* Botulism
Western equine encephalitis (WEE), 44–45, 473, 477–478
West Nile virus, 479–482
clinical signs and pathology, 480–481
chickens, 480–481
geese, 480, 480f–481f
turkeys, 481
diagnosis, 481–482
differential diagnosis, 482
history, 479
immunity, 481
incidence and distribution, 479
intervention strategies, 482
natural and experimental hosts, 479–480
public health significance, 44–45, 473
serology, 481–482
transmission, carriers, and vectors, 480
vaccination, 482
virus isolation, 481
in waterfowl, 419
Whole genome scans, 74
Wild birds, disease control and, 17
Wilm's tumor, 578
Wing web vaccination, 37
Worker Protection Standards (WPS), 13
World Organization for Animal Health, 9
World Trade Organization (WTO), 9–10
WPS (Worker Protection Standards), 13
WTO (World Trade Organization), 9–10

Xanthoma, 620

Yellow jessamine toxicity, 1306
Yew toxicity, 1306
Yolk sac infection, *E. coli,* 766–768, 767f

Zanamivir, 206
Zearalenone, 1275–1276
Zinc
deficiency, 1225–1226
excess, 1226
toxicity, 1294
Zinc phosphide toxicity, 1302
Zoalene, for coccidiosis, 1160
Zoning, 10
Zoonosis. *See specific diseases*
Zoos, 17
Zygomycosis, 1092

Keep up with critical fields

Would you like to receive up-to-date information on our books, journals and databases in the areas that interest you, direct to your mailbox?

Join the **Wiley e-mail service** - a convenient way to receive updates and exclusive discount offers on products from us.

Simply visit **www.wiley.com/email** and register online

We won't bombard you with emails and we'll only email you with information that's relevant to you. We will ALWAYS respect your e-mail privacy and NEVER sell, rent, or exchange your e-mail address to any outside company. Full details on our privacy policy can be found online.



WILEY-BLACKWELL

www.wiley.com/email

17841