

Neurology[®]

Neurology.org



Clinical Reasoning in Neurology: A Case-Based Approach



Cases from the *Neurology*[®] Resident & Fellow Section

Edited by Aaron L. Berkowitz, MD, PhD, Sashank Prasad, MD,
and Mitchell S.V. Elkind, MD, MS

Note regarding print appearance: Because the Clinical Reasoning section appears almost exclusively online, the reader may notice color variations among these printed selections.

© 2016 American Academy of Neurology. All rights reserved. All articles have been published in *Neurology*[®].

Opinions expressed by the authors are not necessarily those of the American Academy of Neurology, its affiliates, or of the Publisher. The American Academy of Neurology, its affiliates, and the Publisher disclaim any liability to any party for the accuracy, completeness, efficacy, or availability of the material contained in this publication (including drug dosages) or for any damages arising out of the use or non-use of any of the material contained in this publication.

Clinical Reasoning in Neurology: A Case-Based Approach

Cases from the *Neurology*[®] Resident & Fellow Section

Editors

Aaron L. Berkowitz, MD, PhD

Assistant Professor of Neurology
Harvard Medical School
Brigham and Women's Hospital
Boston, Massachusetts

Sashank Prasad, MD

Associate Professor of Neurology
Harvard Medical School
Brigham and Women's Hospital
Boston, Massachusetts

Mitchell S.V. Elkind, MD, MS

Professor of Neurology and Epidemiology
College of Physicians and Surgeons and Mailman School of Public Health
Columbia University
New York, New York

This publication is also available on Neurology[®] for the iPad[®] and Android[™] devices
and features additional content.

Neurology[®]

Table of Contents

Neurology.org

THE MOST WIDELY READ AND HIGHLY CITED PEER-REVIEWED
NEUROLOGY JOURNAL



INTRODUCTION

- 1 Clinical reasoning in neurology: A case-based approach: Cases from the *Neurology*[®] Resident & Fellow Section
A. L. Berkowitz, S. Prasad, and M. S. V. Elkind

DISORDERS PRESENTING WITH IMPAIRED AROUSAL OR COGNITION

- 2 *Editors' Introduction*
- 4 A 59-year-old man who became lost in his own home
K. Mondon, E. Beaufils, D. Perrier, A. Matysiak, and C. Hommet
April 20, 2010; 74: e66-e68
- 7 A 57-year-old woman who developed acute amnesia following fever and upper respiratory symptoms
B.A. McCray, D. Forst, J. Jindal, and G. V. Henderson
April 7, 2015; 84: e102-e106
- 12 A 28-year-old pregnant woman with encephalopathy
Z.M. Grinspan, J.Z. Willey, M. J. Tullman, and M. S.V. Elkind
October 13, 2009; 73: e74-e79
- 18 A 52-year-old man with spells of altered consciousness and severe headaches
T. M. Burrus, J. D. Burns, J. Huston III, G. Lanzino, A. A. Rabinstein, and J. H. Uhm
May 26, 2009; 72: e105-e110
- 24 A 27-year-old man with rapidly progressive coma
J. M. Wong, M. Chandra, R. VanDeBogart, B. Lu, and A. H. Yee
September 1, 2015; 85: e74-e78
- 29 Encephalopathy in a 10-year-old boy
L. Rodan and I. Tein
July 17, 2012; 79: e12-e18
- 36 A 14-year-boy with spells of somnolence and cognitive changes
C.M. de Gusmao, K.P. Maski, and D. K. Urion
April 22, 2014; 82: e142-e146

- 41 Psychomotor regression in the young
E. M. Mc Govern and T.J. Counihan
April 2, 2013; 80: e152-e155
- 45 A 72-year-old man with rapid cognitive decline and unilateral muscle jerks
M. Duncan, J. Cholfin, and L. Restrepo
June 3, 2014; 82: e194-e197

DISORDERS PRESENTING WITH WEAKNESS

- 49 *Editors' Introduction*
- 51 A woman with rapidly progressive apraxia
P. Pressman, E. H. Bigio, D. Gitelman, and C. Zadikoff
April 9, 2013; 80: e162-e165
- 55 A 51-year-old woman with acute foot drop
D. Rallis, A. Skafida, G. Alexopoulos, A. Petsanas, A. Foteinos, S. Katsoulakou, and E. Koutra
February 17, 2015; 84: e48-e52
- 60 A 38-year-old woman with childhood-onset weakness
P. S. Ghosh and M. Milone
August 12, 2014; 83: e81-e84
- 64 A 70-year-old man with walking difficulties
F.M. Cox, J. J.G.M. Verschuuren, and U. A. Badrising
November 9, 2010; 75: e80-e84
- 69 A 47-year-old man with progressive gait disturbance and stiffness in his legs
A. Fontes-Villalba, J.-A. Palma, M. A. Fernández-Seara, M. A. Pastor, and P. de Castro
May 21, 2013; 80: e223-e227
- 74 A 79-year-old man with polyneuropathy and dysautonomia
C. Karam and S. N. Scelsa
May 10, 2011; 76: e93-e97
- 79 A 62-year-old man with right wrist drop
G. Cirillo, V. Todisco, A. Tessitore, and G. Tedeschi
September 10, 2013; 81: e81-e84

CONTINUED

Neurology[®]

Table of Contents

continued



- 84 A 48-year-old woman with generalized weakness
C. Karam and S. N. Scelsa
May 4, 2010; 74: e76-e80
- 89 A 40-year-old man with CIDP-like illness resistant to treatment
R. Lahoria, C. Karam, A. Dispenzieri, and P.J. B. Dyck
September 3, 2013; 81: e65-e70
- 95 A 55-year-old man with weight loss, ataxia, and foot drop
E. P. Flanagan, A. N. L. Hunderfund, N. Kumar, J. A. Murray, K. N. Krecke, B. S. Katz, and S. J. Pittock
June 17, 2014; 82: e214-e219
- DISORDERS PRESENTING WITH ABNORMAL SENSATION**
- 101 *Editors' Introduction*
- 103 An 85-year-old man with paresthesias and an unsteady gait
A. L. Berkowitz, R. M. Jha, J. P. Klein, and A. A. Amato
March 19, 2013; 80: e120-e126
- 110 A 27-year-old man with hand numbness: Exploring new horizons and reinventing the past
J. Vijayan, C. Y. Chuen, A. M. Punzalan, and E. Wilder-Smith
March 11, 2014; 82: e80-e84
- 115 A 34-year-old woman with recurrent bouts of acral paresthesias
C. Karam and S. N. Scelsa
March 2, 2010; 74: 9 775-778
- DISORDERS PRESENTING WITH ABNORMAL MOVEMENTS**
- 119 *Editors' Introduction*
- 120 An 83-year-old woman with progressive hemiataxia, tremor, and infratentorial lesions
K. Aquino, I. J. Korolnik, and D. Silvers
July 12, 2011; 77: e7-e10
- 124 A 6-year-old boy with uncontrollable right-sided movements
K. Gurcharran
January 24, 2012; 78: e23-e26
- 128 A 52-year-old woman with subacute hemichorea
S.M. Kranick, R. S. Price, S. Prasad, and H. I. Hurtig
November 11, 2008; 71: e59-e62
- 132 A 13-year-old boy presenting with dystonia, myoclonus, and anxiety
J. S. Blackburn and M. L. Cirillo
March 13, 2012; 78: e72-e76
- 137 A 39-year-old man with abdominal cramps
S.R. Jaiser, M. R. Baker, R. G. Whittaker, D. Birchall, and P. F. Chinnery
July 9, 2013; 81: 2 e5-e9
- 142 A middle-aged man with episodes of gait imbalance and a newly found genetic mutation
M. S. Yugrakh and O. A. Levy
October 16, 2012; 79: e135-e139
- DISORDERS PRESENTING WITH VISUAL DEFICITS**
- 147 *Editors' Introduction*
- 149 A 75-year-old man with 3 years of visual difficulties
A. L. Berkowitz, M. F. Rose, K.R. Daffner, and S. Prasad
October 21, 2014; 83: e160-e165
- 155 A video analysis of eye and limb movement abnormalities in a parkinsonian syndrome
M. Pouloupoulos and D. Silvers
August 4, 2009; 73: e20-e23
- 159 A 64-year-old man with painful, unilateral external ophthalmoplegia
M. T. Bhatti
August 24, 2010; 75: e35-e39
- 164 A 36-year-old man with vertical diplopia
S. Prasad, N. J. Volpe, and M. A. Tamhankar
May 12, 2009; 72: e93-e99

CONTINUED

Neurology[®]

Table of Contents

continued



172 Optic disc swelling in a patient with AIDS
M.A. Almekhlafi, G. Williams, and F. Costello
August 2, 2011; 77: e28-e32

177 A 75-year-old woman with visual disturbances and
unilateral ataxia
M. C. Eugene, D. Kitei, and D. Silvers
August 17, 2010; 75: e29-e33

DISORDERS PRESENTING WITH HEADACHE, DIZZINESS, OR SEIZURES

182 *Editors' Introduction*

183 A 2-day-old baby girl with encephalopathy and burst
suppression on EEG
R. Dhamija and K. J. Mack
July 19, 2011; 77: e16-e19

187 A 55-year-old woman with vertigo: A dizzying
conundrum
D. R. Gold and S. G. Reich
October 23, 2012; 79: e146-e152

194 A 33-year-old woman with severe postpartum occipital
headaches
N. Maalouf and S. I. Harik
January 31, 2012; 78: 366-369

198 A 22-year-old woman with headache and diplopia
J. S. Kim
July 7, 2009; 73: e1-e7

205 A child with pulsatile headache and vomiting
*L. Morin, A. Smail, J.-C. Mercier, and
L. Titomanlio*
April 14, 2009; 72: e69-e71

MANAGEMENT DILEMMAS

208 *Editors' Introduction*

209 A 42-year-old man who developed blurred vision and
dropped his iPod while jogging
*A. L. Berkowitz, P. E. Voinescu, and
S. K. Feske*
August 19, 2014; 83: e89-e94

215 A 24-year-old woman with progressive headache and
somnolence
*S. Bhattacharyya, A. L. Berkowitz, and
R. M. Jha*
June 3, 2014; 82: e188-e193

221 An 87-year-old woman with left-sided numbness
S. Yaghi and M.S.V. Elkind
October 13, 2015; 85: e110-e115

Acknowledgment and Note

ACKNOWLEDGMENT Drs. Berkowitz, Prasad, and Elkind wish to thank the editorial staff of the Resident & Fellow Section of *Neurology*[®] for their tireless enthusiasm for the section, and the AAN and Wolters Kluwer for their generous support of this project. This book would not have been possible without the encouragement of Patty Baskin, Executive Editor, and the leadership of Dr. Bob Gross, Editor-in-Chief, both of whom have always been tremendous supporters of the Resident & Fellow Section. Finally, and in particular, we acknowledge Kathy Pieper, Managing Editor of *Neurology*, for her dedication, passion, and commitment to excellence in this project, as in so many others.

EDITOR-IN-CHIEF'S NOTE When the Resident & Fellow section was started, it would have been difficult to predict how successful it would become. The quality of the content is superb, submissions are plentiful, and our staff of young editors is enthusiastic and talented. This venture, a compilation of Clinical Reasoning cases, grew out of an idea from within the section; the hard work and dedication of the RFS team made it a reality. Kudos to all who were involved! These case discussions are the stuff by which we all learned neurology, and are here collected to educate trainees across the country. This effort also serves as a reminder of the educational mission of the section, which is now giving back to our community beyond its usual publications.

Clinical reasoning in neurology: A case-based approach

Cases from the *Neurology*[®] Resident & Fellow Section

Aaron L. Berkowitz, MD,
PhD
Sashank Prasad, MD
Mitchell S.V. Elkind,
MD, MS

The eminent neurologist C. Miller Fisher was known to say that neurology is learned “stroke by stroke.” Although neurology training requires the acquisition of extensive “book knowledge”—neuroanatomy, neurophysiology, neuropharmacology, neuropathology, and more—the practice of clinical neurology is indeed ultimately learned case by case, patient by patient. To see the clinical effects of precise lesions firsthand, to hear the stories of patients suffering from neurologic disease, and to discuss these findings with one’s clinical teachers at the bedside: these are the experiences that transform students of neurology into clinical neurologists.

The process of clinical reasoning is learned through practice: trying to localize the lesion that explains a patient’s symptoms and signs, attempting to reconcile disparate elements of the history and examination, judging when to obtain and how to interpret neurodiagnostic tests, conferring on complex cases with one’s peers and mentors, and seeing the evolution of neurologic disease and how it may be modified by treatment. Yet such experiences shared between colleagues or between teachers and students are rarely recorded and even more rarely presented in pedagogical form.

The Clinical Reasoning section of the Resident & Fellow Section of *Neurology*[®] has provided a forum for case reports that capture the art and science of clinical neurology. Rather than encouraging case reports that describe obscure diagnoses with heroic leaps of diagnostic gymnastics, the Clinical Reasoning section has focused on the process of arriving at a localization, diagnosis, and treatment plan for diseases both mundane and rare. Each Clinical Reasoning case describes an approach to interpreting the history, examination, and diagnostic testing, as well as determining the localization, clinical formulation, and management plan. Some Clinical Reasoning cases

report surprising and unexpected diagnoses. Others describe how to approach common clinical problems. All cases, however, emphasize the reasoning element that is at the core of clinical neurology. Beyond the “what” of neurologic diagnosis and treatment, these cases explore the “how” and “why.”

Over nearly 10 years, 155 cases have been published in the Clinical Reasoning section describing diverse diagnoses, challenging clinical quandaries, and daunting management dilemmas. Most were written by residents and fellows, supervised by faculty, and are thus geared toward those learning clinical reasoning themselves. Many of these fascinating cases and the accompanying discussions, however, are likely to be as informative to experienced neurologists as to trainees. For this anthology we have compiled cases that span the major cardinal presentations of neurologic disease. Each section begins with a brief introduction to the clinical approach for a particular realm of neurology, but leaves the detailed discussions of diagnosis and treatment to the cases themselves.

We hope that our readers will enjoy the opportunity to learn from this collection, case by case.

DISCLOSURE

Dr. Berkowitz has received speaker honoraria from Stevens Institute of Technology and AudioDigest, and receives publishing royalties for *Clinical Pathophysiology Made Ridiculously Simple*, MedMaster, 2007 and *The Improvising Mind*, Oxford, 2010. Dr. Prasad receives royalties for the eBook *Modern Neuro-Ophthalmology*, independently published by Modern Neurology, LLC, which he owns. Dr. Elkind receives compensation for providing consultative services for Biogen IDEC, Biotelemetry/Cardionet, BMS-Pfizer Partnership, Boehringer-Ingelheim, Daiichi-Sankyo, Janssen Pharmaceuticals, and Sanofi-Regeneron Partnership; serves on the National, Founders Affiliate, and New York City chapter boards of the American Heart Association/American Stroke Association; receives royalties from UpToDate for chapters related to stroke; and participated in legal proceedings related to Organon/Merck (NuvaRing and stroke), BMS-Sanofi Partnership (Plavix and stroke), and Hi-Tech (DMAA and stroke). Go to Neurology.org for full disclosures.

Disorders presenting with impaired arousal or cognition

Most students of neurology become enthralled with the subject because it encompasses disorders of human consciousness, comprising arousal as well as complex cognitive functions including attention, memory, language, visuospatial processing, and emotional processing. These are the quintessential functions that make us human. In the context of neurologic illness it is possible to witness the extent to which the elements of cognition can become fractured and separable; dysfunction in individual cognitive domains helps us to understand their fundamental nature. Although cognitive processes depend upon distributed networks, focal lesions are capable of disrupting these networks, producing unique clinical syndromes. A careful examination of a patient's mental state can therefore yield enormous information about the localization and differential diagnosis of lesions affecting the cerebral hemispheres.

- Arousal relies upon connections from the ascending reticular activating system, which originates in the rostral brainstem and projects to both thalami and diffusely throughout the cerebral hemispheres. Lesions in the rostral brainstem or in both hemispheres can impair arousal, placing a patient on a spectrum of states of altered consciousness that includes drowsiness, somnolence, obtundation, a minimally responsive vegetative state, and coma.
- Attention depends, to a large degree, upon the function of the frontal lobes. To evaluate attentional mechanisms, one can observe the patient's ability to answer directed questions and avoid distractions. Working memory can be evaluated by assessing digit span, having the patient spell a word backwards, or having the patient continue specific patterns. Patients with lesions affecting the dorsolateral prefrontal cortex demonstrate impaired attention and working memory. Lesions of the medial frontal lobes can produce akinetic mutism, which is a syndrome of psychomotor retardation resembling severe depression. Lesions of the orbitofrontal cortex produce disinhibited behaviors that may transgress accepted social norms.
- Memory can be divided into declarative memory (which encompasses episodic memory for autobiographical events and recognition memory for

object identification) and nondeclarative memory (which includes procedural memory, emotional memory, and priming). Declarative memory relies upon the integrity of the Papez circuit in the mesial temporal lobes and diencephalon, including entorhinal cortex, the hippocampus, the fornix, the mammillary bodies, the mammillothalamic tract, the anterior nucleus of the thalamus, and the cingulate cortex. Diseases that affect these structures produce anterograde amnesia, with impaired ability to recall newly encoded information.

- Language networks in the brain include auditory and visual inputs to the Wernicke area in the superior temporal lobe, the arcuate fasciculus, and the Broca area in the inferior frontal lobe. This network is typically represented in the left hemisphere, but there may be bilateral or right hemispheric representation in some individuals. Homologous areas in the right hemisphere contribute to the generation and processing of music as well as prosody of language (i.e., the melody and rhythm of speech, as opposed to syntax and grammar). The evaluation of language function includes an assessment of fluency, naming, repetition, comprehension, reading, and writing. Lesions in the language networks produce aphasia, which may be characterized as receptive, expressive, conductive, or global based upon the predominant abnormalities on examination.
- Visuospatial processing relies upon distributed networks that compose the "dorsal stream," which includes parietal areas specialized for processing motion and spatial relationships. Lesions that disrupt right parietal areas and their networks may produce the clinical syndrome of hemispatial neglect. Higher-order visual processing also relies on a "ventral stream," which includes inferior temporal areas specialized for processing visual features of an object, a face, or a scene.
- Emotional processing is one of many functions performed by the limbic system of the brain, which includes the cingulate cortex, amygdala, thalamus, and hypothalamus. These regions contribute to consciously experienced emotions but also have strong connections with functions unconsciously carried out by the autonomic nervous system.

Pathology of the limbic system can have complex cognitive and behavioral manifestations that blur the distinction between neurologic and psychiatric disease.

The cases in this section illustrate principles regarding the localization, diagnosis, and management of conditions that impair arousal or other cognitive functions.

Clinical Reasoning: A 59-year-old man who became lost in his own home

K. Mondon, MD
E. Beaufils
D. Perrier
A. Matysiak
C. Hommet, MD, PhD

Address correspondence and reprint requests to Dr. Karl Mondon, Centre Mémoire de Ressources et de Recherche, Hôpital Bretonneau, 2 Bd Tonnellé, 37044 Tours, Cedex, France
karl.mondon@med.univ-tours.fr

SECTION 1

A 59-year-old right-handed man was referred to the Memory Center of an academic hospital for progressive cognitive decline. His past medical history included hypertension, diabetes mellitus, and prostate cancer. There was no family history of any psychiatric or neurologic disorders.

The patient's symptoms began 3 years prior to presentation with memory loss and word-finding difficulties. Six months later, his wife observed a progressive loss of interest in his previous hobbies and increasing apathy. Twelve months after symptom onset, the patient began having trouble finding his way home when driving. At the same time, his wife observed a personality change, describing her husband as "childlike," and said he began to follow her wherever she went. A year later, the patient developed difficulties with reading and spelling and became unable to plan ahead. His memory for events deteriorated and he had difficulty recognizing

familiar faces. He became preoccupied over an old conflict with his son. He was unable to perform everyday activities autonomously. His difficulties in spatial orientation progressed until he ultimately got lost in the home he had lived in for 10 years. Prior to presentation, he began making sexually inappropriate comments that contrasted with his concurrent loss of libido.

The neuropsychological evaluation upon admission revealed a severe amnesic syndrome, difficulties in naming and verbal comprehension, visuospatial impairment, a cognitive and behavioral prefrontal syndrome, and multimodal visual agnosia including prosopagnosia. The rest of the neurologic examination was normal.

Questions for consideration:

1. What is early-onset dementia?
2. What are the etiologies of early-onset dementia?
3. What is the diagnostic strategy?

GO TO SECTION 2

From the University Memory Center (K.M., D.P., A.M., C.H.) and the Departments of Neurology (E.B.) and Geriatrics (C.H.), CHU Tours; and INSERM U930 (K.M., C.H.), Tours, France.

Disclosure: The authors report no disclosures.

SECTION 2

The International Classification of Diseases–10 criteria¹ for dementia include “impairment of memory, thinking, orientation, comprehension, calculation, learning capacity, language and judgment.” Early-onset dementia (EOD) is defined as dementia occurring before the age of 65,² a cutoff determined by prevalence rates in epidemiologic studies.

The clinical characteristics of EOD are different from those of late-onset dementia. EOD affects males more often than females, the duration from disease onset to the first consultation is longer, the progression of the dementia is slower, finding a non-degenerative etiology (e.g., traumatic brain injury, toxin) is more likely, and the prevalence of frontotemporal lobe degeneration is higher than in late-onset dementia.³

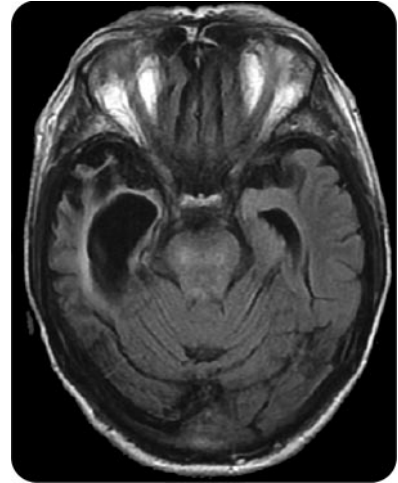
In this case, progressive worsening over a 3-year period is a strong argument in favor of a neurodegenerative process. Nevertheless, as mentioned above, the high prevalence of nondegenerative causes of dementia, the heterogeneity of etiologies, and potentially curable diseases in EOD⁴ all require a systematic approach.

First, potentially curable causes of dementia should be excluded. MRI can evaluate for neoplastic, vascular, traumatic (traumatic brain injury, dementia pugilistica), or inflammatory (multiple sclerosis) lesions. Laboratory tests assess the most frequent endocrine and metabolic disorders (thyroid, parathyroid, B12, thiamine, folate and niacin deficiencies, hypoglycemia, hepatic encephalopathy, renal failure). Viral and bacterial serologies can rule out HIV and syphilis. An EEG looks for epileptic disorders and encephalopathies. Lumbar puncture for CSF can detect infectious causes of dementia such as chronic infectious meningitis, Creutzfeldt-Jakob disease, and other prions.

Depending on the results of the abovementioned studies and the clinical context, the evaluation could also include testing for Lyme disease, Whipple disease, subacute sclerosing panencephalitis, progressive multifocal leukoencephalopathy, sarcoidosis, Hashimoto encephalopathy, paraneoplastic encephalopathy, and heavy metal poisoning. Laboratory tests of the adrenal and pituitary functions could be performed. Metabolic studies can assess for leukodystrophies, encephalopathies, and porphyria. If sleep apnea is suspected, polysomnography can be undertaken. If imaging suggests normal pressure hydrocephalus, a CSF depletion test could be done.

If the evaluation remains inconclusive, degenerative etiologies should be considered. When pyramidal, pe-

Figure Fluid-attenuated inversion recovery MRI



Axial section through the temporal lobes showing significant right temporal lobe atrophy.

ripheral, or bulbar signs are present, electroneuromyogram should be performed to document dementia associated with a motor neuron or muscle disorder. When pyramidal, cerebellar, or choreiform movements are observed, a genetic study for Huntington disease or spinocerebellar ataxia should be performed. Motor impairment or a concurrent movement disorder suggests subcortical causes of dementia such as Parkinson disease dementia, progressive supranuclear palsy, and corticobasal degeneration. Finally, global (Alzheimer disease) or lobar predominant (frontotemporal lobe degeneration) cortical dementias need to be considered.

If the pattern of atrophy is not suggestive of a specific type of degenerative disease, metabolic imaging can be performed (brain perfusion imaging) to further differentiate between the cortical dementias. Positive Tau, phosphotau, and beta-amyloid titers in CSF can help diagnose AD.⁵

In this patient, the routine laboratory tests, vitamin levels (B12, folate), CSF analysis (presence of cells, protein and glucose levels, A-beta42, and tau protein levels), and serologies (HIV, syphilis) were all normal. The EEG showed a preserved alpha rhythm with a widespread increase in theta activity, predominately in the temporal regions. The MRI showed bilateral temporal lobe atrophy, markedly more severe on the right side (figure), while the other cortical regions, including the frontal lobes, were normal. There were no white matter abnormalities.

Question for consideration:

1. What is the most probable diagnosis?

GO TO SECTION 3

SECTION 3

The most likely diagnosis is a right temporal variant of frontotemporal lobe degeneration (RV-FTLD).

The clinical syndrome of FTLD is characterized by the insidious onset of behavioral disturbances, personality changes, and aphasia.⁶ Despite a wide overlap between the FTLD subtypes, 3 different syndrome variants are recognized depending on the preeminent symptoms and the pattern of brain atrophy.⁷ The behavioral variant of FTLD is characterized by personality changes and behavioral disturbances associated with a severe dysexecutive syndrome. In this subtype, atrophy occurs predominately in the right frontal regions. The progressive nonfluent aphasia variant of FTLD is characterized by a progressive loss of vocabulary, nonfluent speech output, and agrammatism. Atrophy predominates in the left frontal regions. The semantic dementia variant of FTLD is a verbal-associative agnosia characterized by a progressive loss of word sense and object knowledge with personality changes appearing later. This subtype is characterized by left temporal atrophy.

From a neuropathologic point of view, more than 15 different pathologies can underlie FTLD syndromes, which can be divided into 3 groups: 1) tauopathies with an accumulation of microtubule-associated protein tau (MAPT); 2) accumulation of ubiquitinated neocortical lesions called TAR DNA binding protein 43 (TDP-43); and 3) atrophy and gliosis without specific abnormalities, called “dementia lacking distinctive histopathology.”⁷

The right temporal variant is a fourth and rare subtype of frontotemporal lobe degeneration. For a long time, prosopagnosia was considered the main and earliest clinical feature of the syndrome. Affected patients exhibit progressive difficulties in recognizing and identifying the faces of familiar persons due to the multimodal loss of person-based knowledge.⁸ Thus, the right temporal variant of frontotemporal lobar degeneration can be considered to be the right hemispheric variant of semantic dementia.

Recently, investigators delineated the cognitive profile of RV-FTLD.⁹ They observed that the most frequent symptom is impaired episodic memory (90% of patients) which can appear prior to prosopagnosia, which is less frequent, affecting 60%. Another common symptom is topographic disorientation (getting lost) in

familiar places (65%). Some additional symptoms are less frequently observed but are suggestive in this context: hyper-religiosity (15%), complex visual hallucinations (10%), and difficulties in performing calculations (5%). Finally, more typical symptoms of FTLD are also seen, such as apathy, disinhibited social conduct, alteration in eating habits, changes in food preferences, and mood disturbances. There is significant overlap in symptomatology between the different subtypes of FTLD, but the core symptoms of RV-FTLD are getting lost, prosopagnosia, and behavioral disorders.⁹

RV-FTLD is an unusual subtype of FTLD. Neurologists need to be aware of the clinical characteristics of this entity, which have recently been described, in order to avoid misdiagnosis and potentially deleterious interventions.

ACKNOWLEDGMENT

The authors thank Donald Schwartz, MD, for revising the English version.

REFERENCES

1. International Classification of Diseases and Health Related Problems, 10th Revision. Geneva: World Health Organization; 1992.
2. McMurtray A, Clark DG, Christine D, Mendez MF. Early-onset dementia: frequency and causes compared to late-onset dementia. *Dement Geriatr Cogn Disord* 2006; 21:59–64.
3. Shinagawa S, Ikeda M, Toyota Y, et al. Frequency and clinical characteristics of early-onset dementia in consecutive patients in a memory clinic. *Dement Geriatr Cogn Disord* 2007;24:42–47.
4. Mendez MF. The accurate diagnosis of early-onset dementia. *Int J Psychiatry Med* 2006;36:401–412.
5. Dubois B, Feldman HH, Jacova C, et al. Research criteria for the diagnosis of Alzheimer's disease: revising the NINCDS-ADRDA criteria. *Lancet Neurol* 2007;6:734–746.
6. Neary D, Snowden JS, Gustafson L, et al. Frontotemporal lobar degeneration: a consensus on clinical diagnostic criteria. *Neurology* 1998;51:1546–1554.
7. Josephs KA. Frontotemporal dementia and related disorders: deciphering the enigma. *Ann Neurol* 2008;64:4–14.
8. Joubert S, Felician O, Barbeau E, et al. Progressive prosopagnosia: clinical and neuroimaging results. *Neurology* 2004;63:1962–1965.
9. Chan D, Anderson V, Pijnenburg Y, et al. The clinical profile of right temporal lobe atrophy. *Brain* 2009;132(Pt 5):1287–1298.

Clinical Reasoning: A 57-year-old woman who developed acute amnesia following fever and upper respiratory symptoms

Brett A. McCray, MD,
PhD
Deborah Forst, MD
Jenelle Jindal, MD
Galen V. Henderson, MD

Correspondence to
Dr. McCray:
bmccray@partners.org

SECTION 1

A 57-year-old woman with a history of depression and hyperlipidemia presented with 2 days of confusion and memory loss. Four days prior to presentation, she developed fevers, myalgias, and rhinorrhea. On the day prior to presentation, the patient began having memory difficulties and was noted by her husband to have completely forgotten many events and details of the previous days. She presented to an outside hospital where a comprehensive neurologic

examination disclosed a nonfluent expressive aphasia but was otherwise unremarkable. Basic laboratory tests including electrolytes, complete blood count, and liver function tests had normal results.

Questions for consideration:

1. What is the differential diagnosis for subacute memory disturbances and confusion in this patient?
2. What are the initial steps in evaluation?

[GO TO SECTION 2](#)

SECTION 2

The differential diagnosis for the subacute onset of amnesia and speech difficulties is broad. In a patient with recent fevers, meningitis or encephalitis must be considered. Seizures with postictal confusion or exposure to psychoactive medications or drugs of abuse could produce the changes described. Stroke or cerebral hemorrhage must be considered, but the purely cognitive abnormalities without associated motor or sensory changes on examination would be atypical. Finally, transient global amnesia is a consideration, but is a diagnosis of exclusion. The initial workup would include intracranial imaging to assess for mass lesion, stroke, or hemorrhage. Lumbar puncture and systemic infectious workup should be considered

given the recent fevers, upper respiratory symptoms, and changes in cognition. Urine and blood toxicology could also be helpful.

Chest X-ray and CT scan of the head were unremarkable. Infectious workup was notable for a rapid influenza swab that was positive for influenza A. The following day, the patient had a generalized tonic-clonic seizure. MRI of the brain showed symmetrical T2 hyperintensities of the bilateral mesial temporal lobes, thalami, and cingulate cortex.

Questions for consideration:

1. What is the differential diagnosis of subacute altered mental status and seizures in association with mesial temporal lobe changes?
2. What are the next steps in management?

[GO TO SECTION 3](#)

SECTION 3

The acute abnormalities of the temporal lobes are concerning for a viral or bacterial encephalitis. The constellation of seizures and temporal lobe abnormalities is suggestive of herpes simplex virus (HSV) encephalitis, but this typically produces asymmetric inflammation and hemorrhage of the medial temporal lobes rather than the symmetric changes as in this case. Seizure activity itself can lead to transient T2 hyperintensities in the medial temporal lobes. However, seizures could not account for the other MRI abnormalities; thus, the seizures should be viewed as symptomatic of another pathologic process until proven otherwise. Other considerations in this patient would be a paraneoplastic or autoimmune encephalitis, but the acute onset and rapid decompensation is atypical. Given the concern for an acute infectious process, the patient needs urgent lumbar puncture and empiric antiviral therapy for HSV encephalitis. An antiepileptic drug should be administered and EEG monitoring should be considered, especially if there is concern for ongoing seizures.

The patient was treated with acyclovir and levetiracetam. EEG showed generalized slowing without epileptiform activity. Lumbar puncture showed total

protein of 443 mg/dL, glucose of 98 mg/dL, with 4 leukocytes and 11 erythrocytes per mm³. The patient became progressively more somnolent, requiring transfer to an intensive care unit, and she was transferred to our hospital for further evaluation and management.

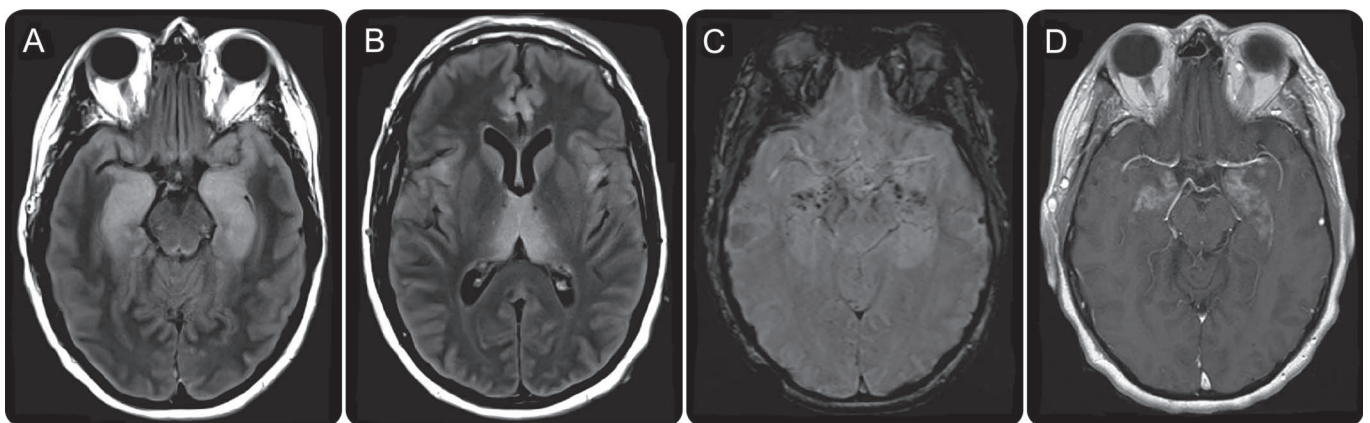
On arrival, the patient had a rectal temperature of 101.9°F and was somnolent, only opening her eyes to deep nasopharyngeal suctioning, but not to sternal rub or nail bed pressure. Her cranial nerves were normal, and she was able to localize to noxious stimuli in all extremities. Reflexes were brisk, measuring 3/4 in all 4 extremities, and the patient had positive Hoffman signs, flexor plantar response on the right, and equivocal response with fanning of the toes on the left. Repeat MRI showed interval progression and worsening of the previously noted T2 signal abnormalities with new multifocal hemorrhage within the hippocampi and thalami and worsening contrast enhancement throughout the hippocampal heads (figure).

Questions for consideration:

1. How do you interpret the results of lumbar puncture?
2. What additional CSF studies could be useful in determining the cause of this patient's encephalitis?

GO TO SECTION 4

Figure MRI of the brain shows symmetric bilateral T2 signal hyperintensity involving multiple deep structures as well as hemorrhage and contrast enhancement



(A) T2 hyperintensity of the mesial temporal lobes, hippocampi, and amygdala. (B) T2 hyperintensities of insular cortex and thalami. (C) Susceptibility artifact in the mesial temporal lobes consistent with microhemorrhage and necrosis. (D) T1 postcontrast enhancement of the mesial temporal lobes consistent with active inflammation.

SECTION 4

The patient has a markedly elevated total protein concentration in the CSF but an overall noninflammatory profile with normal leukocyte and erythrocyte counts. This is inconsistent with most typical bacterial and viral forms of meningitis. A comprehensive workup for viral encephalitis and atypical CNS infections should be initiated. CSF testing should include Gram stain, bacterial culture, and serology for HSV and varicella-zoster virus (VZV). Additional serum and CSF testing could include cytomegalovirus (CMV), Epstein-Barr virus (EBV), human herpesvirus-6 (HHV6), adenovirus, mycoplasma, *Legionella*, influenza, and *Cryptococcus* as well as testing for enteroviruses or arboviruses depending on the season. In addition, further immunologic CSF studies including testing for oligoclonal bands and measuring CSF immunoglobulins and cytokines could be useful in defining the nature of the cerebral pathology.

Acyclovir was continued, and the patient was empirically treated for bacterial meningitis with vancomycin and ceftriaxone. Repeat lumbar puncture showed total protein of 794 mg/dL, glucose of 84 mg/dL, with 4 leukocytes and 19 erythrocytes per mm³. Opening pressure was 8 cm of water. Repeat CSF testing was negative for HSV, VZV, EBV, CMV, HHV6, adenovirus, and *Cryptococcus*; serum was negative for HHV6 and mycoplasma, and urine was negative for *Legionella* antigen. HSV PCR was also negative from the CSF obtained at the referring hospital. CSF oligoclonal bands and immunoglobulins were not tested. CSF Gram stain and culture were negative, and vancomycin and acyclovir were stopped. Influenza A testing was repeated and was again positive, but CSF PCR testing for influenza virus was negative. Chest X-ray demonstrated a left lower lobe opacity, and the patient was treated with a 7-day course of ceftriaxone and azithromycin for pneumonia.

Based on the patient's prodromal viral illness, positive influenza A testing, and negative workup for other bacterial or viral encephalitides, her presentation was believed to be most consistent with a subtype of so-called influenza-associated encephalitis/encephalopathy (IAE) known as acute necrotizing encephalopathy (ANE). She was enrolled in a clinical trial comparing oseltamivir to zanamivir for treatment of influenza. However, her condition continued to deteriorate despite antiviral therapy, and she required intubation for airway protection. Over the next several days, her examination results worsened such that she no longer spontaneously moved her extremities and only demonstrated stereotyped movements in response to noxious stimuli. Studies of IAE have generally failed to show direct viral infection of the CNS, suggesting an

immune-mediated mechanism of tissue injury rather than direct viral toxicity.¹⁻³ Based on these observations and limited case reports of success of immune-modulating therapy in IAE, the patient was treated with a 5-day course of IV methylprednisolone 1000 mg daily as well as 1 mg/kg IV immunoglobulin (IVIg) given over 2 days. She demonstrated some purposeful movements on hospital day 9 and was extubated on hospital day 11. Her condition slowly improved over the next week, and she was discharged to a rehabilitation facility on hospital day 21. On discharge, she was alert, was able to speak in 2-word sentences, could follow simple commands, and was able to walk with assistance. On follow-up 8 months later, the patient was fully ambulatory without residual aphasia, but had significant persistent deficits in anterograde and retrograde memory.

DISCUSSION We present the case of a 57-year-old woman who developed influenza A infection followed by amnesia and encephalopathy that progressed rapidly to coma. Brain MRI showed symmetric changes in the mesial temporal lobes and thalami consistent with necrotizing encephalitis. Additional extensive workup for infectious encephalitis was negative. She was treated with a course of steroids and IVIg for presumed influenza A encephalitis and her condition improved significantly.

CNS complications of influenza are rare and diverse, and include seizures, Reye syndrome, Guillain-Barré syndrome, movement disorders, numerous forms of encephalopathy or encephalitis, and cerebral hemorrhage.^{1,2} IAE is a rare complication of influenza infection, most commonly described in children under 5 years of age (82.6% of 1998–1999 Japanese cases), and the ANE variant is defined by its association with symmetric hemorrhagic brain lesions.³ The most common clinical features of ANE are generalized seizures and alterations of mental status including reduced level of consciousness, abnormal speech, and delirium.^{1,3} Radiographic findings include symmetrically distributed lesions of the cerebral white matter and deep structures including the thalami and brainstem, with bilateral necrotic or hemorrhagic thalamic lesions being characteristic.^{3,4} Multiple case series of IAE have demonstrated that CSF is generally noninflammatory, and virus can seldom be detected in CSF or in brain tissue.^{1,3,4} Neuronal injury in IAE is thought to relate to robust cytokine release and immune activation rather than direct CNS virus penetration.⁵ Based on this putative model of pathogenesis, severe cases of IAE have been treated with immune-modulating therapies with some anecdotal reports of success. However, the rarity of IAE has precluded any controlled trials to assess the efficacy of such approaches.

AUTHOR CONTRIBUTIONS

Brett A. McCray cared for the patient presented, wrote the text, and helped to assemble the figures. Deborah Forst cared for the patient presented, helped edit the text, and helped to assemble the figures. Jenelle Jindal cared for the patient and helped in discussion of the manuscript. Galen V. Henderson cared for the patient presented and helped edit the text.

STUDY FUNDING

No targeted funding reported.

DISCLOSURE

The authors report no disclosures relevant to the manuscript. Go to Neurology.org for full disclosures.

REFERENCES

1. Surana P, Tang S, McDougall M, Tongy CY, Menson E, Lim M. Neurological complications of pandemic influenza

A H1N1 2009 infection: European case series and review. *Eur J Pediatr* 2011;170:1007–1015.

2. Jeganathan N, Fox M, Schneider J, Gurka D, Bleck T. Acute hemorrhagic leukoencephalopathy associated with influenza A (H1N1) virus. *Neurocrit Care* 2013;19:218–221.
3. Wang GF, Li W, Li K. Acute encephalopathy and encephalitis caused by influenza virus infection. *Curr Opin Neurol* 2010;23:305–311.
4. Ormitti F, Ventura E, Summa A, Picetti E, Crisi G. Acute necrotizing encephalopathy in a child during the 2009 influenza A(H1N1) pandemic: MR imaging in diagnosis and follow-up. *AJNR Am J Neuroradiol* 2010;31:396–400.
5. Akins PT, Belko J, Uyeki TM, Axelrod Y, Lee KK, Silverthorn J. H1N1 encephalitis with malignant edema and review of neurologic complications from influenza. *Neurocrit Care* 2010;13:396–406.

Clinical Reasoning: A 28-year-old pregnant woman with encephalopathy

Zachary M. Grinspan,
MD
Joshua Z. Willey, MD
Mark J. Tullman, MD
Mitchell S.V. Elkind,
MD, MS

Address correspondence and
reprint requests to Dr. Zachary
M. Grinspan, Division of
Pediatric Neurology, Harkness
Pavilion, 5th Floor, 180 Fort
Washington Ave., New York, NY
10032-3791
zg2126@columbia.edu

SECTION 1

A 28-year-old woman at 37 weeks' gestation became increasingly confused and forgetful. She slept 12 hours daily, mistook her apartment for previous residences, and forgot her children's names. Her husband helped her eat and walk. She presented to the obstetrical service fully dilated after 2 days of leaking vaginal fluid, and delivered a healthy baby girl. A few hours later, she did not remember giving birth. She was transferred to the neurology service for evaluation.

She had had a febrile seizure at age 4, and several brief convulsions as a teenager. A sleep-deprived EEG had been negative. She took phenytoin for a year, then stopped prior to her first pregnancy. She had no further convulsions.

This was her fifth pregnancy. She had 2 healthy children, 1 abruption at 23 weeks, and 1 elective abortion. Her maternal grandmother had died from a ruptured cerebral aneurysm.

She had no complaints but could not explain why she was in the hospital. She was afebrile with normal blood pressure. She appeared well and had a normal postpartum abdominal examination. She was inattentive and abulic with sparse but fluent speech. She recalled 2 of 3 words at 5 minutes, but had no memory for recent events, including her delivery. She could not describe cocktail ingredients, despite working as a bartender, but correctly recited old addresses. Cranial nerves were normal. Both optic discs had sharp margins by bedside funduscopic examination. Strength was full. Reflexes were brisk, with 3 beats of clonus at her right ankle. Toes were equivocal on the right and downgoing on the left. Sensation and coordination were normal. Gait was narrow-based and slightly unsteady, but she did not fall.

Questions for consideration:

1. What can cause subacute mental status changes in the peripartum state?
2. What studies would you pursue?

[GO TO SECTION 2](#)

SECTION 2

This 28-year-old peripartum woman has subacute onset encephalopathy with memory loss and abulia, as well as long tract signs. Encephalopathy suggests a process affecting large areas of the brain bilaterally due to metabolic derangements or diffuse structural injury to gray and/or white matter. Focal insults to structures responsible for memory or attention, such as the thalamus, hippocampus, and medial temporal lobe, may present similarly. Linking encephalopathy with the focal upper motor neuron sign of right leg hyperreflexia suggests a multifocal process.

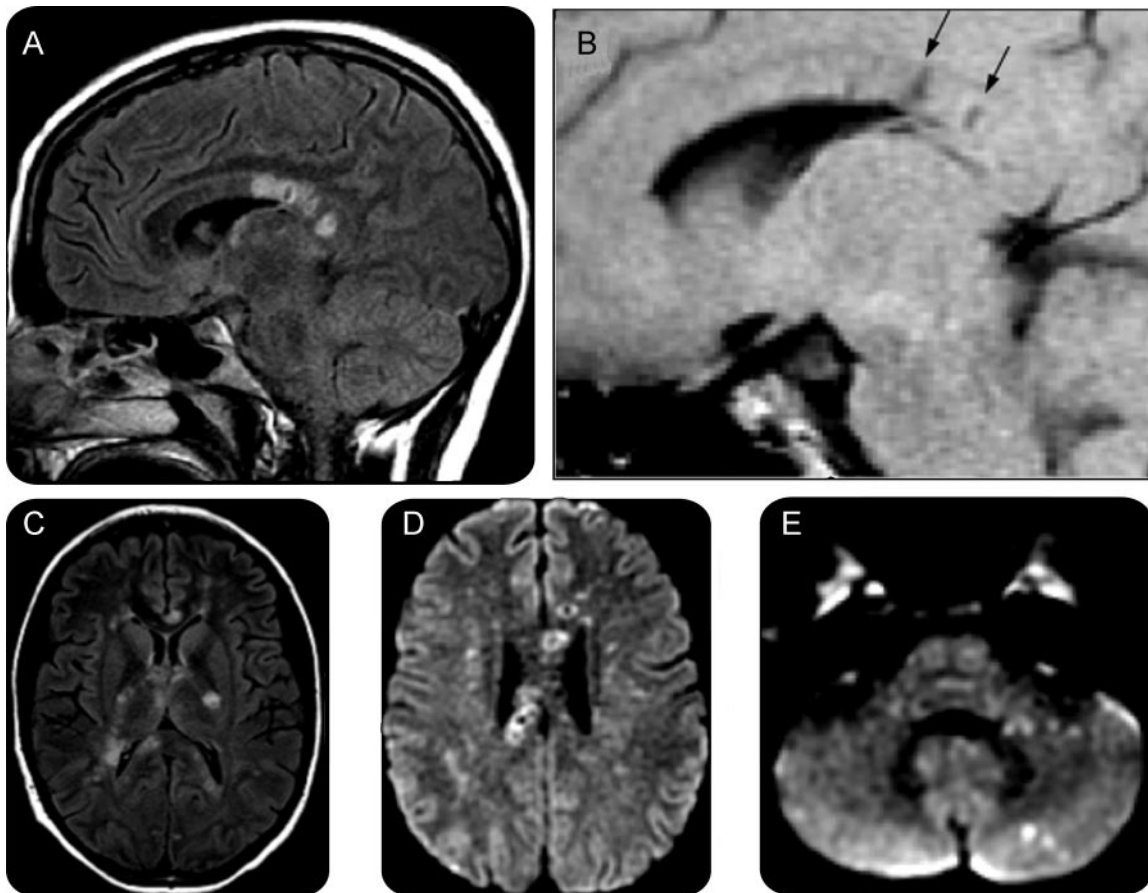
The differential diagnosis includes emergent peripartum conditions, such as dural sinus thrombosis, metastatic choriocarcinoma, and postpartum angiopathy, a form of reversible cerebral vasoconstriction syndrome.¹ Other emergent conditions should be considered, including viral encephalitis (particularly herpesviruses), infectious meningoencephalitis, substance abuse (especially

cocaine), complex partial seizures, and intracerebral hemorrhage. Subacute processes, such as demyelinating diseases and paraneoplastic processes, should also be considered.

The evaluation should be broad, including bloodwork, brain imaging, EEG, and CSF examination.

Serum chemistries were normal except for low total protein (5.6 g/dL), albumin (3 g/dL), and calcium (7.8 mg/dL). A complete blood count showed an elevated white blood cell count (14,000 per mm³). Erythrocyte sedimentation rate (ESR) was 30 mm/hour and C-reactive protein 33.9 mg/L. Lumbar puncture revealed a protein of 121 mg/dL, normal glucose, 3 white blood cells/mm³, and 23 red blood cells/mm³. Urine toxicology was positive for marijuana. The combined herpes simplex virus (HSV) titer was high, the HSV immunoglobulin M slightly above normal, and the CSF HSV PCR negative. The CSF albumin ratio was high at 30.2 (normal 0–9.0). Additional infectious, co-

Figure 1 MRI on the day of presentation



(A) T2 fluid-attenuated inversion recovery (FLAIR) parasagittal view shows corpus callosal lesions, some with a ring of increased signal and a darker center. (B) T1 parasagittal view, similar cut, shows areas of T1 hypointensity (arrows) corresponding to the T2 bright lesions. (C) T2 FLAIR axial views show additional lesions throughout the internal capsule, and the genu, splenium, and tapetum of the corpus callosum. (D) Diffusion-weighted imaging (DWI) (1000b) axial view through the superior extent of the lateral ventricles shows several lesions with restricted diffusion through the central fibers of the corpus callosum, many with bright rings and dark centers. (E) DWI (1000b) axial view of the cerebellum and pons shows pinpoint lesions in the middle cerebellar peduncle and cerebellar cortex.

agulation, endocrine, cardiac, lipid, and immunologic studies were unrevealing.

EEG showed generalized slowing with superimposed bursts of left frontotemporal maximal slowing. Head CT found mild diffuse cerebral atrophy and deep frontal white matter lucencies. Brain MRI revealed multiple T2-hyperintense lesions in the cerebellum and cerebral white matter. Many lesions were hypointense on T1-weighted imaging and some demonstrated restricted diffusion. There were multiple lesions in the corpus callosum, many with a rim of T2 hyperintensity around a center of T1 hypointensity (figure 1). There was no abnormal enhancement. Magnetic resonance angiography showed

caliber changes in the distal branches of both middle cerebral arteries. Magnetic resonance venography was normal.

The patient's husband, who had been unavailable initially, reported that for several weeks she had had headaches, hearing difficulties, and episodic visual loss, occasionally losing vision in 1 eye for 30 minutes. Subtle memory problems had begun 1 month prior.

Questions for consideration:

1. How does this information change your differential diagnosis?
2. What additional information would you like?

GO TO SECTION 3

SECTION 3

The widespread distribution of MRI lesions suggests a multifocal process affecting primarily the white matter. The normal CSF glucose and low CSF cell count argue against an infectious process. The high CSF protein, serum C-reactive protein, and ESR suggest an inflammatory or autoimmune process. The negative CSF HSV PCR and noninfectious CSF cell count rule out HSV encephalitis.

CNS vasculopathy, primary or secondary, could explain the distal caliber changes in the middle cerebral arteries. Postpartum angiopathy, a reversible cerebral vasoconstriction syndrome, is a parsimonious diagnosis linking her headache, pregnancy, elevated CSF protein, MRI findings, and encephalopathy.^{2,3} However, postpartum angiopathy typically follows delivery, rather than precedes it, and often presents with vomiting and/or seizures.

Demyelinating disorders, such as multiple sclerosis (MS) or acute disseminated encephalomyelitis (ADEM), could explain the MRI findings, albuminocytologic dissociation, change in mental status, and visual disturbances (i.e., optic neuritis). However, encephalopathy and the high CSF protein are unusual for MS. Pregnancy tends to protect against flares, especially in the third trimester. Optic neuritis worsens over hours to days, and lasts days to weeks,

rather than 30 minutes. Finally, in the setting of acute symptoms, MS lesions often enhance on MRI and rarely have limited diffusion. ADEM is typically preceded by a viral illness or immunization. Additionally, the lesions in ADEM are usually larger, at the grey–white junction and deep nuclei, and often confluent.

Multiple emboli could explain multifocal restricted diffusion on MRI. Postpartum deep venous thrombosis (DVT), for example, could cause paradoxical embolization to the brain through a patent foramen ovale (PFO). However, the absence of cortical lesions, the predominance of corpus callosum lesions, and the high CSF protein argue against embolism.

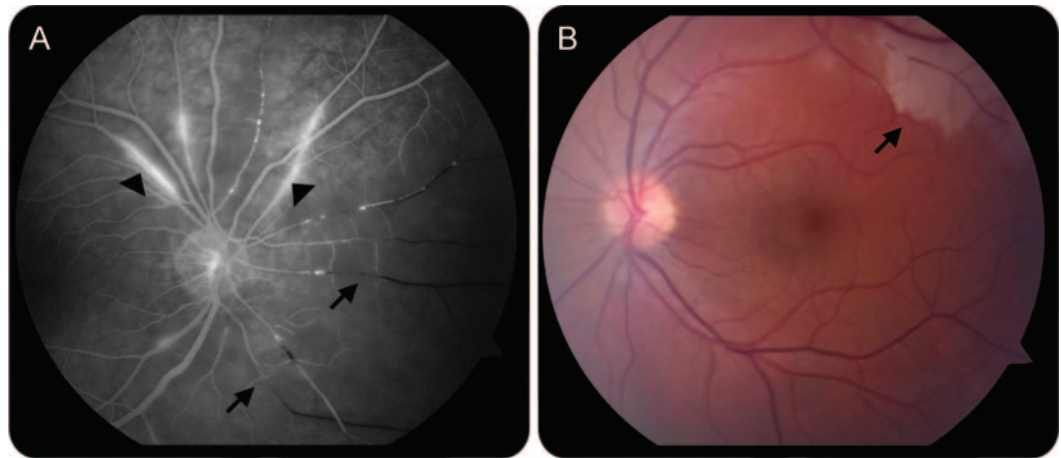
Susac syndrome is a microvasculopathy due to endothelial damage, which links encephalopathy, hearing loss, and visual changes. The distinctive corpus callosum lesions in this patient are like the “snowball” lesions that are characteristic of this disease, and high CSF protein is common.^{4,5} It is not a known complication of pregnancy.

Question for consideration:

1. What further testing would help distinguish among these diagnoses?

GO TO SECTION 4

Figure 2 Ophthalmologic imaging 4 days after presentation



(A) Fluorescein angiogram of the right eye shows retinal artery branch occlusions (black vessels, arrows). Note also hyperfluorescence of the arteriolar walls (arrowheads). (B) Retinography of the left eye shows retinal infarct (arrow).

SECTION 4

Transthoracic echocardiogram with bubble contrast found a small PFO, no evidence of thrombus or vegetation, and normal ejection fraction. Lower extremity Doppler studies found no DVT. Digital subtraction angiography found generalized small caliber arteries intracranially, but no morphologic changes consistent with a large vessel vasculopathy as would be expected in postpartum angiopathy.

To evaluate for Susac syndrome, ophthalmologic and audiologic evaluations were performed. Bedside dilated funduscopy examination revealed bilateral branch retinal artery occlusions with retinal infarcts. Fluorescein angiography found bilateral retinal infarcts, retinal artery branch occlusions, and arteriolar hyperfluorescence, suggesting a retinal vasculopathic process (figure 2). Audiologic evaluation found low frequency sensorineural hearing loss.

Muscle biopsy and additional serum tests to look for evidence of endothelial damage were obtained. Antiendothelial antibody tests were weakly positive, and factor VIII levels were elevated (319%, reference 50–150%). Factor VIII is synthesized and released by endothelial cells, and may rise if they are damaged. A muscle biopsy, including electron microscopy, was normal.

We diagnosed Susac syndrome, or retinocochleocerebral vasculopathy, based on the pathognomonic triad of encephalopathy, branch retinal artery occlusions, and hearing loss. Elevated CSF protein supports vasculopathy, but the affected vessels were too small to be detected by angiography.

Pregnancy was a cognitive distracter in this case. We initially focused on postpartum angiopathy as our leading diagnosis. Only after an unrevealing evaluation for stroke did we learn of the visual and hearing loss. Also of note, initial bedside funduscopy examination found

sharp disc margins, but missed the retinal infarcts. Once we considered the rare diagnosis of Susac syndrome, ophthalmologic examination confirmed the branch retinal artery occlusions. This case underscores the importance of the history in an encephalopathic patient and the utility of a broad differential diagnosis.

DISCUSSION: SUSAC SYNDROME Susac syndrome is an autoimmune endotheliopathy, pathophysiologically akin to dermatomyositis, targeting arterioles under 100 μm in the cochlea, retina, and brain (rather than muscle and skin, as in dermatomyositis). Evidence supporting this etiology includes high serum antiendothelial antibodies, elevated factor VIII (released by damaged endothelium), and tissue pathology with endothelial cell necrosis, basement membrane thickening, and C3d and C4d deposition in vessel walls.^{4,6-8}

The current literature only describes about 100 patients with Susac syndrome, but the disease is underappreciated and may be more common. Women outnumber men 3:1. Age at onset is 20 to 40 years, ranging from 9 to 58. The clinical triad may not present together. Months to years may separate the initial symptom from the development of the others.⁹ Headache, often migrainous, frequently precedes the onset of encephalopathy, and progresses to confusion, memory loss, behavioral changes, dysarthria, and mutism.^{4,5}

CSF typically shows a mild lymphocytic pleocytosis (less than 20) and markedly elevated protein. Oligoclonal bands and elevated immunoglobulin G index may falsely suggest MS.⁴

Brain MRI reveals multiple small (1–7 mm) white matter lesions in the cerebral hemispheres.¹⁰ Many show restricted diffusion, suggesting they represent small infarcts.¹⁰ Deep gray, cerebellar, brainstem, and

gadolinium-enhancing lesions are common. Leptomeningeal enhancement is occasionally seen. The characteristic callosal lesions in Susac syndrome are frequently misdiagnosed as demyelinating disease. However, their central location, “snowball” appearance on T2-weighted imaging, and evolution into pathognomonic T1-hypointensities are atypical of MS lesions, which are smaller and involve the callosal-septal interface.⁵ The size of the affected arterioles is below the resolution of angiography, which is typically normal.

Branch retinal artery occlusions present as flashes of light, black spots, scintillating scotoma, or occasionally monocular amaurosis fugax.⁴ Fluorescein angiography shows retinal artery branch occlusions with hyperfluorescence of the arterial wall and late dye leakage.¹¹ Hearing loss may be gradual, fluctuating, or sudden. Low frequencies are typically lost first, as the apex of the cochlea, which transduces lower frequencies, is more susceptible to infarction.⁴

With no controlled therapeutic trials in Susac syndrome, treatment recommendations are based upon clinical experience.^{6,9} Rennebohm and Susac⁶ outline a detailed aggressive regime, including low-dose aspirin, high-dose IV corticosteroids followed by a prolonged oral taper, monthly IV immunoglobulin, and consideration of cyclophosphamide or mycophenolate mofetil based on disease severity.

Only 7 pregnancies in 6 patients with Susac syndrome have been reported. Two developed symptoms during pregnancy, in 1 symptoms abated with pregnancy, and 3 had recurrent encephalopathy postpartum.⁹ Rennebohm and Susac’s⁶ analogy to inflammatory myopathy may be instructive for care: pregnant women with inflammatory myopathy often respond to steroids alone, and may flare postpartum.¹²

The disease is usually self-limited, lasting 2 to 4 years, and most patients eventually return to work. Most are left with bilateral hearing impairment, some (35%–50%) have residual cognitive dysfunction, and as many as 1/3 have relapse of encephalopathy. Asymptomatic visual field defects are more common than symptomatic visual loss.^{9,13}

FOLLOW-UP The patient was treated with daily aspirin, pulse steroids followed by an oral steroid taper, and IV immunoglobulin. Mycophenolate mofetil was added after a week, as she had not significantly improved, and the disease severity warranted additional immunosuppression.⁶ Mycophenolate mofetil was chosen over cyclophosphamide to be less detrimental to fertility.

Follow-up MRI 2 weeks postpartum showed new lesions, suggesting continuing disease activity. A repeat fluorescein angiogram showed decreased arterial wall hyperfluorescence. However, the patient improved clinically with fluent spontaneous speech and improved

attention and memory. On discharge, 3 weeks postpartum, she demonstrated right visual field deficits, brisk reflexes, and clonus at both ankles, right more than left. Seven months postpartum, she continues to take mycophenolate mofetil, and is slowly tapering prednisone. She still complains of short-term memory problems, right eye visual problems, and poor hearing in her left ear. She fatigues easily, but manages household chores and childcare on her own.

DISCLOSURE

Dr. Grinspan reports no disclosures. Dr. Willey is funded by NIH/NINDS T 32 NS 07153. Dr. Tullman has received research support from Acorda Therapeutics, BioMS, Genentech, and Novartis; and honoraria from Biogen Idec, EMD Serono, Novartis, Pfizer, and Teva Neuroscience. Dr. Elkind serves as Resident and Fellow Section Editor for *Neurology*[®]; serves as a consultant to BMS-Sanofi Pharmaceutical Partnership, GlaxoSmithKline, Jarvik Heart, Tethys Bioscience, and Daiichi-Sankyo; serves on the speakers bureaus of Boehringer-Ingelheim, Inc., and BMS-Sanofi Pharmaceutical Partnership; receives research support from diaDexus, Inc., BMS-Sanofi Pharmaceutical Partnership, and NIH/NINDS [K23 NS42912 (PI), R01 NS050724 (PI), NS048134 (PI), P50 NS049060 (Project PI), R37 NS029993 (co-PI), R01 NS55809 (coinvestigator); and has given expert testimony involving Merck & Co., Inc. (Vioxx), Pfizer (Shiley valve and Celebrex/Bextra), and Novartis (Zelnorm and stroke).

REFERENCES

1. Singhal AB, Bernstein RA. Postpartum angiopathy and other cerebral vasoconstriction syndromes. *Neurocrit Care* 2005;3:91–97.
2. Bogousslavsky J, Despland PA, Regli F, Dubuis PY. Postpartum cerebral angiopathy: reversible vasoconstriction assessed by transcranial Doppler ultrasounds. *Eur Neurol* 1989;29:102–105.
3. Ducros A, Boukobza M, Porcher R, Sarov M, Valade D, Bousser MG. The clinical and radiological spectrum of reversible cerebral vasoconstriction syndrome: a prospective series of 67 patients. *Brain* 2007;130:3091–3101.
4. Susac JO, Egan RA, Rennebohm RM, Lubow M. Susac’s syndrome: 1975–2005 microangiopathy/autoimmune endotheliopathy. *J Neurol Sci* 2007;257:270–272.
5. Susac JO, Murtagh FR, Egan RA, et al. MRI findings in Susac’s syndrome. *Neurology* 2003;61:1783–1787.
6. Rennebohm RM, Susac JO. Treatment of Susac’s syndrome. *J Neurol Sci* 2007;257:215–220.
7. Petty GW, Engel AG, Younge BR, et al. Retinocochleocerebral vasculopathy. *Medicine* 1998;77:12–40.
8. Magro C, Martin L, Susac JO. Susac’s syndrome: an organ specific autoimmune endothelitis (in preparation).
9. Aubart-Cohen F, Klein I, Alexandra JF, et al. Long-term outcome in Susac syndrome. *Medicine* 2007;86:93–102.
10. White ML, Zhang Y, Smoker WR. Evolution of lesions in Susac syndrome at serial MR imaging with diffusion-weighted imaging and apparent diffusion coefficient values. *AJNR Am J Neuroradiol* 2004;25:706–713.
11. Martinet N, Fardeau C, Adam R, et al. Fluorescein and indocyanine green angiographies in Susac syndrome. *Retina* 2007;27:1238–1242.
12. Silva CA, Sultan SM, Isenberg DA. Pregnancy outcome in adult-onset idiopathic inflammatory myopathy. *Rheumatology* 2003;42:1168–1172.
13. Susac JO. Susac’s syndrome: the triad of microangiopathy of the brain and retina with hearing loss in young women. *Neurology* 1994;44:591–593.

Clinical Reasoning: A 52-year-old man with spells of altered consciousness and severe headaches

T.M. Burrus, MD*
J.D. Burns, MD*
J. Huston III, MD
G. Lanzino, MD
A.A. Rabinstein, MD
J.H. Uhm, MD

Address correspondence and
reprint requests to Dr. Joseph D.
Burns, Mayo Clinic, Department
of Neurology, 200 First Street
SW, Rochester, MN 55905
Burns.Joseph@mayo.edu

SECTION 1

A 52-year-old right-handed man with a history of petit mal seizures as a child was transferred to our hospital after a spell of sudden loss of consciousness. His illness began 1 month earlier with fatigue and bilateral hand tremor. Two weeks later, he experienced a severe headache of sudden onset without associated nausea, vomiting, or focal neurologic symptoms. This lasted for a few hours, abating after several doses of ibuprofen and acetaminophen. One week later, he suddenly became confused while driving. He continued to drive normally, but had a befuddled facial expression and did not respond to questions from his wife. He returned to normal within 10 minutes. Over the next 2 weeks, he had several similar spells. He also developed recurrent, sudden, severe headaches that occurred several times per day. The pain began in the shoulders, spreading to the occipital region and then the entire head over 1–2 minutes. It was severe enough to cause him to fall to his knees and cry out in pain. These episodes occurred more frequently when lying in bed than when he was standing or sitting, and were associated with nausea. He was admitted to another hospital for evaluation of these symptoms and transferred to our facility after a 1-hour spell of “unresponsiveness,” which resolved spontaneously, while there.

Further questioning revealed additional symptoms. After the first episode of altered consciousness, his personality changed. His wife described him as “vacant” and “not as active and happy-go-lucky” as usual. He developed a slowly progressive, mild dysarthria; difficulty walking due to frequent “buckling” of the right knee; and numbness in the right medial forearm and little finger. He also described difficulty in using his hands to perform tasks such as putting toothpaste on a toothbrush, which he described as being like “putting two magnets together.” Finally, he had lost about 25 pounds over the preceding 3 months.

In addition to the childhood seizures, his past medical history was notable for a fungal infection of the lung in 1997 for which he had been admitted to an intensive care unit. The details of this illness were not known beyond the fact that he was treated for several months with an antibiotic. He had a remote smoking history.

Questions for consideration:

1. What is the differential diagnosis for this clinical presentation?
2. What features of the history are most useful in narrowing the differential diagnosis?

[GO TO SECTION 2](#)

*Dr. Burrus and Dr. Burns contributed equally.

From the Departments of Neurology (T.M.B., J.D.B., A.A.R., J.H.U.), Radiology (J.H.), and Neurosurgery (G.L.), Mayo Clinic College of Medicine, Rochester, MN.

Disclosure: The authors report no disclosures.

SECTION 2

In developing a differential diagnosis, one must first distill the crux of the clinical syndrome from the history. In this case, the history has two main components: spells of altered consciousness and episodes of severe headache. These occur independently. The spells of altered consciousness are most consistent with complex partial seizures. The sudden, severe headaches have a broader differential diagnosis, including venous sinus thrombosis, posterior reversible encephalopathy syndrome, CNS vasculitis, reversible cerebral vasoconstriction, and meningoencephalitis.¹ A history of multiple recurrences without severe neurologic sequelae argues strongly against subarachnoid hemorrhage and cervical artery dissection. Migraine is unlikely in light of the sudden onset, postural variations, and associated intermittent confusion. Episodic intracranial hypertension from a mass lesion, hydrocephalus, meningitis, or some combination of these diagnoses is an important consideration given the positional nature of the headaches.

Equally crucial to formulating a neurologic differential diagnosis is to begin to localize the disease process within the nervous system from the history. Doing so allows one to narrow the list of possible etiologies. This patient's clinical syndrome points to a multifocal or diffuse disease process. Complex partial seizures localize to the frontal or temporal lobe. While the long duration of the event and the postictal period suggests a temporal lobe focus, it is impossible to precisely localize the seizure focus in this case solely from the history. The personality change suggests dysfunction of anterior portions of the frontal

lobe, caudate nucleus, or the anterior thalamus, while the difficulty with hand coordination suggests a cerebellar or parietal lobe lesion. Numbness in the medial right arm and little finger suggests a lesion of the ulnar nerve or C8 root, while the knee buckling may localize to the femoral nerve, lumbar roots, thoracic spinal cord, or medial left frontal lobe. Without further semiologic characterization, the dysarthria could localize to a number of structures and therefore is of little localizing value.

On examination, the patient was afebrile and had normal vital signs. He was thin and appeared chronically ill. There was no meningismus. The remainder of the general medical examination was unremarkable. On neurologic examination, he was listless, somewhat inattentive, and seemed unconcerned with his illness. The cranial nerves were normal and there was no papilledema. Motor examination revealed a right pronator drift and a low-amplitude, high-frequency action tremor in the arms. Muscle stretch reflexes were normal with the exception of brisk knee reflexes. Plantar responses were equivocal on the right and extensor on the left. Pinprick sensation was reduced on the medial aspect of the right hand, including the little finger. Sensation of light touch and vibration as well as cortical sensory function were normal. There was no appendicular ataxia.

Questions for consideration:

1. Based on the history and examination, what is your clinical formulation?
2. What diagnostic tests would be useful to test this hypothesis?

GO TO SECTION 3

SECTION 3

We are considering the case of a 52-year-old man with a remote history of a fungal lung infection who presents with the following clinical syndrome:

- Severe episodic headaches associated with nausea and vomiting and provoked by assumption of the supine position, most consistent with episodic intracranial hypertension. This suggests the presence of a mass lesion, disease of the leptomeninges, or both.
- Recurrent spells of altered behavior and consciousness consistent with complex partial seizures, indicating focal cortical dysfunction in the frontal or temporal lobes.
- Personality changes suggestive of frontal lobe dysfunction.
- Right upper extremity sensory changes in the C8/ulnar distribution, suggesting involvement of the peripheral nerves or spinal nerve roots.
- Dysarthria.
- Right lower extremity weakness.

While other localizations are possible, this combination of findings best localizes simultaneously to the frontal lobe cortex and the meninges. When considered along with the history of weight loss and remote history of a fungal lung infection, likely etiologies include subacutely progressive meningoencephalitides such as those caused by fungi and mycobacteria, autoimmune inflammatory conditions, and neoplastic processes such as lymphoma and metastatic carcinoma. To narrow this list down, imaging and CSF analysis are necessary.

Results of complete blood count, electrolytes, renal function, and coagulation studies were normal. C-reactive protein and erythrocyte sedimentation rate were not elevated and testing for antinuclear and antineutrophil cytoplasmic antibodies as well as rheumatoid factor was negative. Blood cultures and serologic testing for numerous fungi, HIV, and syphilis were negative. The purified protein derivative test was nonreactive. CT of the chest, abdomen, and pelvis were unremarkable.

Brain imaging revealed a lesion in the anteroinferior right frontal lobe. The CT examination without

contrast showed a hypodense mass with a thin, slightly hyperdense rim. On MRI (figure), the lesion was heterogeneous, with mixed T1 and T2 signal intensity. The center had increased signal on both T1 and T2 sequences, while the rim was hypointense on T1 and T2. There was mild, heterogeneous enhancement along the lesion's rim and diffuse leptomeningeal enhancement. The gradient echo sequence revealed increased susceptibility artifact primarily along the rim. Diffusion-weighted imaging displayed restricted diffusion in the center of the lesion.

MRI of the spine with contrast can be helpful in distinguishing among inflammatory, infectious, and neoplastic diseases and can provide valuable anatomic information. For example, focal enhancing lesions of the leptomeninges at the right C8 nerve root would be supportive of a multifocal neoplastic process and would confirm the findings of our history and physical examination. However, because the patient's severe headaches were provoked by supine positioning and his condition was rapidly deteriorating, a spine MRI was not performed.

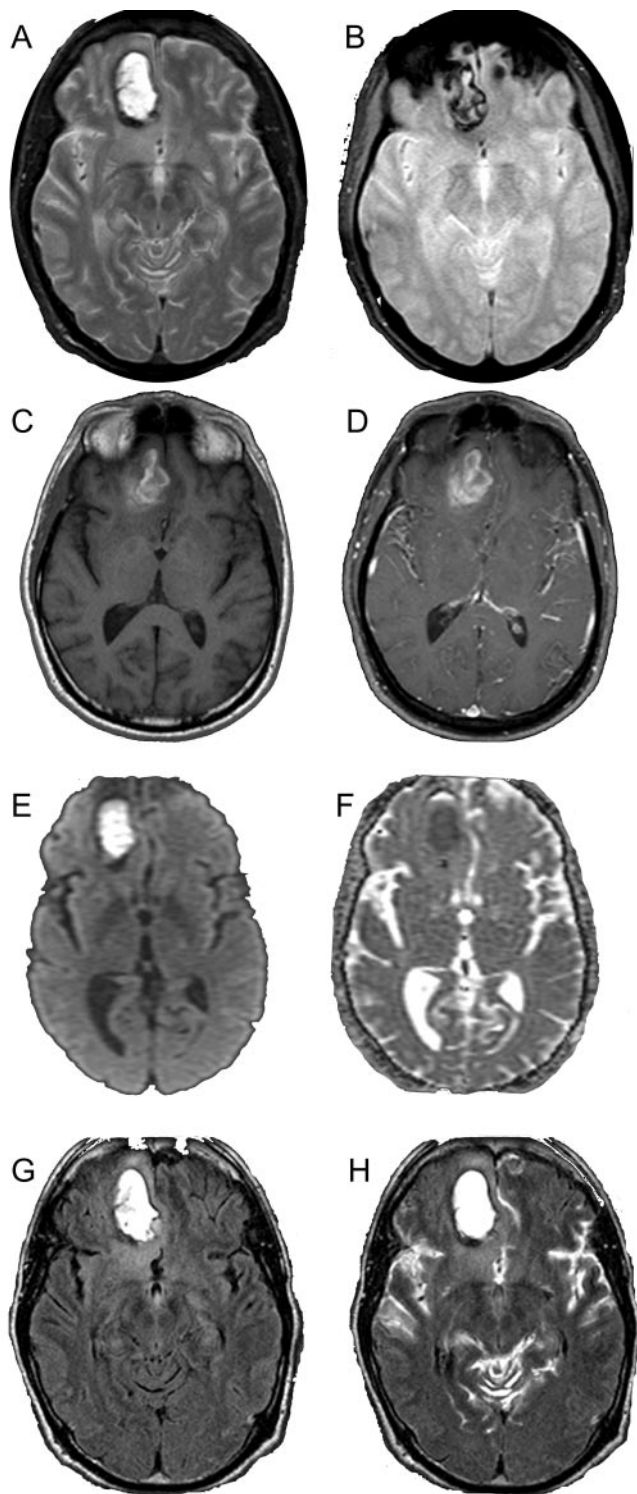
CSF was obtained by lumbar puncture performed after brain imaging. The opening pressure was 360 mm H₂O and the unspun fluid was yellow and viscous. After centrifugation, xanthochromia was present. The protein level was 1,991 mg/dL and the glucose concentration 48 mg/dL. Although a simultaneous serum glucose was not checked, it was never less than 100 mg/dL during the entire admission. The erythrocyte count was 13/ μ L and there were 34 leukocytes/ μ L (34% lymphocytes, 42% monocytes, 4% atypical cells). There was no evidence of malignant cells on cytology and flow cytometry. No organisms were apparent on the gram stain or fungal smear, and cultures for bacteria, fungi, and mycobacteria as well as PCR for herpes simplex virus, Epstein-Barr virus, cytomegalovirus, and varicella zoster virus were negative.

Question for consideration:

1. How does the information provided by the imaging and CSF analysis help your diagnostic process?

GO TO SECTION 4

Figure Magnetic resonance examination without and with contrast showing the mass contains blood products and is associated with diffuse leptomeningeal gadolinium enhancement



The T2 image (A) shows increased signal centrally with a rim of decreased signal. Greater signal loss or ballooning is present on the gradient echo sequence due to susceptibility artifact (arrow B). Increased T1 signal is seen within the mass (C) with mild peripheral enhancement in addition to the leptomeningeal enhancement (D). Abnormal signal is seen on diffusion-weighted imaging (E) with restricted diffusion (F) due to the internal blood products. Fluid-attenuated inversion recovery imaging before (G) and after (H) gadolinium contrast demonstrates diffuse abnormal leptomeningeal signal.

SECTION 4

Imaging studies demonstrated a well-demarcated mass lesion with an enhancing rim in the right frontal lobe and leptomeningitis (figure). These findings confirm the clinical localization and provide information for the generation of an etiologic differential diagnosis.

The signal characteristics of the lesion on MRI provide important information. The T2 hypointense rim is caused by hemosiderin, while the high T1 and T2 signal intensity in its center is indicative of subacute blood. The subacute blood is also responsible for the restricted diffusion. This combination of findings can be seen in a relatively limited number of conditions, including cavernous malformations, arteriovenous malformations, subacute intracerebral hemorrhages, contusions, abscesses, and tumor (primary or metastatic). The intense enhancement of the leptomeninges on the postcontrast images indicates the presence of leptomeningeal inflammation. The combination of hemorrhage and restricted diffusion with diffuse leptomeningitis further narrows the list of possible etiologies to the following: abscess with associated meningitis (bacterial, fungal, or mycobacterial), focal tumor with diffuse neoplastic meningeal infiltration (metastatic tumors from a variety of tissues, lymphoma, or glioblastoma), infarct or hemorrhage with associated meningitis (primary CNS vasculitis, systemic vasculitis with CNS involvement, or meningovascular syphilis), or a focal inflammatory mass with associated meningitis (sarcoidosis).

The highly elevated protein level, slightly low glucose concentration, mild lymphocytic-monocytic pleocytosis, and elevated opening pressure found on CSF analysis are all indicative of an inflammatory process, providing support to the differential diagnosis formulated on the basis of the clinical and imaging findings. However, due to the absence of a more specific finding, such as identification of a pathogen or malignant cells in the fluid, these results do not help to narrow down the list of possible diagnoses.

Question for consideration:

1. Are any other useful diagnostic tests available for this patient?

GO TO SECTION 5

SECTION 5

Empiric treatment for a bacterial abscess with meningitis was started on hospital day 4, but this did not lead to clinical improvement. Because of the severity of the patient's illness and the failure of less invasive testing to establish a diagnosis, a right frontal craniotomy and subtotal resection of the lesion were performed 5 days after his admission to our hospital. Intraoperatively, the frontal lobe appeared swollen and bulged through the dura as soon as it was opened. The lesion itself appeared as a cavity filled with brown/greenish material. Along the floor of the anterior cranial fossa, there was meningeal reaction and the mass was adherent to the underlying dura. Microscopic examination of the resected lesion revealed pseudopalisading nuclei with infiltrating lymphocytes and glial fibrillary acid protein-expressing neoplastic astrocytes, consistent with a WHO grade IV astrocytoma (glioblastoma). Thus, our final diagnosis was a partially necrotic and hemorrhagic glioblastoma of the inferior right frontal lobe with definite intracranial and possible spinal leptomeningeal metastases.

Dexamethasone 2 mg every 6 hours was started once the pathologic diagnosis was made. The patient's postoperative course was unremarkable. He was transferred to a hospital closer to his home on postoperative day 6 and was scheduled to begin treatment with whole brain radiation and temozolomide 4 weeks after the resection. However, his health declined precipitously after transfer, and he died 4 weeks later.

DISCUSSION Meningeal involvement in association with glioblastomas was first described by Guillain and Verdun in 1911.² Bernat posited three mechanisms by which this association might occur: chemical meningitis due to tumor rupture and release of necrotic, lipid-containing contents; tumor hemorrhage with release of blood breakdown products into the subarachnoid space; and tumor seeding of the meninges with resultant inflammation due to an immunologic response, as was the case in the patient described here.²

Autopsy studies have shown that as many as 20% of patients with high-grade cerebral gliomas have leptomeningeal metastases.^{3,4} Only approximately 4% of patients with supratentorial malignant gliomas, however, exhibit symptoms referable to this process.⁵ Furthermore, meningeal metastases from glioblastomas most often present late in the course of the disease, after the primary tumor has been diagnosed.⁶ Few cases have been reported in which meningeal metastases were responsible for the presenting symptoms in patients with glioblastomas.⁷ Interestingly,

younger patients with glioblastomas may be at relatively higher risk for this secondary leptomeningeal seeding.^{3,4}

Meningeal metastatic disease from glioblastomas responds poorly to radiation or chemotherapy and carries a grave prognosis. The average survival after the onset of symptoms due to meningeal involvement was 2–3 months in one study.⁶ These survival data are derived largely from patients in whom meningeal disease was a late manifestation and therefore may not apply to patients in whom meningeal disease manifests early in the course of the disease.

When clinically apparent, leptomeningeal metastases from glioblastomas most often cause a syndrome similar to subacute meningitis with headache, confusion, and neck and back pain.^{4,7,8} A wide variety of focal neurologic symptoms can be seen, the most common being cranial nerve palsies, radiculopathies, and myelopathy. These symptoms are probably caused by infiltration, mass effect, and inflammation at the sites of leptomeningeal tumor deposits.⁸ In addition, symptomatic hydrocephalus can occur.^{4,8} Finally, a vasculopathic syndrome with multifocal infarctions caused by occlusion of small, leptomeningeal-based blood vessels encased by tumor cells has been described.⁸

The CSF in patients with leptomeningeal metastases from a glioblastoma is typically abnormal, with a lymphocytic pleocytosis, elevated protein, and sometimes hypoglycorrhachia.⁷ CSF cytology, however, is negative in more than 50% of patients.⁵ Staining cells found in the CSF for glial fibrillary acidic protein may increase the diagnostic yield of cytology when gliomatosis is suspected.⁹ Imaging findings associated with glioblastoma leptomeningeal metastases include hydrocephalus, periventricular and leptomeningeal enhancement, and sulcal effacement.¹⁰ Unfortunately, with the exception of cytology, none of these findings clearly differentiates glioblastoma leptomeningeal metastases from other causes of subacute meningitis.

The rarity and nonspecific nature of its clinical, laboratory, and imaging manifestations makes the diagnosis of leptomeningeal metastases from glioblastoma difficult when a primary tumor is not apparent. As illustrated by this case, this difficulty can be overcome by the use of a disciplined diagnostic approach that includes systematic consideration and synthesis of all elements of the case, including the history, physical examination, laboratory, and imaging data. Finally, this case demonstrates the utility of brain biopsy when less invasive diagnostic modalities have failed to confirm a diagnosis.

REFERENCES

1. Schwedt TJ, Matharu MS, Dodick DW. Thunderclap headache. *Lancet Neurol* 2006;5:621–631.
2. Bernat JL. Glioblastoma multiforme and the meningeal syndrome. *Neurology* 1976;26:1071–1074.
3. Erlich SS, Davis RL. Spinal subarachnoid metastasis from primary intracranial glioblastoma multiforme. *Cancer* 1978;42:2854–2864.
4. Yung WA, Horten BC, Shapiro WR. Meningeal gliomatosis: a review of 12 cases. *Ann Neurol* 1980;8:605–608.
5. Delattre JY, Walker RW, Rosenblum MK. Leptomeningeal gliomatosis with spinal cord or cauda equina compression: a complication of supratentorial gliomas in adults. *Acta Neurol Scand* 1989;79:133–139.
6. Vertosick FT Jr, Selker RG. Brainstem and spinal metastases of supratentorial glioblastoma multiforme: a clinical series. *Neurosurgery* 1990;27:516–521; discussion 521–522.
7. Wheen LC, Anderson NE, Baker PC, Singh VK, Synek BJ. Leptomeningeal infiltration as the presenting manifestation of a malignant glioma. *J Clin Neurosci* 2006;13:298–301.
8. Onda K, Tanaka R, Takahashi H, Takeda N, Ikuta F. Cerebral glioblastoma with cerebrospinal fluid dissemination: a clinicopathological study of 14 cases examined by complete autopsy. *Neurosurgery* 1989;25:533–540.
9. Wechsler LR, Gross RA, Miller DC. Meningeal gliomatosis with “negative” CSF cytology: the value of GFAP staining. *Neurology* 1984;34:1611–1615.
10. Onda K, Tanaka R, Takahashi H, Takeda N, Ikuta F. Symptomatic cerebrospinal fluid dissemination of cerebral glioblastoma: computed tomographic findings in 11 cases. *Neuroradiology* 1990;32:146–150.



Clinical Reasoning: A 27-year-old man with rapidly progressive coma

Jonathan M. Wong, MD
Mekhala Chandra, MD
Rachael VanDeBogart,
MD
Brandon Lu, MD
Alan H. Yee, DO

Correspondence to
Dr. Yee:
yeeah@sutterhealth.org

SECTION 1

A 27-year-old man was brought to the emergency department by paramedics after being found wandering the street not communicative and with unsteady gait. At the scene, he was noted to have full body tremulousness, which improved after receiving midazolam. He was urgently transported to an emergency department and subsequently developed nausea, vomiting, and progressive deterioration of his mental status. On physical examination, he had tachycardia without fever, and was hemodynamically stable with normal oxygen saturation. He was stuporous; however, all brainstem reflexes were preserved with symmetrically reactive pupils of normal shape and size. He demonstrated spontaneous symmetrical limb movement as well as purposeful withdrawal. He had anicteric sclera, and his dermatologic evaluation showed no rash, needle track marks, or focal signs of external trauma.

Two weeks prior to this admission, he had presented to an emergency department for an upper respiratory illness with signs of mild confusion that spontaneously and completely resolved shortly thereafter.

His only prescription medication was bupropion for depression. His medical history included tetralogy of Fallot with an associated ventricular septal defect that was surgically corrected in youth, as well as pulmonic valve repair 4 years prior. He was employed as the CEO of a start-up Internet company and consumed occasional alcohol and marijuana socially. He had no familial history of neurologic disease.

Questions for consideration:

1. What are your differential diagnoses at this point?
2. What other investigations would help narrow the differential?

[GO TO SECTION 2](#)

SECTION 2

The differential diagnosis for rapidly progressive stupor and coma in young adults is broad (table 1).¹ Meningoencephalitis, toxic ingestion or substance abuse, or a severe systemic metabolic process were the leading diagnostic considerations. Initial evaluation with basic laboratory studies, urine toxicology, and brain imaging are helpful in narrowing the diagnosis.

Our patient's initial complete blood count, metabolic panel with liver enzymes and coagulation studies, cardiac biomarkers, and chest X-ray were normal. An ECG revealed sinus tachycardia with a right bundle-branch block and precordial T-wave inversions. The initial cranial CT was unremarkable. He was found to have lactic acidosis of 5.5 mmol/L (ref: 0.5–2.2 mmol/L) and low thyroid-stimulating hormone but normal

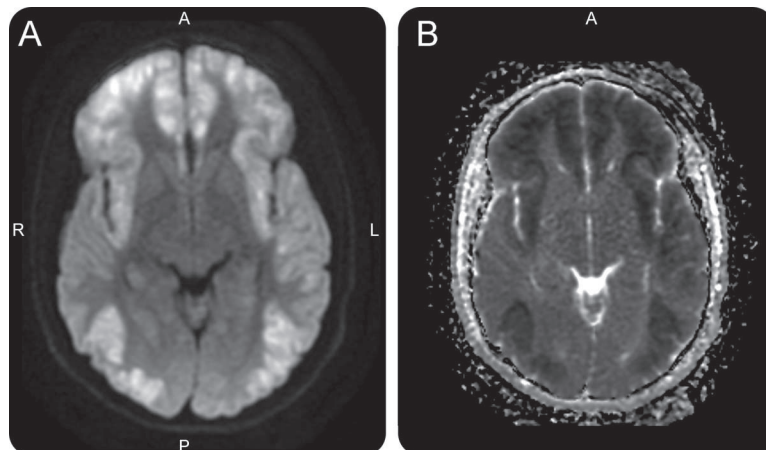
free T4 levels. Urinalysis and toxicology screening identified sterile ketonuria, the presence of benzodiazepines and tetrahydrocannabinol, and a normal salicylate level. Shortly after presentation, he developed airway compromise due to progressive obtundation requiring endotracheal intubation and was admitted to the intensive care unit for suspected meningoencephalitis. CSF analysis immediately following empiric initiation of broad-spectrum antimicrobial therapy yielded largely noninflammatory findings (3 leukocytes, 0 erythrocytes, 72 mg/dL glucose, 54 mg/dL protein). Serologic and PCR studies for herpes simplex virus, varicella-zoster virus, West Nile virus, and syphilis were negative, as well as the presence of HIV antibodies.

Although viral meningoencephalitis can present in an indolent manner, a fulminate bacterial process was unlikely given the diagnostic results thus far.

Table 1 Causes of stupor and coma in adults¹

Primary brain disorders	Metabolic derangements	Drugs and toxins	Organ failure	Injury	Endocrinopathies	Infection
Postictal state	Hyperglycemia/hypoglycemia	Alcohol	Cardiac arrest	Asphyxiation	Myxedema coma	Bacterial meningitis
Status epilepticus	Hypernatremia/hyponatremia	Carbon monoxide	Heart failure	Head trauma	Thyroid storm	Viral meningitis
Ischemic stroke	Hypercalcemia/hypocalcemia	Ethylene glycol	Lung disease	Hyperthermia	Acute adrenal insufficiency	Sepsis
Intracranial hemorrhage	Hypoxia/hypercarbia	Opioids	Kidney failure	Hypothermia	Diabetic ketoacidosis and hyperosmolar hyperglycemic nonketotic coma	Waterhouse-Friderichsen syndrome
Subarachnoid hemorrhage	Acidosis/alkalosis	Sedatives	Liver failure			Typhoid fever
Tumor	Hypophosphatemia	Tranquilizers				Rabies
Abscess	Reye encephalopathy	Anticholinergics				
Vasculitis	Porphyria	Psychotropics				
Hydrocephalus	Lactic acidosis					
	Hyperammonemia					

Figure MRI of the brain



(A) Diffusion-weighted and (B) apparent diffusion coefficient MRI of the brain show extensive cytotoxic injury within the cortex of the bilateral frontal, temporal, and occipital lobes and insular cortex.

Antimicrobial therapy was further tapered to only acyclovir as all bacterial cultures remained negative. Moreover, a focal intracranial process was not seen on initial cranial imaging, making intracranial hemorrhage, tumor, and trauma unlikely.

The patient developed frequent nonstereotypic multifocal myoclonus of the face, trunk, and limbs. His eyes had persistent downward deviation throughout the adventitious body movements but were without accompanying nystagmus. Continuous EEG monitoring did not demonstrate an ictal correlate initially. A brain MRI obtained 12 hours after admission showed diffuse bihemispheric abnormalities (figure). He rapidly deteriorated nearly 48 hours following symptom onset and developed progressive signs of brainstem dysfunction with bilateral fixed and dilated

pupils and pathologic extensor posturing. Repeat cranial imaging confirmed the presence of new extensive cerebral edema and severe bilateral uncal herniation. Given the unusual pattern of diffuse cortical injury noted on MRI, an ammonia level was obtained and found to be markedly abnormal at 569 $\mu\text{mol/L}$, greater than 15 times that of normal levels (ref: 11–32 $\mu\text{mol/L}$). He subsequently developed electrographic status epilepticus refractory to 3 anticonvulsants.

Questions for consideration:

1. What is the differential diagnosis for hyperammonemic crisis?
2. What additional testing would you pursue to narrow your differential diagnosis?
3. What therapy would you initiate?

GO TO SECTION 3

SECTION 3

There are numerous causes of hyperammonemia in adults (table 2).² An ammonia level should be considered in the initial evaluation of young adults who develop rapid decline in mental status without an obvious etiology, even in the absence of liver disease. Medications such as valproic acid can reduce the elimination of ammonia; however, the patient's history and toxicology profile did not suggest inadvertent medication ingestion, toxin exposure, or drug overdose. Herpetic infections and seizures may lead to secondary elevation of ammonia concentrations but not typically to such striking levels. An inborn

Table 2 Causes of hyperammonemia in adults²

Increased ammonia production
Infection
Urease-producing bacteria
<i>Proteus</i>
<i>Klebsiella</i>
Herpes infection
Protein load
Extreme exercise
Seizure
Trauma and burns
Steroids
Chemotherapy
Starvation
Gastrointestinal hemorrhage
Total parenteral nutrition
Other
Multiple myeloma
Renal failure
Decreased ammonia elimination
Liver failure
Fulminant hepatic failure
Transhepatic intrajugular portosystemic shunt
Drugs
Valproate
Carbamazepine
Sulfadiazine
Salicylates
Glycine
Inborn errors of metabolism
Ornithine transcarbamylase deficiency
Carbamyl synthetase deficiency
Hypermethioninemia
Organic acidurias
Fatty acid oxidation defects

error of metabolism was now a much greater diagnostic possibility.

The patient received hyperosmolar therapy with mannitol and hypertonic saline along with other aggressive medical treatment for pathologic elevation in intracranial pressure (ICP) including chemical sedation, paralysis, and mild hypothermia (33°C). Despite this, he continued to demonstrate persistent signs of pathologic ICP elevation. Given the probable poor neurologic prognosis and family's wishes, further surgical intervention, such as ICP monitor placement, was not pursued. Ammonia levels continued to rise and peaked at 2,191 $\mu\text{mol/L}$ despite initiation of continuous renal replacement therapy 72 hours after symptom onset. Additional metabolic investigation revealed marked elevation of urinary orotic acid, consistent with the diagnosis of ornithine transcarbamylase (OTC) deficiency. He died 5 days after admission due to cardiovascular compromise from progressive cerebral herniation and likely brain death. An autopsy confirmed the presence of diffuse cerebral edema with patchy cortical ganglionecrosis and uncal herniation. The liver was of average size and shape, and histologic examination demonstrated sinusoidal congestion but no cirrhosis.

DISCUSSION OTC deficiency is caused by mutations of the *OTC* gene, located on the X chromosome, which is expressed in the liver and gut. The disease tends to affect neonatal boys severely; however, adult-onset disease has been described.³ In hyperammonemic crisis, rapidly progressive encephalopathy with signs of raised intracranial pressure is its most severe phenotype. Neurologic manifestations are common and include myoclonus,⁴ seizure, and status epilepticus, among other signs of cortical dysfunction. Prior case series suggest that OTC deficiency can be characterized on MRI by extensive cortical involvement that includes the insular and cingulate cortices, as these areas may be particularly vulnerable to hyperammonemic-hyperglutaminergic states.⁵ Refractory elevation of ICP and status epilepticus are challenging to manage and may lead to death. Although the precise mechanisms of ammonia-associated cerebral toxicity are not fully understood, it is believed to cause cerebral edema through glutamine accumulation within astrocytes and metabolic disturbances through a variety of mechanisms.⁴

Carriers of the genetic defect may develop mild, nonspecific symptoms that include confusion, nausea, irritability, cognitive deficits, bizarre behavior, and protein aversion. The more severe clinical manifestation is hyperammonemic crisis.⁴ The phenotypic variation seen in OTC deficiency, even among family members who share the same mutation, may result from the *OTC* genotypic heterogeneity as well as

variability in environmental and developmental factors.⁶ Stressors include the postoperative period,⁷ use of high-dose corticosteroids,⁸ and high protein consumption (e.g., Atkins diet).⁹ Plasma amino and urine organic acid levels are typically abnormal in OTC deficiency—elevated concentrations of plasma glutamine or alanine as well as urinary orotic acid and uracil are frequently seen. DNA sequence analysis often identifies an associated mutation. Treatment strategies involve reducing serum ammonia levels quickly with combination therapy including hemodialysis, dietary protein restriction, and sodium scavengers such as sodium phenyl acetate and sodium benzoate.¹⁰

Adult-onset OTC deficiency is rare but may have catastrophic neurologic consequences if not detected early. Early identification and aggressive treatment of hyperammonemia may potentiate its effects with reasonable neurologic outcome.

AUTHOR CONTRIBUTIONS

Dr. Jonathan M. Wong: drafting the manuscript, manuscript concept/design. Dr. Mekhala Chandra: critical revision of the manuscript. Dr. Rachael VanDeBogart: critical revision of the manuscript. Dr. Brandon Lu: critical revision of the manuscript. Dr. Alan H. Yee: manuscript concept/design, critical revision of the manuscript, manuscript supervision.

STUDY FUNDING

No targeted funding reported.

DISCLOSURE

The authors report no disclosures relevant to the manuscript. Go to Neurology.org for full disclosures.

REFERENCES

1. Bradley WG. *Neurology in Clinical Practice*, 4th ed. Philadelphia: Butterworth-Heinemann; 2004.
2. Clay AS, Hainline BE. Hyperammonemia in the ICU. *Chest* 2007;132:1368–1378.
3. Lien J, Nyhan WL, Barshop BA. Fatal initial adult-onset presentation of urea cycle defect. *Arch Neurol* 2007;64:1777–1779.
4. Walker V. Ammonia toxicity and its prevention in inherited defects of the urea cycle. *Diabetes Obes Metab* 2009;11:823–835.
5. Takanashi J, Barkovich AJ, Cheng SF, Kostiner D, Baker JC, Packman S. Brain MR imaging in acute hyperammonemic encephalopathy arising from late-onset ornithine transcarbamylase deficiency. *Am J Neuroradiol* 2003;24:390–393.
6. Finkelstein JE, Hauser ER, Leonard CO, Brusilow SW. Late-onset ornithine transcarbamylase deficiency in male patients. *J Pediatr* 1990;117:897–902.
7. Hu WT, Kantarci OH, Merritt JL II et al. Ornithine transcarbamylase deficiency presenting as encephalopathy during adulthood following bariatric surgery. *Arch Neurol* 2007;64:126–128.
8. Lipskind S, Loanzon S, Simi E, Ouyang DW. Hyperammonemic coma in an ornithine transcarbamylase mutation carrier following antepartum corticosteroids. *J Perinatol* 2011;31:682–684.
9. Ben-Ari Z, Dalal A, Morry A, et al. Adult-onset ornithine transcarbamylase (OTC) deficiency unmasked by the Atkins' diet. *J Hepatol* 2010;52:292–295.
10. Enns GM, Berry SA, Berry GT, Rhead WJ, Brusilow SW, Hamosh A. Survival after treatment with phenyl acetate and benzoate for urea-cycle disorders. *N Engl J Med* 2007;356:2282–2292.

Clinical Reasoning: Encephalopathy in a 10-year-old boy

Lance Rodan, MD
Ingrid Tein, MD,
FRCPC

Correspondence & reprint
requests to Dr. Rodan:
lance.rodan@utoronto.ca

SECTION 1

A 10-year-old, right-handed boy with a several-day history of fever and upper respiratory symptoms presented with acute onset headache, emesis, progressive mental status change, and right-sided focal seizures. Symptoms developed over approximately 3 hours.

There was no history of recent toxic or medication exposures, travel, immunizations, sick contacts, insect bites, or animal exposures.

The general review of systems was negative.

Question for consideration:

1. What is your initial differential diagnosis based on this information?

[GO TO SECTION 2](#)

SECTION 2

Initial differential diagnosis should include infection (encephalitis or meningitis), inflammation (connective tissue disease/autoimmune disease, primary or secondary vasculitis, antineuronal antibody mediated encephalopathy), demyelination (e.g., acute disseminated encephalomyelitis), a vascular event (ischemic or hemorrhage), and a malignancy such as a glioma or lymphoma.

The patient was loaded with phenytoin and treated empirically with acyclovir and antibiotics while further history was obtained.

He was the product of a normal pregnancy and term delivery. His developmental history was normal.

Two years prior, he had a similar episode of fever and encephalopathy, which was associated with left-sided focal seizures and left hemiparesis. CT at that time demonstrated swelling of the right temporal lobe. He was presumptively diagnosed with herpes encephalitis, and received a full course of acyclovir. CSF herpes simplex virus (HSV) PCR was negative on 2 occasions. At his discharge from hospital, he had made a nearly complete recovery, with only mild residual left leg weakness.

Over the 2 years leading to his current admission, he continued to have persistent fatigue. Also, it became evident that he was having more difficulty in school than previously, and his grades dropped from As to Cs and Ds. In addition, when reviewing his growth curve, he had dropped several percentiles on his growth curve for both weight and height.

On family history, the mother has English and the father Hungarian heritage. Parents are nonconsanguineous. He has 2 younger twin male siblings who are healthy and developmentally normal. Family history is otherwise unremarkable.

On the current examination, he was mildly febrile and appeared pale. There was no meningismus. Glasgow Coma Scale (GCS) score was 13 due to confused, but fluent speech. He had a receptive aphasia. Pupils were equal and reactive to light and fundi were normal. He had a right superior quadrantanopia on visual threat. He had bilateral asymmetric ptosis. According to the parents, the ptosis had slowly developed over the last 2 years and was relatively constant throughout the day, but worsened when he was ill or fatigued. Smooth pursuit eye movements were normal. He had no facial weakness. Hearing was grossly normal bilaterally. Gag and jaw jerk were normal. On the motor examination, he had an asthenic build. He had bilateral pes cavus and hammertoes. Tone was decreased in the right arm and leg. Reflexes were 3+ in the right arm and leg and 2+ elsewhere. Plantar responses were upgoing bilaterally. The patient was spontaneously moving all 4 extremities, but had difficulty lifting his right arm and leg against gravity. According to his bedside nurse, his strength was increasing in the right side following his last seizure. He withdrew each of his 4 limbs to nailbed pressure.

Question for consideration:

1. Where is the lesion?

GO TO SECTION 3

SECTION 3

The patient likely has involvement of his left temporal lobe, including Wernicke area and inferior optic radiations. His right hemiparesis is possibly related to a postictal Todd paresis. His seizures could be spreading to his ipsilateral motor cortex from his temporal lesion, although a second lesion of the motor cortex cannot be excluded. His more chronic, bilateral ptosis with sparing of the pupils and extraocular movements could represent a rostral midbrain lesion affecting the central caudal

nucleus, but more likely represents a neuromuscular process (neuromuscular transmission or myopathy). Finally, his pes cavus and hammertoes are possible evidence of a mild chronic polyneuropathy (although the differential diagnosis for these deformities also includes distal myopathy, very chronic myelopathy, inflammatory joint disorders, and familial pes cavus).

Question for consideration:

1. Does this information change your differential diagnosis?

GO TO SECTION 4

SECTION 4

Knowledge of a similar prior episode, and the additional history of longstanding constitutional symptoms, cognitive decline, chronic ptosis, and possible polyneuropathy brings a new dimension to the differential diagnosis.

A chronic vasculitis (primary or secondary) affecting the CNS and peripheral nervous system could be considered, but this would be unlikely since the patient does not have any other organ, joint, or skin involvement.

A paraneoplastic disease could also be considered, but these are relatively rare in children, with the exception of anti-NMDA encephalitis.

Mollaret meningitis or recurrent HSV encephalitis (e.g., from inherited Toll-like Receptor 3 mutations) could be considered. His school difficulties could be explained as the chronic sequelae of temporal lobe damage; however, there was never confirmation of HSV infection and this would not explain his peripheral nervous system involvement.

X-linked Charcot-Marie Tooth Disease (CMT1X) from mutations in connection 32 is rarely associated with transient encephalopathy and stroke-like episodes, but this would not account for the patient's systemic symptoms.

A chronic toxic exposure could be considered, but there is no history to support this.

Finally, an inborn error metabolism should be considered. The acute, recurrent presentation provoked by intercurrent illness suggests a small molecule disorder or disorder of energy metabolism. Involvement of both CNS and peripheral nervous system, and associated systemic symptoms, are common in mitochondrial disease. The history of 2 stroke-like episodes would be highly suggestive of mitochondrial encephalomyopathy, lactic acidosis, and stroke-like episode (MELAS) syndrome. Certain fatty acid oxidation (FAO) defects can present with episodic hypoketotic hypoglycemic encephalopathy, myopathy, exercise intolerance, and peripheral neuropathy (mitochondrial trifunctional protein deficiency and long-chain L-3-hydroxyl-acyl CoA dehydrogenase [LCHAD] deficiency), and patients can have permanent deficits if they have cerebral injury while hypoglycemic, though this tends to be generalized and not focal in distribution. Also, ptosis is not a typical feature for FAO disorders. Another potential metabolic etiology for recurrent strokes with headaches and cognitive decline is homocystinuria, though this is not associated with ptosis, neuropathy, exercise intolerance, or the described systemic involvement and is therefore unlikely.

Question for consideration:

1. What investigations would you order?

GO TO SECTION 5

SECTION 5

Complete blood count demonstrated a mild leukocytosis and normocytic anemia. Blood gas demonstrated a compensated metabolic acidosis. Initial lactate was 9.1 mmol/L, and remained elevated on repeat samples. Pyruvate was not performed. Urine toxicology screen was negative.

CT head demonstrated a nonenhancing, hypodense mass lesion in the left temporal lobe and a small, chronic low density in the right parietal lobe. There was local mass effect, but no midline shift or effacement of quadrigeminal or suprasellar cisterns. Radiologic differential diagnosis included tumor, encephalitis, or infarct.

Lumbar puncture was performed and showed a normal cell count, normal glucose and protein, and a lactate of 5.29 mmol/L (upper limit of normal 2.4). CSF was sent for bacterial culture and viral PCR (HSV1/2, varicella zoster virus, Epstein-Barr virus, cytomegalovirus, HHV6, HHV7, HHV8, enterovirus, arbovirus including West Nile virus). Antimicrobials were discontinued when all cultures and viral studies returned as negative.

MRI was performed (figure) and showed a large, nonenhancing area of signal abnormality in the left temporal lobe with some mass effect and gyriform

cortical diffusion restriction. There were also smaller, ill-defined areas of high fluid-attenuated inversion recovery signal of varying ages in the right superior temporal gyrus, right occipital lobe, left prefrontal gyrus, left superior temporal gyrus, and left postcentral gyrus. Magnetic resonance spectroscopy (MRS) showed a lactate peak at 1.33 ppm (arrow).

Initial EEG was remarkable for slowing over the posterior aspect of the left hemisphere. There were no periodic lateralizing epileptiform discharges.

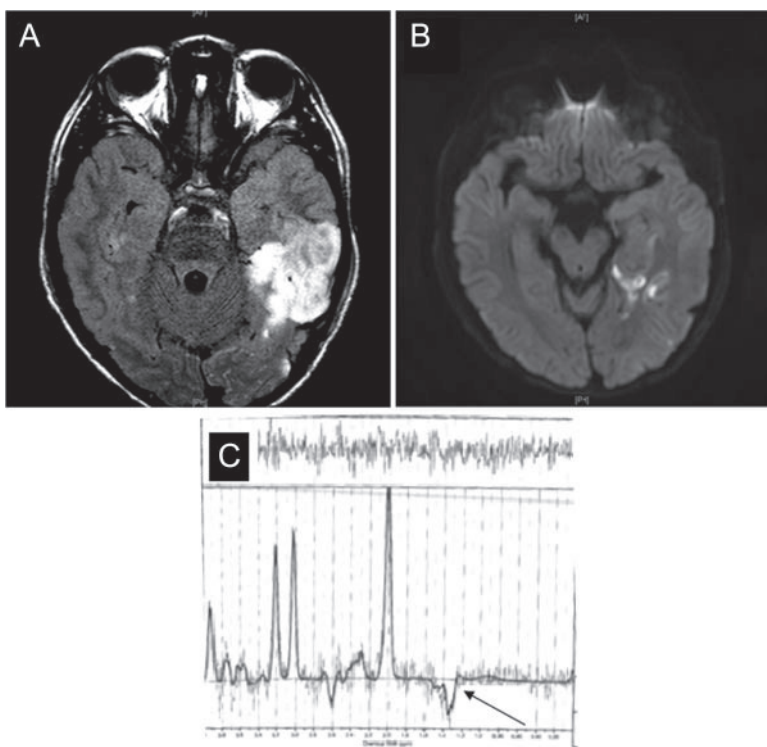
As a result of the clinical phenotype, genetic testing for mitochondrial DNA (mtDNA) 3243 A→G tRNA Leu and 3271 T→C tRNA Leu was sent. The patient was positive for the 3243 A→G tRNA Leu mutation with a mutation load of 32% in muscle.

DISCUSSION **What is the diagnosis?** MELAS refers to the syndrome of mitochondrial encephalomyopathy, lactic acidosis, and stroke-like episodes. The syndrome was first described by Pavlakis in 1984. The core features include 1) stroke-like episodes before the age of 40 years, 2) encephalopathy characterized by seizures, dementia, or both, and 3) lactic acidosis, ragged red fibers, or both, and supportive criteria included normal early development, recurrent headache, or recurrent vomiting.¹ Onset of symptoms is frequently seen between the ages of 2 and 10 years.² Stroke-like episodes refer to episodes of at least partially reversible neurologic deficits (often aphasia, hemianopia, and cortical blindness) that do not obey classic vascular territories. Posterior-parietal, temporal, and occipital cortices are preferentially involved, often asymmetrically. It is currently believed that the pathophysiology of these episodes includes both failure of oxidative metabolism at the cellular level in brain tissue itself as well as small vessel vasculopathy from mitochondrial failure in blood vessel endothelium and smooth muscle.^{3,4}

While patients may recover from these stroke-like episodes, the disease follows a neurodegenerative course with accumulation of deficits over time. Migraine, sensorineural hearing loss, myopathy with exercise intolerance, and peripheral neuropathy are additional common neurologic features. Patients may also have involvement of systemic organs with a high oxidative demand, e.g., heart, gastrointestinal tract, pancreatic islets of Langerhans, and kidneys. Short stature is another common feature.⁵

The diagnosis of MELAS is based on a combination of clinical findings and molecular genetic testing. While most patients with the MELAS phenotype have the A3243G tRNA Leu mutation in their mitochondrial DNA, it is now known that the MELAS phenotype can result from many genetic defects, both in the mitochondrial and nuclear ge-

Figure MRI brain imaging in case patient



(A) Axial fluid-attenuated inversion recovery sequence demonstrates signal abnormality in the left temporal lobe with mass effect. (B) Axial diffusion-weighted sequence demonstrates gyriform cortical diffusion restriction. (C) Magnetic resonance spectroscopy with lactate peak at 1.33 ppm (arrow).

nomes (e.g., complex 1 structural units encoded by mtDNA such as MT-ND5 and polymerase gamma [POLG] nuclear mutations).⁵ The MELAS phenotype may also be part of an overlap syndrome with characteristics of other mitochondrial diseases (e.g., myoclonic epilepsy with ragged-red fibers [MERRF] syndrome, Leigh syndrome).⁵ All mitochondrial defects are maternally inherited, whereas nuclear defects usually demonstrate autosomal recessive inheritance.⁵

Serum commonly demonstrates an elevated lactate with elevated lactate:pyruvate ratio, although lactate may be normal. Serum alanine (on quantitative amino acid analysis) may also be elevated.⁶

MRI often demonstrates signal change in the affected cortex, often sparing the subcortical white matter. The basal ganglia may also be involved. Diffusion-weighted imaging can show selective involvement of the cortical ribbon. MRS often reveals a characteristic lactate peak at 1.33 ppm, although this finding is not specific to mitochondrial disease and can be found in vascular stroke, hypoxic-ischemic injury, and infection.^{5,6}

In MELAS associated with A3243G mitochondrial tRNA Leu mutations, pathology often demonstrates ragged red fibers on modified Gomori trichrome staining, representing the compensatory proliferation of abnormal subsarcolemmal mitochondria. Immunohistochemical staining may reveal variably decreased staining for complexes I and IV, while staining for the exclusively nuclear encoded complex II (succinate dehydrogenase) may be increased as a result of mitochondrial proliferation.^{5,6} In addition, there may be evidence of lipid accumulation.⁶ Electron microscopy may reveal proliferation of mitochondria, giant mitochondria, or mitochondrial inclusions.⁶ It should be stressed that a respiratory chain enzyme biochemistry panel should also be performed by a qualified laboratory on all muscle samples in patients suspected of a mitochondrial disease. The activity of complexes I to III, II to III, and IV are most commonly measured as a first line. The respiratory chain enzyme biochemistry may represent the only abnormality present in a child with a mitochondrial disease, and the pattern of abnormal complexes may suggest a particular molecular diagnosis. For a more detailed review of the in-depth investigation of suspected mitochondrial disease, the reader is referred to a recent review article.⁶

How would you manage this patient? In general, current management is aimed at slowing neurodegeneration and preventing stroke-like episodes, as well as acutely treating stroke-like episodes. Seizure control should be optimized, since breakthrough seizures may trigger stroke-like episodes. Valproate should be

avoided if possible, as it is toxic to mitochondria, inhibits carnitine uptake in cells, and may exacerbate acute metabolic decompensation.⁷ Dichloroacetate may be used acutely to lower significant lactic acidosis but should not be used chronically because it may contribute to a severe peripheral neuropathy to which these individuals are already predisposed due to the mitochondrial disorder and any associated diabetes mellitus.⁸

Children with MELAS are often placed on a vitamin and antioxidant cofactor cocktail, variably including thiamine, riboflavin, creatine, vitamin C, vitamin E, α -lipoic acid, coenzyme Q10/idebenone, and L-carnitine. There is limited prospective randomized double-blind control study evidence to support the use of any of these, but it is generally believed that there may be a theoretical benefit and little risk of harm in supplementing with these agents.⁹ The use of L-arginine in the acute treatment of stroke-like episodes has been studied. IV doses of 500 mg/kg were given within 3 hours of the onset of symptoms. The arginine must be infused slowly over 15–30 minutes, monitoring for hypotension. In the subacute stage, the arginine can be continued orally at 150–300 mg/kg/day in 3 divided doses, provided there is normal renal function. Common side effects include nausea, vomiting, and abdominal pain. Small studies have shown efficacy for IV L-arginine used acutely in this manner. Furthermore, long-term treatment may decrease recurrence of stroke-like episodes.¹⁰ Larger prospective studies will be required to determine treatment efficacy.

DISCLOSURE

The authors report no disclosures relevant to the manuscript. **Go to Neurology.org for full disclosures.**

REFERENCES

1. Hirano M, Ricci E, Koenigsberger MR, et al. MELAS: an original case and clinical criteria for diagnosis. *Neuromuscul Disord* 1992;2:125–135.
2. DiMauro S, Hirano M. MELAS. In: GeneReviews. Available at: www.ncbi.nlm.nih.gov/books/NBK1233. Accessed October 24, 2011.
3. Gilchrist JM, Sikirica M, Stopa E, Shanske S. Adult onset MELAS: evidence for involvement of neurons as well as cerebral vasculature in strokelike episodes. *Stroke* 1996;27:1420–1423.
4. Clark JM, Marks MP, Adalsteinsson E, et al. MELAS: clinical and pathologic correlations with MRI, xenon/CT, and MR spectroscopy. *Neurology* 1996;46:223–227.
5. Sproule DM, Kaufmann P. Mitochondrial encephalopathy, lactic acidosis, and strokelike episodes: basic concepts, clinical phenotypes, and therapeutic management of MELAS syndrome. *Ann NY Acad Sci* 2008;1142:133–158.
6. Mitochondrial Medicine Society's Committee on Diagnosis. The in-depth evaluation of suspected mitochondrial disease. *Mol Genet Metab* 2008;94:16–37.

7. Tein I, DiMauro S, Xie ZW, De Vivo DC. Valproic acid impairs carnitine uptake in cultured human skin fibroblasts: an in vitro model for the pathogenesis of valproic acid-associated carnitine deficiency. *Pediatr Res* 1993;34:281–287.
8. Kaufmann P, Engelstad K, Wei Y, et al. Dichloroacetate causes toxic neuropathy in MELAS: a randomized, controlled clinical trial. *Neurology* 2006;66:324–330.
9. Santa KM. Treatment options for mitochondrial myopathy, encephalopathy, lactic acidosis, and stroke like episodes (MELAS) syndrome. *Pharmacotherapy* 2010;30:1179–1196.
10. Koga Y, Povalko N, Nishioka J, Katayama K, Kakimoto N, Matsuishi T. MELAS and L-arginine therapy. *Mitochondrion* 2007;7:133–139.



Clinical Reasoning: A 14-year-boy with spells of somnolence and cognitive changes

Claudio M. de Gusmao,
MD
Kiran P. Maski, MD
David K. Urion, MD

Correspondence to
Dr. de Gusmao:
claudio.degusmao@childrens.
harvard.edu

SECTION 1

A 14-year-old boy presented for admission after repeated episodes of lethargy and cognitive changes. He had a history of childhood absence epilepsy that had resolved with antiepileptics discontinued 1 year prior to presentation.

Two months prior to admission, the patient had a febrile illness with headache and diarrhea that lasted a few days. It was attributed to a nonspecific viral infection, and he recovered quickly. Over the ensuing days, however, he developed increasing sleepiness, cognitive slowing with difficulty concentrating, and an ill-defined abnormal perception. He stated feeling that

“things were not right, it is as if I am not here.” His parents reported changes in appetite that included hypophagia alternating with hyperphagia, as well as repeated purposeless behaviors such as tapping his fingers and verbal perseveration. His speech was described as “baby talk,” as if he had regressed. This progressed to hypersomnolence, sleeping more than 15 hours/day.

Questions for consideration:

1. What is your differential diagnosis for this presentation?
2. What tests would you order to evaluate this condition?

[GO TO SECTION 2](#)

SECTION 2

Given the history of a febrile illness shortly prior to symptom onset, a postinfectious etiology was strongly considered. Alternative potential diagnoses included infectious encephalitis, recurrent seizures, structural lesions in the arousal system involving the diencephalon or the brainstem reticular activating system, or toxic ingestion.

He was taken to a local hospital and a lumbar puncture (LP) showed 0 leukocytes, glucose 61 mg/dL, and protein 22 mg/dL. He received acyclovir until his herpes simplex virus (HSV) PCR came back negative, and his mental status improved over the course of a few days. About a week later, symptoms recurred and he was brought to another hospital. A repeat LP was noninflammatory. MRI/magnetic resonance angiography of the brain was performed and showed an incidental left frontal developmental venous anomaly but was otherwise negative. Prolonged EEG monitoring was normal. Urine and serum toxicology panels were negative. Cultures and viral studies were sent and negative. His mentation once again gradually improved and he was discharged.

Additional bloodwork included serologies for rapid plasma reagin, HSV, mycoplasma, parvovirus, influenza,

and Epstein-Barr virus. These were negative. Both cytomegalovirus and Coxsackie titers were elevated, and he received a course of ganciclovir with little improvement in his mental status. His thyroid function tests, B₁₂, and folate were normal. In consideration of Hashimoto encephalitis, anti-TPO antibody titer was sent and was negative. A vasculitis panel including antinuclear antibodies, antineutrophil cytoplasmic antibodies, von Willebrand factor antigen, SSA, and SSB was negative. To rule out postinfectious or autoimmune conditions, he had a paraneoplastic panel sent including autoantibodies for NMDA, voltage-gated potassium channel, anti-Ma, anti-Ta, and anti-Hu. These were also normal.

The patient went on to have a relapsing-remitting course, with episodes lasting 10–14 days during which he would sleep for 14–18 hours per day and have cognitive slowing with perseverative behavior and changes in appetite. Episodes would recur every 2–3 weeks and on his fourth relapse he was admitted to our institution.

Question for consideration:

1. Where do these symptoms localize?

GO TO SECTION 3

SECTION 3

Upon further questioning, the parents said that during episodes he was disinhibited, masturbating in public and occasionally not putting his clothes on. During hospitalization, it was also noted that he had wide swings of heart rate with intermittent bradycardia. The combination of sleep changes, hypersexual behavior, autonomic dysfunction, and mild

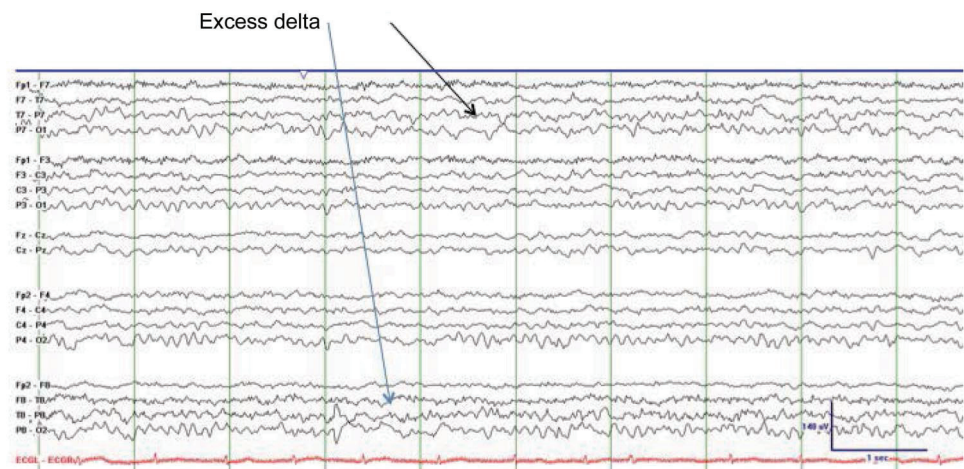
confusion with perceptual changes localizes to diencephalic structures, specifically the hypothalamus, as well as cortical associative areas. A prolonged EEG was performed and showed intermittent delta slowing (figure).

Question for consideration:

1. What disorder would you consider?

GO TO SECTION 4

Figure EEG



Excessive intermittent generalized delta slowing seen in the background.

SECTION 4

The possibility of a primary sleep disorder with recurrent hypersomnia such as Kleine-Levin syndrome (KLS) was strongly considered. Repeat infectious and paraneoplastic workup was done and was negative. The differential diagnosis of recurrent hypersomnia also includes structural lesions, as can be seen with brain tumors, traumatic brain injury, or stroke, all ruled out by previous studies. Given his sex, the possibility of menstrual-related hypersomnia was excluded. Additional psychiatric considerations include somatic symptom disorder, seasonal affective disorder, and bipolar disease. Psychiatry followed him throughout hospitalization. Although there is no single test to rule out any of these disorders, extensive family and patient interviewing suggested these conditions to be less likely. Reinforcing this interpretation were his cycling aspect, the lack of clear stressors, and other clinically relevant symptoms that compound diagnostic criteria in these conditions.

Recurrent hypersomnia with cognitive abnormalities, including mild confusion and hypersexuality, is suggestive of KLS. His perceptual changes, expressed by a sensation that “things did not feel or look right, as if I was not there,” are signs of derealization. This has been suggested as a very specific symptom of this condition.¹⁻³

The EEG results are also compatible, as it has been estimated to be abnormally slow in up to 70% of patients during events. We believe that the fluctuations with swings of bradycardia represented dysautonomias previously described in KLS. Bloodwork was sent for human leukocyte antigen typing and he came back positive for DQB1*0201. Although not specific, this has been previously seen in association with KLS.^{2,4-7}

The patient was started on modafinil and had a striking response. On the first day of medication, he started to have limited conversations with staff. On the second day, he was able to get out of bed and normalized his sleep/wake routine, although he still expressed a sense of derealization. He was discharged on valproic acid intended to prevent future episodes. However, he went on to have 3 more relapses over the course of 4 months and was switched to lithium.

Initially presumed to be a hypothalamic derangement, KLS is a disorder that exists in the borderland between neurology and psychiatry. Typically with onset in adolescence in 80% of cases, frequently in boys, it is usually preceded by a triggering event, such as a mild upper airway infection or fever (in 72%–96% of cases), alcohol intake (alone or combined with sleep deprivation), or head trauma.^{1-3,7}

The diagnostic criteria have been published in the *International Classification of Sleep Disorders–II* and can be seen in the table.⁸

Usually episodes last from a few days to several weeks and end suddenly. Although hypersomnolence, hyperphagia, and hypersexuality have been previously considered mandatory diagnostic criteria, the more recent diagnostic framework reflects the fact that most patients do not have all symptoms but rather some combination. During episodes, the full triad is estimated to occur in fewer than 45% of cases. This underscores the shift in diagnosis to the presence of hypersomnia with at least one of confusion, apathy, or derealization.¹⁻³

The pathophysiology has been elusive, with studies suggesting a localized encephalopathy but with multifocal involvement. Metabolic activity evaluated by SPECT is decreased in cortical (frontal lobe and internal temporal lobe) and deeper structures (especially thalamic and hypothalamic); the latter have also been found to be hypoactive with fluorodeoxyglucose PET studies.^{2,9}

There are no randomized placebo-controlled trials on treatment for KLS. A systematic review suggests that based on case reports, stimulant drugs may improve sleepiness (but not other symptoms) and lithium significantly reduces duration of episodes and decreases relapses, with anticonvulsants having less robust data as preventive medications.¹⁰

Although uncommon, KLS can have significant morbidity and should be recognized within the framework of core symptoms including hypersomnia, slowed cognition, apathy, and derealization. This case exemplifies the difficulties in the diagnosis and management of a syndrome that went underrecognized until appropriate treatment was instituted. Neurologists in training should be mindful of conditions, such as KLS, with core symptoms that could be dismissed as mental illness if clinicians are not careful. Careful history taking, attention to perception changes (derealization), and subtle findings on EEG (slowing) coupled with recurring hypersomnia should suggest consideration of this diagnosis.

AUTHOR CONTRIBUTIONS

Claudio M. de Gusmao: conception, preparation, and drafting of original manuscript. Kiran P. Maski: analysis and review of case discussion, suggestions to differential diagnosis and conclusion. David K. Urion: revision and editing of final text. All authors were directly involved in the care of the patient reported in this article.

STUDY FUNDING

No targeted funding reported.

Table Diagnosis of Kleine-Levin syndrome^{2,8}

Recurrent hypersomnia (recurrent episodes of sleepiness lasting from 2 days to 4 weeks; episodes recur at least once per year; alertness, cognitive function, and behavior are normal between episodes; the hypersomnia is not better explained by another sleep, neurologic, or mental disorder or substance abuse); and at least one of the following:

Cognitive abnormalities (e.g., derealization, confusion, hallucinations)

Abnormal behavior (e.g., irritability, aggression, uncharacteristic behavior)

Hyperphagia

Hypersexuality

DISCLOSURE

The authors report no disclosures relevant to the manuscript. Go to Neurology.org for full disclosures.

REFERENCES

1. Arnulf I, Lin L, Gadoth N, et al. Kleine-Levin syndrome: a systematic study of 108 patients. *Ann Neurol* 2008;63:482–493.
2. Arnulf I, Rico TJ, Mignot E. Diagnosis, disease course, and management of patients with Kleine-Levin syndrome. *Lancet Neurol* 2012;11:918–928.
3. Huang Y-S, Guilleminault C, Lin K-L, Hwang F-M, Liu F-Y, Kung Y-P. Relationship between Kleine-Levin syndrome and upper respiratory infection in Taiwan. *Sleep* 2012;35:123–129.
4. Thacore VR, Ahmed M, Oswald I. The EEG in a case of periodic hypersomnia. *Electroencephalogr Clin Neurophysiol* 1969;27:605–606.
5. Ugoljew A, Kurella B, Nickel B. Sleep polygraphic studies as an objective method for assessing the therapeutic result in a case of periodic hypersomnia (Kleine-Levin syndrome). *Der Nervenarzt* 1991;62:292–297.
6. Hegarty A, Merriam AE. Autonomic events in Kleine-Levin syndrome. *Am J Psychiatry* 1990;147:951–952.
7. Dauvilliers Y, Mayer G, Lecendreux M, et al. Kleine-Levin syndrome: an autoimmune hypothesis based on clinical and genetic analyses. *Neurology* 2002;59:1739–1745.
8. American Academy of Sleep Medicine. *The International Classification of Sleep Disorders—Second Edition (ICSD-2)*. Chicago, IL: American Academy of Sleep Medicine; 2005.
9. Haba-Rubio J, Prior JO, Guedj E, Tafti M, Heinzer R, Rossetti AO. Kleine-Levin syndrome: functional imaging correlates of hypersomnia and behavioral symptoms. *Neurology* 2012;79:1927–1929.
10. Oliveira MM, Conti C, Saconato H, Fernandes do Prado G. Pharmacological treatment for Kleine-Levin syndrome. *Cochrane Database Syst Rev* 2009;CD006685.



Clinical Reasoning: Psychomotor regression in the young

Eavan M. Mc Govern,
MRCPI
Timothy J. Counihan,
MD

Correspondence to
Dr. Mc Govern:
eavanmcgov@hotmail.com

SECTION 1

A 38-year-old right-handed man was referred for investigation of a 20-year history of progressive behavior change and involuntary movements. Symptom onset was in his late teens. Up until that time he had achieved age-appropriate motor and cognitive milestones and had completed normal schooling. There was no family history of dementia or movement disorders.

Initially, family members noted deterioration in his gait, which became increasingly imbalanced and clumsy. By the age of 20, speech and cognitive difficulties emerged. His speech was dysarthric with reduced output. By 25 years of age, he was noted to be inattentive at work. A decline in short-term memory and safety awareness was also noted by coworkers. After several episodes of inappropriate behavior, he was

referred to psychiatric services. By age 30, he was deemed unfit for work. Over the next 8 years, further symptoms emerged: involuntary movements of his upper limbs, dysphagia, and episodes of apparent collapse after raucous laughter. At age 38, he was admitted to the hospital after an episode of unwitnessed collapse, presumed to be a seizure. Head CT confirmed a subdural hematoma requiring evacuation. After recovery, his examination demonstrated generalized chorea, past-pointing and dysarthria, limb and gait ataxia, and impaired vertical gaze eye movements. His Mini-Mental State Examination score was 14/30, with 0/3 recall at 5 minutes.

Questions to consider:

1. What is the differential diagnosis?
2. What are the important examination findings?

[GO TO SECTION 2](#)

SECTION 2

The patient is a young man with a 20-year history of progressive decline in cognition, behavior, and motor function. An important initial step in the evaluation of this clinical scenario is to distinguish between a progressive psychomotor decline, as in this case, and a static encephalopathy.

Static encephalopathies can be broadly classified into antenatal insults (infections [cytomegalovirus, herpes simplex virus, rubella], toxins [alcohol, cocaine]) and perinatal (hypoxic-ischemic encephalopathy, hyperbilirubinemia). It is also important to determine the point at which regression began, and the evolution of the psychomotor symptomatology; were age-appropriate milestones achieved (figure)? In this case, the patient achieved age-appropriate motor and cognitive milestones and thereafter experienced psychomotor regression. The slowly progressive nature of symptoms suggests a degenerative condition. The age at onset in the second decade of life and apparent absence of family history might be consistent with an autosomal recessive condition, rather than an autosomal dominant condition.

When considering a differential diagnosis for early-onset cognitive impairment, it is useful to identify associated neurologic features (figure).

Many of the listed conditions may be deemed unlikely given the mode of inheritance (Huntington disease and similar disorders, spinocerebellar ataxia, dentatorubral pallidolusian atrophy) whereas others may require specific investigation. A paraneoplastic or autoimmune disorder is most unlikely given the slow evolution of symptoms.

An important finding on clinical examination was the presence of a vertical supranuclear gaze palsy. This sign narrows the differential diagnosis considerably in a patient presenting with ataxia and chorea (figure).

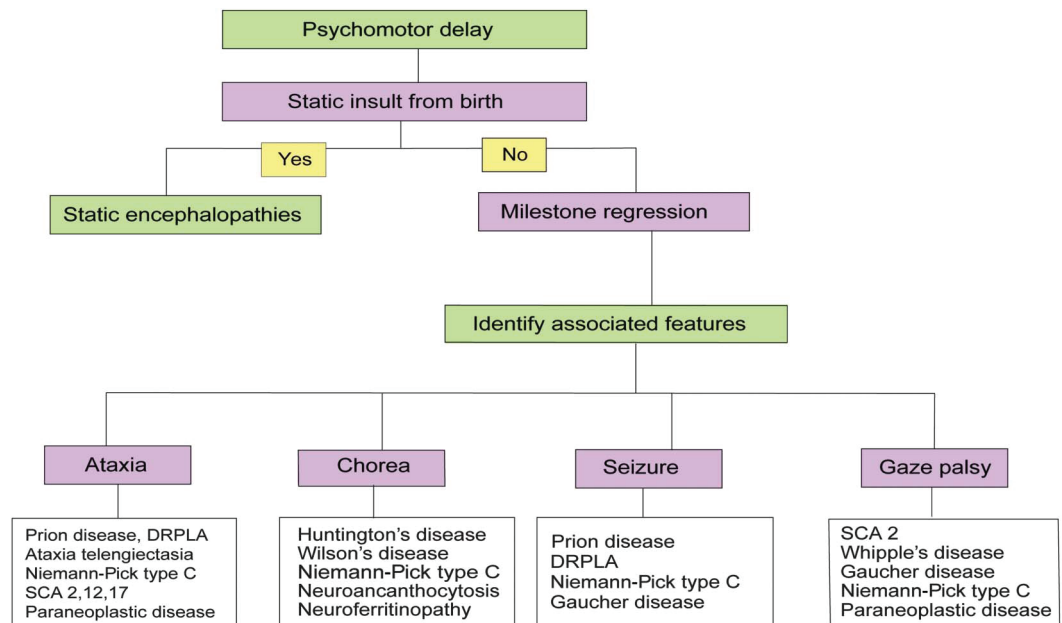
Although not present in this patient, splenomegaly is an important clinical feature to exclude in a young patient presenting with a mixed movement disorder and a key finding in generating a differential diagnosis.

Question to consider:

1. What testing would you perform?

GO TO SECTION 3

Figure Psychomotor delay: Differential diagnosis



DRPLA = dentatorubral pallidolusian atrophy; SCA = spinocerebellar ataxia.

SECTION 3

The combination of progressive cognitive decline, ataxia, chorea, and vertical gaze impairment all suggest a diagnosis of Niemann-Pick disease, type C (NP-C). Therefore, genetic testing for NP-C and a skin biopsy should be performed. We identified our patient as having a compound heterozygote mutation for the *NPC1* gene. A skin biopsy demonstrated polymorphic cytoplasmic bodies on electron microscopy, pathognomonic of NP-C.

Vertical supranuclear gaze palsy is an important clinical sign and invariably present in this disorder when there are neurologic manifestations beyond infancy. It is also the first neurologic sign to develop in individuals who present with organomegaly. The history also provides a useful clue of gelastic cataplexy (muscle atonia after episodes of heightened emotion).

NP-C is an autosomal recessive, inherited, lysosomal storage disorder. The condition results from a defect in

intracellular lipid trafficking. Mutations have been identified in 2 genes: *NPC1* (chromosome 18q11-q12) (94%) and *NPC2* (chromosome 14q24.3) (5%).¹

Impaired function of *NPC1* and *NPC2* is associated with excess accumulation of free cholesterol and glycosphingolipid in endosomal intracellular compartments, including the brain.² There is no difference in clinical presentation between *NPC1* and *NPC2*.

Clinical presentation, disease progression, and severity are strongly influenced by age at onset of neurologic symptoms. Presentation in early infancy is marked by delayed developmental motor milestones. Juvenile onset, as in our case, presents with gait problems, falls, clumsiness, cataplexy, and cognitive problems. Adult onset presents predominantly with neuropsychiatric disease manifestations.^{2,3}

Question to consider:

1. How would you treat this patient?

[GO TO SECTION 4](#)

SECTION 4

Until recently, the treatment for NP-C was supportive, addressing symptomatology including seizures, dystonia, tremor, behavioral problems, and gelastic cataplexy. Our patient was treated with levetiracetam for control of seizures and haloperidol to manage choreiform movements.

Miglustat, an iminosugar successfully used in other lysosomal storage disorders, namely Gaucher type 1, has recently been approved for use in NP-C.⁴ Iminosugars are small molecules that mimic monosaccharides but contain a nitrogen atom in place of the endocyclic oxygen. Miglustat acts by reversibly inhibiting glucosylceramide synthase, which catalyzes the first step of glycosphingolipid synthesis.^{4,5} Miglustat crosses the blood-brain barrier, reduces glucosylceramide synthase, and has demonstrated efficacy in delaying the onset of neurologic symptoms, stabilizing neurologic manifestations of the disease, and prolonging survival.⁵ Our patient has since commenced miglustat and his neurologic symptoms were stable at his last clinical review.

Of note, miglustat is approved for use in NP-C in 42 countries, but not in the United States.

DISCUSSION This case reminds us that when assessing young patients with cognitive decline, we must first distinguish static encephalopathies from progressive encephalopathies, and second, differentiate psychomotor delay from regression. Clues from the history provide valuable information regarding the underlying process, e.g., young onset and absence of family history are more consistent with autosomal recessive inheritance (or X-linked in males), and a progressive evolution of symptoms is consistent with neurodegeneration. Careful attention to seemingly bizarre phenomena, such as

gelastic cataplexy, can inform the diagnosis. Finally, the pattern of neurologic system involvement (chorea, seizure, vertical gaze, palsy) narrows the differential diagnosis further.

Early-onset cognitive and motor impairment, especially with movement disorders such as ataxia, chorea, or dystonia, in the presence of vertical gaze impairment suggests NP-C.

AUTHOR CONTRIBUTIONS

Dr. Eavan Mc Govern: acquisition of case history information, composition of case history and discussion. Dr. Timothy Counihan: critical revision of the manuscript, supervision of the case history and discussion.

STUDY FUNDING

No targeted funding reported.

DISCLOSURE

The authors report no disclosures relevant to the manuscript. Go to Neurology.org for full disclosures.

REFERENCES

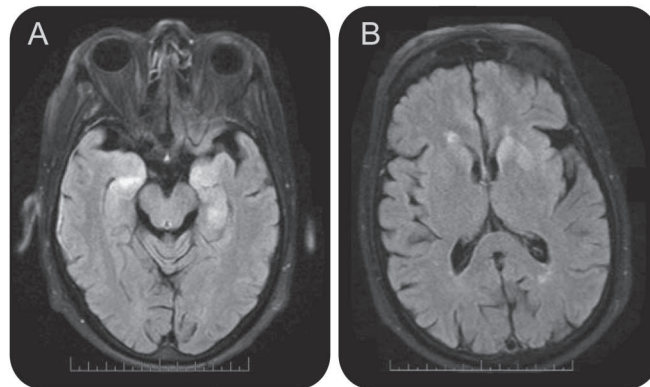
1. Patterson MC, Hendriksz CJ, Walterfang M, Sedel F, Vanier MT, Wijburg F; NP-C Guidelines Working Group. Recommendations for the diagnosis and management of Niemann-Pick disease type C: an update. *Mol Genet Metab* 2012;106:330–344.
2. Vanier MT. Niemann-Pick disease type C. *Orphanet J Rare Dis* 2010;5:16.
3. Wijburg FA, Sedel F, Pineda M, et al. Development of a suspicion index to aid diagnosis of Niemann-Pick disease type C. *Neurology* 2012;78:1560–1567.
4. Patterson MC, Vecchio D, Prady H, Abel L, Wraith JE. Miglustat for treatment of Niemann-Pick C disease: a randomised controlled study. *Lancet Neurol* 2007;6:765–772.
5. Wraith JE, Vecchio D, Jacklin E, et al. Miglustat in adult and juvenile patients with Niemann-Pick disease type C: long-term data from a clinical trial. *Mol Genet Metab* 2010;99:351–357.

Clinical Reasoning: A 72-year-old man with rapid cognitive decline and unilateral muscle jerks

Mark Duncan, BS
Jeremy Cholfin, MD,
PhD
Lucas Restrepo, MD,
PhD

Correspondence to
Dr. Duncan:
MDuncan@mednet.ucla.edu

Figure MRI brain



Fluid-attenuated inversion recovery sequences show hyperintensity in (A) bilateral hippocampi and amygdalae and (B) the left caudate and putamen.

SECTION 1

A 72-year-old man presented with cognitive decline and unilateral muscle jerks. Three months prior to presentation, the patient suddenly developed violent muscle jerks involving the right side of his body and face that impaired his gait and balance. Approximately 1 week later, he acutely developed confusion and memory loss. Over the following weeks, he experienced fluctuating symptoms of confusion, memory impairment, insomnia, and paranoid delusions. His muscle jerks and unstable gait were intermittent with return to baseline in between attacks, but they increased in frequency and occurred many times throughout the day. He was found to be mildly hyponatremic and was eventually admitted to a psychiatric ward for treatment of acute psychosis.

The patient's medical history was significant for hypertension, well-controlled diabetes, and a myocardial infarction 22 years previously. He was a retired mechanical engineer and was physically active prior to the onset of symptoms.

On neurologic examination, the patient was alert and oriented to person only. He registered 3 items but was unable to recall them at 5 minutes and was unable to complete serial 7s. He had no language deficits and could follow 3-step commands without difficulty. His cranial nerve, motor, and sensory examination results were normal. He had a wide-based gait with prominent right lateral pulsion and retropulsion, without any observed muscle jerks during gait examination. Occasional myoclonus involving the right side of his face and right upper extremity were observed, which were associated with loss of awareness and dystonic posturing of the right arm.

The patient was admitted to the general neurology ward and an MRI of the brain was performed (figure).

Questions for consideration:

1. Based on the history and physical examination, what is the differential diagnosis? How does the MRI narrow the differential?
2. What further workup would you order at this time?

[GO TO SECTION 2](#)

Supplemental data
at [Neurology.org](#)

SECTION 2

This patient presents with a subacute encephalopathy of fluctuating intensity, with myoclonus and gait abnormalities preceding the development of cognitive symptoms. Though the right-sided myoclonus may be cortical or subcortical, the localization can be narrowed based on other findings. Retropulsion is an extrapyramidal sign often due to loss of postural reflexes and is seen in disorders that involve the basal ganglia; the asymmetric right lateral pulsion localizes this to the left basal ganglia. The patient also displays cognitive deficits in orientation, memory, and attention, which indicate that there might be further cortical or subcortical involvement. The differential diagnosis should consider subacute encephalopathies that present with this constellation of findings.

The patient's rapid cognitive decline, myoclonus, and gait instability raise concern for Creutzfeldt-Jakob disease (CJD) and other prion diseases; other neurodegenerative conditions are common in this age group but less likely given the rapid clinical progression. Limbic encephalitis can mimic CJD and may result from a paraneoplastic syndrome or autoantibodies in the absence of cancer. Additional diagnostic categories to consider are autoimmune conditions (e.g., Sjögren syndrome, lupus, Hashimoto encephalopathy, sarcoidosis, CNS vasculitis), infections (tuberculosis, Lyme disease, *Listeria*, Whipple disease, *Cryptococcus*, toxoplasmosis), and neoplasms. Potentially reversible causes of encephalopathy can be ruled out with simple blood tests, including complete blood count (CBC), general chemistries, thyroid-stimulating hormone (TSH), vitamin B₁₂, and rapid plasma reagin, and an EEG can be performed to rule out seizures.

The MRI showed T2/fluid-attenuated inversion recovery (FLAIR) hyperintensity in bilateral hippocampi and amygdalae, with FLAIR hyperintensity and postcontrast enhancement in the left caudate

and putamen. There was no cortical ribboning or diffusion restriction on diffusion-weighted imaging, making CJD less likely. The MRI confirms the suspected basal ganglia involvement, and the hyperintensities in the limbic region may explain the patient's cognitive symptoms. These findings are consistent with limbic encephalitis; however, other autoimmune and infectious etiologies should be ruled out.

Plasma sodium level on admission was 132 mM (normal range 135–145 mM) with a nadir of 122 mM during his hospitalization; otherwise his CBC and chemistry panel were unremarkable. TSH and vitamin B₁₂ were normal. CSF studies showed a mildly elevated protein of 69 mg/dL (normal range 15–40 mg/dL) but were otherwise unremarkable, including immunoglobulin G synthesis rate and index with no inflammatory cells or oligoclonal bands. Serum autoimmune and inflammatory workup including erythrocyte sedimentation rate, C-reactive protein, antinuclear antibodies, rheumatoid factor, Sjögren syndrome A/Sjögren syndrome B, angiotensin-converting enzyme, antithyroid peroxidase, and antithyroglobulin were unremarkable. Infectious workup was negative for herpes simplex virus, HIV, syphilis, and a meningoenzephalitis panel. A paraneoplastic antibody panel (table e-1 on the *Neurology*[®] Web site at Neurology.org) of the serum and CSF was pending, although anti-Hu and anti-NMDA receptor were negative by outside records. A 16-hour continuous EEG showed diffuse slowing and was negative for epileptiform discharges. Whole-body PET/CT scan, a serum lymphoma panel, and a scrotal ultrasound were all negative for neoplasm.

Questions for consideration:

1. Can a diagnosis of paraneoplastic limbic encephalitis be made in the absence of cancer or a paraneoplastic antibody?
2. Would you initiate presumptive treatment at this point, or wait for more results?

GO TO SECTION 3

SECTION 3

According to an international guideline developed in 2004, this patient meets the definition of probable (rather than definite) paraneoplastic neurologic syndrome (PNS) given a classic neurologic syndrome (limbic encephalitis) in the absence of antibodies or cancer.¹ If a paraneoplastic antibody is identified and initial cancer screening is negative, the European Federation of Neurological Societies Task Force recommends repeat cancer screening (targeting cancers associated with the identified antibody) at 3–6 months and then every 6 months up to 4 years.² Starting treatment for probable PNS is reasonable while awaiting the identification of an antibody or tumor because of the potential for rapid, often irreversible neurologic decline.

The patient received 5 days of plasma exchange and was discharged. Corticosteroids were not given at this time due to his diabetes, psychiatric symptoms, and availability of plasma exchange. The myoclonic jerks resumed at home, and his other symptoms persisted. During a follow-up visit, the patient was initially alert but became progressively drowsy and unresponsive. Right-sided myoclonic jerks were apparent in his face, arm, and leg. He was readmitted to the hospital, with concern for status epilepticus or worsening of his underlying condition.

An EEG and MRI showed no changes from previous studies. The paraneoplastic panel returned positive for voltage-gated potassium channel (VGKC) antibodies with a level of 190 pM. The patient finished 3 days of IV immunoglobulin (IVIg) treatment and then received 1 g of IV methylprednisolone for 4 days. He was discharged home with a diagnosis of limbic encephalitis associated with VGKC complex antibodies. He received 1 g of IV methylprednisolone weekly, with an additional course of plasma exchange, and started 500 mg of mycophenolate twice daily, which was uptitrated to 1,000 mg twice daily. He also received levetiracetam, which required uptitration to 1,500 mg twice daily to achieve control of the myoclonus. Four months after his discharge from the hospital, he experienced almost complete resolution of symptoms, with only sporadic myoclonus associated with insomnia.

Question for consideration:

1. What prognosis does this diagnosis carry?

DISCUSSION

Limbic encephalitis is an autoimmune process affecting the medial temporal lobes or limbic structures that can present either acutely or subacutely with symptoms of confusion, memory impairment, sleep disturbance, seizures, and psychiatric disturbance.¹ The cause may be paraneoplastic or nonparaneoplastic, and the diagnosis

is usually made with neuroimaging and identification of the associated antibody. CSF studies are typically normal or have a mildly elevated protein level.³ In general, the well-characterized paraneoplastic antibodies (e.g., anti-Hu, anti-Yo) are directed at intracellular antigens, affect older individuals, are more often associated with cancer, and have a poor response to immunotherapy; antibodies targeting cell surface antigens (e.g., VGKC, NMDA receptor) can affect all ages, are less likely to be associated with cancer, and often respond well to immunotherapy.⁴

VGKC antibodies identified on radioimmunoassay have antigenic targets other than the VGKC itself and are therefore more accurately referred to as VGKC complex antibodies.⁴ At least 2 targets are well described: leucine-rich glioma inactivated 1 (LGI1) and contactin-associated protein related 2 (Caspr2). LGI1 antibodies typically produce limbic encephalitis, hyponatremia, and myoclonic-like movements, whereas Caspr2 antibodies can produce encephalitis, Morvan syndrome, painful neuropathy, or neuromyotonia.⁴

Our patient presented with limbic encephalitis, hyponatremia, and myoclonic jerks and was found to be VGKC complex antibody-positive, likely LGI1. The myoclonic jerks are termed faciobrachial dystonic seizures (FBDS), which are highly associated with LGI1 antibodies and can precede cognitive symptoms.^{5,6} Although only a minority of patients with FBDS show basal ganglia involvement on MRI, abnormalities are commonly seen on PET.⁵ FBDS typically show a poor response to standard antiepileptic drugs but may respond to early immunotherapy.^{5,6} A recent prospective study suggests that early recognition of FBDS and treatment with immunotherapy may reduce the frequency of FBDS attacks and prevent the development of cognitive symptoms.⁶

Prognosis is generally favorable, as 80% of patients respond to immunotherapy with improvement in memory and executive functions.^{7,8} Cancer is rarely reported with LGI1 antibodies, and a series of 55 patients with confirmed LGI1 antibodies revealed no cancer after a median follow-up of 3 years⁹; therefore, the utility of cancer screening in these patients is questionable. Though evidence is limited as to the optimal treatment regimen, most patients respond well to initial treatment with corticosteroids, plasma exchange, or IVIg, with maintenance options including corticosteroids or steroid-sparing agents such as mycophenolate, rituximab, or cyclophosphamide.^{6,7,10}

AUTHOR CONTRIBUTIONS

Mark Duncan: drafting/revising the manuscript, study concept and design, acquisition of data, analysis and interpretation, review of the literature. Dr. Cholfin: analysis and interpretation of data, imaging interpretation, critical revision of the manuscript. Dr. Restrepo: analysis and interpretation of data, imaging interpretation, critical revision of the manuscript for important intellectual content and supervision.

STUDY FUNDING

No targeted funding reported.

DISCLOSURE

The authors report no disclosures relevant to the manuscript. Go to Neurology.org for full disclosures.

REFERENCES

1. Graus F, Delattre JY, Antoine JC, et al. Recommended diagnostic criteria for paraneoplastic neurological syndromes. *J Neurol Neurosurg Psychiatry* 2004;75:1135–1140.
2. Titulaer MJ, Sofietti R, Dalmau J, et al. Screening for tumours in paraneoplastic syndromes: report of an EFNS Task Force. *Eur J Neurol* 2011;18:19–e3.
3. Jarius S, Hoffmann L, Clover L, Vincent A, Voltz R. CSF findings in patients with voltage gated potassium channel antibody associated limbic encephalitis. *J Neurol Sci* 2008; 268:74–77.
4. Rosenfeld MR, Titulaer MJ, Dalmau J. Paraneoplastic syndromes and autoimmune encephalitis: five new things. *Neurol Clin Pract* 2012;2:215–223.
5. Irani SR, Michell AW, Lang B, et al. Faciobrachial dystonic seizures precede LGI1 antibody limbic encephalitis. *Ann Neurol* 2011;69:892–900.
6. Irani SR, Stagg CJ, Schott JM, et al. Faciobrachial dystonic seizures: the influence of immunotherapy on seizure control and prevention of cognitive impairment in a broadening phenotype. *Brain* 2013;136:3151–3162.
7. Rosenfeld MR, Dalmau J. Update on paraneoplastic neurologic disorders. *Oncologist* 2010;15:603–617.
8. Frisch C, Malter MP, Elger CE, Hemlstaedter C. Neuropsychological course of voltage-gated potassium channel and glutamic acid decarboxylase antibody related limbic encephalitis. *Eur J Neurol* 2013;20:1297–1304.
9. Irani SR, Alexander S, Waters P, et al. Antibodies to Kv1 potassium channel-complex proteins leucine-rich, glioma inactivated 1 protein and contactin-associated protein-2 in limbic encephalitis, Morvan's syndrome and acquired neuromyotonia. *Brain* 2010;133:2734–2748.
10. Wong SH, Saunders MD, Larner AJ, Das K, Hart IK. An effective immunotherapy regimen for VGKC antibody-positive limbic encephalitis. *J Neurol Neurosurg Psychiatry* 2010;81:1167–1169.

Disorders presenting with weakness

For a task as simple as turning the pages of this book, an intention must be translated into precise, dexterous, coordinated movements of groups of muscles to achieve the desired action. In addition to supporting such mundane movements, the motor system allows athletes, dancers, and musicians to utilize the very same circuitry to achieve millisecond and millimeter precision. Higher-level motor control involves the premotor and supplementary motor cortices in interaction with the basal ganglia and cerebellum. The coordinated motor plan devised by these circuits is transmitted through the corticospinal tracts to stimulate the motor fibers of peripheral nerves that activate select muscles.

The motor system can be divided into the pyramidal system and the extrapyramidal system. The pyramidal system includes the corticospinal tracts that span the brain, brainstem, and spinal cord to communicate with the peripheral nervous system. The extrapyramidal system includes the basal ganglia and cerebellum, which serve to initiate, pattern, and coordinate movements.

Lesions in the pyramidal system produce weakness, lesions in the cerebellum can produce impaired coordination of movements (ataxia and dysmetria), and lesions in the basal ganglia can alter muscle tone (rigidity) and cause pathologically decreased or increased movement (see “Disorders Presenting with Abnormal Movements”). In extrapyramidal disorders, muscle power is generally preserved. Lesions affecting higher-level motor cortices impair the ability to perform complex learned motor tasks (apraxia).

The pyramidal system has 2 main components: upper motor neurons in the central nervous system and lower motor neurons whose axons lie in the peripheral nervous system. The upper motor neurons begin in the precentral gyrus of the frontal lobe and travel in the corticospinal tracts through the subcortical white matter and anterior brainstem, crossing at the cervicomedullary junction to descend in the contralateral spinal cord. The axons of the corticospinal tracts synapse on lower motor neurons in the anterior horn of the spinal cord. These lower motor neurons travel through ventral roots into peripheral nerves and terminate at neuromuscular junctions to stimulate muscle contraction.

The severity of weakness may vary with the location and extent of the lesion. Hemiparesis refers to partial weakness and hemiplegia refers to complete paralysis. Localization in disorders of the pyramidal motor system is guided by determining the distribution of weakness (i.e., where the patient is weak), the characteristics of weakness and associated examination findings (i.e., changes in reflexes, muscle tone or bulk, or the presence of fasciculations), and additional nonmotor symptoms/signs (i.e., abnormal cognition, sensation, and/or bowel and bladder function). As in all neurologic diagnosis, the time course guides the differential diagnosis of the cause of the lesion.

Distribution of weakness. Establishing which parts of the body are weak is fundamental to determining the potential localization of a lesion along the motor pathway.

- Weakness that involves one side of the body can be caused by pathology in the brain, brainstem, or spinal cord.
- When the distribution of weakness includes the face, the lesion must be located at the level of the pons or higher. Unilateral weakness of the face, arm, and leg on one side localizes to the contralateral cerebral hemisphere or cerebral peduncle. Lesions at the level of the facial nucleus/nerve in the pons generally cause weakness in the ipsilateral face and contralateral body, since the facial nerves project ipsilaterally, but the corticospinal tracts have not yet crossed at this level.
- Weakness of only the arm and leg on one side with no facial involvement can occur due to lesions at the level of the lower medulla or cervical spinal cord, but small lesions in the cerebral hemisphere can also produce this pattern.
- Weakness affecting the extensors of the upper extremity more than the flexors and the lower extremity flexors more so than the extensors suggests a lesion in the central nervous system.
- Weakness affecting a single limb in its entirety (monoparesis or monoplegia) can be caused by a small lesion in the cerebral hemisphere, a lesion in the spinal cord, a polyradiculopathy, or a plexopathy.

- Weakness affecting one or more parts of an individual limb may be due to a lesion at the level of the roots, nerves, or muscles. However, small lesions in the cerebral hemispheres can produce patterns that mimic peripheral lesions such as the “pseudo radial nerve palsy” pattern that can be caused by a small stroke in the hand region of the motor cortex.
- Bilateral symmetric weakness suggests pathology at the level of the spinal cord, peripheral nerves, or muscles.
- Bilateral proximal weakness in the arms and/or legs is suggestive of a myopathy, but can also be caused by strokes in a watershed distribution since the proximal limbs are supplied by the border zones between the middle cerebral artery and anterior cerebral artery territories (“man in a barrel” syndrome).
- Bilateral distal weakness often suggests peripheral neuropathy, though the distal muscular dystrophies can also present in this way.
- Lesions in the central nervous system can cause hyperreflexia, increased tone, and abnormal reflexes such as Babinski and Hoffmann signs, but these findings may not be present acutely.
- Lesions in the peripheral nervous system often cause hyporeflexia or areflexia, decreased (flaccid) tone, fasciculations, and atrophy.
- Motor neuron disease causes isolated weakness without sensory changes and may demonstrate UMN features exclusively, LMN features exclusively, or, most commonly, both UMN and LMN features.
- Fatigability is a hallmark of myasthenia gravis, but exercise-induced weakness can also be seen in metabolic myopathies (cramps may also be seen in metabolic myopathies).

Characteristics of weakness and accompanying signs. An initial branch point in localizing lesions along the motor pathway is determining whether the lesion is in the central nervous system (brain, brainstem, and spinal cord; upper motor neuron [UMN] lesion), peripheral nervous system (roots and nerves; lower motor neuron [LMN] lesion), at the neuromuscular junction, or in the muscles. Several aspects of the physical examination help make this distinction:

- Weakness without any sensory changes and with normal reflexes generally suggests a problem at the level of the neuromuscular junction or muscle.

Additional nonmotor symptoms and signs. Cognitive deficits (e.g., aphasia, neglect) associated with weakness suggest a hemispheric lesion. Cranial nerve palsies associated with motor deficits in the extremities suggest localization to the brainstem. Since nearly all cranial nerves project ipsilaterally and the corticospinal tract crosses at the cervicomedullary junction, brainstem lesions cause ipsilateral deficits in the face/eyes and contralateral deficits in the extremities. Bowel and bladder dysfunction generally implies a lesion of the spinal cord or cauda equina.

The cases that follow emphasize these principles in the approach to patients with weakness.

Clinical Reasoning: A woman with rapidly progressive apraxia



Peter Pressman, MD
Eileen H. Bigio, MD
Darren Gitelman, MD
Cindy Zadikoff, MD

Correspondence to
Dr. Pressman:
p-pressman@northwestern.edu

A 56-year-old woman presented with changes in balance, handwriting, and thinking. Approximately 1 year before her first visit, the patient developed difficulty walking, which caused multiple falls without serious injury. She also developed bilateral upper-extremity tremors that worsened with movement. At the time of her visit, she could barely sign her name.

Approximately 4 months before her first visit, the patient's family noticed she was having more difficulty speaking, causing frequent pauses in conversation. Sentence structure in her e-mails was abnormal but her family believed that her comprehension was intact. She was still able to do most of her activities of daily living, but only cooked simple meals, and had stopped driving because of a minor car accident.

The patient's medical history was notable for breast cancer, treated with mastectomy, chemotherapy, and radiation 7 years prior. She also had kidney stones necessitating a total nephrectomy after failed lithotripsy, and experienced urinary incontinence and constipation. Medications included letrozole 2.5 mg daily, polyethylene glycol 17 g daily, and solifenacin 10 mg daily. She had a family history of dementia in her mother when she was in the eighth decade of life, but no other family history of dementia or neurodegenerative illness.

At the time of her first visit to a neurologist, the patient's vital signs were normal. On cognitive testing, the patient's Mini-Mental State Examination score was 28/30, with difficulties in figure copying and writing that were both attributable to a tremor. Further cognitive testing showed decreased naming and difficulty understanding a syntactically complex sentence. Spelling was reduced for longer words. She had some right/left confusion. Ideomotor, limb kinetic, and oral apraxias were prominent, as were bilateral palmar grasp responses. *Gegenhalten* was present. Her cranial nerve examination was notable for saccadic pursuits. On motor examination, her strength was intact. She had postural and action tremors bilaterally. She had severe impairment of fine finger movements and rapid alternating movements due to decreased amplitude and frequent arrests of movement. Her gait was notable for decreased arm swing and en bloc turning.

The patient was referred to a movement disorders specialist who also noted extrapyramidal signs of bradykinesia and postural instability, apraxia, and myoclonus, with apraxia being the dominant component (video).

Question 1: How would you localize the degenerative process? The patient's examination is notable for speech difficulty and apraxia. Apraxia may localize to frontal or parietal lobes. Left parietal lobe lesions, in particular, have been associated with buccofacial and bilateral limb apraxia.^{1,2} These apraxias may also be associated with conduction or Broca aphasia, which may be pertinent to this patient's word-finding difficulty and trouble with complex sentences.³ She also had bradykinesia suggesting involvement of the extrapyramidal system.

Question 2: What is your leading clinical diagnosis? Given her prominent apraxia, postural tremor, and bradykinesia, the patient was diagnosed as having a corticobasal syndrome (CBS).⁴ Whereas corticobasal degeneration implies a unique pathology involving a 4-repeat tauopathy, CBS describes the clinical presentation and has an expanded pathologic differential diagnosis (table e-1 on the *Neurology*[®] Web site at www.neurology.org). For example, cases of CBS have shown Alzheimer pathology, Lewy body disease, or progressive supranuclear palsy at autopsy.^{5,6}

CBS classically begins as a unilateral akinetic-rigid disorder with associated localizing cortical findings that may include cortical sensory loss, alien limb phenomenon, and pyramidal findings. Apraxia is frequently associated with CBS. Patients with CBS may also first present with cognitive problems including a language disorder, and later develop motor symptoms.⁷

Given the rapidity of her decline, other disorders to consider that have also presented with the clinical picture of CBS include a paraneoplastic syndrome or prion disease such as Creutzfeldt-Jakob disease (CJD). Cases of prion disease presenting with abnormal movements, myoclonus, aphasia, and apraxia are well described.⁸

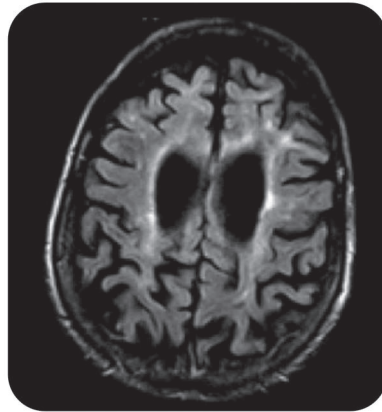
Question 3: What tests would you like to order and review? MRI can be suggestive of CBS if there is asymmetrical cortical atrophy.⁹ For other diagnoses, MRI scans show midbrain atrophy in progressive supranuclear

Supplemental data at
www.neurology.org

From the Departments of Neurology (P.P., D.G., C.Z.) and Pathology (E.H.B.), and Cognitive Neurology and Alzheimer Disease Center (E.H.B., D.G.), Northwestern University Feinberg School of Medicine, Chicago IL.

Go to Neurology.org for full disclosures. Funding information and disclosures deemed relevant by the authors, if any, are provided at the end of the article.

Figure 1 Fluid-attenuated inversion recovery MRI of the patient's brain in the axial plane

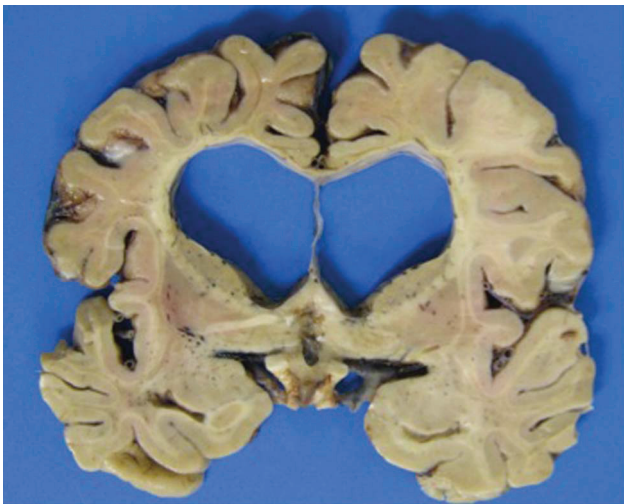

There are confluent T2 hyperintensities involving subcortical white matter of the superior frontal gyri bilaterally and central to the motor strip, with additional T2 hyperintensities in periventricular white matter and atrophy of the paracentral lobules bilaterally.

palsy. MRI has a sensitivity of 91% to 92%, and specificity of 94% to 95% for CJD.⁸ MRI findings suggestive of CJD include cortical ribboning or basal ganglia hyperintensity on fluid-attenuated inversion recovery and diffusion-weighted images with corresponding low signal on the ADC sequences. Conventional MRI scans are neither sensitive nor specific for the diagnosis of Alzheimer disease or Lewy body dementia.

An MRI of the brain done 6 months before her first examination in our clinic demonstrated mild vermian atrophy with some midline frontal atrophy. The lateral and third ventricles were prominent, with periventricular and subcortical T2 hyperintensities. The body and splenium of the corpus callosum were markedly

Figure 2 Coronal section at the level of the anterior commissure



Note marked attenuation of subcortical white matter.

thinned. The caudate nuclei were also thinned bilaterally (figure 1).

Laboratory studies of serum and CSF are also indicated in the workup of a rapidly progressive neurodegenerative process. White and red blood cell counts, glucose, and protein were normal in her CSF. The venereal disease research laboratory test, oligoclonal bands, myelin basic protein, cytology, and cryptococcal antigen were all negative. CSF 14-3-3 protein was indeterminate. A paraneoplastic panel including Hu, Ma1, Ma2, Yo, Ri, LEMS, CV2, VGKC, and Zic4 antibodies was negative. Blood tests including thyroglobulin, thyroid peroxidase, thyroid stimulating hormone, vitamin B1, Lyme disease antibodies, antigliadin immunoglobulin A, immunoglobulin G, serum protein electrophoresis, HIV-1 and -2, methylmalonic acid, erythrocyte sedimentation rate, antinuclear antibody screen, B12, folate, and hemoglobin A1c were all normal.

A 30-minute EEG demonstrated bilateral slowing that was most prominent over the left hemisphere. A PET scan of the brain demonstrated minimal asymmetrical areas of hypometabolism in the left parietal lobe.

Question 4: What therapies might you recommend?

Aside from her cognitive deficits, the patient's dominant problem was her apraxia, the medical treatment of which is limited. The patient also had myoclonus, which can be best treated with trials of levetiracetam, clonazepam, or valproic acid.¹⁰ Carbidopa-levodopa for the associated parkinsonism can also be tried but is typically much less effective than in its use for idiopathic Parkinson disease.

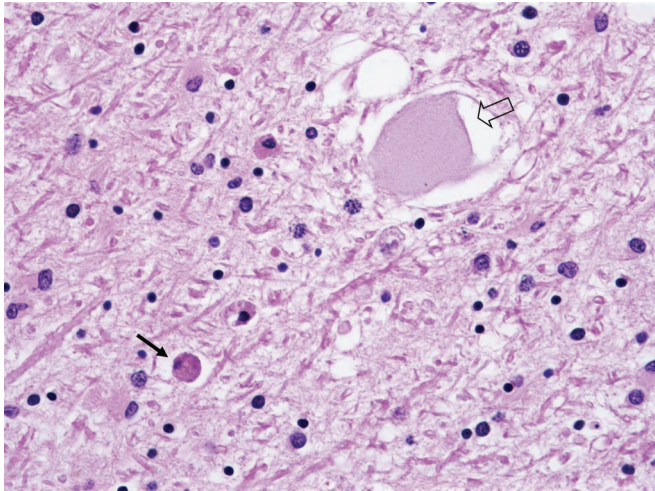
She was started on levetiracetam for myoclonus with no change in her symptoms. It was subsequently discontinued. Clonazepam was also tried without success. A trial of carbidopa-levodopa showed no benefit, and was discontinued. Escitalopram was added for concomitant depression.

Question 5: What other steps should be taken in the care of a patient with incurable, advancing neurodegenerative disease?

Over the course of 2 years, the patient deteriorated significantly. She became globally aphasic, and her difficulty walking progressed so that she required a wheelchair for mobility. She became increasingly apathetic and developed a pseudobulbar affect. Her examination was further marked by myoclonus in the right arm, with mild rigidity in all extremities and dystonic posturing in the left hand. She was unable to initiate eye movement without a head thrust.

Speech therapy was offered. A swallow study was normal. Hospice was notified and brain donation was discussed. The utility of a feeding tube was also discussed but was declined by the family. The patient was maintained on a diet of thickened liquids and pureed foods. While in hospice, she developed aspiration pneumonia and died 3 years after symptom onset.

Figure 3 Marked white-matter rarefaction with neuroaxonal spheroid (open arrow) and glial cell with brownish pigment (arrow)

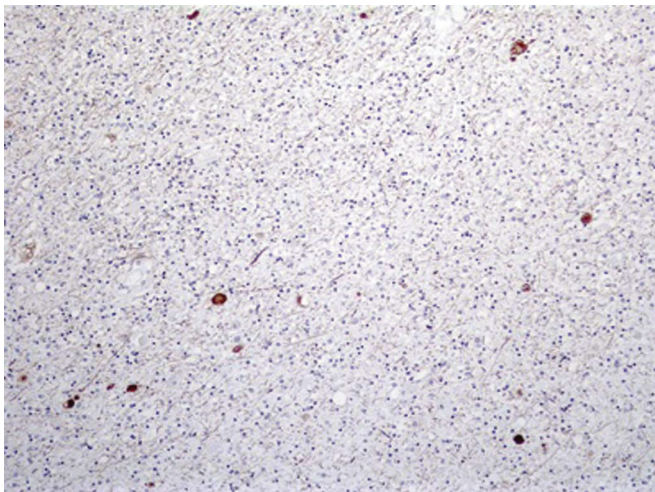


Hematoxylin & eosin, 600× magnification.

Autopsy revealed a 1,190-g brain with moderate frontal and parietal and mild temporal atrophy. Coronal sections revealed severe dilatation of the lateral ventricles and severe attenuation of the subcortical white matter (figure 2). Microscopically, there was severe white-matter rarefaction with loss of both axons and myelin, and frequent neuroaxonal spheroids and pigmented glia and macrophages (figure 3). Spheroids were highlighted with a neurofilament immunostain (figure 4). Two separate neuropathologists confirmed the diagnosis of adult-onset leukodystrophy with neuroaxonal spheroids and pigmented glia.

DISCUSSION Adult-onset leukodystrophy with neuroaxonal spheroids, also known as hereditary diffuse

Figure 4 Neuroaxonal spheroids highlighted by neurofilament immunostain



Neurofilament, 100× magnification.

leukoencephalopathy with spheroids, is an uncommon disorder that usually demonstrates autosomal dominant inheritance. However, sporadic cases have been reported. A recent literature review reported that the age at onset varies from 15 to 78 years, with a mean of 42 years of age. Age of death averages 48 years, with a range of 17 to 89 years of age. The duration of symptoms ranged from 2 months to 34 years, with symptoms including dementia, apraxia, ataxia, urinary incontinence, and extrapyramidal symptoms.¹¹ Depression, aggression, and psychotic features may also develop. The differential diagnosis includes frontotemporal dementia, corticobasal degeneration, and other leukoencephalopathies such as metachromatic leukodystrophy, cerebral autosomal dominant arteriopathy with subcortical infarcts and leukoencephalopathy, and Binswanger disease.^{11,12}

The leukoencephalopathy is most severe in the frontal and temporal lobes, although the thalamus and rostral caudate may be mildly reduced in size, and the corticospinal tracts and basis of the pons may also be atrophic. This gray-matter involvement may reflect neuronal death due to lack of sustaining cortical/subcortical projecting fibers, or may also be due to white-matter damage to tracts that traverse these nuclei.^{12,13} Pre- and postcentral gyri tend to be most involved. U fibers are relatively spared. MRI demonstrates signal abnormality in bilateral white matter. The corpus callosum may be thinned, and cerebellar degeneration may be noted. The MRI findings are nonspecific, however.¹²

Earlier this year, heterozygous mutations in a gene encoding the tyrosine kinase domain of the colony-stimulating factor receptor 1 (CSF1R) were associated with hereditary diffuse leukoencephalopathy with spheroids.¹⁴ The relationship between this gene and sporadic cases is less certain.

Before the recent discovery of the CSF1R mutation, the only way to confirm this diagnosis was by histopathology. Microscopy reveals widespread leukoencephalopathy with axonal spheroids and macrophages in affected white matter. The spheroids are best identified with Bielschowsky, Bodian, and anti-neurofilament immunostains. There is a pronounced loss of Purkinje cells in the cerebellum. At this time, supportive care is the only therapeutic option.

AUTHOR CONTRIBUTIONS

Dr. Pressman wrote the presented case report. Dr. Zadikoff treated the patient in this case report, provided references, and made several revisions to this case report. Dr. Bigio made the pathologic diagnosis for this patient, provided the pathologic description in the case report, provided references, and provided the pathologic figures for this case report. Dr. Gitelman treated the patient in this case report and made substantial revisions to this case report.

ACKNOWLEDGMENT

The authors are grateful to James M. Powers, MD, for review of this case and his confirmation of the pathologic diagnosis.

STUDY FUNDING

No targeted funding reported.

DISCLOSURE

P. Pressman serves on the editorial team of the Residents and Fellows Section of *Neurology*[®], and writes for About.com. E. Bigio reports no disclosures. Dr. Gitelman is a consultant for EMD Serono. C. Zadikoff has served on the speakers' bureau/advisory board of Teva, Merz, Allergan, Ipsen, GSK, and US World Meds. Go to Neurology.org for full disclosures.

REFERENCES

1. Alexander M, Baker E, Naeser M, Kaplan E, Palumbo C. Neuropsychological and neuroanatomical dimensions of ideomotor apraxia. *Brain* 1992;115:87–107.
2. Zadikoff C, Lang AE. Apraxia in movement disorders. *Brain* 2005;128:1480–1497.
3. Benson D, Sheremata W, Bouchard R, Segarra J, Proce D, Geschwind N. Conduction aphasia: a clinicopathological study. *Arch Neurol* 1973;28:339–346.
4. Stamenova V, Roy E, Black S. Limb apraxia in corticobasal syndrome. *Cortex* 2011;47:460–472.
5. Lee SE, Rabinovici GD, Mayo MC, et al. Clinicopathological correlations in corticobasal degeneration. *Ann Neurol* 2011;70:327–340.
6. Litvan I, Agid Y, Goetz C, et al. Accuracy of the clinical diagnosis of corticobasal degeneration: a clinicopathologic study. *Neurology* 1997;48:119–125.
7. Mathew R, Bak TH, Hodges JR. Diagnostic criteria for corticobasal syndrome: a comparative study. *J Neurol Neurosurg Psychiatry* 2012;83:405–410.
8. Geschwind MD, Shu H, Haman A, Sejar JJ, Miller BL. Rapidly progressive dementia. *Ann Neurol* 2008;64:97–108.
9. Soliveri P, Monza D, Paridi D, et al. Cognitive and magnetic resonance imaging aspects of corticobasal degeneration and progressive supranuclear palsy. *Neurology* 1999;53:502–507.
10. Caviness JN. Pathophysiology and treatment of myoclonus. *Neurol Clin* 2009;27:757–777.
11. Wong JC, Chow TW, Hazrati LN. Adult-onset leukoencephalopathy with axonal spheroids and pigmented glia can present as frontotemporal dementia syndrome. *Dement Geriatr Cogn Disord* 2011;32:150–158.
12. Freeman SH, Hyman BT, Sims KB, et al. Adult onset leukodystrophy with neuroaxonal spheroids: clinical, neuroimaging and neuropathologic observations. *Brain Pathol* 2009;19:39–47.
13. Keegan B, Giannini C, Parisi J, Lucchinetti C, Boeve B, Josephs K. Sporadic adult-onset leukoencephalopathy with neuroaxonal spheroids mimicking cerebral MS. *Neurology* 2008;70:1128–1133.
14. Rademakers R, Baker M, Nicholson AM, et al. Mutations in the colony stimulating factor 1 receptor (CSF1R) gene cause hereditary diffuse leukoencephalopathy with spheroids. *Nat Genet* 2012;44:200–205.

Clinical Reasoning: A 51-year-old woman with acute foot drop

Dimitrios Rallis, MD
Anastasia Skafida, MD
Georgios Alexopoulos,
MD
Adamantios Petsanas,
MD, PhD
Argyrios Foteinos, MD
Smaragda Katsoulakou,
MD
Eleni Koutra, MD, PhD

Correspondence to
Dr. Rallis:
jimrallis@hotmail.com

SECTION 1

A 51-year-old woman presented with sudden onset of weakness in her right leg and paresthesiae in the dorsum of her right foot. The symptoms began abruptly 2 hours earlier during her daily work as a housekeeper when she suddenly noticed a “double tap” sound on each step of her right foot. She denied any history of trauma to the lumbar spine or to the affected lower extremity. She had no habits such as crossing her legs, kneeling, or squatting.

The patient’s medical history was significant only for hyperlipidemia, smoking, and depression. No family members were reported to have neurologic disease.

Neurologic examination showed weakness of ankle dorsiflexion (Medical Research Council [MRC] grade 3/5) and great toe extension (MRC grade 3/5) in the right lower extremity. Foot eversion

was affected as well; however, inversion seemed to be preserved. Ankle and toe plantar flexion, knee flexion, as well as hip abduction, extension, and internal rotation, were normal. The Achilles tendon and patellar reflexes were elicited symmetrically (2+) on both sides. Close inspection did not reveal any area of local swelling or tenderness. Sensory examination demonstrated decreased sensation to pinprick on the dorsum of the right foot and the patient reported a vague discomfort in the lateral part of the right lower leg. She was able to walk unaided; however, she could not stand on the heel of her right foot.

Questions for consideration:

1. What is the differential diagnosis?
2. What is the most probable anatomic location of the lesion responsible for these symptoms?

[GO TO SECTION 2](#)

SECTION 2

In cases of foot drop, the clinician initially contemplates neurologic dysfunction at each level of the motor system from the corticospinal tract to the spinal nerve roots, the lumbosacral plexus, the peripheral nerves, the neuromuscular junction, and the muscles. The presence of focal muscle weakness in a nonpyramidal distribution without evidence of corticospinal tract impairment (e.g., increased tendon reflexes, positive Babinski sign) argues against central involvement. Several authors have described rare central causes of foot drop, such as lesions affecting the paracentral lobule¹ (e.g., parasagittal meningiomas, metastases, stroke). Likewise, disorders of the neuromuscular junction or the muscles are usually excluded because they generally manifest with diffuse weakness affecting bulbar, proximal, or distal muscles.

Therefore, foot drop is commonly attributed to lower motor neuron pathology and L5 radiculopathy is often suspected in the context of herniated nucleus pulposus or foraminal stenosis. The second most common cause is fibular (peroneal) neuropathy, particularly at the region of the knee. Preferential injury of fibular nerve fibers can also occur in the sciatic nerve, where the fibular division is separately encased from tibial fibers or at the lumbosacral plexus causing a clinical picture indistinguishable from true fibular neuropathy. The fibular division of the sciatic nerve is considered susceptible to injury because it comprises a smaller number of larger fascicles compared to the tibial division and supportive connective tissue is relatively sparse.

Clinical examination is to a degree an exercise of logical deduction where muscles belonging to the

same myotome but receiving innervation from different peripheral nerves are sequentially examined. In this setting, a diagnostic clue favoring fibular neuropathy is the preservation of ankle inversion. Specifically, ankle inversion is carried out by the posterior tibialis muscle that receives L5-S1 innervation from the tibial nerve. Moreover, ankle and toe dorsiflexion, as well as ankle eversion, are performed by fibular innervated muscles that likewise are partially supplied from the L5 root. Therefore, when ankle inversion is intact, this strongly suggests fibular neuropathy. Furthermore, in cases of L5 radiculopathy, toe extension tends to be more severely affected than ankle dorsiflexion because the extensor hallucis longus muscle receives the major bulk of its innervation from the L5 root. At this point, the exact site where fibular nerve fibers are damaged cannot be identified.

The fibular nerve is extremely vulnerable due to its superficial course particularly at the fibular neck, where the nerve is covered only by subcutaneous fat and skin.² Fibular neuropathy may result from penetrating trauma, operative injury, entrapment, habitual leg crossing or prolonged squatting, immobilization, and marked weight loss. Additionally, it is associated with conditions such as diabetes mellitus, alcohol abuse, malnutrition, polyarteritis nodosa and other systemic vasculitides, anorexia nervosa, bariatric surgery, and hereditary neuropathy with liability to pressure palsy. A subset of cases is due to compression from intraneural or extraneural masses such as ganglia, Schwannomas, neurofibromas, and osteochondromas.

Question for consideration:

1. What investigations would you recommend?

GO TO SECTION 3

SECTION 3

Neurophysiologic examination was performed on the third day. Motor nerve conduction study of the right fibular nerve showed a reduction of compound muscle action potential (CMAP) amplitude stimulating at the fibular neck (figure, A). Distal CMAP amplitude of the right fibular nerve was relatively lower compared to the left side. Additionally, the sensory nerve action potential (SNAP) amplitude of the right superficial fibular nerve was decreased ($2 \mu\text{V}$, reference value $>7 \mu\text{V}$). Motor tibial and sural sensory studies were normal.

Needle EMG of the right tibialis anterior and the right extensor digitorum brevis revealed spontaneous activity in the form of positive sharp waves and fibrillation potentials (+2). Motor unit action potential (MUAP) morphology was not indicative of denervation; however, motor unit recruitment was reduced. Examination of the right tibialis posterior and medial gastrocnemius was normal.

Questions for consideration:

1. How would you interpret the results of the electrophysiologic studies?
2. Would you recommend any further testing?

The above findings indicate conduction block (CB) of the right fibular nerve at the fibular neck. According to the consensus criteria of the American Association of Electrodiagnostic Medicine, CB is defined as a reduction of CMAP amplitude in

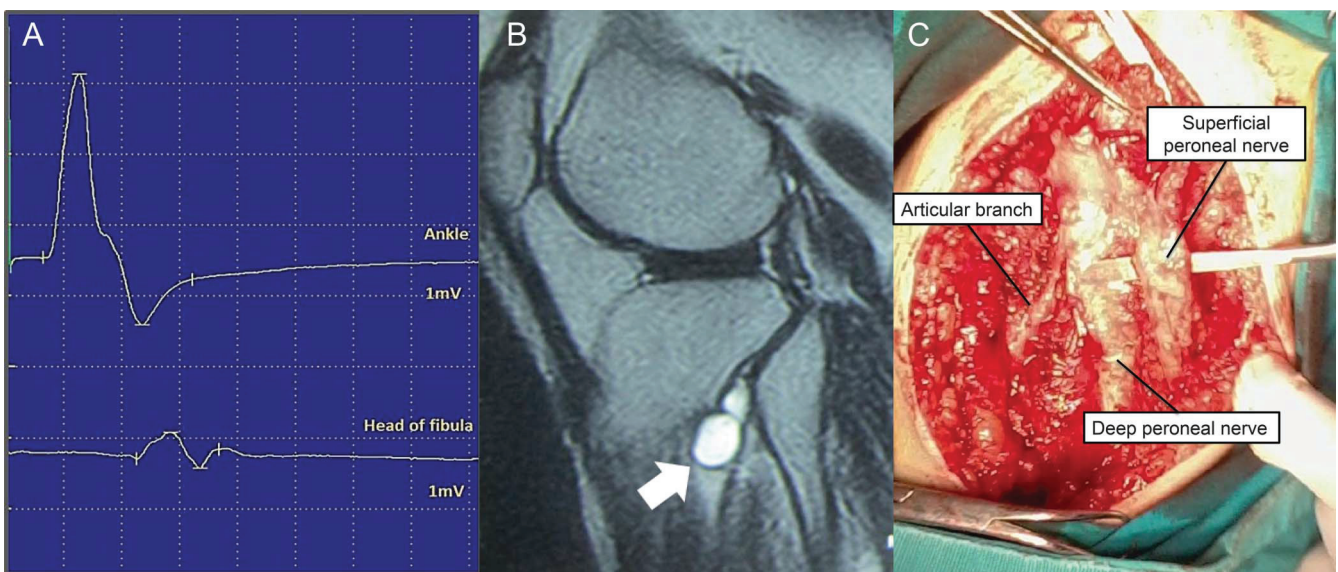
proximal vs distal stimulation exceeding 50% with minimal temporal dispersion (i.e., increase of CMAP duration by 30% or less).³ CB is considered the result of focal demyelination leading to failure of impulse propagation along the affected region.⁴

The distribution of sensory disturbances and the results of electrodiagnostic testing confirm that both the superficial and the deep branch of the common fibular nerve are involved. In addition, the reduction of the superficial fibular nerve SNAP amplitude on the affected side shows that apart from the localized demyelination documented from the motor study, axonal loss is also present. Accordingly, right fibular nerve distal CMAP amplitude is relatively reduced and denervation potentials are observed on the EMG. The latter are usually detected 2–3 weeks after nerve injury; hence axonal damage most likely was already present prior to the appearance of symptoms.

Our patient demonstrated reduced recruitment of normal-appearing MUAPs, a finding associated with subacute axonal and pure demyelinating lesions. Conversely, in chronic neuropathic disease, reinnervation of damaged muscle tissue from sprouting of surviving axons presents as polyphasic MUAPs with increased duration and amplitude. Normal tibial and sural studies, as well as the lack of denervation in nonfibular innervated muscles, rule out a coexisting lumbosacral plexopathy or L5 radiculopathy.

Considering there was no history of trauma or compression at the fibular neck, other disorders that are

Figure Electrodiagnostic testing, imaging, and intraoperative photograph



(A) Right fibular motor conduction study to the extensor digitorum brevis. Stimulation at the neck of the fibula produces a low-amplitude CMAP indicative of conduction block. (B) MRI sagittal T2-weighted image shows a high signal intensity lesion in the region of the proximal tibiofibular joint located along the anatomical course of the deep and superficial peroneal nerves (arrow). (C) Intraoperative photograph shows dilation of the proximal portion of the deep fibular nerve extending to the distal common peroneal nerve and the superficial fibular nerve. The articular branch is noted stemming from the proximal deep fibular nerve.

associated with mononeuropathies should be excluded. Complete blood count, erythrocyte sedimentation rate, fasting blood glucose levels, and hepatic and renal function tests were normal. Testing for antinuclear antibodies, antineutrophil cytoplasmic antibodies, antibodies against double-stranded DNA, anti-Sm antibody, Ro antigen, La antigen, and rheumatoid factor was negative. Serum protein electrophoresis and thyroid function were also normal. Serum antiganglioside antibodies (anti-GM1) were not detected.

On follow-up after 1 month, the clinical picture remained unchanged. An MRI of the right knee was performed. A lobulated cystic mass of longitudinal diameter approximately 2.5 cm, occupying the space between the proximal tibia and the fibular neck, was revealed (figure, B). It was located along the anatomical course of the deep and superficial fibular nerves. The lesion showed low to intermediate signal intensity on T1-weighted images and high signal intensity on T2-weighted images. On T1-weighted images after gadolinium administration, the mass demonstrated a cystic appearance due to peripheral enhancement. These features were consistent with an intraneural ganglion cyst.

Surgical decompression was performed. An incision posterior to the fibular neck dissected the underlying fascia. Proximal enlargement of the deep fibular nerve (DFN) was revealed extending to the bifurcation of the common fibular nerve and the superficial fibular nerve (figure, C). An articular branch that emerged from the proximal DFN towards the proximal tibiofibular joint was recognized. The epineurium was incised and the content of the ganglion cyst consisting of jelly-like mucous material was removed. The articular branch was transected and ligated. Postoperatively the patient displayed significant improvement and several weeks afterwards only minor weakness of foot dorsiflexion remained. After 1 year, her condition remains stable without recurrence of symptoms.

DISCUSSION Intraneural ganglia are benign fluid-containing cystic masses most commonly found in the fibular nerve near the superior tibiofibular joint.^{5,6} However, they may arise in other sites, causing compression of peripheral nerves such as the median nerve at the carpal tunnel or the ulnar nerve at Guyon's canal.⁷ Patients usually seek medical attention due to weakness or sensory symptoms in the distribution of the affected nerve. A palpable mass is often noted in the region occasionally accompanied by local pain. A positive Tinel sign is usually present. Our case featured acute onset of symptoms during physical activity, which is rarely described in previous reports.⁸

There are 2 leading pathogenetic theories. The degenerative theory advocates that connective tissue

degradation of the epineurium or the perineurium is the key process leading to cyst formation. Alternatively, the articular theory posits that fibular ganglia formation is the result of cystic fluid migration from the superior tibiofibular joint through the articular branch.⁹ The inciting event is the development of a capsular defect in the knee or the superior tibiofibular joint as a result of trauma or other disorders that is followed by cystic enlargement of the articular branch. Fibers of the DFN closest to the junction with the articular branch are initially affected. At later stages, proximal expansion may lead to involvement of the superficial peroneal nerve or even the sciatic nerve. Further support to the articular theory is the identification of a pathologic articular branch stemming from a nearby joint in cases of intraneural ganglia located in other nerves, such as the tibial and the median nerve.

Consequently, the persistent pathologic communication between the superior tibiofibular joint and the fibular nerve needs to be addressed in order to avoid postoperative recurrences. Previous studies have shown that ligation of the articular branch is a crucial determinant of outcome.¹⁰

Clinicians should retain a high index of suspicion for intraneural ganglion cysts in atypical cases of fibular neuropathy, even if local pain or swelling in the region of the knee are absent. Long-term success of surgical treatment relies to a great extent on performing careful ligation of the pathologic articular branch, thereby eliminating the underlying pathogenetic mechanism.

AUTHOR CONTRIBUTIONS

Dr. Rallis: outline of original manuscript, elaboration of clinical localization, differential diagnosis, revision of final draft. Dr. Skafta: electrodiagnostic testing, literature search, analysis of case discussion. Dr. Alexopoulos, Dr. Petsanas: design and implementation of surgical approach. Dr. Foteinos: interpretation of imaging studies. Dr. Katsoulakou: diagnostic evaluation, clinical follow-up. Dr. Koutra: review of neurophysiologic study, supervision of clinical care.

STUDY FUNDING

No targeted funding reported.

DISCLOSURE

The authors report no disclosures relevant to the manuscript. Go to Neurology.org for full disclosures.

REFERENCES

1. Westhout FD, Paré LS, Linskey ME. Central causes of foot drop: rare and underappreciated differential diagnosis. *J Spinal Cord Med* 2007;30:62–66.
2. Van den Bergh FR, Vanhoenacker FM, De Smet E, Huyse W, Verstraete KL. Peroneal nerve: normal anatomy and pathologic findings on routine MRI of the knee. *Insights Imaging* 2013;4:287–299.
3. American Association of Electrodiagnostic Medicine, Olney RK. Guidelines in electrodiagnostic medicine:

- consensus criteria for the diagnosis of partial conduction block. *Muscle Nerve Suppl* 1999;8:S225–S229.
4. Feasby TE, Brown WF, Gilbert JJ, Hahn AF. The pathological basis of conduction block in human neuropathies. *J Neurol Neurosurg Psychiatry* 1985; 48:239–244.
 5. Greer-Bayramoglu RJ, Nimigan AS, Gan BS. Compression neuropathy of the peroneal nerve secondary to a ganglion cyst. *Can J Plast Surg* 2008;16:181–183.
 6. Luigetti M, Sabatelli M, Montano N, Cianfoni A, Fernandez E, Lo Monaco M. Teaching *NeuroImages*: peroneal intraneural ganglion cyst: a rare cause of drop foot in a child. *Neurology* 2012;78:e46–e47.
 7. Dailiana ZH, Bougioukli S, Varitimidis S, et al. Tumors and tumor-like lesions mimicking carpal tunnel syndrome. *Arch Orthop Trauma Surg* 2014;134:139–144.
 8. Rubin DI, Nottmeier E, Blasser KE, Peterson JJ, Kennelly K. Acute onset of deep peroneal neuropathy during a golf game resulting from a ganglion cyst. *J Clin Neuromuscul Dis* 2004;6:49–53.
 9. Spinner R, Atkinson J, Tiel R. Peroneal intraneural ganglia: the importance of the articular branch: a unifying theory. *J Neurosurg* 2003;99:330–343.
 10. Spinner RJ, Atkinson JL, Scheithauer BW, et al. Peroneal intraneural ganglia: the importance of the articular branch: clinical series. *J Neurosurg* 2003;99:319–329.

Clinical Reasoning: A 38-year-old woman with childhood-onset weakness

Partha S. Ghosh, MD
Margherita Milone, MD,
PhD

Correspondence to
Dr. Ghosh:
ghosh.partha@mayo.edu

SECTION 1

A 38-year-old woman presented to the neuromuscular clinic for evaluation of progressive muscle weakness. She was born full-term and had normal early developmental milestones. In elementary school she had difficulty with hop-skip and keeping up with her peers. At age 10 years, she was noted to be unable to fully extend her elbows and was walking on toes. In college, she manifested slowly progressive lower limb weakness resulting in difficulty climbing stairs. She would fatigue easily after walking short distances. Subsequently, she developed difficulty lifting objects. At age 31, she delivered a healthy full-term boy uneventfully. She did not have visual symptoms, ptosis, facial weakness, dysarthria, or paresthesias. She developed dysphagia for solids and dyspnea on exertion 3–4 years before presentation. Her medical history includes hypothyroidism and Achilles tendon release. There is no history of parental consanguinity; her parents,

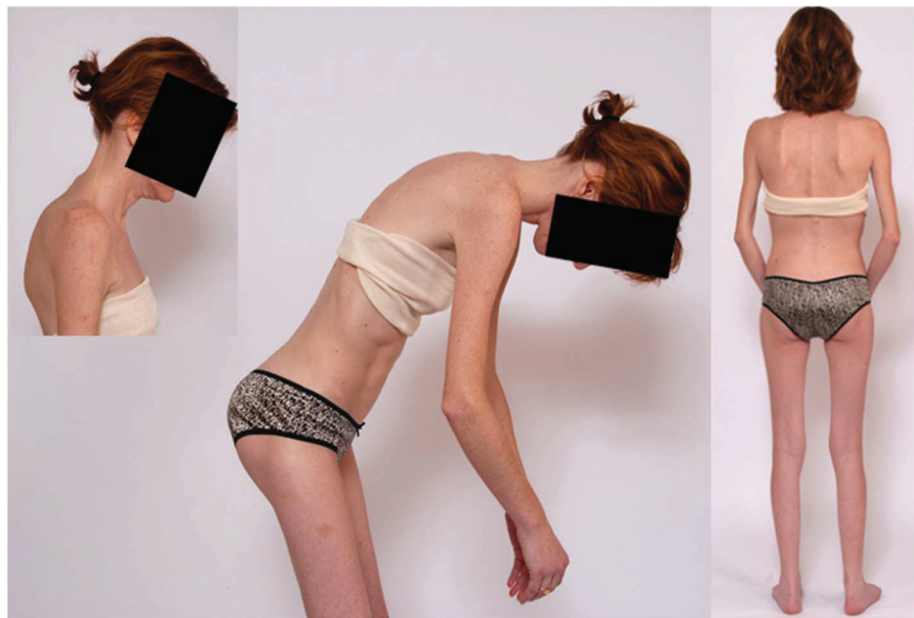2 siblings, and the 7-year-old son had no muscle weakness. Her examination revealed generalized muscle atrophy and no fasciculations or action/percussion myotonia. She had mild facial weakness (Medical Research Council [MRC] grade 4), moderate neck flexor muscle weakness (MRC grade 3), and moderate to severe symmetric proximal (MRC grade 2–3) and mild distal limb weakness (MRC grade 4). Tendon reflexes were absent; sensory examination was normal for all modalities. She had a waddling gait, elbow and ankle contractures, and rigid spine (figure 1). There was no distal joint hyperlaxity or skin rash. Previously performed genetic test for survival motor neuron protein (*SMN1*) was negative.

Questions for consideration:

1. What is the differential diagnosis to this point?
2. What testing would be helpful to narrow the differential?

[GO TO SECTION 2](#)

Figure 1 Patient photograph



Photograph shows diffuse muscle atrophy, elbow contractures, and limited ability to flex neck and trunk.

Supplemental data
at [Neurology.org](#)

From the Department of Neurology, Mayo Clinic, Rochester, MN.

Go to [Neurology.org](#) for full disclosures. Funding information and disclosures deemed relevant by the authors, if any, are provided at the end of the article.

SECTION 2

This patient presented with childhood onset of symmetrical progressive predominantly proximal weakness in the absence of sensory changes and autonomic symptoms. The localization in her case could involve anterior horn cells, motor nerve roots, neuromuscular junction, and muscles. Given the childhood onset of symptoms, acquired disorders are unlikely (inflammatory or infiltrative polyradiculoneuropathies, autoimmune disorders of the neuromuscular transmission such as myasthenia gravis or Lambert-Eaton myasthenic syndrome, inflammatory myopathies). An inherited neuromuscular disease is likely. The lack of affected family members does not exclude the genetic etiology of the disease.

Serum creatine kinase (CK) values were mildly elevated (271–300 U/L; normal <176 U/L). EMG showed myopathic motor unit potentials and sparse

fibrillation potentials in the proximal limb and thoracic paraspinal muscles. Sensory and motor nerve conduction studies and repetitive nerve stimulations at 2 Hz were normal. Muscle biopsy of the quadriceps (performed previously and reviewed at our institute) showed increased number of fibers harboring single or multiple internal nuclei, fiber splitting, and increased endomysial connective tissue. The above information helped to rule out neurogenic processes, such as disorders of the anterior horn cells, and neuromuscular junction transmission defects, such as congenital myasthenic syndromes.

Questions for consideration:

1. Based on these findings, what is the differential diagnosis?
2. What testing would you perform to clarify the diagnosis?

GO TO SECTION 3

SECTION 3

The clinical history and neurologic findings, elevated CK values, and EMG findings point to a myopathic process. The pattern of the weakness points to a limb-girdle phenotype. The differential is broad and includes various forms of limb-girdle myopathies, such as limb-girdle muscular dystrophies (LGMD type 1 and 2), congenital muscular dystrophies, and congenital myopathies. The additional clinical clues that help narrow the differential diagnosis in this case were the early onset of elbow contractures and the rigid spine. Myopathies that can present with early-onset elbow contractures include Emery-Dreifuss muscular dystrophy (EDMD)¹ and collagen type VI–related myopathies (Ullrich and Bethlem myopathy).² EDMD phenotype can develop from mutations in 6 different genes with an X-linked recessive inheritance (mutation in emerin, *EMD*; and four and a half LIM domain protein 1, *FHL1*) and autosomal dominant inheritance (mutations in lamin A/C, *LMNA*; nesprin-1, *SYNE1*; nesprin-2, *SYNE2*; transmembrane protein 43, *TMEM43*).¹ Rigid spine syndrome (RSS) is a neuromuscular phenotype characterized by marked limitation in flexion of the cervical and dorsolumbar spine.³ RSS can be the predominant clinical feature of a number of myopathies, most prominent being various forms of EDMD,¹ various forms of congenital myopathies, in particular myopathies due to mutations in selenoprotein N (*SEPN1*),⁴ collagen type VI–related myopathy,² and very rarely in Pompe disease.⁵ Our patient lacked distal joint hyperlaxity, follicular hyperkeratosis, and abnormal skin scarring, which are characteristic of collagen type VI–related myopathies.

The patient's cardiac workup included an EKG that showed normal sinus rhythm, first-degree A-V block, and nonspecific intraventricular conduction delay. Holter monitoring identified 2 brief episodes of atrial fibrillation lasting less than 1 minute, while echocardiogram revealed no evidence for cardiomyopathy. Biopsy of the deltoid muscle showed nonspecific active and chronic myopathic changes (figure e-1 on the *Neurology*[®] Web site at Neurology.org). There were no vacuolar changes or other structural abnormalities suggestive of any specific congenital myopathy (nemaline rods, cores, mini-cores, fiber type disproportion, or radial distribution of the myofibrils in association with the internalized nuclei). Immunoreactivity for 2 epitopes of collagen VI and laminin B1 were preserved, pointing away from, although pathologically not excluding, a collagen VI myopathy. Video swallow demonstrated mild oropharyngeal dysphagia. Pulmonary function tests showed reduced maximal respiratory pressures (27%–30% predicted) and overnight oximetry showed intermittent oxygen desaturation up to 70%.

Based on clinical phenotype, sex, and cardiac rhythm disturbances, genetic testing for EDMD due to lamin A/C mutation was recommended, but declined by the

patient. Two years later, she had a left middle cerebral artery cardioembolic ischemic stroke and was found to be in atrial fibrillation. She underwent pacemaker placement. At that point, she was referred back to our clinic for additional investigations. *LMNA* sequencing (performed by a commercial laboratory) revealed a novel heterozygous variant c.811_819del9ins3. This variant is predicted to result in an in-frame alteration, consisting of deletion of 3 amino acids and insertion of a missense amino acid (p.Leu271_Asn273delinsThr). The amino acids affected by this deletion in the lamin A protein are all evolutionary conserved across species from human to chimp, nonprimate mammals, chicken, frog, and zebrafish. The novel *LMNA* mutation has not been detected in more than 500 control subjects. In addition, a previously reported missense mutation, p.Leu271Pro (c. c.812T>C), located in the region deleted in our patient, was observed in identical twin brothers with autosomal dominant Emery-Dreifuss muscular dystrophy and cardiomyopathy.⁶ These observations support the pathogenicity of the novel *LMNA* mutation found in our patient.

DISCUSSION Our patient was diagnosed with autosomal dominant EDMD due to lamin A/C mutation. The lamin A and C proteins are intermediate filament proteins of the internal nuclear lamina and derive from alternate splicing of the *LMNA* gene.⁷ Mutations in the *LMNA* gene result in a broad spectrum of phenotypes affecting multiple tissues, including muscle. The *LMNA* myopathy can be phenotypically heterogeneous, manifesting as (1) autosomal dominant EDMD2, characterized by childhood onset of elbow, posterior cervical, and ankle contractures and progressive humeroperoneal weakness; (2) autosomal dominant LGMD1B; and (3) congenital muscular dystrophy (MDCL), characterized by progressive generalized weakness, dropped head, and early contractures.⁸ In addition, *LMNA* mutations can cause dilated cardiomyopathy with conduction system defects, axonal peripheral neuropathy (CMT2B1), progeroid syndromes with systemic involvement, mandibuloacral dysplasia, and insulin resistance with lipodystrophy.⁷

Early diagnosis of *LMNA*-related muscular dystrophy can be challenging.⁸ Neck extensor involvement is a common clinical finding, presenting either as dropped head in those with early-onset disease or as cervical contractures or significant weakness in those with EDMD and LGMD phenotypes. Elbow contractures are early diagnostic clues in patients with EDMD phenotypes (as noted in our patient) but in patients with MDCL and LGMD they usually appear late in the disease course.⁸ Muscle histopathologic findings in these disorders range from mild nonspecific myopathic changes to severe myopathic changes suggestive of muscular dystrophy. Therefore, clinical suspicion

for the disease should lead to *LMNA* testing, despite the subtle pathologic findings.

Cardiac manifestations in laminopathies range from rhythm and conduction defects, including atrial and ventricular arrhythmias, to dilated cardiomyopathy.⁹ Sudden death is the most frequently reported mode of death (46%) in both cardiac and neuromuscular phenotypes.⁹ Implantable cardioverter defibrillator (ICD) implantation is often effective in preventing lethal tachyarrhythmias.¹⁰ Pacemakers alone are not sufficient in preventing sudden death because of the ventricular arrhythmias. Therefore, early diagnosis of laminopathy is essential for proper treatment and prevention of fatal complications. Our patient received anticoagulation therapy and underwent pacemaker and ICD placement after she had a cerebral ischemic infarct and was found to be in atrial fibrillation. An earlier molecular diagnosis would have resulted in a closer cardiac follow-up and more aggressive cardiac care, which may or may have not prevented the cerebral stroke.

Because of the risk of potentially lethal cardiac complications, there should be a low threshold for *LMNA* sequencing in patients with undiagnosed congenital muscular dystrophy having neck extensor weakness and in patients with undiagnosed LGMD and nonspecific myopathic features.⁸ Monitoring of the respiratory status (sometimes requiring noninvasive ventilation, which our patient had) and scoliosis are also important in the management of these patients. Genetic counseling and cardiac evaluation are important for family members due to the risk of fatal cardiac arrhythmias even in asymptomatic individuals.

AUTHOR CONTRIBUTIONS

Dr. Ghosh: drafting/revising the manuscript, study concept or design, analysis or interpretation of data, accepts responsibility for conduct of research and final approval, acquisition of data. Dr. Milone: drafting/revising the manuscript, study concept or design, analysis or interpretation of data, accepts responsibility for conduct of research and final approval, acquisition of data, study supervision.

ACKNOWLEDGMENT

The authors thank Dr. Thomas Winder at PreventionGenetics for performing the *LMNA* gene analysis and for providing the data on controls.

STUDY FUNDING

No targeted funding reported.

DISCLOSURE

The authors report no disclosures relevant to the manuscript. Go to Neurology.org for full disclosures.

REFERENCES

1. Wicklund MP. The muscular dystrophies. *Continuum* 2013;19:1535–1570.
2. Iannaccone ST, Castro D. Congenital muscular dystrophies and congenital myopathies. *Continuum* 2013;19:1509–1534.
3. Dubowitz V. Rigid spine syndrome: a muscle syndrome in search of a name. *Proc R Soc Med* 1973;66:219–220.
4. Moghadaszadeh B, Petit N, Jaillard C, et al. Mutations in *SEPN1* cause congenital muscular dystrophy with spinal rigidity and restrictive respiratory syndrome. *Nat Genet* 2001;29:17–18.
5. Fadic R, Waclawik AJ, Brooks BR, Lotz BP. The rigid spine syndrome due to acid maltase deficiency. *Muscle Nerve* 1997;20:364–366.
6. Kichuk Chrisant MR, Drummond-Webb J, Hollowell S, Friedman NR. Cardiac transplantation in twins with autosomal dominant Emery-Dreifuss muscular dystrophy. *J Heart Lung Transpl* 2004;23:496–498.
7. Broers JL, Ramaekers FC, Bonne G, Yaou RB, Hutchison CJ. Nuclear lamins: laminopathies and their role in premature ageing. *Physiol Rev* 2006;86:967–1008.
8. Menezes MP, Waddell LB, Evesson FJ, et al. Importance and challenge of making an early diagnosis in *LMNA*-related muscular dystrophy. *Neurology* 2012;78:1258–1263.
9. van Berlo JH, de Voogt WG, van der Kooij AJ, et al. Metaanalysis of clinical characteristics of 299 carriers of *LMNA* gene mutations: do lamin A/C mutations portend a high risk of sudden death? *J Mol Med* 2005;83:79–83.
10. Meune C, van Berlo JH, Anselme F, Bonne G, Pinto YM, Duboc D. Primary prevention of sudden death in patients with lamin A/C gene mutations. *N Engl J Med* 2006;354:209–210.

Clinical Reasoning: A 70-year-old man with walking difficulties

Fieke M. Cox, MD
Jan J.G.M. Verschuuren,
MD, PhD
Umesh A. Badrising,
MD, PhD

Address correspondence and
reprint requests to Dr. Fieke M.
Cox, Leiden University Medical
Center, Department of
Neurology, PO Box 9600, 2300
RC, Leiden, the Netherlands
f.cox@lumc.nl

SECTION 1

A 70-year-old man presented with progressive gait unsteadiness for 5 years. He also had to use his arms to climb stairs or to get up from a chair. He reported no pain, sensory symptoms, or fatigue. He had pulmonary sarcoidosis at age 24 years, which remained in remission after treatment with corticotropin and prednisone. There was no family history of autoimmune or muscle diseases.

Clinical examination showed 4/5 strength of the iliopsoas and quadriceps muscles and slight weakness of

the biceps brachii muscles. The results of gait examination, including stance, stride, posture and arm swing, were normal. Toe and heel walking were normal, but the patient was unable to squat. The Romberg sign was negative. Ankle tendon reflexes were absent. The rest of the results of the neurologic examination, particularly the sensory examination, were normal.

Questions for consideration:

1. What is the cause of the walking difficulty?
2. What is the differential diagnosis?

[GO TO SECTION 2](#)

From the Department of Neurology, Leiden University Medical Center, the Netherlands.

Disclosure: Author disclosures are provided at the end of the article.

SECTION 2

Because there was no impairment in the sensory, cerebellar, or extrapyramidal systems, the walking difficulty was most likely due to the proximal leg muscle weakness, which also explains why the patient used his arms when climbing stairs and rising up from a chair. A pure motor disorder in an elderly patient could be secondary to a motor neuron disorder (MND), pure motor neuropathy, neuromuscular junction (NMJ) dysfunction, or myopathy. An acquired MND typically presents with asymmetric distal limb weakness. Hereditary spinal muscular atrophy is characterized by proximal muscle weakness but usually presents at an earlier age. Multifocal motor neuropathy (MMN) with conduction block starts at age 30 to 50 years and usually presents with distal more than proximal weakness of the arms more than the legs. Lambert-Eaton myasthenic syndrome (LEMS), a rare but treatable NMJ disorder, usually presents with proximal leg weakness, low or absent tendon reflexes, and autonomic dysfunction.

Myopathies could be toxic, such as those associated with alcohol, steroid, or statins; metabolic, such

as thyroid myopathy and Pompe disease; or inflammatory. Inflammatory myopathies include polymyositis (PM), inclusion body myositis (IBM), and sarcoid myopathy. In rare cases, genetically determined dystrophinopathies are the cause of limb-girdle weakness at this age. For example, Becker muscular dystrophy (BMD) can present with late-onset limb-girdle weakness. Furthermore, limb-girdle muscular dystrophies (LGMDs) can be considered, although onset of symptoms at older age is rare. A negative family history, as is the case in this patient, could suggest an autosomal recessive LGMD or a new mutation. The level of the serum creatine kinase (CK) is often very high in the recessive form of LGMD, whereas in its autosomal dominant form, the CK is normal or moderately increased.

The prevalence of these disorders at older age and the presence of an associated autoimmune disorder should be considered.

Questions for consideration:

1. Which investigations are at your disposal?
2. Which would you use and in what order?

GO TO SECTION 3

SECTION 3

The next step is to further differentiate between MND, MMN, LEMS, or a myopathy.

CK levels are high in dystrophinopathies, Pompe disease, and thyroid dysfunction but are usually normal in MND, MMN, LEMS, steroid myopathy, and IBM. Thyrotropin testing helps to indicate thyroid myopathy. Anti-voltage-gated P/Q-type calcium channel (VGCC) serum antibodies are specific for LEMS. Alpha-glucosidase level and DNA testing of the dystrophin gene are optional in Pompe disease and BMD.

Electrophysiologic studies would help to differentiate between MND, MMN, LEMS, and myopathy. A muscle biopsy of an affected muscle may suggest the type of myopathy.

In our patient, thyrotropin and CK levels were normal. Nerve conduction studies were normal and

did not show conduction block. Needle electromyography of the left rectus femoris muscle showed no abnormalities. The soleus muscle showed spontaneous muscle fiber activity with high-amplitude, polyphasic motor unit action potentials (MUAPs), more compatible with an axonal neuropathy than with a myopathy. Repetitive nerve stimulation was normal, making LEMS improbable.¹ Anti-VGCC antibodies were not tested. Biopsy of a symptomatic anterior tibial muscle showed nonspecific myopathic changes. DNA testing for BMD showed no deletion or duplication in the dystrophin gene.

Questions for consideration:

1. What is the most likely diagnosis, and does the clinical course help you in the diagnostic process?
2. What would be your therapeutic advice?

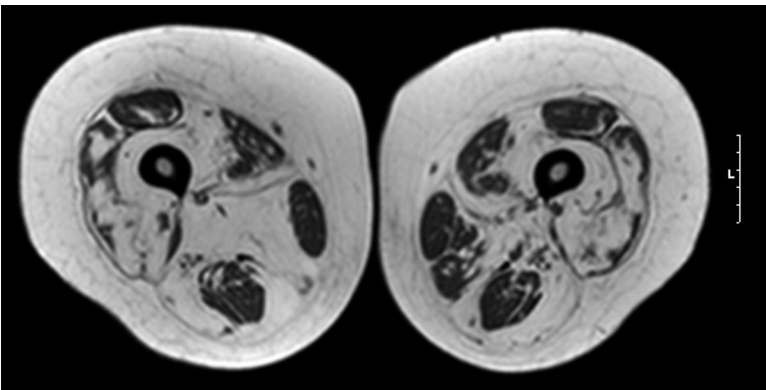
GO TO SECTION 4

SECTION 4

This patient has a slowly progressive pure motor disorder with myopathic and neurogenic aspects. MMN, LEMS, metabolic myopathies, LGMD, and BMD are unlikely as discussed above. Steroid myopathy was also unlikely, because the prednisone was stopped several years previously.² The lack of muscle inflammation on the biopsy and the normal CK rule out PM and sarcoid myopathy. MND and IBM remain possible, IBM being the more likely based on the slow clinical course, autoimmune-prone history, absence of fasciculations, absence of neuropathic features in the muscle biopsy, and the knowledge that in IBM, the EMG may show a neurogenic process and that the muscle biopsy can be negative. Because pharmacotherapeutic options were lacking, the patient was followed up. Over the following years, his muscle weakness progressed and spread to the distal legs and finger flexor of 2 digits of his right hand. Three years later, the patient was partially wheelchair bound. He reported difficulties with swallowing solid foods but did not develop fasciculations, cramps, or pyramidal tract signs.

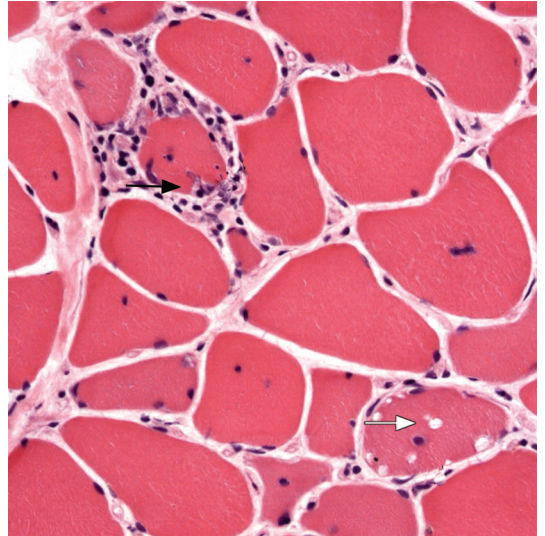
The clinical picture of an elderly patient presenting with slowly progressive, painless proximal leg and finger flexor weakness with dysphagia suggests IBM. A second biopsy of the vastus lateralis muscle showed only fat. A muscle MRI was performed, after 2 negative muscle biopsies, to select an appropriate muscle for a third muscle biopsy³ and to investigate whether a specific pattern of muscle involvement could be detected, which could be helpful in the diagnostic process. The MRI of the muscles showed extensive fatty infiltration of the shoulder, limb-girdle, and leg musculature (figure 1). Muscles in the legs not showing fatty infiltration had a high signal on short-

Figure 1 MRI of the proximal femur



Axial T1-weighted image of the proximal femur of both legs shows fatty infiltration and atrophy of the quadriceps femoris, hamstrings, and adductor muscles. The gracilis muscle is relatively normal, with only minor fatty infiltration. There is asymmetric involvement of the adductor muscles, more pronounced on the right side.

Figure 2 Muscle biopsy



Muscle biopsy in hematoxylin & eosin stain, showing the rimmed vacuoles (white arrow) and invasion of lymphocytes in nonnecrotic muscle fibers (black arrow).

inversion time inversion recovery, indicative of inflammation.

The third biopsy of the anterior tibial muscle showed myopathic changes including mononuclear inflammatory infiltrates with invasion of nonnecrotic fibers and rimmed vacuoles, supporting the diagnosis of IBM (figure 2).

DISCUSSION IBM is an idiopathic inflammatory myopathy with an onset after age 40 years and a male predominance. Although the prevalence is low (5 to 10 patients per million inhabitants), it is considered one of the most frequently acquired myopathies in the elderly. Most patients present with weakness of quadriceps muscles or finger flexors or dysphagia. The onset is insidious, and the course is slowly progressive, painless, and mostly asymmetric.⁴ Diagnosis can be confirmed by the presence of rimmed vacuoles in the muscle biopsy in combination with invasion of lymphocytes in nonnecrotic muscle fibers and interstitial infiltrates. Some criteria also require positive amyloid staining or 16- to 20-nm tubulofilaments on electromicroscopy.⁵

Initially, slight quadriceps weakness can be missed or ascribed to age, leading to diagnostic delay. Important clues for quadriceps weakness are difficulties when climbing stairs, repetitive falls on the knees, and difficulty with rising from a chair.

Diagnostic pitfalls lead to further delay. Electromyography can be misleading because it might suggest a neurogenic origin (in one third of the IBM patients, large polyphasic MUAPs can be demonstrated). It is not unusual for patients with clinically

defined IBM to lack the canonical histologic features of IBM.⁶ This can be because the rimmed vacuoles seem to be more prominent in a later stage of the disease or due to the patchy nature of the histologic abnormalities.⁷ Therefore, after a negative muscle biopsy, additional biopsies may be needed to get confirmation. This case illustrates that the clinical picture was diagnostically more helpful than the histopathologic criteria.

The pathogenesis of IBM remains enigmatic, but there are clues suggesting an autoimmune and degenerative pathway.^{8,9} IBM is associated with other autoimmune disorders. No effective drug therapy is currently available.

DISCLOSURE

Dr. Cox reports no disclosures. Dr. Verschuuren has received research support from Prosensa and the Princess Beatrix Foundation. Dr. Badrising reports no disclosures.

Received January 28, 2010. Accepted in final form July 19, 2010.

REFERENCES

1. AAEM Quality Assurance Committee, American Association of Electrodiagnostic Medicine. Literature review of the usefulness of repetitive nerve stimulation and single

- fiber EMG in the electrodiagnostic evaluation of patients with suspected myasthenia gravis or Lambert-Eaton myasthenic syndrome. *Muscle Nerve* 2001;24:1239–1247.
2. Owczarek J, Jasinska M, Orszulak-Michalak D. Drug-induced myopathies: an overview of the possible mechanisms. *Pharmacol Rep* 2005;57:23–34.
3. Walker UA. Imaging tools for the clinical assessment of idiopathic inflammatory myositis. *Curr Opin Rheumatol* 2008;20:656–661.
4. Badrising UA, Maat-Schieman ML, van Houwelingen JC, et al. Inclusion body myositis: clinical features and clinical course of the disease in 64 patients. *J Neurol* 2005;252:1448–1454.
5. Griggs RC, Askanas V, DiMauro S, et al. Inclusion body myositis and myopathies. *Ann Neurol* 1995;38:705–713.
6. Chahin N, Engel AG. Correlation of muscle biopsy, clinical course, and outcome in PM and sporadic IBM. *Neurology* 2008;70:418–424.
7. Amato AA, Gronseth GS, Jackson CE, et al. Inclusion body myositis: clinical and pathological boundaries. *Ann Neurol* 1996;40:581–586.
8. Askanas V, Engel WK. Inclusion-body myositis: a myodegenerative conformational disorder associated with Abeta, protein misfolding, and proteasome inhibition. *Neurology* 2006;66:S39–S48.
9. Dalakas MC. Inflammatory, immune, and viral aspects of inclusion-body myositis. *Neurology* 2006;66:S33–S38.



Clinical Reasoning: A 47-year-old man with progressive gait disturbance and stiffness in his legs

Ariadna Fontes-Villalba,
MD*
Jose-Alberto Palma, MD*
Maria A. Fernández-Seara,
PhD
Maria A. Pastor, MD,
PhD
Purificacion de Castro,
MD, PhD

Correspondence to
Dr. Fontes-Villalba:
afontes@unav.es

SECTION 1

A 47-year-old man presented with a 5-year history of slowly progressive gait disorder with clumsiness and unsteadiness during walking, as well as stiffness and cramping pain in his legs. He also had erectile dysfunction and nocturia. He denied sensory deficits and other focal neurologic or systemic symptoms. He had a medical history of hypogonadism, diagnosed 1 year before the onset of the gait disorder, attributed to a bilateral orchiectomy due to a testicular tumor, performed elsewhere when he was 37. He was receiving IM testosterone injections every 3 weeks. His family medical history included pes cavus in his mother and siblings, otherwise unremarkable.

Neurologic examination revealed a wide-based spastic gait with positive Romberg sign. Cognition and cranial nerve examination were normal. Strength was 4/5 in both iliopsoas, and 4+/5 in the remaining muscles of the lower limbs, with increased muscle tone. Deep tendon reflexes (DTR) were very brisk, with bilateral Achilles clonus, and bilateral Babinski signs. Vibration sensation was decreased in lower limbs, and joint position sense was lost in the toes. The rest of the examination was normal.

Questions for consideration:

1. What is the syndromic diagnosis?
2. What is the differential diagnosis at this stage?

[GO TO SECTION 2](#)

*These authors contributed equally to this work.

From the Department of Neurology (A.F.-V., J.-A.P., M.A.P., P.d.C.), University Clinic of Navarra; and Neuroimaging Laboratory (M.A.F.-S., M.A.P.), Neurosciences Area, Centro de Investigación Médica Aplicada (CIMA), University of Navarra, Pamplona, Spain.

Go to Neurology.org for full disclosures. Funding information and disclosures deemed relevant by the authors, if any, are provided at the end of the article.

SECTION 2

The pattern of weakness and gait disturbance is consistent with a chronic spastic paraparesis syndrome, beginning in the adulthood, and progressing steadily. The syndrome includes upper motor neuron signs (increased muscle tone, hyperactive DTR, and Babinski signs) and deep sensory disturbances (sensory ataxia) probably involving the dorsal ascending columns. The involvement of sensory peripheral nerves is unlikely because of the hyperactive DTR. Therefore, the signs and symptoms suggest a disease of the spinal cord. Although infrequent, bilateral damage of the frontoparietal cortex (e.g., parasagittal meningioma) may cause a slowly progressive spastic paraparesis syndrome with sensory symptoms and sphincter disturbances.

A syndrome of this type may be indicative of hereditary spinocerebellar degeneration (Friedrich ataxia) or

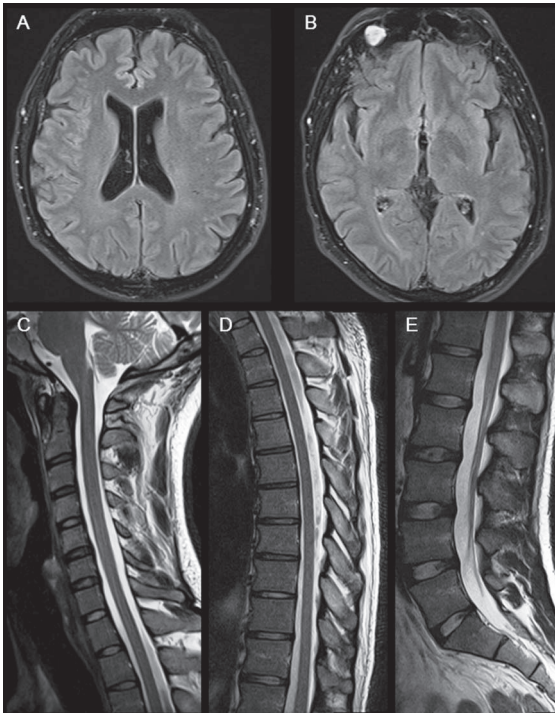
one of its variants.¹ In young adults, progressive multiple sclerosis (MS) is a common cause. In middle and late adult life, a slow compression of the spinal cord by spondylosis is a frequent cause of myelopathy. Subacute combined degeneration (vitamin B₁₂ or copper deficiency), spinal arachnoiditis, spinal arteriovenous shunts, and spinal tumors, particularly meningioma, are important diagnostic considerations. Infections, such as AIDS, tropical spastic paraparesis, syphilis, and Lyme disease, may also cause myelitis. Less common causes include hereditary spastic paraparesis (HSP), adrenomyeloneuropathy (AMN), and primary lateral sclerosis (PLS), although the sensory signs would be atypical for this condition.²

Question for consideration:

1. Which diagnostic studies should be performed?

GO TO SECTION 3

Figure 1 Brain MRI fluid-attenuated inversion recovery images



Images show no white matter lesions or other abnormalities (A), except for an incidental right frontal mucocele (B). Spinal T1-weighted sagittal MRI shows no atrophy or other abnormalities throughout the entire spinal cord (C–E). To check whether there existed any differences in terms of regional atrophy, a volumetric comparison with the supratentorial white matter volume of 10 healthy subjects with similar age (47.9 ± 8.3 years) with voxel-based quantitative analysis (using statistical parametrical mapping) was performed. There were no differences between the white matter volume of the controls (0.327; 95% confidence interval 0.308–0.347) and the patient (0.315).

SECTION 3

Brain and spinal MRI were normal (figure 1). Blood tests, including vitamin B₁₂, folic acid, copper, homocysteine, proteinogram, thyroid hormones, HIV, human T-cell lymphotropic virus (HTLV)–1, Venereal Disease Research Laboratory, and Lyme, were normal or negative. No mutations of *SPG4* (which comprises 40%–50% of all cases of autosomal dominant HSP³) or *frataxin* genes were found. EMG and nerve conduction studies were normal in the 4 limbs. Somatosensory evoked potentials revealed an increased latency in the central components of upper limb potentials, and altered potentials in lower limbs. Transcranial magnetic stimulation showed greater delay in the lower than the upper limbs.

Brain ¹⁸fluorodeoxyglucose PET (FDG-PET) showed bilateral hypometabolism in the paramedian frontal, anterior parietal, and temporal lobes (figure 2).

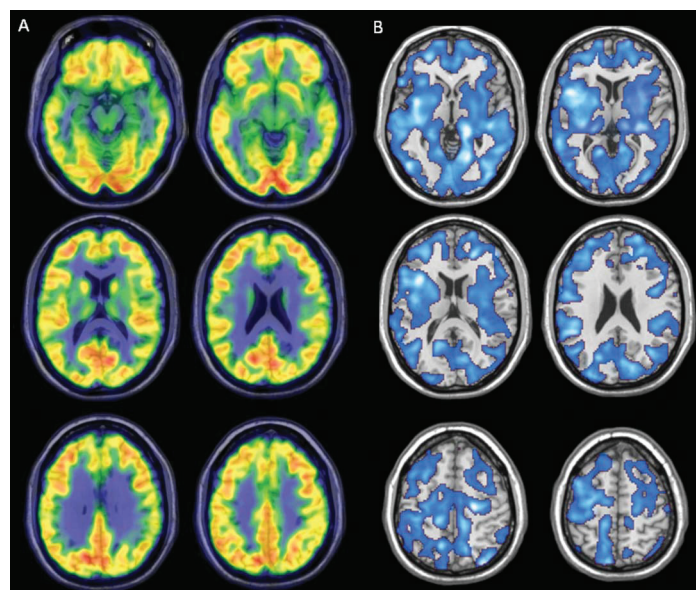
Empiric therapy with coenzyme Q (100 mg, 2 times a day) and symptomatic therapy with baclofen to reduce spasticity (10 mg, 3 times a day) and sildenafil citrate to treat erectile dysfunction were initiated.

Questions for consideration:

1. How do the results of the tests narrow the diagnosis?
2. What is the significance of the FDG-PET finding?

[GO TO SECTION 4](#)

Figure 2 Brain MRI FDG-PET image



Brain MRI-¹⁸fluorodeoxy-glucose PET fusion image, axial view (A), shows bilateral hypometabolism in the paramedian frontal, anterior parietal, and temporal lobes. (B) Comparative analysis, using statistical parametrical mapping, with the brain metabolism of 10 healthy subjects with similar age, shows a global hypometabolism, involving the cortex and the white matter ($p < 0.01$).

SECTION 4

Normal neuroimaging ruled out the possibilities of MS, spondylosis, brain and spinal tumors, and other spinal diseases such as arachnoiditis or arteriovenous shunts. In addition, blood tests ruled out B₁₂ and copper deficiency, AIDS, Lyme disease, syphilis, and HTLV-1 infection. Interestingly, B₁₂ deficiency can be present even with normal B₁₂ levels. However, the normal serum homocysteine levels and a normal mean corpuscular volume ruled out this possibility. Genetic tests ruled out Friedrich ataxia and HSP type 4. EMG and nerve conduction studies dismissed the occurrence of myopathy or polyneuropathy. Thus, other types of HSP, variants of Friedrich ataxia, PLS, and AMN remained as diagnostic possibilities.

Brain FDG-PET hypometabolism suggests diffuse brain damage, even in light of a negative MRI. This finding makes PLS (in which the typical finding is an isolated hypometabolism in the motor cortex) improbable. In patients with HSP, diffuse brain hypometabolism is not usually present.^{4,5} Although the absence of white matter lesions in brain or spinal MRI makes highly unlikely the diagnosis of AMN or other forms of adrenoleukodystrophy (ALD), several cases of MRI-negative ALD have been described.^{6,7}

At 6-month follow-up, the patient reported increasing walking difficulties and pain in his legs. He also complained of severe asthenia, dizziness with postural changes, and generalized skin hyperpigmentation. Blood tests revealed decreased cortisol basal level (3.8 µg/dL) and increased basal ACTH level (1,945 pg/mL) with negative anti-21-hydroxylase antibodies, consistent with nonautoimmune adrenal insufficiency (AI). Due to the concurrence of AI and spastic paraparesis, we suspected AMN, which was confirmed by high plasma levels of very long-chain fatty acids (VLCFA), and a mutation in the *ABCD1* gene (c.1415_1416delAG).

Question for consideration:

1. How does adrenomyeloneuropathy present and what are the main therapeutic options?

DISCUSSION ALD can be classified into 4 main categories: cerebral inflammatory, AMN, Addison-only, and asymptomatic.⁸

AMN, which is often misdiagnosed as MS, HSP, or PLS, presents in adults (second to fourth decade of life) as a slowly progressive spastic paraparesis syndrome, with sensory and sphincter disturbances, and impotence, such as the present case. AI is present in two-thirds of patients. Hypogonadism may be present as well. Although it was absent in our patient, peripheral nerve involvement is present in most cases.⁹

AMN is subdivided further into pure AMN (in which radiologic, clinical, and pathologic features are

limited to the spinal axonopathy) and AMN-cerebral (in which there is also cerebral involvement).⁸ MRI may show white matter abnormalities in brain and atrophy in the spinal cord.¹⁰ Interestingly, both findings were absent in this case. However, brain FDG-PET showing a metabolic brain dysfunction suggested an AMN-cerebral form.

Treatment includes supportive and symptomatic treatment for patient and family, with rehabilitation and social support. Adrenal hormone replacement therapy, which can be lifesaving, is mandatory in those patients with ALD and AI.⁸ We initiated treatment with hydrocortisone 30 mg/day and fludrocortisone 0.05 mg/48 hours with calcium carbonate and vitamin D to prevent osteopenia. Dietary therapy with 4:1 glyceryl trioleate–glyceryl trierucate (Lorenzo oil) was not recommended in our case because its benefit has been proven only in asymptomatic boys whose brain MRI is normal.¹¹ The utility of hematopoietic stem cell transplantation is limited in adulthood and it is not known whether it can benefit patients with AMN.⁸

This case argues for the inclusion of AMN in the differential for any progressive spastic paraparesis syndrome regardless of the brain or spinal MRI findings. Thus, we suggest that plasma levels of VLCFA be obtained in any patient with spastic paraparesis in which the initial workup for other common causes is negative, especially if endocrine disturbances such as AI coexist. Brain FDG-PET also may be helpful in the diagnosis, as it may be more sensitive than MRI for detecting metabolic brain dysfunction in ALD.

AUTHOR CONTRIBUTIONS

Drafting/revising the manuscript for content: A.F.-V., J.-A.P., P.d.C. Study concept or design: A.F.-V., J.-A.P. Analysis or interpretation of data: A.F.-V., J.-A.P., M.A.F.-S., M.A.P., P.d.C. Acquisition of data: A.F.-V., J.-A.P., M.A.F.-S., M.A.P. Study supervision: P.d.C.

STUDY FUNDING

No targeted funding reported.

DISCLOSURE

The authors report no disclosures relevant to the manuscript. Go to Neurology.org for full disclosures.

REFERENCES

1. Harding AE. Early onset cerebellar ataxia with retained tendon reflexes: a clinical and genetic study of a disorder distinct from Friedrich's ataxia. *J Neurol Neurosurg Psychiatry* 1981;44:503–508.
2. Ropper AH, Samuels MA. Syndrome of subacute or chronic spinal paraparesis with or without ataxia. In: Ropper AH, Samuels MA, eds. *Adams and Victor's Principles of Neurology*, 9th ed. New York: McGraw Hill; 2009.
3. Fink JK. The hereditary spastic paraplegias: nine genes and counting. *Arch Neurol* 2003;60:1045–1049.
4. Samaranch L, Riverol M, Masdeu JC, et al. SPG11 compound mutations in spastic paraparesis with thin corpus callosum. *Neurology* 2008;71:332–336.

5. Nielsen JE, Johnsen B, Koefoed P, et al. Hereditary spastic paraplegia with cerebellar ataxia: a complex phenotype associated with a new SPG4 gene mutation. *Eur J Neurol* 2004;11:817–824.
6. Liang JS, Lee WT, Hwu WL, et al. Adrenoleukodystrophy: clinical analysis of 9 Taiwanese children. *Acta Paediatr Taiwan* 2004;45:272–277.
7. Renard D, Castelnovo G, Collombier L, et al. Brain fludeoxyglucose F 18 positron emission tomography hypometabolism in magnetic resonance imaging-negative x-linked adrenoleukodystrophy. *Arch Neurol* 2011;68:1338–1339.
8. Moser HW, Mahmood A, Raymond GV. X-linked adrenoleukodystrophy. *Nat Clin Pract Neurol* 2007;3:140–151.
9. Berger J, Gärtner J. X-linked adrenoleukodystrophy: clinical, biochemical and pathogenetic aspects. *Biochim Biophys Acta* 2006;1763:1721–1732.
10. Israel H, Ostendorf F, Stiepani H, et al. Spinal cord atrophy in adrenomyeloneuropathy. *Arch Neurol* 2005;62:1157.
11. Moser HW, Raymond GV, Lu SE, et al. Follow-up of 89 asymptomatic patients with adrenoleukodystrophy treated with Lorenzo's oil. *Arch Neurol* 2005;62:1073–1080.

Clinical Reasoning: A 79-year-old man with polyneuropathy and dysautonomia

Chafic Karam, MD
Stephen N. Scelsa, MD

Address correspondence and reprint requests to Dr. Chafic Karam, Neuromuscular Division and ALS Center, Beth Israel Medical Center, Albert Einstein College of Medicine, Phillips Ambulatory Care Center, 10 Union Square East, Suite 5 D, New York, NY 10003
chafickaram@hotmail.com

SECTION 1

A 79-year-old man was referred to the neuromuscular clinic for evaluation of severe polyneuropathy. Four years ago, he noted bilateral lower extremity numbness below the knee, particularly in his shins. At the time he also had a right transcarpal ligament release at an outside institution for a diagnosis of carpal tunnel syndrome. This procedure did not provide any relief of his right-hand numbness. He also had numbness in his left hand. One year ago, he began tripping over his feet due to ankle weakness, resulting in falls on several occasions. Concurrently, he complained of burning in the hands more than in the feet, and treatment with gabapentin and a topical Lidoderm patch was started. Six months ago, he started having bilateral hand weakness with trouble opening jars or manipulating buttons. At the same time, he developed near-syncope and was found to have orthostatic hypotension, and treatment with midodrine was started.

A Foley catheter was placed 1 year ago because of urinary retention and bilateral hydronephrosis,

attributed at the time to benign prostatic hypertrophy. He also noted erectile dysfunction and constipation for a few years. The patient reported an involuntary 25-pound weight loss in the last year.

His medical history included bilateral cataract surgery at 75 years but was otherwise negative. He denied any family history of neuropathy. He was a heavy smoker but did not drink or use illicit drugs. There were no toxic exposures. His general examination showed a drop of 20 mm Hg in his systolic blood pressure when standing without an increase in pulse rate. His mental status and cranial nerves were normal. His intrinsic hand muscles were atrophic. He had bilateral mild proximal and severe distal weakness in his arms and legs. He had loss of sensation to pinprick up to the knees and midforearms bilaterally and vibratory sensation loss in his toes and fingertips. His reflexes were absent except for those for the biceps and brachioradialis, which were diminished.

Question for consideration:

1. What is the differential diagnosis at this stage?

GO TO SECTION 2

From the Neuromuscular Division and ALS Center, Beth Israel Medical Center, Albert Einstein College of Medicine, Phillips Ambulatory Care Center, New York, NY.

Disclosure: Author disclosures are provided at the end of the article.

SECTION 2

This patient had chronic sensorimotor polyneuropathy with pronounced autonomic symptoms. His dysautonomia included constipation, erectile dysfunction, orthostatic hypotension, and urinary retention. His weight loss could be related to a systemic condition that resulted in neuropathy or could be part of the dysautonomia, which may cause early satiety from reduced gastric emptying. Most polyneuropathies have some involvement of the autonomic system, but when autonomic signs are prominent as in this patient, the differential diagnosis is narrower.¹ The differential diagnosis of chronic polyneuropathy with prominent dysautonomia can be divided into acquired vs hereditary. Acquired etiologies include metabolic causes such as diabetes mellitus, toxic causes such as chemotherapy or other medication or heavy metal toxicity, infectious causes such as HIV and Chagas disease, autoimmune conditions such as Sjögren syndrome or rheumatoid arthritis, paraneoplastic disease such as anti-Hu–associated polyneuropathy, and amyloid neuropathy due to multiple

myeloma or light-chain (AL) amyloidosis. Some of these etiologies can be ruled out by history. For example, this patient denied any toxic exposures and did not have risk factors or clinical findings suggestive of infectious disorders. Anti-Hu neuropathy is primarily a sensory neuropathy and does not result in motor weakness. Screening for other etiologies such as metabolic and autoimmune disease is necessary because neuropathy may be the only manifestation of the disease.

Inherited autonomic neuropathies include familial amyloid polyneuropathy (FAP) and the hereditary sensory autonomic neuropathies (HSANs). HSANs are unlikely in this patient because of his age. FAP still needs to be considered; although the patient's parents are asymptomatic, there may be genetic anticipation.

Question for consideration:

1. What tests should be ordered to narrow the differential diagnosis?

GO TO SECTION 3

SECTION 3

At this time EMG and nerve conduction studies (NCS) should be performed to define the underlying

pathology (demyelinating vs axonal) and the extent and distribution of the neuropathy (generalized vs multifocal). In addition, the patient should be screened for acquired causes.

In this patient, the EMG and NCS showed a severe, mixed, but predominately axonal sensorimotor polyneuropathy that has resulted in prominent motor axon loss in distal limb muscles (table). His laboratory workup included complete blood count, comprehensive metabolic panel, hemoglobin A1c, Lyme disease titer, anti-hepatitis C antibodies, HIV testing, antinuclear antibodies, rheumatoid factor, erythrocyte sedimentation rate, C-reactive protein, vitamin B12 level, anti-Ro and anti-La antibodies, immunofixation of serum (IFE), quantitative immunoglobulins in the blood and urine, and cryoglobulins. Test results were all unremarkable. A chest X-ray and skeletal survey were also done to rule out myeloma, and results were negative.

Question for consideration:

1. What is the next step in this patient's workup?

GO TO SECTION 4

Table Motor nerve conduction studies showing diffuse reduction in amplitude and velocity^a

Motor NCS	Recording site	Latency	Amplitude, mV	Velocity, m/s
R median: wrist	APB	7.65 ^b	0.6 ^b	
Elbow	APB	16.25	0.7 ^b	30.2 ^b
R ulnar: wrist	ADM	5.45 ^b	2.6 ^b	
Below the elbow	ADM	10.60	2.3 ^b	33.0 ^b
Above the elbow	ADM	14.80	2.5 ^b	28.6 ^b
R tibial: ankle	AH	NR ^b	NR ^b	NR ^b
Popliteal fossa	AH	NR ^b	NR ^b	NR ^b
R common peroneal: fibular head	TA	3.30	4.5 ^b	
Knee	TA	6.15	2.7	45.6

Abbreviations: ADM = abductor digiti minimi; AH = abductor hallucis; APB = abductor pollicis brevis; NCS = nerve conduction studies; NR = not recordable; TA = tibialis anterior.

^a Sensory NCS in the limbs were NR.

^b Abnormal values.

SECTION 4

The most likely diagnosis is polyneuropathy associated with transthyretin (TTR) amyloidosis, AL amyloidosis, or amyloidosis due to multiple myeloma. In these 3 diagnoses, autonomic neuropathy tends to occur relatively early in the course of the disease and results in sexual impotence in men, gastrointestinal motility problems, and bladder retention. In addition, carpal tunnel syndrome is frequently seen in amyloidosis. However, the normal IFE, renal function, and quantitative immu-

noglobulin level favor TTR amyloid neuropathy. Other causes of hereditary amyloid neuropathy are ruled out because of the clinical features. For instance, gelsolin amyloidosis typically manifests with lattice corneal dystrophy, often by age 20–30 years, followed a decade later by progressive cranial neuropathies, which was not the case in our patient.

Question for consideration:

1. What test can be ordered to diagnose TTR amyloidosis?

GO TO SECTION 5

SECTION 5

A tissue biopsy can be obtained to prove the diagnosis but one can also test for a *TTR* gene mutation. Classically, a subcutaneous fat aspiration (FA) has been used successfully to diagnose systemic amyloidosis. The procedure is easy to perform and is a safe and less invasive alternative to a nerve biopsy, but the sensitivity of 72% is relatively low.² Moreover, it has been shown that in patients with isolated polyneuropathy due to amyloidosis who do not have autonomic symptoms, the yield of FA is null, as none of the 143 such patients in one study had positive FA results.³ Hence, the gold standard for diagnosing amyloid neuropathy is sural nerve and muscle biopsy. However, in this patient, genetic testing should be done first for diagnosis of a potential *TTR* mutation. If results of genetic testing are negative, one can then proceed with a sural nerve and muscle biopsy.

In this patient, the genetic testing showed a DNA sequence alteration (Val30Met) in the first *TTR* allele, which confirmed the diagnosis of TTR amyloidosis.

DISCUSSION In this patient, the presence of prominent dysautonomia and the chronicity of the symptoms narrowed the diagnosis. After acquired causes of chronic polyneuropathy and autonomic neuropathy were ruled out, the most likely diagnosis was amyloid polyneuropathy. The clinical presentation, normal IFE, and normal renal function suggested TTR amyloidosis, which was proven by genetic testing.

TTR amyloidosis is the most common form of autosomal dominant hereditary systemic amyloidosis.⁴ Our patient denied any familial history but later revealed that his brother also had the *TTR* mutation and died of complications of liver transplantation. His parents may have died before developing severe symptoms, or genetic anticipation may have occurred. FA is a reasonable test when patients have systemic amyloidosis, but readers should be aware that the sensitivity of this test is relatively low, and in the setting of isolated polyneuropathy, one should biopsy the sural nerve and muscle directly.³

Autonomic neuropathy in FAP typically occurs early in the course of the disease and results in sexual impotence in men, gastrointestinal motility problems, and bladder retention as in our patient. Carpal tunnel syndrome is often an early feature and may be the only clinical manifestation.⁵ The recurrent laryngeal nerve may be involved, manifesting as vocal hoarseness.⁶ The “scalloped pupil” deformity, which is due to amyloid deposition in the ciliary nerve is pathognomonic for FAP.⁵ Vitreous opacities are more common, seen in 20% of those with *TTR* mutations and may be the first manifestation of FAP.⁶ Restrictive cardiomyopathy is an important cause of morbidity and mortality in pa-

tients with TTR amyloidosis. It should be noted that not all amyloid disorders are associated with a peripheral neuropathy. For example, peripheral neuropathy is not seen in reactive (secondary) amyloidosis or in most of the inherited amyloidoses characterized by renal, hepatic, or cardiac deposition. Furthermore, there are nonneuropathic forms of familial TTR amyloidosis.⁷ Further testing in patients with TTR amyloidosis includes echocardiogram, EKG, gadolinium-enhanced MRI of the brain and spinal cord to evaluate CNS amyloidosis, and ophthalmologic evaluation.

The only effective treatment for patients with the *TTR* mutation is liver transplantation. This procedure is typically reserved for patients with polyneuropathy restricted to the lower extremities or with autonomic neuropathy alone. These patients should be younger than 60 years, should have disease duration of less than 5 years, and should not have significant cardiac or renal dysfunction.⁸ Without treatment, the disease is progressive and unremitting, resulting in death in 10 years after the onset of symptoms. With liver transplantation, the estimated survival rate at 5 years is 60%.⁹

DISCLOSURE

Dr. Karam serves on the editorial board of the *Neurology*[®] Resident & Fellow Section. Dr. Scelsa has served on scientific advisory boards for Avanir Pharmaceuticals and GlaxoSmithKline; receives publishing royalties for *Peripheral Neuropathies in Clinical Practice* (Oxford University Press, 2010); receives research support from the NIH; and has served as an expert witness in a medicolegal case.

REFERENCES

1. Freeman R. Autonomic peripheral neuropathy. *Lancet* 2005;365:1259–1270.
2. Gertz MA, Li CY, Shirahama T, Kyle RA. Utility of subcutaneous fat aspiration for the diagnosis of systemic amyloidosis (immunoglobulin light chain). *Arch Intern Med* 1988;148:929–933.
3. Andrews TR, Colon-Otero G, Calamia KT, et al. Utility of subcutaneous fat aspiration for diagnosing amyloidosis in patients with isolated peripheral neuropathy. *Mayo Clin Proc* 2002;77:1287–1290.
4. Andrade C. A peculiar form of peripheral neuropathy: familial atypical generalized amyloidosis with special involvement of the peripheral nerves *Brain* 1952;75:408–427.
5. Murakami T, Tachiban S, Endo Y, et al. Familial carpal tunnel syndrome due to amyloidogenic transthyretin His114 variant. *Neurology* 1994;44:315–318.
6. Benson MD, Kincaid JC. The molecular biology and clinical features of amyloid neuropathy. *Muscle Nerve* 2007;36:411–423.
7. Mitsuhashi S, Yazaki M, Tokuda T, et al. Biochemical characteristics of variant transthyretins causing hereditary leptomeningeal amyloidosis. *Amyloid* 2005;12:216–225.
8. Adams D, Samuel D, Goulon-Goeau C, et al. The course and prognostic factors of familial amyloid polyneuropathy after liver transplantation. *Brain* 2000;123:1495–1504.
9. Parrilla P, Ramirez P, Andreu LF, et al. Long-term results of liver transplantation in familial amyloidotic polyneuropathy type I. *Transplantation* 1997;64:646–649.



Clinical Reasoning: A 62-year-old man with right wrist drop

Giovanni Cirillo, MD
Vincenzo Todisco, MD
Alessandro Tessitore,
MD, PhD
Gioacchino Tedeschi,
MD

Correspondence to
Dr. Tedeschi:
gioacchino.tedeschi@unina2.it

SECTION 1

A 62-year-old man presented to our neurology outpatient clinic with a 3-week history of progressive right wrist drop. He had been complaining of generalized asthenia, numbness, and tingling involving the soles of both feet for the last year. He had a history of chronic renal failure due to type 2 diabetes, for which he was on maintenance hemodialysis. He had hypertension and hyperlipidemia, treated respectively with propranolol and simvastatin. He denied smoking and alcohol abuse.

Family history was unremarkable. General examination was normal, heart rate was 80 bpm, and orthostatism was not observed. Neurologic examination revealed mild ataxic gait with negative Romberg sign; right mild ptosis, which did not fluctuate after 60 sec-

onds of upward gaze; equally sized pupils, briskly reacting to light and accommodation; full range and no clinical evidence of extraocular movement fatigability. Medical Research Council strength score was 4/5 in distal muscles of upper and lower limbs, with the exception of 1/5 score in wrist and finger extensors (extensor carpi ulnaris and radialis, extensor digitorum, extensor indicis); there was no evidence of fatigability. Deep tendon reflexes (DTRs) were symmetrically reduced. Sensory examination showed increased thermo-nociceptive and vibration threshold at distal lower limbs bilaterally.

Question for consideration:

1. What is the differential diagnosis suggested by the clinical history and neurologic examination?

[GO TO SECTION 2](#)

SECTION 2

Our patient presented with progressive right wrist and finger drop. This clinical presentation includes the following differential diagnosis:

1. Focal compression or entrapment of the radial nerve
2. Restricted forms of brachial plexitis and mono-neuritis of radial nerve
3. Multifocal motor neuropathy (MMN) with conduction blocks
4. Hereditary neuropathy with liability to pressure palsies (HNPP)
5. Neuromuscular junction (NMJ) disorders
6. CNS subacute lesions

Wrist and finger drop could be due to radial nerve focal compression by a number of causes, including nerve tumors (e.g., schwannomas). The focal entrapment of the posterior interosseous nerve (PIN, the radial nerve motor branch) at Frohse ligament manifests as finger drop with variable weakness of wrist extension and radial deviation of the extended wrist (PIN syndrome).

Numbness of the lateral dorsum of the hand (including thumb and proximal phalanges of index, middle, and ring fingers), associated with wrist and finger drop, is the common presentation of the Saturday night palsy, due to focal compression of the radial nerve at the spiral groove.

Subacute wrist drop, beginning with deep pain and followed by weakness, could be due to a limited form of brachial plexitis (Parsonage-Turner syndrome) or peripheral nerve vasculitis (mononeuritis multiplex).

MMN begins with a painless, usually distal, motor mononeuropathy (weakness of the wrist or foot drop), associated with conduction blocks and circulating anti-ganglioside antibodies.

HNPP is a dominantly inherited disorder characterized by multiple recurrent focal painless neuropathies caused by deletion of *PMP22* gene and provoked by slight or brief compression. In our case, the negative family history and late disease onset argued against this diagnosis.

Distal hand weakness also may be an atypical presentation of NMJ disorders¹ or CNS mass lesion and ischemic stroke (pseudoperipheral palsy) of the frontal (precentral gyrus) or parietal lobe (angular gyrus).²

Symmetrical sensory-motor impairment at distal lower limbs and reduced DTRs in a patient with diabetes and chronic renal failure would suggest a diagnosis of metabolic polyneuropathy with length-dependent pattern, characterized by distal clinical presentation, often symmetrical, first affecting the lower than upper extremities.

The differential diagnosis of a chronic sensory-motor neuropathy includes the following:

1. Metabolic polyneuropathy (diabetic, uremic, alcoholic, malnutrition)
2. Paraproteinemias and paraneoplastic-associated neuropathy
3. Chronic idiopathic inflammatory/dysimmune neuropathy (CIDP)
4. Hereditary motor and sensory neuropathy (HMSN)
5. Vasculitic neuropathy

Laboratory and instrumental examinations are mandatory for paraproteinemias and paraneoplastic-associated neuropathy, characterized by slowly progressive distal limb paresthesias, deep sensory loss, and gait ataxia.

CIDP is characterized by symmetrical proximal and distal weakness over more than 2 months, associated with absent/diminished DTRs and sensitive impairment. Other forms of chronic acquired polyneuropathy³ include 1) distal acquired demyelinating symmetric neuropathy and 2) focal/multifocal acquired demyelinating sensory and motor neuropathy (the Lewis-Sumner syndrome), associated with motor and sensory deficits, asymmetrical distal presentation, and conduction blocks.

HMSN is a complex group of autosomal dominant, recessive, or X-linked inherited disorders, divided into demyelinating, axonal, and intermediate forms according to nerve conduction velocities (NCV). Most forms present with early onset of symmetrical distal limb weakness, sensory loss, pes cavus, altered nerve conduction studies (NCS), and a strong family history, although a de novo presentation is frequently observed.

Vasculitis affects systemic organs as well as peripheral nervous system and CNS. The clinical presentation of vasculitic neuropathies is an acute/subacute onset of mono/multiple painful neuritis or, rarely, bilateral, symmetric, distal sensory-motor polyneuropathy.

It is noteworthy that our patient also had a mild right ptosis. Unilateral ptosis, occurring with third nerve palsy or Horner syndrome, is unlikely because of undetected pupil and extraocular movement alterations. However, it could also suggest a diagnosis of myasthenia gravis (MG), even if the ptosis is not fluctuating and extraocular movements are in full range. In contrast, ptosis is less frequently observed in Lambert-Eaton myasthenic syndrome, typically characterized by fluctuating proximal limb weakness.

Question for consideration:

1. Which investigations would you consider to distinguish among the differential diagnoses?

GO TO SECTION 3

SECTION 3

To narrow the diagnosis, blood tests, NCS, needle EMG, and brain MRI are necessary. Blood count, complete metabolic panel, HbA_{1c}, serum protein electrophoresis/immunofixation electrophoresis, C-reactive

protein, GM-1 antibodies, antinuclear antibodies, and rheumatoid factor were all normal except for creatinine 3.3 mg/dL (normal 0.8–1.2), blood glucose 180 mg/dL (normal 90–110), and HbA_{1c} 7.8% (normal <6). Creatine kinase levels and anti-neoplastic markers were within normal ranges. Brain MRI is consistent with chronic cerebrovascular disease. A lumbar puncture was performed and all studies were negative.

NCS in the lower limbs showed sensory nerve action potential amplitude at the lower limit of normal range in the superficial peroneal (left 3.3 μ V, right 3.5 μ V; normal >3) and sural (left 3.4 μ V, right 3.8 μ V; normal >3) nerves, and slightly reduced sensitive NCV (36–38 m/s) consistent with incipient damage of sensory peripheral nerve fibers. The distal motor response of the right deep peroneal nerve from extensor digitorum brevis with single stimulus was normal. The subsequent stimulus at fibular head showed a 50% drop of the amplitude and 40% drop of the area of the compound muscle action potential (CMAP). A second distal stimulus at the ankle showed a 58% drop of the amplitude and 60% drop of the area of the CMAP, compared to the first one (figure, A).

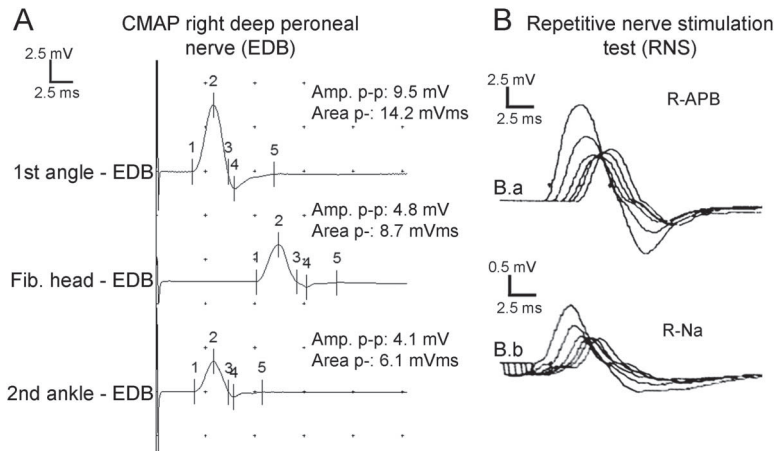
Needle EMG of the upper limbs (right biceps and finger extensors) and lower limbs (left quadriceps and anterior tibialis) was normal.

Question for consideration:

1. What is the most likely diagnosis?

GO TO SECTION 4

Figure Nerve conduction study findings of right deep peroneal nerve and repetitive nerve stimulation test findings



(A) Distal nerve stimulation at ankle from extensor digitorum brevis (EDB) resulted in a normal compound muscle action potential (CMAP); subsequent single proximal stimulus at fibular head showed a significant drop of CMAP amplitude and area, which was still evident at the second single distal stimulus. (B) Postexercise 3-Hz repetitive nerve stimulation (RNS) of the right median to abductor pollicis brevis (R-APB) (B.a) and right facial to nasalis (R-Na) (B.b) muscles showed significant decrement in both muscles. Amp. p-p = amplitude measured at peak to peak; Area p- = area of negative peak; Fib. head = fibular head.

SECTION 4

The significant reduction of CMAP amplitude/area following fibular head stimulation would suggest a conduction block of right deep peroneal nerve. However, the reduction of the amplitude/area of the distal CMAP after a second nerve stimulus at ankle is not consistent with a conduction block and is suggestive of NMJ disorder.

Therefore, a repetitive nerve stimulation (RNS) test at 3 Hz of the median nerve (recording from right abductor pollicis brevis [R-APB]) and facial nerve (from nasalis [R-Na]) was performed (figure, B). The RNS test showed significant reduction of motor response at basal and 1 minute after exercise (R-APB: -66.3% ; R-Na: -46.2%) that is consistent with a marked alteration of neuromuscular transmission (table). A high titer of serum binding antibodies against acetylcholine receptors (anti-AchR Ab) (2 nmol/L, normal <0.25) was detected.

Therefore, the diagnosis of seropositive MG was confirmed.

Chest CT scan ruled out the presence of thymic abnormalities (i.e., thymic hyperplasia or thymoma), usually correlated to high titer of anti-AchR Ab.

The patient started taking oral prednisone (25 mg/day) and pyridostigmine (120 mg/day) with complete resolution of right ptosis and wrist/finger drop. Six months follow-up demonstrated a long-lasting response to pharmacologic treatment.

DISCUSSION MG is an autoimmune disorder determining a postsynaptic defect in neuromuscular transmission. The presence of binding anti-AchR Ab is responsible for weakness that frequently involves extraocular, bulbar, and proximal extremity muscles.⁴

Whereas classic clinical presentations of MG usually lead to a straightforward diagnosis, a distal and asymmetric muscle weakness has been reported in several MG cases.¹ This atypical and unusual pattern of weakness can lead to diagnostic confusion, especially, as in our case, if the underlying diagnosis of

MG is not yet defined. Moreover, in the case of moderate to severe or untreated disease, muscle weakness may become fixed without showing any fluctuation. Distal weakness is observed in fewer than 5% of patients with MG at disease onset, usually involving hand muscles, particularly finger extensors.⁵⁻⁹

In patients presenting with anamnestic and clinical findings of fluctuating/fatigable weakness (particularly involving extraocular and bulbar muscles), diagnosis may be confirmed by electrophysiologic testing with RNS or single-fiber EMG, and serologic demonstration of binding anti-AchR or muscle-specific tyrosine kinase antibodies.¹⁰

The present case reports an atypical and uncommon presentation of a well-known neurologic disorder, showing that distal MG should be taken into account in the differential diagnostic process of focal distal limb weakness.

AUTHOR CONTRIBUTIONS

Dr. G. Cirillo: clinical data acquisition, analysis and interpretation, drafting the manuscript, and review of literature. Dr. V. Todisco: clinical data acquisition, revising the manuscript. Dr. A. Tessitore: drafting and revising the manuscript. Prof. G. Tedeschi: supervising and editing the manuscript.

STUDY FUNDING

No targeted funding reported.

DISCLOSURE

Dr. Cirillo and Dr. Todisco report no disclosures. Dr. Tessitore has received speaker honoraria from Novartis, Schwarz Pharma/UCB, Lundbeck, and Glaxo. Prof. Tedeschi has received speaker honoraria from Sanofi-Aventis, Merck Serono, Bayer Schering Pharma, Novartis, and Biogen-Dompè AG; and has received funding for travel from Bayer Schering Pharma, Biogen-Dompè AG, Merck Serono, Novartis, and Sanofi Aventis. Go to Neurology.org for full disclosures.

REFERENCES

- Nations SP, Wolfe GI, Amato AA, Jackson CE, Bryan WW, Barohn RJ. Distal myasthenia gravis. *Neurology* 1999;52:632-634.
- Takqahashi N, Kawamura M, Araki S. Isolated hand palsy due to cortical infarction: localization of the motor hand area. *Neurology* 2002;58:1412-1414.
- Köller H, Kieseier BC, Jander S, Hartung HP. Chronic inflammatory demyelinating polyneuropathy. *N Engl J Med* 2005;352:1343-1356.
- Drachman DB. Myasthenia gravis. *N Engl J Med* 1994;330:1797-1810.
- Iwasaki Y, Igarashi O, Kawabe K, et al. MG with distal muscle involvement. *Acta Neurol Scand* 2004;110:270.
- Karacostas D, Mavromatis I, Georgakoudas G, Artemis N, Milonas I. Isolated distal hand weakness as the only presenting symptom of myasthenia gravis. *Eur J Neurol* 2002;9:429-430.
- Scola RH, Iwamoto FM, Mainardi MA, et al. Distal myasthenia gravis: case report. *Arq Neuropsiquiatr* 2003;61:119-120.
- Werner P, Kiechl S, Löscher W, Poewe W, Willeit J. Distal myasthenia gravis frequency and clinical course in a large prospective series. *Acta Neurol Scand* 2003;108:209-211.
- Nicolle MW. Wrist and finger drop in myasthenia gravis. *J Clin Neuromuscul Dis* 2006;8:65-69.
- Grob D, Brunner N, Namba T, Pagala M. Lifetime course of myasthenia gravis. *Muscle Nerve* 2008;37:141-149.

Table Repetitive nerve stimulation test findings ^a							
Muscle	Amp. p-, mV	4-1, %	6-1, %	Area, mV	4-1, %	6-1, %	Frequency, Hz
R-APB							
Basal	9.5	-53.5	-45.2	33.5	-57.8	-51.3	3
Postexercise 1 minute	9.4	-66.3	-62.1	34.0	-69.0	-66.5	3
R-Na							
Basal	1.3	-33.6	-30.7	3.4	-47.3	-45.6	3
Postexercise 1 minute	1.4	-46.2	-47.2	3.6	-59.6	-60.1	3

Abbreviations: Amp. p- = amplitude measured at negative peak; APB = abductor pollicis brevis; Na = nasalis.

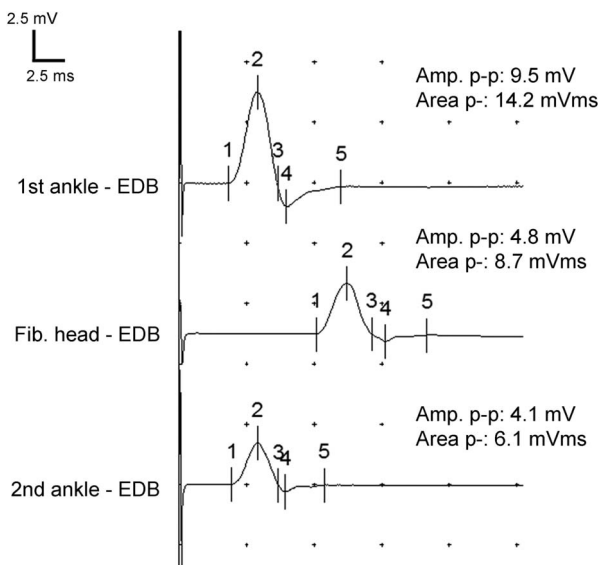
^aSignificant reduction of motor response in both examined muscles at basal and after 1 minute of exercise.

CORRECTION

Clinical Reasoning: A 62-year-old man with right wrist drop

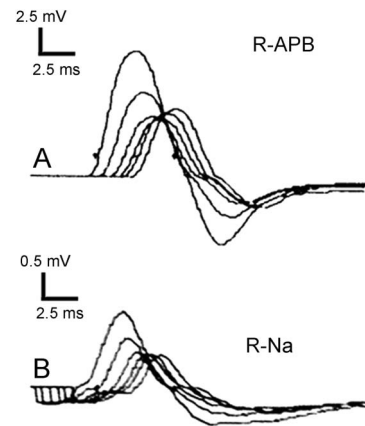
In the Resident & Fellow article “Clinical Reasoning: A 62-year-old man with right wrist drop” by G. Cirillo et al. (*Neurology*® 2013;81:e81–e84), there is an error in the corresponding author’s title, which should have read Prof. Tedeschi, as well as errors involving the figure. The published figure should have been split into 2 figures and the first y-axis label in figure 1, panel A, should have read “1st ankle – EDB.” See corrected figures with titles and legends below. The publisher regrets the errors.

Figure 1 Nerve conduction study findings of right deep peroneal nerve



Distal nerve stimulation at ankle from extensor digitorum brevis (EDB) resulted in a normal compound muscle action potential (CMAP); subsequent single proximal stimulus at fibular head showed a significant drop of CMAP amplitude and area, which was still evident at the second single distal stimulus. Amp. p-p = amplitude measured at peak to peak; Area p- = area of negative peak; Fib. head = fibular head.

Figure 2 Repetitive nerve stimulation test findings



3-Hz repetitive nerve stimulation of the right median to abductor pollicis brevis (R-APB) (A) and right facial to nasalis (R-Na) (B) muscles showed significant decrement in both muscles.

Clinical Reasoning: A 48-year-old woman with generalized weakness

Chafic Karam, MD
Stephen N. Scelsa, MD

Address correspondence and reprint requests to Dr. Chafic Karam, Neuromuscular Division and ALS Center, Beth Israel Medical Center, Albert Einstein College of Medicine, Phillips Ambulatory Care Center, 10 Union Square East, Suite 5 D, New York, NY 10003
chafickaram@hotmail.com

SECTION 1

A 48-year-old woman was referred to the neuromuscular clinic because of progressive generalized weakness for 4 months. Her symptoms started after she had a thyroidectomy and radioactive iodine treatment for a thyroid papillary carcinoma.

She had proximal arm weakness when washing her hair and had trouble climbing steps and getting out of her chair without using her arms. About 2 months later, she developed fluctuating bilateral ptosis and blurred vision. Her symptoms were associated with episodes of transient horizontal binocular diplopia that would last for a couple of minutes and get worse by the end of the day. She also had dry eyes and mouth. A month later, she started having episodes of transient dysarthria. At that time she was found to have a low AM cortisol level by the medical team while being evaluated for her symptoms. She was treated with a hydrocortisone taper which partially improved her weakness and a follow-up cortisol level suggested resolution of the adrenal insufficiency. The patient was on levothyroxine with normal thyroid gland function. She smoked 1 or 2

cigarettes daily for 10 years. She denied head drop, shortness of breath, lightheadedness, constipation, or weight loss.

Her general examination, including orthostatic blood pressure, was normal. Her mental status was normal; visual acuity could be corrected to 20/20. Her pupils were symmetric with a sluggish response to light. Extraocular movements were intact and there was no ocular misalignment on alternate cover testing. There was no lid-twitch. She had mild right ptosis that worsened with sustained upgaze. Facial sensation was intact. There was no facial weakness, dysarthria, or dysphagia. The palate was midline and elevated symmetrically. The tongue movements were normal. No fasciculations were observed. Her strength was 4/5 in both biceps and psoas, which improved on repeated testing. The remaining neurologic examination, including deep tendon reflexes and sensory testing, was normal.

Question for consideration:

1. What is your differential diagnosis at this stage?

GO TO SECTION 2

From the Neuromuscular Division and ALS Center, Beth Israel Medical Center, Albert Einstein College of Medicine, Phillips Ambulatory Care Center, New York, NY.

Disclosure: Author disclosures are provided at the end of the article.

SECTION 2

This patient has subacute onset of proximal limb weakness associated with fluctuating ocular and bulbar symptoms, which suggests a myasthenic syndrome. The differential diagnosis includes myasthenia gravis (MG) or Lambert Eaton myasthenic syndrome (LEMS). Congenital myasthenic syndromes typically present in childhood and patients with botulism intoxication have a rapid descending weakness that develops over hours to days, which is not the case here. Patients with MG most commonly present with double vision and ptosis. They may report blurred vision instead of diplopia but this resolves while covering either eye. Patients with LEMS complain of blurred vision because of dry eyes, difficulty with accommodation, or both.

The pupillary reflex to light, while normal in MG, is usually sluggish in LEMS. Other signs of dysautonomia found in LEMS but not in MG include dry mouth and skin, constipation, and orthostasis.

Unilateral ptosis and ptosis fatigability are, however, more characteristic of MG. Patients with LEMS almost always present with limb weakness, especially in the proximal lower extremities, and commonly have normal facial and extraocular muscles. The improvement of this patient's proximal weakness on repeated testing is characteristic of LEMS. Reflexes, while normal or brisk with MG, are usually weak or absent in LEMS, and can reappear after sustained contraction of the specific muscle. The improvement of the patient's weakness with steroids is nonspecific as both MG and LEMS are autoimmune conditions.

In our patient, acetylcholine receptor (AChR) binding antibodies were positive (1,040 nmol/L), but voltage-gated calcium channel (VGCC) antibodies were negative.

Question for consideration:

1. Does the serology confirm the diagnosis of MG and rule out LEMS?

GO TO SECTION 3

SECTION 3

Antibodies (Abs) that bind AChR proteins are specific serologic markers for acquired MG. AChR-binding Abs are detected in 85% of patients with generalized MG and have very high specificity for MG (>97%).¹ Testing for AChR modulating Abs, blocking Abs, and anti-muscle-specific receptor tyrosine kinase Abs (anti-MuSK) are helpful in patients with generalized MG when they test negative for AChR Abs.² Anti-MuSK-positive patients often have bulbar dysfunction, shoulder girdle weakness, and respiratory symptoms. Note that elevated titers of AChR Abs can also be found in patients with thymoma without MG, systemic lupus erythematosus, amyotrophic lateral sclerosis, inflammatory neuropathy, rheumatoid arthritis on D-penicillamine, and in normal relatives of patients with MG. They can also be seen in patients with LEMS.^{3,4} Thus, relying only on the serology to diagnose MG can be misleading. In this patient in particular, the complaints related to the autonomic nervous system and strength improvement on repetitive testing are unusual for MG.

Antibodies against the P/Q-type VGCC are found in more than 90% of patients with LEMS.^{4,5} In addition, VGCC Abs are found in less than 5% of patients with MG, and they may be found in patients with paraneoplastic cerebellar degeneration associated with small cell lung cancer.^{4,5} Our patient tested negative for VGCC Abs. But VGCC Abs may rapidly fall to zero after initiation of steroid therapy, which might have been the case in our patient.⁴ The presence of these Abs, in the correct clinical setting, confirms the diagnosis of LEMS but does not indicate the risk for cancer. Antibodies against SOX1, however, are highly associated with small cell lung cancer in patients with LEMS.⁶ PET studies are necessary to screen for cancer in patients with LEMS. If PET scan is negative, patients should have a chest MRI and be monitored for malignancy—mainly small cell lung carcinoma—since they can have LEMS several months before the manifestation of the cancer.

Question for consideration:

1. What is the role of electrodiagnostic testing?

GO TO SECTION 4

SECTION 4

Electrodiagnostic studies are essential to differentiate between LEMS and MG,¹ and the physician should not rely solely on the serology. In LEMS, the CMAP amplitudes are generally reduced and decrement further at low frequencies of repetitive nerve stimulation (RNS at 2 Hz to 3 Hz). Voluntary isometric muscle contraction for 10 seconds (or high-frequency RNS at 50 Hz) will result in a facilitation of CMAP amplitude, usually by higher than 100% in LEMS. In MG, low frequency RNS causes progressive decrement in the CMAP amplitude of at least 10%. In ocular MG, the sensitivity of RNS is low (about 30%).¹ If the RNS is normal and a high suspicion for a neuromuscular junction (NMJ) disorder exists, single fiber EMG (SFEMG) should be performed. SFEMG is very sensitive for detection of a defect in NMJ, and its sensitivity allows for demonstration of abnormalities in clinically unaffected muscles. The SFEMG specificity is, however, very low, and it does little in helping to differentiate LEMS from MG or another NMJ process such as an immature NMJ junction from acute neuropathy with resprouting. As

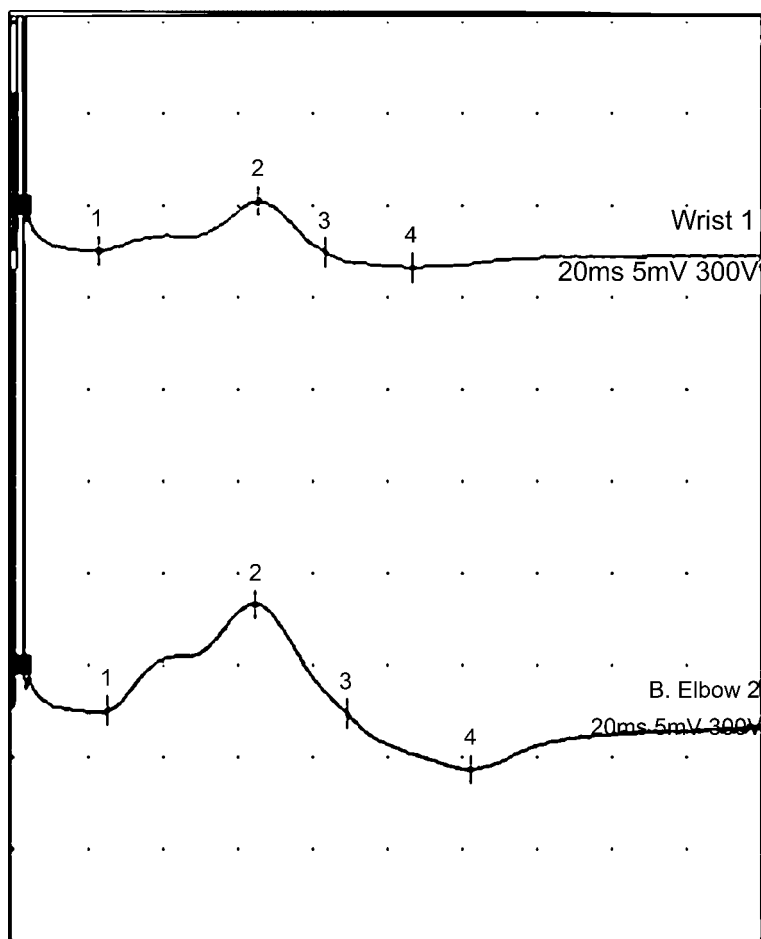
in MG, SFEMG in LEMS and other NMJ processes shows marked motor unit instability (increased jitter and impulse blocking) in most muscles tested. In LEMS, with increased rates of voluntary activation or stimulation, the jitter and blocking may decrease at some endplates.²

In our patient, the right median sensory and ulnar motor conduction velocities were normal. The right median and ulnar motor response amplitudes were reduced (3.1 and 2.8 mV). Immediately following 15 seconds of maximal exercise, there was a 110% increment in the CMAP amplitudes (figure). The right spinal accessory muscle motor response amplitude was normal. RNS of the right median nerve and spinal accessory nerve at 3 Hz showed no significant decrement. Needle EMG in limb muscles showed no spontaneous activity at rest. Motor unit potentials durations were normal except for long duration potentials in the right psoas muscle.

DISCUSSION In this patient, the autonomic symptoms suggested LEMS. In LEMS, VGCC Abs block the release of acetylcholine vesicles from the presynaptic endplate and affect not only the NMJ, but also the synapses between axons of the autonomic system. In MG, the AChR Abs block the nicotinic receptors, but do not affect the muscarinic ones, hence the absence of autonomic symptoms. In our patient, brief exercise caused significant facilitation in the CMAP amplitudes, which is consistent with a presynaptic NMJ disorder. The NMJ safety factor (SF) is the difference between the end plate and threshold potentials (EPP and TP) for initiating an action potential (AP). EPP is generated when acetylcholine binds to its receptor on the postsynaptic membrane. In intact NMJs, the SF is high and an AP is always achieved, even after RNS. In MG, fewer receptors are present, which results in reduced EPP and, as a result, a low SF. Slow RNS causes a decrement in the EPP, which becomes subthreshold, resulting in no AP in some muscle fibers. In LEMS, the baseline EPP is low and with slow RNS, there is also further decrement of the EPP and CMAP, as in MG. In rapid RNS and brief exercise, however, there is accumulation of calcium in the presynaptic end plate, resulting in a facilitation and incremental response in the CMAP.

Our patient had LEMS, which was suggested by the autonomic symptoms and strength improvement on repetitive testing, and confirmed by the increment in the CMAP amplitudes after rapid brief exercise. The ophthalmoparesis and normal reflexes are, however, more characteristic of MG and the AChR Abs are more than 97% specific for MG.¹ One⁷ may conclude that this is a case of concomitant

Figure Pre-exercise (top) and 15 seconds postexercise (bottom) compound muscle action potential of the ulnar nerve



LEMS and MG, while others³ would argue that the presence of AChR in this patient might reflect a “nonpathogenic epiphenomenon.”

DISCLOSURE

Dr. Karam serves on the editorial team for the *Neurology*[®] Resident and Fellow Section. Dr. Scelsa reports no disclosures.

REFERENCES

1. Benatar M. A systematic review of diagnostic studies in myasthenia gravis. *Neuromuscul Disord* 2006;16:459–467.
2. Mahadeva B, Phillips LH 2nd, Juel VC. Autoimmune disorders of neuromuscular transmission. *Semin Neurol* 2008;28:212–227.
3. Katz JS, Wolfe GI, Bryan WW, Tintner R, Barohn RJ. Acetylcholine receptor antibodies in the Lambert-Eaton myasthenic syndrome. *Neurology* 1998;50:470–475.
4. Lennon VA. Serologic profile of myasthenia gravis and distinction from the Lambert-Eaton myasthenic syndrome. *Neurology* 1997;48:S23–S527.
5. Lennon VA, Kryzer TJ, Greisman GE, et al. Calcium channel antibodies in the Lambert-Eaton syndrome and other paraneoplastic syndromes. *N Engl J Med* 1995;332:1467–1474.
6. Sabater L, Titulaer M, Saiz A, et al. SOX1 antibodies are markers of paraneoplastic Lambert-Eaton myasthenic syndrome. *Neurology* 2008;70:924–928.
7. Sha SJ, Layzer RB. Myasthenia gravis and Lambert-Eaton myasthenic syndrome in the same patient. *Muscle Nerve* 2007;36:115–117.



Clinical Reasoning: A 40-year-old man with CIDP-like illness resistant to treatment

Rajat Lahoria, FRACP
Chafic Karam, MD
Angela Dispenzieri, MD
P. James B. Dyck, MD

Correspondence to
Dr. Dyck:
dyck.pjames@mayo.edu

SECTION 1

A 40-year-old man developed tingling and numbness in the feet 2 years ago. Three months later, he noticed difficulty standing on his toes. Outside evaluation showed a small immunoglobulin G (IgG) lambda paraprotein, elevated CSF protein of 335 mg/dL (<40 mg/dL), and nerve root thickening with mild gadolinium enhancement in the cauda equina region on lumbar spine MRI. He

was presumed to have Guillain-Barré syndrome (GBS) and was treated with IV immunoglobulin (IVIg).

Questions for consideration:

1. What is the differential diagnosis of this patient's neuropathy?
2. How do the CSF, serum, and MRI findings help you with this differential?

[GO TO SECTION 2](#)

SECTION 2

The differential diagnosis for the patient's initial presentation, i.e., acute to subacute onset lower limb predominant, sensorimotor neuropathy, is wide. Inflammatory neuropathies such as GBS, chronic inflammatory demyelinating polyneuropathy (CIDP), or sarcoidosis can present in this manner. Infectious etiologies such as HIV, Lyme disease, and West Nile virus need to be ruled out but are less likely due to the absence of systemic features and absence of inflammatory cells in the CSF. Toxins and metabolic causes are important considerations but the history and initial laboratory studies are not suggestive. The presence of monoclonal gammopathy is concerning and warrants further workup as it may be associated with an underlying hematologic disorder such as amyloidosis, lymphoma, or myeloma. A tumor causing a paraneoplastic syndrome needs to be excluded. The MRI findings and elevated CSF protein would support an inflammatory etiology. The progression of symptoms over 3 months is longer than expected for GBS, and would favor a chronic inflammatory process such as CIDP or sarcoidosis.

The patient's symptoms progressed despite initial IVIg treatment. Within 3 months, he developed paresthesias in his hands and severe ankle weakness. Nerve conduction studies (NCS) showed a demyelinating sensorimotor neuropathy without conduction block. The

patient was diagnosed with CIDP and treated with oral prednisone 60 mg daily, mycophenolate mofetil 1g bid, and monthly 1 g/kg IVIg infusion. His condition stabilized during the next 12 months. Thereafter, over a period of 3 months he had a rapid neurologic decline and became wheelchair-bound. During that time, the patient noticed a left clavicular mass. X-ray of the lesion suggested chronic osteomyelitis, and ultrasonography was nondiagnostic. An excisional biopsy showed large collections of inflammatory cells. The patient was diagnosed with osteomyelitis and treated with antibiotics. Because of his worsening weakness, the IVIg was increased to once every 10 days and 1 g of weekly IV methylprednisolone was added.

Over the next 2 months, the patient's strength improved dramatically, and he was able to climb stairs again. Subsequently, he was seen at our institution. Neurologic examination showed mild proximal and severe distal weakness in all limbs, absent ankle jerks, and length-dependent sensory loss. He had plethoric facies, early clubbing, and bilateral papilledema. Visual acuity was normal. Additionally, he reported erectile dysfunction of 1 year's duration.

Question for consideration:

1. What further testing is warranted in a patient with apparent CIDP who is requiring increasing amounts of immunotherapy?

GO TO SECTION 3

SECTION 3

Laboratory evaluation demonstrated mild thrombocytopenia of $140 \times 10^9/L$ (normal $150\text{--}450 \times 10^9/L$) and elevated prolactin of 24 ng/mL (3–13 ng/mL). The rest of the blood workup, including kidney and liver function tests, B₁₂, folate, HbA1c, inflammatory markers, vascular endothelial growth factor (VEGF), and copper levels, was normal. HIV, Lyme, syphilis, cytomegalovirus, Epstein-Barr virus, and viral hepatitis serologies were negative. Immunofixation was normal, although he previously had an IgG lambda monoclonal protein. Repeat CSF analysis showed elevated protein of 166 mg/dL without other abnormalities. Skeletal bone survey showed the known left clavicular lesion. Chest x-ray was unremarkable.

NCS showed absent peroneal and tibial compound motor action potentials (CMAPs) and reduced

ulnar and median CMAPs of 0.6 mV and 0.7 mV, respectively. Motor conduction velocities were slow, ranging from 16 to 24 m/s. F-waves were markedly prolonged bilaterally. No conduction block or temporal dispersion was present. Sensory nerve action potentials were absent in the right arm and leg. Needle EMG showed widespread fibrillation potentials and large motor unit potentials. Autonomic tests were normal. Quantitative sensory testing showed length-dependent dysfunction of large myelinated sensory nerve fibers (abnormal vibration).

Questions for consideration:

1. What is your interpretation of the clinical findings and test results?
2. How do these findings affect your differential diagnosis?

GO TO SECTION 4

SECTION 4

The test results reveal a mixed demyelinating and axonal sensorimotor polyradiculoneuropathy, predominantly involving large myelinated fibers. Blood workup is unremarkable except for mild thrombocytopenia that is probably due to immunosuppressive therapy, and raised prolactin level, which may account for the erectile dysfunction.

A chronic sensorimotor polyneuropathy with proximal and distal involvement (polyradicular pattern) and demyelination (slowed conduction velocities and long F-wave latencies) is suggestive of CIDP. Temporal dispersion and conduction block are often but not always present, and axonal loss may occur with severity and chronicity. However, both the poor response to immunosuppressive therapy and initial IgG lambda paraprotein are concerning for an alternative etiology. The repeat immunofixation was negative, but a small amount of monoclonal protein may be either suppressed by high-dose methylprednisolone or obscured by hypergammaglobulinemia caused by IVIg therapy. The clinicopathologic features of paraproteinemic neu-

ropathies depend on a combination of factors including type of paraprotein (immunoglobulin M, IgG, immunoglobulin A, light chains), underlying disorder (plasmacytoma, myeloma), and associated amyloid deposition.¹ The clavicular lesion and monoclonal paraprotein could be clues to an underlying hematologic disorder such as multiple myeloma, lymphoma, or polyradiculoneuropathy, organomegaly, endocrinopathy, monoclonal plasma cell neoplasm and skin changes syndrome (POEMS). A paucity of blood test abnormalities may argue against it, but much of the POEMS-specific testing was done after high doses of corticosteroids, which are known to temporize the syndrome. The dramatic neurologic improvement after resection of the bone lesion is noteworthy. Neurosarcoidosis can cause chronic, asymmetric, sensory-greater-than-motor polyradiculoneuropathy. Thickening and enhancement of nerve roots and plexus may be seen on MRI. Demyelinating features are rare and would make it less likely.

Question for consideration:

1. What further evaluation would be helpful?

GO TO SECTION 5

SECTION 5

A nerve biopsy is indicated when the peripheral neuropathy is atypical, severe, and progressive, such as in this case, to rule out vasculitis, amyloidosis, malignancy, sarcoidosis, or other inflammatory cause. The sural nerve biopsy in this patient showed segmental demyelination (6%) and axonal degeneration (15%) on teased fiber analysis, and moderately reduced myelinated nerve fiber density. Endoneurial edema, epineurial perivascular inflammation, and mild neovascularization were present (figure). Reevaluation of the clavicular biopsy slides with additional immunostaining revealed extensive infiltration of monotypic lambda light chain restricted plasma cells, scattered foamy macrophages, and fibrosis.

The nerve biopsy results suggest an inflammatory neuropathy with some demyelinating features. Severe and long-standing CIDP often results in a hypertrophic neuropathy and onion bulbs are often seen on nerve biopsy. Axonal degeneration can be seen in severe, long-standing CIDP. Absence of granulomas makes sarcoid less likely, but there could be proximal granulomas missed on the biopsy. The immunostaining pattern on the clavicular biopsy confirms a lambda-restricted plasmacytoma. The increased number of small blood vessels in the nerve biopsy may relate to increased levels of VEGF seen in POEMS

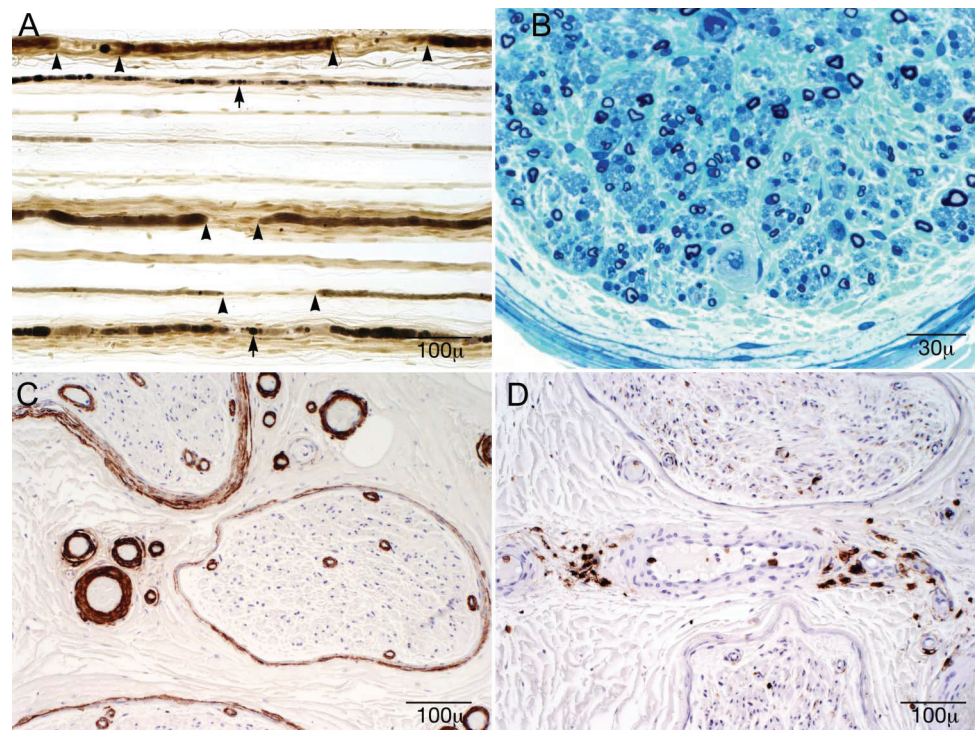
syndrome.² In this patient, a polyradiculoneuropathy in the setting of a monoclonal plasma cell disorder is consistent with POEMS syndrome, both of which are mandatory criteria for the diagnosis.

The diagnosis of CIDP should be questioned when patients do not respond to standard immune-modulating treatments, although some patients eventually respond to other potent agents like rituximab.³ The most likely explanation for the clinical improvement and disappearance of the IgG lambda is the removal of the plasmacytoma (not the increased immunotherapy), which was initially thought to be osteomyelitis.

Not all the features within the POEMS acronym are necessary for diagnosis, and other important features outside the acronym include papilledema, extravascular fluid overload, sclerotic bone lesions, elevated VEGF, thrombocytosis, and abnormal pulmonary function. Full diagnostic criteria have been described by one of the authors.⁴

Hypogonadism is the most common endocrine abnormality. Monoclonal protein in the serum is found in about 75% of cases, and associated light chain is almost always lambda. Serum or plasma VEGF levels tend to be 5- to 10-fold elevated, but may be affected by corticosteroid treatment. Interleukin-1 β , tumor necrosis factor- α , interleukin-6, and interleukin-12 are often elevated.^{5,6}

Figure Sural nerve biopsy



(A) Axonal degeneration (arrows) and demyelination (between arrowheads) on teased nerve fiber preparations; (B) reduced myelinated fiber density, with selective decrease of large fibers, occasional degenerating profiles, and subperineurial edema on methylene blue-stained epoxy sections; (C) mildly increased number of blood vessels on smooth muscle actin staining; and (D) small epineurial perivascular inflammatory collections with CD45 immunostaining.

Neuropathy is the dominant clinical feature in POEMS syndrome, and the most common presentation is of a slowly progressive, symmetrical, sensorimotor polyradiculoneuropathy.¹ Sensory symptoms often precede motor involvement; tingling and prickling are common; and neuropathic pain is reported in 10% to 15% of cases. The autonomic system is usually unaffected. Nerve conduction studies may suggest POEMS syndrome rather than CIDP. Greater reduction in motor amplitudes, greater slowing of conduction velocities, less prolonged distal motor latencies, less frequent temporal dispersion and conduction block, no sural sparing, greater number of fibrillation potentials in a length-dependent pattern, and higher terminal latency indices are present in POEMS cases compared to CIDP.⁷

Prognosis is dependent on the extent of plasma cell involvement, and is independent of the number of clinical criteria present. Major long-term disability is due to neuropathy but long-term outcomes have not been studied. Solitary plasmacytoma can be treated with radiotherapy; more extensive disease requires systemic chemotherapy or hematopoietic stem cell transplant.⁸ This case demonstrates 2 important points: 1) the value of thoroughly investigating a monoclonal protein in the context of neuropathy and 2) the value of questioning the diagnosis of CIDP when the neuropathy does not clearly respond to immunotherapy.

AUTHOR CONTRIBUTIONS

R.L.: study concept and design, drafting and revising the manuscript. C.K., A.D., and P.J.D.: drafting and critical review of the manuscript.

STUDY FUNDING

No targeted funding reported.

DISCLOSURE

R. Lahoria reports no disclosures. C. Karam served on the editorial team for the *Neurology*[®] Resident & Fellow Section. A. Dispenzieri and P. Dyck report no disclosures. Go to Neurology.org for full disclosures.

REFERENCES

1. Silberman J, Lonial S. Review of peripheral neuropathy in plasma cell disorders. *Hematol Oncol* 2008;26:55–65.
2. Dyck PJ, Engelstad J, Dispenzieri A. Vascular endothelial growth factor and POEMS. *Neurology* 2006;66:10–12.
3. Immunosuppressive treatment in refractory chronic inflammatory demyelinating polyradiculoneuropathy: a nationwide retrospective analysis. *Eur J Neurol* 2011;18:1417–1421.
4. Dispenzieri A, Kyle RA, Lacy MQ, et al. POEMS syndrome: definitions and long-term outcome. *Blood* 2003;101:2496.
5. Dispenzieri A. POEMS syndrome: 2011 update on diagnosis, risk-stratification, and management. *Am J Hematol* 2011;86:591–601.
6. Kanai K, Sawai S, Sogawa K, et al. Markedly upregulated serum interleukin-12 as a novel biomarker in POEMS syndrome. *Neurology* 2012;79:575–582.
7. Mauermann ML, Sorenson EJ, Dispenzieri A, et al. Uniform demyelination and more severe axonal loss distinguish POEMS syndrome from CIDP. *J Neurol Neurosurg Psychiatry* 2012;83:480–486.
8. Dispenzieri A. How I treat POEMS syndrome. *Blood* 2012;119:5650–5658.

Clinical Reasoning: A 55-year-old man with weight loss, ataxia, and foot drop

Eoin P. Flanagan, MBCh
Andrea N. Leep
Hunderfund, MD
Neeraj Kumar, MD
Joseph A. Murray, MD
Karl N. Krecke, MD
Brian S. Katz, MD
Sean J. Pittock, MD

Correspondence to
Dr. Flanagan:
flanagan.eoin@mayo.edu

SECTION 1

A 55-year-old man with prior alcohol abuse and an 80 pack-year smoking history was referred for evaluation of a 3-month history of subacute-onset, progressively worsening imbalance without back pain. He began using a cane to ambulate after multiple falls. He also described recent right foot weakness, numbness in his feet and fingertips, and unintentional 25-pound weight loss over the past year. His medical history was significant for hypertension, gastroesophageal reflux disease, diverticulitis, and pelvic abscesses. A paternal grandfather had lung cancer. He reported a remote history of IV drug use. General examination revealed cachexia. Neurologic examination findings were complex. Gait examination revealed severe ataxia, a high steppage gait on the right, and a positive Romberg sign. The total ataxia score using the Scale for Assessment and Rating of Ataxia (higher scores indicate increased severity)¹ was 14/40, including gait, 5/8; stance, 4/6;

sitting, 1/4; speech disturbance, 0/4; finger chase, 0/4; nose-finger test, 0/4; fast alternating hand movements, 2/4; and heel-shin slide, 2/4. Nystagmus was not present. Strength testing revealed hip and knee flexion weakness bilaterally (grade 4/5) and severe (grade 2/5) weakness of right ankle dorsiflexion and eversion but preserved inversion strength. Reflexes were brisk in the upper extremities and normal in the lower extremities and plantar responses were flexor. Sensory testing revealed absent lower extremity vibration, absent joint position at the toes, and reduced pinprick in the feet without a sensory level. Initial laboratory testing revealed a hemoglobin of 9.3 g/dL (normal range 13.5–17.5).

Questions for consideration:

1. Where is the neurologic localization in this case? Is it peripheral, central, or both?
2. What is the differential diagnosis?

[GO TO SECTION 2](#)

SECTION 2

Some clues from the history and examination were helpful in correctly localizing the lesion. Inversion strength, typically involved in a sciatic neuropathy or L5 radiculopathy, was spared, suggesting a common peroneal neuropathy. The patient had his legs crossed during the clinic visit, suggesting that habitually doing so may predispose to a common peroneal neuropathy given his recent weight loss.

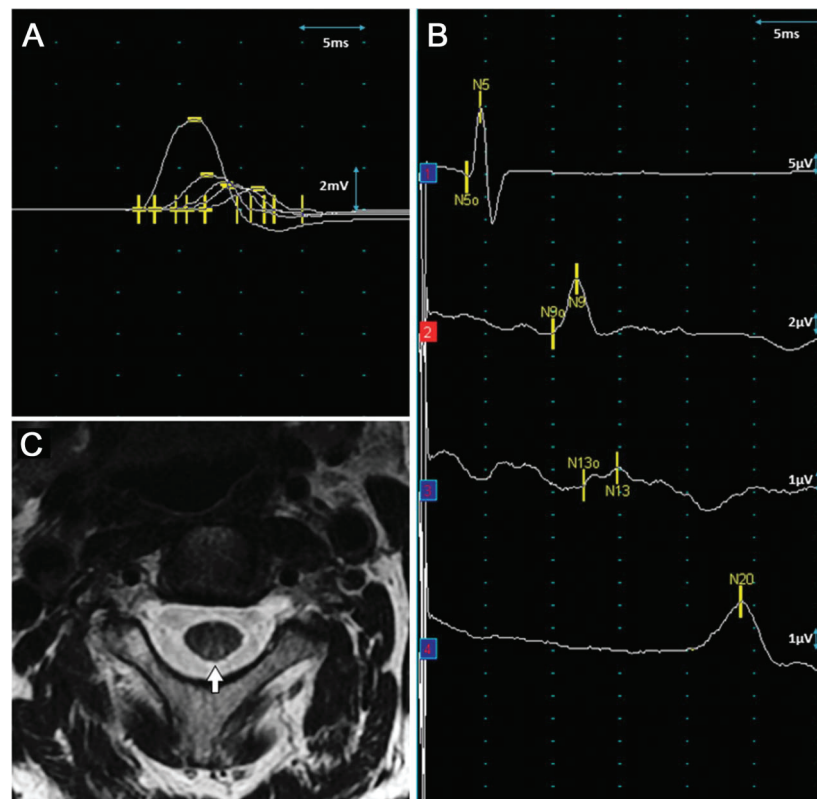
The remaining findings of sensory ataxia with mild lower extremity weakness localized to either peripheral nerve (e.g., sensory ganglionopathy/polyradiculopathy) or spinal cord (dorsal and lateral columns). Brisk upper extremity reflexes with discordant preservation of lower extremity reflexes in the setting of severe vibration sensory loss and pyramidal distribution weakness favored a spinal cord process.

The differential diagnosis included the following:

1. Paraneoplastic neuropathy/myelopathy
2. Inflammatory/autoimmune etiologies (e.g., chronic inflammatory demyelinating polyneuropathy [CIDP], Sjögren syndrome, demyelinating disease)
3. Neoplastic disorders
4. Nutritional deficiencies (e.g., vitamin B₁₂)
5. Cervical spondylosis
6. Toxic/metabolic (e.g., pyridoxine excess, chemotherapeutic agents)
7. Infectious (e.g., syphilis, HIV, cytomegalovirus, Lyme disease)

Sensory ganglionopathy or polyradiculopathy was a diagnostic consideration, but nerve conduction studies and EMG revealed only a right common peroneal neuropathy with conduction block at the fibular head (figure, A). Chronic immune sensory polyradiculopathy

Figure Nerve conduction study, somatosensory evoked potentials, and MRI in our patient



(A) Short segmental stimulation (“inching”) across the fibular head with stimulation of the peroneal nerve (recording over the right extensor digitorum brevis muscle) demonstrates a 77% drop in amplitude between the first waveform (4.4 mV, stimulating 26 mm below the fibular head) and last waveform (1.0 mV, stimulating 66 mm above the fibular head), consistent with conduction block. (B) The right median somatosensory evoked potential revealed prolongation of the cortical N20 latency (24 ms; normal 16.9–21.9), clavicle-to-cortical (N9–N20) interpeak latency (12.1 ms; normal 7.8–10.5), and cervical-to-cortical (N13–20) interpeak latency (9.2 ms; normal 4.7–6.6), with a normal clavicle-to-cervical (N9–N13) interpeak latency. These findings indicate impaired conduction in central proprioceptive pathways serving the right upper extremity. Waveforms (numbers reflect average latency in ms in normal individuals; the letter N [negative] refers to upward deflections as per standard neurophysiology nomenclature): N5 = elbow; N9 = clavicle; N13 = cervical region; N20 = primary somatosensory cortex. (C) MRI cervical spine axial T2-weighted images at the C2/3 interspace revealed hyperintense signal within both dorsal columns (white arrow). Abbreviation: o = onset.

(a variant of CIDP)² remained a possibility as slowing proximal to the dorsal root ganglion may only be detectable by somatosensory evoked potentials (SSEPs). However, CSF examination was normal, including cell count, protein, immunoglobulin G index, and oligoclonal bands. The patient did not complain of dry mouth or eyes and lacked antinuclear antibodies, making Sjögren syndrome unlikely.³ Other investigations for potential causes of a polyradiculopathy/ganglionopathy, including serum protein electrophoresis with immunofixation, fasting glucose and hemoglobin A1C, and Lyme, HIV, and syphilis serologies, were unremarkable.

A paraneoplastic process was considered at an outside facility due to the weight loss, long history of smoking, and potentially multifocal neurologic process. Antineuronal nuclear antibody type 1 (Anti-Hu) is associated with a sensory neuronopathy and underlying small-cell lung cancer in smokers.³ However, a serum paraneoplastic autoantibody evaluation, brain MRI, body PET-CT, prostate-specific antigen, and colonoscopy were all normal, and no suspicious skin lesions for melanoma were seen.⁴

SSEPs were undertaken and revealed impaired conduction in central proprioceptive pathways serving the right upper extremity (figure, B) and lower

extremity. MRI cervical and thoracic spine revealed no multiple sclerosis lesions, which favor the dorsal spinal cord, and no impingement dorsally to suggest cervical spondylosis, both of which cause sensory ataxia.³ However, subtle dorsal column T2 signal hyperintensity was present (figure, C).

Malabsorption and nutritional deficiencies are an additional consideration in patients with weight loss and neurologic complaints. Vitamin B₁₂ deficiency was suspected, as subacute combined degeneration could explain the clinical syndrome, electrophysiology abnormalities, and MRI pattern.³ However, serum B₁₂ was normal (573 pg/mL; normal range 211–946). For low-normal B₁₂ values (<400 pg/mL in our laboratory), testing for elevations in methylmalonic acid is also important as it is more sensitive for detecting cellular deficiency. The alcohol abuse history and potential for thiamine deficiency to cause polyneuropathy led to empiric thiamine treatment followed by serum testing, which was normal. Serum vitamin E and folate were normal. There was no history of excess pyridoxine intake or chemotherapy use to suggest a toxic/metabolic etiology.³

Question for consideration:

1. What investigation would you recommend next?

GO TO SECTION 3

SECTION 3

Serum copper and ceruloplasmin levels were obtained. The patient's serum copper was 0.27 $\mu\text{g}/\text{mL}$ (normal range 0.75–1.45) and ceruloplasmin was 9.8 mg/dL (normal range, 15–30). Copper deficiency myelopathy was diagnosed. Serum zinc was normal. Laboratory analysis demonstrated a ferritin

of 5 mcg/L (normal range 24–336), and peripheral blood smear revealed hypochromic microcytic erythrocytes.

Question for consideration:

1. What is the cause of the copper deficiency and unifying diagnosis?

[GO TO SECTION 4](#)

SECTION 4

Serum immunoglobulin A tissue transglutaminase antibodies were evaluated and found to be markedly elevated (>100 U/mL; normal range <4). Subsequent duodenal biopsies revealed total villous atrophy diagnostic of celiac sprue. In this case, celiac disease led to (1) duodenal malabsorption of copper resulting in copper deficiency myelopathy; (2) weight loss contributing to the common peroneal neuropathy in the setting of habitual leg crossing; and (3) probable combined iron and copper deficiency anemia (from duodenal malabsorption).

We prescribed 8 mg of oral copper daily for 1 week followed by a taper of 2 mg each week until a maintenance dose of 2 mg daily was reached. A gluten-free diet was recommended and iron was replaced IV. Serum copper normalized after 6 weeks, and treatment was maintained at 2 mg/day. Two months after diagnosis, improvements in energy level, numbness, and foot drop were noted (with discontinuation of leg crossing), but imbalance had yet to improve.

DISCUSSION This case underscores that while ataxia, anemia, and weight loss should prompt consideration of a paraneoplastic process, neurologic manifestations of malabsorption should also be considered. Second, we highlight the differential diagnosis of sensory ataxia. Third, our case demonstrates that ataxia in association with celiac disease may reflect copper deficiency rather than a primary immune-mediated gluten ataxia.

The most common neurologic manifestation of copper deficiency-associated myelopathy is sensory ataxia.⁵ SSEPs often demonstrate dorsal column conduction slowing, and MRI may reveal nonenhancing dorsal column T2 signal hyperintensities—both were evident in our patient.⁵ Copper may cause a hypochromic microcytic anemia sometimes accompanied by sideroblasts,⁵ although these were not seen in our case. The low ferritin suggested potentially combined iron and copper deficiency as the cause of anemia and malabsorption in the proximal duodenum (where both are absorbed) as the underlying etiology.

Copper has a role in maintaining the structure and function of the nervous system through the mitochondrial respiratory chain via cytochrome *c* oxidase-associated electron transport and oxidative phosphorylation.⁵ Dysfunction of this process is thought to cause dorsal column degeneration and the associated sensory ataxia. This is not surprising, as similar dorsal spinal cord imaging abnormalities are described with mitochondrial disorders including leukoencephalopathy with brainstem and spinal cord involvement and high lactate⁶ and rarely with Leber hereditary optic neuropathy.⁷ Dorsal column T2 signal hyperintensities have also been reported with a variety of sensory ganglionopathies (from dorsal root ganglia degeneration and associated loss of central

projections), other nutritional deficiencies (vitamin B₁₂ and E), infectious etiologies (syphilis [tabes dorsalis], HIV [vacuolar myelopathy], and human T-lymphotropic virus type 1 [tropical spastic paraparesis]), paraneoplastic myelopathies (often with gadolinium enhancement),⁴ hereditary causes (e.g., Friedreich ataxia), and toxic/metabolic causes (methotrexate, cytarabine, and heroin).

In addition to the proximal duodenum, copper is also absorbed in the stomach. The most common cause of acquired hypocupremia is gastric surgery for peptic ulcer disease or bariatric surgery, but it may occur with excessive zinc intake (usually from denture creams or supplements).⁵ Oral iron may worsen copper deficiency by competing for absorption; therefore, we recommended IV iron in our patient.⁵ Due to its ubiquitous distribution and low daily requirement, dietary deficiency is rare and typically occurs with malabsorption or iatrogenic causes (e.g., total parenteral nutrition deficient in copper).⁵

Celiac disease is an immune reaction in the small intestine in response to eating gluten.⁸ Gluten-associated ataxia is postulated to be immune-mediated as cerebellar T-cell infiltration and Purkinje cell loss may occur, but its exact pathogenesis remains uncertain.⁹ Our case and prior reports of copper deficiency-associated sensory ataxia¹⁰ suggest that it may account for a proportion of patients previously suspected to have an immune-mediated gluten-associated ataxia and should prompt the clinician to closely scrutinize spinal neuroimaging and to obtain SSEPs to evaluate preganglionic sensory pathways.¹⁰

NOTE ADDED IN PROOF

During the processing of this article, the patient died of an unrelated aneurysmal subarachnoid hemorrhage. An autopsy performed at our institution showed, in addition to his basilar tip aneurysm and subarachnoid hemorrhage, severe axonal degeneration of posterior columns with wallerian degeneration and neuropil vacuolation; the cerebellum showed no evidence of inflammation.

AUTHOR CONTRIBUTIONS

Eoin P. Flanagan: drafting/revising the manuscript, study concept or design, analysis or interpretation of data, accepts responsibility for conduct of research and final approval, study supervision. Andrea N. Leep Hunderfund: drafting/revising the manuscript, analysis or interpretation of data, accepts responsibility for conduct of research and final approval, acquisition of data. Neeraj Kumar: drafting/revising the manuscript, accepts responsibility for conduct of research and final approval, study supervision. Joseph Murray: drafting/revising the manuscript, accepts responsibility for conduct of research and final approval. Karl N. Krecke: drafting/revising the manuscript, study concept or design, analysis or interpretation of data, accepts responsibility for conduct of research and final approval. Brian J. Katz: drafting/revising the manuscript, accepts responsibility for conduct of research and final approval, contribution of vital reagents/tools/patients. Sean J. Pittock: drafting/revising the manuscript, study concept or design, analysis or interpretation of data, accepts responsibility for conduct of research and final approval, study supervision.

STUDY FUNDING

No targeted funding reported.

DISCLOSURE

E. Flanagan reports no disclosures relevant to the manuscript. A. Leep Hunderfund has contractual rights to receive royalties from the licensing of software unrelated to this research. N. Kumar, J. Murray, K. Krecke, and B. Katz report no disclosures relevant to the manuscript. S. Pittock is a named inventor on patents (12/678,350 filed 2010 and 12/573,942 filed 2008) that relate to functional AQP4/NMO-IgG assays and NMO-IgG as a cancer marker; and receives research support from Alexion Pharmaceuticals, Inc., the Guthy-Jackson Charitable Foundation, and the NIH (NS065829). Dr Pittock has provided consultation to Alexion Pharmaceuticals but has received no personal fees or personal compensation for these consulting activities. All compensation for consulting activities is paid directly to Mayo Clinic. Go to Neurology.org for full disclosures.

REFERENCES

1. Schmitz-Hubsch T, du Montcel ST, Baliko L, et al. Scale for the assessment and rating of ataxia: development of a new clinical scale. *Neurology* 2006;66:1717–1720.
2. Sinnreich M, Klein CJ, Daube JR, Engelstad J, Spinner RJ, Dyck PJ. Chronic immune sensory polyradiculopathy: a possibly treatable sensory ataxia. *Neurology* 2004;63:1662–1669.
3. Koontz DW, Maddux B, Katirji B. Evaluation of a patient presenting with rapidly progressive sensory ataxia. *J Clin Neuromuscular Dis* 2004;6:40–47.
4. Flanagan EP, McKeon A, Lennon VA, et al. Paraneoplastic isolated myelopathy: clinical course and neuroimaging clues. *Neurology* 2011;76:2089–2095.
5. Kumar N. Copper deficiency myelopathy (human sway-back). *Mayo Clinic Proc* 2006;81:1371–1384.
6. Steenweg ME, Pouwels PJ, Wolf NI, van Wieringen WN, Barkhof F, van der Knaap MS. Leucoencephalopathy with brainstem and spinal cord involvement and high lactate: quantitative magnetic resonance imaging. *Brain* 2011;134:3333–3341.
7. Jaros E, Mahad DJ, Hudson G, et al. Primary spinal cord neurodegeneration in Leber hereditary optic neuropathy. *Neurology* 2007;69:214–216.
8. Rubio-Tapia A, Murray JA. Celiac disease. *Curr Opin Gastroenterol* 2010;26:116–122.
9. Hadjivassiliou M, Sanders DS, Grunewald RA, Woodroffe N, Boscolo S, Aeschlimann D. Gluten sensitivity: from gut to brain. *Lancet Neurol* 2010;9:318–330.
10. Goodman BP, Mistry DH, Pasha SF, Bosch PE. Copper deficiency myeloneuropathy due to occult celiac disease. *Neurologist* 2009;15:355–356.

Disorders presenting with abnormal sensation

The somatosensory system constantly collects and conveys tactile information about the external environment and proprioceptive information about body position, allowing one to identify objects in one's pocket by touch alone, balance carefully when walking on an icy sidewalk, and quickly detect pain or heat and withdraw the limb before incurring injury.

The sensory pathways for the body include peripheral receptors, peripheral nerves, dorsal root ganglia, dorsal roots, anterolateral (spinothalamic) and dorsal column-medial lemniscal pathways in the spinal cord and brainstem, the ventral posterior lateral nucleus of the thalamus, thalamocortical connections, and the somatosensory cortex in the parietal lobes. The somatosensory pathways for the face travel in the trigeminal nerve to the trigeminal nerve nuclei (the main sensory nucleus in the pons conveys light touch, the spinal nucleus and tract in the medulla and upper cervical cord mediate pain and temperature, and the mesencephalic nucleus in the midbrain receives jaw proprioceptive afferent signals). The trigeminal nuclei project to the ventral posterior medial nucleus of the thalamus, which projects to the somatosensory cortex.

The anterolateral (spinothalamic) tracts cross shortly after entering the spinal cord and the dorsal column-medial lemniscal pathways cross in the medulla. These pathways then travel together from the level of the pons to the thalamus and cortex.

Localizing sensory disturbances relies upon understanding the distribution of sensory symptoms and the sensory modalities that are affected.

Distribution of sensory symptoms.

- Sensory symptoms limited to the face can be caused by lesions in the trigeminal nerve or its brainstem connections, though brainstem lesions often cause additional symptoms/signs.
- Sensory symptoms involving the face in addition to the arm and leg require a lesion in the brainstem, thalamus, thalamocortical connections, or somatosensory cortex. Lesions in the lateral medulla cause diminished pain and temperature in the ipsilateral face and contralateral body (since the spinothalamic tract has already crossed in the spinal cord).
- Sensory changes limited to one side of the body but not involving the face can occur with lesions in the lower medulla or cervical spine, but can rarely be caused by small hemispheric lesions.
- Sensory changes limited to one limb may be caused by disease in the spinal cord, multiple dorsal roots, the brachial or lumbar plexus, or more rarely by a small lesion in the contralateral hemisphere.
- Incomplete sensory involvement of one limb can be due to spinal cord, root, or peripheral nerve disease, but can rarely be caused by a small lesion in the contralateral hemisphere.
- Symmetric sensory loss suggests a disorder of the spinal cord, dorsal root ganglia, or peripheral nerves. Symmetric confluent sensory loss with a spinal level suggests spinal cord disease. Symmetric distal sensory loss is most commonly due to peripheral polyneuropathy.

Affected sensory modalities. Pain and temperature travel in small unmyelinated fibers in peripheral nerves and travel in the anterolateral tract, crossing immediately after entering the spinal cord. Vibration and proprioception travel in large myelinated fibers and then in the dorsal column/medial lemniscal pathway, which does not cross until the level of the medulla. A region of dissociated sensory loss, in which one modality is affected while another is spared, therefore suggests either a neuropathy selective for a particular fiber type (e.g., small fiber neuropathy or large fiber neuropathy), a lesion limited to one-half of the spinal cord causing ipsilateral loss of vibration/proprioception and contralateral loss of pain and temperature (Brown-Séquard syndrome), or a lesion in the medulla, inferior to the level where these pathways become adjacent and travel together to the thalamus.

Loss of proprioception can lead to sensory ataxia, distinguished from cerebellar ataxia by impaired joint position sense and lack of other cerebellar features such as dysarthria and nystagmus. Reflexes are typically diminished when sensory ataxia is due to ganglionopathy or neuropathy, or increased if there is a spinal cord lesion causing dorsal column dysfunction. The Romberg sign is indicative of proprioceptive dysfunction and can be caused by large-fiber neuropathy, dorsal root ganglionopathy (also known as sensory

neuropathy), or spinal cord disease affecting the dorsal columns.

Associated features. Sensory loss accompanied by decreased or absent reflexes suggests a lesion in the peripheral nervous system such as radiculopathy, ganglionopathy, or neuropathy. Sensory loss associated with increased reflexes suggests

involvement of the corticospinal tracts and implicates a spinal cord, brainstem, or hemispheric lesion. Lesions at the level of the brainstem can cause crossed signs with ipsilateral diminished or absent facial sensation and contralateral diminished bodily sensation.

The cases in this section demonstrate an approach to patients with abnormal somatosensory function.



Clinical Reasoning: An 85-year-old man with paresthesias and an unsteady gait

Aaron L. Berkowitz, MD,
PhD
Ruchira M. Jha, MD
Joshua P. Klein, MD,
PhD
Anthony A. Amato, MD

Correspondence to
Dr. Berkowitz:
aberkowitz3@partners.org

SECTION 1

An 85-year-old man developed tingling in his feet, followed 1 week later by a similar sensation in both hands. He reported difficulty buttoning his shirt and unsteadiness when walking. There was no ascent of his symptoms proximal to the wrists and ankles. He denied pain, orthostasis, and bowel or bladder symptoms. He had had no prior similar symptoms, preceding illnesses, or recent changes in his health or medications. He had received the influenza vaccine 1 week prior to symptom onset.

His medical history included congestive heart failure and idiopathic pulmonary fibrosis for which he took low-dose prednisone. There was no history of illicit drug use, excessive alcohol consumption, toxic exposures, or family history of neurologic disorders.

On examination, he had no cranial nerve deficits and full strength. He had preserved light touch, temperature, and pinprick sensation, but symmetrically diminished vibration sense and proprioception to the level of both wrists and ankles. Reflexes were absent bilaterally in his upper and lower extremities. On pronator drift testing, his arms drifted upward, and his fingers made small involuntary movements. On finger-nose testing the patient had difficulty reaching and maintaining contact with a target, which worsened with eyes closed. He had no Romberg sign, but had mild gait instability.

Questions for consideration:

1. What is the localization of his deficits?
2. What further evaluation should be undertaken?

[GO TO SECTION 2](#)

SECTION 2

The patient's gait unsteadiness, upward drift of the arms with pseudoathetosis of the fingers (subtle movements suggestive of a proprioceptive deficit), and worsening of finger-nose testing with eyes closed suggest a sensory ataxia. Sensory ataxia, diminished vibration sense, decreased proprioception, and areflexia localize to the posterior columns, large fibers of peripheral nerves, or intervening dorsal root ganglia or nerve roots; the bilaterality, symmetry, and areflexia make a supratentorial etiology improbable.

The differential diagnosis for disease processes causing peripheral neuropathy, ganglionopathy, polyradiculopathy, or posterior column dysfunction includes infections, nutritional deficiencies, endocrine dysfunction, inflammatory/autoimmune conditions, malignancy, paraneoplastic processes, toxic exposures, medications, and hereditary conditions (table).

Before referral to a neurologist, the patient had undergone laboratory evaluation for etiologies of peripheral neuropathy, revealing normal vitamin B12, thyroid-stimulating hormone, hemoglobin A1C, serum and urine protein electrophoresis, and liver enzymes. Given the rapidly evolving nature of his symptoms and absent reflexes, he was admitted due to concern for possible Guillain-Barré syndrome (GBS). CSF analysis to assess

for inflammation or infection revealed normal glucose (60 mg/dL), mildly elevated protein (64.2 mg/dL), and no red or white blood cells. EMG and nerve conduction studies (NCS) were performed to distinguish between axonal and demyelinating etiologies of presumed polyneuropathy. NCS demonstrated reduced amplitudes of sensory nerve action potentials (SNAPs) in the sural (left 3.3 μ V, right 0.60 μ V; normal >5 μ V), superficial peroneal (left 3.7 μ V, right 3.3 μ V; normal >5 μ V), median (left 6.0 μ V, right 6.1 μ V; normal >30 μ V), and ulnar nerves (left not recordable, right 5.2 μ V; normal >10 μ V); slightly reduced amplitudes of combined motor action potentials (CMAPs) of bilateral median (left 4.5 mV, right 2.5 mV; normal >5 mV), left ulnar (3.4 mV; normal >5 mV), and bilateral peroneal nerves (left 1.7 mV, right 1.9 mV; normal >2 mV); and normal nerve conduction velocities (NCV), distal latencies, and F waves. EMG was normal in bilateral tibialis anterior, left first dorsal interosseous, and left extensor digitorum brevis muscles.

Questions for consideration:

1. How can the NCS be interpreted?
2. What features are suggestive of GBS or one of its variants, and which aspects would be inconsistent with a diagnosis of GBS?

GO TO SECTION 3

Table	Causes of peripheral neuropathy, ganglionopathy, radiculopathy, or posterior column disease			
	Peripheral neuropathy	Ganglionopathy	Radiculopathy	Posterior column dysfunction
Infectious				
Syphilis			X	X
HIV	X	X	X	X
Hepatitis B (polyarteritis nodosa)	X			
Hepatitis C (cryoglobulinemia)	X			
Leprosy	X			
Lyme	X		X	
HSV			X	
CMV	X		X	
EBV	X	X		
VZV		X	X	
HTLV-1	X	X		
Diphtheria	X			
Nutritional				
Vitamin B ₁₂ deficiency	X			X

Continued

Table Continued

	Peripheral neuropathy	Ganglionopathy	Radiculopathy	Posterior column dysfunction
Vitamin E deficiency	X	X		X
Copper deficiency	X			X
Endocrine				
Diabetes	X		X	
Thyroid dysfunction	X			
Inflammatory/autoimmune				
AIDP/CIDP	X		X	
Sjögren syndrome	X	X		
Sarcoidosis	X		X	
Vasculitis	X			
Amyloid	X		X	
Anti-MAG	X			
Neoplastic/paraneoplastic				
Multiple myeloma	X			
Waldenstrom macroglobulinemia	X			
Lymphoma	X		X	
POEMS	X			
Anti-Hu		X		
Anti-CRMP-5		X		
Toxic				
Alcohol	X			
Heavy metals (lead, arsenic, thallium, mercury)	X			
Nitrous oxide	X			
Organophosphates	X			
Ciguatera toxin	X			
Medication-related				
Chemotherapies including vincristine, taxols, bortezomib, suramin	X			
Platinum-based chemotherapy including cisplatin, carboplatin		X		
Isoniazid (due to B ₆ deficiency)	X			
Amiodarone	X			
Chloroquine/hydroxychloroquine	X			
Pyridoxine (vitamin B ₆) excess	X	X		
Hereditary				
Charcot-Marie-Tooth	X			
Friedreich ataxia	X			X
Hereditary sensory and autonomic neuropathy	X	X		
Porphyria	X			

Abbreviations: AIDP = acute inflammatory demyelinating polyradiculoneuropathy; CIDP = chronic inflammatory demyelinating polyradiculoneuropathy; CMV = cytomegalovirus; CRMP-5 = collapsin response mediator protein 5; EBV = Epstein-Barr virus; HSV = herpes simplex virus; HTLV = human T-cell lymphotropic virus; POEMS = polyneuropathy, organomegaly, endocrinopathy, monoclonal gammopathy, and skin changes; VZV = varicella-zoster virus.

SECTION 3

Reduced SNAP and CMAP amplitudes with preserved NCV and distal latencies in multiple nerves suggest a disease process affecting sensory and motor axons. Distal paresthesias and areflexia can be seen in GBS; however, lack of weakness several weeks into the illness would be atypical for the classic form of the disease. Subtypes of GBS can be broadly divided into acute inflammatory demyelinating polyradiculoneuropathies (AIDP) and axonal forms (acute motor axonal neuropathy and acute motor and sensory axonal neuropathy). AIDP variants include Miller Fisher syndrome (ophthalmoplegia, ataxia, areflexia), paraparetic, pure sensory, pure motor, pandysautonomic, cervico-brachial-pharyngeal, oculo-pharyngeal, and ophthalmoplegic forms^{1,2}; these variants of AIDP share decreased tendon reflexes, electrographic features of demyelination, and cytoalbuminologic dissociation in the CSF, despite the diversity of other aspects of their clinical phenotypes.¹ This patient did not fit into any of the above categories given the lack of weakness or bulbar symptoms and NCS lacking features of demyelination with preserved F waves.

He underwent extensive but unrevealing evaluation for possible autoimmune, infectious, or paraneoplastic processes (serum antinuclear antibodies, SS-A [Ro], and SS-B [La]; rapid plasma reagin and HIV; anti-Hu, anti-GQ1B, and anti-GM1 autoantibodies; and CT of the chest, abdomen, and pelvis). Although the etiology of his illness was unclear, intravenous immunoglobulin (IVIg) 0.4 g/kg/day was administered for 5 days. His symptoms remained stable and he was discharged for rehabilitation.

He initially noted improvement in his gait and only minimal persistent numbness of his hands and feet. One month later, however, his gait acutely worsened over several days, such that he was too unsteady to walk or stand unassisted. He had a Romberg sign, swayed from side to side when standing, and had a magnetic gait. His sensory, motor, and reflex examinations were otherwise unchanged from his initial examination.

Questions for consideration:

1. What is the differential diagnosis at this point?
2. What further evaluation should be undertaken?

GO TO SECTION 4

SECTION 4

The differential diagnosis of the patient's progressive sensory symptoms includes chronic inflammatory demyelinating polyradiculoneuropathy (CIDP) and ganglionopathy. Like AIDP, CIDP has many variants, including sensorimotor (e.g., classic, Lewis-Sumner syndrome/multifocal acquired demyelinating sensory and motor neuropathy) and solely sensory (e.g., chronic sensory demyelinating neuropathy, distal acquired demyelinating symmetric neuropathy).^{3,4} Demyelination is a characteristic electrodiagnostic feature of CIDP; however, the nerve conduction studies in our patient showed normal NCV. Ganglionopathy presents with sensory ataxia and deficits in proprioception and vibration sense with reduced

SNAPs (subclinical reduced CMAPs may also be seen),⁵ all seen in our patient.

EMG/NCS were repeated and demonstrated relatively unchanged SNAPs and CMAPs compared to his prior NCS. Since worsening axonal neuropathy or ganglionopathy would have been expected to result in further decrement in his SNAPs, his clinical progression in the setting of stable electrodiagnostic studies suggested a more proximal lesion at the level of the nerve roots or posterior columns.

Question for consideration:

1. What diagnostic studies can aid in distinguishing between posterior column disease, radiculopathy, ganglionopathy, and peripheral neuropathy?

GO TO SECTION 5

SECTION 5

Somatosensory evoked potentials (SSEPs) measure the response to peripheral nerve stimulation at several levels along the somatosensory pathway: dorsal root ganglia (Erb's point above the clavicle for the upper extremity; over the lumbar spine for the lower extremity), nuclei cuneatus and gracilis (electrode placed over the second cervical vertebra; records N13 potential), and somatosensory cortex (recorded over the contralateral scalp; records N19-P22 potentials).^{6,7} In this patient, SSEPs revealed no reproducible waveforms at any site. Given the presence of SNAPs on routine NCS, the absence of SSEPs suggests block of conduction more proximally (e.g., at the level of proximal nerve roots or posterior columns). MRI of the spine with gadolinium was performed, demonstrating enhancement of numerous lumbosacral nerve roots and dorsal root ganglia with a normal-appearing spinal cord (figure). Nerve biopsy was proposed, but

deferred by the patient and his family. This constellation of clinical, electrodiagnostic, and imaging features is suggestive of chronic immune sensory polyradiculopathy (CISP).

DISCUSSION CISP was described in a case series of 15 patients with sensory ataxia, proprioceptive deficits, gait ataxia, paresthesias, and absent reflexes, but full strength; normal SNAPs; normal MRI of the brain and spinal cord with enlargement or enhancement of lumbar nerve roots; abnormal SSEPs suggestive of a lesion at the level of the nerve root; elevated CSF protein; and biopsy-proven inflammatory hypertrophic changes of sensory nerve rootlets.⁸ The clinical, laboratory, electrophysiologic, radiologic, and pathologic features of CISP suggest dorsal root inflammation as the underlying etiology. Our patient's SNAPs and CMAPs were reduced, suggesting some degree of ganglionopathy or axonal neuropathy. The asymmetry of SNAP and CMAP amplitude reduction suggests that concurrent idiopathic sensorimotor polyneuropathy or age-related changes alone would not entirely explain these findings. Since his disease progressed dramatically in the presence of unchanged SNAPs and CMAPs, and his MRI showed no dorsal column enhancement (which is often seen in advanced ganglionopathy), but rather nerve root and dorsal root ganglion enhancement, his predominant underlying pathophysiology was believed to be sensory polyradiculopathy, albeit with some component of ganglioneuropathy.

Patients with CISP may respond to IVIg or high-dose steroids, returning to normal ambulation with reversal of sensory abnormalities.⁸ Our patient was treated with another course of 5 days of IVIg followed by 1 g/kg over 2 days monthly for 4 months and prednisone 60 mg daily. His neurologic status did not improve with therapy, suggesting that he had developed irreversible damage to his proximal nerve segments. He died several months later from complications of his underlying cardiopulmonary disease.

AUTHOR CONTRIBUTIONS

A. Berkowitz drafted the initial manuscript, revised the manuscript, and was involved in the clinical care of the patient. R. Jha drafted the initial manuscript, revised the manuscript, and was involved in the clinical care of the patient. J. Klein revised the manuscript, interpreted the neuroradiology, and created the figure. A. Amato revised the manuscript and was involved in the clinical care of the patient.

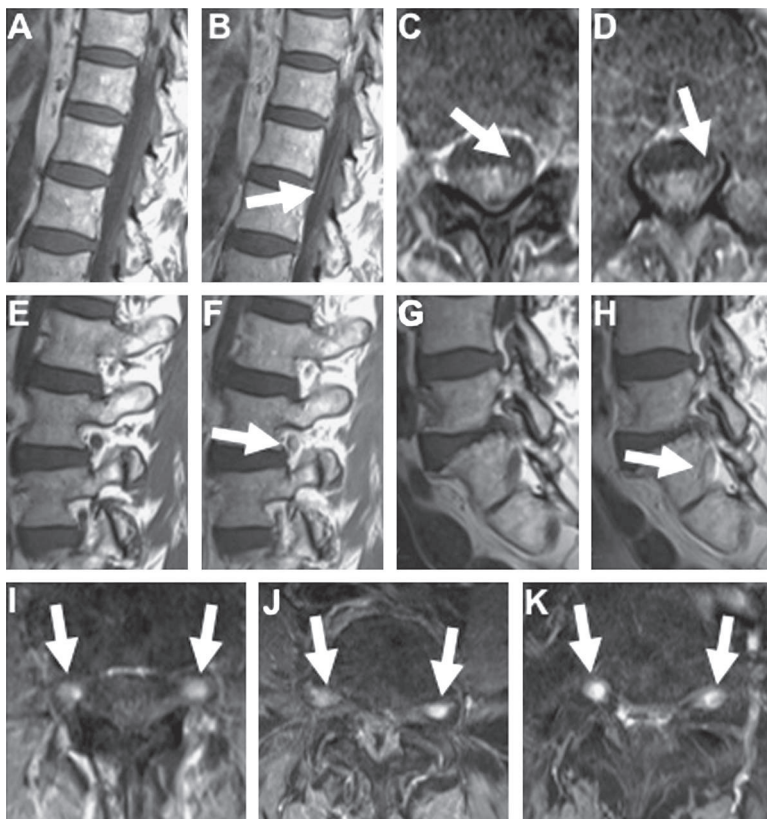
STUDY FUNDING

No targeted funding reported.

DISCLOSURE

A. Berkowitz reports no disclosures relevant to the manuscript. R. Jha and J. Klein report no disclosures. A. Amato has served as a medical consultant for MedImmune, Amgen, and Biogen. Go to Neurology.org for full disclosures.

Figure MRI of the patient's lumbosacral spine



Sagittal T1-weighted MRI with fat saturation before (A) and after (B) IV administration of gadolinium contrast shows abnormal enhancement of a left-sided nerve root at the T12-L1 vertebral level (B, arrow), also seen on axial postcontrast images (C, D, arrows). Multiple other nerve roots of the cauda equina demonstrated abnormal contrast enhancement though none were enlarged or clumped. Sagittal precontrast (E, G) and postcontrast (F, H) images of the intervertebral foramina show abnormal enhancement of right-sided dorsal root ganglia at L2-L3 (F, arrow) and L4-L5 (H, arrow). Axial postcontrast images show abnormal enhancement of the bilateral dorsal root ganglia at L2-L3 (I, arrows), L4-L5 (J, arrows), and L5-S1 (K, arrows).

REFERENCES

1. Ropper AH. The Guillain-Barré syndrome. *N Engl J Med* 1992;326:1130–1136.
2. Hughes RA, Cornblath DR. Guillain-Barré syndrome. *Lancet* 2005;366:1653–1666.
3. Lewis RA. Chronic inflammatory demyelinating polyneuropathy. *Neurol Clin* 2007;25:71–87.
4. Vallat JM, Sommer C, Magy L. Chronic inflammatory demyelinating polyradiculoneuropathy: diagnostic and therapeutic challenges for a treatable condition. *Lancet Neurol* 2010;9:402–412.
5. Sheikh SL, Amato AA. The dorsal root ganglion under attack: the acquired sensory ganglionopathies. *Pract Neurol* 2010;10:326–334.
6. Chiappa KH, Ropper AH. Evoked potentials in clinical medicine (second of two parts). *N Engl J Med* 1992;306:1205–1211.
7. Yiannikas C, Vucic S. Utility of somatosensory evoked potentials in chronic acquired demyelinating neuropathy. *Muscle Nerve* 2008;38:1447–1454.
8. Sinnreich M, Klein CJ, Daube JR, et al. Chronic immune sensory polyradiculopathy: a possibly treatable sensory ataxia. *Neurology* 2004;63:1662–1669.

Clinical Reasoning:

A 27-year-old man with hand numbness

Exploring new horizons and reinventing the past



Joy Vijayan, MD
Chan Yee Chuen, MRCP
Aubrey M. Punzalan, MD
Einar Wilder-Smith, MD

Correspondence to
Dr. Wilder-Smith:
mdcwse@nus.edu.sg

SECTION 1

A 27-year-old crane operator presented with left hand numbness of 3 months' duration. He reported pain above the left elbow following a trivial trauma prior to symptom onset. There was no involvement of other extremities. On examination, there was no wasting of the hand intrinsic muscles but mild weakness of the left abductor digiti quinti with normal power of long hand flexors. Sensation was impaired over the dorsal and volar medial one and

half fingers and palm. Deep tendon reflexes were 2+ with normal neurologic examination of the other extremities. There was tenderness and fullness over the left medial elbow. Systemic examination was unremarkable.

Questions for consideration:

1. What differential diagnoses would you consider?
2. What investigations would you suggest to confirm the diagnosis?

[GO TO SECTION 2](#)

**Supplemental data
at Neurology.org**

From the Division of Neurology, National University Hospital, Singapore.

Go to Neurology.org for full disclosures. Funding information and disclosures deemed relevant by the authors, if any, are provided at the end of the article.

Table Electrodiagnostic studies of the upper extremities

	Right	Left
Hand temperature	30.2	31.4
Median nerve studies		
Sensory nerve conduction		
Median (digit 3) orthodromic		
Sensory peak latency, ms	3.10	3.15
Sensory nerve action potential, μ V	21.8	18.1
Conduction velocity, m/s	57.9	51
Motor nerve conduction		
Median abductor digiti minimi		
Distal latency, ms	3.20	2.95
Motor amplitude (wrist), mV	7.3	10.4
Proximal motor latency, ms	7.30	6.10
Motor amplitude (elbow), mV	7.3	10.7
Conduction velocity, m/s	56.8	69.8
F-wave latency, ms	24.30	23.65
Ulnar nerve studies		
Sensory nerve conduction		
Ulnar (digit 5) orthodromic		
Sensory peak latency, ms	2.50	2.80
Sensory nerve action potential, μ V	11.5	7.4
Conduction velocity, m/s	53.7	53.7
Dorsal ulnar cutaneous nerve		
Sensory peak latency, ms	1.90	—
Sensory amplitude, μ V	4.1	Absent
Conduction velocity, m/s	40	—
Motor nerve conduction		
Ulnar abductor digiti quinti		
Distal motor latency, ms	2.10	2.8
Motor amplitude (wrist), mV	9.30	6.3
Motor latency (below elbow), ms	5.55	7.10
Motor amplitude (below elbow), mV	8.4	6.6
Conduction velocity (below elbow-wrist), m/s	63.8	46.8
Motor latency (above elbow), ms	7.15	10.3
Motor amplitude (above elbow), mV	8.5	3.0
Conduction velocity (across elbow), m/s	62.5	40.0
F-wave latency, ms	27.70	31.80
Ulnar first dorsal interossei		
Distal motor latency, ms	3.45	2.65
Motor amplitude (wrist), mV	7.2	7.3
Motor latency (below elbow), ms	7.25	7.40
Motor amplitude (below elbow), mV	6.2	7.3
Conduction velocity (below elbow-wrist), m/s	52.6	40.0
Motor latency (above elbow), ms	9.10	10.50
Motor amplitude (above elbow), mV	5.9	4.1

Continued

SECTION 2

The clinical scenario presented is compatible with a left-sided ulnar neuropathy. Other differential diagnoses that need to be considered include involvement of the medial cord or lower trunk of the brachial plexus and a C8-T1 radiculopathy. The clinical sign that confirms the clinical impression of an ulnar neuropathy is sensory loss confined to the dermatomal distribution of the ulnar nerve. The left elbow pain suggests the site of ulnar nerve pathology.

Further evaluation would help narrow the etiologic diagnosis. An elbow joint pathology with compression of the nerve as a result of arthritis, synovitis, osteophytes, or loose articular bodies is common. Other common causes of an ulnar neuropathy at the elbow include cubital tunnel syndrome or compression of the nerve in the retrocondylar groove. Less common causes are nerve compression in the retrocondylar groove as a result of past trauma, ganglia, lipoma, a primary nerve tumor, or presence of a variant anconeus epitrochlearis muscle. Rarely, entrapment of the ulnar nerve in the arm can occur beneath and proximal to the ligament of Struthers. Systemic diseases associated with ulnar neuropathy include acromegaly and leprosy.

The initial investigations should include electrodiagnostic studies and an x-ray of the elbow. X-ray of the left elbow showed no deformity or joint effusion. Electrodiagnostic studies are important for confirming the diagnosis of ulnar neuropathy and help distinguish it from a medial cord or lower trunk brachial plexopathy and a C8-T1 radiculopathy. Furthermore, they assist in localizing the lesion in case of a mononeuropathy and in differentiating axonal from demyelinating pathology. The table shows the nerve conduction study report.

Question for consideration:

1. How would you interpret the electrodiagnostic studies?

GO TO SECTION 3

Table	Continued	
	Right	Left
Conduction velocity (across elbow), m/s	63.2	41.9
F-wave latency, ms		
Short segment incremental studies		
6 cm below elbow, ms		6.60
4 cm below elbow		7.15
2 cm below elbow		7.35
At elbow		7.50
2 cm above elbow		7.70
4 cm above elbow		9.90
6 cm above elbow		10.55
Radial nerve studies		
Radial cutaneous sensory nerve		
Sensory peak latency, ms	1.85	2.00
Sensory amplitude, μ V	47.4	49.3
Sensory conduction velocity, m/s	55.2	58.1

SECTION 3

Electrodiagnostic studies demonstrated a left-sided ulnar mononeuropathy. Normal medial antebrachial cutaneous potentials make a medial cord or lower trunk brachial plexopathy less likely. Sensory potentials are preserved in vertebral foraminal compression of sensory nerve roots as the lesions are preganglionic. The absent dorsal ulnar cutaneous nerve potential and the presence of normal median compound muscle action potential make the diagnosis of left-sided C8-T1 radiculopathies unlikely.

A comprehensive electrodiagnostic study of the ulnar nerve should include ulnar motor studies with recordings from the abductor digiti quinti and first dorsal interossei and stimulating at the wrist, below and above elbow, axilla, and supraclavicularly.¹ Ulnar sensory studies include recording or stimulating digit 5, digit 4, and the dorsum of the medial hand. Further studies include mixed nerve stimulation at the wrist and recording from below and above the elbow and comparison of conduction velocity between the wrist-to-below-elbow segment and the across-elbow segment.

Further techniques to localize the lesion at the elbow segment include short segment incremental stimulation (inching) studies and needle EMG. These techniques can reveal an abnormality even when routine ulnar nerve studies are normal.²⁻⁴ Inching studies are performed across the elbow by stimulating the ulnar nerve

at 2-cm increments starting 6 cm below the elbow to 6 cm above and looking for abrupt change in latency or drop in amplitude between adjacent segments.

Short segment incremental stimulation studies can localize the compression to any of the following sites: proximal to Struthers ligament, the retrocondylar groove, proximal to the humeroulnar arcade, or as the ulnar nerve exits from underneath the flexor carpi ulnaris (FCU). However, the effectiveness of this technique is limited with subluxation of the ulnar nerve, which would make the points of stimulation along the ulnar nerve inaccurate.^{5,6} Ulnar subluxation is common, occurring in 10%–20% of the population.

Needle EMG studies mainly help in excluding a lower brachial plexopathy or a C8-T1 radiculopathy. Their main value in localization of ulnar nerve lesions is in differentiating proximal from distal lesions. Proximal lesions are associated with denervation potentials from the FCU and flexor digitorum profundus. The variable exit of the motor branch to the FCU above or below the elbow, selective fascicular sparing (the first dorsal interossei branch is most commonly affected), and mild compression of the ulnar nerve can, however, decrease the sensitivity of EMG studies in localizing the site of compression of the ulnar nerve at the elbow.

Our patient demonstrated unequivocal evidence of a conduction block with more than 50% drop in amplitude when stimulating the ulnar nerve segment from below and above the elbow and recording from the abductor digiti quinti. In addition, there is segmental conduction slowing across the elbow. This is compatible with an ulnar neuropathy at the elbow of demyelinating type. The absence of response from the left dorsal ulnar cutaneous nerve and the slowing in the motor conduction velocity of the wrist to elbow ulnar nerve segment when recording from the first dorsal interossei suggest mixed demyelinating and axonal involvement.

Short segment incremental studies for further localization, however, indicated a more proximal lesion in the above elbow segment. The latency difference and drop in amplitude were greatest between sites 2 cm and 4 cm above the elbow, suggesting localized nerve pathology in that location. Needle EMG was not performed as localization was achieved through nerve conduction studies.

Question for consideration:

1. What investigations would further characterize the ulnar neuropathy at the elbow?

GO TO SECTION 4

SECTION 4

Peripheral nerve ultrasound is an important adjunct investigative modality in peripheral nerve disorders, especially in entrapment neuropathies. Its role in detecting and confirming ulnar neuropathies at the elbow has been established.^{7,8} The diagnostic yield is highest when electrodiagnostic studies show signs of ulnar neuropathy without being able to localize. Studies have also shown its value in nerve lesions outside the elbow.⁹

The differential diagnoses of neuropathies with nerve enlargement include Charcot-Marie-Tooth disease, hereditary neuropathy with liability to pressure palsies (HNPP), chronic inflammatory demyelinating polyneuropathy, leprous neuropathy, amyloid neuropathy, neurofibromatosis, and primary nerve tumors.

Further characterizations include the following:

1. Localizing the site, length, and pattern of enlargement
2. Differentiating a focal neural enlargement involving one nerve vs a generalized disease process involving multiple nerves
3. Demonstrating preservation or loss of fascicular architecture

Nerve enlargement with preservation of fascicular architecture is seen in Charcot-Marie-Tooth disease and acromegaly. There is diffuse enlargement of the

nerves not restricted to entrapment sites. This is in contrast to HNPP, where the nerve enlargement tends to be pronounced at usual sites of entrapment. The pattern and length of enlargement can be helpful, with focal nodular enlargement being commonly associated with neurofibromatosis as opposed to diffuse fusiform swelling seen in leprosy. Entrapment neuropathies result in focal nerve enlargement with loss of fascicular architecture at the site of entrapment.

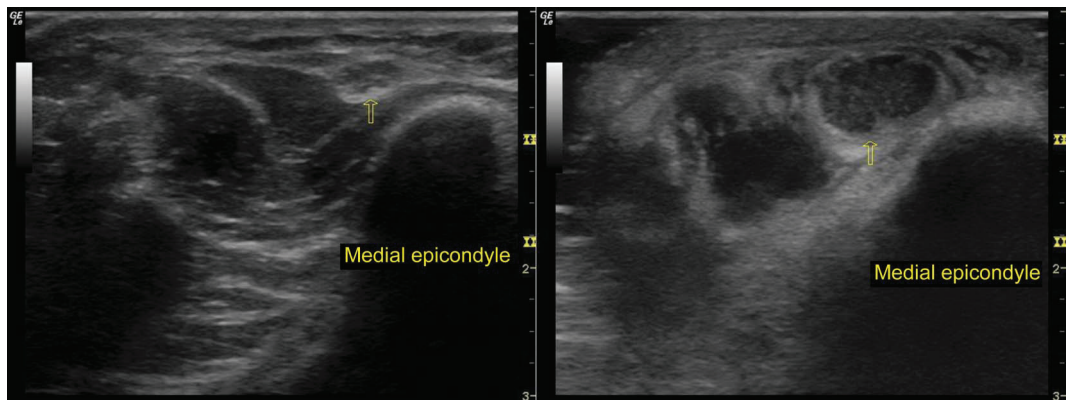
Our patient demonstrated fusiform swelling of the ulnar nerve at the elbow, which extended proximally up to the midarm with alteration of fascicular architecture and nerve echogenicity (figure; video on the *Neurology*[®] Web site at Neurology.org). The latter 2 features suggest nerve edema as a result of an inflammatory process. In addition, there was enlargement of asymptomatic nerves of both the upper extremities, including the right ulnar nerve at the elbow, the right dorsal ulnar cutaneous nerve, and both superficial radial sensory nerves. The presence of nerve tenderness, enlargement of asymptomatic nerves, and preferential involvement of the superficial cutaneous nerves makes the diagnosis of pure neuritic leprosy highly probable.

Question for consideration:

1. What would your next line of management be?

[GO TO SECTION 5](#)

Figure Sonographic images of ulnar nerve at the sulcus ulnaris



Normal-sized ulnar nerve, with a cross-sectional area of 0.09 cm², at the sulcus ulnaris on the left; and a grossly enlarged nerve, cross-sectional area of 0.43 cm², on the right.

SECTION 5

Left dorsal ulnar cutaneous nerve biopsy revealed solid nests and sheets of foamy, vacuolated cells and histiocytes with accompanying chronic inflammatory infiltrate. There were numerous acid-fast bacilli on the FITE stain confirming the diagnosis of leprosy. Leprosy can be diagnosed based on the triad of enlarged nerves, localized patches of skin anesthesia, and positive acid-fast bacilli on tissue samples. In the absence of typical skin patches, as in our patient, leprosy is diagnosed based on enlarged nerves and demonstration of acid-fast bacilli in nerves or skin. Our patient was started on rifampicin, dapsone, and clofazamine with oral prednisolone.

This case demonstrates the role of peripheral nerve ultrasound in aiding the diagnosis of an Old World disease like leprosy. Its value in detecting the involvement of asymptomatic nerves with normal electrodiagnostic studies can be of significant value in narrowing the differential diagnoses.¹⁰

AUTHOR CONTRIBUTIONS

Drs. Vijayan, Punzalan, and Wilder-Smith performed the initial diagnostic assessment and investigations. Dr. Vijayan, C.Y. Chuen, and Dr. Wilder-Smith helped in compilation of the text, literature search, and editing of the manuscript.

STUDY FUNDING

No targeted funding reported.

DISCLOSURE

J. Vijayan, C. Cheun, and A. Punzalan report no disclosures. E. Wilder-Smith received a travel grant from GlaxoSmithKline French to attend an American Epilepsy Society annual meeting, serves as an Associate Editor of *Neurology Asia*, and serves as a consultant to a diagnostic laboratory that performs the investigations described in this article. Go to Neurology.org for full disclosures.

REFERENCES

1. American Association of Electrodiagnostic Medicine. American Academy of Neurology, American Academy of Physical Medicine and Rehabilitation: practice parameter for electrodiagnostic studies in ulnar neuropathy at the elbow: summary statement. *Muscle Nerve* 1999;22:408–411.
2. Campbell W, Pridgeon R, Sahni KS. Short segment incremental studies in the evaluation of ulnar neuropathy at the elbow. *Muscle Nerve* 1992;15:1050–1054.
3. Herrmann DN. Localization of ulnar neuropathy with conduction block across the elbow. *Muscle Nerve* 2001;24:698–700.
4. Visser LH, Beekman R, Franssen H. Short-segment nerve conduction studies in ulnar neuropathy at the elbow. *Muscle Nerve* 2005;31:331–338.
5. Campbell W, Pridgeon R, Riaz G, Astruc J, Sahni KS. Variations in anatomy of the ulnar nerve at the cubital tunnel: pitfalls in the diagnosis of ulnar neuropathy at the elbow. *Muscle Nerve* 1991;14:733–738.
6. Won SJ, Yoon JS, Kim JY, Kim SJ, Jeong JS. Avoiding false-negative nerve conduction study in ulnar neuropathy at the elbow. *Muscle Nerve* 2011;44:583–586.
7. Beekman R, Van Der Plas JP, Uitdehaag BM, Schellens RL, Visser LH. Clinical, electrodiagnostic, and sonographic studies in ulnar neuropathy at the elbow. *Muscle Nerve* 2004;30:202–208.
8. Beekman R, Schoemaker MC, Van Der Plas JP, et al. Diagnostic value of high-resolution sonography in ulnar neuropathy at the elbow. *Neurology* 2004;62:767–773.
9. Ng ES, Vijayan J, Therimadasamy AK, et al. High resolution ultrasonography in the diagnosis of ulnar nerve lesions with particular reference to post-traumatic lesions and sites outside the elbow. *Clin Neurophysiol* 2011;122:188–193.
10. Elaias J Jr, Nogueira-Barbosa MH, Fletrin LT, Furini RB, Foss NT, Marques W Jr. Role of ulnar nerve sonography in leprosy neuropathy with electrophysiologic correlation. *J Ultrasound Med* 2009;28:1201–1209.

Clinical Reasoning: A 34-year-old woman with recurrent bouts of acral paresthesias

Chafic Karam, MD
Stephen N. Scelsa, MD

Address correspondence and
reprint requests to Dr. Chafic
Karam, Phillips Ambulatory Care
Center, 10 Union Square East,
Suite 5 D, New York, NY 10003
chafickaram@hotmail.com

SECTION 1

A 34-year-old, previously healthy woman presented with a 3-year history of persistent numbness and tingling in her feet ascending to the knees. She was a lifelong long-distance runner, and she normally experiences numbness and tingling in both feet while running that resolve within minutes of stopping her exercise.

Three years ago, she developed diarrhea that was followed a week later by paresthesias in her feet and legs with a stocking distribution to the knees. Her symptoms were associated with a transient feeling of overwhelming fatigue, limiting her ambulation to 1 city block. She did not, however, have any functional weakness. After 2 weeks, milder hand and left face paresthesias developed. Four weeks later, her symptoms plateaued and persisted. Three months later, she developed more intense paresthesias and a sensation of “crawling” below both knees. At that time, she was seen at another hospital, where the examination showed bilateral pes cavus and hammertoes. There was no nerve thickening. Cranial nerves were

intact. Strength was normal except for mild bilateral thenar weakness and slight difficulty with heel walking. The deep tendon reflexes were decreased at the arms and ankles. There was decreased pinprick sensation in the feet in a stocking-glove distribution with hyperalgesia. Vibration was moderately diminished at the ankles.

Nerve conduction studies and electromyography (NCS/EMG) at that time showed uniform, mild conduction velocity slowing of both sensory and motor conduction with borderline prolonged distal latencies in the median and ulnar nerves. She was treated with a 1-month taper of prednisone beginning with 80 mg daily. The crawling sensation resolved and the paresthesias became less intense and stabilized. She was able to resume distance running, but still had persistent, mild numbness in her feet with bouts of increasing intensity every several months. Three years later, the patient presented to us for a second opinion.

Question for consideration:

1. What is the differential diagnosis?

[GO TO SECTION 2](#)

SECTION 2

The acute onset of acral paresthesias after an episode of diarrhea raises the possibility of Guillain-Barré syndrome (acute inflammatory demyelinating polyneuropathy). The patient did not seek medical attention at that time. If she had, CSF examination would have been helpful in making the diagnosis. For example, a marked elevation in CSF protein, although nonspecific, is suggestive of an acquired demyelinating polyneuropathy. Her symptoms resolved but recurred 3 months later. This recurrence of symptoms makes Guillain-Barré syndrome less likely. Several clinical and electrophysiologic clues can help the clinician differentiate acquired from inherited neuropathies. Clinically, patients with inherited neuropathies present with a long, slowly progressive history, while patients with acquired neuropathies usually present with more acute or subacute weakness and sensory changes. Foot deformities such as pes cavus and hammertoes are usually indicative of an inherited neuropathy. Paresthesias and tingling are generally seen in acquired polyneuropathies, while painless loss of motor and sensory function are usually observed in hereditary motor and sensory neuropathies. Motor nerve conduction studies in inherited neuropathies are usually uniformly slow, with no temporal dispersion or conduction block. Acquired polyneuropathies frequently have focal slowing or conduction block in a multifocal and segmental pattern on the nerve conduction studies. It should be kept in mind that rare cases of Charcot-Marie-Tooth 1C (CMT1C), as well as hereditary neuropathy with liability to pressure palsies (HNPP) and X-linked Charcot-Marie-Tooth (CMTX), may have multifocal

conduction block or temporal dispersion mimicking chronic inflammatory demyelinating polyneuropathy (CIDP).

In our patient, the conduction velocity slowing of both sensory and motor conduction with preserved motor response amplitude is suggestive of demyelinating polyneuropathy. The clinical course suggested an acquired, distal, symmetric sensory variant of CIDP. In addition, the response to steroids reported by the patient raises the possibility of an immune-mediated demyelinating neuropathy. Other forms of immune-mediated demyelinating polyneuropathy that could be included in the differential diagnosis include polyneuropathy with antibodies to myelin-associated glycoprotein (anti-MAG), which is uncommon before the sixth decade; CIDP with or without IgA or IgG monoclonal gammopathy of unknown significance (MGUS); and multifocal motor neuropathy (MMN), characterized by multifocal motor involvement. In the presence of systemic involvement, one should consider POEMS syndrome (polyneuropathy, organomegaly, endocrinopathy or edema, M protein, and skin changes). The patient presented here did not have features suggestive of POEMS.

On the other hand, the presence of pes cavus and hammertoes suggests a chronic peripheral neuropathy despite the relatively short duration of symptoms. Furthermore, the uniform slowing on nerve conduction studies suggest a demyelinating form of Charcot-Marie-Tooth (CMT) disease.

Question for consideration:

1. What further evaluation should be obtained?

GO TO SECTION 3

SECTION 3

At this point, a detailed familial history should be obtained, keeping in mind that sporadic genetic mutations are possible. In 2008, the American Academy of Neurology issued an evidence-based practice parameter on the laboratory and genetic evaluation of distal symmetric polyneuropathies.¹ Based on this practice parameter, patients with a distal symmetric polyneuropathy may undergo screening laboratory tests. The tests that provide the highest yield are blood glucose, serum B12 with methylmalonic acid, and serum protein immunofixation electrophoresis. Genetic testing may be considered in patients with cryptogenic polyneuropathy who exhibit a hereditary neuropathy phenotype. Genetic testing should be guided by the clinical phenotype, inheritance pattern, and electrodiagnostic features and should focus on the most common abnormalities, such as CMT1A duplication/HNPP deletion (severe demyelinating), Cx32 (GJB1) (mixed axonal and demyelinating), and MFN2 (axonal) mutation screening.

When the patient presented to us 3 years after the initial onset of symptoms, she reported persistent, mild numbness in her feet with bouts of increasing intensity every several months. She never stopped her long-distance running. A detailed personal and familial history showed that she had normal developmental milestones, particularly no delay in walking. Apart from her brother, who also had foot numbness, the family history was negative. She had 2 children with no neurologic complaints. Repeat EMG/NCS showed mild, uniform slowing of sensory and

motor conduction, prolonged peroneal F wave minimal latencies, no conduction block, and normal needle EMG of the leg (table). In order to rule out other causes of demyelinating polyneuropathies, laboratory tests were performed, including routine chemistries and blood count; hemoglobin A1C (diabetes may be associated with a demyelinating neuropathy); anti-MAG (NCV show diffuse slowing but distal latencies are usually markedly increased); antibody GM1 (which can be increased in patients with acquired, demyelinating polyneuropathies, and particularly motor neuropathies); quantitative immunoglobulins; immunofixation (IgM MGUS is usually associated with demyelinating polyneuropathy with MAG or Waldenstrom macroglobulinemia); B12 and Lyme ELISA (usually associated with axonal neuropathy but demyelinating neuropathies may occur); cryoglobulin (cryoglobulin-associated neuropathies may have motor conduction slowing); and erythrocyte sedimentation rate (ESR) and rheumatoid factor (RF). All of these were negative or normal.

Because of the negative evaluation for acquired causes of neuropathies, the presence of hammertoes and pes cavus, and the uniform slowing of sensory and motor conduction, the diagnosis of CMT neuropathy was entertained and genetic testing was performed. Patients with intermediate motor nerve conduction studies could have mutations in DNMT2 (dynamitin2) and YARS (tyrosyl-tRNA synthetase), PMP22, MPZ, MFN2 (mitofusin 2), NEFL (neurofilament light), GJB1/Cx32 (gap junction protein, beta-1 gene), or GDAP1 (ganglioside-induced differentiation-associated protein 1 gene).² Testing for each of these genes is neither practical nor cost-effective. If an inheritance pattern could be identified, one could test for specific genes accordingly. In our patient, however, the family history was unclear (no symptoms in her family apart from her brother). Relying on clinical and electrophysiologic data are helpful but can be misleading. Mutation in the same gene can result in different phenotypes, even within the same family. To determine which genetic tests to perform, the physician is guided by a combination of clinical and electrophysiologic findings, and on the relative frequencies of known gene defects. Thus, testing for PMP22, MPZ, and Cx32 mutations will lead to a diagnosis in 66% of the patients with inherited neuropathies,³ and is reasonable when motor conduction slowing is evident on NCS.

In our patient, MPZ variant 1 showed an 8–base pair deletion at the nucleotide position 130–137 and the codon position 44–46, which resulted in a frameshift mutation. Cx32 (GJB1) and PMP22 analysis showed no sequence alteration. Genetic testing

Table Nerve conduction studies showing mild, uniform slowing of sensory and motor conduction

Nerve stimulation	Recording site	Latency, ms	Amplitude, μ V	Velocity, ms
Sensory NCS				
R median (digit II)	Wrist	3.6	22	49
R ulnar (D5)	Wrist	3.7 ^a	10	41 ^a
R sural (calf)	Lat mall	4	25	39
R superior peroneal	Ankle	4.7 ^a	9	34 ^a
Motor NCS				
R median wrist	APB	3.7	12.6	
Elbow	APB	8.9	12.2	42.3 ^a
R ulnar wrist	ADM	2.9	10.4	
Below the elbow	ADM	7.8	9.1	47.4
Above the elbow	ADM	10.4	8.3	46.2 ^a
R comm peroneal ankle	EDB	4.3	4.6	
R comm peroneal B fib head	EDB	15.7	2.9	30.7 ^a
R comm peroneal A fib head	EDB	18.4	2.8	29.6 ^a

Abbreviations: ADM = abductor digiti minimi; APB = abductor pollicis brevis; comm = common; EDB = extensor digitorum brevis; fib = fibular; NCS = nerve conduction studies.

^aAbnormal values.

for mutations in the above genes was negative in the patient's mother.

DISCUSSION Our patient's initial presentation of acute acral paresthesias after an episode of diarrhea raised the possibility of acute inflammatory demyelinating polyneuropathy. Later, the initial response to prednisone was consistent with an inflammatory polyneuropathy. In addition, there was no clear familial history apart from the brother who had foot numbness.

However, symptoms of numbness in her feet while running for several years and the presence of hammer-toes and pes cavus on examination suggested CMT. This was further supported by generalized and uniform slowing on nerve conduction studies and the negative evaluation for acquired causes of neuropathies. CMT is classified as demyelinating (CMT1) when the median or ulnar nerve motor conduction velocities are less than 25 m/s and axonal (CMT2) when the median NCV are above 42 m/s. Application of the term "intermediate" to describe NCVs in the 25–42 m/s range can be confusing since NCVs in affected individuals with CMT types 1 or 2 can also lie in that range, and because of the overlap of values in axonal CMT2A and the demyelinating form of CMT and CMT1A.² The term "intermediate" is correctly applied to the form of CMT and not the NCV value. Intermediate forms of CMT should also have evidence of both demyelinating and axonal pathology.²

Peripheral myelin protein zero (MPZ) accounts for more than half of the peripheral nervous system myelin. It plays an essential role in myelination, particularly in myelin compaction, which is related to its homophilic adhesion properties.⁴ Mutations in the MPZ gene, located on 1q22, account for about 5% of patients with CMT.⁵ Transmission is usually autosomal dominant, but sporadic cases occur.⁶

Our patient had an 8-bp deletion at the nucleotide position 130–137, resulting in a frameshift mutation of MPZ. This mutation predicts an autosomal dominant form of CMT. In this family, it appeared as a novel mutation, which is common for MPZ.⁷ To our knowledge, this frameshift mutation has not been described.

More than 95 different mutations (mostly point mutations) in the MPZ gene have been identified so far. Thirteen are caused by a frameshift mutation.⁸ Mutations in the MPZ gene are associated with a great variety of clinical phenotypes, ranging from a severe disease with onset of weakness and sensory loss (e.g., Dejerine-Sottas syndrome) to a mild form of demyelinating neuropathy with or without papillary involvement (CMT 1B) or an axonal neuropathy (CMT2).

Genetic testing is required to confirm the diagnosis and identify the specific subtype. The site of the mutation is thought to predict the severity of the disease. An evaluation of 73 patients with CMT1B related to mutations in the MPZ showed that most patients presented with either an early onset or a late onset neuropathy.⁶ The type of frameshift mutation that was observed in our patient appears to cause a mild form of CMT. The acute exacerbations (i.e., the paresthesias) may be precipitated by a viral infection. It is unclear if the resolution of these sensory symptoms is part of the natural history of the disease or is secondary to the steroids. The response to prednisone has been described previously in patients with CMT1, where sudden deterioration in symptoms was relieved by steroids or IVIg.⁹ This could be explained by the lymphocytic infiltration of the nerve that occurs in some cases of CMT.¹⁰

DISCLOSURE

Dr. Karam serves on the editorial team for the *Neurology*[®] Resident & Fellow Section. Dr. Scelsa reports no disclosures.

REFERENCES

1. England JD, Gronseth GS, Franklin G, et al. Practice parameter: evaluation of distal symmetric polyneuropathy: role of laboratory and genetic testing (an evidence-based review): report of the American Academy of Neurology, American Association of Neuromuscular and Electrodiagnostic Medicine, and American Academy of Physical Medicine and Rehabilitation. *Neurology* 2009;72:185–192.
2. Nicholson G, Myers S. Intermediate forms of Charcot-Marie-Tooth neuropathy: a review. *Neuromol Med* 2006;8:123–130.
3. Szigeti K, Garcia CA, Lupski JR. Charcot-Marie-Tooth disease and related hereditary polyneuropathies: molecular diagnostics determine aspects of medical management. *Genet Med* 2006;8:86–92.
4. Giese KP, Martini R, Lemke G, Soriano P, Schachner M. Mouse P0 gene disruption leads to hypomyelination, abnormal expression of recognition molecules, and degeneration of myelin and axons. *Cell* 1992;71:565–576.
5. Nelis E, Van Broeckhoven C, De Jonghe P, et al. Estimation of the mutation frequencies in Charcot-Marie-Tooth disease type 1 and hereditary neuropathy with liability to pressure palsies: a European collaborative study. *Eur J Hum Genet* 1996;4:25–33.
6. Shy ME, Jáni A, Krajewski K, et al. Phenotypic clustering in MPZ mutations. *Brain* 2004;127(Pt 2):371–384.
7. Boerkoel CF, Takashima H, Garcia CA, et al. Charcot-Marie-Tooth disease and related neuropathies: mutation distribution and genotype-phenotype correlation. *Ann Neurol* 2002;51:190–201.
8. Available at: <http://www.molgen.ua.ac.be/CMTMutations>. Accessed March 1, 2009.
9. Dyck PJ, Swanson CJ, Low PA, et al. Prednisone-responsive hereditary motor and sensory neuropathy. *Mayo Clin Proc* 1982;57:239–246.
10. Ginsberg L, Malik O, Kenton AR, et al. Coexistent hereditary and inflammatory neuropathy. *Brain* 2004;127:193–202.

Disorders presenting with abnormal movements

Normal motor function requires not just power and proprioception, but also normal tone and an appropriate quantity of movements over time. Whether we are physically active or in a state of repose, the outflow of both voluntary and involuntary movement commands must be precisely regulated. Among their many functions, the basal ganglia contribute to these extrapyramidal aspects of movement, including movement initiation, patterning, and control. Disorders of the basal ganglia can therefore cause movement disorders in which there is either decreased movement (hypokinetic movement disorders) or increased movement (hyperkinetic movement disorders).

Unlike other types of neurologic problems that rely on accurate localization to frame a differential diagnosis, the evaluation of movement disorders caused by diseases of the basal ganglia generally rests upon a careful characterization of the type of abnormal movement to guide the differential diagnosis. The most common hypokinetic movement disorder is parkinsonism, which can be seen in idiopathic Parkinson disease, other neurodegenerative Parkinson plus syndromes (e.g., multiple systems atrophy, dementia with Lewy bodies, progressive supranuclear palsy, corticobasal degeneration), and in secondary parkinsonism (e.g., drug-induced, vascular). Hyperkinetic movement

disorders include tremor, chorea, athetosis, ballism, tics, myoclonus, and dystonia.

Unilateral movement disorders warrant a search for an underlying structural lesion in the basal ganglia, but neurodegenerative movement disorders and some toxic and metabolic etiologies can also present unilaterally or asymmetrically. Bilateral movement disorders can be caused by immune disorders (e.g., Sydenham chorea), medications or drugs, underlying systemic disease (e.g., hyperthyroidism-induced tremor or chorea), or an underlying genetic or idiopathic disorder of the basal ganglia (e.g., Huntington disease, essential tremor, myoclonic epilepsy syndromes, genetic generalized dystonias).

Along with the basal ganglia, the cerebellum is also considered part of the extrapyramidal movement system. A lesion of the cerebellum can cause ataxia, dysmetria, dysdiadochokinesia, nystagmus and other eye movement abnormalities, and dysarthria. Midline cerebellar lesions affecting the vermis cause impaired gait, whereas lesions in the cerebellar hemispheres cause appendicular symptoms and signs ipsilateral to the affected hemisphere.

The cases in this section illustrate principles underlying the diagnosis and management of disorders of movement.

Clinical Reasoning: An 83-year-old woman with progressive hemiataxia, tremor, and infratentorial lesions



Karen Aquino, MD
Igor J. Koralnik, MD
David Silvers, MD

Address correspondence and
reprint requests to Dr. Karen
Aquino, Hartford Neurology,
85 Seymour Street, Suite 800,
Hartford, CT 06106
kmgquino@gmail.com

SECTION 1

An 83-year-old woman was hospitalized with 6 weeks of progressive left hand incoordination, dysarthria, and gait ataxia, followed by oscillopsia, dysphagia, and left upper limb tremor. She denied cognitive decline, headaches, diplopia, and sensory or systemic symptoms. Ten years previously, she had been diagnosed with locally invasive intraductal breast cancer and treated with lumpectomy, radiation, tamoxifen, and letrozole without recurrence. She denied tobacco or alcohol use. There was no family history of neurologic disease.

Results of the general medical examination were unremarkable. Her mental status was normal, although she had severe cerebellar dysarthria. On

cranial nerve examination, visual acuity degraded during attempted reading. She had saccadic pursuits and gaze-evoked, rebound, and downbeat nystagmus, without ophthalmoparesis. Saccades had a normal latency and velocity but were inaccurate. She had a left upper limb tremor and slight head tremor (videos 1–3 on the *Neurology*[®] Web site at www.neurology.org). Strength, sensation, and tendon reflexes were normal, with flexor plantar responses. She had significant dysmetria, dysdiadochokinesis, and rebound of the left limbs. Her gait was wide-based and ataxic.

Questions for consideration:

1. What are the findings displayed in the videos?
2. What is their localization?

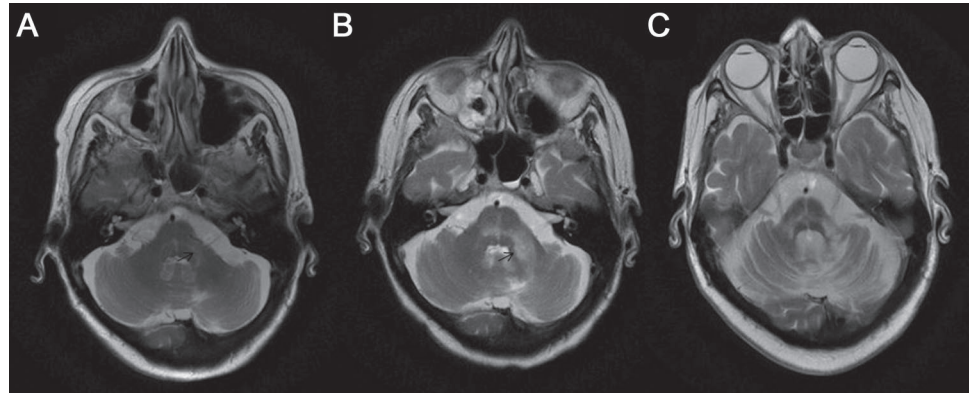
[GO TO SECTION 2](#)

Supplemental data at
www.neurology.org

From the Department of Neurology (K.A.), University of Connecticut, Hartford, CT; HIV/Neurology Center (I.J.K.), Beth Israel Deaconess Medical Center, Harvard Medical School, Boston, MA; and Department of Neurology (D.S.), University of Connecticut, Hartford, CT.

Disclosure: Author disclosures are provided at the end of the article.

Figure Axial T2-weighted images at the level of the pons



(A) Initial MRI scan showed increased signal intensity in the left medial cerebellum and a subtle crescent-shaped hyperintensity in the left middle cerebellar peduncle (arrow). (B) At 6 weeks, there was significant expansion of the crescent-shaped lesion (arrow) with extension of hyperintensity into the right pons and midbrain. (C) At 20 months, there was atrophy of the cerebellar vermis and hemispheres, with left greater than right. There was also increased signal intensity in the brainstem and caudal right cerebral peduncle with associated atrophy. No mass effect, gadolinium enhancement, or hypothalamic abnormality was seen on any of the studies.

SECTION 2

Video 1 demonstrates bilateral saccadic hypermetria, with macrosaccadic oscillations, which may be due to a fastigial nucleus lesion. Videos 2 and 3 illustrate a low-frequency kinetic > postural > rest tremor (i.e., Holmes tremor), which localizes near the red nucleus.

Normal or negative blood test results included complete blood count (absolute lymphocytes $1,535$ cells/ mm^3), chemistry panel, thyroid function, Lyme titer, HIV, vitamin E, anti-GAD₆₅ antibody, antinuclear antibody, paraneoplastic panel (anti-Hu, Ma1, Ma2, Yo, Ri, CV2, and Zic4), and antibodies to anti-Ro, anti-La, gliadin, endomysium, and tissue transglutaminase. Brain MRI performed on initial presentation was reported as normal, but in retrospect showed subtle abnormalities (figure, A). CSF revealed 5 white blood cells (WBCs)/ mm^3 (3 lymphocytes, 1 neutrophil, and 1 monocyte), protein 96 mg/dL, glucose 58 mg/dL, and 3 oligoclonal bands absent in serum, with negative results for a Lyme

titer, bacterial culture, and cytology. Results of mammography were negative. Chest/abdomen/pelvis CT showed biapical lung lesions, indicating a mass or scarring. Fluorodeoxyglucose PET showed regions of increased activity in the lung and colon, but subsequent biopsy results were negative. Hyponatremia (nadir 119 mmol/L) developed 2 months into the illness, spontaneously resolving after several weeks. The syndrome of inappropriate antidiuretic hormone secretion (SIADH) was the suspected cause of hyponatremia. A paraneoplastic syndrome was considered, and after the MRI scan, methylprednisolone (1 g) was given for 3 days with no improvement. The brainstem and cerebellar MRI abnormalities were more clearly evident 6 weeks later (figure, B).

Questions for consideration:

1. What is the differential diagnosis of a brainstem-cerebellar syndrome, with or without tremor, associated with multifocal T2-hyperintense infratentorial lesions?
2. What additional CSF studies would you perform?

GO TO SECTION 3

SECTION 3

Although the subacute onset, brisk progression, and oligoclonal bands suggest an inflammatory, autoimmune, or infectious etiology, the broader differential diagnosis includes neurodegenerative, neoplastic, and vascular conditions. Cerebellar-type multiple system atrophy and fragile X-associated tremor/ataxia syndrome cause insidiously progressive ataxia and intention tremor, sometimes with cerebellar peduncle T2 hyperintensities. The brain MRI was inconsistent with brain metastases or strokes. CNS lymphoma typically shows contrast enhancement on MRI and hypermetabolic activity with PET imaging, although brain biopsy remains the gold standard for diagnosis. Although Sjögren syndrome may rarely present with cerebellar ataxia, the history does not support Behçet disease or systemic lupus erythematosus. CNS Whipple disease and neurosarcoidosis may produce brainstem-cerebellar and hypothalamic dysfunction (e.g., SIADH). A brainstem syndrome may result from *Listeria monocytogenes*, *Borrelia burgdorferi*, herpesviruses, enterovirus 71, and JC virus (JCV) infection. The diagnosis of Bickerstaff brainstem encephalitis requires encephalopathy or pyramidal tract signs. A paraneoplastic process was suggested by the history of breast cancer, relatively rapid disability, and hyponatremia. As in multiple sclerosis (MS), progressive multifocal leukoencephalopathy (PML) may cause brainstem-cerebellar dysfunction and Holmes tremor.^{1,2} Our patient's advanced age at onset and crescent-shaped cerebellar lesion favor PML over MS.³

Repeat CSF analysis showed 13 WBCs/mm³ (8 lymphocytes, 2 neutrophils, and 3 monocytes), pro-

tein 78 mg/dL, and glucose 135 mg/dL; negative PCRs for herpes simplex virus (HSV), varicella zoster virus (VZV), and *Tropheryma whipplei*; and negative HSV, VZV, and cytomegalovirus immunoglobulin (Ig) G. PCRs were positive for JCV (24,272 copies/mL) and Epstein-Barr virus (EBV) (882 copies/mL, normal <200 copies/mL). The CD4 count was 141 cells/mm³ (absolute lymphocytes 224) 3 weeks after steroids and normalized by 8 weeks (780 cells/mm³). IgM was deficient (13 mg/dL [normal 56–357 mg/dL]), with normal IgA and IgG levels.

Her symptoms progressed for 6 months before stabilizing, leaving the patient with persistent dysarthria, tremor, and left-sided incoordination. Her functional status, including her ability to swallow and ambulate, later showed modest improvement with time. Mirtazapine, a serotonin receptor antagonist, which may block JCV cell entry, was started 9 months into the disease. IgM replacement was not given. A follow-up lumbar puncture was declined. Repeat MRI done at 20 months (figure, C) showed atrophy of the left cerebellar hemisphere extending to the brainstem and right cerebral peduncle. Our patient's survival was attributed to her relatively normal underlying immune status, with a detectable T-cell response against JCV in her blood.

Questions for consideration:

1. What are typical risk factors for PML?
2. What other JCV disorder might the patient have?
3. What is the significance of the elevated CSF EBV PCR?

GO TO SECTION 4

SECTION 4

PML is due to JCV infection of oligodendrocytes and astrocytes, primarily in hosts with impaired cellular immunity. It typically presents subacutely with visual, motor, sensory, cognitive, and gait dysfunction, whereas tremor is rare. MRI reveals asymmetric subcortical and cortical U-fiber T2 hyperintensities. The posterior fossa is often affected but rarely selectively.⁴ Involvement of glial cells within gray matter structures, such as the thalamus, basal ganglia, and cortex, is not uncommon. Ninety percent of lesions are nonenhancing, with minimal or no mass effect. In contrast, enhancement is common when PML occurs in the context of an immune reconstitution inflammatory syndrome (IRIS).⁵ Excluding PML-IRIS, CSF in PML is typically normal, although mild elevations in cell count and protein may be seen. CSF JCV PCR has a specificity of ~95%, but sensitivity varies, depending on the population tested (58%–95%). Brain biopsy may be required in CSF JCV PCR–negative patients.

Risk factors include HIV/AIDS, hematologic malignancies, organ transplantation, chronic inflammatory diseases, immunotherapies (e.g., natalizumab), idiopathic CD4+ lymphocytopenia, and, rarely, common variable immunodeficiency (CVID).⁶ Our patient's transient lymphopenia seemed to be due to steroids and acute medical illness.⁷ Adult-onset selective IgM deficiency has been associated with particular infections, but not PML. Occasionally chronic disease or advanced age is the only predisposing factor.⁸ Our patient possibly also had JCV cerebellar granule cell neuronopathy, a condition that eventually leads to cerebellar atrophy (figure, C).⁹

The elevated EBV PCR may reflect asymptomatic reactivation due to JCV infection. Alternatively, it may indicate a superimposed EBV encephalitis, which can range from a restricted brainstem encephalitis to a widespread meningoencephalomyeloradiculitis, which may include SIADH.¹⁰ Our patient's mildly elevated CSF cell count and protein may also support the possibility of an additional CNS infection such as EBV. EBV serology would have been necessary to provide definitive evidence for or against active infection. Elevated EBV PCR in patients with HIV/AIDS or recipients of organ transplants supports the diagnosis of a CNS lymphoproliferative disorder. Because hypothalamic dysfunction has not been reported in PML, the cause of hyponatremia in our patient remains uncertain.

PML can thus be entirely infratentorial and may rarely occur without overt immunosuppression. The contribution of IgM deficiency remains unclear, although it could be a *forme fruste* of CVID. A crescent-shaped cerebellar lesion may be a clue to the diagnosis.

AUTHOR CONTRIBUTIONS

K.A., I.J.K., and D.S. drafted/revised the manuscript. I.J.K. analyzed or interpreted the data and contributed vital reagents, tools, and patients.

DISCLOSURE

Dr. Aquino reports no disclosures. Dr. Koralnik has served on scientific advisory boards for Roche, GlaxoSmithKline, and Merck Serono; serves on the editorial board of *Journal of Neurovirology*; receives publishing royalties from UpToDate; has served as a consultant for Bristol-Myers Squibb, Ono Pharmaceutical Co. Ltd., Merck Serono, Antisense Therapeutics Limited, Alnylam Pharmaceuticals, Roche, and GlaxoSmithKline; and receives research support from Biogen Idec, the Neuro-AIDS research consortium, and the NIH. Dr. Silvers has received research support from Teva Pharmaceutical Industries Ltd. for neurology resident education.

REFERENCES

1. Rieder C, Ziolkowski S. Head tremor and progressive multifocal leukoencephalopathy in AIDS patients. *Arq Neuropsiquiatr* 2005;63:150–153.
2. Sporer B, Seelos K, Asmus F, et al. Posterior fossa tremor induced by HIV-associated progressive multifocal leukoencephalopathy. *Eur Neurol* 2005;53:96–97.
3. Boster A, Hreha S, Berger J, et al. Progressive multifocal leukoencephalopathy and relapsing-remitting multiple sclerosis: a comparative study. *Arch Neurol* 2009;66:593–599.
4. Svensson P, Larsson E. Infratentorial progressive multifocal leukoencephalopathy (PML) in a patient with SLE. *Eur Radiol* 2008;18:1526–1528.
5. Tan CS, Koralnik IJ. Progressive multifocal leukoencephalopathy and other disorders caused by JC virus: clinical features and pathogenesis. *Lancet Neurol* 2010;9:425–437.
6. Snyder MD, Storch GA, Clifford DB. Atypical PML leading to a diagnosis of common variable immunodeficiency. *Neurology* 2005;64:1661.
7. Buysmann S, van Diepen FN, Yong SL, et al. Mechanisms of lymphopenia following administration of corticosteroids. *Transplant Proc* 1995;27:871–872.
8. Gheuens S, Pierone G, Peeters P, Koralnik IJ. Progressive multifocal leukoencephalopathy in individuals with minimal or occult immunosuppression. *J Neurol Neurosurg Psychiatry* 2010;81:247–254.
9. Koralnik IJ, Wuthrich C, Dang X, et al. JC virus granule cell neuronopathy: a novel clinical syndrome distinct from progressive multifocal leukoencephalopathy. *Ann Neurol* 2005;57:576–580.
10. Portegies P, Corssmit N. Epstein-Barr virus and the nervous system. *Curr Opin Neurol* 2000;13:301–304.

Clinical Reasoning: A 6-year-old boy with uncontrollable right-sided movements

Kevin Gurcharran, BA

Correspondence & reprint
requests to Dr. Gurcharran:
Kevin.Gurcharran@mssm.edu

SECTION 1

A 6-year-old boy with no significant medical history presents for uncontrollable abnormal movements of the right side for 3 days. Four days prior to presentation, he complained to his mother that “something was wrong” with his right hand. Three days prior to presentation, his mother noticed he would drop things like books and pencils and be unable to pick them up, had difficulty feeding himself, and when he would try to run he would hop. He complained of difficulty writing and his handwriting was

uncharacteristically messy. His mother began to notice odd movements of his right upper extremity, such as rolling his wrist and rotating his shoulder. One day prior to presentation, he was complaining of generalized right-sided weakness and his mother noted he had difficulty lifting his right arm.

Questions for consideration:

1. What is the differential diagnosis?
2. What would you look for on review of systems? On physical examination?

[GO TO SECTION 2](#)

SECTION 2

The differential of a child with chorea is large and includes collagen vascular diseases, Wilson disease, Sydenham chorea (SC), paroxysmal dyskinesia, hyperthyroidism, drug intoxication, Tourette syndrome, and encephalitis, among others (table). Although its existence is unproven, pediatric autoimmune neuropsychiatric disease associated with streptococcal infection (PANDAS) should be kept in mind as it shares characteristics with SC.

Table Features of selected differential diagnoses of chorea		
	Age at onset	Features
Wilson disease	5–40 y	Liver disease is most common initial presentation. Neurologic symptoms can include chorea, parkinsonian symptoms, and incoordination. Kayser-Fleischer rings may be present. Common findings: abnormal liver function tests, low serum ceruloplasmin.
Tourette syndrome	Before age 18	Multiple motor and vocal tics nearly every day for a whole year. Cannot be asymptomatic for >3 consecutive months.
Sydenham chorea	3–15 y	Typically insidious chorea. Emotional lability and OCD may occur. May see other signs of RF at presentation.
PANDAS	Similar to SC	Abrupt onset OCD and tic disorder (vocal, motor, or TS). Must have evidence of recent strep infection. None of the non-neuropsychiatric symptoms of RF are present.
Paroxysmal kinesogenic dyskinesia	Early adolescence	Paroxysmal dystonic, choreic, or ballistic movements. Can have >100 attacks a day, which last seconds to minutes. Triggered by startle, or sudden movement. Associated with aura of muscle tightening or tingling.
Paroxysmal nonkinesogenic dyskinesia	Same as PKD	Movements similar to PKD. Only several attacks per day or per year, which last seconds to hours. No motor triggers, but provoked by caffeine, stress, alcohol, hunger.

Abbreviations: OCD = obsessive-compulsive disorder; PANDAS = pediatric autoimmune neuropsychiatric disease associated with streptococcal infection; PKD = paroxysmal kinesogenic dyskinesia; RF = rheumatic fever; SC = Sydenham chorea; TS = Tourette syndrome.

The patient denied any fever, chills, nausea, headache, sore throat, recent infections, throat clearing, history of seizures, recent trauma, rashes, dizziness, numbness, tingling, or joint pains. He was unable to suppress the movements, although they disappeared during sleep. His mother denied any changes in mood, appetite, or sleep. No obsessive thoughts or compulsive behaviors were noticed. No recent travel or sick contacts were reported. He was not on any medications or supplements. His last illness was a sore throat 14 months ago.

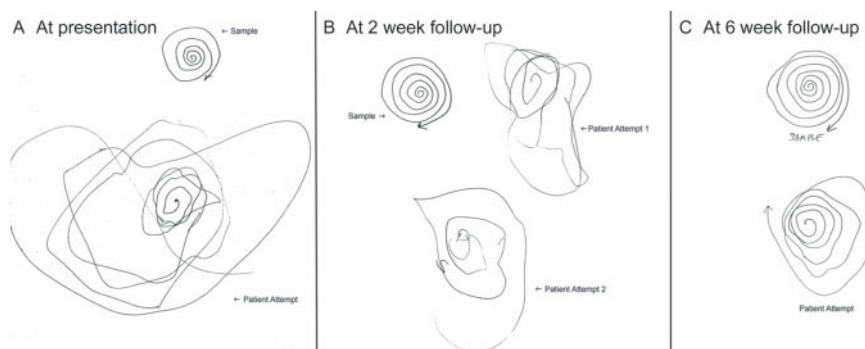
Neither past medical history nor family history was significant. There was no history of developmental delay. He is right handed.

On examination, he appeared well-developed and was alert and oriented to person, place, and time with reading and math skills above his grade level. Vital signs were within normal limits. No Kayser-Fleischer rings were present. Cardiac examination was significant for a III/VI blowing systolic ejection murmur loudest at the apex; his mother was not aware of a heart murmur before then. Motor examination was significant for nonstereotyped choreiform movements of the right arm and foot; subtle choreiform movements on the left; pronation on right arm extension overhead; milkmaid's grasp on the right; piano movements in the fingers and toes, worse on the right; and poor reproduction of Archimedes spiral (figure). Sensation was intact. Coordination and gait were normal, although choreiform movements sometimes interfered with smooth movements.

Questions for consideration:

1. What is your leading diagnosis?
2. What tests would you order?

Figure Patient reproduction of Archimedes spiral at presentation (A), at 2-week follow-up (B), and at 6-week follow-up (C)



GO TO SECTION 3

SECTION 3

Given his chorea and new murmur, SC was the working diagnosis. Tests ordered included head CT, EKG, complete blood count, erythrocyte sedimentation rate, metabolic panel, antistreptolysin O (ASLO), anti-DNAse B strep antibodies, thyroid tests, rapid plasma reagin, blood culture, and serum levels of ionized calcium, ceruloplasmin, copper, folate, parathyroid hormone, and vitamin B12. Given no changes in cognition or personality, no alteration of consciousness, and no abnormal sensations, EEG was not warranted. All tests were negative except for the ASLO and anti-DNAse B. In rheumatic fever (RF), the most common EKG finding is first-degree heart block; however, saddle ST elevation and T wave inversion can be seen.¹ EKG is not sensitive for early valvular lesions and a normal EKG does not preclude the presence of carditis. Echocardiography is more sensitive for cardiac lesions seen in RF and can identify silent carditis in patients with a normal EKG.¹ Therefore, if SC is suspected, echocardiography is vital.

A cardiology consult was obtained. Repeat EKG was normal. Echocardiography revealed mitral regurgitation and left ventricle diastolic dysfunction. With the clinical picture of carditis and chorea and the antistreptococcal studies, the diagnosis of RF was given and the chorea was confirmed as SC. He was discharged with IM penicillin as monthly antibiotic prophylaxis.

DISCUSSION SC is the neuropsychiatric manifestation of the poststreptococcal autoimmune disease, RF. SC is the most common acquired chorea.² It typically manifests during ages 5–15 and is twice as common in girls as in boys.³ Due to the recognition and appropriate treatment of streptococcal pharyngitis, the incidence of both SC and RF has decreased. However, RF is still significantly present in developing nations and still occasionally occurs in the United States.⁴

SC typically occurs 1–6 months after group A streptococcus (GAS) pharyngitis. While the exact pathophysiology is still under investigation, it is proposed that antibodies formed against GAS cross-react with neurons of the basal ganglia, ultimately leading to dopamine dysregulation and chorea.⁵ PANDAS is proposed to have this mechanism as well.

Clinical manifestations of SC are divided into neurologic and psychiatric. Neurologic manifestations include chorea, muscle weakness, and other motor symptoms. Chorea is described as abrupt, involuntary, irregular dance-like movements that flow from one body part to the next randomly. They are nonstereotyped and usually improve during sleep.

The face and extremities are typically affected; however, any muscle can be involved. Usually the chorea is generalized, although hemichorea is not uncommon.⁶ Other motor manifestations include grimacing, dysarthria, difficulty with writing, and hypotonia.⁷ Rarely, these patients become bedridden because of generalized hypotonia, referred to as chorea paralytica.² Psychiatric symptoms include mood lability and obsessive-compulsive disorder (OCD) and usually start 2 to 4 weeks before the movement symptoms.⁷

SC usually self-resolves within 6 months, but can last for as little as a week or as long as 3 years.⁴ Recurrent chorea is a possible long-term effect. Although SC has a relatively benign course, it is important to identify because it is often a presenting sign of RF.⁶ Sometimes carditis silently co-occurs and if not present at the time of presentation, there is a significant chance that carditis will develop later.^{2,6}

Imaging, EEG, and CSF studies, while not helpful in the diagnosis of SC, can help rule out other etiologies. Diagnosis of SC is clinical. Signs include motor impersistence, the inability to sustain muscle contraction, which can be demonstrated with tongue protrusion or testing grip strength (milkmaid's grasp); pronator sign, the pronation of one or both hands when held overhead; choreic hand, holding of the arms outstretched causing hyperextension of the fingers with dorsiflexion of the wrist; and diffuse hypotonia.³ The Jones criteria for RF (major: migratory arthritis, carditis, SC, erythema marginatum, subcutaneous nodules; minor: arthralgia, fever, elevated acute phase reactants, heart block on EKG) should be kept in mind and a thorough cardiac examination should be performed. No laboratory study is diagnostic of SC; however, ASLO and anti-DNAse can aid in the diagnosis. ASLO titers peak around 5 weeks then decline and may not be useful since the presentation of SC is often later. Anti-DNAse peaks around 8 weeks and remains elevated longer, making it more useful.⁸

Treatment is divided into treatment of the underlying infection, prophylaxis, and symptomatic treatment. The efficacy of antibiotic treatment of streptococcal pharyngitis is questionable and usually SC presents well after pharyngitis, but if present a 10-day course of oral penicillin is recommended. While SC is not particularly dangerous, the carditis associated with RF is. Therefore, once RF is diagnosed, prophylactic penicillin is started and maintained depending on the severity of carditis at the time of presentation. Without carditis, prophylaxis is continued for 5 years or until age 18, whichever is longer. With carditis, prophylaxis is continued for 10

years or until age 25, whichever is longer. With severe valvular disease, prophylaxis is lifelong.⁹

Symptomatic treatment of chorea is not necessary unless it is debilitating. In this case, drugs that antagonize dopamine or increase γ -aminobutyric acid (GABA) help to regulate dysfunctional neurons. Dopamine receptor antagonists like haloperidol have been effective. Antiepileptic drugs like valproate, which increase GABA, have been effective. The use of both classes of these drugs is off-label and they have side effects that require monitoring. Recently, tetrabenazine has been approved for the use of hyperkinetic disorders; it also is a dopamine receptor antagonist but does not carry the risk of tardive dyskinesia.

Treatment of the autoimmune component of SC may be helpful and includes corticosteroids, IV immunoglobulins (IVIg), and plasma exchange therapy. Small studies have shown corticosteroids improve chorea and reduce relapses.² IVIg is thought to inactivate autoantibodies, while plasma exchange removes the autoantibodies. A double-blind study compared plasma exchange and IVIg with prednisone and showed no significant difference between groups.² Given the lack of research, significant side effects, and high costs of IVIg and plasma exchange, the use of these 3 drugs should be reserved for patients with significant symptoms that are refractory to the other treatments. Finally, the psychiatric symptoms usually resolve with use of the treatments mentioned but selective serotonin reuptake inhibitors can help obsessive-compulsive disorder symptoms.

Despite the decreased incidence of SC, it is still present and can be the initial sign of RF. The long-term effects of RF are life-threatening, but can be

prevented. Therefore maintaining suspicion of SC in the evaluation of chorea is vital and can be lifesaving.

ACKNOWLEDGMENT

The author thanks Megan Alcauskas, MD, Department of Neurology, Mount Sinai School of Medicine, as a contributor (editing of nonintellectual content and general guidance).

REFERENCES

1. Kiliç A, Ünüvar E, Tatlı B, et al. Neurologic and cardiac findings in children with Sydenham chorea. *Pediatr Neurol* 2007;36:159–164.
2. Walker KG, Wilmshurst JM. An update on the treatment of Sydenham's chorea: the evidence for established and evolving interventions. *Ther Adv Neurol Disord* 2010;3:301–309.
3. Aron AM, Freeman JM, Carter S. The natural history of Sydenham's chorea. *Am J Med* 1965;38:83–95.
4. Bonthius DJ, Karacay B. Sydenham's chorea: not gone and not forgotten. *Semin Pediatr Neurol* 2003;10:11–19.
5. Kirvan CA, Swedo SE, Kurahara D, Cunningham MW. Streptococcal mimicry and antibody-mediated cell signaling in the pathogenesis of Sydenham's chorea. *Autoimmunity* 2006;39:21–29.
6. Zomorodi A, Wald ER. Sydenham's chorea in western Pennsylvania. *Pediatrics* 2006;117:675–679.
7. Swedo SE, Leonard HL, Schapiro MB, et al. Sydenham's chorea: physical and psychological symptoms of St Vitus dance. *Pediatrics* 1993;91:706–713.
8. Ayoub EM, Wannamaker LW. Streptococcal antibody titers in Sydenham's chorea. *Pediatrics* 1966;38:946–956.
9. Gerber MA, Baltimore RS, Eaton CB, et al. Prevention of rheumatic fever and diagnosis and treatment of acute streptococcal pharyngitis: a scientific statement from the American Heart Association Rheumatic Fever, Endocarditis, and Kawasaki Disease Committee of the Council on Cardiovascular Disease in the Young, the Interdisciplinary Council on Functional Genomics and Translational Biology, and the Interdisciplinary Council on Quality of Care and Outcomes Research. *Circulation* 2009;119:1541–1551.

Clinical Reasoning: A 52-year-old woman with subacute hemichorea

Sarah M. Kranick, MD
Raymond S. Price, MD
Sashank Prasad, MD
Howard I. Hurtig, MD

Address correspondence and
reprint requests to Dr. Sarah
Kranick, Department of
Neurology, Hospital of the
University of Pennsylvania, 3
West Gates Bldg., 3400 Spruce
St., Philadelphia, PA 19104
sarah.kranick@uphs.upenn.edu

SECTION 1

A 52-year-old Korean woman with a history of poorly controlled Type 1 diabetes presented for evaluation of abnormal movements of her right arm and leg. The movements began insidiously in her right hand and arm, progressing over several months to involve the right foot as well. She was unaware of the movements until her husband noticed them. Over time the movements became more violent, eventually leading to severe flinging movements in the right arm. The movements interfered with activity. They were neither suppressible nor associated with any unpleasant internal sensation. In retrospect, her husband felt that the onset had been heralded by several months of subtle personality change: he described her as more quiet, and no longer “the life of the party.”

She was known to the clinic, having presented the year prior with several years of progressive numbness and paresthesias in the feet, lower legs, and hands. An EMG at that time revealed severe sensorimotor polyneuropathy, attributed to her long-standing diabetes. She had no other known medical illnesses. Her only medication was insulin and she was never treated with antipsychotic, antiemetic, or hormone replacement therapies. She denied the use of herbal or over-the-counter medications. There was no history of any toxic exposures. She was married without children and was a homemaker. She was adopted.

Question for consideration:

What is the differential diagnosis of hemichorea/hemiballismus?

[GO TO SECTION 2](#)

From the Department of Neurology, University of Pennsylvania Medical Center, Philadelphia.

Disclosure: The authors report no disclosures.

SECTION 2

This patient presents with excess writhing movements on one side of the body, with occasional superimposed sudden large-amplitude excursions, most consistent with hemichorea, hemiathetosis, and hemiballismus. These three terms describe a range of excessive uncontrollable movement, ranging in speed and amplitude from athetosis to ballismus; this continuum is often seen in the same patient.

Initial important considerations in the history are the acuity of presentation, progression over time, and associated cognitive or behavioral symptoms. Any recent medications are of critical importance given the common occurrence of medication-induced hyperkinetic disorders, such as those associated with levodopa or with estrogen replacement therapy. Remote medication history is also relevant for the possibility of tardive dyskinesia. Family history is important in ascertaining the risk of any inherited neurodegenerative disorder. Concurrent medical conditions must also be noted as the movement disorder may be secondary to a systemic medical illness.

In this patient, the history of severe polyneuropathy suggests the possibility of pseudoathetosis, a writhing movement of the limbs due to decreased proprioceptive input, although this is not usually as severe as hemiballismus. The unilaterality of the movements suggests either a structural lesion (such as a tumor, vascular malformation, or ischemic insult) or an asymmetric presentation of a process affecting both basal ganglia. The subacute nature of her presentation would make an insidious process more likely and argue against a vascular event such as a hemorrhage or infarct.

Diagnostic possibilities include neurodegenerative disorders, toxic-metabolic derangements, and systemic inflammatory or infectious processes. Neurodegenerative disorders that may present with hyperkinesia include Huntington disease, Wilson disease, pantothenate kinase-associated neurodegeneration, Fahr disease, chorea-acanthocytosis, X-linked McLeod syndrome, Huntington disease-like 2, spinocerebellar ataxia (types

2, 3, and 17), aceruloplasminemia, neuroferritinopathy, dentatorubral-pallidoluysian atrophy, and new variant Creutzfeldt-Jakob disease. Benign hereditary chorea is a non-neurodegenerative condition to be considered. Toxic and metabolic insults to the basal ganglia have been described in carbon monoxide poisoning and hyperglycemia. Systemic processes associated with chorea include lupus and antiphospholipid antibody syndrome, uremia, poststreptococcal (Sydenham) chorea, hyperthyroidism, celiac disease, and HIV infection. Although chorea only rarely manifests in paraneoplastic syndromes, the possibility of an underlying malignancy makes this diagnosis an important consideration. Finally, the possibility of a psychogenic movement disorder should be considered in cases marked by the sudden onset of symptoms in the setting of emotional stress.

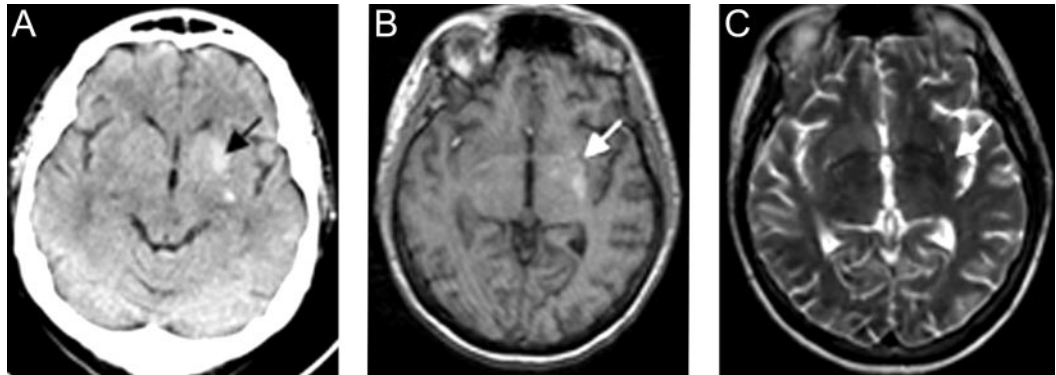Clinical course. On examination, our patient was afebrile, with a blood pressure of 200/100 mm Hg and a heart rate of 120 beats/minute. While she was alert and oriented with fluent language, she demonstrated some impulsivity and required frequent redirection. Primitive reflexes were absent. She correctly performed Luria gestures. Her cranial nerves, strength, and coordination were intact, and the movements did not interfere with walking. Sensation of pain, temperature, and vibration was symmetrically diminished to the mid-thighs and the wrists. Reflexes were absent at the ankles, 1+ at the knees, and 2+ in the arms. Plantar responses were flexor. She had frequent writhing, twisting movements of the right shoulder, arm, and hand, as well as the right foot. These movements were particularly noticeable during voluntary movement. She would occasionally incorporate the writhing movements into semi-purposeful movement; for example, after twisting her arm into the air, she would run her hand over her hair or wave at the people in the room.

Question for consideration:

What testing would you pursue?

GO TO SECTION 3

Figure (A) CT of head showing hyperintensity in left putamen, (B) T1-weighted MRI of brain showing increased signal in left putamen, and (C) T2-weighted MRI of brain showing decreased signal in left putamen



SECTION 3

Initial evaluation should include neuroimaging with contrast to rule out mass lesions or ischemia. In addition, laboratory testing should include basic serum chemistries for metabolic abnormalities, and, depending upon the results, HIV, ANA, ceruloplasmin, thyroid function, serum ferritin, and paraneoplastic antibodies. Further testing could include creatine kinase, liver enzymes, and peripheral blood smear for neuroacanthocytosis. Genetic testing for Huntington disease and pantothenate kinase-associated neurodegeneration can be obtained with the appropriate clinical presentation, even in the absence of family history, although this must be accompanied by thorough genetic counseling as no cure exists for these disorders.

Clinical course. The patient was admitted to the hospital for further evaluation. Initial laboratory results revealed serum glucose of 575 mg/dL. Her anion gap

was normal and measured serum osmolality was 310 mosm/kg.

A CT scan of the head revealed a hyperintensity in the left putamen (figure, A). MRI of the brain showed increased signal in the left putamen on T1-weighted images with corresponding decreased signal on T2-weighted images, without diffusion restriction, mass effect, or contrast enhancement (figure, B and C). Both imaging studies were done during the initial evaluation, while the movements were still occurring.

The patient was started on IV fluids and insulin infusion. Her serum glucose returned to a normal level within 6 hours; by the next morning her movements had almost completely disappeared, and resolved entirely by the time of discharge. Her HgbA1c was found to be 17.7%.

Question for consideration:

What is the diagnosis and prognosis?

GO TO SECTION 4

SECTION 4

In this patient, the resolution of hemichorea with glucose control, as well as characteristic imaging findings, support the diagnosis of nonketotic hyperglycemia-induced chorea-ballism. When properly identified and treated, the condition has an excellent prognosis and may be completely reversible.

DISCUSSION Chorea occurs less frequently than other neurologic manifestations of hyperglycemia, and it usually occurs in the setting of nonketotic hyperglycemic syndrome. In a review of 53 published cases of nonketotic hyperglycemic hemichorea/hemiballism, the mean age was 71 years with a female to male ratio of 1.8:1.¹ The majority of cases have been reported in Asian women, suggesting a genetic predisposition. Patients typically present with hemichorea with or without hemiballism developing over days to months in the setting of elevated serum glucose, hemoglobin A1c (mean 14%), and osmolarity. This syndrome can complicate long-standing type 1 or type 2 diabetes, and has also been described as the presenting symptom of new-onset diabetes.² Given that the symptoms are related to a temporary metabolic disturbance, the abnormal movements usually subside as glucose is corrected. In cases where chorea persists despite glucose normalization, medications (including benzodiazepines, neuroleptics, antiepileptics, and tetrabenazine) may be helpful.^{3,4}

Altered personality has not been previously reported to accompany the syndrome of hyperglycemic hemichorea. We hypothesize that focal basal ganglia dysfunction in this case led to disruption of the frontal-basal ganglionic circuits mediating behaviors such as motivation and organization.⁹ Our patient's improvement after correction of the metabolic derangement suggests that these circuits were reversibly damaged.

The imaging findings in this case are classic for nonketotic hyperglycemia hemichorea. The overwhelming majority of patients with this syndrome will have hyperintensities of the contralateral basal ganglia on T1-weighted MRI sequences with corresponding hypointensities on T2-weighted MRI and hyperdensities on CT.⁵ While multiple locations in the basal ganglia may demonstrate abnormal signal, the putamen is invariably affected.¹ The differential diagnosis of these MRI findings also includes subacute hemorrhage, mild focal ischemia, hypoxic-ischemic encephalopathy, chronic hepatic encephalopathy, manganese toxicity (including long-term total parenteral nutrition), and severe hypoglycemia. An important imaging characteristic of this syndrome is the resolution of signal abnormality on follow-up imag-

ing, although this may lag considerably behind clinical improvement.⁵

The exact mechanisms by which hyperglycemia can cause abnormal movements and characteristic imaging abnormalities remain unclear. Ischemia seems to be a likely etiologic factor, but neural injury from hyperglycemia may also be due to subacute hemorrhage.⁶ Although one autopsy report of a patient with hyperglycemic hemichorea showed basal ganglia gliosis without hemorrhage,⁷ a more recent series demonstrated unilateral focal microhemorrhages.⁸ It seems, therefore, that a spectrum of pathophysiology underlying this disorder likely exists. Furthermore, the etiology by which hyperglycemia induces chorea may differ between patients who recover fully and patients who do not. The infrequent availability of tissue specimens in these cases, particularly those with favorable outcomes, makes this delineation extremely difficult.

Clinical course. Several days after discharge, the involuntary movements reappeared despite a normal serum glucose. The movements slowly worsened over several weeks but did not reach the severity of her initial presentation. She was treated with clonazepam 0.25 mg TID and the movements resolved. She has had no further relapses, although she has persistent mild weakness on the right. Her personality gradually returned to normal.

REFERENCES

1. Oh SH, Lee KY, Im JH, Lee MS. Chorea associated with non-ketotic hyperglycemia and hyperintensity basal ganglia lesion on T1-weighted brain MRI study: a meta-analysis of 53 cases including four present cases. *J Neurol Sci* 2002;200:57–62.
2. Lee BC, Hwang SH, Chang GY. Hemiballismus-hemichorea in older diabetic women: a clinical syndrome with MRI correlation. *Neurology* 1999;52:646–648.
3. Driver-Dunckley E, Evidente VG. Hemichorea-hemiballismus may respond to topiramate. *Clin Neuropharmacol* 2005;28:142–144.
4. Sitburana O, Ondo WG. Tetrabenazine for hyperglycemic-induced hemichorea-hemiballismus. *Mov Disord* 2006;21:2023–2025.
5. Lai PH, Tien RD, Chang MH, et al. Chorea-ballismus with nonketotic hyperglycemia in primary diabetes mellitus. *AJNR Am J Neuroradiol* 1996;17:1057–1064.
6. Altafullah I, Pascual-Leone A, Duvall K, Anderson DC, Taylor S. Putaminal hemorrhage accompanied by hemichorea-hemiballismus. *Stroke* 1990;21:1093–1094.
7. Ohara S, Nakagawa S, Tabata K, Hashimoto T. Hemiballismus with hyperglycemia and striatal T1-MRI hyperintensity: an autopsy report. *Mov Disord* 2001;16:521–525.
8. Mestre TA, Ferreira JJ, Pimentel J. Putaminal petechial haemorrhage as the cause of non-ketotic hyperglycaemic chorea: a neuropathological case correlated with MRI findings. *J Neurol Neurosurg Psychiatry* 2007;78:549–550.
9. Cummings JL. Frontal-subcortical circuits and human behavior. *Arch Neurol* 1993;50:873–880.

Clinical Reasoning: A 13-year-old boy presenting with dystonia, myoclonus, and anxiety

Joanna S. Blackburn, MD
Melissa L. Cirillo, MD

Correspondence & reprint
requests to Dr. Cirillo:
mcirillo@childrensmemorial.org

SECTION 1

A 13-year-old, right-handed boy was referred for movement and speech abnormalities. His mother reports his voice becoming soft and choppy at 8 years of age. Over the past year, he developed head jerking to the right while using his right hand. The patient denied a premonitory urge or ability to suppress these movements. They had become so disabling that he had to eat and write with his left hand. He has no other medical problems, other than a pectus excavatum. His family history is notable for his father being diagnosed with Tourette syndrome as a teen. His father continues to have episodic head jerking to the left at times. The patient's general examination was

notable for an anxious teenager with marfanoid features including pectus excavatum and long limbs. The patient's neurologic examination revealed strained, choppy speech, which was present while speaking but not while singing. He had involuntary forced head turn to the right with right tilt and right upper extremity sustained twisting posturing when trying to use his right hand. He had right upper extremity fast jerking movements with attempts to use his right arm. His deep tendon reflexes were brisk, with crossed adductors. The remainder of his neurologic examination was normal.

Question for consideration:

1. What type of movement is being described in the history?

[GO TO SECTION 2](#)

SECTION 2

Although his father had been diagnosed with Tourette syndrome, the patient's movements were neither suppressible nor preceded by an urge, which are the hallmarks of tics. The strained choppy voice was consistent with spasmodic dysphonia, a form of laryngeal dystonia. His forced head turn to the right and twisting posturing was consistent with cervical dystonia and limb dystonia, respectively. The jerking

movements of his arm suggested a dystonic tremor vs myoclonus. On his initial examination it was difficult to differentiate between these 2 involuntary movements.

Questions for consideration:

1. What is the definition of dystonia?
2. What is the differential diagnosis for dystonia with onset in childhood or early adolescence?
3. What diagnostic tests would you order?

GO TO SECTION 3

SECTION 3

Dystonia in childhood has been defined as a movement disorder with involuntary sustained or intermittent muscle contractions which cause twisting and repetitive movements, abnormal postures, or both.¹

A broad differential diagnosis must be considered in the evaluation of childhood or adolescent onset dystonia, including primary dystonias, dystonia plus syndromes, secondary dystonias, and hereditodegenerative disorders.^{2,3} Primary dystonias do not have other neurologic or systemic findings. The most common primary dystonia is DYT-1 dystonia, which is typically characterized by childhood onset limb dystonia often with subsequent generalization.^{2,3} It is an autosomal dominant disease with a penetrance rate of 30%–40% which is caused by a GAG deletion in the *TOR1A* gene. Dystonia plus syndromes include additional neurologic findings such as parkinsonism and myoclonus.⁴ Two dystonia plus syndromes are dopa-responsive dystonia (DYT 5) and myoclonus dystonia (DYT 11). Dopa-responsive dystonia (DYT 5) typically presents in midchildhood with gait dystonia. There is diurnal variation in symptoms in 75% of patients.² Other possible associated features include parkinsonism and hyperreflexia.^{2,3} A key feature of this condition is a dramatic and sustained response to levodopa.^{2,3} It is caused by a mutation in the GTP-cyclohydrolase-I gene. The presence of myoclonus in association with dystonia is characteristic of myoclonus dystonia (DYT 11).^{2,3} Secondary and hereditodegenerative dystonias typically present with other neurologic and systemic signs and symptoms in addition to dystonia. Secondary dystonia is due to an acquired or exogenous cause including drug exposures, toxins, infections, and focal CNS lesions.³ Important historical information includes drug or toxin exposure, perinatal injury, en-

cephalitis, or head trauma. A focal structural lesion may present with hemidystonia. Hereditodegenerative disorders which have dystonia as a feature are genetic disorders including Huntington disease, Wilson disease, and pantothenate kinase–associated neurodegeneration.² These are often associated with other signs including cognitive impairment, seizures, oculomotor dysfunction, retinal abnormalities, neuropathy, spasticity, as well as liver dysfunction and skeletal abnormalities.

Our patient presented with dystonia, a dystonic tremor vs myoclonus, and marfanoid features. In addition, on further examination of the patient's father, his findings were more consistent with myoclonus rather than tics. His father also reported that his head jerking resolved with alcohol use. This suggests the most likely diagnosis was either a primary dystonia or a dystonia plus syndrome. The patient's abnormal movements were unilateral, so a focal etiology was considered. Given the presence of marfanoid features, abnormal vessels leading to a basal ganglia stroke was considered. Marfanoid features are not associated with a primary dystonia or dystonia plus syndrome. The following laboratory testing was normal: complete blood count, complete metabolic panel, copper, ceruloplasmin, zinc, thyroid function testing, and ferritin. He had MRI of the brain and magnetic resonance angiography (MRA) of the head and neck, which showed no evidence of stroke or abnormal vessels to suggest his presentation was related to his marfanoid habitus. He had a normal ophthalmologic examination with no evidence of Kayser-Fleischer rings or retinal detachment. DYT-1 genetic testing was pending.

Question for consideration:

1. Would you treat the patient while awaiting genetic testing results? If so, with what?

GO TO SECTION 4

SECTION 4

It is recommended that patients with early onset dystonia without an alternative diagnosis undergo a levodopa trial.⁴ Although our patient's presentation was not typical for dopa-responsive dystonia, he was treated with levodopa while additional genetic testing was pending. There was no clinical response to

levodopa, making that an unlikely diagnosis. DYT-1 testing was negative. On repeat examination, his abnormal movements appeared to be consistent with myoclonus in addition to a dystonic tremor.

Question for consideration:

1. What additional diagnostic testing would you send at this time?

GO TO SECTION 5

SECTION 5

Given the constellation of dystonia, myoclonus, anxiety, and his father's history, the patient was evaluated for myoclonus dystonia. Epsilon sarcoglycan gene (*SGCE*) testing revealed a known mutation and a diagnosis of myoclonus dystonia syndrome was made. Our patient was treated with trihexyphenidyl, which resulted in significant improvement of his myoclonus and dystonia. He was able to eat and write with his right hand and was remarkably less anxious.

DISCUSSION Myoclonus dystonia is a rare disorder characterized by myoclonic jerks and dystonia. Presentation is typically in childhood or early adolescence.⁵ The most common presenting symptom is myoclonus, but dystonia can be the initial presentation in 20%.⁵ Myoclonus typically involves the arm and axial musculature and is responsive to alcohol. Dystonia is usually mild and most often manifests as cervical dystonia or writer's cramp. Psychiatric features are common and include depression, obsessive-compulsive behavior, panic attacks, and attention deficit hyperactivity disorder.^{2,5} Severity of symptoms varies. Spontaneous resolution of limb dystonia and improvement of myoclonus occur in 20% and 5%, respectively.⁵ Although spontaneous resolution can occur, myoclonus and dystonia can progress at any time during the disease course.⁵

Inheritance is autosomal dominant with reduced maternal inheritance due to maternal imprinting. Paternal inheritance always results in the disease whereas maternal inheritance has a penetrance of 10%–15%.² Mutations in the *SGCE* gene, which encodes the protein epsilon sarcoglycan, is located in chromosome region 7q21. Mutations in the *SGCE* gene are found in less than 40% of patients with the clinical phenotype.⁵ There are reports of both sporadic cases as well as kindreds with *SGCE*-negative myoclonus dystonia. One notes a kindred presenting with autosomal dominant clinical features of myoclonus dystonia syndrome who was found to have GTP cyclohydrolase I deficiency, which is typically associated with dopa-responsive dystonia.⁶ The pathophysiology of myoclonus dystonia is unknown.

Treatment of myoclonus dystonia is symptomatic. Anticholinergic drugs and benzodiazepines may improve dystonia and myoclonus.⁵ Antiepileptic drugs including levetiracetam, piracetam, valproic acid, and zonisamide have improved myoclonus in some patients.⁵ Levodopa has been shown in isolated cases to improve symptoms.⁷ Botulinum toxin is an option to treat focal dystonia. Deep brain stimulation (DBS) of the globus pallidus interna (GPi) and ventral intermediate thalamic nucleus have been shown to improve symptoms in more than 70% of

patients with DBS-GPi, having fewer adverse effects.^{8,9}

Diagnostic criteria for definite myoclonus dystonia have been proposed and include early onset (<20 years), myoclonus predominating in the upper body either isolated or associated with dystonia, positive family history with paternal transmission when due to *SGCE* mutation or deletion, exclusion of additional neurologic findings such as cerebellar ataxia, spasticity, and dementia, and a normal brain MRI.^{5,10}

Myoclonus dystonia is a rare cause of dystonia in childhood but must be considered in the setting of early onset dystonia when myoclonus is present, especially in cases with potential paternal inheritance. Our patient meets the suggested criteria for the diagnosis of myoclonus dystonia as described above. *SGCE* testing in his father confirmed that his father also has a diagnosis of myoclonus dystonia, rather than the previous diagnosis of Tourette syndrome.

AUTHOR CONTRIBUTIONS

Dr. Blackburn qualifies as an author for drafting and revising the manuscript for content including medical writing for content. Dr. Cirillo qualifies as an author for drafting and revising the manuscript for content including medical writing for content.

REFERENCES

1. Sanger TD, Chen D, Fehlings DL, et al. Definition and classification of hyperkinetic movements in childhood. *Mov Disord* 2010;25:1538–1549.
2. Muller U. The monogenic primary dystonias. *Brain* 2009; 132:2005–2025.
3. Uc EY, Rodnitzky RL. Childhood dystonia. *Semin Pediatr Neurol* 2003;10:52–61.
4. Albanese A, Barnes MP, Bhatia KP, et al. A systematic review on the diagnosis and treatment of primary (idiopathic) dystonia and dystonia plus syndromes: report of an EFNS/MDS-ES Task Force. *Eur J Neurol* 2006;13:433–444.
5. Kinugawa K, Vidailhet M, Clot F, Apartis E, Grabli D, Roze E. Myoclonus-dystonia: an update. *Mov Disord* 2009;24:479–489.
6. Leuzzi V, Carducci C, Cardona F, Artioli C, Antonozzi I. Autosomal dominant GTP-CH deficiency presenting as a dopa-responsive myoclonus-dystonia syndrome. *Neurology* 2002;59:1241–1243.
7. Gerrits MC, Foncke EM, de Haan R, et al. Phenotype-genotype correlation in Dutch patients with myoclonus-dystonia. *Neurology* 2006;66:759–761.
8. Luciano MS, Ozelius L, Sims K, Raymond D, Liu L, Saunders-Pullman R. Responsiveness to levodopa in epsilon-sarcoglycan deletions. *Mov Disord* 2009;24:425–428.
9. Azoulay-Zyss J, Roze E, Welter ML, et al. Bilateral deep brain stimulation of the pallidum for myoclonus-dystonia due to epsilon-sarcoglycan mutations: a pilot study. *Arch Neurol* 2011;68:94–98.
10. Gruber D, Kuhn AA, Schoenecker T, et al. Pallidal and thalamic deep brain stimulation in myoclonus-dystonia. *Mov Disord* 2010;25:1733–1743.

Clinical Reasoning: A 39-year-old man with abdominal cramps



Stephan R. Jaiser, MRCP
Mark R. Baker, MRCP
Roger G. Whittaker,
MRCP
Daniel Birchall, FRCR
Patrick F. Chinnery,
FRCP

Correspondence to
Dr. Jaiser:
stephan.jaiser@ncl.ac.uk

SECTION 1

A 39-year-old lawyer presented with intermittent spasms and pain in his abdominal muscles, particularly the right upper quadrant. These had occurred since his mid-20s and there had been long asymptomatic periods, including 8 years prior to the most recent 4-month exacerbation. Trivial movement triggered a spasm of the abdominal muscles, leading to severe pain, which made breathing uncomfortable and interfered with sleep. The symptoms subsided spontaneously after 4 to 5 days, leaving him with a sore abdomen for several weeks. Past attacks had also been precipitated by specific forms of repetitive exercise such as jogging. He described ill-defined numbness in the left leg, but denied any muscle twitching, weakness, back pain, or sphincter disturbance. There was no significant past medical or family history.

On examination, cranial nerves were unremarkable. Tone and power were normal in upper and lower limbs. Tendon reflexes were brisk throughout, particularly in the lower limbs, where they were brisker on the left than the right; plantar responses were flexor. Abdominal reflexes were brisk on the right and absent on the left (video on the *Neurology*[®] Web site at www.neurology.org). No fasciculations or myokymia were seen throughout. There was no demonstrable sensory asymmetry or loss to any modality in the lower limbs. Gait and cerebellar function were normal.

Questions for consideration:

1. Can you interpret the sign demonstrated in the video?
2. What is the differential diagnosis for this presentation?
3. What is your next investigation of choice?

[GO TO SECTION 2](#)

Supplemental data at
www.neurology.org

From the Institute of Neuroscience (S.R.J., M.R.B.), The Medical School, Newcastle University, Newcastle upon Tyne; and the Departments of Clinical Neurophysiology (R.G.W.), Neuroradiology (D.B.) and Neurology (P.F.C.), Royal Victoria Infirmary, Newcastle upon Tyne, UK.

Go to Neurology.org for full disclosures. Funding information and disclosures deemed relevant by the authors, if any, are provided at the end of the article.

SECTION 2

Superficial abdominal reflexes are not elicitable in all individuals and become less prevalent with age. They may also be absent in obesity, after multiple pregnancies, or after abdominal surgery.¹ One study characterized the reflexes in each abdominal quadrant of normal young adults.² In approximately half the subjects, symmetrical reflexes could be elicited in all quadrants; the remainder showed a variable extent of asymmetrical or absent reflexes. However, in no subjects were the abdominal reflexes consistently present on one side and consistently absent on the other. Such findings in our patient are therefore likely to be significant and—in the absence of sensory loss—suggest a lesion of the upper

motor neurons in the ipsilateral thoracic cord, the corresponding lower motor neurons, or both. Both intrinsic and extrinsic lesions of the spinal cord could produce this picture. The differential diagnosis therefore includes neoplasia (e.g., ependymoma, meningioma, glioma), arteriovenous malformation, syrinx, lateral intervertebral disk prolapse, inflammatory myelitis, and infection (e.g., segmental zoster paresis).

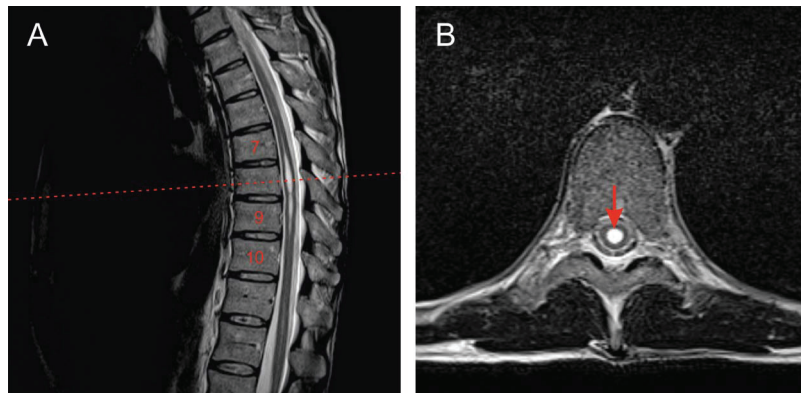
The next investigation of choice is an MRI scan of the thoracic spine (figure 1).

Questions for consideration:

1. What is the abnormality on MRI?
2. What further investigations would you consider?

GO TO SECTION 3

Figure 1 MRI of the thoracic spine



(A) Sagittal T2-weighted MRI demonstrates a syrinx between T7 and T10. (B) Axial T2-weighted MRI at the level of T8 shows central position of the syrinx and expansion of the spinal cord.

SECTION 3

The MRI shows a central fusiform cavity in the mid-thoracic cord, extending from T7 to T10 and measuring 5 mm in diameter. There was no abnormal gadolinium enhancement. This radiologic description would be compatible with either idiopathic syringomyelia or hydromyelia. Hydromyelia is considered to be a congenital, static persistence or enlargement of the central spinal cord canal without secondary cause. While there may be disturbed CSF flow, dilation of perivascular spaces, and subependymal cavitation, hydromyelia is not associated with tissue necrosis and neuronal injury. By contrast, syringomyelia is a progressive condition associated with intramedullary ischemia and tissue necrosis causing cavitation.³

A filiform, or slitlike, appearance on MRI is said to distinguish hydromyelia from syringomyelia, but in some series 20% of patients with filiform dilations of the central spinal cord canal show progression consistent with syringomyelia.⁴ The presence of objective neurologic deficits and certain features on MRI (spinal cavity >6 mm in diameter and >5 segments in length; abnormal contrast enhancement; spinal cord expansion; cavity enlargement over time) or electrophysiologic

testing (abnormalities on EMG, somatosensory evoked potentials [SSEPs], or motor evoked potentials [MEPs]) allows patients with syringomyelia to be distinguished more reliably from those with hydromyelia.⁵

In the present case, the objective neurologic abnormalities were limited to reflex asymmetry and further investigations should be directed at differentiating between syringomyelia and hydromyelia. Structural features associated with syringomyelia (e.g., Chiari malformation type I [CM-I], spinal dysraphism, tethered cord, neoplasms) were excluded radiologically. SSEPs were normal. MEPs showed a prolonged central motor conduction time (CMCT) to the left but not the right lower limb (abductor hallucis CMCT was 24.8 ms on the left and 15.2 ms on the right; normal 16.0 ± 3.3 ms, mean \pm SD). Needle EMG showed neurogenic change with fibrillation potentials and positive sharp waves in the right T8–T12 paraspinal muscles.

Questions for consideration:

1. What are the anatomical limits of the syrinx as defined electrophysiologically?
2. What additional radiologic investigations might help in terms of prognostication?

GO TO SECTION 4

SECTION 4

Syrinxes located centrally on axial MRI are usually asymptomatic. Only a minority produce clinical signs such as spasticity, hyperreflexia, sphincter disturbance, or sensory changes, and these tend to be of limited localizing value. By contrast, clinical signs are common if the cavity has a paracentral extension or is located eccentrically, and in such cases the signs are usually segmental and point to the location of the syrinx.⁶

Here, MRI demonstrated a centrally located syrinx; in keeping with previous reports, clinical signs were limited. However, electrophysiologic data reveal the syrinx to be functionally eccentric. It involves the thoracic ventral horn on the right (as demonstrated by the EMG) and the lateral corticospinal tract on the left (as demonstrated by the reflex asymmetry and corroborated by MEPs) (figure 2). While not clearly defined on examination, the sensory symptoms are likely to represent involvement of postsynaptic spinothalamic neurons crossing the midline anteriorly to ascend in the right anterolateral funiculus.

Beyond structural MRI sequences, cardiac-gated cine MRI can demonstrate abnormal CSF dynamics at the cranio-cervical junction and at the level of the syrinx.

DISCUSSION Syringomyelia classically presents with a centromedullary syndrome, manifesting as pain (burning, electric-shock like, radicular) and dissociated sensory loss with temperature insensitivity. Spasticity, autonomic dysfunction (including Horner

syndrome), and sphincter dysfunction are also recognized.

The most common etiopathogenic association of syringomyelia is CM-I. In addition to the structural causes discussed in section 3, syringomyelia may arise as a result of trauma (including iatrogenic trauma), arachnoiditis/meningitis, and inflammatory myelitis. Such structural pathology alters the CSF dynamics, prompting CSF to be forced into the cord tissue and causing intramedullary venous congestion and cord edema. These result in macrocystic or microcystic changes.³ Where an obvious structural cause cannot be identified, the term idiopathic syringomyelia is applied.

Management is dictated by etiology and neurologic status. Secondary causes such as CM-Is, tumors, and tethered cords are usually amenable to surgery. Stable idiopathic syringomyelia with minimal neurologic deficits should be monitored radiologically and electrophysiologically at intervals of 3–6 months; significant progression should prompt consideration of surgical exploration. Syrinx shunting is rarely appropriate as it does not address any underlying etiology and is associated with high failure rates.⁷ In all cases, symptomatic treatment should be offered. Central pain often responds to carbamazepine, pregabalin, or gabapentin. Cramps can also be managed with gabapentin or potentially with diltiazem. Spasticity may be controlled with baclofen, tizanidine, or diazepam. Syrinxes can be exacerbated by activities involving a Valsalva maneuver, and patients should be counseled to avoid heavy lifting, to minimize coughing, and to ensure regular and soft bowel motions through increased fluid intake and use of laxatives if required.

Our patient was managed conservatively; carbamazepine proved ineffective and he opted not to try alternative drugs. Serial assessments at 6-month intervals demonstrated no functional or radiographic changes.

There are limited data regarding the natural history of syringomyelia. Several case series report that idiopathic syringomyelia with minimal neurologic symptoms only progresses in a minority of conservatively managed cases.⁷ Hence, the risks of nonintervention and regular monitoring appear to be limited in this patient group.

AUTHOR CONTRIBUTIONS

Dr. Jaiser: design/conceptualization of the study, analysis/interpretation of neurophysiology data, drafting/revising the manuscript. Dr. Baker: design/conceptualization of the study, analysis/interpretation of neurophysiology data, drafting/revising the manuscript. Dr. Whittaker: analysis/interpretation of neurophysiology data, drafting/revising the manuscript. Dr. Birchall: analysis/interpretation of MRI images, revising the manuscript. Prof. Chinnery: drafting/revising the manuscript.

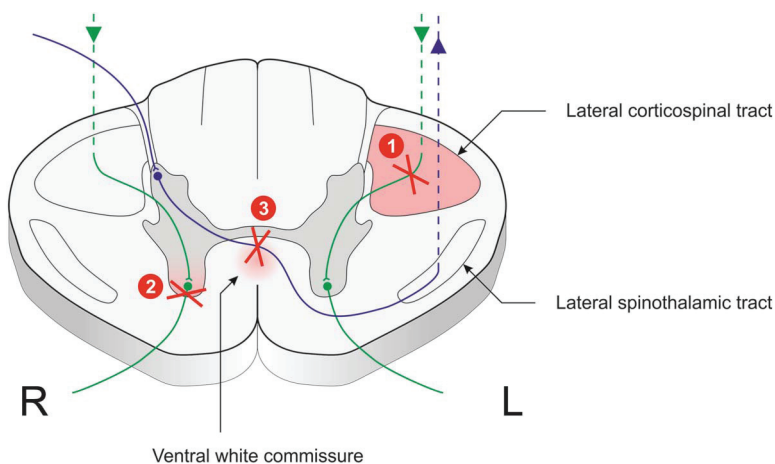
STUDY FUNDING

Wellcome Trust, National Institute for Health Research.

DISCLOSURE

S. Jaiser is a Wellcome Trust clinical research fellow. M. Baker is a NIHR Clinical Lecturer and is supported by grants from UK Medical Research

Figure 2 Schematic cross-section of the midthoracic spinal cord



Small sensory fibers supplying pain and temperature sensation enter the dorsal horn, synapse in the substantia gelatinosa, and decussate in the ventral white commissure to ascend in the lateral spinothalamic tract (blue; illustrated for right-sided primary fibers only). Pyramidal neurons descend in the lateral corticospinal tracts to enter the ventral horn, where they synapse with lower motor neurons, which leave in the ventral nerve root (green). The asymmetrical lower limb hyperreflexia and the delayed motor evoked potentials to the left lower limb suggest a lesion of the left lateral corticospinal tract (lesion 1). A lesion of the right ventral horn is implied by the neurogenic changes on EMG of the right paraspinal muscles (lesion 2). The sensory symptoms probably represent a lesion of the postsynaptic spinothalamic neurons crossing the midline in the ventral white commissure (lesion 3).

Council, Wellcome Trust, and Academy of Medical Sciences. R. Whitaker is supported by a grant from the NIHR. D. Birchall reports no disclosures. P. Chinnery is a Wellcome Trust Senior Fellow in Clinical Science and receives funding from Parkinson's UK, the MRC Translational Muscle Centre, and the UK NIHR Biomedical Research Centre in Ageing and Age-related Disease. Go to Neurology.org for full disclosures.

REFERENCES

1. Madonick MJ. Statistical control studies in neurology: VIII: the cutaneous abdominal. *Neurology* 1957;7:459–465.
2. Yngve D. Abdominal reflexes. *J Pediatr Orthop* 1997;17:105–108.
3. Kobayashi S, Kato K, Rodríguez Guerrero A, Baba H, Yoshizawa H. Experimental syringohydromyelia induced by adhesive arachnoiditis in the rabbit: changes in the blood-spinal cord barrier, neuroinflammatory foci, and syrinx formation. *J Neurotrauma* 2012;29:1803–1816.
4. Holly LT, Batzdorf U. Slitlike syrinx cavities: a persistent central canal. *J Neurosurg* 2002;97:161–165.
5. Roser F, Ebner FH, Sixt C, Hagen JMV, Tatagiba MS. Defining the line between hydromyelia and syringomyelia: a differentiation is possible based on electrophysiological and magnetic resonance imaging studies. *Acta Neurochir* 2010;152:213–219.
6. Milhorat TH, Johnson RW, Milhorat RH, et al. Clinico-pathological correlations in syringomyelia using axial magnetic resonance imaging. *Neurosurgery* 1995;37:206–213.
7. Roy AK, Slimack NP, Ganju A. Idiopathic syringomyelia: retrospective case series, comprehensive review, and update on management. *Neurosurg Focus* 2011;31:E15.

Clinical Reasoning: A middle-aged man with episodes of gait imbalance and a newly found genetic mutation

Marianna Shnayderman
Yugrakh, MD
Oren A. Levy, MD, PhD

Correspondence & reprint
requests to Dr. Yugrakh:
ms3006@columbia.edu

SECTION 1

A 47-year-old right-handed man, with no history of alcohol use, presented with episodic unsteadiness that began in his early 20s. During the episodes, which last several hours, he is unable to walk steadily and has poor control of his limbs. These attacks are often brought on by emotional stress and occurred 1 to 2 times per month into his 30s. There is no association with headache or head movement, no diplopia, tinnitus, or hearing loss. His earlier evaluation included a brain MRI and

routine EEG, which were normal. Though his diagnosis was unknown, he was given a trial of acetazolamide at age 38, and became attack-free on the medication.

Questions for consideration:

1. What is the differential diagnosis for paroxysmal episodes of neurologic dysfunction based on the time course and age at onset?
2. How can medication responsiveness and examination findings be helpful?

[GO TO SECTION 2](#)

SECTION 2

In this patient, the likely etiologies for paroxysmal neurologic events are seizures, migraine, vestibular syndromes, and paroxysmal movement disorders. Pure ataxia as seizure semiology has not been described: cerebellar cortex is not known to be epileptogenic. Vertiginous partial seizures may be localized to the posterior part of superior temporal neocortex, are rare, and typically seen in conjunction with other temporal lobe localizing symptoms (auditory, olfactory). Postictal state of complex partial or generalized seizures can result in gait unsteadiness associated with fatigue and confusion and gradual improvement.

In migraine, paroxysmal neurologic symptoms may occur without headache. Classified as typical aura without headache, the aura must include visual or sensory symptoms, and last less than 1 hour.¹ If migraines, the patient's episodes fit most closely with the aura of basilar-type migraine, which may include dysarthria, vertigo, diplopia, ataxia, tinnitus or hyperacusis, decreased level of consciousness, or bilateral paresthesias. However, as defined by the International Headache Society, this aura may last up to 1 hour and must be associated with migraine headache.¹

Vestibular syndromes include Ménière disease, which is less likely given the lack of auditory symptoms, and benign recurrent vertigo, etiologically thought to be related to migraine.²

Of the paroxysmal movement disorders, the patient's symptoms best fit an episodic ataxia (EA). While many types have been described, the most

common EA syndromes are type 1 (EA1) with episodes lasting seconds to minutes, often precipitated by startle or movement; and type 2 (EA2) with episodes lasting hours, commonly precipitated by emotional stress.^{3,4} Response to acetazolamide, which has limited usefulness in epilepsy due to tolerance, is common in EA2, but is only seen occasionally in EA1.

Several months prior to current evaluation, the patient was taken off acetazolamide after undergoing treatment for squamous cell cancer of the neck, due to concerns for dehydration. Two weeks after stopping the medication, his ataxic attacks recurred, occurring several times per week, lasting several hours, and now associated with slurred speech. He also developed severe pounding headaches during most attacks, without nausea, photophobia, or phonophobia.

His neurologic examination, performed between episodes, was normal, including absence of nystagmus, dysarthria, gait ataxia, or dysmetria. In most paroxysmal disorders in the differential and in some patients with EA, the interictal examination is normal. In EA2, patients may develop mild interictal ataxia, and different forms of nystagmus, including gaze-evoked nystagmus, rebound nystagmus, and spontaneous vertical nystagmus.⁴ In EA1, myokymia can be observed.

Question for consideration:

1. What other historical information is critical for diagnosis?

GO TO SECTION 3

SECTION 3

Many of the paroxysmal movement disorders have typical patterns of inheritance; both EA1 and EA2, caused by mutations in different genes, display an autosomal dominant pattern. The patient's mother has mild episodes of gait instability and dysarthria lasting hours, occurring several times per month, precipitated by anxiety or excitement. Her episodes started at age 11 without progressive nature. The patient's sister, age 41, has episodes of severe vertigo, nausea, and inability to walk that started at age 12.

Ten years ago, acetazolamide was started and led to a dramatic reduction in attack frequency. She also has frequent headaches that meet criteria for migraine with visual aura. Sometimes her migraines trigger an episode of ataxia.

Questions for consideration:

1. How is the clinical diagnosis of episodic ataxia made?
2. What is the definitive diagnostic test for episodic ataxia type 2?

GO TO SECTION 4

SECTION 4

The diagnosis of EA2, consistent with the presentation in this patient, is most commonly made on clinical grounds based on 1) attacks of gait ataxia and nystagmus lasting hours, with possible associated vertigo, nausea, vomiting, dysarthria; 2) possible presence of interictal ataxia and nystagmus or progressive ataxia; 3) attacks provoked by exercise, emotional stress; 4) attacks reduced in frequency by acetazolamide; 5) absence of myokymia; 6) family history consistent with autosomal dominant inheritance; 7) onset before age 20.^{3,4} Other clinical features include associated headache, fluctuating generalized weakness, seizures, and dystonia.³

Definitive diagnosis of EA2 is made with genetic testing. Sequencing of *CACNA1A* gene (Athena Diagnostics) revealed a previously undescribed nonsense mutation at arginine 1346 (i.e., R1346X, corresponding to nucleotide C4036T). The patient was restarted on acetazolamide with titration up to 750 mg/day. He has had only 1 episode of ataxia over the next year and his headache has not recurred.

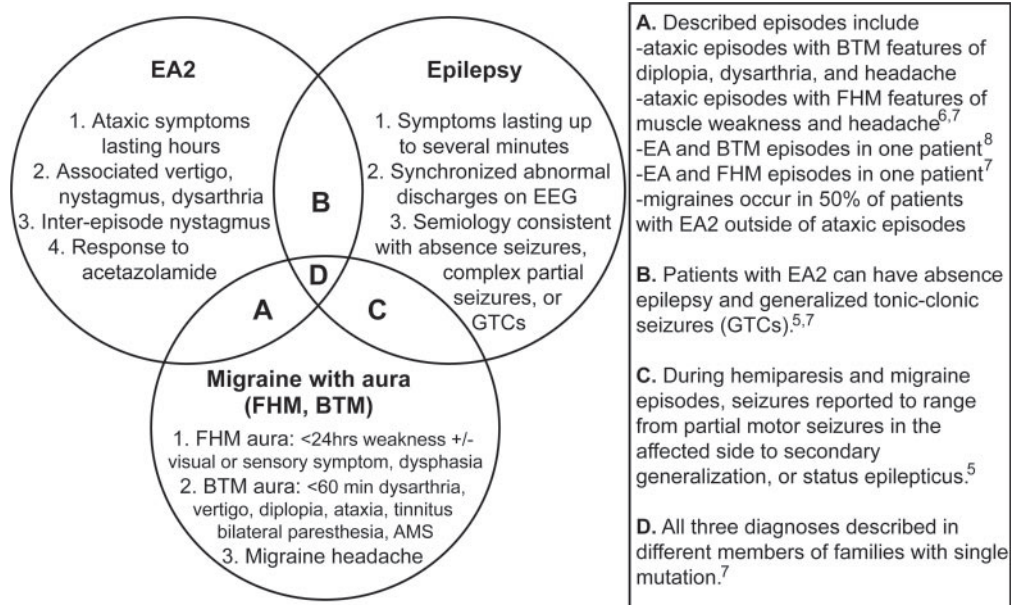
DISCUSSION The *CACNA1A* gene codes for the main transmembrane pore-forming and voltage-sensing subunit of the P/Q-type voltage-gated calcium channel (Ca_v2.1). Mutations in *CACNA1A* cause a spectrum of disorders with overlapping clinical features, termed *CACNA1A* channelopathies.

Clinical syndromes include EA2 (nonsense >missense mutations), familial hemiplegic migraine 1 (FHM1) (missense type), spinocerebellar ataxia type 6 (polymorphic CAG repeat expansions), and epilepsy.⁵⁻⁷

Sequencing of the *CACNA1A* gene in our patient revealed a novel nonsense mutation, R1346X, located in the fourth transmembrane segment of the homologous domain III of the channel pore-forming unit. A missense mutation at the same position, R1346Q, has been described in a family with FHM1 and features of EA2.⁴ Ca_v2.1 channels are involved in the release of neurotransmitter at multiple types of synapses, with a vital role in cerebellar Purkinje cells. Truncating mutations in Ca_v2.1 channels lead to dysfunctional neurotransmission, as supported by a reduction in current density from mutated Ca_v2.1 in ataxic mouse models.⁴ Gain-of-function effects with increased calcium current density are found in FHM1 mouse models, resulting in increased calcium-uptake related glutamate release and a lower threshold for cortical spreading depression, thought to be the pathophysiologic mechanism underlying migraine with aura.⁵ In humans, nearly identical mutations may result in both FHM1 and EA2 phenotypes,⁴ suggesting a more complex relationship between Ca_v2.1 activity and clinical phenotype.

Several paroxysmal disorders, both *CACNA1A*-related and -unrelated, share considerable symptom

Figure Phenotypic overlap of paroxysmal disorders that have been associated with *CACNA1A* mutations



Key diagnostic criteria and overlapping features are summarized for episodic ataxia type 2 (EA2), migraine with aura including familial hemiplegic migraine 1 (FHM1) and basilar-type migraine (BTM), and epilepsy. One individual may have different types of episodes meeting criteria for multiple disorders, or because of many shared symptoms, single stereotyped episodes may meet most criteria for multiple disorders. Overlap between diagnostic categories is indicated on the Venn diagram with a letter, with specific details and references to the described cases listed in the adjacent table.

overlap. Conversely, identical *CACNA1A* mutations may produce phenotypes that meet criteria for 2 or 3 disease categories, either in individual patients or in different family members.^{3,5-7} Furthermore, a single stereotyped episode can have features of multiple disorders. The figure summarizes the overlapping and unique symptoms in paroxysmal disorders that have been associated with *CACNA1A* mutations, including EA2, migraine with aura, and epilepsy.

About half of patients with EA2 (such as this patient's sister) have headaches that meet formal criteria for migraine.⁴ FHM1 diagnostic criteria include an aura of motor weakness with visual, sensory, or speech symptoms lasting less than 24 hours, in addition to migraine headache. Up to 50% of patients with FHM1 will have interepisode progressive cerebellar symptoms.¹ Migraines with muscle weakness have been reported in association with cerebellar dysfunction, meeting criteria for both EA2 and FHM1.^{6,7} Basilar-type migraine (BTM) has the greatest overlap in symptomatology with EA2. Its underlying genetic causes are under investigation. In one case report, 2 different types of episodes were diagnosed as BTM and EA2 in a single patient with a *CACNA1A* truncating mutation, with acetazolamide reducing the frequency of both episodes.⁸ Epilepsy and nonepileptiform EEG abnormalities⁶ in families with *CACNA1A* mutations have also been studied. Absence, complex partial, and generalized tonic-clonic seizures have been described in the setting of severe hemiplegic migraine attacks,⁵ or independent of attacks in patients with FHM1 or EA2.^{3,5,7}

Appreciation of the spectrum of disorders associated with *CACNA1A* mutation may suggest additional treatment options for EA2. The standard of care, acetazolamide, reduces frequency and severity of attacks in 71% of patients,³ but has been reported to fail over time.⁹ An alternative prophylactic agent is 4-aminopyridine, a potassium channel blocker.⁹ Valproic acid is the only other agent that has been reported to have benefit in EA2.¹⁰ Agents with both antiepileptic and migraine prophylaxis properties are potential alternatives for investigation. For example, topiramate and zonisamide possess several antiepileptic channel effects as well as carbonic anhydrase inhibitory activity, similar to acetazolamide.

In our patient, the clinical and genetic diagnosis of EA2 helps guide the selection of first-line therapy

and suggests potential future treatment options. In his sister, identification of comorbid conditions should lead to treatment of both, reducing the likelihood of one triggering another. Our case highlights the clinical heterogeneity and overlap among *CACNA1A* channelopathies and ataxia-related paroxysmal disorders more broadly, which can aid in timely diagnosis and appropriate management of these conditions.

AUTHOR CONTRIBUTIONS

Dr. Yugrakh developed the study concept, participated in analysis and interpretation of data, and drafted and revised the manuscript. Dr. Levy developed the study concept, participated in analysis and interpretation of data, and revised the manuscript.

DISCLOSURE

The authors report no disclosures relevant to the manuscript. **Go to Neurology.org for full disclosures.**

REFERENCES

1. Headache Classification Subcommittee of International Headache Society. The International Classification of Headache Disorders, 2nd ed. Cephalalgia 2004;24(suppl 1):9-160.
2. Cohen JM, Bigal ME, Newman LC. Migraine and vestibular symptoms: identifying clinical features that predict "vestibular migraine." Headache 2011;51:1393-1397.
3. Jen J, Kim GW, Baloh RW. Clinical spectrum of episodic ataxia type 2. Neurology 2004;62:17-22.
4. Jen JC, Graves TD, Hess EJ, Hanna MG, Griggs RC, Baloh RW. Primary episodic ataxias: diagnosis, pathogenesis, and treatment. Brain 2007;130:2484-2493.
5. Haan J, Terwindt GM, van den Maagdenberg AMJM, Stam AJ, Ferrari MD. A review of the genetic relation between migraine and epilepsy. Cephalalgia 2008;28:105-113.
6. Romaniello R, Zucca C, Tonelli A, et al. A wide spectrum of clinical, neurophysiological and neuroradiological abnormalities in a family with a novel *CACNA1A* mutation. J Neurol Neurosurg Psychiatry 2010;81:840-843.
7. Jung J, Testard H, Tournier-Lasserre E, et al. Phenotypic variability of episodic ataxia type 2 mutations: a family study. Eur Neurol 2010;64:114-116.
8. Robbins MS, Lipton RB, Laureta EC, Grosberg BM. *CACNA1A* nonsense mutation is associated with basilar-type migraine and episodic ataxia type 2. Headache 2009;49:1042-1046.
9. Strupp M, Kalla R, Claassen J, et al. A randomized trial of 4-aminopyridine in EA2 and related familial episodic ataxias. Neurology 2011;77:269-275.
10. Scoggan KA, Friedman JH, Bulman DE. *CACNA1A* mutation in EA-2 patient responsive to acetazolamide and valproic acid. Can J Neurol Sci 2006;33:68-72.

Disorders presenting with visual deficits

Vision is among the most complex faculties of the human nervous system. Starting in the eye, visual information is processed, filtered, and relayed through pathways extending to the occipital lobes and then into all hemispheres of the brain. By some accounts, more than 50% of the brain contributes to the incredible computation required for normal visual processing and eye movements to occur. Based on a detailed understanding of the visual system, the bedside neuro-ophthalmologic evaluation will frequently disclose the localization of a lesion with great precision. In fact, the evaluation of a patient with a neuro-ophthalmologic disorder very often demonstrates how the most important tools in clinical neurology are a good history and a careful examination.

Localization of lesions causing visual loss.

- Disorders of the retina produce monocular visual loss and can often be diagnosed on the basis of the fundus examination.
- Disorders of the optic nerve often produce reduced acuity and impaired color vision (dyschromatopsia) on the affected side, and a relative afferent pupillary defect is observed with the swinging flashlight test. The optic disc may appear swollen or pale, but will appear normal when the nerve is acutely compromised by a retro-orbital lesion (i.e., behind the eye). In addition, swollen optic nerves, especially when associated with headache, enlargement of the physiologic monocular blind spot, and peripheral visual field constriction, can be the sign of elevated intracranial pressure.
- Disorders of the optic chiasm produce a visual field defect in the temporal field of each eye, owing to compromise of the crossing fibers from the nasal half of each retina.
- Disorders of the optic tract produce a contralateral homonymous visual field deficit that respects the vertical meridian. The field deficit associated with a lesion of the optic tract may be incongruous, meaning that the pattern of the deficit differs in each eye.
- Disorders of the lateral geniculate nucleus and optic radiations also produce contralateral homonymous field deficits. Lesions that affect the temporal radiations produce a contralateral superior deficit, while parietal lesions cause a contralateral inferior deficit.
- Disorders of the occipital cortex produce a contralateral homonymous field deficit that is congruous, meaning that the pattern of the deficit is similar for each eye. The central portion of the contralateral field is represented at the occipital pole. A lesion that affects the occipital lobe but spares the pole, as occurs with a posterior cerebral artery stroke, therefore produces a contralateral hemianopia with macular sparing.
- Disorders of higher-order visual areas can disrupt some of the complex aspects of visual processing, such as the perception of faces, the visual recognition of objects, and the ability to read.

Localization of eye movement abnormalities. Normal vision also depends upon the coordination of eye movements. The 6 extraocular muscles of each eye are innervated by the third, fourth, and sixth cranial nerves, which are controlled by gaze centers in the brainstem. Eye movement abnormalities can be characterized as supranuclear (referring to disruption of the neural inputs to the nuclei of cranial nerves 3, 4, and 6), nuclear (in these cranial nerve nuclei), or infranuclear (in these cranial nerves). Abnormalities that create ocular misalignment produce the symptom of binocular diplopia, which is present only when both eyes are open.

- The frontal eye fields help initiate saccades, which are rapid coordinated movements of the eyes to a target. The superior colliculi also contribute to saccades, particularly for sudden reflexive eye movements to a new stimulus. Acute lesions in the frontal lobe produce an ipsilateral gaze preference, whereas a seizure in the frontal lobe can cause contralateral gaze deviation.
- The parietal eye fields contribute to pursuit, which are slower eye movements that track a moving object. Parietal lesions impair pursuit in the direction ipsilateral to the lesion.
- The vestibular organs generate signals that contribute to the vestibular-ocular reflex that moves the eyes in the direction opposite the movement of the head. An acute destructive vestibular lesion, such as vestibular neuritis, produces vertigo, nystagmus with the fast-phase away from the side of the lesion, and an abnormal “catch-up” saccade when the patient is asked to maintain visual fixation while

the head is thrust horizontally in the direction of the lesion.

- The cerebellum contributes to the accuracy of both saccades and pursuit and helps hold the eyes in an eccentric position. Disturbances of the cerebellum, particularly the flocculonodular lobe, impair the accuracy of saccades and pursuit and produce gaze-holding nystagmus.
- The third cranial nerve innervates the superior rectus, medial rectus, inferior rectus, and inferior oblique muscles as well as the levator palpebrae (for eyelid opening) and the pupillary constrictors. An isolated third nerve palsy, which often has a compressive or microvasculopathic etiology, often causes ptosis, pupillary dilation, and impaired adduction and elevation of the eye.
- The fourth cranial nerve innervates the superior rectus muscle. A fourth nerve palsy causes vertical double vision that is worse with gaze in the contralateral direction and is worse with head tilt in the ipsilateral direction.
- The sixth cranial nerve innervates the lateral rectus. A sixth nerve palsy causes impaired abduction of the affected eye. A lesion of the nucleus of the sixth nerve causes an ipsilateral gaze palsy, affecting both abduction of the ipsilateral eye and adduction of the contralateral eye. A lesion of the medial longitudinal fasciculus causes internuclear ophthalmoplegia, with impaired adduction of the ipsilateral eye with attempted horizontal saccades. Unilateral or bilateral sixth nerve lesions can also be caused by elevated intracranial pressure, a “false localizing sign.”
- Neuromuscular junction disorders such as myasthenia gravis can cause fluctuating, fatigable ptosis and/or diplopia.
- Orbital disorders, including mass lesions and thyroid eye disease, cause restriction of eye movements resulting in diplopia.

The cases in this section illustrate the richness of the history and examination in determining the cause of neuro-ophthalmic disorders.



Clinical Reasoning: A 75-year-old man with 3 years of visual difficulties

Aaron L. Berkowitz, MD,
PhD
Matthew F. Rose, MD,
PhD
Kirk R. Daffner, MD
Sashank Prasad, MD

Correspondence to
Dr. Berkowitz:
aberkowitz3@partners.org

SECTION 1

A 75-year-old man with hypertension and hyperlipidemia presented with 3 years of progressive visual difficulties. Ophthalmologic evaluation revealed cataracts, but his vision was unchanged following cataract surgery. The patient described difficulty reaching for objects accurately and distinguishing objects from their background (for example, identifying his cat sitting on his couch). On one occasion, he intended to sit on a chair, but inadvertently sat on an adjacent table. He had sustained several car accidents. He had no difficulty reading or recognizing faces.

The patient's initial examination was reported to suggest mild impairment in attention (inability to spell "world" backward) and difficulty performing simple

calculations, but normal memory, speech, and language. Visual acuity and fields were normal. He was unable to interpret Ishihara color plates, but could distinguish individual colors accurately. He had difficulty drawing a clock and copying intersecting pentagons. Ocular ductions were normal, but he could not voluntarily initiate horizontal saccades to a target. On finger-nose testing, he could not accurately reach the target; after happening upon the examiner's palm, he traced up to the finger. Strength, sensation, reflexes, and gait were described as normal.

Question for consideration:

1. What is the localization and differential diagnosis of his deficits?

[GO TO SECTION 2](#)

SECTION 2

The patient has deficits of visuospatial processing including ocular apraxia (inability to initiate saccades), optic ataxia (impaired visually guided movements as demonstrated by his performance on finger–nose testing), and simultanagnosia (impaired processing of simultaneous stimuli, as demonstrated by impaired performance on the Ishihara color plates in spite of preserved color discrimination). These findings suggest Balint syndrome, often caused by bilateral parieto-occipital pathology. Etiologies of Balint syndrome include middle cerebral artery–posterior cerebral artery borderzone infarction, posterior reversible encephalopathy syndrome, malignancy involving the occipital lobes, and neurodegenerative disease.

In this patient, symptom evolution over several years suggests a neurodegenerative process such as posterior cortical atrophy (PCA). PCA is characterized by visual processing deficits and parieto-occipital cortical atrophy,

most commonly due to neurofibrillary tangles and senile plaques (Alzheimer-type pathology), although Lewy body and tau pathology occur less frequently.

Additional history revealed that the patient kicked and shouted during sleep, his handwriting had become smaller, his movements had slowed, his voice had become softer, and his sense of smell had diminished. The patient had not complained of any of these symptoms, describing them only after specific inquiry. He reported no hallucinations, abnormal fluctuations in wakefulness or mood, orthostasis, or incontinence. On examination, he had mildly decreased facial expression, subtle cogwheeling at the wrists bilaterally with reinforcement, and a slightly slow gait with normal arm swing and turning. No tremor was observed.

Question for consideration:

1. How do the additional findings guide the differential diagnosis?

GO TO SECTION 3

SECTION 3

Micrographia, bradykinesia, hypophonia, hypomimia, and cogwheeling are stigmata of parkinsonism. The history of violently acting out vivid dreams suggests REM sleep behavior disorder (RBD). RBD is associated with greater than 50% risk of developing neurodegenerative disease (most commonly synucleinopathy) at 15 years after onset, over 80% risk at 20 years, and over 90% risk at 25 years.¹ These features, along with the patient's cognitive impairment, suggested dementia with Lewy bodies (DLB).

Although definitive diagnosis of DLB requires pathologic confirmation, a probable diagnosis can be made antemortem if the patient has the central feature of dementia with 2 core features (fluctuating cognition, visual hallucinations, parkinsonism) or one core feature with one suggestive feature (RBD, neuroleptic sensitivity, low dopamine transporter uptake in the basal ganglia on PET or SPECT).² Our patient met criteria for probable DLB with cognitive deficits impairing function, one core feature (parkinsonism), and one suggestive feature (RBD).

Whereas the core features of visual hallucinations and parkinsonism are specific for DLB in patients with dementia (99% and 82% specificity, respectively), they are often absent (22% and 26% sensitivity, respectively).³

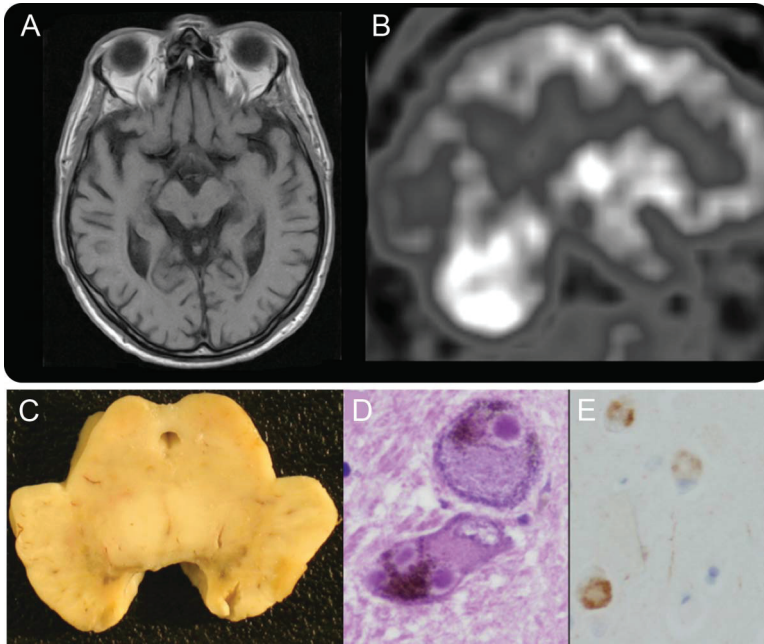
Although RBD is considered only a suggestive feature of DLB, it increases the odds of autopsy-confirmed diagnosis of DLB sixfold compared to each of the core features of DLB, which only increase these odds twofold.⁴ Visuospatial impairment in a patient with dementia, not considered a core or suggestive feature of DLB, may have higher sensitivity (74%) for identifying DLB than either of the core features of hallucinations or parkinsonism, although its specificity is poor (55%), since visual processing deficits may accompany DLB, PCA, and Alzheimer disease (AD).³

Although visual processing deficits can be present in both PCA and DLB, hallucinations are less common in PCA. In one study of patients diagnosed with PCA, all patients who had hallucinations eventually developed RBD or parkinsonism, ultimately meeting diagnostic criteria for probable DLB; no patients with PCA without hallucinations met criteria for DLB.⁵ The authors suggest that if patients diagnosed with PCA develop hallucinations, a diagnosis of DLB should be strongly considered.⁵ Our patient reported no hallucinations.

Question for consideration:

1. What further evaluation can help to distinguish between etiologies of the patient's cognitive deficits?

GO TO SECTION 4



(A) Axial T1-weighted MRI demonstrates symmetrical cortical atrophy. (B) SPECT scan demonstrates occipital and parietal hypoperfusion. (C) Pathologic specimen of the midbrain demonstrates bilateral degeneration of the substantia nigra. (D, E) Hematoxylin & eosin (D) and α -synuclein (E) stains demonstrate Lewy bodies in the substantia nigra (D) and amygdala (E).

SECTION 4

Structural neuroimaging can aid in the diagnosis of neurodegenerative diseases by demonstrating patterns of atrophy suggestive of particular diseases: medial temporal and temporoparietal atrophy in AD, frontotemporal atrophy in frontotemporal dementia, and occipitoparietal atrophy in PCA. Neuroimaging studies may also reveal non-neurodegenerative causes of dementia such as vascular disease, normal-pressure hydrocephalus, or structural lesions (e.g., malignancy).

Nuclear imaging modalities (e.g., PET and SPECT) may be helpful early in a dementing illness before structural changes are evident on MRI. Hypoperfusion and hypometabolism in temporoparietal regions without involvement of occipital or primary sensorimotor regions are highly predictive of AD, whereas occipital and temporoparietal hypoperfusion suggest DLB. At present, amyloid imaging and functional MRI are primarily research tools, but hold promise for the diagnosis of dementia, especially in early or pre-symptomatic stages.

In our patient, MRI demonstrated subtle, symmetrical, diffuse cortical atrophy, without structural lesions, ventriculomegaly, or significant stigmata of vascular disease (figure, A). SPECT showed hypoperfusion of occipital, parietal, and temporal cortices, supporting the diagnosis of DLB (figure, B).

Question for consideration:

1. How should the patient's symptoms be treated?

[GO TO SECTION 5](#)

SECTION 5

Cholinesterase inhibitors such as donepezil and rivastigmine and the NMDA receptor antagonist memantine have been shown to improve cognition and behavior in patients with DLB.

Our patient was treated with rivastigmine with no clear benefit. Over the following year, he experienced several freezing episodes and could no longer ambulate independently. A trial of carbidopa/levodopa (half of a 25/100 mg tablet 3 times daily) was initiated, but led to visual hallucinations and was discontinued. His hallucinations resolved, but over subsequent months he became increasingly disoriented and anxious, and his mobility continued to decline. He and his family decided to transition to hospice care. He died 2 years after presentation.

Brain autopsy revealed degeneration of the substantia nigra (figure, C), moderate to numerous Lewy bodies in the substantia nigra, locus ceruleus, raphe, basal forebrain, amygdala, and transentorhinal cortex (figure, D and E), and sparse Lewy bodies and Lewy neurites in frontal and temporal neocortices. There was limited Alzheimer pathology (Braak stage 1) in the hippocampi and entorhinal cortices. Moderate arteriosclerosis of the intracranial vasculature was noted, but with no evidence of cerebral infarction. These findings confirmed the diagnosis of DLB.

DISCUSSION DLB is the second leading cause of degenerative dementia after AD, accounting for 15% of dementia cases. While the core features of hallucinations, fluctuations, and parkinsonism are easily recognized, prominent visuospatial processing deficits may precede these. Impairment on clinical tests of visuospatial processing (e.g., clock drawing, copying tasks) can aid in distinguishing DLB from AD when core features of DLB are absent.^{3,6} In addition to considering a diagnosis of PCA in patients with subacute decline in visual cognition, it is important to search for clinical features of DLB that the patient may not initially report, such as hallucinations, parkinsonism, and RBD.

Neuroimaging can aid in the distinction between neurodegenerative causes of visual processing deficits: posterior-predominant cortical atrophy occurs in PCA, whereas occipital hypoperfusion without disproportionate occipital atrophy is supportive of DLB. Occipital hypoperfusion in DLB likely relates to decreased cholinergic input from the basal forebrain and brainstem, and treatment with cholinesterase inhibitors has been shown to improve occipital perfusion,⁷ suggesting an important role for the cholinergic system in the pathophysiology of the disease. In spite of occipital hypoperfusion in DLB, there is typically no occipital atrophy⁸ and autopsy studies

show a minimal burden of Lewy bodies in the occipital lobes.⁹

Although occipital hypoperfusion may explain visual processing deficits in DLB, the origin of visual hallucinations remains incompletely understood. Visual hallucinations in patients with DLB correlate with an increased burden of Lewy bodies in the parahippocampal and inferior temporal regions, independent of the severity of dementia.¹⁰ Disrupted input from the hypoperfused occipital lobes to the diseased medial temporal lobes may lead to hallucinations in DLB through a “release” of imagery from medial temporal regions.¹⁰

The study of visual phenomena in DLB—both visual processing deficits and hallucinations—holds promise for developing a deeper understanding of clinical–pathophysiologic correlations in this disease. In order to develop effective therapeutic strategies for neurodegenerative conditions such as PCA and DLB, it is critical to improve the early, accurate identification of these clinically overlapping yet pathologically distinct disorders.

AUTHOR CONTRIBUTIONS

Dr. Berkowitz conceived of the manuscript, drafted the initial manuscript, revised the manuscript, and created the figure. Dr. Rose prepared the pathologic specimens and revised the manuscript. Dr. Daffner was responsible for the care of the patient, including diagnosis and treatment, and revised the manuscript. Dr. Prasad drafted the initial manuscript, revised the manuscript, and created the figure.

STUDY FUNDING

No targeted funding reported.

DISCLOSURE

A. Berkowitz reports no relevant disclosures. He receives royalties from *Clinical Pathophysiology Made Ridiculously Simple* (Medmaster, Inc.) and *The Improvising Mind* (Oxford University Press). M. Rose, K. Daffner, and S. Prasad report no disclosures relevant to the article. Go to Neurology.org for full disclosures.

REFERENCES

1. Iranzo A, Tolosa E, Gelpi E, Molinuevo JL, Valldeoriola F, Serradell M. Neurodegenerative disease status and post-mortem pathology in idiopathic rapid-eye-movement sleep behaviour disorder: an observational cohort study. *Lancet Neurol* 2013;12:443–453.
2. McKeith IG, Dickson DW, Lowe J, et al. Diagnosis and management of dementia with Lewy bodies third report of the DLB consortium. *Neurology* 2005;65:1863.
3. Tiraboschi P, Salmon DP, Hansen LA, Hofstetter RC, Thal LJ, Jody Corey-Bloom J. What best differentiates Lewy body from Alzheimer's disease in early-stage dementia? *Brain* 2006;129:729–735.
4. Ferman TJ, Boeve BF, Smith GE, et al. Inclusion of RBD improves the diagnosis of dementia with Lewy bodies. *Neurology* 2011;77:875–882.
5. Josephs KA, Whitwell JL, Boeve BF, et al. Visual hallucinations in posterior cortical atrophy. *Arch Neurol* 2006;63:1427–1432.
6. Gnanalingham KK, Byrne EJ, Thornton A. Clock-face drawing to differentiate Lewy body and Alzheimer type dementia syndromes. *Lancet* 1996;347:696–697.

7. Mori T, Ikeda M, Fukuhara R, Nestor PJ, Tanabe H. Correlation of visual hallucinations with occipital rCBF by donepezil in DLB. *Neurology* 2006;66:935–937.
8. Middelkoop HA, van der Flier WM, Burton EJ, et al. Dementia with Lewy bodies and AD are not associated with occipital lobe atrophy on MRI. *Neurology* 2001;57:2117–2120.
9. Yamamoto R, Iseki E, Murayama N, et al. Investigation of Lewy pathology in the visual pathway of brains of dementia with Lewy bodies. *J Neuro Sci* 2006;246:95–101.
10. Harding AJ, Broe GA, Halliday GM. Visual hallucinations in Lewy body disease related to Lewy bodies in the temporal lobe. *Brain* 2002;125:291–403.

Clinical Reasoning: A video analysis of eye and limb movement abnormalities in a parkinsonian syndrome



Markos Pouloupoulos, MD
David Silvers, MD

Address correspondence and
reprint requests to Dr.
Pouloupoulos Markos, Department
of Neurology, Hartford Hospital
and University of Connecticut
School of Medicine, 80 Seymour
Street, Hartford, CT 06102-5037
markpou@hotmail.com

SECTION 1

A 72-year-old right-handed man with a history of coronary artery disease, aortic valve replacement, and hypothyroidism presented with 3 years of progressive difficulty using his right upper extremity, which had resulted in a largely nonfunctional limb within a year. In contrast, he reported relatively intact left upper limb function. He had developed gait instability within 6 months of onset and by 2 years he was nonambulatory. He reported slurring of speech and difficulty moving his eyes to either side, but especially to the right. He denied visual loss, diplopia, cognitive decline, visual hallucinations, sensory loss, autonomic symptoms, sleep disturbance, or perception of an alien limb. There had only been a nonsustained levodopa response. His medications included atenolol, monopril, simvastatin, warfarin, and levothyroxine. There was no family history of neurologic disease. He denied toxic exposures and had a distant history of tobacco use.

On examination, he was not orthostatic. He was fully oriented, could recite the months backwards, and had fluent speech and normal comprehension and naming. He recalled 2 out of 3 words after 5

minutes. He accurately drew a clock. He required 3 attempts to correctly imitate the Luria 3-step test (normal ≤ 2 attempts) and he could not sustain the sequence. The go–no go task consistently showed errors of commission and he was concrete with proverb interpretation.

He had abnormal eye movements (videos on the *Neurology*[®] Web site at www.neurology.org) and minimal dysarthria. He had mild hypophonia, a reduced blink rate, and bilateral lead pipe rigidity, greater on the right. Strength was full. There was no tremor or myoclonus. Additional motor features are demonstrated on the videos. He had normoactive reflexes and flexor plantar responses. While primary modality sensation was normal, he had bilaterally impaired 2-point discrimination, right hand astereognosis, and agraphesthesia, without extinction to double simultaneous touch. No cerebellar signs were appreciated. He was able to stand only with assistance. He had a stooped, rigid posture, was unable to initiate steps, and retropulsed when unsupported.

A brain MRI was unremarkable.

Question for consideration:

1. What are the main diagnostic considerations?

GO TO SECTION 2

SECTION 2

The videos were taken 3 years into his illness.

Questions for consideration after review of videos:

1. What eye movement abnormalities are seen on the videos?

2. What is the significance of head movements during saccadic testing?

3. What are the motor abnormalities exhibited?

[GO TO SECTION 3](#)

SECTION 3

The initial section of the first video demonstrates abundant square-wave jerks (SWJ), which are saccadic intrusions on fixation. Subsequently, saccadic pursuit is shown, horizontally and vertically. A very mild upgaze paresis may be appreciated, which is not overcome by the vestibulo-ocular reflex. The second section illustrates optokinetic nystagmus (OKN) testing: quick phases are preserved horizontally, but are less robust vertically. Small and large amplitude saccades are tested on cue and then self-paced. Although not shown, the patient could not initiate saccades when his head was fully stabilized. In the video segment, although the patient was instructed to look at a target without turning his head, he could only initiate saccades with a head thrust, sometimes accompanied by a blink. Horizontal saccadic latency was increased bilaterally, more to the right. The difficulty initiating voluntary horizontal saccades with preserved reflex saccades (i.e., normal horizontal OKN quick phases) defines ocular motor apraxia.

The second video demonstrates a dystonic right hand, with wrist and finger flexion. Dystonia describes sustained muscle contractions, repetitive

twisting movements, and abnormal postures. There is right greater than left upper extremity bradykinesia (while not shown, fine finger movements are also bradykinetic). Note left hand mirror movements, which are contralateral involuntary overflow movements in homologous muscles that accompany voluntary activity. The left hand is also apraxic while attempting a transitive task (i.e., with tool use). Apraxia is the failure to perform a learned act that cannot be otherwise explained, such as secondary to a comprehension or sensorimotor deficit. As he could not approximate tasks with his right hand—possibly due to bradykinesia or dystonia—one must be cautious in applying the term apraxia in this case. The authors speculate that the patient's right arm drift may be a manifestation of an alien limb phenomenon.

DISCUSSION Although idiopathic Parkinson disease is the most common cause of progressive asymmetric parkinsonism, the relatively brisk course, limb and oculomotor apraxia, cortical sensory loss, early postural instability, and nonsustained levodopa response all strongly suggest an alternative parkinsonian syndrome. We considered the nonacute course and absence of confusion incompatible with a potentially treatable autoimmune encephalopathy (Hashimoto disease). The abnormal saccades and absence of dysautonomia, dementia, visual hallucinations, and dream enactment behavior render unlikely the synucleinopathies multiple system atrophy and dementia with Lewy bodies. The tauopathies corticobasal degeneration (CBD) and progressive supranuclear palsy (PSP) are the primary considerations in a patient with parkinsonism and significantly abnormal eye movements (table).

This patient's most striking eye movement abnormality is the ocular motor apraxia. First described by Cogan in 1953, ocular motor apraxia is postulated to result from disruption of descending pathways from the frontal and parietal eye fields to the superior colliculus and brainstem reticular formation. The congenital form is often associated with ataxia, as in ataxia oculomotor apraxia.¹ Acquired oculomotor apraxia can be seen acutely after frontoparietal strokes, or in progressive disorders such as Huntington disease and CBD.¹ Saccadic latencies are consistently increased in CBD (indicating dysfunction of the posterior parietal cortex), greater toward the more apraxic side (as seen in this case), while decreased saccadic velocities are seen in PSP.^{2,3} While this patient's horizontal saccadic velocity was judged normal, typical of CBD, this could be confirmed with eye movement recordings.²

SWJ are small, paired, horizontal conjugate saccades, which move the eyes away from fixation with a brief intersaccadic interval, occurring normally up to

Table	Comparison of eye movement abnormalities in progressive supranuclear palsy (PSP) vs corticobasal degeneration (CBD)	
	PSP	CBD
Supranuclear ophthalmoplegia	<ul style="list-style-type: none"> • Prominent • May be late feature • Vertical plane affected first (especially downgaze) and disproportionate to horizontal 	<ul style="list-style-type: none"> • Less prominent • Often late feature
Horizontal saccadic velocity	<ul style="list-style-type: none"> • Impaired later • Slow 	<ul style="list-style-type: none"> • Impaired later (hypometric)
Vertical saccadic velocity	<ul style="list-style-type: none"> • Impaired early • Slow, especially downgaze • Small, hypometric saccades 	<ul style="list-style-type: none"> • Impaired later (hypometric)
Square-wave jerks (greater than 10–12 times per minute)	<ul style="list-style-type: none"> • Very prominent • Frequent feature 	<ul style="list-style-type: none"> • Usually less prominent and seen late
Saccadic latency	<ul style="list-style-type: none"> • Usually normal 	<ul style="list-style-type: none"> • Delayed initiation, first horizontal (i.e., worse to the side of greater apraxia) • Ocular motor apraxia
Optokinetic nystagmus	<ul style="list-style-type: none"> • Impaired generation of quick phases • Vertical plane affected first, especially downgaze • May occur early • Precedes supranuclear ophthalmoplegia 	<ul style="list-style-type: none"> • Usually retained
Antisaccadic movements	<ul style="list-style-type: none"> • Abnormal 	<ul style="list-style-type: none"> • Accurate, but increased latency

10–12 times per minute.⁴ That this patient has more than 40 SWJ per minute is clearly pathologic. SWJ are due to dysfunction of the superior colliculus and its connections with the mesencephalic reticular formation or the inhibitory input from the substantia nigra, pars reticulata. SWJ are prominent in Friedreich ataxia and PSP, but have been reported in several extrapyramidal disorders, including late in CBD.^{1,3} Saccadic pursuit is similarly nonspecific.⁵ Supranuclear ophthalmoplegia disproportionately affecting downgaze is the hallmark of PSP, although it may occur late or be absent, whereas impaired downward saccades are typically seen early.^{3,6} Supranuclear ophthalmoplegia is less common in CBD, and is generally a late finding.^{6,7} The relatively sparse vertical OKN quick phases may be one point favoring PSP.

Limb kinetic and ideomotor apraxia (IMA) are the 2 types of apraxia most relevant to CBD. In limb kinetic apraxia, which localizes to the frontoparietal cortex, there is a loss of dexterity. IMA, which localizes to parietal association areas, and less frequently to the supplementary motor cortex and basal ganglia, is characterized by complex spatial and temporal errors. IMA is primarily caused by left hemispheric lesions, often producing bilateral, asymmetric deficits. This patient exhibited the spatial organization errors typical of IMA. Although apraxia is one of the major clinical criteria of CBD (most commonly IMA), it can also be a feature of PSP.³

This patient has a persistent right hand dystonia, which in CBD classically becomes fixed. Mirror movements may occur during normal childhood development, but also may be found in various congenital and acquired conditions. For example, mirror movements may develop after a stroke or occur in conditions causing asymmetric parkinsonism such as PD or CBD.⁸ This patient exhibited cortical sensory loss, a core feature of CBD.^{7,9} An alien limb phenomenon is present in about 50% of CBD cases.⁹

Notwithstanding the diminished vertical OKN quick phases, based on the cortical and basal ganglia clinical signs—IMA, cortical sensory loss, asymmetric bradykinesia and rigidity, hand dystonia, mirror movements, and increased horizontal saccadic latency with oculomotor apraxia—CBD is the best clinical diagnosis.^{9,10} Other common findings include apathy, executive dysfunction (as seen in this patient), aphasia/apraxia of speech, yes/no reversals, myoclonus, and an irregular, jerky action and postural tremor.⁷

As CBD progresses, brain MRI may show asymmetric frontoparietal cortical atrophy (more prominent contralateral to the more clinically affected side), whereas atrophy primarily affects the midbrain in PSP. Functional imaging has also been applied to help

distinguish CBD from PSP.⁹ Clinicopathologic studies have shown that the positive predictive value of CBD clinical criteria is only around 50%.¹⁰ Autopsy studies have confirmed that PSP, Alzheimer disease, frontotemporal dementia, and even Creutzfeldt-Jakob disease can cause a CBD-like clinical picture. As there is significant clinical overlap between CBD and PSP, a definitive diagnosis of CBD can only be made pathologically.^{7,10} Typical features include neuronal loss and gliosis with superficial spongiosis, tau-positive neuronal and glial inclusions—astrocytic plaques (the most specific finding), oligodendroglial coiled bodies, and achromatic neurons—mostly in the superior frontal and parietal gyrus, sensorimotor cortex, and striatum.¹⁰

As neurologists are better at making an anatomic than pathologic diagnosis, it may be more appropriate to refer to the corticobasal syndrome or PSP syndrome.^{7,10}

This case of corticobasal syndrome, a rare sporadic cause of parkinsonism, underscores the importance of carefully examining eye movements and performing a detailed motor examination, in order to arrive at an accurate topographic, if not pathologic diagnosis.

DISCLOSURE

Dr. Silvers has received unrestricted type financial support for neurology resident education from Teva Neuroscience, Pfizer, and Merck. Dr. Pouloupoulos reports no disclosures.

REFERENCES

1. Leigh J, Zee D. *The Neurology of Eye Movements*, 4th ed. Oxford; 2006.
2. Rivaud-Pechoux S, Vidailhet M, Gaillet G, Litvan I, Gamar B, Pierrot-Deseilligny C. Longitudinal ocular motor study in corticobasal degeneration and progressive supranuclear palsy. *Neurology* 2000;54:1029–1032.
3. Zadikoff C, Lang AE. Apraxia in movement disorders. *Brain* 2005;128:1480–1497.
4. Shallo-Hoffmann J, Sendler B, Muhlendyck H. Normal square wave jerks in differing age groups. *Invest Ophthalmol Vis Sci* 1990;31:1649–1652.
5. Rottach KG, Riley DE, DiScenna AO, Zivotofsky AZ, Leigh JR. Dynamic properties of horizontal and vertical eye movements in parkinsonian syndromes. *Ann Neurol* 1996;39:368–377.
6. Brooks DJ. Diagnosis and management of atypical parkinsonian syndromes. *J Neurol Neurosurg Psychiatry* 2002; 72:i10–i16.
7. Boeve BF, Lang AE, Litvan I. Corticobasal degeneration and its relationship to progressive supranuclear palsy and frontotemporal dementia. *Ann Neurol* 2003;54:S15–S19.
8. Espay AJ, Li J-Y, Johnston L, Chen R, Lang AE. Mirror movements in parkinsonism: evaluation of a new clinical sign. *J Neurol Neurosurg Psychiatry* 2005;76:1355–1359.
9. Stover NP, Watts RL. Corticobasal degeneration. *Semin Neurol* 2001;21:49–58.
10. Lang AE. Corticobasal degeneration: selected developments. *Mov Disord* 2003;18:S51–S56.

Clinical Reasoning: A 64-year-old man with painful, unilateral external ophthalmoplegia

M. Tariq Bhatti, MD

Address correspondence and reprint requests to Dr. M. Tariq Bhatti, Departments of Ophthalmology and Medicine (Division of Neurology), 2351 Erwin Road, Duke University Eye Center, DUMC 3802, Durham, NC 27710-3802
tariq.bhatti@duke.edu

SECTION 1

A 64-year-old man was referred for evaluation of double vision in March 2009. Four months prior, he experienced daily pain in the region of the right forehead and right eye. Two months later, he noticed constant binocular, vertical double vision. Evaluation by an outside ophthalmologist resulted in the diagnosis of a right 4th cranial nerve (CN) palsy, a normal cranial and orbital MRI study with contrast, and an unremarkable laboratory evaluation. One month later, his right eye began “turning in,” and within a few days he was unable to abduct the eye. Several weeks later, the right eyelid began to droop and progressively worsened over the next several days to complete closure of the eye.

His past medical history was notable for arterial hypertension, depression, rheumatoid arthritis, gastroesophageal reflux disease, nephrolithiasis,

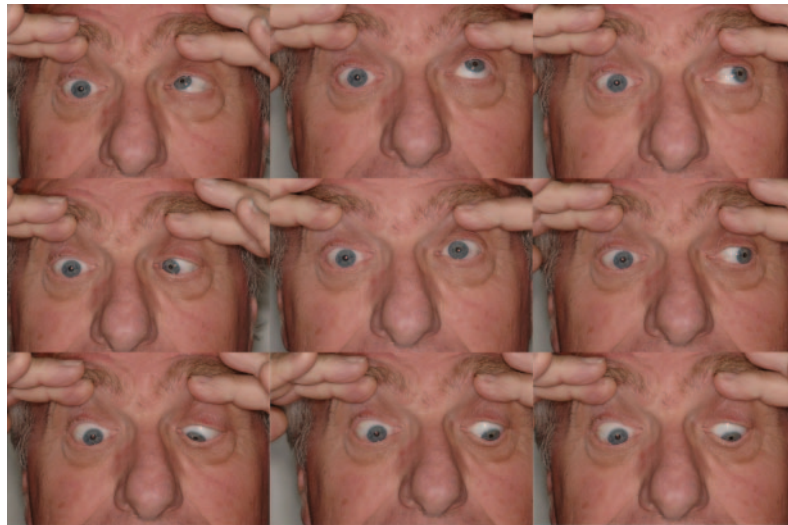
squamous cell carcinoma of the forehead, and a precancerous melanoma of the left ear.

When he was seen in the neuro-ophthalmology clinic, visual acuity was 20/20 in each eye. Color vision was intact in each eye. The right pupil was 2 mm larger than the left and was nonreactive to light or near effort. There was no relative afferent pupillary defect (RAPD). Dilated fundus examination was normal in each eye. Eye movements of the right eye were limited in all directions and there was complete right upper eyelid ptosis (figure 1). Corneal sensation of the right eye was absent and there was numbness over the right forehead. The remainder of the cranial nerve examination was normal.

Questions for consideration:

1. What is the clinical presentation?
2. Where does the lesion localize?

Figure 1 Nine cardinal positions of eye movements



There is limited movement of the right eye in all directions of gaze. There was no intorsion of the right eye on attempted downgaze. The right eyelid is manually elevated because of the complete right eyelid ptosis (center, middle panel). Permission obtained from patient.

[GO TO SECTION 2](#)

From the Departments of Ophthalmology and Medicine (Division of Neurology), Duke University Eye Center and Duke University Medical Center, Durham, NC.

Disclosure: Author disclosures are provided at the end of the article.

SECTION 2

This 64-year-old man presented with a painful, complete external ophthalmoplegia of the right eye. His history and examination were consistent with sequential CN 5, 4, 6, and 3 palsies. To ascribe a lesion in one anatomic location to cause such a clinical picture would require the lesion to be in the superior orbital fissure, cavernous sinus, or both. Although it is possible a more proximal lesion (i.e., as the CNs exit the brainstem) could result in CN 3, 4, 5, and 6 paresis, the fact that the patient did not have any meningeal or brainstem signs or symptoms makes it unlikely. Because CNs 3, 4, and 6 pass through both the cavernous sinus and superior orbital fissure, a lesion in either of these 2 anatomic regions is often difficult to clinically distinguish, resulting in the term sphenocavernous syndrome. However, careful assessment of CN 5 function can aid in differentiat-

ing involvement between a lesion in the cavernous sinus or superior orbital fissure. The second division of CN 5 exits the cavernous sinus into the foramen rotundum; therefore, it is not involved in a superior orbital fissure syndrome. Even though a normal clinical examination of the second division of CN 5 favors a lesion in the superior orbital fissure, this does not completely exclude the possibility of cavernous sinus involvement in the setting of a progressive disease process. Evidence of an optic neuropathy (CN 2 palsy)—as manifested by visual loss, impaired color vision, and a RAPD—in the presence of an ipsilateral external ophthalmoplegia indicates an orbital apex syndrome.

Question for consideration:

1. What is the differential diagnosis?

GO TO SECTION 3

SECTION 3

The differential diagnosis of a sphenocavernous syndrome is extensive and can be the result of systemic disease, metastatic disease, or primary lesions arising from the head and neck, orbit, cranium, paranasal sinuses, or nasopharynx (table). Age, prior medical history, and race of the patient are important determinants in formulating a differential diagnosis. The onset of symptoms and the presence of pain are also very important factors. An acute onset of symptoms would favor a vascular event or an infectious process, while a progressive course would raise the possibility

of a neoplastic process, especially given this patient's prior history of malignancy. Ocular or facial pain indicates CN 5 involvement and can be the result of a compressive, inflammatory, or infiltrative condition. The Tolosa-Hunt syndrome is an idiopathic, inflammatory condition involving the cavernous sinus, superior orbital fissure, or orbital apex. It is a diagnosis of exclusion and a thorough evaluation should be performed to exclude more specific etiologies.¹

Question for consideration:

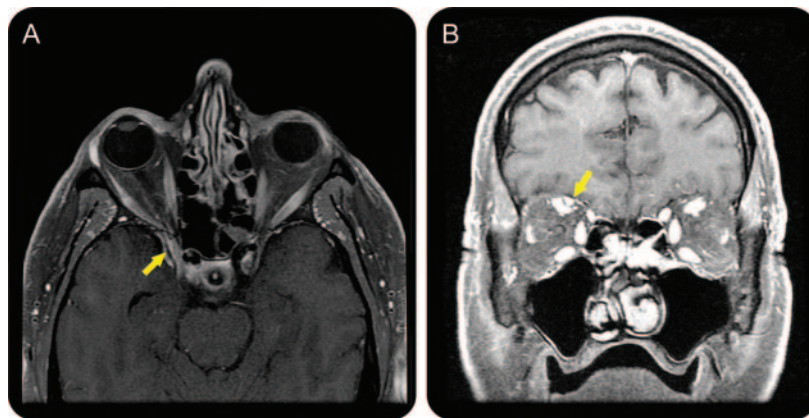
1. What studies and/or tests do you want to perform?

Table Differential diagnosis of sphenocavernous syndrome based on the age, clinical course, and medical history of the patient presented in the text

Neoplastic	Inflammatory	Infectious	Vascular
Intracranial tumors	Sarcoidosis	Fungal	Intracavernous carotid artery aneurysm
Meningioma	Systemic lupus erythematosus	Aspergillus	Carotid artery-cavernous sinus fistula
Pituitary adenoma	Churg-Strauss syndrome	Mucormycosis	Cavernous sinus thrombosis
Orbital tumors	Wegener granulomatosis	Bacterial	
Paranasal sinus tumors	Tolosa-Hunt (idiopathic)	Streptococcus	
Lymphoma/leukemia		Staphylococcus	
Distal metastasis		Actinomyces	
Cutaneous malignancies		Mycobacterium	
		Spirochetes	
		Viral	
		Varicella zoster	
		Herpes simplex	

GO TO SECTION 4

Figure 2 MRI



(A) Axial, postgadolinium, fat-suppressed MRI demonstrates an enhancing lesion of the right superior orbital fissure and anterior cavernous sinus (arrow). (B) Coronal, postgadolinium, fat-suppressed MRI shows enlargement and enhancement of the right supraorbital nerve (arrow).

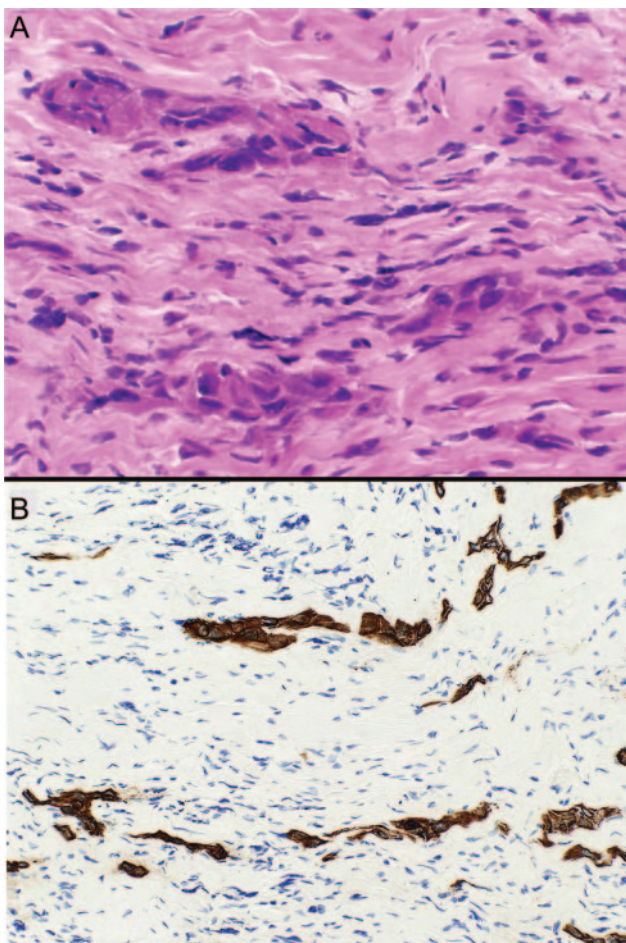
SECTION 4

A cranial and orbital MRI with contrast was performed and demonstrated an enhancing mass in

the right superior orbital fissure, anterior cavernous sinus, and right supraorbital nerve (figure 2).

A right supraorbital nerve biopsy was performed. The histopathologic specimen was consistent with perineural invasion (PNI) from cutaneous squamous cell carcinoma (SCC) (figure 3).

Figure 3 Histopathology



Histopathologic specimen of right supraorbital nerve biopsy showing neoplastic cells scattered among the supraorbital nerve fibers. (A, Hematoxylin-eosin stain; B, keratin stain.)

DISCUSSION Neoplastic cells can metastasize throughout the body by several different mechanisms, including the often overlooked mode of PNI. PNI is defined by the spread of neoplastic cells via the nerve-nerve sheath complex. Carter et al.² showed, in pathologic specimens of 65 patients with SCC of the head and neck, varying degrees of demyelination, axonal degeneration, and segmental infarction of the infiltrated nerves, possibly due to hypoxic/anoxic injury.

PNI has been reported to occur in approximately 5% of cutaneous SCC cases.³ The most common CNs involved are the 5th (second and third division) and 7th. CN 5 involvement can be misinterpreted as trigeminal neuralgia in some cases, and in other cases the dysesthesia and hypesthesia can be vague, nonspecific, and non-localizing. Facial muscle weakness is indicative of CN 7 involvement.⁴ PNI from cutaneous SCC resulting in ophthalmologic and orbital involvement most commonly arises from the forehead and eyebrow regions.

The radiologic study of choice in cases suspected of PNI is a cranial and orbital MRI with contrast and fat suppression. MRI findings include an enhancing mass, enlargement and enhancement of CNs, obliteration of normal fat planes, and enlargement of foramina or canals.⁵

The diagnosis of PNI can be challenging for several reasons, including negative neuroimaging in as many as 50% of cases,⁶ diagnostic mimickers, vague symptomatology, incomplete or absent medical history of a cutaneous malignancy, and an extended interval from the

time of the primary diagnosis of cutaneous malignancy to onset of clinical manifestations. Fine-needle aspiration biopsy, open surgical biopsy, or peripheral nerve biopsy can often establish the diagnosis.

The prognosis of PNI of cutaneous SCC is poor. The 5-year survival rate of cutaneous malignancies with PNI is approximately 50%.³ Definitive radiation therapy, preferably conformal or intensity-modulated radiation therapy, is recommended for nonresectable cases of PNI.³ Orbital exenteration may be warranted for some patients with disease confined to the orbit.

Follow-up. The patient received a total dose of 5,600 cGy delivered by fractionated intensity modulated radiation therapy. At his 6-month follow-up, the neuroophthalmic examination was essentially unchanged.

DISCLOSURE

Dr. Bhatti has served on speakers' bureaus for and received speaker honoraria from EMD Serono, Inc., Pfizer Inc., Bayer Schering Pharma, and Novartis.

REFERENCES

1. Kline LB, Hoyt WF. The Tolosa-Hunt syndrome. *J Neurol Neurosurg Psychiatry* 2001;71:577–582.
2. Carter RL, Foster CS, Dinsdale EA, Pittam MR. Perineural spread by squamous carcinomas of the head and neck: a morphological study using anti-axonal and antimyelin monoclonal antibodies. *J Clin Pathol* 1983;36:269–275.
3. Mendenhall WM, Amdur RJ, Hinerman RW, et al. Skin cancer of the head and neck with perineural invasion. *Am J Clin Oncol* 2007;30:93–96.
4. Scurry WC, Jr, Isaacson JE, Fedok FG. New-onset facial paralysis and undiagnosed recurrence of cutaneous malignancy: evaluation and management. *Am J Otolaryngol* 2006;27:139–142.
5. Gandhi D, Gujar S, Mukherji SK. Magnetic resonance imaging of perineural spread of head and neck malignancies. *Top Magn Reson Imaging* 2004;15:79–85.
6. Williams LS, Mancuso AA, Mendenhall WM. Perineural spread of cutaneous squamous and basal cell carcinoma: CT and MR detection and its impact on patient management and prognosis. *Int J Radiat Oncol Biol Phys* 2001; 49:1061–1069.

Clinical Reasoning: A 36-year-old man with vertical diplopia

Sashank Prasad, MD
Nicholas J. Volpe, MD
Madhura A. Tamhankar,
MD

Address correspondence and
reprint requests to Dr. Sashank
Prasad, Department of
Neurology, Division of Neuro-
ophthalmology, Hospital of the
University of Pennsylvania, 3
Gates Bldg., 3400 Spruce St.,
Philadelphia, PA 19104
sashank.prasad@uphs.upenn.edu

SECTION 1

A 36-year-old man with Von Hippel-Lindau syndrome presented with binocular vertical diplopia following suboccipital craniotomy for resection of a cerebellar hemangioblastoma. His diplopia was worse in left gaze. He was effectively treated with a 6-diopter base-down

prism in the right eye. With-out spontaneous improvement after 10 months of using prisms, he desired an alternative to prism correction.

Question for consideration:

1. What features of the examination will help determine the cause of vertical diplopia?

[GO TO SECTION 2](#)

Table	Examination techniques in the diagnosis of vertical diplopia
Observation	Comment
Head tilt or head turn	May be identified in prior photographs, indicating chronicity of strabismus and adaptation
Ocular ductions	Identify overt motility deficit, although ductions can often be normal in patients with ocular vertical misalignment
Forced ductions	Distinguish muscle restriction from paresis
Parks-Bielschowsky three-step test	Assessment of hypertropia in horizontal gaze and head tilt to identify the paretic cyclovertical muscle
Cover testing	Identify misalignment (tropia) by covering the preferred eye and observing a movement of redress in the fellow eye
Cover-uncover testing and alternate cover testing	Identify latent misalignment (phoria) by assessing movement of redress in the eye under cover when cover is removed, after disrupted binocular fusion
Maddox rod testing	Identify phoria for misalignment by preventing binocular fusion with disparate images
Double Maddox rod testing	Identify relative cyclotorsion by presenting disparate images
Dilated funduscopy	Identify cyclotorsion by direct visualization of position of macula with respect to optic disc
Upright and supine testing	Assess any improvement of hypertropia or cyclotorsion in the supine position
Fusional amplitude measurement	Identify higher-order adaptive mechanisms for binocular fusion of disparate images

SECTION 2

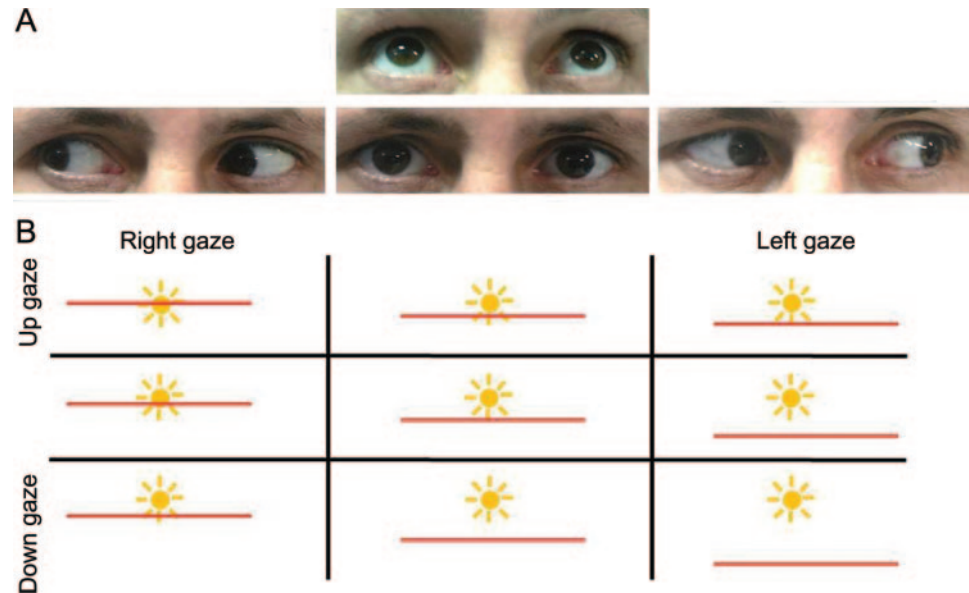
A detailed neuro-ophthalmologic history and examination is critical for evaluation of double vision (table). First, it should be established whether double vision is monocular (persists with the fellow eye closed) or binocular (abates with one eye closed). Binocular diplopia results when misaligned eyes relay contradictory visuospatial information; it therefore does not occur when viewing through one eye only. Examination should include observation of abnormal posture, such as a head tilt or head turn that the patient may use to minimize symptoms; these may also be evident on old photographs. Ocular ductions (movements of each eye individually) and versions (movements of the eyes together) should be carefully examined in all directions, to identify abnormalities of muscle weakness or overaction.¹ Weakness in a particular direction of gaze may be partial or complete, and may result from dysfunction at the level of the cranial nerve, eye muscle, or neuromuscular junction. Muscle overaction in a direction of gaze often signifies compensation for a long-standing or congenital process. The possibility of mechanical restriction (for example, from an orbital mass or extraocular muscle fibrosis) may be tested by evaluating forced ductions, using a cotton-tipped applicator or ophthalmic forceps to rotate the globe after applying topical anesthesia. In patients with nonrestrictive paresis, the eye can be moved the full extent of a normal duction.

It is common for patients with vertical misalignment to have no visible impairment in ocular motility. In this situation, cover testing is a useful technique to identify the ocular misalignment. While the subject fixates upon a target with both eyes, the examiner covers one eye and observes for a corrective

saccade in the uncovered fellow eye. This correction, termed the movement of redress, occurs if the fellow eye is misaligned and refixates. Cover testing is repeated for the second eye, and is repeated in the nine cardinal positions of gaze. In this manner, an overt misalignment of the eyes will be identified as a hypertropia (relative elevation of one eye), exotropia (relative outward position of one eye), or esotropia (relative inward position of one eye). Variations of cover testing are the cover-uncover test and the alternate cover test, in which the movement of redress is observed in the eye under cover at the time the cover is removed. The period of monocular cover causes disruption of binocular vision, allowing a latent deviation (phoria) of the eyes to be detected. Detecting a latent deviation is critical because decompensation (for example, during periods of fatigue) is a common cause of intermittent binocular diplopia. To quantify a tropia or phoria in each direction of gaze, the methods of cover testing can be performed with prism held before one eye. The apex of the prism should point in the direction of the deviation (i.e., a base-down prism over the right eye would aid in quantifying a right hypertropia).

The Parks-Bielschowsky three-step test allows identification of the paretic cyclovertical muscle in patients with vertical misalignment. First, the hypertropic eye is identified; the paretic muscle must therefore be a depressor of one eye (inferior rectus or superior oblique) or an elevator of the other eye (superior rectus or inferior oblique). Second, it should be identified whether the hypertropia is worse in lateral gaze; hypertropia worse in contralateral gaze narrows the possibilities to weakness of the ipsilateral superior oblique or contralateral inferior rectus.

Figure 1 Eye movements and Maddox rod testing



(A) Ocular motility. Note very small right hypertropia in primary gaze and upgaze, increased in left gaze. (B) Simulation of patient's view through Maddox rod in each direction of gaze. Note greatest vertical separation in down-and-left gaze.

Third, it should be identified if the hypertropia is worse with head tilt; hypertropia worse with ipsilateral head tilt must be due to weakness of either the ipsilateral intorter (superior oblique) or the contralateral extorter (inferior oblique). In cases where an isolated muscle is weak, application of these three rules allows the examiner to successfully identify the specific abnormality through a process of elimination. In some cases, however, the results of the three-step test may be misleading; these situations include chronic extraocular muscle paralysis or mechanical ocular muscle restriction (for example, due to an orbital floor fracture or thyroid eye disease).

Vertical misalignment of the eyes can also be evaluated with the Maddox rod, placed by convention over the right eye. This device prevents binocular fusion, because the viewer simultaneously sees disparate images (a point of light with the left eye and a red line with the right). If the eyes are misaligned, the red line does not intersect the point of light; it is displaced in the direction of weakness (opposite the direction of the deviation) because the image becomes projected onto extrafoveal retina (figure 1). The images are maximally separated during gaze in the direction of action of the paretic muscle. The Maddox rod provides a sensitive method to evaluate a small deviation or latent phoria that may not be evident on cover-uncover or alternate cover testing.

Torsional diplopia often accompanies vertical diplopia, resulting from ocular cyclotorsion. Cyclotorsion can be evaluated with the double Maddox rod or dilated funduscopy (by assessing the

position of the macula with respect to the optic disc). Assessing cyclotorsional and vertical misalignment in both the upright and supine position may be helpful in distinguishing specific causes of vertical misalignment.²

The patient's ability to fuse disparate images (fusional amplitude) is an important clue in assessing the chronicity of vertical strabismus. With progressively increased prism placed over one eye, the patient is asked to report double vision. A vertical fusional capacity greater than 8–10 diopters suggests the presence of higher compensatory mechanisms that occur with long-standing misalignment.

Differential diagnosis. Binocular vertical diplopia has a limited differential diagnosis, which includes third nerve palsy, fourth nerve palsy, skew deviation, extraocular muscle restriction (for example, thyroid eye disease), and neuromuscular junction impairment (for example, myasthenia gravis). In third nerve palsy and fourth nerve palsy, the amount of hyperdeviation of one eye is greatest in the direction of action of the affected muscle. This unequal amount of misalignment in each direction of gaze is termed incomitance. Skew deviation, on the other hand, is a cause of vertical alignment in which the amount of misalignment does not follow an incomitant pattern typical of third or fourth nerve palsy. In contrast to those conditions, the hyperdeviation in a skew may be fairly equal (comitant) in each direction of gaze. Skew deviation is thought to be caused by imbalanced utricular inputs from the inner ear, leading

to a compensatory, reflexive cyclovertical ocular deviation.

On examination, the patient's ocular ductions were full, without evidence of inferior oblique overaction (figure 1). There was a very small right hypertropia, greatest in left gaze. Maddox rod testing confirmed a right hypertropia of 6–8 diopters in primary position, increasing in left gaze to 8–10 diopters, and increasing further in down-and-left gaze to 10–12 diopters (figure 1). The misalignment was significantly less in upgaze, measuring 4 diopters. On right head tilt, the deviation

increased to 12 diopters, and on left head tilt it decreased to 4 diopters. Measurements taken in the supine position were not different from those in the vertical position. Cyclotorsion was not appreciated on funduscopy, but double Maddox rod testing revealed 5 degrees of relative excyclotorsion of the right eye. Except for mild dysarthria and gait ataxia, the remainder of the examination was normal.

Question for consideration:

1. What cause of vertical ocular misalignment does this examination confirm, and why?

GO TO SECTION 3

SECTION 3

The findings of right hypertropia greatest in contralateral gaze and ipsilateral head tilt suggest a right fourth nerve palsy. According to the Parks-Bielschowsky three-step test, right hypertropia suggests weakness of the right superior oblique, right inferior rectus, left inferior oblique, or left inferior rectus muscles. Next, increased right hypertropia in contralateral gaze narrows the possibilities to right superior oblique or left inferior rectus weakness. Finally, increased right hypertropia on ipsilateral head tilt further reduces the possibilities, ultimately identifying right superior oblique weakness.

The reason that superior oblique dysfunction causes this pattern of impaired motility relates to its mechanical properties. The superior oblique arises from the orbital apex, passes through a fibrocartilaginous trochlea just inside the superior medial orbital rim, and then inserts on the superior lateral aspect of the globe, posterior to the equator. Its main action, therefore, depends upon the position of the eye: when the eye is abducted, the superior oblique is a strong intorter, and when the eye is adducted, it is a depressor. Its tertiary action is abduction of the globe in depression.

The reason that hypertropia is exacerbated in contralateral gaze is that there is weakness of depression in adduction (or, in long-standing cases, the hypertropia is due to overaction of the ipsilateral inferior oblique,

which further elevates the eye in adduction). The reason hypertropia is worse with ipsilateral head tilt is that the ocular counter-roll reflex stimulates ipsilateral intorters (superior oblique and superior rectus) and contralateral extorters (inferior oblique and inferior rectus); when the superior oblique is weak, this reflex causes compensatory increase in ipsilateral superior rectus action, resulting in additional hypertropia (since the superior rectus is an elevator). In skew deviation, head tilt does not worsen hypertropia, since these ocular counter-roll mechanisms are intact.

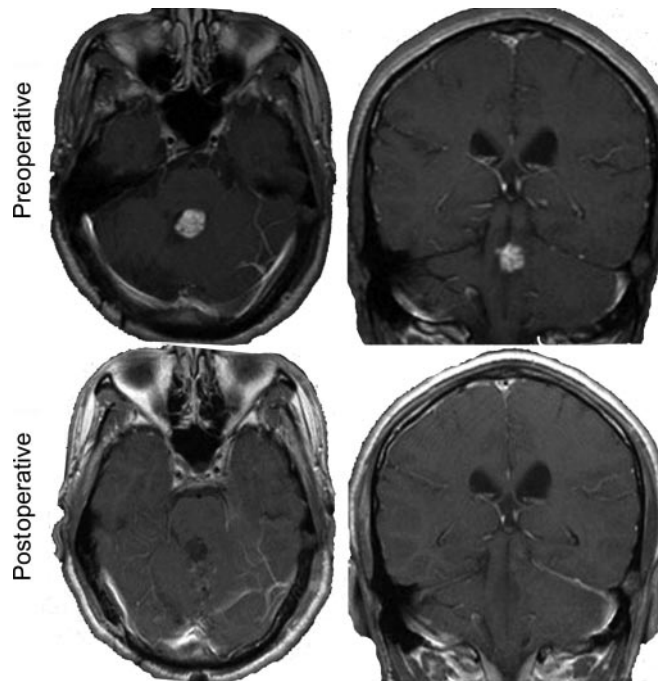
Additional findings that indicate fourth nerve palsy over skew deviation are excyclotorsion of the eye and persistence of hypertropia in the supine position. Excyclotorsion of the hypertropic eye suggests fourth nerve palsy, because of weakened intorsion; in contrast, intorsion of the hypertropic eye occurs in skew deviation, due to decreased stimulation of the inferior oblique subnucleus. The reason that hyperdeviation is mitigated in the supine position in skew deviation, but not fourth nerve palsy, relates to the fact that utricular inputs depend upon head position; the utricular imbalance that causes a skew deviation is lessened in the supine position, and the amount of ocular hyperdeviation is reduced.²

Question for consideration:

1. What is the differential diagnosis for a fourth nerve palsy and what testing would you pursue?

GO TO SECTION 4

Figure 2 Preoperative and postoperative gadolinium-enhanced T1-weighted MRI scans, demonstrating fourth ventricle hemangioblastoma



SECTION 4

In patients with a fourth nerve palsy, the etiology can often be determined by history and examination alone. Neuroimaging is required when the cause is unclear.

The most common cause of acquired fourth nerve palsy is trauma. The trochlear nerve is the longest and thinnest of all the cranial nerves, coursing along the free edge of the tentorium through the prepontine cistern, where it is vulnerable to crush injury. In cases of bilateral traumatic fourth nerve palsies, both nerves are often injured at the anterior medullary velum, where they decussate.³

Decompensated congenital fourth nerve palsy is also common and may present in adulthood. Characteristic features of congenital fourth nerve palsy include head tilt, inferior oblique overaction, large vertical fusional amplitude, hypertropia greater in upgaze, and minimal torsional diplopia. The precise etiology of congenital fourth nerve palsy is unclear but may include hypoplasia of the nucleus, birth trauma, anomalous muscle insertion, muscle fibrosis or adhesion, or structural abnormalities of the tendon.⁴ The cause of decompensation is likely breakdown of vertical fusion that leads to symptomatic diplopia, rather than progressive superior oblique dysfunction.⁵

Ischemic fourth nerve palsy is less common, but occurs most often in patients over age 50 with vascular risk factors. There is often periorbital aching pain on presentation, and excellent spontaneous recovery is expected over several months.

Less frequent causes of fourth nerve palsy include midbrain hemorrhage or infarction, schwannoma, aneurysmal compression, meningitis, demyelination, giant cell arteritis, hydrocephalus, and herpes zoster ophthalmicus. Finally, when ancillary testing fails to support a definitive etiology, a diagnosis of idiopathic acquired fourth nerve palsy can be made.

In our patient, brain MRI revealed postoperative changes related to resection of a hemangioblastoma within the fourth ventricle. The etiology of his right fourth nerve palsy was most likely intraoperative trauma (figure 2).

Question for consideration:

1. How should a patient with a fourth nerve palsy be managed?

GO TO SECTION 5

SECTION 5

There are several treatment options for the patient with superior oblique palsy. Occlusion of the affected eye (or, if diplopia occurs only in down-and-contralateral gaze, occlusion of the lower half of the lens over the affected eye) can serve as a temporary measure, when spontaneous recovery is expected. Alternatively, base-down prism over the affected, hypertropic eye may alleviate diplopia (by shifting the image downward to the fovea). Temporary press-on Fresnel prisms may be tried before permanent prisms are ground into the lenses. The disadvantage of prisms is that the patient may have an unequal amount of misalignment in each direction of gaze (i.e., an incomitant deviation), yet the prism is only capable of providing a fixed amount of correction for misalignment. The patient may therefore continue to experience diplopia in eccentric gaze. Furthermore, torsional diplopia cannot be corrected by prisms.

Surgery may be necessary for persistent symptomatic fourth nerve palsy when conservative measures fail, as long as measurements of misalignment have been stable over several months. The general principle behind strabismus surgery is to detach and reattach the appropriate extraocular muscles in a position that achieves better ocular alignment, particularly in primary gaze. Patients with decompensated congenital fourth nerve palsy generally have a better progn-

osis after surgery than patients with acquired fourth nerve palsy, because they often have increased vertical fusional amplitude that reduces the likelihood of postoperative diplopia.⁶

To improve ocular alignment, we performed a left inferior rectus weakening procedure. Postoperatively, the patient had 1 diopter right hypertropia in primary and eccentric gaze, measured by Maddox rod testing. Subjective vertical diplopia was successfully eliminated.

REFERENCES

1. Kushner BJ. Multiple mechanisms of extraocular muscle "overaction." *Arch Ophthalmol* 2006;124:680–688.
2. Parulekar MV, Dai S, Buncic JR, Wong AM. Head position-dependent changes in ocular torsion and vertical misalignment in skew deviation. *Arch Ophthalmol* 2008;126:899–905.
3. von Noorden GK, Murray E, Wong SY. Superior oblique paralysis: a review of 270 cases. *Arch Ophthalmol* 1986;104:1771–1776.
4. Helveston EM, Krach D, Plager DA, Ellis FD. A new classification of superior oblique palsy based on congenital variations in the tendon. *Ophthalmology* 1992;99:1609–1615.
5. Mansour AM, Reinecke RD. Central trochlear palsy. *Surv Ophthalmol* 1986;30:279–297.
6. Maruo T, Iwashige H, Kubota N, et al. Long-term results of surgery for superior oblique palsy. *Jpn J Ophthalmol* 1996;40:235–238.

CORRECTION

Clinical Reasoning: A 36-year-old man with vertical diplopia

In the Resident & Fellow Section article “Clinical Reasoning: A 36-year-old man with vertical diplopia” by S. Prasad et al. (*Neurology*[®] 2009;72:e93–e99), section 3 (page e97), the abnormal muscles identified by the Parks-Bielschowsky test are given incorrectly. The correct explanation should read as follows (revisions in italics):

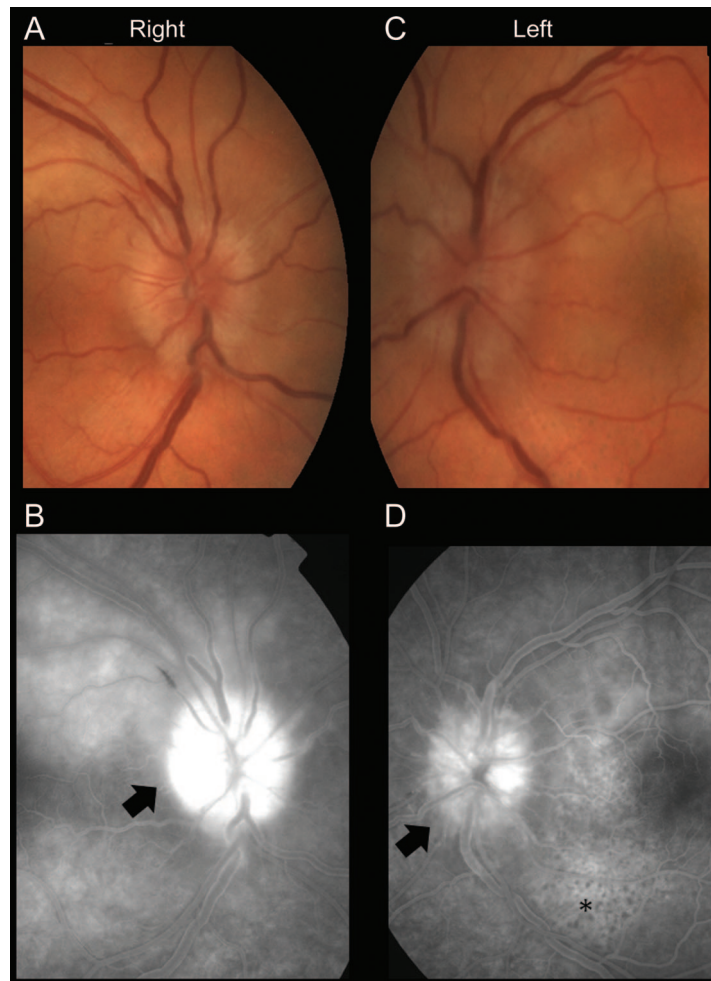
“According to the Parks-Bielschowsky three-step test, right hypertropia suggests weakness of the right superior oblique, right inferior rectus, left inferior oblique, or left *superior* rectus muscles. Next, increased right hypertropia in contralateral gaze narrows the possibilities to right superior oblique or left *superior* rectus weakness.” The authors regret the error.

Clinical Reasoning: Optic disc swelling in a patient with AIDS

M.A. Almekhlafi,
MD, FRCPC
G. Williams, MD,
FRCSC
F. Costello, MD,
FRCPC

Address correspondence and
reprint requests to Dr.
Mohammed A. Almekhlafi,
Department of Clinical
Neurosciences, University of
Calgary, Foothills Medical
Centre, 1403-29 St NW,
Calgary, AB T2N 2T9 Canada
malmekhl@ucalgary.ca

Figure 1 Imaging



Ophthalmoscopic photographs (A, C) show bilateral elevated optic discs with no evidence of hemorrhage or exudates. Fluorescein angiogram (B, D) shows optic nerve hyperfluorescence bilaterally (arrows) with left stippled hypofluorescent spots representing choroidal leakage with nonfilling infiltrates (D, asterisk).

SECTION 1

A 51-year-old man, known to have AIDS and hepatitis C, presented with a 1-week history of painless blurred vision in the left eye. He denied any symptoms of raised intracranial pressure including head-

ache, pulse-synchronous tinnitus, transient visual obscurations, or diplopia.

Two months prior, he developed pain in his lower back radiating into both legs and an associated band-like sensation around his waist. He ini-

Supplemental data at
www.neurology.org

From the Departments of Clinical Neurosciences (M.A.A., F.C.) and Surgery (Ophthalmology) (G.W., F.C.), University of Calgary, Calgary, Canada; and Department of Internal Medicine (M.A.A.), King Abdulaziz University, Saudi Arabia.

Disclosure: Author disclosures are provided at the end of the article.

tiated a course of oxycodone medication, and the pain subsided in 4 weeks.

On examination, he was normotensive. Visual acuity was 20/20 in the right eye and 20/150 in the left. There was no relative afferent pupil defect (RAPD). Color vision was normal in the right eye (17/17 Hardy Rand and Rittler HRR pseudoisochromatic plates) and absent in the left eye (0/17 HRR plates). Ophthalmoscopy showed marked bilateral optic disc swelling (figure 1, A and C) and macular edema in the left eye. Visual field testing showed a small inferotemporal scotoma in the right

eye, with a larger central scotoma in the left eye. Ocular motility and external ocular examinations were normal. There was subjective decrease in light touch and pinprick sensations up to the midshin level bilaterally. There was no spinal sensory level. Deep tendon reflexes were present throughout with flexor plantar responses. The patient's CD4 count was 189 cells/mm³.

Questions for consideration:

1. What is your differential diagnosis at this point?
2. What initial investigations would you order?

GO TO SECTION 2

SECTION 2

Bilateral optic disc edema is an alarming sign, particularly in this patient with AIDS. It commonly indicates raised intracranial pressure (ICP) due to a space-occupying lesion, a CNS infection, or an obstruction of venous or CSF flow. However, uncomplicated papilledema is not typically associated with reduced visual acuity or dyschromatopsia.

Differential diagnosis includes chronic meningitis due to fungal infections, which can cause subacute increase in ICP. Primary CNS lymphoma (PCNSL) causes disc edema through increased ICP or direct infiltration of the optic nerve. Lymphoma can also invade the meninges, producing multiple cranial neuropathies and polyradiculopathies. This patient had a history suggestive of prior polyradiculopathy, but the spontaneous resolution of his symptoms was atypical of lymphoma.

Bilateral simultaneous or sequential optic neuropathy due to inflammation (as in neuromyelitis optica, sarcoidosis, and Wegener granulomatosis) is not typ-

ically associated with HIV infection. Infections such as cryptococcus, toxoplasmosis, tuberculosis, herpes zoster, cytomegalovirus, and herpes simplex virus can also affect the optic nerves or the retina. Syphilis is another potential etiology for optic neuropathy in the setting of HIV infection.

Enhanced MRI scan of the brain and entire spinal cord did not demonstrate any pathology. There was no evidence of venous sinus thrombosis or abnormal meningeal enhancement. Lumbar puncture yielded a slightly high opening pressure (27 cm H₂O), high white cell count (21.1/ μ L [76% lymphocytes]), elevated protein (1.12 g/L), and glucose of 3.1 mmol/L (serum glucose 7.2 mmol/L). CSF was negative for a comprehensive viral PCR panel, *Cryptococcus* antigen, bacterial cultures, acid-fast bacilli, and cytology.

Questions for consideration:

1. How do these results change your differential diagnosis?
2. What additional investigations would you consider?

GO TO SECTION 3

SECTION 3

The abnormal CSF with lymphocytic pleocytosis and low glucose can be seen in fungal and mycobacterial infections. However, the opening pressure associated with these conditions is typically much higher than that observed in this case. Although HIV can cause CSF pleocytosis and elevated protein, cell counts higher than $20/\mu\text{L}$ are considered significant.¹ In addition, viral infections do not classically lower the CSF glucose level. PCNSL is still a potential etiology for this clinical presentation, despite normal imaging.

To better tailor further workup, reconsideration of the localization of the problem is important. Although reduced visual acuity and color vision in the context of optic disc edema suggest an optic nerve problem, the lack of RAPD in the left eye argues against this localization because it indicates relatively symmetric function between both optic nerves. Processes affecting the afferent visual pathway posterior to the chiasm should produce visual field deficits that

respect the vertical meridian in both eyes. The field defects in this case crossed the vertical meridian, indicating a process affecting the visual pathway anterior to the chiasm. Therefore, given the lateralizing defects in visual acuity, visual field sensitivity, and color vision in the left eye, further assessment of the anterior and posterior segments, with focused examination of the macular regions, is necessary to identify any pathology and to elucidate the mechanism of vision loss in this case.

Assessment of the anterior segment was normal. In addition to the optic disc edema, there was a slightly creamy appearance to the choroid around the disc, greater in the left than the right eye. Fluorescein angiogram showed an infiltrative process around the optic nerves in both eyes, and extension through the macula in the left eye (figure 1, B and D).

Question for consideration:

1. What tests would you consider now?

GO TO SECTION 4

SECTION 4

This infiltrative picture is atypical for cytomegalovirus, varicella zoster virus, or toxoplasmosis. The differential diagnosis of this appearance is limited given the patient's HIV status. Possibilities include lymphoma and syphilis.

Further testing showed a reactive plasma syphilis antibody that was confirmed with enzyme immunoassay. Although syphilis serology does not differentiate active disease from previous infection, this man was known to have unreactive syphilis testing in the recent past.

He was treated with parenteral penicillin with significant improvement in his visual symptoms. When assessed in follow-up after 2 months, his visual acuity was 20/20 in both eyes. He had minor reduction in color vision in the left eye. Fundus examination demonstrated mild optic disc hyperemia bilaterally (figure e-1 on the *Neurology*[®] Web site at www.neurology.org).

DISCUSSION Neurosyphilis has a broad clinical picture. In the early infection phase, acute meningitis, meningovascularitis, and myelitis have been described. Cognitive impairment (general paralysis of the insane) and tabes dorsalis, characterized by sensory ataxia and lancinating pains, are seen in the late stages of the disease.²

Ocular syphilis is a rare complication of HIV infection, occurring in fewer than 1% of patients.³ However, about 10% of patients with syphilis develop ocular involvement, with posterior uveitis being the most common presentation.⁴ The neuro-ophthalmologic manifestations include Argyll Robertson pupil (unilateral or bilateral light-near dissociation in small pupils), ocular motor nerve palsies, papillitis, optic neuritis, and optic perineuritis.⁵ Given the reversibility of these changes with treatment, detailed ophthalmologic examination is essential in all cases of suspected ocular syphilis.

The diagnosis of syphilis is based on serology. This can pose a challenge in the immunocompromised patient since serology relies on the immune response to the infection. A reactive CSF–Venereal Disease Research Laboratory (VDRL) testing establishes the diagnosis of neurosyphilis in the absence of CSF contamination with blood.⁶ However, the test lacks sensitivity, as up to 70% of neurosyphilis patients test negative, especially in the early stages.^{2,7} In these circumstances, the fluorescent treponemal antibody-absorbed (FTA-ABS) test is a more sensitive, but less specific, test than the CSF-VDRL.⁸ Other clues include CSF lymphocytic pleocytosis (>20 cells/ μ L in HIV-positive patients) and elevated CSF protein, which is less specific than pleocytosis.¹ Therefore, the diagnosis of neurosyphilis in patients with HIV relies on the

proper interpretation of a combination of clinical, serologic, and CSF studies.

The treatment for neurosyphilis and ocular syphilis is similar. The recommended regimen is parenteral penicillin G administered as 3–4 million units every 4 hours (or continuous infusion of 18–24 million units per day), for 10–14 days.⁶ Treatment response can be assessed clinically and followed using serum rapid plasma reagin (RPR) titer. Alternatively, if CSF pleocytosis was present initially, serial CSF examination can be performed every 6 months until the cell count normalizes. Changes in CSF-VDRL or CSF protein are much slower than cell count and may even persist in those with more advanced immunosuppression.⁹ In immunocompetent patients and HIV-positive patients on highly-active antiretroviral therapy, normalization of the serum RPR titer was found to predict normalization of clinical and CSF abnormalities, with the exception of CSF protein, in more than 80% of 110 patients at 4 months.⁹ Retreatment should be considered if the cell count is persistently high after 6 months or if the CSF cell count or protein is not normal after 2 years.⁶

AUTHOR CONTRIBUTIONS

Dr. Almekhlafi: concept and drafting of the manuscript. Dr. Williams: critical review of the manuscript and review of the literature. Dr. Costello: drafting and critical review of the manuscript.

DISCLOSURE

Dr. Almekhlafi reports no disclosures. Dr. Williams serves on scientific advisory boards for Bausch + Lomb, Novartis, Regeneron Pharmaceuticals, Inc. (Bayer Schering Pharma), and Arctic DX; has received an honorarium from Novartis; serves as a consultant for Bausch + Lomb; serves on the speakers' bureau for Novartis; and interprets fluorescein angiography (2% clinical effort) at Rockyview General Hospital. Dr. Costello has received research support from the MS Society of Canada and Neuroscience Canada.

REFERENCES

1. Marra CM, Maxwell CL, Collier AC, Robertson KR, Imrie A. Interpreting cerebrospinal fluid pleocytosis in HIV in the era of potent antiretroviral therapy. *BMC Infect Dis* 2007;7:37.
2. Ghanem KG. Neurosyphilis: a historical perspective and review. *CNS Neurosci Ther* 2010;16:e157–e168.
3. Biotti D, Bidot S, Mahy S, et al. Ocular syphilis and HIV infection. *Sex Transm Dis* 2010;37:41–43.
4. Balba GP, Kumar PN, James AN, et al. Ocular syphilis in HIV-positive patients receiving highly active antiretroviral therapy. *Am J Med* 2006;119:448.
5. Gaudio PA. Update on ocular syphilis. *Curr Opin Ophthalmol* 2006;17:562–566.
6. Workowski KA, Berman S. Sexually transmitted diseases treatment guidelines. *MMWR Recomm Rep* 2010;59:1–110.
7. Hart G. Syphilis tests in diagnostic and therapeutic decision making. *Ann Intern Med* 1986;104:368–376.
8. Marra CM, Tantalo LC, Maxwell CL, Dougherty K, Wood B. Alternative cerebrospinal fluid tests to diagnose neurosyphilis in HIV-infected individuals. *Neurology* 2004;63:85–88.
9. Marra CM, Maxwell CL, Tantalo L, et al. Normalization of cerebrospinal fluid abnormalities after neurosyphilis therapy: does HIV status matter? *Clin Infect Dis* 2004;38:1001–1006.

Clinical Reasoning: A 75-year-old woman with visual disturbances and unilateral ataxia



Marie Carl Eugene, DO
Daniel Kitei, DO
David Silvers, MD

Address correspondence and
reprint requests to Dr. Marie Carl
Eugene, Hartford Neurology, 85
Seymour Street, Suite 800,
Hartford, CT 06106
mceugene@gmail.com

SECTION 1

A 75-year-old woman presented in July 2007 with 2 months of oscillopsia when looking downward and horizontal diplopia during rapid rightward gaze. She reported 3 weeks of progressive clumsiness of the right limbs, weakness of the right leg, and an unsteady gait. She denied cognitive dysfunction, headache, bulbar or sensory symptoms, muscle stiffness/spasms, antecedent infection, fever, or other systemic complaints.

Nine years earlier, the patient had experienced an episode of diplopia and unsteadiness which resolved spontaneously after 3 months. Her neurologic examination in 1998 had revealed downbeat nystagmus, a right internuclear ophthalmoparesis (INO), and gait ataxia. Brain MRI and stroke evaluation had been negative. Type I diabetes mellitus was diagnosed several months after this initial episode.

In the 1980s, a low vitamin B₁₂ level (value unknown) was thought to have been an incidental finding; levels >500 ng/L have been maintained with a B₁₂ supplement. There was also a history of well-controlled hypertension. A grandparent had type I diabetes, but no relatives had neurologic disorders. She rarely consumed alcohol and never used tobacco or recreational drugs.

General medical examination had normal results, including the absence of vitiligo. Mental status exam-

ination was unremarkable with clear speech. Funduscopic, pupillary, visual field, and monocular acuity examinations were unremarkable. Near card straight-ahead binocular acuity was 20/20, but only 20/50 in lateral downgaze due to oscillopsia. The eye movement abnormalities were saccadic pursuit, gaze-evoked nystagmus, downbeating nystagmus maximal on lateral downgaze, and saccadic slowing but full range of the left adducting eye (i.e., left INO) (see videos 1, 2a, and 2b on the *Neurology*[®] Web site at www.neurology.org). Convergence was normal. There was no rigidity or stiffness of limb or axial muscles. There was 4+/5 right leg weakness (hip/knee flexors, toe extensors), with hyperreflexia, downgoing plantar responses, and normal sensation. There was right-sided dysmetria, dysdiadochokinesia, loss of check, and exaggerated rebound. The patient could sit upright unsupported but required assistance to ambulate due to weakness and ataxia.

Steady progression lasted 4 months, with deficits persisting without improvement. Hashimoto thyroiditis was diagnosed several months after the second episode began.

Question for consideration:

1. How would you localize the lesions?

[GO TO SECTION 2](#)

Supplemental data at
www.neurology.org

From the University of Connecticut/Hartford Hospital (M.C.E.), Hartford; Harvard's Brigham and Women's Hospital and Massachusetts General Hospital (D.K.), Boston; and University of Connecticut (D.S.), Hartford.

Disclosure: Author disclosures are provided at the end of the article.

SECTION 2

The INO localizes to the medial longitudinal fasciculus. The hemiataxia and leg weakness may localize to the pontocerebellar and corticospinal tracts, respectively. While downbeat nystagmus, often seen in conjunction with saccadic pursuit and gaze-evoked nystagmus, traditionally localizes to the flocculus-paraflocculus, it is hypothesized to also occur with pontomedullary paramedian tract lesions.¹ Thus, a single left pontine lesion may account for the patient's findings.

Brain MRI was unremarkable at presentation (with head/neck magnetic resonance angiography) and unchanged at 1 month, 8 months, and 2 years (no restricted diffusion, abnormal enhancement, or atrophy).

Our patient had a subacute, apparently recurrent, sporadic ataxia.

Questions for consideration:

1. What is the differential diagnosis of a sporadic ataxia with or without brainstem features?
2. Which entities typically cause recurrent attacks?
3. What tests should be performed?

GO TO SECTION 3

SECTION 3

Unilateral brainstem dysfunction is rare in neurodegeneration and toxic-metabolic conditions, but not uncommon in mass lesions and infectious/postinfectious syndromes and typical, particularly with INO, of demyelinating disease and stroke. The sporadic ataxias may also be split (imperfectly) into 2 groups according to their tendency to recur: 1) disorders that are either progressive or typically monophasic (but may recur) and 2) a smaller group that includes inherently recurrent conditions and recurrent stroke. Group 1 includes neurodegeneration (e.g., spinocerebellar ataxia, late-onset Friedreich ataxia, olivopontocerebellar atrophy, cerebellar-type multisystem atrophy); brainstem abscess/tumor (e.g., glioma, lymphoma); toxic-metabolic (e.g., alcohol, lithium, amiodarone, anticonvulsants, hypothyroidism, vitamin E deficiency, thiamine deficiency [includes INO, but corticospinal tracts spared]); infection (e.g., progressive multifocal leukoencephalopathy and JC virus cerebellar granule cell neuronopathy, viral brainstem encephalitis [e.g., herpes simplex virus (HSV) 1 and 2, varicella zoster virus (VZV), cytomegalovirus (CMV) (primarily immunocompromised host), Epstein-Barr virus (EBV)], *Listeria* rhombencephalitis, Lyme encephalomyelitis); prion (e.g., Creutzfeldt-Jakob disease); paraneoplastic cerebellar degeneration; progressive/monophasic forms of demyelinating disease; and immune disorders (e.g., postinfectious cerebellitis, gluten sensitivity, Bickerstaff brainstem encephalitis [BBE]). Viral encephalitis can present as a unilateral brainstem syndrome, possibly recurrent, but typically with systemic symptoms (e.g., fever, headache) and progression over days to weeks. While BBE may present with hemiataxia and ophthalmoplegia, there must be an altered sensorium, long tract signs (sometimes asymmetric), or an abnormal MRI; serum immunoglobulin G (IgG) anti-GQ1b antibodies are elevated in roughly two-thirds of cases. As long tract signs were absent during our patient's first attack, a BBE-forme fruste can be considered. Arguments against BBE include the lack of antecedent infection, progression beyond 4 weeks, and absence of recovery. IgG anti-GQ1b titers should be measured in the acute phase, as titers decline over time.

The recurrent ataxias include the episodic ataxias, relapsing multiple sclerosis, and strokes. Episodic ataxia 2 is characterized by episodes ranging from

minutes to weeks but usually hours (vs seconds to minutes in type 1), with a typical age at onset from 5 to 15 years. Allelic to episodic ataxia 2, spinocerebellar ataxia 6 occasionally presents with episodic ataxia. A paramedian basilar artery branch occlusion could cause the patient's signs, but would not explain the steadily progressive course. Multiple sclerosis is an unlikely diagnosis given the patient's advanced age and normal MRI.

No improvement occurred after administration of IV thiamine. Vitamins B₁₂ (911 ng/L) and E, thyroid function tests, Lyme titer, and celiac and paraneoplastic panels (including amphiphysin) were normal or negative. CSF revealed 6 leukocytes/mm³ (5 lymphocytes, 1 monocyte), 335 erythrocytes/mm³, glucose 118 mg/dL (serum 268), protein 75 mg/dL, and normal/negative Lyme serology/PCR, cryptococcal antigen, VDRL, *Tropheryma whipplei* PCR, anti-Hu/Yo/Ri, cytology, and flow cytometry. CSF for HSV (acutely) and VZV/CMV/EBV PCR and HSV/VZV CSF:serum antibody ratios would have been of interest. An intensive malignancy search (body CT, mammogram, breast MRI, FDG-PET) was negative. AntiGAD₆₅-antibody (antiGAD-Ab) levels were elevated (>30 U/mL [normal ≤1], Quest Diagnostics, and 46.6 nmol/L [normal ≤0.02], Mayo Medical Laboratories). Thyroperoxidase/thyroglobulin, pancreatic islet cell, and gastric parietal cell/intrinsic factor antibody levels were also elevated.

We hypothesized a glutamic acid decarboxylase (GAD) brainstem syndrome, probably recurrent, associated with polyendocrinopathy. Our patient's ataxia cannot be attributed to pernicious anemia (myelopathy/myeloneuropathy) or thyroid antibodies (Hashimoto ataxia generally applies to the cognitively impaired patient). Repeat lumbar puncture (for antiGAD-Abs, oligoclonal bands, IgG index) was declined. Human leukocyte antigen typing was not performed. Nerve conduction studies and needle EMG were normal, without continuous motor unit activity at rest. Serum anti-IgG GQ1b antibody titers were not measured acutely, but were normal 2.5 years later.

Questions for consideration:

1. What are antiGAD-Abs?
2. What are the neurologic associations?

GO TO SECTION 4

SECTION 4

GAD catalyzes the synthesis of γ -aminobutyric acid (GABA), the primary CNS inhibitory neurotransmitter. Low-titer serum antiGAD-Abs (<20 nmol/L) are found in newly diagnosed type I diabetes (80%) vs normal controls (1%), whereas high titers (>20 nmol/L) are associated with polyendocrinopathy or rare neurologic disorders.^{2,3} Our patient's titer (46.6 nmol/L) was modestly elevated; much higher median titers have been reported (1,429 nmol/L²). The relationship between titers and clinical characteristics, and whether antiGAD-Abs are directly pathogenic, require further study.

The most well-recognized neurologic associations are stiff-person syndrome (SPS), with >80% affected having high titers, and cerebellar ataxia.⁴ SPS is characterized by fluctuating axial and limb muscle stiffness with superimposed episodic painful spasms. Similarities between GAD-associated SPS and cerebellar ataxia include female predominance; associated type I diabetes and polyglandular autoimmunity; asymmetric presentations (e.g., stiff-limb syndrome); and potential for immunotherapy responsiveness.⁴⁻⁷ A paraneoplastic variant of SPS with amphiphysin antibodies occurs primarily in older women with breast cancer. HLA-DRB1*0301 and DQB1*0201 are susceptibility alleles for SPS.⁸ In patients with unexpectedly high-titer antiGAD-Abs, neurologic characteristics were typically multifocal, most commonly with cerebellar ataxia and brainstem manifestations. The clinical course was usually subacute but could be insidious, and only rarely relapsing. MRI was frequently normal.² Other manifestations are seizures, periodic alternating nystagmus, idiopathic limbic encephalitis, and paraneoplastic syndromes.^{2,4,9}

The CSF in GAD-associated disorders is typically acellular, with a normal to modestly elevated protein; CSF-specific oligoclonal bands and increased IgG index are common.^{2,4} Intrathecal antiGAD-Ab synthesis is often elevated, confirming that GAD autoimmunity is neurologically related.⁵

Potential diagnostic clues for a GAD-associated ataxia include the following:

1. Acute/subacute onset or quick progression (although insidious onset/progression is not uncommon), late onset, relapses, prominent asymmetry/unilaterality, and stiff-person phenomenon
2. Type I diabetes
3. Associated autoimmune conditions/marker
4. Strong family history of autoimmunity
5. CSF oligoclonal bands and elevated IgG index

Treatment options are primarily immunotherapies or enhancers of GABAergic neurotransmission. While response to immunotherapy is often limited, significant improvement may occur.¹⁰ In our patient, IV methylprednisolone (1 g/day for 5 days) and IV immunoglobulin (0.4 g/kg/day for 5 days) were ineffective and poorly tolerated; mycophenolate mofetil and azathioprine were poorly tolerated. Side effects limited the use of GABA-enhancers baclofen/tiagabine and glutamate-antagonist memantine, which were empirically employed to treat the oscillopsia associated with downbeat nystagmus. While treatment effects on antiGAD-Ab levels were not studied, titers remained >30.0 U/mL 2.5 years later.

Our patient with a relapsing unilateral brainstem syndrome after 9 years was found to have elevated antiGAD-Abs and polyendocrinopathy. The evidence supporting an antiGAD-Ab-related syndrome would have been significantly enhanced by demonstrating elevated CSF antiGAD-Abs. The striking asymmetry sometimes observed in GAD-ataxia remains unexplained. Less likely diagnostic possibilities include recurrent demyelination, stroke, Bickerstaff or viral brainstem encephalitis, or that the episodes were unrelated to each other.

ACKNOWLEDGMENT

The authors thank the patient for allowing the videos to be used to further medical education.

DISCLOSURE

Dr. Eugene and Dr. Kitei report no disclosures. Dr. Silvers has received honoraria for educational activities from Teva Pharmaceutical Industries Ltd., Merck Serono, and Pfizer Inc.

REFERENCES

1. Hüfner K, Stephan T, Deutschländer A, et al. Structural and functional MRIs disclose cerebellar pathologies in idiopathic downbeat nystagmus. *Neurology* 2007;69:1128-1135.
2. Pittock S, Yoshikawa H, Ahlskog JE, et al. Glutamic acid decarboxylase autoimmunity with brainstem, extrapyramidal, and spinal cord dysfunction. *Mayo Clin Proc* 2006; 81:1207-1214.
3. Meinck H, Faber L, Morgenthaler N, et al. Antibodies against glutamic acid decarboxylase: prevalence in neurological diseases. *J Neurol Neurosurg Psychiatry* 2001;71:100-103.
4. Saiz A, Blanco Y, Sabater L, et al. Spectrum of neurological syndromes associated with glutamic acid decarboxylase antibodies: diagnostic clues for this association. *Brain* 2008; 131:2553-2563.
5. Ances BM, Dalmau JO, Tsai J, Hasbani MJ, Galetta SL. Downbeating nystagmus and muscle spasms in a patient with glutamic-acid decarboxylase antibodies. *Am J Ophthalmol* 2005;140:142-144.
6. Saiz A, Arpa J, Sagasta A, et al. Autoantibodies to glutamic acid decarboxylase in three patients with cerebellar ataxia, late-onset insulin-dependent diabetes mellitus, and polyendocrine autoimmunity. *Neurology* 1997;49:1026-1030.

7. Honnorat J, Saiz A, Giometto B, et al. Cerebellar ataxia with anti-glutamic acid decarboxylase antibodies: study of 14 patients. *Arch Neurol* 2001;58:225–230.
8. Dalakas MC, Fujii M, McElroy B. The clinical spectrum of anti-GAD antibody-positive patients with stiff-person syndrome. *Neurology* 2000;55:1531–1535.
9. Tilikete C, Vighetto A, Trouillas P, Honnorat J. Anti-GAD antibodies and periodic alternating nystagmus. *Arch Neurol* 2005;62:1300–1303.
10. McFarland N, Login I, Vernon S, et al. Improvement with corticosteroids and azathioprine in GAD65-associated cerebellar ataxia. *Neurology* 2006;67:1308–1309.

Disorders presenting with headache, dizziness, or seizures

Headache, dizziness, and seizure are 3 of the most common conditions for which neurologists are consulted. Headache and dizziness can be the presenting symptoms of both benign and potentially fatal conditions. Seizures may be due to idiopathic epilepsy syndromes or can be symptomatic of underlying neurologic or systemic pathology. Each symptom therefore requires a detailed history, neurologic examination, and evaluation to distinguish between the diverse potential etiologies of these common “chief complaints.”

Headaches. Headaches may be determined to be a primary headache syndrome or may be secondary to an underlying disease process. The primary headache syndromes (e.g., migraine, tension headache, and the trigeminal autonomic cephalalgias) are benign but can be disabling, requiring precise diagnosis to provide tailored treatment. The differential diagnosis for secondary causes of headache is extensive and includes pathology of any cranial structure, as well as a variety of systemic diseases. Headaches that have any of the following “red flags” require thorough evaluation for underlying intracranial pathology:

- Acute onset and maximal intensity at onset (“thunderclap headaches”), suggesting a vascular etiology
- New in adulthood, suggesting a mass lesion
- Progressive, suggesting a mass lesion
- Accompanied by focal neurologic signs, suggesting a focal lesion
- Accompanied by seizures, suggesting a focal lesion
- Accompanied by fever, concerning for meningitis or intracranial abscess
- Accompanied by papilledema, suggesting elevated intracranial pressure
- Worse in the supine position, at night, or with coughing/sneezing/Valsalva/laughing, suggesting elevated intracranial pressure (the opposite pattern, headache that is worse in the standing position and relieved when supine, suggests low intracranial pressure)

- Occurring in patients with cancer, concerning for metastases
- Occurring in immunocompromised patients, concerning for CNS opportunistic infections

Dizziness. The term dizziness can have diverse meanings and may represent vertigo, light-headedness, unsteadiness, or even anxiety. Dizziness can occur in the setting of benign inner ear conditions (e.g., benign paroxysmal positional vertigo, vestibular neuritis), life-threatening neurologic conditions (e.g., posterior circulation stroke), life-threatening cardiac conditions (e.g., arrhythmias), toxicity from medications (e.g., antiepileptics, antihypertensives), and systemic conditions (e.g., severe anemia). The evaluation of a patient with dizziness therefore requires a search for potential systemic causes, and, if excluded, the primary task of the neurologist is to distinguish dizziness of peripheral etiology (due to pathology of the inner ear and/or vestibulocochlear nerve) from dizziness due to central pathology (due to pathology of the brainstem and/or cerebellum). This requires an intimate familiarity with subtle neuro-ophthalmologic and neuro-otologic examination maneuvers and the interpretation of their findings.

Seizures. Like headaches, seizures may have a primary etiology (i.e., idiopathic/genetic epilepsy syndromes) or can be secondary to neurologic or systemic conditions (i.e., symptomatic or provoked seizures). New-onset seizures therefore require a thorough evaluation for an underlying trigger: intracranial pathology (e.g., prior or acute cerebrovascular disease, CNS infection, head trauma, CNS tumor), systemic disease (e.g., renal failure, electrolyte abnormalities, hypo- or hyperglycemia, systemic infection with fever), medications (e.g., quinolones, carbapenems, tramadol, bupropion), or drug/alcohol intoxication/withdrawal.

The cases in this section depict the clinical approach to patients presenting with headaches, dizziness, or seizures.

Clinical Reasoning: A 2-day-old baby girl with encephalopathy and burst suppression on EEG

Radhika Dhamija, MD
Kenneth J. Mack, MD,
PhD

Address correspondence and
reprint requests to Dr. Radhika
Dhamija, Department of
Pediatric Neurology, Mayo
Building, 16th Floor, Mayo
Clinic, 200 First Street SW,
Rochester, MN 55905
dhamija.radhika@mayo.edu

SECTION 1

A 2-day-old baby girl was transferred to our facility for evaluation and management of seizures. She was born to nonconsanguineous parents from Somalia at 41½ weeks of gestation. The pregnancy was uneventful. The mother was group B streptococcus-positive and was appropriately treated with antibiotics during labor. Labor and vaginal delivery were uncomplicated (no history of prolonged rupture of membranes or birth trauma). The baby's Apgar scores were 9 at 1 and 5 minutes. The baby appeared to be well on the first day of life but began having seizures on the second day.

On presentation to our facility, the patient exhibited rhythmic jerking movements of her extremities, consistent with myoclonic seizures. She also had multiple apneic episodes and was therefore intubated and mechanically ventilated. EEG recording showed an asynchronous burst suppression pattern with occasional

generalized epileptiform discharges that were associated with body jerking, consistent with severe encephalopathy with seizures. On general physical examination, she was normocephalic and nondysmorphic. There were no abnormal skin findings and no hepatosplenomegaly. Neurologic examination revealed diffuse hypotonia with symmetrically hypoactive reflexes in all 4 extremities. Bedside funduscopic examination revealed normal Moro; suck and rooting reflexes were poor, but palmar grasp reflex was present bilaterally.

There was no family history of neurologic or metabolic disorders (including seizures).

Questions for consideration:

1. What is the differential diagnosis for neonatal seizures?
2. Does the burst suppression pattern on EEG limit the differential diagnosis?
3. Can this infant's presentation be classified as an epilepsy syndrome?

GO TO SECTION 2

SECTION 2

The diagnostic possibilities for neonatal seizures are broad and include common causes such as electrolyte imbalance (hypocalcemia, hypomagnesemia, hyponatremia, or hypoglycemia), hypoxic ischemic encephalopathy, neonatal stroke (ischemic or hemorrhagic), maternal drug withdrawal, benign neonatal seizures, and infectious diseases (e.g., group B streptococcus sepsis or meningitis) and less common but important causes such as metabolic encephalopathies (e.g., mitochondrial disease, organic acid disorders, amino acid disorders, sulfite oxidase deficiency, molybdenum cofactor deficiency, and glucose transporter 1 deficiency), storage diseases (including neuronopathic Gaucher disease, Tay-Sachs disease, and neuronal ceroid lipofuscinosis), CSF tetrahydrobiopterin, folate deficiency, pyridoxine deficiency, and a supratentorial structural lesion (table e-1 on the *Neurology*[®] Web site at www.neurology.org). The presence of burst suppression on EEG suggests severe encephalopathy

and either a significant hypoxic-ischemic insult or a severe metabolic disorder.

The patient's hemoglobin was 15.3 (10–20) g/dL, platelet count was 281 (150–450) $\times 10^9$ /L, and leukocyte count was 11.2 (5–20) $\times 10^9$ /L. Blood glucose was 102 mg/dL. The patient underwent lumbar puncture for CSF examination; this revealed a white blood cell count of 3 cells/ μ L, glucose of 54 mg/dL, and protein of 50 mg/dL. Results of blood and CSF cultures were negative. Liver function tests showed that aspartate transaminase, alanine transaminase, and total bilirubin levels within normal limits. Serum ammonia and lactate levels and values for a complete electrolyte panel were normal. Given the initial normal electrolytes and no evidence of hypoxic-ischemic encephalopathy or infection at birth, a metabolic disorder was considered. Urine organic acid levels, serum biotinidase activity, a serum acyl-carnitine panel, a chromosomal microarray, and a serum peroxisomal panel composed of very-long-chain fatty acids, phytanic acid, and pristanic acid were all normal. Serum and CSF amino acid profiles showed markedly elevated glycine, with a CSF/serum ratio of 0.138 (normal <0.03), which was diagnostic for nonketotic hyperglycinemia.

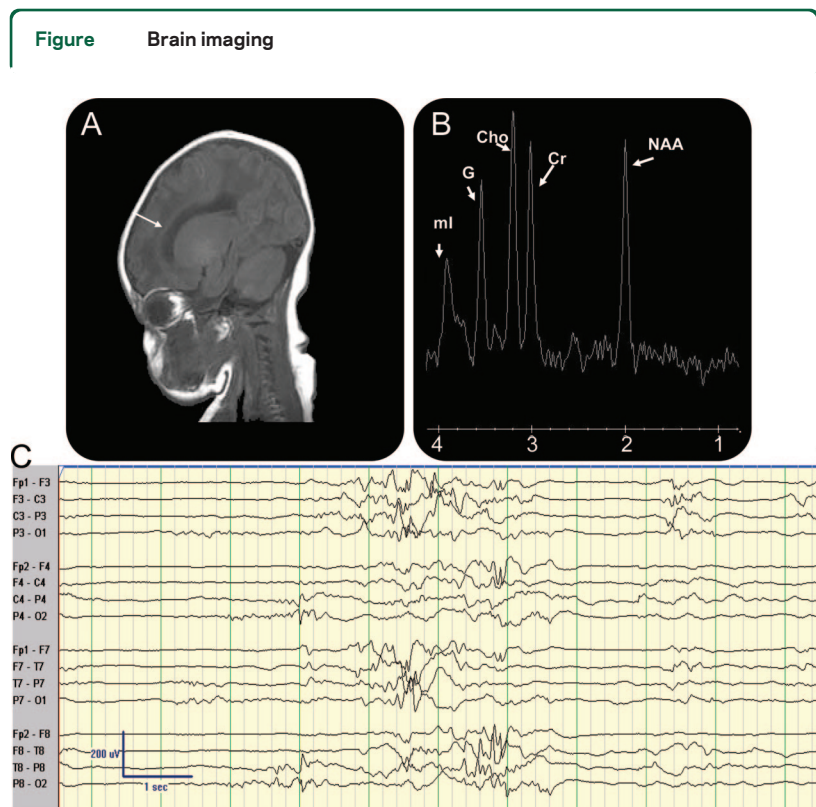
The infant's seizures can be classified as early myoclonic encephalopathy, a symptomatic epilepsy syndrome characterized by seizure onset between birth and the first few weeks of life and burst suppression on EEG. The overall prognosis for this epilepsy syndrome is poor with high mortality in the first few years of life.

Results of a head ultrasound examination were normal. MRI of the brain without gadolinium done at day 3 of life showed agenesis of the corpus callosum and an immature sulcation pattern. There was no evidence of hypoxic-ischemic injury on diffusion-weighted imaging or any evidence of intracranial hemorrhage. Magnetic resonance spectroscopy revealed no elevation of brain lactate or *N*-acetylaspartate and normal creatine but showed an elevated glycine peak (figure).

Questions for consideration:

1. What are the medications used to treat this condition?
2. Which specific antiepileptic medications should be avoided in this condition?
3. What is the overall prognosis?

GO TO SECTION 3



(A) MRI (T1 sagittal) shows agenesis of corpus callosum (arrow). (B) Magnetic resonance spectroscopy shows a glycine peak (G), *N*-acetylaspartate (NAA), choline (Cho), creatine (Cr), and myoinositol (ml). (C) EEG shows burst suppression.

SECTION 3

The elevated ratio of CSF to serum glycine (>0.08) confirms the diagnosis of nonketotic hyperglycinemia (NKH). Patients with atypical NKH can have ratios between 0.03 and 0.08. A liver biopsy was not performed in our patient for confirmatory enzymatic analysis because the parents did not consent. Our patient's seizures were initially controlled with IV phenobarbital but then recurred. A ketamine (NMDA receptor antagonist) drip and sodium benzoate (an agent that binds excessive glycine in the CSF) were started, which resulted in control of seizures. High doses of sodium benzoate can lower the serum carnitine concentration and thus blood levels of carnitine should be measured and supplemented accordingly.

She was weaned off phenobarbital, given its potential to cause respiratory suppression, and transitioned to topiramate. She was slowly weaned off mechanical ventilation. A gastric tube was placed, given her continued poor feeding.

Valproate should be avoided in infants with NKH because it increases blood and CSF glycine concentrations by further inhibiting the glycine cleavage enzyme and increases seizure frequency.¹ As a general rule, valproate should not be used in any child with an undiagnosed suspected metabolic disorder because it can worsen seizures due to urea cycle disorders, fatty acid oxidation defects, and mitochondrial disorders. Given the higher likelihood of a metabolic disorder being the underlying cause of seizures in younger children, valproate is typically avoided in children younger than 2 years.

The overall prognosis for NKH is dismal. Most patients die in infancy of central apnea, if they are not supported by mechanical ventilation. Intractable seizures and feeding problems are common. Those who survive are left with severe intellectual disability.

At the last follow-up at 4 months of age, our patient continues to have diffuse hypotonia, no social smile, and poorly controlled seizures and is dependent on a gastric tube for feeding.

DISCUSSION NKH, also known as glycine encephalopathy, is an autosomal recessive metabolic disorder characterized by the accumulation of glycine in the brain due to a defect in the glycine cleavage enzyme system. The neonatal form presents in the first few days of life with progressive lethargy, hypotonia, hiccups, and seizures, and progresses to central apnea and often death. Surviving infants often have profound developmental delay and intractable seizures. The infantile form presents in the first few months of life and is also characterized by hypotonia, developmental delay, and seizures. An increased CSF glycine

level (typically 20–30 times normal) along with an elevated CSF/plasma glycine ratio suggests the diagnosis. Enzymatic confirmation can be done by measurement of glycine cleavage (GCS) enzyme activity in liver obtained by biopsy and is clinically available. The 3 genes known to be associated with NKH are *GLDC* (encoding the P-protein component of the GCS complex, accounting for 70%–75% of disease), *AMT* (encoding the T-protein component of the GCS complex, accounting for ~20% of disease), and *GCSH* (encoding the H-protein component of the GCS complex, accounting for <1% of disease). Mutations associated with residual enzyme activity seem to be associated with a milder outcome and infantile presentation, and 2 mutations with no residual enzyme activity seem to be associated with severe outcome and neonatal onset.^{2–4}

The initial EEG typically shows a burst-suppression pattern that evolves into hypsarrhythmia or multifocal spikes over the next few months. MRI can be normal or show agenesis of the corpus callosum. Delayed myelination can be seen later in life. Agenesis of the corpus callosum is not specific and can be seen in various migrational and structural disorders of the CNS (e.g., Dandy-Walker malformation and lipoma of the interhemispheric fissure).⁵ Less common findings include retrocerebellar cysts with subsequent hydrocephalus.⁶ A glycine peak on magnetic resonance spectroscopy is seen in the most severely affected infants and carries a poor prognosis.

No effective treatment exists for this disorder. Therapy is focused on managing seizures by using sodium benzoate to reduce the plasma concentration of glycine. NMDA receptor antagonists (ketamine, dextromethorphan, felbamate, and topiramate) are also used in this condition.⁷

AUTHOR CONTRIBUTIONS

R.D. provided the study concept or design. R.D. acquired data. R.D. and K.J.M. drafted/revised the manuscript. K.J.M. supervised the study.

DISCLOSURE

Dr. Dhamija reports no disclosures. Dr. Mack serves on the editorial board of *Pediatric Neurology*, *Journal of Child Neurology*, and *Brain and Development* (2006–present) and is Book Review Editor for *Neurology*®.

REFERENCES

1. Morrison PF, Sankar R, Shields WD. Valproate-induced chorea and encephalopathy in atypical nonketotic hyperglycinemia. *Pediatr Neurol* 2006;35:356–358.
2. Suzuki Y, Kure S, Oota M, et al. Nonketotic hyperglycinemia: proposal of a diagnostic and treatment strategy. *Pediatr Neurol* 2010;43:221–224.
3. Kikuchi G, Motokawa Y, Yoshida T, et al. Glycine cleavage system: reaction mechanism, physiological significance, and hyperglycinemia. *Proc Jpn Acad Ser B Phys Biol Sci* 2008;84:246–263.

4. Demirel N, Bas AY, Zenciroglu A, et al. Neonatal nonketotic hyperglycinemia: report of five cases. *Pediatr Int* 2008;50:121–123.
5. Mourmans J, Majoie CBLM, Barth PG, et al. Sequential MR imaging changes in nonketotic hyperglycinemia. *Am J Neuroradiol* 2006;27:208–211.
6. Van Hove JL, Kishnani PS, Demaerel P, et al. Acute hydrocephalus in nonketotic hyperglycinemia. *Neurology* 2000;54:754–756.
7. Van Hove JL, Vande Kerckhove K, Hennermann JB, et al. Benzoate treatment and the glycine index in nonketotic hyperglycinaemia. *J Inherit Metab Dis* 2005;28:651–663.

Clinical Reasoning: A 55-year-old woman with vertigo

A dizzying conundrum



Daniel R. Gold, DO
Stephen G. Reich, MD

Correspondence & reprint
requests to Dr. Gold:
Daniel.Gold@uphs.upenn.edu

SECTION 1

A 55-year-old woman presented to the emergency department complaining of dizziness. Several hours earlier she abruptly felt “the room spinning and moving back and forth.” Simultaneously, she experienced nausea, vomiting, and gait unsteadiness. The dizziness exacerbated with head movement. She denied head or neck pain, photophobia,

phonophobia, auditory symptoms, weakness, numbness, diplopia, dysarthria, dysphonia, dysphagia, history of recent illness, prior dizziness, or headache. Medical history included hyperlipidemia and hypertension.

Question for consideration:

1. What is the differential diagnosis for acute vertigo?

GO TO SECTION 2

Supplemental data at
www.neurology.org

From the Department of Neurology, The University of Maryland School of Medicine, Baltimore. Dr. Gold is currently with the Department of Neurology, University of Pennsylvania, Philadelphia.

Go to Neurology.org for full disclosures. Disclosures deemed relevant by the authors, if any, are provided at the end of this article.

SECTION 2

To determine the cause of acute vertigo, it is important to know whether it is transient (seconds to minutes) or prolonged (hours to days); a single episode of vertigo or a recurrence; if it is positionally provoked (e.g., benign paroxysmal positional vertigo); and if there are any accompanying symptoms or signs. The most common causes of acute prolonged vertigo include a peripheral vestibulopathy, Ménière syndrome, migrainous vertigo, or brainstem or cerebellar ischemia.¹ This discussion is limited to the distinction between a peripheral vestibulopathy and ischemia.

The acute vestibular syndrome (AVS) develops over seconds to hours and is characterized by vertigo, nausea, vomiting, gait instability, head motion intolerance, and nystagmus.²⁻⁴ It is caused by either an acute peripheral vestibulopathy (APV) or brainstem/cerebellar ischemia, and similarities in presentation often make the distinction a diagnostic challenge. Transient ischemic attacks can cause acute vertigo with rapid resolution but vertigo resulting from a

stroke, like an APV, may last days to weeks. Vertigo caused by ischemia is almost always accompanied by other neurologic symptoms and signs but may occur in isolation.²⁻⁵

An APV is characterized by acute prolonged vertigo, oscillopsia (the visual illusion of movement of a stationary object due to spontaneous nystagmus), unilateral canal paresis with a positive head impulse test (HIT), nausea, vomiting, exacerbation of vertigo with head movement, and imbalance.²⁻⁴ Depending on the presence or absence of auditory symptoms, an APV is further classified as either labyrinthitis or vestibular neuritis, respectively. Vertigo is maximal within minutes to hours and can persist for days to weeks. There may be a viral prodrome or a history of brief vertiginous attacks in the days prior to the onset of prolonged vertigo.¹

Questions for consideration:

1. What is the pathophysiology of nystagmus?
2. How is the vestibular system assessed on physical examination?

GO TO SECTION 3

SECTION 3

In an acute destructive lesion affecting 1 labyrinth, such as an APV, symptoms result from ipsilesional afferent hypoactivity and relative contralesional hyperactivity from the vestibulocochlear nerve. During a normal head turn to the left, there is left-greater-than-right asymmetry in afferent vestibular signals and the eyes drift to the right to maintain stable vision (i.e., vestibulo-ocular reflex or VOR).⁶ A right APV is perceived as a leftward head turn even though the head is still. As a result, the eyes continuously drift to the right (slow phase of nystagmus), and a position reset mechanism (fast phase) quickly brings the eyes back to the left (to midline) (figure 1).⁶ The nystagmus is of larger amplitude when gazing in the direction of the fast phase (i.e., Alexander law). The horizontal component of peripheral vestibular nystagmus is inhibited with fixation (there is a poor torsional fixation mechanism),⁷ which does not occur with central causes of vestibular nystagmus.

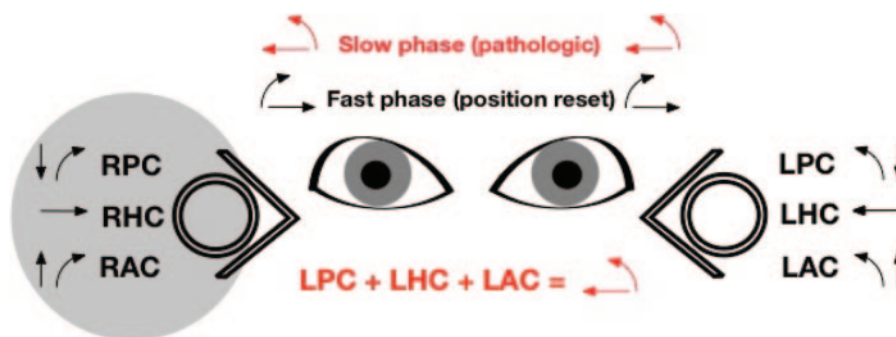
Since the intensity of peripheral nystagmus is influenced by fixation, observation under various conditions can help distinguish central vs peripheral causes of vertigo as peripheral nystagmus inhibits with fixation, and conversely, increases with fixation removed. Occlusive funduscopy is performed by visualizing the optic disc with an ophthalmoscope and then covering the patient's viewing eye, thus removing fixation, which enhances peripheral nystagmus but has no effect on central nystagmus.⁷

Similarly, the penlight cover test involves having the patient fixate on a penlight, and then covering 1 eye, thus removing fixation as the uncovered eye continues to view only the bright penlight.⁸ Having the patient view a featureless scene such as a piece of white paper has a similar effect: since there is no feature available for foveation, fixation is suppressed.⁷

Dynamic assessment of the vestibular system includes the HIT, which tests angular VOR function (figure 2).⁹ Although a peripheral pattern of nystagmus with an abnormal HIT implies labyrinthine or vestibular nerve dysfunction, it is important to recognize that the etiology may be ischemia. The vascular supply to the inner ear is via the internal auditory artery, so a "peripheral" lesion can be from infarction.¹⁰

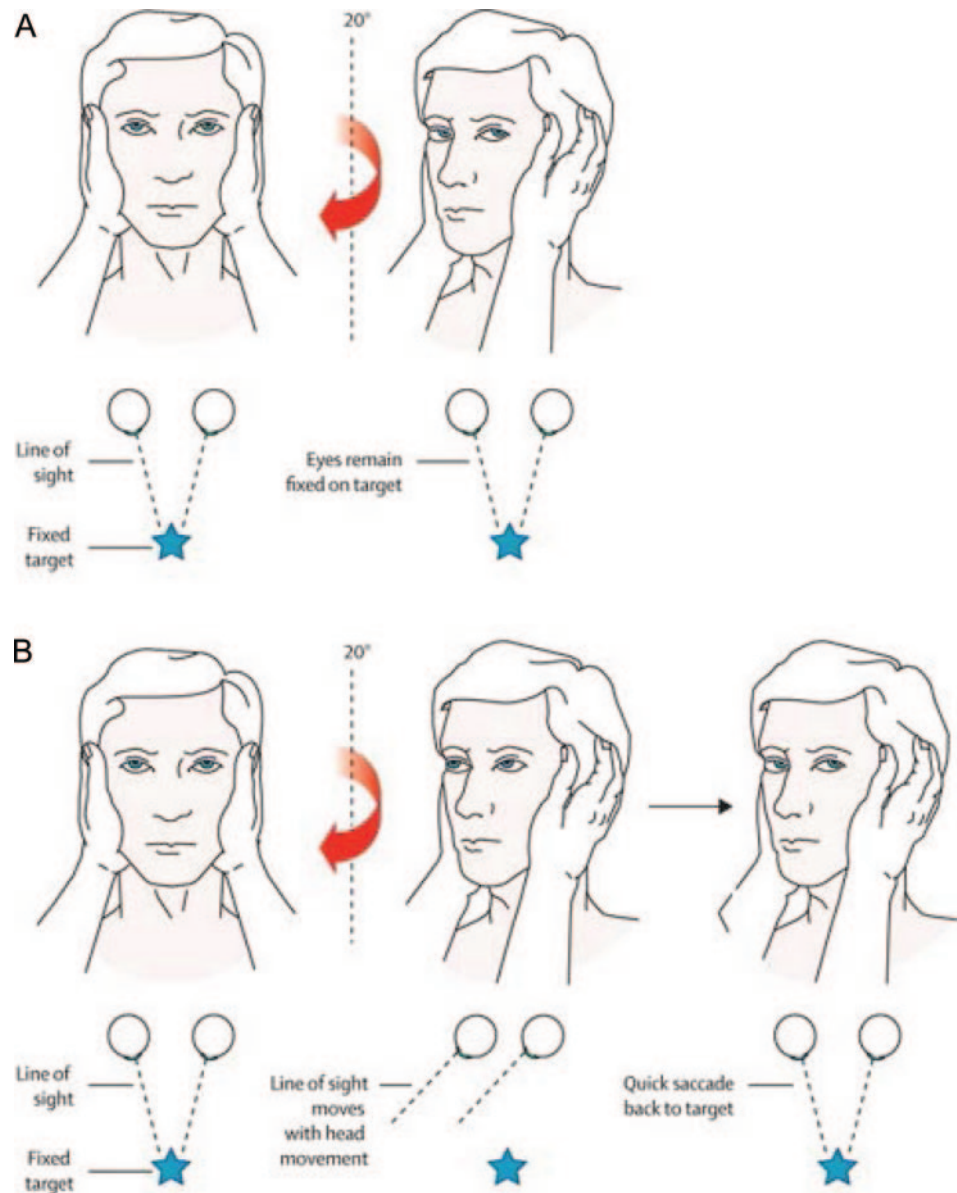
Another important sign to look for in the AVS is a skew deviation, which is a nonparalytic preocular vertical ocular misalignment due to an imbalance of utricular inputs to the ocular motor system. It is often accompanied by features of the ocular tilt reaction (OTR), which includes the triad of skew deviation, head tilt, and ocular counterroll.¹¹ A skew deviation is best demonstrated during alternate cover testing demonstrating vertical correction of the uncovered eye to maintain fixation, or subjectively with Maddox rod testing. A skew deviation and a fourth nerve palsy may present similarly (figure 3). A skew deviation occurs most

Figure 1 Pathophysiology of peripheral nystagmus in an acute peripheral vestibulopathy



Nystagmus from an acute peripheral vestibulopathy (APV) is mixed horizontal-torsional, indicating a lesion of the entire vestibular nerve or all semicircular canals within one labyrinth. Stimulation of individual canals move the eyes in distinct planes (i.e., horizontal, vertical, or torsional). In a right APV, the direction of nystagmus is determined by the intact left labyrinth: the 2 oppositely oriented left anterior and posterior canals cancel out vertical movement, leaving only a slight torsional component contributed from each, while the horizontal vector is attributable to the unopposed left horizontal canal.⁷ This generates a slow (pathologic) phase (in red) toward the affected ear with a fast (position reset) phase (in black) away from the affected ear. Nystagmus is named for the direction of the fast phase. The nystagmus is present in primary position and beats in the same direction (unidirectional) with gaze to either side. LAC = left anterior semicircular canal; LHC = left horizontal semicircular canal; LPC = left posterior semicircular canal; RAC = right anterior semicircular canal; RHC = right horizontal semicircular canal; RPC = right posterior semicircular canal. Redrawn and modified from Leigh RJ, Zee DS. *The Neurology of Eye Movements (Contemporary Neurology Series)*, 4th ed. New York: Oxford University Press, Inc.; 2006: figure 2-2. By permission of Oxford University Press, Inc.

Figure 2 Assessment of the angular vestibulo-ocular reflex (VOR) with the head impulse test



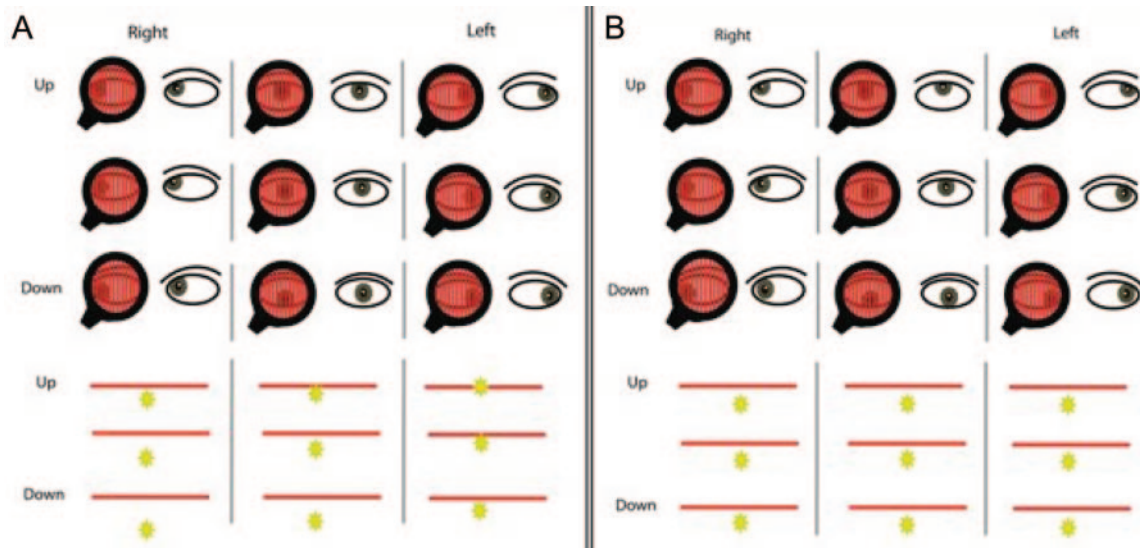
(A) Normally, during a quick 20° head turn to the right, the patient will be able to maintain fixation on the examiner's nose (i.e., the target). (B) With a right peripheral vestibulopathy, when the head is turned quickly to the right, the line of sight moves with the head due to a hypoactive VOR, necessitating a compensatory catch-up saccade to the left to refixate on the examiner's nose. Reprinted from: Edlow JA, Newman-Toker DE, Savitz SI. Diagnosis and initial management of cerebellar infarction. *Lancet Neurol* 2008;7:951–964. With permission from Elsevier.

commonly with brainstem or cerebellar lesions, but also may be seen with a lesion anywhere from the utricle to the interstitial nucleus of Cajal in the rostral midbrain.¹¹

Other signs of central localization of acute vertigo include direction-changing (i.e., gaze-evoked or bidirectional) nystagmus, pure horizontal, torsional, or vertical nystagmus, impaired or asymmetric smooth pursuit, inability to suppress the VOR (combined eye-head tracking of moving targets), dysmetric saccades, and associated brainstem and long tract signs.^{1,7}

In our patient, blood pressure was 143/79 mm Hg and general medical examination including otoscopy were normal. In primary gaze there was left-beating horizontal-torsional jerk nystagmus that intensified with left gaze, and lessened but remained left-beating in right gaze (video, first half, on the *Neurology*® Web site at www.neurology.org). The nystagmus intensified with removal of fixation during occlusive funduscopy and the penlight cover test. The HIT was normal to the left but abnormal to the right (video, second half), demonstrating a catch-up saccade, confirming a hypoac-

Figure 3 Distinguishing a fourth nerve palsy from skew deviation with Maddox rod testing



(A) Left fourth nerve palsy compared with (B) skew deviation. By convention, the Maddox rod is placed over the right eye. In both (A) and (B) there is a vertical misalignment in primary gaze with the left eye higher than the right (i.e., left hypertropia). A left fourth nerve palsy is diagnosed in (A) by demonstrating greater vertical separation between the light and the horizontal line (i.e., greater degree of left hypertropia) in contralateral gaze (with the paretic eye adducted), downgaze, and ipsilateral head tilt (not shown). A left hypertropia caused by a skew deviation in (B) is typically comitant, meaning the degree of vertical misalignment is consistent in all directions of gaze. In contrast to the head tilt seen in a fourth nerve palsy, which is compensatory (i.e., a contralateral head tilt minimizes ocular misalignment due to impaired intorsion of the affected eye), the head tilt in the OTR occurs in the same direction as the cyclotorsion (ocular counterroll).¹¹ Reprinted from: Kheradmand A, Bronstein A, Zee DS. Clinical bedside examination. In: Eggers SD, Zee DS, eds. *Vertigo and Imbalance: Clinical Neurophysiology of the Vestibular System: Handbook of Clinical Neurophysiology*. New York: Oxford University Press, Inc.; 2012: figure 2 (in press 2012). By permission of Oxford University Press, Inc.

tive right VOR. Suppression of the VOR, smooth pursuit, and saccadic eye movements were normal. There was no vertical misalignment. When testing tandem gait, there were multiple side-steps to the right, and she could not maintain balance with Romberg testing. The remainder of the neurologic examination was normal.

Questions for consideration:

1. What are the most common manifestations of cerebellar ischemia?
2. What are the 3 most important bedside ocular motor tests to differentiate a stroke from an APV?
3. How has the examination narrowed the differential diagnosis in this patient?

GO TO SECTION 4

Table Distinguishing peripheral vs central localization in the acute vestibular syndrome

Clinical sign	Peripheral	Central	Comments
Nystagmus	Unidirectional; mixed horizontal-torsional; obeys Alexander's law; slow phase with constant velocity; more intense when lying with affected ear down	May change direction; pure horizontal, torsional, or vertical; slow phase with constant, increasing or decreasing velocity	Peripheral nystagmus suppresses with fixation and increases with fixation removed, while central nystagmus is poorly suppressed by fixation ^{4,7}
Head impulse test (horizontal)	Abnormal	Typically normal	Lesions of the vestibular nucleus, root entry zone of 8th cranial nerve, or caudal cerebellum may cause an abnormal head impulse test ¹²
Skew deviation	Absent	May be present	Rarely, a small skew may be apparent from a utricular lesion, but a large skew with diplopia suggests central localization ¹
Associated symptoms or signs	Hearing loss or tinnitus, minor gait instability, and veering toward the side of the lesion	Headache or neck pain (particularly concerning if abrupt onset, prolonged, or severe), weakness, numbness, diplopia, dysarthria, dysphonia, dysphagia, Horner sign, drop attack (abrupt fall with preserved level of consciousness), incoordination, marked gait instability, and lateropulsion	A central lesion presents uncommonly as isolated vertigo

SECTION 4

In a series of 66 patients with isolated cerebellar infarctions, vertigo and lateropulsion (defined as an irresistible sensation of falling to one side) were the most common symptoms.⁵ Although vertigo and lateropulsion can each occur in isolation with a cerebellar stroke, other signs and symptoms are typically present, including limb ataxia, nausea/vomiting, truncal ataxia, dysarthria, nystagmus, headache, confusion, or somnolence.^{3,5}

A stroke in the posterior inferior cerebellar artery territory can cause a “pseudovestibular neuritis” manifesting as isolated vertigo without auditory or other symptoms, but typically has a normal HIT.³ A superior cerebellar artery stroke can cause a “pseudointoxication” picture because of gait or truncal ataxia with dysarthria, or “pseudogastroenteritis” with nausea and vomiting.

The internal auditory artery (IAA) is an end artery from the anterior inferior cerebellar artery (AICA) that supplies the vestibulocochlear nerve, cochlea, and vestibular labyrinth. Due to a paucity of collaterals, the IAA is vulnerable to ischemia. A labyrinthine infarction usually presents with sudden loss of hearing and vertigo accompanied by other AICA-territory signs (e.g., cerebellar, lateral pontine, or midbasilar syndromes).^{2,3} However, isolated labyrinthine ischemia may herald AICA infarction.^{2,10} In a series of 82 patients with AICA strokes, 80 had acute prolonged vertigo and vestibular dysfunction of peripheral, central, or combined origin; 35 had acute prolonged vertigo with audiovestibular loss; 24 had acute prolonged vertigo without audiovestibular loss, while a selective loss of vestibular

lar (4) or cochlear (3) function was much less common.¹⁰ AICA strokes have also been referred to as “pseudolabyrinthitis.”³

In patients presenting with the acute vestibular syndrome, the combination of direction-changing nystagmus, skew deviation, and a normal HIT were more sensitive in detecting stroke than MRI (table).⁴ A normal HIT strongly indicates a central process, but an abnormal HIT is a less reliable indicator of a peripheral lesion because of APV mimics (i.e., ischemia of the vestibular nucleus, root entry zone of the eighth cranial nerve, or caudal cerebellum may cause an abnormal HIT).^{12–14} In addition to the findings on bedside examination, vertigo due to cerebrovascular disease should be considered if any of the following factors are present: stroke risk factors, risk of vertebral artery dissection, abrupt onset, inability to ambulate, paucity of nausea and vomiting with marked gait instability or severe nausea and vomiting with little gait instability, or other accompanying central neurologic symptoms and signs.³

Our patient had a right APV without auditory symptoms, and was diagnosed with vestibular neuritis. Prior to evaluation by the authors and within 24 hours of symptom onset, a brain MRI was found to be normal. Although brainstem/cerebellar infarctions may be missed acutely on MRI, the positive HIT, unidirectional nystagmus, and absent skew deviation all pointed away from a central process, and therefore an MRI was arguably unnecessary.⁴ Her symptoms improved significantly over several days with only antiemetics, and vestibular rehabilitation was recommended.

AUTHOR CONTRIBUTIONS

Daniel R. Gold, DO: conceptualization, drafting, and revising the manuscript. Stephen G. Reich, MD: drafting and revising the manuscript.

ACKNOWLEDGMENT

The authors thank Dr. David Zee for providing resources and expertise.

DISCLOSURE

D. Gold reports no disclosures. S. Reich has received research support from Chiltern and NINDS. **Go to Neurology.org for full disclosures.**

REFERENCES

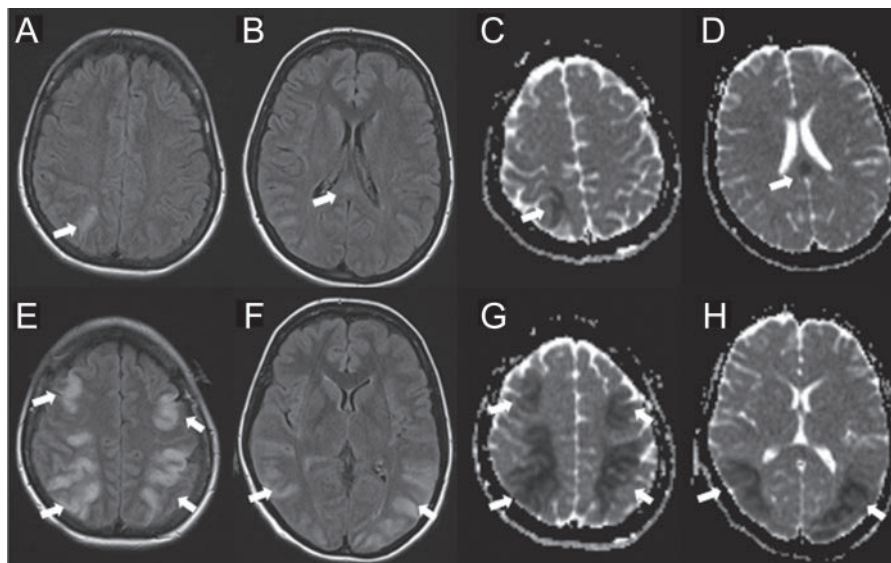
1. Bronstein A, Lempert T. *Dizziness: A Practical Approach to Diagnosis and Management*. New York: Cambridge University Press; 2007:23–156.
2. Lee H. Neuro-otological aspects of cerebellar stroke syndrome. *J Clin Neurol* 2009;5:65–73.
3. Edlow JA, Newman-Toker DE, Savitz SI. Diagnosis and initial management of cerebellar infarction. *Lancet Neurol* 2008;7:951–964.
4. Kattah JC, Talkad AV, Wang DZ, Hsieh YH, Newman-Toker DE. HINTS to diagnose stroke in the acute vestibular syndrome: three-step bedside oculomotor examination more sensitive than early MRI diffusion-weighted imaging. *Stroke* 2009;40:3504–3510.
5. Ye BS, Kim YD, Nam HS, Lee HS, Nam CM, Heo JH. Clinical manifestations of cerebellar infarction according to specific lobular involvement. *Cerebellum* 2010;9:571–579.
6. Newman-Toker DE, Reich SG. Wrong-Way nystagmus in the AICA syndrome. *Laryngoscope* 2008;118:378–379.
7. Zee DS. Pathophysiology of vestibular symptoms and signs: the clinical examination. *Continuum* 2006;12:13–32.
8. Newman-Toker DE, Sharma P, Chowdhury M, Clemons TM, Zee DS, Della Santina CC. Penlight-cover test: a new bedside method to unmask nystagmus. *J Neurol Neurosurg Psychiatry* 2009;80:900–903.
9. Halmagyi GM, Curthoys IS. A clinical sign of canal paresis. *Arch Neurol* 1988;45:737–739.
10. Lee H, Kim JS, Chung EJ, Yi HA, Chung IS, Lee SR, Shin JY. Infarction in the territory of anterior inferior cerebellar artery: spectrum of audiovestibular loss. *Stroke* 2009;40:3745–3751.
11. Brodsky MC, Donahue SP, Vaphiades M, Brandt T. Skew deviation revisited. *Surv Ophthalmol* 2006;51:105–128.
12. Kim HA, Lee H. Isolated vestibular nucleus infarction mimicking acute peripheral vestibulopathy. *Stroke* 2010;41:1558–1560.
13. Cnyrim CD, Newman-Toker D, Karch C, Brandt T, Strupp M. Bedside differentiation of vestibular neuritis from central “vestibular pseudoneuritis.” *J Neurol Neurosurg Psychiatry* 2008;79:458–460.
14. Newman-Toker DE, Kattah JC, Alvernia JE, Wang DZ. Normal head impulse test differentiates acute cerebellar strokes from vestibular neuritis. *Neurology* 2008;70:2378–2385.

Clinical Reasoning: A 33-year-old woman with severe postpartum occipital headaches

Nancy Maalouf, MD
Sami I. Harik, MD

Correspondence & reprint
requests to Dr. Maalouf:
maaloufnancy@yahoo.com

Figure 1 Head MRI axial cuts: Fluid-attenuated inversion recovery (FLAIR) (A, B, E, F) and apparent diffusion coefficient map (C, D, G, H) sequences



Upper panel MRI, performed on admission, showed FLAIR hyperintensities and diffusion restriction in the right parietal lobe and in the splenium of the corpus callosum (arrows). Lower panel, done on hospital day 3 when the patient deteriorated, showed worsening lesions involving the cortex and subcortical white matter of the parietal, posterior frontal, and occipital lobes, bilaterally (arrows).

SECTION 1

A 33-year-old woman with history of occasional “migraines” complained of severe occipital headache, following an uncomplicated full-term vaginal delivery under epidural anesthesia. This headache was qualitatively and quantitatively different from her usual headaches. The diagnosis of low intracranial pressure headache related to inadvertent dural puncture was considered and 2 epidural autologous blood patches were performed with no relief. One week postpartum she presented to an outside hospital with complaints of poor concentration, difficulty in finding words,

getting dressed, and feeding herself, and left arm numbness. Examination showed a blood pressure of 179/119 mm Hg, poor attention span, apraxia, and decreased sensation in the left hand. General physical examination was unrevealing.

Head MRI (day 0) showed fluid-attenuated inversion recovery (FLAIR) hyperintensities (figure 1, A and B) and diffusion restriction with positive apparent diffusion coefficient (ADC) map (figure 1, C and D) in the right parietal lobe and in the splenium of the corpus callosum. The diagnosis of posterior reversible encephalopathy syndrome

From the University of Arkansas for Medical Sciences, Little Rock, AR.
Disclosure: The authors report no disclosures.

(PRES) was entertained and the patient was treated for that condition with the antihypertensive agents nifedipine and lisinopril. The patient's condition deteriorated. On the third hospital day, she became cortically blind and mute, and had motor perseverations and left-sided weakness. Repeat head MRI showed marked worsening

with lesions involving the cortex and subcortical white matter of the parietal, posterior frontal, and occipital lobes, bilaterally (figure 1, bottom panel).

Question for consideration:

1. What is the differential diagnosis?

SECTION 2

The differential diagnosis of multifocal infarcts in the distribution of many vascular territories is wide. It includes emboli from heart and aorta, disseminated intravascular coagulopathy, thrombotic thrombocytopenic purpura, moyamoya disease, vasculitis secondary to connective tissue and autoimmune systemic diseases, or viral/bacterial/fungal infections. Another possible rare entity is primary CNS angitis. The presentation of this patient with postpartum headache, elevated blood pressure, and focal neurologic deficits suggested the diagnosis of PRES to the treating neurologist.

The sudden occurrence of severe headache in a young woman postpartum should also raise concern for sentinel headaches and subarachnoid hemorrhage because of their considerable morbidity and mortality and because they are eminently treatable if diag-

nosed early. These headaches are usually explosive, reach maximum intensity within minutes, and can last for hours to days. Subarachnoid hemorrhage is usually associated with symptoms and signs of meningeal irritation, altered consciousness, and focal neurologic signs. The presence of these signs in a peripartum woman should also raise the possibility of cerebral venous sinus thrombosis. Although these headaches commonly have a subacute onset, they might have a more acute presentation during puerperium. Pituitary apoplexy occurs as well in association with late pregnancy, presenting with acute headache, nausea, decreased visual acuity, ophthalmoplegia, and visual field defects.

Question for consideration:

1. What studies/tests should be performed?

SECTION 3

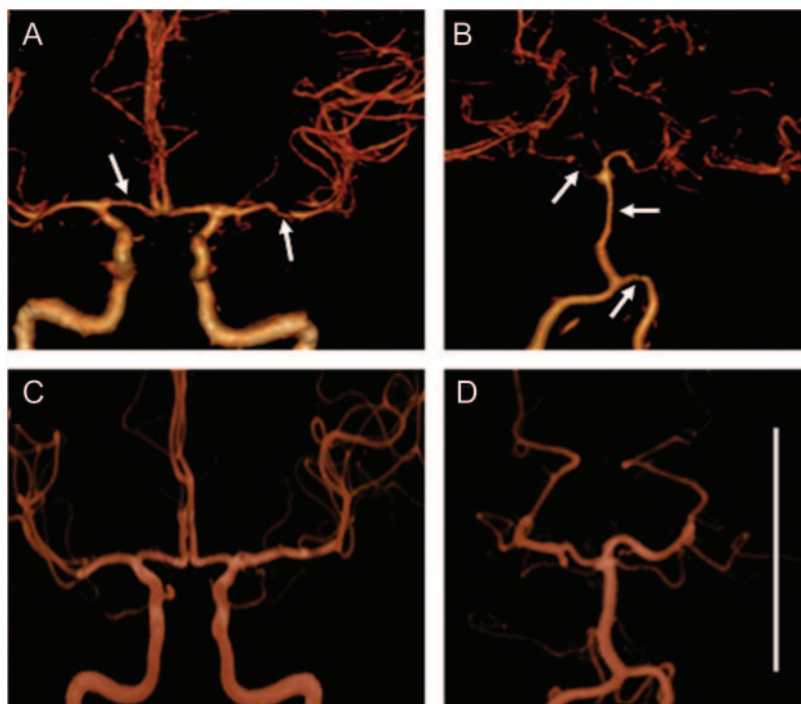
In the outside hospital, head magnetic resonance (MR) venography was unrevealing. EEG showed mild diffuse slowing. Lumbar puncture yielded clear CSF that was acellular with normal glucose and protein content. Bacterial and fungal cultures, cryptococcal antigen, herpes simplex virus PCR, VDRL, and cytology were all negative.

Because of clinical deterioration, the patient was transferred to our university hospital where a head CT angiography (CTA) revealed segmental narrowing of many intracranial vessels but primarily involving the vertebral, basilar, posterior, and middle cerebral arteries (figure 2, A and B). Transcranial sonography measured increased flow velocities in right middle (170 cm/s), right posterior (230 cm/s), left middle (130 cm/s), and left posterior (140 cm/s) cerebral arteries. Vasculitis workup including erythrocyte sedimentation rate, C-reactive protein, rheumatoid factor, antinuclear antibody, anti-neutrophil cytoplasmic antibody, double-stranded DNA, anti-SSA/Ro, anti-SSB/La antibodies, cryoglobulin, and angiotensin-converting enzyme was negative.

Based on the above, reversible cerebral vasoconstriction syndrome (RCVS) was suspected. The patient was treated with oral nimodipine, 60 mg every 4 hours; aspirin, 81 mg daily; and methylprednisolone, 125 mg IV every 6 hours for 6 days before the results of the vasculitis workup became available. The patient gradually improved: she became more alert but remained apathetic with partial expressive aphasia, apraxia, and perseveration. She perceived light and shades but her visual acuity remained below 20/200. She also had residual mild left hemiparesis with diffuse hyperreflexia and bilateral ankle clonus. Nimodipine was gradually tapered after 10 days and she was transferred to a rehabilitation facility.

Follow-up at 2 months after discharge showed her to be alert, with near-normal visual acuity (20/25) and intact color vision. She had residual right inferior quadrantanopia, apraxia, mild left hand weakness, and diffuse hyperreflexia. Head MRI showed evidence of encephalomalacia in the frontoparietal lobes, left occipital lobe, and splenium of the corpus callosum. Head MR angiography revealed complete

Figure 2 Head CT angiography (CTA) (A, B) and magnetic resonance angiography (MRA) (C, D)



Head CTA at day 6 reveals segmental narrowing of the left middle cerebral artery and the A1 segment of the right anterior cerebral artery (A, arrows); segmental narrowing of the posterior cerebral and left distal vertebral arteries with broad narrowing of the basilar artery (B, arrows). Head MRA 2 months after discharge shows complete reversal of arterial pathology (C and D). The magnification is similar in all parts of the figure; the white vertical band denotes 5 cm.

resolution of the previously noted vasoconstriction (figure 2, C and D).

DISCUSSION The most important information regarding the diagnosis and treatment of this patient was obtained before transfer to our hospital. The findings of positive diffusion-weighted imaging and ADC map in the right parietal lobe and splenium of the corpus callosum was indicative of ischemic stroke which is rarely seen in PRES.¹ The clinical and MRI worsening after antihypertensive treatment makes the diagnosis of ischemic strokes more convincing. What is the cause of cerebral ischemia? She had no clinical evidence of heart disease. CTA ruled out moyamoya and premature atherosclerosis, and clearly revealed segmental narrowing of large and medium-sized arteries at the base of the brain, highly suggestive of RCVS.

RCVS refers to a group of disorders sharing angiographic and clinical features including reversible segmental and multifocal vasoconstriction of cerebral arteries, and sudden severe headaches with or without focal neurologic deficits or seizures. These disorders were previously reported as Call-Fleming syndrome, benign angiopathy of the nervous system,

and postpartum angiopathy.² The pathophysiology of RCVS remains unknown, though transient disturbance in the control of cerebral vascular tone was hypothesized.³

There is gender preponderance of RCVS in women. Half of the patients give history of migraine.² The condition is idiopathic or related to a number of factors, including late pregnancy/postpartum and use of vasoactive substances such as triptans, selective serotonin reuptake inhibitors, pseudoephedrine, cannabinoids, cocaine, amphetamines, methylenedioxymethamphetamine (ecstasy), bromocriptine, and nasal decongestants.⁴ Postpartum angiopathy is an extremely rare complication that usually occurs in a normal pregnancy, as was the case in our patient. Two-thirds of those patients present in the first postpartum week.⁵ In 50%–70% of cases, it is associated with the use of vasoconstrictors, mostly ergots, to treat postpartum hemorrhage or to inhibit lactation. Intracranial hypotension, whether spontaneous⁶ or secondary to dural puncture,⁷ was also reported as a possible etiology of RCVS.

The diagnosis of RCVS is usually made on cerebral arterial imaging which shows diffuse and multifocal segmental narrowing of large and medium-sized arteries. The anterior and posterior brain circulations are involved. Occasional dilated segments, like strings and beads or sausage strings, were described. The diagnosis is confirmed only by documenting reversal of the vasoconstriction within few months.²

Vasoactive medications should be stopped. Clinical and angiographic resolution occurs spontaneously; however, calcium channel blockers like nimodipine are used with variable success. Long-term measures include secondary stroke prevention and treatment of complications.^{6–8} A short course of steroids may be justified to cover for cerebral vasculitis while awaiting results of workup, although a recent retrospective case-series study found worse outcome in patients who received steroids. However, this matter is confounded by the possibility that steroids were administered to sicker patients.⁹

The clinical outcome is usually good, with most patients recovering completely within days to weeks. The major complications of RCVS are localized cortical subarachnoid hemorrhages (20%–25% of cases) and ischemic strokes (5%–10%).⁵ Hemorrhagic complications and seizures occur earlier (within the first 10 days) compared to ischemic events (around 12 days from headache onset).² Association with PRES⁷ and recurrence¹⁰ were reported.

Patients with severe new-onset headache and focal neurologic deficits must be assessed urgently and several diagnoses must be considered. Initial diagnostic

studies should include an unenhanced head CT and lumbar puncture. If both studies are normal, head MRI, MR angiography of the head and neck, and MR venography are necessary. When this workup reveals segmental vasoconstriction, normal or near normal CSF studies, and a lack of any other underlying pathology, RCVS should be considered. In the case we presented, PRES was initially suspected, so blood pressure was aggressively controlled, which worsened brain ischemia. Thus, antihypertensive agents should be used with caution in RCVS, just like any other condition causing ischemic strokes.

AUTHOR CONTRIBUTIONS

Dr. Maalouf: drafting/revising the manuscript, study concept or design, analysis or interpretation of data. Dr. Harik: drafting/revising the manuscript, study concept or design, analysis or interpretation of data.

REFERENCES

1. Finocchi V, Bozzao A, Bonamini M, et al. Magnetic resonance imaging in Posterior Reversible Encephalopathy Syndrome: report of three cases and review of literature. *Arch Gynecol Obstet* 2005;271:79–85.
2. Ducros A, Boukobza M, Porcher R, Sarov M, Valade D, Bousser MG. The clinical and radiological spectrum of reversible cerebral vasoconstriction syndrome: a prospective series of 67 patients. *Brain* 2007;130:3091–3101.
3. Schwedt TJ, Matharu MS, Dodick DW. Thunderclap headache. *Lancet Neurol* 2006;5:621–631.
4. Calabrese LH, Dodick DW, Schwedt TJ, Singhal AB. Narrative review: reversible cerebral vasoconstriction syndromes. *Ann Intern Med* 2007;146:34–44.
5. Ducros A, Bousser MG. Reversible cerebral vasoconstriction syndrome. *Pract Neurol* 2009;9:256–267.
6. Schievink WI, Maya MM, Chow W, Louy C. Reversible cerebral vasoconstriction in spontaneous intracranial hypotension. *Headache* 2007;47:284–287.
7. Chaves C, Freidberg SR, Lee G, Zerris V, Ries S, Chavali R. Cerebral vasospasm following intracranial hypotension caused by cerebrospinal fluid leak from an incidental lumbar durotomy: case report. *J Neurosurg* 2005;102:152–155.
8. Calado S, Viana-Baptista M. Benign cerebral angiopathy; postpartum cerebral angiopathy: characteristics and treatment. *Curr Treat Options Cardiovasc Med* 2006;8:201–212.
9. Singhal AB, Hajj-Ali RA, Topcuoglu MA, et al. Reversible cerebral vasoconstriction syndromes: analysis of 139 cases. *Arch Neurol* 2011;68:1005–1012.
10. Ursell MR, Marras CL, Farb R, Rowed DW, Black SE, Perry JR. Recurrent intracranial hemorrhage due to postpartum cerebral angiopathy: implications for management. *Stroke* 1998;29:1995–1998.

Clinical Reasoning:

A 22-year-old woman with headache and diplopia

Ji Soo Kim, MD, PhD

Address correspondence and reprint requests to Dr. Ji Soo Kim, Department of Neurology, Seoul National University College of Medicine, Seoul National University Bundang Hospital, 300 Gumi-dong, Bundang-gu, Seongnam-si, Gyeonggi-do, 463-707, Korea
jisookim@snu.ac.kr

SECTION 1

A 22-year-old woman without medical history presented with sudden headache, blurred vision, and binocular diplopia. Two weeks previously, she had developed headache after a neck massage in a public bath. The headache was initially severe and generalized including the posterior neck. The next day, the headache improved mildly but persisted without a specific pattern of positional modulation or diurnal fluctuation. One week later, she began to have binocular horizontal

diplopia which was more severe on distant viewing. She denied fever, chills, nausea, vomiting, photophobia, phonophobia, tinnitus, transient visual blurring on standing, or sensorimotor symptoms. Her family history was noncontributory except for hypertension in her father.

Questions for consideration:

1. What is the differential diagnosis?
2. What features of the history help make certain entities more or less likely?

[GO TO SECTION 2](#)

From the Department of Neurology, Seoul National University College of Medicine, Seoul National University Bundang Hospital, Seoul, Korea.

Supported by a grant from the Korea Health 21 R&D Project, Ministry of Health & Welfare, Republic of Korea (A080750).

Disclosure: The author reports no disclosures.

SECTION 2

A previously healthy young woman developed severe headache which was followed by horizontal diplopia several days later. Given the sudden severe headache with horizontal diplopia, increased intracranial pressure (ICP) with or without a space-occupying lesion is a prime suspicion.¹ In view of the severe headache and diplopia without other focal neurologic signs in a young overweight woman, idiopathic intracranial hypertension (IIH) should be the top differential.¹ The absence of other neurologic symptoms makes an intraparenchymal mass lesion less likely. Aneurysmal rupture and resultant subarachnoid hemorrhage may cause sudden headache and diplopia due to abducens palsy from increased ICP or due to oculomotor palsy by aneurysmal compression.¹ Some patients experience sudden severe headache hours to weeks earlier than the aneurysmal rupture, which may be ascribed to aneurysmal enlargement, thrombosis, meningeal irritation, or leakage (sentinel hemorrhage). Infectious, inflammatory, or neoplastic meningitis may cause headache and diplopia without other neurologic deficits. However, the headache in these disorders is of rather gradual onset and is usually accompanied by systemic symptoms or signs of other cranial nerve palsies. Intracranial hypotension is also a cause of severe headache and diplopia. However, the headache is mostly orthostatic, being induced only during the upright posture.

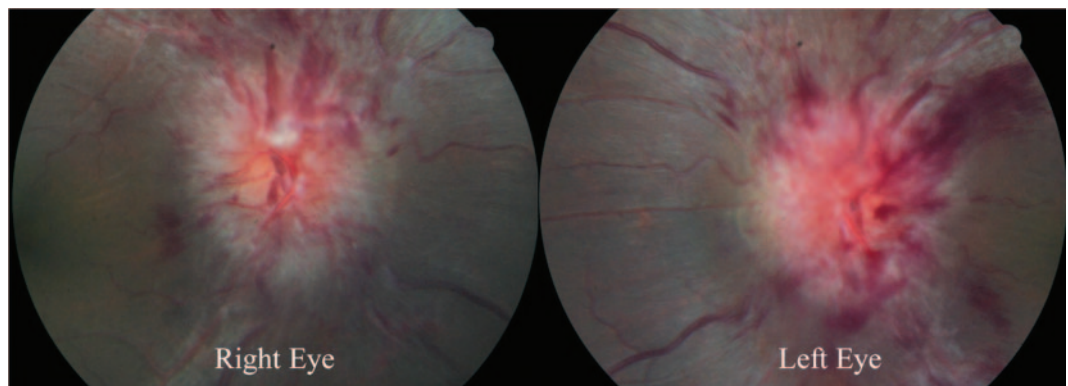
Given the development of headache after neck massage, traumatic vertebral artery dissection should be considered. However, vertebral artery dissection mostly gives rise to dizziness/vertigo, posterior neck pain, and other focal neurologic deficits. Migraine is a common cause of headache in young women and rarely accompanies diplopia (ophthalmoplegic migraine).¹ However, ophthalmoplegic migraine is an unlikely diagnosis in an adult since it usually develops before age 10. Furthermore, the interval of 1 week from the headache onset to diplopia in our patient is also unusual for ophthalmoplegic migraine.¹

On admission, examination showed an overweight woman with a body mass index of 28.3. Her blood pressure was elevated at 192/122 mm Hg with normal heart rates and body temperature. Corrected visual acuities were 20/20 in both eyes with normal confrontation visual fields and pupillary responses without a relative afferent pupillary defect. However, fundusoscopic examination revealed optic disc swelling with peripapillary hemorrhages in both eyes, more severe in the left eye (figure 1). Both eyes were esotropic with limitation of abduction on attempted lateral gaze. Other findings of physical and neurologic examinations were normal.

Questions for consideration:

1. How does the examination modify the differential and help guide the workup?
2. What testing would you obtain at this point?

Figure 1 Fundus photography showing bilateral papilledema with peripapillary hemorrhages



GO TO SECTION 3

SECTION 3

Bilateral optic disc swelling in the presence of normal optic nerve function frequently indicates an increased ICP.¹ Bilateral abduction deficit is also common in increased ICP and is frequently due to abducens palsy.¹ In view of the absence of other focal neurologic signs, IIH seems most likely, especially in a young overweight woman.^{1,2} Diagnosis of IIH is based on 1) symptoms and signs solely attributable to increased ICP, 2) elevated CSF pressure, 3) normal CSF profiles, 4) no ventriculomegaly, mass, or vascular lesions on neuroimaging, and 5) no other etiology of intracranial hypertension identified.²

However, other causes of increased ICP should be considered, which include brain tumor, infectious, inflammatory, and malignant disorders involving the meninges, and a venous sinus thrombosis.² In endemic areas, obstructive hydrocephalus due to neurocysticercosis is an important differential diagnosis. A markedly elevated blood pressure (malignant hypertension) could give rise to disc swelling in addition to headache, but bilateral abduction deficits are an exception.^{1,2} Diabetes mellitus (diabetic papillopathy) also could generate disc swelling without affecting optic nerve function in the presence of normal ICP.^{1,2}

Since loss of central vision develops only during the advanced stage of papilledema (optic disc swelling from increased ICP), visual acuity is not a

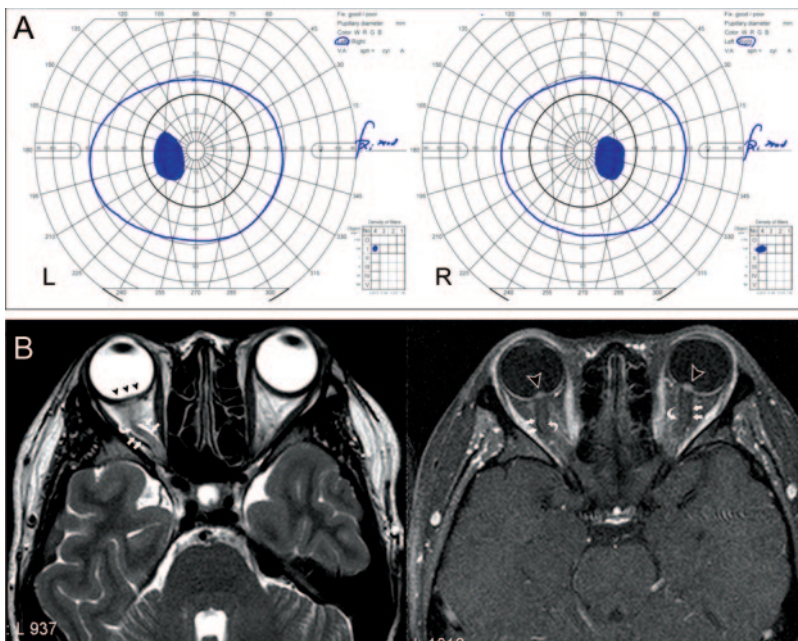
reliable indicator of visual loss, especially during the early stage of papilledema.^{2,3} If central visual acuity is reduced in a patient with acute papilledema, the cause is typically intraretinal fluid/edema.² In contrast, visual field testing may disclose enlargement of the blind spot in almost all patients with papilledema.^{2,3} Other common visual field defects are generalized constriction and inferonasal loss (nasal step).²

In patients with suspected papilledema, neuroimaging should be performed immediately, prior to lumbar puncture, to exclude disorders with a risk for herniation during the procedure and to search for any secondary cause of increased ICP.² MRI is superior to CT and enhanced imaging would aid in better detection of mass lesions including tumors and parasites, and meningitis of infectious, inflammatory, or carcinomatous origin.² However, CT is adequate to detect mass lesions that are responsible for the increased ICP, especially when MRI is not readily available.⁴ CT or MR venography should be included to rule out venous sinus thrombosis.^{2,4} Rarely conventional catheter angiography with venous phase is required. In IIH, MRI is mostly performed to exclude other intracranial pathologies which may increase ICP.^{2,4} However, MRI may exhibit radiographic evidence of increased ICP, which includes slit ventricle, empty sella, flattening of the posterior sclera, distension of the perioptic subarachnoid space, tortuous optic nerve, protrusion and enhancement of the optic discs, and Chiari type 1 malformation.⁵ Scrutinized evaluation of MRI may assist in establishing the diagnosis of IIH.

If the neuroimaging does not show a mass lesion, obstructive hydrocephalus, or evidence of cerebral venous thrombosis, a lumbar puncture should be followed to confirm increased ICP (>250 mmH₂O) and to rule out malignant, infectious, or inflammatory disorders simulating IIH.² The CSF examination should include cytology, IgG index, viral and syphilis markers, and serology for parasites and fungi, if indicated.² The profiles should be normal in IIH.² Patients also should undergo blood tests including complete blood counts, erythrocyte sedimentation rate, coagulation battery, electrolytes, tests for syphilis, and thyroid function tests.²

In our patient, blood tests included complete blood counts, routine chemistry, erythrocyte sedimentation rate, C-reactive protein, coagulation panel, thyroid function tests, rheumatoid factor, antinuclear antibody, anti-ds-DNA antibody, and antineutrophil cytoplasmic antibodies, which were all normal. Goldmann perimetry showed enlarged blind spots in both eyes (figure 2A). MRI exhib-

Figure 2 (A) Goldman perimetry demonstrating bilaterally enlarged blind spots; (B) T2-weighted and gadolinium-enhanced MRIs exhibiting flattening of the posterior sclera (arrowheads), perioptic dilation of the CSF space (arrows), tortuosity of the orbital optic nerve (curved arrows), and protrusion into the vitreous and enhancement of the optic discs (empty arrowheads)



ited flattening of the posterior sclera, distension of the perioptic subarachnoid space, tortuous optic nerve, and protrusion and enhancement of the optic discs (figure 2B). MR venography was normal. Lumbar puncture revealed an elevated opening pressure of 430 mmH₂O with normal CSF pro-

files, no white blood cell, 52.6 mg/dL of protein, 67 mg/dL of glucose, and IgG index of 0.3.

Questions for consideration:

1. What is the diagnosis?
2. What is the pathomechanism of the disease?
3. What is the treatment for this patient at this point?

GO TO SECTION 4

SECTION 4

In view of the characteristic symptoms of headache and diplopia, elevated CSF pressure, normal CSF profiles, and normal neuroimaging without other etiologies of intracranial hypertension, a diagnosis of IIH can be made.²

The pathophysiology of IIH remains unknown.² The proposed hypotheses mostly concern deranged CSF homeostasis, and include diffuse brain edema, excessive CSF production, reduced CSF absorption, and increased cerebral venous pressure, which require further elucidation.^{2,4} Various conditions also have been implicated in IIH.² However, apart from female sex, recent weight gain, and obesity, there are no proven associations.²⁻⁴

In IIH, the primary goals of treatment are preservation of vision and alleviation of the symptoms.^{2,6} Treatment options may depend on several factors including the severity of symptoms, presence and progression rate of visual loss, severity of disc swelling, and association with obesity or systemic hypertension.^{2,6}

Medical treatments of IIH include carbonic anhydrase inhibitors (acetazolamide, methazolamide,

topiramate) and diuretics (furosemide, chlorthalidone).^{2,4,6} Systemic corticosteroids may be used in urgent cases of impending or progressive visual loss while arranging a surgical procedure.^{2,6} Since weight reduction may relieve disc swelling, weight loss should be advised for patients with obesity.² Coexisting systemic hypertension confers a poor visual prognosis in patients with IIH and should be controlled appropriately.⁷

Our patient began acetazolamide 500 mg and furosemide 20 mg twice a day and her headache improved over the following several days even though the papilledema and diplopia persisted. She was discharged with the medication and arranged for a weight reduction program. However, 2 weeks later, she reported transient visual obscuration on standing and hissing sound in the right ear. Her visual acuity had decreased to 20/30 in the left eye and funduscopic examination revealed a progression of the papilledema and newly developed macular star in both eyes. Goldmann perimetry also documented further aggravation of the enlarged blind spot.

Question for consideration:

1. What are the other treatment options for this patient?

GO TO SECTION 5

SECTION 5

Our patient showed an aggravation of symptoms and deterioration of the papilledema even with the medical treatments. Furthermore, the visual acuity had decreased in the left eye with newly developed macular star in both eyes. The macular star is formed by hard exudates accumulated in Henle's fiber layer around the fovea. In IIH, it indicates an involvement of the macula and impairment of the central vision.²

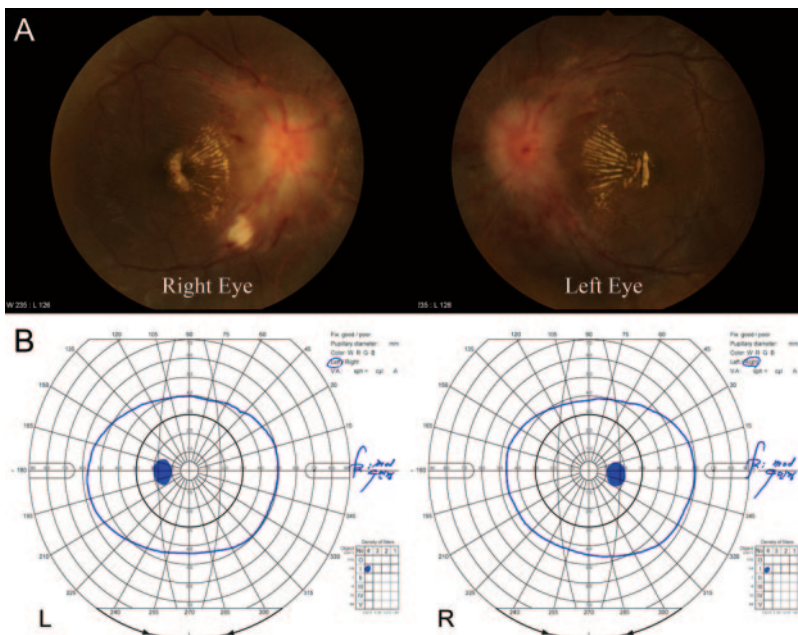
Some patients with IIH may show a rapid development of symptoms and precipitous visual decline.² They often have significant visual field loss, decline in the visual acuity, and marked papilledema at presentation. A rapid deterioration requires urgent treatments to preserve vision, which include IV corticosteroids, IV acetazolamide, and surgery.^{2,6}

Surgical procedure is indicated when patients present with severe papilledema and visual loss or when the medical treatments fail to control papilledema or prevent visual loss.^{2,6} Surgery also should be considered in patients with intractable headache or inability to perform visual function studies.⁶ CSF shunting and optic nerve sheath decompression (ONSD) are two major options and the choice of the procedure depends on the availability of a surgeon and the patient status.^{2,4} ONSD is preferred to treat significant visual symptoms, especially when severe papilledema extends into the macula, while CSF shunting is performed when headache is a major complaint.⁴ ONSD has little effect on ICP in most cases.^{2,4} Visual loss, diplopia, and infection may be complications of ONSD.² Ventriculo- or lumboperi-

toneal shunting can effectively control ICP in IIH.² Ventriculoperitoneal shunt may be technically difficult when the ventricle is not enlarged.² Lumboperitoneal shunting can be rather easily performed but intracranial hypotension and tonsillar herniation are serious complications even though adopting a programmable valve may prevent many of the complications from lumboperitoneal shunts.² CSF diversion surgery usually results in prompt normalization of ICP, resolution of papilledema, and improved visual function.² However, shunting procedures require frequent revisions due to complications, which include shunt obstruction, intracranial hypotension with tonsillar herniation and lumbar radiculopathy, infection, and abdominal pain.² Overall, shunt malfunction rate is approximately 50% in IIH.² Infection is a rare (1%) but serious complication.⁸ Repeated lumbar puncture may be considered in selected patients with intermittent symptom exacerbations or in pregnant patients.²

In view of the aggravated papilledema with newly developed transient visual obscuration, tinnitus, and visual decline in the left eye despite the medical therapy, our patient was readmitted for close monitoring of her visual function and a shunt surgery to reduce her ICP. Three days later, her visual acuity deteriorated further to 20/30 in the right eye. She underwent a lumboperitoneal shunt operation. After the operation, she reported mild headache on standing for several days, probably due to low-pressure syndrome, but the tinnitus, visual obscuration, and diplopia disappeared over the following several days. Follow-up funduscopy 10 days after the operation showed a marked improvement of the papilledema (figure 3A). The enlarged blind spots on Goldmann perimetry also resolved (figure 3B) along with improvement of the bilateral abduction limitation.

Figure 3 Improved papilledema (A) and normal Goldmann perimetry (B) 10 days after lumboperitoneal shunt



DISCUSSION IIH is typically a disorder of obese women of childbearing age, rarely occurring after the age of 45 years.² IIH is occasionally asymptomatic, but typical symptoms include headache, transient visual loss, diplopia, and tinnitus. Headache is mostly generalized, continuous, and often associated with neck pain.² The headache may be worse in the morning or increased by Valsalva maneuvers. Transient visual obscurations usually last less than a minute, and are often precipitated on standing from a stooped posture.² Transient visual obscurations are explained by transient ischemia of the optic nerve head induced by papilledema.² Diplopia is usually horizontal resulting from abducens nerve palsy even though vertical diplopia rarely occurs due to trochlear or oculomotor nerve palsies or skew deviation.² Unilateral or bilateral pulsatile tinnitus is

also common and may be ascribed to flow disturbances in the cerebral venous system.²

Since enlarged blind spots and peripheral field defects are early visual losses,^{2,3,7} and impaired central vision (visual acuity) is usually a late phenomenon in IIH, a careful evaluation and monitoring of visual field defects are required using quantitative perimetry, especially during the early stage.² With progression of disease, ischemic optic neuropathy may occur, producing irreversible impairments of central vision² even though visual loss may occur due to macular edema complicated by papilledema.² Most visual defects in IIH are reversible if ICP is controlled before severe visual loss or optic nerve ischemia develops.² Early central visual loss with rapid progression is a grave sign and requires prompt intervention.^{2,3,7}

Even though IIH is usually a self-limiting condition,^{2,7} visual loss occurs in 4% to 31% and blindness in up to 5% of the patients.^{3,7-9} Furthermore, recurrence rate of IIH ranges from 10% to 40%, depending on the follow-up period,⁸ and some patients have delayed worsening or recurrences even several years after resolution of papilledema.^{7,10} Many patients with IIH also show increased ICP several years after onset of the disease.⁷ Accordingly, IIH may be a chronic condition, warranting long-term follow-up.¹⁰

REFERENCES

1. Burde RM, Savino PJ, Trobe JD, eds. *Clinical Decisions in Neuro-ophthalmology*. 3rd ed. St. Louis: Mosby; 2002.
2. Friedman DI. Pseudotumor cerebri. *Neurol Clin* 2004;22:99–131.
3. Wall M, George D. Idiopathic intracranial hypertension: a prospective study of 50 patients. *Brain* 1991;114:155–180.
4. Mathews MK, Sergott RC, Savino PJ. Pseudotumor cerebri. *Curr Opin Ophthalmol* 2003;14:364–370.
5. Brodsky MC, Vaphiades M. Magnetic resonance imaging in pseudotumor cerebri. *Ophthalmology* 1998;105:1686–1693.
6. Corbett JJ, Thompson HS. The rational management of idiopathic intracranial hypertension. *Arch Neurol* 1989;46:1049–1051.
7. Corbett JJ, Savino PJ, Thompson HS, et al. Visual loss in pseudotumor cerebri. Follow-up of 57 patients from five to 41 years and a profile of 14 patients with permanent severe visual loss. *Arch Neurol* 1982;39:461–474.
8. Skau M, Brennum J, Gjerris F, Jensen R. What is new about idiopathic intracranial hypertension? An updated review of mechanism and treatment. *Cephalalgia* 2005;26:384–399.
9. Ball AK, Clarke CE. Idiopathic intracranial hypertension. *Lancet Neurol* 2006;5:433–442.
10. Shah VA, Kardon RH, Lee AG, Corbett JJ, Wall M. Long-term follow-up of idiopathic intracranial hypertension. The Iowa experience. *Neurology* 2008;70:634–640.

Clinical Reasoning: A child with pulsatile headache and vomiting

Laurence Morin, MD
Assia Smail, MD
Jean-Christophe Mercier,
MD, PhD
Luigi Titomanlio, MD,
PhD

Address correspondence and
reprint requests to Dr. Luigi
Titomanlio, Pediatric Emergency
Dept., Robert Debré University
Hospital, 48, Bld. Sérurier, 75019
Paris, France
luigi.titomanlio@rdb.aphp.fr

SECTION 1

A child was born to nonconsanguineous, healthy parents. Pregnancy and delivery were uneventful, and psychomotor development was normal. At the age of 6 years and 10 months, he was admitted to a local hospital because of vomiting and nonfebrile unilateral headache. Neurologic examination had normal results. Blood tests (complete blood count, C-reactive protein, electrolytes, blood urea nitrogen, creatinine, glucose, serum bicarbonate and pH, anion gap, transaminase, and urine culture) were within normal limits. Abdominal x-ray and abdominal ultrasound imaging had normal results. Based on these results and on clinical observation, common medical and surgical causes (viral illness, gastroenteritis, diabetes, intestinal obstruction) were ruled out. Head CT scan had normal results. The EEG showed some irregular activity in the occipital regions, with rare sharp waves, more prevalent on the right side. One week later, a further awake EEG was performed and had normal results. A presumptive diagnosis of migraine with aura was made after 2 months by a pediatric neurologist because of several episodes of unilateral pulsatile headache and vomiting (one to two episodes per week). The episodes were preceded by a sensation of sickness, and lasted about 5–10 minutes each. Pallor, poorly defined abnormal ocular

movements, and transitory unresponsiveness were also reported by his parents. After the episode, the child asked to sleep. Acetaminophen and ibuprofen were prescribed to control symptoms.

Five months later, the patient was brought to the Emergency Department of our hospital because of recurrent and long-lasting episodes of headache beginning the same day. He had four episodes of nausea, vomiting, pallor, and unilateral (right-sided or left-sided) pulsatile headache, each one lasting from 5 to more than 30 minutes. The prescribed treatment was ineffective, and the child was considered to be in a migraine aura status by his pediatrician.

A critical episode was observed during clinical examination: the child reported a sudden feeling of sickness and a severe unilateral pulsatile headache, followed by nausea. Left eyelid myoclonus followed, and the child described a short-lasting sensation of blindness. Then his head turned toward the right and he became unresponsive for about 20 seconds. Soon after, he vomited and became bradycardic (sinus rhythm, 35–40 bpm).

Questions for consideration:

1. What is the differential diagnosis?
2. What features of the history help make certain entities more or less likely?

[GO TO SECTION 2](#)

From the Departments of Pediatric Emergency Care (L.M., A.S., J.-C.M., L.T.) and Pediatric Neurology (L.T.), APHP-University Hospital R. Debré, Paris, France.

Disclosure: The authors report no disclosures.

SECTION 2

The differential diagnosis in children presenting with pulsatile headache and vomiting, sensation of sickness, pallor, or other autonomic symptoms includes emergent etiologies such as intracranial mass (tumor, bleed, infection) and encephalitis, and non-emergent diseases such as migraine (mainly basilar migraine), gastroenteritis, vagal syncope, cyclic vomiting syndrome, intoxication, and partial seizures (occipital or temporal lobe epilepsy). Other rare etiologies to consider are vascular syndromes (Klippel-Trenaunay-Weber, arteriovenous malformations of the brain), familial dysautonomia (e.g., Riley-Day syndrome), breath-holding spells of early infancy progressing to isolated syncope, postural orthostatic tachycardia syndrome (POTS), and metabolic diseases. This child showed prolonged and severe autonomic symptoms (nausea, vomiting, pallor, bradycardia) that are mainly due to acute cerebral insults, but can also be diagnosed as status migrainosus or autonomic status epilepticus. In his personal history, we can identify shorter but similar episodes, suggesting that the two latter hypotheses are most likely correct. Migraine and epilepsy are highly comorbid conditions that may share the same pathophysiology, but the nature of their association is unclear. Our case does not fulfill the diagnostic criteria for migraine with aura of the *International Classification of Headache Disorders*, 2nd edition (ICHD-II).¹ The aura, which can be visual, sensory, or dysphasic, is the consequence of focal cerebral dysfunction that immediately precedes or coincides with the headache onset. In our patient, autonomic symptoms could be related to a basilar-type migraine rather than to an aura. Differential diagnosis between seizure and migraine could be complicated by the presence of headache in both. Seizures can be followed by postictal headache (headache attributed to seizure, ICHD-II 7.6) and can also occur during or within 1 hour of a typical migraine aura attack (migraine-triggered seizure, ICHD-II 1.5.5). In migraineurs, interictal EEG findings are usually normal, although various abnormalities, including mainly diffuse slowing, have been reported. Sharp waves, observed in our patient, are not seen in migraine.

A clinical diagnosis of autonomic status epilepticus was made, and a rectal dose of 0.5 mg/kg of diazepam was administered, stopping the episode. The diagnosis of autonomic seizures is suggested by the episodic recurrence of unexplained vomiting or abdominal pain, migraine, or other autonomic symptoms, with EEG showing focal seizure activity.

The child fulfills the clinical and likely the EEG criteria for Panayiotopoulos syndrome (PS), a form of benign focal epilepsy of early childhood: several nonfebrile

occipital seizures, occipital spike-wave activity at EEG (clinical history), absence of known etiologic factors, normal psychomotor development, and benign clinical evolution under treatment (when prescribed). PS is a common, benign, and idiopathic childhood autonomic epilepsy that has recently been incorporated into the international classification of epileptic syndromes.² Of children aged 1 to 15 years who have had one or more nonfebrile seizures, PS affects approximately 6%, and 13% of children aged 3 to 6 years. Age at onset is between 1 and 14 years with a peak between 4 and 5 years. Crises are focal, initially characterized by a complaint from the child of not feeling well, followed by autonomic signs or symptoms frequently characterized by emetic symptoms (nausea, retching, vomiting), paleness (or, less often, cyanosis or facial blushing), mydriasis (or, less often, miosis), coughing, hypersalivation, urinary and fecal incontinence, and cardiorespiratory and thermoregulatory alterations.³ In nearly all critical episodes, consciousness is initially intact. During seizure evolution, the child can become flaccid and unresponsive in 20% of cases (ictal syncope), with tonic eye and head deviation. Headache is often concurrent with other autonomic symptoms. Speech arrest, visual hallucinations, oropharyngolaryngeal movements, and behavioral disturbances occur less frequently. Autonomic seizures in PS are frequently prolonged, more than 30 minutes in nearly half of cases (autonomic status epilepticus).⁴

In PS, the neuroanatomic and neurophysiologic pathways involved in the generation of autonomic signs are unknown. Usually, autonomic manifestations are generated by activation or inhibition of parts of the central autonomic network that involves the insular cortex, medial prefrontal cortex, amygdala, hypothalamus, and ventrolateral medulla. In PS, the epileptogenic zone is wide and bilateral. Therefore, ictal discharges may easily activate the lower threshold autonomic centers. In children with PS, autonomic manifestations also may be attributed to a maturation-related susceptibility of the central autonomic network.⁵ Seizures remain purely autonomic if ictal neuronal activation of non-autonomic cortical areas fails to reach the threshold to produce other symptoms; otherwise autonomic and localization-related cortical symptoms occur.

The child had a complete recovery and was kept under medical supervision for 1 day. No more episodes occurred.

Questions for consideration:

1. What testing would you obtain at this point to confirm the diagnosis?
2. What is the prognosis for this patient?
3. Would you prescribe a treatment, and, if yes, which one?

GO TO SECTION 3

SECTION 3

Interictal EEG testing was repeated to confirm the EEG criteria for PS, and it showed independent bilateral occipital spike-wave complexes. Brain MRI had normal results. Antiepileptic therapy was started (valproic acid, 20 mg/kg/day). At 8 years and 4 months of age, he remained symptom-free.

An awake and asleep EEG is the only investigation that commonly shows abnormal results (90% of cases). The epileptiform activity is characterized by spikes or spike-wave complexes of great amplitude, with multifocal localization predominating in the posterior regions.⁶ Interictal EEG findings show intraindividual variability.⁵ High-resolution brain MRI has normal results. The overall prognosis of PS is excellent, with remission usually occurring within 1 or 2 years after onset. Children have normal physical and neuropsychological development and the risk of epilepsy in adult life appears no higher than in the general population. Treatment might not be necessary because in one-third of cases there is only a single seizure, but benzodiazepines, administered by IV, rectal, or buccal preparations, are commonly used to terminate autonomic status epilepticus. Whereas PS is benign in terms of long-term evolution, autonomic seizures can be associated with potentially life-threatening cardiorespiratory arrest and death.⁷ To date, therapeutic management of PS and autonomic status epilepticus is based on consensus. There is no evidence of the superiority of any antiepileptic drug, and carbamazepine and valproic acid are both widely used.⁸ If antiepileptic treatment is started, it is suggested to consider its withdrawal within 2 years. Because of autonomic status epilepticus and bradycardia in our patient, valproic acid therapy was started and symptoms resolved completely.

DISCUSSION Diagnosis of autonomic status epilepticus can be difficult, especially if this possibility is not considered by the clinician in an emergency setting. Most general practitioners and pediatricians are not familiar with the notion that prominent autonomic symptoms and signs may occur as epileptic seizure manifestations of occipital origin. As a consequence, this diagnosis can be easily missed and have potentially life-threatening sequelae.⁹ Detecting key symptoms usually associated with PS may prevent erroneous diagnoses, shorten the length of clinical observation, and prevent unnecessary investigations. Early recognition of PS can also provide rapid reassurance to families in situations that can be very alarming.

Cardiovascular changes in PS have received the most attention, probably because of their possible contribution to sudden death in these patients.⁷ The association between seizures and heart rate changes has already been

documented in several studies, tachyarrhythmias being more common than bradyarrhythmias. Ictal bradycardia is seen primarily in association with focal seizures, particularly involving the temporal and limbic lobes.¹⁰ Conversely, there are very few cases of ictal cardiorespiratory arrest reported in PS⁷; therefore, its best management is unclear. In our case, an intrarectal dose of diazepam was rapidly effective in normalizing heart rate, possibly preventing a cardiorespiratory arrest, with all its consequences.

CONCLUSIONS PS often eludes diagnosis as it presents with manifestations that could be overlooked and symptoms that are frequently mistaken for more common childhood disorders (migraine in the present case). The risk of cardiorespiratory arrest in PS should be known by practitioners in clinical emergency medicine. Some children have been reported to be resuscitated, intubated, and mechanically ventilated as a consequence of PS attacks. Our case illustrates the efficacy of an intrarectal dose of diazepam in case of ictal bradycardia, possibly preventing a cardiorespiratory arrest. Although more studies are needed on the subject, supportive family management should also include specific education about autonomic status epilepticus symptoms.

REFERENCES

1. International Classification of Headache Disorders, 2nd edition. *Cephalalgia* 2004;24 suppl 1:9–160.
2. Covanis A, Panayiotopoulos CP. Improving the diagnostic yield in Panayiotopoulos syndrome. *Eur J Neurol* 2008; 15:317–319.
3. Panayiotopoulos CP. Autonomic seizures and autonomic status epilepticus peculiar to childhood: diagnosis and management. *Epilepsy Behav* 2004;5:286–295.
4. Dura-Trave T, Yoldi-Petri ME, Gallinas-Victoriano F. Panayiotopoulos syndrome: epidemiological and clinical characteristics and outcome. *Eur J Neurol* 2008;15:336–341.
5. Panayiotopoulos CP, Michael M, Sanders S, et al. Benign childhood focal epilepsies: assessment of established and newly recognized syndromes. *Brain* 2008;131:2264–2286.
6. Ferrie C, Caraballo R, Covanis A, et al. Panayiotopoulos syndrome: a consensus view. *Dev Med Child Neurol* 2006;48:236–240.
7. Verrotti A, Salladini C, Trotta D, et al. Ictal cardiorespiratory arrest in Panayiotopoulos syndrome. *Neurology* 2005;64:1816–1817.
8. Caraballo R, Cersosimo R, Medina C, Fejerman N. Panayiotopoulos-type benign childhood occipital epilepsy: a prospective study. *Neurology* 2000;55:1096–1100.
9. Covanis A. Panayiotopoulos syndrome: a benign childhood autonomic epilepsy frequently imitating encephalitis, syncope, migraine, sleep disorder, or gastroenteritis. *Pediatrics* 2006;118:e1237–1243.
10. Schuele SU, Bermeo AC, Alexopoulos AV, et al. Video-electrographic and clinical features in patients with ictal asystole. *Neurology* 2007;69:434–441.

Management dilemmas

Despite the ever-increasing number of randomized controlled trials for treatment of neurologic diseases, individual patients present unique clinical dilemmas, and it can be challenging to determine how best to apply the findings from large studies in individual cases. In the field of vascular neurology, for example, clinical trial data are perhaps more extensive than in

any other neurologic subspecialty, yet significant controversy persists over how to interpret these data. In the cases in this section, the authors describe the management of patients with cerebrovascular disease, exploring both how existing data can be used to guide complex clinical reasoning and the limitations of existing data when applied to individual patients.



Clinical Reasoning: A 42-year-old man who developed blurred vision and dropped his iPod while jogging

Aaron L. Berkowitz, MD,
PhD
P. Emma Voinescu, MD,
PhD
Steven K. Feske, MD

Correspondence to
Dr. Berkowitz:
aberkowitz3@partners.org

SECTION 1

A 42-year-old man noted sudden onset of blurriness in his left eye and dropped his iPod from his right hand while jogging. In the emergency room, it was noted that visual blurring resolved with right eye closure, but his ophthalmologic examination was otherwise normal. He had subtle right nasolabial fold flattening and right arm pronator drift. His examination was otherwise normal.

He reported no headache, neck pain, prior trauma, prior transient neurologic deficit, or palpitations. He took no medications and did not smoke, drink alcohol, or use illicit drugs.

Question for consideration:

1. What is the localization and differential diagnosis of the patient's deficits?

[GO TO SECTION 2](#)

SECTION 2

The differential diagnosis for acute-onset neurologic deficits includes vascular causes, seizures, and migrainous phenomena. There was no history to suggest seizure, and the monocular visual deficit and lack of headache would be atypical (albeit not impossible) for complex migraine. Extraocular muscle weakness causing ocular misalignment can cause the phenomenon of blurred vision resolving with closure of one eye, but no extraocular muscle weakness was detected on examination. Abrupt onset of unilateral blurred vision with contralateral face and arm weakness suggests simultaneous retinal and ipsilateral frontal hemispheric ischemia. Potential etiologies include embolism or hypoperfusion due to pathology of the internal

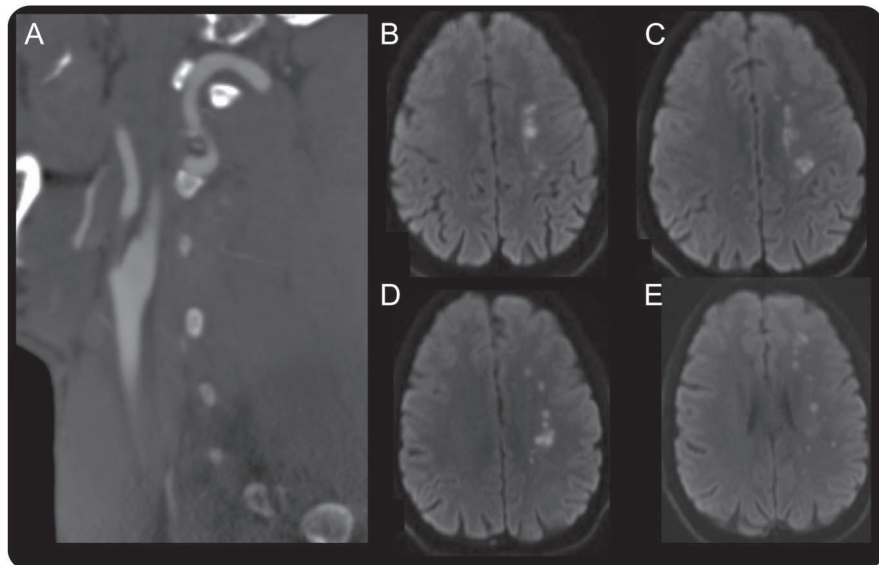
carotid artery, aortic arch, or heart. In a series of 1,008 patients age 15–49 with first stroke, cardioembolism and cervical artery dissection were the 2 most common causes of stroke, causing 19.6% and 15.4% of strokes, respectively.¹ Under age 45, dissection was even more common (18.6%). In our patient, initial CT and MRI revealed no evidence of infarction, but CT angiogram demonstrated dissection of the left internal carotid artery (figure, A). On further questioning, there were no identifiable inciting events for the dissection.

Question for consideration:

1. How should the patient's carotid dissection be managed?

[GO TO SECTION 3](#)

Figure CT angiogram and MRI



(A) CT angiogram demonstrates "flame-shaped" tapering of the left internal carotid artery consistent with dissection. (B–E) MRI diffusion-weighted imaging demonstrates infarction in the middle cerebral artery-anterior cerebral artery (B–C) and internal (D, E) borderzone territories.

SECTION 3

There are no randomized trials comparing antiplatelet agents and anticoagulation for stroke prevention in cervical artery dissection. The most recent meta-analysis of nonrandomized data included 1,636 patients from 39 studies in which 1,137 patients were anticoagulated (with unfractionated heparin, low-molecular-weight heparin, or warfarin) and 499 received antiplatelet agents (with aspirin, clopidogrel, or dual therapy with aspirin and clopidogrel or aspirin and dipyridamole).² Thirty-three patients had strokes across both groups (2.6% in the antiplatelet group, 1.8% in the anticoagulation group) and 14 patients died (1% in the antiplatelet group, 0.8% in the anticoagulation group). There were no statistically significant differences in rates of stroke or mortality between the 2 treatment strategies. However, it has been noted that most studies of carotid dissection failed to capture patients during the acute period when stroke risk is highest.³ In patients with cervical artery dissection–related strokes who could pinpoint the precise onset of their initial prestroke symptoms (e.g., headache, Horner syndrome, or TIA), 82%

had a stroke within 1 week, and 44% of those strokes were within the first 24 hours.⁴ Based on the presumed artery-to-artery embolic mechanism of stroke in cervical dissection and until more definitive data are available, it is reasonable to consider anticoagulation in such patients,⁵ though this decision must be individualized, weighing the risks of intracranial hemorrhage, especially in cases of large stroke or intradural extension of dissection.

Given that our patient had clinical evidence of cerebral ischemia and had neither intradural extension of his dissection nor a large stroke, the benefits of anticoagulation were believed to outweigh the risks, and he was initiated on IV heparin.

Approximately 24 hours after his presentation and 12 hours after initiation of anticoagulation, he developed worsening right arm weakness and aphasia. His blood pressure was 100/60 mm Hg. An MRI was repeated (figure, B–E).

Question for consideration:

1. What does the pattern of infarction suggest with respect to stroke mechanism?

GO TO SECTION 4

SECTION 4

The MRI reveals cerebral infarction in the watershed or borderzone regions between the middle cerebral artery (MCA) and anterior cerebral artery territories (figure, B and C) and in the internal borderzone at the juncture of the superficial (leptomeningeal) and deep (lenticulostriate) perforating branches of the MCA (figure, D and E). While borderzone infarction is classically attributed to hypotension, there is evidence that embolism may also play a role. The end-arterial territories are potential sites for the smallest emboli, and patients with borderzone infarction due to carotid disease have been noted to have evidence of ongoing embolization on transcranial Doppler high-intensity transient signal studies.⁶

Hypoperfusion and embolism may therefore interact in the pathophysiology of borderzone infarction through impaired clearance of emboli in states of hypoperfusion.⁶

Carotid dissection can cause stroke through both embolism and hypoperfusion: artery-artery embolism of intraluminal thrombus or cerebral hypoperfusion due to carotid occlusion from enlarging intramural hematoma. In our patient, radiologic evidence of carotid occlusion and a blood pressure of 100/60 mm Hg suggested hypoperfusion as the mechanism of his new strokes.

Question for consideration:

1. How can ongoing cerebral ischemia attributable to hypoperfusion be managed?

GO TO SECTION 5

SECTION 5

Induced hypertension can increase cerebral blood flow to maximize collateral circulation and decrease brain ischemia. The largest prospective trial of induced hypertension included only 13 patients,⁷ and the largest retrospective study only 46 treated patients.⁸ Existing studies are heterogeneous with respect to methodology, duration of induced hypertension, and concurrent use of anticoagulation with induced hypertension. However, several important observations emerge from these studies. Patients with acute ischemic stroke most likely to benefit from induced hypertension are those with large-vessel occlusion or stenosis (e.g., of the carotid or MCA stem) and those with a demonstrable blood pressure threshold, i.e., a specific blood pressure above which a neurologic deficit is reversed and below which the deficit is present. There appears to be no increased incidence of hemorrhagic complications or other adverse outcomes in patients undergoing induced hypertension after acute ischemic stroke, even in patients who have been simultaneously anticoagulated. While larger controlled trials are necessary, preliminary data suggest that induced hypertension may be both safe and beneficial in selected patients.

It is unclear whether any of the patients in studies of induced hypertension reported as having large-vessel stenosis or carotid stenosis/occlusion may have had carotid artery dissection as the etiology. However, because our patient had new strokes while receiving anticoagulation in the setting of flow-limiting carotid dissection and a low blood pressure, phenylephrine was initiated. At systolic blood pressures of 130 mm Hg and above, he was able to maintain his right arm against gravity, but below this threshold, he could not lift this arm from the bed. His aphasia persisted even at systolic blood pressure of 180. This blood pressure threshold for his right arm strength persisted for several days, and oral midodrine and fludrocortisone were initiated in order to wean him from phenylephrine. He was discharged to rehabilitation on warfarin, midodrine, and fludrocortisone. At follow-up 1 month later, he had full right arm strength, and his aphasia had begun to improve. Midodrine and fludrocortisone were tapered without recurrence of symptoms.

Questions for consideration:

1. How long should anticoagulation be maintained?
2. Should the patient undergo repeat imaging to aid in this decision?

GO TO SECTION 6

SECTION 6

Current guidelines recommend antithrombotic treatment for 3–6 months after dissection, acknowledging that this duration is “arbitrary.”⁹ The recommended duration of 6 months is based in part on the largest study of stroke recurrence after cervical artery dissection (459 patients followed for mean 31 months, 384 of whom had carotid dissections).¹⁰ In this study, there were 4 recurrent strokes: 2 within the first 6 months of follow-up in patients with incompletely healed dissections and 2 at around 2 years due to recurrent dissection contralateral to the original dissection. Some practitioners recommend repeat vascular imaging as early as 6 weeks following initiation of anticoagulation, with discontinuation of anticoagulation if the artery remains occluded, and continuation of anticoagulation if arterial patency has returned but with persistent significant stenosis.⁵ In patients with no recurrent stroke or TIA, we typically anticoagulate patients with cervical artery dissection for 6 months and then convert from anticoagulation to an antiplatelet agent at that time. We also obtain vessel imaging at 6 months. Although our decision to discontinue anticoagulation and initiate an antiplatelet agent at 6 months is not influenced by findings on vascular imaging, this imaging establishes a new radiologic baseline for the patient, should a subsequent new ischemic event occur. Six months following his initial presentation, our patient had made substantial progress in his speech with speech therapy. CT angiogram revealed persistent occlusion of his left internal carotid artery, anticoagulation was discontinued, and aspirin was initiated.

DISCUSSION Cervical artery dissection is a common cause of stroke in the young.¹ Predisposing factors include trauma, chiropractic manipulation, and connective tissue diseases, although many patients have no clear predisposing factor. Patients may present with ischemic symptoms (i.e., TIA or stroke) or local symptoms such as headache, neck pain, Horner syndrome, or cranial nerve palsies (most commonly IX, X, XI, or XII, though III, V, VI, and VII have rarely been reported in carotid dissection¹¹). Up to 43% of patients with cervical artery dissection presenting with local symptoms alone may ultimately have strokes,⁴ so discovery of dissection warrants stroke preventative therapy, even if initial symptoms are nonischemic in nature. There are no data from randomized controlled trials to guide therapeutic decision-making. Therefore decisions about the use of antiplatelet agents or anticoagulants, optimal duration of therapy, and when or if to repeat cervical arterial imaging

must be individualized for each patient. The Cervical Artery Dissection in Stroke Study (CADISS) is currently recruiting patients into a randomized trial of anticoagulation vs antiplatelet therapy. This will hopefully yield answers to long-controversial questions in the management of cervical artery dissection.

AUTHOR CONTRIBUTIONS

Dr. Berkowitz conceived of, wrote, and revised the manuscript; created the figure; and cared for the patient. Dr. Voinescu revised the manuscript and cared for the patient. Dr. Feske revised the manuscript and cared for the patient.

STUDY FUNDING

No targeted funding reported.

DISCLOSURE

A. Berkowitz reports no relevant disclosures, but receives royalties from *Clinical Pathophysiology Made Ridiculously Simple* (Medmaster, Inc.) and *The Improvising Mind* (Oxford University Press). P. Voinescu and S. Feske report no disclosures relevant to the manuscript. Go to Neurology.org for full disclosures.

REFERENCES

1. Putaala J, Metso AJ, Metso TM, et al. Analysis of 1008 consecutive patients aged 15 to 49 with first-ever ischemic stroke: the Helsinki young stroke registry. *Stroke* 2009;40:1195–1203.
2. Kennedy F, Lanfranconi S, Hicks C, et al. Antiplatelets vs. anticoagulation for dissection: CADISS nonrandomized arm and meta-analysis. *Neurology* 2012;79:686–689.
3. Caplan LR. Antiplatelets vs. anticoagulation for dissection: CADISS nonrandomized arm and meta-analysis. *Neurology* 2013;80:970–971.
4. Biousse V, D’Anglejan-Chatillon J, Toubol P, Amarencu P, Bousser M. Time course of symptoms in extracranial artery dissections: a series of 80 patients. *Stroke* 1995;26:235–239.
5. Caplan LR. Dissections of brain-supplying arteries. *Nat Clin Practice Neurol* 2008;4:34–42.
6. Caplan LR, Hennerici M. Impaired clearance of emboli (washout) is an important link between hypoperfusion, embolism, and ischemic stroke. *Arch Neurol* 1998;55:1475–1482.
7. Rordorf G, Koroshetz WJ, Ezzeddine MA, Segal AZ, Buonanno FS. A pilot study of drug-induced hypertension for treatment of acute stroke. *Neurology* 2001;56:1210–1213.
8. Koenig MA, Geocadin RG, de Grouchy M, et al. Safety of induced hypertension therapy in patients with acute ischemic stroke. *Neurocrit Care* 2006;04:3–7.
9. Furie KL, Kasner SE, Adams RJ, et al. Guidelines for the prevention of stroke in patients with stroke or transient ischemic attack: a guideline for healthcare professionals from the American Heart Association/American Stroke Association. *Stroke* 2011;42:227–276.
10. Touze E, Gauvrit J-Y, Moulin T, et al. Risk of stroke and recurrent dissection after a cervical artery dissection: a multicenter study. *Neurology* 2003;61:1347–1351.
11. Sturzenegger M, Huber P. Cranial nerve palsies in spontaneous carotid artery dissection. *J Neurol Neurosurg Psychiatry* 1993;56:1191–1199.



Clinical Reasoning: A 24-year-old woman with progressive headache and somnolence

Shamik Bhattacharyya,

MD

Aaron L. Berkowitz, MD,

PhD

Ruchira M. Jha, MD

Correspondence to
Dr. Bhattacharyya:
sbhattacharyya3@partners.org

SECTION 1

A 24-year-old woman presented with progressive somnolence and headache following 2 days of nausea and vomiting. She had a history of developmental delay, attention-deficit disorder, and remote seizures. Medications included combined estrogen-progestin oral contraceptives. On presentation, she was afebrile, somnolent but arousable, groaning incoherently, and unable to

follow commands. Optic disc margins were blurred bilaterally. Gaze was midline and deviated downward with restricted spontaneous upward gaze but full lateral gaze. She moved the right side less briskly than the left.

Question for consideration:

1. What is the localization and differential diagnosis of the examination findings?

[GO TO SECTION 2](#)

SECTION 2

Progressive somnolence, blurred optic disc margins, and forced downgaze indicate elevated intracranial pressure (ICP) with dorsal midbrain compression. Decreased spontaneous movement of the right side could point to a left-sided lesion, although localization can be challenging in the setting of herniation. The progression of symptoms over 2 days indicates a subacute process; the differential diagnosis includes vascular (expanding hematoma, venous sinus thrombosis), neoplastic (intraparenchymal or leptomeningeal

disease), infectious (meningitis, encephalitis), and inflammatory (acute disseminated encephalomyelitis) conditions, any of which may lead to CSF flow obstruction. There was no history of trauma suggestive of intracranial injury, progressive localizing neurologic deficits indicating an expanding mass lesion, fever implicating intracranial infection, or prior infection suggestive of postinfectious demyelinating syndrome.

Question for consideration:

1. How would you evaluate and manage the patient?

GO TO SECTION 3

SECTION 3

In a patient with signs of elevated ICP, diagnostic evaluation and immediate therapy must proceed in parallel. Our patient received mannitol en route to head CT. Her head CT showed a “cord sign” in the left transverse sinus consistent with cerebral venous sinus thrombosis (CVST) (figure). CT venogram revealed contrast filling defects in the superior sagittal, straight, and left transverse and sigmoid sinuses with significant dilation of cortical veins.

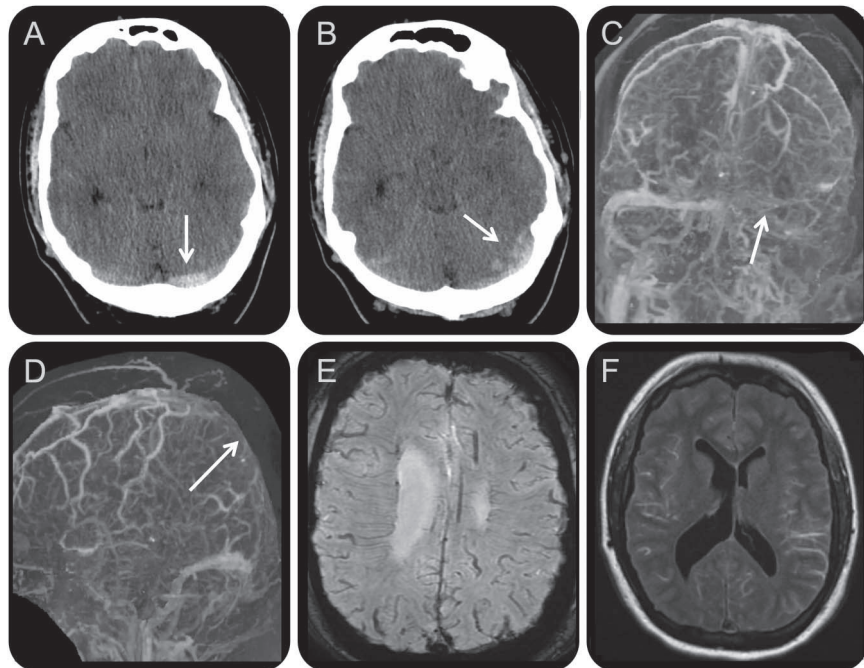
MRI demonstrated sulcal susceptibility signal and T2 hyperintensity in fluid-attenuated inversion recovery sequence representing diffuse cortical venous dilation. There was no evidence of infarct, hemorrhage, vascular malformation, or structural abnormality.

Question for consideration:

1. How should the venous sinus thrombosis be managed?

[GO TO SECTION 4](#)

Figure Radiographic findings



Noncontrast head CT shows diffuse sulcal effacement indicating cerebral edema and hyperdensity in left transverse sinus (A; white arrow) extending into sigmoid sinus (B; white arrow) representing acute thrombus. CT venography shows lack of contrast opacification in left transverse sinus (C; white arrow) and posterior segment of the superior sagittal sinus (D; white arrow). MRI shows sulcal susceptibility signal (E) and sulcal fluid-attenuated inversion recovery sequence hyperintensity (F) representing diffuse cortical venous dilation.

SECTION 4

The acute management of CVST involves systemic anticoagulation along with monitoring and management of ICP. The data for systemic anticoagulation come from 2 controlled trials of patients with angiographically confirmed CVST. The initial trial included 20 patients randomized to saline infusion or IV heparin with goal partial thromboplastin time (PTT) of 80–100 seconds for 8 days.¹ Outcome scores using a custom nonvalidated “sinus venous thrombosis severity scale” (headache severity, focal signs, presence of seizures, and degree of consciousness) demonstrated improved outcome in the heparin group starting from day 3 of therapy to 3-month follow-up (8/10 in heparin group recovered completely compared to 1/10 in control group). Three new hemorrhages occurred in the control group, while none occurred in the heparin group. Recanalization rates were not assessed.

A larger randomized controlled trial compared placebo with anticoagulation with nadoparin (a low-molecular-weight heparin [LMWH]) followed by 10 weeks of oral anticoagulation.² At 3 weeks, there was no difference in primary outcome (death or Barthel Index <15 points). Secondary analyses showed trends toward decreased death and improved outcome in the treatment group at 3 and 12 weeks. No new sympto-

matic intracerebral hemorrhages (ICHs) occurred in either group.

These trials demonstrated that heparin and LMWH are safe in patients with CVST even in the presence of ICH and suggested a possible benefit from anticoagulation. No trials have compared heparin and LMWH, but prospective studies suggest that LMWH is associated with increased independence at 6 months with decreased incidence of ICH.³ Observational studies estimate the risk of ICH from anticoagulation for CVST at 0%–5.4%.⁴

Our patient was treated with IV heparin (continuous infusion without bolus; goal PTT 60–80 seconds) after review of her neuroimaging. She was monitored closely in the neurology intensive care unit given her decreased level of consciousness and increased ICP. After 6 days of treatment, the patient was interactive and able to follow commands, but she was blind and had decreased strength on the right side. Repeat neuroimaging showed new left temporoparietal hemorrhagic infarction and unchanged extensive venous sinus thrombosis.

Question for consideration:

1. What is the role for catheter-directed local therapy, ICP monitoring, or other surgical procedures?

GO TO SECTION 5

SECTION 5

Interventional procedures for CVST include catheter-guided thrombolysis, mechanical thrombectomy, and decompressive hemicraniectomy. These procedures are typically reserved for patients with refractory seizures, ongoing ischemic or hemorrhagic strokes, or coma due to persistently elevated ICP despite anticoagulation.⁴ There are no controlled trials comparing these interventional procedures with each other, with or in conjunction with anticoagulation, or with no therapy in this severely ill patient subgroup. Similarly, there are no guidelines regarding the use of ICP monitoring devices to direct therapeutic options.

In catheter-directed thrombolysis, a catheter is guided to the occluded sinus for direct infusion of thrombolytics. A meta-analysis including 169 patients concluded that thrombolysis (most frequently with urokinase) is associated with ICH in 17% of cases.⁵ Catheter-directed thrombectomy has more recently been used to treat CVST using rheolytic thrombectomy, clot retraction, balloon venoplasty, or a combination of techniques as initial therapy or rescue therapy for refractory symptoms despite anticoagulation.^{4,6} A meta-analysis of published case series of 64 patients with CVST treated with mechanical thrombectomy concluded that about 14% died following thrombectomy and 11% had major disability.⁶ To address the question of additional efficacy of interventional treatment compared to anticoagulation alone in a critically ill subpopulation of patients with CVST, the Thrombolysis or Anticoagulation for Cerebral Venous Thrombosis (TO-ACT) trial is an ongoing randomized trial comparing systemic anticoagulation and endovascular thrombolysis with or without thrombectomy.⁷

For patients with extensive hemorrhage or cerebral edema from venous infarction, decompressive hemicraniectomy has been used to relieve elevated ICP. In a review of 69 patients who had decompressive hemicraniectomy for impending herniation in the setting of CVST, 26 patients (37.7%) had complete recovery (modified Rankin Scale score 0–1) while 15 patients (21.7%) were dead or severely disabled (modified Rankin Scale score 4–6) after 12 months median follow-up.⁸ In our patient, since her level of arousal improved with anticoagulation alone, endovascular therapy was not pursued.

DISCUSSION

The estimated incidence of CVST is 5 cases per million annually, accounting for 0.5%–1% of all strokes.⁴ A total of 78% of cases of CVST occur in individuals younger than age 50.⁴ Clinical symptoms result from elevated ICP, venous infarction, or ICH. Headache is present in 89% of patients, accompanied by a wide spectrum of signs including paresis (37%), seizures (39%), and depressed level of consciousness

(14%).⁹ In the International Study on Cerebral Vein and Dural Sinus Thrombosis, the largest observational study of CVST (624 patients), congenital and acquired thrombophilia were the most frequent risk factors (34% of cases), followed by pregnancy and puerperium (20%), intracranial infection (10%), medications such as oral contraceptives (7.5%), intracranial or systemic malignancy (7.4%), mechanical compression of the venous sinuses (e.g., traumatic or postsurgical) (4.5%), inflammatory diseases such as systemic lupus erythematosus (5%), and dehydration (1.9%).⁹ A total of 44% of patients with CVST had more than one risk factor identified, while no identifiable risk factor was found in 12.5%.⁹ Therefore, even in patients with an identified risk factor (such as use of oral contraceptives or recent intracranial infection), we recommend laboratory evaluation for hypercoagulability (including assessment for antithrombin III deficiency, protein C or S deficiency, resistance to activated protein C, factor V Leiden, factor II G20210A mutation, antiphospholipid/anticardiolipin antibodies, hyperhomocysteinemia, and systemic lupus erythematosus) as some patients have an underlying predisposition that increases their susceptibility to thrombotic events when a second hit is introduced. Our patient had no family history or laboratory evidence of hypercoagulability; use of oral contraceptives appeared to be her only risk factor.

Definitive diagnosis of CVST requires neuroimaging. Noncontrast head CT has low sensitivity, estimated between 25% and 56%.¹⁰ While digital subtraction angiography is the traditional gold standard, CT and magnetic resonance venography (CTV and MRV) are more readily available in the acute setting. No large comparative trials exist, but CTV and MRV appear to have comparable sensitivity, estimated at 90% or higher depending on the location and caliber of the affected veins.⁴ Isolated cortical vein thrombosis can be difficult to image by either technique. The primary advantage of CTV is rapid acquisition time, though MRI/MRV is more sensitive for acute infarction and avoids nephrotoxic contrast.¹⁰ There are no laboratory indicators sensitive or specific enough to confirm or exclude CVST. The fibrin degradation product D-dimer has reported sensitivity greater than 90% though the test is nonspecific.⁴ Opening pressure in lumbar puncture is elevated in 83% of patients,⁹ but lumbar puncture may be contraindicated in patients like ours with elevated ICP because of the risk of precipitating herniation.

While anticoagulation is the currently recommended treatment for CVST, 14% of patients are dead or dependent 6 months after diagnosis despite modern therapy.⁹ Our patient's arousal level improved significantly, but she was left with severely diminished vision potentially from prolonged elevated ICP. Would she have benefited from catheter

thrombolysis/thrombectomy or from invasive ICP monitoring and management? When and for how long should ICP-lowering agents be used? Data from controlled trials do not yet exist to guide interventional therapies or ICP management in patients with CVST. Pending the results of ongoing controlled trials such as TO-ACT, such decisions must be made on an individual basis, balancing principally the hemorrhagic risks of intervention and the deficits accrued from prolonged elevation of ICP.

AUTHOR CONTRIBUTIONS

Drs. Bhattacharyya, Berkowitz, and Jha all participated in conception of this article and drafting/ revising the manuscript for content.

STUDY FUNDING

No targeted funding reported.

DISCLOSURE

S. Bhattacharyya reports no disclosures relevant to the manuscript. A. Berkowitz reports no disclosures relevant to the manuscript but receives royalties from *Clinical Pathophysiology Made Ridiculously Simple* (MedMaster) and *The Improvising Mind* (Oxford). R. Jha reports no disclosures relevant to the manuscript. Go to Neurology.org for full disclosures.

REFERENCES

1. Einhaupl KM, Villringer A, Meister W, et al. Heparin treatment in sinus venous thrombosis. *Lancet* 1991;338:597–600.
2. de Bruijn SF, Stam J. Randomized, placebo-controlled trial of anticoagulant treatment with low-molecular-

weight heparin for cerebral sinus thrombosis. *Stroke* 1999;30:484–488.

3. Coutinho JM, Ferro JM, Canhao P, Barinagarrementeria F, Boussier MG, Stam J. Unfractionated or low-molecular weight heparin for the treatment of cerebral venous thrombosis. *Stroke* 2010;41:2575–2580.
4. Saposnik G, Barinagarrementeria F, Brown RD, et al. Diagnosis and management of cerebral venous thrombosis: a Statement for Healthcare Professionals from the American Heart Association/American Stroke Association. *Stroke* 2011;42:1158–1192.
5. Canhao P, Falcao F, Ferro JM. Thrombolytics for cerebral sinus thrombosis: a systematic review. *Cerebrovasc Dis* 2003;15:159–166.
6. Borhani Haghighi A, Mahmoodi M, Edgell R, et al. Mechanical thrombectomy for cerebral venous sinus thrombosis: a comprehensive literature review. *Clin Appl Thromb Hemost Epub* 2013 Jan 7.
7. Coutinho JM, Ferro JM, Zuubier SM, et al. Thrombolysis or anticoagulation for cerebral venous thrombosis: rationale and design of the TO-ACT trial. *Int J Stroke* 2013;8:135–140.
8. Ferro JM, Crassard I, Coutinho JM, et al. Decompressive surgery in cerebrovenous thrombosis: a multicenter registry and a systematic review of individual patient data. *Stroke* 2011;42:2825–2831.
9. Ferro JM, Canhao P, Stam J, Boussier MG, Barinagarrementeria F. Prognosis of cerebral vein and dural sinus thrombosis: results of the International Study on Cerebral Vein and Dural Sinus Thrombosis (ISCVT). *Stroke* 2004;35:664–670.
10. Vijay RK. The cord sign. *Radiology* 2006;240:299–300.



Clinical Reasoning: An 87-year-old woman with left-sided numbness

Shadi Yaghi, MD
Mitchell S.V. Elkind,
MD, MS

Correspondence to
Dr. Yaghi:
shadiyaghi@yahoo.com

SECTION 1

An 87-year-old woman with a history of hypertension, hyperlipidemia, and peripheral vascular disease presented with acute left paresthesias. On evaluation, blood pressure was 152/77 mm Hg and heart rate 78 and regular. Physical examination had normal results. On neurologic examination, she had normal mental status, decreased sensation on the left face, and normal strength, tone, and reflexes. Cerebellar examination and gait were normal. There was reduced light touch and pinprick sensation of the left arm and leg, with no extinction. Complete blood count and comprehensive metabolic panel were within normal limits, and ECG showed normal sinus rhythm. Head CT scan was

unremarkable. She was prescribed aspirin and admitted for evaluation. Symptoms lasted 48 hours. Brain MRI showed no acute infarction. Magnetic resonance angiography showed normal intracranial vessels and mild bilateral internal carotid disease. Echocardiography showed an ejection fraction of 55%–60% and no structural abnormalities, though the left atrium was not visualized. On telemetry, she had 2 self-limited episodes of asymptomatic paroxysmal supraventricular tachycardia. She started a low dose β -blocker.

Questions for consideration:

1. What is your differential diagnosis?
2. How would you evaluate and manage the patient?

[GO TO SECTION 2](#)

SECTION 2

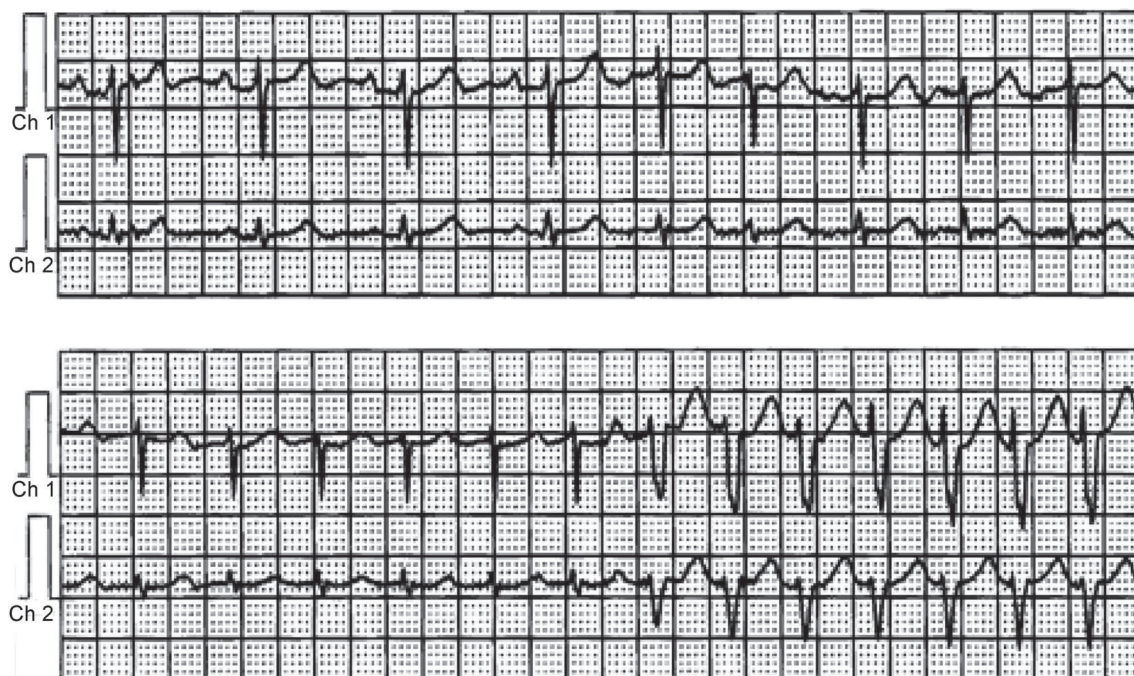
Given the acuity of symptoms, her focal neurologic deficits, and the fact that her deficits lasted over 24 hours, a clinical stroke was diagnosed.¹ The CT scan did not reveal hemorrhage. Although her brain MRI did not show evidence of infarction, this did not eliminate the diagnosis of stroke as a negative diffusion-weighted imaging (DWI) MRI sequence can be seen in up to 20% of patients with ischemic stroke.² Absence of DWI signal abnormality is more common in patients with small subcortical strokes.² In some instances, repeat MRI detects infarcts even when initial MRI scan is negative.²

The mechanism of stroke remained uncertain. Vessel imaging did not show significant large artery intracranial atherosclerotic disease, no cardioembolic etiology was identified on transthoracic echocardiography, and no atrial fibrillation (AF) was detected on inpatient telemetry. The patient's presentation with a pure sensory syndrome was suggestive of a clinical lacunar stroke affecting the right lateral thalamus, despite her negative diffusion imaging. Although lacunar strokes are classically attributed to intrinsic small vessel disease, up to 25% are due to other mechanisms of stroke, including cardioembolism.³

Cryptogenic, or unexplained, stroke comprises about 30%–40% of ischemic strokes.⁴ Potential stroke mechanisms in cryptogenic stroke include paroxysmal AF, substenotic atherosclerotic plaque, and other low-risk cardiac sources such as patent foramen ovale (PFO) and aortic arch atheroma. Paroxysmal

AF is one of the most common causes identified in patients with cryptogenic stroke.⁴ Admission ECG or 24-hour telemetry is useful in the diagnosis of persistent or paroxysmal frequent AF, with a yield up to 7% in ischemic stroke patients.⁴ These tests, however, are not very useful in detecting infrequent paroxysmal episodes of AF. Recent evidence from the 30-day cardiac Event Monitor Belt for Recording Atrial Fibrillation after a Cerebral Ischemic Event (EMBRACE) study supports the superiority of mobile continuous outpatient telemetry (MCOT) over inpatient telemetry or 24-hour Holter monitoring in detecting AF in patients with cryptogenic stroke (16.1% vs 3.2% detection).⁵ In addition, the Cryptogenic Stroke and Underlying Atrial Fibrillation (CRYSTAL AF) study randomized patients with cryptogenic stroke and negative transesophageal echocardiography to either an implantable loop recorder or standard of care. This study showed higher detection rates of paroxysmal AF with implantable loop recorders (detection rates of 8.9% vs 1.4%).⁶ Although outpatient cardiac monitoring is therefore more likely to detect AF than inpatient telemetry and ECG, the optimal duration and monitoring method remain unclear in the absence of trials comparing different methods and durations of outpatient monitoring. Atrial ectopy also predicts detection of AF with monitoring. In the EMBRACE study, for example, patients who had AF detected during 30 days of monitoring had significantly more atrial premature beats.⁷

Figure Mobile continuous outpatient telemetry shows a 6-second episode of paroxysmal atrial fibrillation vs paroxysmal supraventricular tachycardia with aberrancy



Noninvasive testing in patients with cryptogenic stroke via transcranial Doppler with agitated saline may also be useful in detecting PFO.

Because of the absence of confirmed subcortical stroke on MRI, and the presence of atrial ectopy on telemetry, the patient underwent further cardiac monitoring after discharge. MCOT showed a single equivocal

episode of paroxysmal supraventricular tachycardia, vs AF, lasting for less than 6 seconds (figure).

Questions for consideration:

1. How would you treat the patient?
2. What is your next step, if any, in evaluating this patient?

GO TO SECTION 3

SECTION 3

There was uncertainty about whether the patient had experienced paroxysmal AF (PAF) or paroxysmal supraventricular tachycardia (PSVT) with aberrancy, and the episode was very brief. Recent evidence suggests the possibility of an increased risk of stroke in patients with PSVT. In a study using administrative inpatient data, patients with PSVT had a higher risk of stroke in the absence of AF after adjusting for stroke risk factors (hazard ratio, 2.10; 95% confidence interval, 1.69–2.62).⁸ In the absence of trials of specific antithrombotic regimens among patients with PSVT, however, there is no evidence supporting the use of anticoagulants for stroke prevention

in those patients. The benefit of chronic anticoagulation in patients with AF episodes lasting less than 30 seconds is also unclear. There is evidence to suggest, however, that episodes of AF lasting ≥ 5 minutes are associated with a 2-fold increase in risk of stroke or death.⁹ Given the uncertainty that the episode was AF and its brief duration, the patient was maintained on aspirin and another 3 weeks of MCOT was prescribed, during which she had clear episodes of AF. She had no contraindications to anticoagulation.

Question for consideration:

1. How would you manage the patient now?

GO TO SECTION 4

SECTION 4

The patient was diagnosed with PAF. The risk of ischemic stroke could now be calculated using well-accepted risk stratification schemes. The congestive heart failure, hypertension, age ≥ 75 years, diabetes, stroke (CHADS₂) and congestive heart failure, hypertension, age ≥ 75 years, diabetes mellitus, stroke/TIA, vascular disease, age 65–74 years, sex category (CHA₂DS₂-VASc) scores predict the risk of stroke in patients with AF (table). For each point of the CHADS₂ score, there is an approximate 2% increase in absolute risk of stroke or systemic thromboembolism. A limitation of the CHADS₂ score is that it discriminates poorly among those at the lower end of the risk spectrum. The CHA₂DS₂-VASc score incorporates additional risk factors, including levels of age, sex, and other atherosclerotic and vascular diseases that increase stroke risk. Those with CHA₂DS₂-VASc scores of 0–1 appear to be at very low risk of stroke. In large cohorts analyzed thus far, the CHA₂DS₂-VASc score demonstrated better predictive value than

the CHADS₂ score. However, the predictive value of all scores remains limited, and these scores are based on analyses of prior cohorts of patients, and current risks may be lower due to advances in treatment and increasing use of other preventive medications, such as statins.

The patient had a CHADS₂ score of 4 (corresponding to annual stroke or systemic thromboembolism risk of 8.5%) and a CHA₂DS₂-VASc score of 7 (annual stroke or thromboembolism risk of 11.2%). Anticoagulation has been shown in randomized controlled trials to be superior to antiplatelet therapy in primary stroke prevention in patients with AF who are considered to be at high risk of stroke, i.e., those with CHADS₂ score >1 or CHA₂DS₂-VASc score >1 , and for secondary stroke prevention in patients with AF.

Recent evidence suggests that non-vitamin K oral anticoagulants (NOACs) are as effective as vitamin K antagonists (VKAs) such as warfarin in the prevention of stroke and systemic embolism in patients with AF with a lower risk of intracranial hemorrhage. As compared to warfarin, dabigatran was associated with reduced risk of ischemic stroke and systemic embolism as well as intracranial hemorrhage, but with a higher rate of gastrointestinal hemorrhage.¹⁰ Apixaban was similarly superior to warfarin in the prevention of stroke and systemic embolism with a lower risk of intracranial hemorrhage. Rivaroxaban had a similar efficacy in the prevention of stroke and systemic embolism but lower risk of intracranial hemorrhage when compared to warfarin.¹⁰ Dabigatran is the only NOAC thus far associated with reduced risk of ischemic stroke as compared to warfarin, whereas only apixaban was superior to warfarin in reducing major bleeding risks.¹⁰ Furthermore, in patients with AF deemed unsuitable for warfarin, the Apixaban vs Acetylsalicylic Acid to Prevent Strokes (AVERROES) trial showed that apixaban was superior to aspirin in reducing risk of stroke and embolic events (hazard ratio, 0.45; 95% confidence interval, 0.32–0.62) with similar risk of major bleeding events and intracranial hemorrhage.¹¹ Taking the available evidence together, in our patient, apixaban was chosen for its reduced risk of stroke and its lower risk of hemorrhagic complications than warfarin. Aspirin was stopped given the increased risk of bleeding when aspirin is used with anticoagulation.

DISCUSSION Cryptogenic stroke constitutes 30%–40% of ischemic strokes and up to 30% of those are due to PAF. The detection of AF appears higher among those with evidence of atrial ectopy.⁷ MCOT and loop recorders increase detection rates in patients with cryptogenic stroke when compared to inpatient telemetry and ECG. The detection of AF in those patients is an indication for the use of oral

Table Commonly used stroke and thromboembolism risk prediction schemes for atrial fibrillation

CHADS ₂ items	Points	CHA ₂ DS ₂ -VASc items	Points
C = Congestive heart failure	1	C = Congestive heart failure	1
H = Hypertension	1	H = Hypertension	1
A = Age ≥ 75 y	1	A ₂ = Age ≥ 75 y (double value)	2
D = Diabetes mellitus	1	D = Diabetes mellitus	1
S ₂ = history of stroke, TIA, or thromboembolism (double value)	2	S ₂ = History of stroke, TIA, or thromboembolism (double value)	2
		V = Vascular disease (prior myocardial infarction, peripheral arterial disease, aortic plaque)	1
		A = Age 65–74 y	1
		Sc = sex category (female sex)	1
Range	0–6		0–9
Annual risk of stroke and systemic embolism per CHA ₂ DS ₂ -VASc and CHADS ₂			
CHADS ₂		CHA ₂ DS ₂ -VASc	
0: 1.9% per year		0: 0.2% per year	
1: 2.8% per year		1: 0.6% per year	
2: 4% per year		2: 2.2% per year	
3: 6% per year		3: 3.2% per year	
4: 8.5% per year		4: 4.8% per year	
5: 12.5% per year		5: 7.2% per year	
6: 18% per year		6: 9.7% per year	
		7: 11.2% per year	
		8: 10.8% per year	
		9: 12.2% per year	

Abbreviations: CHA₂DS₂-VASc = congestive heart failure, hypertension, age ≥ 75 years, diabetes mellitus, stroke/TIA, vascular disease, age 65–74 years, sex category; CHADS₂ = congestive heart failure, hypertension, age ≥ 75 years, diabetes, stroke.

anticoagulants for secondary stroke prevention. NOACs have a better safety profile than VKAs, and may be considered as alternatives to warfarin.

AUTHOR CONTRIBUTIONS

Dr. Yaghi: manuscript preparation and literature review. Dr. Elkind: literature review, manuscript revision, supervision.

STUDY FUNDING

No targeted funding reported.

DISCLOSURE

S. Yaghi received funds from NINDS StrokeNet. M. Elkind received personal compensation for serving on advisory boards and consulting from Boehringer-Ingelheim, Inc., BMS-Pfizer Partnership, Daiichi-Sankyo, Janssen Pharmaceuticals, and BioTelemetry/Cardionet. Go to Neurology.org for full disclosures.

REFERENCES

1. Easton JD, Saver JL, Albers GW, et al. Definition and evaluation of transient ischemic attack: a scientific statement for healthcare professionals from the American Heart Association/American Stroke Association Stroke Council; Council on Cardiovascular Surgery and Anesthesia; Council on Cardiovascular Radiology and Intervention; Council on Cardiovascular Nursing; and the Interdisciplinary Council on Peripheral Vascular Disease: the American Academy Of Neurology affirms the value of this statement as an educational tool for neurologists. *Stroke* 2009;40:2276–2293.
2. Sylaja PN, Coutts SB, Krol A, Hill MD, Demchuk AM. When to expect negative diffusion-weighted images in stroke and transient ischemic attack. *Stroke* 2008;39:1898–1900.
3. Gan R, Sacco RL, Kargman DE, Roberts JK, Boden-Albala B, Gu Q. Testing the validity of the lacunar hypothesis: the northern Manhattan Stroke Study experience. *Neurology* 1997;48:1204–1211.
4. Yaghi S, Elkind MS. Cryptogenic stroke: a diagnostic challenge. *Neurol Clin Pract* 2014;4:386–393.
5. Gladstone DJ, Spring M, Dorian P, et al. Atrial fibrillation in patients with cryptogenic stroke. *N Engl J Med* 2014;370:2467–2477.
6. Sanna T, Diener HC, Passman RS, et al. Cryptogenic stroke and underlying atrial fibrillation. *N Engl J Med* 2014;370:2478–2486.
7. Gladstone DJ, Dorian P, Spring M, et al. Atrial premature beats predict atrial fibrillation in cryptogenic stroke: results from the embrace trial. *Stroke* 2015.
8. Kamel H, Elkind MS, Bhavne PD, et al. Paroxysmal supraventricular tachycardia and the risk of ischemic stroke. *Stroke* 2013;44:1550–1554.
9. Ziegler PD, Glotzer TV, Daoud EG, et al. Detection of previously undiagnosed atrial fibrillation in patients with stroke risk factors and usefulness of continuous monitoring in primary stroke prevention. *Am J Cardiol* 2012;110:1309–1314.
10. Gomez-Outes A, Terleira-Fernandez AI, Calvo-Rojas G, Suarez-Gea ML, Vargas-Castrillon E. Dabigatran, rivaroxaban, or apixaban versus warfarin in patients with nonvalvular atrial fibrillation: a systematic review and meta-analysis of subgroups. *Thrombosis* 2013;2013:640723.
11. Connolly SJ, Eikelboom J, Joyner C, et al. Apixaban in patients with atrial fibrillation. *N Engl J Med* 2011;364:806–817.