
A GUIDE TO COMMON ORAL LESIONS

**DR. CHARLES L. DUNLAP AND
DR. BRUCE F. BARKER**

Department of Oral and Maxillofacial Pathology
UMKC School of Dentistry

Table of Contents

| | |
|--|----|
| Foliate papillae | 3 |
| Lymphoid aggregates | 4 |
| Varix (plural: varices) | 5 |
| Torus palatinus and torus mandibularis | 6 |
| Idiopathic osteosclerosis | 7 |
| Osteoporotic bone marrow defect | 8 |
| Fordyce granules | 9 |
| Leukoedema | 10 |
| Aphthous stomatitis (Canker sores, recurrent aphthous stomatitis, RAS) | 11 |
| Herpes simplex virus infections | 12 |
| Denture sore mouth (DSM) and Papillary hyperplasia (PH) | 13 |
| Epulis fissuratum (Inflammatory fibrous hyperplasia) | 14 |
| Irritation fibroma (traumatic fibroma) | 15 |
| Mucocele | 16 |
| Papilloma | 17 |
| Peripheral ossifying fibroma | 18 |
| Pyogenic granuloma | 19 |
| Peripheral giant cell granuloma | 20 |
| Traumatic ulcer | 21 |
| Nicotine stomatitis | 22 |
| Drug-induced gingival hyperplasia (Dilantin hyperplasia) | 23 |
| Geographic tongue (benign migratory glossitis, erythema migrans) | 24 |
| Lichen planus | 25 |
| Angular cheilosis | 26 |
| Candidiasis (Moniliasis, Thrush) | 27 |
| Pulpitis | 28 |
| Dental caries | 29 |
| Plaque induced gingivitis | 30 |
| Necrotizing ulcerative gingivitis (Vincent's infection, trench mouth) | 31 |
| Periodontitis | 32 |
| Periapical cyst (radicular cyst) | 33 |
| Periapical dental granuloma | 34 |
| Condensing osteitis | 35 |
| Pericoronitis | 36 |
| Amalgam tattoo | 37 |
| Hairy tongue (coated tongue) | 38 |
| Nasopalatine duct cyst | 39 |
| Dentigerous cyst | 40 |
| Leukoplakia | 41 |
| Erythroplasia (erythroplakia) | 42 |
| Squamous cell carcinoma (epidermoid carcinoma) | 43 |
| Snuff lesion (smokeless tobacco lesion) | 44 |
| Cementoma (periapical cemental dysplasia) | 45 |
| Acquired immune deficiency syndrome (AIDS) | 46 |

Foliate papillae

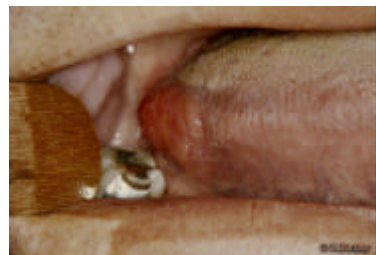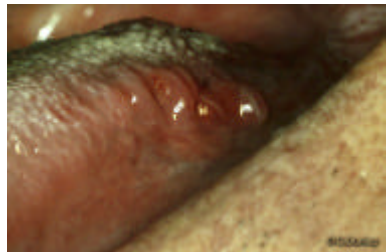Description: Foliate papillae appear as an area of vertical folds and grooves located on the extreme posterior-lateral surface of the tongue. They are occasionally mistaken for tumors or inflammatory disease. The grooves are best seen when air from an air syringe is directed at them. Their long axis is “up and down”, that is they are at right angles to the long axis of the tongue. Our experience has been that they are usually bilaterally symmetrical. In most people, the papillae are small and inconspicuous, whereas in others they are prominent. Lingual tonsils are found immediately beneath the foliate papillae and, when hyperplastic, cause a prominence of the papillae. Those familiar with the basic fold and groove structure of the foliate papillae are not apt to confuse these normal structures with an abnormality.

ETIOLOGY: They are normal anatomical structures.

TREATMENT: None required.

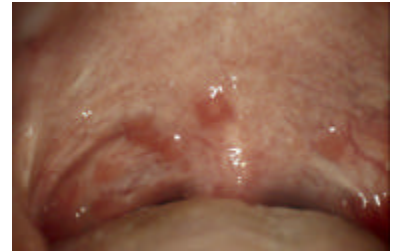PROGNOSIS: Good

DIFFERENTIAL DIAGNOSIS:
Hyperplastic lingual tonsils, squamous carcinoma, soft tissue tumors.



Lymphoid aggregates

DESCRIPTION: Lymphoid aggregates appear as small, slightly elevated nodules that may be normal colored or have a slight yellow-orange hue. Those illustrated here are in the soft palate. They may be found anywhere in the mucosa but are especially common where the mouth meets the throat, including the base of the tongue. This lymphoid rich area has been called Waldeyer's ring. When they occupy the same area as the foliate papillae, the papillae may take on a more nodular appearance. In the tongue they have been referred to as "lingual tonsils."



ETIOLOGY: They are normal structures, components of Waldeyer's ring.

TREATMENT: None required.

PROGNOSIS: Good. They may enlarge or regress in relationship to oral or upper respiratory infections.

DIFFERENTIAL DIAGNOSIS: Although foliate papillae and lymphoid aggregates of lingual tonsils may occupy the same area, they are different entities.

Varix (plural: varices)

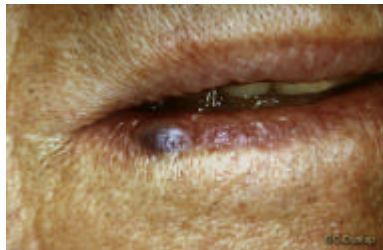DESCRIPTION: Varices appear as red, blue, or deep purple broad-based elevations in oral mucosa. The size is usually less than 5 mm. The buccal mucosa is a common place to find them, however, they are also found in lip mucosa and ventral and lateral mucosa of the tongue and floor of the mouth. On ventral tongue they are apt to be multiple and the term “caviar tongue” has been commonly used to describe them. They are seen more commonly in the elderly.

ETIOLOGY: A varix is a distended vein that elevates the overlying mucosa. The reason for venous distention is unclear but may be related to weakening of the vessel wall secondary to aging.

TREATMENT: None usually required. They often thrombose but this is of little clinical consequence.

PROGNOSIS: Good

DIFFERENTIAL DIAGNOSIS: Mucocele, hemangioma and angina bullosa hemorrhagica.



Torus palatinus and torus mandibularis

DESCRIPTION: Bony exostoses in the midline of the hard palate and on the lingual aspect of the mandible are referred to as torus palatinus and torus mandibularis respectively. Some studies suggest they are inherited whereas others suggest environmental factors. Fig. 1 shows a palatal torus and Fig. 2 is a mandibular torus. They start in childhood and reach peak incidence in young adults. Once they have reached “programmed size”, their growth stops. Some are so subtle they hardly constitute an abnormality, whereas others are so large they frighten the uninitiated observer. In the mandible, they may form a row of nodules as illustrated. In most individuals they occur bilaterally. Those in the palate may be divided by deep grooves to form a cluster of nodules. Exostoses entirely similar to tori occur elsewhere on the alveolar bone, but there is no specific name for them. It has been estimated that palatal tori occur in 20-35% of the population. Mandibular tori are less common, about 10% of the population are affected.

ETIOLOGY: Tori are developmental over-growths of normal bone and as previously stated they may be inherited.

TREATMENT: Tori and other exostoses seldom cause symptoms. Because they extend above the level of surrounding normal mucosa, they invite trauma. Small traumatic ulcers are therefore commonly seen on the mucosa that cov-

ers tori, more commonly palatal tori. Tori may interfere with prosthetic appliances and, for that reason, may require removal.

PROGNOSIS: Good

DIFFERENTIAL DIAGNOSIS: Tori have such a characteristic clinical appearance and history that differential diagnosis is seldom a problem.

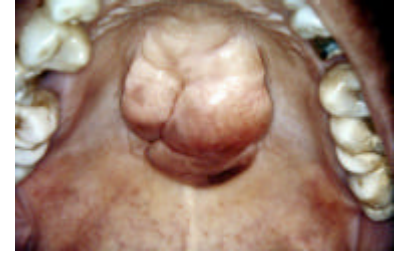

Figure 1

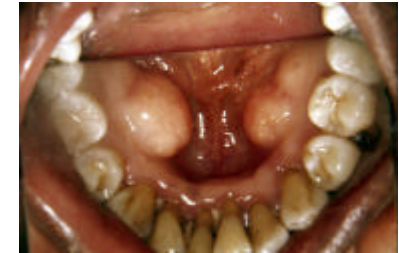

Figure 2

Idiopathic osteosclerosis

DESCRIPTION: Osteosclerosis is an area of dense but normal bone in the jaws. It may occur anywhere in the jaws and in some instance may appear to be attached to a tooth as shown in Fig. 1. The shape ranges from round to linear streaks to occasional angular forms. They are more common in the mandibular molar-premolar area. They are usually discovered on radiographs taken during the course routine dental care.

ETIOLOGY: Osteosclerosis is presumably of developmental origin although a reaction to past trauma or infection is difficult to rule out in some cases.

TREATMENT: Because osteosclerosis is not a disease, no treatment is required. If there is doubt about the diagnosis, periodic X-rays are taken. Although some lesions may slowly enlarge, most remain unchanged with time.

PROGNOSIS: Good

DIFFERENTIAL DIAGNOSIS

Condensing osteitis, sclerosing osteomyelitis, cementoblastoma, hypercementosis. Condensing osteitis may resemble idiopathic osteosclerosis, however, associated teeth are always nonvital in condensing osteitis.

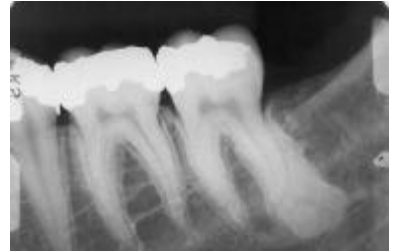

Figure 1

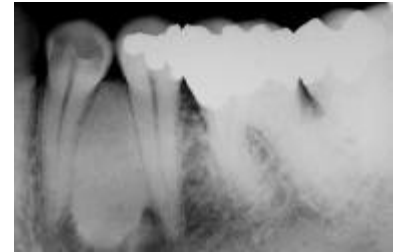

Figure 2

Osteoporotic bone marrow defect

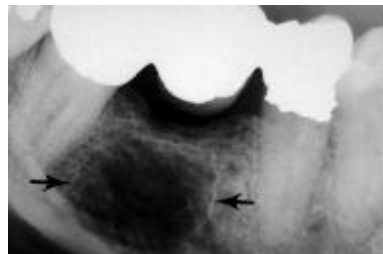
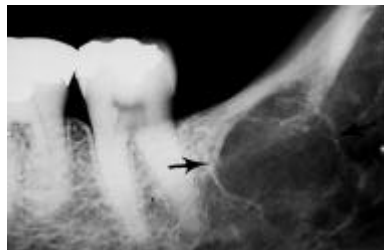DESCRIPTION: As the name implies, this is a localized increase of hematopoietic bone marrow that creates a radiolucent radiographic defect. They occur more commonly in women in the midyears and show a predilection for the molar region of the mandible. They are especially common in extraction sites. Scattered trabeculae may extend short distances into the defect or, in some instances, through it giving the defect a fairly characteristic appearance. Naturally there are no clinical symptoms.

ETIOLOGY: The etiology remains unknown. No connection has been found linking the osteoporotic bone marrow defect with anemia or systemic need for increased erythrocytes.

TREATMENT: Once the diagnosis is established, no treatment is required.

PROGNOSIS: Good

DIFFERENTIAL DIAGNOSIS: This defect may easily be mistaken for a cyst or tumor. In those cases where there is doubt about the diagnosis, biopsy should be done.



Fordyce granules

DESCRIPTION: Fordyce granules appear as flat or elevated yellow plaques just beneath the mucosal surface. The most common site is buccal mucosa although they may be found anywhere in oral mucosa. Development of the oral glands parallels those of the skin, reaching maximum numbers at puberty. Eighty percent of the population are affected. The number of granules is quite variable. Fig. 1 illustrated a large number of granules on buccal mucosa.

ETIOLOGY: They are normal sebaceous glands and considering they are found in approximately 80% of the population, should be considered normal anatomic structures.

TREATMENT: None required.

PROGNOSIS: Good

DIFFERENTIAL DIAGNOSIS: The clinical appearance is characteristic

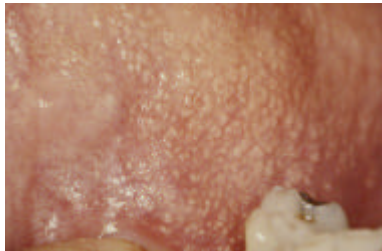
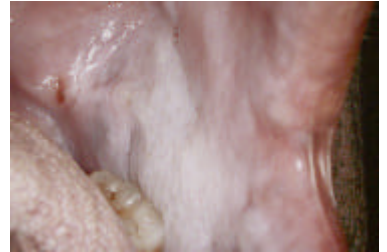
Figure 1

Leukoedema

DESCRIPTION: Leukoedema appears as a filmy, opaque, white to slate gray discoloration of mucosa, chiefly buccal mucosa. Redundancy of the mucosa may impart a folded or wrinkled appearance to the relaxed mucous membrane. It partially disappears when the mucosa is stretched. It is stated to be seen in 90% of Blacks and 10–90% in Whites. This variation may be due to the difficulty in observation of leukoedema in non-pigmented mucosa. Leukoedema is accentuated in smokers.



ETIOLOGY: Leukoedema is a variation of normal that should not be confused with something ominous. Intracellular edema of the superficial epithelial cells coupled with retention of superficial parakeratin is thought to account for the white appearance. Microscopic examination reveals superficial squamous cells have a clear, seemingly empty cytoplasm but it has not been shown

that there is an increase in intracellular water. Thus, the term edema is questionable.

TREATMENT: None required.

PROGNOSIS: Good

DIFFERENTIAL DIAGNOSIS: White sponge nevus, hereditary benign intraepithelial dyskeratosis, and dyskeratosis congenital. All are extremely rare.

Aphthous stomatitis

(Canker sores, recurrent aphthous stomatitis, RAS)

DESCRIPTION: This is one of the most common oral diseases. The exact incidence is unknown, but estimates range from 20% to 60% of the population. Lesions appear as painful ulcers ranging in size from less than 1 mm to 2 centimeters. They may be single or multiple. Small lesions (less than 0.5 cm) have been referred to as minor aphthae (Fig. 1) and large lesions (more than 0.5 cm) have been called major aphthae (Fig. 2). An uncommon presentation of this disease appears as multiple, pinpoint areas of ulceration that seldom exceed 1 mm (Fig. 3). This has been referred to as the herpetiform pattern, an unfortunate term since herpes virus is not the cause.

Each lesion begins as a red macule, less often a papule but not as a blister. It soon ulcerates and the ulcer becomes covered by a pyogenic membrane producing the characteristic yellow-white center with surrounding erythematous flare. The shape is usually round to oval but may be elongated in natural folds such as the vestibule.

Aphthous stomatitis occurs on freely movable mucosa that does not overlie bone. The lips, cheeks, soft palate, floor of mouth, ventral and lateral tongue are often involved but attached gingival, hard palate and dorsal tongue are seldom affected.

Aphthous lesions affect all age groups from young to old but young adults and females are more affected. Elapsed time between recurrences is extremely variable; some unfortunate patients have almost continuous disease whereas others go from months to years between episodes.

ETIOLOGY: The cause is unknown. The concept that canker sores are caused by a microbiologic agent has been superseded by theories revolving around an immunopathogenesis. The deposition of antibodies and complement within epithelium and basement membrane during the early stages of the disease suggests a humoral immune response, and the influx of lymphocytes rather than neutrophils in early lesions points to a cellular immune reaction as well. It is yet to be learned if the immune response is directed against self (autoimmunity) or against an extrinsic antigen such as bacteria or viruses. To further cloud the issue, a variety of other factors have been implicated. Withdrawal of certain foods such as cheese, tomato products and gluten, as well as sodium lauryl sulfate-containing toothpastes, has been claimed to help some patients whereas in others, correction of iron, B12 and folate deficiencies have brought about a cure. Improvement of aphthous lesions during the last stages of pregnancy with exacerbation after delivery suggests that gonadal hormones may lay a role. The occurrence of canker sores during menstruation also suggests a hormonal basis. To add a final element of mystery, aphthous stomatitis has been reported to worsen when cigarette smoking is discontinued. There are too many theories for them all to be correct. Aphthous stomatitis may not be a single disease with a single cause but instead a variety of diseases all manifested by painful mouth sores.

TREATMENT: To reduce pain, patients with few lesions may be treated with topical medications such as Orabase® with Benzocaine, Zilactin®, or Soothe-N-Seal®. Anti-inflammatory agents such as topical steroids or Aphthasol® have also been shown to be effective. For severe or widespread disease, systemic prednisone such as a Medrol 4 mg Dosepak® is helpful. Long-term systemic steroid therapy may be associated with numerous adverse effects, including osteoporosis, aseptic necrosis, cataracts, depression, fluid retention and exacerbation of diabetes.

PROGNOSIS: Cure is seldom achieved but palliation and long-term remission may be achieved by above mentioned treatment. Without treatment, healing time varies from 4 days for a small lesion to a month or more for major aphthae. Major aphthae may also cause scarring.

DIFFERENTIAL DIAGNOSIS: Aphthous stomatitis must be differentiated from herpetic stomatitis, the disease with which it is most often confused. Recurrent intraoral herpes occurs almost exclusively on mucosa overlying bone. The hard palate is the most common site. Lesions indistinguishable from aphthous stomatitis have been reported in Behcet's syndrome, Reiter's syndrome, Crohn's disease and celiac disease.

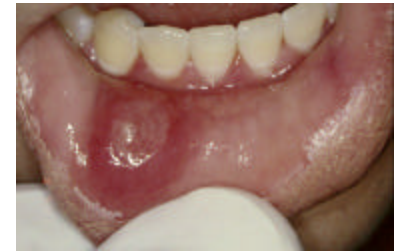

Figure 1

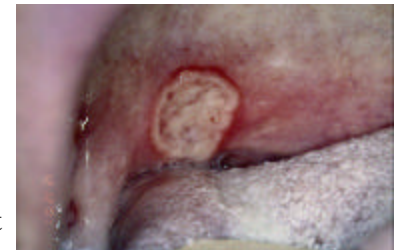

Figure 2

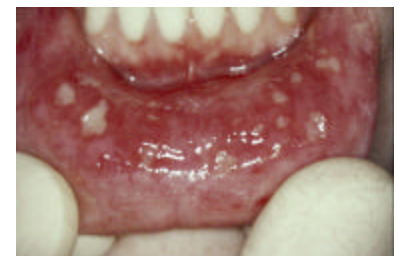

Figure 3

Herpes simplex virus infections

DESCRIPTION: Oral infection with herpes simplex virus occurs in three clinical forms. The most common type consists of recurrent small blisters on the lips commonly referred to as fever blisters or secondary herpes labialis. The second type is a generalized oral infection called primary herpetic stomatitis. The third and least common form of oral herpes infection consist of small ulcers usually localized on palatal mucosa.

Herpes labialis is illustration in Figs. 1 and 2. This lesion is well known and unlikely to be a diagnostic problem. It tends to be a recurrent disease in teenagers and adults. Elapsed time between recurrences varies from person to person. Recurrences are thought to be triggered by exposure to sunlight, febrile diseases, physical and psychogenic trauma, and other irritants.

Generalized involvement of the oral mucous membrane is called primary herpetic stomatitis and represents the initial exposure to the virus. This is a one time infection, but the patient remains susceptible to recurrent or secondary oral herpes infections (Figs. 3 and 4). It is more commonly seen in children, but teenagers and adults are also affected. Patients initially have gingivitis with swollen and red gingiva, then small blisters may appear on other mucosal surfaces. The blisters break quickly and are seldom seen by the dentist or physician. After they break, the lesions appear as small ulcers that resemble small aphthous lesions. The primary, generalized infection is accompanied by fever, cervical lymphadenitis, and inability to eat or drink without considerable pain.

Patients who suffer recurrent intraoral herpes are few. Recurrent intraoral herpes infections tend to occur as vesicles followed by small ulcers, mainly on the hard palate mucosa (Fig. 5) and often follow trauma to the area, such as palatal injections or periodontal therapy.

ETIOLOGY: Herpesvirus hominis (herpes simplex virus). Most oral lesions are caused by Type I virus but approximately 10% are thought to be caused by Type II.

TREATMENT: Antiviral drugs such as Acyclovir, Famciclovir, Penciclovir, Valacyclovir and over-the-counter Abreva have all shown that they can decrease the time of disease as well as help with pain management. To be beneficial, they must be started at the first sign of disease. Most studies indicate that the drugs decrease the duration of disease by about one day. Acyclovir, Penciclovir and Abreva are available in a topical ointment.

PROGNOSIS: Primary infection usually resolves in 10-14 days. Once the virus has entered the body, it travels through nerve trunks to the nearest ganglion where it may lie dormant for the remainder of the patient's life. Future recurrences are thought to be brought about by the "reawakening" of the virus which retraces its steps to cause new lesions in the same general area as the original point of entry. Thus, each recurrence is not a new and different infection from the outside but a recrudescence of the original infection. The ability of the virus to remain latent in deep ganglia makes total eradication almost impossible and will likely frustrate attempts at prevention for the foreseeable future.

Patients with widespread herpetic stomatitis should drink liquids to prevent dehydration. A broad-spectrum antibiotic is commonly given to control secondary bacterial infection, but does not shorten the viral infection. Antiviral drugs may shorten the duration of the disease if they are started early.

Clinicians should be aware that the herpesvirus may cause disseminated infection including encephalitis in which case the prognosis is extremely grave.

DIFFERENTIAL DIAGNOSIS: Primary herpetic stomatitis may resemble oral lesions of erythema multiforme, but herpes can be diagnosed by exfoliative cytology. A characteristic multinucleated cell appears in the smear of herpes infections. Culture of the virus is possible if a viral laboratory is available. Lesions of herpangina and hand, foot and mouth disease, both caused by Coxsackievirus, may clinically resemble oral herpes virus infections. Recurrent intraoral herpes may be confused with herpes zoster. Aphthous can be differentiated since it usually does not occur over bone, does not form vesicles and is not accompanied by fever or gingivitis.

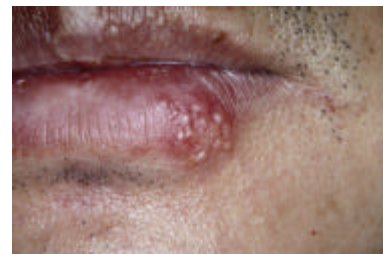

Figure 1

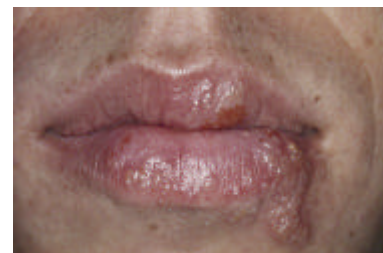

Figure 2

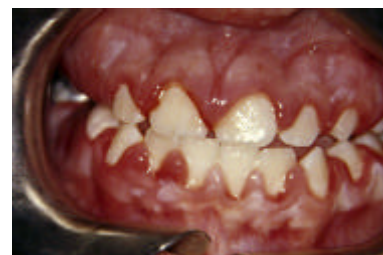

Figure 3

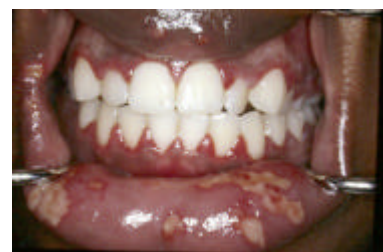

Figure 4

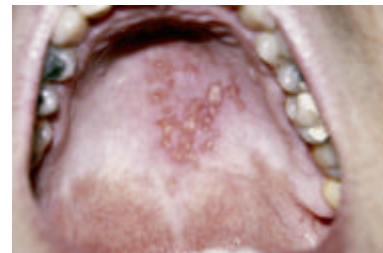


Figure 5

Denture sore mouth (DSM) and Papillary hyperplasia (PH)

DESCRIPTION: Long treated as separate entities, there is evidence that PH and DSM may be different expressions of the same disease. Both are related to the wearing of dentures. The mildest form of denture sore mouth appears as small, localized and asymptomatic red spots on the posterior palatal mucosa. As the condition worsens, large confluent areas turn crimson red (Fig. 1). This is the classic form of DSM. In later stages, hyperplasia of palatal mucosa occurs and produces the red, pebbly appearances of papillary hyperplasia (Fig. 2). In some cases of PH, the mucosa has a more mossy than mulberry appearance and the hyperplasia is not apparent until a gentle blast of air opens the crevices revealing the papillary nature of the lesion. Whether or not DSM.

ETIOLOGY: The cause is unknown but there is evidence that *Candida albicans* is at least contributory. DSM has been called chronic atrophic candidiasis. Organisms are found more often in PH and DSM than in normal controls. Treatment with the antifungal drugs such as nystatin, clotrimazole and fluconazole have been reported to bring about remission in most cases, especially in DSM. Since organisms have been shown to colonize the tissue surface of the denture, sterilization of the denture with fungicide is indicated.

Factors other than *Candida albicans* seem to be involved, but it is difficult to assess the role of denture trauma and bacterial pathogens. Because the disease is limited to the area covered by the denture, it is often assumed that the patient is allergic to denture base material. There is little evidence to support his view. Patients with palatal lesions ordinarily do not have lesions under the lower denture as would be expected if the patient were truly allergic.

TREATMENT: We know of no effective therapy other than fungicides such as nystatin, clotrimazole, ketoconazole or fluconazole in the usual doses for oral candidiasis. Good oral and denture hygiene may help. The denture should fit well and not be worn at night. In cases of excessively redundant papillary hyperplasia, surgical reduction may provide a better denture base.

PROGNOSIS: The condition is benign. For many years, papillary hyperplasia had the undeserved reputation of being pre-malignant. It is not.

DIFFERENTIAL DIAGNOSIS: The disease has such a characteristic appearance that diagnosis is seldom a problem.

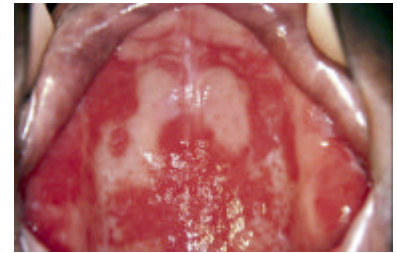


Figure 1: denture sore mouth

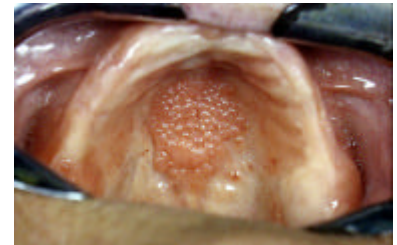


Figure 2: papillary hyperplasia

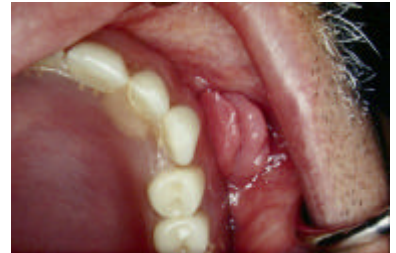Epulis fissuratum (Inflammatory fibrous hyperplasia)

DESCRIPTION: This lesion occurs in those who wear prosthetic appliances. The lesion consists of two or more folds of soft tissue separated by a central groove into which fits the appliance border. It most often is found in the buccal vestibule of the anterior maxilla, but any mucosal area touched by a denture border is vulnerable including the lingual aspect of the mandible. In a study of 583 cases, 64% were found in females. Those in the fifth and sixth decade are most often affected. Duration ranged from one week to 10 years, 40% of the patients reported a duration of 6 months to two years. Symptoms are absent except in ulcerated lesions which may be painful. Histologically, the excessive tissue is composed of cellular, inflamed fibrous connective tissue.

ETIOLOGY: This is an inflammatory fibrous hyperplasia of oral mucosa caused by ill-fitting or over-extended denture borders.

TREATMENT: Surgical excision of the lesion and reduction of the denture border.

PROGNOSIS: Good



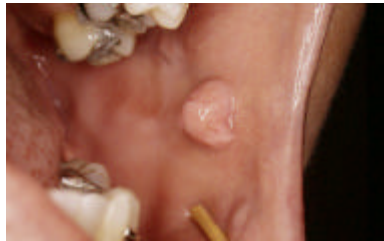DIFFERENTIAL DIAGNOSIS: The lesion has such a characteristic clinical appearance that differential diagnosis is not a problem. Persistent ulcerated areas in epulis fissuratum should be biopsied to rule out squamous carcinoma. Folds similar to epulis fissuratum may be seen in Crohn's disease.

Irritation fibroma (traumatic fibroma)

DESCRIPTION: Traumatic fibroma is a dome-shaped soft tissue mass usually found on buccal mucosa along the line of occlusion. Less frequently they may be found on lips and tongue. They are among the most common oral soft tissue lesions. The color is usually the same as the surrounding mucosa and the consistency is surprisingly soft. Patients are generally aware of the lesion being present months to years with little change. Histologically, they exhibit fibrous hyperplasia that is collagenous and acellular.

ETIOLOGY: The presumed etiology is trauma to the affected mucosa. Accidental biting probably accounts for most of these lesions.

TREATMENT: Excision



PROGNOSIS: Good

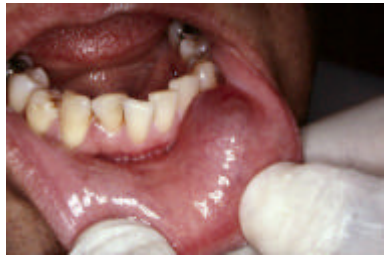DIFFERENTIAL DIAGNOSIS: Salivary gland tumors and other soft tissue tumors may have a similar appearance but are usually more firm. Other lesions such as mucocele may also resemble traumatic fibroma.

Mucocele

DESCRIPTION: A mucocele is a collection of saliva in the oral mucosa. They are soft elevations whose color ranges from that of normal mucosa to light blue or even white. Patients with mucoceles regularly state that the lesion “gets larger, then smaller, then larger again.” This has become an important diagnostic sign. The mucosa of the lower lip and buccal mucosa are the most common sites, but any area that contains intraoral salivary glands is a potential site.

ETIOLOGY: Traumatic severance of salivary ducts permitting salivary escape into mucosa is the accepted etiology.

TREATMENT: Surgical excision deep enough to include the underlying gland that feeds it.

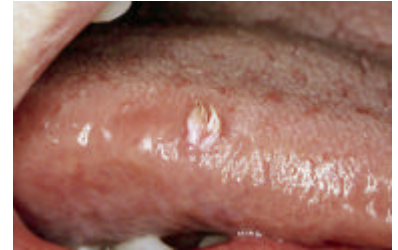

PROGNOSIS: Good

DIFFERENTIAL DIAGNOSIS: Salivary gland neoplasms (especially mucoepidermoid carcinoma), varix, and hemangioma.

Papilloma

DESCRIPTION: Papillomas appear as pedunculated or sessile, white or normal colored cauliflower-like projections that arise from the mucosal surface. In a study of 464 oral papillomas, it was learned that the average size is less than 2.0 cm. Our experience has been that they are smaller, many are only 3 or 4 millimeters. The same study revealed the mean age of patients with papilloma was 36.4 years with a range from 2 to 91 years. There was no strong sex preference. The most common site was the palate-uvula area followed by tongue and lips. Of all sites, the soft palate was the most common and accounted for 20% of the lesions. The durations ranged from weeks to 10 years but 50% of the papillomas were present between 2 to 11 months.



ETIOLOGY: Immunoperoxidase stains have identified antigens of the human papilloma virus (HPV) types 6 and 11 in approximately 50% of cases. The same virus may be found in verruca vulgaris, condyloma acuminatum and focal epithelial hyperplasia all of which may resemble papillomas both clinically and microscopically.

TREATMENT: Conservative surgical excision, recurrence is rare.

PROGNOSIS: Good, there is no evidence that papillomas are premalignant.

DIFFERENTIAL DIAGNOSIS: The rare intraoral verruca vulgaris, condyloma acuminatum, and focal epithelial hyperplasia resemble papillomas and microscopic examination may be required to distinguish between them. Large papillomas may resemble early verrucous carcinoma.

Peripheral ossifying fibroma

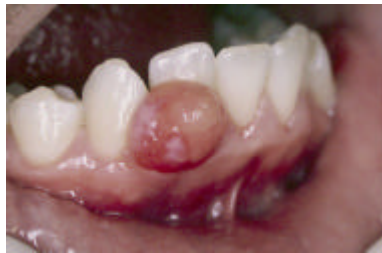DESCRIPTION: This lesion appears as a mass arising from the gingiva adjacent to teeth or between teeth. It favors teenagers and young adults. Those arising between teeth may separate the teeth and produce pressure resorption of the interdental bone. It's not unusual to see a "saddle" lesion straddling the ridge with a labial and lingual lobe. Color is normal or slightly red.

Histologically the bulk of this lesion is moderately cellular fibrous connective tissue frequently containing foci of bone, cementum, or dystrophic calcification. When inflammation is present, plasma cells frequently predominate.

ETIOLOGY: Unknown

Treatment: Excision. The recurrence rate is about 15%. Extraction of the adjacent teeth is seldom necessary.

Prognosis: Good



Differential Diagnosis: Peripheral fibroma bears a great resemblance to pyogenic granuloma and peripheral giant cell granuloma. Histologic examination is necessary to distinguish between them.

Pyogenic granuloma

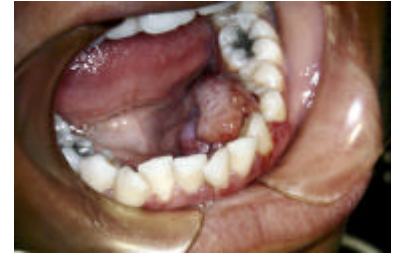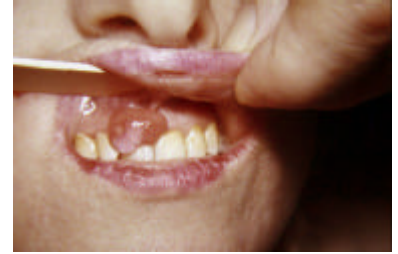DESCRIPTION: Pyogenic granuloma is a red, nodular overgrowth of granulation tissue that arises from the mucosal or skin surface. Approximately two-thirds of oral lesions are found on the gingival followed in descending order by the lips, tongue, buccal mucosa, palate, vestibule and edentulous areas. The interdental papilla of the maxillary facial gingival is the single most common site. A review of more than 800 cases disclosed the mean size to be approximately 1.0 cm with a range of 3 mm to 4 cm. Females were more often affected (72%). Duration varied widely with a mean of 5.5 months. Because of the vascular nature of pyogenic granuloma, they bleed easily and some cause mild pain. They commonly develop during pregnancy. The association with pregnancy is so common that the lesion has also been called granuloma gravidarum or pregnancy tumor. Because pus is infrequently found in this lesion, the term pyogenic granuloma is a misnomer but remains the preferred term.

ETIOLOGY: The stimulus that provokes this overgrowth of granulation tissue is unknown although mild trauma and infection are prominently mentioned.

TREATMENT: Conservative excision. They may recur.

PROGNOSIS: Good.

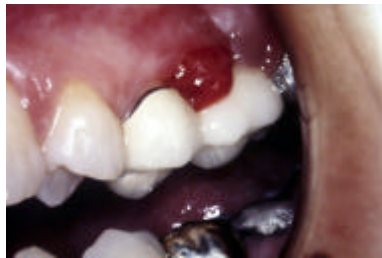DIFFERENTIAL DIAGNOSIS: Peripheral giant cell granuloma and peripheral ossifying fibroma.



Peripheral giant cell granuloma

DESCRIPTION: The peripheral giant cell granuloma appears as a nodular soft tissue mass arising from gingival or alveolar mucosa. The color may be red but is often a blue-grey. Most are approximately a centimeter in size, although they may be larger. The peak age is around 40 years but they occur in all ages with a female prevalence. There is almost equal distribution between maxillary and mandibular gingival. The term “peripheral” is included in the name to separate this lesion from a histologically similar lesion which occurs inside the jaws. Jaw lesions are referred to as the “central” giant cell granuloma.

The peripheral granuloma may cause pressure resorption of underlying alveolar bone and less commonly resorption of the adjacent tooth. They are not painful. Histologically this lesion consists of fibroblasts and multinucleated giant cells.



ETIOLOGY: Unknown

TREATMENT: Conservative excision. The recurrence rate is approximately 10%.

PROGNOSIS: Good.

DIFFERENTIAL DIAGNOSIS: Pyogenic granuloma and peripheral ossifying fibroma.

Traumatic ulcer

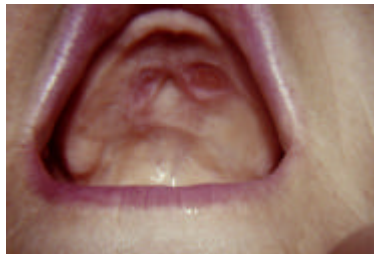DESCRIPTION: An ulcer by definition is a localized area on the skin or mucosa in which the surface epithelium has been destroyed. The shape and size of traumatic ulcers are so variable as to defy a simple description. They are usually painful and of short duration.

ETIOLOGY: Common causes of traumatic ulcers include: denture irritation, biting injuries, burns and friction irritation from sharp or fractured teeth.

TREATMENT: The treatment is to remove the cause if it is known. Relief of pain can be achieved with topical agents such as Orabase-B® with Benzocaine, Zilactin® or Soothe-N-Seal.

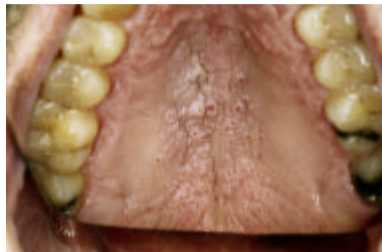PROGNOSIS: The ulcer should heal if the cause is removed. An ulcer which does not heal within two to three weeks should be biopsied to rule out malignancy.

DIFFERENTIAL DIAGNOSIS: Traumatic ulcers must be differentiated from squamous carcinoma , bacterial, fungal and viral diseases, and other oral mucosal diseases.



Nicotine stomatitis

DESCRIPTION: The classic form of this disease occurs in the palate of those who smoke pipes and cigars. The typical appearance is that of numerous, slightly raised, white, papular lesions of the posterior hard palate and soft palate. The central portion of the papules are red and represent inflamed orifices of minor salivary gland ducts. In more severe cases, the palatal mucosa is white and criss-crossed by fissures. There are no symptoms and lesions may be discovered in a routine oral examination.



ETIOLOGY: This lesion is caused by smoking, chiefly pipe and cigar smoking. A report of thermally induced “nicotine” stomatitis in a woman who drank scalding hot tea and soup suggests heat rather than tobacco products are responsible for this condition.

TREATMENT: This disease usually disappears after discontinuance of the causative factor.

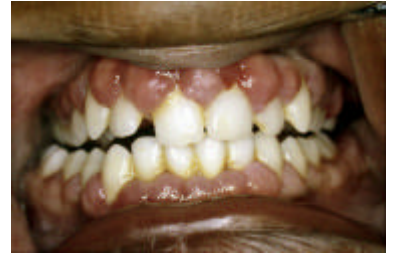DIFFERENTIAL DIAGNOSIS: The clinical appearance of nicotine stomatitis coupled with a history of smoking is virtually diagnostic. Biopsy is seldom necessary.

Drug-induced gingival hyperplasia (Dilantin hyperplasia)

DESCRIPTION: Drug-induced gingival enlargement was first described almost 50 years ago with the use of the anticonvulsant Dilantin (phenytoin). Other drugs especially calcium channel blockers such as Procardia (nifedipine) and cyclosporine have also been implicated. Dilantin causes gingival enlargement in almost 50% of those that regularly take it, while only about 25% of patient taking cyclosporine and calcium channel blockers have enlargement. Poor oral hygiene and especially dental plaque accentuate the enlargement. Superimposed gingivitis also causes boggy and red tissues that mask the true nature of the enlargement.

ETIOLOGY: Drug induced. As stated above, the condition may become aggravated by superimposed gingivitis and periodontitis. There is evidence that associated drugs may impair the secretion of collagenase by gingival fibroblasts permitting the accumulation of excessive gingival collagen.

TREATMENT: The inflammatory component may be reduced by good dental hygiene. The fibrous overgrowth



requires surgical removal. Discontinuance of associated drugs may result in gradual regression of the overgrowth within one year.

PROGNOSIS: Good

DIFFERENTIAL DIAGNOSIS: Hereditary gingival fibromatosis, hyperplastic gingivitis from dental neglect, and leukemic infiltrates of the gingiva.

Geographic tongue

(benign migratory glossitis, erythema migrans)

DESCRIPTION: The lesions of this disease on the tongue are so characteristic that recognition should be instantaneous. The dorsal tongue displays map-like areas that are smooth and red with a whitish-yellow perimeter. The disease may involve any oral mucosal surface in which case the name erythema migrans is more appropriate. Atrophy of the filiform papillae is usually a finding on the dorsal tongue.

All ages are affected. We have seen it in a child six months old. The number of lesions varies from one to many. Old lesions heal and new ones form, waxing and waning in rhythm with most due to unknown forces. Some complain of a burning sensation.

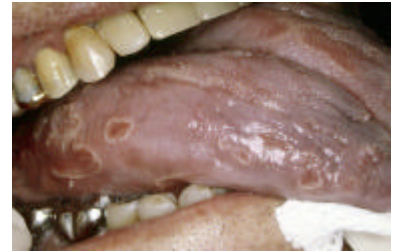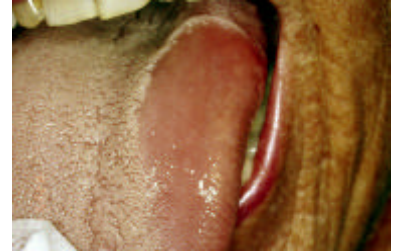ETIOLOGY: Unknown although a hypersensitivity reaction to unknown antigens has been suspected.

TREATMENT: None is usually required. In those with symptoms, topical steroid ointment or gel may be beneficial. Secondary fungal colonization should also be suspected in symptomatic

lesions.

PROGNOSIS: This is a chronic disease lasting months to years with periods of remission and exacerbation.

DIFFERENTIAL DIAGNOSIS: Typical lesions are diagnostic. Variable clinical presentation may suggest lichen planus or candidiasis.



Lichen planus

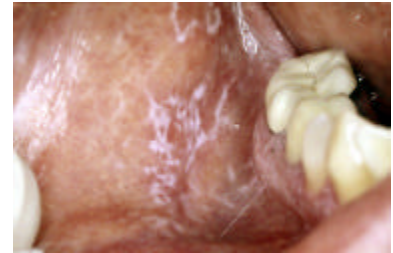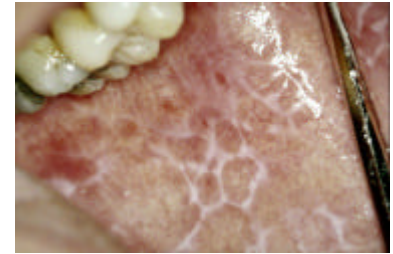DESCRIPTION: Mucosal lesions of this disease appear in several forms; reticular and erosive with some forms appearing as plaques. In the reticular pattern, lacy, white lines is characteristic. In the erosive type, the same reticular pattern is seen but there are areas of erosion or ulceration. This is the most common form of lichen planus. In the plaque type, the lacy pattern is lost, lesions appear as white macules. Both skin and oral mucosa may be involved. Early skin lesions appear as purple, maculopapular pruritic areas. The term PPP has been used in describing skin lesions (purple, pruritic, and papular). Oral lesions may occur on any surface but the buccal mucosa is the most common site.

ETIOLOGY: The cause is unknown but it is currently believed to be an immune mediated disease. The target antigen is yet to be identified. Recent reports discount the role of stress. Numerous dental materials have been implicated in oral lichenoid lesions. While unproven these include amalgam, semiprecious metals, gold and composite restorations. Stomatitis caused by drugs may resemble lichen planus, so-called lichenoid drug reactions. The most common drugs include high blood pressure medications and non-steroidal anti-inflammatory drugs. Over 100 medications are implicated.

TREATMENT: The reticular and plaque types of the disease are ordinarily asymptomatic and require no treatment. In the erosive or ulcerative variety, relief is often achieved with topical steroids. If ulceration is too widespread to control with topical treatment, systemic prednisone is indicated. Alternative drugs include topical tretinoin, cyclosporine, and tacrolimus.

PROGNOSIS: The outlook is variable. The disease may last for years, few patients with oral lesions experience spontaneous remission. Topical drugs provide relief but not a cure. Systemic steroids are effective but there is the risk of adverse effects and the disease may recur following discontinuance of therapy. There are reports that lichen planus predisposes the patient to oral cancer. The risk is placed at approximately 1%. The premalignant nature of lichen planus is not universally accepted. Some authors cite evidence that examples of lichen planus turning into cancer were originally dysplastic lesions masquerading as lichen planus. Such lesions have been referred to as lichenoid dysplasia. Until the dispute is settled, it is prudent to advise patients to have regular oral examinations for as long as they have the disease.

DIFFERENTIAL DIAGNOSIS: Squamous carcinoma (dysplasia), lupus erythematosus, benign mucous membrane pemphigoid, candidiasis and lichenoid drug eruptions.



Angular cheilosis

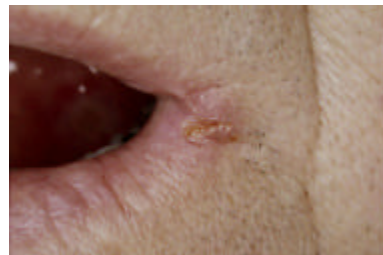DESCRIPTION: This lesion appears as fissuring and maceration at the labial commissures. The term cheilitis and cheilosis have both been used to describe the same disease.

ETIOLOGY: It is doubtful that this condition is caused by vitamin deficiency in the United States. Studies have shown that the two most common organisms responsible for this condition are *Candida albicans* and *Staphylococcus aureus*. This condition is commonly seen in older patients having loss of vertical dimension, in younger patients with orthodontic appliances, and those with a lip licking habit.

TREATMENT: In those patients who have obvious overclosure, restoration of vertical dimension is of benefit. Application of antifungal ointment to eliminate *Candida* organisms is indicated.

PROGNOSIS: Good

DIFFERENTIAL DIAGNOSIS: The disease is so characteristic that it cannot be confused with any other lesion.

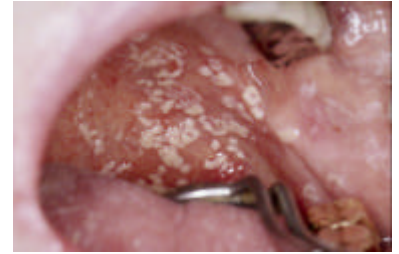


Candidiasis (Moniliasis, Thrush)

DESCRIPTION: Infection with *Candida* species is known as candidiasis. There is virtually no organ or tissue immune to this fungus but skin, mouth, and genital lesions are most common. Severity of infection varies from small localized areas to generalized stomatitis. Involved mucous membrane develops a white slough consisting of necrotic mucosa and organisms. Because of uneven distribution of lesions, a speckled white on red appearance is common. In contrast to most other white lesions, the white pseudomembranes of Candidiasis often can be wiped off. *Candida* may also present as red lesions have been referred to as erythematous candidiasis. This is especially common under dentures.

ETIOLOGY: As previously stated, this disease is caused by an infection with *Candida* organisms. It is frequently stated that this disease occurs in groups including: (1) the very young; (2) the very old; (3) those with xerostomia, (4) those on long-term antibiotic therapy, (5) those who are immunosuppressed, and (6) those undergoing systemic chemotherapy or radiation to the head and neck.

TREATMENT: There are several topical and systemic drugs available. One of the more common treatments consists of a mouthwash of nystatin oral suspension 400,000 to 600,000 units four times daily for at least one week. This



is the adult dose. The drug works by direct contact and thorough swishing in the mouth for 3-5 minutes before swallowing is required. A clotrimazole troche is available. Each troche is 10 mg, adult dosage is 1 troche dissolved in the mouth 5 times each day for 10 days. It should be noted that the above drugs contain a high sugar content. As a sucrose-free treatment, either ketoconazole or fluconazole tablets are often used.

DIFFERENTIAL DIAGNOSIS: Squamous cell carcinoma, geographic tongue.

Pulpitis

DESCRIPTION: Inflammation of the pulp is one of the most common lesions seen in dental practice. No illustration is shown because pulpitis is not amenable to clinical photography. Pulpitis usually causes a toothache (pulpalgia) ranging from mild to excruciating, although in some cases, there are no symptoms.

ETIOLOGY: Pulpitis is usually brought about by pulp infection occurring as a consequence of caries, but may also be caused by physical trauma, dental instrumentation, and irritating restorative materials.

TREATMENT: Treatment consists of elimination of the responsible agent. Irreversible cases are treated by endodontic procedures or extraction.

PROGNOSIS: The prognosis depends on the extent and severity of the pulp involvement.

DIFFERENTIAL DIAGNOSIS: It is frequently stated that periodontal infections, sinusitis, and referred pain may masquerade as pulpitis. When patients complain of pain in vital teeth, the diagnosis of atypical odontalgia or phantom tooth pain should be considered.

Dental caries

DESCRIPTION: Caries ranks with gingivitis and periodontitis as one of the most common oral diseases. Treatment of these diseases and their sequelae constitutes the bulk of the practice of dentistry. Caries is the only disease that attacks that portion of the tooth exposed to the oral environment. Typical caries are most commonly located in the occlusal pits and fissures of molars and premolars, as well as beneath the contact points on the interproximal surfaces. Special consideration should be given to two types of caries, namely radiation type caries and early childhood caries (nursing bottle caries). Radiation type caries characteristically occur as multiple lesions in the cervical region of the teeth immediately adjacent to the gingival. These may completely encircle the tooth causing amputation at the gingival. Early childhood caries are multiple and rampant occurring in deciduous teeth of nursing infants and small children.

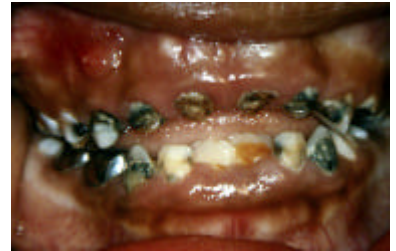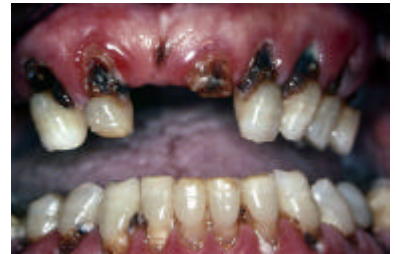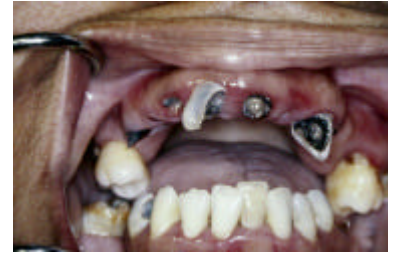ETIOLOGY: Caries is caused by the decalcification of tooth enamel and destruction of the protein matrix. Acid produced by bacteria, mainly *Streptococcus mutans*, in dental plaque is the precipitating factor. After the enamel is destroyed bacteria enter the dentin and may extend to the pulp of the tooth. Radiation or cervical caries are usually related to xerostomia and/or chemical changes in saliva. Radiation therapy exceeding 4000 cGy to salivary glands is the most common cause. However, many common medications and systemic chemotherapy may also cause dry mouth and radiation type caries. Sjogren's syndrome is a cause of xerostomia and a cause of radiation-type caries. Early childhood caries is due to frequent nursing with solutions containing high concentrations of sugar such as milk, soft drinks, and juices.

TREATMENT: Prevention is the best treatment. Caries can be prevented by brushing and flossing to remove plaque. A well-balanced diet without excessive sugars is also beneficial. Topical and systemic fluoride are highly effective in reducing caries, especially if given during the formative years of the teeth. Fluorides have significantly reduced the incidence of caries in the United States in the last several decades. Radiation type caries can also be prevented by a daily regime of topical fluoride. Fluoride applications applied with a custom mouth guard should begin as soon as radiation is started. Patients who have received head and neck radiation should continue daily treatments for life to prevent caries that could lead to extractions and possible osteoradionecrosis.

Once caries have developed, dental restorative procedures are the only treatment, although there is now evidence that very early lesions, under intact surface enamel (white spots), may be remineralized with topically applied agents.

PROGNOSIS: Prognosis is good if the disease is treated early. If ignored, caries is a major cause of tooth loss and suffering from infection of bone and soft tissues.

DIFFERENTIAL DIAGNOSIS: None



Plaque induced gingivitis

DESCRIPTION: Inflammation of the gingiva is among the mildest but most common human ailments. The gingival that envelops the neck of the teeth is swollen, red and bleeds easily. It is not painful. It may show patchy involvement with skip areas or it may involve virtually the entire marginal gingiva. If untreated, some patients show progression to bulky enlargement of the gingiva called hyperplastic gingivitis. Gingivitis is stated to be enhanced by pregnancy and puberty.

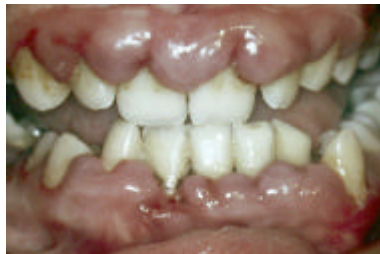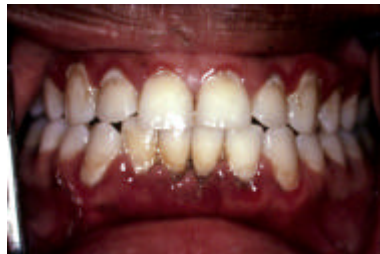ETIOLOGY: The gingival inflammation is the response to bacterial plaque on the adjacent tooth surface.

TREATMENT: Treatment consists of regular dental prophylaxis and the good oral hygiene.

PROGNOSIS: The disease is easily treat-

ed and the prognosis is good. If ignored, inflammation may spread to deeper periodontal tissues in which case the patient is said to have periodontitis.

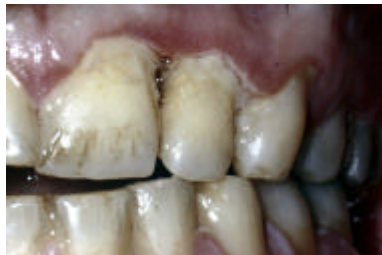DIFFERENTIAL DIAGNOSIS: Mucosal pemphigoid, lichen planus, dilantin hyperplasia, and leukemic infiltrate.



Necrotizing ulcerative gingivitis

(Vincent's infection, trench mouth)

DESCRIPTION: This is a specific type of infection of oral mucosa whose lesions are found chiefly on marginal gingiva. Necrosis of the interdental papillae that spreads to involve adjacent facial and lingual surfaces is virtually diagnostic. The ulcerated gingiva is covered by creamy exudates. Patients have pain and halitosis and in severe cases, fever and cervical lymphadenitis. Spread of lesions into the throat has been referred to as Vincent's angina. The disease occurs in all age groups but is uncommon in children.



ETIOLOGY: Treponema, Selenomonas, and Prevotella species have been identified in the lesions. They are suspected of being the chief etiologic agents although reinoculation of these organisms into tissues of volunteers has not reproduced the disease. Reduction of patient resistance is thought to play an etiologic role.

TREATMENT: Treatment consists of debridement and cleaning the teeth plus a broad spectrum antibiotic in those with fever and cervical lymphadenitis. Topical anesthetics may provide palliation.

PROGNOSIS: Good

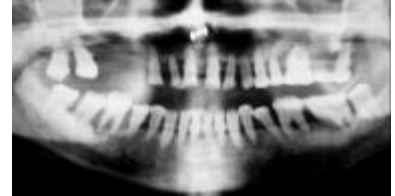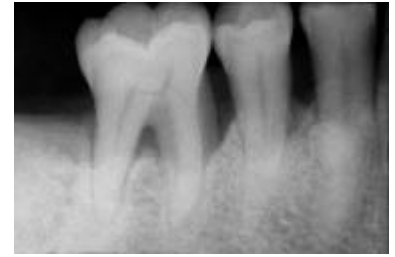DIFFERENTIAL DIAGNOSIS: Agranulocytosis

Periodontitis

DESCRIPTION: Extension of gingival inflammation into the underlying bone and periodontal ligament is referred to as periodontitis. Since bone resorption is the outstanding feature, it is best seen on radiographs. Periodontitis is a silent disease with an occasional acute exacerbation in the form of local, painful abscesses. The gingiva is usually inflamed. The chief indicators of this disease are increased gingival sulcus depth as determined by gingival probing, and loss of alveolar bone as seen on radiographs. The conventional form of this disease starts in the teens or early adult years and without treatment shows gradual progression throughout life. It is the major cause of tooth loss in adults.

Three subtypes have been identified: (1) rapidly progressive periodontitis (RRP) affecting young adults; it resembles the conventional disease except that bone destruction is accelerated and occurs over a period of weeks or months rather than years; (2) juvenile periodontitis (JP) formerly known as periodontosis and typically affecting teenagers and characterized by destruction of alveolar bone around only first permanent molar teeth and incisor teeth; and, (3) prepubertal periodontitis (PP) affecting the deciduous teeth.

ETIOLOGY: Bacterial plaque is thought to be responsible for periodontitis. In the rapidly progressive type, there is evidence for increased activity of *Bacteroides*, *Actinobacillus*, *Porphyromonas*, and *Prevotella* organisms coupled with defects of leukocyte chemotaxis. In the juvenile (periodontosis) type, research has implicated a similar array of gram negative anaerobic rods as pathogens but there is no plausible explanation for the selective involvement of first molar and incisor teeth other than the “first erupted-first involved” theory. In the prepubertal form of periodontitis, genetically determined leukocyte adhesion molecule deficiency has been implicated. Disabling mutations in the gene for Cathepsin C account for the Papillon-Lefevre syndrome. From the above, it is obvious that alterations in plaque flora and reduced immunity are encountered in the subtypes of periodontitis.



TREATMENT: In conventional periodontitis, prevention is achieved through good dental hygiene. Unless treated, continued loss of alveolar bone eventually necessitates extraction of teeth. In those patients who still have adequate bone support, periodontal surgery to reduce the sulcus depth may be of benefit.

PROGNOSIS: The prognosis depends on the stage of the disease at the time treatment is instituted.

DIFFERENTIAL DIAGNOSIS: Most forms of periodontitis are easily recognized with periodontal probing and dental radiographs. Langerhans granulomatosis and Burkitt's lymphoma should be ruled out in prepubertal periodontitis. Children with prepubertal periodontitis combined with hyperkeratosis of the palms and soles are said to have the Papillon-Lefevre syndrome. Prepubertal periodontitis has also been described in children with Ehlers-Danlos syndrome.

Periapical cyst (radicular cyst)

DESCRIPTION: This is a cyst at the apex of a tooth with a necrotic pulp and is a sequelae of pulpitis. Periapical cysts bear a radiographic resemblance to dental granulomas. About the only substantive difference is the presence of an epithelium lined central cavity in the cyst. The associated tooth is usually asymptomatic. Acute infectious episodes may cause pain. The lesion appears as a sharply circumscribed radiolucent lesion around the apex of the associated tooth. It is often stated to have a thin sclerotic rim at the border but this feature is absent as often as it is present.

ETIOLOGY: This cyst is a direct sequela of inflammation of the pulp that has extended into the adjacent periapical tissues.

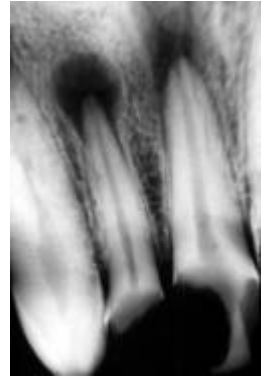
TREATMENT: Treatment consists of endodontic therapy or extraction of the associated tooth with curettage of the cyst.

PROGNOSIS: Good

DIFFERENTIAL DIAGNOSIS: Dental granuloma. Lesions such as keratocyst, ossifying fibroma, giant cell granulomas, and the lytic

stage of osseous dysplasia may occur at the apex of a tooth and masquerade as a periapical cyst. Several odontogenic tumors may also present in a similar fashion.

COMMENT: A periapical infection with suppuration is correctly called a periapical abscess. An abscess may arise de novo or in a preexisting granuloma or cyst. Drainage of pus provides considerable relief of pain and hastens healing.



Periapical dental granuloma

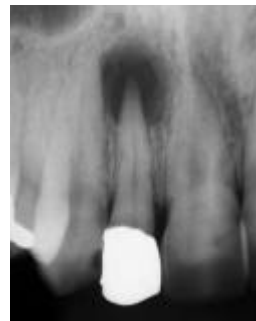DESCRIPTION: The dental granuloma is a foci of chronic inflammation around the apex of a tooth root and is a sequela of pulpitis. Radiographically it appears as a periapical radiolucency. The border is usually distinct but this cannot be relied upon. The overlying tooth is ordinarily insensitive to electric pulp testing. While sensitivity to percussion may be present, many patients are asymptomatic. An acute infectious episode will result in pain, and often results in a formation of an abscess with a draining sinus tract and/or parulis formation. Osteomyelitis and cellulitis are an ever present danger.

ETIOLOGY: Like the periapical cyst, the dental granuloma is a direct sequela of inflammation of a pulp that has extended into the surrounding periapical tissue. Pulpitis is usually caused by infection secondary to caries but may be caused by trauma.

TREATMENT: Treatment consists of endodontic therapy or extraction.

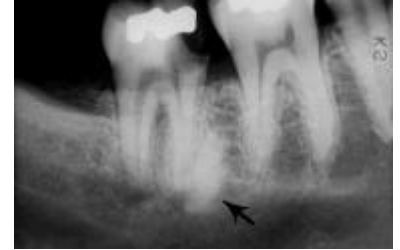
PROGNOSIS: Good

DIFFERENTIAL DIAGNOSIS: If the tooth is nonvital, the differential diagnosis includes radicular cyst and periapical abscess.



Condensing osteitis

DESCRIPTION: Condensing osteitis is a reaction to infection. It differs from other periapical inflammatory diseases in that there is a bone production rather than bone destruction. The result is a radiopaque lesion. This sclerotic reaction is apparently brought about by good patient resistance coupled with a low degree of virulence of the offending bacteria. It is more commonly seen in the young and seems to show special predilection for the periapical region of lower molars. The associated tooth is carious or contains a large restoration. We are reluctant to state the reaction of the tooth to pulp testing because of lack of sufficient personal experience and paucity of published information. Theoretically, the results should be abnormal. Current level of knowledge suggests that the pulp is irreversibly inflamed. Uncommonly, condensing osteitis occurs as a reaction to periodontal infection rather than dental infection.



ETIOLOGY: Infection of periapical tissues by organisms of low virulence.

TREATMENT: Vitality of the overlying tooth should be investigated. If the pulp is inflamed or necrotic, endodontics or extraction are the options.

PROGNOSIS: In those cases in which the offending tooth is extracted, the area of condensing osteitis may remain in

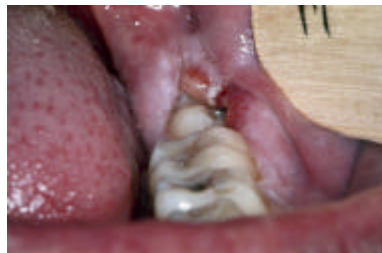the jaws indefinitely, and is termed osteosclerosis or bone scar.

DIFFERENTIAL DIAGNOSIS: Idiopathic osteosclerosis and cementoblastoma. An abnormal result with pulp testing strongly suggests condensing osteitis and tends to rule out osteosclerosis and cementoblastoma.

Pericoronitis

DESCRIPTION: The term pericoronitis refers to inflammation in the gingival tissue around the crown of a partially erupted tooth. The lower molars are the usual site. Gingiva around the crown is red, swollen, and painful. It is seen exclusively around teeth that are partially erupted.

ETIOLOGY: Pericoronitis is caused by bacterial infection of the gingiva. The anatomical circumstances that sets the stage for this disease develops when the crown of a tooth that has partially erupted through gingiva. The pericoronal dental follicle becomes a cul-de-sac extension of the mouth. This is an excellent place for bacterial growth, nurtured by stagnant fluid movement and accumulation of debris.



TREATMENT: Treatment consists of flushing the space with sterile water or saline. Systemic antibiotics are indicated in severe infections. If the associated tooth will not erupt completely, it should be extracted.

PROGNOSIS: Good

DIFFERENTIAL DIAGNOSIS: The disease is so characteristic that differential diagnosis is no problem.

Amalgam tattoo

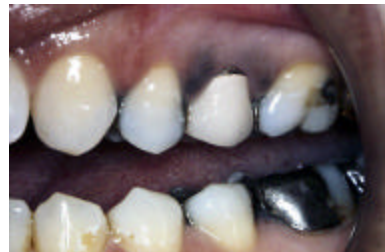DESCRIPTION: An amalgam tattoo is a localized area of blue-gray pigmentation. The amalgam is relatively inert and usually causes no tissue damage. The discoloration is permanent.

ETIOLOGY: The accidental and usually unavoidable implantation of dental amalgam in oral soft tissues produces this lesion.

TREATMENT: None required.

PROGNOSIS: Good

DIFFERENTIAL DIAGNOSIS: Differential diagnosis is ordinarily not a problem. Amalgam tattoo should easily be distinguished from nevi which are usually brown. Amalgam tattoos are usually blue-grey. The rare blue nevus may resemble amalgam tattoo. It should be remembered that melanoma occurs in the mouth. Any tattoo that changes in a short period of time should be biopsied.



Hairy tongue (coated tongue)

DESCRIPTION: This is an ignoble name for a lesion. The dorsal surface of the tongue appears hairy and is discolored. The hairy texture is imparted by excessive keratinization of the filiform papillae. The keratin may take on the color of extrinsic stains and display a variety of colors.

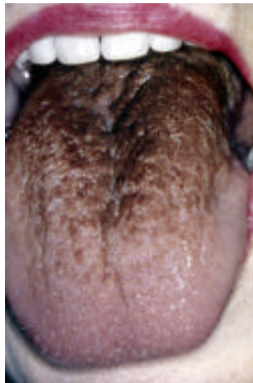ETIOLOGY: It occurs more frequently among heavy smokers, those taking wide-spectrum antibiotics, those with xerostomia, and those with poor oral hygiene. The exact cause is unknown.

TREATMENT: Treatment consists of brushing the tongue with a soft bristle toothbrush or

the use of a commercial tongue scraper. If there is an obvious cause, it should be eliminated. Oral lubricants may assist those with xerostomia.

PROGNOSIS: Good

DIFFERENTIAL DIAGNOSIS: Candidiasis.



Nasopalatine duct cyst

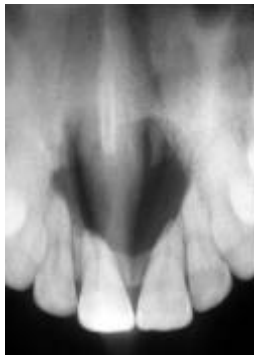
DESCRIPTION: This developmental cyst forms from remnants of the nasopalatine duct, in the incisive canal in the midline of the anterior maxilla. The cyst may overlap the roots of the maxillary central incisor teeth. It is usually asymptomatic and discovered on routine dental films where it appears as an oval or heart-shaped radiolucent lesion. Rarely this cyst will expand overlying mucosa. It does not interfere with tooth vitality and seldom causes root resorption. It may be found in edentulous patients. This cyst is differentiated from other cysts by the histologic presence of respiratory epithelium and the presence of nerves and muscular arteries in the wall.

ETIOLOGY: This is a developmental cyst presumably arising from epithelial remnants of the nasopalatine duct.

TREATMENT: Surgical enucleation.

PROGNOSIS: Good

DIFFERENTIAL DIAGNOSIS: Radicular cyst, keratocyst, and central bone tumors.

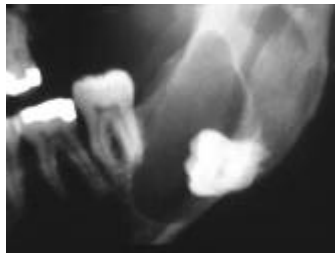


Dentigerous cyst

DESCRIPTION: This is a cyst that forms around the crown of an unerupted tooth and therefore, appears on x-ray as a pericoronal radiolucency. The size is extremely variable. Small ones are only slightly greater than a normal follicle whereas large ones may hollow out the jaw. The cyst occurs in all age groups. The teeth most commonly affected are third molars and maxillary cuspids. No tooth is immune, but deciduous teeth are scarcely ever affected. Small cysts are without symptoms but large ones expand the affected jaw and may cause mild pain. They may encroach on and erode adjacent teeth.

ETIOLOGY: The accumulation of fluid between the unerupted tooth and the surrounding dental follicle is the accepted cause. What precipitates fluid accumulation is unknown.

TREATMENT: Surgical enucleation. All dentigerous cysts should be submitted for histopathologic examination.



PROGNOSIS: Good, rarely recurs.

DIFFERENTIAL DIAGNOSIS: Odontogenic keratocyst. In the first two decades, cystic ameloblastoma, adenomatoid odontogenic tumor, and ameloblastic fibroma should be considered.

Leukoplakia

DESCRIPTION: We use the term leukoplakia to mean a white lesion of mucous membrane that cannot be identified as any other “white” disease such as candidiasis or lichen planus. It carries no histologic connotation. Using this definition, biopsy is required for accurate diagnosis.

Biopsy of oral leukoplakia will most often show hyperkeratosis, a purely reactive and harmless lesion. About 20%, however, will show dysplasia, a premalignant lesion or cancer.

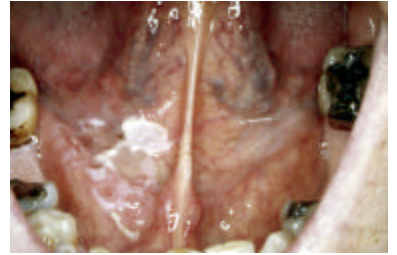
Leukoplakia is more common in males and favors older age groups. There are usually no symptoms.

ETIOLOGY: The exact cause is unknown although physical trauma, smoking, excessive alcohol intake and vitamin A deficiency are suspected.

TREATMENT: The treatment depends on the histologic findings and the extent of the lesion. For simple hyperkeratosis, removal of any apparent cause is indicated. Those showing dysplasia, or carcinoma, should be treated with the usual methods used in treatment of cancers.

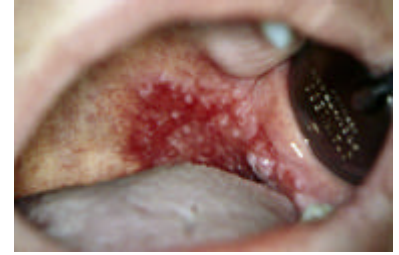PROGNOSIS: As stated above, the prognosis depends to a great extent on the precise histologic findings. One study indicates approximately 20% of oral leukoplakia lesions are dysplastic or malignant on the day of biopsy. Leukoplakia in the floor of the mouth and lateral/ventral tongue mucosa are more likely to be precancerous.

DIFFERENTIAL DIAGNOSIS: Lichen planus, candidiasis, and hairy leukoplakia.



Erythroplasia (erythroplakia)

DESCRIPTION: This is a clinical description designating a velvety red but not ulcerated area on mucous membrane. The texture may be normal or roughened. Size is variable, some so small as to virtually escape discovery, whereas large areas are conspicuous to casual inspection. There are usually no symptoms. Being neither elevated nor depressed, they present as quiet, unpretentious lesions. The border may be sharp or blend imperceptibly into surrounding normal mucosa. It must constantly be kept in mind that early carcinoma frequently appears as an area of erythroplasia.



ETIOLOGY: There are many different diseases that appear as erythroplasia. Local irritants and infection, especially *Candida*, are responsible for some lesions. For those that prove to be dysplastic or neoplastic, the etiology is unknown. Tobacco and alcohol are chief suspects.

TREATMENT: Treatment depends on the histologic findings. If the biopsy shows dysplasia or carcinoma, total excision is indicated.

PROGNOSIS: This depends on the histologic diagnosis and extent of the lesion. In one study, more than 90% of oral erythroplakias were dysplastic (pre-malignant) or malignant on the day of the biopsy. Invasive carcinomas will require more extensive surgery that may include

removal of cervical lymph nodes followed by radiation therapy.

DIFFERENTIAL DIAGNOSIS: Lesions of physical trauma, chemical burns, infections, candidiasis and mucositis.

COMMENT: As mentioned in the section on carcinoma, there are certain areas of the oral mucosa that are more prone to develop malignancy. Additionally, oral cancer is more often seen in those over age 40. Because of this, an area of erythroplasia in a cancer prone area in a patient past 40 is highly suspicious for malignancy and should be biopsied the day it is seen. This is especially true for those lesions whose duration exceeds two weeks.

Squamous cell carcinoma (epidermoid carcinoma)

DESCRIPTION: In excess of 90% of all oral cancers are of the squamous cell type. As stated in other sections in this monograph, early carcinoma may clinically appear as leukoplakia or erythroplasia. It may also appear as a mixture of erythroplasia and leukoplakia as is illustrated in Fig. 1. Another common clinical appearance is an area of chronic ulceration as in Fig. 2.

Squamous carcinoma is about three times as common in men as in women. Risk of acquiring the disease increases with each passing decade but is seldom seen in those under forty. According to the American Cancer Society, there are about 21,000 new cases of oral cancer in the United States each year, an incidence rate of approximately 8 cases per 100,000 persons. Although no area of oral mucosa is immune, certain areas are more vulnerable. Soft palate, lateral and ventral tongue mucosa, and floor of the mouth are especially prone to develop squamous carcinoma. The tongue and floor of the mouth are the most common areas.

ETIOLOGY: The cause is unknown. Smoking and alcohol are risk factors, and the human papilloma virus is suspect. Time will show that mutations in genes that control the cell cycle, protooncogenes and tumor suppressor genes, are at the heart of many forms of cancer including oral cancer.

TREATMENT: Usual treatment consists of surgical excision and possible irradiation. Chemotherapy is adjunctive at this time.

PROGNOSIS: The overall five year survival rate is about 50%. Early diagnosis increases the chance of survival.

DIFFERENTIAL DIAGNOSIS: All ulcerations present for more than 2-3 weeks in which there is no apparent cause should be biopsied to rule out carcinoma, especially in adults whose lesions are in high risk areas.

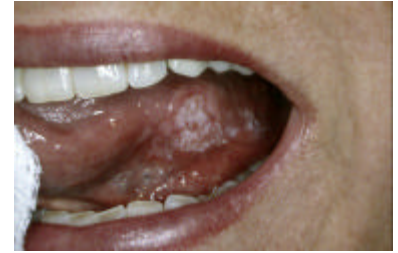

Figure 1

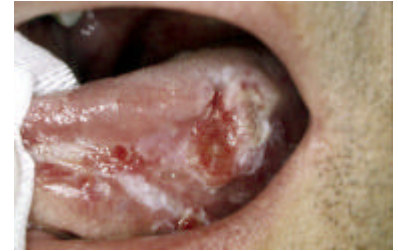

Figure 2

Snuff lesion (smokeless tobacco lesion)

DESCRIPTION: The lesion develops on the mucosa where smokeless tobacco is held. The usual appearance is white, wrinkled or corrugated mucosa. Gingival recession is a common manifestation with cervical erosion of teeth a less frequent finding. Symptoms are uncommon.

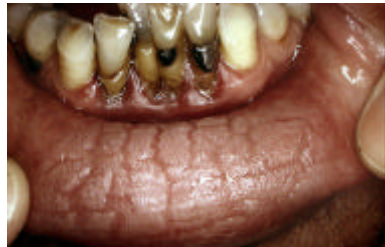ETIOLOGY: Prolonged use of smokeless tobacco produces such as chewing tobacco or snuff.

TREATMENT: Biopsy should be done to rule out dysplasia, otherwise no treatment is necessary.

PROGNOSIS: Verrucous and squamous carcinomas arise in smokeless tobacco lesions more than chance alone can explain. One article noted almost a 50-fold increased risk

of cancers of the gingival and buccal mucosa in females who were chronic users. The duration necessary to induce dysplastic or malignant change is unknown but appears to be at least 20 years.

DIFFERENTIAL DIAGNOSIS: The clinical appearance of the lesion plus a history of using smokeless tobacco establishes the diagnosis.



Cementoma (periapical cemental dysplasia)

DESCRIPTION: Cementoma occurs as a self-limiting lesion around the apices of anterior vital teeth, mostly in middle-aged black females. Lesions are confined to the anterior maxillary and mandibular areas (cuspid to cuspid). The initial lesion is a periapical proliferation of benign fibrous connective tissue in the periodontal ligament. There are no symptoms and X-ray shows periapical radiolucencies. Cementum is slowly formed in the central area and the entire lesion becomes converted to a mineralized mass that appears radiopaque on X-ray. Often a thin radiolucent halo persists around the circumference of the opaque lesion.

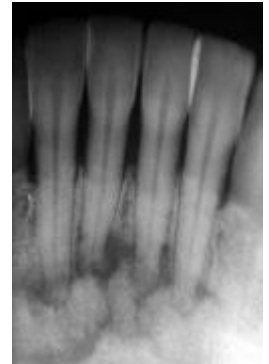
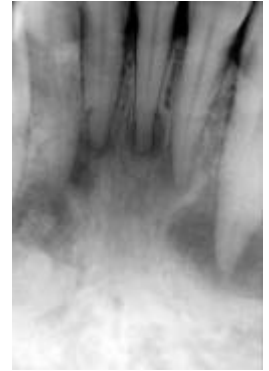ETIOLOGY: Unknown.

TREATMENT: No treatment required.

PROGNOSIS: Good, the lesion is self-limiting.

DIFFERENTIAL DIAGNOSIS: Differential diagnosis during the lytic stage includes periapical cysts, abscesses, and granulomas. The

opaque stage must be distinguished from condensing osteitis and osteosclerosis. Pulp vitality tests of associated teeth are necessary to arrive at accurate diagnosis. If similar lesions occur in posterior quadrants, the diagnosis of florid osseous dysplasia is likely.



Acquired immune deficiency syndrome (AIDS)

DESCRIPTION: Acquired immune deficiency syndrome is characterized by relentless destruction of CD4 T lymphocytes, key cells of the immune system. The eventual collapse of both the cellular and humoral arms of immunity leaves the host vulnerable to a wide variety of pathogenic organisms including bacteria, viruses, fungi and protozoa.

It is important for health care workers to recognize that it is difficult to transmit the AIDS virus in the health care setting, from patient to worker or the reverse. However, opportunistic infectious diseases that AIDS patients are apt to have including tuberculosis, herpes-virus infections, hepatitis B and hepatitis C are readily transmissible.

ETIOLOGY: The causes of AIDS is an RNA retrovirus of the lentivirus group. It is designated the human immunodeficiency virus (HIV) and there are several variants: HIV-1 is the most common cases of AIDS. The virus attaches to the surface of cells that bear the CD4 receptor including helper T lymphocytes, B lymphocytes and macrophages. Although they lack a CD4 receptor, microglia, skin fibroblasts, and bowel epithelium become infected. The virus destroys the infected cells. With gradual depletion of the cells of immunity, especially T-helper lymphocytes and macrophages, the host becomes increasingly vulnerable to pathogenic organisms.

ORAL MANIFESTATIONS:

Candidiasis – Colonization and infection of the oral mucosa by *Candida* species is among the earliest and most common findings in HIV-infected patients. In one study, 88% had oral candidiasis. Lesions range from white to red or red/white combinations. Fig. 1 illustrates the typical appearance of candidiasis. The lesions may be asymptomatic or there may be mild discomfort. For stubborn infection, fluconazole is recommended.

Kaposi's sarcoma – AIDS patients are vulnerable to a variety of oral malignancies including Kaposi's sarcoma, malignant lymphoma and squamous carcinoma. Kaposi's sarcoma is the most common. In one study, 20% of AIDS patients had Kaposi's sarcoma and of these, the tumor was in the oral cavity in 1 of every 5 patients; the palate is the most common site. In the early stage, the tumor appears as a red to purple bruise (Fig. 2). The tumor grows and eventually appears as a hemorrhagic mass (Fig. 3). The cell of origin is endothelium; thus Kaposi's sarcoma is a variety of angiosarcoma. They are locally invasive, cause pain and bleeding and interfere with normal function. Low-dose radiation therapy and intralesional or systemic chemotherapy are the treatments of choice. Herpes virus type VIII is thought to play a role in the pathogenesis of this tumor.

Hairy leukoplakia – This variety of leukoplakia was first recognized in HIV-infected patients but has been encountered in other immune deficiency states such as organ transplant patients who are intentionally immune suppressed. The lateral tongue is the most common location (Fig. 4). Lesions are of rough texture, adherent and asymptomatic. The diagnosis of hairy leukoplakia can be suspected on routine biopsy specimens, but confirmation requires demonstration of the presence of the causative virus, the Epstein-Barr herpesvirus. This is ordinarily achieved by DNA in situ hybridization. A word of caution: hairy leukoplakia may be confused with candidiasis. A patient who presents with a white lesion should be treated with antifungal therapy first. If it fails to heal, it most likely is hairy leukoplakia.

Gingival and periodontal lesions – HIV-infected patients are vulnerable to necrotizing gingivitis and periodontitis (Fig. 5). The organisms recovered from these lesions are the same as those in non-HIV-positive patients. Lesions are treated by dental prophylaxis, debridement, and metronidazole. Good oral hygiene and daily rinses with chlorhexidine are beneficial.

Others – HIV patients also develop major aphthous-like lesions that respond to tetracycline and topical steroid therapy. Thalidomide has been used successfully in their management. The human papillomavirus has also been found in both condylomas and focal epithelial hyperplasia. Cytomegalovirus infections and several fungal infections such as histoplasmosis and coccidioidomycosis are also common. Lastly, xerostomia secondary to salivary gland destructions has been reported.

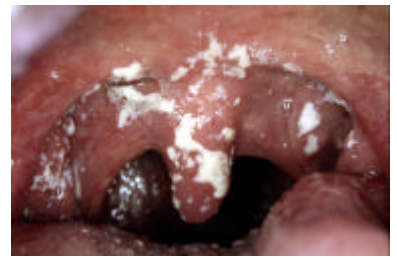

Figure 1

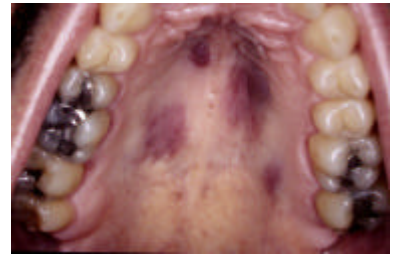

Figure 2

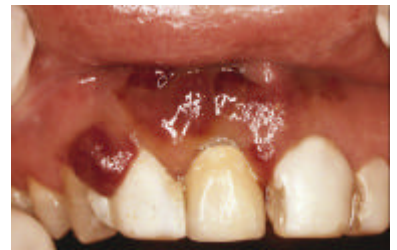

Figure 3

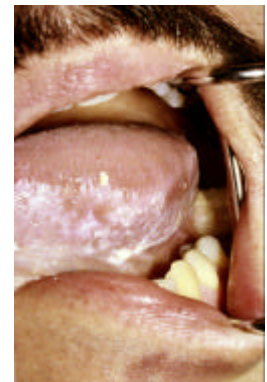


Figure 4

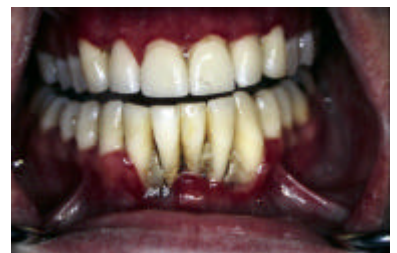

Figure 5