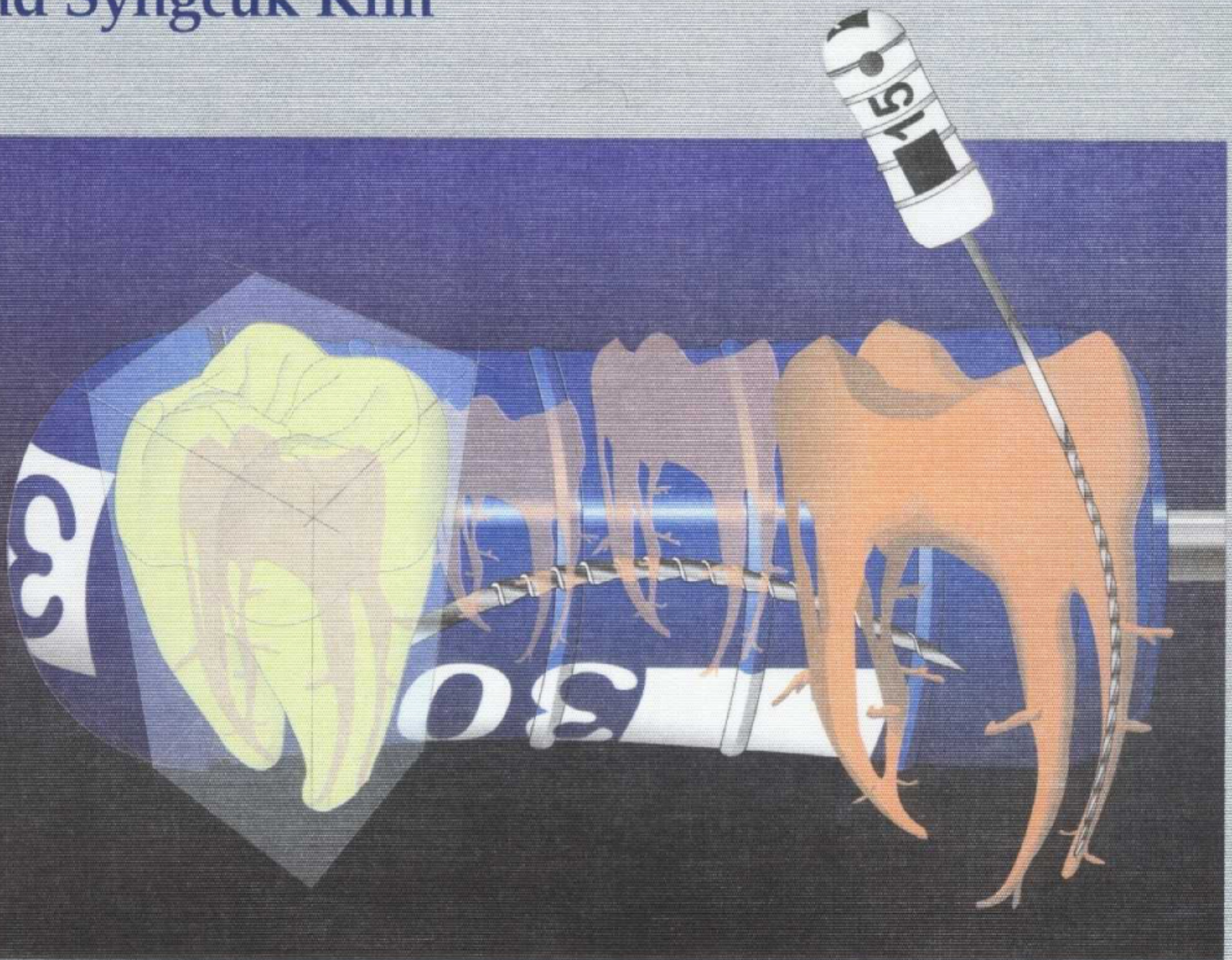


Color Atlas of Dental Medicine

Editors:
Klaus H. Rateitschak
Herbert F. Wolf

Endodontology

Rudolf Beer, Michael A. Baumann,
and Syngcuk Kim



Thieme

Color Atlas of Dental Medicine

Editors: Klaus H. Rateitschak and Herbert E Wolf

Endodontology

Rudolf Beer, Michael A. Baumann,
and Syngcuk Kim

Translated by
Richard Jacobi, D. D. S.
Belton, TX, U.S.A.

1533 Illustrations



Thieme
Stuttgart . New York . 2000

Authors' Addresses

Rudolf Beer, D. D. S., Ph. D.
Dentist in Private Practice
Essen, Germany

Michael A. Baumann,
D. D. S., Ph. D.
Department of
Conservative Dentistry
Oral and Maxillofacial Clinic
University of Cologne
Cologne, Germany

Syngcuk Kim, D. D. S.,
M. Phil., Ph. D.
Professor and Chairman
School of Dental Medicine
Department of Endodontics
University of Pennsylvania
Philadelphia, PA, USA

Lowenstrasse

Editors' Addresses

Klaus H. Rateitschak, D.D.S., Ph.D.
Dental Institute, Center for Dental Medicine
University of Basle
Hebelstr. 3, 4056 Basle, Switzerland

Herbert F. Wolf, D.D.S.
Private Practitioner
Specialist of Periodontics SSP
55, 8001 Zurich, Switzerland

Library of Congress Cataloging-in-
Publication Data

Beer, R. (Rudolf) [Endodontologie.
English] Endodontology/Rudolf
Beer, Michael A. Baumann, and
Syngcuk Kim ; translated by Richard
Jacobi ; [illustrations by Albrecht
Ruech]. p. cm. - (Color atlas of
dental medicine) Includes biblio-
graphical references and index.
ISBN 3-13-116461-1 (hardcover :
GTV). - ISBN 0-86577-856-6
1. Endodontics Atlases.

2. Root canal therapy Atlases.
1. Baumann, Michael A. 11. Kim,
Syngcuk. 111. Title. IV. Series.
[DNLM: 1. Dental Pulp Diseases
Atlases. 2. Root Canal Therapy-
instrumentation Atlases. 3. Root
Canal Therapy-methods Atlases.
WU 17 B415e 1999] RK 351.B4413
1999 617.6'342-dc21 DNLM/DLC
for Library of Congress 99-28377
CIP

Illustrations by
Albrecht Ruech, Spay

This book, including all parts
thereof, is legally protected by
copyright. Any use, exploitation, or
commercialization outside the
narrow limits set by copyright
legislation, without the publisher's
consent, is illegal and liable to
prosecution. This applies in particu-
lar to photostat reproduction, copy-
ing, mimeographing or duplication
of any kind, translating, preparation
of microfilms, and electronic data
processing and storage

This book is an authorized transla-
tion of the German edition published
and copyrighted 1997 by Georg
Thieme Verlag, Stuttgart, Germany.

Title of the German edition:
Endodontologie

© 1999 Georg Thieme Verlag, Rudi-
gerstr. 14, 70469 Stuttgart, Germany
Thieme New York, 333 Seventh
Avenue, New York, N.Y 10001 USA
Typesetting by G. Miiller, Heilbronn
Printed in Germany
by K. Grammlich, Pliezhausen

ISBN 3-13-116461-1 (GTV)
ISBN 0-86577-856-6 (TNY) 1 2 3

In the Series "Color Atlas of Dental Medicine"

K.H. & E.M. Rateitschak, H.F. Wolf,
T.M. Hassell
Periodontology, 2nd edition

A.H. Geering, M. Kundert, C. Kelsey
• Complete Denture and Overdenture
Prosthetics

G. Graber
Removable Partial Dentures

F.A. Pasler
• Radiology

T. Rakosi, I. Jonas, T.M. Graber
Orthodontic Diagnosis

H. Spiekermann
* Implantology

H. F. Sailer, G. F. Pajarola
* Oral Surgery for the General Dentist

R. Beer, M. A. Baumann, S. Kim
Endodontology

Important Note: Medicine is an
ever-changing science undergoing
continual development. Research
and clinical experience are contin-
ually expanding our knowledge, in
particular our knowledge of proper
treatment and drug therapy. Insofar
as this book mentions any dosage or
application, readers may rest assured
that the authors, editors, and pub-
lishers have made every effort to
ensure that such references are in
accordance with the state of knowl-
edge at the time of production of
the book.

Nevertheless this does not in-
volve, imply, or express any guar-
antee or responsibility on the part of
the publishers in respect of any dosage
instructions and forms of application
stated in the book. Every user is
requested to examine carefully the
manufacturers' leaflets accompany-
ing each drug and to check, if neces-
sary in consultation with a physician
or specialist, whether the dosage
schedules mentioned therein or the
contraindications stated by the
manufacturers differ from the state-
ments made in the present book.
Such examination is particularly
important with drugs that are either
rarely used or have been newly
released on the market. Every
dosage schedule or every form of
application used is entirely at the
user's own risk and responsibility.
The authors and publishers request
every user to report to the publishers
any discrepancies or inaccuracies
noticed.

Some of the product names,
and registered designs
patents referred to in this book are in fact
registered trademarks or proprietary
names even though specific refer-
ence to this fact is not always made
in the text. Therefore, the appearance
of a name without designation as
proprietary is not to be construed as
a representation by the publisher
that it is in the public domain.

Preface

In recent years development was rapidly accelerated by the introduction of rotating instruments made of nickel-titanium alloys. With these instruments the root canal system can be prepared more efficiently, more predictably, more precisely, and with greater conservation of tooth structure than before. Continuing perfection of the alloys and new improvements in cutting designs, along with reliance on the fixed ISO standards of taper and cutting lengths, have contributed to vigorous advancement in the field.

-Gutta-percha, now as before, is considered the material of choice, and very good results can be achieved with it using a wide range of thermoplastic filling methods.

-The apicoectomy has been completely redefined through the use of ultrasonic device and microinstruments under the surgical microscope, making it possible to operate more precisely and with less sacrifice of tooth structure.

-The operating microscope has already commanded an important place for itself in that, since 1999, all postgraduate courses in dental schools have made its use mandatory. This adds to endodontic treatment a greater measure of sureness, precision, quality, and efficiency. The presence of four or more canals in maxillary molars will be recognized more frequently, many complications (e.g., fractures of instruments) will be avoided, removal of posts with newly introduced instruments will be facilitated, and monitoring of treatment progress will be made simpler.

A few completely new techniques that are finding increasing usage have the potential to change our understanding of, and approach to, endodontic treatment. For example, diagnosis may be complemented by true sensitivity testing through laser Doppler measurements. Use of magnetic resonance techniques to produce images in the microscopic range would open the way to a three-dimensional reproduction of the endodontium without the ionizing radiation of conventional radiographs, and perhaps will even reveal the histopathologic condition of the pulp tissue.

Unlike conventional textbooks, this atlas of endodontology covers a large number of endodontic cases in their entirety through the extensive use of illustrations, and demonstrates the practical interchangeability of the methods presented. Through the familiar step-by-step manner of presentation that has proven so effective in previous Color Atlases of Dental Medicine, the practicing dentist is provided with a convenient [guide](#).

Essen, Cologne, and Philadelphia,
in the summer of 1999

Rudolf Beer,
Michael A. Baumann,
and Syngcuk Kim

Acknowledgments

Thanks are due first to those colleagues who by their contributions from their special areas have helped make this presentation of endodontology as complete as possible:

Dr. Adrian Lussi, Chief Physician of the Clinic for Conservative Dentistry, Dental Clinics of the University of Bern, Switzerland for his contributions related to certain aspects of caries diagnosis and especially for his new ideas on preparation and filling of the root canal system.

Dr. Christoph Benz, Professor and Chief Physician in the Polyclinic for Conservative Dentistry and Periodontology, Ludwig-Maximilians University, Munich, Germany for his contribution on radiovisiography.

Dr. Theodore P. Croll, Doylestown Pediatric Dentistry, Doylestown, USA, for his cooperation with the topic of microabrasion and bleaching of teeth.

Dr. Matthias Frentzen, Professor and First Chief Physician at the Polyclinic for Conservative Dentistry and Periodontology, Rhenish Friedrich Wilhelms University, Bonn, Germany. He prepared the chapter on lasers in endodontia.

Dr. James L. Gutmann, Professor and Director of the Baylor College of Dentistry, Dallas, USA, who contributed photographs for the chapters Root Canal Obturation and Traumatic Tooth Injuries.

Dr. Markus D. W. Lipp, Clinic for Anesthesiology, Johannes Gutenberg University, Mainz, Germany, who presented information on local anesthesia.

Dr. Clifford J. Ruddle, Assistant Professor, Department of Graduate Endodontics, University of California, Los Angeles, and Santa Barbara, USA, who made a contribution concerning vertical condensation of gutta-percha.

The essential component of an illustrated atlas for conveying the scientific content is visualization. Therefore we must thank Albrecht Ruech who, with great expertise, breathed life into the drawings. He combines, in a unique way, the artistic gift with the ability to illustrate technical concepts. Throughout the project he maintained a spirit of enthusiasm and joy, and always kept an open ear to any discussion or suggestions dealing with the presentation.

Mr. Stephan Gutbier and Mr. Thies Schoning (Department of Photography of the Dental Clinic, University of Cologne) expertly produced a large portion of the photographs of instruments and materials. We are grateful to them, as well as to Mrs. Susanne Urbanek (MTA of the Department of Conservative Dentistry and Periodontology, Dental Clinic, University of Cologne) who prepared the SEM images of the instruments, and to Dr. Gerd Mayerhofer for the excellent prosthetic treatment shown in some of the cases.

From the people at Thieme Verlag we always received ideal support and attention to all details and questions that arose. In this regard our very special thanks are due to Dr. Bergman for his attention to the English language publications, and to Dr. Urbanowicz, Mr. Fleischmann, and Mr. Pohlmann. In addition, Mr. Schwarz from the Reproanstalt Porupsky in Stuttgart had a large part in the transposition of all the illustrations and the excellent technical production of the entire atlas. We thank the two editors of the series Color Atlases of Dental Medicine, Prof. Dr. Klaus Rateitschak and Dr. Herbert F. Wolf, for their many valuable suggestions during the planning and formation of the book into its present layout in keeping with the unique spirit of the series.

Such a large and comprehensive project as this Atlas of Endodontology arises from the effective and open-minded interaction of all those involved. Therefore we would like to thank not only those mentioned by name, but everyone who contributed to its success by giving a part of themselves, be it in the form of a photograph, a useful piece of information, a technical consultation, or simply a word of encouragement.

It requires more than an ideal medium for the success of an idea. Therefore the special thanks we give to Dentsply Endodontics applies as well to all the other firms that gave us their generous assistance.

Table of Contents

v	Preface	
vi	Aknowledgement	
viii	Table of Contents	
1	Pathology and Diagnosis	
2	Diagnosis of Proximal Caries	
4	Diagnosis of Fissure Caries	
7	Smooth Surface Caries	
8	Reversible Pulpitis	
10	Acute Irreversible Pulpitis	
12	Presumptive Diagnosis	
14	Carious Pulp Exposure	
16	Necrosis of the Pulp Tissue	
18	Intentional Devitalization	
20	Filling Materials and Pulp Necrosis	
22	Bacterial Infection in the Root Canal	
24	Treatment of Bacterial Infection	
26	Acute Apical Periodontitis	
28	Periapical Abscess	
30	Chronic Apical Periodontitis	
32	Chronic Apical Periodontitis and Radicular Cysts	
34	Radicular Cysts	
35	Examination and Diagnosis	
36	Extraoral Examination	
37	Intraoral Examination	
38	Sensitivity Tests	
39	Clinical Examination and Selection of Therapy	
40	Radiographic Diagnosis and Interpretation	
42	Radiography in Endodontics	
44	Digital Radiographic Technique	
44	-Intraoral Systems	
44	-Contrast Enhancement	
44	-Positive-Negative Representation	
44	-False Color Representation	
44	-Millimeter Grid	
45	-Resolution	
45	-Dynamic	
45	-Filters	
45	-Projection Angle	
46	Uses of Digital Radiography	
47	Anatomy	
48	Methods of Reproducing Root Canal Anatomy	
49	-Three-dimensional Computer Reconstruction	
50	-Magnetic Resonance Imaging (MRI)	
51	Fundamentals	
51	-Classification of Canal Configurations	
52	-Maxillary Anterior Teeth	
53	-Mandibular Anterior Teeth	
54	-Maxillary Premolars	
55	-Mandibular Premolars	
56	-Maxillary Molars	
57	-Characteristics of Maxillary First Molars	
58	-Mandibular Molars	
59	Instruments and Materials	
60	The Three Basic Instruments...	
61	... and Their Modifications	
62	Instruments from Titanium Alloys	
64	Engine-Driven Instrumentation	
66	Sonic and Ultrasonic Systems	
68	Microsurgical Endodontics	
69	Lasers in Endodontics	
70	-Vitality Test with the Laser Doppler Probe	
70	-Laser Treatment of Cut Dentin and the Pulp	
71	-Vital Amputation	
71	-Sealing the Root Canal	
72	-Root Canal Preparation	
72	- <i>Root Canal Disinfection</i>	
73	Irrigating, Drying, and Medicated Dressings	
74	Gutta-percha	
76	Cold and Warm Condensation of Gutta-percha	
77	Rubber Dam	
78	Rubber Dam Material	
79	Rubber Dam Clamps	
80	Additional Preparations	
81	Placing the Rubber Dam	
81	-Rubber Dam Application I (Bow Technique)	
82	-Rubber Dam Application II (Wing Technique)	
84	-Rubber Dam Application III (Rubber First)	
85	-Rubber Dam Application IV (Clamp First)	
86	Special Cases	
87	Local Anesthesia	
88	Anesthetic Solutions	
90	Selection	
90	Side Effects	
91	Access Preparation	
92	Interim Restorations	
94	Opening the Pulp Chamber	
95	Uncovering the Canal Entrances	
96	Probing the Canal Entrances	
98	Straight-Line Access to the Canals	
100	Obliterated Root Canals	
102	Locating Canals with the Surgical Operation Microscope	
104	Chemical Aids	
107	Root Canal Preparation	
108	Radiographic Length Determination	
110	Difficulties in Length Determination	
112	Loss of Working Length	
114	Working Length with Apical Resorption	
116	Electronic Length Determination	
118	Cleaning and Shaping	

120	Balanced Force Technique	209	Retreatment of Endodontic Failures
122	Step-Back Technique	210	Failures and Root Canal Anatomy
124	Step-Down Technique (Crown-Down Technique)	212	Indications for Retreatment
126	Problem Solving during Instrumentation	214	Pain Following Root Canal Treatment
126	-Step Formation	216	Removal of Post-Cores
126	-Funnel Formation	218	Retreatment of Gutta-percha filled canals
127	-Perforation	222	Removal of Broken Instrument Fragments
127	-Overinstrumentation	228	Bypassing Fractured Instruments
128	Surface of the Canal Wall Following Hand Instrumentation	230	Repair of Lateral Perforations
130	Instrumentation under the Surgical Microscope	232	Repair of Coronal Perforations
132	Instrumentation of Maxillary Molars	233	Microsurgical Endodontics
134	Engine-Driven Canal Instrumentation	234	Principles of Endodontic Microsurgery
136	Instrumentation with Profile	235	Illumination and Magnification
138	Instrumentation with Tri Auto ZX	236	Indications for Surgical Procedures
140	Instrumentation with the Quantec Series 2000	237	Presurgical Examination
142	Instrumentation with Lightspeed	238	Flap Design
144	Canal Surface After Engine-Driven Instrumentation	238	-Mucoperiosteal Flap
145	Disinfection	239	-Full Thickness Flaps
146	Microbial Infection of Root Canals	240	Apical Resection
148	Root Canal Irrigation	241	Resection Angle
150	Irrigation of the Periapical Lesion	242	Hemostasis
152	Ultrasonic Root Canal Irrigation	243	Microscopic Inspection of the Resected Surface
154	Removal of the Smear Layer	244	Isthmus
156	Antibacterial Interim Dressings	246	Clinical Treatment of the Isthmus
158	Application of Calcium Hydroxide (Ca[OH]2)	248	Retrograde Preparation with Ultrasonic Instruments
160	Interim Dressing for Chronic Apical Periodontitis	250	Drying the Retrograde Preparation
162	Interim Dressing for Acute Apical Periodontitis	251	Retrograde Obturation
164	Clinical Results	252	Super EBA (ethoxybenzoic acid) Cement
165	Root Canal Obturation	254	Effect of Sutures on Soft-Tissue Healing
166	Biological Properties	255	Traumatic Tooth Injuries
167	Physical Properties	256	Classification
168	Prerequisites for Filling the Root Canal	258	Crown Fractures
170	Lateral Condensation of Gutta-percha	260	Crown-Root Fractures
172	Adaptation of Gutta-percha	262	Vertical Root Fractures
176	Corrections During Condensation	264	Cracked Teeth
178	Gutta-percha Master Point Too Long	267	Postendodontic Restoration
180	Gutta-percha Master Point Too Short	268	Provisional Coronal Seal
182	Thermomechanical Condensation	270	Fracture Risk and Partial Veneer Crowns
183	Thermafil	272	Coronal Restoration
184	Thermoplastic Injection Technique	274	Endodontic Posts
186	Three-Dimensional Gutta-percha Fillings	278	Cast Post-Cores
188	Vertical Condensation: Part I	280	Coronal Restorations and Treatment Results
190	Vertical Condensation: Part II	282	Restoration of Hemisected Teeth
192	Clinical Results	283	Bleaching of Teeth
194	Fully Automatic Method of Root Canal Preparation	284	Causes of Tooth Discoloration
196	Fully Automatic Method of Root Canal Obturation	286	Thermocatalytic Bleaching
198	Heated Gutta-percha	287	Walking Bleach Technique
199	Endodontics in the Deciduous and Mixed Dentitions	288	Microabrasion Method
200	Pulpotomy in the Deciduous Dentition	290	Nightguard Vital Bleaching
202	Pulpectomy in the Deciduous Dentition	293	References
203	Direct Pulp Cap	305	Illustration credits
204	Pulpotomy in the Mixed Dentition	306	Index
206	Teeth with Developmental Defects		
206	-Dens Invaginatus		
207	-Lingual Groove in the Root		
208	Apexification		

My thanks go to my wife Marianne
who substantially furthered the success of this work
through her special contributions.

Rudolf Beer

My wife Uta Annette and
our daughter Helena Uta Regina
deserve my special thanks for their loving support.

Michael A. Baumann

Pathology and Diagnosis

Intensive microbiologic, immunologic, and morphologic research investigations, especially during the past decade, have shown that colonization of tooth surfaces by pathogenic bacteria is accompanied by humoral and cellular defense mechanisms of the organism not only during the more advanced stage of infection, but also throughout the initial stages. Penetration of these complex defenses, which is usually of limited duration, disturbs the equilibrium of the system and results in disease. Within the dental pulp, this biologic equilibrium has to do with the balanced calcium and phosphate ion exchange during the continuous demineralization and remineralization of the enamel and exposed dentin. As long as a disease process is reversible, as is incipient caries, the capacity for progression and regression is present. Carious breakdown means that enamel is being demineralized by acidogenic plaque more rapidly than it can be remineralized. Now, in its early stages, the caries has become a chronic destructive process, in which irreversible structural changes will preclude any further remission.

If one looks at the dynamics of demineralization and remineralization, and the etiology of caries against the epidemiologic background, and compares these with the results of therapy, a pattern of active disease spurts alternating with resting phases emerges. During these periods of remission, the chronic destructive process is not reversed, but is only brought to a standstill. This *concept of progression and stagnation* (Socransky et al. 1984) is strongly influenced by the defensive capability of the organism.

Progression is defined by invasion of caries into dentin with inflammation and loss of connective tissue. Stagnation means the defenses are increased, there are defensive inflammatory cells in the tissues, and connective tissue is being replaced by secondary dentin or granulation tissue. Histologically, this ever-changing dynamic process in carious teeth is recorded over the years through deposition and destruction of dentin.

For the practitioner, the obvious questions that arise are how to classify the histopathologic condition of the pulp and the apical periodontal tissues, and how to initiate treatment that is appropriate, considering the background of stagnation or progression. Based upon clinical findings, differentiations are made between a clinically sound pulp, reversible pulpitis, irreversible pulpitis, a necrotic pulp, and apical periodontitis. These distinctions are based solely upon clinical observations; generally, a correlation between certain symptoms and a specific pathologic entity cannot be expected. Making the distinction between reversible and irreversible inflammations of the pulpal tissues can be a diagnostic problem, because they can present similar clinical symptoms. Histologically, the diagnosis of acute inflammation is based upon the predominance of neutrophilic granulocytes. However, this diagnostic picture does not always coincide with the appearance of pain symptoms because neutrophilic granulocytes can also be found in cases where there is no pain (Langeland 1981, Lin and Langeland 1981 b, Lin et al. 1984).

Diagnosis of Proximal Caries

Caries begins with microscopic demineralization of the affected enamel or cementum surface. As it progresses, the enamel first becomes chalky, then its surface is broken through. In this stage, the caries is easy to detect, but has frequently progressed so far that extensive restorative and endodontic treatment is necessary. More difficult to diagnose, on the other hand, are lesions that are in their early stages and dentinal lesions with macroscopically intact surfaces. Finally, a decision must be made as to whether preventive measures will suffice or whether invasive restorative measures must be taken.

Epidemiologic studies have shown that-coincident with a general decrease in caries prevalence in industrialized countries-the occlusal surfaces of the permanent molars of children and young adults are the surfaces most frequently attacked by caries. In contrast to fissure caries, proximal and smooth surface caries is much less frequent. Radiographically evident incipient lesions in enamel of the proximal surfaces have likewise shown a decline. In adults, the probability that these lesions would penetrate further has increased, and this has caused the proportion of proximal caries to rise again.

In the diagnosis of proximal caries, clinical examination, bitewing radiographs, and fiberoptic transillumination (FOTI) can be called upon. During examination with an explorer, many carious lesions with cavity formation go undiagnosed. Bitewing radiographs are still the method of choice for the diagnosis of approximal caries, and account for the detection of approximately three-fourths of dentinal carious lesions (Mile-

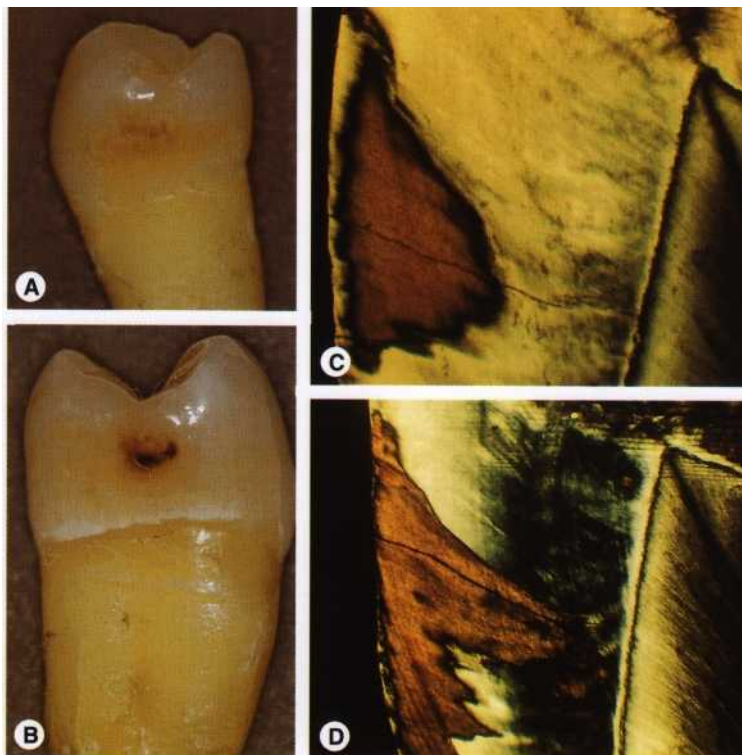
man and van der Weele 1990, Noar and Smith 1990). Most studies found that where there is a dentinal lesion, there is a surface that has been broken through, which precludes any chance for remineralization (Marthaler and Germann 1970; Bille and Thylstrup 1982; Mejare and Malmgren 1986). Even though the actual extent of caries is underestimated with the radiograph, it may be concluded that the specificity, that is, the ability to recognize sound teeth as sound, is approximately 95% (Mileman and van der Weele 1990). New, more sensitive X-ray films seem to be the equal of earlier films as far as caries diagnosis is concerned. Because they produce the same degree of contrast with significantly less radiation, their use is now highly recommended. Preventive measures can impede further penetration and even promote remineralization, provided that the enamel surface has not yet been disrupted. The progression of caries can be monitored with periodic radiographs. Their interval depends, among other things, upon the individual's susceptibility to caries. Patients at high risk of caries should be radiographed every year while those at very low risk need only be radiographed every 2-4 years. The time in which it takes caries to penetrate the enamel of a mature permanent molar in a patient with good oral hygiene can exceed 5 years. This offers the opportunity to postpone invasive restorative treatment and to observe whether the caries progresses or regresses. The rate at which penetration progresses can be estimated by comparing radiographs produced at different times by a standardized technique. Recently erupted teeth, on the other hand, demonstrate a markedly reduced pene-

1 Incipient enamel caries
A Extracted tooth with incipient proximal caries just below the contact point.

B The histologic preparation demonstrates an intact surface layer (10-30 μm thick). It is sharply demarcated from the body of the lesion. This region shows a markedly decreased mineral content. In the adjacent dark zone there are relatively large as well as small micropores. The first carious structural changes appear in the transparent zone.

C Clinical appearance of a brown-spot lesion with cavitation.

D A completely intact surface layer can no longer be distinguished. The body of the caries has already penetrated through the enamel as early dentinal caries.

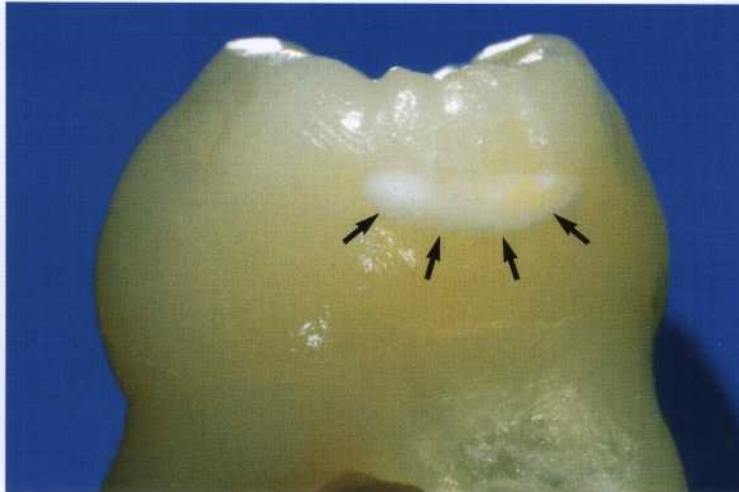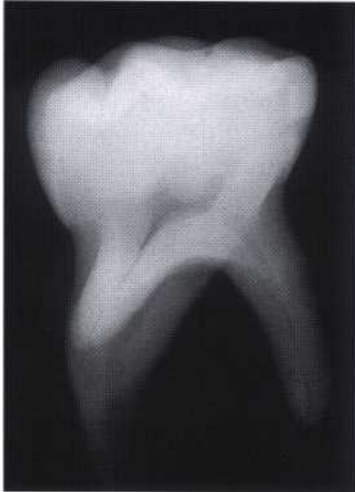


tration time (Marthaler and Wiesner 1973, Shwarz et al. 1984).

In order to minimize overlapping of the images of approximating tooth surfaces, a film holder is recommended. A deviation of the horizontal angle of the X-ray tube by only a few degrees will result in a substantial decrease in correct diagnoses. The image of enamel caries projected into the dentinal area can lead to a false positive diagnosis. Radiolucency in dentin should be treated as invasive only if there is also an unmistakable radiolucency in the enamel region. The ra-

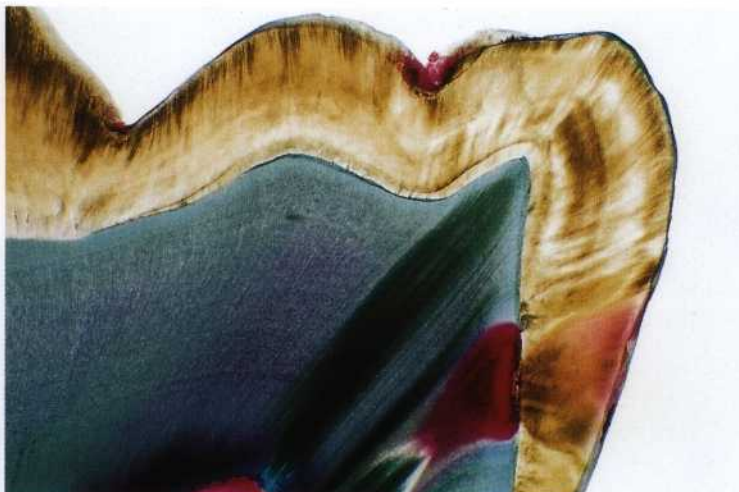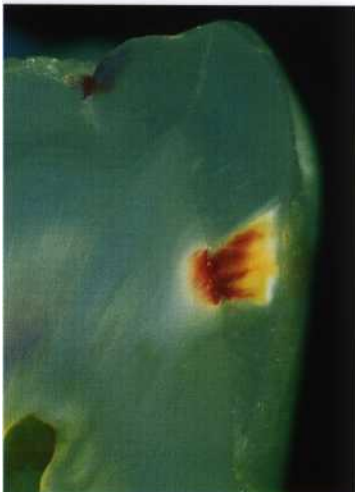diograph should be inspected carefully under magnification and away from the influence of any light coming from the sides.

FOTI can be used in addition to bitewing radiographs if there is no interference from adjacent interproximal fillings that are other than tooth colored. More than 70% of dentinal lesions in anterior teeth can be detected by means of FOTI. Dentinal lesions in posterior teeth, however, can be differentiated only with great difficulty (Pieper and Schurade 1987, Choski et al. 1994).



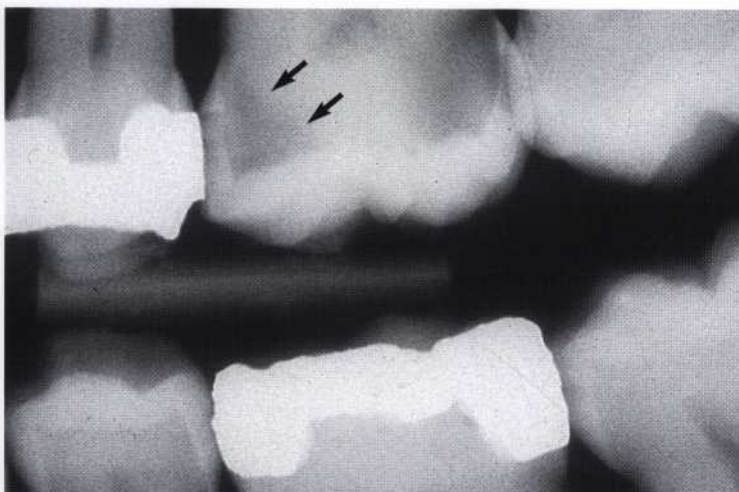
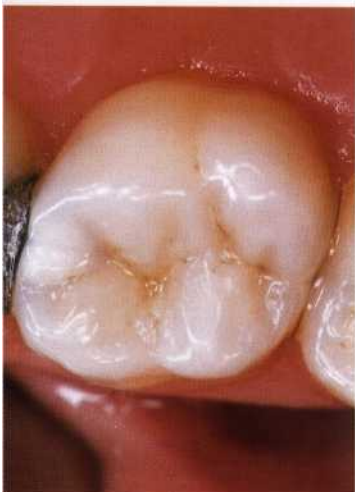2 Extent of caries
The radiograph does not reveal the full extent of the caries.
View of the proximal surface of a deciduous tooth with incipient caries.

Left: Radiograph of the deciduous tooth. The radiolucency barely extends into the dentin.



3 Extent of caries
A histologic section through the center of the lesion reveals a definite invasion into the dentin.

Left: A histologic section through the border of the lesion shows extension into the dentin (UV light).



4 Clinical appearance and bitewing radiograph
The bitewing radiograph reveals extensive destruction of tooth structure in both the mesial and distal regions of the upper left first molar.

Left: Under clinical inspection, an alteration of color can be clearly seen only on the mesial of the same molar.

Diagnosis of Fissure Caries

In addition to clinical examination, bitewing radiographs, and fiberoptic transillumination, another diagnostic method that can be used is the measurement of a tooth's resistance to an applied electrical current.

Studies have clearly demonstrated that the additional use of an *explorer* does not improve the diagnostic results (Lussi 1991, 1993). It appears that an explorer sticks in a fissure more because of the anatomy than because of caries. The explorer has additional disadvantages in that microorganisms are transferred from one place to another, and superficially decalcified areas can be damaged. In some situations, this can lead to accelerated caries progression. It is recommended, therefore, that the explorer-if it is to be used at all-be used only as a tactile instrument with light pressure. It can also be used to remove plaque from the depths of the fissures.

Bitewing radiographs, on the other hand, permit more accurate diagnosis and should therefore be appreciated for their value in diagnosing fissure caries also. It should be mentioned in this regard that only the occlusal caries that extends into the dentin can be identified on radiographs.

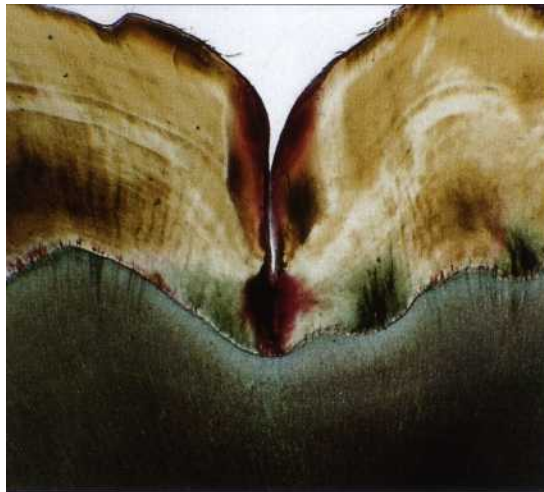The electrical resistance between a tooth and a hand electrode depends upon the condition of the tooth. The greater the amount of tooth structure that has been destroyed and replaced by a more conductive medium, the less the resistance (Lussi et al. 1995 a). This property is utilized in caries diagnosis by means of the *electric caries meter*. It is expected that in the future, the measurement of electrical resistance will be used more and more. This method is especially valuable for detecting caries under a seemingly intact surface (Flaitz et al. 1986). Because the electric caries meter measures the extent of caries only at individual points, we recommend that this method be used as additional verification when the clinical diagnosis is uncertain. Furthermore, it can be used for longitudinal observation of a suspicious area and provides information on the success of intensive preventive treatment.

FOTI of fissure caries is difficult to interpret because of interference from stained fissures and fillings that are not tooth colored. Apart from this, occlusal dentinal caries frequently affects only a small part of the total mass of tooth that is transilluminated and therefore may not stand out clearly.

5 Fissure anatomy

Left: The fissure on this molar extends almost to the dentinoenamel junction and exhibits varying areas of red-stained decalcification.

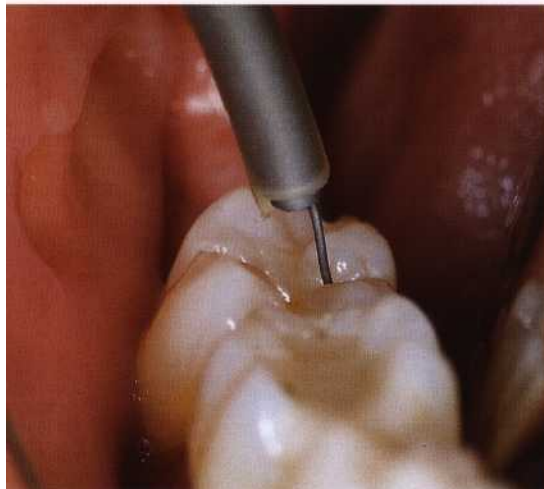
Right: Scanning electron micrograph of the occlusal surface of this molar.



6 ECM caries meter

Left: Use of the ECM caries meter on a patient: air reaches the tooth through the opening in the measuring probe and dries it so that the resistance between the tooth and hand electrode can be measured.

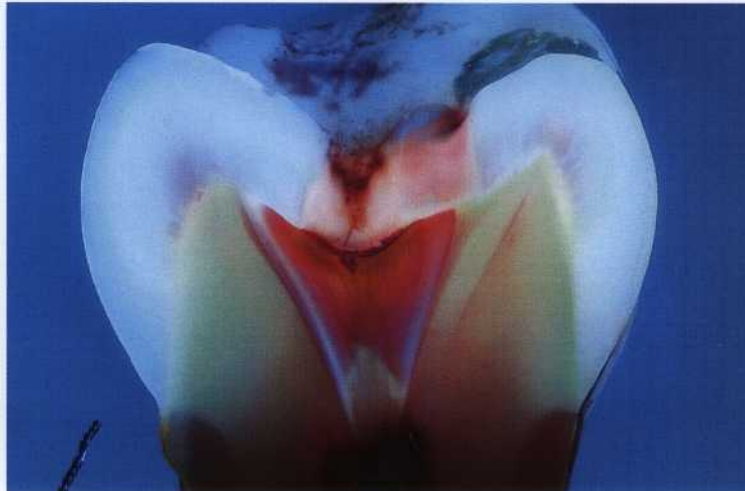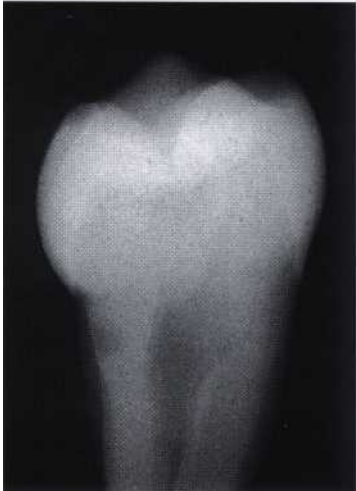
Right: This overview shows, from left to right, the measuring probe, air-flow regulator gauge, and the hand electrode.





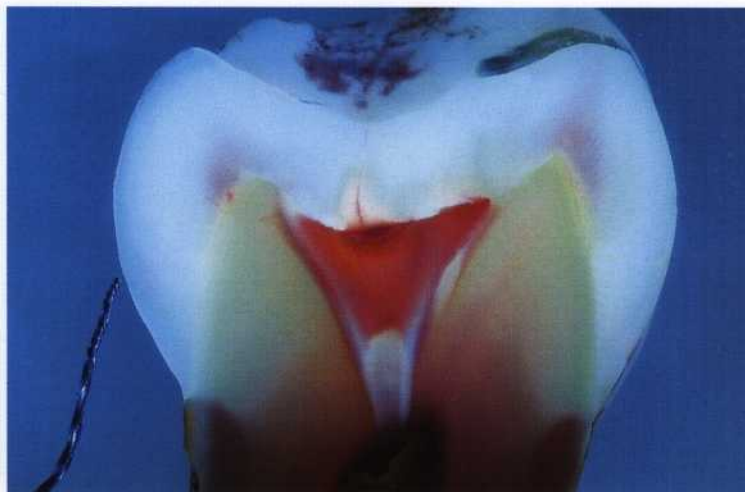
7 Extent of fissure caries
 A histologic section through the center of the fissure of a molar unmistakably shows dentin involvement (UV light).

Left: Occlusal surface of the molar that was judged to be intact by 20 out of 26 dentists.



8 Extent of fissure caries
 Farther toward the periphery the dentinal caries is still clearly visible (UV light).

Left: Radiograph with dentinal radiolucency.



9 Extent of fissure caries
 Even a section through an area with no overlying fissure shows definite decalcification (UV light).

Histology by H. Stich

10 Summary

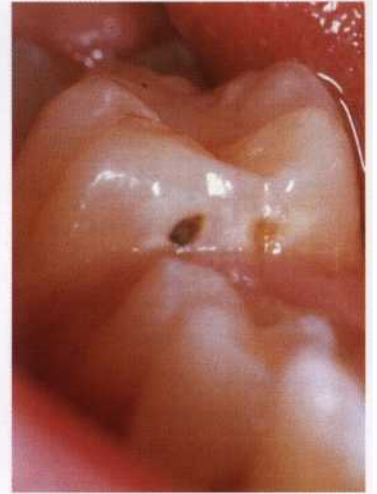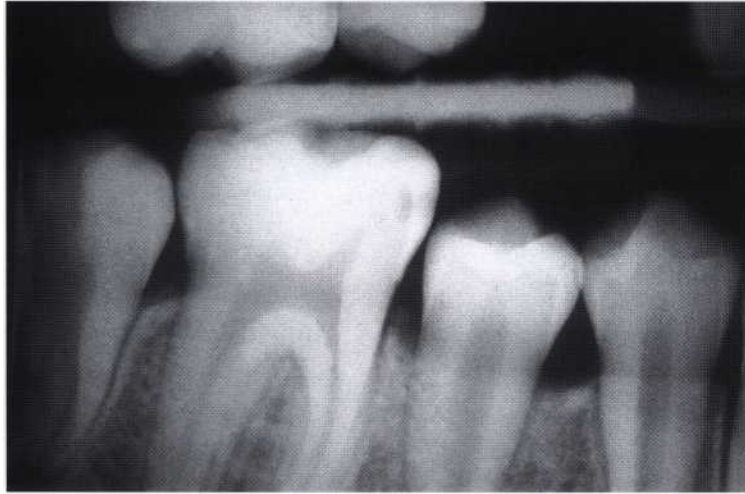Findings, diagnosis	Treatment
<ul style="list-style-type: none"> ● Discolored and/or decalcified areas in fissures (minimal extent), surface intact 	<ul style="list-style-type: none"> ● Fissure sealant ● Prophylaxis
<ul style="list-style-type: none"> ● Definite zone of decalcification at entrance to fissure. Surface intact 	<ul style="list-style-type: none"> ● Small preparation and either more extensive sealant or conventional filling, as conditions dictate ● Prophylaxis
	<ul style="list-style-type: none"> ● Small preparation and either more extensive sealant or conventional filling, as conditions dictate ● Prophylaxis

6 Pathology and Diagnosis

11 Breakdown of the enamel surface

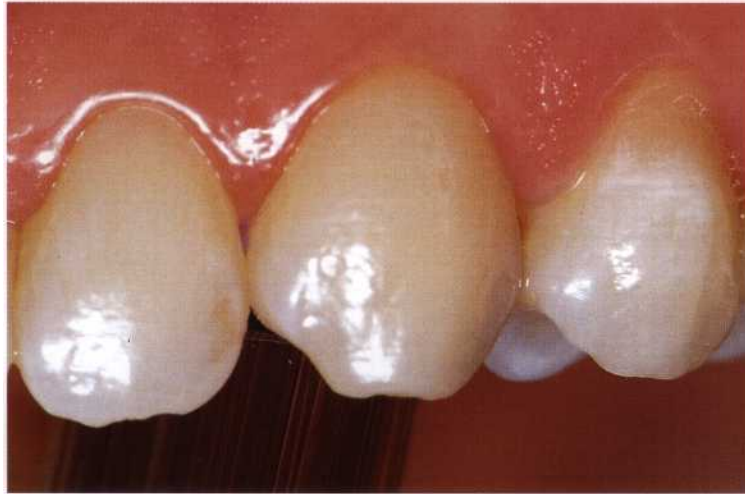Dental lesions that are clearly visible on the radiograph frequently show a breakthrough to the surface, especially in caries-active patients. In these cases, remineralization is not possible. This radiograph shows a distinct radiolucency on the mesial of the lower right first molar.

Right: Clinically, a breakdown of the mesial surface of the molar can be seen.



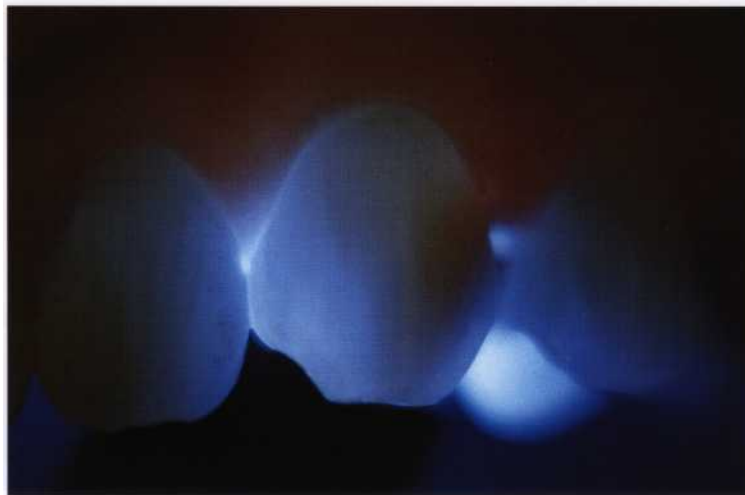
12 Fiberoptic transillumination (FOTI)

This is especially useful for examining anterior teeth and proximal surfaces that are free of interfering opaque restorations.



13 Fiberoptic transillumination (FOTI)

Transillumination clearly discloses caries on the distal of the canine.



Collection A. Lussi

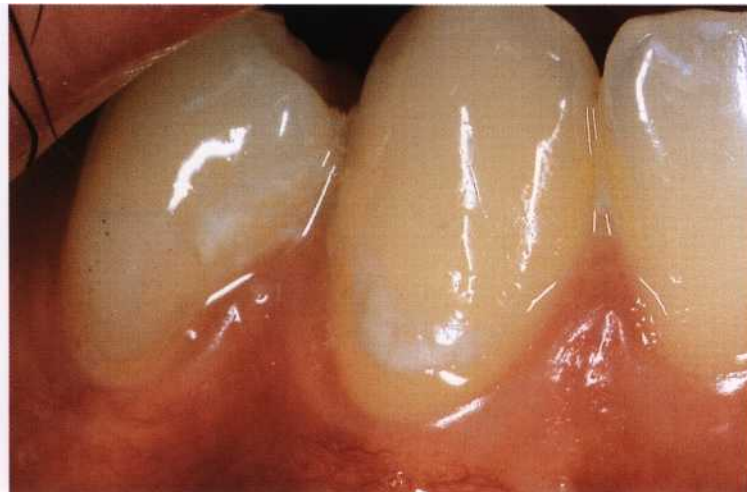14 Summary

Findings, diagnosis	Treatment
● Radiographic lesion, grades 1 & 2	● Prophylaxis only (interdental cleaning, fluoride)
● Radiographic lesion, grade 2 (→ 3)	● Prophylaxis if risk of caries is low ● Restoration if risk of caries is high. Reduce risk of caries!
● Radiographic lesion, grades 3 & 4. Surface broken through	● Restoration

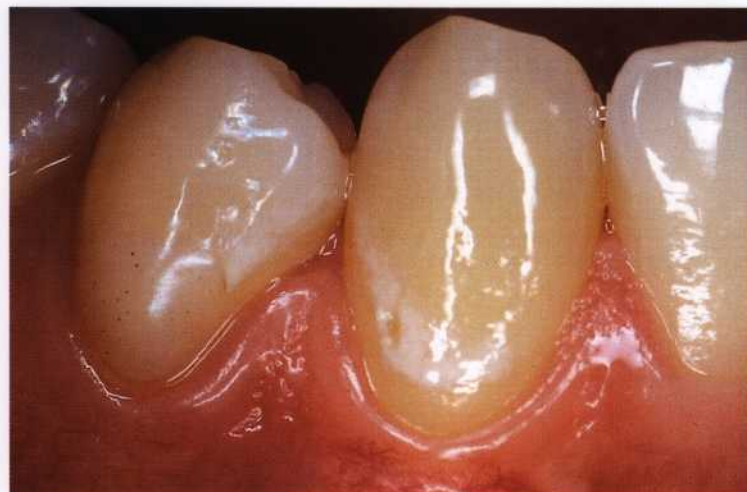Smooth Surface Caries

Today, facial and lingual smooth surface caries is seen only infrequently in Switzerland, Germany, other European countries, and in the USA. If oral hygiene is good these lesions progress slowly, remain static, or even remineralize very well, as has been shown in the classic study by Baker-Dirks (1966). After a 7-year observation period with good oral hygiene, more than half of the incipient lesions ("chalky spots") had changed so much that they were reclassified as sound. Very few of the initial lesions had developed into cavities 8 years later. A band of sound enamel between

the chalky spot and the gingiva is evidence of a prolonged inactive phase (Fig. 15). Smooth surface lesions with intact surfaces are "treated" with optimized prophylaxis, including fluoride applications. A restoration is necessary only when the surface has broken down.



15 Incipient lesion (chalky spot)
With good oral hygiene, smooth surface caries progresses slowly or may even become invisible over time. The area of well-calcified enamel gingival to the lesion indicates that there has been a lengthy caries-inactive phase.



16 Incipient lesion (10 years later)
The chalky area has increased only slightly. The minimal breakdown of the surface in the distal portion of the incipient lesion does not require restoration at this time.

Collection A. Lussi

Findings, diagnosis	Treatment
<ul style="list-style-type: none"> ● Chalky spot (possibly discolored); surface intact or with only localized breakdown 	<ul style="list-style-type: none"> ● Prophylaxis only
<ul style="list-style-type: none"> ● Widespread breakdown of surface 	<ul style="list-style-type: none"> ● Restoration ● Reduction of caries risk!

17 Summary

Reversible Pulpitis

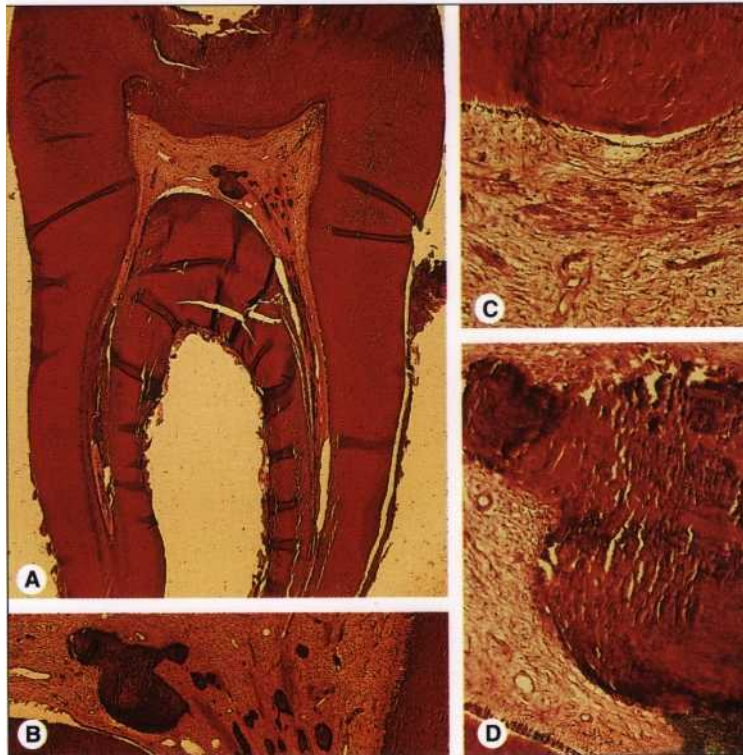
The first inflammatory reactions within the pulp occur when caries from an enamel lesion invades the dentin (Langeland et al. 1973). Histologically, neutrophilic granulocytes, lymphocytes, and macrophages are seen in the odontoblastic layer. The odontoblastic processes end in a layer of sclerosed dentin, where at first mostly peritubular dentin is formed, followed by mineralization of the odontoblastic processes (Frank and Voegel 1980). The processes in the uppermost layer of carious dentin exhibit fringed ends with membranous fragments in the lumens of the tubules. Here are also

found large numbers of bacteria (Yamada et al. 1983). If a chronic superficial carious lesion is present, a small amount of tertiary dentin will have formed and there will be a reduction of the odontoblastic border (Kuwabara and Massler 1966, Baume et al. 1970).

Arrested *caries media* is characterized by the formation of tertiary dentin, reduction of the odontoblastic layer, and cellular infiltration. Where active caries is present, there is not only damage to the odontoblasts, but also massive infiltration of inflammatory cells (Massler and Pawlak 1977).

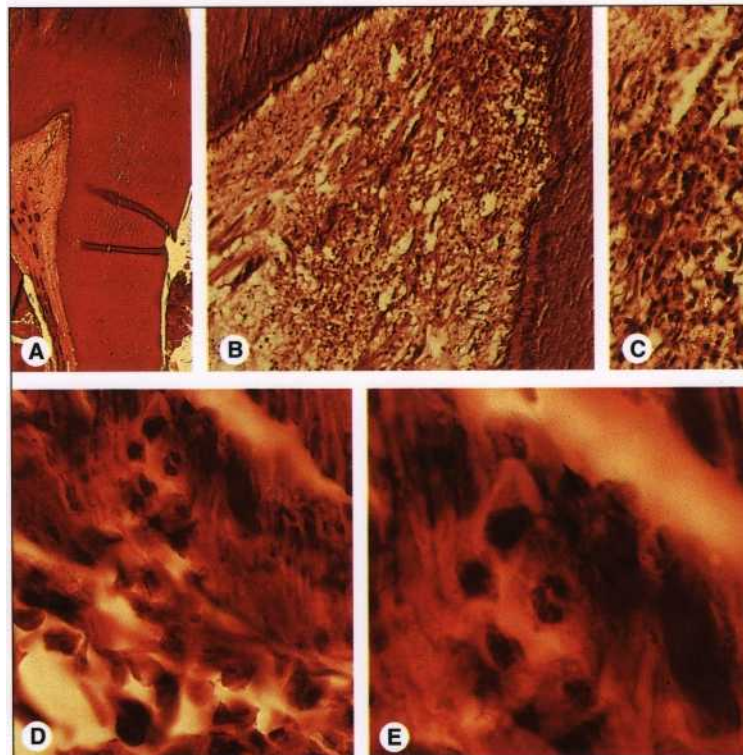
18 Dentinal caries and pulpitis

- A Slowly progressing dentinal caries with clear destruction of the dentinoenamel covering has led to the formation of irregular stimulated dentin as protection against further infiltration of toxins.
- B Within the coronal pulp tissue, several hard-tissue deposits or fibrodenticles can be seen.
- C An enlarged section of the region of stimulated dentin shows an odontoblastic layer that is badly destroyed in places. The stimulated dentin (tertiary dentin) has relatively few tubules and is bounded by a few, relatively newly differentiated, odontoblasts. The adjacent pulp tissue is nearly normal in structure.
- D Fibrodenticles (as intrapulpal dentin) arise as the result of pathologic stimuli. Atubular osteoid denticles are formed by remote pulpoblasts (Baume 1980).



19 Reversible pulpitis

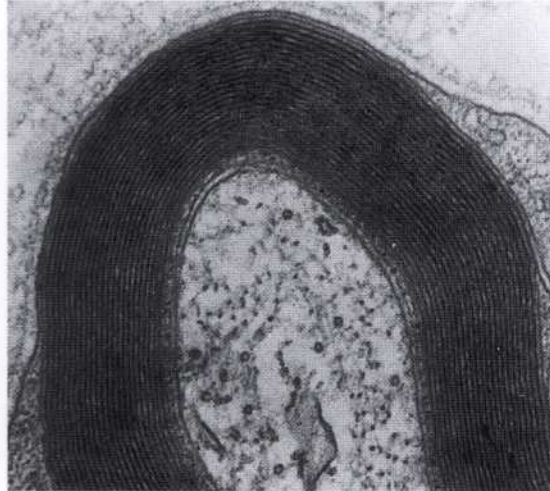
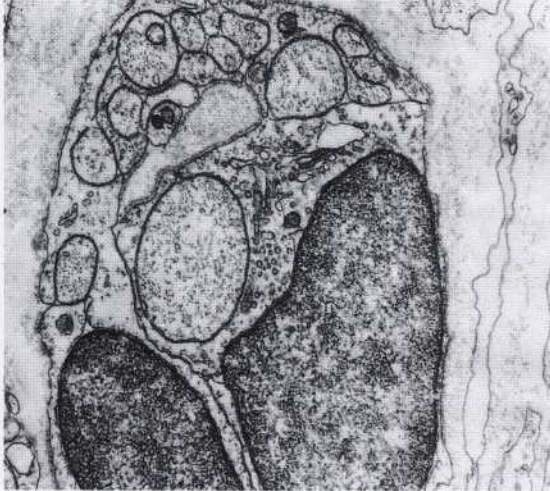
- A There is no evidence of hard-tissue formation in the pulp horn-endotoxins can penetrate unimpeded into the pulpal tissue.
- B Close to the deepest part of the caries the odontoblastic layer and capillary plexus are disrupted, and frequently only fragments can be found.
- C Lysosomal enzymes cause necrosis of endothelial cells, increased vascular permeability, and extravascular edema.
- D/E As bacteria move into the dentinal tubules from the coronal side, neutrophilic granulocytes migrate into the entrances of the corresponding tubules on the pulpal side, decompose, and release tissue-destroying enzymes.



Under the deepest part of the caries, dissolution of the odontoblastic border and loosening of the capillary plexus occurs, and frequently only isolated fragments of blood vessels can be seen (Gangler and Seinige 1979). The enzymes released by damaged granulocytes and macrophages cause necrosis of the endothelial cells, and this results in increased vascular permeability and extracellular edema (Torneck 1981). Nerve fibers appear to remain relatively undamaged in this stage of the carious attack (Torneck 1974). The inflammation gradually spreads, but is still confined to small

regions within the coronal pulp, although damage to the remaining pulp tissue is a real danger. Pathologic mineralization along the canal wall and the first appearance of denticles are further changes that occur (Langeland 1981, Beer and Gangler 1986).

If a restoration is performed at this stage, the endodontic inflammation is reversible, although changes within the pulp tissue may remain as "scar tissue" (Beer 1992b).

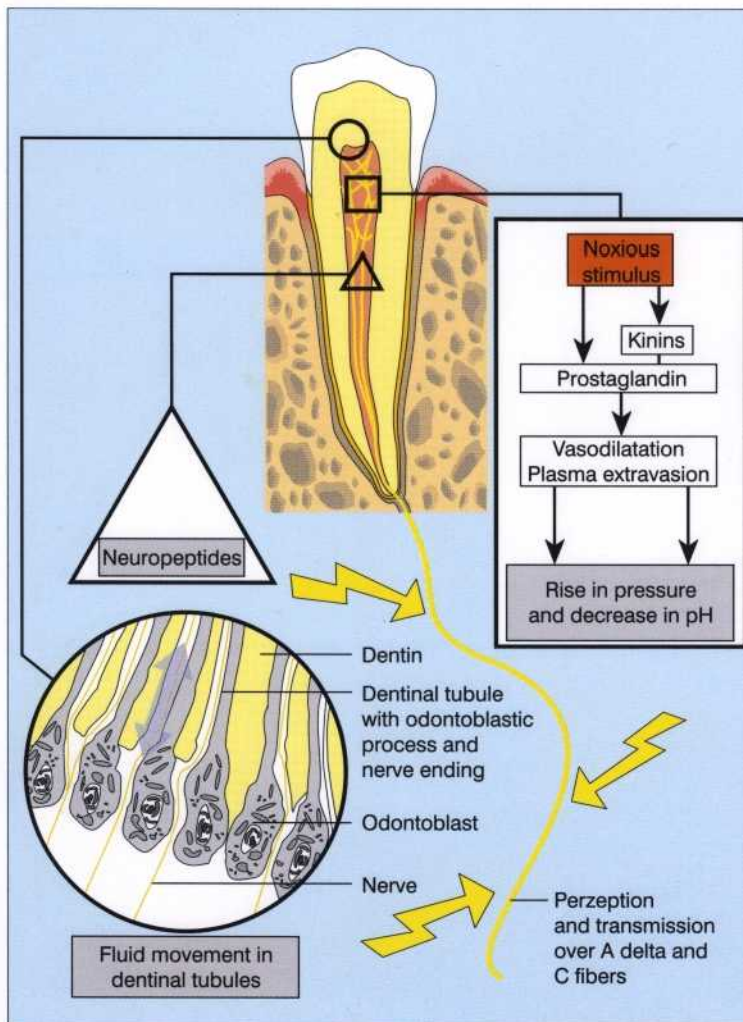


20 Nerve fibers in the pulp
Irritation of free nerve endings can be at the root of dental pain. Electron microscopic studies have shown nonmyelinated nerve fibers contiguous with odontoblastic processes at the dentinoenamel junction (Frank and Nalbandian 1989).

Left: nonmyelinated nerve fibers.

Right: myelinated nerve fibers.

Transmission electron microscope (TEM): F. F. Eifinger



21 Pain mechanism

Afferent innervation of the dental pulp is through thin myelinated A delta fibers and nonmyelinated C fibers. Both are responsible for conduction of pain signals. The former are said to mediate a sharp, well-localized pain sensation while the latter are associated with dull, diffuse pain.

Three theories of the origin of dental pain will be discussed: first, the hydrodynamic theory with movement of fluid within the dentinal tubules; second, direct nerve stimulation; and third, odontoblasts functioning as receptors and synaptic transmitters. Sensory nerve endings in an inflamed region may be stimulated by an increase in intrapulpal pressure, a change in pH, and through the release of prostaglandin and other mediators of inflammation as well as decomposition products. This process is enhanced by the release of neuropeptides from nerve fibers so that normally tolerable stimuli are perceived as painful (Raab 1993).

Acute Irreversible Pulpitis

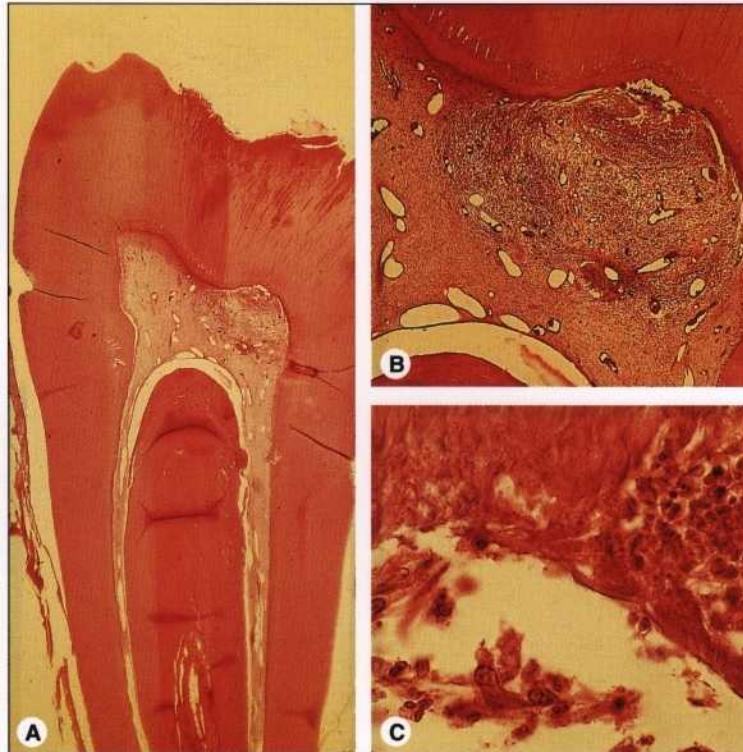
As bacteria spread into the dentinal tubules, neutrophilic granulocytes migrate toward the entrances of the tubules bordering on the pulp, disintegrate, and in doing so release lysosomal enzymes that cause destruction of pulp tissue. During the associated phagocytosis of the destroyed tissue by polymorphonuclear and mononuclear phagocytes, these leukocytes ingest cell fragments, and release lysosomal enzymes that subsequently cause tissue destruction and a chemotactic attraction of more inflammatory cells (Wright 1982).

The irritants that intensify the inflammatory reaction are bacteria, their metabolites and decomposition products, and lastly, decomposition products of the affected dentin. At this time a vicious cycle is established and irreversible pulpitis becomes manifest (Langeland 1981).

The pulp closely surrounding the necrotic region becomes permeated by neutrophilic granulocytes that phagocytize bacteria. This causes liquefaction of entire regions of pulp tissue with the process spreading in an apical direction (Lin et al. 1984).

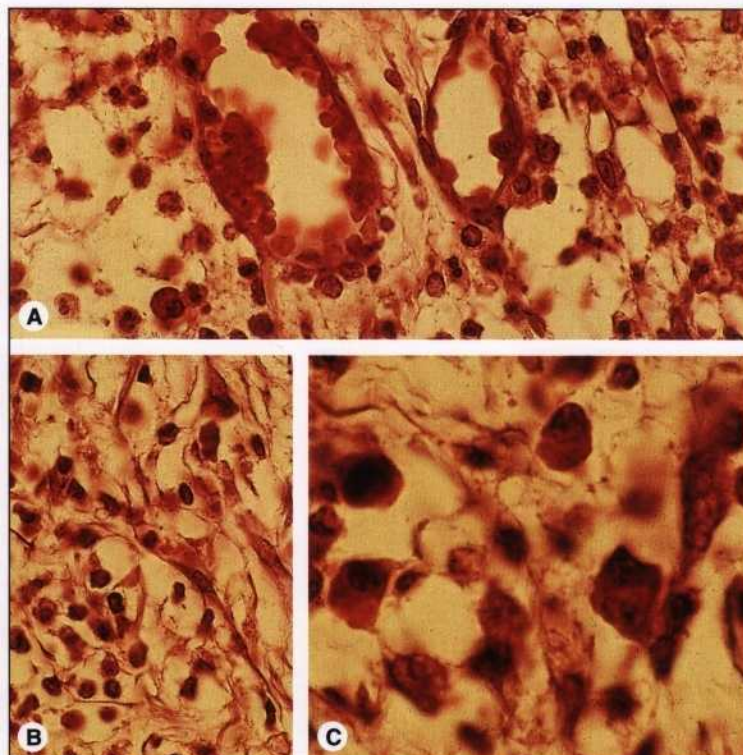
22 Caries and pulpitis

- A Advanced dentinal caries beneath the fissure has reached the pulp tissue, causing a circumscribed area of inflammation.
- B The enlarged section shows a circumscribed area of odontoblastic destruction with no formation of secondary dentin as a protective reaction. There is also massive infiltration of inflammatory cells in the adjacent pulp tissue.
- C The penetration of bacteria into the dentinal tubules triggers chemotactic attraction of neutrophilic granulocytes. These granulocytes can be seen in both the adjacent pulp tissue and the affected dentinal tubules. "Empty spaces" within the subodontoblastic layer are areas of micronecrosis with accumulations of pus, and contain additional polymorphonuclear granulocytes.



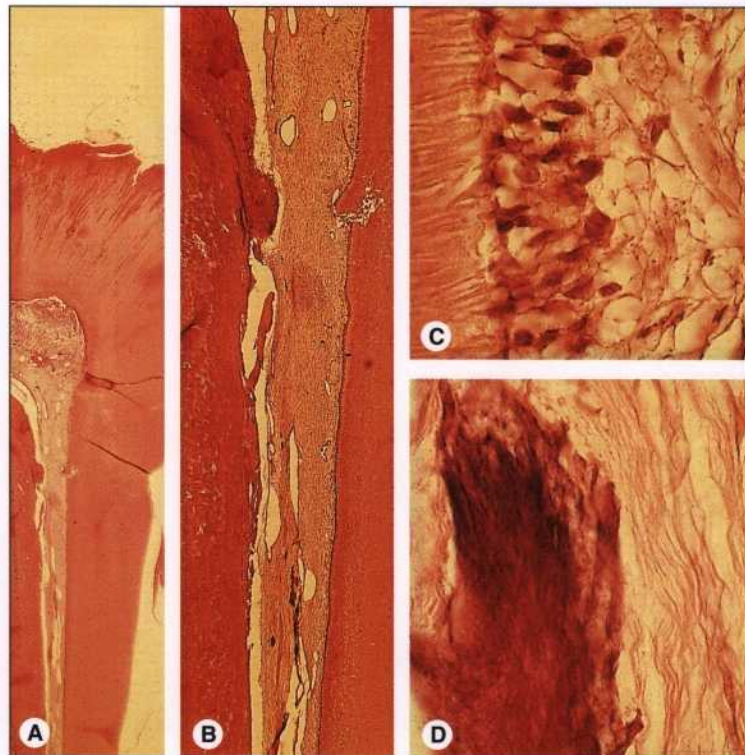
23 Accumulation of inflammatory cells

- A The region opposite the carious destruction of the odontoblastic layer is dominated by neutrophilic granulocytes. These can be seen both around and within the blood vessels; the expression of a persistent chemotactic attraction. The large "empty spaces" indicate incipient tissue necrosis.
- B The surrounding tissue contains both acute polymorphonuclear granulocytes and chronic mononuclear granulocytes.
- C In the adjacent area are plasma cells and lymphocytes that can produce, among other things, lymphokines. A distinction is made between factors that activate macrophages and dentinoclasts and those that impede cell migration. As lymphotoxins they can also have a direct destructive effect upon tissues.



The histologic picture of acute inflammation with a predominance of acute inflammatory cells does not mean, however, that all the clinical symptoms of acute inflammation will be present. Langeland (1981) could uncover no history of pain symptoms in 81 of 224 teeth with deep caries, partial pulp necrosis, and severe inflammation. In addition, there was no correlation between the depth of caries and the occurrence of pain. Frequently in cases of irreversible pulpitis with necrosis within the pulp, widening of the apical periodontal space also occurred. The cause of this early periapical

reaction appears to be the penetration of toxins through intact radicular pulp tissue. Endotoxin that is released from the outer membrane of Gram-negative bacteria is able to initiate a complement reaction. The activation of complement causes the release of biologically active peptide, whereupon the vascular permeability increases and neutrophilic granulocytes and macrophages are attracted. Enzymes that are released during phagocytosis then produce destruction of bone tissue (Pitts et al. 1982).



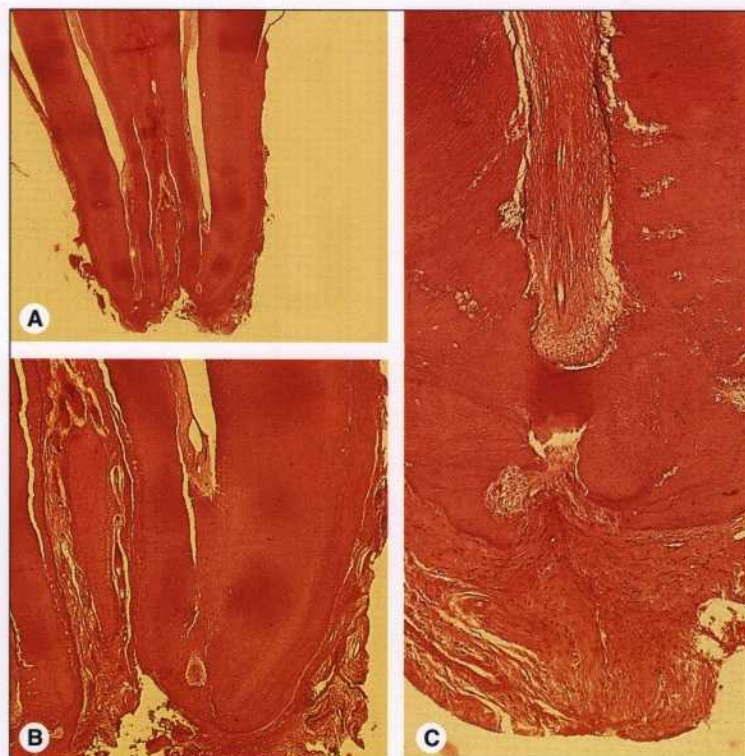
24 Inflammation-free root canal pulp tissue

A The carious invasion and the region of inflammation in the coronal pulp can be seen in this wide-angle view, whereas the pulp of the root canal is vital and free of inflammation.

B The root canal pulp contains a few diffuse calcifications and hard-tissue deposits on the dentin of the canal wall.

C The odontoblastic layer is intact without inflammatory cell infiltration. In addition, the subodontoblastic space is normal in structure. The course of the dentinal tubules shows no irregularities that would indicate toxic damage.

D Under higher magnification a single calcification can be seen in the root canal. The adjacent pulp tissue is vital and free of inflammation.



25 Periapical inflammation

A The pulp of the root canal is free of inflammation, but there is granulation tissue in the periapical region. A periapical radiolucency is also visible on the radiograph.

B The pulp of the root canal is totally free of inflammation. The isolated hollow spaces are artifacts caused by the preparation technique. The formation of vacuoles can be the result of delayed fixation of the tissue, too short a fixation time, and fixation under pressure which can cause postmortem settling of tissue. These are not related to degenerative changes (Langeland 1957, Beer 1983). Mononuclear cells are visible periapically.

C In this enlarged view of the periapical region the adherent granulation tissue can be identified.

Presumptive Diagnosis

The objective of endodontic diagnosis is to determine which teeth are to be treated and to define the pathological condition of the pulp and the periradicular tissue. Aside from the clinical findings, the subjective phenomenon of *pain* presents an essential criterion for estimating the condition of the pulp, although generally a direct correlation between the histopathologic condition and the patient's clinical symptoms cannot be expected. Tooth pain is an expression of an irreversible tissue change in only about one-third of patients.

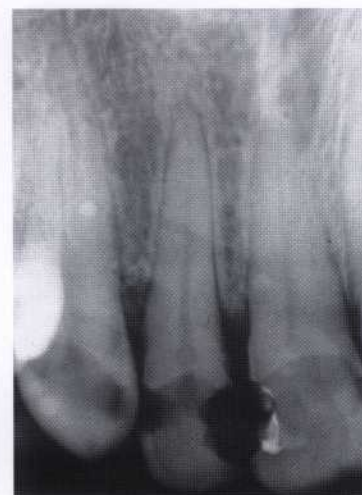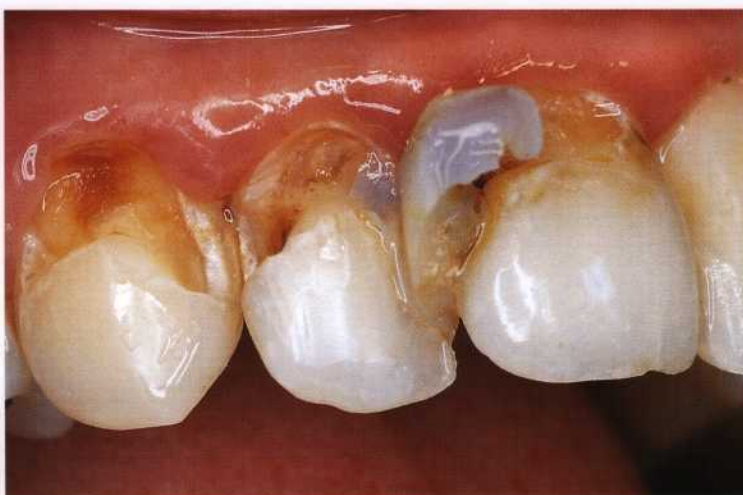Tenderness to percussion of the tooth in question is an early and sure sign of endodontic inflammation, but does not mean that there is complete necrosis. It is not possible to differentiate precisely between a clinically healthy pulp, reversible pulpitis, and irreversible pulpitis by means of a *sensitivity test*. A positive reaction can occur even in the presence of a small periapical radiolucency (Lin et al. 1984). The radiographic examination can support the differential diagnosis only in conjunction with the clinical examination.

26 Inadequate restorations

This 31-year-old patient had composite fillings placed in the upper anterior teeth 3 months earlier, after which recurring pain was experienced, initiated by eating and drinking and ceasing only briefly.

The fillings are easily removed with an explorer. Residual caries is found under the defective fillings in the maxillary right incisors and canine.

Right: Radiograph of the affected anterior teeth following caries removal.

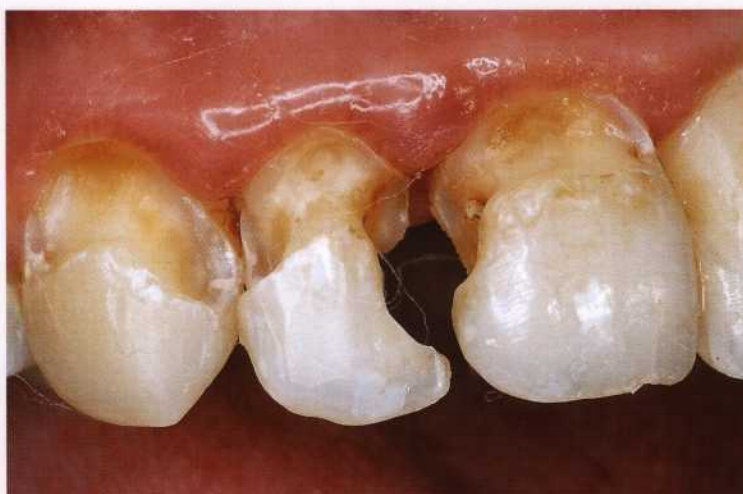

27 Caries excavation

After removal of the restorations, all secondary caries is removed under anesthesia, care being taken not to expose pulp. It is important during caries excavation to use radiographs to gauge the proximity to the pulp.

The photograph shows a few small areas of residual caries. These must be completely removed.

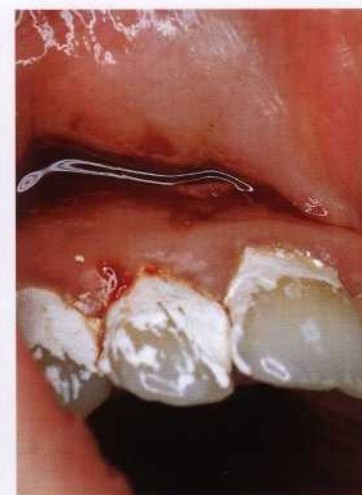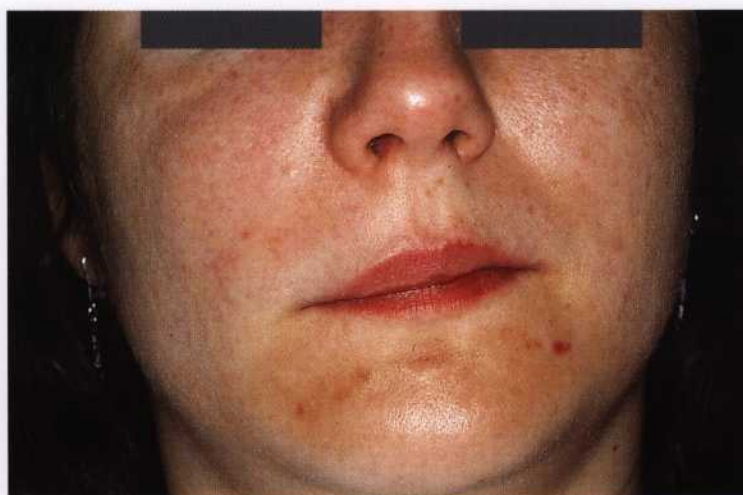Finally, a thick mix of zinc oxide-eugenol (with no other additives) is applied and left in place for 24 hours.



28 Acute reaction

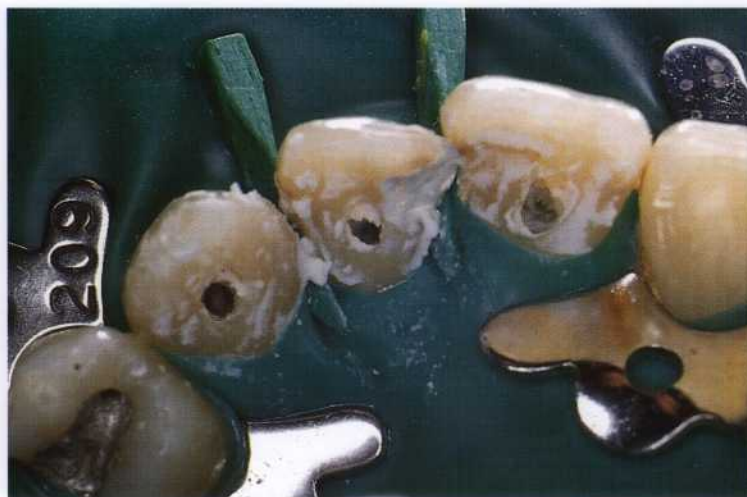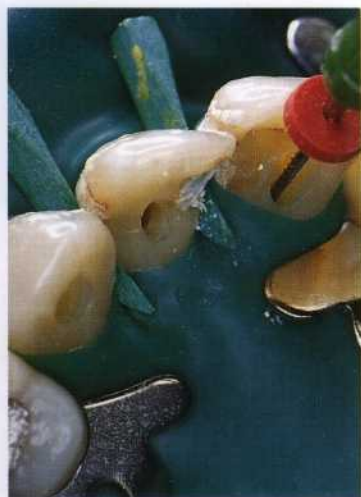The next morning the patient presents with pronounced swelling over the canine fossa. The patient's general condition has also deteriorated. The diagnosis is revised to irreversible pulpitis in the involved teeth. Treatment of the carious lesions has precipitated acute inflammation.

Right: The abscess is opened by means of an incision at the transition to moveable mucosa with reflection of the periosteum.



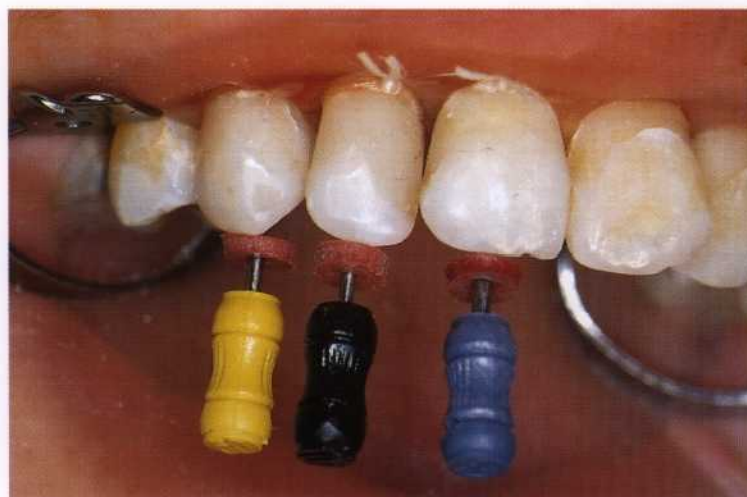Where there is *reversible pulpitis* the caries has not yet entered the pulp. There may be exposed dentin or a defective restoration. Pain is initiated by cold, sweet, and sour stimuli with hypersensitivity of short duration. The radiograph usually shows a deep carious lesion or an old filling with nothing abnormal about the periapical region. Treatment for the reported pain is initiated by removing old fillings and thoroughly excavating all caries. Under no circumstances should any caries be left remaining. While waiting for the clinical symptoms to subside, a palliative filling is indicated.

The cavity is filled with a stiff paste of zinc oxide-eugenol with no additives. After the tooth has been asymptomatic for no less than 48 hours, it may be restored by placing a biologically neutral base and covering this with a permanent filling material. If pain persists or increases, we are dealing with *irreversible pulpitis*. In this case the root canal(s) must be instrumented and later filled.



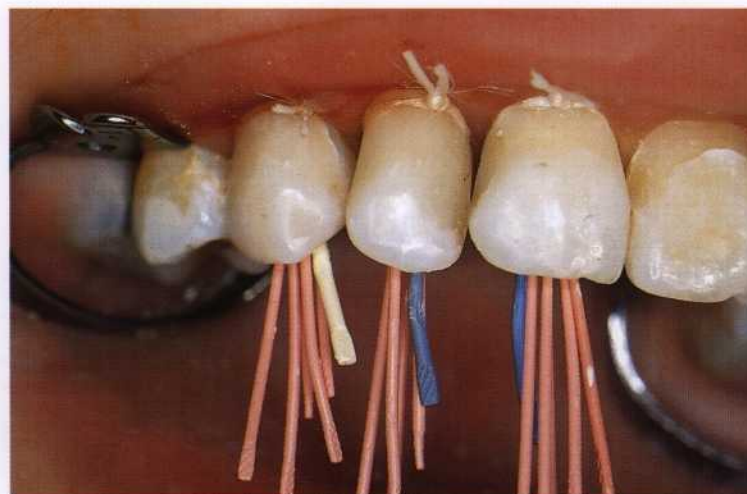
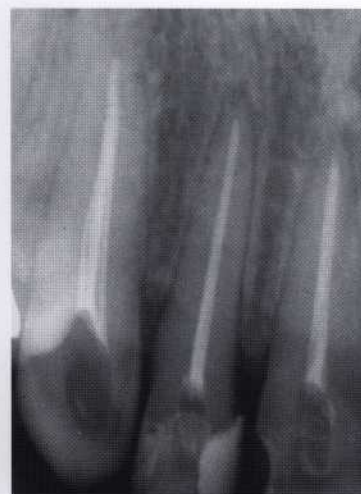29 Access preparations and root canal treatment
Three days following opening of the abscess, all three root canals are instrumented under a rubber dam. Because the pulps are already partially necrotic, the canals should not be obturated until at least 3 weeks after canal preparation. At this stage, therefore, the canals were loosely filled with a calcium hydroxide paste by means of a spiral filler.

Left: Preparations are completed in all three root canals because the source of infection cannot be more precisely determined.



30 Root canal preparation
At the next appointment, 3 weeks after the initial preparation, the patient is free of symptoms so the interim dressings are removed. The three root canals are cleaned to the depths of the master files, then dried with paper points.

At the same appointment the cervical cavities are restored under the rubber dam. Glass ionomer bases are placed, the margins beveled, the cavities etched, treated with a bonding agent, and filled with a microfilled hybrid composite.



31 Root canal filling
The root canals are filled after measuring and insertion of the gutta-percha master points following the lateral condensation technique. A calcium hydroxide based sealer is used. The primary gutta-percha points are of standard ISO sizes and are the same colors as the corresponding master files.

Left: The control radiograph shows homogenous filling of the root canals. The patient has remained symptom-free.

Carious Pulp Exposure

With carious pulp exposure, a large number of dying and necrotic cells can be seen within the pulp tissue under the electron microscope. Lymphocytes, plasma cells, and macrophages can be identified bordering on the focus of necrosis. Polymorphonuclear leukocytes dominate superficially, some intact and some fragmented with organelles spread through the extracellular space (Torneck 1981). Microorganisms can be found inside neutrophilic granulocytes and macrophages. The endothelial cells of the blood vessels are damaged and leukocytes have been released. If carious

dentin in a deep cavity has been broken through, inflammation will occur in the pulp after 7 days. The odontoblastic layer becomes disorganized and infiltrated with neutrophilic granulocytes. Bacteria, necrosis, and cell fragments are present, and there is very little production of tertiary dentin (Furseth et al. 1980).

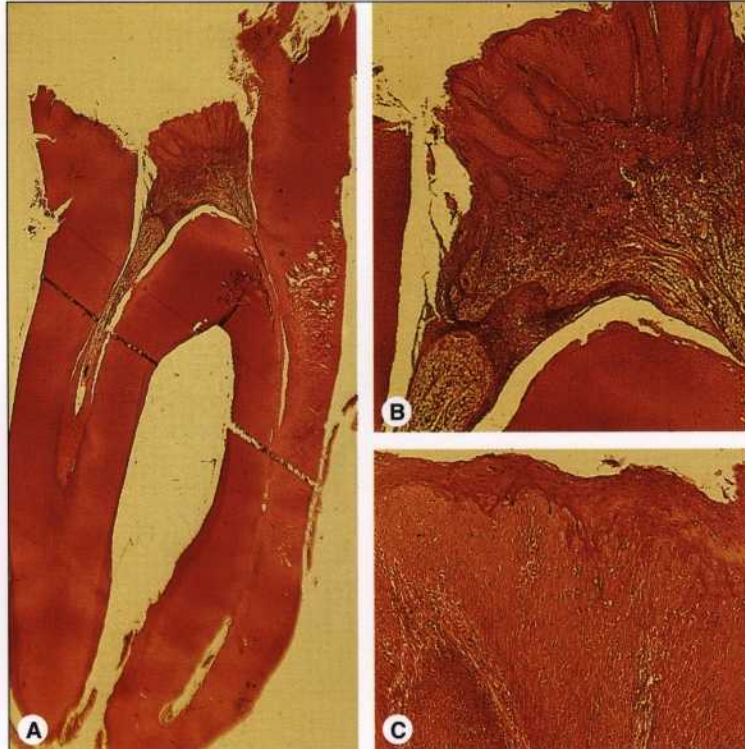
Injection of a bacterial extract into exposed pulp will cause local abscess formation with resorption of bone, cementum, and dentin (Stabholz and Sela 1983).

32 Pulpitis aperta granulomatosa, "pulp polyp"

A Extensive carious exposure of the pulp is observed. Bacteria reaching the pulp have caused ulceration and a massive gathering of inflammatory cells. Granulation tissue has begun to sprout out of the ulcerated pulp tissue and extrude through the coronal opening.

B The coronal pulp tissue is epithelialized and composed predominantly of firm connective tissue. It is rich in collagen fibers with relatively few blood vessels, and contains numerous nerve fibers reaching into the epithelium. Areas of chronic inflammatory infiltration are also present.

C The surface is colonized by epithelial cells from the gingiva. The stratified squamous epithelium corresponds to keratinized gingival epithelium.

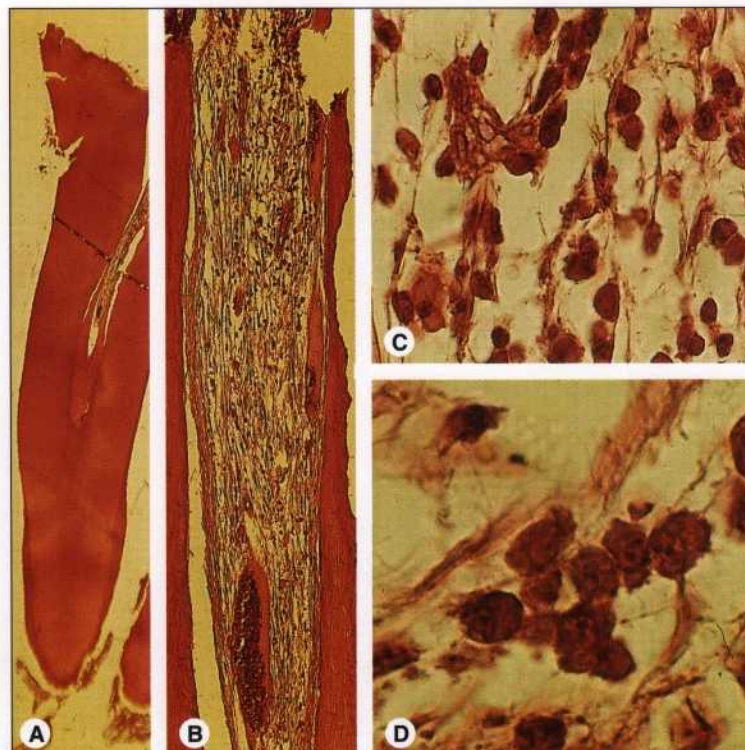


33 Necrosis of the pulp tissue in the root canal

A The bacterial infiltration of the coronal pulp tissue leads to necrosis with destruction of tissue. An accumulation of polymorphonuclear leukocytes is found within the ulcerated tissue bounded at the transition to the root canal entrance by a wall of mononuclear leukocytes. Granulation tissue can also be seen in the periapical region.

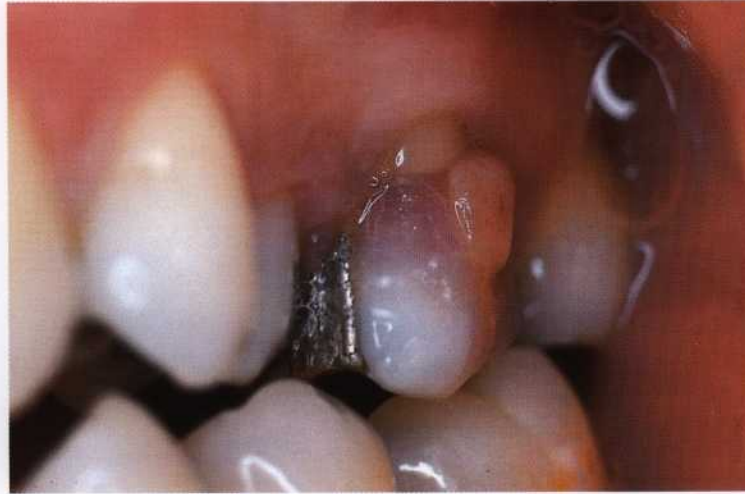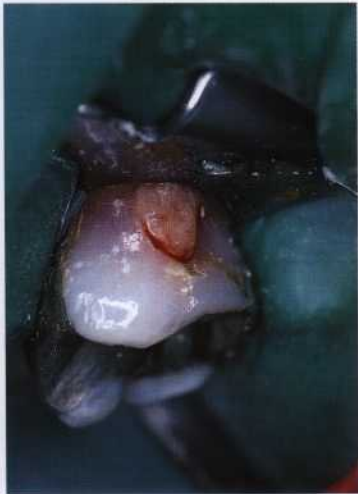B The enlarged section of the coronal third of the root canal exhibits infiltration with inflammatory cells, tissue destruction, and disruption of the odontoblastic layer.

C/D Monocytes dominate the inflammatory infiltration. After lymphocytes, plasma cells are the most numerous, indicating a local immune response.



Granulation tissue may begin to grow out from exposed and ulcerated pulp and swell out of a wide coronal opening as an enlarging tissue mass. This pink globular tissue can become colonized by epithelial cells from the junctional epithelium and then become epithelialized. A distinction is made between "young pulp polyps" that arise from hyperplastic granulation tissue, and "old pulp polyps" which are tough connective tissue with epithelialized surfaces (Schroeder 1991).

This *chronic open pulpitis* is, in contrast to the closed forms of pulpitis, easy to diagnose clinically. If the progression of caries has created a wide opening in the roof of the pulp chamber, secretions can flow out and the clinical situation is painless. The treatment consists of first removing the pulp tissue down to the entrance to the root canals, after which the canals are instrumented. Because tissue necrosis is present, the canals are not filled until an intermediate dressing has been in place for 1 month.

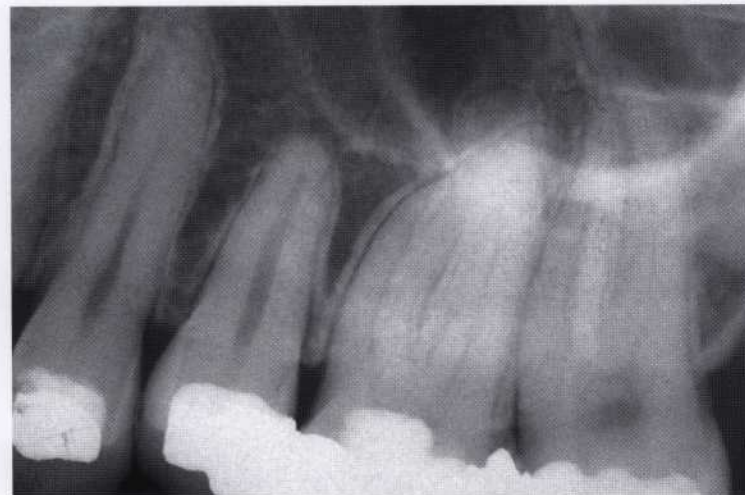
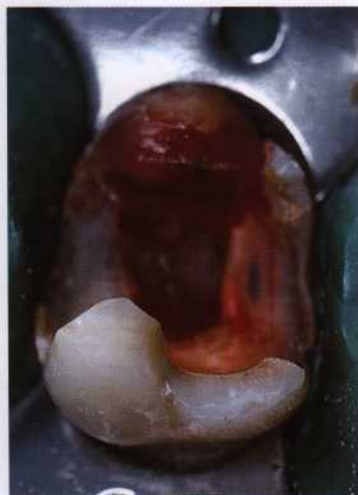
34 Open pulpitis

Hyperplastic pulp tissue has broken through the buccal surface of an upper molar. As a result of the release of lymphokinin, dentinoclasts were activated in the surface of the tissue and these produced resorption of the buccal wall.

Four years previously a pulpotomy was performed due to pulp exposure during caries excavation.

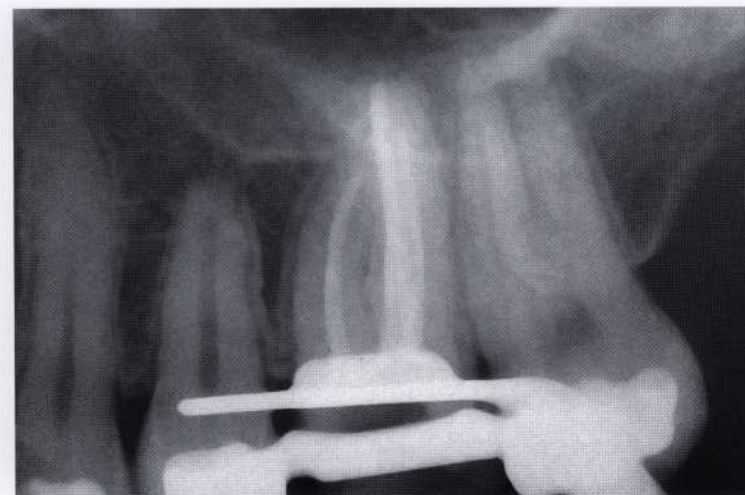Left: The tooth is anesthetized in preparation for root canal treatment.



35 Tissue removal

The preoperative radiograph reveals the pulp amputation and the covering of the tissue stump with a radiopaque material. There is nothing remarkable about the periapical tissues and no indication of decreased bone density.

Left: The heavily bleeding, ulcerated pulp tissue is removed from the coronal pulp chamber to the orifices of the root canals by means of a bur rotating at high speed. The entrances of the canals are located and the root canals prepared.



36 Treatment of the open pulpitis

After preparation of all three root canals and absence of further clinical symptoms, the canals are obturated. The radiograph shows a dense filling and a normal periapical region.

Left: View during filling of the root canals by the lateral condensation technique.

Necrosis of the Pulp Tissue

Pulpal necrosis is an irreversible condition characterized by tissue decomposition. It can be localized in otherwise vital pulp tissue, or involve all the coronal and radicular pulp. The primary cause of pulpal necrosis is bacterial infection, in which case the amount of necrosis is correlated with the extent of the bacterial invasion (Schroeder 1991). If a cavity is constantly exposed to contamination with saliva, after only 6 days extensive abscess formation and necrosis can be demonstrated even before bacteria have penetrated into the pulp tissue (Lundy and Stanley 1969).

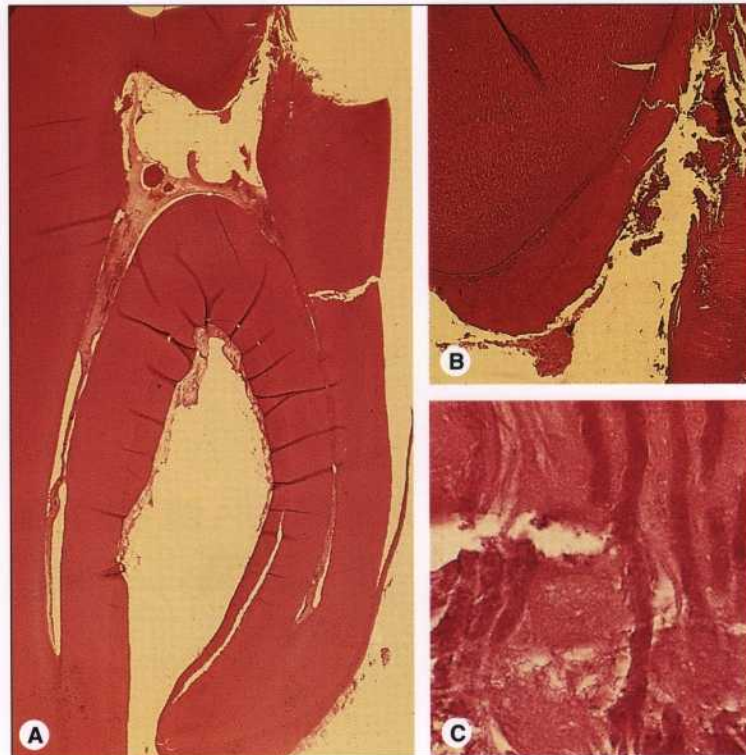
According to a study by Lin et al. (1981 a), if caries has reached and exposed the pulp, necrosis will always occur in the coronal pulp tissue. Partial or complete necrosis was found in the coronal pulp of all 15 teeth studied, but in the radicular pulp of only nine. Both acute and chronic inflammatory cells were found. Bacteria could be demonstrated in the coronal pulp of all teeth, but in the root canals of only one-third of the teeth. In 14 cases, periapical radiolucencies had already occurred.

37 Carious exposure of the pulp with necrosis

A The carious process has exposed a wide area of coronal pulp tissue. The coronal pulp is necrotic and an abscess has formed. Surprisingly, the tooth exhibits no painful symptoms.

B In the area where caries has advanced into the pulp chamber, hard-tissue deposits in the form of tubule-poor tertiary dentin with relatively few tubules are still visible. The odontoblastic processes have been damaged by bacterial toxins leading to an inflammatory reaction, and after limited destruction of odontoblasts, stimulated (tertiary) dentin is formed.

C This tertiary dentin cannot stop the penetration of small amounts of bacterial toxins. Bacteria are present even in the atubular dentin.

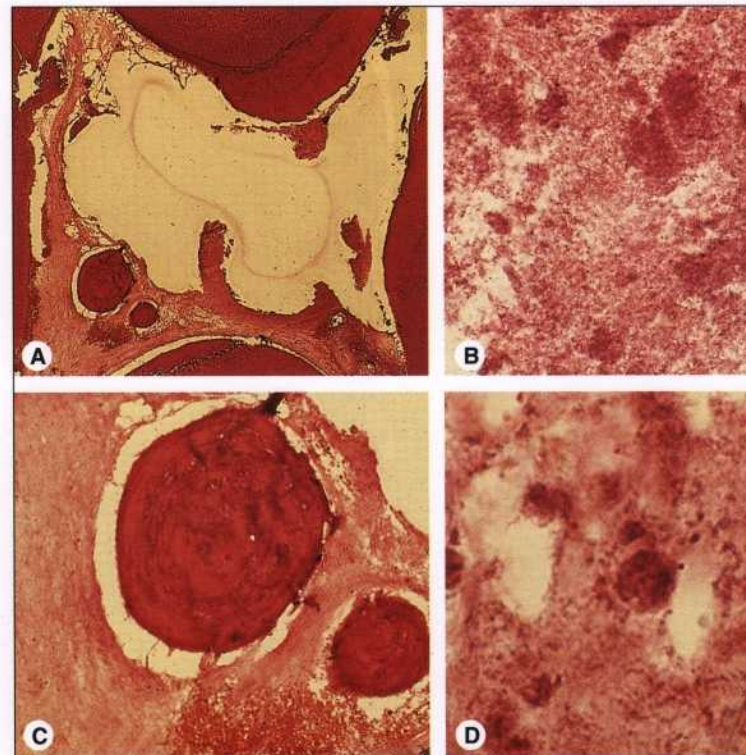


38 Tissue necrosis

A There is a large "empty" space within the coronal pulp that corresponds to an accumulation of pus. The adjoining tissue is necrotic and contains hard-tissue deposits.

B The coronal pulp is completely necrotic. The adjacent tissue has become liquefied and no longer contains stainable cell nuclei.

C As the result of chronic inflammation, more denticles and diffuse mineral deposits are encountered within the pulp tissue. Denticles are round or oval formations of fibrodentin that usually arise in response to external stimuli, chronic inflammation, or following cell destruction.

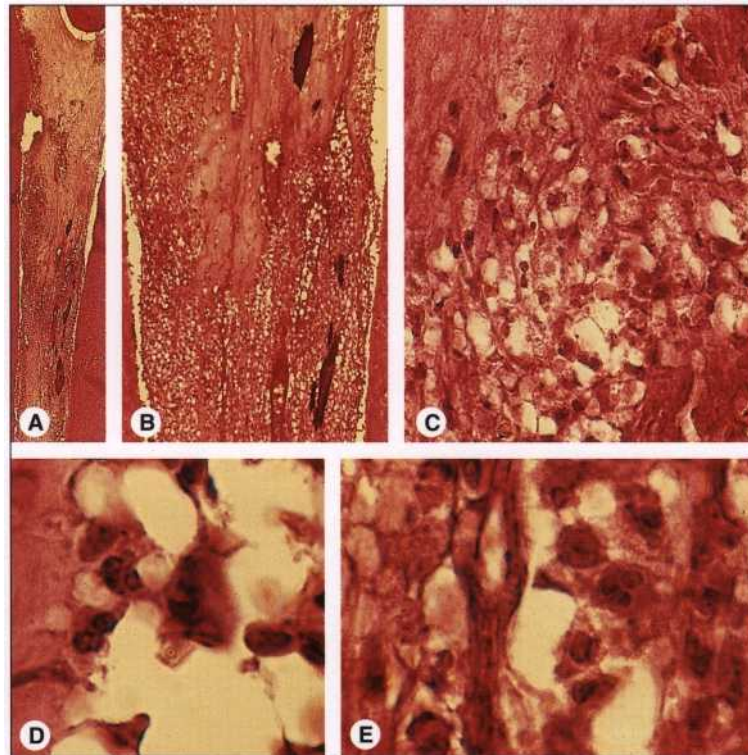


The time at which carious infiltration of the pulp occurs cannot be determined clinically. The agents bringing early severe pulp destruction are *bacterial toxins*. High levels of endotoxins cause tissue necrosis, whereas low levels cause more rapid cell division and collagen synthesis as a defensive reaction (Pintero et al. 1983).

Bacteria bring about tissue necrosis and are not seen outside of the field of necrosis. As part of a normal host reaction, the zone of necrosis becomes surrounded by neutrophilic granulocytes and macrophages, which is

indicative of an active process of phagocytosis. Simultaneously, lysosomal products that are released extracellularly destroy the pulp tissue. Only in areas of necrosis do bacteria also penetrate into the adjoining dentinal tubules.

Lin et al. (1981 a) could find necrosis in the apical portion of the pulp in only one-third of cases in which apical periodontitis was present. Six root canals contained no tissue necrosis, only vital tissue with a few inflammatory cells and no bacteria.



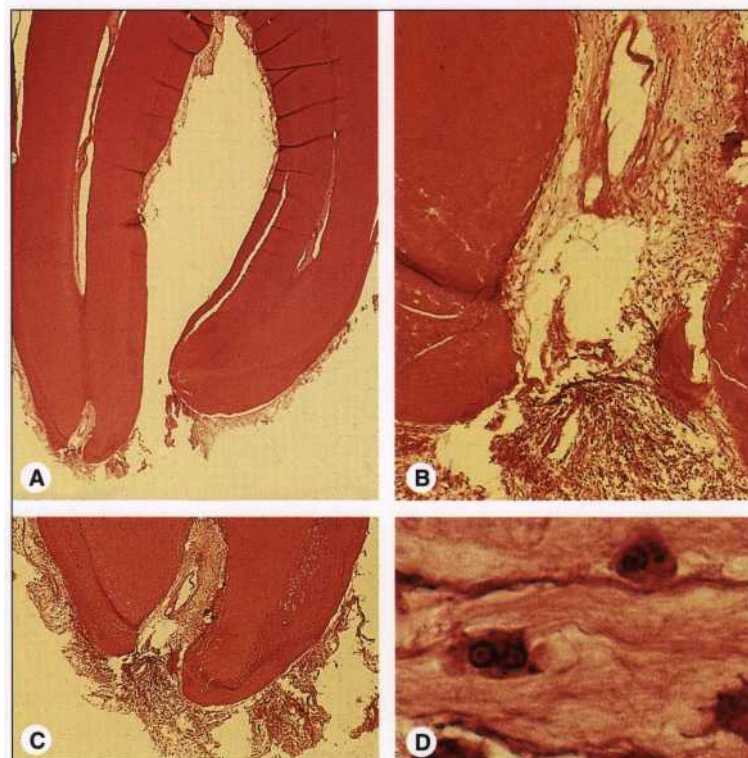
39 The boundaries of necrosis
A At the transition between coronal and radicular pulp, the tissue is necrotic and surrounded by inflammatory cells. Farther apical, no necrosis can be seen.

B Hard-tissue deposits and inflammatory cells are also found in this enlarged section.

C Phagocytes engulf bacteria and at the same time excrete lysosomal enzymes, thus bringing about destruction of vital tissue and ultimately necrosis, visible here as early space formation with microabscesses.

D Neutrophilic granulocytes are found in areas of liquefied tissue.

E Polymorphonuclear granulocytes are predominant.



40 Periapical inflammation
A Soon after the onset of coronal tissue necrosis the first signs of periapical inflammation appear, caused by the penetration of endotoxins through vital pulp tissue.

B The pulp at the transition to the apical foramen is vital and contains no bacteria. However, the periapical periodontal tissue is clearly infiltrated by leukocytes.

C In this area of higher magnification the vital tissue within the apical root canal as well as the periapical inflammation can be seen in the region of the apical foramen.

D This further enlargement from the apical root canal reveals a few polymorphonuclear leukocytes as well as collagen fibrils.

Intentional Devitalization

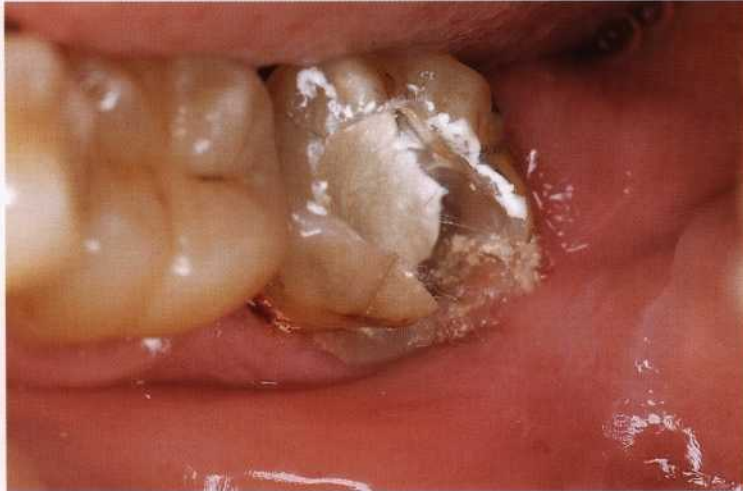An essential component of pastes for devitalizing pulps is *paraformaldehyde*. The mechanism of released formaldehyde rests upon the coagulation of cell wall proteins, which leads to denaturation and finally to disruption of vital cell functions. No extensive alteration of tissue structure occurs as the tissue becomes fixed. This fixation of the pulp tissue is irreversible. The formaldehyde-tissue complex can disintegrate and act as a stimulus for immunologic reactions (Friedmann 1979).

In animal studies, *cytotoxic, mutagenic, carcinogenic, and genotoxic changes* have been observed (Orstavik and Hongslo 1985, Judd and Kenny 1987, Waterhouse 1995). Using radioactively tagged paraformaldehyde, a maximum level of radioactive metabolites was detected in the liver at 14 days after the pulpectomy. In regional lymph nodes the maximal level appeared after only 1 hour (Block et al. 1983). A systemic distribution was found in blood plasma, kidneys, lungs, and brain (Hata et al. 1989).

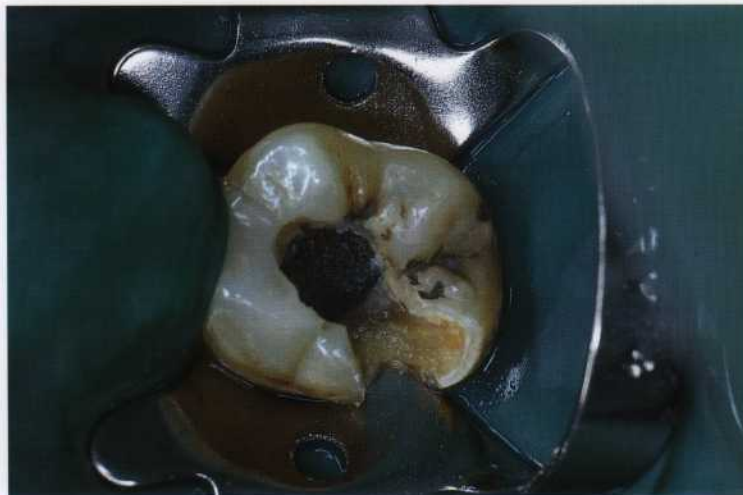41 Emergency treatment

Ten days after visiting an emergency service, the patient presented in our office with no subjective discomfort. The lower left second molar has an access preparation with a temporary filling. Reddened, edematous swelling of the gingiva is also present.

Right: A bony sequestrum about 5 mm long is removed from the interdental region.

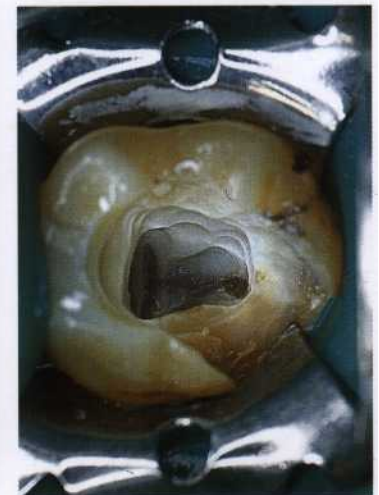
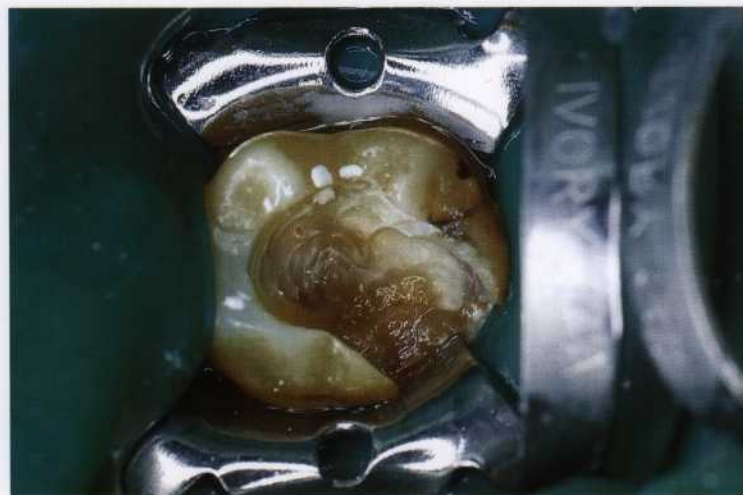
42 Condition following intentional devitalization of the pulp
After removal of the interim filling under a rubber dam, a dark gray devitalization paste can be seen at the entrance to the root canals. Remaining caries is also found at the cavity floor.



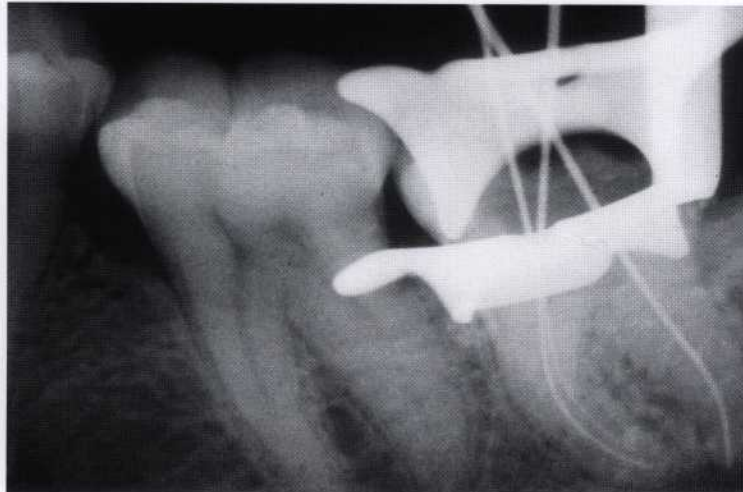
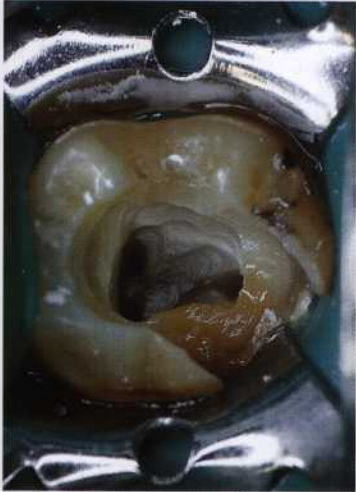43 Uncovering the entrances to the root canals
The caries is completely removed and the rubber dam clamp adjusted to provide a better seal.

Right: After extirpation of the fixed pulp tissue, the three root canals must be located and initially widened.



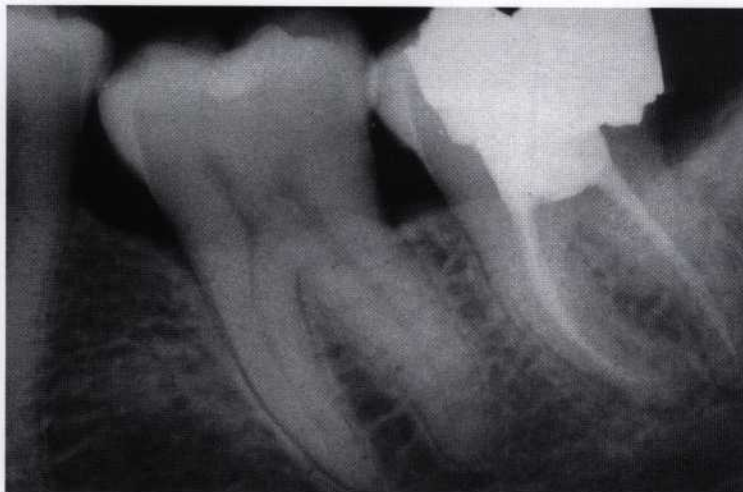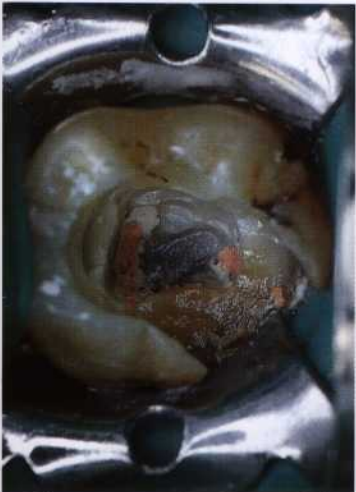In animal experiments, Lost and Geursten (1984) were able to demonstrate the penetration of formaldehyde past the margins of poorly condensed fillings. After 7 days there was formation of sequestra in the adjacent bone, which eventually led to loss of the teeth. Even optimum condensation did not prevent formaldehyde from passing through interradicular connections to reach and damage bone (Goldberg et al. 1987). Heling et al. (1997) reported a case in which necrosis of the interdental papilla and bone sequestration occurred.

Hulsmann (1996c) reported serious consequences of using a devitalizing paste, including breakdown of bone, persistent discomfort, and nerve damage. According to our present state of knowledge, intentional devitalization of pulp tissue is *never* indicated. Treatment of pain is accomplished exclusively through extirpation of the pulp tissue. The numerous side effects of devitalization are out of proportion to its questionable therapeutic value.



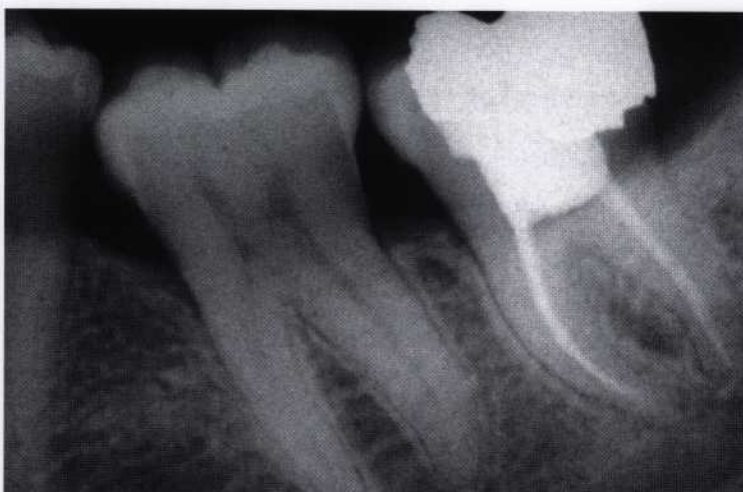44 Root canal preparation
Following radiographic determination of their lengths, the three root canals are prepared to points just short of their apices. Incomplete preparation of the canals will leave behind not only necrotic tissue, but also tissue that has been fixed with formaldehyde that can evoke a long-term immune reaction.

Left: The root canals have been fully prepared and enlarged.



45 Root canal filling
If the tooth is comfortable, the root canals may be filled with gutta-percha and a sealer according to the lateral condensation technique. The coronal cavity is then sealed with a permanent restoration.

Left: The gutta-percha has been cleanly removed to the level of the canal entrances, and the cavity is given a final cleaning.



46 Two-year recall
Two years following root canal treatment the radiograph shows a normal periodontal ligament space at the apex with no evidence of persistent inflammation. There is, however, a slight vertical radiolucency between the roots.

Filling Materials and Pulp Necrosis

With the use of tooth-colored materials, teeth can be restored satisfactorily from a functional and esthetic perspective. Inappropriate selection and manipulation of materials, however, frequently results in fillings that become defective with faulty, stained margins and generalized discoloration, although they may appear perfect initially. While the carious hard substance is being treated, tissue is present that has already been injured. Biologically unacceptable treatment methods inflict further trauma which can lead to irreversible reactions and ultimately to pulp necrosis (Beer 1989). If a tooth

is prepared without sufficient water cooling, displaced odontoblast nuclei and erythrocytes can be found histologically inside dentinal tubules. In the neighboring tissue, dilated capillaries with leukocytes and extravascular erythrocytes are indications of an initial inflammatory reaction (Langeland 1957, Langeland et al. 1973).

The destructive products of odontoblasts and erythrocytes displaced into the dentinal tubules act as chemotactic factors and cause migration of neutrophilic granulocytes (Gangler and Langeland 1981).

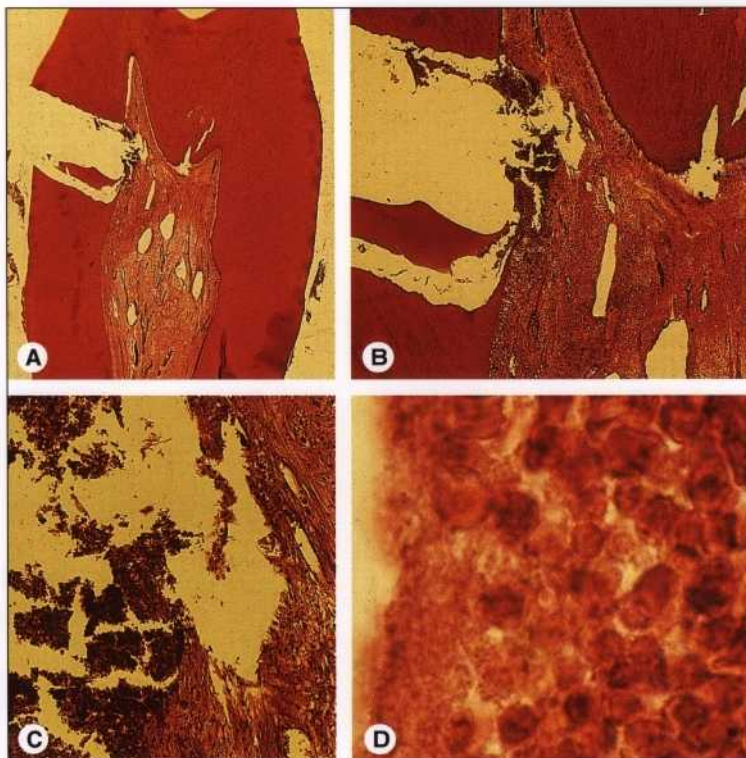
47 Pulp response to acid etching

A Deep cavity preparation and overlooked pulp exposure in a premolar. A weak acid solution is applied for 10 seconds, then the cavity is rinsed and tightly packed with a glass ionomer cement. The tooth is extracted after 30 days.

B Necrosis of pulp tissue can be seen next to the cavity. Adjacent is the border of inflammatory cells.

C A section through the zone of necrosis. No dentinal bridge has formed.

D The inflammatory infiltrate is made up primarily of neutrophilic granulocytes, and walls off the necrosis.



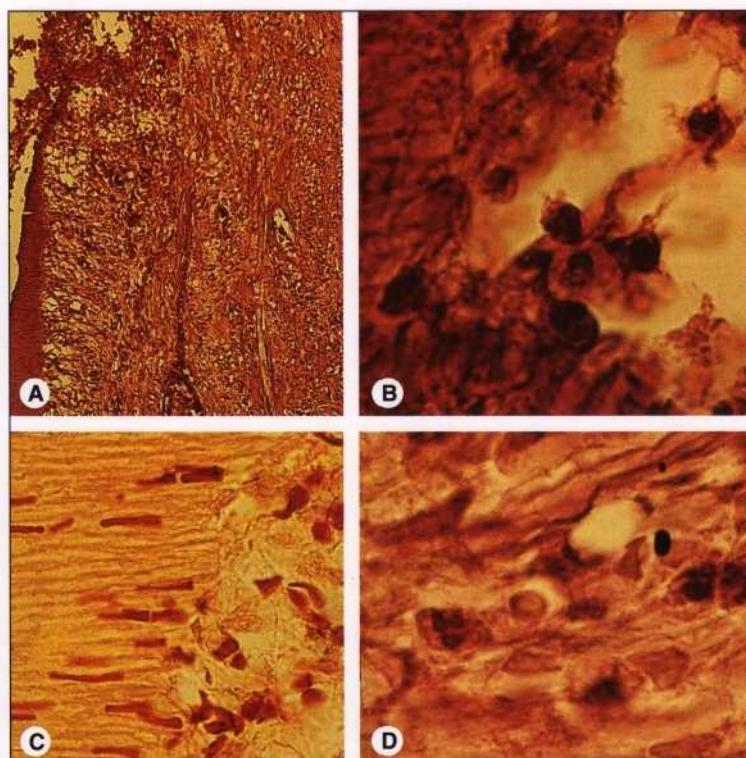
48 Necrosis and aspiration

A Apical to the point of perforation there is a thin layer of remaining dentin. The odontoblastic border in the adjacent pulp tissue is destroyed. In a more coronal and central direction tissue necrosis permeated by inflammatory cells can be seen.

B A section from the coronal region with zones of necrosis, individual spaces as microabscesses, and neutrophilic granulocytes as well as lymphocytes.

C Aspiration of odontoblast nuclei and inflammatory cells into adjacent dentinal tubules as an expression of toxic tissue damage following application of the acid and filling material.

D Neutrophilic granulocytes can also be seen within the dentinal tubules.



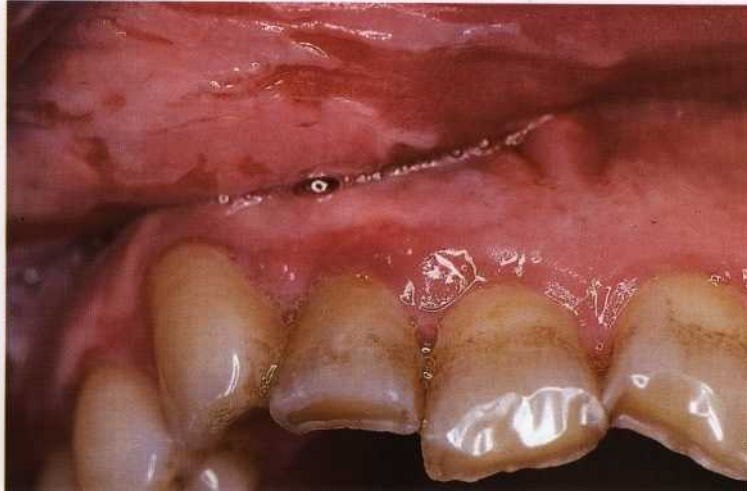
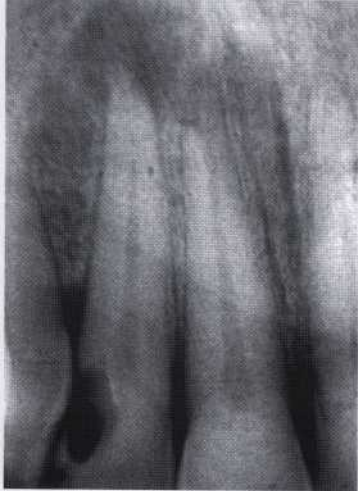A correlation can be shown between imperfect filling margins and bacterial colonization of cavities with inflammatory infiltration in adjacent pulp tissue (Bergenholtz and Warfvinge 1982).

After preparation of a cavity, briefly contaminated with saliva and then sealed with gutta-percha, the pulp tissue became infiltrated with neutrophilic granulocytes (Lilja et al. 1982).

Because microscopic gaps at filling margins permit penetration of bacteria, attempts are made to achieve a chemical bond of the filling material through utilizati-

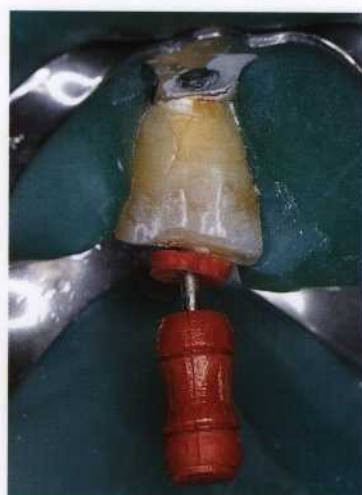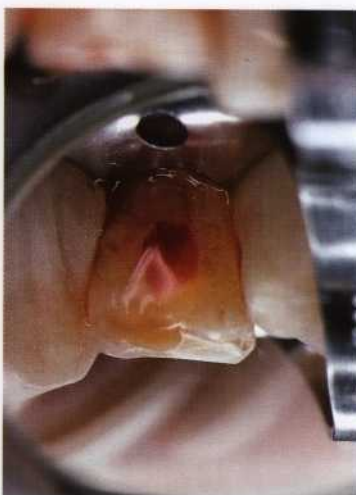
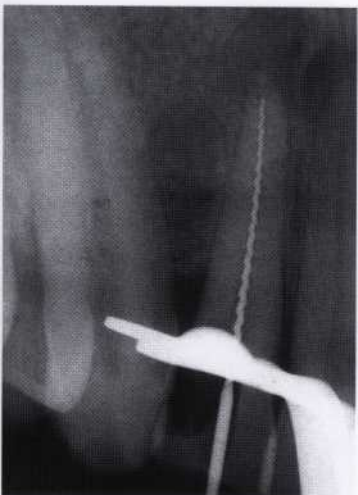on of a dentin adhesive. This requires conditioning of the cavity walls. The application of even low concentrations of acids however, can lead to severe pulp reactions (Cotton and Siegel 1978, McInnes-Ledoux et al. 1985, Beer 1995).

The final application of a dentin adhesive causes a severe tissue reaction only when bacteria are found on the cavity floor. However, this is also evidence that there is inadequate adhesion of the filling material to the dentin (Grieve et al. 1991).



49 Acute inflammation
A 54-year-old patient presented with persisting pain. The intraoral examination revealed a white coating and ulceration of the mucosa in the area of the mucolabial fold, which resulted from application of an acetylsalicylic acid tablet. The lateral incisor has an intact composite restoration on the distal surface.

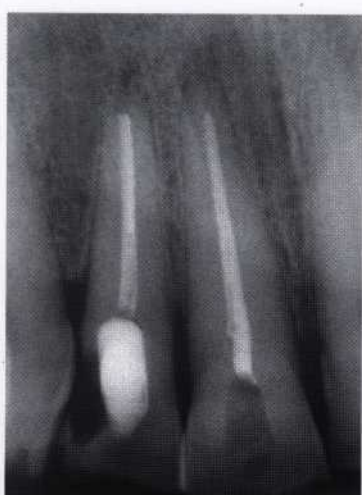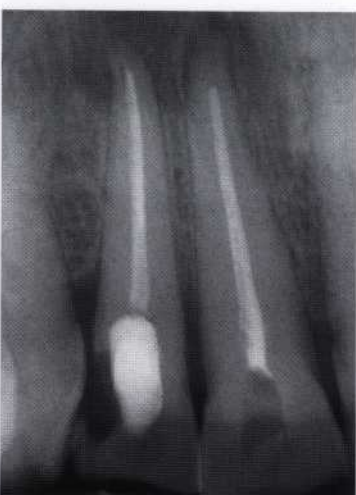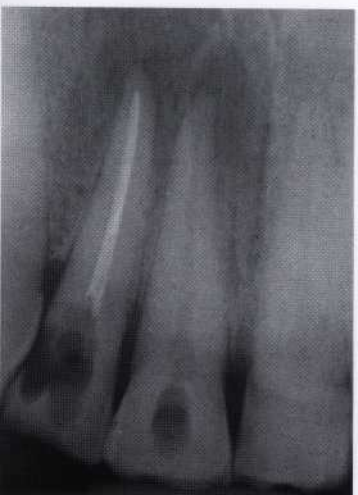Left: On the radiograph a periapical radiolucency and a deep distal cavity can be seen on the lateral incisor.



50 Root canal preparation
Left: A diagnostic radiograph was used to determine the working length at just short of the radiographic foramen.

Center: After the pulp chamber was entered and the initial enlargement made with a Hedstrom file, pus mixed with blood flowed from the root canal.

Right: The root canal was prepared to the working length with a size 55 master file and flushed with a sodium hypochlorite solution.



51 Root canal filling
Left: One month following the endodontic treatment, the patient returned to the dental office. The pulp chamber of the right central incisor had already been opened in an emergency clinic. Radiographically, a periapical radiolucency is evident on the central as well as lateral incisor.

Center: Endodontic treatment of the central incisor.

Right: Recall radiograph 2 years after surgical intervention because of a persisting radiolucency. The tooth is now symptom free.

Bacterial Infection in the Root Canal

The types of bacteria present in an infected root canal are small in number compared with the 300 or so that make up the total oral flora. Only one to twelve different strains can be isolated, while the number of individual bacteria can range from 100 to more than 10 000 000. There is a direct relationship between the size of a periapical lesion and the number of types of bacteria as well as the total number of bacteria. Thus, most strains of bacteria can be isolated from the root canals of teeth with the largest lesions (Sundqvist 1992).

The dynamics of bacterial infection in a root canal were revealed in a series of animal experiments by Fabricius et al. (1982). In this study, teeth were infected with bacteria from saliva and then tightly sealed for a time span of up to 3 years. Significantly more facultative anaerobes were isolated initially. After 6 months, however, the number of these bacteria had declined to less than 2%, while the percentage of strictly anaerobic strains of bacteria increased. A selective mechanism within the root canal promoted the development of specific environmental conditions.

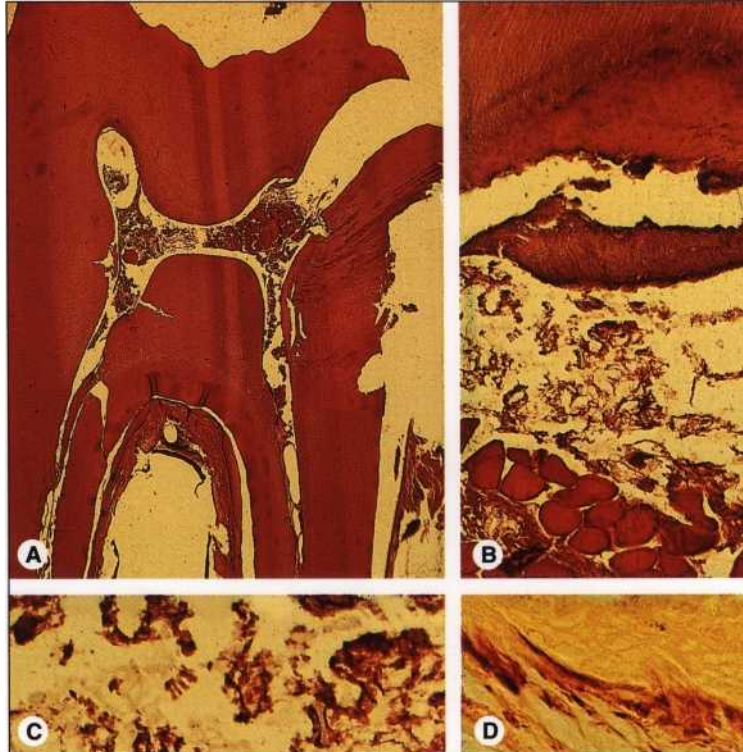
52 Penetration of caries into the pulp tissue

A The progression of caries has led to exposure of the pulp with necrosis of the coronal pulp tissue and part of the root canal pulp.

B In this necrotic section of the coronal region, tissue destruction is visible with bordering aggregation of foreign-body particles.

C Bacteria in the necrotic tissue are stained red by the special staining method of Brown and Brenn.

D Bacteria are found within the dentinal tubules. Not even the irregular irritation dentin can prevent bacterial penetration into the pulp.



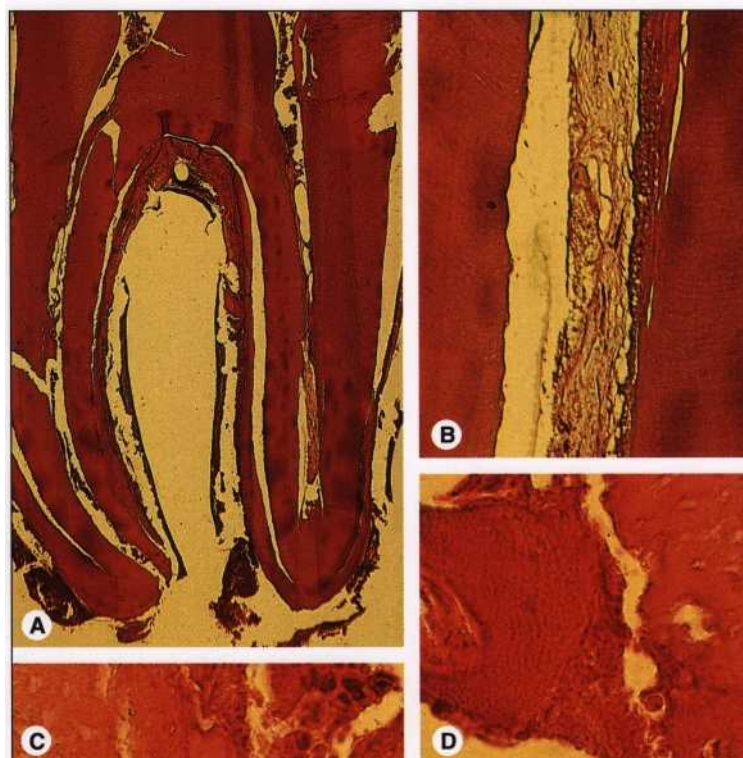
53 Necrosis in the root canal with apical periodontitis

A There is extensive necrosis of the radicular pulp, and inflammation and adherent granulation tissue in the periapical region.

B Necrosis of the root canal pulp: the gap on the left is a histologic artifact. Necrotic pulp without bacterial infection never causes a periapical lesion. Apical periodontitis develops only when bacteria are present (Moller et al. 1981).

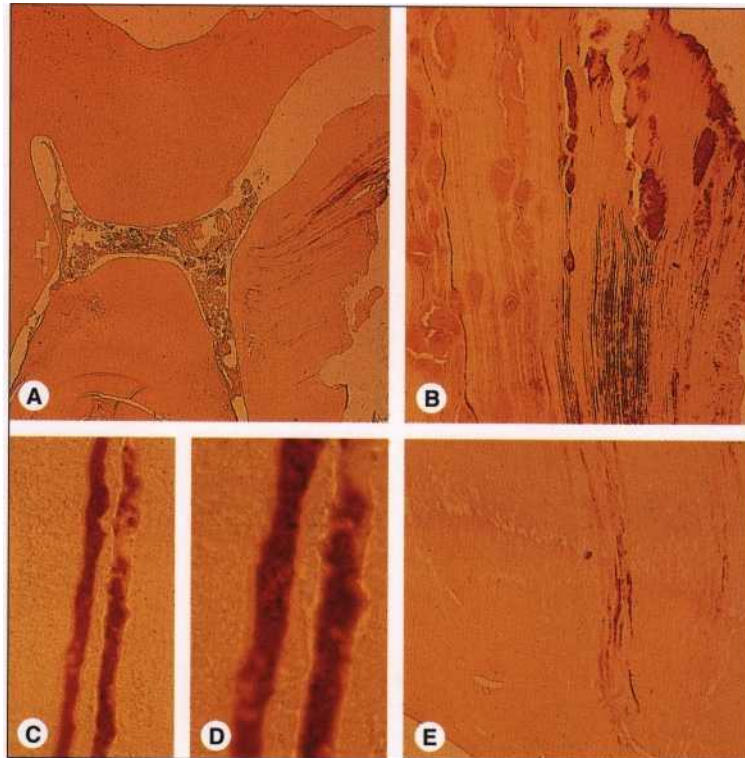
C The first obliterations in the root canal take place with formation of irregular tertiary dentin in response to inflammatory stimuli. Adjoining them, accumulations of neutrophilic granulocytes can be seen.

D Formation of new hard tissue in the form of a fibrodenticle.



Often, bacterial symbiosis can be observed in root canals. Thus Sundqvist et al. (1989) frequently found *Fusobacterium nucleatum* growing together with *Peptostreptococcus micros*, *Wolinella recta*, *Porphyromonas endodontalis*, and *Selenomonas sputigena*. Many factors can influence the bacterial colonization of the root canal. For example, some bacteria may use metabolic products from other bacteria as nutrients (Loeche 1968), and *bacteriocins*, released from certain microorganisms, can inhibit the growth of other bacteria (Van Winkelhoff et al. 1987).

The bacteria present in infected root canals release enzymes that increase their pathogenicity. Thus immune globulin of the host organism can be inactivated by organisms such as *Parphyromonas asaccharolyticus* and *P. endodontalis*. *P. intermedia* and *p. gingivalis* break down the complement factor C3. Both of these are important opsonins for the phagocytosis of these bacteria during the defense process. *P. gingivalis* can at the same time break down proteinase inhibitors that are important for maintaining the integrity of the tissue surrounding the infection (Carlsson et al. 1984, Kato et al. 1984).



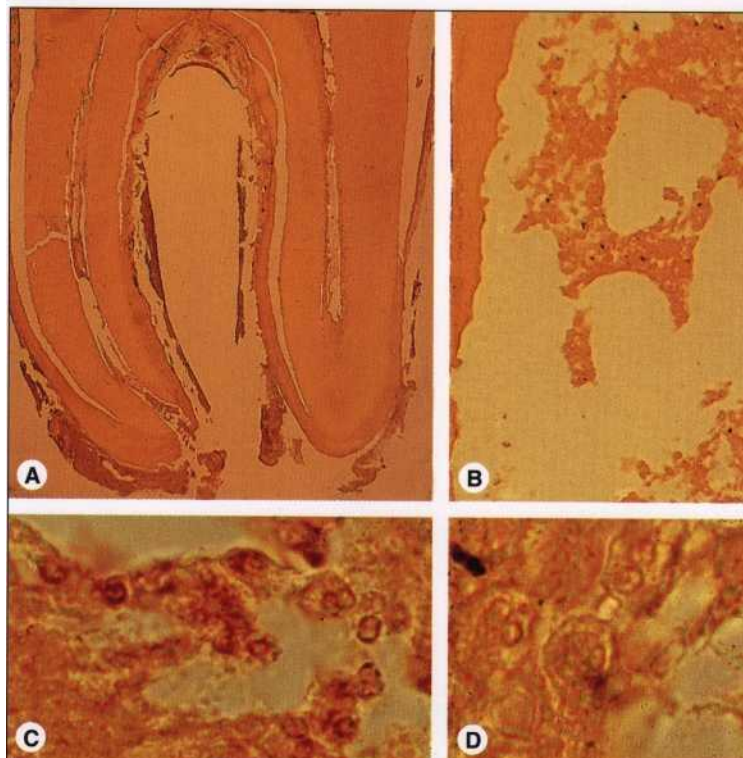
54 Bacteria within dentin

A Stained histologic sections allow differentiation between noninfected (yellow) and infected (red) tissue. In the coronal region bacteria can be found in the dentinal tubules as well as in the pulp tissue.

B The bacteria cause dissolution of dentin resulting in widened tubules, sacs, or caverns. The caverns are filled with bacteria and remnants of matrix.

C/D Two enlarged dental tubules containing bacteria.

E The irritation dentin cannot completely block penetration of bacteria in spite of the paucity and irregular course of its tubules.



55 Bacteria in the root canal

A The tissue inside the root canal is necrotic, and the periapical accumulation of inflammatory cells can be clearly seen. Of course, many bacteria are not clearly revealed by histobacteriologic techniques.

B Both the coronal pulp and the coronal portion of the root canal contain bacterial aggregations.

C High magnification also reveals intracellular bacteria inside neutrophilic granulocytes in the middle portion of the root canal.

D Histologically, no bacteria can be seen in the area of periapical infiltration.

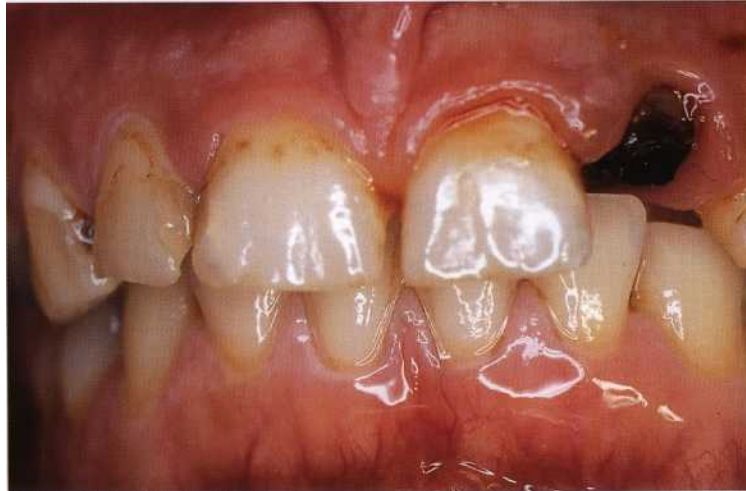Treatment of Bacterial Infection

Because microorganisms and their toxic metabolic products are responsible not only for pulpal necrosis but also for periapical lesions, the goal of endodontic treatment is to eliminate pathogenic bacteria and prevent reinfection. This is accomplished through cleansing of the root canal, the antibacterial effects of irrigating solutions and interim dressings, a closely adapted filling of the root canal, and a good coronal seal to reduce the risk of new infection (Sundqvist 1992).

Mechanical cleansing without irrigation can reduce the number of bacteria by a factor of about 1000. Following instrumentation and irrigation of the canal with saline solution, a bacteria-free root canal could be achieved in 20% of cases. It was also possible to eliminate all bacteria from the canals solely through mechanical cleansing over several appointments. On the other hand, the canals could be rendered bacteria-free in a single appointment in 50% of the cases by flushing with sodium hypochlorite, and in 70% of cases by *ultrasonic irrigation* (Bystrom et al. 1985).

56 Bacterial infection

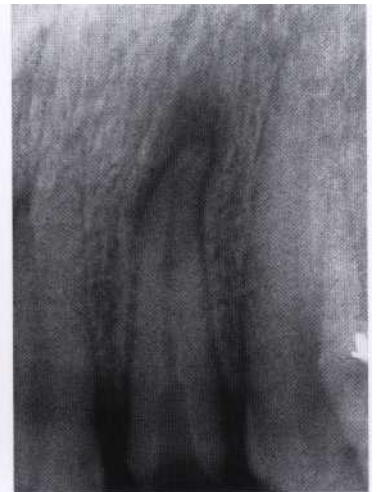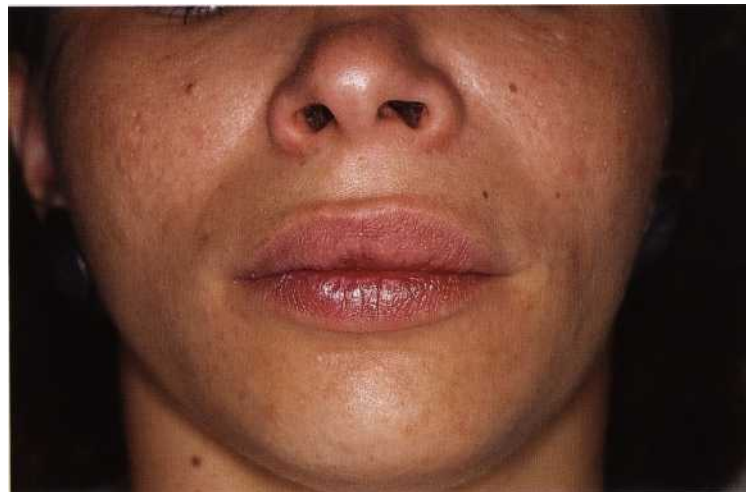The maxillary left lateral incisor is fractured at the level of the gingiva and is stained black by pigmented bacteria. Palpation reveals a filled-in mucogingival fold, and the tooth is tender to percussion. The tooth was in this condition for approximately 1 year before pain compelled the patient to seek dental care.



57 Apical periodontitis

This 41-year-old patient suffered for a week with increasing pain, intermittent at first, but constant for the past day. A swelling of the upper lip extended into the canine fossa.

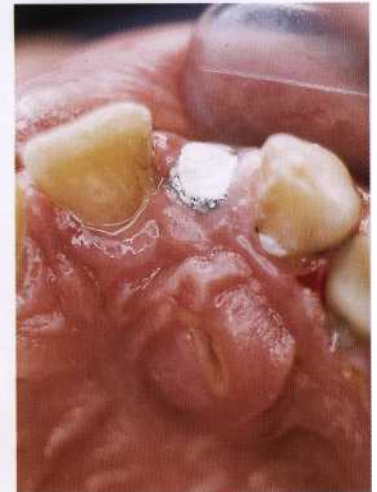Right: A radiolucency is apparent on the radiograph. The pulp chamber was opened 1 year previously and then left open.



58 Emergency treatment

The carious dentin is removed and the entrance to the root canal cleared under a rubber dam and strict aseptic conditions. The coronal portion is enlarged and flushed with sodium hypochlorite.

Right: Before definitive endodontic treatment, an inadequate palatal incision was made at a weekend emergency clinic. It would have been better to perform an excisional opening to prevent the mucosa from closing prematurely.

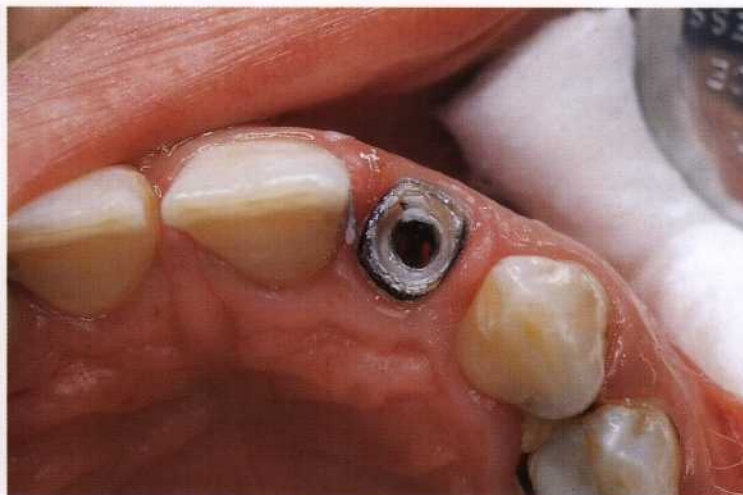

Remaining bacteria that are not removed by the mechanical preparation and the antibacterial irrigating solutions can multiply and cause failure. Phenolic compounds used in *interim dressings* result in bacteria-free root canals in 70% of cases. Calcium hydroxide has an even better effect. Almost all root canals were already free of bacteria after the first appointment (Bystrom et al. 1985). The application of an antibacterial dressing between appointments is absolutely necessary.

An inadequate coronal seal is just as often the cause of failure as incomplete elimination of bacteria from the root canal. Therefore an *impervious coronal filling* must be inserted between each appointment as well as at the conclusion of root canal treatment to prevent recontamination with bacteria. The temporary filling must be at least 3.5 mm thick. When coronal buildups did not adequately seal the preparation, bacteria were found in the periapical tissues within 42 days in 50% of cases where root canals had been filled by lateral condensation (Torabinejad et al. 1990).



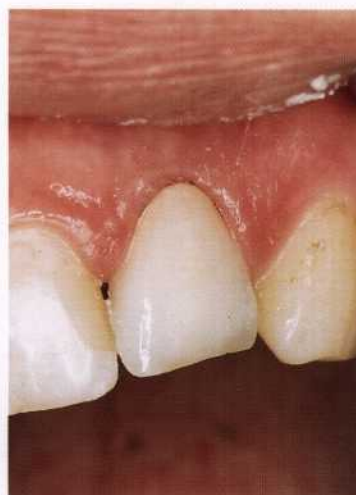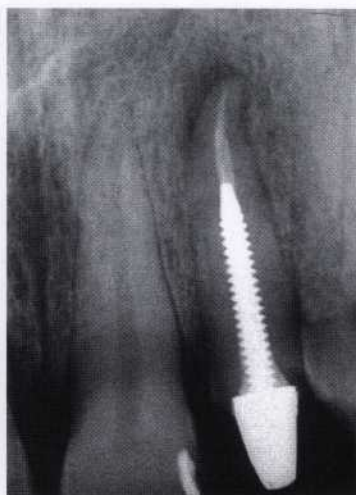
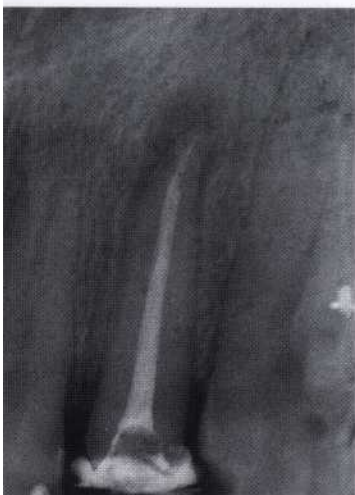59 Removal of bacterially infected material from the canal
After establishing the working length and a coronal reference point, the root canal is prepared from coronal to apical to remove the majority of the bacteria. It is then irrigated with a 1% sodium hypochlorite solution.



60 Interim dressing and coronalseal

After complete instrumentation of the root canal at the first appointment, the canal is prepared for a provisional restoration and the coronal portion of the root canal tightly sealed.

Left: Calcium hydroxide is first introduced into the root canal with paper points for its antibacterial effect.



61 Root canal filling and coronal restoration

Left: Three months after instrumentation, the canal is sealed with gutta-percha and sealer using the lateral condensation technique.

Center: At the third appointment a standardized screwpost and core are placed in the canal and a provisional crown is cemented.

Right: When the tooth is asymptomatic, the permanent crown can be cemented.

Acute Apical Periodontitis

A periapical lesion arises only in the *presence of bacteria within the root canal*. Kakehashi et al. (1965) were able to demonstrate this with germ-free rats. These developed periapical inflammation only after their teeth had been inoculated with bacteria. When the pulp chambers were opened and left exposed to the germ-free oral environment, no apical periodontitis developed. Similar results were obtained by Moller et al. (1981) in the teeth of apes: no periapical lesions developed after the pulp tissue had been necrotized, provided the access preparation was tightly sealed.

Of the 31 periapical lesions studied by Nair (1987), bacteria could always be demonstrated within the root canals, some of them adhering tightly to the dentinal wall and others within the dentinal tubules. In 18% of the cases investigated, bacteria were found in the periapical tissue, which in one case were unmistakably actinomyces. In three other lesions, bacterial plaque was adhering to the outer dentinal surface, continuing to the center of the apical periodontitis, and caused either limited or extensive necrosis and acute inflammatory cell response.

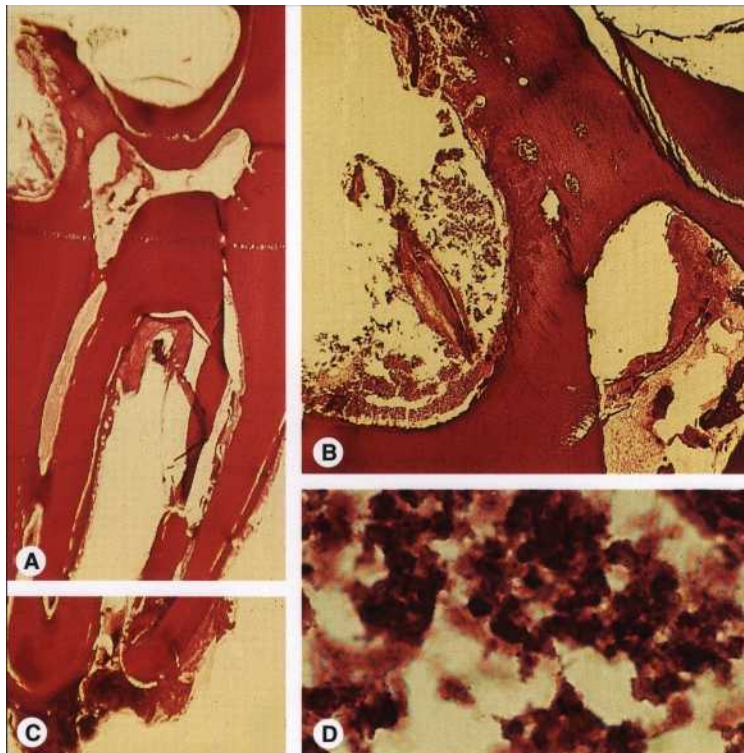
62 Caries progression and apical periodontitis

A Despite a thin layer of dentin, bacteria and their products have penetrated into the pulp chamber causing inflammation and, ultimately, destruction of pulp tissue.

B Carious destruction of the enamel-dentin covering. Bacterial irritants promote a reaction in the neighboring pulp with tissue necrosis.

C Acute periodontitis has developed around the apex.

D In the area closely surrounding the necrotic region, the pulp tissue is infiltrated by neutrophilic granulocytes that phagocytize bacteria and release inflammation-promoting lysosomal material.

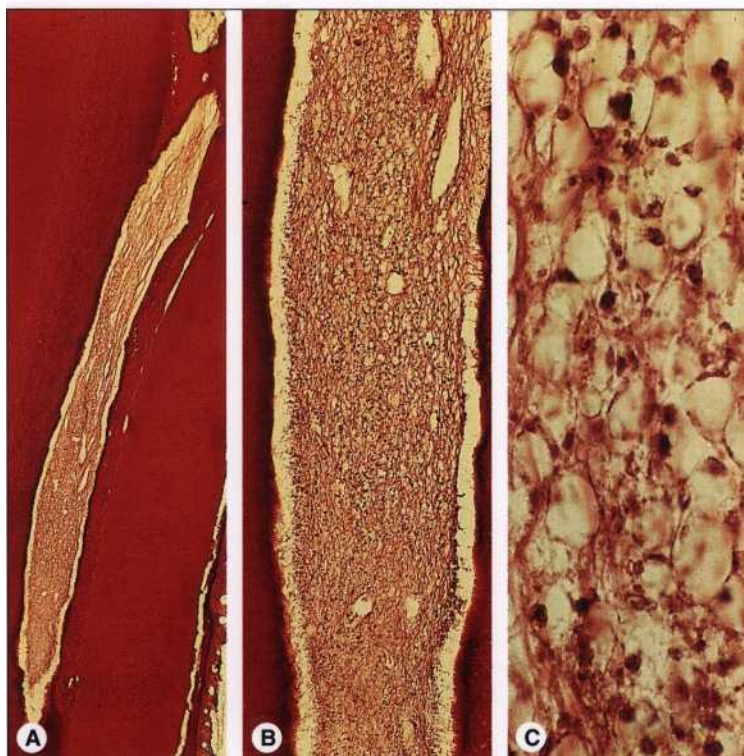


63 Necrosis and lysis of the radicular pulp

A Bacteria and necrosis can be seen in the entire coronal pulp and extending into the root canal.

B Pulpal necrosis is characterized by cell death and tissue destruction that may appear localized within vital tissue or throughout the entire root canal.

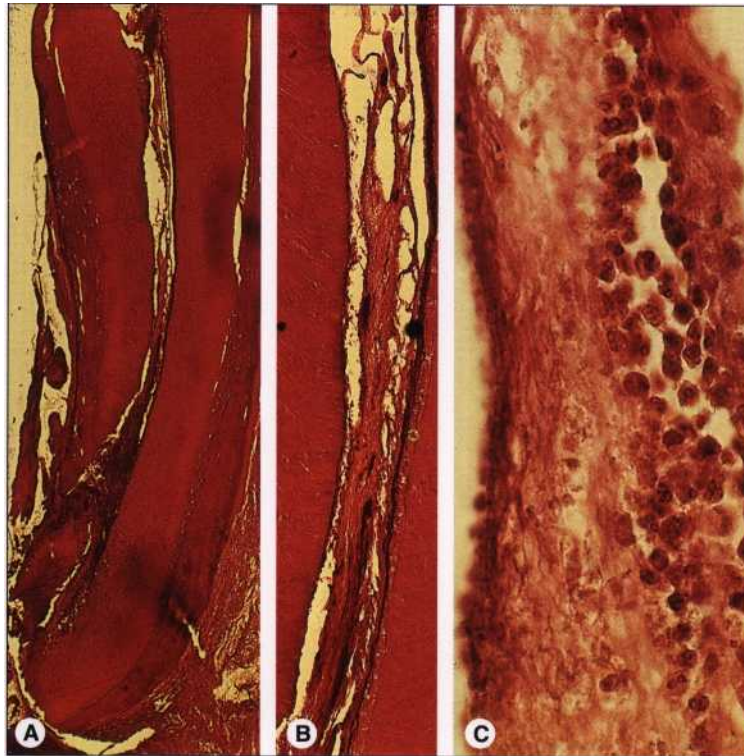
C Under high magnification, the disrupted and necrotic tissue is visible. Inflammatory cells, some intact and some destroyed, can be seen within the tissue. There is a progression toward complete liquefaction of pulp-tissue areas with the process spreading in an apical direction. In many cases, nerve fibers can be found with their structure still completely intact (Lin and Langeland 1981 a).



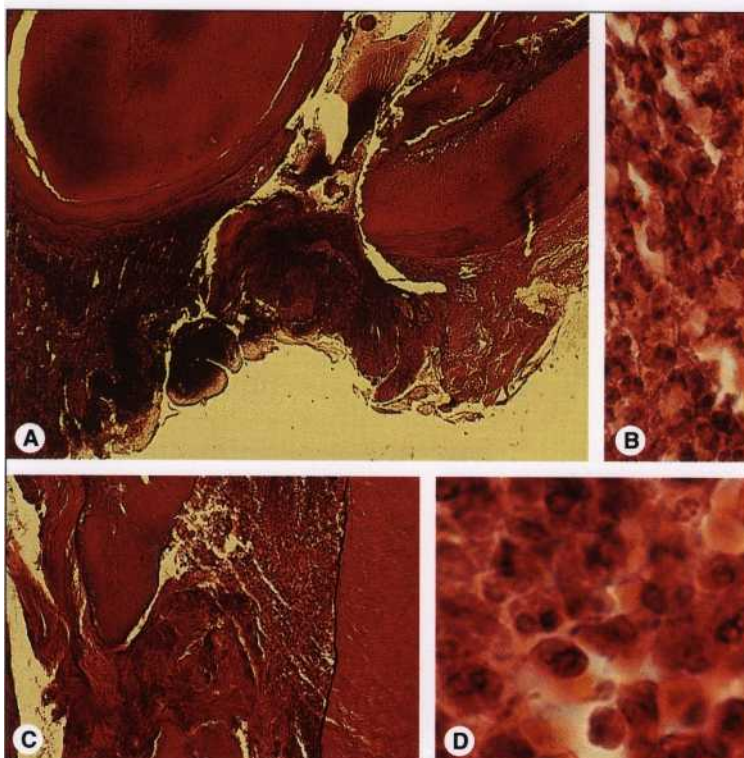
Acute apical periodontitis is characterized *histologically* by an exudate of PMNL limited to the periodontal space that has been widened by osteoclastic activity. Macrophages play a prominent role in the breakdown of immune and complement complexes, while the defense against foreign substances is dominated by the neutrophilic granulocytes. Macrophages take up bacterial antigens and raise the immunogenic potential. This brings about a further massive accumulation of neutrophilic granulocytes with necrosis and liquefaction of tissue to the point of abscess formation.

Where there is a periapical abscess, the necrotic tissue around the apex is permeated by bacteria and bordered by a wall of neutrophilic granulocytes (Nair 1987).

The flora of a periapical abscess is polymicrobial with the involvement of five types of bacteria. Gram-negative, anaerobic rods and peptostreptococci dominate the flora. Periapical abscesses contain black-pigmented bacterial forms that are thought to play an active role in the etiology of periapical lesions. *P. intermedia* can be found in 63% of the cases and *P. endodontalis* in 53% (van Winkelhoff et al. 1985).



64 Inflammation in the apical root canal pulp
A The apical portion of the pulp is partially necrotic and infiltrated by inflammatory cells. The toxins set free during this inflammatory process cause a periapical inflammatory reaction. At the same time, sections pulp that are still vital can be demonstrated throughout by histopathologic methods.
B Necrotic coronal tissue is identified. In a more apical location the tissue is vital and contains only a few inflammatory cells. The formation of voids and separation of pulp tissue from the canal wall are artifacts.
C Section from the coronal zone of necrosis that is isolated from the adjacent pulp tissue by a wall of neutrophilic granulocytes.



65 Acute apical periodontitis
A Periapically, an aggregation of inflammatory cells is visible. At the same time, resorption lacunae within the dentin are evidence of dentinoclastic and osteoclastic activity. The transitional zone within the root canal contains significantly fewer inflammatory cells.
B In addition to neutrophilic granulocytes, eosinophiles, plasma cells, foreign-body giant cells, and mast cells can be identified. The constant replenishment of inflammatory cells is characteristic.
C This enlarged section of the periapical region shows a mass of inflammatory cells bordered by a collagen fiber-rich layer of granulation tissue.
D Periapical accumulation of neutrophilic granulocytes.

Periapical Abscess

If infection persists, acute apical periodontitis can progress into a periapical abscess.

The clinical symptoms of acute apical periodontitis are a sensation that the tooth is elongated and pain elicited by percussion or axial pressure.

The abscess may be present in an acute form or in a chronic encapsulated form. At first, the acute abscess is not visible on the radiograph. The massive inflammatory cell infiltration and the osteoclastic activity do not bring about a visible bone defect until 3-4 weeks later. During this time an acute abscess can

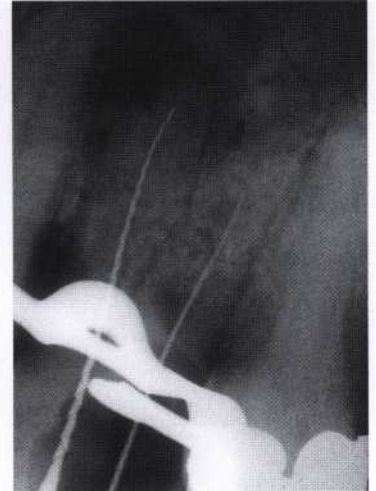
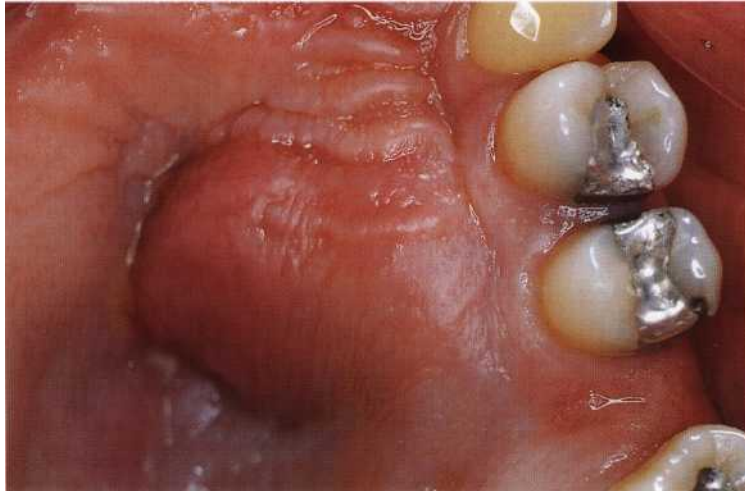evolve into the chronic encapsulated form (Schroeder 1991).

When chronic apical periodontitis is subject to secondary bacterial infection, a "phoenix abscess" arises as an acute exacerbation. The radiograph will show a periapical radiolucency. The clinical symptoms of a secondary acute abscess are the same as those of a primary abscess: extreme sensitivity to percussion, tooth elongation, severe pain, and reddening of the mucosa.

66 Palatal abscess

A plum-sized, fluctuant swelling has formed in the palate, caused by periapical inflammation extending from the upper first premolar. The tooth is definitely tender to percussion and appears to be elongated.

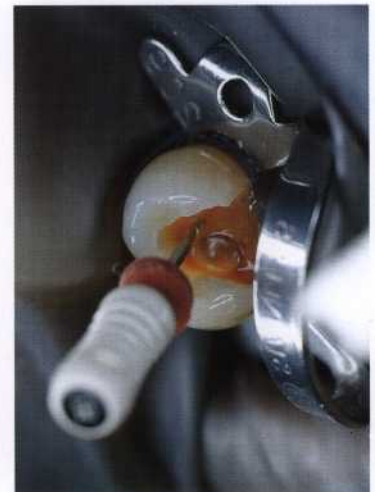
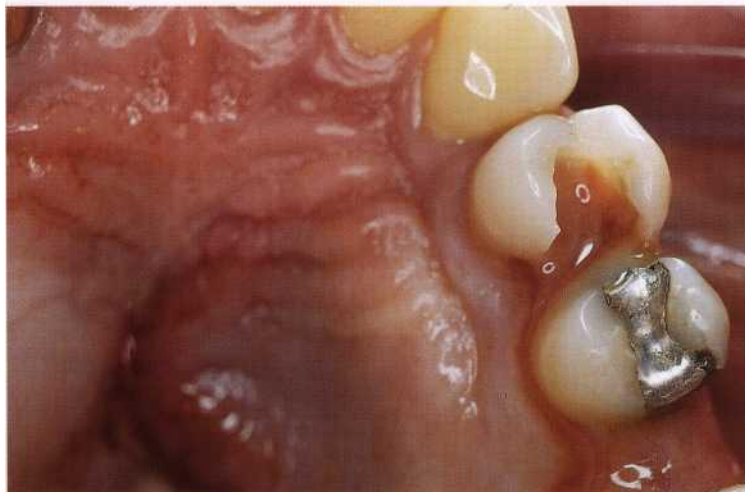
Right: Radiograph showing files in the root canals and a clearly visible periapical radiolucency.



67 Opening and drainage through the root canal

After making an opening into the pulp chamber, a large amount of pus emerges from the root canal. The palatal swelling is noticeably reduced within only a few minutes.

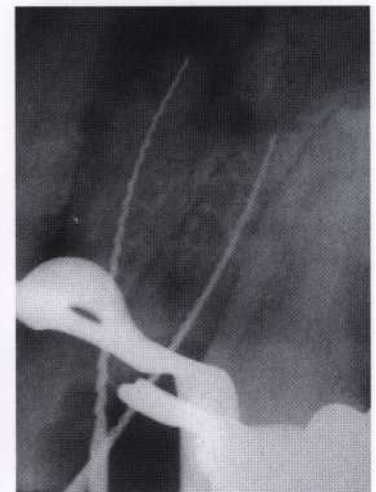
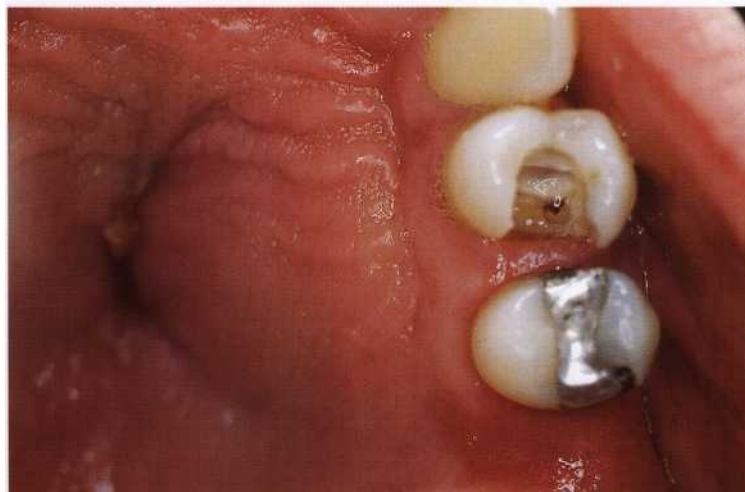Right: Drainage of pus is accomplished exclusively through the root canal that is left open for approximately 20 minutes. Thereafter, the canals are fully prepared.



68 Root canal preparation

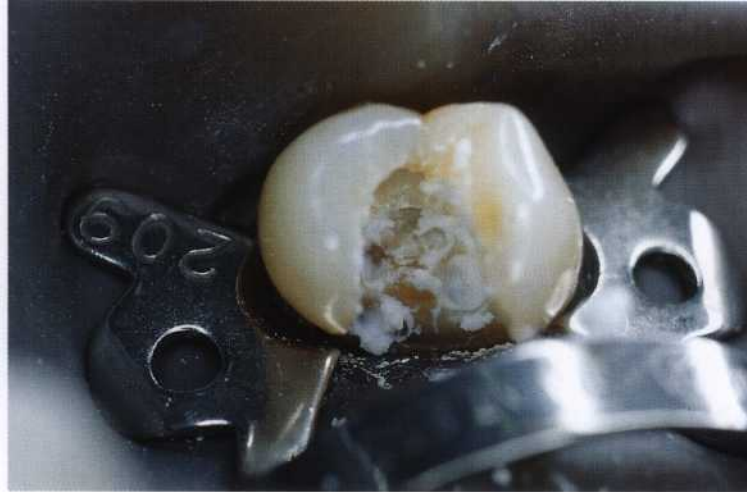After allowing the greater portion of the pus and secretions to drain out through the root canal, the infected tissue is removed at the first sitting and calcium hydroxide loosely spun into the canal. Three days after the initial instrumentation, there is a marked decrease in the swelling.

Right: At the second appointment the working length is determined with a radiograph.

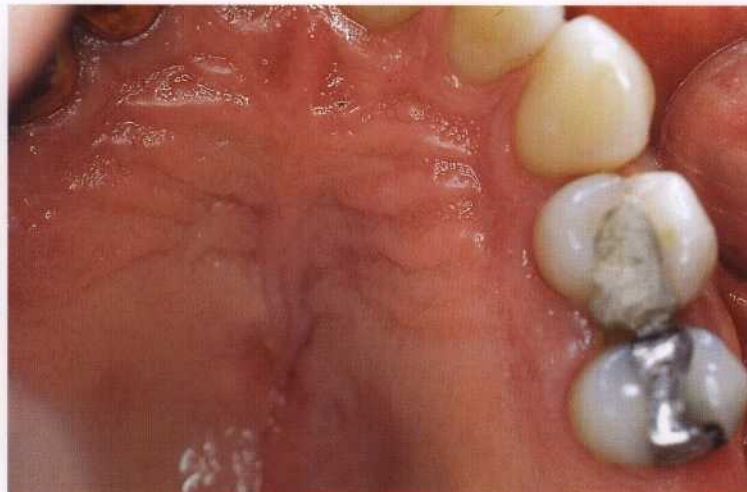
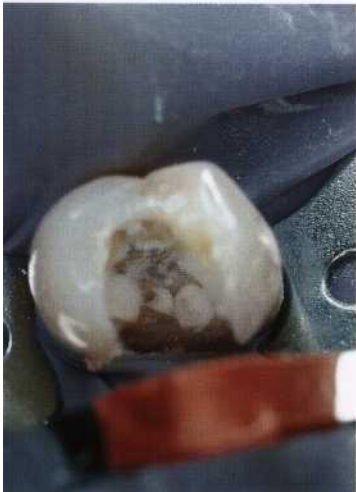
Histologically, the periapical lesions of teeth associated with pain, swelling, or fistulae appear no different from those of teeth that are asymptomatic (Block et al. 1976). However, with spontaneous pain or pain upon percussion, there is a much greater bacterial presence within the root canal than with no clinical symptoms. Peptococci, peptostreptococci, eubacteria, porphyromonas, and *Bacteroides* are predominantly associated with percussion, pain, exudation, and swelling. The latter are responsible for the typical odor of an infected root canal (Hashioka et al. 1992).

If the bacterial infection persists and the body's defenses weaken, the pus can break out into the surrounding soft tissues with swelling or spontaneous drainage, or osteomyelitis may develop. In these cases, systemic symptoms appear. The first priority of treatment is the *evacuation of pus*. If drainage can be established through the tooth, an incision is not necessary. An incision is indicated only when drainage cannot be accomplished otherwise.

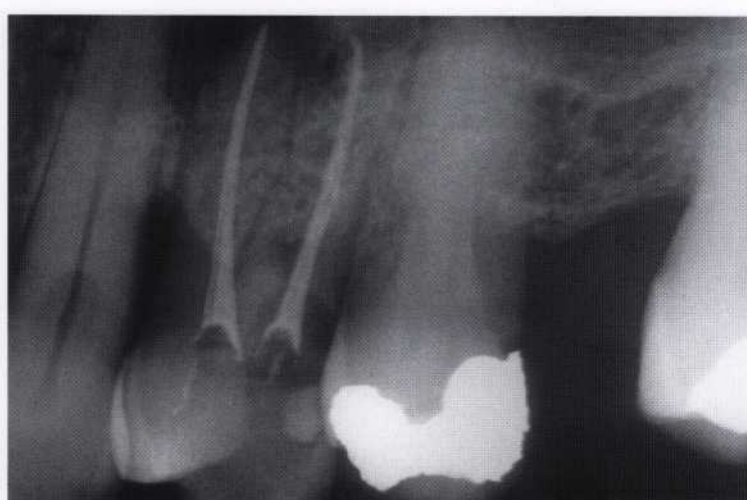

69 Interim dressing
After the canals are prepared and dried, they are firmly packed with calcium hydroxide. Only if the antibacterial dressing is in contact with the canal walls can a long-term effect be assured.



70 Antibacterial effect
After 3 months the palatal swelling and the original clinical symptoms have disappeared. The temporary filling is still intact, protecting the root canal from any renewed bacterial infiltration.

Left: The filling was removed under a rubber dam. The intact interim dressing can be seen in the canals.



71 Root canal filling
The root canals have been filled with gutta-percha and a sealer, using the lateral condensation technique. A reduction in the size of the radiolucency is already visible.

Chronic Apical Periodontitis

Between the 7th and 20th day after apical periodontitis was induced in the molars of rats, an active phase with severe *bone destruction* could be observed histologically. This was followed by a chronic phase with slower expansion. The cell forms that predominated at both 15 days and thereafter up to 90 days were lymphocytes (50-60% of all cells) followed by polymorphonuclear leukocytes (25-40%), macrophages, plasma cells, and fibroblasts. Thelper cells predominated in the acute lesions, while Tsuppressor cells predominated in chronic lesions. The former play an important

role in bone resorption whereas the latter stabilize the lesion, tending to make it chronic. First, Thelper cells induce the production of an interferon that excites the macrophages to produce the bone resorption factor IL-1. Secondly, a bone resorption cytokine is produced and thirdly, Thelper cell factors stimulate the formation of antibodies and immune complexes. High IL-1 concentrations inhibit formation of new bone by suppressing protein synthesis of osteoblasts (Stashenko et al. 1994).

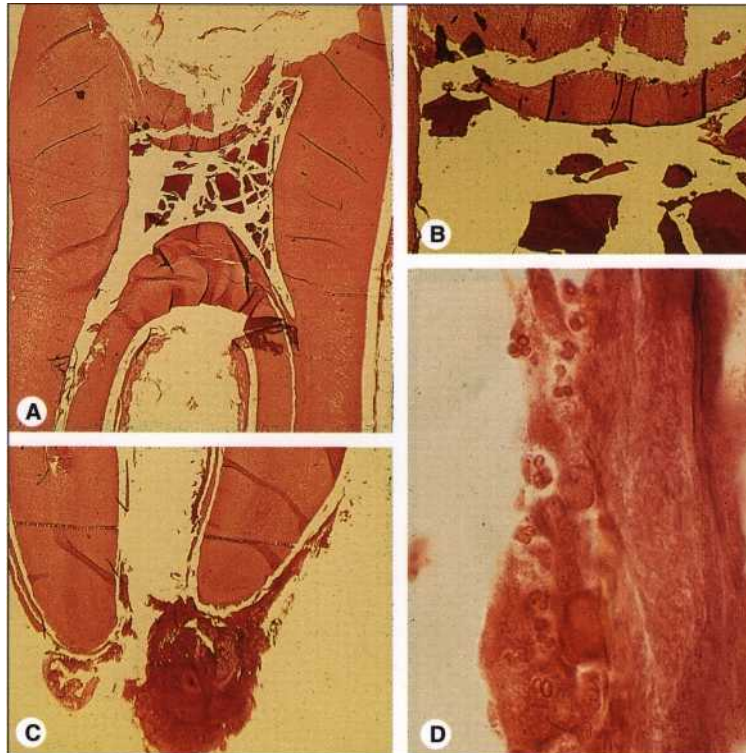
72 Necrosis and chronic periapical lesion

A Carious exposure through the roof of the pulp chamber with pulpal necrosis.

B Enlarged section from the region of the necrotic coronal pulp.

C Periapically, a large encapsulated mass of inflammatory cells can be seen. Numerous small encapsulated spaces are located in the center of the periapical lesion.

D The tissue in the root canal is necrotic and contains mainly neutrophilic granulocytes that have been partially destroyed by cytolysis and have released further tissue-destroying enzymes.

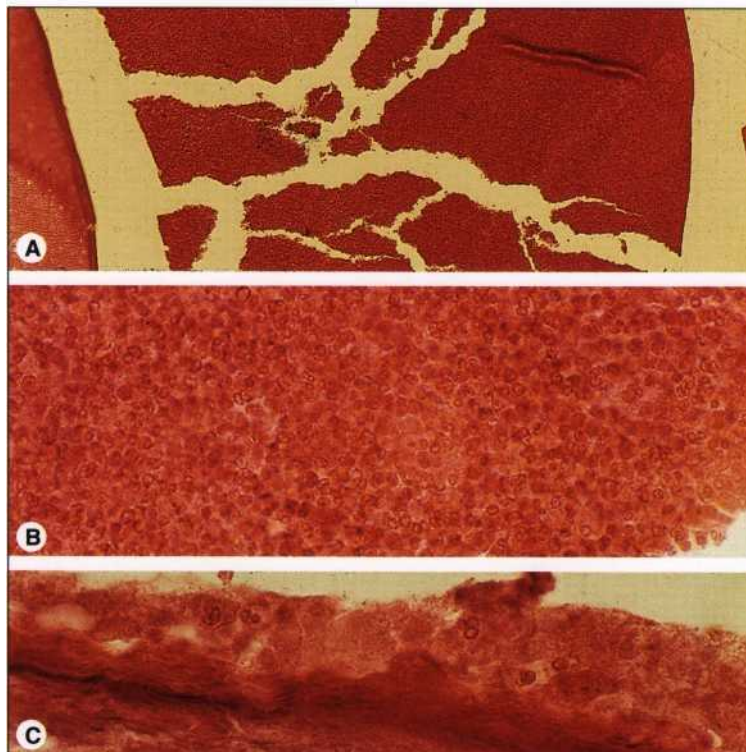


73 Necrosis of the coronal pulp

A The tissue at the mouth of the root canal has disintegrated. The tears in the necrotic area are histologic artifacts.

B The tissue is totally infiltrated by polymorphonuclear granulocytes, lymphocytes, and monocytes. There are no remaining tissue elements.

C The granulocytes are chemically attracted by bacteria and their toxins, and phagocytize both cell fragments and foreign matter pushed in from outside. They then disintegrate, thereby destroying the surrounding intact tissue. In spite of the severe inflammation and tissue necrosis, nerve fibers still remain relatively intact.

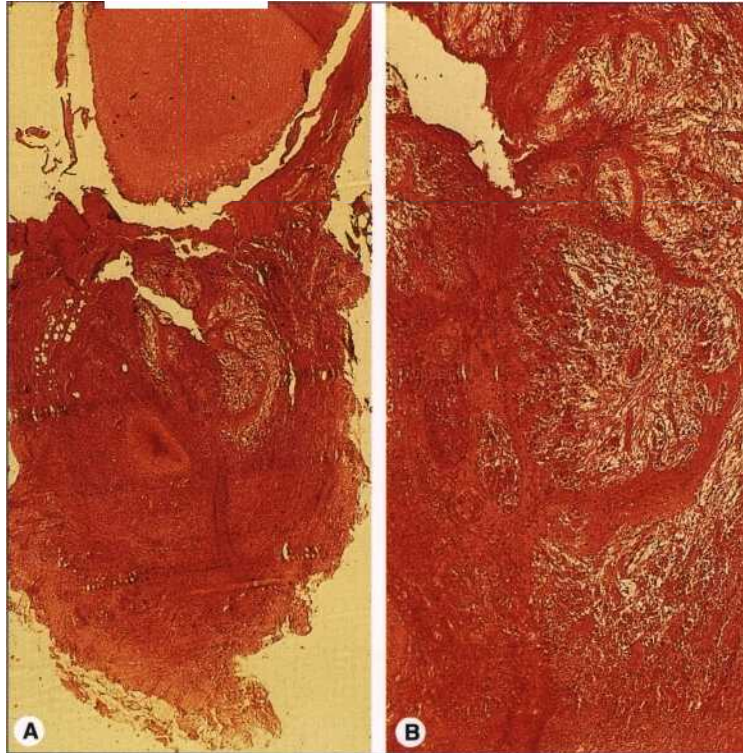


Chronic apical periodontitis is clinically asymptomatic. There is a direct relationship between the size of the periapical lesion and the extent of bacterial invasion and tissue necrosis within the root canal. Teeth with small periapical lesions still give a positive response to the sensitivity test, but if the lesion is large, no response is to be expected (Lin et al. 1984).

The chronic periapical lesion consists of three or four main components: 1) an infiltrate of lymphocytes and plasma cells; 2) presence of granulation tissue; 3) proliferation of epithelial rests of Malassez, and

4) a connective tissue capsule with fibroblasts and collagen fiber bundles (Schroeder 1991).

The high concentration of antibodies associated with acute lesions and the reduction of these following endodontic treatment shows that the preparation of the root canal and the removal of tissue infected with bacteria that is associated with chronic apical periodontitis is the treatment of choice (Kettering and Torabinejad 1984).

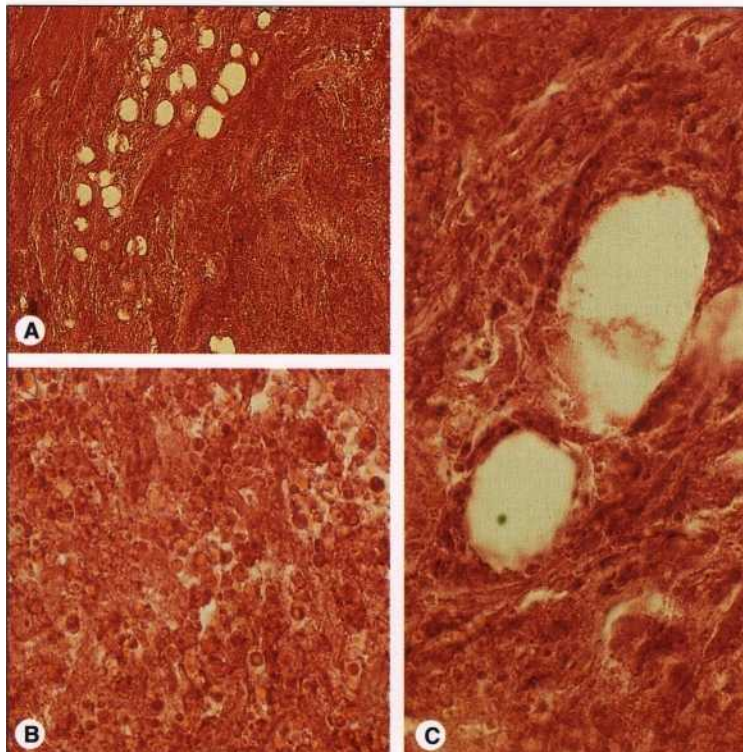


74 Periapical granulation tissue

A The chronic periapical lesion is surrounded by a tough connective-tissue capsule that contains mast cells, fibroblasts, and collagen fiber bundles. Centrally, a semicircular cluster of mononuclear inflammatory cells such as lymphocytes, plasma cells, and macrophages can be found.

B In the enlarged section epithelial strands can be identified, not only immediately adjacent to the apex, but also in bizarre arrangements in the core of the periapical lesion.

These epithelial strands presumably arise from epithelial rests of Malassez, although the latter are found in only 20-40% of all chronic periapical inflammations (Langeland et al. 1977).



75 Periapical microcysts

A Granulation tissue with fibroblasts and mononuclear inflammatory cells. Also, in the center of the lesion, encapsulated microabscesses are found as is true in 30-60% of all cases. These are visible here as voids in the upper part of the image.

B Enlarged section with epithelial strands and a mononuclear infiltrate. No epithelial rests of Malassez are evident.

C Under high magnification several encapsulated dormant abscesses, which are potentially the initial substrate for future cystic epithelium, can be identified. Epithelial strands are threaded through the granulation tissue and envelop it as arched or net-like structures.

Chronic Apical Periodontitis and Radicular Cysts

Figures pertaining to the incidence of radicular cysts vary from 6 to 55%. Based upon a study of serial sections, the incidence is around 15% (Nair 1995).

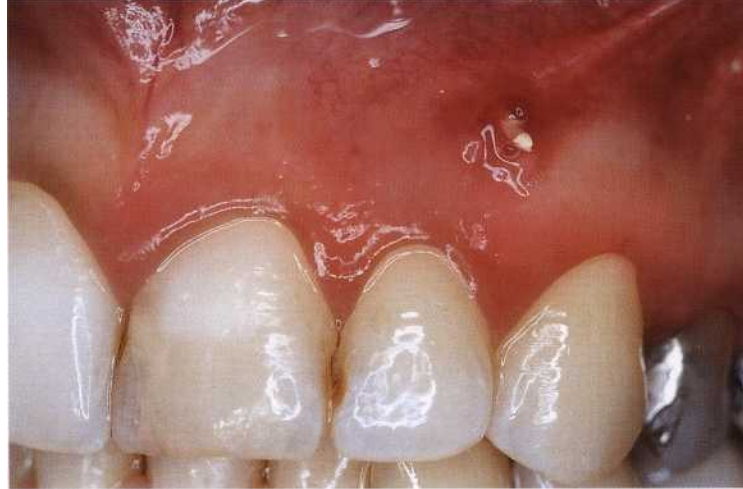
In one clinical-histologic study of 230 root tip biopsies where periapical radiolucencies and clinical symptoms were present, only 14 cysts (6%) were confirmed (Block et al. 1976).

The chronic periapical lesion is usually asymptomatic. Occasionally the tooth feels slightly elongated. It may be tender to percussion, and in 20% of cases fistulae can appear (Mortensen et al. 1970).

On the radiograph, chronic apical periodontitis appears as a round or oval radiolucency that is usually sharply demarcated. Sometimes a diffuse boundary is observed. Average-sized radicular cysts are indistinguishable from chronic periapical lesions. The percentage of radiolucencies that represent cysts rises among lesions larger than 10 mm, although even among radiolucencies that are 10-15 mm in diameter, less than 50% are likely to be cysts. Only a computer tomographic study can provide the differential diagnosis (Trope et al. 1989).

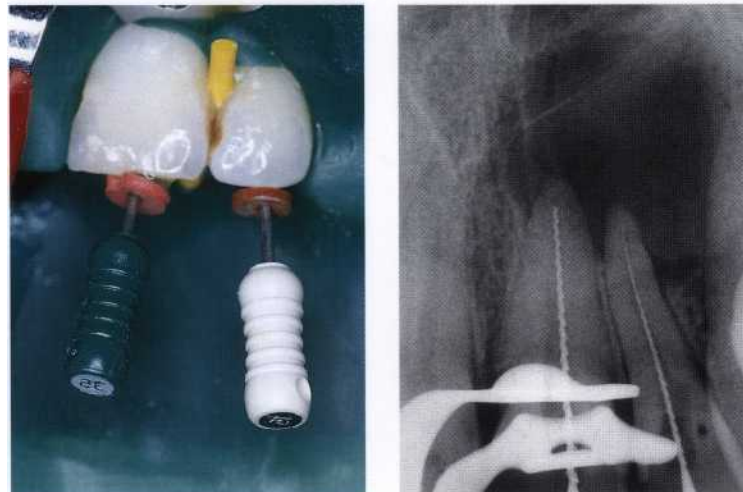
76 Fistula and radiographic periapical lesion
In approximately 20% of cases of chronic apical periodontitis and approximately 10% of radicular cysts, a fistula occurs labial to the alveolar process. In the photograph a gutta-percha point, inserted to assist in the radiographic interpretation, can be seen.

Right: This radiograph shows an almost plum-sized periapical radiolucency as well as the inserted gutta-percha point.



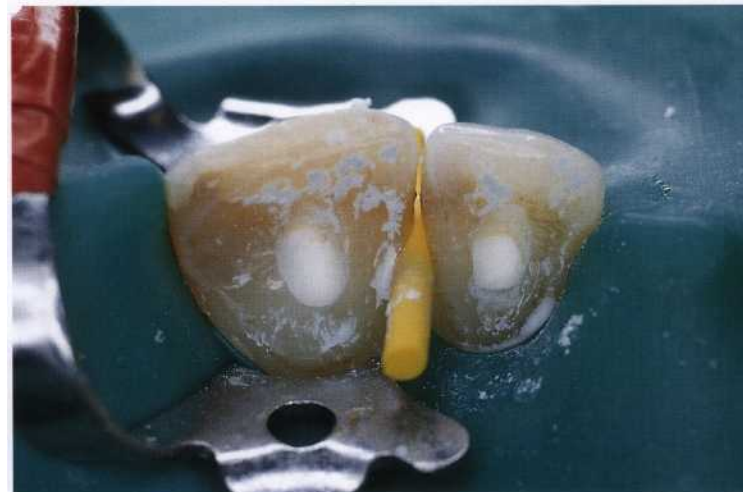77 Root canal preparation
Left: Because the central as well as the lateral incisor give a negative response to the sensitivity test and both are tender to percussion, the root canals of both teeth are prepared. The working lengths are measured radiographically. Overinstrumentation must be avoided where there is apical resorption.

Right: Much of the infected tissue is removed with Hedstrom files before the working length is determined.



78 Interim dressing
Once the canals have been fully prepared they are given a final irrigation, dried, and packed with a thin mix of calcium hydroxide and water using paper points as pluggers. This is left in place for at least 3 and a maximum of 6 months.

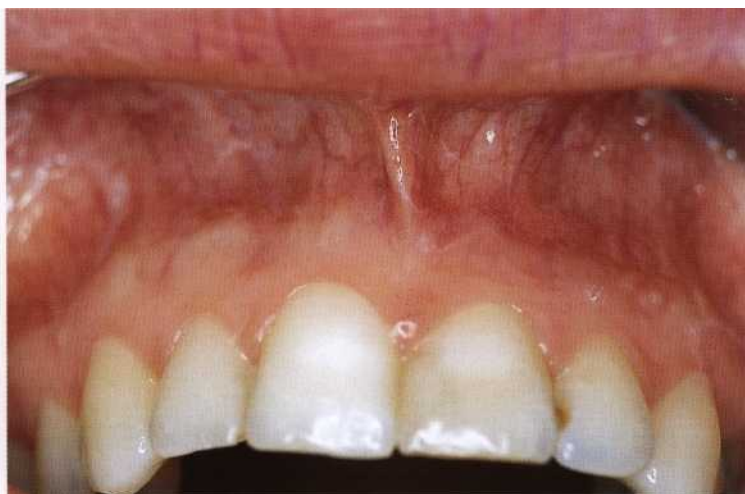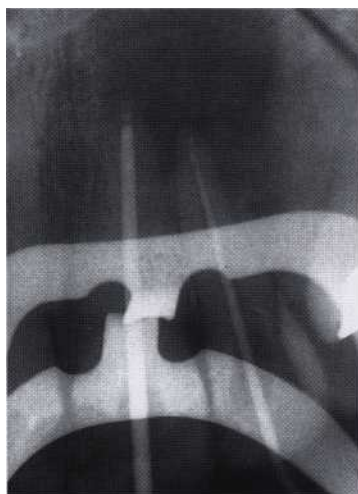
Right: The root canals are instrumented with Hedstrom files and K files and irrigated with a 1% sodium hypochlorite solution.



Recently, a differentiation has been made between the apical *true cyst*, which has a completely enclosed hollow space, and the *pocket cyst*, the lumen of which is continuous with the root canal. Out of 256 periapical lesions 9% were classified as true cysts and 6% as pocket cysts (Nair et al. 1995).

The existence of two different classes of radicular cysts and the inability to clearly distinguish a cyst from chronic apical periodontitis clinically or radiographically have therapeutic implications.

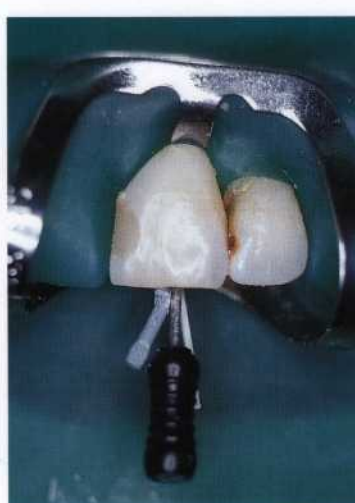
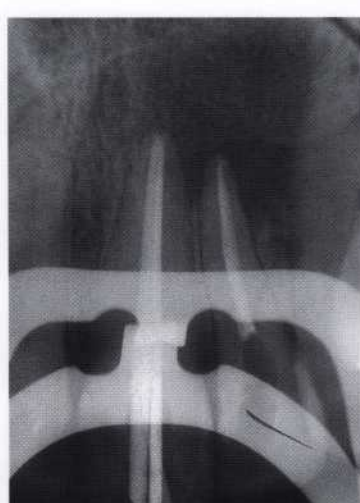The treatment of periapical lesions consists of preparing the root canal and creating a bacteria-proof seal. Because no clear differential diagnosis based upon radiographs can be made, and because the histologic status is unknown, periapical lesions are first treated in the conventional manner. Periapical pocket cysts will usually heal, whereas true cysts will seldom respond successfully to conventional treatment (Nair et al. 1993).



79 Clinical monitoring

After 3 months the interim dressing is changed. The fistula is no longer visible. There are no further signs that would indicate persistence of the periapical inflammation.

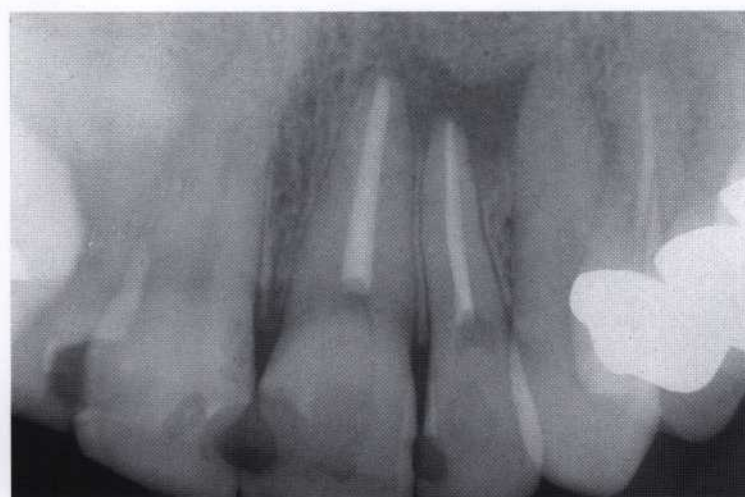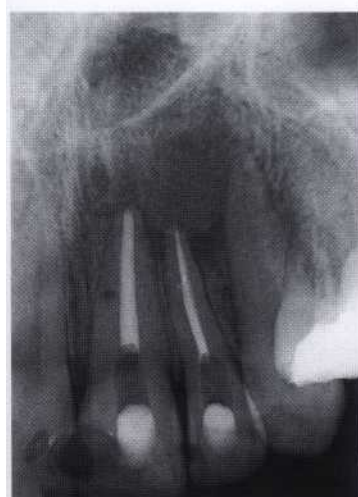Left: After a further 3 months, the interim dressing is flushed out with sodium hypochlorite solution and a radiograph is taken to evaluate the dissolution of the periapical lesion as well as the fit of the gutta-percha points.



80 Root canal obturation

Left: After the sealer-coated gutta-percha points are inserted up to the reference points and the first lateral condensation is accomplished, a radiograph is taken so that any overextension of the filling, in the case of possible periapical resorption, can be detected and corrected early in the procedure.

Right: The root canal filling is completed by lateral condensation of additional gutta-percha points.



81 Radiographic monitoring of the results of conservative treatment

In the follow-up radiograph 2 years later, there is further bony regeneration around the periapical lesion with ingrowth of bone trabeculae. However, a small radiolucency is still visible at the apex of the left lateral incisor.

Left: Radiographic follow-up of the root canal fillings 1 year after the beginning of treatment. The periapical lesion is noticeably reduced in size.

Radicular Cysts

The radicular "true" cyst is defined as a chronic periapical inflammation surrounding a closed, epithelium-lined space. It arises from chronic apical periodontitis in three *developmental phases*. In the first, or initiation, phase, dormant epithelial rests of Malassez begin to proliferate. During the second phase an epithelium-lined space is formed, and in the third phase cystic growth occurs as the result of osmotic and resorption stimulating factors (Nair 1995).

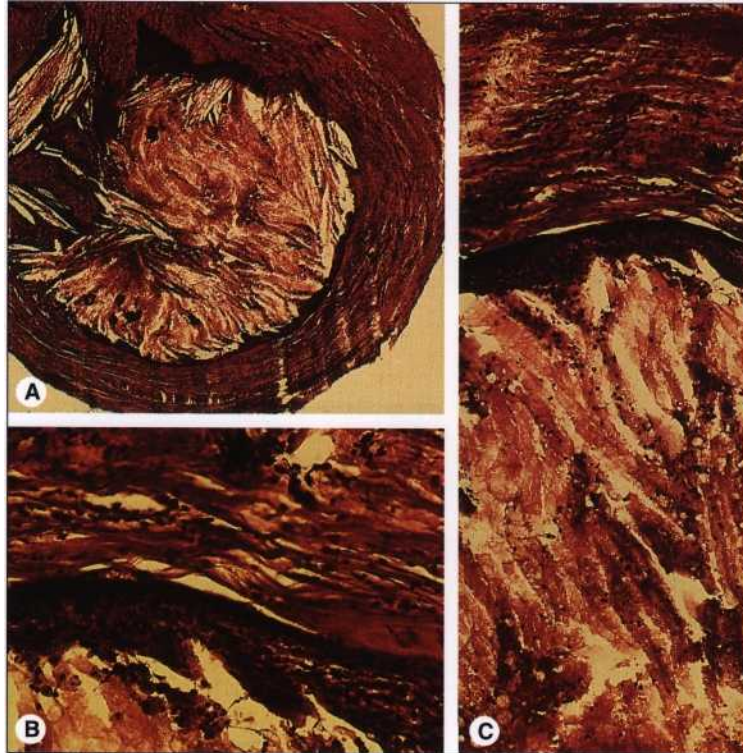
An established radicular cyst is composed of a connective-tissue capsule, a subepithelial zone of inflammatory infiltrate, an epithelial cyst lining, and a cyst lumen. The lumen contains, in addition to sloughed necrotic epithelial cells, cholesterol crystals, inflammatory cells, and remnants of resorbed bone tissue. The cyst wall is a stratified squamous epithelium permeated by granulocytes, macrophages, and lymphocytes. The subepithelial zone contains T and B lymphocytes and plasma cells (Schroeder 1991).

82 Formation and components of a radicular cyst

A Cholesterol crystals are located in the lumen of an established radicular cyst, surrounded by the epithelial lining and the subepithelial zone with infiltration of inflammatory cells. The connective-tissue capsule contains fibroblasts and collagen fiber bundles, and is closely connected with the periapical periodontal fibers.

B The epithelial cyst wall is made up of stratified squamous epithelium with no stratum corneum and is a minimum of 20 and a maximum of 50 cell layers' thick.

C Within the cystic cavity a brownish-yellow liquid containing cholesterol crystals and necrotic tissue is found. Polymorphonuclear granulocytes and mononuclear leukocytes are also evident.



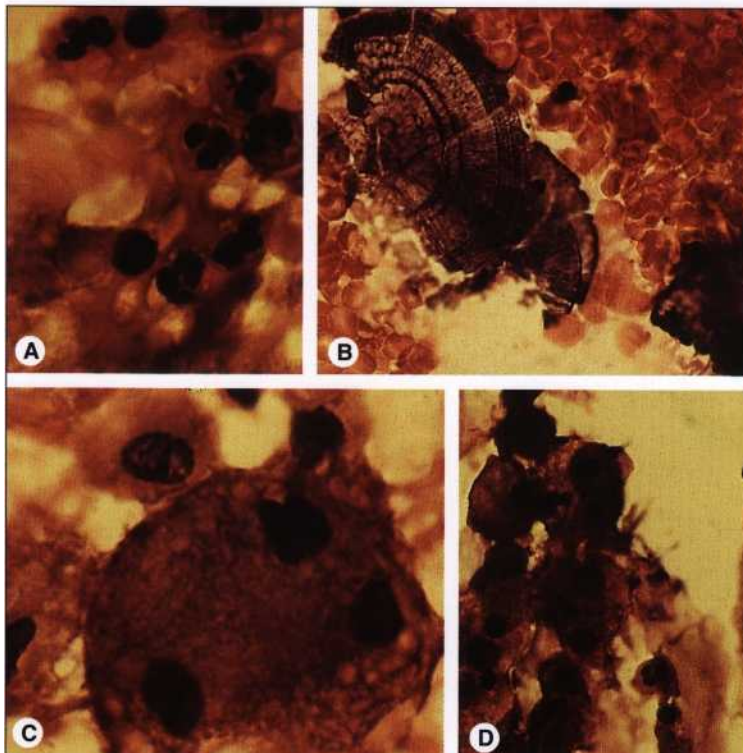
83 Contents of the cystic lumen

A The organic components within the cystic cavity liquify, the ingredients of which can scarcely be identified any longer; this is interspersed with neutrophilic granulocytes and individual lymphocytes that indicate acute exacerbation with infection and inflammation.

B Remnants of lamellar bone within the cystic cavity testify to the resorptive capability of the cystic tissue.

C Multinuclear giant cells are also evidence of a possible foreign-body reaction; neighboring plasma cells produce antibodies, principally IgG and IgA, and to a lesser extent, IgM and IgE.

D The majority of the lymphocytes are T cells, with fewer B cells in a ratio of 3:1.



Examination and Diagnosis

The patient who comes to the dental office with a painful tooth introduces a diagnostic and therapeutic challenge into an otherwise planned and orderly schedule. The goal of endodontic intervention is to remove the cause of the pain. The correct diagnosis can be arrived at through consideration of the subjective and objective symptoms, and treatment appropriate to the diagnosis can then be begun. Because of anatomic limitations, however, diseased pulpal and periapical tissues cannot be directly inspected in vivo. These limitations have led to the development of indirect diagnostic methods. In addition to clinical findings, the subjective phenomenon of pain is an essential criterion for evaluating the pathologic condition of the pulp, even though there is no direct correlation between the histologic condition of the pulp and the various symptoms, especially pain. When pain occurs, it must be determined if it is dental in origin or if it is radiating from neighboring organs.

The examination of the patient includes a medical and dental history, extraoral and intraoral inspection, and possible differential diagnoses. The patient must provide information on past and present medical and dental diseases.

There are no medical contraindications to performing root canal treatment, although medical conditions and the patient's psychological state must be taken into consideration. The medical history should reveal all medical conditions and medications that might influence endodontic treatment or that might themselves be affected by the dental procedures. The existence of systemic diseases such as rheumatic fever, coronary heart disease, high blood pressure, and diabetes must be determined from the history. Patients at risk of bacterial endocarditis must be covered by prophylactic antibiotics.

The dental history includes data important for the treatment plan. Within the scope of a dental history, the patient's history of pain must be explored. The development of the present complaint is recorded briefly in the patient's own words. The questions related to dentistry should bring out information on any past traumatic injuries, and any connections with earlier dental treatments. The patient should report any swelling or spontaneous drainage, and whether pain is induced by pressure or chewing. The history of pain must be specific with regard to the type of pain, the time at which pain occurs, what initiates and relieves it, its location, and whether it radiates into other areas. There are also questions concerning bleeding or suppuration from the gingivae, food impaction between the teeth, and increased tooth mobility.

Extraoral Examination

During the extraoral examination observations of normal conditions and pathologic changes are collected and considered. Anything unusual about the facial form is recorded, such as symmetric or asymmetric defects or swellings.

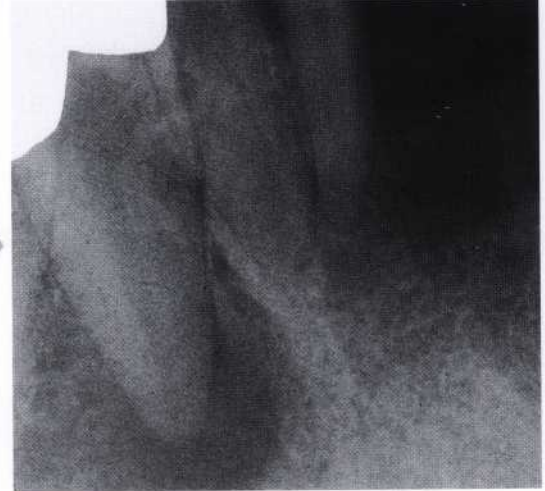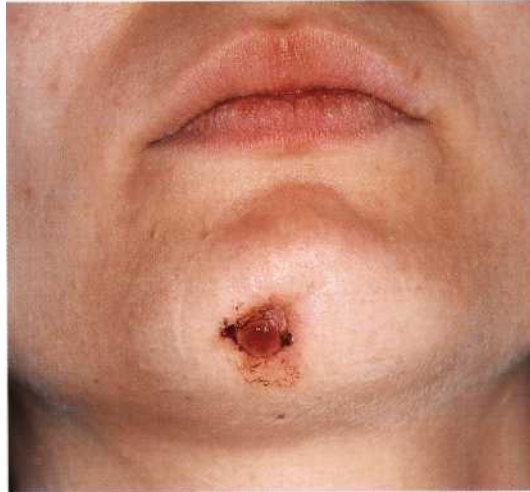The skin surface, for example, can exhibit fistulae, redness, blisters, or scars that require further explanation and that may be evidence of intraoral changes. During the examination it must be clarified whether the conditions are local or systemic.

The neurologic investigation includes tests of motor, sensory, mental, and locomotor functions. Sensitivity is tested bilaterally, comparing the perception of external stimuli on one side against the other.

Examination of the lymph nodes in the head and neck region can provide information relating to inflammatory, infectious, or neoplastic disease. Palpation is performed bimanually, comparing the two sides. Painful lymph nodes are an indication of an acute inflammation (Sailer and Pajarola 1996).

84 Extraoral ulcer

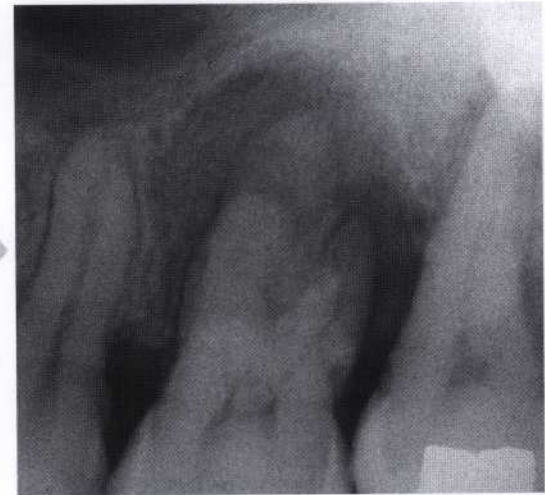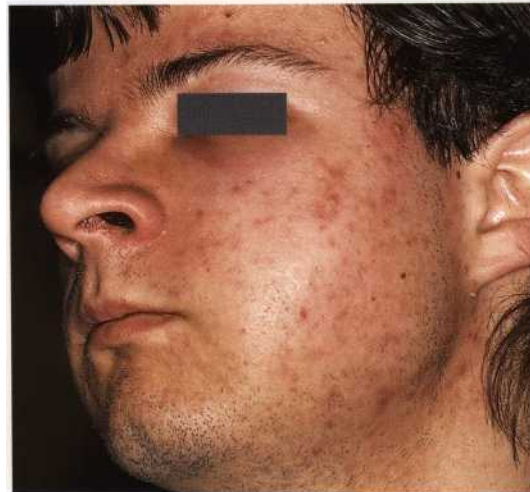Left: This 25-year-old patient presented with a reddened, painless swelling on the chin, almost as large as a cherry pit, that had been present for more than 1 year. In spite of treatment by a dermatologist and surgical closure it perforated again with exudation.



Right: On the radiograph a sharply outlined periapical radiolucency can be seen. After root canal treatment the fistulous tract closed spontaneously.

85 Extraoral swelling

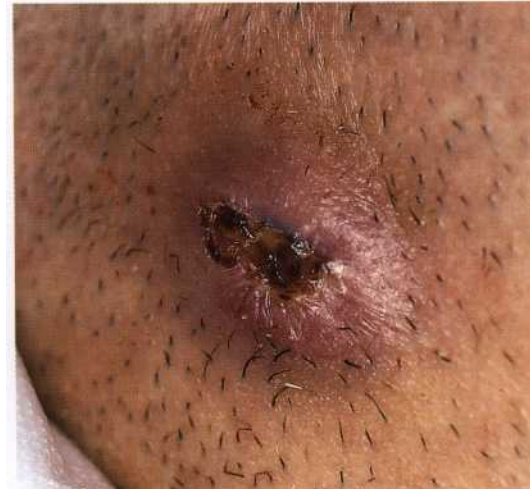Left: Worry about a swelling of 2 days' duration in the left half of the face caused this 27-year-old patient to make an emergency appointment. There was no history of dental pain.



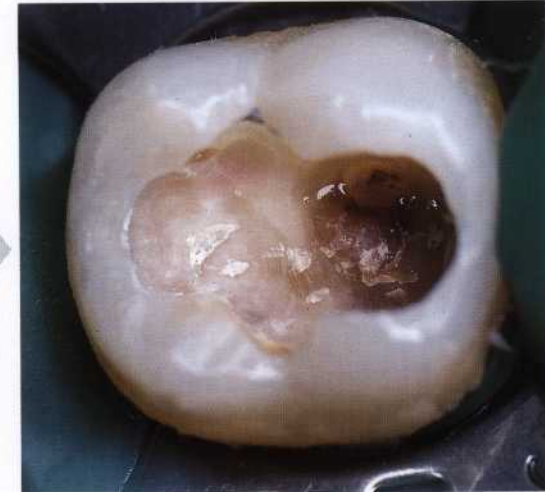Right: Radiographically, a periapical lesion can be seen surrounding the palatal root of the maxillary first molar.

86 Extraoral fistula

Left: Fistulation with suppuration from two openings. In making a differential diagnosis, the following must be considered as possibilities; an ulcer (because of the deep defect that is visible), an aphthous ulcer, and, less likely, carcinoma.



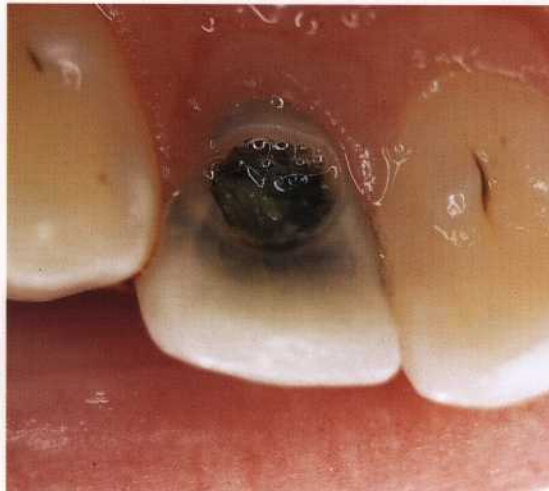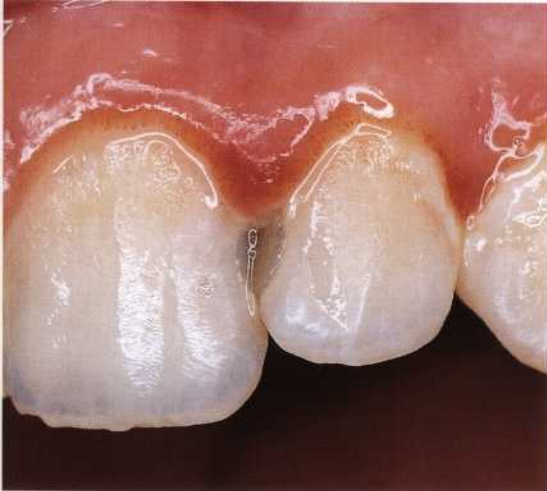Right: Removal of an old filling from the lower right first molar reveals an old pulp exposure with a direct pulp cap in carious dentin.



Intraoral Examination

The visual intraoral examination includes a search for swelling, redness, fistulation, suppuration, periodontal disease, dental caries, discolorations, loose teeth, fillings, and the overall condition of the dentition. Some or all of the following examination procedures should be employed: palpation, percussion, tooth mobility test, periodontal examination, occlusal analysis, cracked tooth test, sensitivity test, transillumination, selective anesthesia test, and a radiographic survey.

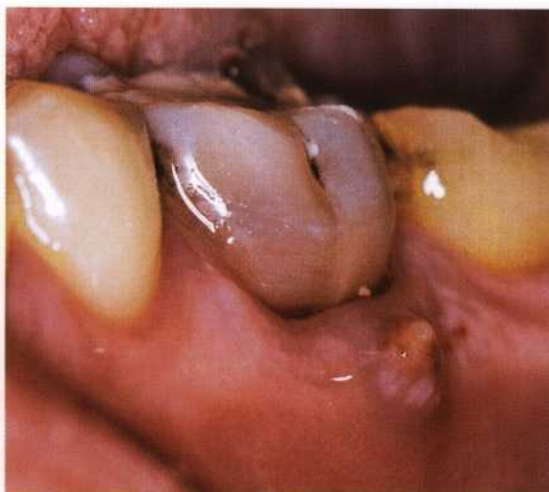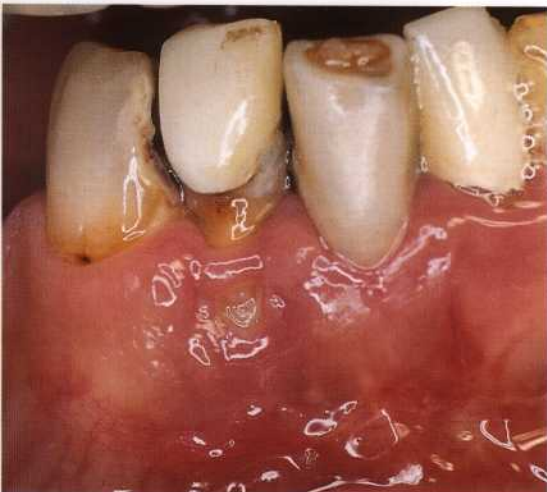Tenderness to percussion of an affected tooth is a sure sign of an early pathologic condition. The question to be answered is whether the cause is periodontal or endodontic or perhaps occlusal trauma in combination with marginal gingivitis. Apical palpation over the root tips in the vestibule can reveal tenderness to pressure, inflammatory infiltration, swelling, or frank fluctuation. A fistula can be diagnosed if exudate comes out of the tissue upon light pressure applied in the area (Beer 1992 b).



87 Caries and filling

Left: Stained fillings must be checked for marginal imperfections. The inadequate oral hygiene also suggests bacterial penetration.

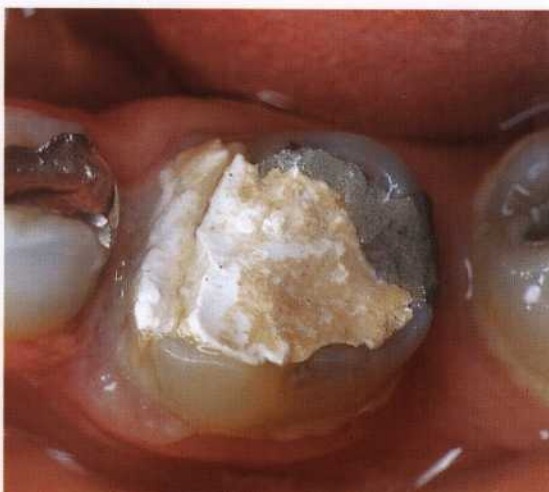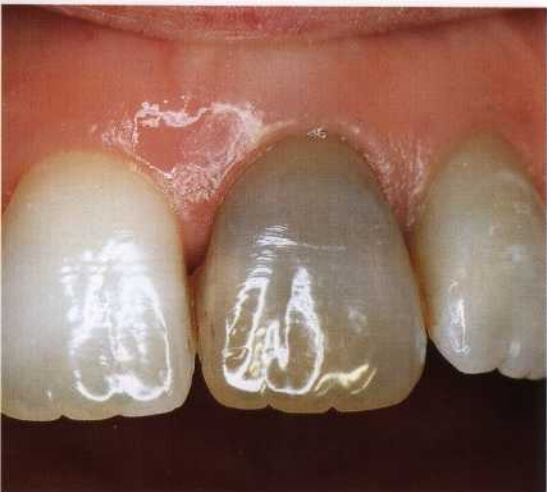Right: A maxillary lateral incisor with deeply penetrating caries. This condition was present at the clinical examination, and the patient's oral hygiene is good. Presumably the carious destruction was started by plaque accumulation in a foramen cecum (lingual pit).



88 Fistulae and perforations

Left: Mandibular incisor region in a 32-year-old patient with a defective full crown restoration coincident with inadequate oral hygiene. The cause of the facial perforation is tissue reaction to corrosion of the core buildup.

Right: In addition to discoloration of the crown of the tooth, the swelling and fistulation are further evidence of a necrotic pulp with periapical involvement. Even though there is no pain, a meaningful diagnosis is possible.



89 Tooth discoloration

Left: Severe discoloration of a maxillary anterior tooth. The radiograph reveals a root canal filling that is insufficient and extends into the coronal cavity.

Right: This tooth continued to be painful after emergency excavation of the caries. The cavity has been filled with a material that takes up moisture during the setting reaction, bringing about pulp damage.

Sensitivity Tests

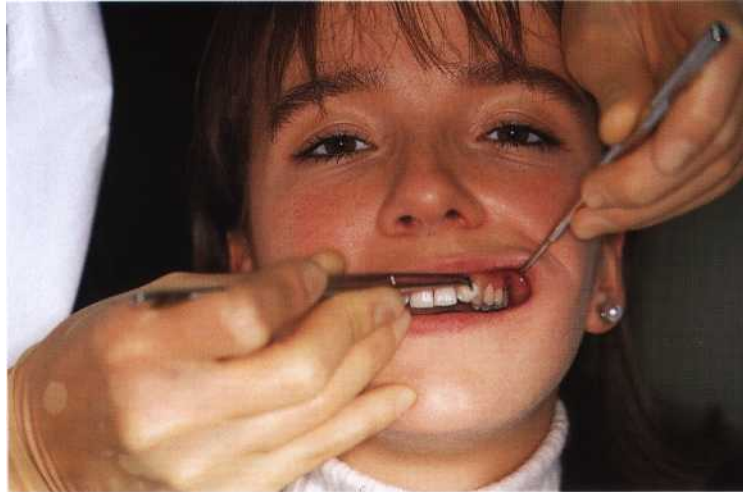Electric or thermal sensitivity tests provide information on whether the pulp tissue is severely damaged or not. Cold tests are the most informative of these. As a rule, a precise differentiation between a clinically sound pulp and reversible or irreversible pulpitis by this test alone is not possible, because intact nerve tissue can be found even in areas of severe inflammation and tissue necrosis. It is even possible to perform a positive sensitivity test in the presence of a small periapical radiolucency (Lin et al. 1984).

90 Cold test

Application of cold for 4 seconds lowers the temperature to between 26 and 30 °C, eliciting pain. Within the pulp the temperature is lowered by only 0.2 degrees (Lutz et al. 1974).

Cones of ice reach temperatures as low as -20 °C; Frigen (US equivalent Freon) from spray containers applied to a tooth surface by means of a pellet can lower the temperature to minimum of -40 °C.

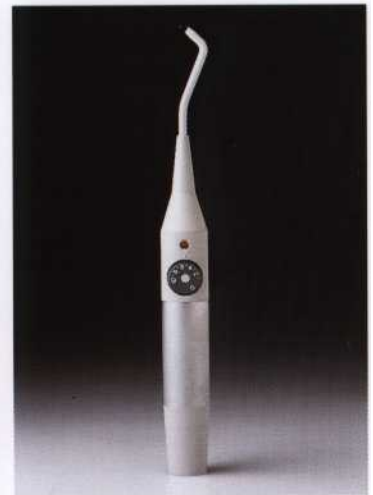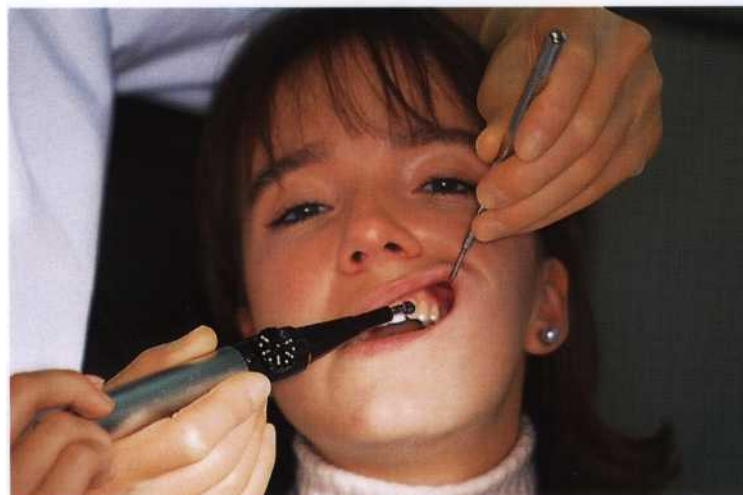Right: Compressed carbonic acid snow reaches -70 °C.



91 Electric pulp test

The electric sensitivity test is simple to use and usually reliable. The tooth surface must be dry. The tip of the pulp tester is moistened. Gloves can result in false results because of their insulating effect. The easiest way to create a closed electrical circuit is to have the patient's hand touch the metal part of the pulp tester.

Right: Electric pulp tester with adjustable current intensity.



The *electric pulp test* is based upon the unique relative conductivity of dental hard tissues. In the test apparatus, the series of voltage-regulated stimulating impulses is so tuned to the impedance of the tooth that should there be an unintended bypass circuit through the mucous membrane, the electric current is interrupted and a false positive reading is avoided. The moistened electrode, usually made of conducting rubber, is rested upon the dry tooth surface. The electrical circuit flows from the handpiece through the body of the operator to the body of the patient via a mouth mirror.

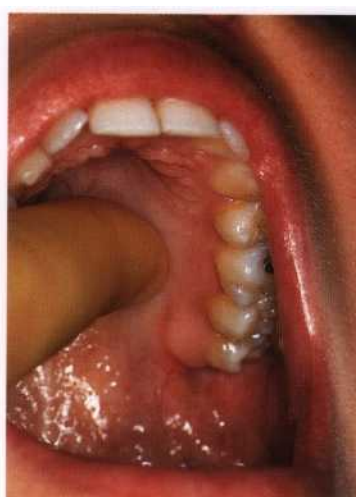
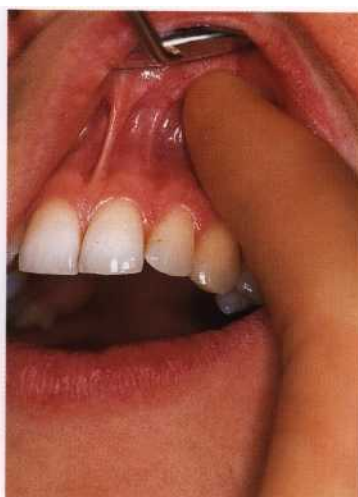Nevertheless, a test of the pulp's sensitivity, which has erroneously been called a "vitality test", is helpful in differentiating pulp diseases. The cold test with carbonic acid snow (dry ice) has great advantages over all other sensitivity tests. Because of the insulating layer of vapor that the CO₂ snow gives off at temperatures above 0 °C, this test is harmful to neither the tooth nor the surrounding tissue. Enamel crazing will not occur until after a 2-minute exposure (Peters et al. 1986).

The test can be used in both deciduous and permanent teeth. Young teeth with wide open apical foramina do not yet have a fully developed sensitivity, thus false negative readings may occur. Furthermore, following trauma the sensitivity test may give a negative result for days or even several weeks. The electric pulp test cannot be used on teeth with metal crowns because of short circuiting, or with ceramic crowns because of their insulating effect. False negative readings can occur where extensive caries is present. The test is contraindicated in patients with cardiac pacemakers.

Clinical Examination and Selection of Therapy

The initial diagnosis can be supplemented and finalized by means of a whole series of tests. Extraoral swelling or discoloration may be obvious and can be differentiated as soft, firm, hard, and/or painful through palpation. The condition of the lymph nodes, whether unilateral or bilateral, provides information on inflammatory processes. Inside the mouth, the appearance of the teeth (including discolorations) and of the gingiva, as well as palpation of the roots in the vestibule and palate all contribute toward a differential diagnosis.

In addition to the radiograph, transillumination makes it possible to detect caries, fractures, and other abnormalities. Selectively anesthetizing a single tooth can help identify which tooth is diseased. Further valuable information for a differential diagnosis can be gained through percussion to determine if a tooth is tender to vertical or horizontal tapping. Biting on a wooden tongue blade can reveal fractures and fissures through pain elicited by application or release of pressure.



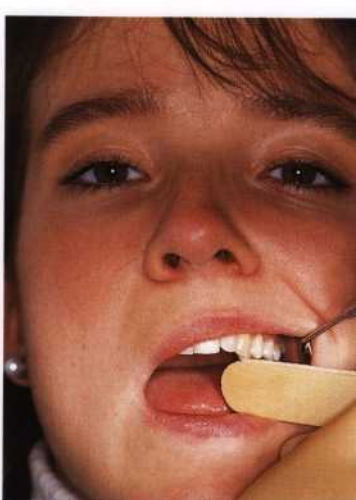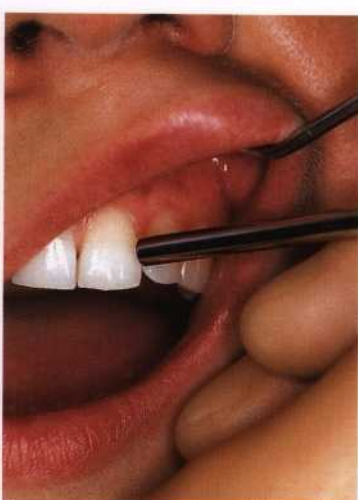
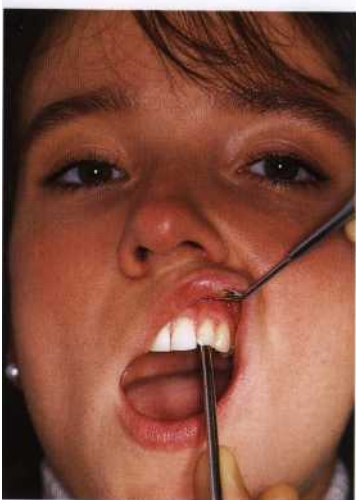
92 Palpation

Digital palpation of soft and hard tissues provides important information for a diagnosis.

Left: Extraoral bimanual palpation of the lymph nodes.

Center: The root surface is palpated all the way to the apex in the vestibule, and the patient is asked to report any unusual sensations.

Right: In the palate the roots and the overlying tissues are palpated.



93 Percussion and biting test

Sensitivity of a tooth to tapping is a sign that periapical inflammation is present. Fractures can also be detected through percussion or the biting test.

Left: The response of a tooth to vertical percussion is always compared with the response of the teeth immediately adjacent to it.

Center: Horizontal percussion.

Right: Biting test using a wooden tongue blade. Pain in response to biting pressure is always evidence of a tooth fracture.

A compilation of the results of these examination procedures, combined with clinical experience, make it possible to identify a clinically healthy pulp, reversible pulp disease, irreversible pulpitis, or pulp necrosis, and to select the appropriate treatment. The clinically healthy pulp is characterized by absence of pain, while with reversible pulpitis the pain can be initiated by cold. In both of these cases the caries has not yet reached the pulp. With irreversible pulpitis pain occurs spontaneously, there may still be a positive response to the sensitivity test, and the results of the percussion test may be either negative or positive.

If there is a history of short or long-lasting continuous pain, the caries must be completely removed as a diagnostic measure. Allowing even small amounts of softened dentin to remain in the cavity floor is absolutely contraindicated. If the pulp becomes exposed during excavation of caries an emergency pulpitis treatment is carried out. Under local anesthesia the coronal pulp is sharply removed to the entrance of the root canal, the entrance is covered with a cotton pellet and the cavity is tightly sealed. At a second appointment the root canal is instrumented and an interim dressing and temporary filling are placed.

Radiographic Diagnosis and Interpretation

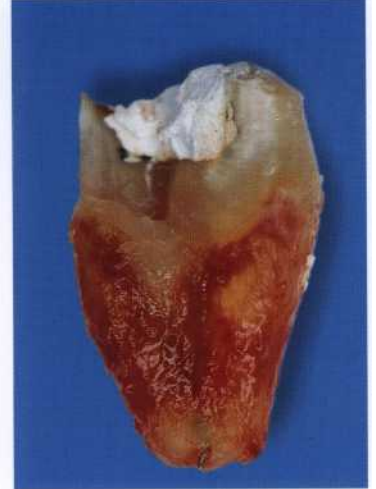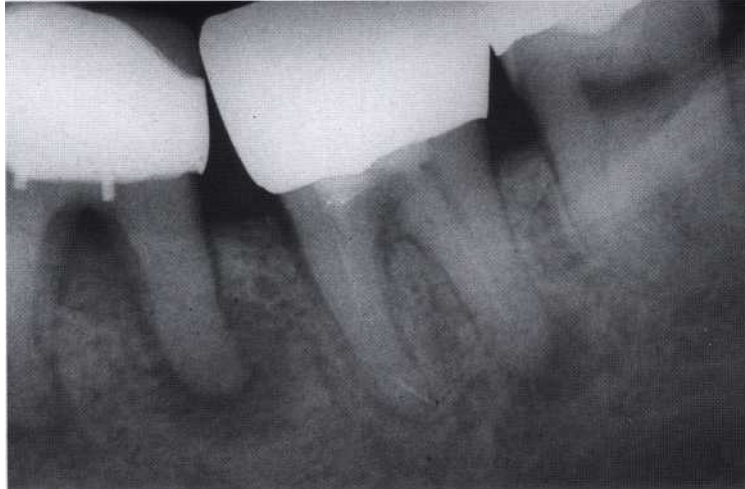Second to the gathering of clinical symptoms, the radiograph is of greatest importance in deciding upon the course of treatment. In the posterior region, for example, 30-70% more caries is diagnosed radiographically than through clinical examination alone (White et al. 1994). Just as surprising was the difference in findings from the same radiographs by different observers: the rate of agreement was less than 50%. In a second reading 8 months after the first, there was only 88% agreement by the examiners with their own first diagnosis (Goldman et al. 1974).

Caries progression is divided into four radiographic grades. Grade 1 caries is entirely in enamel, grade 2 reaches the dentinoenamel junction, in grade 3 the radiolucency extends halfway into the dentin thickness, and grade 4 extends even deeper into the dentin. In a study by Bille and Thylstrup (1982) there was only moderate agreement between radiographic and clinical changes. An unequivocal diagnosis can be made only with grade 4 lesions. No definitive therapeutic decision can be made from a radiograph alone.

94 Broken instrument fragment

This patient underwent prosthetic reconstruction 2 years previously. The discomfort has persisted since then. This radiograph of the mandibular right molars reveals inadequate endodontic treatment, periapical radiolucencies on the first and second molars, and an instrument fragment in the mesial root of the second molar.

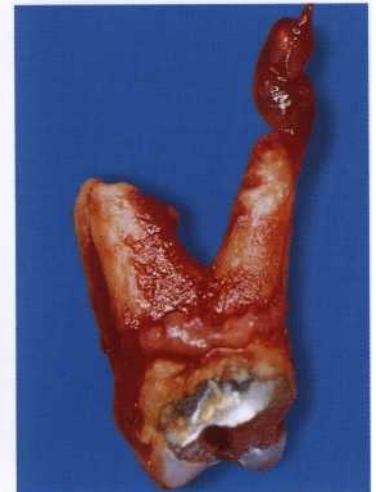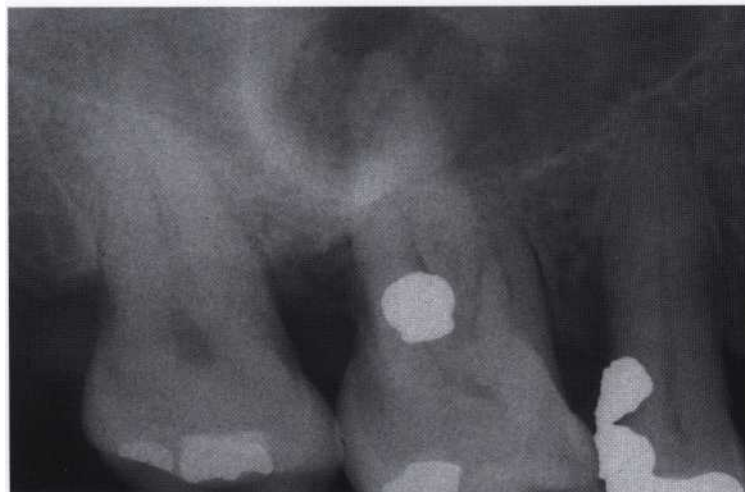Right: Fragment of a Hedstrom file in the mesial root.



95 Maxillary radiolucency

Radiographically visible periapical lesions in the maxilla, presumably on the palatal root of the first molar, with concurrent vertical bone loss.

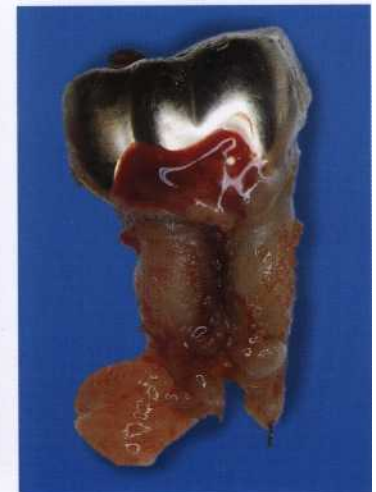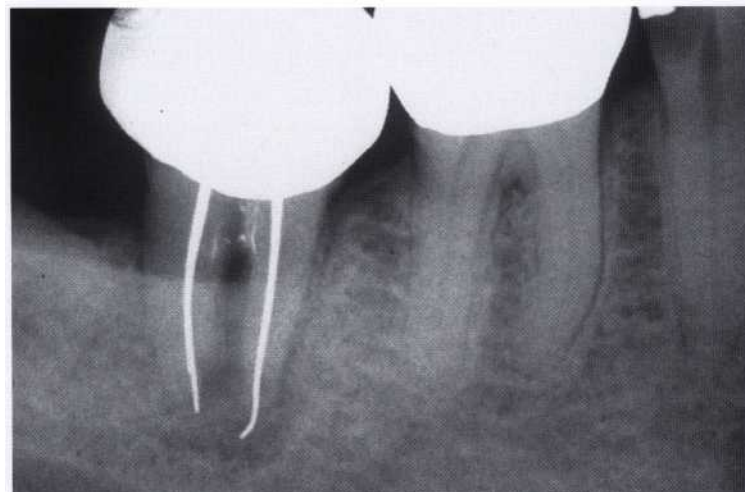Right: Confirmation of the radiographic diagnosis and the extent of the periapical lesion following extraction of the tooth.



96 Mandibular radiolucency

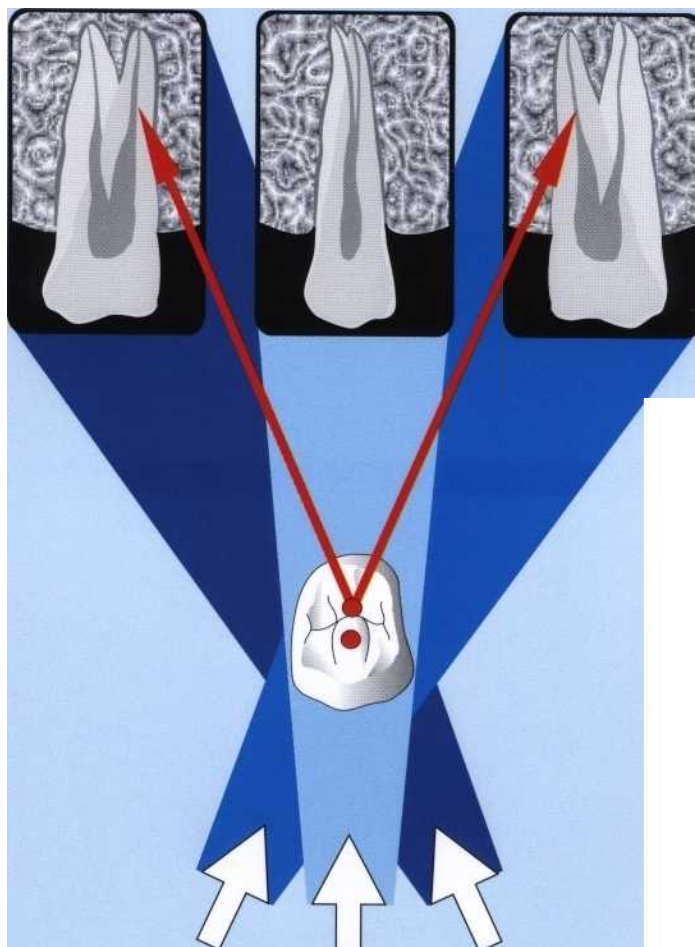
Radiograph of a mandibular second molar that exhibited spontaneous pain as well as tenderness to percussion. A periapical radiolucency and an unsuccessful root canal filling with silver points are evident.

Right: After the tooth is extracted, the extent of the periapical lesion is found to be much greater than was apparent on the radiograph. In addition to bacteria, corrosion products from the overextended silver points were a cause of the periapical lesion.



With a mineral content of 52% in cortical bone, there must be a 6.6% loss of bone mineral in order for the lesion to become radiographically visible. Lesions in the spongiosa of the mandible can be masked by the cortical layer of bone (Bender 1982). Only with destruction of the transition zone between spongy and cortical bone, which shows no clear anatomic demarcation, does a radiographic change become visible due to the alterations in the trabecular bone structure (Shoha et al. 1974, van der Stelt 1985).

Lesions in the periapical region of the mandible do not become recognizable until half the thickness of the buccal cortical bone has been eroded. Because no one X-ray tube alignment is superior to any other in regard to revealing a lesion, Marroquin et al. (1995) recommend the orthoradial projection. Only if the findings from this angle are unclear should an additional eccentric radiograph be taken. In spite of the problematic interpretation of the apical radiograph, to forego this useful diagnostic tool would be unthinkable.

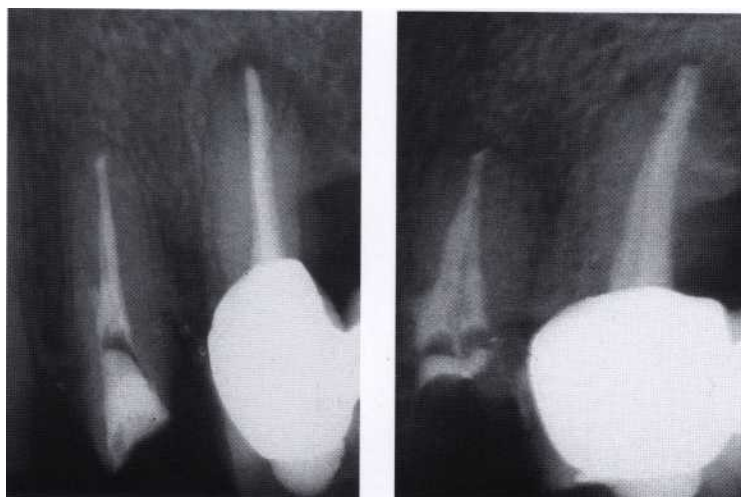

97 Alignment of X-rays

Ray directions for orthoradial, mesial eccentric, and distal eccentric projections. An eccentric projection is usually necessary to supplement an orthoradial projection when certain structures of bone or tooth are to be represented.

In the mesial eccentric radiographic technique the central ray is directed more from the mesial. In the distal eccentric technique it is directed more from the distal.

A distinction is also made between apical and periodontal radiographic techniques, because the sharpest image and the least distortion are produced where the central ray passes through the tissue. In practice, however, one cannot forego making the image of the crown and root on the same film. If in the apical technique the central ray is directed toward the apex, the image of the alveolar crest will be of secondary significance.



98 Eccentric radiograph

Left: The radiograph taken with orthoradial ray alignment shows only one root canal in each premolar. Clinically, however, an additional second canal was found in both teeth. This can be explained by root structures being superimposed on the radiograph.

Right: Two separate root canals are revealed in each tooth when an eccentric ray alignment is used.

Radiography in Endodontics

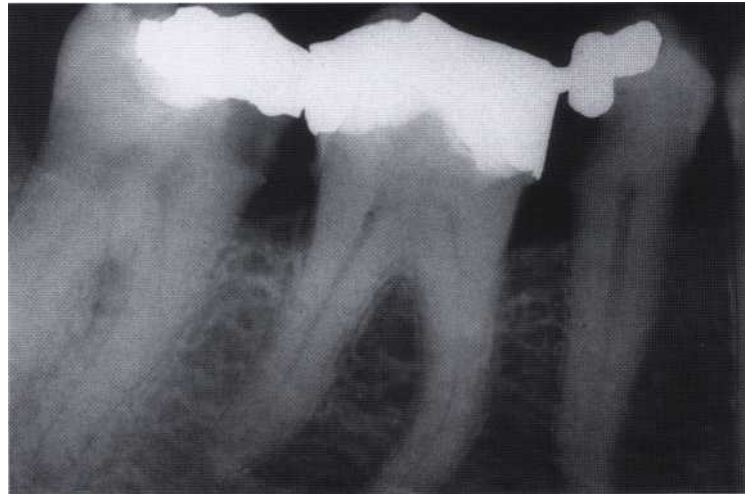The radiograph is an indispensable aid in endodontics, not only in treatment planning but also during treatment and in monitoring the results of treatment. The radiographs must be of high quality: films with poor contrast and severe distortion are as worthless as no information at all. An example is a film that fails to show the root tips. The radiograph must show a sharp outline of the root and reveal the tooth length and the number of roots and canals as accurately as possible. The extent of the pulp chamber and the curves in the roots and canals should also be discernible. In addition,

the diagnostic radiograph must reveal any information on calcifications, hard-tissue deposits, internal or external resorption, the extent and origin of periapical lesions, and perforations and fractures.

Because radiographs are two-dimensional representations of three-dimensional dental structures, the diagnostic interpretation is limited. Magnifying loupes are recommended for a more exact interpretation (Guldenner and Langeland 1993).

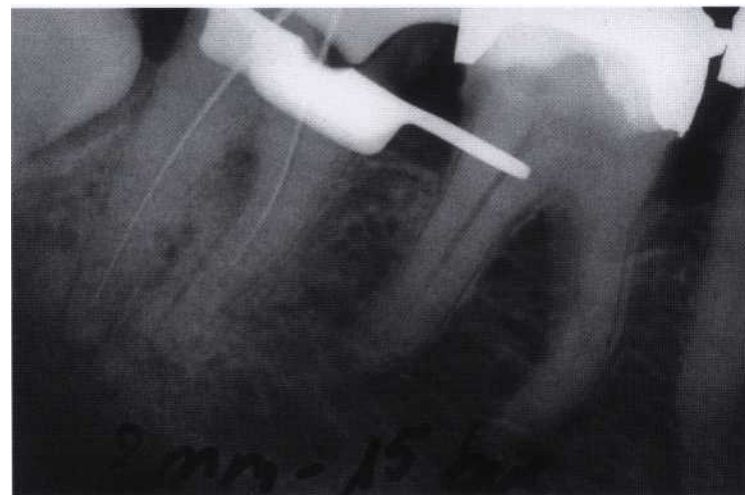99 Diagnostic radiograph

The first radiograph does not show all of the lower second molar that is to be treated, but it does show defective fillings with secondary caries on all three teeth. The cavity on the second molar has penetrated the pulp, causing pulpal necrosis.

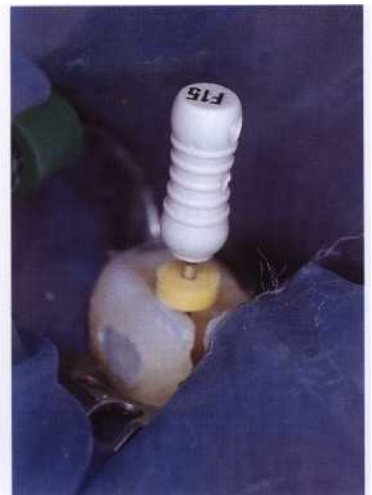

100 First measurement radiograph

To avoid overextending the instruments during preparation of the canals and transporting bacteria from the infected coronal portion of the pulp apically, a radiograph is taken for orientation and measurement.

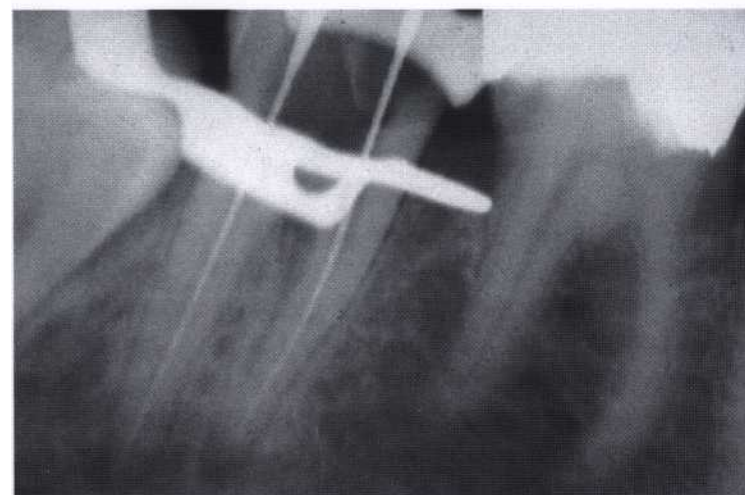


Right: Clinical view with the distal file inserted.

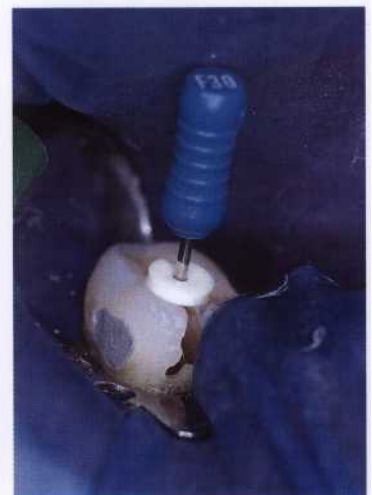

101 Working-length radiograph

Determination of the working length after insertion of files into the three root canals. Because of periapical resorption, the distal instrument is overextended, requiring adjustment of the length. The lack of sharpness and poor quality of the radiograph means that a clear determination of the working length is difficult.

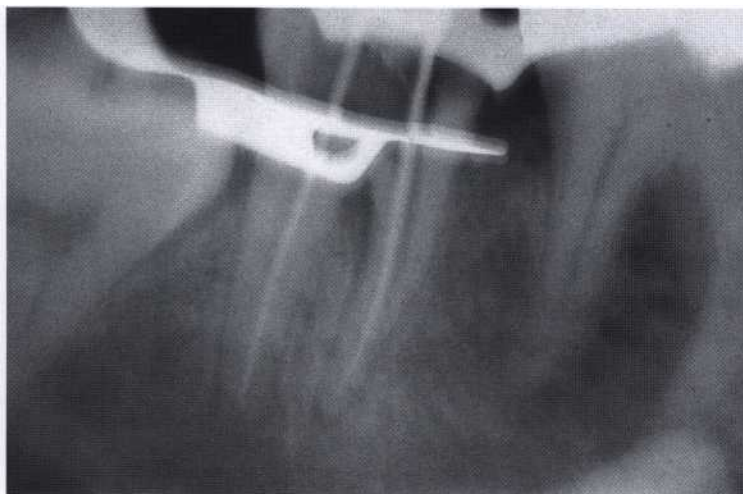
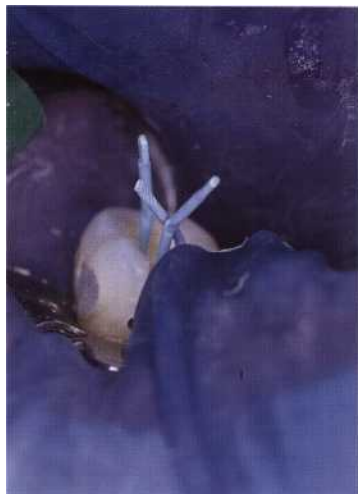
Right: Intraoral view during the subsequent enlargement of the root canals.



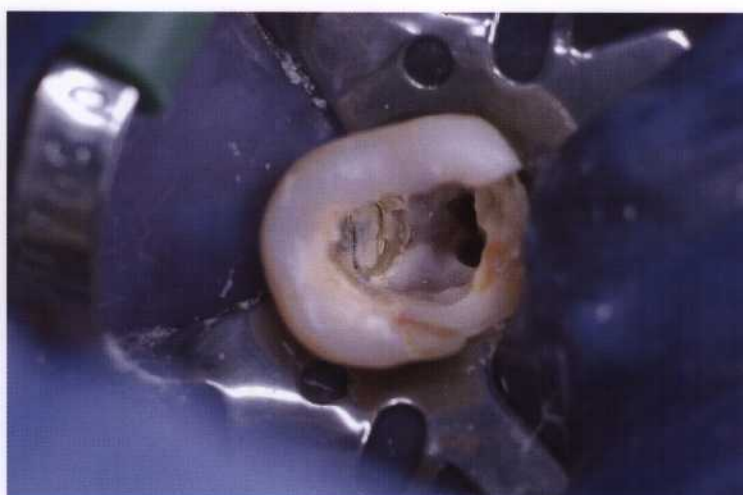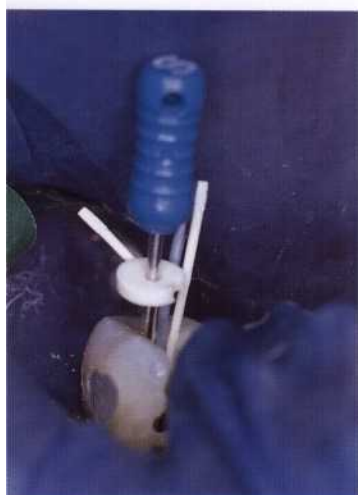During root canal treatment additional radiographs are necessary, their number depending on the specific situation. Besides the diagnostic radiograph, the measuring radiograph is essential. Yet another image with the master points in place allows a recheck of the preparation depth and helps avoid overfilling or underfilling of the root canals. The radiographs of the completed case and at the 1-year recall reveal the quality of canal obturation and any indications for surgical intervention.

The dentist cannot claim a patient's refusal to have radiographs taken as a defense in a lawsuit if radiographs were a necessary part of the diagnosis or treatment. Neglecting to take preoperative radiographs can result in a reversal in the burden of proof if there are related consequences, such as treatment of the wrong tooth. The patient no longer has to prove that treatment was faulty; rather the dentist must prove that the treatment was correct (Hulsmann 1995).



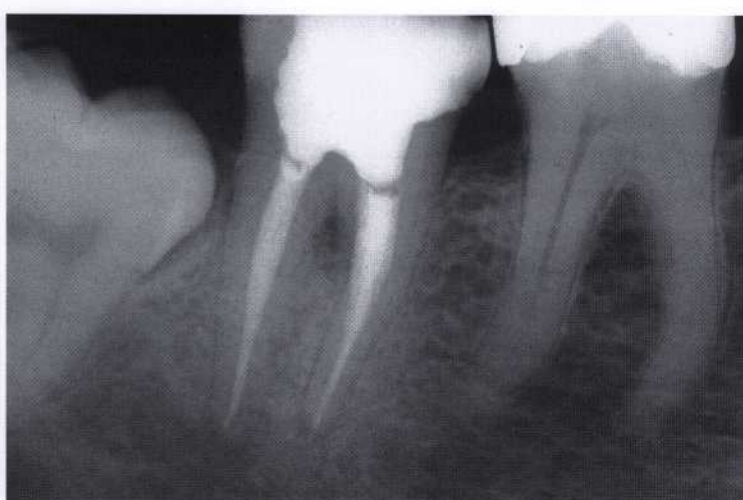102 Master point radiograph
After enlargement of the three canals, three gutta-percha points the same size as the master files are inserted, and their exact position on the radiograph is measured. The lack of sharpness of the radiograph does not permit a clear interpretation.

Left: The clinical view shows the gutta-percha points with the working lengths marked by indentations from pliers.



103 Filling the root canals
After removal of the three gutta-percha points the root canals are thoroughly dried and are ready for the final root canal filling.

Left: Intraoral view during filling of the canals. The working length is transferred to the finger spreader by means of a silicone stop. The gutta-percha is condensed laterally with the finger spreader.



104 Radiographic evaluation of the root canal filling
After the root canal filling is completed, the result is evaluated radiographically. In spite of the measurement of the working length and its monitoring before condensation, a slight apical overextension of the filling is visible on the mesial root. Even if there are no symptoms, a recall radiograph is indicated after 1 year.

Digital Radiographic Technique

Since the discovery of X-rays, radiographs have played a more important role in dentistry than photographic processes. With the rapid developments in semiconductor technology, however, electronic procedures for recording images now permeate all fields of medicine. For this new type of imaging the general term "digital radiography" has been widely adopted.

Intraoral Systems

Digital technology made its entry into dentistry 10 years ago in the form of the intraoral sensor. Diagnostic radiation is always invasive; this sometimes results in the patient refusing radiographs or the dentist, in haste to deliver treatment, failing to take them. However, it is precisely because of the difficult anatomic relationships in the region of tooth roots that the treatment time and the success of endodontic procedures bear a positive correlation with the number of (reasonable) radiographs taken.

Advantages of the new digital radiographic technique are the reduced radiation exposure (80% less than with the best conventional periapical film), the immediate availability of the image, an image presentation that can be adapted to suit the problem, the lack of a

need for processing materials, electronic archiving, and the ability to connect with data networks both inside and outside the office.


A digital image is formed when the image sensor feeds information into a computer point by point, and each point is coordinated with one of, for example, 1024 (10 bit) to 4096 (12 bit) possible intensity gradations depending upon the radiation intensity registered there. This scale coordination or digitization is the prerequisite for image processing in the computer.

Systems for intraoral dental radiographs can be classified as either direct or indirect. For a *direct* image a semiconductor camera in the patient's mouth transforms the distribution of roentgen rays into an electronic signal that is transmitted to the computer over a cable and immediately appears on the monitor. In the *indirect* process, a so-called storage phosphor plate stores the image for transfer to the computer; it has no cable connection to the computer. After exposure it is read by a scanner. The appearance of the image is delayed by the time required for scanning.

105 Sensor of an intraoral digital system

The accumulator foil of the Gendex Digora System (center) is sealed in a foil envelope before it is used. The image surface of this foil corresponds to a dental film (left) and is wider than that of a CCD sensor (right).

The semiconductor camera (CCD camera) as an example of a direct imaging unit is shown on the right (Sirona).



Contrast Enhancement

Contrast is a measure of the difference in brightness between neighboring areas of the picture. The human eye has a threshold value at which the variations in brightness of different areas of an image can first be recognized. Subsequently, the contrast can be increased electronically as desired.

Positive-Negative Representation

From the negative image a positive picture can be produced electronically. This corresponds more closely to what the eye is accustomed to seeing than does the usual negative image on a radiograph.

False Color Representation

The rays falling upon the sensor can not only be transformed into shades of gray but also into different colors. The effect of this random color arrangement depends upon the translating table used.

Millimeter Grid

With the stroke of a key, a grid with 1-mm spacing, relative to the surface of the sensor, is made to appear on the monitor screen.

This aids in estimating lengths, but may not be used as a substitute for the object ruler, however.

Resolution

Resolution is expressed in line pairs per millimeter (Lp/mm). The higher the resolution, the smaller the details that can be distinguished in the picture. A resolution of at least 6 Lp/mm is necessary for clinical use. However, since complex filters generally make the image more coarse, higher resolution capability is desirable.

Dynamic

The *dynamic* indicates the number of possible grades of intensity or number of gray scales that can be digitized. A greater dynamic with at least 1024 shades of gray helps to avoid overexposure and underexposure. High dynamic combined with high resolution provides a greater choice for application of filters.

Filters

Filters serve to distinguish more clearly fine variations in the structure of the object that are indistinguishable to the eye in the original image.

The selection ranges from simple filters (positive-negative representations, contrast enhancers, rainbow colors) to more involved processes such as suppression of occasional variations in intensity (*noise*),

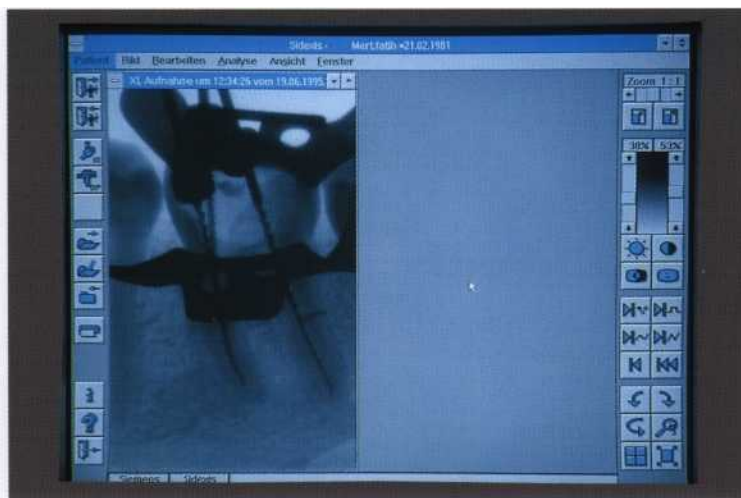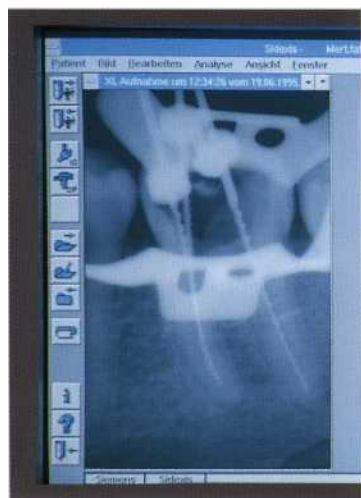
sharpening the image in the corner areas, or even creating the appearance of images in relief.

In general, the more involved filters make the image resolution more coarse and, if used uncritically, can make important regions disappear or create images of structures that do not exist in the object.

Apart from the "good feeling" of the operators, there have been few scientifically based presentations on the usefulness of different filters. The relief filter, however, seems to be very helpful in endodontic procedures.

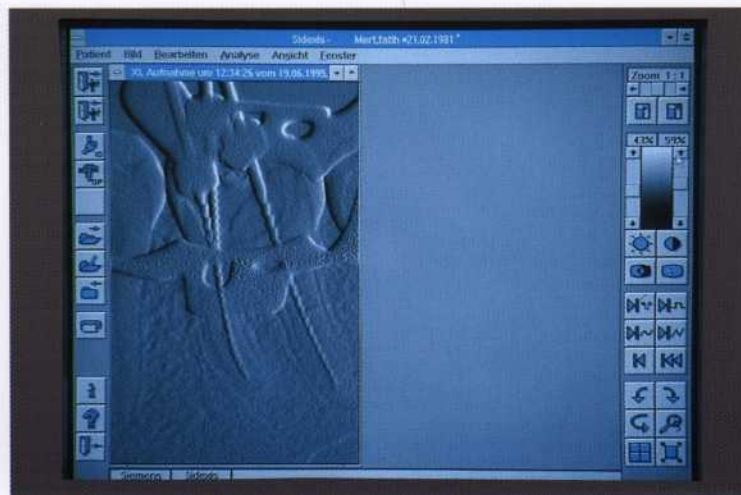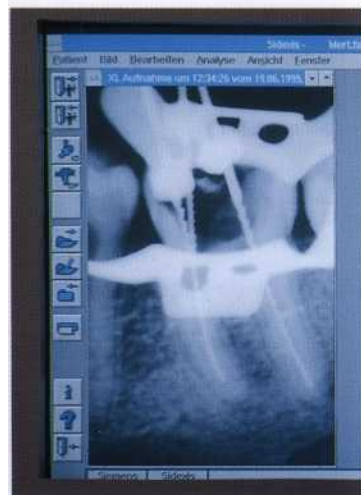
Projection Angle

Digital technology has not changed the fundamentals of producing an image. With the intraoral procedure the objective now as ever is to obtain the best possible representation of the individual teeth. The old rules still apply to projection angles. Positioning, at least with the CCD sensor, is made easier by a film holder that is to be used with the right-angle technique, which moreover has advantages for producing quality images. The long cone technique produces a geometrically superior projection with the digital systems.



106 Digital measurement picture
Positive image

Left: Standard image



107 Digital measurement picture
Relief image

Left: Contrast enhancement

Collection C. Benz

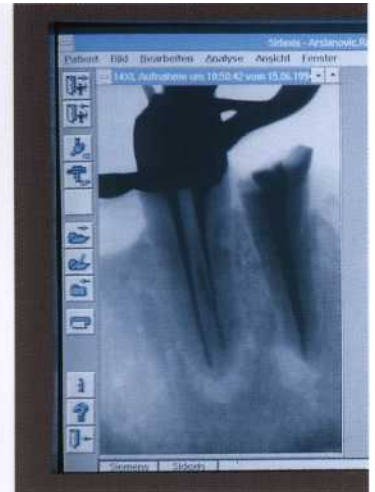
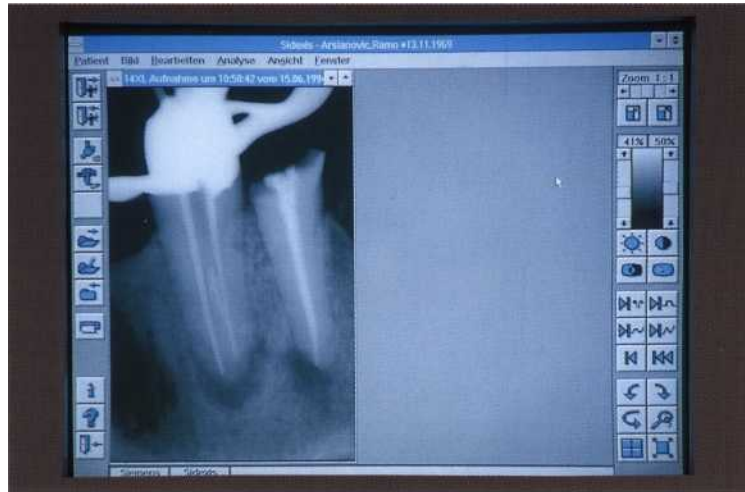Uses of Digital Radiography

The digital technique has not yet revolutionized the viewing habits in the field of diagnostic radiography. It can, however, provide a completely new impetus to meeting the main challenges in endodontics. Numbered among these challenges is the representation of a three-dimensional tooth such that the disclosure of the position and size of relevant structures is possible. Fine variations in the image, such as small-sized files in the root canals of maxillary molars, are more readily identified. The digital image, like X-ray film, only records a two-dimensional shadow of the object.

Gathering information in the third dimension is easier with a digital CCD system than a film or a storage phosphor plate. The digital image can be seen immediately and the position of the sensor that produced it can be maintained. Starting from this position, other angulations can be selected and multiple digital radiographs made without exceeding the radiation dose of one conventional radiograph. The representation of fine variations in the object should be the showpiece of the digital technique. That this is not yet the case is the fault of an insufficient number of gray scales in the system.

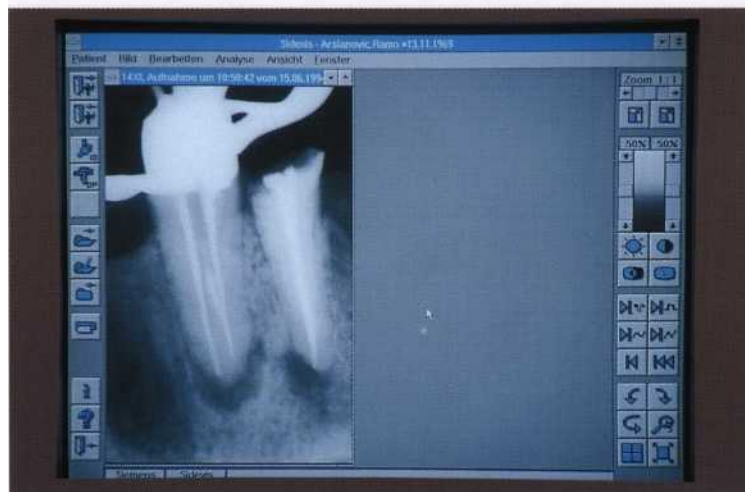108 Digital follow-up radiograph (Sidexis) Standard image

Right: Positive image



109 Digital follow-up radiograph (Sidexis) Enhanced contrast

Right: Relief image



Collection C. Benz

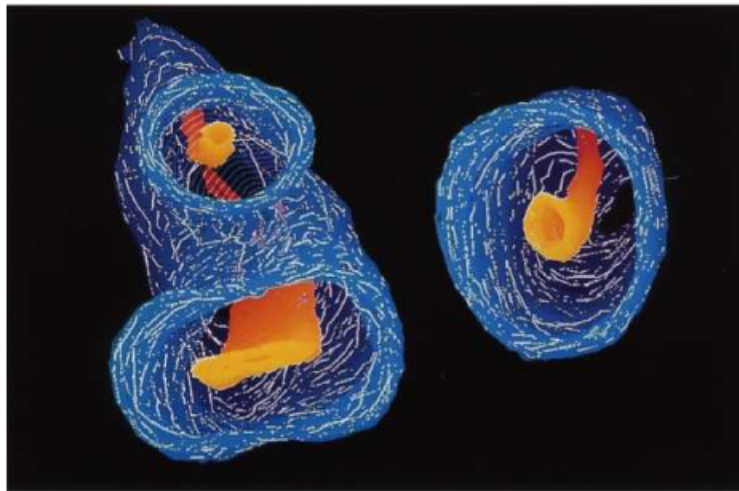
A diagnostic radiograph must use an orthoradial projection, i. e. the parallel technique, so that the proximal surfaces stand out clearly and distances parallel to the tooth's main axis are reproduced with relative accuracy. On a measuring radiograph the images of canals lying in the same faciolingual plane should be separated. With mandibular molars this can be done with a minimum of distortion by using a slightly distal-eccentric projection angle.

Also, in order to best display the tip of the instrument and the border between the radiographic apex and the periodontal area, the sensor should be tipped so that it diverges away from the long axis of the tooth

coronally. In this way root apices are more clearly visible because the canal nearest the sensor will appear more coronal than the canal farther from the sensor. A system that delivers a lower dose of radiation with each exposure makes more exposures possible, varying the projection angle until the goal is reached. Instruments down to size 08 should be identifiable. If these instruments cannot be seen, the cause usually lies with errors in the projection. In order to avoid overlapped images, the shortest distance through the object is chosen, i. e. horizontal and vertical projection angles near 90° (Benz 1992).

Anatomy

The interior of a tooth, the endodontium, is to a large extent hidden from direct inspection by the operator. Even passing roentgen rays through the tooth provides only limited clues to the structure. For this reason, much time and energy have been invested in research into the "normal" anatomy and the statistical incidence of different variations in form (review: Baumann 1995). It is hoped that this information will be helpful in the daily practice of endodontics. This research has already created awareness of the complexity of the root canal system, which is not simply a conical tube, but rather a branching system with a pulp chamber, primary canals, lateral canals (communicating with the periodontium), and accessory canals (multiple ramifications in the apical third of the root). This knowledge is a basic requirement for successful endodontic treatment. The theoretical pulpal anatomy that we expect to encounter, though, can only provide initial orientation because the actual situation encountered during treatment always reveals new variations.



110 **Three-dimensional reconstruction**

By means of computer reconstruction based upon serial histologic sections, the root tips of a maxillary molar have been reproduced as a three-dimensional lattice work with a computer-generated surface. The outer contours of the tooth are colored blue, the root canals are yellow-orange.

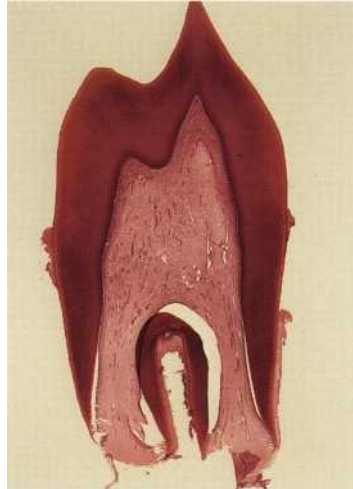
The first detailed systematic description of root canal anatomy found in the literature is by Carabelli (1844). The same manner of representation with longitudinal and transverse sections in different planes is still used in modern textbooks (e. g., Cohen and Burns 1994). Some of these illustrations go back to the original sections and serial sections (Black 1902; Miller 1904). In addition to direct observation with the unaided eye and the microscope, the chemical dissolution method has provided much valuable information. In this process the tooth is opened, the pulp digested, and the empty pulp space filled. The famous Swiss pulp researcher Hess (1917) perfected this technique in which

he filled the pulp space with vulcanized India rubber and then dissolved the surrounding tooth substance with 50% hydrochloric acid. This acid dissolution preparation showed for the first time, and very impressively, the complex branching of the pulp tissues and, with it, the root canal system. Whereas the previous sections, slides, and drawings were only two-dimensional, now for the first time it was possible to see a spatial representation of the entire root canal system. Hess studied 2800 teeth of the permanent human dentition and his student Zurcher (1922) studied deciduous teeth. Together they gathered statistical data on the number of canals and their ramifications.

Methods of Reproducing Root Canal Anatomy

Most techniques require the destruction of the tooth. However, at the beginning of the twentieth century the transparency method was developed (Adloff 1913) in which the integrity of the tooth and the spatial relationships of the root canal and its outer contours were preserved. Various substances (from colored gelatin and paraffin to silicone) were introduced into the pulp space through an access opening, and the tooth was then made transparent by means of oil of cedar, benzol, or salicylic acid compounds.

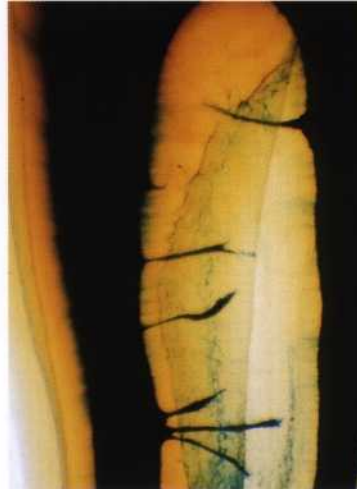111 Methods for visualizing the anatomy of the root canals 1
Left: Histologic longitudinal section through a devitalized premolar (Collection W. Ketterl).



Center: Transparency technique. An opening is made into the tooth, the pulp digested, and the space filled with stained (Berlin blue) gelatin. The hard structure is made transparent by soaking in methyl salicylate.

Right: Wax reconstruction of the pulp of a premolar based upon histologic serial sections.

The work of Vertucci (1974-1984) deserves special consideration. While histologic sections have long provided information on the structure of the root canal and the pulp tissue, Meyer (1955-1970) set new standards. From serial sections of all 16 types of permanent teeth he made 50x scale models of the apical canals (the last 6 mm of each) of 800 teeth by projecting the circumference of the canals and building wax models layer by layer. This study further clarified the complexity of the pulp space, from then on called the root canal system (Meyer 1955 b, 1960).

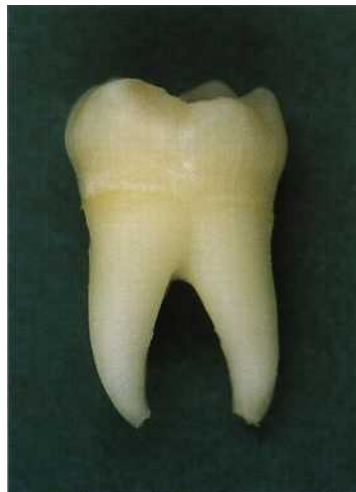

Awareness of the existence of large numbers of lateral canals and diverticula renders obvious the impossibility of full preparation of all the branches during root canal treatment. A significant outcome of this is the technique of combined chemical-mechanical preparation. Meanwhile, after radiographs began to be used in laboratory studies, images in two planes became standard. Pineda and Kuttler (1972) performed what is probably the largest *in vitro* study on over 4000 teeth. Their study covered the extent of branching and variations in canals, roots, and apical deltas, and the influence of age on their occurrence.

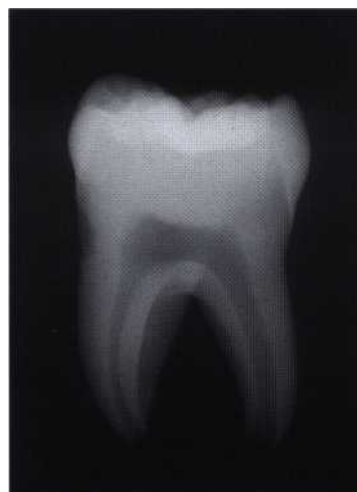Hession (1977a-d) showed the shape of the root canal system radiographically before and after *in vitro* treatment. The abundant range of research tools is complemented by *in vivo* radiographs, microradiographs, scanning electron microscopy (SEM), computer reconstructions, monographs of individual cases, and many other aids (Baumann 1995). Subsequently, an immense body of facts has been accumulated and these are presented in excellent didactic style in books, videos, slide series, reports, seminars, and demonstrations. This new information should be offered in further education courses (Baumann 1994, 1995).

112 Methods for visualizing the anatomy of the root canals II

Left: Macroscopic anatomy of a molar.



Center: A radiograph of the same molar allows a look at the inner configuration of the root canal system.



Right: Sectioned teeth have long served to help visualize the internal architecture of the pulp chamber. The SEM makes possible detailed inspection and to some extent creates the effect of spatial depth.

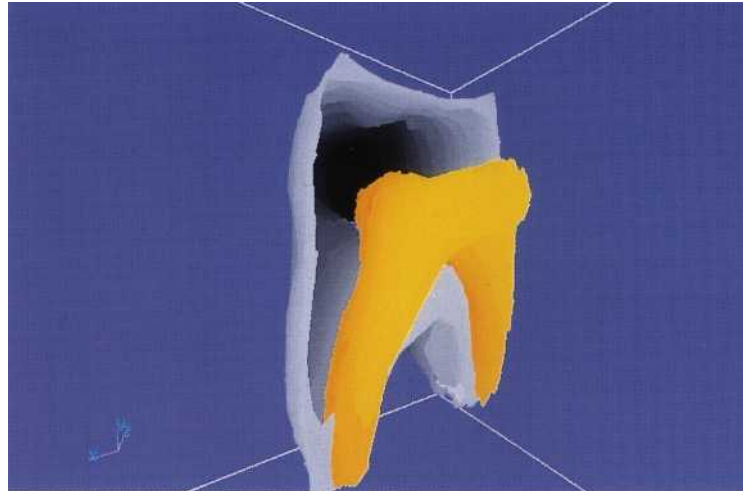

Three-dimensional Computer Reconstruction

From a historical perspective we see a long tradition of striving to better describe the anatomy of the teeth. Recently, preparations of 20- μ m-thick frozen sections were continuously recorded on videotape, producing data to serve as the basis for computerized three-dimensional reconstructions. In a *contour-based* reconstruction only the surface outlines of the tooth and the canals are used for input (Baumann et al. 1993 d, 1994b). From this emerges a contour line, surface, or solid body model that can be viewed from any desired angle.

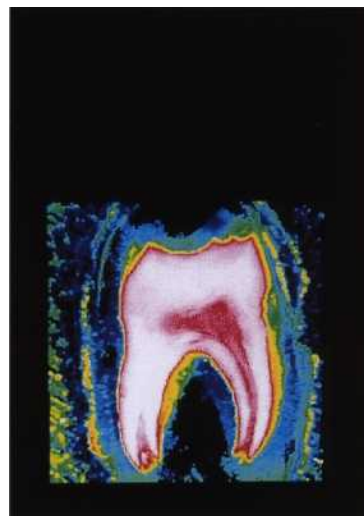
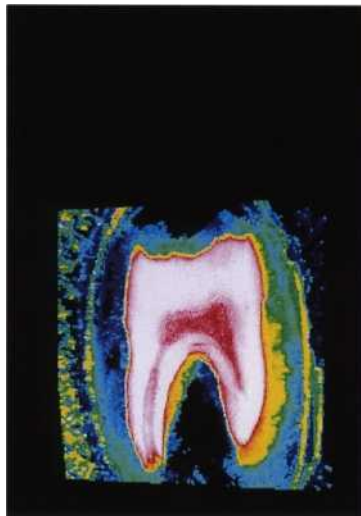
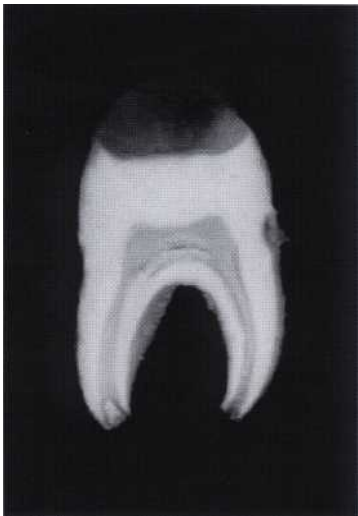Newer, faster computers permit the use of all shades of gray in a video image to create a *volume-based reconstruction* (volume rendering). Through ray-tracing, isotropic voxels (points in space) are created in which the raw unaltered data is drawn upon for three-dimensional reconstruction (Baumann 1995, Bauman et al. 1993 d).

Images are created that can be viewed, sectioned, colored, zoomed, or rotated in any desired plane. This makes possible views into the endodontic space that were previously unknown.



113 Contour-based reconstruction

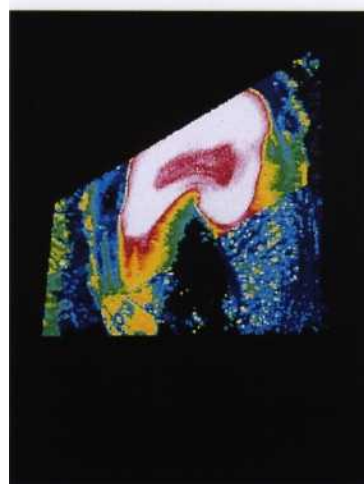
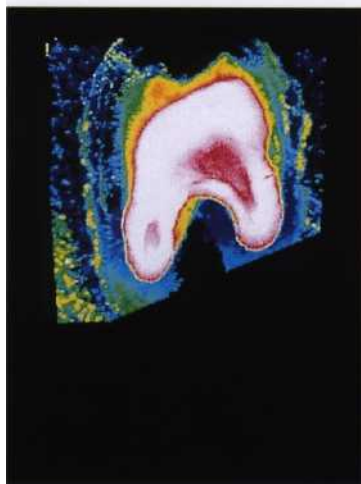
In the beginning of three-dimensional reconstruction by computer, most attention was usually given to the contours of the object. By limiting the essential image content (here: outer shell of the tooth and the canals) the data to be processed was greatly reduced. The dentin mantle of the tooth in Figure 112 is represented here in the surface mode and the pulp in solid body mode. The cutaway allows a view of the tooth's interior. The special selection of colors increases the impression of solid form in the reconstruction.



114 Volume rendering

A sequence of histologic serial sections is transferred to a computer as a digitized series of images. With special software, all shades of gray in the video image are drawn upon to create a spatial reconstruction of the data set. The images thus generated are aligned by coordinating the colors instead of the gray shades to allow observation in any desired plane.

Left: Video image of a tooth prepared by the frozen section method.



Magnetic Resonance Imaging (MRI)

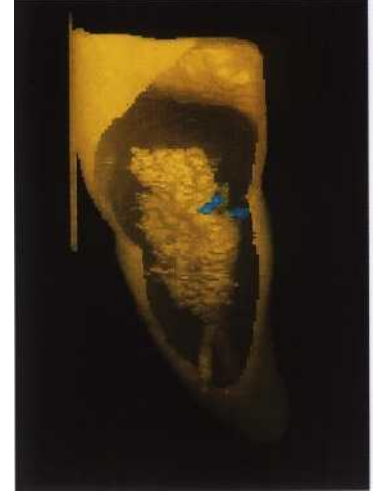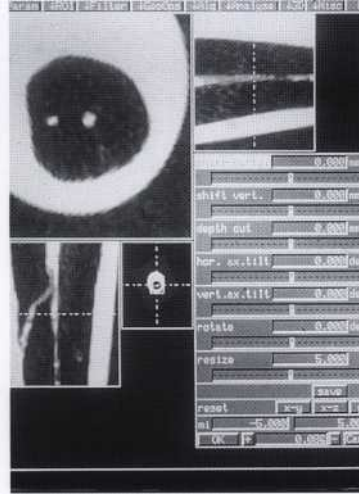
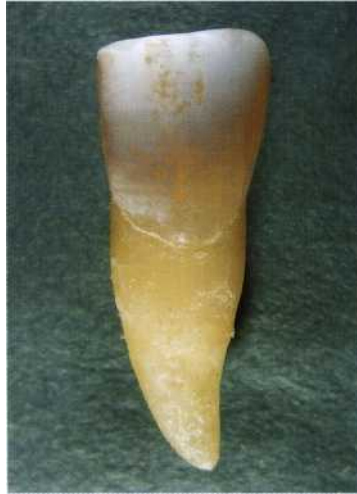Normally, only vague images of bone and tooth can be obtained by magnetic resonance tomography (MRT). Baumann (1995; Bauman et al. 1993 a-d) was the first to succeed in producing a visual representation of the H^+ protons of dental hard structures by using measurement sequences from solid body spectroscopy and especially strong magnetic fields. The soft pulpal tissue is elusive because of the small scale of the MRI. The first magnetic resonance images have now been realized with the Bruker spectrometer AMX 300 WB (7 tesla, 300 MHz).

115 MRI of an incisor tooth

Left: Macrophotograph of the incisor.

Center: Two-dimensional reconstruction from the MRI data set. The cross-section (upper left) through the root shows the main canal in the center and another white spot. On the longitudinal section parallel to the horizontal (lower left), the course of a lateral canal can be recognized.

Right: The cutaway three-dimensional reconstruction clearly shows the lateral canal in its course from the main canal to the outer labial surface.

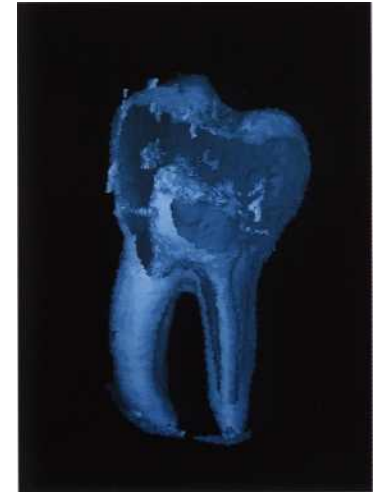
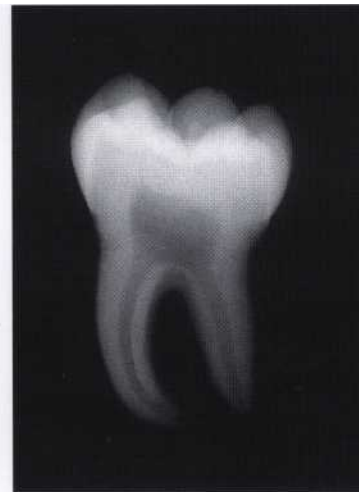
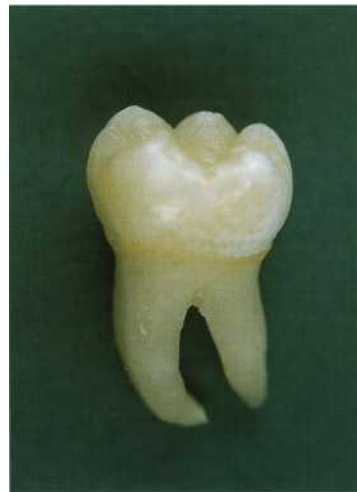116 MRI of a molar I

Left: Macrophotograph of a mandibular molar.

Center: Radiograph of the molar.

Right: The three-dimensional reconstruction based on the MRI data. The form and course of the root canal system are visible through a window cut electronically through the tooth's outer surface.

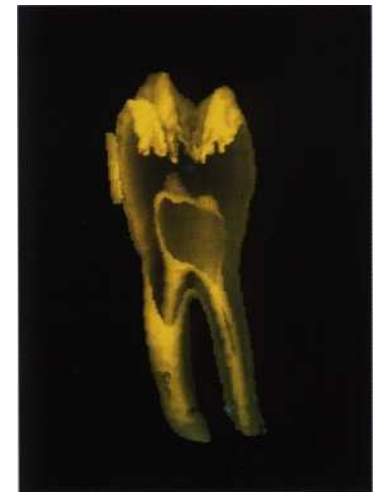
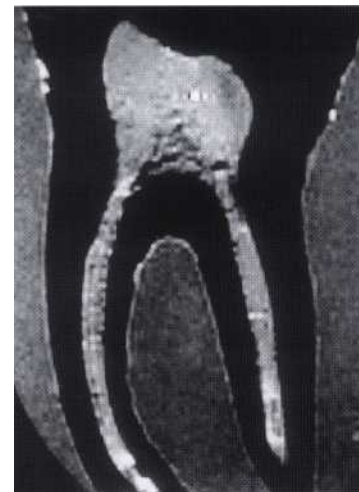


117 MRI of a molar II

Left: The three-dimensional reconstruction of the molar at a viewing angle similar to the macrophotograph demonstrates the accuracy of and detailed reproduction of the MRI method.

Center: This two-dimensional reconstruction shows up the differences in texture in the pulp tissue, which in the left root resembles a blood vessel.

Right: A different three-dimensional image shows the root canals from yet another angle.



Computer processing of data from the MRI permits creation of two and three-dimensional reconstructions that can be rotated and sectioned (Bauman 1995; Baumann and Doll, in press). Now for the first time we have a nondestructive method that does not use ionizing radiation. Two-dimensional sections of molars give rise to the hope that it will be possible to depict differences in tissue texture, which would be a great aid in the diagnosis of pulpitis. The spatial reconstruction of an individual canal configuration would be a great enlightenment for endodontic treatment.

Fundamentals

A detailed description of the forms of root canal systems that are to be "normally" expected, with the number and course of the canals, is a basic requirement for successful endodontic treatment. The endodontium consists of a pulp chamber and the root canals. The *pulp chamber* is a wide space in the coronal region that is similar in shape to that of the outer contours of the crown. It ends under the cusps in pointed pulp horns. The pulp chamber becomes progressively narrower with increasing age (Soeno 1977) or as a consequence of caries, restorative treatment, or abrasion, and acquires an irregular shape. The root canal is the portion within the root of the tooth that tapers to the root tip. Here too, there may be obliteration by secondary dentin. The natural entrance to the interior of the tooth is the physiologic foramen, the constriction where root dentin and cementum meet. Here, according to international consensus, is where the root canal filling should end (review: Hulsmann 1989).

The great number of facts that had now become available had to be integrated into dental practices. Thus, the profession changed many of its views: even though Hess (1917, 1925 a, b) and Fischer (1912) had described much earlier the multiple branching in the apical delta, it was not until Meyer (1955-1970) produced his wax models that lively discussion began over whether it was at all possible to completely clean the complex canal system. In a similar way, Rankine-Wilson and Henry (1965) shook the profession with their study showing that a second root canal was present in mandibular incisors much more frequently than had previously been assumed.

Similar revelations unfolded with the maxillary first molar. Beginning with Weine et al. (1969), the observation was confirmed that 30-60% (depending on the design of the study) of mesiobuccal roots have two canals, and therefore, practically every other maxillary first molar has four canals (review: Grossman et al. 1988).

Another quantum leap was made at about that time with the introduction of the surgical microscope for root canal preparations and apicoectomies introduced by Pecora and Kim 1992.

Classification of Canal Configurations

In order to better grasp the many anatomic variations, different classifications have been proposed. Weine (1982) listed four categories for the pathways one or two canals may follow within one root. Here, however, the more comprehensive division by Vertucci (1984) will be presented and used. With it, distinctions are made based on the number of canals that

- begin at the floor of the pulp chamber,
- arise along the course of the canal, and
- open through an apical foramen.

Out of this grew eight types of canal configurations, which were derived from transparency preparations of an abundant supply of extracted teeth:

- Type I a single canal with one foramen
- Type II two canals that join in the apical third
- Type III one canal that divides into two that subsequently reunite and exit as one
- Type IV two separate canals all the way to the apex
- Type V one canal that divides just short of the apex
- Type VI two canals that unite in the root and then divide again at the apex
- Type VII one canal that divides, reunites, and finally exits through two apical foramina
- Type VIII three separate canals in one root.

In conclusion, the classification of the grades of difficulty of endodontic treatment by Ingle (1976) is presented:

- Type I a canal that is only slightly curved
- Type II anatomic difficulties such as pronounced curvature, complex apical region, bending or dividing of the canals, and multiple apical foramina
- Type III open foramen, incompletely formed root
- Type IV deciduous teeth, resorption of the root tip.

In spite of all the efforts to systematize and clarify all possible canal configurations, the actual treatment situation always confronts the dentist with a unique and individual tooth form. Conventional radiographs have been helpful now for more than a century, but are unfortunately only two-dimensional images and provide no information on the condition of the pulp tissue. It will still be some time before they are replaced by three-dimensional magnetic resonance images that may be able to reveal the pathophysiological state of the pulp.

Maxillary Anterior Teeth

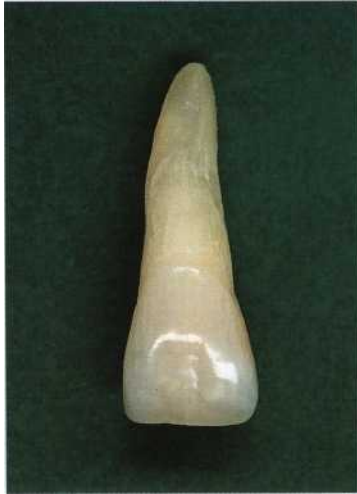All upper anterior teeth have one root and one canal. They belong, therefore, to Vertucci's type I. Exceptions are very rare. Access preparations are made parallel to the long axis-the roots normally lean distally.

The lumen of all pulp chambers is noticeably wider in the faciolingual direction than in the mesiodistal. This must be considered when preparing the tooth. The coronal pulp of the young tooth extends far incisally and has three pulp horns in central incisors and two pulp horns in laterals. Any overhang of the pulp chamber roof must be removed to prevent later discoloration by

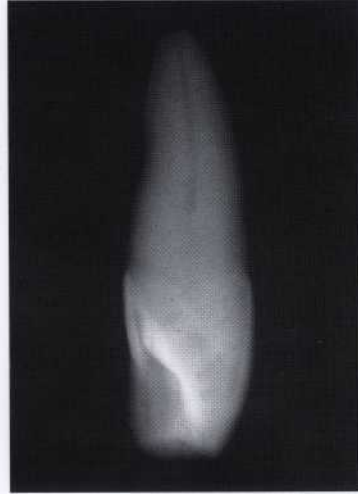blood and tissue fragments retained there.

In the elderly, the pulp is frequently not encountered until the cervical region of the tooth is reached. Therefore, the access opening must usually be located near the incisal edge to create the necessary straight access! Even teeth of older patients that show no canal on the radiograph can often be treated well clinically because the canal may still be wide faciolingually. The lateral incisor has a rather oval canal; the root is often curved toward the buccal or distal and therefore appears shorter on the radiograph than it actually is.

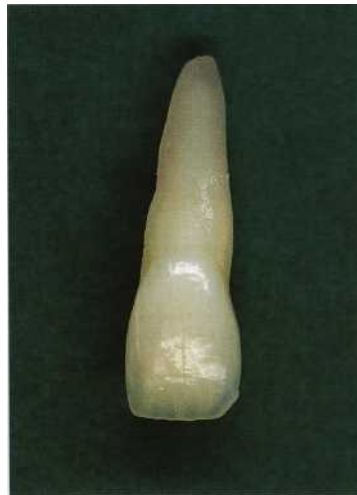118 Maxillary central incisor
Left: This labial view of a maxillary central incisor tooth shows the typical shovel-shaped crown form.



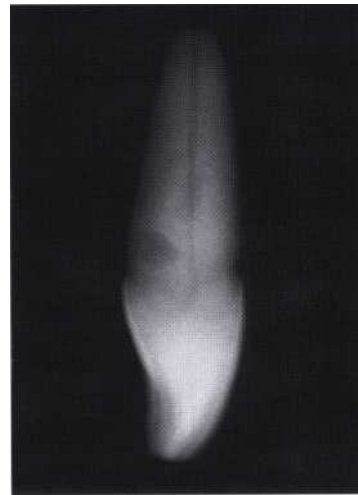Right: A lateral radiograph reveals that the shape of the coronal pulp corresponds to the outline of the crown in the faciolingual plane. The lumen is substantially wider than in the mesiodistal direction. This is not apparent with the normal faciolingual projection used in patients. In the root of the tooth the pulp runs thread-like and thin.



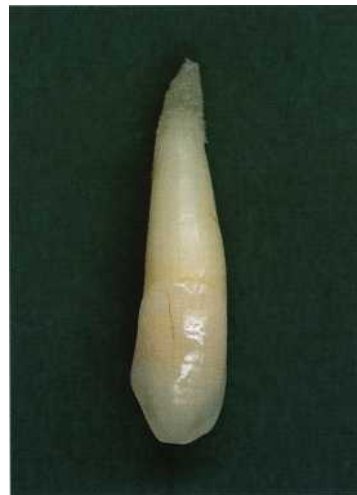119 Maxillary lateral incisor
Left: The lateral incisor is a smaller version of the central incisor (labial view).



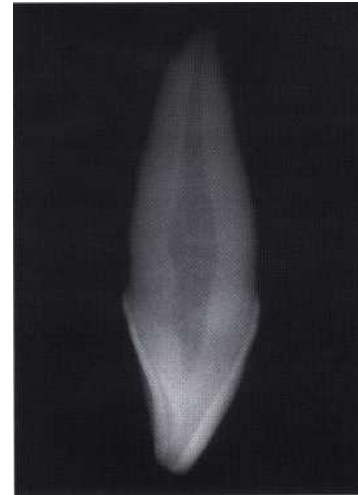
Right: Lateral radiograph.



120 Maxillary canine
Left: The maxillary canine is the longest and most massive tooth in the human dentition. Because it frequently extends close to the orbit it is also called the eyetooth.



Right: The radiograph from the side reveals that not only the coronal pulp, but also a portion of the radicular pulp, occupies a wide space that must be instrumented and cleaned to its full extent during root canal preparation.



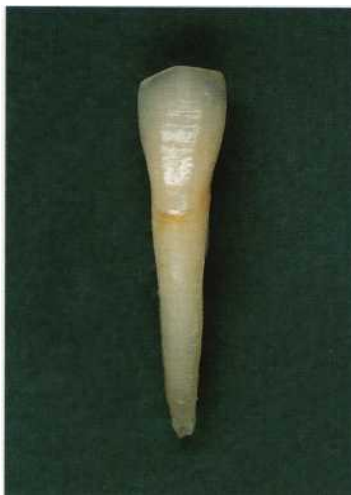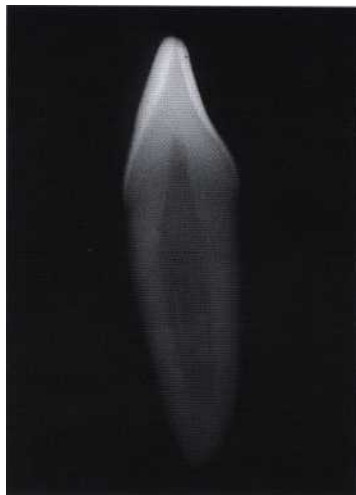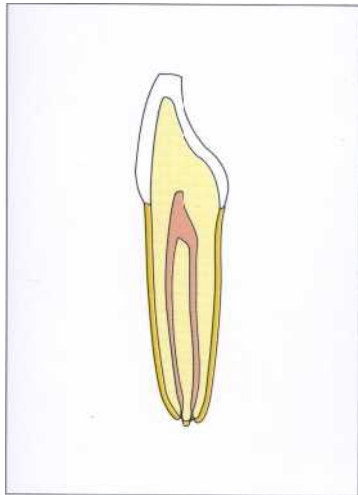
Mandibular Anterior Teeth

Usually, the lower incisors and canines have one root and one canal each (type I = 60%; Rankine-Wilson and Henry 1965). According to Benjamin and Dowson (1974) two canals are encountered in 25-41.4% of cases. The canals either join again past the middle third (type II) or are separate for their entire length (type IV).

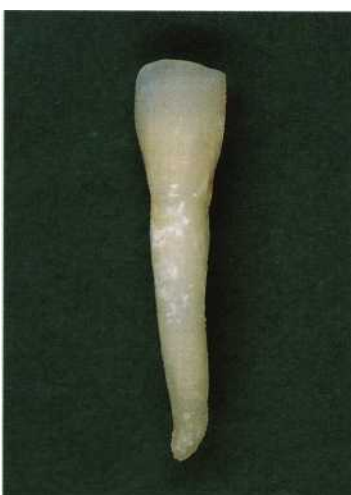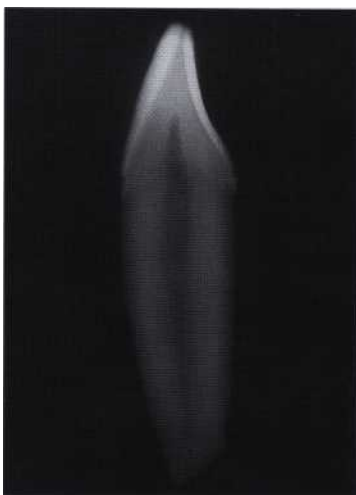The mandibular incisors are delicately formed. In addition, the root is especially narrow mesiodistally with longitudinal concavities. If there is a single canal it is straight and lies more to the labial. If there is a second canal, it courses more lingually and is definitely

curved. Therefore, the access opening must frequently include the incisal edge, and it has even been recommended that the crown be removed (Hulsmann 1992 a).

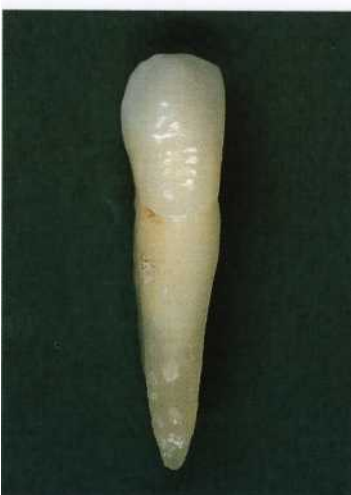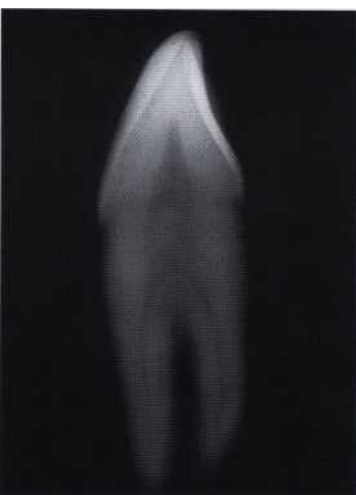- Clues that there are two canals are (Peters 1992 a):
- an eccentric pulp chamber
 - an instrument in the first canal is bent and projects out without touching the incisal edge
 - on a radiograph taken with a 20°-30° distal or mesial eccentric angulation, the instrument does not appear in the center of the root.



121 Mandibular central incisor
 Left: Approximately one-fourth of all mandibular central incisors have two root canals. If the canal found on an eccentric radiograph does not lie in the center of the tooth, there is a strong possibility that a second canal is present.
 Center: The lateral radiograph shows a greater faciolingual width of the coronal pulp, as was the case in the maxilla.
 Right: The mandibular central incisor is very delicate. During access preparation there is a danger of perforating mesially or distally.



122 Mandibular lateral incisor
 Left: Lateral radiograph.
 Right: Unlike the maxillary lateral incisor, the mandibular lateral incisor is larger and longer than its adjacent central incisor. A second root canal is also more frequently found in lateral incisors, but double canals in laterals are much more likely to have two separate foramina than in centrals.

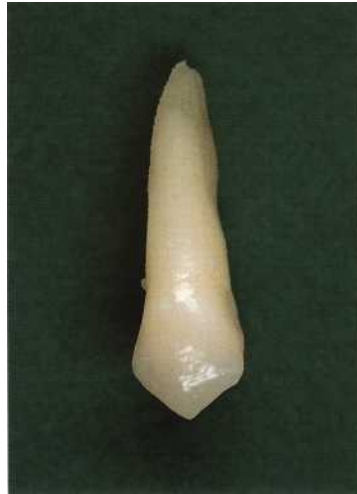

123 Mandibular canine
 Left: The lateral radiograph of the tooth shows a rare variation with two roots and two separate canals.
 Right: Canines in the mandible are also noticeably shorter than in the maxilla and have two root canals in up to 25% of cases, comparable to the lower incisors. Usually, however, their canal form falls under the type I classification (Vertucci 1984) with one canal and one apical foramen.

Maxillary Premolars

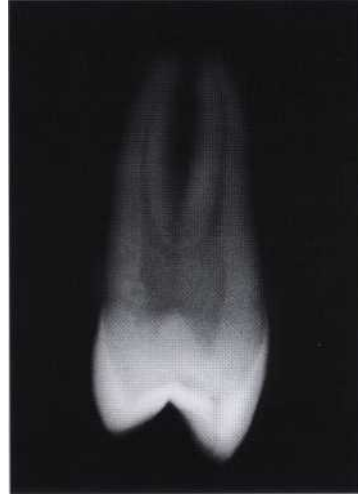Two distinct pulp horns under the cusp tips are characteristics of all premolars of the maxilla and can easily be mistaken for the entrances to the root canals during access preparation. The mesial concavity increases the danger of lateral perforation. Everything that is common in first premolars is rare and reversed in the second premolars. A preoperative radiograph is often helpful because a single root with only one canal means there will be a penetrable lumen. The presence of two canals, in either one or two roots, is usually clearly visible only in the cervical region (Peters 1992b).

124 Maxillary first premolar
Left: In the maxilla, the first and second premolars can be clearly distinguished from one another. A maxillary first premolar usually has two roots and two separate root canals, whereas a maxillary second premolar usually has one root and one canal.



Right: The lateral radiograph shows the wide coronal pulp with distinct diversion of the pulp horns toward the cusp tips. The two canals lie clearly divided within two sharply tapering roots.

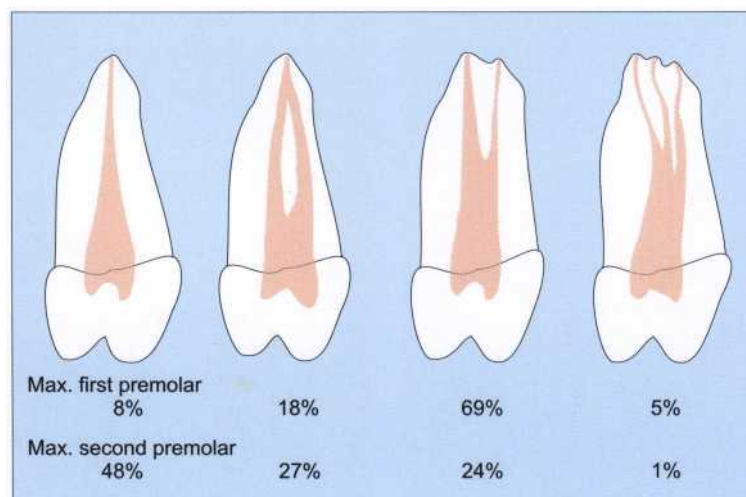
The first premolar typically has two well-formed roots (56%) that divide in the middle third of the root and lie buccal and lingual to one another. About 40% have only one root containing two canals (type IV) that then unite in a common foramen. Three-rooted first premolars are uncommon (4%) and frequently have three canals and three foramina (type III; Vertucci and Gegauff 1979). They then resemble molars in that there are two buccal canals and one palatal canal. Besides the number of roots described here, it is the number of canals per root that is more relevant in endodontics.



125 Range of variations in root canals of maxillary premolars
The data come from a survey by Peters (1992 b).

The first premolar presents itself predominantly with Vertucci's canal types IV-VII, i. e., with two canals that are either completely separate or that more or less run together.

The second premolar belongs approximately half to type I, one-fourth to type II (27%), one-fourth to types IV-VII (24%), and only very rarely to type VIII.



Canal configurations of types I and II are uncommon with frequencies of 8% and 18% respectively (Fig. 125). Most common are two canals that are separate throughout (69%); only rarely are three canals present. At 21 mm, the first premolar is, on average, somewhat shorter than the second premolar. The typical *second* premolar has one root and one canal. The remainder have two roots, each with a separate canal. The dominant canal configuration is type I with a frequency (48%) approximately the same as types II and IV-VII combined. With increasing age and deposition of secondary dentin, the coronal pulp horns and the roof of the pulp chamber decrease in height.

Even when two canals of a premolar have the same working length, the difference in their position and the true canal lengths can cause problems. There are then two methods for distinguishing the two canals:

1. As the X-ray tube is displaced horizontally (eccentric projection), the image of an object nearer the film (palatal canal) is displaced less than that of an object farther from the film (buccal canal) in accordance with the buccal rule.

2. An H file is placed in one canal and a K file in the other. These can then be identified on the radiograph because the K file will appear smoother.

Mandibular Premolars

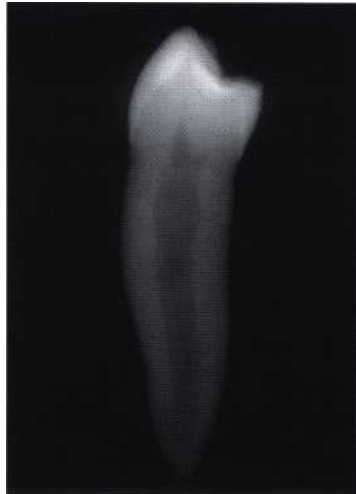The crown of a mandibular premolar appears quite bulky when compared with the mandibular anterior teeth, suggesting a proportionately larger root. However, the root is actually delicate with a mesial concavity. Its cross-section is mostly oval with the greatest width in the faciolingual plane.

Because of the inclination of the crowns of mandibular teeth and the smaller lingual cusp, the access opening should be placed buccal to the central fissure. The preparation is made oval, corresponding to the shape of the root and canal. The coronal pulp is wide with a

large buccal horn and a small lingual horn.

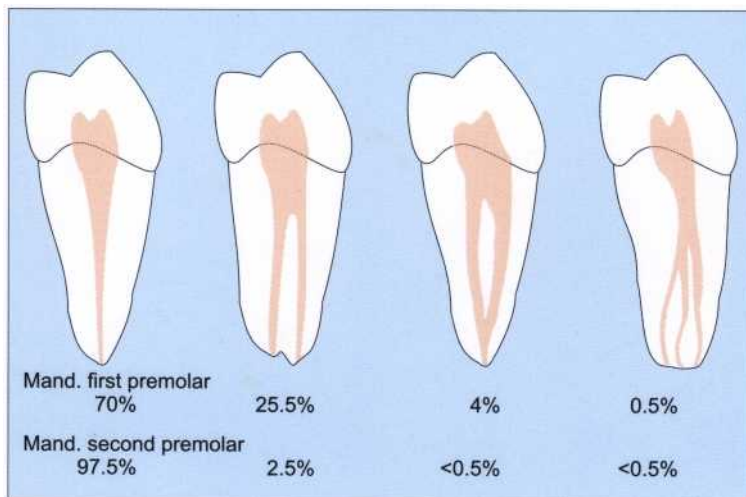
The shape of the canal is similar in first and second premolars. Its buccolingual extension is broad until the middle third of the canal, but is very narrow in the apical third. As a rule, both teeth have a single canal. One-fourth of all first premolars, however, can be expected to have two root canals.

An acute exacerbation of apical periodontitis can sometimes express itself as temporary paresthesia of the mental nerve.



126 Mandibular first premolar
Left: The lateral radiograph shows, as in the maxilla, a wide coronal pulp chamber. Only the extension of the buccal pulp horn is prominent. The lingual pulp horn in first premolars is, as seen here, indistinct. In mandibular second premolars, however, it is usually more pronounced.

Right: In the mandible, the overwhelming majority of both first and second premolars have a single root and only one root canal.



127 Range of variations in root canals of mandibular premolars
The data come from a survey by Peters (1992 b).

In the great majority of cases, both premolars are type I (mandibular first premolar 70%; mandibular second premolar 97.5%). In approximately one-fourth of first premolars, two canals of types IV and V configurations were found, while the occurrence of types II and III configurations was reported at less than 5%. Only rarely does the second premolar have a second root canal.

In up to 25% of mandibular first premolars the most accessible single canal divides into two canals in the middle third (Pineda and Kuttler 1972, Vertucci 1978). This can present a problem during the endodontic preparation. These belong, then, to the Vertucci types IV and V canal configurations. The significance of this for the dental practitioner is that the access opening should be widened lingually to create good access. The single canal runs almost straight at first, but at midroot distinct curves both to the lingual and buccal are encountered.

As a result the preparation instruments must be inserted into the buccal portion of the canal by curving

from the lingual and into the lingual portion, from the buccal. In this situation there is also the danger of overstraightening the canal and excessively widening its delicate apical third.

A smaller proportion of lower first premolars belong to type II/III (<5%). Less than 2% have three canals (review: Hulsmann 1994).

The mandibular second premolar shows few variations (2.5%) of types II, IV, and V. Almost always (97.5%) are only one root and one canal found. Less than 1% have three canals and these are very difficult to prepare.

Maxillary Molars

The access opening should begin in the central fossa toward the lingual where the pulp is large and easy to find. The opening should be made rectangular, corresponding to the floor of the pulp chamber up to the mesial marginal ridge. With age, the chamber becomes smaller through deposition of secondary dentin in all directions, increasing the risk of perforation through the furcation. Therefore, diamond stones should be used only in enamel and round burs in dentin. Developmental concavities and discolorations are important guides to the canals! Up to 75% of upper molars have

endoperiodontal canals (from the pulp chamber to the furcation) that are very short and, if overlooked, can cause failure. The *maxillary second molar* is similar to the first but somewhat smaller with less divergent roots. In about half of these teeth the roots are united and may have canals that are C-shaped in cross-section. Here too, 43% have a second canal in the mesio-buccal root. The distobuccal canal lies farther mesial than in the maxillary first molar on a perpendicular guide line (Fig. 129 [2]). The third molar offers a considerable range of variations.

128 Locating the canals of a maxillary first molar

Left: A first look at the floor of the pulp chamber of a maxillary first molar reveals two buccal and one palatal canal entrances. The canal was instrumented and the tooth was pain free for a time. (Case continued in Fig. 130.)

Right: View after filling of the root canal system.

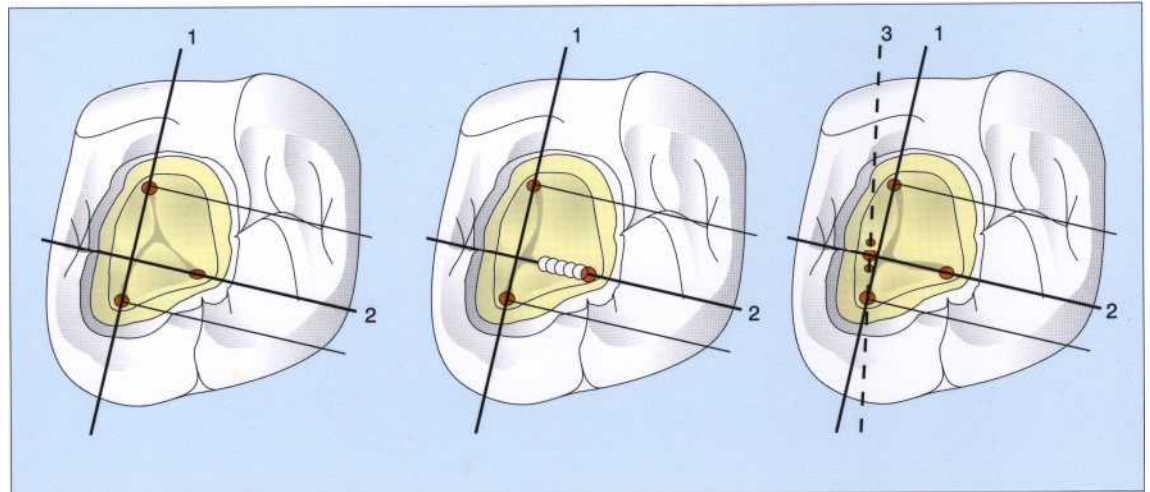


129 Geometric aids

A Line 1 connecting the mesio-buccal and palatal cusps. Line 2, perpendicular to line 1 at a point one-third the intercanal distance from the palatal canal, will pass over the distobuccal canal.

B The distobuccal canal can lie somewhere along line 2.

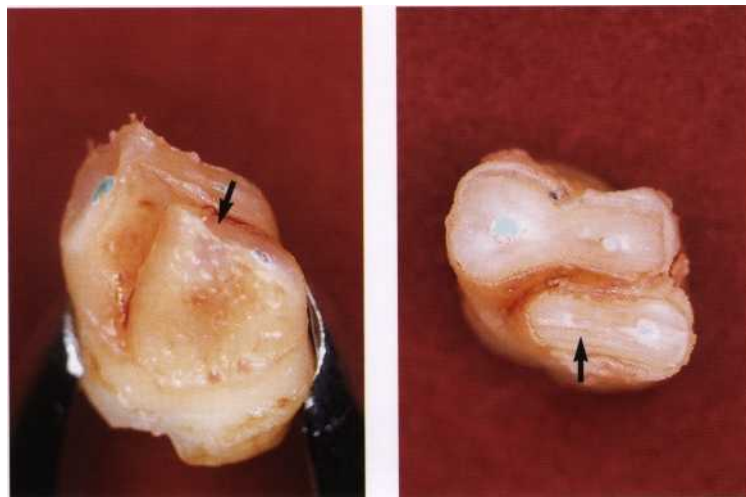
C A fourth canal lies somewhere along line 3, which deviates approximately 10°.



130 Significance of a fourth canal

After some time, the first molar (Fig. 128) again became sensitive to temperature changes. This evolved into a constant pain. A periapical lesion was found on the mesiobuccal root and was treated by an apicoectomy. Even then the pain persisted and the tooth was finally extracted.

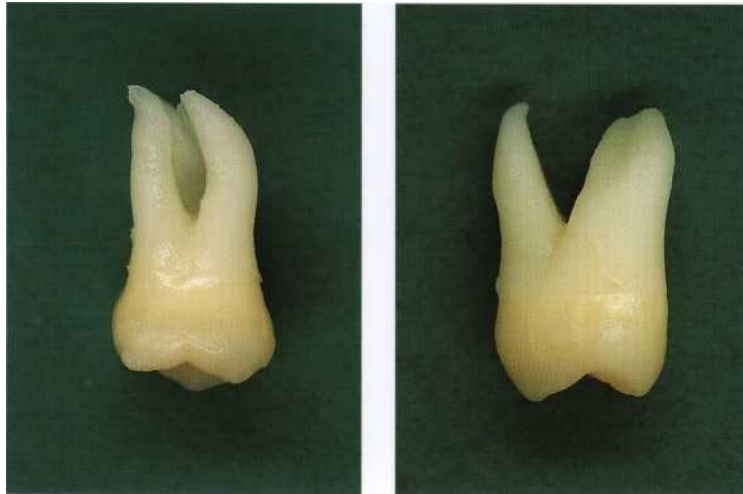
Left and Right: These views of the extracted molar show an additional canal in the mesiobuccal root that was not found in the initial root canal treatment and was not sealed during the apicoectomy (arrow).



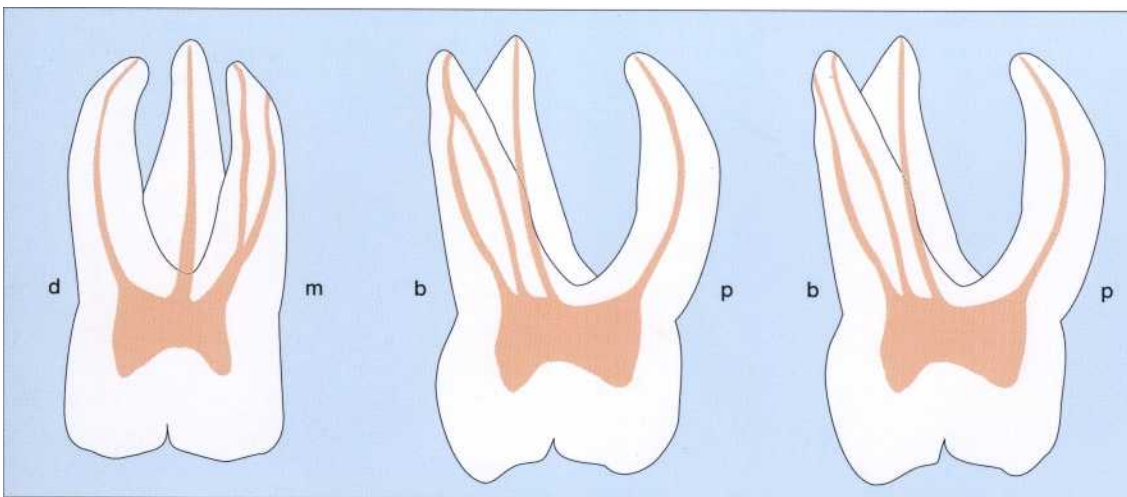
Characteristics of Maxillary First Molars

The maxillary first molar has three roots and four canals. Special attention should be called to the mesio-buccal root, 60% of which have two canals according to *in vitro* studies, 95% when viewed under the microscope (Kulild and Peters, 1990). In *in vivo* studies, two canals were found in only 18-33% (review: Harty 1990). The second canal usually begins beyond a common orifice (Fig. 132). The mesial canals (mesiobuccal and mesiolingual) run first toward the mesial, then buccally and in the apical third in a distolingual direction.

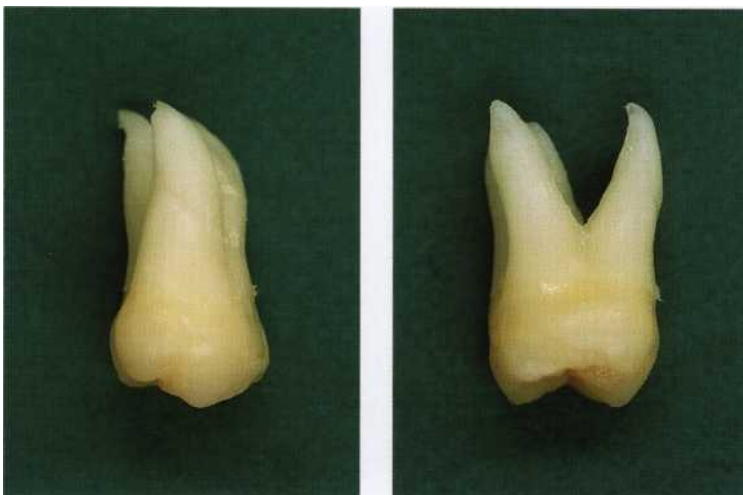
Because the two canals of the *mesiobuccal* root lie in a buccolingual plane, a 20° distal eccentric angulation should be used for the radiograph, which is not the case for the other posterior teeth. The *distobuccal* root usually has one canal in the center of the root. It is the shortest root and it runs first to the distal and curves mesially in the apical third. The entrance to the canal lies more central than distal. The lingual root (type I) is the longest and has the largest lumen. The apical end is bent buccally so that the file used for the measuring radiograph should be pre-bent.



131 Complexity of the maxillary first molars
 Left: The buccal view shows the familiar configuration of two separate buccal roots, the tips of which angle distally. Mesially there is a large curvature distributed uniformly along the root, while distally only the last two millimeters of the root tip is sharply bent.
 Right: In the mesial view the merging of the mesial and palatal roots catches the eye (cf. Fig. 132 center and right).



132 Various forms of the mesiobuccal root
 In *in vitro* studies report a second canal in the mesiobuccal root of maxillary first molars in 55-69% of cases.
 Left: Mesiobuccal and mesiolingual canals usually have a single common opening into the pulp chamber.
 Center: Commonly, both canals exit apically through a single canal as a type II configuration.
 Right: The variation with two separate canals and two foramina must also be considered.



133 Complexity of the maxillary second molars
 Left: This palatal view shows the familiar shape of a single massive lingual root. Here, too, the root tip turns distally, betraying a pronounced curve in the overall course of the canal.
 Right: The distal view reveals a wide separation of the buccal and lingual root. All root tips are turned buccally.

Mandibular Molars

The access opening for a mandibular molar is made from the center of the occlusal surface and approximates a trapezoid shape with the wider base at the mesial marginal ridge. It avoids the distal third of the crown. As in maxillary molars, denticles are frequently found, which must be removed before the canals are prepared. Usually one mesial and one distal root are found, of which the distal is more slender and round. There are often five pulp horns, the lingual being the longest and most pronounced. The dentin overhanging the mesial orifice must be removed in order to reduce the danger of zipping.

The *mandibular first molar* has two roots; the mesial usually has two canals; ending in a common foramen. The mesiobuccal canal is the more difficult because of its multiple curves. An initial mesial turn is followed by one to the distal in the middle third. The distobuccal canal is wider and straighter, but may bend mesially near the apex. Between the two mesial canals there are often complex anastomoses (Peters 1992 d). The single distal canal is normally larger and oval shaped and in 60% of cases exits short of the anatomic apex through the distal surface of the root (Tamse et al. 1988).

Furthermore, more than one-fourth of all mandibular first molars have two canals in the distal root (Skidmore and Bjorndal 1971). According to Pineda and Kuttler (1972), approximately equal numbers of these are of type II (13%) and type IV (14%).

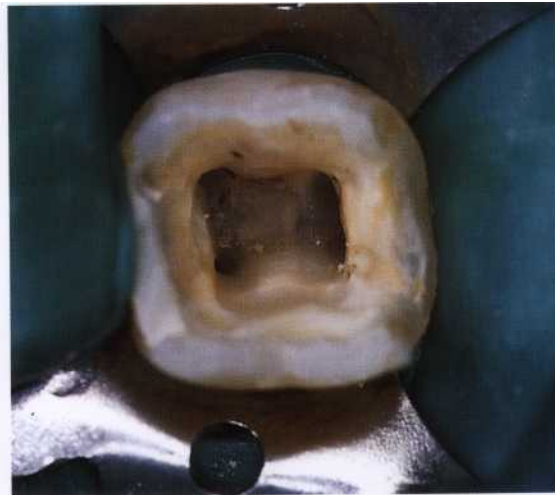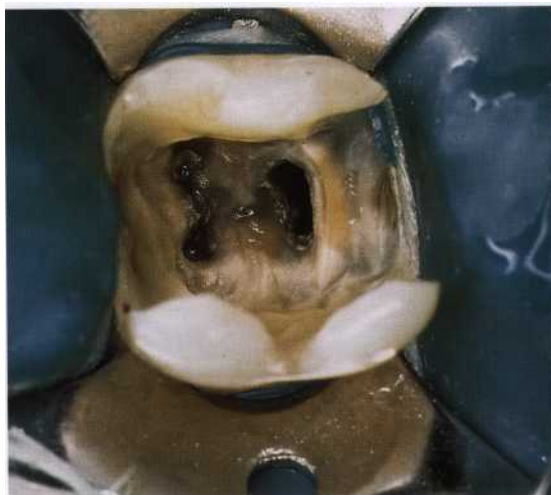The *mandibular second molar* is similar to the first, except that the roots are shorter, the canals more curved, and the range of variations broader. Very often (58%) the mesial root has either a single canal or two canals of type II or IV (approximately 21% incidence of each; Pineda and Kuttler 1972). In the distal root there is almost always only one canal, (>94%) rarely type II (2.1%) or type IV (3.5%; *ibid.*).

The C-shaped canal is a unique feature. First described by Cooke and Cox (1979) with an incidence of 8%, it is found predominantly in mandibular second molars, but may also occur in mandibular first molars, premolars, and maxillary molars (review: Simon 1993 a). In the Chinese population, the incidence can be 33-52%. The diagnosis is difficult. Clinical clues to its presence are constant residual pain, intermittent bleeding from the canal, and confluent lumina. In the radiograph the roots appear rather conical or fused and the furcation can barely be seen, if at all (Peters 1992 d).

134 Canal entrances in a mandibular molar

Left: As a rule, the mesial root has two canals (87%) and the distal one canal (73%). The mesial canals are rather round, and in 40-45% of cases terminate in a common foramen (type II). The distal canal is oval, wider than the mesial, and usually ends on the distal surface of the root short of the anatomic apex (Peters 1992 d).

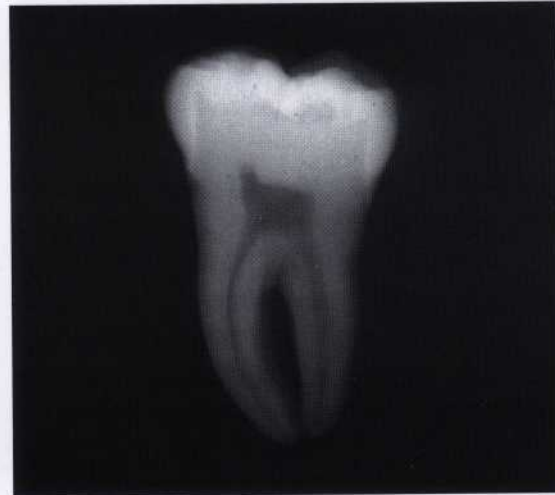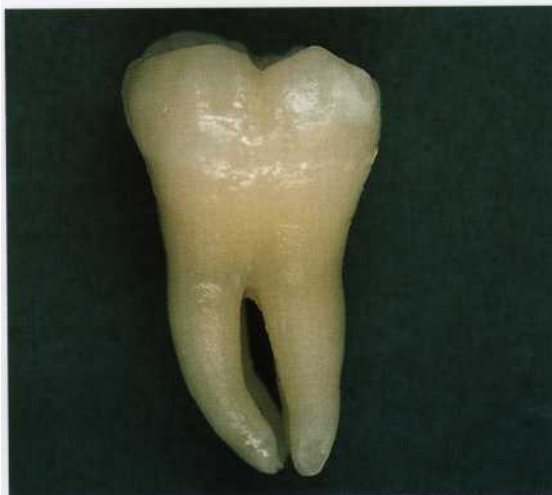Right: Approximately one-fourth of all mandibular molars have a second canal in the distal root, equally distributed between type I and type IV.



135 Mandibular molars

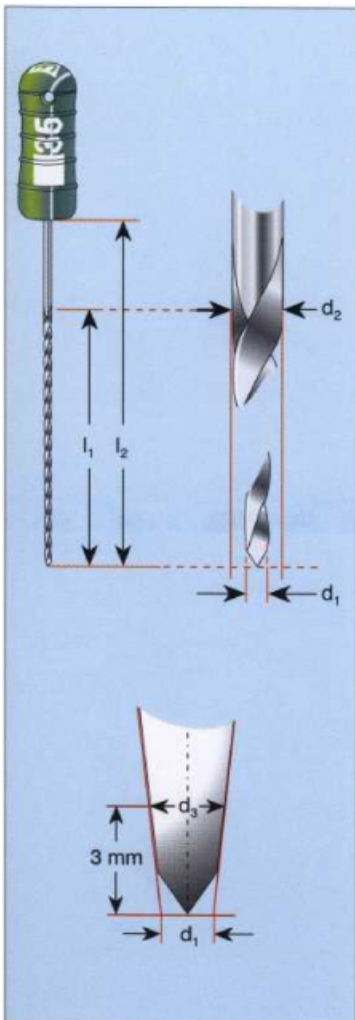
Left: As a rule, one mesial root and one distal root are found in both first and second lower molars. The end of the mesial root frequently curves distally as it does here, making instrumentation more difficult. A characteristic of first molars that bears mentioning is the presence of three buccal cusps: mesiobuccal, mediobuccal, and distobuccal.

Right: The radiograph shows the expected form of a wide coronal pulp chamber with its prominent mesial pulp horn. In this projection each root appears to have only one canal.



Instruments and Materials

From the access preparation through the root canal obturation to the follow-up procedures (e. g., apicoectomy, post-core), root canal treatment requires a large, varied armamentarium. While some aids have remained virtually unchanged for decades, important developments have occurred in other areas, such as Ni-Ti instruments, thermoplastic gutta-percha filling techniques, and retrograde ultrasonic preparations. In the 1950's, endodontic instruments were standardized. The American Dental Association's Council on Dental Materials, Instruments, and Equipment (CDMIE, founded 1966) has been in existence for only a little more than 30 years. The governing authority is the American National Standard Institute (ANSI). Internationally the TC-106 JW6-1 Group (Technical Committee, Joint Working Group) under the mandate of the International Standards Organization (ISO) and the Federation Dentaire Internationale (FDI) is concerned with establishing standards, of which ISO 3630 (ANSI 28.58.63.71) is the best known (Miserendino 1994, Orth 1995).



Color code	ISO size	$d_1 \pm 0.02$ mm	$d_2 \pm 0.02$ mm
	006	0.06	0.38
	008	0.08	0.40
	010	0.10	0.42
	015	0.15	0.47
	020	0.20	0.52
	025	0.25	0.57
	030	0.30	0.62
	035	0.35	0.67
	040	0.40	0.72
	045	0.45	0.77
	050	0.50	0.82
	055	0.55	0.87
	060	0.60	0.92
	070	0.70	1.02
	080	0.80	1.12
	090	0.90	1.22
	100	1.00	1.32
	110	1.10	1.42
	120	1.20	1.52
	130	1.30	1.62
	140	1.40	1.72

136 ISO standardization

The dimensions of endodontic instruments arranged according to the recommendations of the International Standard Organization. Color coding permits rapid visual identification of the diameter. After the three smallest sizes #6 pink, #8 grey, #10 violet, the sequence white-yellow-red-blue-green-black is repeated three times.

Left: The cutting section is, in accordance with the ISO standard, 16 mm long (11). Three diameters are specified: d_1 at the tip, d_2 at the end of the cutting portion 16 mm from the tip, and d_3 3 mm from the tip.

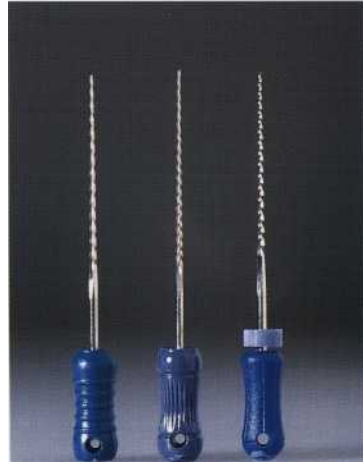The Three Basic Instruments...

All instruments for preparing canals come from three basic forms: K reamer, K file, and Hedstr6m file. First made of carbon steel, since the 1960's they have been made from Cr-Ni stainless steel that is less affected by frequent sterilization. K types are made by twisting a steel wire of square (for smaller sizes) or triangular (#30 and larger) cross-section. The square shape is more stable and rigid; its smaller chip space (36%) does not allow the removal of much loosened material. The triangular shape is more flexible, has a larger chip space (60%), but is more susceptible to fracture. The

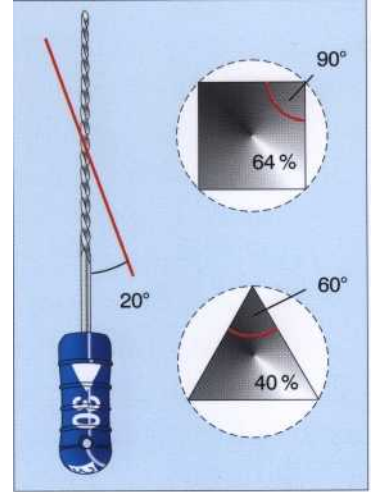

angle between the long axis of the instrument and the cutting edge (cutting edge angle) is an indication of how it works and its effectiveness. With angles less than 45°, a rotating-scraping technique works best. This applies to K reamers (with 20° the smallest) and K files (~40°). H files, with their sharp edges milled from round steel wire and an angle of approximately 60°, are extremely efficient. They are clearly superior to K files, which are often recommended for a purely filing technique, even though they are more effective when rotated (Schafer 1995 a).

137 K reamers

Left: The K reamer is one of the basic types of endodontic instrument. From left: VDW, Kerr, Maillefer.



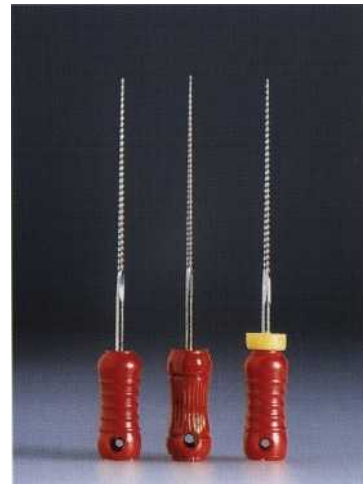Center: The SEM picture at 25x magnification shows the number of cutting edges and the geometry of a reamer (0.5-1.0 turn/mm).



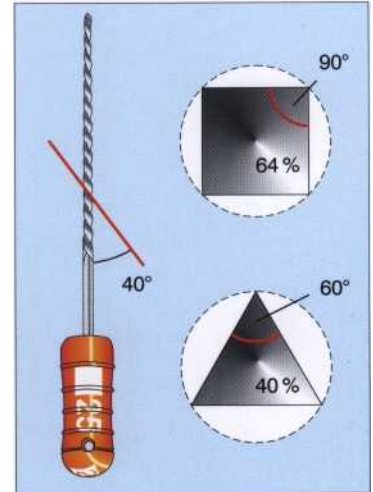
Right: While the triangle is the symbol for a reamer, the smallest sizes are quadrangular in cross-section with smaller chip spaces (flutes) of 36%. Larger sizes are triangular with 60% chip space.

138 K file

Left: As early as 1915 the Kerr Manufacturing Corporation obtained a patent for all instruments later known as K-type instruments, e.g. the K file.



Center: Note: the greater number of cutting edges (1.5-2.5 turn/mm) compared with the K reamer.



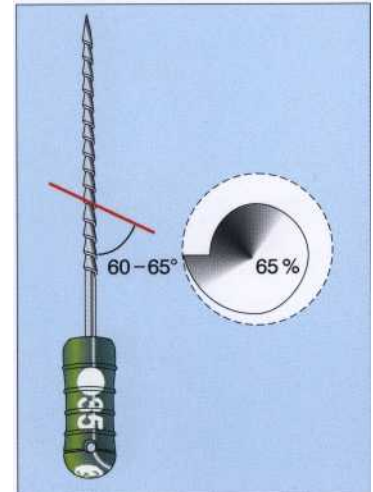
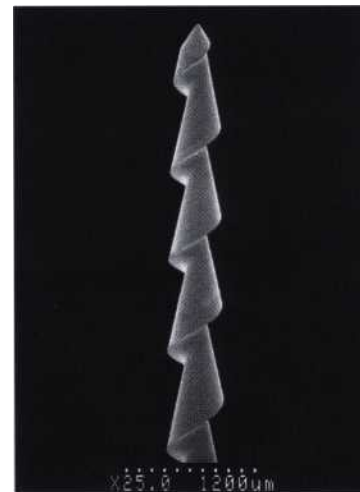
Right: K files also have a cross-section that is quadrangular in the finest sizes and triangular in larger sizes. Their symbol, however, is the quadrangle. The cutting edge angle, at 25°-40° is approximately twice as large as that of a reamer.

139 H files (Hedstr6m files)

Left: Hedstr6m files, in contrast to the K types, are milled from a steel rod of round cross-section.



Center: The SEM picture (25x magnification) clarifies the different geometry with the helical cutting edge.




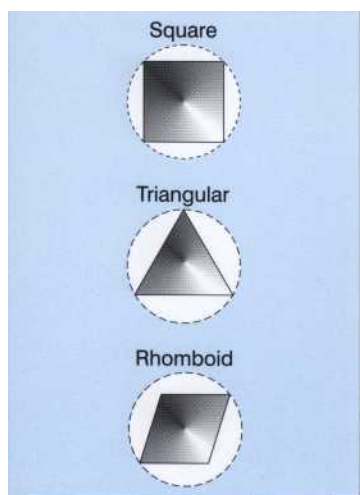
Right: The cross-section of an H file is round with a spiral milled into it, permitting a chip space of 35%. Its symbol is a circle. The angle of the cutting edge is 60°-65°.

...and Their Modifications

In order to overcome the disadvantages of the original types, hybrid instruments were developed in attempts to combine the advantages of the K types with the aggressive cutting ability of the H types. Higher flexibility was achieved by changing the cross-section and by using special steel (Flexicut). With the introduction of the Flex-R file (Roane et al. 1985) a new era began. It was recognized that the sharp angles at the instrument's tip were causing some of the preparation mistakes, and so they were beveled in conformance with the non-cutting tin principle. This was also effected

with Flexofiles and Flexreamers. Otherwise, the Flex-R is a modification of the K type because of its triangular cross-section, but it is milled out of a round steel blank like the H file. Unifiles and S files with the double helix are also made in a similar manner. In some instruments (Canal Master U, Flexogates, Heliapical) the cutting portion has been made short in order to minimize distortion.

Because until recently the ISO numbers increased linearly, whereas the diameter increased in steps, intermediate sizes were introduced-

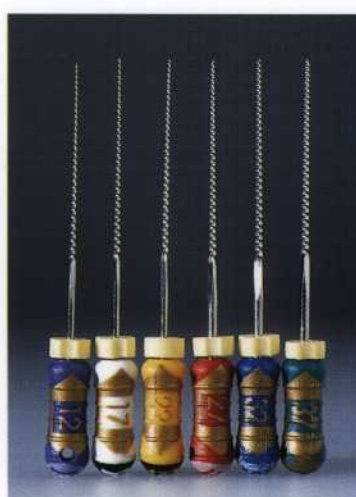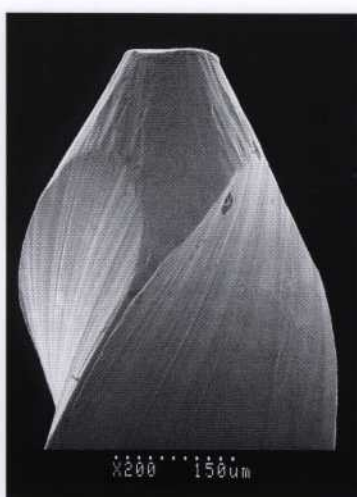



140 Flexible instruments

Left: The square cross-section is larger and therefore more rigid than the triangular one. Newer instruments are therefore triangular, even in the smaller sizes (A-C). The rhomboid (D) is also more flexible, but allows only two cutting edges.

Center: The number of edges of the Flexofile (B) is substantially higher. In the K-Flex (D), thicker sections alternate with thinner because of the rhomboid form.

Right: A = Flexicut (VDW), B = Flexofile (Maillefer), C = Flexoreamer (Maillefer), D = K-Flex (Kerr).



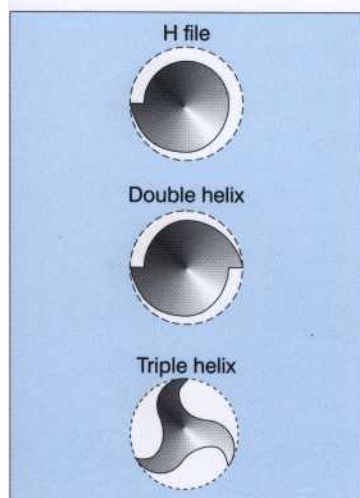141 Non-cutting tip

The Flex-R file by Roane (1985) is the first to utilize a noncutting tip that helps avoid ledge formation in curved canals.

Left: The principle of the Flex-R is based upon removal of the sharp corners at the instrument tip (dual conical form).

Center: The SEM reveals the geometry of the tip (200x magnification).

Right: The intermediate sizes (# 12-37) of the Maillefer Golden Mediums are also made with noncutting tips.



142 Further modifications

Some manufacturers have greatly reduced the length of the cutting portion of their instruments, leaving a longer shaft of round steel.

Left: The simple helicoidal cross-section of the Hedstrom file is modified to a double helix in the S file and a triple helix in the Helifile (Micro-Mega).

Center: Flexogates (Maillefer) with a 2-mm-long cutting portion.

Right: Heliapical (Micro-Mega) with a 5-mm-long cutting portion.

Instruments from Titanium Alloys

Nickel-titanium alloys have long been utilized in the field of orthodontics because of their high flexibility and resistance to fatigue fracture (Andreasen and Hilleman 1971). For the past few years Ni-Ti alloys have been used for endodontic instruments, most commonly with 56% Ni and 44% Ti from China (Nitalloy), Japan, and the USA (Nitinol [name derived from Ni-Ti Naval Ordnance Laboratory], Silver Spring). One of the alloy's interesting special properties is the memory effect (or pseudoelasticity), which means that Ni-Ti resumes its original shape even after having been

deformed. The residual deformation is 0° whereas for stainless steel K files it is 10°-18° (Camps and Pertot 1995). Of course, this means that Ni-Ti instruments cannot be pre-bent. Significantly lower bending moment and modulus of elasticity, each only one-fifth that of Cr-Ni steel instruments, are indicators of its great flexibility. Surprisingly, the torsion strength is less than that of stainless steel, while the rotation is comparable. This could be the result of its manufacture by milling, which is difficult with Ni alloys and frequently results in notching (Schafer 1995 b).

143 Titanium alloys

A modulus of elasticity that is five times lower and a smaller bending moment make titanium alloys interesting for use in curved canals.

Left: Nitiflex instruments from Maillefer are K files made of Ni-Ti.

Center: Hyflex-X files (Hygienic) combine the Ni-Ti material with a new cutting design.

Right: The new geometry of the Hyflex (left) compared with the conventional geometry of the K file of Ti-Al by Micro-Mega (right).



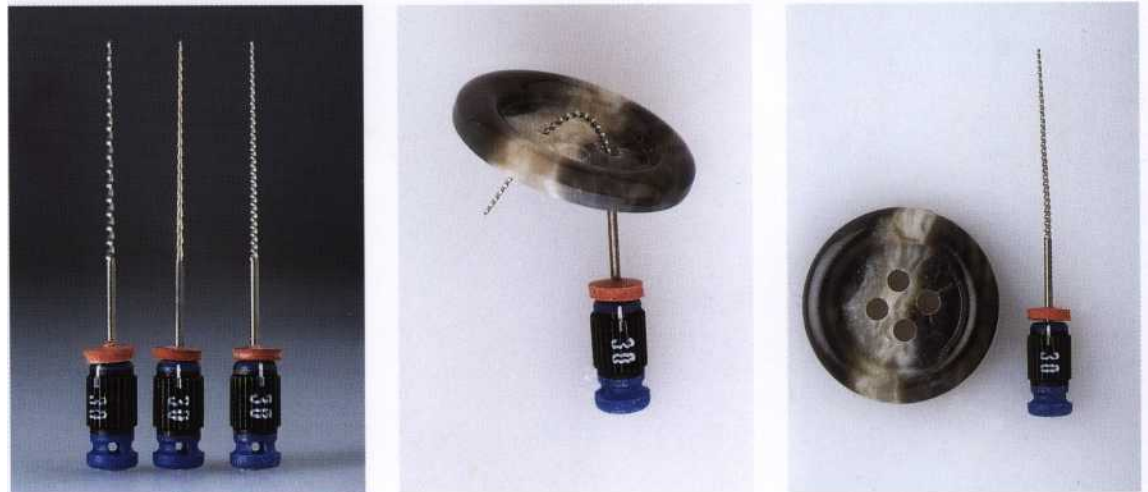
144 Titanium-aluminum alloy

One of the newest developments in hand instruments is the microtitanium instrument from Micro-Mega. It is made of a new alloy that is 95% (by weight) Ti and 5% Al.

Left: Microtitanium instruments are available as K reamers, H files, and K files.

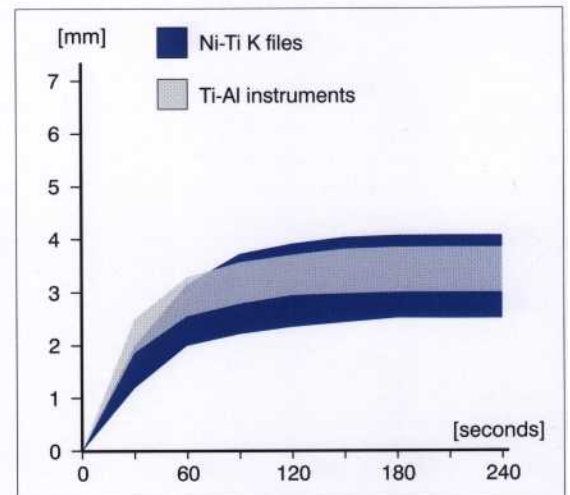
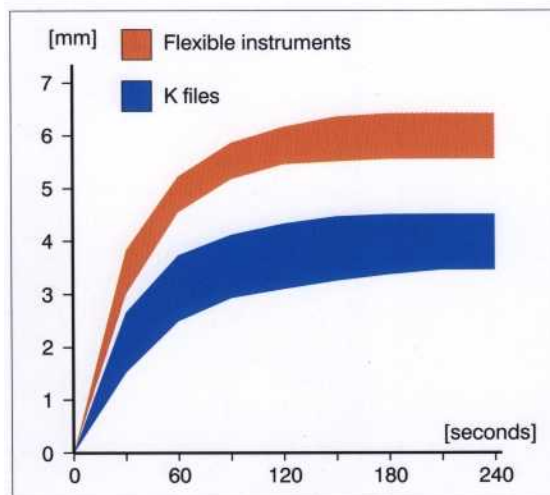
Center: Titanium instruments can be severely bent and distorted.

Right: Ti-Al does not have the pseudoelasticity (see text above) of Ni-Ti so that while it is true that no fractures are seen, permanent deformation can occur.



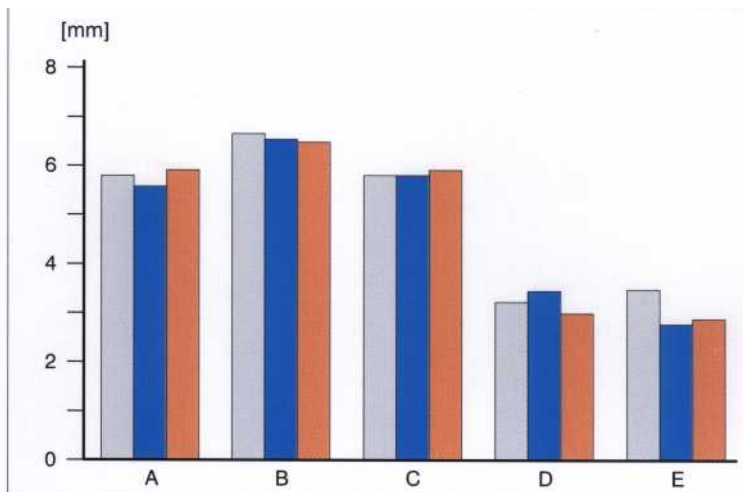
145 Penetration depth of endodontic instruments

The maximum penetration depths of instruments ISO sizes #25 and 35 were determined by rotating and scraping in plastic test blocks. Flexible refined steel instruments forced openings to the greatest depths, regardless of whether they had conventional or noncutting tips. Conventional K files of refined steel proved better than K reamers. The poorest cutters were Ni-Ti K files, while the results with Ti-Al instruments were better, coming close to the results with conventional steel instruments (Schafer 1995b).



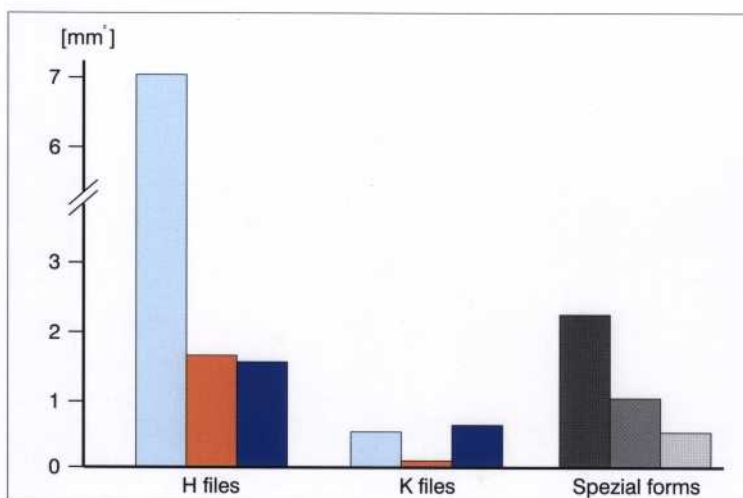
The cutting efficiency of Ni-Ti instruments used as hand files is approximately 60°-90° lower than that of conventional instruments and still worse than the more flexible instruments (40-60%) (Schafer et al. 1994 a). Saliva, Sodium hypochlorite, and sterilization can lead to corrosion, and just one sterilization procedure can significantly reduce the cutting efficiency. This means that two or three Ni-Ti files are needed to work to the same depth reached by flexible files, resulting in a longer working time. Furthermore, Ni-Ti instruments are approximately four times as expensive.

Ni-Ti files gave very good results with regard to the trueness of form of the preparation, although near the apex, they removed almost no structure at all. Micro-titanium instruments (Micro-Mega: 95% Ti and 5% Al by weight) represent another advancement. These have greater flexibility than stainless steel instruments with similar cutting performance and almost the same fracture resistance. They exhibit no pseudoelasticity, and perform poorly in crooked canals (Schafer 1995 b).



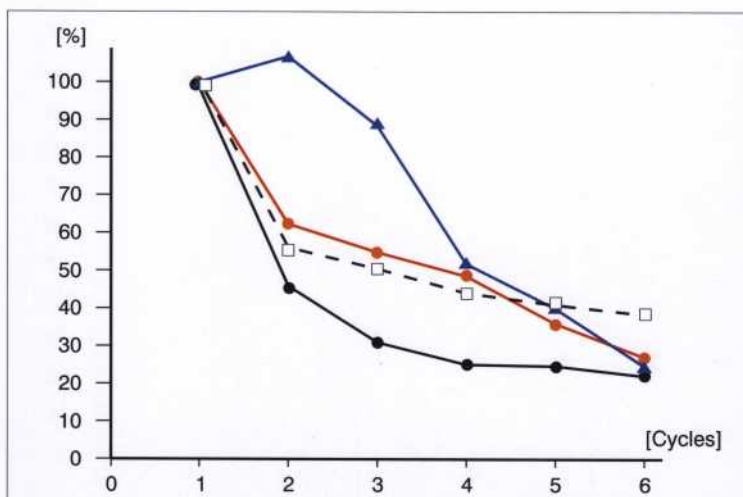
146 Effects of sterilization (Schafer 1995 c)

Steel instruments (A) as well as the flexible types (B, C) experienced no significant deterioration in their cutting ability. It was once again demonstrated that flexible steel instruments (B) achieved the greatest depth of penetration, while the Ti-Al instruments (D, Micro-Mega) cut only about 40% as deep. Ni-Ti instruments (E, Mity K file) showed a significant reduction in cutting efficiency after only one sterilization.



147 Cutting efficiency (Stenman and Spangberg 1990 a, b)

The cutting ability of endodontic instruments was determined by measuring and averaging how much of the surface of a plexiglas block was worn away by 300 strokes of each instrument. The greatest overall effect was achieved with H files, among which the instruments from Antaeos (VDW) once again led all the others. There was a smaller difference among the K files where the K-Flexofiles (Maillefer) were the most effective. Among the special forms, S files (similar to Hedstrom files) performed best.



148 Wear of endodontic files (Kazemi et al. 1995)

All files tested were used inside a plexiglas block 600 times (starting value). This was followed by 300 working strokes in human dentin alternating with 600 in plexiglas (cycles 2-6). Only the H file from Maillefer still performed at 90% of its starting efficiency in the third cycle, and then fell to 50%. The cutting efficiency of the other files fell to only 45-65% in the second cycle. *Endodontic files are disposable.*

Engine-Driven Instrumentation

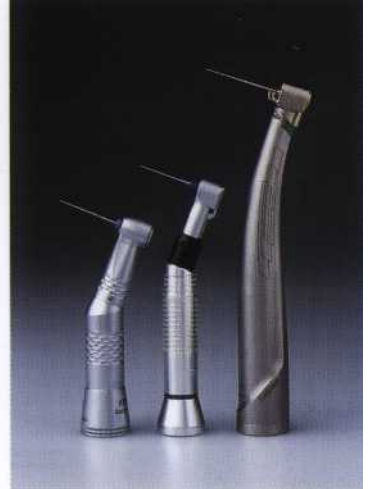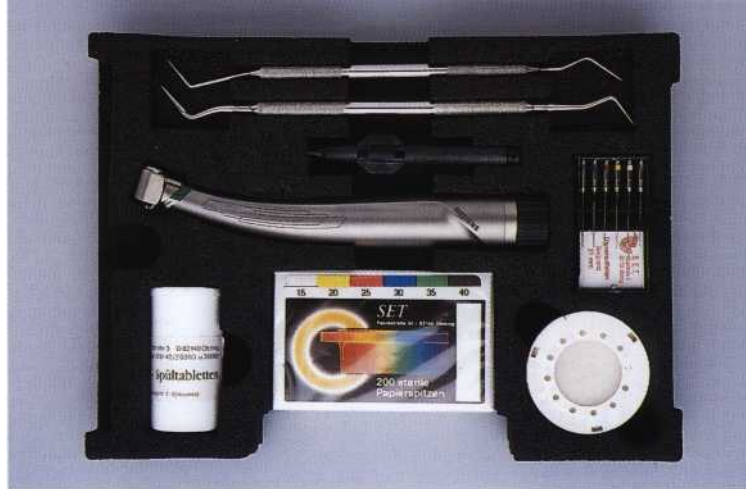It should be possible to prepare the complex root canal systems better and more quickly with engine-driven instruments. Over the past 40 years, a number of mechanical instrumentation techniques using various flexing movements have been developed. Some of these employ reciprocal rotational movements (Giromatic), lifting movements combined with quarter turn rotations (Kerr Endolift), pure rotational movement (Endocursor), or pure lifting movements (Intra-Endo). Others use a scraping action on the pull strokes (Endoplaner) or oscillations that vary with conditions inside the canal

(Excalibur).

The Giromatic System, with a recommended engine speed of 3000 rpm for canal preparations, may be considered the best-known engine-powered system. However, its ability to shape the canals is criticized because of step formation, deviation from the path of the canals, and overstraightening of curved canals. In 1984, the Canalfinder System marked the transition to more flexible drive systems with longitudinal movement occurring at 1000 to 8000 rpm. However, it also produced canal straightening (Hulsmann 1993a).

149 Engine-driven preparation
The primary direction of movement with the Canalfinder is longitudinal in a low-frequency range with a variable amplitude. If the rotational speed increases, the amplitude becomes smaller, measuring 0.3 mm at a speed of 2000 rpm.

Right: A selection of handpieces for mechanical preparation: Endolift (Kerr), Giromatic (Micro-Mega), and Canalfinder in titanium (SET Siemens).



150 Instruments for powered handpieces
Some of the instruments available for engine-powered preparation and filling of root canals.

Left: Spiral paste fillers (Lentulo) in sizes 20 and 30, plugger;

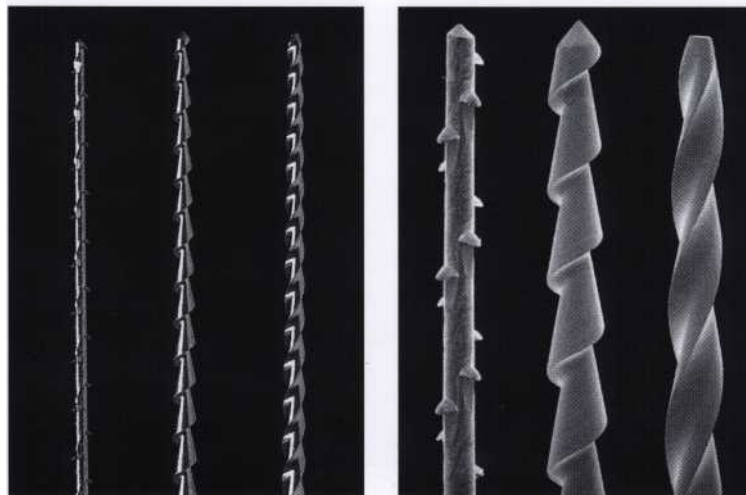
Center: K files and Hedstrom files (Girofiles, HeliFile);

Right: Hedstrom files in various lengths.



151 Engine-driven instruments
Left: Giromatic instruments: Rispi File, Giro-File, and Heli-File.

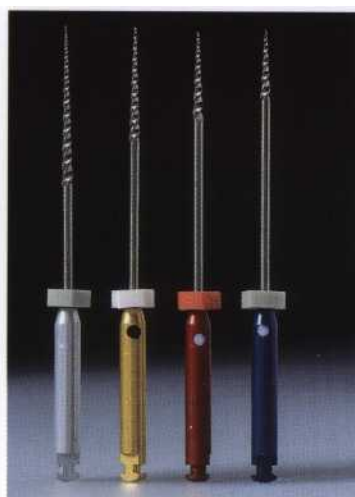Right: In the SEM the Cleanser is shown on the left, the Giro-File (Hedstrom file) in the center, and the Heli Giro-File (K file) on the right.



A major advance in engine-driven preparation techniques occurred with the introduction of Ni-Ti instruments. Ni-Ti instruments of the Profile Series 29 (Tulsa) have either a 0.04 or a 0.06 taper and are characterized by an increase in the cross-section of 29.2%. The rotational speed is 250 to 350 rpm. The GT File series consists of taper sizes 0.06, 0.08, 0.10, and 0.12. The standard file set consists of only four instruments, each with the same tip diameter. This is a great departure from ISO-tapered files, which come in 21 different tip sizes (Buchanan 1998).

The Quantec Series 2000 uses Ni-Ti instruments of graduating tapers that range from the conventional 0.02 to a 0.06 taper. New design configurations include a more ideal cutting angle of the blades, flutes and wide radial lands, asymmetry of the cutting surfaces, and a faceted cutting edge (Korzen 1996).

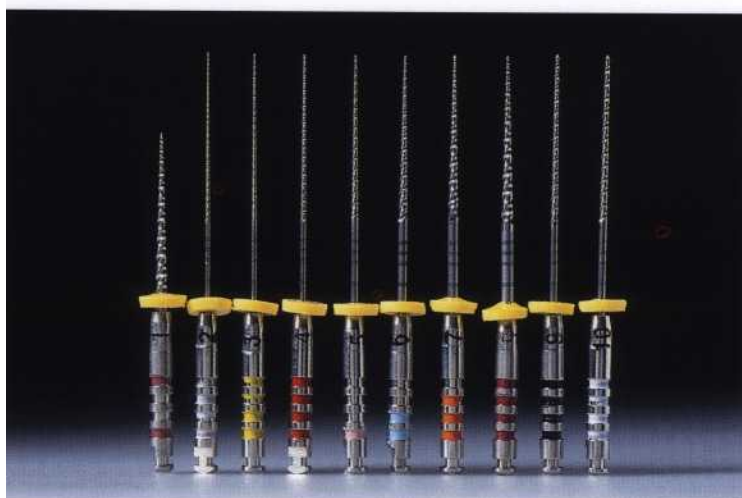Lightspeed instruments (Willey and Senia 1993) operate with an engine speed of 750 to 2000 rpm. The instrument set contains 22 sizes. The end of each instrument has a noncutting pilot tip and a cutting portion, and the shaft is thinner than the cutting head.



152 Profile instruments

Left: The Profile .04 is an instrument with a U-shaped cross-section and a taper of 0.04.

Right: The GT files come in four different tapers (0.06, 0.08, 0.10, and 0.12) and three different lengths (21, 25, and 31 mm). All four files have the same tip diameter (0.02 mm), the same 1-mm maximum flute diameter, and the same variable-pitch flute pattern.



153 Quantec instruments

The Quantec instruments are made of Ni-Ti and have graduating tapers ranging from the conventional 0.02 taper to a 0.06 taper. These instruments are designed to be used with a rotational speed of approximately 340 rpm. The ten instruments all have a slightly positive cutting angle permitting cutting of the dentin without plowing into the surface.



154 Lightspeed instruments

A set of Lightspeed instruments contains 22 sizes with additional intermediate sizes. The head of the instrument consists of a noncutting pilot tip and the working part in lengths of 0.25 to 1.75 mm, depending upon the instrument size. The pilot tip becomes longer as the diameter of the head increases. The shaft is thinner than the cutting head and is very flexible.

Sonic and Ultrasonic Systems

The first ultrasonic system goes back to Richman (1957). A breakthrough was made 20 years later when Martin and Cunningham (1976-1984) provided instruments that were set into vibration at frequencies of 25 000 to 40 000 Hz by magnetostriction or the piezoelectric effect. Shortly thereafter, sonic vibration systems were presented that were powered at frequencies of 1500 to 5000 Hz by the air pressure from the dental unit. All systems produce a transverse vibration in the instrument being used, but the motion is dampened if the instrument is pressed against the wall or binds in

the canal. Therefore, small instruments are more effective and sonic files have the advantage in that they vibrate longitudinally under load and the tip of the instrument has a greater amplitude than ultrasonic instruments.

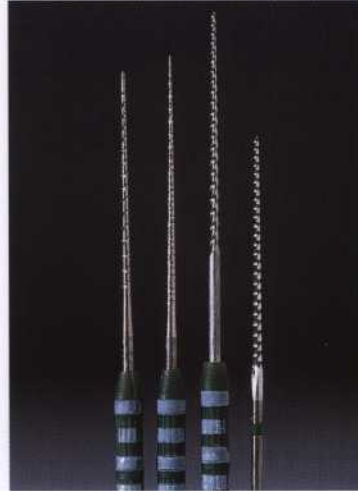
Furthermore, fractures and problems such as step formation and compaction of filings occur less frequently with a sonic system because of the lower frequency. The shaping of the canal as a whole and preparation of the apical third are not optimal, so that often it is used in combination with hand instruments.

155 Instruments

Left: The Sonic Air 1500 from Micro-Mega. This sonic instrument oscillates in the lower range of up to 6000 Hz.



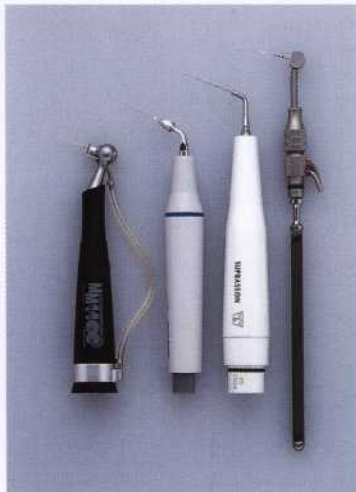Center: Instruments that oscillate in the sonic range: Shaper, Rispisonic, Helisonic (Micro-Mega, beginning at the left) and the ultrasonic Endosonore file (Dentsply-Maillefer, far right).




Right: The Shaper and Rispisonic have a new design with barbs spiraling around the instrument (left). On the right are ultrasonic files of the K-file design.

156 Handpieces

Left: Handpiece for sonic instrumentation: Mecasonic 1400 (Micro-Mega, left). Ultrasonic handpieces: Piezon Master 400 (System 401, EMS), Suprasson (Satelec), and the magnetostrictive system of Cavi Endo (De Trey).



Center: The K-file for ultrasonic use exposes dentinal tubules. The wall is clear.



Right: The diamond coated file caused intensive roughness.

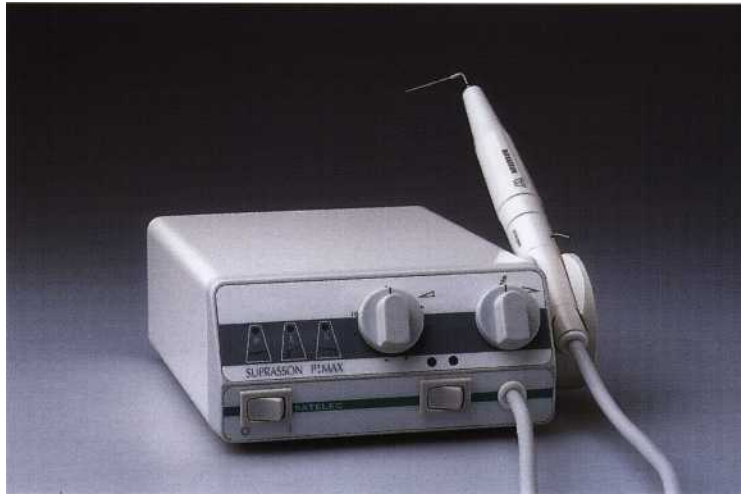157 Piezo Ultrasonic System

The Piezo Ultrasonic System from Spartan can be used for both orthograde and retrograde endodontic instrumentation. CPR advanced endodontic instruments with a zirconium nitride coating (left) were designed with a contra-angle bend and are scaled to improve operative access in both anterior and posterior teeth. These tips can be used to eliminate pulp stones, break down dental restorations and cores, dislodge posts and broken instruments, and remove obturation materials from canals.

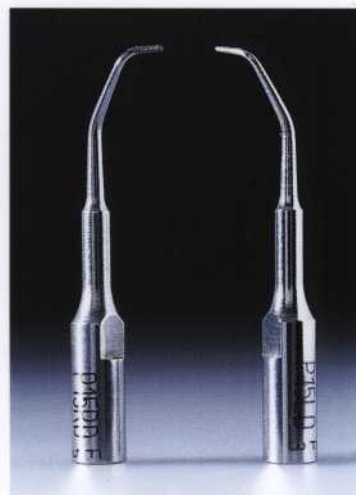
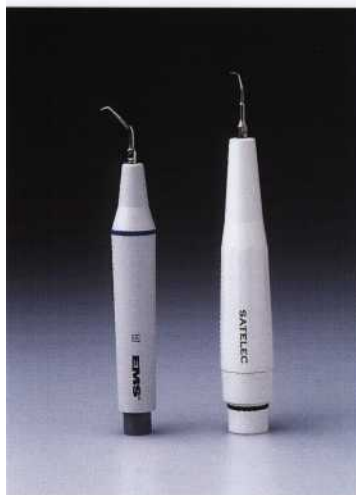
For a long time, the cavitation effect was considered to be the essential mechanism in ultrasonic cleaning. Meanwhile, it was recognized that only microacoustic currents with small primary vortices in the region of the oscillation crest and large secondary, or outer, vortices produce shearing forces that tear apart tissue remnants, bacteria, and blood cells. Since this effect only occurs in liquids, however, Martin and Cunningham (1984) coined the term "endosonic ultrasonic synergistic system." Therefore the use of an irrigating solution is a basic prerequisite. Cleaning and disinfection with a

combination of ultrasound and sodium hypochlorite is superior. Unfortunately, the actual preparation is again plagued by the problems of roughness, alterations of shape, and blockages in the canal, so that hand instruments cannot be dispensed with, even with ultrasound. The field of application of ultrasound in endodontics is now being widened by its use in micropreparations during apicoectomies. The fineness of the instruments and their quick, efficient cleansing action make it possible to prepare excellent retrograde [cavities](#).



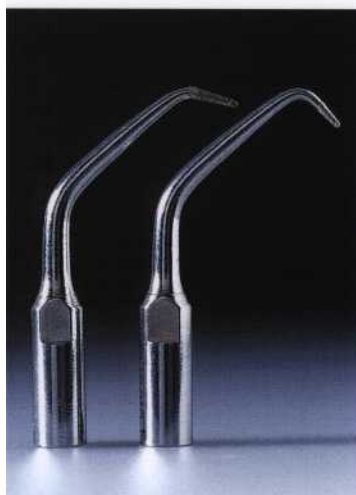158 Ultrasonic apparatus
The Suprasson P-Max (Satelec) is set up as a multiclinic generator (MCG). Four different intensities (weak, medium, strong, and powder jet) are available from one ultrasonic generator. In this way a wide selection of dental applications, such as endodontics, retrosurgery, microretrosurgery, and gutta-percha condensation (not to mention calculus removal, periodontal therapy, crown and bridge removal, crown preparation, and cementation of inlays) are made available by changing the hand-piece insert.



159 Retrosurgery with ultrasound

Left: The endodontia handpieces from Satelec and EMS are quickly adapted for use in retrograde preparation of the root canal following root resection by screwing on specially formed microcutting tips.

Right: The no. 15 inserts are longer and thinner and thereby designed for microretrosurgery. Again, they are paired, one for the upper right and lower left teeth and one for the opposite sides. They are also diamond coated (D).



160 Retrosurgery

The diamond-coated tips should speed up the canal preparations and shorten the time required for the entire operation.

Left: Diamond-coated tips with angles of 120° and 90° (S 12/90 D and S 12/120 D from Satelec) are universally applicable for retrosurgery.

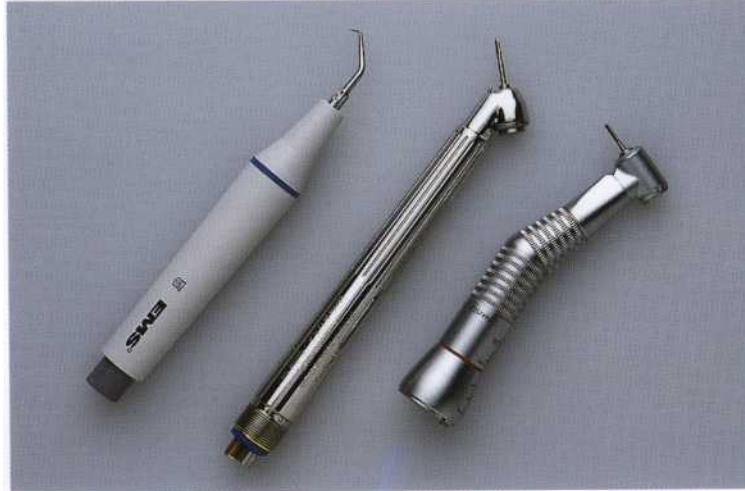
Right: The S 13 LID retrotip insert on the left was designed for the upper left and lower right teeth. Its mate on the right, the S 23 RD, is for the upper right and lower left.

Microsurgical Endodontics

Formerly, retrograde treatment of the root canal was performed when, for example, the conservative endodontic treatment was not successful or the apical lesion was very large. In contrast to conventional procedures, a sulcular entrance incision is made with a microsurgical scalpel in microsurgery. A flap is then prepared and the root tip is exposed. The tip is removed using a microhandpiece (e. g., Impact Air 45, EIE), the head of which is already fixed at the 45° resection angle. Furthermore, no air is exhausted at the working end of the handpiece so that air emboli, which have occurred


with the commonly used standard handpieces, are avoided. Following the removal of 3 mm of the root tip, a retrograde cavity is prepared another 3 mm into the root using special ultrasonic retrotips. These are very fine and suitably angled for optimum access. However, the miniaturization will not be fully completed until improved visual microscopic monitoring of the preparation is available. The microset is rounded out by precisely designed instruments for preparation and filling, as well as a micromirror.

161 Apicoectomy handpieces
A direct size comparison shows the great difference between the new and the conventional instruments for apicoectomies and retrograde canal preparation: ultrasonic handpiece with retrotips (EMS, left), surgical handpiece with carbide steel drill (Impact Air 45, USA), and contra angle handpiece with diamond stone (KaVo).



Right: Tips for retrograde preparations CT 1-5 (universal, right, left, instrument removal, and isthmus) to be used with EMS, Enac, and spartan, satelec ultrasonic units.

162 Special instruments for microapicoectomy
Only a few manufacturers offer a complete microinstrumentarium for apicoectomies (shown here, Dep-peler, CH). Some of the instruments included are a microexplorer (VA 7), spatula (VA 9, 10), plugger (VA 9-14), spoon (VA 16), and carver (VA 20) designed by Dr. Velvart.



Upper right: Microsurgical scalpels CK1-5 (EIE: Excellence in Endodontics, USA).

Lower right: The micromirrors (Sapphire Plus Retro Mirrors, EIE) with a size 4 regular mouth mirror for size comparison.



Lasers in Endodontics

An ever-growing number of possible indications for the application of lasers in endodontics are reported in the scientific literature. Most publications are indeed concerned with themes from the field of basic research. The question of a reasonable clinical application of lasers in endodontics is gaining importance since the introduction of laser units for dental use. Because of difficult access, manipulations in the root canal system of a tooth place great demands on such laser systems. Therefore, as a rule, different types of lasers are offered whose rays can be transmitted over a fiberoptic cable.


The effect of laser radiation on the pulp is comparable to the effect of laser light on other oral soft tissues (Frentzen 1994). It must, however, be taken into account that the regenerative potential of a pulp surrounded by a hard-tissue mantle is very low. The pulp tissue and dentin of the root canal can be affected both directly and indirectly by laser energy.



Indications	Laser type
Vitality test (laser Doppler)	HeNe, diode lasers
Treatment of deep caries	CO ₂ , Nd:YAG lasers
Sterilization of root canals	Nd:YAG, CO ₂ , Ho:YAG lasers
Vital amputation	CO ₂ , Nd:YAG lasers
Root canal preparation	Excimer, Nd:YAG, Er:YAG laser
Sealing the apical delta	CO ₂ , Nd:YAG laser
Thermoplastic root canal filling	CO ₂ , Nd:YAG laser

163 Indications for laser use in endodontia
Range of applications in endodontia for different types of lasers.

Left: Examples of various dental laser systems.



Laser type	Delivery system
CO ₂	Mirror, grooved director (fiber)
Er:YAG	Mirror, grooved director (fiber)
Ho:YAG	Fiber
Nd:YAG	Fiber
HeNe	Fiber
XeCl-Excimer	Fiber

164 Delivery systems
The types of lasers recommended for endodontic applications require different delivery systems.

Left: Fiberoptic guide for delivering the laser energy into the root canal.

Direct radiation of the root canal system, for example during vital amputation or root canal preparation, can lead to warming, coagulation, carbonization, vaporization, or ablation of the pulpal soft tissues and the dentin of the canal wall, depending upon the type of laser used and the energy parameters.

The pulp can be affected *indirectly*, for example, through transmitted laser energy (heating and desiccation of the dentin) or through injury to the odontoblastic processes from photoacoustic effects (ultrasound). In these cases the pulpal reaction appears as hyperemia or necrosis. A laser-induced hyperemia can evolve over a long period of time into a degenerative process, such

as increased formation of dentin or partial necrosis. These changes can bring about extensive obstruction of the pulp chamber and root canal, substantially increasing the difficulty of performing root canal treatment.

An accurate estimate of the long-term side effects of many applications is not yet possible with the present state of research.

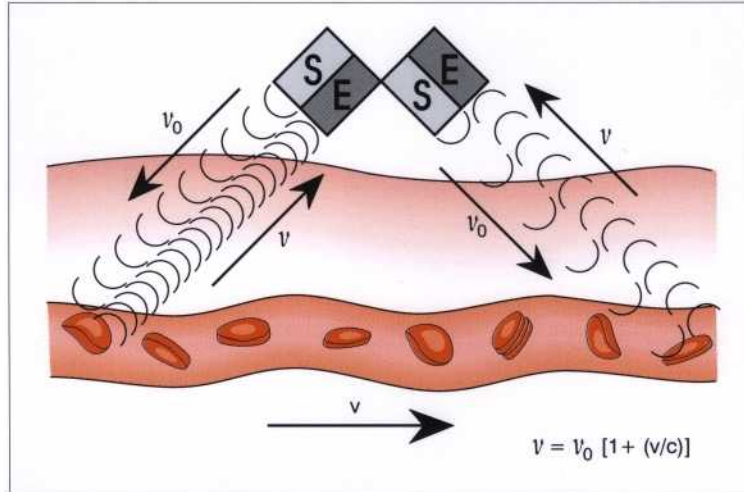
Vitality Test with the Laser Doppler Probe

One measuring procedure that has already proven itself in dental diagnosis is laser Doppler flowmetry (Tenland 1982). It can, for example, be used to determine the circulation of blood in the pulp. The principle rests upon variations in the signals reflected from moving erythrocytes when radiated with laser light, the variations depending upon the direction and speed of movement. HeNe or diode lasers are used for laser Doppler probes. Because of the greater penetration depth of laser rays of 750-800 nm, diode lasers are preferred for clinical measurement. Laser Doppler flowmetry can be

used in basic research to measure changes in the circulation of blood in the pulp due to influences such as thermal stimuli or local anesthetics (Raab and Muller 1989, Raab 1989). It is already possible to use this procedure as a "true" vitality test of the dental pulp following trauma. However, this still requires high technical expense in order to achieve reproducible, valid diagnostic data.

165 Principle of the laser Doppler flow measurement

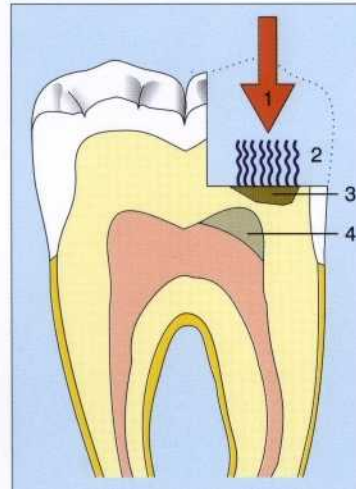
- S Sender
- E Receiver
- v_0 Frequency of the emitted laser beam
- v Frequency of the reflected laser beam
- v Velocity of flow



166 Laser treatment of a "pulp wound"

Left: Carbonization of the cavity floor. A histologic preparation following sealing of a cavity in dentin with a CO₂ laser.

Right: Schematic of the sterilization and sealing of the cavity surface. After preparation and removal of the carious structure, altered dentin near the pulp is exposed to a CO₂ laser beam. The laser-induced "sealing" of the dentin is supposed to stimulate the pulp tissue to produce new dentin.



- 1 CO₂ laser beam
- 2 Vaporized water
- 3 Sealed dentin layer
- 4 Tertiary dentin formation

Laser Treatment of Cut Dentin and the Pulp

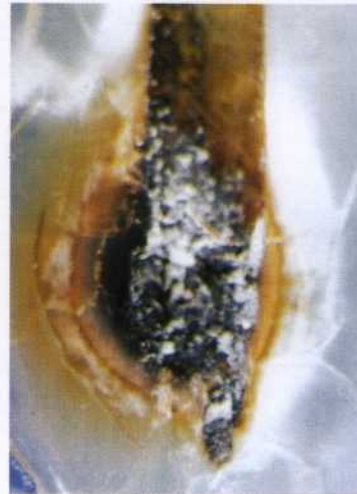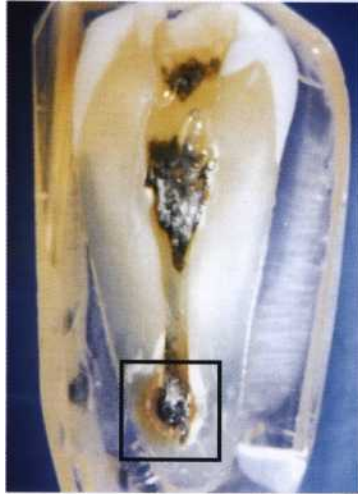Removal of deep caries produces what may be called a *dentin wound*. Usually, the possibility that the remaining dentin might still be infected with bacteria cannot be excluded. In these cases it has been recommended that the floor of the cavity be irradiated with an infrared laser beam (Melcer et al. 1984). *In vitro* studies have shown that the smear layer can be fused. The dentinal tubules can be sealed through denaturation of the organic structural elements (Melcer 1982, Tani and Kawada 1987). The biologic effect of the denatured dentin products had not previously been investigated.

The infrared laser beam induces reactions in the pulp lying under the irradiated surface that apparently can lead to hyperemia followed by an increased formation of tertiary dentin (Melcer et al. 1985, Yamamoto et al. 1989). Still open to discussion is whether the thermal stimulation associated with conventional therapeutic methods produces any chronic changes in the pulp evoking chronic pulpitis, which in turn would make later endodontic treatment of the tooth more difficult.

Vital Amputation

Vital amputation of the pulp of a deciduous tooth sometimes becomes necessary during caries removal in order to preserve the tooth as a space maintainer. Pulp amputation may also be indicated when there is incomplete root growth to bring about apexification. As an alternative to conventional procedures that utilize pulp amputation pastes, the vaporization or superficial coagulation of the pulp stump with CO₂ and Nd: YAG lasers has been proposed. In vitro studies and experiments on animals have shown that this can produce good hemostasis.

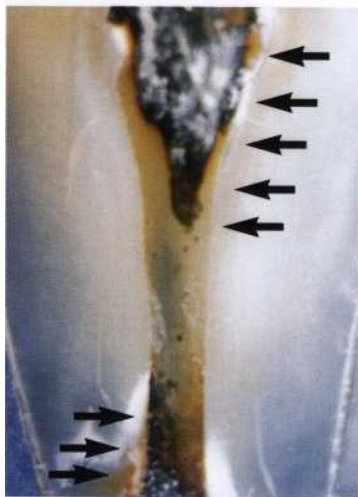
The zone of coagulation following irradiation with a CO₂ laser is approximately 100 µm deep, with appropriate selection of the parameters (Shoji et al. 1985). The thermal load on the surrounding tissue is small (Arrastia et al. 1994). The tissue surface at the amputation site suffers minimal trauma. Formation of a dentinal bridge has been observed in the region of the amputation following the application of both CO₂ lasers and Nd: YAG lasers (Kato et al. 1991, Mungo and Richardson 1993). Clinical studies on the efficacy of laser amputation are not yet available, however.



167 Root apex after attempted laser sealing with an Nd: YAG laser

Left: Pulp tissue and superficial canal dentin were carbonized, formation of cracks into deeper dentin layers (1.75 W; sectioned tooth).

Right: Enlarged section.



168 Root canal preparation with Nd: YAG laser (1.75 W; sectioned tooth)

Left: Carbonization of the dentin surface. The effect of the laser beam is dependent upon the surface structure of the canal wall. A uniform result was not achieved.

Right: Fractured delivery fiber from an attempt to prepare the root canal with an XeCl* laser. The fiber fragment (arrow) could not be removed (nondemineralized thin section at 30x magnification).

Sealing the Root Canal

Fundamental studies are primarily concerned with the question of whether the walls of the root canal can be sealed and sterilized through laser irradiation (Dedrich et al. 1984). The ability of dyes to diffuse through the dentinal surface is reduced by treatment with an infrared laser (Tani and Kuwada 1987). The main reason for this is the laser-induced fusion of the smear layer. The surface of the root canal is covered by a glass-like layer of melted dentin, interrupted by hairline cracks. Attempts have been made to seal the apex by melting the dentin near the apex into a glass-like mass with

higher energy levels (Weichmann and Johnson 1971). However, the high thermal load from the infrared radiation leads to a loss of continuity between the various layers of dentin and cementum, and so this method is not applicable in clinical use at the present time. An interesting variation is the melting of dentin chips into a more or less homogenous mass in the periapical region (Zakariassen et al. 1985).

Root Canal Preparation

A few studies have been directed at the possibility of laser preparation of root canals (Levy 1992, Liesenhoff et al. 1989). Attempts to perform root canal preparations with an Nd: YAG laser, however, have produced substantial changes in the canal wall (Fig. 168, left). With the XeCl* laser, an ablation of pulp tissue and dentin, primarily through its side effects, is possible; the ability to remove material is poor, however. In vitro studies have shown that the ablation threshold could not yet be reached (Fig. 169). Furthermore, the effect of pressure from the expansion of plasma in the root

canal cannot be ignored, as it could damage the periapical tissues.

Because of their low level of effectiveness, it is doubtful whether these procedures will have any clinical usefulness (Frentzen et al. 1991). One special problem in the use of fiberoptic conductors in endodontics is the danger of fibers breaking; the fiber fragments cannot usually be removed (Fig. 168, right).

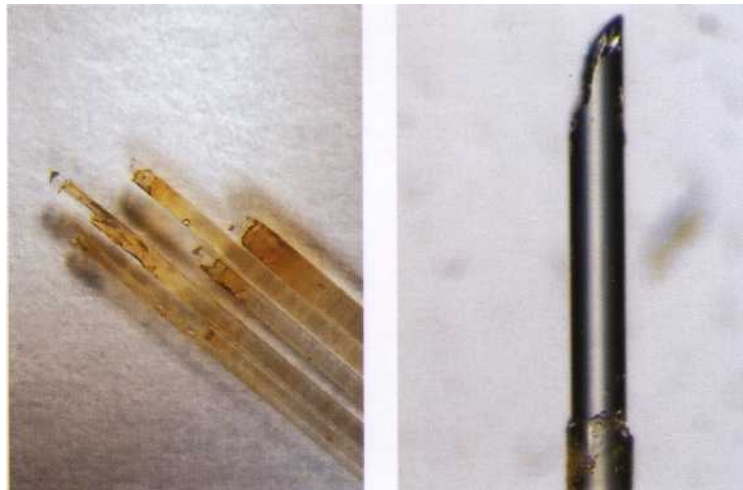
169 Histologic investigations following root canal preparation
Mechanical systems are superior to laser applications; in all cases the histologic result was improved by the use of sodium hypochlorite solution.

	Irrigating solution	Canal surface	
		Treated	Untreated
*XeCl Laser	Physiologic NaCl solution (0.9%)	51.9%	48.1%
	NaOCl solution (5%)	73.1%	26.9%
Ultra sonic	Physiologic NaCl solution (0.9%)	82.8%	17.2%
	NaOCl solution (5%)	88.9%	11.1%
K files	Physiologic NaCl solution (0.9%)	80.0%	20.0%
	NaOCl solution (5%)	81.2%	18.8%

170 "Burnt-off" fiber ends
The light-conducting fibers frequently develop signs of wear in the form of melting and chipping away of the ends. The biologic effect of this burn-off has not yet been clarified.

Left: Fiber bundle.

Right: Fiber tip.



Root Canal Desinfection

It is usually not possible to achieve a thoroughly clean preparation of a curved root canal with hand instruments or an engine-driven instrument system alone because of the morphology of the canal walls. Therefore, the canal is also flushed with a tissue-dissolving disinfecting solution to complete the mechanical preparation and create the most aseptic conditions possible for the canal filling.

The use of lasers has been suggested to complement these methods. Comparative studies verify that antimicrobial effects comparable to those of conventional

methods (e.g. irrigation with NaOCl) can be achieved (Hardee et al. 1990). At this time, the problem in disinfecting root canals with laser beams lies in guiding the beam within the canal. Most of the energy from a light-conducting fiber is emitted in the axial direction and not toward the canal wall. Because of this, laser-induced necrosis in the periapical region has been demonstrated following attempts to "sterilize" the root canal, especially with the Nd:YAG laser beam (Bahcall et al. 1992).

Irrigating, Drying, and Medicated Dressings

As an irrigating solution, sodium hypochlorite is used almost exclusively today. A 1% solution has the unique ability to selectively dissolve necrotic tissue without injuring the vital pulp tissue. Its disinfecting and bleaching effects are additional advantages. It is important to flush the canal frequently (after every change to the next size of instrument) with a large quantity (5 ml) of solution. It is necessary to carefully dry the canal before the introduction of each and every material.

If treatment cannot be completed at an appointment because of time constraints or medical reasons (exudation, bleeding, fetid odor, etc.) a medicated dressing must be applied. Strong disinfectants or antibiotic-containing substances have been promoted for a long time, but today we know that every endodontic-related lesion will heal if the canal is carefully prepared, cleansed, and then tightly sealed (Ehrmann 1987). The only dressing needed, therefore, is a thin suspension of calcium hydroxide, which has very good biocompatibility, stimulates osteoblastic activity, and is a disinfectant.


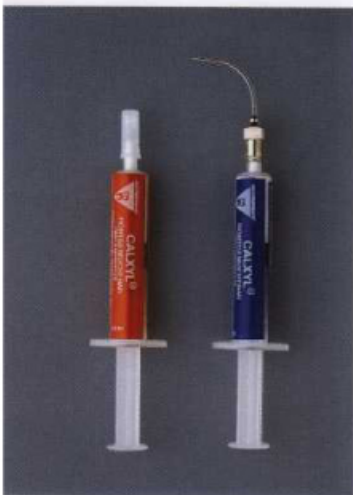


171 Paper points for drying canals

The chemical-mechanical preparation must be followed by thorough drying. For this purpose, paper points in ISO sizes # 15-140 are available. In addition to the conventional white points, paper points are becoming increasingly available in colors corresponding to the ISO coding (center).

Left: Close-up photograph of color-coded paper points # 15-40.


Right: Sealed packets containing small numbers of sterilized paper points, both white and colored, are also available.



172 Interim dressing

A thin aqueous suspension of calcium hydroxide can be used as a medicated dressing. The most familiar brand is Calxyl (OCO-Präparate). The addition of barium (Calxyl Blue) provides good visibility in radiographs. Calxyl Red is barium-free. The suspension can also be used for irrigation.

Left: Calxyl is also offered in a syringe system to facilitate application into the canal. It is important that the cap is airtight when replaced because otherwise the suspension will quickly dry out.



173 Application system (paste fillers)

Full spirals have long been used to place final pastes and cements. Today, because of their high risk of fracture, they should only be used for inserting provisional dressings.

Left: The #4 full spiral (Maillefer, black) is indicated for sizes # 70-90 canals. Attached to the shank of the VDW instrument (right) there is a safety spiral to reduce the danger of fracture.

Right: The gutta-percha condenser (Maillefer) is especially suited for inserting Calxyl.

Gutta-percha

The term "getah pertja" is Malay and means "threads from sticky plant sap." The gutta-percha tree produces the raw substance (a gray, translucent mass with a pink sheen) for dental material. Chemically, it is the trans-form of polyisoprene, that is harder, more brittle, and less elastic than the more familiar natural rubber. Through the addition of wax and resins as softeners (1-4%), metal sulfate for radiopacity (1-15%), and zinc oxide filler as the main component (59-76%), the familiar consistency of the gutta-percha point is reached (Weine 1994). Gutta-percha exists in different mod-

ified forms:


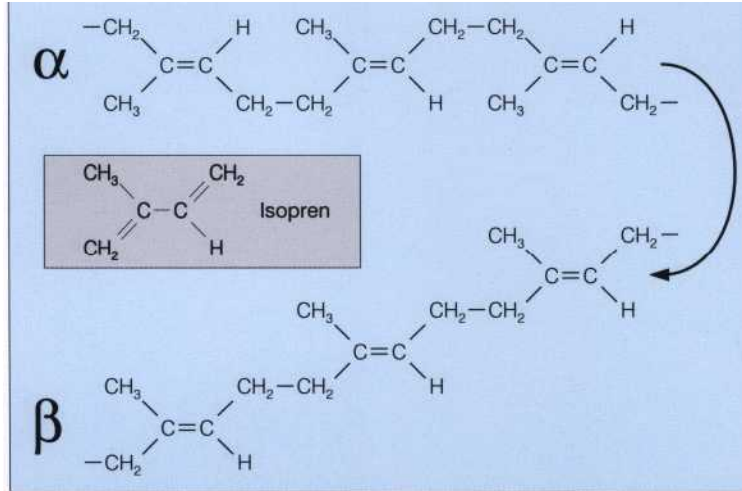
- a form 42-49 °C
- B form (room temperature; 53-59 °C)
- γ form (56-62 °C).

The gutta-percha used in dental practice is usually in the B form. The warm gutta-percha technique (e. g., Obtura, Ultrafil, Thermafil) was the first to utilize the a form. At high temperatures, gutta-percha behaves like a thermoplastic synthetic resin: softening above 65 °C, melting at 100 °C and, in the a form, fluid without decomposition above 160 °C.

174 Gutta-percha

The sap of the isonandra gutta tree is the raw material for gutta-percha. Chemically, it is the polymer of the trans-form of the isoprene molecule. Normally, gutta-percha occurs in the 0-form (dental gutta-percha points at room temperature). When it is heated to softening (65 °C) and cooled slowly (0.5 °C/h), at 42-49 °C the (x-form appears, which is sticky, fluid, and too soft to be condensed.

Right: Standardized gutta-percha points in ISO sizes # 15-40.


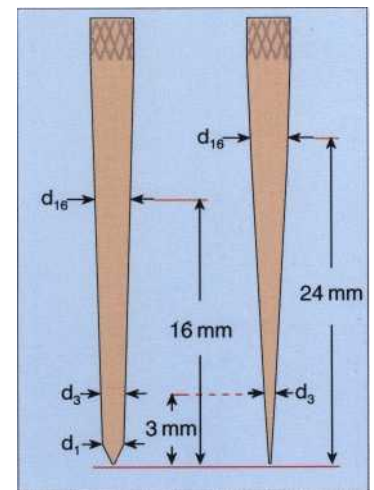


175 Standardization of gutta-percha

Gutta-percha points often exhibit superficial irregularities (SEM at 130x magnification).


Upper right: The dimensions of a gutta-percha point are specified in several measurements. The standards identify three points (d1 at the tip, d3, and d16), and also describe nonstandard points. On the left a standardized gutta-percha point is represented and on the right, one that is nonstandardized.

Lower right: A gauge (Maillefer) is indispensable for determining the true diameter, because gutta-percha points can have a tolerance of ± 0.04 mm.



Gutta-percha points should be standardized according to the ADA and ISO norms. The familiar pink-colored points are available in sizes #15 to #140. Color-coding the points according to size by the ISO color code facilitates their selection. The SEM picture and abundant investigations (Schafer and Gohring 1993) show, however, that manufacturing inconsistencies do occur. According to the ISO standard requirement, the diameter d_l as a projection of the tip of the gutta-percha point, may deviate no more than ± 0.04 mm from the stated ISO size. This requirement was

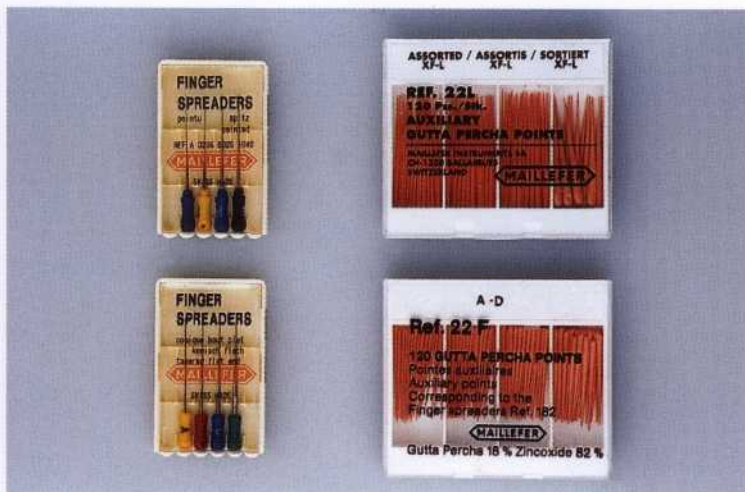

met by only approximately 50% of the points. The remainder were too thin. Based upon this, it is recommended that the diameter of each individual point be measured with a gauge (Maillefer) to verify that the master point will be the same size as the apical master instrument—the last preparation instrument used—at the level of the stop. In the final analysis, a root canal filling can be only as good as the degree to which the filling corresponds to the preparation in shape and size.



176 Standardized gutta-percha points

A great number of manufacturers offer standardized gutta-percha points showing a great variance in exactness and stiffness. Pink points (left half of the big picture) are familiar, but color-coded points are now becoming more widespread.

Left: Gutta-percha points white (# 15)-black (# 40) in ISO colors.



177 Accessory gutta-percha points

Some condensation techniques use accessory, nonstandardized gutta-percha points. Most suppliers offer them in five sizes (XX fine-large) with greater taper than the ISO standard. The auxiliary points A-D from DeTrey Maillefer are a novelty: finger spreaders and gutta-percha points match each other (details: left).

Gutta-percha is the material of choice today for sealing the root canal system because it combines many positive properties (Hulsmann 1993 b). It is bioinert, nonirritating to the periapical tissue, easily inserted and removed, dimensionally stable (shrinks only with the warm technique), radiopaque, impermeable to and unaffected by moisture, and does not discolor the tooth.

Of course, gutta-percha cannot be sterilized. It can, however, be disinfected by 70% isopropyl alcohol, 2% chlorhexidine, or 5% sodium hypochlorite. Its principal defect is that it does not sufficiently seal the complex canals, so a sealer is necessary.

A single gutta-percha point cannot completely and

uniformly fill a canal that, in spite of a standardized preparation, is usually irregular in shape. Therefore nonstandard accessory points, which are more conical, have been inserted in the past with the help of spreading instruments with nonmatching shapes.

Contrary to a widely held opinion, gutta-percha is not compressible except under very high pressures above 2000 psi (low compressibility). However, because of spaces related to its preparation, it can be pressed together (compactibility). Therefore, it is recommended that the first two accessory points be standardized, or even better, that the new matched points and spreaders be used.

Cold and Warm Condensation of Gutta-percha

While the insertion of a single gutta-percha cone is obsolete, vertical and lateral condensation with hand or finger instruments is still used today.

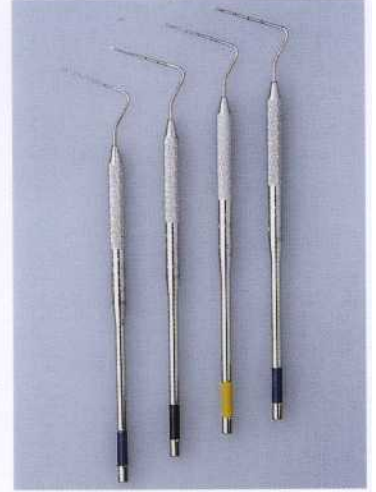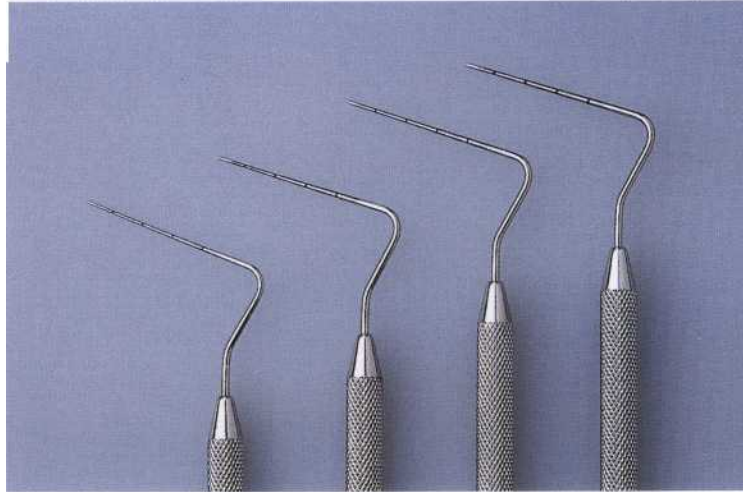
The technique of lateral condensation uses a well-fitting master point with friction at the apical region. Then a spreader is chosen which is 1 mm short of the working length. The remaining space is filled with one gutta-percha point after the other, working "step back" 1 mm until a dense compaction is reached. Pluggers enable a vertical compaction.

Starting with the "sectional gutta-percha technique" (Coolidge 1946) warm condensation techniques have been widespread within the last decade. Vertical condensation (3D obturation) by Schilder (1967) can be excellent, but is complex and time-consuming, needing special instruments. A variety of other systems are available:

- Obtura (Yee et al. 1977)
- Thermafil (Johnson 1987)
- Ultrafil (Michanowicz and Czonstokowsky 1984)
- System B, SuccessFil, JS Quick-fill, Trifecta, etc.

178 Hand spreaders

Hand spreaders in sizes # 30-60 for the lateral condensation of gutta-percha (Hu-Friedy). Many hand spreaders are calibrated so that the depth of insertion can be monitored during condensation.



179 Finger spreaders


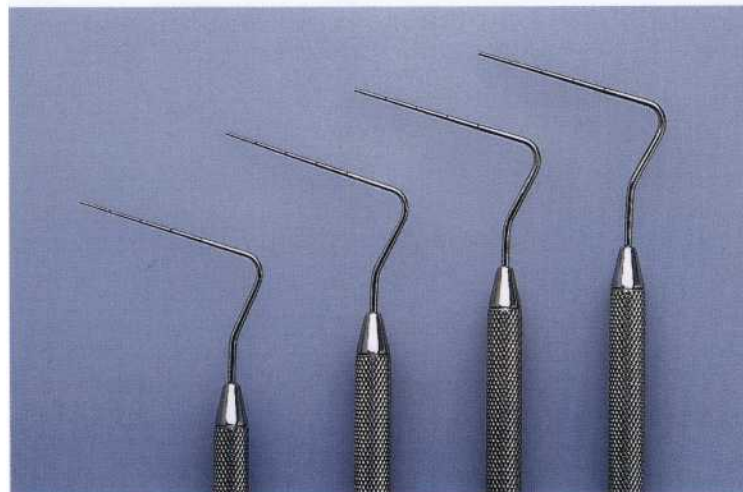
Left: Finger spreaders are often preferred because of a finer sense of feel for the direction of the canal, the resistance met, and the force being exerted.



180 Hand pluggers

The working end of the hand pluggers has markings every 5 mm to enable measurement of the penetration depth (#30-#60 by Hu-Friedy).

Right: The heat carrier pluggers (Dentsply Maillefer) have one spreader-like end and one plug-like end with diameters of 0.5, 0.6, 0.8, and 1 mm. They can be used either for cold or warm condensation (3D technique after Schilder).



Rubber Dam

During endodontic treatment, use of a rubber dam to keep the tooth absolutely dry is mandatory. Only in this way can we fulfill the requirement of creating an aseptic field and thereby protect both the patient and the treatment team from infection. In spite of the numerous additional advantages (such as protection from aspirating and swallowing instruments, improved view and access to the operating field, saving of time, etc.) there is still widespread skepticism and reluctance among dentists to use the rubber dam. According to one survey, the rubber dam is used in 60% of endodontic procedures in the United States and Scandinavia, whereas in Germany 5% of the respondents used the rubber dam in all cases and 65% never used it (Winkler 1991). The reasons for this nonacceptance are many, often repeated, but nonetheless obscure. A quotation from Cragg (1972) describes the phenomenon well:

"The most time-consuming thing about the rubber dam is the time required to convince the dentist to use it."

Trends have emerged in recent years that are bringing about increased use of the rubber dam. For one thing, some very good books (e. g., Reid et al. 1991; Winkler 1991, with videotape) and articles (e. g., Zeppenfeld 1990) have appeared. For another, many continuing education courses are being offered on use of the rubber dam, and dentists are sure to be motivated by these.

Furthermore, the increasing use of adhesive bonding and luting of ceramic and composite restorations is providing insight into the necessity and usefulness of the rubber dam and, very importantly, future dentists are becoming more and more familiar with the rubber dam as a routine procedure and will later incorporate it into their practices.

Much time has passed since the innovative idea occurred to the New York dentist S. Bamum, who on 15 March, 1864, while treating a lower molar, spontaneously made a hole in a sheet of rubber and stretched it over the tooth to keep it dry. Even though rubber dam clamps in their present form were developed only later and rubber dam frames did not yet exist, many of the aspects of rubber dam utilization have been modified

only slightly since then. As early as 1894 one would have found the Ivory clamps that are still used today, the Ainsworth hole-punch (almost unchanged today) and a large number of other highly developed accessory items. In the 1920's the New York Academy of Medicine emphasized the importance of rubber dam use in endodontics, although at that same time the beginning of the focal infection theory, the use of silver amalgam, and improved suction techniques led to a decline in its use. Throughout its tumultuous history, the rubber dam's value in endodontics and placement of gold foil restorations was further emphasized in textbooks (Winkler 1991).

It is intended that the following pages will give added support to this development process, in that the preferred instruments and materials introduced for utilizing the rubber dam in endodontics and the actual application technique are presented in a series of pictures. Those with further interest may deepen their knowledge through the books, reports, and articles dealing exclusively with the rubber dam that are mentioned.


Rubber Dam Material

A sheet of rubber 6 inches square (15 cm x 15 cm) is the most commonly used rubber dam material. The raw material for this, as well as for latex gloves, is the sap of the caoutchouc tree. This is primarily cis-1,4 polyisoprene (as opposed to gutta-percha which is the trans-form). Of the five thicknesses available, the medium, heavy, and extra heavy are preferred in endodontia. Latex allergies are becoming more and more common and this must be taken into account. Consequently, a PVC or silicone material must be substituted if the patient is allergic to latex (Denis and Ott 1993).

181 Armamentarium

Latex rubber sheets come in various thicknesses and colors. The size is 5 in x 5 in (12.5 cm x 12.5 cm) (green) or 6 in x 6 in (blue, cream). The napkin prevents the rubber from resting directly against the skin. A silicone rubber (bright green) has recently become available for patients allergic to latex.

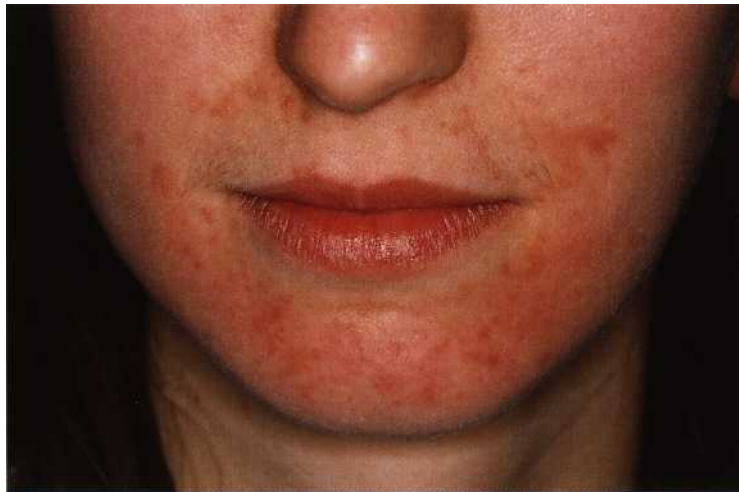Lubricants (e. g., Dentaglide, Sigma Dental, or Vaseline) make it easier to pull the rubber dam over the teeth. The spacing of the holes is facilitated by using a template or a stamp.



182 Latex allergy

Redness appeared around the mouth of this patient shortly after placement of a latex rubber dam. Vesiculopapular changes in the skin and itching also occurred. This is an immediate allergic reaction (type I according to Coombs and Gell).

Latex allergies are known to rapidly grow worse, and the condition can progress to a life-threatening state of shock. Therefore, the dentist must uncover any history of such reactions beforehand and be able to correctly comprehend the situation.

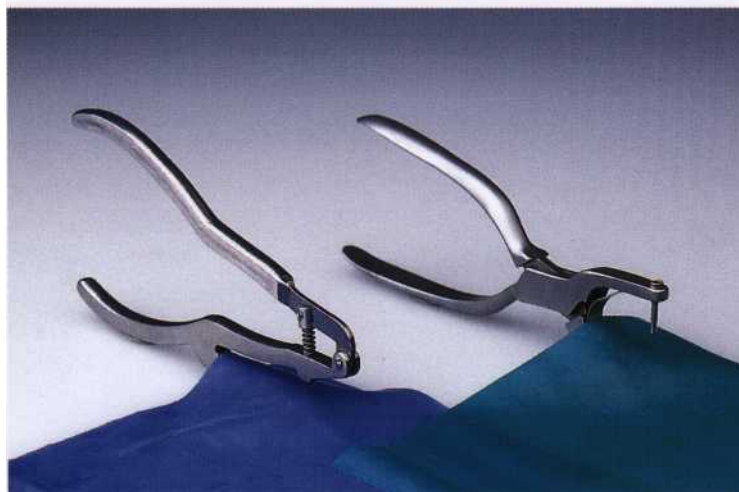

183 Rubber dam punches

The Ivory rubber dam punch is the best instrument for perforating the rubber sheet (left). It is constructed so that it can reach quite far toward the center of the dam. The placement of the hinge ahead of the hole plate permits a precise, almost vertical, punching motion.

The Ainsworth punch (right) has remained unchanged for approximately 100 years.

Right: This close-up view of the Ivory punch shows the hole plate with six openings ranging in size from 1-2 mm.



During endodontic treatment it is usually necessary to isolate only one tooth, and therefore a single hole, centrally located or slightly off-center, is often all that is necessary. For isolation of larger areas, hole patterns or stamps can be used to orient the holes. The Ivory rubber dam punch is recommended for making the holes. Shaving soap, Vaseline, or special lubricants make it easier to slide the rubber dam over the teeth. The patient's comfort is greatly increased by spreading lotion on the lips and by applying a paper napkin that is either commercially prepared or cut at chairside.

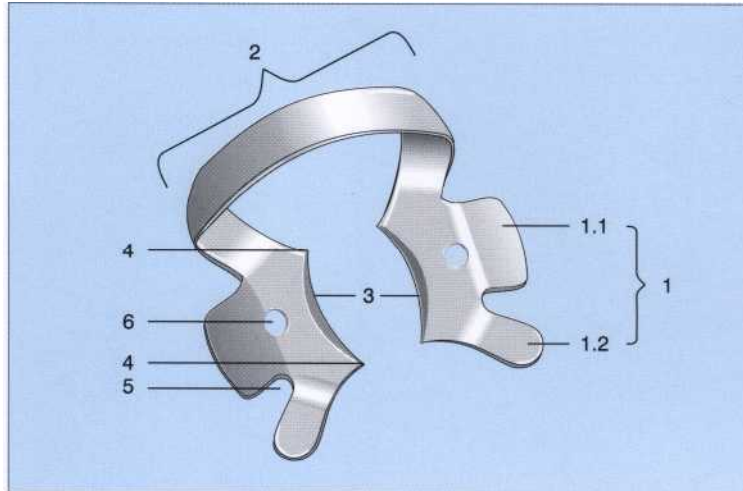
Rubber Dam Clamps

In the early days of rubber dam usage, the rubber sheet was held in place by wooden wedges or dental floss. Soon, many different forms of clamps appeared that were designed to fit the individual teeth and irregular areas. Today, steel clamps are the most prevalent, although there are a few available that are made of synthetic resin.

The clamp should make only point contacts with the tooth. In addition to retention, which is achieved through spring action and the engagement of undercuts, retraction of the gingiva is also desirable.

Rubber dam clamps can be divided into the following types:

- normal clamps (with wings, Fig. 185)
- wingless clamps (wingless = W)
- distal clamps (distal = D)
- anterior tooth, premolar, and molar clamps
- cervical or labial clamps
- retention clamps (to hold the rubber sheet)
- retraction clamps (to press down the gingiva; e. g., Brinker tissue retractors, Schultz clamps).



184 Rubber dam clamp

- 1 Clasp arm (lingual and buccal) with:
 - 1.1 central wing
 - 1.2 anterior wing
- 2 Bow (distal)
- 3 Jaws
- 4 Contact point
- 5 Notch
- 6 Perforation



185 Clamp selection
Because there are so many different shapes of rubber dam clamps and so many manufacturers, the choice is not easy. Therefore, a clamp set can serve as a good orientation aid. The selection shown here is from the Ivory company and contains eight types:

- 8A Molar with broken-down crown
- 14A Molar, partially erupted
- 8 Maxillary molar
- 7 Mandibular molar
- 212 Anterior teeth
- 0 Premolar (high bow)
- 1 Premolar, general
- 2 Mandibular premolar



186 Individual types of clasps
Left: The #212 clamp for anterior teeth (and some premolars). The two bows hold the rubber dam out of the way on both sides, or can be used to attach Kerr compound to the dental arch.

Center: Molar clamps. The jaws of the #7 lie in a flat plane. The inwardly curved jaws of the #8A help secure the clamp on a badly damaged tooth.

Right: Two wingless clasps: Hygenic B 2 (mandibular molar left) and Hygenic B 3 (maxillary molar right).

Additional Preparations

Once the rubber dam material and clamp have been selected, the rubber dam forceps is used to grasp and spread the clamp. The Ivory model is preferred because injury to the gingival tissues is more easily avoided.

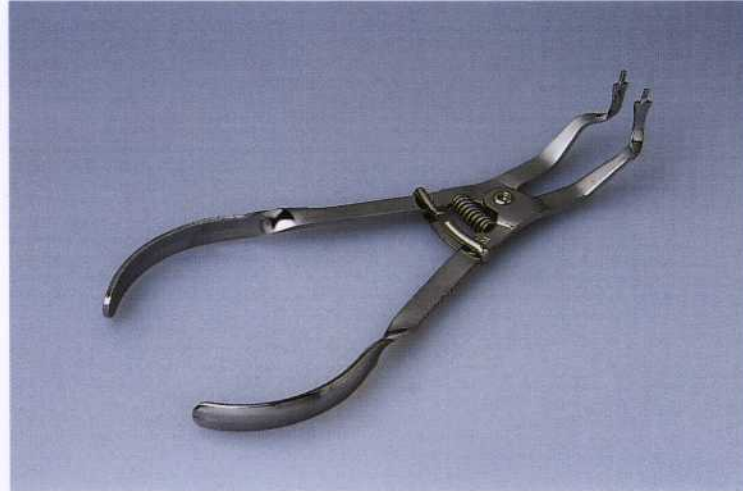Rubber dam frames are available in a wide array of models. Some authors prefer plastic frames because they will not show up on radiographs and therefore the dam need not necessarily be removed for radiographs. On the other hand, plastic frames undergo deterioration during autoclaving so that they become unsightly and the pegs break off. Metal frames should be provided

with plastic caps on the ends to protect the patient's skin and eyes from injury. To facilitate and speed up the procedure, the assistant should routinely prepare a complete rubber dam tray in advance. *Wedjets*, dental floss, and either composite, cement, or impression compound (e. g. Kerr) should be within reach to use as retentive aids. Cavit or periodontal dressing can be used for sealing the rubber dam after it is in the patient's mouth.

187 Clamp forceps


The Ivory clamp forceps is preferred. A steel spring behind the hinge combined with a sliding steel strap can hold the forceps at any desired degree of opening. The working arms are bent at two angles, facilitating introduction into the mouth.

Right: The Ivory forceps has retention pegs that join the arms at a wide surface, which helps prevent the pegs from projecting through the clamp's perforations and injuring the gingiva.



188 Rubber dam frames

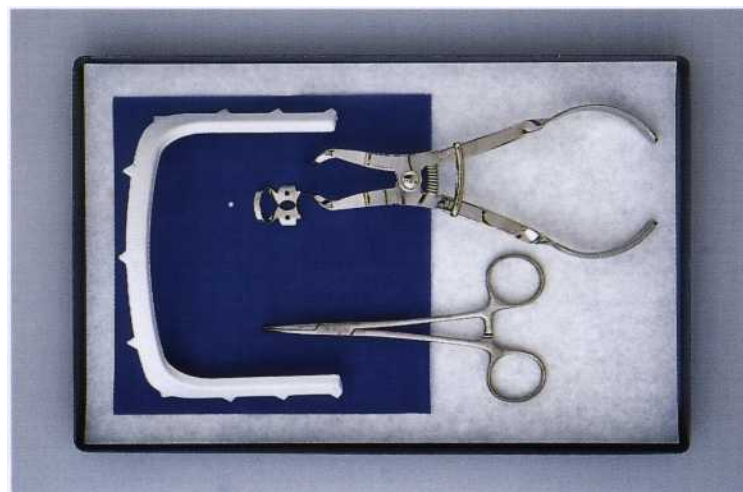Many of the frames for stretching the rubber dam are U-shaped so that the lower bar lies against the chin and the open part is near the nose. Among these are plastic frames (upper left) and radiopaque metal frames such as the 5 in (12.5 cm) and 6 in (15 cm) sizes from Young, shown on the lower right. A new development is the folding frame by Sauveur (lower left) that has hinges so that one side can be folded away from the mouth for the placement of an X-ray film.



189 Complete rubber dam tray

Advance preparation of a rubber dam tray by the assistant facilitates and speeds up the placement of a rubber dam. A prepunched rubber sheet, frame, clamp forceps, clamp, and hemostat lie ready for use.

Right: Some examples of additional aids for securing the rubber dam are *Wedjets* (rubber bands in different thicknesses from a dispenser), dental floss, wooden wedges, and Kerr impression compound.



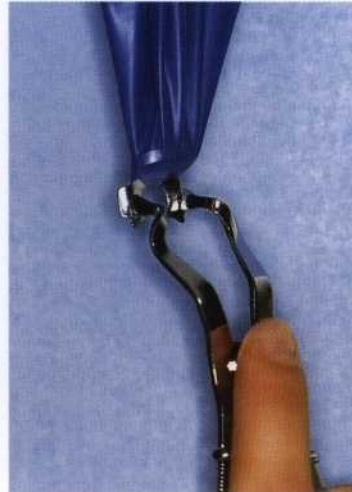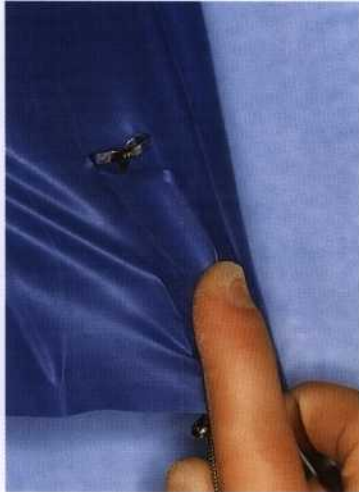Placing the Rubber Dam

There are many methods for applying the rubber dam. In the following text, four commonly used techniques will be described. In general, it is a good idea to keep the following considerations in mind:

- If the clamp is attached to the rubber before it is carried to the mouth, ligation with dental floss to prevent the clamp from being swallowed is not necessary.
- Having the rubber already stretched over the frame makes it easier to mount it symmetrically and reduces the time it takes to apply it in the mouth.

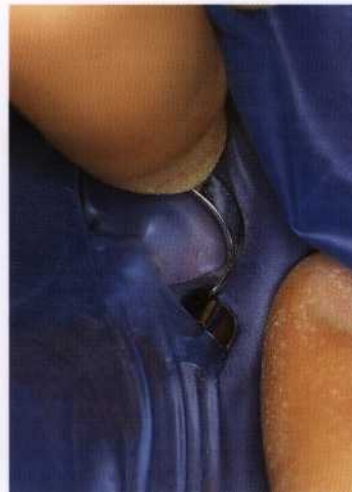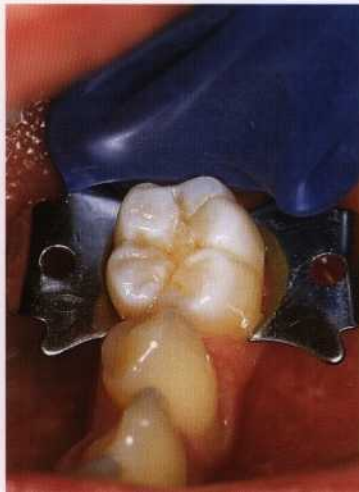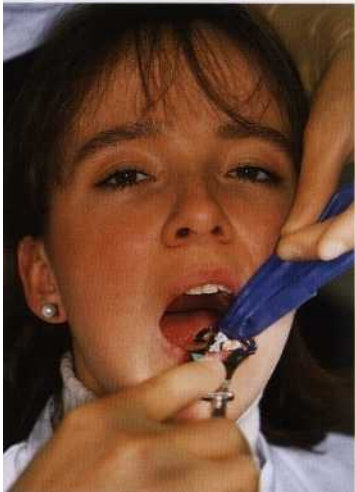
Rubber Dam Application I (Bow Technique)

The bow technique can be employed without an assistant if the steps outlined here are followed. An additional advantage is that it provides a good view into the mouth as the clamp is being placed on the tooth. A disadvantage is that the rubber must be stretched over the wings and this can cause it to tear. To avoid this, the largest punch should be used for making the hole. The frame cannot be applied until last.



190 The bow technique
Left: First, the retaining pegs of the forceps are placed through the perforations in the clamp. Then the index finger is used to press the dam against the forceps at the level of the hinge. The dam is stretched with the other hand and pulled over the bow of the clamp.

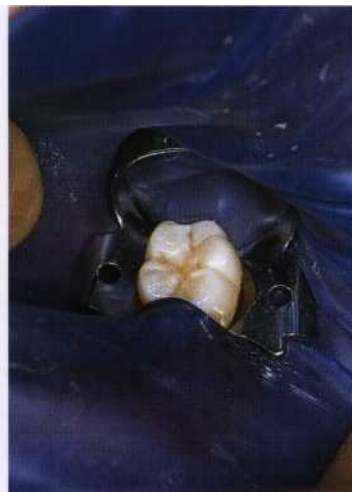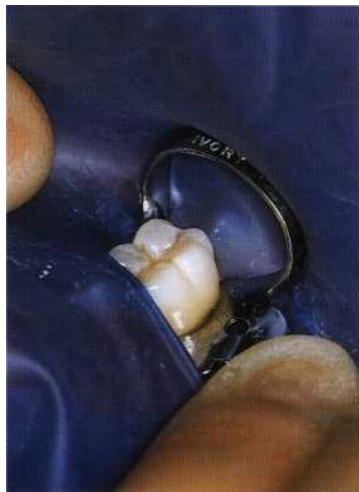Right: The opening in the rubber sheet is pulled completely over the bow of the clamp, and the rubber is gathered together for better handling.



191 Insertion phase I
Left: The rubber-clamp-forceps assembly is placed against the patient's mouth.

Center: The clamp is attached to the tooth. With this technique the view is unobstructed and the involved tooth can be easily found.

Right: The dam material is pulled buccally over the central wing of the clamp.



192 Insertion phase II
Left: The buccal wing is completely exposed.

Right: The rubber dam lies in its final position after it has been pulled over the lingual wing also.

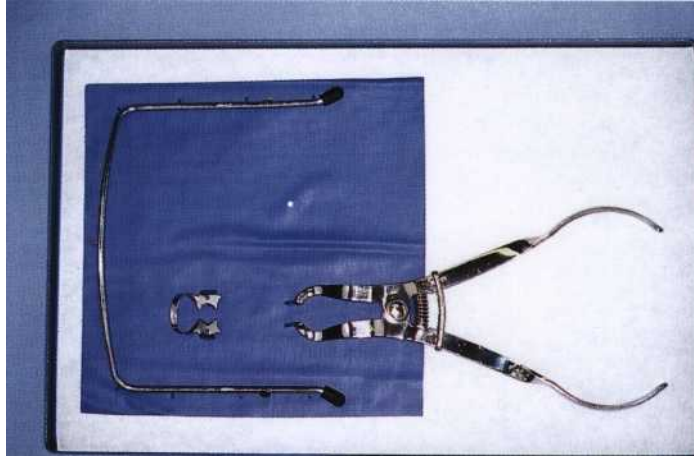Rubber Dam Application II (Wing Technique)

One widely used method for placing the rubber dam is to insert both wings of the clamp into the hole punched in the dam, hence the name wing technique. It is considered to be the most simple technique (Winkler 1991) and permits a single-handed application.

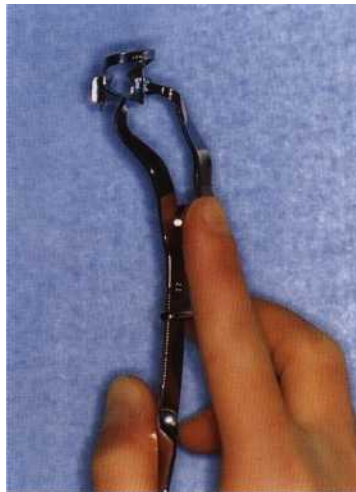It can be divided into two stages: the preliminary steps (shown in the pictures on this page) that can be accomplished by the assistant working alone, and the actual placement (pictures on following page) that is completed in the patient's mouth.

Starting with a tray holding all the necessary instruments, the assistant, without the help of a second person, inserts the selected clamp into the hole in the rubber sheet at an angle of 45° with the bow toward the distal, relative to the dental arch. Next comes the attachment to the rubber dam frame during which it is helpful and practical to first stretch the rubber diagonally. If the position of the dam relative to the frame is planned correctly, two pockets can be formed at the lower edge of the frame to catch liquids for evacuation.

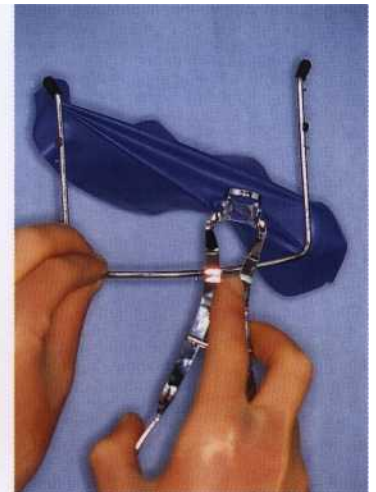193 Tray for the wing technique
A rubber sheet with holes punched, #7 Ivory clamp for mandibular molars, Young rubber dam frame (6 in x 6 in), and Ivory clamp forceps are ready on the tray.



194 Preparatory phase I
Left: The clamp is picked up with the clamp forceps. The index finger lies on the hinge of the forceps or on the steel strap.



Center: Next the free hand is used to pull the rubber sheet first over one wing, then over the other.



Right: The rubber dam is stretched diagonally from one upper end of the frame to the opposite lower corner.

195 Preparatory phase II
Left: The rubber sheet is pulled over all the small pegs on the frame so that it extends somewhat beyond the base of the frame.



Center: The overextension is used to form pockets right and left by folding the rubber on the sides to the inside and then stretching each lower corner up to the upper corner of the frame on the same side.



Right: The patient assists by holding the napkin in front of her face and mouth.



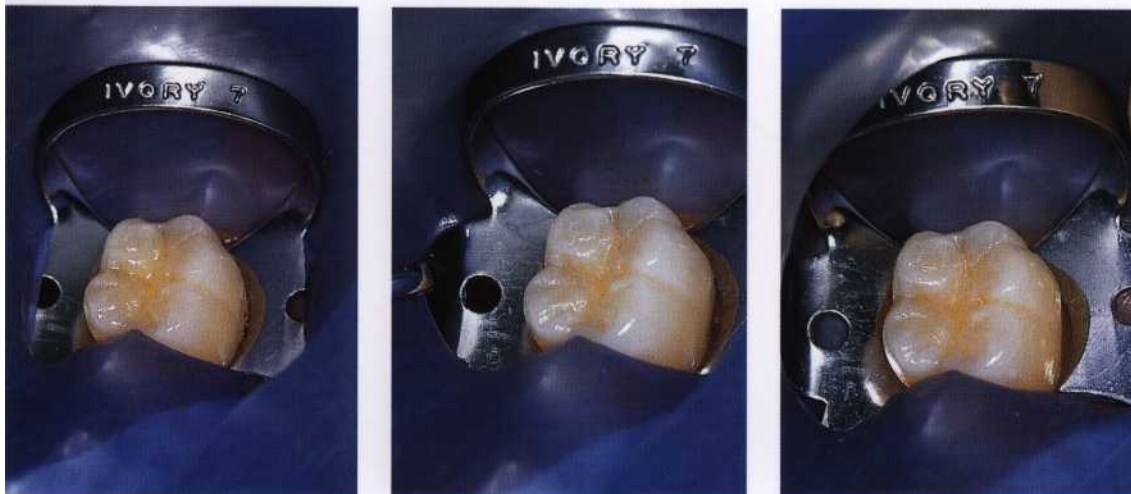Assembling the clamp, forceps, rubber sheet, and frame as a unit reduces the necessary intraoral working time to a minimum. Disadvantages of the wing technique are the reduced visibility as the dam is brought to the mouth and the resistance of the rubber dam as the clamp is guided into the correct position, especially on the more distal teeth. In addition, care must be taken not to pinch or injure soft structures such as the tongue, lips, or cheeks. Before the clamp is carefully placed into undercut areas of the tooth, the patient must be instructed to signal if there should be any pinching or

discomfort in the gingiva. Once the rubber dam is released from the wings of the clamp with the aid of a spatula and adapted interproximally with dental floss, the placement is completed.

Many situations can be handled quickly and effectively with the technique just described. It should be part of the standard repertoire of every practice.



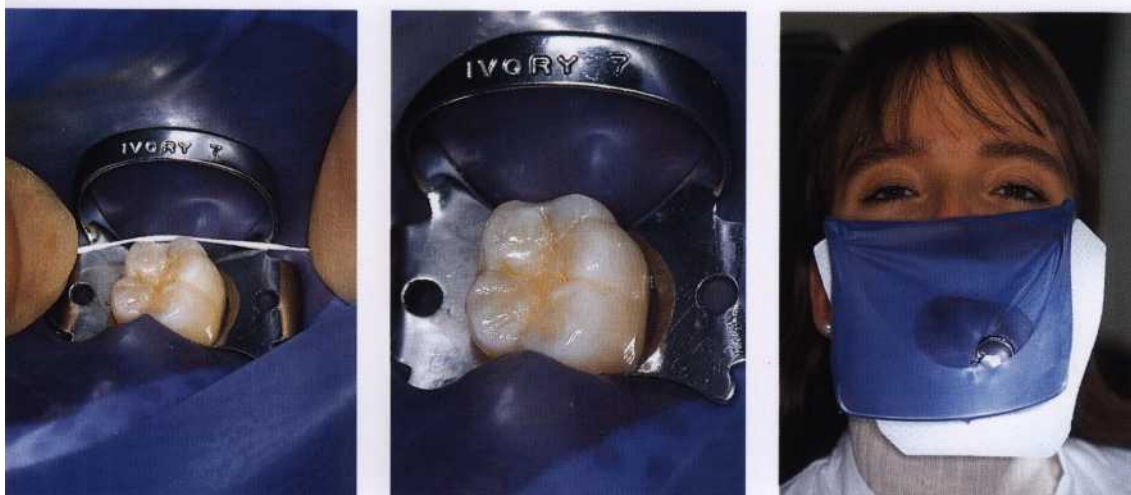
196 Application phase I
The rubber dam, frame, clamp, and clamp forceps are guided to the patient's mouth as a unit. By gently spreading the clamp, enough of an opening is made for the operator to find the involved tooth.



197 Application phase II
Left: The clamp is guided over the first molar, and the forceps is disengaged from the clamp.

Center: A spatula is helpful in stretching the dam over the lingual wing.

Right: The rubber dam is pulled over the buccal wing, also with the aid of the spatula, and now lies against the buccal and lingual surfaces of the tooth.



198 Application phase III
Left: Finally, dental floss is used to guide the rubber gingivally into the interproximal spaces, thus completing the circular adaptation to the tooth.

Center: Application of the rubber dam is now complete. The corners of the clamp jaws make point contacts with the cervical region of the tooth.

Right: This full facial view shows the napkin and rubber dam in place with the pockets that facilitate evacuation of irrigating fluids.

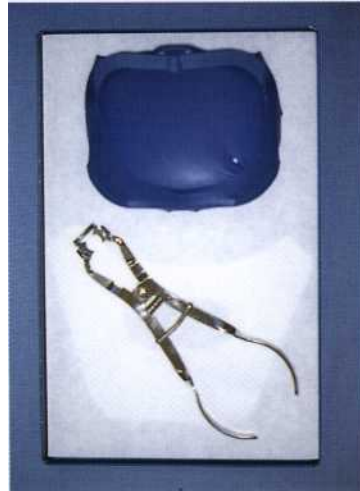Rubber Dam Application III (Rubber First)

A tray should be prepared in advance by an assistant. The clamp and forceps should be preassembled, and the rubber sheet stretched over the frame. A special feature shown here is the Sauveur rubber dam frame, which has guiding grooves for a saliva ejector at the lower right and left borders. The next step is the fitting of the clamp. If it fits well, the rubber dam with frame attached is carried to the mouth, the hole is spread wider with the index fingers, and the rubber is pulled down around the tooth. The clamp is then placed over the isolated tooth.

Some of the advantages of this procedure are that:
 -from the very beginning the rubber dam affords protection against aspiration and swallowing of objects;
 -the tooth is exposed to view as the clamp is placed;
 -except for a few clamps such as the double-bow #212 that can only be applied in combination with the rubber sheet, all types of clamps can be used.

199 Tray for the rubber first technique

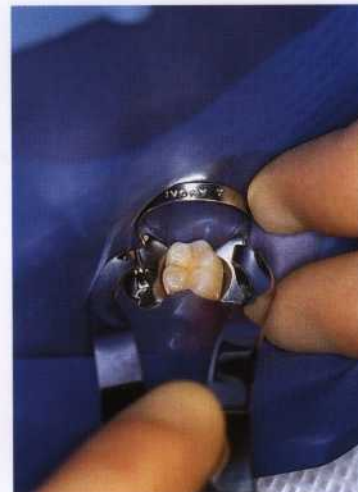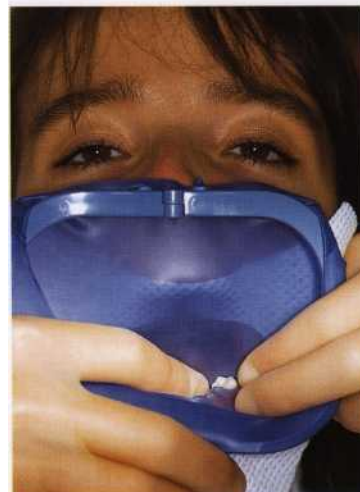Left: The rubber sheet has a hole punched for the mandibular left first molar and is mounted on the Sauveur folding frame, complete with evacuation pockets formed as in Figure 195. The # 7 molar clamp is already attached to the clamp forceps.



Right: The combined rubber dam and frame is held, centered, in front of the patient's mouth. The saliva ejector (lower left of picture) has been inserted from the side.

200 Application phase I

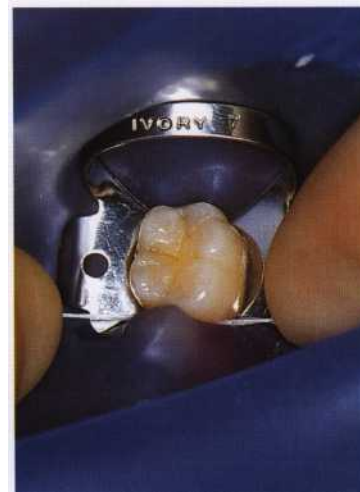Left: The rubber is moved toward the first molar. The previously punched hole is expanded with the fingers of both hands and pulled over the crown of the tooth.



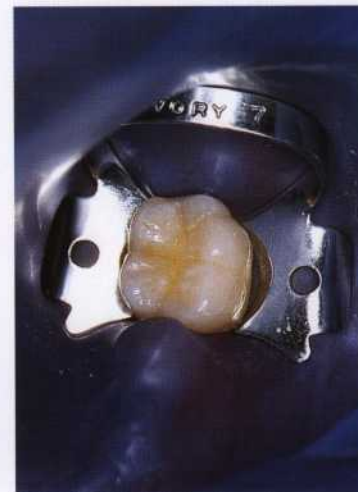
Right: The forceps-clamp assembly is introduced into the mouth and the clamp is carefully placed over the tooth toward the cervix. In doing so, the clamp should always lie against the tooth and never slide over the rubber.

201 Application phase II

Left: With the help of dental floss, the rubber dam is pushed past the proximal contact points.



Right: The rubber dam and clamp are shown in their final position.

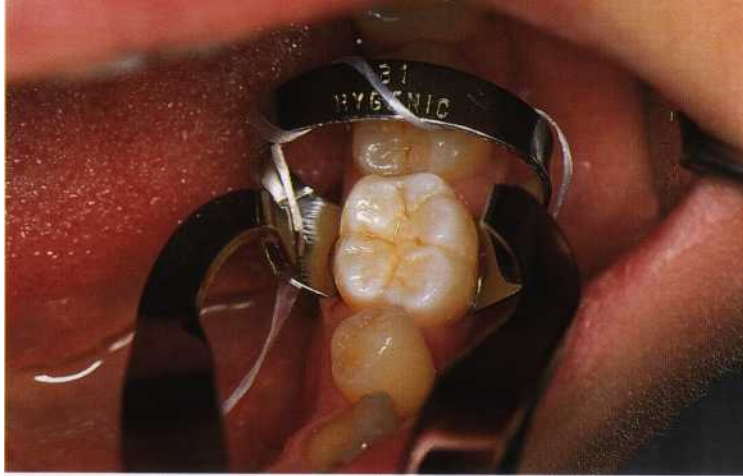

Rubber Dam Application IV (Clamp First)

With this technique the clamp is placed on the tooth first. As in application III, the two combinations of clamp-forceps and rubber sheet-frame should be pre-assembled. Only the order in which they are brought to the mouth is reversed. It is essential that the clamp be secured against the possibility of its slipping into the pharyngeal cavity. This is accomplished by looping a long piece of dental floss over the bow of the clamp and letting it hang out of the mouth where it can be quickly grasped in an emergency.

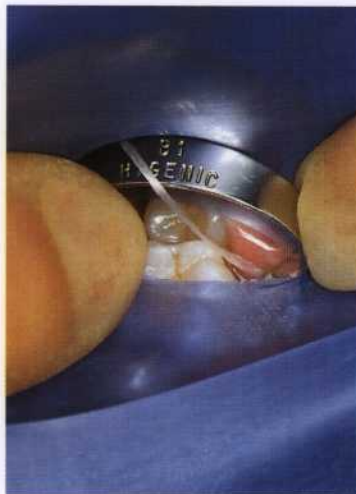
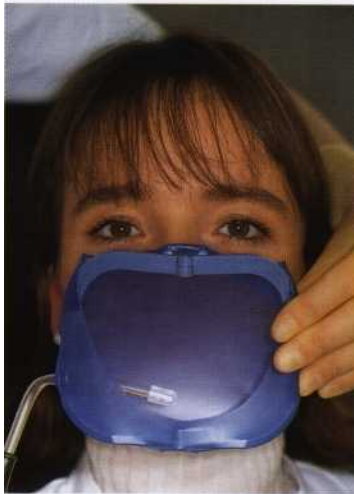One special problem arises during placement of the rubber dam in that the hole must be stretched wide to pass over the selected clamp. Therefore, the use of wingless clamps is recommended because their smaller width makes it less likely that the dam will tear. One great advantage is the unobstructed view as the clamp is being applied.

No matter which technique is used, the final step is to disinfect the operating field as for any surgical procedure. Chlorhexidine is a suitable disinfecting agent for dental use.



202 Clamp first technique

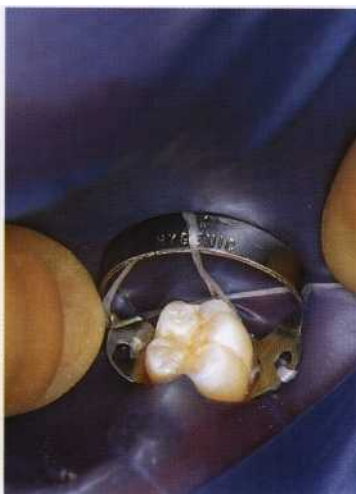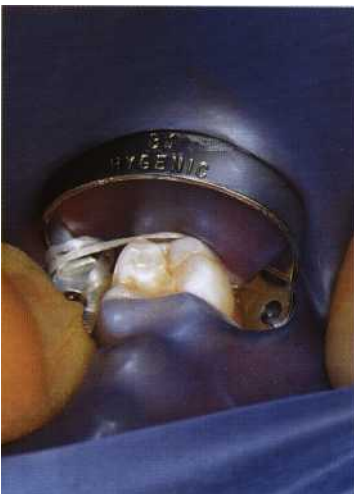A wingless clamp (Hygenic B 1), with a piece of dental floss attached to prevent aspiration, is placed directly on the first molar using a clamp forceps. As this is done, the operator should feel the clamp pass over the height of contour and to the level of the gingiva, then slowly release the tension on the clamp forceps.



203 Rubber-frame assembly

Left: The rubber sheet has previously been attached to the Sauveur folding frame. The dam is pulled over the frame at the lower left and lower right so that a waterproof pocket is formed on each side. The folding frame shown has a groove at the lower border that can serve as a guide and retainer for a saliva ejector.

Right: Next, the rubber dam is pulled over the bow of the clamp.



204 Securing the dam

Left: The fingers are used to pull the rubber sheet over the lingual wing of the clamp.

Right: Finally, the rubber dam is pushed into the proximal spaces with dental floss.

Special Cases

In a few cases, the techniques just described will have to be modified in order to achieve a well-placed, tightly fitting rubber dam. Some aids such as dental floss, Wedjets, Kerr compound, or even a second clamp have already been mentioned.

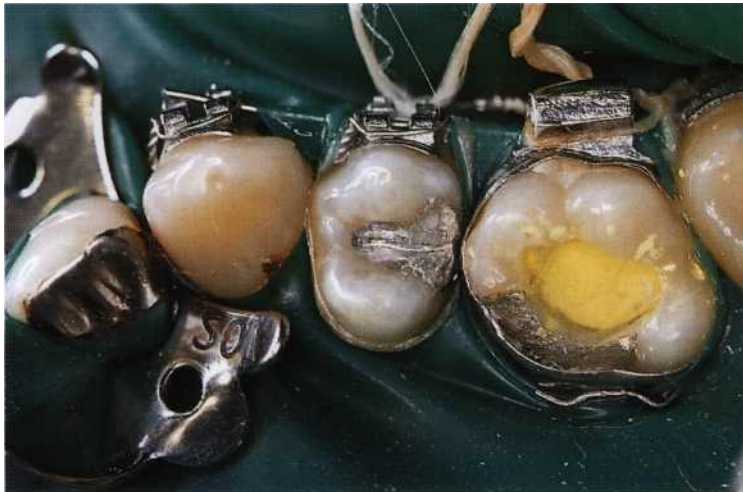Patients with fixed orthodontic appliances pose special problems. Even in these difficult situations, it is possible to place a rubber dam by using one's imagination and ingenious variations of the accessory materials. Dental floss ligatures serve well here.

Teeth with fixed prostheses frequently need endodontic treatment also. Where only a single tooth is involved, it is often a good idea to remove the crown to obtain a better view. If, as is frequently the case, the underlying tooth is severely damaged, it may be necessary to attach the dam to the adjacent teeth or to employ a clamp designed especially for deeply damaged teeth. For radiographic exposures it is often necessary to unfasten part of the dam from the pegs on the frame. For these situations, the Sauveur folding frame with its hinges offers an elegant alternative.

205 Application of a rubber dam over a fixed orthodontic appliance

The adaptation of the rubber sheet can be difficult in many treatment situations. With some ingenuity, however, a solution can always be found.

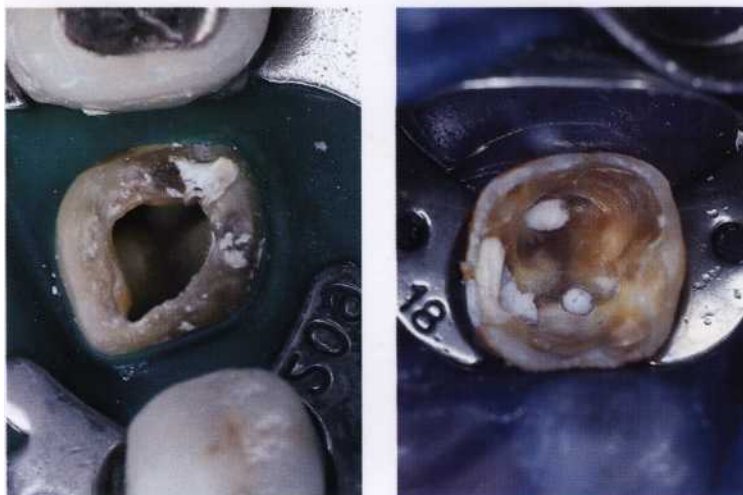Here, in spite of brackets, ligature wire, tight spacing, and multiple angles, a rubber dam is successfully applied by carefully pulling the perforated dam over the teeth and then securing it by means of a clamp on the canine and a dental floss ligature on the premolar.



206 Deep coronal destruction

Even teeth with extensively damaged crowns can and should have a rubber dam applied. *Left:* Here, three holes are punched in the rubber dam that is anchored by means of a clamp on each of the two teeth adjacent to the tooth under treatment. This tooth is then exposed by tucking the border of the middle hole into the sulcus.

Right: This molar with no crown is isolated using a wingless clamp with a safety line of dental floss attached.

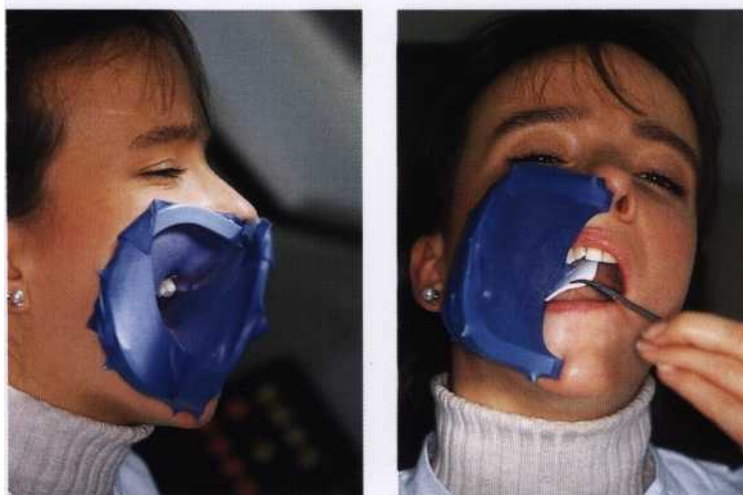

207 Radiograph with rubber dam in place

Normally the rubber dam frame must be partially or completely removed. The Sauveur folding frame has centrally placed hinges that allow one side to be opened.

Left: The maxillary right first molar is isolated. This lateral view shows the frame folded to the right side in preparation for a radiograph.

Right: The patient is instructed to hold the film in the desired position with a hemostat.



Local Anesthesia

Local anesthesia is regarded as the primary form of pain control for endodontic treatment (Cavino and Vasallo 1977, Lipp 1992). Only in extreme and exceptional situations is it necessary to use conscious sedation (e. g. with patients at risk because of medical conditions) or, more rarely, general anesthesia (e. g. absolute contraindication to local anesthetics) (Tolksdorf 1985, Daublander 1989 a, b). Lidocaine, mepivacaine, or articaine can be used for eliminating pain in endodontia, depending upon the depth of anesthesia required and the medical risk factors present. The types of injection used are infiltration and conduction (block) anesthesia, and less frequently, intraligamentary injection.

Topical anesthesia serves primarily to reduce the pain of the injection, which more than two-thirds of patients consider to be uncomfortable or anxiety producing. The local anesthetic of choice here is lidocaine, which is the only amide that has a strong topical effect. The mucosa should be dried first to enhance the effect. After spraying or swabbing the anesthetic onto the mucosa, 2.5 or 3 minutes should be allowed for the onset of anesthesia.

For *infiltration anesthesia* the solution is injected under the mucosa to make direct contact with bone. Subperiosteal injection should be avoided because of the severe pain it produces. The local anesthetic must diffuse through spongy bone to the terminal nerve endings. This is possible only where the cortical layer is thin. Therefore, infiltration anesthesia can only be used in the maxilla of adults, but in both jaws of children. In the mandible of children, 4% articaine is recommended.

Conduction anesthesia makes it possible to anesthetize a large treatment area with only a small amount of anesthetic. For successful conduction anesthesia it is necessary to precisely deposit the anesthetic solution immediately adjacent to the corresponding nerve. A small deviation of the needle tip can lead to a "missed block."

For an *intraligamentary injection* a very fine (0.3 mm) needle is introduced approximately 2-4 mm into the gingival sulcus (Einwag 1985, Erlemeier 1990). Its alignment should be parallel to the long axis of the tooth. To anesthetize a tooth, multiple injections, each of approximately 0.2 ml of solution, are made mesial and distal to the root. Four injections are made for a molar and two for other teeth. For most systems, 0.2 ml corresponds to one stroke of the syringe. During the actual injection, definite resistance should be felt because a "resistance free" injection means the needle is improperly placed. If the needle is not placed deep enough, anesthetic solution will flow out of the gingival sulcus and into the oral cavity. Furthermore, it is essential that the local anesthetic be injected slowly. It is recommended that each injection take 20 to 30 seconds. After the injection, the anesthetic solution spreads to the marginal sections of alveolar bone and to the surrounding gingiva. Results of recent research indicate that the pressure of an intraligamentary injection causes the anesthetic solution to enter the circulatory system. The anesthetic effect may be the result of selective perfusion of the material into arterioles of the alveolar process and blocking of the nerve endings of the pulp and periodontium.

Anesthetic Solutions

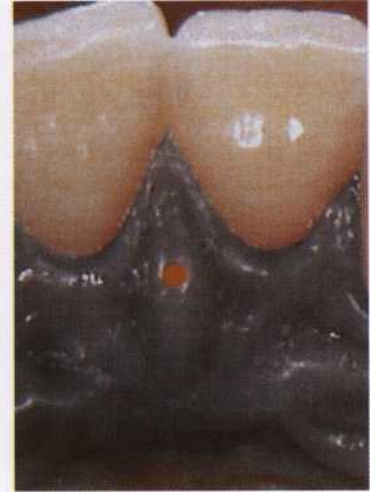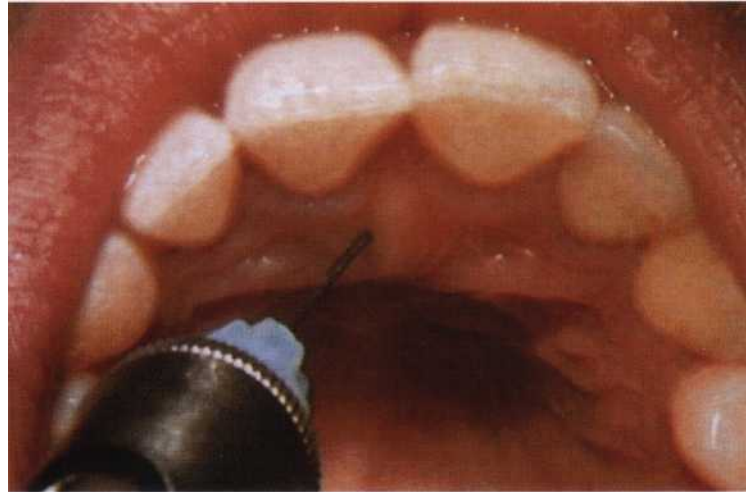Lidocaine is the first classic amide preparation. It was introduced into clinical use in 1948 and has become the most widely used local anesthetic around the world. Lidocaine has replaced procaine as the reference standard for toxicity and effectiveness. Epinephrine is almost always added as a vasoconstrictor because lidocaine alone is a strong vasodilator and would be rapidly carried away from the injection site. Lidocaine with a added vasoconstrictor produces profound pulpal anesthesia for 30 to 60 minutes and soft-tissue anesthesia for 120 to 150 minutes.

Mepivacaine was approved for use in 1960. It differs from lidocaine in that it can be used for local anesthesia without the addition of vasoconstrictors. This chemical has its own vasoconstrictor effect which, however, is not very strong. Mepivacaine is the agent of choice for patients with contraindications to added vasoconstrictors, patients with an allergic predisposition, and asthmatic patients (no preservative or sulfite additives). The duration of anesthesia when no vasoconstrictor is added is 20 to 40 minutes in the pulp and 45 to 90 minutes in the soft tissues.

208 Anesthesia of the nasopalatine nerve

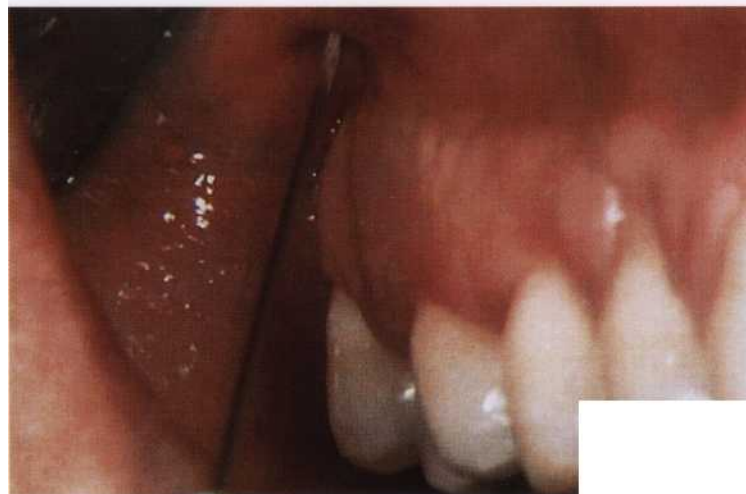The anesthetic solution is deposited at the exit of the nasopalatine canal directly under the incisive papilla. Anesthesia extends through the palatal mucosa in the region of the incisor teeth.

Right: Field of anesthesia and injection site.



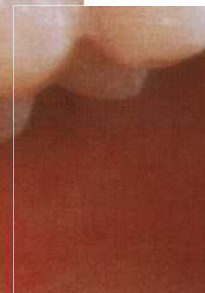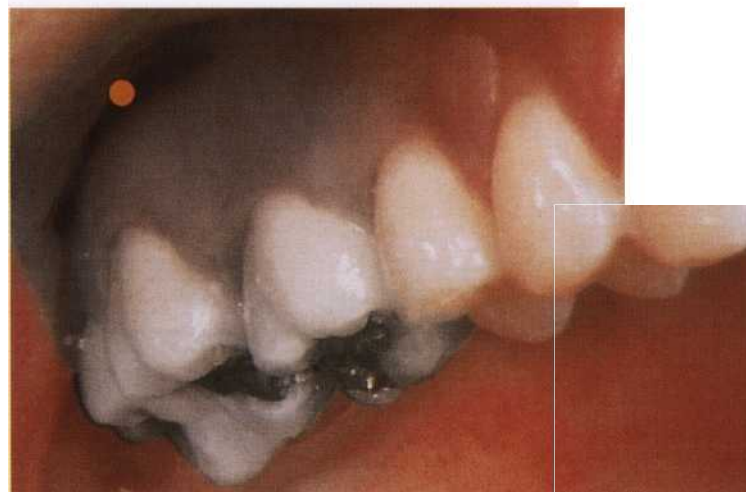209 Anesthesia of the posterior superior alveolar nerve

The needle is inserted near the tuberosity at the posterior surface of the maxilla at an angle of approximately 30° to all reference planes. The insertion depth is 0.5-1.0 cm. Contact with bone is verified before depositing the solution.



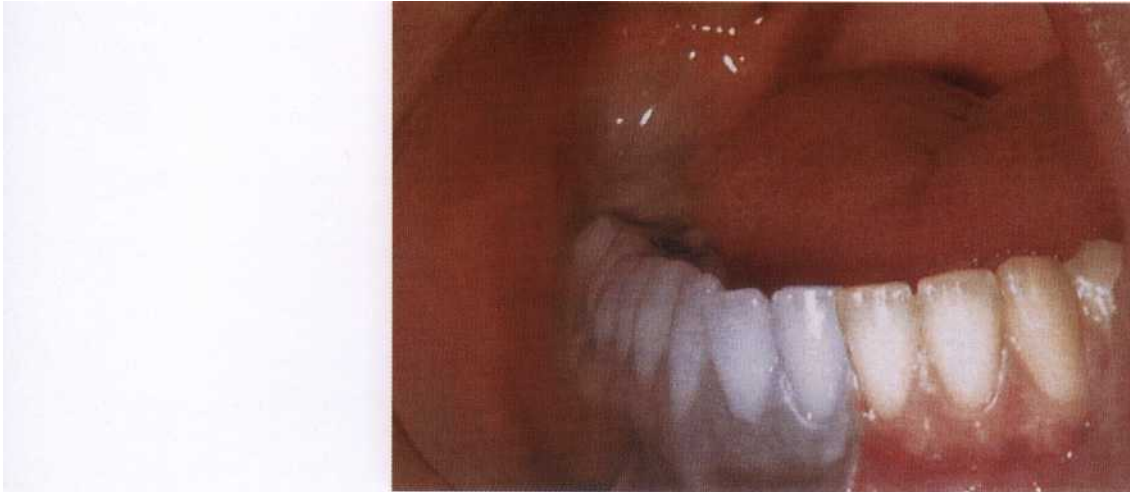210 Anesthesia of the posterior superior alveolar nerve

Anesthesia is produced in the molars and buccal gingiva of the maxilla. A complication can occur if contact with the bone is lost and the needle is inserted too deeply, namely puncture of the maxillary artery with formation of a retromaxillary hematoma. In the photograph the injection site and field of anesthesia have been highlighted.

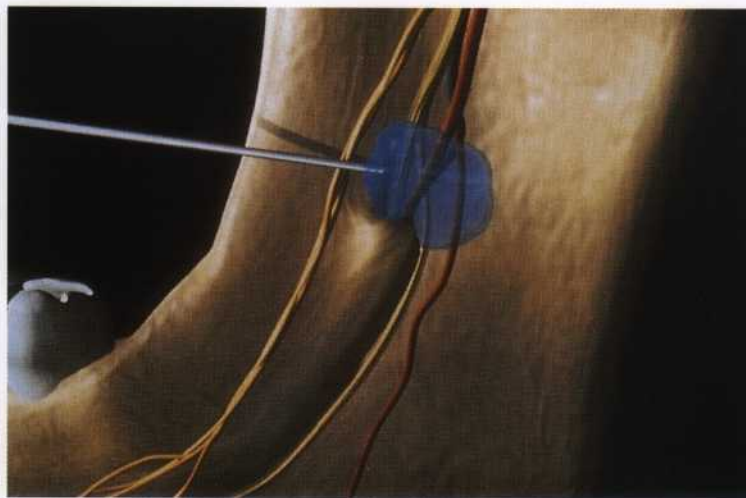


Since its introduction 20 years ago, *articaine* has been the dominant anesthetic agent in dentistry and is distinguished by its good ratio of strength to toxicity (from 2.5-3). In addition to its long duration of action when injected with epinephrine added (pulpal anesthesia 75-100 minutes, soft-tissue anesthesia up to 240 minutes), it has a pronounced ability to penetrate bone. It is also the agent of choice in pregnant patients because its high plasma protein binding ability reduces its passage across the placenta.

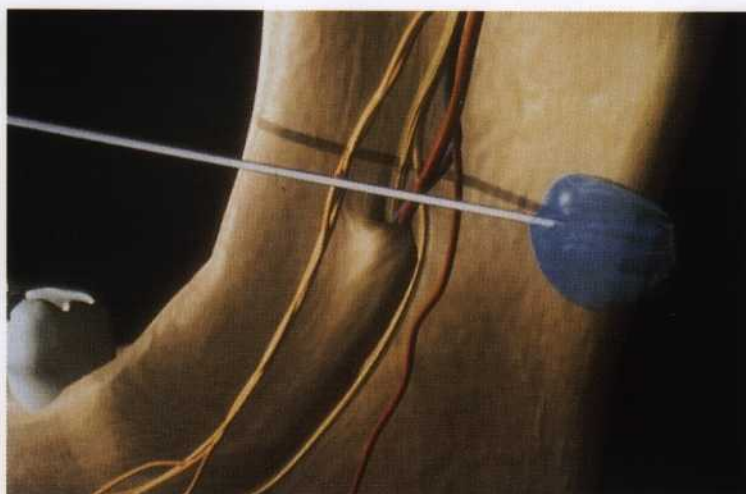
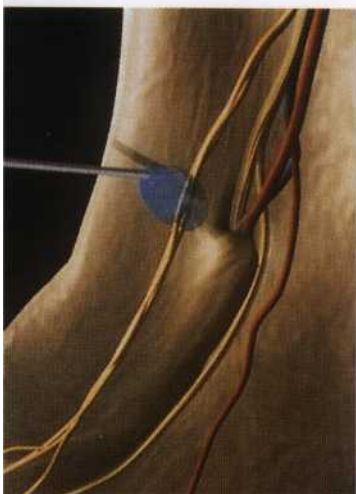Epinephrine is the only vasoconstrictor worth recommending. In concentrations of 1 : 100 000 or 1 : 200 000 it exerts extensive vasoconstriction at the injected area. Complications such as tachycardia, increased blood pressure, arrhythmias, and angina pectoris occur only with high doses or inadvertent intravascular injection. Because of its short plasma half-life (2-3 minutes) these symptoms are not prolonged, however. Norepinephrine is obsolete because of its significantly higher rate of side effects and the longer duration of its effect.



211 Anesthesia of the mandibular nerve
The injection is made in the sulcus colli mandibulae over the mandibular foramen approximately 1 cm above the occlusal plane. This anesthetizes the teeth and the vestibular mucosa in that half of the mandible, except for the buccal mucosa in the molar region.



212 Anesthesia of the mandibular nerve
A needle that is correctly positioned will deposit the local anesthetic solution above the lingula and the mandibular foramen. 1-1.5 ml solution will provide satisfactory local anesthesia if the position is correct.



213 Problems with incorrect positioning
If the tip of the needle stops anterior to the lingula (*left*) or is inserted beyond it (*right*), the anesthetic may be deposited away from the targeted nerve. A side effect of injection too far posteriorly is anesthesia of the facial nerve.

Figures 212-213 are taken from:
Lipp, M.D.W. Die *Lokalanästhesie*.
Berlin: Quintessenz Verlag; 1992.

Selection

Criteria for selecting a local anesthetic agent in the presence of a systemic illness include the type and duration of the procedure and the experience of the operator with the anesthetic agents under consideration. The recommendations below will serve as a decision-making aid. The decision for or against a particular agent must be an individual one. To provide safe local anesthesia when there is suspicion of a cardiac risk factor and when monitoring is not available, it is prudent to employ the appropriate procedure; for example, unaugmented mepivacaine on patients with cardiac arrhythmia (Lipp 1992).

Side Effects

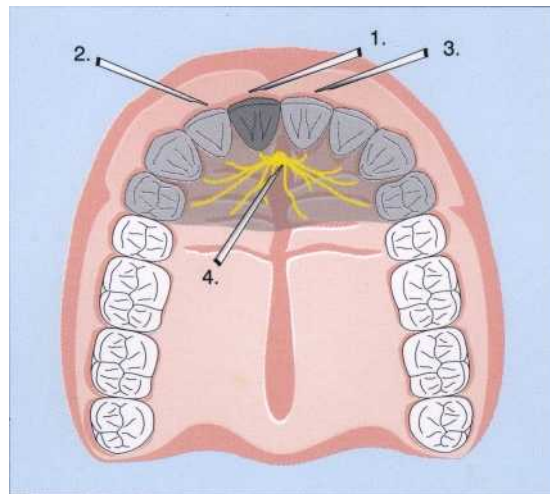
It is important to recognize the early signs of untoward reactions (such as a metallic taste from anesthetic intoxication or increasing tachycardia because of a hypersensitivity to epinephrine) and to implement appropriate emergency procedures: discontinue injection, remove foreign objects, position the patient correctly, check (and if necessary, restore) the vital functions, and call for qualified assistance. In the rare event of an emergency arising from local anesthesia, immediate emergency treatment by the dental team is crucial to the outcome.

Patient with no systemic disease	Type of treatment	Patient with systemic risk factors
Lidocaine with epinephrine	Short procedure	Mepivacain without vasoconstrictor
Lidocaine with epinephrine or articaine with epinephrine	Routine treatment	Mepivacain without vasoconstrictor or articaine with epinephrine (max. 1:200 000)
Articaine with epinephrine	Lengthy procedure	Articaine with epinephrine (max. 1:200 000)
Lidocaine with epinephrine	Treatment over a wide area	Lidocaine with epinephrine or articaine with epinephrine (max. 1:200 000)

214 Anesthesia for surgical endodontic procedures in the maxilla

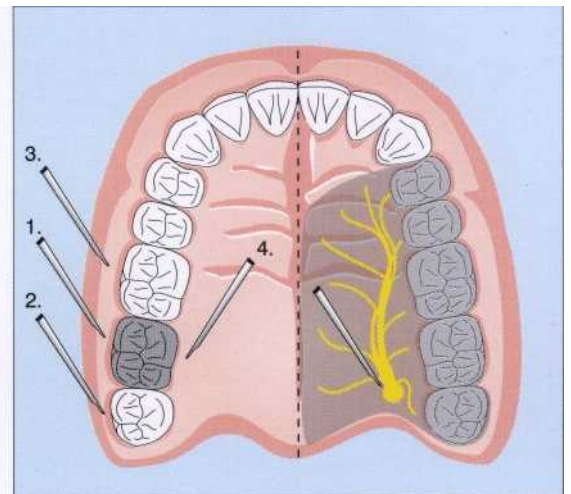
Left: Anterior region.

Begin with injections at three separate sites labial to the targeted tooth (here, right central incisor), then inject into the palate for the nasopalatine nerve.



Right: Posterior region.

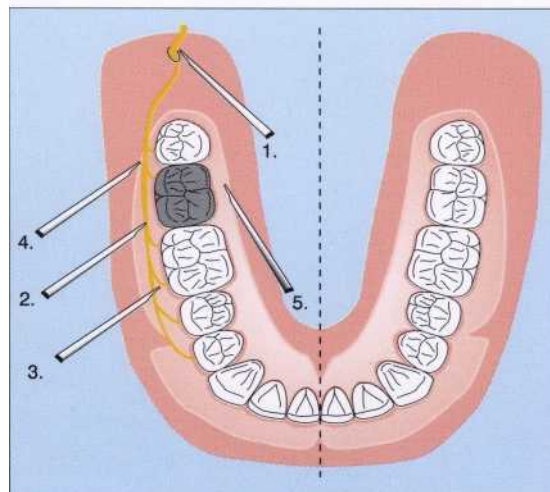
Begin the injections buccal to the targeted tooth (right second molar) and finish with a palatal injection. The right half of the drawing shows the injection for an operation on the lingual root of the left first molar.



215 Anesthesia for surgical endodontic procedures in the mandible

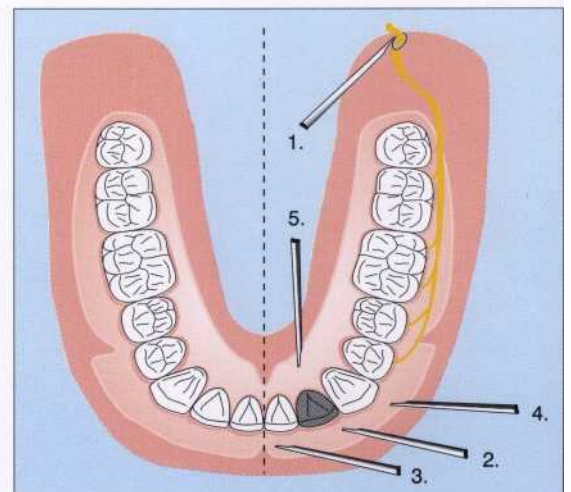
Left: Anesthesia in the posterior region.

The injections begin with a mandibular block (conduction anesthesia of the mandibular canal), followed by injections buccal and lingual to the involved tooth.



Right: Anesthesia in the anterior region.

First, a mandibular block, followed by additional labial and lingual injections.



Access Preparation

Root canal treatment begins with the creation of an access opening in the tooth, which should be performed under a rubber dam. Difficulties in instrumenting the root canal are usually the result of inadequate access preparation and lack of straight-line access to the root canals. Direct visualization into the canal orifice is essential. This is aided by the use of loupes or an operation microscope. A substantial amount of coronal tooth structure must be preserved, of course, and only as much enamel and dentin may be removed as is absolutely necessary. However, locating the entrances to the canals must never be hindered by an access preparation that is too small. Mistakes in forming the access preparation can generate a multitude of problems throughout the entire endodontic procedure. Among these mistakes is the failure to remove all caries as well as weak and unsupported tooth structure. Incomplete removal of inadequate and leaky fillings and crowns leads to contamination of the prepared root canals with saliva and, therefore, with bacteria. Lack of direct access to the root canal orifices can result in overstraightening of curved canals and perforations. Knowledge of tooth and root canal anatomy is important to the proper formation of the access preparation because the access preparation should represent an elongated version of the pulp chamber.

Compromised treatment during root canal instrumentation is usually the result of an inadequately formed access preparation. Endodontic treatment includes at the very beginning the complete removal of all carious lesions and defective prosthetic restorations. Caries removal reduces the risk of bacterial contamination of the root canals. Otherwise, bacteria could be transported by an instrument from the coronal region into the apical portion of the canal and could set off a postoperative reaction. Insufficient excavation of caries and leaving old fillings or defective crowns in place can result in diffusion of saliva and contamination of the root canal. Bacteria can thereby spread into the root canal system and penetrate unhindered into the apical portions of the canal with long-term endodontic failure as a possible consequence.

Bacteria can penetrate as much as 700 μ m into dentinal tubules, attach themselves there, multiply relatively unhindered, and later initiate periapical inflammation and bone destruction (Perez et al. 1993). If old restorations are not completely removed, particles of filling material may become loosened during root canal instrumentation and block the canal. If an existing filling is intact and shows no evidence of leakage on the radiograph, it may be left in place. On the other hand, it is only through complete removal of previous restorations that the extent of carious penetration and the presence of leaking margins can be determined for certain, the canals can be found more readily, and straight line access for canal instrumentation can be facilitated. This does require additional effort in that either an interim crown or an adhesively bonded filling must be made to protect the tooth from fracture between appointments (Gutmann et al. 1991).

Interim Restorations

Only those teeth that have a favorable prognosis and that can be successfully restored should be included in the endodontic treatment plan.

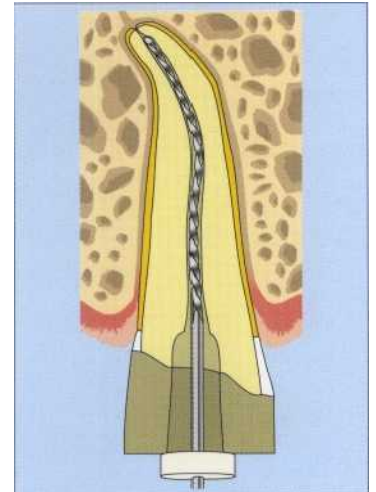
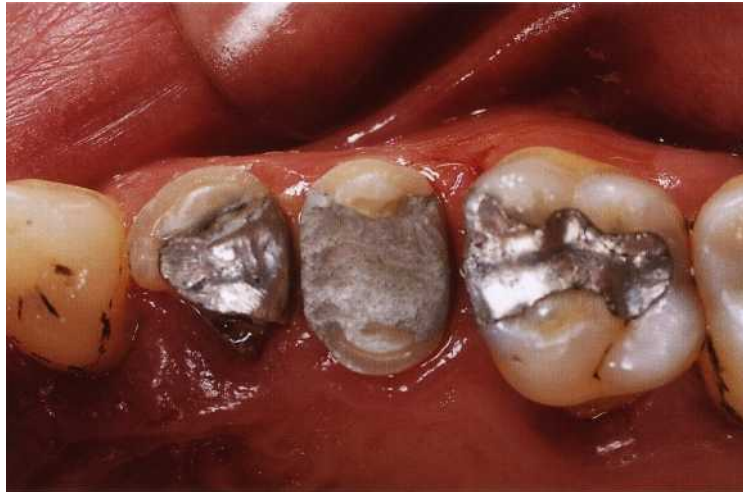After removal of all previous restorations, it is desirable to construct an interim restoration. This will provide a coronal reference point for determining the working length, as well as protect the tooth from an overload fracture between appointments. Furthermore, a tight seal against the oral environment is important in preventing contamination with saliva. The interim restoration can be a direct composite filling, a composite

inlay with adhesive cement, or a cemented synthetic resin crown. The latter can also serve as a short-term or long-term provisional restoration. The amount of tooth structure missing and the length of time the restoration must be worn determine which type should be used. Glass ionomer cements provide very good marginal adaptation initially, but during function they undergo extensive occlusal wear and deterioration of marginal integrity (Krejci et al. 1996b).

216 Destruction of hard tissues

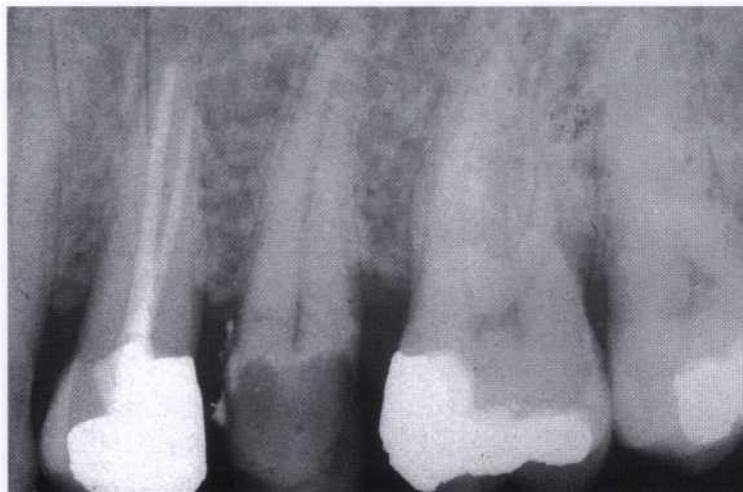The hard structures of the teeth have been severely damaged and must be restored before root canal treatment is started. The first and second premolar both show inadequate amalgam restorations. The missing cusp will make the build-up more difficult.

Right: A crown with impermeable margins must be placed so that a reproducible working-length measurement can be established.



217 Radiograph

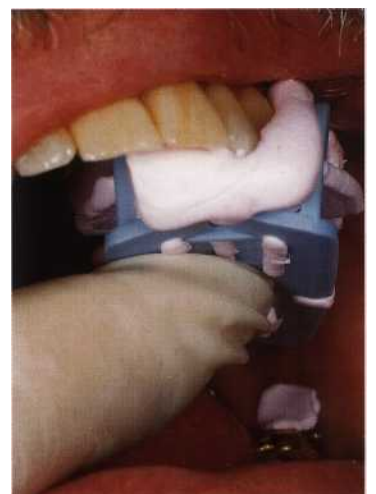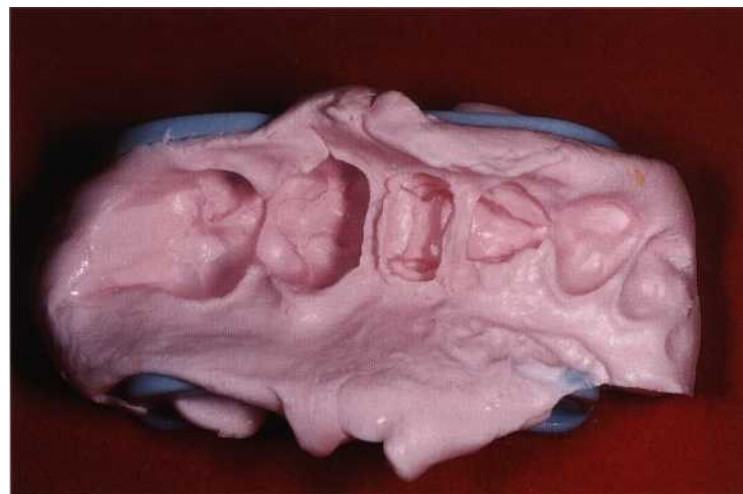
On this diagnostic radiograph taken at the beginning of root canal treatment, destruction of the tooth structure of the second premolar is evident. The periapical region appears normal. Radiographically the root canal filling in the first premolar appears intact and well condensed. Retreatment is not necessary.



218 Preparation and impression

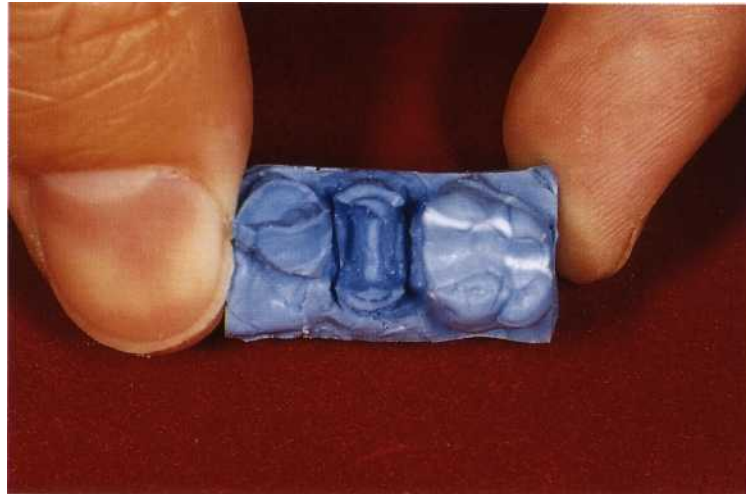
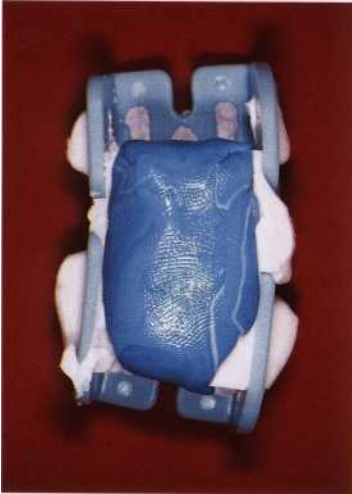The filling in the second premolar is completely removed. The shape of the cavity preparation is largely dictated by the extensive loss of tooth structure. Next, a sectional impression is made to include the affected tooth as well as the two immediately adjacent teeth.

Right: Making of the impression with an addition reaction silicone material. Finally, a direct composite provisional restoration is made at chairside.



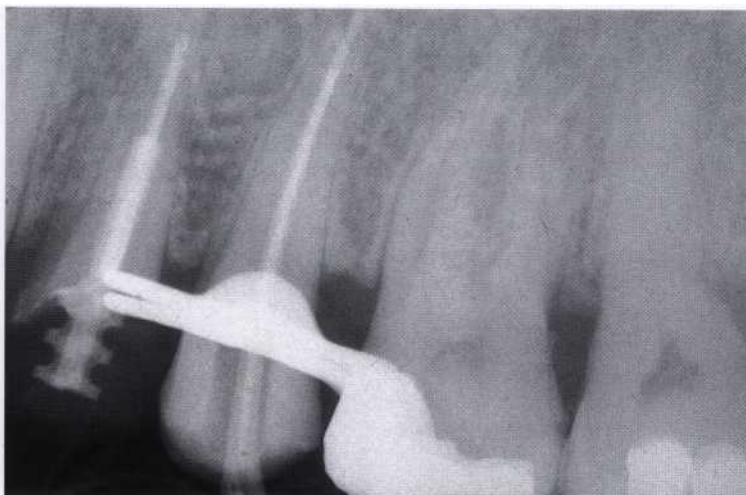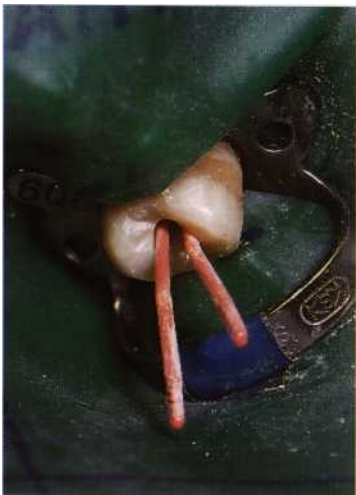For moderate-sized composite fillings in posterior teeth a conservative U-shaped preparation is conducive to good marginal adaptation. Only 74% of fillings inserted into box-shaped cavities and cured in two incremental layers exhibited ideal margins after masticatory function (Krejci et al. 1996 a). If conventional cavity forms are used, time-consuming insertion and polymerization techniques must be used to compensate for the rapidly progressing polymerization shrinkage of composites (Lutz et al. 1991).

Immediate provisional restorations can also be made indirectly on a model by making an impression of the prepared tooth. A provisional crown can be formed directly in the mouth inside a prefabricated crown form or a vacuum-formed matrix if it will not have to be worn for more than 1 to 3 months. For longer-term provisionals, egg shell crowns can serve as long as 6 months. Provisional crowns consisting of a synthetic resin veneer over a thin metal framework can be cemented for a period of 6 months to 2 years, but require extensive laboratory fabrication (Peitrobon et al. 1996).



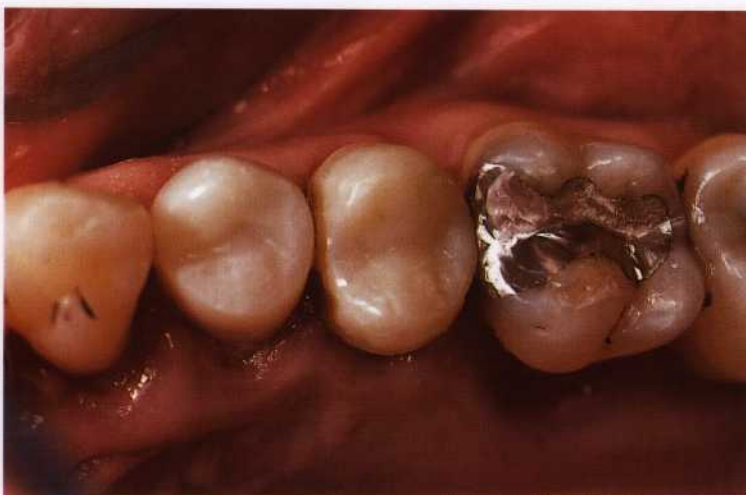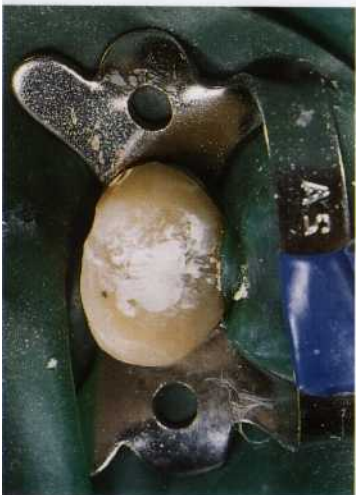219 Cast fabrication
The impression is coated with a separating medium, and a positive cast is made with a special silicone material. The sides of the resulting resilient cast are trimmed. Vertical interproximal cuts are made so that the die of the tooth being treated can be separated from its neighbors.

Left: Making a positive impression of the jaw segment in the intraoral impression.



220 Bonded restoration
An indirect composite provisional restoration has been made, adjusted, and bonded to the tooth with an adhesive cement. Subsequently, a coronal reference point, easily seen and reproduced on radiographs, was established. The gutta-percha master point can now be adjusted to the correct length without a problem.

Left: After bonding of the composite crown to the tooth, an access opening is made through it and the root canal prepared. The working length can be measured repeatedly.



221 Coronal seal
After completion of the root canal treatment, the access preparation is sealed once more with composite. The definitive prosthetic treatment must be completed within a timespan of 3 to a maximum of 6 months, during which a new provisional crown has to be made.

Left: The access opening can be sealed for a short time between appointments with eugenol-free temporary cement.

Opening the Pulp Chamber

Besides insufficient preparation of the access cavity, a primary source of problems in opening into the pulp chamber is incorrect estimation of the angle between the long axes of the crown and root. This makes finding the entrances to the canals more difficult. The diagnostic radiograph is helpful in locating the canal orifices. When large restorations are present, an additional bitewing radiograph should be taken. To help avoid perforation or excessive dentin removal at the floor of the cavity, the alignment of the diamond cutting instrument should be determined on the radiograph.

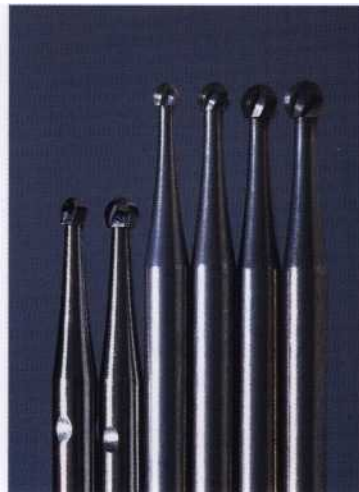The first depth cut is made with a round diamond stone, while cylindrical burs are good for extending the cavity laterally. A useful combination of instruments for making the entire access preparation is the Endo Access bur by H. Martin (Maillefer) and a cylindrical or tapered fissure bur with a rounded, noncutting end. If trouble is encountered in finding the canal orifices, the largest root canal is used for orientation. The floor of the coronal pulp chamber gives clues to the number and location of the canal orifices by its ridges and depressions. The roof must first be completely removed.

222 Rotary instruments

Left: Spherical and cylindrical diamond cutting instruments that can be used for making the access preparation. The Endo Access bur by Dr. Martin (right) is ideal.



Center: Round burs with different shaft lengths.

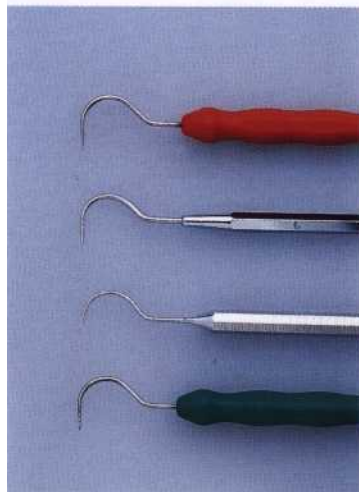


Right: Cylindrical and tapered burs with smooth, round ends are similar to ordinary fissure burs except for the noncutting tip that prevents perforating the floor of the pulp chamber.

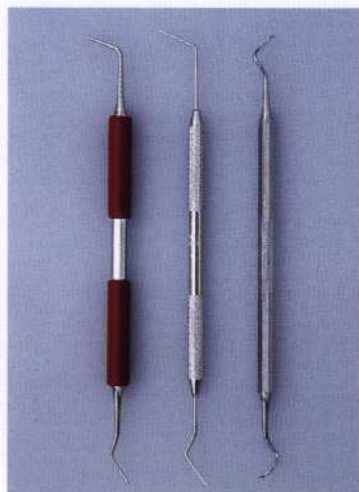


223 Uncovering and probing canal orifices

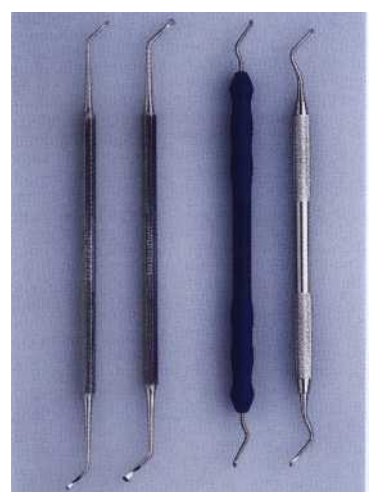Left: The most important instruments for finding a root canal entrance are long, rigid explorers that do not penetrate into sound dentin but will catch in a canal orifice, and so help locate it.



Center: Hand instruments for probing and locating root canal entrances.

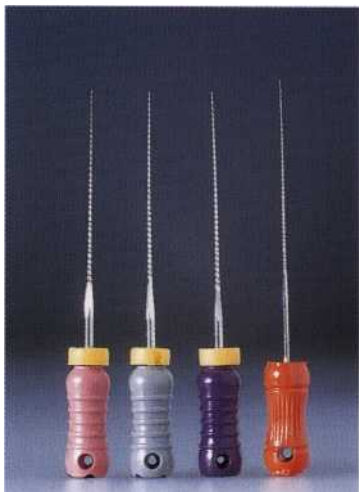

Right: Spoon excavators are used to remove soft-tissue remnants from the floor of the pulp chamber.

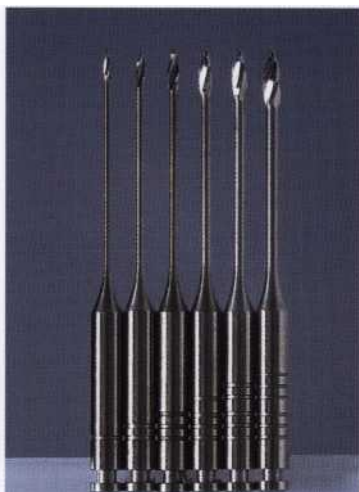

224 Exploring and enlarging

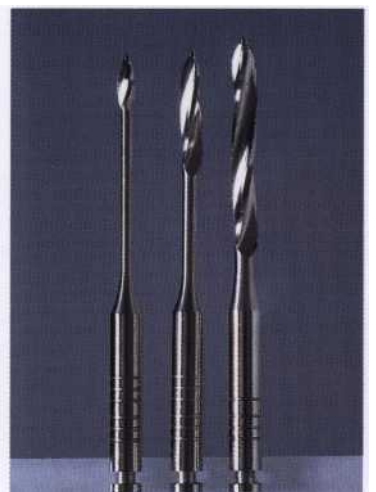Left: If the explorer catches in dentin at the floor of the access preparation, a fine file of size 6, 8, or 10 or a Pathfinder is used to determine whether a root canal or a perforation is present.



Center: Gates-Glidden drills are used for the initial coronal enlargement of canals. The size is indicated by the number of rings.



Right: Differing shapes of instruments for enlarging canal entrances (Gates, Peeso).



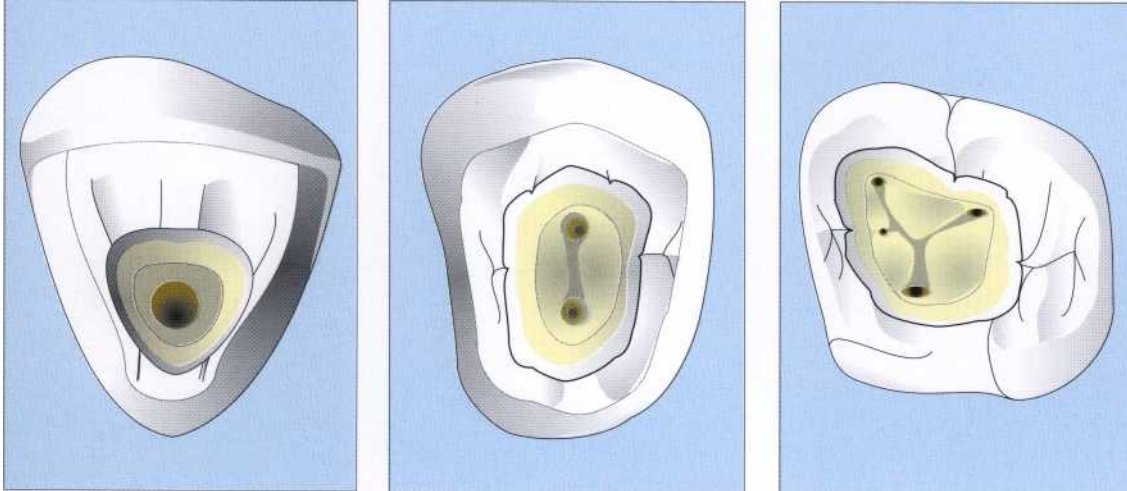
Uncovering the Canal Entrances

The circumferential form of the endodontic access preparation should correspond to the outline of the roof of the pulp chamber. The cavity outline form in maxillary incisors is triangular and lies in the center of the lingual surface. It must be widely extended mesially and distally to include all of the pulp horns and allow removal of any soft-tissue remnants. Any tissue left behind can later cause discoloration of the clinical crown. The pulp chamber is prepared at a 45° angle to the long axis of the tooth (Peters 1992 a).

The outline form of the access preparation on man-

dibular molars is trapezoidal. The cavity is started in the center of the tooth with the axis of the bur directed distally because the space over the distal canal is the easiest to locate (Peters 1992 b).

In maxillary molars the access preparation begins centrally with the bur directed toward the mesiolingual cusp where the pulp space is greatest. After the pulp chamber is reached, the cutting instrument is moved buccally, maintaining noncutting contact with the floor of the pulp chamber, to remove the overhanging roof (Peters 1992 c).

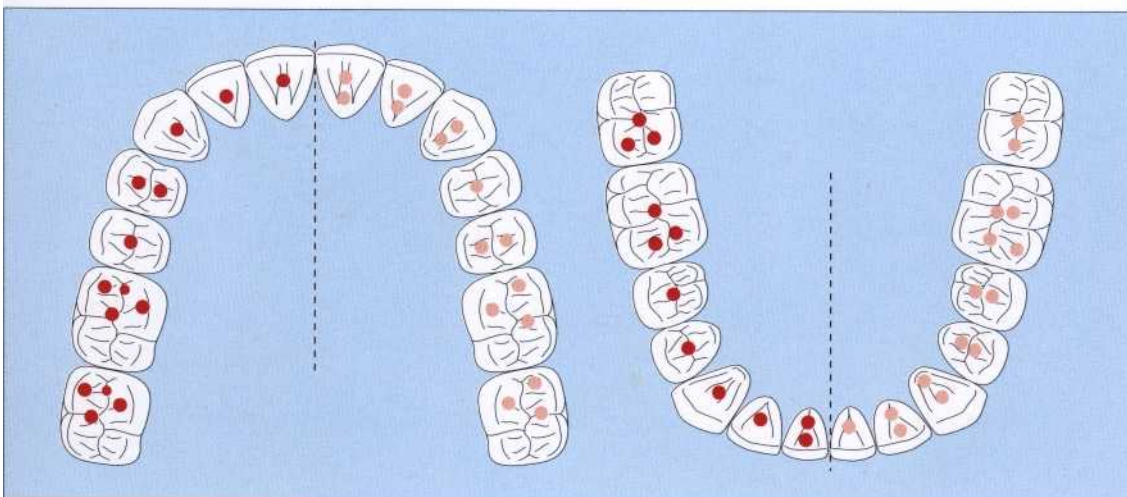


225 Access preparations in maxillary teeth

Left: Anterior teeth are opened from the lingual aspect. The cavity is triangular and the canal, usually single, lies in the center of the tooth.

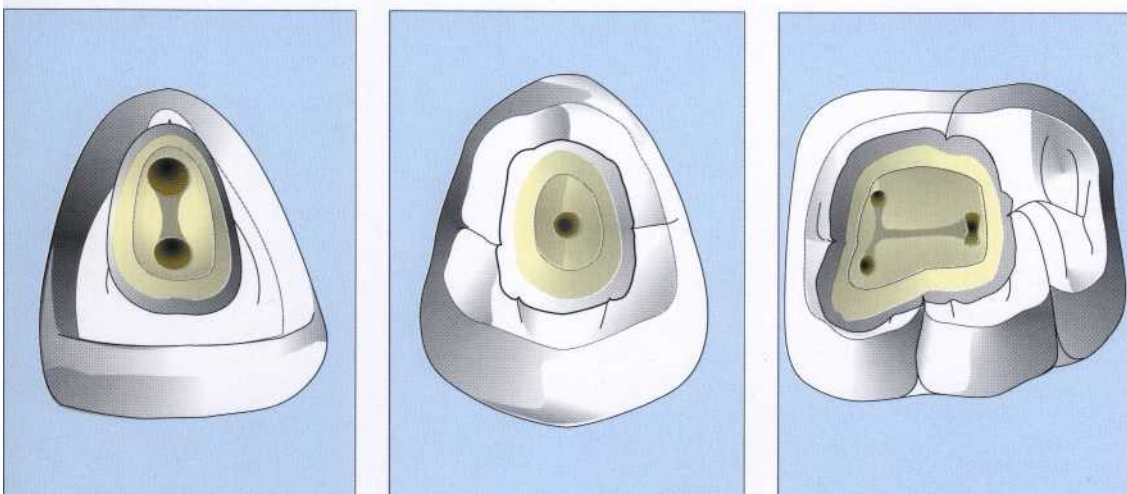
Center: In premolars the preparation is oval-shaped and oriented buccolingually.

Right: The access preparation for maxillary molars is rhomboidal or trapezoidal. The majority have a fourth orifice opening into a mesiolingual canal in the mesiobuccal root.



226 Overall view of possible canal locations

The drawings of the maxilla (left) and the mandible (right) show the number of root canals commonly encountered at the floor of the pulp chamber and their usual positions in relation to the occlusal surface.



227 Access preparations in mandibular teeth

Left: Mandibular anterior teeth have two root canals in up to 25% of cases. A triangular preparation is made from the lingual.

Center: Premolars are opened with a buccolingually oriented oval-shaped access preparation through the occlusal surface.

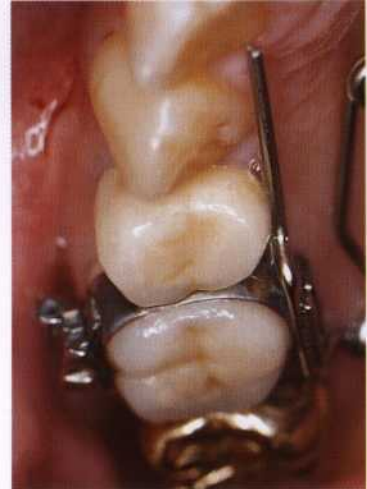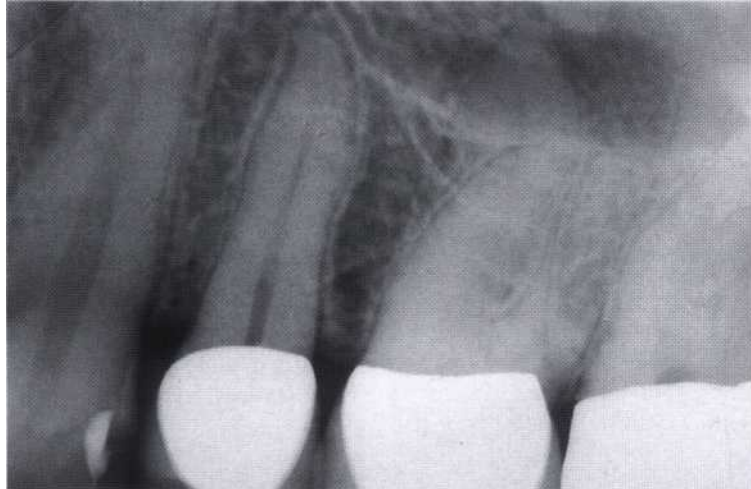Right: In mandibular molars the opening should be trapezoidal, usually wider mesially than distally, and bordered mesially by the marginal ridge.

Probing the Canal Entrances

After the roof of the pulp chamber has been penetrated and the access cavity prepared, the entrances to the pulp canals must be probed. Insufficient removal of the roof of the pulp chamber always causes problems. The overhanging dentin can be removed by lateral bur movements and the cavity tapered to the occlusal surface. A hooked explorer can be used to determine if enough dentin has been removed. With the aid of magnifying loupes a visual determination is made whether or not the preparation provides unimpeded access to the canals. If it is necessary to make the prep-

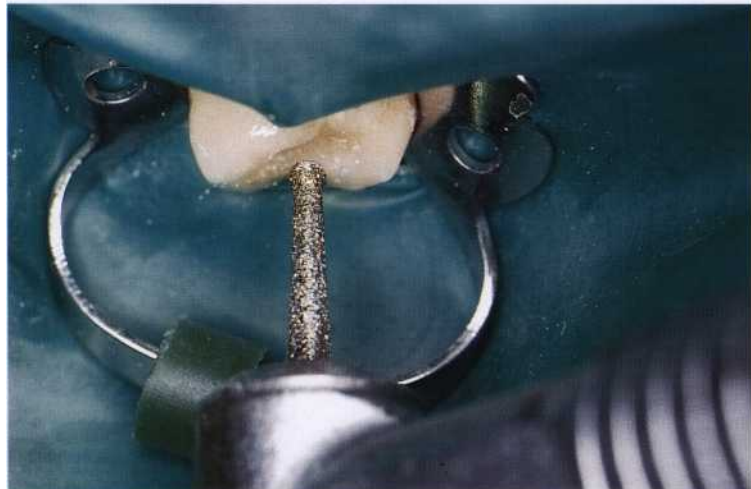
aration through an artificial crown that will not be removed, then the angle between the crown and the long axis of the tooth should be determined on a radiograph. If the dentist is not aware that the crown is tilted, a perforation can result or the canals may not be found. Large core buildups under the crown make it more difficult to find and uncover the canal orifices. Access preparations must be made under a copious water spray for cooling and ensuring that metal particles do not block the narrow openings into the canals (Gutmann et al. 1991).

228 Diagnostic radiograph
An attempt is made to locate the position of the root canal and its orifice on the first radiograph. In the root region of the crowned maxillary first premolar, superimposed, slit-like shadows indicate that there is more than one canal.



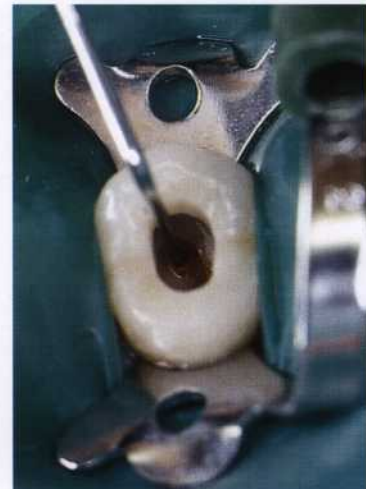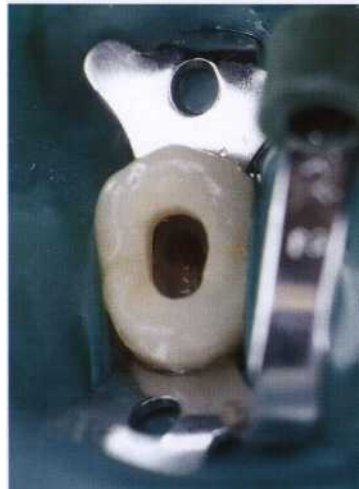Right: A clear radiographic determination of the canal orifices can be made difficult by fixed orthodontic appliances, as well as by crowns.

229 Access preparation
With a rubber dam in place, the crown is penetrated by using the long, diamond-coated Endo Access bur. The preparation is then continued. Only when there is a large discrepancy between the orientation of the crown and the long axis of the tooth should the preparation be started before the rubber dam is placed.



Right: Preparation to the roof of the pulp chamber. The access preparation must allow unimpeded access to the canal orifices.

230 Probing the root canal orifices
Left: The preparation has been carried through the roof of the pulp chamber, and all pulp tissue remnants as well as any overhanging dentin have been removed.

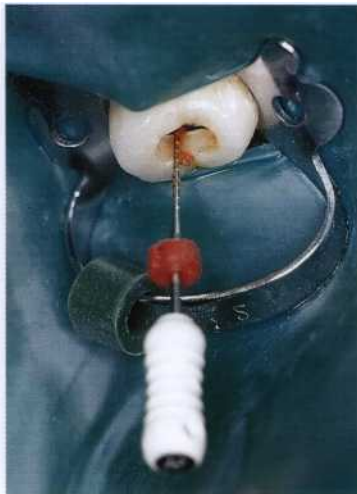
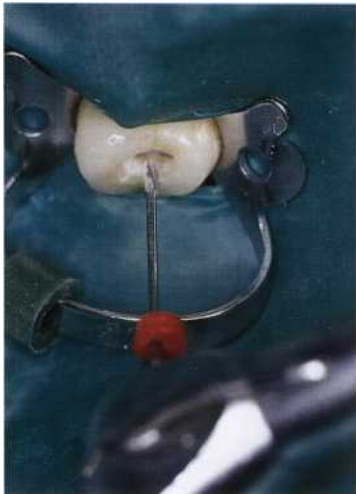

Center: Locating the entrances to the root canals by feeling along the floor of the pulp chamber with a special endodontic explorer (Maillefer GR 16, DG 16).

Right: View of both canal orifices. Although bleeding is minimal, it can make locating the canals more difficult.

The canal entrances are found by feeling with a thin, stiff explorer. If the explorer sticks in a spot, a size 15 Hedström file is used to verify that the spot is indeed the entrance to a root canal and not a perforation. Only then is the opening gently enlarged. Narrow root canals must first be enlarged coronally with a Hedström file before the deep preparation can be started. While K files are certainly flexible enough to get past curves and calcifications, they do cause blockages within the root canal more frequently.

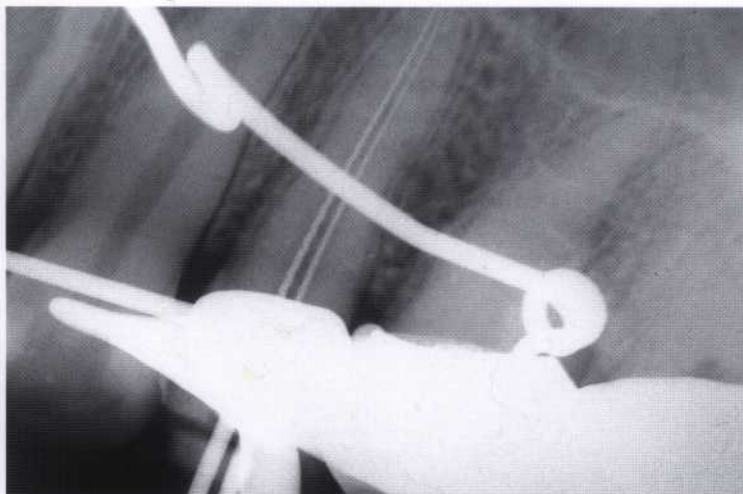
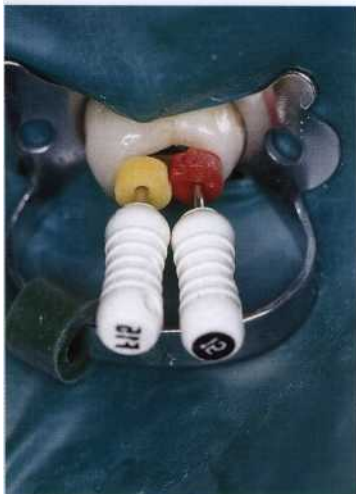Because the 16-mm-long cutting segments of the instruments are about 0.32 mm larger in diameter near the handle than at the tip, they frequently bind in the midroot area. For this reason, a narrow root canal is enlarged in segments by advancing the instrument 1 mm at a time, aided by a chelating agent. Only after the canal is made patent is the coronal portion prepared with a Gates-Glidden drill. The entire root canal can then be instrumented without problems.



231 Initial enlargement
Left: The entrance to the canal is carefully widened with a small Gates drill.

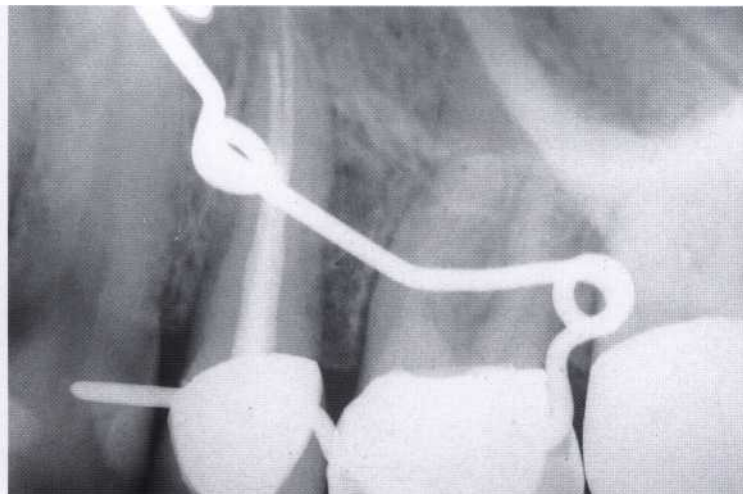
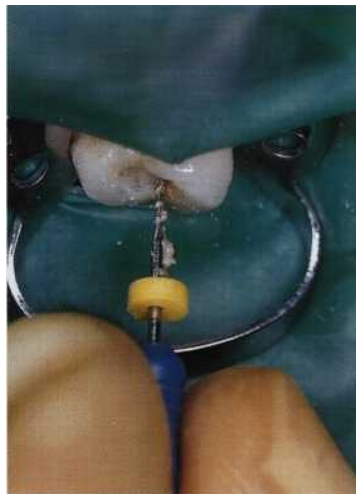Center: Working millimeter by millimeter from the coronal opening toward the apex with a size 15 Hedström file, the canal is carefully enlarged as necrotic pulp tissue is removed. No attempt is made to widen an area before it can be penetrated.

Right: View into the cavity showing the widened coronal portions of both canals.



232 Length determination
After the initial coronal enlargement and before preparing the deeper apical portion of the root canals, the length is measured on a radiograph. (The fixed orthodontic appliance interfered with precise placement of the X-ray film.)

Left: For easier differentiation on the radiograph, different types of instruments were inserted into the two root canals: a Hedström file in the lingual and a Flexicut file in the buccal canal.



233 Root canal treatment
After preparing both canals, they are filled with gutta-percha and a sealer, and the result of the treatment is evaluated by means of a final radiograph.

Left: Following determination of the working length, instrumentation is continued before the canals are filled.

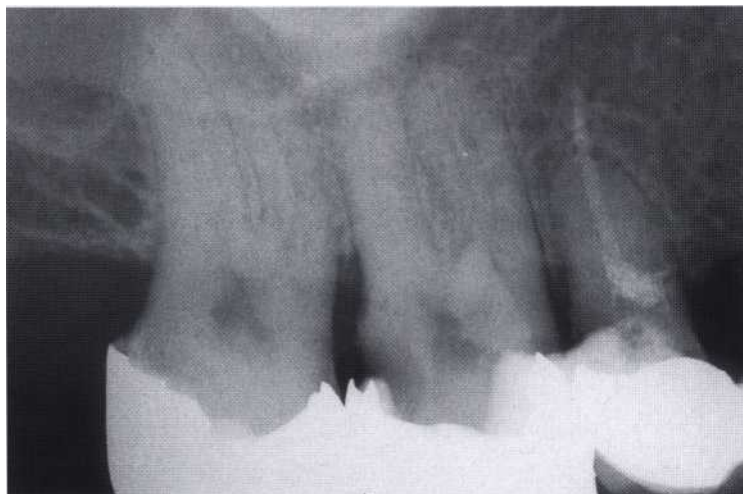Straight-Line Access to the Canals

Initial penetration of the pulp chamber of an upper molar is made over the orifice of the lingual canal. The cavity is then extended to its final outline. The lingual canal serves as a reference point for finding the other canals. The diamond-cutting instrument is moved buccally while contacting the floor of the pulp chamber in order to remove the overhanging roof and uncover the mesiobuccal and distobuccal canals. The preparation is then completed using a smooth-tipped cutting instrument. The cavity walls should be made to diverge slightly (Peters 1992 a-d).

The final shape creates unimpeded access to all root canals. This is the only way to ensure that the instruments can be inserted straight into the canals. Because many canals are curved at their coronal ends, the cervical ledge, or coronal bulge, must be carefully removed. In cases where the pulp chamber is difficult to find, the cavity is dried and the preparation is extended to a depth of 2 mm toward the presumed locations of the canal orifices by means of a slowly rotating round bur. Chelating agents are of no real help in finding the entrances to canals.

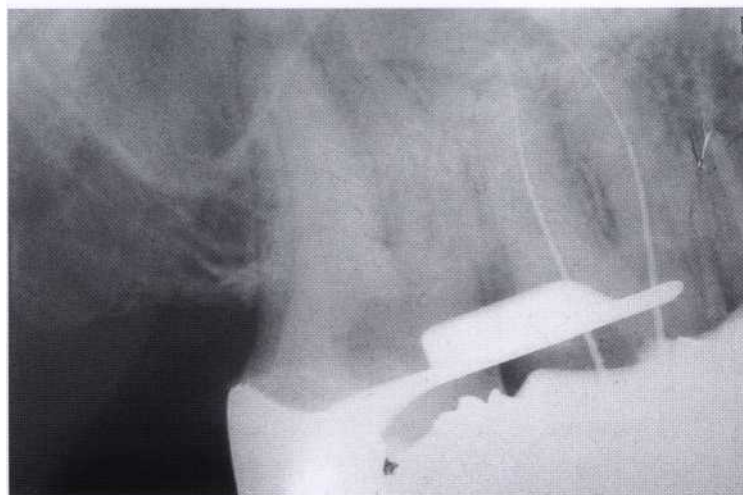
234 Radiographic diagnosis
Maxillary first molar with deep, penetrating secondary caries on the distal surface. The depth of the cavity can be determined from its relation to the proximal box of the restoration.

Right: Emergency pulp extirpation at the first appointment: only the canal orifice that was easiest to find is opened, and the largest root canal (here the lingual) instrumented.



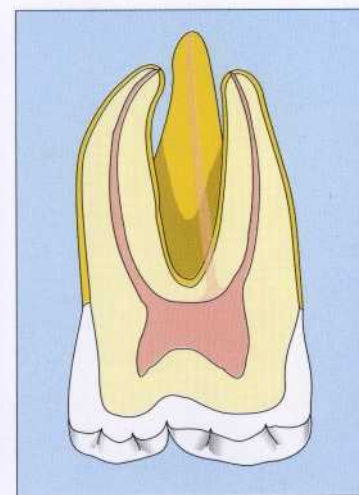
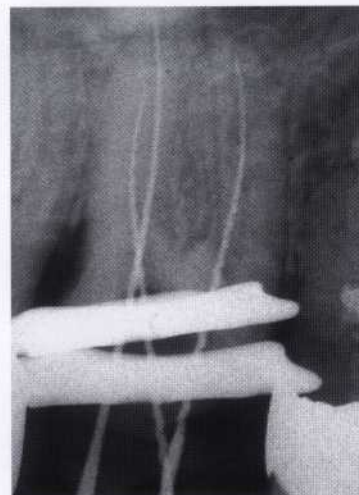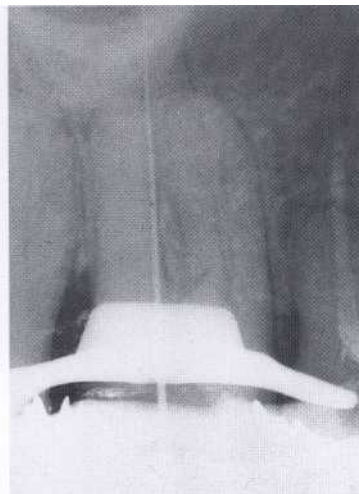
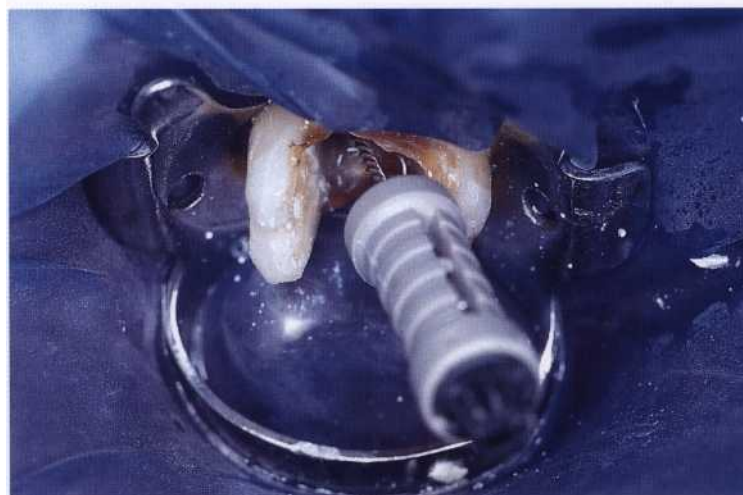235 Working-length radiograph
To avoid superimposition of the lingual root canal on the radiograph, the buccal root canals may be measured separately. The overhanging dentin has yet to be completely removed.

Right: Removal of the old crown facilitates removal of all caries and dentin overhangs and creates straight-line access for the instruments.



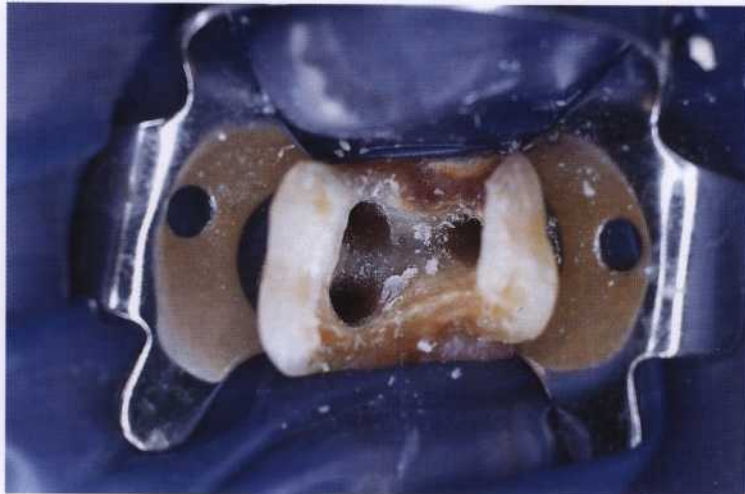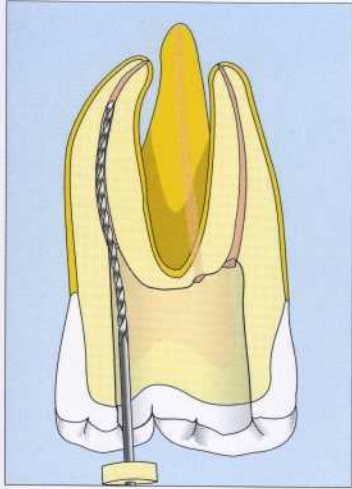
236 Preparation of the root canals
The root canal instruments must be able to enter the root canals in a straight line and pass unimpeded to the working length.

Right: Initial situation before making the access preparation. This shows the dentin overhanging the entrances to the root canals that will have to be removed before the canals are instrumented.



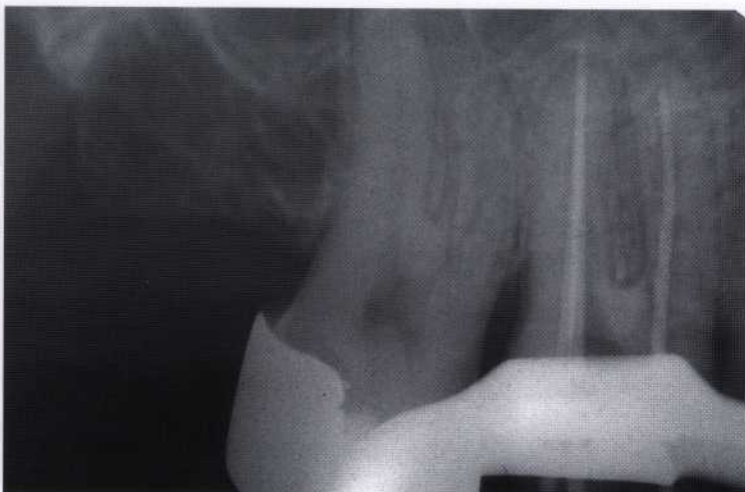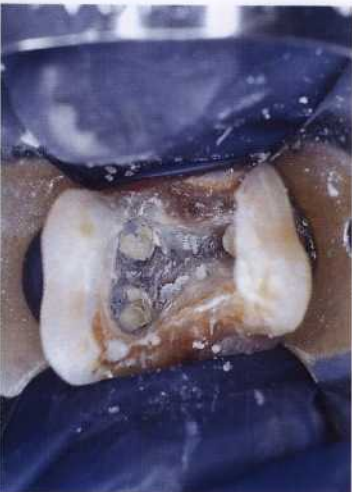The floor of the pulp chamber lies 1-2 mm below the level of the cementoenamel junction. If the location of the pulp chamber is difficult to find, the distance can be measured on a radiograph and transferred to the Endo Access bur. Measurements made with a periodontal probe are also helpful for avoiding perforations. Normally, maxillary first molars have three roots with four root canals; the fourth canal, the mesiolingual, is located in the mesiobuccal root. Images of the two mesial canals may be superimposed on the radiograph. They can be better differentiated on an eccentric projection.

One complication is the curvature to the distal and lingual near the apex. Before instrumenting this portion, the direction of the curve must be determined tactually with a prebent instrument. First, the notch on the rubber stop is turned to face in the direction of the bend and then the instrument is inserted into the canal. The mark on the stop will indicate the course of the canal and the direction of the curve. The stop provides the only check on the orientation of the instrument within the root canal.



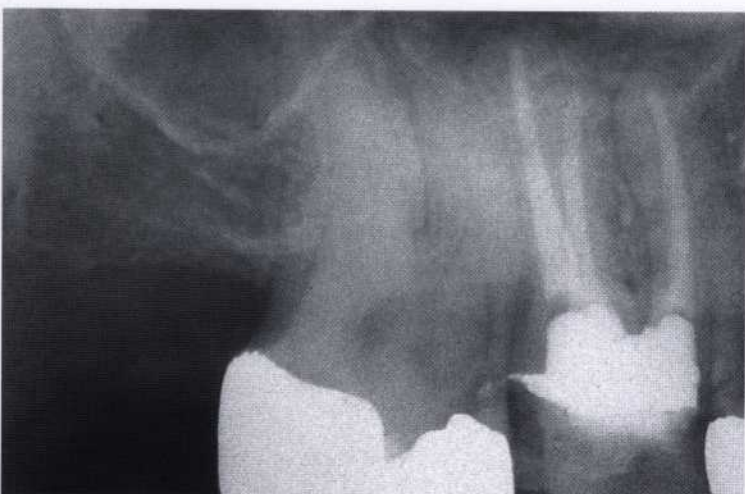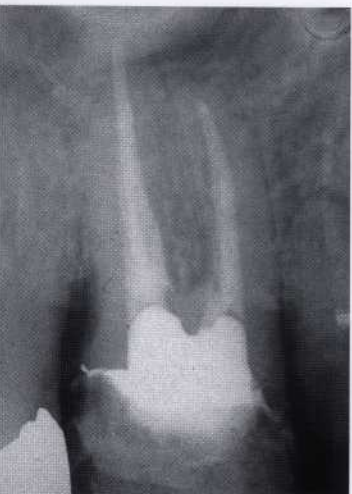
237 Coronal enlargement
The three root canals are first enlarged in their coronal portions and then fully prepared. Visibility into the cavity is excellent, and unimpeded instrumentation is possible.

Left: The walls of the access preparation have been made parallel so that the instrument can pass into the root canal in a straight line.



238 Root canal filling
Removal of the old restoration, a generous access preparation, and unimpeded root canal preparation facilitate fitting and adjusting of the three gutta-percha points with ease.

Left: At the conclusion of lateral condensation, the portions of the gutta-percha points protruding coronally are removed.



239 Follow-up radiograph
Six months after the beginning of root canal treatment and before cementation of the permanent restoration, the periapical region appears normal on the radiograph.

Left: The radiograph taken immediately after treatment shows a dense root canal filling that seals the canals completely.

Obliterated Root Canals

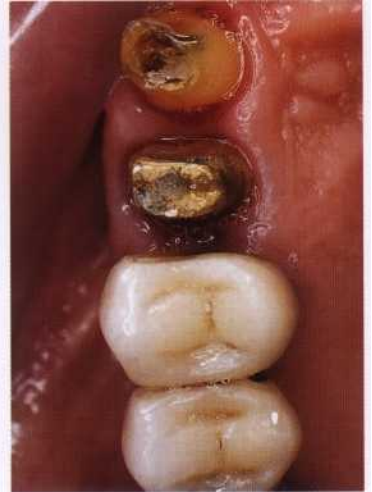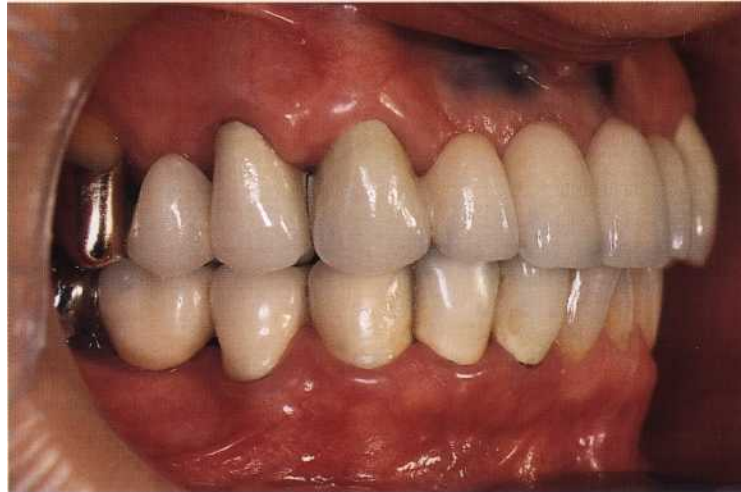The ability of pulp tissue to form hard tissue is not limited to the odontoblastic layer. Fibrodentin can also be deposited in the center of pulp tissue as denticles (pulp stones). These can be found not only in erupted teeth but also in teeth that are still unerupted, in deciduous as well as permanent teeth, and in both young and old teeth (James et al. 1959).

With increasing age comes increased formation of intrapulpal dentin with narrowing of the root canals. These hard-tissue formations are mostly the result of inflammatory processes. With the exception of well-

organized tubular denticles that are formed by odontoblasts, atubular osteoid or lamellar dentinoid hard-tissue formations consist of fibrodentin. They are thought to be formed by spaced pulpoblasts that are identical to the mesenchymal cells of the dental papilla (Baume 1980). There are different hypotheses regarding the origins and classification of denticles. In response to external influences some cells within the pulp die, and concentric denticles form around them. Temperature changes may also play a role.

240 Preoperative clinical appearance
Clinical appearance of a 63-year-old patient before replacement of fixed restorations.

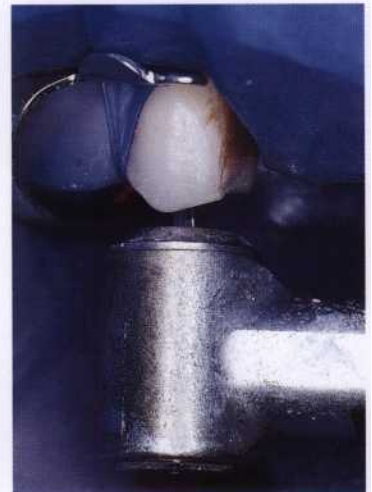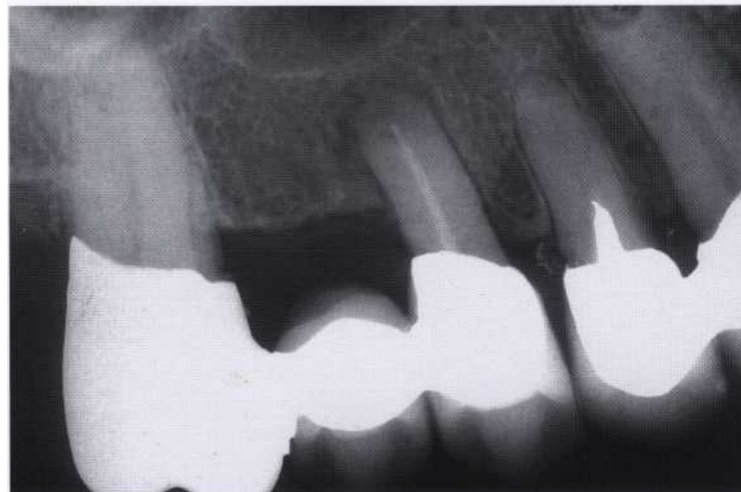Right: Removal of the cosmetically and functionally unsatisfactory fixed partial denture extending from the maxillary right canine to the left first premolar reveals a post-core on the first premolar.



241 Preoperative radiographic appearance

The second premolar appears to have a single root canal with an inadequate root canal filling and a distinct periapical radiolucency. The first premolar has a post-core that is much too short and no root canal filling. The root canal is partially obliterated and barely identifiable.

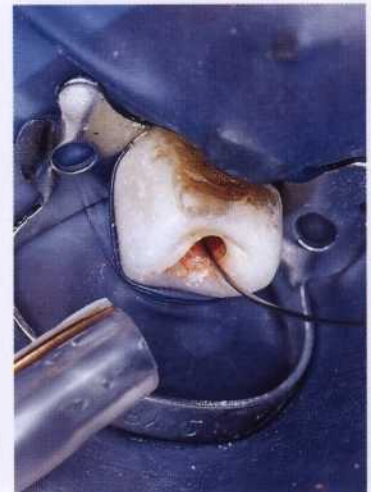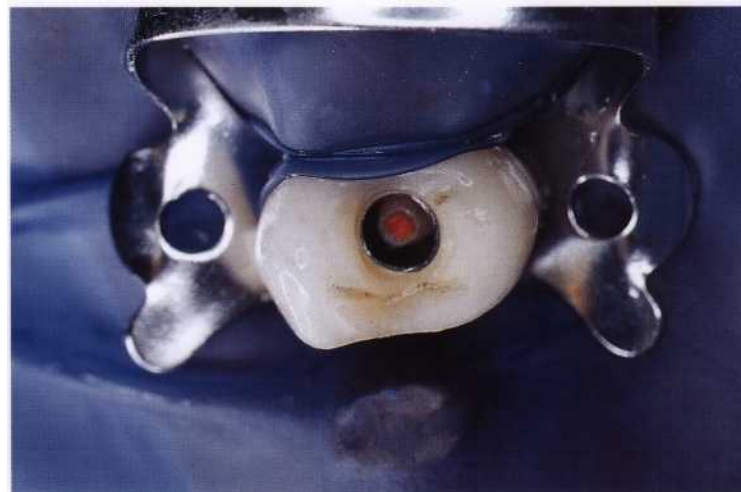Right: Opening through the artificial crown on the second premolar under copious water spray.



242 Root canal situation

After making an access preparation through the metal-ceramic crown on the second premolar, low magnification loupes are used to find a single canal that has been filled with cement and one gutta-percha point according to the central point technique.

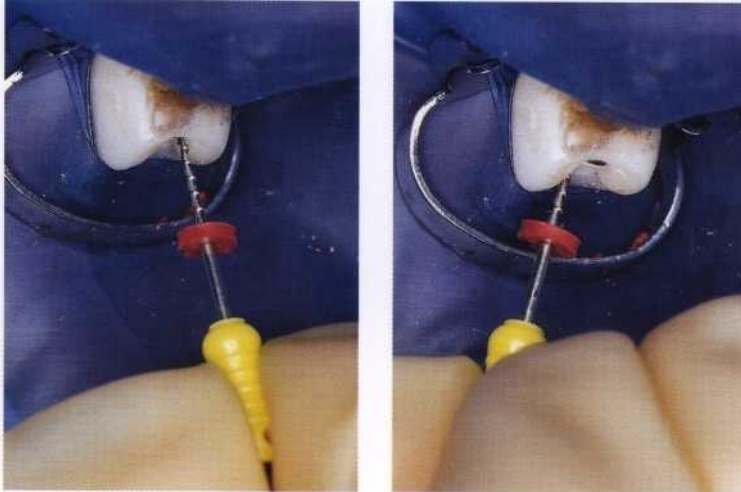
Right: The inadequate root canal filling of gutta-percha and cement is removed and the canal flushed with sodium hypochlorite solution.



Diffuse mineral deposits within the root canal are composed of amorphous calcium phosphate. They are found along blood vessels or collagen fibers and occur even in clinically intact teeth. In carious teeth, however, a significant increase in mineralization can be noted (Seltzer et al. 1963). As a result of chronic inflammation, denticles and mineral deposits in the pulp are rather the rule. With advanced caries, mineralization becomes even more extensive. This can lead to complete obliteration of the canal (Beer et al. 1986 b).

Cvek and Lundberg (1983) found mineralization with lamellar denticles and diffuse deposits in 50% of teeth with fractured crowns. In 25% of the cases, inflammatory cells could also be found.

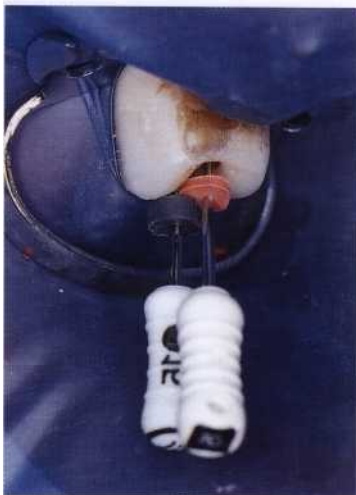
In patients 10-20 years of age, mineralization appears in only 8% of the pulps, whereas carious teeth in the same age-group experience an incidence of 36%. In the 45-63-year age-group, 90% of the teeth investigated exhibited calcifications. These cannot be clearly seen in radiographs until they reach a size of 200 μm , however (Tamse et al. 1982).



243 Canal enlargement

Left: Circumferential filing with Hedstrom files for uniform instrumentation of the root canals. At the same time the entrance to a second canal is found.

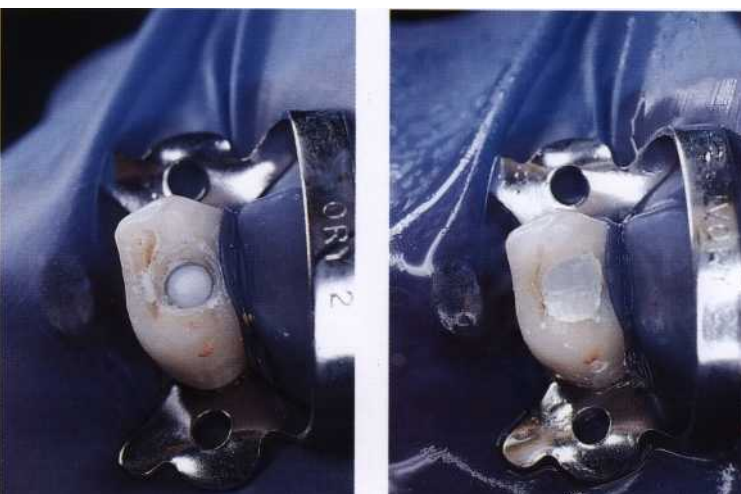Right: The initial coronal enlargement is accomplished with Hedstrom files using a circumferential filing technique.



244 Length determination

After opening and reinstrumentation of the previously filled canal, the working lengths and the exact positions of the files within the canals are determined.

Left: In order to better differentiate the canals in the radiograph, a Hedstrom file is placed in one canal and a size 15 K file in the other.



245 Provisional closure

Left: As an interim dressing, a thin suspension of calcium hydroxide is packed into the canals with paper points. The coronal portion of the cavity is then thoroughly cleaned.

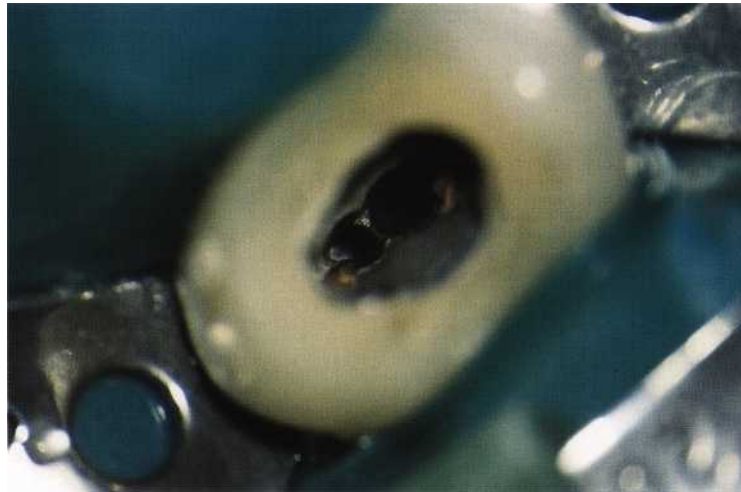
Right: The access opening must be carefully sealed to prevent recontamination with bacteria.

Locating Canals with the Surgical Operation Microscope

The surgical operation microscope has been used for microsurgical procedures in the head and neck region for years. Microsurgery was introduced approximately 38 years ago in a report by Jacobsen and Suarez (1960) in which they described suturing tiny blood vessels under a microscope. As much as 40 years earlier, otorhinolaryngologists had recognized that operations on the smallest structures were limited primarily by the capacity of the human eye. Nylen employed a monocular microscope for surgery on the inner ear as early as 1924.

Viewing the root canal by means of a surgical microscope demanded a completely new system of instrument use. The operator must work in the 12-o'clock position with the help of a mirror for both maxillary and mandibular teeth, and the working time is significantly increased. The working field must be dried more frequently for a better view. A specially developed irrigating syringe (Stropko, EIE) is well suited for this. The surgical operation microscope is brought into position to search for the canal orifices only after the access cavity has been prepared.

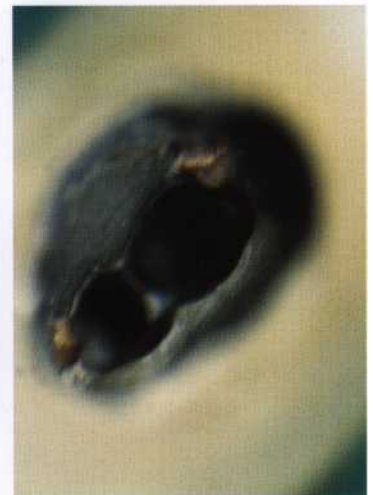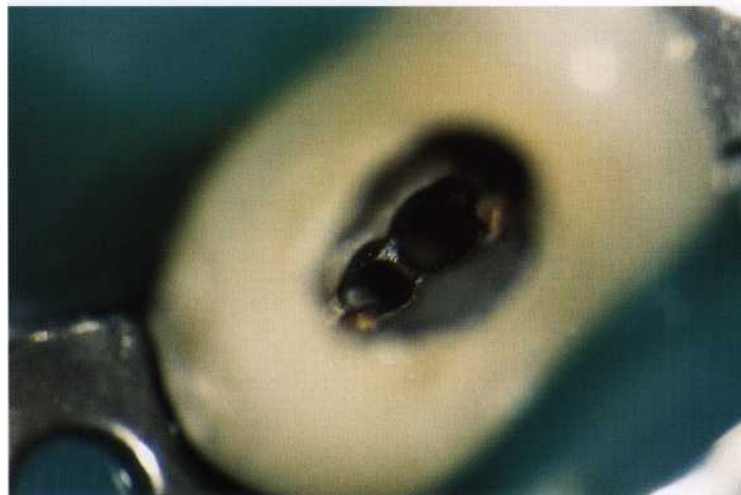
246 Access preparation
With the use of a surgical operation microscope at 10x magnification, two separate root canals can be seen in the second premolar, which appears on the radiograph (Fig. 241) to have only one canal.



247 Locating obliterated canal entrances
In the clinical case described on pages 100 and 101, the two separate root canal orifices can be seen very clearly under higher magnification.

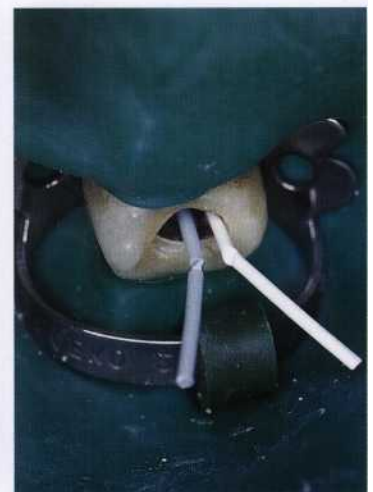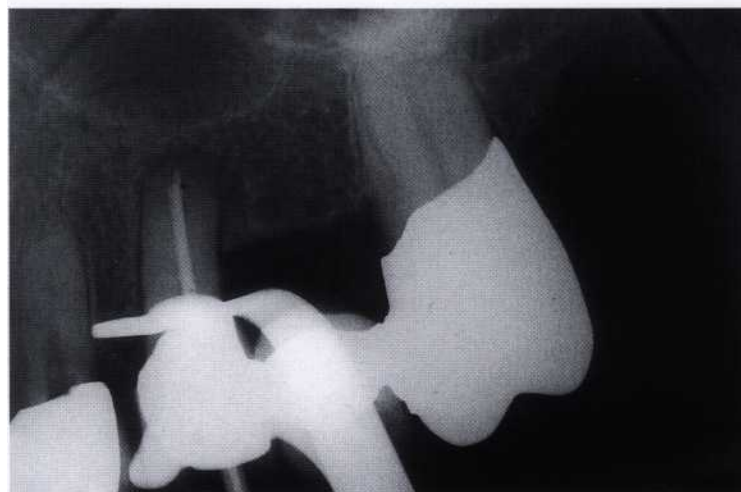
Also, the floor of the pulp chamber can be probed and the straight portions of the root canals can be followed visually.

Right: Evaluation of the access preparation under 25x magnification.



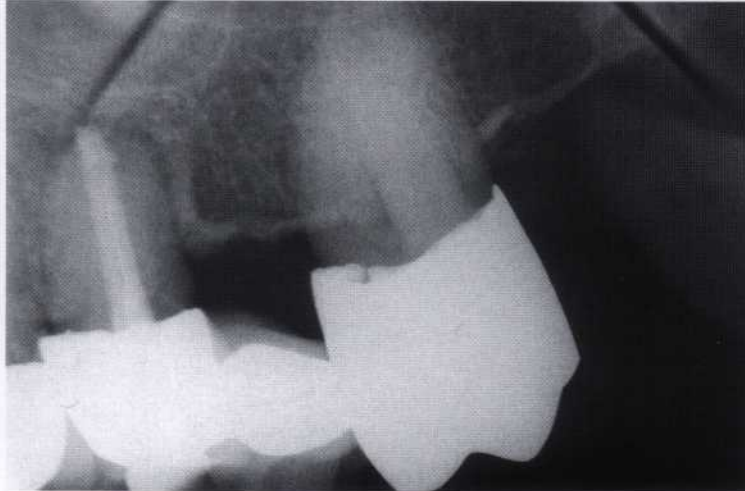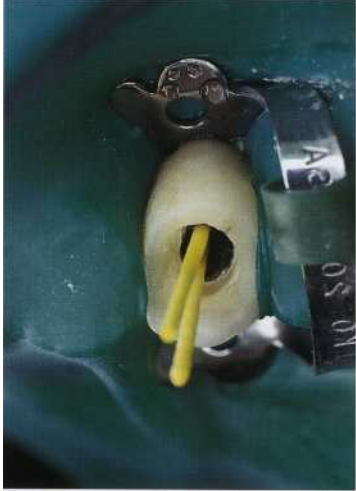
248 Filling the root canals
Following completion of instrumentation, the two gutta-percha master points are fitted. Their exact position is then checked with a radiograph.

Right: The working length is marked on the gutta-percha points by marking them with cotton pliers. Both points are then placed into the canals.



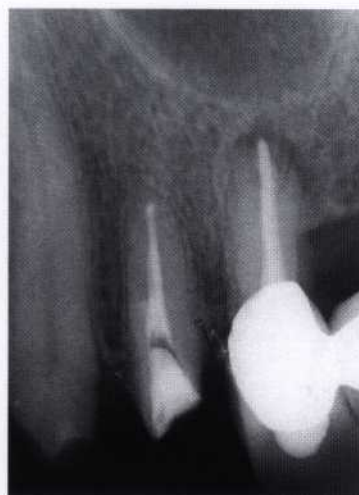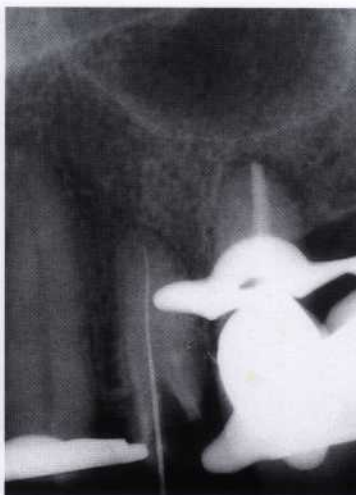
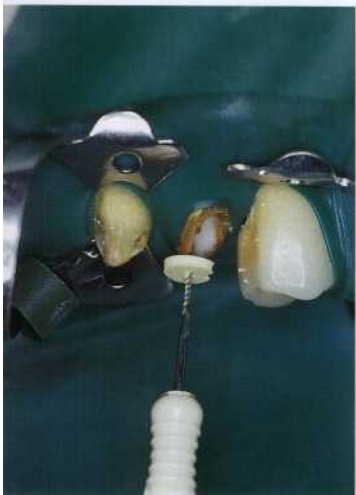Once the entrance to a root canal has been located, a size 08 K file, 21 mm long, is slowly inserted. A size 10 instrument is too thick for the initial entry and a size 06 is too flexible. The apical portion of the instrument is prebent and the direction of the bend is identified by the notch on the rubber stop. The 21-mm size 08 file is flexible enough to work past calcifications and curves without contributing to an iatrogenic blockage. During the preparation a switch can then be made to larger and longer instruments.

The instrument is inserted into the root canal with only light pressure. The correct position and insertion depth must be repeatedly checked with measurement radiographs in order to prevent creating a false path. Each time the file is removed, it is thoroughly cleaned and sterilized before reinsertion. Copious irrigation with sodium hypochlorite will not only remove dentin filings but will also dissolve the pulp tissue. Ultrasonic files must not be used until after the working length has been reached with hand instruments (Gutmann et al. 1991).



249 Radiographic evaluation
By using an eccentric radiograph the two separate root canal fillings can be easily followed all the way to the radiographic foramina.

Left: Before the final filling of the root canals, they are thoroughly dried with paper points and evaluated once more with the surgical operation microscope.

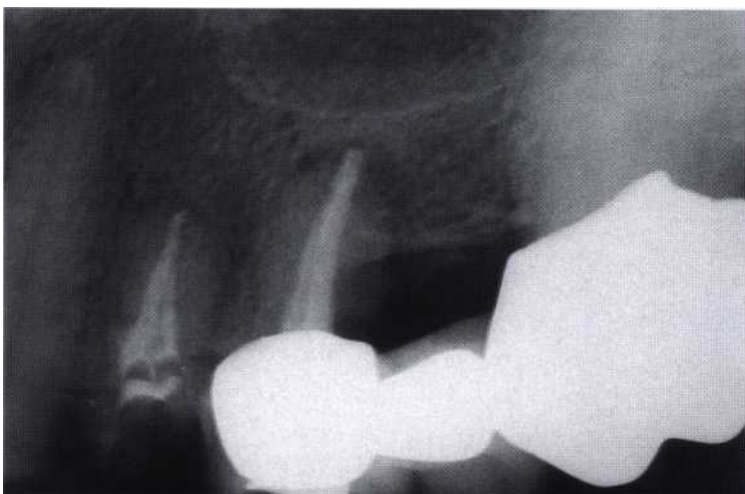

250 Opening obliterated root canals

Left: One canal of the first premolar (case presented in Fig. 240) is carefully opened millimeter by millimeter using a K file and a chelating agent.

Center: A radiograph is taken to determine the location of the file. When the correct working length has been reached it is measured and recorded.

Right: A final radiograph is taken in the orthoradial direction to evaluate the root canal filling.



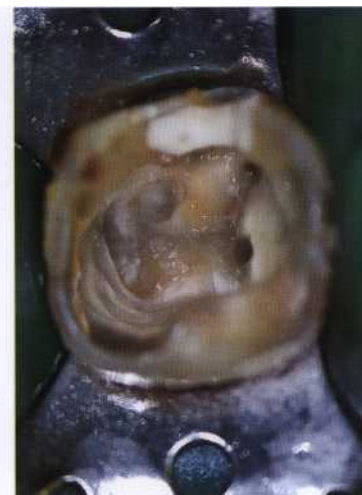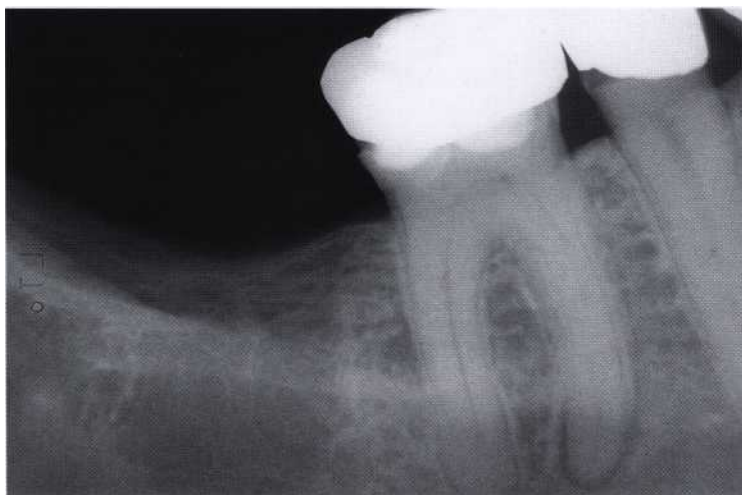
251 Radiographic follow-up
On this radiograph taken at an eccentric angle 4 months after root canal treatment, two separate canals can be clearly distinguished in each of the two maxillary premolars. Those of the first premolar unite shortly before the apex to form a single canal.

Chemical Aids

Some of the dangers associated with the initial instrumentation of curved root canals are blockage with dentin chips, excessive apical enlargement, and perforation. Obstructions in the apical regions of root canals are seldom present before treatment is started. The majority are created by improper instrumentation. These obstructions can only rarely be overcome. A lubricant that contains ethylenediamine tetraacetic acid (EDTA) should be used prophylactically to avoid creating obstructions.

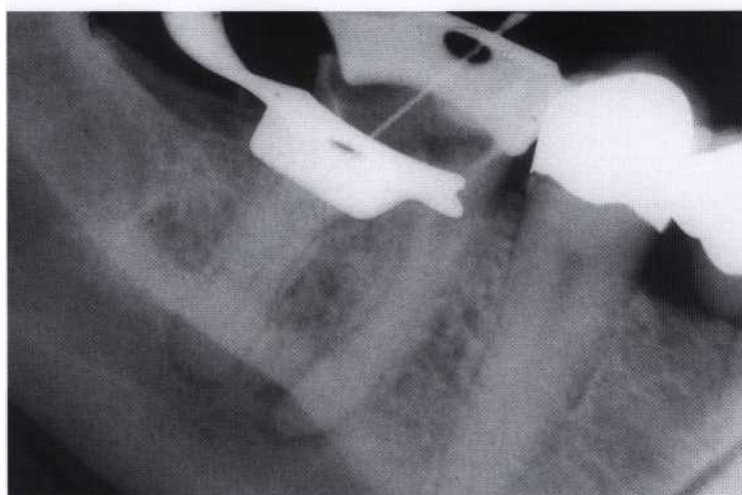Such lubricants can prevent compaction of pulp-tissue remnants and dentin fillings until the coronal portion of the canal has been enlarged enough to permit sufficiently deep penetration of the irrigating solution. As early as 1957, Nygaard-Ostby employed the chelating agent as an aid in endodontic instrumentation. It decalcifies dentin by binding the calcium in an electro-negative complex, and in this way can overcome blockages within the root canal (Burck 1988).

252 Obliterated canals
Mandibular first molar with periapical radiolucency and necrotic pulp. On the radiograph it appears that all canals are patent. What appears to be a pulp exposure that has been directly capped can be seen in the mesial part of the crown.



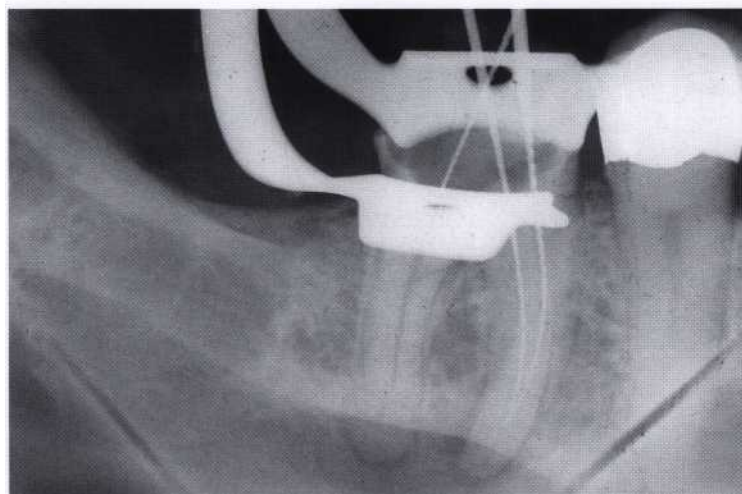
Right: After removal of the crown, the orifices of the root canals, especially that of the distal, were not easy to identify.

253 Locating the canals
After successful location of the entrances to the canals with an explorer, the distal canal proves to be blocked so that the file cannot be inserted into the entire length of the canal. On the first working-length radiograph the shallow penetration depth can be seen, although the file is within the root canal.



Right: Before penetrating deeper, the length of the root canal must be determined with a measuring gauge.

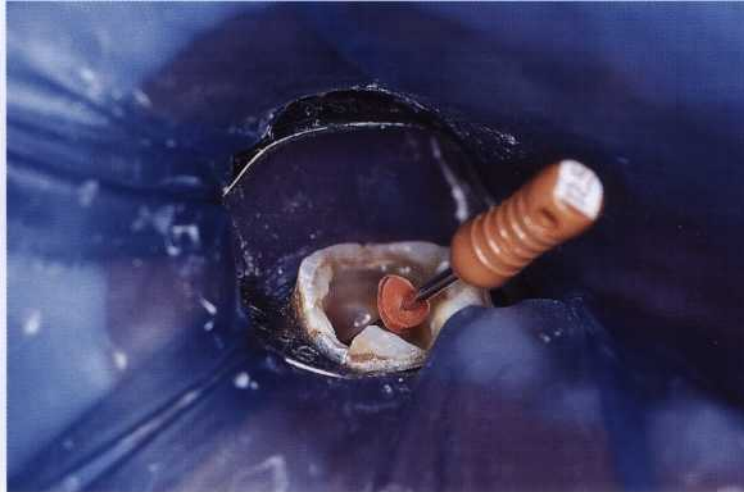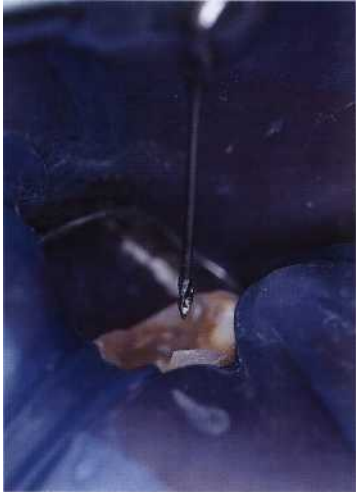254 Overcoming obstructions in the root canals
The second working-length radiograph shows that both mesial canals have been penetrated, though not yet all the way to the apical constriction. The distal canal is still largely blocked.



Right: Intraoral view of files in place for radiographic determination of their progress.

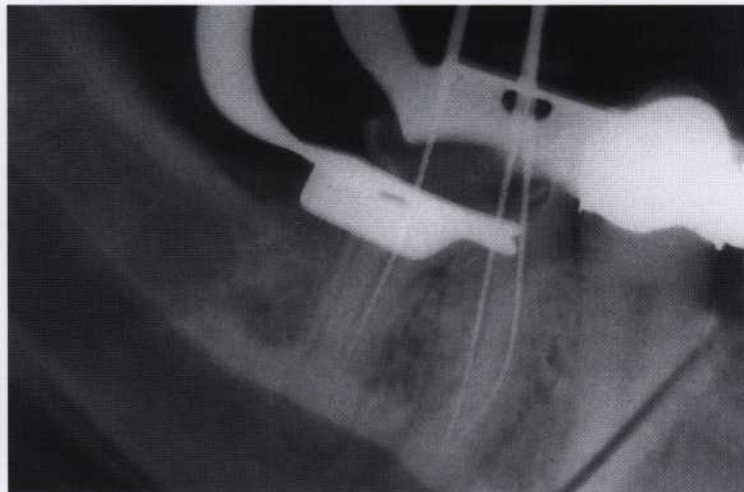
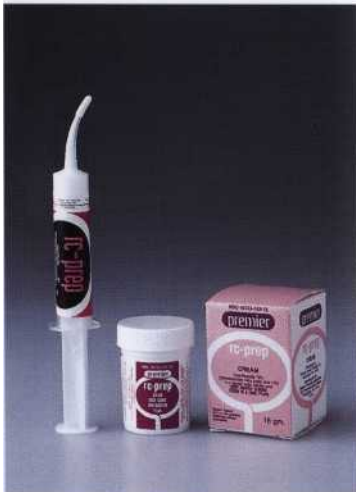EDTA can increase dentin permeability and thereby have a positive effect of the debridement of the root canal (Goldberg and Abramovich 1977). Because of the slow action of this hard-tissue demineralizing agent, decalcification of the dentin is not very apparent. Stewart et al. (1969) recommended use of the product RC-Prep (Premier Dental; 15% EDTA and 10% urea peroxide in a water-soluble glycol base) during instrumentation. RC-Prep has a very good lubricating and cleansing action.

To establish initial penetration of an obliterated root canal, the tip of a K file is moistened with a small amount of RC-Prep and then inserted into the root canal with small rotating motions. Working past an obstruction is very time-consuming. Immediately after removal from the canal, the file must be carefully cleaned with a sterile gauze sponge. Finally the canal is flushed with Sodium hypochlorite solution that increases the dentin permeability, releases more oxygen, and neutralizes the EDTA.



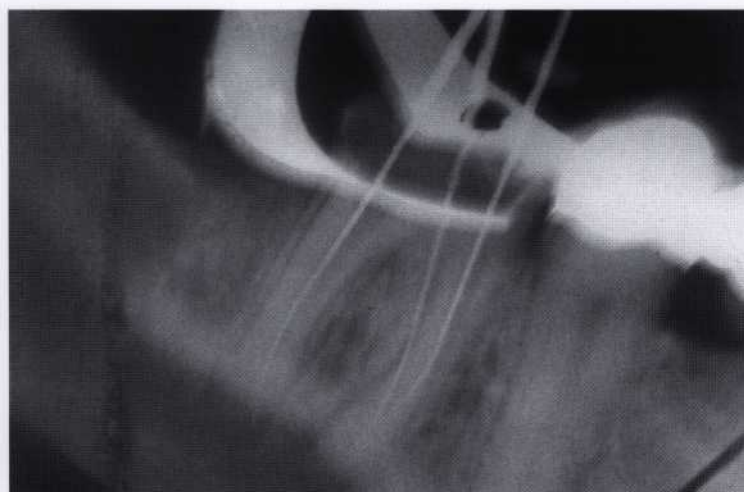255 Coronal enlargement
Using K files and gentle quarter-turn motions, the distal canal is instrumented until clear passage is achieved. In order to avoid blockages, file sizes are increased by half steps.

Left: Once the root canal has been made patent manually, it is carefully enlarged with Gates-Glidden drills so that the working part of the files will not bind.



256 Chelating agents
Deeper penetration was not possible without the help of a chelating agent for demineralizing and lubricating the canals. On the radiograph, penetration of the mesial canals appears to be almost complete, but the distal file is still well short of the final working length.

Left: RC-Prep contains EDTA and urea peroxide. It has very good lubricating and cleansing properties.



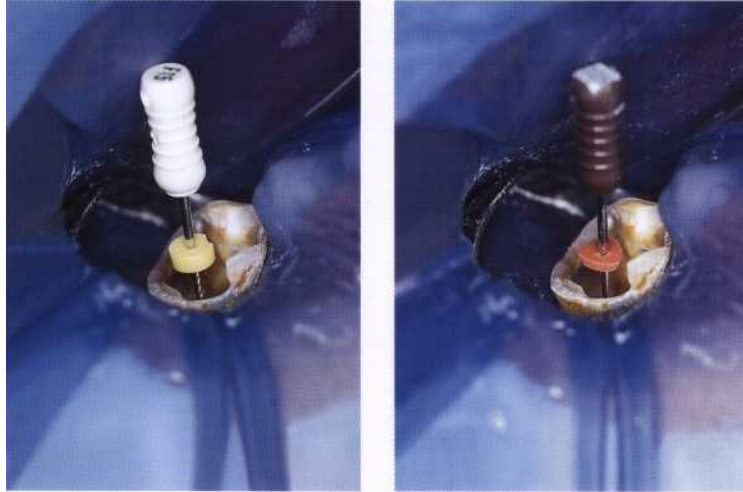
257 Working depth
The obliteration is finally cleared after a lengthy procedure using finger instruments and the chemical solution. The fourth radiograph verifies that passage through the canal has been achieved.

Left: Different types of files are inserted into the two mesial canals for easier radiographic differentiation. The stops are set at the coronal reference point.

258 Instrumentation

Left: Enlargement of the root canals is started with a size 15 K file to the working length as determined on the radiograph.

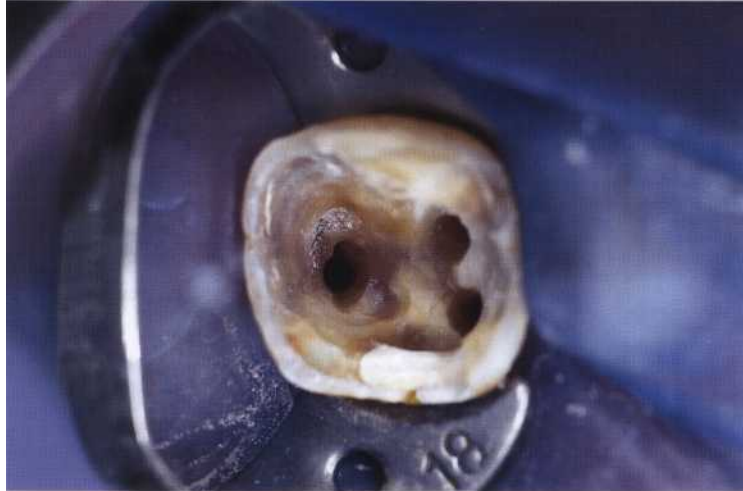Right: Because the canals are narrow and more sharply curved in the apical region, it is necessary to use intermediate-sized files in the initial phase of instrumentation. To avoid creating a blockage, instrument sizes are not increased by full-step increments until after size 7.5.



259 Conical shaping

The root canal is prepared through three or four instrument sizes and then enlarged more coronally to create a conical form. Notice the almost circular and substantially wider cross-section of the root canals.

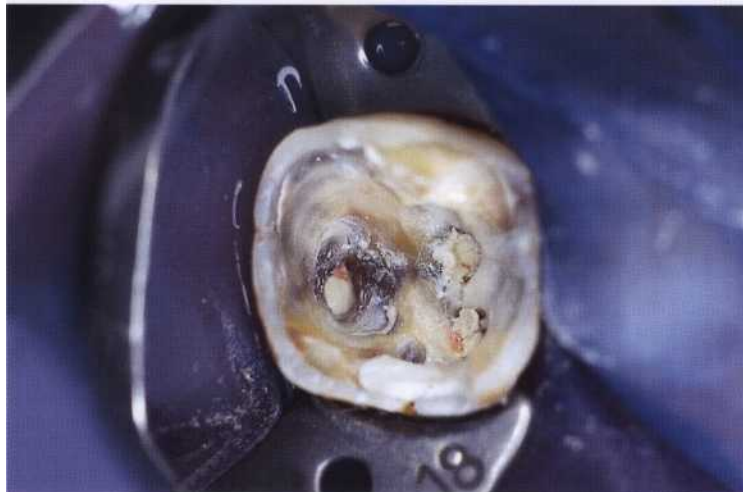Right: The conical canal form can be achieved either with the step-back technique using only K files or by engine-driven instrumentation.



260 Root canal obturation

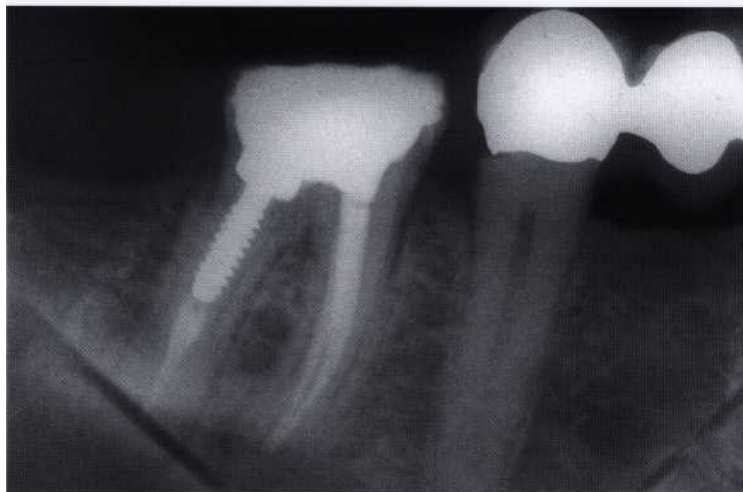
After drying the canal it is tightly packed with gutta-percha and a sealer. The excess is then removed at the level of the canal orifices.

Right: The root canals are filled with gutta-percha using the lateral condensation technique.



261 Final radiograph

After filling all three canals, the distal canal is prepared for a threaded post-core which is cemented at the same sitting. A radiograph is taken to evaluate the endodontic treatment. Comparison with the initial radiograph (Fig. 252) shows that it is possible to achieve good length and enlargement of the canals even though they were originally very narrow and partially obliterated.

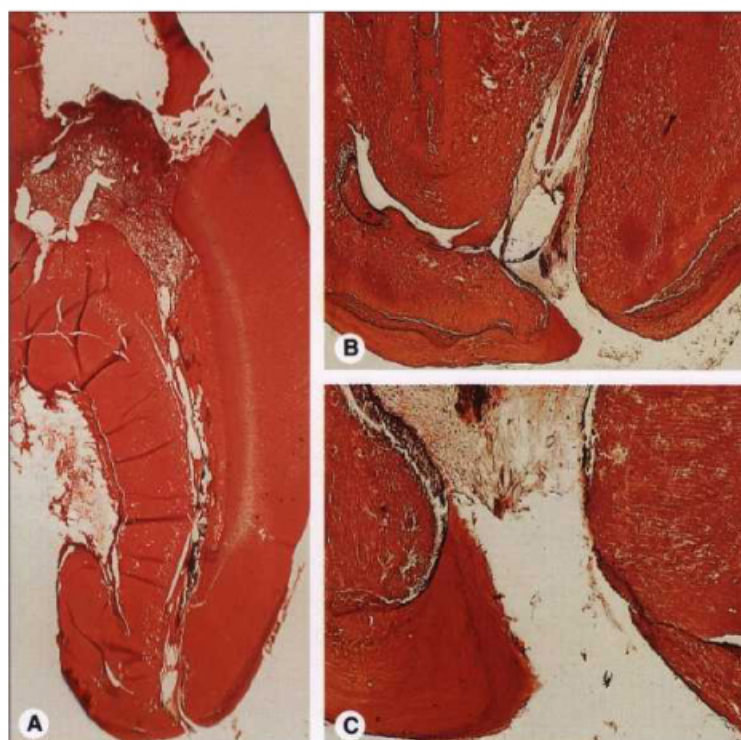


Root Canal Preparation

The goals of root canal preparation are to clean all bacteria and necrotic pulp-tissue remnants from the canal and to give it a shape that will allow the entire canal to be filled with a biologically inert material. The preparation should extend to the narrowest part of the root canal, the apical constriction. The prognosis of root canal treatment is then clearly at its best (Beer and Baumann 1994 a).

In most teeth the apical constriction corresponds to the dentinocemental junction, which is where the dentin of the root canal meets cellular cementum. The apical foramen is the circumference at the end of the root canal where pulp tissue is continuous with the apical periodontal tissue.

In 1931, Grove recommended the dentinocemental junction as the ideal end-point for root canal preparation. Kuttler (1955) further developed this idea with his extensive histologic investigation on more than 400 teeth, and described very precisely the location of the apical constriction and its relationship to the apical foramen. In 56% of the teeth studied the dentinocemental junction was found to be at the same level on both sides of the root canal. In the remaining teeth it lies at different levels on the two sides of the canal. The mean distance between the center of the apical foramen and the apical constriction in people younger than 25 years of age was 0.52 mm, and 0.66 mm in those older than 55 years. However, the reference point for this measurement was not the radiographic apex.



262 Details of the apex

A Histologic section of the lingual root canal of a maxillary first molar with necrosis and ulcerating pulpitis. The root canal is partially constricted by hard tissue, contains pathologic calcifications, and has an S-shaped curvature with a bend to the distal near the apex.

B The constriction above the apical foramen lies at the level of the dentinocemental junction. The apical foramen opens laterally above the anatomic apex.

C This enlarged section shows the dentinocemental junction that lies at different levels on the two sides of the apical constriction.

Radiographic Length Determination

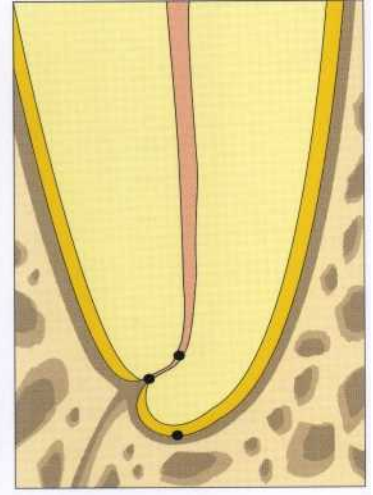
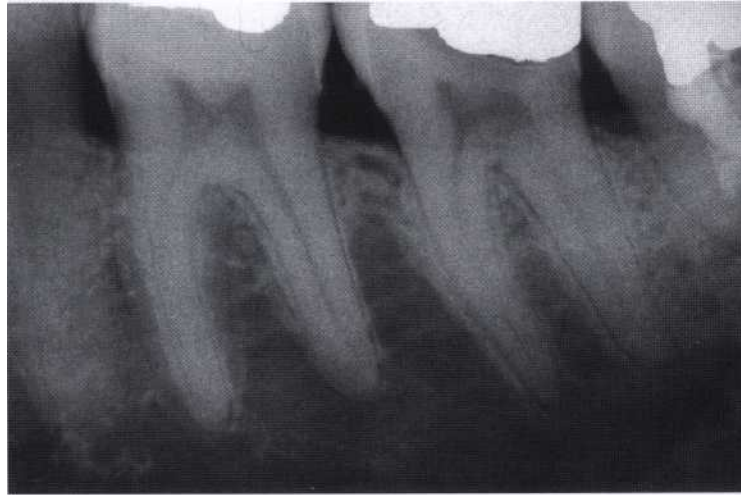The root canal preparation should end shortly before the apex. The anatomic apex is defined as that point on the root that is farthest from the incisal edge or occlusal surface. The radiographic apex, on the other hand, is the furthestmost point on the radiograph. Its location may be different from that of the anatomic apex. The apical foramen is the opening at the end of the root where pulp tissue and periodontal tissue merge. The apical constriction lies within the root canal just coronal to the apical foramen and represents the narrowest part of the canal (Simon 1993b).

The exact determination of the working length is one of the most important steps in endodontic treatment and makes the difference between success and failure. This determination can be made on the radiograph and may be supported by tactile feedback and electronic aids. Blood or exudate on the paper point while the canal is being dried are also important clues to the working length. Blood on the tip is evidence of excessive enlargement of the apical foramen with overinstrumentation, while blood on the side of the paper point indicates a slit-like lateral perforation (Beer 1995).

263 Diagnostic radiograph

A radiograph taken before treatment for diagnostic purposes can provide information on the anatomy of the root canals.

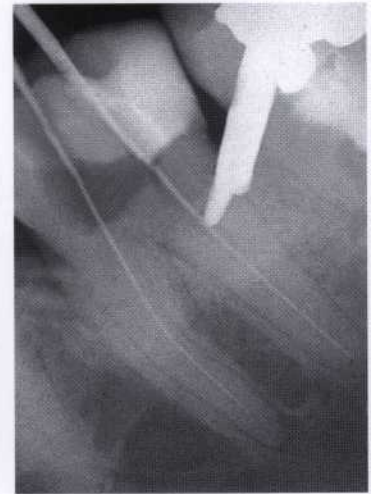
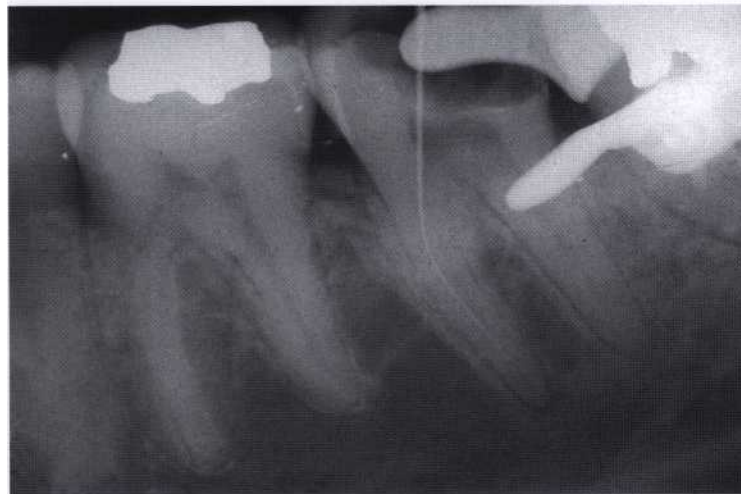Right: Schematic representation of the anatomic details in the apical region showing the apical constriction (2) as the narrowest part of the root canal and the anatomic apex (3). Necrotic and infected tissue may be present between the beginning of the apical curve (1) and the apical constriction.



264 First working-length radiograph

After making an access opening in the lower second molar and identifying the canal orifices, the root canals were probed. The two mesial canals are superimposed and so they were measured one at a time. The K file in the mesiobuccal canal is 2 mm too short.

Right: The next measurement of the distal and mesiolingual canals shows that the preparations in both of these canals are also too short.




265 Measurement correction

Measuring instruments for transferring the determined working length to the root canal instruments.

Above left: Guldener measuring block. Below this is a measuring device (Maillefer) to be worn over the ring finger.

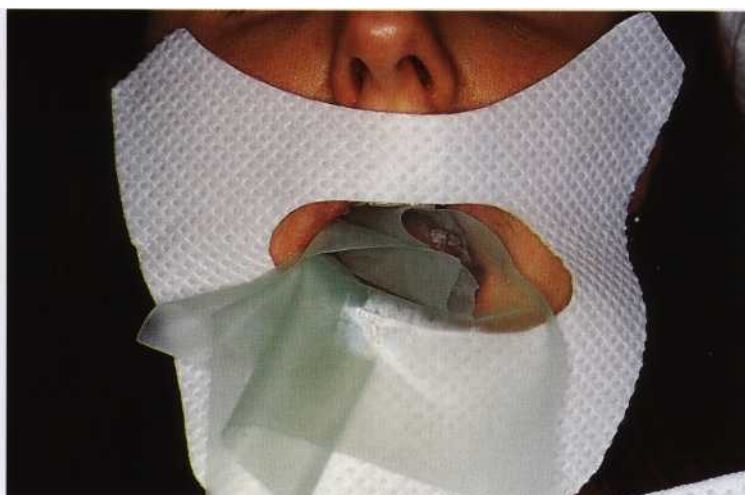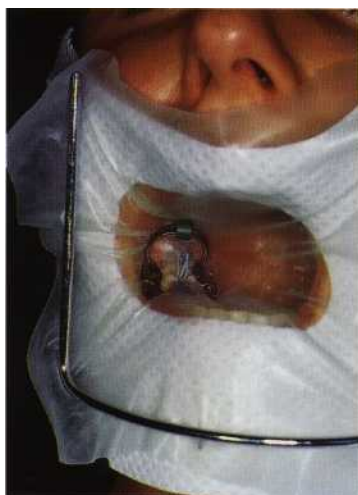Right: Ruler with a sponge to hold files (by Buchanan).



Because the apical constriction cannot be directly determined on the radiograph, the tooth length is determined by the distance between a coronal reference point and the radiographic apex. For this a radiopaque object must be placed in the root canal. The working-length radiograph with a size 15 steel file inserted into the canal(s) provides information on, among other things, root canal anatomy, the number of root canals, and the direction of canal curves. The establishment of a reproducible fixed reference point is essential for determining the working length. If the images of multiple

canals might be superimposed on the radiograph, a Hedstrom file is placed in one canal and a K file in the other. In addition, another exposure can be taken eccentrically with the X-ray tube directed more mesially or more distally.

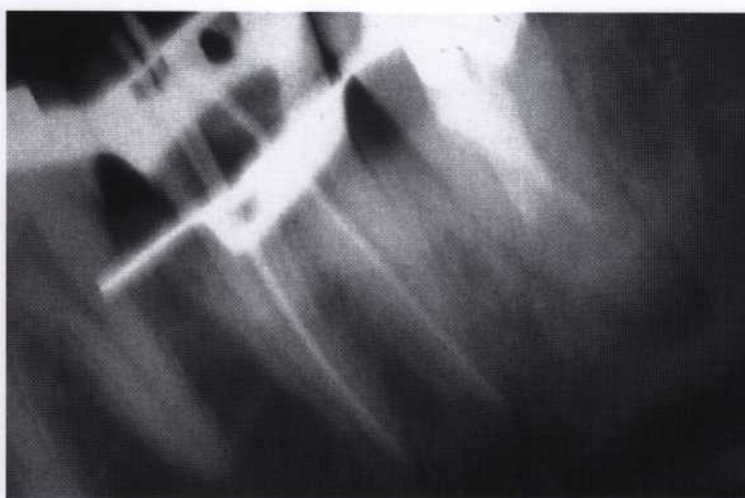
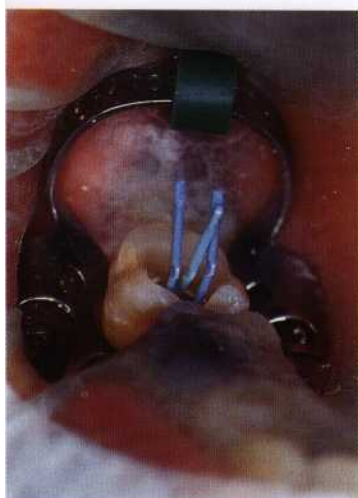
The canal length can be somewhat altered during the instrumentation process through reduction of the curvature of the canal, so that additional working-length radiographs may become necessary. Deviations in length greater than 2 mm must be clarified and corrected with the help of an additional radiograph.



266 Radiograph with rubber dam

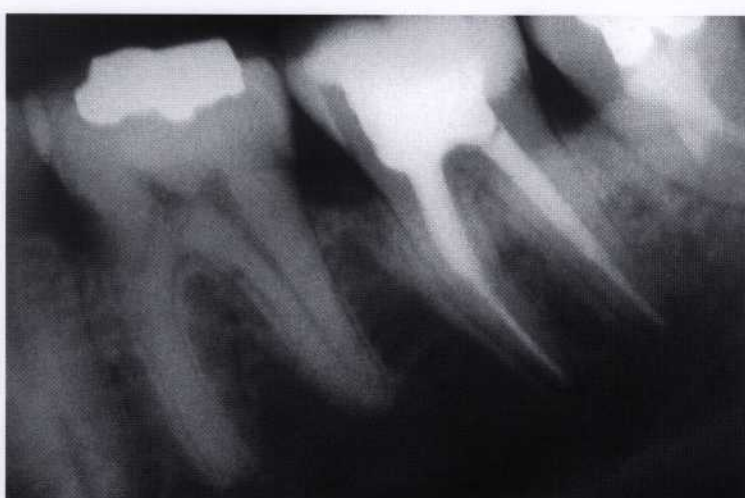The metal frame must be removed when the working-length radiograph is taken. Plastic frames or folding frames can be left in place. However, this does make exact placement of the film more difficult.

Left: After the film is exposed the rubber dam is stretched over the frame again. In the meantime the radiograph is developed by a rapid process.



267 Master point radiograph
After completion of the root canal preparation, three gutta-percha master points are inserted and measured on another radiograph so that the preparation can be reevaluated. Corrections of the root canal treatment can be made at this stage without great expenditure of time.

Left: The working length is marked on each gutta-percha point by making an indentation with pliers. This is a relatively imprecise indicator, however.



268 Immediate postoperative radiograph

After completion of the root canal filling, the result is evaluated with a final radiograph. The filling length is correct, being neither overfilled nor underfilled.

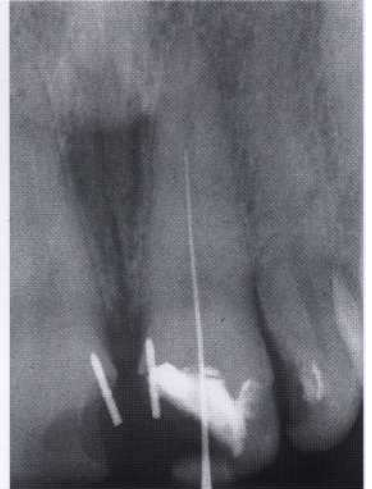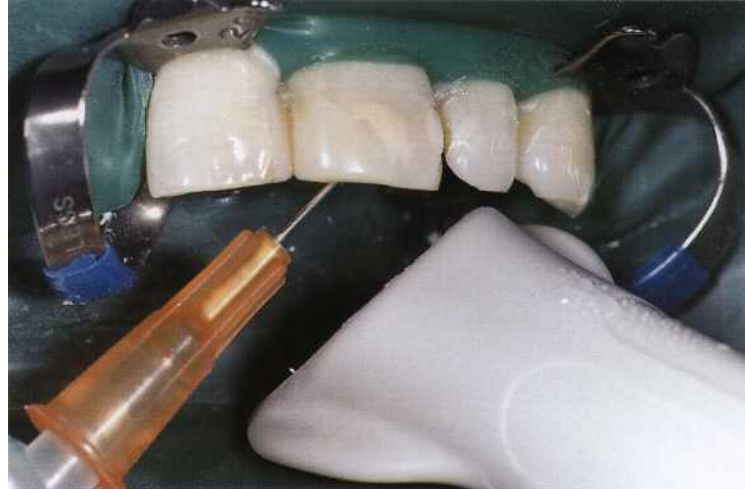Difficulties in Length Determination

The tooth length corresponds to the distance between the coronal reference point and the anatomic apex, while the working length is that between the coronal reference point and the apical constriction. The apical constriction, however, cannot be definitely determined clinically. The philosophy of the correct end-point for root canal instrumentation is derived from a study by **Kuttler (1955)** who determined the average distance between the apical constriction and the center of the apical foramen to be 0.52 mm. The preparation should end 0.5 mm short of the radiographic apex (**Voss 1993**).

This arbitrarily chosen end-point should protect the apical foramen from being enlarged and help prevent bacteria from being forced into the periapical space. To be sure, this length determination can leave masses of bacteria remaining in the critical apical zone so that a periapical lesion can develop after endodontic treatment. The critical zone comprises the apical 3 mm of the canal. Therefore, to completely eliminate all bacteria and their products it makes sense to instrument all the way to the radiographic apex (**Simon 1993b**).

269 First instrumentation

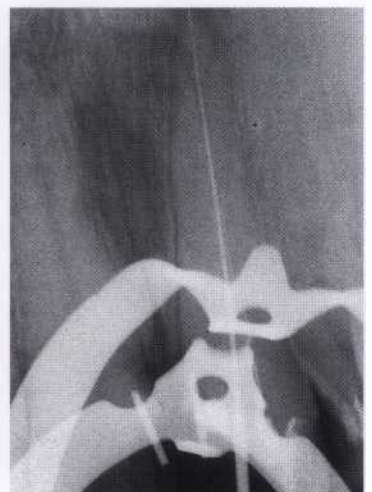
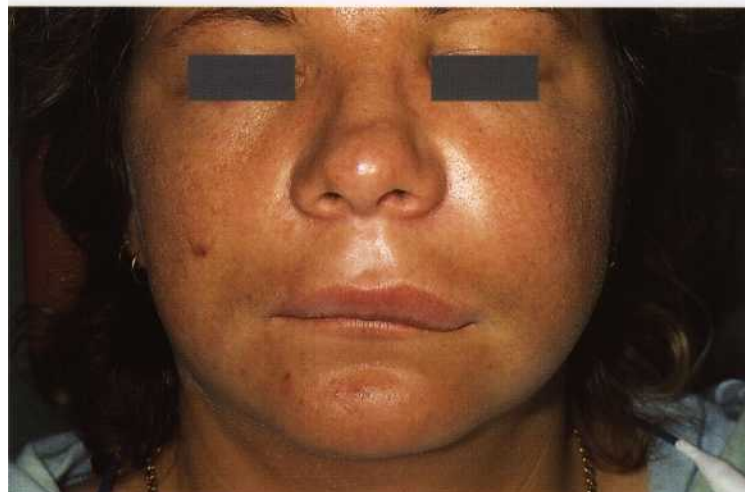At the first appointment, the canal of the left central incisor is instrumented and irrigated with sodium hypochlorite, and a corticosteroid-antibiotic dressing is spun into the canal.



Right: The first radiograph shows that the file is 4-5 mm short of the desired working length, and a calculated correction is made. However, no definite length determination is made, thus bacteria are still present in the uninstrumented apical portion of the canal.

270 Overinstrumentation

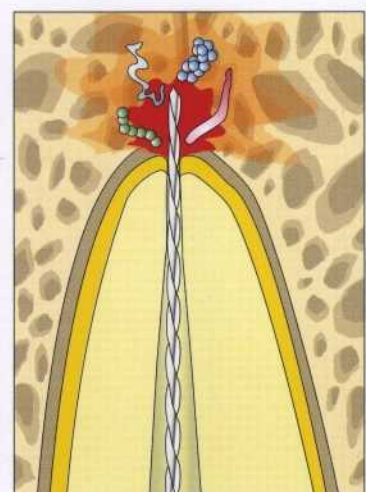
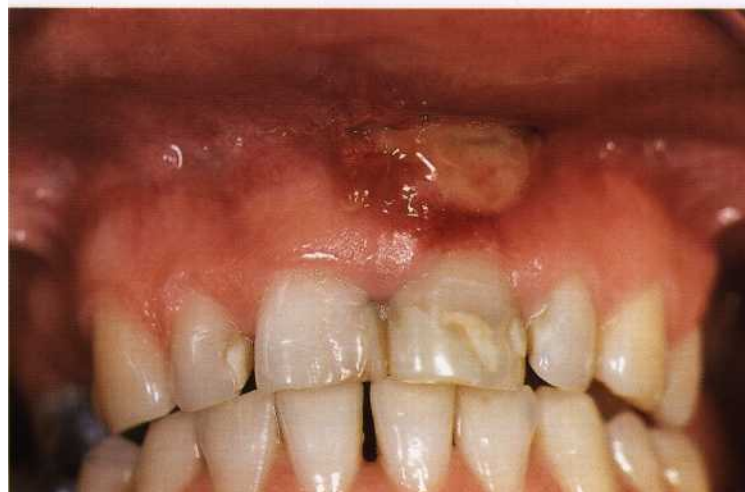One week later the root canal is reopened, completely instrumented, and filled with calcium hydroxide as an interim dressing. Twenty-four hours later the patient returns with severe swelling.



Right: The cause of the acute postoperative reaction with massive pus formation was a slight overextension of the measurement file with transportation of bacteria.

271 Emergency treatment

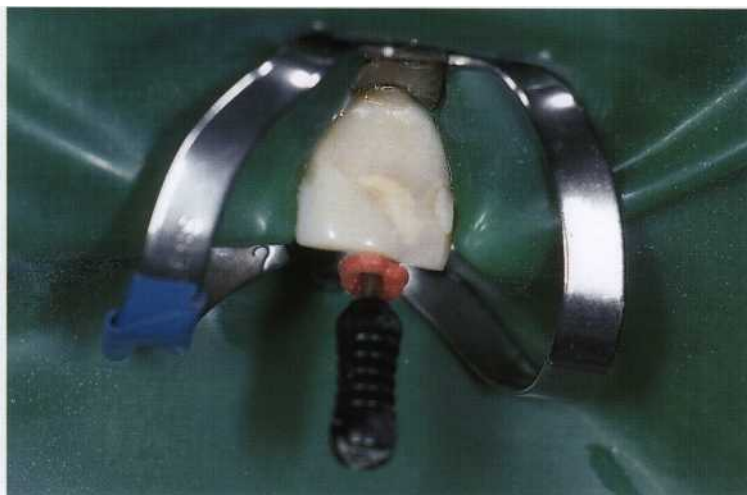
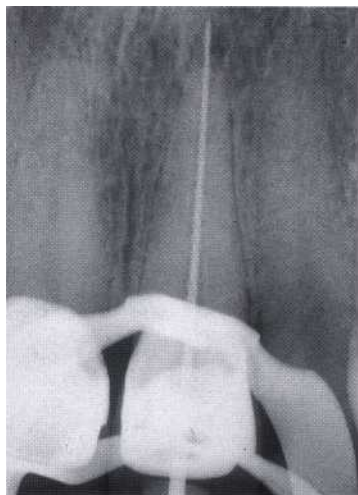
Because drainage of pus cannot be accomplished through the root canal, it is necessary to make an incision. This brings about an immediate improvement in the clinical symptoms.



Right: When the length determination is incorrect, bacteria can multiply in the untreated portion of the canal and then be transported past the apex into the periapical space by instruments, causing an acute postendodontic infection.

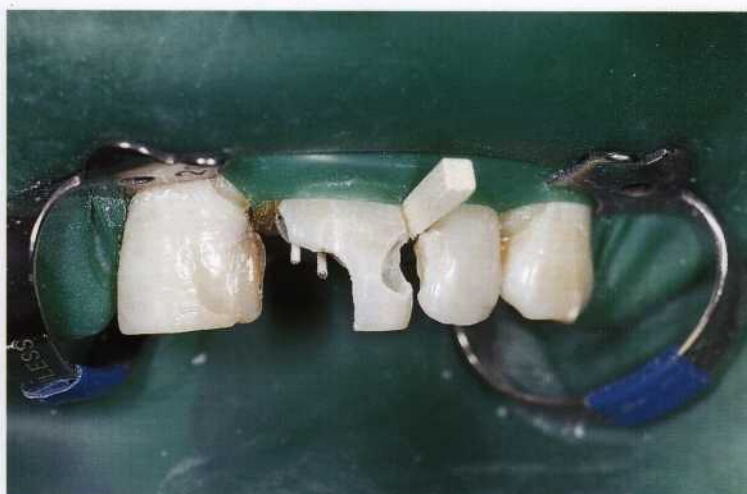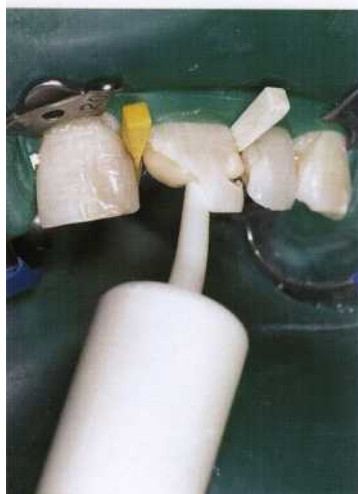
The radiographic apex is the only point that can be used for measurements. The distance between the apex and the constriction cannot be clearly determined. Van de Voorde and Bjorndahl (1969) found that on average, the distances from the anatomic apex are 1.1 mm to the apical constriction and 0.3 mm to the apical foramen. The working length was determined with absolute precision in 75 % of cases (Negm 1983). Forty-five percent of instruments that ended slightly short of the radiographic apex actually extended out of the apical foramen (Chunn et al. 1981).

Upon visual evaluation after surgical exposure, only 30% of the measurement files were found to be in the correct position (Kollmann 1985). One-fourth of root canal treatments that appeared correct radiographically proved to be inadequate after the teeth were extracted (Kersten et al. 1987). A direct adjustment of the working length from the radiograph is hardly possible because of distortion due to the projection technique. The right-angle technique increases the true tooth length by approximately 7% (Rocke 1993).



272 Length determination
Five days after incision and drainage the symptoms have subsided and the root canal is reinstrumented. Calcium hydroxide is then tightly packed into the canal.

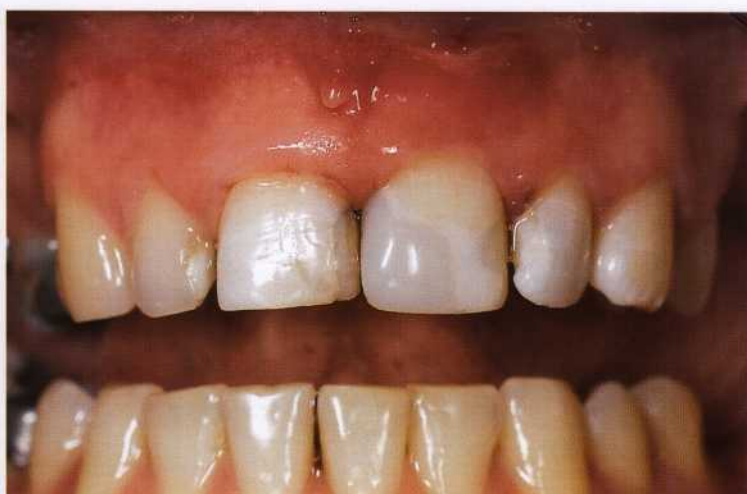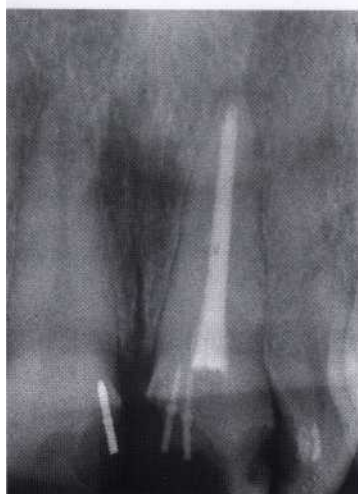Left: Determination of the working length before further instrumentation. The radiograph reveals the position of the K file and the need for an additional correction of approximately 1 mm.



273 Root canal filling and coronal seal

Two months after the beginning of root canal treatment there are no clinical symptoms, and the canal is obturated with gutta-percha. The existing composite restoration is then completely removed and two threaded parapulpal pins are placed in the mesial portion of the cavity.

Left: The root canal filling is covered with a glass ionomer cement, over which an interim composite restoration will be placed.



274 Radiographic evaluation
The restoration has been polished and the rubber dam removed. Slight scarring can be seen where the previous incision has healed.

Left: The final radiograph shows the root canal filling to be well condensed and at the correct length.

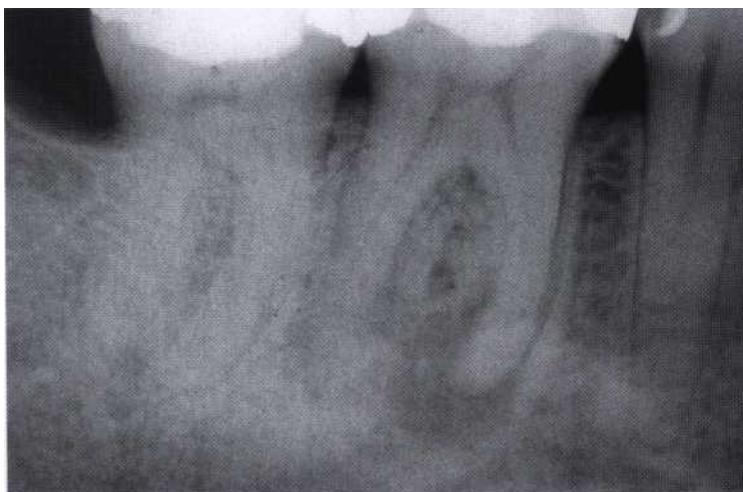Loss of Working Length

During instrumentation of the root canals, an unintentional blockage of the canals may occur. This is caused by the accumulation of dentin shavings that have not been removed, compression of pulp-tissue remains, or the creation of an apical step with collection of hard-tissue and soft-tissue fragments. As a result, unimpeded access of the file to the apical constriction is impossible. Constant monitoring of the position of the stop, which controls the depth of insertion, and careful introduction of the root canal instrument can prevent blockage.

Compression of soft tissue can be avoided by careful extirpation of the pulp. After clearing the entrance to the canal, it should first be instrumented exclusively with a size 15 Hedstrom file, rotating it gently to remove the pulp and avoid compressing it. Clinical experience has shown that RC-Prep used at this stage of treatment emulsifies the pulp stump and breaks up the collagen fibers. Irrigating solutions will not reach deeply enough into the canals to dissolve the tissue at this stage (Baumgartner and Mader 1987).

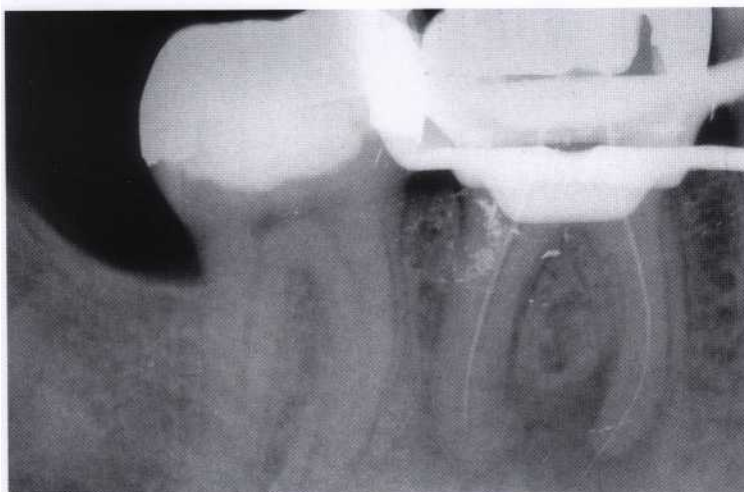275 Apical periodontitis

On this diagnostic radiograph taken using the parallel technique, a radiolucency the size of a cherry pit can be seen on the mesial root of the mandibular left first molar. Although the root canals appear to be rather narrow, difficulty in instrumenting the canals because of obliteration is not expected.



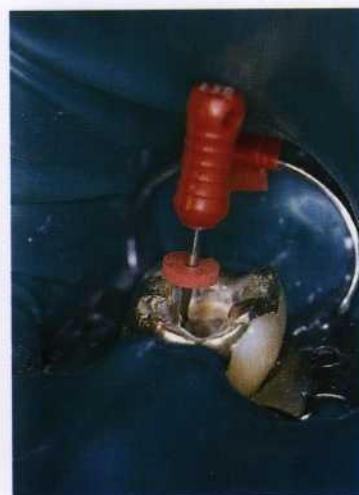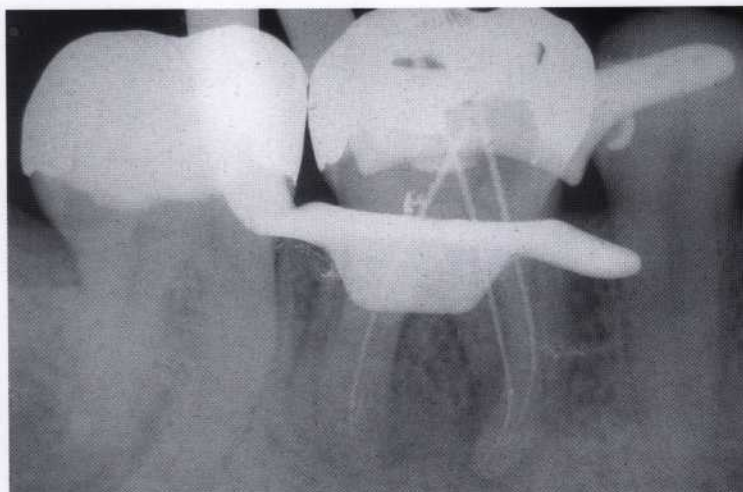
276 Working-length radiograph

On this radiograph the measuring file in the mesiolingual canal is slightly overextended because of apical root resorption. The file in the distal canal is still short of the desired working length by 1.5 mm.



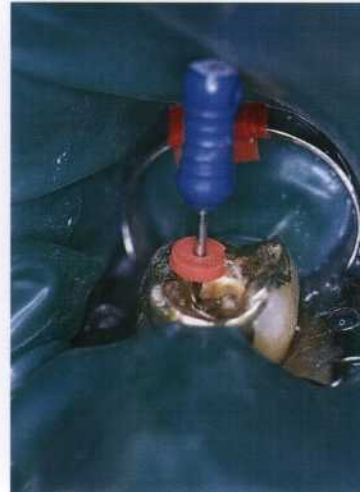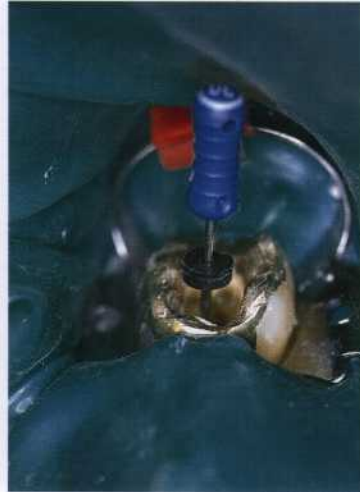
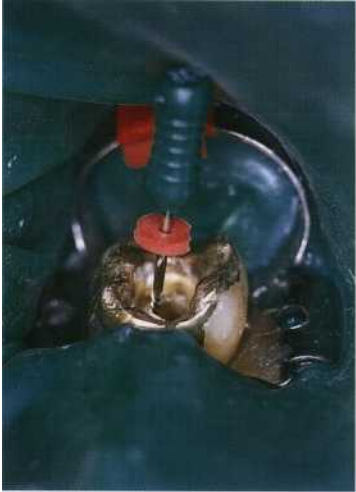
277 Working-length radiograph

Different types of files are placed in the two mesial canals for easier differentiation. The K file in the mesiolingual canal has reached the working length but the Hedstrom file in the mesiobuccal canal is still too short. In the distal canal no change in the working length can be seen compared with the first working-length radiograph.



If compression of the pulp tissue does occur, a lubricant must be used in the depth of the root canal. It is only through gentle rotating motions of a size 15 Hedstrom file that these tissue impactions can be penetrated. The file must be repeatedly cleaned and sterilized between insertions. If a loss of working length does occur during instrumentation, forceful instrumentation of the deep canal region in an attempt to overcome the obstruction should be avoided. Spinning a demineralizing substance into the canal as an interim dressing is absolutely contraindicated. Dentin fragments can

collect in the apical region during canal preparation with a rotating K file or the Canal Master system (Beer 1993 c). The use of engine-driven NiTi-instruments is not contraindicated both for preparation of the apical portions of very narrow canals and for overcoming obstructions, because the very important tactile sense is not lost. The preparation of a wide coronal access cavity with Gates-Glidden burs and frequent irrigation can help prevent a blockage. Such an obstruction can only be passed by using a prebent Hedstrom File (West et al. 1994).

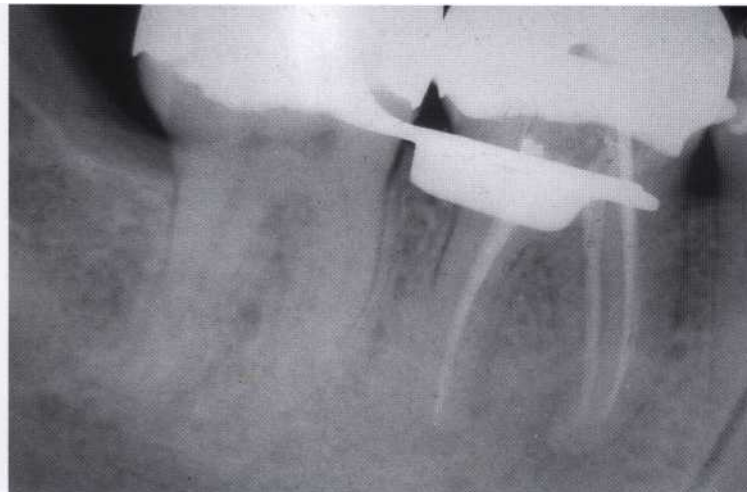
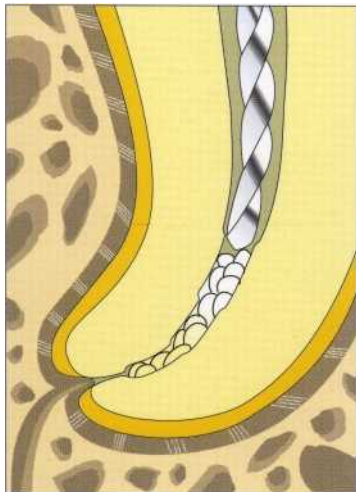
278 Adjustment of working length

Left: The working length of the mesiobuccal instrument is lengthened by 1.5mm but the stop has not yet reached the coronal reference point.

Center: Because of slippage of the rubber stop an incorrect working depth is reached with the Hedstrom file.

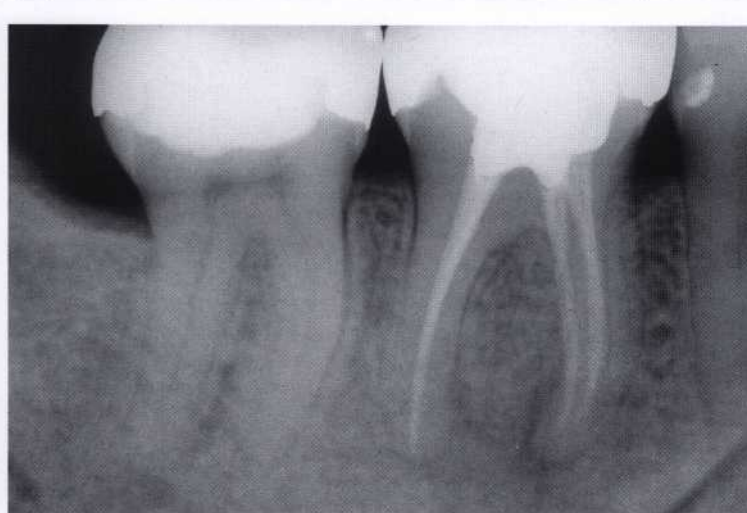Right: The incorrect setting of the working length with the rubber stop causes the mesiobuccal canal to become blocked.



279 Root canal obturation

In the absence of clinical symptoms the root canals are filled with gutta-percha and a calcium hydroxide sealer. During lateral condensation another radiograph is taken so that any corrections can be made if necessary. The master points and a finger spreader can be seen in the canals.

Left: A schematic illustration showing accumulation of dentin chips as the result of inadequate working length.



280 Follow-up radiograph

This radiograph taken 3 months after preparation of the root canals and treatment with a calcium hydroxide dressing shows a significant reduction in the periapical radiolucency. The iatrogenic blocking of the mesial canals that were patent at the beginning of treatment cannot be surmounted. In spite of this, healing is taking place.

Working Length with Apical Resorption

Chronic apical periodontitis is characterized by four main components: a focal inflammatory infiltration of predominantly plasma cells and lymphocytes, granulation tissue with fibroblasts and capillary branching, proliferating strands of stratified epithelium, and a connective-tissue capsule (Schroeder 1991). Bacteria are found in the apical portion of the root canal, bounded by a wall of neutrophilic granulocytes. Bacteria venture out of the apical foramen into the periapical tissues only when there is an acute exacerbation (Nair 1987).

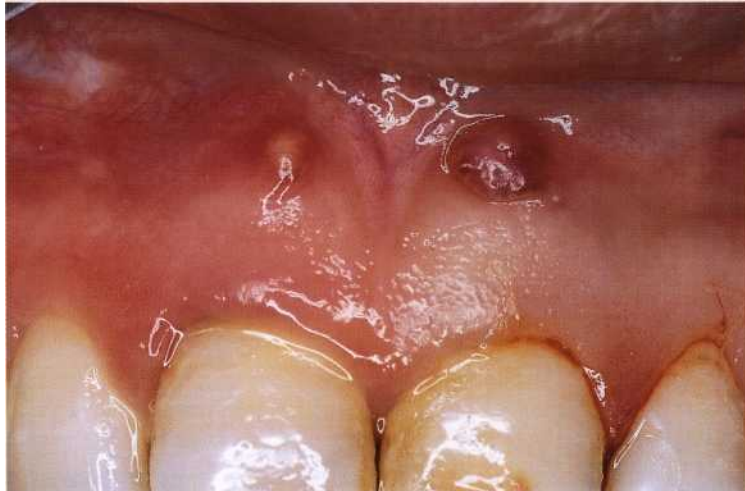The surrounding periapical bone contains osteoclasts, and the root apex in an area of chronic inflammation shows signs of resorption of cementum and dentin. At the same time, wide areas of resorption can be found along the canal wall, not just in the apical part of the root, but even farther coronally.

Chronic apical periodontitis shows not only resorption with enlargement of the apical canal region and apical constriction, but also signs of repair with deposition of cementum (Delzangles 1988).

281 Periapical lesion

Fistulas in the mucolabial fold over the root tips of both central incisors with no other symptoms are evidence of chronic apical periodontitis with periodic acute exacerbation; both teeth give a negative response to the sensitivity test and a positive response to percussion.

Right: Because of the periapical resorption process there is no longer a periapical constriction.

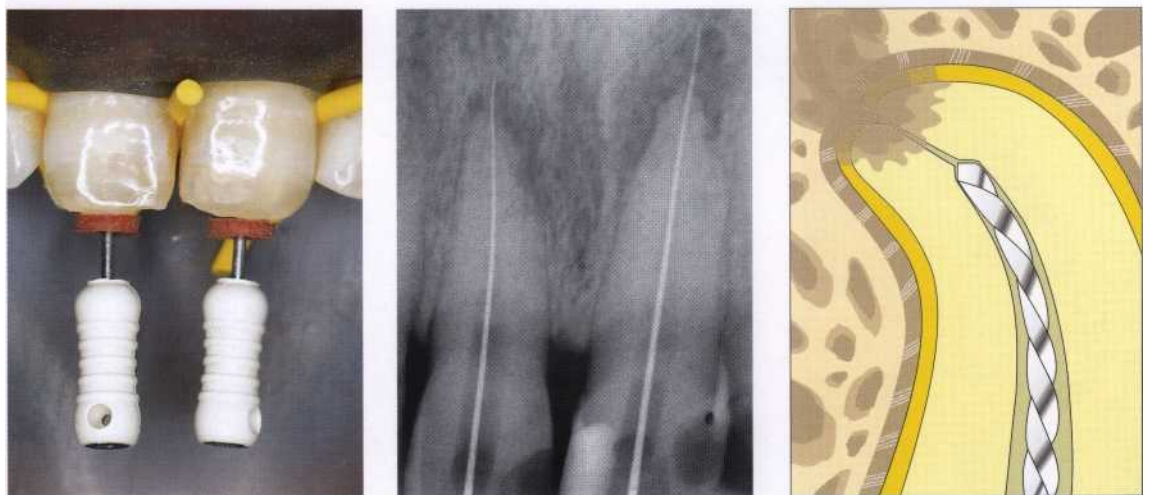

282 Root canal preparation

Left: Following coronal canal enlargement, size 15 files are inserted into the canals until the first resistance is felt.

Center: The radiograph reveals a substantial overextension of the files past the apices and into the areas of resorbed periapical bone.

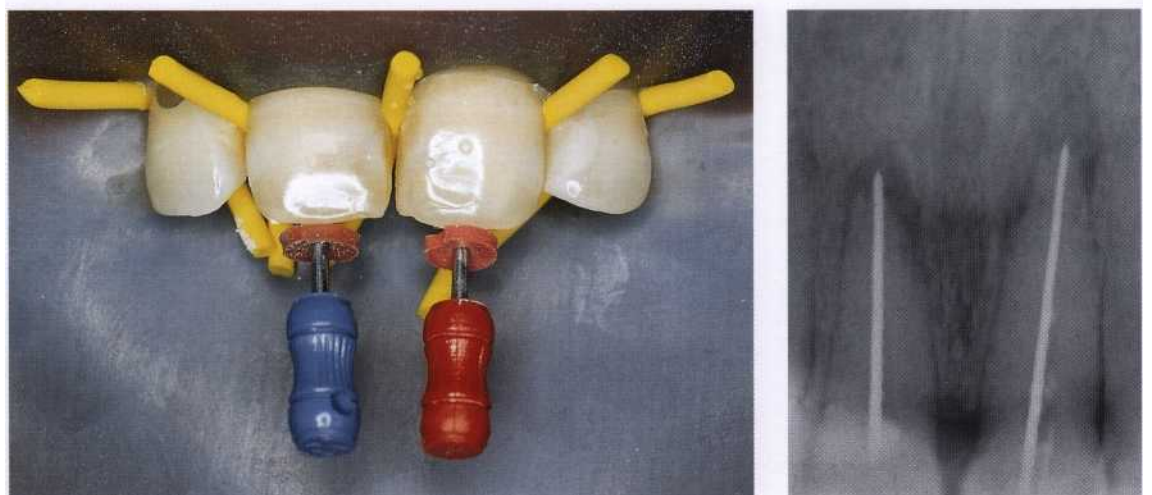
Right: Illustration of the creation of an apical stop.



283 Adjustment of the preparation depths and apical stops

After the working length has been adjusted the root canals are instrumented. The last files used are given a few final counterclockwise turns to create an apical stop out of dentin filings. These must not be infected, however.

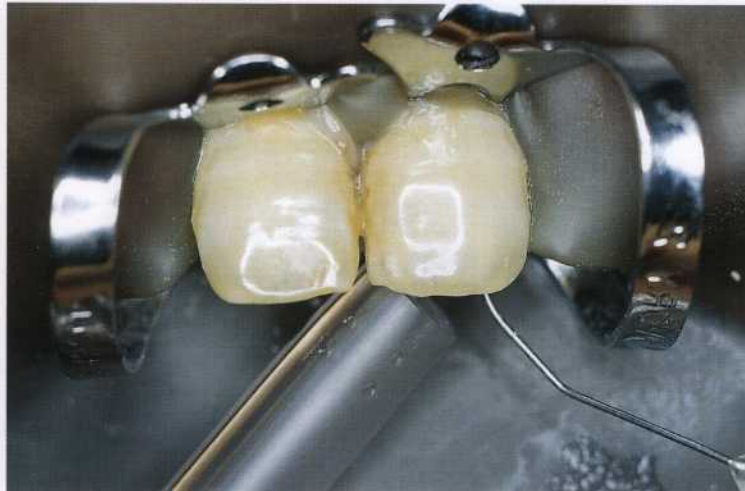
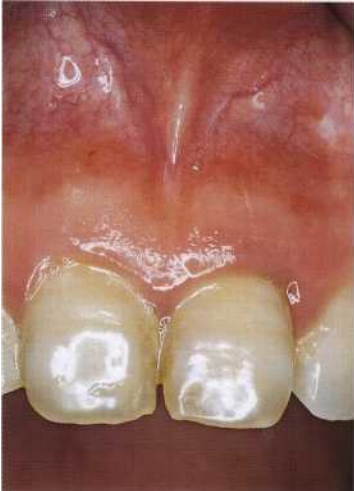Right: On the monitoring radiograph, slight overinstrumentation can be seen. The length must be corrected further and a new apical stop made using a larger instrument.



Working Length with Apical Resorption

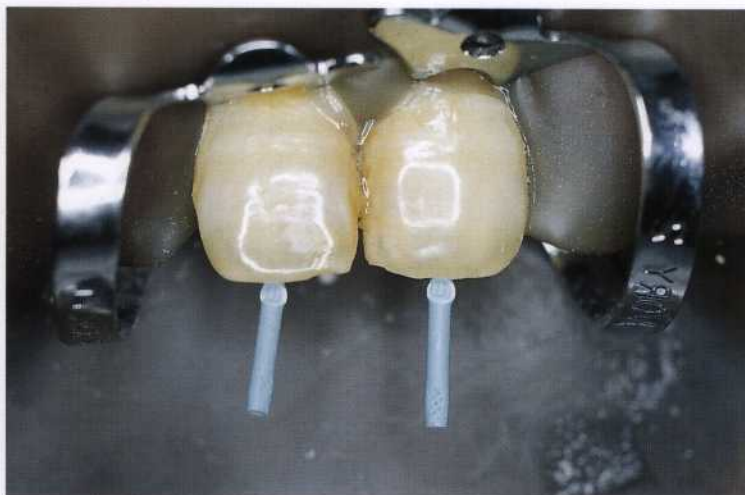
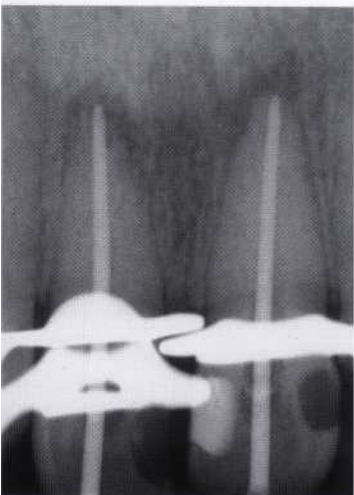
Most root canals associated with periapical lesions no longer have an apical constriction or dentinocemental junction and for this reason an apical stop should be prepared. This should lie as close as possible to the apical foramen so that all the bacteria located in this area will be eliminated through the instrumentation. The arbitrary procedure of setting the instrumentation depth at 0.5-1.5 mm from the apex does not fulfill the objective of endodontic treatment, which is to completely cleanse the infected apical region (Simon 1993).

The apical stop helps prevent overextension of the root canal filling. The reaction of periapical tissue to overinstrumentation is acute inflammation with resorption of bone and root. This can evolve into persistent chronic inflammation (Seltzer et al. 1973). When apically transported dentin filings are used to create an apical stop ("dentinoplasty") just short of the apex at the conclusion of instrumentation, the histologic results are good, almost without exception (Tronstad 1978).



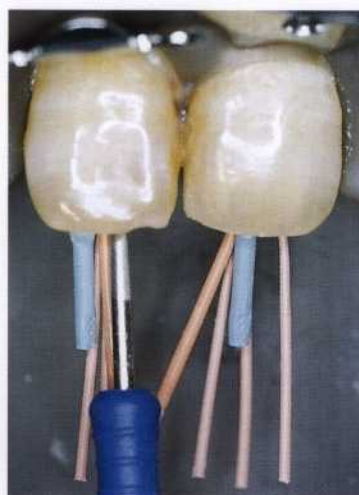
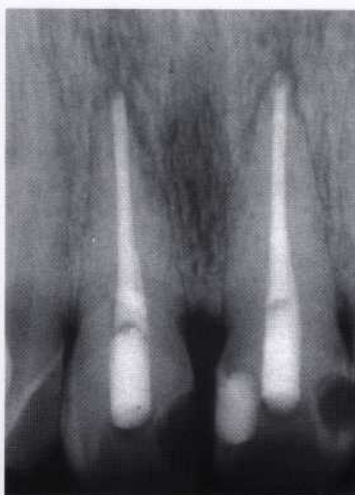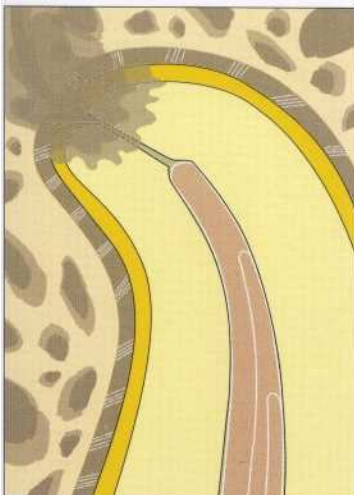
284 Interim dressing
After the canals have been instrumented they are tightly filled with a calcium hydroxide dressing, which is supposed to stimulate regeneration of the apical hard tissues. After 3 months it is removed again and the canals are irrigated.

Left: Just 3 weeks after the first appointment the two fistulas are no longer visible.



285 Master point radiograph
The working length is marked on each gutta-percha point by an indentation made with pliers.

Left: The master point radiograph permits important evaluation of the working length. Here, the gutta-percha points still need to be shortened slightly.



286 Root canal obturation
An artificially created apical stop ensures a root canal filling of the correct length.

Center: Radiographic evaluation of the root canal filling; good regeneration of the periapical lesions can also be seen.

Right: After the gutta-percha master points have been shortened apically, the canals are obturated following the lateral condensation technique.

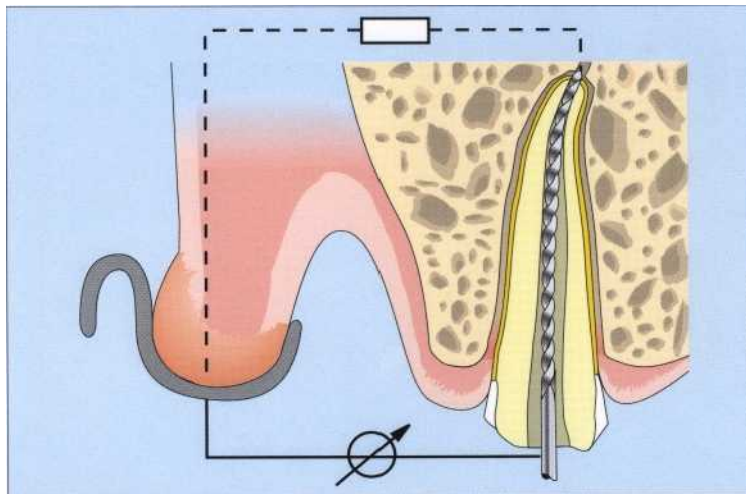
Electronic Length Determination

Methods of determining the working length with the help of electricity are based upon the measurement of absolute impedance, changes in electrode impedance, or the measurement of an impedance profile. Most of the devices available today incorporate the measurement principle put forth by Sunada (1961): when the resistance between the measurement electrode and its counter electrode is a certain value, the instrument tip has reached the apex. Sunada observed that teeth that had not had the canal contents removed offered a resistance of 6.5 kW.

This principle of length measurement defines either an absolute resistance or a range of resistance. The impedance of the tissue between the apex and the mucosa cannot be measured directly, however. If, during the measurement procedure, the root canal is dry all the way to the apical foramen, the measurement circuit is closed upon contact with the periapical tissue. The margin of error increases with the diameter of the canal. If the root canal is moist and contains pulp-tissue remnants, the preset resistance value will be reached before the instrument is at the apex (Voss 1988).

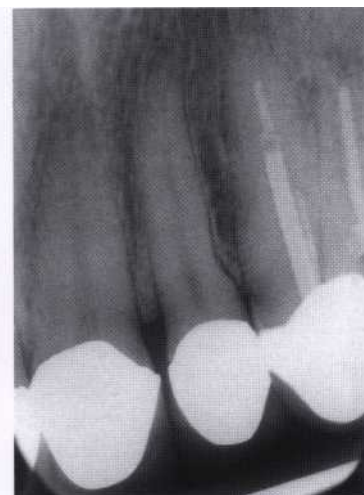
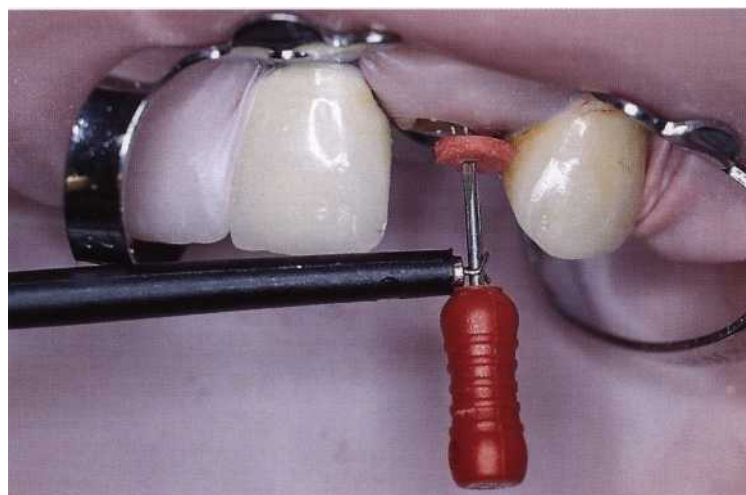
287 Principle of measuring absolute impedance

A root canal instrument is connected to the measuring device with a clip. An electric current is passed through the file into the root canal. A lip or hand electrode serves as the opposite electrode. The device indicates the apical foramen by an absolute resistance value that is presented by the manufacturer. Currents alternating at different frequencies minimize the influence of electrochemical polarizing processes (Voss 1993).



288 Clinical measurement

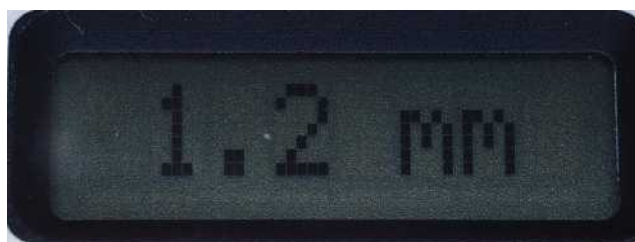The apex finder produces a right-angled measuring current of 20 mA at a frequency of 800 Hz. The root canal instrument is connected to the circuit by means of a clip, and the U-shaped opposing electrode is hung over the patient's lip.



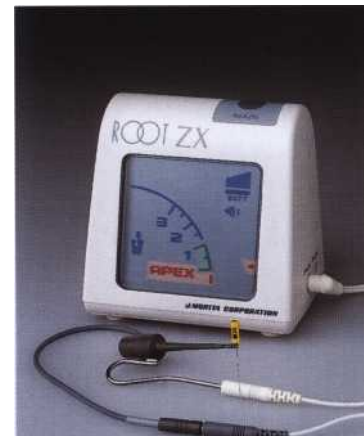
Right: Diagnostic radiograph of a maxillary lateral incisor with necrotic pulp but no clear indication of periapical radiolucency.

289 Voltage drop

The drop in voltage measured between the two electrodes is shown on a scale of light-emitting diodes. The digital display does not give the true distance of the file from the apical foramen, however, but should be considered only as a complement to the diode scale.

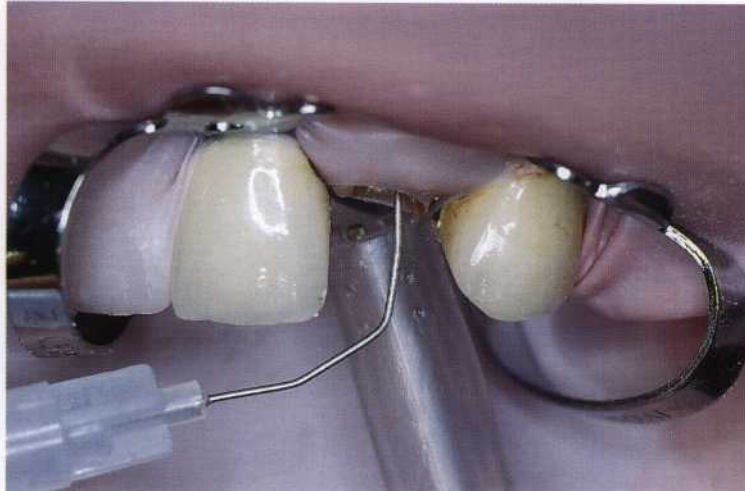
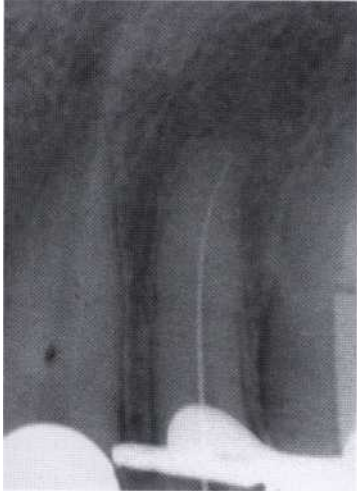


Right: Newer endodontic measuring devices, which operate with the root canal filled with an electrolyte, provide a narrower range of variation with repeated measurements.



When electronically and radiographically determined canal lengths are compared, significant differences are found. The rate of correct length determination is 83.5% with radiographs and 73.1% with electronic measurement (Hembrough et al. 1993). If the canals are dry the accuracy rate is between 67% and 90%; if they are filled with ethanol the rate is from 50-73%, depending upon the type of apparatus used; when filled with Sodium hypochlorite, exact measurements are obtained in 37-73% of cases (Fuad et al. 1993 a).

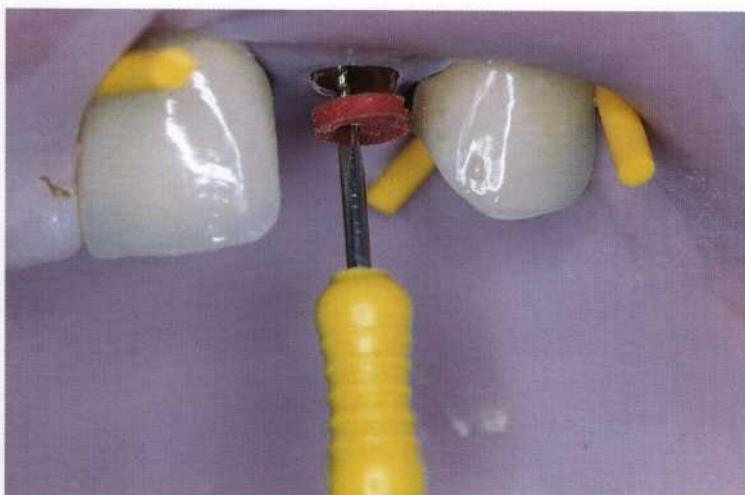
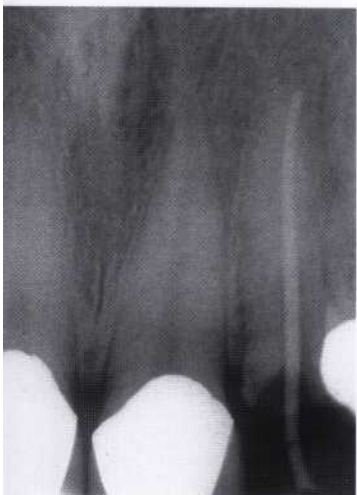Even the newer units, which register the change in impedance as the electrode leaves the canal, cannot reveal the exact apical constriction. It is only through measurement of an impedance profile that the location of the apical constriction can be determined. However, present-day endometric technology cannot accomplish this consistently. For it is only by means of a radiograph that the position of an instrument within the canal can be recorded (Voss 1993).



290 Working-length radiograph

After the canal is irrigated, and before the electrical measurement is made, it is dried with paper points so that the measurement will not be influenced by the amount of electrolyte contained within the root canal.

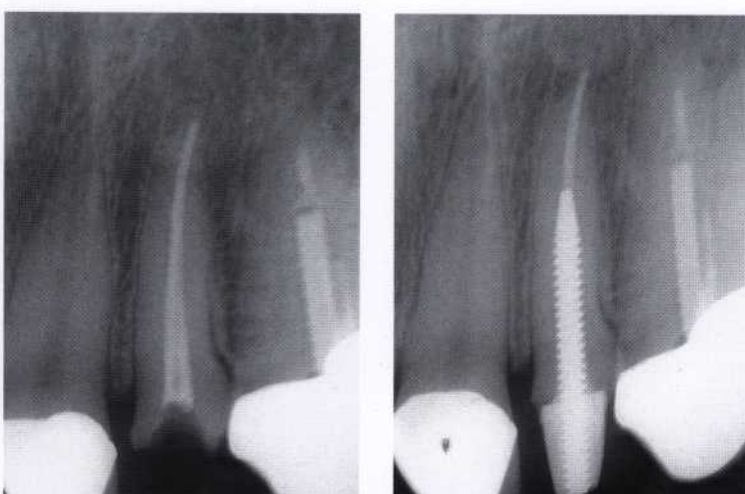
Left: On the radiograph the file has reached the working depth and reveals an apical curvature of the canal. Using electronic measurement alone, without subsequent radiographic confirmation, is too uncertain (Cohen 1986).



291 Root canal preparation

After the final determination of the working length is made, the root canal is prepared using prebent files. Meanwhile, the length can be monitored electronically.

Left: Although electronic measurements have been made, a radiograph with the master cones in place should be taken to ensure the accuracy of the obturation length.



292 Radiographic monitoring

Left: When the root canal filling is completed, a radiograph is taken to evaluate the result as well as to serve as a permanent record. It should show a dense filling and a clear picture of the apical obturation.

Right: An additional postoperative radiograph shows a threaded post well situated within the root canal. The core can now be prepared for a crown.

Cleaning and Shaping

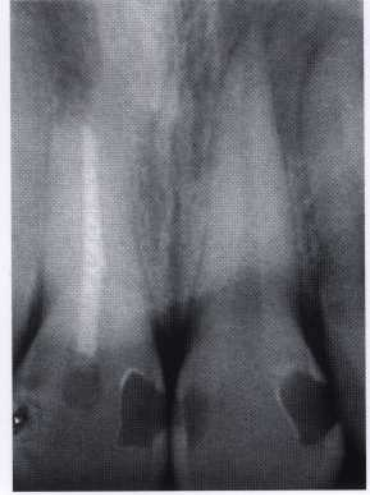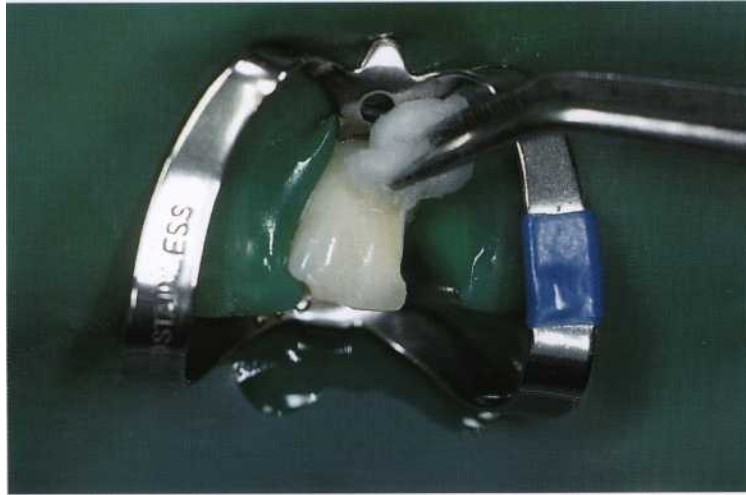Almost 30 years ago, Schilder (1967) introduced the concept of "cleaning and shaping." Most obturation problems are really problems of cleaning and shaping. Cleaning refers to the removal of all contents of the root canal system. Shaping refers to a specific cavity form with five objectives: develop a continuously tapering conical form in the root canal preparation (1), make the canal narrower apically, with the narrowest cross-sectional diameter at its terminus (2), make the preparation in multiple planes (3), never transport the foramen (4), and keep the foramen as small as is practical (5).

With a good access cavity and the use of RC-Prep (Premier), the precurved #10 K file is guided gently into the root canal. The dentist must tactually feel with the instrument and follow the path to the radiographic terminus. If the file does not bypass denticles or obstructions, it is withdrawn. After gentle irrigation with 5% sodium hypochlorite, the sequence is repeated until the apical terminus is reached. Once the first instrument has reached the terminus, the file is moved in vertical strokes of a 1-2 mm amplitude. The fundamental techniques are patency confirmation and serial carving.

293 Access opening

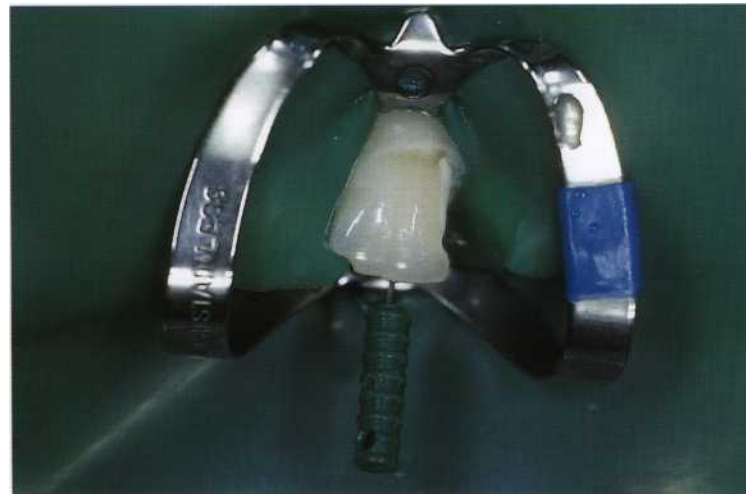After the rubber dam is applied to the anterior teeth, the dam and teeth are disinfected and then the pulp chamber is opened and the canal orifice identified.

Right: In the diagnostic radiograph the upper right central incisor is seen to have a root canal filling, and has apparently undergone apical resection. The left central exhibits a periapical radiolucency and a canal that is almost perfectly straight.



294 Extirpation

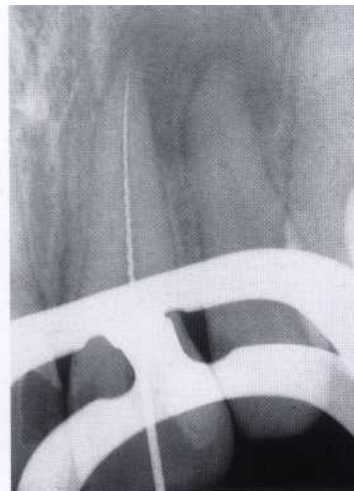
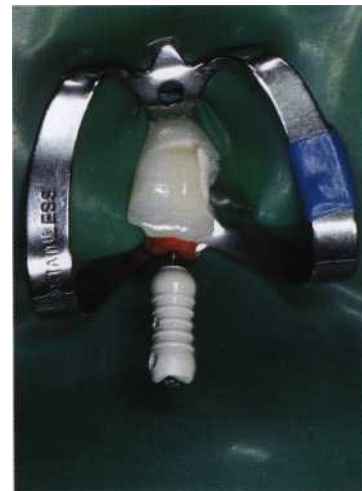After probing of the entrance to the root canal, a barbed broach is inserted, rotated, and withdrawn to separate the pulp tissue, or what is left of it, from the dentinal wall and to remove it from the canal.



295 Canal preparation

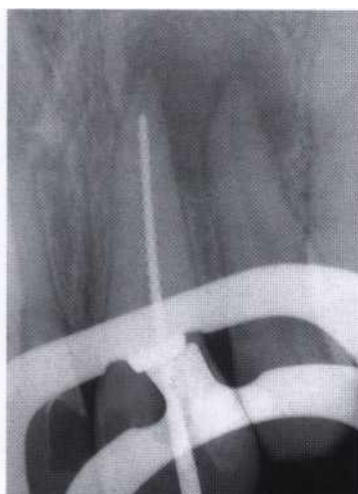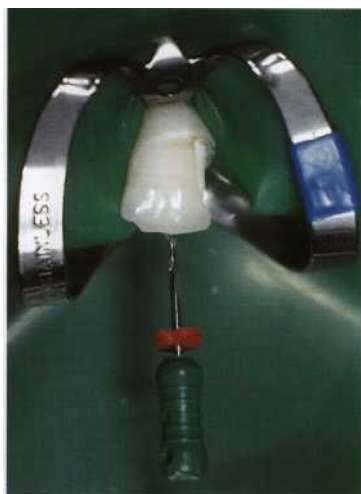Left: Using gentle rotational movement, an instrument is introduced into the canal until it reaches the apical region.

Right: The working length is determined with a radiograph. Instrumentation is begun with the insertion of the K file to the apex with light rotating motions. This is followed by in-and-out movements with an amplitude of 1-2 mm.



The first K file loosens dentin mud and after withdrawing the file the root canal is irrigated. The #15 K file follows in the same manner as the #10 file. Once the K file is loose, the canal is irrigated and a precurved #20 reamer will slide short of the radiographic terminus. Reamers are for carrying away dentin shavings and debris, and for carving. Random sculpting occurs on withdrawal of the reamer and this is how to avoid ledges. Reamers carve in relatively straight canals. Now a precurved #25 reamer shaves the dentinal walls to a point of resistance and is withdrawn in a carving fashion.

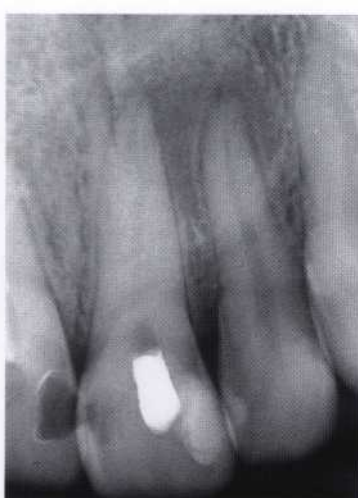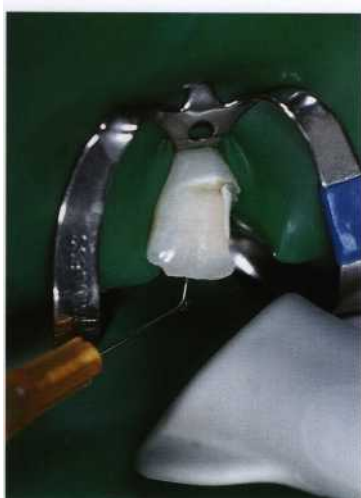No. 30-45 Reamers are used in the same way. Gates-Glidden drills are used in the coronal third of the root canal. In the first recapitulation the #20 K file and the reamer advance to the foramen, and all following instruments should advance deeper into the root canal. After irrigation, the smallest instrument confirms patency and a second recapitulation begins. Patency is also confirmed before the third recapitulation. If recapitulation is done properly, no instrument reaches to the same place twice, but extends deeper. The cleaning and shaping is complete when the cone fits (West et al. 1994).



296 Preparation

Left: Following instrumentation with the K file, reamers are inserted and then pulled out of the canal as they are twisted clockwise. Random sculpting occurs on withdrawal of the reamer.

Right: The reamer shaves the dentinal walls at the point of maximum resistance.

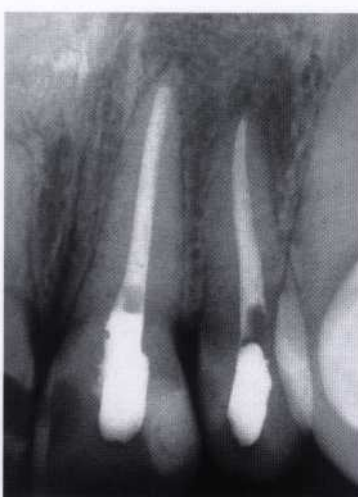
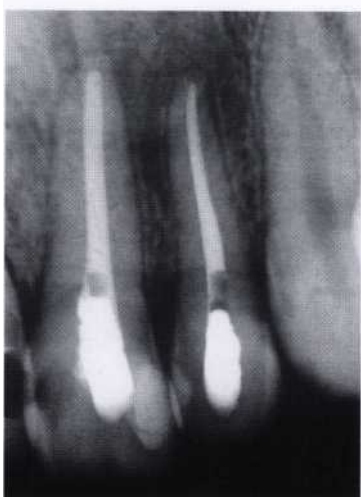
297 Irrigation

Left: Any dentinal shavings or other debris that has accumulated within the root canal will be drawn away.

Center: Between each change of instruments the canal must be generously irrigated with sodium hypochlorite.

Right: Calcium hydroxide is firmly packed into the root canal. After 3 months the periapical radiolucency has almost completely disappeared.



298 Root canal filling

Left: The canal of the left lateral incisor has been prepared in the meantime. After removal of the interim dressing from the left central, both canals are obturated with gutta-percha.

Right: Regeneration of the periapical tissues can be seen in the 1-year follow-up radiograph, indicating success of the instrumentation and filling technique on these anterior teeth with virtually straight root canals.

Balanced Force Technique

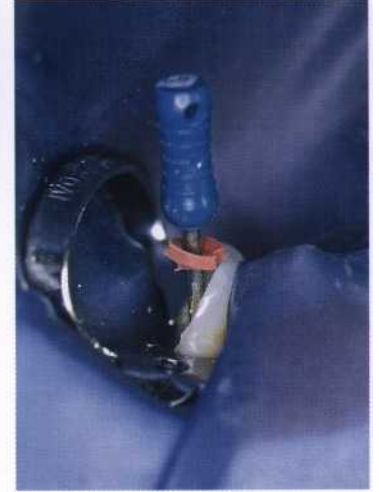In 1985 Roane et al. introduced a new method of preparing curved canals in which the instrument is used with a modified rotational movement. The procedure uses special root canal instruments with noncutting, dual-conical tips.

Earlier investigations had shown that by rounding the cutting tip of a K file, the danger of step formation and perforation could be significantly reduced (Miserendino et al. 1986). Roane's Flex-R file (Union Broach) was the first file to utilize this special instrument geometry (see Fig. 141).

The instrument tip is noncutting and has a 70° taper (a 35° inclination of each side). It is made up of an initial tip (wide cone) and a secondary guiding surface (narrower cone), followed by the cutting edges of the instrument. The objective of this special tip design is to guide the instrument through the curved canal with minimum alteration of the canal's course (Calhoun and Montgomery 1988). Changes in the path of the canal result from the exertion of unbalanced forces (Miserendino 1994).

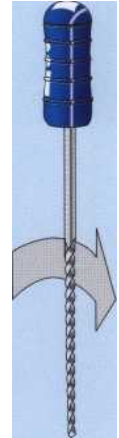
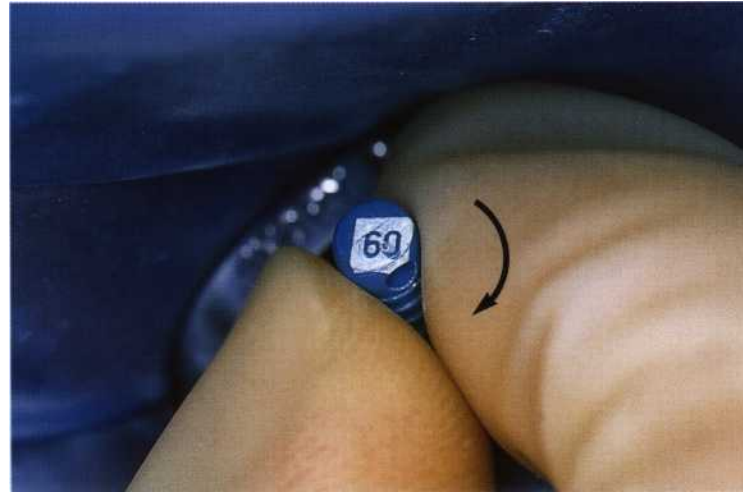299 Introduction of the file
After the coronal portion of the root canal has been opened, K files are inserted with very little force into the root canal. Following the noncutting tip, the instrument advances into the canal without danger of forming a step.

Right: The K-file is inserted into the root canal.



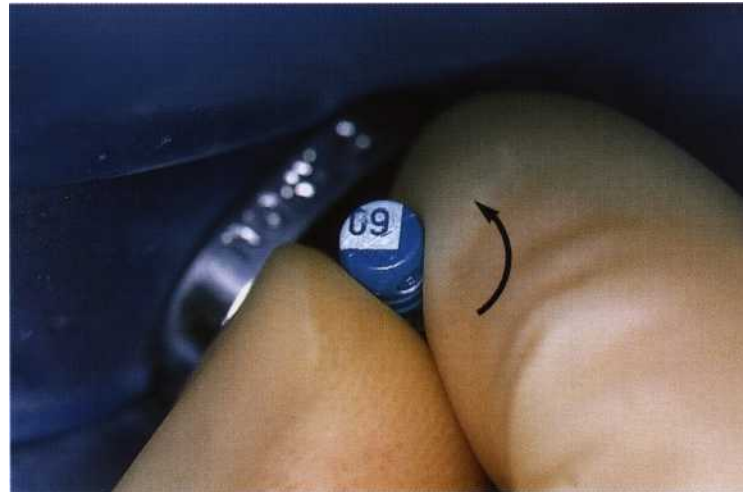300 Clockwise rotation
As the file is inserted into the canal or just before it reaches the working length, the file is rotated approximately a quarter-turn to the right.

Right: By turning the file a quarter-turn to the right it is brought into direct contact with the canal wall without being forced deeper into the dentin.



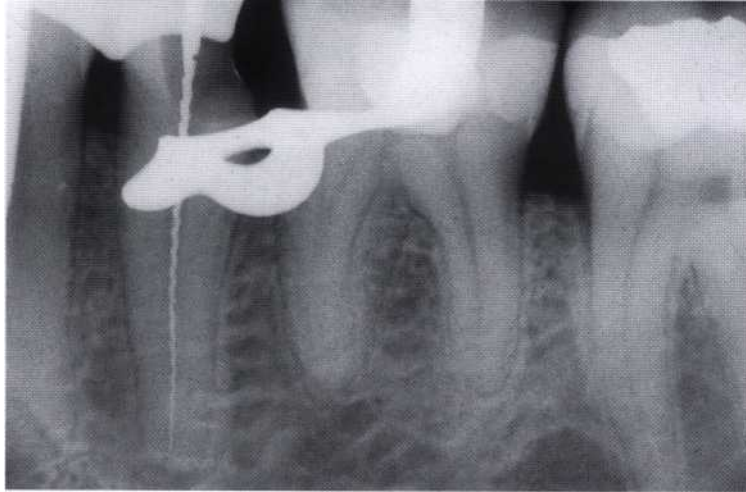
301 Counterclockwise rotation
A subsequent three-quarter turn to the left removes dentin from the surface of the canal. Simultaneously, gentle apical pressure is exerted to prevent outward movement of the file. Following the three-quarter turn counterclockwise rotation, the instrument is withdrawn with a clockwise movement until it is at its starting position, and then removed from the canal.

Right: The file is rotated approximately a three-quarter turn to the left.



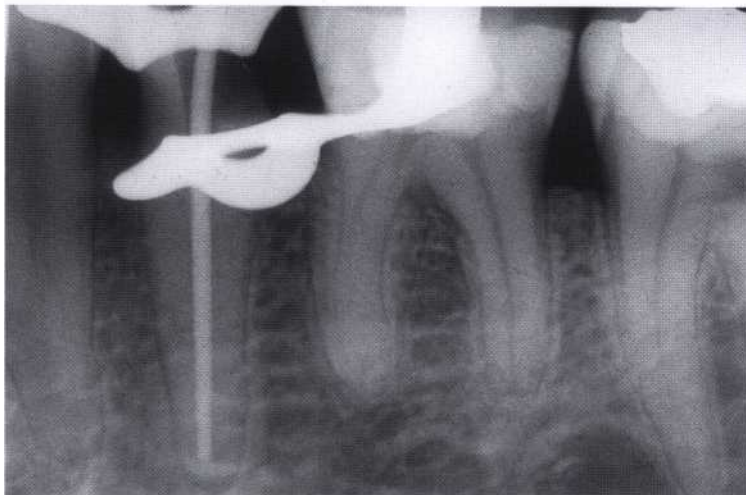
With the balanced force technique, the K file is introduced into the canal without exerting force. Simultaneously the instrument is rotated one-quarter turn to the right (clockwise). This movement moves the cutting blades of the instrument against the dentinal wall. Next the file is given a three-quarter turn to the left (counterclockwise) while maintaining light apical pressure to keep the file at the same depth in the canal and prevent it from moving outward. During this turning movement dentin is scraped from the canal wall without a high risk of instrument fracture. Next the dentin

shavings are picked up by half a turn clockwise and removed from the canal with the instrument. Using this technique, 80% of crooked canals up to size 40 can be prepared without altering their course (Southard et al. 1987). Furthermore, significantly less dentin debris is pushed out through the apical foramen than with the step-back technique (McKendry 1990).



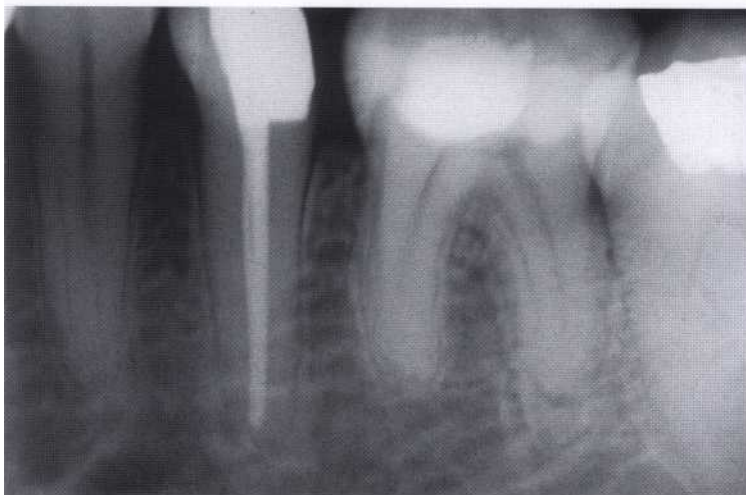302 Working length

Instrumentation with rotational movements is continued until the full working length, previously measured on a radiograph, is reached.



303 Master point

Rotational instrumentation of a straight canal produces a round cross-section, which facilitates accurate placement of a gutta-percha point. The length is verified by means of a master cone radiograph.



304 Evalutaion

A dense, homogenous root canal filling can be seen on the immediate postoperative radiograph. It was placed by the lateral condensation technique.

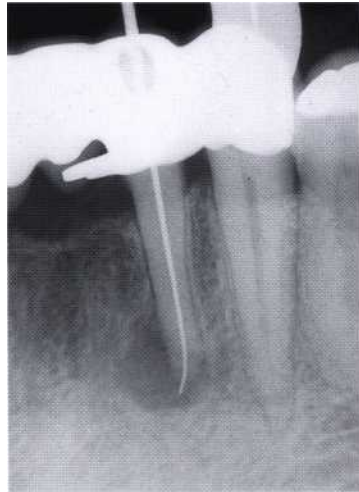Step-Back Technique

The demise of the silver point filling and its replacement by plastic, inert gutta-percha required a change in the concept of root canal preparation. The relatively parallel walled preparation form with very little taper was abandoned in favor of a more conical canal form. This instrumentation technique forms an apical stop and thereby avoids irritation of the periapical tissues by medicaments or filling material. Because there is very little canal enlargement and removal of dentin near the apex, the danger of perforation is reduced.

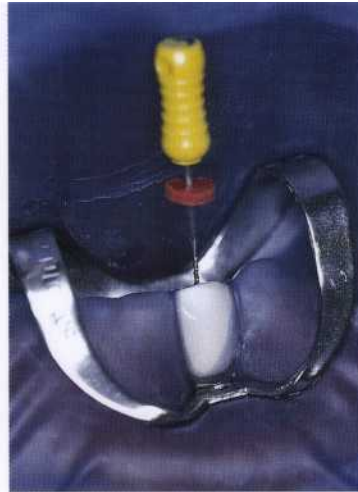In a study by Goldman et al. (1988) the cleanliness of root canals as well as their form and course were evaluated following instrumentation with K files, Hedstrom files, and Unifiles. The only file that created a definite apical stop, an almost round canal cross-section, a good apical preparation without irregular widened areas, and a conical canal form from apex to the cervical region was the K file used with the step-back technique. However, 46% of the curved canals studied showed an alteration in their course in the apical region (Cinnis et al. 1988).

305 Apical preparation

Left: At the beginning of instrumentation, the length of the canal and the size of the initial apical file (IAF) are determined on a radiograph. Notice the periapical radiolucency and the slight overextension of the measurement file.

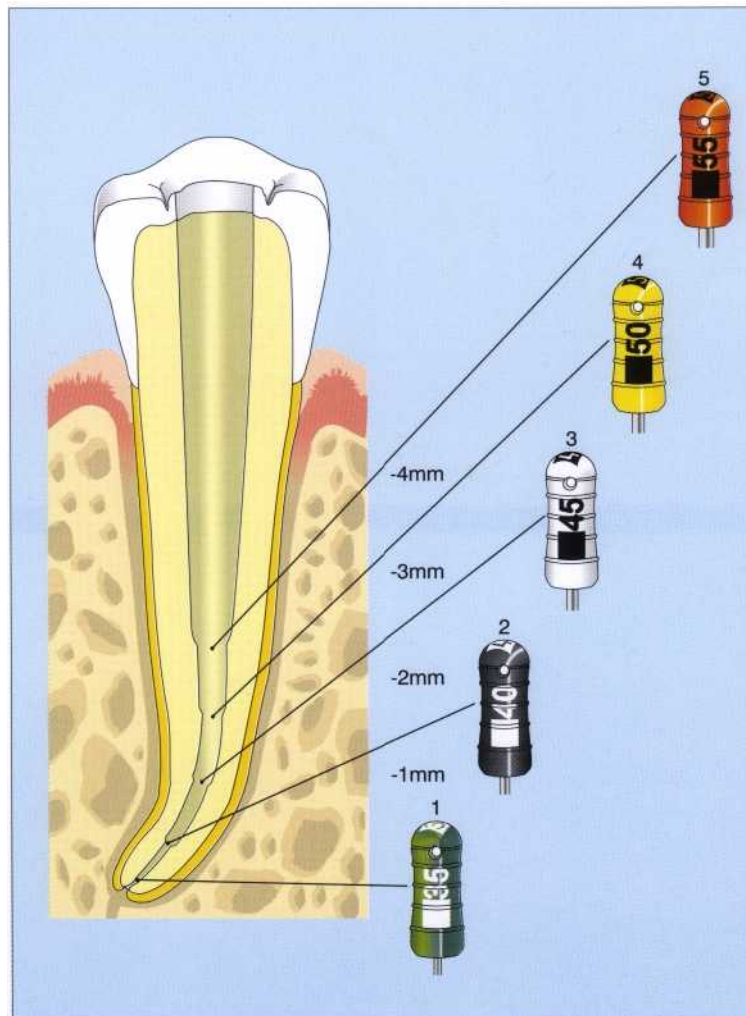


Right: Starting with the IAF, the root canal is enlarged to the working length through four file sizes.



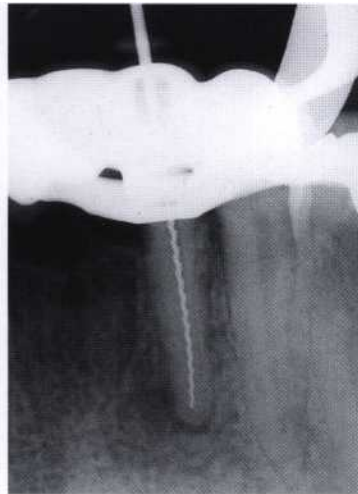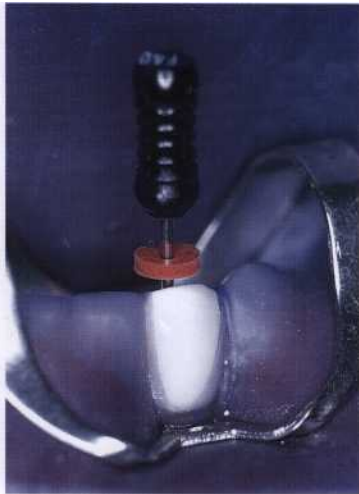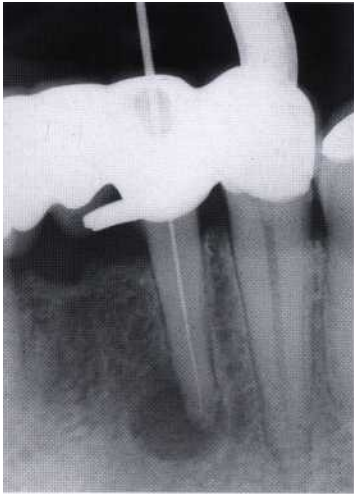306 Step-back technique

After the root canal has been enlarged throughout its entire length to the size of the apical master file, here size 35, the subsequent files are each made 1 mm shorter than the previous file. Thus, the insertion length of the size 40 K file is shortened by 1 mm, size 45 by 2 mm, size 50 by 3 mm, and size 55 by 4 mm. The drawing clearly shows the tapered root canal preparation that is formed by this procedure. The steps are smoothed by the intermittent reintroduction of the AMF. This simultaneously prevents blockage of the apical canal by dentin chips and verifies accessibility to the apical constriction. K files are used exclusively in this preparation technique.



In the step-back technique, the apical portion is instrumented first, and then the coronal portion is shaped. After the access opening is made, the working length is determined on a measurement radiograph. The first file that binds in the canal at the working length is considered the initial apical file (IAF). The root canal must then be enlarged by circumferential filing through an additional four instrument sizes. During this initial phase of preparation, no instrument sizes may be skipped or a blockage may be created.

The last file manipulated to the working length should remove only white dentin shavings, and is designated the apical master file (AMF). Its size determines the size of the gutta-percha master point that will be used later. Next, the coronal portion of the root canal is instrumented in step-back fashion through four additional sizes. Each subsequent larger size K file is set 1 mm shorter than the preceding size so that a conical canal configuration with a definite apical stop is formed. Frequent recapitulation with the AMF ensures that the canal remains patent.

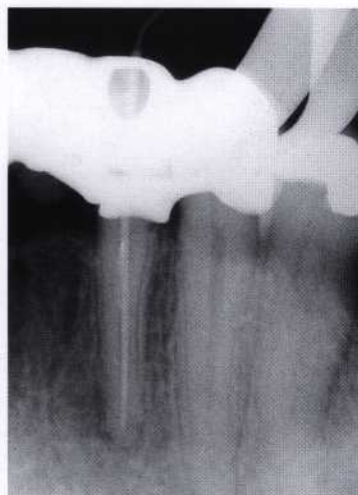
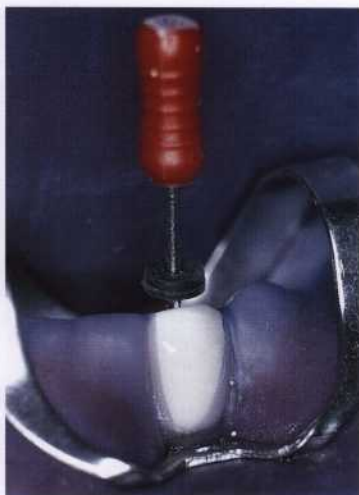
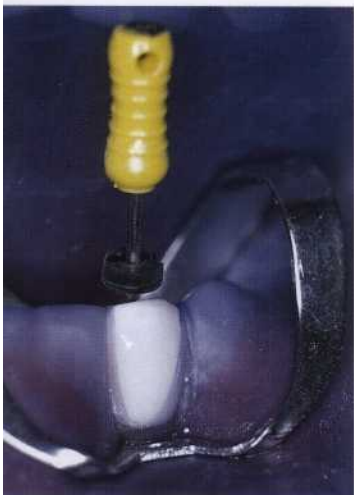
307 First step

Left: The canal is prepared to the apex with the AMF. The radiograph shows the corrected working length.

Center: The first file after the AMF prepares the canal to a depth 1 mm shorter than the AMF. The length is marked with a rubber stop.

Right: The radiograph shows the correct working length and a reduction of the periapical radiolucency after 3 months with a dressing in place.

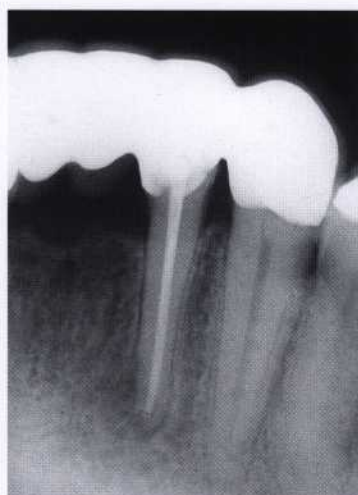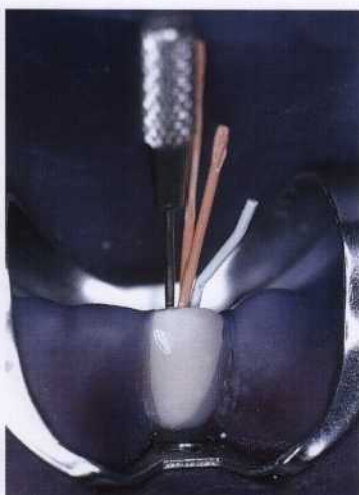
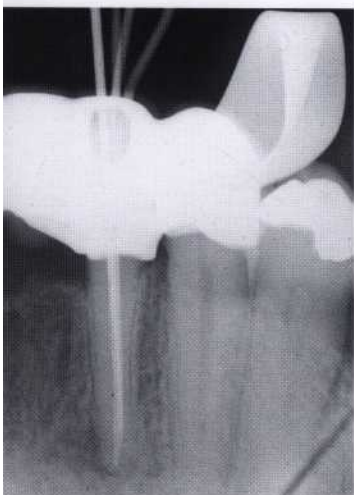


308 Final file

Left: A size 50 K file has a working length approximately 3 mm shorter than that of the AMF.

Center: The final file enlarges the root canal to a depth 4 mm less than the original working length.

Right: After the conical canal form is created, a gutta-percha point the same size as the AMF is fitted.



309 Filling the canal

Left: The tapering shape of the root canal permits lateral condensation to near the apex.

Center: By condensing multiple gutta-percha points, a biologically neutral obturation can be created.

Right: On the final radiograph a homogenous, lightly tapering root canal filling with an apical stop can be seen.

Step-Down Technique

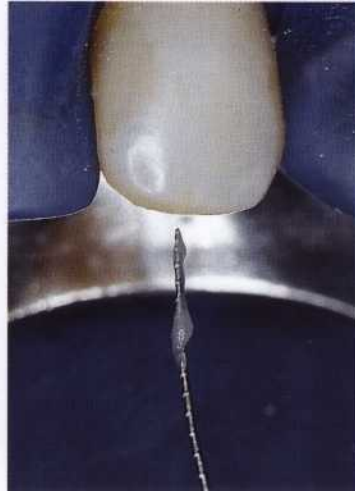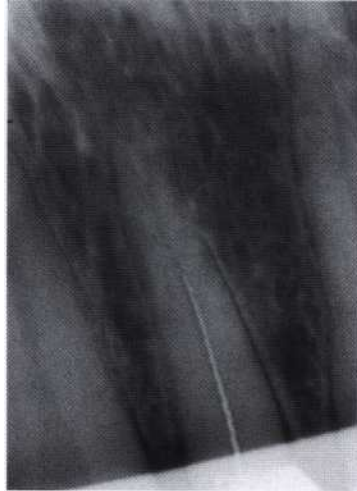Narrow, curved root canals are prepared by means of the coronal-apical ("crown down") instrumentation technique. In this method the coronal portion is enlarged first, and only then is the apical region of the root canal prepared. An advantage of this technique over the apical-coronal technique is that the coronal enlargement makes it possible to insert the irrigating canula quite deeply into the root canal. During the final instrumentation of the apical region necrotic pulp tissue is thus loosened and flushed away with sodium hypochlorite.

After the access preparation is made, the canal preparation is begun by assuring complete patency of the canal. This is done by inserting a size 15 Hedstrom file, employing one-eighth circle rotations and only light pressure. Next the root canal is enlarged coronally with a Gates-Glidden drill to the beginning of the canal's curvature using the step-back technique. It is important to coat the tip of the instruments with a lubricant (e. g. RC-Prep) in order to prevent binding within the canal.

310 Patency

On the first radiograph the measuring instrument has been inserted only into the coronal third because of the narrowness of the root canal. Excessive force must be avoided.

Right: A Hedstrom (coated with RC-Prep) file has been advanced through gentle rotational movements to test the patency of the canal.

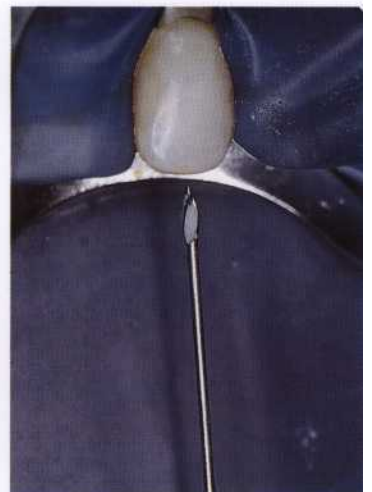
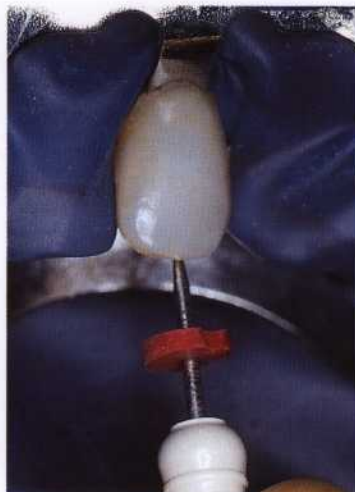
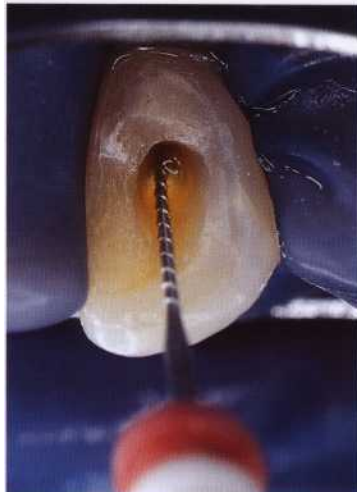

311 Coronal enlargement

Left: The Hedstrom file has reached the farthest extent of the patent canal.

Center: The canal is carefully enlarged through circumferential filing. There is no danger of creating a blockage during this phase of preparation.

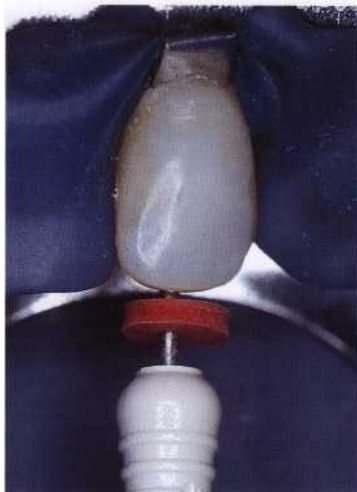Right: The coronal portion of the canal is widened with Gates drills before the deep preparation is completed.



312 Apical preparation


Left: Widening of the coronal portion makes it possible to irrigate the root canal. A prebent K file is then advanced to the apical region.

Right: The instruments must be prebent to conform to the curvature of the canal.



Following enlargement of the coronal portion, the working length is determined radiographically with a size 15 K file in place. If the instrument tip falls more than 2 mm short, a second measurement radiograph is made after further careful instrumentation. If the root canal is too narrow to allow the K file to be inserted to the working length, passage to the apex must be carefully established with a Hedstrom file also. Only then can the size of the initial apical file be determined and the canal enlarged by four sizes.

Apical preparation is accomplished by alternating instruments—first a Hedstrom file is used for circumferential filing and this is followed by a K file (*non-cutting* tip) in a rotating working movement (balanced force technique). Following this, the canal is widened coronally with a size 20 Hedstrom file, and finally the entire root canal is instrumented to the working length with a prebent size 20 K file. If this file does not reach the working length, under no circumstances should any attempt be made to advance the instrument apically by rotating it.

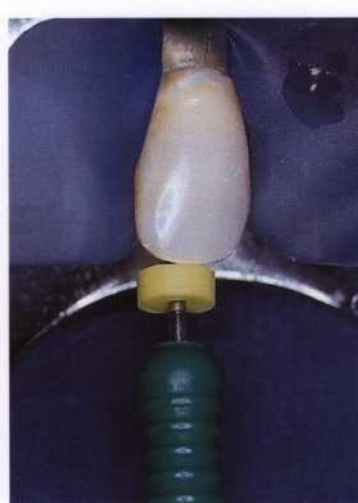
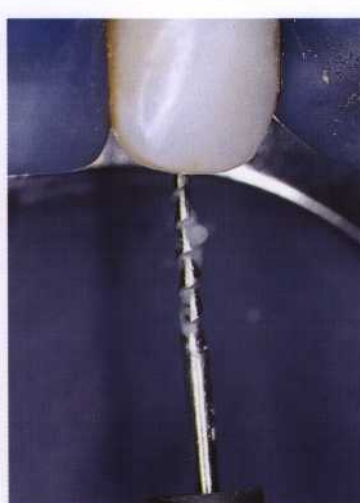
313 Balanced force

Left: The root canal is enlarged along its entire length by using the balanced force technique: first the instrument is introduced into the canal with rotations to the right. Then the file is rotated to the left to cut dentin from the canal wall.

Center: A prebent K file prior to apical instrumentation.

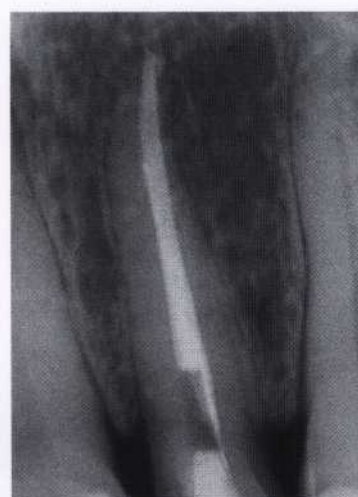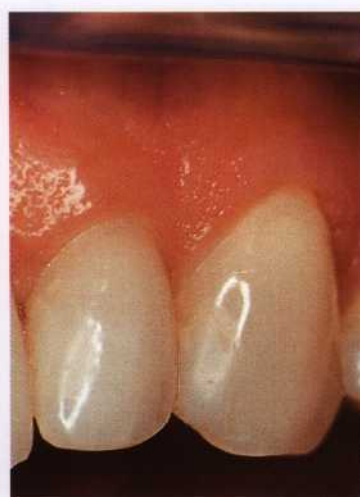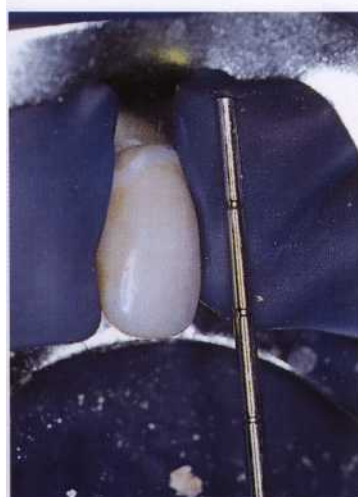Right: The instrument has become slightly straightened after being rotated apically.



314 Creating a conical form

Left: Following preparation of the apical region, the canal is tapered by circumferential filing with Hedstrom files.

Right: Finally, the entire canal is smoothed by using the #35 AMF with balanced force rotations.



315 Root canal filling

Left: In order to prevent discoloration of the crown of the tooth by ingredients of the root canal filling material, the filling must be removed to a level 2 mm below the cemento-enamel junction.

Center: Follow-up evaluation of the composite restoration 2 years after the root canal treatment.

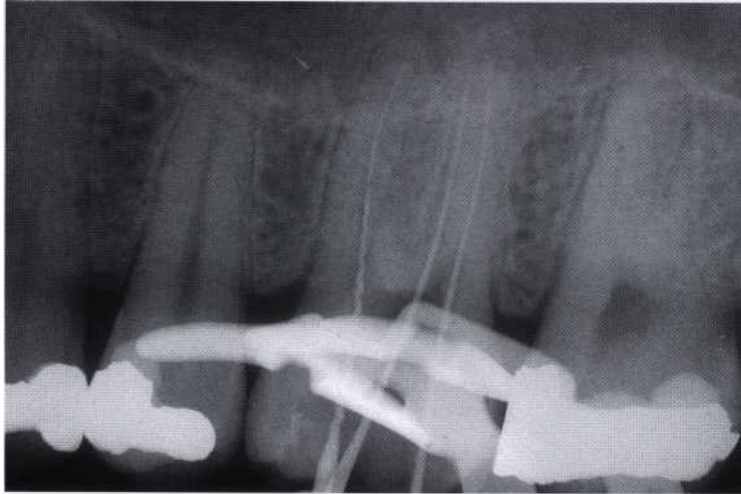
Right: Radiograph of the treated tooth showing slight straightening of the canal.

Problem Solving during Instrumentation

Step Formation

Root canal files must be prebent in order to prevent step formation or other blockage in the apical 4 mm. Inadequate working space can be a problem when using instruments 25 mm or more in length, or when mouth opening is restricted. During the initial enlargement, therefore, the instrument should be rotated into the mesial canals of molars first. The notch in the stop indicates the direction of the bend and faces first toward the mesial, then toward the distal.

316 Working length
Size 15 files that were not prebent are inserted into the three root canals of the maxillary first molar to determine the working lengths. The curvature of the canals is noted at the same time.



Funnel Formation

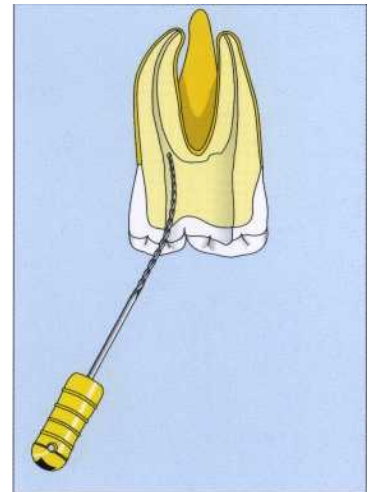
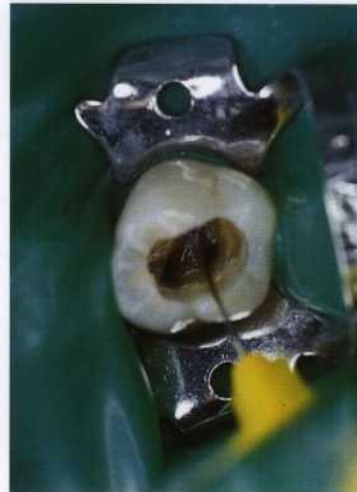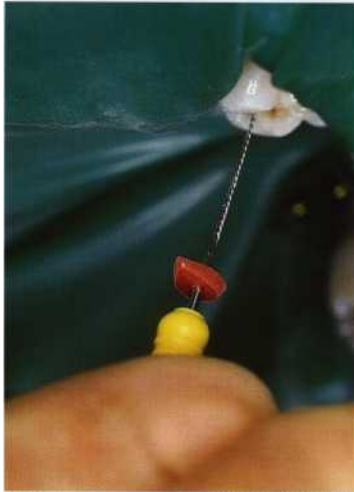An apical funnel is the result of improper instrumentation and straightening of the apical portion of the root canal. To avoid this, the apical end of the instrument must be bent even more than the curvature of the canal on the radiograph. Only by sufficiently prolonged instrumentation with thin, flexible files can apical enlargement be avoided. Following every rotation during the balanced force technique the instrument must be removed from the canal, carefully cleaned, and rebent.

317 Prebending the instruments

Left: The apical segment of each instrument is bent more sharply than the curvature of the canal, and the direction of the bend is marked by the point of the bend, which initially points toward the mesial.

Center: Insertion of the instrument.

Right: The instrument is inserted into the mesiobuccal canal with its curvature opposite that of the canal.


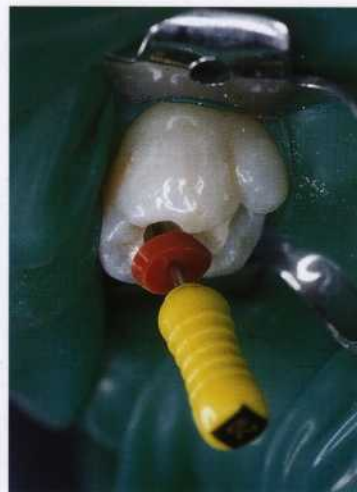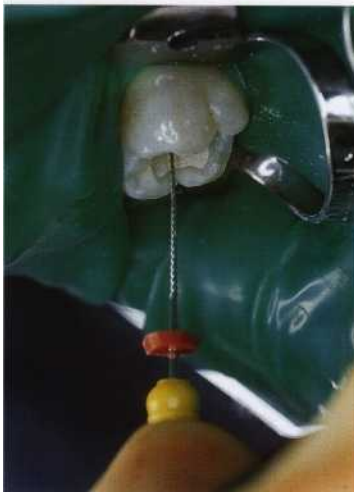


318 Rotation of the instrument into the canal

Left: The file is rotated as it is advanced farther into the root canal with almost no force. The point of the silicone stop indicates the amount of rotation.

Center: The K file was able to be rotated into the root canal to the working length with no problem. The point on the stop now faces distally.

Right: Rotation of the instrument by 180°.



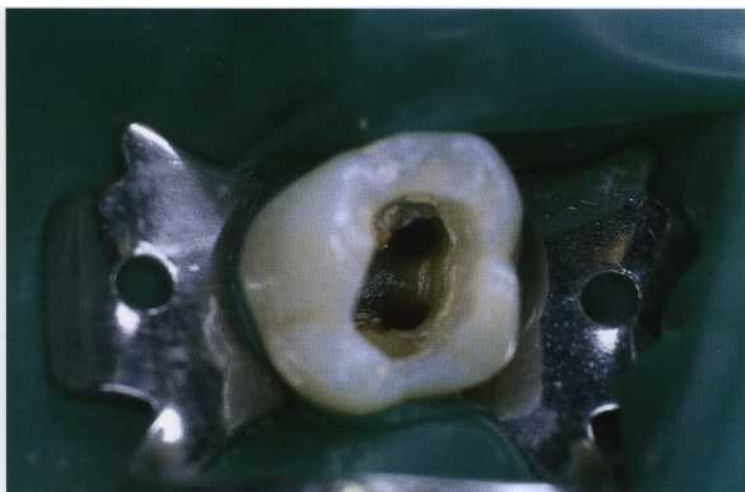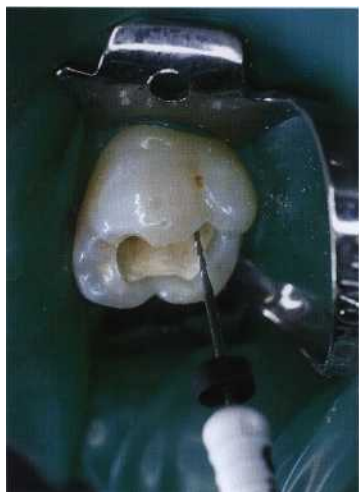Perforation

Excessive initial enlargement of the mesial canal of a molar can lead to penetration of the canal wall. The path of the root canal must be carefully evaluated on the diagnostic radiograph before the decision to use Gates-Glidden drills is made. Hedstrom files up to size 25 can be used just as well for the initial enlargement of the canal. Excessive removal of dentin can be avoided by filing toward the curvature of the canal.

Overinstrumentation

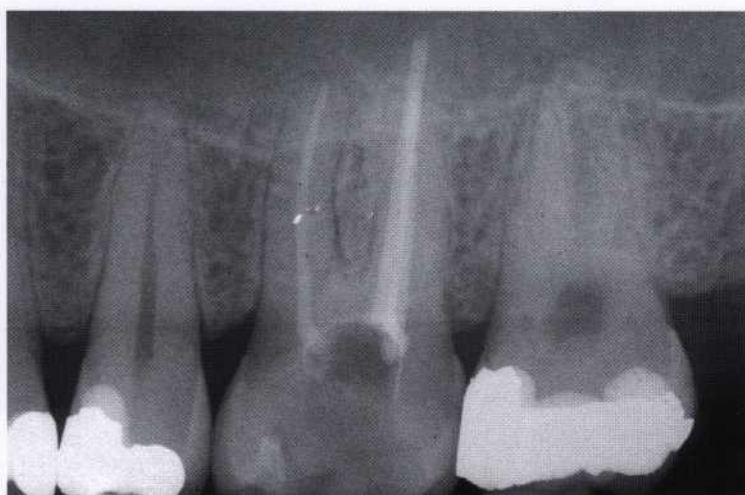Enlargement of the apical constriction can result in postendodontic reactions. This danger can be reduced by accurate radiographic determination of the length with identification of the correct apical reference point, which can be different for every root canal.

Additional radiographs make it possible to correct changes in the canal length brought about by the straightening of curved sections of the canal.

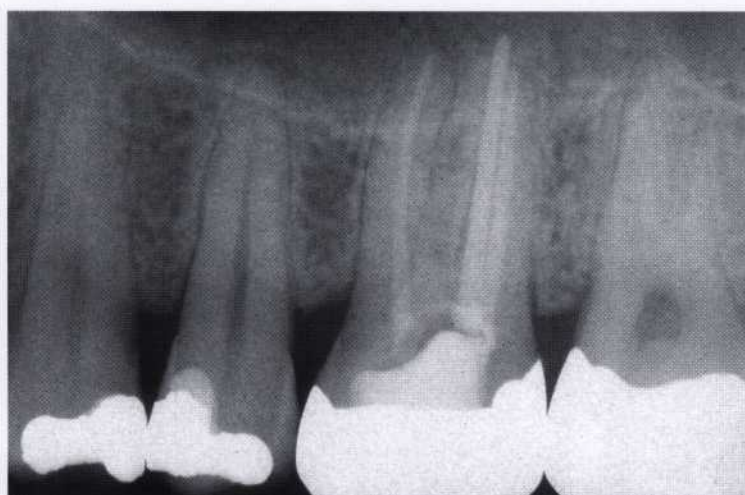

319 Canal instrumentation
The curved root canals have been completely prepared by this instrumentation technique.

Left: Shaping of the coronal region and tapering of the canals by means of flexible Hedstrom files.



320 Root canal filling
The three canals are filled with gutta-percha to the apical reference point by means of the lateral condensation technique. No straightening of the paths of the canals has occurred.



321 Radiographic follow-up
An examination 2 years after completion of the endodontic and restorative treatment reveals nothing unusual. There are no signs of pathologic changes and the patient is free of discomfort.

Surface of the Canal Wall Following Hand Instrumentation

During hand instrumentation of the root canal with hand instruments, dentin and pulp-tissue fragments are macerated and most of these are removed from the root canal by the instruments and by irrigation. Some remnants, however, do remain on the surface of the canal and can be pressed against the canal wall and into the adjacent dentinal tubules. The adhesion of this smear layer on the underlying dentin is not especially pronounced (Kockapan 1995).

This 2-5-µm-thick superficial deposit consists of a mixture of ground and fragmented dentin and pre-dentin and, if canal enlargement is inadequate, some bacterially infected necrotic pulp tissue (McComb et al. 1976). In the SEM the surface of the canal appears relatively smooth. The dentin tubules are covered with deposits of abraded dentin. The coarse dentin particles (smear plugs) can be demonstrated as deep as 40 µm within the tubules (Mader et al. 1984).


322 Root canal after extirpation

A After extirpation of the pulp and before instrumentation almost all soft tissue has been removed from the root canal surface. A uniform covering of the canal wall with residual pulp tissue can be seen.

B At higher magnification pulp-tissue fragments, which have been torn from the canal wall, and partially opened dentinal tubules are visible.

C The residual tissue holds odontoblastic processes that have been torn away and may be infected with bacteria.

(SEM images)



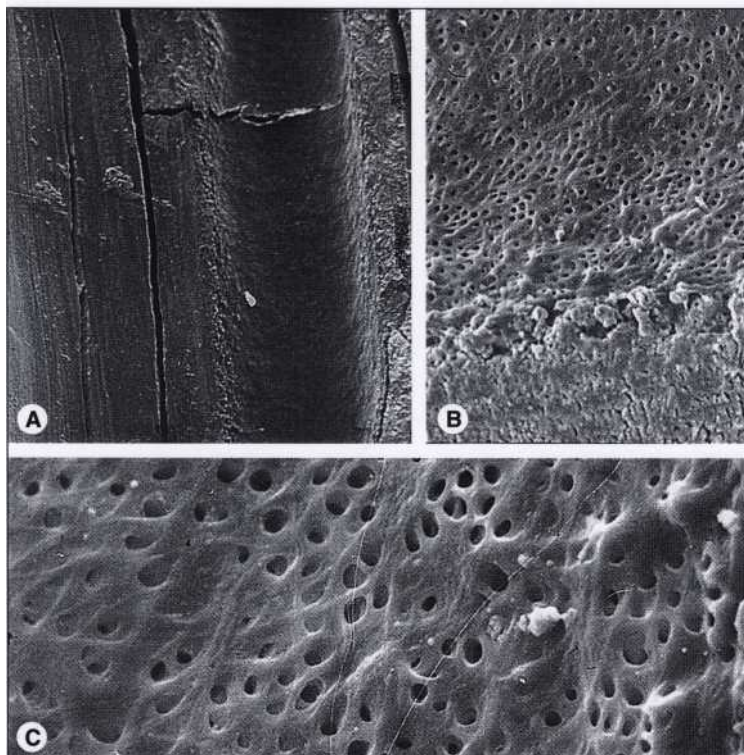
323 Root canal after instrumentation with Hedstrom files

A In its middle portion the root canal is smooth and free of residual pulp tissue, although there are large longitudinal grooves resulting from nonuniform circumferential filing.

B The dentin of the canal wall has been smoothed. A smear layer partially covers the orifices of the dentinal tubules, although uncovered sections are also present.

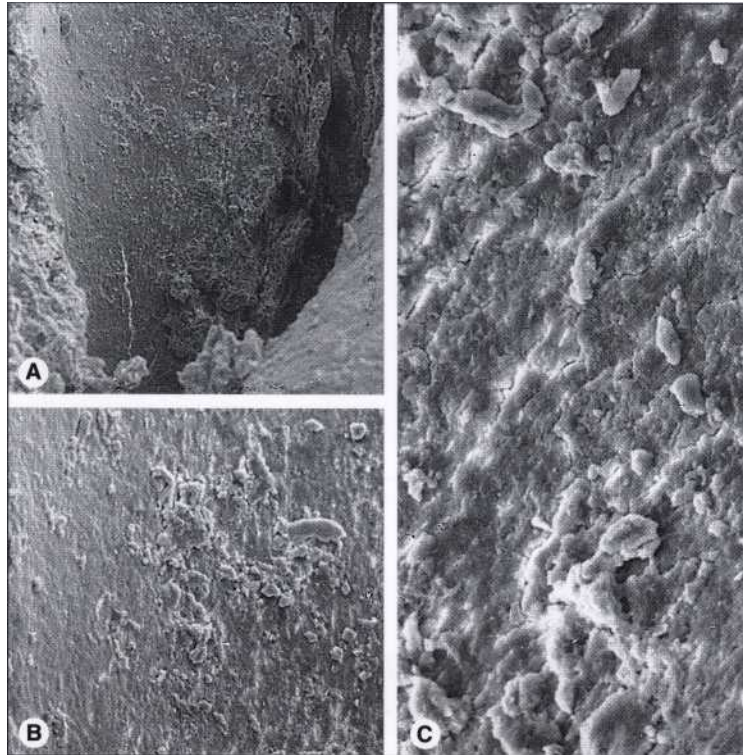
C At higher magnification the entrances to the dentinal tubules are visible. The canal has been irrigated with sodium hypochlorite solution during instrumentation.

(SEM image)



Following pulp extirpation alone, larger pulp-tissue remnants are found on the surface of the root canal with individual pieces of tissue torn loose from the underlying dentin. Instrumentation of straight root canals with Hedstrom files produces a surface that is free of larger tissue remnants, but the canal walls exhibit longitudinal grooves. The middle third of the canal is clean with partially opened dentinal tubules. Only rotational instrumentation with reamers leads to a smooth surface with no large dentinal fragments (Beer and Gangler 1989). Straight root canals can be fully pre-

pared and filled at the same sitting, irrespective of the method of instrumentation used. Approximately 80% of curved canals can be cleaned well over their entire lengths with either Hedstrom files or K files (Haikel and Alleman 1988). Regardless of which technique is used, curved canals can be only incompletely cleansed of infected pulp-tissue remnants. The anatomy of the root canal has a greater influence on the effectiveness of canal preparation than does the specific method of preparation (Langeland et al. 1985).




324 Instrumentation with rat-tail files

A The surface of the prepared root canal appears roughened. Irregularities and longitudinal grooves are visible.

B The dentin is fissured and torn. There is no regular smear layer visible.

C At higher magnification dentin flakes of various sizes can be seen loosely covering the dentin. The entrances to the dentinal tubules, however, are wide open and not plugged with dentin shavings.

(SEM image)



325 Instrumentation with K files

A After rotational instrumentation using the balanced force technique the apical region of the root canal is likewise smooth and free of residual tissue. A lateral canal is occluded with dentin shavings.

B The surface of the canal is uniformly covered by a smear layer as the result of direct contact by the instruments.

C At higher magnification the clean canal surface is visible with complete closure of the dentinal tubules.

(SEM image)

Instrumentation under the Surgical Microscope

There is a limit to our ability to make ever finer details more visible simply by bringing the observed object closer to the eye. When the object comes too close to the eye it no longer appears sharp because of the limited ability of the eye to accommodate. Adults with normal vision can still perceive objects sharply if they are at least 10 cm away from the eye, but fatigue occurs rapidly at this distance. Only when the distance is increased to 25 cm can the object be seen clearly for longer periods of time without special effort. This distance is referred to as the conventional visual dis-

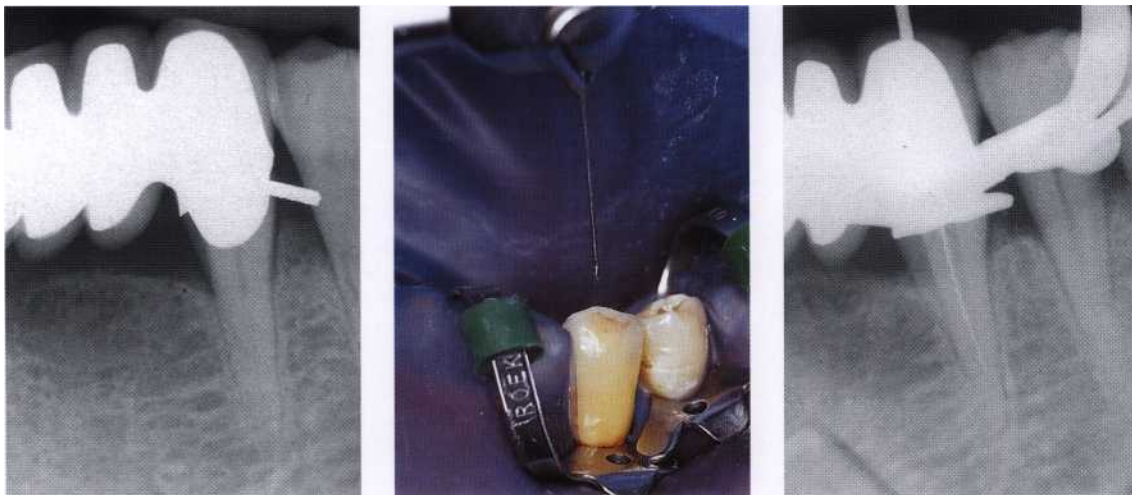
tance (Gerlach 1985). At this distance an observer can distinguish two points equally if they are at least 0.15 mm from one another, which corresponds to a visual angle of 2 minutes of angle. In a microscope the light from the object being viewed passes through the objective lens and its image is projected toward infinity. The lens inside the tube projects an intermediate image to the ocular lens in the eyepiece, which presents the enlarged image to the eye. The resulting visual angle is now much larger so that much smaller details can be recognized (Kapitza 1994).

326 Trepanation

Left: The patient experienced acute symptoms from the mandibular left canine following cementation of an extensive fixed prosthesis.

Center: An access opening is made and enlarged through the crown.

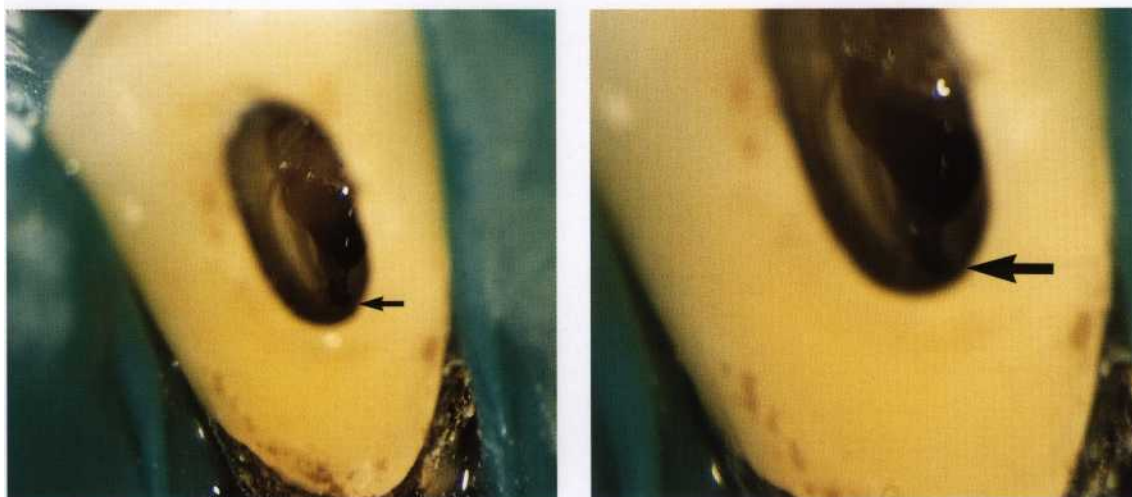
Right: The working-length radiograph taken at a slightly eccentric angle suggests a second root canal.



327 Access preparation

Left: With a 20x magnifying surgical microscope, the entrance to a second canal can be seen lingual to the first instrumented canal.

Right: At 25x magnification the second canal entrance can be easily located.

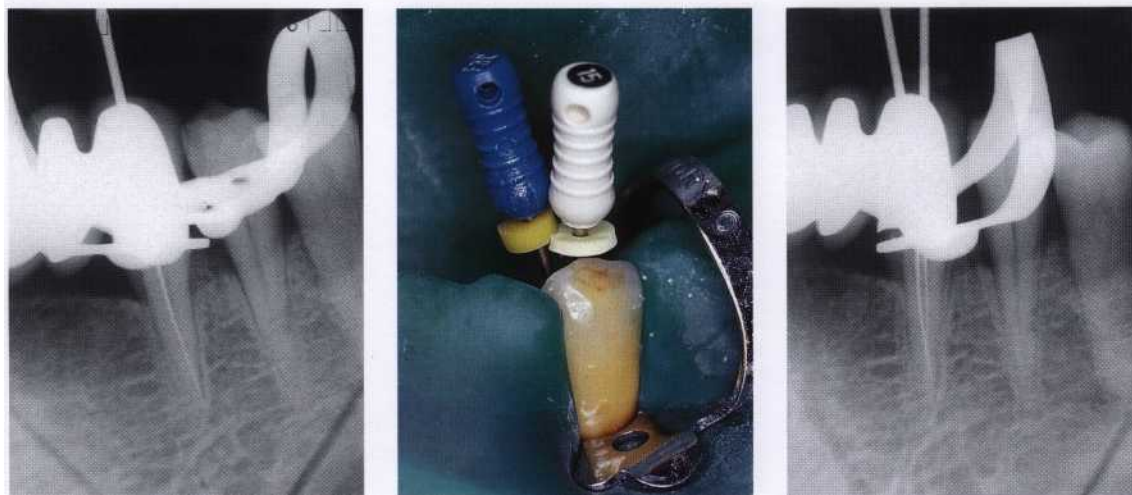


328 Length determination

Left: After the length from the first radiograph is adjusted, the file reaches the apical constriction. To avoid overlapping, the two canals can be measured separately.

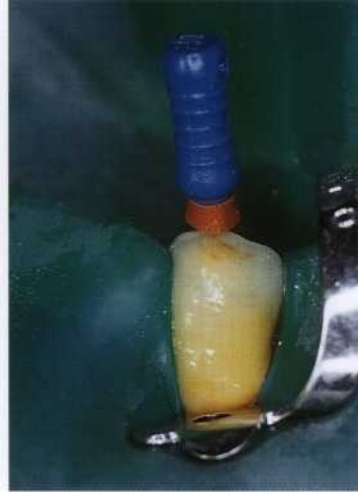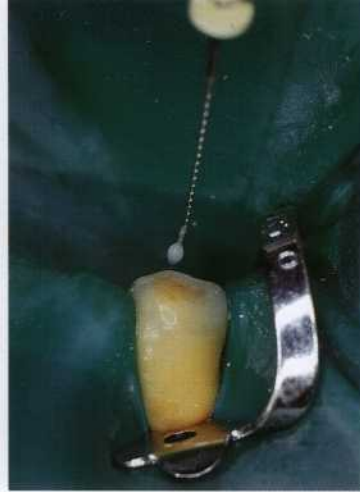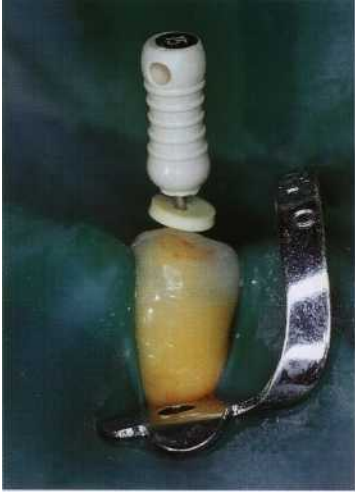Center: Two different types of files are inserted into the root canals.

Right: The course of the two instruments reveals that there are two separate canals with two separate foramina.



In 1894, Greenough recommended the use of two separate tubes, each fitted with an objective and an ocular and inclined toward one another at an angle of 14° - 16° so that the object could be viewed with both eyes simultaneously. This angle corresponds to the convergence angle of the eyes when accommodated to an object at a distance of 25 cm. To ensure that the image will not appear reversed in either its vertical or horizontal orientation, an image-erecting Porro prism is incorporated between the objective and ocular lenses (Czapski and Gebhard 1897).

Stereoscopic vision with the surgical microscope is based upon the fact that because of the distance between the eyes, the viewing angle is different for each eye, and therefore the two retinal images are not quite identical. Only in the brain are they processed into one single overall impression that produces a three-dimensional representation of the object. The stereoscopic effect is possible only if the object viewed is within the area of sharp focus (depth of field), which is shallower at higher magnifications. Therefore, the surgical microscope is used only at lower magnifications.

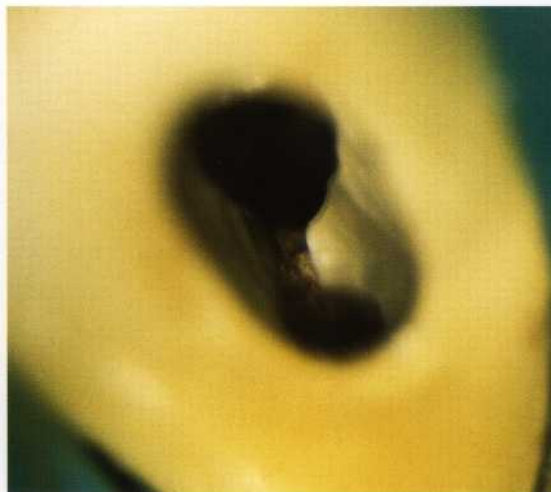
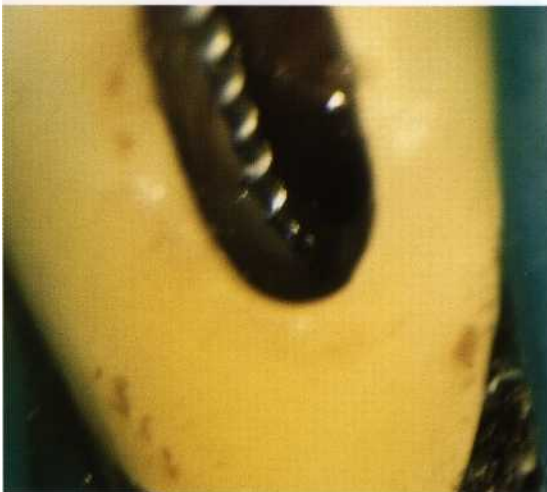
329 Deep preparation

Left: Preparation under a microscope begins with enlargement of the canal with Hedstrom files under 10-16x magnification.

Center: To help open the root canals a lubricant containing EDTA is placed on the tip of the file.

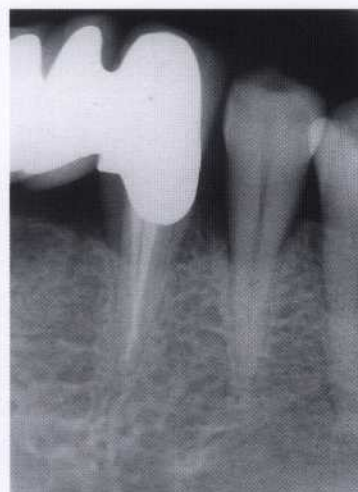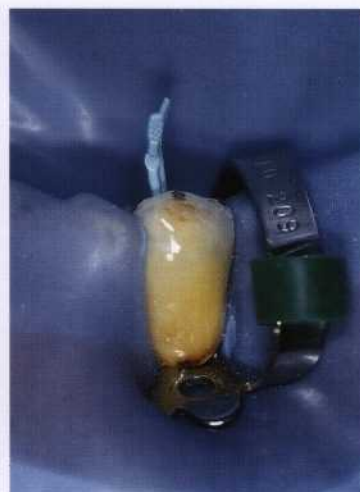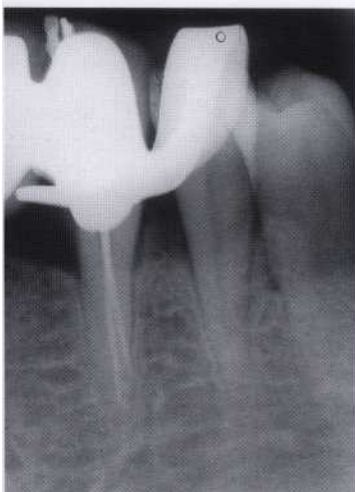Right: After progressive enlargement, the canal is instrumented with the final AMF.



330 Use of a microscope

Left: Between changes of files the floor of the cavity is checked with 16-25x magnification. Because of the better overall view, instrumentation should be carried out under lower magnification.

Right: The two root canals are connected by an isthmus that still contains tissue fragments. The second canal is now completely instrumented also.



331 Root canal obturation

Left: With the absence of clinical symptoms at the second appointment, the gutta-percha points are fitted.

Center: The two master points are placed into the canals up to the indentations that mark the working lengths.

Right: The canals are filled using the lateral condensation technique and a final radiograph is taken that shows a precise apical fit.

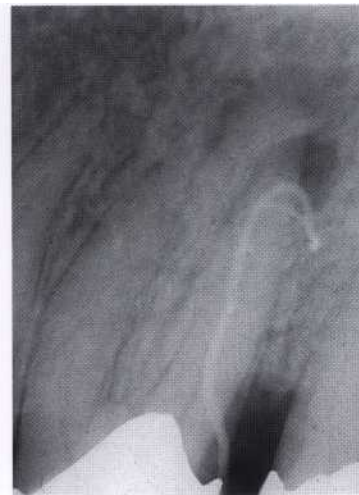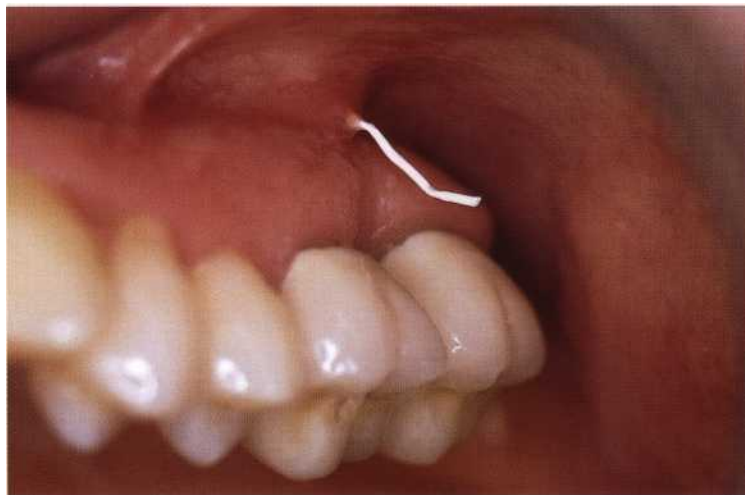
Instrumentation of Maxillary Molars

Aside from an inadequate treatment concept, the underlying cause of endodontic failures is unfamiliarity with the complex anatomy of root canals: the specific cause is usually the failure to detect apical ramifications or additional canals that are infected with bacteria. For example, the incidence of a fourth root canal in a maxillary first molar varies between 19% and 77% according to the method of investigation, and in maxillary second molars it varies between 10 and 38% (Weine et al. 1969, Seidberg et al. 1973, Vertucci 1984, Neaverth et al. 1987).

More recent studies indicate that in maxillary molars, the incidence of a second canal in the mesiobuccal root is 90% for first molars and 70% for second molars. This means that the majority of these teeth have four root canals. In 52.4% of cases there are two separate canals that unite shortly before the apex; 33% have two separate canals; and 4.8% have one canal that divides apically into two separate canals. Mesiolingual canal entrances have been reported in 81% of first molars and 59% of second molars (Gilles and Reader 1990).

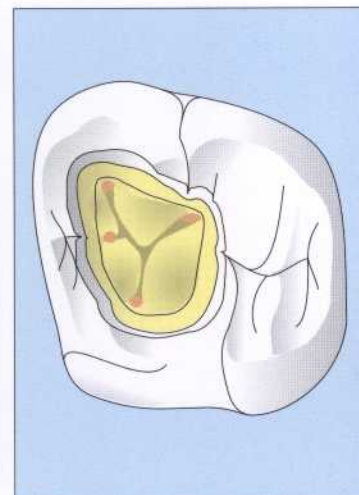
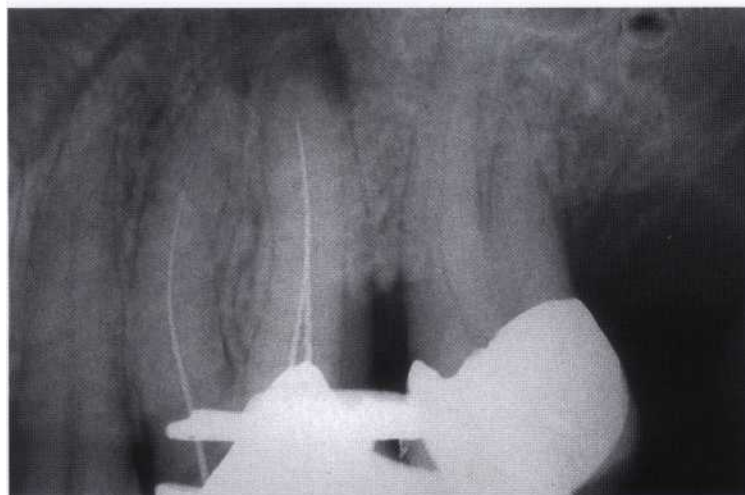332 Fistula formation
Maxillary first molar with a fistula. A gutta-percha point has been inserted into the fistulous tract.

Right: On the radiograph a periapical radiolucency can be seen on the distobuccal root. The fistulous tract has been made visible by the gutta-percha point.



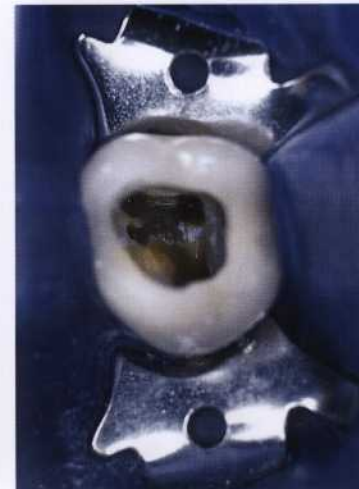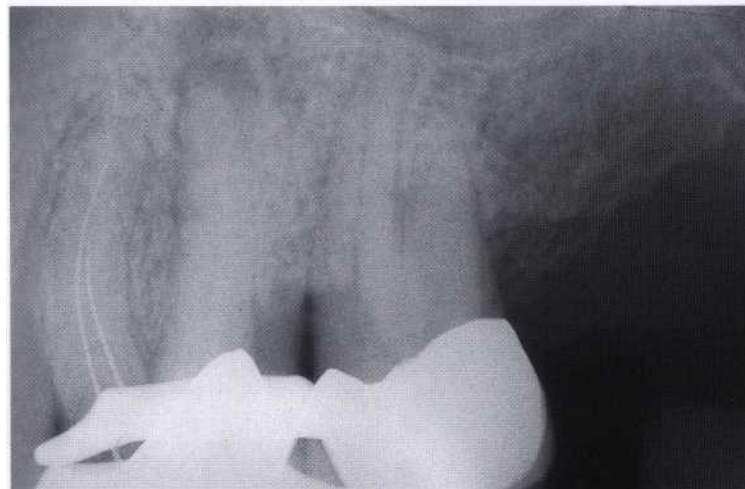333 Access cavity
After preparation of the access cavity, the entrances to the canals are located and the canals with files inserted are identified on a radiograph. Initially, only one canal was found in the mesiobuccal root.

Right: Access opening with the four canal orifices exposed.



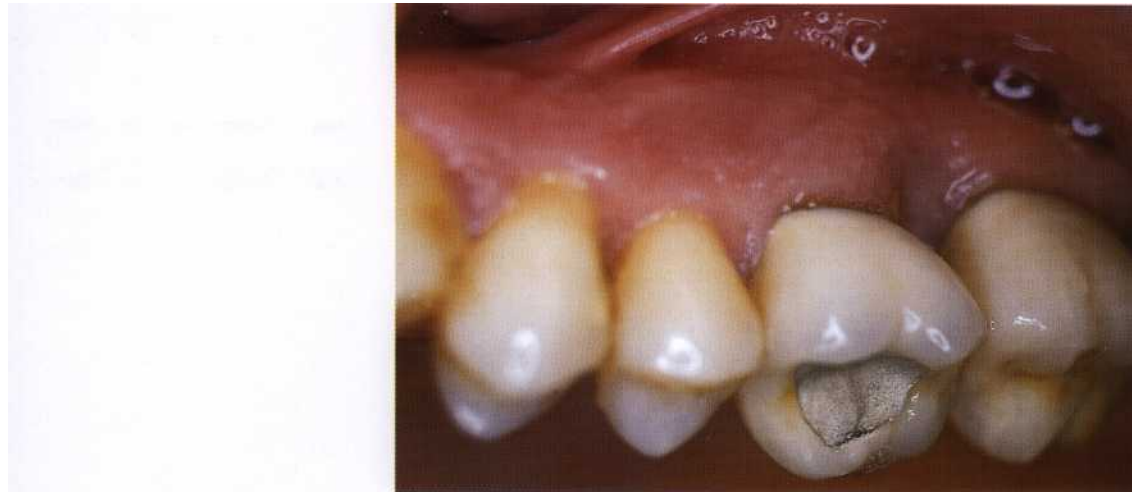
334 Mesiobuccal root
Two separate root canals can be distinguished.

Right: Long endodontic round burs (Endo Access burs) are used sequentially to open the subpulpal groove to locate the orifice of the second canal. Dentin is carefully removed at the expense of the mesial wall away from the trifurcation area, thereby moving the entire access preparation mesially and apically. The burs are used until the subpulpal groove is reduced to a level 2 mm below the original pulpal floor.



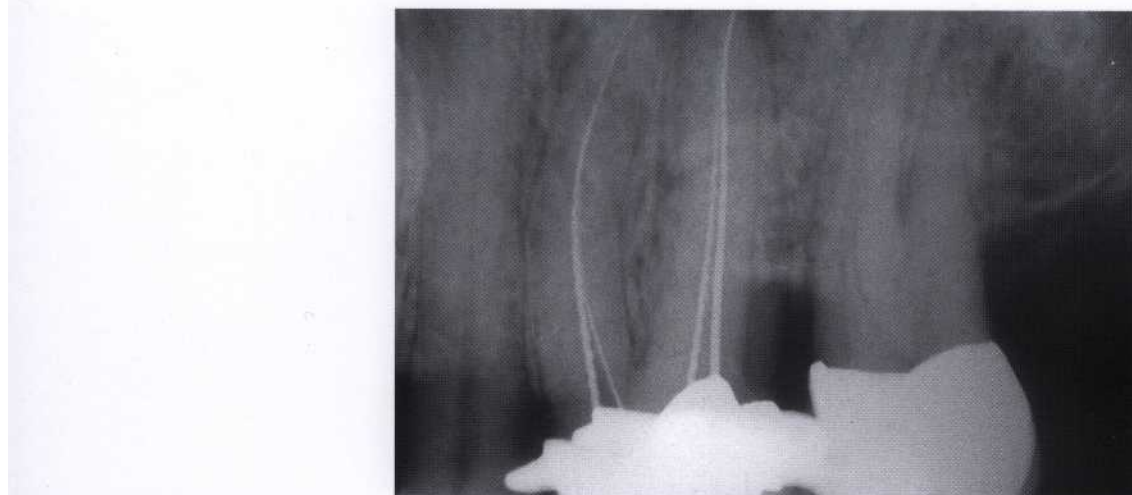
Weine (1982) has stated that the frequent failure of endodontic treatment of the maxillary first molar is likely due to the failure to locate and fill the second mesiobuccal canal. Obviously, before the dentist can clean and shape this canal, it must be located. This has proved to be a difficult procedure. Hartwell and Belizzi (1982) demonstrated this when they reported treating a second canal in only 18% of 538 first and in 10% of 176 second molars. Acosta and Trugeda (1978) have stated that the canal orifice is covered by a rounded dentinal growth that conceals the funnel-shaped struc-

ture of this canal from view. In the in-vitro study of Kulild and Peters (1990) a bur was next used carefully to locate any additional second mesiobuccal canal. This second canal was located in the coronal half of 95.2% of the roots: by hand instruments in 54.2%, by bur in 31.3%, and microscope in 9.6%. There were no root perforations. The mesiopalatal canal orifice averaged 1.82 mm palatal to the mesiobuccal canal orifice. The canal systems were divided into types I-III: type I, 4.8%; type II, 49.4%; type III, 45.8%.



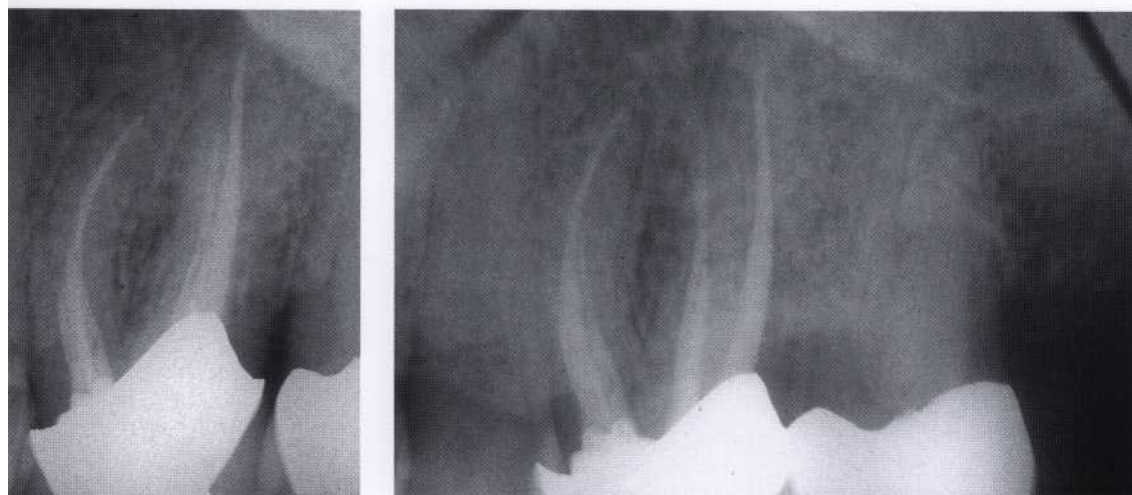
335 Interim dressing

Three weeks after the root canal preparation, the fistula has already healed. The access cavity is sealed with a glass ionomer cement.



336 Radiographic evaluation

The working-length radiograph shows that all four canals are patent, although the instruments cannot be clearly differentiated because of overlapping.



337 Root canal filling

This follow-up radiograph was taken with an eccentric projection 1 year after the endodontic treatment. It shows healing of the periapical radiolucency and two separate canals in the mesiobuccal root.

Left: The radiograph taken immediately after filling of the canal shows a dense obturation.

Engine-Driven Canal Instrumentation

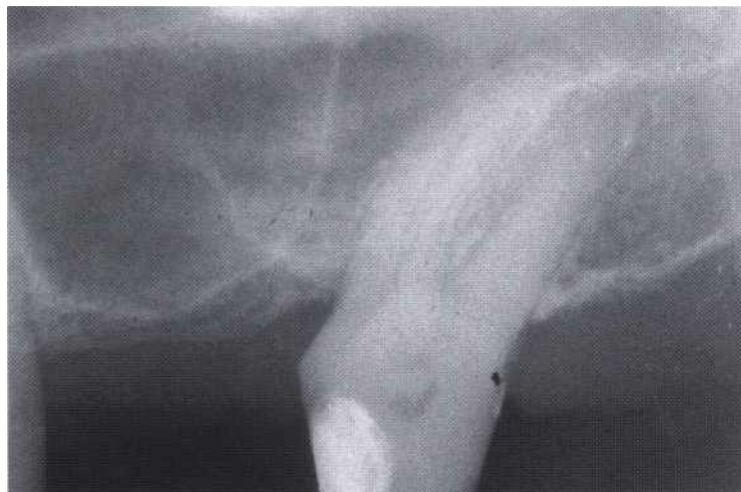As early as 1899 a needle-shaped root canal drill driven by a dental motor was developed by Rollins to facilitate the fatiguing, time-consuming task of root canal instrumentation for the dentist. In order to minimize instrument fracture, the rotational speed was later limited to 100 rpm. However, it was not until the introduction of the Racer file handle in 1958 and the Giromatic handpiece in the year 1964 that the epoch of engine-driven root canal instrumentation began in earnest (Hulsmann 1993 a).

The Racer file handle allows the instrument to make a piston-like movement. The Giromatic handpiece produces reciprocating one-quarter turns and has been imitated by many other handpieces. The Intra-Endo 3LD utilizes alternating 80° rotations. The Endolift 1, in addition to making reciprocating quarter turns, also produces vertical strokes. The primary movement of the Canalfinder system is a vertical stroke with an amplitude that depends upon the rotational speed and the resistance offered by the canal. In the Excalibur handpiece, the files execute multilateral movements, or so-called aleatoric oscillations.

The Racer file handle allows the instrument to make

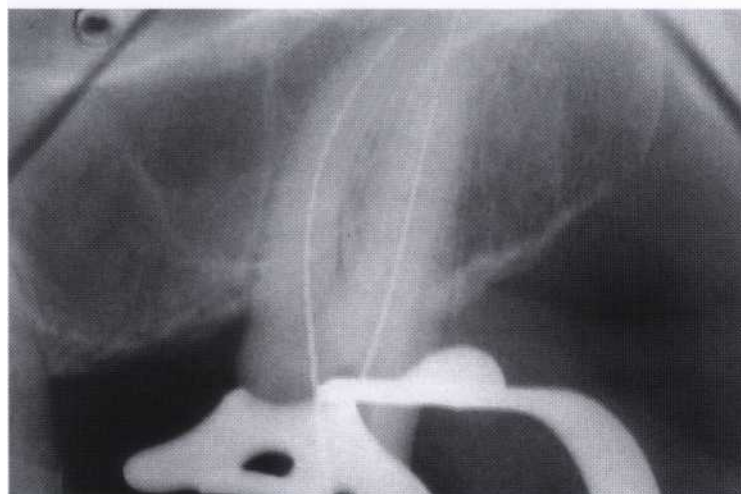
338 Beginning situation

Diagnostic radiograph of a maxillary molar with distally curving root canals. Ideally, engine-driven instrumentation should produce uniformly tapered canals without enlarging the apical foramen, and at the same time prepare apical stops. The canal walls should be completely cleansed of all residual necrotic tissue.




339 Working length

After the access cavity has been prepared, the working lengths of the root canals are determined with the help of radiographs. Because of the tendency of all engine-driven aids to straighten curved root canals, sometimes to a great extent, the working lengths may become shortened.

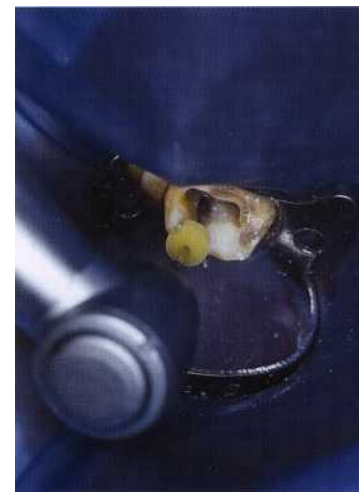

340 Mode of operation

The mode of operation of the Giromatic and Endolift 2 instruments is a reciprocating quarter-turn movement. In the latter system, regular hand instruments can be latched onto the handpiece.

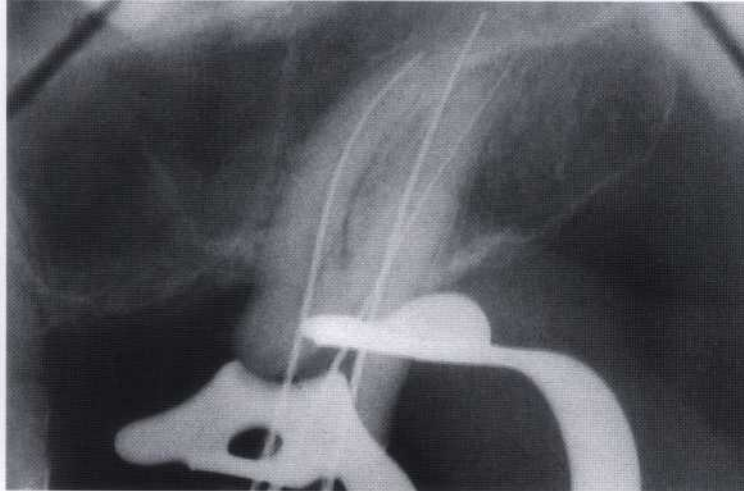
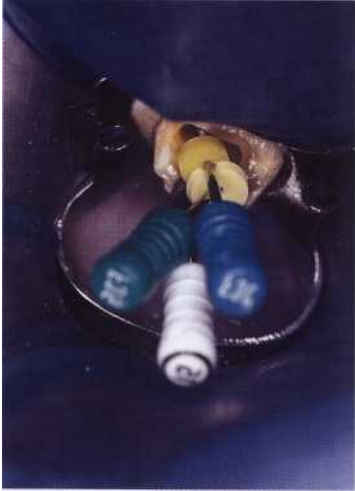

Right: During clinical use the working length must be maintained with a stop. The instruments are prebent and must be frequently checked for surface integrity.



The technique used with the Racer and the Endolift I was associated with the occurrence of acute painful reactions due to apical compaction of infected dentin shavings. Satisfactory preparations were found in only two-thirds of curved root canals instrumented through size 35. A reduction of the apical curvature occurred in all of the canals. Excalibur instrumentation produced an acceptable form in only one-third of the canals. Compared with other powered systems, the Endolift proved to be the system that removed the least amount of material. The Giromatic, on the other hand, removed

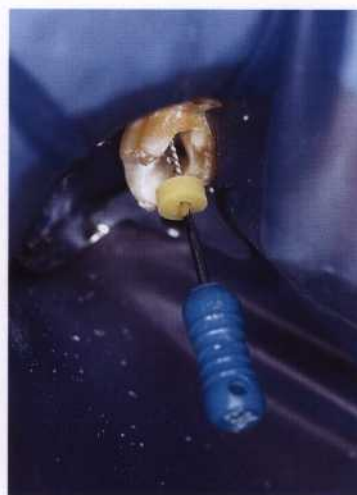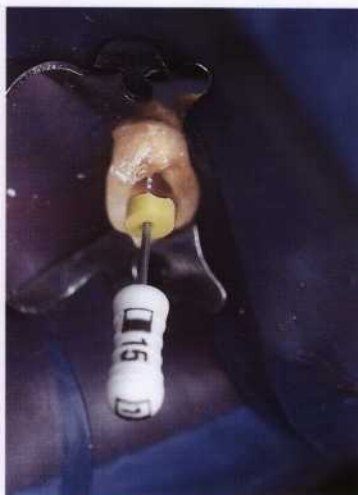dentin most efficiently. Its shaping of the canal, however, was designated as critical because it could quickly alter the apical structures and the original canal morphology. The Canalfinder also provided inadequate instrumentation of curved root canals, and regions with uninstrumented canal surfaces could be observed. None of the canals studied were completely cleaned or thoroughly smoothed. The reduction of tactile feedback accompanied by loss of working length is common to all the handpieces studied (Hulsmann 1992, 1993).



341 Length reassessment

The working length is checked once more with the last file used for canal preparation. The radiograph shows acceptable canal morphology and preparation depth.

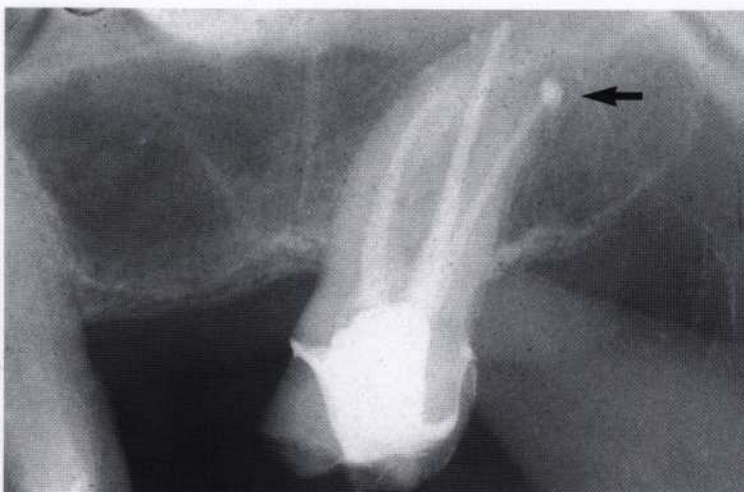
Left: The three working files have been removed from the handpiece and inserted into the canals to evaluate the lengths.



342 Final instrumentation

Left: For the initial preparation the highly flexible Nitinol files may be used in an angled handpiece, although these remove significantly less material.

Right: The mechanical preparation should be followed up with hand instruments to give the canal its final form.



343 Overfilling

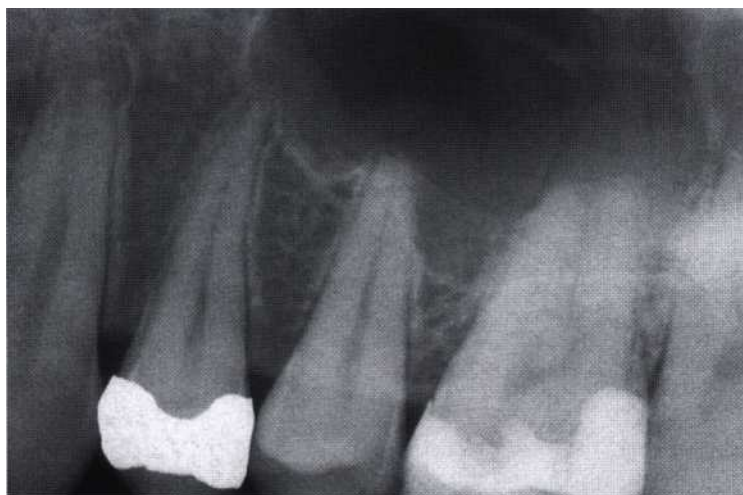On the control radiograph a slight straightening of the mesiobuccal canal can be seen with loss of working length as well as overinstrumentation of the distobuccal canal. Causes include inadequate shaping with step formation and apical blockage as well as perforation with overfilling through lack of tactile feedback.

Instrumentation with Profile

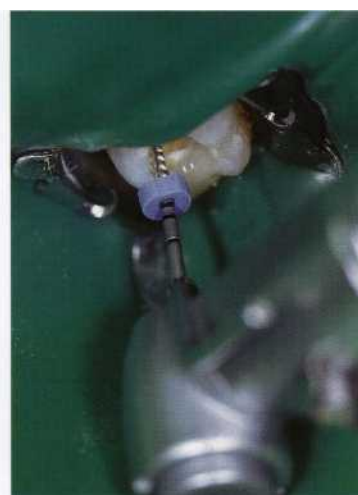A new generation of instruments has been developed from nickel-titanium that potentially allow shaping of narrow and curved canals. Himel et al. (1995) evaluated Ni-Ti hand files using dental students to prepare curved canals. These preparations were rated higher than preparations using stainless steel files with significantly less zipping and ledging. Ni-Ti instruments with increased taper have been developed in the hope that greater flare along the shaft would automatically create the flare required in the canal shape. The taper of these instruments (0.04 mm/mm) is twice that of convention-

al instruments that have a taper of 0.02 mm/mm. The increase in taper, when used in a modified crown-down technique, allows the smaller files to function under reduced stress and higher tactile sensation at working length. The Profiles (Tulsa-Dentsply) are made by grinding three equally spaced, U-shaped grooves around the Ni-Ti shaft. The instruments have flutes with flat outer edges, known as radial lands, which cut with a planing action. The Profile 04 Series 29 has a novel range of sizes including a series that increases in diameter by a consistent 29% (Wolcott and Himel 1997).

344 Diagnostic radiograph
 The maxillary first molar has a necrotic pulp, but no visible periapical radiolucency. The patient reported continuous pain that increased in the evenings. The root canals are slightly curved and both buccal roots are shorter than the palatal root.

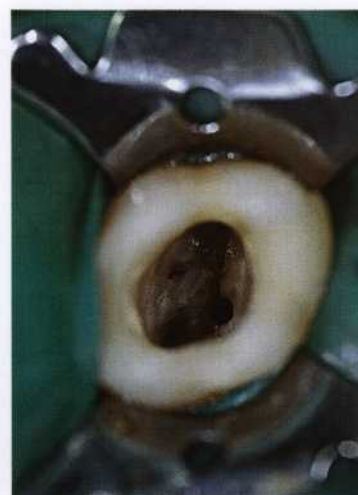
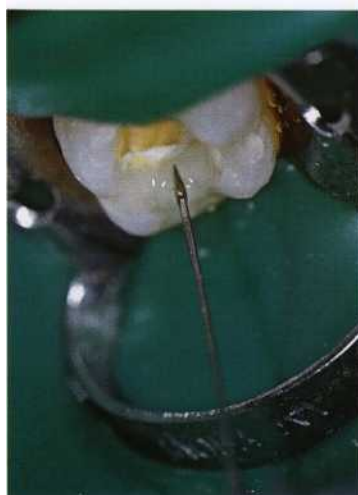

345 Coronal enlargement
Left: First the coronal portions of the canals are enlarged with a Orifice shaper, followed by Profile 06 and then by Profile 04 without reaching the working lengths.



Right: The canals are further widened with the Profile 04 and irrigated with sodium hypochlorite solution.

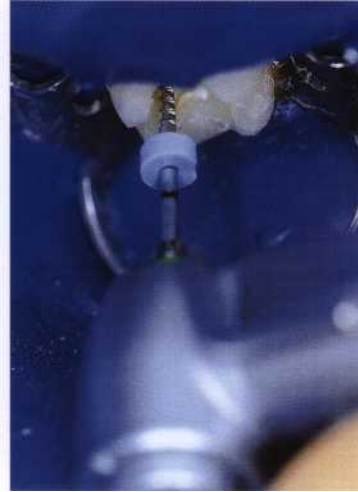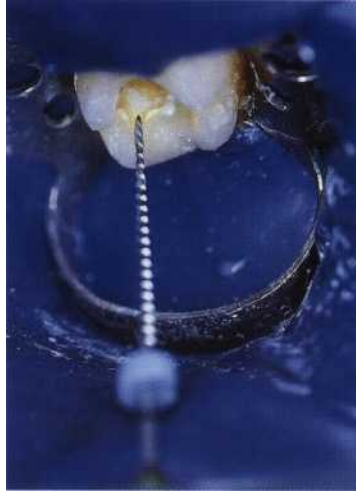346 Gates-Glidden drills
Left: The coronal portions of the canals are given a conical shape with Gates-Glidden drills, sizes 1 through 4.



Right: Shaping with Gates-Glidden drills is necessary only if the canals are to be obturated by using lateral or vertical condensation techniques. If a Thermafil filling is to be placed, these drills need not be used.

The type of root canal instrumentation used with the Profile system varies depending upon the filling technique to be used later. If the canals are to be filled by the Thermafil technique, instrumentation is started with a size Orifice shaper, preparing only the straight portion. The files rotate at speeds of 350 rpm. If the first file reaches this length and rotates freely in the canal, a Profile 06 is inserted to the same working length. A profile 04 is then used in the apical segment of the canal. Only then is the size 2 Profile inserted to the entire working length. Apical enlargement is ac-

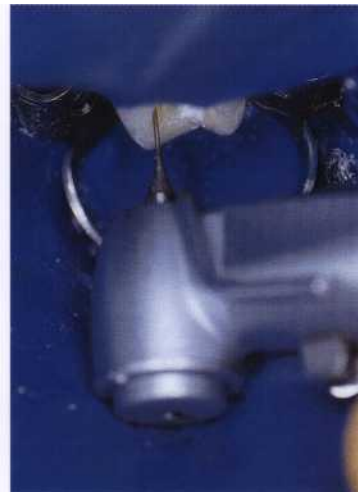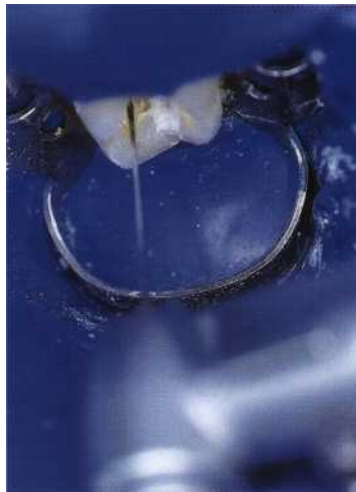complished with Profile instruments of sizes 3 through 7. No further coronal enlargement is performed. If, on the other hand, the canal is to be filled by lateral condensation, Gates-Glidden drills are used again as in the step-down technique to form a more strongly tapered preparation. Rotary Ni-Ti Profiles provide a more centered preparation with less apical transportation than hand files (Cotti et al. 1998). Even students with no endodontic experience can easily learn to use Profile with success and achieve good root canal geometry (Bauermann and Roth 1999).



347 Cleaning

Left: Instrumentation at a second sitting following emergency treatment with the Profile 04.

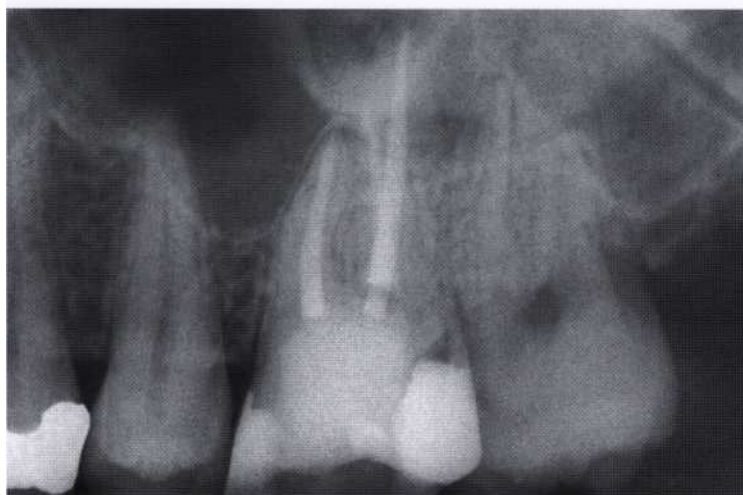Right: Apical enlargement by three to four sizes and the beginning of conical shaping with the Profile 06.



348 Shaping

Left: For lateral condensation the root canals are tapered further with Gates-Glidden drills.

Right: Each canal is tapered with Gates-Glidden drills using wiping movements from the midcanal region outward. This will facilitate the later condensation of gutta-percha points.



349 Radiographic evaluation

Radiograph of the completed root canal filling showing well-formed canals and no periapical abnormalities.

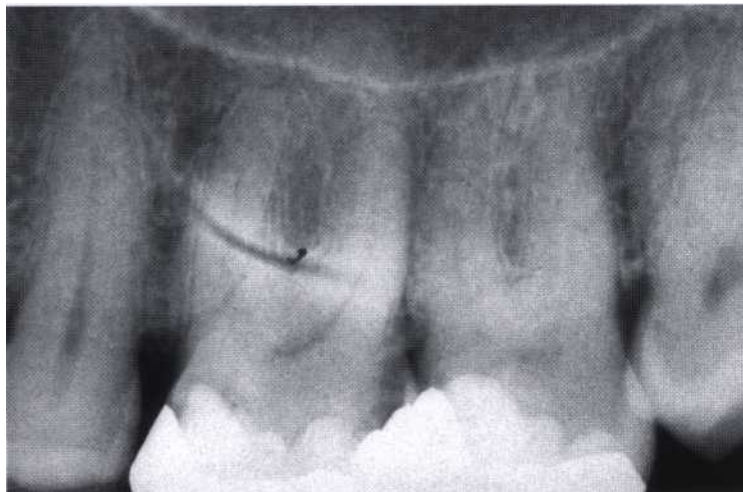Instrumentation with Tri Auto ZX

In an effort to obtain complete debridement of a root canal system, debris such as dentinal filings, necrotic pulp tissue, bacteria, or irrigants may be extruded into periradicular tissue. This debris may lead to postoperative pain and discomfort. Hand or engine-driven instrumentation with Ni-Ti files that uses rotation seems to reduce significantly the amount of debris extruded apically when compared with a push-pull (filing) technique (Reddy and Hicks, 1998). Significantly more debris was extruded when filing was performed up to the apical foramen, irrespective of the technique used

(Beeson et al. 1998). Safety features include Auto Apical Reverse (AAR) to prevent overinstrumentation. In a study, 60 extracted teeth were instrumented. On average, the electronic length was 0.54 mm shorter than the actual length, and the instrumented length was shorter than the electronic length. Instrumentation to AAR level 1.0 consistently approximated and frequently violated the apical constriction, without consequent extrusion of vertically condensed gutta-percha (Campbell et al. 1997).

350 Clinical situation

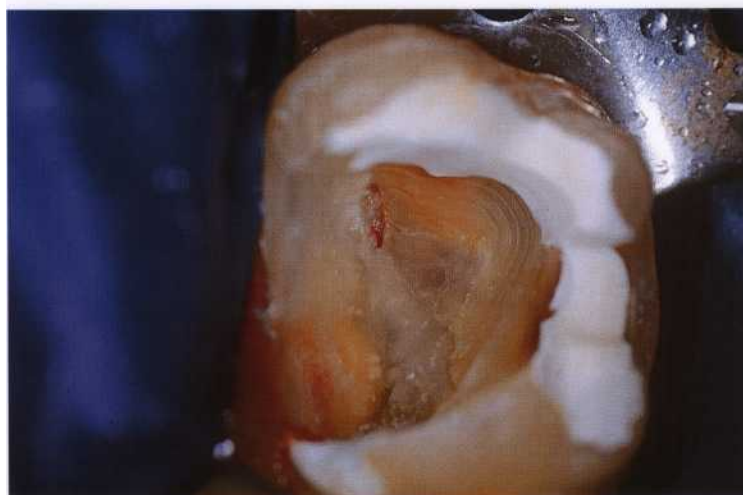The diagnostic radiograph of a maxillary second molar with penetrating secondary caries reveals curved mesiobuccal and distobuccal root canals. The tooth is very painful but does not yet react to percussion.



351 Access Opening

The inlay is removed and the caries excavated under anesthesia, exposing the pulp.

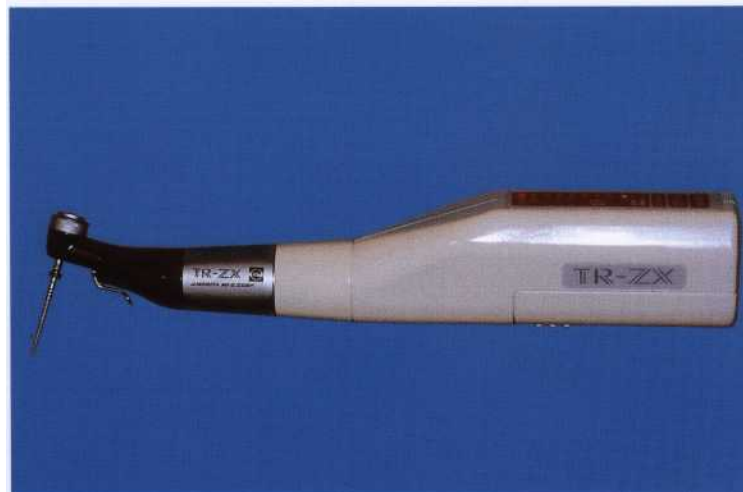
Right: Following preparation of the access cavity and extirpation of the pulp tissue, patency of the canals is established.



352 Tri Auto ZX

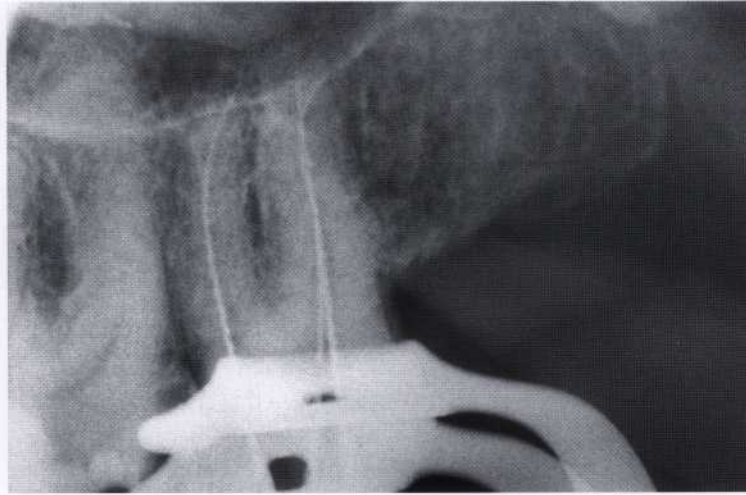
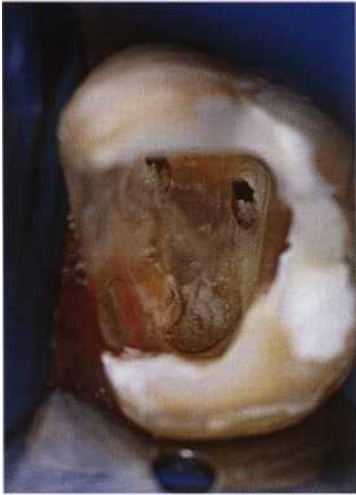This low-speed handpiece, combined with the technology of the Root ZX, gives the clinician the capability to electronically monitor the root canal before, during, and after instrumentation.

Right: The Tri Auto ZX has three functions: automatic start/stop (1), automatic torque reverse (2), and automatic apical reverse (AAR) (3). The handpiece stops and reverses the rotation of the file when the tip reaches the apex or when too much pressure is applied.



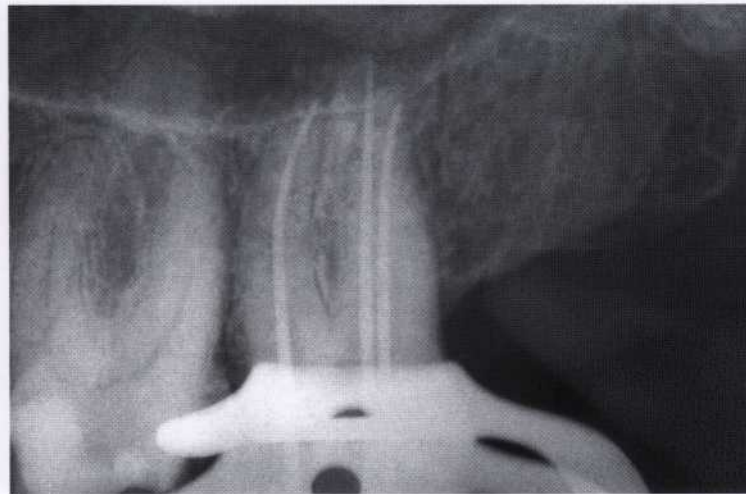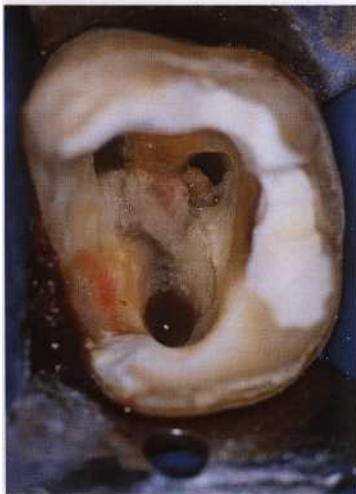Ni-Ti endodontic instruments were introduced to facilitate instrumentation of curved canals. Despite their increased flexibility, separation is still a concern with Ni-Ti instruments, and they have been reported to undergo unexpected fracture. Separation can occur without any visible signs of previous permanent deformation, apparently by forces within the elastic limit of the instrument (Pruett et al. 1997). In a study by Rowan et al. (1996), Ni-Ti files with 0.02 taper fractured significantly earlier than comparable steel files. Wolcott and Himel (1997), however, demonstrated a

higher load strength for Ni-Ti instruments with a 0.04 taper than for instruments of the same material with 0.02 taper. Therefore, a second safety feature of the Tri Auto ZX handpiece is the inclusion of an automatic torque reversal to prevent file breakage. Canal instrumentation with a handpiece setting of 1.0 consistently allowed approximation of the apical constriction without file breakage or canal transportation (Campbell & Friedman 1997). Breakage of Ni-Ti files is less likely if the file is run at the lowest recommended speed (Dietz et al. 1998).



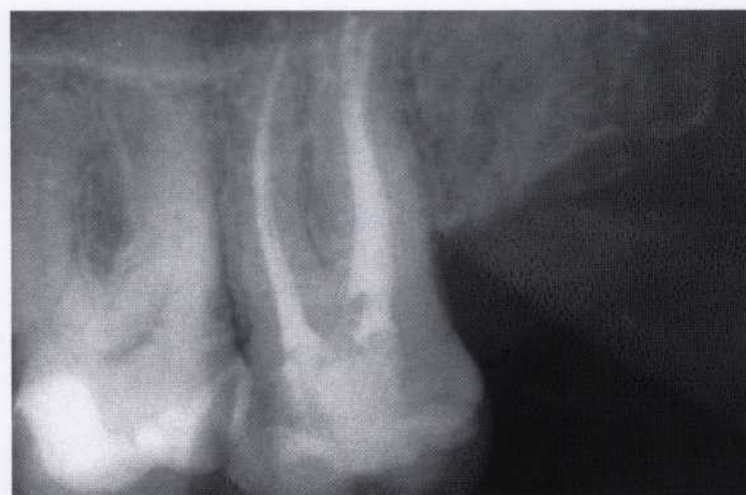353 Engine-powered canal enlargement
Radiographic evaluation for patency of the root canals. There is distinct bending of the measuring files near the apices.

Left: The initial mechanical enlargement with Gates-Glidden drills is followed by apical instrumentation.



354 Master point
After preparation of the curved root canals with a combination of steel and Nitinol files and before obturation of the canals, the preparation is evaluated with gutta-percha points inserted.

Left: Visual evaluation of the resulting preparation.



355 Filling
After the root canal filling has been placed the results of the treatment are checked with a radiograph.

Instrumentation with the Quantec Series 2000

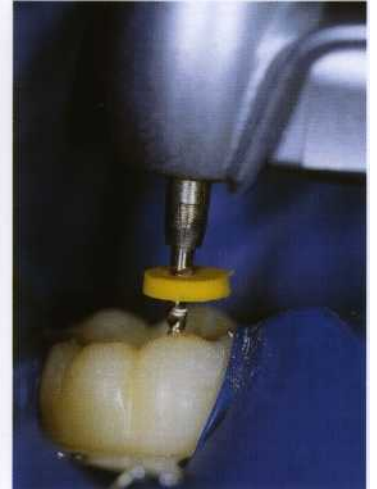
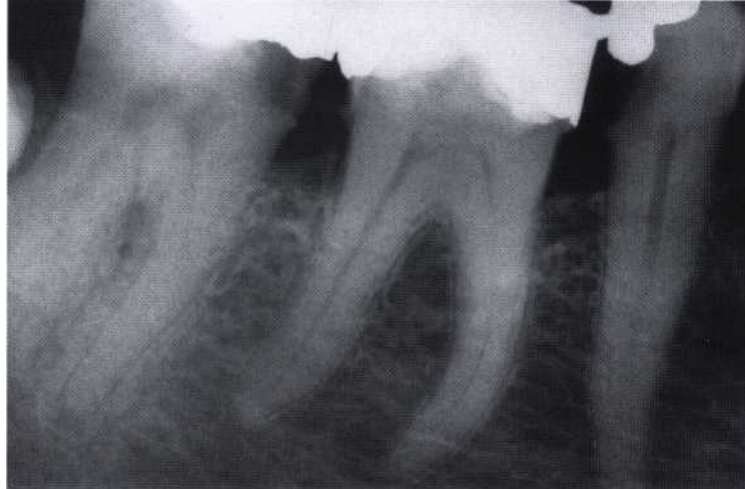
The Quantec Series 2000 uses Ni-Ti instruments of graduating tapers. The Quantec instrument incorporates many new design configurations including a more ideal cutting angle of the blade, flutes designed to help remove the dentin debris as it is being formed, wide radial lands to prevent crack formation in the instrument and help deflect the instrument around curvatures, asymmetry of the cutting surfaces to help maintain the integrity of the central axis of the canal, and, finally, a faceted cutting tip to help prepare narrow, curved, calcified canals. The Quantec instruments prepare the root

canal in three stages. The Quantec #1, a 17-mm-long size 25 instrument with a 0.06 taper, is used as an orifice opener. The Quantec #2, a size 15 instrument with a 0.02 taper, is used to estimate the working length. In the second stage, the apical seat is enlarged to a size 25. The Quantec #5, a 0.03-tapered size 25 instrument, is used to merge the coronal and apical preparation in the beginning of the third stage. The Quantec #8, a 0.06-tapered size 25 instrument completes the flaring of the canal.

356 Pretreatment situation

The diagnostic radiograph of the lower right first and second molars reveals penetrating secondary caries and a periapical radiolucency on the second molar. The first molar already shows probable signs of inflammation from the secondary caries under the deep filling.

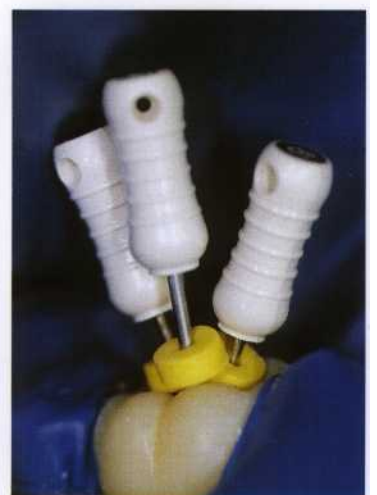
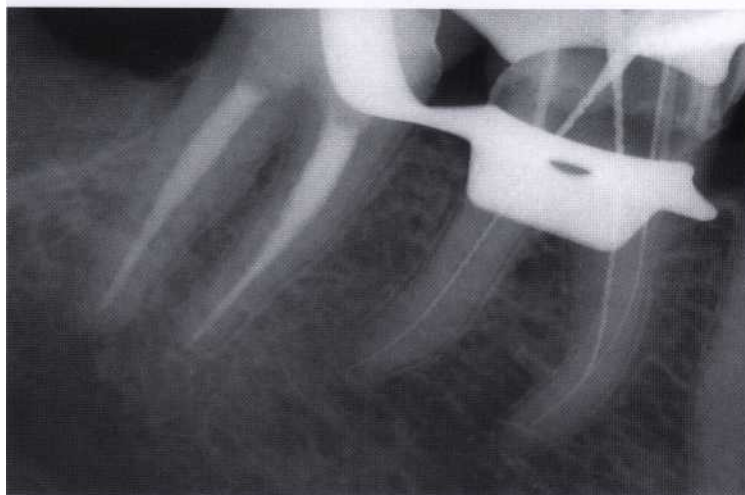
Right: The Quantec # 1, a 17-mm-long instrument with a 0.06 taper, is used to open the orifices.



357 Working length

After preparation of the access cavity, the working lengths of the canals in the first molar are determined with a radiograph. The second molar has already been endodontically treated, and regeneration of the periapical radiolucency is clearly evident.

Right: Three files with stoppers are inserted into the canals.

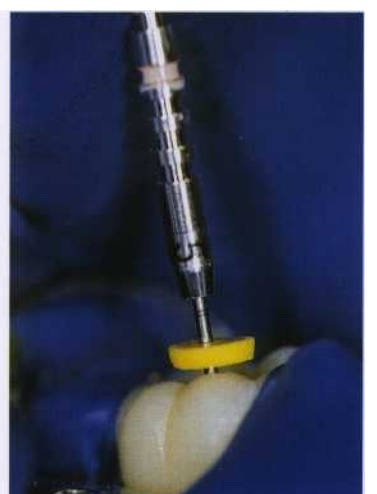
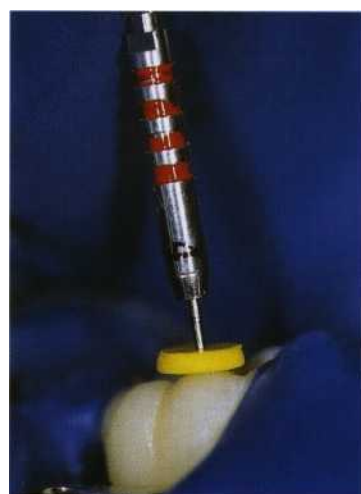
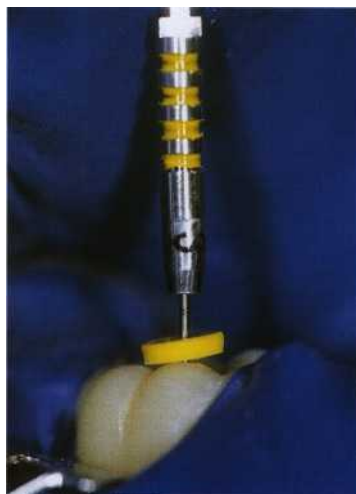358 Apical enlargement

Left: The Quantec 2 and 3 (# 20), a 0.02 tapered # 15 file, is carried to the estimated working length.

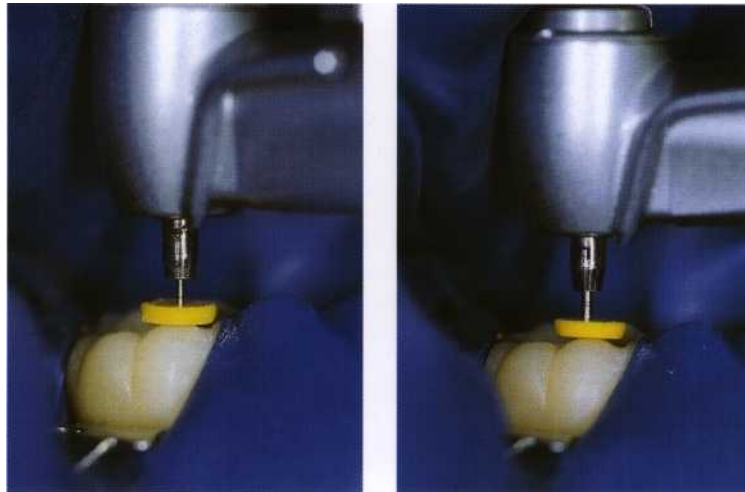
Middle: Quantec 4 (#25) instrument is then taken to the full working length.

Right: The Quantec 5, a 0.03 tapered #25 instrument, is used to merge the different regions of the preparation.



Quantec instruments yielded higher centering ratios at the apical level. There were no differences in the direction of canal transportation. Canal preparation time was the shortest for Profile, followed by Fley-R files in the Endo Gripper, the Quantec system, and Shaping Hedstrom files in the M 4 handpiece (Kosa et al. 1998). The SEM examination of the internal surface of the prepared root canal showed a smooth internal surface after hand preparation with Flexofile but with scratches in the axial direction. Quantec instrumentation showed smoother and straight cutting surfaces with no axial

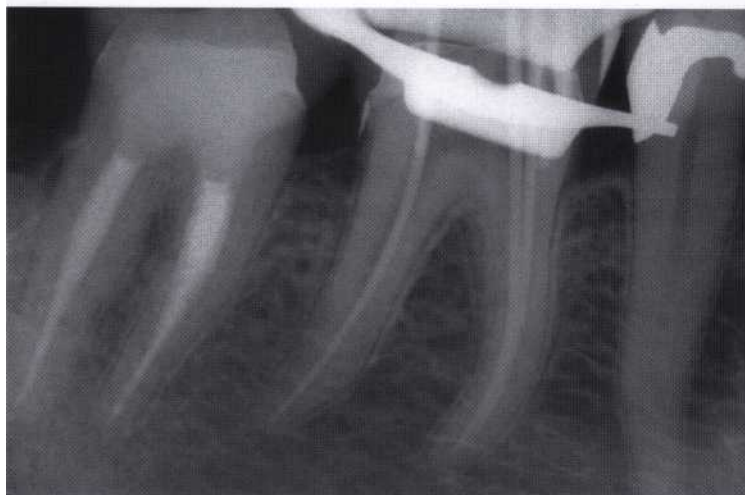scratching. Quantec instruments were effective in the removal of major amounts of tissue from the root canal but this removal was incomplete (Jeong-along et al. 1998). The purpose of the study by Uemura et al. (1998) was to quantify the amount of remaining obturation material on the canal walls, extruded debris, and the retreatment time when Quantec, K files, and Hedstrom files were used. The Hedstrom file group required less time; the automated devices did not prove to be better than hand instrumentation techniques.



359 Shaping

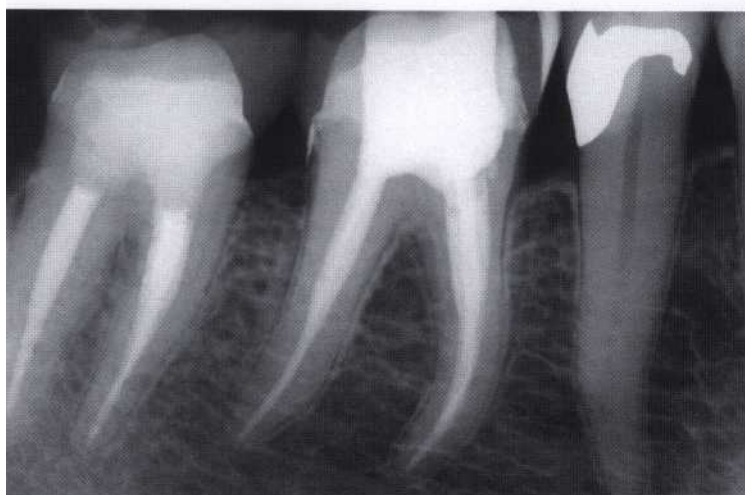Left: During the first phase of apical instrumentation the canal is enlarged from size 15 to size 25 all the way to the working length.

Right: In the second phase of apical preparation the root canal is flared with instruments that are all size 25 but of progressively increasing taper (0.03, 0.04, 0.05, and 0.06). Finally, the last two 0.02 tapered instruments (#40 and #45) can be used in step-back fashion for further enlargement.



360 Evaluation

The depth of the preparation is evaluated on the master point radiograph.



361 Root canal filling

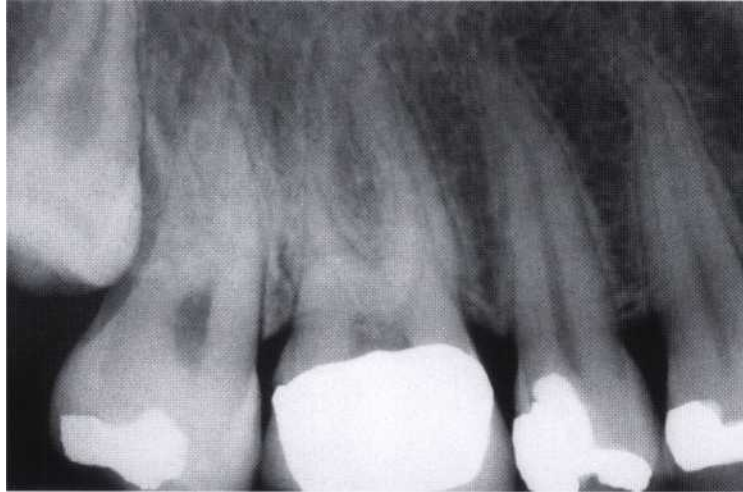The final radiograph of the completed endodontic treatment reveals well-formed root canals.

Instrumentation with Lightspeed

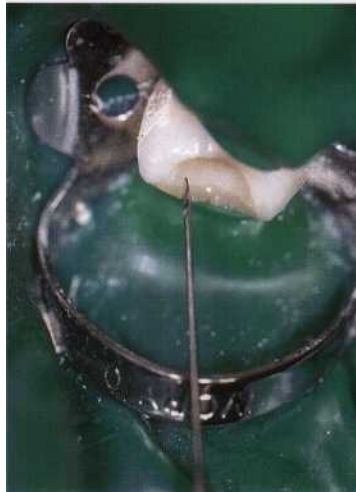In 1989 Wildey and Senia introduced a new instrument, the Canal Master, which has a noncutting tip, a very short cutting blade, and a constant-diameter flexible shaft. This instrument was reported to produce rounder canal preparations, cause less transportation, remain more centered, and show less apical extrusion of dentin debris (Leseberg and Montgomery 1991, Myers & Montgomery 1991). However, these stainless-steel instruments were disposed to rapid wear and breakage (Zuolo et al. 1992, Massa et al. 1992). A more recent change in the Canal Master design was made possible

by the introduction of nickel-titanium. This alloy led to the development of Lightspeed with good flexibility. A recent study showed that Lightspeed instrumentation was faster than hand instrumentation and also produced a better quality of root canal preparation (Closson et al. 1996). In the study of Ramirez-Salomon (1997), six instruments separated during treatment. Five of them were bypassed and treatment was completed. Cycles to failure significantly decreases as the radius of curvature decreases from 5 mm to 2 mm and as the angle of curvature increases beyond 30° (Pruett et al. 1997).

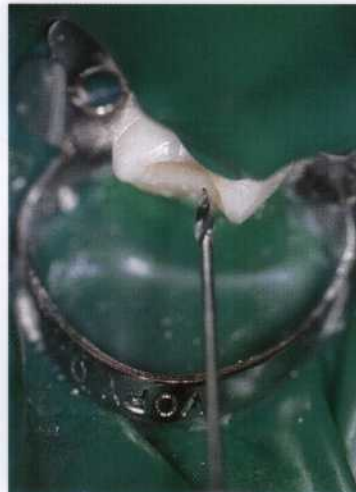362 Diagnostic radiograph
A maxillary premolar with a direct pulp cap that failed, resulting in persistent pain. The root canal is slightly curved to the distal. There is no sign of periapical radiolucency.



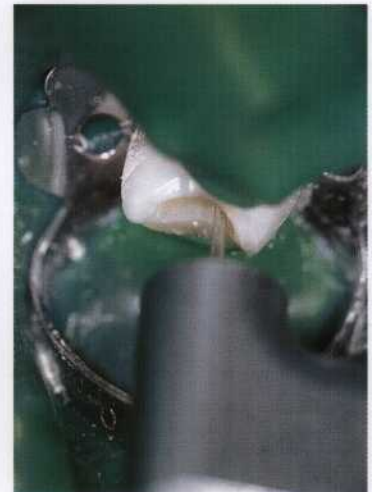363 Coronal enlargement
Left: First the patency of the root canal is established with a size 15 K file. Next a # 1 Gates-Glidden drill is used to enlarge the canal to its middle third.



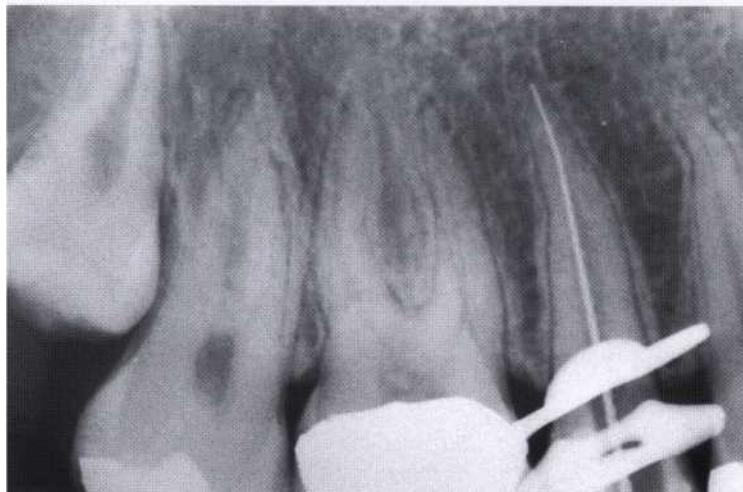Center: Progressively larger Gates-Glidden drills are inserted, each 1 mm shallower than the previous one, in the step-back technique.



Right: Crown-down preparation with Gates-Glidden drills.

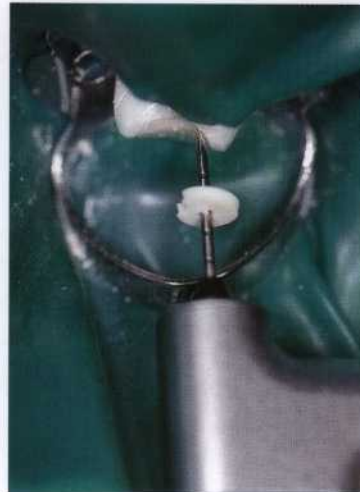
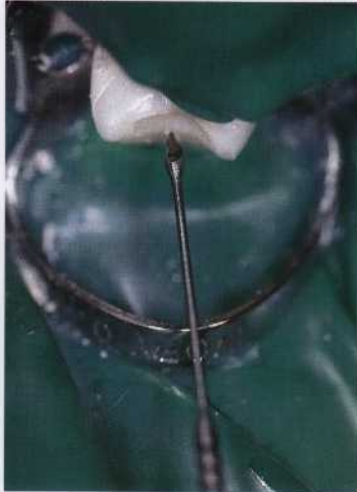
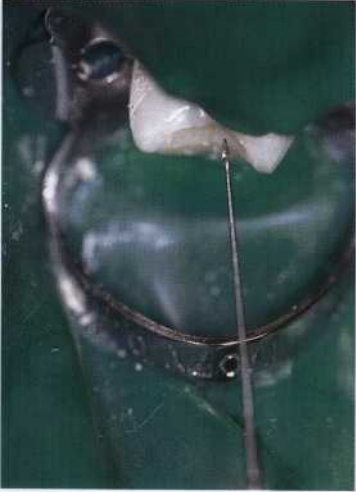364 Length determination
Length determination on a radiograph following coronal enlargement. Preflaring of the coronal portion enables precise determination of the working length and prevents binding of the files in the canal. It also facilitates irrigation of the deepest parts of the canal.



The initial step in Lightspeed instrumentation is to establish patency of the root canal with a size 15 K file. Next the coronal portion is enlarged with Gates-Glidden drills in a step-down technique. The canal is widened to the middle section with a no. 1 Gates drill (corresponding to a size 50 file), and each larger size is inserted 1 mm shorter than the preceding drill. After the working length has been determined radiographically, the apical preparation is begun with the smallest sized Lightspeed instrument (size 20). The instrumentation is then repeated with the intermediate size 22.5.

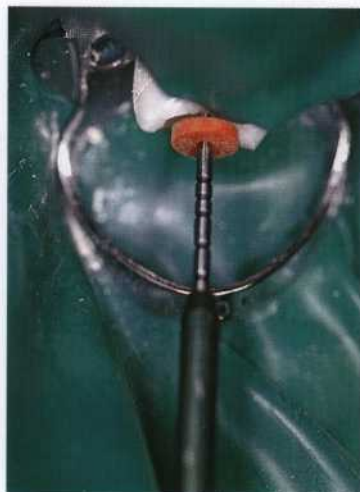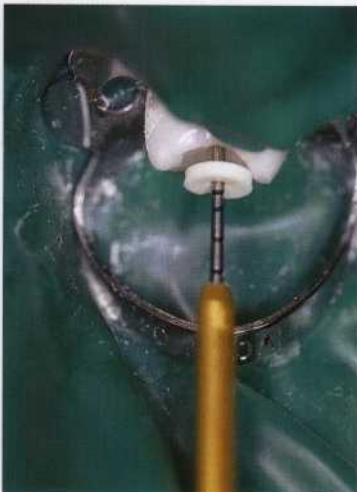
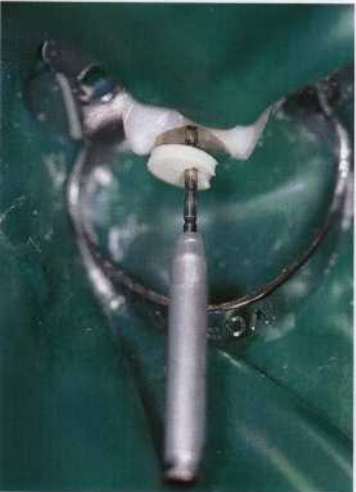The apical region must be prepared to at least a size 40 without skipping any sizes. The last instrument inserted to the working length is designated as the master apical rotary. Finally, additional instruments are employed in a step-back manner. In a study by Thompson and Dummer (1997) the Lightspeed instruments prepared canals more quickly but with a slight loss of length. All the canals had inferior characteristics, however. The three-dimensional form was less than ideal, presumably as the result of an ineffective step-back procedure.



365 Apical instrumentation
Left: Initial instrumentation to the working length with a size 20 Lightspeed instrument.

Center: The apical segment of the root canal is prepared with instruments up to size 45, including the intermediate sizes. The Lightspeed instruments are used at a speed of 750 rpm.

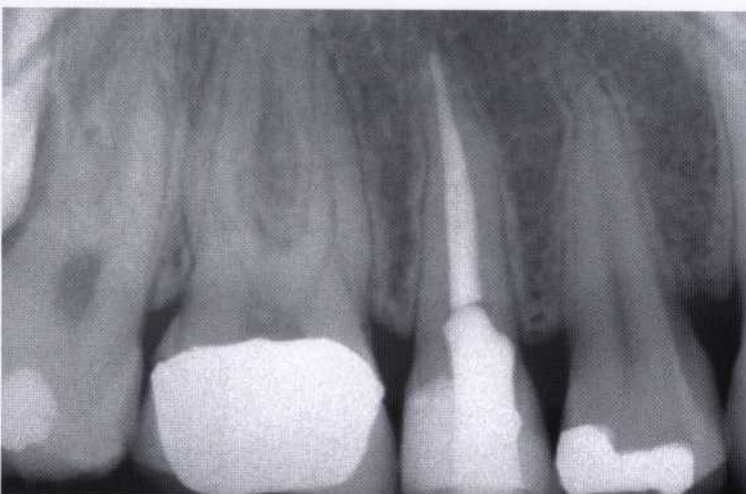Right: The last instrument inserted to the working length is designated as the master apical rotary.



366 Step-back instrumentation
Left: Following the apical preparation the canal is further shaped by means of the step-back technique.

Center: A size 50 instrument is inserted 1 mm shorter than the size 45 one.

Right: The size 70 instrument is inserted 2 mm shorter than the size 50 one (left).



367 Radiographic evaluation
The final radiograph shows excellent adaptation of the root canal filling and a well-shaped canal. An apical stop has been prepared just short of the radiographic apex.

Canal Surface after Engine-Driven Instrumentation

Straight root canals can be fully prepared manually or with sonic or ultrasonic oscillating files. Curved canals, on the other hand, cannot be completely freed of infected residual pulp tissue, irrespective of the technique used. The anatomy of the root canal has a greater influence on the effectiveness of canal preparation than any special method of preparation (Langeland et al. 1985). More than 50% of curved root canals were inadequately prepared near the apex following sonic instrumentation (Haikel and Alleman 1988). None of the canals instrumented with Canalfinder were found to

be completely cleansed or their walls thoroughly smoothed (Hulsmann et al. 1988, 1989).

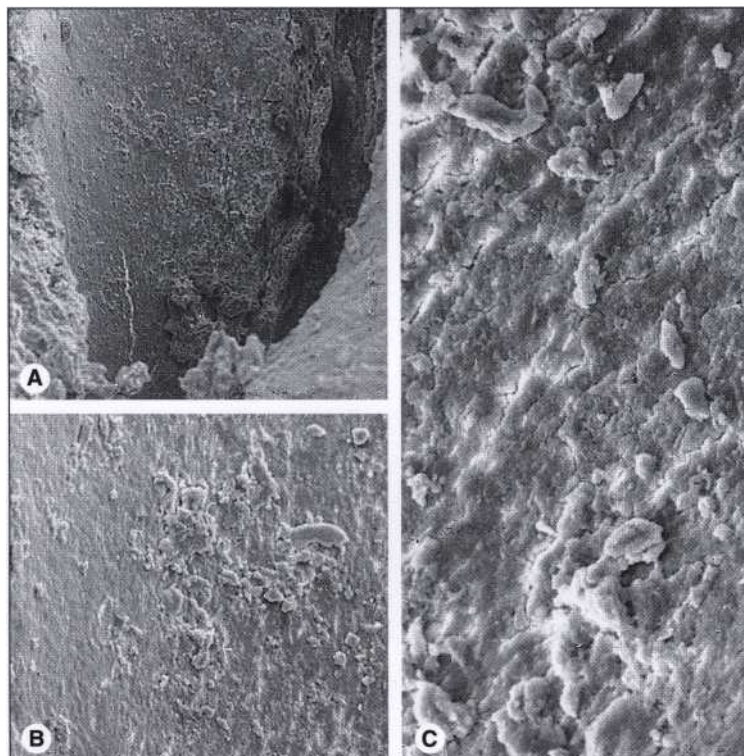
Ni-Ti instruments used in a reaming technique caused less canal transportation, removed a smaller volume of dentin, required less instrumentation time, and produced better-centered and rounder canal preparations than K-Flex stainless-steel files (Gambill et al. 1996). Rotary Ni-Ti instrumentation seems to reduce the amount of debris extruded apically compared with a push-pull filing technique (Reddy and Hicks 1988).

368 Surface after apical instrumentation

A Following instrumentation of the apical segment of a root canal, its surface is irregular with various-sized deposits of dentinal debris, which indicates inadequate tissue removal.

B Under higher magnification a uniform smear layer can be seen with larger deposits of hard-tissue and soft-tissue remnants that may be infected.

C Further enlargement of a section from B reveals an irregular surface. No smoothed areas can be observed that would be evidence of adequate instrumentation.




369 Instrumentation of the midcanal region

A The canal was instrumented with special Hedström files fixed in an Endoplaner hand-piece, which produces piston-like lifting strokes exclusively in contact with the canal wall. This has created deep grooves in the surface, and the canal is quite irregularly formed overall.

B The middle portion of the canal, however, is well cleaned and free of larger deposits of tissue debris.

C Higher magnification shows that the dentin tubules are almost completely covered by a uniform smear layer, which indicates a uniformly instrumented canal.



SEM images

Disinfection

Bacteria can still be present in the root canal after instrumentation is completed, and can be responsible for the return of painful symptoms. The use of antibiotics cannot compensate for inadequate instrumentation or failure to employ appropriate disinfectants. Medications applied through the root canal should eliminate all remaining bacteria, reduce the periapical inflammation, and stimulate bone repair. The dressing must serve as a barrier in case there is coronal leakage, combat embedded microorganisms, and prevent the entry of apical secretions into the instrumented root canal (Chong and Pitt Ford 1992).

If the root canal is not filled with a disinfecting dressing between appointments, bacteria can multiply and approach the numbers present at the beginning of the root canal treatment (Bystrom and Sundqvist 1981). In clinical practice it is recommended either that an interim dressing containing an antibacterial agent be placed (Bystrom et al. 1985), or that the root canal be obturated at the first appointment in order to deprive the microorganisms of nutrients and space to multiply (Soltanoff 1978, Oliek 1983).

It is true that the localized application of a corticosteroid (e.g. Ledermix) will eliminate clinical symptoms, but at the same time, it reduces the overall regenerative ability. Corticosteroids reduce all stages of inflammation, but they likewise inhibit the transformation of fibroblasts and the production of antibodies. Because inflammation is not primarily a pathologic state, but rather a useful defense reaction of tissue, a corticosteroid dressing does not treat the cause of the problem (Raab 1993).

The interim dressing should also loosen remnants of tissue that could not be reached during the first appointment. Two studies (Turek and Langeland 1982, Langeland et al. 1985) reported failure to achieve totally clean dentin surfaces in root canals that were crooked, partially obliterated, or altered by resorption, regardless of the method of instrumentation used. Not only necrotic tissue cells but also bacteria or their metabolic byproducts can be found within dentinal tubules and pulp-tissue remnants. Therefore, in addition to their antimicrobial effect, disinfectant irrigating solutions and interim dressings have as their objective the loosening and removal of remaining areas of soft tissue (Spangberg et al. 1973, Barnett et al. 1985).

Because medications can diffuse into the pulp tissue or be transported through the apical foramen during root canal instrumentation, strong antimicrobial agents can cause considerable postendodontic problems (Walton and Langland 1978).

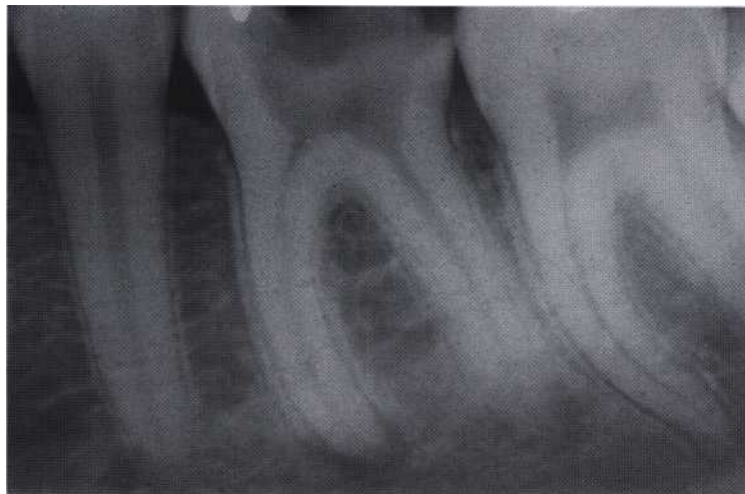
Microbial Infection of Root Canals

The presence of bacteria can be demonstrated in necrotic pulp tissue, on the root canal surface, and in dentinal tubules (Nair et al. 1990b).

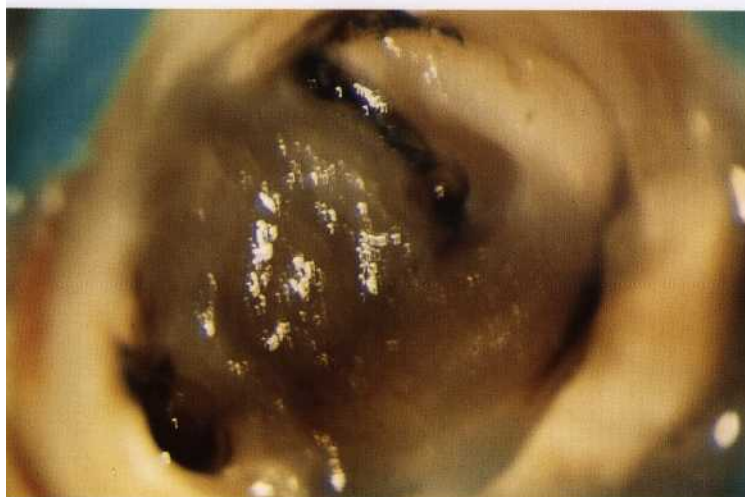
Bacteria in the endodontium are always accompanied by apical periodontitis (Takehashi et al. 1965). Periapical lesions are associated with a mixed infection, with Haapasolo (1989) reporting four to six types of bacteria and Sundqvist (1976) reporting two to twelve types. There is a direct relationship between the size of the periapical lesion and the number of microorganisms in the root canal (Bystrom et al. 1987).

Periapical lesions with symptoms are linked to the presence of certain microorganisms in the endodontium. *Prevotella buccae*, *Porphyromonas endodontalis*, and *Porphyromonas gingivalis* have been found in teeth that are painful, tender to percussion, and associated with fistulas (Haapasolo 1989). Yoshida et al. (1987) were able to find a relation between black-pigmented infections and clinically acute lesions with spontaneous pain. The presence of this microorganism has also been connected with persistence of pain following root canal treatment (Haapasolo 1989).

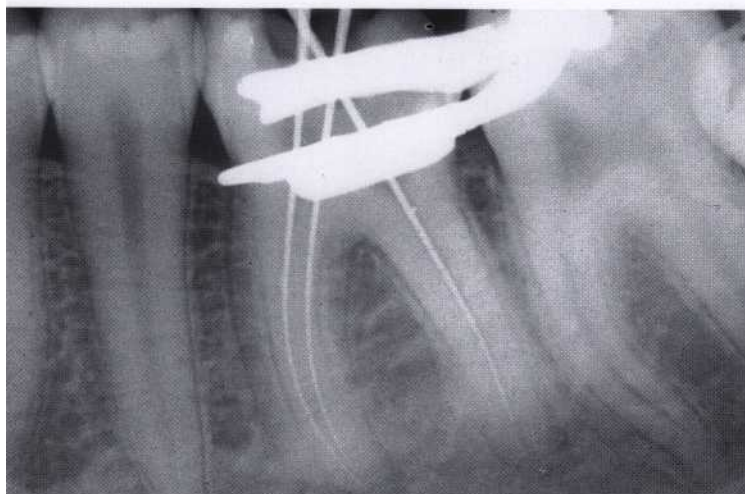
370 Apical periodontitis
Radiograph of a mandibular molar with mesial and distal periapical radiolucencies. The crown has undergone carious destruction and the pulp tissue is necrotic.



371 Bacterial infection
After placing the rubber dam, an access opening is made and the necrotic coronal pulp tissue excavated. Under the surgical microscope at 25x magnification the black stained entrances to the canals can be seen. A strong foul odor also supports the assumption of massive bacterial infection.

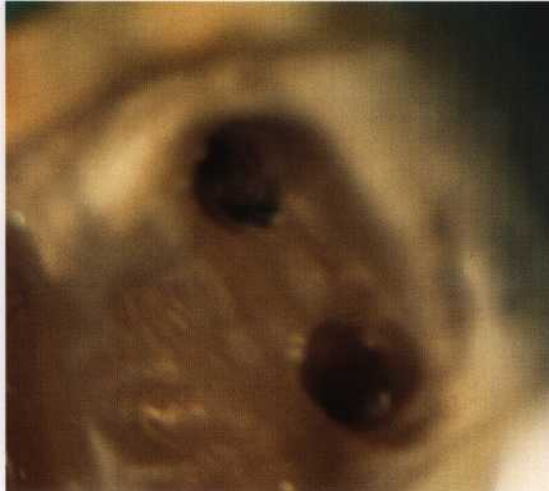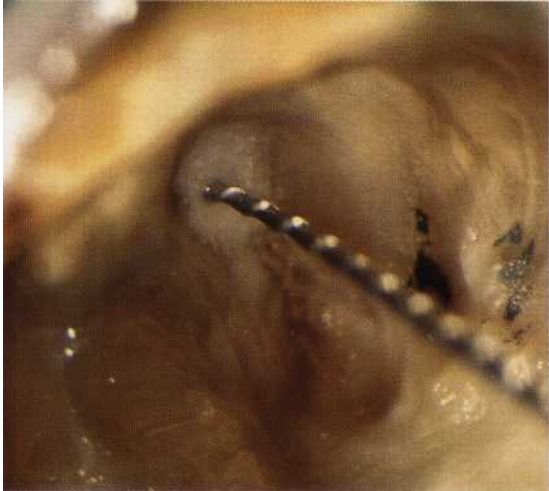


372 Length measurement
The three root canals are enlarged coronally. Next the working lengths are determined with the help of a radiograph, and then the apical instrumentation is begun.



In another study Orstavik et al. (1991) investigated the effect of root canal instrumentation and placement of a dressing upon the endodontic bacterial flora. A total of six symptomatic and 17 asymptomatic periapical lesions received endodontic treatment, during which 22 of the 23 teeth tested positive for bacteria. Following rotational instrumentation with size 25 files and irrigation with physiologic saline, 20 of the root canals still contained bacteria. After they were enlarged to size 35, 14 of the canals were still infected. Further enlargement through size 80 did not result in any

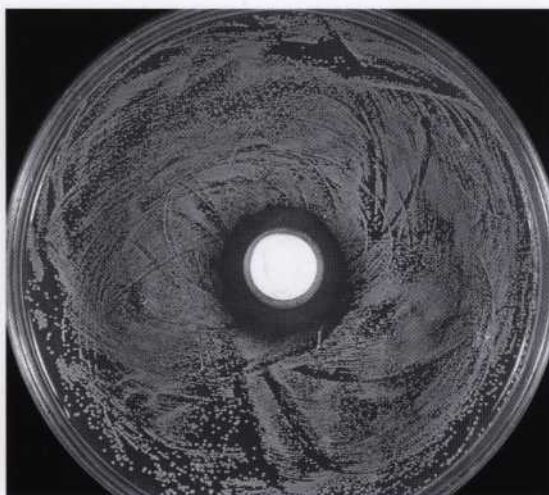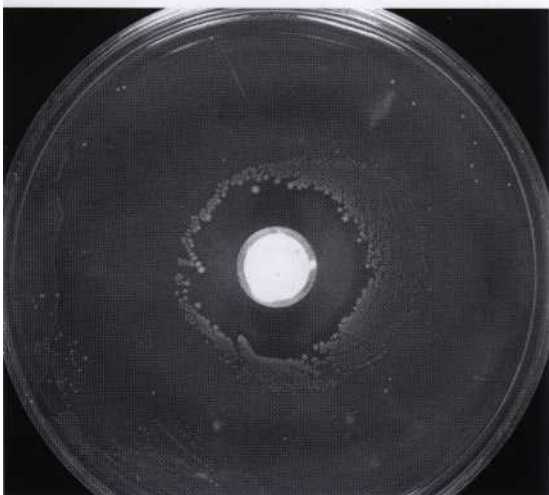significant improvement. After 7 days with calcium hydroxide dressings in place, only eight root canals were infected with bacteria. Following one more enlargement of each canal by one instrument size, only one or two dentin samples were still infected. The results of this study clearly demonstrate how important a purely mechanical instrumentation of the root canal is for reducing the bacterial flora, and they document the antimicrobial effect of the interim dressing.



373 Instrumentation

Left: With the help of RC-Prep the canals are enlarged coronally and then, using the balanced force technique, are shaped apically. Canals are irrigated with a sodium hypochlorite solution.

Right: The complete instrumentation of the root canals has eliminated most of the bacteria.

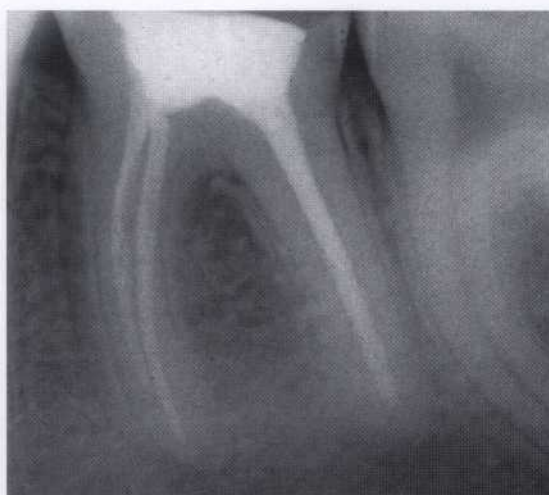
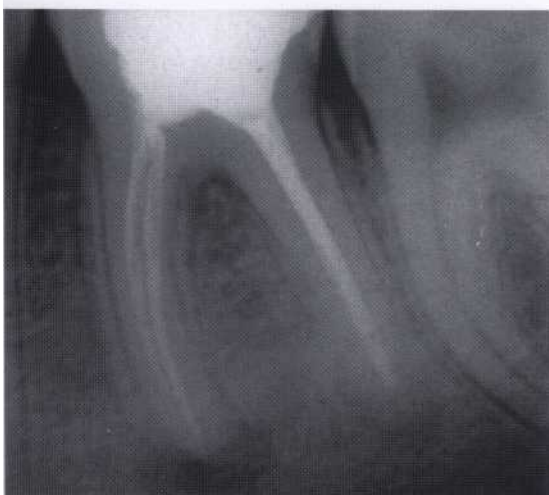
374 Antibacterial effect

The zone of inhibition around the calcium-hydroxide-filled test tube in the center indicates antibacterial activity.

Left: A zone of inhibition on an agar dish inoculated with Bacteroides.

Right: A zone of inhibition on an agar dish inoculated with Streptococcus.



375 Clinical effect

Treatment is accomplished by mechanical cleansing and the antibacterial action of medicated irrigants and dressings. It is important to allow enough time for the medicaments to exert their full effect.

Left: Condition immediately after root canal obturation.

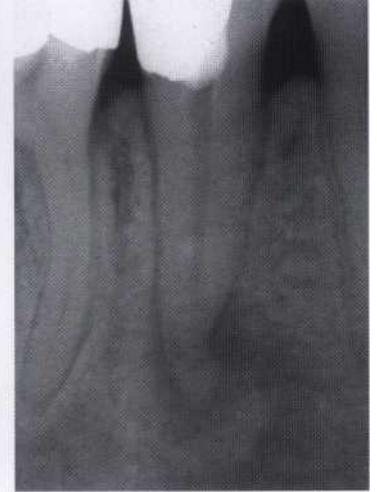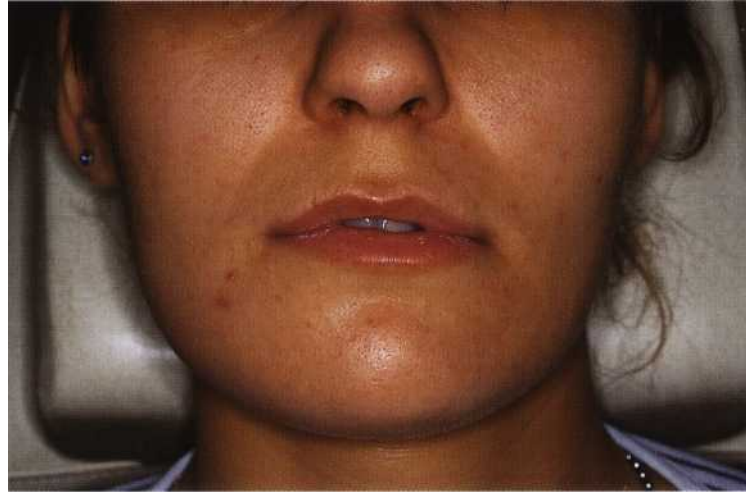Right: Regeneration of the periapical radiolucency after 8 months.

Root Canal Irrigation

Martin (1976) compared the effects of sodium hypochlorite solution and a saline solution (PBS) used to irrigate infected teeth. Only the use of sodium hypochlorite solution brought about a reduction in microorganisms. This has also been confirmed in the teeth of dogs and humans by Bystrom and Sundqvist (1983) and Barnett et al. (1985). Compared with a 0.5% sodium hypochlorite solution, the antibacterial effect of a 2.5% solution was 3.5 times greater, and that of a 5.25% solution was 5.5 times greater (Yesilsoy et al. 1995).

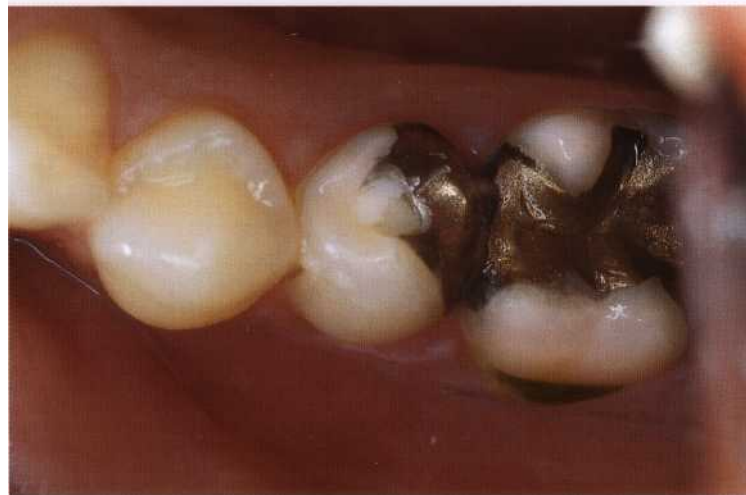However, as a 5% solution, sodium hypochlorite is distinctly toxic, and for this reason Spangberg et al. (1973, 1986) recommend a 1% solution. Yesilsoy et al. (1995) determined that subcutaneous injections of 2.5% and 5.25% sodium hypochlorite solutions and a 0.12% chlorhexidine solution produced inflammation and foreign-body reactions after 2 weeks. While irrigating with 11.6% alcohol is hardly toxic, it does not develop any antibacterial activity. From a biological perspective therefore, only the 1% and 2% sodium hypochlorite solutions can be recommended (Beer 1989).

376 Apical periodontitis
During the extraoral examination, a swelling at the right border of the lower jaw is apparent. A dental origin can be assumed from the tenderness to pressure, the symptoms described, and the intraoral examination.



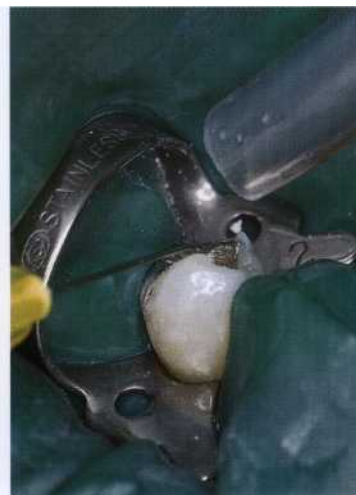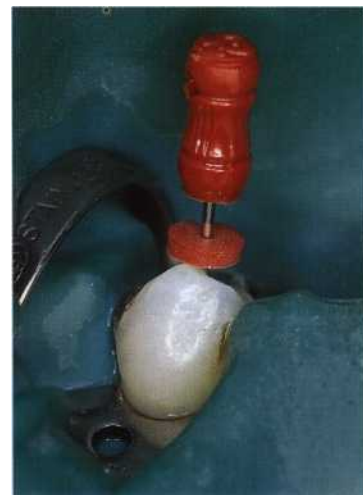Right: The mandibular right second premolar is slightly tender to percussion, but otherwise exhibits no symptoms. A distinct periapical radiolucency is visible on the radiograph.

377 Access opening
The tooth (mirror image) has been filled with amalgam. After making the access opening, a rubber dam is placed.



Right: A wisp of cotton is removed from the root canal. The patient remembered undergoing root canal treatment more than a year ago. There was no periapical radiolucency at the first radiographic examination.

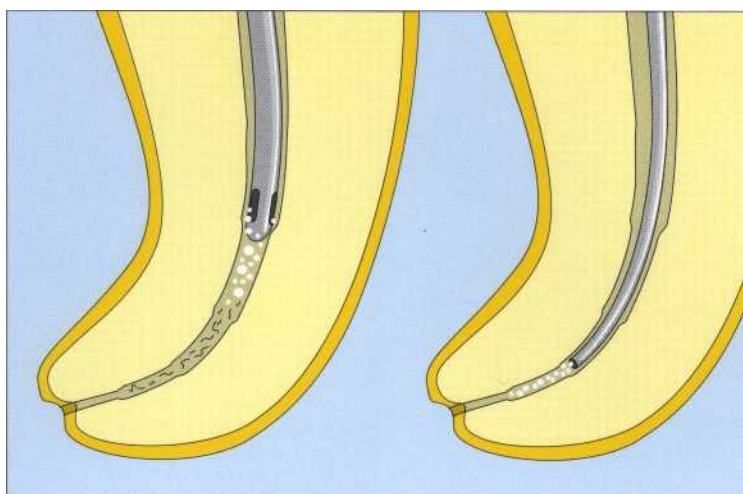
378 Instrumentation and irrigation of the root canal
Left: After the coronal portion of the canal is opened and the working length determined; the canal is instrumented all the way to the apical constriction.



Right: Intermittently before every change of files, the canal is irrigated with at least 2 ml of a 1% sodium hypochlorite solution.

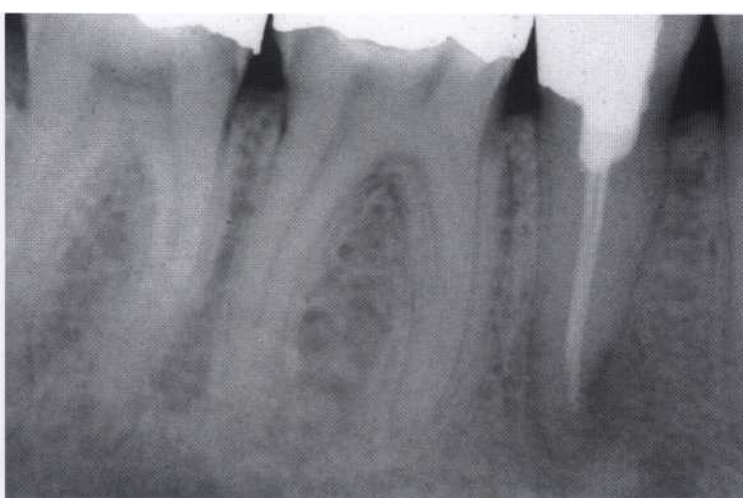
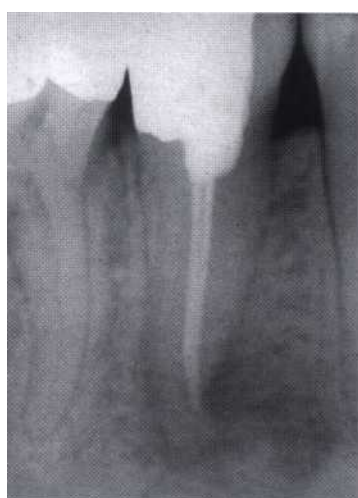The dissolution of necrotic pulp tissue is one of the most important functions of the irrigating solution. In a test of cleansing effectiveness, instrumented root canals displayed clean surfaces after irrigation with a 2% sodium hypochlorite solution (Beer et al. 1988 a). In the first 15 minutes, a 2% sodium hypochlorite solution had dissolved 15% of the pulp tissue, after 60 minutes 45% of the pulp tissue, and after 2 hours all of the pulp tissue, which demonstrates the importance of the treatment time (Andersen et al. 1992).

For effective antibacterial and cleansing action to occur, it is important that the cannula carrying the irrigating solution be inserted deeply into the root canal (Abou-Rass and Piccinino 1982). If the irrigating cannula is inserted too close to the apex, however, there is a danger that the irrigating solution will be forced through the foramen and into the periapical tissue. If a reservoir for the fluid is formed more coronally, from which it can be carried deeper with a file, the sodium hypochlorite will be extruded less frequently and in smaller amounts (Brown et al. 1995).



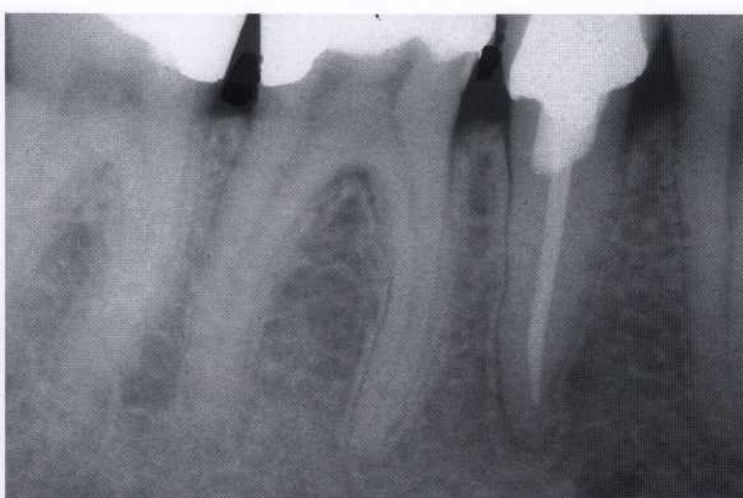379 Insertion depth
Initially, because of its large diameter, the irrigating cannula with openings on the side (left) cannot be inserted deeply enough into the canal. The apically rounded cannula designed by Dr. Buquet (right) can be introduced more deeply into the root canal, thereby increasing the effectiveness of the irrigating solution.

Left: The 6% sodium hypochlorite solution product should be diluted to a 2% concentration.



380 First recall evaluation
The follow-up radiograph taken 6 months after the root canal filling shows definite reduction of the periapical radiolucency.

Left: Three months after the first root canal instrumentation, the canal is filled to the apical constriction with gutta-percha. The position of the apical foramen in the side of the root at a distance from the apex can be clearly seen. The periapical radiolucency already appears to be somewhat reduced when compared with the initial radiograph.



381 Second recall evaluation
Two years after the completion of endodontic treatment, the periapical lesion has completely healed. In the meantime, the tooth has been restored and a coronal seal established with a crown.

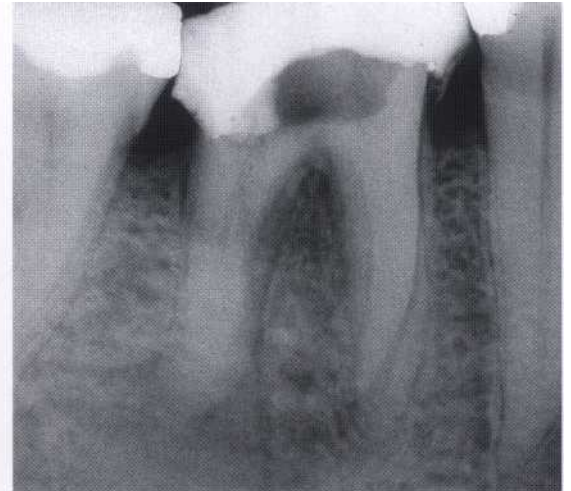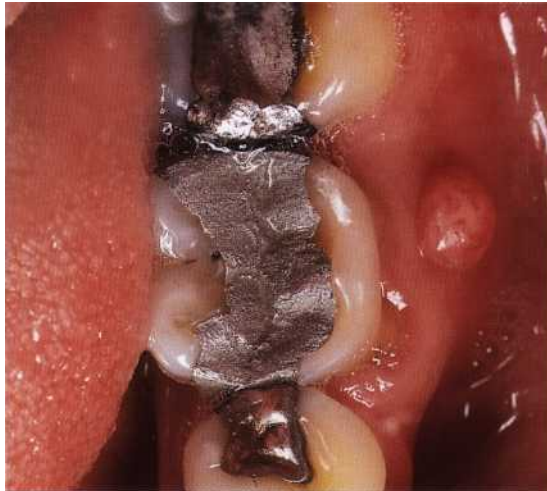Irrigation of the Periapical Lesion

In the great majority of cases, periapical lesions resolve after conservative endodontic treatment. A clinical study by Morse et al. (1983) reported a success rate of 94.5%. In 458 root canals treated, the failure rate was 1.8% when there had been vital pulp extirpation and 6.7% when the pulp was already necrotic. The success rate achieved through conservative treatment depends strongly upon the absence of bacteria, which can be achieved through effective canal instrumentation, antibacterial irrigation, and a bacteria-proof coronal seal (Beer and Mayerhofer 1995).

If a periapical lesion is greater than 20 mm in diameter, it can generally be assumed that it is a cyst (Lalonde 1976), although no clear distinction can be made from the clinical or radiographic appearance (Block et al. 1976, Lin et al. 1996). When treating such a large periapical lesion, communication with the oral cavity can be established through marsupialization, even without the surgical removal of bone as in a cystotomy. The communication can be established by inserting a small tube from the vestibular side (Freedland 1963, Wong 1991).

382 Periapical lesion

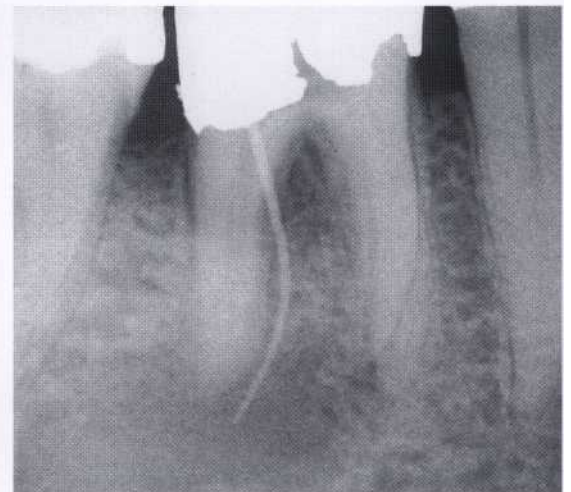
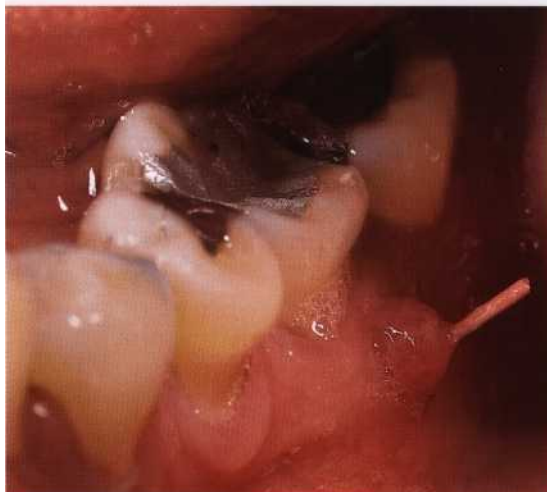Left: A lower first molar with a fistula in the buccal vestibule. The tooth is tender to pressure and percussion, but otherwise there is nothing remarkable in its history.



Right: A large periapical radiolucency, approximately 20 mm in diameter, can be seen on the diagnostic radiograph. The lesion does not appear sharply defined against the surrounding bone.

383 Fistulous tract

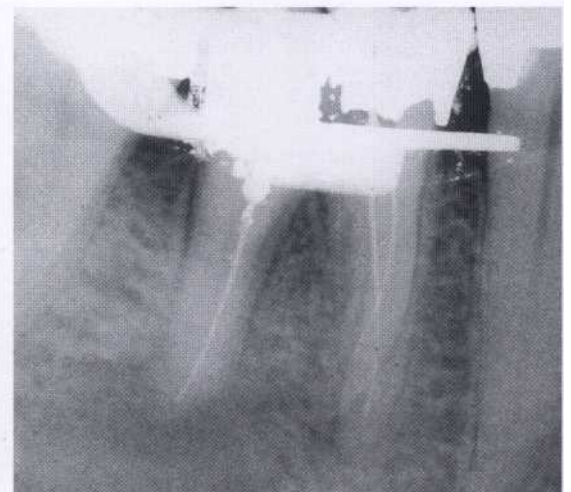
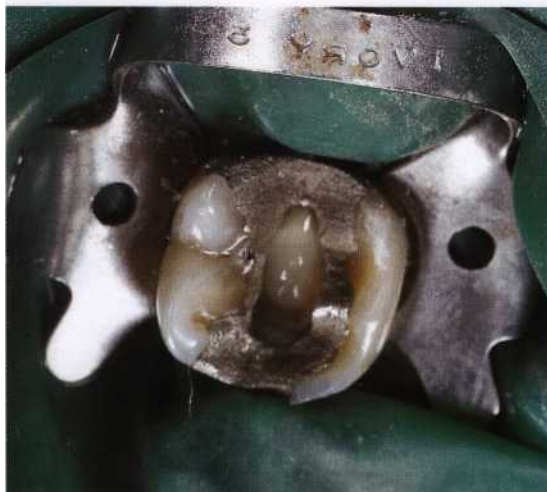Left: A gutta-percha point has been inserted into the fistulous tract to determine its origin.



Right: On the radiograph the path of the fistulous tract is revealed by the radiopaque gutta-percha point that ends near the tip of the distal root.

384 Instrumentation


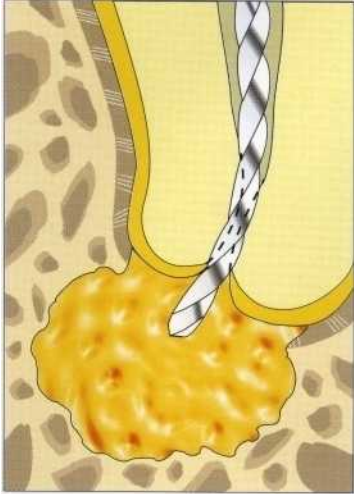
Left: After making the access preparation under the rubber dam and carefully instrumenting the canals, a large amount of pus empties from the distal root canal.



Right: In conjunction with the coronal instrumentation the working length to the apical constriction is determined on the radiograph.

Decompression can also be achieved by opening the periapical lesion through the root canal. After the canal has been enlarged with Gates-Glidden drills, a 1.2-mm diameter stainless-steel tube is cemented in the canal. The patient is called back to the office once each week to have the canal flushed with a 0.9% sodium chloride solution. At the same appointment, the tube is cleaned ultrasonically. After 3-4 months it can be removed, the exudation evaluated, and an interim dressing inserted (Tsurumachi and Saito 1995).

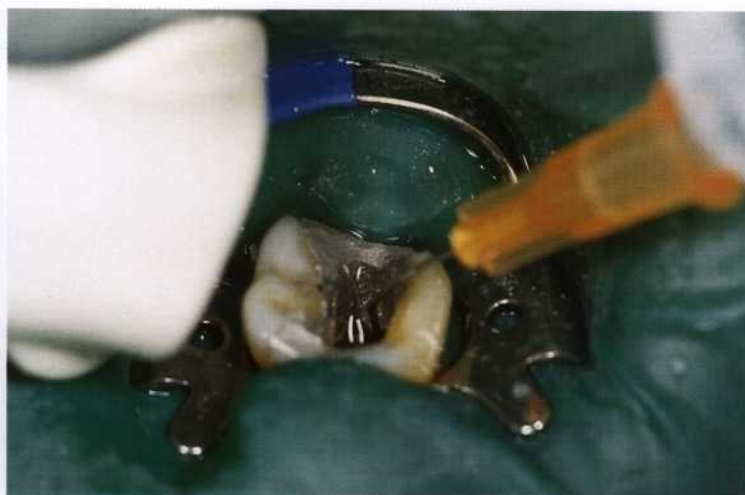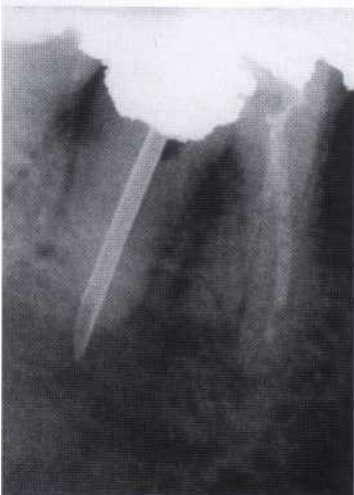
The enlargement of the apical constriction and irrigation of the periapical lesion brings with it a number of dangers. If the bacterially infected root canal is over-instrumented, a bacteremia will occur in almost every case, with *peptostreptococci*, *fusobacteria*, and other microorganisms being found in the bloodstream (Debelian et al. 1992, 1995). The infusion of sodium hypochlorite solution produces acute reactions with pain, swelling, and tissue necrosis necessitating immediate surgical intervention (Gatot et al. 1991) and must therefore be avoided as a routine endodontic procedure.



385 Apical enlargement

As the root canal is instrumented it should be enlarged in the coronal and middle thirds to a diameter of at least 1.2 mm.

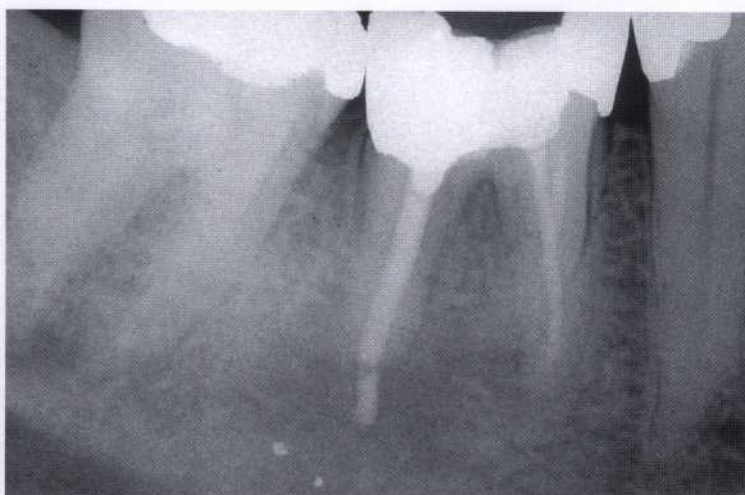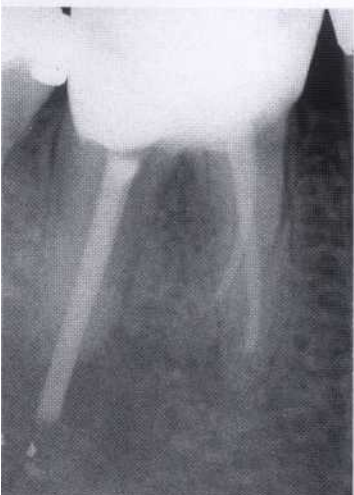Left: The apical constriction is intentionally enlarged to allow drainage through the root canal. A great risk is associated with this procedure, however.



386 Periapical irrigation

The root canal and the periapical lesion can be irrigated through a hollow needle every 2 days with saline solution, but under no circumstances should sodium hypochlorite (!) be used here. Once a week the needle should be removed from the canal, cleaned, and sterilized.

Left: A cannula or stainless-steel needle is cemented in the canal and the coronal portion of the cavity sealed with a provisional filling.



387 Dangers

Six months after filling the root canals, the overextended apical gutta-percha has separated; a surgical procedure is indicated. The treatment procedure did not meet the challenge.

Left: After 8 weeks of marsupialization and another 3 months with an interim dressing, the root canals are filled. Even though the gutta-percha points are measured and fitted, the absence of an apical stop allows a severe overextension to occur.

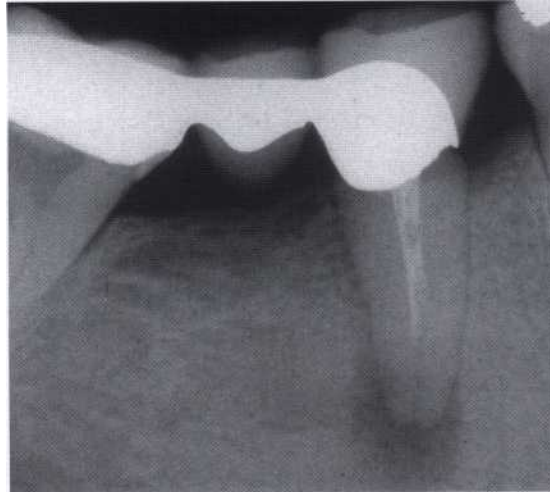
Ultrasonic Root Canal Irrigation

The ultrasonic frequencies of the units used range from 25-40 kHz. During instrumentation the energy is transmitted mainly in the longitudinal direction with only a small portion being converted into transverse oscillations. Only a small load is required to inhibit the oscillations. Two important ultrasonic phenomena are cavitation and microstreaming. While the cavitation effect can be observed at the tip of an ultrasonic scaler, it does not occur within the root canal (Ahmad et al. 1987, Lumley et al. 1988, Walmsley and Williams 1989).

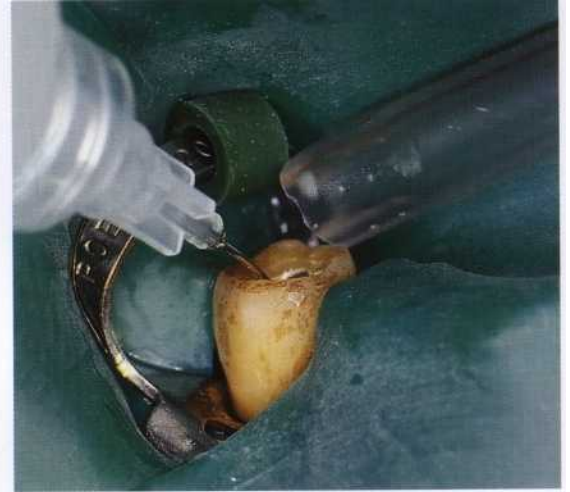Microstreaming is apparently the only advantage that is useful in endodontics. It can be defined as the production of a steady unidirectional circulation of fluid in direct proximity to a small, oscillating object. Numerous small eddy currents can arise, the most rapid of which are observed at the tip of the root canal instrument. These vortices have the effect of producing a directed stream of fluid (Ahmad et al. 1987). This acoustic microstreaming can cause the disintegration of bacteria and enzymes (Stock 1992).

388 Access opening

Left: Radiograph of a lower premolar showing an inadequate root canal filling and a periapical radiolucency. The tooth is tender to percussion.

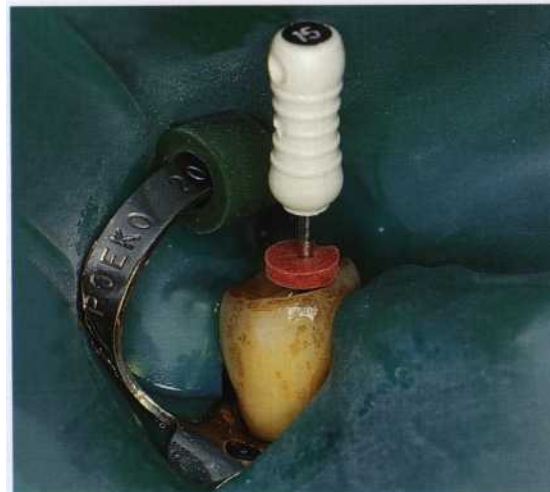


Right: The pulp tissue is necrotic and decomposed by bacteria, evidenced by a foul odor during extirpation of the tissue remnants. Sodium hypochlorite irrigation removes the contents of the pulp chamber and begins the antibacterial action.

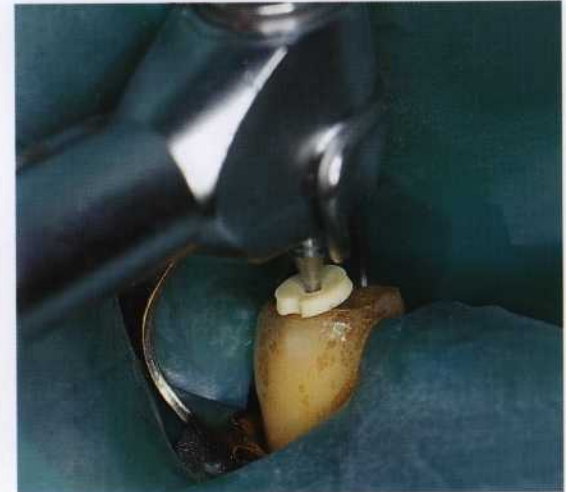

389 Instrumentation

Left: The root canal preparation is initiated with hand instrumentation beginning with coronal enlargement and then instrumentation of the apical region.

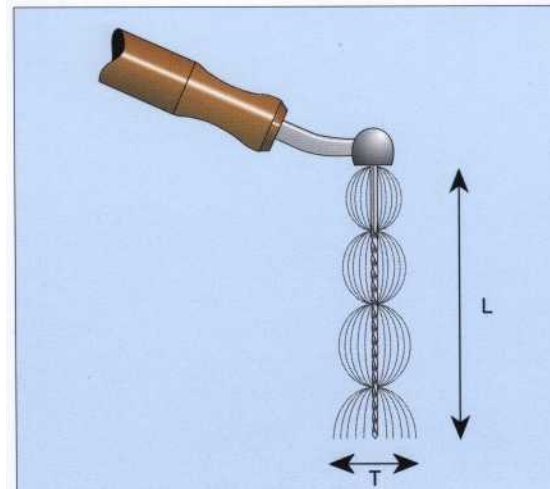


Right: The coronal portion of the canal is further enlarged with Gates-Glidden drills to permit free oscillation of an ultrasonic file within the root canal.

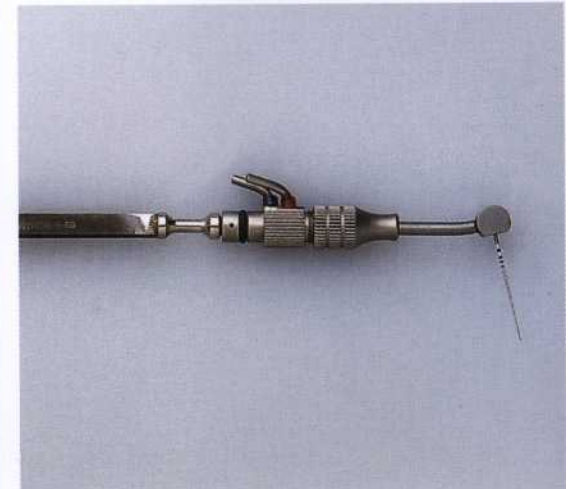


390 Mode of action

Left: The oscillation at right angles to the long axis is made up of oscillation nodes with minimum amplitude and antinodes, or loops, with maximum amplitude. The tip of the file vibrates freely with the maximum amplitude (Stock 1992).

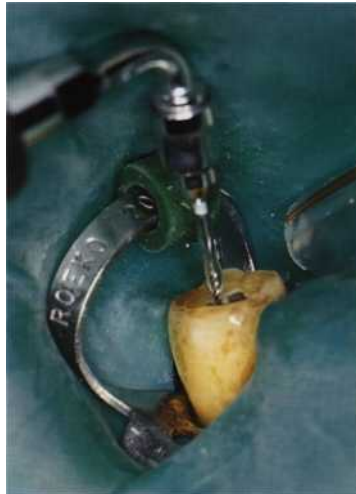

Right: Magnetostriction occurs when a bar-shaped ferromagnetic body is exposed to an alternating magnetic field. This produces mechanical vibrations.



In studies on models, Krell et al. (1998) have shown that during the use of ultrasound the irrigating solution reaches the end of the root canal only if the file can oscillate freely. If, on the other hand, oscillation is prevented by interference from the canal wall, the irrigating solution does not get past the first oscillation node. Only size 15 K files are recommended and they should be bent to fit the course of the canal so that reduction of canal curvature and step formation will be avoided (Lumley et al. 1992).

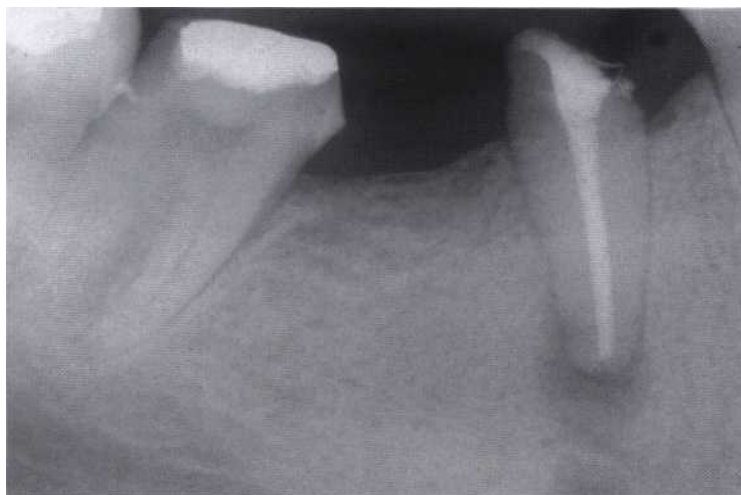A final manual rinsing with a 1 % sodium hypochlorite solution has proved effective in reducing the number of microorganisms. This is followed by a 2% irrigating solution. Ultrasonic irrigation with sodium hypochlorite solutions have a definitely weaker antibacterial effect (Briseno et al. 1991). A histologic study failed to demonstrate any difference between periapical tissue response after ultrasonic instrumentation and after manual instrumentation. Necrotic tissue remnants, partially infiltrated with bacteria, were still present after both procedures (Watts and Patterson 1993).



391 Irrigation

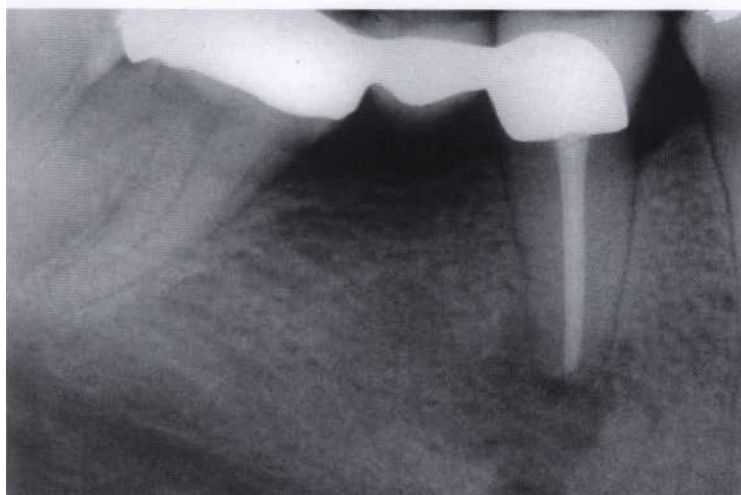Left: When using ultrasound, at a flow-through rate of 20 ml per minute, it takes at least 30 seconds for the irrigating solution to reach the apical region of the root canal (Krell et al. 1988).

Right: After the root canal has been irrigated and dried, it is packed with calcium hydroxide as an antibacterial interim dressing.



392 Radiographic follow-up

Three months after the beginning of root canal treatment the canal is filled. The follow-up radiograph shows that the periapical radiolucency is beginning to reduce in size compared with the initial radiograph (Fig. 388).



393 Radiographic follow-up

After 1 year there is definite, although not yet complete, regeneration of bone in the area of the periapical lesion.

Whether it is clinically advantageous to use ultrasound as an aid in root canal irrigation is still debated. The necessity of irrigation with a sodium hypochlorite solution remains undisputed, however, and the method shown in Fig. 388 appears to be completely sufficient (Briseno et al. 1991).

Removal of the Smear Layer

The smear layer is formed on the canal surface as the result of instrumentation, and closes the openings of the tubules. Even ultrasonic instrumentation of the root canals does not prevent formation of the smear layer (Baumgartner and Cuenin 1992, Lumley et al. 1992). A distinction is made between the dentin shavings pressed into the dentinal tubules and the smear layer lying superficially on the wall of the canal. Under the electron microscope the smear layer cannot be clearly differentiated from the remaining dentin of the root (Kockapan 1987).

The smear layer forms a diffusion barrier that reduces the permeability of the dentin by 25-30% (Pashley et al. 1988). When the smear layer is removed, medicated dressings can penetrate more readily into the dentin of the canal wall and the antibacterial activity is increased (Orstavik et al. 1990). The use of EDTA and ethylenediamine as a final rinse removes the smear layer completely and also enlarges the tubule openings by dissolving peritubular dentin (Goldberg and Abramovich 1977, Aktener and Bilkay 1993).

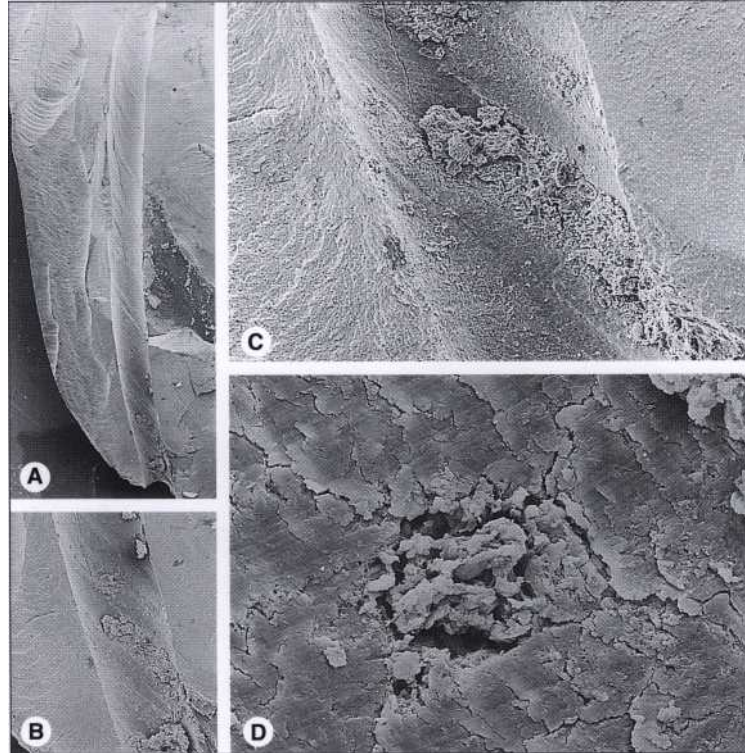
394 Smear layer

A SEM picture of a root split lengthwise showing a root canal that was prepared with hand instruments.

B A closed smear layer and displaced dentin can be seen on the surface of the canal.

C The smear layer is formed as a result of instrumentation of the root canal. Larger particles of dentin can be seen.

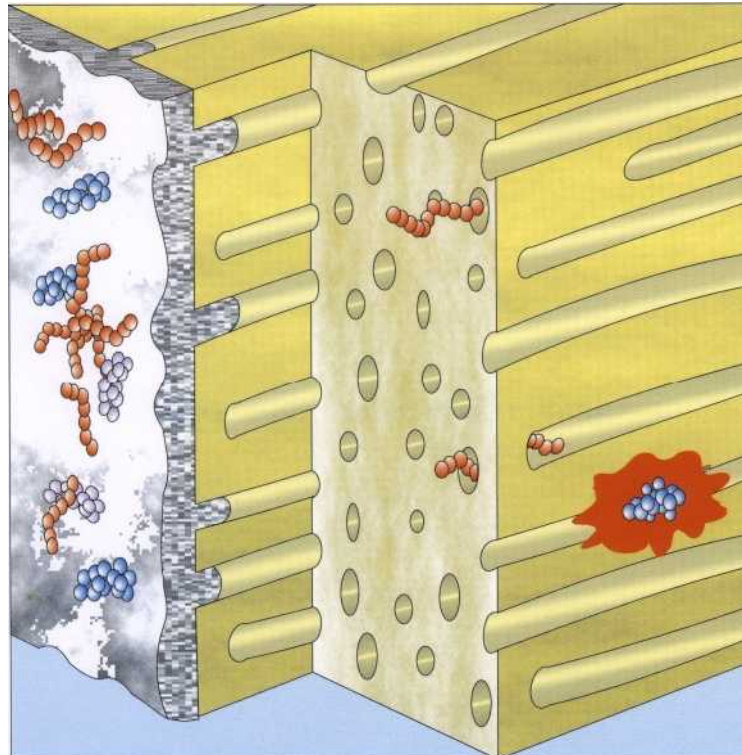
D The smooth surface of the smear layer is characteristic. The entrances to the dentinal tubules cannot be seen because of the covering of abraded dentin. The smear layer is composed of innumerable small particles, and it can even seal lateral canals.



395 Root canal surface with and without the smear layer

On the surface to the left the smear layer is represented in white. (Normally there is no clear demarcation between the smear layer and the underlying dentin.) Coarse dentin plugs block the dentinal tubules to depths of up to 5 μm. The smear layer can delay or even prevent penetration of microorganisms into the tubules.

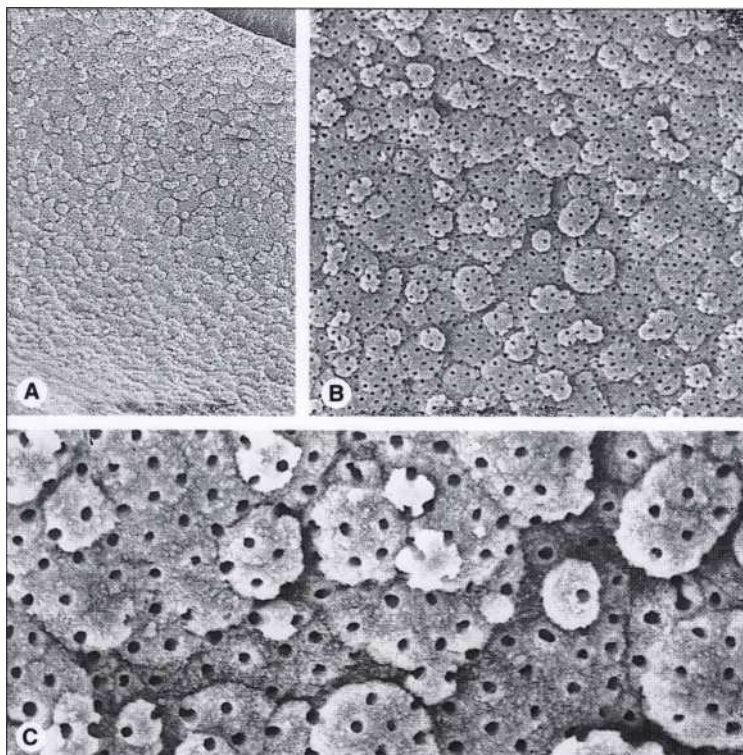
On the right side of the drawing, irrigation with an acidic solution has removed the smear layer and exposed the openings of the dentinal tubules. This promotes the penetration of microorganisms. The tubules can be entered and colonized by bacteria more rapidly (Drake et al. 1994).



It is relatively easy for bacteria to adhere to the smear layer. The removal of the smear layer with 6% citric acid solution and a final irrigation with sodium hypochlorite reduces the number of bacteria by 15% as it simultaneously cleans the canal wall (Calas et al. 1994).

However, there are also inherent dangers in removing the smear layer with chelating agents and acids. Safavi et al. (1989) removed the smear layer with 50% citric acid and inoculated the root canals. Three weeks later they found deep penetration of *Streptococcus faecium* into the adjacent dentinal tubules.

In the control group without removal of the smear layer, bacteria were observed only on the surface of the canals. Drake et al. (1994) also found that an intact smear layer made it more difficult for bacteria to adhere and penetrate. It should be pointed out, however, that the smear layer can only delay and not prevent the penetration of bacteria into the tubules (Akpata and Blechman 1982). Twenty-one days after inoculation, the test bacteria had penetrated through the dentin all the way to the outer root surface (Nii et al. 1994).

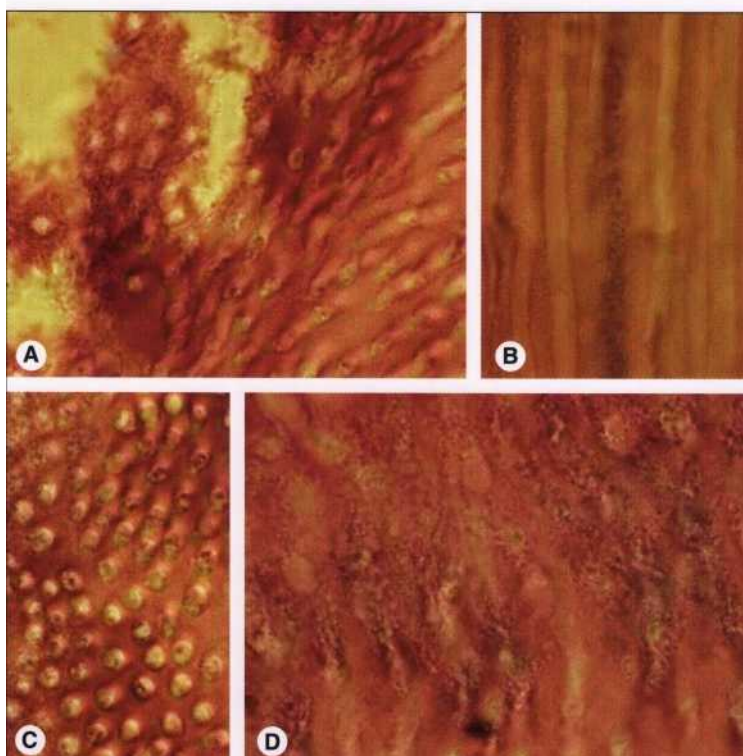


396 Surface after removal of the smear layer

A The root canal surface is depicted under the SEM after final rinsing with 6% citric acid and 2% Sodium hypochlorite solutions.

B The root canal surface is clean, the smear layer has been removed, and the dentinal tubules are open.

C Under higher magnification the openings of the dentinal tubules can be clearly seen. Removal of the smear layer should increase their permeability (Cohen et al. 1970). However, no increase in permeability through the root could be determined when there was no external root resorption and the cementum was intact (Tao et al. 1991).



397 Bacterial penetration

A This microscopic photograph of a transverse section of dentin shows completely open dentin tubules.

B After removal of the smear layer and inoculation of the dentinal surface with a test microorganism, bacteria penetrate deeply the dentinal tubules.

C Tubules sectioned transversely display bacteria as well as early demineralization.

D The prolonged action of demineralizing substances from bacteria can lead to dissolution of hard tissue and failure of endodontic treatment.

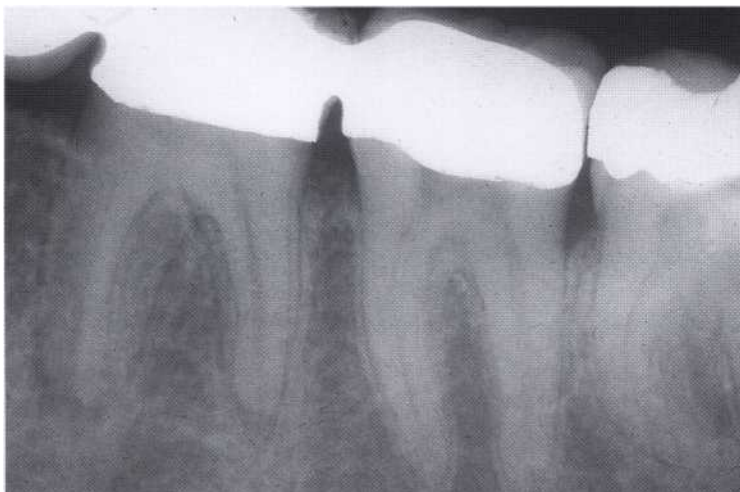Antibacterial Interim Dressings

In an infected root canal there can be more than 10^8 bacteria (difficult-to-detect anaerobes) in each milliliter of canal contents (Bystrom and Sundqvist 1991). Instrumentation of the root canal physically reduced their numbers by a factor of 1000; sodium hypochlorite irrigation reduced them again by 50% (Sundqvist 1992). Medicated interim dressings used after thorough instrumentation and irrigation can kill remaining microorganisms and prevent reinfection (Staehele 1993).

Medications in fluid form are carried into the canal on paper points, while paste dressings are inserted with a rotating spiral. Because bacteria are present in the dentinal tubules, interim dressings must make direct contact with the wall (Armitage et al. 1983). In one study of infected root canals, medicated dressings were removed from the canals after periods of 1, 3, 7, and 45 days, and their antibacterial effect was determined. After only 1 day, fluid medications exerted no further antibacterial activity (Tronstad et al. 1985).

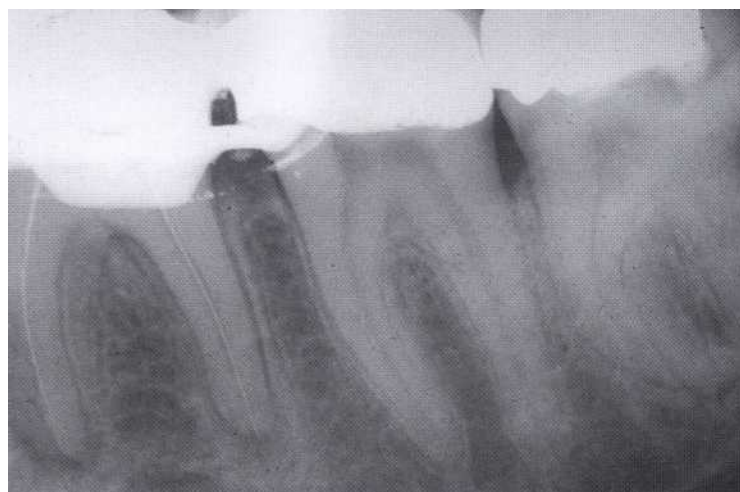
398 Pulp necrosis

A crowned mandibular first molar with periapical radiolucency and pulp-tissue necrosis. Leaking margins of the restorations and secondary caries have led to infection of the root canals. Viable bacteria can be found in dentinal tubules up to 2 mm from the canal wall (Ando and Hoshino 1990). Endotoxins can also penetrate as far as 300 μ m into the dentinal tubules (Horiba et al. 1990).



399 Emergency treatment

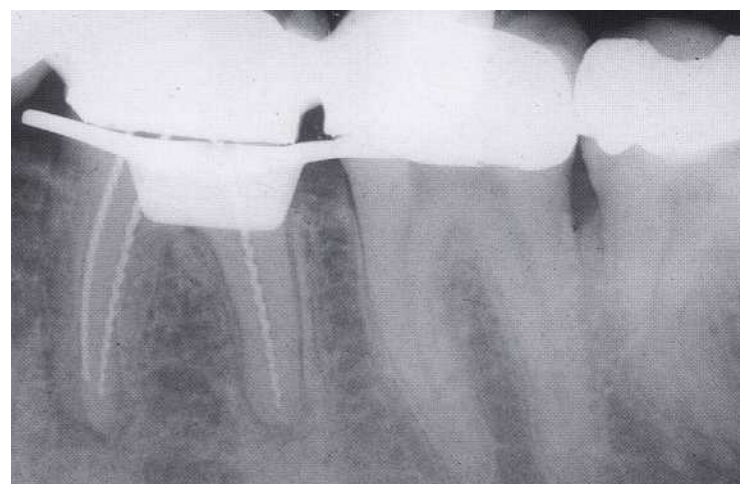After coronal opening and pulp extirpation the working length is determined and the root canals instrumented. A cortisone-antibiotic preparation can be used as a short-term dressing to prevent the painful symptoms of irreversible pulpitis, but its use is contraindicated when the pulp is necrotic and the root canal is infected because it will interfere with the body's own defense mechanisms (Seltzer and Naidorf 1985).



400 Instrumentation

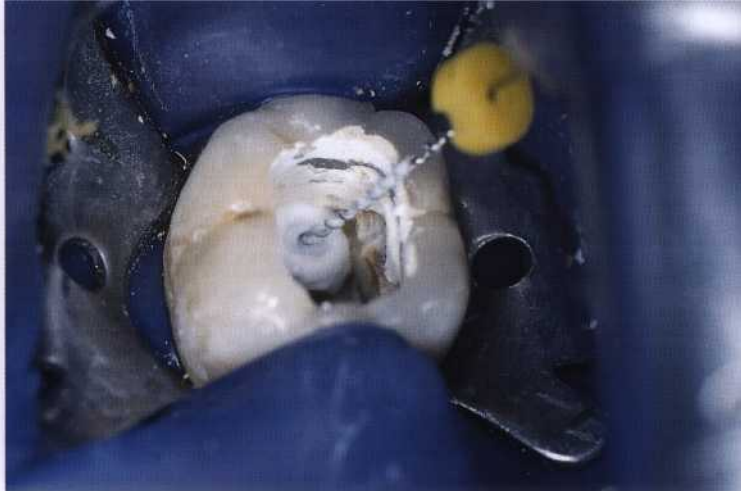Most of the bacteria are eliminated by instrumenting the canals to the apical constriction and irrigating them with sodium hypochlorite solution. Interim dressings have some ability to kill bacteria and dissolve tissue, but they cannot compensate for inadequate mechanical and chemical cleansing.

Right: One component of effective instrumentation is the determination of the working length.



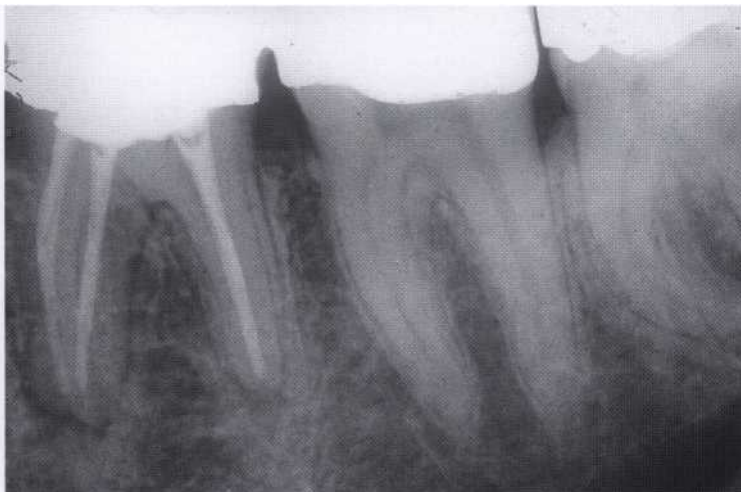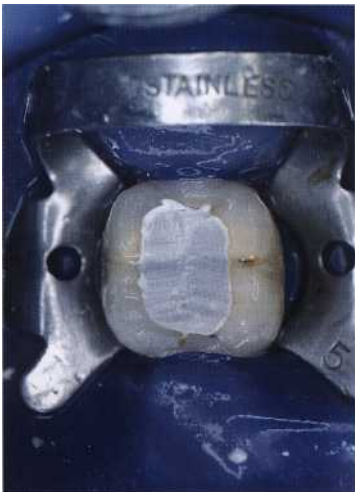Phenolic compounds such as cresol, thymol, and chlorophenol are expected to produce microorganism-reducing and, to some extent, pain-alleviating effects. In a risk-benefit comparison, the microorganism-reducing effect outweighed the intrinsic toxic properties only in the short term (Tronstad 1991). Fehr et al (1992) warn strongly against the use of formaldehyde and its derivatives because of possible allergenic effects; Belanger (1988) refers to their mutagenic effects. Similar side effects can be expected from glutaraldehyde (Yacobi et al. 1991).

There is no indication for the use of dressings containing cortisone and antibiotics in asymptomatic teeth, nor can these be depended upon to prevent postendodontic pain (Trope 1990). Cortisone preparations can impair the body's own defense mechanisms and may have undesirable side effects. The inflammatory process, which is necessary for defense and healing, is suppressed and the pulp tissue is thereby made more susceptible to bacterial invasion and toxins (Seltzer and Naidorf 1985, Staehle 1993).



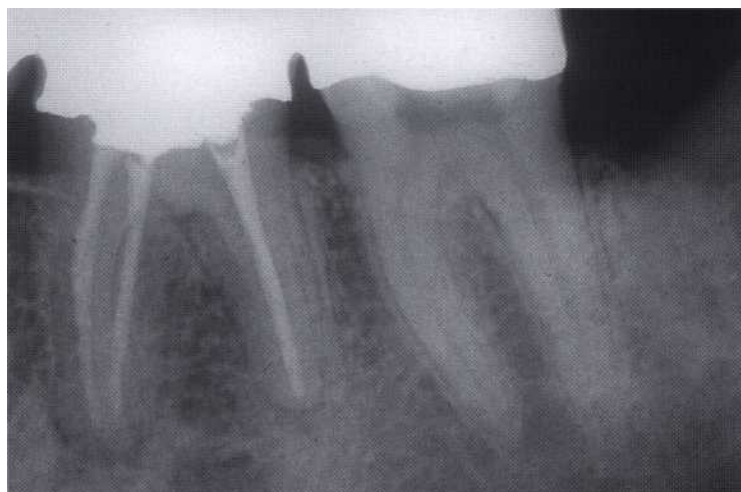401 Interim dressing
The most prominent temporary dressing medication at the present time is calcium hydroxide ($\text{Ca}[\text{OH}]_2$) that is placed into the root canal as an aqueous suspension by means of a rotating spiral.

Left: Calcium hydroxide (Calxyl) is easy to apply and remove. It has a very good antimicrobial action when in direct contact with dentin and no undesirable side effects.



402 Treatment result
After at least 1-3 months the interim dressing is flushed from the canal with sodium hypochlorite solution. Further instrumentation is not desirable. The canals are dried and filled with gutta-percha.

Left: After every treatment the access opening must be tightly sealed to prevent bacterial reinfection.



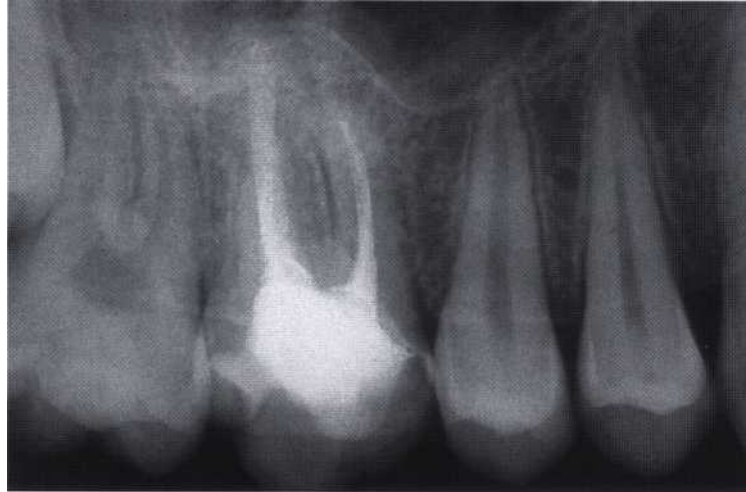403 Radiographic follow-up
A radiograph taken after 1 year shows complete regeneration of the periapical bony lesion. The overfilling of the root canal with iodoform to "sterilize" the pulp tissue is without any scientific foundation, leads to uncontrolled inflammation, and is indicated neither as an interim dressing nor as a definitive filling (Martin 1991).

Application of Calcium Hydroxide (Ca[OH]₂)

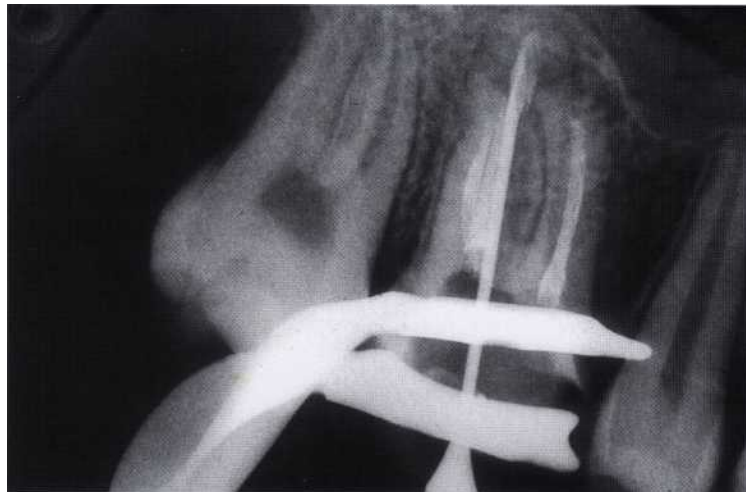Sundqvist (1992) found 66% of root canals to be bacteria-free after the application of a phenol-containing dressing, compared with a 97% bacteria-free rate after a calcium hydroxide dressing. Bacterial lipopolysaccharides (endotoxins), which are released from their cell walls when bacteria disintegrate, are regarded as an etiologic factor in periapical bone resorption. The discovery by Safavi and Nichols (1993) that calcium hydroxide causes destruction of these lipopolysaccharides clarifies its antibacterial action.

Selection of the carrier and suspension medium for the calcium hydroxide powder has an important bearing on its antimicrobial and bone-regenerating effects. Mixing the powder with the phenolic preparation CMCP produces no better effect than does mixing it with distilled water because the formation of calcium p-chlorophenolate prevents dissociation and release of calcium. Next to water, the best suspension medium for extended duration is propylene glycol, which releases (OH)⁻ and Ca²⁺ ions over a long period of time and also controls changes in the pH (Simon et al. 1995).

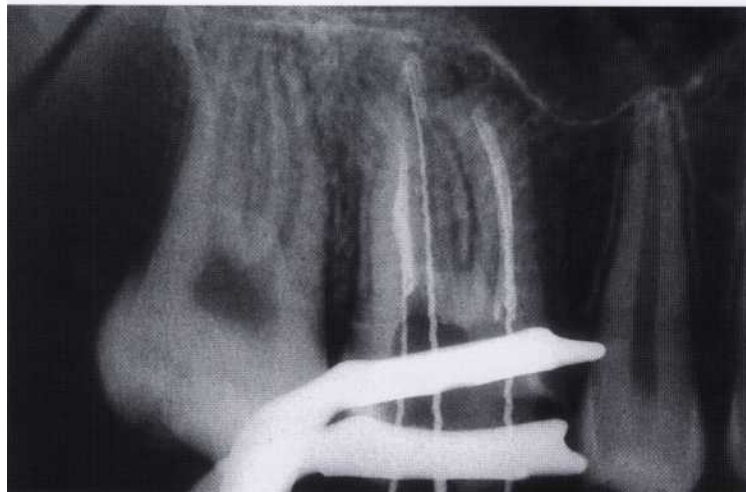
404 Canal instrumentation
A maxillary first molar with an inadequate root canal filling and clinical symptoms. There is no definite periapical radiolucency on the radiograph.



405 Deep preparation
The position of the Gates-Glidden drill must be monitored radiographically during instrumentation to avoid perforation or step formation.

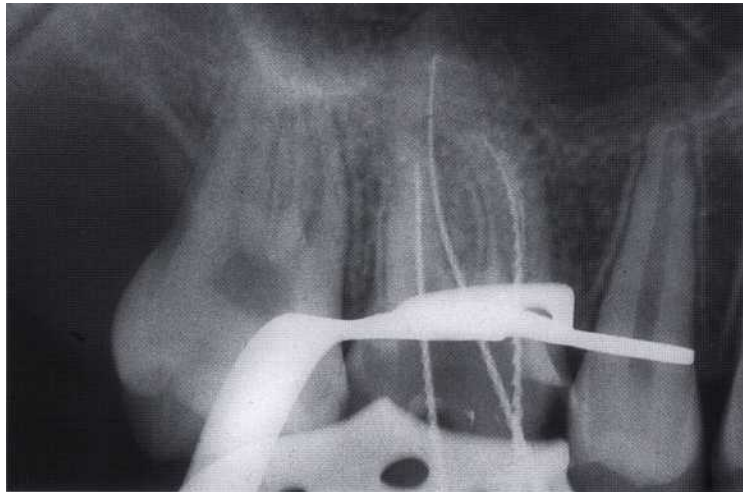


406 Apical instrumentation
The preparation is carried to the apex with hand instruments. In the study by Yared and Dagher (1994) there was less bacterial growth following apical preparation through size 40 instruments than when preparation was carried only through size 25. After 1 week with a calcium hydroxide dressing in place, however, a difference between the two groups could no longer be discerned and no quantitative increase in bacteria could be determined.



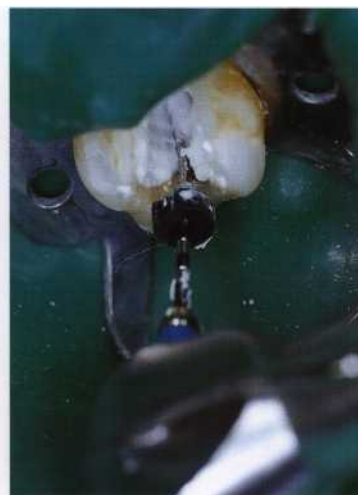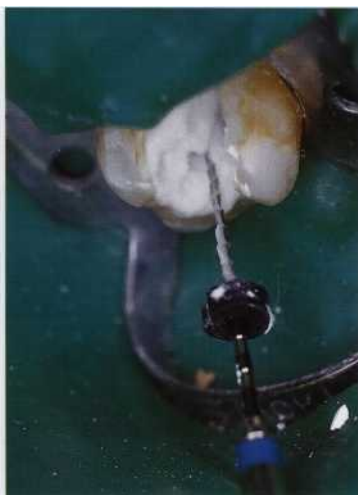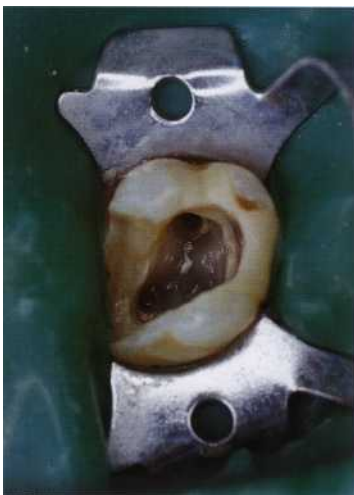Calcium hydroxide powder alone can be introduced into sharply curved root canals only incompletely and with difficulty, and therefore must be mixed with a liquid. When a paste of calcium hydroxide suspended in synthetic glycerin is spun into curved root canals with a Lentulo spiral, a more complete and homogenous filling is produced than when the calcium hydroxide is mixed with sterile water. A dense filling of the apical third was achieved in half of the canals by using this glycerin-based paste, but in none of the canals when the aqueous mixture was used (Rivera and Williams 1994).

For curved canals prepared through size 25, flexible McSpadden Compactors or Lentulo Spiral Paste Fillers are recommended. With these the interim dressing can be conveyed to the apical region in 87% of cases. The injection technique adequately filled 48% of the root canals, and a K file rotated counterclockwise placed the paste correctly in only 21.7% of the cases. Over-extended calcium hydroxide is quickly resorbed but can cause a brief acute inflammatory response (Orstavik et al.1991).



407 Interim dressing

During instrumentation the working length and the efficiency of canal enlargement are monitored radiographically with files in place. Finally, an interim dressing is inserted. The antibacterial dressing should reach any remaining bacteria that were not removed during instrumentation and that would otherwise multiply rapidly between appointments if the canals remained unfilled (Bystrom et al. 1985, 1987).

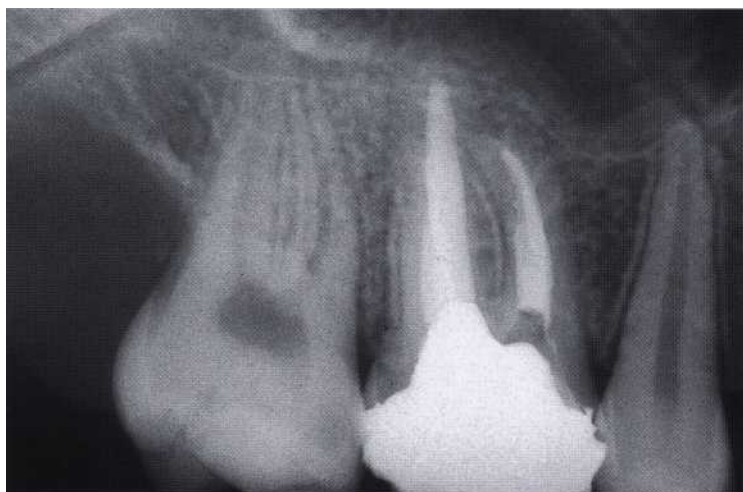


408 Insertion of the interim dressing

Left: The three root canals have been instrumented, irrigated, and dried.

Center: A McSpadden Compactor coated with an aqueous calcium hydroxide suspension is inserted into the root canal while rotating at low speed.

Right: As the rotating compactor is withdrawn from the canal with a circumferential movement, the dressing is applied to the canal walls.



409 Root canal obturation

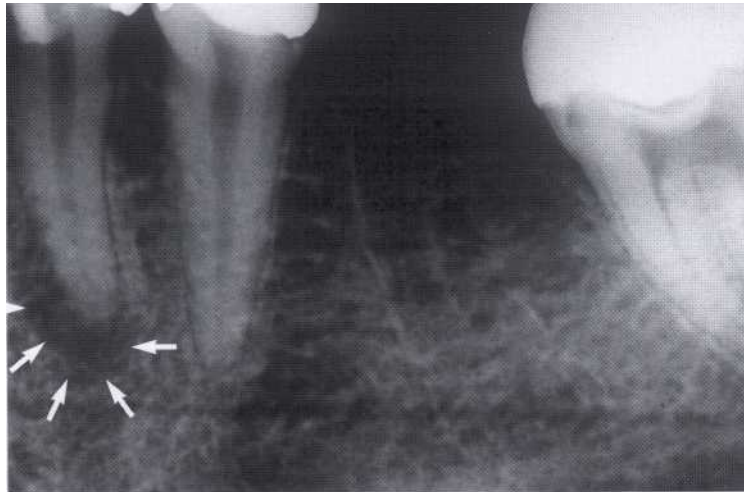
The presence of a calcium hydroxide interim dressing for 1 week enables a more tightly sealed gutta-percha root canal filling. In a study, the linear penetration of a dye past the gutta-percha measured 1.3 mm after a calcium hydroxide dressing had been used, compared with 6.6 mm in the control group with no interim dressing (Porkaew et al. 1990). An interim dressing should always be used regardless of the initial radiographic appearance.

Interim Dressing for Chronic Apical Periodontitis

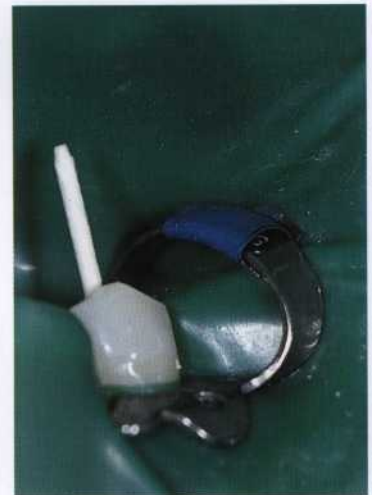Because chemomechanical instrumentation alone does not remove all tissue remnants from curved canals (Langeland et al. 1985), the importance of the interim dressing is equal to that of root canal irrigation. The anaerobic conditions within a sealed root canal have no influence on the dressing's tissue-removing properties. After 7 days calcium hydroxide had dissolved the tissue quite well. Its tissue-removing effect is slower and more continuous than the initial rapid effect of sodium hypochlorite solution (Yang et al. 1995).

Pulp tissue is loosened up after 3 hours in 0.5% sodium hypochlorite if the solution is renewed every 30 minutes. In a calcium hydroxide suspension it is completely broken down after 12 days. If the tissue has been pretreated in calcium hydroxide, it will be completely broken down in sodium hypochlorite after only 60 minutes (Hasselgren et al. 1988). A calcium hydroxide dressing in place for only 1 week will break up an uninstrumented odontoblastic layer, and a 4-week treatment will erode a predentin layer with no further dissolution of hard tissue (Wakabayashi et al. 1995).

410 Apical periodontitis
Accidental discovery of chronic apical periodontitis during radiographic examination preliminary to a prosthodontic reconstruction. There was no pain or other symptoms associated with the mandibular first premolar, and the patient had reported no painful episodes in the past.

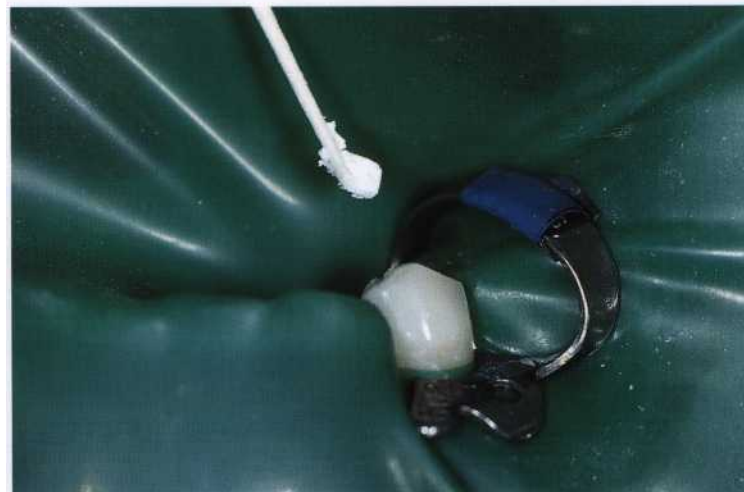


411 Root canal irrigation
After the pulp chamber is opened, the tissue remnants extirpated, and the root canal instrumented, the canal is irrigated freely with a 2% sodium hypochlorite solution. The duration of this treatment has an influence on the result. The irrigating solution should be allowed to work for at least 1 hour during instrumentation, as this will flush out 50% of the pulp-tissue remnants (Anderson et al. 1991).



Right: Drying of the root canal with paper points.

412 Interim dressing
The dressing must be carefully packed into the root canal with paper points to ensure good contact with the dentin walls.

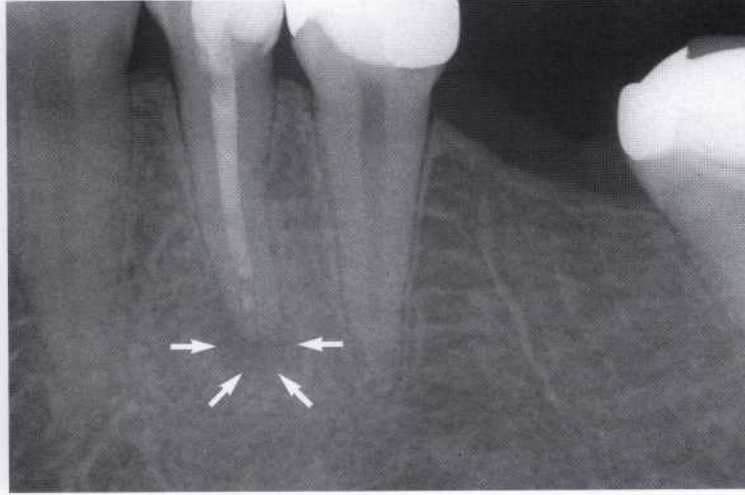
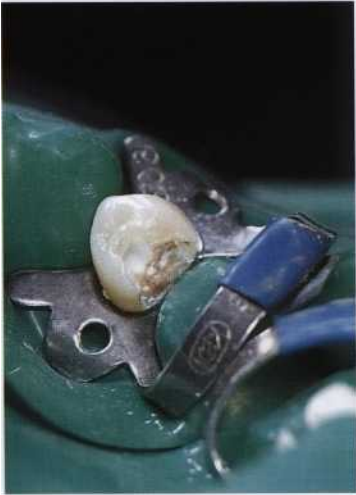
Right: Compacting the aqueous suspension with dry paper points draws out excess water and stabilizes the calcium hydroxide. In this way a homogenous filling extending to the apex is achieved.

Interim Dressing for Chronic Apical Periodontitis

Investigations under the light microscope indicate that a 1-week dressing in conjunction with irrigation with sodium hypochlorite during instrumentation will completely clean the isthmus of the mesial canals of mandibular molars. The addition of ultrasonic oscillations does not improve the cleansing effect (Metzler and Montgomery 1989). Hydroxyl ions diffuse through dentin with a maximum pH value when the dressing is in place for at least 3 weeks. The maximum pH value of 10.8 is reached on the inner dentinal wall of the canal after 24 hours (Nerwich et al. 1993).

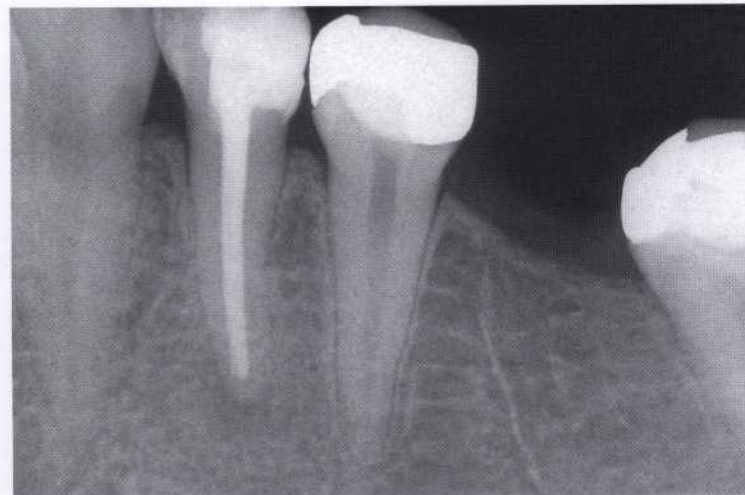The longer the interim dressing acts in the root canal, the better the regeneration of the inflamed pulp tissue. Trope et al. (1995b) compared the short-term and long-term effects of calcium hydroxide histologically in experimentally induced apical periodontitis and found that regeneration of bone occurred in only 50% of the cases treated with a dressing for 1 week. If, however, the medication was changed every week for 12 weeks, complete tissue regeneration with cementum apposition occurred.



413 Evaluation of the interim dressing

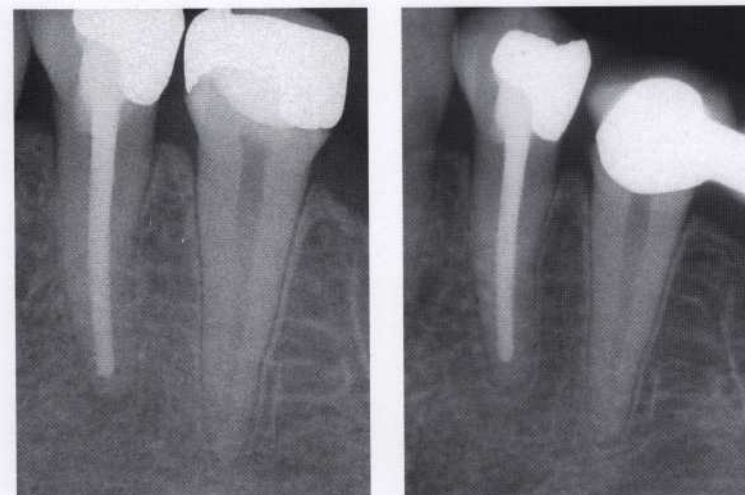A radiograph taken after the interim dressing has been in place for 3 weeks already shows incipient regeneration of the periapical lesion. While the addition of a radiopaque substance to the calcium hydroxide interim dressing would facilitate its radiographic identification, it would also make any periapically extruded paste less resorbable.

Left: The root canal is filled to just below the dentinoenamel junction.



414 Root canal obturation

The medicated dressing is changed after 3 weeks because it was beginning to break down. After an additional 3 months the interim dressing is loosened up with a Hedstrom file and flushed out with sodium hypochlorite solution without further instrumentation of the canal. The canal is then obturated. In the meantime, the periapical radiolucency has become substantially reduced.



415 Radiographic follow-up

Left: The 8-month radiograph shows further regression of the periapical lesion.

Right: After 1.5 years the periapical lesion can no longer be seen on the radiograph.

Interim Dressing for Acute Apical Periodontitis

With acute apical periodontitis the transition to an alveolar abscess in the endosseous phase is fleeting and this makes a clear diagnosis difficult. Classic symptoms are a pulsating, radiating pain, a feeling of tooth elongation, and increased tooth mobility.

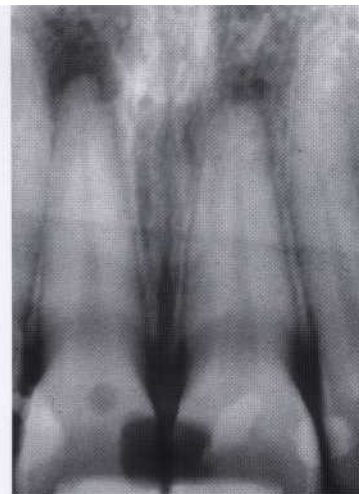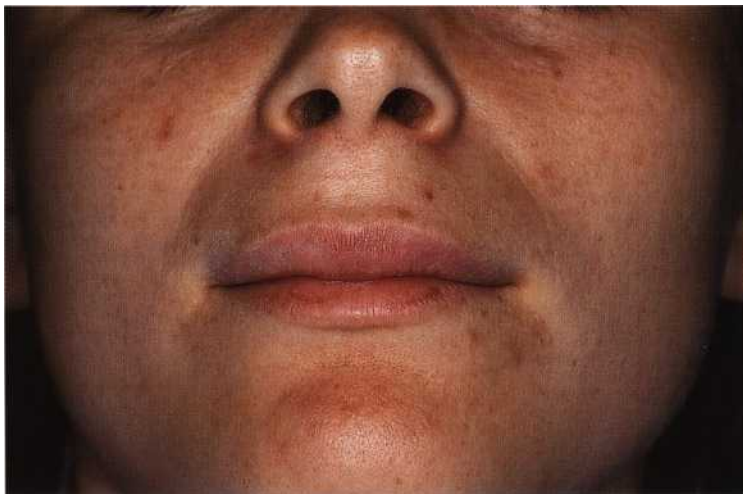
An access opening is made with a rubber dam in place, and in many cases this is followed by spontaneous drainage of purulent exudate, usually mixed with blood. Intensive irrigation with sodium hypochlorite is carried out with interruptions for 15 minutes or more until the exudation ceases. The root canal is dried and

a calcium hydroxide suspension is loosely inserted with a rotating instrument. In one study, teeth with apical periodontitis that were obturated at the first appointment were found after 9 months to have persisting acute inflammation with resorption of cementum and dentin. Eighty percent of these cases had abscess formation. If, on the other hand, a calcium hydroxide dressing was left in place for 7 days before obturation, the periapical lesion was replaced by new bone even though leucocytic infiltration could be observed in 18.8% of these cases (Leonardo et al. 1995).

416 Swelling

The patient complained of severe problems in the maxillary anterior region with radiating pain and a swelling that was visible extraorally.

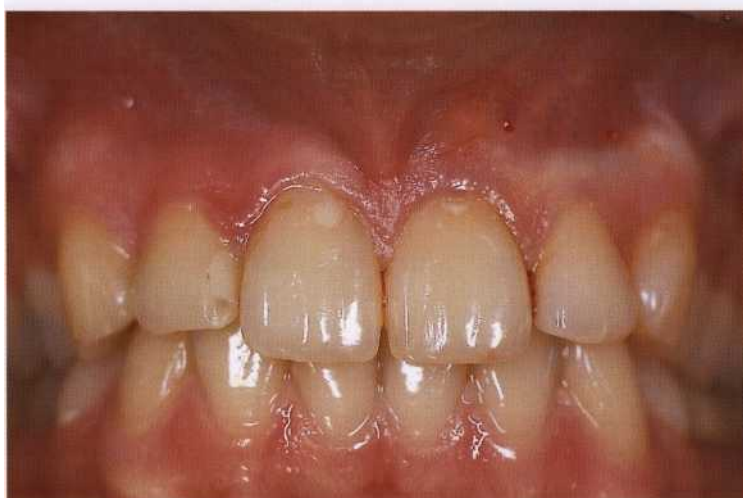
Right: The radiograph shows periapical radiolucencies on both central incisors. Based on the clinical and radiographic findings, it is assumed that this is an acute exacerbation of previously chronic apical periodontitis.



417 Intraoral appearance

Primary and secondary acute abscesses present the same clinical symptoms: increased tooth mobility, sensitivity to pressure in the apical region, and vestibular swelling. Here the swelling is not yet fluctuant.

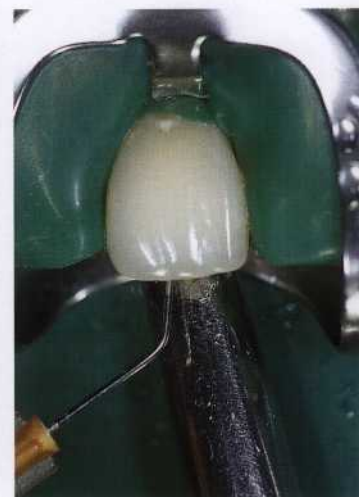Right: The anesthetized tooth is stabilized while the pulp chamber is opened with a diamond stone in a high-speed handpiece with cooling spray.



418 Drainage

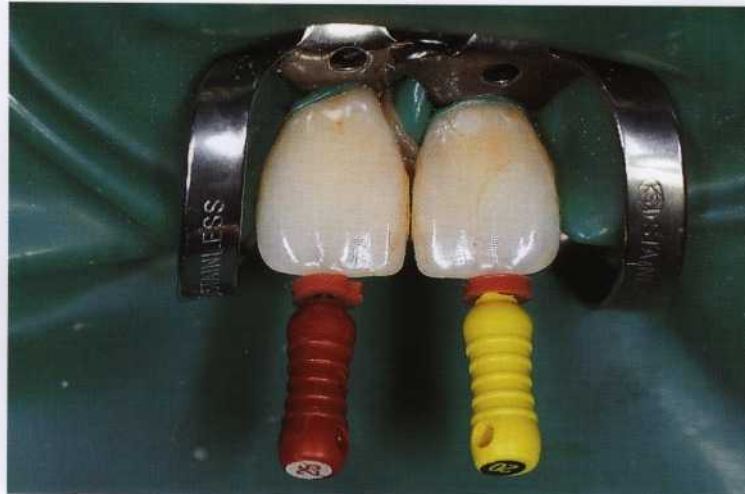
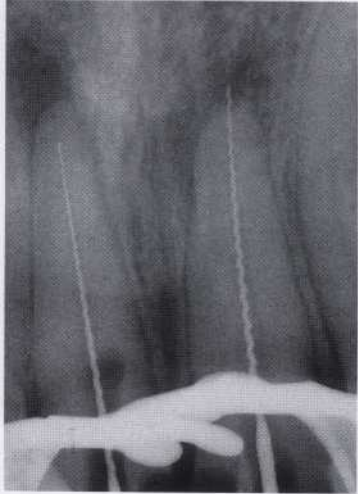A Hedstrom file is inserted short of the apical constriction. This is followed by a spontaneous outflowing of pus.

Right: The root canal is enlarged, instrumented, and irrigated with sodium hypochlorite for 15 minutes or more until the exudation subsides.



The access opening is sealed after the interim dressing is inserted. After 7 days the dressing is changed and calcium hydroxide is packed into the root canal with paper points. Acute reactions occur in only 5% of teeth with alveolar abscesses that had the coronal opening sealed (August 1982). The interim dressing and the definitive seal prevent reinfection and increase the success rate for conservatively treated teeth to 61.1% compared with a success rate of 22.2% with no insertion of antibacterial dressing (Leonardo et al. 1994).

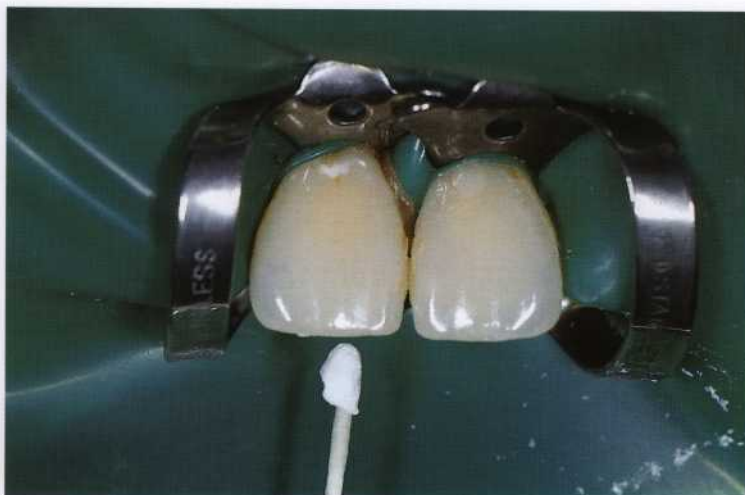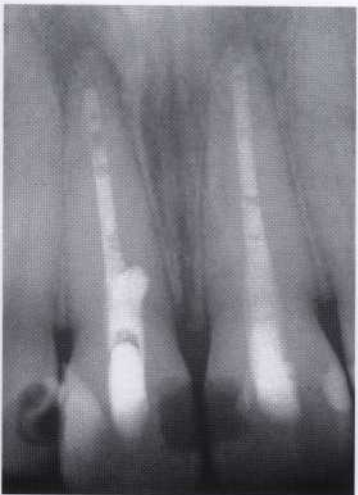The second dressing is allowed to act for a longer period and should remain in the root canal for at least 3 months. Calcium hydroxide exerts an excellent antimicrobial action within a sealed root canal. In vitro, anaerobic strains of bacteria such as peptostreptococci, porphyromonas, and fusobacteria could no longer be found (Georgopoulou et al. 1993). The relatively high pH value of 13.1 was kept constant for a period of 30 days during the study so that a good antimicrobial effect over a long period of time was assured (Fuss et al. 1996).



419 Instrumentation

The working length and the size of the initial apical files are determined and then, at the first appointment, both root canals are completely instrumented.

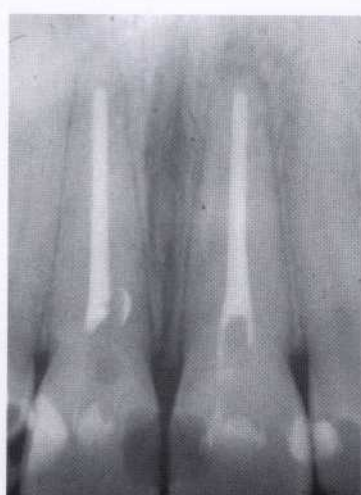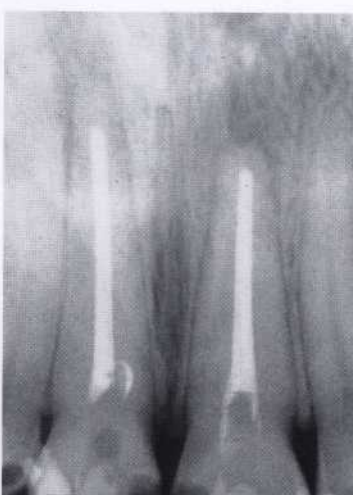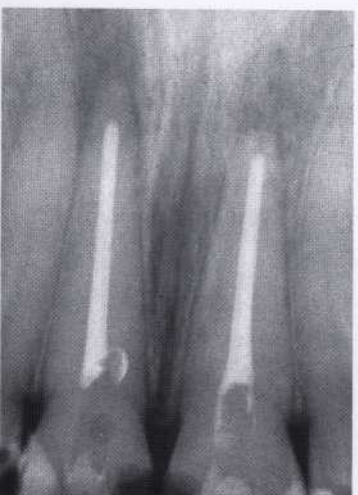Left: Radiographic determination of the working length. The lengths are corrected for the underinstrumentation in one and the overinstrumentation in the other.



420 Interim dressing

If there is little or no purulent exudate the root canals are dried and filled with calcium hydroxide.

Left: The radiographic follow-up at 1 week shows resorption of the interim dressing. Because the initial secretion persisted, it was necessary to change the dressing. The clinical symptoms had already subsided after the first appointment.



421 Monitoring the course of healing

Left: Three months after instrumentation there are no clinical symptoms, and the periapical lesion shows signs of healing, the root canals are therefore obturated.

Center: At 6 months, further reduction of the periapical radiolucency is visible.

Right: On the follow-up radiograph after 1.5 years no periapical lesions are visible.

Clinical Results

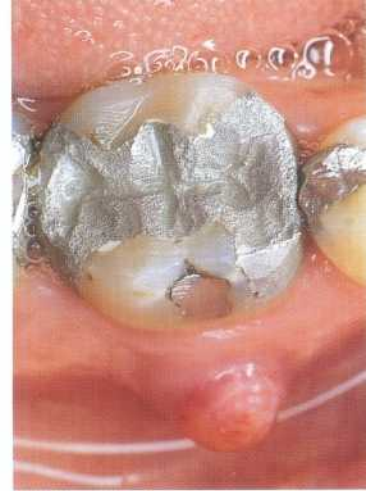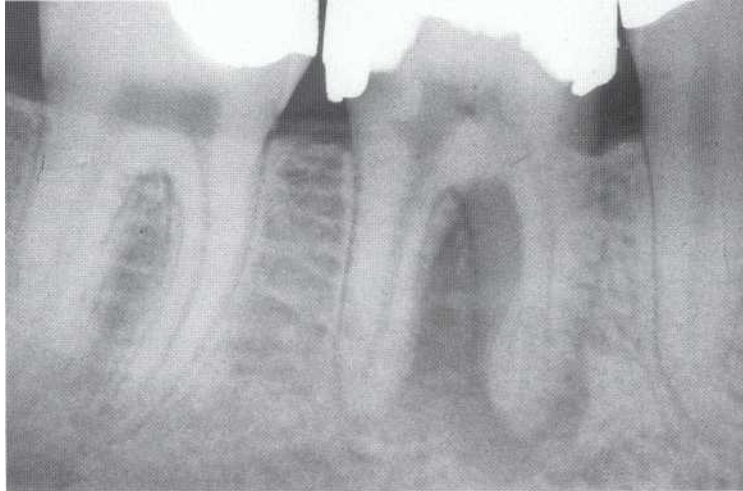When calcium hydroxide is used as an interim dressing, after 3 years there is complete regeneration of 82% of all periapical lesions, even the larger ones. In 18% of the cases periapical radiolucencies persist or are only slightly reduced. The greatest reduction of a periapical lesion occurs during the first year (Eriksen et al. 1988). The first evidence of healing is seen on the conventional radiograph after 12 weeks at the earliest, but can be detected as early as 3-6 weeks in digitized images (Orstavik 1991).

Pain occurs much more frequently in small than in large periapical lesions (Torabinejad et al. 1988). Prophylactic administration of an antibiotic does not reduce postendodontic pain any more than a placebo (Walton and Chiapinelli 1993). If a tooth is left open, periapical inflammation, microabscesses, and resorption of dentin, cementum, and bone can be observed. If the canal is packed with an interim dressing, reparative cementum will form and the size of the periapical lesion will be reduced (Holland et al. 1992).

422 Apical periodontitis

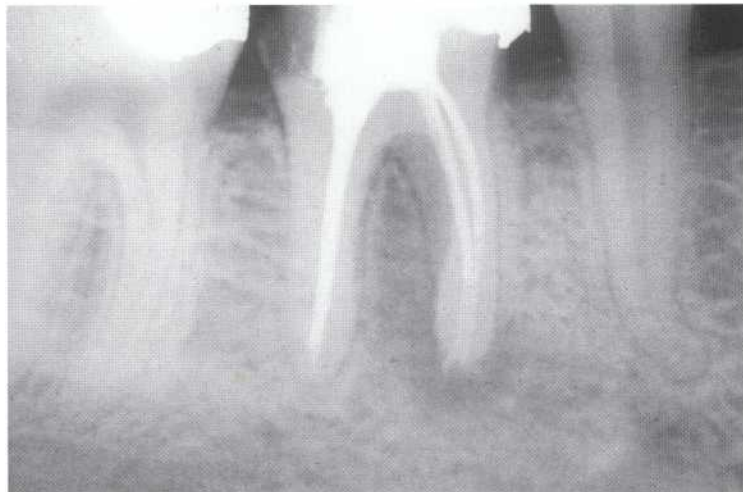A mandibular molar with a defective amalgam filling and extensive periapical lesion. This is located primarily on the mesial root and extends into the bifurcation space.

Right: A vestibular fistula from which pus drains periodically is visible clinically.



423 Root canal treatment

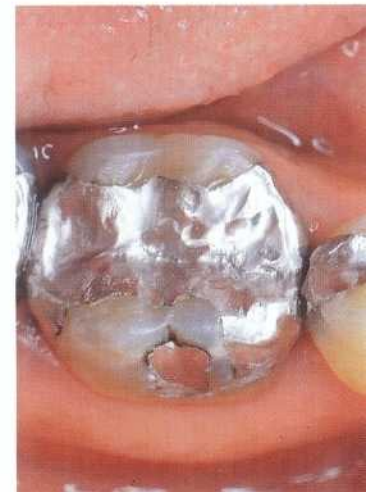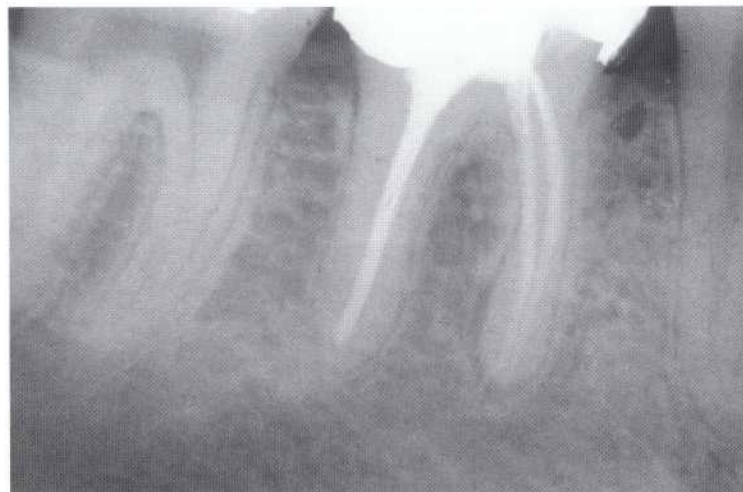
The root canal is instrumented, generously irrigated with sodium hypochlorite solution, treated with a calcium hydroxide interim dressing for 6 months, and then obturated. Incipient regeneration of bone can be seen radiographically in the area of the periapical lesion.



424 Radiographic and clinical follow-up

The radiograph made after 1.5 years shows complete healing of the once extensive periapical lesion.

Right: Clinically, the fistulous tract can no longer be found. The teeth can now receive fixed restorations.



Root Canal Obturation

The last step in root canal treatment is to create the best possible hermetic seal with a filling material that is nonirritating to the tissues. The basic mechanical instrumentation and shaping of the canal is the most important prerequisite for endodontic success. If the root canal is only partially instrumented, successful treatment cannot be expected. The root canal filling should leave the tooth in the most biologically inert condition possible, and it must prevent reinfection as well as growth of any microorganisms remaining in the canal (Beer 1993 a). In animal experiments it was found that resorbable pastes extruded into the periapical space led to infiltration of acute inflammatory cells, resorption of the adjacent alveolar bone, and in a few cases, to abscess formation (Erasquin and Muruzabal 1969). When a canal was filled with a polyketone-based synthetic resin cement, the pulp tissue became inflamed with macrophages and foreign-body giant cells predominating. Here, too, an acute inflammatory reaction could be seen in a few instances (Erasquin and Muruzabal 1970). Over-filling with this cement prompted necrosis and varying degrees of resorption of cement and bone. After 80 days, a capsule had formed around the over-extended material. Resorption of the cement did not occur but there was a definite foreign-body reaction. Filling a root canal with the formaldehyde-containing root canal cement N2 brought about a foreign-body reaction: zones of necrosis and accumulations of leukocytes were observed bordering on the fixed tissue. This filling material is continuously resorbed and diffuses through the pulp tissue to be distributed throughout the entire body (Horsted et al. 1982).

The ideal root canal filling material would be nonirritating to the pulp tissue, would tightly seal the canal both laterally and vertically, and would be dimensionally stable so as not to shrink within the canal. It should not support bacterial growth and should even be bacteriostatic, while at the same time being biologically compatible and nontoxic. The filling material should be easy to sterilize before use. It should be radiopaque and should not discolor the tooth. A root canal sealer should not harden too quickly and after hardening should exhibit good adhesion to both the dentin and the root canal filling. It should be insoluble in tissue fluids and have a slight expansion (Ngyuen 1994). No one formulation can fulfill all these requirements, however, and a great number of different endodontic filling materials and techniques fall short. Filling the root canal with gutta-percha points and a sealer is the most biologically favorable and surest method in the long term (Orstavik et al. 1987). Widely used methods of gutta-percha application include lateral condensation, vertical condensation, thermomechanical condensation, and injection techniques.

Biological Properties

All root canal cements are tissue irritants and only gutta-percha is biologically inert (Beer 1986). One hundred and eighty days after they implanted chloropercha subcutaneously, Olsson et al. (1981) found chronic inflammation with small foci of necrosis followed by a zone of disintegrated cells at the end of the carrier tube. Acute inflammation predominated after chloropercha had been implanted in bone for 180 days, whereas chronic inflammation was evoked by AH-26 and Kerr Sealer. All sealers tested experienced resorption by macrophages (Olsson et al. 1981).

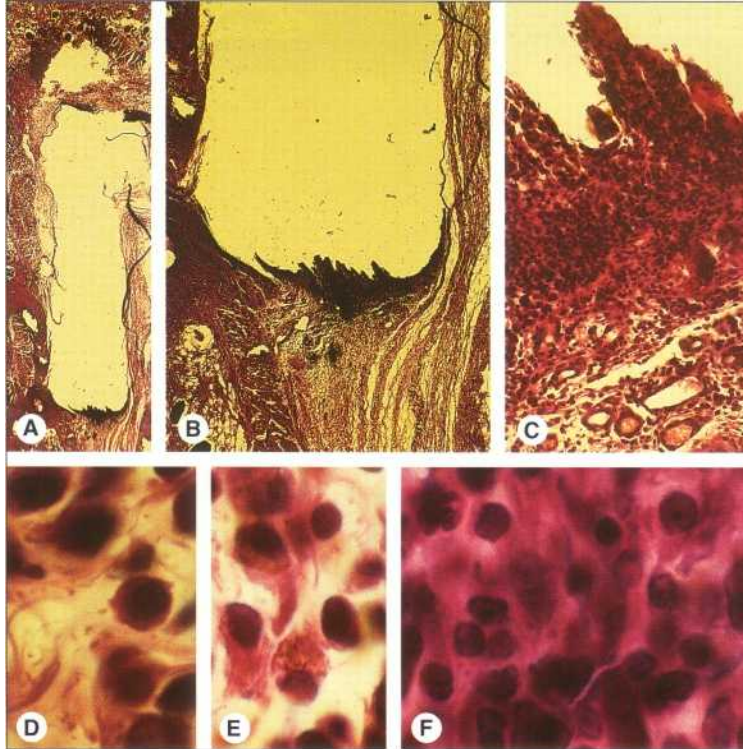
Under clinical conditions, AH-26 produced severe reactions in pulp tissue with infiltration of neutrophilic granulocytes and macrophages after 7 days. No bacteria could be found in any of the teeth investigated. After 30 days a chronic cellular infiltrate predominated, regardless of which of the filling cements being tested was used. The reaction to AH-26 was severe at first but markedly less so after 3 years. In contrast, the reaction to chloropercha was mild initially but became severe during the time frame of the study (Pascon et al. 1991).

425 Subcutaneous implantation of Grossman cement
A Soft and hard cements can be investigated by using Teflon tubes as carriers.

B A severe tissue reaction to the test material can be seen facing the opening of the tube.

C Accumulation of acute and chronic inflammatory cells.

D, E, F An accumulation of mononuclear inflammatory cells composed of lymphocytes, plasma cells, and macrophages is an expression of a persistent inflammatory stimulus. Particles of the material found throughout the tissue as well as within the macrophages testify to its resorbability.



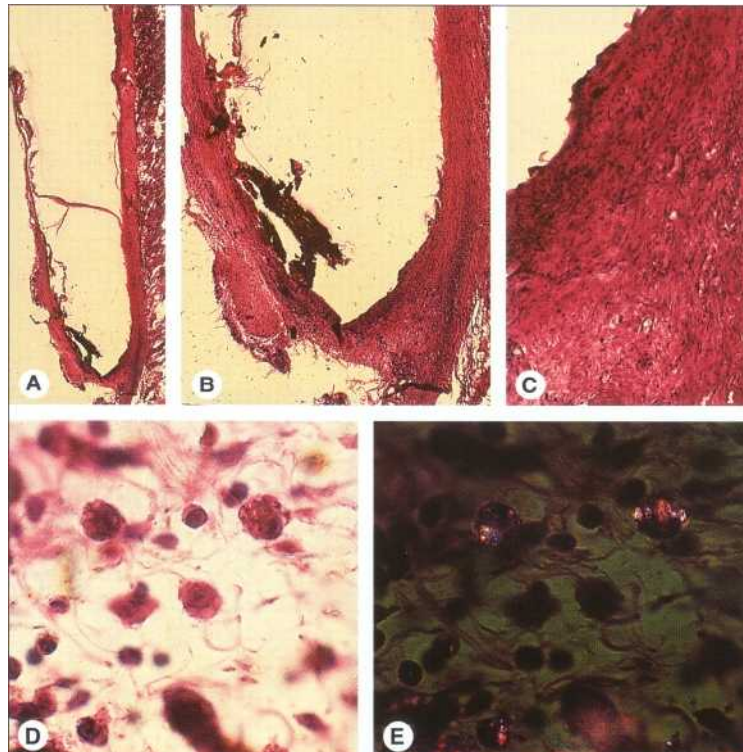
426 Tissue reaction to implanted Diaket

A The tissue tube has been removed from the rat connective tissue.

B, C Facing the opening of the tube a moderate inflammatory reaction with massive lymphocytic infiltration is found.

D The accumulation of macrophages is evidence of active phagocytosis of cement particles, and the appearance of lymphocytes and plasma cells in an expression of an immunologic reaction.

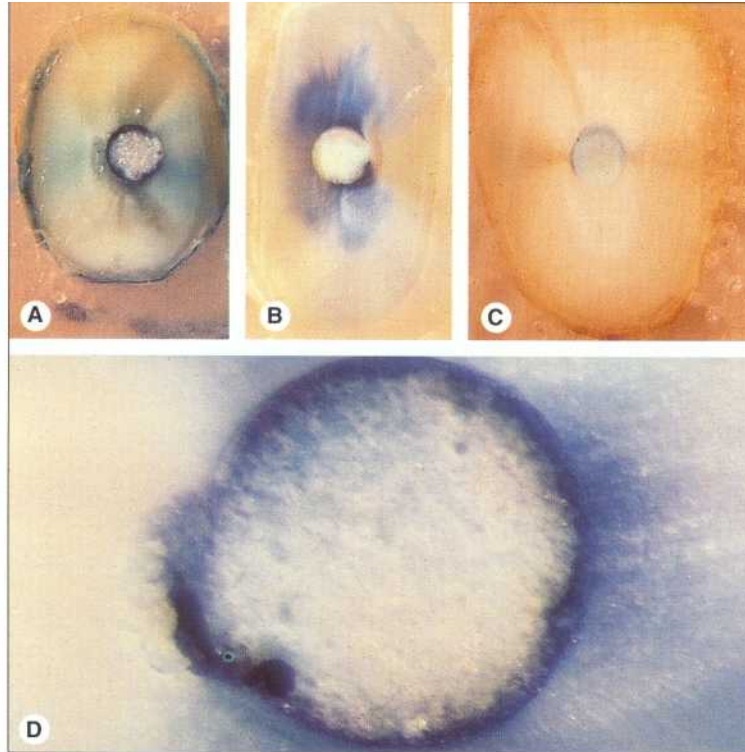
E The image under polarized light reveals individual particles of cement distributed both through the tissue and inside the phagocytes.



Physical Properties

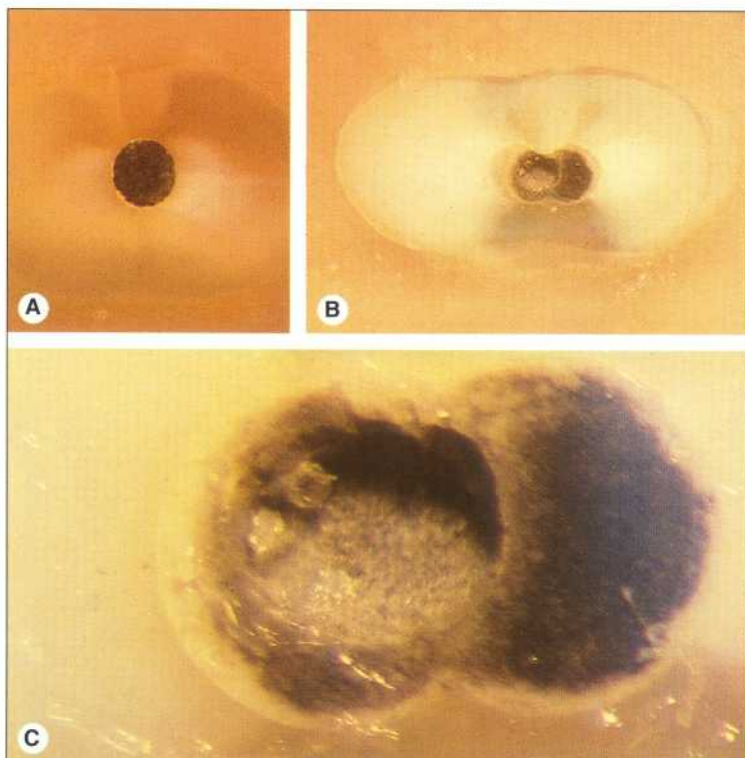
Among the physical properties of a sealer are the capacity to provide a marginal seal, condensability, shrinkage, and viscosity. Many studies have been conducted to evaluate these criteria and have produced various results. Wiener and Schilder (1971) investigated the dimensional changes by filling micropipettes as models for root canals. The sealers that had detached most were also the first to show signs of shrinkage. Only AH-26 expanded slightly after 7 days, and then exhibited a slight shrinkage after 30 days.

Orstavik (1982) investigated the film thicknesses of 28 sealers. These ranged from 4.5 to 10 μ m. There was a relationship between the film thickness and the complete seating of the gutta-percha points: the greater the film thickness, the greater the force required to bring the point to the measured position. The best values were achieved with Kerr sealer and Proco-Sol. Osinus et al. (1983) compared various sealers and obturation methods: the best seal was obtained with the vertical condensation technique and AH-26, and the techniques that used no sealer produced the worst results.



427 Dye penetration test of a glass ionomer cement. Extracted teeth are instrumented, and their canals filled and subjected to a dye penetration test to evaluate the tightness of the seal.

- A Dye is found 1 mm above the apex between the root canal filling and the canal wall.
- B There is visible penetration 2 mm above the apex.
- C Only at a distance of 8 mm is there almost no dye present.
- D Dye between the canal wall and the filling as well as within the glass ionomer cement indicates an inadequate seal.



428 Dye penetration test of AH-26. In comparing different obturation methods the difference in their sealing abilities is of great importance. Penetration tests provide results that, while not absolute, are a basis for comparison.

- A 1 mm from the apex almost no dye penetration is seen; the root canal is obviously well-sealed.
- B At a distance of 2 mm the first void is found within the filling material.
- C This higher magnification shows a bubble formed within the material, which indicates insufficient homogeneity.

Prerequisites for Filling the Root Canal

A root canal can be obturated when there is no pain, swelling, tenderness to percussion, or fistulation associated with the tooth, and when the instrumented canal is dry and free of odor. If the pulp is necrotic or a periapical lesion is present, the root canal cannot be filled before the second appointment. At the first appointment vital pulp tissue can be completely removed by means of hand instruments or ultrasonic instruments from only 54% of root canals that have a 35° curvature (Walker and delRio 1989).

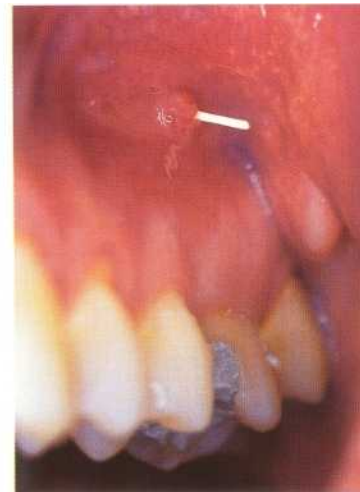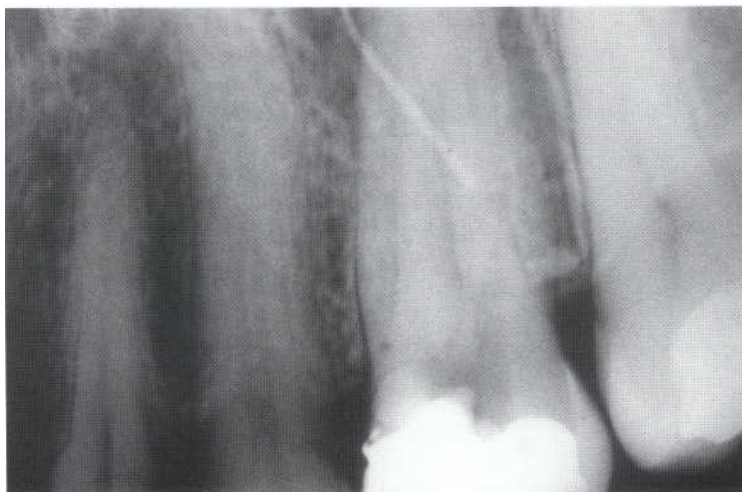Therefore curved canals should also not be filled until the second appointment.

When apical periodontitis is present, endodontic treatment in a single visit produces a significantly poorer result than treatment that includes antibacterial dressings in place between multiple appointments (Holland et al. 1992).

429 Initial clinical situation

The diagnostic radiograph shows a periapical radiolucency at the tip of the mesial root of the maxillary first molar. The gutta-percha point reveals the origin of the fistulous tract.

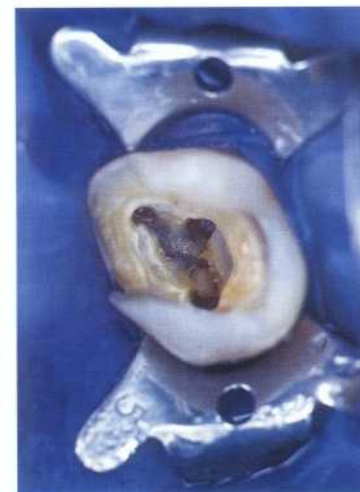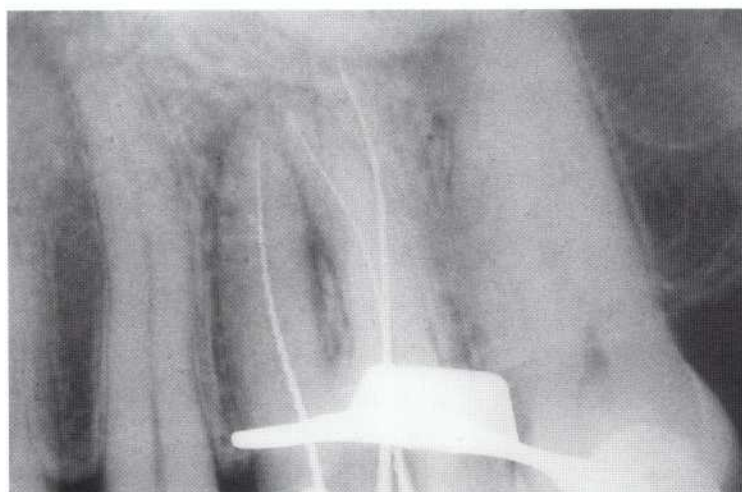Right: A gutta-percha point has been inserted into the fistulous tract. Because of its radiolucency, the gutta-percha should point to the origin of the fistula on the radiograph.



430 Canals disclosed

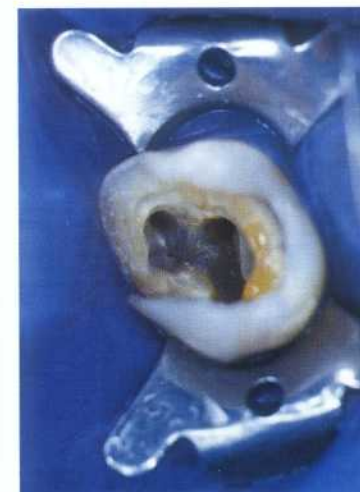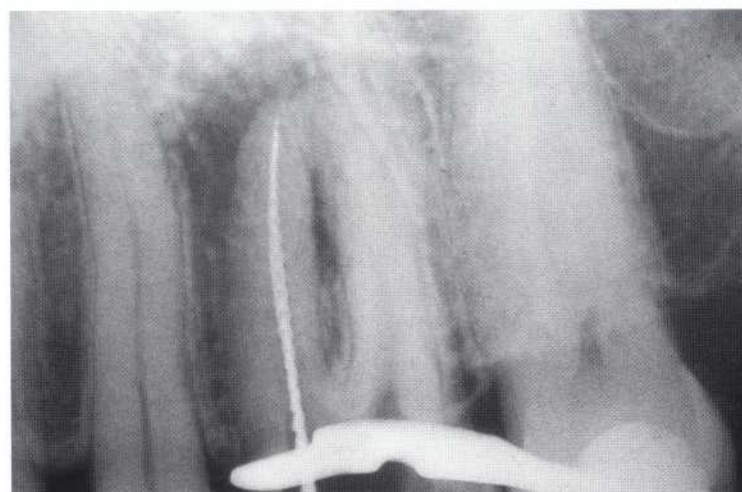After making the coronal access opening, the working lengths of the three root canals are determined radiographically. Then they are instrumented and filled with calcium hydroxide.

Right: Because the fistula persisted, the tooth is opened again and the floor of the pulp chamber inspected for entrances to any additional canals.



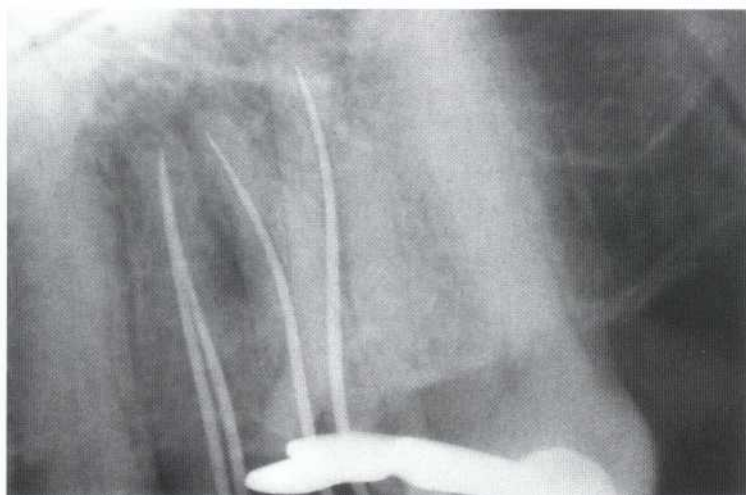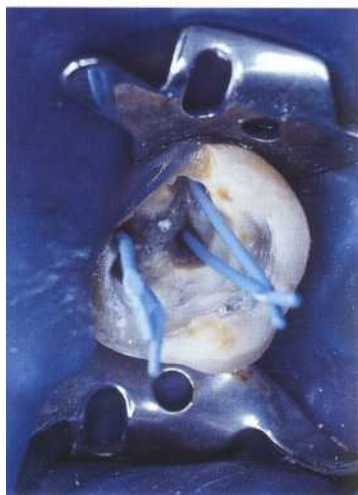431 Fourth root canal

A fourth, mesiolingual canal is found in the mesiolingual root. Two files are then inserted to determine the patency and relationship of the two canals in the same root. The fourth canal is located with the help of a small, long-shanked, round bur. Then it is carefully probed and instrumented.



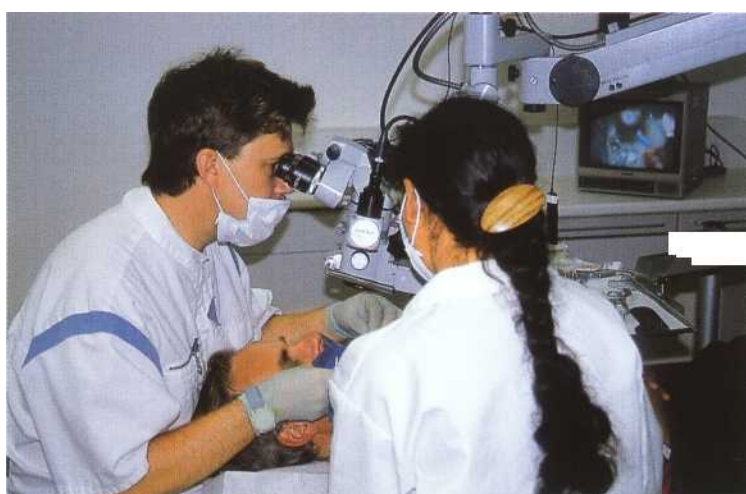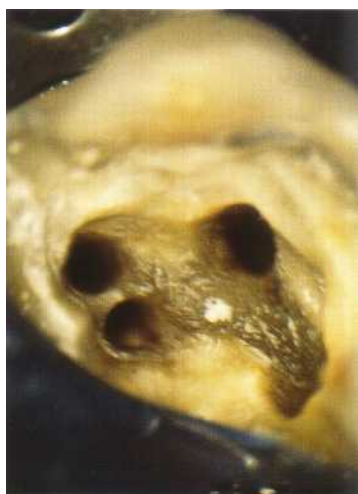If the root canal is infected, the filling material should have a strong antibacterial action. In diffusion tests, the strongest antibacterial effect was produced by Endomethasone and N2, followed by AH-26 (Pumarola et al. 1992). In biologic implantation tests, however, Endomethasone and N2 brought about the most severe tissue reaction. AH-26 prompted a tissue reaction that was severe initially but became milder over the period of the study, while Grossman cement caused a persisting moderate irritation (Orstavik and Mjor 1988).

Sealers containing calcium hydroxide were somewhat more efficient in destroying bacteria than resin based sealers (Canalda and Pumarola 1989). AH-26 and Sealapex exhibited strong antibacterial activity within adjacent dentin tubules (Heling and Chandler 1996). Their biologic reaction is objectionable, however. Sealapex triggered a foreign-body reaction with infiltration of giant cells and macrophages. The reaction in implantation tests intensified during the 30 and 90 days of the investigation (Zmener et al. 1988).



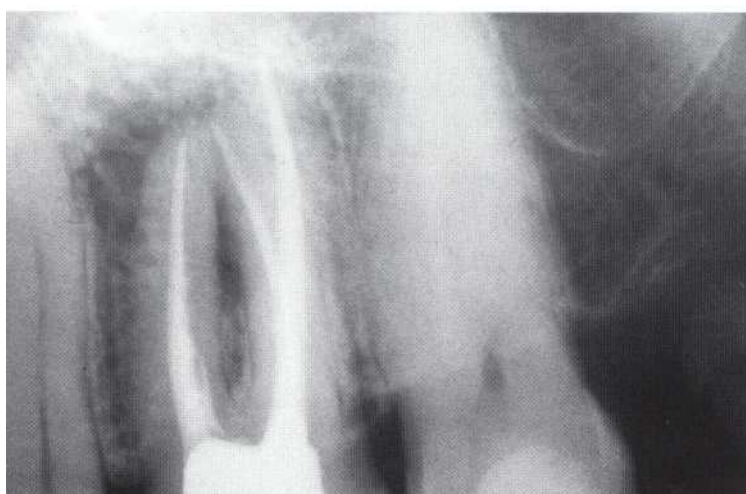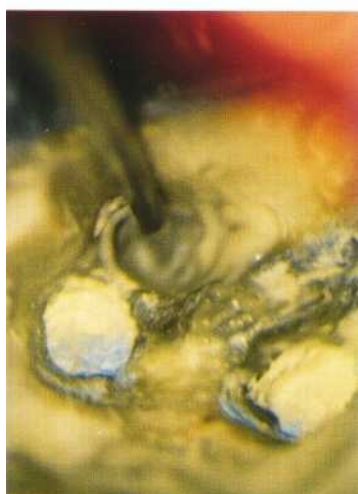
432 Radiographic evaluation
The position of all four gutta-percha points within the root canals is checked with the master point radiograph.

Left: The root canals were not completely dried before the master point radiograph and can still be instrumented further if necessary.



433 Optical evaluation
The results of the instrumentation are evaluated under the surgical operation microscope. Using stronger magnification straight root canal segments can be "traveled" from their apical ends to their coronal regions by adjusting the focus.

Left: The view into the prepared cavity shows the canal enlargement and the round-shaped root canal entrances.



434 Root canal filling
The root canals are obturated with gutta-percha and a sealer by the lateral condensation technique. The image of the mesiobuccal canal is superimposed over that of the fourth canal so that their fillings appear as one.

Left: Under the surgical operation microscope the gutta-percha points are shown to be well condensed. The working depth in the mesiolingual canal is being rechecked with a spreader.

Lateral Condensation of Gutta-percha

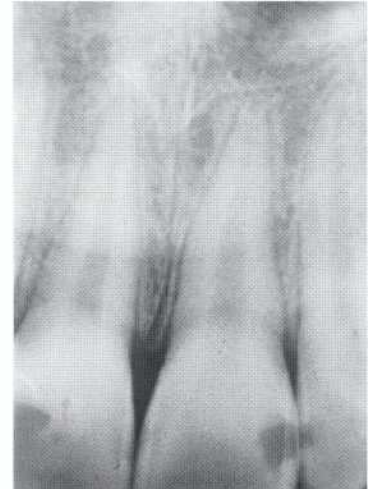
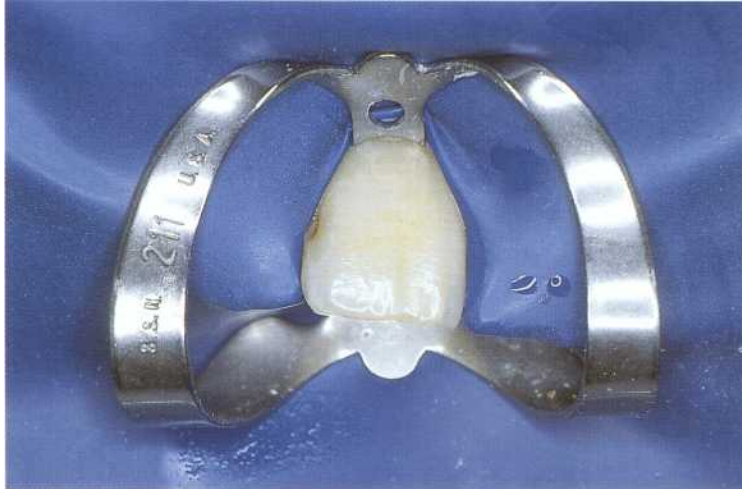The root canal filling procedure starts with the selection of the gutta-percha master point. Gutta-percha should not be stored too long or it will become brittle and weak and will no longer be easily condensed. This problem can be traced back to its transformation into crystalline form, which is accelerated by light and heat. Gutta-percha that has not dried out can be shaped more readily (Kolokuris et al. 1992). When stored in a refrigerator, gutta-percha contracts and becomes harder, but not more brittle (Best et al. 1963). Softer gutta-percha points can be better condensed (Hulsmann 1993 b).

Before the gutta-percha master point is tried in the canal, a suitable spreader is selected. The compactness achieved in a root canal filling depends upon the insertion depth and the shape of the spreader. The distance within the root canal between the tips of the gutta-percha point and the conically tapered D-11 spreader is more than 2 mm. The ISO standardized finger spreader, on the other hand, can be inserted to 1 mm from the tip of the gutta-percha point, resulting in a more homogenous and denser root canal filling (Chohayeb 1993).

435 Vital extirpation

A maxillary incisor with irreversible pulpitis. After the rubber dam is placed, an access opening is made and vital extirpation of the pulp is performed.

Right: The root canal is almost straight with a slight distal curvature so that it can be prepared and obturated at the same appointment.

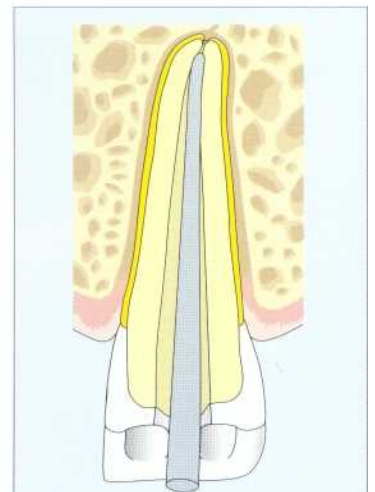
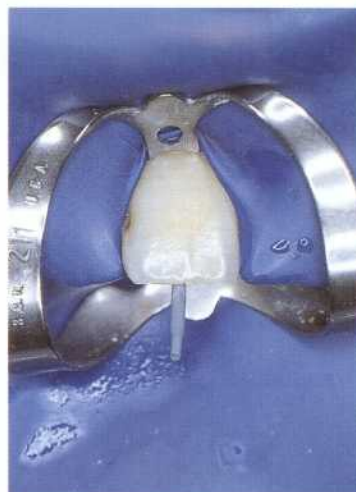
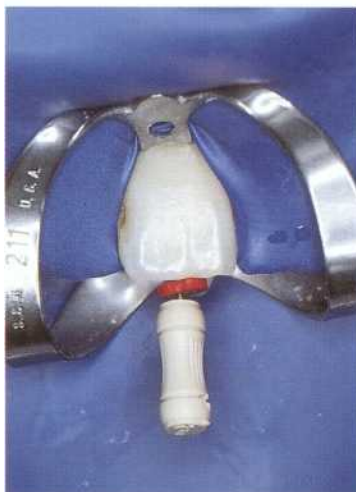
436 Master point

Left: The working length is determined. The root canal is then prepared, irrigated, and dried.

Center: A gutta-percha master point corresponding to the size of the AMF is selected and the working length marked by the imprint of a pair of pliers.

Right: The gutta-percha point is tried in the canal for correct fit and length. It should end slightly short of the apical extent of instrumentation.

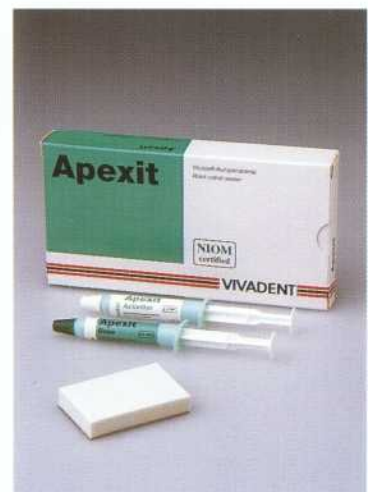
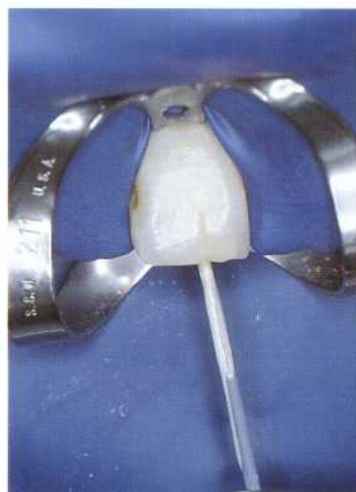
437 Root canal cement

Left: The cement is mixed and given the spatula test to determine the desired consistency.

Center: The apical half of the master point is coated with sealer and inserted into the canal to the pre-determined depth.

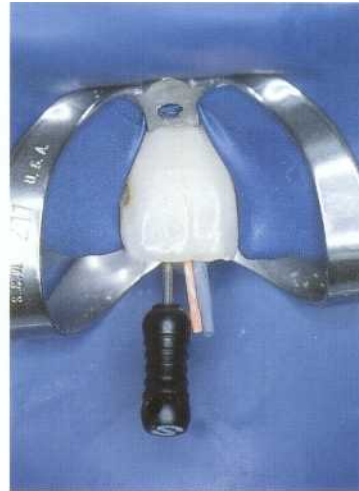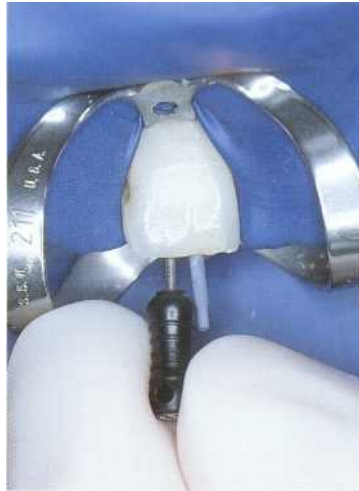
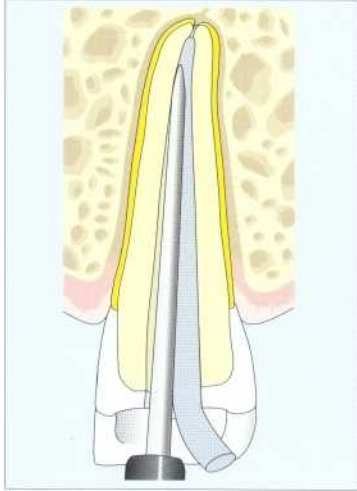
Right: Apexit, a resin-based sealer containing calcium hydroxide, seals the root canal better than Sealapex and Tubliseal (Limkangwalmongkol et al. 1991).



In slightly curved root canals, finger spreaders condense the gutta-percha better than hand spreaders of the same shape, presumably because of the freer movement and rotation of the finger spreaders (Simons et al. 1991).

The risk of a vertical fracture during condensation is very small and depends upon the design of the spreader. Conical spreaders produce dentin deformation with expansion four times more frequently than standardized finger spreaders. Vertical root fractures occurred in 5% of the obturated teeth (Dang and Walton 1989).

After the first condensation of the gutta-percha master point, additional accessory points are condensed against the canal wall. In a study by Jerome et al. (1988), root canal fillings that were placed with ISO standardized size 25 accessory points using a finger spreader were significantly more homogenous, better condensed, and exhibited no overfilling or crumpling. The use of nonstandardized fine-fine accessory points resulted in overfilling in 30% of the canals; the fillings frequently contained wrinkles, voids, and nonhomogeneous areas.

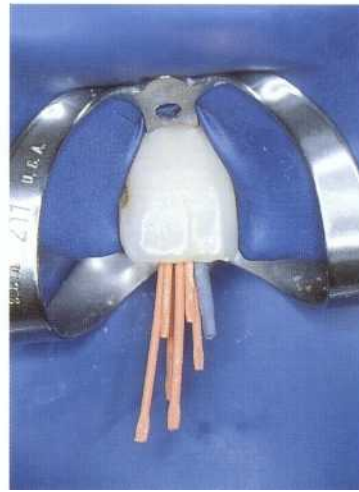
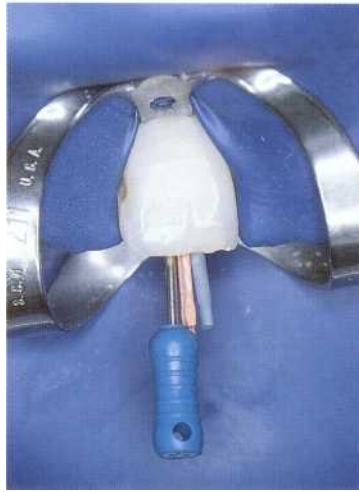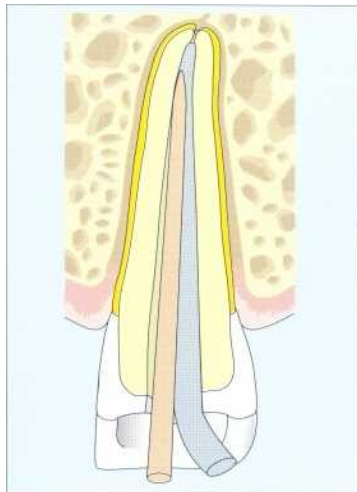


438 Lateral condensation of gutta-percha

Left: The finger spreader is inserted between the canal wall and the point to a depth 1 mm short of the working length.

Center: When the working length is reached, the spreader is left in place for 15 seconds before being withdrawn. This will prevent rebounding of the gutta-percha.

Right: The accessory point, coated with a small amount of sealer, is condensed against the master point with the finger spreader.

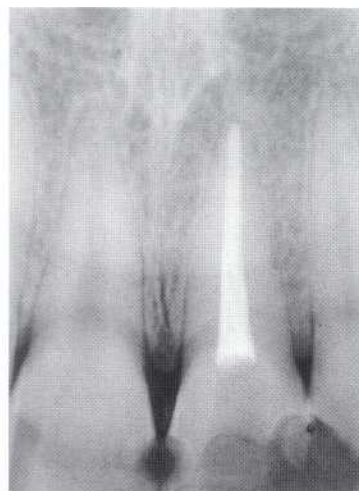
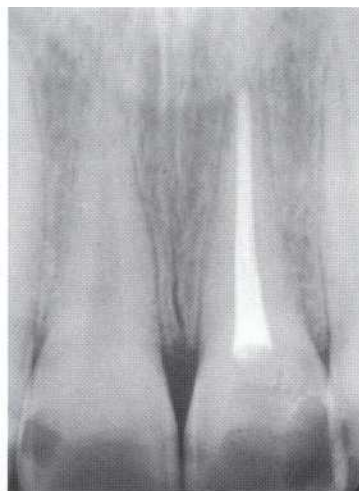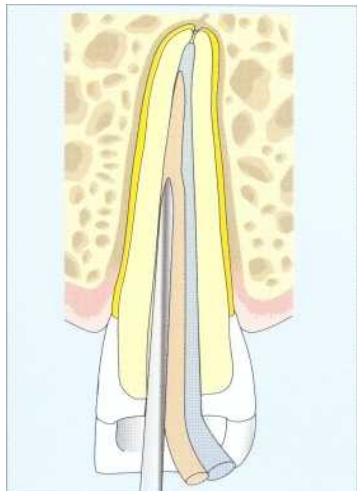


439 Accessory points

Left: The spreader is removed with a gentle rotating movement, and a standardized accessory point is inserted into the space.

Center: Accessory gutta-percha points in sizes 25 and 20 are coated with sealer and condensed one upon another.

Right: The gutta-percha is condensed to a homogeneous canal filling.



440 Radiographic evaluation

Left: Vertical force applied to the spreader deforms the accessory point laterally.

Center: The gutta-percha points protruding from the access preparation are cut off 1 mm apical to the canal entrance. The filling is then evaluated for precision of fit and homogeneity.

Right: Radiographic follow-up 3 years after the completion of endodontic treatment shows no evidence of periapical irritation.

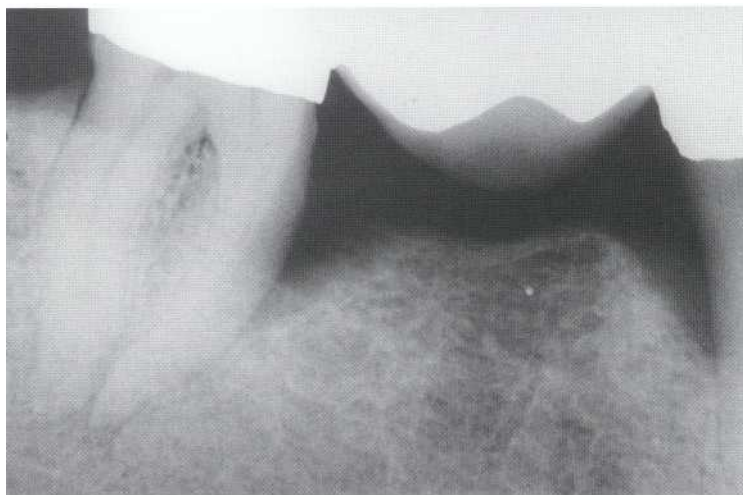
Adaptation of Gutta-percha

Once the fit of the gutta-percha master point has been verified radiographically, it is removed from the canal, rinsed, and dried. Then the AMF is inserted into the dried root canal and, using balanced force rotating movements, a few more dentin shavings are removed. A final flushing with 1 ml of isopropyl alcohol does not improve the application of sealer compared with sodium hypochloride. In one-third of root canals studied, less than 50% of the walls in the apical third were covered with sealer (Wilcox and Wiemann 1995).

The sealer does not coat the wall uniformly, regardless of the method used to carry it into the canal. When the sealer was introduced on a K file, which was then removed while being rotated counterclockwise, only one-third of the canal walls were covered. Application with an ultrasonic file did not improve the results. The sealer could be applied well in half of the cases with a Lentulo spiral. When the gutta-percha point was coated with sealer and pushed into the canal, the highest success rate was observed at 70% (Wiemann and Wilcox 1991).

441 Initial condition

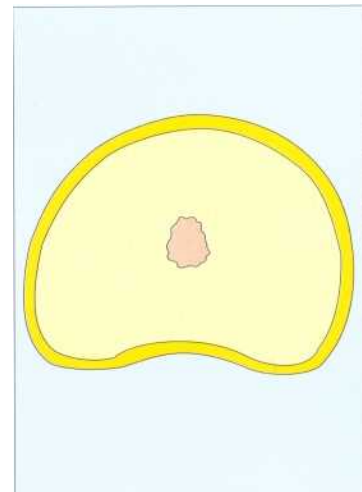
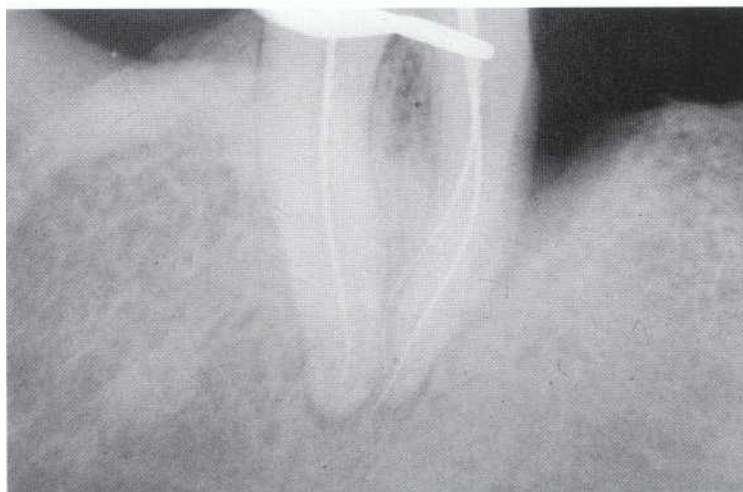A mandibular molar with a periendo lesion and a primarily periodontal problem. The infection extends from the periodontal pocket. Bacteria from the periodontal lesion have penetrated into the root canal leading to pulpal necrosis and then to apical periodontitis.



442 Working length

After coronal enlargement, size 15 files are inserted and the working length is determined. The file in the mesiolingual canal exits the root laterally and is greatly overextended in contact with bone.

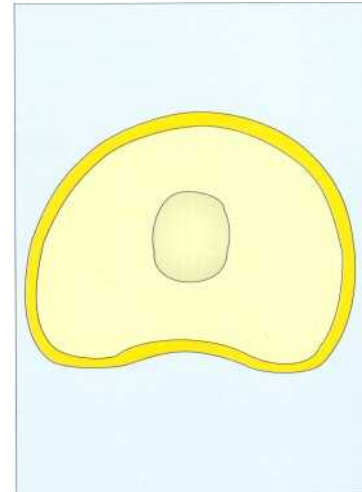
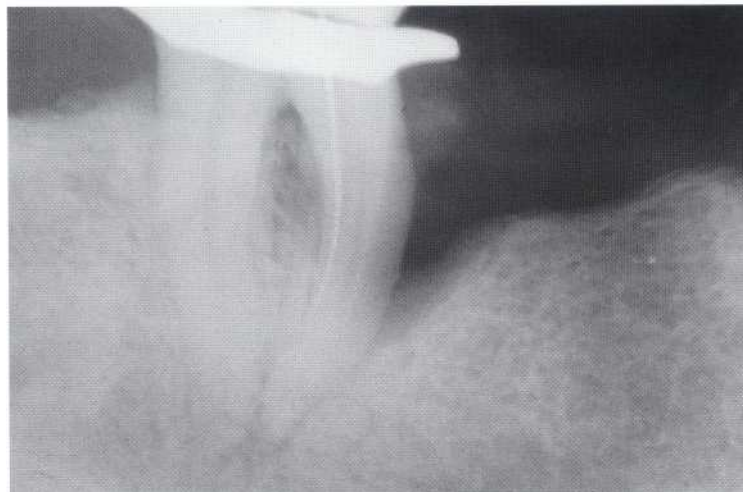
Right: The drawing represents a cross-section of the distal root before it has been instrumented and enlarged.



443 Length adjustment

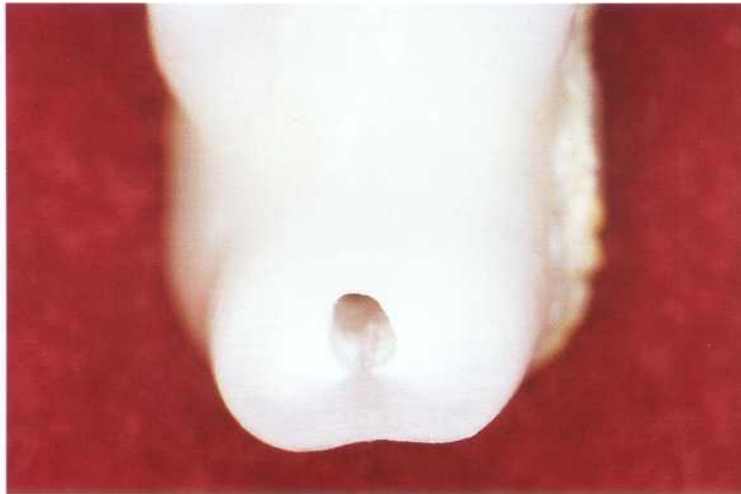
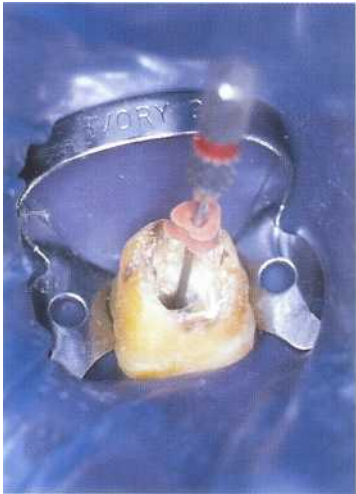The working-length radiograph with one file in the mesiolingual canal reveals the correct length and the communication with the periodontal pocket.

Right: The root canal is then enlarged and shaped. Curved canals never have circular cross-sections in the apical region.



For the biologic evaluation of a root canal, the extent to which sealer comes into contact with the periapical tissue is of great importance. A ratio of approximately 95% biologically inert gutta-percha to 5% resorbable sealer is required. A study by Eguchi et al. (1985) reported a value of 94.5% gutta-percha at a distance of 1 mm from the root tip using lateral condensation of gutta-percha points dipped in chloroform with Proco-Seal as a sealer. Vertical condensation did not perform as well with a value of 91.7%.

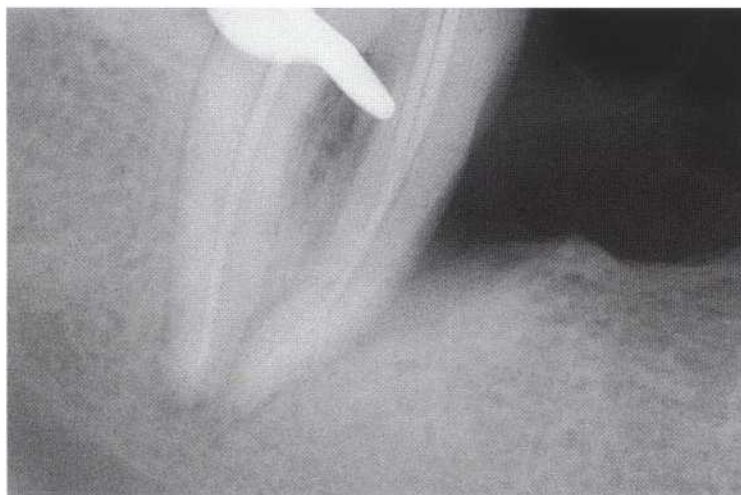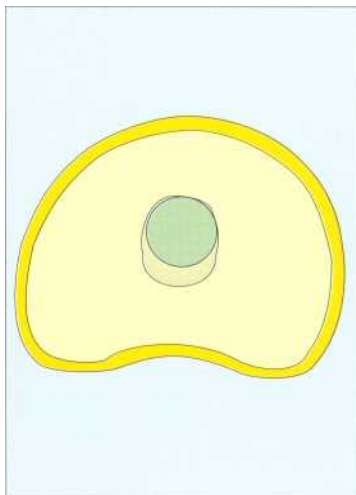
The film thickness of the sealer also influenced the condensation of the root canal filling. AH-26 and Sealapex were condensed to film thicknesses of 0.3 mm, but Kerr sealer was best with a film thickness of 0.05 mm (Georgopoulou et al. 1995). Nitinol spreaders seemed to have an advantage over steel spreaders in condensing into curved root canals because they induced less stress. In straight canals, however, no difference in the force developed nor in the condensation could be discerned (Dwan and Glickman 1995).



444 Trial insertion of the spreader

After the canal has been completely instrumented it is given a final irrigation but is not completely dried. Some moisture facilitates the fitting of the spreader and the gutta-percha point. The model represents the root sectioned transversely 3 mm above the apex.

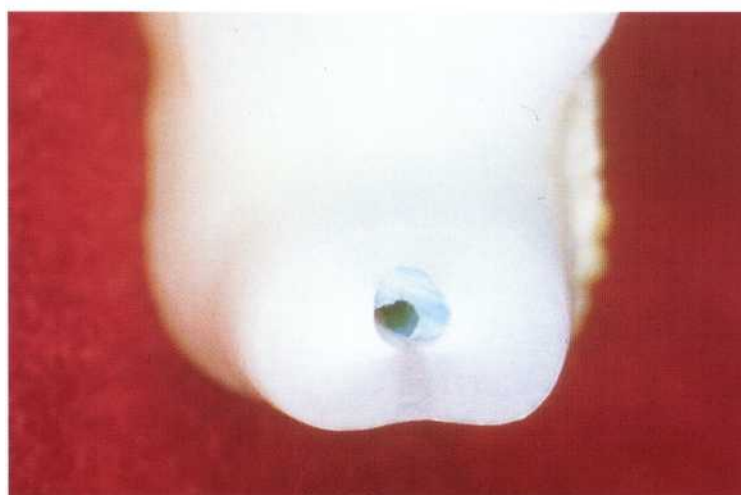
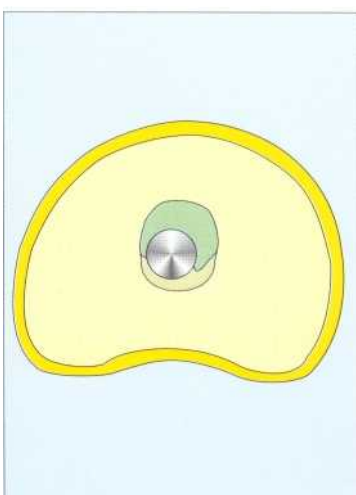
Left: A suitable finger spreader is selected. It should contact the canal walls 1 mm before it would reach the working length. The length can be marked by means of a rubber stop.



445 Trial insertion of the master points

Gutta-percha master points are selected that match the sizes of the AMFs. Their lengths and positions within the root canals are determined with a working-length radiograph.

Left: The cross-section demonstrates good wall contact by the first gutta-percha point (green). It cannot completely fill the canal because of the irregular shape of the latter.



446 First condensation

The finger spreader is inserted between the gutta-percha point and the root canal wall with vertical force as close as possible to the premeasured depth, held there for 15 seconds, and then removed again with a rotating motion. The gutta-percha is now pressed against the canal wall.

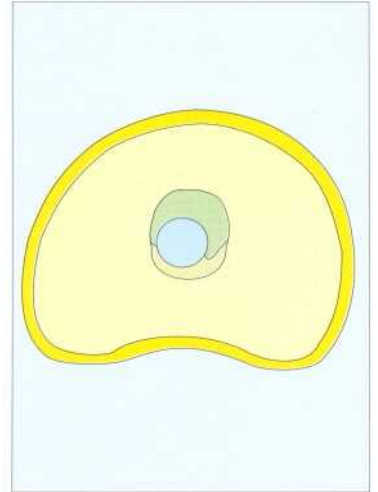
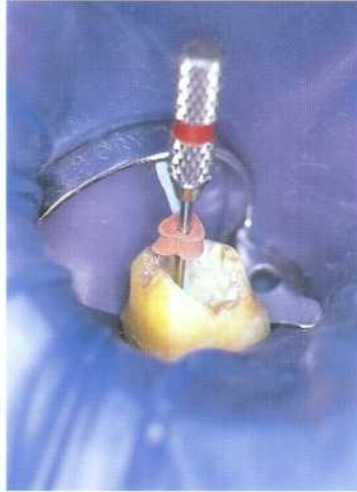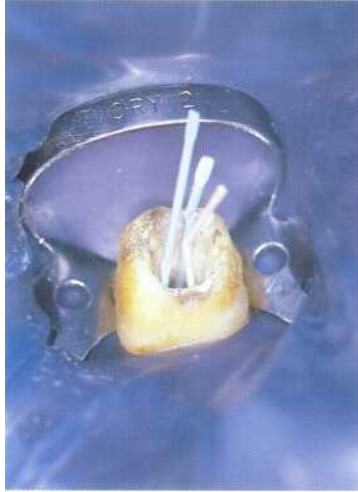
Left: The transverse section shows the first condensation procedure with lateral deformation of the gutta-percha.

447 Second gutta-percha point

Left: The desired length has been transferred to the gutta-percha point with plier beaks.

Center: The Nitinol spreader is pushed into the root canal to the depth of the rubber stop, left there for at least 15 seconds, and then removed with a gentle twisting motion.

Right: A standardized size 20 gutta-percha accessory point is inserted into the space created by the spreader.

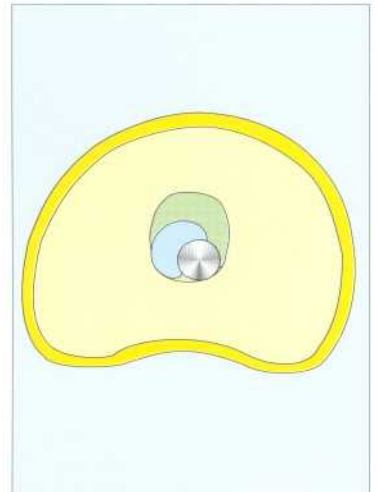
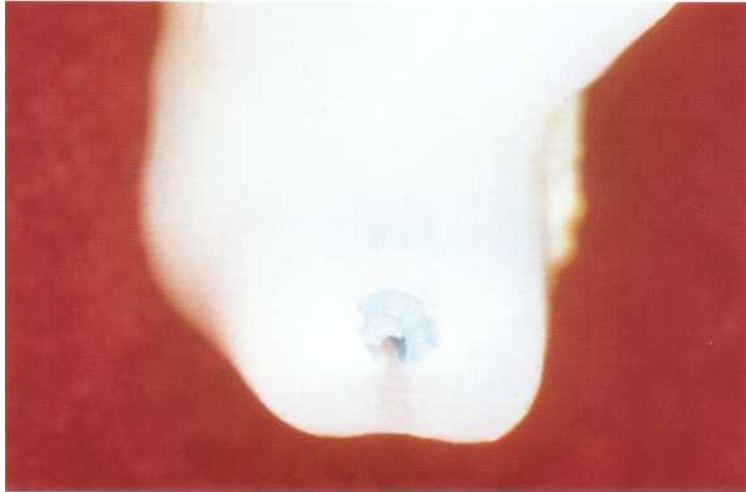

448 Lateral condensation

The second gutta-percha point is pressed against the first point and the canal wall by the spreader. Deformation of the gutta-percha creates an empty space once again.

Right: The metal-colored spreader condenses the second (blue) gutta-percha point against the first (green) master point.

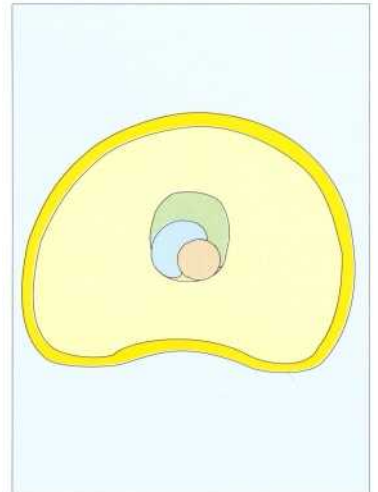
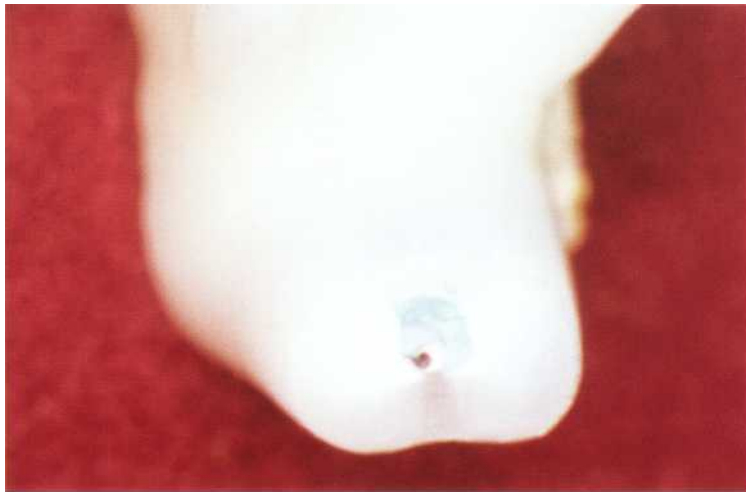(The colors of the gutta-percha correspond to the ISO color codes.)



449 Third gutta-percha point

The third gutta-percha point is deformed by yet another condensation procedure with the spreader and pressed against the first two points.

Right: In the cross-sectional drawing, the third gutta-percha point (pink) is shown before lateral condensation. The tips of all the accessory points are dipped in a small amount of sealer before being inserted into the canal.

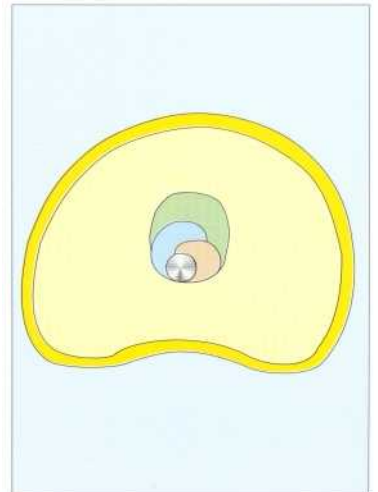
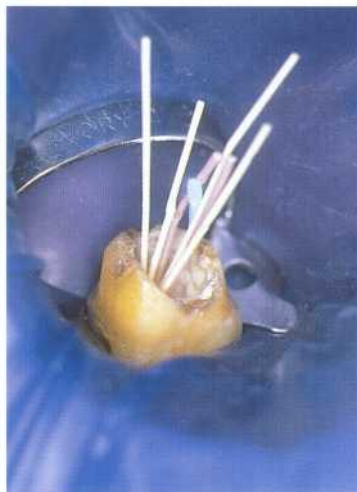
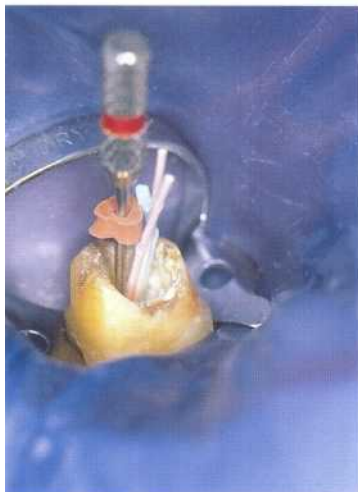

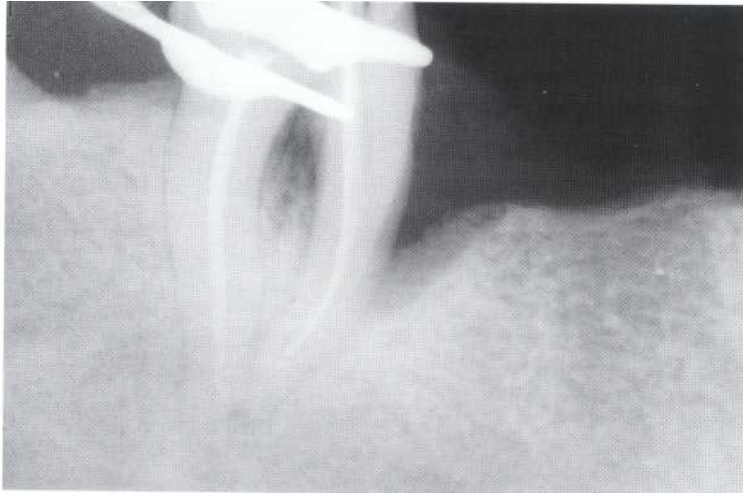
450 Condensation

Left: Condensation is continued with the finger spreader until it can be inserted no farther than the coronal one-third of the canal.

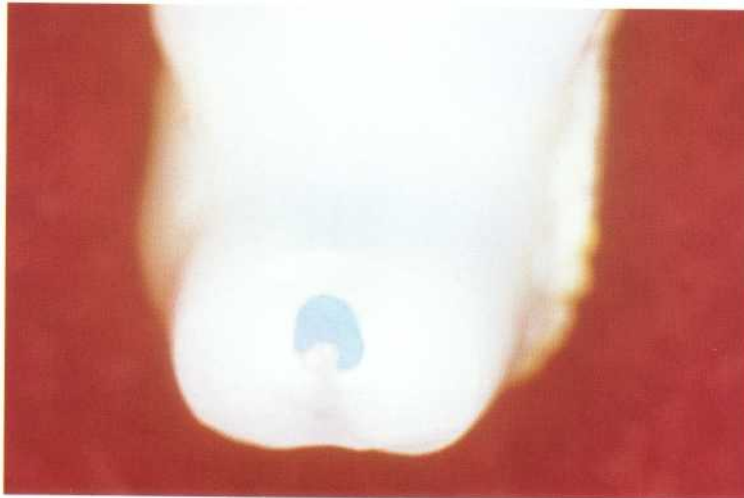
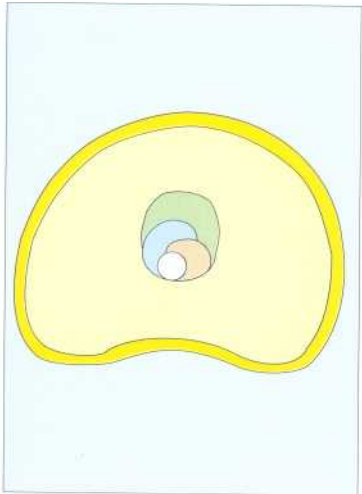
Center: Additional gutta-percha points are added and condensed to produce a homogeneous root canal filling.

Right: The drawing illustrates the lateral deformation of the third gutta-percha point against the first two by the metal-colored spreader.



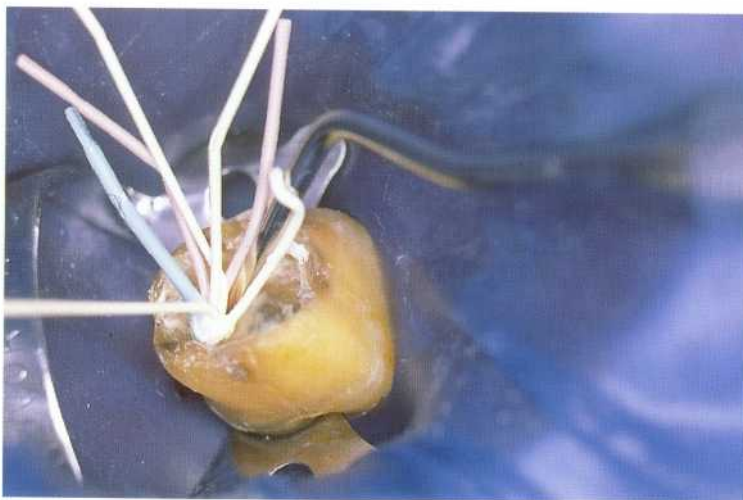

451 Radiograph during the condensation procedure
Before the coronal excess of gutta-percha is removed, the position and depth in the mesiobuccal canal can be checked by inserting a finger spreader and taking a radiograph. In this way corrections can still be made. The distal canal has already been completely and densely obturated.

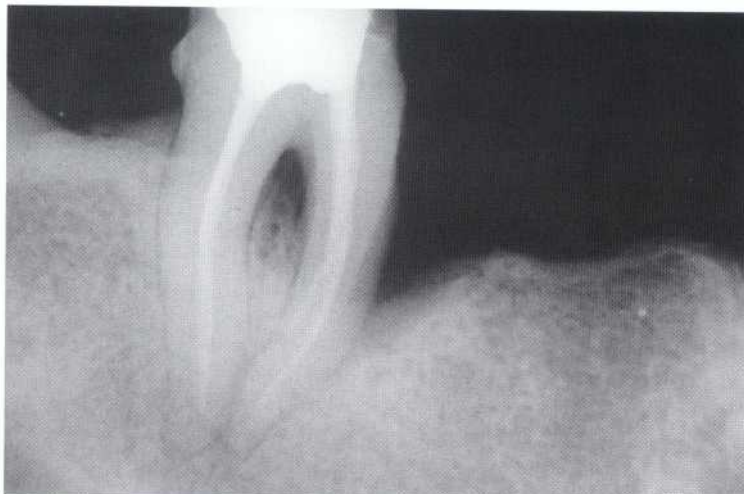
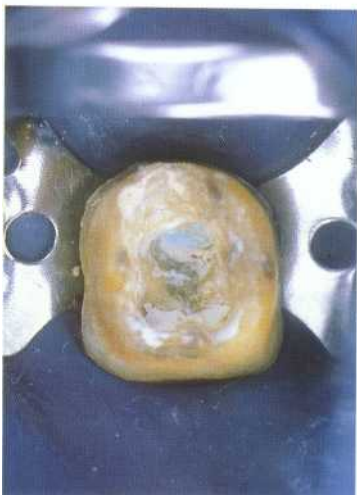
452 Homogeneity of the root canal filling
The cross-section shows the molding of the individual gutta-percha points into one homogeneous mass so that the proportion of sealer in the entire filling is less than 5%.

Left: The drawing illustrates the laterally condensed gutta-percha points. The white point fills the last space created by the spreader.



453 Removal of the excess gutta-percha from the crown
The gutta-percha protruding from the canals is removed with an excavator that has been heated in an alcohol flame.



454 Radiographic evaluation
The exact position of the root canal filling is evaluated in a radiograph. The periodontal condition appears to have become worse than it was initially. Periodontal surgery will follow the endodontic treatment.

Left: After the gutta-percha is separated, it is condensed vertically with a plugger.

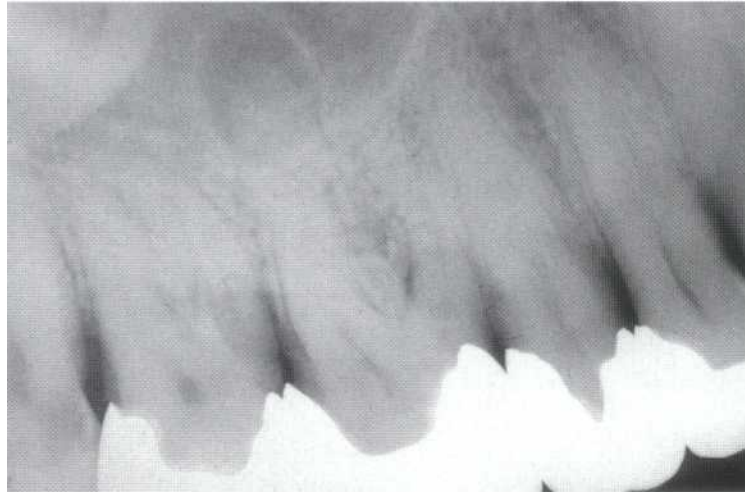Corrections During Condensation

Failure of the spreader to seat deeply enough when it is tried in the canal is usually an indication that the root canal does not have the correct shape. The form and taper must then be refined with prebent Hedstrom files. The cause could also lie in the wrong spreader size. If the condensing instrument binds in the midregion of the canal, then either the canal should be widened coronally with a Gates-Glidden drill or a smaller spreader should be selected. Wedge-shaped spreaders are contraindicated because of the danger of vertical tooth fracture (Lindauer et al. 1989).

The average force that can cause a fracture with a D-11 spreader is over 7.5 kg. This force fractured 3% of the teeth, whereas none were fractured during lateral condensation with forces of 1-3 kg (Onnink et al. 1994). Comparison of the apical density showed no difference when condensation was carried out with forces between 1 and 2.5 kg (Hatton et al. 1988). Root fractures occur when the dentin is overloaded because of local irregularities near the tip of the spreader (Telli et al. 1994).

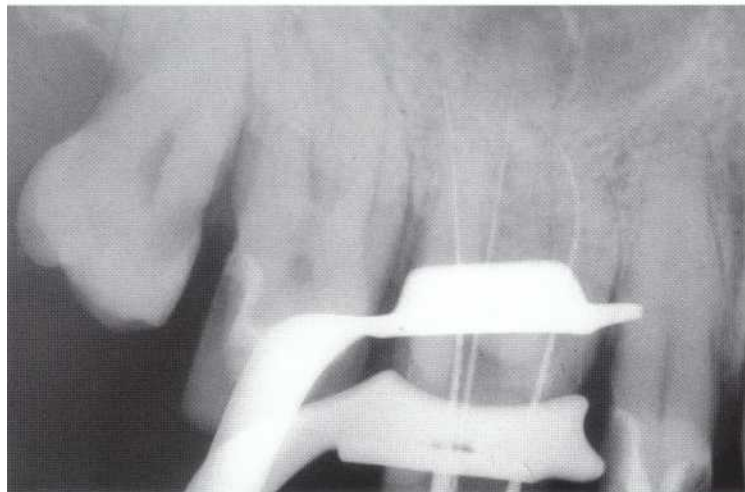455 Coronal enlargement
A maxillary molar with periapical radiolucency and a presumed resorption defect in the apical region of the palatal root.

Right: Before the deep preparation is begun, the coronal portion is enlarged with Gates-Glidden drills using the step-down technique.



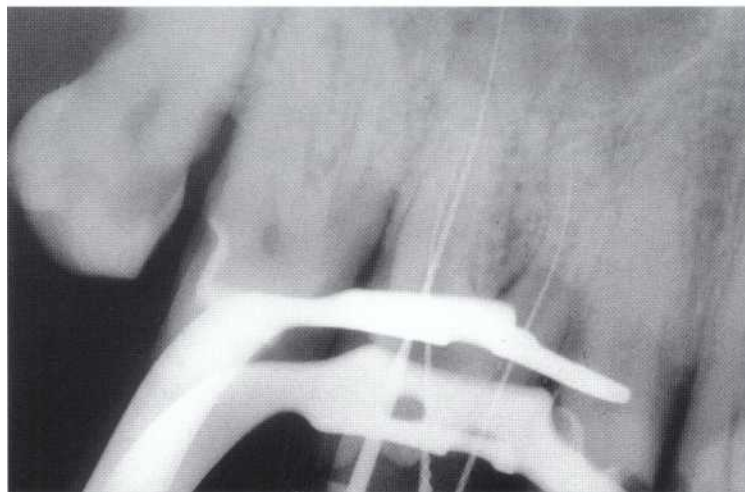456 Working-length radiograph
The first radiographic test of the working length with size 15 files. The working length has not yet been reached in the lingual canal.

Right: The root canals are further prepared coronally and then instrumented to the measured or corrected working lengths.



457 Working-length radiograph
If the working length has to be adjusted by more than 2 mm, an additional radiograph should be taken to verify the corrected length.

Right: The root canals are instrumented apically to the new working length using the balanced force technique.

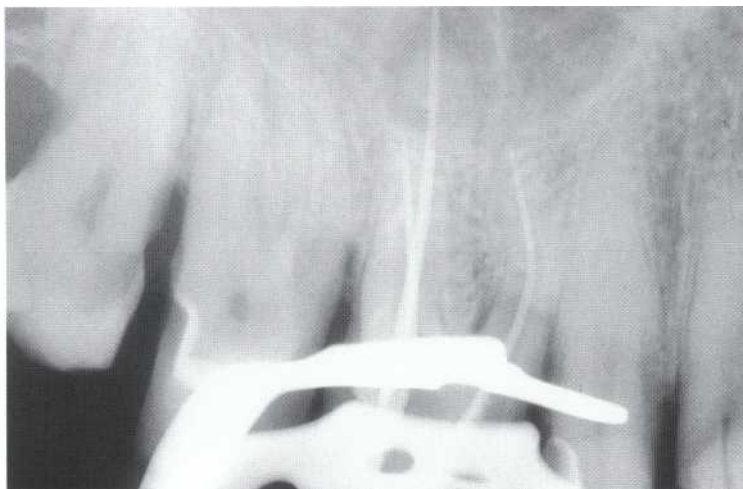
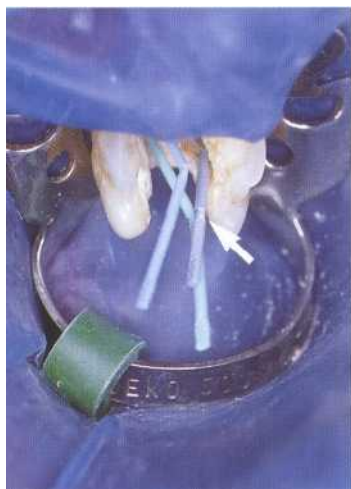
During condensation, the gutta-percha is not only deformed laterally, but also pushed apically as the spreader is inserted. Total elongation is indeed, small, with an average value of 0.29 mm reported by Yared and Dagher (1993). If an apical stop has been prepared there should be no overextension. This danger does arise, however, during vertical condensation and when there is an open apical foramen (Yared et al. 1992).

The usual causes of overextension of the gutta-percha filling are excessive instrumentation past the apical constriction, unexpected resorptive defects,

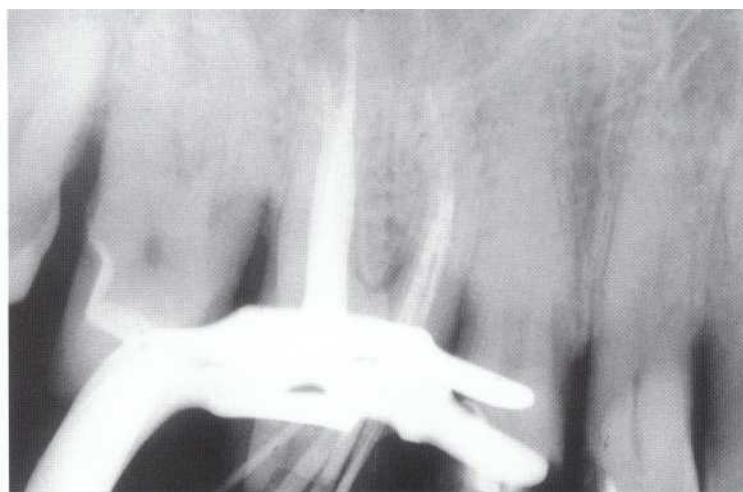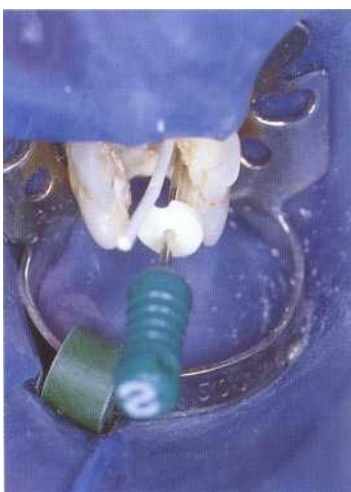iatrogenic defects such as perforations, zips and funneling, excessive force during condensation, and the use of gutta-percha points that are too small (Gutmann et al. 1991).

A radiograph of the master point is essential for evaluating its position and preventing overextension. Another radiograph can be taken during the condensing procedure for monitoring purposes.



458 Master point radiograph
Following completion of the root canal preparation the three gutta-percha master points are fitted and evaluated with another radiograph. The length of the lingual point must be reduced by 2 mm.

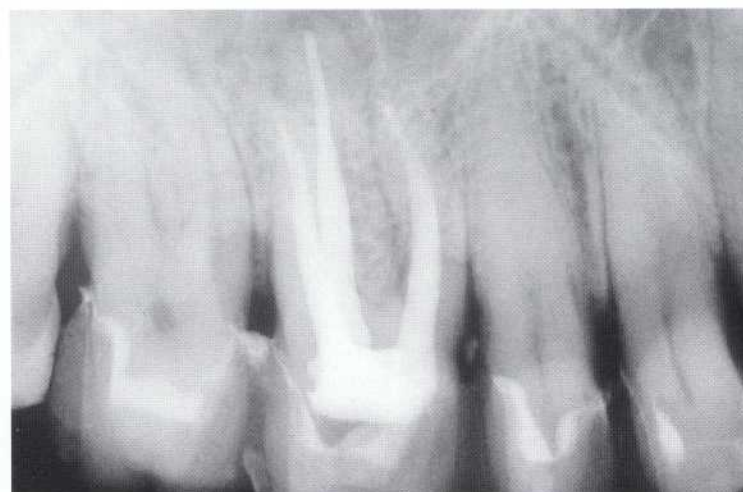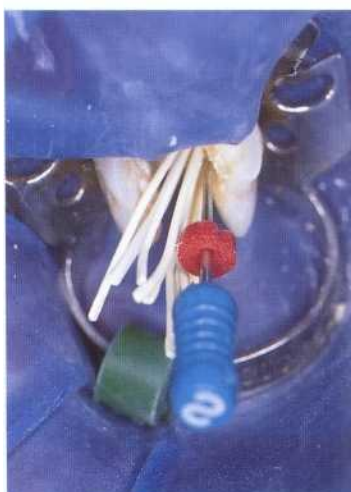
Left: The three master points correspond in size to the AMFs and are inserted into the canals to the length mark (arrow). A size 40 point is placed in the lingual canal.



459 Radiographic monitoring during lateral condensation
If concerned that the lingual canal might be overfilled, another radiograph can be taken after the first condensation with the spreader in place.

Left: A size 45 gutta-percha point, a size larger than the overextended point, is condensed with a finger spreader.

The overextended gutta-percha point is replaced by one a size larger (size 45), and the first condensation with a finger spreader is repeated.



460 Final evaluation
A radiograph of the completed root canal filling is taken to evaluate its homogeneity and apical seal. At this stage, corrections can be made only through complete retreatment.

Left: Lateral condensation of additional gutta-percha points in the lingual canal. The excess protruding from the tooth will then be removed.

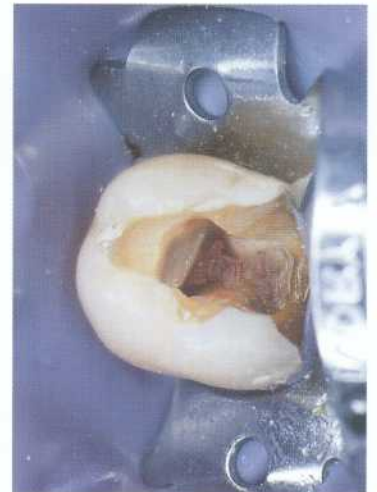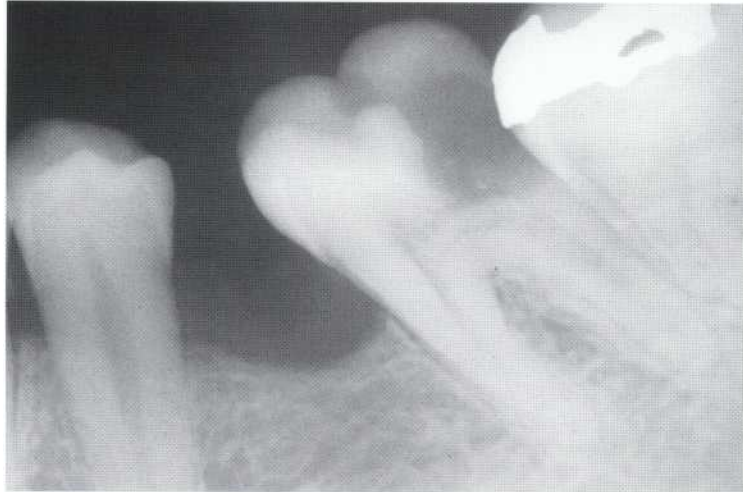
Gutta-percha Master Point Too Long

Root canal sealing cements are irritating to the tissues and can be resorbed, whereas gutta-percha is biologically inert. Because gutta-percha by itself does not adhere to the walls to form a hermetic seal, a sealer must be used with it. If gutta-percha and Grossman cement are overextended, the tissue reaction in most cases is slight: a circumscribed inflammatory reaction surrounds extruded particles of sealer, and a thin connective-tissue capsule with fibroblasts and scattered lymphocytes forms around the gutta-percha point (Beer 1989).

If overinstrumentation with enlargement of the apical constriction has occurred, the fitting of the gutta-percha master point must be given special attention. An advantage of the lateral condensation technique is that corrections are still possible during the condensation procedure. On the other hand, the danger of extruding pastes and cements into the periapical tissue with a spiral filler is relatively high (Kockapan 1993). Ehrenfeld et al. (1992) report that when the excess filling extended into the mandibular canal there was never full recovery in spite of microsurgical procedures.

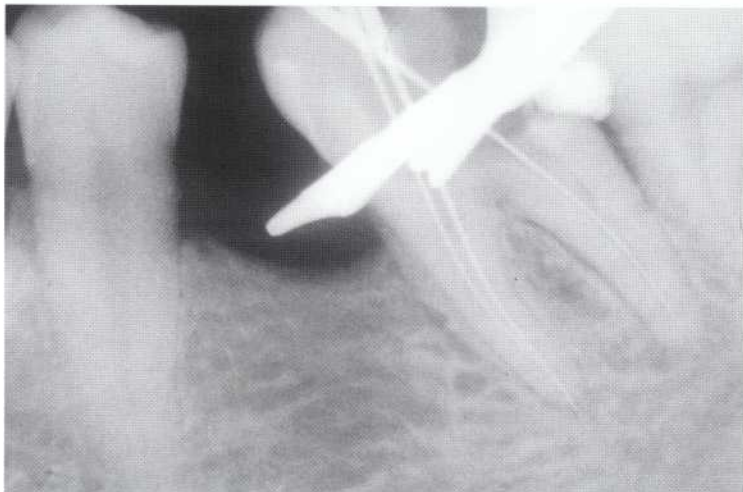
461 Presenting condition
A lower molar with carious pulp exposure, pulpal necrosis, and periapical radiolucency.

Right: With the rubber dam in place, an access opening is made, the caries completely excavated, and the dentinal roof removed. The canal orifices are then probed and enlarged.



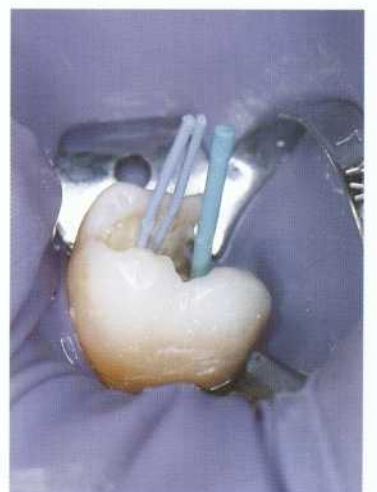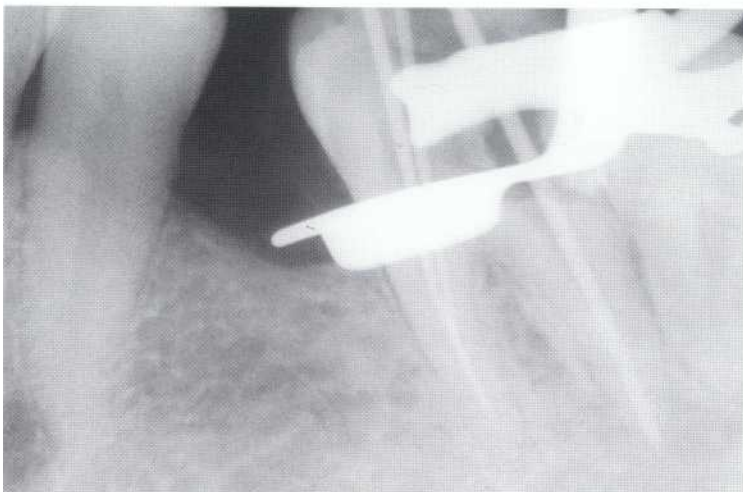462 Working-Length radiograph
After the pulp space is opened and enlarged coronally, the working length is estimated, checked with a radiograph, and adjusted if necessary.

Right: For better differentiation, different files are inserted in the three root canals.



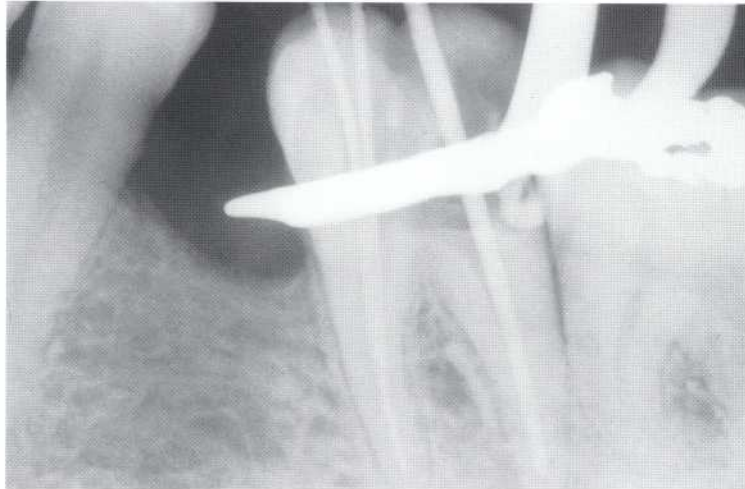463 Master point radiograph
The first working-length radiograph after instrumentation is completed shows the distal gutta-percha point to be overextended. Mesially the working length is too short and has to be corrected by additional instrumentation.

Right: The three gutta-percha points are inserted into the canals to their working lengths.



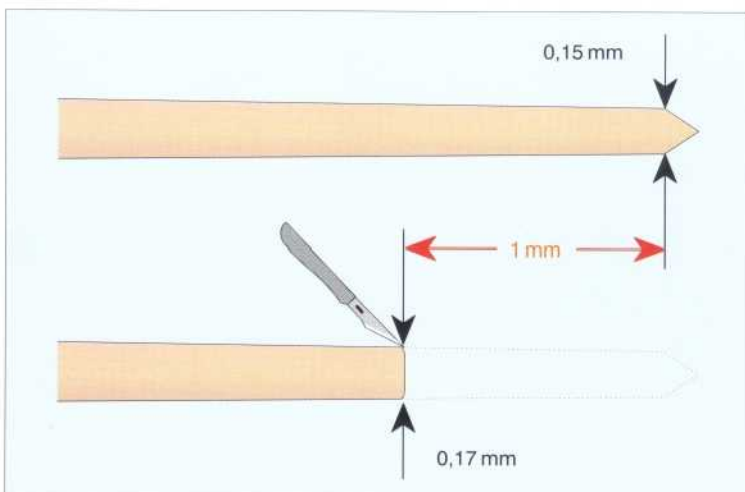
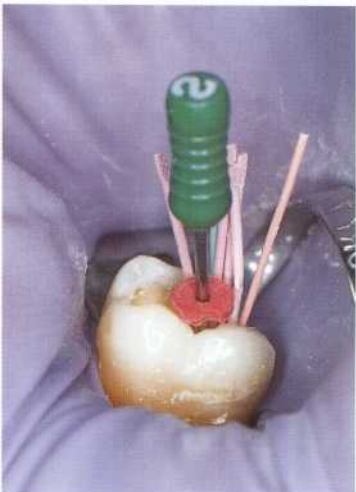
If the master point is too long it is shortened by 1 mm with a scalpel on a glass slab to leave a tip with a greater diameter. The cut end must then be smoothed by gentle rolling. Next, the gutta-percha point is dipped in a solvent and fitted to the shape of the individual root canal. The root canal must not be completely dry or else the gutta-percha point will stick to the canal wall as it is being fitted. The apical 5 mm of the gutta-percha point is softened by either 5 seconds in chloroform, 15 seconds in halothane, or 25 seconds in eucalyptol (Yancich et al. 1989), Smith and Montgomery

(1992). In only 1 second gutta-percha absorbs 0.35 mg of solvent, of which 62% will have diffused away after 3 minutes. Twenty percent chloroform remains on the surface of the point (Metzger et al. 1988). The point is inserted into the canal to the depth marked and after approximately 15 seconds it is removed again. After the canal is dried, the point is coated with sealer, reinserted, and condensed to a homogeneous, well-adapted filling (Moyer et al. 1995).



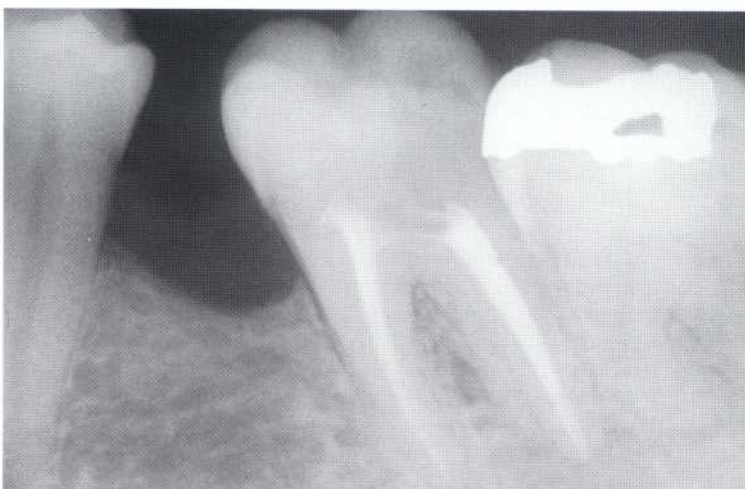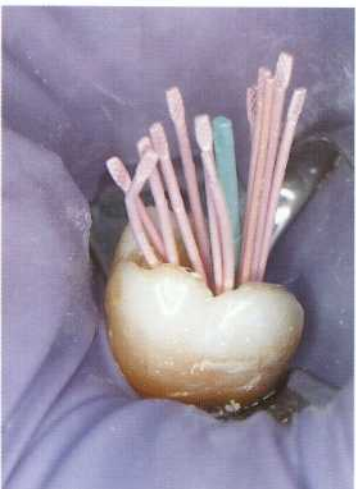
464 Master point radiograph
After shortening and customizing the distal gutta-percha master point and further enlarging the mesial canals, the second master point radiograph shows the three master points to be at the correct depth.

Left: After a gutta-percha point is dipped in eucalyptol its surface is softened (*right*), whereas it can be almost completely broken down by chloroform (*left*).



465 Length correction
Because gutta-percha points have a slight conical taper, an intermediate size can be made by trimming 1 mm from the tip of a standard point.

Left: Only the first gutta-percha point matches the size of the root canal. Noncustomized, standard points are then added and condensed laterally.



466 Gutta-percha filling
The final radiograph of the completed gutta-percha filling shows a well-adapted root canal filling. Comparison with the second master point radiograph shows that the filling in the distal root was slightly displaced apically during condensation.

Left: Laterally condensed gutta-percha points in the distal canal.

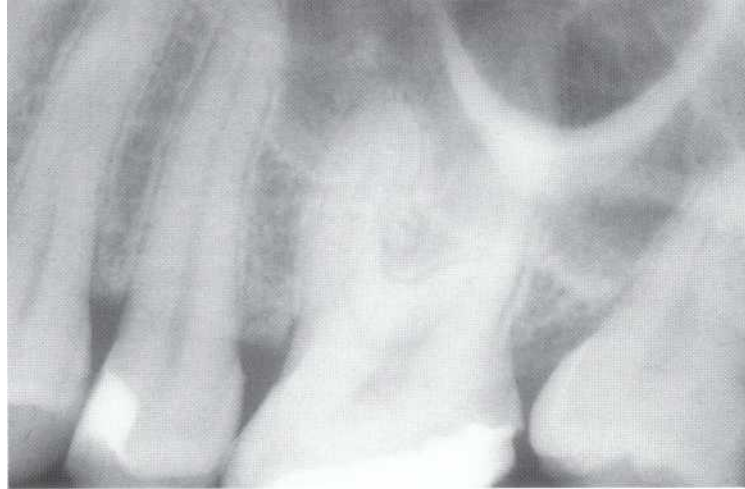Gutta-percha Master Point Too Short

If the gutta-percha master point does not extend to the full working length it usually means that dentin shavings have accumulated in the apical third of the canal and blocked it. Other causes are coronal step formation, a stepped transition from the middle to the apical canal section, flattening of the canal curvature with creation of either an apical enlargement or a false path, or the gutta-percha point itself possibly being too thick. A blockage can be removed with twisting movements of a Hedstrom file and RC-Prep (Beer and Baumann 1994).

Acids and chelating agents can be used to help get through obliterations and blockages. However, the introduction of RC-Prep to overcome an obstruction can have a negative influence on the root canal filling and its seal. Apparently some EDTA can remain on the surface of the canal and in the tubules and in the course of time reduce the seal of the root canal filling (Cooke et al. 1976). If, on the other hand, the canal is rinsed intermittently with sodium hypochlorite and Salvizol, no difference in the seal can be detected (Biesterfeld and Taintor 1980).

467 Initial situation

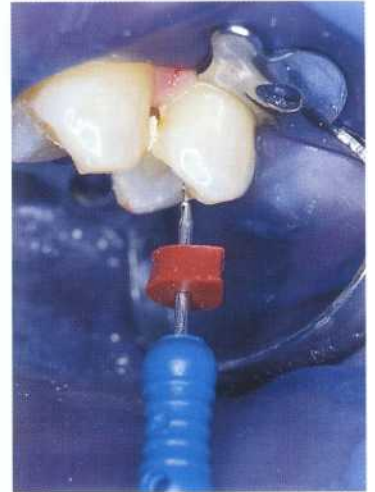
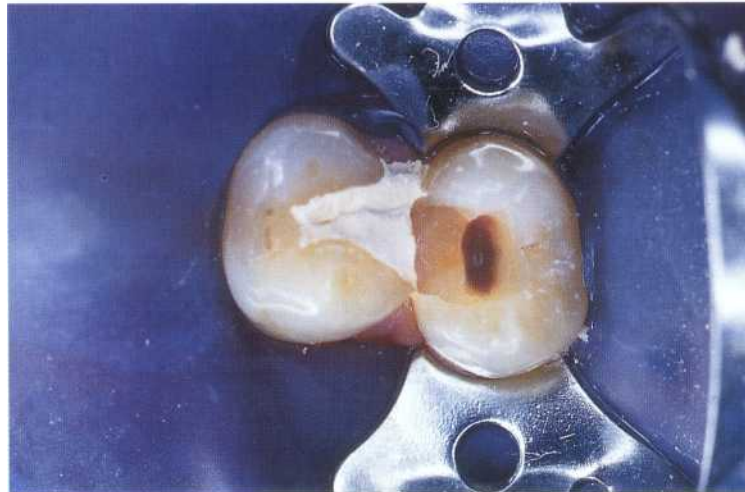The patient suffered indistinct discomfort in the maxillary posterior region, seemingly originating in the second premolar, that had a deep resin filling with secondary caries. The molar lying distal to it was subsequently extracted because of a fracture.



468 Access opening

The filling and caries are removed, an access opening made, and the coronal segment of the canal enlarged.

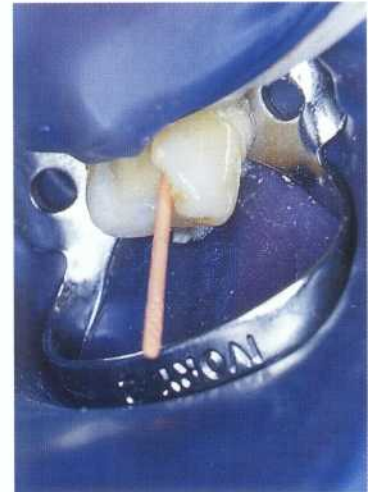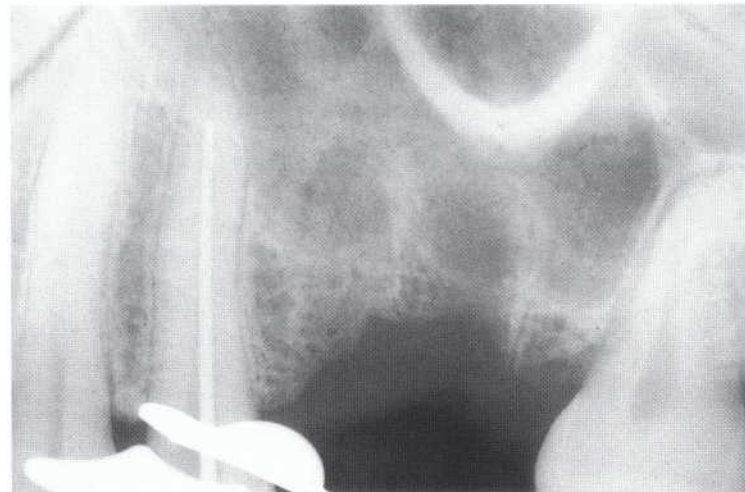
Right: During instrumentation of the root canal a blockage by dentin shavings is encountered so that the Hedstrom file cannot be inserted to the calculated working length.



469 Master point radiograph

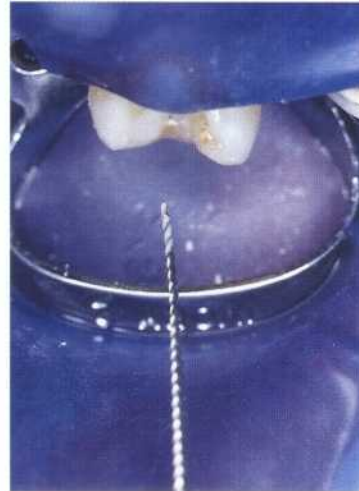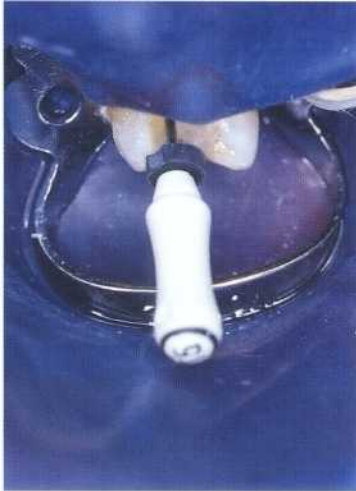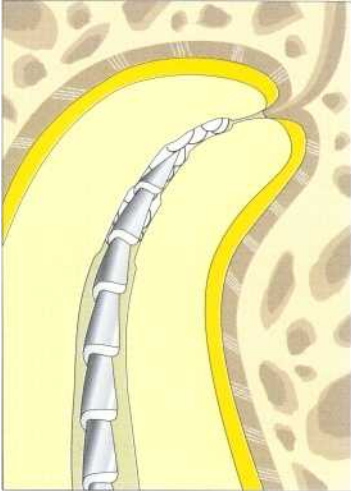
The gutta-percha point fails to reach the desired working length. It is still short of the apical constriction by 2.5 mm due to an obstruction in the apical region.

Right: The gutta-percha master point shown in the canal is removed.



Rinsing the root canal with acid or a chelating agent enhances penetration of sealer into the adjacent dentinal tubules (White et al. 1987). Injected gutta-percha also better penetrates the tubules after removal of the smear layer (Gutmann 1993, Gencoglu et al. 1993). Interestingly, Vassiliadis et al. (1994) found that Grossman cement was forced up to 300 µm into the dentinal tubules even when a smear layer was present. Therefore the smear layer did not prevent penetration of sealer into the tubules.

An accumulation of dentin shavings is caused by improper rotation of the K file and by inadequate irrigation with sodium hypochlorite solution. The dentin particles can be loosened with Hedstrom files and a chelating agent, and removed by thorough irrigation. Next, the full working length must be instrumented once more with the AMF and the canal enlarged and tapered through circumferential filing. The canal is recapitulated with the small H file, and the gutta-percha point is then fitted (Gutmann et al. 1991).

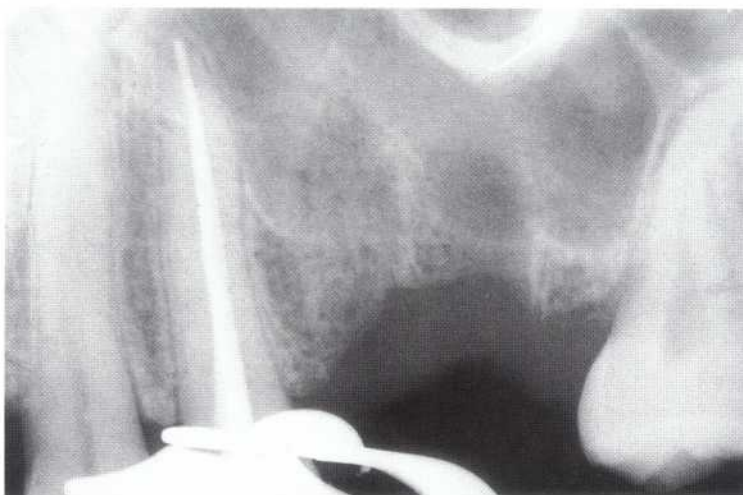

470 Overcoming the obstruction

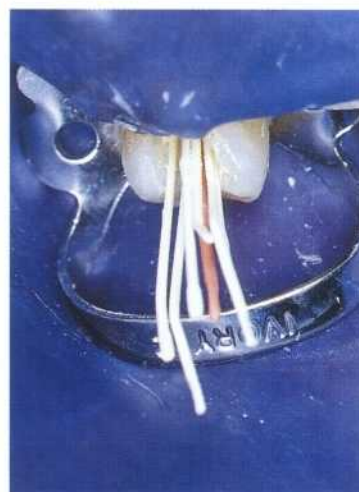
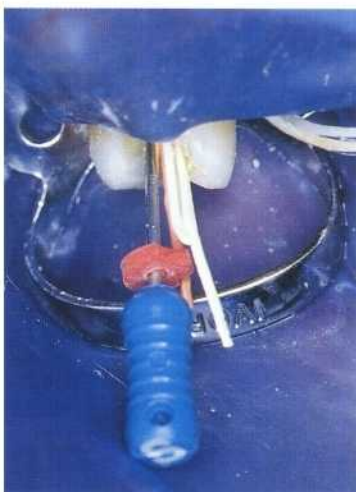
Left: The Hedstrom file penetrates into the compacted particles of dentin and loosens them.

Center: The dentin chips are loosened with a Hedstrom file using gentle rotational movements.

Right: After the desired additional depth is gained, the AMF is used to remove the dentin shavings and to shape the apical segment of the root canal.



471 Radiographic monitoring during the obturation procedure. The canal is dried and the master point fitted again. During the second condensation procedure the position of the root canal filling is evaluated on a radiograph with the spreader inserted.



472 Root canal obturation

Left: A third standardized gutta-percha point is shown being laterally condensed against the first two points.

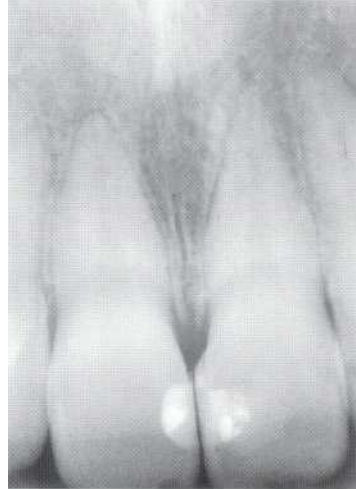Right: The root canal obturation is completed by incorporating additional size 15 and 20 gutta-percha points. Then, after removal of the excess gutta-percha, the access cavity is closed.

Thermomechanical Condensation

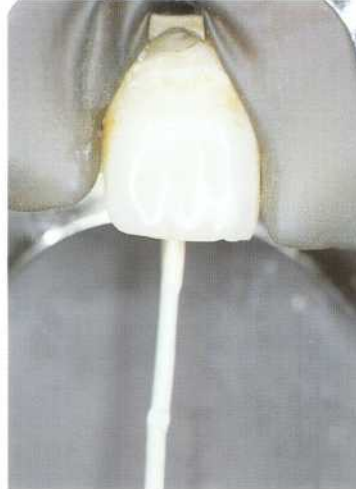
A compactor in the form of a reverse Hedstrom file running at 8000 rpm is inserted with light force parallel to the gutta-percha master point that has been coated with sealer and placed into the canal. The rotating compactor heats and condenses the gutta-percha and is withdrawn while still rotating. Some disadvantages of this filling method are nonuniform heating of the gutta-percha resulting in spiral-shaped sections of condensation, as well as abrasion of dentin from the canal wall. In comparison, the lateral condensation technique produces more homogeneous fillings (Wong et al. 1981).

Tagger et al. (1983) reported no difference between the thermomechanical and the lateral condensation methods in their ability to seal the root canal. A hybrid technique, in which the master point is first condensed laterally and then thermomechanically, was shown in a dye penetration test to produce a better seal than lateral condensation alone. However, the dangers of instrument fracture, overfilling, void formation, and incomplete canal obturation have limited its use (Beer et al. 1986 a).

473 Introduction of the gutta-percha master point
Left: The straight root canal of the maxillary right central incisor is enlarged and tapered.

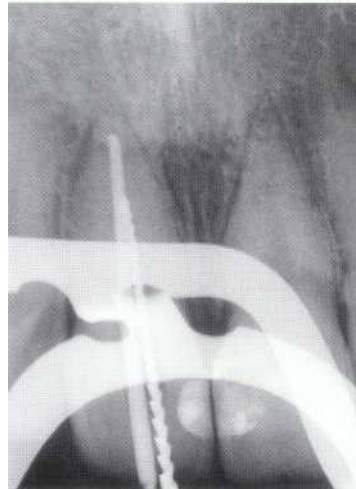

Right: A gutta-percha master point equal in size to the AMF is tried and measured, then coated with sealer and inserted into the prepared root canal.

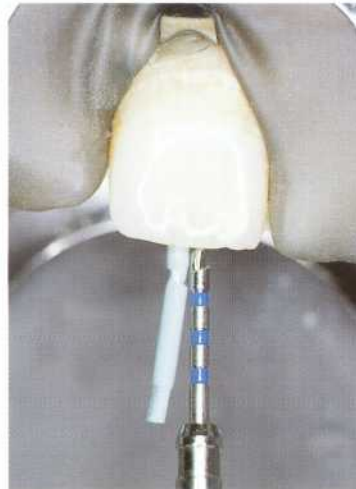


474 Thermomechanical condensation

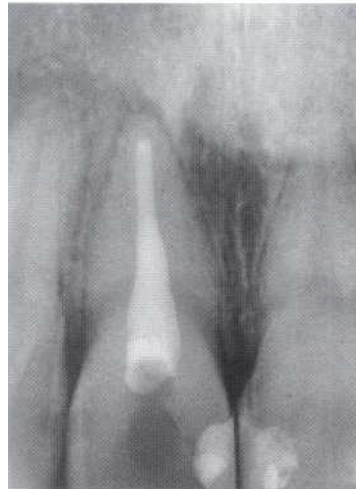Left: The rotating compactor is inserted with light pressure along the canal wall until it is approximately 2 mm short of the working length.



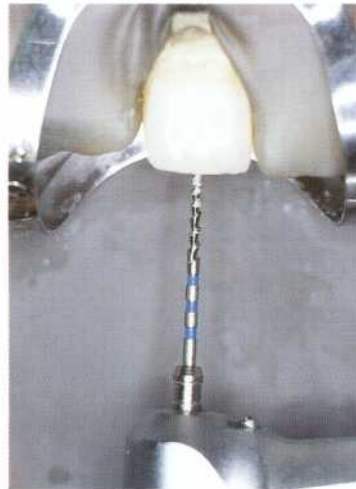Right: After 2-3 seconds, a definite resistance is felt. This signifies that the gutta-percha has become heated and forced farther into the canal.



475 Removal of the compactor
Left: A very homogeneous root canal filling is seen on the radiograph. If an apical stop has been prepared, the danger of overfilling is minimal.



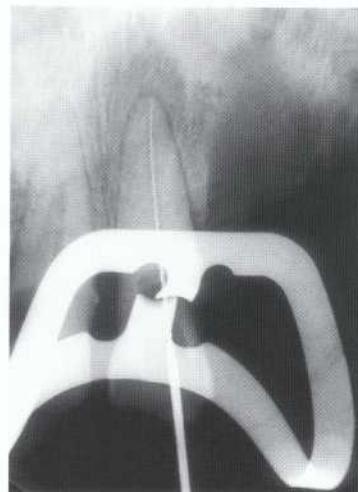
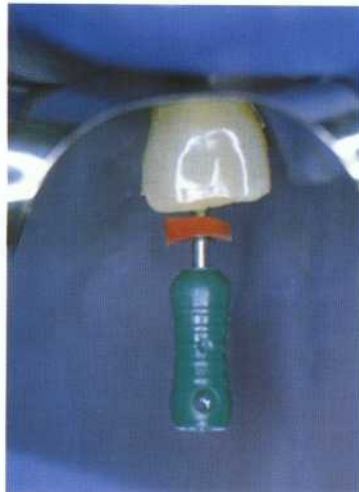Right: The still-rotating compactor is slowly withdrawn from the root canal as it compacts the gutta-percha.



Thermafil

By using the Thermafil system, root canals can be filled with gutta-percha with much less time and effort. This system uses standardized plastic points that are coated with a-gutta-percha. The gutta-percha is softened by heating and the root canal can then be obturated in one step. However, canals that are enlarged to size 25 are frequently underfilled, and while the point almost always reaches the apex after instrumentation through size 35, overfilling often results (Chohayeb 1993).

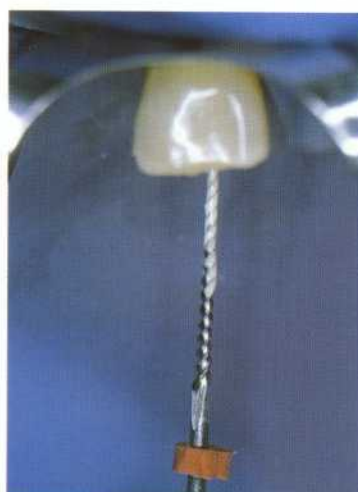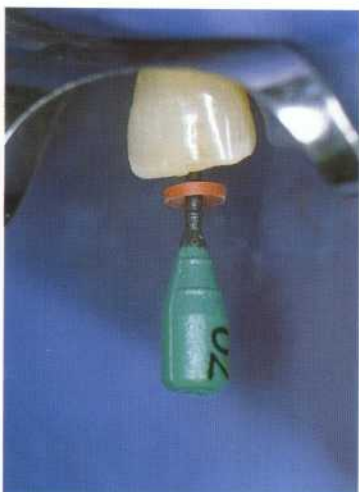In the study by Clark and E]Deeb (1993) overfilling occurred more frequently with the Thermafil technique than with lateral condensation. Furthermore, the Thermafil fillings were less dense (Chohayeb 1992, McMurtrey et al. 1992). Gutta-percha tends to be partially stripped from the point during insertion so that the plastic carrier point comes into direct contact with the periapical tissue (Juhlin et al. 1993).



476 Enlargement and fitting
Left: Special oven for warming the gutta-percha-coated Thermafil points.

Center: Instrumentation of the straight root canal is carried out with hand-held instruments through size 70.

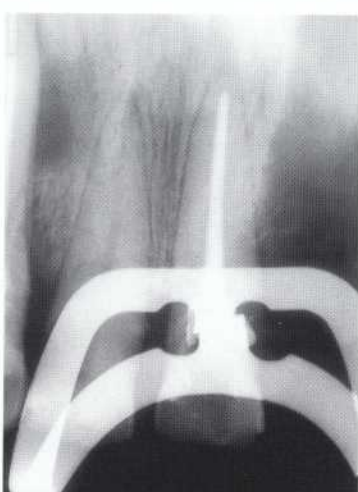
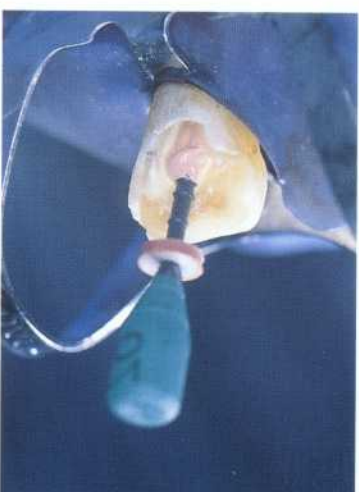
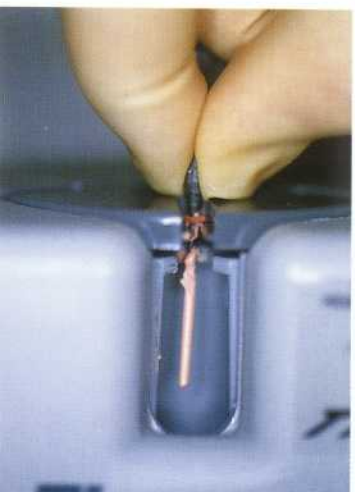Right: The working length is checked with a radiograph.



477 Thermafil obturation
Left: Special synthetic resin points coated with gutta-percha. Before they are used, the gutta-percha is heated to make it plastic.

Center: The root canal preparation is evaluated with a carrier point that is not coated with gutta-percha.

Right: Sealer is conveyed into the dried root canal by means of a K file rotated counterclockwise.



478 Separation and radiographic evaluation
Left: A Thermafil point is heated in the oven immediately before it is used.

Center: The Thermafil point is inserted in the root canal to the depth marked by the rubber stop. The plastic carrier is then cut off at the level of the canal entrance with a long-shank diamond stone.

Right: The final radiograph shows a filling that is somewhat short, but

Thermoplastic Injection Technique

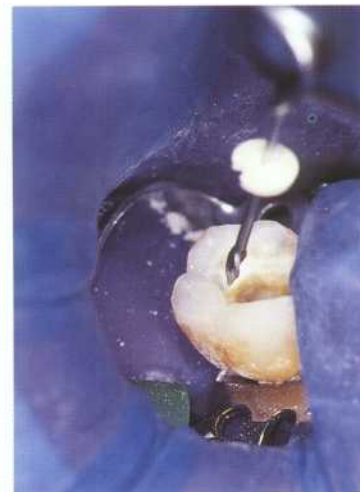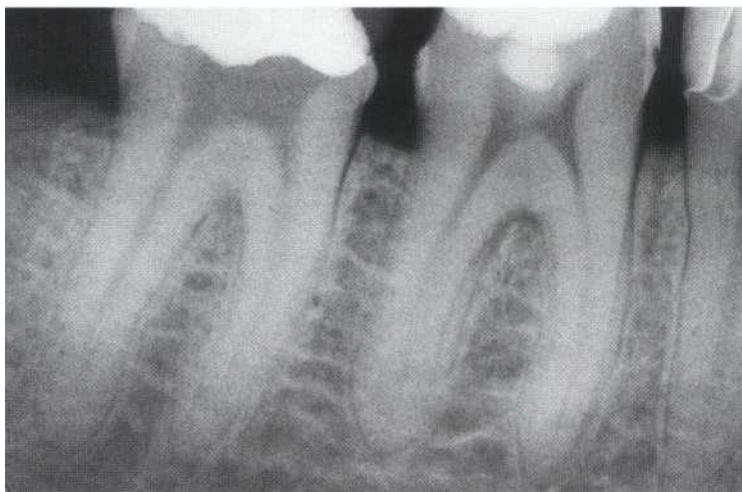
The Ultrafil system was presented in 1984 by Michanowicz and Czonstokowsky: gutta-percha heated to 70 °C (158 °F) is injected into the root canal by means of a Peripress syringe, and is supposed to fill all ramifications. Ampules containing gutta-percha are heated for 15 minutes in the apparatus to plasticize the gutta-percha. Gutta-percha is provided in three compositions that differ in their fluidity and hardening time. A short cannula with a diameter of 0.7 mm is attached to each ampule.

It is recommended that the middle third of the canal be instrumented through size 70 so that the injecting cannula can be inserted adequately (Heidemann and Ramil-Diwo 1993). In the Trifekta technique, warm gutta-percha is rotated into the canal with a K file and condensed vertically with a plugger. During the subsequent injection, care must be taken to ensure that gutta-percha flows continuously through the injection cannula. The cannula is pushed passively out of the root canal by the gutta-percha exiting through the tip.

479 Instrumentation

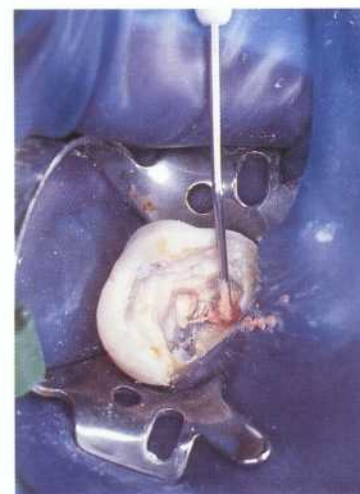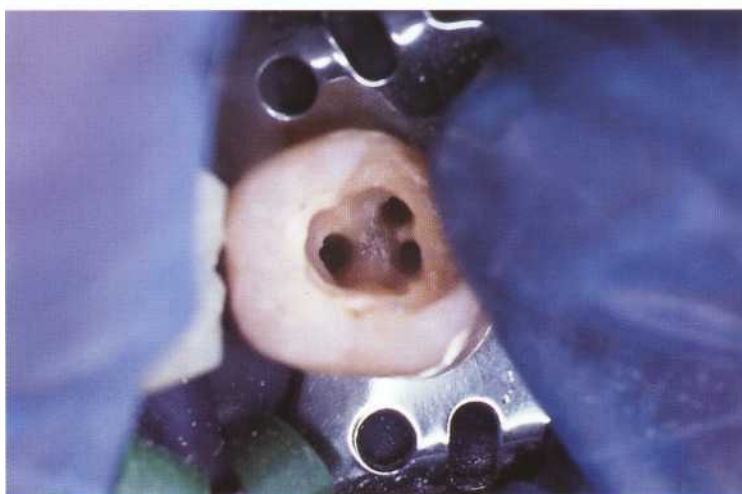There is irreversible pulpitis in the mandibular second molar. First, the coronal portion of the root canal is enlarged, then the apical portion is enlarged to size 30.

Right: To ensure penetration of a 0.7-mm-thick cannula to an adequate depth, the coronal portion requires additional enlargement after the apical instrumentation.



480 Insertion of the cannula

The root canals are thoroughly irrigated and dried. Their cross-sections are almost round because of the final instrumentation with engine-driven instruments.



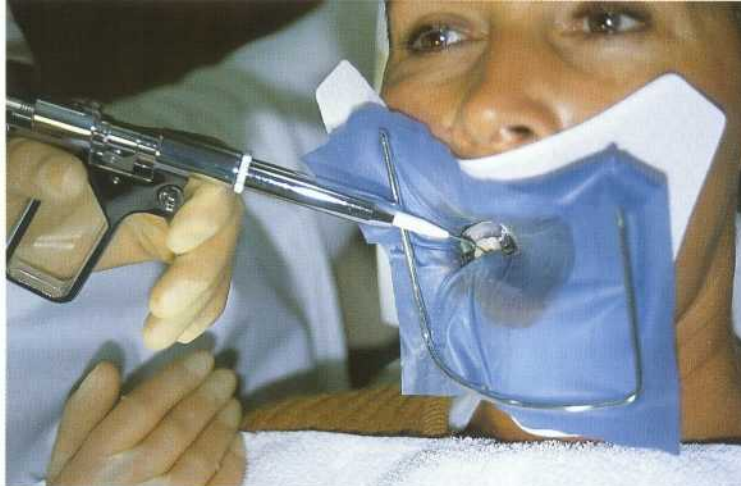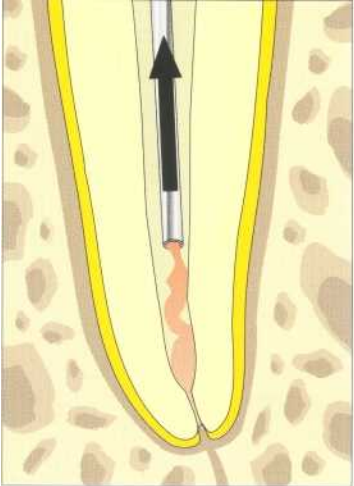
481 Ultrafil set

The Ultrafil filling system uses ampules that contain gutta-percha of different viscosities and hardening times. The more rapidly the gutta-percha hardens, the greater is the possible contraction during the cooling phase. As soon as 5 minutes after injection, distinct separations from the canal wall occur and these can be only slightly reduced through vertical condensation (Capurro et al. 1993).



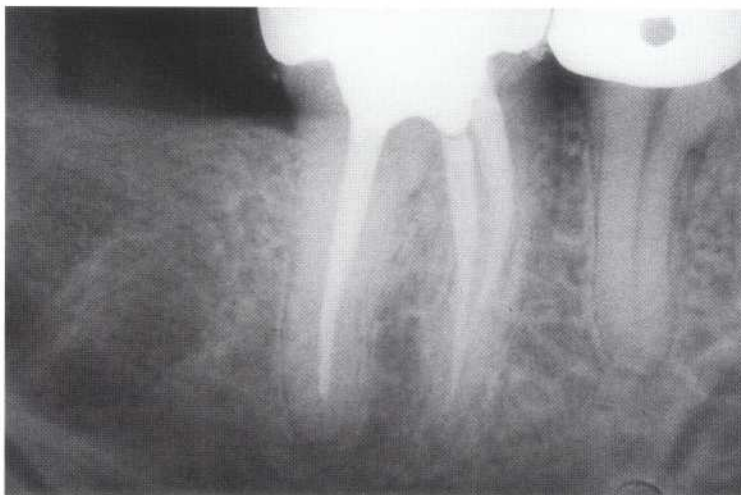In dye penetration tests on extracted teeth, signs of a poor seal were found in 23% of the canals filled with the Ultrafil regular gutta-percha, but in only 11.8% of canals filled with Ultrafil Firm. Use of a sealer did not significantly improve the results. In contrast, all canals filled using lateral condensation and a sealer were well sealed (Rata et al. 1995). The study by Hulsmann and Meinert (1994) also found the performance of the Ultrafil system significantly inferior to that of lateral condensation (dye penetration 2.1 mm versus 0.15 mm).

Similar results were obtained with Trifekta fillings (1.1 mm versus 0.5 mm for lateral condensation; Goldberg et al. 1995). Thermoplastic injection more often leads to either overfilling or underfilling and to non-homogeneity in the body of the filling. The extrusion of gutta-percha past the apical foramen depends upon the size of the canal. Canals prepared through size 40 were overfilled with 1.94 mg more gutta-percha than those instrumented only through size 20 (0.53 mg; Ritchie et al. 1988).

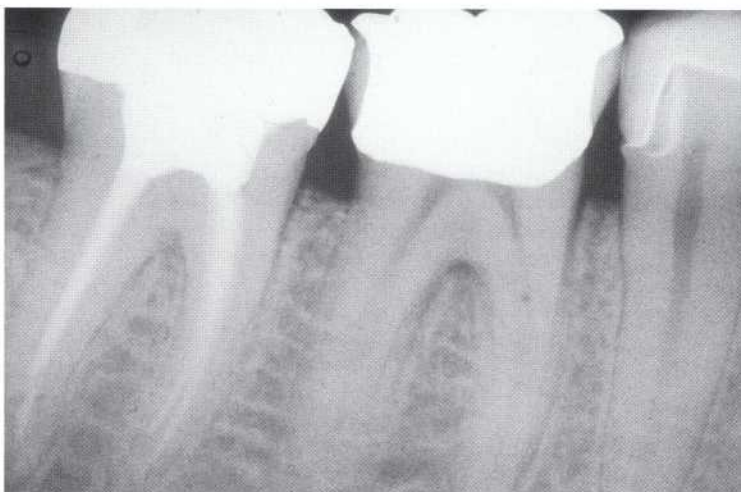

482 Gutta-percha injection
The gutta-percha is injected with a modified Peripress syringe.

Left: As the gutta-percha is injected, its pressure "floats" the cannula passively out of the root canal. It is not possible to monitor the penetration of the gutta-percha during the filling procedure so that underfilling is possible.



483 Radiographic evaluation
The radiograph shows a satisfactory root canal filling. Overfilling has been avoided by heavy coronal enlargement combined with lighter apical instrumentation and preparation of an apical stop.



484 One-year recall
The follow-up radiograph taken after 1 year reveals no periapical irritation. A dentist familiar with the injection technique can produce satisfactory gutta-percha fillings with it. The radiograph, of course, tells us nothing about any physical changes that may take place within the gutta-percha after it is applied.

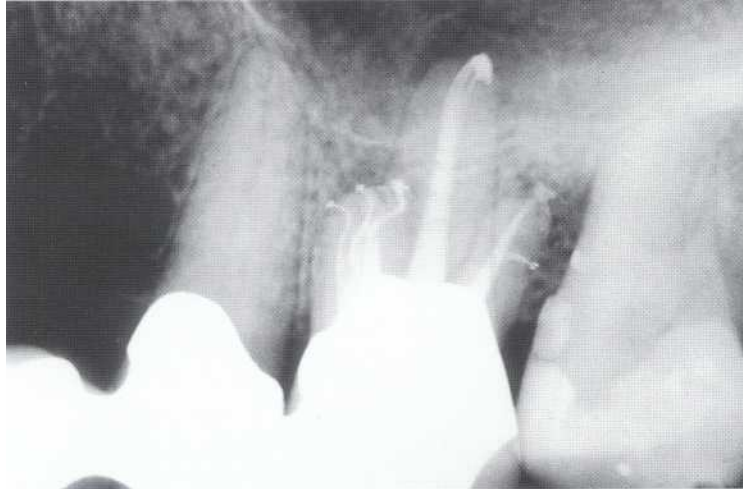
Three-Dimensional Gutta-percha Fillings

The root canal system contains lateral canals that communicate with the periodontal tissue in the furcation or at the apex (Hess 1925 a, b; Scianamblo 1977). Every exit from the root canal is to be regarded as a possible route for decomposition products where there is a necrotic pulp (Ruddle 1989). The tendency for periodontal lesions of endodontic origin to heal depends upon a number of factors, including complete filling of the root canal system in three dimensions. A technique to accomplish this was presented in 1967 by Schilder.

Walton and Langeland (1978) demonstrated the biological importance of the root canal filling to the organism as a whole. In an animal study, pulp tissue was removed from the coronal pulp chamber, sealer was placed over the pulp stumps, and the cavity was sealed. After 40 days particles of sealer were found in the lymph nodes. The systemic distribution of resorbable cements was also demonstrated by Block et al. (1983). They observed particles of radioactively marked sealer not only in lymph nodes but also in the kidneys and livers of experimental animals.

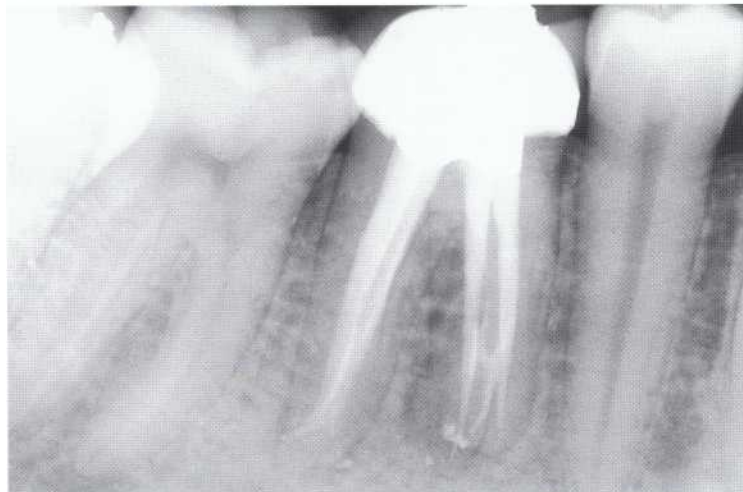485 Three-dimensional root canal filling

Postoperative radiograph of a maxillary first molar with a three-dimensional filling of the complex root canal system. Vertical condensation produced a slight overfilling with gutta-percha that, unlike sealer, is biologically inert and therefore tolerated by the tissues.



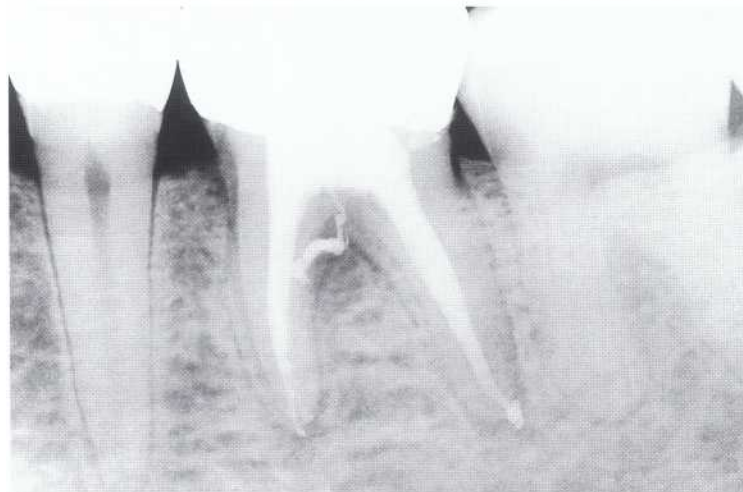486 Filling of lateral canals

Radiograph taken after vertical condensation in the root canal system of a mandibular first molar with four root canals, anastomoses between the main mesial canals, and apical ramifications, all of which have been filled with gutta-percha.



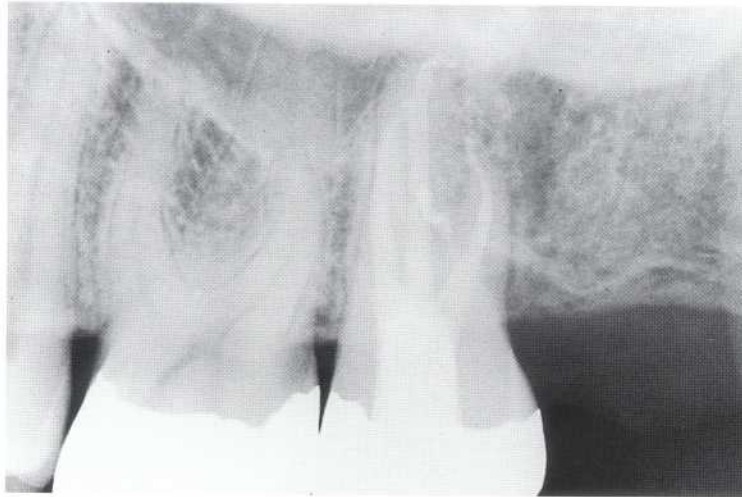
487 Periodontal lesion

Radiograph of a root canal filling in a mandibular first molar. The connection of the root canal to the periodontal lesion reveals the endodontic origin of the periodontal lesion caused by bacterial toxins.



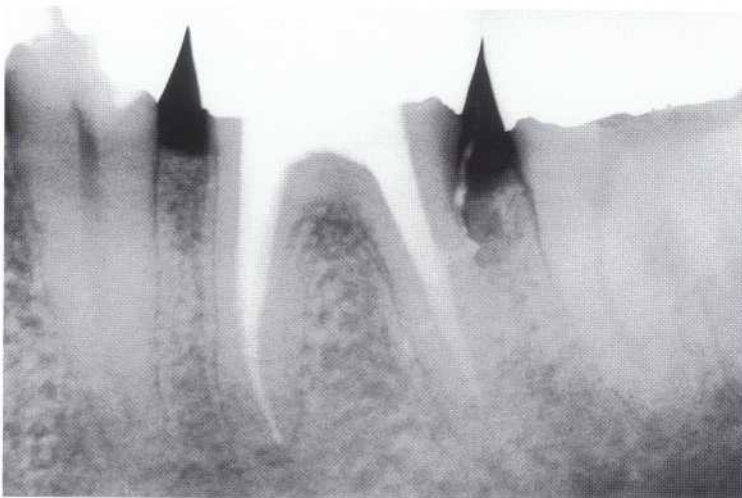
It is possible to produce a three-dimensional bioinert root canal filling by heating a gutta-percha point within the canal. The gutta-percha conducts the heat for 4-5 mm into the root canal where it can be condensed. By repeated heating of the gutta-percha to 40-45 °C (104-113 °F) the point can be plasticized all the way to its apical end. As it is cooling down to 37 °C (98.6 °F), it is condensed vertically with a plugger. This adapts and stabilizes the gutta-percha in all three dimensions and fills even the lateral canals (Goldman et al. 1971).

Although anatomic features, such as multiple canals, can be correlated with the occurrence of endodontic failures, operator errors such as incomplete cleansing, shaping, and obturation of the primary canals are the most frequent causes of failure. For this reason, Scianamblo (1993) recommended that all root canal systems be filled to the radiographic apex. In a clinical study by Morse and Wilcko (1980) it was shown that 97.9% of large periapical lesions became filled with bone after condensation with biologically inert gutta-percha.



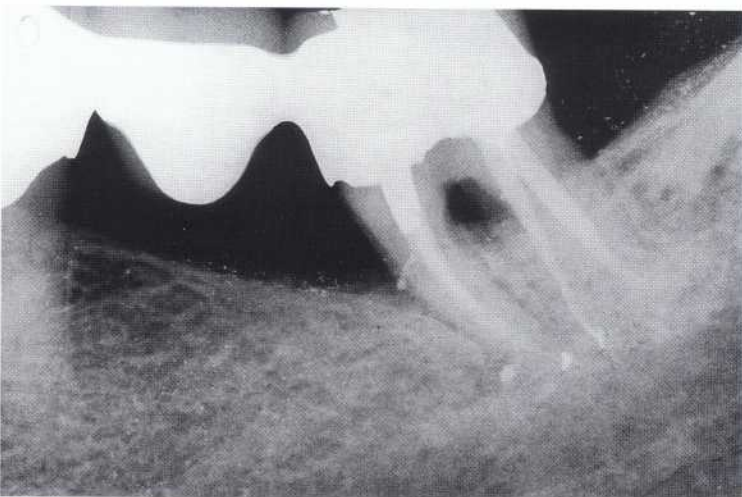
488 Obturation of curved root canals

The maxillary second molar has a dense filling of the entire canal system. The sharp mesial curvature of the distobuccal root presented no obstacle to a complete filling. An accessory canal filled with gutta-percha can be seen in the furcation.



489 Periodontal pocket formation

Postoperative radiograph of a mandibular first molar. There is a filled lateral canal on the distal that communicates with the periodontal lesion. The excess extruded gutta-percha can be removed by scaling.



490 Obturated tooth with a perio-endo lesion

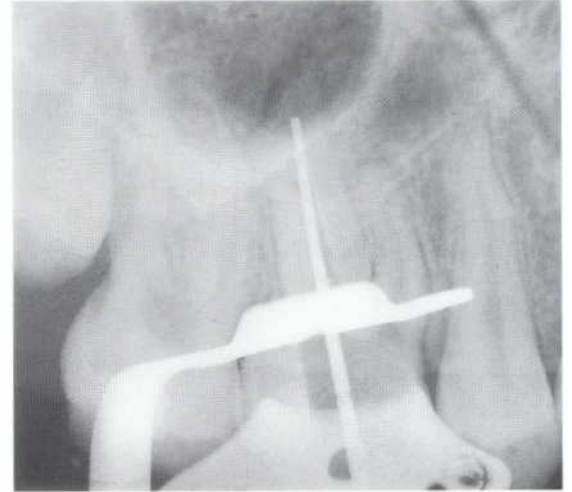
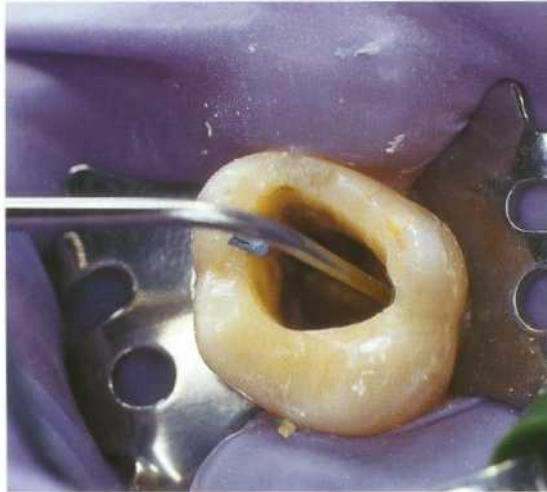
A mandibular second molar bridge abutment with a furcation problem that has been stable for 10 years. The two lateral canals in the mesial root are evidence of a combined periodontal and endodontic problem.

Vertical Condensation: Part I

The armamentarium consists of a plugger set of nine instruments. The diameter of the size 8 instrument is 0.4 mm, and each increase in size through size 12 represents an increase in the diameter of 0.1 mm. The pluggers are marked at 5-mm intervals so that the depth of insertion into the root canal can be monitored. Three pluggers are used that are slightly smaller than the diameter of the prepared root canal at three different depths. The smallest plugger should reach to a point 4-5 mm from the apical foramen without binding in the canal. In the coronal third the thickest plugger must be

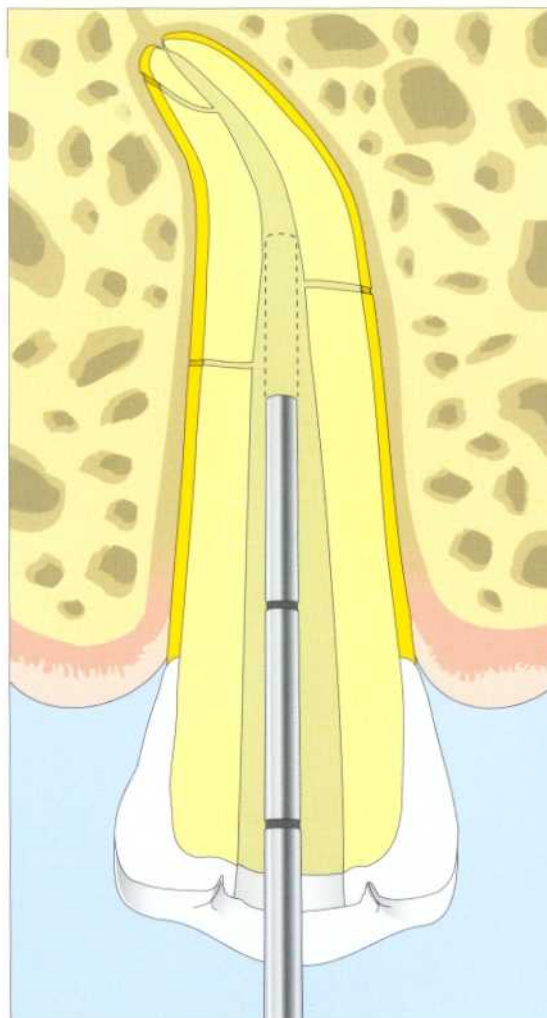
able to work without resting against the canal wall. An intermediate-sized plugger is selected for the middle third of the canal. The pluggers are selected before the master point is fitted and the canal dried. A spreader heated over an alcohol flame can be used to heat the gutta-percha. Better, however, are heating devices such as the Touch'n-heat 5004 (Analytic Technology) that heats the gutta-percha within the canal to a maximum of 45 °C (113 °F), thereby plasticizing it in stages (Ruddle 1993).

491 Trial insertion of pluggers
 Left: A thick plugger is inserted into the junction of the coronal and middle thirds without touching the canal walls. A plugger one size smaller is inserted to the midcanal region, and an even thinner plugger is introduced to approximately 4-5 mm from the apical foramen.



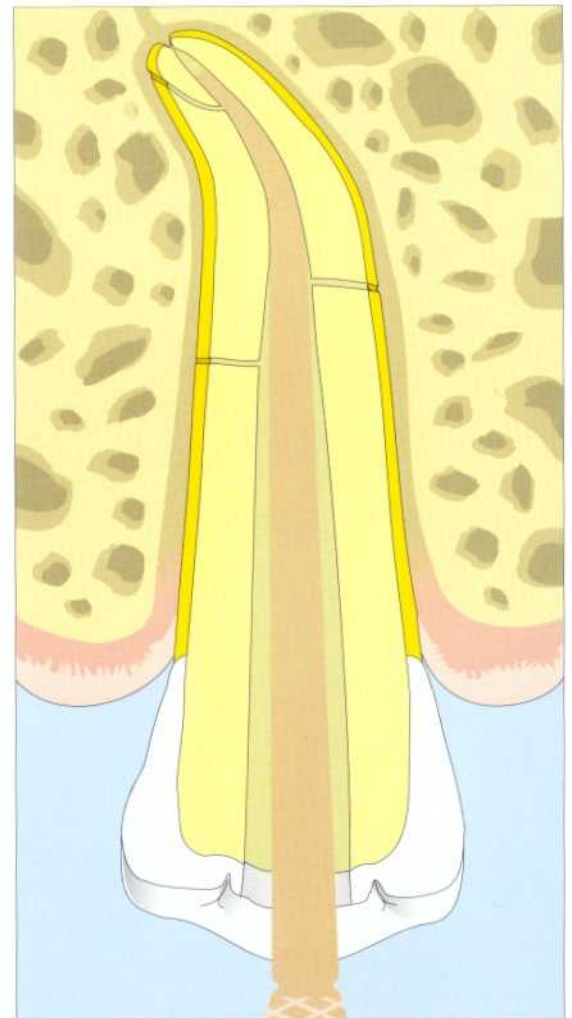
Right: The expected insertion depth of the thinnest plugger can be checked with another radiograph.

492 Trial insertion of plugger and master point
 Left: The thinnest plugger should extend as far as the apical curvature without scraping against the canal wall. The distance to the apical constriction should be no more than 4-5 mm. A middle-sized plugger should reach the middle third of the canal passively. The length can be marked either with a rubber stop or by noting its relation to the length marks on the surface of the plugger.



Selecting the correct plugger ensures that during the condensation procedure the instrument presses only against the plasticized gutta-percha and does not hang up against the thin canal wall. Otherwise, further vertical condensation is not possible.

Right: The gutta-percha master point is made 0.5 mm short of the apical constriction, coated with sealer, and inserted into the canal.

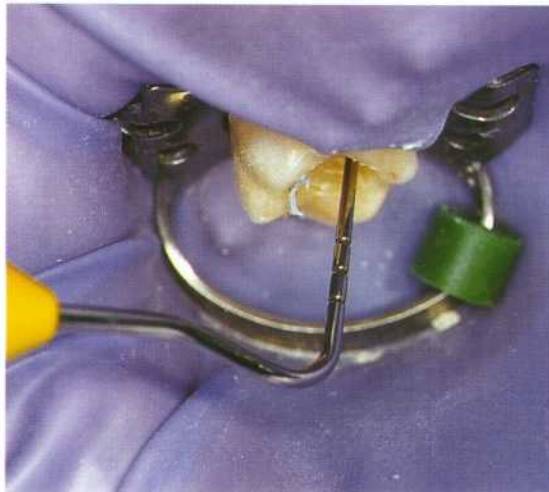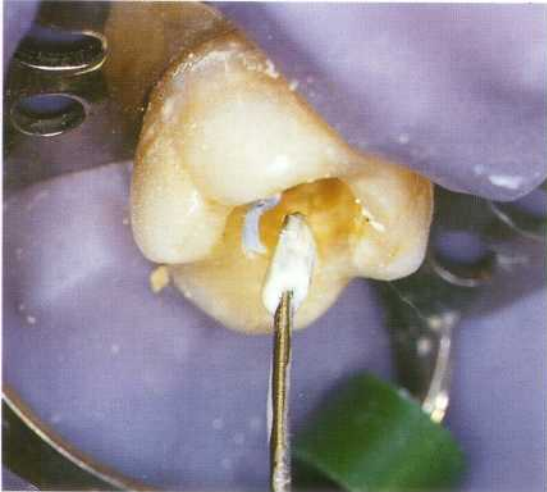


After instrumentation is completed a tapered, non-standardized, medium-sized gutta-percha point, corresponding to the shape of the tapered root canal preparation, is selected. This master point is tried in the canal and its length is checked with a radiograph. As the point is withdrawn, a slight resistance, or "tug back" at its apical end should be felt. Before the final insertion of the gutta-percha point, 0.5 mm is cut from its tip.

The last K file used is covered with sealer and placed into the root canal to the working length. For vertical condensation, Kerr sealer is recommended

because it hardens within 30 minutes, and in a comparison with 27 other sealers it had the least film thickness as well as very good fluidity and viscosity (Orstavik 1982).

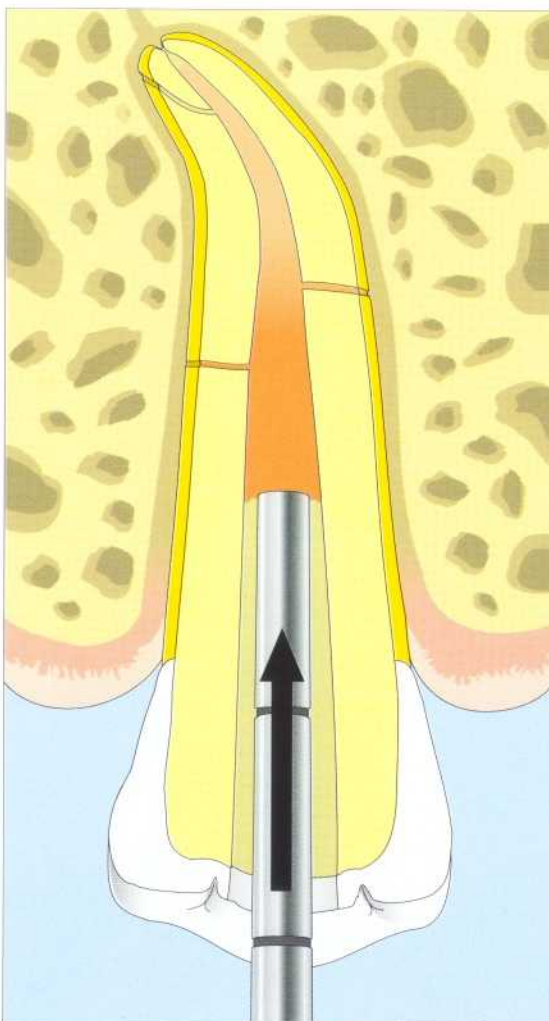
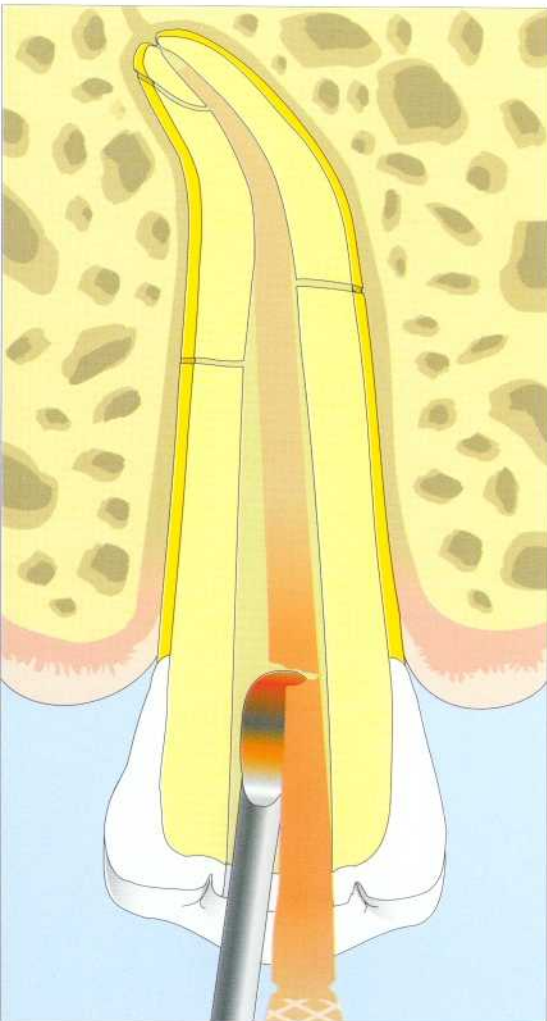
Once the sealer and master point are in place the first "down pack" phase is begun with separation of the gutta-percha by a hot instrument at the level of the canal orifice, followed by the first condensation with the largest plugger.



493 Vertical condensation

Left: A gutta-percha master point is inserted to the working length in the root canal, and the coronal portion of the gutta-percha is then removed with a hot probe.

Right: After the gutta-percha has been heated and plasticized with a hot spreader, vertical condensation is accomplished with a plugger.



494 Heating and packing

Left: The master point is shortened apically by 0.5 mm, coated with sealer, and placed into the root canal. The excess gutta-percha is cut away with either an excavator or a heated explorer, and the heat is used to warm the superficial layers of gutta-percha.

Right: Dipping the thick plugger in cement powder will keep it from sticking to the plasticized gutta-percha. Short circumferential strokes are then made into the gutta-percha to condense it. Finally, firm apical pressure is applied and the gutta-percha will be felt to become firm. The pressure from the plugger combined with the apical counter pressure from the gutta-percha that is not heated presses the plasticized filling material into the lateral canals.

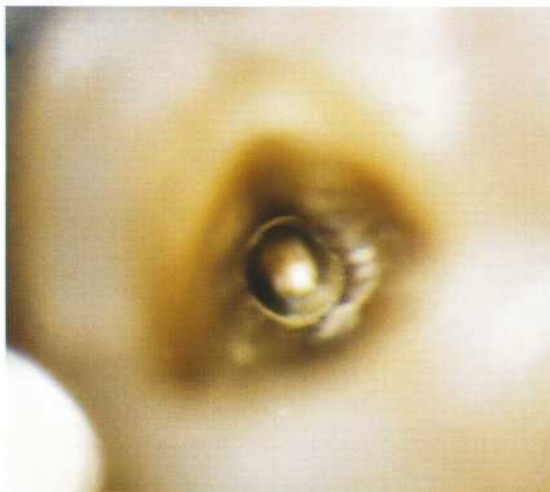
Vertical Condensation: Part II

After the first vertical condensation the Touch'n-heat probe is again inserted into the gutta-percha, the heat conduction is interrupted at the handpiece, and after a brief moment the probe is withdrawn from the canal. During this procedure the metal cools and a small amount of gutta-percha clings to the probe and is thereby removed. Now the smaller plugger can enter deeper into the root canal and condense the heated gutta-percha. In this way gutta-percha and sealer are distributed three-dimensionally over a 4-5-mm-long segment and into any lateral canals.

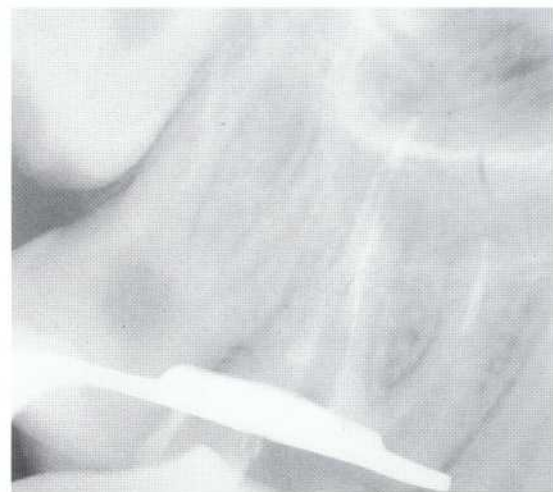During this last heating procedure, the heating probe extends to the apical region. The thinnest plugger is inserted to within 5 mm from the apical constriction and condenses filling material into fine branches of the apical delta. In order to compensate for the thermal shrinkage, the plugger is held there with strong apically directed force until the gutta-percha has cooled. The danger of overfilling is relatively small if the master point has been shortened by 0.5 mm and fitted accurately to the root canal (Dagher and Yared 1993).

495 Apical condensation

Left: The surgical operation microscope can be focused on the root canal from its coronal opening to its apical end, permitting inspection of its entire length. The condensed gutta-percha can be seen in the apical region.

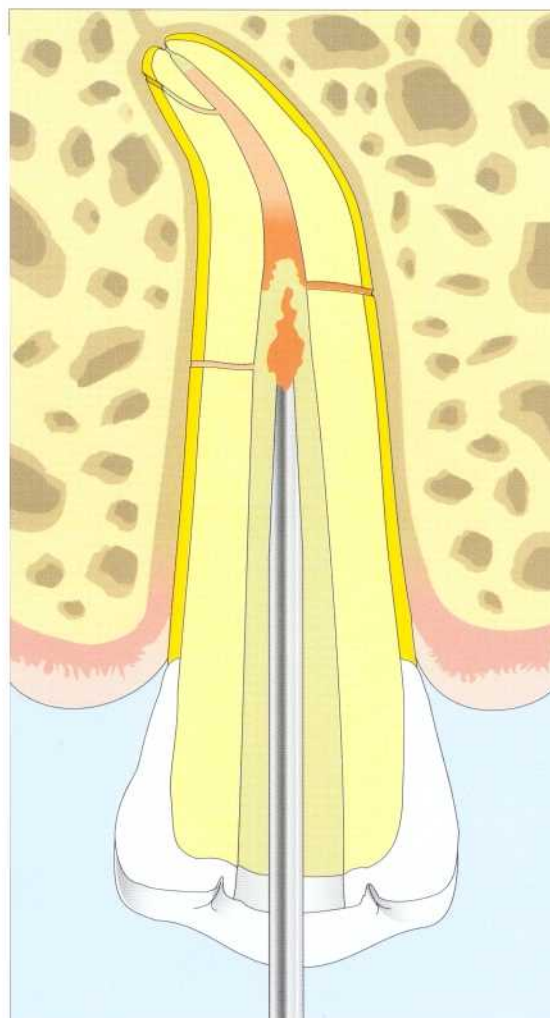


Right: After the first phase of vertical condensation ("down pack") is completed, the filled apical portion of the root canal is evaluated with a radiograph.

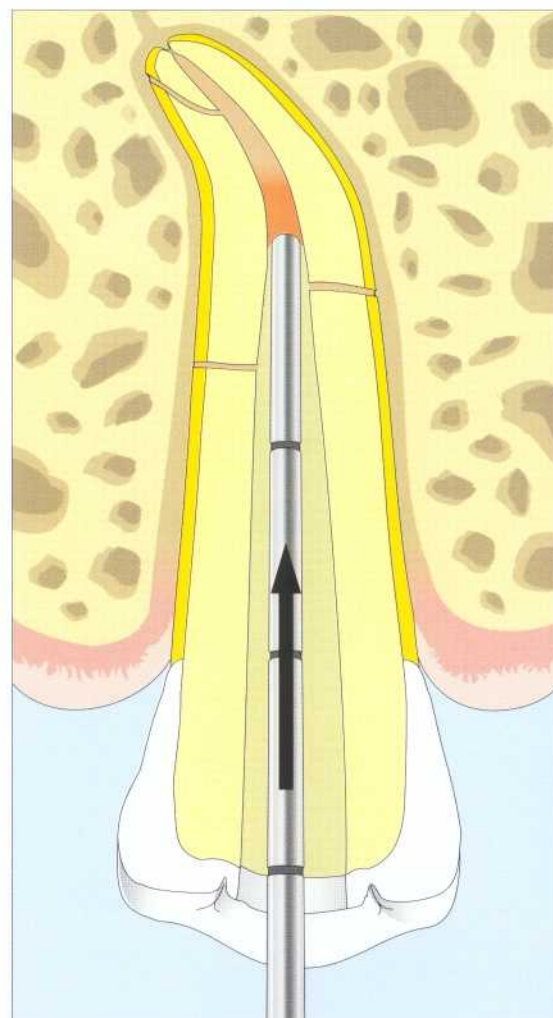


496 Apical condensation

Left: The heated probe is inserted to the apical region once again and pressed 3-4 mm into the gutta-percha, heating and plasticizing it. Upon withdrawal, the probe removes a small amount of gutta-percha.



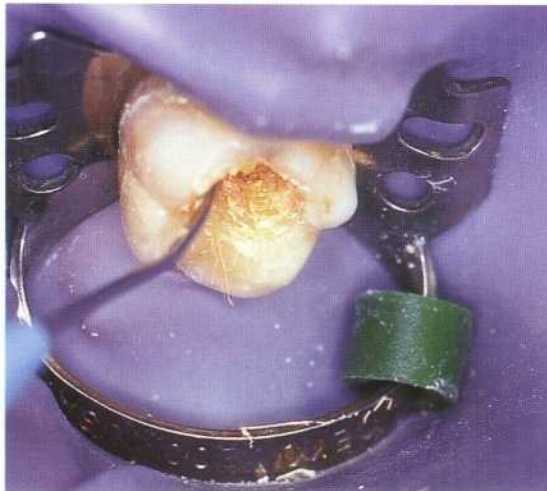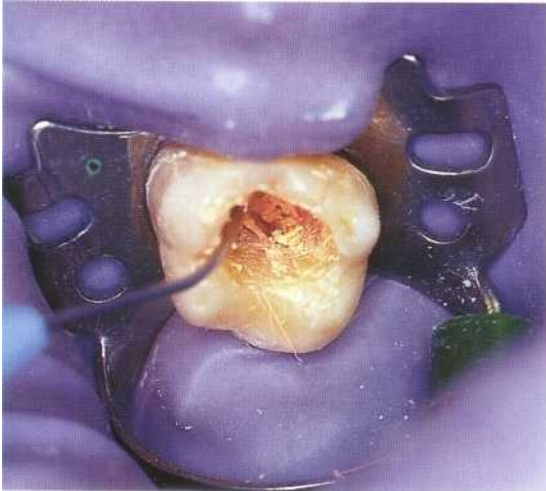
Right: The smallest of the three pluggers condenses the heated gutta-percha apically, thereby filling any lateral canals or apical ramifications. This process of heating and vertically condensing the gutta-percha is repeated three or four times until the narrowest plugger reaches a point 4-5 mm from the previously determined working length.



There is no danger of overfilling the canal if it has been enlarged to a conical shape, the master point has been fitted accurately, the temperature does not exceed 45 °C (113 °F), and the heated probe is brought no closer than 4 mm to the apical foramen (Ruddle 1993).

After completion of the first phase of vertical condensation ("down pack"), a post can be inserted or the rest of the canal completely filled with gutta-percha ("back pack"). For the latter, a gutta-percha gun, the Obtura 11, which heats the gutta-percha to 160 °C (320°F), can be employed (Yee et al. 1977). The temperature of the plasticized gutta-percha ranges from 47°C (117 °F) to a maximum of 81 °C (178 °F) as it leaves the injection cannula. This does not damage the adjacent marginal periodontal tissue (Gutmann et al. 1987 a, b).

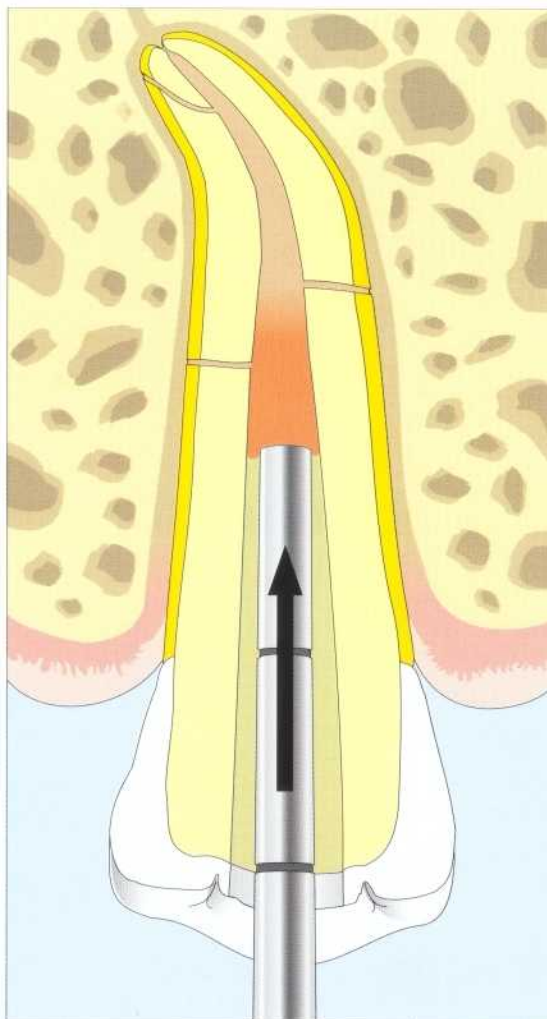
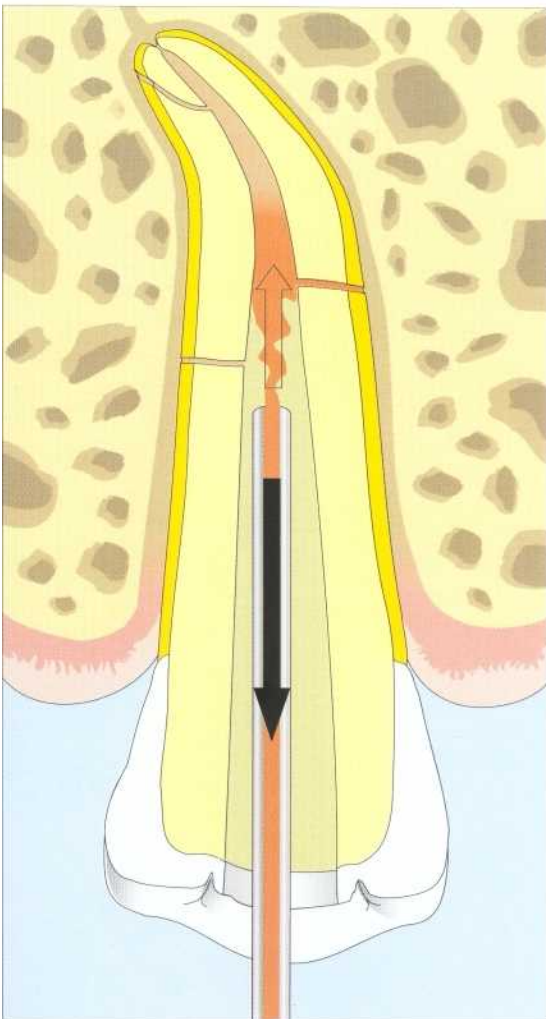
The hot injection cannula warms the gutta-percha already condensed in the apical region, thereby providing good adhesion to the portion of gutta-percha that is pressed into place next. The thinnest plugger is then used to condense this 4-5-mm-long segment until it has cooled in the canal. More gutta-percha is alternately injected and condensed until the root canal is completely filled. Lugassi and Yee (1982) investigated how effectively the canals of extracted teeth were sealed by vertical condensation and found that the root canal system was completely obturated when a sealer was used.



497 Coronal filling

Left: After the apical portion of the root canal has been filled, the more coronal portion is filled with a gutta-percha gun in the second "back packing" phase.

Right: The gutta-percha gun is brought into direct contact with the apical filling and then gutta-percha, 4-5 mm long, is injected into the canal.



498 Coronal filling

Left: The cannula of the gutta-percha gun has contacted the apical gutta-percha filling and softened its surface. Then pressure on the cannula is gently released as a small amount of gutta-percha is expressed. One can feel the injection cannula being pushed out of the root canal.

Right: The medium-sized plugger pushes the gutta-percha apically and then, through circumferential condensation, a homogeneous filling is achieved. The plugger remains in the canal until the gutta-percha has cooled. This additional vertical condensation also fills any lateral canals that may be present.

Upon completion of the obturation, its density is evaluated on a radiograph.

Clinical Results

In a clinical study by Morse et al. (1983) 458 root canals were filled by lateral condensation using eucapercha as a sealer. Some teeth had extensive periapical radiolucencies. The success rate after 1 year was 94.5%. Premolars, with a rate of 98.2%, were more successful than molars with 92.5%. After vital extirpation, failure occurred in only 1.8% of the cases, compared with a 6.7% failure rate for necrotic pulps. If the root canal was underfilled the success rate was only 71%. Clinical success was recorded in almost 100% of teeth with fillings all the way to the apical foramen.

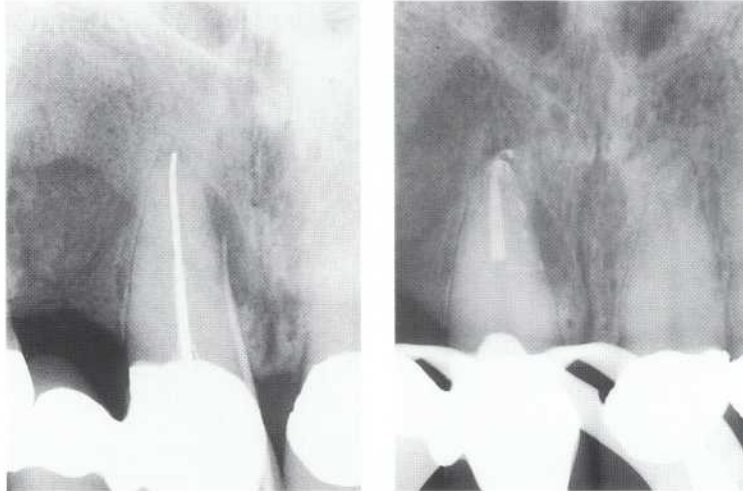
From radiographs of 650 treated teeth, Weisz (1985) found that after 2 years 56% of the periapical bone defects were two-thirds filled in and 40% were completely filled in with new bone.

In a clinical study by Schilder (1962), 100 maxillary anterior teeth with periapical lesions 8-35 mm in diameter were treated conservatively and filled with gutta-percha by vertical condensation. Radiographs taken after 6 months revealed 90-100% regeneration in 56% of the cases, and after 2 years the rate of healing was 99%.

499 Down pack

Left: A maxillary anterior tooth serving as a bridge abutment has a lateral radiolucency. A gutta-percha point has been placed into the fistulous tract. The old, inadequate root canal filling will be replaced.

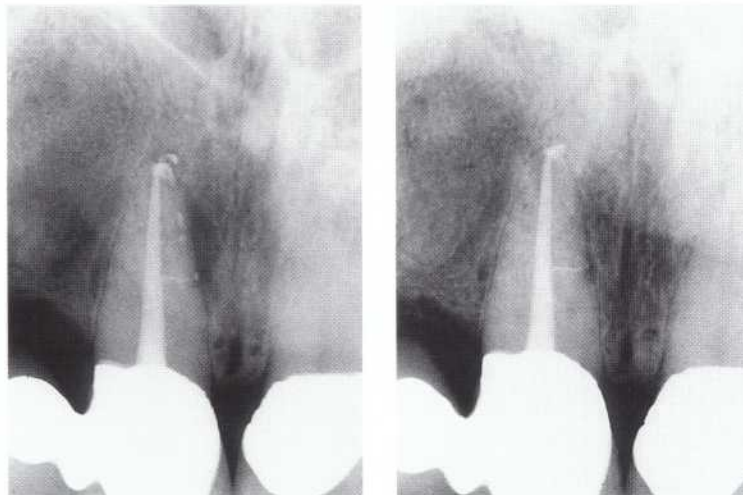
Right: A radiograph taken after the first phase of vertical condensation shows filled ramifications.



500 Backpack

Left: After the apical portion has been filled, the coronal portion is filled with a gutta-percha gun. Lateral canals, through which bacterial toxins presumably spread to the lateral lesion, are now sealed.

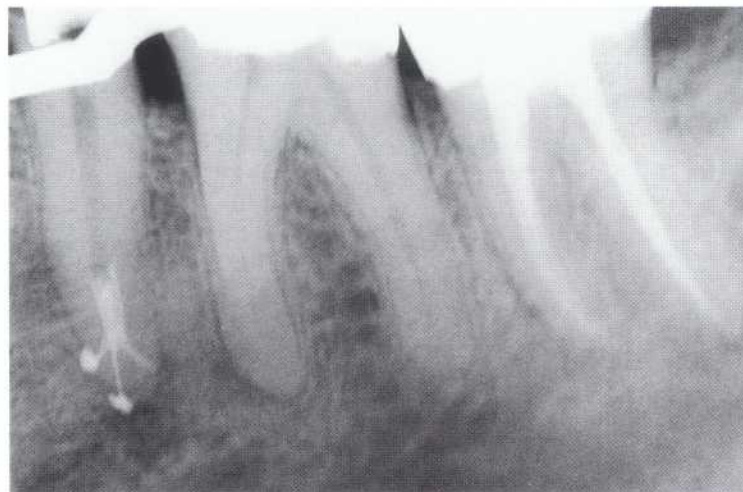Right: The follow-up radiograph at 5 years shows complete healing of the lesion.

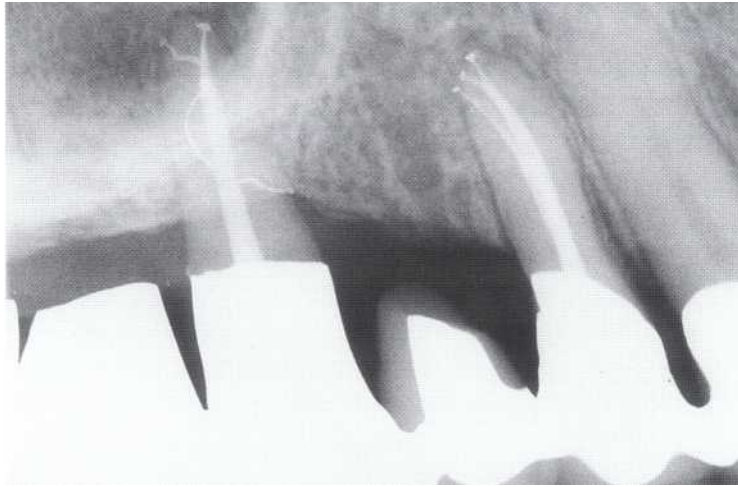

501 Apical delta

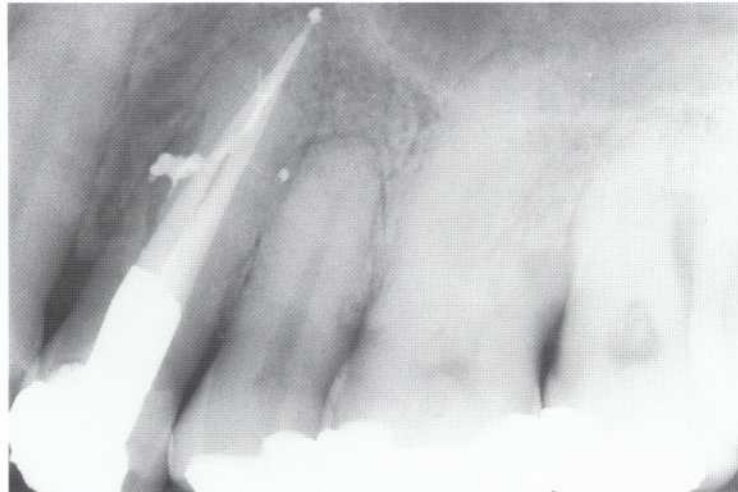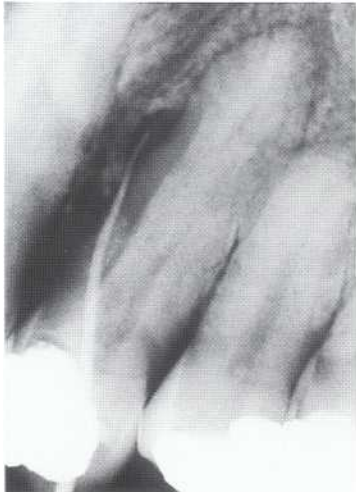
Three branches of the canal of this lower premolar have been filled during the first phase of vertical condensation.

Right: A radiograph of the maxillary incisor reveals three lateral canals filled after the first phase of condensation. The remainder of the canal will be filled in the second phase using the Obtura II system.

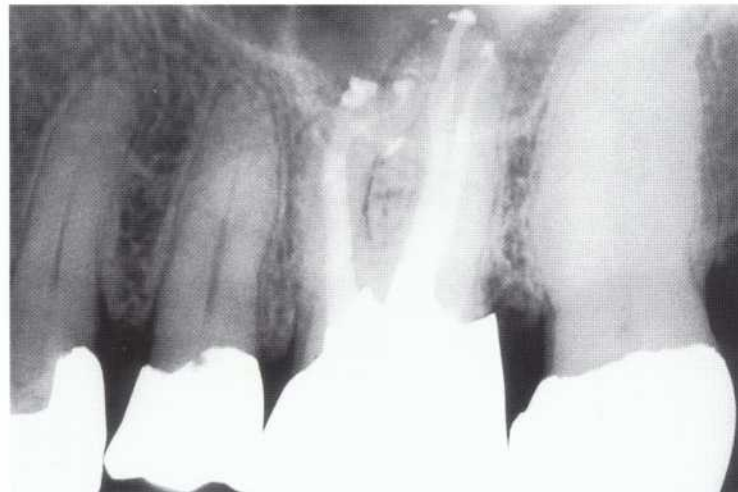
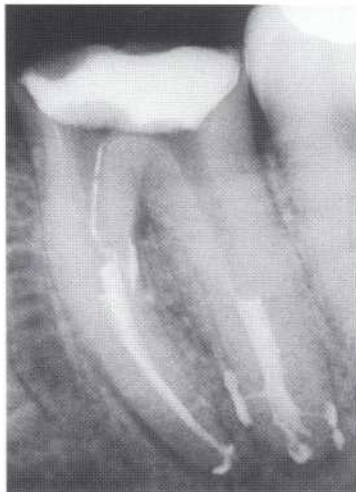


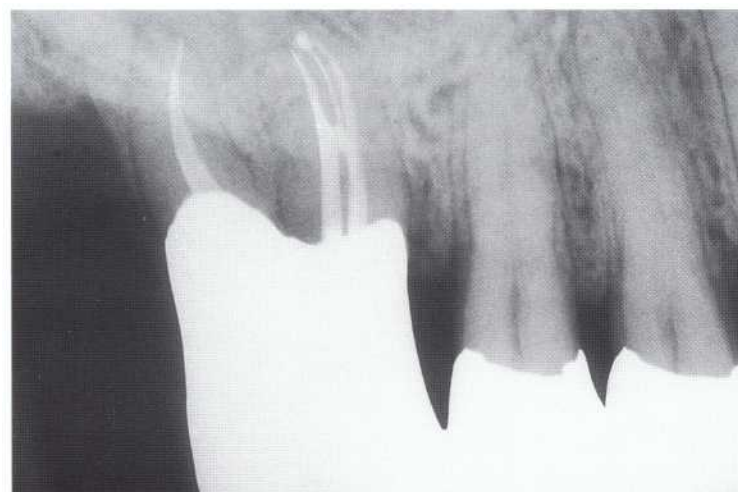502 Complex root canal systems
Through complete cleaning, shaping, and vertical condensation, the complex root canal systems of these two maxillary teeth are successfully treated in a purely conservative manner. The teeth should serve for a long time as bridge abutments.



503 Root canal system and lateral lesions
Right: The 3-year follow-up radiograph of this maxillary premolar shows regeneration of a bone lesion and the complex root canal anatomy with anastomoses between the buccal and lingual primary canals.
Left: Preoperatively there was an extensive lateral radiolucency on the first premolar. A gutta-percha point inserted into the fistulous tract can also be seen.



504 Obturation of curved canals
Right: A postoperative radiograph of an endodontically treated maxillary first molar with a slight overfill of gutta-percha. The two mesio-buccal primary canals separate near the apex to form four branches.
Left: In the mesial root of the lower second molar a filled lateral canal that leads to the lesion in the bifurcation can be seen. The canal of the distal root has four foramina.



505 Root canal filling and hemisection
The lingual root of the first molar has been amputated and the mesiobuccal and distobuccal roots are included in the fixed reconstruction. The mesial root canal has three filled apical foramina.

Treatment C. Ruddle

Fully Automatic Method of Root Canal Preparation

The objective of endodontic treatment as a tooth-saving measure is the complete elimination of irreversibly damaged and infected pulp tissue and sealing of the root canal system against bacterial penetration. The complex anatomy of the root canal presents an obstacle to the realization of this objective. Even though good clinical results are obtained with the previously presented instrumentation techniques, it is not always possible to prepare and seal all the accessory canals. With a new fully automatic method the entire root

canal system can be reached, prepared, and filled (Lussi et al. 1993, Portmann and Lussi 1994, Lussi et al. 1995 c).

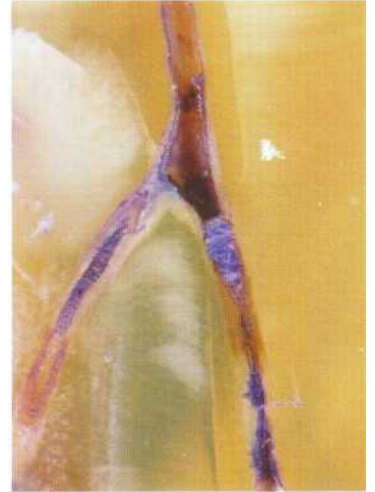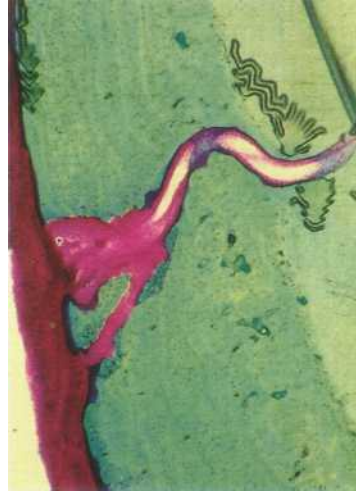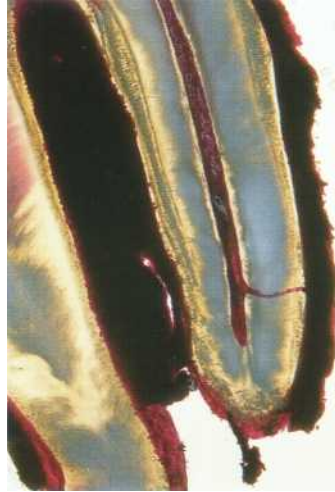The biologic compatibility of endodontic irrigating and cleaning solutions plays a dominant role in achieving successful therapy (Barnes and Langeland 1966, Block et al. 1983). A 5% sodium hypochlorite solution dissolves not only necrotic tissue but also vital pulp tissue. Hence Spangberg et al. (1986) recommend a maximum concentration of 1%.

506 Anatomy of the endodontium with lateral canals

Left: A lateral canal in the apical region is seen on a histologic slid(

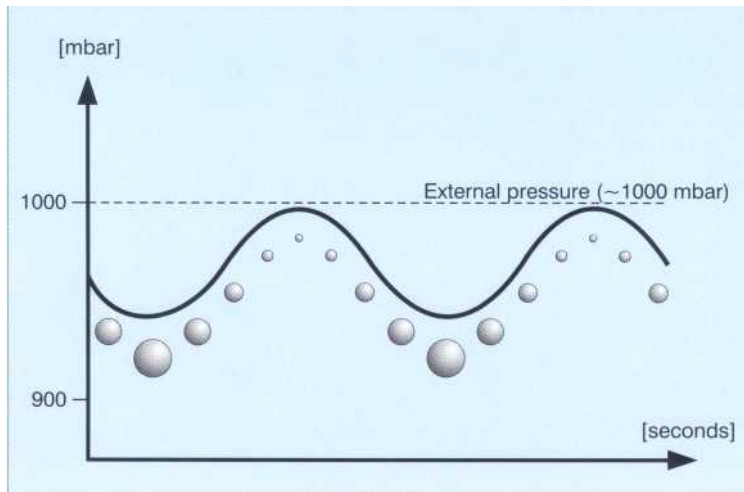
Center: A higher magnification of the lateral canal with granulation tissue, cementum, and root dentin.

Right: The incomplete root canal treatment led to pain and, ultimately, to extraction of the tooth.



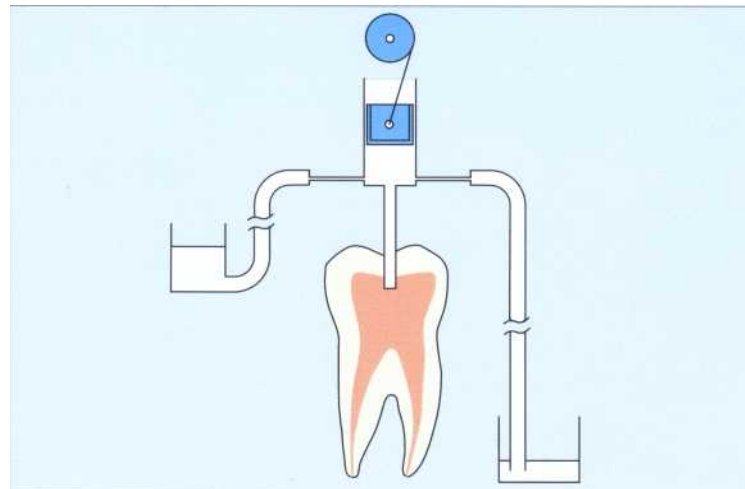
507 Mechanism of fully automatic cleaning

With pulsating pressure changes, bubbles are repeatedly formed and imploded. This process takes place under low pressure and leads to hydrodynamic turbulence that in turn agitates and exchanges the irrigating solution.



508 Schematic drawing of the cleaning apparatus

A motor generates pressure oscillations which create the bubbles. The storage vessel for the sodium hypochlorite irrigating solution (left), the system of tubes, and the container for the used irrigating solution are all designed and constructed so that the cleaning process can take place under negative pressure. This prevents passage of the cleaning solution into the periapical tissue.



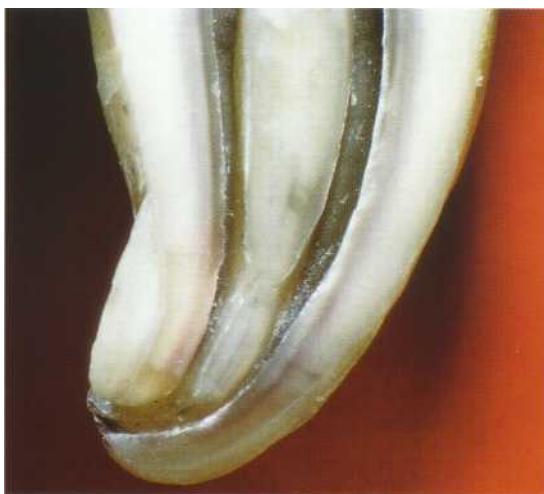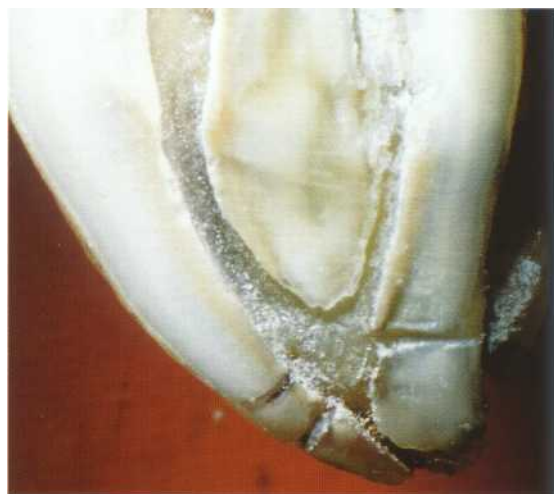Right: Size comparison of the cleaning apparatus.



An opening is made through the crown of the tooth that is to be endodontically treated, and the interior of the tooth is isolated so that the cleansing can be carried out under reduced pressure. Rapid pressure changes under a partial vacuum cause bubbles to form that then implode (cavitation). This process takes place at up to 250 times per second and produces an intense exchange of the sodium hypochlorite cleaning solution within the primary and secondary canals. The strong tissue-dissolving effect of sodium hypochlorite (Barnett et al. 1985, Baumgartner and Cuenin 1992) removes the

pulp tissue within 10-15 minutes. It is not necessary to expose the canal orifices; it is sufficient to merely create an access opening into the pulp chamber.

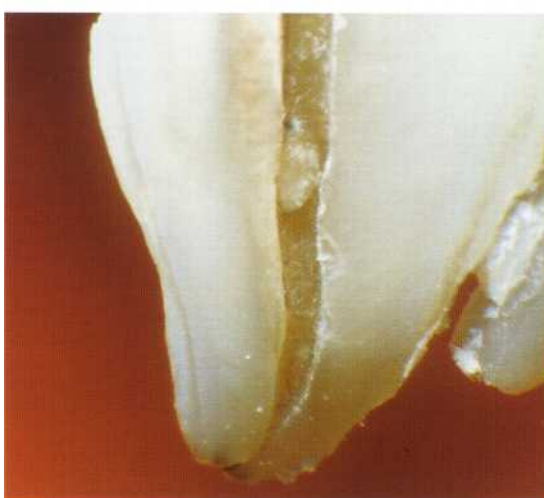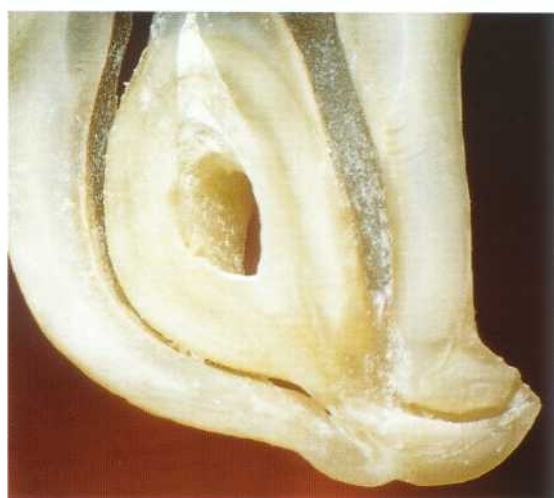The bubbles, which have a maximum diameter of 50 μm , act to distribute the sodium hypochlorite solution throughout the entire root canal system. Penetration of the periodontal tissue by the solution is supposed to be prevented by the influx of blood at the foramina.



509 Prepared root canals
The teeth have been sectioned longitudinally for histologic preparation and then stained.

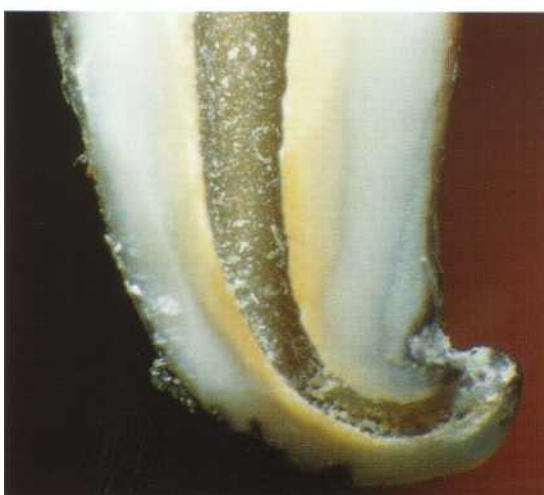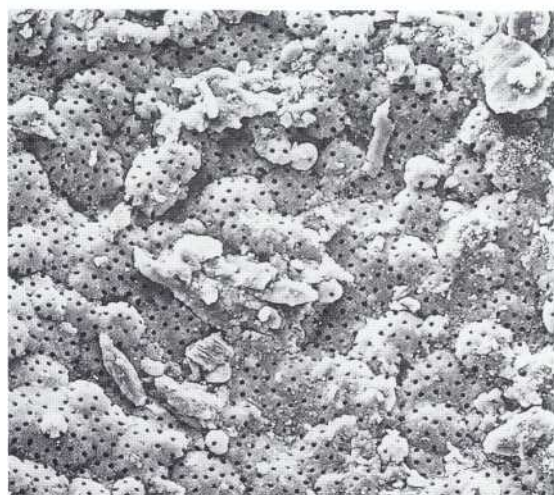
Left: The apical delta is clearly shown. Tissue remnants can be seen in the accessory canal on the left.

Right: Two root canals that reunite at the apex. Small tissue remnants are still present there.



510 Prepared root canals
Left: The root canal system is well cleaned except for small tissue remnants in the apical third of the left canal.

Right: Hard-tissue deposits (denticles) do not interfere with the preparation. The bubbles that produce the turbulence have a maximum size of 50 μm and can still bring about an exchange of the cleansing solution in spite of obstructions.



511 Prepared root canal
Left: The SEM image of the tooth in the picture on the right clearly shows calcospherites with open dentinal tubules. No smear layer is visible.

Right: A clean root canal system with the pulp tissue completely removed. The white particles were produced by cutting the tooth in half to expose the canal.

Histology by A. Lussi

Fully Automatic Method of Root Canal Obturation

During cleaning of the canals with the fully automatic method described by Lussi et al. (1993) no dentin is removed and therefore the tooth is not weakened. However, this makes it impossible to obturate the canals by the conventional techniques.

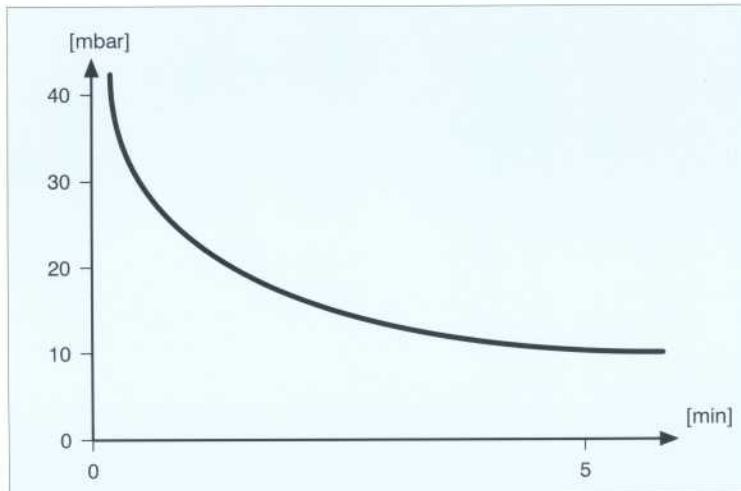
A method employing a partial vacuum below 10 millibars has produced perfect obturations both *in vitro* and *in vivo* under clinical conditions (Lussi et al. 1995 c). An airtight connection is made between the pulp chamber and a high-efficiency vacuum pump, and after approximately 10 minutes the required partial

vacuum is reached. Meanwhile, the filling material is mixed and placed into the special container. By opening a stopcock it becomes connected with the root canal system and the paste is sucked into the canals by the partial vacuum. It is recommended that gutta-percha points then be inserted into the canals to facilitate any later retreatment.

Because the fully automatic preparation method has only been tested on a few patients, the fully automatic obturation has so far been performed almost exclusively on conventionally prepared root canals.

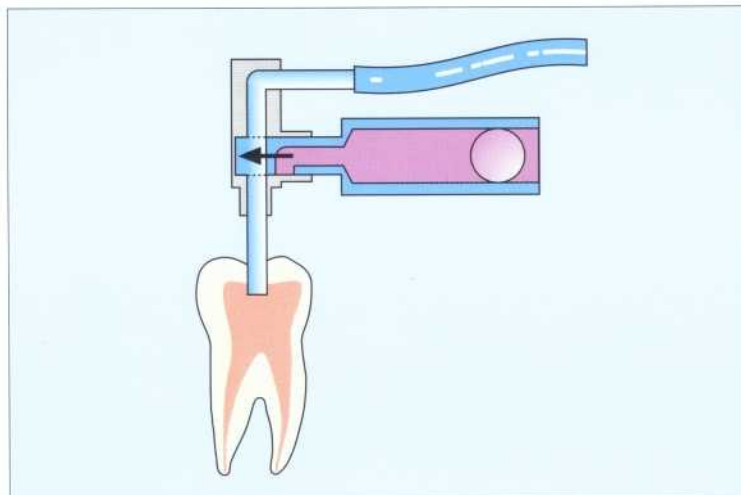512 Mode of action

A multistage vacuum pump enables production within the tooth of a partial vacuum of 10 millibars or less (0 bar = absolute vacuum). This completely vaporizes any remaining fluid. The root canal filling paste is then sucked into the canals.

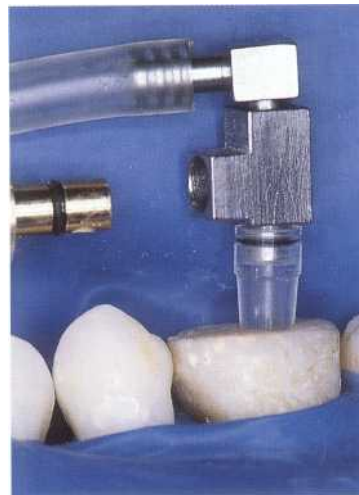

513 Schematic drawing of the apparatus

The tube (above) leads to the vacuum pump and the reservoir below it holds the filling paste. After the desired degree of vacuum is reached, the filling material is pushed in allowing the paste to flow into the root canal system. The ball is necessary to prevent air from being sucked into the reservoir.



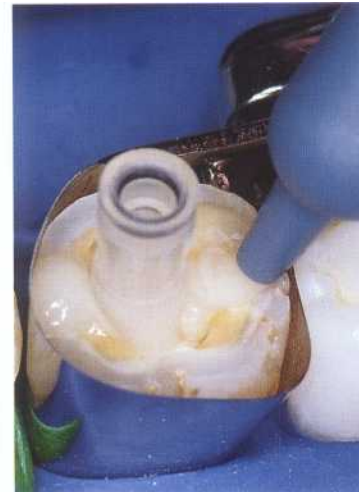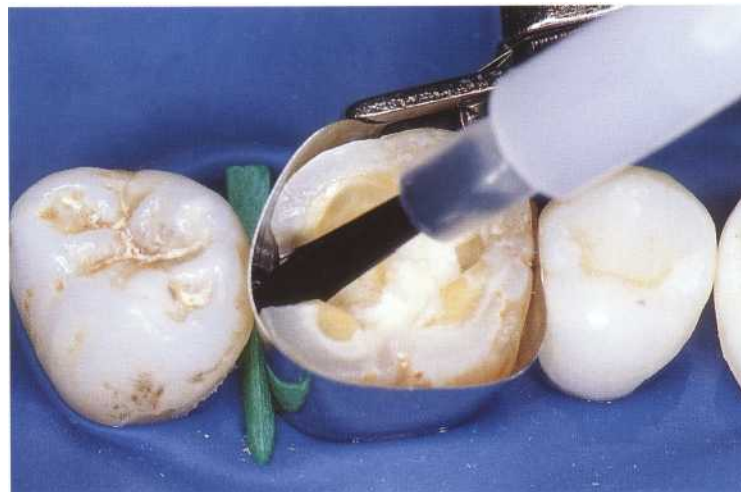Right: The apparatus is connected to produce the partial vacuum.

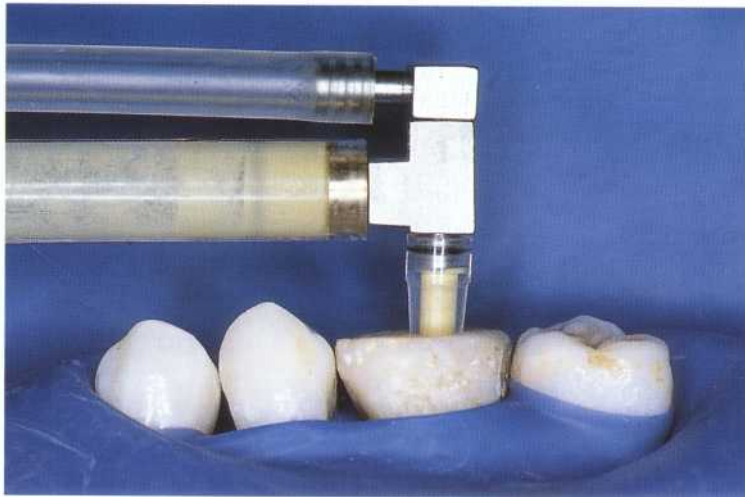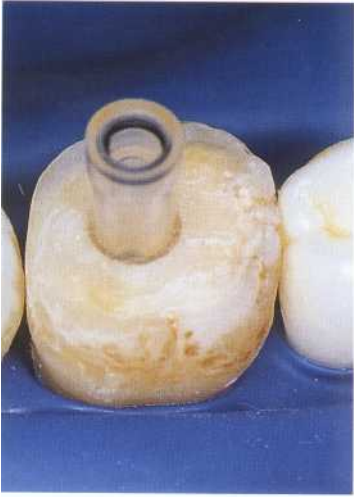


514 Tooth buildup with composite

Left: It is essential for both the root canal preparation as well as the obturation to create a partial vacuum in the root canal system. One possibility is to build the tooth up with composite using a dentin and enamel bonding agent.

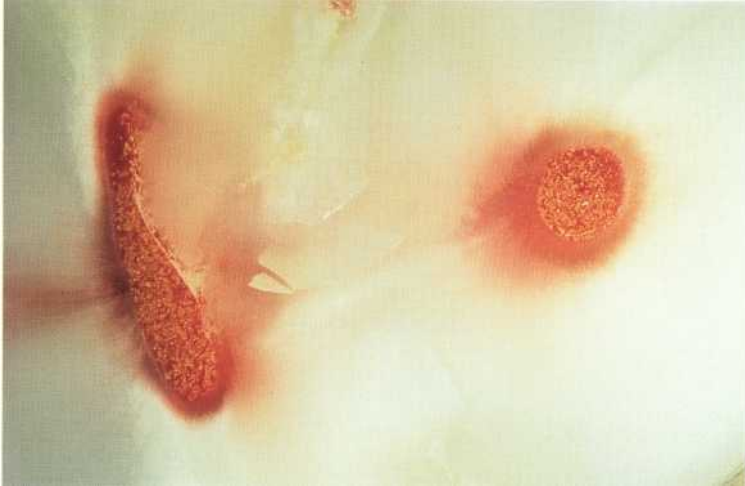
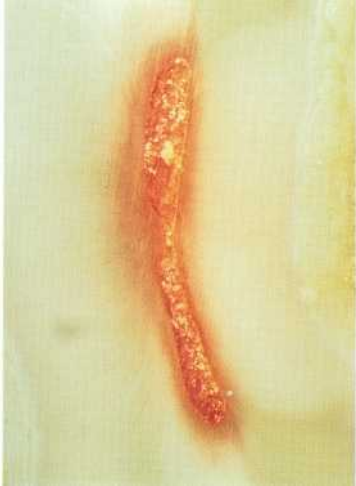Right: A sheath is fixed in the access preparation by polymerizing composite around it.



**515 Root canal obturation**

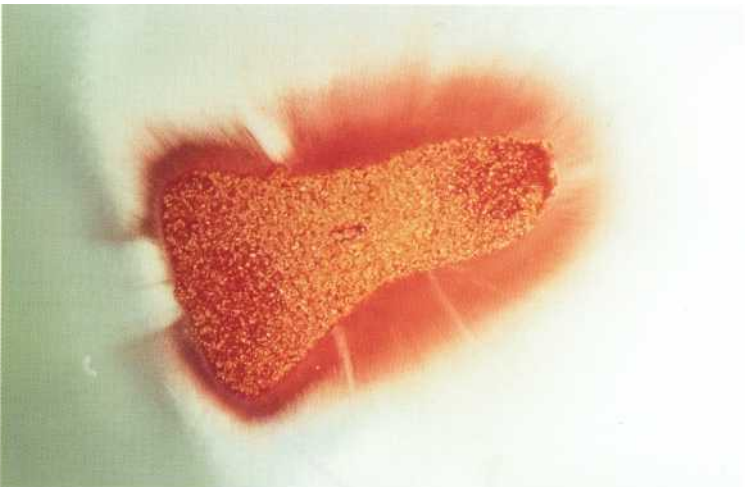
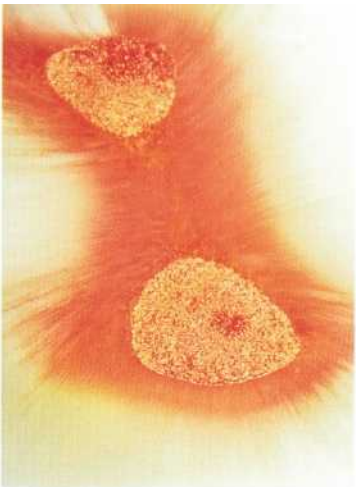
Once the desired negative pressure is reached the filling paste is sucked into the root canal system. To make the filling paste bubble-free, it too is subjected to a partial vacuum.

Left: The size of the sheath is selected according to the size of the tooth. The same sheath can be used for both cleaning and obturation.

**516 Filled canals**

Histologic cross-section through two root canals. It is obvious that the anatomy of the canals was not altered by the cleaning process. The experimental filling paste is stained red.

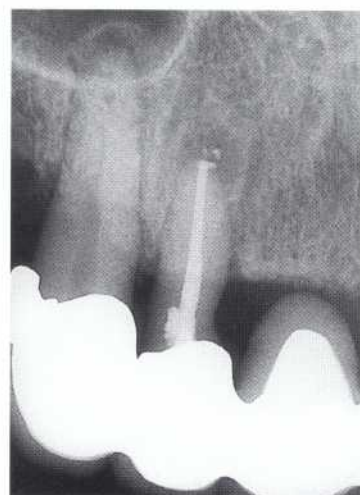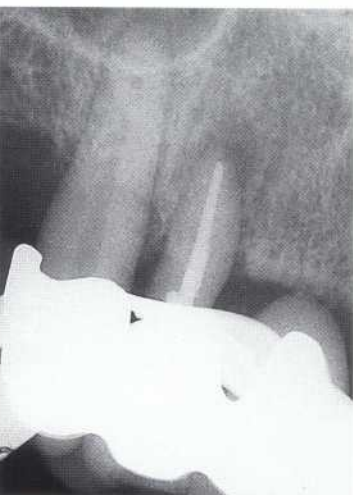
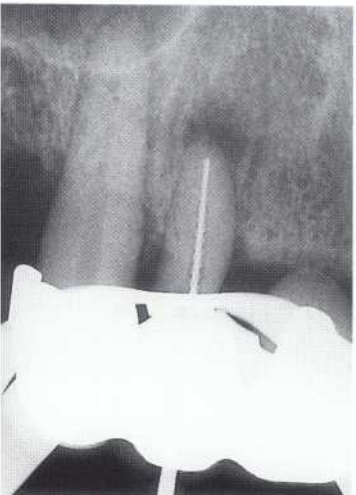Left: Two filled canals connected by an isthmus.

**517 Filled canals**

The histologic cross-section through the root canals shows penetration of the root canal filling paste into the dentinal tubules. This is possible because no smear layer is formed during the cleaning procedure so that the pressure in the dentinal tubules is reduced as well.

Left: Dense obturation of two oval canals.

Collection A. Lussi

**518 A clinical case**

Left: A maxillary second premolar with a root canal instrument in place. This was instrumented by the Roane technique, and a calcium hydroxide interim dressing was used.

Center: After obturation with the new technique. An area of internal resorption has been filled.

Right: Additional lateral condensation causes extrusion of filling paste into the periapical space.

Treated by B. Suter

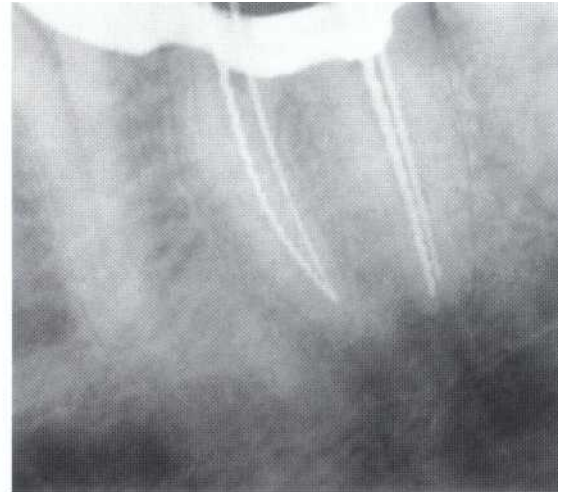
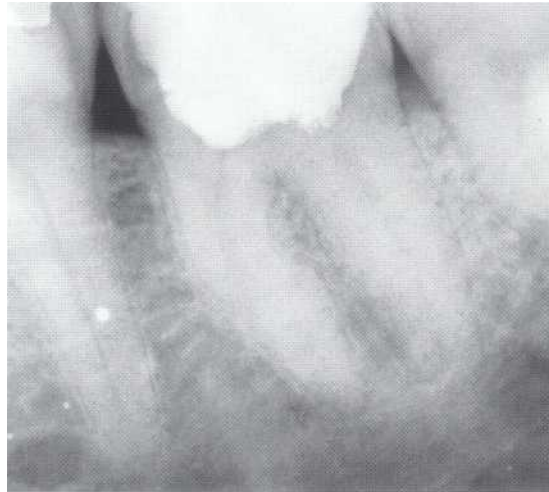
Heated Gutta-percha

The final stage of endodontic treatment is to fill the entire root canal system and all its complex anatomic pathways completely and densely with nonirritating agents. Total obliteration of the canal space and perfect sealing of the apical foramen at the dentin-cementum junction and accessory canals at locations other than the root apex with an inert and dimensionally stable material are the goals for consistently successful endodontic treatment (Nguyen 1994). Nearly 60% of endodontic failures are apparently caused by incomplete obliteration of the canal system (Dow and Ingle 1955).

Complete filling of the root canal system in three dimensions prevents microleakage and reinfection and creates a favorable biologic environment for tissue healing. Over the years numerous methods and techniques of root canal obturation have been advocated, each with their own claims of ease, efficiency, or superiority. Four basic obturation techniques exist: the cold compaction of gutta-percha (1), softened and cold compacted gutta-percha (2), thermoplasticized gutta-percha that has been injected and cold compacted (3) (Gutmann 1998).

519 Cleaning and shaping

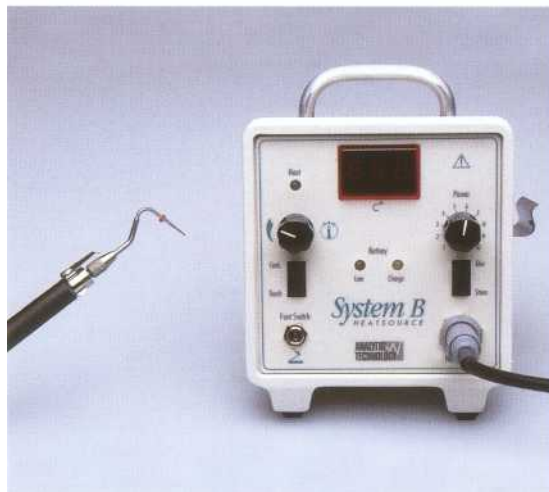Left: The success of endodontic canal obturation is dependent on the excellence of the cavity design and on thorough canal shaping and cleaning.



Right: Regardless of the method employed to obturate the canal, intensive efforts must be made toward obtaining total debridement and complete patency of the complex root canal system.

520 Armamentarium

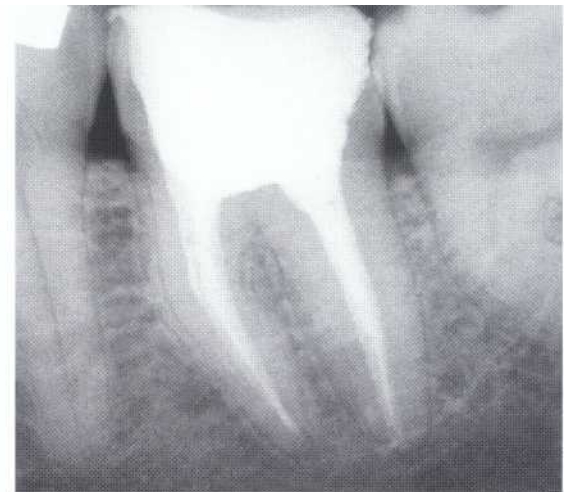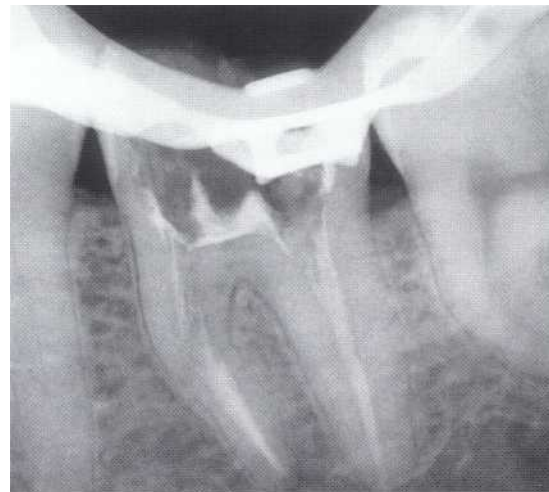
Left: Heat source: analytic Technology has developed several heating units designed to thermosoften gutta-percha (System B, 5004 Touch 'n unit).



Right: Gutta-percha gun: following the down-packing and corking of the apical third, the most efficient way to back the root canal system is to use the Obtura II gun (Texceed, California). It uniformly squeezes off heated aliquots of gutta-percha against the corked apex.

521 Filling

Left: Down-packing: following sealer placement and gutta-percha-cone insertion, the heat carrier (and plugger) is activated. Then the same carrier-plugger is used to vertically pack the thermosoftened gutta-percha apically.



Right: Back-packing: the hot and precurved needle of the Obtura II is inserted into the root canal, and controlled 4-5 mm segments of thermosoftened gutta-percha are injected against the previously corked apical third.

Endodontics in the Deciduous and Mixed Dentitions

Early loss of deciduous teeth can have an unfavorable effect upon the permanent dentition and the entire masticatory system. The majority of children today have little or no caries, and only in a small minority is the caries index high. In order to maximize the effectiveness of preventive measures, the dentist has a duty to determine the patient's caries risk and to introduce an effective, individualized preventive program and early treatment. The same treatment concept is not indicated for all patients. Placing a patient in the "high caries risk" category remains a differential diagnostic procedure specific to the patient and the conditions in which various individual findings must be combined (Axelsson 1989, Lutz et al. 1990.)

The endodontic treatment of children and adolescents deserves special attention for many reasons. For one thing, the psyche of the child must be considered. For another, the deciduous teeth have anatomic characteristics, such as thin dentin mantles and large pulp chambers that are different from those of the permanent teeth. A basic prerequisite for successful therapy, moreover, is the cooperation of the young patient. The possibly limited benefit of endodontically treating a deciduous tooth must be weighed against the burden that will be placed upon the child. Merely opening the tooth can be substituted as a compromise treatment for acute symptoms, but in the long term it leaves an opening for bacteria, and is also an unsatisfactory solution insofar as motivating the patient toward good oral hygiene is concerned (Staehele 1993).

The most important *indications* for endodontic treatment of deciduous teeth are traumatic injury to the pulp of a vital tooth, carious pulp exposure, and symptoms of pulpitis. *Contraindications* are a severely damaged or nonrestorable crown, resorption of more than half of the root length, pronounced resorption of interradicular or periapical bone and a high degree of tooth mobility, a severely neglected dentition, severe systemic disease, and insufficient cooperation by the child (Leisebach et al. 1993).

Endodontic treatment in the deciduous dentition encompasses treatment of dentin near the pulp without opening into the pulp (indirect pulp cap), direct capping of the exposed pulp, pulpotomy (amputation of the coronal portion of the pulp), and pulpectomy followed by filling of the root canals with resorbable materials.

The main objective of endodontic treatment of a permanent tooth with incomplete root growth is to maintain its vitality and allow *completion of root growth*. Where the apical foramen is wide open, conventional root canal treatment can be accomplished only under certain circumstances. In addition to direct pulp capping and pulpotomy, the therapeutic steps that may be required include apexification if the pulp tissue is necrotic, followed by root canal filling (Lenhard and Staehele 1996).

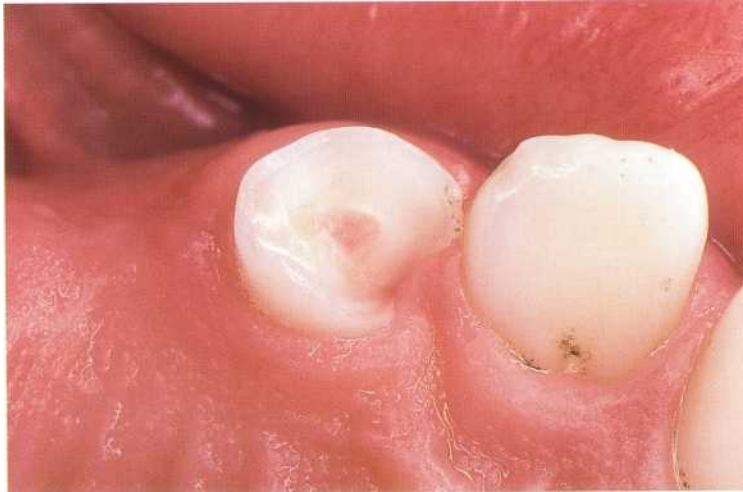Pulpotomy in the Deciduous Dentition

Pulpotomy means the complete amputation of the coronal pulp down to the orifice of the root canal. The special indication is an exposed pulp in a tooth that is vital. In deciduous teeth, pulpotomy is preferable to direct pulp capping. *Contraindications* are clinical symptoms such as pain, swelling, tenderness to percussion, fistulation, and abnormal tooth mobility. Radiographic contraindications are changes such as internal and severe external resorption, as well as periapical and interradicular lesions (Staehele 1993).

When the pulp tissue is vital and exposed the pulpotomy should be performed under local anesthesia. The coronal pulp tissue is removed with a high-speed diamond stone under irrigation with isotonic saline solution. In this way the bleeding can best be controlled. After the pulp chamber has been cleared of all soft tissue and irrigated with saline, bleeding is stopped by applying pressure with a sterile cotton pellet. A pulp capping material is then placed and the coronal cavity is tightly sealed with a restoration.

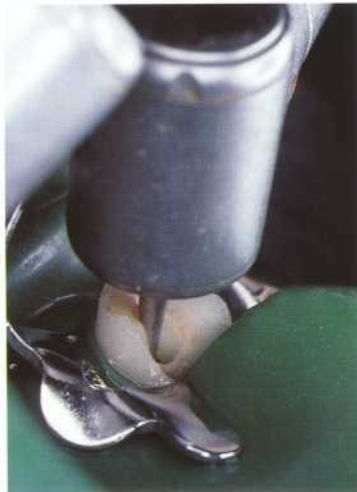522 Tooth fracture

A maxillary deciduous canine with loss of a large part of the crown and pinpoint exposure of the pulp. The tooth is asymptomatic, gives a positive response to the sensitivity test, and is not tender to percussion. There is no fistula or palpable swelling. A pulpotomy will be performed under local anesthesia.

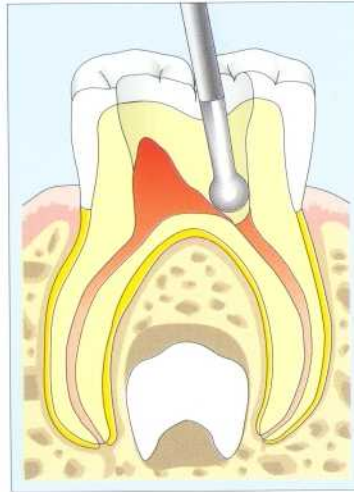


523 Pulp amputation

Left: The coronal pulp tissue is removed with a diamond bur turning at high speed, and the pulp chamber is cleaned of all tissue, remnants and irrigated with isotonic saline solution.

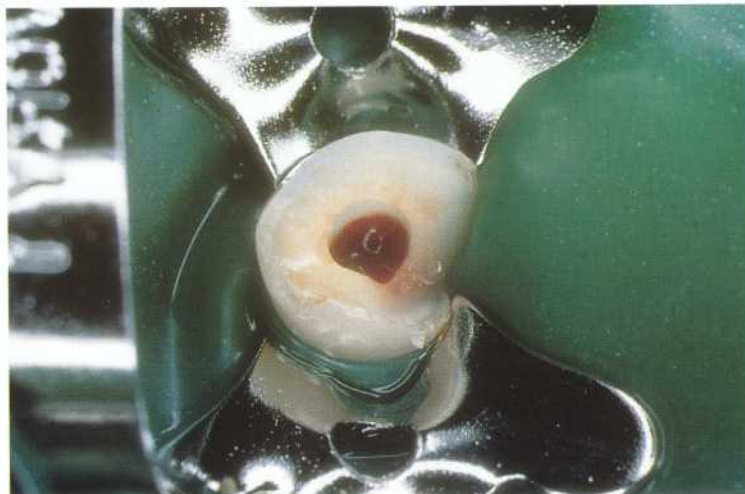


Right: Vital pulp tissue is severed cleanly at the level of the root canal orifice under constant irrigation with sterile saline solution.



524 Hemostasis

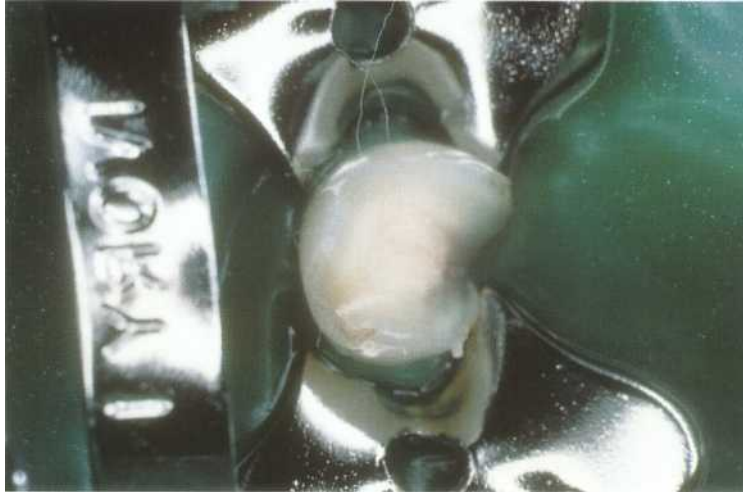
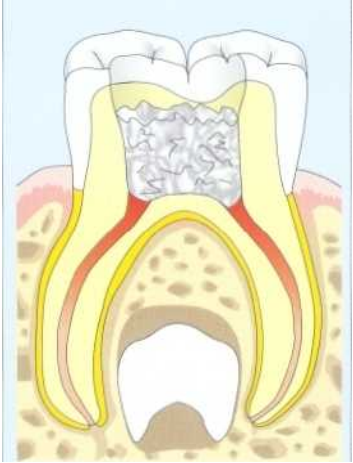
A sterile cotton pellet is pressed against the remaining pulp tissue and changed several times until the bleeding has completely stopped. If hemostasis cannot be achieved, severely inflamed pulp tissue may be present. In this case a pulpotomy is no longer indicated (Leisebach et al. 1993).



After placement of calcium hydroxide, deciduous teeth too can form a bridge of hard tissue. If hemostasis is inadequate, a coagulum forms that will induce chronic inflammation and subsequent internal root resorption (Schroder 1985).

Clinical studies indicate a success rate of 31-100% of cases treated (Schroder 1978, Heilig 1984). Histologically, however, only 50% show a dentinal bridge and healing while the rest show inflammation and internal resorption (Doyle et al. 1962).

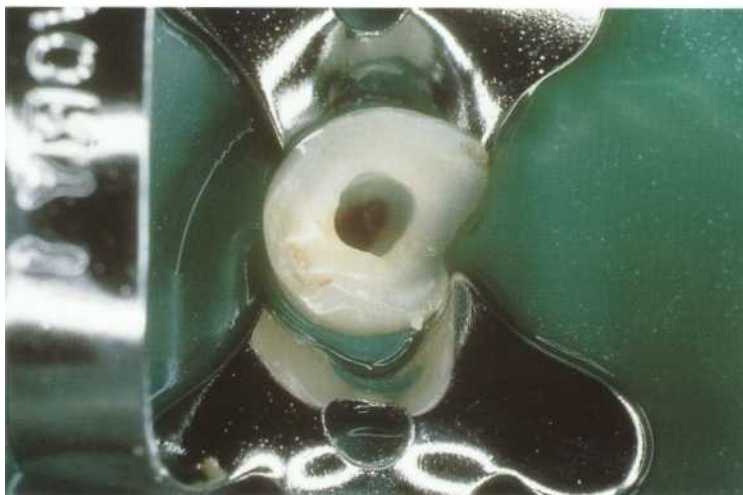
Even today formocresol, a mixture containing 19% formaldehyde and 35% cresol, is still used in deciduous teeth. A 5-minute application leads to superficial fixation, bordered by vital, but chronically inflamed pulp tissue. Pure zinc oxide-eugenol should be placed on the remaining tissue and the cavity is then filled. In spite of the 94-98% clinical success rate (Verco et al. 1984, Hicks et al. 1986), the distribution of the chemicals throughout the system is an argument against their use in deciduous teeth (Araki et al. 1993).



525 Formocresol

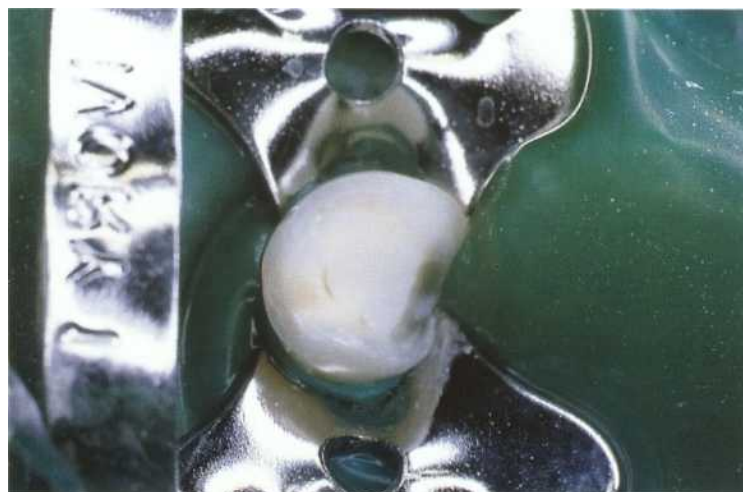
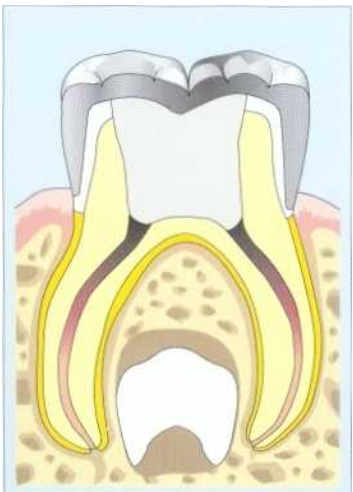
A cotton pellet moistened with formocresol is applied against the exposed pulp tissue for 5 minutes.

Left: Formocresol must be brought into direct contact with the pulp tissue for fixation to occur. The underlying tissue then becomes partially necrotic and infiltrated with leukocytes.



526 Tissue reaction

The pulp tissue has a brownish color after removal of the cotton pellet. In spite of removal of the excess formocresol, a systemic distribution reaching the periodontal ligament, bone, liver, kidneys, and lungs has been shown in animal experiments (Pashley et al. 1980). Toxic effects can be avoided, however, by using a concentration of no more than 0.38 pM (Ranly 1985, 1987).



527 Coronal restoration

Only those endodontically treated deciduous teeth that are restored with crowns will be long-term clinical successes.

The mutagenic and carcinogenic potential of formocresol makes the use of this type of therapy in deciduous teeth questionable (Goldmacher and Thilly 1983, Friedberg et al. 1990).

Left: Pure zinc oxide-eugenol cement is placed over the points of amputation. This is covered with glass ionomer cement, then a pre-fabricated crown is inserted.

Pulpectomy in the Deciduous Dentition

Root canal treatment of a deciduous tooth is indicated when irreversible pulpitis or pulpal necrosis is present.

Contraindications are an unrestorable tooth, radiographically visible internal resorption, carious or mechanical perforation of the floor of the pulp chamber, extensive pathologic resorption of more than one-third of the root, bone resorption with furcation involvement, and a well-delineated periapical lesion. If these cases are excluded, pulpectomy can have a success rate of 90% (Camp 1994).

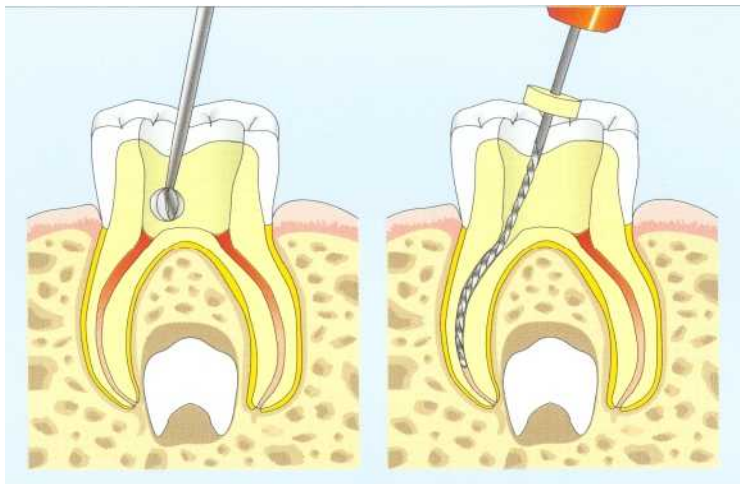
In the anterior region the access opening is made on

the lingual, and in the posterior region the thin dentin at the floor of the pulp chamber must be considered. The canals are prepared with prebent hand instruments to a depth 2-3 mm shorter than the radiographic length. Care must be taken not to perforate the thin walls. Because the apical ramifications cannot be instrumented mechanically, they must be generously irrigated with sodium hypochlorite solution. In necrotic teeth the canals of the unanesthetized tooth are filled with resorbable zinc oxide-eugenol without additives and the crown of the tooth is restored (Goerig and Camp 1983).

528 Canal instrumentation

Left: With a rubber dam in place the deciduous tooth is opened for access and the coronal pulp is removed. The floor of the pulp chamber is thinner than in permanent teeth, therefore the danger of perforation is greater.

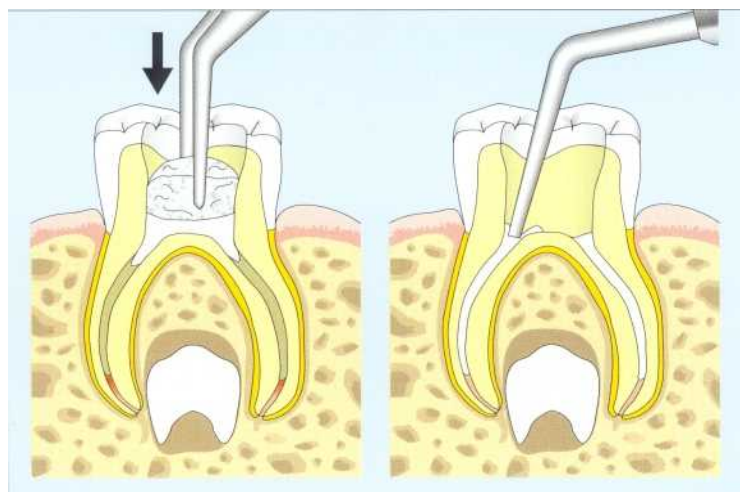
Right: The expected working length is verified on a diagnostic radiograph. Then the canal is carefully enlarged to the working length, 2-3 mm short of the apex.



529 Canal filling

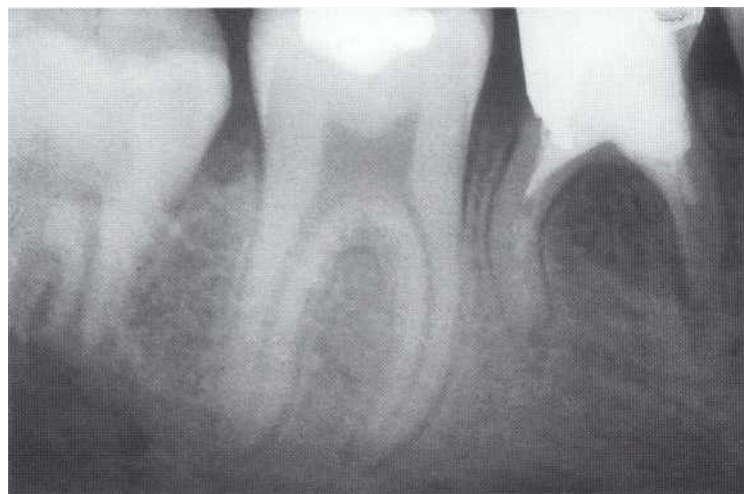Left: Zinc oxide-eugenol without additives is applied over the cavity floor in a creamy consistency and pressed into the root canals with a sterile cotton pellet.

Right: A plugger with the working length marked is used to slowly pack the cement into the canal without overfilling it.



530 Radiographic monitoring

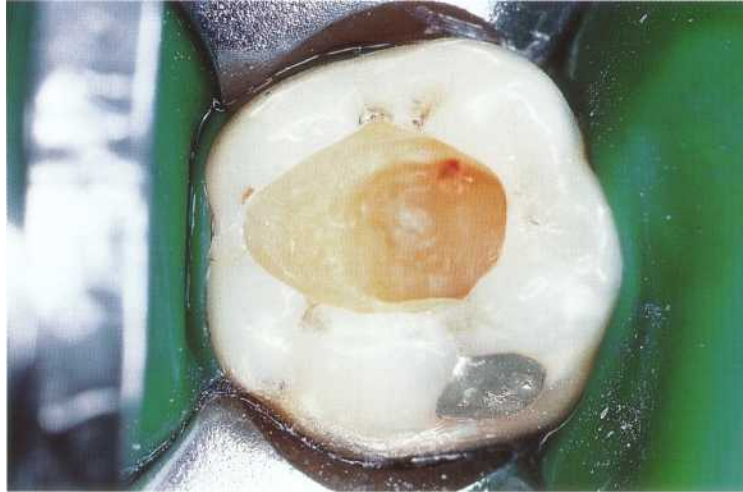
Radiographs are taken immediately after treatment and at 1 year and 2 years afterward to evaluate the success of the treatment, normal root resorption, and resorption of the filling material. In a controlled 2-year study on 1363 endodontically treated deciduous teeth, there were only seven failures. The risk of damage to the tooth germ of the succedaneous tooth was no higher than with formocresol pulpotomies (Rabinowicz 1953).



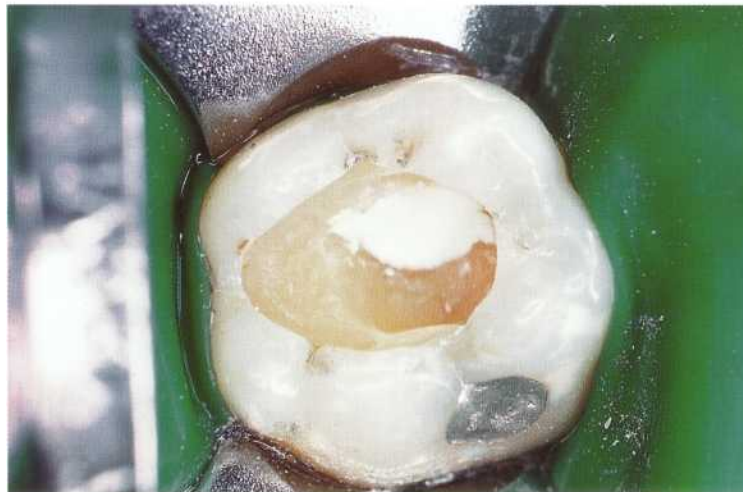
Direct Pulp Cap

Direct capping of a permanent tooth with incomplete root development means covering the exposed pulp with a wound dressing that will induce formation of new hard tissue. The potential for regeneration is at its highest if the pulp tissue is not inflamed at the beginning of treatment (Heys et al. 1985). If there is bacterial contamination due to caries or through contact with saliva for more than 24 hours, treatment success cannot normally be expected. It is also very important that the restoration provide a bacteria-tight seal (Cox and Bergenholz 1982).

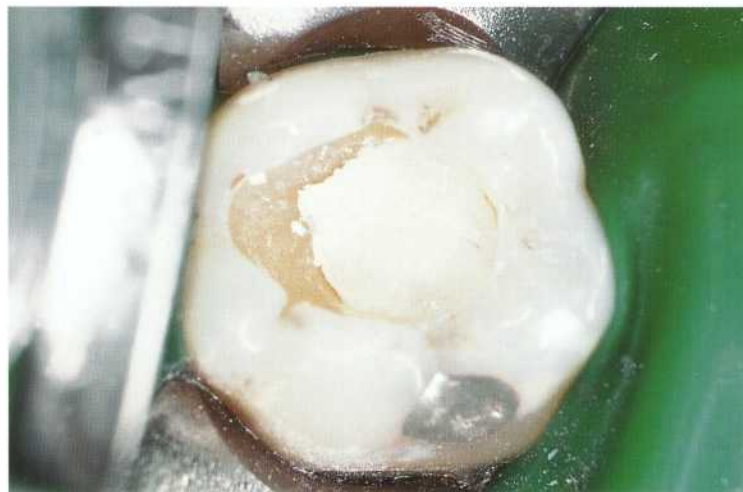The greatest release of calcium ions, and therefore the greatest stimulus for hard-tissue formation, is provided by aqueous calcium hydroxide preparations (Schubich et al. 1978). However, the calcium necessary for a dentinal bridge is available from the body's own tissue (Pisanti and Sciaky 1964). Beneath the zone of tissue necrosis induced by the calcium hydroxide, differentiation of secondary odontoblasts takes place, and irregular osteodentin or tubular tertiary dentin is formed (Schröder and Granath 1971, Fitzgerald 1979, Schröder 1985).



531 Uncovering the pulp
A pulp that does not appear inflamed when it is uncovered during the access preparation has a high potential for regeneration. Bleeding is arrested with a sterile cotton pellet. If a blood clot forms between the pulp and the capping material, the probability of healing is reduced by about 50% (Schröder 1973). In teeth with incomplete root growth the prognosis is quite good, but the chance of success declines with increasing age (Horsted et al. 1985).



532 Pulp capping
Aqueous calcium hydroxide is thinly applied and gently condensed with a sterile cotton pellet. Then it is observed for possible oozing of blood. If blood appears, the capping material must be flushed out, hemostasis must be achieved, and new capping material applied. The paste form of calcium hydroxide is substantially superior to cements because its rate of ion release is twice as high (DeFritas 1982).



533 Restoration
Once again, a prerequisite for successful treatment is a perfectly sealed coronal restoration. If bacteria penetrate through the occlusal filling, inflammation will develop and the pulp tissue will become necrotic. The calcium hydroxide is covered with zinc oxide-eugenol, which in turn can be covered with either zinc phosphate or glass ionomer cement; a restoration is then placed.

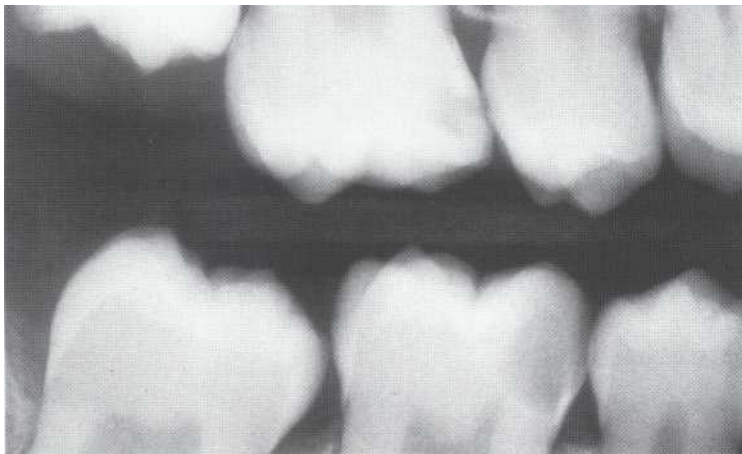Pulpotomy in the Mixed Dentition

The *indication* for a pulpotomy on an asymptomatic permanent tooth with incomplete root development is a wide pulp exposure with or without inflammation limited to the coronal pulp. Pulp amputation is of an interim nature. Besides formation of a hard-tissue bridge, islets of tertiary dentin are formed after 4 months that can almost completely obliterate the root canal. After the completion of root development, root canal treatment should be performed even if the tooth is asymptomatic (Subay et al. 1995).

The goal of a pulpotomy is to maintain the vitality of the pulp in the root canal for a limited period of time so that *further root development* with the formation of an apical constriction can take place (Magnusson 1981). Under anesthesia the coronal pulp is removed with a high-speed diamond bur, the cavity is rinsed with isotonic saline solution, and a sterile cotton pellet is pressed over the entrances to the root canals for hemostasis. A blood clot between the capping medium and the remaining pulp will delay or prevent the formation of a hard-tissue bridge (Masterton 1966).

534 Caries progression

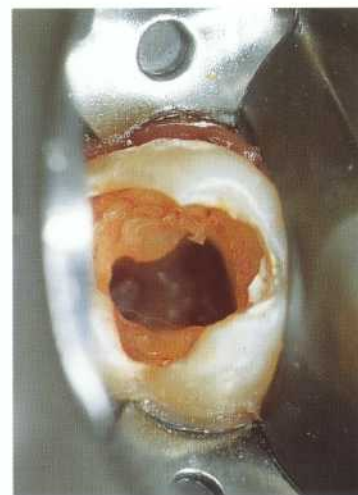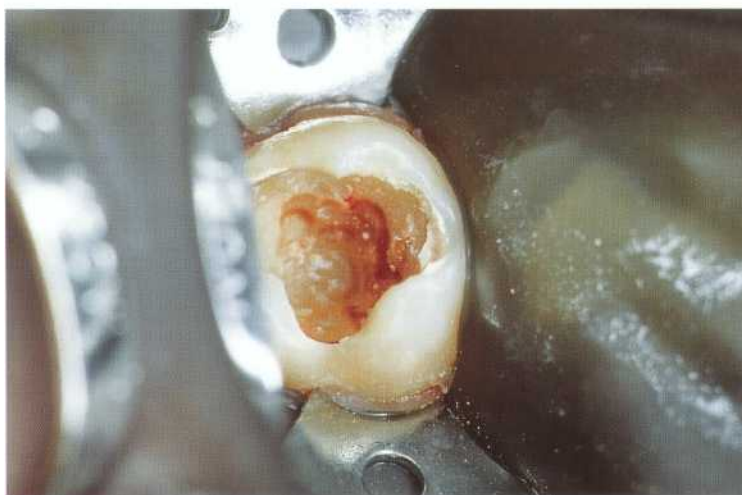The bitewing radiograph in the left posterior region of a 13-year-old girl reveals deep caries on the mesial surface of the lower first molar. There have been no clinical symptoms as yet. Carious lesions can also be seen on the maxillary second premolar and first molar.



535 Access opening

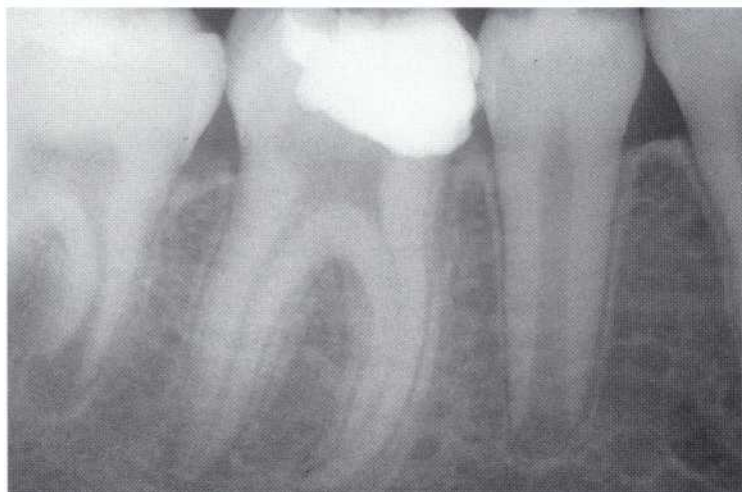An extensive opening into the pulp chamber is created during excavation of caries. As an interim treatment the coronal pulp tissue is removed, and only after completion of root growth is root canal treatment performed.

Right: A high-speed diamond bur is used to remove the coronal pulp tissue down to the level of the canal orifices.



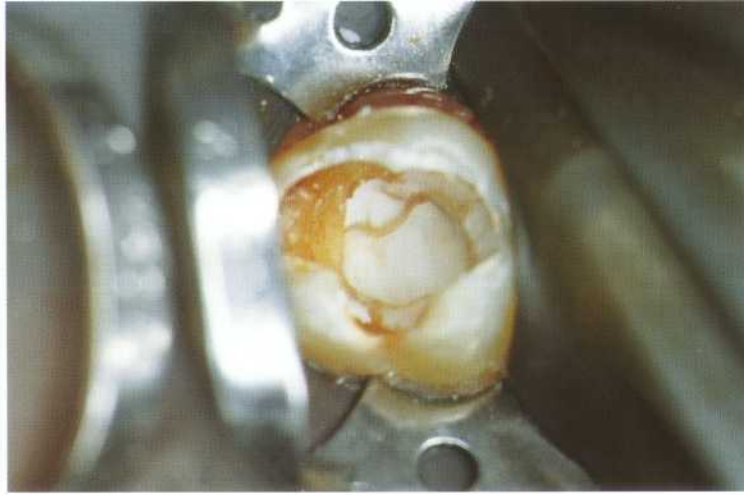
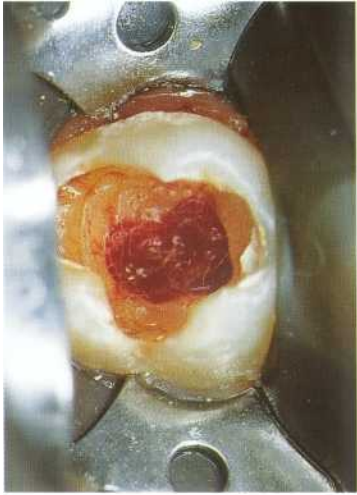
536 Root development

Before root canal treatment is begun, a radiograph is taken to determine the stage of root development. If root growth has progressed sufficiently the pulpotomy is viewed only as an interim measure until the roots have completely developed. Deposition of hard tissue can lead to blockage of the root canals and complicate later canal instrumentation.



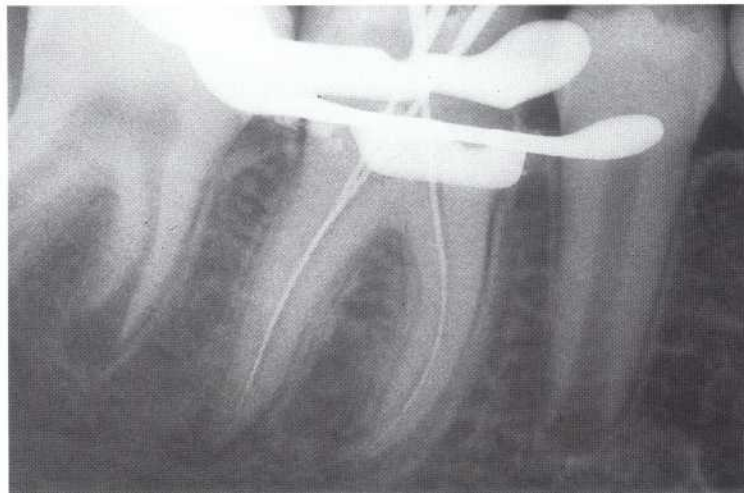
Calcium hydroxide is applied thinly and the cavity is checked for any oozing of blood. Then the layer is built up to a thickness of 2 mm and covered with IRM and glass ionomer cement. Calcium hydroxide is the material of choice for pulp capping in young permanent teeth. When mixed with tricalcium phosphate it induces hard-tissue formation without the initial destruction of the adjacent pulp tissue that is typical of pure calcium hydroxide (Yoshida et al. 1994). Here too, a tight coronal seal appears to be just as important for success (Snuggs et al. 1993).

At regular recall appointments every 3-6 months the treatment result is evaluated clinically and root development is monitored radiographically. Sensitivity tests on teeth with pulpotomies are of little value (Leisenbach et al. 1993). In a clinical investigation on 37 permanent teeth, 93.5% of the cases were successful with no clinical or radiographic evidence of disease. Furthermore, pulpotomy achieved the desired objective even in many cases of symptomatic teeth with periapical lesions (Mejare et al. 1993).



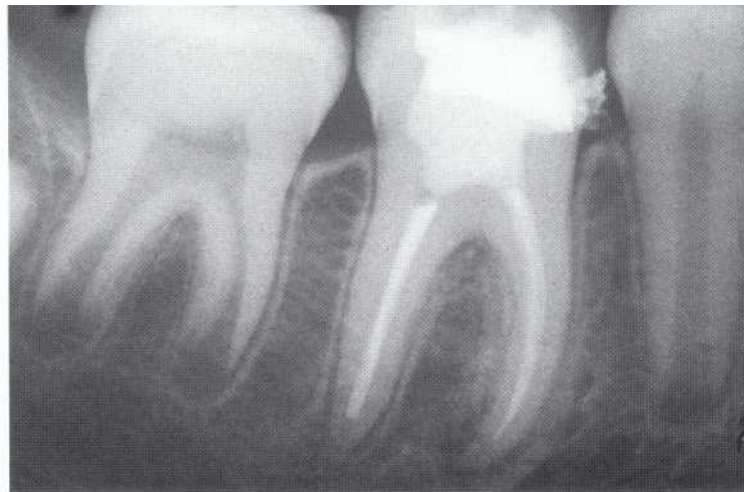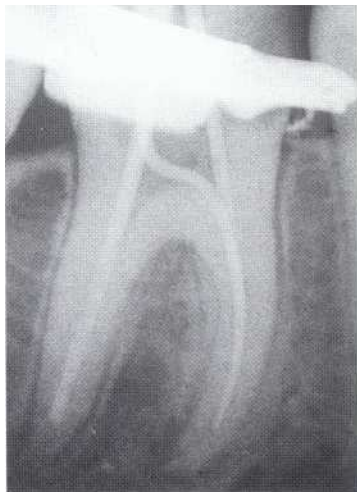537 Pulp capping material
Calcium hydroxide in an aqueous suspension is applied as a thin layer over the pulp stump. A visual inspection then ensures that there is no seepage of blood. Next, the layer is built up to a thickness of 1-2 mm and the coronal cavity is tightly sealed.

Left: Before the capping material is applied, complete hemostasis is achieved through pressure with sterile cotton pellets.



538 Root canal instrumentation

If symptoms recur after the pulpotomy, the amputation is expanded to an apexification procedure because, with irreversible pulpitis, the pulp must be removed. If, on the other hand, no symptoms appear, root canal treatment is delayed until after completion of root development. The tooth is then anesthetized, the working length determined with a radiograph, and the root canals completely instrumented.



539 Root canal obturation

After treatment with an interim dressing, the canals are obturated with gutta-percha and a eugenol-free sealer. Then an adhesive bonding agent is used to seal the cavity and the tooth is prepared for a partial veneer crown.

Left: Before the canals are filled, gutta-percha points corresponding to the sizes of the AMFs are selected and their fit in the canals checked by a master point radiograph.

Teeth with Developmental Defects

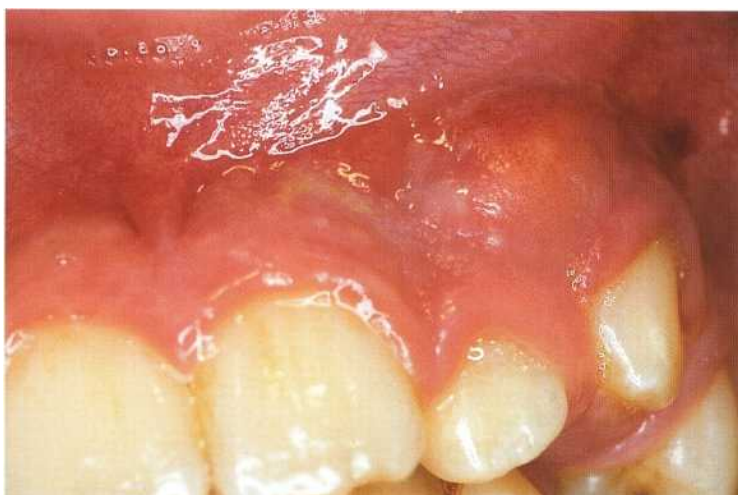Dens Invaginatus

This developmental defect results from the invagination of the mineralized part of the crown: the root may also be included. The incidence of such a *dens in dente* can be as high as 10% of both deciduous and permanent teeth. It is most frequently found on maxillary lateral incisors. A *dens in dente* usually occurs with a conical crown and an enlarged root canal. An enlarged crown and either a normal-sized or enlarged root can also occur (Bimstein and Shteyer 1976). Pulpal necro-

sis can develop as soon as these teeth erupt into the oral cavity. The cause is bacterial invasion through the coronal invagination. If the invagination is small, it can be removed during preparation of the access cavity. When there is a complex invagination, instrumentation should be carried out carefully following the anatomic form. If a *dens invaginatus* is diagnosed early, pulpal necrosis can be prevented by sealing the coronal defect (Rotstein et al. 1992).

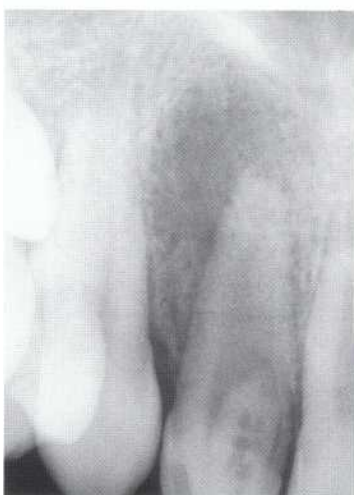540 Abscess formation

A vestibular submucosal abscess at the level of the root tip of the lateral incisor. After drainage of the accumulated pus the incision is irrigated for 5 days and kept open by means of a rubber drain.

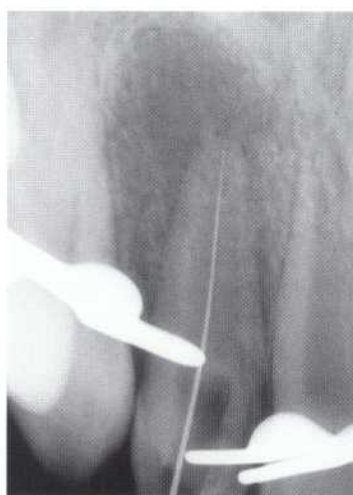

541 Instrumentation

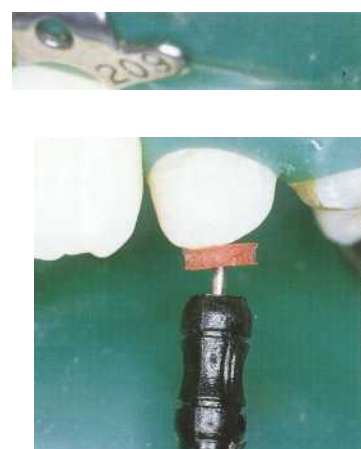Left: The radiograph shows an abnormality in the coronal region that indicates a dens invaginatus. A cherry-sized periapical radiolucency can also be seen.



Center: After the tooth is opened, a wider than usual access preparation is made through which pieces of the invagination have already been removed.

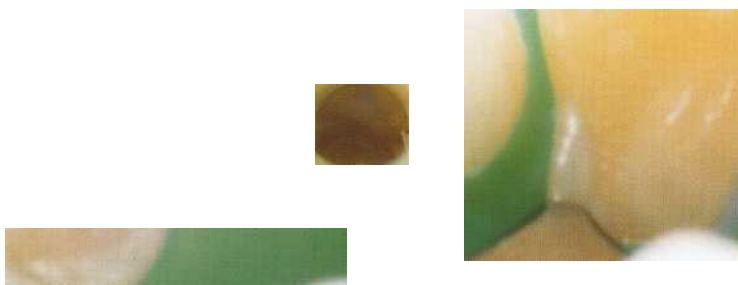


Right: The root canal is prepared to the working length with files.



542 Cleansing

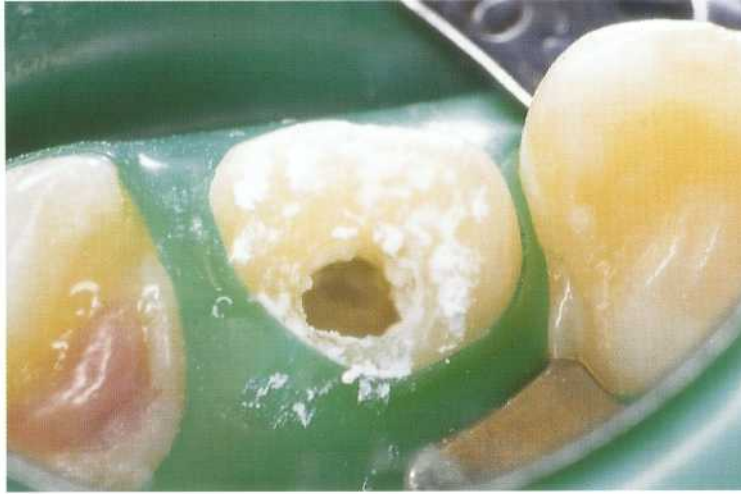
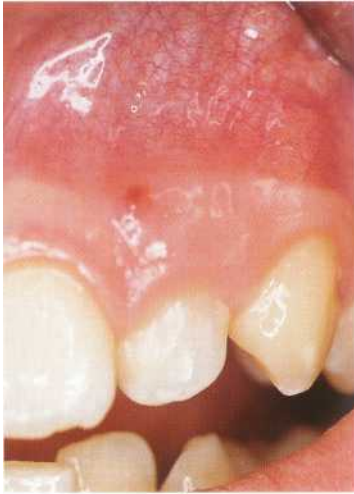The root canal is cleaned with hand instruments. Because of the irregular canal morphology, tissue remains behind. This has to be loosened and flushed out with generous and frequent sodium hypochlorite irrigations.



Lingual Groove in the Root

About 8.5% of teeth exhibit this developmental anomaly. The most frequent location of this developmental defect is also on the maxillary lateral incisors. Lingual root grooves can lead to periodontal bone resorption as a result of bacterial toxins along the groove (Whiters et al. 1981). The bone defect extends as far apically as the groove. An extension of the groove beyond the cervical region is associated with a poor prognosis (Lee et al. 1968).

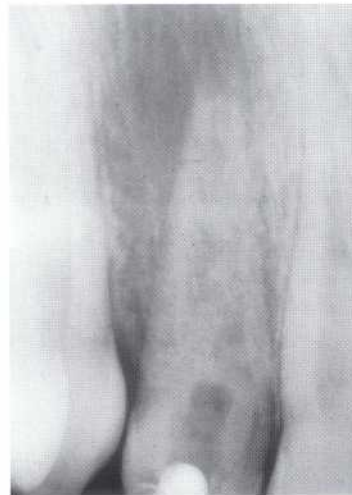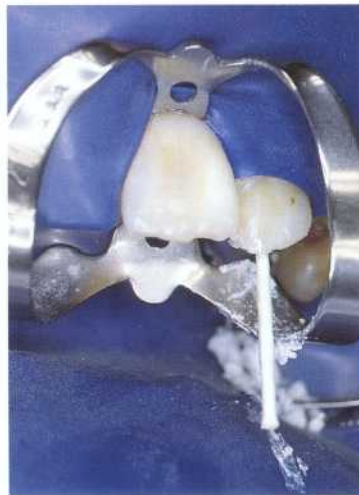Pulpal necrosis can occur as a complication when bacteria penetrate through deep root grooves into the pulp tissue. A lingual groove in a root can be diagnosed on the radiograph as a thin, radiolucent, parapulpal line. A gutta-percha point introduced into a fistulous tract will lead to the lateral periodontal defect. Conservative therapy consists of laying a surgical flap and eliminating, or at least reducing, the root groove by smoothing the root or filling the defect (Rotstein et al. 1992).



543 Interim dressing

Calcium hydroxide is packed into the dried root canal with paper points. If the exudate is heavy the interim dressing is changed after 7 days and again after an additional 30 days.

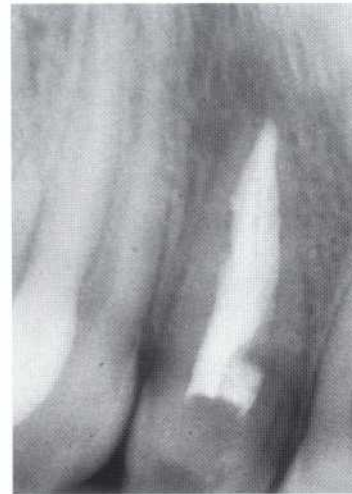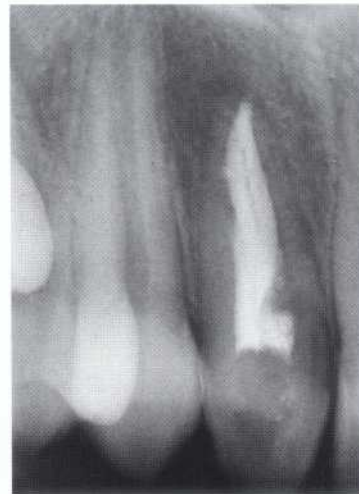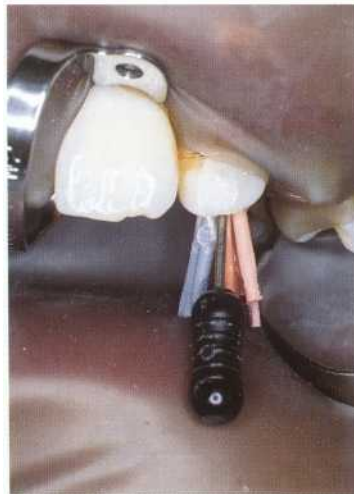Left: After only a few days the swelling has receded and the blood supply to the mucosa is nearly normal.



544 Apical regeneration

Left: The last interim dressing is left in the root canal for another 3-6 months to exert its tissue-dissolving and antibacterial effects.

Right: The radiograph taken after 3 months shows definite regeneration of the periapical bone. The outline of the root canal appears indistinct because of the calcium hydroxide filling.



545 Root canal obturation

Left: After the gutta-percha master point is fitted and adjusted, the root canal is obturated with additional gutta-percha and sealer following the lateral condensation technique.

Center: The radiograph taken immediately after placement of the filling shows a good apical seal.

Right: The follow-up radiograph after 1.5 years.

Apexification

The *indication* for an apexification procedure on a tooth with incomplete root development and either with or without clinical and radiographic symptoms is pulpal necrosis. Further root development in a necrotic tooth is unlikely. The walls of the root canal diverge apically, preventing the preparation of an apical stop. Treatment is therefore directed at inducing the formation of a hard-tissue buttress that can help prevent overfilling of the canal. The material best suited to this purpose appears to be calcium hydroxide (Heithersay 1975).

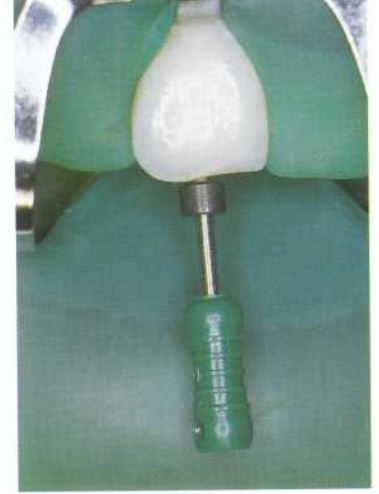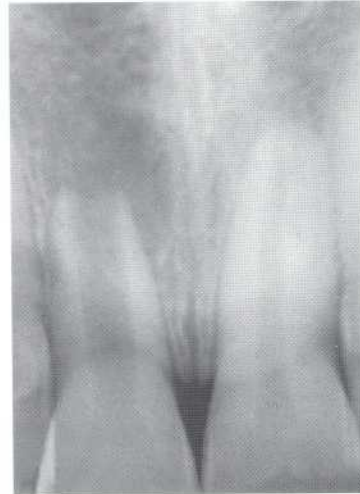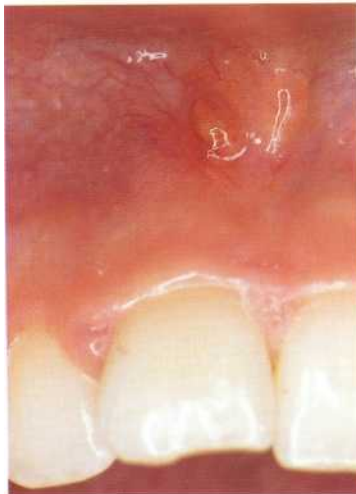The working length is set 2 mm shorter than normal to avoid overinstrumentation. Also, because of the thin dentinal walls, the canal must not be widened excessively, and thus must be irrigated generously. If root canals with open apices are filled for 3 months with Calasept and if the dressing is changed every 4 weeks, the periapical radiolucency will regenerate with the formation of cementoid hard tissue. When the root canals are not filled with calcium hydroxide, the inflammation persists and an apical seal cannot be achieved (Leonardo et al. 1993).

546 Pulpal necrosis

Left: This maxillary right central incisor of a 14-year-old girl is asymptomatic but has a vestibular fistula and an enamel defect that is presumably of traumatic origin.

Center: The radiograph shows the tooth to have a periapical lesion and an apical foramen that, in comparison with the adjacent tooth, is wide open.

Right: The working length is set 2 mm shorter than the length of the tooth as measured on the first radiograph.

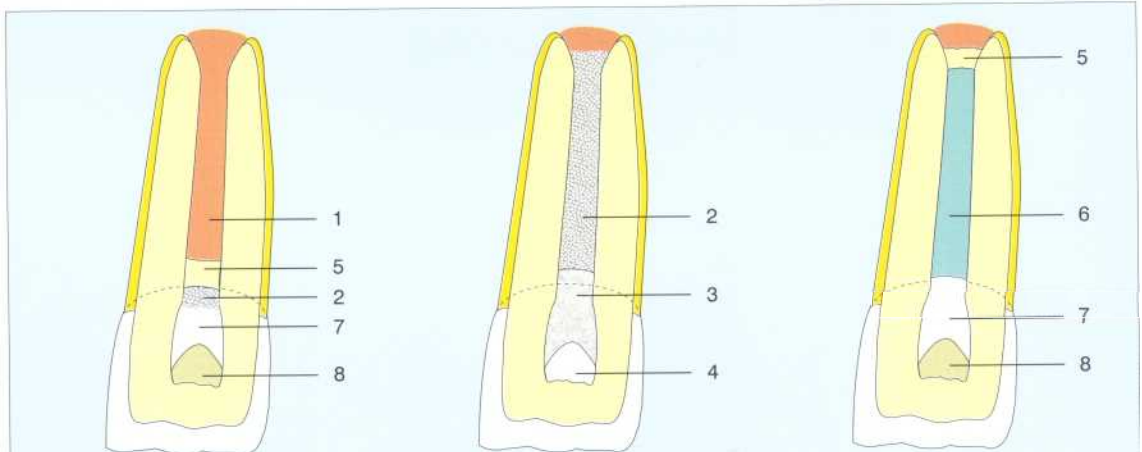


547 Root canal dressing

For a vital amputation (left) the pulp tissue (1) is covered with calcium hydroxide (2), glass ionomer cement (7), and composite (8), and a dentinal bridge (5) is formed.

For apexification (center) on the other hand, the entire root canal is filled with calcium hydroxide (2), and the coronal cavity is sealed with ZnOE (3) and a dense provisional filling (4).

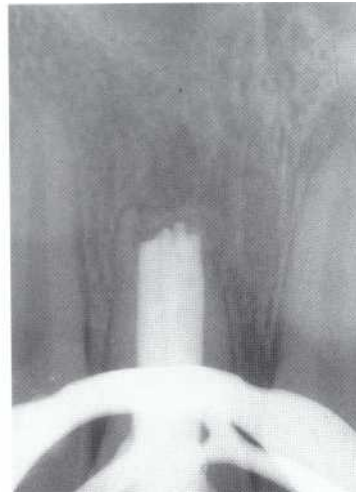
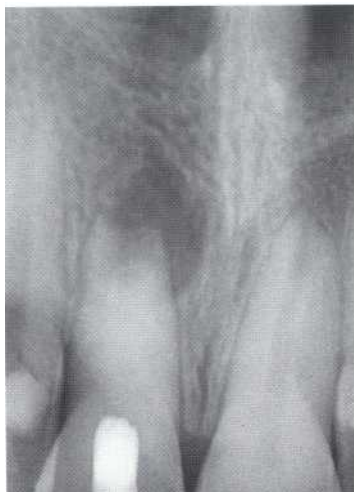After a period of no less than 9 months (right) a hard-tissue bridge (5) will have formed at the apex and the canal can be filled with gutta-percha (6).



548 Monitoring progress

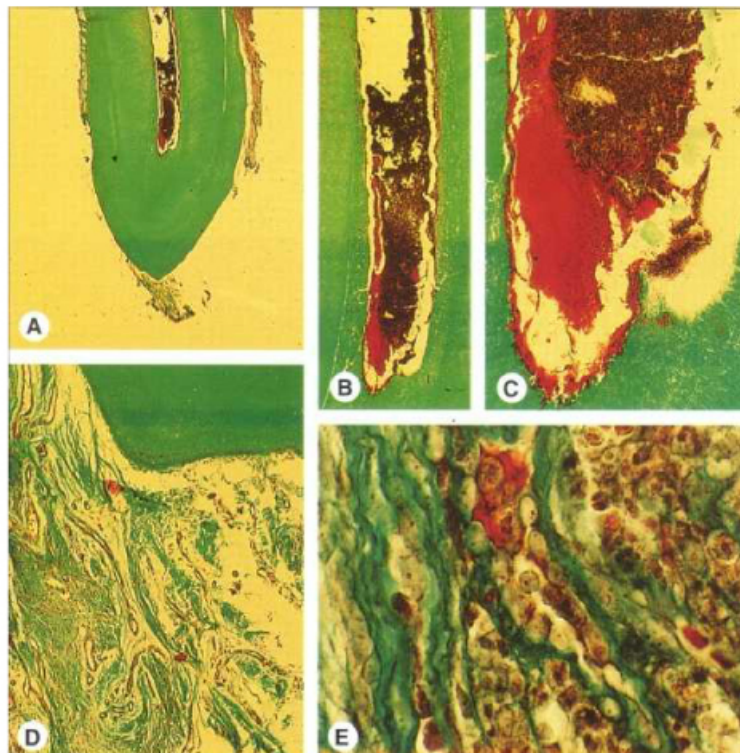
Left: After careful instrumentation, the root canal is filled with calcium hydroxide. Because of its resorption by periapical inflammation, the dressing has to be changed initially every 4 weeks.

Right: After 20 months the dressing is removed and the root canal filled with gutta-percha. The radiograph shows healing of the periapical lesion and a hard-tissue bridge.



Retreatment of Endodontic Failures

Endodontic failure following insufficient instrumentation and removal of microbial infections or inadequate obturation is often ultimately due either to carelessness of the operator, a misunderstanding of the treatment concepts, or the use of toxic materials. It could also be traced back to inadequate familiarity with root canal anatomy or failure to follow complex root canal systems (Scianamblo 1993). Reasons for retreatment include failure because of a root canal filling that is too short, a significantly overfilled or underfilled root canal, or a perforation. A distinction is made between retreatments of teeth without clinical symptoms or radiographic changes and retreatments in the presence of clinical symptoms and/or radiographic lesions. Retreatment is indicated with symptoms such as fistulation, swelling, pain, percussion tenderness, discomfort during chewing, and in cases in which the apical lesion becomes larger or is not diminishing. In these cases there is chronic apical inflammation and persistence of the periapical radiolucency. Such failures are most common with paste fillings that not only fail to seal the root canal sufficiently, but are also resorbed to a greater or lesser extent over time. Retreatment of an inadequate root canal filling should eliminate the infection and prevent reinfection (Beer and Baumann 1994 a).



549 Inadequate root canal filling

- A A paste filling that contains formaldehyde in an incompletely instrumented root canal. There is periapical accumulation of inflammatory cells.
- B A poorly adapted filling with voids is visible at higher magnification.
- C An even greater magnification shows remnants of fixed pulp tissue at the end of the paste filling.
- D The periapical region shows signs of inflammation.
- E Particles of filling material are distributed throughout the tissue and have attracted clusters of foreign-body giant cells and neutrophilic granulocytes.

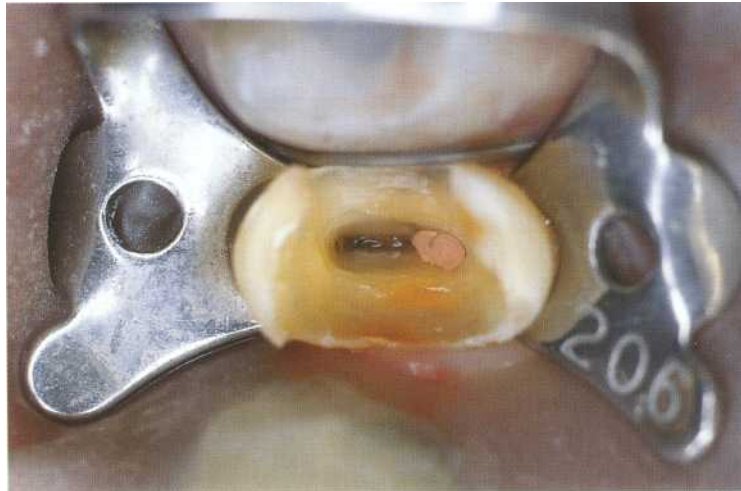Failures and Root Canal Anatomy

Overlooked primary canals or apical ramifications are the most common causes of endodontic failure. About 40% of all mandibular incisors have two root canals, whereas two apical foramina are found in only 1%. During retreatment, both orthoradial and eccentric radiographs must be taken to better reveal anatomic variations. Eighty-four percent of all maxillary first premolars and 58% of all maxillary second premolars have a second root canal. Furthermore, 8% of the first premolars have three or more primary ramifications (Vertucci 1974).

During embryonic development the mesiobuccal and mesiolingual root canals of the maxillary first molar originally have one primary canal each. As development progresses, the tendency to invagination and deposition of hard tissue arises so that the canal in the lingual portion of the mesiobuccal root is reduced and becomes partially or completely obliterated (Pineda 1973). When a failure occurs in a maxillary molar, failure to instrument and treat one or more canals or foramina is the probable cause.

550 Overlooked canal

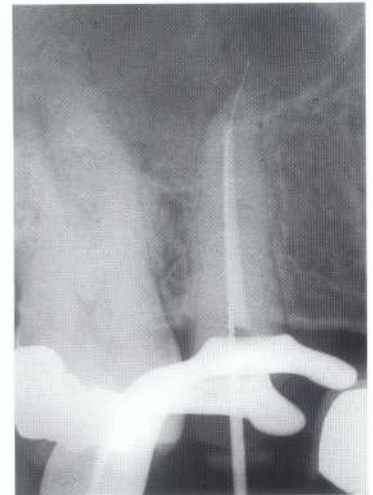
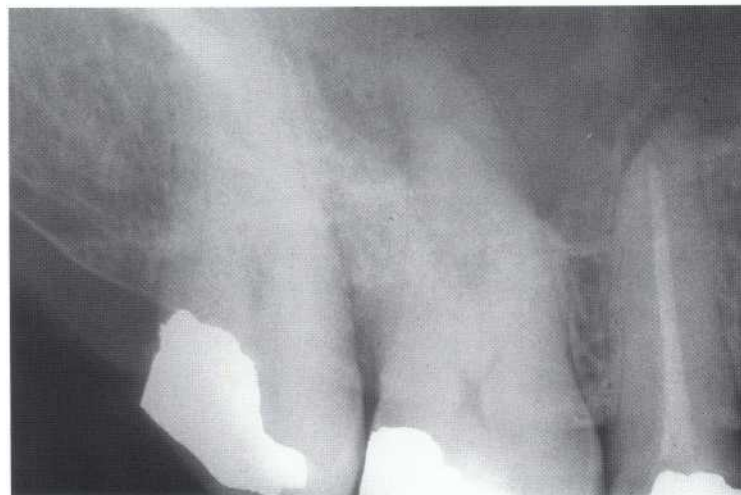In the access preparation of a maxillary second premolar, one filled canal and a second unfilled canal are found. Since completion of the first endodontic treatment the patient has been complaining of severe spontaneous pain, but this did not lead the dentist who placed the filling redoing the treatment.



551 Periapical radiolucency

Left: A periapical radiolucency and root canal filling, which appears to be successful, can be seen in the diagnostic radiograph. The filling however, does not extend into the apical curvature.

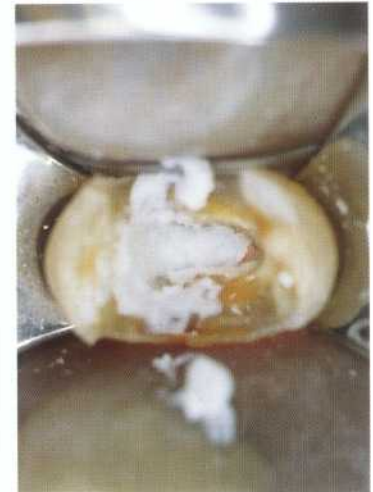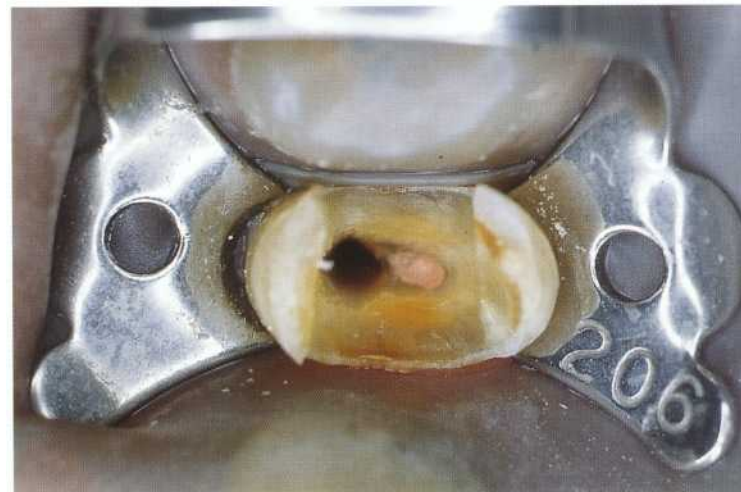Right: The working-length radiograph shows a patent second canal. The length is adjusted before further instrumentation.



552 Instrumentation

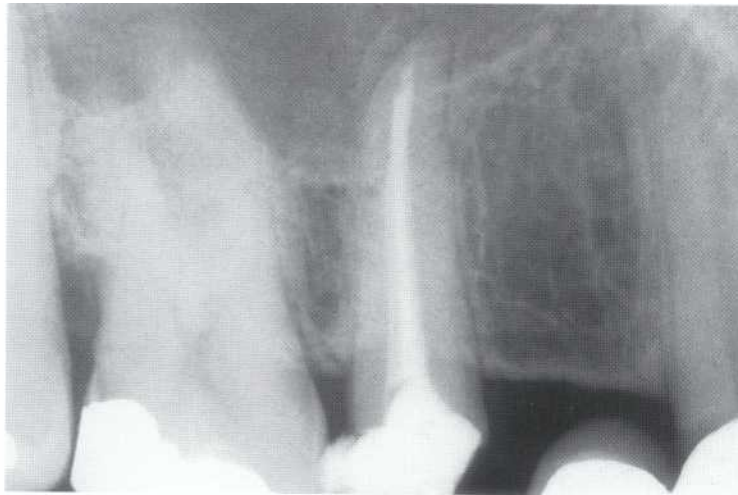
The second canal is completely instrumented all the way to the apical constriction. It is decided to leave the filling in the first canal in place, because on the radiograph it appears to be well adapted.

Right: Calcium hydroxide is packed firmly into the root canal and the cavity is then sealed with a bonded restoration.



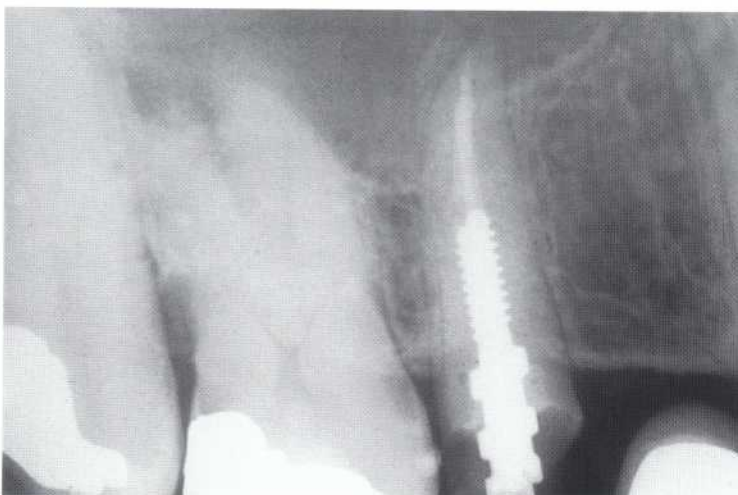
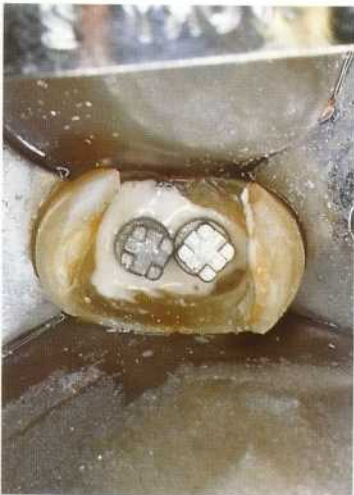Mandibular premolars have the most complex root canal system. DeDeus et al. (1975) discovered two primary ramifications in approximately 31% of first premolars and 11 % of second premolars; 3% even had a third main canal. The root canals must be probed with a fine prebent size 08 file. Here the file is advanced along the outer wall of the first canal located until resistance or a branching is felt. The additional canal is then made fully accessible through gentle rotating movements (Scianamblo 1993).

Secondary and tertiary ramifications as lateral or accessory canals are branches of the primary root canal that open into the periodontal space. More than 20% of all anterior teeth and 50% of posterior teeth have multiple ramifications (Burch and Hulen 1974). These branches are difficult to find with instruments, but can be cleaned effectively by copious irrigation with sodium hypochlorite. During reinstrumentation they usually become closed by paste or dentin shavings so that not all tissue can be completely removed (Scianamblo 1993).



553 Canal filling

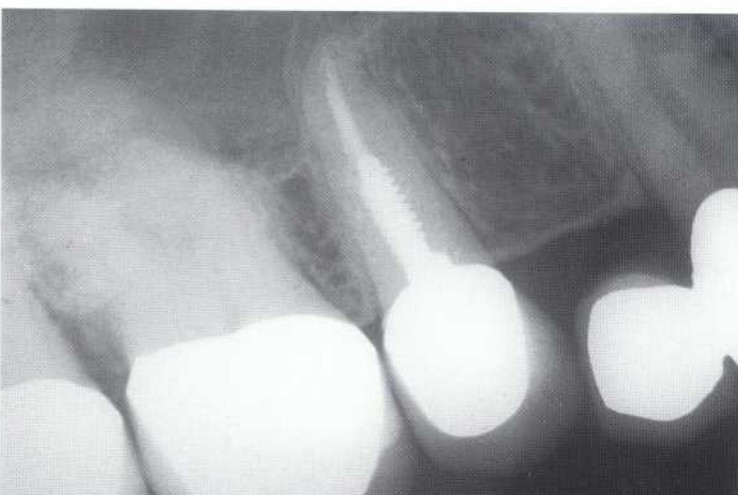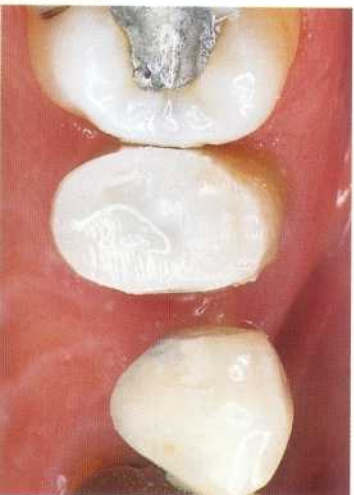The interim dressing is flushed out 3 months after it is placed, and the second root canal is filled with gutta-percha and sealer. The beginning of bone regeneration can be seen in the area of the periapical radiolucency.



554 Post and core buildup

After an additional 2 months the crown of the tooth is built up again. Two threaded posts (Endofix-A) are placed passively into the prepared post spaces, and their positions are checked with a radiograph.

Left: Threads are cut into the post spaces and the posts are then inserted with polycarboxylate cement.



555 Crown restoration

One year after the beginning of endodontic retreatment the periapical radiolucency has completely healed and the tooth is restored with a full coverage crown. The root canal treatment is not considered complete until the definitive restoration is placed.

Left: Before the artificial crown is made, the tooth is built up with a bonded composite restoration, then the crown preparation is cut.

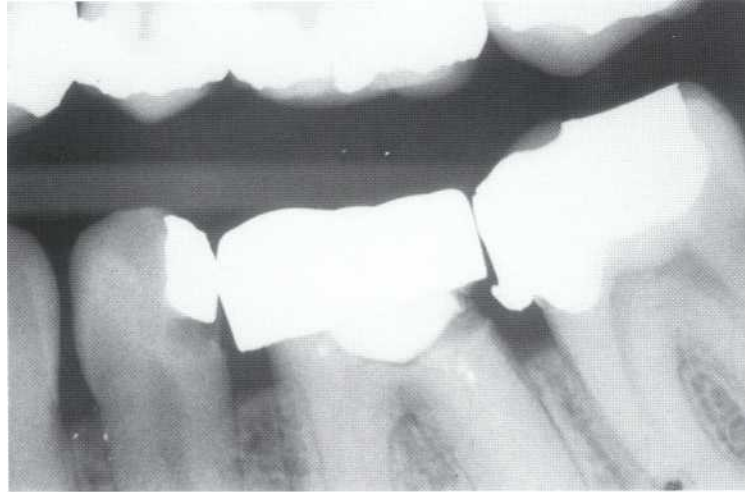
Indications for Retreatment

The primary cause of endodontic failure is bacteria remaining in the root canal system. Grossman (1972) classified the causes as: (1) incorrect diagnosis, (2) poor prognosis, (3) technical difficulties, and (4) careless treatment. In the Washington study (Ingle 1985) the primary cause of 76% of the failures was treatment error, such as incompletely filled canals, unfilled canals, perforations, severe overfilling, and broken instruments. Poor case selection was responsible for 22% of the failures.

Nair et al. (1990a) conducted a study with optical and electron microscopes to determine the cause of therapy-resistant periapical lesions associated with asymptomatic teeth. Within a time span of 4-10 years 10% of the endodontically treated teeth required surgical retreatment. Six out of nine biopsies revealed microorganisms in untreated apical sections of the root canals and four of these contained multiple bacterial species. In other cases without evidence of bacteria, giant cell granulomas were present as foreign-body reactions to the filling material.

556 Prosthetic treatment

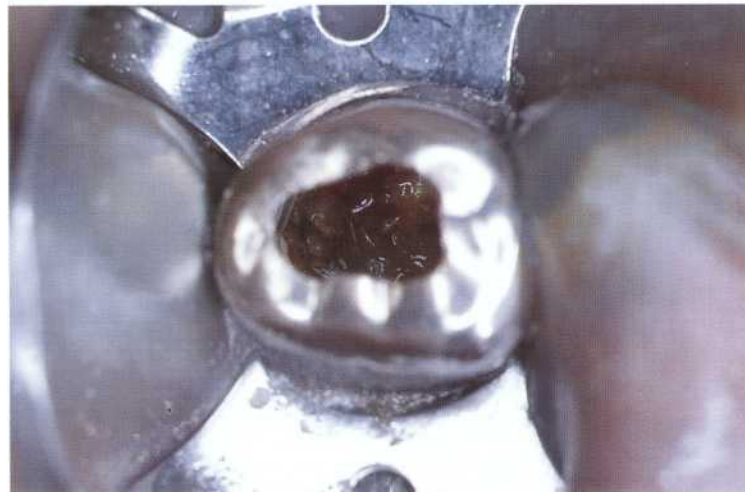This pretreatment bitewing radiograph of the right posterior region of a 41-year-old patient shows inadequate crowns and fillings with overhanging margins, as well as recurrent caries on the lower second premolar and first molar. The first molar exhibits no clinical symptoms and presumably endodontic treatment had been attempted earlier, as evidenced by the remnants of root canal filling material found in the canals.



557 Access preparation

When the access opening is made through the crown, carious destruction of the hard structures is found. All carious dentin is removed to the level of the canal orifices and these are then probed.

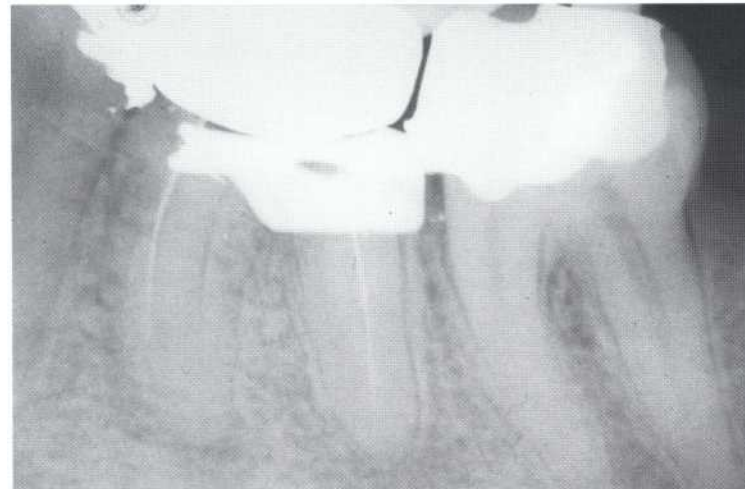
Right: To prevent penetration of the root canals by saliva and microorganisms between appointments, Cavit is placed in the cavity and condensed.



558 Instrumentation

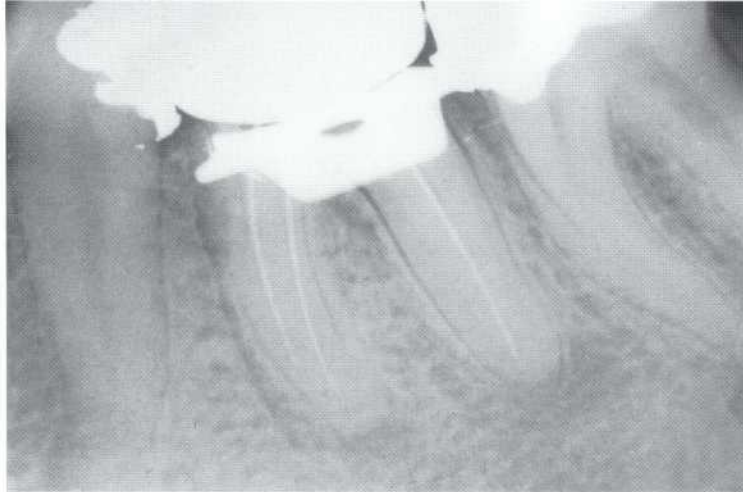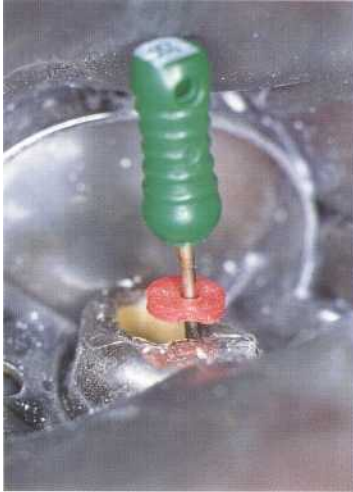
The partially obliterated root canals are carefully probed with thin files and their locations verified with a first radiograph.

Right: Copious irrigation with sodium hypochlorite loosens tissue remnants and helps to overcome obstructions.



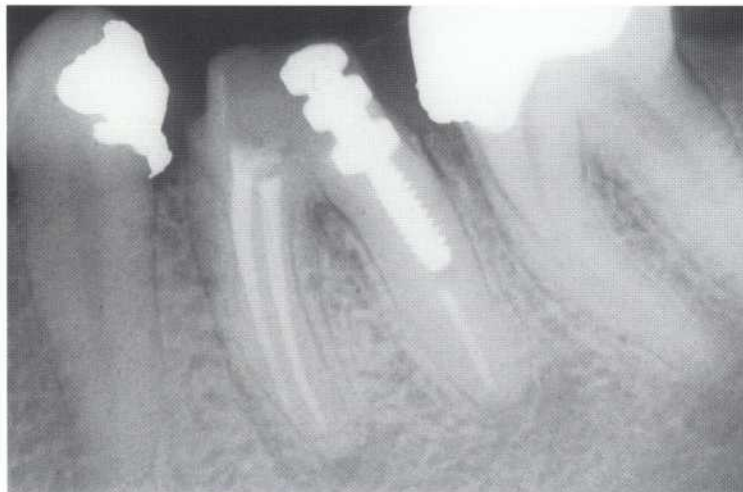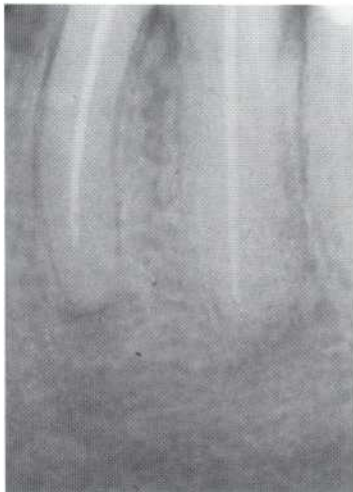
Indications for retreatment of endodontically treated teeth are periapical radiolucencies that have not decreased in size after 4 years, and newly formed periapical radiolucencies. Further indications are exclusively clinical symptoms such as tenderness to percussion, apical pain as a response to pressure, fistula formation, and swelling of the soft tissues, all of which are indications of apical periodontitis. Incomplete root canal fillings must be replaced before prosthodontic treatment, even if the teeth are asymptomatic. The same is true of root canal fillings that have been exposed to the oral

environment for any length of time. Neglecting to take adequate radiographs can also lead to treatment failures in endodontia. The dentist cannot plead that the patient did not wish, or refused, to have radiographs taken when they were necessary for diagnostic purposes or for selection of appropriate treatment (Hulsmann 1995). According to Gunther (1967), the radiograph is indispensable for reviewing and complementing the clinical diagnosis, monitoring the progress of the root canal treatment, evaluating the filling, and for making the final restoration.



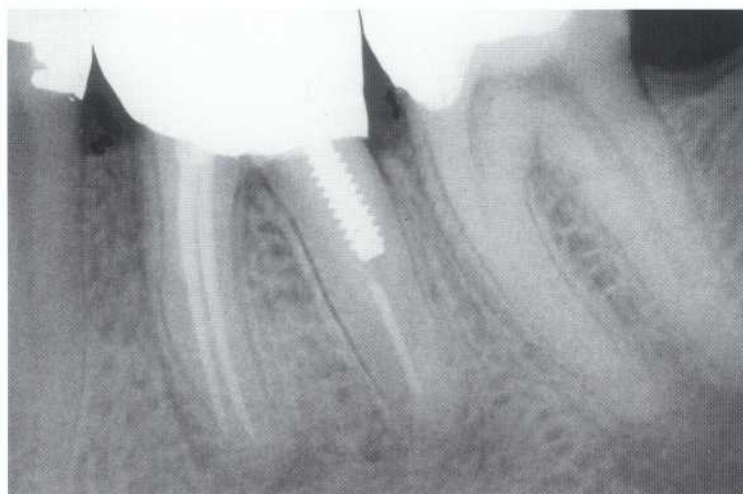559 Instrumentation
After the initial uncovering and enlargement of the coronal segments of the root canals, a second radiograph is taken to determine the working length.

Left: The root canals are enlarged by four sizes to the apical constriction. The AMF is size 35.



560 Canal obturation
At the second appointment at least 4 weeks later, the asymptomatic tooth is filled with gutta-percha and sealer. The interim crown is then removed and a threaded post is inserted into the distal canal.

Left: Gutta-percha points are fitted to evaluate the adequacy of the canal enlargement. The mesiobuccal canal preparation has to be lengthened by an additional 1 mm.



561 Artificial crown
A core buildup is placed, the tooth is prepared for a crown, and an impression is made for a full gold crown. The fillings in the adjacent teeth are replaced or recontoured as needed. This radiograph taken 3 years after root canal treatment shows no indication of periapical inflammation.

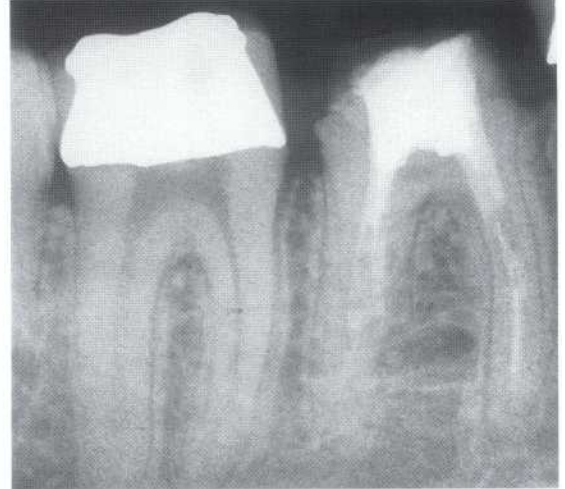
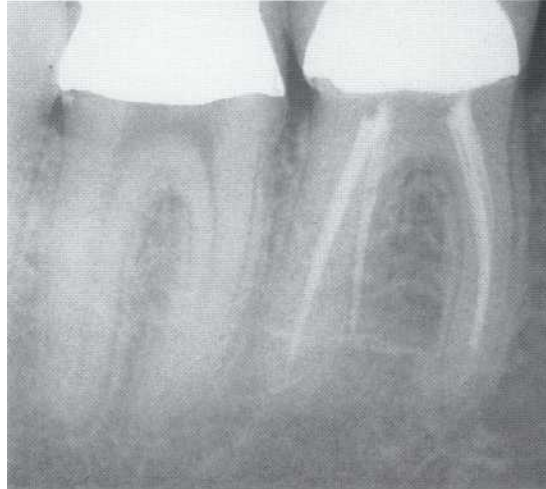Pain Following Root Canal Treatment

Within hours or a few days, pain in combination with swelling can appear. In the investigation by Walton and Fuad (1992), pain occurred in only 32% of 946 endodontically treated teeth. Pain was associated with a necrotic pulp in 6.5% of the cases, and with irreversible pulpitis in only 1.3%. Nineteen percent of cases with severe pain present at the beginning of treatment also experienced postoperative problems, but postendodontic problems occurred in only 1.7% of cases with slight initial pain.

In the study by Lin et al. (1991) more than half of 150 failures were not associated with clinical symptoms. Pain was present in only one-fourth of the cases. In two-thirds of the teeth bacteria were found, and the severity of the inflammation was correlated with the presence of bacteria in the canal. Bacteria were found in 80% of teeth with pain as the only symptom, and in 75% of teeth with swelling as the only symptom. Pain combined with swelling occurred only in the simultaneous presence of bacteria, and bacteria were responsible for the formation of 84.6% of fistulas.

562 Postoperative pain

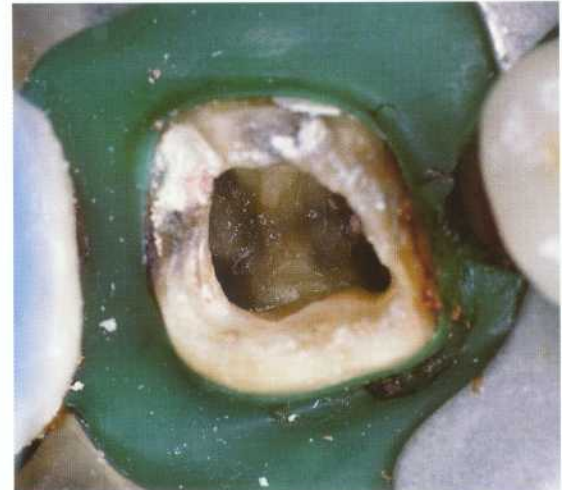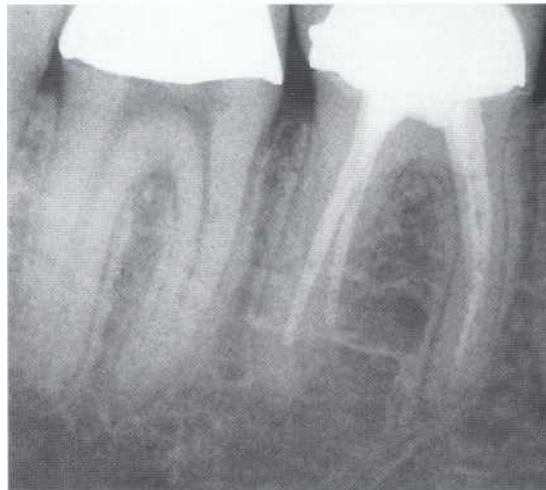Left: The mandibular first molar had four canals endodontically treated and filled. In spite of this, the severe pain that was present before treatment persisted.



Right: The crown and root canal filling are removed and the root canals retreated. The canals are temporarily filled with a prednisolone-antibiotic mixture (Ledermix) to relieve the pain.

563 Instrumentation

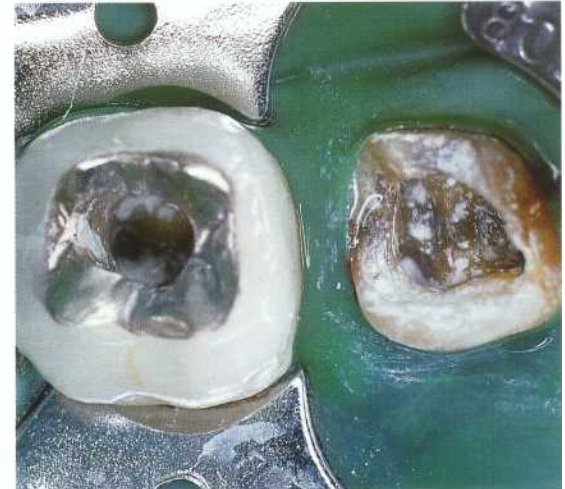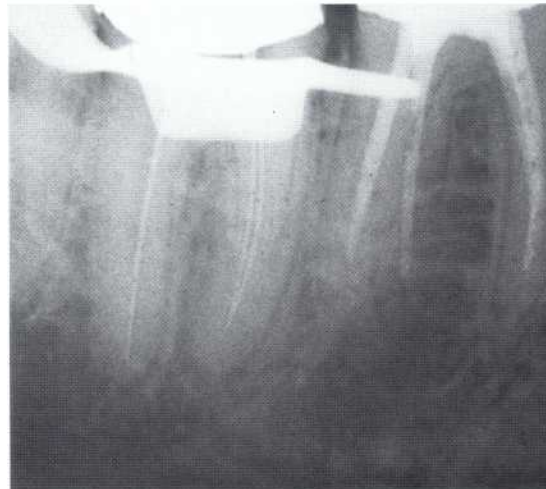Left: Due to persisting pain the interim dressing is removed and the canals are filled with a calcium hydroxide paste.



Right: The dressing is removed again within 1 week because the patient described the pain as almost unbearable.

564 Alleviation of pain

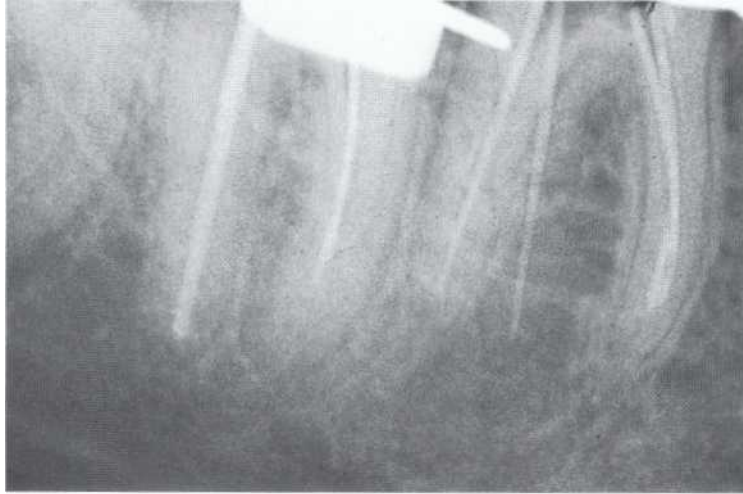Left: Due to persisting pain the second molar is also endodontically treated. This radiograph determines the working length.



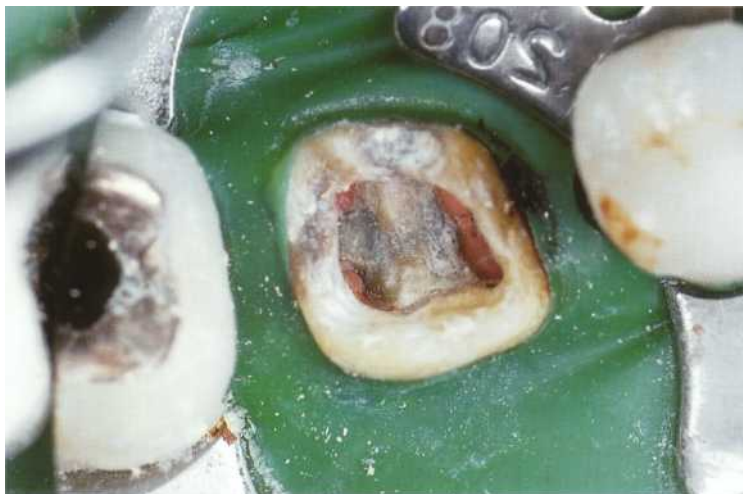Right: After the interim dressing was placed in the canals and the tooth was closed once again, the patient was free of pain.

Of all the parameters investigated in another study, only the following three were related to the occurrence of postoperative pain: pain at the beginning of treatment, anxiety before treatment, and certain medications administered after the endodontic procedure. When postoperative pain was mild, no difference was found between the placebo and a specified medication. However, when the pain was severe, ibuprofen and especially erythromycin and penicillin were significantly more effective than a placebo (Torabinejad et al. 1994).

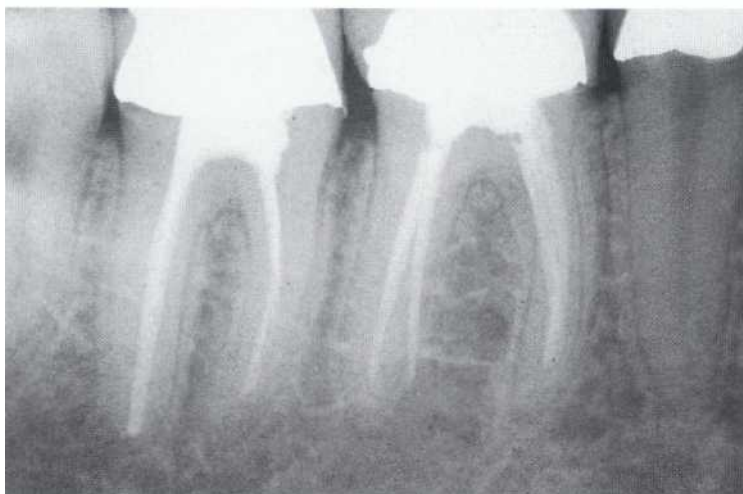The type and manner of instrumentation of the root canal and the extrusion of potentially infected dentin shavings into the pulp tissue favored the occurrence of postoperative pain (Bystrom and Sundqvist 1985). The root canal anatomy, however, can also influence the postoperative results. In histologic sections of root canals that were C-shaped in cross-section (occurring in 13.9% of all molars), the amount of debris remaining and the portions of uninstrumented canal walls were especially noticeable, especially in the middle and apical thirds (Simon 1993 a).



565 Root canal obturation
After the patient was free of pain for 4 weeks the root canals were filled. This radiograph shows the fitted gutta-percha master points in both teeth.



566 Root canal obturation
A bacteria-impervious obturation of the seven root canals is accomplished by lateral condensation, and the coronal openings of both teeth are then sealed.



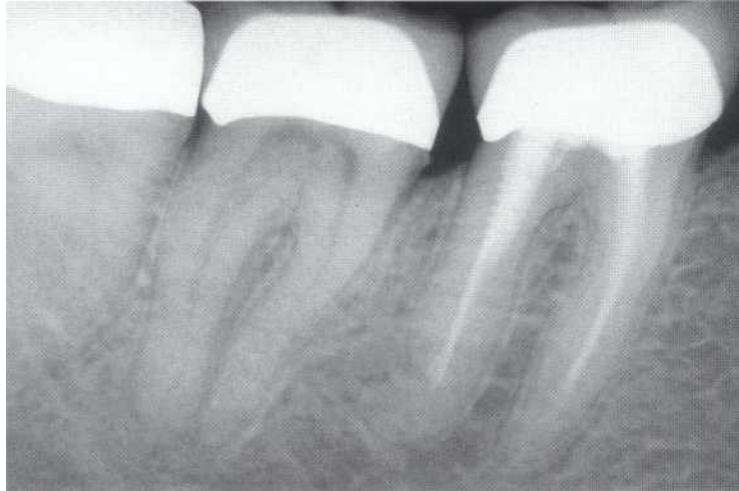567 Freedom from pain
The follow-up radiograph taken 2 years after treatment shows normal periapical bone structure. The patient has been completely free of pain since both teeth were endodontically treated.

Removal of Post-Cores

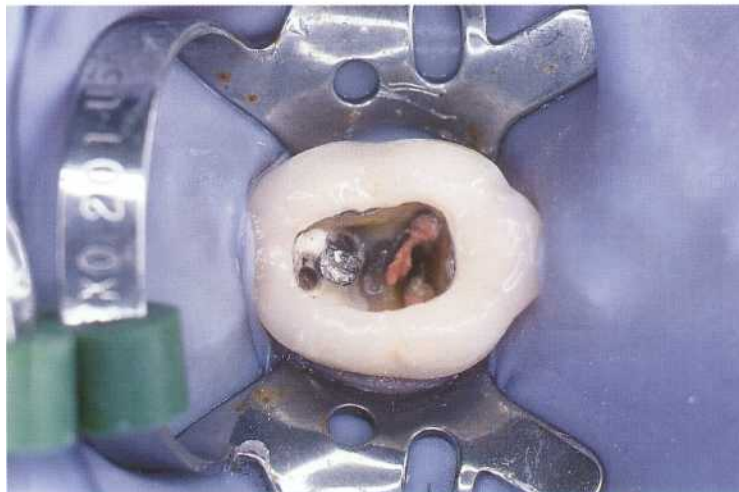If the tooth has been treated with a post-core and crown, these should be removed before the tooth is retreated. Once the artificial crown has been removed, the tooth anatomy can be better verified and a better access preparation can therefore be made. With the restoration removed, it is easier to evaluate the diagnostic radiograph in regard to perforations and the length of a silver point or other obstruction in the region of the canal orifices. A vertical fracture and the extent of carious demineralization can also be better evaluated with the crown removed (Stabholz and Friedman 1988).

The preparation for a post-core weakens the tooth structure. When such a restoration must be removed there is a risk of tooth fracture. The removal of a screw post is usually less dangerous, with the risk rising in direct proportion to the increase in contact area. Ultrasound weakens the adhesion to the canal wall and greatly simplifies removal of the post. Cement remnants must be broken up with a sharp ultrasonic scaler before the post is loosened. Use of diamond or carbide steel burs is contraindicated.

568 Pain as an indication for retreatment
 The mandibular first molar had an artificial crown, a post-core, and a root canal filling that was too short. Intermittent pain led to the decision to repeat the 2-year-old endodontic treatment, even though there were no radiographic signs of pathology.

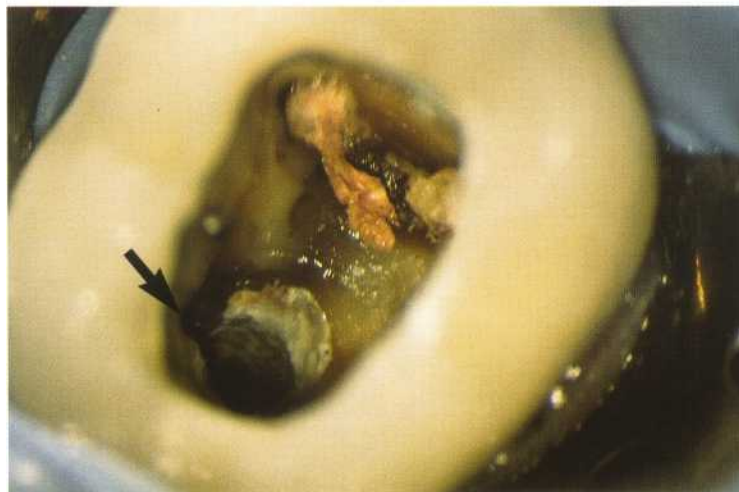


569 Removal of the core and threaded post
 A relatively large occlusal cavity is milled through the clinically acceptable crown and most of the core material is removed. All the cement is then removed from around the post with a sharp tapered ultrasonic scaler.



Right: Next, a broad ultrasonic insert is guided around the threaded post at a height of approximately 2 mm to loosen it.

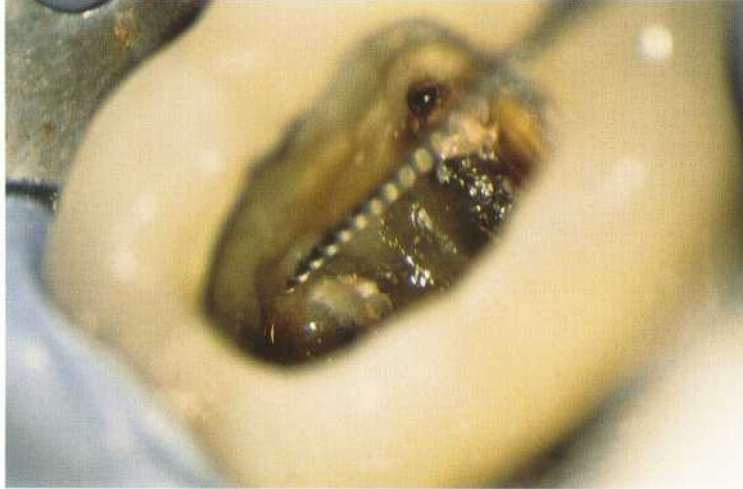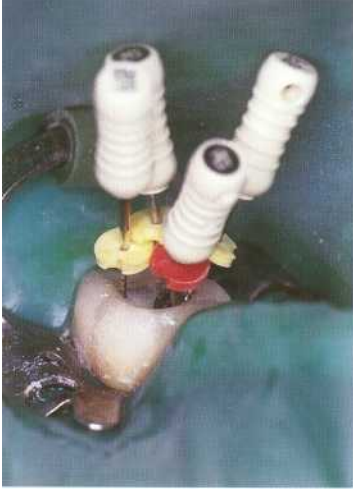
570 Locating the canal orifices
 After about 6 minutes the threaded post became noticeably loosened and was removed from the canal with forceps.



Right: With the help of an operating microscope and an explorer the floor of the cavity is inspected. No fracture line is found, but the entrance to a fourth canal is detected next to the filled distal canal.

Parallel-sided paraposts were cemented with zinc-phosphate cement in preparations 4 mm deep within root canals. By using an ultrasonic device it was possible to loosen them within 8 minutes and then remove them with a Luer forceps, using a force of approximately 1 kg. Scalers vibrating in the sonic range, on the other hand, were unable to even partially loosen the posts within 60 minutes, and therefore are not indicated as an aid to post removal (Buoncrisiani et al. 1994).

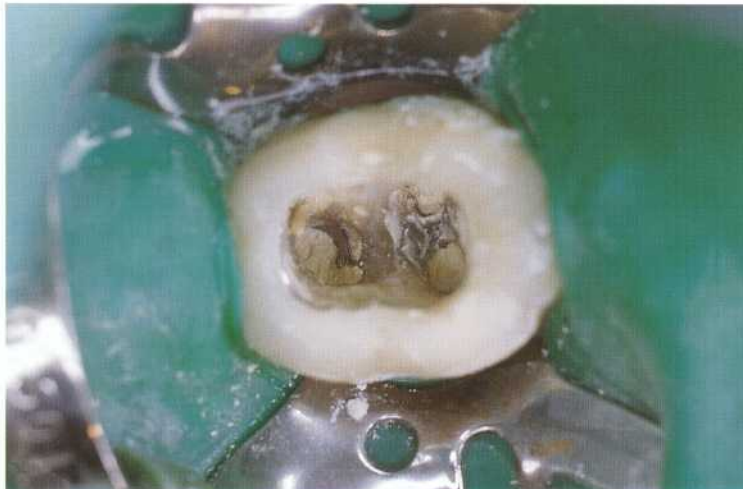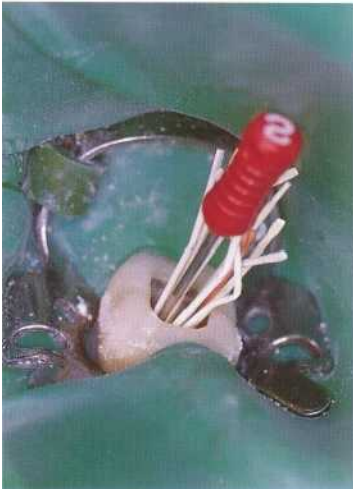
A very effective method for removing post-and-cores is by using the Gonon post remover. After the post-core has been removed, the canal orifices must be located, preferably with the help of magnifying loupes or an operating microscope. At this time the floor of the cavity should be examined visually for fracture lines that would indicate that a vertical fracture had occurred during removal of the post, and that the chance for a successful retreatment is greatly reduced. If no fracture is detected, the root canals are then reinstrumented.



571 Necrotic tissue

The cause of the pain is presumed to be the untreated fourth root canal that contains necrotic tissue, although no bacterial infection or periapical radiolucency were apparent.

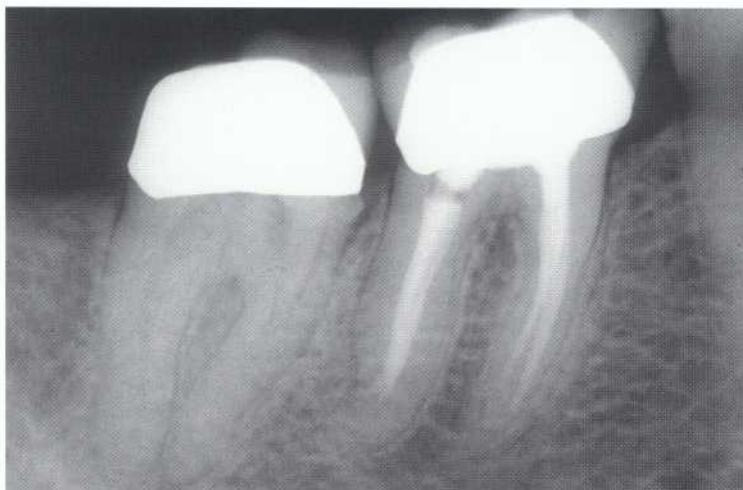Left: The newly found root canal is instrumented and the three previously treated canals are reinstrumented. Files are shown in place for a working-length radiograph.



572 Root canal obturation

After 3 months with a calcium hydroxide interim dressing in place, all four root canals of the now asymptomatic tooth are filled with gutta-percha.

Left: The photograph shows gutta-percha being condensed by the lateral condensation technique.



573 Radiographic evaluation

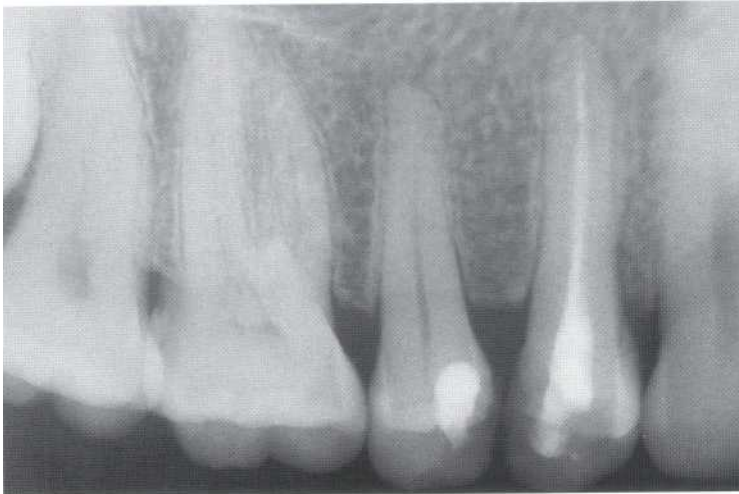A radiograph taken after completion of the retreatment shows greater enlargement of the root canals and a more dense obturation when compared with the initial radiograph. The distal canals end 2 mm above the radiographic apex, as can be seen by the laterally branching filling material.

Retreatment of Gutta-percha Filled Canals

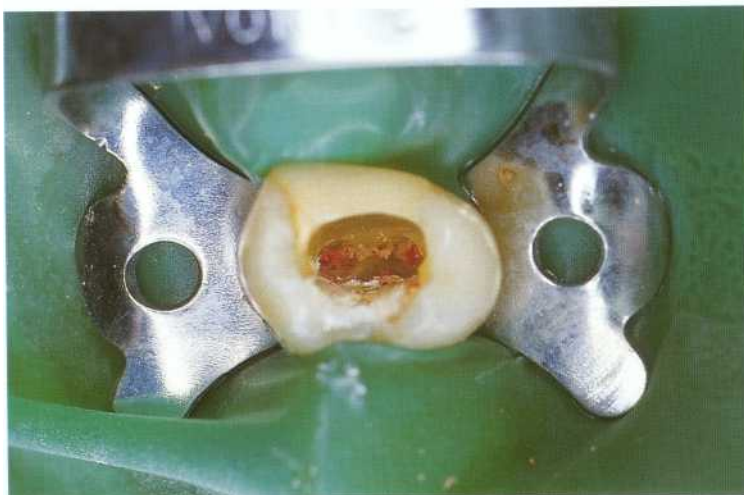
The success of retreatment of a gutta-percha root canal filling depends on the quality of condensation, the length of the filling, and the curvature of the canal. Coronal portions are softened and removed with a hot explorer. Then a 3-mm-long section of gutta-percha is drilled out with a Gates-Glidden drill or a GPX-instrument in order to create space for application of a solvent. Dissolution of the gutta-percha is indicated when the filling is well condensed and not overextended. The softened filling material is subsequently removed with Hedstrom files.

Chloroform is an effective solvent for gutta-percha. A few years ago, however, chloroform was classified as a possible carcinogen. If the container is left open during treatment, exposure to the dentist is twice as high as to the assistant. If the chloroform is kept in a syringe, on the other hand, exposure is greatly reduced and can be considered relatively harmless (Allard and Andersson 1992). Meanwhile, other chemicals such as eucalyptol and halothane are recognized as possessing almost equally good solvent properties (Hunter et al. 1991).

574 Diagnostic radiograph
On the diagnostic radiograph the maxillary first premolar has a widening of the periapical space and a poorly adapted root canal filling. The patient reported discomfort to biting pressure and the percussion test elicited some tenderness.

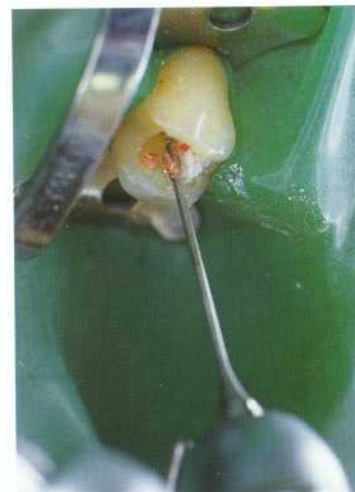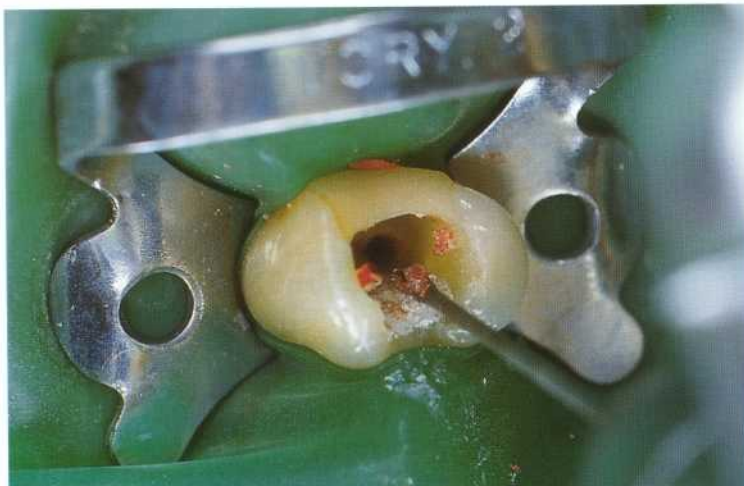


575 Access opening
An opening is made through the synthetic resin filling, and the access preparation is extended so that the entrances to both root canals are clearly exposed. This creates straight-line access for engine-driven instruments.



576 Gutta-percha removal
A size 3 Gates-Glidden drill is used to remove the gutta-percha to a depth of approximately 4 mm.

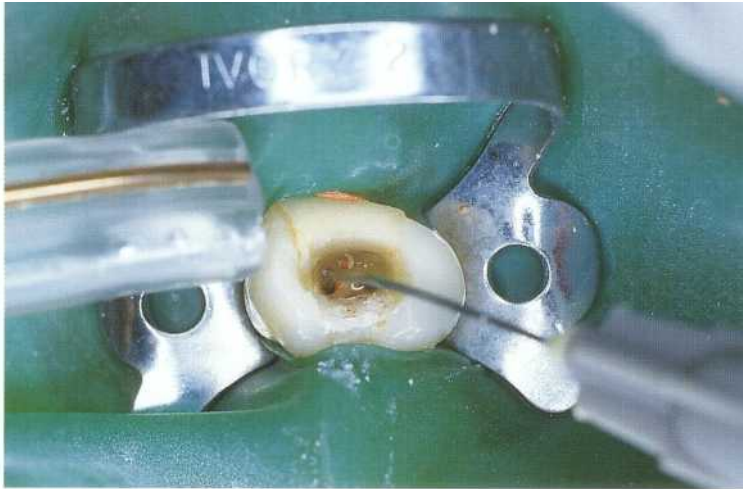
Right: To prevent instrument fracture, excessive pressure must be avoided. The flutes of the drill should be cleaned of gutta-percha fragments before reinsertion into the canal.



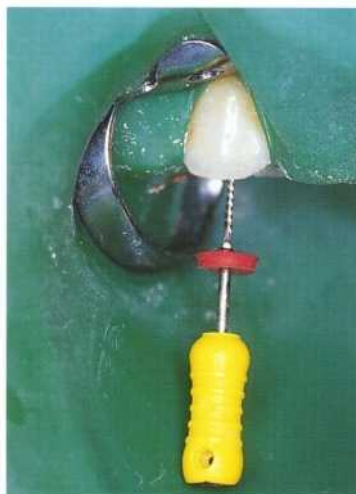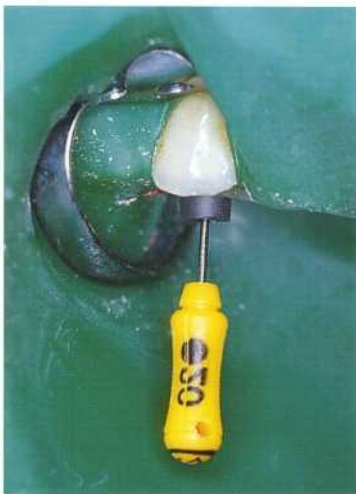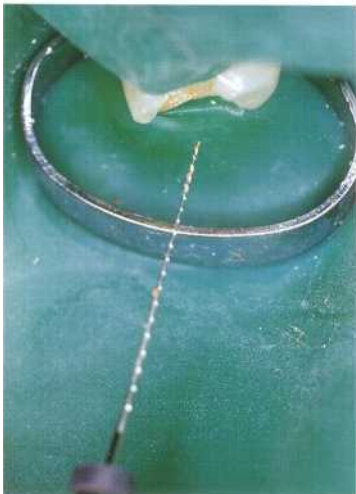Eucalyptol is less irritating than chloroform. It does, however, produce a tissue reaction if forced into the pulp tissues (Friedman et al. 1990). Chloroform dissolves gutta-percha to a depth of 1.1 mm, eucalyptol penetrates to 0.9 mm, and halothane to 0.8 mm. All three solvents allow insertion of a Hedström file to a depth of 10 mm into the softened gutta-percha within 70 seconds (Hunter et al. 1991). Reinstrumentation with halothane requires more time (Wilcox and Wiemann 1995).

The softened filling can be removed in small in-

crements with Hedström files. Ultrasonic instruments are of no help and do not make the removal of gutta-percha easier. Following irrigation with only sodium hypochlorite, 0.1 % of the canal surface was still covered with remnants of gutta-percha, and 20% with sealer. When a solvent was used, 0.6% was coated with gutta-percha, but only 12.6% was still covered with sealer (Wilcox 1989). The average time required for reinstrumentation depended upon the sealer that had been used, namely 7 minutes for AH 26 and more than 10 minutes for Ketac-Endo (Moshonov et al. 1994).



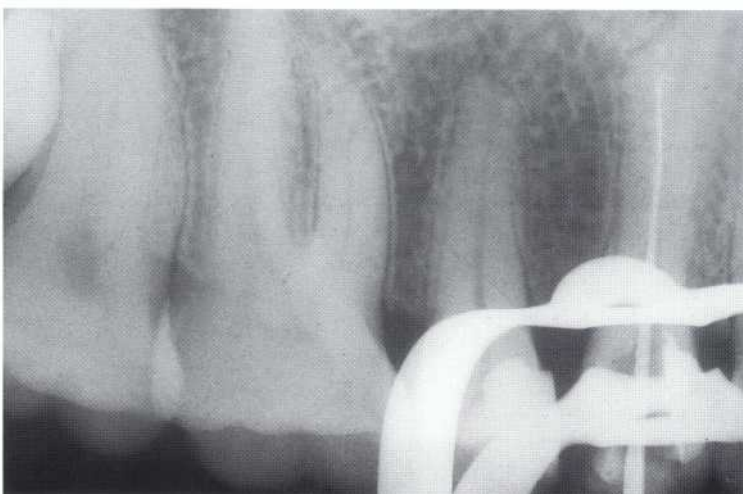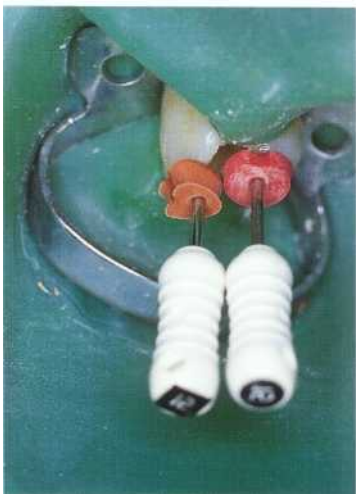
577 Solvent injection
A small amount of the solvent eucalyptol DAB 6 is injected with a syringe into the space created. This dissolves and softens the gutta-percha to a depth of approximately 1 mm.



578 Removal of the filling
Left: Using a size 20 Hedström file, most of the remaining gutta-percha is removed millimeter by millimeter. The file is cleaned after each insertion to help prevent it from binding within the root canal.

Center: The Hedström file has reached the expected working length.

Right: The coronal portions of the root canals are carefully enlarged and smoothed.

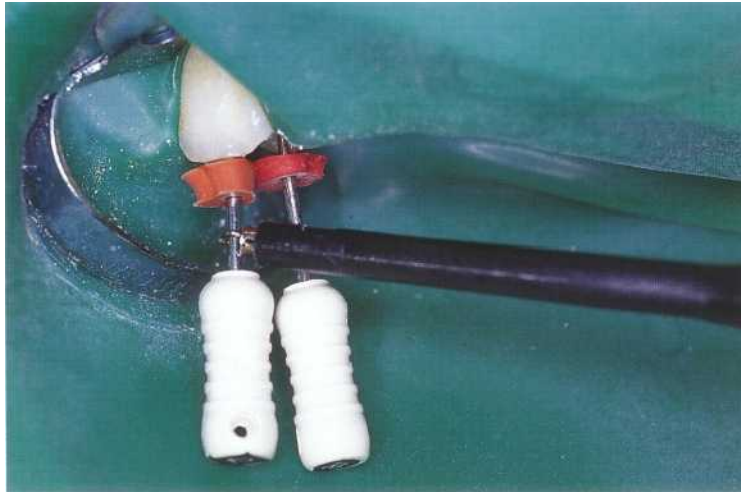


579 Length measurement
After most of the filling material has been removed from the root canals, the working length is determined with a radiograph.

Left: For easier identification a different type of file is inserted into each canal for measurement of the working length.

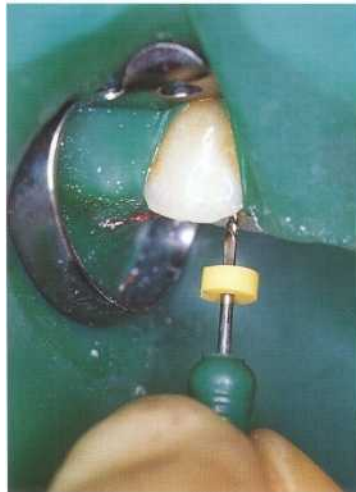580 Length measurement

To avoid perforation of the apex, instrumentation should be frequently monitored with an electronic apex locator. However, electronic measurement is no substitute for the working-length radiograph because it does not provide information about the anatomy of the canals.

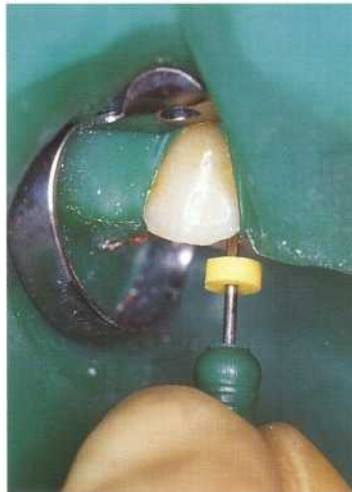

581 Canal enlargement

Left: The root canals are enlarged with hand-held instruments to the working length and canal preparation is completed. This removes all the old filling material from the canal walls.

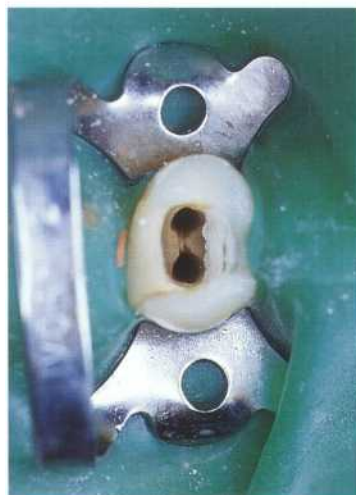

Right: In the apical portion K files were employed with rotating motions according to the Balanced Force technique to make the cross-sections of the canals as round as possible.

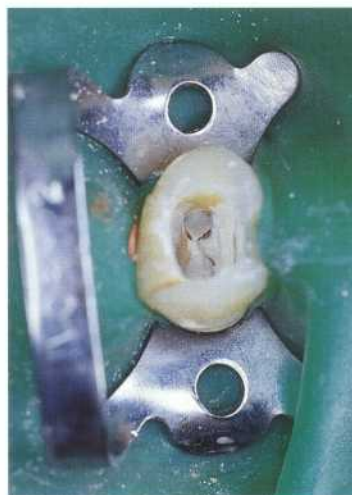


582 Interim dressing

Left: On average, reinstrumentation has been found to increase the diameters of straight canals by 25% in the apical region and by 3% in the coronal region (Wilcox and van Surksun 1991).



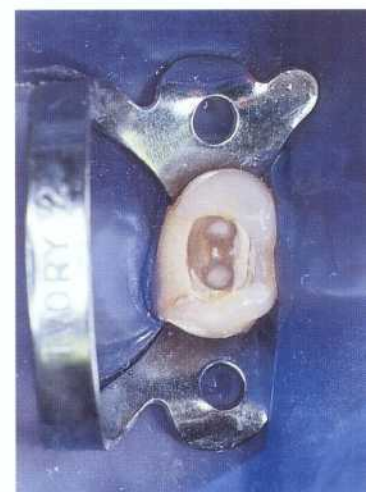
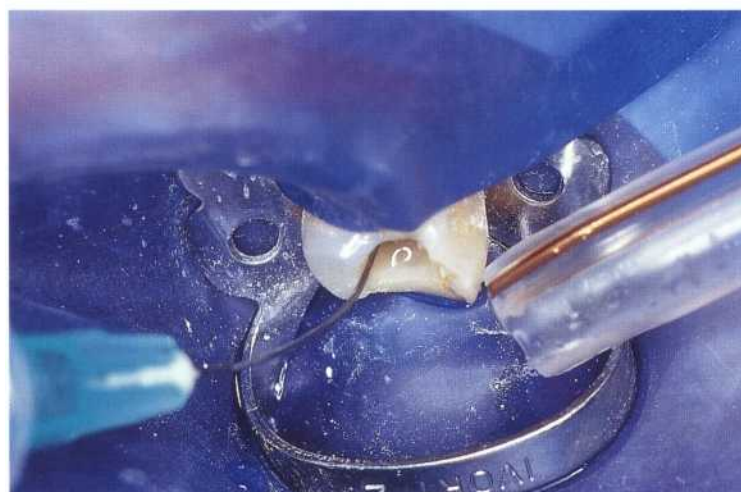Right: After final irrigation, the canals are dried and calcium hydroxide is inserted as an interim dressing.

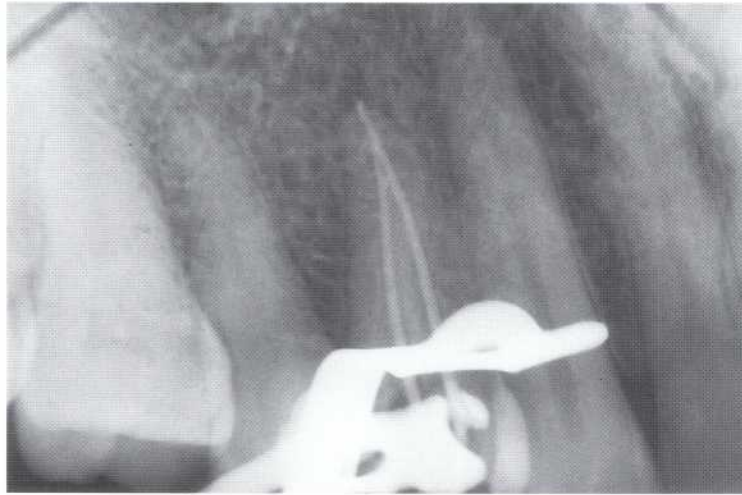

583 Removal of the dressing

After 3 months the tooth is reopened. The interim dressing is loosened with a fine Hedstrom file and flushed out with sodium hypochlorite solution.

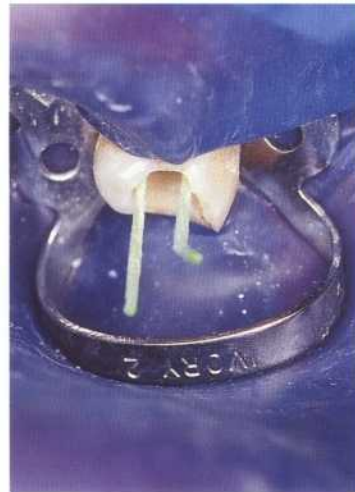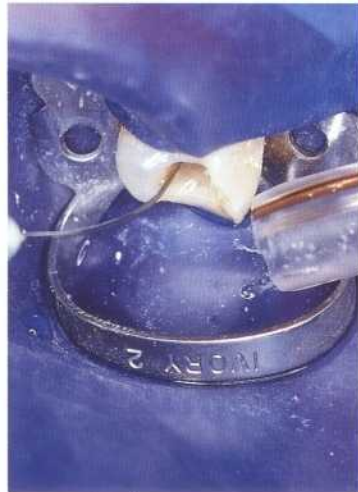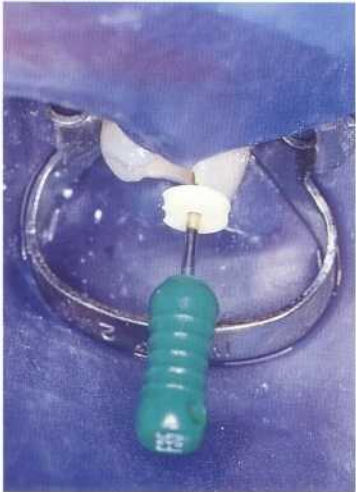
Right: Before a dressing is removed it should be inspected visually for signs of dissolution by fluids seeping through a poorly sealed interim filling. If the dressing is intact, the root canals can be safely obturated.





584 Trial insertion of the master points

After completion of the root canal preparation, two gutta-percha master points are inserted and their lengths measured. An eccentric radiograph makes it easy to distinguish the two gutta-percha points. The two canals unite near the apex and end in a common foramen.

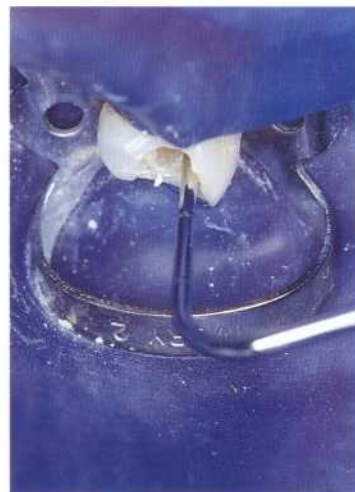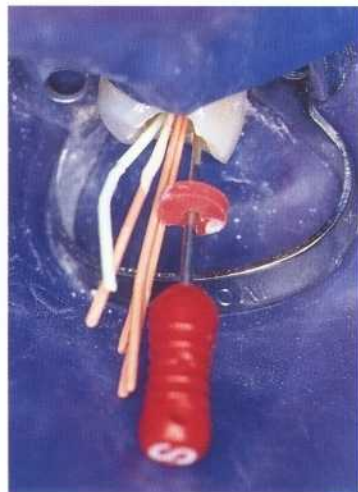


585 Final preparations for obturation

Left: After fitting the gutta-percha points, the AMFs are inserted to smooth the surfaces of the canals once more.

Center: The canals are given a final irrigation with sodium hypochlorite solution to remove any remaining traces of tissue, filling materials, or solvents.

Right: The canals are dried with paper points.

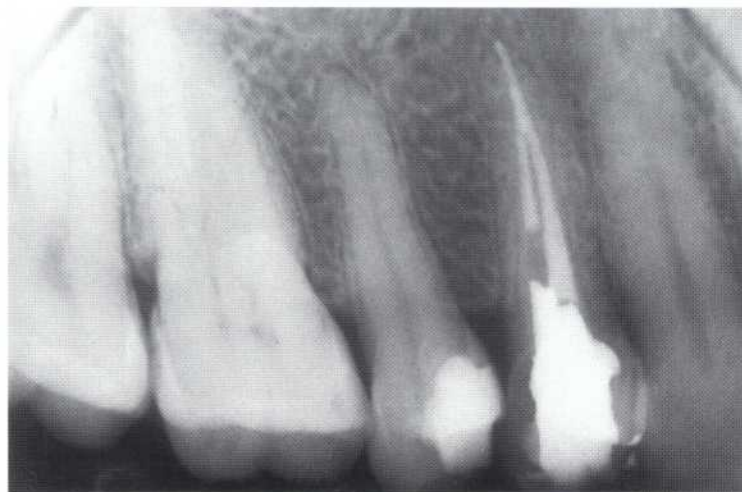

586 Root canal obturation

Left: The gutta-percha master point is coated with a small amount of sealer, inserted, and pressed laterally against the canal wall with a spreader.

Center: Additional gutta-percha points are inserted into the spaces created by each condensation step.

Right: After the excess gutta-percha is removed, the filling is condensed vertically with a plugger.



587 Radiographic evaluation

The postoperative radiograph shows good periapical bone regeneration and a very well-adapted root canal filling. A post will be placed in the lingual canal before a crown is fabricated, and post space has already been provided.

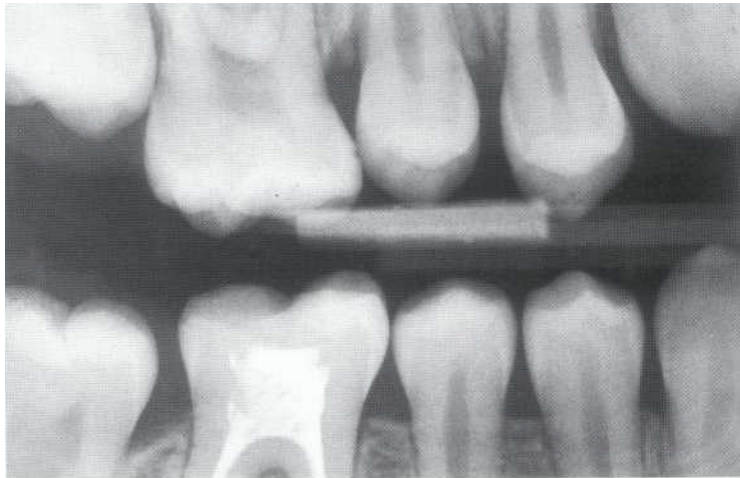
Removal of Broken Instrument Fragments

Instrument fragments should be removed from the root canal whenever possible, and the canals should then be reinstrumented. In a study by Allen et al. (1989), successful retreatment was accomplished in 69% of 253 defective silver point fillings and in 63% of 697 gutta-percha fillings. Eighty percent of broken instruments were successfully removed. Root canal fillings were successfully placed in 47% of teeth that had already been retreated once, but in only 33% of cases previously treated with surgery.

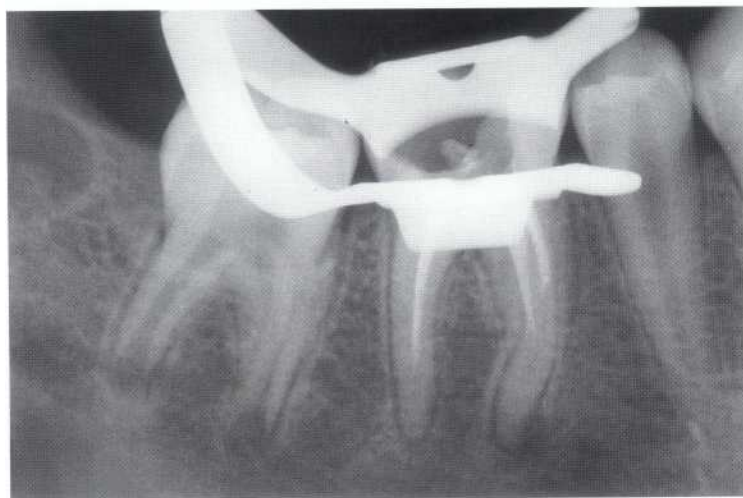Reinstrumentation should begin with an analysis of

the type of fragment present and its position in the canal. The more coronal the broken piece lies within the canal, the better the chance of successful retreatment. When an instrument has been screwed into the dentin with excessive force, strong friction results so that the chance of successful revision is minimal. When fracture is the result of fatigue, on the other hand, the friction is less and the possibility of recovery is good. Fractured spiral paste fillers are extremely flexible and can be easily bypassed and removed (Hulsmann 1996 b).

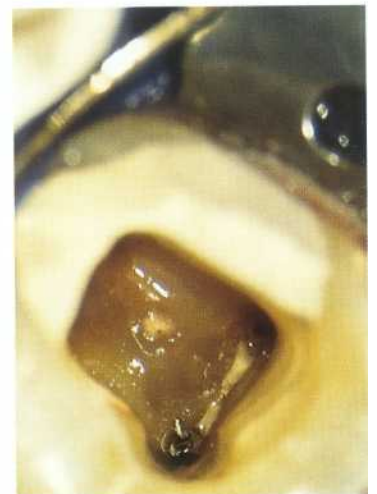588 Radiographic diagnosis
The 16-year-old patient complained of indefinite discomfort and intermittent pain in the lower right molar region. Upon clinical inspection his dentition was found to be almost caries free. The bitewing radiograph reveals a root canal filling in the mandibular first molar.



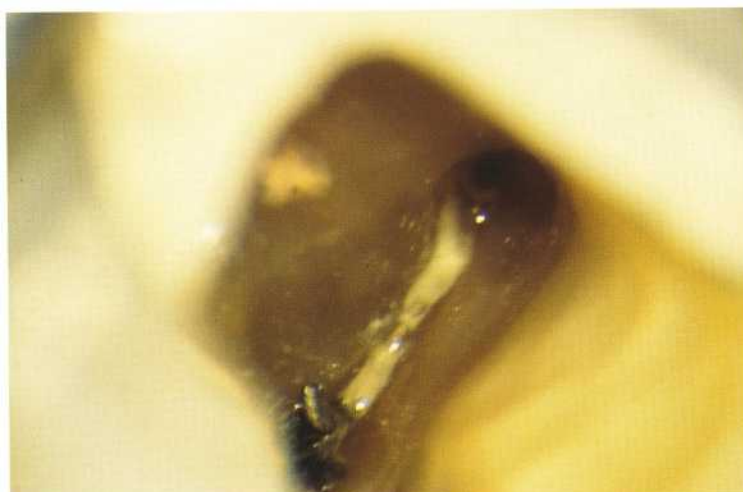
589 Radiographic diagnosis
This periapical radiograph taken during endodontic retreatment shows periapical radiolucencies on the mesial and distal roots, a root canal filling that is too short, and a fractured spiral paste filler in the mesiobuccal root.



Right: The plastic filling and cement base are removed to expose the entrances to the root canals.

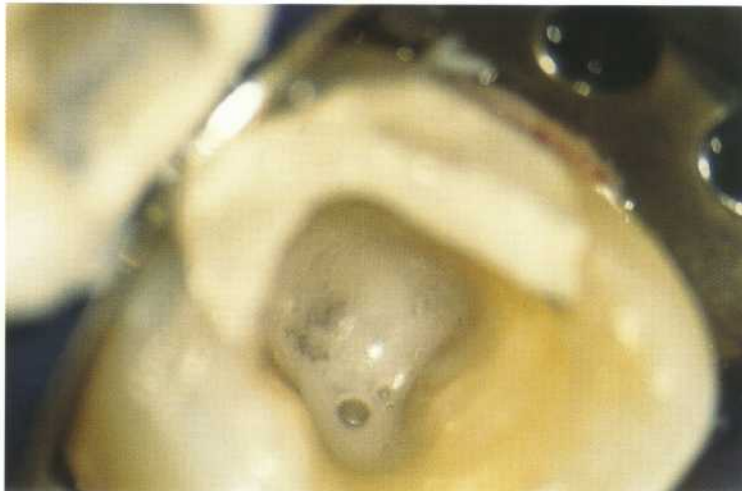
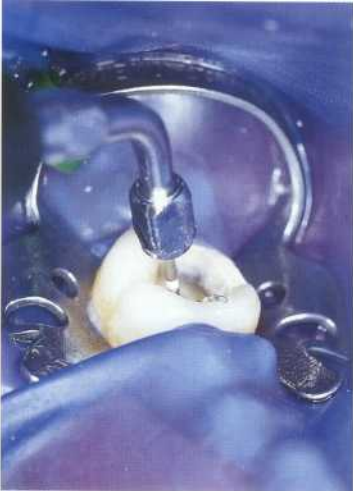

590 Instrument fragment
Inspection using an operating microscope at 25x magnification reveals the broken instrument in the entrance to the mesiobuccal canal. The cement is removed from around it with a slender ultrasonic scaler.



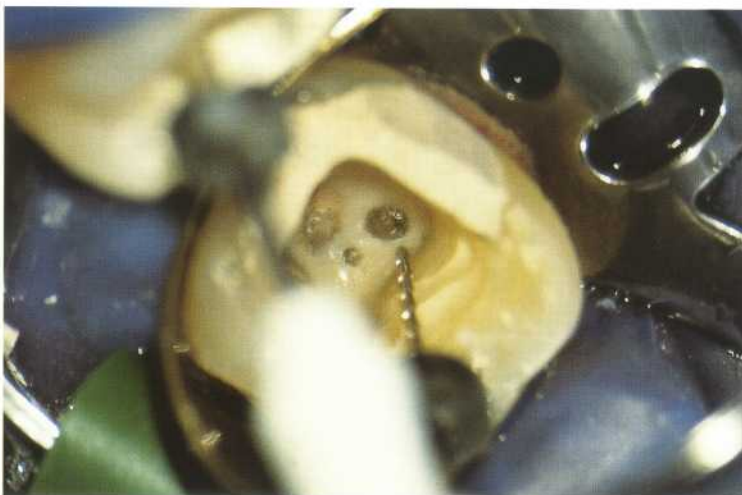A generous access preparation with coronal enlargement of the root canal facilitates determining the location of the broken instrument. Removal of instrument fragments is a microscopic procedure. A lubricant containing EDTA facilitates reinstrumentation. A series of Gates-Glidden burs is modified with a carborundum disk: The working end is flattened to the midbud level, creating a true side-cutting bur. These burs are used to create a straight-line path from coronal access to the level of the fragment. After the platform has been established, the root canal must be irrigated. A UT-4 ultra-

sonic tip is moved over the staging platform and the instrument head. After a final rinse with 100% ethyl alcohol the root canal is dried. If the fragment does not move coronally, it can be removed with the Cancellier instrument, a series of cannulas that can be attached to a threaded hand carrier. These instruments requires 2 mm of exposed fragment. The Cancellier with cyanoacrylate glue is placed over the fragment. After the glue sets, gentle coronal pressure is used to deliver the fractured fragment. Even Ni-Ti instruments in the apical third can be removed (Carr 1994).

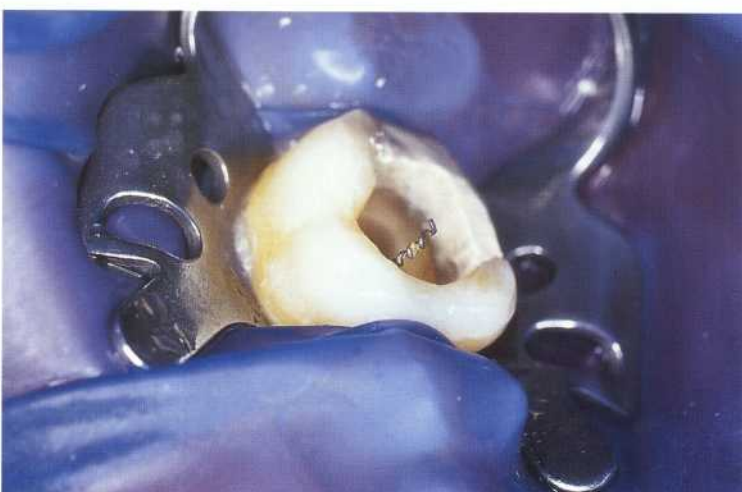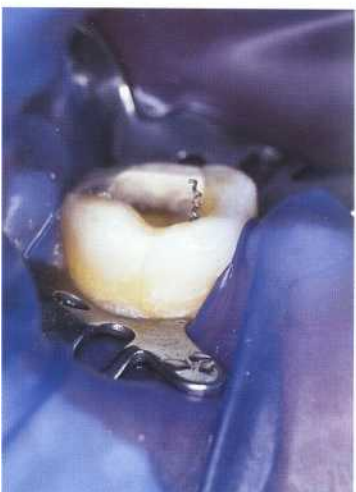


591 Loosening the fragment
The cavity is filled with a chelating agent to slightly soften the dentin and help loosen the close contact of the instrument with the canal wall.

Left: An ultrasonic file is worked around the fragment in the root canal to loosen it.



592 Reinstrumentation
The coronal portion of the canal is enlarged with a Hedstrom file and the poorly adapted root canal filling is removed from around the fractured instrument, thereby further loosening the fragment.

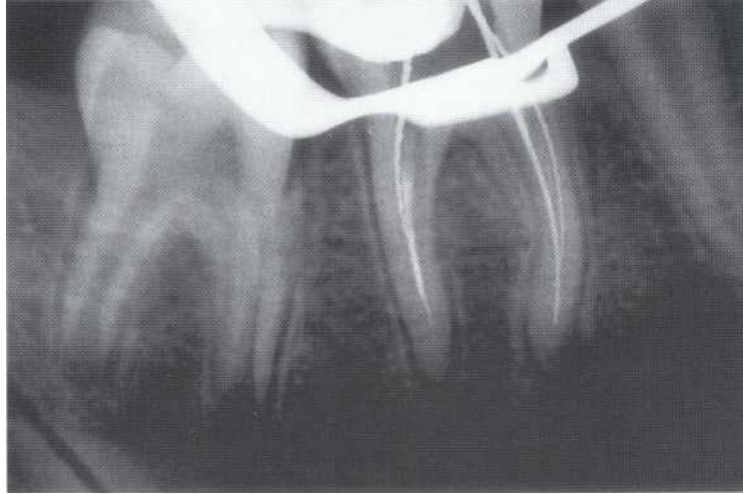

593 Removal of the broken instrument
Through repeated insertion of the ultrasonic file and the Hedstrom file with a chelating agent, the spiral filler is freed.

Left: Once the instrument fragment is loose, it is grasped with a microsurgical needle holder and removed with no problem.

594 Radiographic monitoring

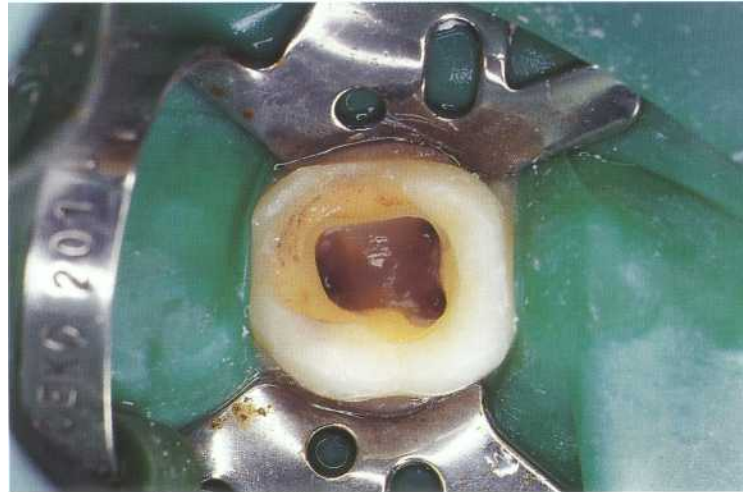During location and instrumentation of the root canals, radiographs must be used to verify that the paths of the canals are being followed and that no perforations are created. The radiographs also provide information on the distance of the files from the apices.



595 Deep preparation

The coronal and middle sections of the root canals are enlarged with Gates-Glidden drills, thereby providing unhindered access to the apical sections for the irrigating solution.

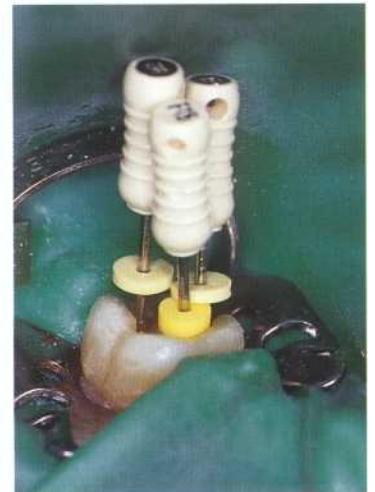
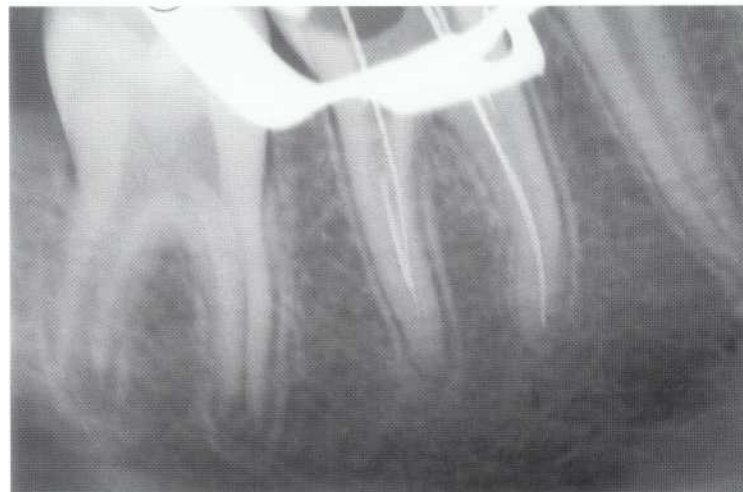Right: A Hedstrom file is carefully worked through apical obstructions by using one-quarter turn rotations as in winding a watch.



596 Working length

The working length is determined with a radiograph. In the mesial root both files have almost reached the working length, but the file in the distal root is still at least 3 mm short. Some of the old filling material is still visible distally.

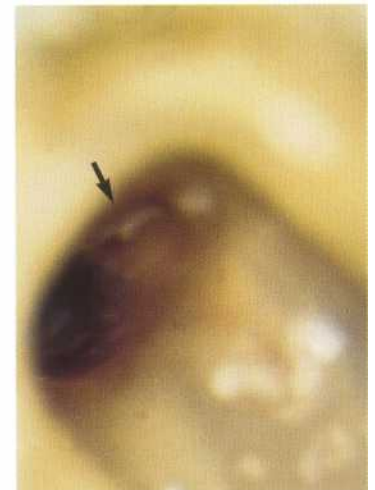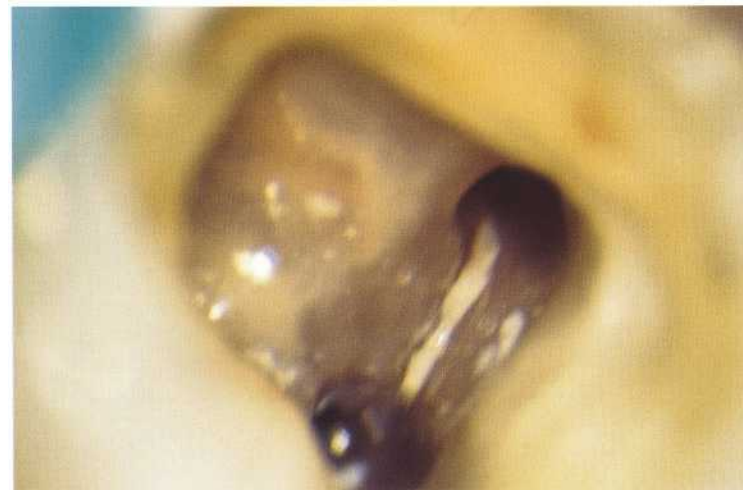Right: The working length is measured with Hedstrom and K files.

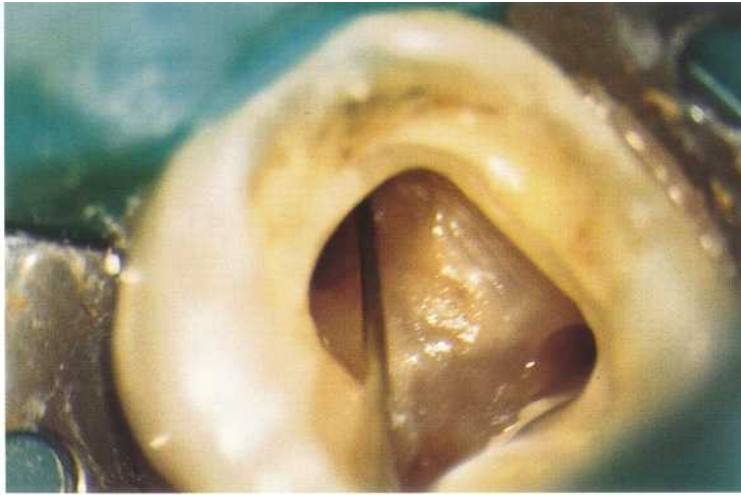

597 Microscopic inspection

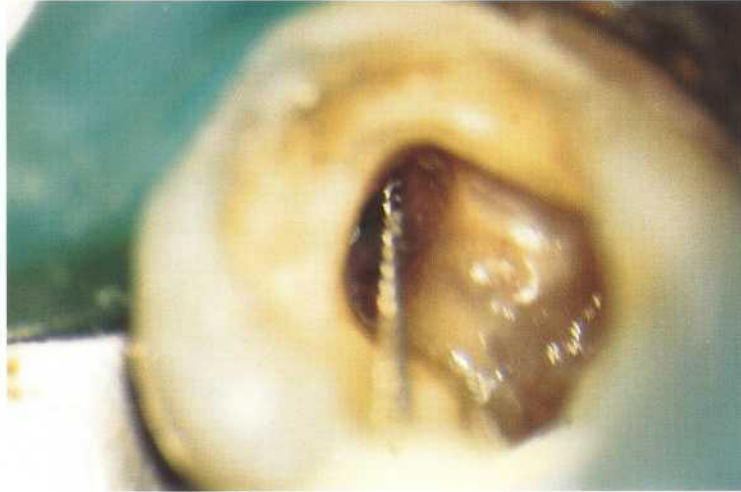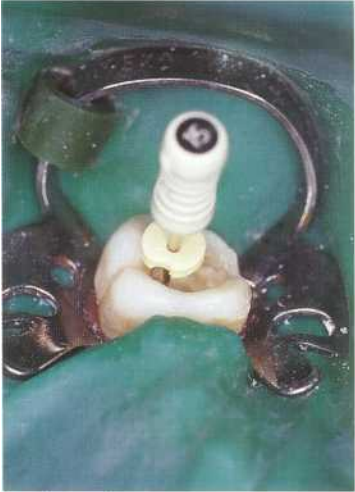The results of the reinstrumentation are evaluated with the operation microscope, and the straight portions of the root canals are explored visually.

Right: Inspection of the distal root canal reveals a thin adjoining line with residual necrotic tissue. A differential diagnosis has to be made between a fracture or an additional canal entrance.



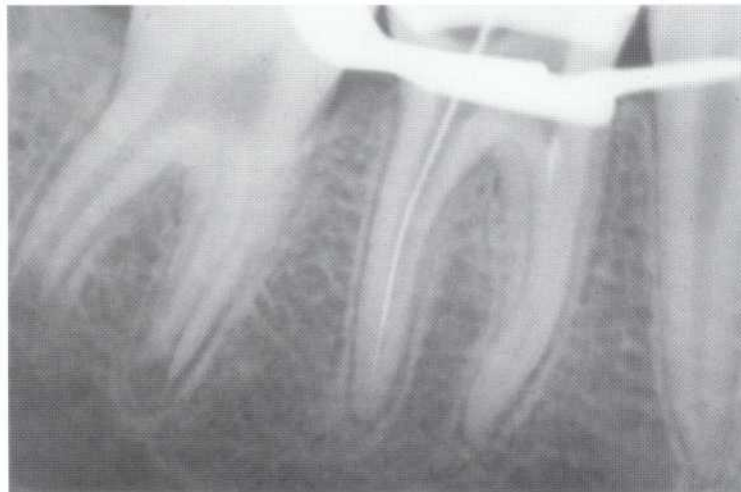
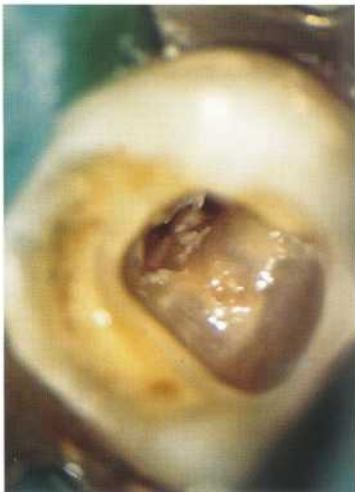
598 Probing the canal entrance
A long, stiff, sharp explorer is used to evaluate whether this is another canal orifice or a perforation. Because the tip of the explorer sticks firmly in the [hole.it](#) is assumed



599 Fourth root canal
The deeper portion of the root canal is explored with a fine file, then carefully enlarged beginning in its more coronal section. The absence of bleeding from the canal indicates that the tissue is completely necrotic.

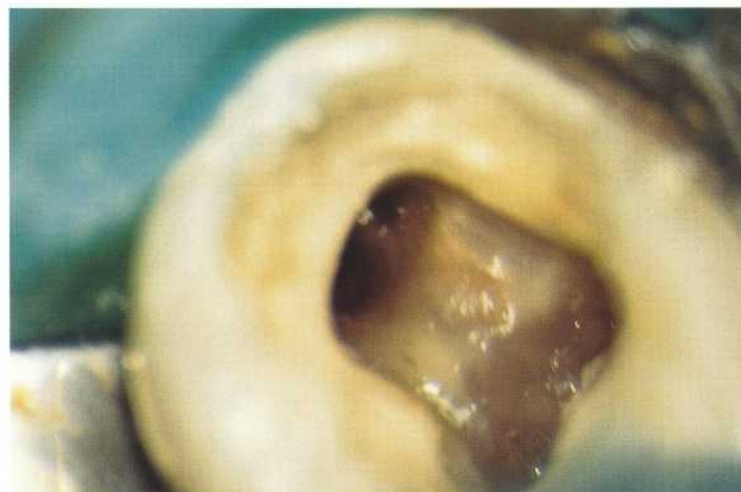Left: The canal is enlarged by using a size 15 Hedstrom file and a chelating agent, and is then prepared to the same depth as the distobuccal root canal.



600 Working-length radiograph

The length of the distolingual canal is determined with the file in place. By comparison with the first working-length radiograph (Fig. 596) it can be seen that it follows a different path.

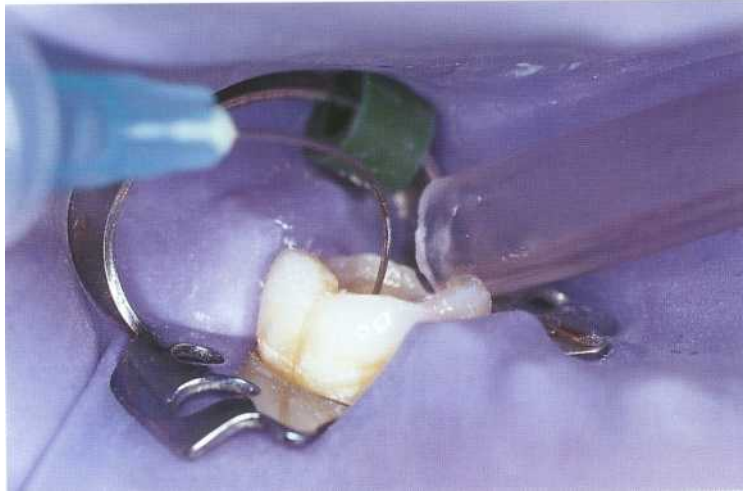
Left: The fourth root canal is instrumented further, and necrotic tissue is removed.



601 Microscopic evaluation
The two distal root canals, separated coronally only by a thin wall of dentin, are seen through the microscope. Excessive coronal enlargement must be avoided until a visual search has been made for an additional root canal orifice. Otherwise, the location of any second orifice will be shifted farther into the first canal.

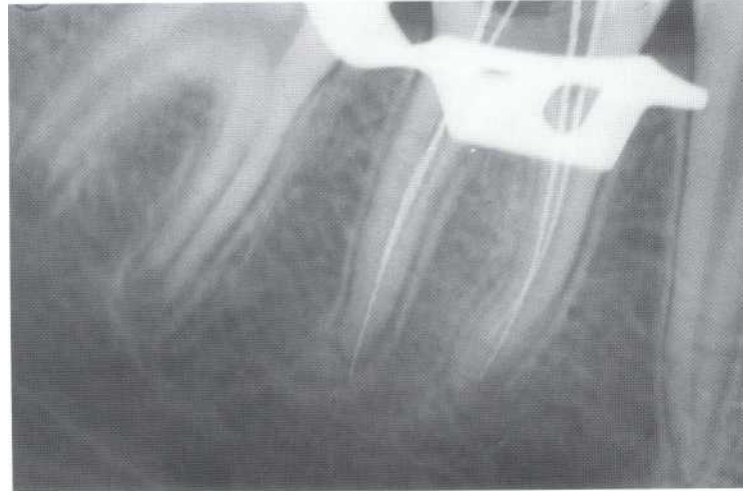
602 Irrigation

During instrumentation the root canals must be irrigated frequently with 1% sodium hypochlorite solution to loosen any remaining tissue, clear blockages, and neutralize remnants of the lubricant.

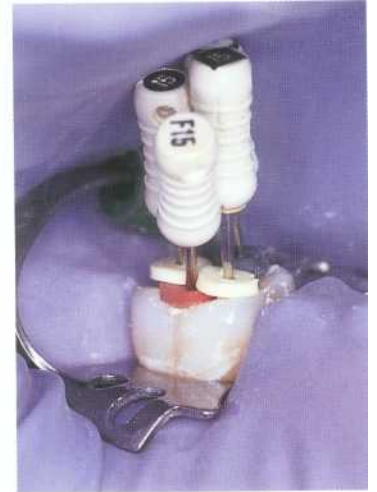

603 Working-length radiograph

The third working-length radiograph reveals that the apical constriction has been reached in the mesial canals and the obstructions in the distal canals have been overcome. After a slight correction in the working length, the apical canal segments are enlarged by three to four instrument sizes.

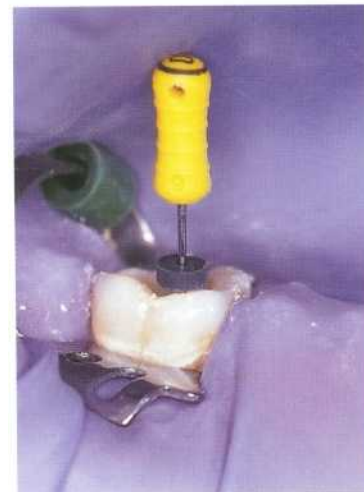

Right: Files are placed in all four canals. Both Hedstrom and K files are used for better differentiation.

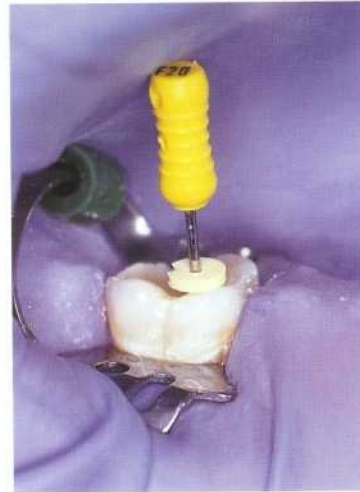

604 Instrumentation

Left: The apical instrumentation is carried out by alternating instruments-Hedstrom files, then K files. Both are used to the working depth. Hedstrom files enlarge the root canal purely by a filing action.



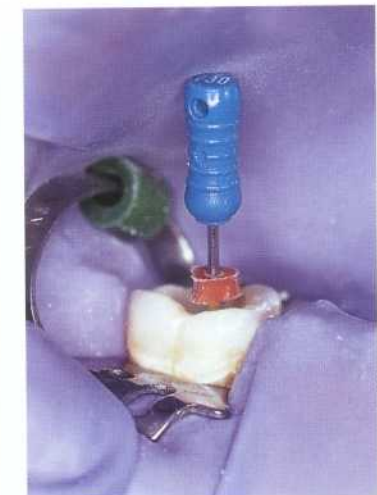
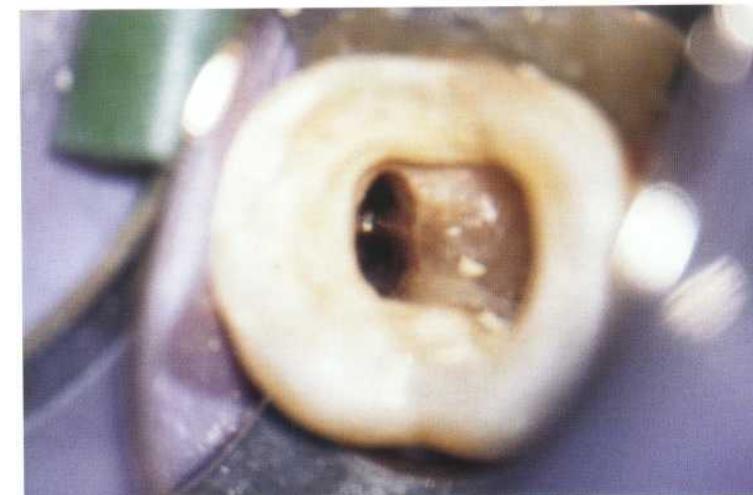
Right: Because of the special geometry of its tip, rotation of the K file produces an almost perfectly round cross-section in the apical region.

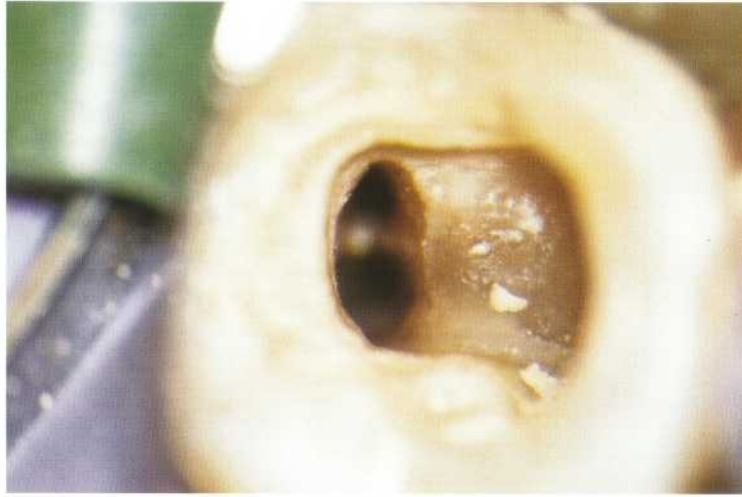
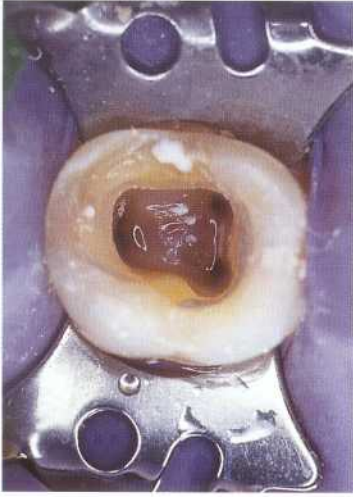
605 Apical master file

The root canals are enlarged apically by four sizes. Both distal root canals can be seen through the microscope.

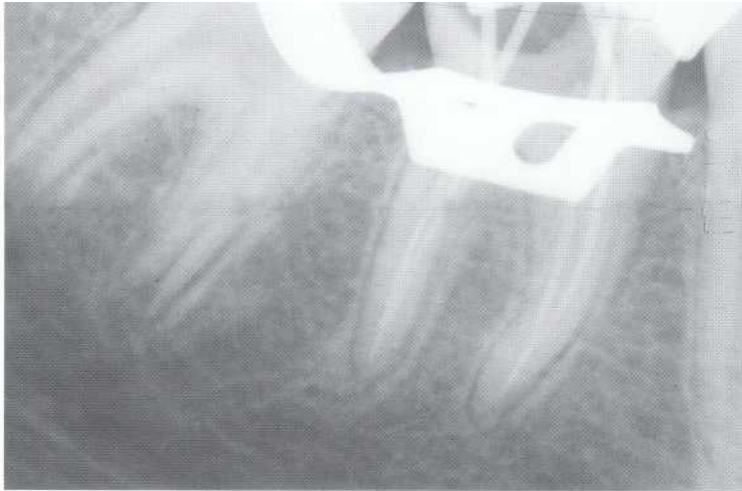Right: The canals are enlarged to size 30, and the last file used to the full working length is designated as the AMF



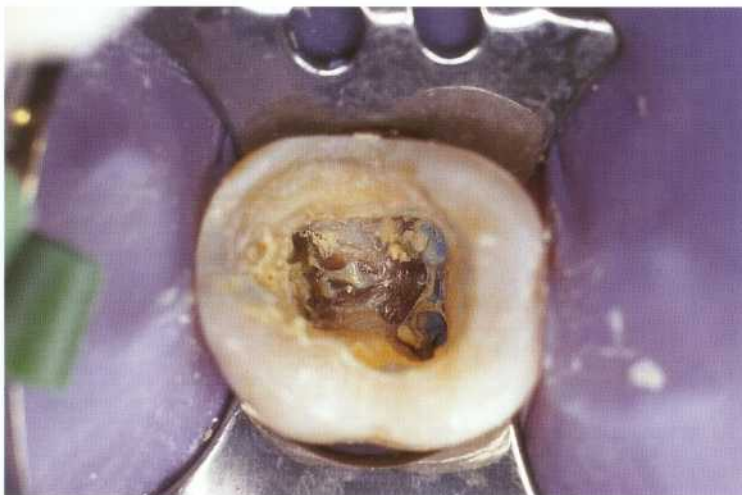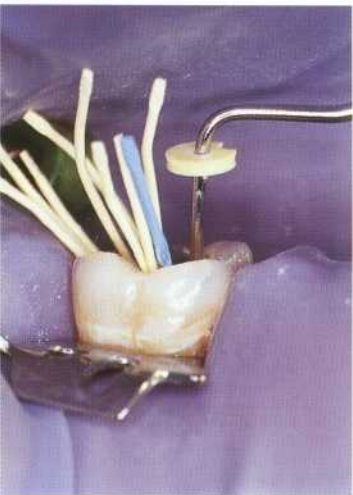
**606 Irrigation and drying**

The effectiveness of reinstrumentation and cleansing of the canals is evaluated with the operation microscope.

Left: After the final instrumentation the root canals are extensively irrigated and dried with paper points before being filled.

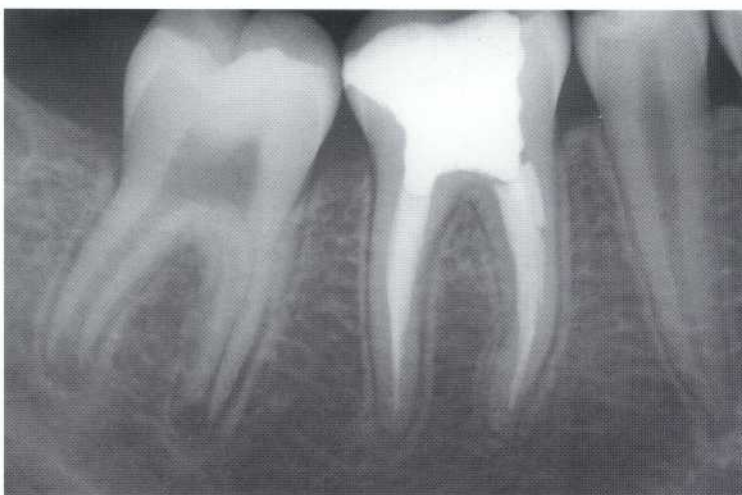**607 Master point fitting**

Gutta-percha points the same size as the AMFs are marked with the working length and then inserted into the still incompletely dried root canals. The length is checked with a radiograph to reveal the exact depth of the gutta-percha points.

**608 Root canal obturation**

The root canals are filled with gutta-percha and the sealer AH-Plus. The gutta-percha that protruded occlusally is cut off and the cavity is cleaned with alcohol.

Left: First the master point (blue), then additional accessory points are molded against the canal wall by lateral force from a spreader to produce a homogeneous filling.

**609 Postoperative radiograph**

The radiograph taken 3 months after retreatment of the formerly inadequate root canal filling shows a filling that is homogeneous and ends at the level of the apical constriction. The periapical radiolucency has also reduced in size.

Bypassing Fractured Instruments

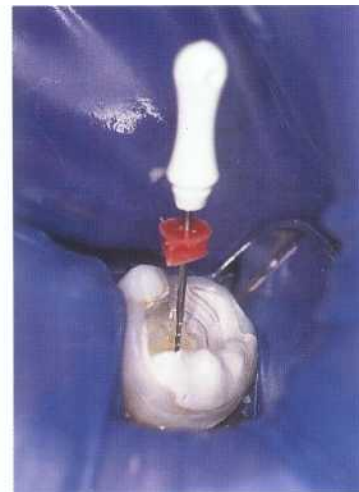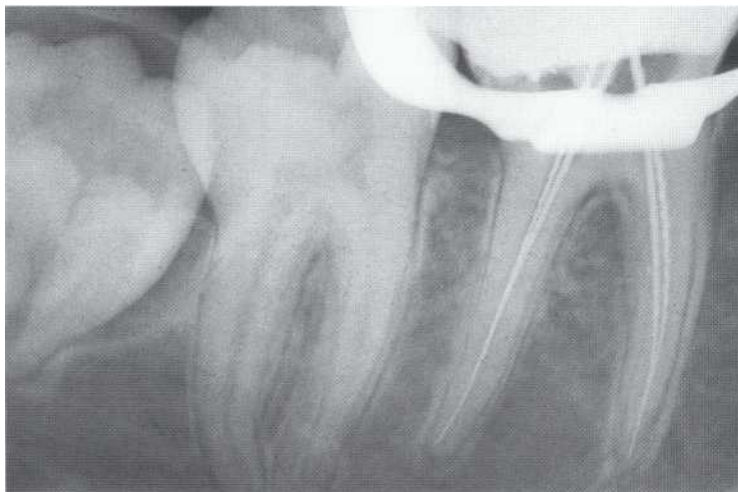A detailed explanation must be given to the patient before an endodontic failure is retreated. Possible complications during removal of an inadequate root canal filling include perforation of the root, instrument fracture, and the pushing of filling material or a fractured instrument beyond the apex. In considering the possible alternatives it is the patient who must decide whether or not he or she wants to undergo the expenditure of time and the physical stress of attempting to salvage the tooth.

Masseran (1966, 1972) developed a set of instruments consisting of trephining drills in different lengths and diameters. These are used to cut around a fractured instrument in the root canal so it can be grasped and removed with a small forceps. Their use is limited if the root is curved or slender and the fragment lies apical to the curvature. Great enlargement of the root canal by a trephine to a size 120 or 150 weakens the root or can even cause perforation.

610 Instrument fracture

During the initial exploration of the canals a Hedstrom file fractured. A fragment approximately 3 mm long lies in the distal root canal. It cannot be dislodged but a K file is able to bypass it.

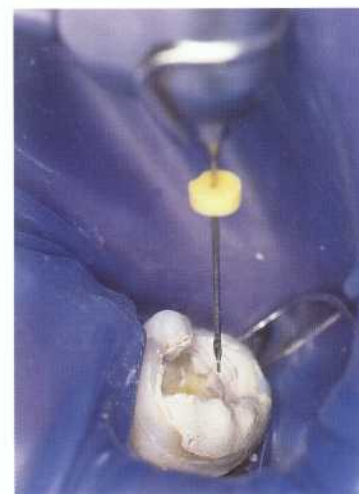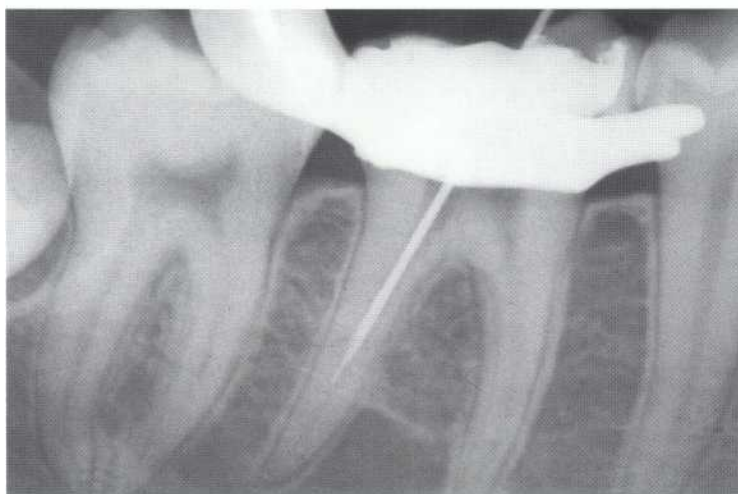
Right: The position of the broken piece in the distal canal is determined with a Hedstrom file.



611 Exposure of the fragment

After patency is verified with hand instruments, the coronal and middle sections are enlarged with a Gates-Glidden drill. Even the concomitant insertion of an ultrasonic file does not succeed in loosening the instrument fragment.

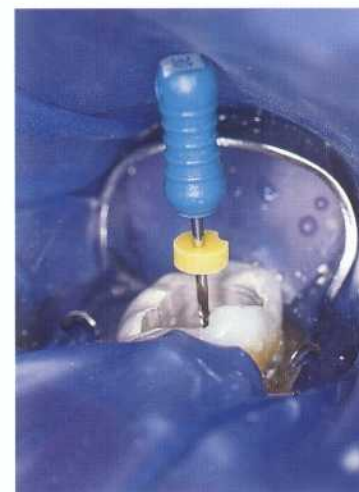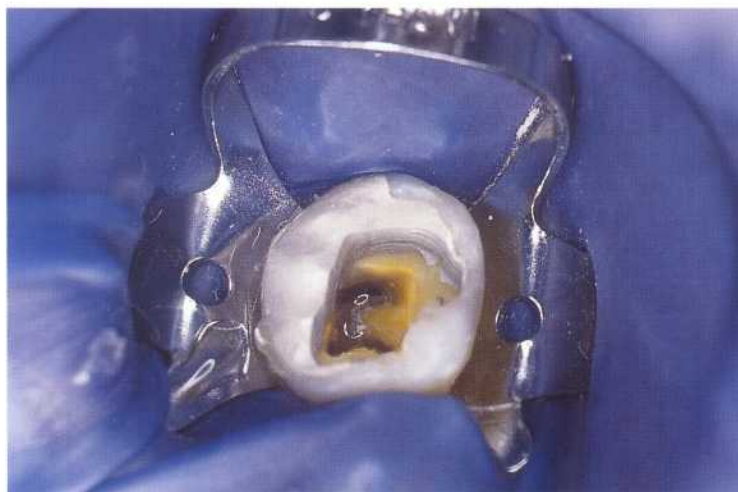Right: The coronal portion of the canal is enlarged with a Gates-Glidden drill.



612 Instrumentation

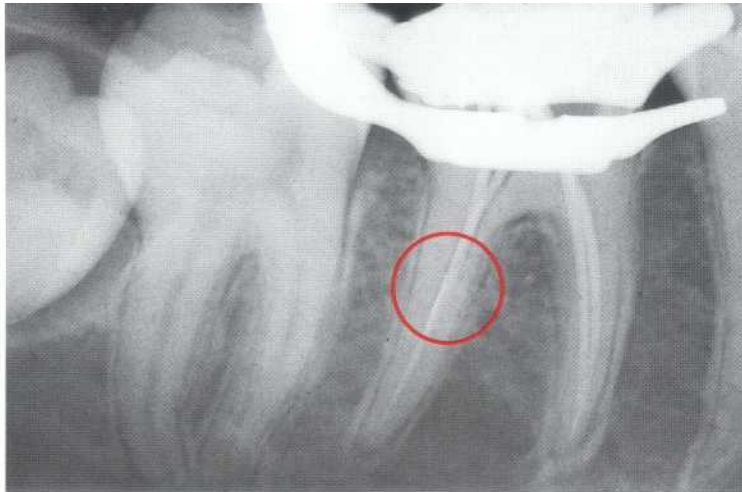With extensive irrigation and the help of chelating agents, the fragment is bypassed with a file. The canal is then enlarged by three sizes.

Right: The distal root canal is enlarged to size 30 all the way to the apical constriction.

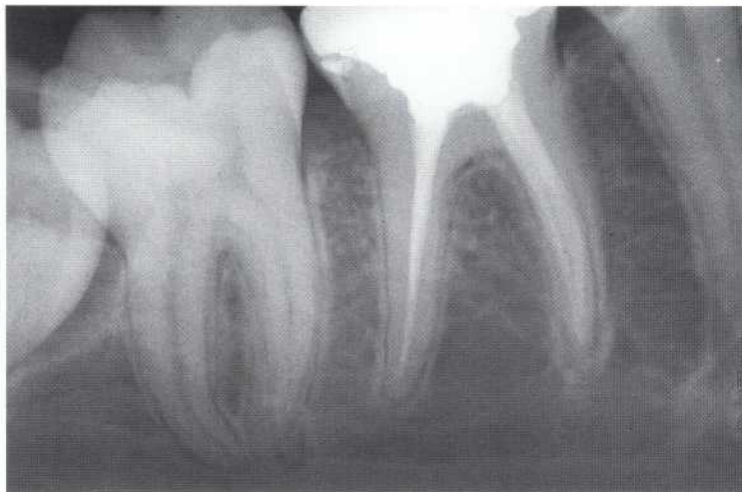
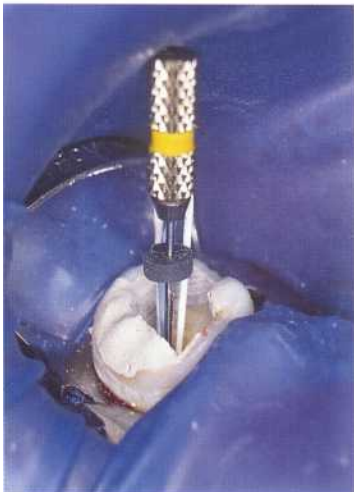
If an instrument breaks off in the apical third of a narrow, curved canal and the fragment is stuck too tightly to be removed, an attempt is made to bypass the fragment, to carefully enlarge the canal, and to fill it with gutta-percha. Steel instrument fragments that are left in the canal are classified by Eleazer (1991) as relatively inert, and no signs of corrosion were detected by either the SEM or by microanalytic methods. Silver point fragments, on the other hand, do corrode and must be removed.

An acute inflammatory reaction may occur following removal of a defective root canal filling (13% of cases) even if the tooth has previously been pain-free. With a periapical radiolucency the risk is even greater. In 69% of the cases the cause of this acute reaction is bacteria remaining in the canal, and in 10% of the cases it is bacteria forced through the apex during instrumentation (Lin et al. 1991). Therefore, after every reinstrumentation, calcium hydroxide must be packed into the canal and left there for 4-12 weeks.

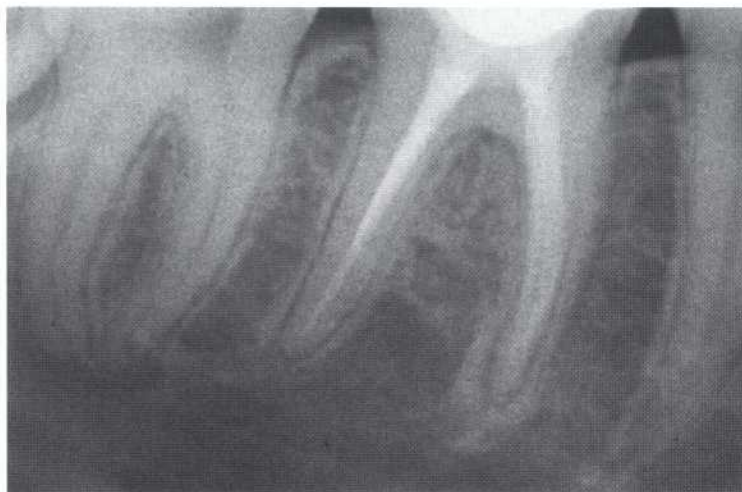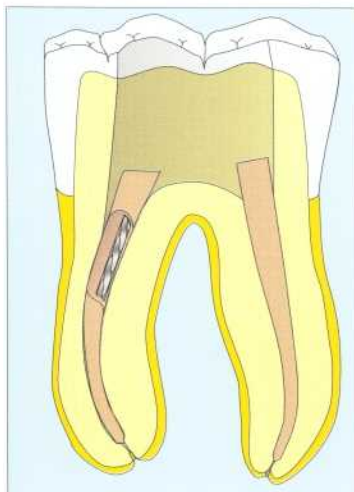


613 Master point fitting
After instrumentation and 3 weeks with an interim dressing in place, the gutta-percha points are measured, fitted, and their exact positions determined by means of a master point radiograph. The location of the instrument fragment in the distal canal is indicated by the red circle.



614 Root canal obturation
The root canals are obturated by lateral condensation of additional gutta-percha points. The instrument fragment is enveloped with gutta-percha in the process and the canals are tightly sealed.

Left: Coronal to the instrument fragment the root canal is filled separately with more gutta-percha points.



615 Follow-up radiograph
The radiograph taken after 2 years shows no sign of periapical inflammation. There is a faint indication of the fragment embedded in the gutta-percha.

Left: The schematic drawing indicates the position of the fractured instrument in the canal. Its presence is not considered to represent a danger to the patient's systemic health.

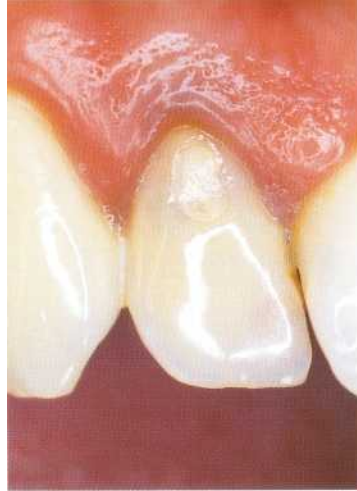Repair of Lateral Perforations

Perforations are considered to be the second most common cause of endodontic failure. The prognosis is most favorable if the perforation is sealed immediately, and improves with increasing distance from the apex (Sinai et al. 1989). If the perforation is in the coronal third of the root, orthograde treatment and repair is possible. A surgical flap is indicated most frequently with perforations in the middle third of the root, and an apicoectomy, amputation, or hemisection for perforations in the apical third (Kaufman and Keila 1989).

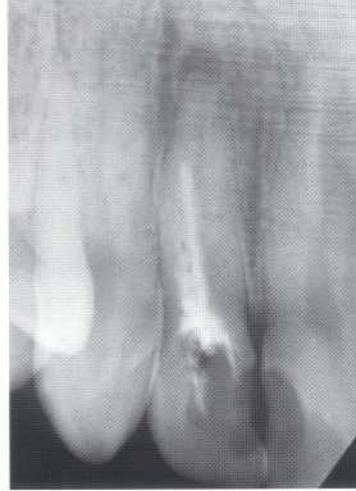Perforation of the root can be diagnosed by inserting a dry paper point into the root canal. Blood on the tip means apical overinstrumentation and blood on the side means lateral perforation or a slit root. After bleeding has been stopped, the exact location of the perforation can be determined with an electronic apex locator. Next, a prebent K file is inserted and fixed at the coronal opening with IRM cement while a radiograph is taken to determine the distance to the reference point. The direction of the notch in the rubber stop keeps track of the three-dimensional position.

616 Perforation

Left: The discoloration of the crown of the maxillary lateral incisor, which is under consideration for treatment with an artificial crown, suggests an inadequate root canal filling.

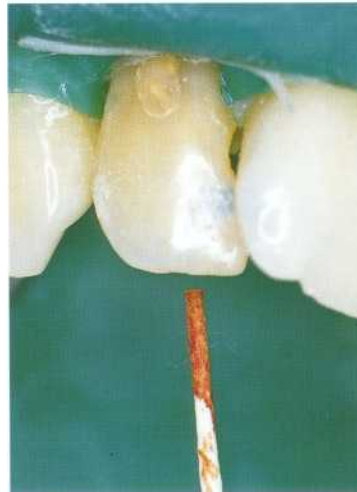

Right: A double perforation of the root, which is filled with a cement, can be seen on the radiograph. The main canal has not been instrumented or filled, and a periapical radiolucency is visible.

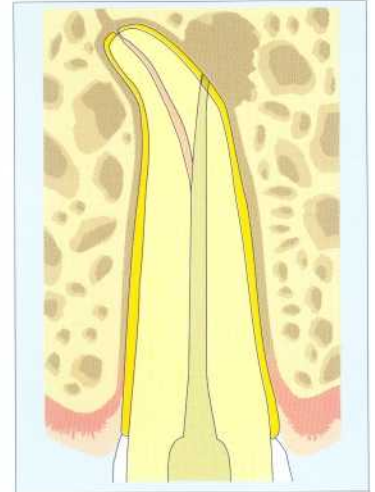
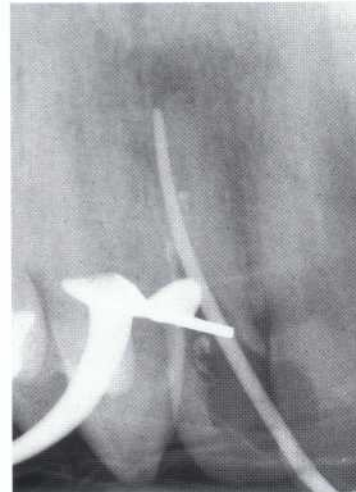

617 Localizing the perforation

Left: Blood on the paper point is evidence of a large lateral perforation.



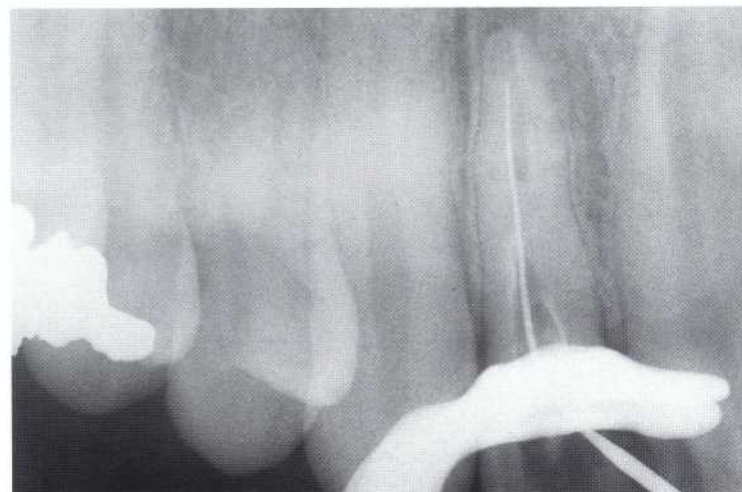Center: After the coronal portion is opened, the old filling material is carefully removed and the point of perforation is located with a gutta-percha point.



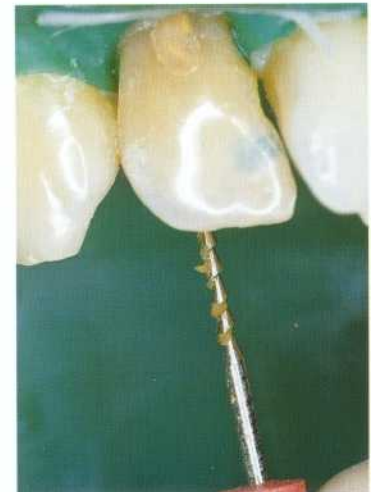Right: At the first appointment the main canal is not instrumented, but instead the root is perforated.

618 Finding the main canal

The true root canal is located and instrumented with a fine prebent K file. The radiograph with file inserted serves to determine the length and to verify that the root canal has actually been found.



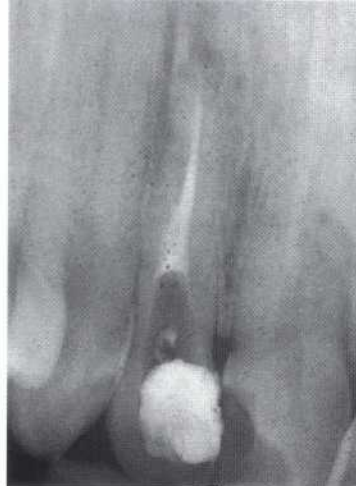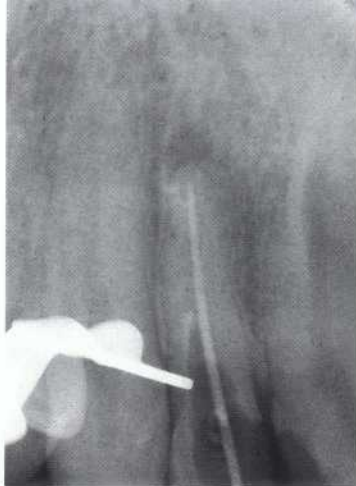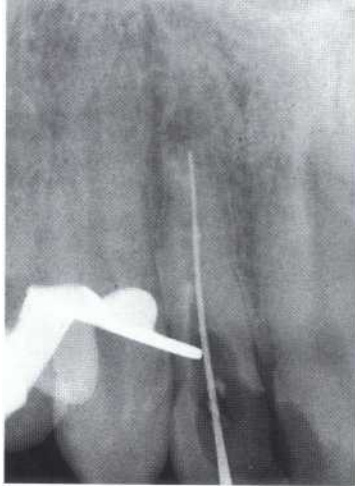Right: The necrotic tissue is removed and the main canal is then enlarged.



After the perforation has been located, a small piece of denatured collagen (Gelfoam, Upjohn) is pushed with a plugger through the perforation into the periodontal space, as indicated by the size and location of the perforation, to create a barrier to the filling material. Next, a fine Hedstrom file is inserted into the primary canal and left in place. Then the perforation is sealed by placing small portions of a thickly mixed MTA cement into the perforating canal and packing them against the Gelfoam barrier.

The tissue reaction to Gelfoam was found to be

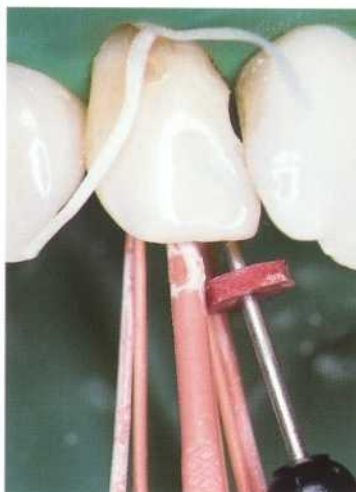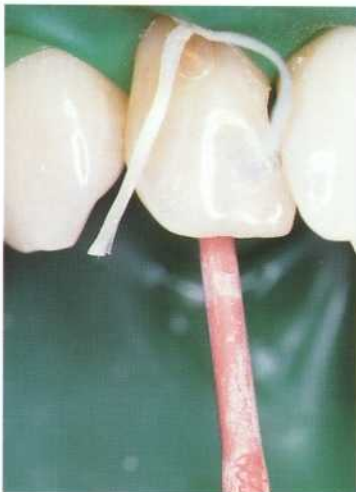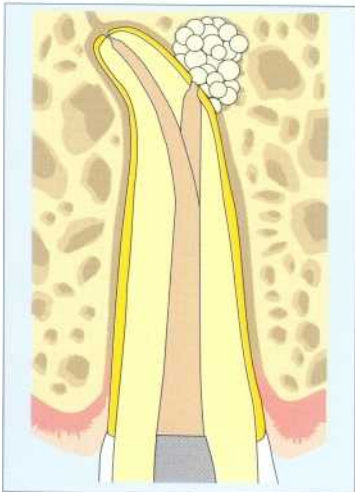
acceptable when compared with other hemostatic agents; when placed in experimental defects the material resorbed completely and was replaced by new bone (Ibarrola et al. 1985). Perforations that were repaired with freeze-dried bone granules exhibited only the formation of connective-tissue capsules after 6 months (Hartwell and England 1993). Mineralized tri-oxide (MTA), on the other hand, induced new formation of osteoid cementum in both the short and long term with a distinctly better tissue response than to amalgam (Pitt Ford et al. 1995).



619 Obturating the main canal
Left: At a second appointment after treatment with an interim dressing the canal length is measured and the root canal completely instrumented.

Center: The gutta-percha master point is measured and fitted in the canal.

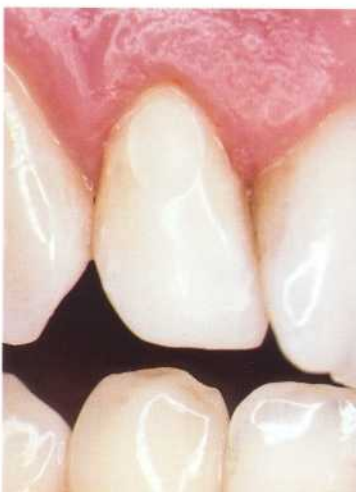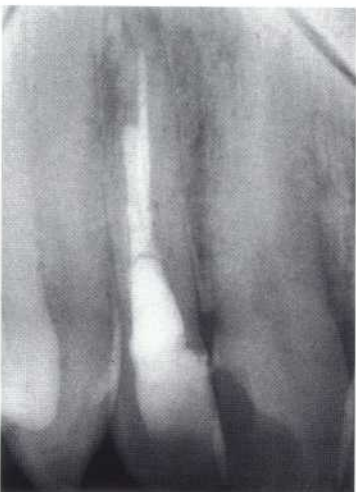Right: The main canal is completely obturated and the gutta-percha is removed from the perforation.



620 Sealing the perforation
Left: Gelfoam (Upjohn) is placed in the perforation and packed with a plugger to serve as a buttress against which the root canal filling can be condensed.

Center: A large gutta-percha point is made to fit the canal.

Right: Additional gutta-percha points are added to fill the second canal.



621 Follow-up
Left: Regeneration of the peri-apical bone is visible on the radiograph taken 3 months after the re-treatment was initiated.

Right: The crown of the tooth is bleached and the defective composite filling replaced.

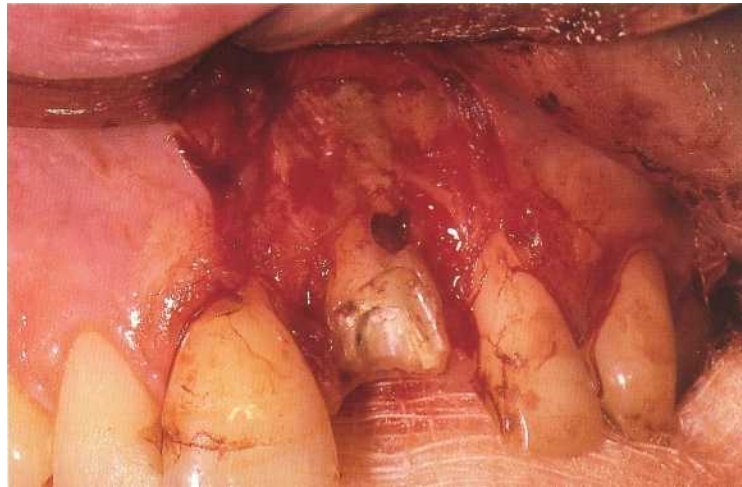
Repair of Coronal Perforations

Perforations in the coronal portion of the root can occur while preparing the access cavity, searching for obliterated root canals, and preparing an endodontic post space. In addition to blood on a paper point, other signs of a perforation are pain upon probing the canal at an unusually shallow depth and heavy bleeding after the root canal preparation is completed. Further diagnostic indicators are tenderness to lateral percussion and exudation from the sulcus in an otherwise inflammation-free gingiva (Seltzer et al. 1967, Alhaddainy 1994).

Perforations coronal to the gingival margin are easily treated with a tooth-colored filling material. With a large, inaccessible perforation or a large amount of extruded filling material beneath the gingiva, a surgical procedure is necessary (Nichols 1962). A flap is reflected, the defect is exposed-with an osteotomy when necessary-and the perforation exit is sealed with IRM, ZOE-EBA cement, glass ionomer cement, or Cavit. The surface of the root is then smoothed and, if necessary, a resorbable membrane is placed (Moloney et al. 1993, Duggins et al. 1994).

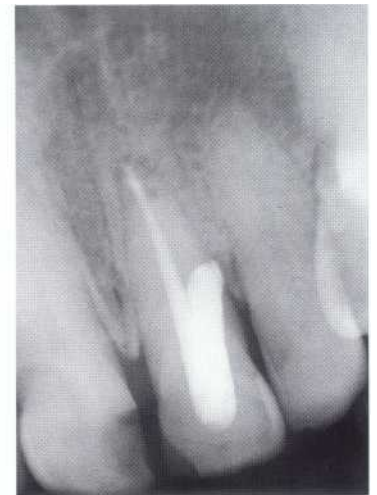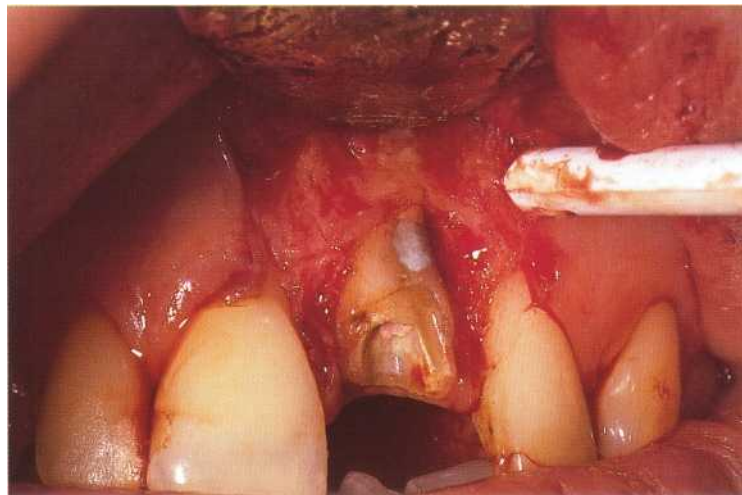
622 Perforation

A crown was planned for the endodontically treated maxillary central incisor, but the tooth was still painful to pressure. Probing the facial surface elicited pain and a flow of exudate. When a mucoperiosteal flap was reflected, a pinhead-sized perforation filled with granulation tissue was discovered 3 mm below the gingival margin.



623 Sealing the perforation

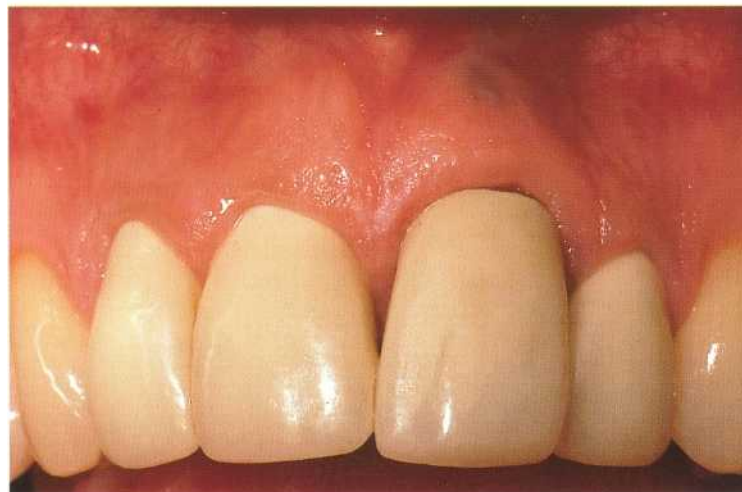From the coronal access preparation the perforation is identified, cleaned, and dried. Next, capsule-mixed glass ionomer cement is injected into the perforation path and adapted with a matrix over the perforation. After hardening, the outer surface is polished.



Right: Before the flap is replaced, the result is evaluated with a radiograph.

624 Follow-up

The mucoperiosteal flap is sutured, a provisional crown is placed, and after 7 days the sutures are removed. After 3 months the treatment is completed with cementation of a crown. One year after the surgical procedure the tooth is clinically free of problems and there is no inflammation of the surrounding tissues.



Treatment by J. L. Gutmann

Microsurgical Endodontics

If conservative endodontic treatment does not result in complete healing, surgical intervention may be indicated. In the early 1960's some dentists in Europe were already using the microscope for dental operative procedures (Ducomin and Boussens 1977, Boussens and Ducomin 1982), but the opportunities it presented were not fully appreciated at first. Its first use in endodontic surgery was reported by the Italian Dr. Gabriela Pecora (Pecora and Abbondenos 1990, Pecora and Andreana 1993). In the mid 1980's the American Dr. Gary Carr was the first to design ultrasonic tips and micromirrors for endodontic surgery under the microscope (Carr 1992).

At present more than one-fourth of all endodontic specialists in the USA use the microscope, and in Europe and Asia, too, there is a large movement toward microsurgical endodontics, as indicated by the success of international conferences on this topic. From 1998 on, all endodontic postgraduate education programs in the United States are required to teach "endodontics and endodontic surgery under the microscope." It is possible that within 10 years all endodontic procedures will be performed with the microscope as a basic instrument.

The primary advantage of microsurgery is the ability to make small osteotomies and shallow bevel angles which help preserve cortical bone and root structure. In addition, the microscope quickly reveals the anatomic details on the resected surface of the root. In conjunction with ultrasonic instrumentation it is possible to make a conservative preparation in the root tip following the long axis of the tooth and to precisely place the filling. Surgical mistakes can be significantly reduced or even eliminated. The differences between conventional surgery and microsurgery can be summarized as follows:

Procedure	Surgery	Microsurgery
Osteotomy	large	small
Inspection of the root surface	difficult	simple
Bevel angle	sharp (45°)	shallow (<10°)
Finding the isthmus	impossible	simple
Retropreparation	approximate	parallel to root
Retrofilling	imprecise	precise

Principles of Endodontic Microsurgery

The introduction of the surgical operating microscope and ultrasonic instruments has elevated endodontic surgery to a new, more rational level. The result of this technical innovation is microsurgical treatment.

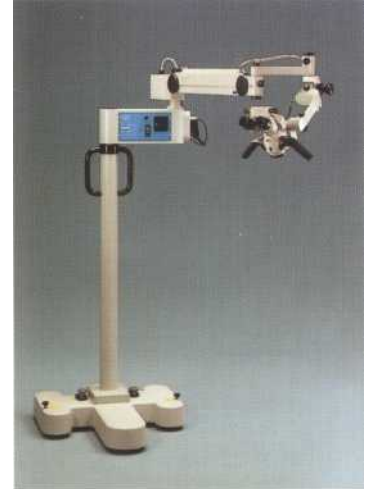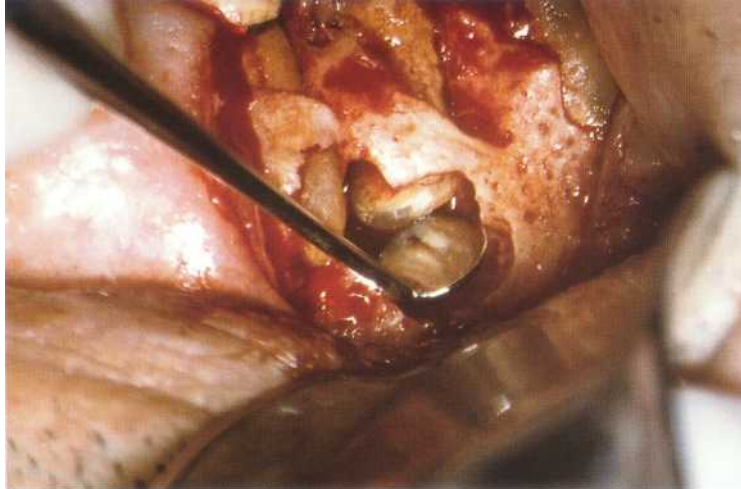
Illumination, magnification, and instrumentation form the basic triad of microsurgery. The microscope and new microinstruments specially designed for the demands of microsurgery have made the use of microsurgery a practical reality. Surgical procedures on the root tip can now be carried out with a higher degree of precision and greater confidence than ever. The

uncertainty and imprecision of conventional surgery have thereby been conquered. With the bright, focused light all the details at the apex are visible, making more precise treatment possible. Smaller osteotomies with less sacrifice of bone mean quicker healing with less discomfort for the patients. Therefore, the microscope has brought about a fundamental change in how apicoectomies are performed (Carr 1994).

625 Microscopic surgery

The resected surface of the root of a maxillary first premolar is seen in a micromirror. At this low level of magnification (4x) few details are recognizable. The field of vision is very broad so that the neighboring structures including the adjacent teeth are visible.

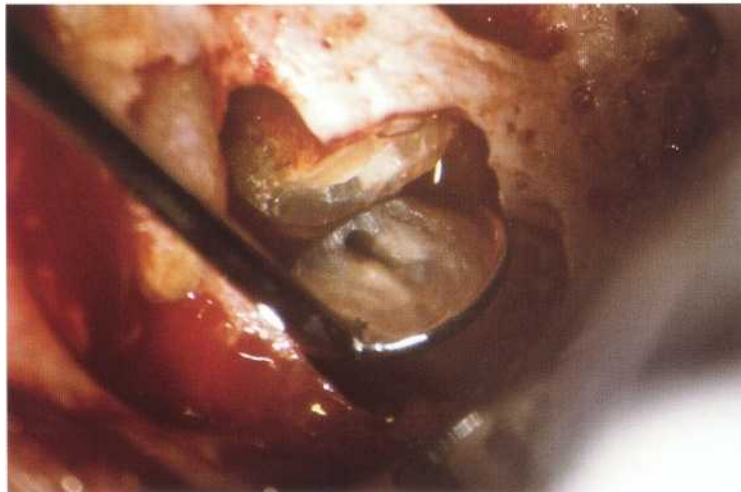Right: A typical operating microscope (Zeiss) with a floor stand as it would be used in endodontic microsurgery.



626 Low magnification

At the next level of magnification (6x) of the same tooth, no isthmus can be seen between the buccal and lingual regions of the resected root surface.

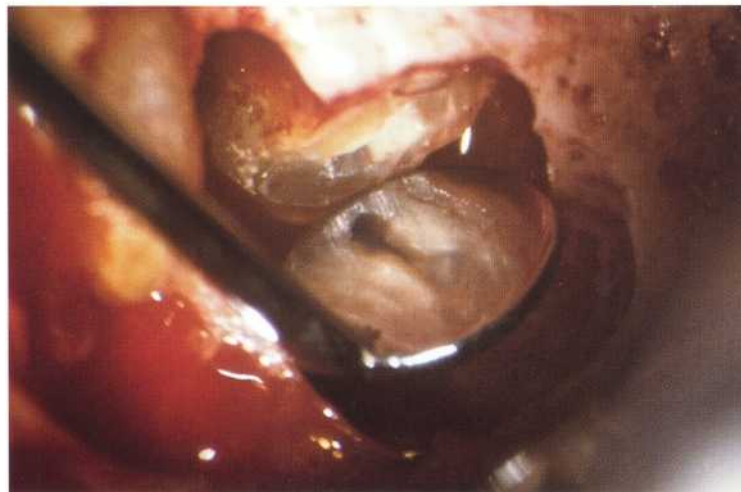
All intraoral illustrations on this and the facing page show images reflected in a round micromirror.



627 8x magnification

The 8x magnification is well suited for many surgical manipulations because the depth of field is great enough and the field of vision is sufficiently broad. Anatomic details are not yet completely clear, however.

Right: Components of the actual microscope: binocular eyepieces, videocamera, beam splitter, objective lens.

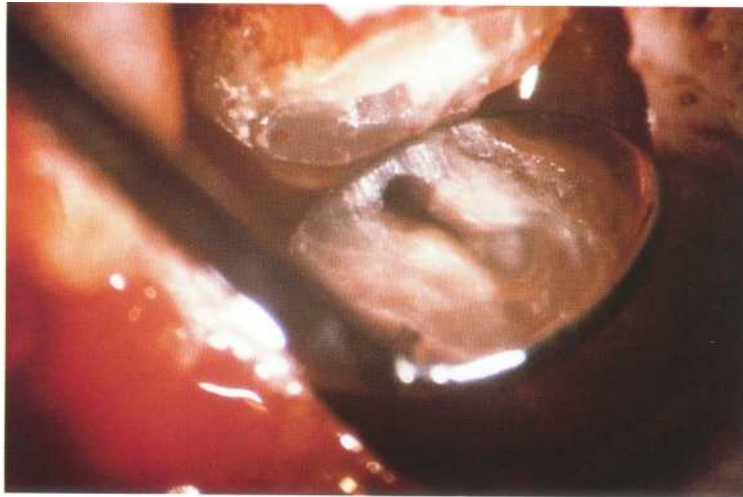

Illumination and Magnification

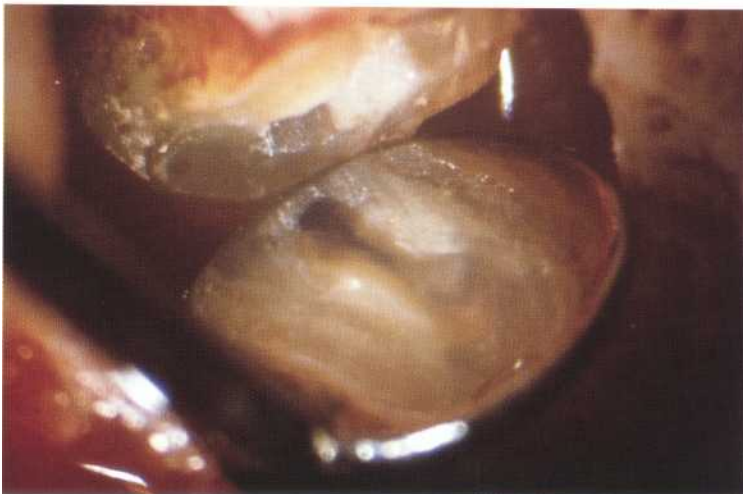
The microscope embodies two elements of the microsurgical triad: illumination and magnification. A mirror image of the resected surface in the micromirror under focused illumination and magnified up to 25 times offers the operator an impressive experience: extensions of the canal (lateral canals and blind diverticula), accessory apices, isthmus formations, microfractures, C-shaped apices, as well as poorly condensed ortho- grade and retrograde fillings.

To comfortably perform endodontic microsurgery, a surgical operating microscope is required with five-

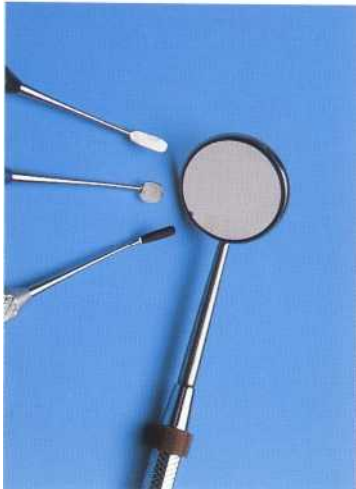stage magnification (4x, 6x, 10x, 16x, 25x), a 180° pivoting binocular, and a 200-250 mm objective lens. For more demanding work and greater efficiency, an automatic zoom can be built in. Among the many types of micromirrors, the rectangular type is the most practical because the resected root surfaces of premolars and molars are oriented with their greater dimension lying in a buccolingual direction. The round micromirror is well suited for the round or oval resected surfaces of anterior teeth.



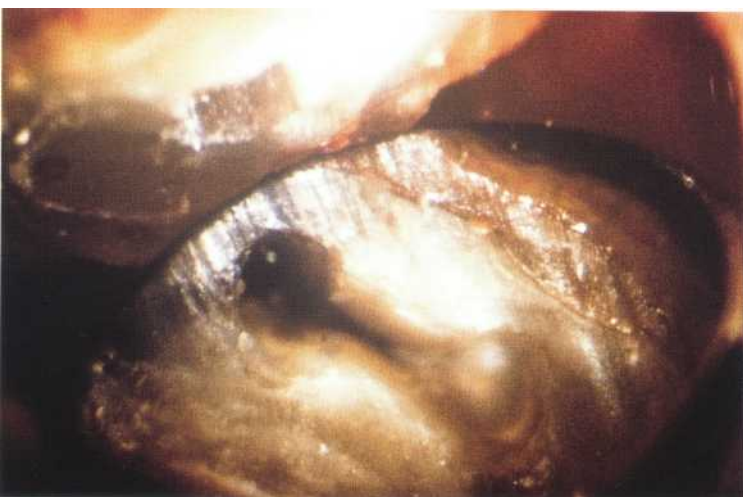
628 Mid-range magnification
The 12x magnification is most often used for surgical procedures because the characteristics of the resected surface can be clearly recognized at this level.



629 16x magnification
The 16x magnification allows inspection precise enough to discover any peculiarities or abnormalities on the cut root surface. Because of the shallow depth of field and narrow field of view, surgical manipulations are difficult at this magnification.



Left: Three types of micromirrors are pictured beside a regular dental mirror for size comparison.



630 Highest level of magnification
The 25x magnification is suitable for finding and examining the finest details that are not visible at lesser magnifications. Because of the physical laws, the depth of field and field of view are very restricted, however.

Indications for Surgical Procedures

Among the factors that must be considered in deciding whether or not surgical intervention is indicated are: clinical signs such as pain, swelling, and fistulation; obvious radiolucencies in the periapical region; the appearance of root canal filling defects on the radiographs; and the case history of the tooth. Essentially there are four *main indications*:

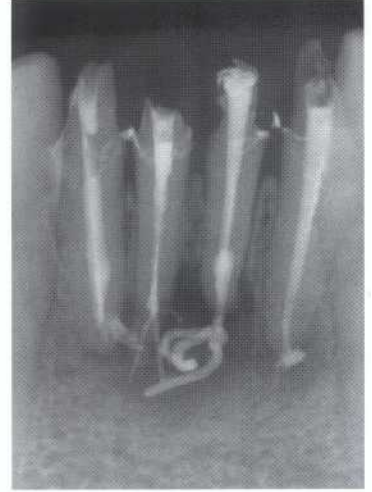
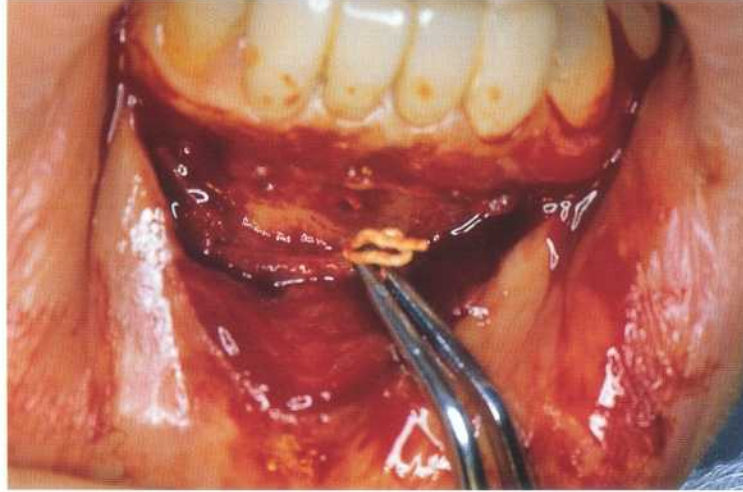
- 1 Failures in conservative endodontic therapy.
- 2 Enlargement or persistence of apical changes following conservative endodontics and placement of a post.
- 3 Anatomic deviations.

4 Mishaps during root canal treatment such as perforation, instrument fracture within the canal, and overfilling of the root canal system.

In addition, there are some cases in which the tooth is symptomatic even though clinical and radiographic evaluations reveal nothing remarkable. In these cases an exploratory surgical procedure is indicated and will usually reveal the source of the problem. In these situations the final treatment plan is not decided until a flap has been reflected and the root surface observed directly.

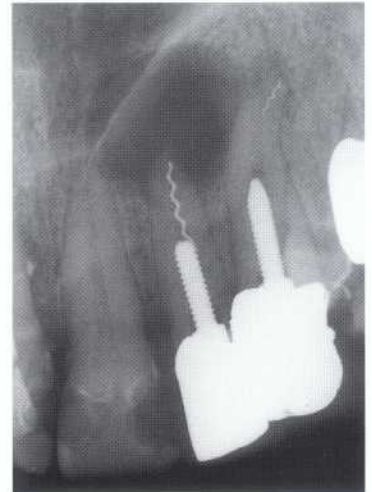
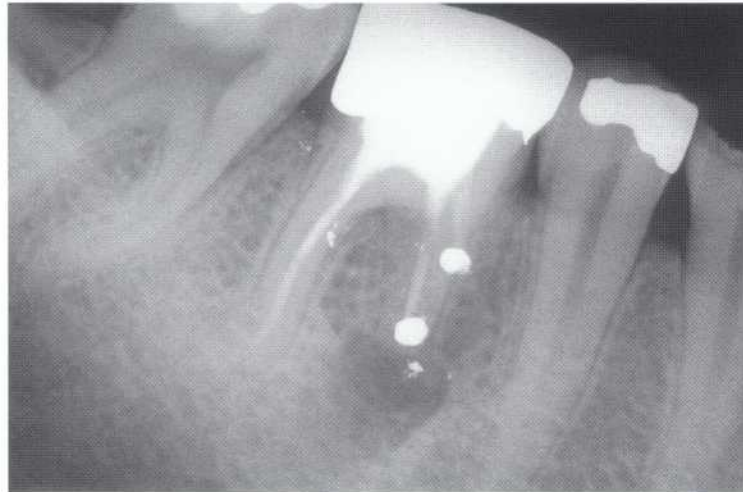631 Failed endodontic therapy
Surgical exposure of the root tip of a mandibular anterior tooth reveals that the root canal has been overfilled with gutta-percha. This example of failed endodontic treatment caused swelling and pain.

Right: The radiograph of this case shows the "spaghetti" phenomenon that occurs when a root canal is grossly overfilled.



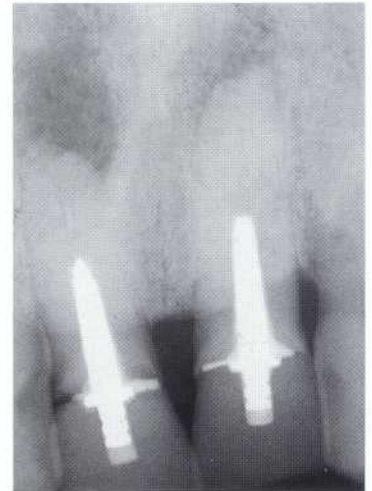
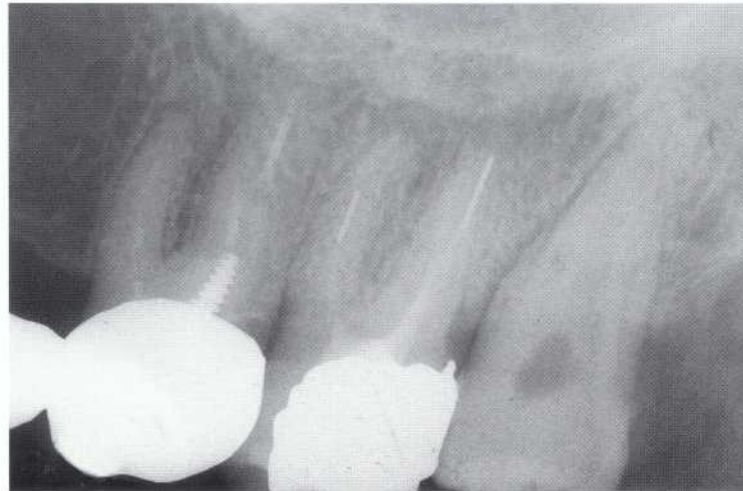632 Additional failures
Example of failed endodontic surgery with retrograde amalgam fillings. The periapical lesion has not healed and the patient reported persistent swelling and pain.

Right: Large periapical lesion associated with an inadequate root canal filling, a fractured instrument, and a threaded post. With conventional retreatment there would be a high risk of root fracture.



633 Treatment error
This example shows fractured instruments that were left in the root canals, as well as inadequate root canal fillings.

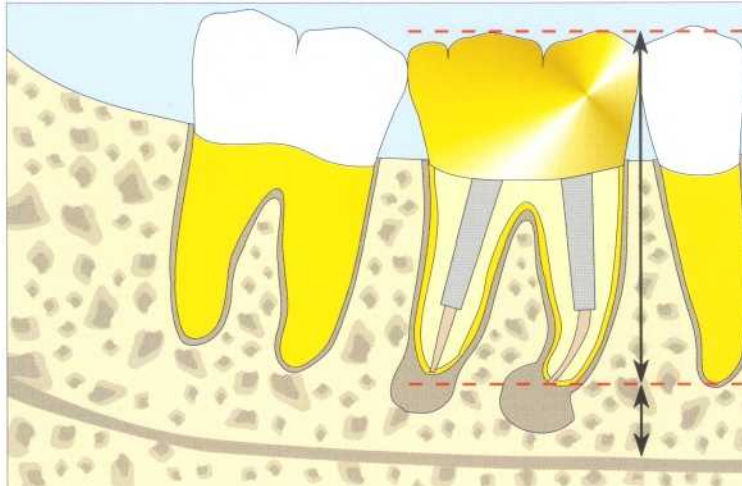
Right: Persisting apical lesion with swelling and a large post-retained restoration. Here a microsurgical procedure would help preserve much of the tooth structure, whereas an attempt to remove the threaded post would require the sacrifice of more root structure and entail a high risk of fracture.



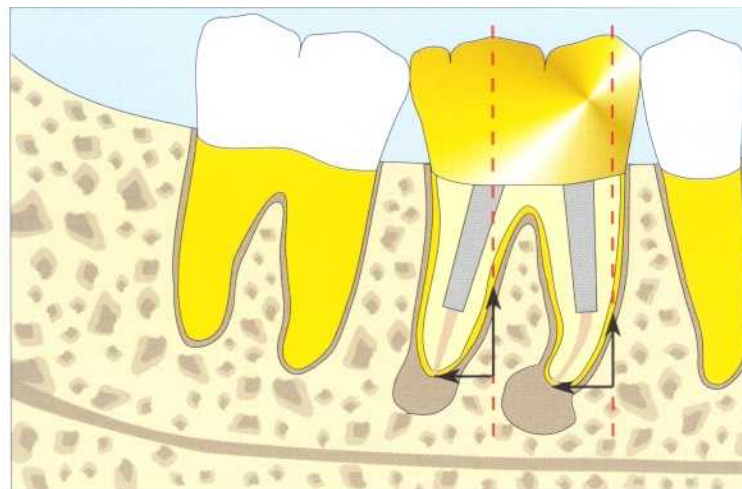
Presurgical Examination

A thorough visual and radiographic examination of the involved teeth and the adjacent structures is essential before surgery. The soft tissues must be carefully inspected for any swellings or fistulous tracts. Furthermore, access for the contemplated surgery must be evaluated, especially in the molar region. A radiographic examination is indispensable for this purpose because it clarifies the spatial relationships between neighboring roots and the proximity to important anatomic structures such as the mental foramen, inferior alveolar canal, and the maxillary sinuses.

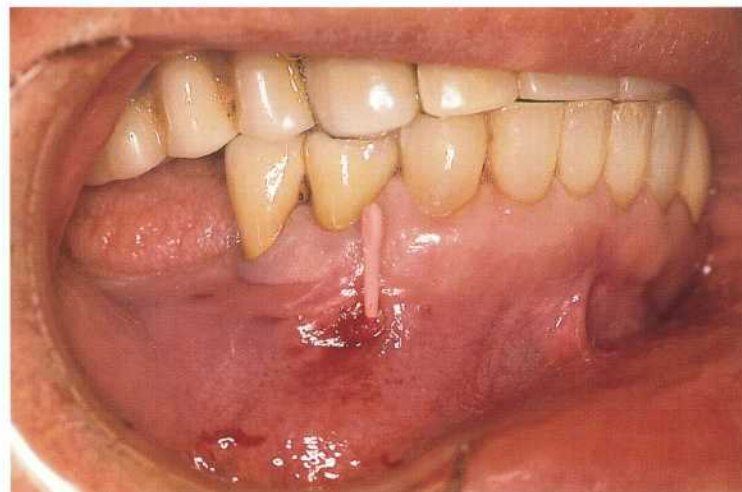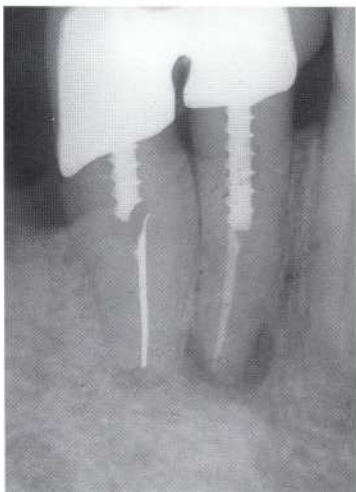
For premolars and molars, two radiographs should be taken at different projection angles: one perpendicular to the root surface and another at an eccentric angle of 25°-30° from the mesial or distal to establish the spatial relationships of the roots before the operation is begun. In this way it can be determined, for example, if the lingual root of a maxillary premolar is completely separated from the buccal root by thick bone, or if the mesial roots of a mandibular molar are fused (Gutmann 1984).



634 Planning the osteotomy I
To closely estimate the distance between the cusp tips and root apices (tooth length) and the distance to the inferior alveolar nerve, a periapical radiograph must be taken perpendicular to the occlusal plane. The radiographic distance between cusps and root tips is transferred to the mouth and determines the location of the initial osteotomy opening.



635 Planning the osteotomy II
The curvature in the apical third of the roots must be evaluated in relation to the cusp tips as shown in Figure 634. Precise radiographic technique and exact measurements on the film are essential for establishing the correct locations of the osteotomies and determining their size.



636 Localizing the periapical lesion
A gutta-percha point has been inserted in the mandibular canine-premolar area in order to visualize the course of a fistulous tract.

Left: The radiograph reveals the pathologic situation in the periapical region of the mandibular first and second premolars with threaded posts and crowns.

Flap Design

The two principle goals of an orderly preparation of the soft tissue are adequate access and good healing of the osteotomy. According to the location of the tooth to be treated, one of the two preferred flap designs is used with one or two releasing incisions.

Mucoperiosteal Flap

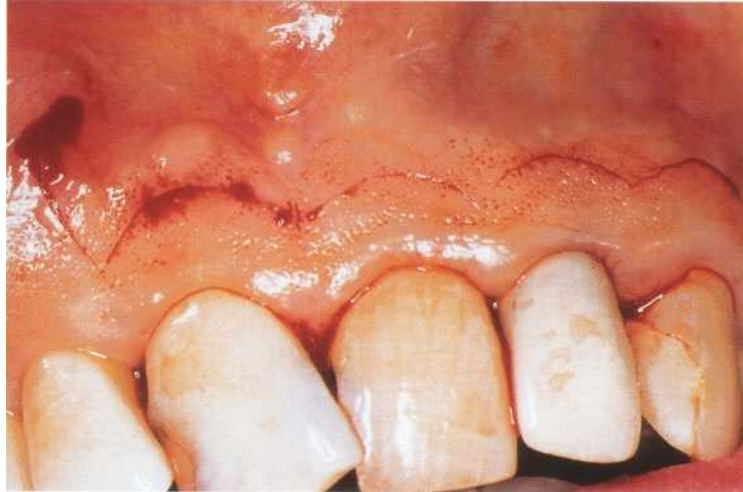This type is best suited for crowned teeth where the esthetic appearance of the gingival margin might be unfavorably affected by the surgical procedure. An incision is made parallel to the gingival margins in the

center of the attached gingiva. The scalpel is held at a 45° angle to the cortical bone because this will produce a wider cut surface at the edges and facilitate later re-adaptation of the flap. One vertical releasing incision is made mesially and another may be made distally. This allows adequate access without disturbing the integrity of the attached gingiva around the teeth and the crown. The vertical incision should follow the direction of the mucosal fibers, which run straight toward the root tips.

637 Incision line for a mucopereosteal flap

The photograph of the maxillary anterior region clearly illustrates the design of the mucopereosteal flap. At a level half the height of the attached gingiva a scalloped incision has been made that extends well to either side of the tooth to be treated.

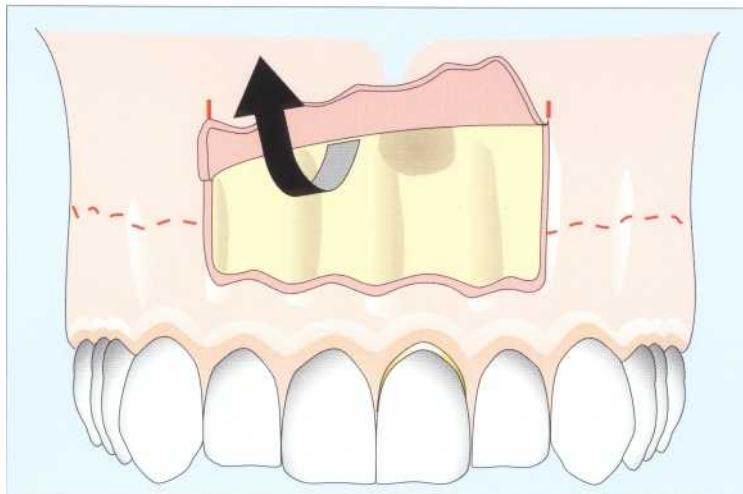
Right: Schematic drawing of the flap design. Both releasing incisions are strictly vertical and follow the alignment of the mucosal fibers.



638 Schematic of the mobilized mucoperiosteal flap

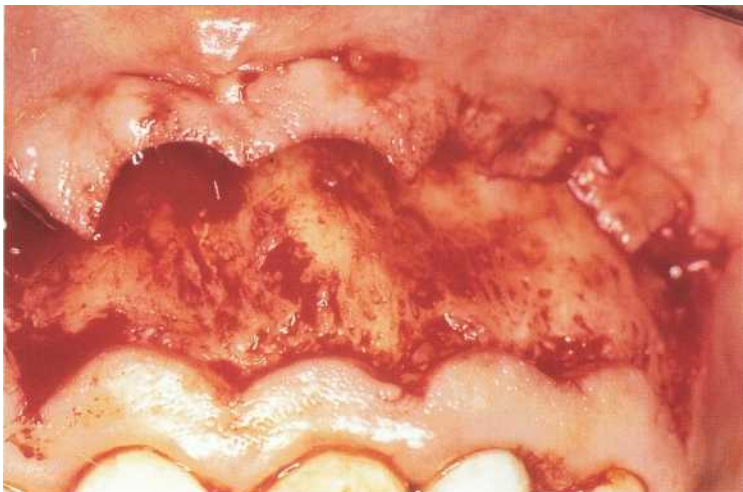
A rectangular flap has been prepared and retracted in the anterior region of the maxilla. This provides the surgeon with excellent access to the apex and to the root surface.

Right: The incision begins in the midregion of the attached gingiva with a 15C scalpel or a Beaver microblade.



639 Clinical appearance

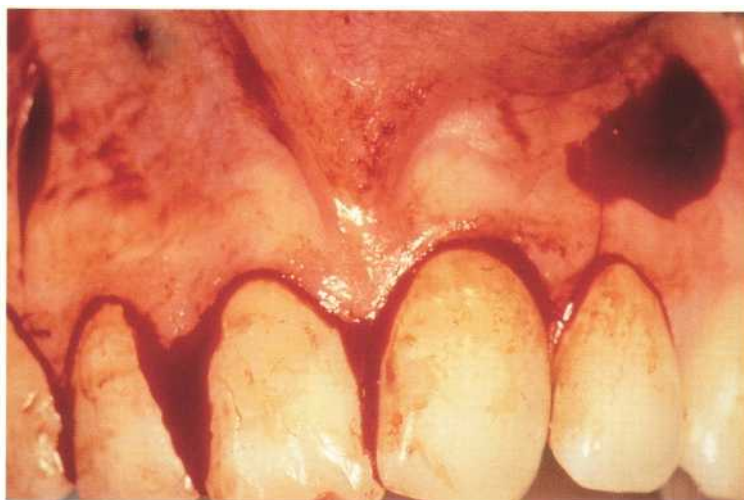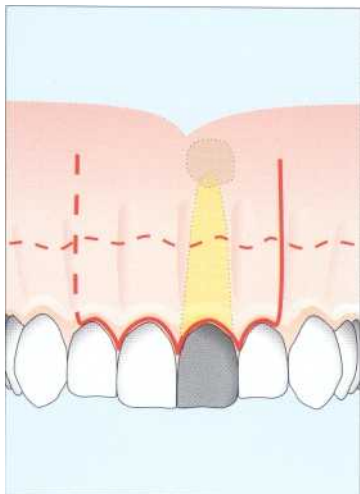
The mucogingival tissue has been reflected with a small, sharp elevator.



Full Thickness Flaps

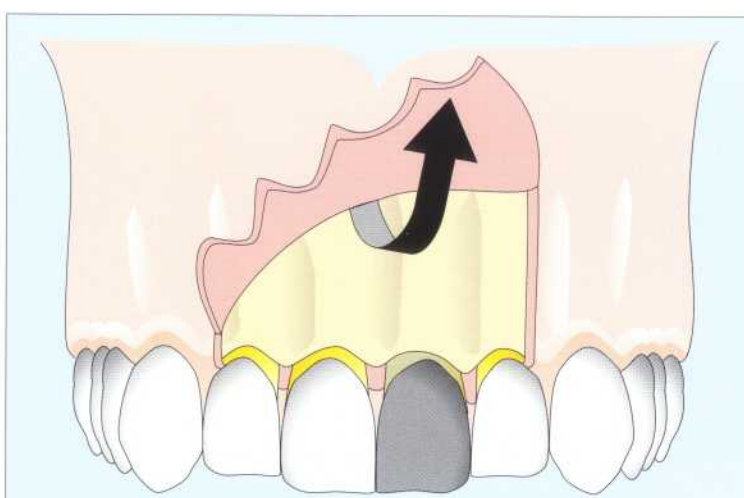
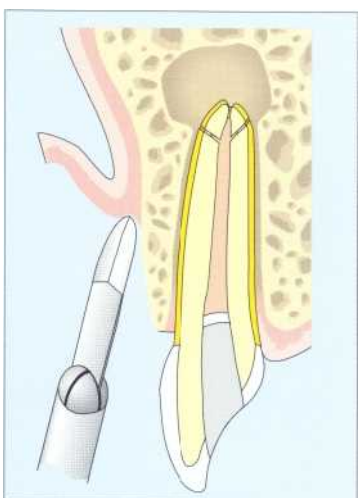
This flap design provides the best access with the least trauma. With only one releasing incision a triangular flap is produced, while two releasing incisions produce a rectangular flap. Regardless of the incision variation that is finally selected, this type of flap is the one most frequently used in endodontic microsurgery because of its advantages. It leaves a scar that is barely visible after healing. The releasing incision is made one tooth-width mesial and/or distal to the involved tooth. For

anterior teeth the rectangular flap is preferred. It has one disadvantage, however, in that it can cause gingival recession to occur around crowned teeth, and therefore for esthetic reasons this flap design should not be used on anterior teeth with artificial crowns (Harrison and Jurosky 1991). In the posterior region the distal releasing incision produces no real advantage. Instead it creates a problem in suturing because of the restricted working space. Therefore, the triangular flap is preferred in the posterior region.



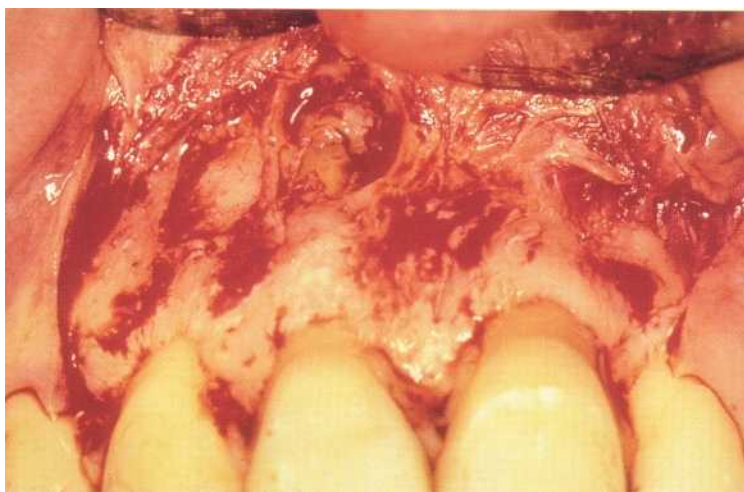
640 Full thickness flap
Clinical photograph of the maxillary anterior region after an intrasulcular incision for a full thickness flap.

Left: Schematic drawing of the full thickness flap with an incision line in the sulcus. The vertical releasing incision is made parallel with and over the long axis of the tooth, simplifying the suturing. The scalpel (15C or microblade) should cut through the full thickness of the attached gingiva.



641 Schematic of the full thickness flap
The mucoperiosteal flap is mobilized with an elevator. A vertical releasing incision should be employed.

Left: Incision to release the gingiva. The complete reflection of the attached gingiva deserves special attention.



642 Clinical appearance
There is excellent access to the opened surgical field. Generally, the bleeding following the releasing incision is minimal and the tissue heals with little or no scarring.

Apical Resection

The actual removal of the root tip would appear to be a simple matter. Nevertheless, there are two essential questions that have a bearing on whether or not the microsurgery will be successful.

The first is how much of the apex should be removed, and the second is at what angle the cut should be made. These questions are related to the frequency and distribution of lateral canals and apical branches near the apex. In vitro resections of the apices of human teeth at distances of 1, 2, 3, and 4 mm from the root tip showed that branching of the root canal system

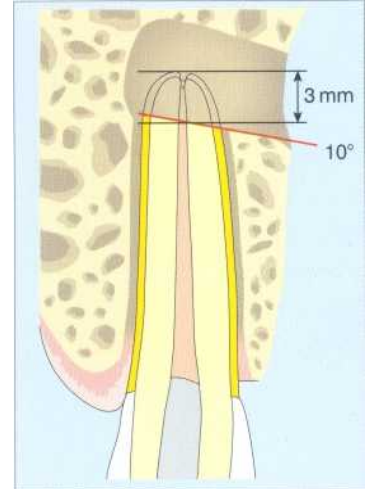
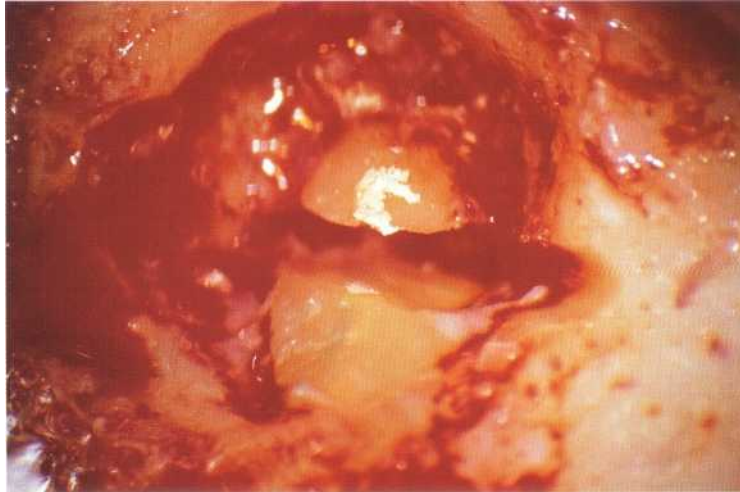
occurred in every one of these planes. However, at the 3-mm level their numbers decreased to less than 10%. Therefore 3 mm of the root tip should be resected to ensure elimination of 90% of the lateral canals and apical ramifications.

From the biologic point of view, a resection angle of 0° would be optimum, that is the cut would be made at a right angle to the root. If the patient is positioned correctly, the angle of 10° that is used in practice allows excellent visual access and a good working posture (Gilheany et al. 1994).

643 Root tip resection

The root tip of the maxillary first premolar has been separated through a plane 3 mm from the apex and can now be removed in one piece.

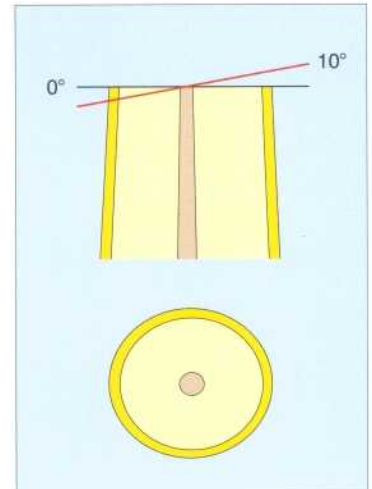
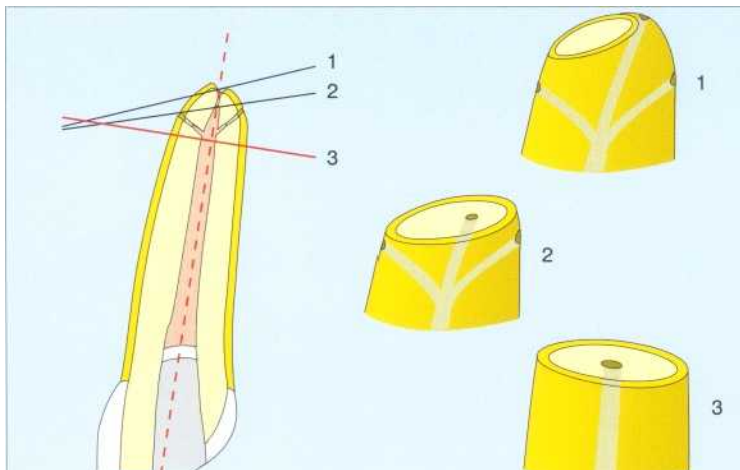
Right: Schematic drawing of the resection. To remove the major portion of the apical ramifications, the root must be shortened by 3 mm. A resection angle of 10° has proven to be reasonable and adequate.



644 Variations in the resection angle

Ideally, the root should be resected at a right angle to the long axis along line 3. This ensures removal of the greater part of the apical delta with the branchings of the canal. Root tip resections that follow lines 1 or 2 will not be successful.

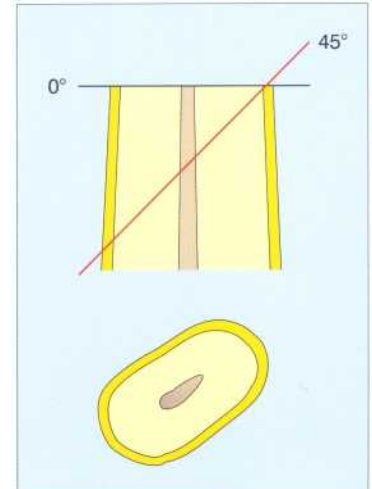
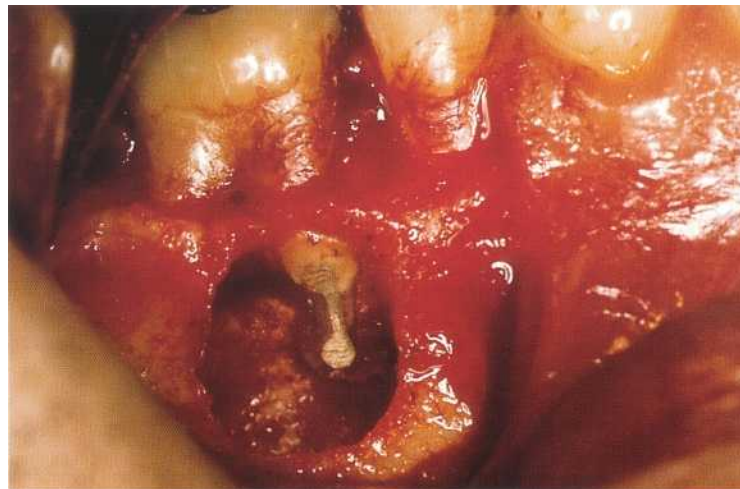Right: A flat resection angle spares tooth structure without making access to the root surface more difficult.



645 Common errors in endodontic microsurgery

An excessively large osteotomy and a steep bevel greater than 45°.

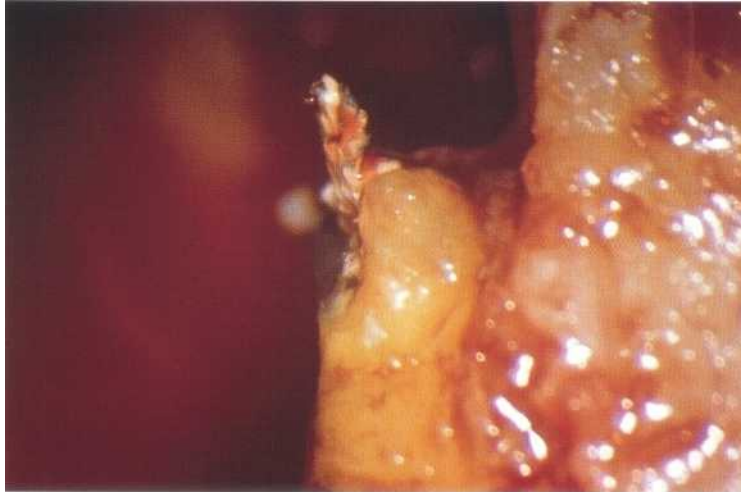
Right: In the past, an angle of 45° was necessary to allow the surgeon to see and prepare the entrance to the canal. Because of the present microinstrumentation, the removal of such a large amount of root structure is no longer necessary.



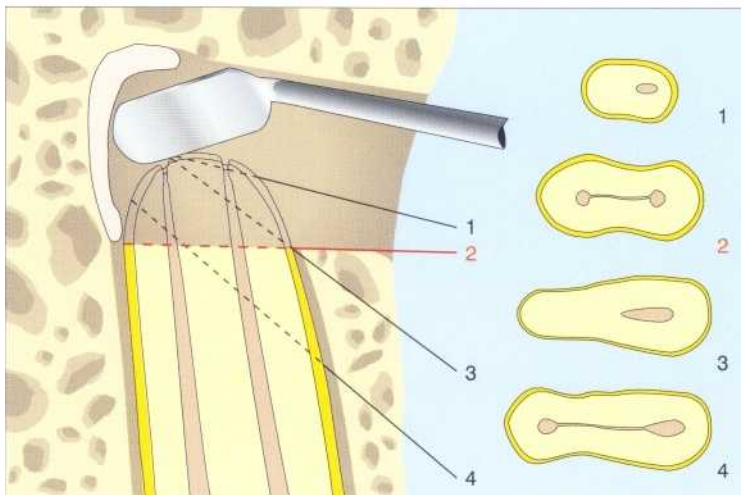
Resection Angle

Until recently an angle of 45° was recommended in textbooks. There is no biologic or clinical need for this, however. The only basis for this style of preparation was the surgeon's need for visual and operative access to the resected surface to enable placing of the material for the retrograde filling. In the process, however, the mesiobuccal surface of the root was extensively reduced, and this often resulted in communications between the periodontium and the endodontium. In many cases this resulted in loss of the tooth.

With use of the surgical operating microscope and microsurgical instruments, the amount of bone and root tip removed can be minimized. First of all, the size of the opening made in the buccal bone is reduced, thus the tooth is left more stable. Secondly, fewer dentinal tubules are exposed, thus root permeability and contamination are reduced. Thirdly, potential communications between the endodontium and periodontium are avoided, thereby improving the chances of retaining the tooth. Figure 645 shows a representative case.

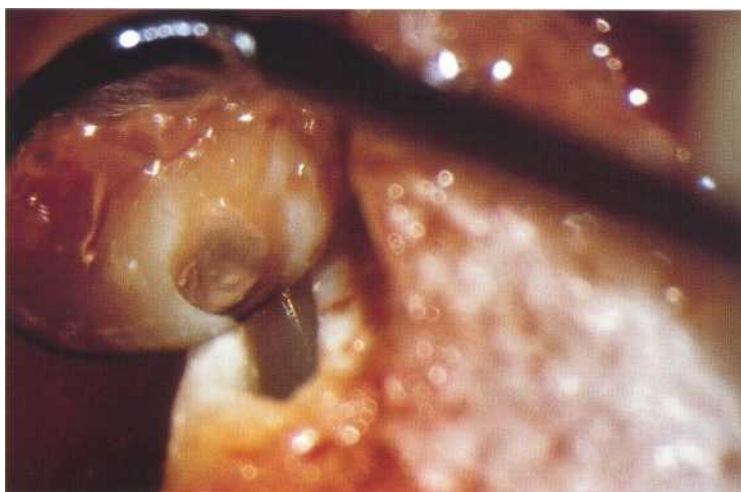


646 Overfilled root canal
After removal of the granulation tissue, the excess gutta-percha can be seen. The filling material has extruded through a clearly visible isthmus. The angle of the attempted resection is too steep.



647 Resection angle
If the root tip were cut away at different angles, the resected surface when viewed in the mirror would have the different appearances shown on the right.

With a shallow resection angle but too conservative a cut, insufficient tooth structure would be removed (line 1). A steep angle (3 and 4) results in the removal of a large part of the buccal plate of bone and may not even reach the lingual part of the root tip (line 3). An angle of 10° is ideal (line 2) with the removal of 3 mm of the root tip.



648 A prepared isthmus
The root tip of the tooth in Figure 646 is removed at an angle of 10° . Then the isthmus is prepared with an ultrasonic instrument.

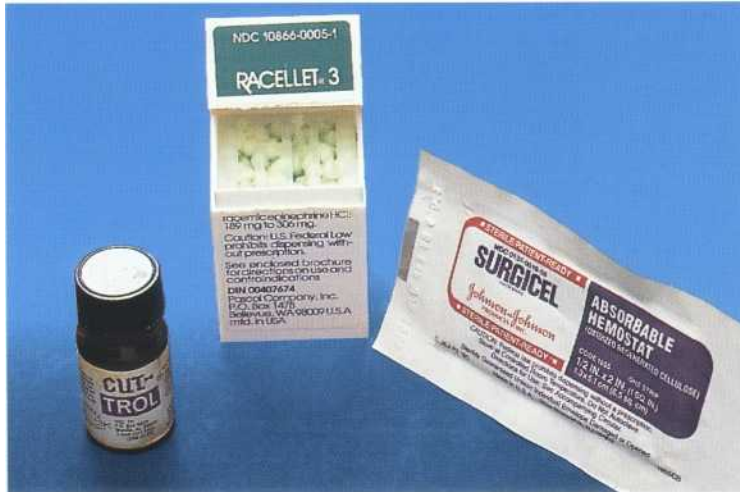Hemostasis

Successful hemostasis begins with effective local anesthesia. Normally, profound anesthesia with an agent containing 1:50 000 parts epinephrine is adequate to achieve a blood-free field. In many cases, however, it is necessary to employ additional hemostatic preparations such as ferric sulfate solution, cotton pellets soaked with epinephrine, bone wax, Gelfoam (Upjohn), or Surgicel. The most effective way to arrest heavy bleeding from a bony cavity is to place a cotton pellet with epinephrine into the depths of the cavity, then cover it with several dry sterile cotton pellets and

hold them in place with light pressure. After a few minutes these are removed one by one, except for the first epinephrine-impregnated pellet that is left in place until the operation is completed. This procedure is effective even when there is considerable bleeding from the blood vessels within the bone. After the surgical wound has been closed with sutures, a gauze sponge moistened with saline solution and placed over the site will help to stabilize the flap and stop oozing of blood.

649 Hemostatic agents

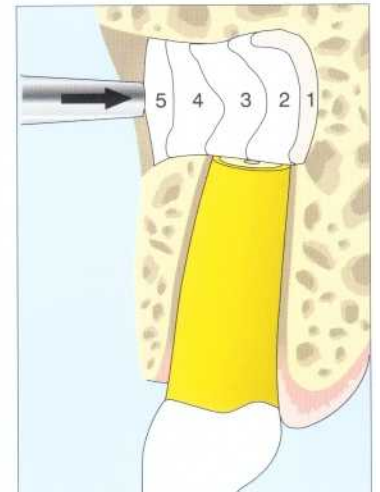
Ferric sulfate solution (Cut-Trol), epinephrine pellets (Racellet), and resorbable cellulose sponges (Surgicel) can be used to stop bleeding.



650 Pellet technique

Two cavities in the bone left by removal of the root tips and granulation tissue are packed with Racellet pellets impregnated with epinephrine.

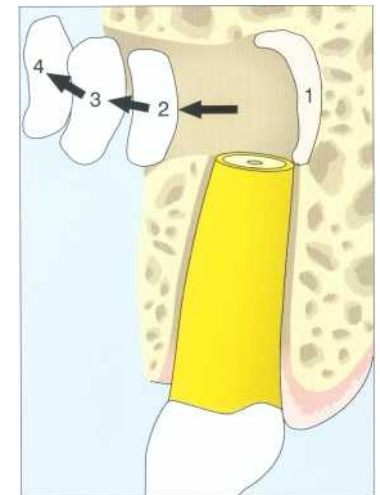
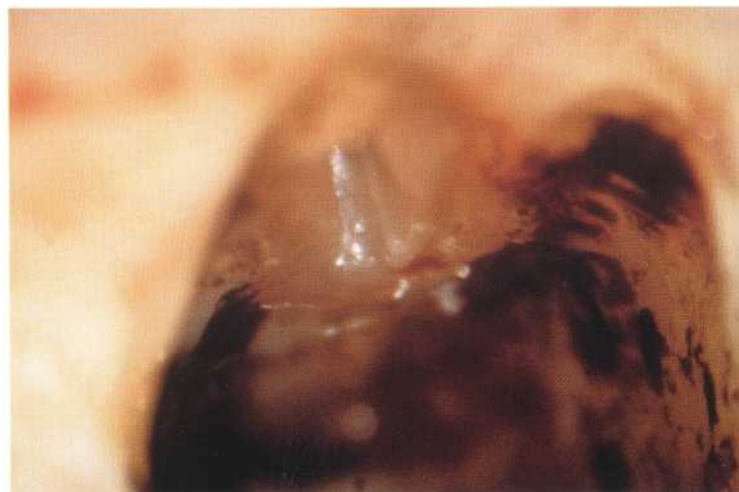Right: Schematic representation of the packing technique. Only the first pellet contains the hemostatic agent. The additional pellets numbered 2-5 are untreated. These are pressed into the cavity with a blunt instrument and left for approximately 3 minutes.



651 Blood-free operative field

Cut-Trol successfully stops the bleeding, and the resection cavity is free of blood.

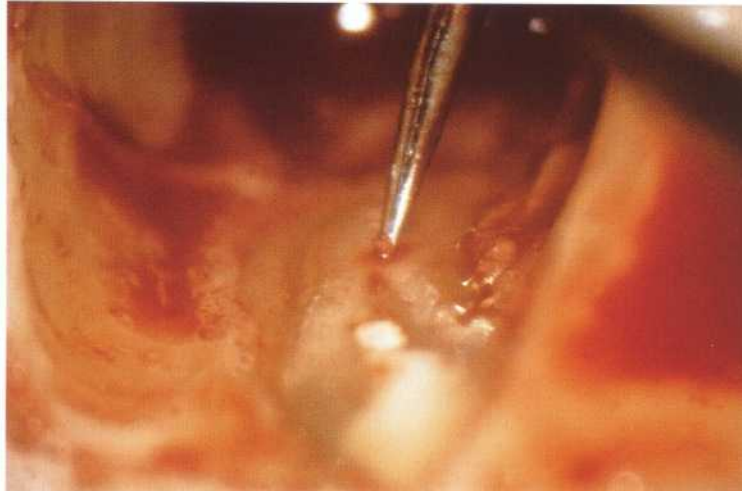
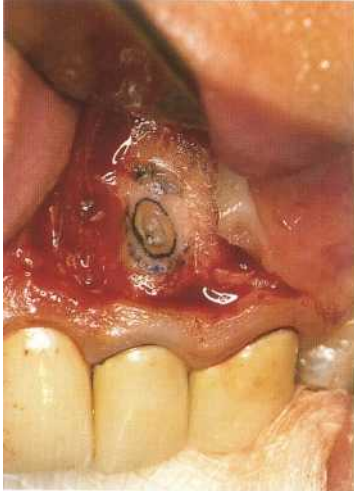
Right: All pellets except the first epinephrine-moistened pellet are removed. This makes the operative site accessible while the hemostatic effect continues.



Microscopic Inspection of the Resected Surface

Once hemostasis has been achieved the surface of the resected root is carefully examined with a CX-1 micro-explorer under 12-25x magnification. To make the anatomic structures more readily discernible, the surface of the root can be stained with methylene blue. After removal of the excess dye, the periodontal ligament and porous areas are clearly visible. Frequently, anatomic details will be recognized, such as an isthmus, C-shaped canals, accessory canals, canal diverticula, apical microfractures, and unsealed canals incompletely filled with gutta-percha and/or sealer.

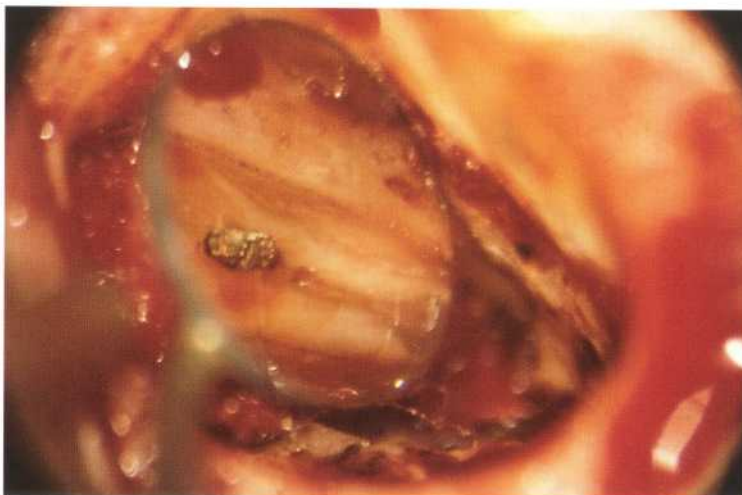Close inspection under the operating microscope of the carefully prepared root surface and the area of the treated canals also helps the operator to evaluate the quality of any root canal fillings that are encountered. One of the most frequent causes of failure of conventional as well as surgical endodontic treatment lies in the poor marginal adaptation of the root canal filling material.



652 Searching out the root canal

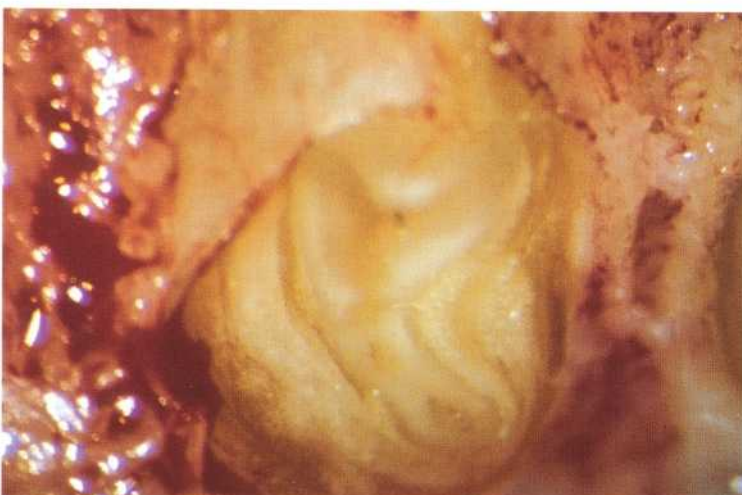A frequent cause of endodontic failure is an untreated root canal that can only be found and filled using the microscope. The explorer (CX-1) helps in finding the second canal entrance that was at first overlooked (12x magnification).

Left: The resection surface is stained with methylene blue to make the circumference of the canal and the periodontal tissue stand out visually (6x magnification).



653 Inspection of the resected root surface

Under 16x magnification an isthmus that connects two apical foramina can be clearly seen. The buccal canal has been filled but the lingual canal remains untreated and the isthmus is wide open, which means there are two reasons for failure of the previous treatment.



654 Complexity of the root tip
One of the primary causes for the failure of conventional and surgical endodontic procedures is the failure to remove necrotic tissue from an isthmus. With the complex form of isthmus shown here, a number of apical foramina are interconnected (16x magnification). Such a situation can be handled very effectively through ultrasonic instrumentation.

Isthmus

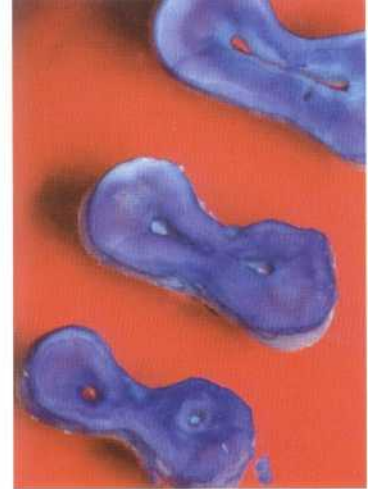
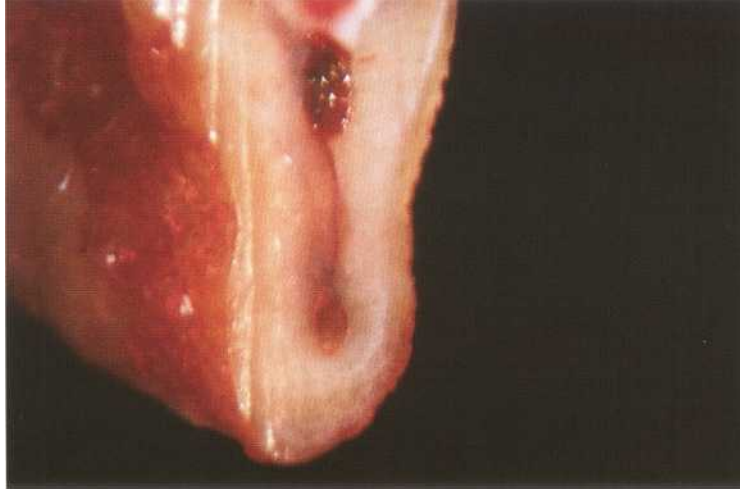
The success rate of endodontically treated posterior teeth is lower than that of anterior teeth. Friedman et al. (1991) reported success in only 44.1% of premolars and molars retreated by apicoectomy. Other authors indicate clinical success in 71-73% of molars with resected root tips (Altonen and Mattila 1976, Joannides and Borstlap 1983). By contrast, the success rate among anterior teeth is 85-90% (Rapp et al. 1991). The tips of mesiobuccal roots of maxillary first molars are relatively easy to resect, but the success rate is significantly lower than for mandibular first molars, even

though the surgical procedure can be more difficult for the latter (Nordenram and Svardstrom 1970).

Preeminent among the possible causes of these failures are, besides the technical inaccessibility during the course of the operation, untreated canals and insufficient condensation of the filling. One underlying cause of treatment failure that is greatly underestimated is an undiscovered canal isthmus that represents a corridor, that is a lateral communication or anastomosis between two separate root canals (Pineda 1973).

655 **Isthmus**
Failure resulting from an untreated isthmus.

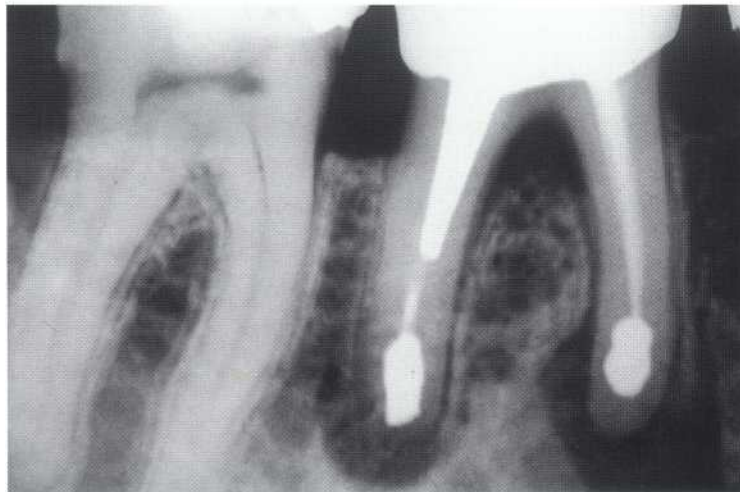
Right: Sections of a root that was cut off at a distance of 3-5 mm from the apex and stained with methylene blue.



656 **Root tip resection without identification of the isthmus**

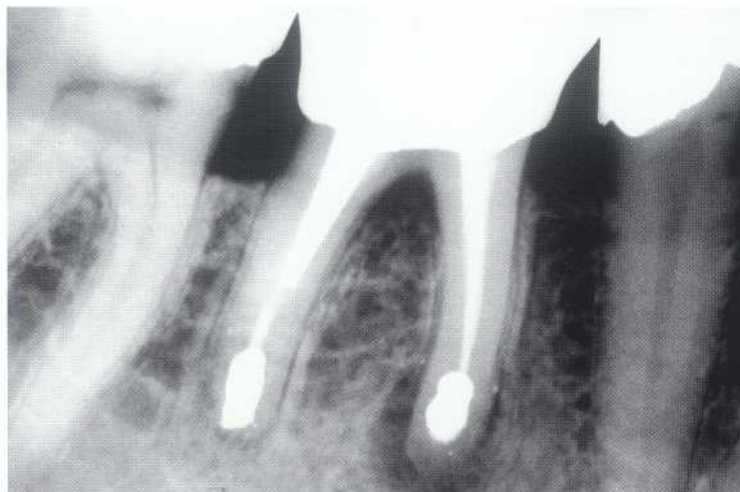The radiograph shows the condition of a mandibular molar immediately following conventional surgery. Retrograde amalgam fillings are placed in both root tips.

Collection S. Friedman



657 **Failure after apicoectomy**

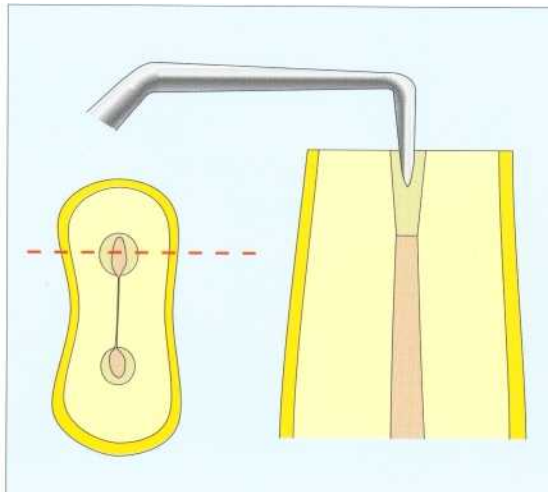
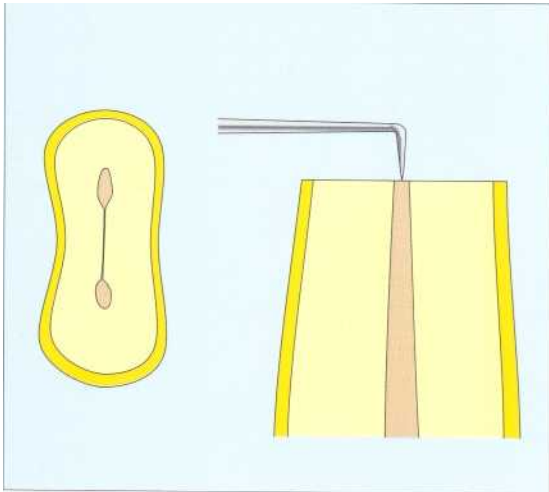
Follow-up radiograph after 3 years. Why has the distal root healed and not the mesial? It is highly probable that an untreated isthmus is present.



An isthmus is a narrow connection between two separate root canals and may contain pulp tissue or, in the case of a necrotic pulp, necrotic tissue that is infected with bacteria. The frequency of occurrence varies according to the type of tooth, and in multirooted teeth it also varies among the different roots. Thus an isthmus is found in only 15% of anterior teeth and in 20% of the distal roots of maxillary molars. In a study by Weller et al. (1995) 40% of the mesiobuccal roots of maxillary first molars had a single root canal and, conversely, there were two canals present in 60% of the

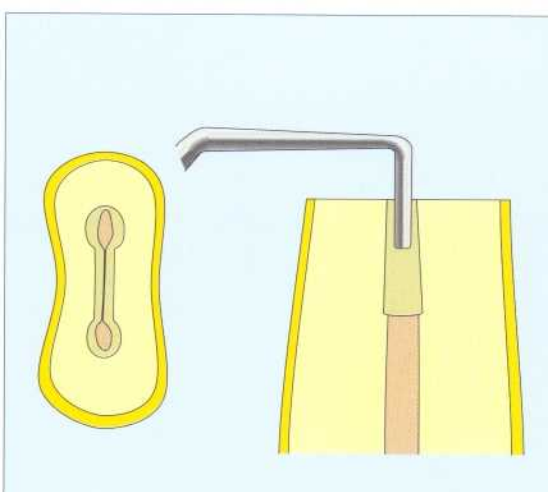
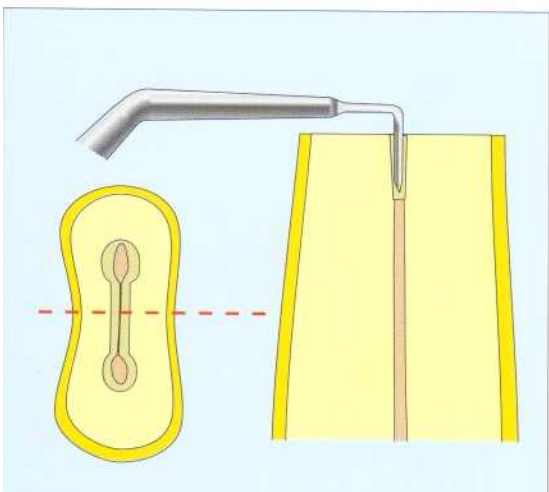
cases. An isthmus was encountered most frequently at a distance of 3-5 mm from the apex. All roots with two canals also had an isthmus that either completely or partially connected the canals.

A 2% methylene blue solution is useful not only in histologic studies but also in clinical applications to help make an isthmus visible. Application of the dye to the resected root surface stains the canal entrances and the pulp tissue in the connecting corridor, and the latter can then be removed with an ultrasonic retrotip.



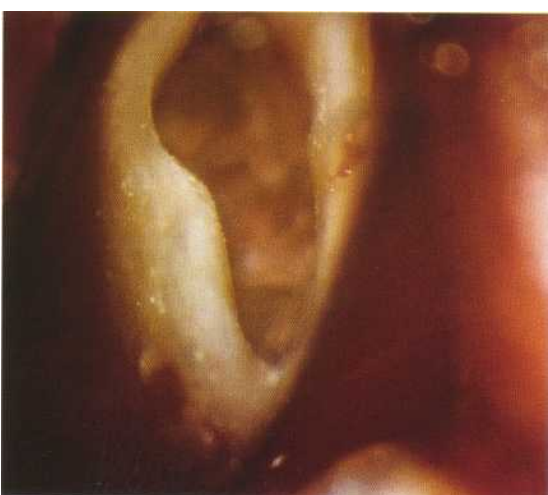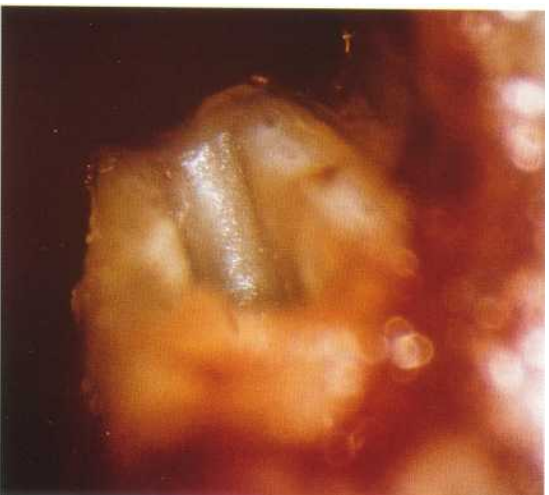658 Isthmus preparation I
Left: The schematic drawing represents the situation of an isthmus between two canals. The isthmus is probed with a micro-explorer (CX-1).

Right: The CT-1 ultrasonic tip is passed along the groove that was probed to prepare the isthmus.



659 Isthmus preparation II
Left: The preparation should be made under copious irrigation to a depth of 3 mm using the full length of the ultrasonic tip.

Right: The CT-5 tip is used for the final preparation. With this the walls can be made either parallel or slightly undercut for retention of the retrofilling. The drawing on the left represents an apical view of the completed preparation.



660 Isthmus preparation in clinical photographs
Left: The completed isthmus preparation is sharply demarcated and its lingual surface can be seen near the top of the photograph.

Right: The interior is seen here with the help of a micromirror at 16x magnification. The pink gutta-percha point seen at the floor of the cavity is within the canal at a depth of 3 mm from the resected surface.

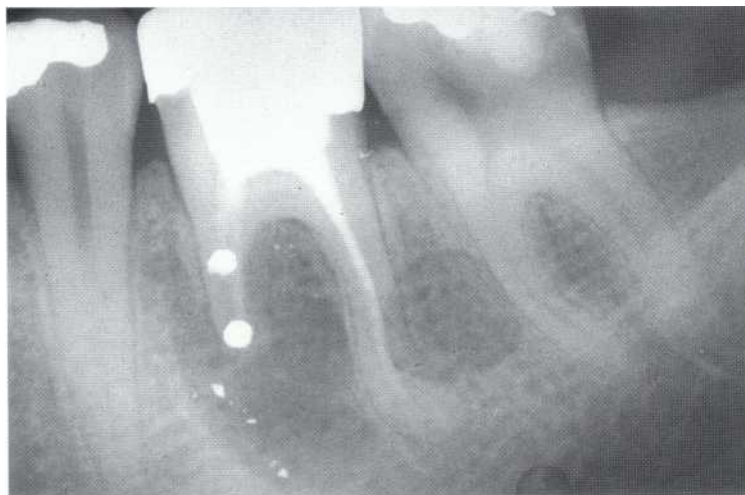Clinical Treatment of the Isthmus

The existence of an isthmus has been known on a theoretical level for some time from anatomic and histologic studies (Hess 1925 a, b; Meyer 1955 a), but until recently there was no inference that the presence of an isthmus could also have therapeutic consequences and must be taken into consideration when performing root tip resections in a dental practice.

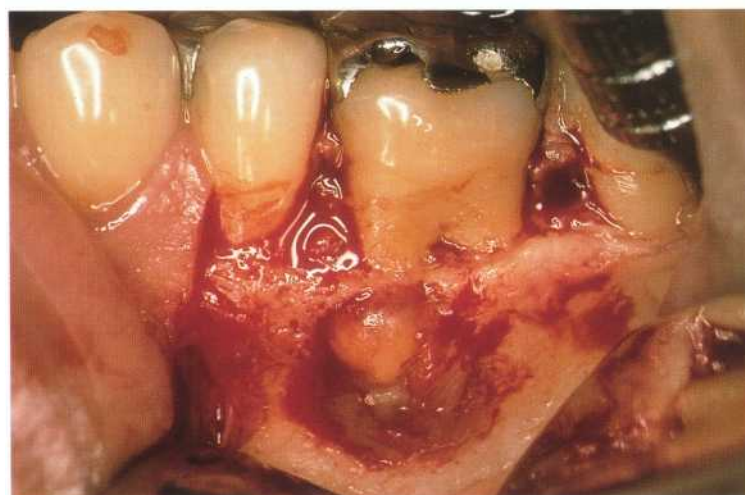
Because a necrotic root canal contains infectious microorganisms not only in the apical region but also within the isthmus, a thorough cleaning followed by a thorough seal is the primary objective of the micro-

surgical procedure. Our clinical investigations show that the main cause of surgical failure in over 80% of cases is an isthmus that was treated either improperly or not at all. There is a wide range of variation in the shape of an isthmus. The ultrasonic preparation of this anatomic structure demands a careful and delicate touch, because the isthmus is located in a slender, fragile part of the tooth that can easily become perforated or roughened.

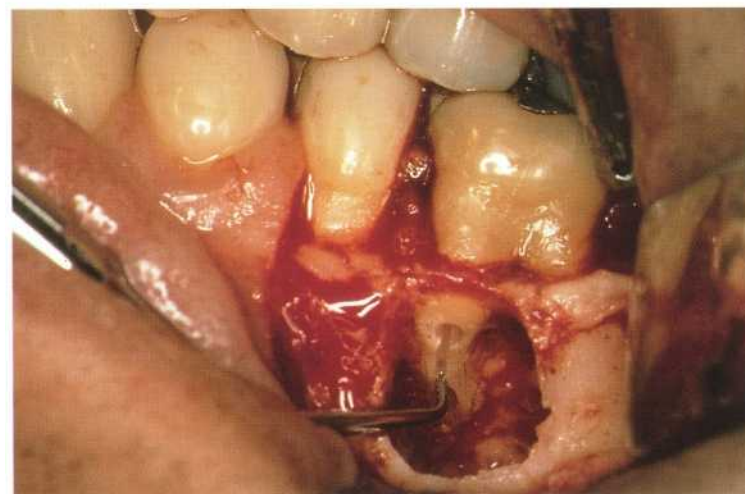661 Preoperative radiograph
This mandibular left first molar had been treated with surgery and a retrograde amalgam filling. Three years later the patient presented with a swelling of the cheek. The radiograph shows a periapical radiolucency on the mesial root, presumably associated with reinfection.



662 Reflection of the flap
Immediately upon lifting the flap extensive bone destruction and granulation tissue that adhered to the root became visible. Here, too, the origin of the periapical lesion is an isthmus that contains tissue infected with bacteria.



663 Ultrasonic preparation
The bone cavity is thoroughly curetted and the old amalgam filling removed from the mesial root canals of the lower molar. The canals have been instrumented poorly and the isthmus not at all. Therefore the apical portion of the canals as well as the isthmus are reinstrumented with ultrasonic instruments in line with the long axis of the tooth.

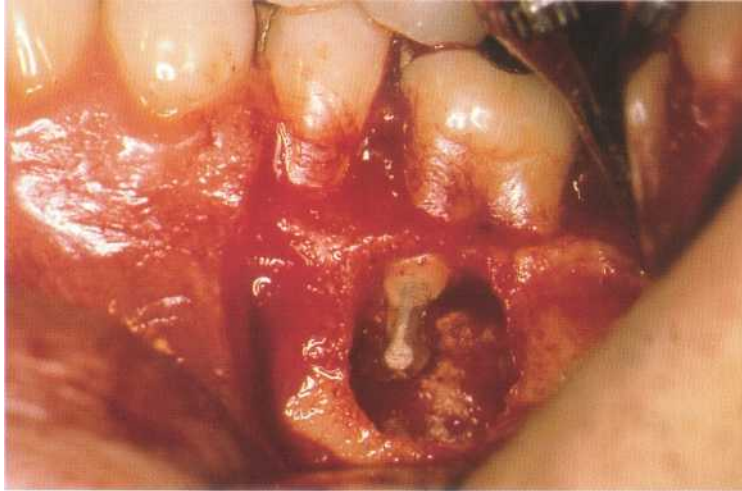


The selection of the ultrasonic tips depends therefore upon the shape of the root tip to be resected. If the isthmus lies in a delicate region of the root, the preparation should be made with the CT -1 tip that has a sharp, pointed working end. If it lies in an area of more abundant tooth structure, the ultrasonic insert CT-5 is effective.

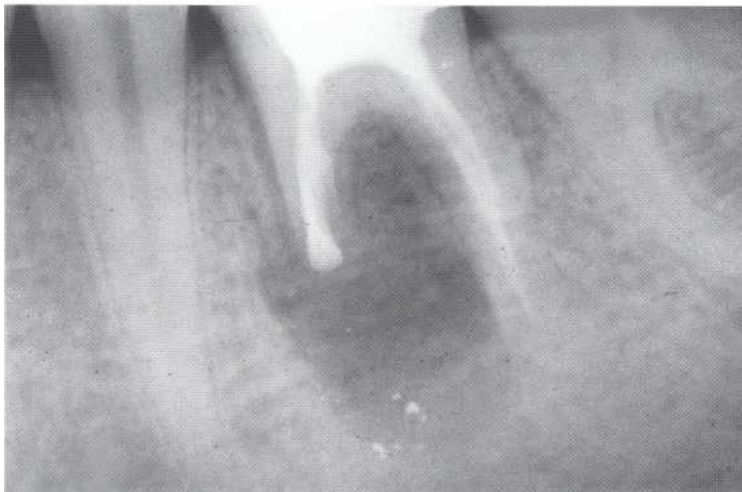Normally, the isthmus runs in a buccal to lingual direction. Instrumentation is performed initially in short intervals without a cooling water spray so that the isthmus can be followed. A line is cut connecting the

two canals, and this is followed with quick, light strokes. An immediate check under moderate (12-16x) magnification will show whether the path of the isthmus has been followed and the correct location for deepening the cavity has been established. The preparation is then continued with the CTS tip under a plentiful flow of water.

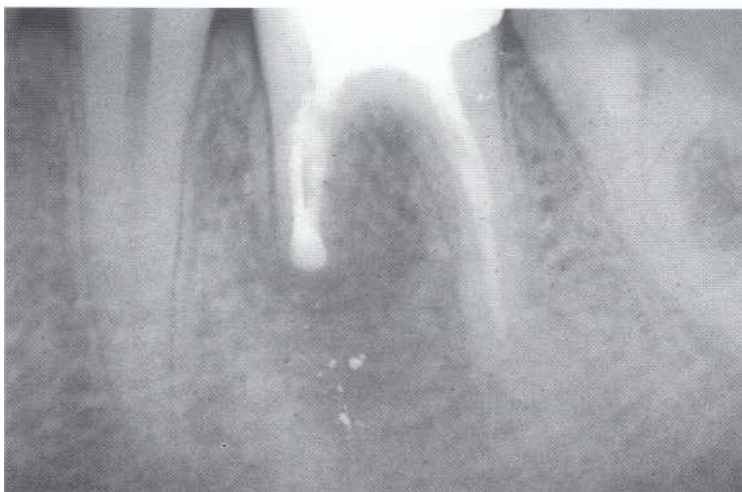For retrograde preparation of the root canal the entire 3-mm length of the active working tip must be used. Finally, the form and cleanliness of the isthmus are evaluated at higher magnification (> 16x).



664 Retrograde filling
The canals and isthmus are filled with Super EBA, a reinforced zinc oxide-eugenol cement. Then the flap is repositioned and sutured.



665 Postoperative radiograph
Super EBA cement is not as radiopaque as amalgam. The filling connects the two mesial canals and so marks the isthmus location. Most fillings of an isthmus have a similar radiographic appearance. Separated, round, dot-like retrofillings (e.g., Fig. 661) will not be encountered in microsurgery on molars in the future.



666 Follow-up examination
At the 6-month recall appointment the radiograph shows definite signs of regeneration of the bone. This confirms that the isthmus, overlooked at the initial treatment, was the cause of the previous problem.

Retrograde Preparation with Ultrasonic Instruments

The third part of the microsurgical triad, the ultrasonic unit, is indispensable for proper cleaning and shaping of the root canal. A series of different ultrasonic inserts, called Carr Tips (CTI-5) after their originator, Gary B. Carr, are available in Germany through Satelec and EMS. With these it is possible to operate in the different regions of the mouth because the working ends of the tips are manufactured with different angulations. The tips are shaped in accordance with the anatomy of the root canal systems so that it will not be necessary to remove additional tooth structure for the

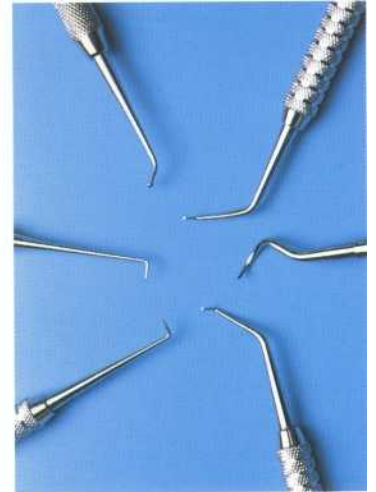
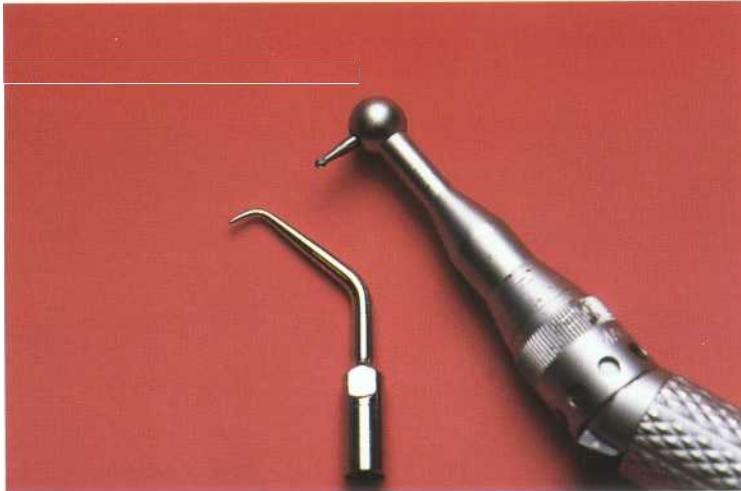sake of achieving good access to the operative site. The wide selection of shapes and sizes of ultrasonic inserts available helps to overcome all the weak points of conventional preparation with rotary instruments:

- 1 Ultrasonic preparation requires substantially less bone removal for access.
- 2 The cavity can easily be extended in a buccolingual direction.
- 3 The cutting tip is aligned parallel with the long axis of the root.
- 4 The isthmus can be prepared easily.

667 Size comparison of the instruments used for retrograde cavity preparation

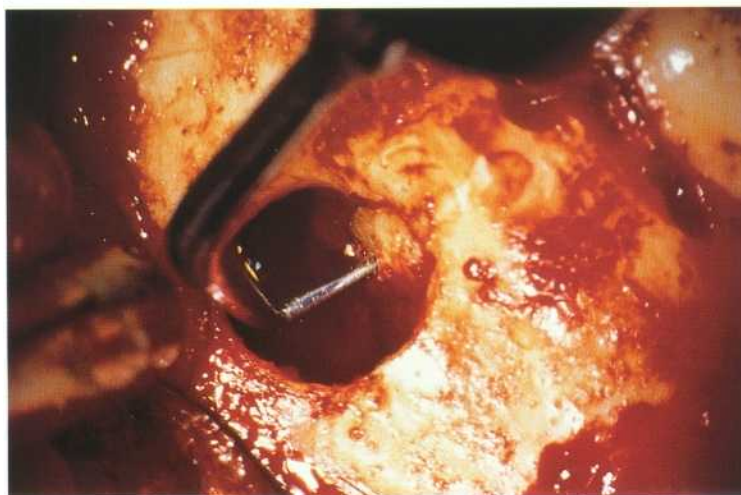
The standardized ultrasonic tip designed by Carr is much more slender than a small round bur in a microangle handpiece. The ultrasonic tip is 3 mm long and has a diameter of 0.25 mm, whereas the microhandpiece and bur have a combined length of 10 mm.

Right: Instruments for refining and filling the retrograde cavity.



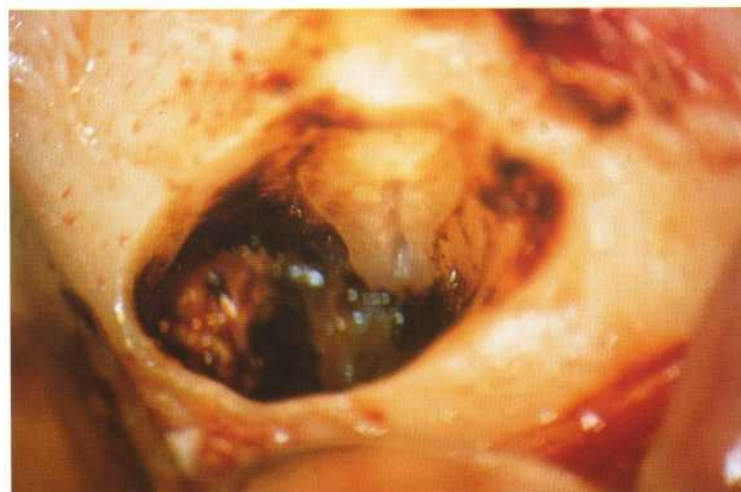668 The CT-1 ultrasonic tip

Here, the CT-1 tip is being activated to begin a retrograde preparation on a mandibular first molar. Notice the small size of the osteotomy. The ultrasonic tip is directed along the long axis of the tooth (see also Fig. 671 left). The full 3 mm length of the tip will be sunk into the canal as the cavity is prepared.



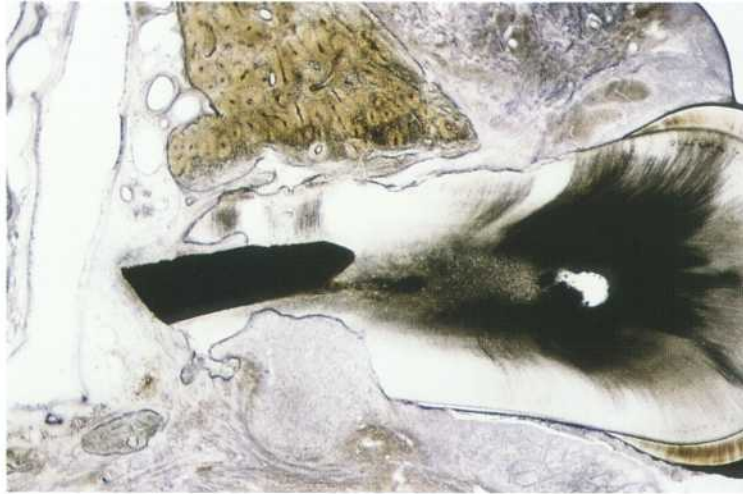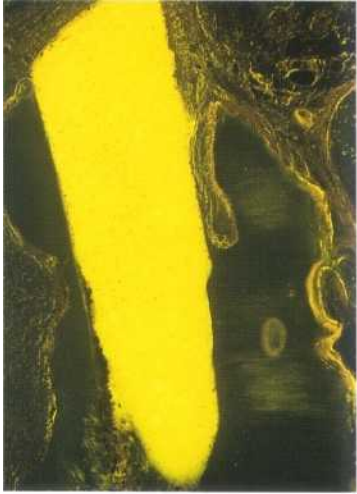669 Retropreparation

The mesial root of the lower molar is now completely prepared by ultrasonic instruments. Note the isthmus between the mesiobuccal and mesiolingual canals that has also been identified and prepared.



The main problem in conventional endodontic retro-surgery is the inability to follow the direction of the root with the bur because of the relatively immense size of even the smallest handpiece and the excessive length of the burs. For this reason, perforations often occurred in the lingual portion of the apex that lay on the side turned away from the operative field and that could not be seen on the radiograph. Furthermore, preparation with rotary instruments requires a 10-mm osteotomy opening to create enough space for the handpiece and bur. For ultrasonic instrumentation an

opening less than 5 mm in diameter is adequate because the cutting tip of the ultrasonic insert is only 3 mm long and the shaft is slender. The reduced trauma to the bone means that healing of the osteotomy site will be substantially quicker and better another example of the superiority of microsurgical endodontics (Rubinstein and Kim 1996).

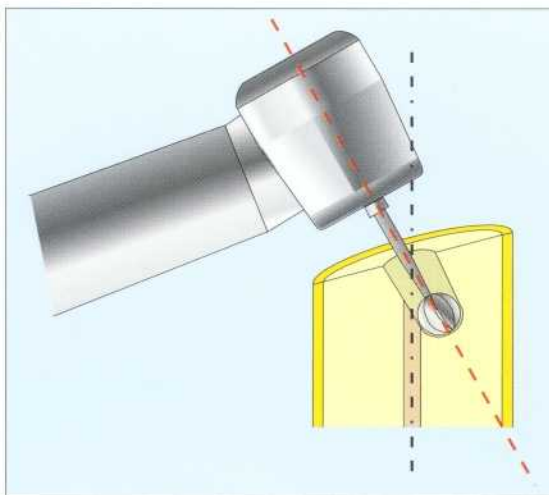
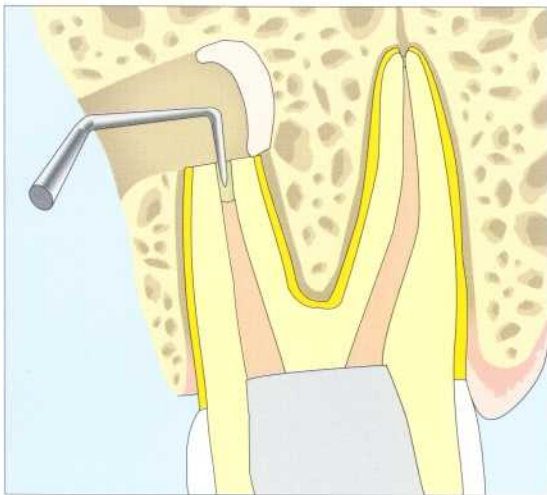


670 Histology of an ultrasonic preparation

A decalcified histologic section of a dog's tooth that has been ultrasonically prepared and filled from the apical end with Super EBA. The filling extends 3 mm into the root canal.

Left: Staining with fluorochrome dye provides even greater contrast between the retrofilling (yellow) and the surrounding root structure.

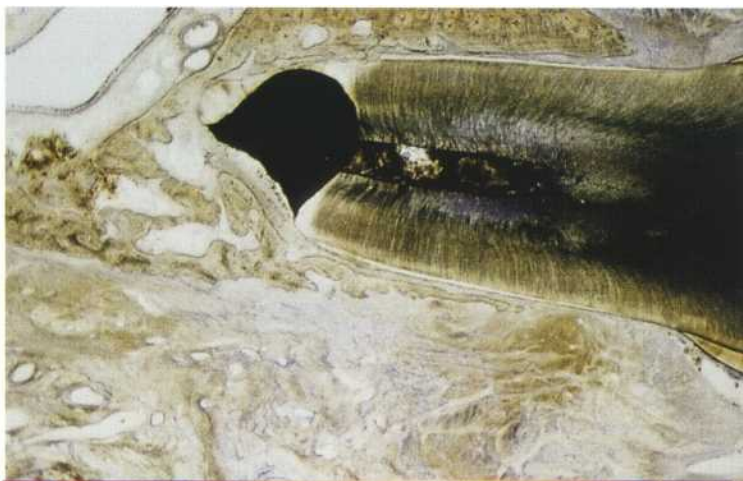Histology by H. Plenck, University of Vienna



671 Retropreparation

Left: The ultrasonic tip is placed at the canal entrance parallel with the long axis of the root.

Right: The schematic drawing illustrates the problem encountered when making a retrograde preparation with a rotating instrument. Because of the size and shape of the handpiece, the preparation cannot be made to follow the long axis of the root. This frequently leads to perforation of the root, especially when preparing lingual canals that lie far to the lingual.



672 Histology of a retrofilling prepared with rotary instruments

A tissue section similar to the one in Figure 670 reveals that the apex of this tooth has almost been perforated by the conventional retro-preparation method. The resection was performed at an angle of 45°.

Left: The fluorochrome stain and greater magnification of the region of the resection clearly reveal the near perforation at the apex.

Drying the Retrograde Preparation

None of the known materials used for retrograde obturation—amalgam, cements based on zinc oxide, synthetic resin—can tightly seal the canal if the operative field is wet. Paper points are often used for drying the cavity although they are usually not very effective.

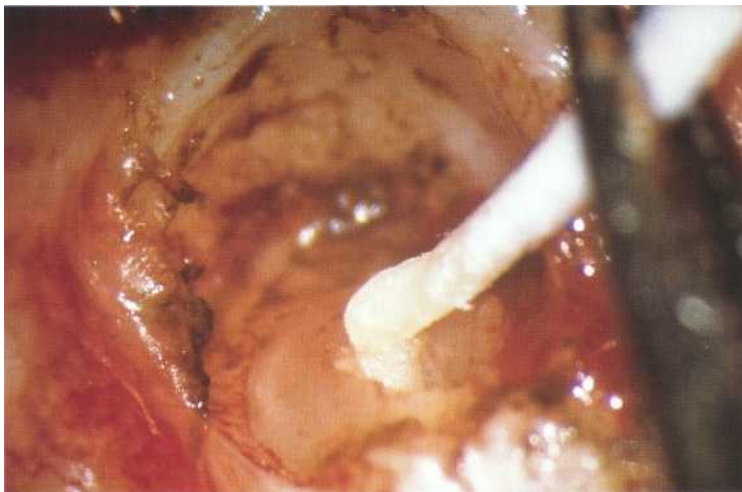
A method that is much more effective and elegant employs the Stropko Irrigator and Dryer (EIE, USA). This is a device that fits onto the standard multifunction syringe (air, water, spray) and can be fitted with a blue Ultradent Microtip by means of a Luer-Lok connection. Because the Microtip is very small, it can

be turned freely in all directions to completely dry the retropreparation.

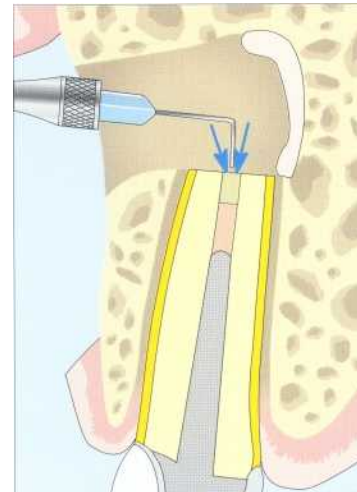
The Endo Vacuum Set offered by the German firm DVG is a similar system that attaches to the vacuum hose and can be used for drying root canal preparations. The Stropko attachment, however, fits onto the standard water syringe and therefore can also be used for irrigating the retrograde preparation.

673 Drying the cavity

After completion of the retropreparation, the apex is dried with the aid of paper points. Notice the poor fit of the paper point, which will result in inadequate drying.

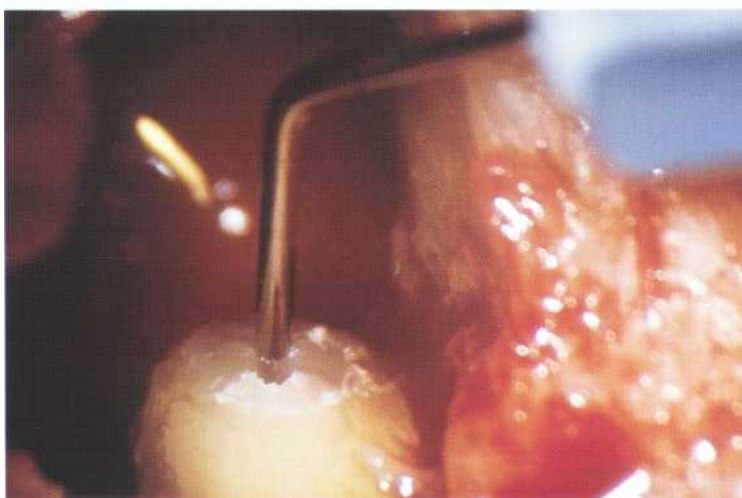


Right: Stropko Irrigator/Dryer. A fine, blunt canula is tightly connected to the combination device developed by Stropko. This is used to deliver compressed air into the retrograde preparation, thereby drying it completely.



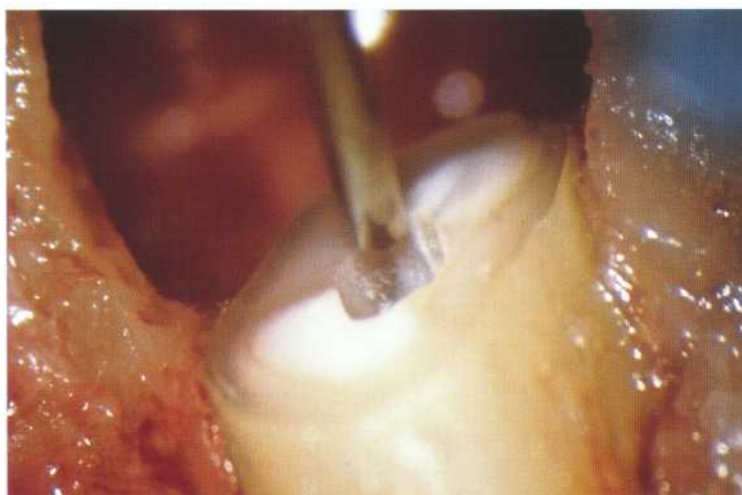
674 Stropko insert

Under 6x magnification the Stropko insert can be seen at the entrance to the canal. This makes careful, precise drying of the retrograde cavity possible.



675 Stropko Dryer

Under high (16x) magnification the close proximity of the special air blower to the canal preparation is demonstrated. This makes effective drying possible for the first time without the danger of emphysema.



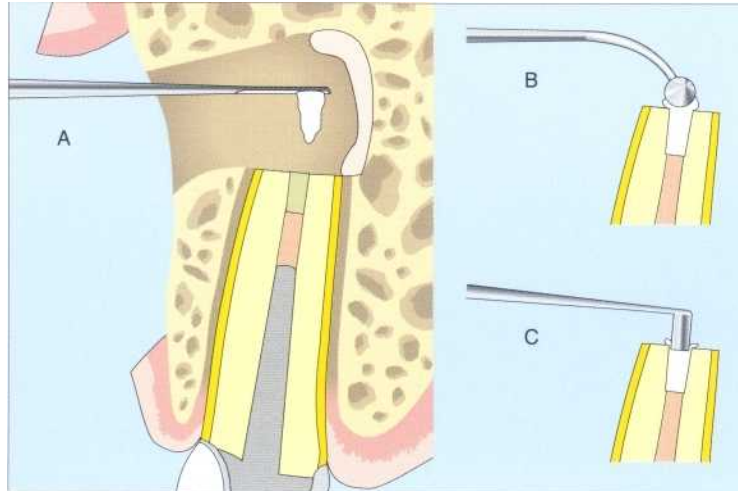
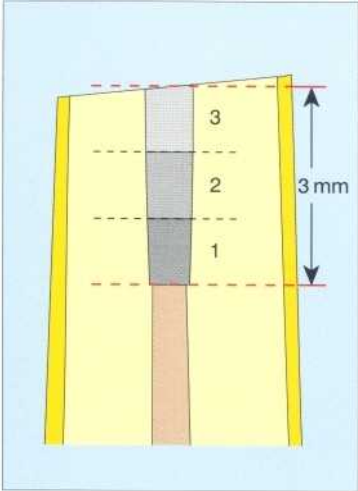
Retrograde Obturation

The requirements of the ideal material for retrograde filling of the resected root canal are:

- biocompatibility
- resistance to water
simplicity of use
- hermetic seal of the preparation
dimensional stability (nonshrinking)
- resistance to resorption
- radiopacity.

At present, however, no one material satisfies all of these requirements.

For many decades silver amalgam was the material of choice for reverse obturation following an apicoectomy. Because of the controversy over the toxicity of its mercury component, amalgam is now used less frequently. For some time it has been observed that retrograde amalgam fillings exhibit signs of corrosion and produce discoloration in the periapical tissues and the overlying mucosa and gingiva.



676 Depth of the retrograde filling

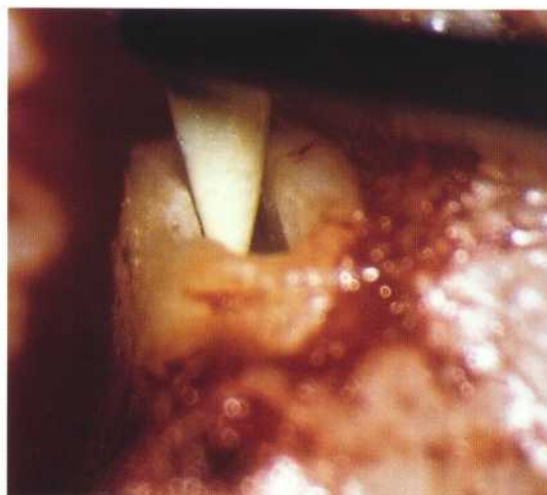
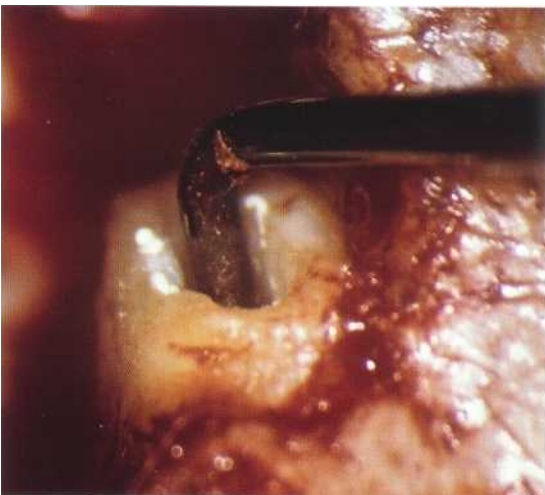
Super EBA cement is rolled into a small cone on a glass slab. The cone is picked up with a cement carrier and carried to the retrocavity as shown in the drawing (A). Then the cement is packed into the canal in small increments with the help of a microball burnisher (B) and a microcondenser (C).

Left: To ensure that the canal is well sealed, a retrograde preparation 3 mm deep is necessary.

Presently there is a wide selection of alternative materials for retrograde root canal fillings (Beer 1996, Bauman and Gerhards 1996). While gold foil fillings and composite resins have not proven practical, and trials with dentin bonding agents are still in their early stages, the materials to be considered at this time are Diaket, gutta-percha, Biocem, glass ionomer cements, and above all the products most popular in the United States, Super EBA and IRM. Diaket, best known as a sealer, and thermoplastic forms of gutta-percha are of a satisfactory consistency for obturation, but demand special skill in their application.

Biocem (equal parts of acrylate, hydroxyapatite, and zirconium dioxide) has received favorable evaluations, but has not been widely adopted in practice. Glass ionomer cements in capsules are convenient to use and can be polished after 10 minutes. If a few studies, both in vivo and in vitro, they have exhibited good sealing ability and biocompatibility, although there are fewer positive investigation results (Beer 1989).

A new preparation that shows much promise is Mineral trioxide aggregate (MTA), developed at Loma Linda University (Torabinejad et al. 1995).



677 Retrograde filling with Super EBA cement

Left: Preparation of the 3-mm-deep cavity.

Right: The cement is shown carried into the cavity. If the entire cone can be inserted successfully, additional portions may not be necessary.

Super EBA (Ethoxybenzoic Acid) Cement

The material most frequently used in the United States today is Super EBA cement (Bosworth). Its composition is as follows:

- Liquid: 37.5% eugenol, 62.5% o-ethoxybenzoic acid.
- Powder: 60% Zinc oxide, 30% aluminum oxide, 6% natural resin.

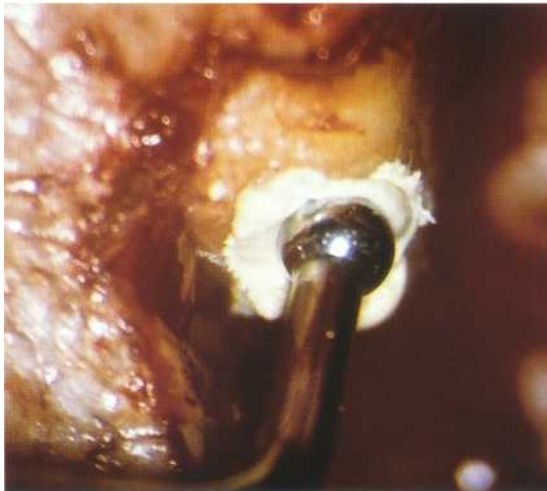
Super EBA is therefore a reinforced modification of ordinary zinc oxide-eugenol cement. The powder component is reinforced by the addition of natural resin and aluminum oxide, and the liquid is supplemented with

EBA that is familiar from its use in EBA cements and in the precursors of the glass ionomer cements.

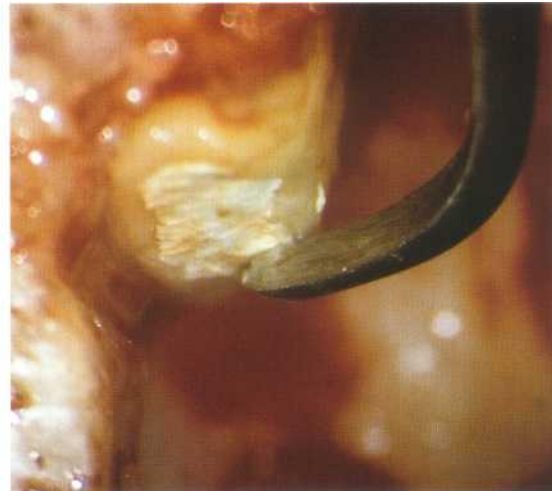
Super EBA cement has produced excellent results in many clinical as well as histologic studies. A retrospective study of 94 of the investigators' own clinical cases that had periapical lesions but intact cortical plates was completed recently. Super EBA was used as the only reverse obturation material and resulted in a healing rate of 96.8% within a period of 1 year (Rubinstein and Kim 1999).

678 Condensation of the Super EBA cement

Left: A microball burnisher is well suited for condensing the filling. The excess is pressed into the canal.

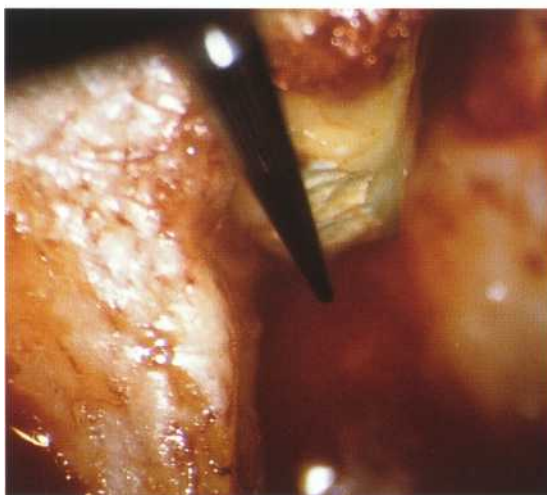


Right: The condensed Super EBA cement is carefully scraped with periodontal curettes (e.g., Columbia) to remove the remaining excess.

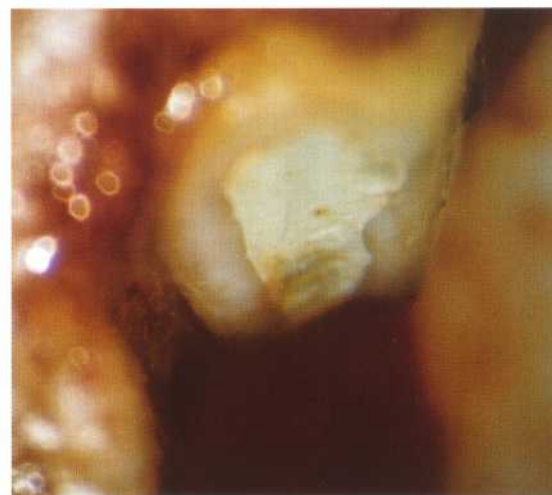

679 Finishing

Left: The condensed and trimmed surface is smoothed with a diamond finishing bur under generous water spray.

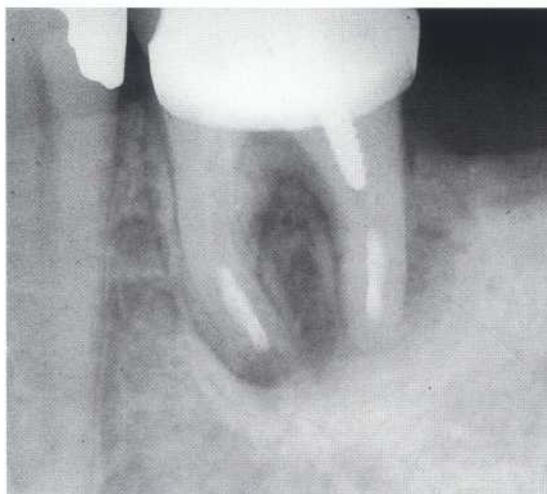

Right: At the final inspection, more than just the quality of the filling is evaluated. It is also appropriate to look for any possible problem spots or microfractures that were not observed previously. This is normally done under high magnification (26x) with the micromirror.

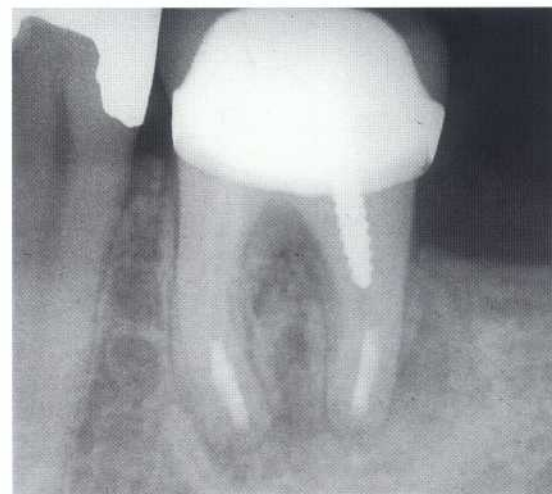

680 Postoperative radiograph

Left: This radiograph of the mandibular first molar was taken immediately after the microsurgical procedure. The retrograde obturation material is Super EBA. There is an isthmus at both the mesial and distal apices.

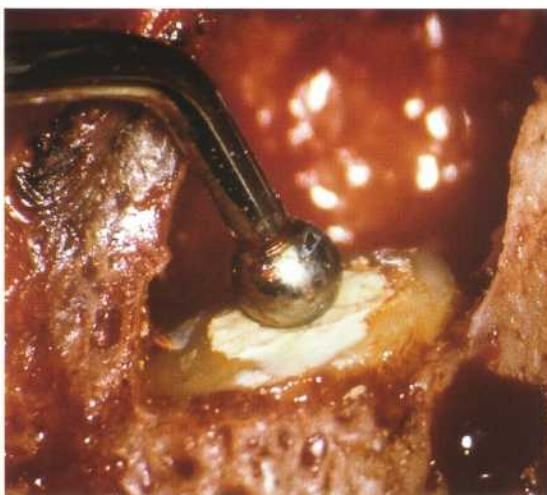
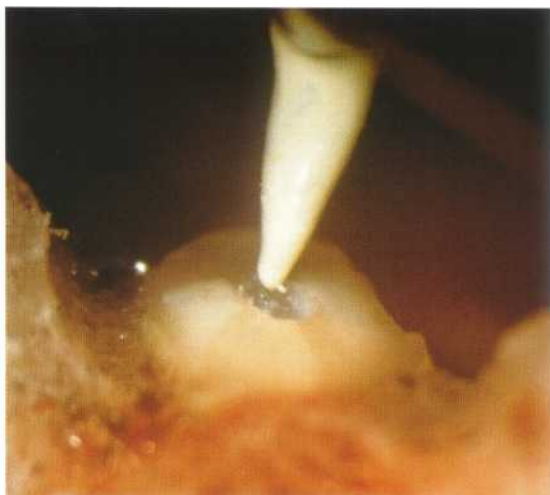


Right: The follow-up radiograph of the mandibular molar after 1 year reveals periapical regeneration.



The manufacturer's instructions call for a small amount of liquid to be mixed with plenty of powder on a glass slab. When mixing is completed the consistency should be such that the mixture still sticks to the glass slab and the surface has a slightly glossy appearance. The cement is carefully rolled on the glass slab into a cone from 2-3 mm long and about 1 mm thick. A portion of the cement is then picked up and placed into the retrograde preparation. The hardening process can be accelerated by placing a cotton pellet that has been dipped in hot water over the filling. Excess filling

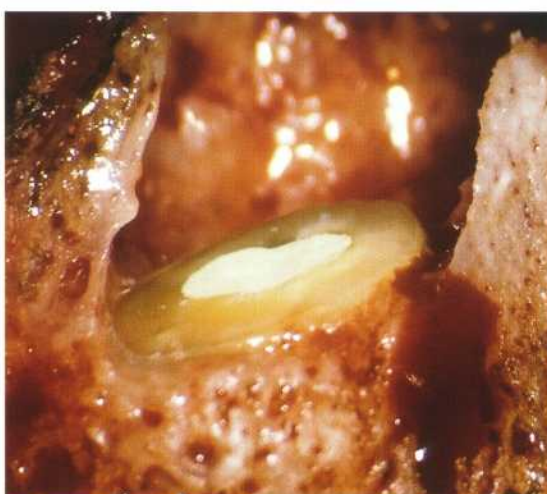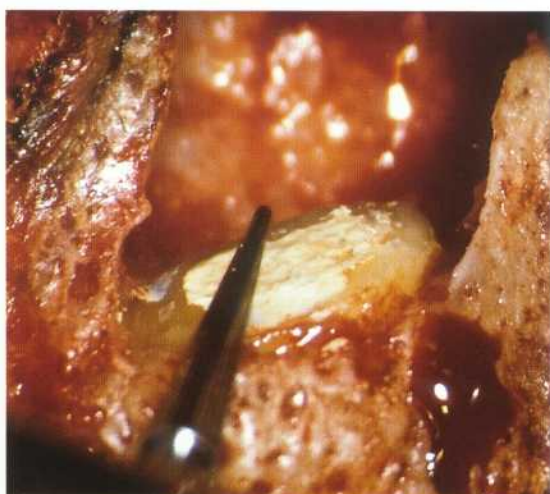
material is removed and the resected root surface is freshened with a fine diamond bur and then polished. Following this the surface is evaluated once more under the microscope to look for any anatomic irregularities or defects in the filling. The operative steps are carried out under 6-12x magnification, and the final inspection of the surgical field is performed with 16-25x magnification.



681 Retrograde filling

Left: The cement is formed into a cone before it is carried to the tooth. At this consistency Super EBA is soft enough for manipulation but already stiff enough to be condensed.

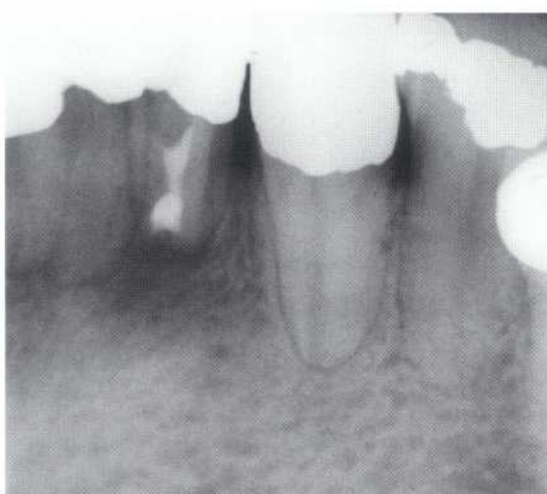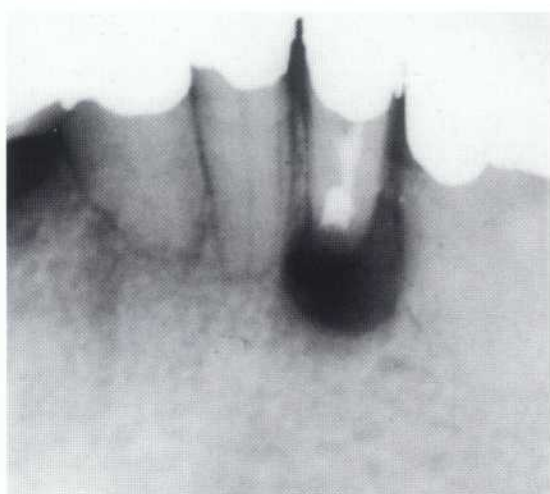
Right: After initial condensation, the excess Super EBA is removed and carefully adapted to the margins of the preparation with a microball burnisher.



682 Finishing with a diamond bur

Left: As the retrofilling is smoothed with a diamond bur, not all of the excess Super EBA is removed, but it is given a smooth surface with clean margins.

Right: Final evaluation of the quality of the retrograde preparation, the surface of the filling, and the tooth surface under high magnification.



683 Radiographic follow-up

Left: Radiograph of a mandibular anterior tooth immediately after surgical intervention.

Right: At a recall examination 12 months later, good bone regeneration can be seen.

Effect of Sutures on Soft-Tissue Healing

At the present time a smooth suture material such as Nylon (Supramid) is used most frequently because it allows the accumulation of little or no plaque in the sutured area. For many years silk was the preferred suture material, but because silk is braided it collects food debris and plaque much more readily. Special oral hygiene procedures are essential for good wound healing. Therefore, the patient is instructed to rinse several times each day with chlorhexidine or Listerine. Vertical incisions in the molar region have the tendency to open during the healing phase. While this is undesirable, it is

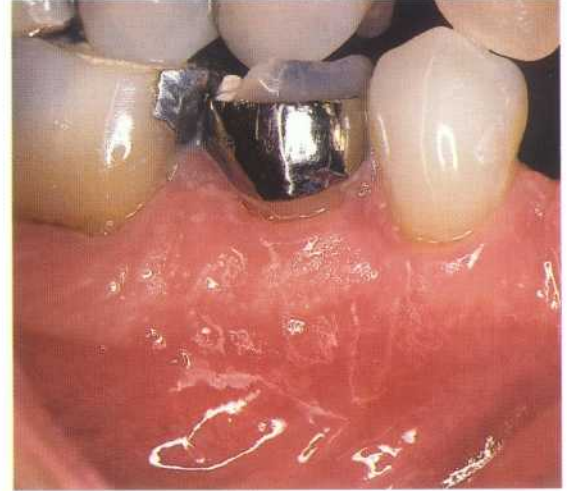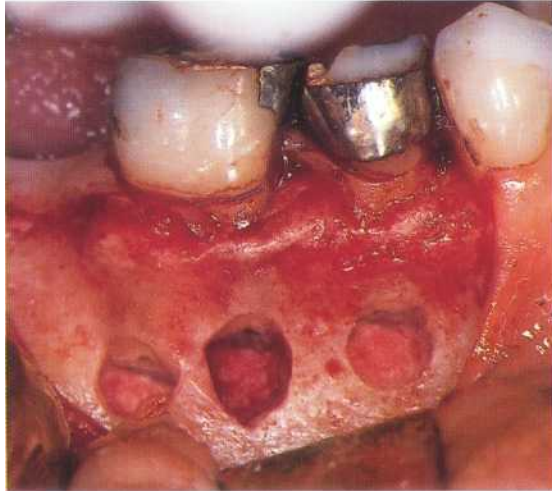
not dangerous because the wound will still heal by secondary intention with the ingrowth of granulation tissue. Healing will take longer, but will not result in scar formation. After successful suturing, the most important factor in wound healing is strict adherence to oral hygiene instructions.

To achieve optimal regeneration the sutures should be removed 2-3 days after the operation. A longer delay increases the risk of secondary infections because of the accumulation of food debris and plaque around the sutures.

684 Clinical view at low magnification

Left: The microsurgical procedure has been carried out on the mandibular right second premolar and first molar. Mesial to the surgical site only one vertical releasing incision was made and then three small osteotomies were created.

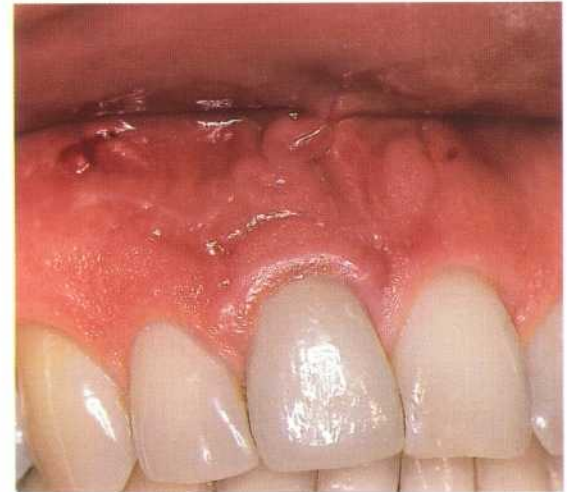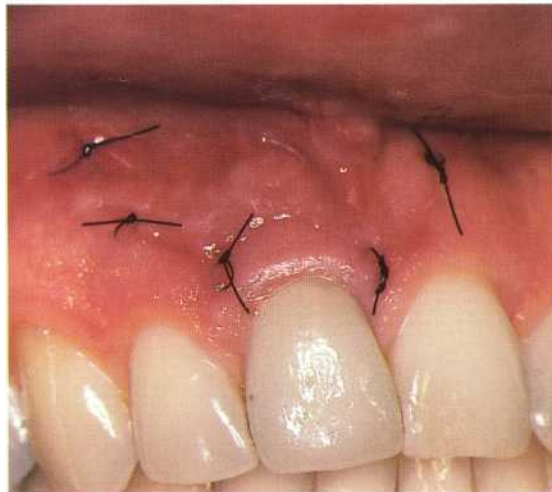
Right: At the end of a 1-month evaluation period no scar tissue is visible. Supramid is used as the suture material and removed after only 48 hours.



685 Supramid sutures

Left: The full thickness flap with intrasulcular incision is closed with Supramid nylon suture material. The photograph on the left was made immediately after the sutures were placed.

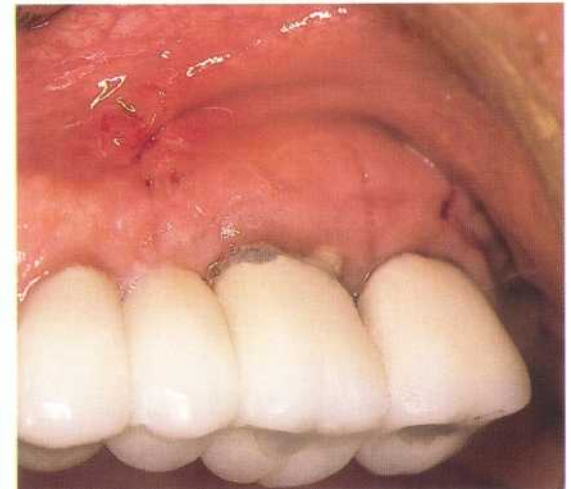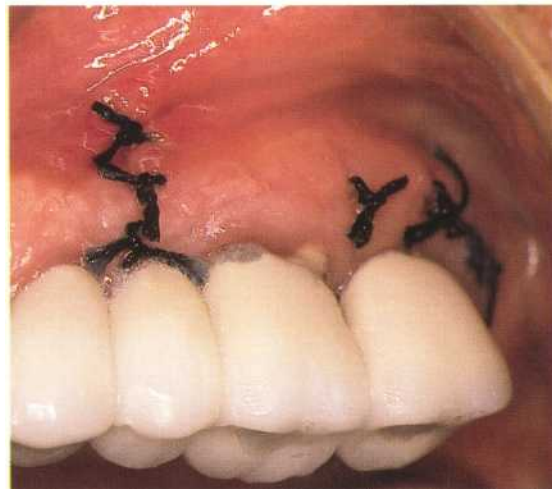
Right: When the sutures are removed 48 hours after the operation, the tissue appears clean and well adapted. There is no sign of inflammation or swelling.



686 Silk sutures

Left: Silk sutures were placed following surgery on this molar. The large diameter of this material is quite evident when compared with the nylon Supramid thread in Figure 685 (left).

Right: Healing is acceptable when the silk sutures are removed 1 week after the operation. However, a slight swelling can be seen. The postoperative reaction of the tissue following suturing with silk depends to a great extent upon the patient's oral hygiene.



Traumatic Tooth Injuries

Tooth injuries are the most common injuries in the region of the face and jaws. Depending upon the type and severity of the injury, arriving at the correct diagnosis and treatment plan can be difficult. Treatment may involve surgical, restorative, endodontic, and prosthodontic procedures. While up to 30% of child and adolescent accident victims suffered injuries to their permanent teeth and up to 20% suffered injuries to the deciduous teeth, tooth injuries occurred in 24.2% of adults injured in accidents (Zerfowski et al. 1995). Because of their exposed position, the maxillary central incisors were affected most frequently, comprising 75% of all tooth injuries, followed by the mandibular central incisors and the maxillary lateral incisors as well as the canines and premolars with 6-8% (Forsberg and Tedestam 1990). Tooth luxation with and without displacement occurs in the deciduous dentition with a frequency of 81.4% and in the permanent dentition with a frequency of 43%. Extra-alveolar tooth fractures are reported much more frequently in permanent teeth with a rate of 40.5%, compared with 5.7% in deciduous teeth. Avulsions occur equally frequently in both dentitions with a rate of 12-14% (Zerfowski et al. 1995).

Tooth injury can be the result of either direct or indirect trauma. In direct trauma the tooth itself is struck. Indirect trauma occurs when the mandible is pressed forcibly against the maxilla. The force of the impact, the elasticity and shape of the striking object, and the direction of the impacting force determine the extent of the resulting injury. A heavy blow tends to fracture only the crown, whereas a dull blow transmits the force to the apical region and can produce a luxation or root fracture. If the tooth is struck by an elastic object or if the blow is dampened by the lip, the risk of a crown fracture is reduced and that of a luxation or fracture of the alveolar process is increased. An impact at lower velocity produces more damage to the supporting structures of the tooth. At higher velocities a fracture of the crown is more likely to occur; the energy of impact is to a large extent expended in fracturing the crown and very little is transmitted to the root (Andreasen 1988).

Tooth injuries must always be regarded as emergencies. In cases studied, pulp necrosis occurred in 1% of those with enamel fracture only, in 3% with fracture of enamel and dentin, in 4% of complicated crown fractures with pulp exposure, in 20% with root fracture, in 58% with lateral luxation, and in 85% with intrusion (Andreasen and Vestergaard 1985; Andreasen et al. 1986; Ravn 1981 a, b; Cvek 1978; Zachrisson and Jacobson 1975). Treatments of initial pulp exposures that were delayed more than 1 month after the trauma were followed by pulp necrosis in all 114 cases investigated. Apical periodontitis also developed. Of all cases of enamel-dentin fracture with no pulp exposures that were studied, tissue necrosis occurred in 53%, and 7% already exhibited external root resorption (Al-Nazhan et al. 1995).

Classification

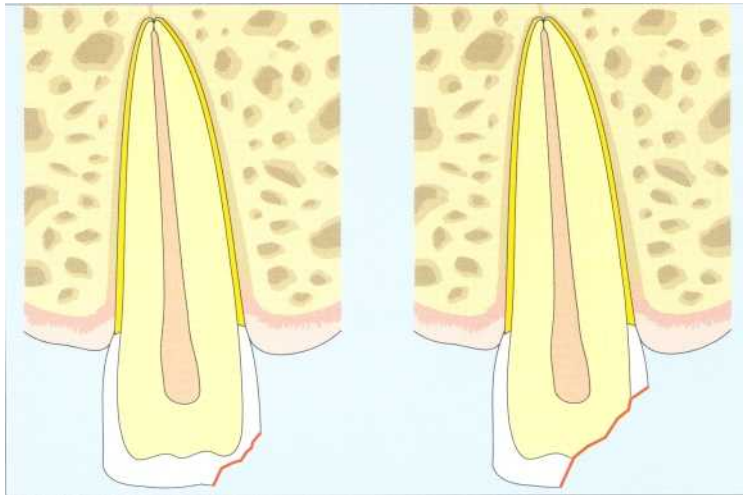
Extra-alveolar crown fractures can be further divided into uncomplicated fractures (without pulp exposure) and complicated fractures (with pulp exposure). Enamel fractures are uncomplicated fractures limited to the enamel, and in a study of 2862 such teeth only 1 % underwent pulp necrosis (Ravn 1981 a). This confirms that enamel fractures present only a very low risk of injury to the pulp tissue. By comparison, tissue necrosis occurred in 3.2% of 3044 teeth with uncomplicated enamel-dentin fractures studied (Ravn 1981 b).

Crown-root fractures involve cementum as well as enamel and dentin. Andreasen (1985) classified this type of injury as a separate form of fracture in which pulp exposure may also occur. Five percent of all injuries to the permanent teeth and 2% of deciduous dentition injuries can be assigned to this class of fracture. Crown-root fractures are usually brought about by direct trauma. Often only minimum displacement of the coronal fragment can be detected clinically, and for this reason these fractures are sometimes overlooked, especially in the posterior region (Andreasen 1988).

687 Uncomplicated fracture

Left: Uncomplicated extra-alveolar enamel fracture without involvement of the dentin or direct exposure of the pulp tissue.

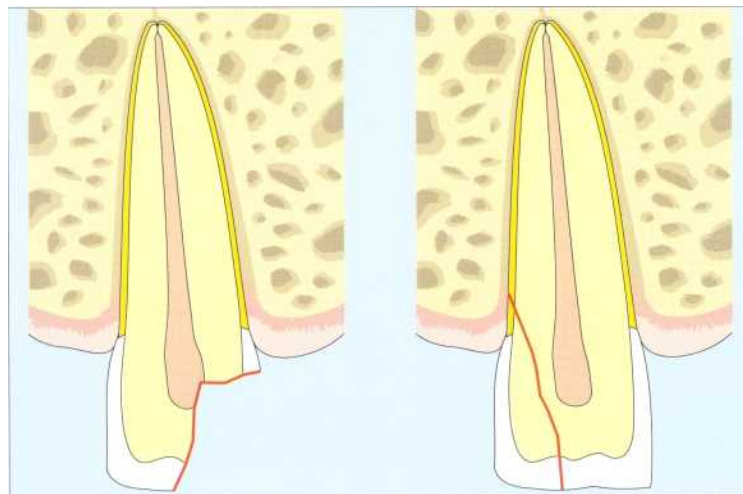
Right: Uncomplicated enamel-dentin fracture without exposure of the pulp, but with extensive dentin involvement and, therefore, exposure of dentinal tubules.



688 Complicated and uncomplicated fractures

Left: Complicated extra-alveolar crown fracture with involvement of enamel and dentin and exposure of pulp tissue.

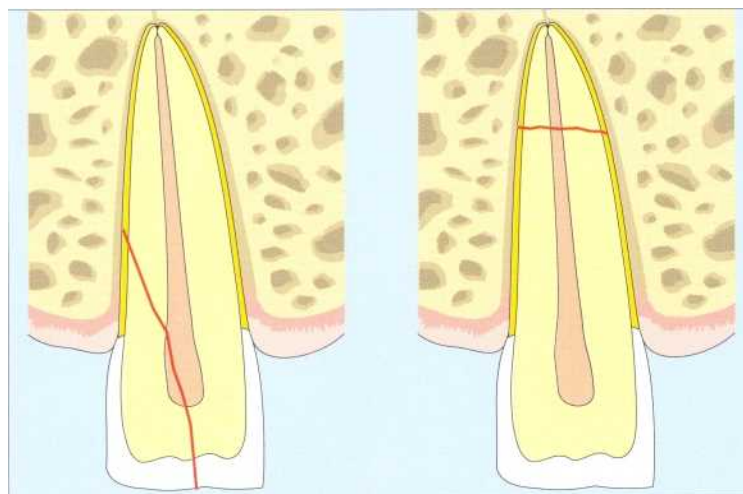
Right: Uncomplicated crown-root fracture. An oblique fracture with involvement of enamel, dentin, and cementum, but without pulp exposure.



689 Complicated fractures

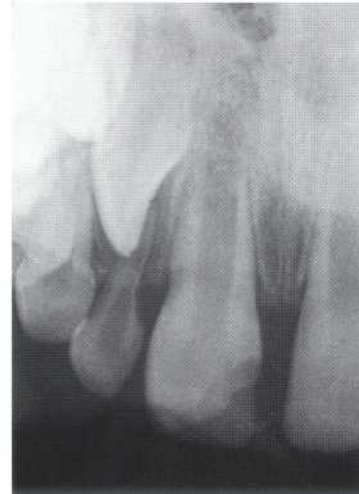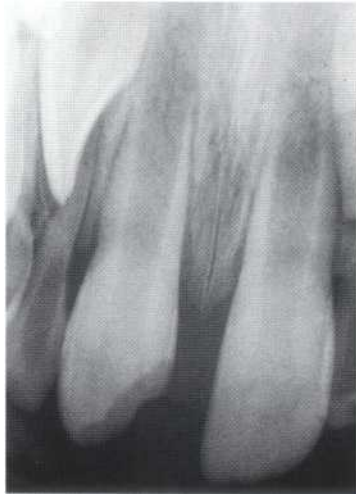
Left: Complicated crown-root fracture. This oblique fracture involves enamel, dentin, and cementum.

Right: Intra-alveolar transverse root fracture in the apical third. There is involvement of dentin and cementum as well as exposure of the pulp.



Root fractures are injuries to dentin, cementum, pulp, and periodontal tissue combined. Fractures occurring in the apical and middle thirds usually run obliquely. A force impacting from the front moves the coronal fragment lingually and slightly out of the socket. Healing of the wound depends on whether or not the pulp is severed and bacteria have entered through the fracture line. Stable fixation is fundamental to the success of treatment. In 20-44% of cases pulp necrosis will ensue (Andreasen 1985).

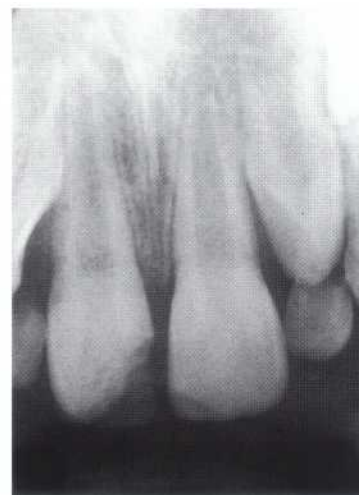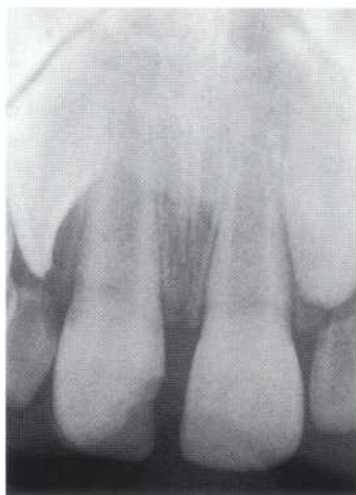When there is luxation with avulsion from the alveolus the tooth must be immediately replanted, fixed with a splint for 4 weeks, endodontically treated after 7 days, and filled with calcium hydroxide for 6-12 months. If the tooth is luxated without dislocation, it is simply left alone for 2-4 weeks. After subluxation, pulp necrosis may appear in 26-47% of all cases. When there is luxation with incomplete dislocation, on the other hand, pulp necrosis occurs in 64-98% of the cases, and in 24% the canal may become obliterated (Andreasen et al. 1995).



690 Uncomplicated crown fracture

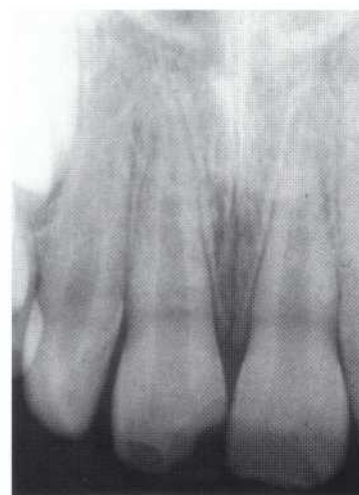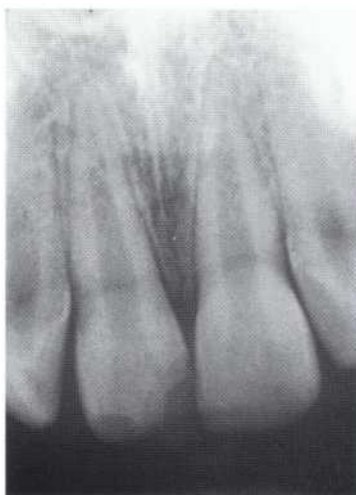Left: Fracture of a young permanent tooth with incomplete root development. The pulp tissue is not exposed.

Right: No sign of root fracture or luxation can be seen on the radiograph. The exposed dentin is covered with a thin layer of calcium hydroxide and the tooth is restored with composite.



691 Radiographic monitoring
Left: Three months later the tooth is asymptomatic showing nothing extraordinary on the radiograph. Root development has progressed further.

Right: Six months after the trauma the tooth responds normally to percussion. The sensitivity test is positive again, and the periapical region appears normal on the radiograph.



692 Radiographic monitoring
Left: One year after the traumatic loss of dentin the clinical and radiographic findings are within normal limits.

Right: Three years after treatment, root development is completed and there is no indication of an apical lesion on the radiograph.

Treatment by J. L. Gutmann

Crown Fractures

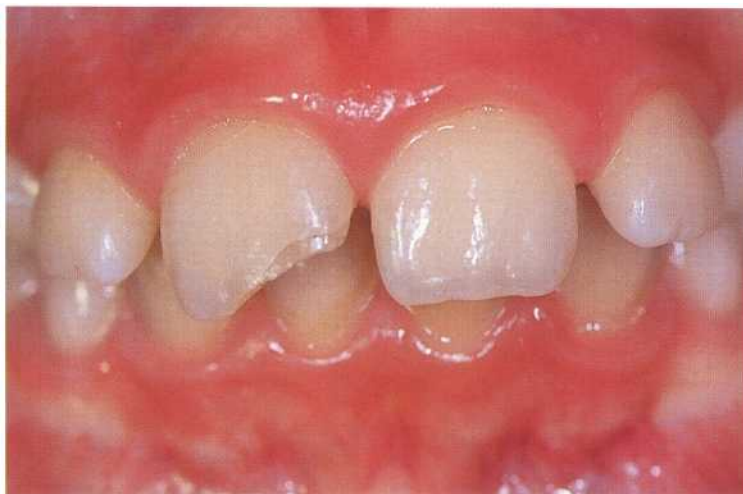In an extra-alveolar uncomplicated crown fracture the fracture lies entirely within enamel with no involvement of dentin. Immediately following the trauma the tooth should be evaluated for changes in color, altered opacity (by transillumination), mobility, and possible luxation. A sensitivity test should also be performed. If the sensitivity test is positive and there is no discoloration of the crown, no immediate endodontic treatment is indicated. The tooth must then be reevaluated every 6 months because calcifications that would complicate later root canal treatment may appear over time.

For small defects, smoothing of sharp edges and application of fluoride will suffice. For larger defects with exposure of dentin, the dentin wound is covered and a composite restoration is placed. Exposed dentin in deciduous teeth need not be treated except for the rounding of sharp angles.

With a complicated crown fracture the untreated opening to the pulp will eventually lead to necrosis. The selection of treatment from a variety of methods depends largely upon the tooth's stage of development.

693 Complex fracture

Maxillary anterior tooth with a complex extra-alveolar enamel-dentin fracture and exposure of the pulp in a 12-year-old boy. Sensitivity tests were negative. Because the tooth has already gone untreated for 1 week, it is necessary to proceed from a partially necrotic pulp.

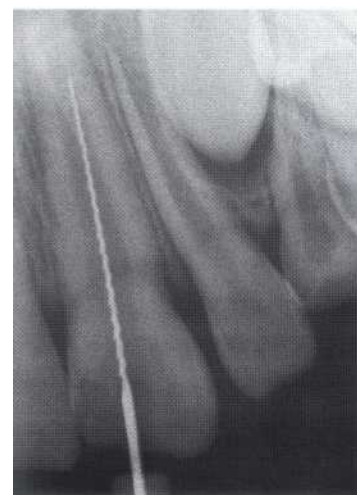
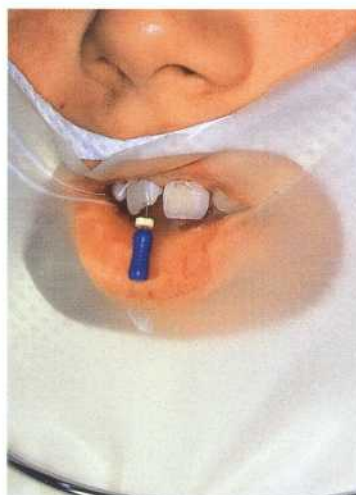
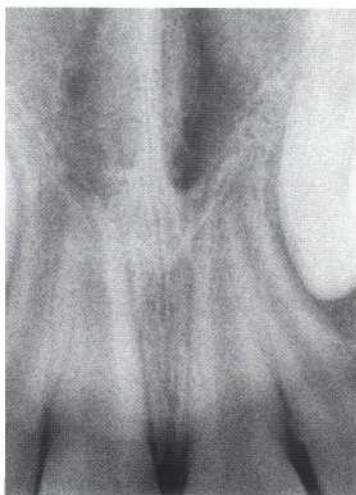

694 Access opening

Left: Diagnostic radiograph showing an almost completely developed root and ambiguous signs of a periapical lesion.

Center: After a rubber dam is applied, the still partially vital pulp is extirpated.

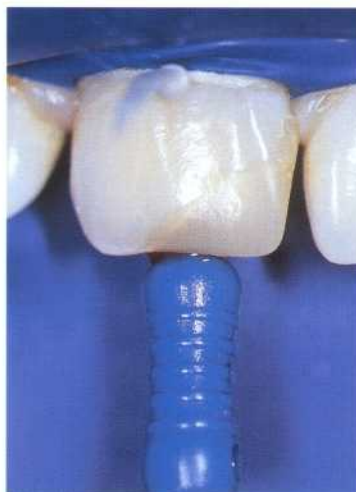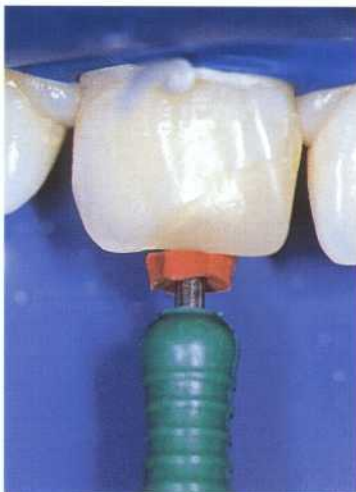
Right: First radiographic length determination. The working length still requires correction.



695 Instrumentation

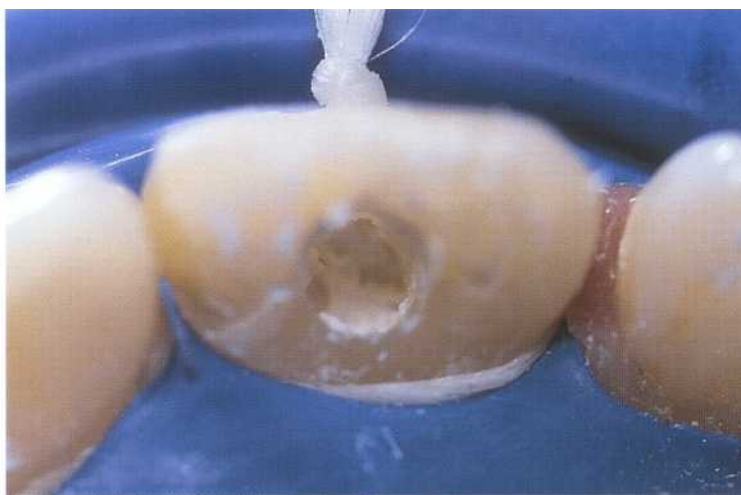Left: Opening of the coronal root canal and preparation to the working length.

Right: After the working length is adjusted the canal is prepared 2 mm deeper.



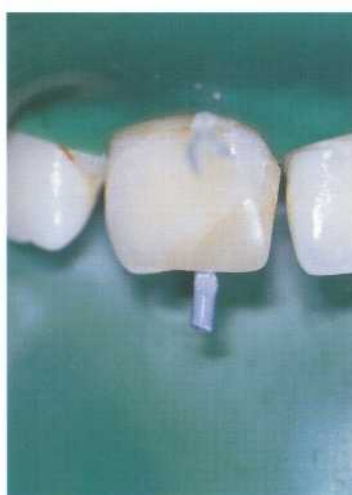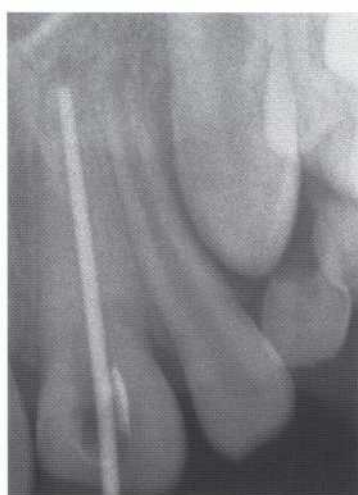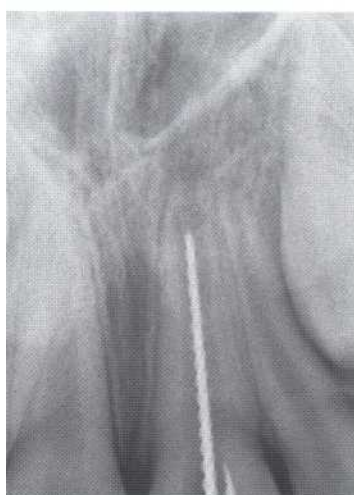The exposed pulp of a young tooth with incomplete root development should be treated by direct pulp capping (Cvek 1988). With progressive root growth and the absence of symptoms or radiographic evidence of periapical changes, there should be a successful outcome. Twenty-two percent of traumatically damaged teeth can develop an obliterated root canal over a period of 4 years, and for this reason, endodontic therapy should be initiated even if there are no clinical symptoms (Schindler and Gullickson 1988).

In a complex crown fracture the breaking away of dentin leaves the pulp tissue exposed. Here direct pulp capping gives a success rate of 90.5% with formation of a dentinal bridge if the root is incompletely formed the success rate is 94% compared with 88% for teeth with completed root development (Ravn 1982). Pulp amputation at a level 2 mm below the exposure was successful in 96% of young teeth, regardless of the location and size of the exposure or the time of treatment (Cvek 1978).



696 Interim dressing

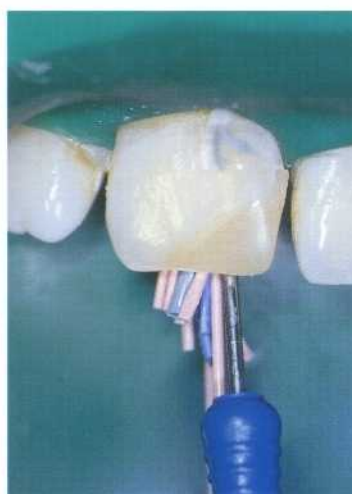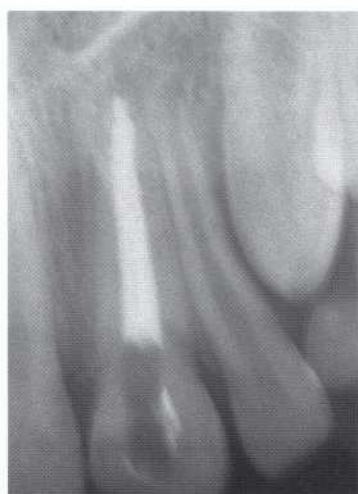Following instrumentation and generous irrigation with sodium hypochlorite solution the canal is dried and a calcium hydroxide dressing is packed firmly into it. After 3 months the dressing will be changed and the new material left in place for an additional 6 months while further development of the root tip takes place.



697 Radiographic monitoring
Left: After 3 months the tooth is free of symptoms and the radiograph shows nothing unusual. Root development has progressed further.

Center: The gutta-percha master point is fitted and measured.

Right: Nine months after the trauma the radiograph of the tooth shows no periapical pathology and at the same time provides a check on the position of the master point.



698 Root canal filling
Left: Radiographic evaluation of the root canal filling. Even the internal resorption in the apical region of the canal has been filled. There is no sign of pathology in the periapical area.

Right: The canals have been filled by lateral condensation. In conjunction with the endodontic treatment, a new composite filling has been placed.

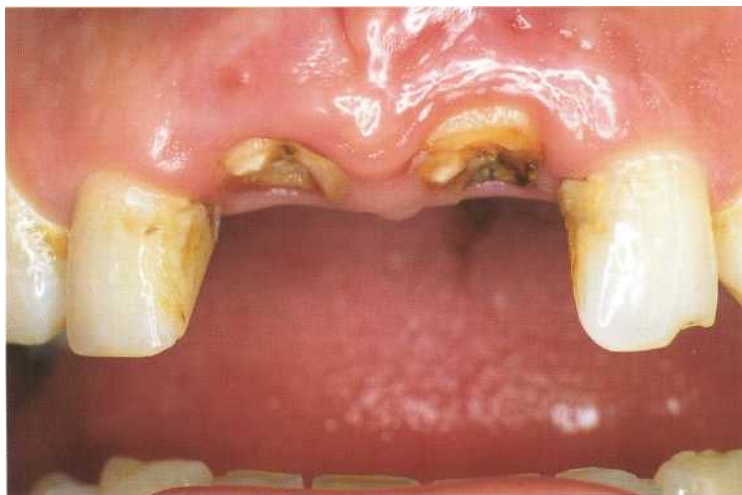Crown-Root Fractures

Crown-root fractures cause discomfort during chewing but are otherwise asymptomatic. The clinical diagnosis is relatively simple when the coronal fragment is loosened, but radiographic diagnosis is difficult, especially of the lingual extent. If the fracture line runs perpendicular to the central ray, the crown-root fracture cannot be seen distinctly. Vertical fractures are difficult to diagnose radiographically if they run mesiodistally but are easier to diagnose if they lie in a labiolingual plane (Andreasen and Andreasen 1992).

The coronal fragment must be removed to make an accurate evaluation of the damage. If the pulp has not been exposed the coronal segment can be reattached by means of the acid-etch resin bonding technique, or the tooth can be restored with composite. In approximately 20% of cases, a spontaneous loss of the adhesively bonded crown fragment can be expected. During the first year this treatment failed in half of the 334 teeth studied. The overall 10-year success rate for teeth restored in this manner was 20–25% (Andreasen et al. 1995).

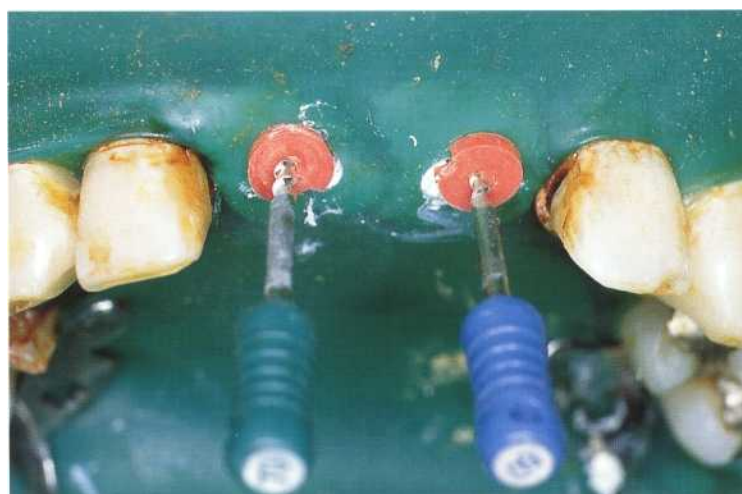
699 Crown-root fracture
Transverse fracture of both maxillary central incisors of a 22-year-old man resulting from a blow. The teeth remained untreated for over a year and were clinically asymptomatic. The pulp tissue was necrotic.

Right: The radiograph shows no unequivocal signs of periapical radiolucency in spite of the necrotic pulps.



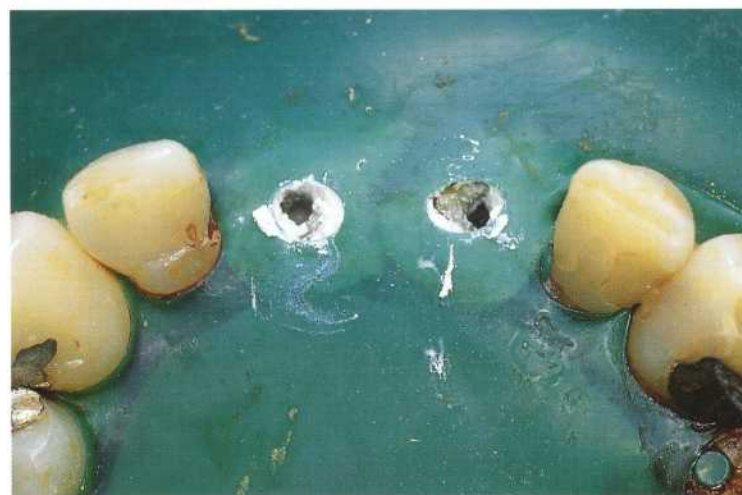700 Canal instrumentation
Following excavation of all caries the root surfaces are covered with Cavit and a rubber dam is placed. The canal entrances are exposed through the Cavit and the root canals are instrumented.

Right: The working lengths are determined, and the depth of instrumentation is subsequently corrected by 3 mm in one root and 2 mm in the other.



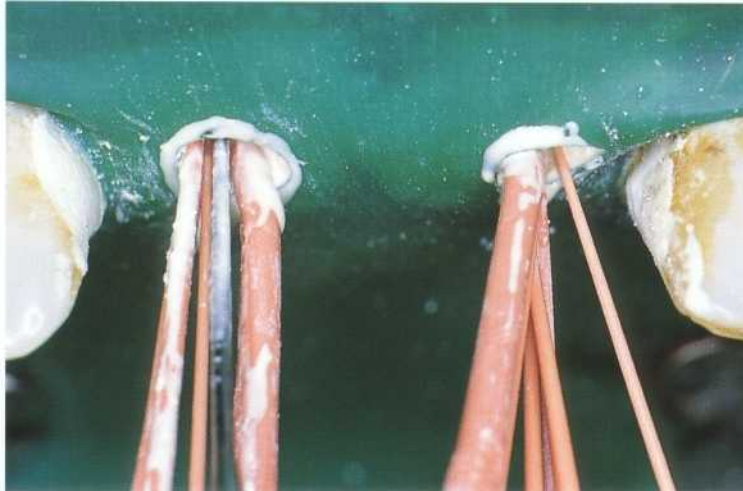
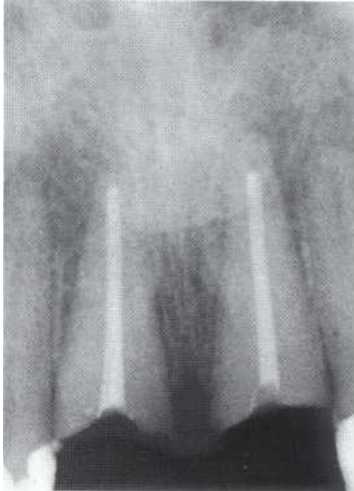701 Interim dressing
Because of the pulp-tissue necrosis and the contamination by saliva and bacteria, placement of calcium hydroxide interim dressings is necessary for a period of at least 1 month after instrumentation.

Right: The dressings are seen to be intact on the radiograph and there are no signs of periapical radiolucencies.



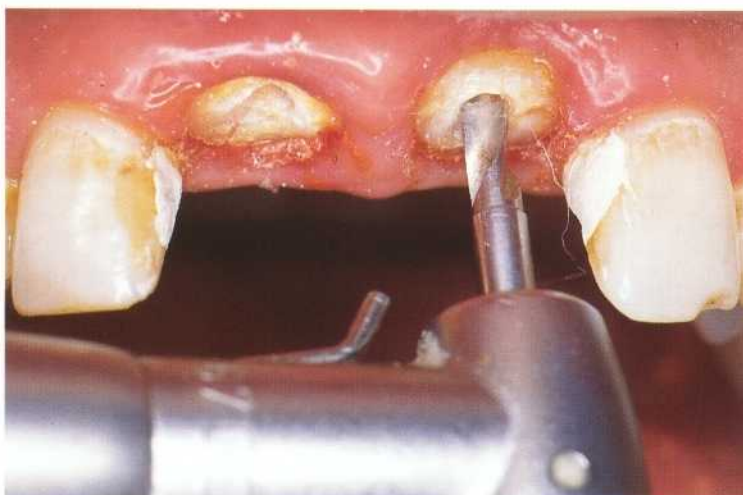
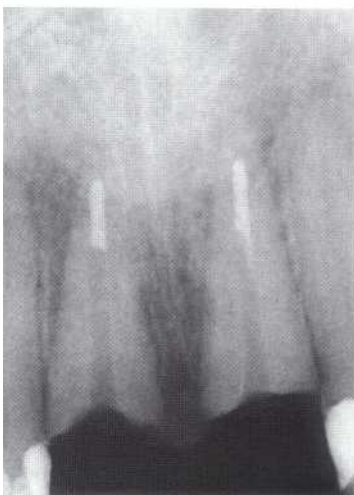Fractures within the middle third of the root with no dislocation of the fragment carrying the crown were splinted for 6-8 weeks. In young patients it is possible to maintain pulp vitality. With adequate fixation of the tooth the fracture gap becomes bridged over with partially mineralized connective tissue. If there is dislocation, the crown must be repositioned and splinted. If pulpal necrosis is revealed on the radiograph by a radiolucency or resorption, then the root canal must be prepared and filled temporarily with calcium hydroxide.

If the fracture is longitudinal or involves one-third or more of the root, the tooth should be extracted. When there is a complicated, deep crown-root fracture the surface of the fracture must be surgically exposed and bone removed to a level 2 mm below the fracture line. If the root is straight the canal can be obturated and a post and core placed at the same sitting after the vital pulp is extirpated. Prefabricated post systems are well suited for this. If the canal is curved or the pulp is necrotic, the tooth must first be treated with an interim dressing before the canal can be filled and the tooth restored.



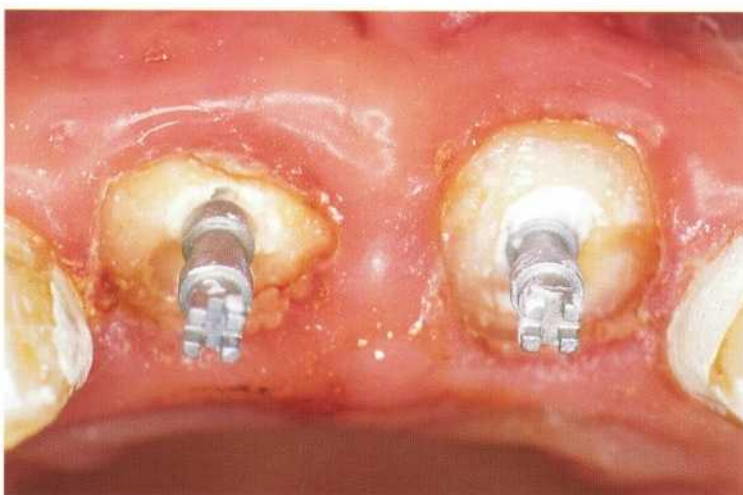
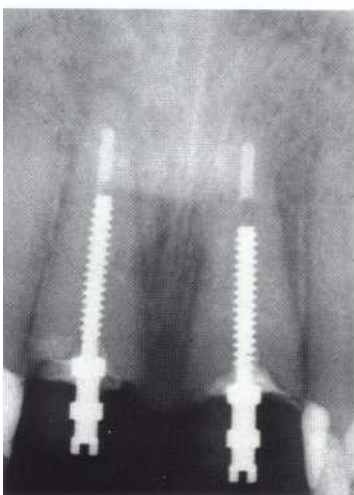
702 Root canal obturation
After the interim dressing is flushed out, the canals are dried and then filled with gutta-percha and sealer by the lateral condensation technique.

Left: Radiograph showing dense obturation of the root canals with gutta-percha.



703 Preparations for post-cores
Immediately after filling the two canals the coronal portion of the gutta-percha is removed with a hot spreader; the canals are subsequently enlarged with a standardized drill system and a standardized drill from the post kit.

Left: Approximately 3 mm of apical root canal filling should be left in each canal.



704 Restoration
After cutting internal threads in the roots, the canals are irrigated once more and dried. Then the two posts are coated with Durelon cement and slowly screwed into place without creating stresses.

Left: Radiographic evaluation of the threaded posts. Next, interim composite crowns are built up on the teeth.

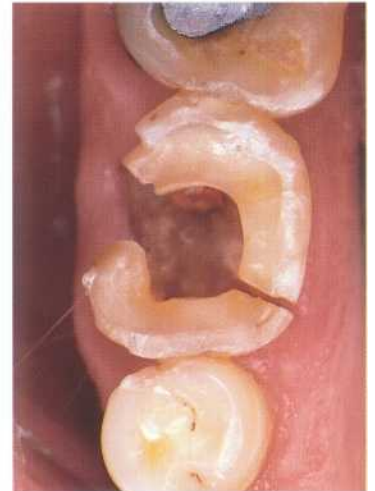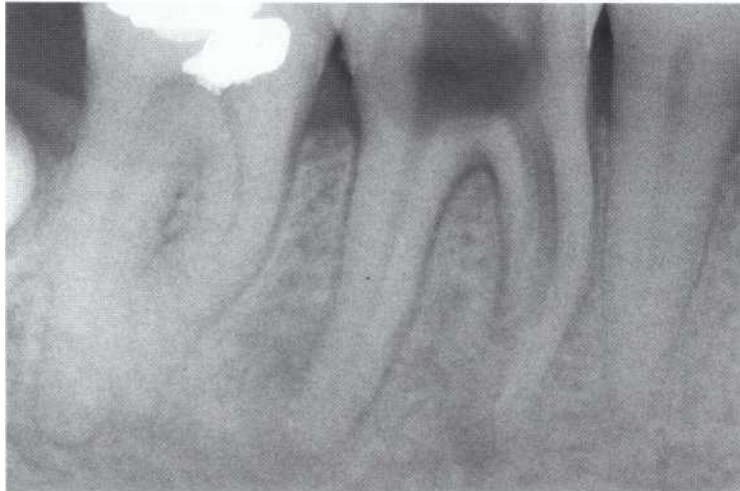
Vertical Root Fractures

A vertical, longitudinal fracture includes both crown and root and usually involves the root canal. Predisposing factors are a weakening of the root structure by heavy enlargement of the canal and mechanical stress from unfavorable placement of endodontic screws and posts. In a study by Morfis (1990) vertical fractures were found in 3.7% of 460 endodontically treated teeth. The age of patients experiencing vertical fracture was usually between 40 and 50 years (Gher et al. 1967). At 83% of the total, premolars and molars are most frequently involved (Testori et al. 1993). Clinical

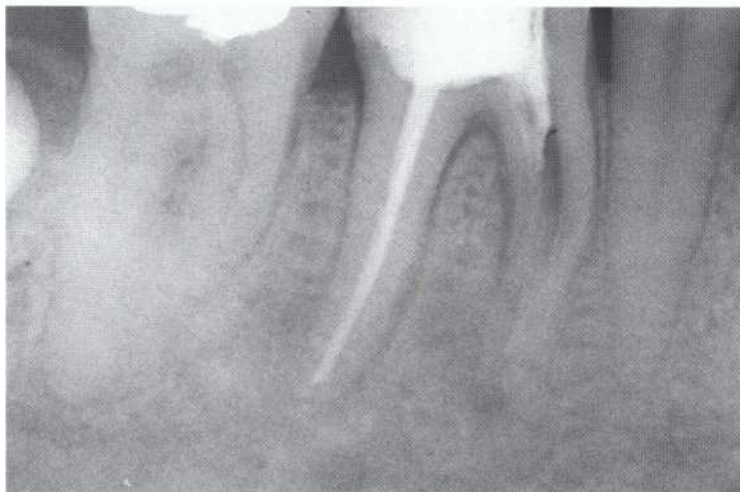diagnosis is difficult because there are no unambiguous symptoms for this type of root fracture. In 95% of cases, periodontal pockets formed, in 66% dull pain occurred, in 28% there were periodontal abscesses, and in 13% fistula formation, according to a study by Meister et al. (1980). Further, clinical signs are bone defects, suppuration, swelling, and loosening of the tooth (Tamse 1994). The average time elapsed between endodontic treatment and the diagnosis of a vertical fracture has been reported as 52 months (Gher et al. 1987).

705 Vertical root fracture
A mandibular first molar with a vertical fracture of the mesial root 1 week after the first root canal instrumentation. The patient has only slight pain. The radiographic diagnosis is unequivocal and shows a separation in the mesial root.

Right: The crown is also fractured and the mesial segment is mobile.

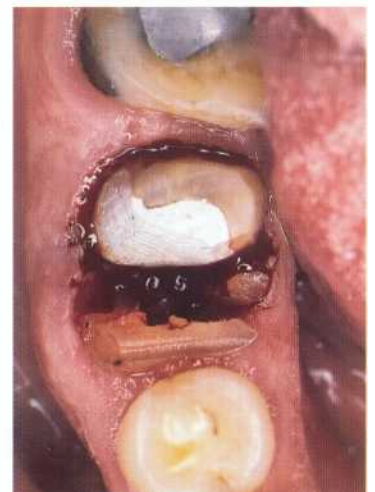
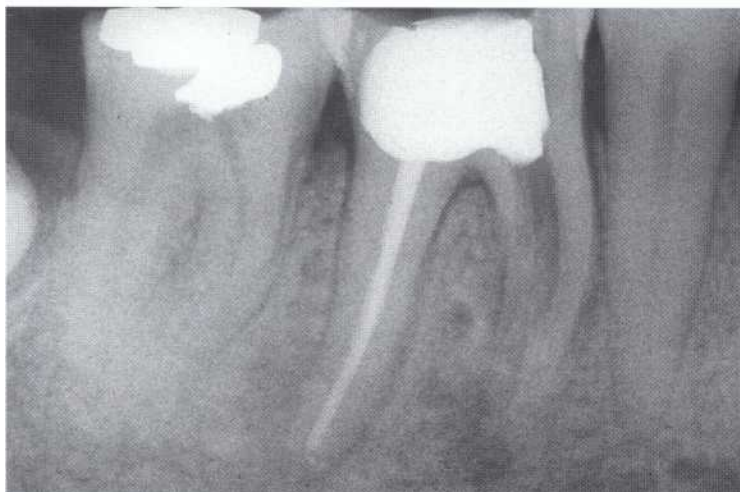
706 Presurgical root canal treatment
The distal root will be retained. The root canal has been prepared, treated for 3 weeks with a calcium hydroxide interim dressing, and then obturated. Next the crown is restored with glass ionomer cement to seal the canal entrance.



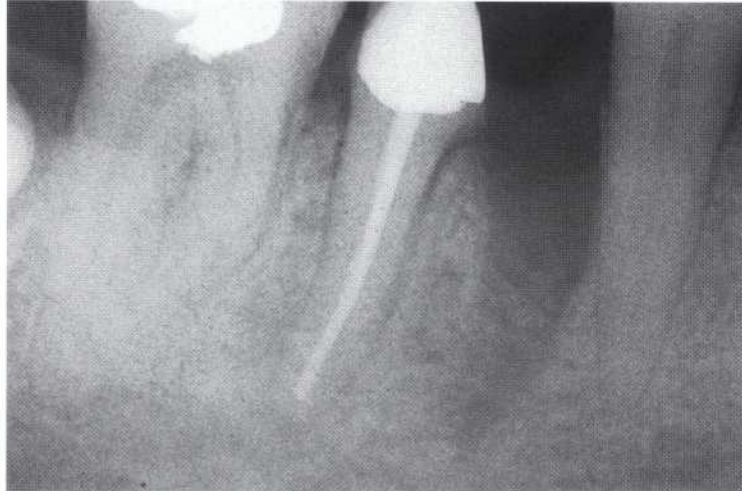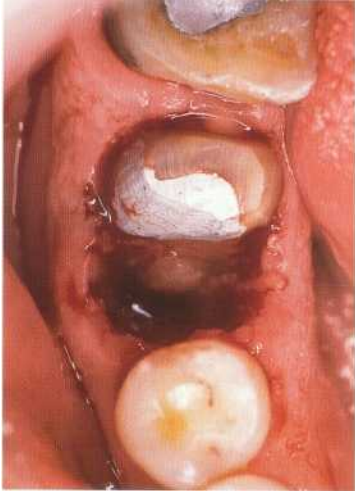707 Hemisection
One week after the vertical root fracture the periapical lesion on the mesial root is still visible. The distal radiolucency has not increased, thus long-term retention of the distal root can be expected.

Right: Using a sharp, tapered diamond, the crown is sectioned buccolingually at the expense of the half of the tooth that is to be removed.



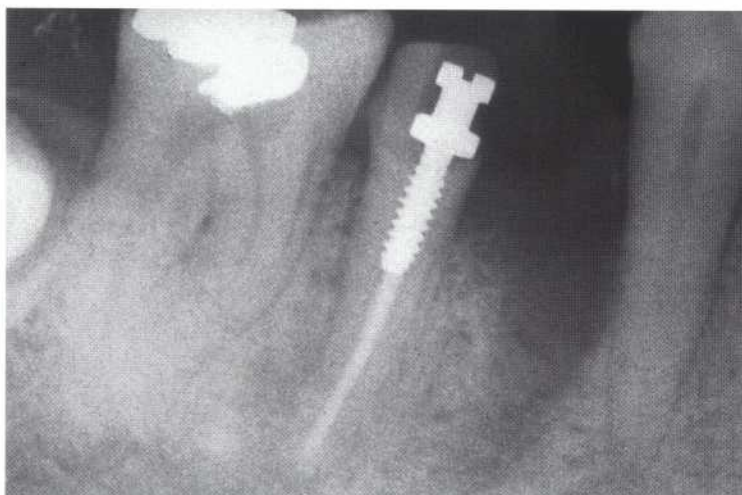
The radiograph is an essential component in making a diagnosis. In 75% of cases there appeared to be a periodontal lesion, in 22% an apical radiolucency, but in only 3% of the teeth studied could displacement of a root segment be determined (Meister et al. 1980). Important diagnostic signs are a radiolucency from the apical region to the middle of the root, an angular periodontal bone defect from the alveolar bone to the end of the fracture line, and a uniformly enlarged periodontal space (Tamse 1994).

Ninety percent of all vertical fractures are complete and extend from one side of the tooth to the opposite side of the root, and from the crown to the tip of the root. Regeneration is not possible (Walton et al. 1984). The goal of treatment is to eliminate the fracture space, which represents a communication with the oral cavity. Single-rooted teeth are usually extracted, and a multi-rooted tooth can be hemisected with removal of only the affected root. If the fracture is limited to the apical region, an apicoectomy should be performed (Wechsler et al. 1978).

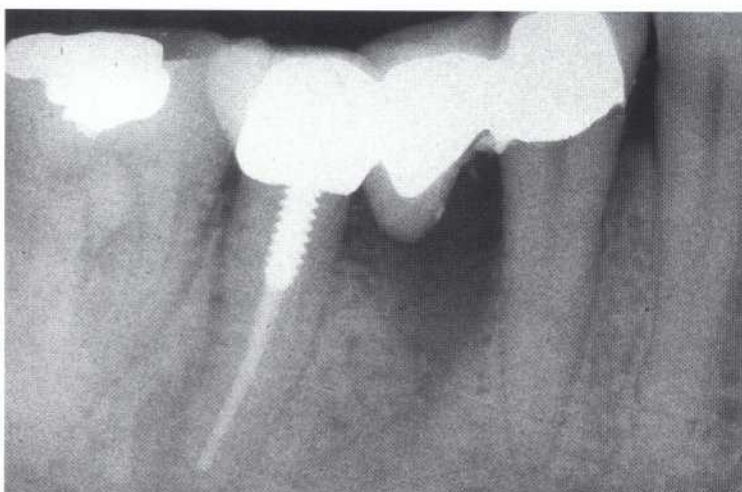
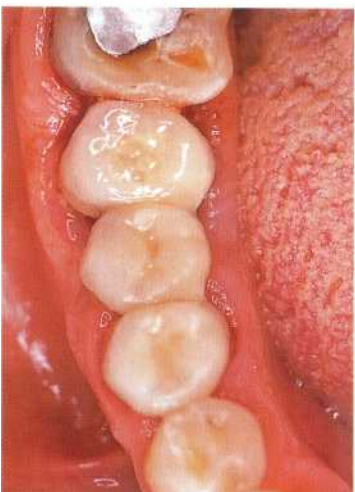
708 Extraction and radiographic evaluation
Following the hemisection the mesial half of the tooth is extracted. A radiograph is then taken to evaluate whether the overhang in the furcation has been completely eliminated. A small overhang can still be seen and has to be cut away.

Left: Clinical evaluation after extraction of the mesial root and preparation of the distal root with correction of the overhanging dentin.



709 Post and core buildup
The cement filling and coronal portion of the root canal filling are removed and the canal prepared and tapped to receive a threaded post. The Endofix-P screw is then inserted without creating stress within the root. Next, the remaining half of the tooth is built up and prepared for a crown.



710 Restoration
Failures after hemisection can usually be traced back to deficiencies in planning the prosthetic reconstruction. Every postponement of the reconstruction is detrimental to the postendodontic regeneration of bone. The missing tooth segment must be replaced by a fixed partial denture within a short time.

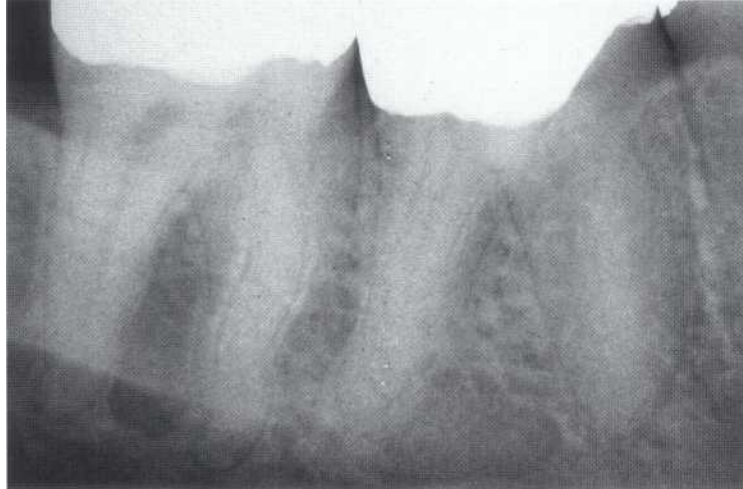Left: The occlusal surfaces of the prosthesis should direct the force along the long axes of the teeth.

Cracked Teeth

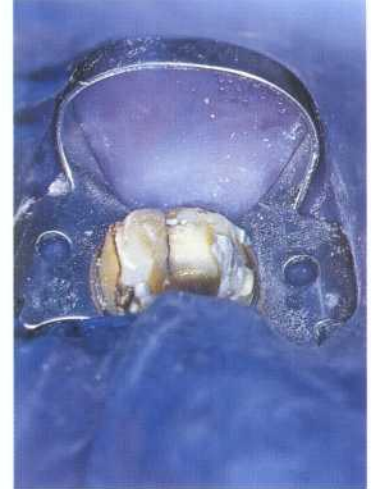Crown infractions are incomplete fractures that can occur in both restored and unrestored teeth. Most infractions run in a vertical direction, with horizontal cracks being rather rare. Vertical infractions usually run through the crown in a mesiodistal direction and can involve one or both proximal surfaces. The risk is increased by all factors that compromise the structural integrity of the tooth, such as parafunction, masticatory trauma, extensive caries, parapulpal retentive pins, and improperly formed cavity preparations (Abou-Rass 1983). Crown infraction occurs most frequently in

mandibular first molars and maxillary premolars. The clinical symptoms depend on the depth of the crack. Pain occurs infrequently with superficial cracks. Discomfort during chewing is often reported, with pain occurring mainly when the tooth is loaded. Deep cracks that reach the pulp exhibit the signs of acute irreversible pulpitis. The coronal infraction is linked, not with any special symptom, but rather with a multitude of complaints (Guertsen 1992).

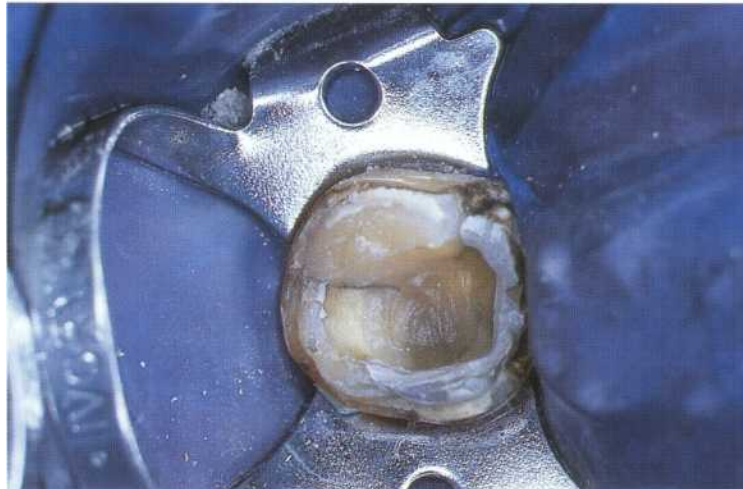711 Diagnosis
On the radiograph the mandibular second molar shows a periapical radiolucency. No fracture line or other sign of a fracture can be identified anywhere.



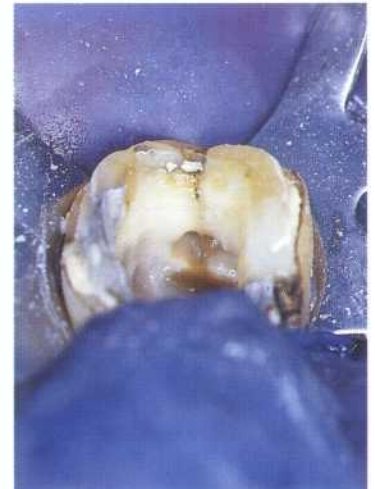Right: After the 8-year-old artificial crown is removed an infraction line can be seen on the floor of the cavity.



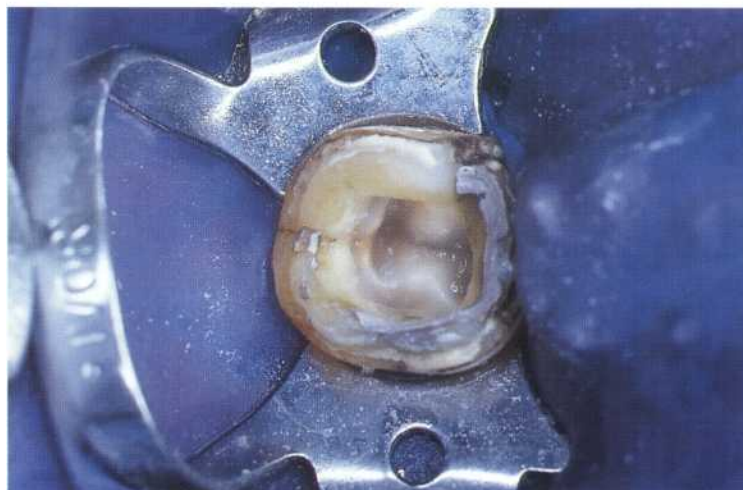712 Caries
Following excavation of carious dentin, the fracture line can be seen more clearly. The tooth segments cannot be moved relative to one another, however, and so a diagnosis of infraction can be assumed.



Right: It can be seen that caries has penetrated under the distal margin of the crown and extended all the way to the inner floor of the cavity.

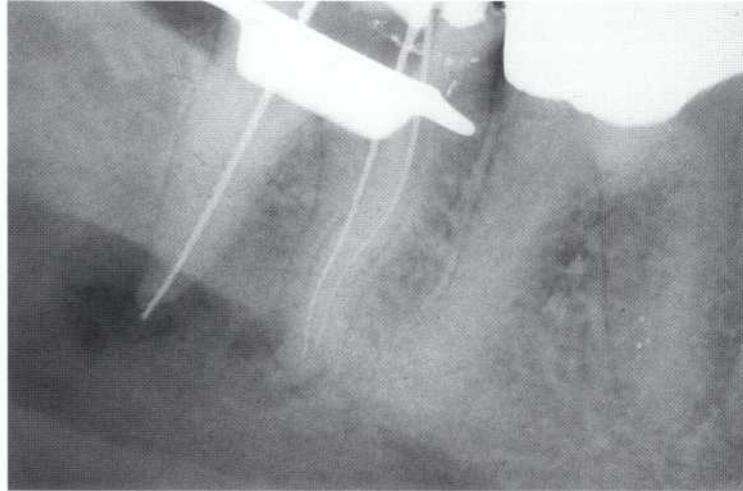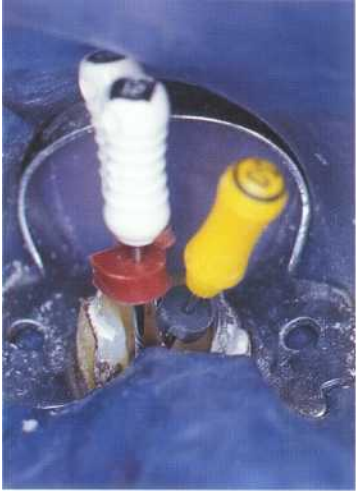


713 Access opening
After the roof of the pulp chamber is removed it can be seen that the infraction line crosses the entire floor of the cavity to the orifice of the mesial canals. The root canals are probed, the necrotic tissue extirpated, and the coronal portions of the canals enlarged.



Next, a careful inspection of the affected region is made with loupes, ultraviolet light, and the electronic caries meter. If there is still doubt, the occlusal region is stained with methylene blue. These techniques do not reveal the exact length, depth, or direction of the crack. After other potential causes have been excluded the patient should be asked to rapidly close the teeth several times. Pain upon loading is evidence of an incomplete vertical fracture. The first therapeutic procedure is the stabilization of the crown with a steel band (Liu and Sidhu 1995).

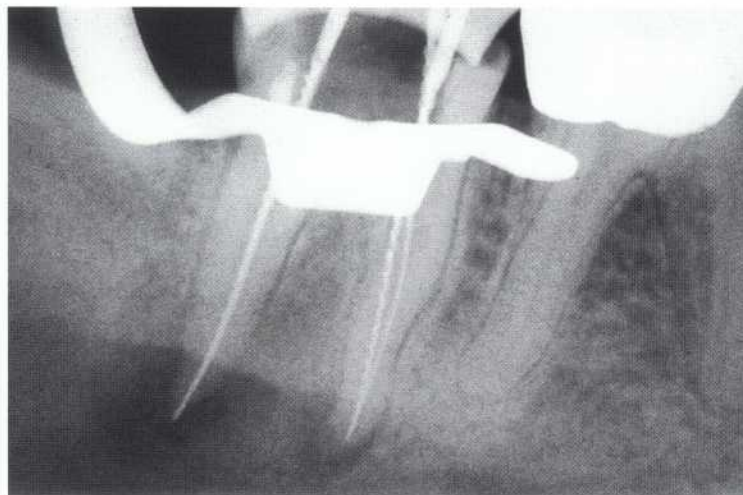If symptoms of pulpitis are present the tooth is opened and endodontically treated. The root canals should not be enlarged excessively. If the tooth is asymptomatic after placement of an interim dressing, the canals are filled with thermoplastic gutta-percha. However, complications did not occur following root canal treatment of teeth in one study, irrespective of the technique used (Liu and Sidhu 1995). The coronal portion of the tooth is then sealed with an adhesive cement and composite material. The final restoration should be an onlay or a crown (Friedman et al. 1993).



714 Working-length radiograph

After careful coronal enlargement of the canals, the first radiograph is taken to determine the working length. The distal length is then corrected.

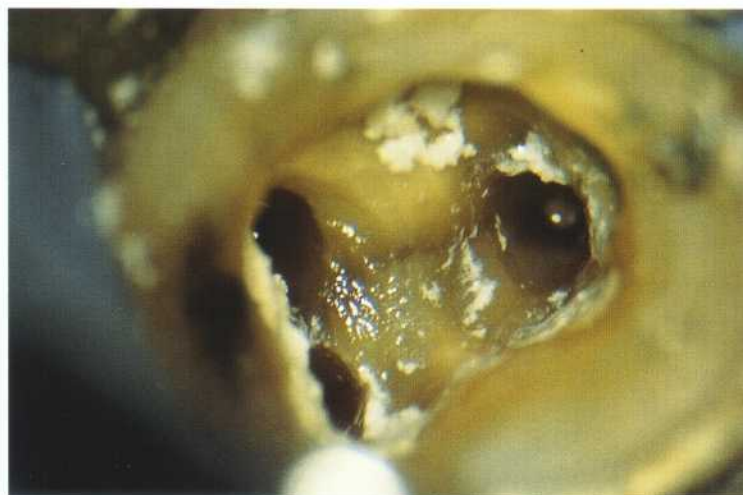Left: Different-sized measurement files were inserted into the root canals—size 15 in the mesial and size 20 in the distal.



715 Working-length radiograph

After conservative instrumentation of the root canals to size 30 and with no sign of heavy bleeding, a second check of the length is made with a radiograph. A slight reduction in the curvature of the mesial root canals can be seen. The working length in the distal canal is shortened once more.

Left: After irrigating and drying the root canals, they are firmly packed with calcium hydroxide.



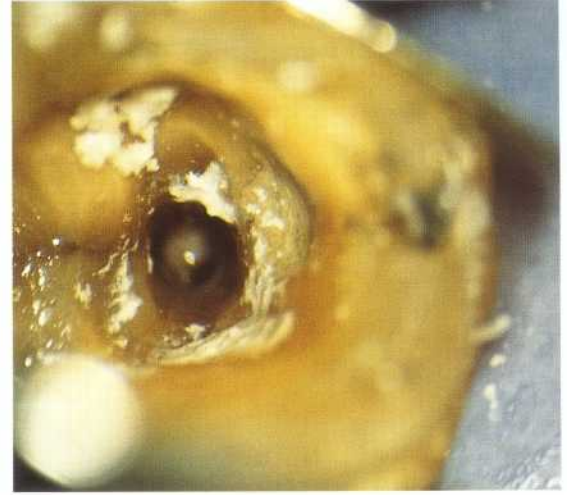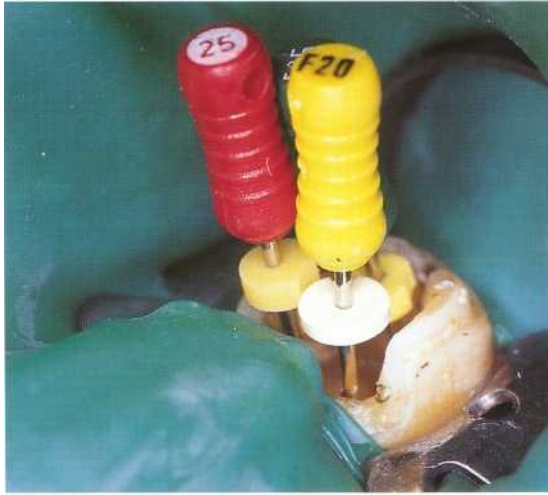
716 Reinstrumentation

After 3 months there are no clinical symptoms, and pain upon percussion is greatly reduced; thus the interim dressing is flushed out. Under the operating microscope at 20x magnification the course of the infraction line can be followed into the canal entrances.

717 Instrumentation

Left: The mesial root canals are once more carefully instrumented to the size of the AMF and irrigated with sodium hypochlorite.

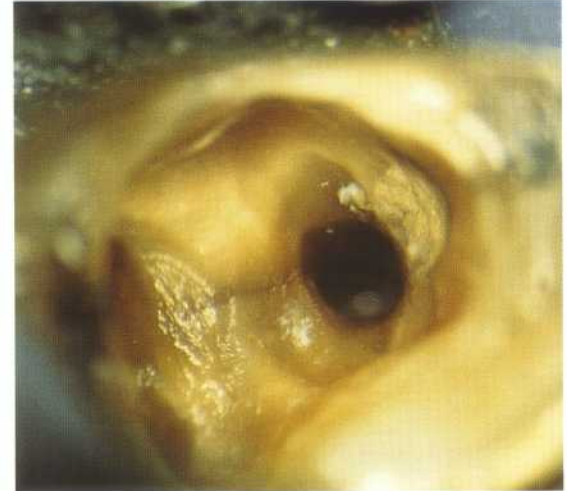
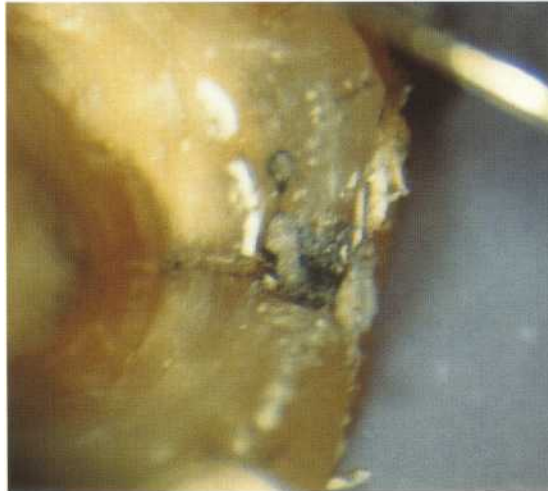Right: The surgical microscope is used to determine if any calcium hydroxide has remained in the depths of the root canals.



718 Microscopic evaluation

Left: The distal course of the fracture is inspected under 25x magnification and all remnants of caries are excavated.

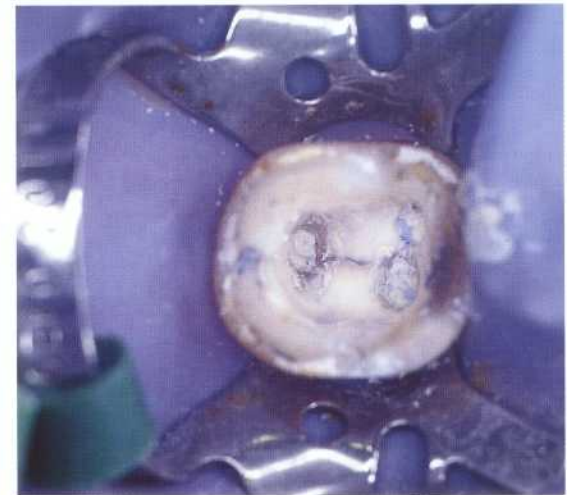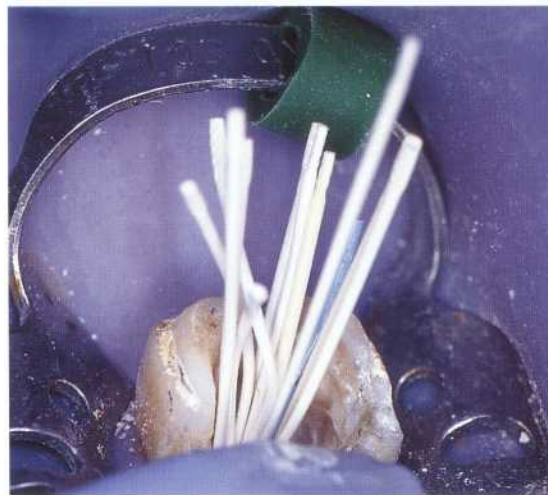Right: After the final irrigation the canals are thoroughly dried and a paper point is used to test for the presence of lateral bleeding, which would indicate a complete fracture. No lateral bleeding is found.



719 Root canal filling

Left: After the size 30 gutta-percha master point is tried and adjusted to fit, the root canal filling is completed with additional gutta-percha points, taking care not to exert excessive lateral force.

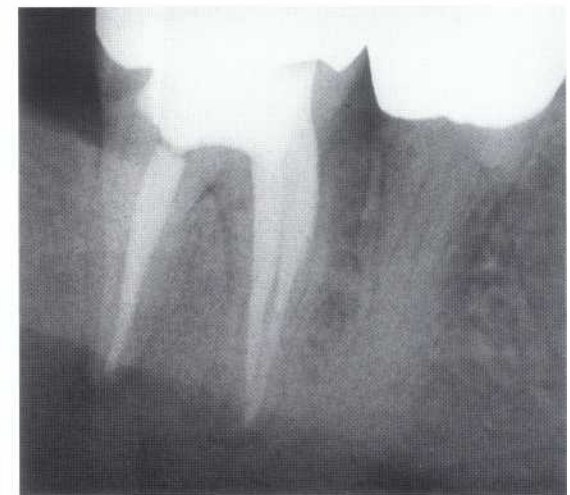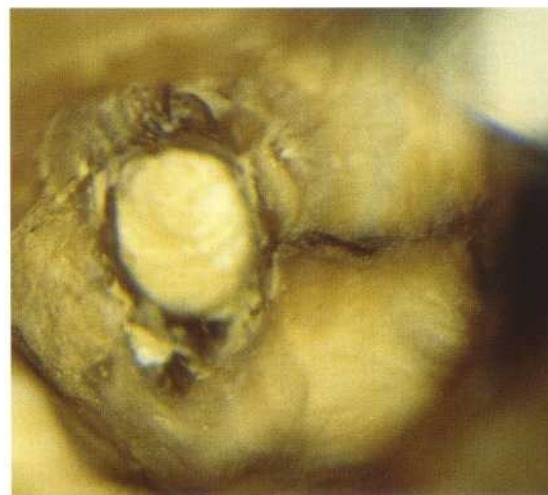Right: Next, the gutta-percha protruding from the canals is removed with a hot excavator.



720 Evaluation and follow-up

Left: The gutta-percha should be removed to a level at least 1 mm below the canal orifices. Any bleeding through the infraction gap would complicate the treatment, but no bleeding is seen through the microscope.

Right: The radiograph shows a dense, homogeneous root canal filling. Three months after the first appointment the periapical radiolucency is seen to have greatly diminished in size.



Postendodontic Restoration

The coronal restoration is an integral component of the endodontic treatment. Obturated root canals can become recontaminated with microorganisms if the coronal restoration is delayed too long, the temporary filling leaks between appointments, the restoration or tooth structure fractures, or the post space preparation extends too near the apex (Saunders and Saunders 1994). Klein et al. (1996) evaluated 742 root canal fillings and found the lowest success rate (46%) with both a defective coronal restoration and an inadequate root canal filling. A defective restoration in combination with a good root canal filling led to success in 71 % of the cases. Treatment was rated as successful in 79% of the cases with a good coronal restoration but a defective root canal treatment, and in 86% of cases with a good seal of both the coronal and apical regions. This investigation showed that the quality of the coronal seal had as great an influence on success as did the quality of the root canal treatment.

The choice of the coronal restoration also had a decisive effect on the overall success. In a 2-year study by Safavi et al. (1987) the highest success rate at over 70% was found among endodontically treated teeth that were restored with crowns. By comparison, temporary restorations of IRM cement and amalgam fillings were significantly inferior with success rates of 57% and 51% respectively. If no coronal seal was placed after endodontic instrumentation, bacteria were able to penetrate through the unfilled root canal within 48 hours. Well-condensed root canal fillings over which the access preparation was left open were thoroughly contaminated with bacteria after 4-48 days. On the other hand, no bacterial penetration could be found in any of the canals under tightly sealed access cavities (Torabinejad et al. 1990, Khayat et al. 1993). Bacterial endotoxins can also penetrate through exposed root canal fillings within 3 weeks, but no endotoxins were found in canals of teeth that had tight coronal seals (Trope et al. 1995 a).

The temporary filling should be at least 3 mm thick in order to resist degradation and penetration of bacterially contaminated saliva. Thinner fillings make it possible for bacteria to colonize the canal. Within 3 days up to 85% of teeth that had inadequate temporary fillings became contaminated with saliva and bacteria. If a tooth is left open to the oral environment for more than 3 days, the entire root canal must be reinstrumented and irrigated and a calcium hydroxide interim dressing placed before the final root canal filling. If a coronal filling or crown has been damaged and the canal has been exposed to salivary contamination for more than 3 months, the entire root canal filling must be removed and the canal completely reinstrumented (Magura et al. 1991).

Provisonal Coronal Seal

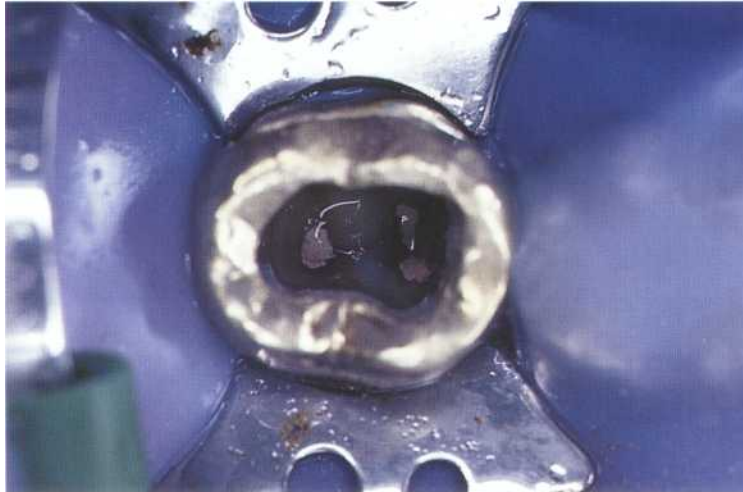
The provisional restoration should tightly seal the access opening between appointments to prevent bacterial penetration into the root canal system. Two of the most frequently used sealing materials are Cavit and IRM cement. In an investigation of the effectiveness of filling materials by Kazemi et al. (1994), Cavit permitted partial penetration of a dye to a depth of 4.3 mm through the filling material and 4.4 mm along the marginal interface.

IRM was penetrated to a depth of only 0.5 mm at the surface, but 4.9 mm at the margins.

The depth of penetration allowed by these temporary filling materials counters the suggestion by Saunders and Saunders (1994) that a thickness of 3.5 mm is adequate. It would be much better to aim for a thickness of 4 mm or more (Hansen and Montgomery 1993). The penetration of saliva into endodontically treated teeth after 3 months was equally severe, regardless of whether the access cavity was closed with a 3-mm-thick IRM filling or left open. These fillings should be replaced within 1 month because thereafter the extent of leakage more than doubled (Magura et al. 1991).

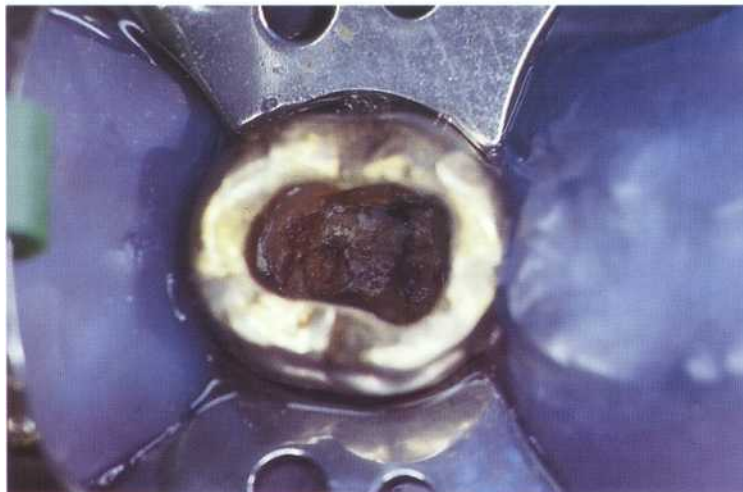721 Access opening
 Due to pain in this mandibular second molar, the patient's first dentist had instrumented the canals and placed gutta-percha and N-2 paste in them as an interim dressing. The canals were then reopened since the pain persisted.

Right: The first radiograph, taken prior to the initial treatment, shows a periapical radiolucency on the distal root.



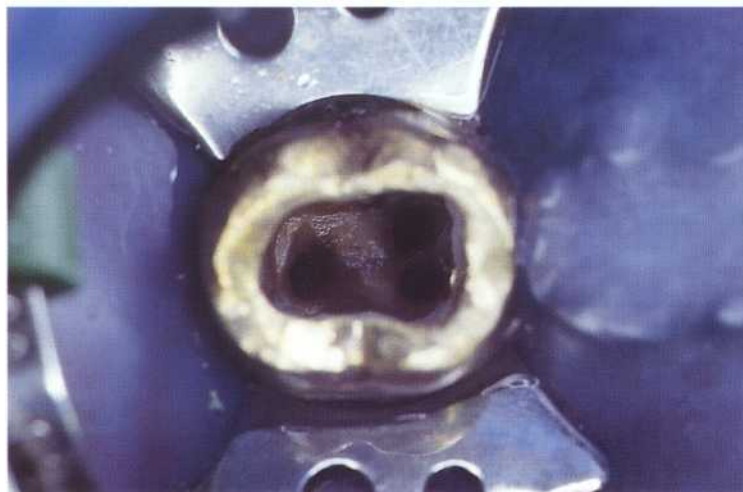722 Instrumentation
 Due to leakage and partial loss of the provisional filling, bacteria has penetrated the cavity and, presumably, the canals. The canals are completely reinstrumented and irrigated with sodium hypochlorite solution.

Right: The working depth is determined with a radiograph.



723 Interim dressing
 After instrumentation is completed, the root canals are subjected to a final irrigation and dried. There is no evidence of foul odor or secretions. The interim dressing is then inserted with a rotating spiral paste filler.

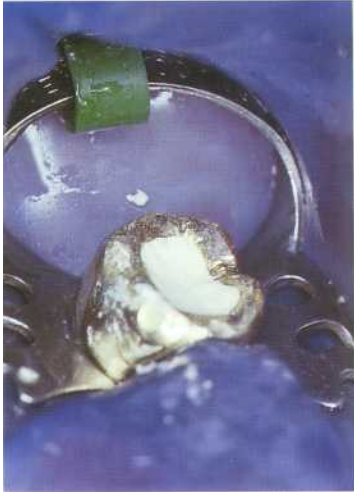Right: The aqueous mix of calcium hydroxide is packed firmly into the canals to provide solid contact with the dentinal walls.



The type of provisional filling material can have an adverse influence on the seal of the definitive restoration. IRM cement, Cavit, and Dycal-but not Grossman cement reduced the adhesion of a composite material to dentin to one-half that of the control specimens (Macchi et al. 1992). The type of interim dressing within the root canal had no significant effect on the ability of the restorative material to seal the cavity, however. Neither eugenol, formocresol, nor chlorophenol resulted in greater penetration around the final filling (Rutledge and Montgomery 1990). Placing a

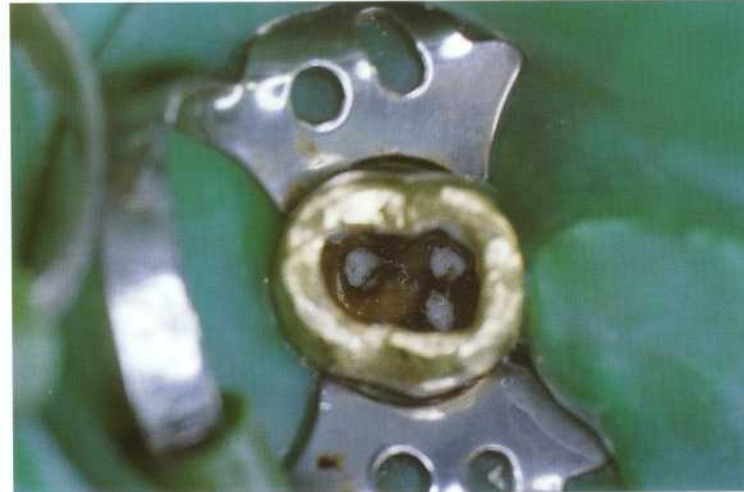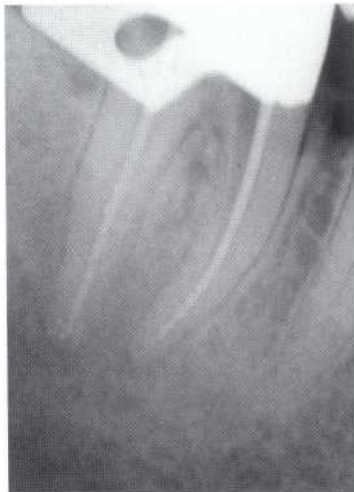cotton pellet over the canal entrance before insertion of the provisional filling is not recommended because it increases the possibility of penetration. Cotton pellets were placed on cavity floors directly under 5-mm-thick provisional fillings; when IRM was used, the pellets were discolored twice as often as when Cavit was used (Kazemi et al. 1994).

If the orifices of the canals are sealed with the temporary filling material, it is very unlikely that the interim dressing will be softened by saliva that might penetrate under the leaky margins of a crown or filling.



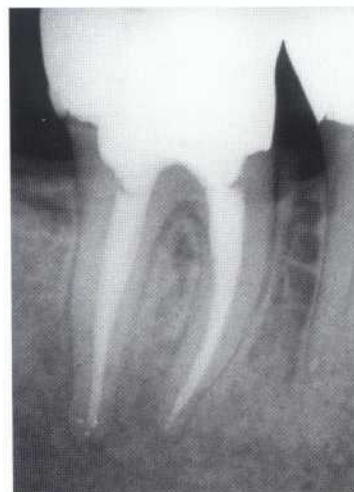724 Provisional coronal filling
Three months after the initial treatment the integrity of the 4-mm-thick provisional zinc phosphate cement filling is evaluated under a rubber dam. Only a minimal amount of cement loss is detected.

Left: The interim filling placed after the first sitting covers the entrances to the canals and seals the access cavity from the oral environment.



725 Checking the integrity of the interim dressing
The pulp chamber is reopened, all the cement filling removed, and the calcium hydroxide interim dressing checked. No breakdown is evident, thus contamination with saliva can be ruled out.

Left: The master point radiograph is used to evaluate both the position of the gutta-percha point and the reduction in size of the periapical radiolucency.



726 Evaluation of the final root canal filling
The three canals are filled with gutta-percha and AH-Plus by the lateral condensation technique. Then the gutta-percha is cut off below the canal orifices and the cavity sealed with zinc phosphate cement and an adhesive filling.

Left: The radiograph shows a homogeneous root canal filling with a dense apical seal.

Fracture Risk and Partial Veneer Crowns

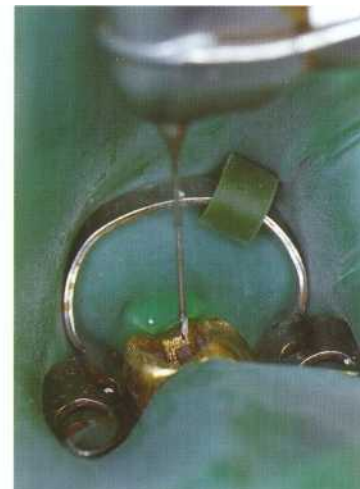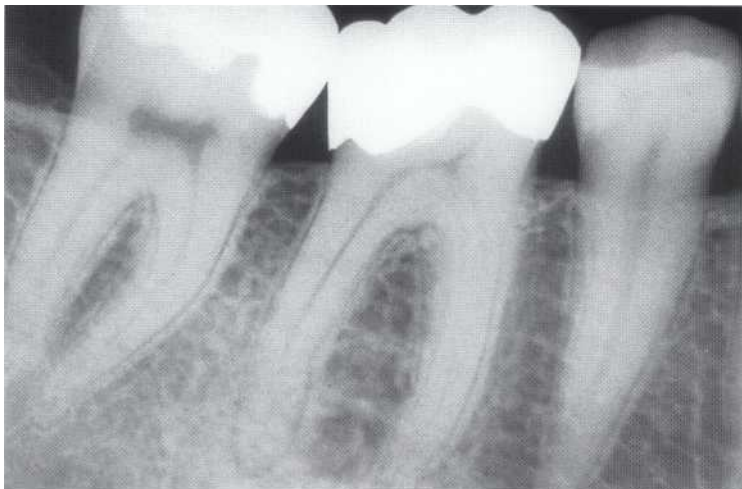
Fractures of endodontically treated teeth are frequently attributed to reduced physical properties of the dentin. There is, however, no difference between the strength of the dentin of endodontically treated teeth and that of vital teeth. The type of access cavity and final restoration do influence the risk of fracture, however. Cutting a small preparation reduces the load a tooth can withstand to 81 % that of an intact tooth; a more extended preparation reduces it to 61 %. An endodontic access preparation further reduces the strength of the crown by half (Panitvisai and Messer 1995).

The dentin of endodontically treated teeth is no less resistant to fracture than that of vital teeth. Neither dehydration nor the age of the patient has a significant effect on the elasticity of dentin (Huang et al. 1992). It is the removal of the roof of the pulp chamber and the marginal ridges that substantially reduces the strength of the tooth. Intact molars fractured under a load of 241 kg, and an extended preparation reduced the maximum load to 222 kg. Teeth that also had an endodontic access cavity fractured under a load of only 121 kg (Howe and McKendry 1990).

727 Access preparation

The mandibular first molar with a three-quarter crown is associated with clinical symptoms of pain and tenderness to percussion and also has a small radiolucency around the tip of the distal root.

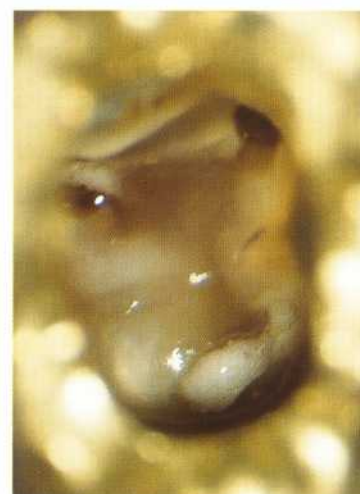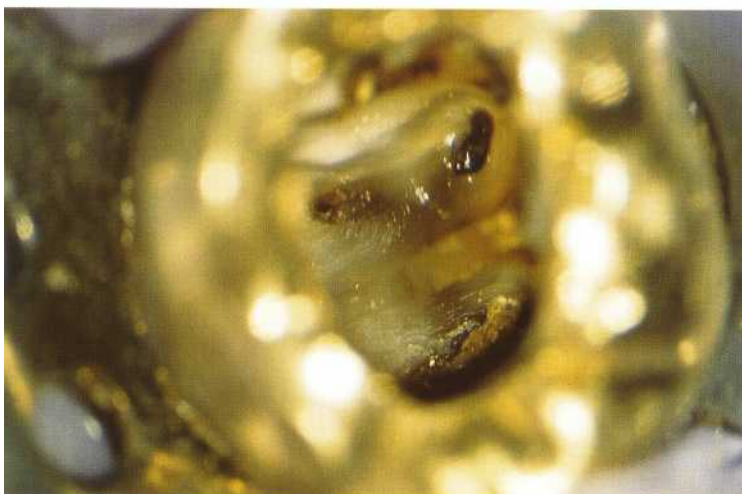Right: After preparing a generous access cavity, the integrity of the crown is evaluated. The coronal portion of each canal is subsequently prepared with rotary drills.



728 Necrosis

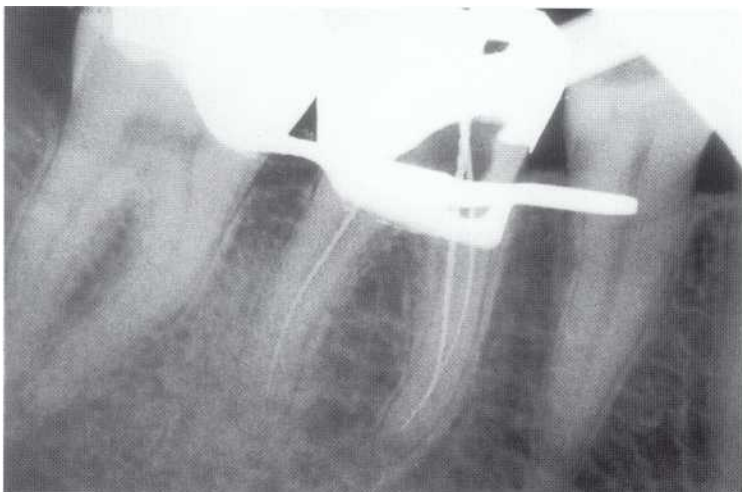
The roof of the pulp chamber is removed and the entrances to the root canals located. With the operating microscope necrotic tissue can be seen in all three canals.

Right: The canals are irrigated and instrumented with the help of RC-Prep.



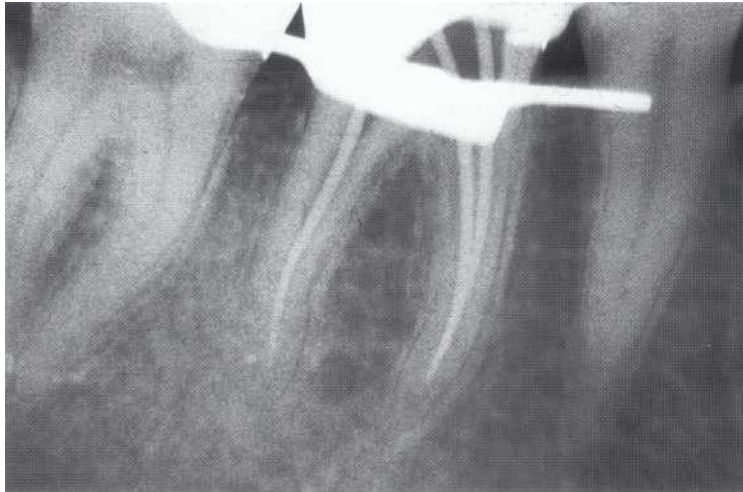729 Instrumentation

After establishing the working length on a radiograph, the three canals are instrumented and the apical portions prepared to size 30. The canals are enlarged coronally with Gates-Glidden drills.



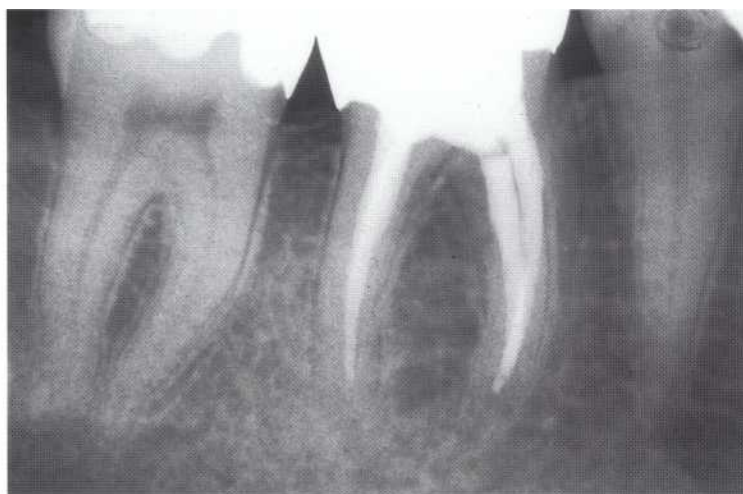
The altered mechanical properties of the prepared tooth increase its susceptibility to fracture. The restoration of endodontically treated teeth with amalgam has produced rather disappointing results over an observation period of 20 years. Teeth with MOD fillings fractured much more frequently than mesio-occlusodistal (MOD) teeth with intact marginal ridges. Only 30-40% of premolars restored in this way were still intact at the end of the observation period. Teeth with smaller restorations had a much higher survival rate at 80% (Hansen et al. 1990).

MOD amalgam restorations reduced the danger of fracture and increased the strength of prepared teeth by 61-82%; the load that could be withstood was increased by 125% by binding the cusps together by means of cast partial veneer crowns. An amalgam restoration that covered the cusps increased the strength of the mesial cusp by 175%, and the distal cusp by 102%. Endodontically treated posterior teeth therefore should be restored with at least a metal casting that encompasses the cusps to ensure protection against tooth fracture (Linn and Messer 1994).



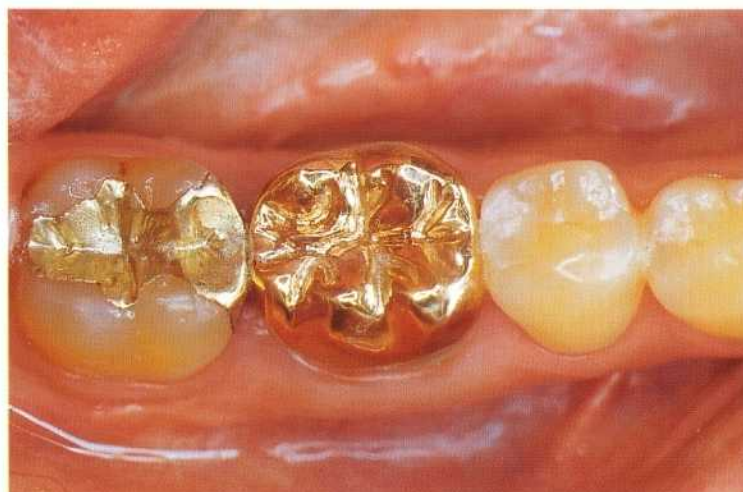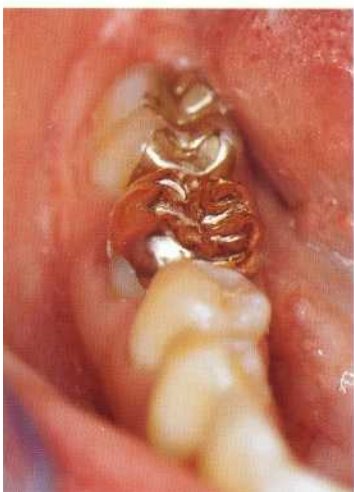730 Master point

An interim dressing is left in place for 4 weeks. At the second appointment the root canals are irrigated and dried and three gutta-percha master points are fitted and measured on a radiograph. At the same time, the depth of the instrumentation is verified.



731 Root canal obturation

The canals are completely filled with gutta-percha points and a resin sealer. The results are then checked with a radiograph. The root canal treatment is successful, with freedom from clinical symptoms and healing of the periapical lesion.



732 Restoration

Immediately after the root canal filling is placed the crown is built up with glass ionomer cement. The tooth is prepared for a new partial veneer crown, an impression is made, and a provisional crown placed. One week later the final restoration is cemented.

Left: The partial veneer crown, which protects the tooth from overloading and recontamination, is evaluated for marginal adaptation.

Coronal Restoration

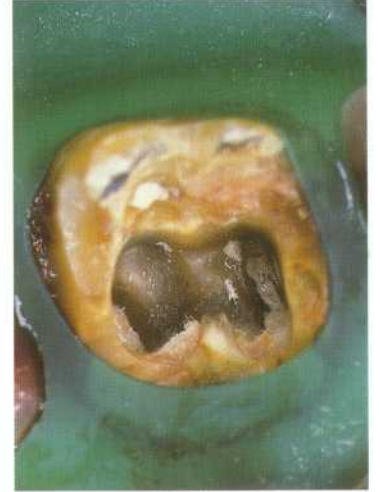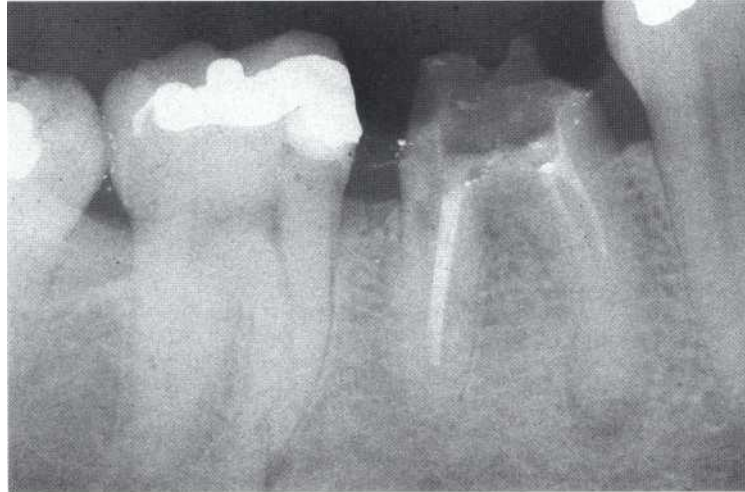
Root canal treatment itself does not substantially change the mechanical properties of the tooth. In a study by Sedgley et al. (1992), 23 teeth that had been endodontically treated and the same number of vital teeth extracted from the same patients were tested for their biomechanical properties. The microhardness was measured at 66.8 for endodontically treated teeth and 69.1 for vital teeth. Endodontically treated teeth fractured under a force of 611 N, and vital teeth under 574 N. The dentin of endodontically treated teeth exhibited no reduction in strength. The type of restoration

placed after root canal treatment depends upon the amount of remaining tooth structure and the force to which the tooth will be subjected. Anterior teeth with small to moderate defects are treated only with a composite filling. According to a clinical study by Sorensen and Martinoff (1985), placement of a crown on an endodontically treated anterior tooth reduced its risk of fracture by only 2%. Posterior teeth, on the other hand, were much more prone to fracture when left uncrowned (38-48%) than when treated with crowns (less than 10% for premolars and 5% for molars).

733 Retreatment

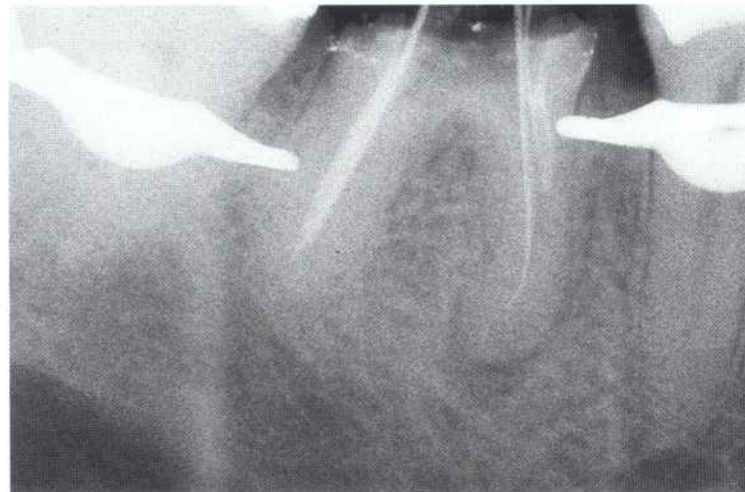
A mandibular first molar with inadequate root canal filling and periapical radiolucency. The old crown has been removed. There are no clinical symptoms.

Right: A large part of the clinical crown is missing, and finding the entrances to the canals proves unproblematic.



734 Instrumentation

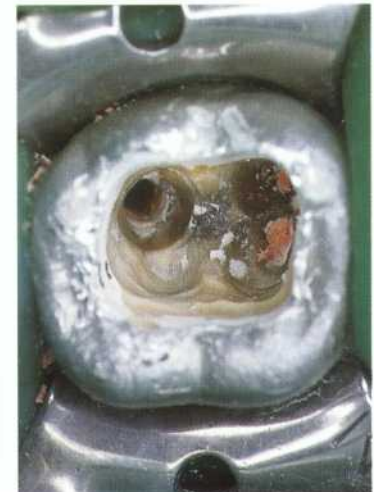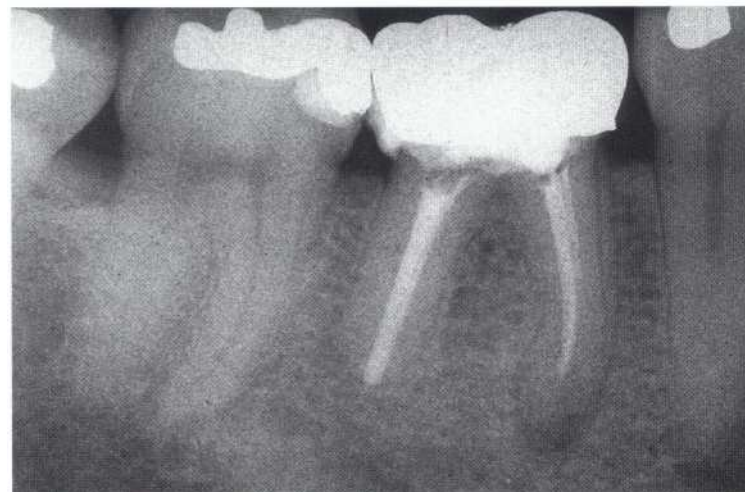A rubber dam is clamped to both adjacent teeth and the working lengths are determined radiographically. The canals are then reinstrumented.



735 Root canal filling

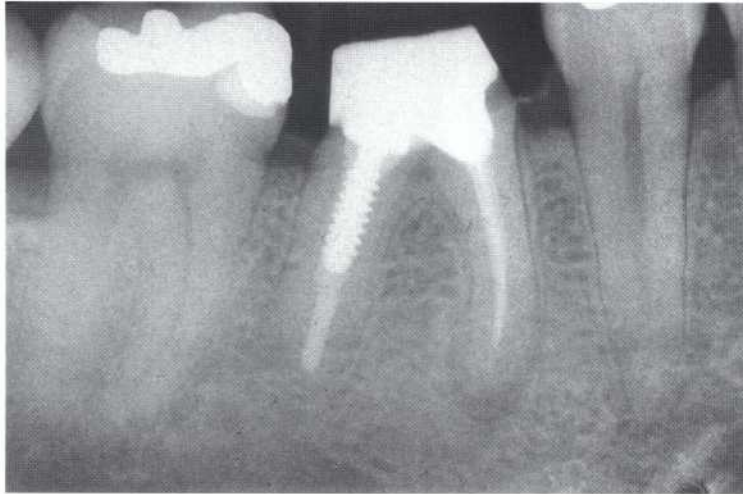After 3 months with a calcium hydroxide interim dressing in place, the tooth is asymptomatic and so the canals are filled with gutta-percha. The result is evaluated on a postoperative radiograph.

Right: The excess coronal gutta-percha is removed and the distal root canal is prepared to receive a screw post.



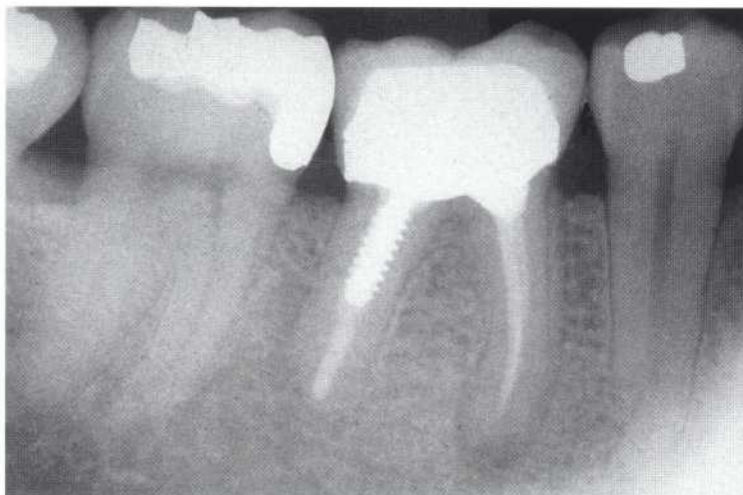The loss of tooth structure can have an adverse effect on the mechanical properties of a tooth. Thus it is the quantity of dentin remaining in the crown that largely determines the strength of an endodontically treated tooth. If the tooth is prepared for an artificial crown, its fracture resistance under an oblique load is reduced to 46 kg, compared with 54 kg for teeth that have not been prepared. If the prepared dentin is pretreated with EDTA and built up with composite, the tooth's resistance is once more comparable with that of an untreated tooth (Sornkul and Stannard 1992).

Before a crown is made, an adhesively bonded core must be placed. Then a veneered cast crown can be placed over it. Success is also influenced by the choice of cementing agent. Under *in vivo* dye penetration tests, crowns cemented with composite cement showed the least leakage at 16%, followed by a glass ionomer cement at 33.2%. More than half of the crowns cemented with polycarboxylate or zinc phosphate cement showed marginal leakage (White et al. 1995).



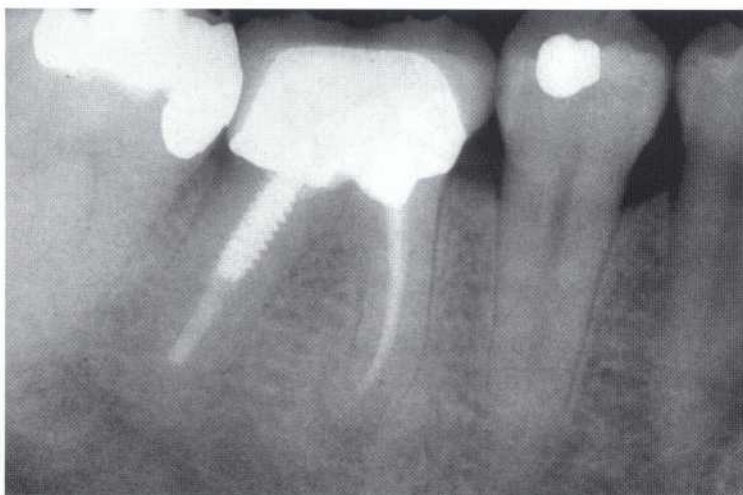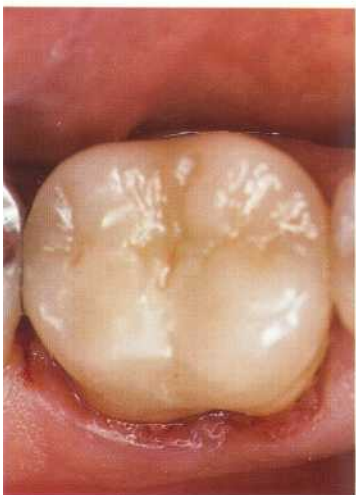736 Post-retained core
Threads are cut into the walls of the post space and the post is gently screwed into place. The remaining tooth structure is etched, treated with a dentin bonding agent, and built up with composite.

Left: The screw post is coated with polycarboxylate cement and slowly screwed into the distal canal.



737 Artificial crown
After 1 more week the definitive crown is cemented with glass ionomer cement. This 1-year follow-up radiograph shows optimum marginal adaptation. The adjacent filling has also been replaced.

Left: Screw posts for treating posterior teeth (Straumann).



738 Follow-up
The radiograph taken 3 years after treatment shows almost total regeneration of the periapical bone at the apex of the mesial root.

Left: The tooth can withstand normal loading. Before the metal-ceramic crown is placed, the crown is lengthened surgically to provide greater retention.

Endodontic Posts

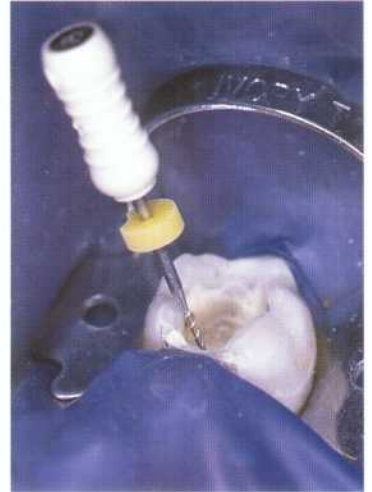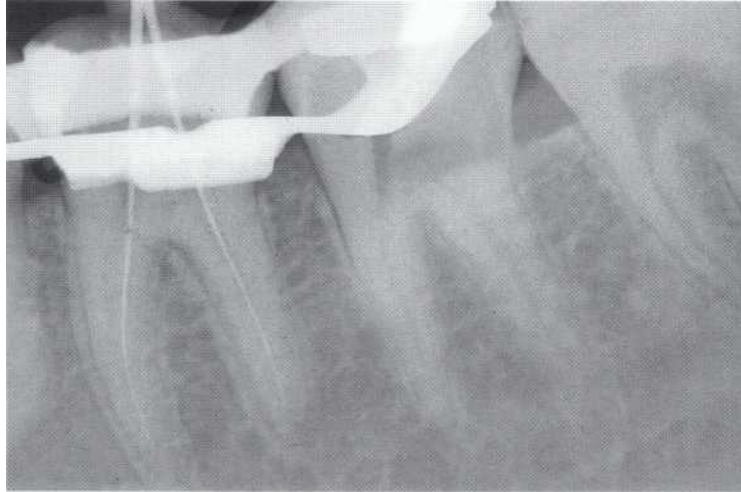
A post-and-core anchored in the root canal was once thought to actually strengthen the weakened root. However, laboratory studies have shown that the preparation of a post space further weakens the tooth structure, and the placement of the post does not leave the tooth any stronger than it was before the preparation was made. Posts anchored in the root canals have no strengthening effect on the roots and serve only to provide additional retention for the core and artificial crown (deCleen 1992).

The gutta-percha can be softened by placing a drop of organic solvent such as eucalyptol on the coronal end of the root canal filling. It can also be softened with a hot spreader. However, the apical seal is said to be better preserved after mechanical removal than after chemical dissolution (Camp and Todd 1983). Basically, it makes no difference whether the post space is prepared as soon as the root canals are filled or whether this is delayed to a later appointment. Portell et al. (1982) view the immediate removal of excess gutta-percha as advantageous.

739 Instrumentation

Radiographic length determination following preparation of the access cavity on a mandibular first molar.

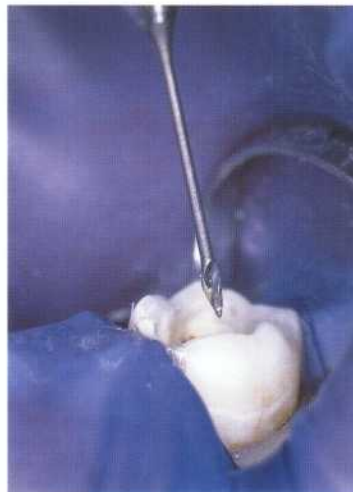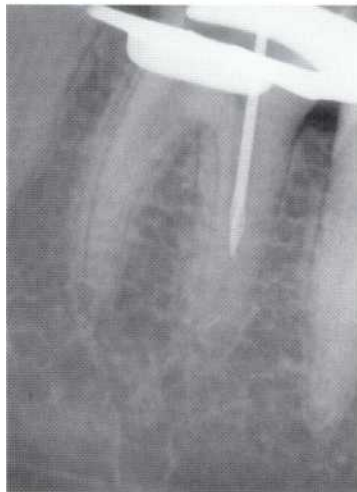Right: Patency of the root canals is tested with a size 15 Hedstrom file. Then the canal is enlarged by circumferential filing.



740 Enlargement of the coronal portion

Left: The straight portion of the root canal is enlarged with Gates-Glidden drills of different sizes following a modified step-down technique.

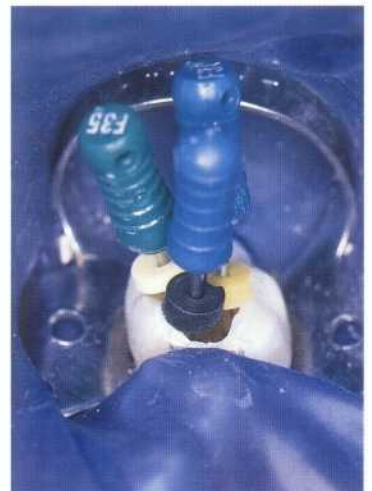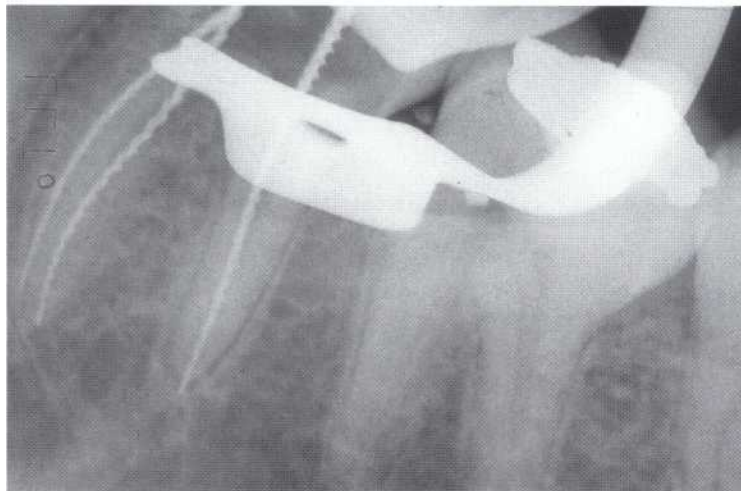Right: The length and size of the Gates-Glidden drill used is recorded so that later the size of the point can be selected to match the coronal enlargement.



741 Preparation of the deep portion

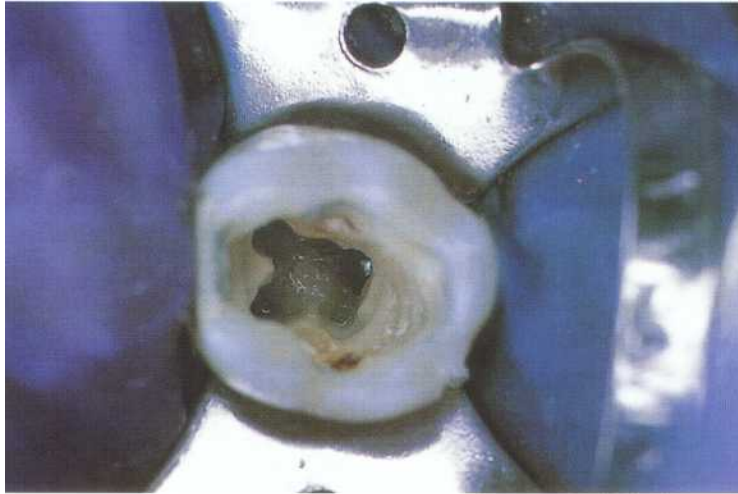In spite of the initial length measurement, the canals were over-instrumented. The working length is checked again with the AMFs and found to require a reduction of 1 mm in the distal root and 0.5 mm in the mesial root.

Right: The two mesial root canals are enlarged to size 30 and the distal canal to size 35. They are shaped by using the balanced force technique.



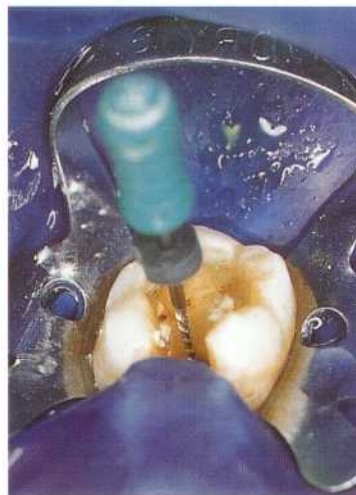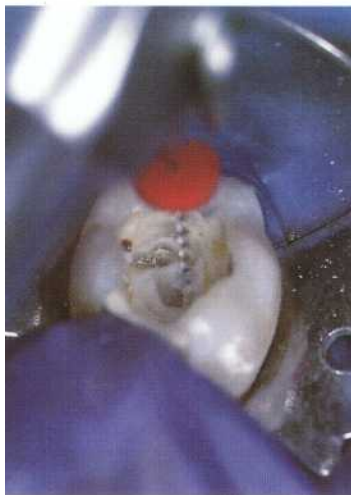Whether the gutta-percha was removed mechanically or thermally, the seal provided by 4 mm of remaining root canal filling was good (Hiltner et al. 1992). Portell et al. (1982) compared the seal of a 7-mm-long filling with one shortened to 3 mm and found a tighter seal of the canal with the longer filling. Kvist et al. (1989) recommend a minimum length of 3 mm at the apex based upon their clinical investigations. When the length of the root canal filling was 5 mm, the rate of failure with periapical lesions was less than 10%, but when only 2 mm of filling remained, the rate was almost 30%.

Using the pilot drill of the post system, the post space is prepared to its final length, which should be at least as great as the length of the final crown (deCleen 1994). Then a flat surface is created around the entrance to the post space with a special facing bur before the post space is finalized. A tapping instrument is used to cut threads into the moist canal wall, and then the canal is rinsed and dried. The threaded post, coated with cement, is first rotated to the left to engage the first thread, and then rotated clockwise and screwed into place.



742 Disinfection

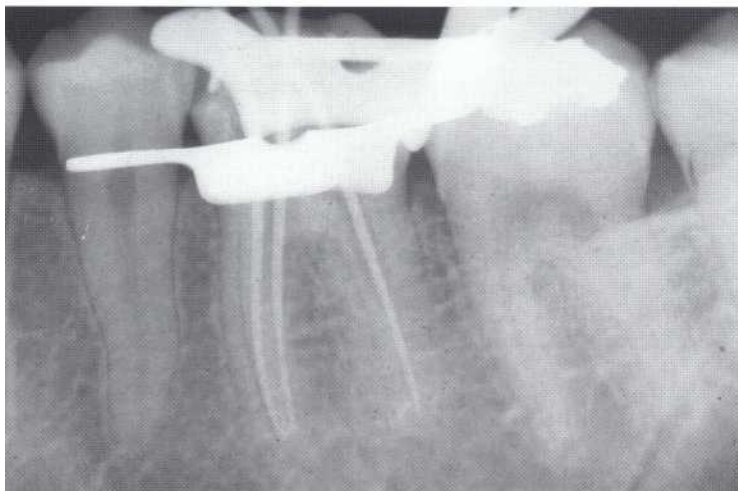
During instrumentation the root canals are irrigated with 1% sodium hypochlorite solution. This view into the cavity shows round canal entrances. The canals are subsequently dried with paper points.



743 Interim dressing

Left: An aqueous mix of calcium-hydroxide is placed into the canals with a spiral paste filler, then the access cavity is tightly filled.

Right: At the next appointment there are no symptoms, thus the dressing is loosened with a Hedstrom file and flushed out.



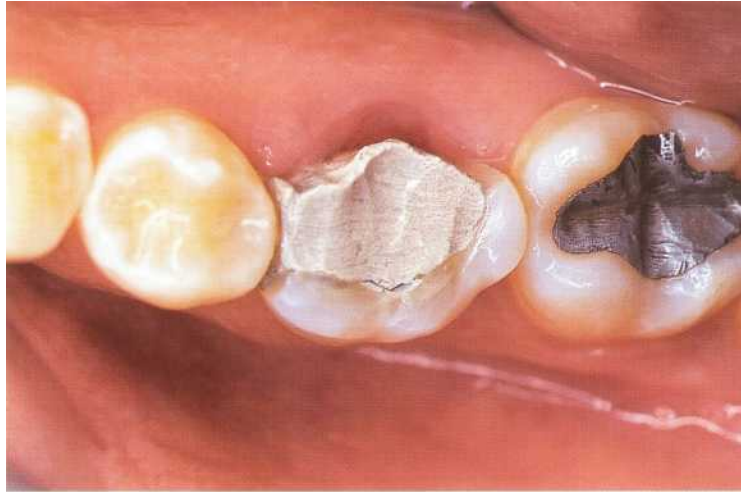744 Trial insertion of the master points

Gutta-percha points with length markings are inserted into the canals and the lengths checked on a radiograph. In spite of the initial overinstrumentation there is no fear of overextending the root canal filling because apical stops were created during instrumentation.

276 Postendodontic Restoration

745 Tooth fracture

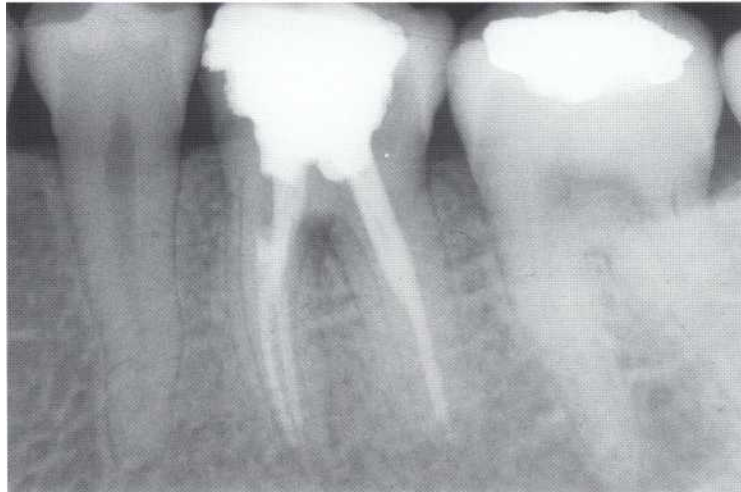Even though the tooth was filled with a glass ionomer cement after the initial treatment, the lingual wall of the crown has fractured away. This complication makes it necessary to insert a post to increase the retention of the core buildup.



746 Radiographic evaluation

This radiograph, taken immediately after the root canals were filled with gutta-percha, shows dense, homogeneous obturation of the apices and verifies that there is no over-extension of the filling material.

Right: Next, part of the gutta-percha is removed with a Gates-Glidden drill.

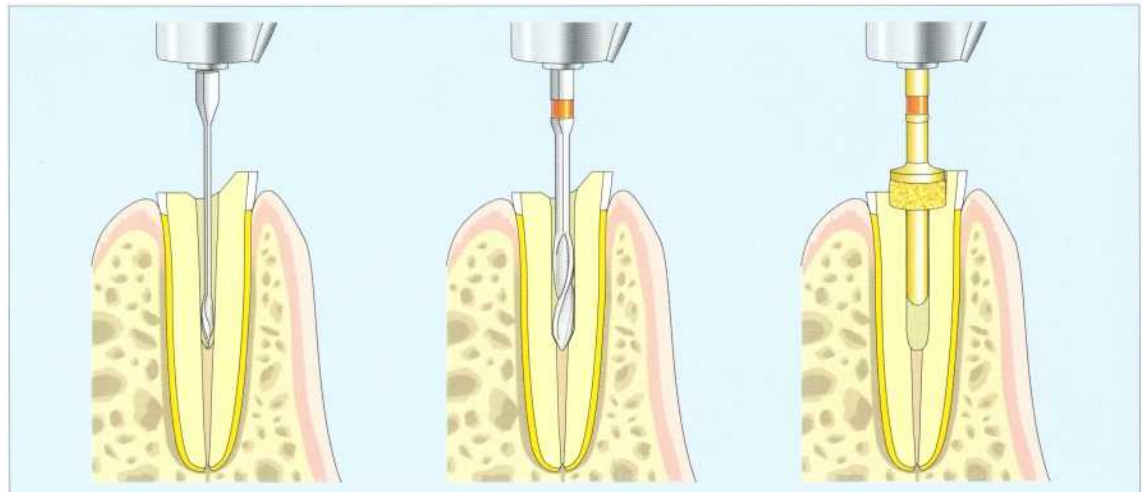


747 Preparation

Left: A coronal portion of the gutta-percha is removed to a depth of 4-5 mm with size 1 and size 2 Gates-Glidden drills.

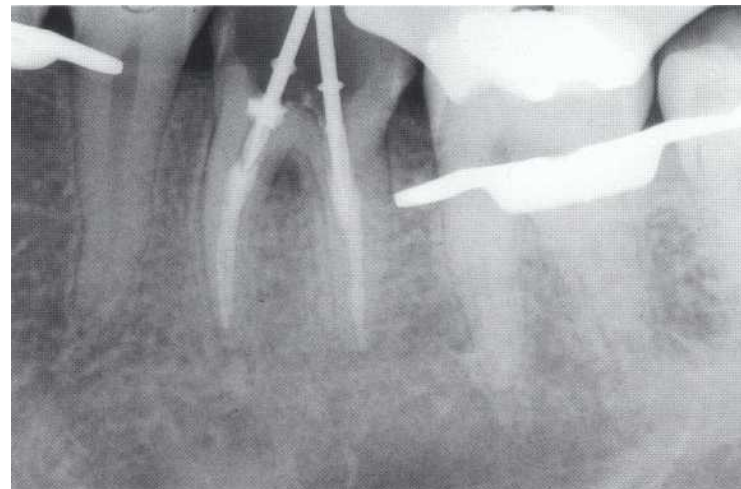
Center: The pilot drill specified in the Radix Anchor system is used to make a preliminary channel to the desired depth.

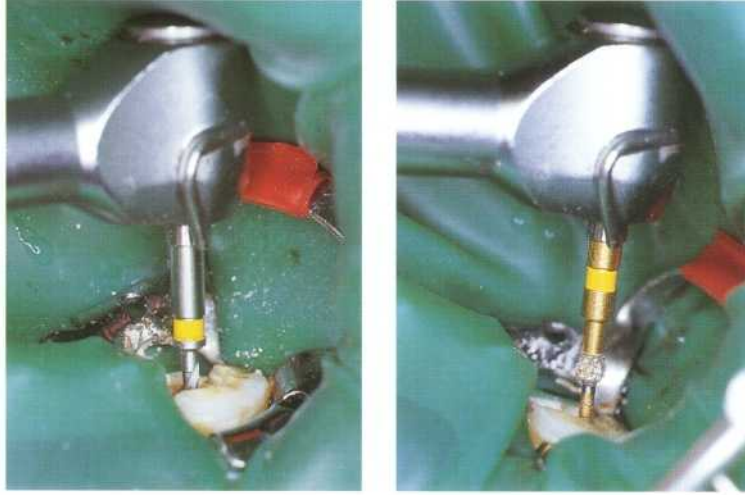
Right: A flat seat is prepared around the entrance to each post space with the special diamond-coated instrument.



748 Monitoring radiograph

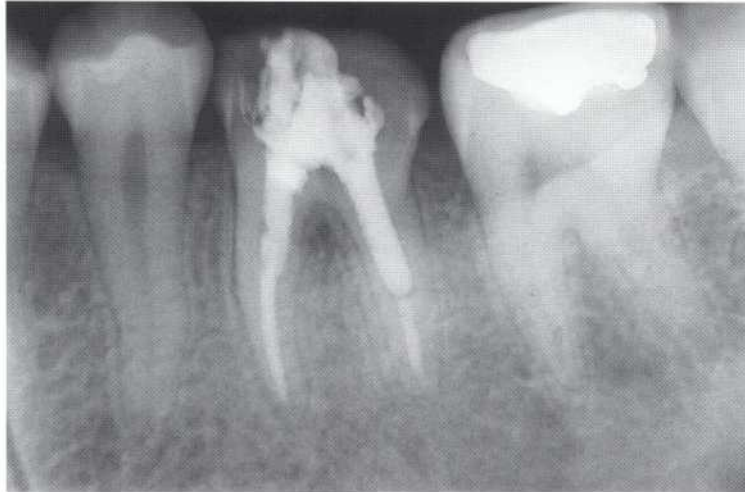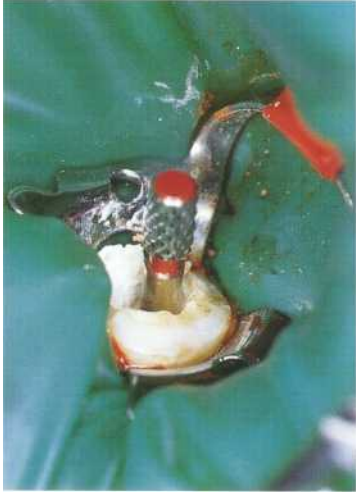A radiograph is taken during preparation of the post spaces. This is recommended to help avoid perforations. It is evident that the instrument deviates slightly from the center of the canal, but this can still be easily corrected.



**749 Preparation**

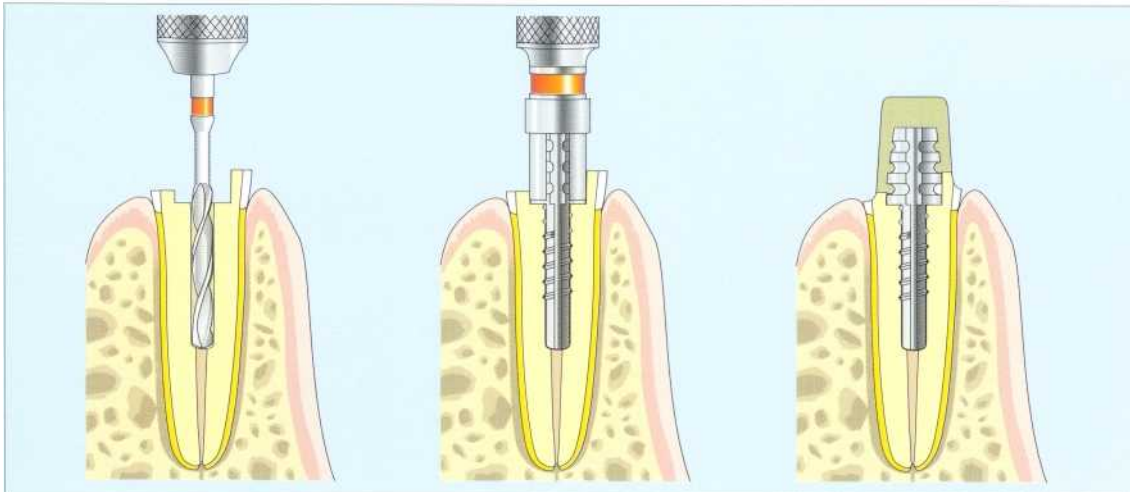
Left: After the pilot hole is drilled, a special drill with a diameter corresponding exactly to the size of the Radix Anchor is used to finish preparing the post space.

Right: Next, the entrance to the channel is flattened once more to minimize splitting forces.

**750 Radix Anchor**

After the Radix Anchor is cemented, a radiograph is taken to check the depth of the post and the length of remaining root canal filling.

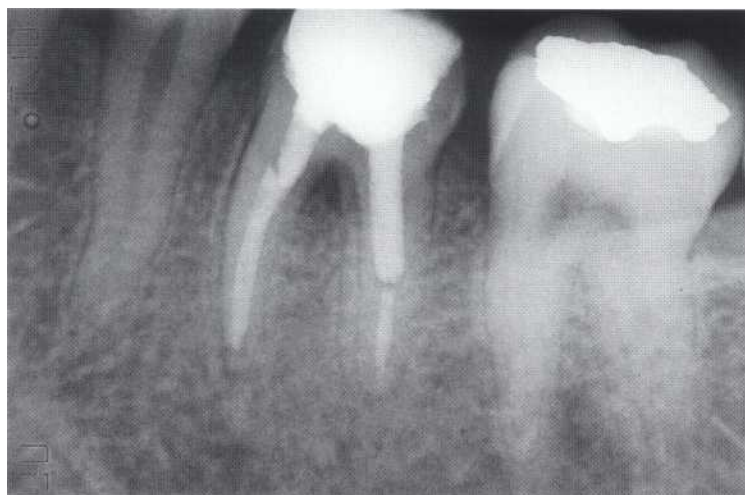Left: A measuring gauge is used to check the depth reached by the drill before the internal threads are cut.

**751 Insertion of the post**

Left: The post space is finished with a standardized drill.

Center: After cutting internal threads, the Radix Anchor is coated with cement and gently screwed into place.

Right: A composite core is built up over the fins radiating from the coronal portion of the post.

**752 Core buildup**

After both Radix Anchors have been cemented, the cavity is etched and treated with a dentin bonding agent, and then a light-curing composite is applied. Thereafter, the tooth is prepared for a cast crown, and an impression is made.

Cast Post-Cores

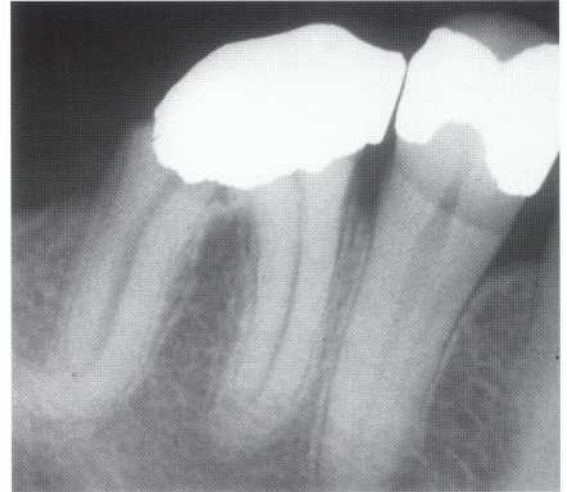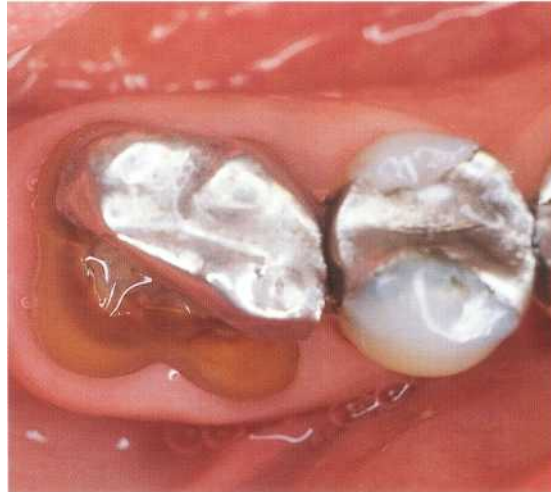In order to test specific post-and-core systems, Plas-mans et al. (1988) inserted 7-mm-long post-cores into the distal canals of extracted teeth and found the highest fracture resistance (4460 N) with a cast post-core system. Every test ended with fracture of the entire tooth and so it was not possible to make more than one restoration on the same tooth. Prefabricated posts with composite cores withstood 2750 N but were insignificantly stronger than an adhesive composite buildup extending 3 mm into the canal with no post. Here, however, only one fracture occurred within the

composite material.

As with all systems, a cast post-core must have adequate length. Increasing the length of the post from 5 mm to 8 mm increased its retention by 47%. Guide lines for the length of the post space are: first, it should measure two-thirds of the total canal length; second, it should be as long as the future crown length; and third, it should equal half of the bone-supported root length. Marginally, at least 2 mm of root dentin should surround the cast post. This will double the resistance to fracture (Wagnild and Mueller 1994).

753 Presenting condition

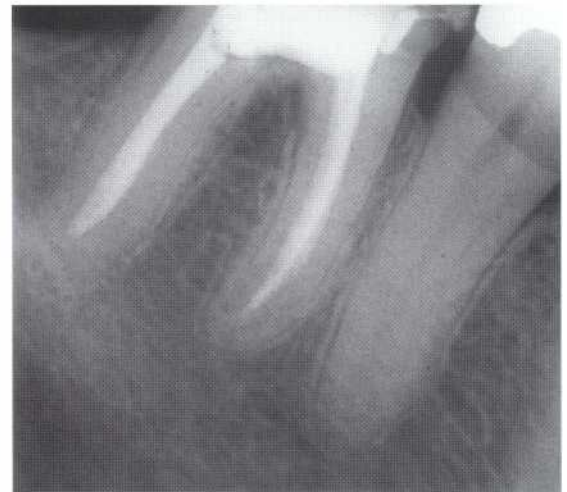
Left: The lingual wall of the lower molar has fractured off, leaving an inadequate amalgam filling. There are no clinical symptoms. To save this posterior-most tooth in the arch it would be necessary to perform endodontic treatment and place a core and crown.



Right: The radiograph taken before the beginning of treatment shows nothing unusual in the periapical region.

754 Root canal treatment

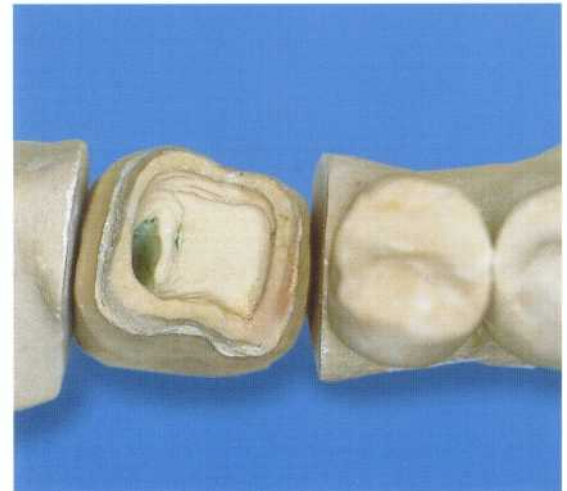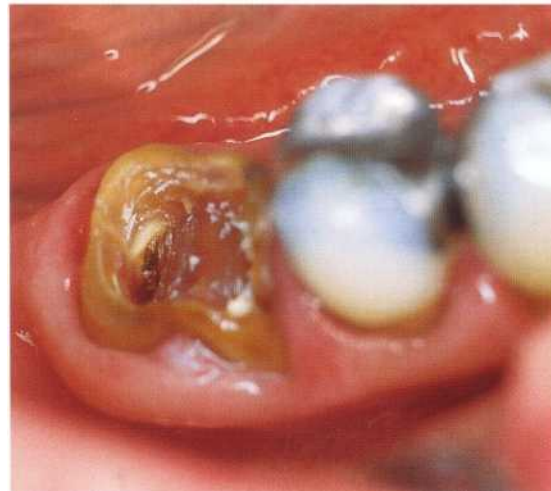Left: The three root canals are instrumented and a calcium hydroxide interim dressing is placed. At the second appointment gutta-percha points are condensed into the canals and cut off at the level of the canal orifices.



Right: Homogeneous root canal fillings can be seen on the post-operative radiograph.

755 Post-core preparation

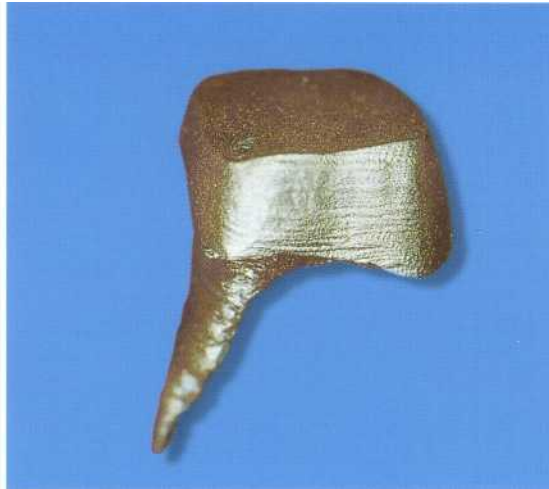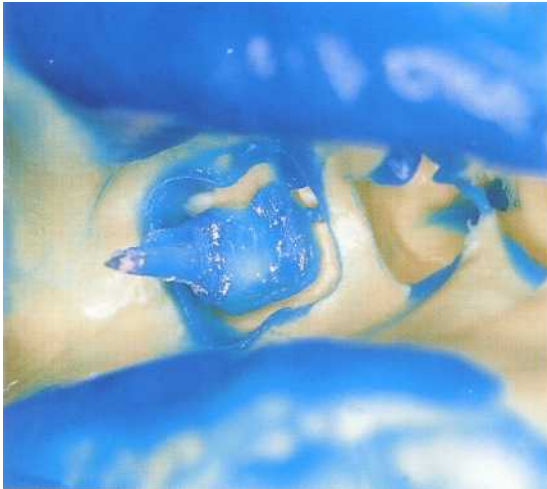Left: To create space for the post, some of the gutta-percha is removed from the distal canal and the canal is widened with a Peeso reamer to half of the working length.



Right: The remaining coronal tooth structure is shaped to create resistance form and to permit a casting to embrace the tooth at the margins. An impression is then made of the arch, and a stone cast is made in the laboratory.

Parallel-sided posts provide two to four times more retention than do tapered posts. They also provide better distribution of force over the walls of the canal and a lower risk of fracture (Sorensen and Engelman 1990). Tapered post systems are indicated only in mandibular anterior teeth with small diameters. Here, only cast post-cores are recommended because they provide the best resistance to fracture. If cast-to, serrated Parapost dowels are used, fractures are more likely to occur within the dowel-core (Gluskin et al. 1995).

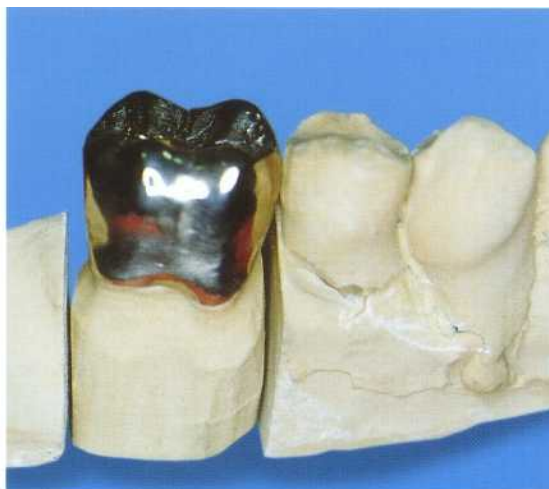
The definitive cast dowel-core is cemented at a subsequent appointment. In a dye penetration study the best seal was achieved with a cyanoacrylate cement, followed by polycarboxylate cement and a composite cement placed after etching the dentin and applying a bonding agent. The poorest seal was provided by zinc phosphate cement (Fogel 1995). If a root canal sealer containing eugenol was used, the dentin surface must be conditioned and rinsed with ethanol before cementation (Tjan and Nemetz 1992).



756 Post-core

A silicone material used in a double mix technique is employed to obtain an impression of the post space and coronal tooth preparation simultaneously.

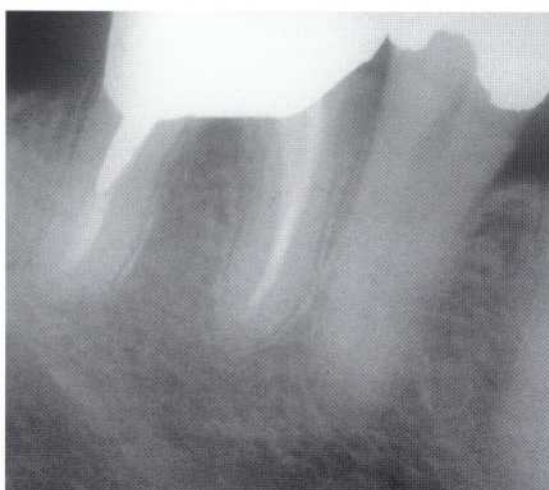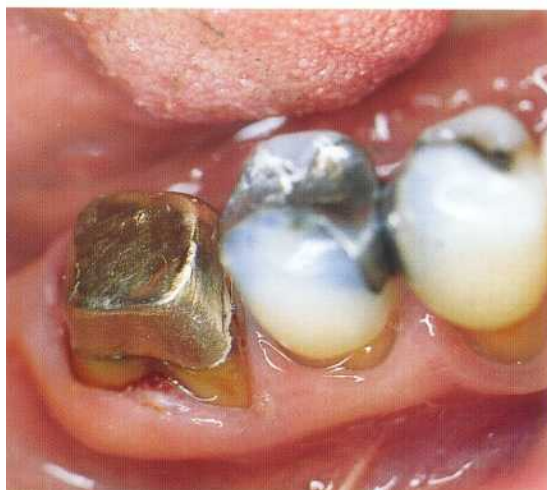Right: The post-core is cast in an alloy with high gold content. It is then rough-finished and sand-blasted. Polishing will only reduce the retention and should therefore be avoided.



757 Crown restoration

Left: The fit of the cast dowel-core is tested on the die.

Right: The patient did not insist on a tooth-colored veneer, thus a full cast crown is made. Placing cast crowns on endodontically treated posterior teeth increases the success rate to 97% compared with 50% for similar teeth not fitted with crowns (Sorensen and Martinoff 1984 b).



758 Cementation

Left: An adhesive conditioner is applied and the post-core is cemented with a resin-based cement. After removal of the excess resin the crown is cemented with zinc phosphate cement.

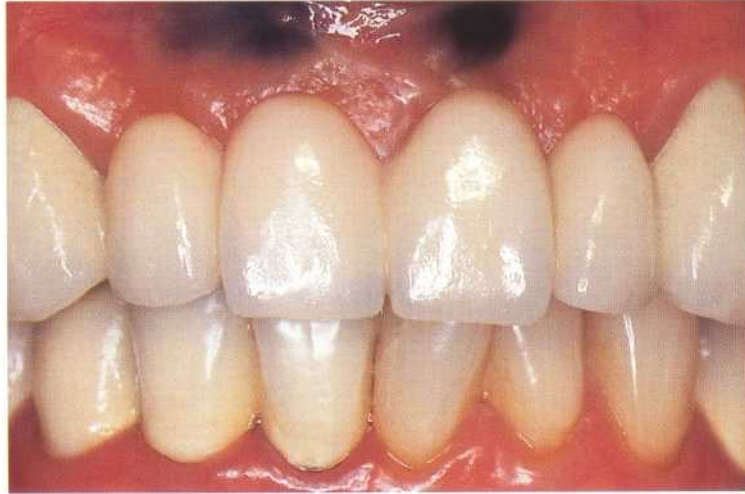Right: Two years after treatment there is no sign of periapical inflammation or loosening of the restoration.

Coronal Restorations and Treatment Results

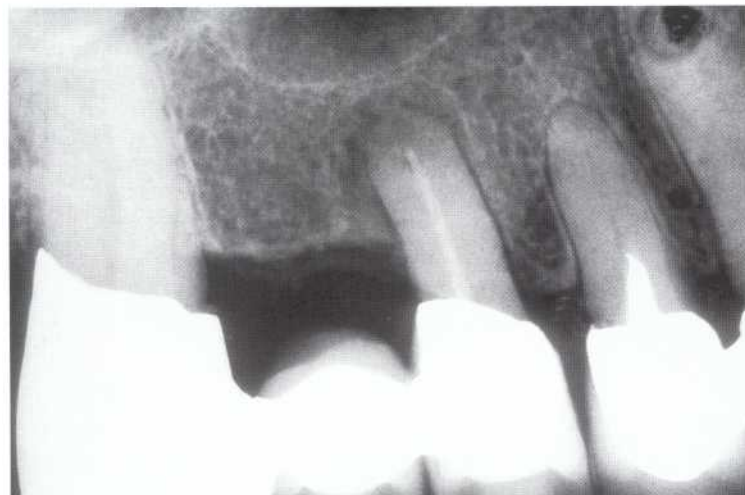How successfully a tooth functions following root canal treatment is determined to a large extent by the amount of remaining tooth structure and the final restoration. A crown that bodily encircles the cervical tooth structure increases the resistance of an endodontically treated tooth to fracture, irrespective of whether a post-core is present. A band of metal at least 1 mm wide at the margin of the crown should lie on dentin. A tooth that is extensively damaged may require surgical or orthodontic crown lengthening. If a dowel-core is also necessary, it must have strong retention. Caputo

and Standlee (1987) found the lowest retention with a smooth, tapered dowel; a parallel-sided dowel with slight indentations was better, but one with threads provided the best retention. However, the danger of a vertical fracture is greater when screw threads are cut into the sides of the canal. This places twice as much stress on the root as when the post is only cemented. The internal threads must be cut very slowly with light force and frequent reverse rotations in a moist canal (Ross et al. 1991).

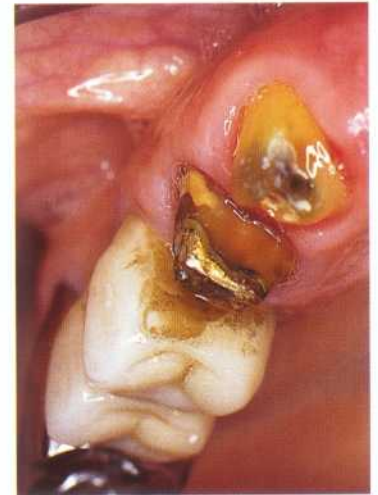759 Condition before prosthetic replacement
Clinical appearance in a 63-year-old patient before beginning new restorative treatment. The color of the existing bridge is unsatisfactory, and the pontics jut out.



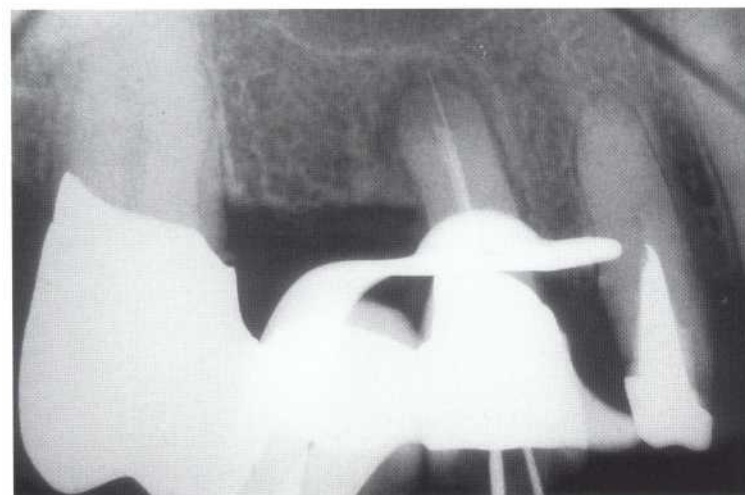
760 Radiographic diagnosis
On the radiograph the maxillary second premolar displays an inadequate root canal filling and a distinct periapical radiolucency. In the first premolar there is a short post but no root canal filling!



Right: After removal of the bridge extending from the right canine to the left canine and first premolar, the first premolar is seen to have a post-core.

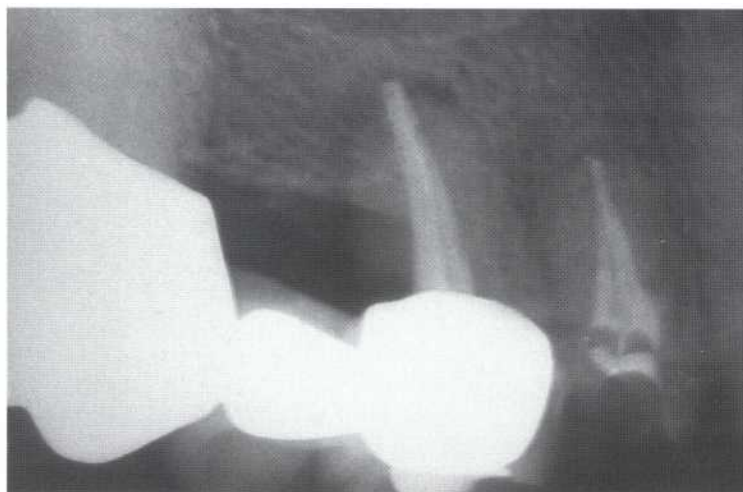
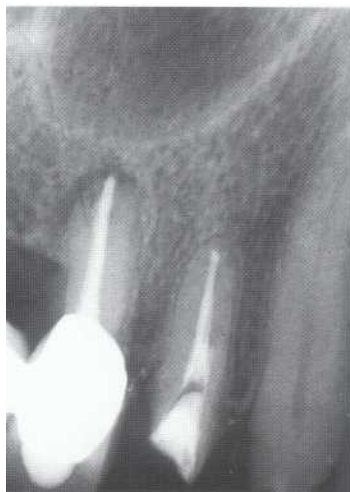
761 Retreatment of the inadequate root canal filling
The gutta-percha point is removed from the second premolar with a Hedstrom file and a solvent. The canal is reinstrumented and the working length determined. At this time a second root canal is identified and also instrumented. The canals are then filled with an interim dressing.



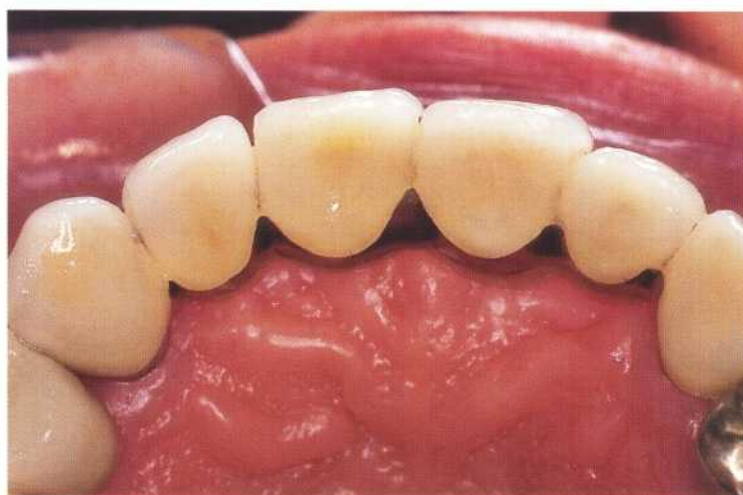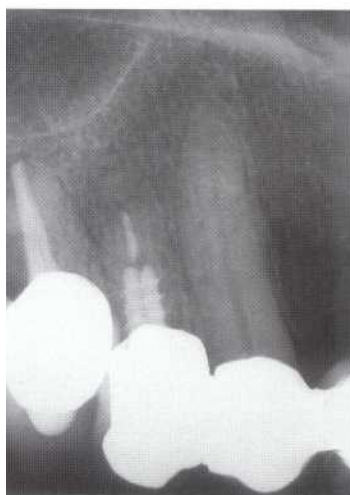The most important factor in preventing a fracture is not the design of the post but the final crown. The majority of studies on fractures of roots treated with posts were carried out with no coronal restorations in place. However, the differences between the individual post systems disappear when a crown is cemented (Gelfand et al. 1984). Sorensen and Martinoff (1984 a) showed in a clinical study that the frequency of fractures depends much less on the post than on the type of coronal restoration.

Weine et al. (1991) followed 138 teeth treated with parallel-sided posts and crowns and reported a failure rate of only 6.5% after 10 years. The quality of the coronal restoration plays an important role in the success of the overall treatment. In an evaluation of 1010 radiographs, teeth with good coronal restorations were successful in 80% of the cases, while a good root canal filling was associated with success in 75.7%. A poor coronal restoration, however, was associated with a periapical lesion in 48.6% of the cases and an inadequate root canal filling in 30.2% (Ray and Trope 1995).



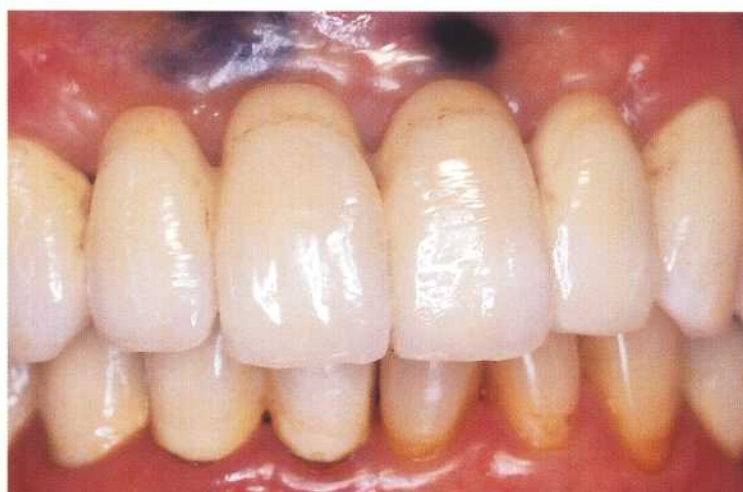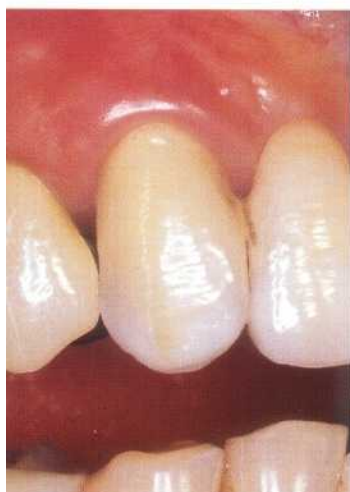762 Root canal obturation
The radiograph shows a homogeneous and well-adapted root canal filling. Because of the eccentric projection angle, the separate canals can easily be seen.

Left: On the radiograph taken with an orthoradial projection there appears to be only one root canal. The reason for this is the superimposition of the two canals.



763 Bridge fitting
With the old bridge, the upper lip would occasionally hang on the cervical edge of the pontics. The newly constructed fixed partial denture exhibits a good arch form; the upper lip appears full again and glides over the cervical margins of the pontics without interference.

Left: A follow-up radiograph 2 years after treatment shows regeneration of the periapical bone and the success of the treatment.



764 Completed restoration
The alveolar ridge is augmented labially with a subepithelial connective-tissue transplant. At the patient's request, the amalgam tattoo is left in place. The pontics are intentionally recessed slightly into the soft tissue.

Left: The teeth are bound together with a custom-milled precision attachment.

Prosthetic treatment
by G. Mayerhofer

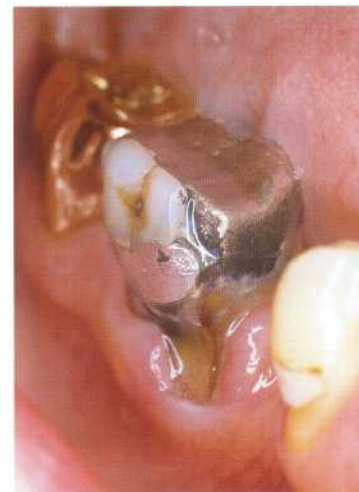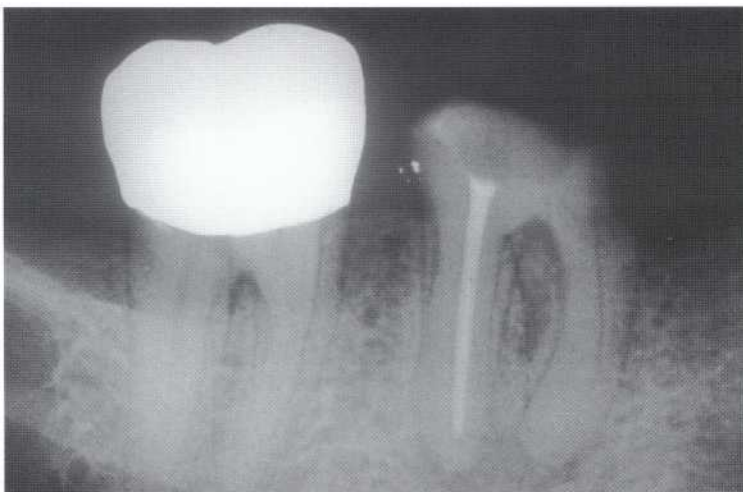Restoration of Hemisected Teeth

Through hemisection an unnecessary sacrifice of tooth structure can be avoided and the length and integrity of the dental arch maintained. Intact adjacent teeth need not then be included in the reconstruction. A prefabricated, standardized post is cemented into the root canal if there is still adequate coronal tooth structure remaining. With extensive loss of tooth structure, a cast post-core is indicated. These post buildups do not serve to reinforce the root, but only to replace lost tooth structure.

The prosthodontic reconstruction normally takes place after wound healing, and is delayed only if the prognosis is doubtful. The crown must encircle the prepared tooth. If little dentin can be encompassed the ferrule effect is reduced, causing less resistance to fracture (Milot and Stein 1992). Failures after hemisection can usually be traced back to deficiencies in the restoration. Langer et al. (1981) reported a failure rate of 38% that was frequently associated with a fracture of the tooth.

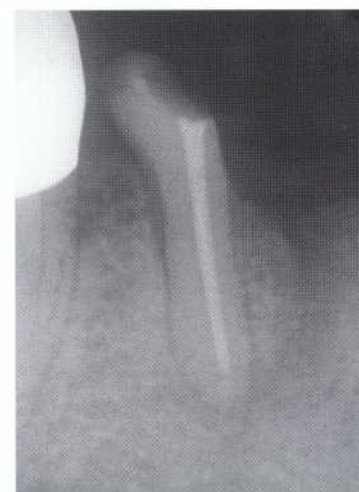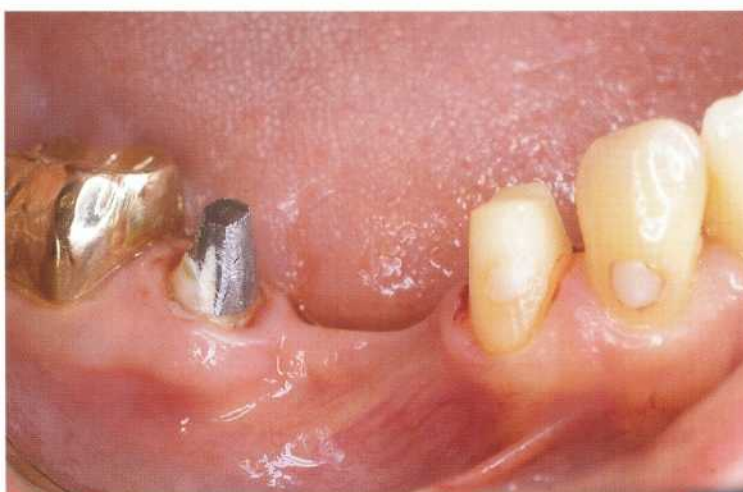765 Root canal treatment
The distal root of the mandibular first molar is endodontically treated before the hemisection. The mesial root canals are obliterated and their orifices cannot be found.

Right: The tooth has been treated with an amalgam filling and reveals a wedge-shaped cervical defect that presumably led to exposure of the mesiobuccal portion of the pulp.

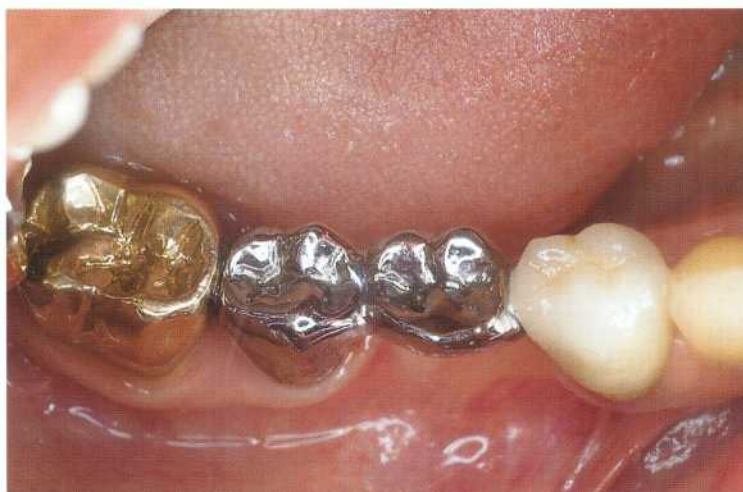

766 Hemisection
The tooth is separated through the half that is to be removed. The mesial root is then luxated and extracted. After the wound has healed, a prefabricated post is cemented into the distal root canal. The core buildup and the first premolar are prepared for a fixed partial denture and an impression is made.

Right: A radiograph taken after the hemisection and before insertion of the post and core.



767 Reconstruction
The bridge is cemented with zinc phosphate cement and the occlusion is adjusted. Due to financial considerations, the second molar is not included in the reconstruction. The dentin of the treated root is completely encircled by the crown to provide maximum resistance to fracture.



Bleaching of Teeth

Discolorations of the crowns of endodontically treated teeth and even vital anterior teeth present an esthetic problem. The *cause of tooth discoloration* can be a delayed reaction to trauma with rupture of blood vessels, or remnants of necrotic pulp tissue or root canal filling material in the coronal pulp chamber. Discolorations can also be brought about by filling materials, medications, and external influences. If a root canal filling is not removed to a level at or below the cemento-enamel junction, ingredients of root canal filling pastes and metallic salts from silver points can penetrate along the coronally curving dentinal tubules to discolor the clinical crown. Inadequate root canal fillings must be replaced before the beginning of the tooth-bleaching procedure. Bleaching is a noninvasive method of lightening a tooth's color without resorting to prosthodontic treatment (Beer 1995).

Concerning the prognosis of the bleaching procedure, Brown (1965) reported relapse (i. e., renewed darkening of the tooth) in 25% of cases observed over a period of 5 years. One of the causes was leakage around fillings that permitted penetration of stains or recolonization of the cavity by bacteria. The risk of relapse also seemed to depend on the extent of the original discoloration and the rapidity with which the discoloration appeared. Over a period of 8 years Friedman et al. (1988) found the color stability to be good in more than half of the bleached teeth they followed, and still acceptable in 29%.

Relapse does occur after the crowns of endodontically treated teeth have been bleached, but now the cases requiring subsequent restorative treatment can be reduced to half the number originally considered necessary. Pre-eruptive deposits of tetracycline respond well for a short time to a combined bleaching procedure, but the result does not always last. Relapse often occurs quite soon so that repeated bleaching becomes necessary after 1 year. Presumably the deposits of stain reoccur in the tooth, or the opaque effect decreases with remineralization of the enamel surface and allows the deeper-lying discoloration to show through the enamel once more (Walton et al. 1982).

External root resorption can occur over a long period of time following tooth bleaching. Harrington and Natkin (1979) described seven cases in which teeth bleached with hydrogen peroxide activated by a heat source experienced root resorption 2-7 years later. Lado et al. (1983) postulated that dentin was denatured by the bleaching. In all the cases reported, however, resorption was preceded by trauma. Covering the root canal filling with a layer of cement approximately 2 mm thick at a level 1 mm below the cemento-enamel junction should impede the penetration of the dentinal tubules by hydrogen peroxide. It is assumed that the bleaching agent diffuses from the cavity through defects in the cement within the root, through the dentinal tubules, and into the periodontal tissue where it can initiate an inflammatory reaction by altering the

In two studies conducted independently of one another, it was observed that with the application of a mixture of sodium perborate and hydrogen peroxide the pH value was reduced after 4-11 days to 6.5 in one instance, and increased to 8.3 in the other. When calcium hydroxide was placed in the cavity after the last bleaching, the pH was neutral at 7.2 within 4-10 days (Fuss et al. 1982, Kehoe 1987).

Causes of Tooth Discoloration

Bacterial, mechanical, and chemical irritations can lead to necrosis of the pulp. Decomposition products penetrate the dentinal tubules and stain the surrounding dentin. This discoloration can be removed by internal bleaching. Intrapulpal hemorrhage with lysis of erythrocytes can occur following traumatic injury.

Disintegration products such as iron sulfide penetrate the dentinal tubules in these cases. If the pulp tissue does not become necrotic the tooth discoloration will fade. Remaining discolorations can be lightened by internal bleaching (Freccia et al. 1982).

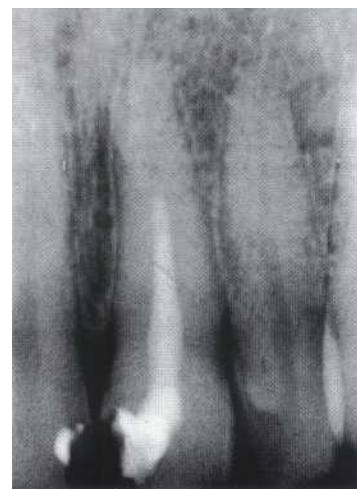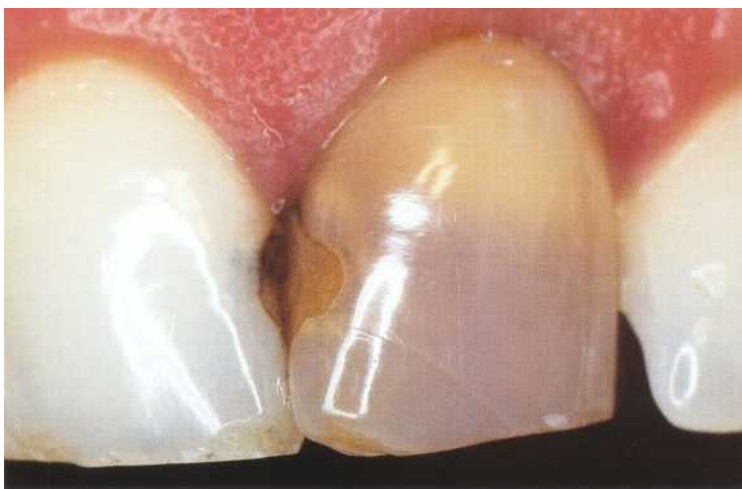Traumatic injuries lead to destruction of blood vessels and odontoblasts and this can stimulate the formation of large amounts of tertiary dentin, causing obliteration of the root canal. These crowns slowly lose their translucency and may assume a yellowish-brown color. In these cases, bleaching must be preceded by root canal treatment (Jacobsen and Kerkes 1977).

Discolorations can also arise through the incorporation of substances during tooth development. The best known of these are tetracycline and fluoride discolorations that can be bleached externally (Arens et al. 1972).

768 Crown discoloration

The maxillary central incisor is severely discolored and has a defective composite filling. It no longer responds to a sensitivity test.

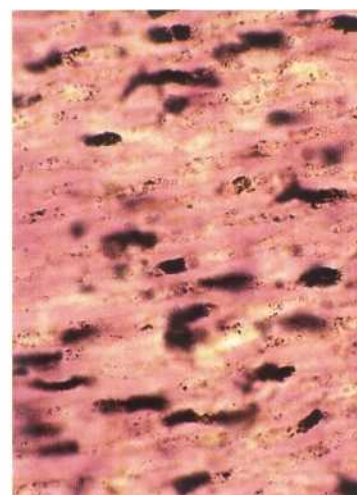

Right: The radiograph shows an inadequate root canal filling that is too short apically but extends into the coronal access cavity, rather than being cut off beyond the canal orifice.



769 Stain deposits

A section through the enamel surface under polarized light shows fracture lines and a broad area of incipient caries. These are contraindications to vital bleaching.

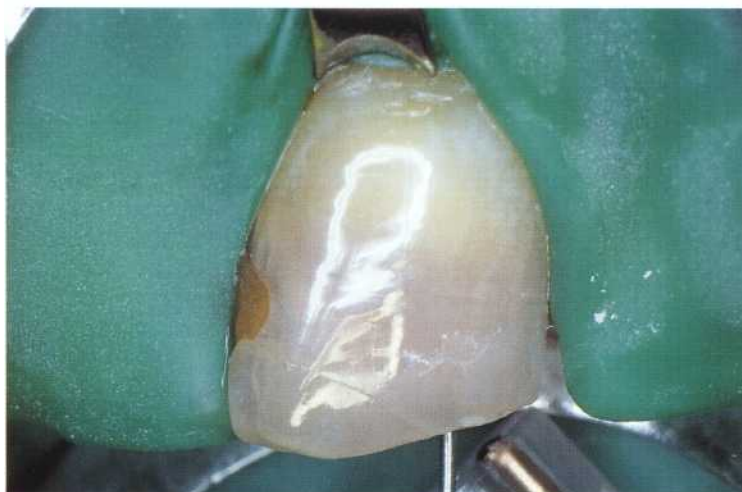
Right: Under the optical microscope, remnants of root canal filling material can be seen in the dentinal tubules. This causes the type of discoloration seen in the case shown above.



770 Retreatment

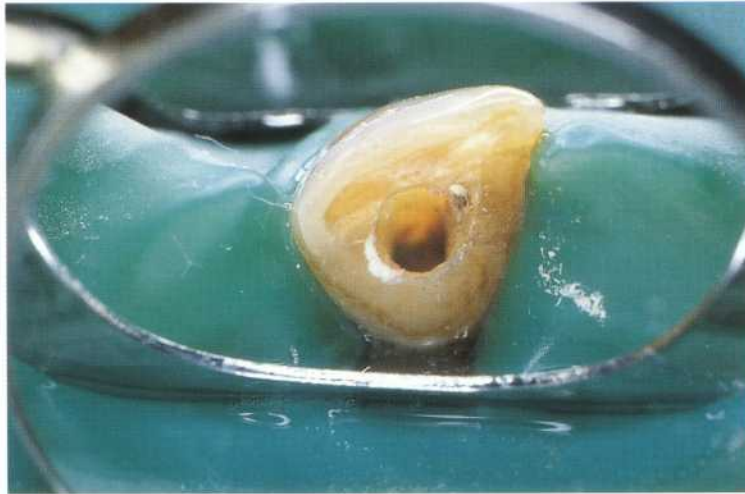The root canal filling is removed under a rubber dam and the canal is instrumented, irrigated, and filled with a calcium hydroxide interim dressing. Ten days later the canal is obturated.

Right: Radiograph of the root canal filling, removed to a level 2 mm beyond the entrance to the root canal and then covered with a cement base.

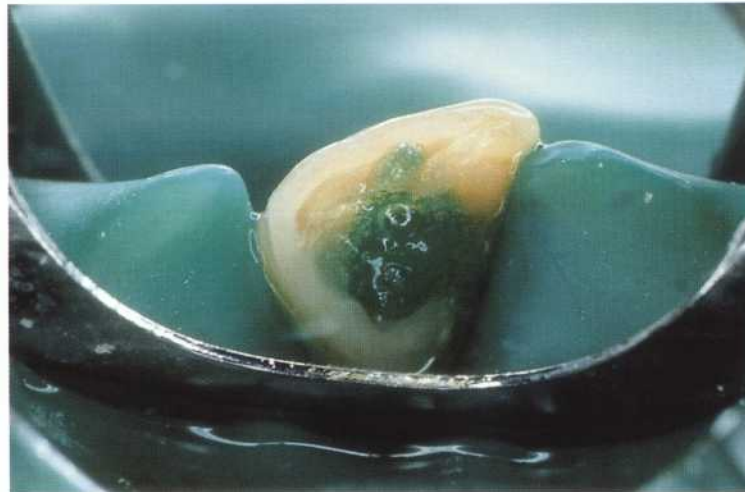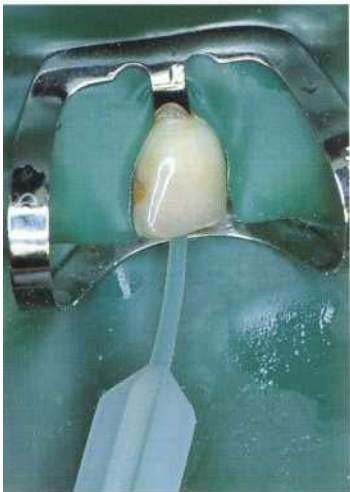


In addition to natural causes, tooth discoloration can also have *iatrogenic causes*. Root canal filling material is the most frequent and important cause of tooth discoloration. Filling material left in the cavity results in a gray-to-black discoloration of the tooth crown. This can be lightened using the internal "walking bleach" method, alone or combined with external bleaching. The prognosis for the bleaching effect depends on the composition of the sealer: metal components are difficult to remove and retreatment is often necessary after the bleaching procedure (Burgt and Plasschaert 1986).

Remnants of necrotic pulp tissue in the coronal cavity produce little discoloration but are easy to remove and bleach. Medications introduced into the canal such as phenol or iodoform pastes can produce various degrees of discoloration after long contact with dentin (Boksman et al. 1983). Poorly sealed composite fillings are penetrated by stains and bacteria. Placement of a lingual amalgam filling can result in a gray discoloration of the crown that is difficult to bleach.

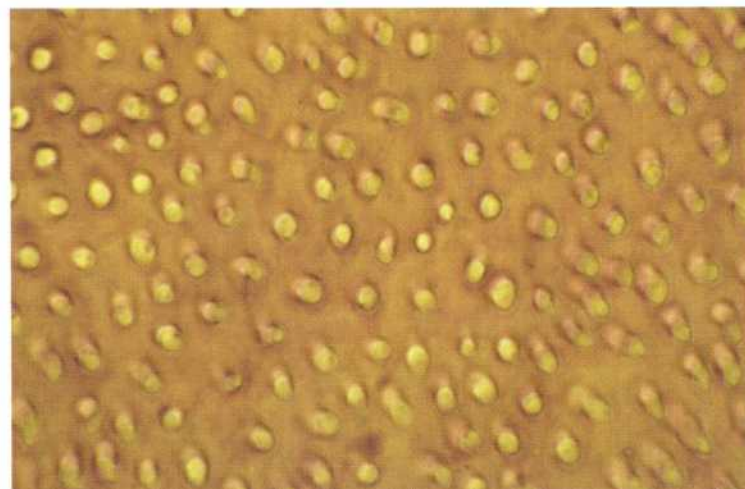


771 Stain deposits
The view into the opened cavity reveals the deposits of staining material that must be removed by the bleaching process. The smear layer on the dentinal surface blocks entrance to the dentinal tubules and must be removed before bleaching is attempted.



772 Etching the cavity
A phosphoric acid gel is placed in the cavity for 10-20 seconds and then washed out with a water spray for 30 seconds.

Left: A syringe can be used to apply the etching gel in a controlled manner.




773 Dentinal tubules
After the dentin in the cavity is etched, the dentinal tubules are wide open and the bleaching agent can penetrate them unimpeded. However, because of the danger of causing external root resorption, the etching agent must be used with restraint and its use limited to severely discolored teeth.

Thermocatalytic Bleaching

The thermocatalytic method uses hydrogen peroxide solution placed on gauze strips stretched over the tooth surfaces. This is warmed by means of a special lamp or a thermostatically controlled heating wand with the temperature never exceeding 55 °C (130 °F). A brief etching of the surface with phosphoric acid is recommended before vital bleaching. Professional tooth cleaning will remove the pellicle and superficial stains (Spasser 1961, Nutting and Poe 1967). The enamel is cleaned, the gingiva is coated with Vaseline to prevent irritation of its surface, and an extra heavy rubber dam

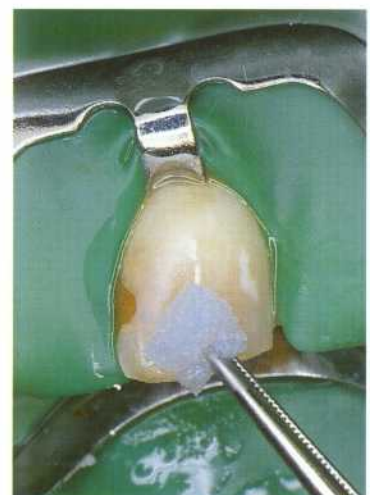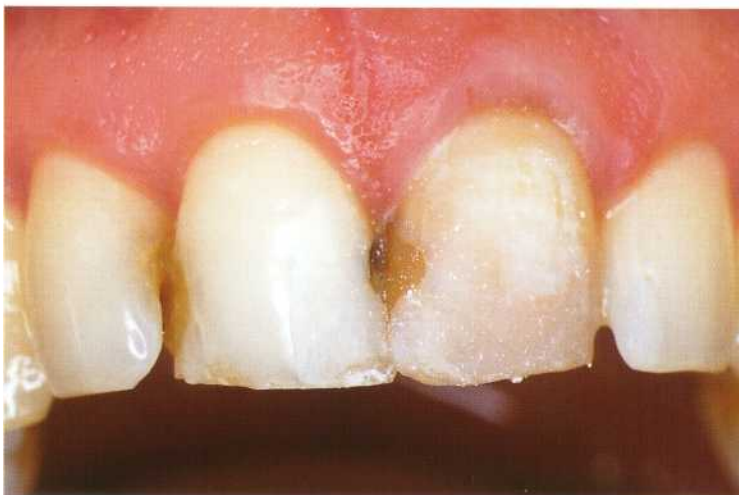is applied. When the discoloration is severe or the stain is especially stubborn, the entire enamel surface is etched for 10 seconds. Cotton pellets are pulled apart and loosely stretched over the tooth surface. Next, they are moistened with a few drops of 30% hydrogen peroxide and warmed with a special heating wand (Touch'n Heat) for 2 minutes. Fresh solution is then applied and the bleaching procedure is repeated about three to five times.

774 Bleaching solution
Thirty percent hydrogen peroxide solution is dropped onto the surface of the tooth and warmed for 2 minutes with a special heating element (Touch'n Heat, Analytic Technology).



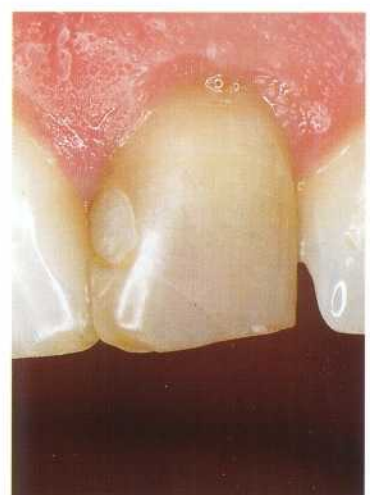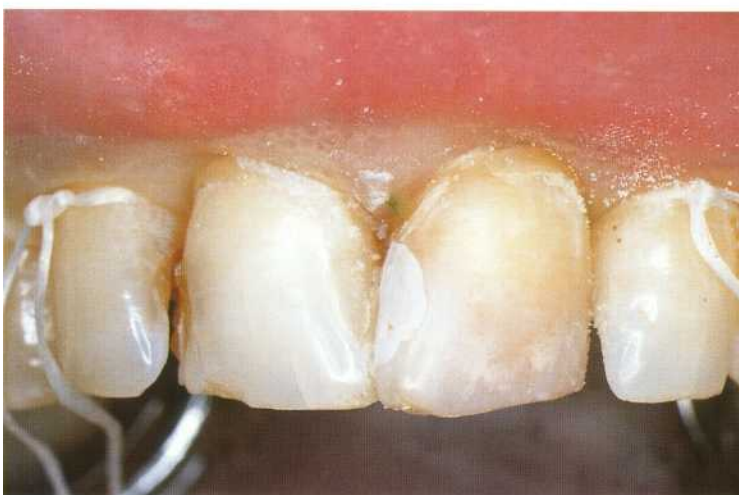Right: The patient's head is covered with a surgical drape. The bleaching agent must be changed several times and the bleaching procedure can be repeated three to five times. Then, all traces of bleach must be thoroughly rinsed away.

775 Lightening of the shade
A noticeable whitening is seen already after the first bleaching procedure. The bleaching can be repeated several times until the tooth assumes the same shade as its neighbors.



Right: Following bleaching, a fluoride preparation is applied to promote remineralization.

776 Filling replacement
Before the crown of the tooth is bleached further, the old composite filling is removed and replaced temporarily with a glass ionomer filling.

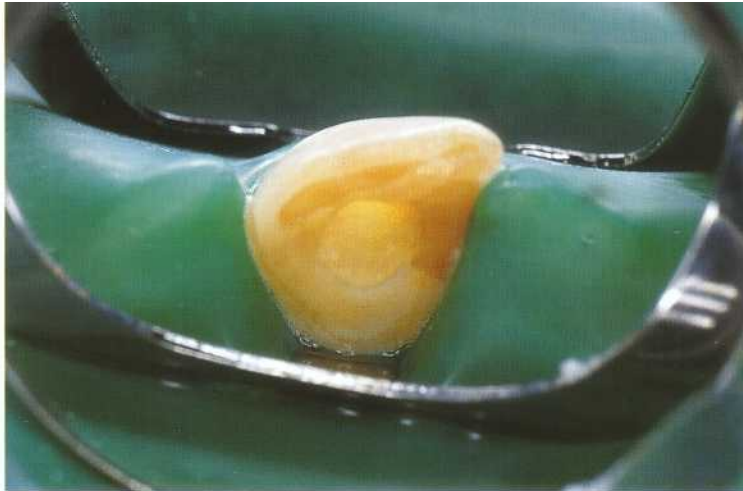

Right: After being bleached five times, the tooth has become much lighter in color. Through a combination of other bleaching techniques the color can be brightened even further.

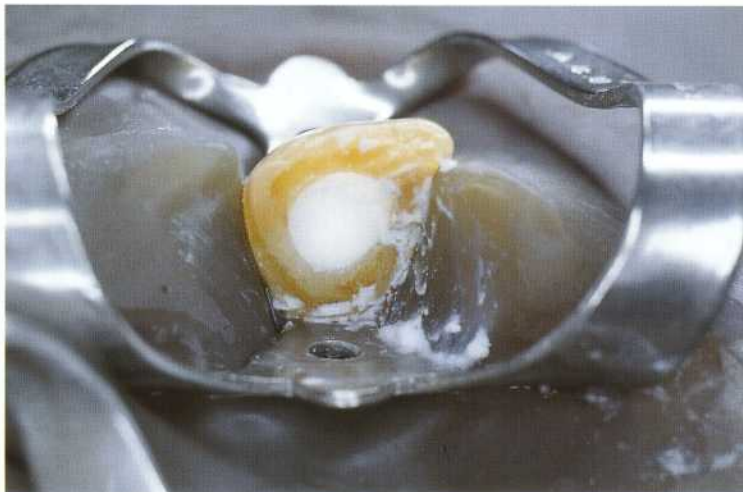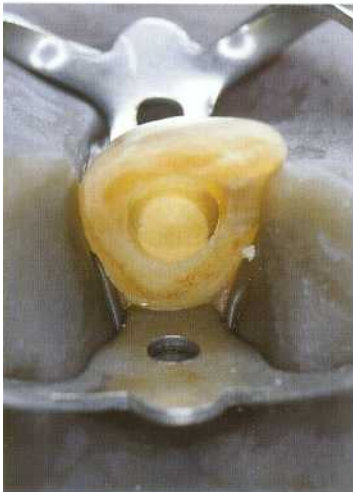Walking Bleach Technique

This bleaching method is indicated only for endodontically treated teeth. Any inadequate root canal fillings must be removed, replaced, and covered by a 2-mm-thick layer of glass ionomer cement. Next, a mixture of hydrogen peroxide and sodium perborate is placed in the cavity and the excess moisture is removed with paper points. The walking bleach mixture is covered with Cavit or glass ionomer cement and changed in 2-7-day intervals. Finally, Calxyl is inserted and covered with Cavit. In a study by Ho and Goerig (1989) it was found that the effect of the bleaching

agent diminished with time, even with appropriate placement. A mixture of fresh sodium perborate and fresh hydrogen peroxide lightened the tooth in 93% of the cases, whereas fresh sodium perborate mixed with hydrogen peroxide that had been stored for 1 year effectively bleached 73% of the teeth. Sodium perborate mixed with water bleached only 55% of the discolored tooth crowns. Caution must be used with this method of bleaching because of the possibility of external resorption (Cvek and Lindvall 1985).

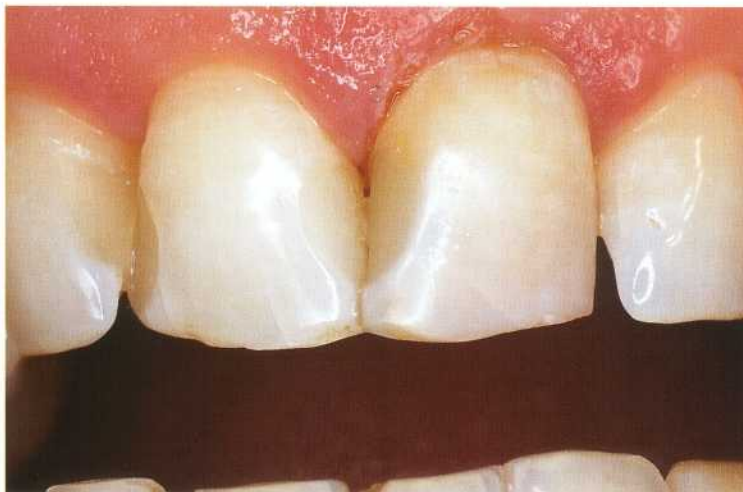
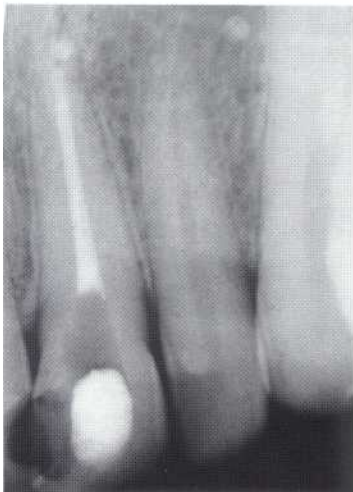
777 Walking bleach paste
The mixture of sodium perborate and hydrogen peroxide is carried to the cavity, the excess liquid removed with a cotton pellet, and the bleaching agent compressed. The bleaching agent is then covered with Cavit and left in the cavity for 2-7 days.



778 Calcium hydroxide
After the last bleaching treatment, calcium hydroxide is inserted. Bleaching agents cause a reduction in the adhesion of composite filling materials, but after storage of test teeth in water for 7 days, the adhesive strength is again restored to that of untreated, acid-etched enamel (Torneck et al. 1991).

Left: A view into the cavity showing the cement base. The color is already significantly lighter.



779 Composite filling
After treatment with the interim dressing, the cavity is cleaned, irrigated, and dried. Next, the temporary filling is removed, the cavity etched, and a bonding agent applied. Then the cavity is filled with a composite material corresponding in shade to that of the bleached tooth.

Left: The radiograph taken before placement of the final composite restoration shows no signs of external resorption.

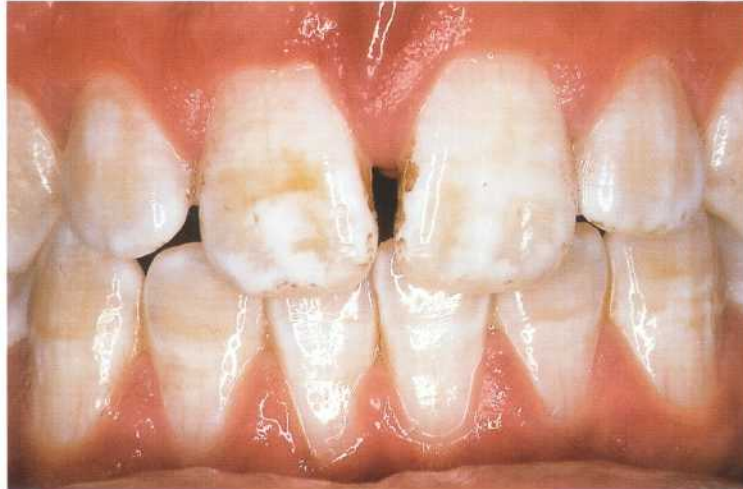Microabrasion Method

Croll (1989 a, b, 1993) used an abrasive slurry composed of 18% hydrochloric acid, carborundum, and silica gel (Prema). During microabrasion of the enamel, up to 75 μm of the surface is polished away. Following this a definite smoothing of the surface can be seen microscopically. Microabrasion erodes the enamel and wipes out smaller surface discrepancies. Thin sections of enamel that had been treated 20 times showed a noticeably denser surface layer when viewed under the light microscope. The abrasion process seems to produce a more thoroughly mineralized sur-

face layer. This reduces the reflection of light and changes the refraction and dispersion of incident light rays. In this way, even deep-lying tooth stains can be masked (Croll 1992). A stable, long-term improvement in superficial defects of mineralization can be achieved by this treatment with the microabraded surface taking on a smooth, glass-like appearance. The microabrasion procedure can also be used to smooth the enamel for the purpose of caries prophylaxis (Donly et al. 1992).

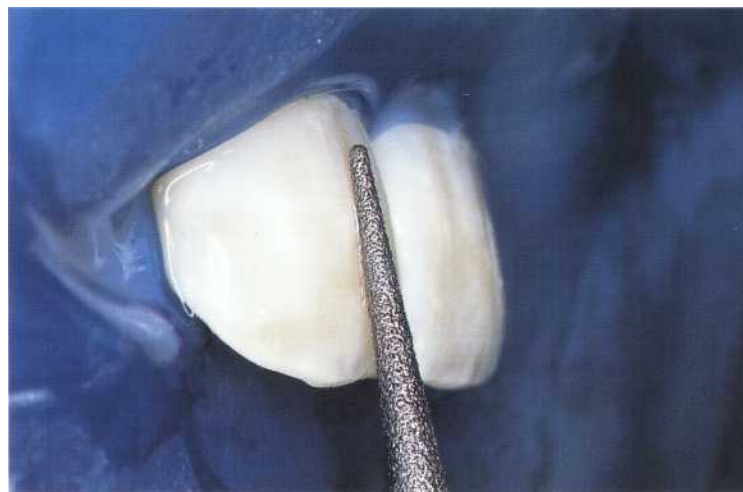780 Fluorosis

The teeth of a 15-year-old girl are all heavily discolored due to excessive exposure to fluoride. White and brown discolorations and pronounced roughness in the enamel surfaces can be observed.



781 Smoothing the enamel

A rubber dam is placed before the microabrasion treatment is begun. The enamel surfaces are then carefully smoothed with a fine-finishing diamond stone.



Right: A microabrasion set consisting of Prema abrasion paste, a mandrel with stiff rubber cylinders, and a hand-held applicator.

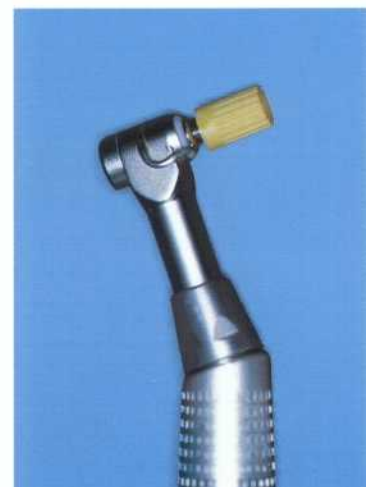

782 Microabrasion

With the patient's eyes protected by eyeglasses, the microabrasion paste is picked up with the end of a rubber cylinder, mounted on a special mandrel, and spread evenly over the tooth.

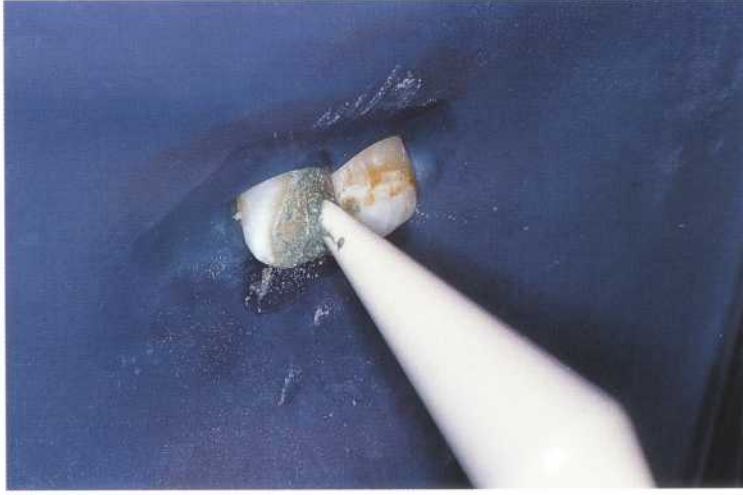

Right: The mandrel is used in a contra-angle handpiece with a 10:1 gear reduction.



If developmental tooth defects are combined with the discoloration, they can be filled with composite material following microabrasion. A combination treatment with nightguard vital bleaching is also a possibility. Before the treatment is started it is important to place a rubber dam and seal its margins to prevent penetration of the acid-abrasive mixture. Exposure of the gingiva to Prema for 15 seconds proved to be harmless, but exposure for 30 seconds produced ulceration of the tissue with complete healing occurring after 7 days (Croll 1993).

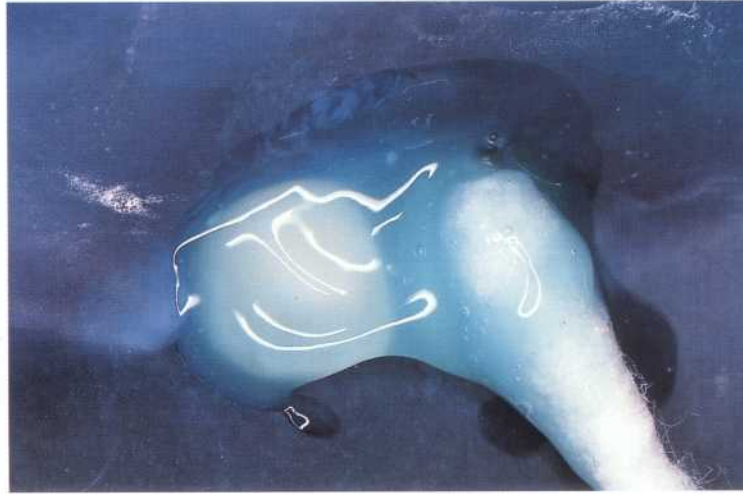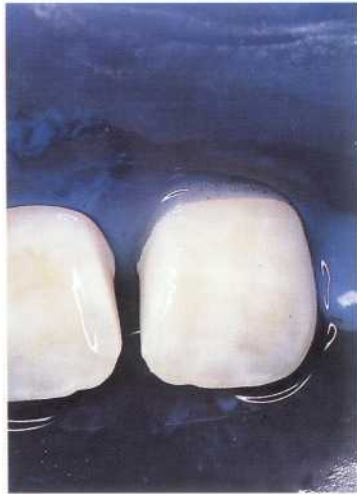A stiff rubber cup picks up the microabrasion mixture and, turning at low speed (10:1 gear reduction), is used to abrade the surface for 7-10 minutes. The outer side of the rubber cylinder has ridges and is used to apply pressure, and the concave end is used to distribute the Prema over the surface of the tooth. The paste can also be applied to heavier stains with a hand applicator. Next, the tooth is polished with prophylaxis paste and the residue is thoroughly removed with water spray. Finally, a fluoride solution is applied for 4 minutes before the rubber dam is removed.



783 Microabrasion

The tip of the hand applicator, which must be shaped with a bur to fit the individual situation, is used to spread the abrasive paste over the tooth and to rub it into the surface irregularities.

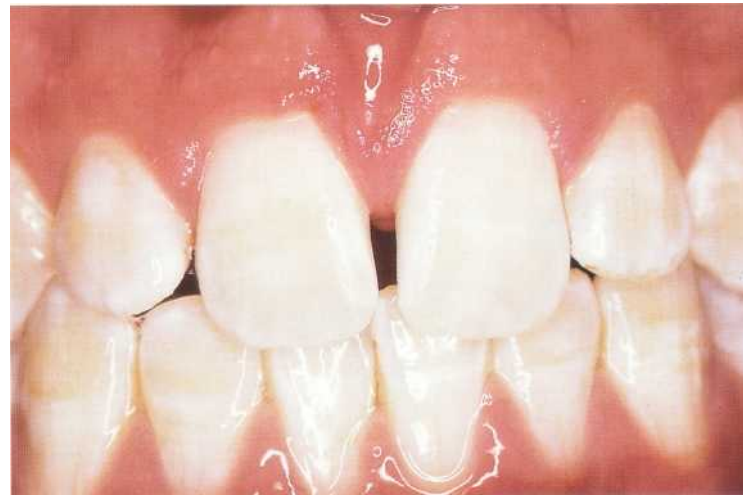Left: Under light pressure, the side of the rotating rubber cylinder is used for 7-10 minutes to abrade the surface.



784 Fluoride treatment

After the abrasion is completed, the teeth are rinsed, polished with a fluoridated prophylaxis paste on a rubber cup, and thoroughly rinsed again with a water spray. Thereafter, a fluoride gel is applied and allowed to work for 4 minutes.

Left: Immediately after microabrasion the enamel discoloration is only barely visible.



785 Clinical evaluation

After microabrasion of all the teeth their color is much lighter and the mineralization defects and malformations are masked. The tooth surfaces are also noticeably smoother.

Treatment by T. P. Croll

Nightguard Vital Bleaching

Carbamide peroxide solution, which corresponds to a 3% hydrogen peroxide and 7% urea solution, is used to bleach individual teeth or entire groups of teeth. A 6% or 10% carbamide peroxide gel is also recommended. This uses a resin polymer of high molecular weight to increase the viscosity and reduce diffusion during the night. Depending upon the cooperation of the patient, the whitening of the teeth begins after 2-3 weeks and is completed after 5-6 weeks (Haywood 1992).

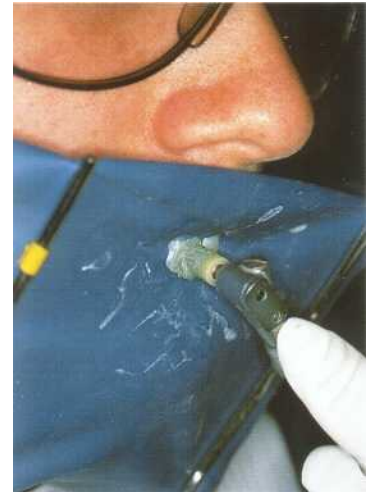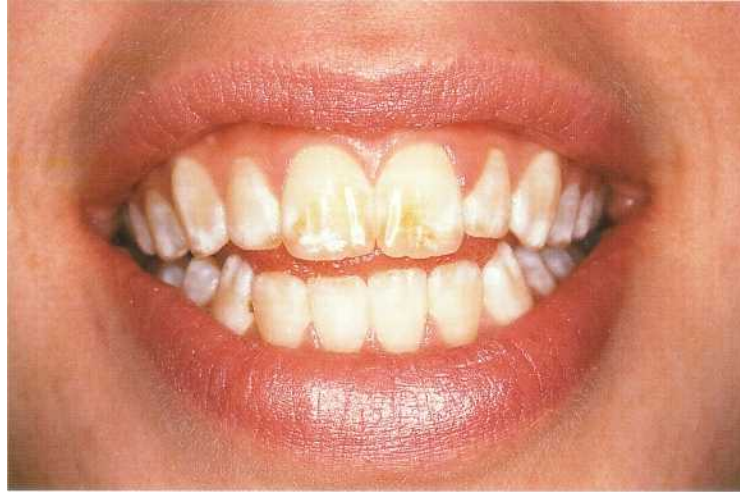This home bleaching technique is indicated for external stains such as coffee, tea, or tobacco. Internal

discolorations can also be treated by using this method in combination with other bleaching techniques. Bleaching may even be desirable for age-related changes in tooth color. Because the bleaching solution is allowed to work all night, questions naturally arise concerning its biological safety and possible damage to the marginal gingiva. Woolverton et al. (1991) demonstrated that the solution is not mutagenic and elicits only a slight toxic reaction from isolated cells.

786 Microabrasion

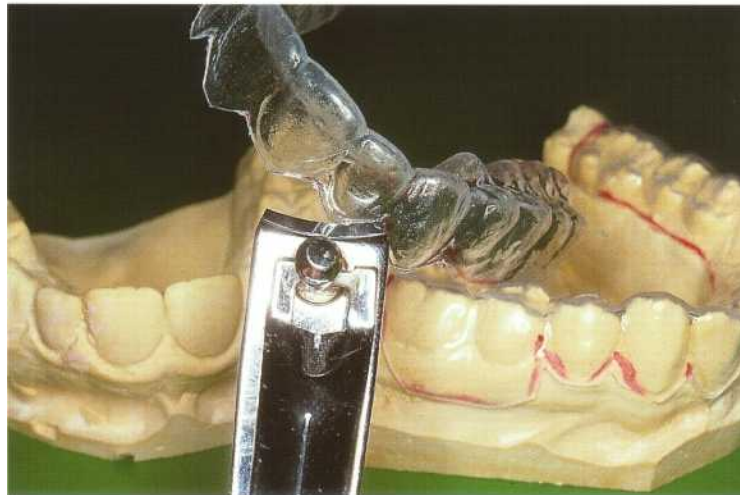A young female patient with generalized brown and white mineralization defects. The patient was especially unhappy with the appearance of the maxillary anterior teeth.

Right: Because the discoloration is located deeper within the enamel, the teeth are microabraded before attempting bleaching with a mouthpiece.



787 Fabrication of the mouthpiece

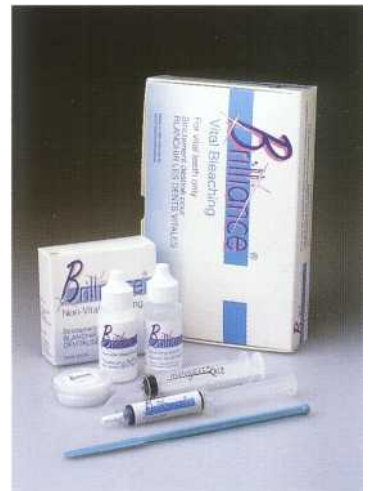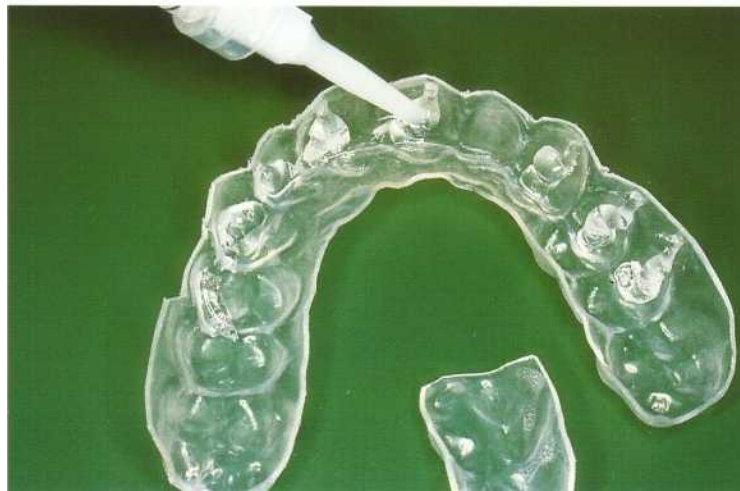A stone cast is made from an impression, and on this a mouthpiece is vacuum-formed. The margins of the mouthpiece are then smoothed.



788 Bleaching gel

The bleaching gel is placed into the mouthpiece by the patient. It is important that the gel is placed only in the regions to be bleached and that it is applied sparingly. If the mouthpiece is to be worn all day, the gel should be changed every 2-3 hours.

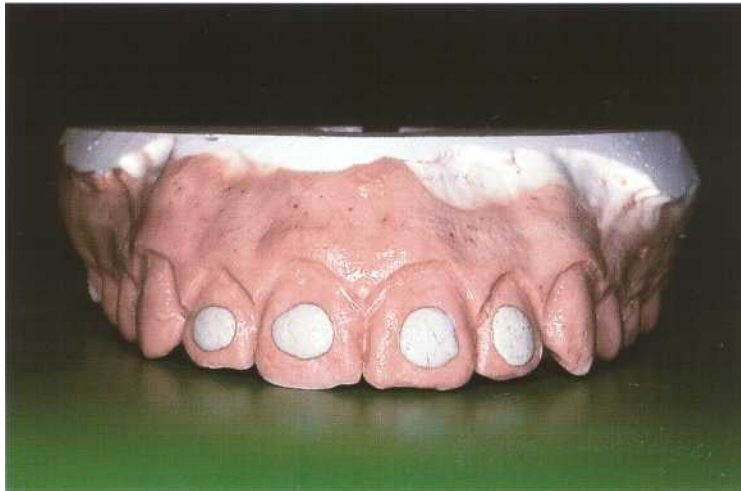Right: There are a number of vital bleaching agents, besides carbamide bleaching gel, that can be used either in a similar manner or as a tooth cream without a tray.



Before bleaching, the teeth are cleaned and a stone cast is made from an alginate impression. On the cast, resin spacers are placed on the labial surfaces of the teeth that are to be bleached. These are brought no closer than 0.5 mm to the gingival margins to prevent irritation. A thin, soft mouthpiece is then vacuum-formed over the cast. At the following appointment the mouthpiece is first tried and the patient is instructed how to wear it. After evening toothbrushing the patient places a small amount of the gel inside the mouthpiece, seats it slowly over the teeth, and removes the excess

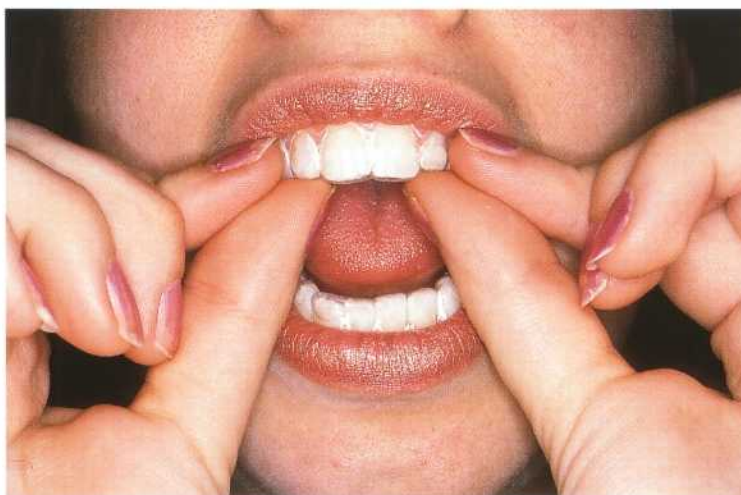
gel with a cotton swab or a toothbrush. If the mouthpiece is worn only at night, treatment may require 4-6 weeks. If the bleaching tray is also worn all day and the solution or gel is changed every 2-3 hours, maximum whitening can be achieved in only 7-10 days.

In a study by Haywood (1991) a success rate of 91 % is reported for this bleaching method. In 66% of the test subjects, slight gingival irritation appeared and it was necessary to interrupt treatment for 1-2 days (Haywood et al. 1992).



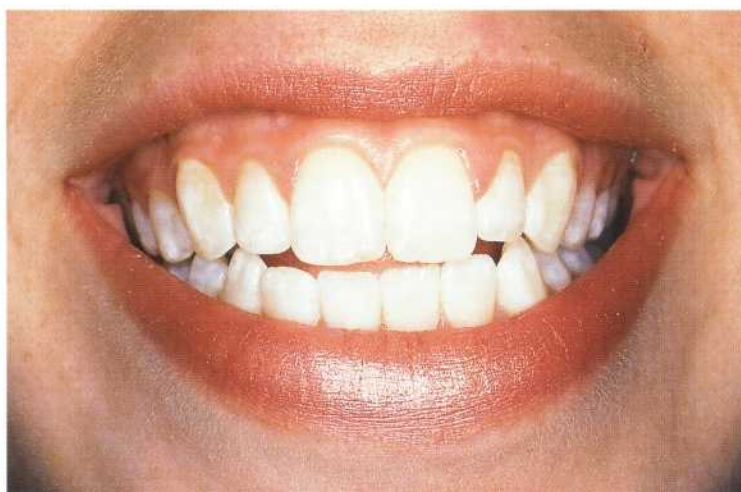
789 Gel spacers

Spacers are placed on the casts of the teeth to be bleached to create spaces for the bleaching gel. The spacers should be placed no closer than 0.5 mm from the gingiva so that the gel will not irritate the mucosa. If the gingivae do become inflamed, bleaching should be interrupted for 2 days.



790 Insertion

After the mouthpiece is lined with bleaching gel it is slipped over the teeth to be bleached with gentle, uniform pressure. Any overflowing gel is then removed with a cotton swab or a toothbrush.



791 Duration of treatment

The teeth are significantly lighter after 3 weeks of combined treatment. The mouthpiece is worn day and night. The clinical photograph shows the persisting results 8 months after completion of treatment.

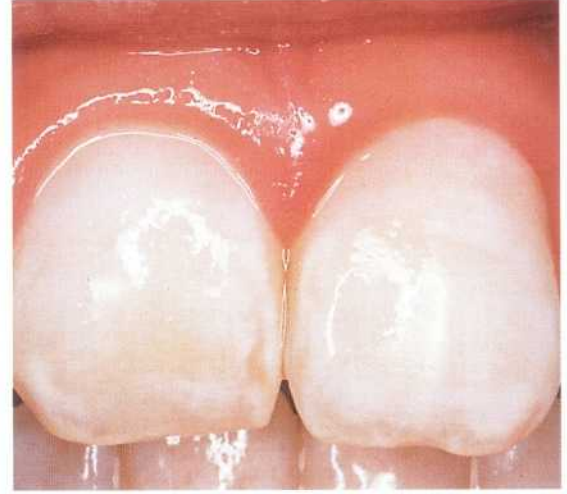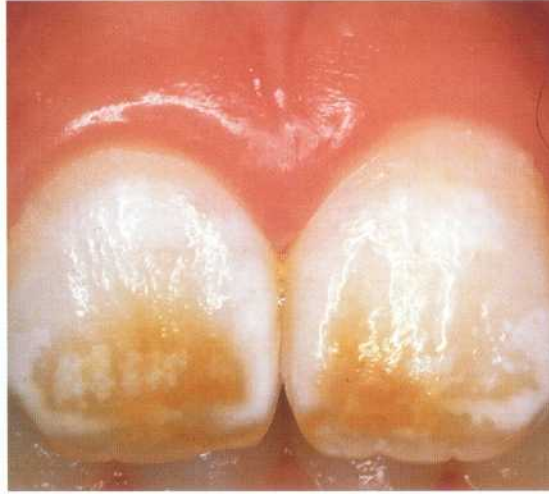Treatment by T. P. Croll

292 Bleaching of Teeth

792 Clinical results

Left: Severe discoloration and superficial enamel defects as a result of multiple fluoride applications in an 11-year-old child. The two central incisors were microabraded and then further bleached with carbamide peroxide gel for 21 days.

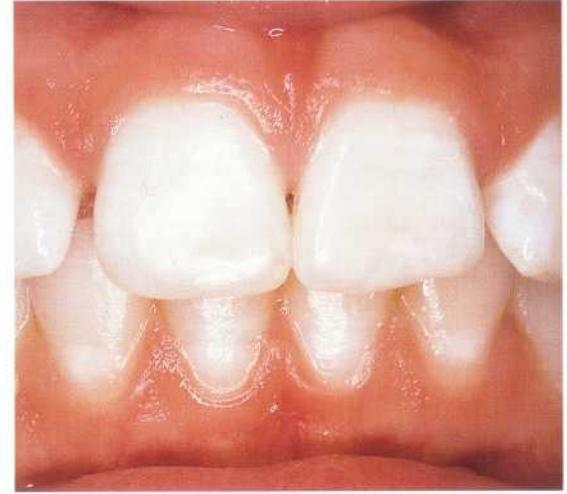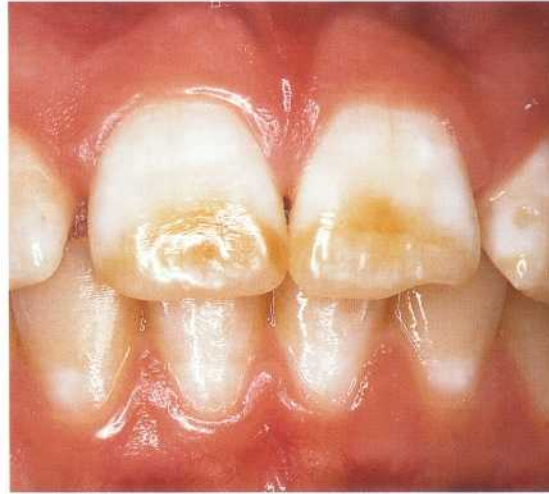Right: One year after treatment the two teeth no longer exhibit the brownish discoloration.



793 Clinical results

Left: The upper central incisors of this 13-year-old girl were not as severely discolored as in the previous case. They were also bleached by the combined techniques.

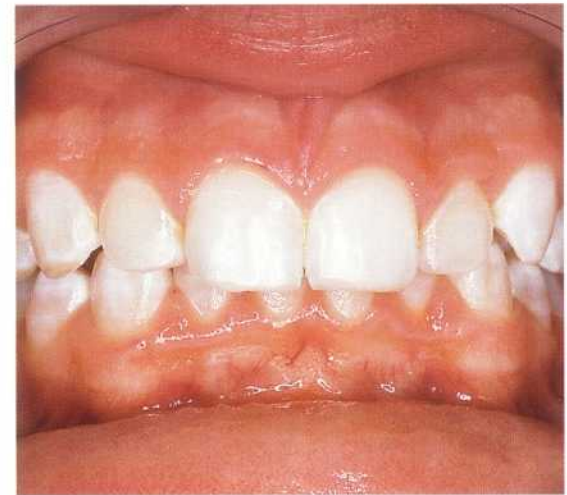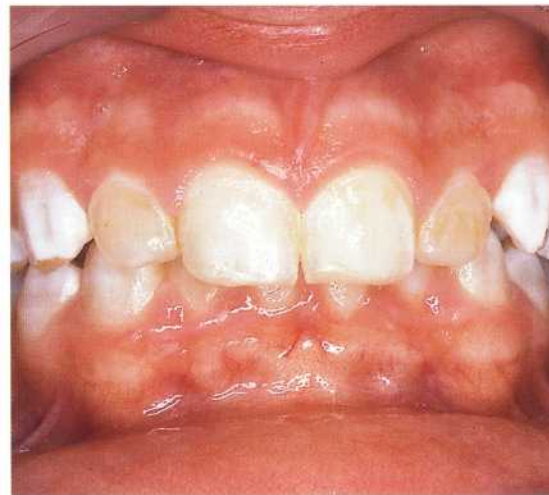Right: Six months after treatment the discoloration is still gone and the teeth are clearly whiter.



794 Treatment relapse

Left: Three years before this photograph was taken, the four maxillary incisors were treated by microabrasion because the patient had generalized white demineralization. The teeth subsequently assumed a light yellow coloration.

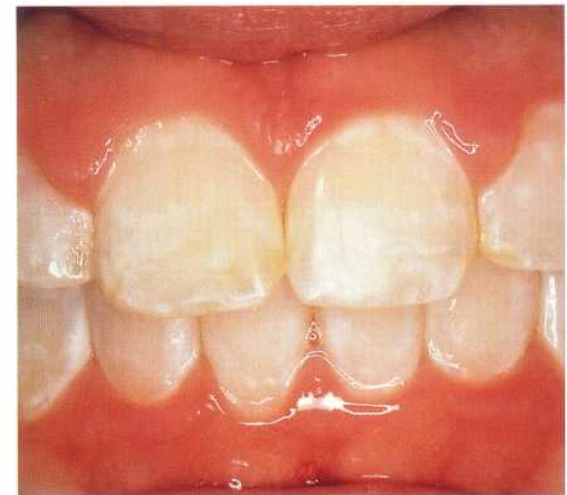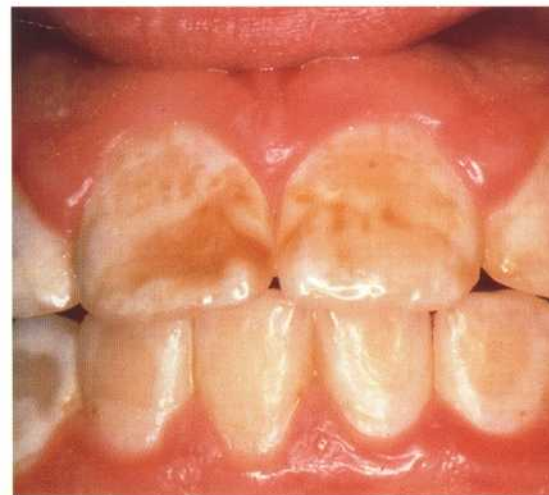Right: Six months after a 21-day-long vital bleaching procedure with carbamide peroxide, all the maxillary teeth are harmonious in color.



795 Partial success

Left: Severe defective mineralization of the enamel with brown and white spots in a 14-year-old girl.

Right: Fifteen months after microabrasion followed by the night-guard vital bleach method and improved oral hygiene, the teeth appear lighter and the brown discolorations are gone.



Treatment by T. P. Croll

References

The flood of new literature in the field of endodontics is continuously increasing. For the dental practitioner, and even for the specialist, it is hardly possible to survey it all. The authors have attempted to document as thoroughly as possible the originators of the clinical and scientific innovations described in the text. The

list below makes no pretext of being all-inclusive, however. There are not only many historical works but also newer publications that remain unmentioned. A comprehensive list of references will gladly be made available by the authors upon request.

A

- Abou-Bass, M., Frank, A. L., Glick, D. H.: The anticurvature filing method to prepare the curved root canal. *J. Am. Dent. Assoc.* 101: 792, 1980.
- Abou-Rass, M.: The elimination of tetracycline discoloration by intentional endodontics and internal bleaching. *J. Endodont.* 8: 101, 1982.
- Abou-Rass, M., Piccinino, M.: The effectiveness of four clinical irrigation methods on the removal of root canal debris. *Oral Surg.* 54: 323, 1982.
- Abou-Rass, M.: Cracked lines: the precursors of tooth fractures-their diagnosis and treatment. *Quintessence Int.* 14: 437, 1983.
- Adloff, P.: Das Durchsichtigmachen von Zahnen and unsere Wurzel-füllungsmethoden. *Dtsch. Monatsschr. Zahnheilkd.* 31: 445, 1913.
- Alhadainy, H. A.: Root perforations. A review of literature. *Oral. Surg.* 78: 368, 1994.
- Akpata, II Blechman, H.: Bacterial invasion of pulpal dentinal wall in vitro. *J. Dent. Res.* 61: 435, 1982.
- Aktener, B.O., Bilkay, U.: Smear layer removal with different concentrations of EDTA-ethylebamine mixtures. *J. Endodont.* 19: 228, 1993.
- Al-Nazhan, S., Andreasen, J.O., Al-Bawardi, S., Al-Rouq, S.: Evaluation of the effect of delayed management of traumatized permanent teeth. *J. Endodont.* 21: 391, 1995.
- Allen, R. K., Newton, C. W., Brown, C.E.: A statistical analysis of surgical and nonsurgical endodontic retreatment cases. *J. Endodont.* 15: 261, 1989.
- Altonen, M., Mattila, K.: Follow-up study of apicoectomized molars. *Int. J. Oral Surg.* 5: 33, 1976.
- Andersen, M., Lund, A., Andreasen, J.O., Andreasen, FM.: In vitro solubility of human pulp tissue in calcium hydroxide and sodium hypochlorite. *Endodont. Dent. Traumatol.* 8: 104, 1992.
- Ando, N., Hoshino, E.: Predominant obligate anaerobes invading the deep layers of root canal dentine. *Int. Endodont. J.* 23: 20, 1990.
- Andreasen, F., Vestergaard, B.: Prognosis of luxated permanent teeth - the development of pulp necrosis. *Endodont. Dent. Traumatol.* 1: 207, 1985.
- Andreasen, F., Zihjie, Y., Thomsen, B.: Relationship between pulp dimensions and development of pulp necrosis after luxation injuries in the permanent dentition. *Endodont. Dent. Traumatol.* 2: 90, 1986.
- Andreasen, G. F., Hilleman, T. B.: An evaluation of 55-cobalt substituted Nitinol wire for use in orthodontics. *J. Am. Dent. Assoc.* 82: 1373, 1971.

- Andreasen, J. O.: Luxation of permanent teeth due to trauma. *Scand. J. Dent. Res.* 78: 273, 1970.
- Andreasen, J.O.: Challenges in clinical dental traumatology. *Endodont. Dent. Traumatol.* 1: 45, 1985.
- Andreasen, J. O.: Traumatologie der Zahne. Schlutersche Verlagsanstalt, Hannover 1988.
- Andreasen, J.O., Borum, M. K., Jacobsen, H. L., Andreasen, F. M.: Replantation of 400 avulsed permanent incisors. *Endodont. Dent. Traumatol.* 11: 51, 1995.
- Arens, D. E., Rich, J. J., Healey, H.J.: A practical method of bleaching tetracycline-stained teeth. *Oral Surg.* 34: 812, 1972.
- Armitage, G.C., Ryder, M.I., Wilcox, S.E.: Cemental changes in the teeth with heavily infected root canals. *J. Endodont.* 9: 127, 1983.
- Arrastia, A. M., Wilder-Smith, P, Berns, M. W.: Thermal effects of CO2 laser pulpotomy on human primary [teeth. J. Dent. Res. 73](#) (Spec. Iss. 318): Abstr. 1734, 1994.

B

- Bahcall, J., Howard, P, Miserendino, L., et al.: Preliminary investigation of the histological effects of laser endodontic treatment on the periradicular tissues in dogs. *J. Endodont.* 18: 47, 1992.
- Baker Dirk, O.: Postoperative changes in dental [enamel. J. Dent. Res. 45](#) (Suppl. 3): 503, 1986.
- Barnett, F, Trope, M., Khoja, M., Tronstad, L.: Bacteriologic status of root canal after sonic, ultrasonic and hand instrumentation. *Endodont. Dent. Traumatol.* 1: 228, 1985.
- Baumann, M.A., Appel, T., Zick, K.: New insights into dental anatomy using NMR-microscopy. *Eur. Microsc. Analys.* 25: 7, 1993a.
- Baumann, M.A., Doll, G.M., Zick, K.: Stray-field imaging (STRAFI) of teeth. *Oral Surg.* 75: 517, 1993b.
- Baumann, M.A., GroB, D., Lehmann, V., Zick, K.: Magnetresonanz-mikroskopie - Neue Perspektiven für die Endodontie. *Schweiz. Monatsschr. Zahnmed.* 103: 1407, 1993c.
- Baumann, M.A., Schwebel, T., Kriete, A.: Dental anatomy portrayed with microscopic volume investigations. *Comput. Med. Imaging Graph.* 17: 221, 1993d.
- Baumann, M.A.: A new approach to demonstration of root canal anatomy. *J. Dent. Educ.* 58: 704, 1994a.
- Baumann, M., Beer, R.: Der endodontische [Notfall. Zahnarztl. Welt/Reform](#) 103: 584, 1994b.

- Baumann, M.A., Scharf, H.: Moderne Bildverarbeitungsverfahren als Unterstützung der räumlichen Rekonstruktion histologischer Strukturen. *Anat. Anz.* 176: 185, 1994c.
- Baumann, M.A.: Die räumliche Darstellung des Endodonts. Hanser, München 1995.
- Baumann, M.A., Gerhards, F.: Die retrograde Wurzelkanalfüllung. *Quintessenz* 47: 1463, 1996.
- Baumann, M.A., Roth, A.: Effect of experience on quality of canal preparation with rotary nickel-titanium files. *Oral Surg Oral Med Oral Pathol Oral Radiol Endod.* 1999 (in press).
- Baumann, M. A., Doll, M. A.: Spatial reproduction of the root canal system by magnetic resonance microscopy. *J. Endodont.* 23: 49, 1997.
- Baume, L.J., Conne, F., Fiore-Donno, G.: L'etat de la pulpe sous la carie dentaire et ses consequences therapeutiques. *Rev. Fr. Odontostomatol.* 4: 511, 1970.
- Baume, L.J.: The Biology of Pulp and Dentine. A Historic, Terminologic-Taxonomic, Histologic-Biochemical, Embryonic and Clinical Survey. *Monographs in Oral Science*, Vol. 8. Karger, Basel 1980.
- Baumgartner, J. C., Mader, C. L.: A SEM evaluation of four root canal irrigation regimens. *J. Endodont.* 13: 147, 1987.
- Baumgartner, J.C., Falkner, W.A.: Bacteria in the apical 5 mm of infected root canals. *J. Endodont.* 17: 380, 1991.
- Baumgartner, J. C., Cuenin, P.R.: Efficacy of several concentrations of sodium hypochlorite for root canal irrigation. *J. Endodont.* 18: 605, 1992.
- Beaudry, R.J.: Prevention of rubber dam hypersensitivity. *J. Endodont.* 10: 544, 1984.
- Beckham, B. M., Anderson, R. W., Morris, C. F.: An evaluation of three materials as barriers to coronal microleakage in endodontically treated teeth. *J. Endodont.* 19: 388, 1993.
- Beer, R., Gangler, P.: Reaktionen des Endodonts bei Initialkaries - eine histopathologische Studie. *Dtsch. Stomatol.* 36: 491, 1986.
- Beer, R., Gangler, R., Beer, M.: In-vitro Untersuchungen unterschiedlicher Wurzelkanalfülltechniken und -materialien. *Zahn Mund Kieferheilkd.* 74:800, 1986a.
- Beer, R., Gangler, P., Benkert, O.: Zur Entstehung und Klassifikation intrapulper Dentinbildungen. *Zahn Mund Kieferheilkd.* 74: 675, 1986b.
- Beer, R., Gangler, P.: Rasterelektronenmikroskopische Untersuchungen zur Effektivität unterschiedlicher Wurzelkanalspülösungen. *Zahn Mund Kieferheilkd.* 75: 476, 1987.
- Beer, R., Gangler, R., Rupprecht, B.: Investigation of the canal space occupied by gutta-percha following lateral and thermomechanical condensation. *Int. Endodont. J.* 20: 271, 1987.
- Beer, R., Keitel, S., Gangler, P., Wutzler, P., Pfister, W.: Biologische and mikrobiologische Prüfung chlorhaltiger Wurzelkanalspülösungen. *Dtsch. Stomatol.* 38: 513, 1988a.
- Beer, R., Wutzler, P., Gangler, P., Pfister, W.: Vergleichende biologische and mikrobiologische Prüfung von Wurzelkanalfüllmaterialien. *Zahn Mund Kieferheilkd.* 76: 473, 1988b.
- Beer, R.: Vergleichende biologische Prüfung zahnärztlicher Füllungs-materialien. *Med. Habilitationsschrift*, Erfurt 1989.
- Beer, R., Gangler, P.: Rasterelektronenmikroskopische Untersuchung der Wurzelkanalaufbereitung mit Ultraschall. *Dtsch. Zahnärztl. Z.* 44: 334, 1989.
- Beer, R., Gangler, P., Krehan, F., Wutzler, P.: Das Dentinbondingmaterial Scotchbond in der biologischen Testkette - ist eine haftvermittelnde Composite-Füllungstechnik pulpaverträglich? *Zahn Mund Kieferheilkd.* 77:243, 1989.
- Beer, R., Gangler, P., Wutzler, P., Krehan, F.: Vergleichende biologische Prüfung des Glasionomerzementes Ketac-Bond. *Dtsch. Zahnärztl. Z.* 45: 202, 1990.
- Beer, R.: Biologische Prüfung des Glasionomerzementes Ketac-Fil unter [Anwendungsbedingungen](#). *Zahnärztl. Welt/Reform* 100: 756, 1991.
- Beer, R.: Optimale Wurzelkanalaufbereitung, welche Technik führt zum Ziel? *Phillip J.* 9: 261, 1992a.
- Beer, R.: Pathohistologische Grundlagen der Wurzelkanalbehandlung. *Phillip J.* 9: 69, 1992b.
- Beer, R.: Revision von Mißerfolgen in der Endodontie. *Phillip J.* 11: 531, 1992c.
- Beer, R.: Die biologischen Eigenschaften von Wurzelkanalfüllmaterialien. *Zahnärztl. Praxis* 44: 126, 1993a.
- Beer, R.: Prophylaxe in der [Endodontie](#). *Zahnärztl. Welt/Reform* 102: 596, 1993b.
- Beer, R.: Maschinelle vs Hand instrumentation des Wurzelkanals: das Canal [master-System](#). *Zahnärztl. Welt/Reform* 102: 856, 1993c.
- Beer, R.: Glasionomerzemente - Biologisch unbedenkliche Füllungs-materialien? *Quintessenz* 45: 1073, 1994.
- Beer, R., Baumann, M.A.: Klinische Untersuchung der Guttaperchawurzelkanalfüllung mit Apexit als [Sealer](#). *Zahnärztl. Welt/Reform* 103: 365, 1994a.
- Beer, R., Baumann, M.A.: *Praktische Endodontie*. Urban & Schwarzenberg, München 1994b.
- Beer, R.: Bleichen - ein zahnschonendes Verfahren zur Verbesserung der Ästhetik. *Quintessenz* 46: 873, 1995.
- Beer, R., Mayerhofer, G.: Fortschritte in der Endodontie - Die operationmikroskopgestützte Wurzelkanalbehandlung. *Quintessenz* 46: 1437, 1995.
- Beer, R.: Kariesdiagnostik im Seitenzahnbereich. *Quintessenz* 47: 607, 1996a.
- Beer, R.: Biologische Einschätzung zahnärztlicher Füllungs-materialien. In Heinenberg, B.J.: *Innovationen für die Zahnheilkunde*, Teil 8. Spitta, Balingen 1996b.
- Beer, R.: Revision endodontischer Mißerfolge unter dem [Operationsmikroskop](#). *Zahnärztl. Welt/Reform* 105: 98, 1996c.
- Benjamin, K.A., Dowson, J.: Incidence of two root canals in human mandibular incisor teeth. *Oral Surg.* 38: 122, 1974.
- Benkert, O., Beer, R., Gangler, P., Koch, I. L.: Biologisch-experimentelle Untersuchungen zahnärztlicher Füllungswerkstoffe im Anwendungstest am Hausschwein. *Zahn Mund Kieferheilkd.* 75: 555, 1987.
- Berbert, A., Filho, M. T., Ueno, A. H., Bramante, C. M., Ishikiriama, A.: The influence of ultrasound in removing intraradicular posts. *Int. Endodont. J.* 28: 100, 1995.
- Bergenholtz, G., Warfvinge, J.: Migration of leucocytes in the dental pulp in response to plaque bacteria. *Scand. J. Dent. Res.* 90: 354, 1982.
- Berude, J. A., Hicks, L. M., Sauber, J. J., Li, S. H.: Resorption after physiologic and rigid splinting of replanted permanent incisors in monkeys. *J. Endodont.* 14: 592, 1988.
- Biggs, J. T., Benenati, F. W., Sabala, C. L.: Treatment of iatrogenic root perforations with associated osseous lesions. *J. Endodont.* 14: 620, 1988.
- Bille, J., Thylstrup, A.: Radiographic diagnosis and clinical tissue changes in relation to treatment of approximal carious lesions. *Caries Res.* 16: 1, 1982.
- Bimstein, E., Shteyer, A.: Dilated type of dense invaginated in the permanent dentition. *J. Dent. Child.* 43: 410, 1976.
- Black, G.V.: An investigation of the physical characters of the human teeth in relation to their disease, and to practical dental operations, together with the physical characters of filling materials. *Dent. Cosmos.* 37:353, 1895.
- Black, G.V.: *Descriptive Anatomy of the Human Teeth*, 4th ed. White, Philadelphia 1902.
- Blinkhorn, A. S., Leggate, E. M.: An allergic reaction to rubber dam. *Br. Dent. J.* 156: 402, 1984.
- Block, R. M., Lewis, R. D., Hirsch, J., Coffey, J., Langeland, K.: Systemic distribution of ¹⁴C-labeled paraformaldehyd incorporated within formocresol following pulpotomies in dogs. *J. Endodont.* 9: 176, 1983.
- Block, R. M., Pascon, E. A., Langeland, K.: Paste technique retreatment study: a clinical, histopathologic and radiographic evaluation of 50 cases. *Oral Surg.* 60: 75, 1985.
- Boussens, J., Ducomin, J.R.: La microchirurgie dentaire (M.C.D.). *Quintess. Int.* 6: 1, 1982.
- Briseno, B. M., Wirth, R., Hamm, G., Standhartinger, W.: Efficacy of different irrigation methods and concentrations of root canal irrigation solutions on bacteria in the root canal. *Endodont. Dent. Traumatol.* 8: 6, 1992.
- Brock, H.: *Geratekompendium Mikrochirurgie*. Zeiss Oberkochen Produktmanagement Chirurgische Geräte, Oberkochen, 1988.
- Brown, D. C., Morre, B. K., Brown, C. E., Newton, C. W.: An in vitro study of apical extrusion of sodium hypochlorite during endodontic canal preparation. *J. Endodont.* 21: 587, 1995.
- Brown, G.: Factors influencing successful bleaching of discolored root filled tooth. *Oral Surg.* 20: 238, 1965.
- Buchanan, L. S.: *Cleaning and Shaping the Root Canal System*. In Cohen, S., Burns, R. C.: *Pathways of the Pulp*. Mosby, St. Louis, 1991 (p. 112).
- Burch, J.G., Hulen, S.: A study of the presence of accessory foramina and the topography of molar furcations. *Oral Surg.* 38: 451, 1974.

- Buoncristiani, J., Seto, G. B., Caputo, A. A.: Evaluation of ultrasonic and sonic instruments for intraradicular post removal. *J. Endodont.* 20: 486, 1994.
- Bystrom, A., Claesens, R., Sundqvist, G.: The antibacterial effect of camphorated paramonochlorophenol, camphorated phenol and calcium-hydroxide in the treatment of infected root canals. *Endodont. Dent. Traumatol.* 1: 170, 1985.
- Bystrom, A., Sundqvist, G.: Bacteriologic evaluation of the efficiency of mechanical root canal instrumentation in endodontic therapy. *Scand. J. Dent. Res.* 89: 321, 1981.
- Bystrom, A., Sundqvist, G.: Bacteriological evaluation of the effect of 0,5% sodium hypochlorite in endodontic therapy. *Oral Surg.* 55: 307, 1983.
- Caicedo, R., vonFraunhofer, J. A.: The properties of endodontic sealer cements. *J. Endodont.* 14: 527, 1988.
- Calas, P., Rochd, T., Michel, G.: In vitro attachment of *Streptococcus sanguis* to the dentin of the root canal. *J. Endodont.* 20: 71, 1994.
- Camp, L. R., Todd, M. J.: The effect of dowel preparation on the apical seal of three common obturation techniques. *J. Prosthet. Dent.* 50: 664, 1983.
- Camps, J. J., Pertot, W. J.: Torsional and stiffness properties of nickel-titanium K files. *Int. Endodont. J.* 28: 239, 1995.
- Canalda, C., Pumarola, J.: Bacterial growth inhibition produced by root canal sealer cements with a calcium hydroxide base. *Oral Surg.* 68: 99, 1989.
- Capurro, M.A., Goldberg, F., Balbachan, L., Macchi, R. L.: Evaluation of the dimensional stability of different thermoplasticized gutta-percha fillings using simulated glass root canals. *Endodont. Dent. Traumatol.* 9: 160, 1993.
- Carabelli, G.: *Systematisches Handbuch der Zahnheilkunde.* Braunmuller & Seidel, Wien 1844.
- Carr, G.: Microscope in endodontics. *J. Calif. Dent. Assoc.* 11: 55, 1992.
- Carr, G. B.: *Surgical Endodontics.* In Cohen, S., Burns, R.C.: *Pathways of the Pulp.* Mosby, St. Louis 1994 (p. 531).
- Carr, G. B.: *Retreatment.* In: Cohen, S., Burns R.C., *Pathways of the Pulp.* 7th ed., Mosby, St. Louis 1998 (p. 791).
- Chailertvnikul, P., Saunders, W. P., Mackenzie, D.: The effect of smear layer on microbial coronal leakage of gutta-percha root fillings. *Int. Endodont. J.* 29: 242, 1996.
- Chohayeb, A.A.: Evaluation of the apical condensation of gutta-percha by a tapered calibrated spreader/plugger. *J. Endodont.* 19: 167, 1993.
- Choksi, S. K., Brady, J. M., Dang, D. H., Rao, M. S.: Detecting approximal dental caries with transillumination: A clinical evaluation. *J. Am. Dent. Assoc.* 125: 1098, 1994.
- Chong, B.S., Pitt Ford, T. R.: The role of intracanal medication in root canal treatment. *Int. Endodont. J.* 25: 97, 1992.
- Cleen, M.J.H.: *Richtlinien zur Restauration wurzelkanalbehandelter Zahne.* Endodontie 4: 289, 1994.
- Cohen, S., Burns, R.C.: *Pathways of the Pulp,* 6th ed. Mosby, St. Louis 1994.
- Colermen, C.L., Svec, T.A.: Analysis of Ni-Ti versus stainless steel instrumentation in resin simulated canals. *J. Endod.* 23: 232, 1997.
- Cooke, H.G., Cox, FL.: C-shaped canal configurations in mandibular molars. *J. Am. Dent. Assoc.* 99: 836, 1979.
- Coolidge, E. D.: *Clinical Pathology of Treatment of Dental Pulp.* In *Dental Therapeutics,* 2nd ed. Lea & Febiger, Philadelphia 1946.
- Cooper, J. S., Bokmeyer, T. J., Bowles, W. H.: Penetration of pulp chamber by carbamid peroxide bleaching agents. *J. Endodont.* 18: 315, 1992.
- Corcoran, J. F., Zillich, R. M.: Bleaching of vital tetracycline stained teeth. *J. Mich. Dent. Assoc.* 56: 340, 1974.
- Cotton, W. R., Siegel, R. L.: Human pulp response to citric acid cavity cleanser. *J. Am. Dent. Assoc.* 96: 639, 1978.
- Covino, B. G., Vasallo, H. G.: *Local Anesthetics. Mechanism of Action and Clinical Use.* Grune & Stratton, New York 1977.
- Cragg, T. K.: The use of rubber dam in endodontics. *J. Can. Dent. Assoc.* 38:376,1972.
- Croll, T. P.: Enamel microabrasion for removal of superficial discoloration. *J. Esthet. Dent.* 1: 14, 1989a.
- Croll, T. P.: Enamel microabrasion: The technique. *Quintess. Int.* 20: 395, 1989b.
- Croll, T. P.: Enamel microabrasion for removal of superficial dysmineralization and decalcification defects. *J. Am. Dent. Assoc.* 120: 411, 1990.
- Croll, T. P.: Enamel microabrasion followed by dental bleaching: a case report. *Quintess. Int.* 23: 317, 1992.
- Croll, T. P., Kilian, C. M.: Zinc oxide-eugenol pulpotomy and stainless steel crown restoration of primary molar. *Quintessence Int.* 23: 383, 1992.
- Croll, T. P.: *Behandlung des Zahnschmelzes mit Mikroabrasion.* Quintessenz, Berlin 1993.
- Croll, T. P.: Tooth bleaching for children and teens: a protocol and examples. *Quintess. Int.* 25: 811, 1994.
- Cvek, M.: A clinical report on partial pulpotomy and capping with calcium hydroxide in permanent incisors with complicated crown fractures. *J. Endodont.* 4: 232, 1978.
- Cvek, M., Lindvall, A. M.: External root resorption following bleaching of pulpless teeth with oxygen peroxide. *Endodont. Dent. Traumatol.* 1: 56, 1985.
- Cvek, M.: Prognosis of luxated non-vital maxillary incisors treated with calcium hydroxide and filled with gutta-percha. *Endodont. Dent. Traumatol.* 8: 45, 1992.

D

- Dang, D. A., Walton, R. E.: Vertical root fracture and root distortion: effect of spreader design. *J. Endodont.* 15: 294, 1989.
- Daublander, M.: *Zahnärztliche Therapie bei Risikopatienten I.* Quintessenz 40: 741, 1989a.
- Daublander, M.: *Zahnärztliche Therapie bei Risikopatienten II.* Quintessenz 40: 931, 1989b.
- Deardorf, K. A., Swartz, M. J., Newton, C. W., Brown, C. E.: Effect of root canal treatment on dentin permeability. *J. Endodont.* 20: 1, 1994.
- Debelian, G.J., Olsen, I., Tronstad, L.: Profiling of *Propionibacterium acnes* recovered from root canal and blood during and after endodontic treatment. *Endodont. Dent. Traumatol.* 8: 248, 1992.
- Debelian, G.J., Olsen, I., Tronstad, L.: Bacteremia in conjunction with endodontic therapy. *Endodont. Dent. Traumatol.* 11: 142, 1995.
- Dederich, D.N., K.L. Zakariassen, Tulip, L.: Scanning electron microscopic analysis of canal wall dentin following Neodymium-Yttrium-Aluminium-Garnet laser irradiation. *J. Endodont.* 10: 428, 1984.
- DeDeus, O. D.: Frequency, location and direction of the accessory canals. *J. Endodont.* 1: 361, 1975.
- Deemer, J. P., Tsaknis, P.J.: The effect of overfilled polyethylene tube intraosseous implants in rats. *Oral Surg.* 48: 358, 1979.
- Denis, R., Oft, K.H.R.: *Kofferdam-Allergie - ein Fallbericht.* Dtsch. Zahnärztl. Z. 48: 306, 1993.
- Donly, K.J., O'Neill, M., Croll, T.P.: Enamel microabrasion: a microscopic evaluation of the „abrasion effect“. *Quintess. Int.* 23: 175, 1992.
- Dow, P. R., Ingle, J. I.: Isotope determination of root canal failures. *Oral Surg.* 8: 1100, 1955.
- Drake, D. R., Wiemann, A. H., Riviera, E. M., Walton, R. E.: Bacterial retention in canal walls in vitro: effect of smear layer. *J. Endodont.* 20: 78, 1994.
- Driscoll, W. S., Herschel, S. H., Meyers, R. J.: Prevalence of dental caries and dental fluorosis in areas with optimal and above-optimal water fluoride concentrations. *J. Am Dent. Assoc.* 107: 42, 1983.
- Duggins, L. D., Clay, J. R., van Himel, T., Dean, J. W.: A combined endodontic retrofill and periodontal guided tissue regeneration technique for the repair of molar endodontic furcation perforation. *Quintessence Int.* 25: 109, 1994.
- Drake D. R., Wiemann, A. H., Rivera, E. M., Walton, R. E.: Bacterial retention in canal walls in vitro: effect of smear layer. *J. Endodont.* 20: 78, 1994.
- Dumsha, T., Hovland, E. J.: Pulpal prognosis following extrusive luxation injuries in permanent teeth with closed apices. *J. Am. Dent. Assoc.* 36: 410, 1982.

Dwan, J. J., Glickman, G. N.: 2-D Photoelastic stress analysis of NiTi and stainless steel finger spreaders during lateral condensation. *J. Endodont.* 21: 221, 1995.

E

Enguchi, D., Peters, D. D., Hollinger, J. O.: A comparison of the area of the canal space occupied by guttapercha following four gutta-percha obturation techniques. *J. Endodont.* 11: 166, 1985.

Ehrmann, E. H.: Konservative Behandlung großer apikaler Läsionen. In Guldener, P.H.A., Langeland, K.: *Endodontologie*, 2. Aufl. Thieme, 1987 (S. 290).

Einwag, J.: Die intraligamentäre Anästhesie. *Zahnärztl. Mitt.* 75: 693, 1985.

Ekstrand, K., Quist, V., Thylstrup, A.: Light microscopic study of the effect of probing in occlusal surfaces. *Caries Res.* 21: 368, 1987.

Ekstrand, K. R., Kuzmina, I., Bjørndal, L., Thylstrup, A.: Relationship between external and histologic features of progressive stages of caries in the occlusal fossa. *Caries Res.* 29: 243, 1995.

Eleazer, P. D.: Lack of corrosion of stainless steel instruments in vivo by scanning electron microscope and microprobe analysis. *J. Endodont.* 17: 346, 1991.

Eriksen, H. M., Orstavik, D., Kerekes, K.: Healing of apical periodontitis after endodontic treatment using three different root canal sealers. *Endodont. Dent. Traumatol.* 4: 114, 1988.

Erlemeier, E. M.: Aktuelle Aspekte der intraligamentären Anästhesie. *Quintessenz* 41: 471, 1990.

F

Fabricius, L., Dahlen, G., 6hman, A. E., Mol1er, A. J. R.: Predominant indigenous oral bacteria isolated from infected root canals after varied times of closure. *Scand. J. Dent. Res.* 90: 134, 1982.

Fairborne, D. R., McWalter, G. M., Montgomery, S.: The effect of four preparation techniques on the amount of apically extruded debris. *J. Endodont.* 13: 102, 1987.

Fava, R.G.: The doubled flare technique: an alternative for biomechanical preparation. *J. Endodont.* 9: 76, 1983.

Fischer, G.: Der heutige Stand der Wurzelbehandlung mit Rücksicht auf die feinere Anatomie menschlicher Wurzelkanäle insbesondere am Foramen apicale. *Dtsch. Monatsschr. Zahnheilkd.* 30: 81, 1912.

Flaitz, C. M., Hicks, M.J., Silverstone, L. M.: Radiographic, histologic and electronic comparison of occlusal caries: An in vitro study. *Pediatr. Dent.* 8: 24, 1986.

Fogel, B. B.: A comparative study of five materials for use in filling root canal spaces. *Oral. Surg.* 43: 284, 1977.

Fogel, H. M.: Microleakage of posts used to restore endodontically treated teeth. *J. Endodont.* 21: 376, 1995.

Foster, K. H., Kulild, J. C., Weller, R. N.: Effect of smear layer removal on the diffusion of calcium hydroxide through radicular dentin. *J. Endodont.* 19:136,1993.

Frank, R. M., Voegel, J. C.: Ultrastructure of the human odontoblast and its mineralisation during dental caries. *Caries Res.* 14: 367, 1980.

Frank, R. M., Nalbandian, J.: Development of Dentine and Pulp. In Berkovitz, B.K.B., Boyde, A., Frank, R. M., H6hling, H. J., Moxham, B. J., Nalbandian, J., Tonge, C. H.: *Teeth*. Springer, Berlin 1989 (p. 73).

Frank, R. M., Steuer, P., Hemmerle, J.: Ultrastructural study on human root caries. *Caries Res.* 23: 209, 1989.

Freccia, W. F., Peters, D. D., Lorton, L., Bernier, W. E.: An in vitro comparison of nonvital bleaching techniques in the discolored tooth. *J. Endodont.* 8: 70, 1982.

Freedland, J. B.: Conservative reduction of large periapical lesions. *Oral Surg.* 29: 455, 1970.

Frentzen, M., Koort, H.J., Nolden, R.: Aufbereitung von Wurzelkanälen mit Excimer-Lasern. *Dtsch. Zahnärztl. Z.* 46: 288, 1991.

Frentzen, M.: Laseranwendungen in der Zahnerhaltung und Parodontologie - Eine Übersicht. *Dtsch. Zahnärztl. Z.* 49: 113, 1994.

Friedman, S., Rotstein, I., Libfeld, H., Stabholz, A., Heling, I.: Incidence of external root resorption and esthetic results in 58 bleached pulpless teeth. *Endodont. Dent. Traumatol.* 4: 23, 1988.

Friedman, S., Rotstein, I., Sharlev, S.: Bypassing gutta-percha root fillings with automated device. *J. Endodont.* 15: 432, 1989.

Friedman, S., Stabholz, A., Tamse, A.: Endodontic retreatment - case selection and technique. *J. Endodont.* 16: 543, 1990.

Friedman, S., Lustmann, J., Sharabany, V.: Treatment results of apical surgery in premolar and molar teeth. *J. Endodont.* 17: 30, 1991.

Friedman, S., Moshonov, J., Trope, M.: Resistance to vertical fracture of roots, previously fractured and bonded with glass ionomer cement, composite resin and cyanoacrylate cement. *Endodont. Dent. Traumatol.* 9: 101, 1993.

Fuad, A. F., Rivera, E. M., Krell, K. V.: Accuracy of the endex with variations in canal irrigants and foramen size. *J. Endodont.* 18: 63, 1993a.

Fuad, A. F., Walton, R. E., Rittman, B. R.: Healing of induced periapical lesions in ferret. *J. Endodont.* 19: 123, 1993b.

Furseth, R., Mjor, I.A.: Electron microscopy of human coronal dentin - a methodological study with emphasis on the aspiration of odontoblast nuclei. *Acta Odontol. Scand.* 27: 577, 1980.

Fuss, Z., Szajkis, S., Tagger, M.: Tubular permeability to calcium hydroxide and to bleaching agents. *J. Endodont.* 15: 362, 1982.

Fuss, Z., Rafaeloff, R., Tagger, M., Szajkis, S.: Intracanal pH changes of calcium hydroxide pastes exposed to carbon dioxide in vitro. *J. Endodont.* 22: 362, 1996.

G

Gangler, P., Langeland, K.: Biologische Grundlagen der Endodontie. *Zahn Mund Kieferheilkd.* 69: 256, 1979.

Galvan, D. A., Ciarlone, A. E., Pashley, D. H., Kulild, J. C., Primack, P. D., Simpson, M. D.: Effect of smear layer removal on the diffusion permeability of human root. *J. Endodont.* 20: 83, 1994.

Gambill, J. M., Alder, del Rio, C. E.: Comparison of nickel-titanium and stainless steel hand-file instrumentation using computed tomography. *J. Endodont.* 22: 369, 1996.

Gatot, A., Arbellet, J., Leiberman, A., Yanai-Inbar, I.: Effects of sodium hypochlorite on soft tissues after its inadvertent injection beyond the root apex. *J. Endodont.* 17: 573, 1991.

Gelfand, M., Goldman, M., Sunderman, E.J.: Effect of complete veneer crowns on the compressive strength of endodontically treated posterior teeth. *J. Prosthet. Dent.* 52: 635, 1984.

Georgopoulou, M., Kontakiotis, E., Nakou, M.: In vitro evaluation of the effectiveness of calcium hydroxide and paramonochlorphenol on anaerobic bacteria from the root canal. *Endodont. Dent. Traumatol.* 9: 249, 1993.

Georgopoulou, M. K., Wu, M. K., Nikolaou, A., Wesselink, P. R.: Effect of thickness on the sealing ability of some root canal sealers. *Oral Surg.* 80:338,1995.

Geurtsen, W.: Die Kroneninfraktion posteriorer Zähne - klinische Merkmale and Fallberichte. *Int. J. Parodontol. Restaur. Zahnheilkd.* 12: 377, 1992.

Gher, M. E., Dunlap, R. M., Anderson, M. H., Kuhl, L. V.: Clinical survey of fractured teeth. *J. Am. Dent. Assoc.* 114: 174, 1987.

Glosson, C. R., Haller, R. H., Dove, S. B., del Rio, C. E.: A comparison of root canal preparation using NiTi Hand, NiTi engine driven and K-Flex endodontic instruments. *J. Endodont.* 21: 146, 1995.

Gluskin, A. H., Radke, R. A., Frost, S. L., Watanabe, L. G.: The mandibular incisor: rethinking guidelines for post and core design. *J. Endodont.* 21: 33, 1995.

Goerig, A. C., Michelich, R. J., Schultz, H. H.: Instrumentation of root canals in molars using the step-down technique. *J. Endodont.* 8: 550, 1982.

Goldberg, F., Abramovich, A.: Analysis of the effect of EDTAC on the dentinal walls of the root canal. *J. Endodont.* 3: 101, 1977.

Goldman, M., White, R. R., Moser, C. R., Tenca, J. I.: A comparison of three methods of cleaning and shaping the root canal. *J. Endodont.* 14: 7, 1988.

- Goldman, M., Laasonthorn, R., White, R. R.: Microleakage-full crown and the dental pulp. *J. Endodont.* 18: 473, 1992.
- Goldstein, R. E., Haywood, V. B., Heymann, H. O., Steiner, D. R., West, J.D.: Bleaching of Vital and Pulpless Teeth. In Cohen, S., Burns, R.C.: *Pathways of the Pulp*. Mosby, St. Louis, 1994.
- Grieve, A. R., Alani, A., Saunders, W. P.: The effect on the dental pulp of a composite resin and two dentin bonding agents and associated bacterial microleakage. *Int. Endodont. J.* 24: 108, 1991.
- Grossman, L., Oliet, S., delRio, C.: *Endodontic Practice*, 11 th ed. Lea & Febiger, Philadelphia 1988.
- Grung, B., Molven, O., Halse, A.: Periapical surgery in a Norwegian county hospital: follow up findings of 477 teeth. *J. Endodont.* 16: 411, 1990.
- Guldener, R.H.A., Langeland, K.: *Endodontologie*. 3. Aufl. Thieme, Stuttgart 1993.
- Gutierrez, J. H., Villena, F., Gigoux, C.: Microscopic and scanning electron microscope examination of silver point corrosion caused by endodontic material. *J. Endodont.* 8: 301, 1982.
- Gutierrez, J. H., Herrera, V. R., Berg, E. H., Villena, F., Jofre, A.: The risk of intentional dissolution of the smear layer after mechanical preparation of root canals. *Oral Surg.* 70: 96, 1990a.
- Gutierrez, J. H., Jofre, A., Villena, F.: Scanning electron microscope study on the bacteria action of endodontic irrigants on bacteria invading the dentinal tubules. *Oral Surg.* 69: 491, 1990b.
- Gutierrez, J. H., Donoso, E., Villena, F., Jofre, A.: Diffusion of medicaments within root canal dentin. *Oral Surg.* 72: 351, 1991.
- Gutmann, J.L., Dumsha, T.C., Lovdahl, R.E.: *Problemlösungen in der Endodontie*. Hanser, München 1991.
- Gutman, J. L., Witherspoon, D. E.: Obturation of the cleaned and shaped root canal system. In: Cohen, S., Burns R.C., *Pathways of the Pulp*. 7th ed., Mosby, St. Louis 1998 (p. 258).
- Gutmann, J.: Principles of endodontic surgery for the general practitioner. *Dent. Clin. North Am.* 28: 895, 1984.
- Hawkins, R.W., Nii, C.T., Jacobsen, E.L., Murphy, R.A.: The smear layer and bacterial penetration of radicular dentinal tubules. *J. Endodont.* 20:196,1994.
- Haywood, V. B., Heymann, H. O.: Nightguard vital bleaching. *Quintess. Int.* 20: 173, 1989.
- Haywood, V. B.: Overview and status of mouthguard bleaching. *J. Esthet. Dent.* 3: 157, 1991.
- Haywood, V. B., Heymann, H.O.: Nightguard vital bleaching: How safe is it? *Quintess. Int.* 22: 515, 1991.
- Haywood, V. B.: History, safety and effectiveness of current bleaching techniques and applications of the nightguard vital bleaching technique. *Quintess. Int.* 23: 471, 1992.
- Haywood, V. B., Lonard, R. H., Nelson, C.F.: Effectiveness of nightguard vital bleaching. *J. Dent. Res.* 71: 179, 1992.
- Healy, M.J.R.: The mathematics. *Br. J. Oral Maxillofac. Surg.* 22: 330, 1984.
- Heidemann, D., Ramil-Diwo, M.: Die Wurzelkanalfülltechniken mit erwärmter Guttapercha: McSpadden-Technik, Endotec, vertikale Kondensation, Ultrafil. In APW (Hrsg.): *Endodontie: Neue Erkenntnisse aus Praxis und Wissenschaft*. Hanser, München 1993 (S. 107).
- Heithersay, G.S.: Calcium hydroxide in the treatment of pulpless teeth with associated pathology. *J. Br. Endodont. Sec.* 8: 74, 1975.
- Heling, I., Chandler, N. P.: The antibacterial effect within dentinal tubules of four root canal sealers. *J. Endodont.* 22: 257, 1996.
- Hembrough, J. H., Weine, F. S., Pisano, J. V., Eskoz, N.: Accuracy of an electronic apexlocator: a clinical evaluation in maxillary molars. *J. Endodont.* 19: 242, 1993.
- Hermann, B. W.: Calciumhydroxid als Mittel zum Behandeln and Fallen von Wurzelkanalen. *Med. Dissertation, Würzburg* 1920.
- Hess, W.: Zur Anatomie der Wurzelkanäle, des menschlichen Gebisses mit Berücksichtigung der feineren Verzweigungen am Foramen apicale. *Habilitationsschrift, Zürich* 1917.
- Hess, W.: *Anatomy of the Root Canals of the Teeth of the Permanent Dentition, Part I*. Wood, New York 1925a.
- Hess, W.: *The Anatomy of the Root Canals of the Teeth of the Permanent Dentition*. John Bale Sons & Danielson, London 1925b.
- Hession, R. W.: Endodontic morphology I - An alternative method of study. *Oral Surg.* 44: 456, 1977a.
- Hession, R. W.: Endodontic morphology II - A radiographic analysis. *Oral Surg.* 44: 610, 1977b.
- Hession, R. W.: Endodontic morphology III - Canal preparation. *Oral Surg.* 44: 775, 1977c.
- Hession, R. W.: Endodontic morphology IV - A comparative study. *Oral Surg.* 44: 915, 1977d.
- Hiltner, R. S., Kulild, J. C., Weller, R. N.: Effect of mechanical versus thermal removal of gutta-percha on the quality of the apical seal following post space preparation. *J. Endodont.* 18: 451, 1992.
- Ho, S., Goerig, A.C.: An in vitro comparison of different bleaching agents in the discolored tooth. *J. Endodont.* 15: 106, 1989.
- Horsted, P., Attar, K., Langeland, K.: Capping of monkey pulps with Dycal and Ca-eugenol cement. *Oral Surg.* 52: 531, 1981.
- Holland, R., deSouza, V., Nery, M.J., deMelle, W., Bernabe, R F E., Filho, J.A.O.: Reaction of rat connective tissue to gutta-percha and silver points. *Aust. Dent. J.* 27: 224, 1982.
- Holland, R., Soares, I.J., Soares, I.M.: Influence of irrigation and intracanal dressing on the healing process of dogs teeth with apical periodontitis. *Endodont. Dent. Traumatol.* 8: 223, 1992.
- Holland, R., Alexander, A. C., Murata, S. S., dosSantos, C. A., Junior, E.D.: Apical leakage following root canal dressing with calcium hydroxide. *Endodont. Dent. Traumatol.* 11: 261, 1995a.
- Holland, R., Sakashita, M. S., Murata, S. S., Junior, E. D.: Effect of dentine surface treatment on leakage of root fillings with glass ionomer sealer. *Int. Endodont. J.* 28: 190, 1995b.
- Holmstrup, G., Palm, A.M., Lambjerg-Hansen, H.: Bleaching of discolored root-filled teeth. *Endodont. Dent. Traumatol.* 4: 197, 1988.
- Horiba, N., Maekawa, Y., Matsumoto, T., Nakamura, H.: A study of the distribution of endotoxins in the dentin wall of infected root canals. *J. Endodont.* 16: 331, 1990.
- Howe, C. A., McKendry, D.J.: Effect of endodontic access preparation on resistance to crown root fracture. *J. Am. Dent. Assoc.* 121: 712, 1990.
- Huang, T. G., Schilder, H., Nathanson, D.: Effects of moisture content and endodontic treatment on some mechanical properties of human dentin. *J. Endodont.* 18: 209, 1992.

H

- Haapasalo, M., Orstavik, D.: In vitro infection and disinfection of dentinal tubules. *J. Dent. Res.* 66: 1375, 1987.
- Haikel, Y., Frank, R. M., Voegel, J. C.: Scanning electron microscopy of the human enamel surface layer of incipient carious lesions. *Caries Res.* 17: 1, 1983.
- Haikel, Y., Alleman, C.: Effectiveness of four methods of preparing root canals. *J. Endodont.* 14: 340, 1988.
- Haikel, Y., Gasser, P., Allemann, C.: Dynamic fracture of hybrid endodontic hand instruments compared with traditional files. *J. Endodont.* 17: 217, 1991.
- Hansen, E. K., Asmussen, E., Christiansen, N. C.: In vivo fractures of endodontically treated posterior teeth restored with amalgam. *Endodont. Dent. Traumatol.* 6: 49, 1990.
- Hansen, S.R., Montgomery, S.: Effect of restoration thickness on the sealing ability of TERM. *J. Endodont.* 19: 448, 1993.
- Hardee, M., L. Miserendino, Kos, W.: Evaluation of the antibacterial effects of intracanal Nd:YAG laser irradiation. *J. Endodont.* 16: 194, Abstr. 20, 1990.
- Harrington, G., Natkin, E.: External resorption associated with bleaching of pulpless teeth. *J. Endodont.* 5: 344, 1979.
- Harrison, J.W., Jurosky, K.A.: Wound healing in the tissues of the periodontium following periradicular surgery. *J. Endodont.* 17: 425, 1991.
- Harty, F.J.: *Endodontics in Clinical Practice*. Butterworth, London 1990.
- Hasselgren, G., Olsson, B., Cvek, M.: Effects of calcium hydroxide and sodium hypochlorite on the dissolution of necrotic porcine muscle tissue. *J. Endodont.* 14: 125, 1988.
- Hasselgren, G., Reit, C.: Emergency pulpotomy: pain relieving effect with and without the use of sedative dressings. *J. Endodont.* 15: 254, 1989.
- Hatton, J. F., Ferillo, R. J., Wagner, G., Stewart, G. R.: The effect of condensation pressure on the apical seal. *J. Endodont.* 14: 305, 1988.

Hulsmann, M.: Die endometrische Kanallängenbestimmung in der Endodontie - Indikation, Anwendung, Grenzen. *Quintessenz* 16: 1809, 1989.

Hulsmann, M.: Das Auffinden zusätzlicher Wurzelkanäle. *Schweiz. Monatsschr. Zahnmed.* 102: 84, 1992a.

Hulsmann, M.: Das Canal-Finder-System - Wissenschaftliche Erkenntnisse and klinische Erfahrungen. *Endodontie* 1: 45, 1992b.

Hulsmann, M.: Die maschinelle Aufbereitung des Wurzelkanals. In *Schriftenreihe APW. Endodontie: Neue Erkenntnisse aus Praxis and Wissenschaft.* Hanser, Munchen 1993a (S. 63).

Hulsmann, M.: Guttapercha - Geschichte, Chemie, Eigenschaften and Verarbeitung. *Endodontie* 2: 115, 1993b.

Hulsmann, M.: Endodontie. Thieme, Stuttgart 1993c.

Hulsmann, M.: Pramolaren mit drei Wurzelkanalen. Inzidenz, Diagnostik and Therapie. *Endodontie* 3: 277, 1994.

Hulsmann, M.: Juristische Probleme in der Endodontie. *Endodontie* 4: 93, 1995.

Hulsmann, M.: Die Depotphorese - eine Standortbestimmung. *Endodontie* 5: 7, 1996a.

Hulsmann, M.: Strategien zur Entfernung frakturierter Aufbereitungsinstrumente. *Endodontie* 5: 121, 1996b.

Hulsmann, M.: Risiken and Nebenwirkungen bei der Devitalisierung permanenter Zahne. *Zahnärztl. Mitt.* 86: 42, 1996c.

Hulsmann, M.: Zur Geschichte der Wurzelkanalaufbereitung. *Endodontie* 5: 97, 1996d.

Hulsmann, M., Franz, B., Lorch, V.: Reproduzierbarkeit des periapical probability index (PRI). *Zahnärztl. Welt/Reform* 105: 366, 1996.

Hulsmann, M., Rummelin, C., Schafers, F.: Root canal cleanliness after preparation with different endodontic handpieces and hand instruments: a comparative SEM investigation. *J. Endodont.* 23: 301, 1997.

le, Y. L., Verdonschot, E. H., Schaeken, M., vanthof, M. A.: Electrical conductance of fissure enamel in recent erupted molar teeth as related to caries status. *Caries Res.* 29: 94, 1995.

Ingle, J. I.: *Endodontics.* Lea & Febiger, Philadelphia 1985.

Ioannides, C., Bortslap, W.A.: Apicoectomy on molars: a clinical and radiologic study. *Int. J. Oral Surg.* 12: 73, 1983.

J

Jacobsen, E. L., Be Gole, E. A.: A comparison of four root canal obturation methods employing gutta-percha. *Endodont. Dent. Traumatol.* 8: 206, 1992.

Jacobsen, I., Kerkes, K.: Long-term prognosis of traumatized permanent anterior teeth showing calcifying processes in the pulp cavity. *Scand. J. Dent. Res.* 85: 588, 1977.

Jaquot, B. M., Panighi, M. M., Steinmetz, P., Sell, C.: Microleakage of Cavit, Cavit G and IRM by impedance spectroscopy. *Int. Endodont. J.* 29: 256, 1996.

Jerome, C. E., Hicks, L. M., Pelleu, G. B.: Compatibility of accessory gutta-percha cones used with two types of spreaders. *J. Endodont.* 14: 428, 1988.

Johnson, B.R., Remeikis, N.A.: Effective shelf-life of prepared sodium hypochlorite solution. *J. Endodont.* 19: 40, 1993.

Johnson, W. B.: A new gutta-percha technique. *J. Endodont.* 4: 184, 1987.

K

Kato, J., Hashimoto, M., Ono, H.: Pulp reactions after pulpotomy with Nd:YAG laser irradiation. *J. Dent. Res.* 70 (Spec. Iss. 384): Abstr. 943, 1991.

Kaufman, A.Y., Keila, S.: Conservative treatment of root perforation using apex locator and thermatic compactor. *J. Endodont.* 15: 267, 1989.

Kazemi, R. B., Safavi, K. E., Spangberg, L.: Dimensional changes of endodontic sealers. *Oral Surg.* 76: 766, 1993.

Kazemi, R. B., Safavi, K. E., Spangberg, L.: Assessment of marginal stability and permeability of interim restorative endodontic material. *Oral Surg.* 78: 788, 1994.

Kazemi, R. B., Stenman, E., Spangberg, L.: The endodontic file is a disposable instrument. *J. Endodont.* 21: 451, 1995.

Kehoe, J.C.: pH-reversal following in vitro bleaching of pulpless teeth. *J. Endodont.* 13: 6, 1987.

Kerekes, K., Tronstad, L.: Long term results of endodontic treatment performed with a standardized technique. *J. Endodont.* 5: 83, 1979.

Khayat, A., Lee, S.Y., Torabinejad, M.: Human saliva penetration of coronally unsealed obturated root canals. *J. Endodont.* 19: 458, 1993.

Kiryu, T., Hoshino, E., Iwaku, M.: Bacteria invading periapical cementum. *J. Endodont.* 20: 169, 1994.

Klein, J., Wei, P., Shayegan, A., White, R., Goldman, P.: Radiographic success or failure compared with coronal restorations and radicular filling. *J. Endodont.* 22: 191, 1996.

Klimek, J., Kockapan, C., Borcher, J.: Häufigkeit and Qualität von Wurzelkanalfüllungen in den Jahren 1983 and 1991. *Dtsch. Zahnärztl. Z.* 50: 154, 1995.

Kockapan, C.: Elektronenmikroskopische Untersuchungen über die Struktur der Schmierschicht. *Dtsch. Zahnärztl. Z.* 42: 1028, 1987.

Kockapan, C.: Die Bedeutung der Schmierschicht bei der Wurzelkanalbehandlung. *Endodontie* 4: 33, 1995.

Kolokuris, I., Arvanitoyannis, I., Robinson, C., Blanshard, J.M.V.: Effect of moisture and aging on gutta-percha. *J. Endodont.* 18: 583, 1992.

Kovarik, R. E., Breeding, L. C., Caughman, W. F.: Fatigue life of three core materials under simulated chewing conditions. *J. Prosthet. Dent.* 68: 584, 1992.

Krejci, I., Lohrer, C., Lutz, F.: Modifizierte Kavitätenformen and Techniken für mittelgroße Kompositfüllungen der Klasse II. *Acta Med. Dent. Helv.* 1: 96, 1996a.

Krejci, I., Petrac, M., Lutz, F.: Wear and marginal adaptation of resin reinforced glass ionomer class II restorations. *Acta Med. Dent. Helv.* 1: 117, 1996b.

Kulild, J. C., Peters, D. D.: Incidence and configuration of canal systems in the root of maxillary first and second molars. *J. Endodont.* 16: 311, 1990.

Kuttler, Y.: Microscopic evaluation of root apexes. *J. Am. Dent. Assoc.* 50: 544, 1955.

Kuwabara, R. K., Massler, M.: Pulpal reaction to active and arrested carious lesions. *J. Dent. Child.* 33: 190, 1966.

Kvist, T., Rydin, E., Reit, C.: The relative frequency of periapical lesions in teeth with root canal retained posts. *J. Endodont.* 15: 578, 1989.

L

Lado, E.A., Stanley, H.R., Weisman, M.I.: Cervical resorption in bleached teeth. *Oral Surg.* 55: 78, 1983.

Lake, F., Odell, N., Walton, R.: The effect of internal bleaching on tetracycline in dentin. *J. Endodont.* 11: 415, 1985.

Langeland, K.: Tissue changes in the dental pulp. *Odont. Tidskr.* 65: 249, 1957.

Langeland, K.: The histopathologic basis in endodontic treatment. *Dent. Clin. North Am.* 11: 491, 1967.

Langeland, K., Dowden, W.E., Tronstad, L., Langeland, L. K.: Human Pulp Changes of Iatrogenic Origin. In Siskin, M.: *The Biology of the Human Dental Pulp.* Mosby, St. Louis 1973 (p. 122).

Langeland, K., Block, R. M., Grossman, L. I.: A histopathologic and histobacteriologic study of 35 periapical endodontic surgical specimens. *J. Endodont.* 3: 8, 1977.

Langeland, K., Cotton, W.: Recommended standard practices for biological evaluation of dental materials. *Int. Dent. J.* 30: 140, 1980.

Langeland, K.: Management of the inflamed pulp associated with deep carious lesion. *J. Endodont.* 7: 169, 1981.

- Lazarchik, D.A., Firestone, A. R., Heaven, T.J., Lussi, A.: Radiographic evaluation of occlusal caries: effect of training and experience. *Caries Res.* 29: 355, 1995.
- Lee, K.W., Lee, E.C., Poon, K.Y.: Palatogingival grooves in maxillary incisor. *Brit. Dent. J.* 124: 14, 1968.
- Lee, Y. C., Yang, S. F., Hwang, Y. F., Chueh, L. H., Chung, K. H. C.: Microleakage of endodontic temporary restorative materials. *J. Endodont.* 19: 516, 1993.
- Leisebach Minder, T., Hotz, RR.: Endodontie im Milchgebief3 and Fruhstadium der bleibenden Dentition. In Guldener, P.H.A., Langeland, K.: *Endodontologie*. 3. Aufl. Thieme, Stuttgart 1993 (S. 328).
- Leonardo, M. R., Almeida, W. A., Ito, I. Y., Bezerra da Silva, L. A.: Radiographic and microbiologic evaluation of posttreatment apical and periapical repair of root canals of dogs teeth with experimentally induced chronic lesions. *Oral Surg.* 78: 232, 1994.
- Leonardo, M. R., Almeida, W. A., Bezerra da Silva, L. A., Utrilla, L. S.: Histopathological observation of periapical repair in teeth with radiolucent areas submitted to two different methods of root canal treatment. *J. Endodont.* 21: 137, 1995.
- Levy, G.: Une nouvelle instrumentation pour realiser mecaniquement l'ensemble de la procedure endodontique: le canal finder. *Rev. Fr. Endodont.* 3: 11, 1984.
- Levy, G.: Interaction between silica and dentin during enlargement of a root canal with Nd:YAG laser beam during a fiber optic: A SEM investigation. In Anderson, R.R., Katzir, A.: *Proceedings of laser surgery. Advanced characterization, therapeutics, and systems III*. SPIE 1643: 398, 1992.
- Liesenhoff, T., Lenz, H., Seiler, T.: Wurzelkanalaufbereitung mit Excimer-Laserstrahlen. *Zahnarztl. Welt* 98: 1034, 1989.
- Lilja, J., Nordenvall, K. J., Brannstrom, M.: Dentin sensitivity, odontoblasts and nerves under dessicated or infected experimental cavities. *Swed. Dent. J.* 6: 93, 1982.
- Limkangwalmongkol, S., Burtscher, P., Abbott, P.V., Sandier, A. B., Bishop, B. M.: A comparative study of the apical leakage of four root canal sealers and laterally condensed gutta-percha. *J. Endodont.* 17: 495, 1991.
- Lin, L., Langeland, K.: Innervation of the inflammatory periapical lesion. *Oral Surg.* 51: 535, 1981a.
- Lin, L., Langeland, K.: Light and electron microscopic study of teeth with carious pulp exposures. *Oral Surg.* 57: 297, 1981b.
- Lin, L., Shovlin, P., Skribner, J., Langeland, K.: Pulp biopsies from the teeth associated with periapical radiolucency. *J. Endodont.* 10: 436, 1984.
- Lin, L.M., Pascon, E.A., Skribner, J., Gangler, R., Langeland, K.: Clinical, radiographic, and histologic study of endodontic treatment failures. *Oral Surg.* 11: 603, 1991.
- Lindauer, P.A., Campbell, A. D., Hicks, M. L., Pelleu, G. B.: Vertical root fractures in curved roots under simulated clinical conditions. *J. Endodont.* 15: 345, 1989.
- Linn, J., Messer, H. H.: Effect of restorative procedures on the strength of endodontically treated molars. *J. Endodont.* 20: 479, 1994.
- Lipp, M. D. W.: *Die Lokalanasthesie in der Zahn-, Mund- and Kieferheilkunde*. Quintessenz, Berlin 1992.
- Lipp, M.D.W.: *Notfalltraining fur Zahnarzte*. 2. Aufl., Schliltersche Verlagsanstalt, Hannover 1996a.
- Lipp, M. D. W.: *Komplikationen bei der Lokalanasthesie*. Merktafel. Schlutersche Verlagsanstalt, Hannover 1996b.
- Liu, H. H., Sidhu, S. K.: Cracked teeth treatment rationale and case management: case report. *Quintessence Int.* 26: 485, 1995
- Lloyd, A., Thompson, J., Gutmann, J. L., Dummer, P.M. H.: Sealability of the Trifecta technique in the presence or absence of a smear layer. *Int. Endodont. J.* 28: 35, 1995.
- Lumley, P.J., Walmsley, A. D., Walton, R. E., Ripplin, J. W.: Effect of precurving endosonic files on the amount of debris and smear layer remaining in curved root canals. *J. Endodont.* 18: 616, 1992.
- Lundy, T., Stanley, H.R.: Correlation of pulpal histopathology and clinical symptoms in human teeth. *Oral Surg.* 27: 187, 1969.
- Lussi, A.: Validity of diagnostic and treatment decision of fissure caries. *Caries Res.* 25: 296, 1991.
- Lussi, A.: Comparison of different methods for the diagnosis of fissure caries without cavitation. *Caries Res.* 27: 409, 1993.
- Lussi, A., Nussbacher, U., Grosrey, J.: A novel non-instrumented technique for cleansing the root canal system. *J. Endodont.* 19: 549, 1993.
- Lussi, A., Firestone, A., Schoenberg, V., Hotz, P., Stich, H.: In vivo diagnosis of fissure caries using a new electrical resistance monitor. *Caries Res.* 29: 81, 1995a.
- Lussi, A., Hotz, P., Stich, H.: Die Fissurenkaries. *Schweiz. Monatsschr. Zahnmed.* 105: 1165, 1995b.
- Lussi, A., Messerli, L., Hotz, P., Grosrey, J.: A new non-instrumental technique for cleaning and filling root canals. *Int. Endodont. J.* 8: 1, 1995c.
- Lutz, F., Krejci, I., Barbakow, F.: Quality and durability of marginal adaptation in bonded composite restorations. *Dent. Mater. J.* 7: 107, 1991.

M

- Macchi, R.L., Capurro, M. A., Herrera, C. L., Cebada, F.R., Kohen, S.: Influence of endodontic materials on the bonding of composite resin to the dentin. *Endodont. Dent. Traumatol.* 8: 26, 1992.
- Macko, D.J., Rutberg, M., Langeland, K.: Pulpal response to the application of phosphoric acid to dentin. *Oral Surg.* 45: 930, 1978.
- Madison, S., Walton, R. E.: Cervical root resorption following bleaching of endodontically treated teeth. *J. Endodont.* 16: 570, 1990.
- Magura, M. E., Kafrawy, A. H., Brown, C. E., Newton, C. W.: Human saliva coronal microleakage in obturated root canals. *J. Endodont.* 17: 324, 1991.
- Malamed, W. F.: *Handbook of Local Anesthesia*. Mosby, St. Louis 1986.
- Mandel, E., Machtou, P., Torabinejad, M.: Clinical diagnosis and treatment of endodontic and periodontal lesions. *Quintess. Int.* 24: 135, 1993.
- Marlin, J.: Injectable standard gutta-percha as a method of filling the root canal system. *J. Endodont.* 12: 354, 1986.
- Marsicovetere, E. S., Clement, D. J., delRio, C. E.: Morphometric video analysis of the engine driven Nickel-Titanium lightspeed instrument system. *J. Endodont.* 22: 231, 1996.
- Marthaler, T. M., Germann, M.: Radiographic and visual appearance of small smooth surface caries lesions studied on extracted teeth. *Caries Res.* 4: 224, 1970.
- Marthaler, T. M., Wiesner, V.: Rapidity of penetration of radiolucent areas through mesial enamel of first permanent molars. *Helv. Odontol. Acta.* 17: 19, 1973.
- Martin, H.: Ultrasonic disinfection of the root canal. *Oral Surg.* 50: 566, 1976.
- Martin, H., Cunningham, W.: The effect of endosonic and hand manipulation on the amount of root canal material extruded. *Oral Surg.* 53: 611, 1982.
- Martin, H., Cunningham, W.: Endosonic endodontics: the ultrasound synergistic system. *Int. Dent. J.* 34: 198, 1984.
- Massler, M., Pawlack, J.: The affected and infected pulp. *Oral Surg.* 43: 929, 1977.
- McCann, J. T., Keller, D. L., LaBounty, G. L.: Remaining dentin/cementum thickness after hand or ultrasonic instrumentation. *J. Endodont.* 16: 109, 1990.
- McInerney, S.T., Zillich, R.: Evaluation of internal sealing ability of three materials. *J. Endodont.* 18: 376, 1992.
- Mc Spadden, J.T.: Self study course of the thermatic condensation of guttapercha. Form no. 33410/80 USA, 1980.
- Meister, F., Lommel, T.J., Gerstein, H.: Diagnosis and possible causes of vertical root fracture. *Oral Surg.* 49: 243, 1980.
- Mejare, I., Cvek, M.: Partial pulpotomy in young permanent teeth with deep carious lesions. *Endod. Dent. Traumatol.* 9: 238, 1993.
- Mejare, I., Malmgren, B.: Clinical and radiographic appearance of proximal carious lesions at the time of operative treatment in young permanent teeth. *Scand. J. Dent. Res.* 94: 19, 1986.
- Melcer, J.: Apport du laser à CO₂ dans la sterilisation de certaines infections d'origine dentaire. *Rev. Stomatol. Chir. Maxillofac.* 83: 146, 1982.
- Melcer, J., Chaumette, M.T., Melcer, F., et al.: Treatment of dental decay by CO₂ laser beam: preliminary results. *Laser Surg. Med.* 4: 311, 1984.
- Melcer, J., Chaumette, M.T., Melcer, F., et al.: Preliminary report on the effect of the CO₂ laser beam on the dental pulp of the Macacca Mulatta primate and the Beagle dog. *J. Endodont.* 11: 1, 1985.

- Metzger, Z., Assif, O., Tamse, A.: Residual chloroform and plasticity in customized gutta-percha master cones. *J. Endodont.* 14: 546, 1998.
- Metzler, R.S., Montgomery, S.: The effectiveness of ultrasonics and calcium hydroxide for the debridement of human mandibular molars. *J. Endodont.* 15: 373, 1989.
- Meyer, W.: Die Darstellung der Wurzelkanäle. *Zahnärztl. Rdsch.* 64: 532, 1955a.
- Meyer, W.: Die Probleme der sogenannten Gang ranbehandlung. *Dtsch. Zahnärztl. Z.* 10: 529, 1955b.
- Meyer, W.: Zu den anatomischen Grundlagen der Wurzelbehandlung. *Dtsch. Zahnärztl. Z.* 15: 777, 1960.
- Meyer, W.: Die Divertikel der Wurzelkanäle. *Dtsch. Zahnärztl. Z.* 18: 520, 1963.
- Meyer, W.: Die Anatomie der Wurzelkanäle, dargestellt an mikroskopischen Rekonstruktionsmodellen. *Dtsch. Zahnärztl. Z.* 25: 1064, 1970.
- Michanowicz, A., Czonstokowsky, M.: Sealing properties of an injection-thermoplasticized low temperature (70°C) gutta-percha. A preliminary study. *J. Endodont.* 10: 563, 1984.
- Mileman, P. A., Weele, L.T.: Accuracy in radiographic diagnosis. Dutch practitioners and dental caries. *J. Dent. Res.* 18: 130, 1990.
- Miller, W.D.: Lehrbuch der konservierenden Zahnheilkunde. Thieme, Leipzig 1904.
- Milot, P., Stein, R. S.: Root fracture in endodontically treated teeth related to post selection and crown design. *J. Prosthet. Dent.* 68: 428, 1992.
- Miserendino, L.J.: Instruments, Materials and Devices. In Cohen, S., Burns, R.C.: *Pathways of the Pulp*, 6th ed. Mosby, St. Louis 1994 (p. 377).
- Mitsis, F. J.: Flap operation technique for the treatment of certain endodontic and periodontic problems. *J. Brit. Endod. Soc.* 4: 6, 1970.
- Mjor, I.: Usage test for restorative materials. *J. Endodont.* 4: 308, 1978.
- Morfis, A.S.: Vertical root fractures. *Oral Surg.* 69: 631, 1990.
- Morgan, R. W., Carnes, D. L., Montgomery, S.: The solvent effects of calcium hydroxide irrigating solution on bovine pulp tissue. *J. Endodont.* 17: 165, 1991.
- Morse, D. R., Esposito, J. V., Pike, C., Furst, M. L.: A radiographic evaluation of the periapical status of teeth treated by the gutta-percha - eucapercha method. *Oral Surg.* 56: 190, 1983.
- Moyer, P. W., Osetek, E. M., Ashkenaz, P., Gilbert, J. L.: Evaluation of a solvent softened gutta-percha obturation technique in curved canals. *J. Endodont.* 21: 459, 1995.
- MUller, H., Raab, W.H.M.: Temperaturabhängige Veränderungen der Mikrozirkulation der Zahnpulpa. *Dtsch. Zahnärztl. Z.* 44: 496, 1989.
- Mungo, R., Richardson, J.: Use of the CO₂ laser as a Non-Pharmacological Alternative to the Formocresol Vital Pulpotomy. A Histological Comparison. In Powell, G.L.: *Proceedings of the Third International Congress on Laser in Dentistry*. University of Utah Printing Services, Utah 1993 (p.167).
- Myers, G. L., Montgomery, S.: A comparison of weights of debris extruded apically by conventional filing and canal master techniques. *J. Endodont.* 17: 275, 1991.
- Nguyen, T. N.: Obturation of the root canal system. In: Cohen, S., Burns R.C., *Pathways of the Pulp*. 6th ed., Mosby, St. Louis 1994 (p. 219).
- Nichols, E.: Treatment of traumatic perforation of the pulp cavity. *Oral Surg.* 15: 603, 1962.
- Noar, S. J., Smith, B. G. N.: Diagnosis of caries and treatment decision in approximal surfaces of posterior teeth in vitro. *J. Oral Rehabil.* 17: 209, 1990.
- Nordenram, A., Svardstrom, G.: Results of apicoectomy. *Swed. Dent. J.* 63:593,1970.
- Nutting, E., Poe, G.: Chemical bleaching of discolored endodontically treated teeth. *Dent. Clin. North Am.* 11: 1967, 655.
- Ohara, P. K., Torabinejad, M., Kettering, J.D.: Antibacterial effects of various endodontic irrigants on selected anaerobic bacteria. *Endodont. Dent. Traumatol.* 9: 95, 1993.
- Oliet, S.: Single-visit endodontics: a clinical study. *J. Endodont.* 9: 147, 1983.
- Olsson, B., Sliwowski, A., Langeland, K.: Subcutaneous implantation for the biological evaluation of endodontic materials. *J. Endodont.* 7: 355, 1981.
- Onnink, P. A., Dvis, R. D., Wayman, B. E.: An in vitro comparison of incomplete root fractures associated with three obturation techniques. *J. Endodont.* 20: 32, 1994.
- Orstavik, D., Kerekes, K., Eriksen, H. M.: Clinical performance of endodontic sealers. *Endodont. Dent. Traumatol.* 3: 178, 1987.
- Orstavik, D., Mjor, I.A.: Histopathology and X-ray microanalysis of the subcutaneous tissue response to endodontic sealers. *J. Endodont.* 14: 13, 1988.
- Orstavik, D., Haapsalo, M.: Disinfection by endodontic irrigants and dressings of experimentally infected dentinal tubules. *Endodont. Dent. Traumatol.* 6: 142, 1990.
- Orstavik, D.: Radiographic evaluation of apical periodontitis and endodontic treatment results: a computer approach. *Int. Dent. J.* 41: 89, 1991.
- Orstavik, D., Kerekes, K., Molven, O.: Effects of extensive apical reaming and calcium hydroxide dressing on bacterial infection during treatment of apical periodontitis. *Int. Endodont. J.* 24: 1, 1991.
- Orstavik, D., Mjor, I.A.: Usage test of four endodontic sealers in Macaca fascicularis monkeys. *Oral Surg.* 73: 337, 1992.
- Orth, U.: Die chemisch-mechanische Wurzelkanalaufbereitung. Historische Entwicklung der Wurzelkanalinstrumente, Spulmittel und Aufbereitungsmethoden. Dissertation, Mainz 1995.

N

- Nair, P N. R., Sjogren, U., Krey, G., Sundquist, G.: Therapy resistant foreign body giant cell granuloma at the periapex of a root-filled human tooth. *J. Endodont.* 16: 589, 1990a.
- Nair, R.N.R., Sjogren, U., Krey, G., Kahnberg, K. E., Sundqvist, G.: Intraradicular bacteria and fungi in root filled asymptomatic human teeth with therapy resistant periapical lesions. *J. Endodont.* 16: 580, 1990b.
- Nair, P N. R.: Eine neue Sicht der radikularen Zysten - sind sie heilbar? *Endodontie* 4: 169, 1995.
- Nakamura, M., Kawahara, H., Imai, K., Tomoda, S., Kawata, Y.: Long term biocompatibility test of composite resins and glass ionomer cement. *Dent. Mater. J.* 2: 100, 1983.
- Neaverth, E.J., Burg, H.A.: Decompression of a large periapical cystic lesion. *J. Endodont.* 8: 175, 1982.
- Nerwich, A., Figdor, D., Messer, H. H.: pH changes in root dentin over a 4-week period following root canal dressing with calcium hydroxide. *J. Endodont.* 19: 302, 1993.

P

- Panitvisai, P, Messer, H.H.: Cuspal deflection in molars in relation to endodontic and restorative procedures. *J. Endodont.* 21: 57, 1995.
- Pascon, E.A., Introcaso, J.H., Langeland, K.: Development of predictable periapical lesion monitored by subtraction radiography. *Endodont. Dent. Traumatol.* 3: 192, 1987.
- Pascon, E. A., Leonardo, R. M., Safavi, K., Langeland, K.: Tissue reaction to endodontic materials: methods, criteria, assessment and observations. *Oral Surg.* 72: 222, 1991.
- Pashley, D. H., Tao, L., Boyd, L., King, G. E., Horner, J.A.: Scanning electron microscopy of the substructure of smear layer in human dentine. *Arch. Oral Biol.* 33: 265, 1988.
- Pashley, D. H.: Clinical consideration of microleakage. *J. Endodont.* 16: 70, 1990.
- Patterson, C. J. W.: Polydam - polythene sheet, a practical alternative to rubber dam for patients allergic to rubber compounds. *Int. Endodont. J.* 22:252,1989.

- Pecora, G., Abbondenos, C.: The indications and advantages when using the operatory microscope in endodontic surgery. IAS 3: 47th annual section AAE April 25, 1990.
- Pecora, G., Andreana, S.: Use of dental operating microscope in endodontic surgery. *Oral Surg.* 75: 751, 1993.
- Peters, D. D., Baumgartner, J. C., Lorton, L.: Adult pulpal diagnosis. I. Evaluation of the positive and negative responses to cold and electrical pulp tests. *J. Endodont.* 20: 506, 1994.
- Peters, L. B.: Preparation der endodontischen Zugangskavitat and Darstellung der Kanäle. Teil I: Schneidezähne and Eckzähne. *Endodontie* 1: 57, 1992a.
- Peters, L. B.: Preparation der endodontischen Zugangskavitat and Darstellung der Kanäle. Teil II: Pramolaren. *Endodontie* 1: 141, 1992b.
- Peters, L. B.: Preparation der endodontischen Zugangskavitat and Darstellung der Kanäle. Teil III: Obere Molaren. *Endodontie* 1: 225, 1992c.
- Peters, L. B.: Preparation der endodontischen Zugangskavitat and Darstellung der Kanäle. Teil IV: Untere Molaren. *Endodontie* 1: 291, 1992d.
- Pieper, K., Schurade, B.: Die Untersuchung mit der Kaltlicht-Diagnose-sonde. Eine Alternative zum Flugelbih-Status. *Dtsch. Zahnarztl. Z.* 42: 900, 1987.
- Pietrobon, N., Lehner, C. R., Scharer, P.: Langzeitprovisorien in der Kronen- and Brückenprothetik. *Schweiz. Monatsschr. Zahnmed.* 106: 237, 1996.
- Pineda, F., Kuttler, Y.: Mesiodistal and buccolingual roentgenographic investigation of 7275 root canals. *Oral Surg.* 33: 101, 1972.
- Pineda, F.: Roentgenographic investigation of the mesiobuccal root of the maxillary first molar. *Oral Surg.* 36: 253, 1973.
- Pineda, F.: Roentgenographic investigation of the mesiobuccal root of the maxillary first molar. *J. Am. Dent. Assoc.* 88: 119, 1974.
- Pinero, G. J., Kiatpongah, S., Hutchins, M.O., Hoover, J.: The effect of endotoxins on the synthesis of connective tissue matrix components by pulp fibroblasts in vitro. *J. Endodont.* 9: 2, 1983.
- Pitt Ford, T. R., Torabinejad, M., McKendry, D. J., Hong, C. U., Kariyawasam, S. P.: Use of mineral trioxide aggregate for repair of furcal perforations. *Oral Surg.* 79: 756, 1995.
- Pitts, D. L., Williams, B. L., Morton, T. H.: Investigation of the role of endotoxins in periapical inflammation. *J. Endodont.* 8: 10, 1982.
- Plasmans, P. J. J. M., Welle, P. R., Vijrehoef, M. M. A.: In vitro resistance of composite resin dowel and cores. *J. Endodont.* 14: 300, 1988.
- Porkaew, P., Retief, D. H., Barfield, R. D., Lacefield, W. R., Soong, S.: Effect of calcium hydroxide paste as an intracanal medicament on apical seal. *J. Endodont.* 8: 369, 1990.
- Portell, F.R., Bernier, W. E., Lorton, L., Peters, D. D.: The effect of immediate versus delayed dowel space preparation on the integrity of the apical seal. *J. Endodont.* 8: 154, 1982.
- Portmann, P., Lussi, A.: A comparison between a new vacuum obturation technique and lateral condensation: An in vitro study. *J. Endodont.* 20: 292, 1994.
- Pumarola, J., Berasategui, E., Brau, E., Canalda, C., deAnta, T. J.: Antimicrobial activity of seven root canal sealers. *Oral Surg.* 74: 216, 1992.
- Ravn, J. J.: Follow up study of permanent incisors with enamel dentin fractures after acute trauma. *Scand. J. Dent. Res.* 89: 355, 1981a.
- Ravn, J.J.: Follow up study of permanent incisors with enamel fractures as a result of an acute trauma. *Scand. J. Dent. Res.* 89: 213, 1981 b.
- Ravn, J.J.: Follow up study of permanent incisors with complicated fractures after acute trauma. *Scand. J. Dent. Res.* 90: 363, 1982.
- Ray, H. A., Trope, M.: Periapical status of endodontically treated teeth in relation to the technical quality of the root filling and the coronal restoration. *Int. Endodont. J.* 28: 12, 1995.
- Reddy, S. A., Hicks, M. L.: Apical extrusion of debris using two hand and two rotary instrumentation techniques. *J. Endod.* 24: 180, 1998.
- Rehman, K., Saunders, W. P., Foye, R. H., Sharkey, S. W.: Calcium ion diffusion from calcium hydroxide-containing materials in endodontically treated teeth. *Int. Endodont. J.* 29: 271, 1996.
- Reid, J. S., Callis, P. D., Patterson, C.J.W.: *Rubber Dam in Clinical Practice.* Quintessence, London 1991.
- Richman, M.: Use of ultrasonics in root canal therapy and root resection. *J. Dent.* 12: 12, 1957.
- Rivera, E. M., Williams, K.: Placement of calcium hydroxide in simulated canals: comparison of glycerin versus water. *J. Endodont.* 20: 445, 1994.
- Roane, J., Sabala, C., Duncanson, M.: The balanced force concept for instrumentation of curved canals. *J. Endodont.* 11: 203, 1985.
- Robertson, W.D., Melfi, R.C.: Pulpal response to vital bleaching procedures. *J. Endodont.* 6: 645, 1980.
- Rock, W. P., Grundy, M. C.: The effect of luxation and subluxation upon the prognosis of traumatized incisors teeth. *J. Dent.* 9: 224, 1981.
- Ross, R. S., Nicholls, J. I., Harrington, G. W.: A comparison of strains generated during placement of five endodontic posts. *J. Endodont.* 17: 450, 1991.
- Rotstein, I., Friedman, S., Mor, C., Katznelson, J., Sommer, M., Bab, I.: Histological characterization of bleaching-induced external root resorption in dogs. *J. Endodont.* 17: 436, 1991.
- Rotstein, I., Friedman, S., Stabholz, A.: Endodontische Behandlungskonzepte bei Zehnen mit entwicklungsbedingten Mißbildungen. *Endodontie* 1: 117, 1992.
- Rotstein, I., Zyskind, D., Lewinstein, I., Bamberger, N.: Effect of different protective base material on hydrogen peroxide leakage during intracoronary bleaching in vitro. *J. Endodont.* 18: 114, 1992.
- Rubinstein, R., Kim, S.: Results of 94 endodontic microsurgeries using Super EBA retrofill. *AAE abstracts Vol. 22:* 188, 1996.
- Ruddle, C.J.: Endodontic failures: The rationale and application of surgical retreatment. *Rev. Odontol. Stomatol.* 5: 17, 1988.
- Ruddle, C. J.: Dreidimensionale Wurzelkanalfüllung. *Endodontie* 4: 7, 1995.
- Rudolph, M.P., vanAmerongen, J. P., tenCate, J. M.: Radiopacities in dentine under amalgam restorations. *Caries Res.* 28: 240, 1994.
- Rudolph, M. P., vanAmerongen, J. P., Penning, C., tenCate, J. M.: Grey discoloration and marginal fracture for the diagnosis of secondary caries in molars with occlusal amalgam restorations. *Caries Res.* 29: 371, 1995.
- Rupprecht, B., Beer, R., Beer, M., Rupprecht, P.: Klinisch kontrollierte Studie zur Erfolgsbewertung der lateralen and thermomechanischen Guttaperchakondensation. *Dtsch. Stomatol.* 39: 83, 1989.
- Rutledge, R. E., Montgomery, S.: Effect of intracanal medicaments on the sealing ability of TERM. *J. Endodont.* 16: 260, 1990.
- R
- Raab, W.H.M.: Die Laser-Doppler-FluBmessung: Untersuchung zur Mikrozirkulation der Zahnpulpa. *Dtsch. Zahnarztl. Z.* 44: 198, 1989.
- Raab, W.H.M., Müller, H.: Temperaturabhängige Veränderungen der Mikrozirkulation der Zahnpulpa. *Dtsch. Zahnarztl. Z.* 44: 496, 1989.
- Raab, W.H.M.: Diagnose and Pathologie entzündlicher Pulpaerkrankungen. In APW (Hrsg.): *Endodontie.* Hanser, München 1993 (S. 9)
- Raiden, G. C., Gendelman, H.: Effect of dowel space preparation on the apical seal of root canal fillings. *Endodont. Dent. Traumatol.* 10: 109, 1994.
- Rankine-Wilson, R. W., Henry, P.: The bifurcated root canal in lower anterior teeth. *J. Am. Dent. Assoc.* 70: 1162, 1965.
- Rapp, E. L., Brown, C. E., Newton, C. W.: An analysis of success and failure of apicoectomies. *J. Endodont.* 17: 508, 1991.
- S
- Safavi, K., Pascon, E.A., Langeland, K.: Evaluation of tissue reaction to endodontic materials. *J. Endodont.* 9: 421, 1983.
- Safavi, K.E., Horsted, P., Pascon, E.A., Langeland, K.: Biologic evaluation of the apical dentin chip plug. *J. Endodont.* 11: 18, 1985.
- Safavi, K. E., Dowden, W. E., Langeland, K.: Influence of delayed coronal permanent restoration on endodontic prognosis. *Endodont. Dent. Traumatol.* 3: 187, 1987.
- Safavi, K. E., Spangberg, L., Langeland, K.: Smear layer removal on root canal dentin tubule infection. *J. Endodont.* 15: 175, 1989.
- Safavi, K. E., Nichols, F. C.: Effect of calcium hydroxide on bacterial lipopolysaccharide. *J. Endodont.* 19: 76, 1993.

- Sailer, F., Pajarola, G.G.: *Orale Chirurgie. Farbatlanten der Zahnmedizin*, Band 11, Thieme, Stuttgart 1996.
- Saunders, W. R., Saunders, E. M.: Coronal leakage as a cause of failure in root-canal therapy. *Endodont. Dent. Traumatol.* 10: 105, 1994.
- Schafer, E., Gohring, C.: Untersuchungen zur Normierung von Wurzelkanalinstrumenten and Guttaperchastiften. *Endodontie* 2: 269, 1993.
- Schafer, E., Tepel, J., Hoppe, W.: Vergleichende Untersuchungen von Wurzelkanalinstrumenten aus herkömmlichem Stahl and Nickel-Titan-Legierungen. *Endodontie* 3: 185, 1994a.
- Schafer, E., Tepel, J., Hoppe, W.: Wurzelkanalinstrumente aus Nickel-Titan-Legierungen zur Wurzelkanalaufbereitung. *Zahnärztl. Welt.* 103: 90, 1994b.
- Schafer, E.: Das Instrumentarium zur manuellen Wurzelkanalaufbereitung. Teil 1: Wurzelkanalinstrumente aus Edelstahllegierungen. *Endodontie* 4: 205, 1995a.
- Schafer, E.: Das Instrumentarium zur manuellen Wurzelkanalaufbereitung. Teil 2: Wurzelkanalinstrumente aus Titanlegierungen. *Endodontie* 4:305, 1995b.
- Schafer, E.: Auswirkungen verschiedener Sterilisationsverfahren auf die Schneidleistung von Wurzelkanalinstrumenten. *Dtsch. Zahnärztl. Z.* 50: 150, 1995c.
- Schiffer, E.: Das Instrumentarium zur manuellen Wurzelkanalaufbereitung. *Endodontie* 4: 205, 1995d.
- Schilder, H.: A New Concept in Instrument Design. In Cohen, S., Burns, R.C.: *Pathways of the Pulp*, 6th ed. Mosby, St. Louis 1994 (p. 386).
- Schilder, H.: Filling root canals in three dimensions. *Dent. Clin. North Am.* 11: 723, 1967.
- Schilder, H.: Cleaning and shaping the root canal. *Dent. Clin. North Am.* 18:269, 1974.
- Schrader, U., Granath, L. E.: Early reaction of intact human teeth to calcium hydroxide following experimental pulpotomy and its significance to the development of hard tissue barrier. *Odontol. Rev.* 22: 379, 1971.
- Schrader, U.: Effects of the calcium hydroxide-containing pulp capping agents on pulp cell migration, proliferation and differentiation. *J. Dent. Res.* 64: 541, 1985 (Spec. issue).
- Schroeder, H. E.: *Pathobiologie oraler Strukturen*. Karger, Basel 1991 (S. 117).
- Scianamblo, M.J.: Mißerfolge nach Wurzelkanalbehandlung and deren Revision. *Endodontie* 2: 191, 1993.
- Sedgley, C. M., Messer, H. H.: Are endodontically treated teeth more brittle? *J. Endodont.* 18: 332, 1992.
- Seghi, R.R., Denri, I.: Effects of external bleaching on indentation and abrasion characteristics of human enamel in vitro. *J. Dent. Res.* 71: 1340, 1992.
- Segura, A., Donly, K. J., Wefel, J. S.: The effect of microabrasion on demineralization inhibition of enamel surface. *J. Dent. Res.* 72: 318, 1993.
- Seltzer, S., Bender, I. B., Smith, J., Freedman, I., Nazimov, H.: Endodontic failures: an analysis based on clinical, roentgenographic, and histologic findings. *Oral Surg.* 23: 500, 1967.
- Seltzer, S., Farber, P.A.: Microbiologic factors in endodontology. *Oral Surg.* 78: 634, 1994.
- Shoji, S., Nakamura, M., et al.: Histological changes in dental pulps irradiated by CO₂ laser: a preliminary report on lasers in pulpotomy. *J. Endodont.* 11: 379, 1985.
- Short, J. A., Morgan, L.A., Baumgartner, J. C.: A comparison of canal centering ability of four instrumentation techniques. *J. Endodont.* 23: 503, 1997.
- Shwartz, M., Grondahl, H. G., Pliskin, J., Boffa, J.:** A longitudinal analysis from bite-wing radiographs of the rate of progression of approximal carious lesions through human dental enamel. *Arch. Oral Biol.* 29: 529, 1984.
- Sigurdson, A., Stancill, R., Madison, S.: Intracanal placement of Ca(OH)₂: a comparison of techniques. *J. Endodont.* 18: 367, 1992.
- Silverstone, L. M.: Structure of carious enamel including the early lesion. *Oral Sci. Rev.* 3: 100, 1973.
- Simon, J.H.S.: Diagnostik and Behandlung C-formiger Wurzelkanäle. *Endodontie* 2: 7, 1993a.
- Simon, J.H.S.: Der endodontische Behandlungserfolg in Abhängigkeit von der Definition des Apex. *Endodontie* 2: 97, 1993b.
- Simon, S. T., Bhat, K. S., Francis, R.: Effect of four vehicles on the pH of calcium hydroxide and the release of calcium ions. *Oral Surg.* 80: 459, 1995.
- Simons, J., Ibanez, B., Friedman, S., Trope, M.: Leakage after lateral condensation with finger spreaders and D-11-spreaders. *J. Endodont.* 17: 101, 1991.
- Siqueira, J. F., Goncalves, R. B.: Antibacterial activity of root canal sealers against selected anaerobic bacteria. *J. Endodont.* 22: 79, 1996.
- Skidmore, A. E., Bjorndal, A. M.: Root canal morphology of the human mandibular first molar. *Oral Surg.* 32: 778, 1971.
- Snuggs, H. M., Cox, C. F., Powell, C. S., White, K. C.: Pulpal healing and dentinal bridge formation in an acidic environment. *Quintessence Int.* 24: 501, 1993.
- Socransky, S. S., Haffajee, A. D., Goodson, J. M., Lindhe, J.: New concepts of destructive periodontal disease. *J. Clin. Periodont.* 11: 21, 1984.
- Soeno, K.: A roentgenological study of morphologic change of pulp cavity with aging of human lower first molar. *Odontol. J. Nippon Dent. Univ.* 64: 1389, 1977.
- Soltanoff, W.A.: A comparative study of single visit and the multiple visit endodontic procedure. *J. Endodont.* 4: 278, 1978.
- Sorensen, J.A., Martinoff, J.T.: Clinically significant factors in dowel design. *J. Prosthet. Dent.* 52: 28, 1984a.
- Sorensen, J.A., Martinoff, J.T.: Intracoronal reinforcement and coronal coverage: a study of endodontically treated teeth. *J. Prosthet. Dent.* 51: 780, 1984b.
- Sorensen, J.A., Martinoff, J.T.: Endodontically treated teeth as abutments. *J. Prosthet. Dent.* 52: 631, 1985.
- Sorensen, J. A., Engelman, M.J.: Ferrule design and fracture resistance of endodontically treated teeth. *J. Prosthet. Dent.* 63: 529, 1990.
- Sornkul, E., Stannard, J.G.: Strength of roots before and after endodontic treatment and restoration. *J. Endodont.* 18: 440, 1992.
- Spangberg, L.W.S., Barbose, S. V., Lavigne, G. D.: AH26 releases formaldehyde. *J. Endodont.* 19: 596, 1993.
- Spangberg, L.W.S.: *Endodontic Filling Materials*. In Smith, D.C., Williams, D.F.: *Biocompatibility of Dental Materials*. CRC, Boca Raton 1982 (p. 213).
- Spasser, H. F.: A simple bleaching technique using sodium perborate. *N.Y. State Dent. J.* 27: 332, 1961.
- Stabholz, A., Sela, M. N.: The role of oral microorganisms in the pathogenesis of periapical pathosis. *J. Endodont.* 9: 171, 1983.
- Stabholz, A., Friedman, S.: Endodontic retreatment-case selection and technique. Part 2. *J. Endodont.* 14: 607, 1988.
- Staehele, H. J., Pioch, T., Hoppe, W.: The alkalizing properties of calcium hydroxid compounds. *Endodont. Dent. Traumatol.* 5: 147, 1989.
- Staehele H. J.: Calciumhydroxid in der Endodontie. *Endodontie* 1: 19, 1992.
- Staehele, H. J.: Medikamentöse Einlagen - Temporäre Wurzelfüllungen. *Z. Stomatol.* 90: 203, 1993.
- Staehele, H.J.: *Endodontie im Milchgebiss*. In APW (Hrsg.): *Endodontie*. Hanser, München 1993 (S. 135).
- Staehele, H.J., Spiess, V., Heinecke, A., Müller, H.R.: The effect of root canal filling materials containing calcium hydroxide on the alkalinity of root dentin. *Endodont. Dent. Traumatol.* 11: 163, 1995.
- Stashenko, P., Yu, S. M., Wang, C. Y.: Kinetics of immune cell and bone resorptive responses to endodontic infections. *J. Endodont.* 18: 422, 1992.
- Stenman, E., Spangberg, L.S.W.: Machining efficiency of endodontic K-Files and Hedstroem Files. *J. Endodont.* 16: 375, 1990a.
- Stenman, E., Spangberg, L.S.W.: Machining efficiency of Flex-R, K-Flex, Trio-Cut, and S Files. *J. Endodont.* 16: 575, 1990b.
- Stuart, K. G., Miller, C. H., Brown, C. E., Newton, C. W.: The comparative antimicrobial effect of calcium hydroxide. *Oral Surg.* 72: 101, 1991.
- Siibay, R. K., Suzuki, S., Suzuki, S.: Human pulp response after partial pulpotomy with two calcium hydroxide products. *Oral Surg.* 80: 330, 1995.
- Sundqvist, G., Johansson, E., Sjagren, U.: Prevalence of black-pigmented Bacteroides species in root canal infections. *J. Endodont.* 15: 13, 1989.
- Sundqvist, G.: Ecology of the root canal flora. *J. Endodont.* 18: 427, 1992.
- Sundqvist, G.: Microbiology in endodontics. *J. Endodont.* 18: 427, 1992.
- Swanson, K., Madison, S.: An evaluation of coronal microleakage in endodontically treated teeth. *J. Endodont.* 13: 56, 1987.

T

- Tagger, M., Szajkis, S.: Revision of root canal fillings. *J. Endodont.* 16: 338, 1990.
- Tamse, A., Littner, M. M., Kaffe, I., Moskona, D., Gavish, A.: Morphological and radiographic study of the apical foramen in distal roots of mandibular molars. Part I. The location of the apical foramen on various root aspects. *Int. Endodont. J.* 21: 205, 1988.
- Tamse, A.: Aetiologie, Diagnose und Behandlung vertikaler Wurzelfrakturen bei endodontisch behandelten Zehnen. *Endodontie* 3: 175, 1994.
- Tani, Y., Kawada, H.: Effects of laser irradiation on dentin. I. Effect on smear layer. *Dent. Mater. J.* 6: 127, 1987.
- Tavares, T., Soares, I. J., Silveira, N. L.: Reaction of rat subcutaneous tissue to implants of gutta-percha for endodontic use. *Endodont. Dent. Traumatol.* 10: 174, 1994.
- Tenland, T.: On Laser Doppler Flowmetry. *Methods and Microvascular Applications. Linköping Studies in Science and Technology Dissertations No. 83/ Linköping University Medical Dissertations No. 136, Linköping 1982.*
- Testori, T., Badino, M., Castagnola, M.: Vertical root fractures in endodontically treated teeth: a clinically survey of 36 cases. *J. Endodont.* 19: 87, 1993.
- Thylstrup, A., Bille, J., Quist, V.: Radiographic and observed tissue changes in approximal carious lesions at the time of operative treatment. *Caries Res.* 20: 75, 1986.
- Titley, K. C., Torneck, C. D., Ruse, N. D.: The effect of carbamide-peroxide gel on the shear bond strength of a microfil resin to bovine enamel. *J. Dent. Res.* 71: 20, 1992.
- Tolkdorf, W.: *Der preoperative Stref3.* Springer, Berlin 1985.
- Torabinejad, M., Kettering, J. D., McGraw, J.D., Cummings, R.R., Dwyer, T. G., Tobias, T.S.: Factors associated with endodontic interappointment emergencies of teeth with necrotic pulps. *J. Endodont.* 14: 261, 1988.
- Torabinejad, M., Ung, B., Kettering, J. D.: In vitro bacterial penetration of coronally unsealed endodontically treated teeth. *J. Endodont.* 16: 566, 1990.
- Torneck, C. D.: Changes in the fine structure of the dental pulp in human carious pulpitis. I. nerves and blood vessels. *J. Oral Pathol.* 3: 71, 1974.
- Torneck, C. D.: A report of studies into changes in the fine structure of the dental pulp in human carious pulpitis. *J. Endodont.* 7: 8, 1981.
- Torneck, C. D., Titley, K. C., Smith, D. C., Adibfar, A.: Effect of water leaching on the adhesion of composite resin to bleached and unbleached bovine enamel. *J. Endodont.* 17: 156, 1991.
- Tronstad, L., Yang, Z. P., Trope, M., Barnett, F., Hammond, B. F.: Controlled release of medicaments in endodontic therapy. *Endodont. Dent. Traumatol.* 1: 130, 1985.
- Trope, M., Tronstad, L.: Resistance to fracture of endodontically treated premolars restored with glass ionomer cement or acid etch composite resin. *J. Endodont.* 17: 257, 1991.
- Trope, M., Ray, H.L.: Resistance to fracture of endodontically treated roots. *Oral Surg.* 73: 99, 1992.
- Trope, M., Moshonov, R., Nissan, R., Buxt, P., Yesilsoy, J.: Short vs long term Ca(OH)₂ treatment of inflammatory root resorption. *J. Endodont.* 20:196,1994.
- Trope, M., Chow, E., Nissan, R.: In vitro endotoxin penetration of coronally unsealed endodontically treated teeth. *Endodont. Dent. Traumatol.* 11: 90, 1995a.
- Trope, M., Moshonov, J., Nissan, R., Buxt, P., Yesilsoy, C.: Short vs long-term calcium hydroxide treatment of established inflammatory root resorption in replanted dog teeth. *Endodont. Dent. Traumatol.* 11: 124, 1995b.
- Tsurumachi, T., Saito, T.: Treatment of large periapical lesions by inserting a drainage tube into the root canal. *Endodont. Dent. Traumatol.* 11: 41, 1995.
- Tveit, A. B., Espelid, I., Fjellveit, A.: Clinical diagnosis of occlusal dentin caries. *Caries Res.* 28: 368, 1994.

V

- Vahdady, A., Pitt Ford, T. R., Wilson, R. F.: Efficacy of chlorhexidine in disinfecting dentinal tubules in vitro. *Endodont. Dent. Traumatol.* 9: 243, 1993.
- Vanderas, A.P.: Effects of intracanal medicaments on inflammatory resorption or occurrence of ankylosis in mature traumatized teeth. *Endodont. Dent. Traumatol.* 9: 175, 1993.
- Van der Burgt, T.P., Plasschaert, A.J.M.: Bleaching of tooth discoloration caused by endodontic sealers. *J. Endodont.* 12: 231, 1986.
- Van Winkelhoff, A. J., Kippuw, N., van Steenberg, T.J.M., de Graaff, J.: Cross inhibition between black-pigmented *Bacteroides* species. *J. Dent. Res.* 66: 1663, 1987.
- Van Winkelhoff, A. J., van Steenberg, T.J.M., de Graaff, J.: Porphyromonas (*Bacteroides*) endodontalis: its role in endodontal infections. *J. Endodont.* 18: 431, 1992.
- Vassiliadis, L. P., Sklavounos, S. A., Stavrianos, C. K.: Depth penetration and appearance of Grossman sealer in the dentinal tubules: an in vitro study. *J. Endodont.* 20: 373, 1994.
- Verdonschot, E. H., Rondel, P., Huysmans, M. C.: Validity of electrical conductance measurements in evaluating the marginal integrity of sealant restorations. *Caries Res.* 29: 100, 1995.
- Vertucci, F.J.: Root canal anatomy of the mandibular anterior teeth. *J. Am. Dent. Assoc.* 89: 369, 1974.
- Vertucci, F. J., Seelig, A., Gillis, R.: Root canal morphology of the human maxillary second premolar. *Oral Surg.* 38: 456, 1974.
- Vertucci, F.J., Williams, R.G.: Furcation canals in the human mandibular first molar. *Oral Surg.* 38: 308, 1974.
- Vertucci, F.J.: Root canal morphology of mandibular premolars. *J. Am. Dent. Assoc.* 97: 47, 1978.
- Vertucci, F.J., Gegauff, A.: Root canal morphology of the maxillary first premolar. *J. Am. Dent. Assoc.* 99: 194, 1979.
- Vertucci, F.J.: Root canal anatomy of the human permanent teeth. *Oral Surg.* 58: 589, 1984.
- Vertucci, F.J., Anthony, R. L.: A scanning electron microscopic investigation of accessory foramina in the furcation and pulp chamber floor of molar teeth. *Oral Surg.* 62: 319, 1986.
- Vire, D. E.: Failure of endodontically treated teeth, classification and evaluation. *J. Endodont.* 17: 338, 1991.
- Vof3, A.: *Die Wurzelkanallengenbestimmung - Röntgenologisch and/oder endometrisch.* In APW (Hrsg.): *Endodontie.* Hanser, München 1993 (S. 49).

W

- Walia, H., Streiff, J., Gerstein, H.: Use of a hemostatic agent in the repair of procedural errors. *J. Endodont.* 14: 465, 1988.
- Walker, T. L., delRio, C.E.: Histological evaluation of ultrasonic and sonic instrumentation of curved root canals. *J. Endodont.* 15: 49, 1989.
- Walton, R., Fouad, A.: Endodontic interappointment flare-ups: a prospective study of incidence and related factors. *J. Endodont.* 18: 172, 1992.
- Walton, E. E., Langeland, K.: Migration of materials of the dental pulpa of monkeys. *J. Endodont.* 4: 167, 1978.
- Walton, R. E., O'Dell, N. L., Myers, D. L., Lake, F. T., Shimp, R. G.: External bleaching of tetracycline stained teeth in dogs. *J. Endodont.* 8: 536, 1982.
- Walton, R. E., Michelich, R. J., Smith, G. N.: The histopathogenesis of vertical root fractures. *J. Endodont.* 10: 48, 1984.
- Webber, R.T., del Rio, C. E., Brady, J. M., Segall, R.O.: Sealing quality of a temporary filling material. *Oral Surg.* 46: 123, 1978.
- Wechsler, S. M., Vogel, R. I., Fishelberg, G., Shovlin, R.E.: Iatrogenic root fractures. *J. Endodont.* 4: 251, 1978.
- Weichmann, J. A., Johnson, F.M.: Laser use in endodontics, a preliminary investigation. *Oral Surg.* 31: 416, 1971.
- Weine, F. S., Healey, H. J., Gerstein, H., Evanson, L.: Canal configuration in the mesio-buccal root of the maxillary first molar and its endodontic significance. *Oral Surg.* 28: 419, 1969.

Weine, F.S.: Endodontic Therapy, 2nd ed. Mosby, St. Louis 1982.

Weine, F.S., Wax, A. H., Wenckus, C. S.: Retrospective study of tapered, smooth post systems in place for 10 years or more. *J. Endodont.* 17: 293, 1991.

Weine, F.S.: Wurzelkanal-Füllungsmaterialien - ein Ausblick in das 21. Jahrhundert. *Phillip J.* 11: 227, 1994.

Weine, S.W., Rice, R.T.: Handling previously treated silver point cases: removal, retreatment and tooth retention. *Compend. Contin. Educ. Dent.* 7:652, 1986.

Weller, N., Niemczyk, S. P, Kim, S.: Incidence and position of the canal isthmus. *J. Endodont.* 21: 380, 1995.

Weller, N. R., Kimbrough, W. F., Anderson, R. W.: Root surface temperatures produced during post space preparation. *J. Endodont.* 22: 304, 1996.

Wennberg, A., Orstavik, D.: Evaluation of alternatives to chloroform in endodontic practice. *Endodont. Dent. Traumatol.* 5: 234, 1989.

Wenzel, A., Hintze, H., Mikkelsen, L., Mouyen, F.: Radiographic detection of occlusal caries in noncavitated teeth. *Oral Surg.* 72: 621, 1991.

Wesselink, P.R.: Qualitätsrichtlinien endodontischer Behandlung. *Endodontie* 3: 263, 1994.

West, J. D., Roane, J. B.: Cleaning and shaping the root canal system In: Cohen, S., Burns. R.C., *Pathways of the Pulp*, 7th ed., Mosby, St. Louis 1998 (p. 203).

White, S. C., Atchinson, K. A., Hewlett, E. R., Flack, V. F.: Efficacy of FDA guidelines for ordering radiographs for caries detection. *Oral Surg.* 77: 531, 1994.

White, S. N., Furuichi, R., Kyomen, S.M.: Microleakage trough dentin after crown cementation. *J. Endodont.* 21: 9, 1995.

Wiemann, A. H., Wilcox, L.R.: In vitro evaluation of four methods of sealer placement. *J. Endodont.* 17: 444, 1991.

Wilcox, L. R.: Endodontic retreatment: ultrasonics and chloroform as the final step in reinstrumentation. *J. Endodont.* 15: 125, 1989.

Wilcox, L. R., van Surksun, R.: Endodontic retreatment in large and small straight canals. *J. Endodont.* 17: 119, 1991.

Wilcox, L. R., Wiemann, A. H.: Effect of final alcohol rinse on sealer coverage of obturated root canals. *J. Endodont.* 21: 256, 1995.

Williams, C., Reid, J. S., Sharkey, S. W., Saunders, W. P.: In-vitro measurements of apically extruded irrigant in primary molars. *Int. Endodont. J.* 28: 221, 1995.

Winkler, R.: Kofferdam in Theorie and Praxis. Quintessenz, Berlin 1991.

Withers, J. A., Brunsvold, M. A., Killoy, W. J., Rake, A. J.: The relationship of palatogingival grooves to localized periodontal disease. *J. Periodontol.* 52: 41, 1981.

Wolcott, J., Himel, V.T.: Torsional properties of nickel-titanium versus stainless steel endodontic files. *J. Endod.* 23: 217, 1997.

Wong, M.: Surgical fenestration of large periapical lesions. *J. Endodont.* 17: 516, 1991.

Woolverton, C. J., Haywood, V. B., Heymann, H.O.: A toxicologic screen of two carbamide peroxide tooth whiteners. *J. Dent. Res.* 70: 558, 1991.

Wright, D.G.: The Neutrophil as a Secretory Organ of Host Defense. In Gallin, J.I., Fauci, A.S.: *Advances in Host Defense Mechanisms*, Vol I. Raven, New York 1982 (p. 75).

Y

Yahya, A.S., ElDeeb, M. E.: Effect of sonic versus ultrasonic instrumentation on canal preparation. *J. Endodont.* 15: 235, 1989.

Yamada, T., Nakamura, K., Iwaku, M., Fusyama, T.: The extend of the odontoblast process in normal and carious human dentine. *J. Dent. Res.* 62:798, 1983.

Yamamoto, H., Atsumi, K., Kusakari, H.: *Laser in Dentistry*. Excerpta Medica, Amsterdam 1989.

Yancich, P P, Hartwell, G. R., Portell, F R.: A comparison of apical seal: chloroform versus eucalyptol-dipped gutta-percha obturation. *J. Endodont.* 15: 257, 1989.

Yang, S. F, **Rivera, E. M., Baumgardner, K. R., Walton, R. E., Stanford, C.:** Anaerobic tissue-dissolving abilities of calcium hydroxide and sodium hypochlorite. *J. Endodont.* 21: 613, 1995.

Yared, G. M., Chahine, T. I., Dagher, F E. B.: Master cone apical behavior under in vitro compaction. *J. Endodont.* 18: 318, 1992.

Yared, G. M., Dagher, F E. B.: Elongation and movement of the gutta-percha master cone during initial lateral condensation. *J. Endodont.* 19: 395, 1993.

Yared, G. M., Dagher, E. B.: Influence of apical enlargement on bacterial infection during treatment of apical periodontitis. *J. Endodont.* 20: 535, 1994.

Yee, F.S., **Marlin, J., Krakow, A.A., Gron, P.:** Three-dimensional obturation of the root canal using injection molded, thermoplasticized dental guttapercha. *J. Endodont.* 3: 168, 1977.

Yesilsoy, C., Whittaker, E., Cleveland, D., Phillips, E., Trope, M.: Antimicrobial and toxic effects of established and potential root canal irrigants. *J. Endodont.* 21: 513, 1995.

Yoshiba, K., Yoshiba, N., Iwaku, M.: Histological observation of hard tissue barrier formation in amputated dental pulp capped with atricalcium phosphate containing calcium hydroxide. *Endod. Dent. Traumatol.* 10: 113, 1994.

Yoshiba, K., Yoshiba, N., Iwaku, M.: Effects of antibacterial capping agents on dental pulps of monkeys mechanically exposed to oral microflora. *J. Endodont.* 21: 16, 1995.

Z

Zachrisson, B., Jacobson, I.: Long term prognosis of 66 permanent anterior teeth with fractures. *Scand. J. Dent. Res.* 83: 345, 1975.

Zakariasen, K. L., Dederich, D. N., Tulip, J.: Nd-YAG laser fusion of dentin plugs in root canals. *J. Dent. Res.* 64: 239, 1985.

Zeppenfeld, W.: Praxisgerechte Kofferdamtechnik. *Zahnärztl. Mitt.* 80: 1485, 1990.

Zerfowski, M., Bremerich, A., Sadowski, K., Dehbing, K. C.: Kiefer- and Gesichtsverletzungen bei Kindern and Jugendlichen. *Dtsch. Z. Mund Kiefer Gesichts Chir.* 19: 299, 1995.

Zmener, O., Dominques, F.V.: Corrosion of silver cones in the subcutaneous tissue of the rat. *J. Endodont.* 11: 55, 1985.

Zmener, O., Guglielmotti, M. B., Cabrini, R. L.: Biocompatibility of two calcium hydroxide-based endodontic sealers: a quantitative study in the subcutaneous connective tissue of the rat. *J. Endodont.* 14: 229, 1988.

Zircher, E.: Zur Anatomie der Wurzelkanäle des menschlichen Milchgebisses and der 6 Jahr-Molaren. *Schweiz. Monatschr. Zahnheilkd.* 32: 439, 1922.

Illustration credits

Many of the illustrations in this atlas were generously made available to us for publication by the contributors listed below in alphabetical order. All other original photographs are by the principle authors.

Prof. Dr. C. Benz
105 to 107

Dr. T. P. Croll
780 to 795

Prof. Dr. F. F. Eifinger
20, 21

Prof. Dr. M. Frentzen
163 to 168, 170

Prof. Dr. S. Friedman
656

[Prof. Dr. J. L. Gutman](#)
622 to 624, 690 to 692

Prof. Dr. D. Heidemann
111 C

[Prof. Dr. Dr. W. Ketterl](#)
111 L

Prof. Dr. S. Kim
625 to 686

PD. Dr. M. D. W. Lipp
208 to 211

PD. Dr. A. Lussi
2 to 7, 11 to 13, 15, 16, 506, 508 to 511, 513 to 517.

Dr. G. Mayerhofer
763, 764

Prof. Dr. H. Plank
670

Dr. C. J. Ruddle
485 to 490, 501, 503 to 505

Dr. B. Suter
518

Subdivisions of illustrations are indicated by L (left), C (center) and R (right).

The following illustrations have been taken from the book *Die Lokalanästhesie* (M. Lipp, Quintessenz Verlag, Berlin 1992): 208 to 213

The following illustrations have been taken by M.A. Baumann from the work *Die räumliche Darstellung des Endodonts* (M.A. Baumann, Hanser, München 1995): 110, 111 R, 112 L, C, 113, 114, 114 L, 115 C, R, 116C,R, 117L,C,R

The following illustrations have been taken by R. Beer from the work *Praktische Endodontie* (R. Beer, M. A. Baumann, Urban & Schwarzenberg, München 1994): 26 R, 28 R, 29, 31 L, 36, 44, 46, 66, 67 R, 70, 71, 84 L, 96, 270, 271, 274 L, 284 L, 321, 376 R, 380 L, 381, 383, 399, 400, 402, 416 R, 421 R, 422, 424, 461, 463, 464, 466, 474, 475 L, 522, 524 to 526, 530, 531, 532, 534 to 539, 546 L, C, 548L, 553 to 555, 560, 561, 562 L, 563 R, 564 L, 567, 616 R, 617 L, 619 R, 621 C, 706, 708, 710, 733, 734, 737, 738 L, 753 R, 754 R, 758, 768 R, 772, 778

Index

A

abscess
 alveolar 162, 163
 dens invaginatus 206
 palatal 28
 periapical 27, 28-9
 periodontal 262
 phoenix 28
 pulp 14

access cavity, endodontic 270

acid-etch resin bonding technique 260

AH-26 cement 166, 167, 169, 173

Ainsworth punch 77, 78

alveolar nerve anesthesia 88

amalgam
 endodontically treated teeth 271
 retrograde fillings 251
 tooth discoloration 285

anesthesia, local
 agent selection 90
 conduction 87
 infiltration 87
 intraligamentary injection 87
 mandibular surgery 90
 maxillary surgery 90
 solutions 88-9
 topical 87
 vasoconstrictors 89

antimicrobial preparations 145

apex, radiographic 111

apexification 208
 deciduous teeth 199

Apexit 170

apical constriction 107
 working length 110

apical cyst see radicular cysts

apical enlargement 140

apical foramen 107
 excessive enlargement 108

apical master file (AMF) 123, 226
 recapitulation 123

apical periodontitis 1, 112
 acute 26-7
 drainage 162
 interim dressing 162-3
 bacteria 146, 172
 caries 26
 chronic 30-1, 114
 interim dressing 160-1
 radicular cysts 32-3

instrumentation 148

irrigation 148

pulp necrosis 26

retreatment indications 213

root canal necrosis 22

tooth injuries 255
 treatment 24, 168

apical regeneration 207

apical resection 240-1
 angle 240-1
 isthmus preparation 241

apical resorption, working length 114-15

apical seal 208

apical stop 177
 working length 114, 115

apical zone, critical 110

apicoectomy 244
 handpieces 68
 microsurgical endodontics 234
 ultrasound application 67
 vertical root fracture 263

articaïne 87, 89, 90

B

back pack 191, 192

bacteremia 151

bacteria
 apical periodontitis 114, 146
 calcium hydroxide dressings 147
 critical apical zone 110
 dentin 23
 dentinal tubule 26
 dentinal wall 26
 endodontic failure 212
 fistula association 146
 interim dressing 145, 147
 invasion in dens invaginatus 206
 lipopolysaccharides 158
 pain association 146
 pulp tissue 146
 root canal 23, 26
 infection 22-3
 smear layer adherence 155

bacterial endocarditis 35

bacterial infection
 secondary 28
 treatment 24-5

bacteriocins 23

Bacteroides 29

balanced force technique 120-1, 125,
 176, 220

biting test 39

bleaching gel 290, 291

bleaching of teeth 283-92
 filling replacement 286
 home technique 290
 microabrasion method 288-9
 mouthpiece 290, 291
 prognosis 283
 relapse 283
 solution 286
 thermocatalytic 286
 walking bleach technique 287

bleaching tray 291

bone
 breakdown 19
 destruction in apical periodontitis 30
 freeze-dried granules 231
 resorption 14, 165
 apical periodontitis 114

wax 242

bridge
 fitting 281
 fixation 282

bubbles, cavitation 195

C

Calasept 208

calcium binding 104

calcium hydroxide 25, 29, 111, 113,
 158-9
 apexification 208
 application after bleaching 287
 bacterial flora 147
 carrier 158
 coronal restoration 272
 coronal seal 268
 crown-root fracture 261
 direct pulp capping 203
 dressing 73, 115, 119
 glycerin suspension 159
 interim dressing 157, 164, 260
 apical periodontitis 160, 161, 162,
 163
 ion release 203
 lingual root groove 207
 packing after re instrumentation 229
 paste 203
 powder 159
 pulpotomy
 deciduous teeth 201
 mixed dentition 205
 sealed root canal 163
 sealer 170
 suspension medium 158

calcium phosphate 101

Calxyl 73, 287

Canal Master 142

Canalfinder system 64, 134, 135, 144

Cancellier instrument 223

canines
 mandibular 53
 maxillary 52

carbamide peroxide 290, 292

carbonic acid snow 38

caries 1
 apical periodontitis 26
 arrested media 8
 crown infractions 264
 dentinal 8
 excavation 12, 13
 fissure 4-6
 diagnosis 4
 enamel breakdown 6
 extent 5
 incidence in children 199
 index 199
 mineralization 101
 pain 39

progression 1, 40, 204
 proximal 2-3
 pulp tissue penetration 22
 pulpal necrosis 16, 17
 with pulpitis 10
 radiographic diagnosis 40
 removal 91
 smooth surface 7
 stagnation 1

Carr Tips 248

Cavit 232, 260, 268, 269

cavitation
 bubbles 195
 effect 67
 ultrasonic phenomenon 152

cellular defense mechanisms 1

cement
 application systems 73
 coronal restoration agent 273
 root canal 165, 166, 167

cementoamel junction 283

cementoid hard tissue formation 208

cementum
 deposition 114
 fracture 257
 resorption 14

chalky spots 7

chlorhexidine 85
 irrigation 148
 mouth rinse 254

chloroform 218, 219

chloropercha 166

chlorophenol 269

cleaning apparatus 194

cleaning and shaping
 Profile 04 137
 root canal filling 118-19

cleaning solution, biological compatibility
 194

cleansing, mechanical 24

CO₂ laser 71

cold test 38

collagen, denatured 231

complement activation in irreversible pul-
 pitis 11

composite cement, coronal restoration
 273

composite filling, bleaching of teeth 287

conservative endodontics 236

contrast enhancement, digital radiog-
 raphy 44, 45

coronal destruction, rubber dam appli-
 cation 86

coronal filling, impervious 25

coronal pulp chamber floor 94

coronal reference point, working length
 110

coronal seal 267
 calcium hydroxide 268
 interim dressing 268, 269
 provisional 268-9
 sodium hypochlorite irrigation 268

coronal-apical instrumentation technique
 124

- corticosteroids 145, 157
- crown**
- access preparation 212
 - artificial 273
 - discoloration 283
 - flap design 239
 - fracture 255, 258-9
 - complicated 258, 259
 - uncomplicated 257, 258
 - pain 214
 - partial veneer 270-1
 - perforations 232
 - provisional 93
 - removal 214, 216
 - retreatment
 - completion 213
 - indications 212
 - stabilization 265
- crown infractions**
- caries 264
 - pain 264
 - pulpitis 265
 - root canal filling 266
- crown restoration 211, 267, 272-3**
- cast dowel-core 279
 - cementing agent 273
 - failure rate 281
 - fracture risk 272
 - temporary filling 267
 - treatment results 280-1
- crown-root fracture 256, 260-1**
- calcium hydroxide 261
 - complicated 261
 - coronal fragment 260
 - crown fragment bonding 260
 - post-core 261
 - pulp vitality maintenance 261
 - pulpal necrosis 261
 - root canal obturation 261
- cryanoacrylate cement 223**
- post cores 279
- D-11 spreader 176**
- deciduous teeth, early loss 199**
- demineralization 1**
- bleaching of teeth 292
 - endodontic failure 216
- dens in dente 206**
- dens invaginatus 206**
- dental floss**
- frames 84
 - rubber dam application 83, 86
- denticles 100**
- chronic inflammation 101
 - reversible pulpitis 9
- dentin 128**
- adhesive 21
 - bacteria 23
 - in wall 26
 - balanced force technique 121
 - carious 8
 - decalcification 104
 - endodontically treated teeth 270, 272, 273
 - excessive removal 127
 - exposure 258
 - fracture 255, 257
 - fragment accumulation in apical region 113
 - hydroxyl ion diffusion 161
 - intrapulpal 100
 - laser treatment 70
 - lesions 2, 3
 - overloading 176
 - peritubular dissolution 154
 - permeability 105, 154
 - radiolucency 3
 - removal 119, 181
 - resorption 14
 - root canal sealing 71
 - secondary deposition 56
- shavings**
- accumulation 181
 - endodontic failure 215
 - tertiary 8, 14, 70, 284
 - treatment in deciduous dentition 199
 - tubular tertiary 203
- dentinal bridge**
- calcium requirement 203
 - laser vital amputation 71
- dentinal tubules 20, 128**
- bacteria 26
 - penetration 17
 - bleaching agent penetration 285
 - closure 129
 - decomposition product penetration 284
 - hydrogen peroxide penetration 283
 - sealing 70
- dentinoenamel junction 107**
- dentinoplasty 115**
- developmental defects in teeth 206-8**
- devitalization, intentional 18-19**
- diagnosis 35**
- Diaket 166, 169**
- digital radiography**
- contrast enhancement 44, 45
 - dynamic 45
 - false color representation 44
 - filters 45
 - intraoral 44
 - millimeter grid 44
 - positive-negative representation 44, 45, 46
 - projection angle 45
 - resolution 45
 - uses 46
- disinfection 145**
- dressings 145
 - gutta-percha 75
 - posts 275
- dowel-core, cast 279, 280**
- down pack 189, 190, 191, 192**
- dressings**
- disinfection 145
 - medicated 73, 156-7
- dressings, interim 145, 147, 156-7**
- access opening sealing 163
 - apical periodontitis 160-1, 162-3
 - calcium hydroxide 164
 - coronal restoration 272
 - coronal seal 268, 269
 - crown fracture 259
 - crown-root fracture 260
 - endodontic failure 214
 - gutta-percha filling removal 220
 - posts 275
- drills, trephining 228**
- Dycal 269**
- dye penetration test 167**
- E**
- EDTA**
- lubricant 104, 105
 - obstruction removal 180
 - smear layer removal 154
- electric caries meter 4**
- electric pulp test 38**
- enamel**
- caries penetration 2
 - crown fracture 258
 - fissure caries 6
 - fracture 255
 - microabrasion 288-9
- enamel-dentin fractures 256**
- Endo Access bur 94**
- Endo Vacuum Set 250**
- Endocursor 64**
- endodontia, laser therapy 69**
- endodontic diagnosis 12-13**
- endodontic failure**
- broken instrument fragment removal 222-7
- coronal perforations 232**
- demineralization 216**
- fractured instrument bypassing 228-9**
- gutta-percha fillings 218-21**
- interim dressings 214**
- lateral perforation repair 230-1**
- pain 214-15**
- post-core removal 216-17**
- radiographs 213**
- retreatment 209**
- indications 212-13
- root canal anatomy 210-11**
- endodontic inflammation 12**
- endodontics**
- failed therapy 198, 236
 - lasers 69-72
 - radiography 42-3
 - treatment error 236
- endodontium 47**
- communication to periodontium 241
 - components 51
- Endolift 1134, 135**
- Endomethasone 169**
- endosonic ultrasonic synergistic system 67**
- Endosonore file 66**
- periapical bone resorption 158
 - pulp necrosis 17, 156
 - root canal filling penetration 267
- engine-driven instrumentation**
- canal surface 144
 - root canal preparation 134-5
- epinephrine 89, 90, 242**
- epithelial rests of Malassez 34**
- erythrocytes 20**
- erythromycin 215**
- ethoxybenzoic acid cement 252-3**
- ethylenediamine, smear layer removal 154**
- eucalyptol 218, 219**
- eugenol 269**
- Excalibur handpiece 134**
- F**
- facial nerve anesthesia 89**
- fiberoptic cables**
- breakage 72
 - laser transmission 69
- fibroblasts**
- chronic apical periodontitis 30
 - transformation 145
- fibroblastic 100**
- files 60**
- flexible 135
 - nickel-titanium alloy 63
 - wear 63
- filling material**
- foreign body reactions 212
 - pulp necrosis 19-20
 - root canal 165
- fillings, bacterial penetration 37**
- fistula**
- bacterial association 146
 - extraoral 36
 - intraoral 37
 - maxillary molar 132
- fistulous tract**
- gutta-percha point 168
 - irrigation 150
 - lingual root groove 207
- flaps, microsurgical endodontics 238-9**
- Flex-R file 61, 120**
- Flexicut file 97**
- Flexofile 61**
- Flexogates 61**
- Flexoreamer 61**
- fluoride treatment 289**
- tooth discoloration 284
- fluorosis 288**
- foreign body reactions 165**
- filling material 212**
- formaldehyde 18, 19, 157, 201**
- root canal cement 165
- formocresol 201, 269**
- fractures, post removal 217**
- funnel formation 126**
- fusobacteria 151, 163**
- Fusobacterium nucleatum* 23**
- G**
- Gates-Glidden drills 97, 119**
- canal shaping 136, 137
 - Lightspeed instrumentation 142, 143
- Gelfoam 231**
- hemostasis 242
- giant cell granuloma 212**
- gingiva examination 39**
- Giromatic system 64**
- handpiece 134, 135
- glass ionomer cement 92, 111, 232**
- coronal restoration 273
 - crown fracture 276
 - dye penetration test 167
 - partial veneer crowns 271
 - vertical root fracture 262
- Gonon post remover 217**
- Gram-negative bacteria 11**
- granulation tissue, periapical 31**
- granulocytes see polymorphonuclear leukocytes**
- Grossman cement 166, 169, 269**
- gutta-percha 74-5**
- adaptation 172-5
 - condensation 173-5
 - corrections 176-7
 - overextension 177, 178-9
- condenser 73**
- disinfection 75**
- dissolution 218, 219**
- elongation 177**
- filling 179**
- balanced force technique 220
 - endodontic failure 218-21
 - interim dressing 220
 - removal 219
 - retreatment 218-21
 - three-dimensional 186-7
 - working length measurement 219-20
- finger spreaders 75**
- forms 74**
- hand spreaders 75**
- heated 76**
- heating 188, 189, 191**
- instruments 76**
- lateral condensation 170-1, 174**
- master point 139, 170**
- apical condensation 190
 - broken instrument fragment removal 227
 - condensation 171
 - coronal filling 191
 - fractured instrument bypassing 229
 - insertion with posts 275
 - introduction 182
 - overextension 177
 - reinsertion 221
 - short 180-1
 - shortening 179, 190
 - trial insertion 173
 - vertical condensation 189
- overextension 177**
- point 74-5, 99, 100, 182
 - accessory 171
 - fistulous tract 168
 - fitting with overinstrumentation 178
 - inflammatory reaction 178
 - lateral condensation 179, 181
 - master cone 123
 - master cone radiograph 121

- gutta-percha, point
 obturation and operating microscope 131
 pulpotomy in mixed dentition 205
 sealer coated 172, 173
 thermomechanical condensation 182
 working length 102
 working length marking 109, 115
 posts 274
 removal 218
 root canal
 filling 165
 obturation 111, 119, 169, 170-1
 packing 106
 solvents 218, 219
 standardization 74, 75
 Thermafil system 183
 thermoplastic injection technique 184-5
 Trifekta technique 184, 185
 Ultrafil system 184-5
 vertical condensation 188-91
 zinc oxide filler 74
- H**
- H file 60, 97
 halothane 218, 219
 handpieces, sonic instrumentation 66
 Hedstrom file see H file
 Heidemann spatula 83
 Heliapical 61
 Heli file 61
 Helisonic instrument 66
 hemisection 282
 hemostasis
 direct pulp capping 203
 microsurgical endodontics 242
 pellet technique 242
 pulpotomy
 deciduous teeth 200, 201
 mixed dentition 205
 humoral defense mechanisms 1
 hydrogen peroxide 286, 287
 penetration 283
 hydroxyl ions 161
 hyperemia, infrared laser beam 70
- I**
- ibuprofen 215
 impedance measurement of tissue 116
 impression making 92
 incisors
 canal entrance uncovering 95
 magnetic resonance imaging 50
 mandibular 53
 second root canal 51
 maxillary 52
 inflammation 145
 corticosteroid suppression 157
 periapical 11, 17
 inflammatory reaction
 fractured instruments 229
 gutta-percha point 178
 initial apical file (IAF) 122, 123
 instruments
 broken fragment removal 222-7
 apical instrumentation 226
 apical master file 226
 canal entrance probing 225
 deep preparation 224
 drying 227
 irrigation 226, 227
 master point fitting 227
 microscopic inspection 224, 225, 226
 radiographic diagnosis 222
 radiography 224, 225
 instrumentation 223
 root canal obturation 227
 working length 224, 225, 226
 bypassing fractured 228-9
 fragment exposure 228
 inflammatory reaction 229
 instrumentation 228
 steel 229
 trephining drills 228
 cutting efficiency 63
 engine-driven 64-5
 flexible 61
 microapicoectomy 68
 penetration depth 62
 retrograde microsurgery 68
 sonic systems 66-7
 standards 59
 sterilization 63
 titanium alloy 62-3
 ultrasonic systems 66-7
 interleukin-1 (IL-1) 30
 Intra-Endo 3LD 64, 134
 iodoform 157, 285
 IRM cement 232, 268, 269
 iron sulfate 242
 iron sulfide 284
 irrigation 73
 broken instrument fragment removal 226, 227
 canula 149
 fully automated cleaning 194
 medicated 147, 148-9
 microbial control 148-9
 necrotic pulp tissue dissolution 149
 periapical lesion 150-1
 recall evaluation 149
 root canal preparation 110
 sodium chloride 151
 sodium hypochlorite 194, 195
 solutions 67
 biological compatibility 194
 ultrasonic 24, 152-3
 ISO standardization 59
 isthmus 244-5
 cleaning 246
 clinical treatment 246-7
 communication between root canals 244-5
 direction 247
 filling 247
 preparation 245
 shape 246
 ivory punch 77, 78
- J**
- reinstrumentation 223
 root canal obturation 227
 working length 224, 225, 226
 bypassing fractured 228-9
 fragment exposure 228
 inflammatory reaction 229
 instrumentation 228
 steel 229
 trephining drills 228
 cutting efficiency 63
 engine-driven 64-5
 flexible 61
 microapicoectomy 68
 penetration depth 62
 retrograde microsurgery 68
 sonic systems 66-7
 standards 59
 sterilization 63
 titanium alloy 62-3
 ultrasonic systems 66-7
- K**
- K file 60, 97
 step-back technique 122, 123
 titanium alloy 62
 ultrasonic 66
 K flex 61
 K reamer 60
 Kerr compound 80
 Kerr Endolift 64
 Kerr sealer 167, 173
 vertical condensation 189
- L**
- laser
 delivery systems 69
 dentin treatment 70
 direct radiation of root canal 69
 Doppler probe vitality test 70
 endodontics 69-72
 infrared beam 70
 pulp treatment 70
 root canal
 preparation 72
 sealing 71
 vital amputation 71
 lateral condensation technique 127
 latex allergy 78
 Lentulo spiral 73, 159, 172
 lidocaine 87, 88, 90
 Lightspeed instruments 65, 142-3
 lingual canal 98
 lingual root groove 207
 lipopolysaccharides, bacterial 158
 Listerine 254
 lymph nodes of head and neck, examination 36, 39
 lymphokines 10
- M**
- macrophages 8, 14, 17
 AH-26 pulp reaction 166
 apical periodontitis 27
 chronic apical periodontitis 30
 polyketone-based resin cement 165
 McSpedden Compactors 159
 Maillefer 73, 74, 75
 mandible, radiographic diagnosis 41
 mandibular nerve anesthesia 89
 mandibular radiolucency 40
 mandibular teeth
 access preparations 95
 anterior 53
 marsupialization 150
 master cone, radiograph 121
 maxillary radiolucency 40
 maxillary teeth
 access preparations 95
 anterior 52
 membrane, resorbable 232
 mepivacaine 87, 88, 90
 microapicoectomy 68
 microabrasion of teeth 288-9
 microscope, operating 235
 microstreaming, ultrasonic phenomenon 152
 microsurgery, retrograde 68
 microsurgical endodontics 233
 apical resection 240-1
 cavity drying 250
 errors 240
 flap design/execution 238-9
 hemostasis 242
 illumination 234, 235
 indications 236
 instrumentation 234
 isthmus 244-5
 preparation 241
 magnification 234, 235
 osteotomy planning 237
 periapical lesion localization 237
 presurgical examination 237
 principles 234
 radiography 237
 resected surface inspection 243
 resection angle 240-1
 retrograde preparation 248-9
 amalgam 251
 drying 250
 Super EBA cement 252-3
 reverse obturation 250, 251
 Super EBA cement 252-3
 sutures 254
 treatment error 236
 ultrasonic unit 248-9
 microtitanium instruments 62, 63
 mineralization
 advanced caries 101
 reversible pulpitis 9
 mobilized flaps, microsurgical endodontics 239
 MOD amalgam retortations 271
 molars
 canal entrance uncovering 95
 magnetic resonance imaging 50
 mandibular 58
- N**
- N2 cement 169
 nasopalatine nerve anesthesia 88
 Nd:YAG laser 71, 72
 neurologic investigations 36
 neutrophilic granulocytes 8, 10, 14, 17
 AH-26 pulp reaction 166
 apical periodontitis 27
 migration 20, 21
 nickel-titanium alloys 62-3
 corrosion 63
 nickel-titanium instrumentation of canal surface 144
 nickel-titanium instruments
 engine-driven 65
 Profile 04 136
 separation 139
 nightguard vital bleaching 290-1, 292
 Nitinol files 135
 Nitinol spreaders 173, 174
- O**
- odontoblastic layer, calcium hydroxide dressing 160
 odontoblasts 20
 secondary 203
 oral hygiene 254
 orthodontic appliance, fixed 86
 osteoblasts 30
 osteoclasts 114
 osteodentin 203
 osteomyelitis 29
 osteotomy planning 237
 overinstrumentation 110
- P**
- pain
 bacterial association 146
 caries 39
 cracked teeth 264
 crowns 214
 endodontic failure 214-15
 history 35
 mechanism 9
 origin 35
 patient examination 39
 periapical lesions 164
 pulp condition 12, 13
- C-shaped canal** 58
 crown infraction 264
 first 58
 second 58
 maxillary 56-7
 access cavity 132
 distobuccal root 57
 embryonic development 210
 endodontic failure 210
 first 51, 57
 fistula 132
 fourth canal 56
 instrumentation for root canal preparation 132-3
 lingual root 57
 mesiobuccal root 57, 132, 133
 mesiolingual entrance to canal 132
 mesiopalatinal canal orifice 133
 second canals 132, 133
 periapical lesion 36
 mucoperiosteal flap, microsurgical endodontics 238

- pulp tissue extirpation 19
 reversible pulpitis 13
 root canal treatment 214-15
- paper points 73, 103, 250
 paper tips 108
- Para-post dowels 279
- paraposts 217
- parapulpal pins 111
- pastes
 application systems 73
 fillers 73, 159
- patient examination 35
 clinical 39
 extraoral 36
 intraoral 37
 therapy selection 39
- penicillin 215
- peptostreptococci 151, 163
- Peptostreptococcus micros 23
- percussion test
 intraoral examination 37, 39
 tenderness 12
- perforations
 coronal 232
 lateral 230-1
 location 230-1
 repair 231
 sealing 231
- periapical abscess 27, 28-9
 pus evacuation 29
- periapical inflammation 11
 pulpal necrosis 17
- periapical lesion
 apical enlargement 151
 coronal restoration 281
 decompression 151
 irrigation 150-1
 localization for microsurgical endodontics 237
 size 30
 sodium chloride irrigation 151
 therapy-resistant 212
- periapical radiolucency, retreatment indications 213
- periapical resorption 42, 114
- periodontal abscess, root fracture 262
- periodontal fracture 257
- periodontal pocket
 formation 187
 vertical root fracture 262
- periodontium communication to endodontium 241
- phenol, tooth discoloration 285
- phenolic compounds 25
- phosphoric acid etching 285
- Piezo Ultrasonic System 66
- plasma cells, chronic apical periodontitis 30
- pluggers 188, 189, 190, 191
 pulpectomy in deciduous teeth 202
- polycarboxylate cement 273
 post-cores 279
- polymorphonuclear leukocytes 10, 14
 apical periodontitis 27, 30
- Porphyromonas spp. 23, 27, 29, 146, 163
- post
 coronal portion enlargement 274
 disinfection 275
 endodontic 274-7
 insertion 211, 273, 277
 interim dressing 275
 parallel-sided 279
 prefabricated systems 261
 removal 216, 217
 screw 216
 tapered systems 279
- post and crown, failure rate 281
- post space 274
 preparation 275, 276, 277
- post-core 274
 build-up 277
 cast 278-9
 cementation 279
 crown-root fracture 261
 hemisected teeth 282
 preparation 278
- removal in endodontic failure 216-17
 vertical root fracture 263
- postendodontic care 267
- postendodontic infection 110
- predentin 128
 calcium hydroxide dressing 160
- Prema 289
- premolars
 mandibular 55
 root canal system 211
 maxillary 54
 crown infraction 264
- Prevotella buccae 146
- Proco-Seal 173
- Proco-Sol 167
- Profile 04 136-7
- propylene glycol 158
- pulp
 abscess 14
 amputation
 crown fracture 259
 deciduous teeth 200
 mixed dentition 204
 vital 71
 apical periodontitis 27
 bacteria 146
 capping
 direct 199, 203, 259
 indirect 199
 material 205
 carious exposure 14-17
 chamber
 access for pulpotomy 204
 anatomy 51
 floor 99
 internal architecture 47, 48
 location 99
 opening 94
 roof penetration 96
 roof removal 270
 compression 113
 extirpation 112
 fracture 257
 innervation 9
 intentional devitalization 18-19
 laser treatment 69, 70
 necrosis 14, 16-17, 156
 apexification 208
 apical periodontitis 26
 bacterial penetration 172
 crown fracture 258
 crown-root fracture 261
 dens invaginatus 206
 endodontically treated teeth 270
 filling materials 19-20
 lingual root groove 207
 tooth discoloration 284, 285
 tooth injuries 255, 257
 necrotic tissue dissolution 149
 polyp 14, 15
 stump emulsification 112
 tissue
 removal in deciduous teeth 200
 toxin penetration 11
 vital extirpation 170
 pulpectomy, deciduous teeth 199, 202
- pulpitis 1
 acute irreversible 10-11
 crown infractions 265
 inflammatory cell accumulation 10
 inflammatory reaction 10-11
 irreversible 12, 13, 39
 reversible 8-9, 13, 39
- pulpitis aperta 14, 15
 chronic 15
 granulomatosa 14
- pulpoblasts 100
- pulpotomy
 deciduous teeth 199, 200-1
 mixed dentition 204-5
- Quanteq instruments 65
 series 2000 140-1
- R
- Racer System 134, 135
- radicular cysts 34
 chronic apical periodontitis 32-3
 pocket 33
 true 33, 34
- radiographic diagnosis 40-1
 endodontics 42-3
- radiography
 diagnostic 42
 digital technique 44-6
 eccentric 41
 endodontics 42-3
 first measurement 42
 lawsuit defense 43
 master point 43
 root canal anatomy 48
 rubber dam 86
 working length 42
- radiolucencies, diagnosis 40
- Radix Anchor 277
- RC-Prep 112, 118
 obstruction removal 180
- reamers 60, 119
- remineralization 1
 smooth surface caries 7
- resin cement, polyketone-based 165
- retrosurgery
 inserts 67
 microscopic 68
 with ultrasound 67
- reverse obturation 250, 251
 Super EBA cement 252-3
- Rispisonic instrument 66
- root
 development assessment 204
 external resorption 283
 growth completion 199
 perforation 230
 resected surface 243
 resorption with tooth injuries 255
 tip
 apical palpation 37, 39
 complexity 243
- root canal
 amputation 193
 anatomy 47, 51
 3D computer reconstruction 49
 contour-based reconstruction 49
 histologica sections 48
 magnetic resonance imaging 50
 methods of reproduction 48-9
 radiography 48
 volume-based reconstruction 49
- anterior mandibular teeth 53
- anterior maxillary teeth 52
- apical constriction 107, 108
- apical ramifications 210
- bacteria 23, 26
 infection 22-3
 penetration 172
- biological evaluation 173
- C-shaped 58
- configuration classification 51
- conical shaping 106
- curvature 98, 99
- curved 120-1, 129
 calcium hydroxide filling 159
 obturation 187, 193
- dressing for apexification 208
- drying 73, 103
- enlargement 101
- fourth 168
- gutta-percha
 obturation 111, 169, 170-1
 packing 106
- infection 29, 169
 microbial 146-7
- isthmus communication 244-5
- laser
 expansion 72
 preparation 72
 treatment 69
- lateral 194
- lateral canals 186-7
- length determination 101
- mandibular molars 58
- mandibular premolars 55
- maxillary molars 56-7
- maxillary premolars 54
- mineral deposits 101
- multiple ramifications 211
- obliterated 100-1
- obliteration 76
 crown fracture 259
- obstructions 104
- overfilled 241
- overlooked primary 210
- periapical abscess 28
- pulp necrosis 14
- retrograde surgery 68
- sealer wall coating 172
- sealers 169, 170
- sealing 71
- straight 129
- system 193
- treatment
 cast post-cores 278
 gutta-percha filling 97
 irreversible pulpitis 13
 mishaps 236
 pain 214-15
 radiography 43
 tooth mechanical properties 272
- root canal filling 13, 19, 21, 76, 102, 168
- apical 190
- bubble formation 198
- calcium hydroxide dressing 119
- cement covering 283
- chronic apical periodontitis 32, 33
- cleaning 118-19
- condensation 173, 174-5
 inadequacy 198
- coronal 191
 restoration 25
 seal 111
- crown infractions 266
- defective 213
- failure 198
- fully automated obturation 196-7
- glass ionomer cement 111
- gutta-percha points 99, 100
 master 139
 obturation 119, 131
 reinsertion 221
- hemisection 193
- inadequate 209
- inflammatory reaction to removal 229
- interim dressing 115
- lateral canals 186-7
- lateral condensation 259
- marginal adaptation 243
- material 165
- overextension prevention 115
- overfilling 135
- periapical abscess 29
- postoperative radiograph 109
- radiography 43, 117
- retrograde 251
- shaping 118-19
- step-down technique 125
- Thermafill 137, 183
- thermomechanical condensation 182
- thermoplastic injection technique 184-5
- three-dimensional 186-7
- tooth discoloration 285
- Ultrafil system 184
- vertical condensation 188-91
 see also working length

- root canal obturation 106, 113, 159, 161, 165, 169
 broken instrument fragment removal 227
 crown-root fracture 261
 curved canals 193
 endodontic failure 217
 fractured instrument bypassing 229
 fully automated 196-7
 healing 192
 lateral perforation repair 231
 lingual root groove 207
 partial vacuum method 196-7
 retreatment 213, 215, 217
 success rate 192-3
 tooth fracture 271
- root canal preparation 91, 107
 access opening 118
 Tri Auto ZX 138
 acid rinse 180, 181
 after extirpation 128
 antimicrobial preparations 145
 apical enlargement 151
 apical instrumentation 144
 bacterial flora 147
 balanced force technique 120-1, 125, 176
 blockages 180
 bonding of provisional restoration 93
 broken instrument fragment removal 222-3
 canal enlargement 139
 canal entrance
 probing 96-7
 uncovering 95
 canal location 95, 97
 with surgical operation microscope 102-3
 caries removal 91
 cast fabrication 93
 cervical ledge removal 98
 chelating agent rinse 180, 181
 chemical aids 104-6
 coronal enlargement 99, 223
 Lightspeed 142
 Profile 04 136
 crown penetration 96
 curved canals 120-1
 deep preparation 131
 dentin removal 119
 end-point 107
 entrance enlargement 97
 extirpation 118
 fully automated 194-5
 funnel formation 126
 glass ionomer cement 92
 impression making 92
 instrumentation 106, 110, 112, 113, 118, 119, 127
 apical periodontitis 148
 bacterial control 147
 bacterial elimination 156
 balanced force technique 176
 Canalfinder 144
 deciduous teeth 202
 endodontic failure 215, 217
 engine-driven 134-5
 H files 128
 K files 129
 Lightspeed 142-3
 maxillary molars 132-3
 midcanal 144
 periapical lesion 150
 problems 126-7
 Profile 04 136-7
 pulpotomy in mixed dentition 205
 Quantec series 2000 140-1
 rat-tail files 129
 smear layer formation 154
 step-down technique 176
 surgical microscope 130-1
 Tri Auto ZX 138-9
 ultrasonic irrigation 152
- instruments 94
 prebending 126
 interim restorations 92-3
 irrigation 110, 119, 148-9
- apical periodontitis 160
 ultrasonic 152-3
- lateral condensation technique 127
 length determination 97, 101
 lubricants 104
 medication diffusion into pulp 145
 necrotic pulp removal 97, 98
 obliterated canal 100-1
 entrance location 102, 104
 opening 103, 104
 overinstrumentation 110, 127
 gutta-percha master point fitting 178
- patency
 confirmation 119
 testing 124
- perforation of wall 127
 previous restoration removal 91
 provisional closure 101
 provisional crowns 93
- pulp chamber
 floor 99
 opening 94
- pulp removal 118
 radiographic length determination 108-9
 reamers 119
 recapitulation 119
 re instrumentation 223
 retrograde 247
 shaping with Quantec series 2000 instrumentation 141
 step formation 126
 step-back technique 122-3
 Lightspeed instrumentation 143
 step-down technique 124-5
 straight-line access 98-9
- surface
 after engine-driven instrumentation 144
 following manual instrumentation 128-30
 trepanation 130
 wide coronal access cavity 113
- working length
 determination 111
 loss 112-13
 radiograph 108
- root fracture 176, 255, 257
- rubber dam 77
 bow technique 81
 clamp first technique 85
 clamps 79, 81, 86
 forceps 80
 frames 80, 86
 function 77
 insertion phases 81
 ivory punch 77, 78
 latex allergy 78
 lubricants 78
 material 78
 operating field disinfection 85
 placement 81-5
 punches 78
 radiography 86
 root canal preparation 109
 rubber first procedure 84
 tray 80
 wing technique 82-3
- S**
- S files 61
 Sealapex 169, 170, 173
 sealer 169, 170
 apical 177
 materials 268
 post-core 279
 root canal wall coating 172
- Selenomonas sputigena* 23
 sensitivity test 12, 38
 Shaper instrument 66
 shaping, root canal filling 118-19
- silver amalgam, retrograde fillings 251
 silver point fragments 229
 smear layer removal 154-5
 smear plugs 128
 sodium chloride, irrigation of periapical lesion 151
- sodium hypochlorite 24, 25
 contraindication in bacteremia 151
 cytotoxicity 194
 interm dressing flushing 157
 irrigation 73, 124, 148, 149, 194, 195
 coronal seal 268
 gutta-percha filling removal 220
 root canal 103
 ultrasonic 152
 tissue-dissolving 195
 ultrasound combination 67
- sodium perborate 287
 soft tissue healing, sutures 254
 Sonic Air instrument 66
 spirals 73, 159
 spreaders 173
 conical 171
 corrections during condensation 176-7
 finger 170, 171, 173
 hand 171
 insertion 173
 material 173
- stagnation of disease 1
 stains, external 290
 step formation 126
 step-back technique 122-3
 Lightspeed instrumentation 143
 step-down technique 124-5, 176
 apical preparation 125
 instrumentation 124, 125
 lubrication 124
- sterilization of instruments 63
 Streptococcus faecium 155
 Stropko Irrigator and Dryer 250
 Super EBA cement 252-3
 Suprasson P-Max 67
 surgical operation microscope 102-3
 sutures 254
- T**
- T cells, radicular cysts 34
 T-helper cells 30
 T-suppressor cells 30
 tetracycline 284
 Thermafill technique 137, 183
 thermocatalytic bleaching 286
 thermoplastic injection technique 184-5
 tissue remnant removal 145
 titanium alloy instruments 62-3
 titanium-aluminium alloy 62
- tooth
 developmental defects 289
 examination 39
- tooth discoloration 283
 causes 283, 284
 iatrogenic 285
- tooth fracture
 coronal restoration 272
 endodontic access cavity 270
 MOD amalgam restorations 271
 prevention 281
 protection 271
 risk 270
- tooth injuries
 classification 256-7
 complicated fracture 256
 cracks 264-6
 luxation with avulsion 257
 pulp necrosis 257
 replanting 257
 stable fixation 257
 traumatic 255
 uncomplicated fracture 256
- Touch'n-heat probe 188, 190
 trepanation 130
- Tri Auto ZX 138-9
 file breakage prevention 139
- tricalcium phosphate 205
 Trifekta technique 184, 185
 trioxide, mineralized 231
 Tubiseal 170
- ulcer, extraoral 36
 Ultrafil system 184-5
 ultrasonic cleaning 67
 ultrasonic phenomena 152
 ultrasound
 isthmus preparation 246, 247
 post removal 216
 retrograde preparation for micro-surgical endodontics 248-9
- Unifiles 61
- vasoconstrictors 89
 vitality test, laser Doppler probe 70
- W**
- walking bleach technique 287
 Wedjets 80
 Wolinella recta 23
 working length
 adjustment 113
 anatomic points 110
 apical resorption 112, 114-15
 apical stops 114, 115
 balanced force technique 121
 determination 111
 electronic 116-17
 problems 110-11
 engine-driven instrumentation 134
 gutta-percha point marking 115
 impedance profile 116, 117
 Lightspeed instrumentation 142
 loss 112-13
 measurement correction 108
 overinstrumentation 110
 preparation length adjustment 114
 Quantec series 2000 instrumentation 140
 radiographic determination 108-9
 radiographic distortion 111
 radiographic measurement 117
 resistance measurement 116
 step-down technique 125
 wound healing 254
- X-ray alignment 41
 XeCl laser 72
- Z**
- zinc phosphate cement 273, 279
 ZOE-EBA cement 232