
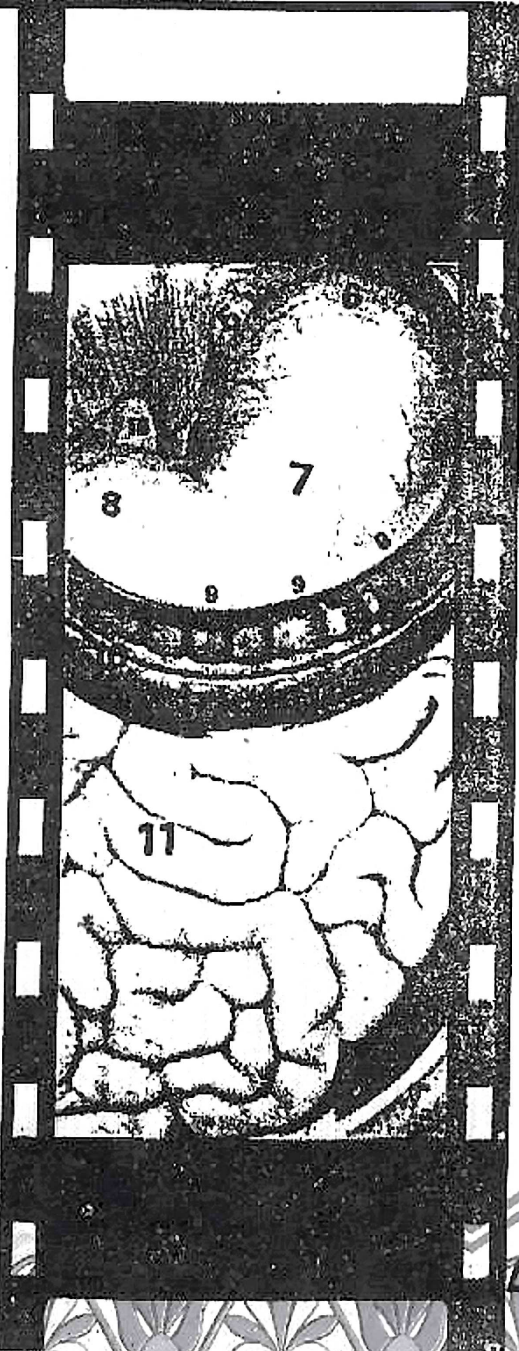


Dr Khaled Omar

PRINCIPLES OF

GENERAL SURGERY



VOL. 2

DR. MOHAMED METWALLY ELMED

Contents

Vol. (2)

Chapter	Page
1. The Oesophagus	1
2. The Stomach & Duodenum	20
3. Portal Hypertension	50
4. The Spleen	63
5. The Liver	70
6. The Biliary System	85
7. The Jaundice	102
8. The Pancreas	113
9. The Peritoneum	122
10. The Appendix	131
11. Small & Large Intestine	138
12. Intestinal Obstruction	163
13. The Anal Canal	181
14. Abdominal Injuries	193
15. Acute Abdomen, Haematemesis and Bleeding Per-rectum	196
16. DD of Abdominal Swellings	205

With my Best Wishes
Dr. Wael Metwaly

Tel : 7237606

Mob : 012 2466443

Chapter [1]

The Oesophagus

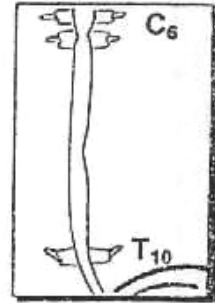
Chapter (1)

The Oesophagus

Anatomical Considerations

★ Oesophagus is a Muscular Tube

- Length : 25 cm.
- Begins : From the lower border of cricoid cartilage [C₆ Vertebra] as a continuation from pharynx.
- Ends : At Cardiac orifice of stomach. i.e. [T₁₀ Vertebra]



(A) Arterial Supply

- Cervical Oesophagus : From Inferior Thyroid Artery.
- Thoracic Oesophagus : From Aorta & Bronchial branches.
- Abdominal Oesophagus : From Oesophageal branch from Lt. Gastric artery.

(V) Venous Drainage

- Sub-epithelial Venous plexus
 - Sub-mucus Venous plexus
 - Peri-oesophageal Venous plexus
- Drained into →
- Inferior Thyroid vein
 - Azygos vein.
 - Lt. Gastric vein

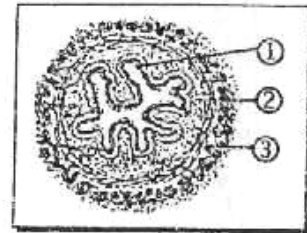
(L) Lymphatic Drainage

- Cervical Oesophagus : To Lower Deep Cervical & Supra-clavicular L.Ns.
- Thoracic Oesophagus : To Tracheo-bronchial & Para-oesophageal L.Ns.
- Abdominal Oesophagus : To Lt. Gastric & Coeliac group of L.Ns.

Histological Considerations

★ Oesophagus is formed of 3 layers

- ① Mucosa : Stratified Squamous Epithelium.
- ② Submucosa : Contains Vessels & Lymphatics.
- ③ Musculosa :
 - Upper 1/3 : Striated Muscles.
 - Lower 2/3 : Smooth Muscles
 which is inner circular & outer longitudinal.



N.B. : No serosa (Except the abdominal part)
 Because of No peritoneal covering but there is an adventitia which is layer of loose areolar connective tissues.

Dysphagia

Odynophagia
= painful dysphagia

★ **Definition** : It means Difficulty in swallowing

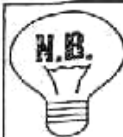★ **Causes** : It may be ↷

[A] Causes in the Mouth :

- ① Stomatitis.
- ② Glossitis.
- ③ Neoplasm of Tongue & Check.

[B] Causes in the Pharynx :

- ① Pharyngitis.
- ② Pharyngeal Diverticulum.
- ③ Retro-pharyngeal Abscess.
- ④ Tonsillitis.
- ⑤ Para-tonsillar Abscess.
- ⑥ Post-cricoid carcinoma (See later)
- ⑦ Plummer Vinson syndrome ↷



Plummer-Vinson syndrome: (Rare)

- **Incidence** : Common with post-menopausal female.
- **Aetiology** : It is due to Fe deficiency Anaemia.
- **Characters** : It is characterized by dysphagia (spasm), microcytic Anaemia, splenomegaly, Achlorohydrria glossitis, Angular stomatitis and spooning of Nails.
- **Treatment** : ① Dilatation for dysphagia.
② Fe therapy for Anaemia

[C] Functional Causes :

- ① Neuritis of glossopharyngeal or vagus nerve.
- ② Myasthenia gravis or Tetanus.
- ③ Hysterical.
- ④ Motility disorders e.g. Corkscrew (Diffuse spasm)



Diffuse oesophageal spasm : (Cork screw)


- *The disease differs from...* achalasia by characteristic presence of multiple areas of spasm may be seen throughout the oesophagus.
- Corkscrew oesophagus presented with mild dysphagia with pain of swallowing felt mainly in the root of the neck.
- **Treatment**. Dilatation or long myotomy.

[D] Causes in the Oesophagus :

- Causes in the Lumen :
e.g. Foreign bodies.


[The Oesophagus]

- **Causes in the Wall** (→)
 - ① Congenital : Oesophageal Atresia.
 - ② Traumatic : Corrosive stricture.
 - ③ Neuromuscular : Achalasia.
 - ④ Hiatus Hernia.
 - ⑤ Neoplastic : Carcinoma.
 - ⑥ Inflammatory as Reflux Oesophagitis.
- **Causes outside the Wall**
 - ① Malignant Thyroid (Rare).
 - ② Aortic Aneurysm.
 - ③ Malignant L.Ns.
 - ④ **Dysphagia Lusoria** ↻



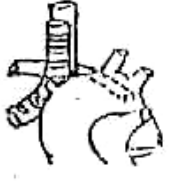
N.B.

Dysphagia Lusoria :



double aortic arch

- **Aetiology:**
Dysphagia by compression by congenitally Abnormal vessel e.g. Double aortic arch or aberrant Rt. subclavian artery.
- **C/P :**
 - Age > 50 years.
 - Atherosclerotic where it develops rigid arterial wall compress the oesophagus.
- **D.D. :**
Cancer oesophagus.
- **Treatment :**
Division of constricting vessels if possible or vascular reconstruction.



Aberrant Rt. subclavian ar t

★ Comparison between the common causes of dysphagia :

	Benign Stricture	Achalasia	Hiatus Hernia	Cancer
1. Age	Yong (Child)	Adult (20-40)	Old (40 – 50)	Old (above 50)
2. Sex	More in male	Male = Female	More in female	More in male
3. Course	Stationary	Remissions & exacerbations	Stationary	Progressive
4. Emotional disturbances	No effect	Aggreavte the dysphagia	No effect .	No effect
5. Pain	-	-	On lying flat	Late
6. Type	More to solids	More to <u>fluids</u>	More to solids	More to solids

7. Bleeding	-	-	-	+
8. General state	Good	Good	Good	Very bad
9. L.Ns.	-	-	-	+

★ **Investigations** : According to Suspected Cause

- Chest (X-ray & CT scan).
- Barium Swallow & Oesophagoscopy.
- Manometric Studies.
- Direct & Indirect laryngoscopy

★ **Management** : According to the Diagnose.



Congenital Oesophageal Atresia

★ **Definition** : It is a defect in the division of the proximal Fore-gut into, Ventral Tracheo-bronchial tube & Dorsal Oesophageal tube.

★ **Incidence** : 1 : 4000

★ **Types** : It may be

▪ Atresia with Fistula →

① 85% Proximal blind atresia with Distal Tracheo-oesophageal fistula.

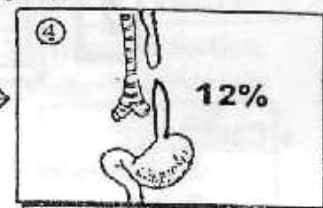
② 2% Distal blind atresia with proximal Tracheo-oesophageal fistula.

③ 1% Both ① & ② at same time.



▪ Atresia without Fistula

④ 12% which is blinding both proximal & distal ends →



★ **Pathology** : If Atresia with Fistula only

- The Saliva & Milk → Trachea → Bronchopneumonia.
- The Acidic gastric juice → Trachea → Acid Pneumonia (fatal).

★ **Clinical Picture** :

[Any newborn presenting with frothy saliva should be considered as having oesophageal atresia until proved otherwise].

- Ante-natal Diagnosis : • Mother : Polyhydramnios.
- Foetus : U/S shows → Dilated upper pouch.

- At birth : • General : ① Milk Regurgitation.
- ② Frothy Saliva & Attacks of Cyanosis.

- Local : ① Chest shows Pneumonia.
- ② Abdomen shows Distention If Atresia with fistula. & Scaphoid if atresia without fistula.

*** Associated Congenital lesions :**

VACTERL syndrome (2 of them at least)

- *Vertebra* : Spina bifida.
- *Ano-rectal* : Imperforate anus.
- *Cardiac* : Fallot, AS or VSD.
- *Trachea* : Treacheo-oesophageal fistula.
- *Esophagus* : Atresia.
- *Renal* : Polycystic kidney.
- *Limb* : Usually anomalies in the radial side of the upper limb.

*** Investigations :**

[A] X-ray : After injection of diluted lipidol, through the Ryle in supine position, showing pouch and fistula.

N.B. : Barium is not done to avoid tracheal obstruction & destruction of bronchial mucosa

[B] Introduce catheter No. 10 through the nose, it will be arrested at about 10 cm from the nostrils.

[C] Fiber-optic pediatric oesophagoscope.

*** Treatment : It Depend on types** ↗

- **Atresia with Fistula** : Through Rt. Thoracotomy (5th space). We ligate the fistula then lry anastomosis of both oesophageal ends.
- **Atresia without Fistula** : (usually the gap is long i.e. difficult anastomosis) So we do gastrostomy at birth then further surgery to restore oesophageal continuity is done months later.

2

Oesophageal Injuries

*** Causes :**

- ① *Instrumental Iatrogenic*. During oesophagoscopy or dilatation of a stricture.
- ② *Traumatic* :
 - a. Penetrating or blunt injuries to the neck or the chest.
 - b. Foreign bodies.
 - c. Swallowing corrosives.
- ③ *Pathological* e.g. carcinoma.
- ④ *Emetogenic* :
Following forcible repeated vomiting with inco-ordinate oesophageal motility i.e Mallory Wiess syndrome

*** Clinical picture** : Painful dysphagia ± pneumothorax.

*** Investigations** : X-ray chest & oesophagogram by lipidol.

*** Treatment :**

- ① Thoracotomy to repair the tear.
- ② *Gastrostomy* as feeding & to prevent leakage of saliva to mediastinum.

3

Corrosive Injury of the Oesophagus

★ **Actiology** : It is a Chemical burn due to ↗ swallowing of corrosive acids or alkalis (The common example is Potash)

★ **Pathology** :

[The Extent of Damage depend on the concentration or type of chemical burn & the duration of tissue contact].

- Alkalis → Liquefactive necrosis of all layers.
- & Acids → Coagulation necrosis of superficial layer.
- The End result is replacement of oesophageal wall by fibrous tissue which leads to stricture.

★ **Clinical Picture** :

- General : High fever ± shock.
- Local : Inflammation & oedema of Lips, Tongue & Oesophagus.

N.B.: Complete Oesophageal Obstruction may be occurred Due to inflammatory oedema.

★ **Complications** :

- ① Shock.
- ② Chest infection.
- ③ Perforation → mediastinitis.
- ④ Late malnutrition due to dysphagia.
- ⑤ Dehydration.
- ⑥ Malignant transformation.

★ **Management** : It is an Emergency Case :

[A] First Aid ttt : ① Washing The corrosive by Water or Egg or White starch.

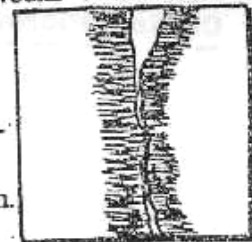
N.B. : Chemical Antidote for acids or alkali not used to avoid gas production i.e. Rupture of Oesophagus.

- ② Medical ttt such as • A.B. to avoid 2ry (chest) infection.
 • Steroids for 6 weeks → ↓ Fibrosis
 • Pain killer

★ Then we do Investigations ↗

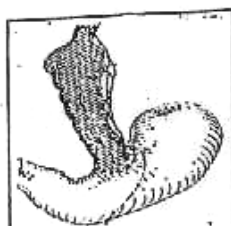- ① Oesophagoscopy (after 24 hours).
- ② Barium Swallow : Shows →

 - Smooth multiple strictures.
 - No marked proximal dilatation.



[B] Subsquant ttt : ① Regular Dilatation after 1st week when the acute stage has subsided, dilate stricture with a Bougie guided by Oesophagoscopy.

- ② Surgical ttt (Indicated if)
 - Complete stenosis or Failure of dilatation.
 - If Tracheo-broncho-oesophageal fistula occur.



Colon by-pass

Procedures → Preoperative : Gastrostomy or better I.V hyper-alimentation then we do either ↗ Oesophagectomy if short segment or Colon by-pass if long segment.

4

A Chhalasia of the Oesophagus

★ **Definition** : It is a **Functional Disorder** Characterized by :

- **Weak Peristaltic wave** in the body of the oesophagus.
- **Failure of** the cardiac sphincter to relax during swallowing This leads to functional obstruction with progressive dilatation of the oesophagus.

★ **Incidence** :

- **Age** : 20-40 years i.e. Middle age
- **Sex** : Male = Female (but more common in Neurotic Female)

★ **Aetiology** : **Unknown** but may be due to degeneration of vagal fibers and the ganglia of **Auerbach's Plexus** of the oesophagus itself.
or Infection with Trypanosoma cruzi (chaga's disease) which leads to degeneration of Auerbach's plexus or Autoimmune

★ **Pathology** :

Because of failure of the cardia to relax in response to swallowing this leads to progressive dilatation which ends abruptly in a "narrow" neck below the hiatus of the diaphragm.

So Stages are ① **Funnel** shaped oesophagus.

② **Club** shaped oesophagus.

③ **Sigmoid** shaped oesophagus.

If stagnation invites infection → fibrosis → organic obstruction.

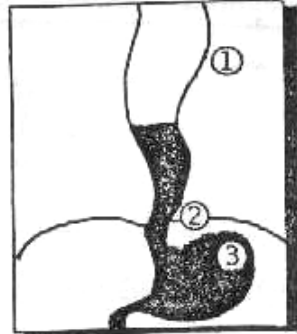
★ **Clinical Picture** : **Patient is** usually (20-40 years & **Neurotic** female).

- **Dysphagia** : • Painless.
 • **More to fluid than solid** (++)
 • At 1st intermittent then slowly progressive.
- **Regurgitation** : • **Alkaline** fluid.
 • Foul smell fluid & Halitosis
 • More Nocturnal.
- **Retro-sternal Discomfort** from Retention oesophagitis.
- **C/P of Complications as** : ① Aspiration Pneumonia.
 ② Oesophagitis & Ulceration i.e. Barrett's ulcer
 ③ Malignant Transformation (5%)
 From Chronic mucosal irritation.
 ④ Oesophageal diverticulum.

★ Investigations :

[1] Barium Swallow : →

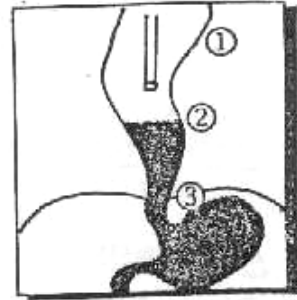
- ① Moderate to Huge dilated oesophagus
If it shows tortuosity called sigmoid oesophagus.
- ② Smooth (**Hen's beak**) shaped
i.e. Narrowing of the lower segment.
- ③ Lack of gas bubble in the fundus of the stomach
due to continuous stagnation of fluid in the oesophagus.



[2] Oesophagoscopy : →

[The aim is exclusion of carcinoma]

- ① Huge Proximal segment.
- ② Detection of fluid level.
- ③ Detection of Retention oesophagitis.
- ④ Cardia doesn't relax & may be eccentric in position



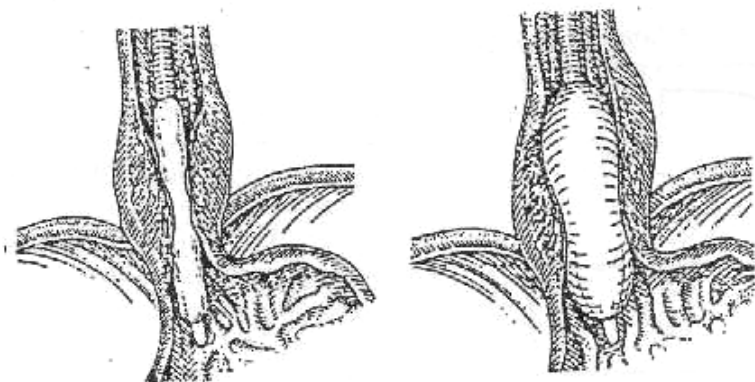
[3] Manometric Studies : (More specific)

- Show weak peristaltic waves in the body of oesophagus
After deglutition & Failure of relaxation of cardia in response to Swallowing.

★ Treatment : As (octyle Nitrate) has limited value So →

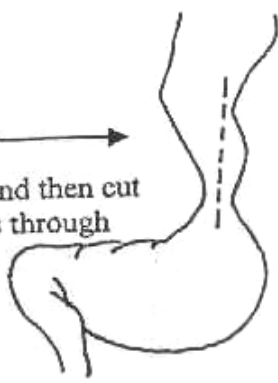
① Dilatation by "Plummer Hydrostatic bag"

- ★ The idea is to place a special balloon through oesophagoscopy to the cardia then inflate it → Rupture of circular muscle fibers to relieve the distal oesophageal obstruction.
- ★ It relieves symptoms in (80%) of cases with small risk of perforation (5%)



or ② Heller's cardiomyotomy Oesophago-cardiomyotomy →

- ★ The idea is to expose the lower part of the oesophagus and then cut the muscle fibers completely until the mucosa bulges through
- ★ Done via Abdominal on thoracic approach.
- ★ The main disadvantage is reflux oesophagitis so some surgeons prefer to do Anti-reflux procedure as Nissen's Fundoplication with this operation.



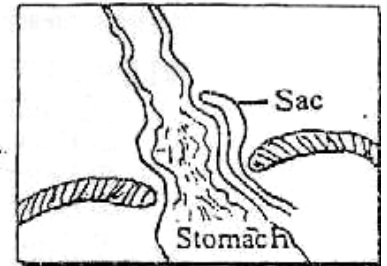
5 Oesophageal Hiatus Hernia

[Hernia at the Oesophageal Hiatus]

- (A) Sliding (85%)
- (B) Para-oesophageal (10%)
- (C) Mixed (5%)

(A) Sliding Hiatus Hernia

[GORD] = Gastro-Oesophageal Reflux Disease



★ **Definition** : Herniation of the Cardio-oesophageal sphincter with part of stomach upwards in the Post. Mediastinum through the oesophageal hiatus

★ **Aetiology** :

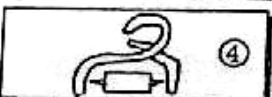
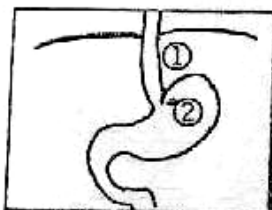
- ↑ Intra-abdominal Pressure (I.A.P) as in pregnancy, large ovarian cyst, tight corset. ... etc.
- ↑ Fatty tissues in the hiatus as in Obesity.

★ **Pathology** :

- Herniation is associated with a small peritoneal sac on the L.t. side of stomach.
- Disturbance of the cardio-oesophageal sphincter → Regurgitation from the stomach to lower oesophagus → Reflux Oesophagitis then → Ulcer (Barrett's)

N.B. : Oesophageal Sphincters

- Upper end: Anatomical Sphincter formed by Crico-pharyngeus muscle.
- Lower end: Non anatomical (Physiological) Sphincter i.e Cardio-oesophageal which formed by



★ **Factors prevent the Reflux**

- ① Presence of an intra-abdominal segment of the oesophagus about 4 cm.
- ② The valvular effect by (Angle of His) at the Cardio-oesophageal junction.
- ③ The Rosette-like arrangement of the cardiac gastric mucosa.
- ④ The Pinch-Cock action of the Rt. Crus of the diaphragm.
- ⑤ Phreno-oesophageal ligament.

★ **Incidence** : (85%)

- Age : > 40 years.
- Sex : Obese Female.

★ **Clinical Picture** : Patient is usually (>40 years & Fatty female)

- **Retro-sternal burning pain** due to reflux oesophagitis which is characterized by :
 - ↑ by lying flat & heavy meals.
 - ↓ by standing upright
- **Regurgitation** : • Water brach
• Acidic & bitter fluid.
- **Dysphagia** : 1st due to reflex spasm of the oesophagus but later due to fibrous stricture 2^{ry} to ulceration.
- **C/P of Complications as** : ① Aspiration Pneumonia.
② **Barrett's ulcer** [Columnar Epithelium lined the lower oesophagus] → Pre-cancerous.
③ **Bleeding** from ulcer → Chronic anaemia.
④ Stricture oesophagus

N.B. : **Saint's Triade** which is ⇨
Hiatus Hernia + Diverticulosis Coli + Chronic Calcular Cholecystitis

★ **Investigations** :

[1] **Barium Meal** : Trendlenburg Position →

- ① Part of stomach protruding through the Hiatus towards the chest.
- ② Reflux of barium from stomach to oesophagus.
- ③ Widening of oesophageal Hiatus.



[2] **Oesophagoscopy** :

- ① Normally the Cardia closes on inspiration, but in hiatus hernia the cardia opens on inspiration.
- ② Reflux of gastric juice through the cardia.
- ③ Complications as Oesophagitis, Ulceration or Strictures.

N.B. **Belsy grading reflux Endoscopy**

- ① Grade I : Hypaemia.
- ② Grade II : Erosions.
- ③ Grade III : Ulcers.
- ④ Grade IV : Strictures & Barrett's ulcer.

[3] **Manometric Studies** :

- Loss of normal (High) pressure zone at the lower end of the oesophagus due to displacement of cardio-oesophageal junction to the chest.

[4] **PH Monitoring** : (More specific)

- The most diagnostic for **Reflux Oesophagitis** so it shows (PH < 4) which is acidic at lower 5 cm.

★ Treatment :(A) Conservative ttt :

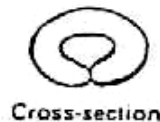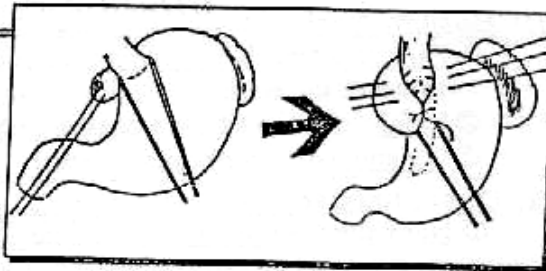
- Reduction of body weight.
- Semi-sitting position during sleep.
- Frequent small meals & Avoidance of Smoking, Caféetc.
- Drugs : **Antiacids + Omeprazole** (Proton pump blocker)
or **Ranitidine (Zantac)** (H₂ Blockers) → ↓ Gastric acidity

(B) Surgical ttt :

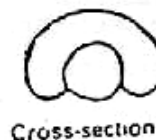- Indications : ① Failure of medical ttt.
② Presence of complications as Oesophagitis or Stricture
- Principles : ① Reduce the Herniation and maintain a segment of the oesophagus intra-abdominally.
② Reduce the size of Oesophageal Hiatus.
- Anti-reflux procedures :

★ Anti-Reflux Procedures :1) Nissen's fundoplication :

- *It is called (valvuloplasty)*
- *Approach* :
Trans-abdominal.
- *Principle* : The fundus of the Stomach is wrapped (360° wrap) around the lower 5 cm of the oesophagus by a series of sutures inserted between the stomach & the oesophagus. [It can be done laparoscopically]
- *Advantages* :
Recurrence is rare.
- *Disadvantage* :
"Gas-bloat syndrome"
which is considerable amount of abdominal gaseous distensions due to inability to eructate or to vomit.

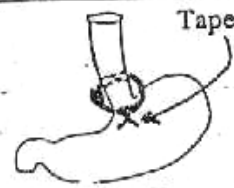
2) Taupe's fundoplication :

- *It is called (cardioplasty)*
- *Approach* :
Only Trans-thoracic (Lt. 8th space).
- *Principle* : The fundus of the stomach is wrapped (270° wrap) around the lower 5 cm of the oesophagus by a series of sutures inserted between the stomach & the oesophagus.
- *Advantages* :
No "Gas-bloat syndrome"
- *Disadvantage* :
Less effective than the Nissen's fundoplication.



13) Angel chick prosthesis :

A plastic ring is encircled around the lower oesophagus to prevent re-herniation.

**14) Coll's gastroplasty :**

(If stricture oesophagus occur)

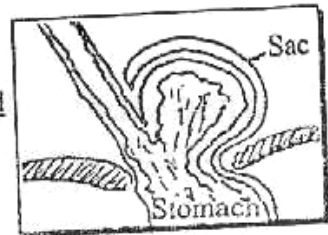
The stricture is excised and a tube of gastric Fundus is fashioned to replace the stricture oesophagus.

15) Belsey Mark IV operation :

This is restoration of angle of His by Interrupted silk suture between anterior wall of the oesophagus & adjacent fundus of stomach + suturing the gastric fundus to the under surface of diaphragm.

(B) Para-oesophageal (Rolling) Hernia

★ **Definition** : It is a True Hernial sac in which the greater curvature of the stomach "Rolls" upwards to herniate into the mediastinum within a peritoneal sac.



★ **Aetiology** : The Same.

★ **Incidence** : 10%

★ **Pathology** : Unlike Sliding Hiatus Hernia, The Cardio-oesophageal Junction remain below the diaphragm So No Reflux Oesophagitis.

★ **Clinical Picture** : Symptomless until becomes very large

- Post-prandial Chest pain from distended stomach.
- Bouts of Hiccough from irritation to the phrenic nerve.
- Intermittent Dysphagia .
- Complications : ① Strangulation → Rupture → Mediastinitis.
② Pressure on Heart → Cardiac symptoms.

★ **Investigations** :

[1] Barium Meal Trendlenburg position shows ↯
Herniation of stomach in the Chest & The cardio- oesophageal Junction
at it's normal position.

[2] Chest X-ray : Shows Gastric gas shadow in the chest.

★ **Treatment** :

Surgical : Stomach is retracted down, Hernial sac is excised and hernial defect in the diaphragm is closed

Reflux Oesophagitis

- ★ **Causes :** **[GORD] [Gastro-Oesophageal Reflux Disease]**
- 1ry = Incompetent cardio-oesophageal junction due to **Sliding Hiatus Hernia**
 - 2ry = Delayed Emptying of stomach due to :
 - ① Pyloric stenosis.
 - ② Pyloro-spasm 2ry to Duodenal ulcer.

- ★ **Pathology :**
- ★ **C/P :** (See Sliding Hiatus Hernia)
- ★ **Investigations :**
- ★ **Treatment :**

If **1ry** : Anti-reflux measures as **Sliding Hiatus Hernia**
 But if **2ry** : Treated the cause.

6

Diaphragmatic Hernia

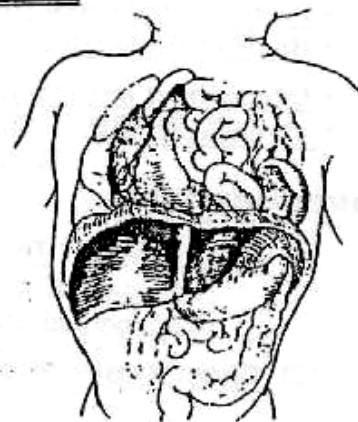
[1] Acquired Diaphragmatic Hernia :

- 1- *Post-Traumatic or post-operative (Rare) :*
- The left diaphragm is more affected than the right (which is protected by liver)
 - Plain x-ray: Show gas-filled stomach in the chest differential diagnosis tension pneumothorax (passage of nasogastric tube or injection of contrast material).
 - Treatment : urgent surgical repair.
- 2- *Hiatus Hernia* : See Before.

[2] Congenital Diaphragmatic Hernia :

★ **Types :**

- 1- *Posterior Bochdalek (90%) :*
- It is a herniation through foramen of Bochdalek i.e. persistency of the pleuro-peritoneal hiatus between vertebral & costal fibers.
 - The **left** more common than Right.
 - Compression on lungs may leads to severe hypoplasia of lung.

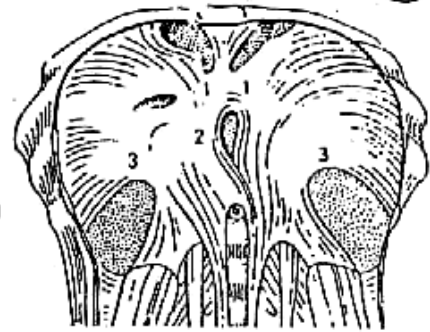


2- Anterior or Morgagni : (not important)

- It is a herniation through foramen of morgagni i.e. failure of fusion between the costal & sternal parts of the diaphragm.

3- Eventration of diaphragm (Rare & Not True Hernia)

- It is a partial or total developmental diaphragmatic defect replaced by fibrous tissue → Herniation of viscera to chest.



1- Parasternal (Foramen of Morgagni)
2- Esophageal hiatus
3- Pleuroperitoneal canal (foramen of Bochdalek)

★ Pathology :

The main problem in diaphragmatic Hernias are Ipsilateral lung hypoplasia & Contralateral lung compression

★ Clinical Picture :

[Any newborn presenting with cyanosis & scaphoid abdomen in absence of heart disease should be considered as having congenital diaphragmatic hernia until proved otherwise]

- Ante-natal diagnosis : ♦ Mother : polyhydramnios.
♦ Faetus : U/S is diagnostic.
- At birth : ♦ General : Cyanosis & Tachycardia.
♦ Local : ① Chest : heart sounds are good.
② Abdomen : scaphoid.

★ D.D. :

From oesophageal atresia & Hyaline membrane disease.

★ Investigations :

- ① Chest X-ray reveals gas shadow of the stomach or bowel in the thorax.
- ② Blood gases to assess the degree of hypoxia.
- ③ Other investigations to exclude associated anomalies.

★ Treatment :

[A] 1st Aid Treatment :

- Naso-gastric tube insertion to deflate the stomach.
- Endo-tracheal tube intubation.
- Ventilatory support and correction of hypercapnea and acidosis.

[B] Surgery :

Through an abdominal approach, the herniated abdominal contents are reduced and the defect is closed directly or by a mesh if the defect is big.

[C] Intra-uterine surgical correction :

Was tried with limited success.

7

Carcinoma of the Oesophagus

★ Incidence :

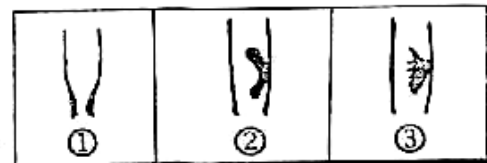- (Less common GIT cancer) about 4% only.
- Age : > 50 year.
- Sex : 3 Male : 1 Female.

★ Predisposing Factors :

- ① Chronic Irritations 5 S (Spirits, Spices, Smoking, Sepsis & S).
- ② Corrosive Strictures of the oesophagus.
- ③ Achalasia.
- ④ Long standing Reflux Oesophagitis.
- ⑤ Barrett's ulcer of the oesophagus 5%
- ⑥ Plummer vinson syndrome.

★ Pathology :

- Site : • Upper 1/3 → 17 %
• Middle 1/3 → 50 %
• Lower 1/3 → 33 %
- N/E picture : ① Annular Stenotic type.
② Ulcerative type.
③ Cauliflower (Fungating) type



- Microscopic picture : (Squamous cell carcinoma) 95 %
& (Adenocarcinoma) 5% Barrett's ulcer of oesophagus.
or from cancer stomach spreading upwards.

★ Spread :

- Direct Spread : Both in (Transverse & Longitudinal) direction then infiltrate the surrounding :
 - Cervical Oesophagus → Trachea, Thyroid, RLN & Carotid sheath.
 - Thoracic Oesophagus → Trachea, Pleura, Lung & Aorta.
 - Abdominal Oesophagus → Lt. lobe Liver, Diaphragm & Stomach.
- Lymphatic Spread :
 - Cervical Oesophagus → Supra-clavicular L.Ns & Lower Deep Cervical L.Ns.
 - Thoracic Oesophagus → Tracheo- bronchial L.Ns & Para- oesophageal L.Ns.
 - Abdominal Oesophagus → Coeliac L.Ns & Lt. gastric L.Ns.
- Blood spread : (lung, Bone, Liver & rarely Brain)
 - ♦ Upper 1/3 tumor : mainly to lungs.
 - ♦ Lower 1/3 tumor : mainly to liver.
- Transcaelomic spread : (only with abdominal oesophagus)
leading to peritoneal nodules & Malignant ascitis then krakenberg's tumor & nodules in douglus pouch.

*** Staging :**

T	N	M
<p>T_{is} = Cancer in situ T₁ = confined to the mucosa T₂ = confined to the musculosa T₃ = Any size with extra-oesophageal spread</p>	<p>N₀ = No L.Ns N₁ = Mobile L.Ns (unilateral) N₂ = Mobile L.Ns (bilateral) N₃ = Fixed L.Ns</p>	<p>M₀ = No Distant metastasis M₁ = Distant metastasis</p>

*** Clinical Picture :**

▪ **Type of patient :** [> 50 years & Male > Female] .

▪ **Symptoms :**

- ① **Dysphagia :** Characterized by ↗
 - (a) Insidious **Onset**, slowly progressive **Course** & short **Duration**.
 - (b) **More to solid than fluid:**
 i.e. Mechanical obstruction. But later to both fluids & solids, So patient cannot swallow his own saliva leading to continuous dripping of saliva → Aspiration pneumonia
 - (c) At the time of it's presentation about 2/3 of circumference of oesophagus has been involved.
- ② **Regurgitation:** It is (oesophageal-pseudo-vomiting) which is ↗
 - (a) Alkaline fluid.
 - (b) Mixed with saliva & possibly streaked with blood.
 - (c) More nocturnal.
- ③ **Pain :** Late Manifestations.
- ④ **Clinical Picture of complications :**
 - (a) Recurrent Laryngeal Nerve Paralysis. Leads to Hoarseness of voice.
 - (b) Phrenic Nerve Paralysis. Leads to Hiccough & Diaphragmatic paralysis
 - (c) Trachco-oesophageal Fistula. Leads to Recurrent Chocking.

▪ **Signs :** ① Cachexia.
 ② Weight loss.
 ③ **Metastasis.** So (pleural effusion, Ascitis, Jaundice & Hepatomegaly) should be looked for.

*** Deferential Diagnosis : From other causes of dysphagia**

as Oesophageal Stricture, Hiatus Hernia & Mainly Achalasia

	Achalasia	Carcinoma
① Age	• <u>Middle</u> (20-40) *	• <u>Old</u> (> 50)
② Sex	• More with <u>Female</u>	• More with <u>Male</u> .
③ Emotional Disturbance	• <u>Aggravates</u> the dysphagia.	• <u>No</u> effect.
④ Dysphagia	• More to <u>Fluids</u> .	• More to <u>Solids</u> .
⑤ Pain	• May be	• <u>No</u> or <u>Late</u>
⑥ General Condition	• <u>Good</u> General condition.	• <u>Very Bad</u> General condition.

★ **Investigations :**

[1] **Laboratory :**

Complete Blood picture, serum electrolytes, kidney function tests ... etc.

[2] **Endoluminal U/S :** The most recent.

[3] **Barium Swallow :**

① **Annular lesions** will show Irregular, Narrow filling defect with characteristic [**Shouldering + Rate Tail Appearance**].

② **Mild proximal dilatation** due to short duration of cancer i.e. unlike Achalasia.

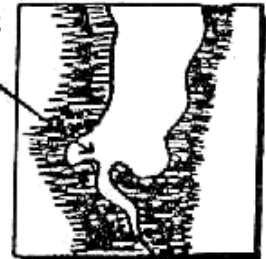[4] **Oesophagoscopy & Biopsy :** Demonstrates the lesion.

[5] **Metastatic Work-up :** e.g. Liver (U/S), Chest (X-rays) etc.

e.g. Liver (U/S), Chest (X-rays) etc.

[6] **Exfoliative cytology :**

Collection of shed of malignant cells via endoscopy



★ **Treatment :**

[Many of patients are diagnosed when the lesion has reached an advanced stage, So The chance of cure is very low].

(A)

Operable Cases

★ **Radical surgery:**

• **The Idea:**

The idea is to resect the lesion with adequate safety margin on either side (10 cm) & then restore the continuity of gastro-intestinal tract.

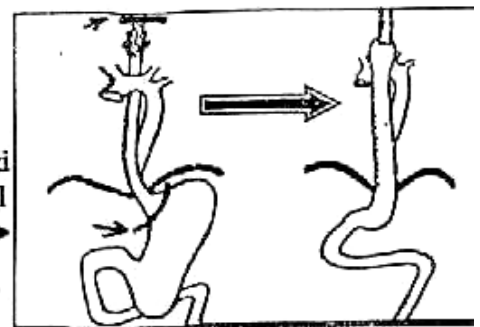
• **Types of operation:**

Nowadays, Many surgeons prefer to do

Total Oesophagectomy, Then pulling the mobilized stomach up to neck to be anastomosed to cervical oesophagus in the neck i.e. **Gastric pull up** → Through Cervical & thoraco-abdominal incision.

Advantage of this operation :

The Oesophago-gastric anastomosis is performed in the neck. So if leakage occur it will be in the neck So doesn't lead to mediastinitis.

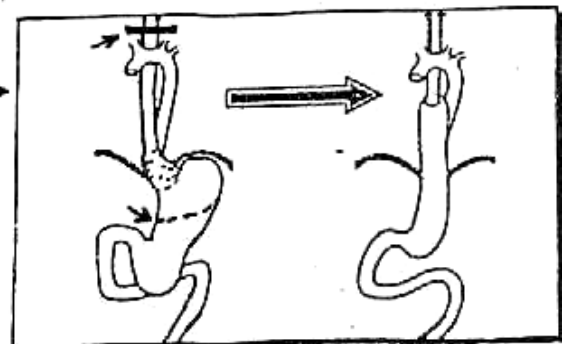


▪ **If Middle 1/3 Tumors : (Ivor-Lewis operation).**

We resect up to cardia through thoraco-abdominal incision then oesophago-gastric anastomosis.

▪ **If lower 1/3 Oesophageal Tumor :** →

We add to resected part portion of stomach through thoraco-abdominal incision then oesophago-gastric: hilum. anastomosis.



N.B : Oesophageal Replacement surgery:

- | | | |
|--------|----------------------|---------------------------------------|
| Either | 1) Gastric pull-up | 3) Pectoralis major myocutaneous flap |
| | 2) Colon replacement | 4) Free jejunal replacement. |

8 Inoperable Cases

▪ **Criteria of Inoperability:**

- ① Unfit patient e.g. Poor Cardio-pulmonary Status.
- ② Patient with Distant Metastasis as lung & liver metastasis.
- ③ Patient with Marked complications "see before".

▪ **Palliative Procedures:**

[The Idea is to enable patient to Swallow].

① Intubation : By insertion of a Tube into the oesophagus through the growth e.g Soumar or Celestin Tube →



② Palliative surgery
e.g. Colon - bypass or Gastric pull-up but these operations with high mortality for patient with short life Span

③ Other Procedures as ⇨

- Radiotherapy : Adose of 4500 rads over period of 4 Weeks especially for the upper oesophageal carcinoma.
- Laser Therapy : Through Vaporizing the tumor to provided a temporary patent lumen.
- Gastrostomy : The Last option as the patient remains unable to swallow his saliva. → Aspiration pneumonia

Continuous Follow up: for the patient to detect any progression occur.



Postcricoid Carcinoma

* **Definition** : Carcinoma of the Hypopharynx at the level of cricoid cartilage.

* **Aetiology** : It may occur on top of (**Plummer Vinson Syndrome**) Which is much more common in female.

* **Pathology** :

- Site : It arises from pharyngeal mucosa.
- N/E : Usually fungating mass.
- M/P : Squamous cell carcinoma.

* **Spread** :

- Direct : To surrounding tissues.
- Blood : Mainly to lung.
- Lymphatic : To cervical L.Ns.

* **Clinical Picture:**

- **Symptoms** : The Early symptom is pain in the throat referred to side of the neck or the ear due to stimulation of (Arnold nerve). The Late symptom is Dysphagia.
- **Signs** : Inspection : Bulge of Thyroid cartilage & Trachea.
Palpation : Loss of laryngeal click.

* **Complications :**

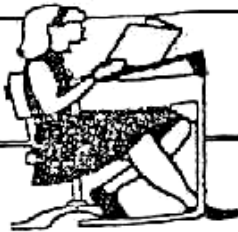- ① Obstruction : (Oesophageal) = Dysphagia
(Laryngeal) = Stridor & Dyspnea
- ② Hoarseness of voice.
- ③ Ulceration, Bleeding & Infection..
- ④ Metastasis.

* **Investigations :**

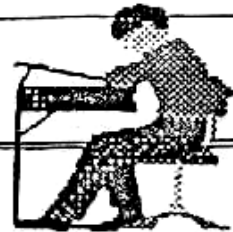- **Pharyngoscopy & Laryngoscopy** :
It shows the tumor & take a biopsy.
- **Plain x-ray** (Lat. view)
It shows widening of the space between the larynx & vertebrae.
- **Barium swallow** :
It shows filling defect in the pharynx.

* **Treatment :**

- **Operable**: Total laryngopharyngectomy with block dissection of L.Ns + permanent tracheostomy + oesophageal replacement.
- **Inoperable** : Radiotherapy.



Final Written Exams



- | | | |
|------|--|---------------------|
| 1990 | • <u>Discuss</u> the management of <u>Achalasia of Cardia</u> | (10 Marks) |
| 1992 | • <u>Discuss</u> C/P, diagnosis & tt of <u>Achalasia</u> | (20 Marks) |
| 1993 | • <u>DD</u> between <u>Achalasia</u> of Cardia & <u>Carcinoma</u> of lower third oesophagus | (15 Marks) |
| 1997 | • <u>Give a short account</u> on Clinical Picture and Management of <u>Achalasia</u> of lower end oesophagus | (10 Marks) |
| 2000 | • <u>Discuss</u> C/P & Investigations of sliding Hiatus Hernia | (10 Marks) دور ثانی |
| 2002 | • <u>Discuss</u> cancer lower 1/3 oesophagus | (12 Mark) |
| 2003 | • <u>Enumerate</u> causes of Dysphagia | (9 Mark) دور ثانی |
| | • <u>Discuss</u> path., & treatment of corrosive stricture | (9 Mark) دور ثانی |
| | • <u>Enumerate</u> causes of Dysphagia | (10 Marks) |



Chapter [2]

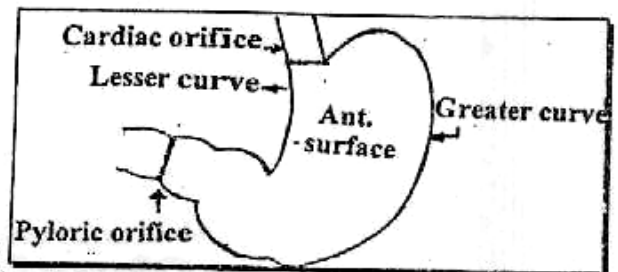
**The Stomach
&
Duodenum**

Stomach & Duodenum

Anatomical Considerations

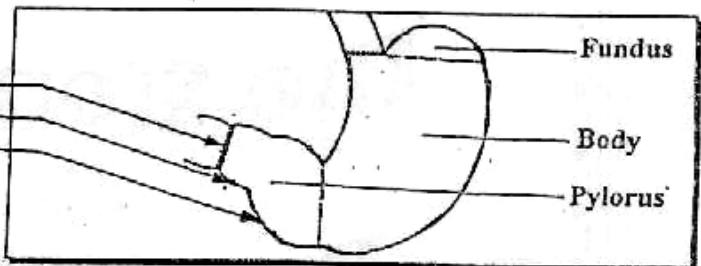
★ The Stomach is Formed of

- 2 Orifices (Cardiac & Pyloric).
- 2 Curves (Greater & Lesser).
- 2 Surfaces (Anterior & Posterior).



★ The Stomach is Divided Into

- Fundus.
- Body.
- Pylorus : ① Pyloric Sphincter.
② Pyloric Canal.
③ Pyloric Antrum.



Ⓐ Arterial Supply :

• Arteries along "Lesser Curve"

▪ Lt. Gastric artery :

Branch from Coeliac Trunk runs in the lesser omentum then along the lesser curve to end by anastomosing with Rt. Gastric artery. It gives an Oesophageal branch.

▪ Rt. Gastric artery :

Branch from the Hepatic artery supply the lower part of lesser curve.

• Artery at "Fundus of Stomach"

▪ Short Gastric branches

2,3 branches of Splenic artery which runs on Gastro-splenic ligament & supplying the fundus of stomach.

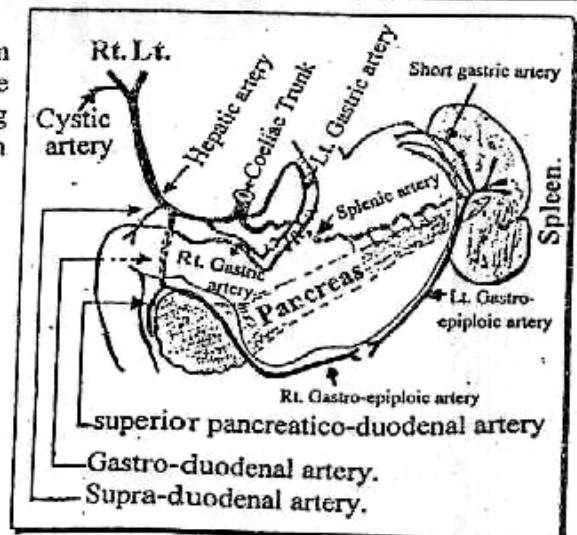
• Arteries along the "Greater Curve"

▪ Lt. Gastro-epiploic artery :

Branch of Splenic artery runs downwards along greater curve & end by anastomosing with Rt. Gastro-epiploic artery.

▪ Rt. Gastro-epiploic artery :

Branch from Gastro-duodenal artery supplying the Rt. side of greater curve then end by anastomosing with Rt. Gastro-epiploic artery.

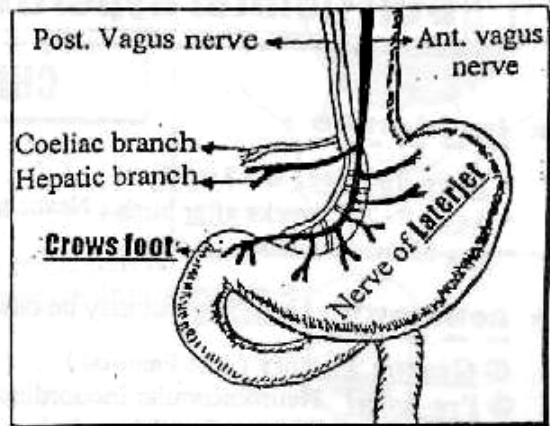


V Venous Drainage :

- Corresponding to the arteries then drained into Portal vein.

N Nerve Supply :

- Parasympathetic supply :
 - Responsible for stimulation of acid secretion & gastric motility.
 - Reach the stomach through :
 - ★ Ant. Vagus Nerve :
Give Hepatic branch to liver & gall bladder then continuous on the Ant. surface of stomach as nerve of laterjet and end at the pylorus in a Crows Foot shaped For motor power
 - ★ Post. Vagus Nerve :
Give Coeliac branch to supply intestine then continuous on the Post. surface of stomach like ant. vagus nerve.



- Sympathetic supply :
 - Responsible for Visceral Sensation.
 - Reach the stomach From Greater splanchnic nerve from Coeliac ganglion.

L Lymphatic Drainage :

- Knowledge of Lymphatic Drainage For stomach is essential for \Rightarrow proper treatment of cancer stomach.
- For Details see cancer stomach

Histological Considerations



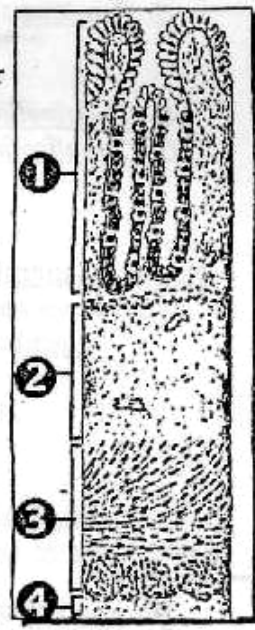
★ The Stomach is Formed of 4 Layers

- ① Mucosa : Lined by Columnar Epithelium which secretes mucus for lubrication.

N.B. : Containing Special Cells :

- Chief cells : Present at Fundus. & Secretes Pepsin.
- Parietal cells : Present at Body. & Secretes HCL.
- G. cells : Present at Pyloric antrum. & Secretes Gastrin \rightarrow \uparrow HCL


- ② Submucosa.
- ③ Musculosa : (a) Inner oblique.
(b) Middle circular.
(c) Outer longitudinal.
- ④ Serosa : Peritoneal covering.



I

Congenital Hypertrophic Pyloric Stenosis

CHPS



★ Incidence :

- Rare disease (8 : 1000).
- Age : 2-3rd weeks after birth (Never at birth)
- Sex : Male : Female (4 : 1).

★ Aetiology : Unknown but may be due to ↷

- ① Genetic Factors (7 % Familial)
- ② Pre-natal : Neuromuscular incoordination leading to Failure of pylorus to relax.
- ③ Post-natal : Hypertrophy of the pyloric muscles.

★ Pathology :

- The Pylorus : Hypertrophy of circular muscle layer, which stopped suddenly at the duodenum.
- The Stomach : At 1st Hypertrophied to overcome the obstruction, but Later on dilated with gastritis from retention.
- The Intestine : Normal, Collapsed & Empty:

★ Clinical Picture :

[Any neonate presenting with Projectile, Non-bile stained vomiting should be considered to have CHPS until proved otherwise]

- Type of patient : [Usually Male baby at 2-3rd week after birth]

▪ Symptoms :


- ① Vomiting : (a) Starts 2-3 weeks after birth.
(b) Projectile, Progressive, Non-bile stained.
(c) After vomiting, the infant is V. Hungry.
- ② Constipation : Infrequent & Dry stool.
- ③ Complications : (a) Dehydration & Loss of weight.
(b) Chest Infection (Aspiration pneumonia)
(c) Metabolic Alkalosis → Tetany from repeated vomiting.

- Signs : General : "Signs of Dehydration"

(Dry Inelastic Skin, Dry Tongue, Sunken Eyes & Oliguria).

Local : "Test Feed"

(After a feed & In a good Light → Examine Abdomen) ↷

- Upper abdominal Distention.
- Visible peristalsis from Lt. to Rt. 
- Palpable, Firm & Olive Like mass under costal margin & to the Rt. of the middle line.
- Succussion splash by Auscultation.

★ D.D :

[From other causes of Neonatal vomiting] as ↷

- | | |
|---------------------|------------------------|
| ① Gastro-enteritis. | ④ Intestinal Atresia. |
| ② Pylorospasm. | ⑤ Volvulus neonatorum. |
| ③ Duodenal Atresia. | ⑥ Birth Head injuries. |

★ Investigations :

[1] Laboratory : "Serum Electrolytes"

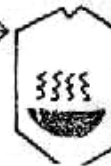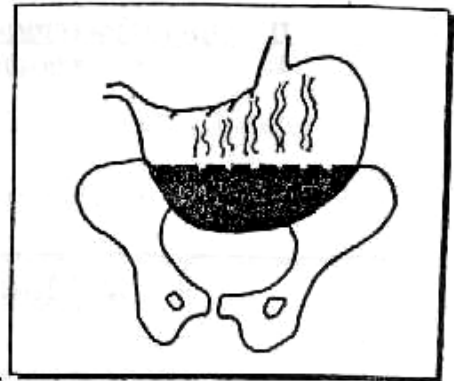
- Metabolic (Hypochloremic) Alkalosis & ↓ Na

[2] Ultrasound : "Diagnostic"

- Thickened pyloric muscles.

[3] Barium Meal :

- ① Huge Dilated Stomach may reach down to the pelvis.
- ② Fluid level in the stomach so it has **soup dish Appearance** →



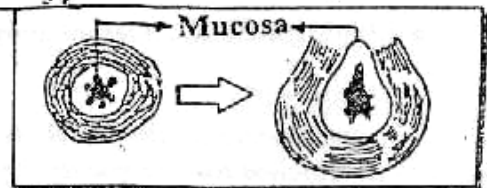
★ Treatment : "Only Surgical"

- 1st Line of ttt : Correct the Dehydration & Electrolytes Imbalance.
- Pre-operative preparations : ① Stop feeding, then Naso-gastric suction with normal saline.
② High protein diet with I. V hyperalimentation.
③ Chest Antibiotics.

• Operation :

Ramsted's Pyloromyotomy

- A small upper abdominal incision
- The hypertrophied pylorus is grasped between Index & Thumb fingers.
- Pyloromyotomy is done until the mucosa of pylorus bulges out.
(Any perforation of mucosa should be sutured).



II

Traumatic Disorders

① Foreign Bodies

★ Types :

- ① Ingested F.B., e.g. coins, pin etc.....
- ② Locally formed F.B. (Bezoars)
 - a. Trichobezoars : formed from hair which may be eaten by children or mentally retarded girl.
 - b. Phytobezoars : from some plant fibres.
 - c. Shellac bezoars : in person swallowing furniture polish.

★ Treatment :

- I. Conservative ttt: In most cases waiting for spontaneous passage in stool :
 - Giving cotton wool in jam or honey sandwiches to wrap the F.B.
 - Daily x-ray abdomen and close observation in the hospital.
- II. Endoscopic Removal : Indicated in small ingested FB in the stomach.

III. Operative removal :

- **Indications :** 1. Large FB (bezoars)
2. Sharp or irregular FB.
3. Failure of conservative ttt.
4. Complications as Haematemesis.
- **Procedure :** Removal of the F.B through a gastrotomy.

② Mallyory Weiss Syndrome

* **Definition :** Upper GIT bleeding due to longitudinal mucosal laceration at oesophagogastric junction.

* **Aetiology :**

Violent vomiting (90% of case) (gastric pressure against closed cardia).

* **Clinical picture :**

- Common in alcoholic males > 50 years.
- The condition usually occurs after repeated attacks of severe vomiting. The gastric contusion causes profuse haematemesis.
- Severe cases may pass into shock and death.

* **Investigations :** Oesophagogastroscopy is diagnostic.

* **Treatment :**

- **Conservative ttt :** Most cases respond to sedation, IV fluids and Bl. transfusion.
If failed **Endoscopic ttt :** By photocoagulation or Electrocoagulation.
- **Surgical ttt :** in resistant cases, by suturing the linear tear through a Gastrotomy.

III**Acute Gastric Dilatation*** **Definition :**

It is a condition where the stomach loses its tone (mostly post-operative) so it rapidly dilates to a huge size.

* **Predisposing Factors :**

- ① Abdominal operations especially (biliary, pelvic or prostate).
- ② Opiates → ↓ gastric emptying.
- ③ Labour.
- ④ Fractures especially with (Femur, Pelvis & spine).
- ⑤ Ventilators.
- ⑥ Aerophagia

* **Aetiology :** Unknown

But may be ↑ sympathetic tone over activity → Hypotonia.

★ **Pathology**: Hugely dilated stomach with ulceration from stagnation & collapsed intestine.

★ **Clinical Picture** :

- **Symptoms** : ♦ *At 1st* : Hicough & Eructation on the 3rd post-operative day.
 - ♦ *Vomiting* : EFFORTLESS (large, dark & watery).
 - ♦ *Complications* : ① *Tetany* from metabolic Alkalosis.
 - ② Dehydration, electrolytes imbalance & shock.
- **Signs** : ♦ *General* : Dehydration, tachycardia & ↓ ABP.
 - ♦ *Local* : Distended dead silent abdomen.

★ **D.D.**: From causes of **post operative vomiting**
e.g. intestinal obstruction, peritonitis, paralytic Ileus ... etc.

★ **Investigations**:

Na⁺ & K⁺ serum level. Never Barium meal as it worsen the case.

★ **Treatment**:

[A] **Prophylactic** : Ryle's tube is inserted post-operative to decompress the stomach.

[B] **Curative** : Continue Ryle's tube + correct electrolytes (No Role For Surgery).

IV

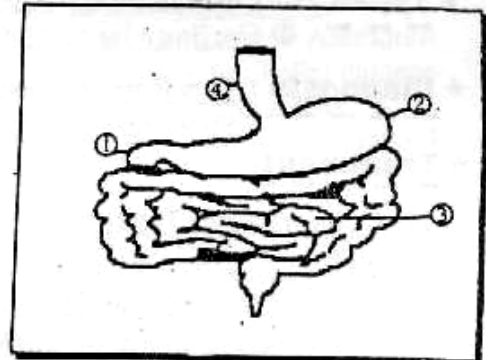
Peptic Ulcer

مهم جدا

⊙ **Definition** : Ulceration of the Gastric mucosa

⊙ **Sites** : In order to frequency

- ① Duodenum "The Commonest"
- ② Stomach.
- ③ Jejunum after gastrojejunostomy.
- ④ Lower Oesophagus if Reflux oesophagitis.
- ⑤ Meckel's Diverticulum "The Rarest".



⊙ **Factors Affect on HCL Secretion** :



[A] **Nervous Phase** : • Stimulated by Psychic stimulus.
• Mediated by Vagus From parietal cells at Body.
• Effect → ↑ HCL secretions.

[B] **Hormonal Phase** : • Stimulated by food in stomach with dilated antrum.
• Mediated by Gastrin from G cells at Antrum.
• Effect → ↑ HCL secretion.

[C] **Intestinal Phase** : • Stimulated by Acid Chyme in stomach.
• Mediated by Enterogastone.
• Effect → ↓ HCL secretions.

A Acute Peptic Ulcer

The Disease is described as being of 2 varieties

	Multiple Erosions	True Stress Ulcer
		
★ <u>Aetiology</u> :	★ <u>Disruption of gastric mucosa due to uses of NSAIDs (Non-Steroidal Anti-inflammatory Drugs)</u> which leads to → ↓ mucosal blood flow by it's Anti-prostaglandin effect.	★ <u>Disruption of gastric mucosa due to</u> <ul style="list-style-type: none"> • <u>Mucosal Ischaemia</u> try to vascular injury. • <u>Reflux of bile</u> into stomach • <u>Patient At (I.C.U)</u> with severe trauma or major burn.
★ <u>Pathology</u> :	★ <u>Multiple Shallow Erosions</u> limited to mucosa and sub-mucosa i.e. Superficial Ulcers.	★ <u>Multiple Erosions</u> if <u>not</u> recognized and treated they will <u>coalesce</u> to becomes <u>Acute Haemorrhagic Gastritis</u>
★ <u>Clinical Picture</u> :	★ <u>Mild to Moderate</u> Haematemesis	★ <u>Severe</u> Haematemesis So may leads to <u>Shock</u> .

★ Types : ① Cushing ulcer : After Cerebral Trauma & Neurosurgical Operations.
 --- ② Curling ulcer : After Major Burn.

★ Diagnosis : [An Emergency Case]
 --- So we do Endoscopy [Ba. Meal is useless as the ulcer is superficial].

★ Treatment :

[1] Conservative Treatment :

- ① Withdrawal of NSAIDs.
- ② Blood Transfusion to Correct Shock.
- ③ I.V. Antacids e.g. Oméprazole (Proton Pump Blocker).

[2] Recent Treatment :


- ① Endoscopy then local injection of Vasoconstrictors.
- ② Endoscopy then LASER Photocoagulation.
- ③ Ice Cold Saline Wash mixed with Adrenaline.


[3] Surgical Treatment :

- Total or Subtotal Gastrectomy (if all the above are failed).



Chronic Peptic Ulcer

	Duodenal Ulcer	Gastric Ulcer
<p>★ Incidence :</p> <ul style="list-style-type: none"> ▪ <u>Age :</u> ▪ <u>Sex :</u> 	<div style="border: 1px solid black; padding: 2px; display: inline-block;">25 : 1</div>	<ul style="list-style-type: none"> • Usually <u>Elderly</u> (50-60) years • <u>2</u> Male : <u>1</u> Female.
<p>★ Types :</p>	<div style="border: 1px solid black; padding: 2px; display: inline-block;">Only One Type</div>	<div style="border: 1px solid black; padding: 2px; display: inline-block;">There are 3 Types</div>
<p>★ Aetiology :</p>	<div style="border: 1px solid black; padding: 2px; display: inline-block;">Increased Gastric Acidity (i.e Hyperacidity)</div>	<div style="border: 1px solid black; padding: 2px; display: inline-block;">Decreased Mucosal Barrier (i.e Devitalization)</div>
<p>★ Pathology :</p> <ul style="list-style-type: none"> ▪ <u>Acidity :</u> ▪ <u>Motility :</u> 	<p>• Present at the <u>1st inch</u> of the <u>1st part</u> of duodenum & it shows <u>hyperacidity</u>.</p> <p>① Genetics : Acts by producing large parietal cell Mass So leads to <u>High HCL</u> secretions.</p> <p>② ↑ Vagal Tone : due to Mental stress & Nervousness.</p> <p>③ Increased Gastrin Hormone</p> <ul style="list-style-type: none"> • ↑ Secretion : Due to (Zollinger Ellison's Syndrome) i.e. Gastrinoma. • ↓ Inactivation : Due to Liver Cirrhosis. <p>④ Helicobacter pylori (Recent) which is gram (-ve) → Antral Gastritis → ↑ Gastrin Release.</p> <p>⑤ The uses of (NSAIDs)</p> <p>⑥ Other causes as Smoking & Irritant food etc.</p> <div style="border: 1px solid black; padding: 5px; margin-top: 10px;"> <p>N.B. : Blood group (0) & +ve family history are also risk factors</p> </div> <p>• <u>Hyperacidity.</u></p> <p>• <u>Hypermotility.</u></p>	 <ul style="list-style-type: none"> • <u>Type I</u> : ulcer at <u>lesser curve</u> • <u>Type II</u> : GU & DU • <u>Type III</u> : ulcer at <u>the antrum</u> <p>IAI ↓ Protective Layer of Mucosa :</p> <p>① Duodeno-gastric Reflux : Due to disturbed pyloric sphincter so it will leads to damage of gastric mucosa. .</p> <p>② Antral stasis: Due to defect in gastric emptying → Atrophy of mucosa.</p> <p>③ Helicobacter pylori (Recent) which split urea → Ammonia so ↑ PH → Epithelial damage</p> <p>④ The uses of (NSAIDs)</p> <p>⑤ Other causes as Smoking & Irritant food etc.</p> <p>IBI ↓ Regenerative power of the gastric mucosa</p> <p>⑥ Atherosclerosis → Ischaemia at the mucosa.</p> <p>• <u>Hypoacidity or Normoacidity</u> TYPE I & Hyperacidity TYPE II & III</p> <p>• <u>Hypomotility.</u></p>

	Duodenal Ulcer	Gastric Ulcer
<ul style="list-style-type: none"> • Number • Site • Shape • Size 	<ul style="list-style-type: none"> • Usually <u>Single</u>, but may be 2 (<u>kissing ulcers</u>) are present <u>one</u> on Ant. surface & <u>other one</u> on post. Surface. • <u>In the posterior surface</u> of the duodenum. (1st inch of 1st part) • <u>Rounded or oval</u> shape. • Usually <u>Small < 2cm.</u> 	<ul style="list-style-type: none"> • Usually <u>Single</u> • <u>At junction</u> of the Body & Antrum on lesser curve of stomach. i.e. (<u>ulcer bearing area</u>). • Usually <u>Irregular</u> shape. • Usually <u>large > 2cm.</u>
<ul style="list-style-type: none"> • Edge • Margin • Floor • Discharge 	<ul style="list-style-type: none"> • <u>Sloping</u> (Healed) or <u>Punched out</u> (Unhealed). • The surrounding mucosa is thrown into folds which converge on the ulcer. i.e. <u>Regul convergence</u>. • Filled with Granulation tissue with <u>No</u> muscle layer. • <u>+ve stippling sign</u> : By Rubbing the site of ulcer with a <u>gauze</u>. The ulcerative mucosa shows <u>Minute Petechial Haemorrhage</u> →  	
<ul style="list-style-type: none"> • Base 	<ul style="list-style-type: none"> • The ulcer is <u>deep</u> & penetrate the muscle coat <u>So</u> the Base is thin. 	
<p>★ Clinical Picture :</p> <p><u>I- Pain</u></p> <p>① <u>Site</u></p> <p>② <u>Character</u></p> <p>③ <u>Time</u></p> <p>④ <u>Increased by</u></p> <p>⑤ <u>Decreased by</u></p> <p>⑥ <u>Referred</u></p>	<p>The complications may be the 1st presentation</p>	
	<ul style="list-style-type: none"> • <u>Epigastric</u> Region & to the <u>Rt.</u> of middle line i.e. <u>Pointing sign.</u> • <u>Burning</u> pain. • <u>2 hours after meal</u> <u>N.B.:</u> may be ½ hour <u>before</u> meal due to irritation of nerve endings by Excess <u>HCL</u> → Reflex Spasm i.e. <u>Hunger pain.</u> (Maximum at night) i.e. <u>Nocturnal pain.</u> • Irritant food, <u>Stress & Hunger.</u> • Alkalis & Antacids <u>Also Eating</u> (patient has always some Biscuits). • <u>Boring pain</u> at back i.e. penetrates Pancreas 	<ul style="list-style-type: none"> • <u>Epigastric</u> Region & to the <u>Lt.</u> of middle line. i.e. <u>Pointing sign.</u> • <u>Burning</u> pain. • <u>½ - 1 hour after meal.</u> <u>N.B.:</u> <u>No Hunger pain</u> or <u>Nocturnal pain.</u> • Irritant food. • Alkalis & Antacids <u>Also Vomiting</u> (May be self induced). • <u>Boring pain</u> at back i.e. penetrates Pancreas (if Post.)
<p><u>II- Appetite</u> →</p>	<ul style="list-style-type: none"> • <u>Good</u> 	<ul style="list-style-type: none"> • <u>Bad</u> the patient <u>Afraid</u> to eat
<p><u>III- Nausia &</u> → <u>Vomiting</u></p>	<ul style="list-style-type: none"> • <u>Rare</u> Except if pyloric stenosis has occurred. 	<ul style="list-style-type: none"> • <u>Common</u> (self Induced) to bring <u>Alkaline bile</u> to stomach.
<p><u>IV- Periodicity</u> →</p>	<ul style="list-style-type: none"> • <u>Marked</u> (pain occur at periods of ulcer activity). 	<ul style="list-style-type: none"> • <u>Less Marked.</u>

N.B. : Wilkie's Triade which is ⚡
 Chronic Peptic Ulcer + Chronic Appendicitis & Chronic Calcular Cholecystitis

★ **Complications** : "May 1st Presentation"

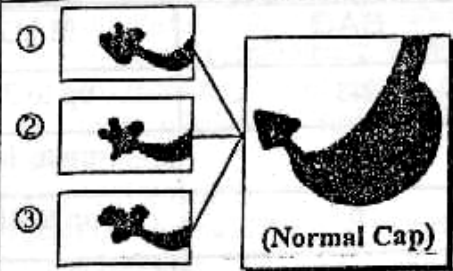




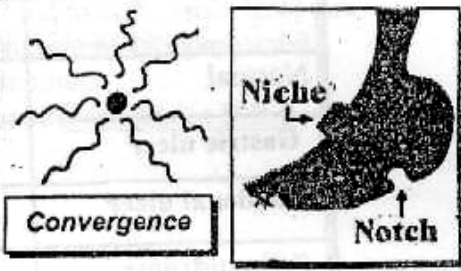


- ① **Perforation** : with penetration to nearby organs as pancreas.
- ② **Bleeding** : • Duodenal ulcer : Melena is common.
 • Gastric ulcer : Haematemesis is common.
- ③ **Stenosis** : • Duodenal ulcer → Pyloric Stenosis.
 • Gastric ulcer → Tea-Pot Stomach or Hourglass
- ④ **Malignancy** : "Never with duodenal ulcer & occur with Gastric ulcer only"

N.B. **Criteria of Malignant ulcer :**

- ① Gastric ulcer outside ulcer bearing area.
- ② Giant ulcer.
- ③ Achlorohydia. .
- ④ Old patient with short history.
- ⑤ Resist to medical treatment. .

★ **Investigations** :

[1] Barium Meal :

Duodenal Ulcer	Gastric Ulcer
 <p>①  →  (Normal Cap)</p> <p>② </p> <p>③ </p>	 <p> Convergence</p> <p> Niche Notch</p>
<ul style="list-style-type: none"> • Ulcer Niche (Fig ①) full of Barium in duodenal cap which is normally [Triangular with rounded corners]. • Chronic Ulcer may end by Spasm & Fibrosis → Deformity as ★ Irregular (Fig ②) & ★ Trifoliate (Fig ③). • Persistent deformity of the duodenal cap detected by [At least 3 serial films with 15 minute Interval]. • Rapid Gastric Emptying i.e. Hypertonic. • Localized Tenderness (under Screen) 	<ul style="list-style-type: none"> • Ulcer Niche full of Barium on the lesser curve of stomach. • Ulcer Notch will be seen at the greater curve (<i>opposite to ulcer niche</i>) due to spasm & fibrosis of circular Muscles. • Post-evacuation Film : show convergence of mucosal fold towards the ulcer i.e. Barium at ulcer & seen radiating from it. • Delayed Gastric Emptying i.e. Hypotonic . • Localized Tenderness (under Screen).

[2] Endoscopy :

- For visualization of ulcer & Follow up of medical treatment
N.B. : Biopsy to Exclude carcinoma with Gastric ulcer only.

[3] Investigation for *H. pylori* :

- As Serological test & Culture from biopsy.

[4] Investigation for Z/E syndrome :

- As serum gastrin level If ↓ 100 Pgm/ml = Normal.
 If > 200 Pgm/ml = Abnormal high.
 If > 1000 Pgm/ml = Gastrinoma.

[5] Stool Analysis :

- By Benizidine Test (mainly prognostic if +ve = Active ulcer.
 If -ve = Healed ulcer.

[6] Gastric function test : (G.F.T)

- To Evaluate Acid secretions **So** it will show Hyperacidity with duodenal ulcer & Normo-acidity or Hypo-acidity with Gastric ulcer.

(A) Measurement of Basal Acid Output (BAO) & Maximum Acid Output (MAO):**a. Basal Acid output (BAO) :**

The acid of an empty fasting stomach is collected over 1 hour (Aspirated/ 15 min. through Ryle's tube. Normal = 2-5 mmol/h.

b. Maximal acid output (MAO) :

After measuring (BAO) we will give (pentagastrin) I.M. or S.C then we collect the acid of stomach over 1 hour Normal 20-30 : mmol/h.

Value of BAO & MAO :

	BAO	MAO
Normal	2-5	up to 30
Gastric ulcer	2	up to 15
Duodenal ulcer	6	up to 40
Z/E syndrome	> 60% of MAO	

(B) Measurement of Effect of Vagal Tone on Gastric Secretion :**a. Insulin-Test (Hollander)**

- **The idea** : Insulin → Hypoglycaemia → ↑ vagus → ↑ HCL
- **The steps** : 2 units soluble insulin/10 mg I.V for fasting patient → hypoglycaemia → vagus → HCL then do gastric aspiration, 15 min. for 4 hours = 16 times.
- **The value** : Test the efficiency of vagus.
- **The results** : ① **Early +ve test** : Rise of acid conc. At 1st hour above basal level (20 mmol/L) → Do vagotomy.
 ② **Delayed +ve test** : Rise of Acid conc. between 1st & 4th hour → Do vagotomy & Antrectomy.

b. Chew & Spit Test :

It depend on effect of chewing on the vagus. It give the same result of Hollander test but very safe.

★ Treatment :Ⓐ Treatment of Chronic Duodenal Ulcer[I] Conservative ttt

★ The Aim : Reduction of Gastric acidity to allow the ulcer to heal & Maintaining it's healing.

★ The Indications : If not complicated or associated with gastric ulcer.

★ The Measures : ↷

[A] General Measures :

- ① Physical Rest & Mental Rest.
- ② Diet : Frequent small meals & Avoid irritant Food.

N.B. : Milk given as a some only Because Inspite of it's neutralizing effect a potent stimulus for HCL.

- ③ Stop smoking, coffee, tea & Alcohols

[B] Drug Therapy :

- ① H₂ Receptor Blockers Such as ↷

★ Cimetidine (Tagamet)

- ♦ Dose : 800 mg at bed time.
- ♦ Effect : The ulcer heals within 6 weeks but full dose continued for few weeks more. Endoscopy is repeated to evaluate healing.
- ♦ Side effects : [Rare] only 5%.
 - (a) Anti-androgenic : Because it bind to androgenic receptors causing (Impotence, Gynaecomastia & Oligospermia).
 - (b) Increase Risk of gastric carcinoma.
 - (c) Confusion : If High dose because it can passes B.B.B.

★ Ranitidine (Zantac)

150 mg/ twice daily.

★ Famotidine (Antodine) [The most recent]

40 mg at bed time.

- ② Proton Pump Blocker Such as ↷

★ Omeprazole (Losec)

- ♦ Dose : 20 mg Orally in the morning.
- ♦ Effect :
 - (a) It Blocks The proton pump action of pareital cells.
 - (b) It Reduces gastric acidity up to Zero by 99%.
 - (c) The Best ttt : of "Zollinger Ellison Syndrome".
- ♦ Side effects : Long Term of treatment → Atrophic Gastritis.

③ Antacids :

★ Combined [Aluminum Hydroxide Gel + Magnesium Oxide].

[C] Specific ttt for Helicobacter pylori : (Combination of) ↷

- ① Metronidazole (Flagyl)
- ② Tetracycline or Amoxicyllin
- ③ Colloidal Bismuth (De Nol)

} Give for 2 weeks to give good result (90%)

[II] Surgical ttt

- ★ The Aim: Permanent & Adequate reduction of gastric secretions.
- ★ The Indications:
 - ① Complications e.g. pyloric stenosis.
 - ② Combined gastric & duodenal ulcers.
 - ③ Poor patient (financial factor) i.e. can't afford medical ttt.
 - ④ Poor compliance i.e. unwilling to take tablets.
 - ⑤ Resist to medical treatment i.e. No response.
 - ⑥ Recurrent after adequate medical ttt.
- ★ The Techniques: ↷

- (A) Abolishing the Nervous Phase of gastric acid secretions by **Vagotomy**.
- (B) Abolishing the Hormonal Phase of gastric acid secretions by **Antrectomy**.

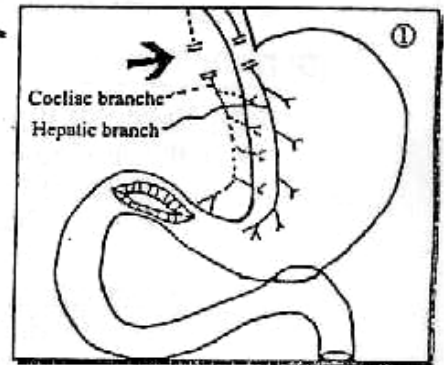
N.B. : Some Surgeons Combine Vagotomy & Antrectomy Phases.

- (C) Reduction of Parietal Cell Mass (Only of Historical Interest) by **Billroth II**.

[A] Vagotomy

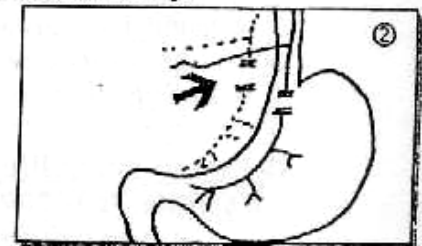① Trunkal Vagotomy :

- Dividing Both Ant. & Post. Vagal Trunks at the lower end of oesophagus But complicated by ↷
 - Denervation of pylorus → Pyloric Spasm → Pyloric Antral stasis → Gastrin Release → HCL secretions → Recurrency of ulcer.
 - Entire Denervation of whole Abdomen (till hind gut) → Distention & Biliary dyskinesia
- 80% Reduction of HCL secretions but Recurrence Rate (5-10%).
- Drainage procedures is done as Pyloroplasty or Gastro-jejunostomy.



② Selective Vagotomy :

- Dividing Both Ant. & Post. Vagal Trunks sparing both coeliac & hepatic branches
- There is still Pylorospasm only.
- Drainage procedures is still done.



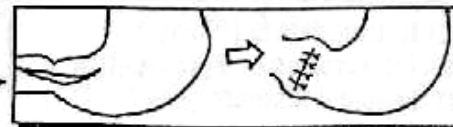
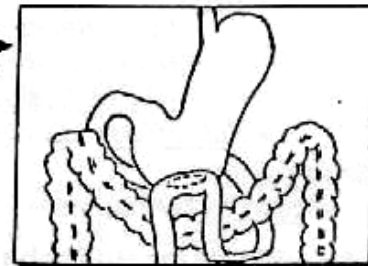
N.B. Drainage Procedures : ↷

★ Gastro-jejunostomy :

Anastomosis of the most dependent part of stomach to the jejunum with no gastric resection.

★ Pyloroplasty :


This operation destroys the pyloric sphincter by cutting it (It has many types) the most popular is **Heineke-Mikulicz** Type where the pylorus is divided longitudinally & sutured Transversely →



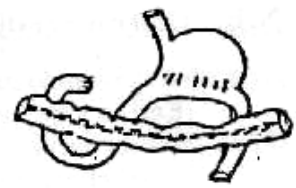
N.B. : Other procedures of gastrojejunal anastomoses :

[1] **Polya Anastomosis :**
(End to side) gastro-jejunostomy.

[2] **Hofmeister valve :**
Partial closure of the stoma to form a valve that ↓ Dumping



Hofmeister valve



Polya anastomosis

B. Treatment of Chronic Gastric Ulcer

[I] Conservative ttt

★ **As Chronic Duodenal Ulcer**

But with the following considerations ↗

- ① **Because of high risk for occurrence of carcinoma** [Endoscopy] should be carried out of after 6 weeks regardless of symptomatic improvement,
So If ulcer shows (no attempts) of healing → It should be considered carcinoma & surgery is performed.
- Or If ulcer shows (partial) healing → Continue the medical treatment for another 6weeks.

② **We can use Cytoprotective drugs :**

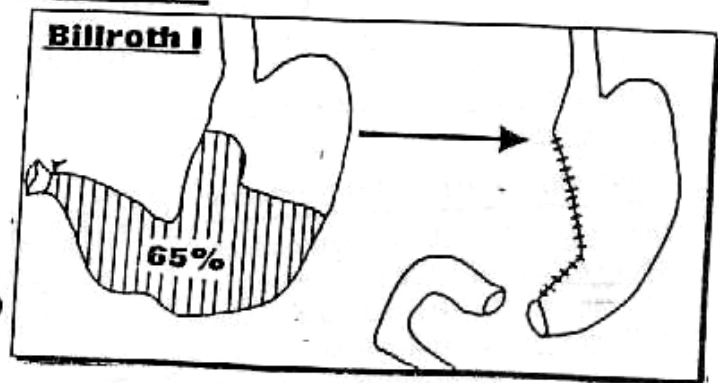
1. **Colloidal Bismuthate (De Nol):**
 - It form protective coat on the mucosa.
 - **Bacteriostatic** for Helicobacter pylori.
 - **Dose :** 2 tab. before breakfast & Dinner.
2. **Sucralfate (Gastrofaiit)**
 - Pepsin-Antagonist.
 - ↑ Prostaglandins activity which protect gastric mucosa.
 - **Dose :** 1gm before meal.
3. **Prostaglandins** Cytoprotective for gastric mucosa.
4. **Carbenoxolone sodium :** ↓ prostaglandin dehydrogenase enzyme → ↑ prostaglandins which protect gastric mucosa.

[II] Surgical ttt

- ★ **The Aim :** Removal of ulcer
- ★ **The Indications** AS Duodenal ulcer.
- ★ **The Techniques** ↗

(Billroth I) Partial Gastrectomy

- **Indicated only** with the gastric ulcer.
- **About 65%** of distal part of stomach is removed i.e. (Partial Gastrectomy)
- **Followed by** Gastric-duodenal anastomosis



Partial Gastrectomy

Post-gastrectomy Complications



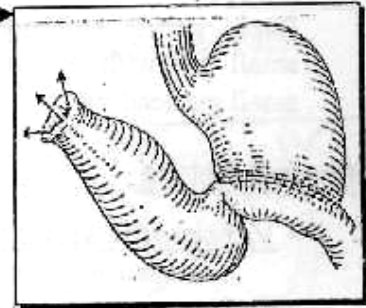
[1] Early Complications

[A] General Complications

- Shock, infection and pulmonary complications
- Iry Hge from bleeding vessels.
- *Injuries of important structures* at stomach bed.

[B] Local Complications

- *Haematemesis* : Due to bleeding from suture line of anastomosis.
- *Stomal obstruction* : i.e. obstruction at line of anastomosis, by oedema at stoma
- *Duodenal blow out* : Follow **Billroth II** anastomosis after gastro-jejunostomy the blind duodenal stump may be distended with pancreatic and biliary juice → ↑ pressure → Disruption of suture line → Biliary peritonitis.



[2] Late Complications

[A] Recurrent ulceration

☆ Aetiology :

A) Inadequate surgery :

- e.g. ① Missing a vagal nerve (usually the posterior)
 ② Missing a vagal branch running over the lower oesophagus which is called "Criminal nerve".
 ③ Leaving part of gastric antrum.

B) Other causes as Zollinger-Ellison syndrome i.e. Gastrinoma.

C) Uses of ulcerogenic Drugs : Corticosteroids, Aspirin, NSAIDs ... etc.

☆ Site :

- Stomal (on the anastomotic line). i.e. Flase
e.g. gastro-jejunal ulcer or gastro-duodenal ulcer.
- Site of original ulcer : i.e. True.

☆ Clinical picture :

Recurrancy of ulcer symptoms.

☆ Investigations :

Same as peptic ulcer especially Endoscopy and Estimation of circulating gastrin in blood by radio-immuno-assay for Z/E syndrome.

☆ Treatment :

[A] Medical ttt :

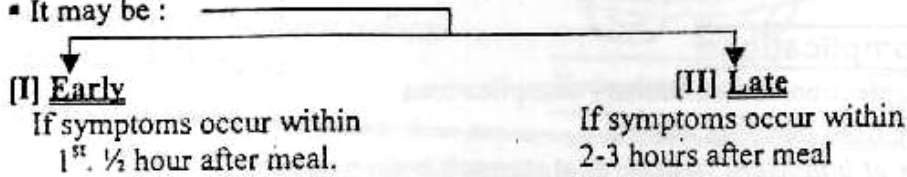
- H₂ receptor blocker as Cimitidine.
- Proton pump blocker as Omeprazole.

[B] Surgical ttt :

- *Following vagotomy* : Antrectomy is preformed.
- *Following Gastrectomy* : Vagotomy is performed.

[B] Dumping [Post-cibal syndrome]

- It is a syndrome with Vasomotor & G.I.T symptoms after meal.
- It may be:

**[I] Early Dumping**☆ **Aetiology:**

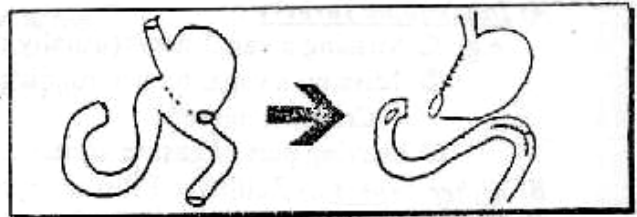
Rapid gastric emptying with the delivery of a hyperosmolar solution to the proximal small gut with the result of shift of fluid from the circulatory plasma to the proximal small gut leading to ↑ Intestinal activity and ↓ blood volume.

☆ **Clinical Picture:**

- **Vasomotor symptoms:**
As sense of weakness, Flushing and palpitation.
- **G.I.T. symptoms:**
As Epigastric Fullness and pain with nausea ending by explosive diarrhea.

☆ **Treatment:**

- Frequent small meals.
- **Beladonna** may reduce Intestinal motility.
- **If symptoms persist** convert gastro-jejunosotomy to gastro-duodenostomy if possible.

**[II] Late Dumping**☆ **Aetiology:**

Overshot of **Insulin** which is caused by rapid delivery of large amounts of carbohydrates to the small intestine.

☆ **Clinical picture:**

Picture of **Hypoglycaemia**, sweating, palpitation and confusion which relieved by carbohydrate ingestion.

☆ **Treatment:**

- **Avoid** high carbohydrate in diet.
- **Olive oil** with diet may delay emptying of stomach.

[C] Biliary Gastritis

Alkaline reflux gastritis.

[D] Increase Incidence of Cancer

In gastric remnant properly related to Biliary gastritis

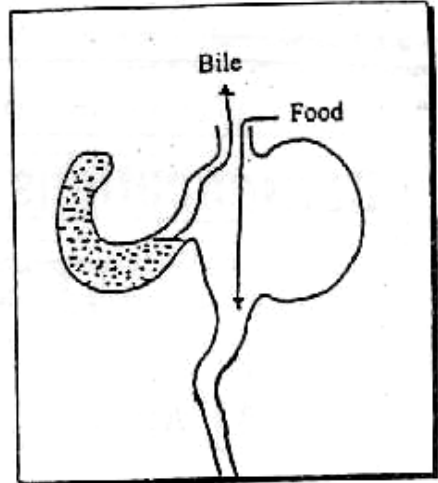
[E] **Afferent Loop syndrome**

☆ **Definition :**

It is a periodic vomiting of large quantities of bile and pancreatic secretions free of food with sudden relief of epigastric pain.

☆ **Aetiology :**

It is a mechanical obstruction of the long afferent jejunal loop because of its kinking at the anastomosis so that the bile and pancreatic juice accumulate in this loop until the obstruction is suddenly relieved.

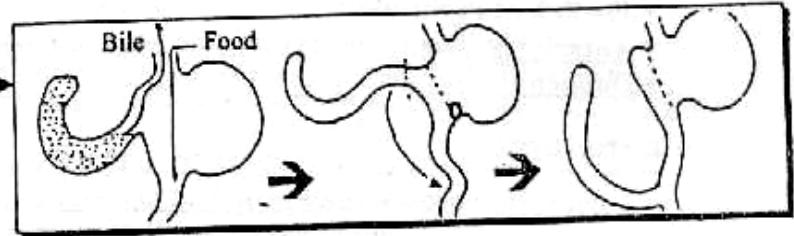


☆ **Clinical picture :**

Fullness and Epigastric pain following meals & followed by projectile bilious vomiting.

☆ **Treatment :**

Operative
Consists of conversion of Anastomoses to a Raux-en-Y loop.



[F] **Gastro-jejuno-colic Fistula**

It is a complication of gastro-jejunal ulcer, occurring in 4-8% of cases the ulcer penetrates & erodes the Transverse colon.

[G] **Intestinal obstruction**

It is due to internal herniation of Intestinal loops through a gap in the mesocolon.

[H] **Gall stone formation**

Commonly after Trunkal vagotomy due to associated denervation of the gall bladder
→ Impairment of its contractility → stasis → gall stone Formation.

[I] **Post-vagotomy Diarrhea**

[J] **Post-gastrectomy nutritional disturbances**

- ① Weight loss.
- ② Steatorrhea & diarrhea :
Due to lack of mixing of food with pancreatic & biliary secretions.
- ③ Vit. D Deficiency :
Treated by Vit. D supplement.
- ④ Ca Deficiency :
Treated by Ca supplement.
- ⑤ Fe Deficiency Anaemia :
Treated by I.M Vit. B₁₂.

Complications of Chronic Peptic Ulcer

I Perforation

- (A) Acute
(B) Subacute
(C) Chronic

(A) Acute Perforated Peptic Ulcer

★ Incidence :

- 10-15 % of Peptic ulcer.
- Anteriorly situated ulcers perforate more commonly.
- Duodenal ulcer perforates more commoner than Gastric ulcer.

★ Aetiology :

- Perforation occur during periods of exacerbation of an ulcer.
i.e. during worry, work & weather etc...
- Perforation occur due to relapse precipitated by Alcohol & Irritant food.
- Perforation occur due to continuous using of Ulcerogenic drugs.

★ Pathology : [3 Stages].

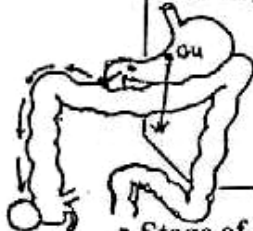
- Stage of Perforation : Escape of gastro-duodenal contents into the peritoneal cavity.
- Stage of Chemical Peritonitis : The peritonium will react by production of Alkaline fluid neutralizing the Acidity → Peritonitis which is Sterile so called "**Chemical Peritonitis**". This stage lasts from 3-6 hours
N.B. : This stage called (**Lucid Interval**).

N.B. : The Length of This Stage Depends On ↗

- The Size of perforation : The smaller in size the longer in time .
- The Contents : Longer duration with empty stomach.
- The General condition of the patient : The better it is, the longer the duration.

N.B.: Duodenal Perforation is LESS Serious than gastric Perforation, due to

- The Perforation is smaller in size.
- The Contents are Less Irritant & More Sterile.
- Poured out contents flow along the Rt. para - colic gutter to be localized at Rt. Iliac Fossa But Gastric ulcer perforates directly into the General Peritoneal Cavity → Generalized peritonitis.



- Stage of Septic Peritonitis : Occur when the body resistance fails.
Micro-organisms invade peritoneal cavity then pus is formed.

★ **Clinical Picture** : [Corresponding to Path. Stages]

[About **80%** of cases with "+ve" History for peptic ulcer but only **20%** of cases with "Silent" chronic ulcer that perforate].

- ★ **Stage of Perforation** : Sudden severe upper abdominal pain & Collapse from pain i.e. **Neurogenic shock**.

- ★ **General** : • **Pallor & Sweating**.
 - **Pulse** : Increased.
 - **Temp.** : Subnormal.

★ **Local** : **Upper Abdomen** shows Tenderness & Rigidity.(Board like)

- ★ **Stage of Chemical Peritonitis** : Patient is relieved from shock & He comes walking to the Hospital i.e. **Lucid Interval**.

- ★ **General** : • **No Pallor or Sweating**.
 - **Pulse** : Still Increased.
 - **Temp.** : Normal.

- ★ **Local** : • **Inspection** : No Abdominal Movement with respiration.
 - **Palpation**: **Tenderness** (Maximum at epigastrium) & **Board Like Rigidity** of the Abdomen.

- **Percussion** : **Obliterated liver Dullness** due to
-escape of gas from perforated gut under diaphragm & **Shifting Dullness** due to escape of free bile in the peritoneal cavity.

- ★ **Stage of Septic Peritonitis** : Patient shows Toxic symptoms then Finally Septicaemia & Shock i.e. **Septic Shock**.

- ★ **General** : • **Patient** is Toxic.
 - **Pulse** : **Marked** Increased.
 - **Temp.** : Increased.

[Patient also complains of Constipation, Distension & Vomiting]

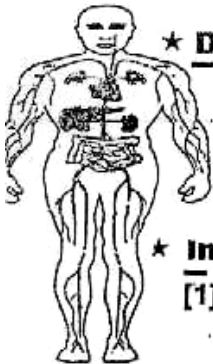
- ★ **Local** : **Dead silent distended Abdomen** on Auscultation.

[Patient will **Die** in few days **if untreated**].

★ **D.D** : "Other Causes of **Acute Abdomen**" as →

- e.g. ① Acute perforated peptic ulcer.
- ② Acute Cholecystitis.
- ③ Acute Pancreatitis.
- ④ Acute Appendicitis.

N.B. : See Acute Abdomen (Chapter 15)



★ **Investigations** : "After Resuscitation"

[1] **Plain X-ray "Abdomen"** : "**In Erect position**"

- **Reveal Air** under diaphragm.

[2] **Peritoneal Tapping** :

- **Reveal Bile** if perforated D.U

[3] **Gastro-graffin Swallow** :

- **Reveal** Escape of **Dye** through the perforation.

[4] **U/S** :

- **Reveal** Intra-abdominal fluid.



★ **Treatment** :▪ **Pre-operative**: [Urgent Resuscitation]

- A Ryle Tube for suction & Careful attention to respiration.
- I.V Fluids guided by Electrolytes Estimation.
- I.V A.B. & Omeprazole.

N.B. : Blood Transfusion indicated only with late cases with Toxaemia

▪ **Urgent operation**: [Laparotomy]

- ① The simplest procedure : Closure of perforation with Covering Omental Patch, then peritoneal Toilet then Abdominal Closure with Drain.
- ② Some Surgeons perform definitive operation provided that good general condition of patient. But may increases the Morbidity & Mortality Rate.
 - ★ If Duodenal Ulcer → Vagotomy + Drainage procedures.
 - ★ If Gastric ulcer → Partial Gastrectomy + Gastro-duodenostomy.

N.B.: Whether ① or ② BIOPSY is taken to exclude Malignancy if G-U.

▪ **Post-operative**: The patient is treated medically For his ulcer disease.

B

Sub-acute Perforated Peptic Ulcer

- This is a Small Perforation allowing only a minimal amount of contents to enter the peritoneal cavity and is rapidly sealed.
- It Gives the same early signs but much less severe.
- If Diagnosed Correctly it can be treated Conservatively.

C

Chronic Perforated Peptic Ulcer

- It Means Penetration into an adjacent structures.
- The Most Common Example is penetration to pancreas.
- It is suspected when the pain becomes referred to BACK.

II

Bleeding★ **Incidence** :

- 20% of Peptic ulcer.
- Haematemesis → More common with Gastric ulcer.
- Melena → More common with Duodenal ulcer.

★ **Aetiology** : "Same As Perforated ulcer"★ **Pathology** : [3 Degrees]

- Mild Degree : Bleeding from Granulation tissue of the floor of ulcer caused from Trauma by Solid food.
- Severe Degree : Erosion of a Small Vessel in the ulcer.
- Fatal Degree : Penetration of a Large Extra-gastric Vessels as splenic artery or gastro- duodenal artery running near the ulcer.

★ Clinical Picture :

[In Most of cases there is History of ulcer dyspepsia. Occasionally the Bleeding is the 1st presentation].

- Haematemesis : Dark red & Acidic with food particles.
- Melena : Altered blood in stool.
- Sign of Progressive Shock : [If Severe or Fatal Types].

★ D.D : "Other Causes of Upper "GIT" Haemorrhage"▪ Causes of upper GIT Hge ⇨

[A] General Causes : Hypertension, purpura or Hypoprothrombinaemia.

[B] Local Causes : (Oesophageal Causes)

- ① Oesophageal Varices.
- ② Oesophageal Carcinoma.
- ③ Oesophagitis (Retention or Reflux).
- ④ F.B. Impacted.
- ⑤ Mallary weiss syndrome.

(Gastro-duodenal Causes)

- ① Chronic Peptic Ulcer.
- ② Gastric Carcinoma.
- ③ Acute Gastric Erosions & Acute peptic ulcer

In Egypt : The Commonest 3 causes are : ⇨

- ① Oesophageal Varices 50%.
- ② Chronic Peptic Ulcer.
- ③ Acute Gastric Erosion.

D.D	Haematemesis	Haemoptsis
<ul style="list-style-type: none"> • <u>History</u> : • <u>Preceded by</u> : • <u>Followed by</u> : • <u>The Blood</u> : 	<ul style="list-style-type: none"> • <u>GIT Troubles</u>. • <u>Vomiting</u>. • <u>Melena</u>. • <u>Dark Red, Acidic</u> with Food particles. 	<ul style="list-style-type: none"> • <u>Chest Troubles</u>. • <u>Cough</u>. • <u>Blood stained Sputum</u>. • <u>Bright Red, Alkaline</u> with frothy sputum.

D.D	Bleeding Ulcer	Bleeding Varices
<ul style="list-style-type: none"> • <u>History</u> : • <u>Endoscopy</u> : • <u>Portal Pressure</u> : • <u>Sengestaken Tube</u> : 	<ul style="list-style-type: none"> • Dyspepsia relieved By <u>Antacids</u>. • <u>+ve Ulcer</u>. • <u>Normal Pressure</u> • <u>No Effect</u>. 	<ul style="list-style-type: none"> • <u>β</u>, Liver Cirrhosis & Hepatosplenomegaly • <u>+ve Varices</u>.. • <u>High Pressure</u>. • <u>Control Bleeding</u>.

★ Investigations : "After Resuscitation"[1] HB% & Haematocrite value:

- For proper replacement of Blood & Plasma expander.

[2] Endoscopy :

- The ulcer may show Blood clot at the floor.

[3] Blood Examination :

- To exclude Blood diseases as Purpura.

★ Treatment :

[1] Conservative Treatment :

(A) Resuscitation

(The Aim is to restore the blood volume & Arresting the bleeding).

- Absolute Bed Rest under opiate sedation.
- Ryle's Tube : To
 - ① Asses the amount of bleeding.
 - ② Prevent it's propagation to the gut.
 - ③ Irrigate the stomach with copious amounts of Ice-cold saline which help to arrest the bleeding.
- I.V Blood Transfusion to correct the hypovolaemia.

(B) Diagnosis :

- When the condition of the patient becomes stabilized, Investigations are carried out (as before) to detect the cause of bleeding.

(C) Sub-sequent treatment

- The patient is given the routine treatment for peptic ulcer including **Cimetidine (Tagamet) I.V & Antacids.**
- Frequent & light diets.
- Observation charts : For Pulse, A.B.P., Temp., CVP, Urinary output & Amount of bleeding.

[2] Surgical Treatment :

(A) Indications Mandatory in ↗

- ① If patient is already under medical ttt, but conservative treatment has nothing more, So operation is essential.
- ② If the bleeding is recurrent while patient still in hospital.
- ③ If Initial bleeding is severe & equal 2 liter or more.
- ④ If the bleeding is continued inspite of transfuse 1 liter or more per day to maintain stability.
- ⑤ If old atherosclerotic patient.
- ⑥ If the patient with long history of ulcer disease.

(B) Operative procedures with [Fit] patient

- The decision should be Taken early (within 48- 72 hours)
 - ★ If Duodenal Ulcer → Vagotomy + Drainage procedures.
 - ★ If Gastric ulcer → Partial Gastrectomy + Gastro-duodenostomy.
- Gastrotomy or Duodenotomy is done to visualize the ulcer, the bleeding vessel is ligated under-vision.

(C) Operative procedure with [unfit] patient "Control of bleeding only"

- If bleeding coming from the ulcer floor : Obliterate ulcer by sutures.
- If bleeding coming from eroded vessels at the edge : Underrunning on either side of ulcer.
- If bleeding coming from extra-gastric vessels : ligate them.


[3] Endoscopic Treatment : (The Most Recent)

- ★ By using : LASER Photocoagulation.
Or Diathermy Coagulation.
Or Vasoconstrictor agents as Noradrenaline.

III Fibrous Contractures of Peptic Ulceration

(A) Pyloric stenosis (B) Hour-glass stomach (C) Tea-pot stomach

(A) Pyloric Stenosis

- ★ **Definition** : It is a narrowing of pyloric canal interfering with the downwards passage of gastric Content
- ★ **Aetiology** : It is due to ↗
Excessive fibrosis around the duodenal ulcer.
- ★ **Pathology** :
- The Pylorus : Cicatrized & Stenosed.
 - The Stomach : At 1st Hypertrophied to overcome the obstruction, but Later on dilated (may reach the pelvis) with gastritis from retention.
 - The Intestine : Normal & Collapsed.
- ★ **Clinical Picture** :
- Patient with long history of ulcer dyspepsia, although some cases occur as 1st presentation.
- **Symptoms** :
- ① Vomiting : (a) Occurs once/day at the evening.
(b) Projectile, Non-bile stained & containing food from previous meal with foul odour.
(c) After vomiting, the Initial periodic ulcer pain is lost and replaced by epigastric discomfort.
 - ② Progressive constipation.
 - ③ Complications : (a) Dehydration & Loss of weight.
(b) Chest Infection (Aspiration pneumonia).
(c) Metabolic Alkalosis → Tetany from repeated vomiting
- **Signs** : General : "Signs of Dehydration"
(Dry Inelastic Skin, Dry Tongue, Sunken Eyes & Oliguria).
- Local :
- Upper abdominal Distention.
 - Visible peristalsis from Lt. to Rt. → 
 - Succussion splash by Auscultation.

★ **D.D** :

- [From other causes of Pyloric Stenosis] as ↗
- ① Congenital : Congenital Hypertrophic Pyloric Stenosis (CHPS).
 - ② Traumatic : Impacted F.B or Badly performed pyloroplasty.
 - ③ Inflammatory : Cicatrized Duodenal ulcer & rarely T.B or S.
 - ④ Neoplastic : Cancer pylorus.
 - ⑤ Functional : Pylorospasm or Achalasia of pylorus
 - ⑥ Pressure from outside : L.Ns or Cancer head pancreas.

★ The Commonest causes are : Cicatrized D.U. & Cancer pylorus

★ Investigations :

[1] Laboratory : "Serum Electrolytes"

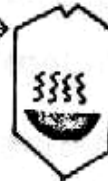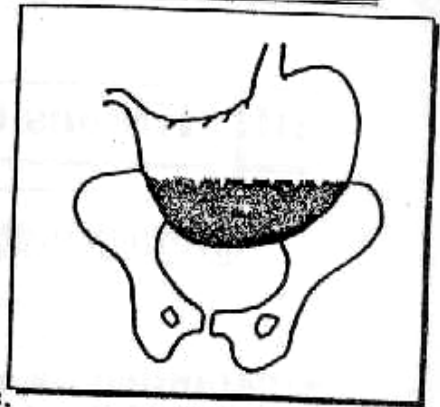
- Metabolic (Hypochloremic) Alkalosis & ↓ Na

[2] Endoscopy :

- Stenosed pyloric ring & Retention gastritis.

[3] Barium Meal :

- ① Huge Dilated Stomach may reach down to the pelvis.
- ② Fluid level in the stomach so it has **soup dish Appearance** →



★ Treatment : "Only Surgical"

- 1st Line of ttt : Correct the Dehydration & Electrolytes Imbalance.
- Pre-operative preparations : ① Stop feeding, then Naso-gastric suction with normal saline.
② High protein diet with I.V hyperalimentation.
③ Chest Antibiotics.

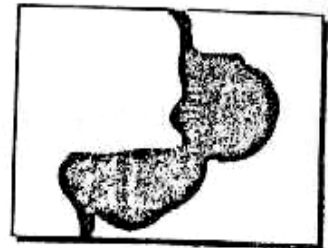
▪ Operation : **Trunkal Vagotomy & Gastro-jejunostomy**

[It the standard treatment but there are other options] ↗

- ① Endoscopic Balloon Dilatation "The Most Recent".
- ② Partial Gastrectomy + Gastro-jejunostomy.
- ③ Gastro-jejunostomy alone in elderly.


B Hour Glass Stomach

- It is due to cicatrized ulcer on lesser curve of the stomach, the stomach is divided into 2 pouches (Proximal & Distal).
- It is diagnosed by Endoscopy & Barium Meal.
- It is treated by Partial Gastrectomy i.e. Removal of distal pouch.



C Tea-pot Stomach

- It is due to ulcer on lesser curve of the stomach causing shortening of lesser curve, thus causing the pylorus becomes relatively higher and represented by features of pyloric obstruction.



IV Malignant Ulcer

- ★ Duodenal Ulcer : **Never** to turn Malignant.
- ★ Gastric Ulcer : **Very rarely** to turn Malignant (<1%).

V

Carcinoma of the stomach★ **Incidence :**

- **The commonest** GIT Cancer.
- **Age:** > 40 years.
- **Sex:** 3 Male : 1 female.

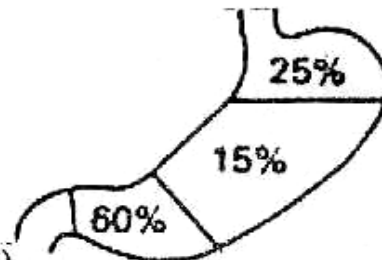
★ **Predisposing Factors :**

- ① **Chronic Irritation causes gastritis:** 5S (**S**pirits, **S**pices, **S**moking, **S**epsis & **S**)

N.B : Other Factors as ↻

- ① **Diet containing carcinogens as Hydrocarbons**
- ② **Blood group (A) & also common in Japanes [Epidemic]**
- ③ **Post-vagotomy & post-gasterctomy (due to reflux of bile)**

- ② **Pernicious Anaemia**
- ③ **Helico-bacter pylori (Recently)**
- ④ **Achlorhydria.**
- ⑤ **Benign Gastric neoplasm as Gastric Polyps.**
- ⑥ **Benign Gastric Ulcer Very rare <1%.**

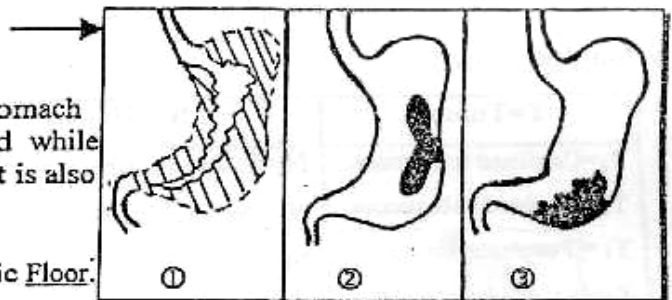
★ **Pathology :**

- **Site:**
 - ① Pyloric (60%)
 - ② Body (15%)
 - ③ Cardia (25%)
 - ④ The whole stomach. very rare

- **N/E Picture: 2 Types:**

* **Advanced gastric carcinoma :**

- ① **Diffusely Infiltrating Type :**
"Linitis Plastica" The wall of stomach is greatly thickened and Indurated while the lumen is greatly reduced. So it is also called "leather bottle stomach".
- ② **Ulcerative Type :**
With Raised Everted Edge & Necrotic Floor.
- ③ **Fungating Cauliflower Type.**

* **Early gastric carcinoma :**

- ① **Protruding Type.**
- ② **Superficial Type.**
- ③ **Excavated (Penetrated) Type.**

- **Microscopic picture: (Adenocarcinoma) 95%**

- **Columnar cell Adenocarcinoma.**
- **Spheroidal cell Adenocarcinoma.**
- **Colloid cell Adenocarcinoma (poor prognosis)**

& (Squamous cell carcinoma) 5% i.e. From oesophageal spread

★ **Spread :**

- **Direct spread:** Both in (Depth & Circumference) of the wall of stomach then infiltrates the surroundings as → Liver, Spleen, Colon & Parcreas.

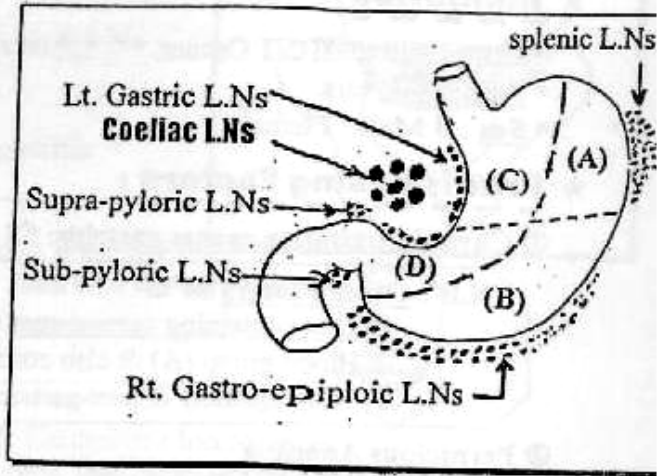
▪ **Lymphatic spread:** By both (Embolization & permeation)

^ **The stomach is divided into 4 areas by :**

- Line parallel & in between the greater & lesser curves.
- Another 2 perpendicular lines pass from this line to the lesser & greater curves.

SQ Both a & b dividing the stomach into 4 areas.

- > **Area (A)** : Drains into the splenic L.Ns then Lt. gastric L.Ns → Coeliac L.Ns.
- > **Area (B)** : Drains into Rt. gastro-epiploic L.Ns → subpyloric L.Ns → suprapyloric L.Ns → Coeliac L.Ns.
- > **Area (C)** : Drains into Lt. gastric L.Ns → Coeliac L.Ns.
- > **Area (D)** : Drains into suprapyloric L.Ns → Coeliac L.Ns.



Finally : The Coeliac L.Ns Drains into para-aortic L.Ns → Thoracic duct → Lt. supraclavicular (Virchow's gland) → +ve Troisier sign.

▪ **Blood spread:** Mainly Liver & Rarely Lung & Bone.

▪ **Trans-peritoneal spread:** The Malignant cells set free in the peritoneal cavity so may spread to the Ovaries in younger female → **Krukenburg's Tumor** and may spread to the Douglas pouch leads to what is known as (**Plummer's Shelf**)

★ **Staging : (NM)**

T=Tumor	N = Nodes	M = Metastases
T ₁ =Confined to mucosa.	N ₀ =LN cannot be assessed	M ₀ = No metastases.
T ₂ =Involved submucosa.	N ₁ =Perigastric LN within 3cm	M ₁ = Distant metastases.
T ₃ = Penetrate serosa.	N ₂ = LN > 3cm.	
T ₄ =Diffuse involvement of stomach wall.	N ₃ = Involvement of other central abd. LN.	

Clinical picture :

• **Type of patient :** [> 40 years & Male > Female]

• **The disease is usually diagnosed at a late stage,**

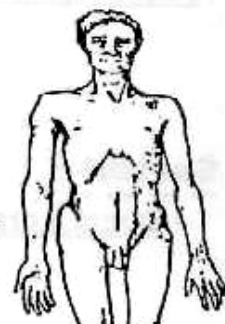
because of vague & mild symptoms

It may be represented by ↗

① **Dyspepsia Group :**

A person > 40 years who start to complain dyspepsia should be fully investigated for possibility of cancer stomach. It differs from Chronic gastric ulcer as in

- Pain** is severe & continuous.
- Not** relieved by antacids.
- Vomiting** is blood stained



② Incidious Group :

- Vague symptoms as (a) Anaemia (Pallor & Easy fatigability).
 (b) Athenia (wasting & weakness)
 (c) Anorexia (especially to Meat)

③ Obstructive Group :

Patient with Manifestations due to obstruction as \rightarrow
Dysphagia with tumor of Cardia or Pyloric obstruction with tumor of Pylorus

④ Mass Group

Patient with Epigastric mass for (D.D) 30% of cases.

⑤ Metastatic Group (i.e. Silent carcinoma)

Patient with metastasis as Hard irregular liver, Jaundice, Virchow's gland, Troisier sign & Krukenberg's Tumors.

⑥ Other Manifestations:

- (a) Haematemesis & Melena (uncommon)
 (b) Superficial Thrombophlebitis i.e. Trousseau's sign.

* D.D.:

[A] Causes of Dyspepsia :

- ① Gastric dyspepsia e.g. peptic ulcer.
- ② Biliary dyspepsia e.g. gall bladder diseases.
- ③ Appendicular dyspepsia from chronic appendicitis.
- ④ Colonic dyspepsia from chronic colitis.

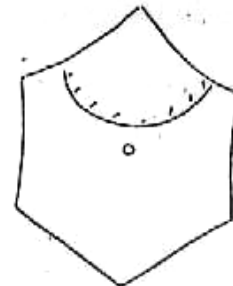
[B] Causes of Epigastric mass :

I. Abdominal wall masses, e.g. lipoma.

II. Intra-abdominal masses :

- ① Stomach : Pyloric obstruction or cancer.
- ② Lt. lobe liver : Tumor or cyst.
- ③ Transverse colon : Carcinoma or Intussusception.
- ④ Pancreas : Cancer head pancreas or pseudo-pancreatic cyst.
- ⑤ Aorta : Aneurysm or para-aortic L.Ns.

III. Epigastric hernia.



[C] Causes of Athenia as presentation :

e.g. cancer stomach, cancer liver & cancer caecum.


* Investigations :

[I] Barium Meal : (75% Accuracy)

① Irregular filling defect in the Pyloric antrum or the Body of the stomach.



② In fundal carcinoma, the patient should be examined in Trendelenburg's position. To see the growth of tumor situated in the fundus.



③ Large ulcer outside ulcer bearing area with no notch if malignant ulcer on greater curve.

④ Linitis Plastica Marked narrowing of the lumen with distorted stomach and the barium flow is interrupted.



- ⑤ Pyloric obstruction with proximal dilatation
- ⑥ Carman's Meniscus sign Crescentic barium shadow around the elevated edge of the ulcer.

[2] Gastroscopy & Biopsy :

- Demonstrates the lesion (Most accurate)

[3] Metastatic Work up :

- Liver (U/S) for Liver metastasis.
- Chest (X-ray) for chest metastasis
- Abdomen (CT scan) for L.N. Involvement.



N.B: Other Investigations

- (a) Blood Picture : For pernicious anaemia
- (b) Gastric Function Test : For Achlorohydrria.
- (c) Tumor Marker : (C.E.A)
Carcino-Embryonic Antigen in 65% of cases.

[4] Exfoliative cytology : Malignant cells can be obtained from the stomach by lavage with saline → collect → cytology.

★ Treatment :

(A) Operable Cases

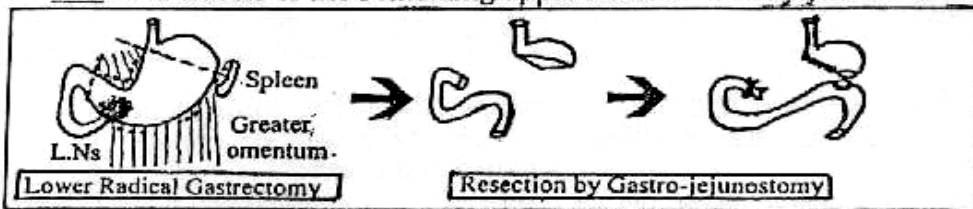
★ Radical Excision :

- Removal of tumor with safety margin at least 5 cm above & 1.5 cm of the duodenum below it.
- Both omenta.
- All Draining L.Ns
- Ligation & Division of vessels.
- Splenectomy..
- Tail pancreatectomy.

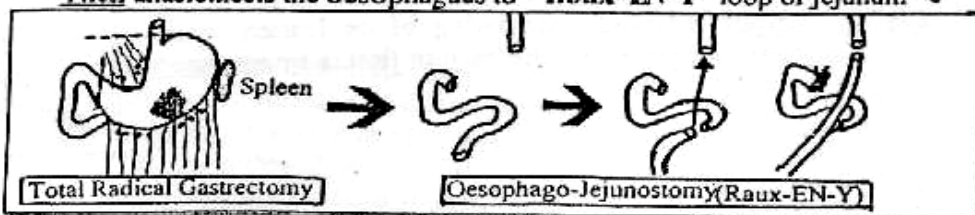


According to the site of neoplasm,
the extent of resection will be determined.

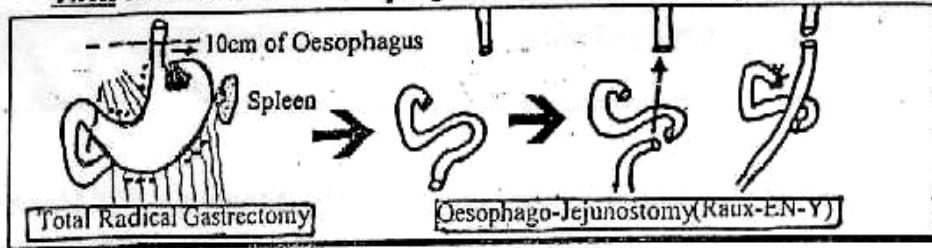
I Tumor of the Pylorus → [Subtotal Lower Radical Gastrectomy]
then anastomosis of the remaining upper stomach to the jejunum



II Tumor of the Body → [Total Radical Gastrectomy]
Then anastomosis the oesophagus to "Roux-EN-Y" loop of jejunum

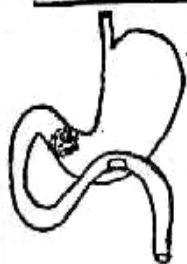

III Tumor of the Fundus → [Oesophago-Gastrectomy] "10cm from oesophagus"
Then anastomosis the oesophagus to "Roux-EN-Y" Loop of jejunum ↷

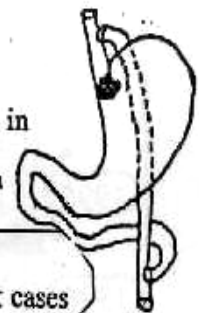


B Inoperable cases

★ Palliative procedures :



- ① Palliative Gastrectomy
- ② Palliative Ant. Gastro-jejunostomy for Irremovable tumors in the Pyloric region.
- ③ Palliative Oesophago-jejunostomy for Irremovable Tumors in the Cardiac regions.



N.B.: Radiotherapy & chemotherapy : (Little value)
Used in Irremovable, Incompletely resectable or Recurrent cases

★ Prognosis : "Very Bad".

Only about 40% are operable and
Only 5% are alive 5 years after surgery.

But cure rate 80% - 90% in Japan because of early detection



Benign Tumors

[1] From Gland (Adenomatous polype of the stomach) ↷ :

★ Incidence :

- Rare & in 50% ass. With pernicious anemia.
- Single or multiple (precancerous 40%)
- Common in distal 1/2 of the stomach → pyloric obstruction.

★ C/P: Epigastric pain (+) vomiting (+) bleeding.

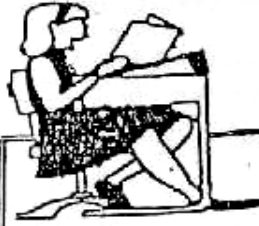★ Investigations: - Barium meal. - Endoscope.

★ ttt: - Localized: excision (Endoscope-gastrotomy).
- Multiple: partial gastrectomy.

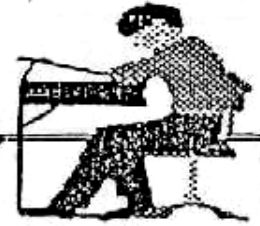[2] From Muscles : Leiomyoma.

[3] From Nerves : Neurofibroma.

[4] Polyps of Peutz-Jegher syndrome.



Final Written Exams



1992

- Discuss ttt of Congenital Hypertrophic Pyloric Stenosis (10 Marks) دور ثانی
- Discuss C/P, Diagnosis & ttt of Perforated Chronic D.U (20 Marks)

1994

- Describ the Anatomy of Stomach & Duodenum (10 Marks) دور ثانی
- Discuss Aetiology, Complications & treatment of Pyloric Obstruction. (10 Marks) دور ثانی
- Discuss Complications of Chronic D.U (30 Marks)

1995

- Discuss Path., C/P & Investigations of Cancer Stomach (30 Marks)

1996

- Enumerate the causes of Pyloric Obstruction. How to diagnose the one due to Scarred D.U & How to treat it (20 Marks)

1997

- Discuss C/P & Investigations of Acute perforated duodenal peptic ulcer. (10 Marks)
- Discuss Anatomy of Lymphatic drainage of stomach (10 Marks) دور ثانی
- Discuss Path., C/P & ttt of Cancer Stomach (15 Marks) دور ثانی

1999

- Discuss cicaterized Pyloric stenosis (C/P & Management) (15 Marks) دور ثانی
- Discuss pathology & C/P of Cancer stomach (10 Marks)

2000

- Discuss Path., & C/O of cancer stomach (15 Marks) دور ثانی

2001

- Discuss Aetiology, C/P, I & ttt of chronic DU (20 Marks) دور ثانی
- Mention C/P & management of perforated P.U (20 Marks)

2002

- Discuss cicaterized pyloric stenosis (15 Marks) دور ثانی
- Mention lymphatic drainage of stomach (5 Marks) دور ثانی

2003

- Discuss causes & management of acute gastric ulcer (9 Mark) دور ثانی
- Discuss pathology cancer stomach. (9 Mark) دور ثانی
- Discuss complications after gastrectomy. (9 Mark) دور ثانی

2004

- Discuss C/P, DD & management of acute perforated DU (20 marks) دور ثانی



Good Luck

Chapter [3]

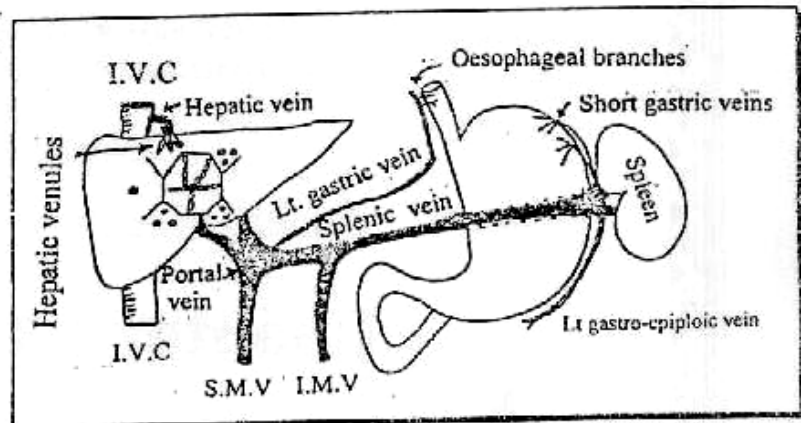
Portal Hypertension

Portal Hypertension

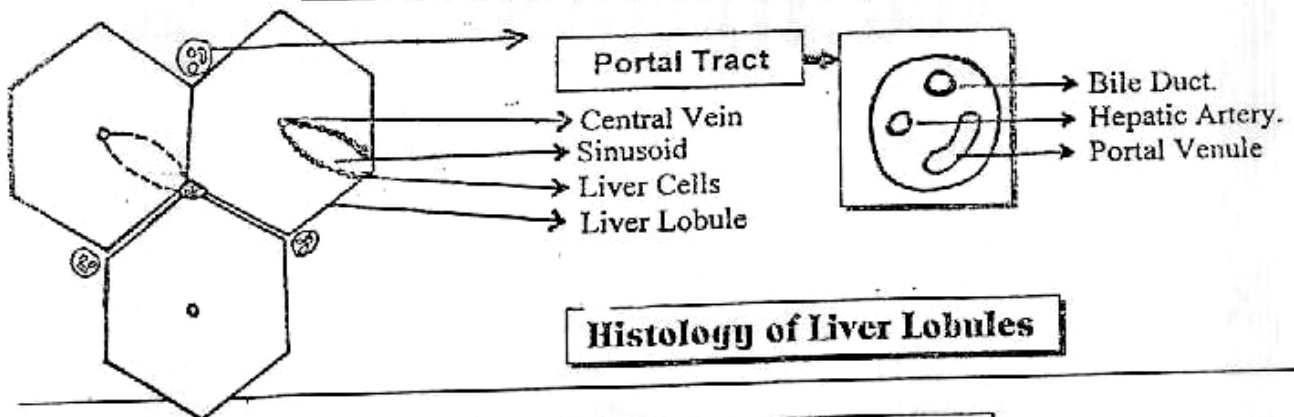
Anatomical Considerations

PORTAL VEIN

- ★ Begins by union of Superior Mesenteric Vein & Splenic Vein.
- ★ End by divided into Rt. & Lt. at the liver.
- ★ It drains GIT from lower oesophagus to the 1st part of anal canal.



Histological Considerations



Histology of Liver Lobules

Physiological Considerations

- ★ Normal Portal Vein Pressure = 7mmHg (8-12 cm H₂O).
- ★ The Liver receives blood from both Hepatic artery & Portal vein SO it derives half of it's oxygen from hepatic arterial blood & the other half from the portal venous inflow.
- ★ The Average blood flow to the liver is **1500** mL/min. which is **2/3** from portal vein and **1/3** from hepatic artery.

★ **Definition :**

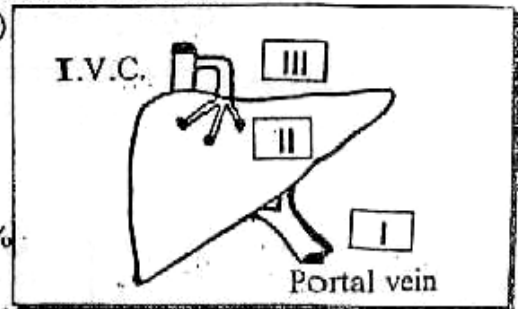
Portal Hypertension is present when portal venous pressure exceeds **20 mmHg (25-30 Cm H₂O)**

★ **Aetiology :**

[Portal Hypertension occurs mainly due to resistance to the portal venous flow] It is Classified as →

I Pre-hepatic causes : (Portal vein obstruction) 19%

- Congenital Atresia or stenosis of portal vein.
- Portal vein Thrombosis due to
 - ① Neonatal Umbilical sepsis.
 - ② Intra-abdominal sepsis.
 - ③ Oral Contraceptive pills.
- Extrinsic Compression e.g. Cancer head pancreas.



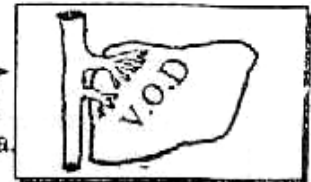II Intra-hepatic causes 80%

- Pre-sinusoidal : e.g. Schistosomiasis through Peri-portal fibrosis.
- Sinusoidal : e.g. Liver Cirrhosis causes portal hypertension

Through :

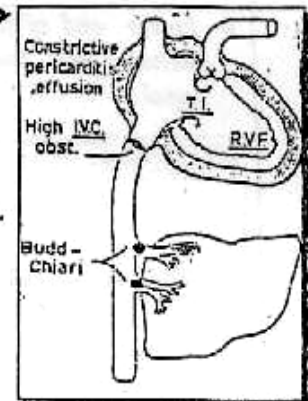
- ① Obliteration & Compression of sinusoids by fibrous tissue.
- ② Compression of small radicals of hepatic artery & portal vein by Regenerating Nodules.

- post-sinusoidal : e.g. Veno-occlusive Disease → Causes portal hypertension through obliteration of small hepatic venules by sub-endothelial inflammation & oedema



III Post-hepatic causes 1%

- Budd-Chiari Syndrome : (Rare) which is caused by obstruction of main hepatic veins at their opening into I.V.C due to
 - ① Malignant invasion by neoplasm.
 - ② Congenital stenosis of suprahepatic I.V.C.
 - ③ Spontaneous thrombosis by polycythaemia.
- Constrictive Pericarditis & Pericardial effusion.
- RVF & TI.



★ **Clinical picture :**

[1] Congestion of whole GIT Tract :

Leads to "Anorexia, Dyspepsia, Indigestion & Malabsorption".

[2] Liver : • In Pre-hepatic causes : Normal Liver.

• In Inter-hepatic causes : Shrunken as cirrhosis, Firm & Not tender.

• In Post-hepatic causes : Congested, enlarged, soft and Tender.

[3] Splenomegaly :

- ★ Causes : ① Congestion due to ↑ portal venous pressure.
 ② Hyperplasia of R.E.S due to Bilharzial Toxins.
 ③ Deposition of living worms & ova at spleen.

- ★ Presentation : ① Firm mass at Lt. Hypochondrium.
 ② Pain : may be • Dull ach i.e. Stretching the of capsule.
 • Dragging i.e. Pulling on the ligaments.
 • Stitching (Stabing) i.e. Perisplenitisrd

↳ Perisplenitis : due to recurrent attacks of splenic infarction (Not inflammation). So the pain result from adhesions of spleen with diaphragm

- ③ Pressure symptoms e.g. dyspepsia due to pressure on Stomach or dyspnea due to pressure on lung.

★ 2ry Hypersplensim (may occur)

It is Splenomegaly + Pancytopenia (Anaemia, Leucopenia & Thrombocytopenia) due to over activity of spleen + Active Bone Marrow

[4] Porto-systemic collaterals :

i.e. Opening of Porto-systemic Anastomosis

Site	Between		Result
	Portal V.	Systemic V.	
◊ Lower end of the Oesophagus & the fundus of stomach.	• Oesophageal veins From Lt. gastric veins & short gastric vein	• Oesophageal veins From Azygos & Hemi-azygos veins	• Oesophageal varices with • Haematemesis • Melena • Fresh blood per rectum if massive.
◊ Lower end of the rectum and anal canal	• Superior rectal vein (inferior Mesenteric veins).	• Middle & Inferior rectal veins (Internal Iliac veins)	• Ano-rectal varices i.e. <u>Piles</u> .
◊ Umbilicus	• Para-umbilical vein	• Superior & Inferior epigastric veins	• Caput Medusae
◊ Retro-peritoneal	• Superior & inferior mesenteric veins	• Post. Abdominal wall veins & sub-diaphragmatic veins	• Silent i.e. <u>No</u> clinical importance

[5] Ascitis :

It is "Multi-factorial" The Most Common Causes are rd

- ① Portal Hypertension → Localized filtration of fluid into the peritoneal cavity.
 ② Hypo- albuminaemia: if associated (L.C.F) liver cell failure.
 ③ Liver Congestion → Failure of liver to inactivate ADH & Aldosterone → Salts & Water retention.

[6] Hepatic Encephalopathy :

- *Duo to* Absorbed Ammonia reach systemic circulation in increased amount through spontaneous porto-systemic collaterals.
- *C/P*: ① Pre-coma:
Hypersomnia Inverted sleep rhythm, Apathy, Micturation or defecation in unsuitable places, childishnessetc.
- ② Coma:

[7] Liver Cell Failure (L.C.F) :

- Manifested by
- ① Low grade fever, Factor hepaticus, Jaundice & Ascitis.
 - ② Gynaecomastia in Male, Atrophy of Female breast & skin manifestations as Palmar erythema & Spider naevi.
 - ③ Bleeding Tendency, Anaemiaetc.

★ D.D : Other Causes of Upper "GIT" Haemorrhage

▪ Causes of upper GIT Hge ↷

[A] General Causes : Hypertension, purpura or Hypoprothrombinaemia.

[B] Local Causes : (Oesophageal Causes)

- ① Oesophageal Varices.
- ② Oesophageal Carcinoma.
- ③ Oesophagitis (Retention or Reflux).
- ④ F.B. Impacted.
- ⑤ Mallary weiss syndrome.

(Gastro-duodenal Causes)

- ① Chronic Peptic Ulcer.
- ② Gastric Carcinoma
- ③ Acute Gastric Erosions & Acute peptic ulcer

In Egypt : The Commonest 3 causes are : ↷

- ① Oesophageal Varices 50%.
- ② Chronic Peptic Ulcer.
- ③ Acute Gastric Erosion.

D.D	Haematemesis	Haemoptsis
<ul style="list-style-type: none"> • <u>History</u> : • <u>Preceded by</u> : • <u>Followed by</u> : • <u>The Blood</u> : 	<ul style="list-style-type: none"> • <u>GIT</u> Troubles. • Vomiting. • Melena. • Dark Red, <u>Acidic</u> with Food particles. 	<ul style="list-style-type: none"> • <u>Chest</u> Troubles. • Cough. • Blood stained Sputum. • <u>Bright Red, Alkaline</u> with frothy sputum.

D.D	Bleeding Ulcer	Bleeding Varices
<ul style="list-style-type: none"> • <u>History</u> : • <u>Endoscopy</u> : • <u>Portal Pressure</u> : • <u>Sengstaken Tube</u> : 	<ul style="list-style-type: none"> • Dyspepsia relieved By <u>Antacids</u>. • <u>+ve Ulcer</u>. • <u>Normal</u> Pressure • <u>No Effect</u>. 	<ul style="list-style-type: none"> • <u>⊘</u>, Liver Cirrhosis & Hepatosplenomegaly • <u>+ve</u> Varices... • <u>High</u> Pressure. • <u>Control</u> Bleeding.

★ Causes of Death :

- ① Hypovolaemic shock.
- ② Hepatic coma.
- ③ Aspiration Pneumonia.



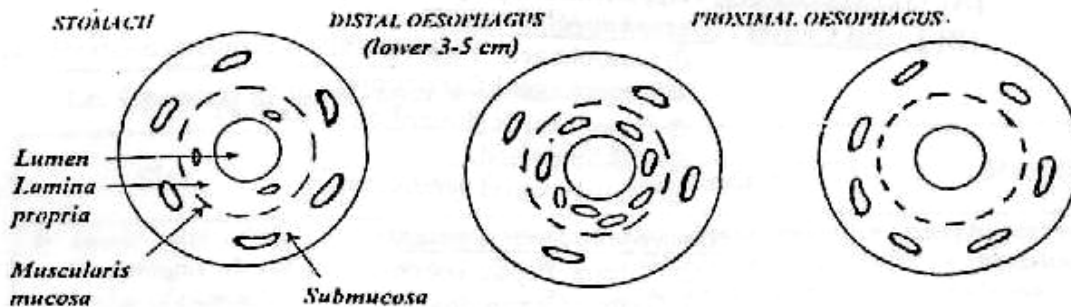
Oesophageal Varices :

★ Definition :

Multiple dilated elongated tortuous veins at the lower end oesophagus & fundus of stomach.

★ Site :

The oesophageal varices present all through the oesophagus but the lower (3-5 cm) are bleed only because veins at this site lies in the lamina propria (between muscularis mucosa & basement membrane, so veins are not supported).



★ Clinical Picture :

- ◆ Asymptomatic.
- Or ◆ Haematemesis which doesn't stop spontaneously due to -ve intra-thoracic pressure which keeps the veins patent.

★ Causes of Bleeding :

Unknown but theories are ↻

- ① Erosion from outside by food trauma.
- ② Explosion from inside by sudden increase in portal pressure.

★ Investigations :

The Aims of investigations in "Cirrhotic patient"

III) Assessment of Liver Functions : which will reveal ↻

- ① Low Albumin level & High Bilirubin level.
- ② SGOT & SG PT usually High
- ③ Prothrombin Time is prolonged & concentration is Low

III) Assessment of Liver State : by ↗


- ① Immunological Test : For Hepatitis Markers.
- ② Liver Biopsy : The only sure method after assessment of Prothrombin Times & Concentration.
- ③ Abdominal U/S : Shows (a) Cirrhotic Liver. (b) ± Splenomegaly. (c) Presence of Ascitis.

III) Detection of Oesophageal Varices : (مهم)

(A) Fiber-optic upper Endoscopy :

Shows Endoscopic grades ↗

- Grade I : Just elevation of mucosa by dilated veins →
- Grade II : Elevated tortuous veins with Normal Mucosa →
- Grade III : Elevated tortuous veins with Abnormal Mucosa →
- Grade IV : Erosion, ulceration and shows cherry red spots i.e. Impending rupture →



(B) Barium Swallow :

Shows Varices as Multiple, Smooth & Rounded filling defect i.e. Grape like Appearance.

(C) Barium Enema :

May reveal presence of Bilharzial polyps in sigmoid colon.



IV) Detection of Hypersplenism :

- ① Blood Picture : Shows pancytopenia
- ② Bone Marrow Examination : Shows Hypercellularity.
- ③ Radio-active Isotopic Studies : Using patient's RBCs tagged with (C_r^{51}) will reveal diminished half life of RBCs & increased radioactivity over spleen. i.e. Increased Spleen/Liver overactivity index more than **2 : 1** → Hypersplenism.

IV) Visualization of portal system :

- ① Ultrasonography.
- ② CT scan.
- ③ Digital Subtraction Angiography (D.S.A.).
- ④ Spleno-portography : A dye can be injected percutaneously into the spleen to demonstrate the anatomy of portal circulation & the site of obstruction.
- ⑤ Hepato-portography : A dye can be injected into small hepatic radicals to visualize the portal circulation.

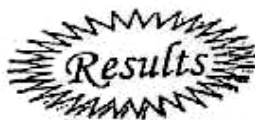IV) Estimation of portal pressure :

- ① Trans-splenic : Percutaneous measurement by splenic puncture.
- ② Trans-hepatic : To estimate portal vein pressure.
- ③ Duplex U/S : (Recent, Accurate & non invasive).
To measure the amount & direction of blood flow in the portal vein.

(VIII) Child's Classification : It Gives "Good Idea about State of patients"

	A	B	C
• Serum Bilirubin (mg %).	< 2	2-3	> 3
• Serum Albumin (gm %)	> 3.5	3-3.5	< 3
• Ascitis	-ve	Easily Controlled	Poorly Controlled
• Nutritional Status.	Excellent	Good	Poor
• Neurological Disorders.	No	Minimal	Coma

[A = 1 point, B = 2 points & C = 3 Points]



Child **A** = 5 - 7 points = Suitable for surgery.
 Child **B** = 8 - 11 points = Marginal Suitable for surgery.
 Child **C** = 12 - 15 points = Unsuitable for surgery.

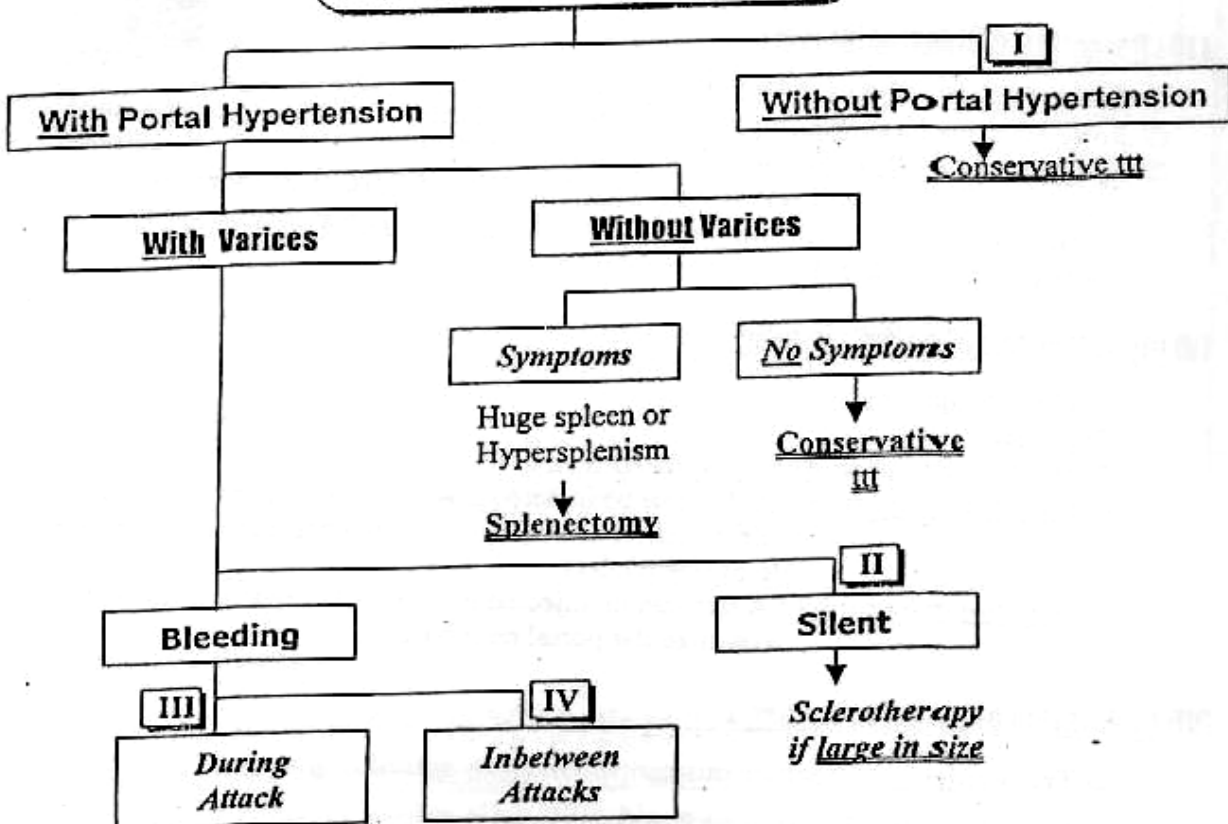


Modified Child's Classification :

Prothrombin time is used instead of the Nutritional status.
 So child **A** = 12 - 16 sec.
B = 16 - 18 sec.
C = > 18 sec.

★ Treatment :

Treatment of Cirrhotic patient



SO

These Patients belong to one of 4 Categories

I Cirrhotic patient without Portal Hypertension

- ★ Conservative ttt : Inform of Avoidance Hepatotoxic drugs and Giving high Carbohydrates & Vitamins in diet

II Cirrhotic patient with Silent Varices

- ★ There is no need for Major surgery but Sclerotherapy is recommended if the varices as large in size & show evidence of impending rupture by Fibre-optic upper Endoscopy.

III Cirrhotic patient with Active Bleeding

لا تترك

① Restoration of Blood Volume :

Fresh Blood Transfusion is the Most important single factor.

N.B. : Morphia or Pethidine are Contraindicated due to liver affection

② Prevention of Hepatic Encephalopathy :

Blood in the intestine will be fermented to Ammonia. So these blood must be evacuated from GIT these occur by ↻

- Strong Laxative as Magnesium Sulphate.
- Stomach Wash must be done hourly and Repeated Enema or colonic lavage.
- Oral Lactulose: It is a disaccharide sugar which is fermented by the intestinal flora to lactic acid. The later will combine with Ammonia & Also it has a mild laxative effect.
- Neomycin : 0.5 gm/4 hours to reduce bacterial flora.

③ Measures to Stop Bleeding :

[A] I.M. Vit. K.

[B] Endoscopic Injection sclerotherapy.

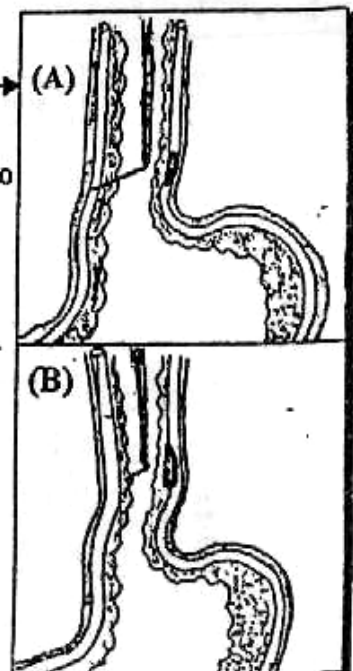
• Methods:

(A) Intra-variceal : 5 ml Ethanolamine Oleate inject to produce Thrombosis

(B) Peri-variceal : 0.5 ml are injected to produce Fibrosis

- Both methods may be combined.
- Injections must be repeated until the varices are Obliterated.
- Side effects :
 - ① Retrosternal Discomfort "few days".
 - ② Fever.
 - ③ Oesophageal ulceration or strictures
 - ④ Oesophageal perforation → Mediastinitis (Rare)

N.B. : Endoscopic Band ligation is the most Recent because → ↓ risk of strictures



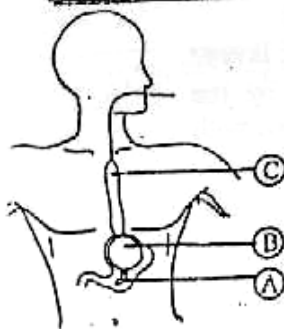
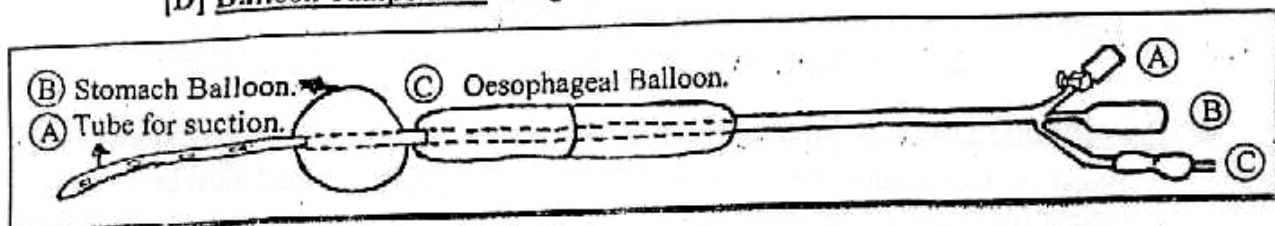
[C] Drugs as

Vasopressin (Pitressin)

- **Dose** : 0.2 unit/kg body weight dissolved in **200 ml** of **5 %** Dextrose and given over **20** min.
- **Action** : Vasoconstriction of Splanchnic arterioles → ↓ Portal venous pressure.
- **Side Effects** : ① Colicky Abdominal pain.
② Diarrhea.
③ Coronary Spasm → Anginal pain.
④ Anti-diuretic Action → Salt's & H₂O Retention.
- **Contraindicated** with Elderly or cardiac patient

N.B. ① In an attempt to prolong it's Action. It is combined with Glycine → (Glypressin)
② Somatostatin like vassopressin but Inspit of it's strong action & less Side effects, It is Expensive.

[D] Balloon Tamponade "Sengstaken [Blackmore] Tube"



- **Method** : The gastric balloon is inflated by **200 ml** of air and pulled upwards to press the gastric fundus.
- **If bleeding not stopped** the oesophageal balloon as well is inflated but pressure should not exceeds **40 mmHg**.
- **It is used** as a temporary measure before urgent surgery.
- **Disadvantages** : ① Discomfort to the patient.
② The patient cannot swallow his saliva → Chest infection
③ Oesophageal ulceration or strictures
④ Recurrent bleeding in 60-80%.

N.B. ① Linton Tube :
Single gastric balloon.
② Minnesota Tube : **4 Tubes** :
The 4th tube is used to aspirate the oesophagus around the oesophageal balloon.

④ Emergency surgery :

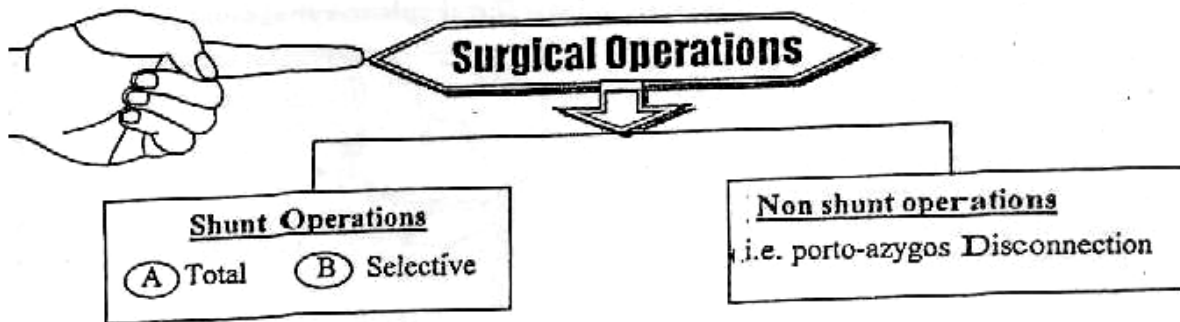
* Indicated if all the previous measures fail to stop the bleeding

IF Fit (Child A or B) : Splenectomy + Porto-azygos disconnection.

IF UnFit (Child C) : Endoscopic stapling of Bleeding in the oesophagus

IV Cirrhotic Patient with History of Attacks

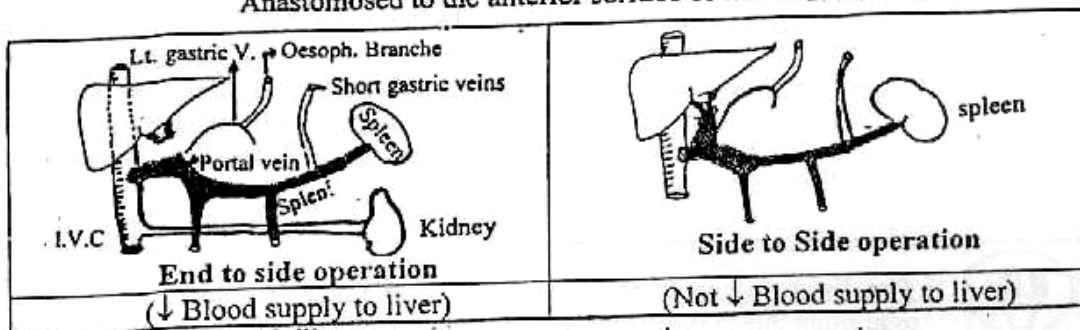
★ Nowada vs : The General Trend is to treat the patient by Sclerotherapy until the varices are obliterated



A Total Shunt Operations

① Porta-Caval Operation :

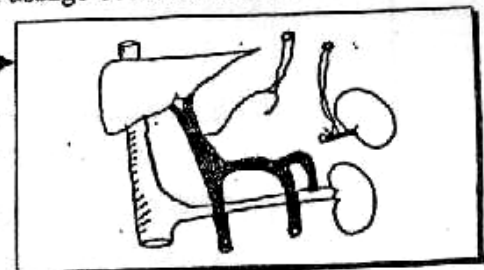
• Technique : The distal end of portal vein is divided and Transfixed then Anastomosed to the anterior surface of I.V.C. It may be



• Advantage : Very sufficient in lowering the portal pressure.
 • Disadvantages : Accelerate Encephalopathy i.e Passage of Ammonia to brain.

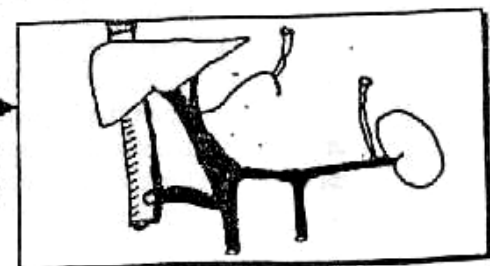
② Proximal Spleno-Renal Shunt :

- Technique: Splenectomy is done then the proximal end of splenic vein is anastomosed to left renal vein.
- Advantage : Less efficient in lowering the portal pressure.
- Disadvantages : The risk of Encephalopathy is still present & good supply to liver



③ Meso-caval Shunt Operation (Drapanas)

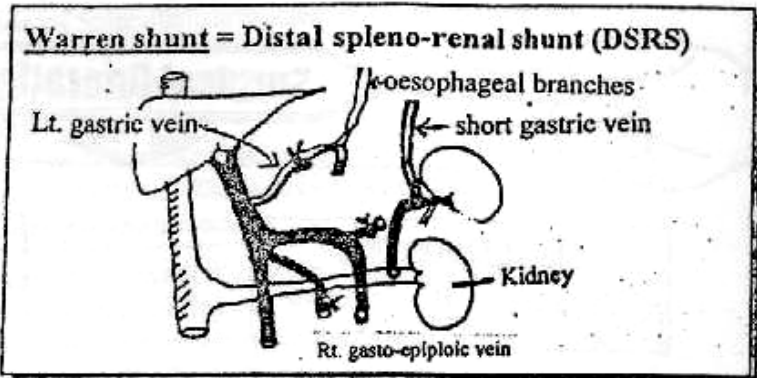
- Through : Insertion of a Graft (Synthetic vein) between the Superior Mesenteric Vein & I.V.C but incidence of thrombosis is high.



(B) Selective Shunt Operation

Warren-salam shunt

- [Distal spleno-renal shunt]
 ★ Splenic vein to renal vein + ligation of Lt. Gastric vein & Rt. gastro-epiploic veins.
 ★ Advantage : Normal liver and very low risk of Encephalopathy.



Thus The portal circulation is divided into 2 halves :

The left half (consists of the splenic vein which drains the oesophageal varices via the short gastric and left gastroepiploic veins into the left renal vein) where the portal pressure is reduced, and the incidence of bleeding from the varices is decreased.

The Right half (consists of the superior and inferior mesenteric veins bringing blood from the small and large intestine and passing as the portal vein to the liver) where the portal pressure is still high and the liver perfusion is not impaired. All the byproducts of bacterial metabolism (ammonia and GABA) will nearly pass through the liver and thus the risk of encephalopathy is not increased.



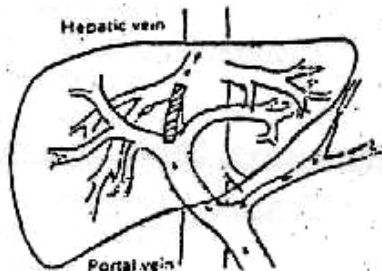
[1] The disadvantage of this operation is that after few years it turn into total shunt due to the presence of connections into the pancreas that connect the 2 halves i.e. Pancreatic siphon. It is called (**Modified warren**)

So to do proper selective shunt, the whole splenic vein should be disconnected from pancreas.

[2] Inokuchi shunt : Less common
 Between Lt. gastric vein & I.V.C by saphenous vein graft.

[3] TIPSS (Trans-Jagular Intra-hepatic porto-systemic shunt)

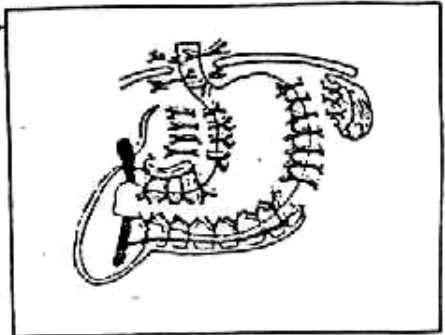
- ◆ The most recent & minimal invasive technique.
- ◆ This is done using self expanding stent which introduced through jagular vein to reach the hepatic veins then manipulated to enter the branch of the portal vein.
- ◆ This produce successful arrest of bleeding especially in patient child C.



Non shunt operation

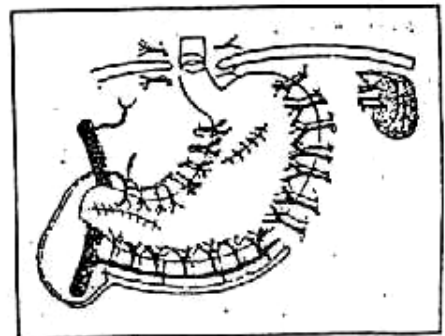
[1] Hassab Khairy Operation : (The popular in Egypt) →

- Entails Splenectomy + ligation of Rt. & Lt. Gastric vessels, short Gastric vessels & Lt. Gastroepiploic vessels. Leaving only the Rt. Gastroepiploic vessels + ligation of all vessels at lower 4-10 cm of the oesophagus.
- Advantages : stope of haematemesis with No risk of Encephalopathy.



[2] Oesophageal transection :

- By interruption of submucosal venous plexus which is still intact after "Hassab Khairy" operation.
- This operation is done by stapling.



[3] Suglura's operation :

- Entails Splenectomy + ligation of abdominal & thoracic oesophageal vesseles.
- It must be followed oesophageal transection.

[4] Liver Transplantation with young patient.

N.B.

TREATMENT OF ASCITES :

☞ *Treatment is mainly medical :*

[1] Correction of (Hypoproteinaemia & Anaemia)

- ◆ I.V. invasion of salt free albumin.
- ◆ Proteins 1gm/kg/day (stopped with encephalopathy).

[2] Salts restriction & diuretics :

e.g. Aldacton is the drug of choice.

[3] Tapping (Paracentesis)

- ◆ Indicated :
With Huge Ascites causing respiratory distress.
- ◆ Advantages :
⊖ Diagnostic.
⊕ Therapeutic → ↓ Respiratory distress.

◆ **Side effects:**

- ① Electrolyte imbalance → ↑ Encephalopathy.
- ② Introduce infection.
- ③ Hypo-albuminaemia.
- ④ Intra-peritoneal haemorrhage.

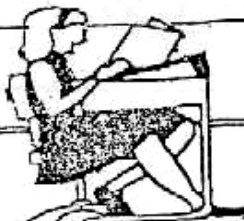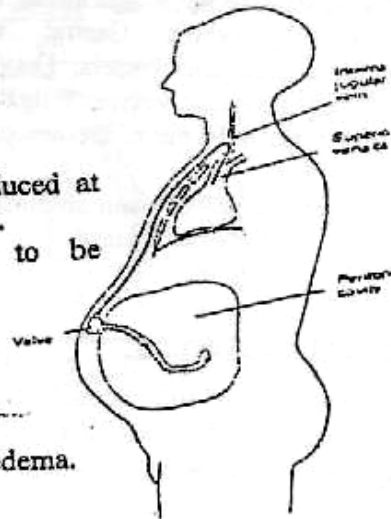
[4] **Surgical shunting: LeVeen shunt**

◆ **Technique:**

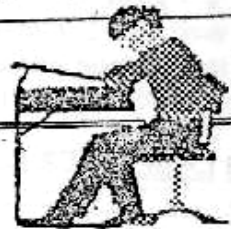Synthetic catheter can be introduced at one end into the peritoneal cavity. Then passed subcutaneously to be introduced to I.J.V.

◆ **Complications:**

- ① Peritonitis.
- ② Septicaemia.
- ③ Hypervolaemia → pulmonary oedema.
- ④ May fail.



Final Written Exams



- 1990 • Discuss the Aetiology and Management of Oesophageal varices (15 Marks)
- 1993 • Discuss Haematemesis (25 Marks)
- 1995 • Give account on Management of Haematemesis of Variceal origin (25 Marks) نور ثانی
- 1998 • Discuss Diagnosis, itt of Acute Haematemesis (25 Marks) نور ثانی
- 2000 • Enumerate causes of Haematemesis & discuss Treatment of bleeding varices. (20 Marks)
- 2002 • Discuss treatment of bleeding oesophageal varices (12 Mark)
- 2003 • Discuss complications of portal Hypertension (9 Mark) نور ثانی
- Discuss DD & management of Haematemesis (20 marks)
- Discuss Aetiology, C/P & Sequelae of portal hypertension (20 marks) نور ثانی



Good Luck

Chapter [4]

The Spleen

The Spleen

Embryology

- The Spleen begins to form in the 5th week when small collections of mesenchymal cells fuse in the dorsal mesogastrium to form the spleen. The mesenchymal cells that fails to fuse : become accessory spleens.
- Sites of Accessory spleens :
 - ① Hilum of the spleen (50%).
 - ② Splenic vessels and tail of the pancreas (30%).
 - ③ Splenic ligaments and mesocolon.
- If Accessory spleens are left after splenectomy : hyperplasia & recurrence of the disorder for which the spleen was removed.

Surgical Anatomy

★ Position : In Lt. hypochondrium, its long axis in the line of 10th rib.

★ Shape : It has

- ① 2nds : - Tapering medial.
- Broad lateral.
- ② 2 borders : - Superior (anterior with notch) (sharp).
- Inferior (smooth).
- ③ 2 surfaces : - Diaphragmatic (smooth, convex).
- Visceral (carries impressions) (stomach, renal & pancreatic).

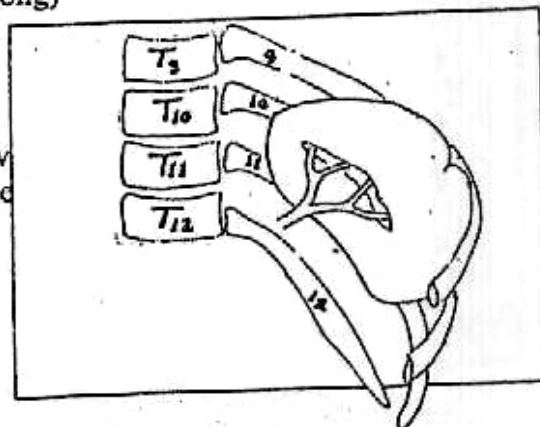
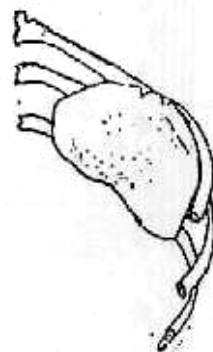
★ Size : 1 inch (thick), 3 inches (wide) & 5 inches (long)

★ Weight : (150 grams).

★ Surface Anatomy :

Draw 2 Transverse lines with 9, 11 ribs & draw 2 vertical lines mid-axillary line & scapular line (from inferior angle of scapula).

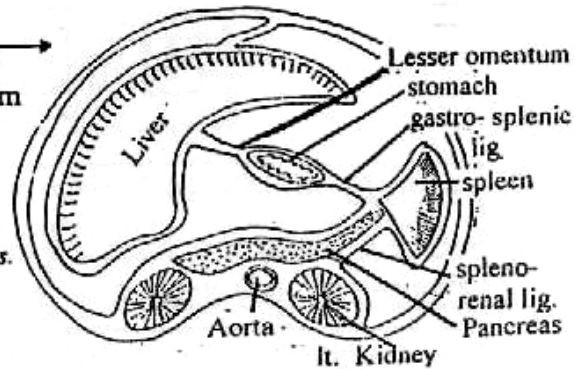
SO Spleen is felt when it is more than 2-3 times it's normal size



★ Peritoneal Coverings :

- The spleen is completely covered with peritoneum
- The related ligament ↗

- ① Leino. (spleno)-renal ligament
 - Between : Spleen & Lt. kidney.
 - Contains: Splenic vessels & tail of pancreas.
- ② Gastro-splenic ligament
 - Between : Spleen & stomach.
 - Contains : short gastric vessels.



N.B. : Phrenico-colic ligament :
Between diaphragm & splenic flexure of colon, it is the main support of the spleen, so it directs to Rt. side when it is enlarged.

★ Relations :

[I] Diaphragmatic surface :

Related to the diaphragm.

[II] Visceral surface :

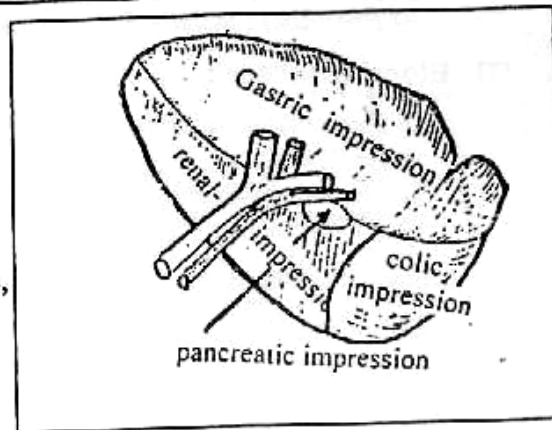
Hilum & 4 visceral impressions

① Hilum :

It is a depression contains splenic, vessels & tail of pancreas.

② 4. Visceral surfaces :

- Gastric impression.
- Renal impression.
- Colic impression.
- Pancreatic impression.



★ Arterial supply : Splenic artery

Arises from celiac trunk, tortuous. At hilum it divided into segmental branches
So partial splenectomy may be done.

★ Venous supply : Splenic vein

Which recives Inferior Mesenteric Vein at neck of pancreas then unites with Superior Mesenteric Vein to form Portal vein.

Physiology of Spleen

★ Functions of spleen :

- ① Immune function : Increased T- and B-lymphocytes and antibodies (IgM and interferon). (So, splenectomy becomes limited now).
- ② Filtration of abnormal and mis-shaped RBCs.
- ③ Phagocytosis of foreign substances by the reticuloendothelial macrophage.
- ④ Synthesis of RBCs, WBCs during foetal life.

I

Splenomegaly

* **The Normal Spleen** Cannot be palpated clinically unless it is enlarged **3** times its normal size

★ **Causes of splenomegally**

[1] **Congenital** e.g. Cyst of spleen (may be Also Acquired).

[2] **Infectious Diseases :**

- ① **Bacterial** : T.B., \$, Typhoid & Para-typhoid.
- ② **Viral** : I.M.N.
- ③ **Parasitic** : Schistosomiasis & Hydatid cyst.
- ④ **Protozoal** : Malaria & Kala Azar.

[3] **Blood Diseases :**

- ① Haemolytic Anaemia
- ② Leukaemia.
- ③ Thrombocytopenia.
- ④ Polycythaemia Rubra Vera.

[4] **Metabolic Diseases :**

- ① Gaucher's Disease.
- ② Prophyria.
- ③ Rickets.
- ④ Amyloidosis.

[5] **Tumors :**

- ① Haemangioma.
- ② Lymphangioma.
- ③ Malignant Lymphoma.
- ④ Fibrosarcoma.

[6] **Circulatory Diseases :**

e.g. Portal vein occlusion i.e. portal hypertension.

[7] **Collagen Diseases :**

e.g. Felty Syndrome & Still's disease.

★ **Causes of Huge spleen**

- Bilharziasis.
- Chronic Malaria.
- Polycythaemia Rubra Vera.
- Kala Azar.
- Chronic Myeloid Leukaemia
- Thalassaemia Major.

★ **Causes of Tender spleen (TIBS)**

T = Typhoid.

I = Infective endoconditis

B = Brucellosis.

S = Septicaemia.

II

Rupture Spleen

★ Predisposing Factors :

- [A] Splenic Enlargement Which makes it more liable to Trauma.
 [B] Diseases of the Spleen e.g. Malaria which makes it soft.

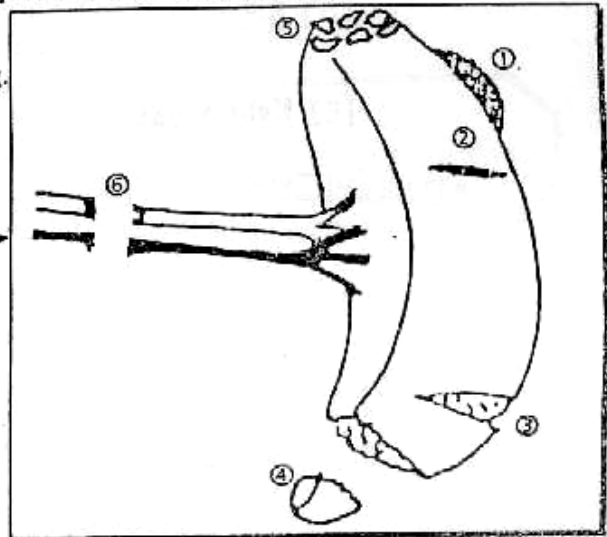
★ Exciting Cause : "Trauma" which may be →

- [A] Closed : ① Direct Trauma : Blunt Trauma e.g. Car Accident.
 ② Indirect Trauma : Fracture Ribs.
 ③ Spontaneous Rupture : Rare with Pathological spleen.
 [B] Opened : ① Gunshot wounds.
 ② Punctured due to stabbing.
 ③ Operative Trauma.

★ Pathology :

Types of Rupture spleen may be →

- ① Subcapsular Haematoma.
- ② Superficial Tear or Tears.
- ③ Deep Tear or Tears.
- ④ Avulsion of a pole of the spleen.
- ⑤ Complete Depulping of the spleen.
- ⑥ Injury of vascular pedicle

★ Complications :

- Haemorrhage which may be Internal or External.
- Splenic Cyst may follow a Peri-splenic Haematoma.
- Associated other Abdominal or thoracic injuries.

★ Clinical Picture :

[A] History of Trauma: To Upper Abdomen or lower Chest followed by an abdominal pain + shock.

[B] Examination: May reveals signs of Internal Hge & Shock + Signs of External Trauma bruises at Lt. Hypochondrium.

- Fatal Type: Sever Haemorrhage with sudden death due to tearing of splenic vessels or complete avulsion of Splenic pedicle.

- Classical Type : It passes in 3 Stages →

① Stage of Shock : i.e. Hypovolaemic Shock.

- Weak rapid pulse & Tachypnea (Air Hunger).
- Hypotension & Hypothermia.
- Pallor & Cold Extremities .

② Stage of Recovery from Shock i.e. Lucid Interval
Due to Temporary arrest of bleeding from Hypotension.

③ Stage of Internal Haemorrhage i.e. Signs of Rupture Spleen
Due to rise again of the blood pressure after Resuscitation

* The Signs are ↗

[A] Tenderness & Rigidity over Lt. hypochondrium

[B] Mass in Lt Hypochondrium (perisplenic Haematoma)

[C] Cullen's sign : 20% of patient have bluish discoloration around umbilicus from blood trickling.

[D] Balances sign : Shifting Dullness on Rt. side from the free blood in the peritoneum & Fixed Dullness on the Lt. side due to blood clots & Retro-peritoneal haematoma.

[E] Kehr's sign : Referred pain to Lt. shoulder from diaphragmatic irritation especially with Trendlenburg's position.

▪ Delayed Type :

[The Initial Shock is followed by a long lucid interval up to 15 days, After which the patient presents with features of Internal Haemorrhage] This delay is due to ↗

[1] Formation of Subcapsular Haematoma which may be ruptured later.

[2] The Greater Omentum seals the splenic tear then retracts later on.

[3] Blood Clots seals the tear then retracts later on.

* Investigations :

[1] Plain X-ray (Upper Abdomen) Shows ↗

① Obliteration of Psoas muscle shadow.

② Obliteration of Splenic outlines.

③ Indentation of Lt. gastric air bubbles to Rt.

④ Elevation of Lt. side (Copula) of diaphragm.

⑤ Fracture one or more of lower ribs.

⑥ + Evidence of cause e.g. Bullet.

[2] Sonar & CT scan (Abdomen) "Diagnostic"

• Show Pathological type of rupture spleen.

[3] Abdominal Paracentesis may reveal Blood.

[4] Diagnostic peritoneal lavage "D.P.L."

Done by inserting an intra-peritoneal catheter at umbilicus under local Anaesthesia & infusing 500 cc saline in the peritoneal cavity. If saline returns bloody or pink in colour = Intra-peritoneal bleeding.

Treatment

[A] Anti-shock Measures : Bl. Transfusion, Warmth, Morphia etc..

[B] Immediate Laparotomy & Splenectomy

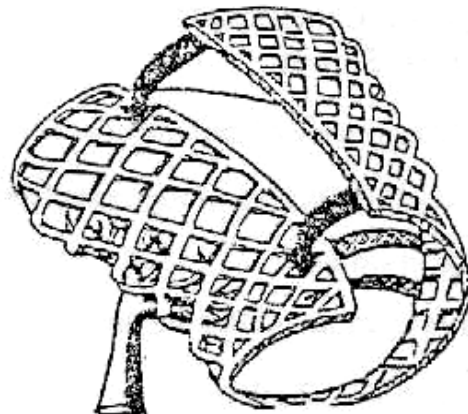
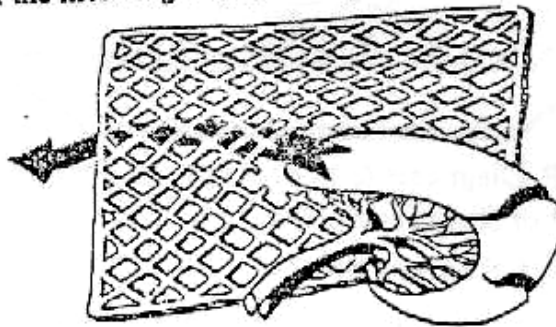
or Splenic preservation especially in children as it plays an important role in immune mechanism especially against Pneumococci.

The preservation through →

- ① Sutures of Small Lacerations or Tears i.e. Splenorraphy.
- or ② Partial Splenectomy : If avulsed one pole.
- or ③ Auto-Transplantation of splenic fragments : Which is wrapped by omentum. This may help if depulped.

N.B. : Pneumococcal Anti-toxin (Pneumovax) :
Should be given in young adult up to 18 years after splenectomy to avoid Overwhelming Post-Splenectomy Infection (OPSI).

- ④ Therapeutic Embolization Through splenic artery by Gel Foam → Splenic infarction
- ⑤ Splenic Mesh Wrap :
Placing the injured spleen in the center of the mesh (polyglycolic) & sewing both ends of the mesh together to Tamponade the bleeding.



Splenic mesh wrap

N.B.

Complication of Splenectomy**A Operative complications**

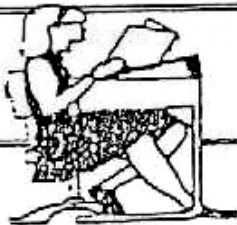- Shock, Infection & pulmonary complications.
- Iry Hge, from bleeding vessels.
- Injury of important structures as Stomach, Pancreas etc...

B Post-operative complications**① General Complications**

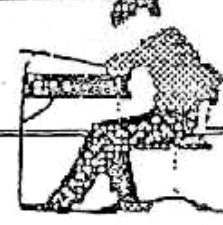
- ① Post-splenectomy fever : unsettled cause.
- ② Vomiting & Hiccough.
- ③ Acute gastric dilatation & Paralytic Ileus.

② Local Complications

- ① Reactionary Haemorrhage : due to stipped ligature or bad Haemostasis.
- ② Haematemsis : due to splenectomy with active oesophageal varices.
- ③ Sub-diaphragmatic collection of blood.
- ④ Splenosis peritoni : in case of ruptured spleen.
- ⑤ Portal vein thrombosis : due to ↑ platelets count.
- ⑥ Burst Abdomen : due to post-operative distension & also if the pancreas is injured → liberation of proteolytic Enzyme → Burst Abdomen



Final Written Exams



- | | | |
|------|--|---------------------|
| 1991 | • Discuss C/P, Diagnosis & tt of Rupture Spleen | (15 Marks) |
| 1994 | • Discuss C/P of Rupture Spleen | (10 Marks) |
| 1996 | • Discuss C/P of Rupture Spleen | (10 Marks) دور ثاني |
| 1997 | • Discuss C/P, Investigations & tt of Rupture Spleen | (15 Marks) |
| 1998 | • Discuss Pathology, Complications and C/P of Rupture Spleen | (15 Marks) دور ثاني |
| 1999 | • Discuss C/P & Management of Intra-peritoneal Hge | (15 Marks) دور ثانی |
| 2000 | • Discuss C/P, Investigations & tt of rupture spleen | (10 Marks) |
| 2001 | • Mention Anatomy of spleen | (15 Marks) دور ثانی |
| 2002 | • Discuss Diagnosis & Treatment of Rupture spleen | (12 Mark) |
| 2003 | • Enumerate causes of Enlarged spleen | (9 Mark) دور ثانی |
| 2004 | • Discuss C/P & mangement of rupture spleen | (20 marks) دور ثانی |



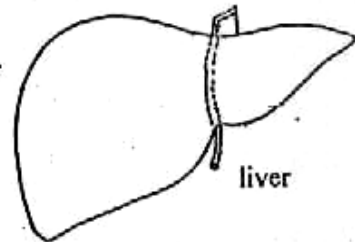
Chapter [5]

The Liver

The Liver

Anatomy of the Liver

- This is the largest organ in the body (1500 gram).
- It occupies the whole right hypochondrium & parts of epigastrium and left hypochondrium.



* Lobes of the Liver :

[A] Anatomical lobes :

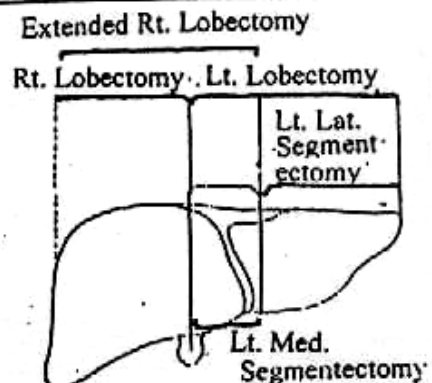
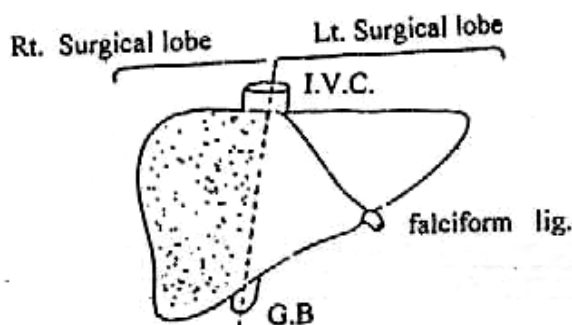
- The liver is divided into small Lt. & very large Rt. lobes.
- The line of division corresponds to
 - a. Falciform ligament : on superior & Anterior surfaces.
 - b. Round ligament : on inferior surface.

[B] Surgical lobes

- The liver is divided into 2 equal surgical lobes by Interlober fissure which extends from
 - ♦ *Anteriorly* : the gall bladder fossa.
 - ♦ *Posteriorly* : (I.V.C).
- a) *Left lobe* : divided by falciform ligament into :
 - ① Left lateral segment.
 - ② Left medial segment.
- b) *Right lobe* : divided by coronal plane into :
 - ① Anterior segment.
 - ② Posterior segment.

All 4 segments are subdivided transversely into 8 segments. So, hepatic resection may be done as follows :

- ① Rt. lobectomy.
- ② Extended Rt. lobectomy.
- ③ Lt. lobectomy.
- ④ Lt. lateral segmentectomy.
- ⑤ Lt. medial segmentectomy.



★ Relations of the liver :

[A] Rt. Lateral surface :

Related to the diaphragm.

[B] Antero-superior surface :

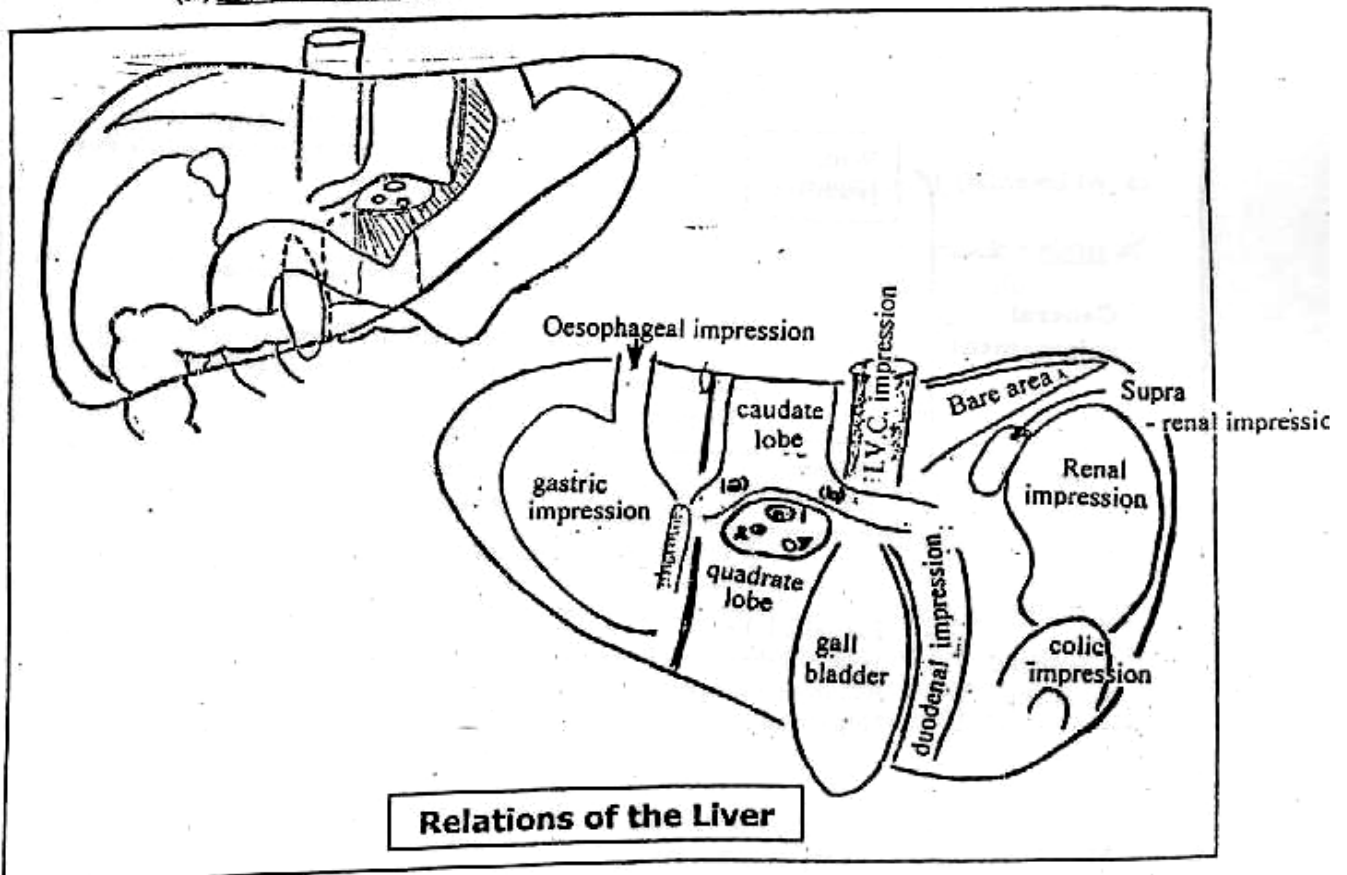
Related to the diaphragm & ant. abdominal wall.

[C] Posterior surface (Rt. To Lt.)

- (1) Bare area of the liver .
- (2) Groove for IVC.
- (3) Caudate lobe with 2 processes :
 - a. Papillary process.
 - b. Caudate process.
- (4) Fissure for ligamentum venosum.
- (5) Oesophageal impression.

[D] Inferior surface : (Lt. to Rt.)

- (6) Gastric impression.
- (7) Fissure for ligamentum teres.
- (8) Quadrate lobe.
- (9) Gall bladder fossae.
- (10) Duodenal impression.
- (11) Colic impression.
- (12) Renal impression.
- (13) Supra-renal impression.
- (14) Porta-hepatis (↔)



★ Peritoneal coverings :

The liver is completely covered with peritoneum except bare areas at upper part of post-surface, G.B fossa, groove for IVC, porta hepatis.

So peritoneal ligament connections are

- ⊙ Falciform ligament.
- ⊙ Ligamentum teres (obliterated umbilical vein).
- ⊙ Ligamentum venosum (obliterated ducts venosus).

★ Arterial supply : 1.5 L/min.

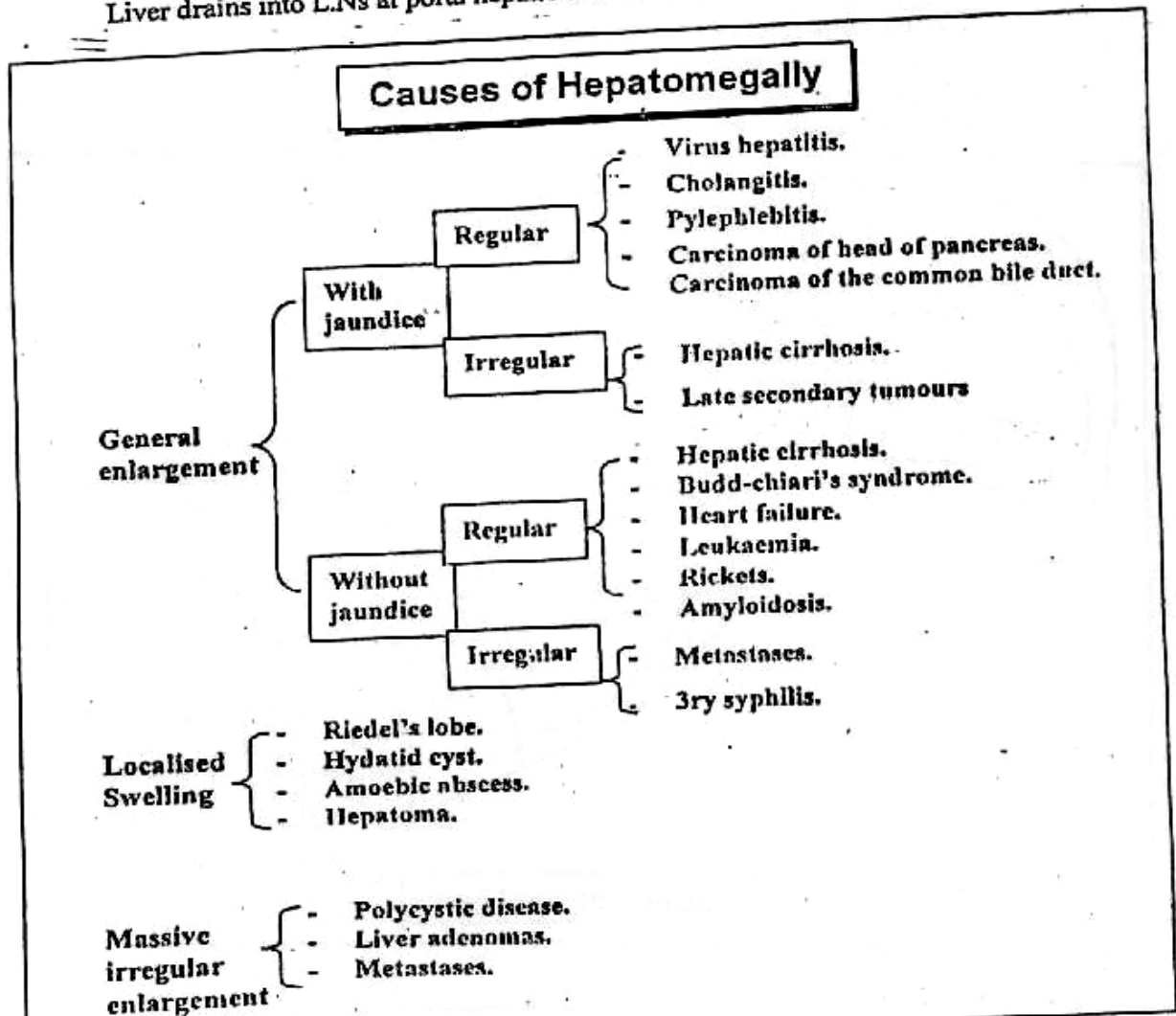
- ⊙ Portal vein : carrying venous blood from GIT & supplies 2/3 of total blood supply.
- ⊙ Hepatic artery : supplies of 1/3 total blood supply.

★ Venous drainage :

3 hepatic veins into L.V.C.

★ Lymphatic drainage :

Liver drains into L.Ns at porta hepatic & then into coeliac L.Ns.



I Liver Trauma

* Predisposing Factors :


- [A] Liver Enlargement: which Makes it more liable to Trauma
 [B] Diseases of liver: e.g congested liver

* Exciting Cause : "Trauma" which may be →

- Closed : ① Direct Trauma : Blunt trauma e.g. Car Accident.
 ② Indirect Trauma : Fracture Ribs.
 ③ Spontaneous Rupture : Rare with pathological liver
- Opened : ① Gunshot wounds.
 ② Punctured wounds due to stabbing.
 ③ Iatrogenic : By Invasive investigations as Percutaneous liver biopsy.

* Pathology :

Same Pathological Types of Splenic injuries (① → ⑥) +
Avulsion of Extra-
 hepatic biliary passage.



* Complications :

As Rupture Spleen, but the liver haematoma sometimes communicates with Torn bile duct leading to "Haemobilia".

* Clinical Picture :

- [A] History of Trauma : To Upper Abdomen or Lower Chest followed by an abdominal pain + shock.
 [B] Examination : May reveals signs of Internal Hge & shock + signs of External Trauma as bruises at Rt. Hypochondrium

* Investigations :

Sonar & CT scan : The most "Diagnostic"

* Treatment :

- [A] Anti-shock Measures : e.g. Blood Transfusion, Morphiaetc
 [B] Immediate Laprotomy: "The priority is to Arrest bleeding"

S0

We control the liver Haemorrhage by a combination of Temporarity packing of the bleeding area & Application of the "Pringle's Manoeuvre" which is application of a Vascular Clamp to the free border of lesser omentum or holding it between 2 fingers, to occlude the hepatic artery & portal vein for 20 minutes.

Then There are 3 Possibilities →

- ① If the Tear is Accessible, it is repaired by deeply placed mattress sutures supported by a pad of peritoneum.
- ② If the Tear is Extensive or Inaccessible, the Incision should be extended into the chest along the 8th intercostal space.
The Aim is To arrest bleeding, To remove the necrotic devitalized tissue, To preserve as much viable tissue as possible & To do external drainage.
- or ③ If There is Extensive Haematoma or Ruptured liver tissue, we must do "Hepatic Resection" then Drainage of peritoneal cavity to avoid peritonitis then prophylactic A.B are prescribed.

*** Prognosis :**

The Mortality Rate = 15 - 20 %.

II

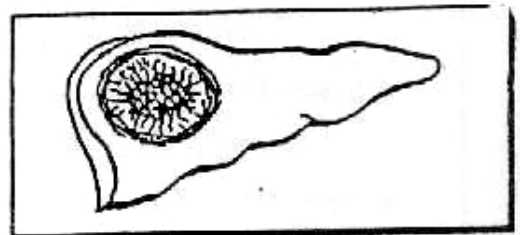
Liver Infections

- * (A) Amoebic Hepatitis & Abscess.
- * (B) Hydatid Disease of the Liver
- * (C) Pyogenic Liver Abscess.
- * (D) Hepatic Schistosomiasis.
- (E) Viral Hepatitis.

[A] Amoebic Hepatitis & Abscess (داء الكبد)

*** Incidence :**

- It is Common in Tropical countries especially. Egypt i.e. It is called "Tropical Abscess".
- It represents 10 - 20% of Liver Abscess.
- It is predominant with young Males.




*** Aetiology :**

- Organism : Entamoeba histolytica
- Source of Infection :
 Ameobic Liver Abscess may follow any stage of Colonic amoebiasis (i.e. from few days after the onset of the disease up to many years).
- Route of Infection :
 Ingestion of Cysts within improper washed vegetables. Then in the intestine, the cyst changed to be "Trophozoites" that induce Colitis. at Rt. side colon mainly i.e. Colonic Amoebiasis.

* Pathology :

[A] Pathogenesis :

- *The Trophozoites invade the portal blood from the colon.*
- *The Rt. lobe of the liver is more affected than the Lt. Lobe* as Portal blood from Rt. side of colon (site of Amoebic Colitis) drains to the Rt. Lobe of the Liver.
- *The parasite starts the process of liquefactive necrosis which result in the formation of An Abscess* →



[B] Pathology of Amoebic Cyst :

- Number : Single (70%) & Multiple (30%)
- Site : In the Postero-superior segment of the Rt. Lobe of Liver as the segmental branch of Rt. portal vein (to this segment) in direct continuity with Rt. portal vein.
- Shape : [The wall] is shaggy, Irregular & containing Entamoeba as they live in healthy not dead Tissues. [The content] is "Anchovy Sauce" or "Chocolate pus" which is brownish necrotic material of Destroyed liver substance, Leucocytes & RBCs, but never Entamoeba.

* Clinical Picture :

- Type of patient : 20-40 years & Male > Female.
- General Examination : • Low grade Fever ($38^{\circ} - 38.5^{\circ}$)
 - Patient usually pale & Looks Toxic. (Early)
 - Anorexia, Nausia & Weight loss.
- Local Examination : • Upper Rt. Abdominal pain.
 - Tender Liver.
 - The patient may have Chest signs :
 - ① Impaired movement at Rt. side of chest.
 - ② Pleural effusion on Rt. side ± lung crepitations.

* Complications :

- 2ry Bacterial infection → Pyogenic Liver Abscess.
- Calcification.
- Rupture : →

[a] Upwards :

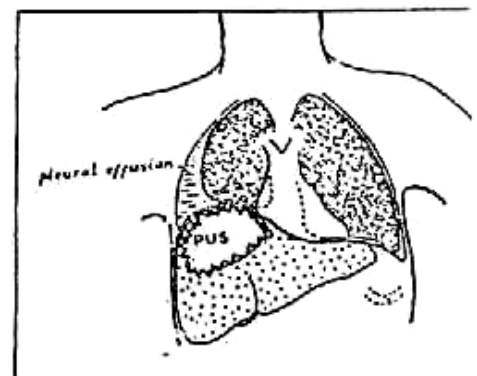
- ① Subphrenic Abscess.
- ② Pleura → Empyema.
- ③ Lung → Amoebic Lung Abscess.
- ④ Pericardium → pericarditis.

[b] Downwards :

- ① Stomach & Duodenum.
- ② Colon.
- ③ Peritoneum → Peritonitis.

[c] Outwards : Rarely below costal margin (Amoebiasis Cutis)

- Destruction of liver cells → Liver cell failure



* **D.D. : Other causes of Tender liver as** ↗

- | | |
|---------------------------|--------------------|
| ① Amoebic liver abscess. | ④ Malignant liver. |
| ② Pyogenic liver Abscess. | ⑤ Portal pyaemia. |
| ③ Congestive liver. | ⑥ Viral hepatitis. |

* **Investigations :**

[A] **Laboratory Investigations :**

- **Stool Analysis** : For Entamoeba Histolytica.
- **Serological Test** : e.g. **Complement Fixation Test (C.F.T.)**
- **Therapeutic Test** : Good response to **Metronidazole** can help in diagnosis.

[B] **Radiological Investigations :**

• **Plain X-ray (Chest-Abdomen)**

- Shows :**
- ① Elevated **Fixed Rt.** Copula of diaphragm.
 - ② Obliterated **Costo-phrenic angle** if **Empyema**
 - ③ Basal lung collapse if present.

• **Imaging by U/S & CT scan :**

Which can detect number, Site, shape & size of the Abscess.

• **MRI** : The Most "Accurate".

* **Treatment :**

- [I] **Medical Treatment** : Amoebicidal Drugs which are **Highly** successful as **Metronidazole (Flagyl)** 750 mg t.d.s. for 7-10 days or **Tenidazole (Fasigyn)** 2 gm orally after lunch for 3 days.
- [II] **Aspiration** : [U/S. guided Percutaneous Aspiration].

■ **Indications :**

- ① **Lack** of Response to 5 days **Flagyl** Treatment.
- ② **Very Large** Abscess or **2ry** infection.
- ③ **Very Toxic** patient.

■ **Technique :**

- ① By **Wide bore** long needle under local anaesthesia.
- ② **At site** of local evidence of underlying Abscess.
- ③ Aspiration can be **repeated**.

[III] **Open Surgical Drainage :**

■ **Indications :**

- ① **Difficult Aspiration** because of multilocular Cyst.
- ② If Associated with **Peritonitis**
- ③ Presence of **Thick** pus.

- **Technique** : **Through** the bed of 12th rib **posteriorly**
As most of Amoebic abscesses present at postero-superior segment of Rt. Lobe of Liver.

[B] Hydatid Disease of the Liver

* Incidence :

It is commonly seen in Iraq, Yemen & Libya.

* Aetiology :

- Organism : Tape worm called [**Echinococcus Granulosus**].
- Definitive Host : [Dogs] where adult worms live.
- Intermediate Host : [Cattles & Man].

* Pathology :

[A] Pathogenesis :

The last segment of adult worm is separated to pass in stool of dogs (**Definitive Host**) which contaminate grass & vegetables. **Then** the Cattles & Man (**Intermediate Host**) eating contaminated grass with eggs i.e. **Infective Stage** which hatch to give [**Onchosphere**] which penetrate the portal circulation & affect the liver in the form of **Hydatid cyst** i.e. **Diagnostic Stage**.

[B] Pathology of Hydatid Cyst :

- Number : usually single.
- Site : Rt. Lobe of the liver is the commonest.
- Shape : Consists of 3 layers →

① The Adventitia (Pseudo-cyst) :

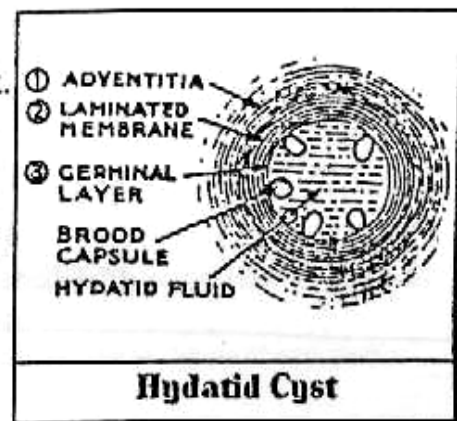
It consists of fibrous tissue which result from reaction of liver with parasite.

② The Laminated membrane (Ecto-cyst) :

It is formed of parasite itself.

③ The Germinal Layer (Endo-cyst) :

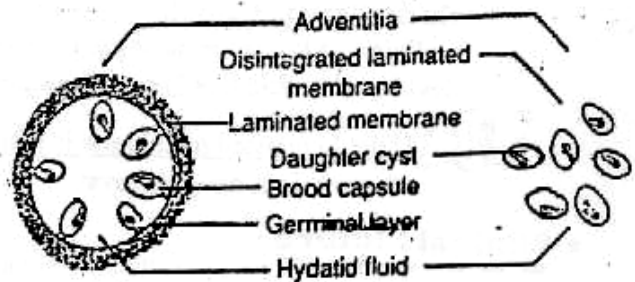
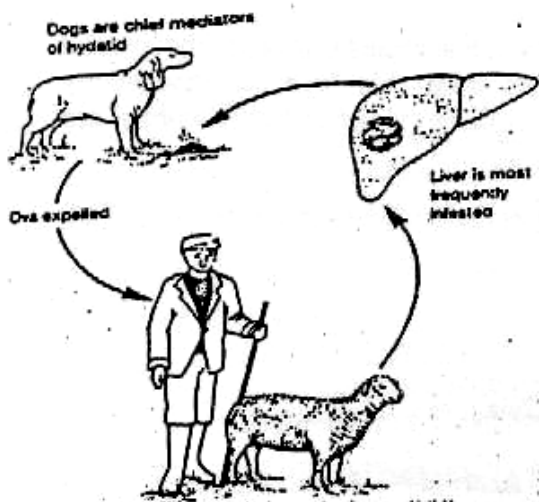
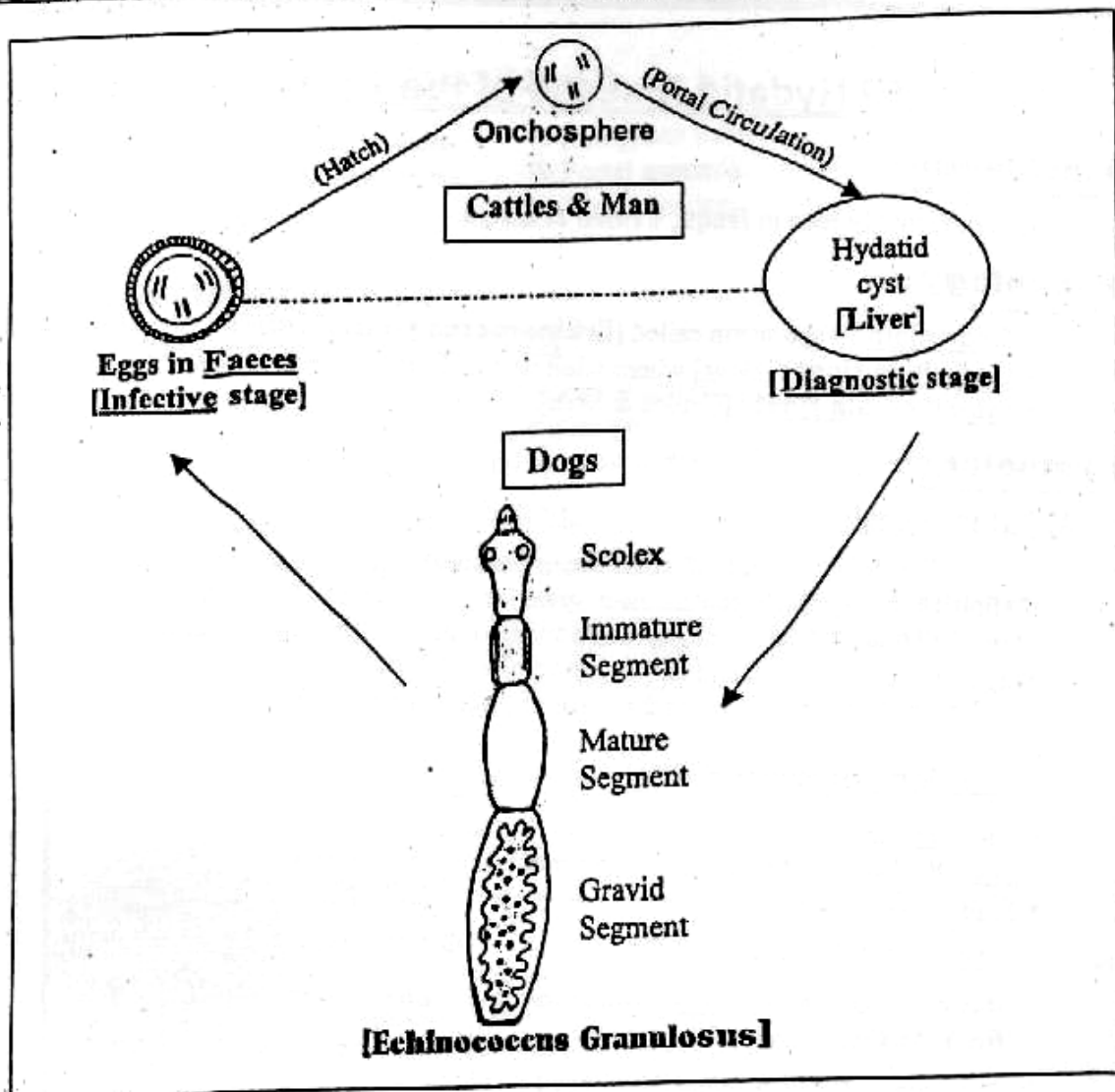
It is the only living part of Hydatid cyst, it secretes internally the hydatid fluid. **Brood Capsules** are developed from this layer & attached by pedicles to it's inner most wall, **Then Scolices** (Head of future worms) are developed within this Brood Capsules.



SO If the Laminated membrane is damaged, the Brood Capsules becomes free & grow into daughter cyst.

* Clinical Picture :

- Type of patient :
Usually Male from Iraq, Yaman & Libia.
- General Examination :
Symptomless or loss of weight inspite of good appetite.



Life cycle of *Echinococcus granulosus*.

▪ Local Examination :

- It may be Asymptomatic for years & Discovered Accidentally.
- There is Intra-abdominal mass related to Rt. Lobe of the liver which is Tense, Cystic, painless & Dull on percussion with continuous dullness with the liver.
- Hydatid Thrill: Thrill felt on percussion due to vibration of daughter cyst against each other on hydatid fluid.

* Complications :

- 2ry Bacterial Infection leads to Pyogenic Liver Abscess.
- Calcification.
- Rupture of cyst
 - (A) Upwards :
e.g. Chest Cavity leads to Empyema.
 - (B) Downwards :
 - ① Peritoneal Cavity → Peritonitis or dissemination & Anaphylactic Reaction which endanger the patient's life.
 - ② Biliary Tract → Obstructive Jaundice.
 - ③ Renal Pelvis → Haematuria & Colics (rare)

* Investigations :

[A] Laboratory Investigations :

- Blood picture : Shows High Eosinophilia.
- Casoni's Test : [+ve in 75% of cases].
Intra-dermal injection of 0.2 cc hydatid fluid, followed after 24 hours by Oedema & Redness at site of injection.
- Serological Test: [Indirect Haemagglutination]. Which is the most accurate.

[B] Radiological Investigations :

- Plain x-ray (Chest-Abdomen).
May show calcification or Lung Empyema.
- Imaging by US & CT scan to detect number, Site, shape & size of cystic.
- MRI : The most "Accurate".

* Treatment :

[A] Surgical Treatment [Excision] is the standard treatment.

▪ Pre-operative :


Estimation of the number & sites of cysts is needed because of missed cyst after excision may leads to spillage of hydatid fluid into the peritoneal cavity which carries the risk of absorption into the circulation leading to an Anaphylactic Reaction

▪ Precautions :

The Liver Cyst (or Cysts) is surrounded by dark green Towels that are moistened with a Scolicidal agent as Betadine or Hypertonic Saline.

▪ **Technique :**

The Cyst is aspirated 1st & Hypertonic saline is injected then the overlying liver substance & the surrounding adventitia are incised then the cavity is filled with a pad of peritoneum.

N.B.  **Other surgical options :**

① **Cystectomy :**
Suitable for pedunculated cyst.

② **Partial hepatectomy :**
Suitable for large or multiple cysts.

[B] **Medical Treatment [MEBENDAZOLE]** 400-600 mg t.d.s for 6 Months. It is not a good substitute for surgery but indicated only with unfit patient or recurrent cases or inaccessible cysts.

[C] Pyogenic Liver Abscess

* **Aetiology:**

[A] **Predisposing Factors:**

- ① Decreased Immunity e.g DM, Leukemiaetc.
- ② 2ry infection: e.g ① Infected Amoebic Abscess.
② Infected Hydatid Abscess.
③ Infected Haematoma of liver.

[B] **Source of infection:**

- ① Biliary Tract: (**Cholangitic Abscess**)
Ascending cholangitis due to biliary obstruction & infection by E-coli & Gram-ve bacilli.
- ② Portal vein: (**Pyæmic Abscess**)
from suppurative apperndicitis, diverticulitis.
- ③ Hepatic artery: (**Haematogenous Abscess**)
- ④ Idiopathic.

* **Clinical Picture:**

- **General:** • Severe Toxaemia, Fever & Rigors.
• Charcot's Triade [Pain + Jaundice + Fever with rigors]
- **Local:** • Pain & Tenderness at Rt. Hypochondrium
• Tender Hepatomegally.

* **Investigations :** U/S & CT scan are diagnostic.

* **Treatment :**

- **Drainage** either ① U/S guided Percutaneous Aspiration.
or ② Open surgical drainage with drain
- Under cover of **strong A. B.**

[D] Hepatic Schistosomiasis

★ Aetiology :

It is caused by : - Schistosoma Mansoni 75%.
- Schistosoma Haematobium 25%.

★ Pathogenesis :

Large number of ova are laid in terminal radicles of mesenteric vessels → portal blood → portal vein → portal Tracts → Induce inflammation → Bilharzial granuloma → Excessive peri-portal fibrosis.

★ Pathology : (3 Types)

① Fine (β periportal fibrosis) Types :

- It follows deposition of few number of ova in small portal Tracts.
- Macroscopically : The surface of the liver is Fine nodular.
- Microscopically : Fine fibrous tissue surrounds small portal tracts with few number of ova.

② Coarse (β periportal fibrosis) Type :

- It follow deposition of large number of ova in large portal tracts.
- Macroscopically : The surface of the liver is Coarse nodular.
- Microscopically : Coarse fibrous tissue surrounds large portal tracts with large number of ova.

③ Mixed type : The commonest.

★ C/P & complications :

Portal hypertension, oesophageal varices, splenomegaly etc.

★ Stages :

- | | |
|-------------------------|-------------------------------------|
| I- Hepatomegaly. | III- Splenomegaly + Shrunken liver. |
| II- Hepatosplenomegaly. | IV- As III + Ascites |
| | V- As IV + L.C.F. |

★ Treatment :

Anti-bilharzial drugs + ttt of complications.


III

Liver Tumors




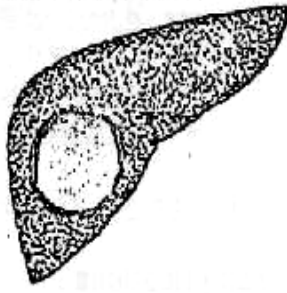
- Benign Tumors as
 - ① Adenoma.
 - ② Haemangioma.
 - ③ Focal Nodular Hyperplasia

- Malignant Tumors as ↻

- ① Primary Tumors : Hepatoma, Cholangiocarcinoma or Mixed Cholangio-Hepatoma.
- ② Secondary Tumors : Metastasis.

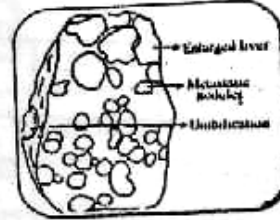


Primary Malignant Tumors

	Hepato-cellular	Cholangio-carcinoma
* <u>Incidence</u>	<ul style="list-style-type: none"> ■ 80% of lry tumor ■ Male > Female. ■ Old age > 50 years. 	<ul style="list-style-type: none"> ■ 20% of lry tumor. ■ Male > Female. ■ Old age > 50 years.
* <u>Predisposing Factors</u>	<ul style="list-style-type: none"> ① <u>Infection</u> : e.g. Hepatitis B & C virus. ② <u>Liver Cirrhosis</u>. ③ <u>Aflatoxins</u> in food Which formed by fungus called [<i>Aspiggillus Flavus</i>] due to poor storage of grains 	<ul style="list-style-type: none"> ① <u>Congenital Cystic liver fibrosis</u>. ② <u>Choledochal Cyst</u>. ③ <u>Clonorchis Sinesis</u> infestation. ④ <u>Sclerosing Cholangitis</u> ⑤ <u>Haemochromatosis</u>.
* <u>Pathology</u> :	<ul style="list-style-type: none"> ① <u>Massive</u> : i.e. Localized Mass "Fibrolamellar Hepatoma"  ② <u>Nodular</u> : i.e. Multiple Nodules which Scattered all over the liver  ③ <u>Diffuse</u> : i.e. which can infiltrate the liver  	<ul style="list-style-type: none"> ① <u>Solitary Mass</u> →  ② <u>Multiple Nodules</u> : with golden yellow appearance and shows area of Hge and Necrosis.
<ul style="list-style-type: none"> ■ <u>N/E</u> → ■ <u>M/E</u> → 	<ul style="list-style-type: none"> <u>Malignant Hepatocyte</u> With little stroma & high vascularity 	<ul style="list-style-type: none"> <u>Adenocarcinoma</u> from epithelial lining duct.
* <u>Spread</u>	<ul style="list-style-type: none"> ① <u>Direct</u> : to liver Substance <u>then</u> to the surroundings ② <u>Lymphatic</u> : L.Ns at Porta-hepatis & Coeliac L.Ns. ③ <u>Blood</u> : Portal vein and I.V.C thrombosis & rarely lung . ④ <u>Peritoneal Nodules</u> leads to Malignant Ascites. 	
* <u>Clinical Picture</u> :	<ul style="list-style-type: none"> ① <u>The common</u> is deterioration of health to cirrhotic pf. ② Cachexia, Athenia & Metastasis. ③ Obstructive Jaundice. 	

	Hepato-cellular	Cholangio-carcinoma
▪ <u>Signs</u> →	① Rt. Hypochondrial or Epigastric mass. ② Slight to moderate <u>Jaundice</u> with low grade <u>fever</u> . ③ Malignant Ascites in 40% of cases.	
* <u>D.D.</u> :	<u>Other causes of Tender Liver</u> as → ① Amoebic liver abscess. ④ Malignant liver. ② Pyogenic liver Abscess. ⑤ Portal pyaemia. ③ Congestive liver. ⑥ Viral hepatitis.	
* <u>Investigations</u> :	① <u>Liver Function Test</u> : ↑ Serum Alkaline Phosphatase and ↑ Serum Bilirubin. ② <u>Alpha feto-protein</u> : as Tumor Marker.	
[A] <u>Laboratory</u> :	① <u>CT Scan, U/S & MRI</u> : the most (Diagnostic). ② <u>Hepatic Angiography</u> : Shows Tumor circulation and vascular hepatic anatomy before resection.	
[B] <u>Radiological</u> :	<u>Biopsy</u> : Is controversial for high risk Cirrhotic patient for bleeding	
[C] <u>Instrumental</u> :	<u>ERCP</u> : Both diagnostic and therapeutic e.g putting internal stent.	
* <u>Treatment</u> :	Hepatic resection is the <u>only</u> hope for cure <div style="border: 1px solid black; padding: 5px; margin: 5px 0;"> N.B. : <u>Cirrhotic patient</u> is contraindicated to surgery because of → ① Bleeding Tendency. ② Poor function of reserved part of liver ③ ↓ Capacity of liver cell for regeneration. </div>	
(A) <u>Operable</u> →	① <u>Systemic Chemotherapy & Radiotherapy</u> . ② <u>Intra - arterial Selective Chemotherapy</u> : as 5 Fluro-uracil & Methotrexate ③ <u>Chemo-embolization</u> (double benefit) as ischemia of tumor & chemotherapy ④ <u>Percutaneous Ethanol Injection</u> under sonar guided leading to tumor necrosis. ⑤ <u>Internal Biliary Stent</u> to relieve Obstructive Jaundice	
(B) <u>Inoperable</u> →		

Liver Metastasis



* **Incidence** : 20 times > 1ry tumor.

* **Routes** :

- ① **Portal Circulation** : From GIT Carcinomas.
- ② **Hepatic artery** : From Breast, Lung, Ovaries & kidney.
- ③ **Lymphatics**.
- ④ **Direct** : From Gall bladder Carcinoma.

* **Pathology** : Adenocarcinoma

- They are Multiple, white, Umbilicated nodules because of central necrosis
- They may occur at some time of 1ry tumor [**Synchronous**] or months or years later after resection [**Metasynchronous**].

* **Clinical Picture** : Picture of 1ry Tumor +

Weight loss, fatigue, Hepatomegaly, Ascites & Jaundice.

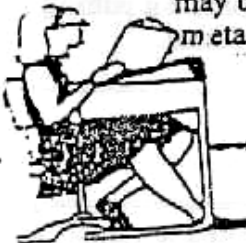* **Investigations** :

↑ Serum bilirubin & Alkaline phosphatase but U/S & CT scan more accurate

* **Treatment** :

(A) Liver metastasis usually means inoperable for chemotherapy or embolisation Via the hepatic artery

(B) Liver Resection As (colo-rectal Carcinoma) may be curable in few cases as solitary nodule & No Extra-hepatic metastasis or Multiple but confined to one lobe.



Final Written Exams



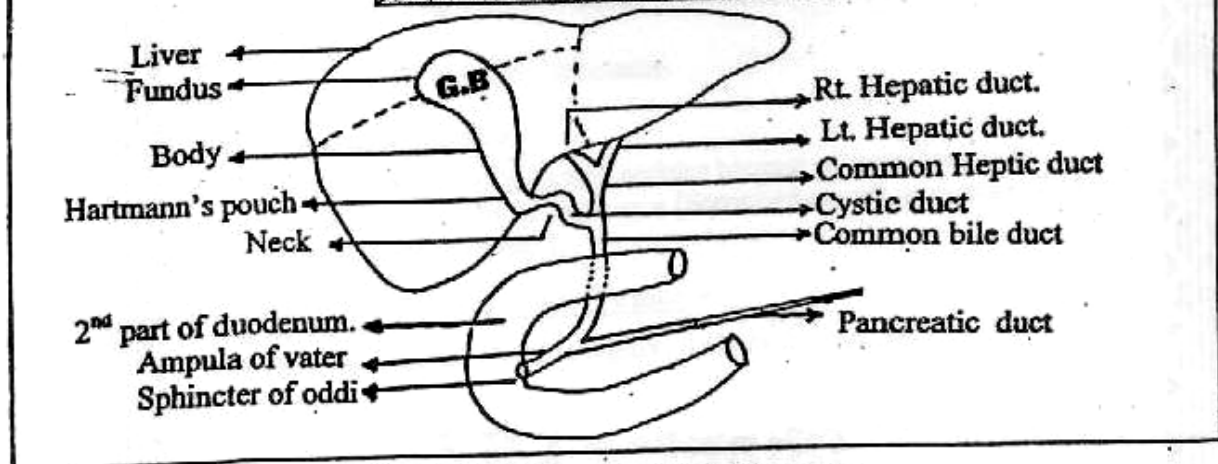
- 1994 • Discuss the diagnosis & Treatment of Amoebic Liver Abscess (15 Marks) نور ثانی
- 1995 • Discuss C/P of Amoebic Liver Abscess (15 Marks)
- 1997 • Discuss C/P & complications of Amoebic Liver Abscess (10 Marks) نور ثانی
- 1999 • Discuss C/P, diagnosis & ttt of Amoebic liver Abscess (15 Marks) نور ثانی
- 2001 • Discuss Amoebic liver abscess (10 Marks) نور ثانی
- 2002 • Discuss C/P, investigations & treatment of lrv liver cancer (12 Mark)
- 2003 • Discuss Management of Liver injuries (9 Mark) نور ثانی
- Discuss Amoebic liver Abscess (9 Mark) نور ثانی
- 2004 • Discuss liver metastasis (20 marks) نور ثانی

Chapter [6]

The Biliary System

The Biliary System

Surgical Anatomy



The Biliary system = Gall bladder + Extra-hepatic Biliary Tracts.

THE GALL BLADDER

- It is pear-shaped hollow organ lying on the visceral surface of the liver, measured about (7.5-12.5 cm) long with normal capacity 50 mL but it may be distended.

- **Morphology** : It is divided into ↲

① **Fundus** : Closed end of the gall bladder & completely covered with peritoneum.

② **Body** : Lies in contact with 1st part of duodenum & occupies the gall bladder fossa of the liver & partially covered with peritoneum.

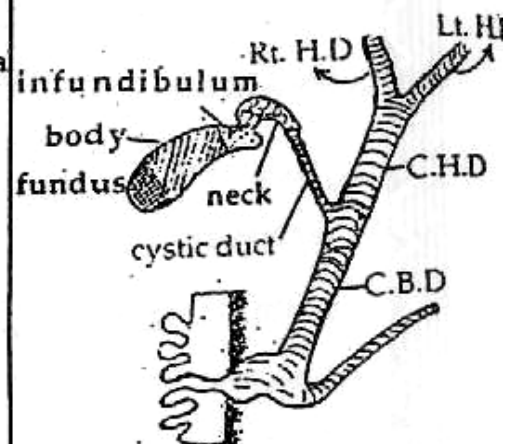
③ **Infundibulum** : it is angulated posterior part of the body which when dilate is called Hartmann's pouch.

④ **Neck** : "S" shaped curve: it's mucosa are arranged in crescentic folds to form spiracle valve of HEISTER.

⑤ **Cystic duct** : starts after Neck, it's length about (2.5 cm). it's mucosa contains Crypts of Luschka.

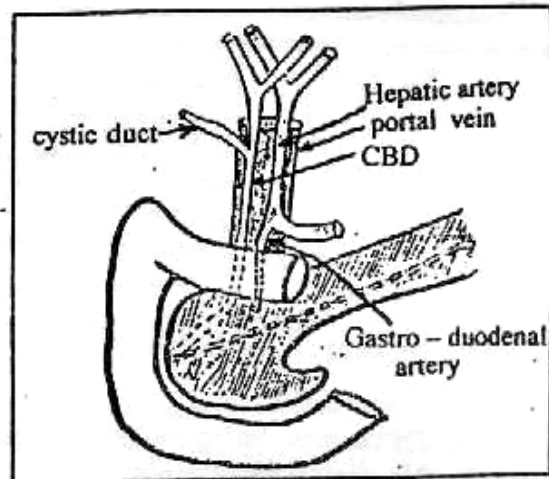
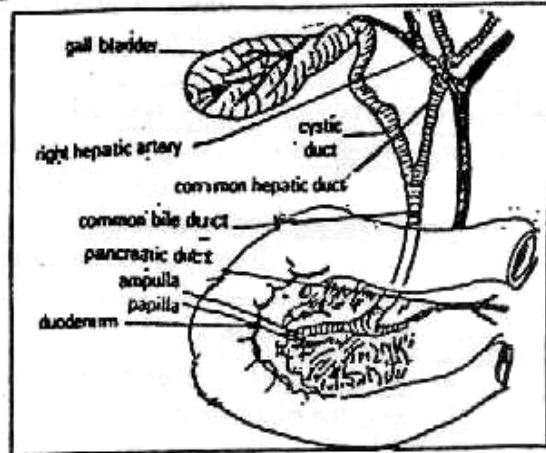
N.B. : Relations of Fundus of G.B. :

- **Anteriorly** : Anterior abdominal wall.
- **Posteriorly** : Transverse colon.



THE EXTRAHEPATIC BILIARY TRACTS

- ① **Rt. Hepatic duct** : is formed by union of Ant. & post. segmental hepatic ducts.
- ② **Lt. Hepatic duct** : is formed by union of med. & Lat. Segmental hepatic ducts.
- ③ **Common Hepatic duct** : is formed by union of Rt. & Lt. hepatic ducts at porta hepatis.
- ④ **Common bile duct** : (C+*)
 - **Begins** : by union of Cystic duct & CHD.
 - **Ends** : at ampula of Vater (with pancreatic duct) in the medial aspect of the 2nd part of duodenum.
 - **Length** : 5-10 cm.
 - **Diameter** : 8 mm.
 - **Parts** : (4 parts)
 - (a) **Supra-duodenal part** : (2.5cm) : runs in the free border of lesser omentum with hepatic artery to the left & portal vein posteriorly.
 - (b) **Retro-duodenal part** (2.5cm) : runs behind 1st part of duodenum with gastroduodenal artery to the left and portal vein posteriorly.
 - (c) **Infra-duodenal part** : i.e. intra-pancreatic part.
 - (d) **Intra-duodenal part** : (2.5 cm) join the pancreatic duct to form Ampula of Vater which opens in the middle part of 2nd part of duodenum, surrounded by sphincter of Oddi.

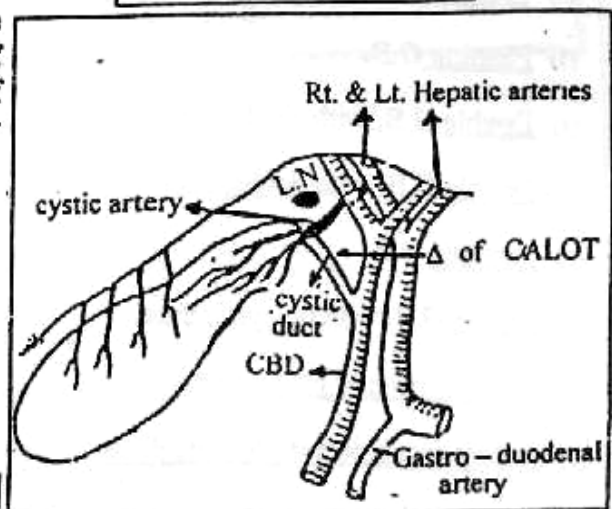


Relations of G.B.

Blood supply of Biliary system

★ Arterial supply :

- **G.B.** : cystic artery from Rt. Hepatic artery.
- **Biliary tracts** : cystic artery & gastro-duodenal artery from common hepatic artery



N.B: Blood supply of bile ducts runs longitudinally at 3 & 9 O'clock position. So avoid (Exploration at this position)

★ Venous drainage : Cystic vein end at Rt. branch of portal vein.

★ **Lymphatic drainage :**

Cystic L.Ns of Lund at junction of cystic duct & CHD → L.Ns in porta-hepatis → coliac L.Ns.

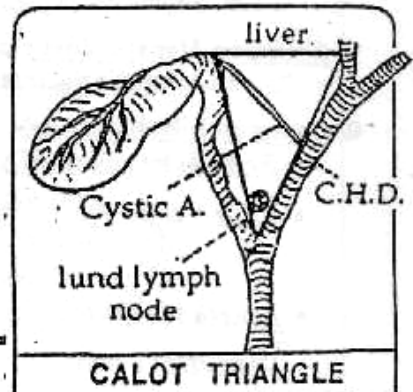
■ **Nerve supply of Biliary system**

a) Parasympathetic : (hepato-biliary branch from ant. vagus nerve). It *increase* the motor activity of G.B.

b) Sympathetic : (coliac plexus). It *inhibits* the motor activity of G.B.

N.B. : Calot Triangle Δ :

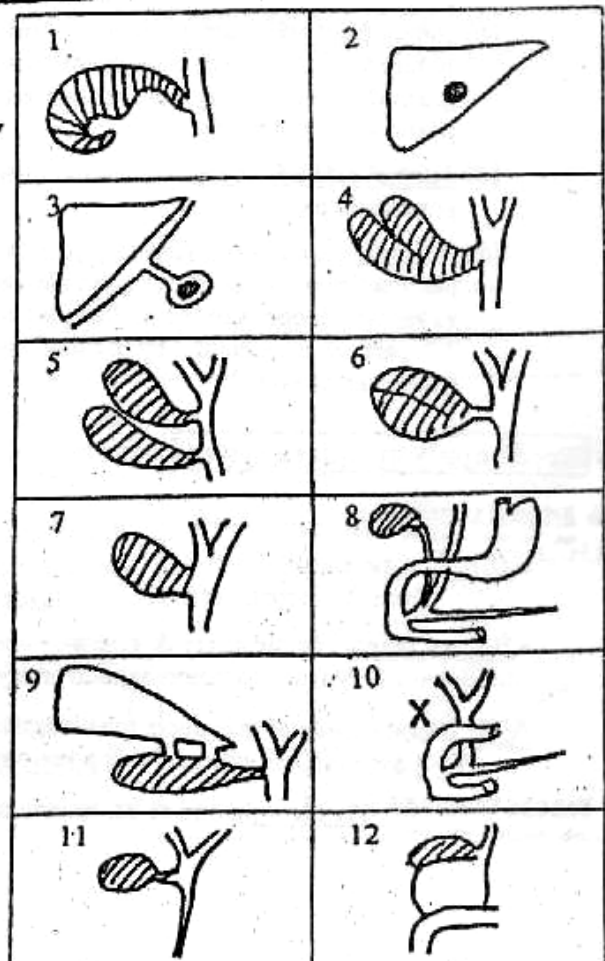
- Bounded by the liver, the common hepatic duct and the cystic duct.
- It contains the cystic artery, lund lymph nodes at the junction of cystic and common hepatic ducts.



Congenital Anomalies

[A] **Anomalies of G.B. & Bile Ducts**

- (1) Phrygian caps : (kinked fundus)
 - About 2.5%.
 - Discovered during cholecystography
 - No clinical significance.
- (2) Intra-hepatic G.B.
- (3) Floating G.B.
- (4) Double G.B. with single duct.
- (5) Double G.B. with double duct.
- (6) Septated G.B.
- (7) Sessile G.B. with no cystic duct.
- (8) Low insertion of cystic duct
- (9) Accessory cholecysto-hepatic ducts
- (10) Agentic absent.
- (11) Biliary Atresia
- (12) Choledocal Cyst : } See Next page





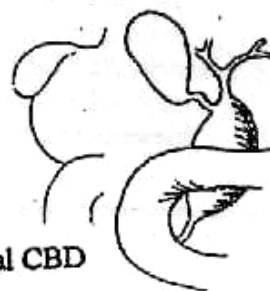
Biliary Atresia :

- **Definition :** Failure of canalization of Biliary ducts.
- **C/P :** O.J. at birth + Hepatomegaly. **DD :** Physiological jaundice
- **Complication :** Biliary cirrhosis → L.C.F. → Death.
- **Pathology :** Extra-hepatic or Intra-hepatic
- **Treatment :** (only surgical)
 - ◆ If **Extra-hepatic :** Hepatico - Jejunostomy (kasoni operation)
 - ◆ If **Intra-hepatic :** Liver Transplantation.



Choledocal cyst :

- **Definition :** Dilatation of C.B.D.
- **Types :** 7 types
 - Type ① Diffuse dilatation (The common).
 - Type ② Localized dilatation of supraduodenal CBD
 - Type ③ Supraduodenal diverticulum.
 - Type ④ Intraduodenal diverticulum.
 - Type ⑤ Solitary intra-hepatic cyst.
 - Type ⑥ Multiple intra-hepatic cyst (**Caroli's disease**)



Types ①, ②, ③ & ④ called Extra-hepatic types.
But ⑤, ⑥ called intra-hepatic types.

- **C/P :** - Attack of jaundice.
- Abdominal pain.
- Pyrexia.
- **Complication :**
 - Cholangio-carcinoma.
 - Biliary obstruction & stasis → stone formation.
- **Investigations**
ERCP - PTC - CT scan - U/S - liver function tests.
- **Treatment :**
 - Excision & Anastomosis.
 - If **not possible** → drainage by choledocho-duodenostomy.
 - Caroli's disease** → Localized → partial hepatectomy.
→ Generalized → liver transplantation.


[B] **Anomalies in the Arteries**

(I) **Anomalies of cystic artery :**

1. *Abnormal course* of cystic artery.
2. *Accessory* cystic artery (may arise from the pancreatico-duodenal or superior mesenteric arteries or from right hepatic artery or common hepatic artery).

(II) **Anomalies of Rt. Hepatic artery :**

1. *Abnormal course of Rt. hepatic artery*, it may be tortuous, passing in front of the bile duct, it is called "Caterpillar turn" (Moynihan's hump deformity), it may be ligated instead the cystic artery.
2. *Accessory Rt. Hepatic artery* may arise from superior mesenteric artery.



Gall Stones

* **Incidence** : Common in [Fatty, Filthy, Fertile, Female & > 40 years].

* **Classifications :**

A) **Old Classification :**

- Bile pigment 8%
- Mixed stones 80%
- Ca Carbonate 2%
- Cholesterol 10%

B) **New Classification :**

		Cholesterol Stones		Pigment Stones	
		Mixed	Pure	Black	Brown
①	Types				3%
②	Incidence	80%	7%		
③	Composition	• Cholesterol • +Ca bilirubin • Ca palmitat	• Pure cholesterol	• Ca bilirubin	• Ca bilirubin • + Ca palmitat • & Cholesterol
④	Number	• Multiple	• Single (Solitaire)	• Multiple	• Multiple
⑤	Size	• < 2.5cm	• > 2.5cm	• < 2.5cm	• < 2.5cm
⑥	Shape	• Faceted 	• Mamillated 	• Spicules 	• Laminated
⑦	Colour	• Yellowish	• Yellowish	• Black	• Brown
⑧	X-ray	• Radio-opaque 15%	• Radiolucent	• Radio-opaque 50%	• Radio-opaque

*** Aetiology :**

[A] Causes of Cholesterol Stones :

1- Disturbed Bile salts : Cholesterol Ratio :

A certain ratio between bile salts : Cholesterol = **25:1** So any lowering of this ratio can lead to super-saturated bile i.e. [Lithogenic Bile] with consequent Cholesterol precipitation.

① Reduced Bile salts : as in ↷

- Liver diseases : i.e Diminished synthesis of bile salts.
- Excess Oestrogen: which reduces the concentration of bile salts.
- Malabsorption of bile salts in Terminal ileum : as in Crohn's disease or small gut resection.

② Increased Cholesterol Synthesis :

e.g. Obesity or High dietary fat .

2- Stasis :

This may occur in the following conditions ↷

- ① Progesterone : Causes relaxation & Impairment of the gall bladder emptying.
- ② D.M. & Obesity.
- ③ Following Trunkal Vagotomy: i.e. Denervation of gall bladder.
- ④ Long term parenteral nutrition: because of prolonged decreasing of oral intake → Decreasing of cholecystokin release which in turn impair the gall bladder motility.

[B] Causes of Pigment Stones :

1- Haemolytic Anaemia.

2- Liver Cirrhosis : Most probably due to decrease secretion of bile acids by Cirrhotic liver leading to diminished the solubility of any unconjugated bilirubin.

3- Infection : Some strains of E.coli Which hydrolyses bilirubin glucuronide into unconjugated bilirubin .

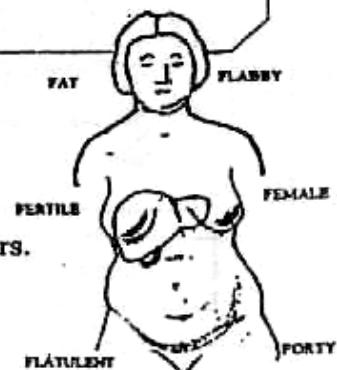
N.B. : All unconjugated bilirubin precipitated with calcium in form of Ca bilirubinate

*** Clinical Picture :**

[Gall Stones & Chronic Calcular Cholecystitis]

▪ **Type of Patient** : Fatty, Filthy, Fertile, Female & > 40 years.

N.B. : Exceptions to this rule is too frequent.



■ **Symptoms :**

[A] **Silent Gall stones:** Discovered accidentally by investigations.

[B] **Symptomatic:**

① **Recurrent Attacks of Biliary Colics :**

- **Site :** Rt. Hypochondrium.
- **Character :** Sever abdominal colics.
- **Radiated to :** Rt. Shoulder & Inferior angle of Rt. Scapula.
- **Precipitated by :** Fatty meals.
- **Relived by :** Anti-spasmodics.

② **Biliary Dyspepsia :**

Nausia, Fatty dyspepsia, Distension, Flatulence & Eructation.

③ **Reflex Symptoms :** i.e. Reflex vagal stimulation

Leading to decrease the coronary blood flow leading to Retro-sternal pain diagnosed as **Anginal pain**.

④ **Picture of complications:** See later.

■ **Signs :**

① **Tenderness in Rt. Hypochondrium.**

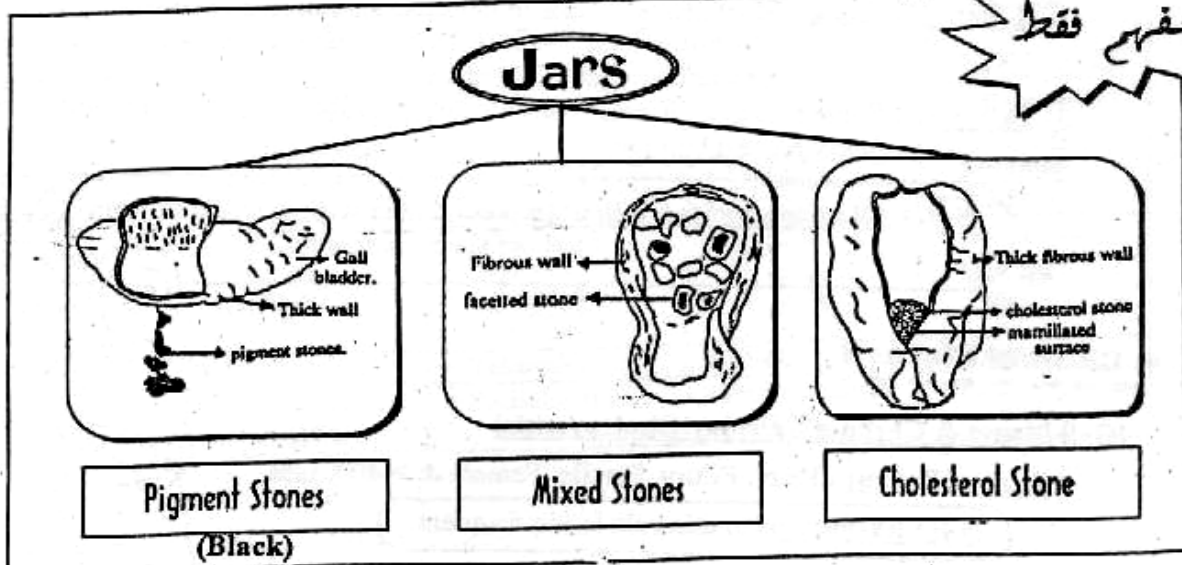
② **+ve Murphy's sign :**

The Gall bladder area is palpated while the patient is asked to take a deep breath, the patient will catch her breath.

N.B. :

- [I] **Saint's Triade :**
- ① Hiatus Hernia.
 - ② Diverticulosis Coli.
 - ③ Chronic Calcular Cholecystitis.

- [II] **Wilkie's Triade :**
- ① Chronic Peptic Ulcer.
 - ② Chronic Appendicitis.
 - ③ Chronic Calcular Cholecystitis.



* **Complications :**

[I] Obstructive Complications :

① Obstruction of the Cystic duct :

Leads to Mucocele or Empyema of the gall bladder.

② Obstruction of the Common bile duct :

Leads to calcular obstructive jaundice & 2ry biliary cirrhosis which occur as a result of intermittent obstruction over several years and ends with portal hypertension & liver cell failure (L.C.F).

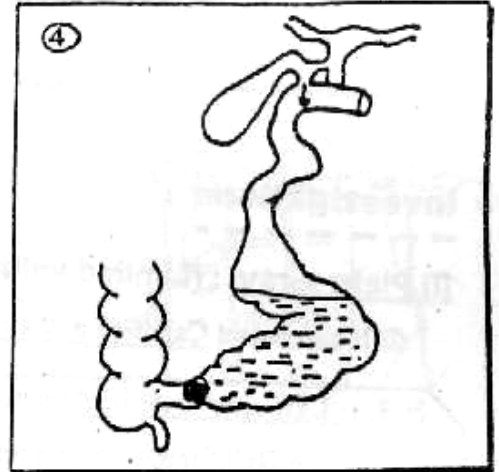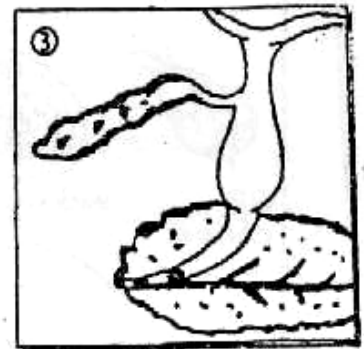
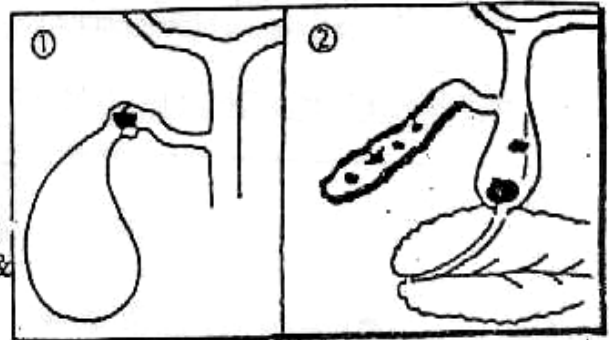
③ Obstruction of Ampulla of Vater :

May precipitates acute pancreatitis due to regurge of bile Into the pancreatic duct.

④ Obstruction of Terminal Ileum :

i.e. [Gall Stone Ileus] (V. rare)

- It is a large stone impacted in the Hartmann's pouch → Pressure necrosis
So Fistulised with the lumen of the duodenum.
- Then it passes through the lumen of small intestine by peristalsis.
- During it's course it may cause multiple phases of incomplete intestinal obstruction until it causes complete obstruction in the terminal ileum by it's size or by faecal accumulation around it.
- Finally it is impacted in terminal ileum 2 feet from Ileo-coecal valve.
- Investigation: Diagnosed only at Laparotomy
- Treatment: Milked upwards to a healthy part & removed by Entrotomy or Resection of affected segment if impacted.



⑤ Mirizzi Syndrome (Rare)

It is a partial obstruction of Common Hepatic Duct (CHD) due to stone in the Hartmann's Pouch. Eventually the stone erodes into CHD Forming single cavity & results in obstructive jaundice. So At operation CHD may be mistaken for cystic duct & ligated.

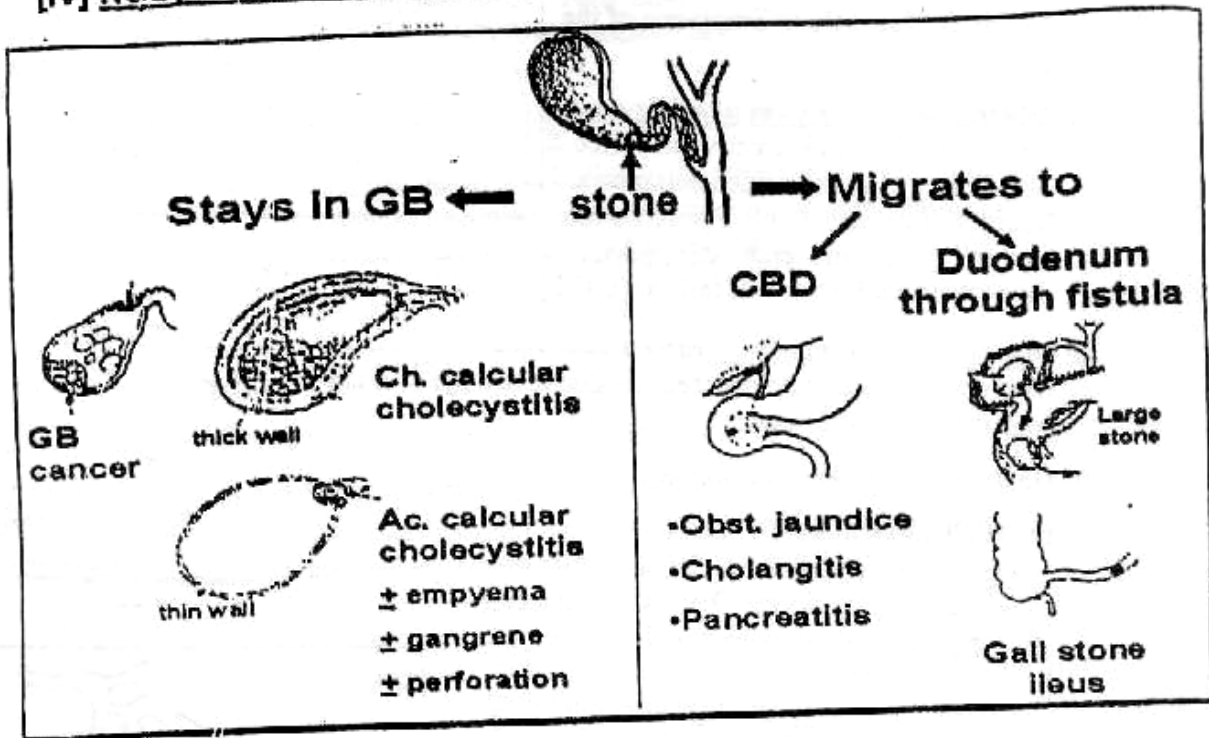
[II] Infective Complications :

- ① Acute Calcular Cholecystitis.
- ② Chronic Calcular Cholecystitis.
- ③ Ascending Cholangitis & Liver Abscess.

[III] Ulcerative Complications :


- ① Chronic Peptic Ulcer from Reflex Pylorospasm & Gastric stasis.
- ② Internal biliary fistula with stomach, duodenum etc ...
- ③ External biliary fistula with skin.

[IV] Neoplastic Complications : <1% e.g. Carcinoma of Gall bladder.



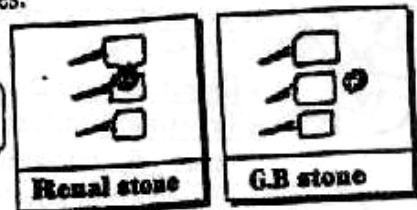
*** Investigations :**

[I] Plain x-ray : (Limited value)



① It can detect Calcified gall stone in only 10-15% of cases.

N.B. : Lat. view must be done to differentiate between The Gall Stones which present in front of spine. and Rt. Renal Stones which present upon supine.



- ② It can detect Calcified gall bladder (Porcelain G.B).
- ③ It can detect Air in biliary system with acute Emphysematous Cholecystitis.

[II] Abdominal Sonar : (95%) Accuracy

- ① It can detect Gall stones in 95% of cases.
- ② It can detect Thickness of gall bladder wall in Chronic Cholecystitis.
- ③ It can detect Dilated bile ducts (Intra-hepatic & Extra-hepatic) in obstructive Jaundice & dilated gall bladder

[III] Oral cholecystography : (Now replaced by U/S)



- **Method** : The patient fasts for 12 hours before the examination and swallows 6 tablets of Telepaque which is secreted by the liver in the bile & passes via cystic duct to be concentrated in the gall bladder.
- **The patient is given a fatty meal** : So the gall bladder will contract & it's size will be shrunken so if The film is taken the radiolucent stones appear as a filling defect.
- **It may be indicated** to assess the contractility of the gall bladder after a fatty meal to diagnose patients with Biliary Dyskinesia

N.B. : Failure of gall bladder to opacify may be due to ↗ :

- ① Vomiting.
- ② Failure of absorption.
- ③ Inability of liver to secrete the dye e.g. Obstructive jaundice.
- ④ Cystic duct obstruction.
- ⑤ Severely Inflamed gall bladder with loss of it's Contractility power.

* Treatment :

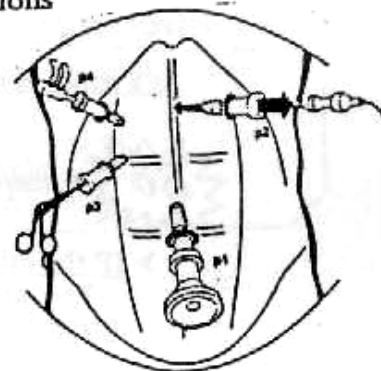
[A] Silent Gall Stones :

- If Young or Fit :
Cholecystectomy is the choice to avoid future complications
- If Old or Unfit :
Leave the patient for follow up.

[B] Symptomatic Stones :

The following options are available ↗

- I- Open Cholecystectomy : The standard
- II- Laparoscopic Cholecystectomy (L.C) :



- **The Advantages** :
 - ① Less post-operative pain.
 - ② Short post-operative hospital stay (1-2) days only.
 - ③ Early return to work.
 - ④ Better cosmetic result.
- **The contra-indications** :
 - ① Pregnancy as no space for pneumoperitoneum.
 - ② Marked obesity as it is difficult to induce the ports.
 - ③ Bleeding Tendency.
 - ④ Liver Cirrhosis.
 - ⑤ Empyema of gall bladder
 - ⑥ Carcinoma of gall bladder.
 - ⑦ Compromize of cardio-vascular or Respiratory function
 - ⑧ Previous upper abdominal surgery is relative contraindicated.

III- Medical Dissolution of gall stones :

(some popularity in 1980s) But not used nowadays

- Drug used :
Chenodeoxy cholic acid (15 mg/kg).
- Side effects :
Diarrhea , Hepatotoxicity & Recurrency.

[C] Treatment of Complications :

According to the type of complications will be discussed in the corresponding chapters.

Acute Cholecystitis

(A)

Acute Calcular Cholecystitis

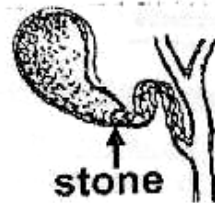
* Definition :

It is Acute inflammation of gall bladder 2ry to obstruction of cystic duct or Hartmann's pouch by a stone.

* Incidence : 98%

* Pathology :

As a result of obstruction the bile salts lead to
Chemical irritation of the gall bladder wall

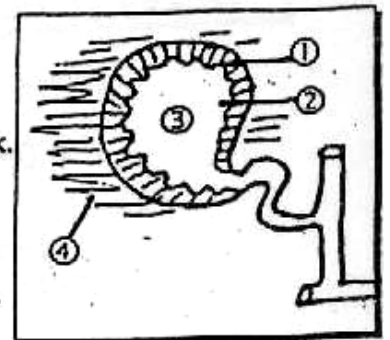


there are 2 possibilities

> IF the bile remains sterile :
The gall bladder becomes distended by mucous and a mucocele of gall bladder develops.

> But IF 2ry infection occur by gram -ve bacilli e.g. E.coli.
The gall bladder becomes distended by pus and a pyocele (Empyema) of gall bladder develops, leading to

- ① The Wall : Becomes Congested, Oedematous & Thick.
- ② The Mucosa : Shows area of ulceration.
- ③ The Content : Becomes Purulent.
- ④ The Omentum & Viscera : e.g Duodenum, Colon... are glued to gall bladder by adhesions which are 1st fibrinous, but later fibrous.




N.B. : Acute Emphysematous Cholecystitis :

- It is a special case occur with Diabetic patients due to infection with Gas forming organism e.g Clostridia
- This infection is highly virulent & accompanied by gas formation → Early gangrene of the gall bladder.

*** Fate :**

- In Most of Cases :
The stone dislodes and the Inflammation is gradually subsided, leaving Chronically inflamed gall bladder.
- But less commonly :
The Inflammation is more severe with progressive distension leading to thrombosis of the blood vessels → Perforation of gall bladder with either localized peritonitis or less commonly generalized peritonitis which is (0.5% only).

N.B. ① The commonest sites of perforation are ↷

- 
- (a) The Fundus : which is the far point from blood supply
 - (b) The Neck : because of pressure necrosis of impacted stone.

N.B. ② The perforation is rarely followed by generalized peritonitis because of surrounding adhesions resulting in Localized peri-cholecystitic Abscess which may be ↷

- (a) Resolve.
- (b) Points externally causing Ext. biliary fistula.
- (c) Points Internally causing int. biliary fistula.

*** Clinical Picture :**

- History of Biliary Colics.
- Symptoms : A or B

[A] Picture of simple obstruction : (Mucocele)

- Site : Diffused pain at upper Abdomen
- Character : Colicky and Paroxysmal pain
- Radiated to Rt. shoulder
- Associated with Localized pain at Rt. Hypochondrium

B) Picture of Inflammation : (Pyocele)

- Site : Localized at right Hypochondrium.
- Character : Throbbing pain
- Associated with Hectic Fever, Rigors & Sweating

▪ Signs :

[A] General Signs :

- ① Temperature : Increased i.e Hyperpyrexia.
- ② Heart Rate : Increased i.e. Tachycardia.
- ③ Jaundice : Because of
 - a) Mirizzi's syndrome.
 - b) Associated Stone in CBD.
 - c) Associated cholangitis.

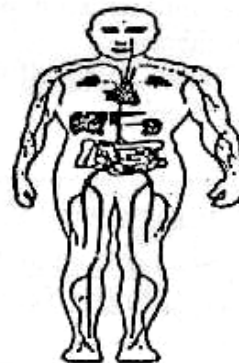
[B] Local Signs : (Abdominal)

- ① Tenderness & Rigidity at Rt. hypochondrium.
- ② G.B is not felt because of Adhesions, Tenderness & Rigidity
- ③ Boa's sign : Area of hyperaesthesia between 9th & 11 ribs posteriorly on the Rt. side.

* Differential diagnosis : (Acute Abdomen)

- e.g.
- ① Acute perforated peptic ulcer.
 - ② Acute Cholecystitis.
 - ③ Acute Pancreatitis.
 - ④ Acute Appendicitis.

N.B. : See Acute Abdomen (Chapter 15)



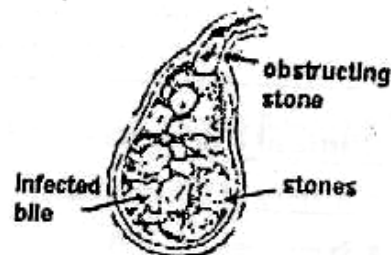
* Investigations :

[A] Laboratory Investigations :

- ① Blood Picture : Increased Leucocytic Count.
- ② Liver Function Test : Normal.

[B] Radiological Investigations :

- ① Abdominal U/S which reveal
 - a. Presence of gall stones.
 - b. Distended gall bladder.
 - c. Thickened wall of gall bladder.



- ② HIDA scan : Hydroxy Imidazole Diacetic Acid (not common)

▪ The Technique :

- a. ⁹⁹Tcm is administered I.V.
- Then b. Secreted by the liver.
- Then c. Excreted along the biliary pathway

▪ The Results :

IF the CBD is visualized while the gall bladder is not seen, this is diagnostic for acute calculous cholecystitis due to cystic duct obstruction.

* Treatment :

[A] Early Surgery : 3 days of onset of attack

"Now recommended" i.e. Cholecystectomy.

- IF ① The diagnosis is sure.
- ② The patient is fit.
- ③ The surgeon is competent.

▪ The Advantages :

- ① Early surgery is not difficult as adhesions are fibrinous & not fibrous.
- ② Avoid possible complications.
- ③ One hospital admission with early return to work.

[B] Conservative ttt followed by surgery : i.e. 6 weeks interval

This policy is to treat the patient as following ↗

- ① Naso-gastric tube & I.V fluid.
- ② Antibiotics 3rd generation e.g **Cephalosporins**.
- ③ Analgesics e.g. **Pethidine**.



Follow up : For Pulse, Temp, Degree of pain and Area of Tenderness (Boa's sign)



IF Deterioration occur for the patient, surgical intervention must be carried out.

N.B. : Acute appendicitis is treated by surgery while acute cholecystitis may be treated conservatively :

- * Because : ① The organism is Low virulence with acute cholecystitis than acute appendicitis
- ② The perforation is low incidence with acute cholecystitis than acute appendicitis
due to ↗
 - a. Gall bladder is Capacious & Distensible.
 - b. Gall bladder has good blood supply.
 - c. Thickened wall of inflammatory gall bladder.
- ③ The gangrene :
Is commoner with acute appendicitis than acute cholecystitis because the appendix has only appendicular artery but the gall bladder has numerous vascular connections to the under surface of the liver in addition to cystic artery.

B Acute Non Calcular Cholecystitis

* **Definition** : It is a serious condition of Acute Inflammation of gall bladder not related to stone formation.

* **Incidence** : Rare about 2% only.

* **Pathology** : Unclear.

But may be due to change in composition of bile or ischaemia of the gall bladder, So it may occur with ↻

- ① Patient suffering from major Burn or major Trauma.
- ② Patient with certain infections such as Brucellosis & Typhoid.

* **Clinical Picture** : As Acute Calcular Cholecystitis.

But usually the diagnosis is delayed because it is not suspected.

* **Investigation** :

Abdominal ultrasound is Diagnostic

* **Treatment** :

Urgent Cholecystectomy.

Chronic Cholecystitis

A Chronic Calcular Cholecystitis

* **Definition** : It is a Chronic inflammation of gall bladder most probably as a fate of Acute Calcular Cholecystitis when the stone is dislodged

* **Pathology** :

[A] Early changes of the gall bladder :

- Opacity of gall bladder wall.
- Fibrosis of liver around the gall bladder bed so the bladder doesn't empty completely.
- Enlargement of cystic L.Ns.

[B] In late cases :

- Calcification of gall bladder wall.

* **Clinical Picture** :

* **Investigations** :

* **Treatment** :

→ See Gall Stones

B Chronic Non Calcular Cholecystitis

* **Definition** : It is a case of chronically biliary dyspepsia not related to stone formation.

* **Pathology** : (3 pathological condition).

[1] **Infection** : e.g. Typhoid gall bladder.

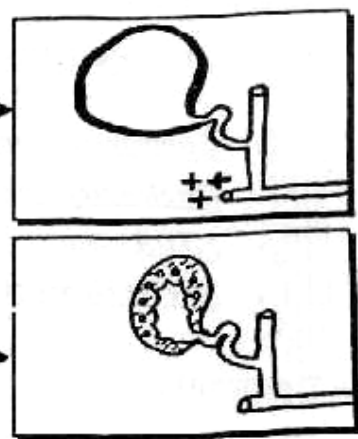
[2] **Biliary dyskinesia** :

Due to achalasia of sphincter of oddi leading to marked dilatation of gall bladder.
i.e. Sphincters doesn't relax when G.B. contracts.

N.B. : Cholecystectomy will aggravates the case.

[3] **Cholesterosis** : [Strawberry Gall bladder]

Due to an error of cholesterol metabolism which causes deposition of cholesterol crystals in the mucosa.



* **Treatment** : Only conservative

- ① Avoid fatty diet & Heavy bulky meal.
- ② Antibiotics & biliary antiseptics.
- ③ Antispasmodics especially for biliary dyskinesia.

Carcinoma of the Gall Bladder

* **Incidence** : ■ Common with Elerly female.
■ Female : male = 4 : 1.
■ Usually due to stones.

* **Aetiology** :

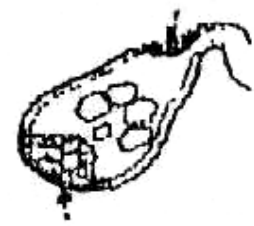- ① Gall stones due to chronic irritation.
- ② Porcelain G.B. (calcified wall of the G.B.).
- ③ Gall bladder polyps.

* **Pathology** :

- Adenocarcinoma (90%).
- Squamous cell carcinoma (10%).

* **Spread** :

- Direct : (Liver & bile passages).
- Lymphatics : Cystic L.Ns (Lund) & Porta hepatis L.Ns.
- Blood : Liver, lung, bone & rarely brain.



GB cancer

★ Clinical Picture:

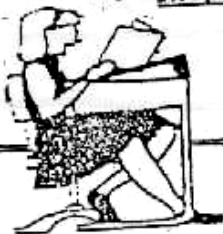- ① Pathological group : discovered by the pathologist, for removed gall bladder after cholecystectomy.
- ② Obstructive group : acute cholecystitis, obstructive jaundice.
- ③ Mass group : (mass in the Rt. hypochondrium).

★ Investigation:

- Abdominal Ultrasound (U/S) : shows an mass inside the gall bladder (accurate > 80%).
- Computed Tomography (CT) and magnetic resonance imaging (MRI)
- Cholangiography.
- HIDA scan.
- Needle biopsy guided by U/S.

★ Treatment:

- Operable cases : cholecystectomy with extended right hepatic resection. If discovered during operation of cholecystectomy : cholecystectomy + resection of underlying liver tissue + any accessible lymph node.
- Inoperable cases : relieving of the jaundice by a stent.



Final Written Exams



- | | | |
|------|---|------------------------|
| 1995 | • Give a short account on the Aetiology, pathology, C/P and treatment of Acute Cholecystitis. | (25 Marks) دور ثانی |
| 1996 | • <u>Discuss</u> Pathology, Diagnosis and treatment of <u>Acute calcular cholecystitis.</u> | (25 Marks) دور ثانی |
| 1998 | • <u>Discuss</u> symptoms of Gall Stones | (15 Marks) |
| 2000 | • <u>Mention</u> Types & composition of gall stones | (10 Marks) |
| 2001 | • <u>Mention</u> path.. & C/P of Acute choecystitis | (15 Marks) |
| 2002 | • <u>Discuss</u> Types & Composition of gall stones. Mention it's complications. | (12 Mark) |
| 2003 | • <u>Discuss</u> complications of cholecystectomy | (9 Mark) دور ثانی |
| 2004 | • <u>Discuss</u> Types , Actiology & C/P of gall stones | (20 marks) rk دور ثانی |

Chapter [7]

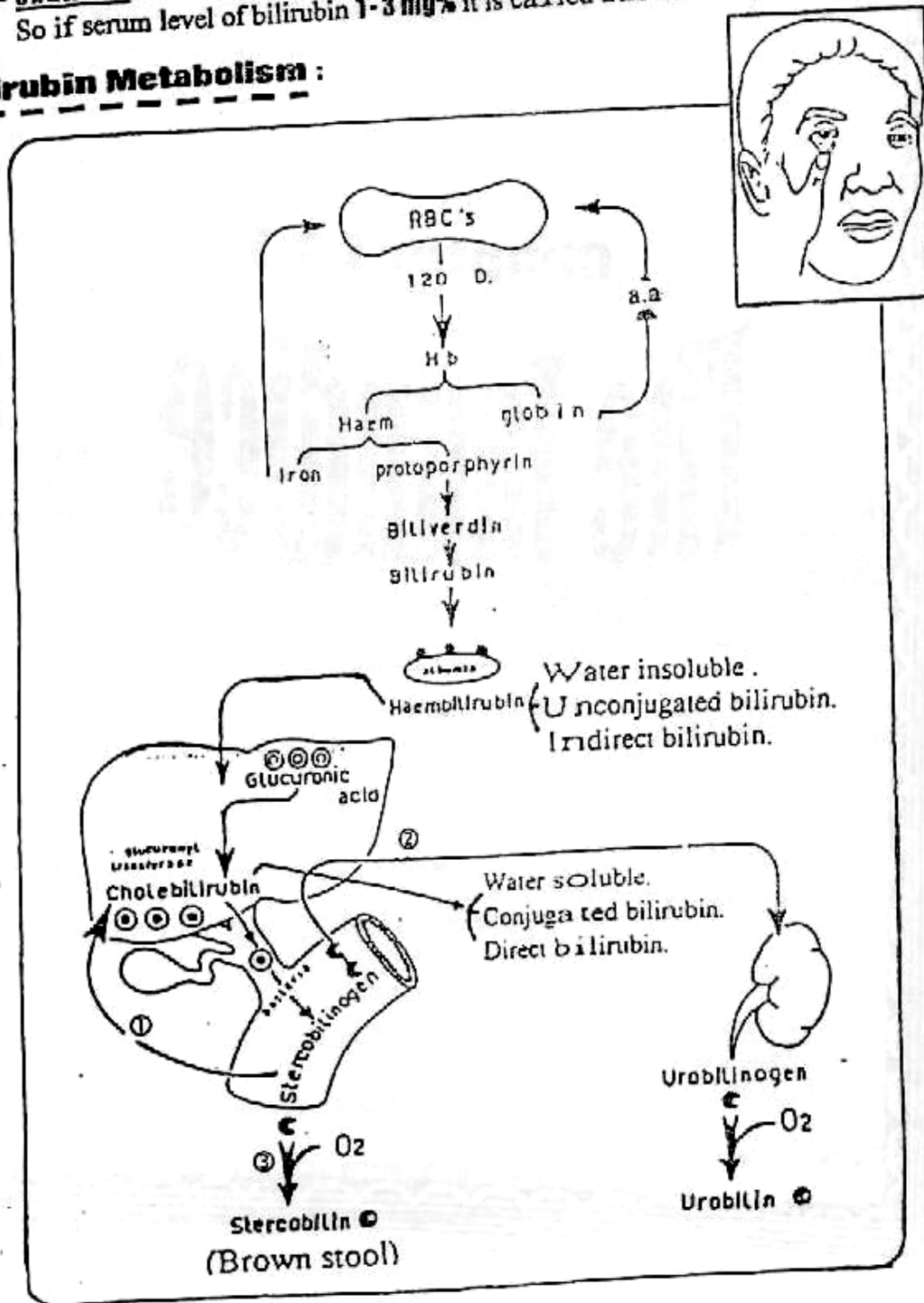
The Jaundice

The Jaundice

*** Definition :**

- **Jaundice** is the yellowish discoloration of the tissues and body fluid Except [brain, CSF, Tears, Saliva and Milk] due to excess bilirubin in blood. [N.B. : Normal level of serum bilirubin < 1 mg%].
- **Jaundice** occurs if serum level of bilirubin > 3 mg%.
So if serum level of bilirubin 1-3 mg% it is called **Sub-icteric jaundice**.

*** Bilirubin Metabolism :**



Obstructive Jaundice

"Surgical (Cholestatic) Jaundice"

* Pathogenesis :- [Sequelae]

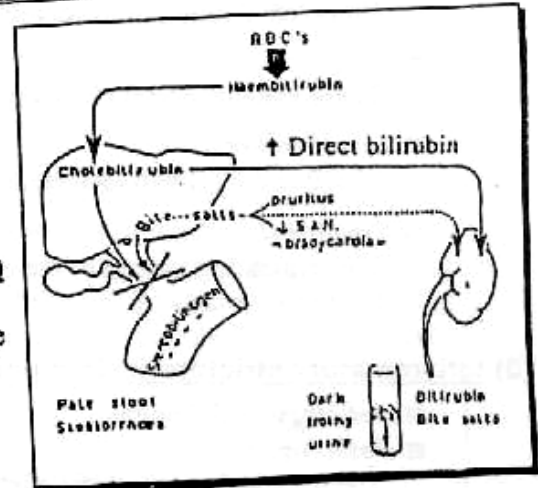
■ Because of the obstruction the direct (conjugated) bilirubin is prevented from reaching to intestine
So →

- ① No Stercobilinogen. This will lead to pale (clay) stool.
- ② The direct (conjugated) bilirubin will regurgitate to the blood & excreted to the urine leading to Dark urine i.e. Tea like urine.
- The bile Salts will increased in blood & decreased in intestine.
 - ① Increased bile salts in blood leads to
 - (a) Bradycardia of Heart.
 - (b) Itching (pruritis) of Skin due to irritation of nerve endings.
 - (c) Frothy urine.
 - ② Decreased bile salts in Intestine leads to
 - (a) Defective absorption of fat & fat soluble vit (A,D,E & K)
Leads to steatorrhoe & bleeding due to ↓ vit. K.

N.B. : (I.V vit K will improve the bleeding)

- (b) Defective bacteriostatic Function.
Leads to Increasing the fermentation → offensive & Bulky stool.
- (c) Defective it's motility effect.
Leads to Constipation, Abdominal distension & Anorexia.

N.B. : Absence of bile salts from intestine → ↑ Absorption of bacterial Endotoxins → Renal vasoconstriction → Acute Renal Failure
I.e. Hepato-renal Failure.



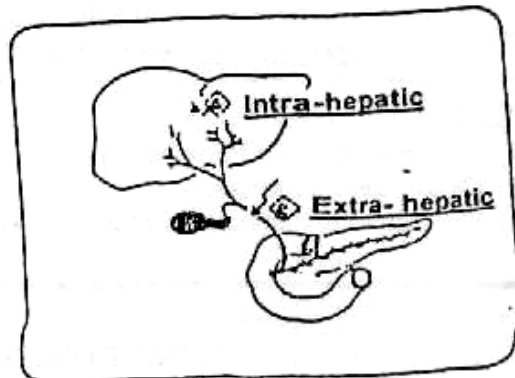
* Aetiology :

[A] Intra-hepatic Obstruction :
e.g Liver tumors, Liver cirrhosis or viral Hepatitis (*Watson syndrome*)

[B] Extra-hepatic Obstruction :
i.e. Common bile duct obstruction

[1] Lumen

- (*) ① Stone. (Cholelithiasis)
- ② Blood e.g Haemobilia
- ③ Parasite e.g. Ascaris or Fasciola.



[2] Wall :

STRICTURE OF THE BILIARY TRACT

1) **Congenital biliary atresia** (see before)

2) **Traumatic strictures:**

- **Aetiology :**
Complete ligation of the common hepatic or bile duct after cholecystectomy
- **C/P:**
These patients present by either fistula or jaundice following cholecystectomy.
- **Investigations:**
ERCP and PTC will localize the site of the stricture.
- **Treatment:**
The remaining stump of the common hepatic duct is anastomosed to a Roux-en-Y loop of jejunum.

3) **Inflammatory stricture (sclerosing cholangitis):**

- **Aetiology :** Unknown
- **Pathology :**
The intra- and extrahepatic ducts are involved by multiple strictures.
- **C/P :**
The patient presents by obstructive jaundice .
- **Treatment:**
These patients are candidates for liver transplantation.

4) **Neoplastic stricture (Cholangiocarcinoma):**

- **Incidence :**
Elderly males .
- **Predisposing factors:**
Calcular disease, ulcerative colitis, sclerosing cholangitis, choledochal cyst and parasitic infestation to clonorchis snesis.
- **Clinical Picture:**
 - They manifest by obstructive jaundice in 90% of patients.
 - **If the Tumour below the insertion** of the cystic duct into the common bile duct, **the gall bladder will be distended.**
 - **If the Tumour at porta hepatis (Klatskin's tumour),** **the gall bladder will be collapsed.**
- **Investigations :**
U/S and PTC will localize the site of the stricture.
- **Treatment :**
 - **Operable lesions** at the lower end of CBD are treated by pancreatico-duodenectomy (**Whipple's operation**).
 - **Inoperable cases** are treated by cholecystojuenostomy .

[3] Outside:

- 1) L.Ns metastasis at Porta-hepatis.
- (*) 2) Cancer head pancreas.
- 3) Peri-ampullary carcinoma of 2nd part of duodenum .

**N.B.: The common 2 causes are :
CALCULAR & MALIGNANT OBSTRUCTIVE JAUNDICE**

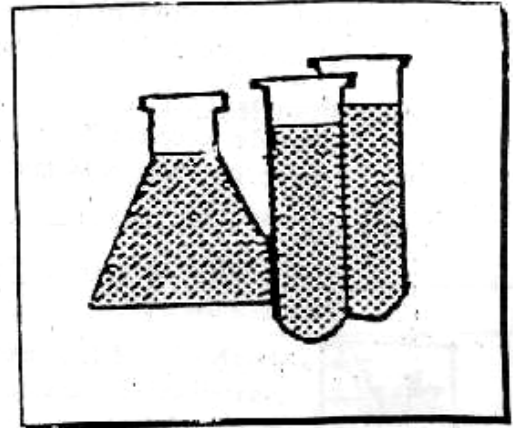
	Calcular Obstructure Jaundice	Malignant Obstructure Jaundice			
* Pathology : <u> </u> <u> </u> <u> </u>	<p>[I] Effects on Bile duct :</p> <ul style="list-style-type: none"> ▪ Proximally to obstruction : The bile duct is <u>dilated</u> i.e. Retention of bile occur. ▪ The content : 1st Thick biliary <u>mud</u> due to stagnation, infection & pus production occur with prolonged obstruction and High pressure in the bile duct, liver damage will occur with <u>no</u> excretion of bilirubin <u>So</u> the bile duct contains mucous (<u>White bile</u>) which is a serious bad sign of liver failure. ▪ Distally to obstruction : The bile duct may be <u>stenosed</u> 				
	<p>[II] Effects on Liver :</p> <ul style="list-style-type: none"> ▪ Dilated Hepatic bile ductules (<u>Hydrohepatosis</u>). ▪ If Infection occurs = Suppurative Cholangitis. ▪ <u>Finally</u>, Acute progressive liver damage occur. 				
	<p>[III] Effects on Gall bladder :</p> <p style="text-align: center;">According to ↻</p> <div style="text-align: center; border: 1px solid black; padding: 5px; margin: 10px auto; width: 80%;"> <p>Courvoisier Law</p> </div> <table border="0" style="width: 100%; border-collapse: collapse;"> <tr> <td style="width: 50%; text-align: center; border-bottom: 1px solid black;"> <p><u>In Calcular O.J</u></p> </td> <td style="width: 50%; text-align: center; border-bottom: 1px solid black;"> <p><u>In Malignant O.J</u></p> </td> </tr> <tr> <td style="vertical-align: top; border-right: 1px solid black;"> <p>The gall bladder is <u>contracted & non palpable</u> (80%) due previous cholecystitis. But in (20%) the gall bladder is dilated and healthy either due to metabolic stone or stone in the cystic duct Causing mucocele of G.B or Empyema if infected.</p> </td> <td style="vertical-align: top;"> <p>The gall bladder is <u>dilated & healthy</u> in (98%). But in (2%) gall bladder doesn't dilated due to ↻</p> <ul style="list-style-type: none"> ⊙ Associated Chronic Cholecystitis with cancer pancreas. ⊙ The L.Ns from Cancer head pancreas at porta hepatis ⊙ Previous cholecystectomy </td> </tr> </table>		<p><u>In Calcular O.J</u></p>	<p><u>In Malignant O.J</u></p>	<p>The gall bladder is <u>contracted & non palpable</u> (80%) due previous cholecystitis. But in (20%) the gall bladder is dilated and healthy either due to metabolic stone or stone in the cystic duct Causing mucocele of G.B or Empyema if infected.</p>
<p><u>In Calcular O.J</u></p>	<p><u>In Malignant O.J</u></p>				
<p>The gall bladder is <u>contracted & non palpable</u> (80%) due previous cholecystitis. But in (20%) the gall bladder is dilated and healthy either due to metabolic stone or stone in the cystic duct Causing mucocele of G.B or Empyema if infected.</p>	<p>The gall bladder is <u>dilated & healthy</u> in (98%). But in (2%) gall bladder doesn't dilated due to ↻</p> <ul style="list-style-type: none"> ⊙ Associated Chronic Cholecystitis with cancer pancreas. ⊙ The L.Ns from Cancer head pancreas at porta hepatis ⊙ Previous cholecystectomy 				
* Clinical Picture					
I- Personal H.					
♦ Age :	• Middle age.	• Old age.			
♦ Sex :	• Usually Female.	• Usually Male.			
II- Complaint :	Yellowish Discoloration or symptoms of the disease.				

	Calculular Obstructure Jaundice	Malignant Obstructure Jaundice
III- <u>Present H.</u> ▪ <u>O.C.D.</u> →	• <u>Sudden</u> onset with <u>Intermittent</u> course & <u>Variable</u> in duration	• <u>Gradual</u> onset with <u>Progressive</u> course & <u>Short</u> in duration.
▪ <u>Pain</u> →	• <u>Mild</u> degree . • colicky in <u>Rt</u> hypo- chondrium • <u>Radiated</u> to Rt. Shoulder • ↑ by fatty meals. • ↓ by antispasmodics.	• Severe degree • Boring • <u>Referred</u> to back • ↑ By lying down. • ↓ by leaning forwards.
▪ <u>Fever</u> →	• <u>Charcot's Triade</u> [pain , jaundice & fever with rigors] • <u>Reynold's pentad</u> As above + Mental confusion & shock.	_____
▪ <u>Wt. Loss & Metastasis</u>	-ve	+ve
<u>See pathogenesis</u>		
▪ <u>Stool</u> →	Pale, Bulky, Offensive & Steatorrhae.	
▪ <u>Urine</u> →	Dark (Tea Like) & Frothy.	
▪ <u>Pruritis</u> →	Present & leads to Scratching Marks.	
▪ <u>Bleeding Tendency</u> →	Present from the orifices & Improved by I.V vit K	
IV- <u>Past H.</u>	Biliary dyspepsia	_____
V- <u>General Ex.</u> ▪ <u>Vital signs</u> : • Temp. • Pulse ▪ <u>Generally</u> : • Appearance • Built	♦ <u>Hyperpyrexia</u> (Charcot's) ♦ <u>Bradycarida</u> . ♦ <u>Alert</u> with Cholongitis ♦ <u>Obese</u> .	♦ Normal. ♦ <u>Bradycardia</u> . ♦ Ill with Chachexia. ♦ <u>Underbuilt</u> .
VI- <u>Local Ex.</u> • Liver • G.B • Spleen • Ascitis	♦ Enlarged. ♦ Courvoisier low. ♦ No ♦ No	♦ Enlarged ♦ Courvoisier low. ♦ No ♦ + as sign of malignancy.

*** Investigations : (6 Problems)**

[1] To Prove Jaundice :

Estimate Serum Bilirubin which is \Rightarrow
 Normal < 1mg%
 Subclinical 1-3 mg%
 Clinical > 3 mg%



[2] To Prove that is Obstructive or not :

- ① Stool Analysis :
Clay, Bulky and Offensive.
- ② Urine Analysis :
Dark (Tea Like) and Frothy.
- ③ Blood Analysis :
 \uparrow Total bilirubin mainly direct (Conjugated).
- ④ Alkaline phosphatase : [N = 3 – 13 king Armstrong Unit].
This enzyme Increased mainly with obstructive Jaundice.
- ⑤ Gamma glutamyl Transferase and 5-Nucleotides :
Both are maximally elevated with obstructive Jaundice.

[3] To Exclude other Types of Jaundice :

- ① Blood Examination :
To Exclude Haemolytic Jaundice.
- ② Liver Biopsy :
To Exclude Hepato-cellular Jaundice.

[4] To Assess it's Effect on Coagulation :

Through prothrombin time and concentration which are \Rightarrow :

- Normal with Haemolytic Jaundice.
- Prolonged Prothrombin time & Diminished prothrombin concentration with both obstructive and Hepatocellular Jaundice.



To Differentiate both conditions, Give I.V vit. K (few days)

- IF Improved prothrombin parameter \rightarrow obstructive jaundice
- IF Not Improved prothrombin parameter \rightarrow Hepato-cellular Jaundice.

[5] To Assess it's Effect on Liver Function :

- ① SGOT & SGPT : [N = 12 – 40 unit/mL]
Which increased with Hepatocellular and late obstructive Jaundice from destruction of Hepatocytes by retained bile.
- ② Serum Albumin : [N = 3.5 – 5gm%].
Which decreased with obstructive Jaundice.

[6] To Prove Cause of Obstructive Jaundice : Stone or Malignancy

① Abdominal Ultrasound :

It will show ↗

- Dilatation of Intra-hepatic Radicals.
- Dilatation of CBD & presence of Stone.
- A mass of head of pancreas may be detected.

② Abdominal CT :

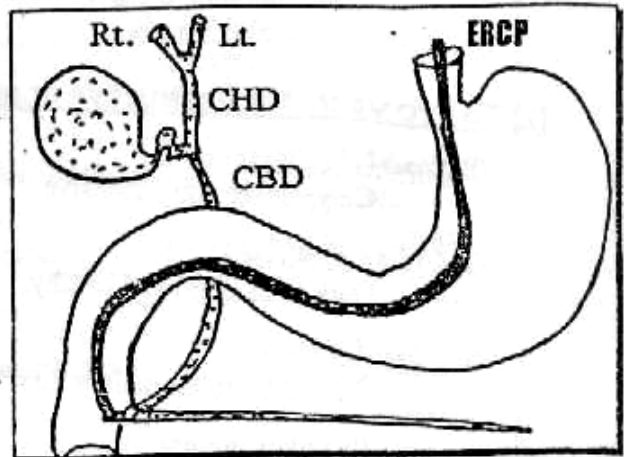
Valuable to detect ↗
Pancreatic mass or Metastatic L.Ns.

③ E.R.C.P. :

[Endoscopic Retrograde Cholangio-Pancreatography]



- Both CBD & Pancreatic ducts are visualised. So the stones appear as a filling defect.
- Also can detect any lesion of ampula & biopsy is taken.

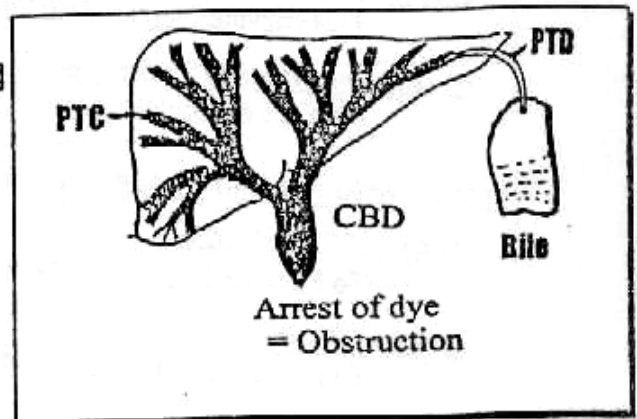


④ PTC :

[Percutaneous Trans-hepatic Cholangiography]



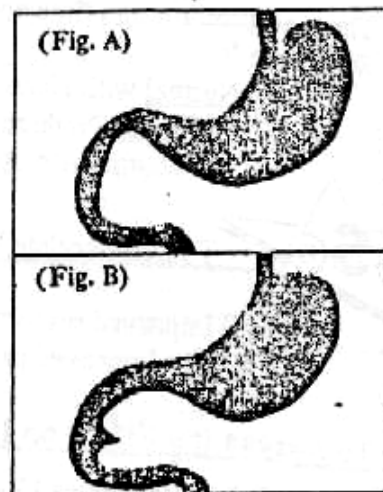
- It is done if malignant lesion (obstruction) is high up in the hepatic duct.
- It End by PTD Percutaneous Trans-hepatic Drainage if the serum bilirubin > 20 mg% to drain bile.



⑤ Barium Meal (Hypotonic Duodenography)

After injection of hyoscin (Buscopan). Barium meal is given to the patient on reaching the duodenum, film can be taken to visualize any abnormality in the duodenum

- e.g. ① Widening of duodenal curve (pad sign) i.e. cancer head (Fig. A)
② Inverted 3 shaped i.e. peri ampullary carcinoma (Fig. B)



[The Jaundice]

Jaundice Sheet

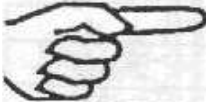	Obstructive Jaundice			Hepatocellular J.		Haemolytic jaundice
	<i>Calcular</i>	<i>Malignant</i>	<i>Intra Hepatic</i>	<i>V.H</i>	<i>Cirrhosis</i>	
I- Personal H. • Age & Sex • Occupation. • Special habits	• <u>Middle</u> • - • -	• <u>Old</u> • . • .	• Any • . • .	• Any • <u>Doctors.</u> • -	• Any • <u>farmers</u> • Alcohol	• <u>Children</u> • - • -
II- Complaint	[Yellowish Discolouration of the skin or (symptoms of the cause)]					
III- Present						
1) O.C.D. • <u>Onset</u> • <u>Course</u>	(Attacks) • Sudden • Intermittent	• Gradually • Progressive	• Acute. • Regressive	• Acute • Regressive	• Gradually • Progressive	(Crisis) • Sudden • Intermittent
2) Urine	• [Dark and Frothy Urine]			• Dark		• Normal
3) Stool	• [Pale, bulky, offensive and steatorrhoe]			• [Normal]		• Dark
4) Anorexia & nausea & vomiting	• No	• No	• No	• +ve	• No	• Crisis
5) Fever	• <u>Charcot's</u>	• No	• No	<u>Pre-icteric</u>	• No	• Crisis
6) Pain • Radiate → • Character → • Degree → • ↑ → • ↓ →	[Biliary] • Rt shoulder • Colicky • Mild • Fatty meals • Antispasmodic	[Epigastric] • Back • Boring • Severe • Lying down • Leaning forwards	[Dullache]	[Dullache]	—	[Crisis]
7) Pruritis	[+ve]	[+ve]	[+ve]	-	-	-
8) Wt, loss	-	[+ve]	-	-	-	-
9) L.B.L.B.	-	[+ve]	-	-	-	-
10) Aetiology	[Bleeding tendency from orifices] but improved by <u>vit K</u> (why?)			[Bleeding tendency] but not improved by <u>Vit K</u>		• Leg ulcer • Anaemia
IV- Past H.	• Fatty dyspepsia • Colics	-	• Halothan • PAS. INH	• Injections	• Alcohol • <u>β</u>	• Blood transfusion.
V- Family H.	-	-	-	-	+ ve if <u>β</u>	+ ve

*** Treatment :**

*** Pre-operative management :**

- ① **Correct Clotting Dysfunction :**
 - Vit K I.V 10-40 mg/d
 - Fresh Blood Transfusion.
- ② **Protect against Liver Cell Failure (L.C.F.) :**
 - High intake of glucose to increase liver glycogen.
 - Lactulose & Liver Tonics.
 - Antibiotics e.g. Cephalosporins to prevent Cholangitis.
- ③ **Protect Against Renal Failure :**
 - Adequate hydration by I.V fluid.
 - I.V Mannitol to induce diuresis.
 - Oral bile salts to decrease liability of Endotoxaemia
i.e. to ↓ Hepato-renal failure.

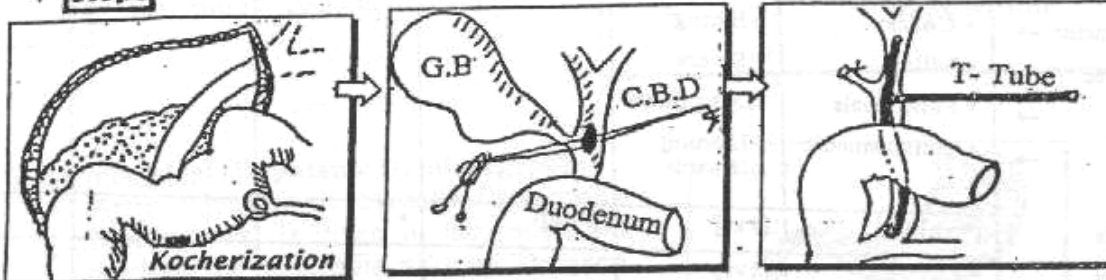
*** Operative procedures :**



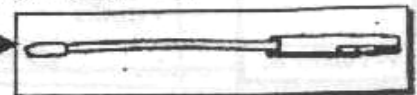
Treatment of Calcular obstructive Jaundice

(A) Cholecystectomy & Choledocholithotomy [If ERCP is not available]

*** Steps**

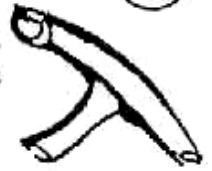

- ① **The 1st step** is to mobilise the duodenum from posterior abdominal wall (Kocherisation of duodenum) to expose the retro-duodenal portion of C.B.D
- ② **2 stay sutures** are taken in the wall of the supra- duodenal portion of C.B.D.
- ③ **A vertical incision** (2cm long) is made in between the 2 stay sutures.
- ④ **Stone forceps** is introduced into the C.B.D to remove the stone, then patency of C.B.D is confirmed by passing a metal dilator (**Bake's dilator**)
- ⑤ **Some surgeons** insert a **Choledochoscope** to check that there are no retained stones
- ⑥ **T-Tube** is inserted in (CBD) which is closed around the tube, the long limb of the tube is brought outside the patient.



[The Jaundice]

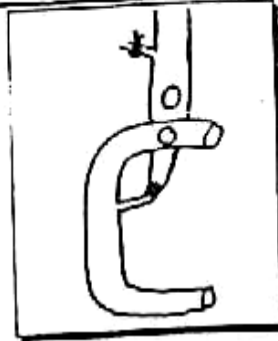
- ⑦ **T-Tube Cholangiogram** can be performed after closure of CBD to check absence of filling defect. i.e. Completion T-tube cholangiography.
- ⑧ **Cholecystectomy** is then performed



In some cases: An additional procedure has to be performed in addition to Choledocholithotomy.

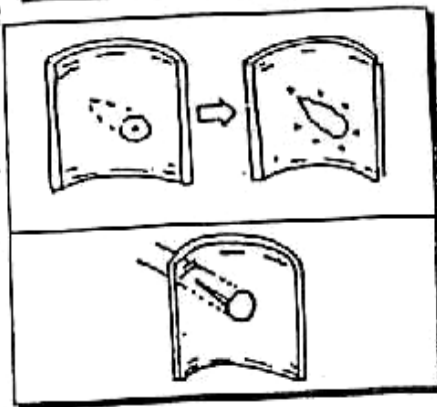
I] Choledocho-duodenostomy: →

- **Indications:**
 - ① Stricture of lower end of CBD.
 - ② A stone impacted at lower end of CBD.
- **Technique:**
An anastomosis between CBD & the 1st part of the duodenum.



II] Sphincterotomy or Sphincteroplasty:

- **Indications:**
 - ① stricture of papilla of sphincter of oddi.
 - ② A stone impacted papilla of sphincter of oddi
- **Technique:**
A longitudinal cut is made in the papilla and Part or all of the sphincter of oddi is divided at The 10 O'clock position to avoid injury of the pancreatic duct.

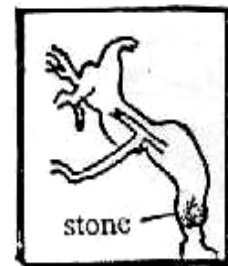

*** Post-operative**

10 days post-operative another cholangiography to ensure that no residual stones before removal of the tube

N.B: management of Missed stones:

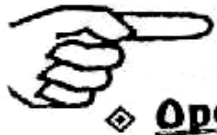- ① Irrigation by saline
- If failed ② Administration of "Dormia basket"
- If failed ③ Re-exploration "surgically"



(B) Endoscopic Extraction of Stones by ERCP [If ERCP is available]

followed by cholecystectomy:

- **Indicated with** High operative risk pt.
- **Technique:**
Stones can be extracted by "Dormia Basket" from CBD but if fails, Crushing the stones through mechanical lithotripsy by a special "Crushing wire Basket"
- **Complicated by**
 - ① Bleeding (Haemobilia) 2 - 9 %.
 - ② Acute cholangitis 1 - 3 %.
 - ③ Acute pancreatitis 1 - 4 %.

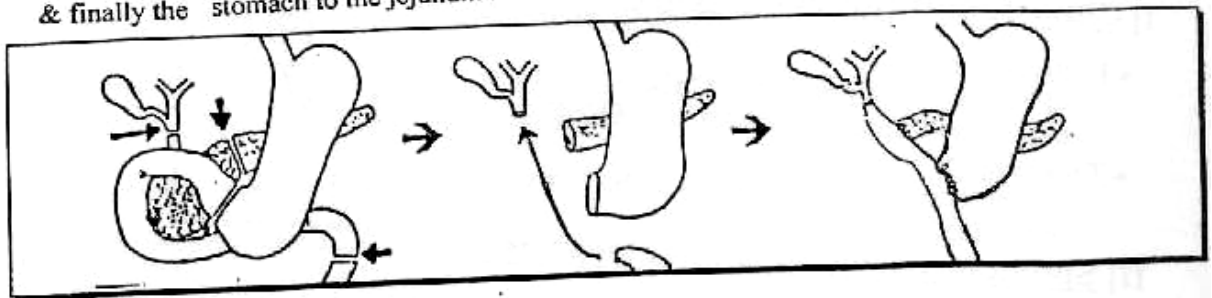


Treatment of Malignant Obstructive Jaundice

◆ **Operable**

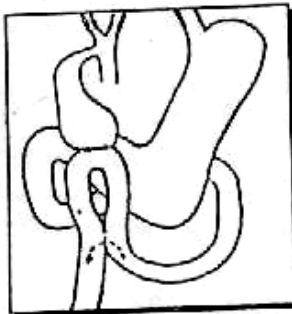
Tumor of the head :

[Pancreatico-duodenectomy] (Whipple's operation) i.e. Removal of duodenum, lower part of CBD & head of pancreas. Then restore the continuity by the following anastomoses : the bile duct to jejunum , the pancreatic duct to the jejunum & finally the stomach to the jejunum .

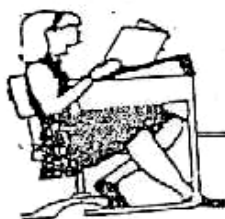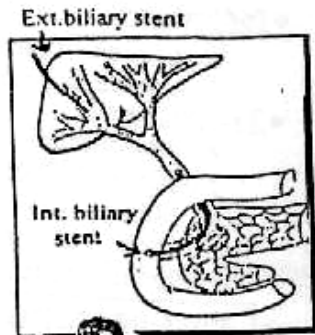


◆ **Inoperable** Either (A) or (B)

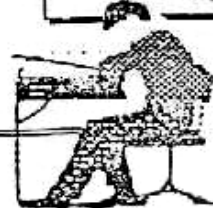(A) Cholecysto jejunostomy with Jejunostomy



(B) Internal or External biliary Stent



Final Written Exams



- 1994 • Give an account on Aetiology, C/P, investigation & outline principles of ttt of Calcular obstructive Jaundice. (30 Marks)
- 1997 • Give a short account on C/P & Investigation of Choledocholithiasis, (Stone CBD) (15 marks)
- 1999 • Discuss C/P, Path. Sequelae of choledicolithiasis (stone in CBD) (10 Marks)
- 2000 • DD (In table) calcular & malignant O.J. (10 Marks) دور ثاني
- 2001 • DD between calcular & malignant O.J. (10 Marks) دور ثاني
- 2002 • Discuss Malignant O.J. (15 Marks) دور ثاني
- Discuss D.D between calcular & Malignant O.J. (12 Mark)
- 2004 • Discuss C/P & investigations of stones in CBD (20 marks) دور ثاني

Chapter [8]

The Pancreas

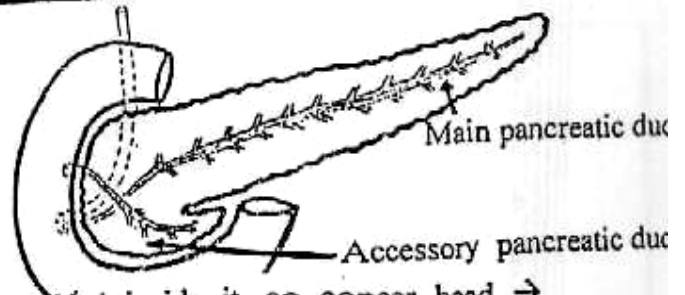
The Pancreas

Surgical Anatomy

◆ It is a **mixed** Exocrine & Endocrine gland.

Its **Embryology** : it develops from 2 buds :

- ① **Ventral** (hepatic diverticulum).
- ② **Dorsal** (duodenal diverticulum).



* Structures & Relations

① **Its head** : The CBD is partially embedded inside it, so cancer head → obstructive jaundice.

② **Its neck** : The beginning of the portal vein.

③ **Its body** : Splenic vein lie behind it and splenic artery runs on its upper border.

④ **Its tail** : Related to the hilum of the spleen, it may be injured during splenectomy.

⑤ **Pancreatic ducts** :

- a. **The main duct (of Wirsung)** begins at the tail, and ends by joining the common bile duct, at the Ampulla of Vater.
- b. **The accessory ducts (of Santorini)** may join the main duct or may open in the minor duodenal papilla which lies 2 cm cranial and slightly anterior to the major papilla.

* Arterial supply :

- ① Mainly from pancreatic branches of splenic artery.
- ② Superior and inferior pancreatico-duodenal arteries.

* **Venous drainage** : Into the corresponding veins : portal vein.

Congenital Anomalies

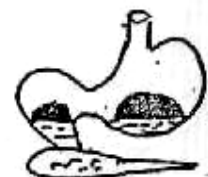[1] **Annular pancreas** :

- It is due to abnormal fusion of ventral & dorsal pancreas to form a collar of tissue surrounding the 2nd part of duodenum & may compress it.
- It presents with repeated bile stained vomiting if below the ampulla.

• **Plain X-ray** : Double-bubble sign. →

• **Treatment** :

- a. Duodeno-jejunostomy or
- b. Duodeno-duodenostomy (Adult).



[2] **Ectopic pancreas**

(Stomach, duodenum, or Meckl's diverticulum).

I Pancreatitis

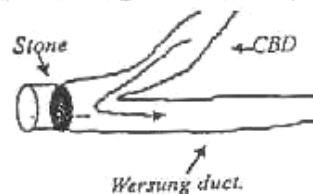
(A) Acute Pancreatitis

* Definition :

Acute inflammation of the pancreas.
Which is a serious condition that leads to death in 10% of cases.

* Aetiology : [Unkown] but the following theories are accepted:

① (50%) Bile duct stone : The stone is impacted at the Ampulla of Vater leading to obstruction of pancreatic duct leading to regurge of bile into the pancreatic duct → Activation of the Pancreatic Enzymes (Trypsinogen) → Auto-digestion of the pancreas.



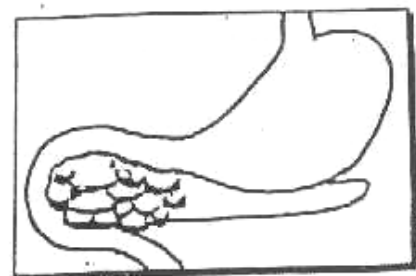
- ② (20%) Excess Alcohol intake.
- ③ (20%) Idiopathic.
- ④ (5%) Traumatic : Either Accidental Operative, ERCP ...etc
- ⑤ Rare causes : e.g. Viral Infection (Mumps) or Hypercalcaemia (Hyperparathyroidism)

* Pathology :

[A] The Pancreas :

The severity of inflammation ranges from ↗

- Mild oedema i.e. Acute Oedematous pancreatitis.
- Haemorrhage i.e. Acute Haemorrhagic Pancreatitis.
- Severe Necrosis i.e. Acute Necrotizing Pancreatitis.



[B] The peritoneal cavity : Shows the followings ↗

- Blood stained Exudate.
- Fat necrosis of greater omentum & mesentery.
Which present in form of yellowish-white areas like wax. If the inflamed pancreas liberate lipase Enzyme → splits fat into fatty acids & Glycerol. Fatty acids combine with calcium → Calcium soap.
- Protein breakdown products e.g. Vaso-active kinines will absorbed leading to widespread vasodilatation with Hypotension.

N.B: The sources of protein:

- ① Loss of Plasma proteins into the peritoneum
- ② ↑ breakdown by the action of Trypsin

*** Complications :**

[A] General Complications :

- **Hypovolaemic shock** : From loss of plasma proteins into the peritoneum & severe hypotension from circulating kinines.
- **Multi-organ failure** : Due to severe loss of blood with acute haemorrhagic pancreatitis as \Rightarrow
 - ① ARDS (Adult Respiratory Distress Sndrome).
 - ② ARF (Acute Renal Failure).
- **Paralytic Ileus + Fluid & Electrolyte Imbalance.**

[B] Local Complications :

- Pancreatic Abscess 5%. (discussed later)
- Pancreatic pseudocyst

*** Clinical Picture :**

- **Type of patient** : Male = female & 30 – 50 years.

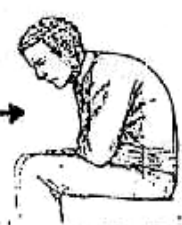▪ **Symptoms** :

- History of the cause.
- Severe upper abdominal agonising pain radiating to back.
- Vomiting & Hiccough are prominent features.

▪ **Signs** :

[A] General Examination :

- ① Hypovolaemic shock with Fever.
- ② Faint Jaundice may be seen in 10 – 20% during the 2nd day 2ry to. oedema of pancreas.
- ③ The patient's pain relieves by leaning forwards \rightarrow

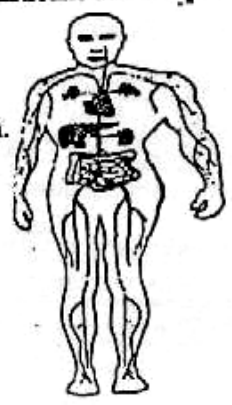


[B] Local Examination :

- ① Mild Tenderness & Rigidity at Epigastric region.
- ② Bluish Discolouration of skin in the loins [**Gray Turner's sign**] & around umbilicus [**Cullen's sign**] after 2 days due to trickling of bloody exudate in retro-peritoneal space.
- ③ **Picture of complications** as \Rightarrow
 - Abdominal distension due to paralytic ileus.
 - Palpable pulsating mass in Epigastrium due to pseudo-cyst.

*** Differential Diagnosis :**

- From the most common causes of Acute Abdomen.
- e.g. ① Acute Perforated peptic ulcer.
 ② Acute Cholecystitis.
 ③ Acute Pancreatitis.
 ④ Acute Appendicitis.



N.B : See Acute Abdomen (Chapter 15)

* Investigations :[I] Laboratory :

- ① Serum Amylase is elevated > 1000 IU/dL (Normal = 100-300 IU/dL)

N.B. : \uparrow Serum Amylase not Specific i.e. Also increased with :

- ① Perforated peptic ulcer.
- ② Acute Cholecystitis.
- ③ Myocardial Infarction.

But all these causes never exceed 500 IU/dL

- ② Serum Lipase is elevated (More specific than Amylase).

- ③ Blood electrolytes & Arterial Blood gases.

- ④ ECG & cardiac Enzymes as creatine phosphokinase (C.P.K) to exclude myocardial infarction.

[II] Radiological :

- ① Plain X-ray : Shows \curvearrowright

- Dilated short segment of small intestine that is commonly known as "Sentinel loop".
- Distended Transverse colon and collapse of the descending colon "Colon cut off sign".

- ② Abdominal Ultrasound : Shows gall stones & Enlarged Pancreas.

- ③ CT scan : The most accurate.

[III] Instrumental :

Abdominal paracentesis to reveal Pancreatic ascites.

* Treatment : [Mainly Conservative]

(A) Conservative ttt : Simply Remembered as the "R" Regimen

- ① Relief of pain by Pethidine.
- ② Replacement of fluid & electrolytes loss.
- ③ Rest of pancreas & bowel by No oral intake + Ryle's Tube.
- ④ Respiratory support by Oxygen mask & Mechanical ventilator.
- ⑤ Resistance of Infection by A.B.
- ⑥ Reassessment after improvement by ERCP to remove any stone

(B) Surgical ttt :

Especially with doubtful diagnosis of causes of acute abdomen.

- Through Exploration, Peritoneal lavage, Removal of necrotic tissues & Finally closure over a drain.

or • Drainage of pancreatic Abscess or pseudocyst.

* Prognosis :

Acute Pancreatitis **10%** Mortality Rate But if Necrotizing **50%** Mortality Rate.

(B) Chronic Pancreatitis

* Aetiology :

- Chronic Alcoholism
- Less commonly stone CBD, Trauma ... etc.

* Pathology :

- Pancreatic Duct : Shows multiple strictures with consequent proximal dilatation.
- Pancreatic Acini : Shows slowly progressive destruction with increasing fibrosis and later calcification with loss of it's Endocrinal and Exocrinal function.

* Clinical Picture :

- Pain : Epigastric, Continous or interrupted & radiating to back.
- Malabsorption with steatorrhea & Loss of weight.
- 30% with Diabetes Mellitus.

* Investigations :

[A] Laboratory :

- ① Serum amylase may be elevated.
- ② Stool analysis shows steatorrhea i.e. measure faecal fat excretion. (Normally = 5g/d)
- ③ Glucose Tolerance Test.

[B] Radiological :

- ① Plain x-ray shows Pancreatic calcifications.
- ② Abdominal U/S & CT scan : The most accurate.
- ③ ERCP shows multiple strictures of pancreatic duct with proximal dilatation

* Treatment :

[A] Conservative ttt :

- Control of pain by Analgesics.
- Correction of malabsorption by pancreatic enzyme tablet's With meals.
- Control of D.M. by Insulin.

[B] Surgical ttt : [If persist uncontrolled pain]

- Resection of part of pancreas i.e. Distal Pancreatectomy.
- Drainage of dilated obstructed pancreatic duct.
e.g Pancreatico- jejunostomy

II

Pancreatic Cyst

[I] True Cyst (20%) :

- Either: [A] Acinar : e.g. Retention cyst, Congenital cyst & Cystadenoma.
[B] Inter-acinar e.g. Dermoid cyst & Hydatid cyst.
- Treated by distal Pancreatectomy.


The Pancreas

III) Pseudo-cyst (80%) :

* Definition :

This is a collection of pancreatic secretions & inflammatory exudate within a lining of inflammatory tissue not epithelium So it is called "pseudo" cyst in lesser sac

N.B. : The commonest Site is Behind & above the stomach.



* Aetiology : As a result from Acute pancreatitis after 2-3 weeks

* Complications : Rupture, Hge, Abscess but Never malignancy.

* Clinical Picture :

Cystic Epigastric swelling above umbilicus and shows Transmitted pulsation from the aorta Which disappears in knee- Elbow position

* Investigations :

- [A] Barium Meal shows displacement & compression on stomach
- [B] CT scan & U/S at upper abdomen (The Best)



* Treatment :

- IF Small : Usually disappear spontaneously (20-40 %)
- IF Large : Drains through the posterior wall of stomach i.e. Cysto-gastrostomy

III) Pancreatic Neoplasms

Endocrinal

- ① Alpha cells → Glucagonoma.
 - * ② Beta cells → Insulinoma.
 - ③ Gamma cells → Somatostatinoma
 - * ④ Non-beta cells → Gastrinoma
- [Z/E syndromes]

Exocrinal

- A) Benign : Adenoma
- B) Malignant :
 - ① Adenocarcinoma.
 - ② Cysta-adenocarcinoma

① Insulinoma [Beta cells]

* Definition :

Endocrinal Pancreatic tumor secreting insulin.

* Clinical picture : [Whipple Triad]

- ① An attack of hypoglycaemia occurs on fasting.
- ② Sweating, Dizziness, blurring of vision & hunger sensation.
- ③ The symptoms are relieved by Glucose.

* Investigation : Blood sugar during the Attack < 50 mg%

* Treatment : Distal Pancreatotomy.

② Gastrinoma [Non Beta cells]

Zollinger Ellison Syndrome

*** Definition :**

Endocrinal Pancreatic Tumor secreting gastrin

*** Clinical Picture :**

Hypergastrinaemia → ↑ HCL → Intractable peptic ulcer which is
Characterized by ↗

- ① Multiple, Recurrent & at Ectopic area as jejunum.
- ② Diarrhoe in 30% because gastrin increase intestinal motility.
- ③ Resistant for tt with H₂ receptor blocker.

*** Investigations :**

- [A] G.F.T. (Gastric Function Test) : to estimate ↑ Acid secretions.
- [B] Radio-Immune assay to estimate serum gastrin.
- [C] CT scan (Abdomen) to localize the tumor.

*** Treatment :**

Total Gastrectomy (to abolish acid secretions) + Resection of pancreatic
 Tumor + Trials by Omeprazole "Less effective"

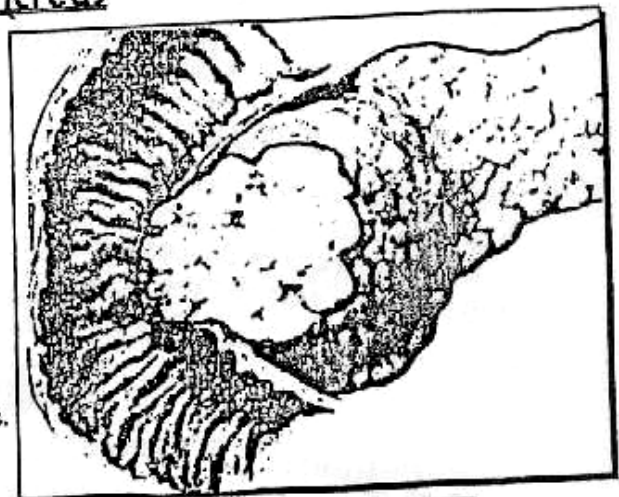
③ Carcinoma of Pancreas

*** Incidence :**

- It represents **3%** of all malignancies of the body & it consider one of causes of death over the world.
- Age : 55 – 70 years.
- Sex : Male : Female = **2 : 1**


*** Predisposing factors :**

- Smoking & High (protein and fat) in diet.
- Pancreatic calcinosis from chronic pancreatitis.



*** Pathology :**

- Site : ① Head 60%
- ② Body & Tail 40%



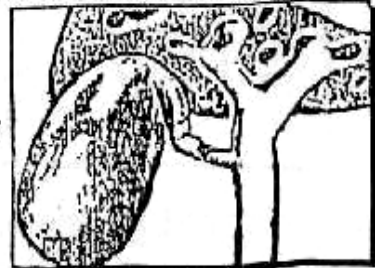
- N/E : Hard mass with central degeneration & Necrosis.
- M/E : • Adenocarcinoma (common) with variable degree of differentiation
- Cysta-adenocarcinoma (less common)

*** Spread :**

- **Direct** : T o CBD, Duodenum, Pyloric antrum, Transverse mesocolonetc.
- **Lymphatic** : To regional L.Ns then to porta -hepatis then coeliac L.Ns then para-aortic L.Ns then thoracic duct then Lt. Supra-clavicular L.Ns (**Virchow's gland**).
- **Blood** : T o the liver mainly.
- **Transperitoneal** : Malignant ascites (10%)

*** Clinical Picture :**

- **Type of patient** : Male > female & (> 50 years).
- **Symptoms** :
 - ① Progressive **Obstructive Jaundice** i.e. (cancer head pancreas) (Discuss)
 - ② **Dull (continous) pain** at Epigastric region or referred to the back, because of infiltration of coeliac plexus.
 - ③ **Pancreatic Athenia** (Anorexia, weight loss, steatorrhea and Anaemia) and metastatic symptoms.



▪ **Signs** :

- ① The patient is **Jaundiced** and the **gall bladder** is **distended** according to **Courvoisier law**.
- ② **Enlarged Firm Liver** & rare Epigastric mass.
- ③ **Migrating thrombophlebitis (Trousseau's sign)**
Try to increasing the coaguability factors → venous thrombosis.

*** Differential Diagnosis :**

- **Other causes** of jaundice.
- **Calcular** obstructive Jaundice (Discuss the table)
- **Chronic pancreatitis**.

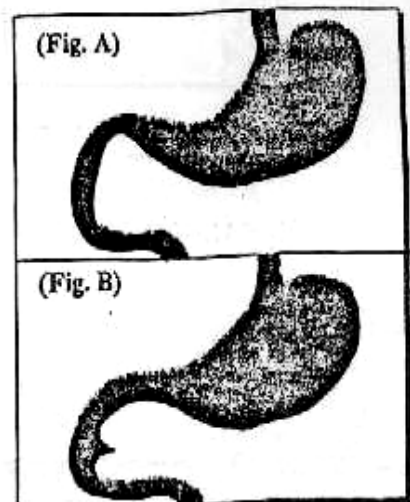
*** Investigations :**

[A] Laboratory Investigations :

Same as obstructive Jaundice (Discuss)

[B] Radiological Investigations :

- ① **Barium meal** : Shows ↗
Widening of duodenal curve i.e.(Cancer head) see (Fig. A) or Inverted 3 shaped i.e.(Peri-ampullary carcinoma) see (Fig. B)
- ② **U/S & CT scan** : The Most "Diagnostic"
- ③ **ERCP** : The best Diagnostic & Therapeutic.
 - **Diagnostic** : Shows dilated duct with localized narrowing.
 - **Therapeutic** : Through putting a **stent**.



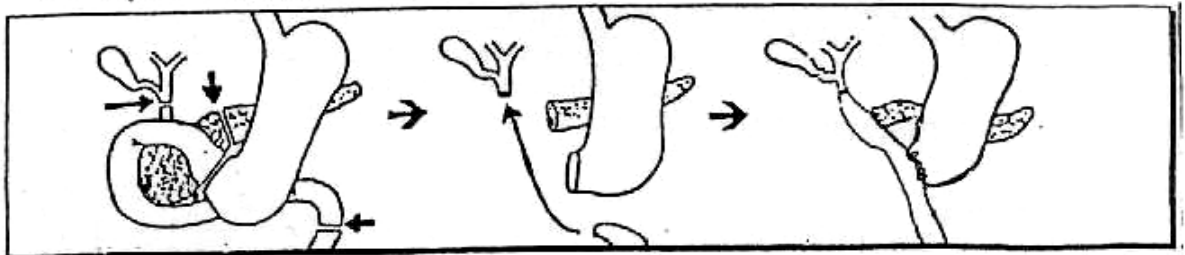
* **Treatment** : Pre-operative preparation "see Jaundice" (Discuss)

Then According to site of Tumor & operability

◆ **Operable**

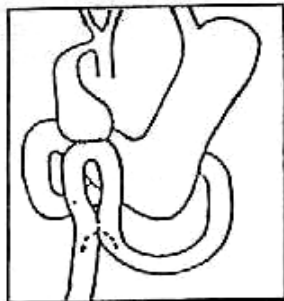
[I] **Tumor of the body & Tail** : Total Pancreatico- duodenectomy or Subtotal pancreatectomy leaving head only.

[II] **Tumor of the head** :
[Pancreatico-duodenectomy] (Whipple's operation) i.e. Removal of duodenum, lower part of CBD & head of pancreas. Then restore the continuity by the following anastomoses : the bile duct to jejunum , the pancreatic duct to the jejunum & finally the stomach to the jejunum .

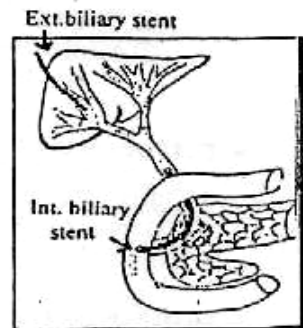


◆ **Inoperable** Either (A) or (B)

(A) Cholecysto jejunostomy with Jejunostomy

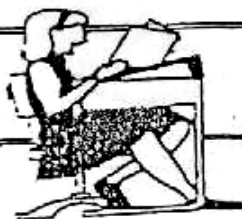

(B) Internal or External biliary Stent

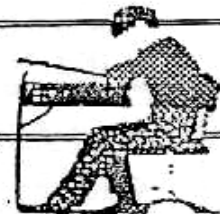


* **Prognosis** : 5 year survival rate.

- Operable cases represent 10-15% of cases.
- Operative mortality 20%



**Final
Written Exams**



1995 • Discuss C/P of Acute Pancreatitis.

(10 Marks) نور ثانی

2003 • Discuss Pancreatic pseudocyst.

(9 Mark)

• Discuss symptoms, signs & complications of acute pancreatitis (12 Mark)

Chapter [9]

**The Peritoneum &
The Mesentery**

The Peritoneum & The Mesentery

I The Peritoneum

(A) Acute Septic Peritonitis

* Definition :

Acute Inflammation of peritoneal cavity by pyogenic organisms.

* Aetiology :

[A] The Organism : Pyogenic organisms such as \Rightarrow
E. coli, Aerobic & Anaerobic streptococci, Bacteroid, Pneumococci.

[B] Rout of Entry :

① Local Spread :

- Infected organs e.g. Appendicitis or Cholecystitis.
- Leaking organs e.g. Perforated peptic ulcer or Rupture gut.

② Direct Entry : as operative or traumatic wounds.

③ Blood Spread (Rare) e.g. Septicaemia or pyaemia.

④ Primary Peritonitis :

- Definition : Peritonitis with no apparent intra-peritoneal pathology.
- Incidence : Usually affects Female children.
- Organisms : Streptococci & pneumococci.
- Pathogenesis : The infection reach the peritoneal cavity through the Fallopian tubes.

* Fate :

The Fate depend on the virulence of organism on one side & the efficiency of ttt and the body resistance on other side.

SO The End result may be \Rightarrow

[A] Resolution : If good resistance & proper ttt.

[B] Localization : [Abscess Formation]

- Around 1ry focus e.g. Appendicular Abscess.
- Away in one of the Anatomical peritoneal compartments.
e.g. ① Iliac Abscess at Rt. or Lt. Iliac fossa.
② Pelvic Abscess at Recto-vesical or Douglas pouch.
③ Sub-phrenic Abscess under the diaphragm.

[C] Flaring up : i.e Becomes Generalized.

- IF
- ① High virulence with low body resistance.
 - ② Sudden perforation of hollow viscus (No time for localization)
 - ③ Spread of infection through stimulation of peristalsis e.g. Eating.
 - ④ Immunosuppression as D.M.
 - ⑤ Children due to small greater omentum which not help in localization of infection.

*** Clinical Picture :**

▪ **Symptoms :**

[A] Picture of the cause e.g. Acute Appendicitis.
But in late cases it may be difficult to tell the original cause.

[B] Picture of peritonitis :

- **Pain** : which is (a) Persistent dull aching in character.
(b) Increased with Movement or coughing.
(c) The site of maximum pain at original lesion.
- **Vomiting** : May be (a) 1st gastric content [*whitish mucoid*]
(b) Then biliary content [*Greenish bile stained*]
(c) Later on Faeculent [*Brownish faecal*]
- **Abdominal Distention** then **Absolute constipation** i.e Paralytic ileus.

▪ **Signs :**

[A] General Signs :

- Vital signs show : (HR) Tachycardia, (Temp.) Fever, (ABP) Hypotension & (RR) ↑ respiratory rate.
- Facies Hippocratica i.e Anxious look.
- Sunken eyes , Dry lip & cold clammy skin

[B] Local Signs :

- **Inspection** : Loss of Abdominal movement with respiration.
- **Palpation** : Tenderness & rigidity, at 1st localized then generalized.
- **Percussion** : Shifting dullness if pus present.
- **Auscultation** : Dead silent Abdomen.

*** Investigations :**

[A] Laboratory Investigation :

Blood picture shows leucocytosis .

[B] Radiological Investigations :

① **X-ray Abdomen** : Demonstrates Paralytic Ileus & may determine the 1^{ry} lesion e.g. Air underdiaphragm i.e. perforated duodenal ulcer.

② **Abdominal Ultrasound** : Shows free fluid in the peritoneal cavity.

[C] Peritoneal Diagnostic Aspiration :

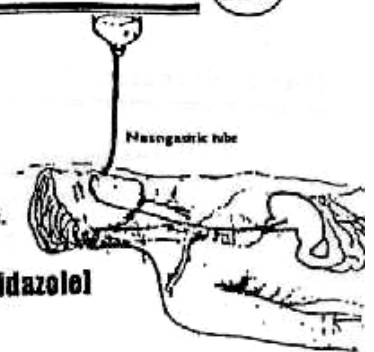
Which detect the nature of peritoneal fluid.

* **Treatment** : [Surgical Emergency]

[A] **Pre-operative preparation** :

- ① **Ryle's Tube** suction to deflate the stomach.
- ② **I.V fluid** to correct the Hypovolaemia & Electrolyte imbalance.
- ③ **I.V Antibiotics** Combination of

[Ampicilline + Aminoglycosides + Metronidazole]



[B] **Exploratory Laparotomy:**

- ① The pus is **aspirated** & the lry lesion is **delt**.
- ② **Peritoneal Toilet** (lavage) with large amounts of sterile saline.
- ③ Closure over peritoneal drains.

[C] **Drainage of pelvic or subphrenic Abscess** if **localized**.

(B) Tuberculous Peritonitis

* **Aetiology** :

The disease is always 2ry to a **T.B focus** elsewhere that reaches the peritoneum **through**

- ① **Direct spread** : e.g. T.B. lymphadenitis & T.B Salpingitis.
- ② **Blood spread** : e.g. Pulmonary T.B.
- ③ **Lymphatic spread** : e.g. from bowel or pleura.

* **Pathology** : (5 types)

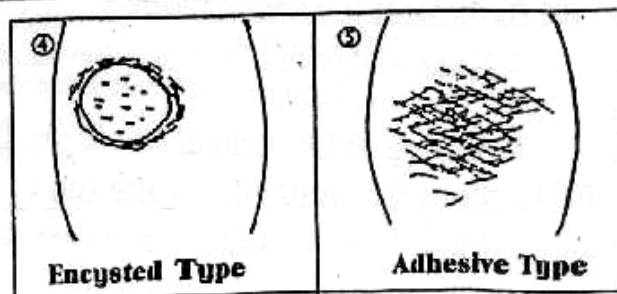
<p>①</p> <p>Acute Miliary Type</p>	<p>②</p> <p>Caseous Type</p>	<p>③</p> <p>Ascitic Type</p>
<ul style="list-style-type: none"> • The peritoneum is studd with T.B. • Exudate is straw in colour 	<ul style="list-style-type: none"> • The peritoneum is studd with T.B. • Multiple collection of caseous T.B. • Cold Abscess : if pointed → T.B sinus or fistulae. • Mainly due to T.B Salpingitis. 	<ul style="list-style-type: none"> • The peritoneum is studd with T.B. • Ascitis fluid in a large amount. • The greater omentum is rolled up → (Sausage shape mass) above the umbilicus.

④ **Encysted Type** :

It is a **localized** form of an Ascitic Type

⑤ **Adhesive Type** : [Fibrous Type]

It is Extensive Adhesions with Intestinal obstruction.



* Clinical Picture :

- Type of patient :
 - Age : Children & Young adults
 - Sex : Both sexes.
- Symptoms :
 - T.B Toxaemia [Night sweat, Night fever, Loss of weight & Loss of appetit].
 - Recurrent attacks of abdominal pain, distention & vomiting.
- Signs :
 - Abdomen is felt doughy with multiple palpable swelling which may be L.Ns, Ascites are common findings.
 - P/V : may reveal a Tubo-ovarian mass.
 - A sausage shape mass above the umbilicus may be felt.

* Investigations :[A] Laboratory Investigations :

- Blood picture : ↑ ESR & Lymphocytosis.
- Tuberculin Test : Highly +ve Test.

[B] Abdominal Tapping : IF Ascitic type

Shows straw coloured fluid rich in lymphocytes.

[C] Laparoscopy : The Choice.* Treatment :

[A] General ttt : Anti-tuberculous drugs at least 1 year.

[B] Local ttt : (Surgical) If complicated with ↗
T.B Fistula i.e (Caseous type) or Intestinal obstruction (i.e Adhesive type)

C

Peritoneal Abscess

* Intra-peritoneal abscess :

May occur as

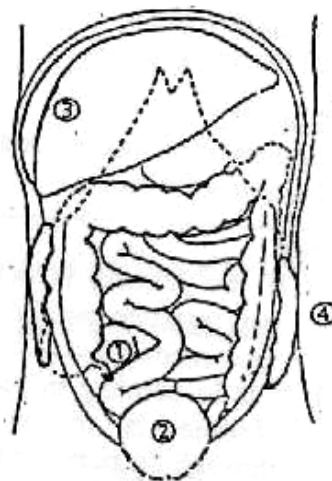
- ① Iliac Abscess.
- ② Pelvic Abscess.
- ③ Subphrenic Abscess.
- ④ Paracolic Abscess.

[1] Iliac Abscess

★ Definition : Collection of pus in Iliac fossa.

★ Aetiology :

- On the Rt. side :
 - due to ① Acute Appendicitis.
 - ② Perforated D.U.
- On the Lt. side :
 - due to perforated diverticulitis.
- On the Both sides :
 - due to ① Tubo-ovarian abscess.
 - ② Osteomyelitis of Iliac bone.



★ **Clinical Picture** : C/P of cause +

- **Symptoms** : ♦ *General* : Toxaemia (Fever, Headache, Malaise & Anorexia)
 ♦ *Local* : Pain at Iliac fossa.
- **Signs** : ① Swelling in Iliac fossa.
 ② Tenderness at Iliac fossa.

★ **Investigations** :

Total leucocytic count + U/S.

★ **Treatment** :

Treatment of the cause + Antibiotics + Drainage of Abscess.

Drainage :

- ① **Percutaneous** : (Nowadays) it is possible to do percutaneous drainage of the abscess guided by ultra-sound or CT scan.
- ② **Open surgery drainage** : The abscess should be drained through an extraperitoneal muscle cutting incision.

[2] **Pelvic Abscess**

★ **Definition** : Collection of pus in Recto-vesical pouch or Douglas pouch.

★ **Aetiology** :

- ① Acute appendicitis.
- ② Localization of resolving diffuse peritonitis.
- ③ Pelvic inflammatory disease in females.

★ **Clinical Picture** : C/P of cause +

- **Symptoms** : ♦ *General* : Toxaemia (Fever, Headache, Malaise & Anorexia)
 ♦ *Local* : - Deep pain in pelvis, perineum or supra-pubic.
 - Diarrhaea and passage of mucous in stools (The most characteristic) due to rectal irritation.
- **Signs** : ① Tense, cystic mass by P/R or P/V.
 ② Tenderness by P/R or P/V

★ **Investigations** : Similar to Iliac Abscess

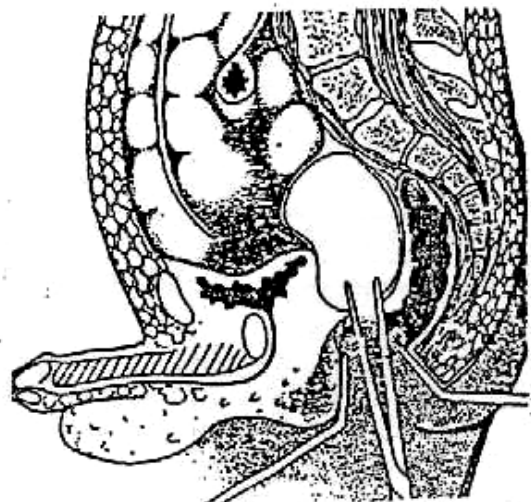
Total leucocytic count + U/S.

★ **Treatment** :

Treatment of the cause + Antibiotics + Drainage of Abscess.

Drainage :

- ① If the abscess is pointing in rectum, transrectal drainage is recommended →
- ② If it is pointing in vagina the abscess is to be drained through the posterior fornix.
- ③ If it is pointing supra-pubically, suprapubic extraperitoneal drainage is done.



Draining a pelvic abscess through the rectum

131 Subphrenic Abscess:

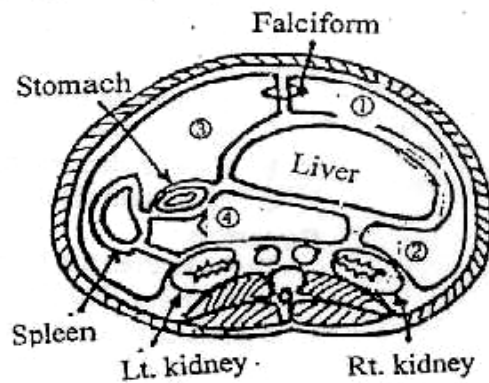
★ Definition :

Collection of pus under the diaphragm.

★ Anatomy : (Subphrenic spaces)

The supracolic compartment is subdivided by liver, stomach, spleen and their peritoneal attachments into :

- ① Rt. anterior intra peritoneal.
- ② Rt. posterior intra peritoneal.
- ③ Lt. anterior intra peritoneal
- ④ Lt. posterior intra peritoneal
- ⑤ Rt. Extra-peritoneal space (Bare area)
- ⑥ Rt. perinephric space.
- ⑦ Lt. perinephric space.



Subphrenic spaces

★ Aetiology :

(I) Four intraperitoneal spaces

① Rt. Anterior intra-peritoneal :

- Between the Rt. lobe of the liver & diaphragm.
- **Causes :** Perforated peptic ulcer, cholecystitis & liver abscess.

② Rt. posterior intra-peritoneal = Morison or hepatorenal pouch (The commonest)

- It lies between the Rt. lobe and the Rt. kidney.
- **Causes :** Perforated peptic ulcer, cholecystitis & acute appendicitis.

③ Lt. Anterior intra-peritoneal :

- It lies between the Lt. lobe of the liver, diaphragm & anterior abdominal wall.
- **Causes :** Post-splenectomy or gastrectomy operations.

④ Lt. posterior intra-peritoneal : (The lesser sac) :

- It lies between the caudate lobe of liver, stomach and pancreas, Lt. kidney.
- **Causes :** acute pancreatitis, and perforated posterior gastric ulcer.

N.B. : Localization of generalized peritonitis is a common cause in all spaces.

(II) Three Extraperitoneal spaces

① Rt. Extra-peritoneal space :

- It lies behind the bare area of the liver.
- **Causes :** Acute retrocaecal appendicitis, liver abscess, and pyelonephritis.

②, ③ The two perinephric spaces are considered subphrenic spaces.

- **Causes :** Renal infection.

★ Clinical Picture :

Subphrenic Abscess should be suspected if there is evidence of Toxaemia with no apparent, cause after upper abdominal operations or pathology

"Pus somewhere, pus no where, pus under the diaphragm"

- **Symptoms** : ♦ **General** : Marked Toxaemia (Fever, Headache, Malaise & Anorexia)
 - ♦ **Local** : - Pain (slight or absent) but if felt at epigastrium or referred to tip of shoulder.
 - Persistent hiccough.
- **Signs** : ♦ **General** : Hectic fever, tachycardia & severe toxemia.
 - ♦ **Local** :
 1. **Inspection** :
 - a. Impaired movements of the chest on the affected side.
 - b. Rarely bulging of the lower ribs or upper abdomen.
 2. **Palpation** :
 - a. Tenderness over the lower ribs or just below the costal margin.
 - b. Upper abdominal rigidity or swelling.
 - c. Downward displacement of the liver.
 3. **Percussion** :

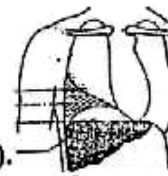
Dullness over the base of the lung due to pleural effusion is often present, but if the abscess contains gas, 4 percussion zones may be elicited :

 - a. Normal lung resonance.
 - b. Dullness of pleural effusion or lung collapse.
 - c. Resonance of gas in the abscess.
 - d. Liver dullness.
 4. **Auscultation** :

Diminished air entry with basal crepitations on the affected side.

★ **Investigations:**

- 1] **White blood cell count** shows leucocytosis.
- 2] **Plain chest x-ray and screen** :
 - ① Thickened, elevated and fixed diaphragm (tented diaphragm).
 - ② Obliteration of costophrenic space by a minimal pleural effusion may be seen.
 - ③ Gas under the diaphragm is sometimes seen when the cause is a perforated viscus, or when there is infection with gas forming organisms.
- 3] **Ultrasound and CT scanning** have proved very useful.



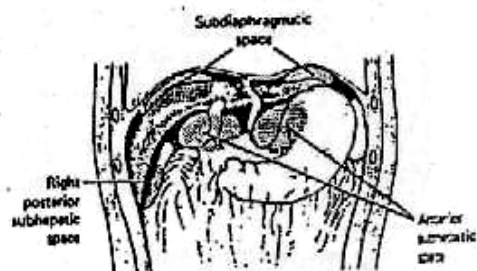★ **Treatment** : A] **Conservative** : Rest, antibiotics & observations.

B] **Drainage** : If failure of conservative treatment, or evidence of suppuration.

Route of Drainage :

- If a swelling can be detected : incision over the site of maximum tenderness.
- If no swelling is apparent, either :
 - Anterior subcostal approach
 - or ○ Posterior approach with resection of the anterior part of the last rib.

Aspiration guided by U/S may be done.



II The Mesentery

A Mesenteric Cysts

★ **Definition:**
It is fluid collection between the layers of the mesentery.

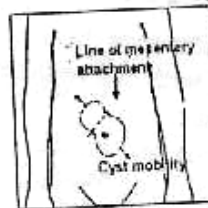
★ **Classification:**

[I] **True:**

1. Chylolymphatic: (The commonest variety), it is a retention cyst (obstructed lymphatic drainage). Distension of sequestered mesenteric lymphatics with afferent but no efferent. It contains lymph.
2. Enterogenous: Due to distension of sequestered part of the small intestine between the two layers of the intestinal mesentery. It contains mucous fluid.
3. Urogenital remanent.
4. Teratomatous dermoid cyst.

[II] **False:**

1. Blood cyst (Haematoma).
2. Breaking down: tuberculosis or tumour.



★ **Clinical Picture:**

Mesenteric cyst is characterized clinically by a triad of signs (Tillaux' triad):

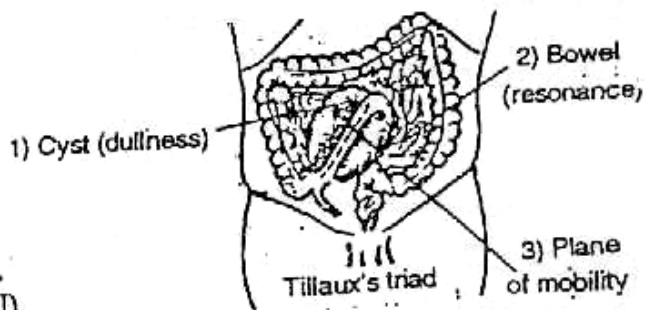
- ① A central abdominal Swelling (near the umbilicus).
- ② Moves across but not along the root of mesentery (the root of mesentery extends from the left hypochondrium to the right iliac fossa).
- ③ The mass is dull on percussion with an overlying band of resonance (corresponding to the related loop of intestine).

★ **D.D.:**

- ① Distended urinary bladder.
- ② Gravid uterus.
- ③ Ovarian cyst.
- ④ Aortic aneurysm.
- ⑤ Pancreatic cyst.

★ **Investigations:**

- ① Abdominal U/S.
- ② Plain X-ray for calcification.
- ③ Intravenous Urography (IVU).
- ④ Barium meal
- ⑤ Computed tomography (CT) scan.



★ **Treatment:**

- ① Chylolymphatic cyst: Excision of the cyst, where it has a separate blood supply (not related to the loop of intestine).
- ② Enterogenous cyst: Excision with related intestine (resection and anastomosis) where its blood supply from the same blood supply of related loop.

B Mesenteric Lymphadenitis

It is a acute lymphadenitis, it may be non-specific or specific (Tabes Mesenterica)

Tuberculous Mesenteric Lymphadenitis
(Tabes Mesenterica)

★ Aetiology:
It is a primary tuberculosis of mesenteric lymph nodes usually affecting children after ingestion of tuberculosis bacilli (bovine type).

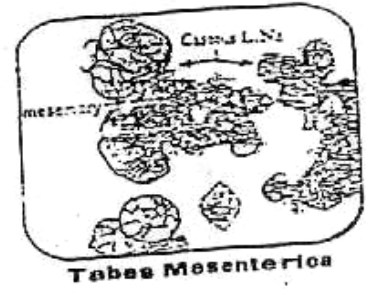
N.B.: Primary sites of tuberculosis are :
1. Lung (Ghon's focus). 2. Cervical lymph nodes. 3. Mesenteric lymph nodes. 4. Skin.

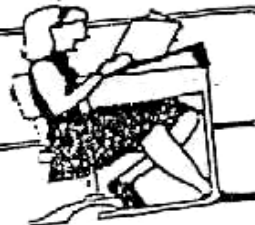
★ Fate and Complications:
- Usually spontaneous healing occurs ± calcification of lymph nodes, some cases persist with active tabes mesenterica, which are liable for the following complications :
① Tuberculosis peritonitis.
② Intestinal obstruction (adhesive obstruction). Mesenteric cyst (false type).

★ Diagnosis:
▪ **History :** - Usually, child with tuberculosis toxemia + recurrent attacks of abdominal pain with vomiting and diarrhoea.
- It may be presented with one of the previous complications.
▪ **On Examination :** Tenderness in the right iliac fossa ± palpable of irregular, firm lymph nodes.


★ Investigations:
Pain X-ray : may show calcified lymph nodes.

★ Treatment:
(I) Medical : Anti tuberculosis drugs.
(II) Surgical : For complicated cases as intestinal obstruction or peritonitis, e.g., adhesive obstruction : dissection and division of adhesion.






Final Written Exams



2003

- **Discuss** C/P & investigations of acute peritonitis.
- **Discuss** Tabes Mesenterica.
- **Discuss** Aetiology, C/P & management of acute septic peritonitis

دور نالی (9 Mark)
دور نالی (9 Mark)
(20 marks)



Chapter [10]

The Appendix

The Appendix

Surgical Anatomy

*** Site :**

Rt. Iliac fossa

*** Shape :**

Narrow Worm like Tube

*** Length :**

Variable from 2-5 inches (Average 10 cm).

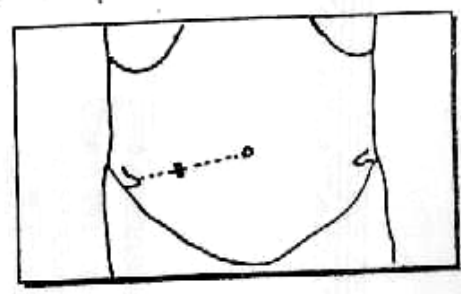
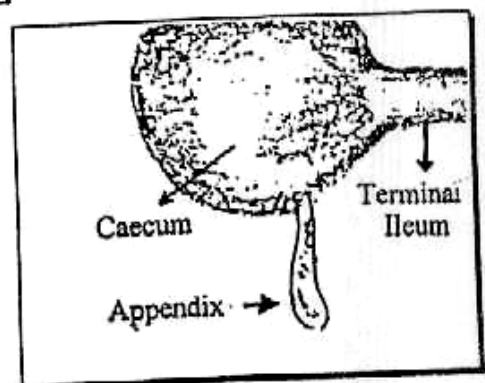
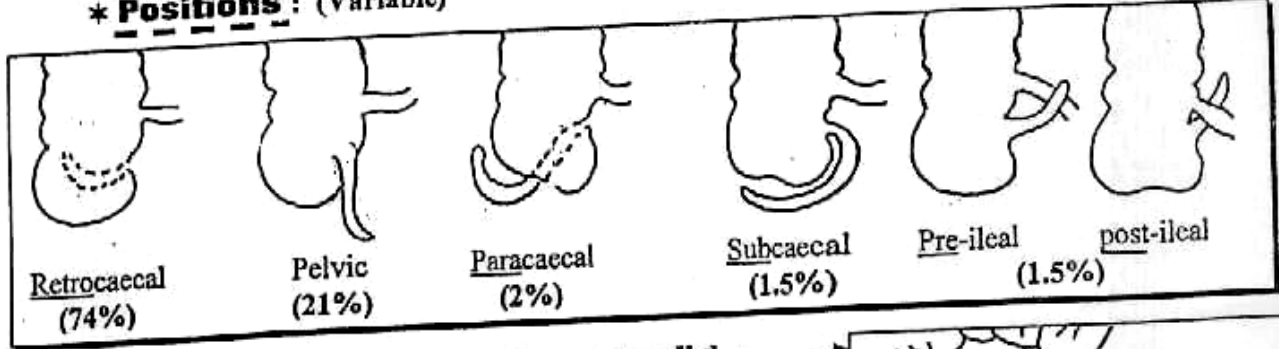
*** Origin : (Base)**

It arises from the postero-medial aspect of the caecum. 1 inch below the Ileo-cecal junction.

*** Surface anatomy :**

It is represented by a point [Mc Burney's point] At the junction of medial 2/3 with lateral 1/3 of a line drawn from umbilicus & Rt. Anterior Superior Iliac Spine (A.S.I.S.)

*** Positions : (Variable)**

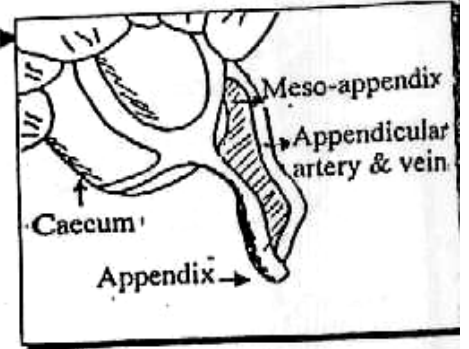


*** Peritoneal Covering : [Meso-appendix]**

It is completely covered by the peritoneum. It lies in the free border of a Triangular fold.

*** Blood supply :**

- (A) **Arterial :** Appendicular artery from Ileo-colic artery which is a branch of superior mesenteric artery.
- (V) **Venous :** Appendicular vein to Ileo-colic vein to superior mesenteric vein to portal vein.



Acute Appendicitis

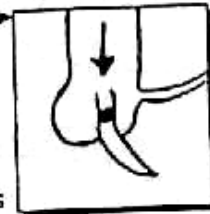
*** Incidence :**

The Commonest cause of acute Abdomen with serious complications.

*** Aetiology :**

▪ Predisposing Factors :

- Age : Rare in infants because of short appendix & wide base.
Common in children up to (20-30) years because of narrow base.
Rare again in Elderly because of senile appendicular atrophy.
- Obstructed Appendix : May occur with fecolith, stricture, kinking, Ascaris, fruit seeds or any foreign bodies.



*** Pathology :**

- Organism : E. coli & streptococcal faecalis.
- Route of spread : Direct from lumen & rarely blood.
- Pathological stages :
 Acute catarrhal → Acute suppurative → Acute gangrenous

*** Types of Acute Appendicitis :**

<u>Non Obstructive Acute Appendicitis</u>	<u>Obstructive Acute Appendicitis</u>
<ul style="list-style-type: none"> • <u>Slowly</u> developing inflammation. • <u>Less</u> common (1/3 cases). • <u>Less</u> serious because of free drainage. • <u>Pathogenesis & Fate</u> : Infection <u>starts</u> in the mucosa (catarrhal). Then either Spontaneous resolution with residual fibrosis or <u>slow</u> spread of infection with <u>little</u> incidence of supuration and perforation. <p>N.B. : <u>Resulting peritonitis is localized</u> as perforation occurs very <u>slowly</u> <u>So</u> giving chance for localization</p>	<ul style="list-style-type: none"> • <u>Rapidly</u> developing inflammation. • <u>More</u> common (2/3 cases). • <u>More</u> serious as pus collects under tension i.e. Empyema. • <u>Pathogenesis & Fate</u> : Infection <u>starts</u> in the mucosa (catarrhal). Then no resolution but <u>rapid</u> spread of infection to all coats with <u>High</u> incidence of supuration and perforation. <p>N.B. : <u>Resulting peritonitis is Generalized</u> as perforation occurs very <u>rapidly</u> <u>So no</u> chance for localization.</p>

N.B. : When the inflammatory process is very slow. The body defense has time to wall the inflamed appendix by Adhesions with intestine & omentum forming Appendicular mass within 3-5 days.
 Then any perforation form Appendicular Abscess

* Clinical Picture :

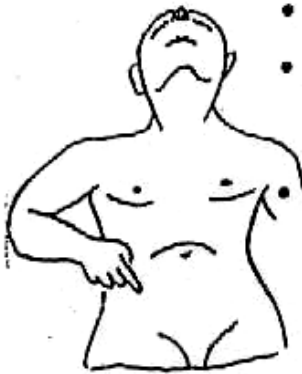▪ Types of patient: Usually 20-30 years.

▪ symptoms:

① Pain :

• Onset : Acute.

• Site : Start at para-umbilical region because both Umbilicus & Appendix are supplied by T₁₀ segment. Later on it will be localized in the Rt. iliac fossa.



• Characters :

- At the onset, it is colicky if obstructive type or dull aching if non-obstructive type *i.e. visceral pain*.
- Later on, it becomes stabbing or stitching due to spread of inflammation to peritoneal coverings *i.e. somatic pain*.
- This pain is aggravated by movement & cough.

② Anorexia & Nausea in non-obstructive type & Vomiting in obstructive type. All are due to reflex pylorospasm.

③ Constipation may present it may be the cause of obstruction.

▪ Signs:

[A] General Signs :

Fever (37.2 – 37.8) but if high fever it means Complications

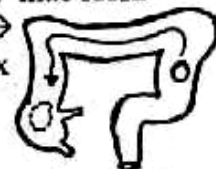N.B. Tachycardia corresponding to fever.

[B] Local signs :

- ① If the patient is asked to cough, the pain becomes sharp and well localized to site of appendix (Cough Tenderness).
- ② Localized Tenderness and Rebound Tenderness over the Rt. iliac fossa. usually but not always, over McBurney's point.

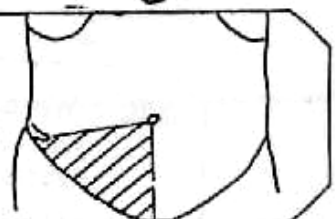
N.B. : P/R and P/V is essential to be done to differentiate Gynecological problems from pelvic appendicitis.

- ③ Rovsing's sign (Crossed Tenderness) pressure on Lt. iliac fossa causes pain in Rt. iliac fossa due to displacement of → gas inside the colon to the caecum & inflamed appendix distending them.



N.B. : Sherrin's Triangle of Hyperaesthesia :

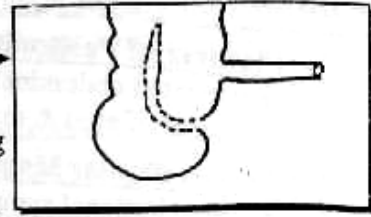
It is a Δ bounded by symphysis pubis, umbilicus & ASIS. Due to reflex irritation of spinal segment supplying this area.



* A Typical clinical Features :

[1] Long Retro-coecal Appendix :

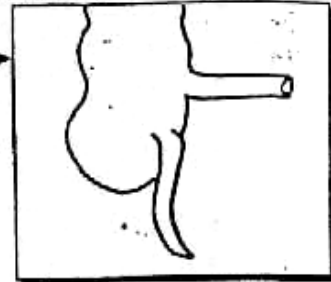
- Tenderness is felt in the Rt. loin.
- IF the appendix touch the ureter → pain simulating the ureteric colic which will be misleading.
- IF the appendix in contact with Psoas muscle. will lead to Psoas spasm, which leads to flexion of hip joint.



SO Hyperextension of the hip leads to abdominal pain which is called Psoas sign.

[2] Pelvic Appendix :

- Tenderness is felt only by P/V or P/R.
- IF the appendix touch the rectum → Irritation which leads to tenismus & diarrhea or touch the bladder → Irritation which leads to dysuria both will be misleading.
- IF the appendix in contact with the Obturator Internus muscle, will lead to obturator Internus spasm, which leads to flexion & External rotation of the Rt. hip joint.



SO Flexion & Internal rotation of Rt. hip leads to abdominal pain which is called Obturator Internus sign (Zachary cope sign)

[3] Sub-hepatic Appendix :

The Tenderness at higher level than Mc Burney's point. So it is misdiagnosed with Acute Cholecystitis.

[4] Appendicitis with Infants & Young children :

usually perforates due to ↗

- (a) Difficult to be examined.
- (b) Greater omentum is small SO localization is very difficult.
- (c) There is prominent Vomiting so wrongly diagnosed as Gastro-enteritis.

[5] Appendicitis with Elderly :

usually perforates due to ↗

- (a) Difficult to be examined because of little tenderness & rigidity.
- (b) Atherosclerosis which leads to early thrombosis & gangrene.
- (c) Natural weakness of Immune system with age.

[6] Appendicitis with Pregnancy :

usually serious due to ↗

- (a) The site of pain is displaced upwards as pregnancy progress.
- (b) The localization by omentum is less efficient.
- (c) The condition is often misdiagnosed as pyelitis.

N.B. : If the perforation occur with pregnancy
There is a higher incidence for Abortion & Pre-mature in 50%

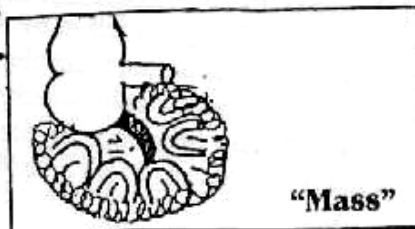
* Clinical Picture of Complications :

[1] Picture of Peritonitis :

Restricted abdominal movement with respiration, Generalized rigidity Shifting dullness (if pus) & may be dead silent abdomen.

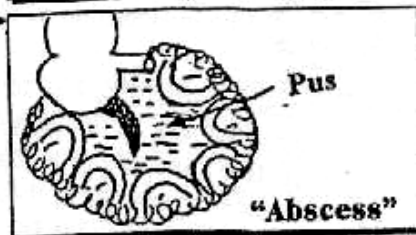
[2] Appendicular Mass :

- Constitutional symptoms with fever $> 38^{\circ}\text{C}$.
- Firm tender mass with ill defined edge and present at Rt. iliac fossa.
- Overlying muscle rigidity.
- Resolute by A.B or form Abscess.



[3] Appendicular Abscess :

- Constitutional symptoms with Hectic fever & Throbbing pain.
- Cystic tender mass with ill defined edge and present at Rt. iliac fossa.
- Overlying muscle rigidity.
- Resolute by drainage

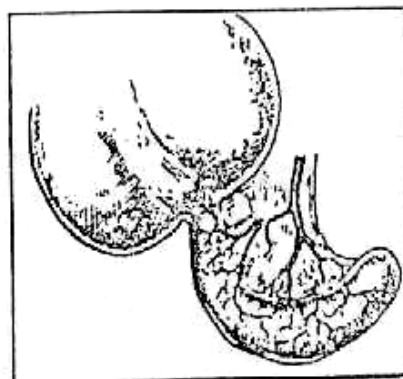


N.B. : IF the Abscess is pelvic, The best is felt by P/R & P/V.

* Differential Diagnosis :

[1] Acute Appendicitis 6 Groups of Disorders : (See chapter 15)

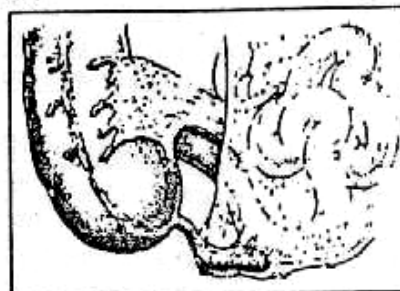
- Group 1 : (Thoracic problems)
e.g Rt. side pleurisy or Rt. side pneumonia
- Group 2 : (Upper abdominal problems)
e.g Perforated peptic ulcer or Acute cholecystitis.
- Group 3 : (Lower abdominal problems)
e.g Gastroenteritis, Meckle,s Diverticulitis, Regional ileitis or Cancer caecum
- Group 4 : (Pelvic problems)
i.e (Female genital system)
e.g Ruptured ectopic pregnancy, Tubal abortion, Twisted ovarian cyst or Pelvic Inflammatory disease
- Group 5 : (Urological problems)
e.g Ureteric colic, Pyelonephritis.
- Group 6 : (Neurological problems)
e.g Herpes Zoster affecting 10th, 11th & 12th thoracic nerves.



[2] Appendicular mass

From (DD of mass in the Rt. iliac fossa)

- ① Carcinoma of the caecum.
- ② Crohn's disease of terminal ileum.
- ③ Hyperplastic ileo-coecal T.B.
- ④ Right iliac lymphadenitis.
- ⑤ Actinomycosis.
- ⑥ Ectopic kidney or undescended testis.
- ⑦ Sarcoma of muscle or bones in the right iliac fossa.
- ⑧ Ant. abdominal wall masses.



*** Investigations :****[A] Laboratory Investigations :**

Total leucocytic count : Increased up to (10,000 – 16,000 U.L.) However normal count doesn't rule out Acute Appendicitis.

[B] Abdominal Ultrasound :

May help in diagnosis, but helpful in female with suspected gynecological problems.

[C] Laparoscopy : Diagnostic & Therapeutic i.e Laparoscopic Appendectomy.*** Treatment :****[A] Non-complicated Acute Appendicitis :**

i.e. No [peritonitis, Appendicular mass or Abscess].

The Treatment is Appendectomy either open or laparoscopic.

[B] Complicated with Peritonitis :

Urgent surgery; open Appendectomy + Peritoneal Toilet (lavage)

[C] Complicated with Appendicular Mass and Abscess :**☆ Appendicular Mass**

Urgent Appendectomy is not performed because ↗

- ① The mass represents success of body to isolate the danger so it is better to be left undisturbed.
- ② Appendectomy is difficult with increased morbidity.
- ③ Appendectomy is carrying hazards of injuring the intestine.

**Initial Conservative [Ochner-Sherren] Treatment :**

- ① Rest in bed & Ryle's tube (No oral intake).
- ② I.V fluid & I.V Antibiotics: as a combination of ↗
[Ampicillin, Aminoglycosides & Metronidazole].
- ③ Good observation for vital signs [Temp, pulse, ABP & RR], size of mass & degree of tenderness.
 - ♦ In 80-90% of cases on conservative ttt → Resolution of the mass for "Interval Appendectomy" 3 months later.

☆ Appendicular Abscess

The pus should be drained by open surgery or ultrasound percutaneous aspiration.

♦ Open surgery :**[1] If the Abscess in pelvis :**

It will be drained through the Rectum & Vagina.

[2] If the Abscess in Rt. Iliac fossa :

It will be drained through an incision of Iliac muscle, then a rubber drain is left.

- ♦ Then "Interval Appendectomy" 3-6 Months later.

Chronic Appendicitis

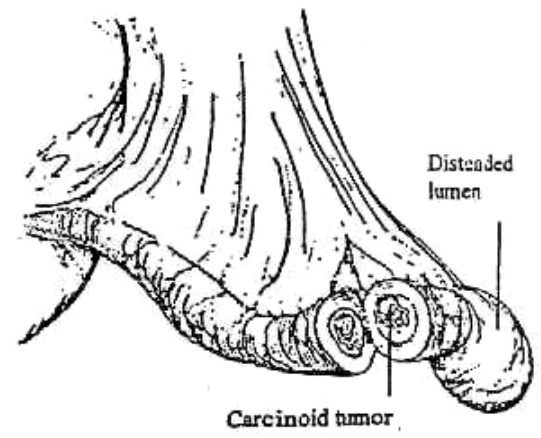
- * It is better called Recurrent subacute appendicitis. It cause recurrent attacks of abdominal pain & dyspepsia. DD from the irritable bowel syndrome. Treated by appendicectomy.

Tumors of the Appendix

① Carcinoid (Argentaffinoma) Rare

★ Pathology :

- Site : Mainly at distal 1/3 of the appendix.
- C/S : golden yellow due to it's lipid content.
- Arises in Kulchitsky cells in the depth of mucosal pits.
- Benign behavior but in minority of cases, the tumor invades & metastasizes to the liver.



★ Manifestations (carcinoid syndrome)

1. Flushing with attacks of cyanosis.
2. Diarrhea with borborygmi.
3. Bronchospasm, and pulmonary stenosis.

★ Treatment :

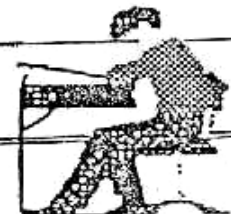
- If < 2 cm = Appendicectomy.
- If > 2 cm = Rt. Hemicolectomy

② Carcinoma : (Adenocarcinoma) Very rare

- It may present as acute appendicitis.
- The tumor behaves as carcinoma of the colon.
- If it is confined to the appendix and the regional lymph nodes, the treatment is right hemicolectomy.



Final Written Exams



1990	• Discuss Complications & ttt of Acute Appendicitis	(15 Marks) دور ثانی
1993	• Discuss Complications & ttt of Acute Appendicitis	(15 Marks)
1994	• Discuss C/P of Acute Appendicitis	(10 Marks)
1998	• Discuss diagnosis & ttt of Appendicular Abscess Acute Appendicitis (symptoms) & DD of Acute Abdomen.	(10 Marks) دور ثانی (20 Marks)
2000	• Enumerate Complications of acute appendicitis & mention ttt of one of them • Mention the treatment of Appendicular mass	(10 Marks) دور ثانی (10 Marks)
2001	• Mention in brief the complications of Acute Appendicitis	(15 Marks)
2002	• Discuss complications of acute appendicitis	(10 Marks) دور ثانی
2003	• Discuss D.D of acute Appendicitis.	(9 Mark) دور ثانی
2004	• Discuss C/P of Acute Appendicitis	(20 marks) دور ثانی



Chapter [II]

**The Small and
Large Intestine**

The Small and Large Intestine

Surgical Anatomy

Ⓐ Arterial supply :

* Arterial supply of colon :

[1] Superior Mesenteric Artery : (The artery of midgut)

▪ Origin :

From the front of abdominal Aorta at the level of lower border (L1).

▪ Course & relations :

- At its origin it lies behind the pancreas then crosses in front of uncinat process.
- It enters the root of mesentery, passes downwards & to the right, in front of 3rd part of duodenum, I.V.C. and Rt. psoas major muscle.

▪ End :

In Rt. Iliac fossa by anastomosing with Ileo branches of Ileo-colic artery.

▪ Branches to the colon : giving

① Ileo-colic artery: Which gives

- Ileo branches to anastomose with the end of superior mesenteric artery.
- Appendicular branch to appendix
- Ant. & post. caecal branches to caecum
- Ascending branch to anastomose with descending branch from RT. colic artery.

② Rt. Colic artery : Which gives

- Descending branch: which anastomose ascending branch of Ileo-colic artery
- Ascending branch which anastomose Rt. branch of middle colic artery.

③ Middle Colic artery :

- Rt. branch which anastomose ascending branch of Rt. colic artery.
- Lt. branch which anastomose upper branch of Lt. colic artery.

[The Small & Large Intestine]

[2] Inferior Mesenteric artery : (the artery of hind gut)

▪ **Origin :**

From front of abdominal Aorta at the level of (L3).

▪ **Course & relations.:**

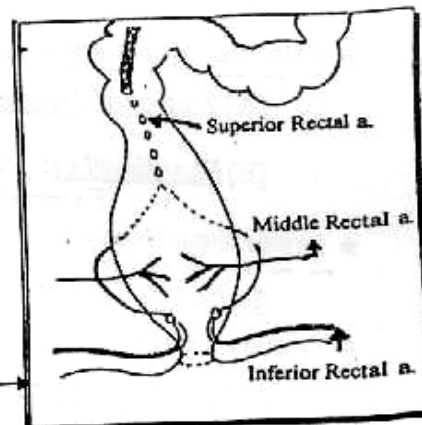
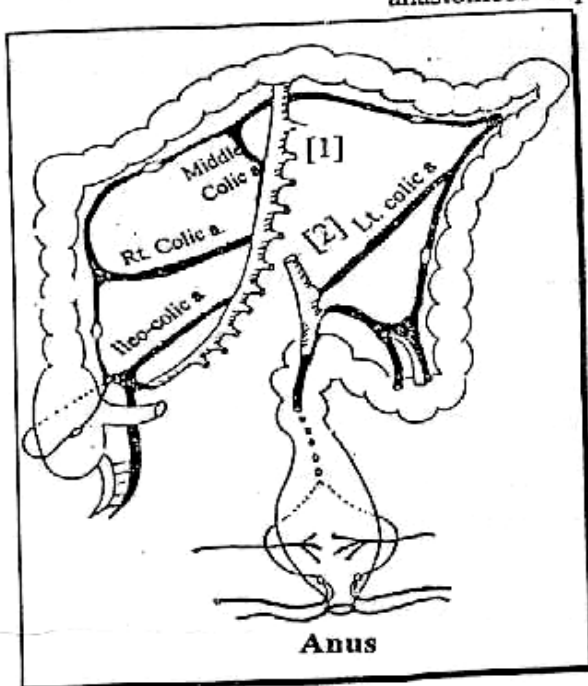
- At its origin it lies behind the 3rd part of duodenum.
- It runs downwards & to the Lt. then lying medial to the inferior mesenteric vein.

▪ **End :**

By becoming superior rectal artery.

▪ **Branches to the colon.:** giving

- ① **Lt. colic artery :** Which gives
 - Upper branch : which anastomose to Rt. Middle colic artery.
 - Lower branch : which anastomose to upper sigmoid arteries.
- ② **Sigmoid arteries (3 or 4) arteries :** which supply sigmoid colon & anastomose superior rectal artery.



*** Arterial supply of Rectum :**

- [1] **Superior rectal artery** : as continuation of inferior mesenteric artery.
- [2] **Middle rectal artery** : from Internal iliac artery.
- [3] **Inferior rectal artery** : from Internal pudendal artery
- Ⓟ **Venous drainage** : Corresponding to arteries.
 1. **Superior mesenteric vein** : anastomose with splenic vein to form portal vein.
 2. **Inferior mesenteric vein** end with splenic vein
- Ⓛ **Lymphatic drainage** : See Colo-rectal carcinoma.

I

Intestinal Trauma

★ Predisposing Factors :

Pathological disease of Intestine.

★ Exciting Cause : "Trauma" which may be ↷

- Closed ① *Direct Trauma* : Blunt trauma e.g. Car Accident.
 ② *Indirect Trauma* : Fracture pelvis
 ③ *Spontaneous Rupture* : Rare diseases of Intestine
- Opened : ① *Gunshot wounds*.
 ② *Punctured wounds* due to stabbing.
 ③ *operative* :

★ Pathology :

Colon surgery are more dangerous than those of the small intestine because of ↷

- ① The Highly infective content of both aerobic & anaerobic organism.
- ② Constant gaseous distention.
- ③ Incomplete serous coat.

★ Complications : [Sequelae]

- ① Peritonitis → Septic shock due to escape of intestinal contents into the peritoneum.
- ② Internal Haemorrhage → Hypovolaemic shock.
- ③ Paralytic Ileus.

★ Clinical Picture :

[A] History of Trauma: To Abdomen followed by an abdominal pain + shock.

[B] Examination: May reveals signs of Internal Hge & Shock + signs of External Trauma as bruises.

★ Investigations :

Sonar & CT scan : The most "Diagnostic"

★ Treatment :

[A] Anti-shock Measures : e.g. Blood Transfusion, Morphia etc...

[B] Immediat Laparotomy: [According to the site of Injury] ↷

[1] Small intestine & Rt. colon injuries :

(a) Sharp injuries : Sutured.

(b) Lacerated injuries : Excise the edges & suturing.

(c) Intestinal resection & Iry Anastomosis :

Indicated with ① Ischaemia or gangrenous segments.

② Extensively contused segments.

③ Multiple Tears that are very closed to each other.

[2] Transverse & Lt. colon injuries

- (a) Localized injuries are exteriorized, it thus acts as a colostomy. →
- (b) If the injured part can't be exteriorized, The tear is sutured & protected by a proximal colostomy.
- (c) Intestinal resection of a gangrenous segment : is done through Hartmann's procedure



[3] Internal Fistula

In spite of spontaneous closure is rare to occur but many Internal fistulae don't require correction.

* The correction is indicated if ↗

- ① The Internal fistulae connect Intestine with the urinary bladder.
- ② The patient with nutritional problems where a fistula by-pass a long segment of intestine producing mal-absorption.

N.B

Principles of Colon Surgery

◆ Colonic anastomosis is more liable to disruption, leakage and peritonitis more than small intestine because :

- ① The highly infective contents by both aerobic and anaerobic organisms.
- ② Constant gaseous distention.
- ③ Incomplete serous coat.
- ④ Peculiar blood supply.



Pre-operative preparation must be done

- a. Improving nutritional status of the patient.
- b. Bowel preparation :

- ☆ Mechanical : ■ Non residue diet 4 days before operation.
- Enemas and laxatives 4 days before operation.

Or ■ Rapid preparation 1 day before operation by :

- Whole gut irrigation using 2 - 4 L/h of balanced crystalloid solution passed via a Ryle tube until the patient passes clear fluid per rectum.
- 1L of Mannitol orally → osmotic diarrhoea.

☆ Chemical : ■ Intestinal antiseptics (Neomycin + Metronidazole) Orally 3 days before operation.

- At the time of anaesthesia I.V. Cephalosporines or aminoglycosides + Metronidazole.

Intestinal Fistulae

★ **Definition :**

A fistula is an abnormal communication between two epithelialized surface.

★ **Classification :**

- ① They classify into Internal (when connect to Hollow Viscera) e.g gut or External (when connect to skin).
- ② Also External fistula classified into
 - Low output fistula that discharge < 500 mL/d.
 - or ▪ High output fistula that discharge > 500 mL/d.

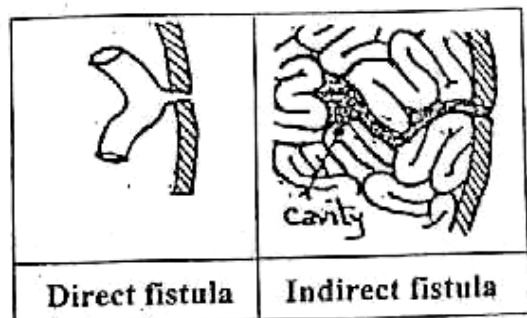
★ **Aetiology :**

[A] After abdominal operations (80%) :

- Because
- ① Unrecognized intestinal injury.
 - ② Failure of intestinal anastomosis because of poor vascularity.
 - ③ Anastomosis undertension.
 - ④ Distal obstruction.
 - ⑤ Lack of proper surgical technique.

[B] Other causes (20%) :

- ① Congenital : patent vitello-intestinal duct.
- ② Traumatic : abdominal injuries.
- ③ Inflammatory : Crohn's disease.
- ④ Neoplastic : Malignant tumors.



★ **Complications :**

- [A] Metabolic effects : Malnutrition, dehydration, hypoalbuminaemia, and acid-base, and electrolyte disturbances such as hyponatraemia and hypokalaemia are particularly common with high output fistulae. These are the results of malabsorption and loss of intestinal contents. Sepsis, if present, aggravates the malnutrition as it leads the patient into severe catabolism.
- [B] Sepsis : In some cases, the fistula track is not effectively walled off, and enteric contents escape producing an intraperitoneal abscess. Sepsis is the major problem in patients with intestinal fistulae.
- [C] Irritation and maceration of the skin due to continuous flow of intestinal contents.

★ **Treatment :**

- [A] Resuscitation & nutritional support : The priority is to save life of the dehydrated patient by I.V fluids.
- [B] Skin protection : Should be started early by an adhesive cover & disposable collection bag.
- [C] Eradications of sepsis : Through fistulogram; barium meal follow-through, U/S & CT scan.

[The Small & Large Intestine]

[D] Defenitive treatment :

1. External fistula :

- Continued conservative treatment with nutritional support is indicated in patients showing progressive diminution of the output. This is successful in most cases.
- Surgical intervention is indicated if : No improvement, distal obstruction and active disease as Crohn's.

2. Internal fistula :

- Spontaneous closure is rare to occur.
- Surgical correction is indicated if patient with nutritional problems.

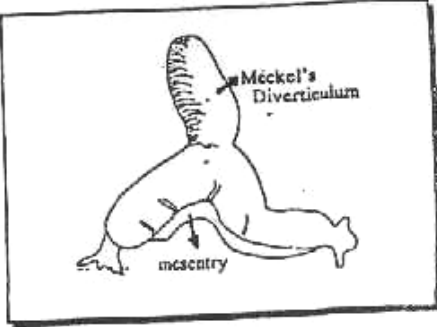
II Intestinal Diverticulae

Diverticulum is a blind... pouch that is continuous with the lumen of a hollow viscus i.e. (gut or urinary bladder).

(1) Meckel's Diverticulum

* **Definition** : Persistent patency of the proximal part of vitello - intestinal duct of embryo.

N.B. Vitello-intestinal duct :
It is a duct present in 1st 4 weeks joining the yolk sac & primitive gut then disappear 6th week of intra-uterine life. Obliteration starts at umbilical end and so intestinal end is the last part

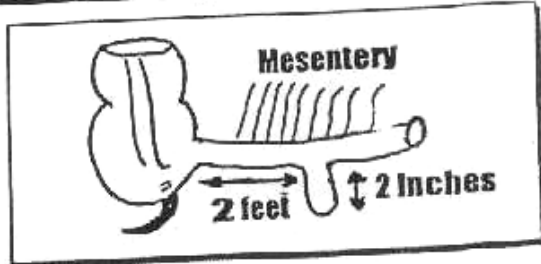


Other Congenital Anomalies from Vitello - intestinal Duct

Foecal Fistula	Meckel's Diverticulum	Umbilical Sinus	Fibrous Band	Enterocyst

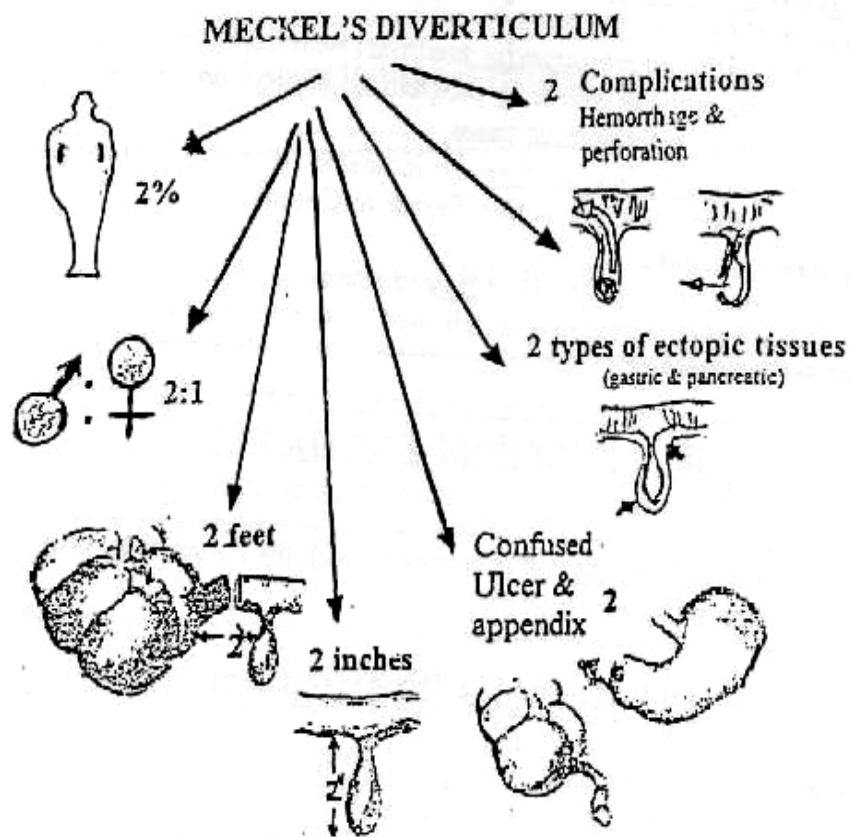
* **Incidence** : Rule of 2

- It occur in 2% of human.
- & it is symptomatic in 2% of patient only.
- It is about 2 Inches in Length.
- It project 2 feet from Ilio - caecal junction



* **Pathology** :

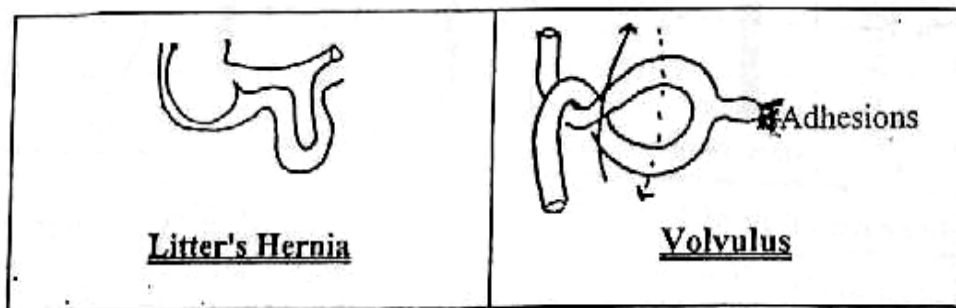
- It is a true Diverticulum i.e. Consists of all layers of bowel wall.
- It projects from Anti- mesenteric borders.
- It may contain 2 Ectopic tissues : Gastric & pancreatic
- It may give 2 major complications Inflammations & Haemorrhage.



*** Clinical Picture & Complications:**

It may be Accidentally discovered at operation for another pathology or may present by one of it's complications

- ① **Acute Diverticulitis** : Simulating Acute Appendicitis. So Clinically impossible to Differentiate the 2 conditions.
- ② **Bleeding Per rectum** from ectopic gastric epithelium i.e. (Peptic ulceration).
- ③ **Intestinal obstruction** ; May be due to
 - (a) Inclusion as femoral hernia → **Littre's Hernia**
 - (b) Band between apex of diverticulum & umbilicus leading to **Volvulus**
 - (c) Swollen inflamed base → **Intussusception**

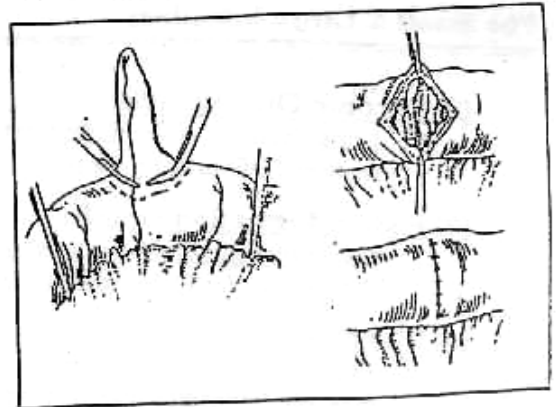


*** Investigations :**

Tc⁹⁹ can localize diverticulum containing gastric mucosa.

[The Small & Large Intestine]*** Treatment :**

- [A] **"Silent" Meckel's Diverticulum.**
If discovered during operations it must be excised to exclude its complications.
- [B] **"Symptomatic" Meckel's Diverticulum**
- ① **Diverticulectomy :**
The diverticulum is amputated at its base to avoid stricture.
 - ② **Resection & Anastomoses :**
Indicated only with indurated base of diverticulum & extending to ileum on each side.

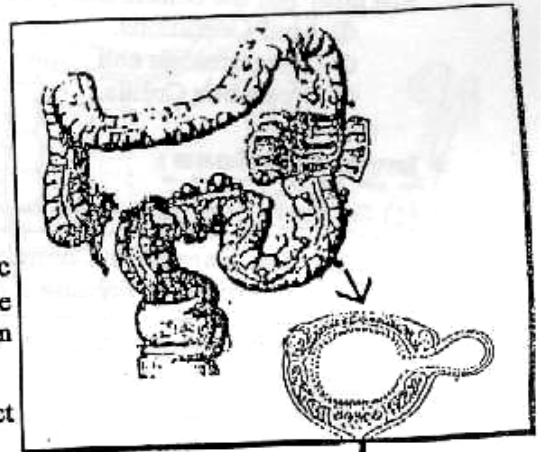
**(2) Diverticular disease of the colon***** Definition :**

It is a pulsion diverticulae of the colonic mucosa through the circular muscle layer at the points of entry of blood vessels between the taenia coli.

*** Aetiology :**

Supposed to be lack of fibers in diet → Colonic constipation → ↑ Intra-luminal colonic pressure → Muscle incoordination → Segmentation of the colon especially sigmoid and not the rectum.

SO the mucosa is pushed outwards through the defect in muscle coat.

*** Clinical Picture :**

[A] **Uncomplicated Diverticulosis Coli = Irritable colon**

- Distention & Flatulence.
- Pain in Lt. Iliac fosse.
- By Examination : Tender palpable colon.

[B] **Complicated Diverticulosis Coli :**

(1) **Acute Diverticulitis :**

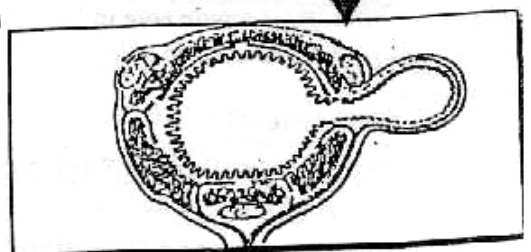
- ◆ **Mechanism :** Obstruction of the mouth of one or more diverticula by faecal plug or inflammatory oedema → Retention of contents.
So if 2ry infection occur → Diverticulitis.
- ◆ **C/P :** Simulate Acute Appendicitis but on Lt. Side

N.B: Perforation of Acute Diverticulitis leads to either

- ① Localized Peritonitis: i. e. peri- colic Abscess.
- ② Generalized Peritonitis with 50% Mortality Rate.

N.B. : Saint's Triad which is

Hiatus Hernia + Diverticulosis Coli + Chronic Calcular Cholecystitis



[2] **Chronic Diverticulitis :**

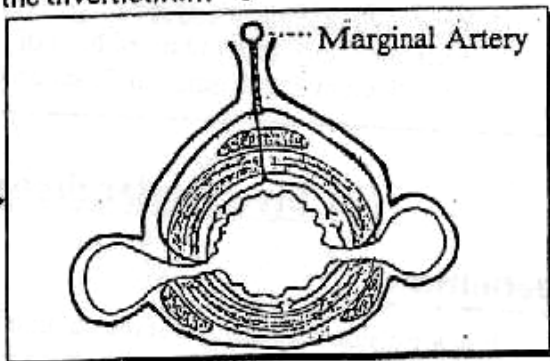
Long history of recurrent attacks of pain with passage of blood per rectum (DD of carcinoma).

[3] **Fistula formation :** may be

- (a) External : Colo- cutaneous after drainage of Peri- colic abscess.
- (b) Internal : Colo- vesical or colo- vaginal or colo-enteric fistula.

[4] **Bleeding :**

The proximity of Marginal artery to the diverticulum may predispose to bleeding which is bright red and massive.



* **D. D :** Bleeding per rectum :

See later but the commonest 3 causes are

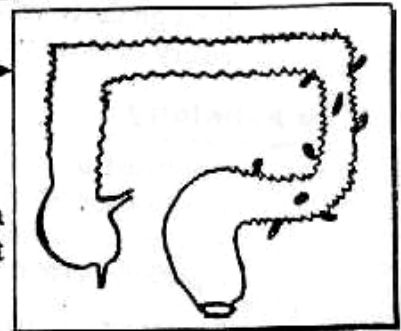
- ① Anal Conditions.
- ② Diverticulosis coli .
- ③ Ulcerative Colitis.

* **Investigations :**

[1] **Barium Enema :**

N.B. : Ba. Enema is Contraindicated with Acute diverticulitis because it predisposes to perforation.

In prediverticular stage, a Sawtooth appearance of colon then fully developed diverticulae will be visualized but (never in the rectum).



[2] **Sigmoidoscopy :** Shows the mouth of diverticula, also it has an important value to diagnose any concomitant lesion .

[3] **Mesenteric Angiography :** (if bleeding occur) which has

- ♦ *Diagnostic role* in localization the source of bleeding.
- ♦ *Therapeutic role* in Embolization the bleeding vessels.

* **Treatment :**

[A] **Uncomplicated Diverticulitis :**

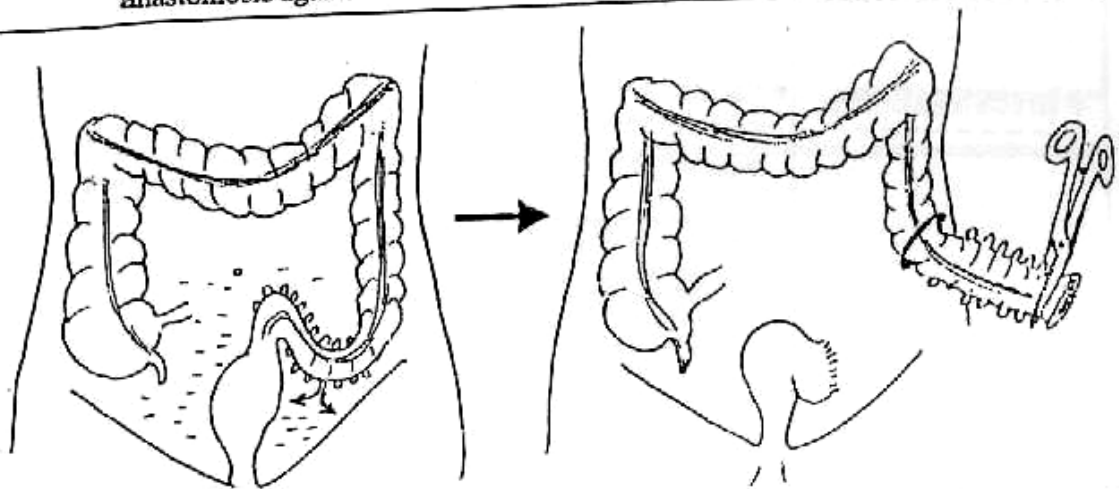
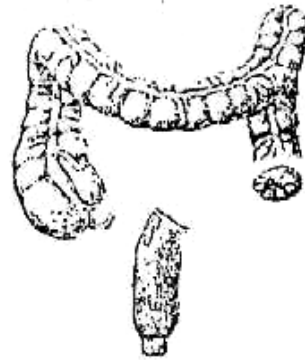High fibre in diet, Laxative & Antispasmodics.

[B] **Complicated Diverticulitis :**

1. *Acute Diverticulitis* : Treated conservatively as appendicular mass i.e. **Ochner Sherren**.
2. *Diverticulitis with Peri-colic Abscess* : Incision & Drainage.
3. *Generalized Peritonitis* : Urgent Laparotomy : Resect the colon by **Hartmann's procedures** then peritoneal toilet & Drainage.
4. *Chronic Diverticulitis* : Colectomy.
5. *Bleeding* : Resuscitation (usually the bleeding stop).
If failed do Embolisation if failed Colectomy is done.

N.B. : Hartmann's Procedure :

- **1st stage :**
Resection of sigmoid colon then the proximal end is brought out on the abdominal wall as a Colostomy & the distal end is closed.
- **2nd stage :**
Restoration of the continuity by anastomosis again.



III Inflammatory Bowel Disease

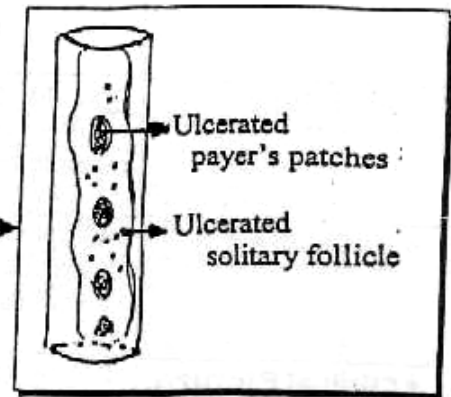
	<u>Ulcerative Colitis</u> (Procto-colitis)	<u>Crhon's Disease</u> (Regional Enteritis)
* <u>Definition</u> :	Non-specific ulceration	Non-specific granulomatous inflammation
* <u>Aetiology</u> :	Unkown, May be genetic or Immunological factors.	Unkown, May be hereditary focal ischaemia
* <u>Pathology</u> :	Ulceration affect <u>mucosa</u> and <u>submucosa</u> of Colon & Rectum (Pancolitis) or Rectum alone (Proctitis).	Inflammation affect <u>all layers</u> of G.I.T. mainly Intestine (Ileum)
* <u>Clinical Picture</u> • Age : • Sex : • Presentation :	<ul style="list-style-type: none"> • 3rd - 4th decades. • Female > Male. ⊙ Watery diarrhea (blood, pus and Mucus) with <u>Tenesmus</u>. ⊙ Weight loss & Dehydration. 	<ul style="list-style-type: none"> • 2nd to 4th decades. • Female = Male. ⊙ Diarrhae with pain at Abdomen & <u>Mass</u> at Rt. iliac fossa. ⊙ Weight loss & Dehydration.

IV

Typhoid & Paratyphoid

Surgical Complications

- ① Paralytic Ileus The Commonest
- ② Intestinal Hge.
- ③ Perforation of Typhoid ulcer See below
which are multiple ulcers & arranged parallel to longitudinal axis of intestine.
- ④ Cholecystitis (Non calcular)
- ⑤ Phlebitis : especially common Iliac vein.
- ⑥ Genito-urinary e.g cystitis.
- ⑦ Arthritis & Osteomyelitis.
- ⑧ Splenic Abscess.
- ⑨ Zencker Degeneration of Rectus abdominis muscle.



Perforated Typhoid Ulcer

* **Path. :**

- In the terminal ileum.
- Longitudinal with the long axis.
- May be multiple

* **G/P :**

Picture of generalized peritonitis but :

- ① History of typhoid fever 3 weeks ago, although the 1st presentation of typhoid fever may be perforation.
- ② Abdominal rigidity and tenderness are due to marked toxæmia with oedematous abdominal muscles (Zenker degeneration).
- ③ Leucocytosis is not markedly high.

* **D.D :** From other causes of acute abdomen & peritonitis.

* **Investigations :**




- ① Plain x-ray → gas under diaphragm.
- ② U/S → free fluid in peritoneal cavity.
- ③ Widal test → may be +ve

* **Treatment :**


① Resuscitation with Anti-shock measures :
Naso-gastric tube, I.V fluid, etc ...

② Exploration :

- Sealing of the perforation.
- If the perforation is multiple in short segment → Resection anaestemosis.
- Closure with drain.

	Ulcerative Colitis (Procto-colitis)	Crohn's Disease (Regional Enteritis)
<p>* Complications</p> <p>[A] Intestinal :</p>	<ol style="list-style-type: none"> 1) Toxic Megacolon (fatal) 2) Haemorrhage. i.e. Bleeding per rectum 3) Cancer colon : If pancolitis more than 10 years. 4) Stricture formation → intestinal obstruction. 	<ol style="list-style-type: none"> 1) Mal-absorption (Extensive) 2) Abscess & Fistula to another bowel or skin. 3) Peri-anal abscess, Anal fistula & fissure. i.e. Peri-anal lesions. 4) Stricture formation → intestinal obstruction
<p>[B] Extra Intestinal</p>	<p>Arthritis, Cholangitis, Liver cirrhosis & Skin lesion</p>	
<p>* Investigations</p>	<p>■ Barium Enema : Shows ↓ colonic shortening & loss of haustrations "Pipe Stem"</p> 	<p>■ Barium Meal follow through shows segmental areas of stricture & narrowing at terminal ileum "String sign of Kantor"</p> 
<p>* Treatment</p> <p>[A] Medical →</p>	<ol style="list-style-type: none"> 1) Correction of Anaemia and Hypoproteinaemia. 2) Local and systemic Corticosteroids with Acute disease. 3) Salazopyrine (Sulphasalaine) 2-6 gm/d. 	<ol style="list-style-type: none"> 1) Correction of Anaemia and Hypoproteinaemia. 2) Anti-spasmodics for pain & antidiarrhoeal. 3) Salazopyrine (Sulphasalazine) with Acute disease.
<p>[B] Surgical</p>	<ol style="list-style-type: none"> 1) Total Procto-colectomy + Terminal ileostomy. 2) Total Colectomy + Ileorectal anastomoses with regular endoscopic follow up of the rectum. 3) Total colectomy + Rectal mucosectomy + Ileo-anal anastomoses. 	<ol style="list-style-type: none"> 1) Localized resection of the affected loop. 2) If Stricture we will do strictureplasty i.e. incise longitudinally & closed transversely. 

V Tuberculosis of the Intestine

	Ulcerative T.B (Enteritis)	Hyperplastic (Ileo-cecal T.B)
* Aetiology	2ry. to pulmonary T.B as a result of swallowing the tubercle bacilli.	1ry to ingestion of the infected milk in high resistance patients.
* Pathology	Multiple ulcers in terminal ileum. The long Axis of the T.B ulcers lies <u>Transversely</u> .	Marked thickening of the intestinal wall mainly the Ileo-cecal region.
* Clinical Picture	① <u>Attacks</u> of diarrhoe, weight loss & Abdominal pain. ② Intestinal obstruction from stricture.	① <u>Attacks</u> of diarrhoe, weight loss & Abdominal pain. ② <u>Mass</u> in Rt. iliac fossa with vague ill health.
* Complications	① Intestinal Obstruction. ② Perforation (<u>Rare</u>).	① Intestinal Obstruction. ② Abscess & Fistula (<u>Rare</u>)
* Investigations	① <u>Laboratory</u> : Bl. Picture, ESR, Tuberculin test & chest x-ray & sputum analysis ② <u>Barium Meal</u> : shows ↷ Ulceration, narrowing & shorting of affected segment.	① <u>Laboratory</u> : Bl. Picture, ESR, Tuberculin test & chest x-ray & sputum analysis ② <u>Barium Meal</u> : shows ↷ narrowing of Ileo-caecal junction ↷ 
* Treatment	① Anti-T.B. drugs. ② Resection & Anastomoses if stricture occur.	① Anti-T.B. drugs. ② Rt. Hemi-colectomy if obstructed lesions occur.

VI Intestinal Bilharziasis

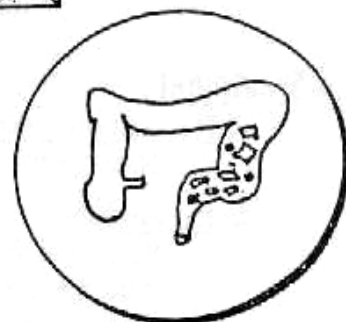“Bilharzial Colitis”

*** Incidence :**

- Common in Endemic area “Egypt”
- Age : Common with young or Adult.
- Sex : Male > Female.

*** Aetiology :**


It is caused by Schistosoma Mansoni & less commonly S. Haematobium.



*** Pathology :**

- Site : Sigmoid colon & Rectum.
- It is a chronic inflammatory cells surround the deposited ova leading to formation of β granuloma or pseudo-polyps.
- Types : 2 forms \Rightarrow

[1] Submucous form : \rightarrow



- The Mucosa shows ulcers & polyps.
- The Submucosa shows localized granuloma.
- The ulcers & polyps arranged in circular (Transverse) manner due to circular arrangement of veins of colon.



[2] Diffuse form : \rightarrow



i.e. (All layers of colon)

- The Mucosa shows ulcers & polyps.
- The Submucosa shows fibrosis.
- The Musculosa & Serosa are fibrosed to form " β peri-colic mass"

*** Clinical Picture :**

- Type of patient : (young or adult & male > female).
- Symptoms : ① Weakness, pallor & Easy fatiguability.
② Diarrhea, Tenismus & passage of blood & mucus in stool.
③ Mass in Lt. iliac fossa.
- Signs :
[A] General signs :
Anaemia, Clubbing fingers, \pm Hepatosplenomegaly.
[B] Local signs :
① Tender & Thickened sigmoid colon.
② Hard nodular mass in Lt. iliac fossa if peri-colic mass.
③ P/R detects multiple rectal polyps.

*** Complications : (Never pre-cancerous)**

Anaemia, Haemorrhage, Complete rectal prolapse & Intstinal obstruction

*** Investigations :**

[1] Laboratory Investigations :

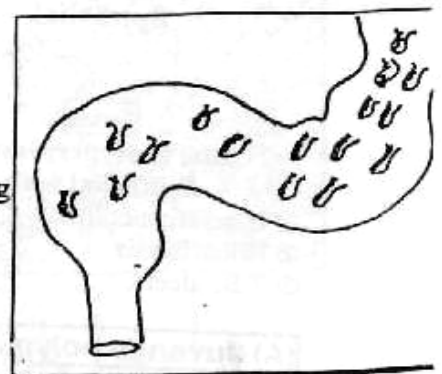
Stool, Urine & Blood Analysis.

[2] Radiological Investigations :

Barium Enema shows multiple, rounded filling defect of variable sized and localized to sigmoid colon & rectum.

[3] Instrumental Investigations :

Sigmoidoscopy shows mucosal polyps.



*** Treatment :**

[A] Anti-bilharzial drugs as [Oxamniquine or praziquantal]

[B] Polyps are removed by sigmoidoscopy.

N.B : Excision of affected sigmoid is (Rarely) in modern surgery .

VII

Colo-Rectal Tumors

Polyps of the Colon & Rectum :

[A] Epithelial

① **Hamartomatous polyps:**

- a. *Solitary* : Juvenile polyp.
- b. *Multiple* : e.g. Multiple Juvenile polyps &



← **Petz-Jegher's polyps**

- It is familial Intestinal polyps
- It is Associated with melanin pigment of oral mucus membrane & Lip.
- It is Not pre-cancerous but complicated with bleeding or Intussusception.

② **Inflammatory polyps :**

- a. *No solitary* polyp.
- b. *Multiple* : e.g. Ulcerative colitis (Pseudo-polyps) & Bilharzial polyps.

③ **Neoplastic polyps :**

- a. *Solitary* : Adenoma or Carcinoma.
- b. *Multiple* : e.g. Familial polyposis coli (F.P.C) } (See below)
& Gardener's syndrome.

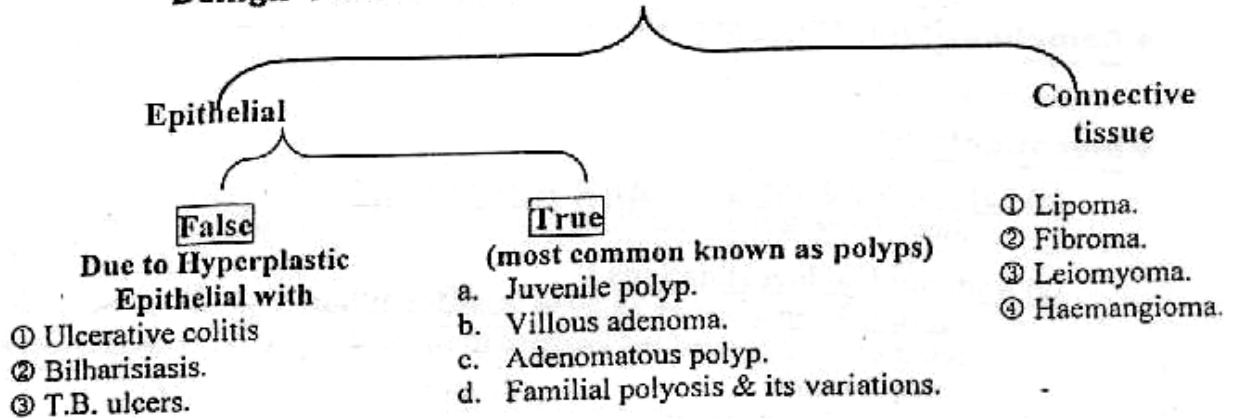
④ **Unclassified polyps :**

- a. *Solitary* : Solitary Hyperplastic polyp.
- b. *Multiple* : Multiple Hyperplastic polyp.

[B] Mesenchymal

As lipoma, Leiomyoma or Haemangioma.

Benign Tumors of the Colon & The Rectum



(A) Juvenile polyp

* **Incidence** : Common in children & common in Rectum.

* **Pathology** : Usually solitary with long. pedicel



[The Small & Large Intestine]


* **C/P**: Commonest cause of bleeding per rectum in children (Never turn malignant).

* **Treatment**: Ligation & Excision.

(B) Villous adenoma (Carpet tumor)

* **Incidence**:
- After 45 years old & common in sigmoid colon & rectum.

* **Pathology**: Multiple sessile polyps with velvety surface & multiple finger like projections so (called carpet tumor)




* **C/P**:
- Bloody & mucous per rectum. Liable to turn malignant.

* **Treatment**:
- If High: Anterior Resection.
- If Low: Abdomino-Perineal Resection.

(C) Adenomatous polyp.

* **Incidence**: After 20 year & common in colon & rectum.

* **Pathology**: Usually multiple, pedunculated & lobulated polyp.



* **C/P**: Bleeding per rectum → Anaemia, (Rarely turn malignant).

* **Treatment**: Excision using sigmoidoscopy.

(D) Familial polyposis coli (F.P.C)

A Benign Tumors

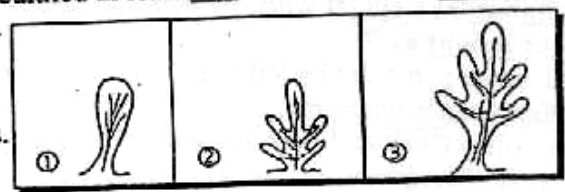
(1) Familial Polyposis Coli (F. P. C)

* **Aetiology**: It is an Autosomal dominant Disease.

* **Incidence**:
▪ Runs in Family.
▪ Age: Between 10-15 years (Never since birth)
▪ Sex: Male > Female.

* **Pathology**:

▪ Site: Multiple polyps at colon & Rectum.
▪ N/E: Sessile or pedunculated at least 100 in number →
▪ M/E: 3 Types →
① Tubular.
② Villous.
③ Tubulo-villous.



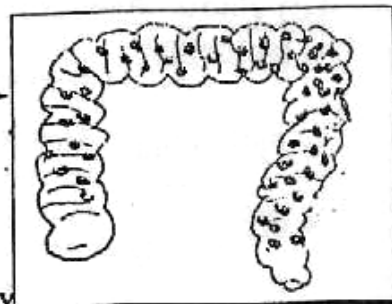
N.B. : (F.P.C.) : Considered pre-cancerous.
So if untreated the carcinoma is developed 100% at 5th decades.

* Clinical Picture :

- Symptoms : Lower abdominal pain, Diarrhoe & Bleeding per rectum.
- Signs : ① Tender colon.
② P/R → Rectal polyps.

* Investigations :

- [A] Barium Enema : (Colon & Rectum)
shows multiple, rounded & same sized defects
- [B] Sigmoidoscopy & Biopsy .



* Treatment :

- [A] The Affected Persons : Many options as →
 - ① Excision of whole colon & Rectum + permanent Ileostomy
This is the standered option.
 - ② Total colectomy + ileo-rectal anastomosis after endoscopic removal of all rectal polyps then regular follow up.
 - ③ Total colectomy + Distal rectal mucosectomy + Ileo-anal anastomosis.

[B] The Family Members :

Regular colonoscopic follow up. i.e. family screening.

[2] Gardner's Syndrome

- It is a rare variant of familial polyposis coli.
- It can turn into malignant.
- It is associated with Extra-colonic lesions include →
 - ① Osteoma of skull & mandible.
 - ② Sebaceous Cysts.
 - ③ Desmoid Tumors.

(B) Malignant Tumors

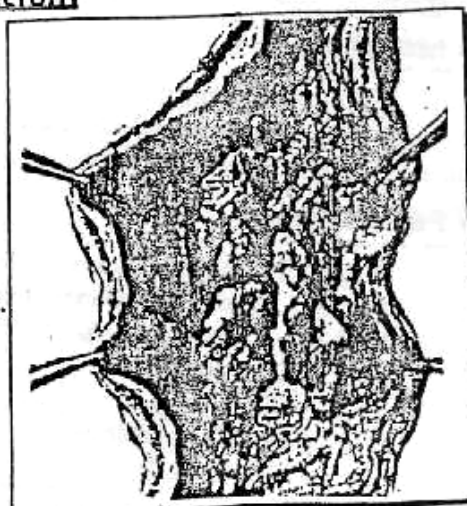
Carcinoma of the Colon & Rectum

* Incidence :

- They consider the commonest tumor of GIT.
- Age : 50 - 70 years.
- Sex : Cancer Caecum common with Female.
& Cancer Rectum common with Male.

* Predisposing Factors :

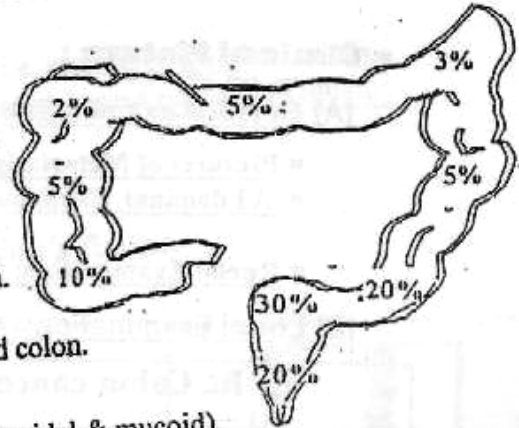
- [A] Chronic Irritation as High fat with low fibers diet.
- [B] Pre-cancerous lesions as →
 - ① Benign adenoma particular by Villous.
 - ② F.P.C. & Gardner's syndrome.
 - ③ Ulcerative colitis (If Pancolitis > 10 years)
 - ④ Uretro-Colic anastomosis



The Small & Large Intestine

* **Pathology :**

- **Site :**
 - 70% in Sigmoid colon & Rectum
 - 10% in Caecum.
 - 20% in Rest of colon.



▪ **N/E Picture :**

- ① Cauliflower mass mostly in the Caecum.
- ② Malignant ulcer mostly in the Rectum.
- ③ Annular scirrhous mostly in the sigmoid colon.

▪ **Microscopic Picture :**

- ① Adenocarcinoma (columnar, spheroidal & mucoid)
- ② Anaplastic carcinoma (poorly differentiated).
- ③ Colloid carcinoma (signet ring) most aggressive type.

* **Spread :**

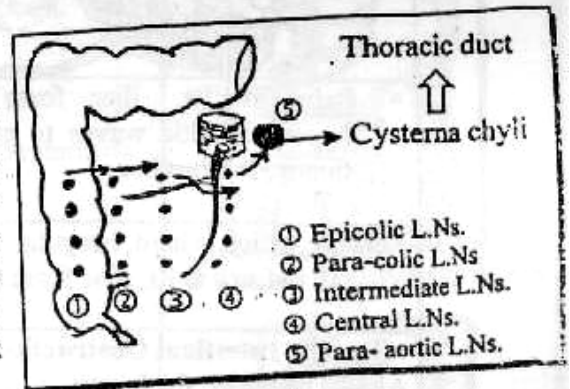
▪ **Direct spread :**

Around the circumference of the bowel then longitudinally (4 cm distal & 7 cm proximal) then to surroundings e.g. Small intestine, liveretc.

▪ **Lymphatic spread :**

[A] **Lymphatic Spread to the colon :** →

1st Epicolic L.Ns (overlying wall of colon) Then to paracolic L.Ns (Along the side wall of colon) then to Intermediate L.Ns (Along branches of meso-colic arteries) then to central L.Ns (Along the superior & Inferior mesenteric arteries) Then to the para-aortic L.Ns then to Cysterna chyli & Thoracic duct



[B] **Lymphatic Spread to the Rectum :**

- **Upper 1/2 :** Para-rectal L.Ns & superior rectal L.Ns then to inferior mesenteric L.Ns then to para-aortic L.Ns → Thoracic duct.
- **Lower 1/2 :** Middle & inferior rectal L.Ns then to internal iliac L.Ns then to para-aortic L.Ns → Thoracic duct.

▪ **Blood spread :** Mainly through portal vein to liver & rarely to the lung

▪ **Transperitoneal spread:** Leads to Peritoneal nodules & Ascitis.

* **Staging : Duke's Classification** Mainly (Cancer Rectum)

The prognosis worsens as the progress of the degree.

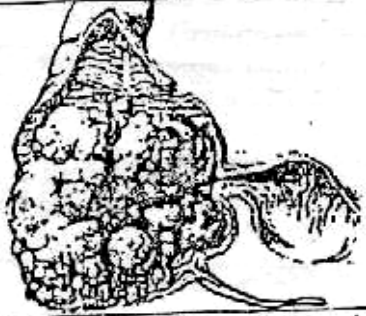

Stage	Definition
A	The growth is limited to the bowel
B	The growth is extended outside with No L.Ns metastasis
C	There are regional L.Ns
c ₁	• Local para-rectal or para-colic L.Ns
c ₂	• Central L.Ns along superior & Inferior mesenteric vessels.
D	Distant Metastasis.

*** Clinical Picture :**

[A] General examination (for all sites)

- Pictures of Metastasis e.g Jaundice.
- Abdominal Examination:
for Ascitis or mass
- Rectal Examination: for any pelvic deposits.

[B] Local Examination: (According to site of Tumor)

[I] Rt. Colon cancer	[II] Lt. Colon cancer
	
<ul style="list-style-type: none"> ▪ <u>Pain</u> at Rt. iliac fosse due to hyperperistaltic waves to get rid of tumor → Diarrhea. 	<ul style="list-style-type: none"> ▪ <u>Irritation</u> by hard impacted stools causing excessive mucus secretions leading to spurious(False) diarrhea.
<ul style="list-style-type: none"> ▪ <u>Mass:</u> which is hard, irregular fixed & ill defined at Rt. iliac fosse (for DD) 	<ul style="list-style-type: none"> ▪ <u>Mass:</u> <u>Not present</u> <u>except</u> if there is faecal impaction above the tumor
<ul style="list-style-type: none"> ▪ <u>Rarely Intestinal Obstruction</u> As ① The <u>wider</u> the lumen ② The stool is still <u>liquid</u>. ③ Carcinoma <u>not</u> stenotic. 	<ul style="list-style-type: none"> ▪ <u>Commonly Intestinal Obstruction</u> As ① The <u>smaller</u> the lumen. ② The stool is more <u>solid</u>. ③ Carcinoma <u>more</u> stenotic.
<ul style="list-style-type: none"> ▪ <u>The patient may present by</u> ⇨ Weakness, loss of weight & 3As i.e Anaemia, Anorexia & Athenia 	<ul style="list-style-type: none"> ▪ <u>The patient may present by</u> ⇨ Change in bowel habits as progressive constipation with short duration & <u>not</u> respond to any purgatives.
<ul style="list-style-type: none"> ▪ bleeding per-rectum. So leading to severe Microcytic anemia <u>not</u> respond to treatment 	<ul style="list-style-type: none"> ▪ bleeding per-rectum as hard stools may injure the mucosa lining of stenotic lesion
<ul style="list-style-type: none"> ▪ Pictures of Complications 	<ul style="list-style-type: none"> ▪ Pictures of Complications

*** Complications :**

- ① Intestinal obstruction especially in Lt. colon tumors.
- ② Perforation & formation of malignant fistulae or peritonitis.
- ③ Bleeding in chronic cases.
- ④ Complications from spread e.g Jaundice, Liver metastasis & Ascitis.

[III] Rectal Cancer : Often present with ↗

- Bleeding per-rectum which is usually slight, i.e. blood streaked on stool.
- Tensmus (Sense of painful incomplete evacuation) and passage of mucus.
- P/R Examination allows ↗
 - ① palpation of lesions in 90% of cases
 - ② Detection of 2ry piles.
 - ③ Detection of blood at tip of examiner's finger.

*** Differential Diagnosis :**

[A] DD from mass :

• Mass in Rt. iliac fossa :

- As ① Rt. cancer colon ④ Ileo-caecal T.B.
 ② Appendicular mass. ⑤ Crhon's disease.
 ③ Iliac lymphadenitis. ⑥ Psoas Abscess.

• Mass in Epigastrium :

- As ① Cancer Transverse colon,
 ② Lt. lobe liver, Tumor or Cyst.
 ③ Small Intestine: lymphoma or Intussusception.

[B] Bleeding per rectum

- as ① Cancer colon & Rectum
 ② Anal conditions as Anal fissure & Anal Carcinoma
 ③ Bilharzial colitis & Diverticular disease

*** Investigations :**

[A] Diagnostic Investigations

[1] Laboratory :

e.g Blood picture show Microcytic hypochromic Anemia.

[2] Radiological: (Barium Enema) →

- Shows ① Cancer caecum.
 Or ② Cancer Transverse Colon.
 Or ③ Cancer Descending
 Or ④ Cancer Sigmoid.
 Or ⑤ Cancer Rectum .

[3] Instrumental: (Colonoscopy)

- Essential in all patients é Altered bowel habits or rectal bleeding.
- Mandatory in patient > 40 years é piles.
- Biopsy: is obtained from suspicious lesions.

[B] Metastatic work up:

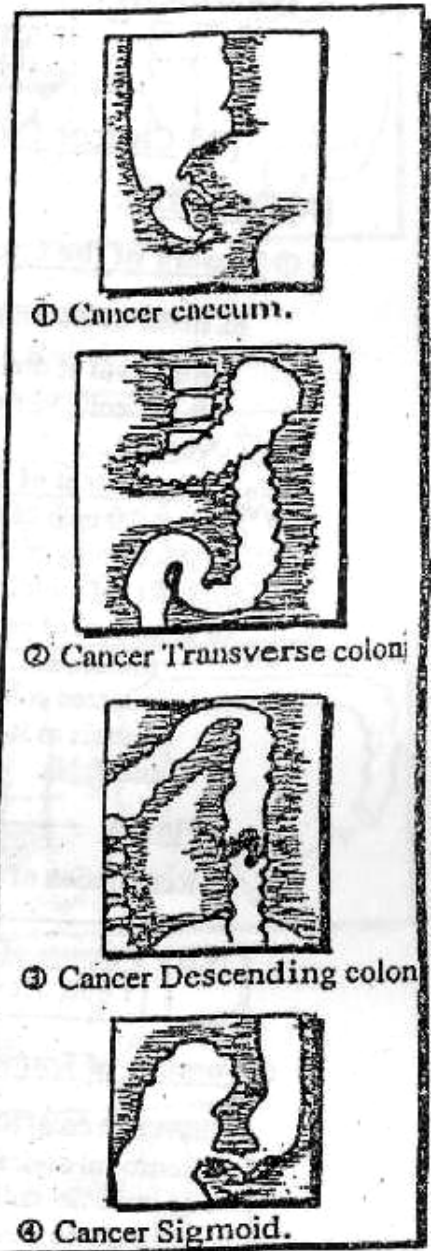
e.g liver Function Test, U/S or C.T. Scan for liver metastasis & Chest x-Ray for lung metastasis.

[C] Tumor markers :

Through Carcino-Embryonic Antigen (C.E.A) which is prognostic only. So replaced Now by (CA 19-9) which is prognostic rather than diagnostic.

[D] Exfoliative cytology :

Examine for malignant cells in the Enema wash fluid.



N.B If Associated Intestinal obstruction. We will do :-
 ① Plain X-ray Abdomen .
 ② Serum & Electrolytes studies.
 ③ Complete blood picture & blood urea

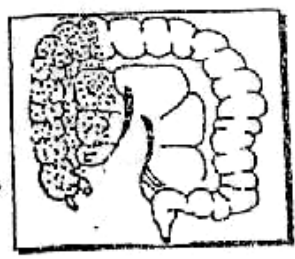
*** Treatment :**

A Treatment of cancer colon

[1] Cancer Colon Without Acute Intestinal Obstruction

[A] Operable:

① **Tumors of the Caecum & Ascending colon :**



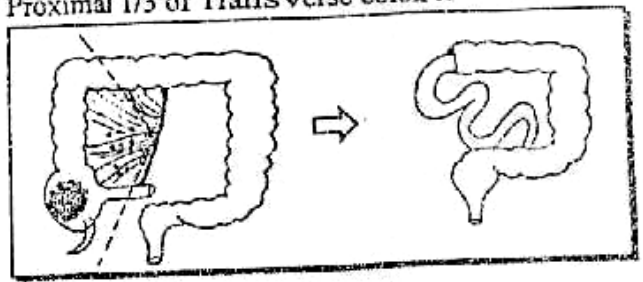
RL Hemi-colectomy is done by :-

- Removal of draining L.Ns & ligation with division of ileo-colic & Rt. colic vessels at their origin from the superior mesenteric vessels

So

The Extent of devascularized resected gut is:

- ① last 10 inch of terminal ileum, Caecum & Appendix.
- ② Ascending colon, Hepatic flexure & Proximal 1/3 of Transverse colon to Rt. of middle colic vessels.
- ③ Removal of peritoncum of post. abdominal wall between the resected colon & sup. Mesenteric vessels as it contains lymph vessels and L.Ns

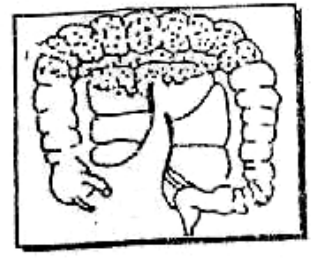


▪ **Finally**

Restoration of continuity by ileo-transverse anastomosis end to end

N.B : Tumors of Hepatic Flexure = Extended Rt. Hemicolectomy
 i.e Rt. Hemicolectomy + Removal of Rt. 2/3 of Transverse colon

② **Tumors of Transverse Colon :**



Transverse colectomy is done by :-

- Removal of draining L.Ns & ligations with division of middle colic vessel at it's origin from superior mesenteric vessels.

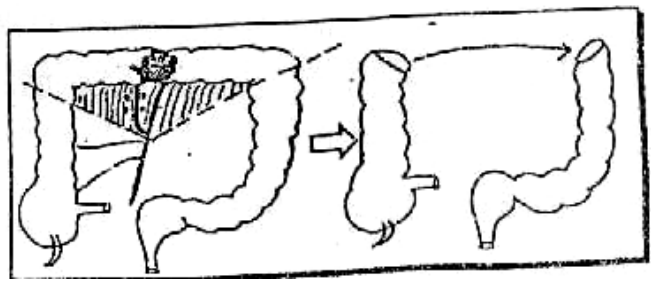
So

The Extent of devascularized resected gut is:

- ① Transverse Colon & Mesocolon .
- ② 2 Flexure (Hepatic & Splenic) .
- ③ Greater Omentum

▪ **Finally**

Restoration or the continuity by end to end Anastomosis.



④ **Tumors of Descending Colon**

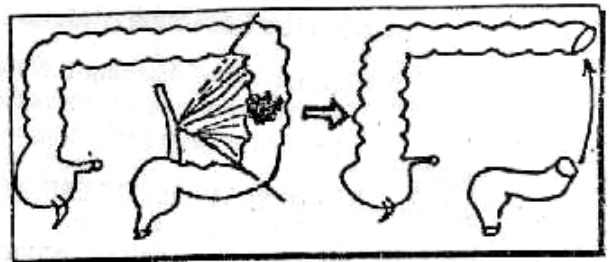
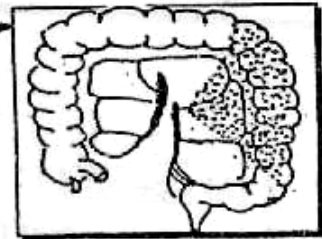
- Lt. Hemi-colectomy** is done by ↗
- Removal of draining L.Ns & ligation with division of Lt. colic vessel at it's origin from inferior Mesenteric vessels.



The Extent of devascularized resected gut is:

- ① The Lt. 1/3 of Transvers colon.
- ② The splenic flexure & descending colon.
- ③ Removal of a wedge of peritoneum of post. abdominal wall i.e base at the resected colon & the Apex at excised vessels

- **Finally** ↗
Restoration of continuity by end to end anastomosis.



N.B: Tumors of the Splenic Flexure = Extended Lt. Hemi-Colectomy
i.e Lt. Hemicolectomy + Removal of Lt. 2/3 of Transverse Colon

④ **Tumor of Sigmoid Colon**

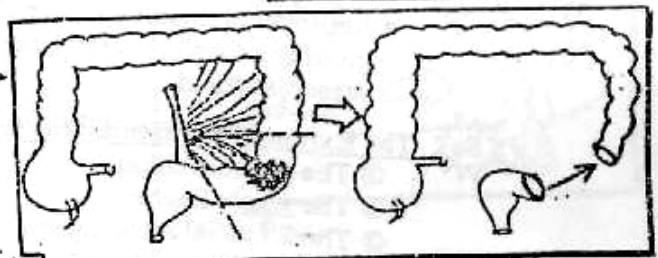
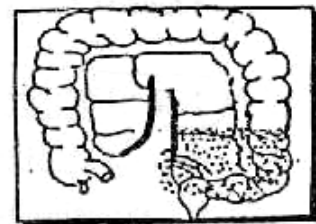
- Sigmoid (Pelvic) colectomy** is done by ↗
- Removal of draining L.Ns with ligation & division of sigmoid vessels at their origin from inferior mesenteric vessels.



The Extent of devascularized resected gut is:

- ① Sigmoid colon.
- ② Sigmoid mesocolon.

- **Finally** ↗
Restoration of the continuity by end to end anastomosis




[B] Inoperable :

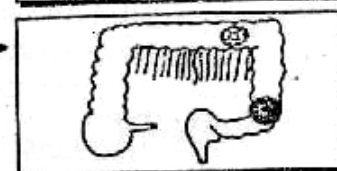
IF Resectable Tumors: Palliative Resection

But If Irresectable Tumor:

• **Rt. colon:** Side to side Ileo-transverse Anastomosis. →



• **Lt. colon:** Proximal colostomy in Transverse Colon. →



N.B : Chemotherapy [5 Fluro-uracil] & Radiotherapy may be Useful.

[2] Cancer colon with Acute Intestinal obstruction

1st Resuscitation & Immediate Laparotomy then the best is colon resection (Radical or Palliative) depending on operability.

N.B : For Clinically ill patient, proximal colostomy is done with later management as above

B Treatment of cancer Rectum

[A] Operable :

① **Tumors at the upper 1/3 of Rectum:**

Anterior Resection (without Colostomy) = **Dixon**

- Removal of draining LNs with Ligation and division of inferior mesenteric vessels or sometimes the Lt. colic vessel is spared



The Extent of devascularized resected gut is:

- ① The sigmoid colon.
 - ② The upper half of rectum.
 - ③ The 2 lateral rectal ligaments.
- With preservation of sphincters & Levator ani.

- **Finally :** Restoration of the continuity by End to End anastomosis of upper sigmoid & lower rectal stump deep in pelvis.

N.B. : The development of circular staplers facilitate this anastomosis

② **Tumors at the lower 2/3 of Rectum :**

Abdomino-perineal Resection (with colostomy) = **Miles**

- Removal of draining LNs with ligation & division of inferior mesenteric vessels, or sometimes the Lt. colic vessel is spared.



The Extent of devascularized resected gut is:

- ① The sigmoid colon
- ② The whole Rectum.
- ③ The 2 Lateral rectal ligaments.
- ④ The whole Anal Canal.
- ⑤ The sphincters & Levators ani.
- ⑥ Peritoneum of pelvic floor & wide ellipse of peri-anal skin.

- **Finally:** it is ended by terminal colostomy at Lt. Iliac fossa.

N.B: It is called Abdomino-perineal Resection because part of operation is done through the Abdomen & the other part is done through the Perineum

[B] Inoperable :

If Resectable: Palliative resection.

But if Irresectable: Chemotherapy & Radiotherapy.

N.B: Hepatic Metastasis :

Usually it means inoperable but with colo-rectal Tumors it may be operable

- If ① Solitary nodule with no Extra-hepatic metastasis
- ② Multiple but confined to one lobe

VIII Rectal Prolapse

* **Definitions** = Protrusion of rectum through the Anus

* **Aetiology** :

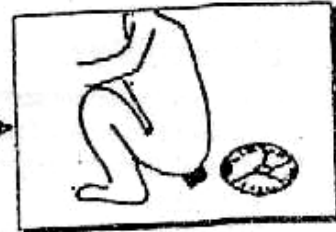[A] **Partial Prolapse** : (Prolapse of mucosa only of rectum)

Common in children due to

- ① Loss of curve of sacrum so rectum is a vertical tube.
- ② Loss of weight → loss of ischio-rectal & para-rectal fat.
- ③ Chronic straining at defecation with prolonged diarrhea.

But may occur with Adult due to

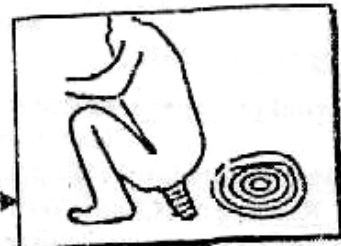- ① Advanced cases of Haemorrhoids.
- ② Atony of sphincters (mainly with Elder)
- ③ Chronic straining due to urethral stricture.



[B] **Complete Prolapse** : (Prolapse of whole rectal wall)

Common in Elderly particularly Female

In Egypt, \bar{X} proctocolitis → Tenismus → straining at defecation.



* **Mechanism** : (Theories)

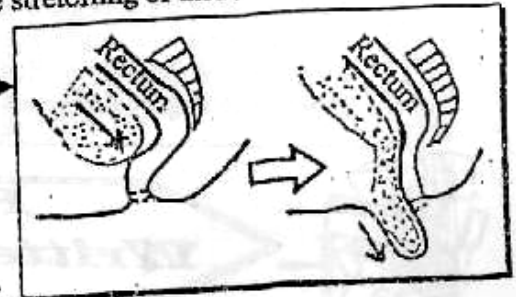
① **Failure of Rectal support** by levators & pelvic fascia due to defective collagen maturation in the pelvic floor. So Excessive stretching of these structures during labour may explain.

② **Rectal Prolapse** may represent as sliding hernia. As most of patients have a deep Recto-vesicle pouch

③ **Abnormal mobility of Meso-rectum** leading to lack of fixation between the rectum and the sacrum.

④ **In Egypt**: [\bar{X} Proctitis & Colitis]

As they lead to continuous tenismus and straining at defecation



* **Clinical picture** :

u **Symptoms** :

- ① *Something* protruding from the Anus at defecation.
- ② *Picture of complications* as Irreducibility, Bleeding fecal Incontinence, ulceration & pruritis.

▪ **Signs**:

- ① **Inspection** : prolapse is seen in squatting or lat. position with straining
- ② **Palpation** for thickness of prolapse & tone of sphincters.

	Partial Prolapse	Complete Prolapse
♦ Incidence	♦ Common	♦ Less common
♦ Age	♦ More in Children	♦ More in Adult
♦ Length of Prolapse	♦ < 5cm	♦ > 5cm
♦ Mucosal Corrugation	♦ <u>Absent</u>	♦ Present
♦ Thickness of Prolapse	♦ Mucosa <u>only</u>	♦ Whole Rectal muscles.

- * **Investigation** : ① Ano-rectal manometer & EMG of Rectal sphincters.
 ② Sigmoidoscopy or Barium Enema To exclude other causes as Bilharziasis

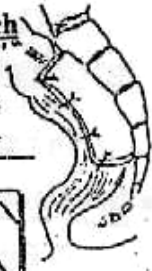* **Treatment** :

[A] **Prolapse in children:**

- ① Partial prolapse: conservative treatment mainly through
 a. Correct the cause of straining & Improve nutritional status.
 b. Manual Reduction by mother after defecation followed by strapping of buttocks.
 c. Submucous injection of 5% Phenol in almond oil.
 ② Complete prolapse : Peri-anal injection of alcohol → Fibrosis which fix the rectum in the sacrum.

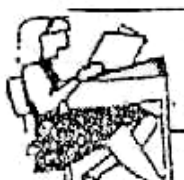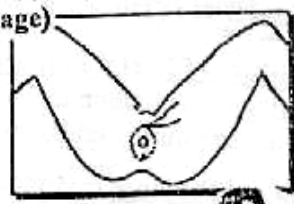
[B] **Prolapse in Adult :**

- ① Partial prolapse : submucus injection of 5% Phenol in almond oil or Excision in a fashion as Haemorrhoidectomy.
 ② Complete prolapse : Surgical only.
 • Rectopexy [Charles Well's Operation] done through Abdominal Approach. The rectum is mobilized and pulled upwards. Then a piece of proline mesh is attached by sutures to pre-sacral fascia and then is wrapped around back side of rectum. So fibrosis leads to fixation.



N.B: [If unfit patient] Thiersch's operation (peri-anal circulage)

May be done which is passage of silver wire S.C Around the anus and tied with the assistant's little Finger in the anus. Then left for 40 days exciting Fibrosis & keeping rectum in place.



Final Written Exams



- | | | |
|------|---|---------------------|
| 1992 | • <u>Discuss</u> path., C/P & management of cancer Sigmoid | (20 Marks) |
| 1993 | • <u>Discuss</u> path., C/P & management of cancer Caecum | (30 Marks) |
| 1995 | • <u>Discuss</u> path., C/P & Investigations of cancer Rectum | (25 Marks) نور ثانی |
| 1996 | • <u>Discuss</u> path., C/P of carcinoma of Caecum | (15 Marks) |
| 1998 | • <u>Discuss</u> path., C/P of cancer Caecum & Rectum | (15 Marks) |
| | • <u>Discuss</u> Pathology, C/P, investigation of cancer caecum | (15 Marks) نور ثانی |
| 2001 | • <u>Mention</u> Pathology & C/P of Bilharzial colitis | (10 Marks) |
| 2002 | • <u>Discuss</u> Pathology, C/P & management of cancer sigmoid | (15 Marks) نور ثانی |
| 2003 | • <u>Discuss</u> Meckel's Diverticulum. | (9 Mark) نور ثانی |
| | • <u>Discuss</u> pathology & complications of cancer rectum. | (9 Mark) نور ثانی |
| | • <u>Discuss</u> pathology , C/P & magement of cancer caecum | (20 marks) |
| 2004 | • <u>Discuss</u> Pathology , C/P & magement of cancer Lt. colon | (20 marks) نور ثانی |

Chapter [12]

Intestinal Obstruction

Intestinal Obstruction

* Definition :

Arrest of downward propulsion of Intestinal contents.

* Classifications :

There are different 3 types of classifications :

[1] According to Pathological Nature of the cause :

[I] Simple obstruction :

Due to Mechanical occlusion of the gut lumen without interference with it's blood supply.

[II] Strangulation:

(a) *Pure* : As in Mesenteric vascular occlusion with patent lumen.

(b) *Mixed* : Both lumen & vessels of Intestinal loops are blocked.

As in ① Strangulated Hernia
② Intussusception.
③ Volvulus

[III] Neurogenic:

Due to paralysis of peristaltic activity of the gut → Paralytic Ileus.
i.e. loss of propulsive power of the bowel.

[2] According to the level of obstruction :

[I] High small bowel obstruction

[II] Low small bowel obstruction

[III] Large bowel obstruction.

[3] According to the onset & the course of obstruction :

[I] Acute obstruction: clinical course is rapid.

[II] Chronic obstruction: clinical course is slowly progressive.

[III] Acute on top of chronic obstruction: As in faecal impaction on top of colonic tumors.

ALSO

It is classified according to (Dynamic state):

- Dynamic : (Increased peristalsis)
Due to Mechanical occlusion of lumen.
- A dynamic : (No peristalsis)
Due to a) Paralytic ileus.
b) Vascular i.e. Mesenteric vascular occlusion.

1 Simple obstruction

* Definition :

It is a mechanical occlusion of the gut lumen without interference with it's blood supply

* Aetiology :

- ◆ In the lumen : As fecal impaction, gall stones, F.B, Tumors etc ...
- ◆ In the Wall : As atresia or stricture (Inflammatory or Neoplastic)
- ◆ Outside the wall : As adhesions or Internal Herniation.



Internal Hernia :

Portion of the small intestine passes into one of retroperitoneal fossa or into a congenital defect in the mesenteries. The potential openings are :

- ① Foramen of WINSLOW or Obturator foramen.
- ② Hole in the mesentery of intestine or transverse mesocolon.
- ③ Defect in the broad ligament of the uterus.
- ④ Congenital or acquired diaphragmatic hernia.
- ⑤ Retro-peritoneal fossa (Around duodenum and caecum).



Causes of Intestinal Obstruction According to Age :

① Newborn :

[A] Dynamic :

- Lumen : Meckonium Ileus & meconium plug syndrome.
- Wall : Congenital atresia, annular pancreas, congenital megacolon & Imperforated Anus.
- Outside : Volvulus neonatorum & Irreducible Hernia

[B] A dynamic :

Necrotizing Enterocolitis & septicaemia.

② Children : Strangulated Hernia, Intussusception, foreign body.

③ Adult : Strangulated Hernia, Tumors, Foreign body.

④ Old age : Strangulated Hernia, Tumors, Vascular occlusive.

* Pathology :

[A] Proximal segment :

■ Hyperperistaltic wave :

Sudden obstruction to the pathway of Intestinal contents → Stretch of the muscle of proximal segment → Increase the power of contraction i.e Hyperperistalsis to dislodge the obstructing agent towards the anus → colics & pain

■ Antiperistaltic wave :

Failure of proximal segment to dislodge the obstructing agent → Antiperistaltic wave is initiated in failure to dislodge the contents. i.e Anti-physiological way → vomiting

▪ Stage of dilatation :

The proximal segment start to fatigue then dilates → stagnation which invites infection & Fermentation → **Gas distention**.

N.B. The Sources of Gas production :

- ① The Bacterial fermentation (10%)
- ② Swallowed atmospheric air (68%)
- ③ Diffusion from blood into bowel lumen (22%)



Severe continuous distention leads, to occlusion of veins → Oedema of the wall of lumen → More distention leading to occlusion of arterioles → Ischaemia & gangrene of the bowel → perforation of the gut → **Peritonitis**.

[B] Distal segment:

Always empty and collapsed leading to **Absolute constipation**

* Clinical picture :

▪ Symptoms :

① Pain: [The 1st & Earliest symptom].

- Onset: Sudden
- Site: (a) Above umbilicus with High small intestine.
(b) Around & below umbilicus with Low small intestine
(c) Peripheral & lower abdomen with large intestine.
- Character: Colicky in nature.

② Vomiting :

- At 1st Gastric juice [*whitish mucoid*]
- Then Jejunal contents [*Greenish bile stained*]
- Finally Intestinal contents [*Brownish faecal*]

③ Distention :

Which is marked in colonic obstruction

④ Absolute constipation :

Which is failure to pass flatus or stools i.e No stool [In spite of desire]

▪ Signs :

[A] General signs :

- Signs of Dehydration: Inelastic dry skin, sunken eye, dry tongue, oliguriaetc.
- Signs of Shock:
 - Weak rapid pulse & Tachypnea (Air Hunger).
 - Hypotension & Hypothermia.
 - Pallor & Cold Extremities.

[B] Local signs :

- > Inspection: Distended Abdomen with visible peristalsis (step ladder)
- > Palpation: Tender abdomen specially over the site of obstruction & palpable mass if tumor is present.
- > Percussion: hyper - resonance.

- **Auscultation** : Early loud exaggerated intestinal sound indicates stage of hyperperistalsis followed by dead silent abdomen indicates Atony.
- **P/R** : may reveal a Rectal carcinoma.

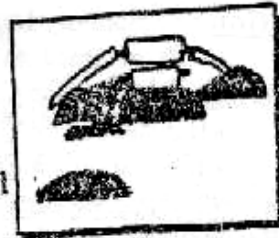
★ **Causes of Death** :

- ① Electrolytes imbalance.
- ② Inhalation pneumonia.
- ③ Peritonitis & septic shock.

★ **Investigations** :

[A] **Laboratory** : Serum electrolytes for Na⁺ & K⁺.

[B] **Plain X-ray** (Abdomen) shows multiple fluid level



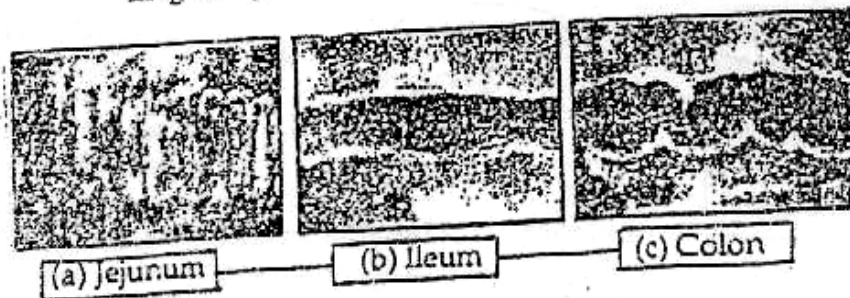
N.B. 3 films may be done :

① **Plain X-ray abdomen (Erect position)**. It shows multiple fluid levels (>3 fluid levels = diagnostic for intestinal obstruction, it may be arranged in a "step-ladder" pattern. Normally, 3 fluid levels may be present :

- a. At the stomach.
- b. At duodeno-jejunal flexure.
- c. Ileo-caecal region.

② **Plain X-ray abdomen (Supine position)** : it shows the pattern of the mucosa of the dilated part as follows :

- (a) **The jejunum** : regular mucosal folds valvulae conniventes, concertina like is seen complete with regular spaces in between, also it may be seen as regular ellipses.
- (b) **The ileum** : featureless with no mucosal pattern.
- (c) **The colon** : irregular mucosal folds incomplete folds and irregular spaces in between.



③ **Plain x-ray chest in Erect position** : it may show free air under diaphragm as in perforated bowels.

[C] **Barium enema** :

May reveal the cause if colonic obstruction.

[D] **Double Enema Test** :

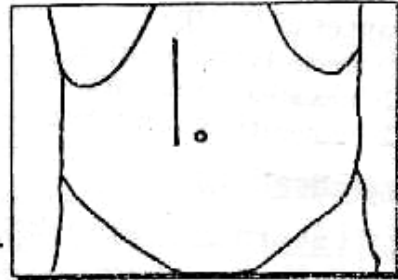
- 1st Enema, to washout the distal segment and wait for 1 hour.
- 2nd Enema, [if obstruction] it will comes out clear (no stools).

* **Treatment** : Urgent surgical relief

[A] **Pre-operative preparation** :

- ① Correction of fluid & electrolyte imbalance (Na^+ & K^+)
- ② Ryle's Tube suction to compress the bowel.
- ③ Foley's Catheter to check the urine out-put.

[B] **Operation** : Exploratory Laparotomy by
Rt. paramedian incision →



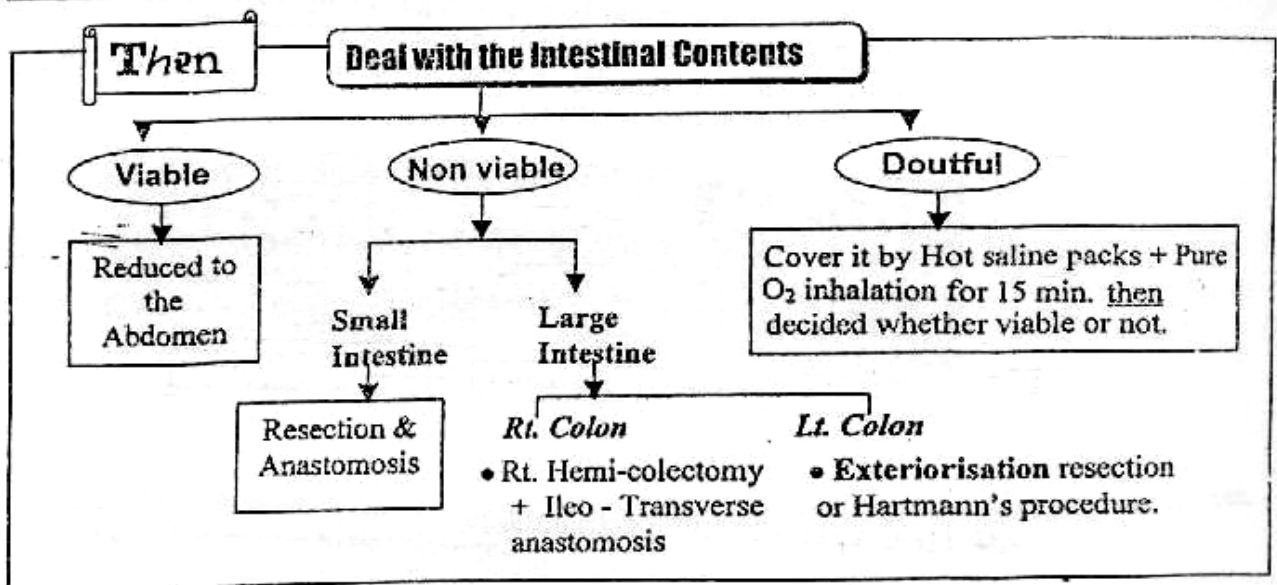
- ① **1st step** : inspect the Caecum
 - If distended → Colonic obstruction.
 - If collapsed → Small bowel obstruction.

② **Intestinal decompression** :
By Retrograde milking or Introduction of a large Tube sucker through a small enterotomy.

③ **Remove** the cause of obstruction.

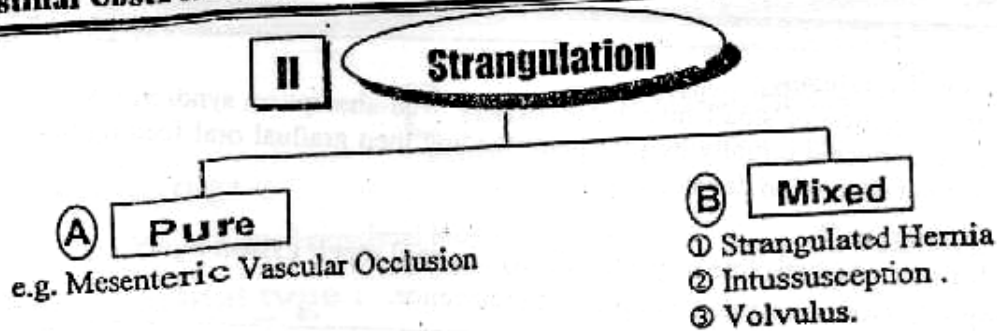
④ **The affected loop is examined** whether viable or not →

	Viable	Non viable
• Intestinal colour.	• Pink or Dark red.	• Brown to Black.
• Peritoneal lusters.	• Present.	• <u>Absent</u> .
• Mesenteric Arteries.	• Pulsating.	• <u>Non pulsating</u> .
• By pinching.	• Contracts.	• <u>No</u> response.
• Consistency.	• Firm.	• Floppy.
• If Injured.	• Bleeding occur	• <u>No</u> Bleeding.



But If the cause is irremovable or inoperable → **Bij - pass procedure.**

- **Small bowel** : Lateral anastomosis between highest distended loop & lowest collapsed loop.
- **Large bowel** :
 - *Rt. colon* : Ileo-Transverse anastomosis. (side to side)
 - *Lt. colon* : Proximal colostomy



(A) Pure strangulation

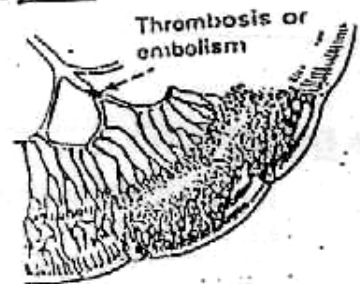
Mesenteric Vascular Occlusion (Ischaemic Colitis)

*** Definition :**

It is a sudden occlusion of major mesenteric vessels with patent lumen.

*** Aetiology :**

- ① Mesenteric Arterial Embolism.
- ② Mesenteric Arterial Thrombosis.
- ③ Mesenteric Venous Embolism.



*** Pathology :**

[A] Ischaemic Damage :

- Mucosa sloughs within 3 hours & blood in the lumen.
- The whole thickness of intestinal wall is affected within 6 hours & Exudes sero- sanguinous fluid in the peritoneum.
- The intestine becomes gangrenous & soon perforates → Peritonitis.

[B] Reperfusion Damage :

After return of blood flow, [either spontaneously or by surgery] result in release of oxygen free radicals from ischaemia bowel.

*** Clinical picture :**

- [A] General : "Hypovolaemic shock"**
- Weak rapid pulse & Tachypnea (Air Hunger).
 - Hypotension & Hypothermia.
 - Pallor & Cold Extremities.

[B] Local :

▪ **Symptoms :**

- Severe Acute Abdominal pain.
- Repeated vomiting.
- Bleeding per- rectum.

▪ **Signs :**

- Signs of Hypovolaemic shock as facial pallor.
- Abdominal Tenderness & Rigidity.
- Absence of bowel sound.

*** Treatment :**

Immediate Resuscitation by blood Transfusion + Urgent Laparotomy

Then resect the gangrenous intestine and restore blood flow of the viable ones by Embolectomy for Embolism or Endarterectomy or By-pass for Thrombosis.

N.B : ① Short Bowel syndrome :

If the resection of small Intestine > 70% → Mal-absorption syndrome which can be corrected initially by parenteral feeding then gradual oral feeding until Intestinal adaptation develops.

② Post-operative ↻

- Allopurinol (Anti- free oxygen radical) to avoid reperfusion injury.
- Heparin (Anti- coagulant) to prevent recurrence.

(B) Mixed strangulation

① Strangulated Hernia

See (volume "1")



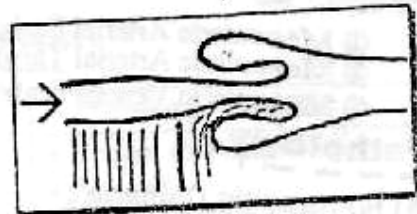
Strangulated hernia

② Intussusception

* Definition :

It is invagination of gut into the other i.e. proximal loop into the distal loop

N.B : Very rare Intussusception is retrograde



* Anatomical types :

- ① Ileo- Ileal : Ileum is invaginated into ileum .
- ② Ileo- caecal : Ileum is invaginated into caecum .
- ③ Ileo- colic : Ileo- Ileal advancing till it's apex enters the colon.
- ④ Colo- colic : Colon is invaginated into colon .

* Pathogenesis :

Partial obstruction of gut lumen by any cause will initiate the hyperperistaltic activity of proximal segment to overcome this obstruction.

But if hyperperistalsis is too much, it will push the wall of the gut of one loop to another.

N.B : Complete obstruction : Never leads to intussusception as the lumen is occluded i.e. No space for passage of a loop

* Clinical type :

- [A] Infantil Type [Common] →
- [B] Adult Type [Rare] ↻

- Usually due to organic lesion at apex, such as carcinoma
- Rarely Idiopathic. In Egypt during Ramadan, probably due to bulky meals taken after long hours of fasting.

Infantile Intussusception

* Definition :

It is invaginated proximal loop into distal one .

* Anatomical type :

Usually Ileo- Caecal type

* Incidence :

- The Most common cause of Intestinal obstruction of Infant.
- Age : 1st 2 year of life
- Sex : Male > Female

* Aetiology :

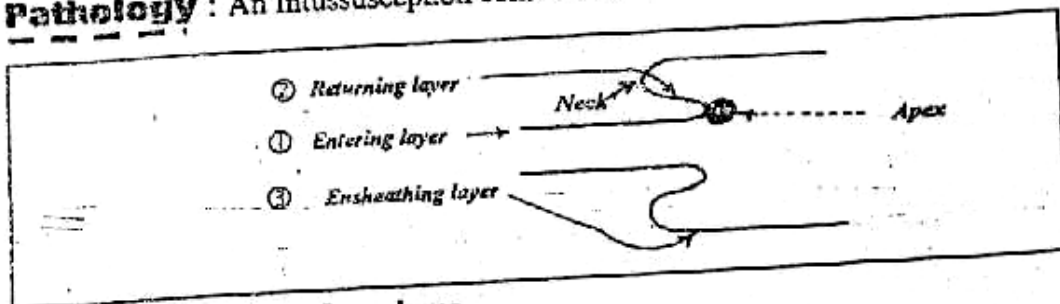
[A] Idiopathic (95%) but may be due to ↗

- ① Repeated gastro-enteritis → swollen lymphoid follicle in the terminal ileum which act as source of partial obstruction.
- ② In Infant : the caecum & colon are mobile. So they Telescope easily over the terminal ileum.
- ③ In infant : the Ileo-caecal valve is bulky & often project into the Caecum

[B] Secondary (5%)

There is an evident cause e.g Meckle's diverticulum

* Pathology : An Intussusception consists of ↗



- ① The Entering or Inner layer.
- ② The Returning or Middle layer
- ③ The Ensheathing or Outer layer.

Also

- * The Entry & Returning layer called Intussusceptum & They met at the Apex
- * The Ensheathing layer called Intussuscepiens & It joins the returning layer at the Neck

N.B. : The Mesentery (Containing blood vessels) may be compressed between the Entering and the Returning layer leading to Ischaemia & gangrene.

* Clinical Picture :

[Any Infants having colicky Abdominal pain with passage of bloody mucus per-rectum should be suspected of having Intussusception until prove otherwise]

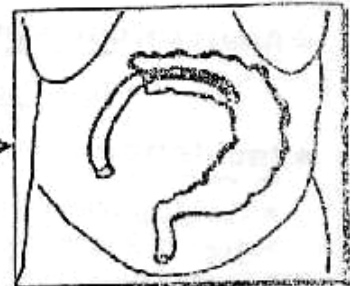
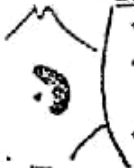▪ **Type of patient** : [3-12 Month & Male > Female]

▪ **Symptoms**

- ♦ Attacks of **colicky pain** denoted by Screaming or drawing the legs up to the abdomen.
- ♦ **Vomiting.**
- ♦ **Passage of bloody mucus** like (red current Jelly) per-rectum.

▪ **Signs** :

- ♦ Distention is **late** with empty Rt. iliac fossa = **Sign of Dans.**
- ♦ A **sausage shaped mass** (i.e Intussusception) any where in the Abdomen **except** Rt. iliac fossa
- ♦ **P/R Examination** : Reveal bloody mucus.



* **D.O** :

From Gastro-enteritis or feeding problems

* **Investigation** :

- **Barium Enema**: shows **Clow sign** —————>
- Occurs with **Ileo-colic** Type only.
- Shows sudden arrest of the dye at a **Cylindrical Filling defect.**



* **Treatment** :

[Resuscitation with correction of fluid & Electrolyte Imbalance]



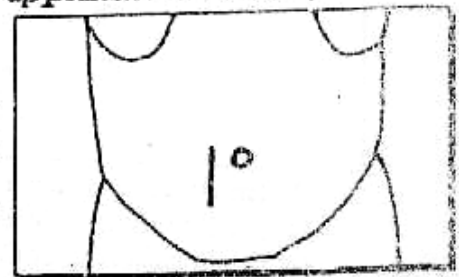
Ther Reduction of Intussusception either by ↗

[A] **Hydrostatic Reduction**: only with early cases.

Barium is running Through rectum under pressure and followed up under screen until complete reduction occurs evident by the appearance of Caecum, Appendix & Terminal Ileum.

[B] **Operative Reduction**:

[It is still the standard Treatment of all cases] through a **Rt. lower Transrectal** incision → the Thumb, Index & Middle fingers are inserted into the Abdomen and the intussusception is reduced by squeezing the apex in a proximal direction.



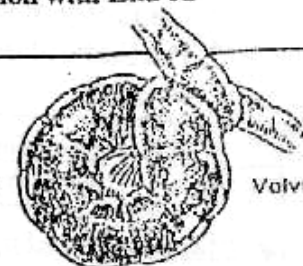
N.B : Don't pull on invaginated segment to avoid intestinal tear

IF The Reduction fails or gangrenous loop occur we do resection with End to End anastomosis.

(3) **Volvulus**

* **Definition** :

Twisting of loop of gut around the axis of it's own mesentery.



Volvulus

* **Pathogenesis** :

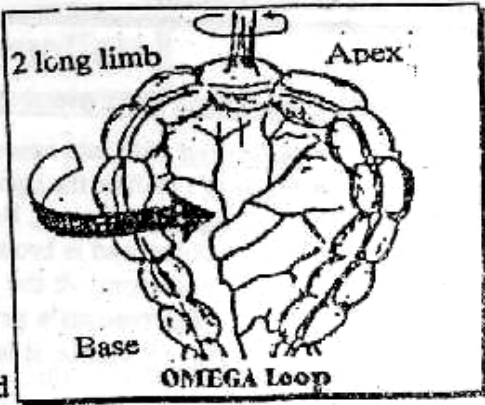
For a **Twist** to occur, the gut should be in the form of a **loop** with a mesentery [**Omega Loop**] = **long** limbs, **Narrow** base & **wide** apex.

[Intestinal Obstruction]

*** Types :**

- Volvulus of Sigmoid colon "The commonest".
- Volvulus of stomach, Small gut & Caecum.
- Volvulus Neonatorum. (see later)

Sigmoid Volvulus



*** Predisposing Factors :**

- [A] Chronic constipation which leading to over distended colon → Abnormal elongation of meso-colon So the base of meso colon becomes narrow.
- [B] Adhesions at the apex of the sigmoid loop facilitate it's Twisting.

*** Pathology :**

- [A] The upper loop usually falls in front of the lower. So that the Twist always in Anti-clockwise direction.

N.B. : Closed Loop obstruction Leading to

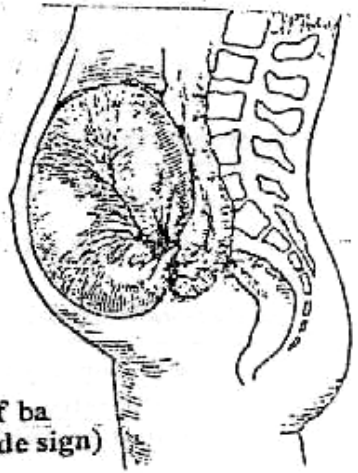
- ① Huge distention of the sigmoid colon with gas and fluid diffusion from congested bowel.
- ② The colon above is distended.
- ③ The Rectum below is collapsed & Empty.



- [B] Any interference with the bowel's blood supply as it Rotates > 1.5 Turn → Ischaemia & gangrene → Perforation & Peritonitis.

*** Clinical Picture :**

- Type of patient : Elderly constipated Male.
- Symptoms :
 - Sudden onset of severe abdominal pain & Distention.
 - Constipation is absolute "Early".
 - Vomiting "Late".
- Signs :
 - P/R Examination shows empty rectum.
 - Neglected cases may show picture of peritonitis.



*** Investigation :**

- Plain x-ray shows Huge gas filled sigmoid loop.
- Barium Enema : distended empty Rectum & arrest of barium at recto-sigmoid junction (Ace of spade sign)

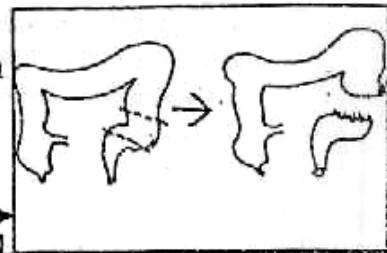
*** Treatment :**

(A) Conservative ttt :

- Indicated with Early cases with no evidence of gangrene.
- Method : Rectal Tube is passed through a sigmoidoscope to untwist the sigmoid loop. Success will lead to gush of gas & fluid stools. Finally the tube is left on place and the patient is prepared for later elective resection of the long sigmoid to prevent recurrence.

(B) Emergency surgical ttt :

- Indicated with late cases or failure of conservative ttt.
- Method : Deflate the sigmoid by untwisting the volvulus then **IF gangrenous**, Resection is done, The proximal colon end is brought out to the skin as terminal colostomy & the distal end is sutured (**Hartmann's procedures**) **But IF** viable, it is fixed to the posterior abdominal wall.

**III****Paralytic Ileus***** Definition :**

It is a paralysis of peristaltic activity of the gut.
i.e. Loss of propulsive power of the bowel.

*** Aetiology :**

- ① Reflex Inhibition of Intestinal motility following abdominal operation or spine fracture. It may be due to sympathetic overtone.
- ② Toxic Inhibition of Intestinal motility as Peritonitis.
- ③ Metabolic Abnormalities as $\downarrow K$ & $\downarrow Na$ etc....
- ④ Drugs overdose as Anticholinergics.

*** Clinical Picture :**

- Abdominal Distention, Absolute Constipation & Vomiting.
- The patient doesn't have colicky abdominal pain.
- Inaudible Intestinal sounds (**Silent Abdomen**).

*** Investigations :**

- [1] Laboratory : Blood urea & Electrolytes.
- [2] Plain X-ray : Multiple gas fluid level in Intestinal loop.

*** Prevention :**

- Pre-operative : Correction of Biochemical disturbances.
- Operative : Gentle Handling of the Intestine.
- Post-operative : Naso-gastric tube to decompress the bowel until return of Intestinal sound or passage of flatus.

*** Treatment :**

- Gastro-Intestinal suction until Intestinal sounds return.
- I.V fluid therapy especially K^+ & Na^+ .
- Drugs : para-sympathomimetics,
e.g. Prostigmine may be helpful.

Neonatal Intestinal Obstruction

★ Introduction:

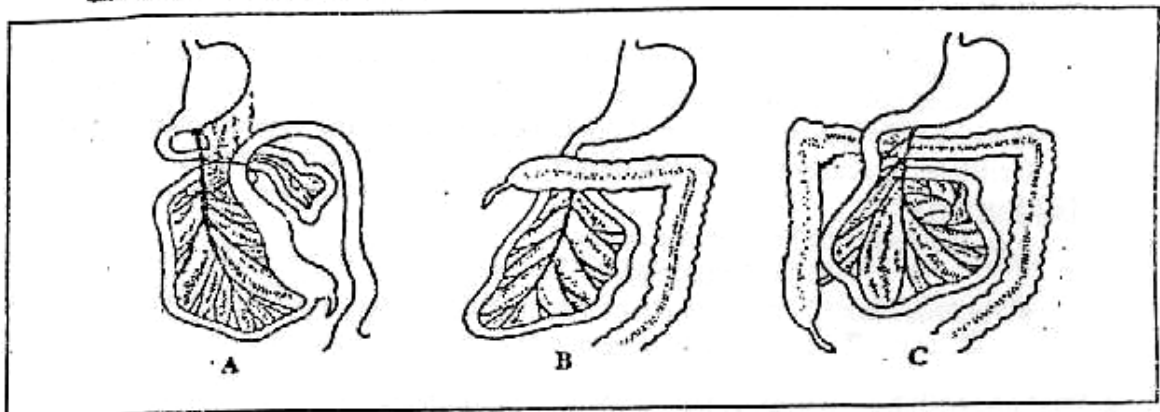
- Neonatal period up to month old.
- Infancy : 1 month – 2 years.
- Child : > 2 years.

★ Incidence : 1 : 1000 births.

★ Embryology:

In the intra-uterine life (at the 4th week) where the intra-embryonic caeleum is very small, so, the mid-gut extrudes into the umbilical cord. Later on reduction and rotation of the mid-gut occurs in 3 stages :

- a. First stage : Anti-clockwise rotation of the mid-gut (90°) : the colon lies to the left while the small intestine lies to the right
Failure of this stage : exomphalos (congenital hernia).
- b. Second stage : Anti-clockwise rotation of the mid-gut for (180°) : the small intestine becomes in the left side and the caecum becomes under the liver
Failure of this stage : malrotation of the mid-gut and volvulus neonatorum.
- c. Third stage : Anti-clockwise rotation of the mid-gut for the last (90°) : the caecum and ascending colon descent to the right iliac fossa, then they are fixed to the posterior abdominal wall.
Failure of this stage : the caecum and the appendix are sub-hepatic.



★ Aetiology:

[A] Dynamic (Mechanical):

- Lumen : ① Meconium Ileus.
 ② Meconium plug syndrome.
- Wall : ① Congenital Atresia. e.g. duodenal Atresia.
 ② Annular pancreas
 ③ Congenital Megacolon
 ④ Imperforated Anus
- Outside the wall : ① Volvulus neonatorum.
 ② Irreducible congenital hernia (vol. 1).

N.B. : The commonest causes duodenal or small bowel atresia 40%, Hirschsprung's diseases 30% and meconium ileus, volvulus neonatorum and other 30%.

[B] Adynamic : Necrotizing Enterocolitis & Septicaemia.

★ **Clinical Picture** : (All causes)

- ① Vomiting & Dehydration is the main symptoms.
- ② Colicky pain is known by continuous crying & withdrawing the legs.
- ③ Constipation & Abdominal distension.

★ **Investigation** :

Plain x-ray (erect) shows Multiple fluid level.

Meconium Ileus

★ **Definition** :

It is a generalized defect of mucous secretion of pancreas i.e. fibrocystic pancreas "Mucoviscidosis".

★ **Pathology** :

The terminal ileum is obstructed by thick meconium.

★ **Clinical Picture** : As General.

★ **Investigation** :

Plain abdominal X-ray : As General +

It show typical mottled "Ground glass appearance" of meconium.

★ **Treatment** :

[A] **Conservative** :

Clearance of the meconium by installation of gastrographin per rectum under x-ray control, the gastrographin is a radio-opaque, hyper-osmolar (drawing fluid into the bowel lumen) and contains an emulsifying agent (Tween) which facilitates evacuation of the meconium.

[B] **Surgery** :

- ◆ **Indications** : ① Failure of clearance.
② Perforation of the bowel.
- ◆ **Techniques** : ① Enterotomy and removal of the inspissated meconium by the lavage.
② If there is gangrene resection and anastomosis.

★ **Post operative** : Oral pancreatic enzymes are essential.

Meconium Plug Syndrome

The left colon is obstructed by a thick plug of meconium, during the 1st 24 hours, after rectal examination or saline washout, a large grayish plug of mucous followed by sticky meconium in a large amount are passed.

Duodenal Atresia

★ **Definition** :

It is imperforation of the duodenum i.e. Atresia.

★ **Pathology** :

It is usually affect the 2nd part of duodenum, it may be partial or complete.

★ **Clinical Picture:** As General +
The vomiting is bile stained with visible distended stomach.

★ **Investigation:**

Plain abdominal X-ray:

It is diagnostic showing distension of the stomach and proximal duodenum with absence of gas throughout the rest of the bowel "The double bubble sign".

★ **Treatment:** Duodeno-jejunostomy or gastro-jejunostomy after rehydration and gastric aspiration.

Volvulus Neonatorum

★ **Definition:**

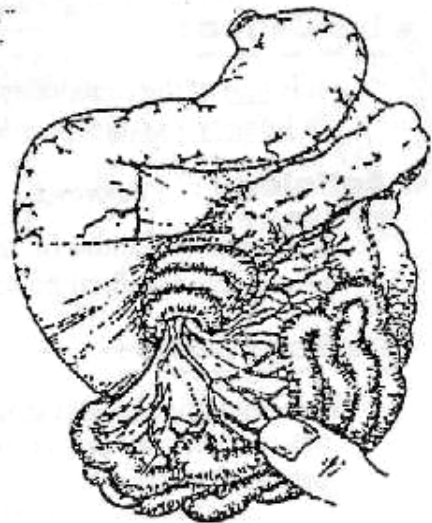
It is a volvulus in the midgut.

★ **Aetiology:**

Arrested rotation of mid gut predispose to volvulus

★ **Pathology:**

The floating caecum, together with small intestine, which has a narrow attachment, revolves in a clockwise direction. The torsion occlude the superior mesenteric vessels → ischaemic necrosis.



★ **Clinical Picture:**

- ⊙ The vomiting is bile stained (Early & Repeated).
- ⊙ Very mild or Absent distension in upper Abdomen.
- ⊙ The passage of bloody stools indicate infarction of the bowel.

★ **Treatment: (Immediate Surgery)**

The entire midgut should be rotated in Anti-clockwise direction. Non-viable gut should be resected (up to 70% of small intestine may be removed with good chance of survival with relatively normal growth & development).

Necrotizing Enterocolitis

Adynamic

★ **Aetiology:**

It is due to gas forming organism entering the wall of the intestine.

★ **Pathology:**

It is characterized by necrosis & gangrene.

★ **Clinical Picture:**

Generalized sepsis & Blood & mucus per rectum.

★ **Investigation:**

Plain abdominal X-ray:

It show distended loops of intestine, and gas bubbles may be seen in the bowel wall "Pneumatosis intestinalis".

★ **Treatment:**

Resuscitation & antibiotics If failed resection of gangrenous or perforated segment.

Large Bowel Obstruction

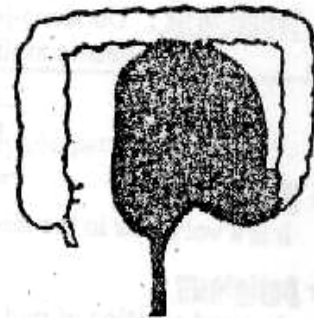
Hirschsprung's Disease (Aganglionic Megacolon)

* Definition :

It is dilatation and hypertrophy of colon, in absence of mechanical obstruction.

* Incidence :

It is one of the commonest cause of Intestinal obstruction in Infancy. (Male > Female) & (Familial 6%)



* Aetiology : [unknown]

It is due to Failure of migration of ganglionic cells of the para-sympathetic plexus into the distal bowel

* Pathogenesis :

The Aganglionic segment lacks the normal peristaltic activity leading to obstruction → progressive stagnation with dilatation & hypertrophy of proximal colon.

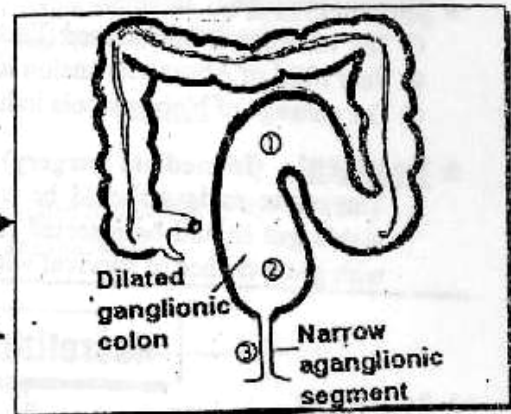
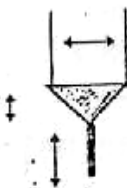
* Pathology :

It is mainly affect the Rectum & Anal Canal .

N.B. : Sigmoid & whole colon is rare.

It is divided into 3 segments

- ① Proximal dilated hypertrophied segment.
- ② Transitional zone (1-5 cm) (conical).
- ③ Spastic Aganglionic segment (collapsed).



* Clinical Picture :

[Any new born presenting with delayed passage of meconium for 24h. should be considered having **Hirschsprung's disease** until prove otherwise].

▪ Symptoms :

- Progressive constipation after birth.
(Motion every few days and only after insertion of a finger or tube).
- Progressive abdominal distention.
- Repeated attacks of Enterocolitis with failure to gain weight.

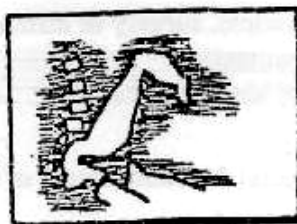▪ Signs :

- Visible peristalsis with Audible Intestinal sound pass along line of colon to terminate in the Lt. iliac fossa.
- Indentable faecal mass felt in the Lt. iliac fossa.
- P/R Examination shows Empty Rectum.

*** Investigations :**

[1] Barium Enema :

It will show 3 segment without preparation to avoid masking the changes of colonic caliber →



[2] Rectal Biopsy :

Only a small segment of mucosa & Submucosa is taken to show absence of ganglionic cell in submucous layer.

[3] Exploration : If intestinal obstruction

*** Treatment :**

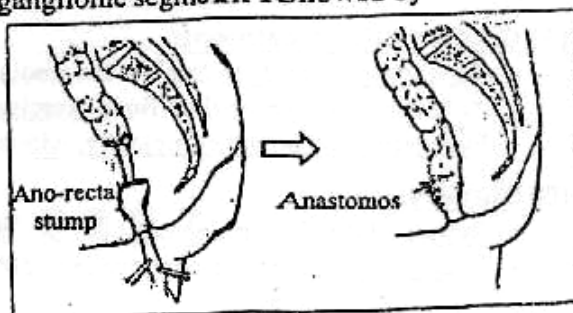
The Aim of ttt is to do complete excision of the Aganglionic segment followed by a colo-rectal anastomosis →

- This operation needs good general condition & prepared colon.

So preliminary Transverse colostomy is 1st performed to prepare the colon mechanically or chemically.



followed later by 2nd stage resection anastomosis of the affected colonic segment.



Faecal incontinence

*** Definition :**

Faecal incontinence is defined as the inability to retain the rectal contents .

*** Causes :**

(1) Damage to the anal sphincter:

- Obstetrical trauma causing complete perineal tear.
- Surgical trauma. e.g., during surgery for a high anal fistula.

(2) Complete rectal prolapse. The prolapsing rectum stretches the anal sphincters damaging them.

(3) Idiopathic faecal incontinence.

(4) Neurological diseases:

- Trauma or Tumours affecting the 2nd, 3rd & 4th sacral nerves.
- Diabetic neuropathy.

*** Assessment :**

(1) Clinical assessment:

- Degree of incontinence, e.g., incontinence to flatus only, flatus and fluid stools, or to solid stools as well.

- History of trauma, surgery or difficult labour.
 - Sphincter contraction.
 - Neurological assessment.
- (2) Manometry:
To detect rectal function, length of the anal sphincters, and their strength.
- (3) Electromyography:
Maps out the sphincters to detect silent areas.
- (4) Trans-anal ultrasound:
Can accurately localize the site of sphincteric damage .

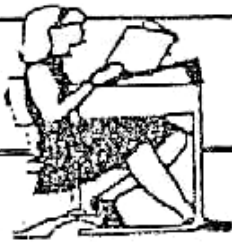* Treatment:

(A) Conservative treatment:

- Constipating agents to thicken the stools.
- Anal sphincters and pelvic floor exercises.
- Evacuating the bowel completely, with a glycerine suppository in the morning.

(B) Surgery:

- Repair of divided sphincters.
- Rectopexy will restore continence to 50% of those having complete Rectal Prolapse.



Final Written Exams



- | | | |
|------|---|----------------------------------|
| 1994 | • <u>Give an account on</u> Aetiology, C/P, investigation & outline briefly the principle of ttt of the volvulus of sigmoid colon | (30 Marks) |
| 1995 | • <u>Discuss</u> C/P & Investigations of acute Infantile Intussusception | (15 Marks) |
| 1997 | • <u>Discuss</u> Infantile Intussusception C/P and Investigations.
• <u>Discuss</u> volvulus of sigmoid colon | (15 Marks) نور ثقی
(10 Marks) |
| 1999 | • <u>Discuss</u> C/P & Management of Infantile Intussusception
• <u>Discuss</u> paralytic Ileus | (15 Marks) نور ثقی
(10 Marks) |
| 2000 | • <u>Discuss</u> C/P, Treatment of volvulus of the sigmoid colon | (10 Marks) |
| 2003 | • <u>Discuss</u> Infantile Intussusception. | (9 Mark) نور ثقی |
| 2004 | • <u>Discuss</u> C/P & managemnt of Ileo-coecal Intussusception | (20 marks) نور ثقی |

Chapter [13]

The Anal Canal

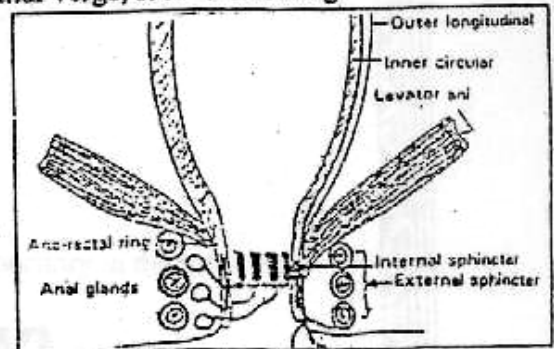
The Anal Canal

Surgical Anatomy

The anal starts at ano-rectal junction and ends at the anal verge, it is 4 cm long.

[A] Ano-Rectal Ring

- It is the junction between the rectum and the anal canal, it is formed by fused parts of :
 - Pubo-rectalis muscle (part of levator ani).
 - External sphincter.
 - Internal sphincter.
 - Longitudinal muscle.
- It can be felt clinically.
- Division of the ano-rectal ring :
Leading to permanent incontinence.



[B] Anal Canal Musculature :

① The Internal sphincter :

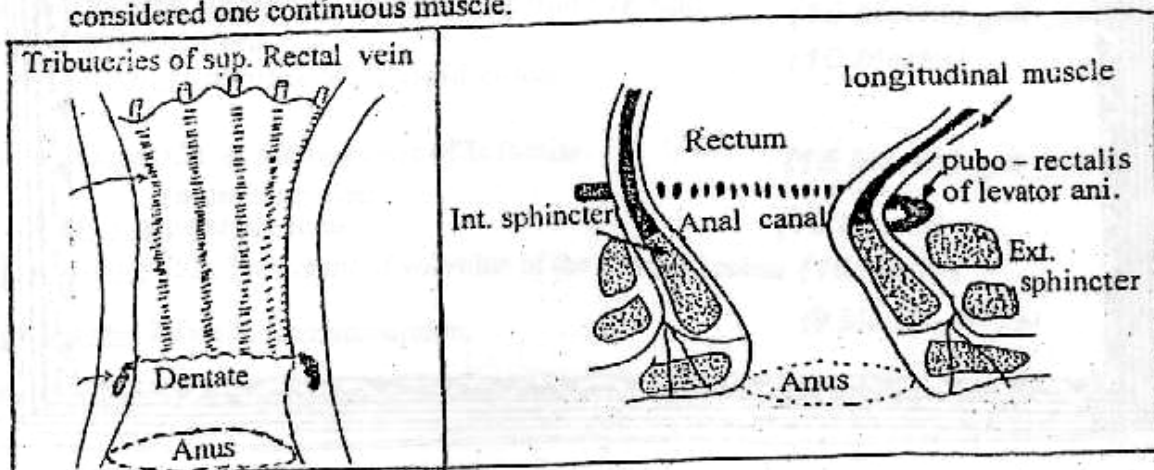
- Continuation of the circular muscle coat of the rectum.
- It is involuntary muscle (most important muscle).
- It is 2.5 cm long and 2-5 mm thick.
- Spasm of this muscle : play a major part in fissure and other anal affections.

② The longitudinal muscle :

- Continuation of the long muscle coat of the rectum.
- It's fibers fan-out through the external sphincter to be inserted into the anal and peri-anal skin (corrugator-cutis ani).

③ The External sphincter : (Voluntary muscle) .

It is subdivided into; deep, superficial, and subcutaneous parts. However, it is now considered one continuous muscle.



[The Anal Canal]

	Internal sphincter	External sphincter
1. Type of muscle	Smooth (involuntary)	Skeletal (voluntary)
2. Innervation	Autonomic	Somatic
3. Role in continence	Responsible for sustained contraction closing anal canal, but has no role in voluntary control of defecation.	Contracts voluntary only to inhibit defecation if surrounding conditions are unsuitable.
4. Effect of injury	No effect of voluntary control	Leads to incontinence.

[D] The Mucosa of the Anal Canal:

⊙ *Anal columns* (columns of Morgagni) : longitudinal folds end in anal valves.

⊙ *Anal valves* :

- Transversely semilunar folds.
- Present half-way in the anal canal.

⊙ *Anal crypts*.

[E] The Dentate Line (pectinate line): It corresponds to the columns of Morgani, it is about 3mm. It is transitional or stratified epithelium, above it the lining epithelium is columnar while below it, it is stratified epithelium. Represent the site of fusion of :

⊙ *Proctodaeum* (which is invagination of the ectoderm).

⊙ *Post allantoic gut* i.e. the union of embryonic ectoderm and the gut endoderm.

	Above dentate line	Below dentate line
☞ <i>Embryology</i> :	- Endoderm- Hind gut	- Ectoderm - proctodaeum
☞ <i>Anatomy</i> :		
<i>Lining</i> :	- Simple columnar.	- Stratified squamous.
<i>Arterial supply</i> :	- Superior rectal artery.	- Inferior rectal artery.
<i>Venous drainage</i> :	- Portal.	- Systemic.
<i>Lymphatic drainage</i> :	- Pelvic, lumbar.	- Inguinal.
<i>Nerve supply</i> :	- Autonomic.	- Somatic.
☞ <i>Physiology</i> :	- Less sensitive	- Excellent sensation.
☞ <i>Pathology</i> :		
<i>Cancer</i> :	- Adenocarcinoma.	- Squamous cell carcinoma.
<i>Piles</i> :	- Internal haemorrhoids.	- External haemorrhoids.

[F] Arterial supply: Superior, middle & Inferior rectal artery.

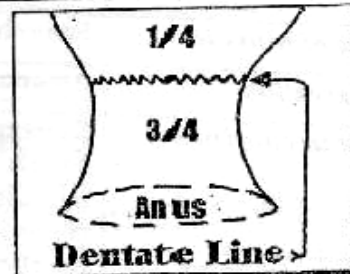
[G] Venous supply: See (piles)

[H] Lymphatic supply : See (cancer rectum)

I

Ano-Rectal Malformation**Embryology**

- The upper $\frac{1}{4}$ of Anal Canal is derived from the distal part of hindgut.
- The lower $\frac{3}{4}$ of Anal Canal is derived from the proctodaeum which is invagination of the Ectoderm.
- The 2 separated developed parts meet at the Dentate or pectinate line.

**Imperforated Anus***** Types :****(A) High Anomalies : (More Common).**

Failure of rectum to pass through the pelvic floor.

① Ano-rectal Agenesis :

- Rectum : Shows A blind end above the level of pelvic floor and usually has a fistulous communication with posterior urethra in Male or vagina in Female.
- Anal Canal : Not present.

② Rectal Atresia :

- Rectum : Shows A blind end above the level of pelvic floor with no fistulous formation.
- Anal Canal : Normal but ends blindly at the level of pelvic floor.

③ Cloaca :

- Only with Female,
The Bowel, Urinary and Genital tracts all are opened as a common wide cavity.

(B) Low Anomalies : (Less Common)**④ Covered Anus (Male)**

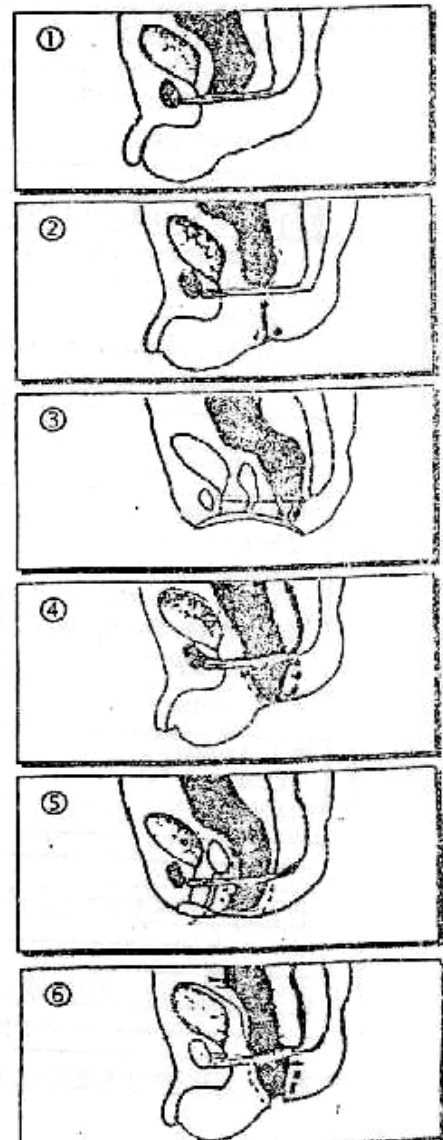
The underlying anal canal is covered by a Bar of skin with a Track running forward to the perineal raphe.

⑤ Ectopic Anus (Female)

The Anus is situated anteriorly and may open in the vulva & rarely in the vagina.

(C) Intermediate Anomalies : (Rare)**⑥ Membranous Anus :**

Anus is normally sited but is covered with a thin membrane which bulges with the retained meconium. The membrane present at dentate line.



*** Clinical Picture :**

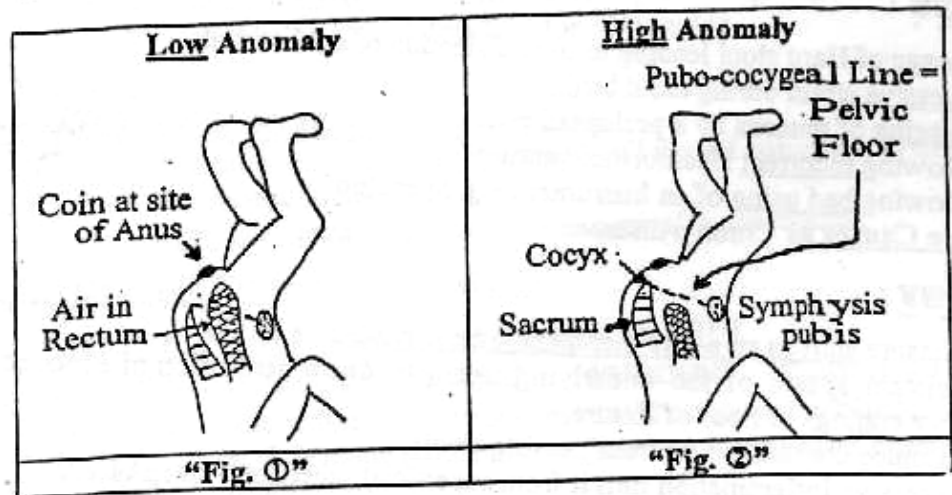
The Diagnosis is easy, provided that the anus has been inspected and examined as essential part of routine examination of any new born.

N.B. : IF Meconium present on the tip of penis this means High defect (Ano-rectal Agensis) with Recto-urethral fistula

*** Investigations :**

■ X-ray "Invertogram"

- 24 hours after birth with the infant held upside down with a radio-opaque marker on the Anus e.g Coin
- Then A line is drawn from the symphysis pubis to the cocyx.



- IF the gas shadow in the Rectum is seen above the Pubo-coccygeal line the anomaly is Low see (Fig. ①).
- But IF below the line the anomaly is High see (Fig. ②).



*** Treatment :** According to ↗

(A) High Anomalies :

- 1st stage : Temporary Colostomy.
- 2nd stage : Abdomino-ano-rectal pull through.
- 3rd stage : Closure of Colostomy.

(B) Low Anomalies :

Local perineal operation, as Excision of skin bar

(C) Intermediate Anomaly :

Cruciate Incision of membrane Anus with Trimming the edge

II **Anal Fissure**

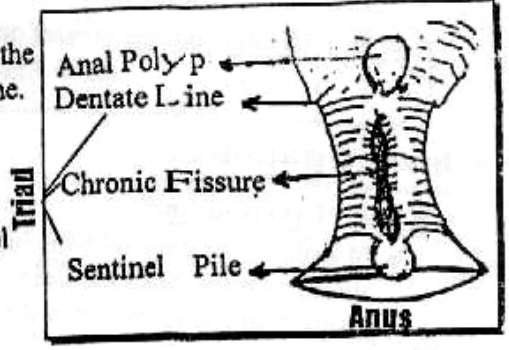
(Fissure In Ano)

*** Definition :**

Elongated ulcer in the long Axis (mid line) of the lower end of anal canal i.e. below the dentate line.

*** Incidence :**

- Posterior Fissure about 90% because less blood supply & Maximum site of trauma by stool
- Anterior fissure 10%



*** Aetiology :**

- ① Passage of Hard stool leading to over distention of anal canal.
- ② Excessive strain during child birth.
- ③ Dragging of mucosa by a prolapsed pile.
- ④ Following incorrect Haemorrhoidectomy.
- ⑤ Following bad using of an Instrument e.g. Speculum.
- ⑥ Rare Causes as Chron's disease.



*** Pathology :**

The Anal fissure start as an acute then turn to be chronic due to

- (a) Persistant spasm of the underlying sphincter due to irritation of exposed nerve endings in floor of fissure.
- (a) Continuous contamination from passing stools.
- (a) Progressive Inflammation turn it from superficial ulcer into deep ulcer.

Acute Anal Fissure	Chronic Anal Fissure
<ul style="list-style-type: none"> ■ <u>Superficial</u> ulcer with <u>little</u> inflammation & oedema. ■ <u>Spastic</u> Internal sphincter. ■ <u>Mobile</u> base (<u>no</u> fibrosis). ■ <u>No</u> sentinel pile. 	<ul style="list-style-type: none"> ■ <u>Deep</u> ulcer with <u>marked</u> inflammation & oedema. ■ <u>Fibrosed</u> internal sphincter. ■ <u>Fixed</u> base (fibrosis). ■ <u>Sentinel</u> pile.

N.B. : Sentinel Pile :

- It is raised (Indurated) Skin tage.
- It occurs due to oedema & spasm of the sphincter.
- It present Just below the fissure.

*** Complications :**

Abscess, Fistula or Perianal Eczema with Pruritis ani.

*** Clinical Picture :**

- Symptoms :
 - Pain during & after defecation especially if constipated.
 - Discharge : Slight sero-sanguinous discharge or Slight bright blood on stools.
 - Reflex symptoms : as Burning micturation, Dysmenorrhea ...etc.

■ **Signs :**

[A] Acute fissure is seen & not felt with severe spasm of Anal sphincter.

[B] Chronic fissure is seen & felt with Sentinel pile below.

* **D.D. :** From Painful Anal Condition.

- e.g
- | | |
|--------------------------|---------------------------------|
| ① Anal Fissure, | ④ Prolapsed strangulated piles. |
| ② Anal Carcinoma | ⑤ Pruritis Ani. |
| ③ Peri-anal suppuration. | ⑥ Perianal Haematoma. |

* **Treatment :**

[The Aim is to obtain complete relaxation of Internal sphincter]

[A] Acute Fissure : (Mainly Conservative).

- ① Relieve constipation by liquid Paraffin & Dieting.
- ② Local Anaesthesia ointment & Analgesics e.g Lignocain
- ③ Warm baths after defecation for 15 minutes.



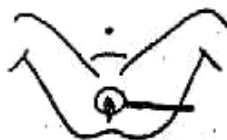IF all the above measures failed.

We must do Temporary paralysis of Internal sphincter to allow the fissure to heal

Through digital dilatation under general Anaesthesia.

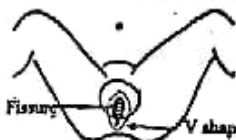[B] Chronic Fissure : (Surgical only)

[1] IF the Fissure is (not) very chronic i.e. Early



[**Closed Lateral Internal Sphincterotomy**] operation is very successful. The Internal sphincter is divided at 3 O'clock position. This leads to relief of spasm & allow healing.

[2] IF the Fissure is very chronic i.e. Late



[**Fissurectomy & Posterior Internal Sphincterotomy**] operation through excision of the Fissure, Polyp & sentinel pile + division of internal sphincter (posteriorly)

III

Haemorrhoids (piles)

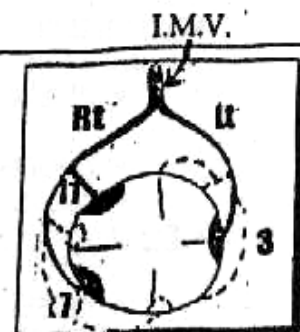
Introduction

Normally, the Terminal branches of the superior rectal vessels (Portal) form a sort of vascular plexus with middle & Inferior rectal vessels (Systemic) beneath the epithelial lining of anal canal called

"Anal Cushions" which arranged at 3, 7, 11 O'clock positions

SI Any congestion, Enlargment & prolapse of this Cushions will constitute piles.

- (a) Internal piles = Above Dentate line & covered by mucosa.
- (b) External piles = Below dentate line & covered by skin.
- (c) Intero-external piles.

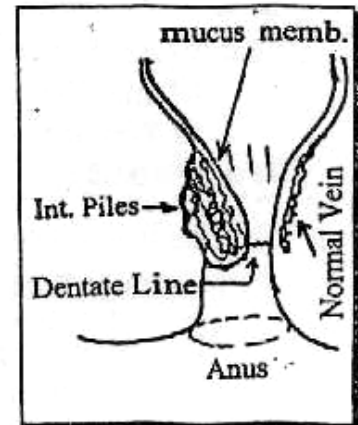


(A) Internal Piles

* Aetiology :

[A] Primary Piles : Predisposed by :

- ① Genetic : Congenital weak mesenchyme.
- ② Sphincter relaxation due to loss of tone as in old age.
- ③ Anatomical Factors ↷
 - (a) The dependency with absence of valves of the tributaries of superior rectal vein.
 - (b) The veins lay in lax submucosa & can be easily compressed by stool.
 - (c) The veins are constricted as they pass through the muscle coat.



[B] Secondary piles :

- ① Pregnancy : Raised Intra-abdominal pressure and laxing effect of the Progesterone.
- ② Pelvic Tumors : Especially Rectal carcinoma (It should be excluded in any patient > 40 years with bleeding per rectum with evident piles).
- ③ Portal Hypertension : Leading to Ano-rectal varices.

* Pathology : [4 Degrees]

I • 1st degree : The patient has only bleeding but no prolapse of piles. They only diagnosed by Proctoscopy.

h • 2nd degree : The piles prolapse only during defecation, but they are spontaneously reduced at the end of the act.

h • 3rd degree : The piles prolapse during defecation, & the patient has to reduce it manually.

h • 4th degree : There is permanent prolapse of piles.

* Clinical Picture :

▪ Symptoms :

- Bleeding per-rectum : Bright red. At 1st, noticed at Toilet paper after defecation, later on becomes profuse.
- Prolapse (swelling) & Anal Discharge.
- Pain is absent except if complicated (The patient use the word pain to mean "I don't like it")

▪ Signs :

- Inspection : for Perianal area for prolapse & Skin tags.
- Palpation Not reveal the presence of piles unless they are thrombosed. Also to exclude Rectal carcinoma.
- Proctoscopy will reveals the piles & Sigmoidoscopy with old patient to exclude Rectal carcinoma.

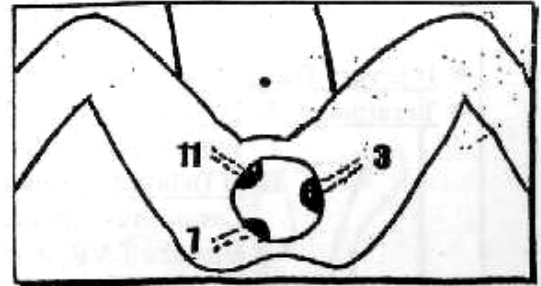
*** Complications :**

- ① Bleeding per rectum: usually mild, moderate or severe Leading to Anemia.
- ② Prolapse of piles.
- ③ Strangulation of prolapsed piles.
- ④ Thrombosis or ulceration following stagnation.
- ⑤ Gangrene if tight strangulation.
- ⑥ Suppuration if infected piles leading to portal pyaemia.

*** Treatment :**

(A) If primary piles:

- ◆ 1st & 2nd degree
 - ① Conservative.
 - or ② Injection Sclerotherapy.
 - or ③ Rubber band ligation.
 - or ④ Cryosurgery.
 - or ⑤ Photocoagulation.
- ◆ 3rd & 4th degree : Surgery is Recommended.



(B) If secondary piles : Treatment of the cause.

① **Conservative Treatment**

- a. Light non-irritant diet.
- b. Small doses of laxatives.
- c. Venous Creams & Suppositories containing Decongestants e.g. proctocedyl

② **Injection Sclerotherapy**

- The Aim : Injection of irritant material produce thrombosis which **stop** the bleeding & prevent prolaps by fibrosis.
- The method : 5-20% Phenol in almond oil injected above dentate line. About 3-5cc are injected one each time is injected at one week Interval.

N.B : NO Need for Anaesthesia because injection is above dentate line (Non sensitive area).

- The complications:
 - ① Stricture of Rectum due to excessive fibrosis.
 - ② Submucous Abscess.
 - ③ Pain if injected too low or too deep in Internal sphincter.

③ **Rubber band ligation " Barron's"**

The Idea is to place a tight elastic rubber band around the pedicle of the pillows leading to Ischaemia, Necrosis & Separation later on

④ **Cryosurgery**

The Idea is to apply a liquid nitrogen (- 196 °C) causes Coagulating necrosis of the piles which separates later. **But** the disadvantage is that patient has prolonged mucous discharge.

⊙ **Photo-coagulation:**

The Idea is to give infra-red photo-coagulation at (100 °C) which cause coagulate necrosis.

* **Surgical treatment:** If 3rd & 4th degree.

We do Haemorrhoidectomy ; Trans-fixation excision operation

N.B

Prolapsed Strangulated piles

* It is very Dangerous because act as source of portal pyaemia.

* Treatment: **A. If Early Diagnosed**

surgical Intervention with strong Antibiotics.

B. If Delayed Diagnosed

Conservative measures including Rest in bed with foot of bed is raised to ↑ VR, Antibiotics, Analgesics, Laxatives & **Lead Subacetate Lotion** to ↓ oedema.

Some Surgeons: Perform maximal anal dilatation under anesthesia to relieve Sphincteric spasm.

B **External piles**

Thrombosed external hemorrhoid
[Perianal Haematoma]

* **Definition:** It is a small clot occurring in the perianal subcutaneous connective tissue.

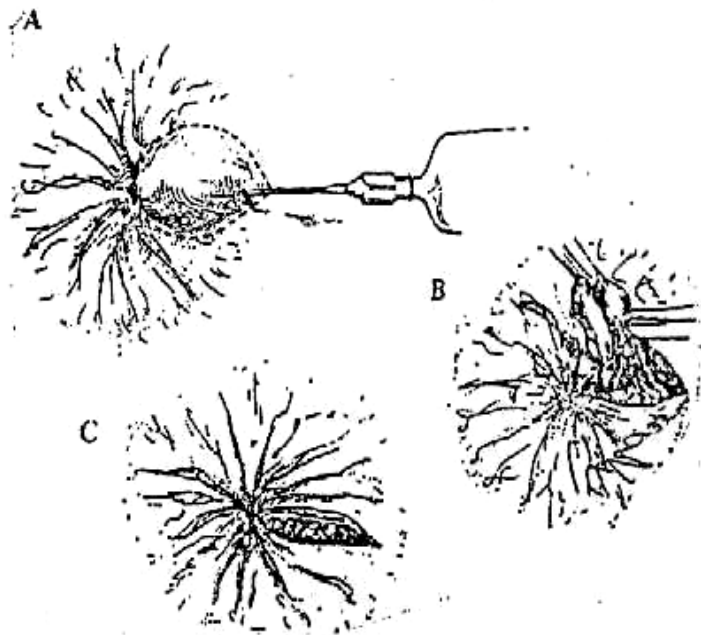
* **Etiology:** It is due to back pressure on an anal venule as a result of straining at stool, coughing or lifting a heavy weight.

* **Clinical Picture:**

- **Symptoms:** the condition appears suddenly and is very painful,
- **Signs:** Tense, tender bluish swelling covered with smooth shining skin.

* **Fate:** Untreated it may resolve, suppurate, fibrose or burst.

* **Treatment:** Under local anesthesia, the hemorrhoid is bisected & the two halves are excised with a small portion of adjacent skin so as to leave a pear shaped wound, which is left open to granulate.



IV Ano-Rectal Abscess

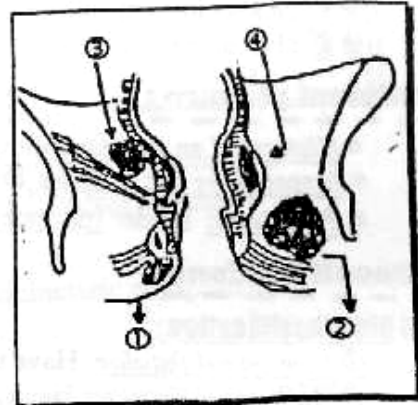
* Aetiology :

Either 1ry or 2ry ⇨

1- 1ry Ano-rectal Abscess:

- Due to infection of the anal glands or 2ry to infected skin.
- Pathology ⇨

- Infection of these glands by Gram -ve bacilli leads to formation of an Inter-sphincteric abscess which may spread ⇨
 - ① Downward → Peri-anal Abscess.
 - ② Out-wards → Ischeo-rectal Abscess.
 - ③ Inwards → Submucous Abscess.
 - ④ Upwards → High Inter-sphincteric Abscess
- In the majority of these abscess, there is an inner opening in the anal canal and drainage of the abscess usually followed by a fistula.



2- 2ry Ano-rectal Abscess: May developed ⇨

- ① Inflammatory bowel disease as in Crohn's disease
- ② Specific Infection as T.B.
- ③ Ano-rectal carcinoma.
- ④ Infection of Peri-anal Haematoma or thrombosed piles.

* Classification :

- ① Peri-anal (60%) The Abscess lies subcutaneously adjacent to the anal orifice. The pain & Toxic symptoms are not marked.
- ② Ischeo-rectal (30%) The abscess shows large indurated, Tender swelling filling the ischeo-rectal space. Toxic symptoms one marked i-e Throbbing pain. If Involve the other side it will lead to (Horse shoe) abscess.
- ③ Submucus (5%) It lies in submucosa above dentate line. The patient has severe pain & Fever But nothing is seen outside the anal verge. P/R reveals tender hoggy swelling.
- ④ Pelvi-rectal (5%) It is actually a pelvic abscess 2ry to Appendicitis, Salpingitis or Diverticulitis. It is localized above the levators ani muscle.

* Treatment : Don't wait for fluctuation

Urgent Surgical Drainage under general Anaesthesia.

V Anal Fistula { (Ano-rectal fistula)
(Fistula in Ano)

*** Definition :**

Chronic Granulating Track opened between the skin of peri-anal region & the cavity of the anal canal or rectum.

*** Aetiology :**

Neglected peria-anal Abscess: [4 Factor] responsible for chronically

- 1st: Anal gland act as reservoir for infection.
- 2nd: presence of Int. opening allows recurrent activation of infection.
- 3rd: Associated specific pathology such as crhon's, T,B etc....
- 4th: Fecal material may, act as foreign body.

*** Clinical picture :**

- History of an abscess followed by purulent discharge.
- Inspection: one or more External peri-anal opening
- Palpation: Tender Indurate cord under skin.

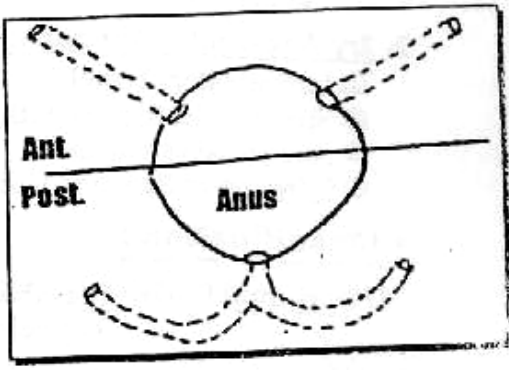
*** Classifications :**

(I) Old Classification :

- ① Low Anal fistulae: Have their Int. opening **below** ano-rectal ring.
- ② High Anal fistulae: Have Int. opening **Above** ano-rectal ring.

(II) Good Sall's Rule :

All Fistulae behind the transverse anal line open by a common int. opening (posteriorly) in the middle line & curved Tracks
While each ext. opening in the Anterior aspect has it's own int. opening & the track is straight



(III) Recent classifications :

Almost all anal fistulas have their opening at the level of the dentate line of the anal canal communicating to an Inter-sphincteric abscess cavity.

① Inter-sphincteric Fistula : (70%)

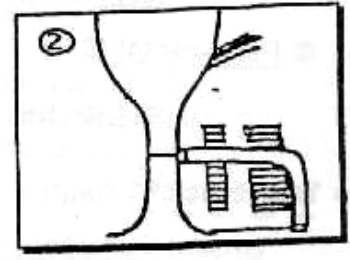
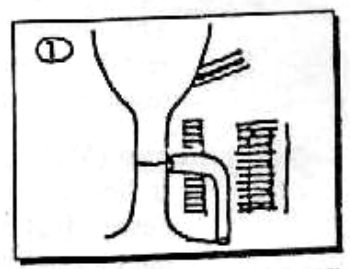
It passes between Internal & External sphincter

② Trans-sphincteric fistula : (25%)

It passes Through both Internal & External sphincters.

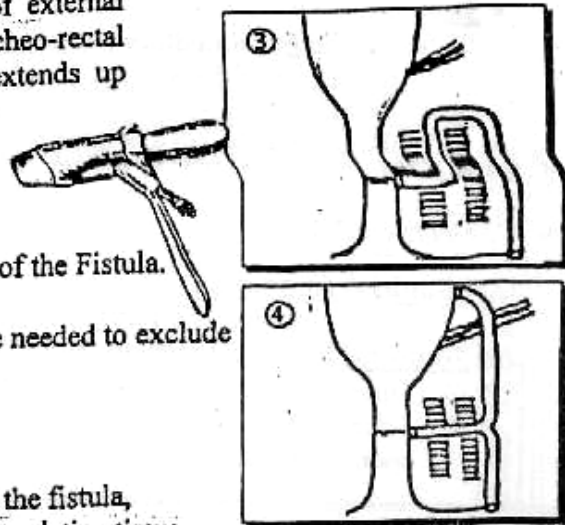
③ Supra-sphincteric Fistula : (4%)

It passes upwards along the inter-sphincteric plane then laterally to above the ano-rectal ring to enter the ischio-rectal fossa to the peri-anal skin.



④ **Extra-sphincteric Fistula : (1%)**

The Track passes outside the plane of external sphincter and passes through the Ischio-rectal fossa to reach the peri-anal skin. It extends up through the levator ani to the rectal wall.



* **Investigations :**

[A] **Proctoscopy:** may show Int-opening of the Fistula.

[B] **Colonoscopy + Ba. Enema:** may be needed to exclude an under lying specific cause.

* **Treatment :**

[1] **Inter-sphincteric : Fistulotomy** .open the fistula, curette then left open to heal by granulation tissue

[2] **Trans-sphincteric : Deroofing the Track** by division of the lower part of Internal sphincter & superficial part of External sphincter.

[3] **Supra- sphincteric : 2 stages**

- ♦ **1st stage :** Deroof the lower part of the Inter-sphincteric component.
- ♦ **2nd stage :** Excision of the remaining track

[4] **Extra-sphincteric :** Proximal colostomy & Staged fistulotomy then treat the underlying cause.

VI

Pilonidal Sinus

* **Definition :**

Common minor condition of skin overlying sacrum. There is a S.C granulating Cavity Containing Hair & connected to skin by midline opening.

* **Aetiology :** 2 Theories

(A) **Congenital Theory :** Infected dermoid cyst which present after puberty.

(B) **Acquired Theory :** (More Accepted)

Loose Hairs from head & back gravitate to the skin over the sacrum and Coccyx → pressure form sitting or bad hygiene → Hair drawn through the Skin to accumulate in S.C Tissue with debris & organism.

* **Clinical picture :**

■ **Type of patient :**

young adult males with dense, dark & strong hair.

■ **Symptoms :**

Patient may be asymptomatic or usually present with discharge or acute abscess or pilonidal sinus if improperly treated.

■ **Signs :**

The discharge at midline and lateral openings are seen. Sometimes with loose hair comes out of them.

★ **D.D. :** Perianal Abscess & Fistula.

★ **Treatment :**

(A) **Pilonidal Abscess :**

Incision & Drainage of pus.

(B) **Pilonidal Sinus :** 2 Options ☺

- ① Opening the resulting wound is allowed to heal by 2ry intention.
- ② Localized excision of the cavity and side Tracks. The wound may be left open to granulate or is closed by sutures.

VII

Anal Carcinoma

★ **Pathology :**

- Upper 1/2 → Adenocarcinoma.
- Lower 1/2 → Squamous cell carcinoma or Basal cell carcinoma.

★ **Spread :**

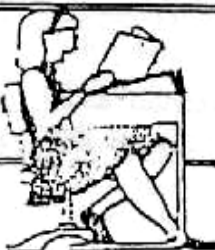
- **Direct :** e.g. Rectum.
- **Blood :** as cancer lower part rectum.
- **Lymphatics :** • Upper 1/2 → as Rectum.
• Lower 1/2 → Inguinal L.Ns.

★ **Clinical Picture :**


- **Symptoms :** ① Perianal pain with defecation.
② Bleeding per rectum.
- **Signs :** ① Inguinal L.Ns (Hard & Not Tender).
② P/R → Tumor is felt.

★ **Treatment :**

- **Operable** → A.P resection ± block dissection of inguinal L.Ns.
- **Inoperable** → Radiotherapy.



**Final
Written Exams**



- 1992 • **Discuss** Imperforated Anus
- 1993 • **Discuss** Fistula in Ano
- 2002 • **Discuss** C/P & complications of piles.
- 2003 • **Discuss** Painful perianal condition.
• **Discuss** Pilonidal sinus.

(15 Marks)

(10 Marks)

(12 Mark)

(9 Mark) نور ثانی

(9 Mark) نور ثانی

Chapter [14]

Abdominal Injuries

Abdominal Injuries

* Aetiology :

- [A] Closed :
- ① *Direct Trauma* : Blunt Trauma e.g. Car Accident.
 - ② *Indirect Trauma* : Fracture Ribs.
 - ③ *Spontaneous Rupture* : Rare with Pathological organs
- [B] Opened :
- ① *Gunshot wounds*.
 - ② *Punctured* due to stabbing.
 - ③ *Operative Trauma*.

* Clinical Picture :

- [A] History of Trauma : To Upper Abdomen or Lower Chest followed by an abdominal pain + shock.
- [B] Examination : May reveals signs of Internal Hge and shock + signs of External Trauma as bruises.

For Example "Rupture Spleen"

▪ Fatal type :

Severe Haemorrhage with sudden death due to tearing of Splenic vessels or Complete Avulsion of Splenic pedicle.

▪ Classical Type : It passes in 3 Stages ↷

① Stage of Shock : i.e. Hypovolaemic Shock.

- Weak rapid pulse & Tachypnea (Air Hunger).
- Hypotension & Hypothermia.
- Pallor & Cold Extremities.

② Stage of Recovery from Shock i.e. Lucid Interval Due to Temporary arrest of bleeding from Hypotension.

③ Stage of Internal Haemorrhage i.e. Signs of Rupture Spleen Due to rise again of the blood pressure after Resuscitation.

◆ The Signs are ↷

[A] Tenderness & Rigidity over the Lt. hypochondrium then becomes all over the Abdomen with Shifting Dullness.

[B] Balance's sign : Shifting Dullness on Rt. side from the free blood in the peritoneum & Fixed Dullness on the Lt. side due to blood clots & Retro-peritoneal haematoma.

[C] Kehr's Sign : Referred pain to Lt. shoulder from diaphragmatic irritation especially with Trendlenburg's position.

▪ Delayed Type :

[The Initial Shock is followed by a long lucid interval up to 15 days, After which the patient presents with features of Internal Haemorrhage].

This delay is due to ↷

- [1] Formation of Subcapsular Haematoma which may be ruptured later.
- [2] The Greater Omentum seals the splenic tear then retracts later on.
- [3] Blood Clots seals the tear then retracts later on.

*** Investigations :**


- [1] Plain x-ray : (upper Abdomen & Lower chest).
- [2] Sonar & CT scan : (Abdomen) Diagnostic.
- [3] Abdominal paracentesis : "D.P.L"
Diagnostic Peritoneal Lavage may reveal blood.

*** Treatment :**

[A] Anti-shock measures : Bl. Transfusion, wormth, morphia etc ...

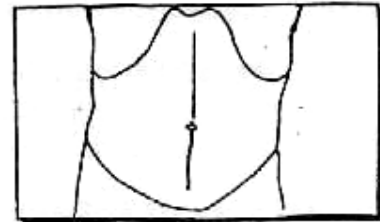
[B] Immediate Laparotomy : (لدا ↷)

- Anaesthesia : General Anaesthesia.
- Position : Supine position
- Incision : Midline incision from xiphisternum to symphysis pubis.



▪ Steps :

- Exploration of all abdominal viscera starting with solid organs, any escaping bowel contents denote hollow viscus injury.
- Injured organs : are delt with as follows ↷



[1] Spleen : Splenectomy

or Splenic preservation especially in children as it plays an important role in immune mechanism especially against Pneumococci.

The preservation through ↷

- ① Sutures of Small Lacerations or Tears i.e. Splenorrhaphy.
- ② Partial Splenectomy : If avulsed one pole.
- ③ Auto-Transplantation of splenic fragments : Which is wrapped by omentum this may help if depulped.

N.B. : Pneumococcal Anti-Toxin (Pneumovax) :

Should be given in young adult up to 18 years after Splenectomy.

[2] Liver :

"The priority is for the Arrest of bleeding"

[S0]

We control the liver Haemorrhage by a combination of Temporary packing of the bleeding area & Application of the "Pringle's Manoeuvre" which is application of a Vascular clamp to the free border of lesser omentum or holding it between 2 fingers, to occlude the hepatic artery & portal vein for 20 minutes.

Then **There are 3 Possibilities** →

- ① **IF the Tear is Accessible**, it is repaired by deeply placed mattress sutures supported by a pad of peritoneum.
- or ② **IF the Tear is Extensive or Inaccessible**, the Incision should be extended into the chest along the 8th intercostal space.
The Aim is **To** arrest bleeding, **To** remove the necrotic devitalized tissue, **To** preserve as much viable tissue as possible & **To** do external drainage.
- or ③ **IF There is Extensive Haematoma or Ruptured liver tissue**, we must do "**Hepatic Resection**" **then** Drainage of peritoneal Cavity to avoid peritonitis **then** prophylactic A.B are prescribed.

[3] **Mesentery** : Tear is sutured.

[4] **Stomach** : Tear is sutured.
 The damaged part is excised & the defect is closed.

[5] **Duodenum** : Tear is sutured.
 A catheter can be inserted into the duodenum to prevent it's narrowing.

[6] **Pancreas** : Tear is sutured.
 IF the Tail is injured → Distal Pancreatectomy with Ligation of distal end of the duct is done.

[7] **Small Intestine** : Tear is sutured
 The damaged segment is Resected & Anastomosed

[8] **Large Intestine : (Colon)**

- *Rt. colon* : As small Intestine.
- *Transverse & Lt. colon* : closure with proximal colostomy.

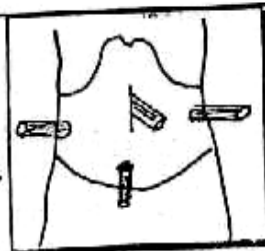
[9] **Gall bladder** : Cholecystectomy.

[10] **Common bile duct** : Tear is suture on **T-tube**.

[11] **Kidney** : Tear is sutured.

N.B. : ① IF Avulsed pole → Partial Nephrectomy.
 Or ② IF Avulsed pedicle → Nephrectomy provided that the other one is good.

[12] **Urinary bladder** : Tear is sutured.
 With **Supra-pubic Tube** for 7-10 days to keep the bladder empty.
 ■ **Closure** : The Abdomen is closed over **Drains** →



Chapter [15]

**Acute Abdomen, Haematemesis
&
Bleeding Per-rectum**

(1) Acute Abdomen

The Items of this chapter are discussed in details in their chapters

* Definition:

Acute Abdomen is any abdominal pain requiring urgent relief.

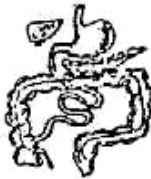* Classification of causes:

[A] According to the mode of presentation:

- (1) *Colics* : Inestinal Appendicular and Biliary .
- (2) *Inflammation* : Appendicitis, Cholecystitis, Pancreatitis, Diverticulitis, as Meckel's diverticulitis.
- (3) *Perforations* : Perforated appendix, Peptic ulcer, Gall bladder, Diverticulum, and typhoid ulcer of the small bowel.
- (4) *Intestinal obstruction*: Simple, Strangulation, and Paralytic ileus.

[B] According to the causes:

(1) Gastro-Intestinal Causes:



- (1) Acute perforated peptic ulcer.
- (2) Acute Cholecystitis.
- (3) Acute Pancreatitis.
- (4) Acute Appendicitis.
- (5) Acute Diverticulitis.
- (6) Intestinal Obstruction.
- (7) Mesenteric Vascular Occlusion.

(2) Urological Causes:

- (1) Calculi of urinary Tract.
- (2) Inflammation of urinary tract.

(3) Internal Haemorrhage.

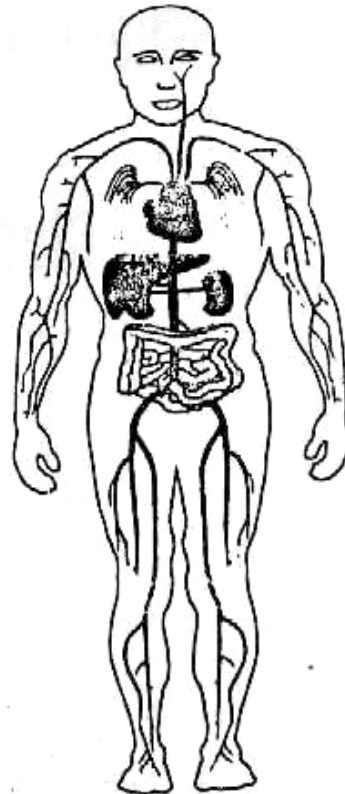
(4) Gynecological Causes:



- (1) Mid menstrual pain.
- (2) Dysmenorrhea.
- (3) Rupture ovarian cyst.
- (4) Twisted ovarian cyst.
- (5) Tubal abortion.
- (6) Rupture ectopic pregnancy.
- (7) Pelvic Inflammatory disease (PID).

(5) Other Causes:

- (1) Basal pneumonia & Pleurisy.
- (2) Myocardial Infarction.
- (3) Severe gastritis & duodenitis.
- (4) Hepatitis
- (5) Diabetic ketoacidosis.
- (6) Uraemia.
- (7) Haemolytic crisis.



[Acute Abdomen]

[C] According to site:

(1) Upper abdominal:

- Perforated peptic ulcer.
- Acute cholecystitis and biliary colic.
- Acute pancreatitis.

(2) Mid-abdominal:

- Intestinal obstruction.

(3) Rt lower abdomen:

- Acute Appendicitis.
- Meckel's diverticulitis.
- Torsion undescended testis.

(4) Lt lower abdomen:

- Colonic diverticulitis.
- Colitis
- Torsion undescended testis.

(5) Pelvic:

- Pelvic inflammatory disease (PID).
- Complicated ovarian cyst.
- Rupture Ectopic pregnancy.

(6) Abdominal and back pain:

- Acute Pancreatitis
- Rupture Aortic Abdominal Aneurysm.
- Posterior duodenal ulcer penetrating pancreas.

*** D D of Acute Abdomen :**

[A] History:

- Age :
 - *Neonate* e.g Neonatal Intestinal Obstruction.
 - *Child* e.g Strangulated Hernia.
 - *Adult* e.g Appendicitis, Cholecystitis, Peptic ulcer ... etc.
 - *Old age* e.g Tumer, Ishaemic colitis ... etc.
- Sex:
 - If Female think about Ectopic pregnancy, Rupture ovarian cyst, etc.

Examples:

The most Common Causes are:

(1) Acute perforated peptic ulcer.	(6) Acute Diverticulitis
(2) Acute Cholecystitis	(7) Rupture ovarian cyst
(3) Acute pancreatitis.	(8) Torsion of ovarian cyst.
(4) Acute Appendicitis.	(9) Pelvic inflammatory disease
(5) Intestinal obstruction	(10) Rupture Ectopic pregnancy

(1) Acute perforated peptic ulcer:

History of ulcer in (80%), sudden onset of severe agonising pain in the epigastrium, followed with short period of (lucid Interval) followed by picture of peritonitis.

(2) Acute Cholecystitis:

History of pain at Rt. Hypochondrium & radiated to Rt, shoulder with fever., Headach, Malaise & Anorexia.

(3) Acute Pancreatitis:

History of Gall stones or Alcohol drinks, with severe agonizing pain at epigastrium & radiated to back, ↑ on flat position & ↓ on leaning forwards.

(4) Acute Appendicitis:

History of pain around umbilicus, shifted to Rt. Iliac.fossa with nausea or vomiting.

(5) Intestinal Obstruction:

History of Absolute constipation, Colics Distention & Vomiting.

(6) Acute Diverticulitis:

History of colicky pain at sigmoid colon of old constipated patient i.e. Diverticulosis coli. Or History of colicy pain similar to Acute appendicitis i.e. Meckl's diverticulitis.

(7) Rupture ovarian cyst:

History of severe lower abdominal pain tenderness & gurdng with no toxaemia.

(8) Torsion of ovarian cyst:

History of severe lower lateral abdominal pain with palpable adnexal mass.

(9) Pelvic inflammatory disease (PID):

History of sever lower abdominal pain with high toxaemia suspected with female in the reproductive period. IUD increases the possibility.

(10) Rupture Ectopic pregnancy:

History of sever lower abdominal pain with patient with High risk factors as Salpingitis, Tubal ligation, Tubal repair or I.U.D.

[B] General Examination:

- Dehydration .
- Shock.
- ± Toxaemia

[C] Local (Abdominal) Examination:

(Inspection, Palpation, Percussion, Auscultation, PR & PV) especially for →

- 1- Murphy's sign = Cholecystitis
- 2- Tenderness & Guarding = Peritonitis
- 3- Tender McBurny's = Appendicitis
- 4- Pointing sign by asking the patient to point of maximum pain

[D] Investigations**[1] Laboratory:**

- Leucocytosis (Inflammation)
- Urine Analysis
- Serum Amylase (Pancreatitis)
- Serum Electrolytes.

[2] Radiological***i.e Role of Radiology in Acute Abdomen****** Examples:**

- Perforated peptic ulcer or gut: Free air under diaphragm
- Intestinal Obstruction: Multiple Fluid levels, distended bowels
- Urological Causes? : Calculi is seen in 80% of cases.
- Rupture Spleen: loss of psoas shadow ± fracture rib, obliterated splenic outline, Indentation of gastric air bubble.

[3] Ultra sonography:***i.e Role of U/S in Acute Abdomen****** Examples:**

- Acute Cholecystitis: Seen enlarged, thick wall (oedema, thick bile (mud), calculi if present is seen in 96% of cases.
- Free fluid (Internal haemorrhage, peritonitis).
- Acute Pancreatitis. Abscess or Pseudocyst
- Rupture liver or spleen (haematoma).
- Intestinal Obstruction (distended bowels with fluid and gas, free fluid if perforation occurs)
- Ureteric Colic (it may show back pressure on the kidney, Renal stones ± ureteric stones).
- Gynaecological conditions: Ectopic pregnancy, Ruptured ovarian cyst.

(II) Haematemesis

*** Definition :**

Vomiting of blood which will be of Dark red in colour, Acidic in reaction, associated with food particles & may be preceded by vomiting & followed by Melena.

*** Causes of Haematemesis :**

Usually due to lesion above duodeno-jejunal junction.

[A] General Causes : Hypertension, purpura or Hypoprothrombinaemia.

[B] Local Causes : (Oesophageal Causes)

- ① Oesophageal Varices.
- ② Oesophageal Carcinoma.
- ③ Oesophagitis (Retention or Reflux).
- ④ F.B. Impacted.
- ⑤ Mallary weiss syndrome.

(Gastro-duodenal Causes)

- ① Chronic Peptic Ulcer.
- ② Gastric Carcinoma.
- ③ Acute Gastric Erosions.

In Egypt : The Commonest 3 causes are :

- ① Oesophageal Varices 50%.
- ② Chronic Peptic Ulcer.
- ③ Acute Gastric Erosion.

*** Diagnosis :**

D.D	Haematemesis	Haemoptsis
<ul style="list-style-type: none"> • <u>History</u> : • <u>Preceded by</u> : • <u>Followed by</u> : • <u>The Blood</u> : 	<ul style="list-style-type: none"> • GIT Troubles. • Vomiting. • Melena. • Dark Red, <u>Acidic</u> with food particles. 	<ul style="list-style-type: none"> • Chest Troubles. • Cough. • Blood stained Sputum. • Bright Red, <u>Alkaline</u> with frothy sputum.

D.D	Bleeding Ulcer	Bleeding Varices
<ul style="list-style-type: none"> • <u>History</u> : • <u>Endoscopy</u> : • <u>Portal pressure</u>: • <u>Sengestaken Tube</u> : 	<ul style="list-style-type: none"> • Dyspepsia relieved By <u>Antacids</u>. • +ve Ulcer. • <u>Normal</u> Pressure. • <u>No Effect</u>. 	<ul style="list-style-type: none"> • <u>⚡</u>, Liver Cirrhosis & Hepatosplenomegaly. • <u>+ve</u> Varices. • <u>High</u> Pressure. • <u>Control</u> Bleeding.

*** Management :**

Investigations & ttt for

- [A] Oesophageal varices → Look for Portal Hypertension.(Chapter 3)
- [B] Chronic peptic ulcer → Look for Stomach.(Chapter 2)

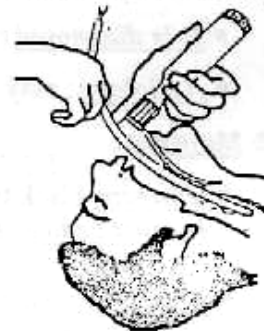* Management of acute upper GI bleeding :

- (1) Estimation of severity of bleeding and resuscitation.
- (2) Localization of the site and cause of bleeding.
- (3) Treatment of specific lesions.

(1) Estimation of severity of bleeding and resuscitation:

(Endotracheal intubation should be considered to avoid Aspiration pneumonia)

- 1- Admit to hospital.
- 2- Insert 2 peripheral venous lines and withdraw blood for cross-matching .
- 3- A central venous is needed for monitoring of severe cases.
- 4- Insert a Foley catheter. Urine output is the best monitor of tissue perfusion.
- 5- A Naso-gastric tube is inserted for all cases.
- 6- If the patient is irritable give, 5-10 mg Morphine IV to sedate him, but contraindicated in cases of liver insufficiency.
- 7- Ringer's lactate are started until blood available.
- 8- Correct coagulopathy by I.V vit. K.



(2) Localization of the site and cause of bleeding:

■ History:

- Previous attacks and their management.
- Hepatitis and Shistosomiasis.
- Medications, particularly NSAIDS.
- Peptic ulcer symptoms.

■ Examination:

- Splenomegaly, Ascites, Nodular Liver.

■ Laboratory tests:

- Hg % and haematocrit value.
- Liver function tests will be disturbed in patient with cirrhosis and oesophageal varices.
- Blood urea and creatinine.

■ Fibreoptic Endoscopy:

Endoscopy is the most important test. It should be performed as early as possible once the patient has been resuscitated. The procedure is done under a mild sedative as diazepam.

- Barium Radiography is loosing because it is less accurate than Endoscopy.

■ Angiography:

In difficult situation where radiology or endoscopy fails to diagnose the lesion.

(3) Treatment of specific lesions:

- Bleeding oesophageal varices (Chapter 3).
- Bleeding peptic ulcers (Chapter 2).

(III) Bleeding per Rectum

* Definition :

Passage of blood per rectum may be →

- ① Occult bleeding per-rectum.
- ② Melena.
- ③ Fresh bleeding per-rectum [Haematochezia].

* Types and Aetiology :

① Occult bleeding per-rectum :

- It means passage of small microscopic quantity of blood in stools that can not be detected by gross appearance.
- It is diagnosed chemically only as by "**Benizidine Test**"
- Aetiology : may be any cause of Int. Haemorrhage.

② Melena :

- It means black tarry stools from lesion above Ileo-caecal valve.
- It must be to differentiated from patient which ingest iron, charcoal or who treated by Bismuth.
- Aetiology : All causes of Haematemesis
 - + ① Meckle's diverticulum.
 - ② Chron's disease.
 - ③ Bleeding Typhoid ulcer.

③ Fresh bleeding per-rectum :

Aetiology →

A) General Causes :

Thrombocytopenia, Purpura, Vit. K deficiency etc--.

B) Local causes :

◆ Anal Canal Causes :

- Piles. (The commonest cause)
- Anal fissure.
- Anal Carcinoma

◆ Colo-rectal causes :

- Congenital : Familial polyposis coli.
- Inflammatory : ① Amoebic or Bacillary desentery.
② Bilharzial colitis.
③ Ulcerative colitis.
- Vascular : Ischaemia colitis.
- Diverticular disease of colon.
- Neoplastic : Cancer colon or rectum.
- Angiomatous malformation of colon.

*** Diagnosis :**

[A] Bleeding + Pain:

it may be ① Anal Fissure
or ② Anal Carcinoma.

[B] Bleeding + No pain:

- ① Blood mixed with stool = Cancer Colon.
- ② Blood Streaked on stool = Cancer Rectum.
- ③ Blood after defecation = Piles
- ④ Blood & mucous = (Ulcerative & Bilharzial) Colitis
- ⑤ Blood alone = Diverticulitis Coli.
- ⑥ Melaena = Peptic ulceration.

*** Management :**

[A] History:

Including all symptoms of upper & lower G.I.T.

Taking in your consideration the following.

*** Age:**

- Neonates & children: e.g Juvenile polyps, Mickles Diverticulum.
- Adult: e.g Piles or Anal fissure
- Old age: e.g Malignancy

*** Examples:**

1- Anal Fissure:

Painful bleeding, bright red & pain lasting long after passing stool.

2- Cancer Colon:

Recent change in bowel habits (progressive constipation not respond to purgative) & Blood mixed with stool.

3- Cancer Rectum:

Sense of Incomplete defecation with Blood streaked an stool

4- Piles:

Blood after defecation at toilet paper

5- Colitis:

Bilharzial or Ulcerative

6- Diverticulosis coli:

Predisposed usually with constipation.

[B] General Examination: Pallor + Shock

[C] Local Examination : P/R for (Piles, Fissure, Polypes)

[D] Investigations:

[1] Laboratory:

Stool analysis (Bilharziasis, Amoebiasis), Haematocrit and full blood picture

[2] Radiology:

- * Abdominal U/S: for liver, ascites, masses.
- * Trans-rectal U/S: for small lesions

[3] Instruments:

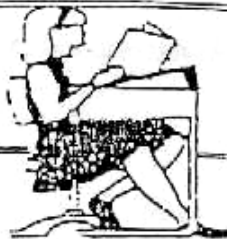- * Endoscopies (the most important investigations).
- * Proctoscopy, Sigmoidoscopy or Colonoscopy).

[4] Exploration:

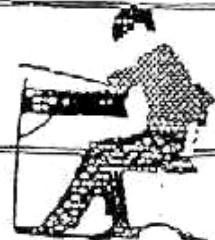- * Laparoscopic or open Laparotomy are the last investigations after failure of all previous investigations.

[E] Treatment:

- In 90% of the cases, the conservative measures stop bleeding and elective surgical treatment according to the causes is carried out.
- In 10% of the cases, the bleeding is massive or continued so one of the followings may be done:
 - 1-Therapeutic Colonoscopy: Polypectomy, Electrocoagulation (Diathermy or LASER) or Injection of vasopressors, or Embolisation.
 - 2- Surgery: (a) Segmental resection of the bleeding site if the source of bleeding is clearly identified.
 - (b) Subtotal or Total colectomy if the source of bleeding is not clearly identified.



Final Written Exams



- 1986 • Discuss the causes of Haematemesis (10 Marks)
- 1994 • Bleeding per-rectum (Differential diagnosis) (15 Marks)
- 1998 • Discuss Diagnosis & ttt of Acute Haematemesis (25 Marks) نور ثانی
- Discuss Acute Appendicitis (symptoms) & DD of Acute Abdomen. (20 Marks)
- 1999 • Discuss causes & Investigations of fresh bleeding non rectum (10 Marks)
- 2003 • Discuss DD & management of Haematemesis (20 marks)



Chapter (16)

DD of Abdominal Swellings

DD of Abdominal Swellings

(1) Right Hypochondrial Swellings

[I] Abdominal wall masses :

e.g. Lipoma, Abscess, Fibrosarcoma of muscles ... etc

[II] Intra-abdominal masses :

① **Liver** : ♦ **Localized** mass due to ↗

1. Amoebic liver Abscess.
2. Hydatid cyst.
3. 1ry carcinoma e.g. Hepatoma.
4. 2ry deposits of liver.

♦ **Diffuse** mass due to ↗

1. Bilharzial liver fibrosis (the commonest).
2. Hepatitis.
3. Obstructive jaundice.
4. Congestive liver due to heart failure.

② **Gall bladder** :

1. Mucocoele or pyocoele (Empyema).
2. Pericholecystic mass.
3. Carcinoma of gall bladder.
4. Palpable according to Courvoisier law.

③ **Rt. kidney & Rt. supra-renal gland** :

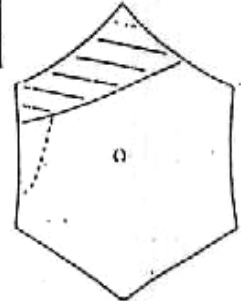
1. Hydronephrosis.
2. Polycystic kidney.
3. Renal tumors.
4. Supra-renal mass (Rare).

④ **Colon** : (Hepatic flexure)

As carcinoma.

⑤ **Retro-peritoneal masses**

The commonest : Gall bladder mass and Hepatomegaly.



(2) Left Hypochondrial Swellings

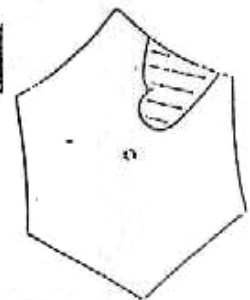
[I] Abdominal wall masses :

e.g. Lipoma, Abscess, Fibrosarcoma of muscles ... etc

[II] Intra-abdominal swellings masses :

① **Spleen** : Causes of splenomegaly.

② **Stomach** : e.g. carcinoma.



② *Lt. kidney & Lt. supra-renal gland :*

1. Hydronephrosis.
2. Polycystic kidney.
3. Renal tumors.
4. Supra-renal mass (Rare).

③ *Colon : (Splenic Flexure) As Carcinoma.*

④ *Retro-Peritoneal masses.*

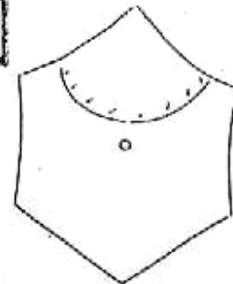
The commonest : Splenomegaly and Renal mass.

(3) Epigastric Swellings

[I] Abdominal wall masses : As before + Epigastric hernia

[II] Intra-abdominal masses :

- ① *Stomach* : Pyloric obstruction or cancer.
- ② *Lt. lobe liver* : Tumor or cyst.
- ③ *Transverse colon* : Carcinoma or Intussusception.
- ④ *Pancreas* : Cancer-head pancreas or pseudo-pancreatic cyst.
- ⑤ *Aorta* : Aneurysm or para-aortic L.Ns.

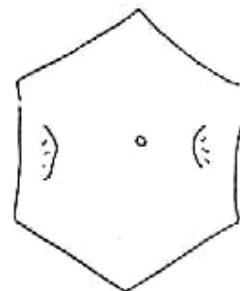


(4) Lumbar Swellings

[I] Abdominal wall masses : As before + lumbar hernia.

[II] Intra-abdominal masses :

- ① Colon.
- ② Kidney.
- ③ Extending from neighboring regions liver & spleen.
- ④ Retro-peritoneal.



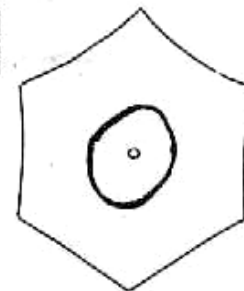
(5) Umbilical Swellings

[I] Abdominal wall masses :

As before + Hernia, Malignant nodules, desmoid tumor or haematoma of rectus sheath.

[II] Intra-abdominal masses :

- ① Transverse colon.
- ② Tabes mesenterica.
- ③ Mesenteric cyst.
- ④ Retroperitoneal.

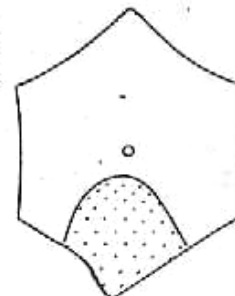


(6) Supra-pubic Swellings

[I] Abdominal wall masses : As before + urachal cyst.

[II] Intra-abdominal masses :

- ① *Urinary bladder* : cancer bladder or retention.
- ② *Uterine* : pregnancy of fibroid.
- ③ *Pelvic abscess.*
- ④ *Retro-peritoneal.*

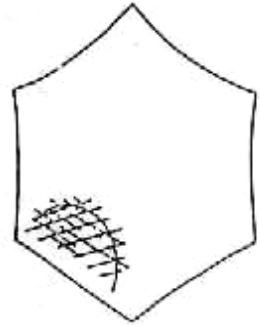


(7) Right Iliac Fossa Swellings

[I] Abdominal wall masses : As before

[II] Intra-abdominal masses :

1. *Appendix* : Appendicular mass and Appendicular abscess.
2. *Caecum* : Cancer caecum.
3. *Ileio-caecal* : Ileocaecal tuberculosis, Crohn's disease, actinomycosis.
4. *Iliac lymph nodes* : Acute iliac lymphadenitis.
5. *Iliac artery* : Aneurysm.
6. *Iliacus muscle* : Myosarcoma and fibrosarcoma.
7. *Psoas abscess* (rare).
8. *Iliac bone* : Tumours or osteomyelitis.
9. *Kidney* : Ectopic kidney or renal transplant.
10. *Genital organs* :
 - *Male* testis : undescended testis with malignant changes.
 - *Female* uterus, ovaries and tubes: fibroid, ovarian cyst. Hydro or pyosalpinx or tubal ectopic pregnancy.
11. *Retroperitoneum* :
 - Retroperitoneal lipoma, Retroperitoneal liposarcoma, Retroperitoneal tumour.



The commonest swellings are :

- | | |
|-----------------------|-----------------------------|
| 1. Appendicular mass. | 2. Appendicular abscess. |
| 3. Cancer caecum. | 4. Ileocaecal tuberculosis. |

Management of a patient with a mass in the Right iliac fossa :

[A] Age :

- ◆ *Young female* : appendicular mass or abscess.
- ◆ *Children* : iliac adenitis.
- ◆ *Old age* : cancer caecum.

[B] History :

- ◆ *History suggestive acute appendicitis* (since few days the patient suffered from pain around the umbilicus shifted to the right fossa).
- ◆ *History suggestive iliac adenitis* : pain, fever and limping (flexion deformity in children).
- ◆ *History suggestive ileo-caecal tuberculosis* : a young patient with abdominal colic and distension.
- ◆ *History suggestive cancer caecum* Anaemia, dyspepsia, diarrhea,

[C] General Examination :

- ◆ *General condition* : ① Looks ill, fissured tongue (appendicular mass).
② Severe cachexia (cancer caecum)
- ◆ *Fever* : ① Appendicular mass.
② Iliac adenitis.
- ◆ *Neck* : ① If supraclavicular lymph node (cancer caecum)
② Matted cervical lymph node (tuberculosis ileo-caecal).
- ◆ *Chest* : ① Tuberculosis.
② Metastasis (pleural effusion).