

THERIOGENOLOGY

BIO-HISTOPATHOLOGICAL STUDIES OF ENDOMETRIUM IN REPEAT BREEDING BUFFALOES (*BUBALUS BUBALIS*)^a

R.B. Singh, R.D. Sharma, Nem Singh^b and G.B. Singh
Department of Obstetrics & Gynaecology
College of Veterinary Science
Punjab Agricultural University
Ludhiana-141004 (INDIA)

Received for Publication: October 7, 1981

Accepted: October 7, 1982

ABSTRACT

A total of 24 uterine biopsies were successfully obtained from 40 repeat-breeding buffaloes. The endometrium of 15 buffaloes showed marked neutrophilic infiltration in the epithelium, stroma and uterine glands. In some cases, lymphocyte and plasma cell infiltration, cystic dilatation of the glands and periglandular fibrosis indicated chronicity of the endometritis. Most of the animals (85.0%) had uterine cultures positive for Streptococci, Staphylococci, Gram positive variable cocci, Gram negative bacilli, Anthracoids, and Gram positive bacilli with a predominance of Corynebacteria. With the treatment based on in vitro drug sensitivity tests, 57.1% repeat-breeding buffaloes conceived.

INTRODUCTION

Sub-clinical endometritis is one of the pathological features in repeat-breeding dairy animals. The condition is not detected on examination per rectum and the bacteriological examination of the uterine mucus does not indicate the state of endometrium. Sometimes the treatments adopted on this basis also fail to provide cure. Moreover, prognosis of the fertility status in these repeat-breeding buffaloes becomes difficult. The histopathological lesions of the uterus at various stages of the reproductive cycle in buffaloes collected in abattoira have been reported (1, 2, 3), but reports are

^a A part of the Ph.D. Dissertation submitted by the Senior author to the Punjab Agricultural University, Ludhiana-141004 (India).

^b Animal Disease Research Centre.

ACKNOWLEDGEMENT

Authors are grateful to Dr. B.S. Gill, Dean, College of Veterinary Science, P.A.U., Ludhiana-141004 for providing necessary facilities.

THERIOGENOLOGY

not available for uteri from repeat-breeding buffaloes. Results of endometrial biopsies in repeat-breeding buffaloes, exhibiting acute or chronic catarrhal endometritis and atrophy of the endometrium, have been published (4). This report pertains to the endometrial biopsy examination of repeat-breeding buffaloes and its treatment on the basis of culture and in vitro drug sensitivity tests.

MATERIALS AND METHODS

Forty repeat-breeding Murrah buffaloes (heifers to 5th calving) of Punjab Agricultural University Farm, Ludhiana, were selected for the present study on the basis of more than three inseminations. The repeat-breeding animals were randomly selected from animals with established reproductive disorders. Of these selected animals, the one's which on rectal palpation revealed no palpable genital abnormalities were taken for the study. Eight buffaloes with normal reproductive function from the same herd were utilized to serve as controls.

All animals were restrained in a trevis for the collection of the uterine biopsy. The vulvar lips and perineal region were cleaned with soap and water and finally swabbed with 90% ethyl alcohol. Using a Neilson biopsy catheter*, the biopsy was obtained from one of the horns during the estrous period. The catheter was introduced into the vulva, vagina, cervix and finally into the uterine horn by manipulation with one hand in the rectum and the material put in a close position in the ice-cooled box. The mucus portion was processed for culture and in vitro drug sensitivity tests in the laboratory and the tissues were preserved in 10% neutral buffered formalin for histopathological examination. The controls and those negative for uterine infections were not treated; all other animals were treated with specific drugs on the subsequent heat period as determined by an in vitro drug sensitivity test. After treatment, a uterine biopsy from 12 buffaloes was taken at the subsequent estrus. The preserved endometrial tissues were routinely processed for microsections and stained with Haemotoxylin and Eosin for histopathological examination.

RESULTS

A total of 24 uterine biopsies was successfully obtained out of 40 biopsy attempts in the repeat-breeding buffaloes. Endometrial tissues from 15 animals revealed various pathological changes and the rest were found to be apparently normal. A marked neutrophilic infiltration in luminal epithelium, stroma and uterine glands was observed in six instances. This was, however, accompanied with lymphocytic and plasma cell infiltration in two, and cystic dilatation of the glands in one case. Cystic dilatation of glands, with wide branched lumina and cuboidal to flattened epithelium was also

* Neilson biopsy catheter modified at Ludhiana.

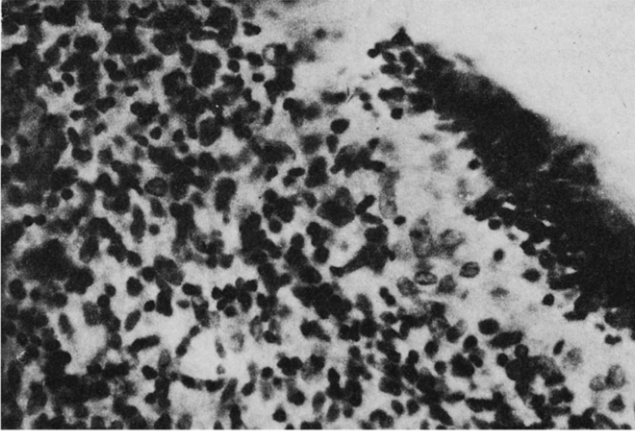


Figure 1. Endometrial biopsy showing massive infiltration of lymphocytes, plasma cells and few neutrophils in epithelial and subepithelial layers. HE (X 400).

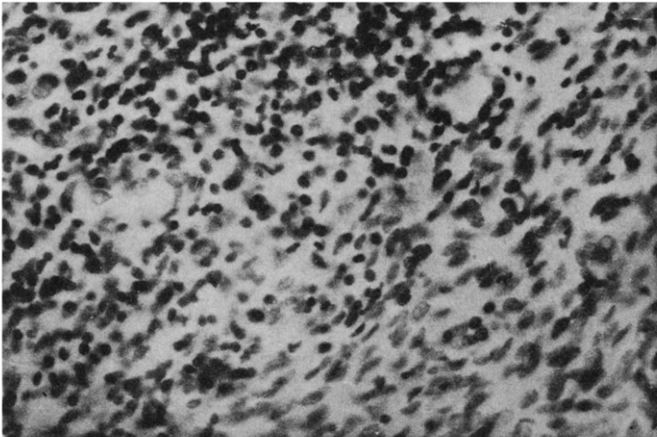


Figure 2. Presence of lymphocytic aggregates around blood capillaries in endometrial stroma. H.E. (X 400).

THERIOGENOLOGY

noted in one case. The lumen contained desquamated epithelial cells and neutrophils. Chronic inflammation, characterized by diffuse infiltration of lymphocytes and plasma cells in the subepithelial connective tissue stroma, was noticed in three buffaloes (Figures 1 and 2). One to three layers of periglandular fibrosis were seen in four, and two to five layers of periglandular fibrosis in one instance (Figure 3). The periglandular fibrosis consisted of closely packed concentrically arranged spindle shaped cells with cylindrical nuclei. Occasionally, the fibrous tissues surrounded the uterine glands to form a nest. The periglandular fibrosis accompanied infiltration of lymphocytes and plasma cells was seen in one case.

Uterine biopsies taken from eight buffaloes after treatment revealed no specific changes in four cases except occasional hyalinization of blood vessels. The remaining four biopsies exhibited periglandular fibrosis. These changes were accompanied by cystic dilatation of uterine glands having low cuboidal to flattened epithelium in two instances (Figure 4). The earlier biopsies from these four animals were unsuccessful.

The histological picture of the endometrial biopsy from the normal buffaloes was characteristic of the estrus period. Hypertrophied luminal epithelium with vacuolation in the cytoplasm and few polymorphonuclear cells were observed at the margin of the venules.

Following treatment with specific antibiotics according to the in vitro drug sensitivity test, 57.1 percent repeat-breeding animals conceived. Most of the animals (85.0%) had uterine infections with Streptococci, Staphylococci, Gram variable cocci, Gram negative bacilli, Anthracoids and Gram positive bacilli with a predominance of Corynebacterium. Two animals having periglandular fibrosis without cellular infiltrations did not conceive. Histologic appearance of the endometrium was normal in three animals although subsequent biopsies revealed them to be positive for bacterial infections. Such animals also did not conceive even after three inseminations.

Control animals with normal bio-histopathological picture of the endometrium conceived within three consecutive inseminations.

DISCUSSION

Since endometrial lesions could not be assessed with any degree of confidence by rectal palpation, biopsy studies proved an excellent approach to clinical diagnosis, prognosis, and rational treatment of repeat-breeding in buffaloes. Such studies already have been reported for the diagnosis and prognosis of infertility in mares (5).

The depth of cellular infiltration of the endothelium, uterine glands and stratum compactum was related to the varying degree of

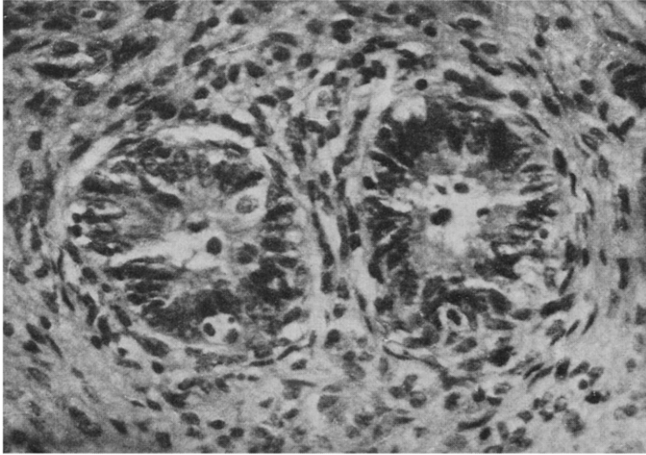


Figure 3. Section of endometrial biopsy showing slight (1-3 layers) periglandular fibrosis and hypertrophy of glandular epithelium. HE (X 400).

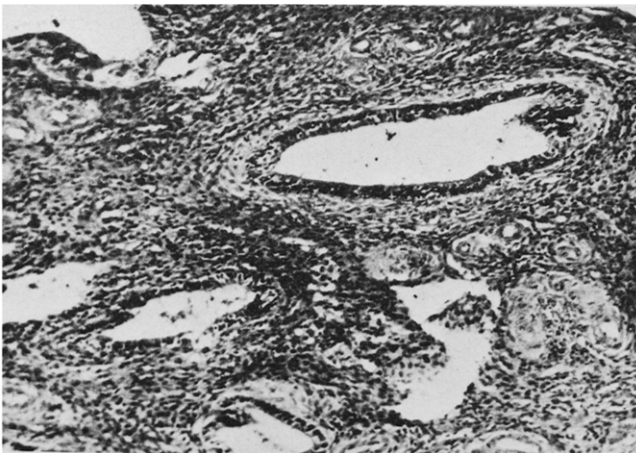


Figure 4. Fibrosis in response to cystic distention. HE (X 400).

THERIOGENOLOGY

inflammation. The diffuse neutrophilic infiltration of the luminal epithelial and sub-epithelial layers, characteristic of acute endometritis due to infection, was observed in six cases. Lymphocytic and plasma cell infiltration in the luminal epithelium and stratum compactum, seen in three cases, could be considered as a sign of chronic endometritis. In addition, periglandular fibrosis and cystic dilatation of the gland are correlated with greater duration of the condition and may be the result of prolonged severe uterine infections. Cystic endometrial glands have been produced with estrogenic hormones in guinea pigs (6) and in the hamster (7). Since ovaries in the buffalo were normal, excess estrogenic hormones cannot be anticipated to have caused these changes. The severity of endometrial changes, especially periglandular fibrosis, with or without plasma cells and lymphocyte infiltration, was probably due to high frequency of Corynebacterial infections seen in this study and reported in cattle (8-10). It is evident from the study that therapy based on bacteriology and histopathological changes in the endometrium obtained by uterine biopsy of repeat-breeder buffalo proved to be effective in lowering infertility problems in these animals.

THERIOGENOLOGY

REFERENCES

1. El-Sheikh, A.S. and Abdelhadi, H.A. Anatomy and Histology of the reproductive tract in the Egyptian buffaloes. *Indian J. Anim. Sci.* 40: 213-222 (1970).
2. Shukla, K.P., Zala, P.M., Shuk Deo, Sarojini, C.K. and Janakiraman, K. Myometrial history of Surti buffaloes uterus during estrous cycle. *Indian Vet. J.* 50: 234-239 (1973).
3. Sundaravandanan, V.K., and Venkataswamy, V. Histology and Histochemistry of bovine uterus. *Indian J. Anim. Sci.* 43: 1050-1053 (1973).
4. El-Naggar, M.A., and El-Sherry, M.I. Incidence and pathological changes in endometrial biopsy of the repeat breeder buffaloes in Assiut Province, Egypt. *Assiut Veterinary Medical Journal* 1: 267-279 (1975) (Abstr. in *Vet. Bull.* 46: No. 3259 (1976)).
5. Kenney, R.M. Cyclic and pathological changes of the mare endometrium as detected by biopsy, with a note on early embryonic death. *J. Am. Vet. Med. Ass.* 172: 241-262 (1978).
6. Nelson, W.O. A typical uterine growth produced by prolonged administration of estrogenic hormones. *Endocrinology* 24: 50 (1939) (cited by Moss, S., Sykes, J.F. and Wrenn, T.R. *J. Anim. Sci.* 15: 631-639 (1956)).
7. Bacon, R.L. Leiomyomas of the uterine in the hamster following treatment with diethylstilbestrol and testosterone. *Anat. Rec.* 109: 265 (1951) (cited by Moss, S., Sykes, J.F. and Wrenn, T.R. *J. Anim. Sci.* 15: 631-639 (1956)).
8. Laing, J.A. Fertility and infertility in domestic animals. *Baillere Tindall and Cassell*, 2nd edition 1970. pp. 298-307.
9. Roberts, S.J. *Veterinary Obstetrics & Genital Diseases*. 2nd edition, published by author. Ithaca, New York (1971) pp. 476-500.
10. Hartigan, P.J., Murphy, J.A., Nunn, W.R. and Griffin, J.F.T. An investigation into causes of reproductive failure in dairy cows. II. Uterine infection and endometrial histology in clinical normal repeat breeder cows. *Ir. Vet. J.* 26: 245-247 (1972).